U SYSTEMS
Automated Breast Ultrasound

Automated Breast Ultrasound

Meeting of the Radiological Devices Advisory Panel

P110006

April 11, 2012

Introduction and Agenda

Ronald Ho

CEO & President

U-Systems, Inc.

U SYSTEMS
Automated Breast Ultrasound

Agenda

Introduction & Technology Overview

Tailored Breast Cancer Screening

Clinical Retrospective Reader Study (CRRS) Design

CRRS Statistical Analysis

Risk/Benefit Analysis

ABUS Training Program

Concluding Remarks

Presenters

Ronald Ho, CEO & President, U-Systems, Inc.

Introduction and Technology

Concluding Remarks

Rachel F. Brem, M.D., Prof. and Vice Chair Radiology and Director, Breast Imaging and Intervention, The George Washington University

Tailored Breast Cancer Screening

Risk/Benefit Analysis

ABUS Training Program

Maryellen L. Giger, Ph.D., Prof. of Radiology, Department of Radiology, University of Chicago

Clinical Retrospective Reader Study Design

Dave P. Miller, M.S.

Senior Director, ICON Late Phase and Outcomes Research

Clinical Retrospective Reader Study Statistical Analysis

U-Systems, Inc. Experts

Jiayu Chen, Ph.D.
Vice President, Engineering

Kathy Quiroz, BSN, RDMS
Senior Director, Clinical Affairs

Heather Rone, B.S.
Research Manager, Clinical Affairs

U-Systems, Inc.

- Headquartered in Sunnyvale, CA
- Privately held
- Dedicated to breast cancer detection and diagnosis
- Developed somo•v® Automated Breast Ultrasound System
- Designed to detect breast cancer at an early stage

somo•v® Automated Breast Ultrasound System

510(k) Cleared Since 2005

Current Indication:

The device is indicated for use as an adjunct to mammography for B-mode ultrasonic imaging of a patient's breast when used with an automatic scanning linear array transducer or a handheld transducer. The device is not intended to be used as a replacement for screening mammography.

somo•v® Automated Breast Ultrasound System

Proposed New Indication For Use Subject to This PMA:

(same device)

The somo·v Automated Breast Ultrasound System (ABUS) is indicated as an adjunct to mammography for breast cancer screening in asymptomatic women for whom screening mammography findings are normal or benign (BI-RADS Assessment Category 1 or 2), and breast parenchymal tissue is dense (BI-RADS Composition/Density 3 or 4), and have not had previous clinical breast intervention. The device is intended to increase breast cancer detection in the described patient population.

U SYSTEMS
Automated Breast Ultrasound

Clinical Need for Supplemental Cancer Screening

- Screening mammography alone misses cancers in women with dense breast tissue
- Women with dense breast tissue have a 4-6x higher risk of breast cancer[1]
- Supplementing mammography with screening breast ultrasound detects more cancers than mammography alone in women with dense breast tissue[1]

1. Boyd, et al, NEJM Jan 2007

U-Systems Clinical Activities Timeline

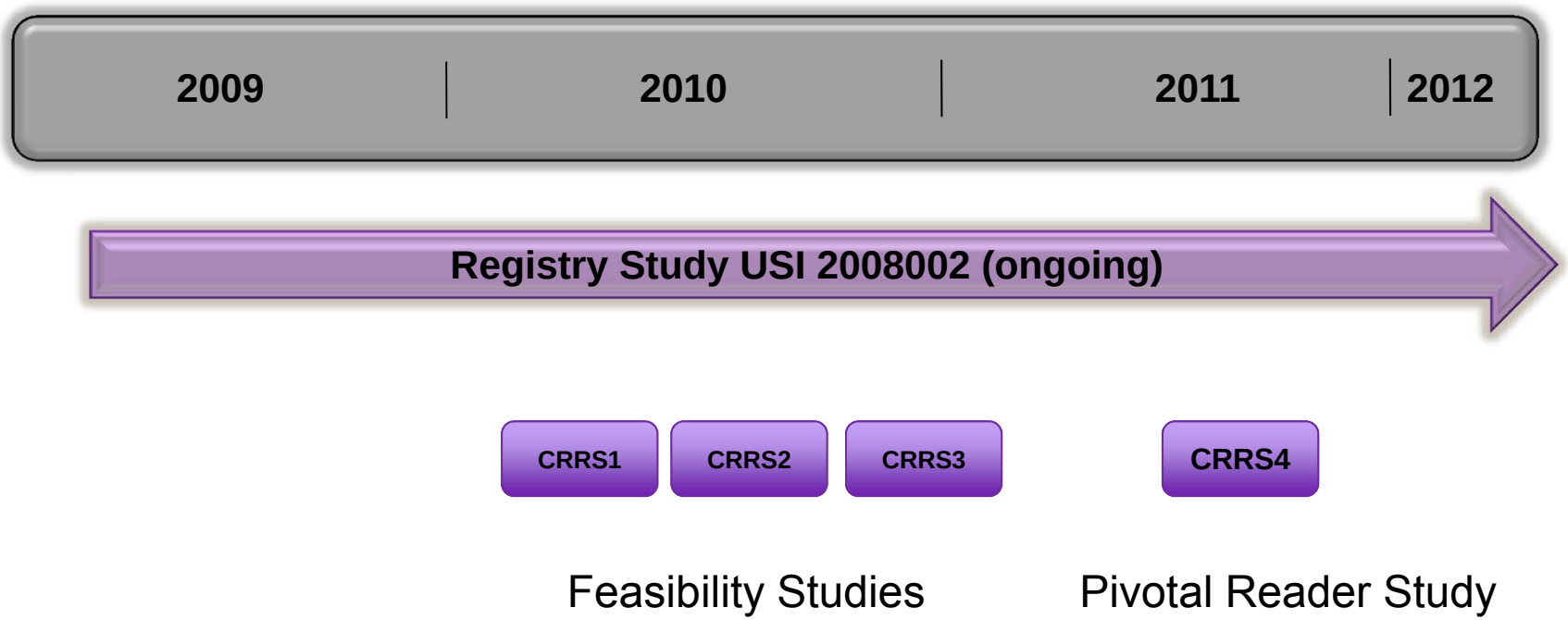

U SYSTEMS
Automated Breast Ultrasound

Pivotal Clinical Retrospective Reader Study

Results from the Reader study demonstrate that use of screening mammography with ABUS provides:

- Substantial statistically significant and clinically meaningful improvement in a Reader's ability to detect mammography-negative breast cancers in women with >50% parenchymal breast density compared to mammography alone
- This significant gain in sensitivity was not accompanied by a statistically significant reduction in specificity

U SYSTEMS
Automated Breast Ultrasound

Technology Overview

Nomenclature

SHORTHAND	DEFINITION
ABUS	Automated Breast Ultrasound System
AUC	Area Under the Curve
CRRS	Clinical Retrospective Reader Study
HHUS	Hand Held Ultrasound
LOM	Likelihood of Malignancy
ROC	Receiver Operating Characteristics Curve
XRM	Conventional Screening Digital Mammography
XRM+ABUS	A review protocol where both digital mammograms and ABUS images are reviewed in combination

somo•v Automated Breast Ultrasound System

ABUS Scan Station

somo·VIEWer™ Advanced 3D Workstation

somo•v Automated Breast Ultrasound System

Acquisition Workflow

- Dedicated System Designed for Operator Independent Imaging
  - Proprietary Scan-Head Technology
  - One-Button Automation

somo•v Automated Breast Ultrasound System



somo•v Automated Breast Ultrasound System

Stabilizing Mesh Membrane

- Stabilizes and Compresses Breast Tissue
- Allows for Acoustic Coupling

somo•v Automated Breast Ultrasound System

Case Review & Interpretation

- Remote somo•VIEWer Work Station
  - Converts 2D image data sets to multi-planar 3D reconstructed images
  - Review entire breast volume in three orthogonal planes (Coronal, Transverse, and Sagittal)

ABUS Exam Sequence

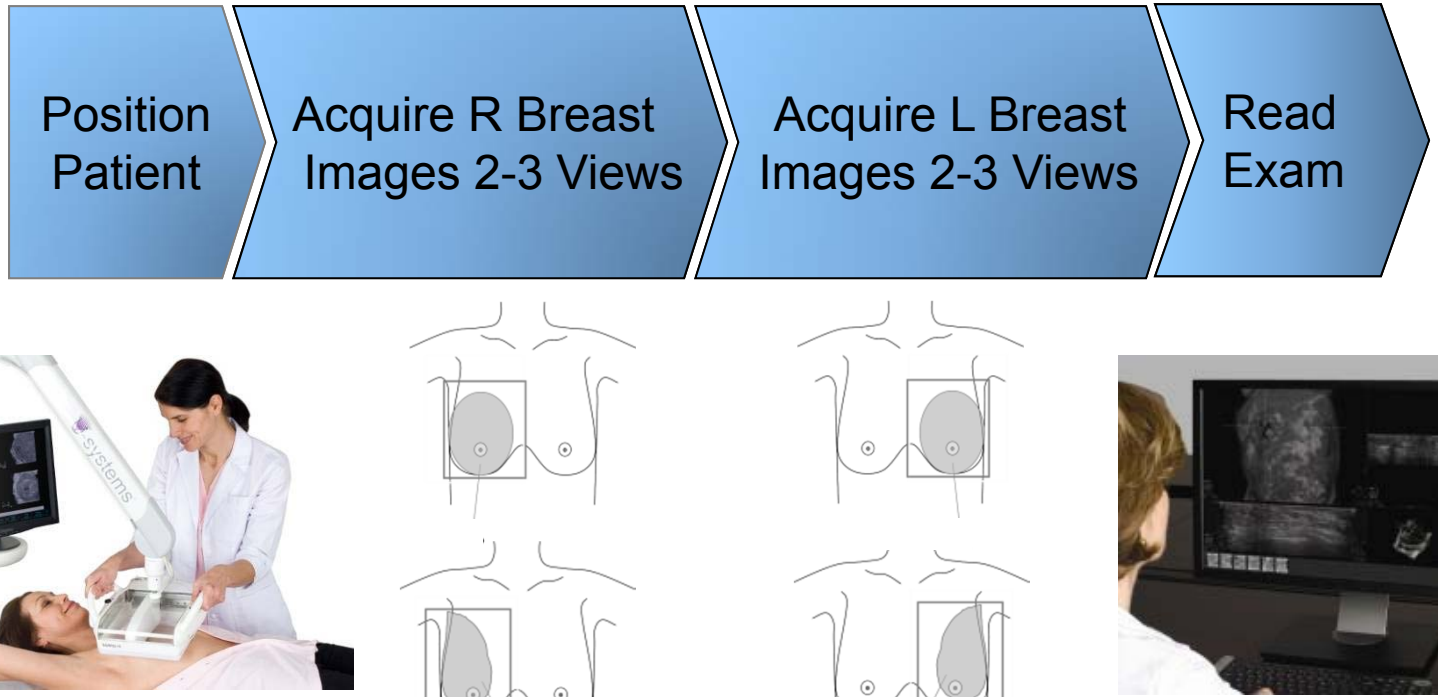

Demo of ABUS Acquisition

Why Automated Breast Ultrasound?

- Allows image interpretation to be separate from the acquisition process
- Image quality is less operator dependent
- Coronal view offers 3D representation of global anatomy and architecture of the breast
- Large FOV (field of view) and correlation to the nipple provides reliable position information
- Reproducibility allows for temporal comparisons
- No ionizing radiation

Tailored Breast Cancer Screening

The Clinical Problem of Breast Density and the Solution Delivered by ABUS

Tailored Breast Cancer Screening

Rachel F. Brem, M.D.

- Professor and Vice Chair, Department of Radiology
  Director, Breast Imaging and Interventional Center
  The George Washington University, Washington, DC
- Principal Investigator, Prospective Multicenter Registry Study
- Medical Advisor and Consultant, U-Systems, Inc.
  - No Financial Interest in U-Systems, Inc.

U SYSTEMS
Automated Breast Ultrasound

Breast Cancer Screening

- Screening mammography is a proven approach to breast cancer mortality reduction
  - Breast cancer mortality reduction ranges from 20-44%
- Non Screen-Detected cancers, found when clinical symptoms develop are:
  - Larger
  - Higher grade (more node positive disease)
  - Poorer prognosis

U SYSTEMS
Automated Breast Ultrasound

Breast Cancer Screening
Implications of Breast Density

- Effectiveness of Screening Mammography
  - All Women
    - Sensitivity: 85%
    - Proven mortality reduction
  - Women with Dense Breasts
    - Sensitivity 65%
    - More than 1/3 of breast cancers not mammographically visible in women with dense breasts

Breast Density

- Significant Clinical Problem:
  - 46.0% of all women in DMIST trial[1]
  - 74% of women between age 40 and 49 years[2]
  - 57% of women in their 50s[2]
  - 44% of women in their 60s[2]
  - 36% of women in their 70s[2]
- Sensitivity of Mammography in Dense Breasts = 65%[3]
  - More than 1/3 of cancers are missed

1. Pisano ED, Gastonis C, Hendrick E et al. Diagnostic Performance of Digital versus Film Mammography for Breast –Cancer Screening. NEJM 2005;353:1773.
2. Checka CM, Chun JE, Schnabel FR, Lee J, Toth H. The relationship of mammographic density and age: implications for breast cancer screening. AJR Am J Roentgenol. 2012 Mar;198(3):W292-5.
3. Mandelson MT, Oestreicher N, Porter PL, et al.Breast density as a predictor of mammographic detection: comparison of interval- and screen-detected cancers. *J Natl Cancer Inst 2000; 92:1081–1087.*

Breast Density is a Qualitative Assessment Graded by ACR Standards Determined by the Interpreting Radiologist

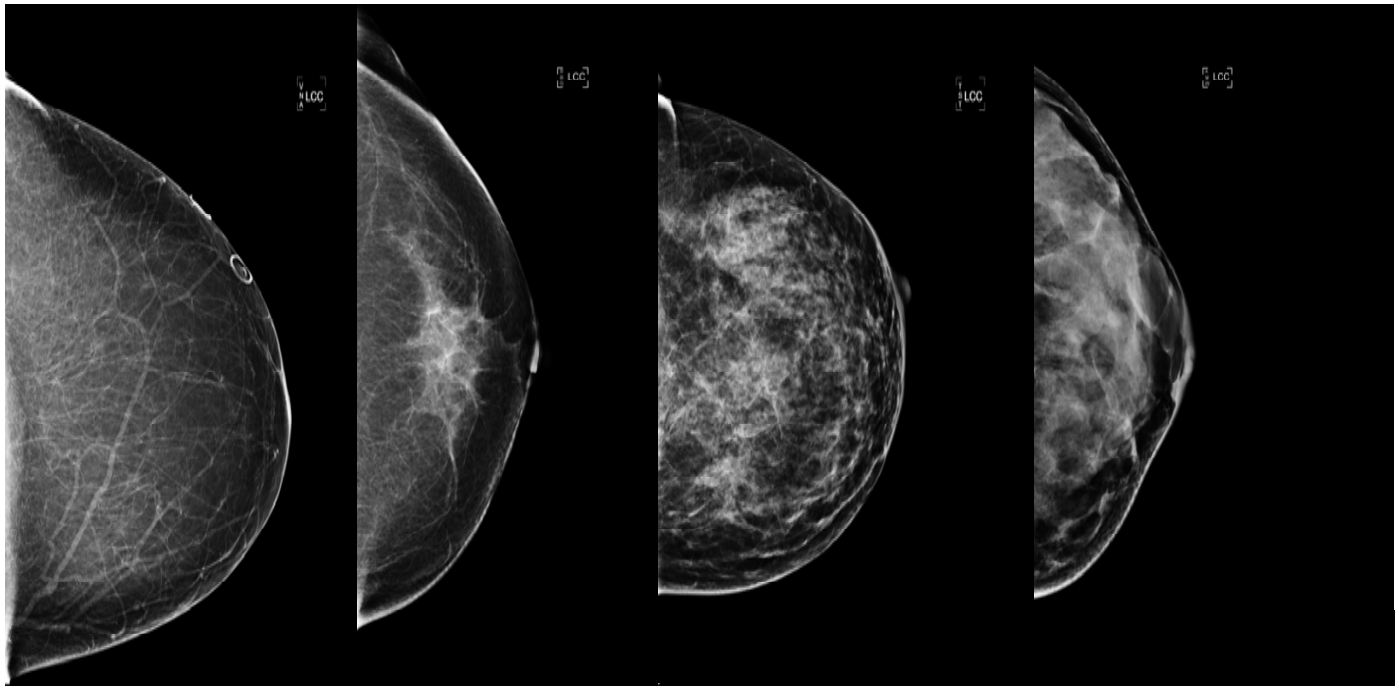

BI-RADS 1	BI-RADS 2	BI-RADS 3	BI-RADS 4
0% - 25%	>25% - 50%	>50% - 75%	>75% - 100%

T
S
T
RCC
T
S
T
LCC

RMLO
LMLO

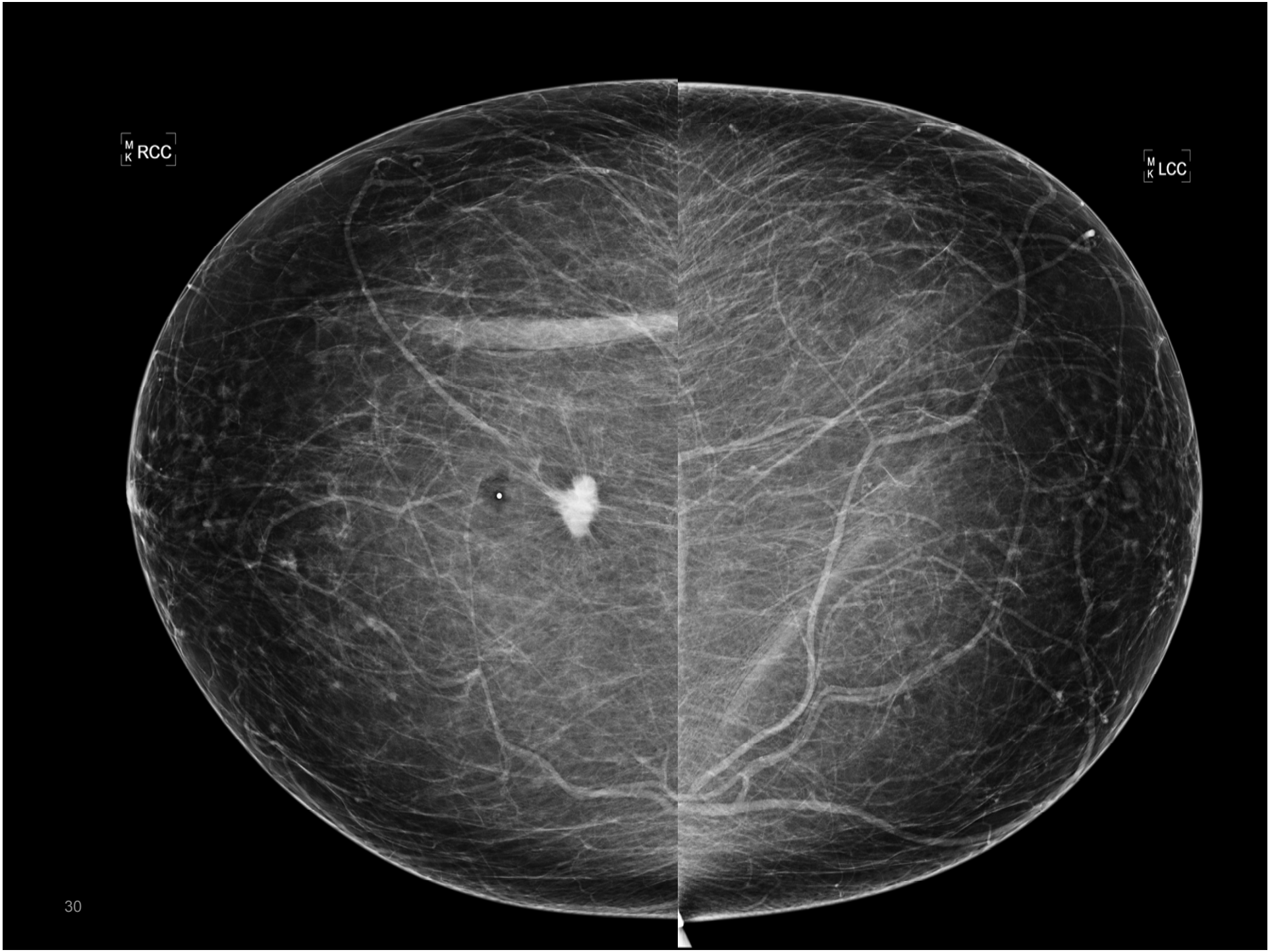
M
K
RCC
M
K
LCC

M
K
RMLO
M
K
LMLO
31

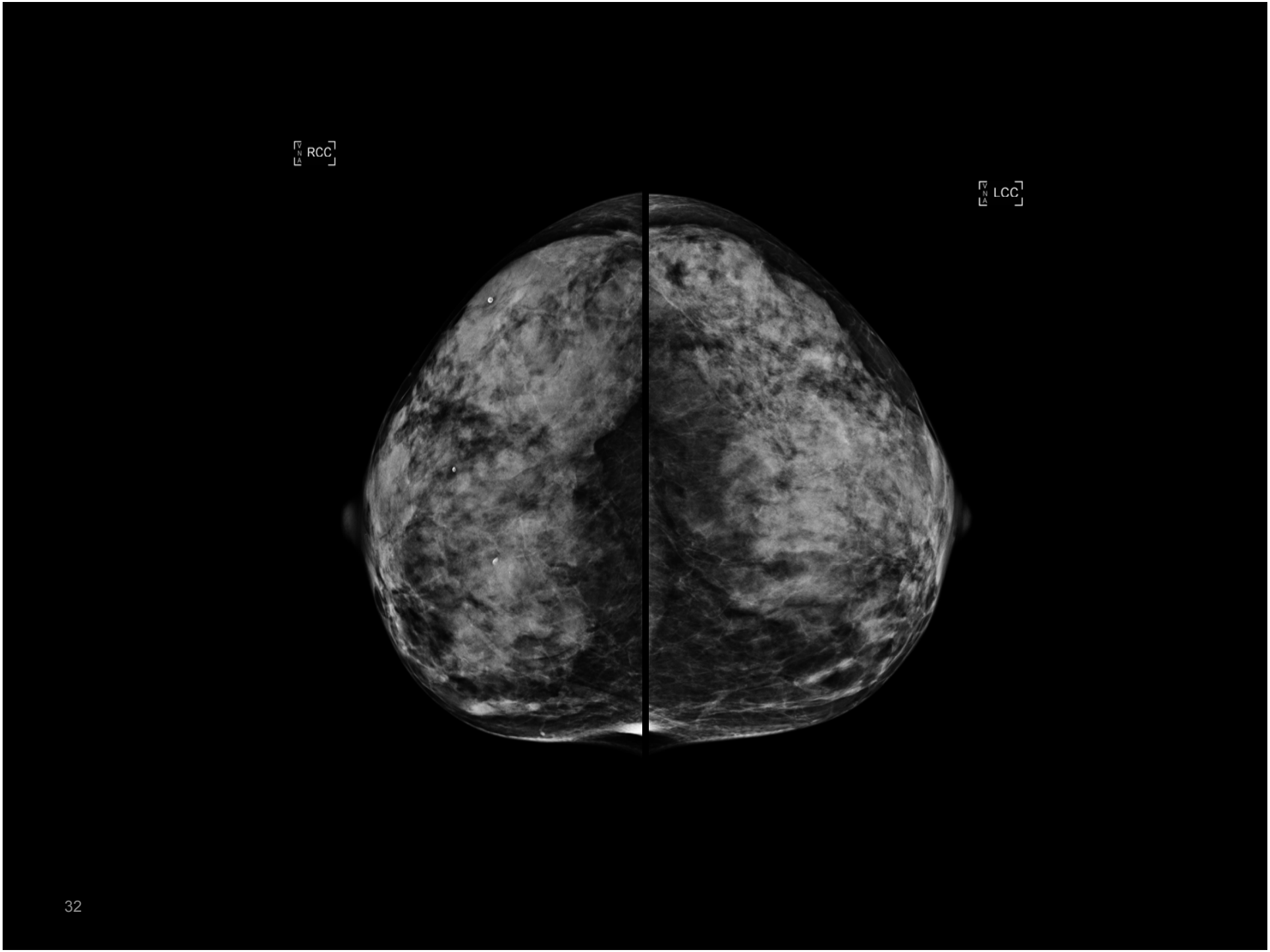
RCC
LCC

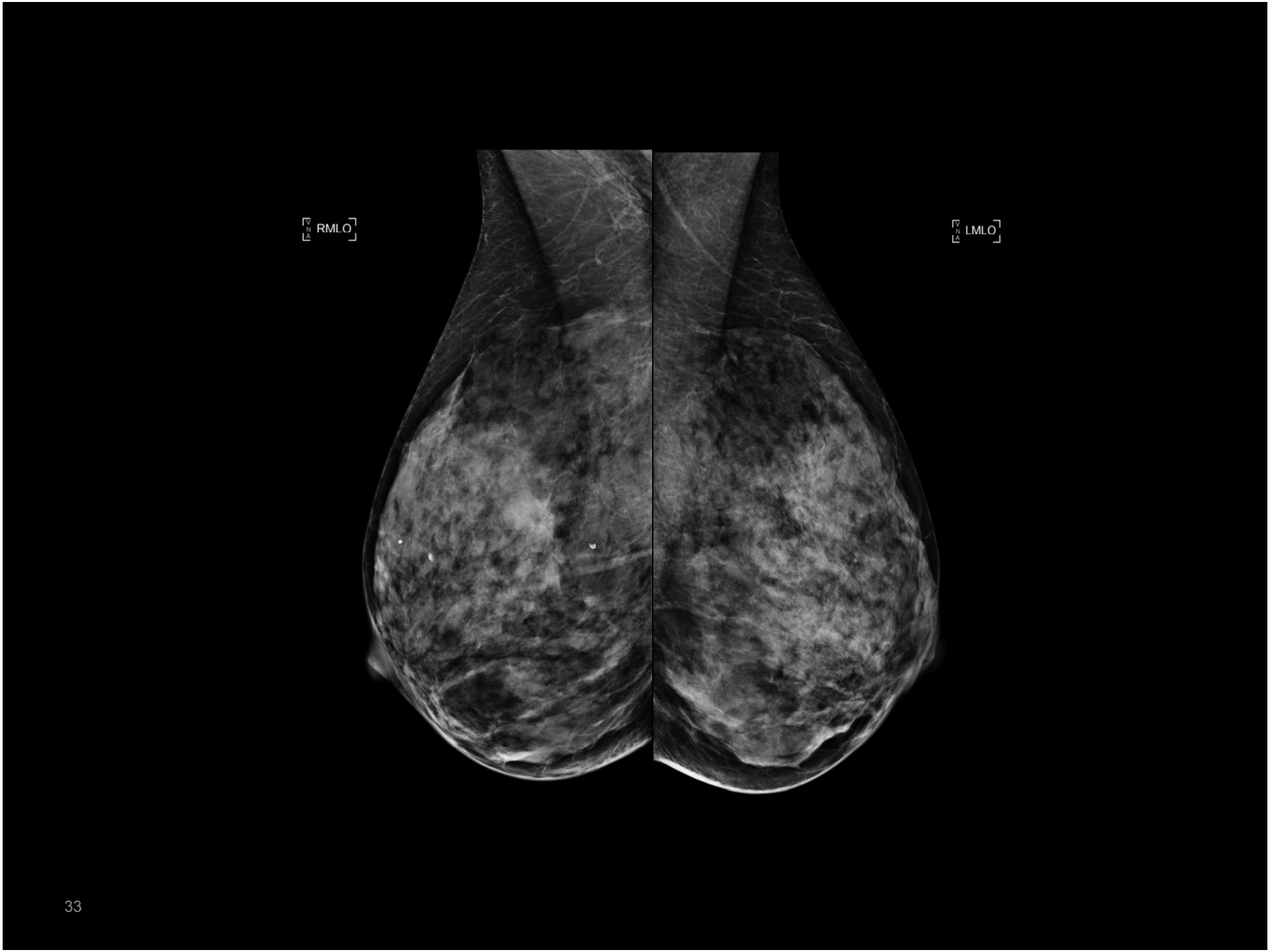
RMLO
LMLO

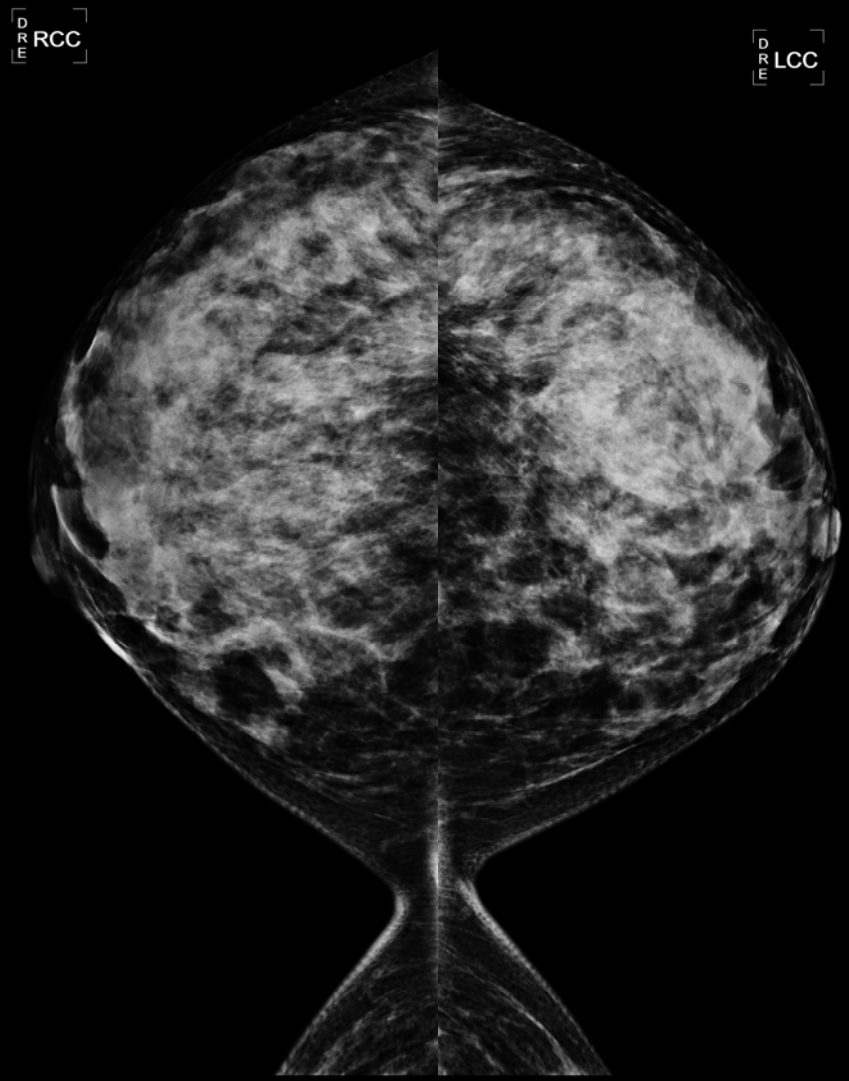
D
R
E
RCC
D
R
E
LCC

D
R
E
RMLO
D
R
E
LMLO

U SYSTEMS
Automated Breast Ultrasound

Breast Density and Cancer Risk

- Breast Density is Strong Independent Risk Factor for Developing Breast Cancer[1]
  - 4-6x increased risk of breast cancer
  - Cancers detected in women with dense breasts are larger, higher grade and more frequently node positive with a poorer prognosis
  - Women with dense breasts have a 17.8x greater risk of breast cancer being detected within 12 months after a negative screening mammogram
- Extensive Literature supports the increased risk of breast cancer with increased breast density

1. Boyd, Guo, Martin et al. Mammographic Density and the Risk and Detection of Breast Cancer. NEJM 2007;356:227.
2. Yahgjyan, Colditz, Collins et al. Mammographic Breast Density and Subsequent Risk of Breast Cancer in Postmenopausal Women According to Tumor Characteristics. 2011. JNCI;103:1179.

U SYSTEMS
Automated Breast Ultrasound

There is a clinical need for additional methods to screen women with dense breasts.

Mammography alone is not enough for these women.

U SYSTEMS
Automated Breast Ultrasound

Ultrasound Detects Additional Cancers

- Studies have confirmed that the addition of hand-held screening ultrasound to mammography in women with dense breasts significantly increases breast cancer detection
- 2.7 to 4.6 cancers per 1000 women screened

1. Crystal P, Strano S D,Shcharynski S, Koretz MJ. Using Sonography to Screen Women with Mammographically Dense Breasts. *AJR July 2003 ;177-182.*
2. Kolb TM, Lichy J, Newhouse JH. Occult cancer in women with dense breasts: Detection with Screening US- Diagnostic Yield and Tumor Characteristics. 1998 Apr;207:191-9.

U SYSTEMS
Automated Breast Ultrasound

Ultrasound Detects Additional Cancers

- Berg, et al. studied 2637 high-risk women with dense breasts who received single screening bilateral hand-held US screening breast ultrasound in addition to mammography[1]
  - 4.2 additional cancers identified on US per 1000 high-risk women
    - IDC
    - Mean size 1.0 cm
    - Almost all were node-negative

1. Berg WA, Blume JD, Cormack JB, Mendelson EB, Lehrer D, Böhm-Vélez M, Pisano ED, Jong RA, Evans WP, Morton MJ, Mahoney MC, Larsen LH, Barr RG, Farria DM, Marques HS, Boparai K; ACRIN 6666 Investigators. Combined screening with ultrasound and mammography vs mammography alone in women at elevated risk of breast cancer. JAMA. 2008 May 14;299(18):2151-63. Erratum in: JAMA. 2010 Apr 21;303(15):1482.

U SYSTEMS
Automated Breast Ultrasound

Additional Cancer Detection: Year 2 and 3

- 30/111 (29%) of cancers were detected by ultrasound alone
  - 30 (92%) were invasive
  - Median size 10 mm (range 2-40 mm)
  - 26/27 (96%) node negative
- Ultrasound detected an additional 3.7/1000 screening mammograms in year 2 and year 3

Berg WA, Zhang Z, Lehrer D, et al. Detection of breast cancer with addition of annual screening ultrasound or a single screening MRI to mammography in women with elevated breast cancer risk. JAMA, 2012:307;1394-1404.

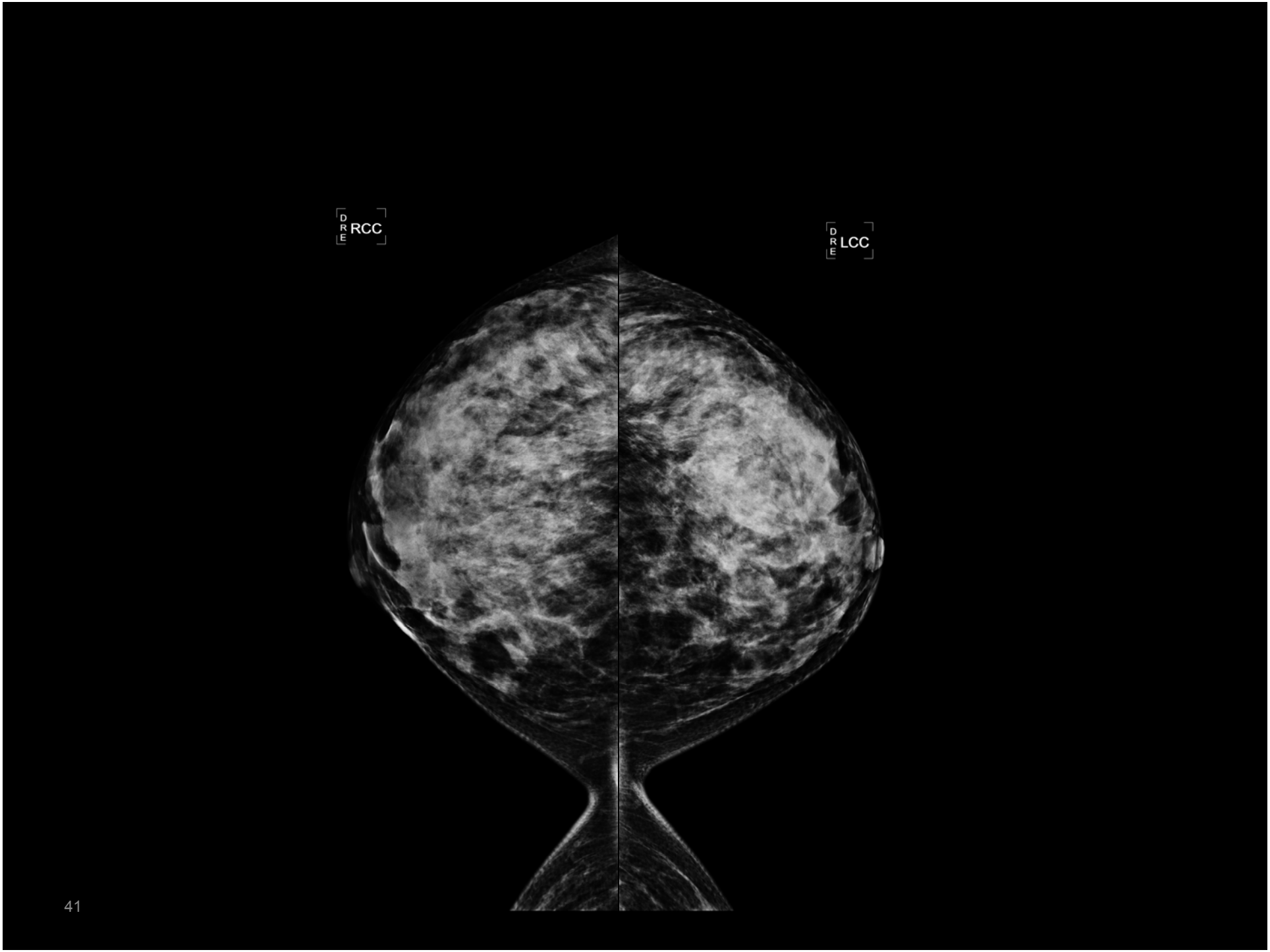
D
R
E
RCC
D
R
E
LCC

D
R
E
RMLO
D
R
E
LMLO

P
X

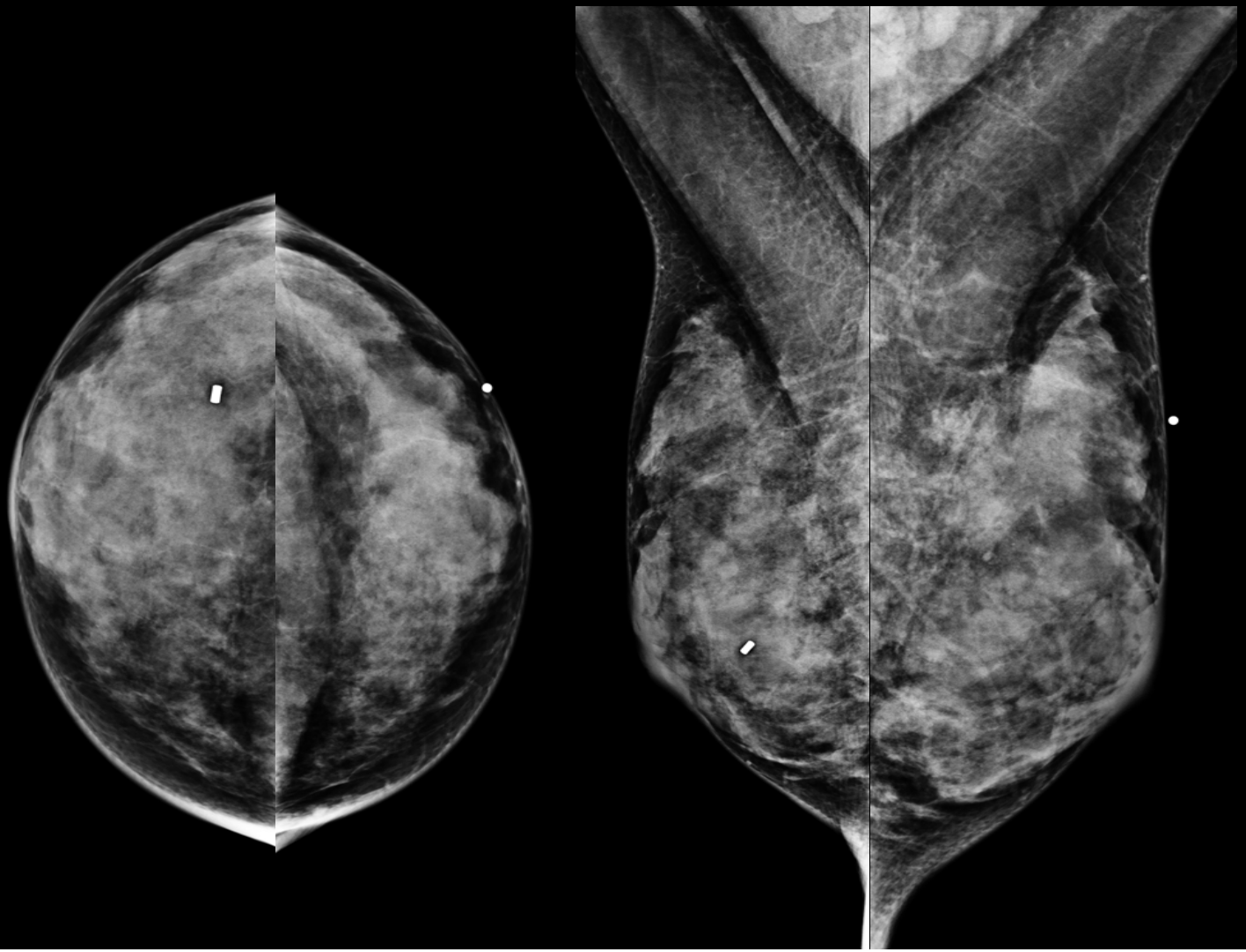

2
1
1
2
lt breast 200 arad

U SYSTEMS
Automated Breast Ultrasound

Disadvantages of HHUS

- Exam must be performed by skilled sonographer or radiologist
- Length of time to acquire images
- Time/resource requirements create workflow issues
- Uncertainty of scan completeness, lack of complete breast coverage
- Operator dependence, variability, low consistency
- HHUS developed for diagnostic use, not screening

Automated Breast Ultrasound System

- U-Systems somo•v ABUS
- FDA-cleared as an adjunct to mammography
- Acquisitions by any trained medical personnel
- Bilateral Exam in under 15 minutes
  - No physician time for image acquisition
  - Less operator dependent
  - 1 minute per view
  - 2 to 3 views of each breast, depending upon size
  - Images available immediately following exam completion
  - Interpretation time less than 3 minutes

Mammography and HHUS

- Combined sensitivity of mammography and ultrasound in BI-RADS Density 2 through 4 has been reported as high as 97%
- By combining mammography and ultrasound in women with dense breasts, more breast cancers can be detected
  - Earlier detection, more curable cancers

Kolb TM, Lichy J, Newhouse JH. Comparison of the performance of screening, mammography, physical examination and breast US and evaluation of factors that influence them: An analysis of 27,825patient evaluations. *Radiology. 2002;225:165-175.*

ABUS is a Solution for this Clinical Problem

- By implementing ABUS, ultrasound can be efficiently and effectively integrated into routine clinical practice for screening women with dense breasts

U SYSTEMS
Automated Breast Ultrasound

Case 1

- 70-year-old woman with stable screening mammogram
  - BI-RADS Density 3, BI-RADS Assessment 2
  - Routine Annual Follow-Up Recommended

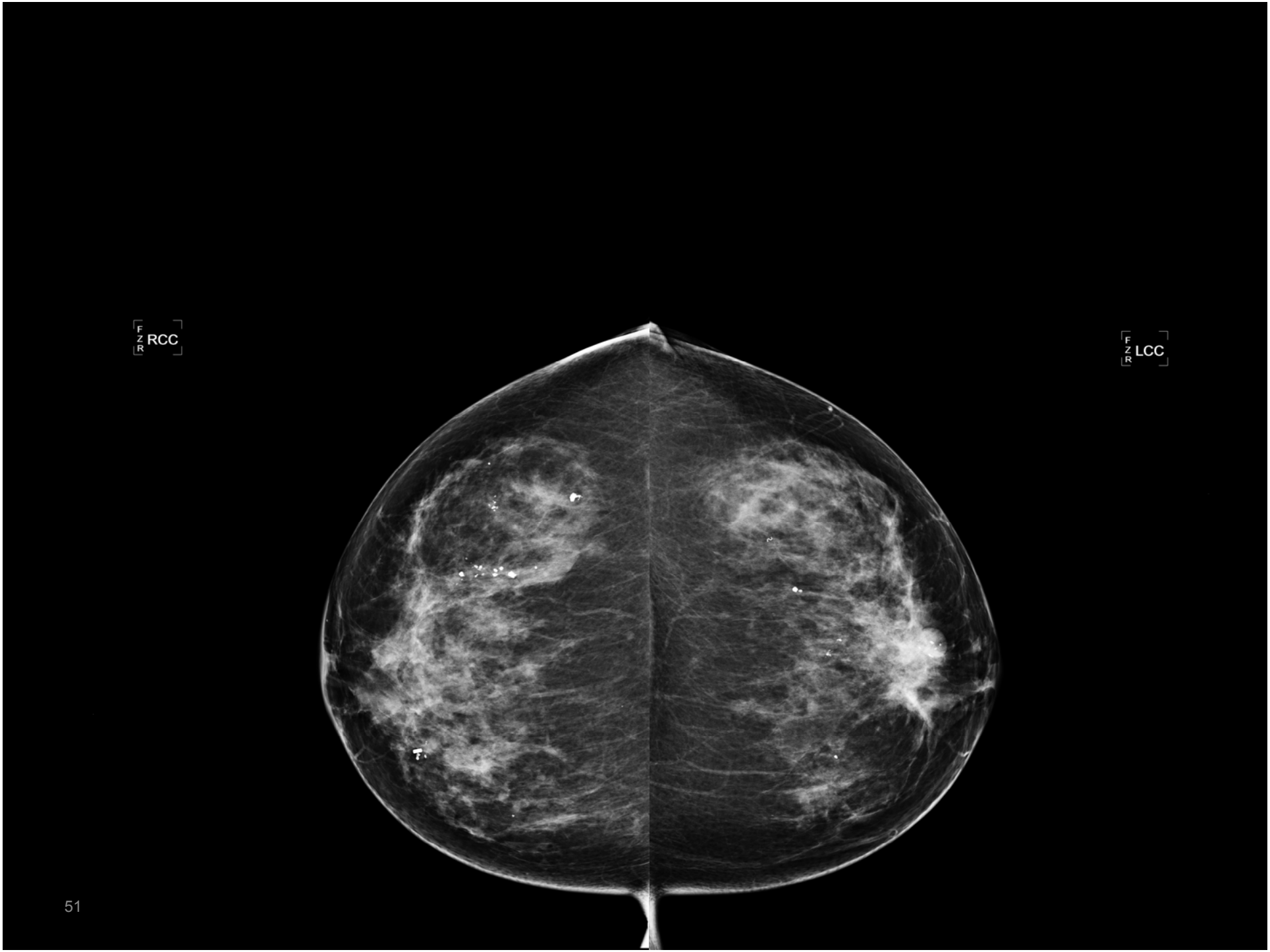
F
Z
R
RCC
F
Z
R
LCC

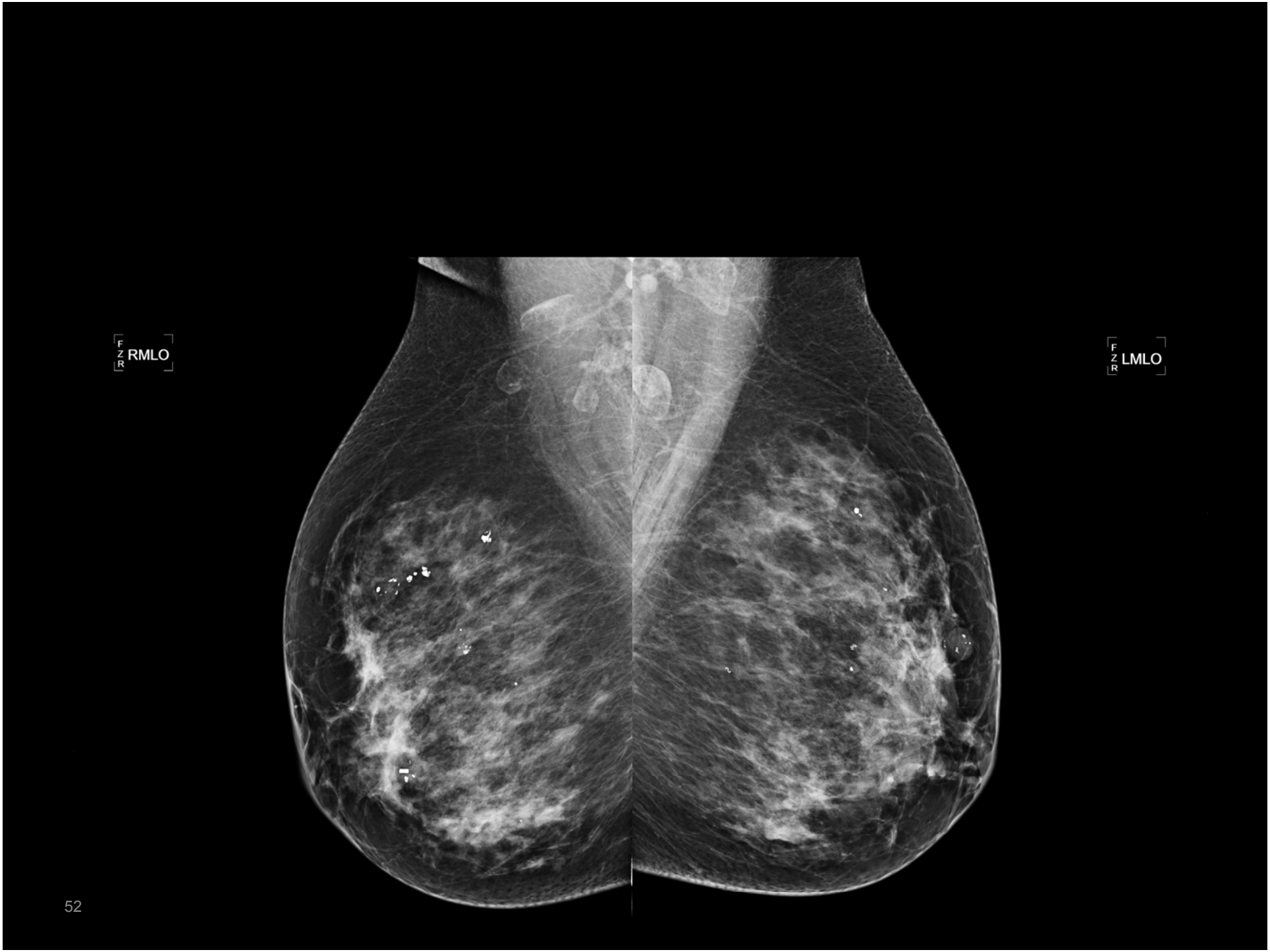
F
Z
R
RMLO
F
Z
R
LMLO

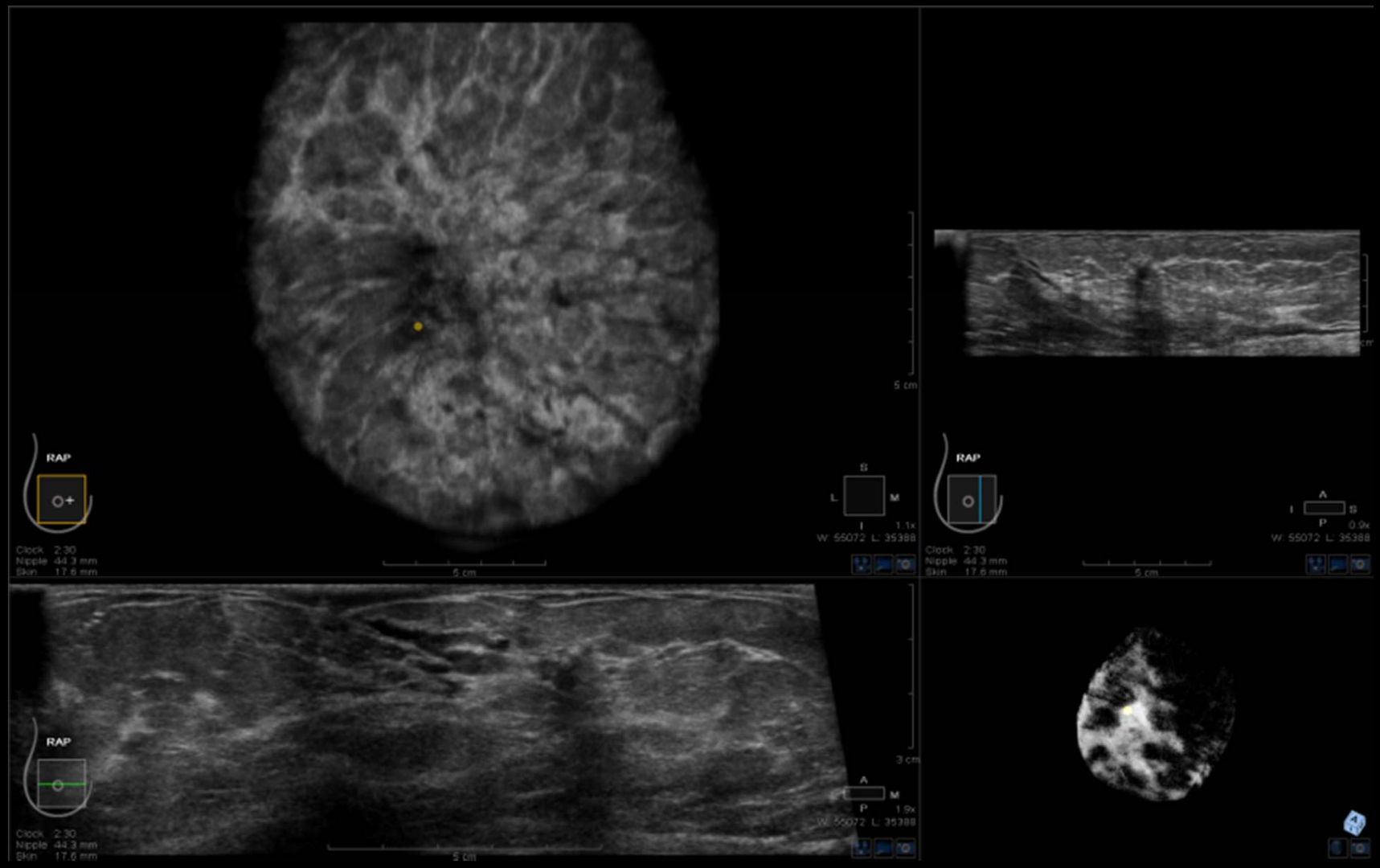
RAP
Clock 2:30
Nipple 44.3 mm
Skin 17.6 mm
5 cm
W: 55072 L: 35388
RAP
Clock 2:30
Nipple 44.3 mm
Skin 17.6 mm
5 cm
W: 55072 L: 35388
RAP
Clock 2:30
Nipple 44.3 mm
Skin 17.6 mm
5 cm
3 cm
W: 55072 L: 35388

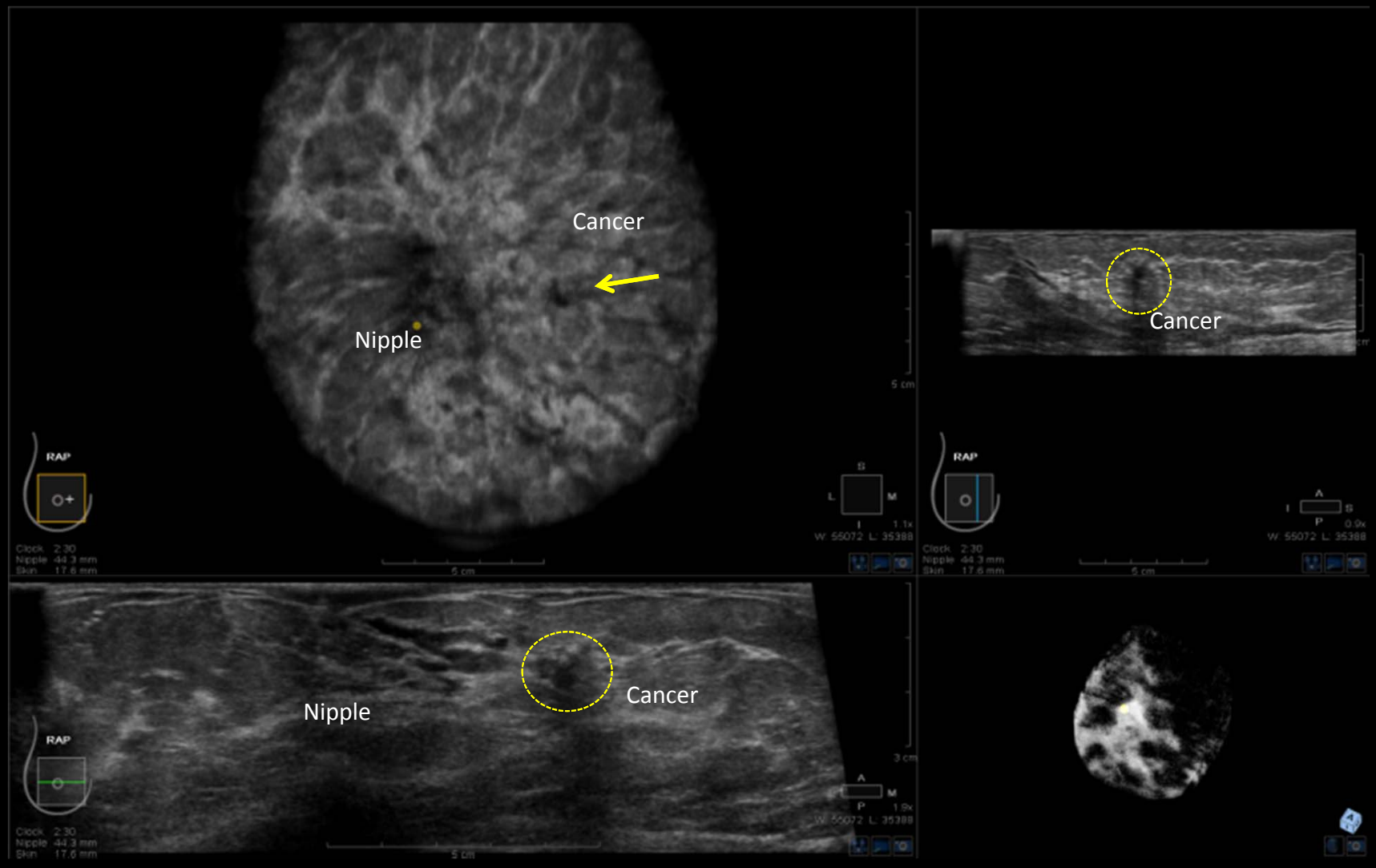
Cancer
Nipple
Cancer
Nipple
Cancer
RAP
RAP
RAP

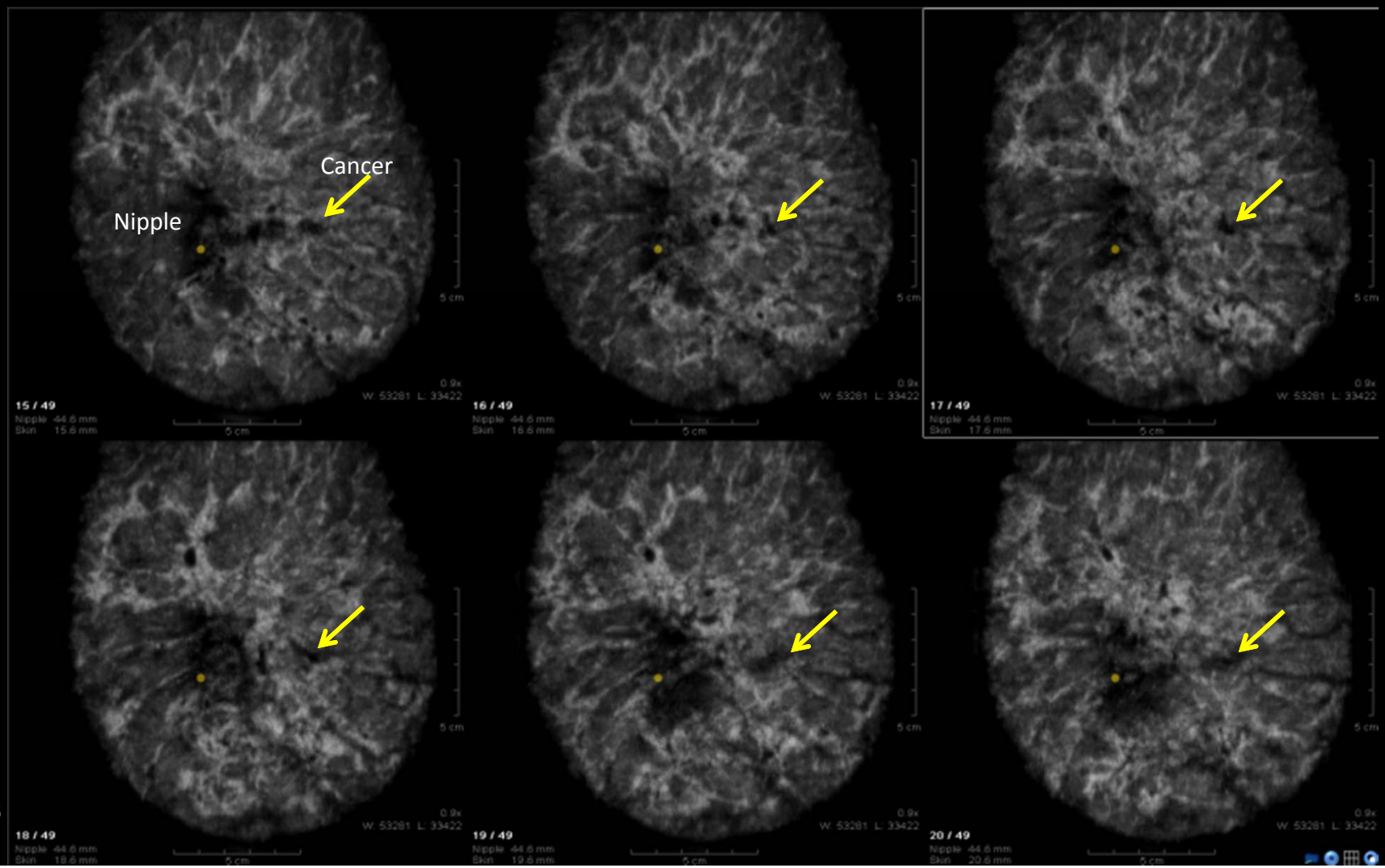
Cancer
Nipple
15 / 49
16 / 49
17 / 49
18 / 49
19 / 49
20 / 49

U SYSTEMS
Automated Breast Ultrasound

Case 1 Conclusion

- Abnormal 3D ABUS
  - BI-RADS 0, Immediate Management Recommended
- Ultrasound-guided core needle biopsy performed
- Pathology revealed Invasive Ductal Carcinoma
  - Seen only with ABUS and mammographically occult

U SYSTEMS
Automated Breast Ultrasound

Case 2

- 59-year-old woman with stable screening mammogram
  - BI-RADS Density 3, BI-RADS Assessment 2
  - Routine Annual Follow-Up Recommended

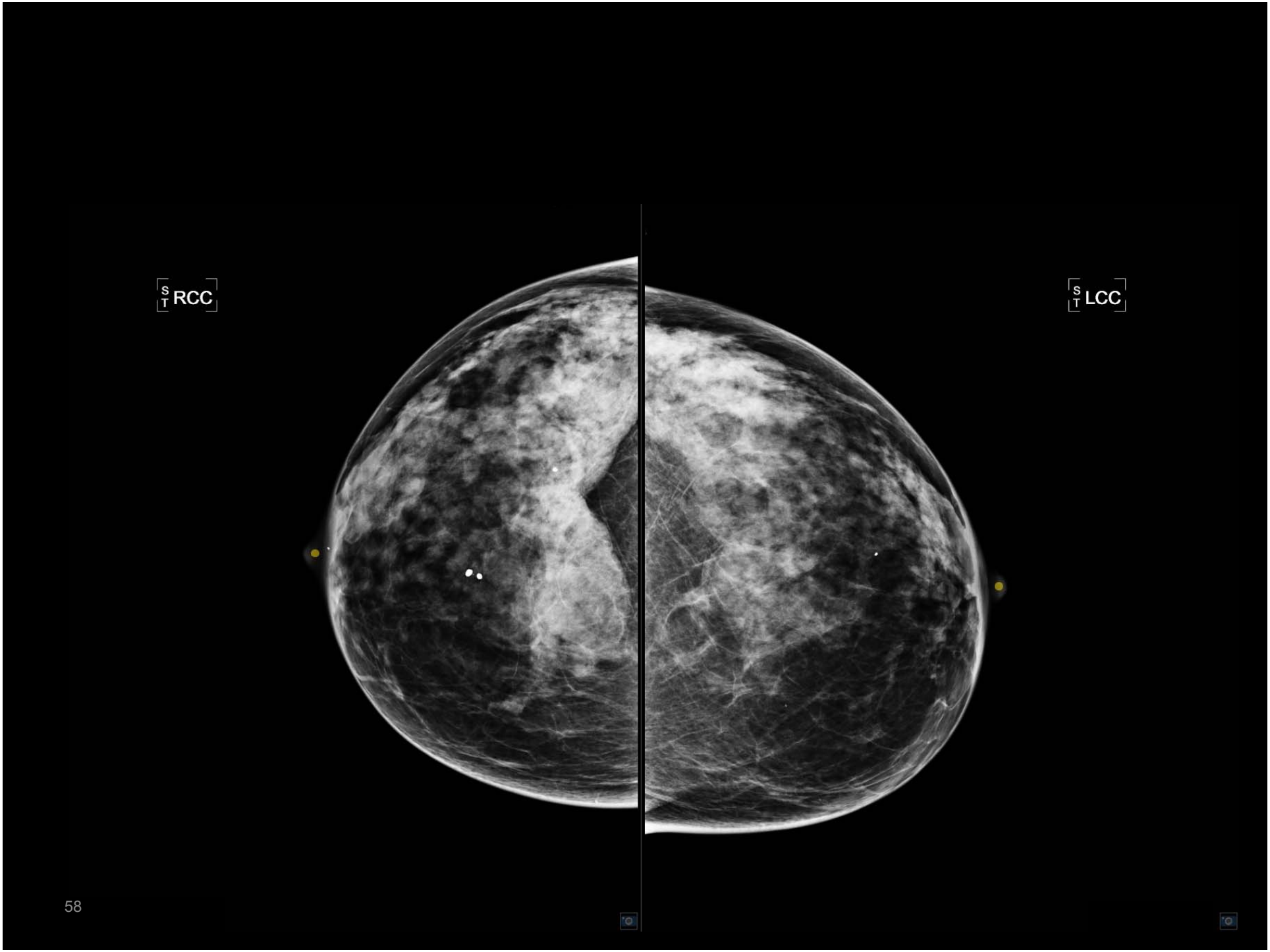
S
T
RCC
S
T
LCC

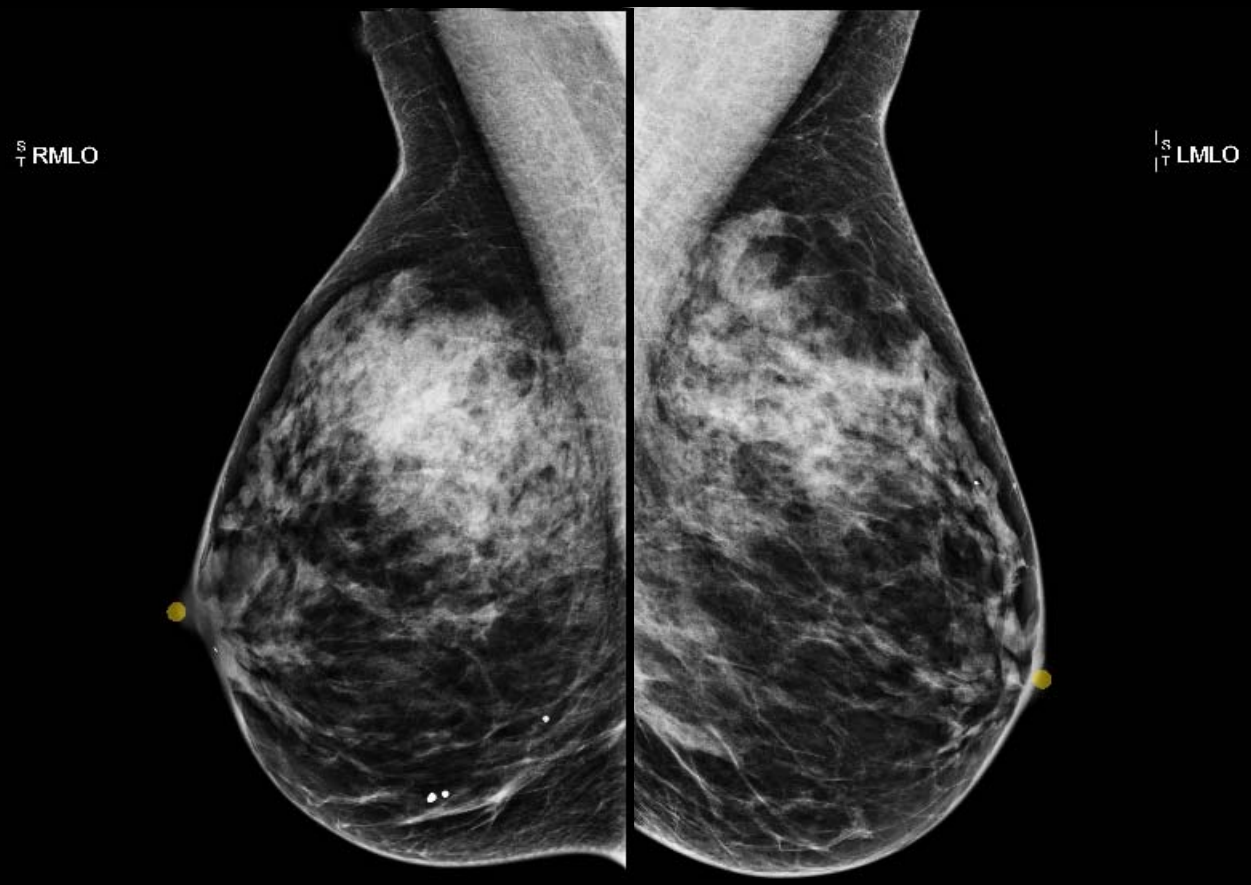
S
T
RMLO
S
T
LMLO

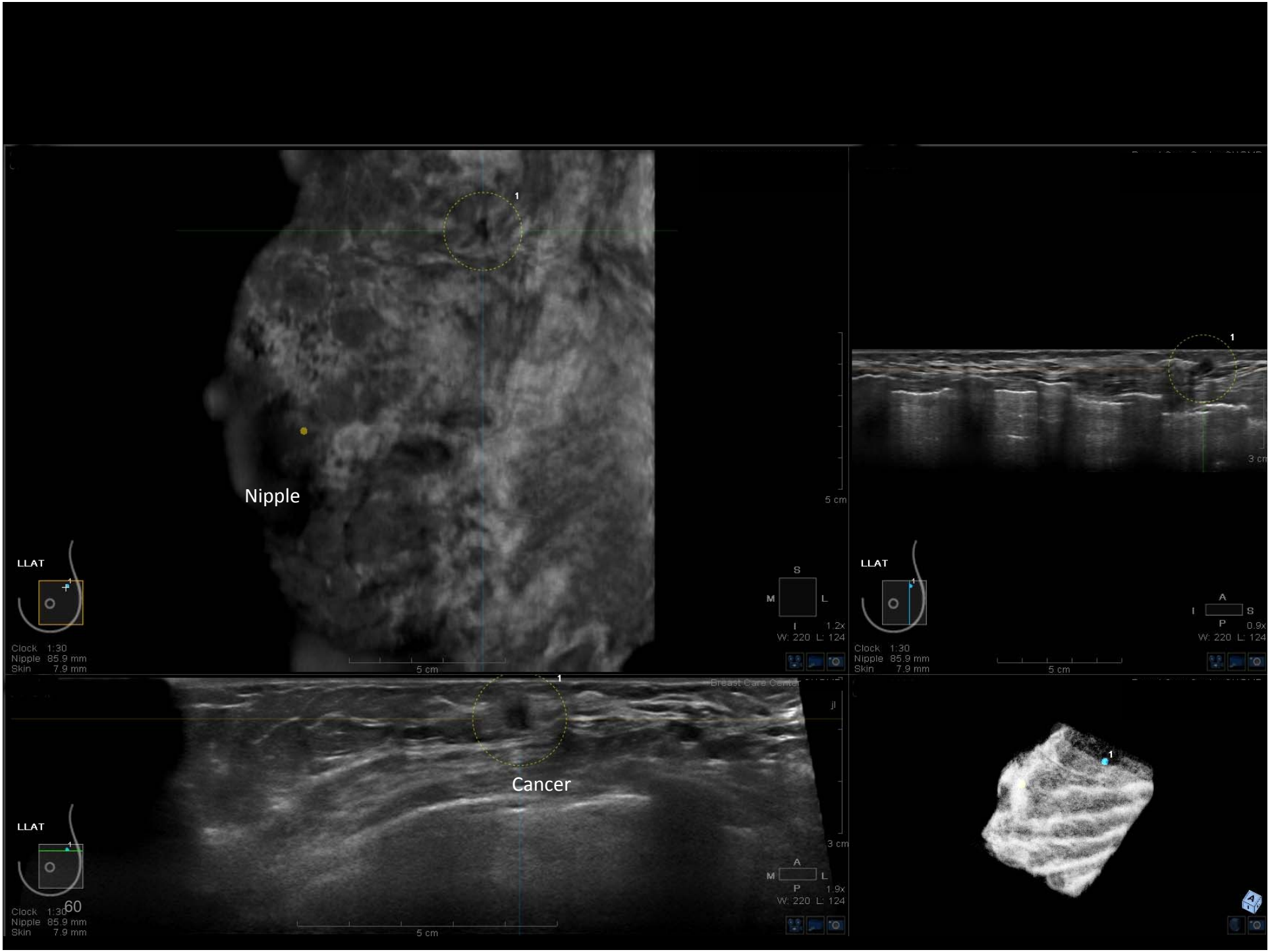
Nipple
LLAT
Clock 1:30
Nipple 85.9 mm
Skin 7.9 mm
5 cm
W: 220 L: 124
Cancer
3 cm
60

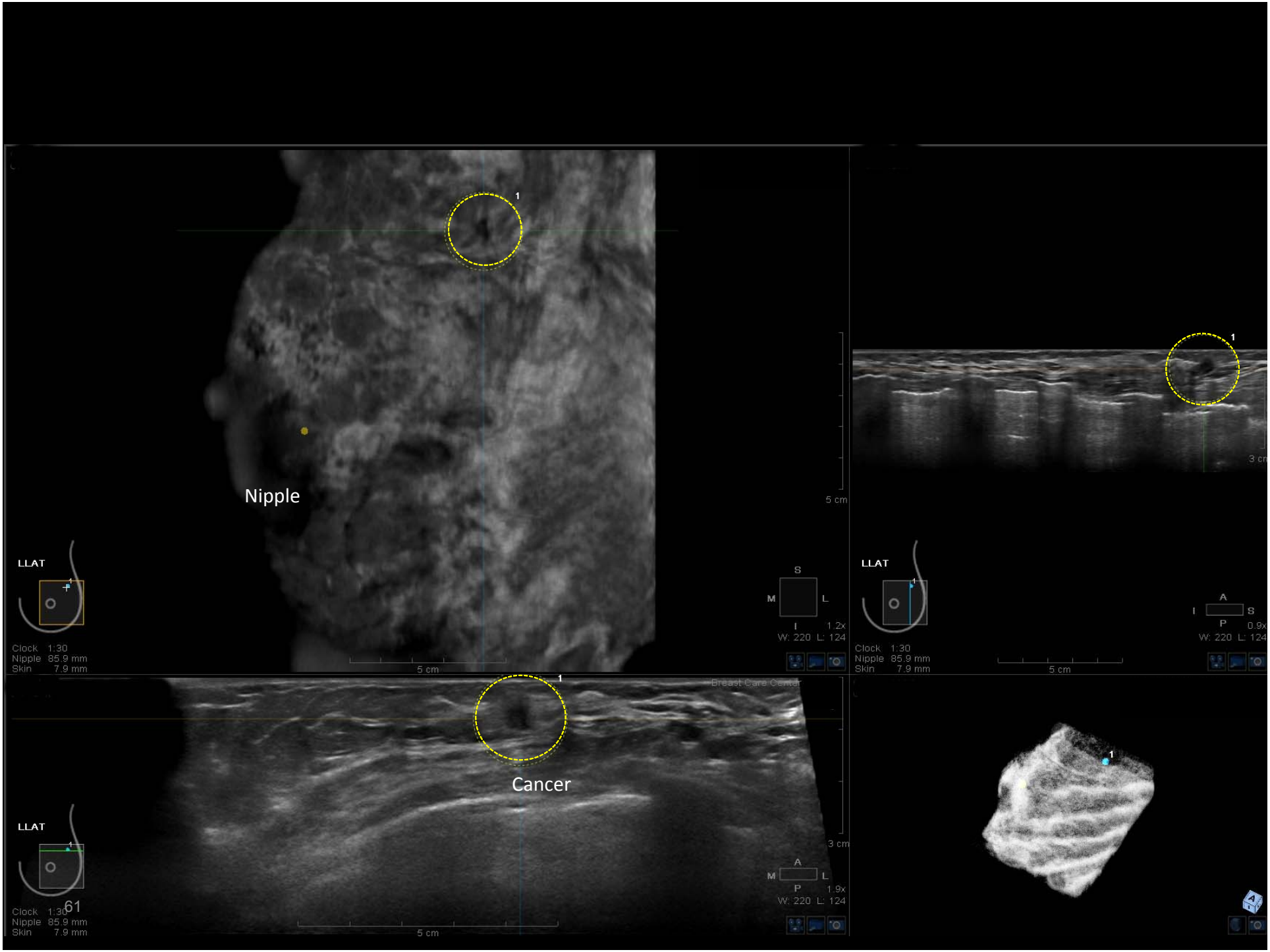
Nipple
Cancer
LLAT
Clock 1:30
Nipple 85.9 mm
Skin 7.9 mm
5 cm
3 cm
W: 220 L: 124
1.2x
0.9x
1.9x
Breast Care Center
61

U SYSTEMS
Automated Breast Ultrasound

Case 2 Conclusion

- Abnormal 3D ABUS
  - BI-RADS 0, Immediate Management Recommended
- Ultrasound-guided core needle biopsy performed
- Pathology revealed Invasive Ductal Carcinoma
  - Seen only with ABUS and mammographically occult

U SYSTEMS
Automated Breast Ultrasound

Case 3

- 60-year-old woman with negative screening mammogram
  - BI-RADS Density 3, BI-RADS Assessment 1
  - Routine Annual Follow-Up Recommended

RCC
LCC
64

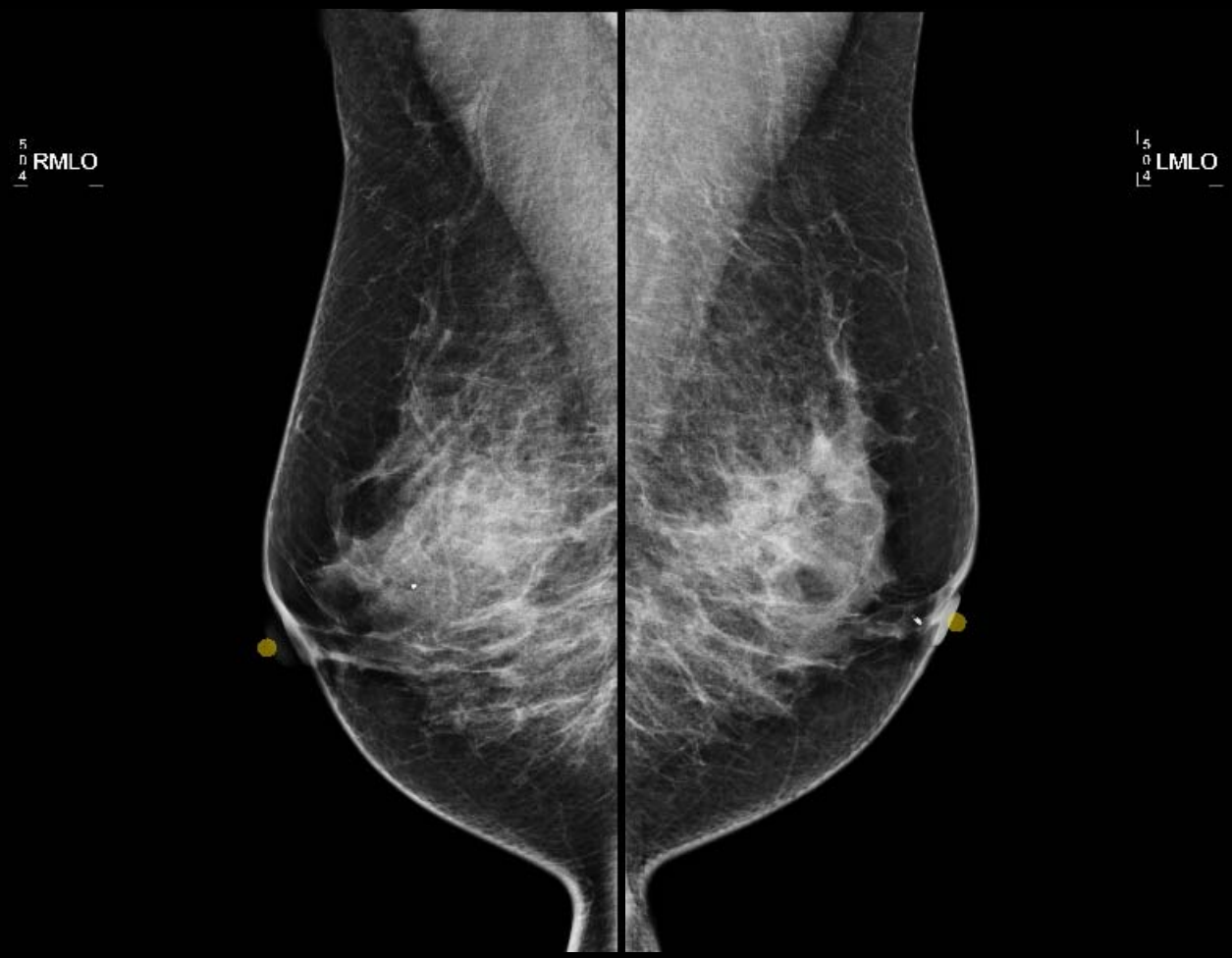
RMLO
LMLO

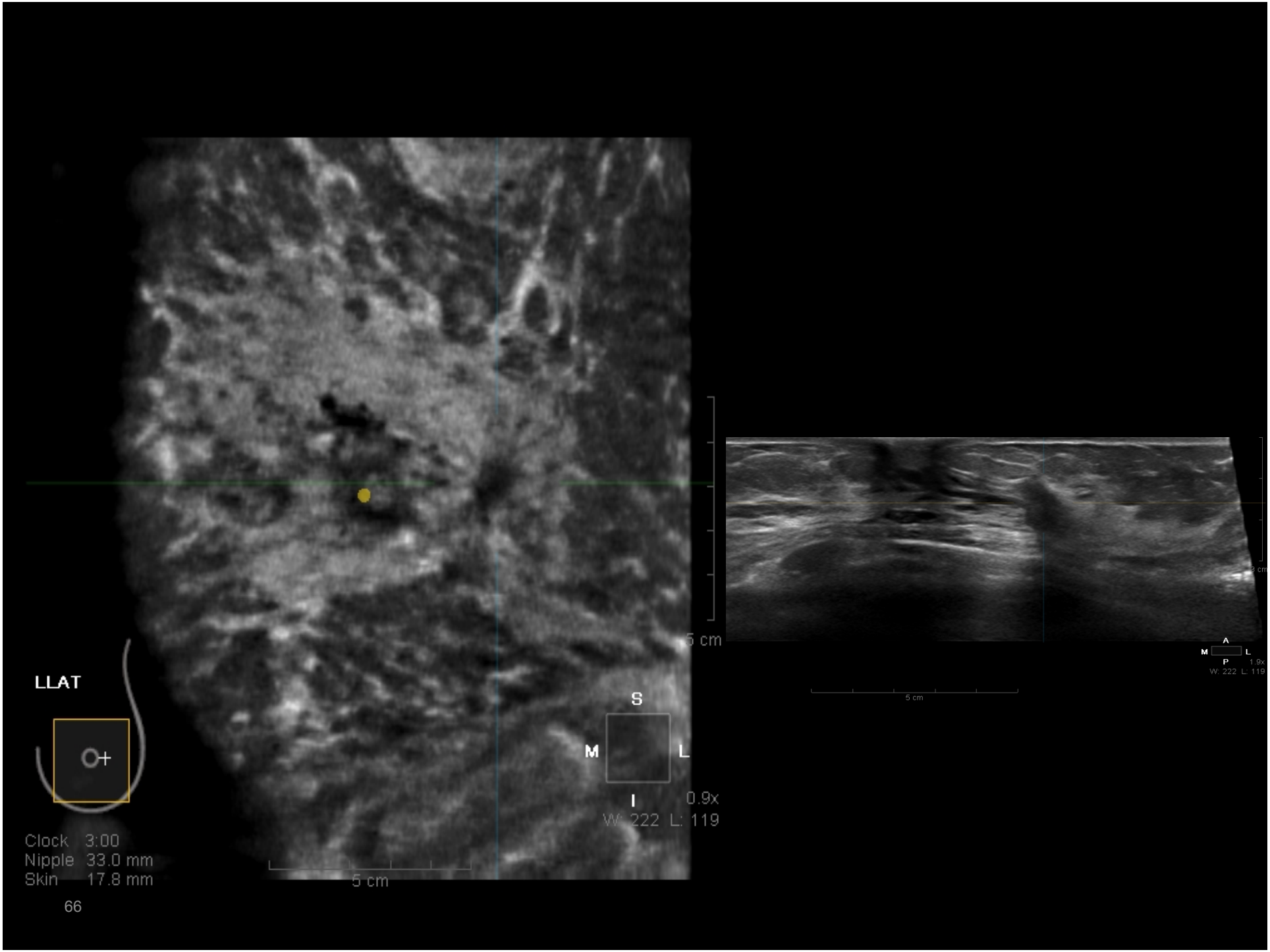
LLAT
Clock 3:00
Nipple 33.0 mm
Skin 17.8 mm
66
5 cm
S
M
L
I
0.9x
W: 222 L: 119
5 cm
5 cm
A
M
L
P
1.9x
W: 222 L: 119
5 cm

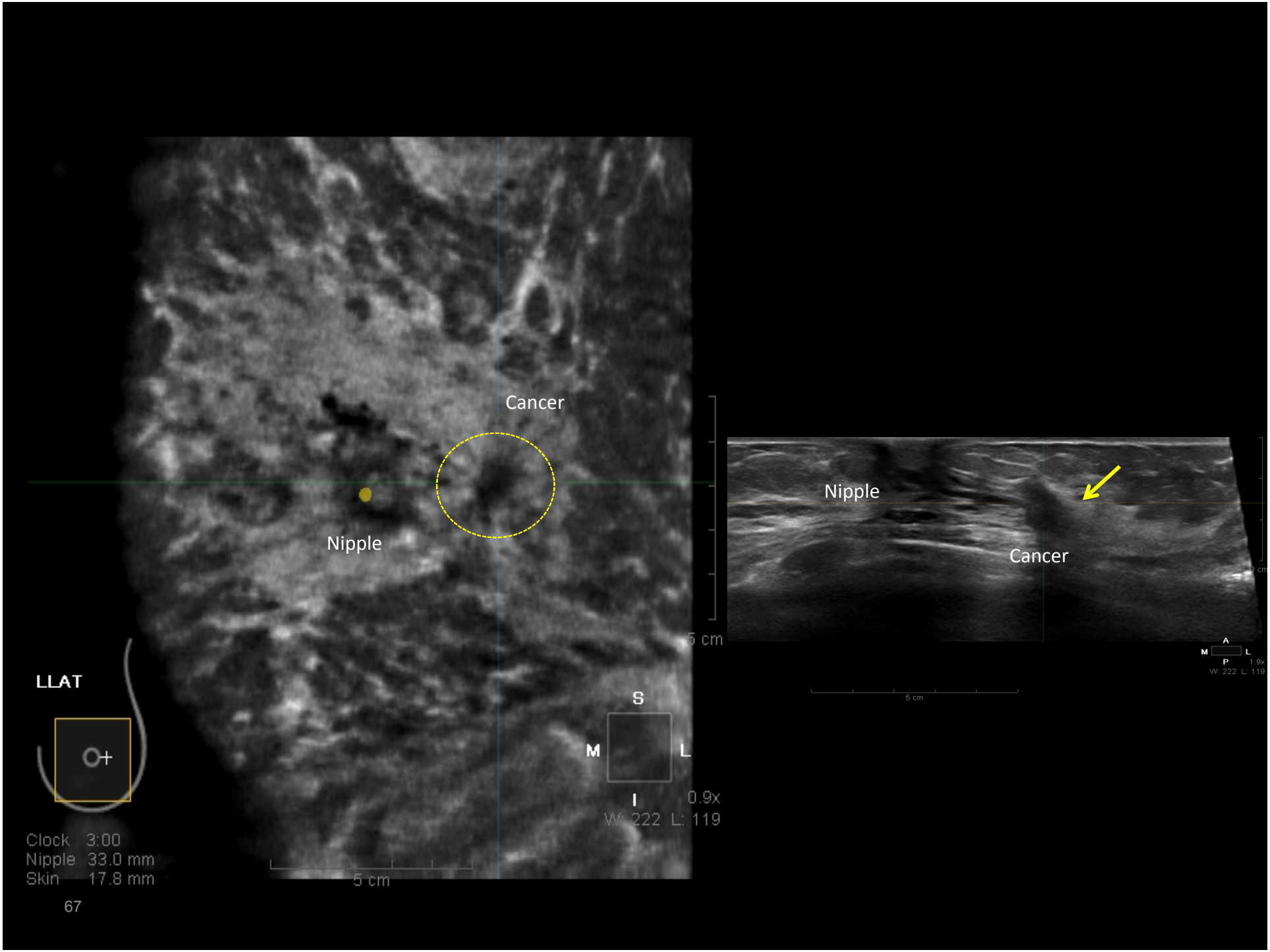
Cancer
Nipple
5 cm
LLAT
Clock 3:00
Nipple 33.0 mm
Skin 17.8 mm
67
5 cm
S
M
L
I
0.9x
W: 222 L: 119
Nipple
Cancer
5 cm
A
M
L
P
1.9x
W: 222 L: 119

U SYSTEMS
Automated Breast Ultrasound

Case 3 Conclusion

- Abnormal 3D ABUS
  - BI-RADS 0, Immediate Management Recommended
- Ultrasound-guided core needle biopsy
- Pathology revealed Invasive Lobular Carcinoma
  - Seen only with ABUS and mammographically occult

Case 4

- 50-year-old woman with negative screening mammogram
  - BI-RADS Density 4, BI-RADS Assessment 1
  - Routine Annual Follow-Up Recommended

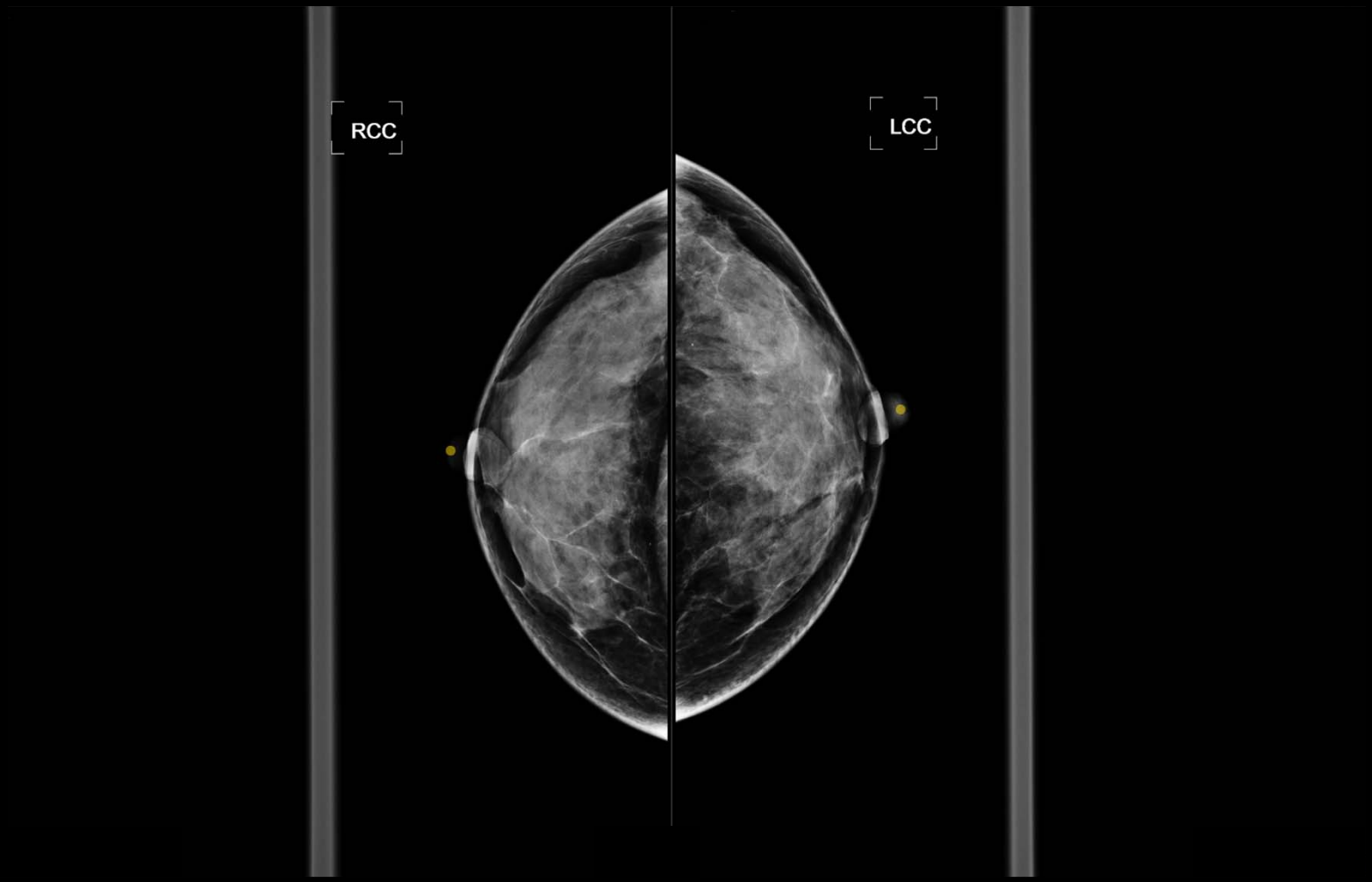
RCC
LCC

R
A
B
RMLO
R
A
B
LMLO

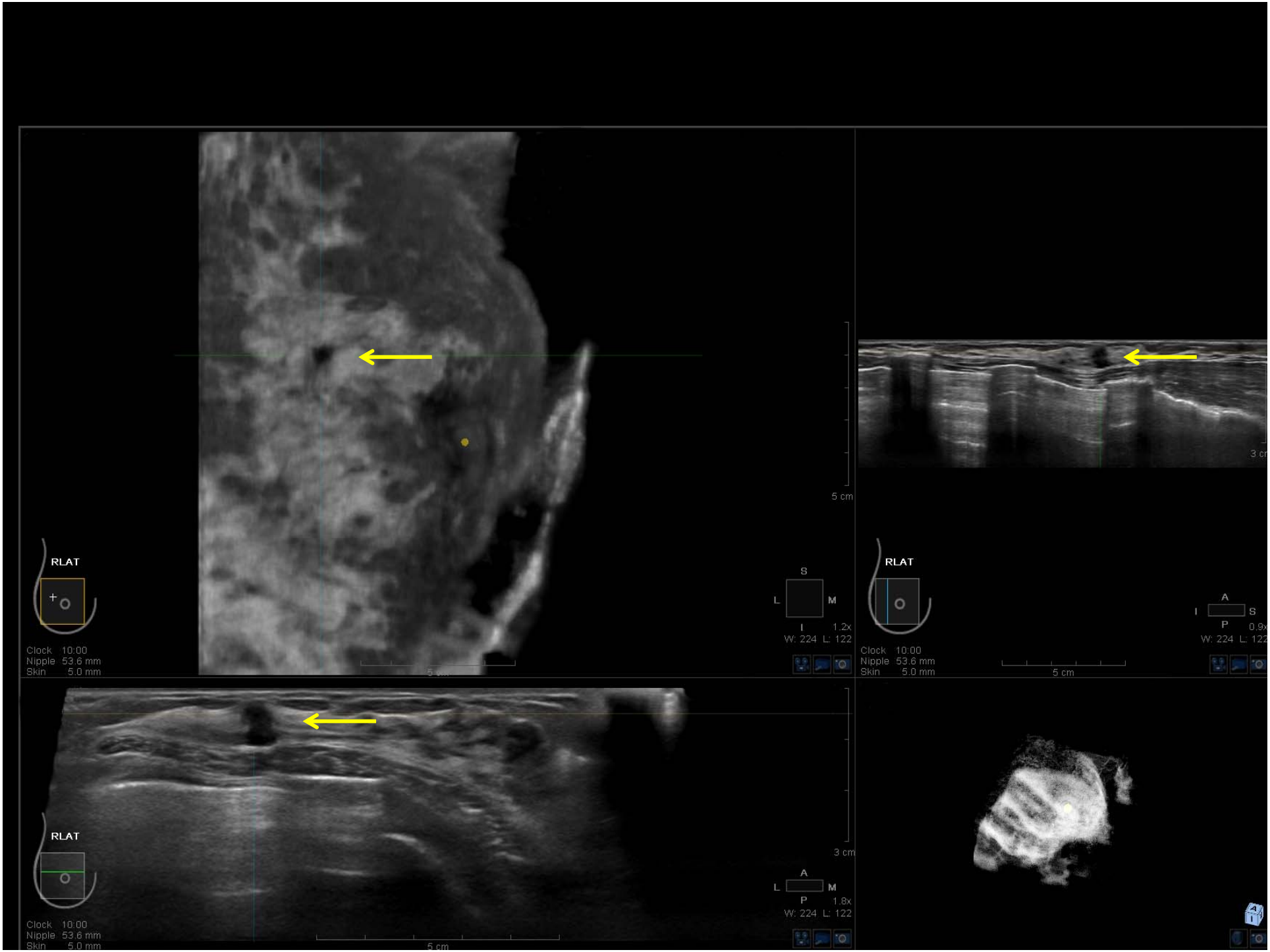
RLAT
Clock 10:00
Nipple 53.6 mm
Skin 5.0 mm
5 cm
S
L
M
I
1.2x
W: 224 L: 122
RLAT
Clock 10:00
Nipple 53.6 mm
Skin 5.0 mm
5 cm
A
I
S
P
0.9x
W: 224 L: 122
RLAT
Clock 10:00
Nipple 53.6 mm
Skin 5.0 mm
5 cm
3 cm
A
L
M
P
1.8x
W: 224 L: 122

Case 4 Conclusion

- Abnormal 3D ABUS
  - BI-RADS 0, Immediate Management Recommended
- Ultrasound-guided core needle biopsy performed
- Pathology revealed Invasive Ductal Carcinoma
  - Seen only with ABUS and mammographically occult

Summary

- Mammography is limited in women with dense breasts
  - Nearly half of American women have dense breasts, regardless of age
- Ultrasound can find additional, mammographically occult breast cancers
- Hand Held Ultrasound cannot be easily integrated into the screening workflow
- Detection of asymptomatic, mammographically occult, node-negative invasive carcinomas with ultrasound should reduce mortality from breast cancer
- ABUS can detect mammographically occult, clinically significant breast cancers
- ABUS can be well integrated into the workflow of a screening environment

U SYSTEMS
Automated Breast Ultrasound

Pivotal Clinical Retrospective Reader Study

Pivotal Clinical Retrospective Reader Study (CRRS): Study Design

Maryellen L. Giger, Ph.D.
- Professor of Radiology, University of Chicago
- Principal Investigator, Clinical Retrospective Reader Study
- Financial Disclosure:
  - Funding to conduct the reader study and analysis was obtained through an University Research Agreement (URA) between U-Systems and my lab at the University of Chicago
  - U-Systems is reimbursing my travel expenses for today.
  - No Financial Interest in U-Systems, Inc.

U SYSTEMS
Automated Breast Ultrasound

Overview of Pivotal Reader Study

- Purpose: To determine the impact on Reader performance in detecting breast cancer when screening mammography and ABUS are combined, compared to a screening mammogram alone
  - (XRM Alone) versus (XRM+ABUS)
- Design:
  - Multi-reader multi-case ROC study design (MRMC ROC)
  - Cancer-enriched analysis dataset
  - Sequential reading design
- Primary endpoint
  - Improvement in the area under the ROC curve (AUC) for XRM+ABUS

Study Design: Cancer-Enriched Dataset

- Current state-of-the-art method for the assessment of a new imaging technology
- Allows for use of a manageable number of cases as opposed to prospective clinical screening trials, which may require tens of thousands of cases over multiple years

- ROC analysis is a preferred method for analyzing enriched Reader Studies as the AUC measures the accuracy of the screening modality without being affected by choice of decision threshold or the cancer prevalence within the reader study.

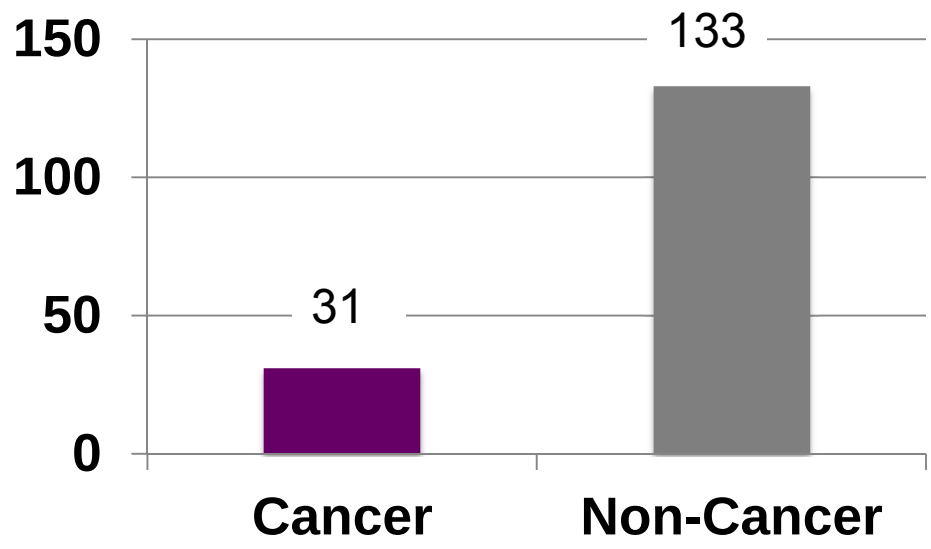

Case Selection Process Summary

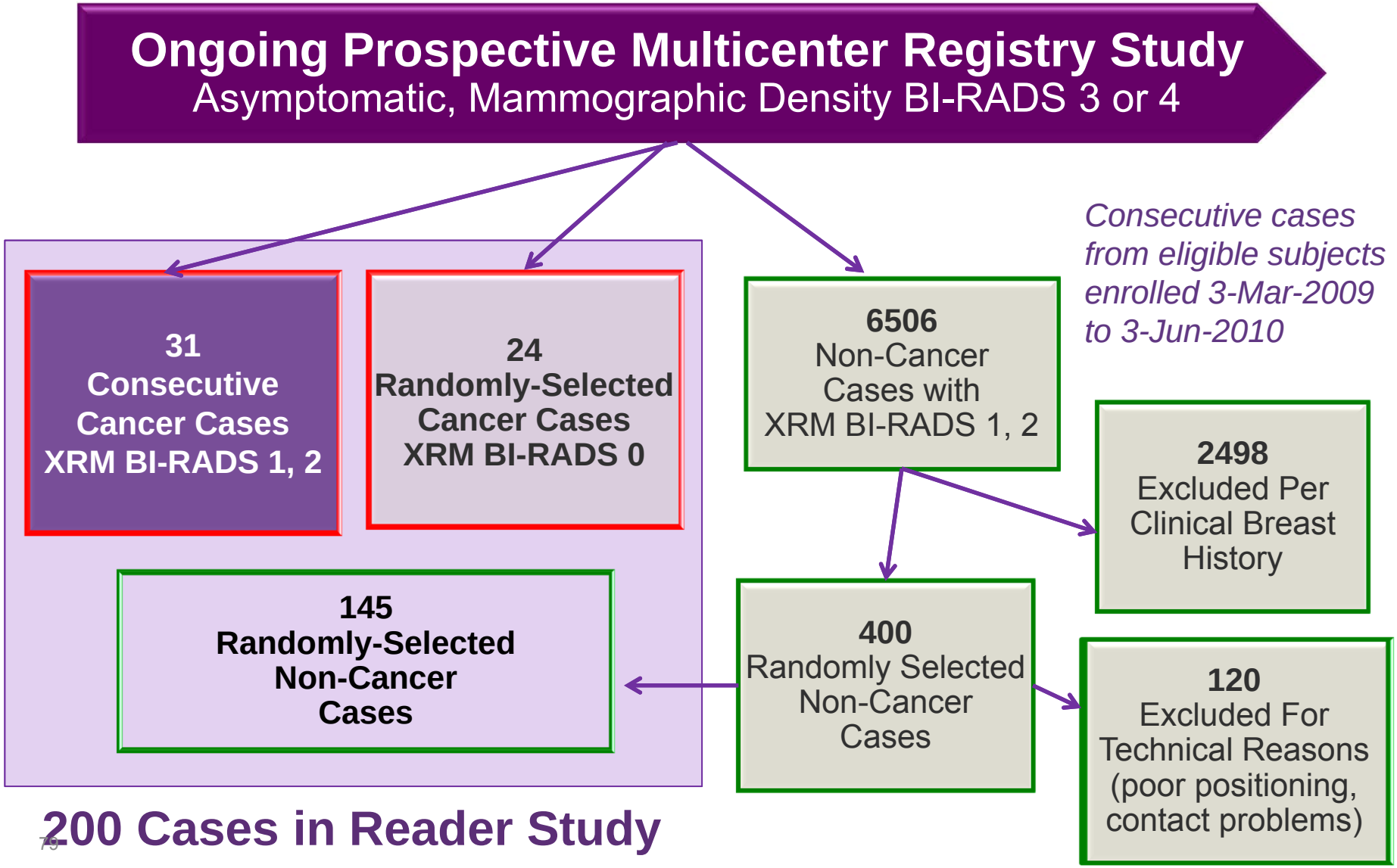

200 Cases in Reader Study

Reader Study: 200 cases

Modalities in a Complete Case	Non-Cancer Cases BI-RADS 1 or 2 for XRM	Cancer Cases BI-RADS 1 or 2 for XRM	Cancer Cases BI-RADS 0 for XRM
XRM+ABUS	**133[P]**	**31[P]**	**21[S]**
XRM Alone	**12[S]**	**0**	**3[S]**

[P] Cases used in Primary Analysis (N=164)
(BI-RADS 1 or 2 on XRM as deemed by the site investigator)

[S] Supplemental Cases (N=36)

- 24 XRM BI-RADS 0 cancer cases to make case mix closer to that in clinical practice
- 15 XRM Alone cases to maintain Reader's vigilance and reduce bias caused by anticipation that an ABUS exam would follow after interpretation of XRM Alone

Age Distribution for Cancer and Non-Cancer Cases

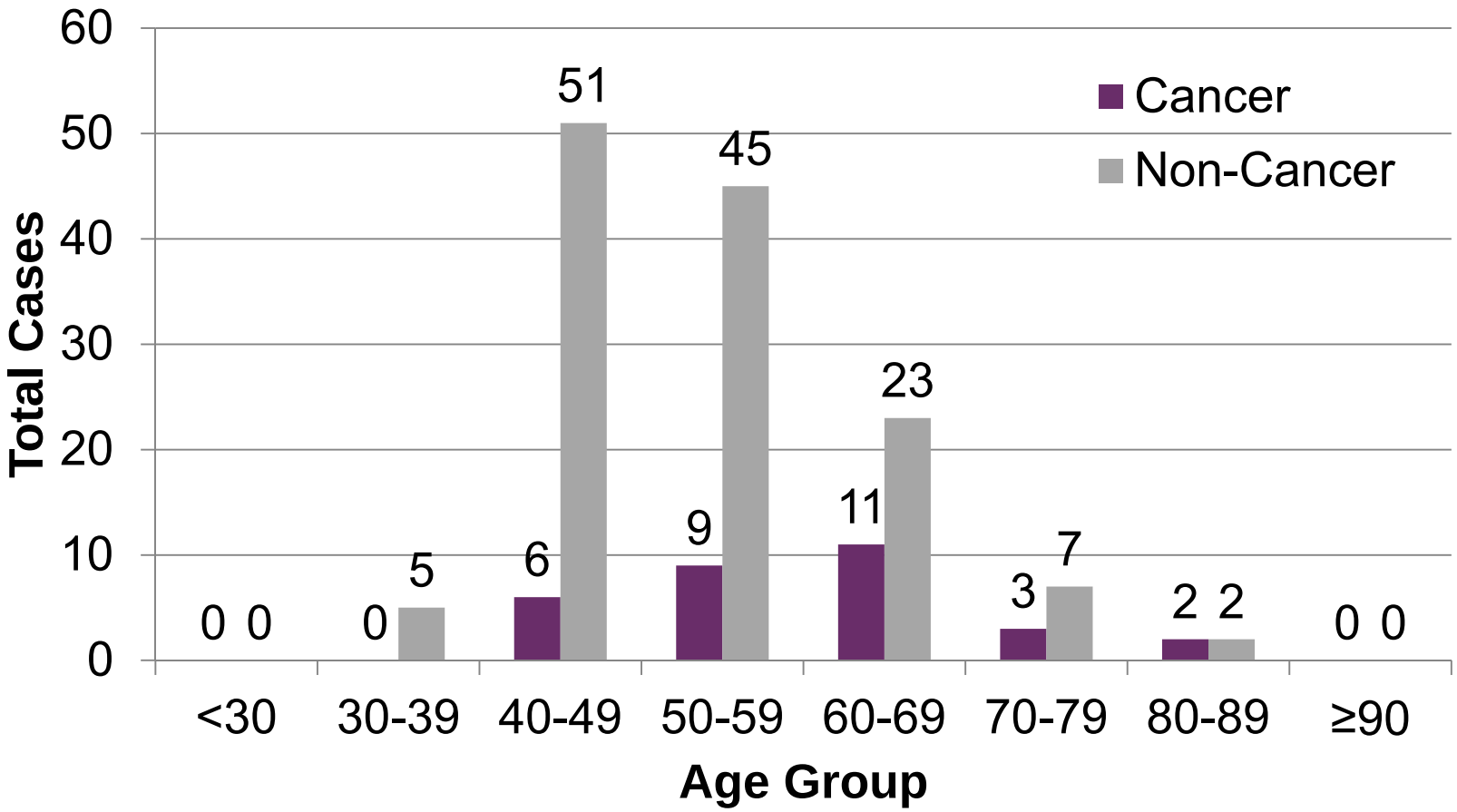

BI-RADS Density Distribution for Cancer and Non-Cancer Cases

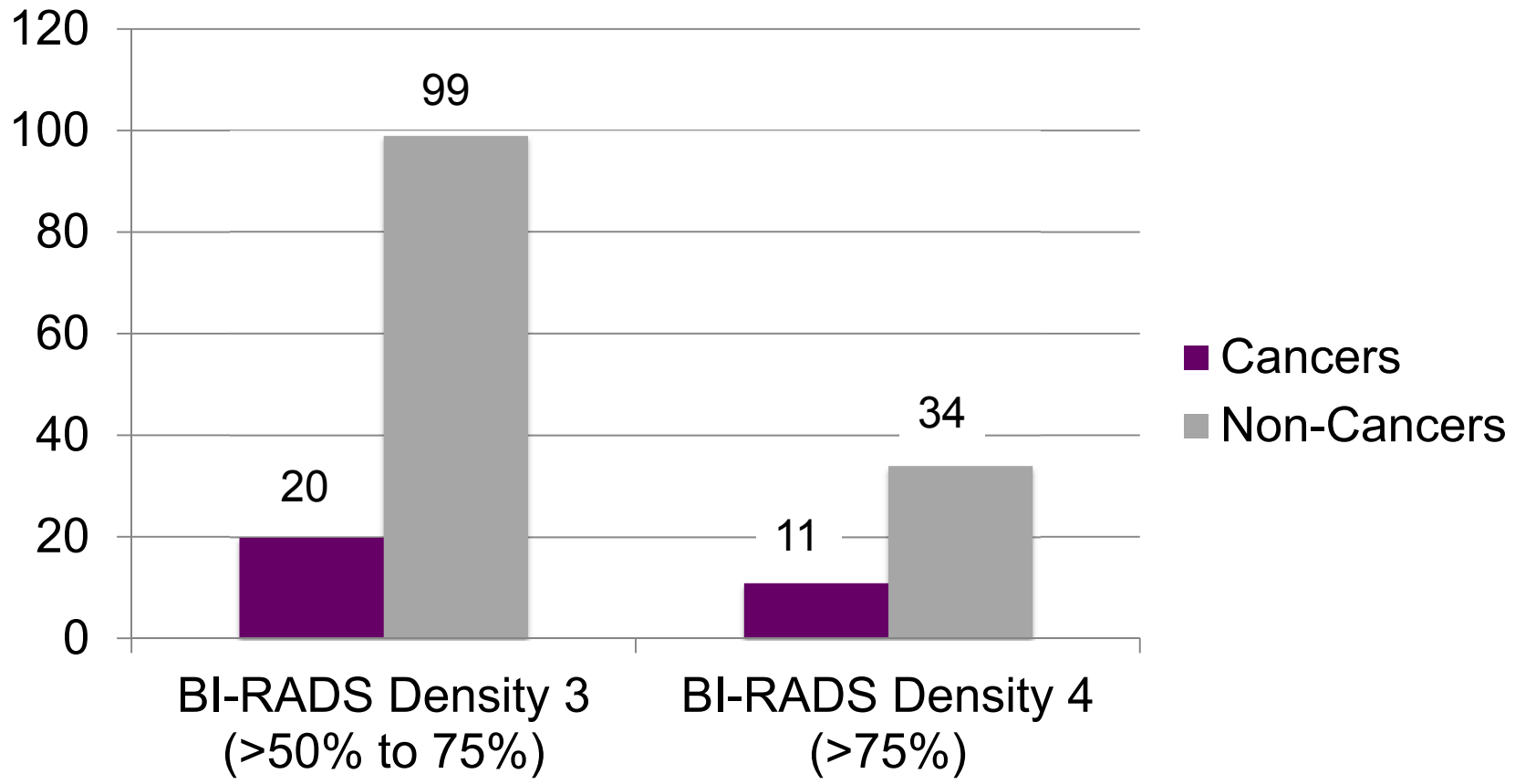

Characteristics of 31 Cancer Cases

Histological Tumor Subtype

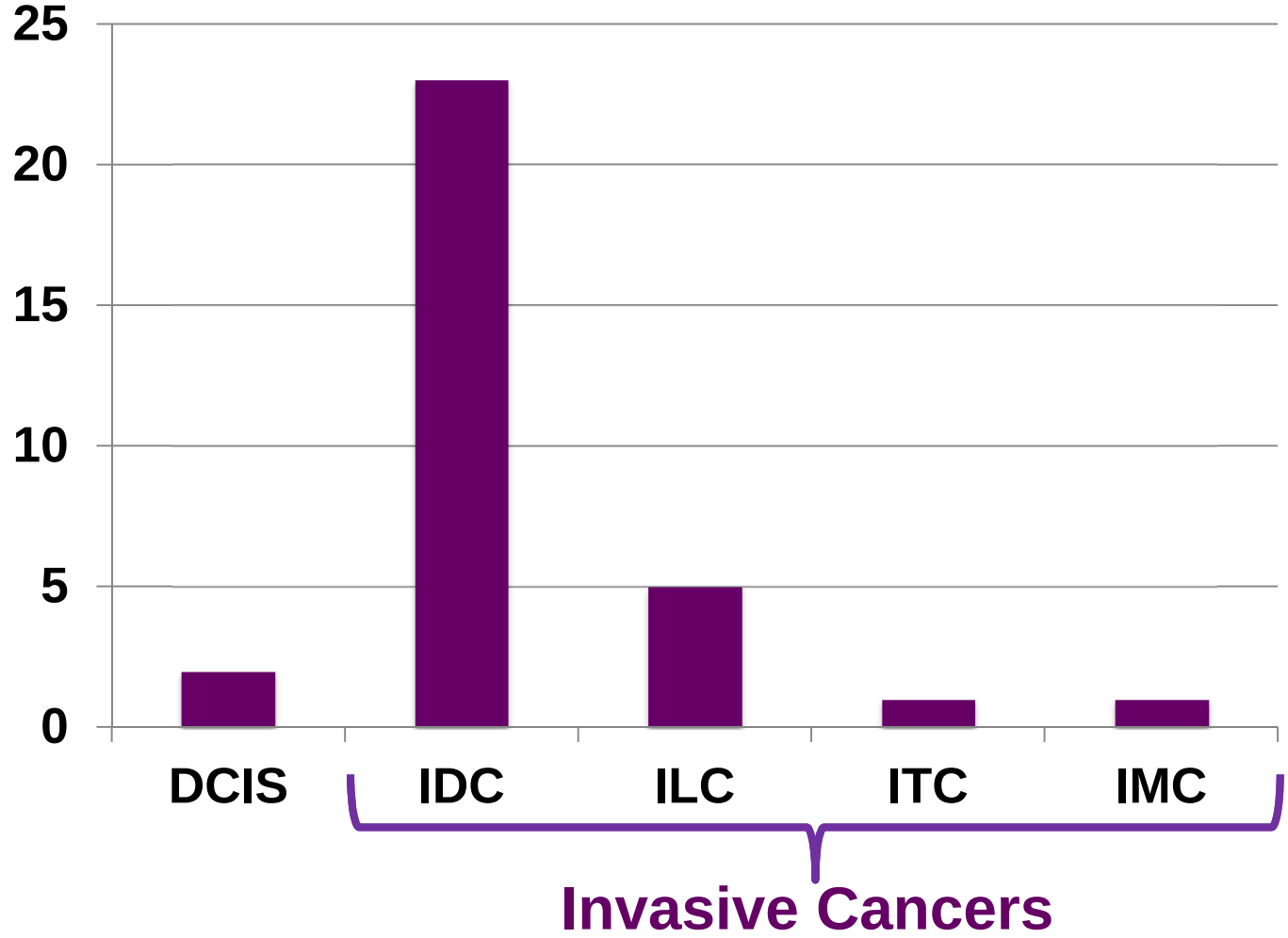

Node Status for 31 Cancer Cases

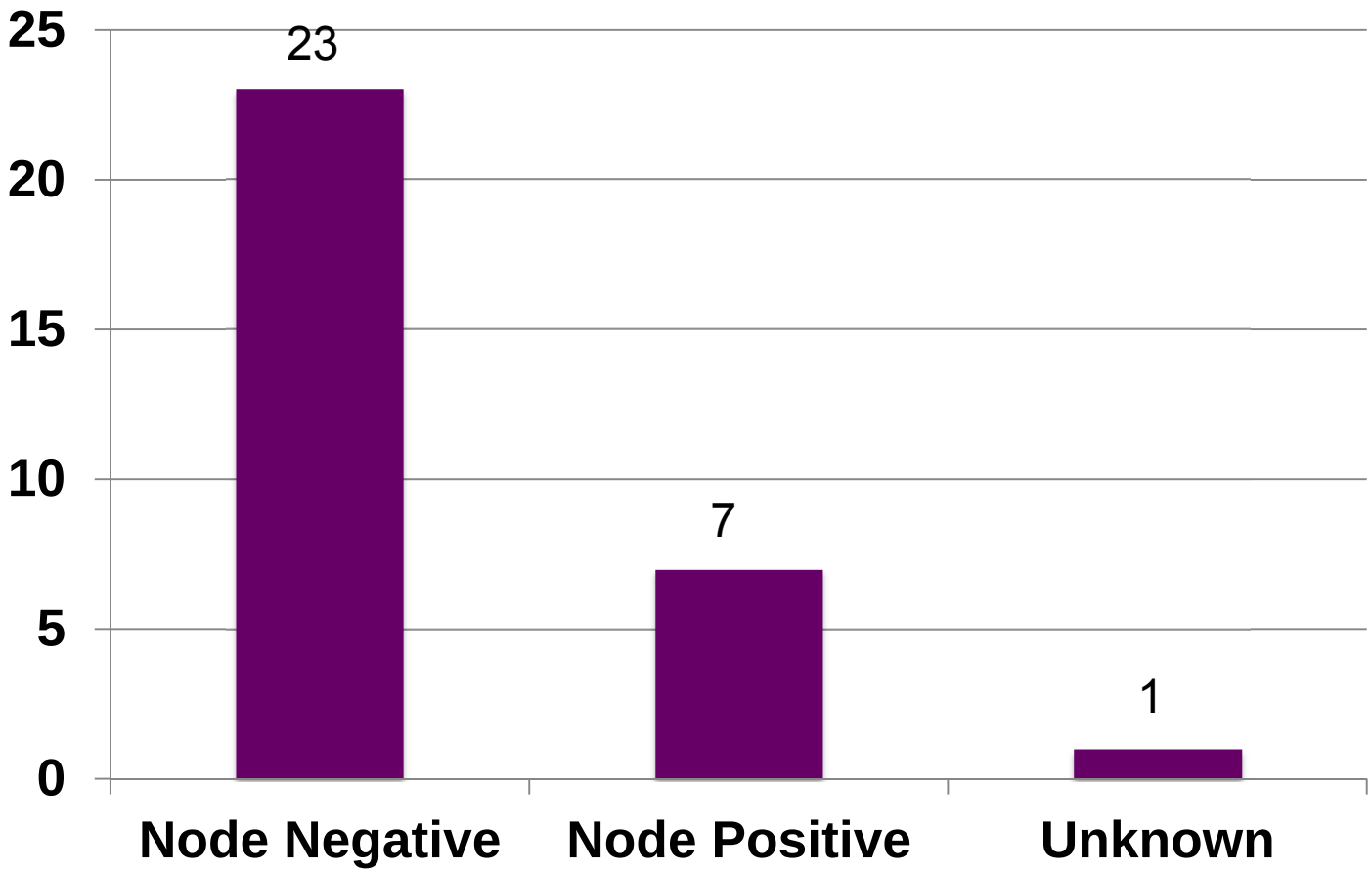

Prognostic Stage for 31 Cancer Cases

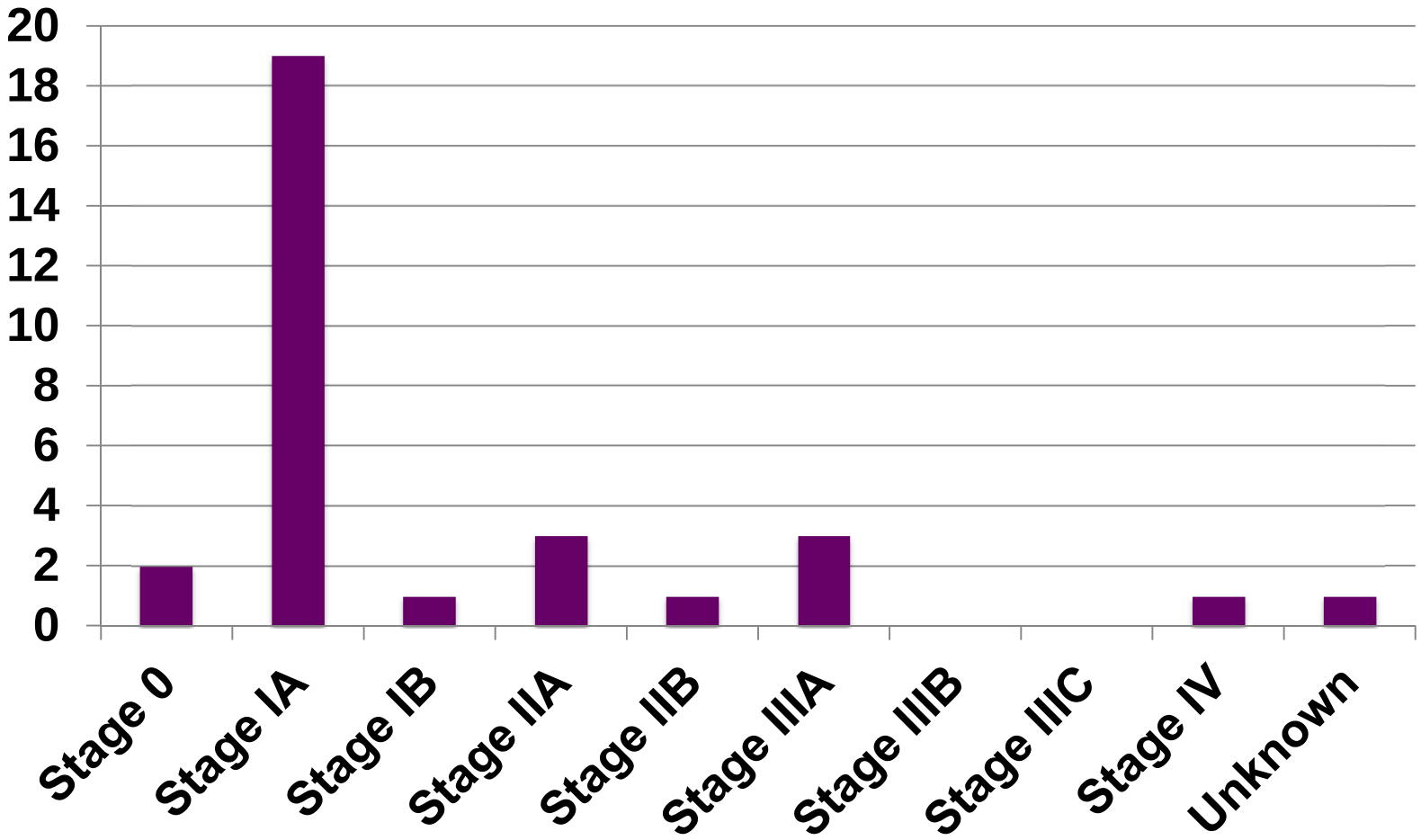

Most cancers were invasive, node negative, early cancers.

Study Design: Readers

- 17 Readers (radiologists)
- MQSA – qualified
- Distribution
  - 7 in academia
  - 6 in private practice
  - 4 in community clinics

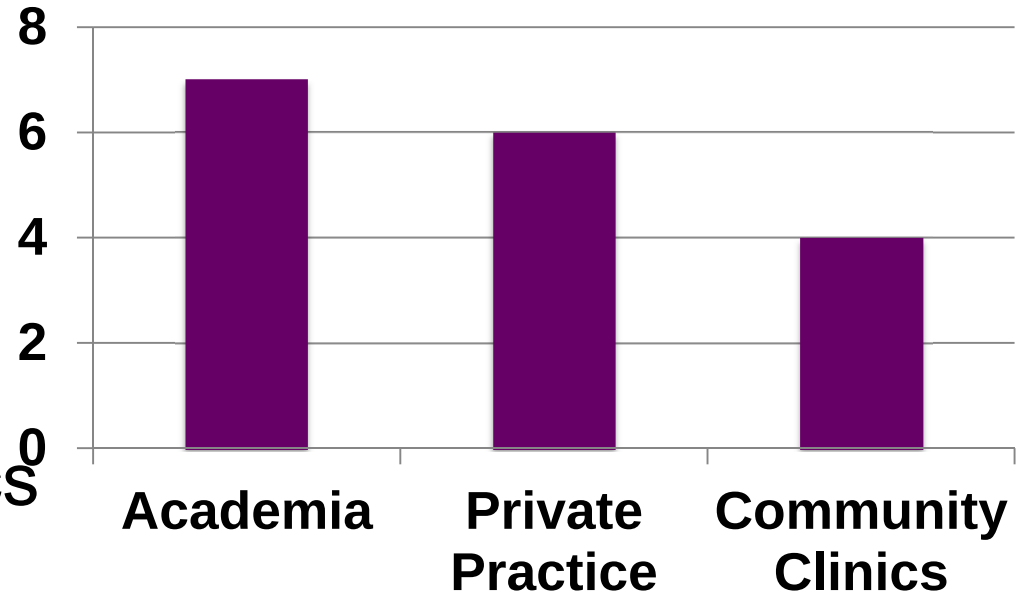

- Reader Study Training
  - ABUS Training and Skills Set Assessment
  - Use of eCRF (electronic case report form)

CRRS Training Modules

MODULE I
2hrs

On-Line Self-Study Tutorials

MODULE II
1hr

Peer-to-Peer Webinar

MODULE III
8hrs



Peer-to-Peer ABUS Interpretation

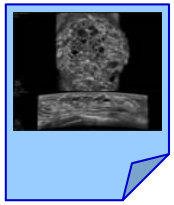

Directed Review

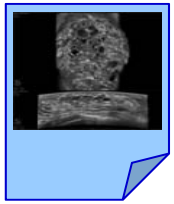

Independent Self Review

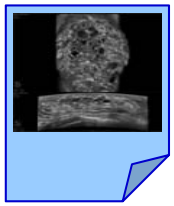

Skill Set Exercise

Reader Participation in CRRS

Study Design: Clinical Image Displays

Hologic SecurView Dx™
(FFDM viewer)

somo•VIEWer Work Station
(ABUS viewer & eCRF Input)

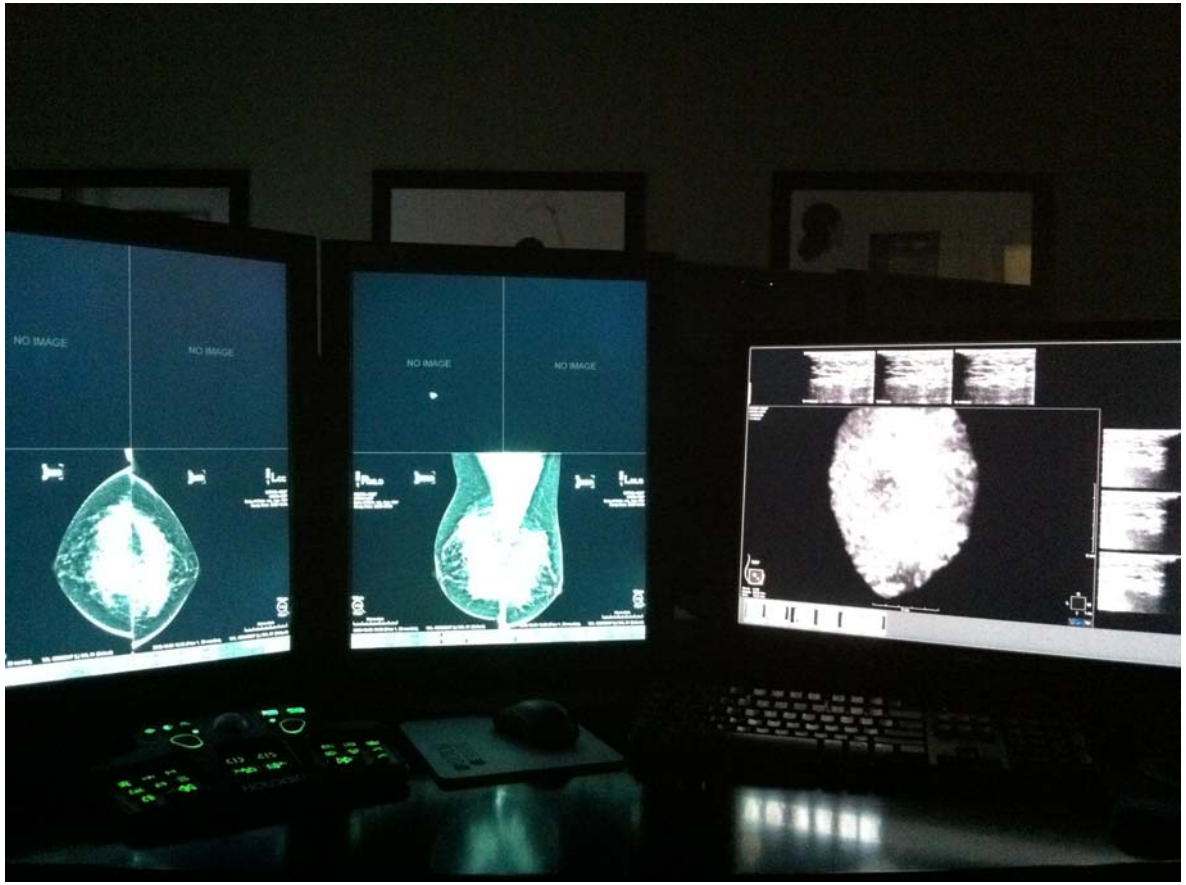

Study Design: Sequential Reading Design

- Clinical use of ABUS involves a sequential read after interpretation of screening mammogram
- Sequential design used in CRRS
  - Each Reader interpreted and scored screening mammography exam [without having access to the ABUS images]
  - Interpretation inputs locked
  - Each Reader then interpreted and scored combination of screening mammograms plus ABUS images
- Only XRM and ABUS study images were presented to Reader
  - No prior images for comparison
  - No clinical information or history provided
  - Thus, excluded non-cancer cases that had prior breast interventions
- Each Reader read the cases in a unique random order

Reader Scores Case Based on Mammogram Only and Inputs Are Locked *(XRM Read)*

- Reader indicates lesion, and then scores **case based on XRM only**
  - Initial BI-RADS assessment of 1, 2, or 0
    - If 0, then forced BI-RADS assessment for overall case using categories: 3, 4a, 4b, 4c, and 5
  - Likelihood that the woman has cancer using 0-100% scale

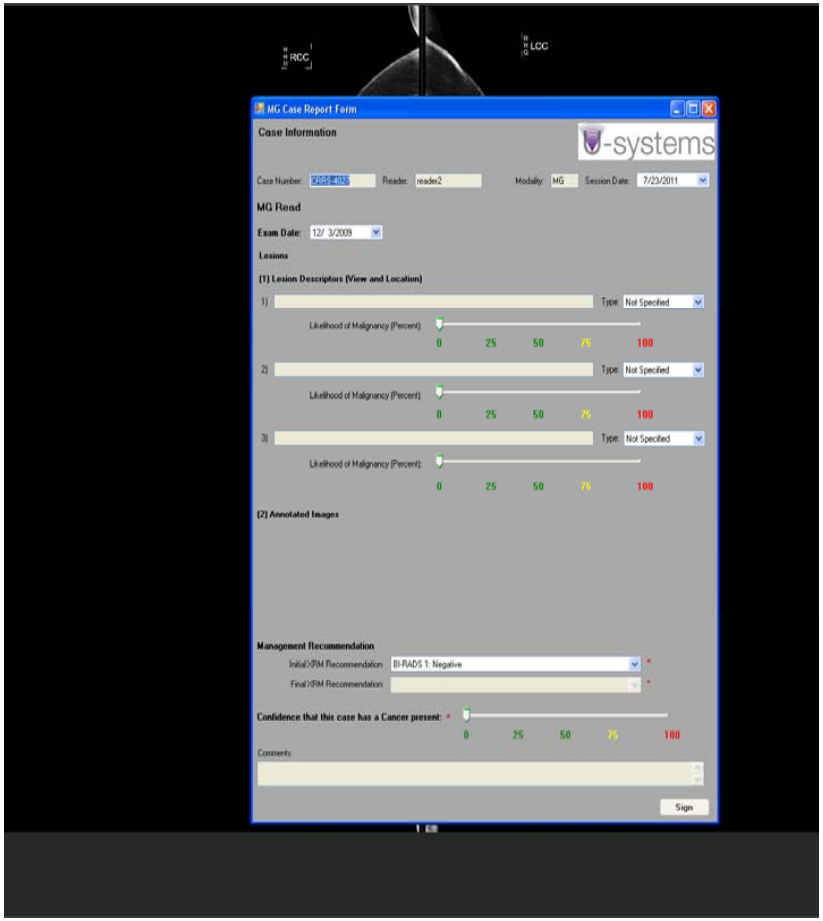

Reader Scores Case Based on Mammograms Plus ABUS & Inputs Are Locked *(XRM+ABUS Read)*

- Reader indicates lesion, and then scores **case using both mammograms+ABUS images**
  - Initial BI-RADS assessment of 1, 2, or 0
    - If 0, then forced BI-RADS assessment for overall case using categories: 3, 4a, 4b, 4c, and 5
  - Likelihood that the woman has cancer using 0-100% scale

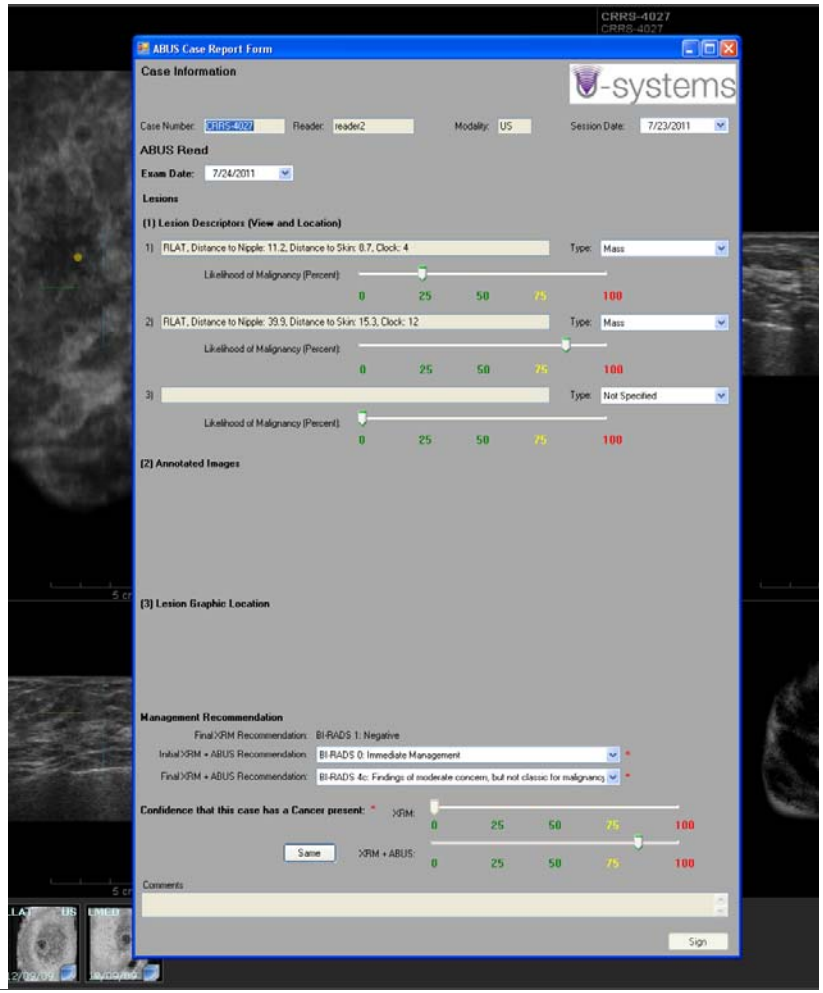

Study Design: Data Analysis

- The Reader Study's primary endpoint was the difference in the areas under the ROC curves for XRM Alone compared to that computed for XRM+ABUS.

XRM versus [XRM + ABUS]

Results: Primary Endpoint

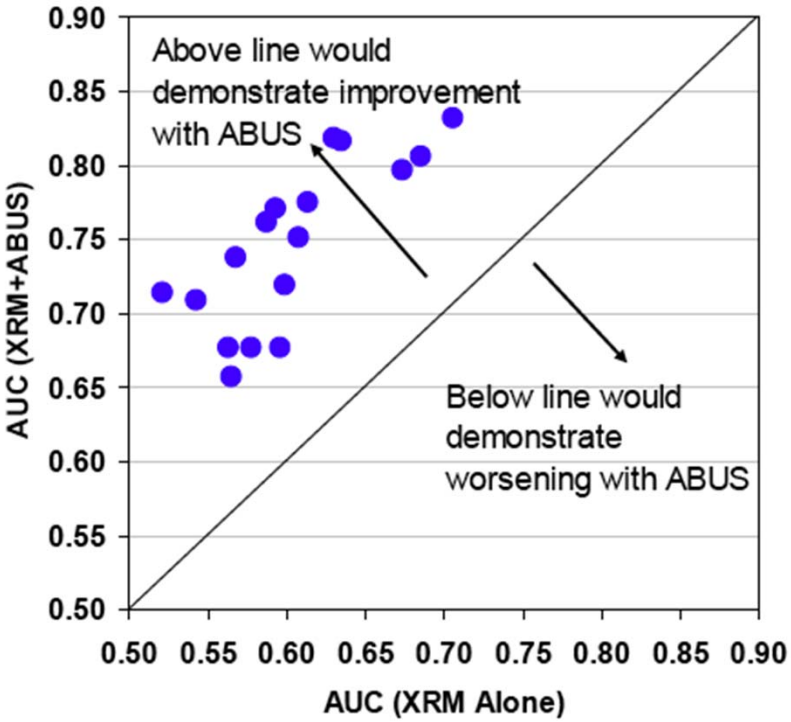

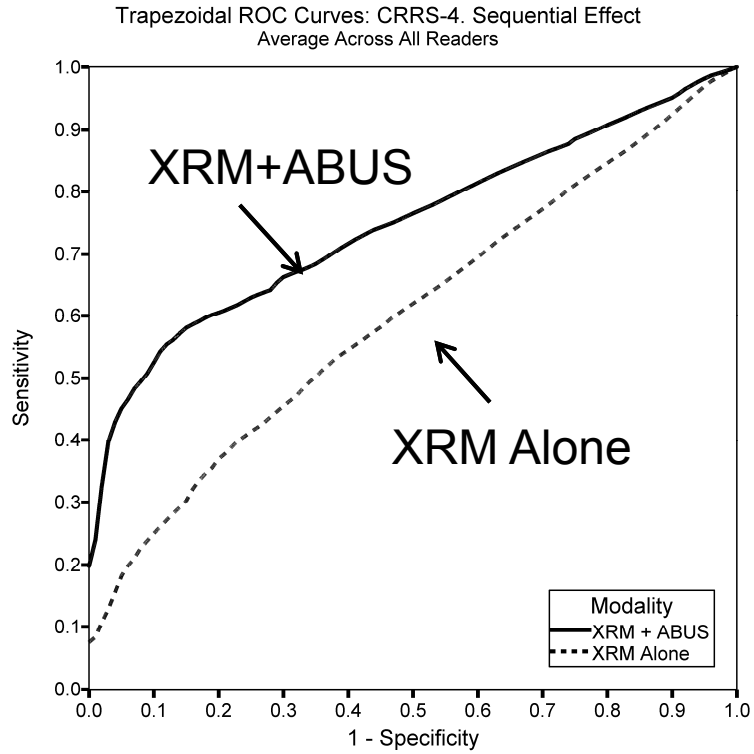

	AUC	Std Error	95% CI	P-value
XRM Alone	0.604	0.034	(0.536,0.672)	
XRM+ABUS	0.747	0.037	(0.637,0.820)	
Difference	0.143	0.035	(0.074,0.212)	<0.001

Summary

- Multi-reader, multi-case ROC clinical reader study
- Cancer-enriched dataset including cancers that had been clinically diagnosed as mammographically-negative
  - Majority of cancer cases were invasive, node-negative cancers
- **Primary endpoint was met.**
  - **Statistically significant improvement in AUC** when screening mammography and ABUS are combined in the detection of mammography-negative breast cancers in women with >50% parenchymal breast density, as compared to mammography alone
  - Statistically significant gain in sensitivity was not associated with a statistically significant reduction in specificity

U SYSTEMS
Automated Breast Ultrasound

Pivotal Clinical Retrospective Reader Statistical Analysis

Pivotal Clinical Retrospective Reader Study Statistical Analysis

Dave P. Miller, M.S.

- Senior Director, Statistical Analysis,
  ICON Late Phase and Outcomes Research
- Disclosures
  - Services provided by ICON have been paid for by U-Systems, Inc.
  - Travel expenses have been paid for by U-Systems, Inc.
  - No Financial Interest in U-Systems, Inc.

Analysis Dataset

- 164 cases (31 cancers + 133 non-cancers)
  - Read with XRM alone followed by XRM+ABUS
  - Read by each of 17 readers

- 5,576 total reads
  - LOM (0-100)
  - BI-RADS Risk Assessment (1-5)
    - 1, 2, 3, 4a, 4b, 4c or 5
  - No missing data

U SYSTEMS
Automated Breast Ultrasound

Endpoints

- Primary
  - Difference in ROC AUC based on Reader LOMs
  - Trapezoidal Curve
  - ANOVA after Jackknife
- Confirmatory Analysis
  - Proper Binormal curves
  - Bootstrap estimates
- Secondary
  - Sensitivity at BI-RADS cutpoint of 3+ vs <3
  - Specificity at BI-RADS cutpoint of 3+ vs <3
  - Cutpoints of 4a+ vs <4a

Top Level Summary

- Primary ROC endpoint
  - Adding ABUS to XRM increased AUC from .604 to .747
  - ΔAUC = .143, 95% CI (.074, .212), p<.001

- Secondary endpoints
  - Adding ABUS to XRM increased sensitivity from 38.8% to 63.1%
  - Based on BI-RADS cut point of 3+ vs < 3
  - ΔSensitivity = 24.3%, 95% CI (10.7%, 37.9%), p=.002

  - Adding ABUS to XRM did not significantly affect specificity
  - 78.0% with XRM alone vs. 76.0% with ABUS
  - ΔSpecificity = -2.0%, 95% CI (-7.7%, 4.3%), p=.518

ROC curves averaged across all 17 Readers

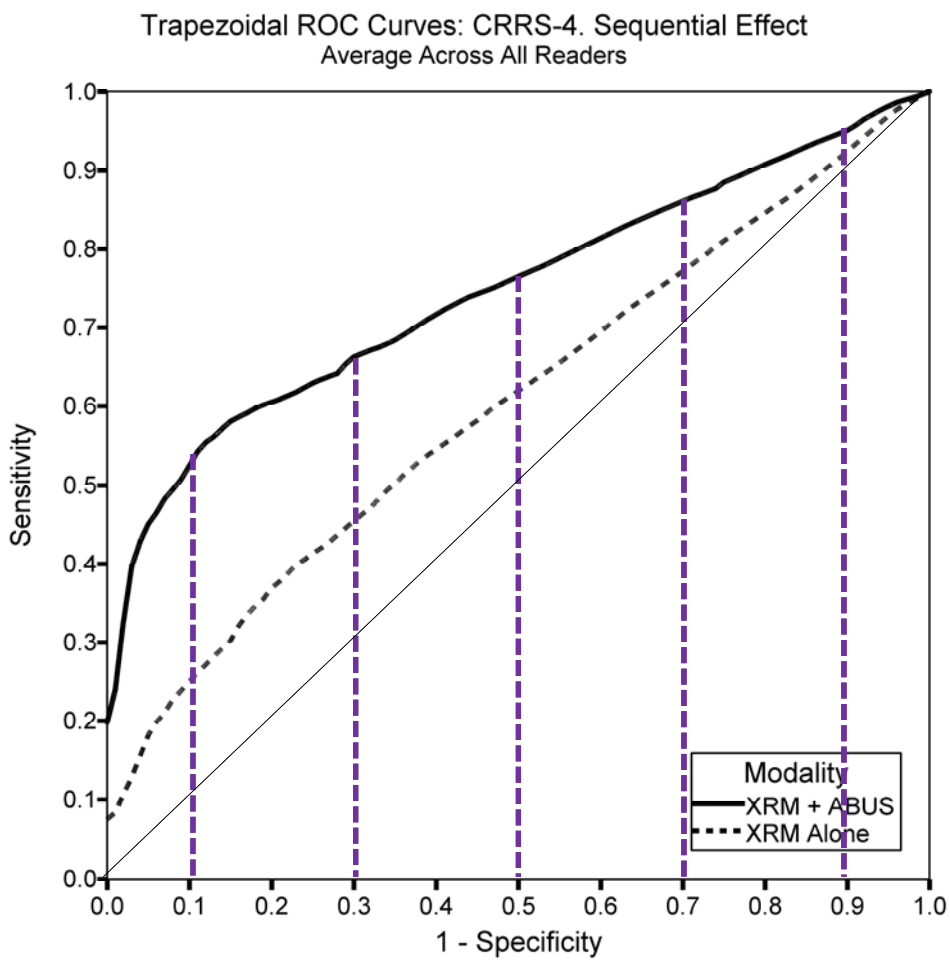

Confirmatory Analysis – Binormal Curves

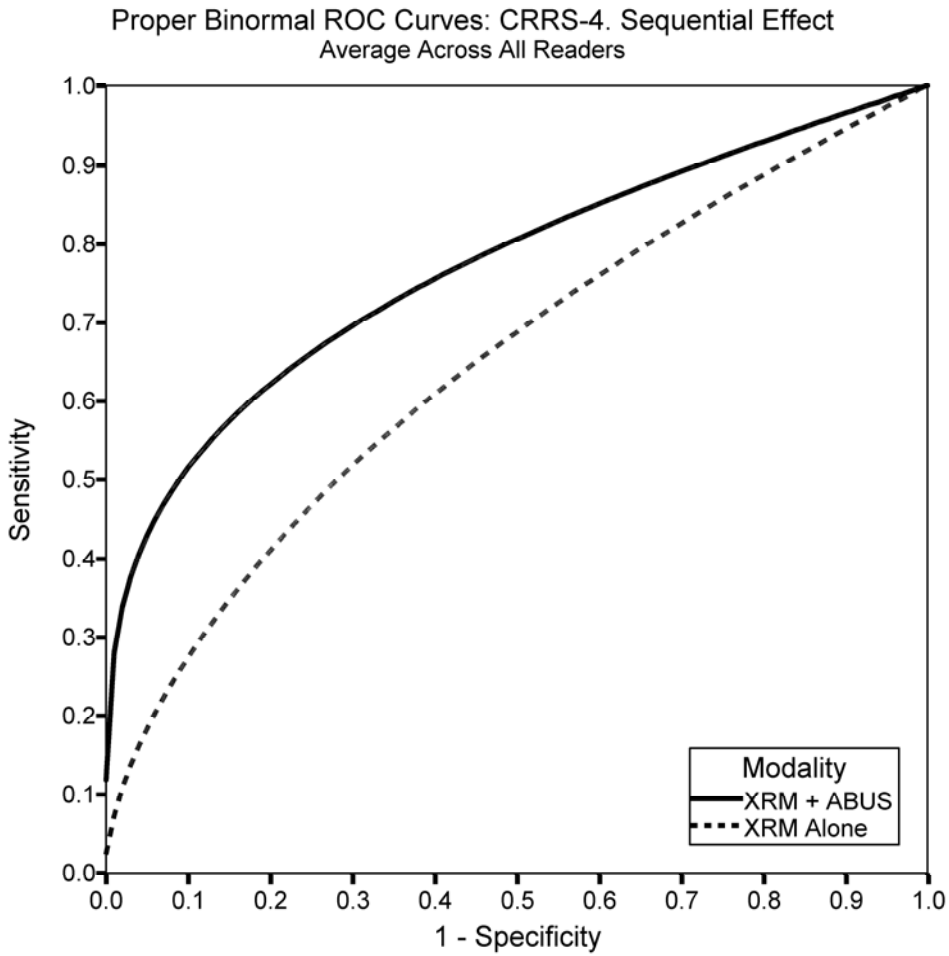

Reader Summary

Reader	Practice Category	Breast Imaging Fellowship Trained	Years in Breast Imaging	Mammography Review Rate/Yr	HHUS Review Rate/Yr
1	Academic	YES	3	6,835	884
2	Private	YES	9	13,964	2,279
3	Private	NO	15	2,000	825
4	Community	YES	4	5,400	1,800
5	Academic	YES	2	2,500	800
6	Academic	YES	12	2,125	938
7	Academic	YES	18	3,283	643
8	Private	NO	16	8,820	743
9	Academic	YES	12	2,259	707
10	Community	YES	3	2,500	1,600
11	Private	YES	16	1,850	1,150
12	Community	NO	14	4,525	603
13	Private	NO	17	10,000	5,000
14	Private	NO	10	4,180	620
15	Academic	NO	18	14,600	1,750
16	Community	NO	10	5,500	750
17	Academic	NO	12	3,000	750

Individual Reader Changes in AUC

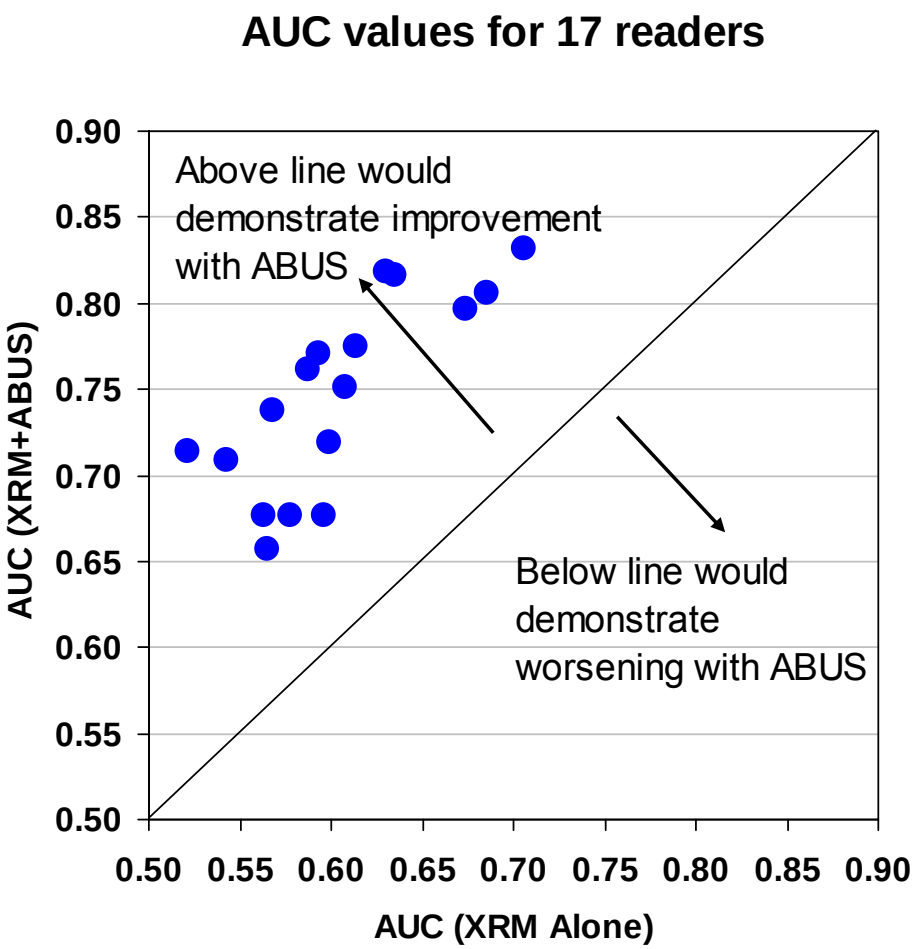

Individual Reader Changes in Sensitivity

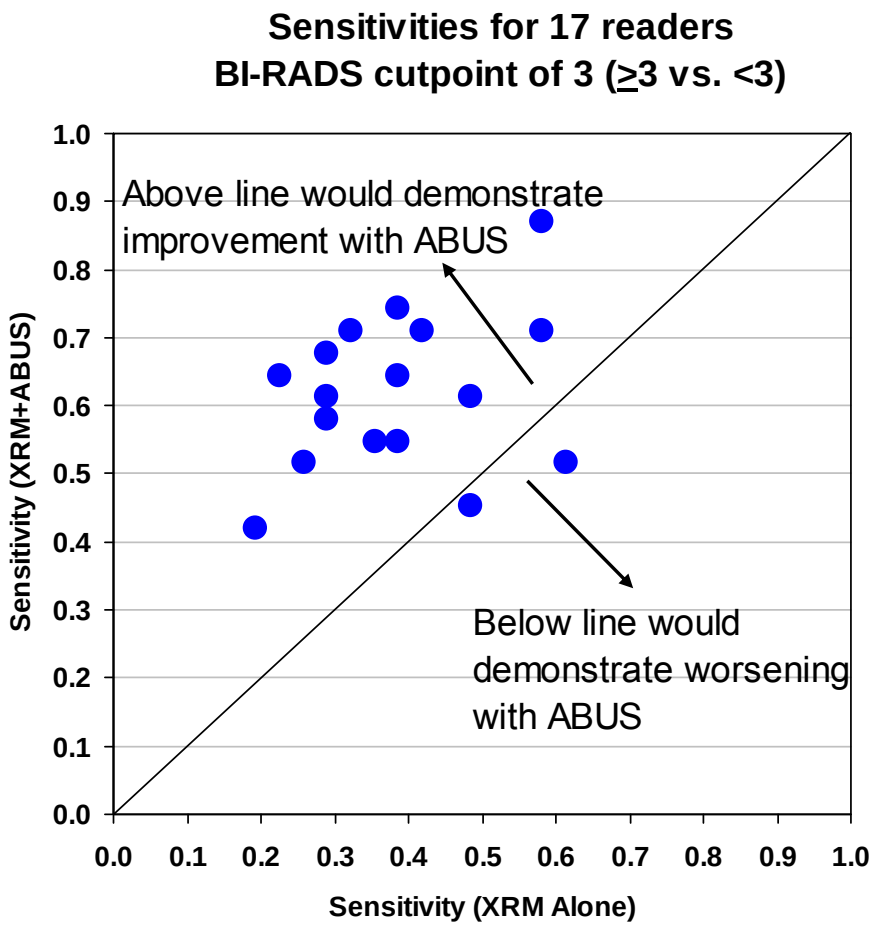

Individual Reader Changes in Specificity

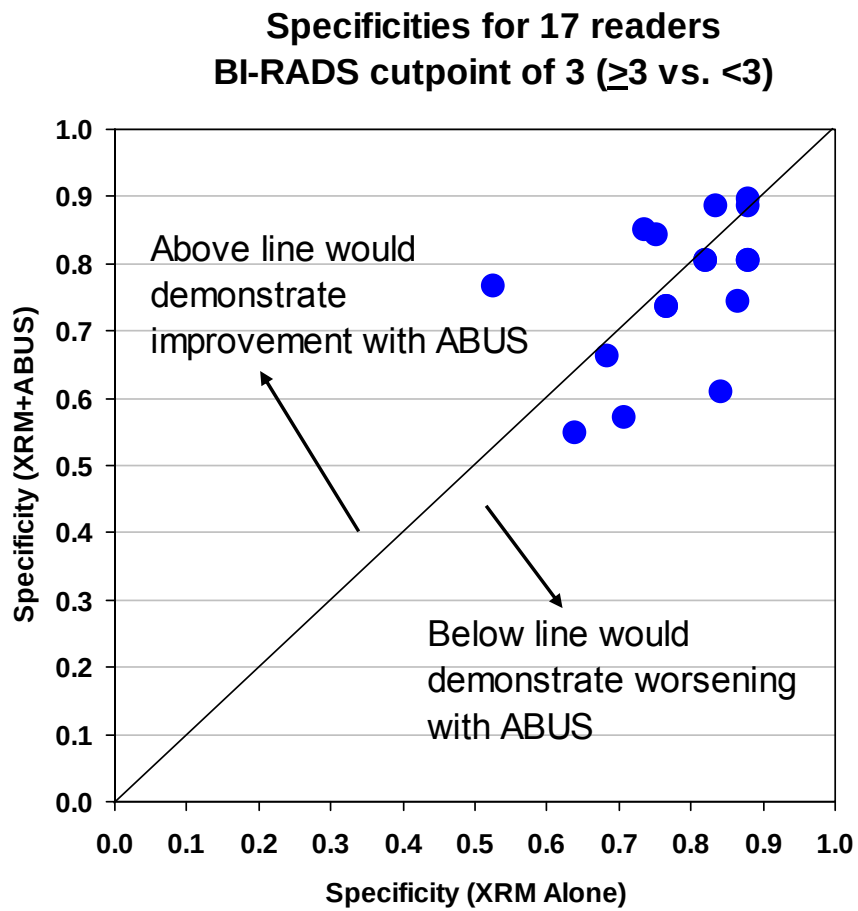

Confirmatory Analysis - AUC

- Trapezoidal versus Binormal Curves
  - Trapezoidal ΔAUC = .143, 95% CI (0.074, 0.212)
  - Binormal ΔAUC = .123, 95% CI (0.060, 0.186)

- ANOVA after jackknife versus Bootstrap
  - ANOVA ΔAUC = .143, 95% CI (0.074, 0.212)
  - Bootstrap ΔAUC = .144, 95% CI (0.092, 0.220)

Robustness Analysis - AUC

- Non-cancer cases selected by random sampling
- By chance, sample includes some unverified normals
  - 23 non-cancers were not verified by follow-up exam

- Primary Analysis assuming no misclassification
  - ΔAUC = .143, 95% CI (0.074, 0.212)

- Simulated Misclassification of Normal Cases
  - 1 case misclassified ΔAUC = .139, 95% CI = (0.065, 0.209)
  - 3 cases misclassified ΔAUC = .128, 95% CI = (0.066, 0.192)

U SYSTEMS
Automated Breast Ultrasound

Confirmatory Analysis: Sensitivity & Specificity

- Location-based sensitivity
  - **23.4% (XRM Alone) vs. 52.2% (XRM+ABUS)**
  - ΔLoc-Sensitivity = 28.8%, 95% CI (17.1%, 42.1%), p<.001
- Sensitivity at 4a cutpoint
  - **27.3% (XRM Alone) vs. 58.3% (XRM+ABUS)**
  - ΔSensitivity = 31.0%, 95% CI (18.7%, 43.9%), p<.001
- Specificity at 4a cutpoint
  - **88.0% (XRM Alone) vs. 83.9% (XRM+ABUS)**
  - ΔSpecificity = -4.1%, 95% CI (-8.8%, 1.0%), p=.106

Conclusions

- The study demonstrated statistically significant superior Reader performance for XRM+ABUS versus XRM alone
  - Consistent findings with confirmatory analysis
- Sensitivity is significantly increased with ABUS
  - Regardless of threshold
  - At case-level and location-level
- Specificity is not significantly affected

U SYSTEMS
Automated Breast Ultrasound

Risk/Benefit Analysis

Risk/Benefit Analysis

Rachel F. Brem, M.D.

- Professor and Vice Chair, Department of Radiology
  Director, Breast Imaging and Interventional Center
  The George Washington University, Washington, DC
- Principal Investigator, Prospective Multicenter Registry Study
- Medical Advisor and Consultant, U-Systems, Inc.
  - No Financial Interest in U-Systems, Inc.

Benefits

Safety

- FDA cleared since 2005 as adjunct to mammography
- Used in over 50,000 exams with No Significant Adverse Events and no MDRs
- Ultrasound is an inherently safe imaging modality
  - No ionizing radiation
  - Non-invasive
  - Painless

Benefits

Effectiveness

- Pivotal Reader Study demonstrated statistically significant superior Reader performance for XRM+ABUS versus XRM alone

- Sensitivity is increased with ABUS
  - Regardless if threshold is BI-RADS 3 or 4a
  - At case-level and location-level

- Specificity is not significantly affected

Benefits

Screening for Breast Cancer

- Proven mortality benefit from early cancer detection
- Goal is to detect early, node negative, curable breast cancer
- Mammography is effective in women with fatty breast tissue
- Increased false negatives with screening XRM in women with dense breast tissue
- Pivotal Reader Study demonstrated a statistically significant increase in cancer detection when ABUS is added to screening XRM

Benefits

Characteristics of 31 Cancer Cases

- 93.5% were ***INVASIVE*** Breast Cancers

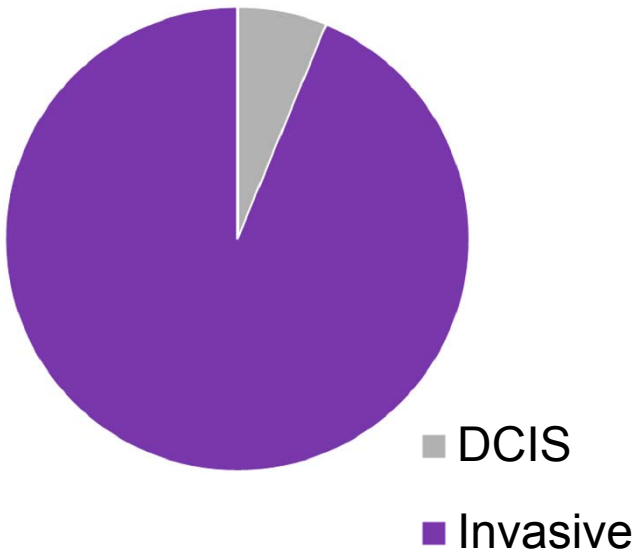

Histological Type for Primary Cancer Cases

Tumor Subtypes	Total
Invasive Ductal	22
Invasive Lobular	3
Invasive Mammary	3
Invasive Tubular	1
Ductal Carcinoma in Situ	2

Benefits

Characteristics of 31 Cancer Cases

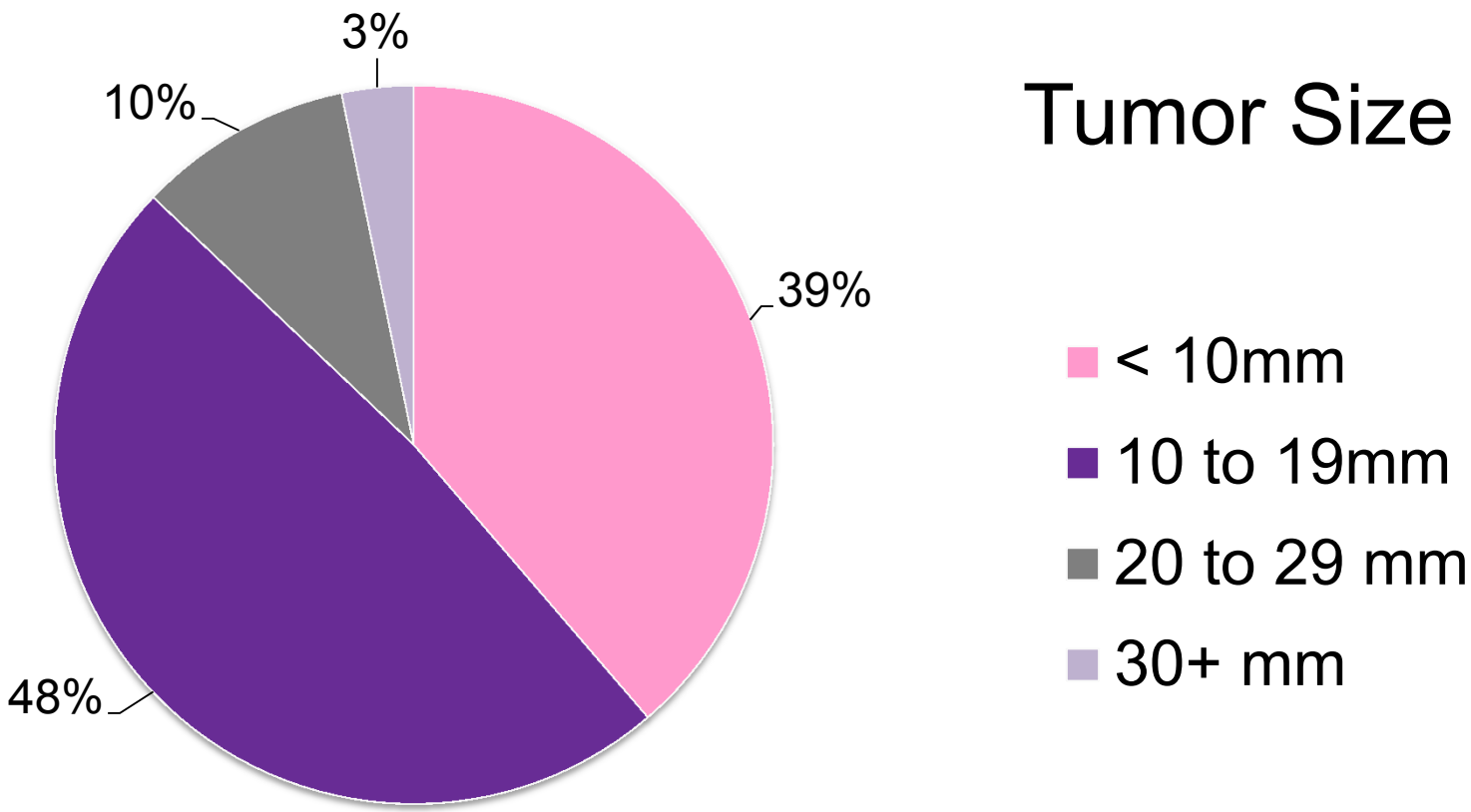

Benefits

Characteristics of 31 Cancer Cases

- Over 75% were ***Stage 1 or 2***

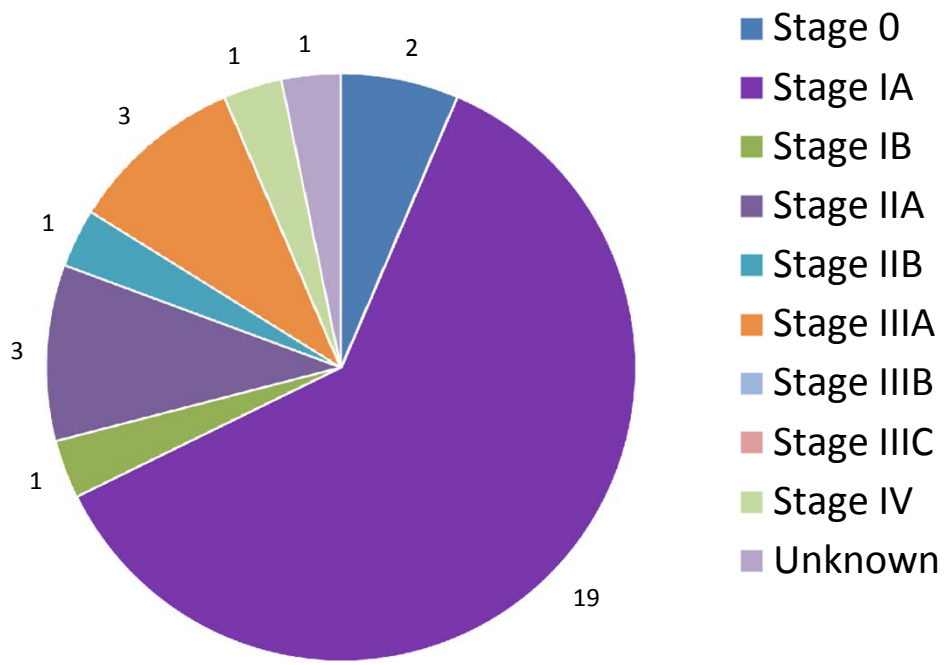

Benefits

Characteristics of 31 Cancer Cases

- 23/31 (74.2%) were ***NODE NEGATIVE***

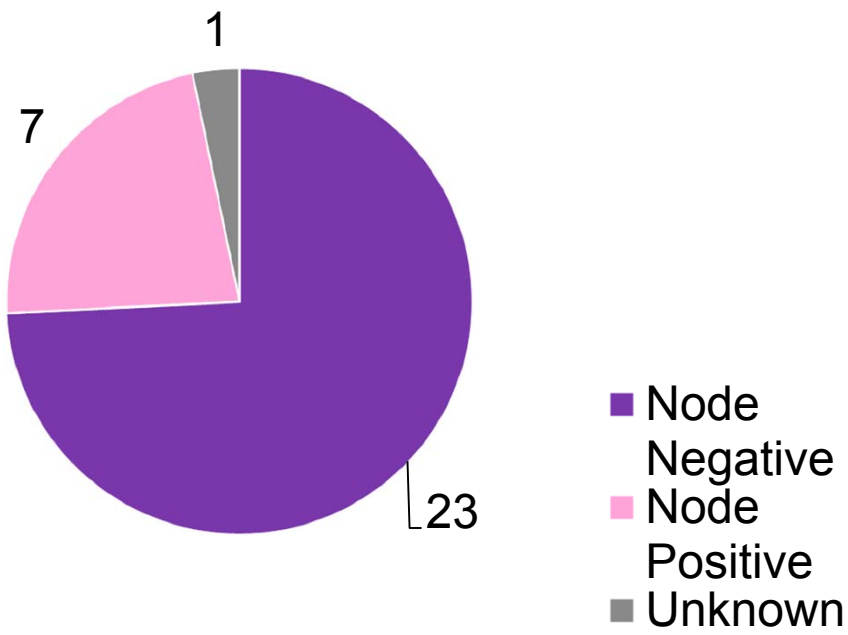

U SYSTEMS
Automated Breast Ultrasound

Benefits

- With 200,000 new cases of breast cancer annually and with 40% of women with dense breasts, ABUS could detect an additional ***25,500*** cases of breast cancer in the US
- Small, node negative, low grade, invasive breast cancers
- Mammographically occult interval cancers
  - Poorer prognosis
  - Invasive
  - Higher grade
- A lower prevalence of interval cancer should result if ABUS detects cancers at time of initial screening

Benefits

24% increase in cancer detection over XRM Alone when ABUS is used in conjunction with screening XRM in asymptomatic women with dense breasts

U SYSTEMS
Automated Breast Ultrasound

Risks

- Pivotal Reader Study demonstrated a statistically insignificant 2% reduction in specificity
- Decreased specificity
- Increased recall rate
- Cannot detect additional cancers without recalling additional patients
  - Acceptable decrease in specificity for additional cancer detection
- Expect improvement in specificity with increased ABUS experience

Risks

Based on the Reader Study the additional number of false positives per cancer found with ABUS is estimated to be 40.

Given 1000 women undergoing screening mammography		
# of cancers found	Estimated practice call back rate	# of false positives per cancer found
4	10%	25
4	15%	38
4	20%	50

Positive and Negative Likelihood Ratios

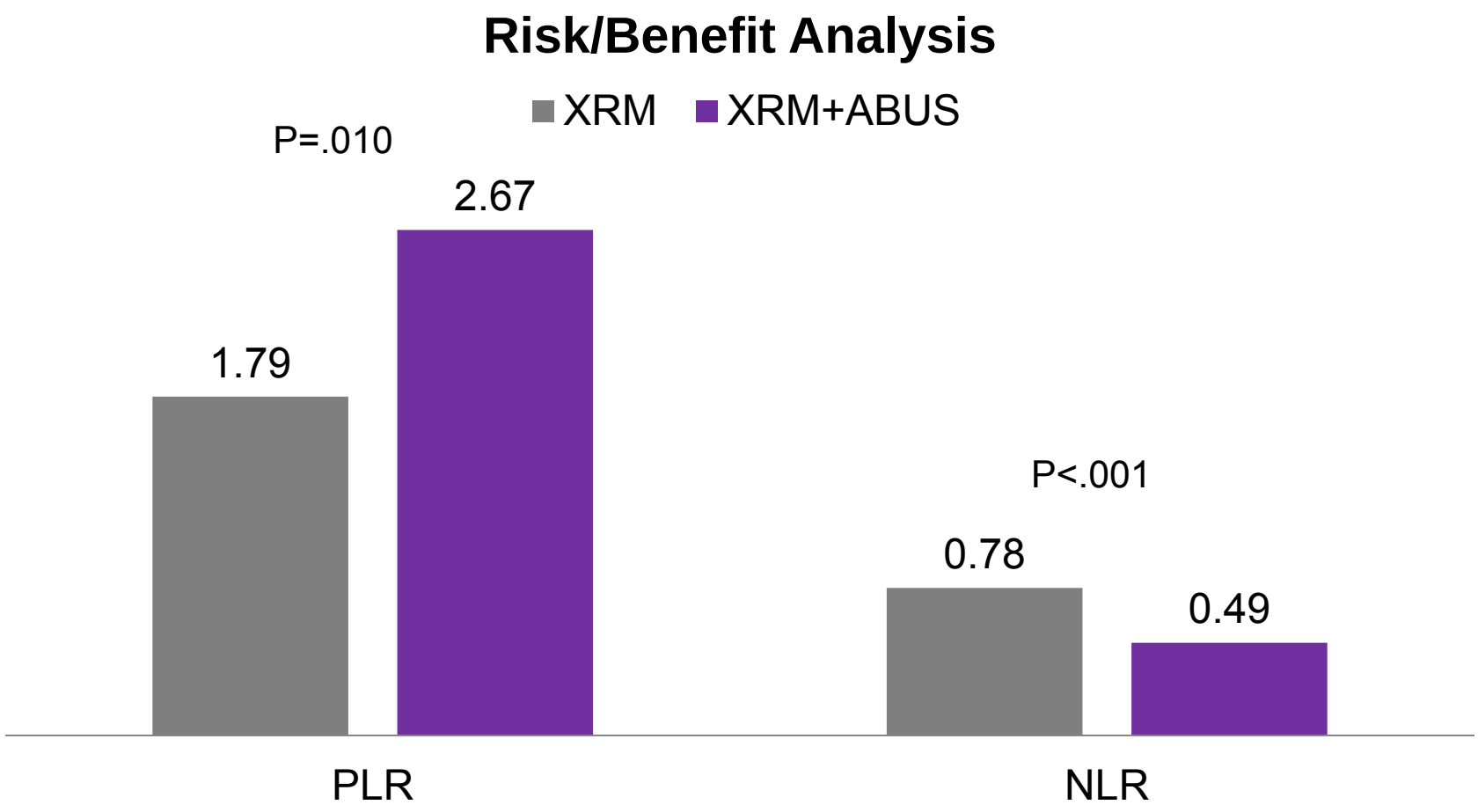

U SYSTEMS
Automated Breast Ultrasound

Risk/Benefit Analysis

Benefits of ABUS outweigh its risks

There is reasonable assurance of safety and effectiveness

ABUS addresses an unmet medical need by providing a clinically meaningful advantage over screening XRM alone

124

Proposed Indication For Use

The somo·v Automated Breast Ultrasound System is indicated as an adjunct to mammography for breast cancer screening in asymptomatic women for whom screening mammography findings are normal or benign (BI-RADS Assessment Category 1 or 2), and breast parenchymal tissue is dense (BI-RADS Composition/Density 3 or 4),

and have not had previous clinical breast intervention.

The device is intended to increase breast cancer detection in the described patient population.

Women with Prior Breast Interventions

- Non-cancer cases with prior breast interventions were excluded to avoid bias
  - Reader Study - research environment
  - No prior images for comparison
  - No clinical history information provided to Readers
- Exclusion of women with prior breast interventions was a necessary construct of the confounding factors of including patients with prior interventions
  - Reader Study purposes only
- Proposed IFU excludes women with prior interventions since that was the population studied

U SYSTEMS
Automated Breast Ultrasound

Women with Prior Breast Interventions

- HOWEVER, there is no reason that this approach would not be equally effective in women with prior interventions
  - Fine needle aspirations
  - Core needle biopsy
  - Stereotactic biopsy
  - Surgical procedures
- Prospective Registry Study allowed for prior breast intervention, more than a year prior
  - Found additional ABUS only cancers in women with prior breast interventions

Case 5

- 46-year-old woman with stable screening mammogram
  - Prior clinical intervention: lumpectomy 2003
  - BI-RADS Density 4, BI-RADS Assessment 2
  - Routine Annual Follow-Up Recommended

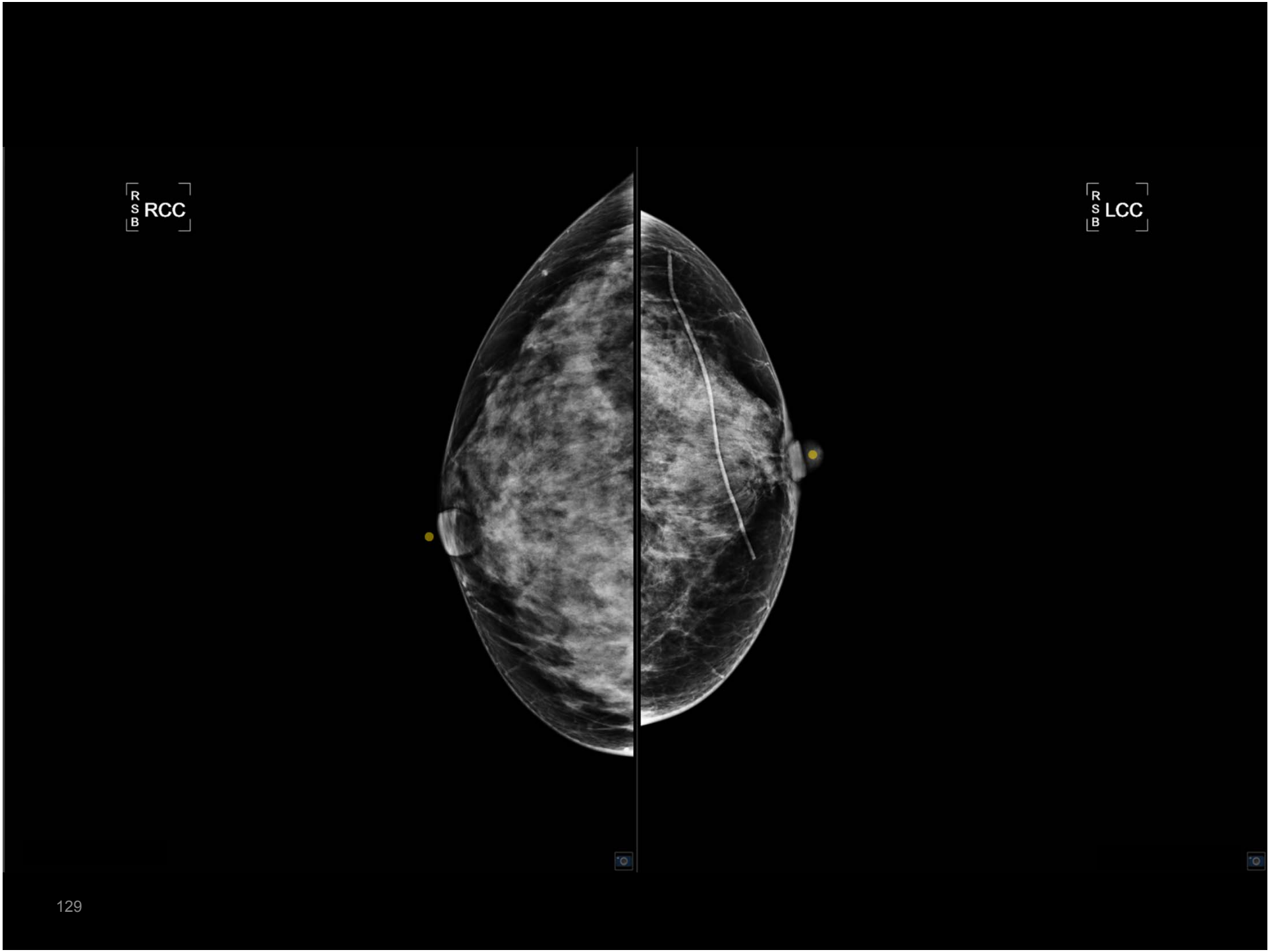
R
S
B
RCC
R
S
B
LCC

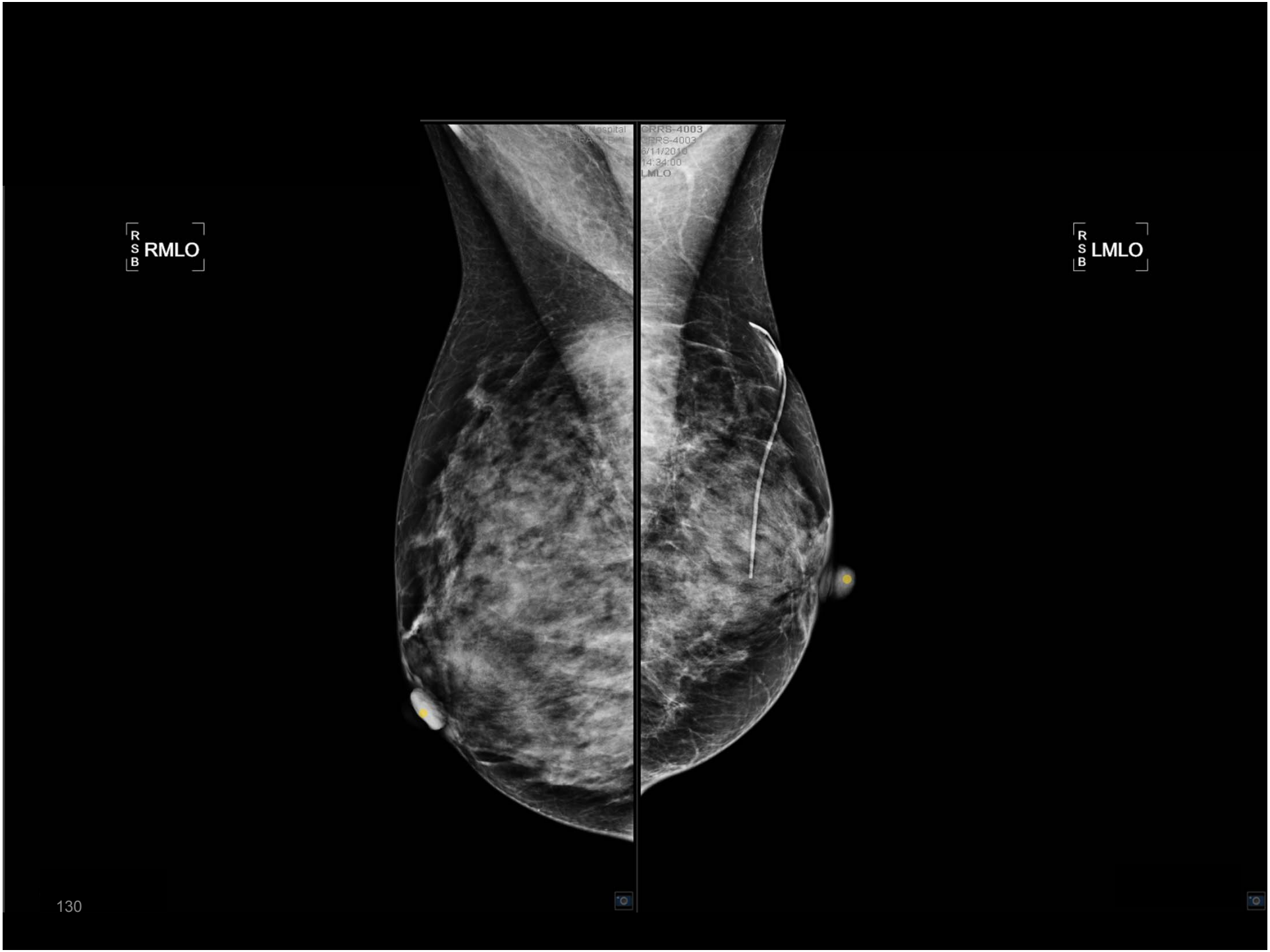
RMLO
LMLO
CRRS-4003
LMLO

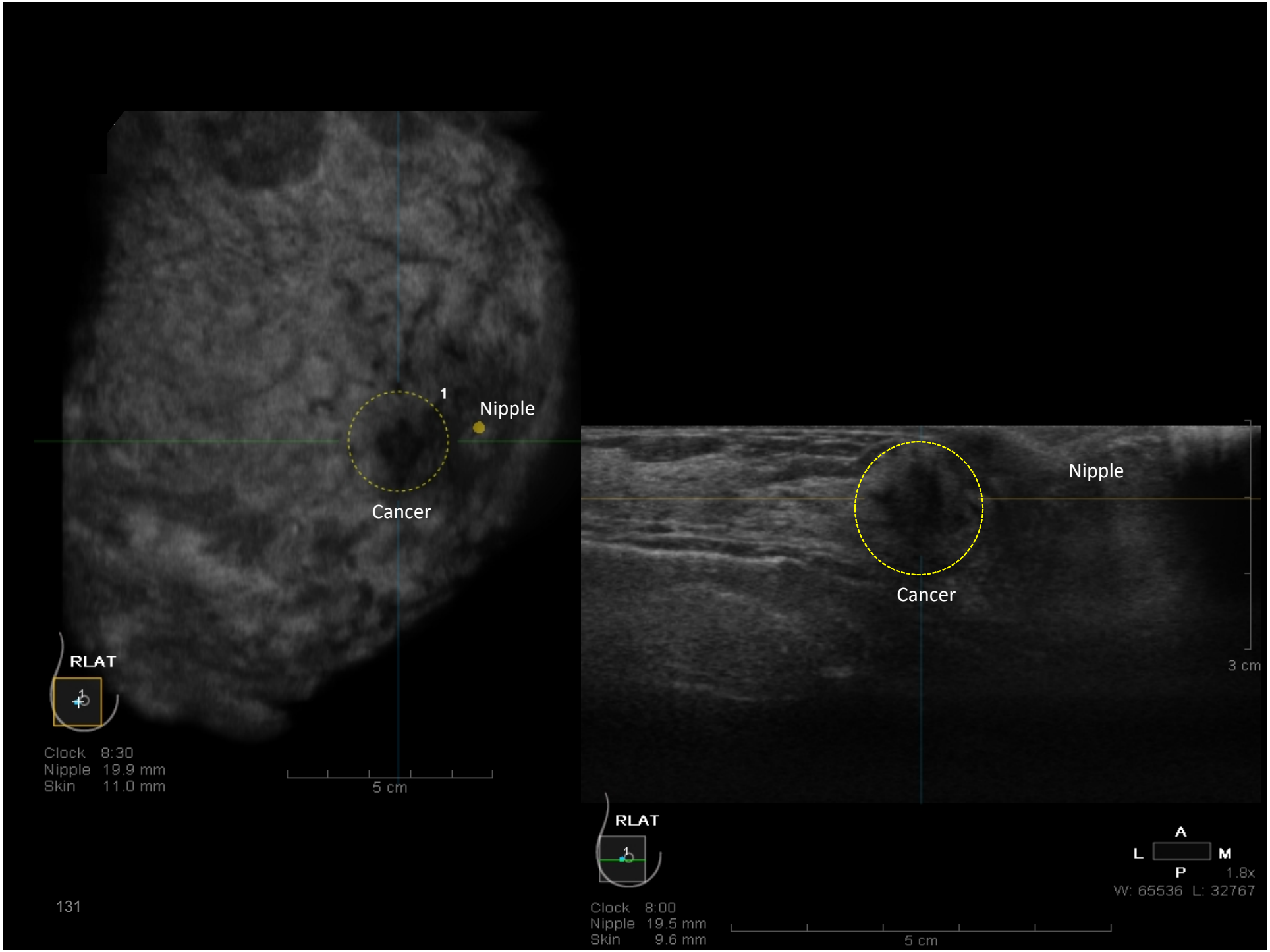
1
Nipple
Cancer
RLAT
Clock 8:30
Nipple 19.9 mm
Skin 11.0 mm
5 cm
131
Nipple
Cancer
3 cm
RLAT
Clock 8:00
Nipple 19.5 mm
Skin 9.6 mm
5 cm
A
L
M
P
1.8x
W: 65536 L: 32767

U SYSTEMS
Automated Breast Ultrasound

Case 5 Conclusion

- Abnormal 3D ABUS
  - BI-RADS 0, Immediate Management Recommended
- Ultrasound-guided core needle biopsy performed
- Pathology revealed Invasive Ductal Carcinoma
  - Seen only with ABUS and mammographically occult in a patient with a prior clinical breast intervention

U SYSTEMS
Automated Breast Ultrasound

Women with Prior Breast Interventions

- Excluding women with prior breast interventions will deny this important population of women the opportunity for detection of early, mammographically occult breast cancer
  - No mammographic or sonographic sequelae
  - With surgical procedures, radiologists have the prior images and clinical history and can correlate location with mammographic identification of scar
- Clinical perspective: need to include women with prior breast interventions so they will also benefit from the improved breast cancer detection

U SYSTEMS
Automated Breast Ultrasound

Solution to an Unmet Clinical Need

- ABUS optimizes the detection of mammographically occult breast cancer in a challenging clinical situation
  - Dense breasts
  - Lower mammographic sensitivity
  - High risk of breast cancer
- Tailored screening based on mammographic breast density
- Solution to a currently unmet critical need
  - Will improve breast cancer detection in this challenging population of women that constitute nearly half of women who undergo screening mammography

U SYSTEMS
Automated Breast Ultrasound

Conclusion

- ABUS is a unique opportunity to build on the public health gains achieved by cancer screening
- ABUS is effective in finding node negative, early stage invasive cancers missed by mammography in women with dense breasts
- The benefits of ABUS as an adjunct to screening mammography greatly outweigh the risks
- Solution to a currently unmet critical need
- ABUS will improve breast cancer detection in this challenging population of women that constitute nearly half of women who undergo screening mammography

Risk/Benefit Analysis for ABUS is highly favorable

U SYSTEMS
Automated Breast Ultrasound

Automated Breast Ultrasound System Training Programs

CRRS Reader Training Program

Case Review & Interpretation

- Provide orientation and instruction on using ABUS images as an adjunct to screening mammography

CRRS Training Modules

MODULE I
2hrs

On-Line Self-Study Tutorials

MODULE II
1hr

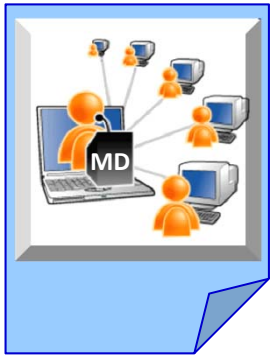

Peer-to-Peer Webinar

MODULE III
8hrs



Peer-to-Peer ABUS Interpretation

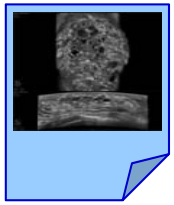

Directed Review

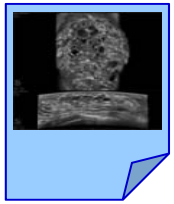

Independent Self Review

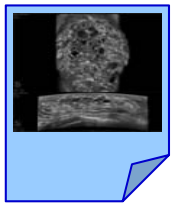

Skill Set Exercise

Reader Participation in CRRS

CRRS Training Program

MODULE I
2hrs

On-Line Self-Study Tutorials

Module I – Online Self-Study Tutorials

- Provides foundation for ABUS training
- 5 self-paced internet based tutorials
- Case study format with mammography and ABUS demonstrating a range of benign and malignant cases

CRRS Training Program

MODULE II
1hr

Peer-to-Peer Webinar

Module II – Peer-to-Peer Webinar

- Interactive webinar with Readers and U-Systems Faculty
- Continues fundamentals of ABUS and expands range of pathologies
- Allowed for direct Q&A with Faculty prior to workshop in Module III

CRRS Training Program

MODULE III
8 hrs

Peer-to-Peer ABUS Interpretation

Module III – Peer-to-Peer ABUS Interpretation

- 3 unique sessions to reinforce and build upon Reader's ABUS knowledge base
- Directed Review: Readers reviewed ABUS cases
- Independent Review: One-on-one post assessment review with Faculty to further instruct and verify accuracy
- Skill Set Exercise: Readers independently reviewed ABUS cases and scored their findings and were assessed

User Training Modules
Radiologist

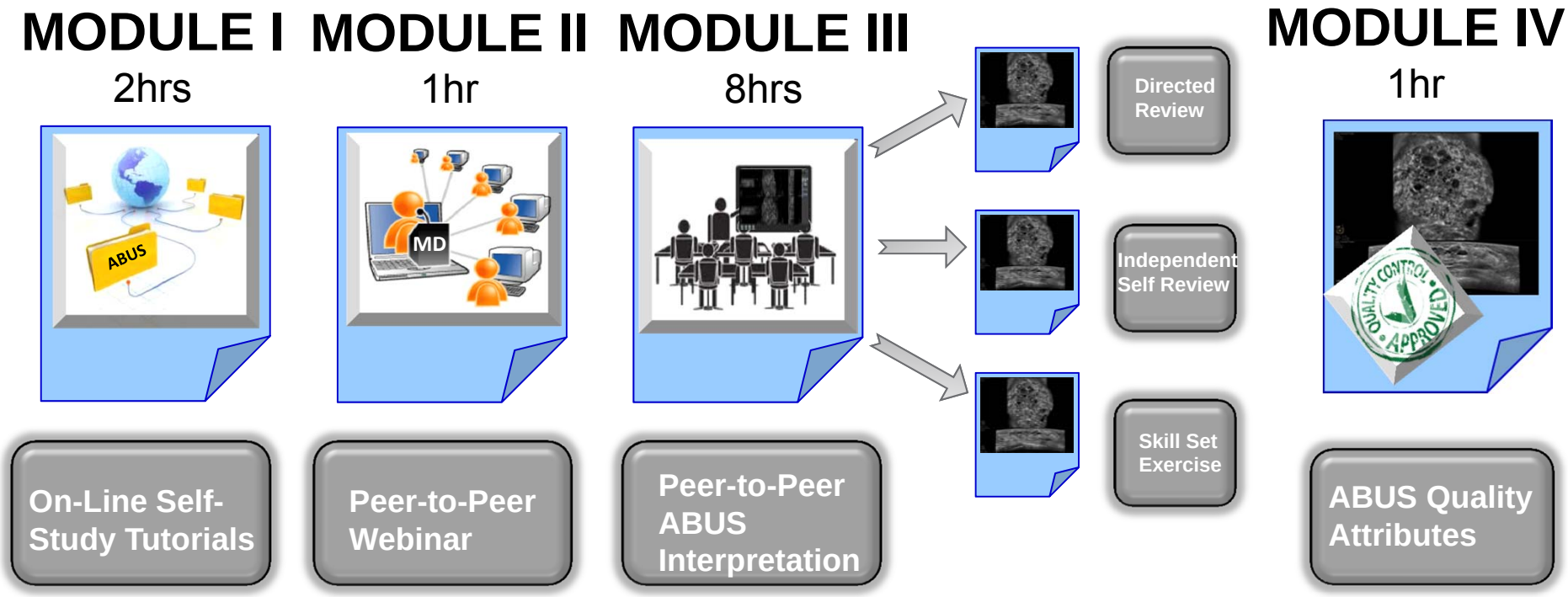

Radiologist Training Program

MODULE IV

1hr

ABUS Quality Attributes

Module IV –Attributes of ABUS Image Quality

- Positioning
- Labeling
- Compression
- Artifacts

Technologist Training Program

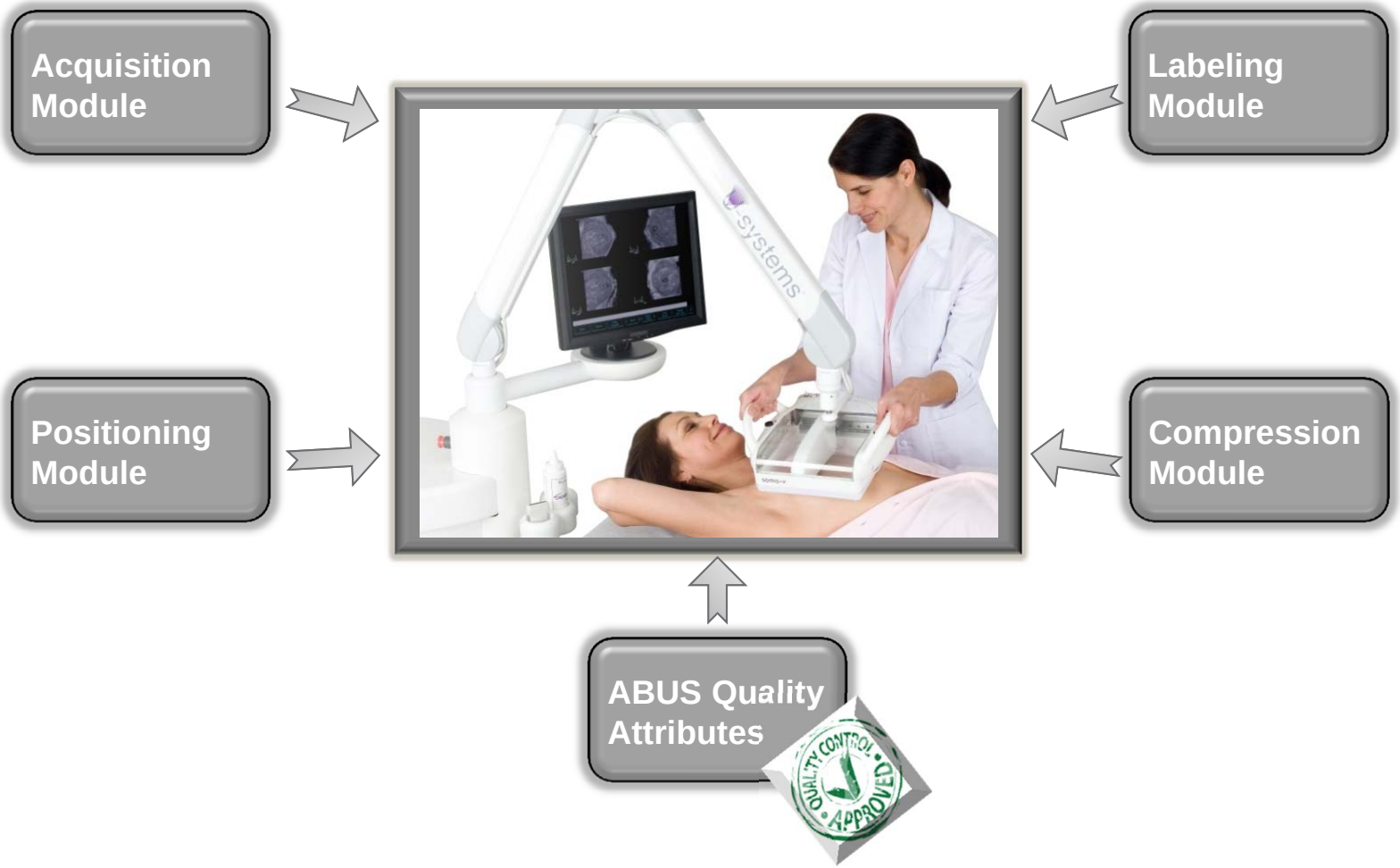

Technologist Acquisition Technique Training

- Attributes of Quality Acquisitions - Positioning

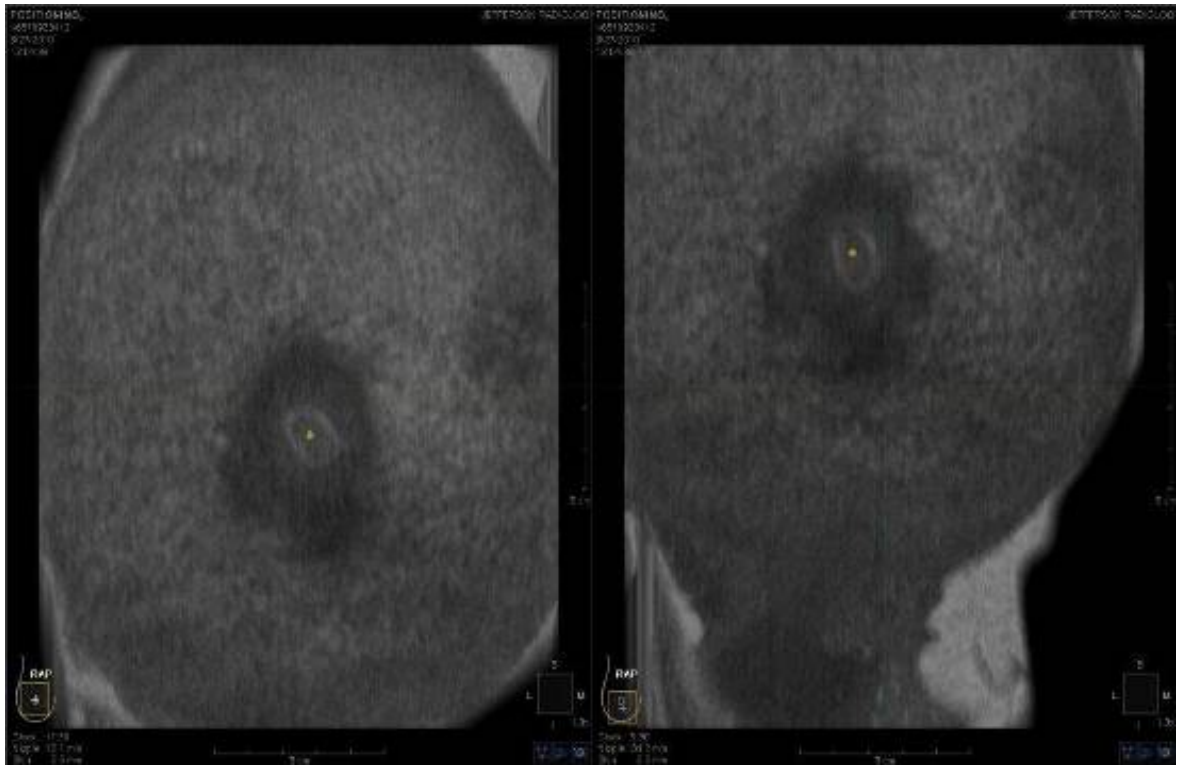

Optimal AP Acquisition Sub-Optimal AP Acquisition

ABUS Radiologist Training Programs

CRRS Reader Training

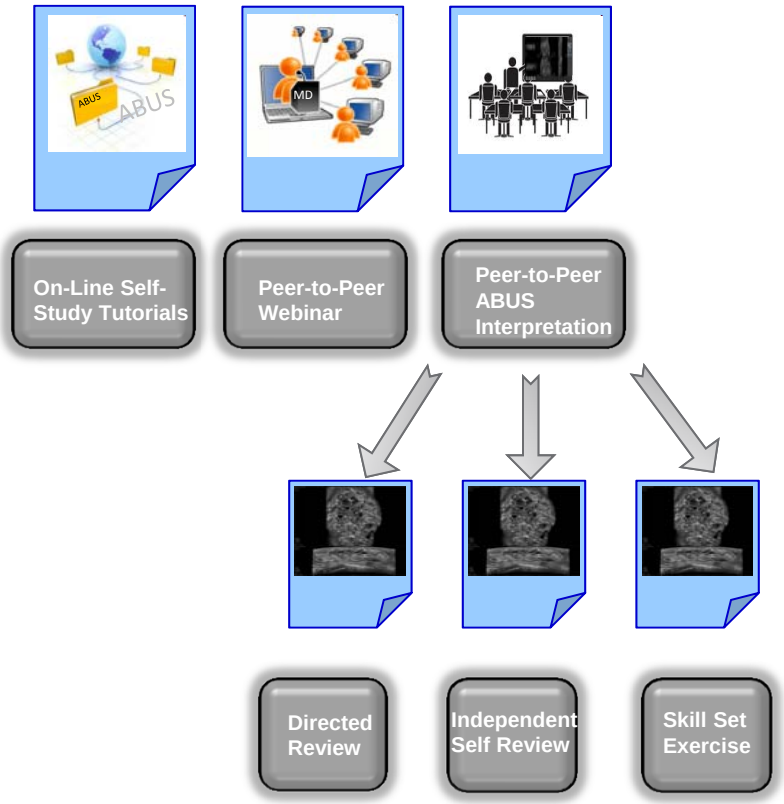

User Training

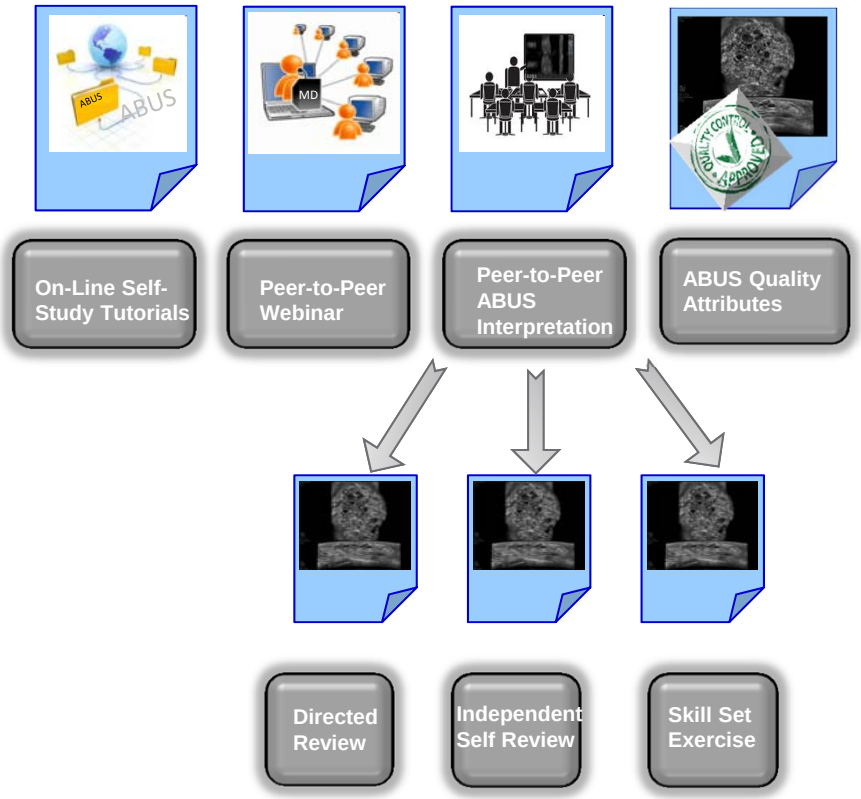

U SYSTEMS
Automated Breast Ultrasound

Concluding Remarks

U SYSTEMS
Automated Breast Ultrasound

Conclusion

- The Pivotal Reader Study demonstrates that XRM+ABUS is effective with a significant increase in cancer detection not offset by a significant decrease in specificity
- The benefits of ABUS greatly outweigh the risks as an adjunct to screening mammography
- ABUS is an important tool that will help radiologists detect more cancers at an earlier, more treatable stage, translating to lives saved

U SYSTEMS

Automated Breast Ultrasound