BRIEFING DOCUMENT

FDA Cellular, Tissue, and Gene Therapies Advisory Committee

CTGTAC Meeting #52

Cellular and Gene Therapies for Retinal Disorders

June 29, 2011

TABLE OF CONTENTS

1. INTRODUCTION 4

2. BACKGROUND 4

2.1 RETINAL DISORDERS 4

2.2 CELLULAR AND GENE PRODUCTS FOR RETINAL DISORDERS 9

3. EFFICACY ENDPOINTS FOR RETINAL DISORDERS 10

3.1 ACCEPTED EFFICACY ENDPOINTS AND ISSUES RELATED TO THEIR USE IN TRIALS OF CELLULAR AND GENE PRODUCTS FOR RETINAL DISEASES 11

3.2 DEVELOPMENT OF EFFICACY ENDPOINTS 16

4. CONTRALATERAL EYE OR REPEAT ADMINISTRATION 24

4.1 SURGICAL CONCERNS IN TREATMENT OF THE SECOND EYE WITH CELLULAR AND GENE THERAPY INVESTIGATIONAL AGENTS 25

4.2 IMMUNOLOGICAL CONCERNS RELATED TO CELLULAR AND GENE THERAPIES FOR RETINAL DISORDERS 27

4.3 SYMPATHETIC OPHTHALMIA (SO) 30

4.4 PRECLINICAL ASSESSMENT OF THE SAFETY OF CONTRALATERAL EYE OR REPEAT ADMINISTRATION 32

5. LOCAL ADMINISTRATION PROCEDURES 41

5.1 INTRAVITREAL ADMINISTRATION 42

5.2 SUBRETINAL INJECTION 43

5.3 USE OF PRECLINICAL DATA TO OPTIMIZE PRODUCT ADMINISTRATION 49

6. ADVISORY COMMITTEE DRAFT DISCUSSION QUESTIONS 56

REFERENCES 58

ABBREVIATIONS

AAV	Adeno-Associated Virus
AAV2	Adeno-Associated Viral Vector, Serotype 2
AMD	Age-Related Macular Degeneration
AO	Adaptive Optics
AOSLO	Adaptive Optics Scanning Laser Ophthalmoscope
AREDS	Age-Related Eye Disease Study
CDER	Center for Drug Evaluation and Research
CMV	Cytomegalovirus
eGFP	Enhanced Green Fluorescent Protein
cDNA	Complementary Deoxyribonucleic Acid
CNTF	Ciliary Neurotrophic Factor
CTGTAC	Cellular, Tissue, and Gene Therapies Advisory Committee
DNA	Deoxyribonucleic Acid
DSMB	Data Safety Monitoring Board
ERG	Electroretinography
ETDRS	Early Treatment Diabetic Retinopathy Study
FDA	Food and Drug Administration
hFIX	Human Factor IX
hRPE	Human Retinal Pigment Epithelium
IHC	Immunohistochemistry
LacZ	β-Galactosidase
LCA	Leber Congenital Amaurosis
MRI	Magnetic Resonance Imaging
NDA	New Drug Application
NAb	Neutralizing Antibody
NEI-VFQ	National Eye Institute Visual Function Questionnaire
NHP	Nonhuman Primate
OCT	Optical Coherence Tomography
PCR	Polymerase Chain Reaction
PDT	Photodynamic Therapy
PEDF	Pigment Epithelial Derived Factor
PET	Positron Emission Tomography
PLR	Pupillary Light Reflex
PRO	Patient-Reported Outcome
qPCR	Quantitative Polymerase Chain Reaction
rAAV	Recombinant Adeno-Associated Virus
RCS	Royal College of Surgeons
RP	Retinitis Pigmentosa
RPE	Retinal Pigment Epithelium
SO	Sympathetic Ophthalmia
SD	Stargardt Disease
US	United States
VEGF	Vascular Endothelial Growth Factor
VF-14	Visual Function Index Questionnaire

1. INTRODUCTION

This Advisory Committee meeting will address several issues that are important to the development of cellular and gene therapies for retinal disorders in both adult and pediatric populations. Topics for discussion include: 1) efficacy endpoints for clinical trials, especially for trials intended to study rare retinal disorders and disorders in very young children; 2) treatment of the contralateral eye and repeat administration of product; and 3) optimization of the administration procedures, including identification of methods to confirm accurate delivery of the intended dose into the target site in both preclinical and clinical studies.

The discussion will not focus on review of specific products. Instead, following presentations from FDA and invited experts in the field, the Advisory Committee will be asked to provide responses to the FDA questions that are provided in Section 6 of this briefing document.

2. BACKGROUND

2.1 Retinal Disorders

The retina is a multi-layered (ten layers) sensorineural tissue lining the interior of the eye. The retina contains millions of photoreceptor cells: the rods and cones. The rods function mainly in dim light and provide black-and-white vision, while the cones support daytime vision and perception of color. The terms that have been used to describe different anatomical areas of the retina can be confusing because the same term has been used in

the published literature to describe more than one area. For purposes of this document, the small central area of the retina where refractive mechanisms of the eye focus light will be referred to as the fovea. The area immediately surrounding the fovea, posterior to the first set of blood vessels in the retina, will be referred to as the macula. The rest of the retina will be referred to as the peripheral retina.

The anatomic distribution of photoreceptors varies within the retina. There is a higher density of photoreceptors in the central, posterior portion of the retina (macula) than in the periphery of the retina. Furthermore, within the photoreceptor cell population, the rods and cones are not distributed evenly throughout the retina. The macula has a higher percentage of cones, compared to rods. In the periphery, where photoreceptors are more widely spaced, there is a predominance of rods. The differences in the distribution of these elements of the retina lead to differences in clinical presentations among retinal disorders.

Retinal disorders vary in etiology, prevalence, diagnosis, and treatment. Etiologies include single-gene and multi-gene defects, certain systemic diseases such as diabetes or hypertension, and multifactorial causes. Published reports describe preclinical and clinical studies of cell and gene therapies[1] for the treatment of a number of inherited retinal diseases, such as Leber congenital amaurosis,[2, 3] Stargardt disease,[4] and retinitis pigmentosa,[5] as well as acquired retinal diseases, such as age-related macular degeneration.[6]

The following is a general overview of specific retinal diseases that have been discussed in the preclinical and clinical literature[1-6] as targets for cellular or gene therapies.

2.1.1 Inherited Retinal Disorders

Inherited retinal disorders are caused by single or multiple gene mutations that result in degeneration of photoreceptors or retinal pigment epithelium. The consequences of these mutations are visual impairment and eventual visual loss. Depending on the underlying mutation(s), the age of onset of visual impairment in patients varies from the first year of life to adulthood. Although individually rare, inherited retinal disorders collectively represent a major cause of untreatable vision loss and blindness in young people in the United States. Current clinical management for these disorders is largely supportive.

Leber Congenital Amaurosis (LCA)[7]

LCA is a group of disorders causing severe dystrophy of the retina. The prevalence of LCA is two to three per 100,000 births. This disorder is the most common cause of inherited blindness in childhood and constitutes more than 5% of all retinal dystrophies.[7] The clinical presentation includes impaired vision at birth which typically progresses to blindness in the third decade of life.

Stargardt Disease (SD)[8]

Stargardt disease is a group of disorders that affect the macula, causing progressive vision loss. This disease affects approximately 30,000-50,000 Americans, with a prevalence of about one in 10,000 individuals. Patients with Stargardt disease typically present with central vision loss in late childhood to early adulthood. Fluorescein angiography reveals

dystrophic changes of the retina with yellowish spots (flecks) termed fundus flavimaculatus. Individuals with Stargardt disease may also have difficulty with night and color vision. Although visual acuity may be severely reduced, peripheral visual fields may remain normal throughout life, and the progression of vision loss is variable, even among family members carrying the same mutation.

Retinitis Pigmentosa (RP)[9]

RP is a group of disorders in which retinal degeneration leads to progressive visual loss. RP affects approximately 100,000 Americans, and the prevalence of RP in the US and Europe is approximately one in 4,000. The age of onset ranges from late childhood to early adulthood. Retinitis pigmentosa can affect the retina alone or can be a part of a syndrome (e.g., Usher syndrome when associated with congenital deafness). Individuals affected with RP first experience defective dark adaptation or night blindness, followed by constriction of the peripheral visual field and, eventually, loss of central vision late in the course of the disease.

2.1.2 Acquired Retinal Disorders

In addition to the inherited retinal disorders, preclinical and clinical publications describe the study of cellular and gene therapies for the treatment of acquired disorders, including age-related macular degeneration[6] and diabetic retinopathy.[10] These two disorders are described below.

Age-Related Macular Degeneration (AMD)[11]

AMD has two major forms, commonly referred to as "dry" and "wet." They are primarily differentiated by the presence or absence of a neovascular (wet) component, although both forms can occur in the same patient. AMD is the leading cause of irreversible blindness in people 50 years of age or older in the developed world.[12] More than 8 million Americans are affected by AMD. Dry AMD, including geographic atrophy, is the more common form. Visual acuity in patients with dry AMD usually deteriorates slowly over years. In wet AMD, exudative fluid leaks from new subretinal vessels. If left untreated, wet AMD can cause significant and rapid visual deterioration, often within weeks to months. Several therapies have been introduced for treatment of neovascular AMD, including anti-VEGF (vascular endothelial growth factor) therapies, laser photocoagulation, photodynamic therapy (PDT) using verteporfin, and surgical treatment of choroidal neovascularization.

Diabetic Retinopathy

Diabetic retinopathy is a progressive retinal condition leading to vascular leakage and subsequent retinal edema, capillary dropout and ischemia, and the growth of new blood vessels with potential bleeding in the retina and vitreous. The first clinically visible signs are generally noted in patients who have had diabetes for 10 to 15 years or longer. Tight control of blood glucose is important in patient management,[13] and laser photocoagulation can minimize or slow progression of the retinopathy.

2.2 Cellular and Gene Products for Retinal Disorders

A variety of cellular and gene therapy products are currently being studied (or are under consideration as candidate products) in clinical trials of retinal disorders. Potential cell sources for products developed as therapies for retinal diseases include adult stem cells and pluripotent stem cells.[14] Hypothesized mechanisms of action for these cellular products include generation of new functional photoreceptor cells or secretion of neuronal growth factors that delay the retinal deterioration process.[15]

Several publications have described novel strategies to improve cell delivery, distribution, and survival. For example, cell encapsulation methods are designed to allow the release of potentially therapeutic factors from the cells while protecting the cells from the host immune system.[16] In another approach, cells may be seeded onto polymer scaffolds for implantation as single or multilayer cell sheets.[17]

Gene therapy products described for retinal diseases include various viral vectors and plasmid DNA vectors into which a transgene(s) has been inserted. When administered to patients, these products are intended to deliver genes that either replace a deficient gene or target underlying pathophysiological processes. Alternatively, viral vectors may be used to deliver genes into cells (then referred to as transduced cells) *ex vivo* prior to administration of the cells to the recipient. Published reports describe the use of replication-deficient adeno-associated virus (AAV) vectors[2] and replication-deficient lentivirus vectors[18] to deliver gene therapy products. The advantage of these two vectors is that they can persist in the transduced cells and achieve long-term gene expression.

3. EFFICACY ENDPOINTS FOR RETINAL DISORDERS

This section describes some of the challenges in selecting appropriate efficacy endpoints for trials of cell and gene therapies for retinal disorders. Selection of appropriate endpoints is critical to the development of a new therapeutic agent. There are a number of efficacy endpoints (visual acuity, visual field, color vision, and area of non-seeing retina) that have been used or accepted in development of drugs for ophthalmologic indications. However, there are special issues related to clinical development of cell and gene therapy products for treatment of retinal diseases that may make endpoint selection particularly challenging. For some retinal disorders, the small size of the target population may not permit a study that is large enough to demonstrate a meaningful effect on an established endpoint. Surrogate endpoints, which offer the potential for smaller and shorter trials, may not have been sufficiently developed. In addition, endpoints that are used in adult populations may not be suitable for pediatric use; for example, young children may not have the physical or cognitive ability to fully participate in testing procedures. Furthermore, some existing endpoints may lack sufficient sensitivity (i.e., responsiveness to change in clinical status) to detect part, or even all, of the possible range of efficacy outcomes in a particular target population, precluding identification of potential beneficial activity of the test product.

The following sections describe accepted efficacy endpoints and their limitations, clinical issues associated with these accepted endpoints in studying cellular and gene products, and considerations for development of ophthalmological efficacy endpoints based on visual function, anatomic measures, functional vision, and patient-reported outcomes.

3.1 Accepted Efficacy Endpoints and Issues Related to Their Use in Trials of Cellular and Gene Products for Retinal Diseases

The visual system provides a means for reception and interpretation of visible light, in terms of light intensity, wavelength discrimination, location of source, and direction of light waves. Terms commonly used to describe these aspects of vision include visual acuity (ability to resolve high contrast visual angles), visual fields (threshold detection of a light source emanating from different locations), color vision (ability to distinguish among different wavelengths of light), and contrast sensitivity (ability to distinguish among different amplitudes of the same wavelength of light). Measurement of these capabilities can be used as endpoints in the evaluation of treatments of diseases that affect the visual system. Effectiveness of a treatment is demonstrated when there is a sufficient change in an endpoint that has been determined to be clinically meaningful. For vision-related therapeutic agents, this change in the endpoint correlates with an increase in the sensitivity of the visual system to detect and distinguish among wavelengths of visible light or to discriminate different locations of light sources. Products can also be considered to be effective if the endpoints remain stable, indicating protection from clinically important decline in vision that is expected to occur during the natural course of a disease, or at least over the observational period of a clinical trial. The following sections describe outcome measures that have been accepted as primary efficacy endpoints in clinical trials to support marketing approval of treatments of ophthalmological diseases.

3.1.1 Visual Acuity

Improvement in best corrected distance visual acuity is considered to be clinically meaningful when the mean visual angle doubles in resolution capacity. On a standard ETDRS (Early Treatment Diabetic Retinopathy Study) visual acuity chart, this change is equivalent to a 15-letter improvement.

Changes in visual acuity can be measured accurately under the following conditions: 1) when individuals are old enough to follow instructions and describe the objects that they see, and 2) when the visual angle is within the range of 20/10 to 20/800. Many of the inherited retinal disorders can affect children before they are old enough to provide reliable best corrected distance visual acuity scores, and some disorders impair visual acuity to levels beyond 20/800. Therefore, in these situations, there are limitations to the usefulness of visual acuity for following disease progression.

Other potential disadvantages of a 15-letter change as an efficacy endpoint have been discussed.[19] These disadvantages include reduced statistical power and the need for a larger sample, and the susceptibility to floor or ceiling effects (i.e., loss of sensitivity at each end of the visual acuity range) in the measurement of visual acuity. These effects may make achieving a 15-letter change difficult for subjects with visual acuity outside the range (that is, those with 20/800 or worse or those with acuities better than 20/40).

3.1.2 Visual Field

Improvement on visual field testing can be considered clinically meaningful when results of multiple points in the visual field meet specific criteria (e.g., an improvement in 7-10 decibels for each of 5 or more independent points, using an automated threshold perimeter).

Accurate visual field measurements require the ability to see and maintain fixation. Conditions that destroy or impair the macula limit the ability of an individual to see and maintain fixation, and therefore limit the utility of visual field measurements as efficacy endpoints.

3.1.3 Color Vision

A statistically significant improvement in the ability to group similar wavelengths together when the full visible color spectrum is measured is considered to be clinically meaningful.

Color vision is dependent on cones in the retina. Conditions that affect only rods are less likely to produce defects in color vision. Since most of the cones are located in the central thirty degrees of the retina, conditions that affect the peripheral retina are also unlikely to produce defects in color vision. Therefore, the value of color vision as an endpoint is dependent on which photoreceptor cells are affected.

3.1.4 Area of Non-Seeing Retina

FDA's Center for Drug Evaluation and Research (CDER) has accepted as an anatomic endpoint a decrease in the rate of growth of an area of retina that no longer has any photoreceptors. This can be measured in one of several ways. It can be most easily measured by spectral domain ocular coherence tomography (OCT), which uses reflected light to generate a cross-section image of the retina, similar to a histology specimen. The layers of the retina can be identified, and the latest generation of spectral domain OCT has the ability to resolve structures of 1-5 micrometers in size. With this instrument, it is therefore possible to evaluate the presence of the photoreceptor layer in part of the retina. A limitation of OCT is its field of view; it is most often used to assess the fovea in the center of the macula (the area responsible for central vision) or the optic nerve head. The hallmark of dry AMD is geographic atrophy in the macula. Geographic atrophy is a breakdown in the retinal pigment epithelium (RPE) and subsequent overlying retinal tissue. There is not a uniform destruction of the retina, and photoreceptors are often spared at the periphery of the lesions. These "fuzzy borders," when viewed by fundus photography or autofluorescence, often surround an area where there is complete destruction of the photoreceptors. Reduction in the rate of progression of these areas of complete destruction of the photoreceptors can sometimes be measured indirectly by fundus photography or autofluorescence. When the area of complete destruction of the photoreceptors in dry AMD can be measured, it is an acceptable endpoint.

A change in the area of non-seeing retina has been used as a clinical endpoint to support New Drug Applications (NDAs) such as ganciclovir and foscarnet in the treatment of

cytomegalovirus (CMV) retinitis. In this disease process, active virus destroys the full thickness of the retina (including photoreceptors); therefore, any progression of the active border of CMV retinitis indicates a destruction of photoreceptors. In clinical trials, ganciclovir and foscarnet slowed the progression of the CMV retinitis border when viewed by fundus photography.

There are potential challenges to using the above accepted efficacy endpoints in clinical trials for cellular and gene therapy products for ophthalmological indications. First, the population of patients affected by the disease in question plays a role in the selection of endpoints for a clinical study of the treatment for that disease. Inherited retinal diseases are individually rare, so that the number of participants (sample size) in a clinical trial is often necessarily small. In such small trials, if the efficacy endpoint is not sufficiently sensitive to change in clinical status, then a clinically important effect might not be detected. Also, the inherited diseases of the retina usually present and have their impact before adulthood. The above efficacy endpoints may be difficult to measure in a pediatric population who does not know all of the letters on a standard ETDRS eye chart or who cannot cooperate with visual field testing. Additionally, because the safety profiles of many of these cell and gene therapy products have not been fully established, initial testing has been in advanced cases with low vision. In such patients, the standard testing modalities may not be able to capture the change effected by the therapy.

Thus, there is a need for development of efficacy endpoints that are both clinically meaningful and suitable for clinical trials of cellular and gene therapies intended to treat

retinal disorders that are progressive, potentially disabling, and with few or no available treatments.

3.2 Development of Efficacy Endpoints

Efficacy endpoints are used in clinical trials to assess the effectiveness of the study intervention. However, Follman notes that "for a study result to be acceptable to the medical community, the endpoint needs also to be meaningful—of either demonstrated or accepted relevance for the population and interventions of the trial."[20] Other endpoint characteristics to consider include the feasibility of measuring the endpoint, the variability of the endpoint measurement, the reliability of endpoint measurements (i.e., both inter-rater and intra-rater reliability), and whether the endpoint is sensitive to treatment differences (i.e., responsive to changes in clinical status) and resistant to bias of both the study subject and the study personnel assessing the endpoint.

Of particular interest for retinal disorders are efficacy measures that accurately document improvements in a patient's activities of daily living or quality of life. However, it may be difficult to adequately characterize such a measure (e.g., with regard to reliability, responsiveness to change, resistance to bias, and clinical meaningfulness) to support the use of the measure as an endpoint in a clinical trial. A surrogate endpoint may be useful if a change in that surrogate (e.g., decrease in the loss of photoreceptors on OCT) can reliably predict a change in a clinically meaningful endpoint of interest.[20]

The following is a discussion of four major categories of outcome measurements for the treatment of eye disorders. These outcome categories include measures of visual function, anatomic measures, measures of functional vision, and patient-reported outcomes.

3.2.1 Measures of Visual Function

Visual function defines how the eye, as an organ, works. Visual function includes the physiology and biochemistry of the eye's specialized anatomy in concert with the eye's own optical system. Visual function measures lend themselves to use in clinical trials because they can be highly standardized. In addition, there is extensive clinical trial experience with these measures, so that their reliability is well-known, and some of these measures (e.g., automated visual field testing) are relatively resistant to the bias of the assessor. Visual acuity, visual field, and color vision measures have been discussed in Section 3.1.

Pupillometry is an objective measure of retinal function.[21] It measures the pupillary light reflex (PLR), which is a consensual response in that a stimulus to either eye will cause both pupils to contract similarly. This reflex is a measure of the amount of signal input from photoreceptors and light-sensitive ganglion cells conveyed through the afferent arc to the brain, with the output driving bilateral pupillary constriction. Maguire et al. tested the pupillary light reflex using pupillometry in the clinical trial for LCA with gene therapy and found improvement of the pupillary light reflex in the treated eyes of 11 subjects (both adults and children).[22] These objective data may be useful in providing

supportive evidence of the effectiveness of the treatment, especially in the group of patients with severe impairment of vision. However, it is not clear whether an improvement in PLR is reasonably likely to predict clinical benefit.

3.2.2 Anatomic Measures

In studies of eye diseases, anatomic outcome measures are feasible because many of the structures of the eye are visible and can be examined in the clinic, treatment response and potential complications can be visualized in real time, and a wide variety of objective, noninvasive imaging modalities have been developed for the eye.[17]

Photography is often used to capture and corroborate fundoscopy findings, while allowing direct measurements of anatomic structures or lesions such as an area of geographic atrophy in dry AMD. The field of the image is most often centered on the macula, although montage images of the periphery can be produced, and some wide-field technology is available. Media opacities such as cataract or blood in the eye can limit the utility of photography.

Photography may be enhanced by the use of filters and fluorescein dye injected through peripheral intravenous infusion. Fluorescein angiography may highlight structural abnormalities, such as new blood vessel growth in wet AMD or diabetic retinopathy, capillary drop-out secondary to blood vessel damage in diabetic retinopathy, and geographic atrophy in dry AMD. Like photography, the utility of fluorescein angiography can be limited in the presence of media opacities. In recent studies that supported

approval of intravitreal drug injections for the treatment of wet AMD, fundus photography and fluorescein angiography have been used as secondary endpoints to monitor changes in anatomic characteristics of new blood vessel lesions.[23, 24]

The use of OCT to identify the layers of the retina has been discussed in Section 3.1 above. OCT has also been used as an endpoint in cell and gene therapy trials. Zhang et al. used OCT to show a difference in the change in total macular volume in eyes with dry AMD, suggestive of a protective effect of treatment with intravitreal implant of encapsulated cells transfected with human ciliary neurotrophic factor (CNTF).[25] However, changes in retinal thickness, as measured by OCT, may be due to changes in retinal tissue cellularity, retinal cell volume, or interstitial fluid.[25] Therefore, the clinical meaningfulness of changes in retinal thickness or macular volume is unclear.

While OCT can provide information about the photoreceptor layer of the retina in a living eye, adaptive optics (AO) ophthalmoscopy, including adaptive optics scanning laser ophthalmoscopy (AOSLO), can produce images of individual cone photoreceptors.[25] Direct visualization of cones allows comparison of cone spacing and density and, in ideal situations, tracking of individual cones over time. It is limited by severe retinal edema, which can distort the anatomy, as well as by media opacities and structures such as blood vessels, which can block visualization of the photoreceptors. Experimentally, AOSLO has been used to measure cone spacing and density in subjects with retinitis pigmentosa.[5] Talcott et al. found that following treatment with encapsulated cells transfected with human CNTF delivered by intravitreal implantation, the cone spacing decreased and cone

density increased, compared to control eyes, while there was no significant change in visual acuity, visual field, or electroretinography (ERG). To date, AOSLO is not widely available and the impact of a change to a relatively small number of cones on a patient's vision is not known.

3.2.3 Measures of Functional Vision

While visual function defines how the eye, as an organ, works, the concept of functional vision applies not just to one eye but to the entire visual system.[26] Functional vision describes how the person performs in vision-related activities of daily living and navigation in the environment. Functional vision measures visual ability/disability or vision-related limitation of activity associated with vision-dependent tasks, such as reading, self-care and grooming, cooking, eating, and walking. As noted by Lepri, assessments of functional vision measure "the impact of all the areas of life affected by the ocular disease … [and document] the symptoms, problems and complaints of the visually impaired patient."[26]

The concept of functional vision assessment is well known in the field of rehabilitation medicine, and is used to assess the patient's level of functioning, with the goal of identifying ways to assist low vision patients in doing what they need and want to do in their daily lives. The large variability in the vision status of different diseases and targeted populations and highly individualized activities of daily life and mobility needs all pose challenges in developing methods for assessing functional vision. Also, the ages of affected subjects and the general physical conditions of their living situations may

have a substantial impact on their mobility or ability to perform daily activities. These factors, which vary substantially between individuals, can make it difficult to interpret group data about functional vision. Another issue is whether quantitative assessments of functional vision in clinical simulations, such as laboratory mobility courses, can adequately reflect a patient's real-world function.[26]

Bainbridge et al.[3] and Maguire et al.[2] described the preliminary results of their clinical trial investigating safety and preliminary efficacy of gene therapy, in which recombinant adeno-associated virus (AAV) was used to deliver the human retinal pigment epithelium-specific 65-kDa protein gene (RPE65) via a subretinal injection following a vitrectomy.

Mobility testing for subjects with severely impaired vision was performed as one of the assessments in the trial.[22] To evaluate orientation and mobility skills, the investigators evaluated the subjects' ability to go through a laboratory obstacle course. The results showed improvement of ability to navigate this short obstacle course. However, it is unclear whether an improvement in the ability to navigate a mobility course represents a benefit that is clinically meaningful to patients.

3.2.4 Measures of Patient-Reported Outcome (PRO)

A PRO is any report of the status of a patient's health condition that comes directly from the patient, without interpretation of the patient's response by a clinician or anyone else. For patients who cannot adequately respond for themselves (e.g., pediatric patients), observer reports should include only those events or behaviors that can be directly observed. The

outcome can be measured in absolute terms (e.g., severity of a symptom, sign, or state of a disease) or as a change from a previous measure.[27]

In clinical trials, a PRO instrument can be used to measure the effect of a medical intervention on one or more outcome variables (i.e., the thing being measured, such as a symptom or group of symptoms, effects on a particular function or group of functions, or a group of symptoms or functions shown to measure the severity of a health condition). The development of a reliable, disease-specific PRO for the target population can facilitate drug development. Such instruments include PROs for children or for the observer (care-giver) for patients who cannot respond for themselves (e.g., pediatric patients). Furthermore, findings measured by a well-defined and reliable PRO instrument in appropriately designed investigations can be used to support a claim in medical product labeling if the claim is consistent with the instrument's documented measurement capability. A guidance document published in 2009 describes how FDA reviews and evaluates existing, modified, or newly created PRO instruments used to support claims in approved medical product labeling.[27]

A questionnaire may also be used as a tool that helps capture the subjective experience of an individual with low vision.[28] The National Eye Institute Visual Function Questionnaire (NEI-VFQ) is a 51-question survey designed to evaluate the effect of visual disability on health-related quality of life of adults with several common eye conditions, including age-related cataracts, AMD, diabetic retinopathy, primary open-angle glaucoma, and CMV retinitis.[29] A shortened version, NEI-VFQ-25, was introduced in the Age-Related Eye Disease Study (AREDS) and showed correlation with NEI-VFQ among patients with AMD, cataract, or reduced visual acuity.[30] The Visual Functioning Index-14 (VF-14)[31]

has been used to evaluate health-related quality of life of adults with late AMD[32] or who have been operated on for cataract.[33, 34] However, it is unclear whether any of these surveys are appropriate as instruments for measuring an improvement in the functional ability of low vision patients secondary to retinal disease.[35] For example, characteristics of the surveys that have not been adequately studied include their ability to detect change in disease status (i.e., sensitivity) in these populations, and how much of an improvement on the survey would be clinically meaningful in these populations.

In conclusion, the evaluation of treatments for retinal disorders with cell and gene therapies offer potential challenges, including smaller numbers of patients, younger patient populations, and patients with severely impaired vision. These challenges limit the utility of some efficacy endpoints that have been well established in studies of therapies for other ophthalmologic populations. We are therefore asking the Advisory Committee to provide advice on how best to develop suitable endpoints to measure clinically-meaningful efficacy in trials of cell and gene therapies intended to treat retinal diseases.

4. CONTRALATERAL EYE OR REPEAT ADMINISTRATION

As with any novel therapeutic agent, the design of trials of cell and gene therapies to treat retinal disorders requires a careful assessment of potential risks to the study subjects. Clinical design considerations to mitigate some of these risks include proceeding cautiously by starting with administration of low doses that have been adequately supported by safety data from preclinical and/or previous clinical experience, single-dose administration, close monitoring for safety, stopping rules for individual subjects and for the trial, limiting the number of subjects exposed, staggering enrollment, and trial oversight by Data Safety Monitoring Boards (DSMBs).

In addition to the general concerns with any novel agent, there are special considerations in the setting of cell and gene therapies in retinal disorders. These include potential safety concerns related to administration of the product to the contralateral eye or repeat administration to the same (first) eye.

Most retinal diseases affect both eyes. Since binocular vision depends on bilateral refractive input, clinical trial designs typically include plans to treat both eyes. Optimization of the timing of surgery is a common practice for bilateral intraocular surgical procedures, and current practice guidelines for timing of the second eye surgery can be informative for designing clinical trials for bilateral eye treatment procedures.

In addition to surgical procedure risks, other concerns in determining the timing of treatment of the contralateral eye of repeat administration to the first eye include the

potential for immunological reactions. Appropriate assessment of these immunological risks requires consideration of both preclinical and prior clinical experience.

This section describes the surgical experience, immunological issues, and preclinical considerations that may influence the design of a clinical development plan to minimize the risks associated with second eye treatment and repeat treatment of the first eye.

4.1 Surgical Concerns in Treatment of the Second Eye with Cellular and Gene Therapy Investigational Agents

Since most eye diseases affect both eyes, intraocular surgeries such as filter surgery for glaucoma, lens implant for cataract, and vitrectomy for vitreous hemorrhage are commonly performed in both eyes. In an effort to improve binocular visual function, attempts to maximize vision in both eyes are generally recommended.[36] An important consideration for contralateral eye administration is timing the interval between the first and the second eye surgery. For some surgical procedures, such as cataract extraction, simultaneous bilateral ocular surgery is rarely considered because of the potential risk for bilateral infections and the preference to avoid simultaneous impairment of vision during the postoperative recovery period.[37] In addition, a rare but potential postsurgical complication related to timing between the first and second eye surgery is sympathetic ophthalmia (SO), which will be further discussed in Section 4.3.

Additional reasons to stagger surgical approaches include the opportunity to use the outcome from the first eye surgery to assist in the planning for the second eye surgery. For example, as part of the surgical planning for cataract surgery, measurements are

taken to help calculate the power of the implanted intraocular lens. In surgical planning, the cataract surgeon will have a target post-operative refraction based on the needs and wants of the patient. If the cataract surgeon finds the post-operative refraction after the first eye-surgery has not achieved the desired target, the calculations to determine the power of the intraocular lens in the second eye may be adjusted accordingly.[36]

Except in rare circumstances, sufficient time between procedures is generally recommended to allow for the healing of the first eye from an intraocular procedure, making it possible to diagnose and treat any postoperative infectious complications, such as endophthalmitis, which while uncommon can cause substantial visual impairment, including blindness. After the immediate safety considerations are addressed, the next goal is to minimize activity limitations caused by the patient's decreased vision during the post-operative period.

In current ophthalmologic practice, local and systemic immunosuppressant regimens, as well as topical anti-infective and anti-inflammatory agents have been used to minimize potential immune toxicity and to improve treatment effects.

In clinical research in which allogeneic cellular and gene therapy products have been administered intraocularly, host immune reactions to potential antigens have been monitored by assessing the humoral or cellular immune responses.[2] However, at present, not enough information is available to determine which laboratory examinations or ophthalmology examinations would best guide the timing for second (contralateral) eye

administration, how to identify patients who are likely to have a strong host immune response, or how to identify patients for whom a repeat administration is contraindicated.

4.2 Immunological Concerns Related to Cellular and Gene Therapies for Retinal Disorders

In addition to the risks of surgical complications, described above, there are concerns about potential immunological reactions that would affect second eye treatment as well as repeat treatment. Immunological concerns are discussed in this section. Sympathetic ophthalmia (SO), a specific immunologically based post-ocular surgery complication, is discussed in Section 4.3.

The eye is considered an immune-privileged site, defined as a place within the body where foreign tissue grafts experience extended, often indefinite, survival, whereas similar grafts placed in conventional sites are promptly rejected.[38] Immune privilege can be compromised in high-risk eyes, a category that includes eyes affected by retinal diseases, as well as those in which there is prior inflammation, neovascularization, or trauma. The underlying pathologic changes are thought to be responsible for the loss of ocular immune privilege. When immune privilege of the vitreous or subretinal space is compromised or lost, products injected into these sites could experience systemic exposure and trigger host immune responses. The immune responses to cellular and gene products administered via subretinal injection, especially in the contralateral (second) eye or repeat administrations to the first eye, are poorly understood.

4.2.1 Allogeneic Cellular Products

As noted in Section 2, the published literature describes a variety of cellular products that have been considered or proposed for the treatment of retinal diseases. One concern with cellular therapy is the potential for immune rejection of allogeneic cellular products, despite the immune privileged status of the eye, particularly the subretinal space. Published clinical (and preclinical) studies[39] describe the use of specific immunosuppressive regimens to mitigate the rejection of cellular product for ophthalmologic indications. However, it is unclear whether immunosuppression is necessary to prevent immune rejection of the product. In addition, if immunosuppression is necessary, it is unclear which immunosuppressive regimen would be optimal for safety and efficacy.

4.2.2 Gene Therapy Products

Clinical research using vector products such as AAV or lentivirus constructs to deliver the transgene of interest is ongoing.

A significant safety concern for vector-mediated gene delivery is the potential for generation of an immune response (humoral and/or cellular) against the vector, or the expressed transgene, or both. Such responses can result in inflammation, significant reduction or abrogation of *in vivo* gene expression, or destruction of transduced cells. These reactions can occur in patients who have pre-existing immunity to the vector or as a result of re-administration of the gene therapy product.[22]

The human is a natural host for AAV. Studies have demonstrated that systemic infusion of AAV vectors induces an increase in neutralizing antibodies (NAbs) and cellular

immune responses to the AAV capsid.[40] These immune responses may cause a decline in transgene protein and a transient increase in liver enzymes (transaminitis). However, because of the immune privilege of the eye (a protection that may be reduced by the presence of retinal disease), the specific immune responses that develop to the AAV capsid when the injection is given subretinally are not known, nor is it known whether the immunity is sustained. In addition to the potential immunologic responses to the vectors themselves, the transgene protein could induce immune responses, especially when replacing a gene containing a mutation that results in complete absence of expressed protein.[2]

For cell and gene therapy products delivered by intraocular injection, it is important to initiate clinical studies in one eye to obtain preliminary information on the safety, biological activity, and efficacy of the product. As previously discussed, in ocular surgery the medical stability of the first treated eye and its outcome measures are often important in planning treatment of the contralateral eye or repeat treatment of the first eye. A special concern in planning treatment of the second eye is the potential host immune response to the product (virus vectors, transgene proteins, and allogeneic cells) after administration to the first eye. Host immune responses may not only pose safety risks, but could also interfere with the product's effectiveness. The duration of efficacy will play an important role in determining the need for, and the optimal timing of, repeat administration into the first eye.

Strategies that can been considered to mitigate these immune safety concerns in clinical studies include proceeding cautiously with single, low-dose administration; limiting and staggering enrollment; timing the procedures if a second eye surgery or repeat administration will be performed; early use of immunosuppression at sufficiently high doses; general clinical and laboratory monitoring for safety; specific monitoring for host immune responses; trial stopping rules; and trial oversight by monitoring boards. While a particular strategy to address a safety issue may be considered mitigating from one point of view, the same strategy could increase the risk from another. For example, while treating both eyes simultaneously might be considered advantageous from an immunology standpoint, doing so could pose surgical safety risks, as previously discussed in Section 4.1.

Developing strategies to mitigate these safety parameters should be guided by adequate preclinical findings and any previous clinical experience. The merits and limitations of animal studies to evaluate immunological responses to support clinical studies will be discussed in Section 4.4 of this document.

4.3 Sympathetic Ophthalmia (SO)

Sympathetic ophthalmia (SO) is a rare bilateral granulomatous inflammation of the eye that usually follows accidental or surgical trauma to one eye. The eye sustaining the injury or initial antigen exposure is referred to as the *inciting eye* and the fellow eye is called the *sympathizing eye*. The etiology of SO is not well understood, but it is believed that the underlying pathophysiology is based on an autoimmune reaction to the exposed,

and previously compartmentalized, ocular antigens from the inciting eye.[41] Exposure of retinal antigens to the lymphatics or the vascular system is believed to initiate SO. Areas of the eye that lack a direct connection to the lymphatic or vascular system (anterior chamber, posterior chamber and vitreous cavity) are generally considered immunoprivileged. While localized inflammation can occur in these areas, immunologic reactions and SO are generally not believed to occur even when foreign antigens are introduced into these sites unless a break has occurred between the immunoprivileged area and the vascular or lymphatic system. Subretinal injections have the potential to cause a break between the immunoprivileged sites and the vascular system, thereby increasing the risk of SO. While the incidence of SO is estimated at approximately 0.03 out of 100,000 per year, with an estimated risk of 1 in 1,152 following retina surgical procedures,[42] this complication can have a significant impact on vision in both eyes.

With some routes of administration, such as subretinal injection, there is a potential risk, although rare, for developing sympathetic ophthalmia following subsequent injections to the contralateral eye (or the same eye). Since immunization takes time to develop, timing the contralateral subretinal eye administration following the injection of the first eye is important.

To minimize the risk for SO in clinical practice, reducing the time between the first and subsequent injections and starting immunosuppressant therapy early and aggressively are generally recommended. While the time needed to immunize the eye following exposure to a retinal antigen has not been conclusively demonstrated, it is generally believed to be

in the range of 10-28 days,[43] and second exposure within 10 days of the first are generally not considered to have the potential to induce SO. Local corticosteroids and systemic immunosuppressive regimens are generally given together for ocular immunosuppression. In the absence of controlled investigations to compare potential immunosuppressive regimens in clinical trials, no optimal regimen has been established for use in clinical practice or in clinical drug development.

4.4 Preclinical Assessment of the Safety of Contralateral Eye or Repeat Administration

Although the healthy eye has an 'immune privileged' status, one of the concerns associated with intraocular administration of allogeneic cellular or gene therapy products into patients with retinal disorders is the potential for generation of an immune-mediated response after repeat or second eye administration. This response may manifest as a cell-mediated immunity that ablates the transplanted allogeneic cells or the gene-transfected host cells, resulting in loss of product efficacy, or damage to the retina, or both.[44-46] In addition, neutralizing antibodies against the vector construct or the expressed transgene could interfere with the product's effectiveness following repeat/contralateral eye administration.[47] There is also a concern that sensitization to ocular antigen(s) may provoke an autoimmune-mediated toxicity directed against the contralateral eye.[48, 49] Preclinical animal studies may help to identify and characterize aspects of the immune response, including the onset and type of immune reaction(s) and any associated toxicities, as well as influence of such reactions on product effectiveness following repeat or contralateral eye administration.

4.4.1 Examples of Preclinical Studies with Repeat Administration of Product

Gene Therapy Products

The safety and effectiveness of ocular re-administration of AAV vectors have been studied in mice, dogs, and non-human primates (NHPs).[47, 50, 51] Table 1 provides examples of some preclinical studies in which various immune response parameters were measured following AAV2 vector re-administration into the contralateral eye.

Table 1. Immune Response Data in Animals Following Contralateral Eye Administration

Species	*Normal/Disease*	*Vector*	*Transgene*	*Delivery procedure*	*Timing between first and subsequent injections*	*Antibodies to viral capsid*	*Antibodies to transgene*	*Cell-mediated response to viral vector/transgene*	*Serum neutralizing antibodies*	*Transgene expression or activity in first eye*	*Transgene expression or activity in contralateral eye*
Mouse[52]	*rd12$^{-/-}$(RPE65$^{-/-}$)*	AAV2	hRPE65	Subretinal	3 weeks	No	No	N/A	N/A	Yes	Yes
Mouse[52]	C57Bl/6	AAV2	GFP	Subretinal	3 weeks	N/A	N/A	N/A	Yes	Yes	Variable
Mouse[47]	C57Bl/6 (CNV)	AAV2	PEDF*	Intravitreal	2 months	Yes	N/A	N/A	N/A	Yes	No
Mouse[47]	C57Bl/6	AAV2	GFP	Intravitreal	2 months	Yes	No	N/A	Yes	Yes	No
Mouse[47]	C57Bl/6	AAV2	GFP	Subretinal	2 months	No	N/A	N/A	No	Yes	Yes
Dog[50]	*RPE65$^{-/-}$*	AAV2	hRPE65	Subretinal	3 to 6 months	N/A	No	N/A	Yes	Yes	Yes
Dog[51]	*RPE65$^{-/-}$*	AAV2	hRPE65v2	Subretinal	2 weeks	Yes	No	No	Yes	Yes	Yes
Non-human primate[51]	Healthy	AAV2	hRPE65v2	Subretinal	51 days	N/A	No	Yes (2/4 animals)	Yes	Yes	Yes

*PEDF: Pigment epithelial derived factor. GFP: Green fluorescent protein. hRPE: Human retinal pigment epithelium
N/A = Not measured

Li et al.[47] found that intravitreal administration of an AAV2 vector expressing green fluorescent protein (GFP) in healthy mice generated a humoral immune response against the AAV capsid, a response that was not observed following subretinal delivery. Intravitreal administration of the same vector two months later into the contralateral eye resulted in lack of measurable transgene expression in the retinal ganglion cells of the contralateral eye. In contrast to these results with intravitreal injections, mice given a subretinal injection in one eye followed by a subretinal injection in the contralateral eye two months later showed transgene expression levels in the photoreceptors and in the RPE cells in the second eye that were comparable to levels in the first eye. These results suggest that although the vitreous cavity and the subretinal space are both considered immune privileged sites,[53] the selection between these two sites of administration influenced the potential for an initial immune response and subsequent response following administration of the vector into the contralateral eye.

Amado et al. injected AAV2-hRPE65v2 into the subretinal space of an AAV2 naïve LCA dog model (with a spontaneous mutation in RPE65), followed by re-administration into the contralateral eye two weeks later.[51] This paradigm resulted in an increase in serum antibodies to the AAV2 capsid only; no antibodies against the transgene were detected. In addition, there was no evidence of a T cell response against the AAV2 capsid or against the RPE65 protein at any time during the two-year study duration. Annear et al. also investigated the safety and effectiveness of contralateral eye administration of AAV2-carrying human RPE65 cDNA in RPE65 deficient dogs.[50] Subretinal injection into the contralateral eye between 3 and 6 months following the initial administration resulted in a

serum neutralizing antibody (NAb) response to the vector capsid, which did not interfere with transgene expression in the contralateral eye. These findings suggest that the induction of an immune response may depend on: 1) the animal species; 2) whether the product is injected into a normal vs. diseased eye; 3) the timing of re-administration; and 4) possibly other factors such as injection technique and instrumentation and the specific injection area within the eye.

Amado et al.[51] conducted a study in healthy NHPs with previous exposure to rAAV2 vector via the intranasal, intravenous, and/or intramuscular route. The study showed that after the first subretinal delivery of AAV2-hRPE65v2 into the right eye, a rise in serum NAbs against the AAV2 capsid was observed in all animals. When the vector was re-administered into the contralateral left eye 51 days later, the serum NAb titers rose higher in three of four NHPs. The Day 51 intraocular NAb titer in the right eye also increased in three of four eyes; however, the NAb titer in the left eye of all animals was unaffected. Ocular fluid samples tested negative for antibodies to the hRPE65 protein for the duration of the study (210-217 days). Two of the four NHPs also developed a CD4+ T cell response against the AAV2 capsid. Despite the immune response, higher persistent expression of hRPE65 occurred in the AAV2-exposed RPE cells compared to unexposed RPE cells, as assessed by histology, suggesting that vector re-administration to the contralateral eye resulted in some level of vector transduction.[51]

Although these reported studies in various animal species with healthy or diseased eyes suggest that repeat subretinal administration of AAV2 vector into the contralateral eye

may be safe and effective, the results need to be interpreted with caution, as discordance in immune response may exist between animals and humans.[54] For example, in a clinical trial evaluating an AAV-mediated gene therapy product for the treatment of hemophilia B, unexpected transient transgene (hFIX) expression was associated with a T cell-mediated response against the vector capsid.[55] This event was not predicted by the preclinical studies conducted in hemophilic dogs and healthy NHPs.[51]

Preclinical studies conducted to evaluate the immune response following repeat administration of AAV vectors into the initially injected eye have not been reported.

Lentiviral vectors, which have a larger insert capacity, enabling the expression of transgene(s) with a greater length than afforded by AAV vectors, are also being investigated for treatment of retinal disorders. Although there have been reports of subretinal injection of lentiviral vectors expressing endostatin/angiostatin or myosin VIIa in animals, these publications did not characterize the immune response associated with single administration or following re-administration into the same eye or the contralateral eye.[56, 57]

Cellular Therapy Products

Immune rejection is a significant obstacle to long-term graft survival in RPE cell transplantation.[39, 58] Hence, allogeneic cell products generally require the use of immunosuppressants.[59] Immune-mediated cell rejection is illustrated in a study of photoreceptor cell transplantation in the subretinal space with partially mismatched donor

(H-$2^{d/b}$ or H-$2^{b/s}$) and recipient (H-2^{b}) mice.[58] T-cell mediated immune rejection resulted in the loss of donor photoreceptor cells at four months post-implantation. To investigate the involvement of the adaptive immune response further, recipient mice in the experimental "primed" group had photoreceptor cell transplantation into only one eye, followed by a second cell transplantation into the contralateral eye three months later. The controls consisted of mice receiving cell transplantation into both eyes at the same time. Recipient mice in the "primed" group showed a more rapid loss of transplanted cells than the control mice, which suggests a specific immune response against the donor cells. Finally, the number of transplanted photoreceptor cells administered into a single eye in mice treated with cyclosporine was significantly higher than in mice not given the immunosupressant.[58] Although the study did not evaluate the safety and effectiveness of repeat cell transplantation and concurrent cyclosporine administration, three important considerations emerged: 1) it is important to avoid sensitization against the cellular therapy product, 2) the local environment/niche of cell administration should be considered, and 3) judicious use of immunosuppressant agents may be important.

4.4.2 Animal Models for Testing Re-administration of the Cellular or Gene Therapy Product

Preclinical studies to support clinical trials of cellular or gene therapy products are often conducted in animal models of disease/injury because such models can provide valuable insight into dose/toxicity and dose/activity relationships in the context of a specific disease. In some instances, the disease process or the injury itself may have significant effects on the safety profile of an investigational product. Utilization of animal models

offers the opportunity for identification of activity- and risk-related biomarkers that may be suitable for monitoring during clinical trials. Use of such animal models of retinal disorders has shown that the 'immune privilege' designation given to the eye, specifically to the subretinal space, is not absolute and may be altered in a disease state.[60, 61] RPE cells, which assist in the maintenance of immune privilege of the subretinal space, are often degenerated in congenital retinal disorders (e.g., retinitis pigmentosa and Stargardt macular dystrophy). For many of these disorders, murine models of the target mutation are available.[62, 63] These murine models capture many of the pathological characteristics of the human disease. Animals with spontaneous mutations include the various canine models of LCA and the Royal College of Surgeons (RCS) rat model of retinal dystrophy.[64]

In addition, according to Morohoshi et al.,[65] a breakdown in immune tolerance is associated with, and may contribute to, the pathogenesis of age-related macular degeneration (AMD). The RPE layer is deficient in AMD, and this may contribute to breakdown of immune privilege. RPE allografts were rejected earlier in subjects with exudative AMD, which has a disrupted blood-retinal barrier, than in subjects with non-exudative AMD.[66] For late-stage, age-related macular degeneration, the characteristics of choroidal neovascularization (CNV) can be modeled in animals with laser-induced injury.[62]

Therefore, the type and extent of an immune response to the intraocular administration of a cellular or gene therapy product may be partially dependent on the pathophysiology of

the injected eye. Use of animals with disease/injured eyes is an important consideration when assessing the safety and possible biological activity of cellular and gene therapy products in humans.

5. LOCAL ADMINISTRATION PROCEDURES

Delivery of therapeutic agents to target tissues in the back of the eye has been a challenge.[67] A number of approaches may be used to deliver therapeutic agents to structures in the back of the eye: systemic, topical to the cornea/conjunctiva, subconjunctival, subtenons, retrobulbar, intravitreal and subretinal. Although systemic administration can deliver drugs to the posterior eye, large doses are often necessary and are associated with substantial side effects.[67] Topically applied drugs may enter the eye by diffusing through the cornea or sclera, but this approach typically does not yield therapeutic drug levels in the tissues in the back of the eye.

Both intravitreal and subretinal injections have been considered or investigated in clinical trials of cellular and gene products for treatment of retinal disorders.[17, 25, 68] While intravitreal injection provides the most direct approach to the tissues of the back of the eye and has become a routine clinical procedure,[17] subretinal injection is a novel procedure. In contrast to intravitreal injection, subretinal injection poses more technical difficulties. Optimization of the delivery procedure and documentation of accurate delivery of the intended dose to the intended target site are a prerequisite in reducing the risk associated with this surgical procedure, as well as in investigating product effectiveness. These two intraocular delivery procedures are discussed in detail below.

5.1 Intravitreal Administration

(See Figure 1)

As noted above, intraocular delivery of therapeutic agents via intravitreal injection provides the most direct approach to the tissues of the back of the eye and has become a routine clinical procedure.[17] However, the procedure is not without risks. The most feared complication of any intraocular procedure is endophthalmitis, an infection within the globe that often threatens vision.[69] The per-injection risk of endophthalmitis for all intravitreal injections varies between nearly zero and 0.87%, depending upon the disease condition and the administered medication.[69] Other risks of intravitreal injection include cataract formation, retinal tears and detachments, and retinal toxicity; the rates of these complications vary by disease condition and medication.[69] With intravitreal injections, there is also a limit to the volume of the therapeutic agent that can be singly administered. Because the eye is essentially a closed space, increasing the volume inside the eye causes a transient increase in intraocular pressure. Therefore, the administered volume is limited to keep intraocular pressure below the pressure of the central retinal and ophthalmic arteries, allowing continued blood flow to the retina and eye.

Further, drugs injected directly into the vitreous can be rapidly eliminated.[67] To avoid repeat injections, intravitreal sustained-release implants have been developed for the administration of corticosteroid or antiviral agents, and are commercially available. Most implanted drug products, however, require intraocular surgery for placement as well as a vitrectomy, a procedure to remove some or all of the thick vitreous, to decrease the risk of retinal detachment. A vitrectomy is also performed in conjunction with most

procedures that involve access to the structures in the back of the eye. Additional complications of vitrectomy are discussed in Section 5.2.

Intravitreal administration of therapeutic agents can be assessed at the time of administration by direct visualization. Perioperatively, the physician can use fundoscopy or the operating microscope to observe the medication or the device in the vitreous cavity. An increase in intraocular pressure may also serve as a perioperative indicator, particularly with administration of clear fluids, that the therapeutic agent was delivered inside the globe. Postoperatively, changes in outcome measures such as visual acuity, fundoscopy, fluorescein angiography, and retinal thickness as measured by OCT are monitored to assess delivery of the product to the target tissue. However, these outcome measures are influenced by not only delivery, but also other factors, such as the activity of the product. The optimal methods for direct measurement of delivery are unclear.

5.2 Subretinal Injection

(See Figure 2)

The ability of a therapeutic agent to target the tissue of choice is assessed in animal models during proof-of-concept studies. In NHPs, the intravitreal administration of viral vectors rarely results in transduction of the retina or RPE, limiting the efficacy of such gene therapies delivered in this manner. The barriers limiting transduction of these NHP tissues are not fully understood.[17] However, the delivery of viral vectors into the subretinal space of NHPs results in more efficient transduction of the retinal photoreceptors and RPE.[17] Therefore, the subretinal space has recently become an

attractive target for preclinical and clinical investigations, and subretinal injection has been investigated for delivering these products. However, subretinal injection is more technically difficult than intravitreal injection.

The subretinal space is a potential space between the retinal photoreceptors and the RPE. Under normal physiological conditions, there is no anatomic space between these two layers. The RPE has many functions, including transport of ions, water, and metabolic end products from the subretinal space to the blood, as well as delivery of nutrients such as glucose, retinol, and fatty acids from the blood to photoreceptors.[70]

While different routes to the subretinal space have been investigated, the delivery of cellular or gene products to the subretinal space usually starts with a standard vitrectomy with removal of the posterior cortical vitreous.[71] The clear gelatinous vitreous can usually be removed without physiological consequence, but there are potential complications associated with vitrectomy as the first step in a retinal procedure. Reported complications occurring within days of the vitrectomy and retinal surgery are as high as 24% for intraoperative retinal breaks, 0.84% for endophthalmitis, and 0.25% for hypotony (abnormally low intraocular pressure) with or without wound leak.[72] Reported complications occurring weeks to months after procedures involving a vitrectomy are as high as 79% for cataracts and 17% for retinal detachment.[72]

The vitrectomy is followed by the injection of the product through the retina using the smallest entry site possible.[2, 3] This injection gently separates a small part of the photoreceptor layer from the underlying RPE, thus generating a temporary, local detachment of retina. The injected product is locally absorbed, bringing the photoreceptors and RPE back together. In addition to the safety concerns generally associated with vitrectomy, special safety concerns associated with use of this procedure in association with subretinal injection include the development of a retinal hole at the site of entry through the retina; reflux of the therapeutic agent back into the vitreous cavity, potentially decreasing efficacy or causing scar formation from proliferation of cells on the retinal surface; and prolonged retinal detachment.

There are also dosing and volume considerations associated with subretinal injection. It has not been established that cell and gene therapies administered to the subretinal space will demonstrate a conventional dose response until a maximal effect is reached.[17] Also, increased volume may lead to increased risks, such as prolonged retinal detachment. While a starting volume to initiate clinical studies is generally extrapolated from animal studies using allometric scaling, the optimal volume for subretinal injection has not been determined.

Similar to intravitreal administration, subretinal administration of therapeutic agents can be assessed by direct visualization through the operating microscope at the time of surgery. Perioperative monitoring of safety and the accuracy of injection with ophthalmological examinations, including fundoscopy examination and OCT, may

provide confirmation that the intended dose (volume) has been delivered to the target area, e.g., injected into the macular area near the fovea for treating macular degeneration. There are currently no clearly reliable methods of monitoring the survival of transplanted cells in the retina, either locally or by serum analysis,[17] but the therapeutic agent's effect on outcome measures such as visual acuity, fundoscopy, fluorescein angiography, and retinal thickness as measured by OCT, can be monitored.

A subretinal injection procedure has been performed in only a small number of subjects in clinical trials, and its safety profile has not been fully characterized. Animal studies may be helpful in optimizing and eventually standardizing this relatively novel approach to delivery of therapeutic products.

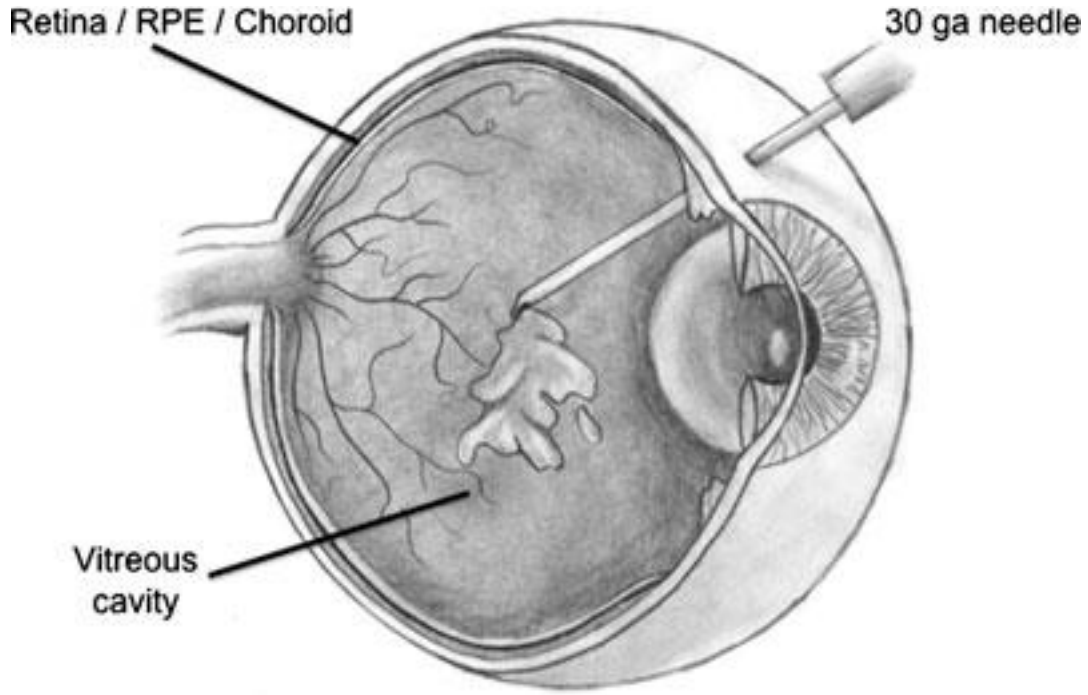

Figure 1. Intravitreal Injection. From Stout JT, Francis PJ. Surgical Approaches to Gene and Stem Cell Therapy for Retinal Disease. *Hum Gene Ther*. 2011 May; 22(5): 531-5.

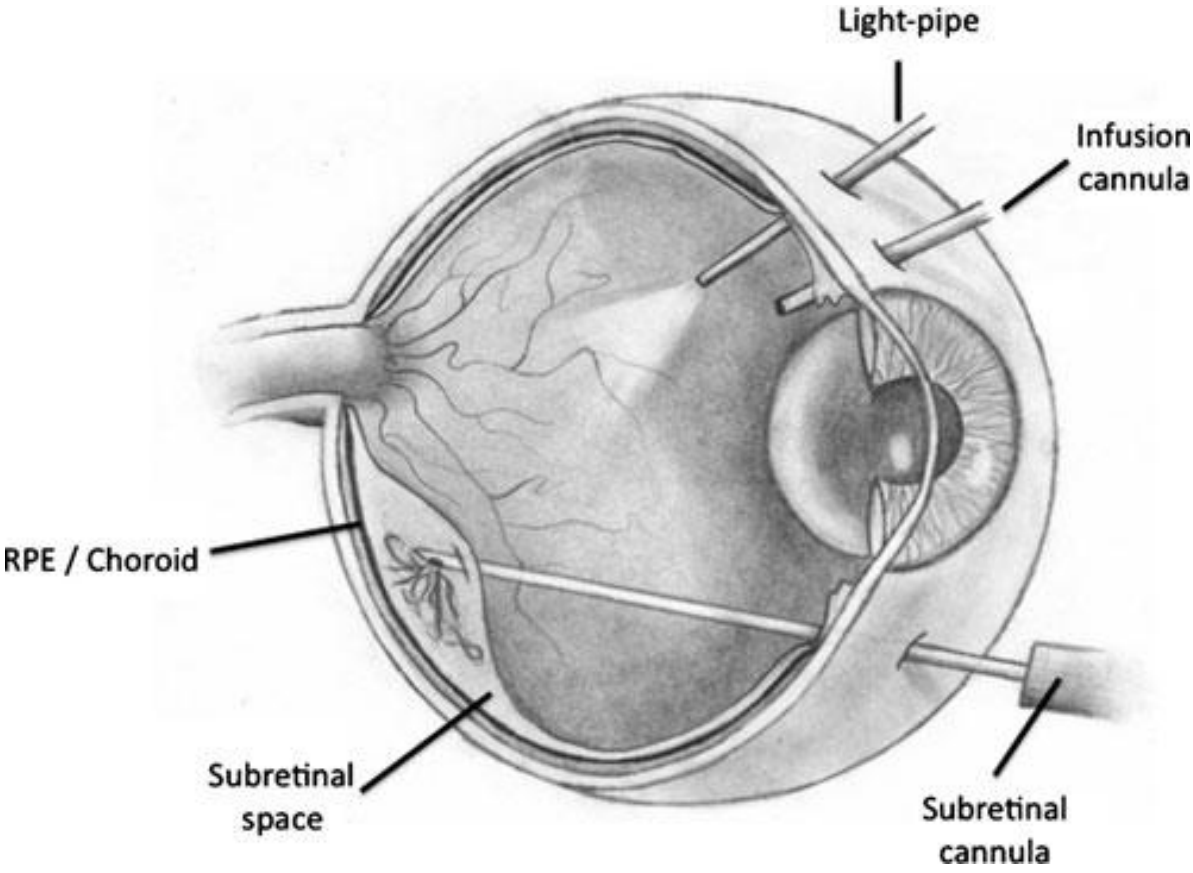

Figure 2. Subretinal Injection. From Stout JT, Francis PJ. Surgical Approaches to Gene and Stem Cell Therapy for Retinal Disease. *Hum Gene Ther*. 2011 May; 22(5): 531-5.

5.3 Use of Preclinical Data to Optimize Product Administration

As discussed above, the intraocular delivery of cellular and gene therapy products usually requires invasive procedures, which can carry safety concerns. In addition, the presumed long-term, if not permanent, persistence of some of these products following their administration is an important consideration, further emphasizing the need for accuracy of delivery. For example, inadvertent leakage of rAAV into the vitreous during a subretinal injection procedure could conceivably result in transduction of ganglion cells, causing transgene expression in visual pathways in the brain, which (although not yet reported) could potentially result in CNS toxicity.[73] Preclinical studies to evaluate the pharmacology and toxicology of an investigational product are critical determinants in allowing the administration of an investigational product into humans. Thus, to provide a better understanding of the risk/benefit profile of cellular and gene therapy products when administered via one of the aforementioned surgical approaches, optimization of the delivery procedure itself (notably if the procedure is novel or involves a novel delivery device), as well as confirmation of the accuracy of product delivery, are important concerns. Documentation of the delivery of these investigational products to the desired/intended target site(s) or into nontarget site(s) can substantially influence interpretation of the resulting efficacy and safety data generated in animals and ultimately in humans.

5.3.1 Preclinical Models for Assessing Product Administration

Various small and large animal species have been used in the preclinical testing of cellular and gene therapy products intended for the treatment of retinal disorders. Mice

and rats are often used to generate proof-of-concept data to support the scientific rationale for conducting clinical trials of these products, due to the availability of genetically manipulated (i.e., transgenic, knockout) models and immune-tolerant (i.e., immunodeficient, immunosuppressed) models. However, these small animal models have limitations due to their ophthalmic size and anatomical differences when compared to the human eye. For example: 1) the rodent eye is substantially smaller (approximate axial eye lengths: 3 mm for mice[74], 6 mm for rats[75], and 24 mm for humans[76]) and 2) rodents have a relatively large lens and small vitreous volume compared to the human eye. Therefore, in rodents, intraocular delivery to a target location (such as the subretinal space) becomes technically challenging; the total product dose that can be administered is limited; and the use of the clinical delivery device system and surgical procedure intended for humans is not feasible.

Utilization of large animals with 'human-sized' eyes, --- these include rabbits, pigs, dogs, and non-human primates (NHPs) --- may provide a solution to the technical and anatomical issues associated with rodent species and may permit product administration via the surgical procedure and delivery device systems that are intended clinically. While laboratory rabbits are readily available, no common genetic models of retinal disease exist in this species, and the normal rabbit eye also has anatomical features distinct from those of the human eye, such as the presence of a merangiotic retina that is only partly traversed by blood vessels.[77, 78] In contrast, the human eye has a holangiotic retina, in which the entire retina is fully vascularized by the central retinal artery or by cilioretinal arteries. Also, compared to humans, rabbit eyes are generally more susceptible to

irritating substances.[79] Because of these anatomical and physiological differences, the procedure- and product-related findings in rabbits may not reflect those in humans.

Pigs and dogs have also been used to evaluate the safety of cellular and gene therapy products.[50, 80] In addition to an eye size that is similar to that of human (approximate axial eye length: 20 mm for dog,[76] 24 mm for pig,[81] and 24 mm for human[76]), the eyes of these two species share other anatomical similarities (e.g., holangiotic retinal vasculature, thickness of sclera) to human eyes.[82-85] Bertschinger et al.[85] have also suggested that the porcine retina closely resembles the human retina with regard to size, cone distribution, and retinal layers. Because of the similarity in eye size to the human and the availability of genetically-defined disease models, the canine species has also been used to evaluate the safety and effectiveness of gene and cell therapy products following intraocular delivery.[86] The similarities of the canine and porcine eye to the human eye make these two animal species a potentially suitable model for use in optimizing surgical delivery procedures for use in clinical trials.

Of the cited large animal species used to test ophthalmic agents, the retinal anatomy and physiology of NHPs most closely resemble those of the human eye. Among mammals, only primates have a fovea,[87] which is the target delivery site of some cellular and gene therapy products. The visual systems of NHPs (e.g., rhesus macaque) and humans are essentially identical in terms of visual sensitivity, anatomy, physiology of aqueous humor circulation, retinal structure and visual pathway.[88] Hence, preclinical studies with NHPs may provide the most meaningful data that can be used to optimize the delivery

procedure and assess target delivery accuracy. However, economical and ethical concerns restrict the number of NHPs used in preclinical studies, and the small sample size of these NHP studies may limit rigorous statistical analysis of results.

5.3.2 Determining Successful Delivery to the Target Site

Verification of successful target site delivery in the animal eye is essential to analysis and translation of the safety and efficacy data generated from the preclinical study. For example, subretinal injection of a cellular or gene therapy product may result in some product efflux into the vitreous or other non-target sites.[39, 89] Such nontarget exposure may result in decreased or transient efficacy and misinterpretation of dose response, as well as raising potential safety concerns. Thus, relatively sensitive technologies that allow for real-time assessment of ophthalmic delivery to the affected cells/intended target site(s) would help to optimize the delivery procedure for these investigational products and confirm the delivery of the cellular or gene therapy product to the target site.

The two most common methods used to verify target-site delivery in animals are immunohistochemistry (IHC) and quantitative real-time polymerase chain reaction (qPCR) analysis. IHC analysis involves staining of the tissue section with antibodies that bind specifically to the desired antigen (in this case, the transgene product or a cellular marker). Use of IHC provides data on the spatial distribution and relative concentration of the investigational product following *in vivo* administration. For cellular products, IHC analysis may additionally provide information on the proliferation profile and phenotype of the exogenously administered cells. However, successful use of this procedure requires

the availability of species-specific antibodies and the processing of a large number of tissue sections. In addition, non-specific background staining or autofluorescence can also affect interpretation of the results.

The use of qPCR analysis can serve to complement IHC analysis, as well as confirm DNA presence in cells and tissues. PCR has high sensitivity, which enables the detection of a few human cells in the presence of millions of non-human cells, using an appropriate set of PCR primers,[90] as well as determination of the biodistribution of a DNA vector in various tissues after intraocular delivery.[91] However, qPCR analysis necessitates the destruction of a tissue sample, which leads to a loss of spatial resolution. In addition, the presence of human DNA may not necessarily indicate the existence of viable human cells for a cellular therapy product. A major disadvantage of IHC and qPCR methods is that in order to obtain the tissue samples, sacrifice of the animal is required. Thus, substantial numbers of animals need to be included in a single study, providing only a 'snapshot' of the distribution of the product into target and nontarget sites at a single time point.

Cellular therapy products can also be genetically modified to express such markers as β-galactosidase (LacZ)[92] or enhanced green fluorescent protein (eGFP),[93] which enable detection of the transduced cells without the need for antibodies. Similarly, for gene therapy products, the administration of the intended clinical vector construct encoding LacZ,[94] eGFP,[95] or luciferase[96] has also been used in numerous animal studies to provide detection of the transduced cells/target site(s). However, in these instances the intended clinical product is genetically modified, introducing an element of uncertainty to the

applicability of the results to the *in vivo* behavior and safety of the clinical product. An advantage to the use of eGFP is that ophthalmic target-site delivery and persistence at the site can be elucidated in a non-invasive manner, serially in the same animal over time (i.e., a non-terminal method), while sacrifice of the animal (i.e., terminal method) is required for affirmation of the accuracy of delivery for products modified to express LacZ.

However, there have been reports of humoral immune response to eGFP and rejection of eGFP transduced cells following subretinal administration of AAV2 or lentivirus expressing eGFP in animals.[95, 97] Thus, the safety and *in vivo* persistence of a surrogate product (e.g., one expressing eGFP) may not be representative of the intended clinical product. The ability to use one or several of the described methods or other emerging technologies without significant modification to the structure or *in vivo* function of the cellular or gene therapy product is highly desirable.

Other non-terminal methods, such as fundoscopic examination and OCT, may provide an indirect means to verify delivery into the subretinal space via visualization of the resulting bleb in the retina.[89, 98] The raised bleb indicates elevation of the retina from the RPE layer. By inference, the persistence of this bleb (which typically regresses within 24-48 hours)[89, 98, 99] suggests that the product remains in the subretinal space. These two methods have the advantage that ophthalmic site delivery can be serially documented in the same animal; in addition, both can also be used clinically. However, neither method can directly detect the presence of the cellular or gene therapy product in the eye.

Non-invasive, non-terminal imaging techniques, such as magnetic resonance imaging (MRI) or positron emission tomography (PET), can be used in small and large animal species to determine location of administered cellular therapy products that are non-genetically labeled with various contrast agents (e.g., superparamagnetic iron oxide particles or fluorine-based compounds). These approaches allow for real-time longitudinal tracking of the product *in vivo*. Although these techniques can also be used in humans, remaining issues include the low sensitivity of detection of non-radioactive contrast agents and the comparability of the labeled cells to the unlabeled clinical product.[100] In addition, contrast agents leaking from any dead cells can be phagocytized by macrophages, yielding false positive signals.[101]

Therefore, there are potential terminal and non-terminal methods that can be used in animals to study the accuracy of delivery of cellular and gene therapy products. It is important that these methods have sufficient sensitivity, reproducibility, and specificity in the selected animal species in order to confirm the accuracy of the surgical procedure planned for use in humans.

6. ADVISORY COMMITTEE DRAFT DISCUSSION QUESTIONS

1. Efficacy Endpoints

Clinical development of cellular and gene therapy products to treat rare and/or pediatric visual disorders may require consideration of novel endpoints. Particularly, there are many components of visual function other than best corrected vision. It may be necessary to define clinical benefits for a specific population based on efficacy endpoints other than visual acuity and visual fields. Please discuss the following:

a. The ability of existing and novel outcome measures to assess product efficacy in both adult and pediatric populations and their role in clinical trials (e.g., as primary, co-primary, secondary, or exploratory endpoints).

   In the discussion, comment on advantages and disadvantages of specific outcome measures for use in clinical trials (e.g., feasibility of measurement; responsiveness to change (i.e., sensitivity); variability of measurement; reliability of measurement; resistance to bias; clinical meaningfulness).

   In the discussion, consider measures of visual function, anatomic/physiologic measures, functional vision, and patient-reported outcomes.

b. Methods to assess the clinical meaningfulness of these measures.

2. Safety Concerns with Contralateral (Second) Eye or Repeat Administration

Retinal diseases/conditions are usually bilateral and chronic. However, after initial administration of a cellular or gene therapy product into one eye, product administration into the contralateral (second) eye or repeat administration(s) into the same eye raises safety concerns related to the potential for immunological response to a vector, transgene product, or allogeneic cellular product.

Regarding administration of the product into the second eye or repeat administration into the same eye in clinical trials, please discuss the following:

a. Factors that may influence the recommended timing of administration, particularly considering any safety concerns. Please specify the following in your discussion:

   i. Any safety concern that would make a specific time interval between first and second administration relatively high-risk.

   ii. Any time interval(s) between first and second administration that you consider to be relatively low-risk for adverse events, particularly those based on immunogenicity.

b. Clinical or laboratory tests to guide the timing of the second eye or repeat administration.

c. The merits and limitations of preclinical studies to model immunological responses that are relevant to the clinical situation, to support the safety of contralateral eye administration or repeat administration into the same eye. Please consider the following in your discussion:

   i. Animal species

   ii. Normal versus diseased/injured eye(s)

   iii. Timing of second eye or repeat administration

3. The Ophthalmic Administration Procedure

Administration of cellular and gene therapy products has involved direct injection into specific ocular locations, such as the vitreous and the subretinal space, in order to target the affected cells/site(s) efficiently. Principal concerns are optimization of the product delivery procedure and assessment of the accuracy of product delivery.

a. Please discuss methods to address these concerns in humans. Please consider the following in your discussion:

   i. Optimization of the administration procedure for accuracy (target delivery), efficacy, and safety.

   ii. Parameters for safety and efficacy assessment of product administration, including imaging and patient monitoring.

   iii. Any training necessary to optimize administration procedure during development and post-marketing.

b. Please discuss the utility of available animal species to assist in addressing the above concerns. Please consider the following in your discussion:

   i. The size and anatomy of the animal eye.

   ii. Various parameters to determine successful injection, such as non-invasive/non-terminal imaging modalities and histology, at various time points following administration.

REFERENCES

1. Liu, M.M., J. Tuo, and C.C. Chan, *Gene therapy for ocular diseases.* Br J Ophthalmol, 2011. **95**(5): p. 604-12.
2. Maguire, A.M., et al., *Safety and efficacy of gene transfer for Leber's congenital amaurosis.* N Engl J Med, 2008. **358**(21): p. 2240-8.
3. Bainbridge, J.W., et al., *Effect of gene therapy on visual function in Leber's congenital amaurosis.* N Engl J Med, 2008. **358**(21): p. 2231-9.
4. Kong, J., et al., *Correction of the disease phenotype in the mouse model of Stargardt disease by lentiviral gene therapy.* Gene Ther, 2008. **15**(19): p. 1311-20.
5. Talcott, K.E., et al., *Longitudinal Study of Cone Photoreceptors during Retinal Degeneration and in Response to Ciliary Neurotrophic Factor Treatment.* Invest Ophthalmol Vis Sci, 2011. **52**(5): p. 2219-26.
6. Lai, C.M., et al., *Long-term evaluation of AAV-mediated sFlt-1 gene therapy for ocular neovascularization in mice and monkeys.* Mol Ther, 2005. **12**(4): p. 659-68.
7. Weleber, R.G., P.J. Francis, and K.M. Trzupek. *Leber Congenital Amaurosis*. GeneReviews 2004 [cited 2011 March 20]; Available from: http://www.ncbi.nlm.nih.gov/pubmed/20301475.
8. *Stargardt macular degeneration*. Genetics Home Reference 2010 [cited 2011 February 25]; Available from: http://ghr.nlm.nih.gov/condition/stargardt-macular-degeneration.
9. Pagon, R.A. and S.P. Daiger. *Retinitis Pigmentosa Overview*. GeneReviews 2000 09/16/2005 [cited 2011 3/20]; Available from: http://www.ncbi.nlm.nih.gov/pubmed/20301590.
10. Mizukami, H., et al., *Gene Therapy for Diabetic Retinopathy in Animal Models and Humans.* The Open Diabetes Journal 2011. **4**: p. 119-122.
11. Jager, R.D., W.F. Mieler, and J.W. Miller, *Age-related macular degeneration.* N Engl J Med, 2008. **358**(24): p. 2606-17.
12. Pascolini, D., et al., *2002 global update of available data on visual impairment: a compilation of population-based prevalence studies.* Ophthalmic Epidemiol, 2004. **11**(2): p. 67-115.
13. Zhang, L., et al., *Risk of developing retinopathy in Diabetes Control and Complications Trial type 1 diabetic patients with good or poor metabolic control.* Diabetes Care, 2001. **24**(7): p. 1275-9.
14. Baker, P.S. and G.C. Brown, *Stem-cell therapy in retinal disease.* Curr Opin Ophthalmol, 2009. **20**(3): p. 175-81.
15. Lamba, D.A. and T.A. Reh, *Regenerative Medicine for Diseases of the Retina*, in *Principles of Regenerative Medicine (Second edition)*. 2011, Academic Press: San Diego. p. 427-449.
16. Tao, W., *Application of encapsulated cell technology for retinal degenerative diseases.* Expert Opin Biol Ther, 2006. **6**(7): p. 717-26.
17. Stout, J.T. and P.J. Francis, *Surgical approaches to gene and stem cell therapy for retinal disease.* Hum Gene Ther, 2011. **22**(5): p. 531-5.

18. Ralph, G.S., et al., *Gene therapy for neurodegenerative and ocular diseases using lentiviral vectors.* Clin Sci (Lond), 2006. **110**(1): p. 37-46.
19. Beck, R.W., et al., *Visual acuity as an outcome measure in clinical trials of retinal diseases.* Ophthalmology, 2007. **114**(10): p. 1804-9.
20. Follmann, D.A., *Primary Efficacy Endpoint*. Wiley Encyclopedia of Clinical Trials. 2007: John Wiley & Sons, Inc.
21. Bergamin, O. and R.H. Kardon, *Latency of the pupil light reflex: sample rate, stimulus intensity, and variation in normal subjects.* Invest Ophthalmol Vis Sci, 2003. **44**(4): p. 1546-54.
22. Maguire, A.M., et al., *Age-dependent effects of RPE65 gene therapy for Leber's congenital amaurosis: a phase 1 dose-escalation trial.* Lancet, 2009. **374**(9701): p. 1597-605.
23. Brown, D.M., et al., *Ranibizumab versus verteporfin photodynamic therapy for neovascular age-related macular degeneration: Two-year results of the ANCHOR study.* Ophthalmology, 2009. **116**(1): p. 57-65 e5.
24. Rosenfeld, P.J., et al., *Ranibizumab for neovascular age-related macular degeneration.* N Engl J Med, 2006. **355**(14): p. 1419-31.
25. Zhang, K., et al., *Ciliary neurotrophic factor delivered by encapsulated cell intraocular implants for treatment of geographic atrophy in age-related macular degeneration.* Proc Natl Acad Sci U S A, 2011. **108**(15): p. 6241-5.
26. Lepri, B.P., *Is acuity enough? Other considerations in clinical investigations of visual prostheses.* J Neural Eng, 2009. **6**(3): p. 035003.
27. FDA/CBER. *Guidance for Industry: Patient-Reported Outcome Measures: Use in Medical Product Development to Support Labeling Claims*. 2009; Available from: http://www.fda.gov/downloads/Drugs/GuidanceComplianceRegulatoryInformation/Guidances/UCM193282.pdf.
28. Virgili, G. and G. Rubin, *Orientation and mobility training for adults with low vision.* Cochrane Database Syst Rev, 2010(5): p. CD003925.
29. Mangione, C.M., et al., *Psychometric properties of the National Eye Institute Visual Function Questionnaire (NEI-VFQ). NEI-VFQ Field Test Investigators.* Arch Ophthalmol, 1998. **116**(11): p. 1496-504.
30. Clemons, T.E., et al., *National Eye Institute Visual Function Questionnaire in the Age-Related Eye Disease Study (AREDS): AREDS Report No. 10.* Arch Ophthalmol, 2003. **121**(2): p. 211-7.
31. Steinberg, E.P., et al., *The VF-14. An index of functional impairment in patients with cataract.* Arch Ophthalmol, 1994. **112**(5): p. 630-8.
32. Riusala, A., S. Sarna, and I. Immonen, *Visual function index (VF-14) in exudative age-related macular degeneration of long duration.* Am J Ophthalmol, 2003. **135**(2): p. 206-12.
33. Steinberg, E.P., et al., *National study of cataract surgery outcomes. Variation in 4-month postoperative outcomes as reflected in multiple outcome measures.* Ophthalmology, 1994. **101**(6): p. 1131-40; discussion 1140-1.
34. Cassard, S.D., et al., *Reproducibility and responsiveness of the VF-14. An index of functional impairment in patients with cataracts.* Arch Ophthalmol, 1995. **113**(12): p. 1508-13.

35. Turano, K.A., et al., *Perceived visual ability for independent mobility in persons with retinitis pigmentosa.* Invest Ophthalmol Vis Sci, 1999. **40**(5): p. 865-77.
36. *Cataract in the Adult Eye Preferred Practice Pattern*. 2006; Available from: http:// www.aao.org/ppp
37. Chang, D.F., *Simultaneous bilateral cataract surgery.* Br J Ophthalmol, 2003. **87**(3): p. 253-4.
38. Streilein, J.W., *Ocular immune privilege: the eye takes a dim but practical view of immunity and inflammation.* J Leukoc Biol, 2003. **74**(2): p. 179-85.
39. da Cruz, L., et al., *RPE transplantation and its role in retinal disease.* Prog Retin Eye Res, 2007. **26**(6): p. 598-635.
40. Manno, C.S., et al., *Successful transduction of liver in hemophilia by AAV-Factor IX and limitations imposed by the host immune response.* Nat Med, 2006. **12**(3): p. 342-7.
41. Sen, H.N. and R.B. Nussenblatt, *Sympathetic ophthalmia: what have we learned?* Am J Ophthalmol, 2009. **148**(5): p. 632-3.
42. Kilmartin, D.J., A.D. Dick, and J.V. Forrester, *Prospective surveillance of sympathetic ophthalmia in the UK and Republic of Ireland.* Br J Ophthalmol, 2000. **84**(3): p. 259-63.
43. Albert, D.M. and R. Diaz-Rohena, *A historical review of sympathetic ophthalmia and its epidemiology.* Surv Ophthalmol, 1989. **34**(1): p. 1-14.
44. Hoffman, L.M., A.M. Maguire, and J. Bennett, *Cell-mediated immune response and stability of intraocular transgene expression after adenovirus-mediated delivery.* Invest Ophthalmol Vis Sci, 1997. **38**(11): p. 2224-33.
45. Reichel, M.B., et al., *Immune responses limit adenovirally mediated gene expression in the adult mouse eye.* Gene Ther, 1998. **5**(8): p. 1038-46.
46. Zhang, X. and D. Bok, *Transplantation of retinal pigment epithelial cells and immune response in the subretinal space.* Invest Ophthalmol Vis Sci, 1998. **39**(6): p. 1021-7.
47. Li, Q., et al., *Intraocular route of AAV2 vector administration defines humoral immune response and therapeutic potential.* Mol Vis, 2008. **14**: p. 1760-9.
48. Chu, D.S. and C.S. Foster, *Sympathetic ophthalmia.* Int Ophthalmol Clin, 2002. **42**(3): p. 179-85.
49. Damico, F.M., S. Kiss, and L.H. Young, *Sympathetic ophthalmia.* Semin Ophthalmol, 2005. **20**(3): p. 191-7.
50. Annear, M.J., et al., *Gene therapy in the second eye of RPE65-deficient dogs improves retinal function.* Gene Ther, 2011. **18**(1): p. 53-61.
51. Amado, D., et al., *Safety and efficacy of subretinal readministration of a viral vector in large animals to treat congenital blindness.* Sci Transl Med, 2010. **2**(21): p. 21ra16.
52. Barker, S.E., et al., *Subretinal delivery of adeno-associated virus serotype 2 results in minimal immune responses that allow repeat vector administration in immunocompetent mice.* J Gene Med, 2009. **11**(6): p. 486-97.
53. Jiang, L.Q., M. Jorquera, and J.W. Streilein, *Subretinal space and vitreous cavity as immunologically privileged sites for retinal allografts.* Invest Ophthalmol Vis Sci, 1993. **34**(12): p. 3347-54.

54. Zaiss, A.K. and D.A. Muruve, *Immunity to adeno-associated virus vectors in animals and humans: a continued challenge.* Gene Ther, 2008. **15**(11): p. 808-16.
55. Mingozzi, F., et al., *CD8(+) T-cell responses to adeno-associated virus capsid in humans.* Nat Med, 2007. **13**(4): p. 419-22.
56. Kachi, S., et al., *Equine infectious anemia viral vector-mediated codelivery of endostatin and angiostatin driven by retinal pigmented epithelium-specific VMD2 promoter inhibits choroidal neovascularization.* Hum Gene Ther, 2009. **20**(1): p. 31-9.
57. Hashimoto, T., et al., *Lentiviral gene replacement therapy of retinas in a mouse model for Usher syndrome type 1B.* Gene Ther, 2007. **14**(7): p. 584-94.
58. West, E.L., et al., *Long-term survival of photoreceptors transplanted into the adult murine neural retina requires immune modulation.* Stem Cells, 2010. **28**(11): p. 1997-2007.
59. Del Priore, L.V., et al., *Retinal pigment epithelial cell transplantation after subfoveal membranectomy in age-related macular degeneration: clinicopathologic correlation.* Am J Ophthalmol, 2001. **131**(4): p. 472-80.
60. Wenkel, H. and J.W. Streilein, *Analysis of immune deviation elicited by antigens injected into the subretinal space.* Invest Ophthalmol Vis Sci, 1998. **39**(10): p. 1823-34.
61. Wenkel, H. and J.W. Streilein, *Evidence that retinal pigment epithelium functions as an immune-privileged tissue.* Invest Ophthalmol Vis Sci, 2000. **41**(11): p. 3467-73.
62. Zeiss, C.J., *Animals as models of age-related macular degeneration: an imperfect measure of the truth.* Vet Pathol, 2010. **47**(3): p. 396-413.
63. Rivas, M.A. and E. Vecino, *Animal models and different therapies for treatment of retinitis pigmentosa.* Histol Histopathol, 2009. **24**(10): p. 1295-322.
64. D'Cruz, P.M., et al., *Mutation of the receptor tyrosine kinase gene Mertk in the retinal dystrophic RCS rat.* Hum Mol Genet, 2000. **9**(4): p. 645-51.
65. Morohoshi, K., et al., *Autoimmunity in retinal degeneration: autoimmune retinopathy and age-related macular degeneration.* J Autoimmun, 2009. **33**(3-4): p. 247-54.
66. Algvere, P.V., P. Gouras, and E. Dafgard Kopp, *Long-term outcome of RPE allografts in non-immunosuppressed patients with AMD.* Eur J Ophthalmol, 1999. **9**(3): p. 217-30.
67. Geroski, D.H. and H.F. Edelhauser, *Drug delivery for posterior segment eye disease.* Invest Ophthalmol Vis Sci, 2000. **41**(5): p. 961-4.
68. Simonelli, F., et al., *Gene therapy for Leber's congenital amaurosis is safe and effective through 1.5 years after vector administration.* Mol Ther, 2010. **18**(3): p. 643-50.
69. Sampat, K.M. and S.J. Garg, *Complications of intravitreal injections.* Curr Opin Ophthalmol, 2010. **21**(3): p. 178-83.
70. Strauss, O., *The retinal pigment epithelium in visual function.* Physiol Rev, 2005. **85**(3): p. 845-81.
71. Joseph, D.P., A.J. Whitehead, and M.A. Thomas, *Surgical removal of subretinal choroidal neovascular membranes* in *Retina*, C. Wilkinson, Editor. 2001, Mosby, Inc: Philadelphia. p. 2562-72.

72. Recchia, F.M., et al., *Small-gauge pars plana vitrectomy: a report by the American Academy of Ophthalmology.* Ophthalmology, 2010. **117**(9): p. 1851-7.
73. den Hollander, A.I., et al., *Lighting a candle in the dark: advances in genetics and gene therapy of recessive retinal dystrophies.* J Clin Invest, 2010. **120**(9): p. 3042-53.
74. Remtulla, S. and P.E. Hallett, *A schematic eye for the mouse, and comparisons with the rat.* Vision Res, 1985. **25**(1): p. 21-31.
75. Hughes, A., *A schematic eye for the rat.* Vision Res, 1979. **19**(5): p. 569-88.
76. Howland, H.C., S. Merola, and J.R. Basarab, *The allometry and scaling of the size of vertebrate eyes.* Vision Res, 2004. **44**(17): p. 2043-65.
77. De Schaepdrijver, L., et al., *Retinal vascular patterns in domestic animals.* Res Vet Sci, 1989. **47**(1): p. 34-42.
78. Osborne, N.N., et al., *Retinal ischemia: mechanisms of damage and potential therapeutic strategies.* Prog Retin Eye Res, 2004. **23**(1): p. 91-147.
79. Roggeband, R., et al., *Eye irritation responses in rabbit and man after single applications of equal volumes of undiluted model liquid detergent products.* Food Chem Toxicol, 2000. **38**(8): p. 727-34.
80. Warfvinge, K., et al., *Retinal progenitor cell xenografts to the pig retina: immunological reactions.* Cell Transplant, 2006. **15**(7): p. 603-12.
81. Sanchez, I., et al., *The parameters of the porcine eyeball.* Graefes Arch Clin Exp Ophthalmol, 2011.
82. Olsen, T.W., et al., *Porcine sclera: thickness and surface area.* Invest Ophthalmol Vis Sci, 2002. **43**(8): p. 2529-32.
83. Gilger, B.C., K.A. Reeves, and J.H. Salmon, *Ocular parameters related to drug delivery in the canine and equine eye: aqueous and vitreous humor volume and scleral surface area and thickness.* Vet Ophthalmol, 2005. **8**(4): p. 265-9.
84. Bode, G., et al., *The utility of the minipig as an animal model in regulatory toxicology.* J Pharmacol Toxicol Methods, 2010. **62**(3): p. 196-220.
85. Bertschinger, D.R., et al., *A review of in vivo animal studies in retinal prosthesis research.* Graefes Arch Clin Exp Ophthalmol, 2008. **246**(11): p. 1505-17.
86. Tao, W., et al., *Encapsulated cell-based delivery of CNTF reduces photoreceptor degeneration in animal models of retinitis pigmentosa.* Invest Ophthalmol Vis Sci, 2002. **43**(10): p. 3292-8.
87. Godfrey, L.R., *General Anatomy*, in *The Laboratory Primate*, W.-C. S, Editor. 2005, Elsevier: London, UK. p. 29-45.
88. Harwerth, R.S., *Primate Glaucoma Models*, in *Animal Models for Retinal Diseases*, I.H. Pang and A.F. Clark, Editors. 2010, Humana Press: New York, NY. p. 165-190.
89. Johnson, C.J., et al., *Technical brief: subretinal injection and electroporation into adult mouse eyes.* Mol Vis, 2008. **14**: p. 2211-26.
90. McBride, C., D. Gaupp, and D.G. Phinney, *Quantifying levels of transplanted murine and human mesenchymal stem cells in vivo by real-time PCR.* Cytotherapy, 2003. **5**(1): p. 7-18.
91. Maclachlan, T.K., et al., *Preclinical safety evaluation of AAV2-sFLT01- a gene therapy for age-related macular degeneration.* Mol Ther, 2011. **19**(2): p. 326-34.

92. Osusky, R., et al., *beta-Galactosidase transgene expression in transplanted rabbit retinal pigment epithelial cells in vivo.* Graefes Arch Clin Exp Ophthalmol, 1995. **233**(4): p. 220-5.
93. Lai, C.C., et al., *Local immunosuppression prolongs survival of RPE xenografts labeled by retroviral gene transfer.* Invest Ophthalmol Vis Sci, 2000. **41**(10): p. 3134-41.
94. Igarashi, T., et al., *Adeno-associated vector (type 8)-mediated expression of soluble Flt-1 efficiently inhibits neovascularization in a murine choroidal neovascularization model.* Hum Gene Ther, 2010. **21**(5): p. 631-7.
95. Bainbridge, J.W., et al., *Stable rAAV-mediated transduction of rod and cone photoreceptors in the canine retina.* Gene Ther, 2003. **10**(16): p. 1336-44.
96. Park, C.Y., et al., *Periocular triamcinolone enhances intraocular gene expression after delivery by adenovirus.* Invest Ophthalmol Vis Sci, 2008. **49**(1): p. 399-406.
97. Doi, K., et al., *Transient immunosuppression stops rejection of virus-transduced enhanced green fluorescent protein in rabbit retina.* J Virol, 2004. **78**(20): p. 11327-33.
98. Le Meur, G., et al., *Restoration of vision in RPE65-deficient Briard dogs using an AAV serotype 4 vector that specifically targets the retinal pigmented epithelium.* Gene Ther, 2007. **14**(4): p. 292-303.
99. Timmers, A.M., et al., *Subretinal injections in rodent eyes: effects on electrophysiology and histology of rat retina.* Mol Vis, 2001. **7**: p. 131-7.
100. Srinivas, M., et al., *(19)F MRI for quantitative in vivo cell tracking.* Trends Biotechnol, 2010. **28**(7): p. 363-70.
101. Amsalem, Y., et al., *Iron-oxide labeling and outcome of transplanted mesenchymal stem cells in the infarcted myocardium.* Circulation, 2007. **116**(11 Suppl): p. I38-45.