5.3.4.1 Rationale for Extension Study

The finding of bone formation medial to the transverse processes was unexpected, because it had been assumed that OP-1 Putty-directed new bone formation would occur as it does for autograft—laterally, along the transverse processes. Stryker Biotech in discussion with surgical experts believes that the difference in the observed pattern of bone formation may relate to the physical properties of the graft materials studied; OP-1 Putty is a compressible, moldable material that does not harden, whereas autograft is not malleable and has a non-compressible physical structure. During the spinal fusion procedure used in the clinical study, the surgeon retracts the paraspinal muscles to lay down the OP-1 Putty or autograft material. (See Figure 3) When the retractors are removed and the muscles are released, the OP-1 Putty product is compressed medially (See Figure 4), leading to medial bone formation. This is not easily detected by plain x-ray because the lumbar vertebrae are retroperioneal structures for which overlying abdominal organs, bowel, bowel contents, and bowel gas can easily obscure new bone formation. In addition, the medial location of the OP-1 putty – directed bone formation may be obscured by the lateral border of the vertebral body and hypertrophied facet joints.

Initial placement of OP-1 Putty

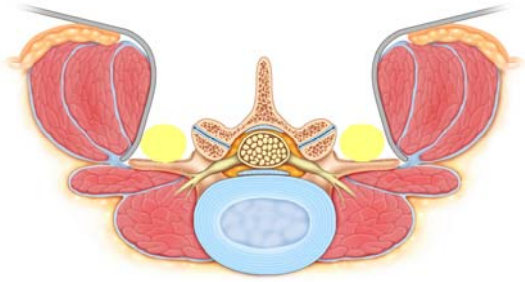

Figure 3

Upon release of muscle retraction, OP-1 Putty conforms to medial, bony anatomy

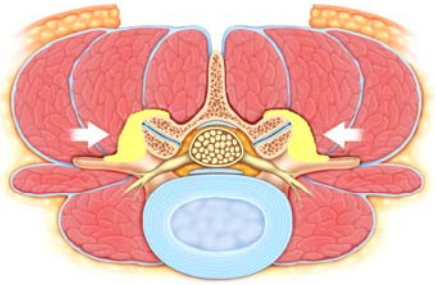

Figure 4

Figure 3 (left): Axial view of the lumbar spine with paraspinal muscle retraction and placement of OP- Putty across the transverse processes

Figure 4 (right): Axial view of the lumbar spine with release of traction and medial displacement of OP-1 Putty

Therefore, to resolve the apparent disparity in outcomes and adequately investigate whether patients in the OP-1 Putty group experienced fusion rates comparable to the autograft group, a radiographic assessment tool more sensitive than the plain films used at 24 months was needed. Stryker Biotech designed and conducted a prospective follow-up study to collect additional radiographic and clinical data on all available study patients at the longer-term follow-up interval of 36+ months. Considerable effort was expended to locate and evaluate as many patients as possible in both the autograft and OP-1 Putty groups. Patients received CT scans to assess for the presence of bone, and repeat flexion/extension films to provide measurements of

angulation and translation at the same time point. All key clinical outcome measures collected in the original study were also collected at the 36+ month interval. Great care was taken to standardize the prospective CT scan including the imaging algorithm and the imaging protocol that was prospectively developed. Each CT scan was read by two blinded orthopedic spine surgeons according to a standardized protocol that was prospectively defined. In case of discrepant readings, the scan was read by a third blinded orthopedic spine surgeon and the opinion of the majority determined the outcome.

Eighty percent (80.5%) of eligible patients (79.7% of autograft group and 80.8% of the OP-1 group) were accounted for in the extension study. The mean time from surgery was 4.4 years in the OP-1 arm and 4.5 years in the autograft group. The follow-up time since surgery ranged from 3.7 to 5.5 years. All key demographic characteristics and 24 month outcome variables of the patients who participated in the extension study, compared to those eligible to participate, were similar and not statistically different.

The results from the 36+ radiographic assessments were then combined with the original 24 month clinical outcome assessments to develop a modified overall success assessment. As discussed above, Stryker Biotech believes it is appropriate to substitute the radiographic success data obtained using CT scans at 36+ months for the original 24 month radiographic information because the original plain film assessment was flawed and did not accurately assess for the presence of medial bone formation that we now know is common with OP-1 Putty. Given that several studies in the literature document greater degrees of failure after two years in patients who were not initially fused, Stryker also believes that the 36+ month follow-up should be a more stringent assessment of the effects of OP-1 and autograft in achieving spine fusion.[15, 16]

Stryker Biotech acknowledges that it would be preferable to have all components of a composite measure assessed at the same time point; however, this was not possible for this study given that CT scans were not obtained at 24 months. Stryker believes that combining the 36+ radiographic assessment with the original 24 month clinical outcome assessments (with the exception of retreatment, discussed below) does not introduce bias because radiographic results would be expected to remain constant between 24 months and 36 months.[17] Therefore, a 36+ month radiographic assessment is an accurate representation of the expected results at 24 months and can be used in the modified Overall Success measure. One additional change that was made to the Overall Success composite was to update the retreatment analysis. Retreatment failures were included in the analysis up to and including the 36+ month follow-up visit due to the critical importance of this outcome to both patients and physicians and that other components are meaningless as measures of the treatment effect if there has been an intervening surgery to promote fusion. Stryker Biotech does not believe that it is appropriate to update all clinical outcomes in the modified Overall Success endpoint because, as patients age, comorbidites increase that are unrelated to the spinal fusion procedure and may confound endpoints such as ODI and neurologic success.[18] Given that the mean age of patients in the 36+ study is approximately 72 years, the level of emerging comorbidities would be expected to be significant. This could lead to inaccurate conclusions regarding clinical outcomes in OP-1 Putty or autograft patients.

References

15 Fischgrund JS, Mackay M, Herkowitz HN, et al. Degenerative lumbar spondylolisthesis with spinal stenosis: a prospective, randomized study comparing decompressive laminectomy and arthrodesis with and without spinal instrumentation. Spine. 1997;22:2807–2812.

16 Kornblum MB, Fischgrund JS, Herkowitz HN, Abraham DA, Berkower DL, Ditkoff JS. Degenerative Lumbar Spondylolisthesis with Spinal Stenosis: A prospective long-term study comparing fusion. Spine 2004; 29(7):726–734

17 Singh, K, Smucker, J., Boden, S. Use of Recombinant Human Bone Morhogenetic Protein-2 as an Adjunct in Posterolateral Lumbar Spine Fusion: A Prospective CT-Scan Analysis at One and Two years. J Spinal Disord Tech 2006; 19(6):416-423

18 Weinstein, J et al. The Impact of Comorbidities on the Change in Short-Form 36 and Oswestry Scores Following Lumbar Spine Surgery. Spine 2006; 31:1974-1980.