1.0 Executive Summary

(Content from P060021 Minor Amendment Executive Summary February 2009)

EXECUTIVE SUMMARY

Osteogenetic Protein-1 (OP-1) is a member of the transforming growth factor (TGF) beta superfamily of ligands. Implants containing OP-1 and collagen matrix have been shown to be osteoinductive and osteoconductive, to speed the rate of bone healing[1,2,3,4,5] and to improve the performance of autograft in animals. Implants containing OP-1 and collagen matrix have been shown to promote stable spinal fusions significantly faster than autograft.[6,7]

Stryker Biotech's OP-1® Putty device consists of osteogenic protein-1 (BMP-7) in a bioresorbable matrix of bovine collagen and carboxymethyl cellulose that is surgically implanted into the lumbar region of the spine. At the time of surgery, the product is reconstituted with normal saline, and mixed to produce a product with a putty-like consistency. The product does not harden with time and retains its moldable consistency. The product is radiolucent, which ensures that when bone is formed and detected during post-operative imaging, it is de-novo bone formation that is seen. This is in contrast to other spinal implants composed of radiopaque materials, which can be difficult to distinguish from de novo bone on plain film X-rays at later time points.

OP-1 Putty has been approved by the FDA under Humanitarian Device Exemption H020008 as an alternative to autograft in compromised patients requiring revision posterolateral (intertransverse) lumbar spinal fusion for whom autologous bone or bone marrow harvest are not feasible or are not expected to promote fusion. OP-1 Implant, a slightly different formulation consisting of OP-1 protein mixed with bovine collagen, was approved by FDA under HDE H010002 as an alternative to autograft in recalcitrant long bone nonunions where use of autograft is unfeasible and alternative treatments have failed. Over 25,000 patients have been treated under the HDEs for OP-1 Putty and OP-1 Implant combined, and over 40,000 patients worldwide. Since the launch of OP-1 Putty in 2004, there has been an average of 0.28 adverse events reported per 100 units of OP-1 Putty sold in the US. The associated post-marketing surveillance program demonstrates no emerging patterns of any serious adverse events associated with the approved use of OP-1 products. In addition, OP-1 Implant is legally marketed as a pharmaceutical product (Osigraft) in the EU and Australia. Ongoing post-marketing surveillance of these markets further supports the safety of OP-1 products.

It was postulated that the use of OP-1 Putty could prove beneficial as a substitute for autograft in the treatment of patients requiring primary decompression and lumbar spinal fusion, because it could stimulate the new bone growth needed for a successful fusion, while eliminating the pain and morbidity associated with surgical harvesting of autograft bone from the iliac crest. Stryker Biotech therefore pursued extensive pre-clinical and clinical research to investigate whether OP-1 Putty is a safe and effective alternative to autograft for primary spinal fusion surgery. A recent pre-clinical study in a primate model of posterolateral fusion demonstrated the safety and efficacy of the OP-1/collagen matrix combination in promoting spine fusion over a broad dose range. Clinical fusion with bridging bone was observed at all dose levels, including a subclinical dose of 0.33 mg/ml OP-1 (4 mg per level) with 3 out of 4 animals fused at 4 months. All animals in the 1 mg/ml (equivalent concentration used in the clinical study), 2 mg/ml and 4 mg/ml

groups were completely fused at 4 months with no safety observations. Fusion in the clinical equivalent dose group to the pivotal trial was better than the autograft group at 3 months and fusion was never observed in the matrix only control group. Safety and efficacy of other BMPs in spinal applications have also been reported in animal models.[8,9,10,11,12]

Stryker Biotech completed a pivotal clinical trial under IDE #G990028, Study S01-01US, a prospective, controlled, randomized, multicenter study comparing OP-1 Putty to autograft for 295 patients undergoing decompression and uninstrumented spinal fusion to treat single-level (L3-S1) degenerative lumbar spondylolisthesis and stenosis. Follow-up evaluations were performed through 24 months which is the interval at which the primary endpoint is calculated. Adverse events were also collected throughout the course of the study. The follow-up evaluations included investigators' clinical assessments and radiographic assessments (flexion/extension plain films to measure angulation and translation and AP films to evaluate for presence of new bone formation). At the time that this study was being designed, plain x-rays were the accepted standard of care for detecting new bone formation in the lumbar spine. However, at this time, CT scans were just beginning to be used for this purpose as well. Because of this, Stryker decided to include a CT scan at an early time point (9 months) when plain x-rays were not being collected for efficacy. They were not designed to be part of the primary endpoint in the original study.

The primary endpoint, Overall Success, was defined as a composite measure that included five parameters:

- Improvement in Oswestry Disability Index (ODI) of at least 20%
- Neurological success
- Absence of retreatment
- Absence of treatment-related serious adverse effects
- and overall radiographic success (a composite measure of presence of bone as assessed by plain x-ray, angular motion success (defined as < 5 degrees on plain film X-ray) and translational movement success (defined as < 3 mm on plain film X-ray). Success in each of these five individual parameters was required for subjects to meet the overall success criterion.

In the original study, OP-1 Putty failed to demonstrate non-inferiority to autograft according to the composite overall success endpoint. Failure to demonstrate non-inferiority of OP-1 compared with autograft was primarily attributable to one component of one parameter, the presence of bone as assessed by plain films. The OP-1 Putty group achieved clinically comparable improvements in all other key clinical outcomes at 24 months post surgery including Oswestry Disability Index (ODI), absence of retreatment, absence of treatment-related serious adverse effects and absence of decrease in neurological status. Comparable success in the other radiographic parameters measuring stability of the fused level (angulation and translation) at 24 months was also observed. In

addition, OP-1 subjects had statistically shorter operative times and less blood loss during surgery on average than autograft subjects.

The results of the original pivotal trial at 24 months post-surgery for overall success and the subcomponents of overall success are summarized below:

Overall Success and Overall Radiographic Success at 24 Months Follow-Up: SAP Analysis, mITT Population

Outcome	OP-1 Putty	Autograft	*P* Value Non-inferiority
Overall Success[1]	38.7%	49.4%	0.331[2]

[1] Calculated with imputation of missing data.
[2] *P* Value is based on one-sided 2-sample test for non-inferiority in the angular scale with a non-inferiority margin of 0.14 (radians); estimates and standard errors are based on logistic regression and multiple imputation.

Overall Radiographic Success at 24 Months Follow-Up: mITT Population

Outcome	OP-1 Putty	Autograft	*P* Value Non-inferiority
Radiographic Success[1]	53.0%	68.9%	0.622[2]

[1] Calculated with imputation of missing data.
[2] *P* Value is based on one-sided 2-sample test for non-inferiority in the angular scale with a non-inferiority margin of 0.14 (radians); estimates and standard errors are based on logistic regression and multiple imputation.

Subcomponents of Radiographic Success at 24 Months mITT Population

Outcome	OP-1 Putty	Autograft	*P* Value for difference
Components of Overall Radiographic Success			
- presence of bone by plain[2] film	51.9	73.5	0.003
- angulation ≤ 5 degrees on[2] flexion/extension films	73.3%	75.6%	0.684
- translation ≤3mm on[2] flexion/extension films	87.7%	87.8%	0.978
ODI Success	74.5%	75.7%	0.839
Absence of Retreatment	92.3%	88.6%	0.347
Absence of Serious Treatment-related AEs	85.6%	84.7%	0.863
Neurological Success	92.1%	84.1%	0.057

[1] *P* value is based on chi-square or Fisher's exact test, as appropriate, to test the difference between treatment groups.
[2] Calculated with missing data imputed by Last Observation Carried Forward

These data revealed a striking disparity between the positive clinical and functional radiographic outcomes (angulation and translation) and the presence of new bone formation reported by plain film x-ray for patients treated with OP-1. Given that clinical experience and the literature demonstrate a high correlation between fusion and positive clinical outcomes in patients undergoing decompression with laminectomy, these results were unexpected.[13,14] Since the OP-1 Putty patients had comparable clinical outcomes to the autograft patients and comparable segmental stability, they should also have shown comparable results for the radiographic assessment of the presence of bone. That is, the OP-1 patients would not be expected to demonstrate improved and durable clinical outcomes at 24 months and beyond if fusion had not occurred. In addition, it would stand to reason that in the absence of a bony fusion, the Op-1 patients would have been expected to demonstrate increased angular and translational instability.

Since the patients in the OP-1 Putty group achieved clinical improvements and radiographic stability comparable to the autograft group, it was reasonable to question whether the radiographic assessments performed at 24 months accurately assessed the presence of bone. In order to better understand these anomalous results, Stryker Biotech brought together two nationally recognized spine surgeons and one academic musculoskeletal radiologist who were blinded to the study data, to examine the 24-month plain films as well as the 9 month CT scans in a subset of study patients. CT scans and plain films were selected from both the autograft and OP-1 group (although selection was heavily weighted towards patients who were failures for presence of bone by plain film) for this exploratory assessment. The independent expert assessment revealed that in many cases, bone was not seen on the 24-month plain films, but *was* seen on the 9-month CT scan medial to the transverse processes and along the lateral border of the facet joints. These findings suggested that the plain film technique used to assess fusion at 24 months was flawed for assessing the medial bone formation associated with OP-1 Putty. Figure 1 and 2 below represents an example where the plain x-ray at 24 months revealed no evidence of new bone formation, but the 9 month CT scan revealed significant new bone formation medially.

24 Month AP X-ray

Figure 1

9 Month Axial CT

Figure 2

The finding of bone formation medial to the transverse processes was unexpected, because it had been assumed that OP-1 Putty-directed new bone formation would occur as it does for autograft—laterally, along the transverse processes. Stryker Biotech in discussion with surgical experts believes that the difference in the observed pattern of bone formation may relate to the physical properties of the graft materials studied; OP-1 Putty is a compressible, moldable material that does not harden, whereas autograft is not malleable and has a non-compressible physical structure. During the spinal fusion procedure used in the clinical study, the surgeon retracts the paraspinal muscles to lay down the OP-1 Putty or autograft material. (See Figure 3) When the retractors are removed and the muscles are released, the OP-1 Putty product is compressed medially (See Figure 4), leading to medial bone formation. This is not easily detected by plain x-ray because the lumbar vertebrae are retroperioneal structures for which overlying abdominal organs, bowel, bowel contents, and bowel gas can easily obscure new bone formation. In addition, the medial location of the OP-1 putty – directed bone formation may be obscured by the lateral border of the vertebral body and hypertrophied facet joints.

Initial placement of OP-1 Putty

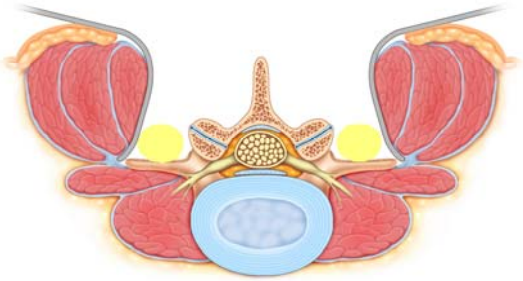

Figure 3

Upon release of muscle retraction, OP-1 Putty conforms to medial, bony anatomy

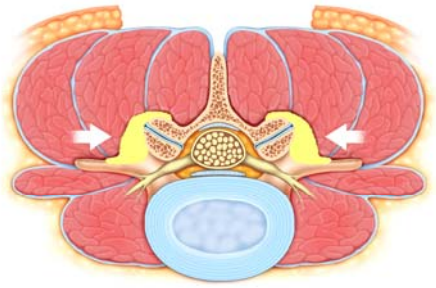

Figure 4

Figure 3 (left): Axial view of the lumbar spine with paraspinal muscle retraction and placement of OP- Putty across the transverse processes

Figure 4 (right): Axial view of the lumbar spine with release of traction and medial displacement of OP-1 Putty

Therefore, to resolve the apparent disparity in outcomes and adequately investigate whether patients in the OP-1 Putty group experienced fusion rates comparable to the autograft group, a radiographic assessment tool more sensitive than the plain films used at 24 months was needed. Stryker Biotech designed and conducted a prospective follow-up study to collect additional radiographic and clinical data on all available study patients at the longer-term follow-up interval of 36+ months. Considerable effort was expended to locate and evaluate as many patients as possible in both the autograft and OP-1 Putty groups. Patients received CT scans to assess for the presence of bone, and repeat flexion/extension films to provide measurements of angulation and translation at the same time point. All key clinical outcome measures collected in the original study were also collected at the 36+ month interval. Great care was taken to standardize the prospective CT scan including the imaging algorithm and the imaging protocol that was prospectively developed. Each CT scan was read by two blinded orthopedic spine surgeons according to a standardized protocol that was prospectively defined. In case of discrepant readings, the scan was read by a third blinded orthopedic spine surgeon and the opinion of the majority determined the outcome.

Eighty percent (80.5%) of eligible patients (79.7% of autograft group and 80.8% of the OP-1 group) were accounted for in the extension study. The mean time from surgery was 4.4 years in the OP-1 arm and 4.5 years in the autograft group. The follow-up time since surgery ranged from 3.7 to 5.5 years. All key demographic characteristics and 24 month outcome variables of the patients who participated in the extension study, compared to those eligible to participate, were similar and not statistically different.

The results from the 36+ radiographic assessments were then combined with the original 24 month clinical outcome assessments to develop a modified overall success assessment. As discussed above, Stryker Biotech believes it is appropriate to substitute the radiographic success data obtained using CT scans at 36+ months for the original 24 month radiographic information because the original plain film assessment was flawed and did not accurately assess for the presence of medial bone formation that we now know is common with OP-1 Putty. Given that several studies in the literature document greater degrees of failure after two years in patients who were not initially fused, Stryker also believes that the 36+ month follow-up should be a more stringent assessment of the effects of OP-1 and autograft in achieving spine fusion.[15,16]

Stryker Biotech acknowledges that it would be preferable to have all components of a composite measure assessed at the same time point; however, this was not possible for this study given that CT scans were not obtained at 24 months. Stryker believes that combining the 36+ radiographic assessment with the original 24 month clinical outcome assessments (with the exception of retreatment, discussed below) does not introduce bias because radiographic results would be expected to remain constant between 24 months and 36 months.[17] Therefore, a 36+ month radiographic assessment is an accurate representation of the expected results at 24 months and can be used in the modified Overall Success measure. One additional change that was made to the Overall Success composite was to update the retreatment analysis. Retreatment failures were included in the analysis up to and including the 36+ month follow-up visit due to the critical importance of this outcome to both patients and physicians and that other components are meaningless as measures of the treatment effect if there has been an intervening surgery to promote fusion. Stryker Biotech does not believe that it is appropriate to update all clinical outcomes in the modified Overall Success endpoint because, as patients age, comorbidites increase that are unrelated to the spinal fusion procedure and may confound endpoints such as ODI and neurologic success.[18] Given that the mean age of patients in the 36+ study is approximately 72 years, the level of emerging comorbidities would be expected to be significant. This could lead to inaccurate conclusions regarding clinical outcomes in OP-1 Putty or autograft patients.

The results for modified overall success and the subcomponents of the modified overall success are summarized below:

Modified Overall Success (with Radiographic and Retreatment subcomponents at 36+ months and clinical outcome assessments at 24 months) :mITT Population

Outcome	OP-1 Putty	Autograft	*P* Value Non-inferiority
Modified overall success[1]	47.2%	46.8%	0.025[2]

[1] Calculated with imputation of missing data.
[2] *P* Value is based on one-sided 2-sample test for non-inferiority in the angular scale with a non-inferiority margin of 0.14 (radians); estimates and standard errors are based on logistic regression and multiple imputation.

Overall Radiographic Success at 36+ Months: mITT Population

Outcome	OP-1 Putty	Autograft	*P* Value Non-inferiority
Radiographic Success[1](36+ months)	60.7	63.1	.138

[1] Calculated with imputation of missing data.
[2] *P* Value is based on one-sided 2-sample test for non-inferiority in the angular scale with a non-inferiority margin of 0.14 (radians); estimates and standard errors are based on logistic regression and multiple imputation.

Subcomponents of Modified Overall Success

Outcome	OP-1 Putty	Autograft	*P* Value Superiority
Components of Overall Radiographic Success at 36+ Months			
▪ Presence of Bone by 36+ month CT Scan	74.8%	77.4%	0.852
▪ Angular motion ≤5° at 36+ Months	69.3%	68.4%	1.000
▪ Translational movement ≤3mm at 36+ Months	75.7%	75.4%	1.000
ODI Success (24 Months)	74.5%	75.7%	0.839
Absence of Retreatment (36+ Months)	87.7%	83.3%	0.529
Absence of Serious Treatment-related AEs (24 Months)	85.6%	84.7%	0.863
Neurological Success (24 Months)	92.1%	84.1%	0.057

P Value is based on Fisher's exact test
Missing or non-evaluable data are excluded

OP-1 Putty was demonstrated to be statistically non-inferior to autograft with regard to the modified Overall Success (47.2% for OP-1 Putty and 46.8% for autograft, P=0.025), demonstrating that OP-1 Putty is comparable to autograft in the important parameters of radiographic success, clinical success and safety.

Overall radiographic success at 36+ months was clinically comparable to autograft but was not shown to be statistically non-inferior (60.7% for OP-1 Putty and 63.1% for autograft, *P*=0.138). There were no statistical differences observed for the various subcomponents of overall success.

The CT scan analysis conducted under the follow-up study, in addition to the accompanying assessments of angulation and translation by flexion/extension films, demonstrated that radiographic success did occur at comparable rates between the OP-1 Putty and autograft groups at 36+ months. In support of our original hypothesis, that led us to collect these additional data, of the OP-1 Putty subjects who were judged negative for the presence of bone based on plain films at 24 months, 71% (27/38) were judged positive for presence of bone based on CT scans at 36+ months and of those 81% (22/27) demonstrated medial bone formation.

In summary, the modified Overall Success composite is an appropriate measure to assess the safety and effectiveness of OP-1 Putty for the proposed indication. The composite includes assessments of key parameters that are important to patients undergoing fusion surgery, including radiographic success, clinical success, neurological success and freedom from reoperation and device related serious adverse events. The modified composite includes data collected at both 24 months and 36+ months. This provides

important additional long-term follow-up information in the analysis without introducing bias. Patients who have undergone decompression with arthrodesis for degenerative spondylolisthesis may exhibit similar clinical improvements at early time points regardless of whether they have achieved definitive fusion or pseudarthrosis[15]; however, significant differences in clinical outcomes have become apparent between these two groups with longer-term follow-up starting at 3 years. It is felt that 36+ month data represents a significant positive addition to the submission by providing longer-term safety and efficacy data than is typically available for spinal devices under consideration for approval. Evaluation of the radiographic and clinical data through the 24-month interval collected in the pivotal study along with the radiographic and clinical data collected through the 36+ month interval in the extension study provides a reliable comparison of the critical factors relevant to an assessment of both the early and longer-term safety and effectiveness of OP-1 Putty as compared to autograft, and demonstrates that OP-1 Putty has equivalent clinical and radiographic outcomes to autograft without the additional comorbidities associated with autograft harvest.

---

1. Cook SD, Wolfe MW, Salkeld SL, Rueger DC. Effect of recombinant human osteogenic protein-1 on healing of segmental defects in non-human primates. *JBJS* 1995;77A: 734-750.

2. Cook SD, Baffes GC, Wolfe MW, et al. The effect of recombinant human osteogenic protein-1 on healing of large segmental bone defects. *JBJS* 1994;76A: 827-838.

3. Cook SD, Baffes GC, Wolfe MW, et al, Recombinant human bone morphogenic protein-7 induces healing in canine long bone segmental defect model. *Clin Orthop* 1994;301:302-312.

4. Cook SD, Rueger DC. Osteogenic protein-1. *Clin Orthop* 1996;324: 29-38.

5. Sampath TK, Rueger DC. Structure, function and orthopedic applications of osteogenic protein-1 (OP-1). *Complications in Orthopedics.* Winter 1994;101-107.

6. Cook SD, Dalton JE, Tan EH, Whitecloud TS and Rueger DC., In vivo evaluation of recombinant human osteogenic protein (rhOP-1) implants as a bone graft substitute for spine fusions. *Spine* 1994;19(15):1655-1663

7. Magin MN. Enhancement of lumbar vertebral interbody fusion by human recombinant osteogenic protein-1, OP-1, in a sheep model. American Association of Orthopedic Surgeons (AAOS), 1998, New Orleans.

8 Sandhu HS. Spinal applications for recombinant bone morphogenetic protein: early experimental results. 1996.

9. Boden SD, Monroe MA, Martin G, Hutton WC. Posterolateral lumbar spinal arthrodesis with rhBMP-2/HA-TCP following laminectomy in the non-human primate. *Trans ORS* 1998;19: 249.

10. Boden SD, Schimandle JH, Hutton WC, Chen MI. The use of an osteoinductive growth factor for lumbar spinal fusion. *Spine* 1995;20(24)2626-2632.

11. Kwiatkowski TC, Meyer RA, Gruber HE, Tabor JR, Murakami T, Howard BA, Wozney JN, Hanley EN. Spinal laminectomy with rhbmp-2 in the canine: a safety study. *Trans ORS* 1997;18: 189.

12. Minamide A, Tamakit T, Kawakami M, Hashizume H, Sakatar R. An experimental spinal fusion with wintered bovine bone and recombinant human bone morphogenetic protein-2. *Trans ORS* 1998;(19): 659.

13 Lombardi JS, Wiltse LL, Reynolds J, Widell EH, Spencer C. Treatment of degenerative spondylolisthesis. Spine. 1985;10(9) 821-827.

14 Johnsson KE, Redlund-Johnell I, Uden A, Willner S. Preoperative and postoperative instability in lumbar spinal stenosis. Spine 1989; 14(6):591-593.

15 Fischgrund JS, Mackay M, Herkowitz HN, et al. Degenerative lumbar spondylolisthesis with spinal stenosis: a prospective, randomized study comparing decompressive laminectomy and arthrodesis with and without spinal instrumentation. Spine. 1997;22:2807–2812.

16 Kornblum MB, Fischgrund JS, Herkowitz HN, Abraham DA, Berkower DL, Ditkoff JS. Degenerative Lumbar Spondylolisthesis with Spinal Stenosis: A prospective long-term study comparing fusion. Spine 2004; 29(7):726–734

17 Singh, K, Smucker, J., Boden, S. Use of Recombinant Human Bone Morhogenetic Protein-2 as an Adjunct in Posterolateral Lumbar Spine Fusion: A Prospective CT-Scan Analysis at One and Two years. J Spinal Disord Tech 2006; 19(6):416-423

18 Weinstein, J et al. The Impact of Comorbidities on the Change in Short-Form 36 and Oswestry Scores Following Lumbar Spine Surgery. Spine 2006; 31:1974-1980.