APPENDIX 15

PHYSICIAN TRAINING INFORMATION

Anterior Segment Surgeon Training for the Implantable Miniature Telescope

The Implantable Miniature Telescope ((IMT™by Dr. Isaac Lipshitz) is an investigational device limited by federal law to investigational use. VisionCare, headquartered in Saratoga, CA, with research facilities in Petah Tikva, Israel, was founded by device inventors Yossi Gross and Dr. Isaac Lipshitz.

Outline

1) Background
   1) AMD and Visual Impairment
   2) Visual Prosthetic Device: IMT™by Dr. Isaac Lipshitz)
   3) Pivotal Clinical Trial Results
2) Patient Selection
3) Product Description
4) Device Implantation Procedure
   1) Corneal Endothelial Protection
5) Complication Management
   1) Intraoperative
   2) Postoperative
6) Post-Surgical Follow-Up

VisionCare OPHTHALMIC TECHNOLOGIES

BACKGROUND

VisionCare OPHTHALMIC TECHNOLOGIES

AMD & VISUAL IMPAIRMENT

VisionCare

Key Ocular Anatomy

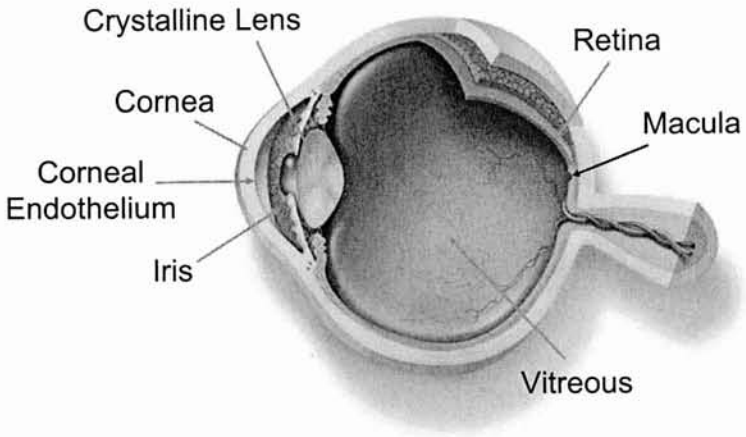

VisionCare

MACULAR LESION

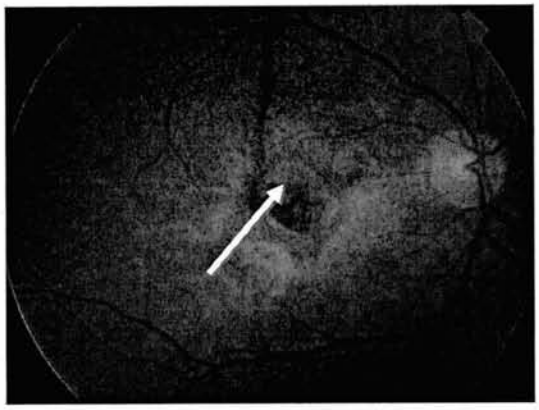

PDT Treated Eye With Small Central Scar

Retinal Image

Scarred Macula (Lesion causing scotoma)

Central Visual Field Projection

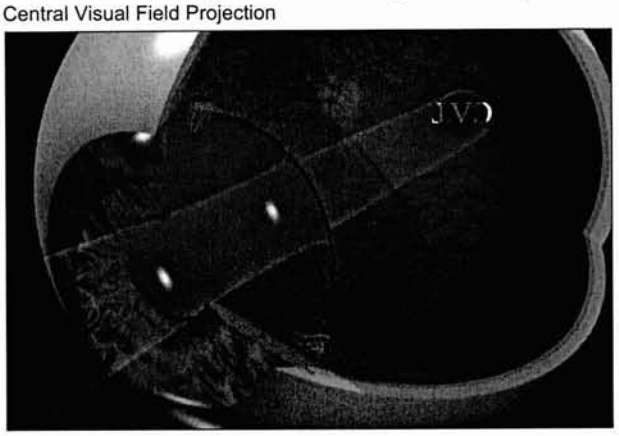

Visual Impairment

Blind spot (scotoma)

Normal Central Vision

End-Stage AMD

VisionCare

Patient Population

- Bilateral End-stage AMD =
  - Geographic atrophy (advanced dry AMD)

  and/or
  - Disciform scar (Treated or stable wet AMD)

  with associated
  - Moderate to profound visual impairment

  Incidence
  - 50K to 80K/year (US)

VisionCare

Current Environment

- AMD therapies
  - Dry
    - No viable therapies
  - Wet
    - PDT/Drugs slow or halt progression of wet AMD
    - Underlying dry AMD still present
- No approved/accepted Tx for end-stage AMD
- Growing elderly population

VisionCare

Current Environment

Limited Tools



VisionCare

VISUAL PROSTHETIC DEVICE

VisionCare

The Implantable Miniature Telescope

(IMT™ By Dr. Isaac Lipshitz)

AMD Visual Prosthetic Device

- Goal: reduce central vision impairment due to scotoma to improve vision and quality of life/ADLs
- Wide-angle properties offer wide field of view



VisionCare

- Micro-optics enlarge central visual field by telephoto effect (2.2 or 3X); macular lesion stable
- Patient utilizes natural eye movements for distance and near vision in either dynamic or static activities

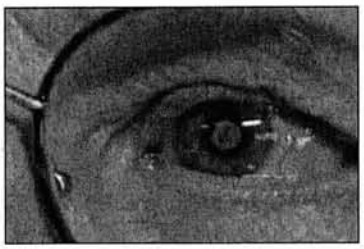

VisionCare

PIVOTAL CLINICAL TRIAL RESULTS

VisionCare

Clinical Trials Program

Indication

- Moderate to profound bilateral central vision impairment
  - End-stage (geographic atrophy, disciform scar)

Status

- Phase I (US)
  - Complete 2002 (n=13)
- Phase II/III (US)
  - Trial complete 2005 (n=217)

VisionCare

Phase II/III Pivotal Trial Results (12 Months)

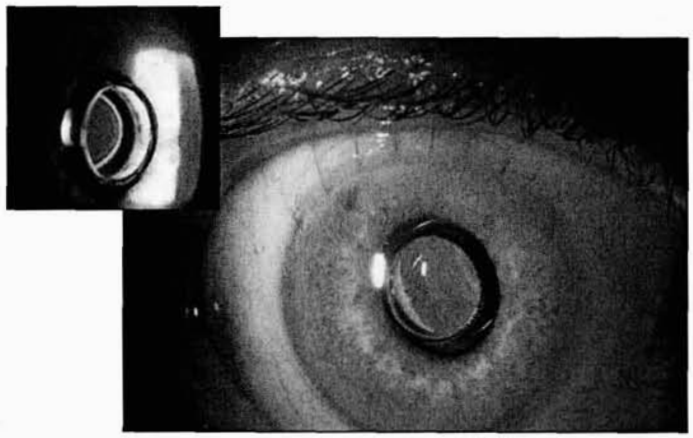

VisionCare

PHASE II/III PIVOTAL TRIAL

- Prospective, open-label (fellow eye control)
- 28 Centers
- 217 patients enrolled
- Multi-disciplinary approach
  - Retina Specialist, Anterior Segment Surgeon, Optometrist, Visual Rehabilitation Specialist
- Visual rehabilitation (6 visits over 3 months) to utilize new visual status in activities of daily living

VisionCare OPHTHALMIC TECHNOLOGIES

KEY ENTRY CRITERIA

✓ End-stage AMD; ≥ 55 years old

✓ Distance VA 20/80 – 20/800

✓ Minimum 5-letter improvement on ETDRS chart using an external telescope

✓ Uncompromised peripheral vision

X Endothelial cell density <1600 cells/mm^2

X Presence or treatment of active CNV within the preceding 6 months

X Previous intraocular or corneal surgery

VisionCare OPHTHALMIC TECHNOLOGIES

OUTCOME MEASURES

- Safety (12 months+)
  - Endothelial cell density (ECD) (target <17% loss)
  - Preservation of vision
- Primary Efficacy (12 months)
  - 50% of patients gain ≥ 2 lines distance or near* VA
- Secondary Efficacy: QoL Outcomes
  - NEI Visual Function Questionnaire (VFQ-25)
  - Activities of Daily Life (ADL) Scale

*8" or 16"

VisionCare
OPHTHALMIC TECHNOLOGIES

BASELINE CHARACTERISTICS

- Mean Age 75.6 years
- 53% Male
- Mean Distance Visual Acuity 20/316
  - ICD-9-CM "Severe" Visual Impairment

VisionCare
OPHTHALMIC TECHNOLOGIES

ONE-YEAR RESULTS SUMMARY

EFFICACY

- VA endpoint met in **90%** (vs 50% target)
- **67%** improved ≥ 3 lines BCDVA
- Meaningful quality of life gains

SAFETY

- Preservation of vision met **95%**
- Endothelial cell density (**-25%** vs -17%)

CLINICAL RESULTS - OPERATIVE

- 206/217 implanted successfully
  - 11 aborted procedures
- Implant removed in 5 eyes postop
  - 2 condensation inside implant
  - 1 patient request (dissatisfaction)
  - 2 corneal decompensation

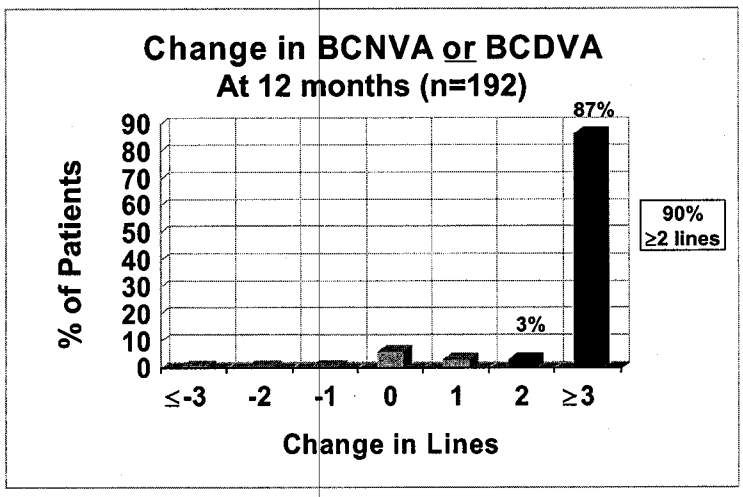

ACUITY VS FELLOW EYE CONTROL

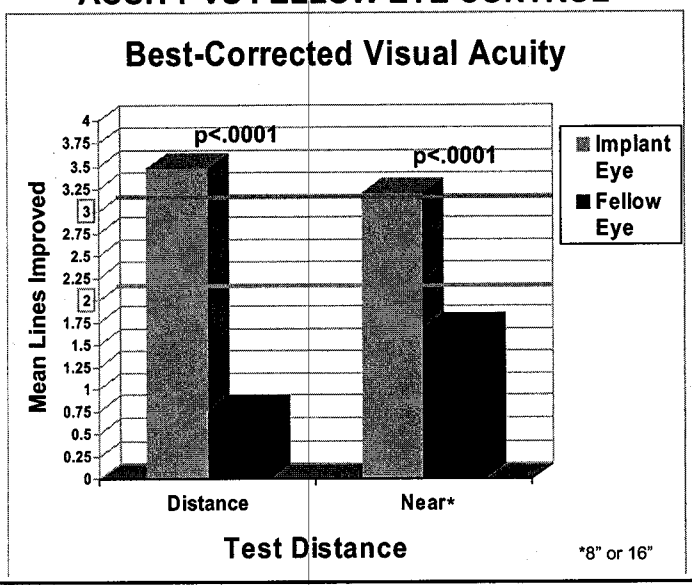

Functional/QoL Improvement

Mean Change for VFQ Subscales

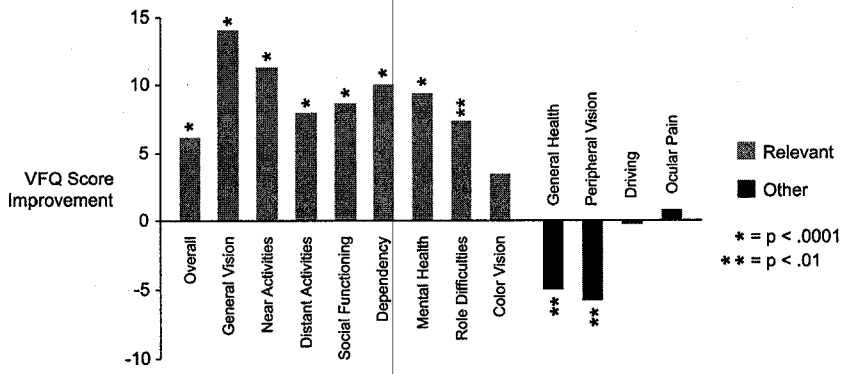

5-point changes clinically meaningful

Functional/QoL Improvement

Mean Change for Activities of Daily Life (ADL) Subscales

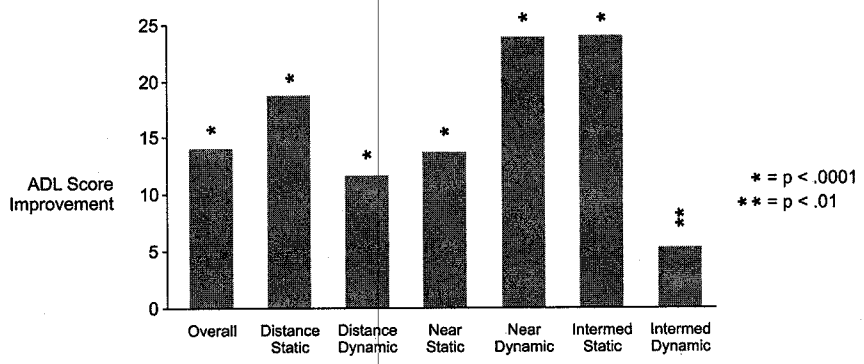

Correlates with VFQ-25 Score Change (r = 0.7339, p < .0001)

VISUAL ACUITY AND QOL

Clinically Meaningful VA Improvement Demonstrates Greater QoL Gain

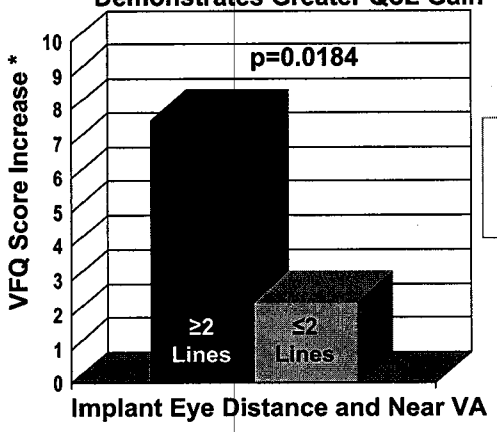

Fellow eye does not show this VA-QoL relationship (p=.5291)

* 8 relevant subscales

SAFETY

- Preservation of vision achieved
- Mean ECD reduction (target 17%)
  - -25% from baseline to 12 months
  - -28% from baseline to 24 months (longer-term available data)
  - Majority of cell loss at time of surgery (-20%)
- Mean ECD stabilizes over time

Operated Eye ECD

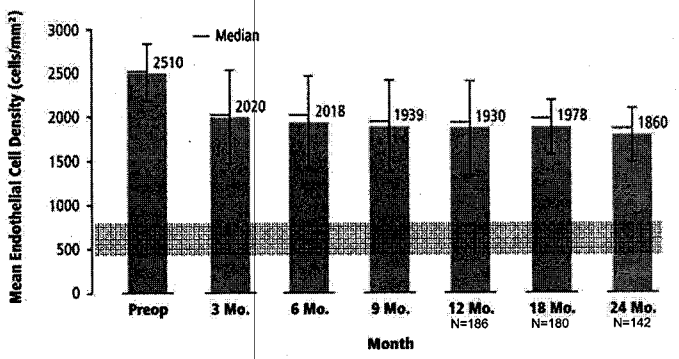

Endothelial Cell Density

3 Mos ECD vs POD1 Corneal Edema

Edema Level POD1	Mean ECD Change	% of IMT002 cases
Normal/1+	-12.8%	(75% of cases)
≥ 2+	-35.1%	(25% of cases)

Difference p<.0001;

Significant through 24 months (interim data)

LEARNING CURVE

ECD from Baseline
Stratified by Surgery Order

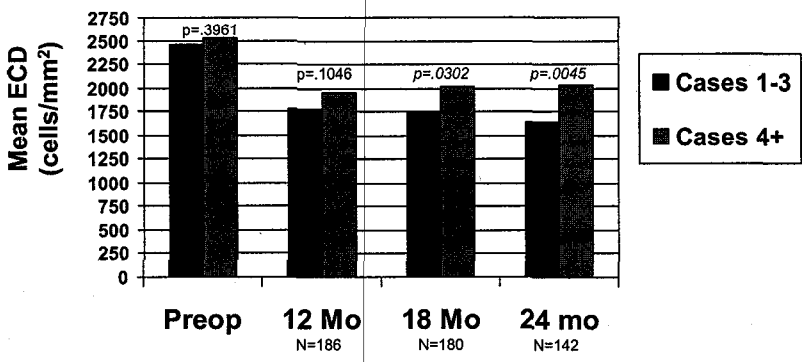

VisionCare OPHTHALMIC TECHNOLOGIES

ADVERSE EVENTS/COMPLICATIONS >5%

Event	Cumulative
Ocular Adverse Events	**N/206 (%)**
Inflammatory deposits on device	44 (21.4)
Pigment deposits on device	20 (9.7)
Guttata	16 (7.8)
Posterior synechiae	13 (6.3)
Complications	**N/206 (%)**
Increased IOP req. Rx ≤ 7 days	57 (27.7)
Corneal edema ≤ 30 days	14 (6.8)
Iris prolapse	12 (5.8)
Corneal abrasion	11 (5.3)

VisionCare OPHTHALMIC TECHNOLOGIES

RETINA SAFETY

- No postop retinal complications >1%
- 1 CNV recurrence at 7 months
  - successfully treated by argon laser photocoagulation through device

VisionCare

PATIENT SELECTION CRITERIA

From US Phase II/III Trial

VisionCare

Clinical Parameters

1) BCVA (distance and near)
2) Manifest refraction
3) A-Scan (baseline only)
4) IOP (by applanation tonometry)
5) Slit lamp examination
6) Fundus exam and photography (baseline only)
7) Fluorescein angiography (baseline only)
8) Endothelial cell density (non-contact specular microscope)
9) Activities of Daily Life questionnaire/VFQ-25
10) Pachymetry

INCLUSION CRITERIA

- Bilateral, stable severe to profound central vision impairment due to bilateral central scotomas associated with end-stage macular degeneration, defined as retinal findings of bilateral geographic atrophy or disciform scar with foveal involvement (*as determined by fluorescein angiography).*
- Severe to profound central vision impairment, i.e., distance BCVA between 20/160 and 20/800, and adequate peripheral vision in one eye (the non-targeted eye) to allow for orientation and mobility.
- Evidence of cataract.

INCLUSION CRITERIA (Cont'd)

- At least 65 years of age.
- AC depth and ECD per product labeling.
- Achieve at least a five-letter improvement on the ETDRS chart in the eye scheduled for surgery using an external telescope.
- Are willing to participate in a postoperative visual rehabilitation program.

VisionCare

EXCLUSION CRITERIA

- *Active CNV or treatment of active CNV within the past 6 months*
- **Hx of intraocular or corneal Sx in study eye**
- **Pathology that compromises peripheral vision in fellow eye**

EXCLUSION CRITERIA

VisionCare

- **Study eye has:**
  - **Myopia >6.0D or Hyperopia >4.0D**
  - **Axial Length <21mm**
  - **Minimum endothelial cell density to be determined using grid of ECD values and patient age**
  - **Minimum ECD of 2000 cells/mm^2 and ACD $\geq$3.0mm for first 5 eyes operated by a new IMT surgeon**
  - **ACD $\geq$ 2.5mm after first 5 eyes operated by a new IMT surgeon**
  - **Narrow Angle (< Schaefer Grade 2)**
  - **Corneal pathology, specifically guttata, or inflammatory ocular disease**
  - *Hx of retinal detachment or untreated tears*
  - *Retinal vascular or optic nerve disease*
  - **Zonular weakness/instability of crystalline lens; pseudoexfoliation**
  - **Uncontrolled glaucoma**

VisionCare OPHTHALMIC TECHNOLOGIES

OTHER MEDICAL CONSIDERATIONS

- MR-conditional status established for the IMT, based on testing
- IMT does not present any risk to a patient undergoing an MRI procedure
- MRI image quality may be compromised if the area of interest is the same as or close to the position of the device
  - In this case, MRI imaging parameters can be optimized to compensate for presence of the IMT

VisionCare OPHTHALMIC TECHNOLOGIES

Other Patient Selection Considerations

- **Patient Satisfaction Factors**
  - Patient must be self-motivated, not pushed into trial (e.g., children, relatives)
  - Patients should have functional goals
  - Patient must understand visual rehabilitation is required for adaptation and best potential outcome
  - No motor or psychiatric challenges

VisionCare

Other Patient Selection Considerations

- **Patient Satisfaction Factors**
  - Psychological: Not a cure, will still have visual impairment
  - Visual Acuity: Pre-op external telescope simulation
  - Outcome dependent on vision rehabilitation, patient actively using implanted eye, and refraction/spectacles
  - Implantation is not the end of treatment, but the beginning

VisionCare

Other Patient Selection Considerations

- **Must understand tradeoff between magnification and visual field in implanted eye**

VisionCare OPHTHALMIC TECHNOLOGIES

Preoperative Testing

- **External Telescope Evaluation**
  - Using ETDRS
  - Patient must achieve at least a 5 letter improvement in study eye (2.2 or 3X)

VisionCare OPHTHALMIC TECHNOLOGIES

Which Eye to Implant?

- **If VA is better than 20/200 in either eye, implant worse seeing eye**
- **If VA is worse than or equal to 20/200 OU, patient and physician decide which eye is to be implanted**

VisionCare OPHTHALMIC TECHNOLOGIES

Which Eye to Implant?

Decide...	OD	OS
Best Corrected Visual Acuity	20/120	20/200
Visual Acuity + Ext. Telescope	20/60	20/80

VisionCare OPHTHALMIC TECHNOLOGIES

Which Eye to Implant?

Decide...	OD	OS
Best Corrected Visual Acuity	20/400	20/400
Visual Acuity + Ext. Telescope	20/200	20/120

Either eye – patient and physician select

VisionCare

Which Eye to Implant?

Decide...	OD	OS
Best Corrected Visual Acuity	20/125	20/160
Visual Acuity + Ext. Telescope	20/50	20/60

VisionCare

Which Eye to Implant?

- **Pseudophakia**
  - OU – excluded
  - Unilateral – other criteria applies, but cannot implant pseudophakic eye

VisionCare
OPHTHALMIC TECHNOLOGIES

PRODUCT DESCRIPTION

VisionCare
OPHTHALMIC TECHNOLOGIES

Specifications

- Glass micro-optical device in PMMA carrier
- Diameter 3.6mm
- Length 4.4mm
- Haptic diameter 13.5mm
- Implanted in one eye in the capsular bag for central vision
- Field of view 20 - 24°
- Fellow eye for peripheral vision



Retinal Image

Scarred Macula (Lesion causing scotoma)

Central Visual Field Projection

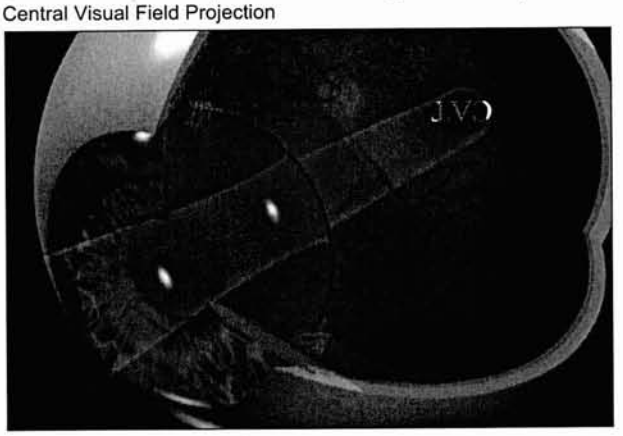

Retinal Image

Wide-Angle Prosthesis

Central Visual Field Projection



SIMULATION

VisionCare

Field of View vs. External Telescope

3.0X Wide Angle Implant: 20°



3.0X Ext. Telescope: 8°

CASE STUDY

VisionCare

BLIND SPOT DUE TO AMD

Simulation

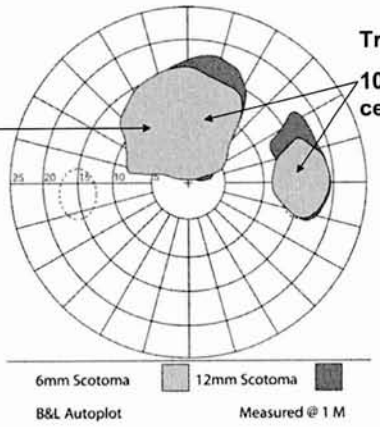

PreOp with Glasses

CASE STUDY

VisionCare

PREOP EXTERNAL TELESCOPE

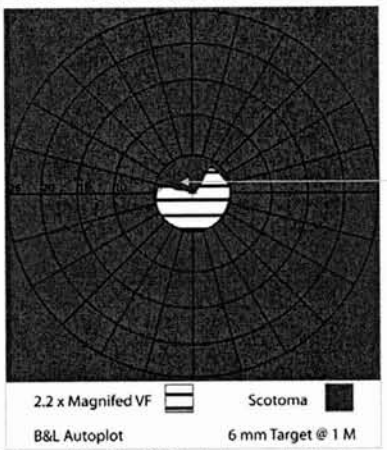

10° (incomplete) field of view

Restricted superiorly by the scotoma

PreOp with 2.2X External Telescope

CASE STUDY

VisionCare

IMPLANT VIEW 3 MOS POSTOP

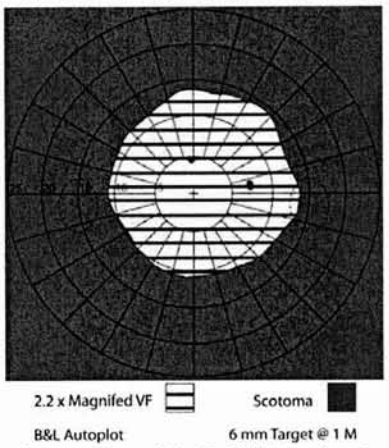

Blind spot reduction (relative) in central visual field

25° field of view

PostOp with 2.2X Implant

Technical Specifications

Design Element	WA 3.0X IMT & WA 2.2X IMT
Optic	Glass tube with microlenses
Dimensions	Diameter: 3.6mm Length: 4.4mm
Haptic diameter	13.5mm
Haptic plate diameter	7.0mm
Carrier (haptics & plate)	Clear PMMA
Light Restrictor	Blue PMMA
Depth of focus	1.5 m – 10 m
Weight	~115mg(air); 60mg(aqueous)

DEVICE IMPLANTATION PROCEDURE

Corneal Endothelial Protection

VisionCare
OPHTHALMIC TECHNOLOGIES

Surgical Procedure Precautions

- Device geometry/volume create challenging procedure with no shortcuts.
- The risk of endothelial cell loss is significantly higher than intraocular lens implantation procedures.
- Special care should be taken to minimize the risk of corneal endothelial cell loss including attention to proper patient selection, appropriate surgical techniques, device handling precautions, selection and use of ocular viscoelastic devices, wound management, appropriate post-procedure medications and patient instructions.

VisionCare
OPHTHALMIC TECHNOLOGIES

Surgical Procedure Precautions

- Corneal decompensation resulting from operative complications necessitating device removal, IOL implantation, and penetrating keratoplasty has occurred in two patients participating in a pivotal clinical evaluation of the device.

VisionCare

Unique Geometrical Considerations

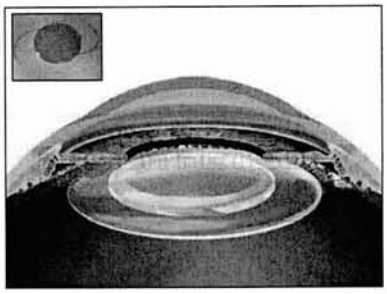

IOL



VISUAL PROSTHESIS

VisionCare

Procedure Overview

- Not an IOL
- 12 mm limbal incision
- Large capsulorrhexis
  - 7 mm ideal
- Implantation entry angle must be away from cornea during implantation (towards PC through limbal incision)
- Depress implant in AC away from cornea
- Viscoelastics critical
  - Cohesive in bag & fill AC
  - Dispersive to coat endothelium/device

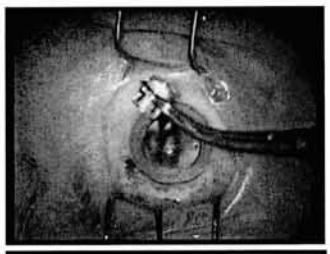

VisionCare

Patient Preparation

1) Anesthesia (retro- or peri-bulbar injection)
2) Mydratic agents to ensure adequate intraoperative pupil dilation
3) Lid speculum placed to provide maximum corneal exposure
4) Operating microscope positioned over front of operative eye with illumination to provide adequate visualization during procedure

VisionCare

Incision Construction

1) Dilate pupil maximally and create 12-13 mm conjunctival incision and achieve hemostasis
2) Create 12 mm partial thickness limbal groove
   a) Note: Less beveled incision allows advantageous device entry angle into AC
   b) CAUTION: DO NOT MAKE SMALLER INCISION AS IT WILL MAKE DEVICE IMPLANTATION MORE DIFFICULT

VisionCare

Ophthalmic Viscoelastic Devices

1) Make paracentesis and inject ophthalmic viscosurgical devices (OVD) into the AC (e.g., "softshell technique")
   a) Coat endothelium with dispersive OVD
   b) Fill AC with cohesive OVD

VisionCare

Capsulorhexis

1) Create capsulorhexis of 7mm
   a) CAUTION: DO NOT MAKE SMALLER CAPSULORHEXIS – MAKES DEVICE IMPLANTATION MORE DIFFICULT
   b) DO NOT IMPLANT DEVICE IF CAPSULE INTEGRITY COMPROMISED

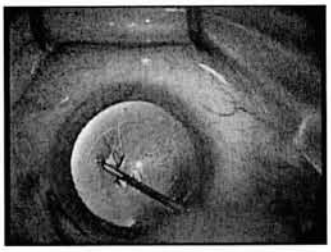

Phacoemulsification is performed to remove the natural lens utilizing settings that help preserve endothelial cells. Special care should be taken to remove any cortical remnants and polish the posterior capsular bag.

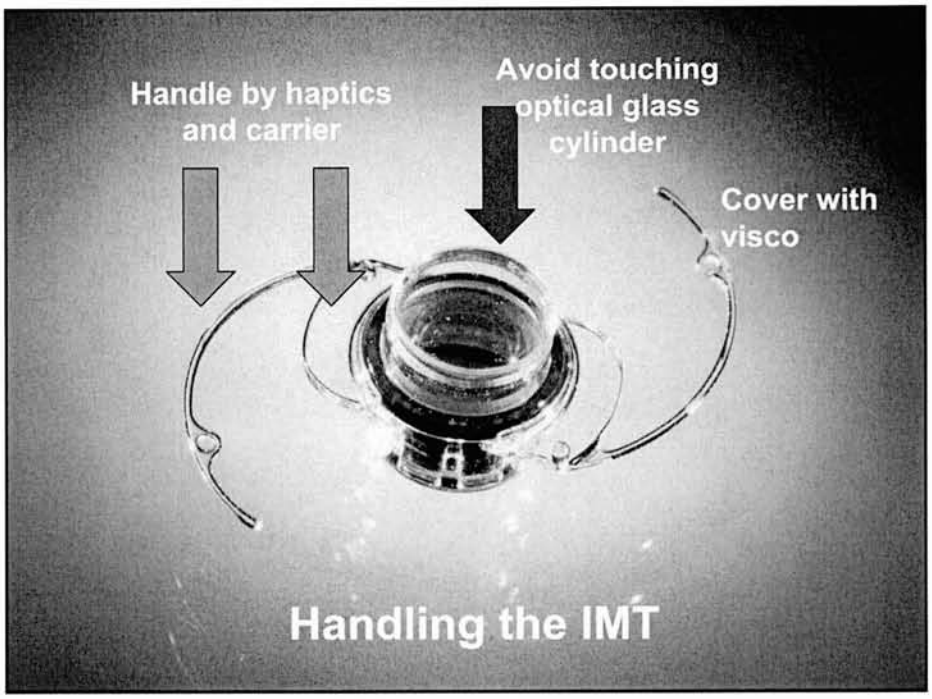

VisionCare

Device Handling

- The device is comprised of a glass optical apparatus. Damage (micro-cracks) can be induced due to trauma to the devices during handling an manipulation.
- Compression of the optical element of the device resulting from improper handling surgical instruments can induce such a failure.
- The haptics are stiff - use of sharp forceps which, when manipulated aggressively, can induce forces sufficient to damage or break the loops of the device.

VisionCare

CONDENSATION DUE TO CRACK IN DEVICE

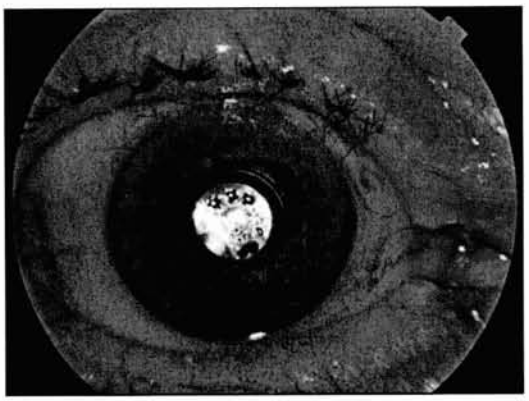

VisionCare

Device Insertion: OVD & Incision Prep

1) Anterior Segment "Softshell technique":
   i. Coat endothelium with dispersive OVD (e.g., Viscoat);
   ii. then cohesive OVD (e.g., Healon V or other viscoadaptive/cohesive OVD) is injected to fill the AC and capsular bag.

   Note: lower viscosity OVDs may "burp" out during device insertion.
2) Device: A dispersive OVD (e.g., Viscoat or equivalent) is used to liberally coat the device (optical portion and leading haptic).
3) Enlarge the incision to 12 mm.

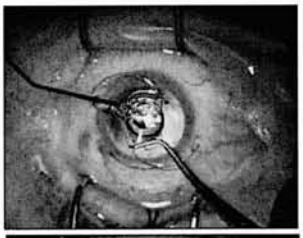

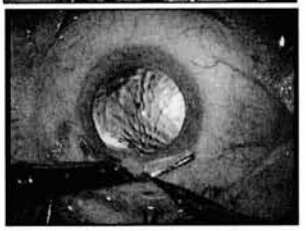

VisionCare

Device Insertion: Implantation

Implant device into capsular bag:

1) Grasp the device by the device's carrier plate;
2) Lift the cornea maximally while avoiding "tenting;"
3) Avoid contact with the corneal endothelium;
4) Insert the leading loop into the bag with device at approximately 45 degrees to the horizontal plane;

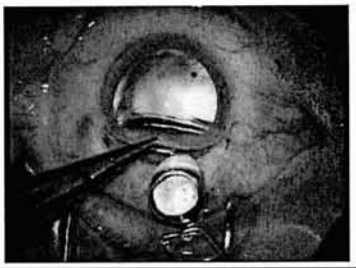

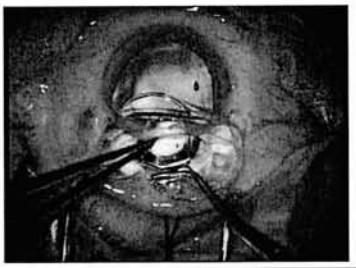

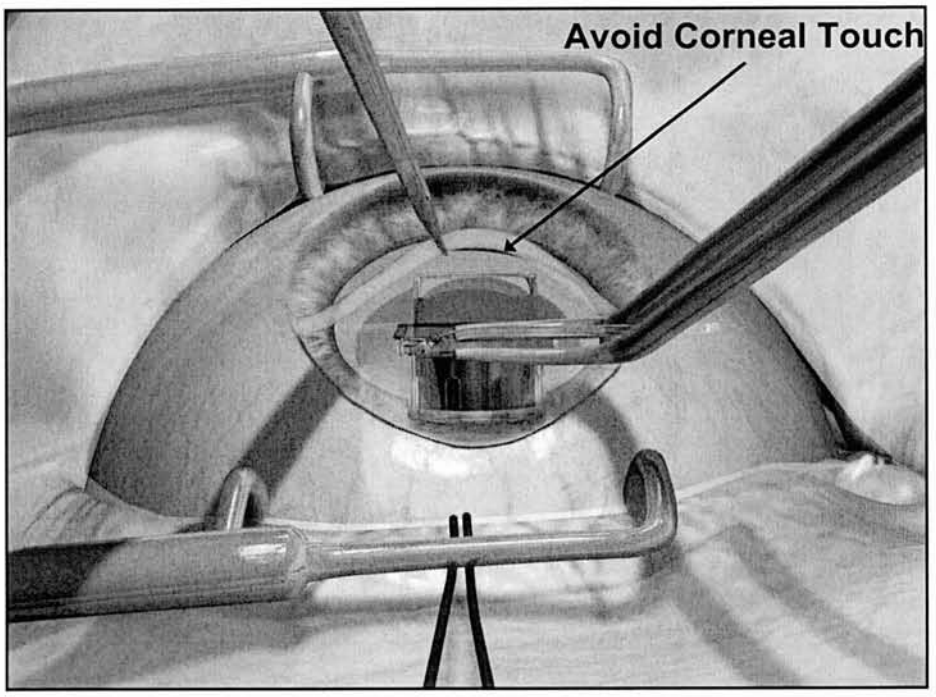

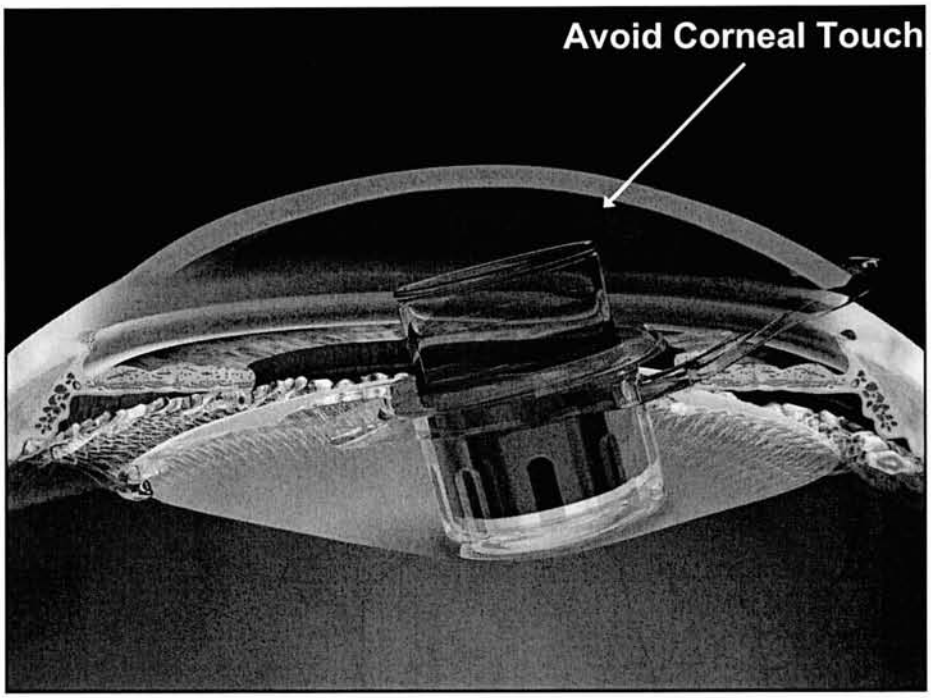

VisionCare

Device Insertion: Implantation

Implant device into capsular bag:

4) Both loops must be placed inside the capsular bag. Direct placement using a superior haptic compression technique should be employed. *Dialing the trailing haptic into position should be avoided as the haptics are too stiff.*
   - A second instrument through the paracentesis incision may be helpful in holding the device steady during trailing haptic placement.

5) The device is bimanually rotated to a 12:6 o'clock position (using clockwise rotation).

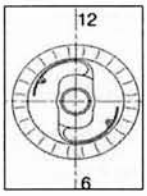



VisionCare

Device Insertion: Precautions

1) Handle the device only by the carrier and haptics.
2) Do not touch or grasp the optical glass cylinder with surgical instruments.
3) Liberally coat the device with dispersive OVD prior to insertion.
4) Avoid corneal touch during the implant procedure.
5) Iris damage increases the risk of endothelial cell loss.

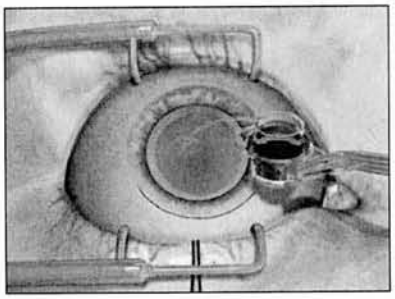



Wound Closure

1) Once device is in place, place several uninterrupted sutures to create water-tight incision and prevent shallowing AC.
2) Constrict pupil.
3) Irrigate and meticulously aspirate OVD to minimize postop IOP spikes.
   a) Special care to be taken to remove OVD between the carrier plate and capsular bag
4) Peripheral iridectomy is performed.
5) Additional sutures are placed to close wound and knots are trimmed and buried.
6) Test incision for leakage.

Anti-Inflammatory Injection

1) Sub-Tenon's steroid injection
   a) betamethasone (Celestone) 6mg
   b) methylprednisolone (Solumedrol) 100mg
   c) *Or appropriate substitute*

VisionCare

SURGICAL VIDEO

VisionCare

COMPLICATION MANAGEMENT

INTRA-OPERATIVE

VisionCare OPHTHALMIC TECHNOLOGIES

Potential Intraoperative Surgical Complications

1) Capsular rupture
2) Small capsulorhexis – inability to place loops
3) Corneal touch
4) Malpositioned IMT
5) Vitreous bulge/loss

VisionCare OPHTHALMIC TECHNOLOGIES

Intraoperative Surgical Complication Management

Complication	Action
Haptic not in the bag, inability to place loops (malpositioned device)	Do not manipulate haptic into the bag, risk of capsular rupture Place haptics in sulcus, or cut haptics and remove device - implant a back-up device or an IOL
Capsular rupture	Cut haptics and remove IMT; implant an IOL
Choroidal hemorrhage	Remove device immediately and close wound
Radial tears in the capsule	Do not implant device, place an IOL

VisionCare

COMPLICATION MANAGEMENT

POST-OPERATIVE

VisionCare

Potential Post-Op Complications/AEs

- Malpositioned IMT
- Mechanical failure of device
- Explant
- Posterior capsule opacification
- Transient shallow AC
- Inflammatory reaction & hypopyon
- Fibrin deposition on IMT
- Photophobia
- Corneal edema
- Synechiae
- Hyphema
- Endothelial cell loss/corneal decompensation

VisionCare

Potential Post-Op Complications/AEs

- Most require actions/management similar to intraocular lenses
- Posterior capsule opacification and explants described next…

VisionCare

Posterior Capsule Opacification

- **Manual capsulotomy**
  - Pars plana entry capsulotomy (needle or vitrector)
- **YAG capsulotomy**
  - do not fire laser through the telescope optic
  - has been performed around periphery of IMT in an animal study with favorable results

VisionCare OPHTHALMIC TECHNOLOGIES

Explanting the IMT

- Explanting the device is possible
- Explanted eyes may be re-implanted with a PC-IOL
  - Cut haptics and remove telescope prosthetic device
- **INSERT EXPLANT VIDEO HERE FOR EXAMPLE**

VisionCare OPHTHALMIC TECHNOLOGIES

POST-SURGICAL FOLLOW-UP

VisionCare
OPHTHALMIC TECHNOLOGIES

Trial Protocol

1) **Medical examinations at:**
   a) 1 day
   b) 1 week
   c) 1, 3, 6, 9, 12, 18, 24 months
2) **Each examination includes:**
   a) Surgical evaluation
   b) Visual acuity (distance & near)
   c) Functional evaluation (3-12 months)
3) **Postop referral to credentialed rehabilitation therapist**

VisionCare
OPHTHALMIC TECHNOLOGIES

Recommended Visit Schedule

EXAM/TEST	Pre-Op	Day 1	Day 7	1 Mo	3 Mos	6 Mos	12 Mos
Distance BCVA	✓	✓	✓	✓	✓	✓	✓
Near BCVA	✓			✓	✓	✓	✓
Manifest Refraction	✓		✓	✓	✓	✓	✓
IOP	✓		✓	✓	✓	✓	✓
Slit Lamp Exam	✓	✓	✓	✓	✓	✓	✓
Fluorescein angiography	✓						
Dilated Fundus Exam	✓					✓	✓
Specular Microscopy (optional)	✓						✓
ADL & VFQ-25 Questionnaire (optional)	✓					✓	

VisionCare

Post-Op Medical Treatment

1) **Topical antibiotic**
2) **NSAID – diclofenac sodium (0.1%)**
3) **Topical steroids – predinisolone acetate (1%)**
   a) q2h for first 2 weeks; q4h for next 2-4 weeks; taper over the next 4-6 weeks. (About 3 months total duration)
4) **Mydriatics**
   a) Homatropine 5% b.i.d. 4-6 weeks
   b) Atropine may be used if homatropine inadequate to maintain cycloplegia
5) **Miotics**
   a) Only in case of glare

VisionCare

Post-Op Medical Treatment

Caution: The above postoperative regimen of anti-inflammatory medications may be too aggressive for some patients and could result in medicamentosa. The physician should exercise clinical judgment in deciding if a more moderate or rapid tapering of the topical steroid regimen is indicated for some patients.

VisionCare

Retinal Examination

- Visualize fundus with 90D hand-held lens: approx. 50-60° of central retina can be observed
- Visualize peripheral retina by indirect ophthalmoscopy with the eye fully dilated, such that examiner can observe the retina outside the telescope prosthesis.
  - If full dilation not possible, view of peripheral retina limited
- If necessary, B-scan images can be obtained to provide clear visualization of physical changes or abnormalities of the retina (e.g., retinal detachment)
- FA and posterior segment OCT have been performed for diagnosis of macular pathology

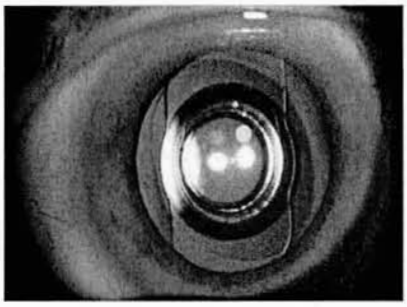

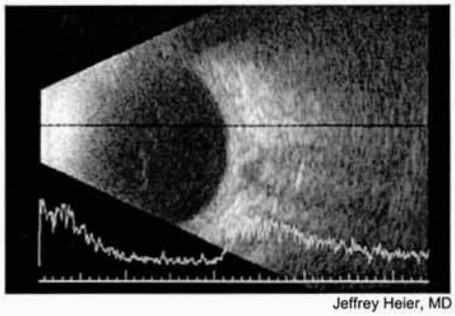

Jeffrey Heier, MD

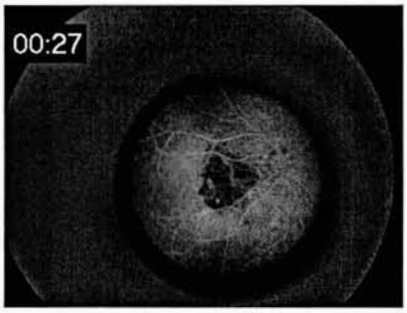

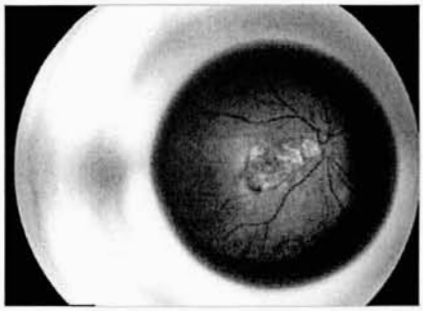

Retina Group of Washington

VisionCare OPHTHALMIC TECHNOLOGIES

Retinal Treatment

- Conduct fundus exam for CNV if patient reports unanticipated decrease in VA
  - Confirm with FA any diagnosis of possible CNV
- 1 case of CNV was reported out of 206 telescope-implanted eyes in IMT002 2-year study
  - Successful treatment using thermal laser photocoagulation (Garfinkel et al. Amer J Ophthalmol 2006;141:766-767)
  - Anticipate 2% CNV ocurrence at 2 years (Sunness JS, et al. Ophthalmology 1999;106:910-919)
- Other: anti-VEGF injection

VisionCare OPHTHALMIC TECHNOLOGIES

Refraction

- Clinical refraction may be evaluated with +/- 1.0 and 2.0 diopter lenses
- Astigmatic correction should be added but is often only minimally helpful
- Add powers may be helpful

VisionCare
OPHTHALMIC TECHNOLOGIES

Keys to Successful Surgical Outcomes

- Challenging surgical procedure
  - Use special implantation technique to avoid corneal touch
  - Use OVD to maintain AC and protect endothelium from device
- At least 12 mm incision necessary
- Large capsulorhexis (7 mm) necessary
- Prescribe extended anti-inflammatory drug regimen

APPENDIX 16

BIBLIOGRAPHY AND SELECTED CITATIONS (ON CD)

BIBLIOGRAPHY

Adams E, Flynn K, Alligod E, Johnson T. Veterans Administration Technology Assessment Program. Optical devices for adults with low vision: A systematic review of published studies of effectiveness. Final Report from the Office of Patient Care Services. May, 2003.

Age-Related Eye Disease Study Research Group (AREDS). Responsiveness of the National Eye Institute Visual Function Questionnaire to Progression to Advanced Age-Related Macular Degeneration, Vision Loss, and Lens Opacity: AREDS Report No. 14. Arch Ophthalmol 2005;123:1207-14.

Age-Related Eye Disease Study Research Group. Potential public health impact of age-related eye disease study results: AREDS report no. 11. Arch Ophthalmol 2003;121:1621-4.

Alio JL, Mulet EM, Ruiz-Moreno JM, et al. Intraocular telescopic lens evaluation in patients with age-related macular degeneration. J Cataract Refract Surg 2004;30:1177-1189.

Altan C, Bayraktar S, Altan T, Eren H, Yilmaz OF. Anterior chamber depth, iridocorneal angle width, and intraocular pressure changes after uneventful phacoemulsification in eyes without glaucoma and with open iridocorneal angles. J Cataract Refract Surg 2004; 30:832-838.

Amann J, Holley GP, Lee SB, Edelhauser HF. Increased Endothelial Cell Density in the Paracentral and Peripheral Regions of the Human Cornea. Am J Ophthalmol 2003;135;584-90.

Apple D. Posterior Capsule Opacification. In: Apple DJ, Auffarth GU, Peng Q, Visessook N. Foldable Intraocular Lenses. Evolution, Clinicopathologic, Correlations, and Complications. Thorofare, NJ: SLACK, Inc.; 2000:157-215.

Armbrecht AM, Findlay C, Kaushal S, Aspinall P, Dhillon B. Is Cataract Surgery Justified in Patients with Age Related Macular Degeneration? A Visual Function and Quality of Life Assessment. Br J Ophthalmology 2000;84:1343-48.

Armitage W, Dick A, Bourne W. Predicting Endothelial Cell Loss and Long-Term Corneal Graft Survival. Inv Ophthalmol Vis Sci 2003;44:3326-31.

Augood CA, Vingerling JR, de Jong PT, et al. Prevalence of age-related maculopathy in older Europeans: The European Eye Study. Arch Ophthalmol 2006;124:529-535.

Azar RG, Holdrook MJ, Lemp M, Edelhauser M, Edelhauser HF, KeraVision Study Group. Two Year Corneal Endothelial Cell Assessment Following Intacs Implantation. J Refractive Surgery 2001;17:542-8.

Bates AK, Cheng, Hiorns RW. Pseudophakic Bullous Keratopathy: Relationship with endothelial cell density and use of predictive cell loss model. A preliminary report. Current Eye Research 1986;5:363-66.

Beltrame G, Salvetat M, Druissi G, Chizzolini M. Effect of Incision Size and Site on Corneal Endothelial Changes in Cataract Surgery. J Cataract Refract Surg 2002;22:118-25.

Bertelmann E, Hartmann C, Scherer M, Rieck P. Outcome of Rotational Keratoplasty. Comparison of Endothelial Cell Loss in Autografts vs. Allografts. Arch Ophthalmol 2004;122:1437-40.

Bourne RA, Minassian DC, Dart KG, Rosen P, Kaushal S, Wingate N. Effect of Cataract Surgery on the Corneal Endothelium: Modern Phacoemulsification compared with Extracapsular Cataract Surgery. Ophthalmol 2004;111:679-85.

Bourne WM, Nelson LR, Hodge DO. Central corneal endothelial cell changes over a ten-year period. Invest Ophthalmol Vis Sci 1997;38:779-782.

Bourne WM, Nelson LR, Hodge DO. Continued Endothelial Cell Loss Ten Years after Lens Implantation. Ophthalmology 1994;101:1014-23.

Bourne WM, Waller RR, Liesegang TJ, Brubaker RF. Corneal Trauma in Intracapsular and Extracapsular Cataract Extraction with Lens Implantation. Arch Ophthalmol 1981;99:1375-76.

Brown GC, Sharma S, Brown MM, Kistler J. Utility Values and Age-Related Macular Degeneration. Arch Ophthalmol 2000;118;47-51.

Brown MM, Brown GC, Stein JD, Roth Z, Campanella J, Beauchamp GR. Age-Related Macular Degeneration: Econonic Burden and Value-Based Medicine Analysis. Can J Ophthalmol 2005;40:277-87.

Brown MM, Brown GC, Shama S, et al. Difference between ophthalmologists' and patients' perceptions of quality of life associated with age-related macular degeneration. Can J Ophthalmol 2000;35:127-33.

Brown MM, Brown GC, Sharma S, et al. The burden of age-related macular degeneration: a value-based analysis. Curr Opin Ophthalmol. 2006;17:257-66.

Brown MM, Brown GC, Sharma S, Landy J. Health Care Economics Analyses and Value-Based Medicine. Surv Ophthalmol 2003;48:204-23.

Cahill MT, Banks AD, Stinnett SS, Toth CA. Vision-related quality of life in patients with bilateral severe age-related macular degeneration. Ophthalmology 2005;112:152-158.

Casten RJ, Rovner BW, Tasman W. Age-related macular degeneration and depression: a review of recent research. Curr Opin Ophthalmol 2004;15:181-183.

Chow Ay, Show VY, Packo KH, et al. The artificial silicon retina microchip for the treatment of vision loss from retinitis pigmentosa. Arch Ophthalmol 2004;122:460-469.

Chun DW, Heier JS, Raizman MB. Visual prosthetic device for bilateral end-stage macular degeneration. Expert Rev Med Devices 2005;2:657-65.

Clemons TE, Chew EY, Bressler SB, McBee W. National Eye Institute Visual Function Questionnaire in age-related eye disease study (AREDS). Arch Ophthalmol 2003;21:211-17.

Colby KA, Chang DF, Stulting RD, Lane SS. Surgical placement of an optical prosthetic device for end-stage macular degeneration: the implantable miniature telescope. Arch Ophthalmol 2007;125:1118-1121.

Collins MJ, Carr JD, Stulting RD, Azar RG, Waring GO III, Smith RE, Thompson KP, Edelhauser HF. Effect of Laser in Situ Keratomileusis (LASIK) on the Corneal Endothelium Three Years Postoperatively. Am J Ophthalmol 2001;131:1.

Diaz-Valle D, Benilez del Castillo Sanchez JM, Castillo A, Sayagues O, Moriche M. Endothelial Damage with Cataract Surgery Techniques. J Cataract Refract Surg 1998;24:951-5.

Dick HB, Kohnen T, Jacobi FK, Jacobi KW. Long-Term Endothelial Cell Loss Following Phacoemulsification through a Temporal Clear Corneal Incision. J Cataract Refract Surg 1996;22:63-71.

Edelhauser HF, Sanders DR, Azar R, Lamielle H, ICL in Treatment of Myopia Group. Corneal Endothelial Assessment After ICL Implantation. J Cataract Refractive Surg 2004;30:576-83.

Edelhauser HF. The resiliency of corneal transparency and edema; The Proctor surgery. Cornea 2000;19:263-72.

Evans JR, Fletcher AE, Wormald RP. Age-related macular degeneration causing visual impairment in people 75 years or older in Britain. Ophthalmology 2004; 111:513-517.

Faye ED et al. Clinical Low Vision. Little, Brown and Co., 1976.

Garfinkel RA, Berinstein DM, Frantz BS. Treatment of Choroidal Neovascularization Through the Implantable Miniature Telescope. Am J Ophthalmol 2006;141:766-7.

Glasser DB, Matsuda M, Gager WE, Edelhauser HF. Corneal Endothelial Morphology After Anterior Chamber Lens Implantation. Arch Ophthalmol 1985;103:1347-9.

Globe DR, Wu J, Azen SP, Varma R, Los Angeles Latino Eye Study Group. The Impact of Visual Impairment on Self-Reported Visual Functioning in Latinos. The Los Angeles Latino Eye Study. Ophthalmology 2004;111:1141-9.

Heuermann T, Hartmann C, Anders N. Long-term Endothelial Cell Loss After Phacoemulsification: Peribulbar Anesthesia Versus Intracameral Lidocaine 1%.Journal of Cataract and Refractive Surgery 2002;28:639-643.

Hudson H, Lane S, Heier J, Stulting D, Singerman L, Lichter P, Sternberg P, Chang DF. Implantable miniature telescope for the treatment of visual acuity loss resulting from end-stage age-related macular. Ophthalmology 2006;113:1987-2001.

Ing JJ, Ing HH, Nelson LR, Hodge DO, Bourne WM. Ten-Year Postoperative Results of Penetrating Keratoplasty. Ophthalmology 1998;105:1855-65.

Jager RD, Mieler WF, Miller JW. Age-Related Macular Degeneration. New Eng J Med 2008;358:2606-17.

Jones SS, Azar RG, Cristol SM, Geroski DH, Waring GO, Stulting RD, Thompson KP, Edelhauser HF. Effect of LASIK on the Corneal Endothelium. Am J Ophthalmol 1998;125:465-71.

Kaufman PL, Alm A. Alder's Physiology of the Eye. Mosby; 10th edition; 2002.

Koziol JE, Peyman GA, Cionni R, et al. Evaluation and implantation of teledioptric lens system for cataract and age-related macular degeneration. Ophthalmic Surg 1994;25:675-684.

Krachmer JH, Mannis MJ, Holland EJ. Cornea: Fundamentals, Diagnosis, and Management. Vol 1; Mosby. 2nd edition; Dec 2004.

Kraff MC, Sanders DR, Lieberman HL. Monitoring for Continuing Endothelial Cell Loss with Cataract Extraction and Intraocular Lens Implantation. Ophthalmology 1982;89:30-4.

Kurimoto Y, Park M, Sakaue H, Kondo T. Changes in the anterior chamber configuration after small-incision cataract surgery with posterior chamber intraocular lens implantation. American Journal of Ophthalmology 1997; 124:775-780.

Lane SS, Kuppermann BD, Fine IH, et al. A prospective multicenter trial to evaluate the safety and effectiveness of the implantable miniature telescope. Am J Ophthalmol 2004;137:993–1001.

Lane, SS, Kuppermann, BD. The Implantable Miniature Telescope for macular degeneration. Curr Opin Ophthalmol 2006;17:94-8.

Levy JH, Pisacano AM. Clinical Endothelial Cell Loss Following Phacoemulsification and Silicone or Polymethylmethacrylate Lens Implantation. J Cataract Refract Surg 1988;14:299-302.

Liesegang TJ, Bourne WM, Ilstrup DM. Short- and Long-Term Endothelial Cell Loss Associated with Cataract Extraction and Intraocular Lens Implantation. Am J Ophthalmol 1984;97:32-9.

Lighthouse National Survey on Vision Loss: Experience, Attitudes, and Knowledge of Middle-Aged and Older Americans. Arlene Gordon Research Institute1995;39-41.

Mangione CM, Lee PP Pitts J, Gutierrez P, Berry S, Hays RD. Psychometric properties of the National Eye Institute Visual Function Questionnaire (NEI-VFQ) Arch Ophthalmology 1998;116:1496-1504.

Mangione CM, Lee PP, Gutierrez P, Spritzer K, Berry S, Hays RD. Development of the 25-item National Eye Institute Visual Function Questionnaire. Arch Ophthalmol. 2001;119:1050-8.

Mangione CM, Orav EJ, Lawrence MG, Phillips RS, Seddon JM, Goldman L. Prediction of visual function after cataract surgery. A prospectively validated model. Arch Ophthalmol 1995;113:1305-11.

Mangione CM, Phillips RS, Seddon JM, Lawrence MG, Cook EF, Dailey R, Goldman L. Development of the Activities of Daily Vision Scale. A measure of visual functional status. Med Care 1992;30:1111-26.

Martin DC. A randomized controlled open trial of population-based disease and case management in a Medicare plus choice health maintenance organization. Prev Chronic Dis 2004;1:A05.

Miskala PH, Hawkins BS, Mangione CM, Bass EB, Bressler NM; Dong LM, Marsh MJ, McCaffrey LD. Submacular Surgery Trials (SST) Research Group. Responsiveness of the National Eye Institute Visual Function Questionnaire to Changes in Visual Acuity: Findings in Patients with Subfoveal Choroidal Neovascularization – SST Report No.1. Arch Ophthalmol 2003;121:531-9.

National Vital Statistics Reports. United States Life Tables 2002. November 2004;53: 1-40.

Olsen T. Prediction of the effective postoperative (intraocular lens) anterior chamber depth. J Cataract Refract Surg 2006;32:419-424.

Olson R, Grandall AS. Silicone versus polymethylmethacrylate intraocular lenses with regard to capsular opacification. Ophthalmic Surg Lasers 1998;29:55-58.

Owen CG, Fletcher AE, Donoghue M, et al. How big is the burdern of visual loss caused by age-related macular degeneration in the United Kingdon? Br J Ophthalmol 2003;87;312-317.

Oxford Cataract Treatment and Evaluation Team (OCTET). Long-term Corneal Endothelial Cell Loss After Cataract Surgery. Results of a Randomized Controlled Trial. Arch of Ophthalmol 1986;104:1170-5.

Patel SV, Hodge DO, Bourne WM. Corneal Endothelium and Postoperative Outcomes 15 years after Penetrating Keratoplasty. Trans Am Ophthalmol Soc 2004;102:57-66.

Periera FA, Cronemberger S. Ultrasound Biomicroscopic Study of Anterior Segment Changes after Phacoemulsification and Foldable Intraocular Lens Implantation. Ophthalmology 2003;110:1799-1806.

Prosdocimo G, Tassinari G, Sala M, Di Biase A, Toschi PG, Gismondi M, Corbanese U. Posterior capsule opacification after phacoemulsification. Silicone CeeOn Edge versus acrylate AcrySof intraocular lens. J Cataract Refract Surg 2003; 29:1551-1555.

Rao G, Aquavella J, Goldberg S, Berk S. Pseudophakic bullous keratopathy. Ophthalmology 1984;91:1135.

Rosner M, Ben-Simon G, Sachs D. Feasibility and safety of laser treatments in eyes with an intraocular implantable miniature telescope. J Cataract Refract Surg 2003;29:1005-1010.

Schein OD, Bressler NM, Price P. Photodynamic Therapy With Verteporfin: Observations on the Introduction of a New Treatment Into Clinical Practice. Arch Ophthalmol 2005;123:58-63.

Schmier JK, Halpern MT, Covert D, Delgado J, Sharma S. Impact of visual impairment on use of care giving by individuals with age-related macular degeneration. Retina 2006;26:1056-62.

Schultz R, Matsuda M, Yee R, Edelhauser HF, Schultz KJ. Corneal endothelial changes in Type I and Type II diabetes mellitus. Am J Ophthalmol 1984;98:401-10.

Sobottka Ventura AC, Walti R, Bohnke M. Corneal thickness and endothelial density before and after cataract surgery. Br J Ophthalmol 2001:85:18-20.

Stein JD, Brown MM, Brown GC, Hollands H, Sharma S. Quality of life with Macular Degeneration : Perceptions of Patients, Clinicans, and Community Members. Br J Ophthalmol 2003:87:8-12.

Submacular Surgery Trials (SST) Research Group. Evaluation of minimum clinically meaningful changes in scores on the National Eye Institute Visual Function Questionnaire (NEI-VFQ) SST Report Number 19. Ophthalmic Epidemiology, 2007;14:205-215.

Submacular Surgery Trials (SST) Research Group. Surgery for Hemorrhagic Choroidal Neovascular Lesions of Age-Related Macular Degeneration: Quality of Life Findings – SST Report No. 14. Ophthalmology 2004;111:2007-14.

Submacular Surgery Trials (SST) Research Group. Surgery for Subfoveal Choroidal Neovascularizatoin in Age-Related Macular Degeneration: Quality of Life Findings – SST Report No. 12. Ophthalmology 2004;111:1981-92.

Sugar A. An analysis of corneal endothelial and graft survival in pseudophakic bullous keratopathy. Tr Am Ophth Soc 1989;762-801.

Sunness JS, Gonzalez-Baron J, Bressler NM, Hawkins B, Applegate CA. The Development of Choroidal Neovascularization in Eyes with the Geographic Atrophy Form of Age-Related Macular Degeneration. Ophthalmology 1999;106:910-19.

The Anecortave Acetate Clinical Study Group. Anecortave acetate as ;monotheraphy for treatment of subfoveal neovascularization in age-related macular degeneration. Ophthalmology 2003;110:2372-2385.

Treatment of Age-Related Macular Degeneration with Photodynamic Therapy (TAP) Study Group. Photodynamic therapy of subfoveal choroidal neovascularization in age-related macular degeneration with verteporfin: two-year results of 2 randomized clinical trials–TAP report 2. Arch Ophthalmol 2001;119:198 –207.

Ursell P, Spalton D, Pande MV, Hollick EJ, Barman S, Boyce J, Tilling K. Relationship between intraocular lens biomaterials and posterior capsule opacification. J Cataract Refract Surg 1998; 24:352-360.

Wang JJ, Mitchell P, Smith W, Cumming RG. Bilateral involvement by age related maculopathy lesions in a population. Br J Ophthalmol 1998;82:743-7.

Williams RA, Brody BL, Thomas RG, et al. The psychosocial impact of macular degeneration. Arch Ophthalmol 1998;116:514-520.

VisionCare
OPHTHALMIC TECHNOLOGIES

VISIONCARE OPHTHALMIC TECHNOLOGIES, INC.
IMPLANTABLE MINIATURE TELESCOPE (IMT™ BY DR. ISAAC LIPSHITZ)
PMA P050034
PANEL PACKAGE FOR OPHTHALMIC DEVICES
ADVISORY PANEL MEETING MARCH 27, 2009

VISIONCARE PMA P050034 AMENDMENTS SUBMITTED TO FDA SINCE OPHTHALMIC DEVICES ADVISORY PANEL MEETING HELD IN JULY 2006

PMA P050034 AMENDMENT 006- JULY 21, 2006

PMA P050034 AMENDMENT 007- JANUARY 31, 2007

PMA P050034 AMENDMENT 008- MARCH 16, 2007

PMA P050034 AMENDMENT 009- MAY 14, 2007

PMA P050034 AMENDMENT 010- OCTOBER 30, 2007

PMA P050034 AMENDMENT 011- DECEMBER 19, 2007

PMA P050034 AMENDMENT 012- FEBRUARY 28, 2008

PMA P050034 EXECUTIVE SUMMARY APRIL 28, 2008

PMA P050034 AMENDMENT 013- SEPTEMBER 2, 2008

PMA P050034 AMENDMENT 014- OCTOBER 1, 2008

PMA P050034 AMENDMENT 015- OCTOBER 14, 2008

PMA P050034 AMENDMENT 016- OCTOBER 29, 2008

PMA P050034 AMENDMENT 017- NOVEMBER 17, 2008

PMA P050034 AMENDMENT 018- DECEMBER 10, 2008

PMA P050034 AMENDMENT 019- JANUARY 6, 2009

VisionCare
OPHTHALMIC TECHNOLOGIES

VISIONCARE OPHTHALMIC TECHNOLOGIES, INC.
IMPLANTABLE MINIATURE TELESCOPE (IMT™ BY DR. ISAAC LIPSHITZ)
PMA P050034
PANEL PACKAGE FOR OPHTHALMIC DEVICES
ADVISORY PANEL MEETING MARCH 27, 2009

VISIONCARE PMA P050034 ORIGINAL PANEL PACKAGE FOR JULY 2006 FDA OPHTHALMIC DEVICES MEETING

PMA P050034 SEPTEMBER 8, 2005

PMA P050034 AMENDMENT 001- NOVEMBER 2, 2005

PMA P050034 AMENDMENT 002- JANUARY 31, 2006

PMA P050034 AMENDMENT 003- APRIL 25, 2006

PMA P050034 AMENDMENT 004- JUNE 5, 2006

PMA P050034 AMENDMENT 005- JUNE 23, 2006