Monograph on **Vitamin A**-Volume 3 #78 1/31/75

MONOGRAPH

ON

VITAMIN A

K31

K31

MONOGRAPH

ON

VITAMIN A

Volume 3

TR-72-1552-65

Submitted Under:
Contract No. FDA 74-104

January 31, 1975

INFORMATICS INC.
6000 Executive Boulevard
Rockville, Maryland 20852

Abbott-'39
Bib. No. 2

Am. J. Physiol. 126(2):245-260. 1939.

EFFECT OF AVITAMINOSIS A ON THE HUMAN BLOOD PICTURE

O. D. ABBOTT, C. F. AHMANN AND M. R. OVERSTREET

From the Division of Physiology in the Department of Home Economics, Agricultural Experiment Station, Gainesville

Received for publication February 27, 1939

During the past few years there has been a shift in the center of interest from the fully developed vitamin A deficiency disease to the mild or latent forms. The former is uncommon, easily recognized, and usually responds promptly to vitamin therapy. On the other hand, there is evidence that mild or minimal vitamin deficiency is more frequent, and therefore constitutes a more serious problem than the rare, advanced cases. In the past the recognition of mild cases has been difficult and uncertain; and especially was this true when this deficiency appeared as a complication of other diseases. The most readily appreciated clinical symptoms of vitamin A deficiency have to do with changes occurring in the eye. Of the several recognizable symptoms of eye changes, it now appears that night blindness, or the inability to see well in dim light, is the earliest, while xerophthalmia, xerosis or keratomalacia, all of which involve various degrees of keratinization of the epithelium of the eyeball, lids, and the paraocular glands, represent the more advanced stages. Fortunately, however, there are available today several methods which, used either singly or together, may prove of value in the diagnosis and study of the mild forms of vitamin A deficiency. The visual photometer or "adaptometer" has been found to be reliable and accurate in measuring small differences in sensitivity to dim light, while light scrapings of the bulbar conjunctiva show the presence or absence of cornified or keratinized epithelia.

In 1937 Abbott and Ahmann found that rats, fed a vitamin A deficient diet until gross symptoms of avitaminosis appeared, had a differential leucocyte count which varied from the normal hematologic standards in several respects. The blood picture of these rats showed a decrease in polymorphonuclears, an increase both in large lymphocytes and in young cells and a general degeneration, especially of the granulocytes. When large amounts of vitamin A were administered daily for several days there was a gradual improvement in the general condition, and in a few weeks the differential count was considered normal. From this work it was concluded that the differential leucocyte count offered a convenient and accurate method of diagnosing avitaminosis A in rats.

The plan of this study was to make differential white cell counts on the blood of individuals whose diets and symptoms indicated a vitamin A deficiency. If the blood picture of these subjects was similar to that of rats fed a vitamin A deficient diet, and if, upon the administration of vitamin A, the blood picture became normal, the differential count would then become of diagnostic value in detecting varying degrees of vitamin A deficiency in man.

METHODS. *Selection of subjects.* The subjects making up the experimental groups consisted of college students, women, and rural school children. For various reasons these individuals had been living on restricted diets for periods which varied from a few months to many years.

Laboratory tests. Each subject was given a physical examination, and blood was taken for total red and white cell counts, hemoglobin estimations, and differential counts. Venous blood was used in all tests. The total counts were made with a Levy-Hausser counting chamber with Neubauer ruling and the percentage of hemoglobin determined with a Dare hemoglobinometer. The differential white blood cell counts were based on 300 cells on fixed smears stained with Wright's stain. In making these counts, 100 cells on each of three cover glasses were counted. The Washburn method for the peroxidase reaction was used to distinguish young lymphocytes from young granulocytes.

If the blood picture indicated a vitamin A deficiency, large doses of vitamin A were administered daily and the effect on the blood picture noted at ten-day intervals.

Dietary histories. Individual case histories showed that all of the experimental subjects were probably receiving minimal or sub-minimal amounts of vitamin A. Accumulated data indicated that this deficiency had prevailed for months in the case of the women and students and practically the entire life of the children. From the study of the diets of the children and students, it was evident that the deficiency was due, in the main, to the continued use of foods low in vitamin A. Such foods as rice, grits, biscuit, corn-meal and pork made up the principal food items included in the diets, while eggs, milk, butter and green and yellow vegetables were used sparingly or only occasionally. Neither milk nor butter had been used in the regular diet of the students for more than a year and the yearly consumption of these foods by the children was limited to a few months. In the case of the women a somewhat different dietary history was found. All the women were overweight and for that reason the daily food intake was restricted to from 1000 to 1200 calories. The diets varied somewhat in detail but all included butter-milk, skim-milk, coffee, leafy vegetables, fruit, lean beef and lamb, fish and chicken. It will be noted that diets made up of foods in this list would not necessarily be low in vitamin A but because of restricted intake and possible decreased absorption and utilization, a deficiency apparently existed.

Descriptive observations. The physical examination of these experimental groups showed that the general symptoms were upon the whole similar. Individual histories revealed that in all cases loss of vigor, nervousness and general weakness were the first noticeable symptoms, while the more specific ones included dry hair and skin, brittle nails, and eye defects.

The children had lost the alertness of health and were listless and inattentive; but conjunctivitis was the most outstanding defect in this group. In a few cases the eye condition had progressed so far that there was an actual involvement of the cornea and the conjunctiva appeared slaty. Also the skin had become dry and desquamated. These flaky, desquamated areas were particularly noticeable on the back of the forearm, the upper arm near the tip of the shoulder, on the calves of the legs and across the chest. Many of the children had no subcutaneous fat so that even the skin on the face was shriveled and dry. The hair was also dry, had lost its normal gloss, and appeared bleached and lifeless.

In the women and students the external symptoms were less clearly defined. Both groups had eye defects which varied in the different subjects from minor ones such as drowsiness, burning and redness of the lids to well defined conjunctivitis. Nearly all the women, and approximately half of the students, wore glasses. Repeated checking of the glasses by reputable oculists showed that the patients were correctly fitted. But in spite of this the continued use of the eyes for several hours, as in reading or sewing, was impossible; and the condition was even more aggravated at night.

Nearly all of the adults had some skin defects. These were particularly noticeable in the women, where they appeared as desquamated areas under chin, on the sides of the neck, and across the chest. A few of the students also had dry patches on the face which became evident immediately after shaving.

DATA AND DISCUSSION. The results presented in figures 1, 2 and 3 and table 1 cover the blood pictures of 157 subjects, including 84 school children, 28 college students and 45 women.

The figures show graphically the differential leucocyte counts for these subjects before and after treatment with vitamin A. In table 1 are given the individual records of 14 women.

The blood picture of all of the subjects showed several variations from normal hematologic standards. Among these were a decrease in total leucocytes and polymorphonuclears, an increase in juveniles and large lymphocytes, and degeneration, especially of the granulocytes. Whether or not the low total leucocyte count is traceable to a deficiency of vitamin A is open to question. The number of leucocytes of normal individuals, if taken without regard to time of day or physiological conditions, which

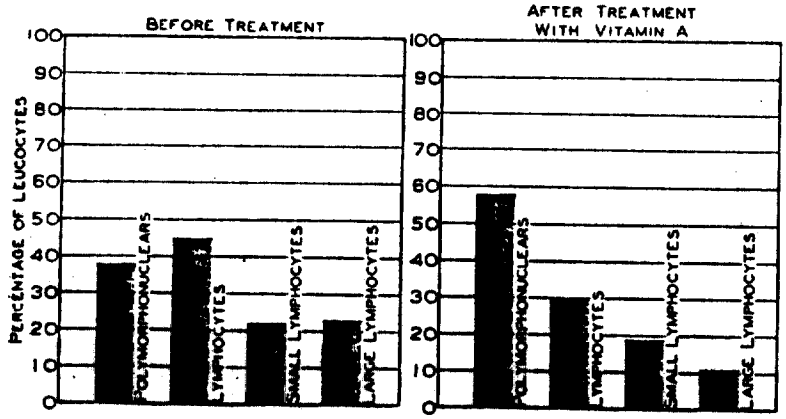

Fig. 1

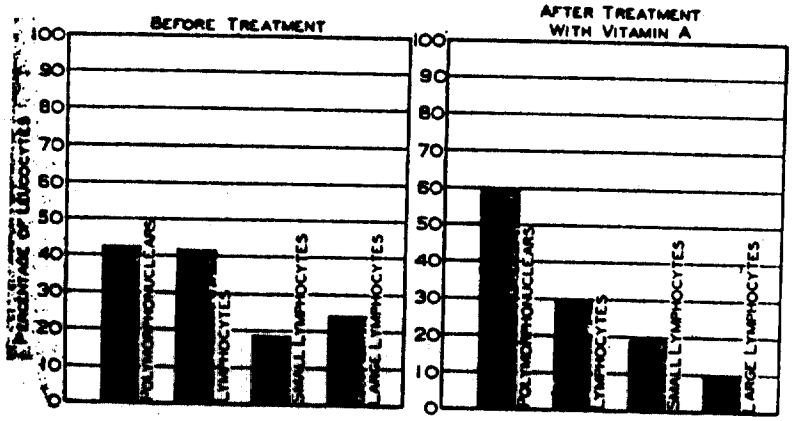

Fig. 2

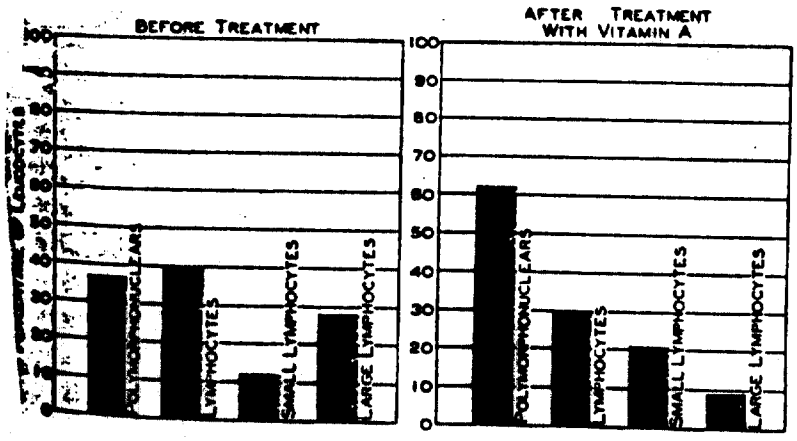

Fig. 3

TABLE I

Blood picture of 14 women on restricted or reducing diets before and after treatment with vitamin A

CASE NO.	BLOOD PICTURE BEFORE AND AFTER TREATMENT	HBG*	TOTAL LEUCOCYTES	TOTAL ERYTHROCYTES	DIFFERENTIAL LEUCOCYTE COUNT								REMARKS
					PMN	Stabs	S. Lymphs.	L. Lymphs.	L. Mono.	Juvenile	Bas.	Eos.	
		gms.			D†								
1	B.T.	15.2	6,900	4,510,000	37 (4)	5	28	22	2	4	1	1	Drastic reducing diet. Dry hair and skin. Marked malnutrition. Eye defects
	A.T.	16.0	7,500	4,700,000	66 (1)	4	17	9	1	2	1		
2	B.T.	14.3	4,000	4,325,000	44 (2)	12	0	25	2	9	1	1	Marked malnutrition. Eye defects
	A.T.	15.2	7,200	4,400,000	68 (1)	4	18	7	1	2			
3	B.T.	12.7	4,500	4,175,000	16 (12)	28	14	26	2	14			Marked malnutrition. Eye defects
	A.T.	13.9	6,500	4,495,000	68 (3)	2	20	5	1	2	1	1	
4	B.T.	11.7	5,400	3,980,000	50 (3)	10	5	20	2	12	1		Malnutrition with sinusitis
	A.T.	13.2	7,900	4,800,000	66 (2)	5	18	7	2	2			
5	B.T.	12.7	5,000	4,650,000	40 (5)	6	14	30	4	3	2	1	Reducing diet with dry hair and skin. Eye defects
	A.T.	14.9	6,800	4,725,000	62 (2)	2	22	6	3	2	2	1	
6	B.T.	12.7	5,000	4,485,000	52 (4)	8	10	20	4	2	2	2	Restricted diet. Eye defects. Dry hair and skin
	A.T.	13.8	5,500	4,625,000	64 (0)	6	18	6	3	2	1		
7	B.T.	13.8	4,800	4,110,000	52 (10)	9	11	21	1	5	1		Reducing diet. Dry hair and skin
	A.T.	14.2	5,000	4,098,000	60 (2)	4	21	5	4	3	2	1	
8	B.T.	15.8	4,300	3,900,000	38 (11)	7	11	34	3	5	1	1	Reducing diet. Ear infection
	A.T.	16.0	6,850	4,400,000	57 (3)	5	21	11	3	1	2		
9	B.T.	16.0	5,650	5,340,000	34 (8)	2	20	36	4	1	2	1	Extreme malnutrition. Inflamed eyes
	A.T.	16.0	8,350	5,500,000	51 (1)	2	26	13	5	0	2	1	
10	B.T.	12.8	4,000	4,175,000	46 (7)	4	14	26	4	3	2	1	Malnutrition. Conjunctivitis
	A.T.	13.7	5,900	4,180,000	58 (1)	2	21	11	3	2	2	1	
11	B.T.	11.8	4,500	3,975,000	42 (9)	4	21	20	3	6	2	2	Restricted diet. Throat infection
	A.T.	11.0	6,000	4,125,000	64 (2)	4	20	6	2	2	1	1	
12	B.T.	12.9	5,400	4,700,000	21 (11)	6	28	38	2	4	1		Food allergy. Dry hair and skin. Minor eye defects.
	A.T.	13.1	6,200	4,816,000	58 (3)	5	24	7	2	1	2	1	
13	B.T.	13.0	5,000	4,515,000	24 (7)	6	19	35	4	9	2	1	Restricted diet. Colitis. Minor eye defects
	A.T.	13.7	6,500	4,600,000	65 (2)	3	22	6		2			
14	B.T.	12.9	4,200	3,917,000	30 (6)	4	17	37	2	7	1	2	Restricted diet. Intestinal disturbance. Dry hair, skin
	A.T.	13.7	6,100	4,125,000	55 (4)	4	27	7	2	3	1	1	

* 16 grams Hb per 100 cc. of blood = 100%.
† D degenerate PMN.

are known to cause variation, shows a fairly wide range. However, by comparison with the leucocyte ranges for normal adults, it will be noted that in many of these cases the number of leucocytes was less than the low limit (5000 per cmm.). Even after the administration of large amounts of vitamin A the count was still in the low range.

Normal blood contains from 65 to 70 per cent of adult segmented neutrophiles; but in this work it was found that these cells make up only 16 to 52 per cent of the total count. The remainder are younger forms as stabs, juveniles, and myelocytes. These young cells sometimes constituted as much as 30 to 42 per cent of the total count. The presence of this unusual number of immature circulating neutrophiles indicated that the bone marrow was being damaged.

In the study of the blood picture of rats on a vitamin A deficient diet, Abbott and Ahmann (1) determined the condition of the marrow in the long bones. The usual finding was a gelatinous degeneration of the marrow, but occasionally an almost complete replacement by fibrous stroma had occurred. It is possible that a similar condition exists in humans suffering from a severe deficiency of vitamin A.

The normal hematologic standards for adults show that the circulating lymphocytes make up from 20 to 35 per cent of the total differential count, while in children the percentage is somewhat higher. About 75 per cent of the lymphocytes are small, the remainder large. But in this study of individuals on a diet low in vitamin A it was shown that the large lymphocytes make up the larger part of the lymphocyte count.

In many cases the small lymphocyte was rarely seen and the typical cell was the large or intermediate form. It is generally agreed that large lymphocytes are the more immature. As a rule it may be assumed that the presence of large lymphocytes in abnormal numbers indicates lymphoid hyperplasia. In this respect the immaturity of the lymphocytes is similar to the granulocytic immaturity, both of which were constant findings in this study.

Degeneration, often occurring in the leucocytes, was most noticeable in the polymorphonuclears. These cells often showed toxic granules and vacuolated cytoplasm, and if the deficiency had progressed to an advanced stage the cytoplasm appeared as faintly stained strands, the nucleus fragmented and granular and the cell wall indistinct and broken. The lymphocytes were also abnormal as to size and shape, and bizarre forms were not uncommon.

With the daily administration of 51,000 U.S.P. units of vitamin A over a period of 2 to 4 weeks a gradual improvement in the general condition of all the subjects was noted and in about 6 weeks the ratio of polymorphonuclears to lymphocytes returned to normal and the other abnormalities gradually disappeared. However, in several cases an unusually high

percentage of large lymphocytes persisted even after the disappearance of the eye defects, and dry hair and skin.

In this investigation a study has been made of the differential leucocyte counts of 157 individuals whose diets and symptoms indicated a vitamin A deficiency. The characteristic changes which were constant in the blood picture of these subjects are as follows: 1, a mild leucopenia; 2, a decrease in the polymorphonuclear neutrophils; 3, a relative increase in large lymphocytes with a corresponding drop in small lymphocytes; 4, the occurrence of degenerate cells, and 5, an increase in the number of juveniles. It will be noted that this blood picture is similar to that of rats fed a diet deficient in vitamin A and, as in the case of the rats, the administration of large amounts of vitamin A brought about a gradual improvement in symptoms and in a few weeks the differential count was within the normal range.

From this work it was concluded that the differential leucocyte counts of value in diagnosing a deficiency of vitamin A in man.

REFERENCE

(1) Abbott, O. D. and C. F. Ahmann. This Journal 122: 589, 1938.

Texas Repts. Biol. & Med. 11(2):181-195. 1953.

Abdulnabi-'53
Bib. No. 9

AMINO ACID METABOLISM IN VITAMIN DEFICIENCY.

I. Free Amino Acids in Tissues of Normal and Deficient Rats

Mohammed Abdulnabi and J. G. Bieri*

Outside of its role in the mechanism of vision, the biochemical function of vitamin A is still unknown. However, it is known to be concerned with various broad physiological activities, the most outstanding of which is the maintenance of the integrity of the epithelial tissues (Wolbach and Howe, 1925). Just how vitamin A maintains the integrity of the epithelial tissues has not been elucidated. Mason and Ellison (1935) stated that the inability of vitamin A deficient rats to produce normal, mucified epithelial cells indicated a definite alteration in the physiological state of the cell. These workers suggested that vitamin A may play a role in protein metabolism or synthesis within the epithelial cells. Since little is known of possible changes in protein metabolism as a result of vitamin A deficiency, a series of studies into this problem has been carried out. In the present paper, the free amino acid patterns in testes and submaxillary glands, organs known to show distinct pathological changes in vitamin A deficiency, have been determined. Blood serum also has been analyzed since no detailed accounts of the free amino acids in rat blood, as determined by paper chromatography, have appeared. In addition, a quantitative investigation by microbiological assay methods of the free amino acids in several rat tissues is reported.

I. Paper Chromatographic Analysis

Experimental. Weanling, male Holtzman rats were divided into two groups and pair-fed either the U.S.P. vitamin A assay ration or a purified, vitamin A-free diet (Bieri and Sandman, 1951). Control animals were fed one drop of cod-liver oil daily. When the first stage of vitamin A de-

* From the Department of Biochemistry and Nutrition, The University of Texas Medical Branch, Galveston. The material in this paper is from a thesis submitted to the Graduate School by Mohammed Abdulnabi in partial fulfillment of the requirements of the Doctor of Philosophy degree. This work was supported, in part, by the Williams-Waterman Fund of the Research Corporation. Received for publication January 30, 1953.

ficiency appeared in an experimental animal, both the depleted rat and its control were fasted twelve hours. Under ether anesthesia, they were bled to death from the carotid artery. The testes and submaxillary glands were quickly homogenized with 2-3 ml. of water. The homogenates, and serum, were immediately deproteinized with ethanol and the amino acids extracted by the procedure of Awapara (1948). The protein-free extracts were adjusted to pH 7-8 with dilute ammonia and desalted by the electrodialysis method of Consden, Gordon, and Martin (1947). With our apparatus, the initial potential of 25-35 volts rose to a maximum of 95 volts when desalting was completed, usually in 6-10 minutes. Under these conditions no conversion of arginine to ornithine occurred, as found by Stein and Moore (1951) with longer desalting periods. The desalted samples were stored at 5° C. until analyzed. Prior to analysis, the extracts were concentrated to 0.2 ml. in a 50° C. water bath. They were then analyzed by the two dimensional ascending technique of Williams and Kirby (1948). The samples were applied to Whatman No. 1 filter paper in portions of 10 microliters. Each sample represented 0.4–0.6 ml. of serum, 0.3–0.5 gm. of testes, or 0.05-0.10 gm. of submaxillary glands from individual animals. The chromatograms were run at 26–28° C. using phenol-water (75:25 by volume) as the first solvent, and 2,4-lutidine-water (65:35 by volume) as the second solvent. Solvents were removed by drying for one hour in a forced air oven at 85° C. When compared with chromatograms dried at room temperature, no significant destruction of amino acids by the heat drying was apparent (Brush, Boutwell, Barton, and Heidelberger, 1951). The amino acids were located by spraying the sheets with 0.2 per cent ninhydrin in water-saturated butanol, followed by heating for 5–7 minutes at 85° C. The spots were located and marked with the aid of a fluorescent X ray viewer.

The identification of the spots was made from a map containing 28 compounds, similar to that of Dent (1948). The map used in this investigation is represented in figure 1. It was constructed by chromatographing standard solutions of amino acids by the two dimensional ascending technique described above. Verification of spots in cases of questionable identification was made by applying to the paper a small amount of the amino acid involved in addition to a portion of the sample in question before chromatographing. If the added amino acid was superimposed on the unidentified spot, the identity was then assumed to be established. It is recognized, however, that this procedure does not constitute positive identification.

Although the majority of the chromatograms from desalted samples were clear and showed distinct spots, a few chromatograms occasionally appeared irregular and revealed overlapping spots. Thus, methionine and valine, spots 9 and 10 on the map, frequently were not separately distinguishable. Similarly, spot 11 represents both leucine and isoleucine. Spots 4 and 5 both correspond to glutamine. Early in this study, β-alanine was thought to be present in some tissues, but the spot in question was found to be part of the larger glutamine spot.

Results. A list of the compounds, and the number of animals in which each amino acid occurred, is given in Table 1. A total of 25 different spots was detected in the three tissues analyzed. The gross examination of Table 1 reveals that the compounds may be grouped as follows: 1. Amino acids, or their derivatives, which were found in all samples studied. These include aspartic acid, glutamic acid, α-alanine, glycine, serine, methionine (or valine), leucine, phenylalanine, and taurine. 2. Compounds that were found in all tissues but appeared less frequently in one or the other tissue. These include glutamine, threonine, proline, arginine, lysine, glutathione, ethanolamine phosphoric acid, and γ-aminobutyric acid. 3. Compounds that were not present in all tissues. These include asparagine, fast peptide, "under-taurine," "under-tyrosine," and hydroxyproline. 4. A single amino acid, α-aminobutyric acid, can be considered differently from other compounds because not only was it infrequent in its appearance, but it was absent from all control samples of testes and submaxillary glands.

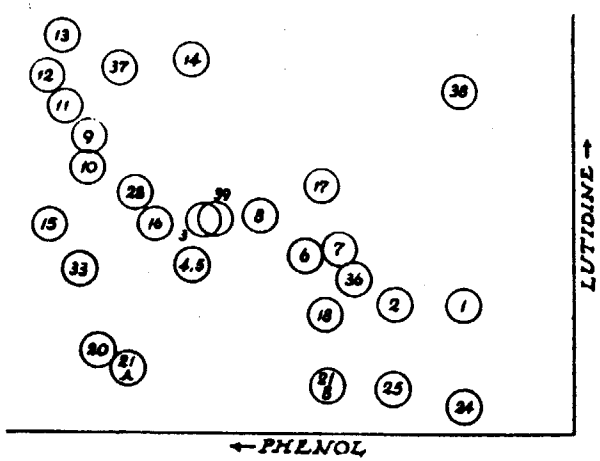

FIG. I. Map used for identifying amino acids.

1. Aspartic acid
2. Glutamic acid
3. Alanine
4, 5. Glutamine
6. Glycine
7. Serine
8. Threonine
9. Methionine
10. Valine
11. Leucines
12. Phenylalanine
13. Tryptophan
14. Tyrosine
15. Proline
16. Hydroxyproline
17. Taurine
18. Asparagine
20. Arginine
21. Lysine
24. Glutathione
25. Ethanolamine Phosphate
28. α-aminobutyric acid
33. γ-aminobutyric acid
36. Isoserine
37. 3, 5-dilodotyrosine
38. Dihydroxyphenylalanine
39. Homoserine

Although the general pattern of ninhydrin-reacting substances was quite similar for the different tissues investigated, a large number of the compounds varied considerably in their frequency of appearance in one tissue to another. Such compounds are represented by those classified under (2). Furthermore, several compounds appeared infrequently in the same tissues from different rats. A few amino acids, for example, α-aminobutyric acid, γ-aminobutyric acid, hydroxyproline, and asparagine were found infrequently and might not have been detected if a large number of animals had not been used.

TABLE 1

Occurrence of Free Amino Acids in Serum, Submaxillary Glands and Testes of Normal and Vitamin A Deficient Rats

Amino Acid*	Serum Deficient (15)†	Serum Normal (17)	Submaxillary Gland Deficient (17)	Submaxillary Gland Normal (15)	Testes Deficient (21)	Testes Normal (19)
1. Aspartic acid	15	17	14	9	19	17
2. Glutamic acid	15	16	15	13	20	18
3. Alanine	12	15	14	12	18	16
4, 5. Glutamine	10	16	6	7	11	16
6. Glycine	15	17	15	12	21	19
7. Serine	12	14	12	7	13	9
8. Threonine	5	8	6	4	3	3
9. Methionine	14	17	12	10	15	15
10. Valine	10	10	6	7	13	13
11. Leucines	13	16	10	10	13	15
12. Phenylalanine	8	8	8	7	13	11
14. Tyrosine	7	6	3	2	11	12
15. Proline	13	15	7	6	13	15
16. Hydroxyproline	1	0	0	1	0	0
17. Taurine	9	10	12	9	19	18
18. Asparagine	0	0	1	2	0	0
20. Arginine	10	10	6	2	11	13
21. Lysine	7	5	4	4	9	12
24. Glutathione	2	2	2	3	13	8
25. Ethanolamine Phosphate	1	2	14	11	20	18
27. Peptide	0	0	11	9	21	18
28. α-aminobutyric acid	4	4	1	0	2	0
33. γ-aminobutyric acid	4	3	2	2	13	13
35. Under-tyrosine	4	2	0	0	0	0
36. Under-taurine	0	0	0	0	4	4

* Numbers refer to identification of spots in Fig. 1.
† Numbers in parentheses indicate number of animals analyzed.

Serum: A typical chromatogram of serum from a normal rat is shown in figure II. Chromatograms from deficient animals were strikingly similar, so that no effect on the free amino acids as a result of vitamin A deficiency could be said to occur. About eighteen spots were generally found in the serum. Most of these spots corresponded to the usual natural amino acids. Spots corresponding to ethanolamine phosphoric acid, α-aminobutyric acid, γ-aminobutyric acid and hydroxyproline appeared in only a few samples.



FIG. II. Chromatogram of free amino acids in normal rat serum. (See Fig. I for identification of spots. Spot 35 is unidentified.)

Of particular interest was the finding in six serums of an unidentified purple spot directly below tyrosine (Fig. II). In some cases, this spot was as intense in color as was the tyrosine spot. From the position of this spot, it appeared that it might have a structure closely related to tyrosine. Hence, two available compounds, 3,5-diiodotyrosine and dihydroxyphenylalanine (Dopa) were chromatographed in an attempt to identify the unknown spot. That this spot was neither of these two tyrosine derivatives was shown by the positions of these two compounds on the chromatograms (See map, Fig. 1).

Testes: A typical chromatogram from normal rat testes is shown in figure III. Chromatograms from normal and deficient

rat testes were also almost identical. About twenty spots were generally found in testes. As in the serum, the majority of these spots corresponded to the usual natural amino acids or their derivaties. The occurrence of amino acids in tests was, in general, more predominant and their spots more intense than those in the submaxillary glands or serums. Ethanolamine phosphoric acid was found in practically all samples, and γ-aminobutyric acid in most of them. The peptide (No. 27) described by Fuerst, Landua, and Awapara (1950) was almost always present. An unidentified, bright blue spot under taurine, and above serine, appeared when a chromatogram was erroneously heated at 120° C., after treatment with ninhydrin (Fig. III). This spot

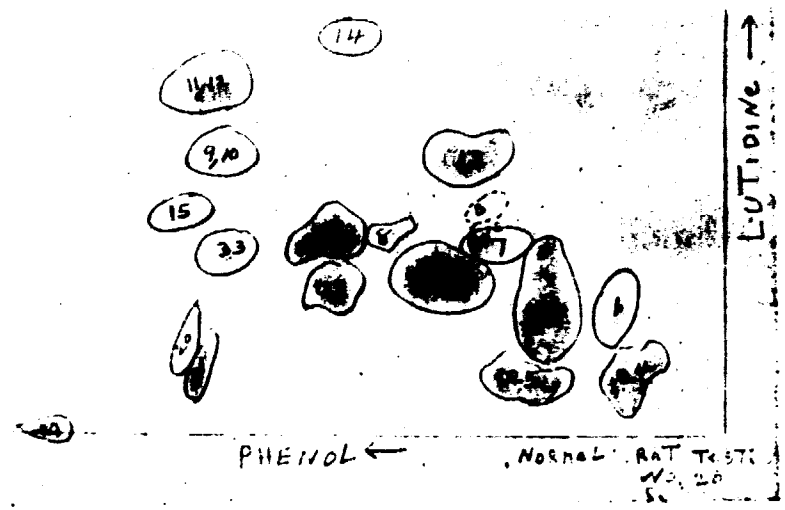

FIG. III. Chromatogram of free amino acids in normal rat testes. (See Fig. I for identification of spots. Spot "B" is unidentified.)

was later found in testes from four normal and four deficient rats. The color would develop only at this higher temperature. From the position of this spot, it appeared that it might be a short chain amino acid or a derivative related to serine, glycine, or taurine. Homoserine and isoserine were chromatographed to see if the unknown spot corresponded to either of these compounds. As is shown in the map, figure I, spots 36 and 39 correspond to isoserine and homoserine respectively and their positions are quite distinct from that of the unknown spot under

taurine. Furthermore, the unknown compound was a distinct blue while that of homoserine was purple and in the case of isoserine, yellow-brown.

Submaxillary glands: A chromatogram of this tissue from a normal rat is represented in figure IV. The chromatograms from this tissue were considerably more variable than from the serums or testes. Generally, only 8–10 spots appeared from any one sample. Since the glands from the animals were fairly uniform in weight, the observed variations in amino acids most probably represent individual variations among animals. In addition to the usual amino acids, ethanolamine phosphoric acid and peptide (No. 27) appeared in more than half of the samples. As with the other tissues studied, no effect of vitamin A deficiency on the ninhydrin-reacting substances in the submaxillary glands was apparent.



FIG. IV. Chromatogram of free amino acids in normal rat submaxillary glands. (See Fig. I for identification of spots. Spot "S" is salt.)

II. Microbiological Analysis

Experimental. The preparation of the normal and deficient animals was similar to that in the preceding section, except that the U.S.P. vitamin A assay ration was used exclusively. When the first stage of vitamin A deficiency appeared in an experimental animal, usually in 18–25 days (body weight 110–140 gm.), both the depleted rat and its control were fasted

24 hours. The animals were then killed by decapitation and the kidneys, testes and medial and right lobes of the liver excised and prepared by a modification of the method of Schurr, Thompson, Henderson, Williams, and Elvehjem (1950). Two or three grams of liver, and both kidneys, from each animal were treated separately, while the testes of two deficient or normal animals were combined. After removal from the animal, the tissues were immediately blotted with filter paper, weighed and dropped into homogenizing tubes containing 0.013 N. acetic acid in a boiling water bath. The time required after decapitation to remove and weigh the tissues and place them in the hot acetic acid was 3 to 4 minutes. Schurr, Thompson, Henderson, and Elvehjem (1950) showed that no apparent change in free amino acids in tissues of rats occurred within 5 minutes after death. The amounts of acetic acid used were 3 ml./gm. of liver or kidney and 1.5 ml./gm. of testes. After 4 minutes in the boiling water bath, the tissues were homogenized thoroughly while hot. The samples were then replaced in the boiling water bath for another 4 minutes with constant stirring. After centrifuging, the supernatants were deproteinized with tungstic acid. One-tenth volume of 0.6 N. sulfuric acid was added for the kidney extracts and 0.2 volumes for the liver and testes extracts. This was followed by 0.2 ml. of 10 per cent sodium tungstate for each gram of tissue. All samples were then stirred thoroughly and permitted to stand for 20 minutes. After centrifuging, the clear supernatants were frozen at —10° C.

Blood serums were deproteinized by the method of Hier and Bergeim (1945) and the filtrates frozen at —10° C. until analyzed. In order to have a sufficient amount of sample for the microbiological analysis, the blood filtrates of three animals were pooled and adjusted to pH 6.8–7.0 with 0.5 N. sodium hyroxide. The tissue filtrates were adjusted to the same pH in a similar manner. The final volumes of samples per gram of tissue (or per ml. serum) were 10 ml. for the kidneys, 5 ml. for the livers, and 3 ml. for the serums and testes.

The microbiological assay method employed here was that of Henderson and Snell (1948). The only changes in technique were those necessitated by the reduction in final volume in each assay tube from 2.0 to 0.5 ml. The composition of the basal medium was that proposed by Henderson and Snell (1948), but in the actual assay single strength medium was used rather than double strength. The amino acids not determined were made up in a dry solid mixture. The amino acids to be determined, namely, lysine, proline, tyrosine, valine, leucine, phenylalanine, arginine, threonine and methionine, were made up as nine solid mixtures. Each mixture contained eight amino acids exclusive of the one to be determined. Due to the large blank values encountered initially in the assays for methionine, this amino acid was not determined in the samples analyzed.

For these analyses a "composite standard," a dry mixture of amino acids, was employed to establish the standard curves. This standard mixture had the same composition as that proposed by Schurr, Thompson, Henderson, and Elvehjem (1950) with the exception of lysine which was made to

provide in the final dilution 20 mcg./ml. rather than 40. Standards, samples and water were dispensed with the Cannon automatic dispenser from an all-glass vessel. After dispensing the inoculated media, the assay tubes were incubated at 37° C. for 65–72 hours in a humidified incubator. The lactic acid produced was titrated electrometrically directly in the assay tubes with 0.04 N. sodium hydroxide. The Cannon automatic titrator was employed and the titration procedure and apparatus used were similar to those adapted by Henderson, Brickson, and Snell (1948).

To determine the reliability of the microbiological assay method employed, amino acid recoveries were performed on extracts from the serum and liver of a stock rat. Recoveries of added amino acids ranged from 99–111 per cent, with the exception of arginine. The recovery of arginine from liver filtrates was unsatisfactory due to the very low concentration of this amino acid in this tissue. With the amounts of filtrate used, the growth response of the microorganism to arginine was frequently too small to be reliable. A similar situation was found for this amino acid in testes. Consequently, only a few determinations of arginine in liver and testes are reported.

Since only small quantities of tissue extracts were obtained from individual rats, duplicate levels of 0.05, 0.10, and 0.15 ml. of each extract were assayed for the eight amino acids to be determined. Agreements among the three levels was generally ±11 per cent. Occasional individual values that were considerably out of line were discarded.

Results. A summary of the determinations of free amino acids in all tissues analyzed is presented in Table 2. It is apparent from this table that large variations are encountered in the values of each single amino acid in any given tissue whether from normal or deficient animals. Furthermore, the average amount of each amino acid tends, in general, to differ from one tissue to another in both normal and deficient animals. This variation was exemplified in practically all amino acids with the exception of lysine, which gave similar values for serum, liver, and kidney. Except for proline and arginine, the concentration of each amino acid in the kidneys was higher than in the other tisues investigated. Proline was present in testes in higher concentration than in kidney, liver, or serum. The average amount of arginine in serum was greater than in the other tissues studied.

As for the total amounts of all amino acids determined, the kidney had the greatest concentration, while liver had greater amounts than did serum or testes. The average values for normal serum, liver and kidney were greater than those for the

TABLE 2

Free Amino Acids in Tissues of Normal and Vitamin A Deficient Rats. Values Expressed as mcg./gm. Fresh Tissue, or mcg./ml. Serum. Figures in Parentheses Indicate Range of Values.

Amino Acid	Serum		Liver		Kidney		Testis	
	Deficient	Normal	Deficient	Normal	Deficient	Normal	Deficient	Normal
Arginine	27.1±10.2* (13.5—38.5)	85.0±10.8 (22.8—47.0)	4.5± 3.3 (2.0—10.8)	4.0± 1.6 (2.5— 6.2)	19.1± 8.7 (11.0—33.0)	19.8±14.5 (5.0—43.2)	3.8± 1.6 (2.0— 5.5)	2.0†
Threonine	36.4±19.7 (12.0—60.8)	60.6±21.0 (36.7—87.6)	42.0±11.2 (28.0—59.0)	78.6± 5.3 (73.0—86.3)	97.5±27.6 (54.0—130.0)	133.5±32.1 (90.5—182.0)	13.7± 2.5 (10.5—17.0)	10.3± 1.5 (9.0—12.0)
Valine	20.4± 3.7 (17.0—23.0)	21.6± 3.0 (18.6—26.6)	41.1±14.3 (21.7—59.5)	38.9±11.7 (25.0—56.0)	56.6±12.2 (43.0—81.0)	57.0±14.1 (43.0—86.5)	23.0± 3.6 (18.0—26.0)	16.1± 1.5 (14.0—17.3)
Leucine	28.6± 3.1 (25.0—32.1)	29.9± 2.2 (27.7—32.1)	58.5±14.3 (32.5—78.0)	53.0± 7.0 (41.0—64.7)	81.2±11.2 (67.5—102.7)	82.8±13.4 (60.0—99.0)	38.6± 3.0 (35.3—42.5)	27.0± 1.2 (25.3—28.0)
Phenylalanine	16.5± 1.7 (14.8—18.2)	21.4± 0.9 (19.6—23.1)	24.2± 3.9 (16.0—28.0)	25.7± 2.8 (21.3—29.0)	37.6± 7.1 (25.3—48.0)	40.9±13.8 (26.3—57.0)	19.8± 1.8 (16.7—21.3)	7.9± 0.9 (7.3— 8.5)
Tyrosine	17.7± 1.8 (15.8—19.2)	16.6± 1.7 (14.4—18.7)	35.0± 5.1 (26.0—41.7)	28.6± 5.7 (21.7—38.7)	52.8±12.7 (29.0—64.0)	49.4±12.8 (33.0—71.3)	23.7± 3.6 (20.3—29.0)	10.1± 1.1 (9.3—11.7)
Lysine	43.4± 0.2 (43.2—43.6)	44.5± 5.5 (39.7—52.2)	42.1±10.6 (26.5—56.0)	45.6± 9.6 (32.3—58.7)	44.0± 5.6 (34.5—50.3)	54.0± 9.6 (42.5—70.0)	37.8± 3.6 (34.0—42.0)	35.6± 2.0 (32.0—38.0)
Proline	8.8± 4.1 (4.7—12.9)	17.8± 1.3 (16.5—19.1)	19.8± 5.7 (13.0—30.0)	15.1± 4.0 (7.3—20.0)	34.9± 9.8 (20.0—47.5)	39.3±13.4 (22.5—61.0)	60.7± 6.6 (51.5—70.0)	67.3±12.6 (52.0—82.5)
Total	198.9	250.4	267.2	289.5	423.7	476.7	221.1	176.3

* Standard deviation.
† One determination only.

deficient tissues, while the opposite was true for testes. That each tissue had its characteristic quantitative pattern of amino acids is in confirmation of the qualitative studies by paper chromatographic analysis, i.e., each tissue was distinguished by a slightly different distribution of amino acids.

It has already been mentioned that there were no significant differences in the qualitative picture of amino acids from normal and deficient animals. The quantitative studies showed no difference between normal and deficient rats for most of the amino acids. However, statistical analysis revealed that the higher values of threonine in normal liver and of phenylalanine and tyrosine in deficient testes were highly significant. The P values were less than 0.001 for threonine and less than 0.01 for both tyrosine and phenylalanine. These are the only instances in which there were significant differences in amino acids between normal and deficient tissues.

Discussion. As was shown in the chromatograms, the general pattern of ninhydrin-reacting substances was quite similar for different tissues. Aspartic acid, glutamic acid, alanine, glycine, serine, methionine (or valine), leucine and taurine were found in practically all of the samples analyzed. The consistent occurrence of the first four of these amino acids is in agreement with the studies made by Awapara, Landua, and Fuerst (1950), who found aspartic and glutamic acids, alanine, and glycine in practically all of the eight rat organs they investigated. Tissues differed from each other, however, in the frequency of appearance of various other amino acids.. Such differences among tissues may be considered as reflections of the different metabolic patterns in any single tissue. The number and distribution of spots in serum were similar to those reported for human plasma (Agren and Nilsson, 1949; Crumpler, Dent, and Lindan, 1950) and for dog plasma (Flock, Mann, and Bollman, 1951). Of interest is the occurrence in six serum samples of the unidentified purple "under tyrosine" spot. No reports of a similar spot have appeared.

Besides the usual (i.e., frequently occurring) natural amino acids, ethanolamine phophoric acid and the "fast peptide" were found in both testes and submaxillary glands. A similar finding was reported by Awapara, Landua, and Fuerst (1950). The

blue spot "under taurine," found in testes, has not been reported previously.

The total average amount of free amino acids in normal rat serums, by microbiological assay, was higher than that reported for human serum (Hier and Bergeim, 1946; Harper, Hutchin, and Kimmel, 1952) and dog plasma (Hier and Bergeim, 1945; Hier and Bergeim, 1946). This total agreed closely, however, with that reported by Henderson, Schurr, and Elvehjem (1949), for the rat. The total amount of free amino acids in the latter case was 260.9 mcg./ml. for fasted rats, compared to 250.4 mcg./ml. for the animals analyzed in the present studies. The single average values of arginine, valine, and tyrosine were substantially the same. Threonine, leucine, and phenylalanine values were considerably higher (44–88 per cent) in the present investigation, while lysine and proline were lower (102–62 per cent) than those reported by the Wisconsin workers. The fluctuation of single amino acid values from one sample to another was noticeable in all the studies quoted above. Lysine, for example, had a two-fold variation in separate studies by the same group (Henderson, Schurr, and Elvehjem, 1949; Schurr, Thompson, Henderson, and Elvehjem, 1950).

The free amino acid concentrations in liver were, in general, lower than those reported by Schurr, Thompson, Henderson, Williams, and Elvehjem (1950), or by Solomon, Johnson, Sheffner, and Bergeim (1951). Similarly, the concentrations in kidney were lower than those found by the latter investigators. If age, strain, and weight of animals are factors which may contribute to the difference in amino acid values, as Schurr, Thompson, Henderson, Williams, and Elvehjem (1950) have stated, then the low values obtained in these studies may be explained on this basis. In both of the studies cited, the animals were considerably older and larger than those used in the present studies.

It appears from the results of our investigation that the qualitative picture of free amino acid in rats as obtained by the paper chromatographic technique is not altered by vitamin A deficiency. Although the results of the microbiological determinations supported those of the paper chromatographic analyses in most cases there were, however, a few exceptions which appear to be of interest. The increases in phenylalanine and tyrosine

concentrations in testes of deficient animals were significant. Of these two amino acids, phenylalanine is essential to the rat. The fact that tyrosine is formed in the body from phenylalanine may lead to the speculation that the increase in tyrosine concentration in deficient testes is a result of phenylalanine accumulation in this organ.

The possibility that vitamin A may be involved in the metabolism of the amino acids threonine, phenylalanine, and tyrosine is suggested by the above results. In a study such as this, however, care must be taken that any changes produced in the tissues are a specific result of insufficient vitamin A and are not due to a deficiency of several nutrients through general inanition. Mason (1933) elaborated on this point and compared the changes produced by vitamin A deficiency and by starvation. He further showed that in vitamin A deficiency lesions in the testes appear as soon as xerophthalmia is evident. In the present study, animals were sacrificed before advanced stages of deficiency set in and before the food intake had decreased sharply.

The considerable variation of many of the free amino acids in tissues as found in this study, and as found by other investigators (above), suggests that the concentrations of free amino acids in tissues are subject to considerable fluctuation and are probably affected by numerous metabolic factors.

Summary

Analysis by paper chromatography of the free amino acids in blood serum, testes and submaxillary glands of normal and vitamin A deficient rats did not reveal any differences due to a lack of the vitamin. Two unidentified spots were detected, one "under taurine" in testes and the other "under tyrosine" in serum. Considerable variation in the occurrence of many amino acids in the same tissue from similar animals was apparent.

The quantitative picture of most free amino acids is essentially not altered from normal by avitaminosis A, using the microbiological assay procedure. The amount of threonine was higher in normal livers than in deficient livers. An increased concentration of phenylalanine and of tyrosine in deficient testes was also found. In general, for any particular amino acid, a comparison of its concentration in the same tissue from different animals revealed large variations.

Acknowledgments. The authors wish to acknowledge the helpful suggestions of Dr. L. M. Henderson concerning various techniques of the microbiological assay. They are also gratefully indebted to Dr. H. B. Lewis for a sample of isoserine, and to Dr. M. D. Armstrong for a sample of homoserine.

REFERENCES

Ägren, G., and T. Nilsson: Paper chromatographic analysis of amino acids and other ninhydrin-reacting substances in deproteinized human plasma. *Acta Chem. Scand.*, 3: 525–538, 1949.

Awapara, J.: Application of paper chromatography to the estimation of free amino acids in tissues. *Arch. Biochem.*, 19: 172–173, 1948.

Awapara, J., A. J. Landua, and R. Fuerst: Free aminoethyl phosphoric ester in rat organs and human tumors. *J. Biol. Chem.*, 183: 545–548, 1950.

———: Distribution of free amino acids and related substances in organs of the rat. *Biochim. et Biophys. Acta*, 5: 457–462, 1950.

Bieri, J. G., and R. P. Sandman: Comparative utilization of carotene administered orally and parenterally. *Proc. Soc. Exptl. Biol. Med.*, 77: 617–619, 1951.

Brush, M. K., R. K. Boutwell, A. D. Barton, and C. Heidelberger: Destruction of amino acids during filter paper chromatography. *Science*, 113: 4–6, 1951.

Consden, R., A. H. Gordon, and A. J. P. Martin: The identification of lower peptides in complex mixtures. *Biochem. J.*, 41: 590–596, 1947.

Crumpler, H. R., C. E. Dent, and O. Lindan: The amino acid pattern in human fetal and maternal plasma at delivery. *Biochem. J.*, 47: 223–227, 1950.

Dent, C. E.: A study of the behavior of some sixty amino acids and other ninhydrin-reacting substances on phenol collidine filter paper chromatograms, with notes as to the occurrence of some of them in biological fluids. *Biochem. J.*, 43: 169–180, 1948.

Flock, E. V., F. C. Mann, and J. L. Bollman: Free amino acids in plasma and muscle following total removal of the liver. *J. Biol. Chem.*, 192: 293–300, 1951.

Fuerst, R., A. J. Landua, and J. Awapara: The presence in animal organs and human blood of a peptide detected by paper chromatography. *Science*, 111: 635, 1950.

Harper, H. A., M. L. Hutchin, and J. T. Kimmel: Concentration of nineteen amino acids in plasma and urine of fasting normal males. *Proc. Soc. Exptl. Biol. Med.*, 80: 768–771, 1952.

Henderson, L. M., W. L. Brickson, and E. E. Snell: A micromethod for the microbiological determination of amino acids. *J. Biol. Chem.*, 172: 31–38, 1948.

Henderson, L. M., P. E. Schurr, and C. A. Elvehjem: The influence of fasting and nitrogen deprivation on the concentration of free amino acids in rat plasma. *J. Biol. Chem.*, 177: 815–823, 1949.

Henderson, L. M., and E. E. Snell: A uniform medium for determination of amino acids with various microorganisms. *J. Biol. Chem.*, 172: 15–29, 1948.

Hier, S. W., and O. Bergeim: Microbiological determination of free leucine, isoleucine, valine, and threonine in dog plasma. *J. Biol. Chem.*, 161: 717–722, 1945.

————: The microbiological determination of certain free amino acids in human and dog plasma. *J. Biol. Chem.*, 163: 129–135, 1946.

Mason, K. E.: Differences in testis injury and repair after vitamin A-deficiency, vitamin E-deficiency, and inanition. *Am. J. Anat.*, 52: 153–239, 1933.

Mason, K. E., and E. T. Ellison: Changes in the vaginal ephithelium of the rat after vitamin A-deficiency. *J. Nutrition*, 9: 735–755, 1935.

Schurr, P. E., H. T. Thompson, L. M. Henderson, and C. A. Elvehjem: A method for the determination of free amino acids in rat organs and tissue. *J. Biol. Chem.*, 182: 29–37, 1950.

Schurr, P. E., H. T. Thompson, L. M. Henderson, J. N. Williams, and C. A. Elvehjem: The determination of free amino acids in rat tissues. *J. Biol. Chem.*, 182: 39–45, 1950.

Solomon, J. D., C. A. Johnson, A. L. Sheffner, and O. Bergeim: The determination of free and total amino acids in rat tissues. *J. Biol. Chem.*, 189: 629–635, 1951.

Stein, W. H., and S. Moore: Electrolytic desalting of amino acids—conversion of arginine to ornithine. *J. Biol. Chem.*, 190: 103–106, 1951.

Williams, R. J., and H. Kirby: Paper chromatography using capillary ascent. *Science*, 107: 481–483, 1948.

Wolbach, S. B., and P. R. Howe: Tissue changes following deprivation of fat-soluble A vitamin. *J. Exptl. Med.*, 42: 753–777, 1925.

Texas Repts. Biol. & Med. 11(2):196-199. 1953.
Abdulnabi-'53
Bib. No. 10

AMINO ACID METABOLISM IN VITAMIN DEFICIENCY:

II. The Glutamic-Aspartic Transaminase Activity in Tissues from Normal and Deficient Rats

Mohammed Abdulnabi and J. G. Bieri*

The possible involvement of vitamin A in protein metabolism has been referred to in the preceding paper (Abdulnabi and Bieri, 1953). Since the transaminases are actively involved in protein and amino acid metabolism, one possible mechanism by which vitamin A might be involved in nitrogen metabolism is through the transamination reaction. Although no information is available in the literature concerning this possibility, it has been reported recently that the transaminase system might be related to a fat-soluble vitamin deficiency (Barber, Basinski, and Mattill, 1949). The present paper deals with the study of the activity of the glutamic-aspartic transaminase system in the kidney, liver, and heart of normal and vitamin A deficient rats. Of these tissues, only the kidney is known to be primarily affected in vitamin A deficiency (Wolbach and Howe, 1925; Tyson and Smith, 1929).

Experimental. The method used for the determination of the glutamic-aspartic transaminase activity was essentially the manometric procedure of Green, Leloir, and Nocito (1945). The preparation of animals for these determinations was similar to that reported in the previous paper (Abdulnabi and Bieri, 1953). The food consumption was equalized by giving restricted amounts of the U.S.P. vitamin A assay ration. When the first stage of vitamin A deficiency appeared in an experimental animal, both the depleted rat and its control were decapitated and the livers, kidneys, and hearts rapidly extirpated and immediately packed in finely cracked ice. After cooling, bits of fat and connective tissue were removed, the tissues blotted between filter paper, and rapidly weighed. A homogenate of the tissue was prepared in ice-cold 0.1 M. sodium phosphate buffer (pH 7.4). This homogenate was pipetted immediately into the pre-cooled reaction vessels. The dry weights of samples were determined by evaporation of 1.0 ml. homogenate to constant weight in an oven at 100° C.

* From the Department of Biochemistry and Nutrition, The University of Texas Medical Branch, Galveston. The material in this paper is from a thesis submitted to the Graduate School by Mohammed Abdulnabi in partial fulfillment of the requirements of the Doctor of Philosophy degree.
This work was supported, in part, by the Williams-Waterman Fund of the Research Corporation. Received for publication January 30, 1953.

Flasks with a single side arm were used in the direct method of Warburg at 37° C. The components of the final reaction mixture were: main chamber: 0.9 ml. of 0.25 M. sodium phosphate buffer (pH 7.4), 1.0 ml. of 0.2 M. sodium aspartate, 0.1–0.3 ml. of tissue homogenate in 0.1 M. sodium phosphate buffer, and a sufficient quantity of this same buffer to yield a total volume of 3.2 ml.; side arm: 1.0 ml. of 0.1 M. sodium α-ketoglutarate; center cup: 0.5 ml. of aniline citrate reagent. Three levels of each tissue were run in duplicate. These were 0.1, 0.2, and 0.3 ml. of 5 per cent liver and 2.5 per cent heart and kidney homogenates. After eight minutes equilibration readings were recorded and the stop-cocks of the manometers closed. The α-ketoglutarate was added from the side arm and the reaction allowed to proceed for exactly ten minutes. At the end of this time, the reaction was stopped by adding aniline citrate from the center well. This was mixed carefully to insure complete decomposition of oxalacetic acid formed during the reaction. After ten minutes, when all of the carbon dioxide had been liberated, the readings of the manometers were recorded. The carbon dioxide produced per mg. of wet tissue of each sample was calculated after subtracting the carbon dioxide evolved from the blank flask. This flask contained all reactants, including homogenate, but the

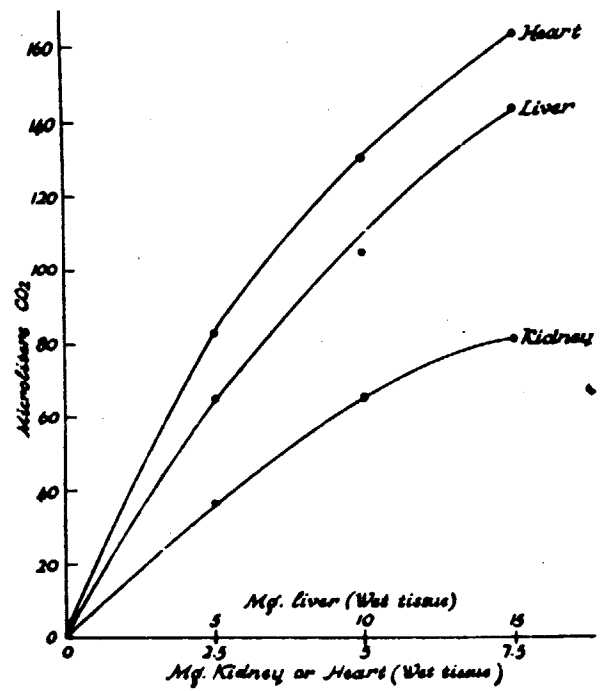

Fig. I. Representative curves of glutamic-aspartic transaminase activity of rat tissue homogenates.

aniline citrate reagent was added to the main chamber at zero time, thus stopping the enzymatic activity of the homogenates. The carbon dioxide liberated from the homogenates was found to be negligible compared with that liberated from the reagents.

Results and Discussion. Typical curves illustrating the aspartic-glutamic transaminase activity of the three tissues studied are shown in figure 1. These curves clearly demonstrate that at the three levels of tissue used there is an essentially linear relationship between the amount of tissue and the observed enzyme activity. The values of carbon dioxide liberated by the three levels of tissue employed agreed, in general, within ±7 per cent for liver, ±15 per cent for kidney, and ±6 per cent for heart. A similar linearity with a purified preparation of this enzyme was shown by Green, Leloir, and Nocito (1945).

Table 1 is a summary of the results obtained from liver, kidney, and heart homogenates expressed on the basis of wet weight of tissue. Values for liver, on a dry weight basis, are also included to demonstrate that the comparison between normal and deficient animals is not altered by considering the tissue

TABLE 1

Transaminase Activity of Tissues of Normal and Vitamin A Deficient Rats. Expressed as Microliters Carbon Dioxide Liberated in 10 Minutes by 1 mg. Tissue

	Liver		Kidney	Heart
	Wet	Dry	Wet	Wet
Normal Rats				
1	8.7	30.4	10.6	20.7
2	10.9	39.8	9.8	23.8
3	11.7	45.0	8.7	23.2
4	13.5	39.9	12.8	23.1
5	12.2	49.2	10.1	22.0
6	12.2	47.3	12.0	26.5
7	6.3	24.2	3.7	19.9
8	11.0	50.5	5.9	19.7
9	10.9	53.4	10.4	22.4
Average ± S.D.	10.8±2.1	42.2±9.1	9.3±2.8	22.4±1.6
Deficient Rats				
10	12.1	40.1	10.6	22.2
11	14.8	54.4	12.7	26.0
12	7.3	25.5	8.1	20.3
13	10.3	38.7	8.2	20.7
14	17.1	75.0	6.3	26.5
15	9.1	31.8	9.5	23.3
16	11.6	48.7	5.6	22.0
17	10.9	36.8	8.8	23.8
Average ± S.D.	11.6±3.1	43.9±8.4	8.7±2.2	23.1±2.1

water content. A similar result was obtained from several kidney and heart samples, consequently, the dry weight values of these tissues were not included.

Of the three tissues studied, the heart was the most active, being about 100 per cent greater than liver, and about 140 per cent greater than kidney expressed on a wet weight basis. The activity of kidney was about 80 per cent that of liver. The values for heart show the least variation from the mean. With liver and kidney, although the variation is greater, the majority of values are grouped closely with only one or two values showing considerable deviation. As to the effect of vitamin A on the transamination reaction studied, there seems to be no difference in the activity of the enzyme in tissues from normal or deficient animals. This indicates that vitamin A deficiency does not affect the glutamic-aspartic transaminase activity.

Summary

The glutamic-aspartic transaminase activity has been studied in homogenates of liver, kidney, and heart from normal and vitamin A deficient rats. Using a manometric method, no differences between normal and vitamin A deficient animals were found. Of the three tissues investigated, the heart was the most active, while the activity of kidney was slightly lower than that of liver.

REFERENCES

Abdulnabi, M., and J. G. Bieri: Amino acid metabolism in vitamin A deficiency. *Tex. Rep. Biol. and Med.*, 10: 181–195, 1953.

Barber, M. A., D. H. Basinski, and H. A. Mattill: Transamination in the muscles of animals deprived of vitamin E. *J. Biol. Chem.*, 181: 17–21, 1949.

Green, D. E., L. F. Leloir, and V. Nocito: Transaminases. *J. Biol. Chem.*, 161: 559–582, 1945.

Tyson, M. D., and A. H. Smith: Tissue changes associated with vitamin A deficiency in the rat. *Am. J. Path.*, 5: 57–69, 1929.

Wolbach, S. B., and P. R. Howe: Tissue changes following deprivation of fat-soluble A vitamin. *J. Exptl. Med.*, 42: 753–777, 1925.

Ames, Swanson, Risley, & Harris-'52
Bib. No. 177

Fed. Proc. 11:181. 1952.

Hypervitaminosis A induced by crystalline vitamin A acetate. STANLEY R. AMES, WILLIAM J. SWANSON,* HUGH A. RISLEY* AND PHILIP L. HARRIS. *Research Labs., Distillation Products Industries, Div. of Eastman Hodak Co., Rochester, N. Y.*

Hypervitaminosis A in the albino rat was investigated, employing cottonseed oil solutions of crystalline vitamin A acetate. Single dose feeding tests indicated an LD_{50} of about 1 million units/100 gm. body weight. Results of 28 day, semi-chronic tests showed no deaths at a level of 15,000 units/100 gm/day and an LD_{50} at 28 days of 20,000–30,000 units/100 gm/day. When animals were supplemented daily over a long period (9–12 months), about ½ the animals died at levels of 20,000 units/animal/day and all died at 30,000 units. Depression of the growth curve proved to be a very sensitive measure of vitamin A toxicity. Supplements as high as 10,000 units/100 gm/day showed normal growth but levels of 15,000–20,000 units/100 gm/day caused marked depression. Organ weights at the end of the experimental periods were essentially normal with the exception of a marked hypertrophy of the adrenals. Liver storage of vitamin A at the 28th day was over 50% of ingested dose up to 12,000 units/100 gm/day. Apparently the liver reaches maximum vitamin A storage at about 50,000 units/gm. of fresh liver tissue. At this level of storage the extractable liver oil has a potency of about 1 million units/gm. Kidney storage of vitamin A was proportional to the dose at all levels. The breaking strength of the excised leg bones decreased with increasing dosage and closely paralleled depression of growth as a measure of vitamin A toxicity.

J. Anim. Sci. 25:1123-1127. 1966.

Anderson-'66
Bib. No. 203

Reproduced by permission
of the copyright owner

HYPERVITAMINOSIS A IN THE YOUNG PIG[1]

M. D. ANDERSON,[2] V. C. SPEER, J. T. MCCALL AND V. W. HAYS
Iowa Agricultural and Home Economics, Experiment Station,[3] Ames

GROSS bone alterations in swine are often incorrectly diagnosed as rickets, according to Runnels *et al.* (1960). Grant (1953) and Grant and O'Hara (1957) reported that natural feed ingredients high in carotenoids can precipitate true rickets in sheep and rats. Ershoff *et al.* (1957) and Ershoff and Hernandez (1960) found that massive but relatively nontoxic doses of vitamin A produced definite symptoms of hypervitaminosis A in rats when their diet was also supplemented with alfalfa meal, and that water extracts from succulent plants contained the potentiating factor. Hendricks *et al.* (1964) found no apparent rachitogenic effect due to carotene in diets relatively low in vitamin D.

The effects of hypervitaminosis A on several species have been summarized by Nieman and Obbink (1954) and Moore (1957); however, little information is available concerning this condition in swine. Experiments were conducted to determine the effects of hypervitaminosis A in young pigs and to determine the dietary levels of vitamin A necessary to produce toxicity symptoms.

Experimental Procedure

This study consisted of two experiments involving 54 crossbred pigs. The pigs were randomly allotted to treatments from outcome groups of similar initial weight with the restriction that littermates be distributed across treatments. A randomized-block design was used in each experiment. Feed and water were allowed *ad libitum*. Any reference to statistical significance refers to a probability level of 5% or less. The basal diets are presented in table 1.

Experiment 1. Thirty pigs averaging 8.4 kg. were allotted three per pen and fed one of the following diet treatments: 0, 1,100, [illegible], 11,000 or 1,100,000 I.U. of vitamin A (palmitate) per kg. of diet.

Pigs were observed daily for toxicity symptoms. At the end of 4 weeks metatarsal bone samples were removed by biopsy as described by Zimmerman *et al.* (1963), and blood samples were taken from the anterior vena cava. Serum calcium was determined by the method of Clark and Collip (1925), and serum inorganic phosphorus and bone ash phosphorus were measured by the method of Fiske and Subbarow (1925). Bone ash calcium was measured gravimetrically as outlined by Diehl and Smith (1952). Serum and bone alkaline phosphatase activity were determined by the method described by Lowry *et al.* (1954) and expressed as nitrophenol released from the buffered (pH 9.8) substrate, 2-amino-2-methyl propanol-nitrophenolphosphate, per hour of incubation at 38° C.

Experiment 2. Twenty-four pigs averaging 4.6 kg. were allotted to individual pens and fed one of the following diet treatments: 0, 220,000, 440,000, 660,000 or 880,000 I.U. of vitamin A (palmitate) per kg. of diet, or 2063 mg. of beta carotene per kg. of diet. Pigs were observed daily for symptoms of hypervitaminosis A for as long as 8 weeks on trial.

Blood samples were taken for analysis 4 weeks after the start of the experiment. Blood hemoglobin (acid hematin method) and hematocrit were determined. Plasma samples were deproteinated with a 3% solution of 5-sulfosalicylic acid, and hydroxyproline in the resulting deproteinated plasma determined by the method of Miyada and Tappel (1956).

Results and Discussion

Experiment 1. Toxicity appeared after 14 days when three pigs fed the diet containing 1,100,000 I.U. of added vitamin A per kg. of diet died. No visible external manifestations of vitamin A toxicity were evident before death. Postmortem examination revealed massive internal hemorrhage. After 21 days all remaining pigs on this diet, but none on the other diets, exhibited symptoms of hypervitaminosis A similar to those previously described for other species (Nieman and Obbink, 1954). The symptoms observed included, in addition to death, rapid deterioration of condition, roughened hair coat, scaly

[1] Journal Paper No. J-5028 of the Iowa Agricultural and Home Economics Experiment Station, Ames. Project No. 1812.
[2] Present address: Hess and Clark Co., Ashland, Ohio.
[3] Department of Animal Science.

TABLE 1. COMPOSITION OF BASAL DIETS

Ingredient	Experiment 1	Experiment 2
Ground yellow corn	71.95	67.39
Solvent soybean meal, 50% protein	23.25	27.90
Calcium carbonate	0.80	0.84
Dicalcium phosphate	1.30	1.17
Iodized salt	0.50	0.50
Vitamin-antibiotic premix	2.00[a]	2.00[b]
Trace mineral premix[c]	0.20	0.20
Total	100.00	100.00

[a] Supplied the following per kilogram of diet: vitamin D_2, 1,093 I.U.; riboflavin, 8.8 mg.; calcium pantothenate, 22 mg.; niacin, 48.3 mg.; vitamin B_{12}, 44 mcg.; and chlortetracycline, 220 mg.

[b] Supplied the following per kilogram of diet: vitamin D_2, 1,100 I.U.; riboflavin, 17.6 mg.; calcium pantothenate, 35.2 mg.; niacin, 79.2 mg.; choline, 88.0 mg.; vitamin B_{12}, 44 mcg.; and chlortetracycline, 110 mg.

[c] Contributed the following in parts per million: Fe, 140; Cu, 9.5; Co, 3.3; Zn, 162; Mn, 113.6; and K, 15.

skin, increased irritability and sensitivity to touch. Swelling was observed especially in the hock joints and occasionally in the elbow and knee joints. Body movements appeared to be painful. Marked petechial hemorrhages appeared over the limbs and abdomen. Cracks in the skin with bleeding developed about the hooves. Lacrimation was prominent in most animals. The animals lost control of their rear legs within a week of the first indications of toxicity, and later strength and control of the front legs diminished. These animals were affected by periodic tremors.

Postmortem examination of the three pigs which succumbed revealed that hemorrhages had occurred in the hock joints, and a massive hemacyst was found between the right scapula and thoracic wall in one of the pigs. Subserosal and mucosal hemorrhages were evident in the intestine. Subpericardial hemorrhage was found as was hemorrhage in the area of the corticomedullary junction of the kidney. Costochondral junctions were enlarged, and when cross-sectioned the metaphysial region appeared decalcified. Histologically, the cartilage columns were disorganized.

Two severely affected animals which survived were placed on the basal diet and after 3 weeks began to gain weight and grow; however, after approximately 5 months they had failed to reach a normal size and appeared to be permanently stunted.

Average values by diet treatment for weight gains, feed conversion, daily feed consumption and values for serum and bone determinations are presented in table 2. Average weight gains of the pigs were depressed markedly by the highest dietary level of vitamin A. Feed required per unit gain was significantly greater with this treatment, and feed intake was reduced.

Serum calcium was higher in pigs fed diets containing vitamin A, except for those receiving the highest subtoxic dosage used in which a very low level (6.9 mg./100 ml.) was found. No adverse effects attributable to low serum calcium were observed in these animals, however. In this experiment pigs with frank vitamin A toxicity had the highest average

TABLE 2. EFFECT OF DIETARY LEVELS OF VITAMIN A ON AVERAGE WEIGHT GAINS, FEED CONVERSION, DAILY FEED CONSUMPTION AND CERTAIN BLOOD SERUM AND BONE MEASUREMENTS

Item	Vitamin A palmitate, I.U./kg. of diet: 0	1,100	11,000	110,000	1,100,000
Weight gain,[a] kg.	12.4	14.1	12.8	13.4	[illegible]
Feed/gain[b]	2.02	1.99	2.07	2.00	[illegible]
Daily feed consumption,[a] kg.	0.89	1.00	[illegible]	0.97	[illegible]
Serum analysis					
Calcium, mg./100 ml.	8.5	11	10.3	6.9	[illegible]
Inorganic phosphorus,[a] mg./100 ml.	9.0	9.1	10.4	11.3	[illegible]
Alkaline phosphatase[c]	0.70	0.82	0.91	0.97	[illegible]
Bone analysis					
Alkaline phosphatase[c,d]	30.0	29.8	31.7	37.6	[illegible]
Dry matter,[b] %	50.4	50.8	49.8	52.3	[illegible]
Ether extract,[a] % of dry matter	8.7	7.3	5.9	6.6	[illegible]
Ash, % of fat-free dry matter	48.0	45.4	46.1	45.5	[illegible]
Calcium, % of ash	39.2	36.0	36.6	38.9	[illegible]
Phosphorus,[a] % of ash	12.5	10.7	12.7	13.5	[illegible]

[a] Significant (P < .05) cubic regression as the logarithm of the units of added vitamin A increased.
[b] Significant (P < .05) linear regression as the logarithm of the units of added vitamin A increased.
[c] Millimoles of nitrophenol released per hour of incubation at 37° C. per 100 ml. of serum.
[d] Millimoles of nitrophenol released per hour per gram of bone.

serum calcium and lowest serum inorganic phosphorus concentrations, although these were not greatly different from those in pigs fed 1,100 I.U. of vitamin A per kg. of feed.

Serum inorganic phosphorus, as well as serum alkaline phosphatase activity, and bone alkaline phosphatase activity increased as the dietary level of vitamin A increased from 0 to 110,000 I.U. per kg. of diet. At the toxic level of vitamin A, 1,100,000 I.U. per kg., however, marked decreases in these activities were found. The pattern of response in these was similar to that for weight gain, in which there was an increase with 1,100 I.U., then a plateauing or slight depression to 110,000 I.U. with a marked depression at 1,100,000 I.U. per kg. of diet.

Bone dry matter increased significantly and bone ether extract decreased as the level of dietary vitamin A increased. Average bone ash, as a percent of moisture- and fat-free bone, decreased with increasing levels of vitamin A, but the variability encountered precluded any statistical significance. A somewhat similar response has been found with rats, since Rodahl (1950) and Moore and Wang (1945) were unable to show reduced bone ash with hypervitaminosis A, although some rats had sustained spontaneous fractures.

No significant effect due to dietary treatment was found in calcium content of metatarsal bone ash, but there was a significantly higher level of phosphorus in the bone ash of pigs as the dietary level of vitamin A increased.

The depressed weight gains and feed consumption, as well as increased feed required per unit gain as a result of vitamin A toxicity, are similar to that found for rats (Rodahl, 1950) and dogs (Maddock *et al.*, 1949). The relatively higher calcium and lower inorganic phosphorus content of the serum of pigs with vitamin A toxicity does not seem to be directly related to skeletal calcium and phosphorus as indicated by metatarsal ash analysis. The correlation coefficients for bone-blood calcium and phosphorus were 0.29 and 0.14, respectively. Neither was significant.

Depressed alkaline phosphatase activity of metatarsal bones in vitamin A toxicity may be a factor in the relatively higher calcium and phosphorus contents of the ash of these bones. Ludwig (1953) found, however, that the alkaline phosphatase activity of the epiphysial junctions of all bones was not necessarily affected in a similar manner by hypervitaminosis A.

The effect of the decreased feed consumption by pigs fed the toxic level of vitamin A on the resulting blood and bone components is unknown and may have confounded the effects of vitamin A toxicity. Alternatively, these data suggest that toxic levels of vitamin A may evoke a different response in certain physiological variables than would be predicted from trends established with subtoxic levels of the vitamin. For example, subtoxic levels of vitamin A increased serum inorganic phosphorus and bone and serum alkaline phosphatase, whereas toxic levels resulted in the opposite effects.

Experiment 2. As soon as a pig displayed definite symptoms of vitamin A toxicity a blood sample was taken and the pig was removed from the experiment. Blood samples were taken from the remaining pigs after 4 weeks. Average hemoglobin and hematocrit values, as well as plasma hydroxyproline concentrations and the average days required to produce toxicity symptoms on each treatment, are listed in table 3.

In contrast to that reported for other species (Nieman and Obbink, 1954), no mean-

TABLE 3. EFFECT OF ADDED VITAMIN A PALMITATE OR BETA CAROTENE TO THE DIET ON BLOOD HEMOGLOBIN, HEMATOCRIT AND PLASMA HYDROXYPROLINE AND THE AVERAGE DAYS FOR SYMPTOMS OF HYPERVITAMINOSIS A TO APPEAR ON THESE DIETS

Item	Vitamin A palmitate, I.U./kg. of diet					Beta carotene, 2064 mg. per kg. of diet
	0	220,000	440,000	660,000	880,000	
Hemoglobin, gm./100 ml.	8.4	10.4	8.4	8.9	10.[illegible]	8.0
Hematocrit, %	29.2	36.8	32.5	31.6	35.0	31.6
Plasma hydroxyproline,[a] mcg./ml.	9.2	9.4	9.8	9.3	11.9	11.0
Avg. days to produce toxicity symptoms	...[b]	...[b]	43	32	17.5	...[c]

[a] Significant (P < .01) linear response
[b] No symptoms appeared by 8 weeks
[c] One pig died after 24 days on test.

ingful statistical relationship between dietary level of vitamin A and blood hemoglobin or hematocrit was found. A highly significant linear increase in hydroxyproline content of blood plasma was observed as the level of vitamin A in the diet increased. This may be due to a general connective tissue breakdown of the blood vascular system accompanying hypervitaminosis A and preceding the appearance of generalized hemorrhages frequently encountered, since Maddock *et al.* (1949) found evidence of vascular lesions in dogs with hypervitaminosis A. The increased plasma hydroxyproline concentration may also be a consequence of bone rarefaction analogous to that observed in rats administered triiodothyronine by Bastomsky and Dull (1962).

The average hydroxyproline content of the blood plasma of pigs consuming the diet containing 2,063 mg. of added beta carotene per kg. was 1.8 mcg./ml. or 19.6% above that of pigs fed the basal diet. One pig fed the diet high in added carotene died after 24 days on the diet. Postmortem examination revealed internal hematocyst formation with death due to severe hemorrhage. Gross internal pathology resembled that of hypervitaminosis A. No pigs on this diet exhibited external symptoms of toxicity. It appears that massive doses of beta carotene can result in toxicity in young pigs.

Pigs on diets containing 880,000, 660,000 or 440,000 I.U. of added vitamin A palmitate per kg. developed symptoms of vitamin A toxicity in an average time of 17.5, 32 and 43 days, respectively. At 8 weeks apparent toxicity symptoms had not appeared in pigs receiving 220,000 I.U. of added vitamin A per kg. of diet.

Summary

Two experiments were conducted to study characteristics of hypervitaminosis A and to determine levels necessary to evoke symptoms of toxicity in young pigs.

Gross toxicity symptoms observed in their general order of appearance included malaise, roughened hair coat, scaly skin, hyperirritability and sensitivity to touch, lacrimation, marked petechial hemorrhages over the legs and abdomen, bleeding from cracks in the skin about the hooves, blood in the urine and feces, loss of strength and control of the legs accompanied by inability to rise, periodic tremors and death.

Observations at necropsy included hemorrhage into limb joints, in the mucosa, submucosa, subpericardium and at the corticomedullary junction of the kidney. Cartilage cell columns were disorganized in the enlarged costochondral junctions, which also appeared to be decalcified. Severe toxicity early in life prevented surviving pigs from reaching normal size.

Vitamin A toxicity decreased weight gains, feed consumption and feed efficiency. Increased dietary levels of vitamin A had a significant effect on serum inorganic phosphorus and alkaline phosphatase, as well as on plasma hydroxyproline. Alkaline phosphatase, ether extract and phosphorus in bone were also significantly affected. No significant effects on hemoglobin, hematocrit, serum calcium, bone ash or calcium content of bone ash were discernible.

Average time required for symptoms of hypervitaminosis A to appear in pigs fed diets containing 1,100,000, 880,000, 660,000 and 440,000 I.U. of added vitamin A per kg. was 16, 17.5, 32 and 43 days, respectively. No symptoms of hypervitaminosis A appeared at 8 weeks in pigs fed diets containing 220,000 I.U. per kg.

Literature Cited

Bastomsky, C. and T. Dull. 1962. Urinary hydroxyproline response in intact and parathyroidectomized rats treated with triiodothyronine. Clin. Res. 10:399. (Abstr.).

Clark, E. P. and J. B. Collip. 1925. A study of the Tisdall method for the determination of blood serum calcium with a suggested modification. J. Biol. Chem. 63:461.

Diehl, H. and G. F. Smith. 1952. Quantitative Analysis. John Wiley and Sons, Inc. New York.

Ershoff, B. and H. Hernandez. 1960. An unidentified water-soluble factor in alfalfa which improves utilization of vitamin A. J. Nutr. 70:313.

Ershoff, B., H. Hernandez and J. M. Muckenthaler. 1957. Potentiating effects of materials of plant and animal origin on symptoms of hypervitaminosis A in the rat. J. Nutr. 62:527.

Fiske, C. H. and Y. Subbarow. 1925. The colorimetric determination of phosphorus. J. Biol. Chem. 66:[illegible]

Grant, A. B. 1955. Carotene: a rachitogenic factor in green feeds. Nature (London) 172:627.

Grant, A. B. and P. B. O'Hara. 1957. The rachitogenic effect of vitamin A. New Zealand J. Sci. Technol. 38:548.

Hendricks, D. G., E. R. Miller, D. E. Ullrey, R. D. Struthers, B. V. Baltzer, D. A. Schmidt, J. A. Hoefer and R. W. Luecke. 1964. Beta carotene as vitamin A for the baby pig and the effect upon vitamin D requirement. J. Animal Sci. 23:[illegible] (Abstr.).

Lowry, O. H., N. R. Roberts, M. Wu, W. S. Hixon and E. J. Crawford. 1954. The quantitative histo-

chemistry of the brain. 2. Enzyme measurements. J. Biol. Chem. 207:19.

Ludwig, K. S. 1953. Vitamin A-Mangel und Uberdosierung und ihre Beziehungen zum Gehalt an alkalischer Phosphatase der Epephysenfuge. Intern. Z. Vitaminforsch. 25:99.

Maddock, C. L., S. B. Wolbach, and S. Maddock. [illegible]. Hypervitaminosis A in the dog. J. Nutr. [illegible]:117.

Miyada, S. S. and A. L. Tappel. 1956. Colorimetric determination of hydroxyproline. Anal. Chem. [illegible]:909.

Moore, T. 1957. Vitamin A. Elsevier Publ. Co. New York, N. Y.

Moore, T. and Y. L. Wang. 1945. Hypervitaminosis A. Biochem. J. 39:222.

Nieman, C. and H. J. K. Obbink. 1954. The biochemistry and pathology of hypervitaminosis A. Vitamins and Hormones 12:69.

Rodahl, K. 1950. Hypervitaminosis A in the rat. J. Nutr. 41:399.

Runnells, R. A., W. S. Monlux and A. W. Monlux. 1960. Principles of Veterinary Pathology. Iowa State University Press, Ames, Iowa.

Zimmerman, D. R., V. C. Speer, V. W. Hays and D. V. Catron. 1963. Effect of calcium and phosphorus levels on baby pig performance. J. Animal Sci. 22:658.

Nature 213(5071):47-49. 1967.

Anderson-'67
Bib. No. 205

Reproduced [illegible]
of the copyright owner

Dietary Retinol and Alpha-Tocopherol and Erythrocyte Structure in Rats

by
O. ROGER ANDERSON
OSWALD A. ROELS
R. M. PFISTER
Marine Biology Division, Lamont Geological Observatory, Columbia University, Palisades, New York

The red blood cells of rats deficient in vitamin A become deformed when vitamin E is added to the diet, but are normal in control rats fed vitamin A

Lucy and Dingle[1] investigated the effects of retinol and alpha-tocopherol on rabbit erythrocytes *in vitro*. They showed that erythrocyte membranes are unstable when the cells are incubated in the presence of large amounts of retinol. This treatment causes internal vacuolization of the red blood cell and eventual haemolysis. Addition of alpha-tocopherol to the incubation mixture *in vitro* inhibited this lysis and stabilized the erythrocyte membrane.

Previous work from this laboratory by Roels *et al.*[2] has shown that changes in the stability of the liver lysosomal membrane from rats deficient in vitamin A caused by different dietary levels of alpha-tocopherol can be reversed by dietary retinol: low dietary alpha-tocopherol weakened the liver lysosomal membrane of rats deficient in vitamin A, whereas animals receiving high levels of dietary alpha-tocopherol and no retinol had unusually resistant liver lysosomal membranes. The addition of retinol to the diet brought the stability of the lysosomal membrane back to normal in both groups of animals.

To determine whether this *in vivo* effect of retinol and alpha-tocopherol on the lysosomal membrane is a more general phenomenon, applicable to other biological membranes, we have examined the effect of different doses of dietary vitamin A and vitamin E on rat erythrocytes. Examination with the electron microscope indicates that erythrocytes from rats deficient in vitamin A receiving high or normal doses of vitamin E are swollen and distorted, whereas erythrocytes from pair fed littermate controls receiving normal doses of vitamin A do not show this distortion.

Male albino Sherman rats 21 days old, weighing 40–44 g, were housed in individual cages and fed an experimental diet containing 18 per cent vitamin free casein; 68 per cent glucose; 5 per cent cellulose; 5 per cent peanut oil and 4 per cent Fox and Briggs salt mixture (all percentages by weight). In addition, 2 mg/kg thiamine hydrochloride; 4 mg/kg riboflavin; 4 mg/kg pyridoxine; 1,000 mg/kg choline; 1,000 mg/kg inositol; 300 mg/kg *p*-aminobenzoic acid; 100 mg/kg nicotinamide; 2·5 mg/kg folic acid; 0·05 mg/kg vitamin B_{12}; 0·1 mg/kg biotin; 0·042 mg/kg ergocalciferol; 10 mg/kg vitamin K and 10 mg/kg calcium pantothenate were added to the mixture.

Vitamins A and E were administered twice weekly by mouth to the different groups of animals as shown in Table 1. There were ten pairs of animals in each group.

Table 1. RETINYL ACETATE AND ALPHA-TOCOPHEROL CONTENT OF THE OIL* SUPPLEMENT ADMINISTERED BY MOUTH TWICE WEEKLY TO EACH EXPERIMENTAL ANIMAL

	Pair fed		Pair fed		Pair fed	
	Deficient	Control	Deficient	Control	Deficient	Control
Group	−AE−	AE−	−AE	AE	−AE+	AE+
Retinyl acetate†	0	120 μg	0	120 μg	0	120 μg
α-Tocopherol‡	0	0	1·75 mg	1·75 mg	17·5 mg	17·5 mg

* Stripped corn oil was used to bring the vitamin supplements to 0·1 ml.
† U.S. Pharmacopeia vitamin A reference standard.
‡ Pure D,L-alpha-tocopherol.

The controls were pair fed with the rats on the vitamin A deficient diet as described previously[3].

Small samples of whole blood were taken from the tails of the rats, fixed in buffered osmium tetroxide (*p*H 7·4), washed with distilled water and deposited on grids coated with carbon. After drying at room temperature, the preparation was shadowed with germanium and observed under an electron microscope.

Examination of erythrocytes from rats 3 weeks after starting the experimental diet indicated that the cells from −AE+ rats were distorted as shown in Fig. 1, whereas erythrocytes from the pair fed controls (AE+) were less distorted. Distorted cells in Fig. 1 appear spindle shaped or prolate. Normal cells in Fig. 2 have circular outlines and central depressions.

A frequency count was made using a haemacytometer to determine the proportion of spindle shaped cells occurring in each treatment. Erythrocytes from −AE+ rats contained 43 per cent spindle shaped cells, whereas a sample of erythrocytes from the pair fed control (AE+) contained 24·9 per cent distorted cells. The mean number of cells examined in each condition was 115.

Additional information about the shape of the erythrocytes was obtained using the electron microscope. Erythrocytes from −AE+ rats appear distorted (Fig. 3). The most severe anomaly is represented by spindle shaped cells which cast irregular shadows with undulating margins or sharp peaks. The form of the shadow indicates that some of the spindle shaped cells are folded once; the portion of the cell which has been folded over projects above

the plane of the cell and therefore casts a long and irregular shadow compared with the cells from the pair fed controls (AE+) which are shown in Fig. 4.

In all cases, observations were made over extended areas of the grid and representative clusters of cells were photographed. Even when the least distorted cells obtained from the experimental animals were compared with control specimens there was still a noticeable difference between the two samples.

Observations were subsequently made on blood samples obtained from the same animals at weekly intervals and the degree of distortion increased as the deficiency progressed.

To gain additional evidence about the shape of the spindle shaped cells, clay models of erythrocytes were constructed and observed under oblique illumination from an electric lamp. Patterns of form and shadow similar to those in Fig. 3 were produced by folding models of normal cells along their diameter. When these models were rotated around their axes, shadows were produced much like those in Fig. 3.

Additional measurements were made to determine the size of cells in each experimental treatment. Spindle shaped erythrocytes from rats receiving −AE+ diets had a mean length of 10·9μ while normal erythrocytes from rats receiving AE+ diets had a mean diameter of 6·6μ.

Erythrocytes from rats receiving no vitamin A and normal levels of alpha-tocopherol (−AE) appear distorted (Fig. 5). much like those from animals receiving high levels of vitamin E and no vitamin A (−AE+).



Figs. 1 and 2. Photomicrographs of whole erythrocytes fixed in osmium tetroxide. Fig. 1. Erythrocytes from rats receiving no retinol and high doses of alpha-tocopherol (−AE+) showing folded cells (F) which appear spindle shaped (×900). Fig. 2. Erythrocytes from rats receiving normal doses of retinol and high doses of alpha-tocopherol (AE+). Most cells appear normal with circular perimeters and a central depression (×900).



Figs. 3–6. Electron micrographs of shadowed whole erythrocytes. Fig. 3. Erythrocytes from rats receiving high doses of alpha-tocopherol and no retinol (−AE+) (×3,780). Fig. 4. Erythrocytes from the pair fed control rat (AE+) (×3,600). Fig. 5. Erythrocytes from rats receiving normal doses of alpha-tocopherol and no retinol (−AE) (×3,125). Fig. 6. Erythrocytes from the pair fed control (AE) (×3,125).

In this case, however, the distortion is much less severe. Folding of the cells is much less marked than in Fig. 3 and the perimeter of the cells more closely approaches a normal circular perimeter. When these erythrocytes from experimental rats are compared with those receiving normal amounts of vitamin A (AE) it is apparent (Fig. 6) that the latter cells are normal.

In most cases, the cells in Fig. 6 show a central depression and the perimeter is almost circular. These cells closely approximate the biconcave disk of the normal erythrocyte, but the tendency toward swelling and folding is not entirely absent.

Erythrocytes from animals receiving a diet low in vitamin E and without vitamin A (−AE−) or normal doses of vitamin A (AE−) contained slightly distorted cells. In addition to normal cells, abnormal erythrocytes appeared with angular margins and a tendency toward swelling.

The perimeter often appears somewhat angular.

Thin sections of erythrocytes were made from all three experimental conditions reported here. In all cases, no differences in internal structure were observed when erythrocytes from rats deficient in retinol were compared with those from the control receiving normal doses of retinol. No internal vacuoles were observed in any of the sections examined.

These results lead us to conclude that in the absence of dietary retinol, dietary alpha-tocopherol administered

in normal or high doses produces anomalies in the structure of the rat erythrocyte which can be counteracted when normal doses of vitamin A are included in the diet.

The severity of the distortion of erythrocytes from vitamin A deficient rats caused by dietary vitamin E appears to be related to the dose administered; normal doses of alpha-tocopherol result in less distortion than high doses. In both cases, the administration of normal levels of vitamin A inhibits this effect of vitamin E.

At present it is not possible to determine whether the effects of these vitamins result from alterations in the synthesis and development of erythrocytes in the haemopoietic tissue or result from changes in the blood plasma bathing the erythrocytes in the circulatory system.

Low dietary alpha-tocopherol caused slight distortion of the red blood cells, both in the absence and presence of dietary retinol.

These observations provide additional evidence in support of our hypothesis that retinol counteracts changes in the structure and/or function of biological membranes caused by different levels of alpha-tocopherol.

This work was supported by a grant from the National Institutes of Health, U.S. Public Health Service.

[1] Lucy, J. A., and Dingle, J. T., *Nature*, **204**, 156 (1964).
[2] Roels, O. A., Trout, M., and Guha, A., *Biochem. J.*, **97**, 353 (1965).
[3] Vakil, U. K., Roels, O. A., and Trout, M., *Brit. J. Nutrit.*, **18**, 217 (1964).

Brit. Med. J. 4091:1141-1142. 1939.

Anon. -'39
Bib. No. 244

BRITISH MEDICAL JOURNAL

LONDON

SATURDAY JUNE 3 1939

CLINICAL STUDIES OF VITAMIN A

Frazier and Hu[1] first suggested that vitamin A deficiency might be the cause of lesions consisting of dry pigmented papules, up to 5 cm. in diameter, found chiefly on the thighs and arms, but sometimes extending to the shoulders, abdomen, back, buttocks, and, rarely, to the face and neck. The papules arose at the site of the pilosebaceous follicles; they were conical or hemispherical, and contained a central intrafollicular plug which projected from the surface and was covered with a loosely adherent scale. Nicholls[2] described similar lesions and named the disease phrynoderma ("toad-skin"). It was associated with night-blindness, and he ascribed it to a deficiency of vitamin A, but thought that other deficiencies might be involved as some of his cases also had dysentery and neuritis. Loewenthal[3 4] found the papules in his negro subjects smooth-topped, black, and shiny and about 0.5 cm. in diameter. They were not coniform or obtuse like the acne papule, and pustulation was rare. The microscopical appearance of the papules in Frazier and Hu's and Loewenthal's cases was the same. All of these workers later reported further cases from their own countries; Sweet and K'ang[5] have reported cases from China, and Aykroyd[6 7] and co-workers from India; Wright[8] in Madras observed papular lesions in association with keratomalacia. Most of these workers observed benefit after giving cod-liver oil, "avoleum" (two cases), a good mixed diet supplemented with cod-liver oil, carotene subcutaneously (one case), halibut-liver oil (one case), milk, or eggs.

Widespread occurrence of phrynoderma in a school of poorer-class children in the Nilgiris was found by Radhakrishna Rao.[9] He gave vitamin A therapy to the worst cases and kept the mild ones as controls. The vitamin A concentrate used for treatment contained 72,000 international units of vitamin A per c.cm. or 4,000 international units per minim. One cubic centimetre was therefore equivalent to 2 drachms of an average cod-liver oil. It contained no added vitamin D, which means that it was probably made from a fish-liver oil very rich in vitamin A and poor in vitamin D, and therefore contained only small amounts of the latter. The doses prescribed varied according to the condition of the patient; one boy 9 years old was given 2½ minims every day for 112 days, during which time the papules entirely disappeared, leaving faint scars; a girl 6 years old was given 4½ minims for sixty-three days, by which time the eruption had completely disappeared from the face and body, though a few papules remained on the arms. Whereas it is true that all the cases treated with vitamin A showed decided improvement, the untreated controls also improved a little during the period, and the author hesitates to ascribe the improvement of the severe cases to vitamin A therapy alone, or, indeed, to ascribe phrynoderma to a deficiency of this vitamin, particularly as in none of his patients were there definite clinical signs of xerophthalmia. He suggests that the vitamin A may have caused a better absorption and utilization of the food consumed and that some substance in the food may have been the active agent in the cure of the phrynoderma. Youmans and Corlette[10] have observed in a number of white patients an eruption which they believe to be due to a deficiency of vitamin A: it was an acne-like lesion, but pustulation was uncommon, and it occurred in patients past the acne age without a history or scars of pre-existing acne. One patient was given a tablespoonful of cod-liver oil three times a day for fourteen weeks before the skin became normal. Another received a similar dose for twelve weeks and then 16,000 international units of a halibut-liver-oil concentrate daily for eight weeks before the skin was normal. Four other cases also required a high dosage of vitamin A before complete cures were effected. There was almost no evidence in these patients of keratomalacia or of night-blindness, and it was thought probable that the skin changes might precede the changes in the eye and might, in fact, be the earliest signs of vitamin A deficiency. It is interesting to note that very large doses of the vitamin have to be given before the eruption begins to disappear, whereas night-blindness can be corrected very quickly. Frazier and Li[11] have recently described a cure of a hyperkeratotic follicular eruption by means of injections of carotene in oil, the patient being kept in hospital throughout the period of treatment, fed on a diet as deficient in vitamin A and "good" protein as possible, bathed only once a week, and

[1] *Arch. intern. Med.*, 1931, **48**, 507.
[2] *Indian med. Gaz.*, 1933, **68**, 681.
[3] *Arch. Derm. Syph.*, Chicago, 1933, **28**, 700.
[4] *E. Afr. med. J.*, 1933–4, **15**, 58.
[5] *Amer. J. Dis. Child.*, 1935, **50**, 699.
[6] *Indian J. med. Res.*, 1936, **24**, 419.
[7] Ibid., 1937, **24**, 707.
[8] Lecture on keratomalacia quoted by Radhakrishna Rao.[9]
[9] *Indian med. Gaz.*, 1938, **73**, 461.
[10] *Amer. J. med. Sci.*, 1938, **195**, 644.
[11] *Chin. med. J.*, 1938, **54**, 301.

given no local skin treatment. The dark-adaptation of this patient was well below normal on admission and did not improve after twenty-eight days of treatment, though by that time the skin had improved greatly. Altogether 73 mg. carotene were given during fifty-one days in hospital. Mainzer and Joel[12] conclude that a lack of vitamin A may be a cause of nutritional anaemia, but few anaemias are due to a single deficiency. Recent experiments on animals by Steiner, Zuger, and Kramer[13] demonstrate that renal and ureteral calculi can be produced in guinea-pigs by feeding them on a diet deficient in vitamin A. Calcium carbonate was early found in the epithelium of the renal pelves and ureters and later formed the sole inorganic constituent of the stones. The guinea-pig has seldom been used for studies on vitamin A, but these experiments indicate that it may offer a valuable alternative or addition to the rat as the main experimental animal by means of which further knowledge of the functions of vitamin A may be obtained. A different line of investigation has been followed by Herfort,[14] who found that vitamin A had no effect on the excretion of free hydrochloric acid in the stomach either of normal subjects or of patients suffering from hypochlorhydria. He observed, however, that it stimulated the secretion of the pancreatic juice in thirty subjects of whom some were normal and some were suffering from various gastro-intestinal disorders. There was an increase not only in the amount of juice secreted but in its lipase and tryptic activity. That the result was not due to the oil in which the vitamin A was dissolved appeared partly from control experiments with the oil alone and partly from the fact that these results were not obtained with similar solutions of vitamin D. Herfort believes that the stimulating action of vitamin A on the secretion of pancreatic juice is the direct cause of the relief noticed in his patients—for example, cessation of diarrhoea, disappearance of undigested food residues from the faeces, and increase in appetite and weight. The vitamin A was given sometimes by mouth, sometimes by intravenous injection.

An excellent review of the relation of disease to lack of vitamin A has been written in German by Lindquist.[15] In it he has reported his own experiments to determine the most satisfactory method of measuring the contents of carotene and vitamin A in the blood serum and a method of determining the "minimum perceptible light," which he found to rise with age and to be the same for the two sexes. He concluded that when serum contained less than 70 international units per 100 c.cm. the condition was pathological. He also investigated the minimum distinguishable differences in diminishing light, and found these to bear an inverse correlation with age and vitamin A content of serum up to an upper limit of 100 international units of vitamin A per 100 c.cm. of serum. He finally determined the range of vitamin values of blood serum in normal people, and concluded that less than 70 international units per 100 c.cm. of blood serum indicated a serious shortage, that 70–100 was also low, that 100–200 was apparently sufficient for many people, and that 200–400 was the amount that might be considered really satisfactory. The second part of Lindquist's review is a very comprehensive study of his own work and of other investigators on the apparent lack of vitamin A in various pathological conditions and its correlation with the low vitamin A content found in the blood serum. Results have been examined by statistical methods to determine their significance. The whole trend of clinical work with vitamin A indicates more and more that much ill-health of a serious nature may be due to a shortage of this factor and that improvement may be brought about by making good the deficiency.

[12] *Acta med. scand.*, 1938, **96**, 533.
[13] *Arch. Pathol.*, 1939, **27**, 104.
[14] *Acta med. scand.*, 1938, **96**, 425.
[15] Ibid., 1938, *Suppl.*, **97**.

Anon.-'71
Bib. No. 314

Can. Med. Assoc. J. 104:521-522. 1971.

Reproduced by p
of the copyright owner

Canadian Paediatric Society:

The use and abuse of vitamin A*

This statement was prepared by the Nutrition Committee of the Canadian Paediatric Society. Members of the Committee: Drs. J. C. Haworth *(Chairman)*, C. P. Rance, C. Roy, R. B. Goldbloom, P. Marchand, J. R. MacLean, C. R. Scriver, J. R. Hamilton, J. W. Gerrard, Z. I. Sabry and T. K. Murray. Portions of this statement are based on a joint commentary on The Use and Abuse of Vitamin A prepared by the Committees on Drugs and Nutrition of the American Academy of Pediatrics.

Vitamin A is an essential nutrient. It is also toxic if administered in excessive quantity. Both aspects must be considered in determining the proper use of pharmaceutical supplements of this vitamin.

Vitamin A occurs in foods in two forms — preformed vitamin A and the precursor carotene, which is somewhat less well utilized. While the precise requirements of vitamin A are uncertain, the Canadian Council on Nutrition[1] has recommended the following intakes from a mixed diet as being adequate: infants and children to 6 years, 1000 I.U.; children 7-9 years, 1500 I.U.; children 10-12, 2000 I.U.; children 13-15, 2700 I.U.; adolescents 16-19, 3200 I.U.; and adults 3700 I.U. During pregnancy and lactation the recommendations are 4200 and 5200 I.U. per day respectively. In Canada the major sources of vitamin A have been dairy products and other fats and green and yellow vegetables, with meats, eggs and other fruits and vegetables making smaller contributions.[1] Under normal circumstances and with a mixed diet, it should be possible to meet dietary requirements from commonly available foods.

Special indication for vitamin A supplementation arises when the pattern of food intake is restricted, either by a specific therapeutic regimen or by individual food habits, in such a way that good sources of vitamin A are eliminated. In the case of infant feeding, one such situation might be the use of skim or partially skimmed milk formulae or, in older children, the extensive use of these foods to the exclusion of fruits and vegetables. Human milk, whole cow's milk and most prepared infant formulae contain adequate amounts of vitamin A; most, but not all, milk substitutes designed for infant feeding contain added vitamin A. At present, certain foods, such as margarine, are fortified with vitamin A; while present legislation permits the addition of the vitamin to skimmed and partly skimmed milk products, it is not yet a common practice in Canada. In those cases where dietary vitamin A intake is likely to be low, there may be value in the provision of a pharmaceutical supplemental source. There would seem to be no benefit to any age group in providing a supplement of more than about 2500 I.U. per day; in the case of infants, this would be twice the total estimated requirement.

Specific indication for vitamin A therapy is also found in the case of chronic intestinal malabsorption. It has been suggested[2] that infants and children with this disorder should be given about 2000 I.U. of vitamin A daily in an aqueous preparation.

Although severe deficiency of vitamin A lowers resistance to infection, as do many other nutritional deficiencies, there is no justification for a claim that it is an "anti-infective vitamin" or that it will prevent colds and other infections in normal children. For many years, massive doses of vitamin A have been advocated for the treatment of skin disorders with abnormalities of keratinization. Some dermatologists use this form of therapy for various forms of ichthyosis, acne and chronic atopic dermatitis although the rationale is not clear and the value has not been validated by properly controlled clinical trials.

Because vitamin A is known to be toxic when administered in excessive amounts, there is a definite hazard attached to the use of high potency preparations on an indiscriminate basis. As noted above, an adequate prophylactic level would be in the order of 2500 I.U. per day or even less in the case of infants. Nevertheless, a great many different preparations of vitamin A are available on the market, including some with very high levels. Those which contain more than 10,000 I.U. per recommended daily dose as stated on the label may, at present, be sold to the public without prescription although there are some minor restrictions, i.e., the bottle must carry a precautionary statement that the drug is for therapeutic use only and the drug may not be advertised to the public. Most of the infant preparations containing vitamins D and C, which are used to supplement the diets of infants fed unfortified (vitamin D and C) formulae, also contain vitamin A, usually in concentrations of about 2500 I.U. per dose, a safe level. Vitamin A toxicity is not likely to occur unless the recommended dose is greatly exceeded.

The literature contains numerous case reports of vitamin A intoxication. In the earlier cases the doses administered ranged from 80,000 to 500,000 I.U. vitamin A per day, often for more than six months.[3] In more recent reports, involving the ingestion of aqueous preparations of vitamin A, the daily dosages have been lower (18,500 to 60,000 I.U.) and the period of overdosage much shorter, varying between one and three months.[4] The reason for this is that ingestion of aqueous preparations results in much higher blood levels and much lower fecal excretion of vitamin A than the oily preparations.[5]

The commonest clinical manifestations of hypervitaminosis A are pain and tenderness over the long bones, often associated with subcutaneous swelling without redness or heat. Radiographic changes are found in most children and consist of cortical hyperostosis most commonly involving the ulna, metatarsals, clavicles and ribs. Involvement of the mandible has

---

*FDD has notified us that Regulations will shortly be promulgated whereby products for human use which contain vitamin A in daily doses exceeding 10,000 I.U., as stated on the label, will be permitted to be sold only on a physician's prescription.— ED.

never been reported and this serves to differentiate the condition from infantile cortical hyperostosis (Caffey's disease).[3] Decalcification of the skeleton may also be found in children. If this involves the skull, craniotabes may be detected clinically.[4] Constitutional symptoms, such as anorexia, irritability and failure to gain weight, are common. Various types of rash, fissuring of the lips and loss of hair are also frequently seen. Hepatomegaly with evidence of liver cell damage has been reported.[6] The spleen is also occasionally enlarged. Central nervous system involvement is a serious manifestation. The signs and symptoms are due to increased intracranial pressure and include bulging of the fontanelle and separation of the cranial sutures in the infant, and headache, nausea, vomiting, papilledema and cranial nerve palsies in the older patient. The cause of the raised intracranial pressure is unknown. Interference with the production or absorption of the cerebrospinal fluid or altered permeability of the blood-brain barrier has been suggested. Laboratory tests in hypervitaminosis A are usually not helpful. Blood calcium and phosphate levels are normal but alkaline phosphatase may be elevated. The fasting blood vitamin A level is greatly elevated.

No therapeutic measures are of value in vitamin A intoxication, but fortunately the symptoms and signs rapidly disappear when the vitamin is withdrawn, and permanent sequelae have not been reported.[3,6]

The administration of large doses of vitamin A to pregnant animals has resulted in congenital malformations in the offspring.[7] Although there is no evidence at present to implicate vitamin A toxicity in the pathogenesis of human congenital malformations, an excessive intake of vitamin A during pregnancy may be a potential hazard to the mother and fetus.

It is necessary to distinguish between ingestion of vitamin A and of carotenes. Although carotenes can fulfil the requirement of vitamin A, their excessive ingestion results in the benign disorder, carotenemia, and not hypervitaminosis A.

Recommendations

1. With reasonable attention to feeding practices there is little reason to expect that Canadian infants and children will receive inadequate intakes of vitamin A. Supplementation with vitamin A from pharmaceutical sources would be indicated only when dietary habits excluded dairy products and vegetables or when, in infant feeding, unfortified skimmed or partly skimmed milk was used as the formula basis. Such supplements should not ordinarily exceed 2500 I.U. per day.
2. Physicians should be aware of the dangers of vitamin A overdosage and should also know the vitamin A content of any vitamin preparation they may prescribe. When prescribing vitamin supplements for infants they should choose a preparation containing less than 2500 I.U. per dose.
3. Physicians should discourage excessive self-medication with vitamin A by their patients, especially children and pregnant women.
4. Massive doses of vitamin A should no longer be used in the treatment of skin disorders. This form of therapy is of doubtful benefit and the hazards of vitamin A toxicity are great.
5. Preparations containing more than 10,000 I.U. of vitamin A per single dose should no longer be available to the public without a prescription. (See footnote on page 521.)

The Committee wishes to acknowledge the help and advice received during the preparation of this report from Dr. G. H. Beaton, Professor and Head, Department of Nutrition, School of Hygiene, University of Toronto.

References

1. CANADIAN COUNCIL ON NUTRITION: Dietary standards for Canada, published as *Canadian Bulletin on Nutrition* 6(1) 1964, revised 1975
2. FOMON S.J: *Infant Nutrition*, Philadelphia Saunders, 1967, p. 114
3. OLIVER TK: *Amer J Dis Child* 95: 57, 1958
4. PERSSON B, TUNELL R, EKENGREN K: *Acta Paediat Scand* 54: 49, 1965
5. LEWIS JM, BODANSKY O, BIRMINGHAM J, et al: *J Pediat* 31: 496, 1947
6. RUBIN E, FORMAN AL, DEGNAN T, et al: *Amer J Dis Child* 119: 132, 1970
7. COHLAN SQ: *Pediatrics* 13: 556, 1954

Arcus-'61
Bib. No. 339

Reproduced by permission
of the copyright owner

Chromatography of some lipids on polytetrafluoroethylene

Chromatographic separations of vitamins A and D and cholesterol have previously been reported from this laboratory on columns of silaned kieselguhr[1] and polyethylene powder[2]. These studies have been extended using polytetrafluoroethylene as column packing.

Teflon (obtained from E.I. Du Pont, 60-100 mesh) was packed in methanol into a column 20 cm in length and 1.1 cm diameter using a perforated disc[3]. When packed, the column was held in a state of tension by a filter paper disc on top held down by a close fitting polyethylene ring. The column was then washed with 100 ml of degassed methanol. The methanol was displaced by water before applying the sample for analysis dissolved in 1 ml of methanol. The column was run using the gradient pump described by ARCUS[4] with 100 ml methanol in the reservoir and a mixture of 30 ml methanol and 20 ml water in the mixer. All solvents were carefully degassed before use. The column effluent was collected in 1.3 ml fractions. The ultraviolet absorption of each fraction was measured in the Beckman DU spectrophotometer at 325 mμ for vitamin A and at 265 mμ for vitamin D. Cholesterol and coprosterol were determined by the nephelometric method[2].

The separations obtained with 0.2 mg each of vitamins A and D and with 0.5 mg each of cholesterol and coprosterol are shown in Figs. 1 and 2.

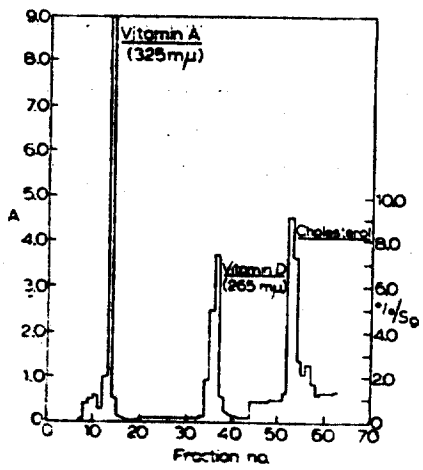

Fig. 1. Elution curve of vitamin A, vitamin D and cholesterol.

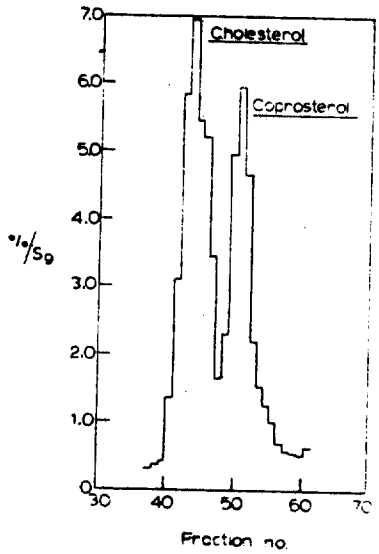

Fig. 2. Separation of cholesterol and coprosterol.

Nutrition Research Department,
Medical Research Council of New Zealand,
Medical School, Dunedin (New Zealand)

A. C. ARCUS
G. G. DUNCKLEY

[1] G. G. DUNCKLEY AND Y. J. MACFARLANE, *J. Sci. Food Agr.*, 6 (1955) 559.
[2] A. C. ARCUS, *Anal. Chem.*, 31 (1959) 1618.
[3] A. J. P. MARTIN, *Biochem. Soc. Symposia (Cambridge, Engl.)*, 3 (1949) 11.
[4] A. C. ARCUS, *J. Chromatog.*, 3 (1960) 411.

Received October 31st, 1960

Nat. Inst. Nutr. Ann. Rept. 1966:42-44. 1967.

Baba-'67
Bib. No. 433

The Effect of Water-Soluble Fraction of Fish-Liver on Liver Storage of Vitamin A in Rats

Haruo Baba and Masako Hirayama

It is well known that some fish store a high potency of vitamin A in the liver. On the other hand, however, there are many reports stating that human and experimental animals are injuried by over dosage of vitamin A. Then, as it was considered that fish has an active factor for the storage or utilization of vitamin A, in the first place tuna liver extract (TLS) was examined whether it has relation to liver storage of vitamin A or not, and also tested for this action of vitamin E and yeast feed.

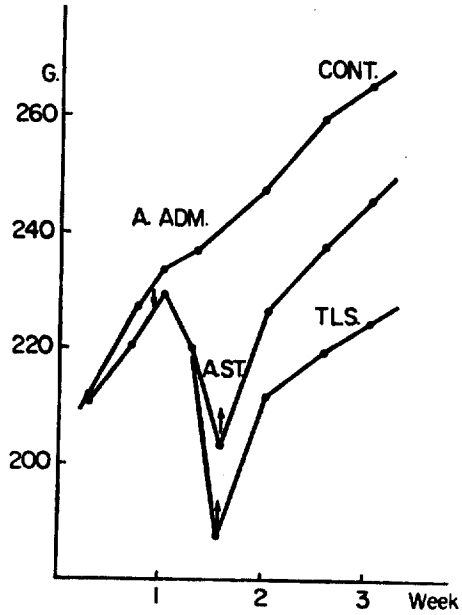

Fig. 1. Effect of TLS on Growth of Rats Receiving Over Dosage of Vitamin A

Method: TLS was made from extract of tuna (*Thunnus thynnes*) liver and its extract was concentrated at 75°C in vacuo. This concentrate contained 29.8% moisture, 54.2% protein and 13.7% ash. TLS was fed to young rats receiving an over dosage of vitamin A and their growth was observed and hepatic vitamin A was determined. Assay method of vitamin A and composition of experimental diet were the same as mentioned in the previous report.

Results: The results obtained are as shown in Table 1-4 and Fig. 1, 2. In many groups, TLS promoted the storage of vitamin A and growth inhibition by over dosage of vitamin A, but TLS administration improved injury and inhibition with hypervitaminosis A on the group receiving feed mixed with 4% yeast instead of B vitamin mixture.

Table 1. Effects of TLS on Rats Receiving Over Dosage of Vitamin A

Group	Vitamin A Per Day I.U.	Initial Weight g.	△	Minimum Weight g.	△	Final Weight g.	Liver Vitamin A I.U.
Casein 18%	65400	238.0±4.5	5.6	216.0	3.5	255.0±20.0	41700±2040
〃 Methionine 0.6%	65400	231.0±4.1	4.3	219.8	3.2	255.0±19.5	42000±1640
〃 TLS 1%	65400	236.6±0.1	6.3	192.6	2.9	224.0±12.5	55200±2320
Glutene 18%	32700	89.8±1.8	1.8	77.2	1.2	85.8± 9.1	—
〃 Methionine 0.6%	32700	88.2±1.5	2.6	69.2	2.2	85.0± 8.5	—
〃 TLS 1%	32700	90.6±1.2	2.6	72.4	1.8	84.8± 9.0	—
〃 Control	10	23.2±4.0	—	—	2.3	264.0±17.0	—

* TLS: Tuna liver soluble.

Table 2. Effects of TLS on Rats Receiving Over Dosage of Vitamin A

Group	Vitamin A Per Day I.U.	Initial Weight g.	△	Min. or Maximum Weight g.	△	Final Weight g.	Liver Vitamin A I.U.
Casein 18%	65400	227.7±4.3	6.2	203	4.1	244±32.9	32060±2550
Casein TLS 1%	65400	238.7±4.6	6.4	213	4.4	257±25.0	25700±1150
Casein 18%	32700	113.5±2.2	3.7	125	4.2	99± 8.8	52800±2400
Casein TLS 1%	32700	112.2±2.3	4.2	123	3.8	94± 8.4	63800±3380
Casein 18%	300	73±1.4	—	—	—	265± 7.0	2200± 160
Casein TLS 1%	300	72±1.4	—	—	—	258± 7.1	2640± 220

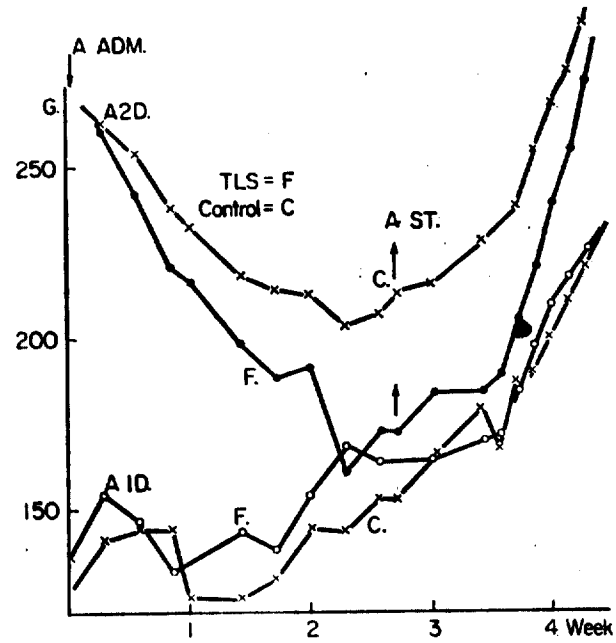

Fig. 2. Effect of TLS on Growth of Rats Receiving Over Dosage of Vitamin A and Yeast Feed

Table 3. Effects of Vitamin E on Rats Receiving Over Dosage of Vitamin A

Group	Intial Weight g.	Delta	Final Weight g.	Vitamin A in Liver I.U.
Casein TLS	90.8±1.2	3.3	92.5±6.0	69700±2980
Vitamin E		−2.9		
Casein	92.5±1.0	3.9	85.0±5.5	51300±4600
Vitamin E		−4.4		
Casein	90.4±1.1	1.9	92.2±5.5	50300±1970

Table 4. Effects of TLS on Rats Receiving Over Dosage of Vitamin A and Yeast Mixing Feed

Group	Administered VitamiZ A Per Day I.U.	Initial Weight g.	Delta	Minimum Weight g.	Delta	Final Weight g.
TLS	65400	262±4.1	7.2	160	6.6	239±23.5
TLS Control	65400	262±4.0	4.3	202	5.0	269±24.0
TLS	32700	154±3.0	6.0	163(124)	4.0	209±17.5
TLS Control	32700	141±2.2	3.2	161(124)	2.5	187±15.2

Baker-'67
Bib. No. 488

HYPERVITAMINOSIS A IN THE CHICK

J. R. BAKER, J. McC. HOWELL AND J. N. THOMPSON*
From the Department of Veterinary Pathology, and the Department of Biochemistry, University of Liverpool*

Received for publication March 30, 1967

BONE lesions have been described in animals given large doses of vitamin A. The bones are reduced in thickness and fractures are frequent (Moore, 1957). Much of this work has been done on the rat (Moore and Wang, 1945; Wolbach, 1947; Thompson and Pitt, 1960), but lesions have been described in other species including guinea-pigs (Wolbach, 1947), calves (Grey, Nielsen, Rousseau, Calhoun and Eaton, 1965) and man (Persson, Tunell and Ekengren, 1965). Rigdon, Rude and Bieri (1951) did not find lesions in the bones of hypervitaminotic ducklings but in contrast Wolbach and Hegsted found that hypervitaminosis A produced bone lesions in chicks (1952*c*) and in ducks (1953). Poumeau-Delille (1943) and Walker, Eylenberg and Moore (1947) recorded a marked reduction in the number of red blood cells in hypervitaminotic rats.

The purpose of the work reported here was to investigate some aspects of the gross, histo- and chemical pathology of hypervitaminosis A in chicks and to contrast the changes in bone with those observed in vitamin A deficient birds bv Howell and Thompson (1967*a*, *b*).

MATERIALS AND METHODS

Thirty 1-day-old male chicks of Thornber's 404 strain were fed a commercial diet for the duration of the experiment. From the time that they were 7 days old the birds were weighed daily and 15 of them received a dose of 20 mg. retinyl acetate per 100 g. body weight per day. This was deposited into the oesophagus using a polythene tube. The other 15 birds were used as controls.

At 14, 21 and 28 days of age, 3, 4 and 5 birds respectively were killed from each of the 2 groups. They were anaesthetised with chloroform, given an intracardiac injection of heparin and exsanguinated, the blood being collected. The carcase was immediately perfused via the heart with normal saline, the right leg was removed and stored at −20° and the remainder of the carcase perfused with formol acetate. After storage in formalin, material was taken for histological examination from the cerebrum, cerebellum, pons and medulla, a transverse section of the face at the level of the posterior commissure of the external nares, a longitudinal section of the bones of the base of the skull, a transverse section of the first lumbar vertebra, a transverse section of the midshaft of the right ulna and a longitudinal section of the lower third of the left tibiotarsus. Tissues were embedded in paraffin wax, sections were cut at 5 μ and stained with haematoxylin and eosin. Sections of the tibiotarsus were also stained with toluidene blue.

The blood samples were examined for packed cell volume, number of red blood cells and haemoglobin content measured as oxyhaemoglobin in a spectrophotometer. The acid and alkaline phosphatases in plasma were estimated by the method of King and Armstrong (1934).

Approximately 2 months after collection the right legs were removed from the −20° refrigerator, and all extraneous tissue was trimmed off the tibiotarsi. These were then weighed and the distances from the top of the tibial crest to the base of the distal inter-

* Present address: Department of Poultry Science, Cornell University, Ithaca, New York.

condylar notch, and the midshaft circumferences, were measured. The periosteum was removed for 2·5 mm. on each side of the midpoint of the shaft of each bone and weighed. Samples of cortical bone weighing 20–50 mg. were obtained from the full thickness of the bone at this site and samples weighing 50–80 mg. were removed from the distal extremity of the bone extending from the articular cartilage to the epiphyseal plate and for an equivalent distance into the metaphasis. These tissues were prepared by the method of Jeffree (1950) and their acid and alkaline phosphatase content was estimated by the method of King and Armstrong (1934).

RESULTS

Gross Pathology.—On the seventh day of the experiment birds given retinyl acetate were seen to have inflamed skin around the external nares, commissures of the beak and eyes. Exudate and food material was encrusted over these areas. The hypervitaminosis birds did not at first grow at the same rate as the controls and 2 of them died at the end of the first week of the experiment. After 2 weeks however, the birds remaining in this group seemed to be less affected by the excessive amounts of vitamin A and their body weights approached those of the controls.

The weights, lengths, midshaft circumferences and periosteal thicknesses of the tibiotarsi are given in Table I. They show that, when compared with the

TABLE I.—*Mean Tibiotarsis Weights, Lengths, Shaft Circumferences, and Periosteal Thickness, Expressed as sq. cm. Periosteum/g.*

Age (days)	14		21		28	
Group	Hyper	Normal	Hyper	Normal	Hyper	Normal
No./group	3	3	4	4	5	5
Mean weight (g.)	0·94	1·22	1·17	2·51	2·26	2·72
Mean length (mm.)	38	45	39	52	46	52
Mean circumference (mm.)	10·0	9·8	10·0	15·0	13·8	16·[illegible]
Sq. cm. periosteum/g.	152·7	93·8	249·0	84·8	126·6	106·[illegible]

controls, the hypervitaminotic birds had shorter, narrower, lighter tibiotarsi with thinner periostea. The only observation that does not fit this pattern is the midshaft circumference of the 14-day-old birds.

Histopathology.—Similar lesions were observed at all sites and at all ages in the bones of the hypervitaminotic birds. The periosteum was thinner and had a smoother surface than that of the controls; there was an increase in the fibrous tissue component and a marked decrease in the number of osteoblasts. The osteoblasts that were present appeared to be less active (Figs. 1 and 2). Similarly

EXPLANATION OF PLATES.

FIG. 1.—Longitudinal section of the cortical bone of the tibiotarsus of a bird that had been given retinyl acetate for 1 week. The subperiosteal osteoblasts appear inactive and are few in number. H. and E. ×42.

FIG. 2.—Longitudinal section of the cortical bone of the tibiotarsus of a control bird of the same age as that in Fig. 1. Numerous and active subperiosteal osteoblasts are present. H. and E. ×42.

FIG. 3.—Section through the epiphyseal cartilage of the tibiotarsus of a bird that had been given retinyl acetate for 1 week. Vascular channels are infrequent, and there is much cartilage. H. and E. ×6.

FIG. 4.—Section through the epiphyseal cartilage of the tibiotarsus of a control bird of the same age as that in Fig. 3. The vascular channels and the cartilage are normal. H. and E. ×6.



Baker, Howell and Thompson.

in the subperiosteal bone the osteoblasts were fewer and less active than in the controls. Evidence of an effect on osteoclasts was not found.

The sites of endochondral ossification in the birds given retinyl acetate all showed similar changes, and the degree of change appeared to be proportional to the rate of growth at that particular site. There was a marked increase in the thickness of the zone that Wolbach and Hegsted (1952*a*) called the epiphyseal or growth cartilage, and this increase was due to larger numbers of apparently healthy hyperplastic chondrocytes and their matrix. Associated with this lesion was a marked decrease in the number and a slight increase in the size of the invading vascular channels (Figs. 3 and 4). In sections of the lower extremity of the tibiotarsi stained with toluidene blue there appeared to be an equal degree of metachromasia in control chicks and in those that had received retinyl acetate. The number of nests of uncalcified hypertrophic chondrocytes in the trabeculae of the primary spongiosa was increased in the hypervitaminotic birds. The cortical bone was thinner and denser than that of the controls, and had a large number of cement lines.

Two of the 4 hypervitaminotic birds killed when 21 days of age had shrunken cells with pyknotic nuclei in the granular layer of cerebellar folia. Evidence of ventricular dilatation and brain swelling was seen in 3 of the 5 hypervitaminotic birds killed when 28 days old.

The skin and subcutis in the region of the external nares of the hypervitaminotic chicks showed a low grade inflammatory change with degeneration and necrosis of the superficial epithelium. Significant changes were not seen in the nasal mucosa nor were lesions observed in the non-ossifying cartilage of the nasal turbinates.

Chemical Pathology.—The results of the analysis of the blood and bones are given in tables II and III. The blood and bone alkaline phosphatase levels were

TABLE II.—*Plasma Acid and Alkaline Phosphatase of Normal and Hypervitaminotic A Chicks Expressed as King Armstrong Units/100 ml. Plasma*

Age (days)	14		21		28	
Group	Hyper	Normal	Hyper	Normal	Hyper	Normal
No./group	2	3	4	4	5	5
Alkaline phosphatase	50·3	93·2	29·1	43·4	26·4	58·8
Acid phosphatase	*	*	2·5	1·5	3·4	1·2

* Blood samples too small for examination.

lower in the hypervitaminotic birds than in the controls except in the first group of birds killed after retinyl acetate had been given for 7 days. At this age the control and hypervitaminotic birds had similar levels in cortical bone. This agrees with the results of shaft circumference measurements taken at this age (Table I).

The acid phosphatase levels were moderately elevated in the blood, epiphyseal and cortical bone of hypervitaminotic birds killed when 21 or 28 days of age, and in the periosteal tissue of such birds killed when 28 days old (Table III).

Haematology.—The results of the red blood cell counts, packed cell volumes and

TABLE III.—*Bone Acid and Alkaline Phosphatase Levels of Normal and Hypervitaminotic A Chicks. The Results are Expressed as KingArmstrong Units/g. wet wt. or per sq. cm. of Periosteum.*

Age (days)	14		21		28	
Group	Hyper	Normal	Hyper	Normal	Hyper	Normal
No./group	2	3	4	3	5	5
Periosteal AlkP/g. wet wt.	0·44	3·51	0·44	0·86	0·74	1·44
„ „ /sq. cm.	0·035	0·036	0·002	0·011	0·005	0·015
„ AcP/g. wet wt.	trace	1·36	1·86	0·59	2·20	2·54
„ „ /sq. cm.	trace	0·004	0·009	0·008	0·014	0·009
Cortical AlkP/g. wet wt.	0·18	0·20	0·25	0·44	0·26	0·27
„ AcP/g. wet wt.	0·07	0·26	0·46	0·35	1·30	0·43
Epiphyseal AlkP/g. wet wt.	1·15	2·69	3·70	4·33	1·86	3·92
„ AcP/g. wet wt.	0·76	1·15	0·85	0·67	1·03	0·54

TABLE IV.—*Haematological Findings in Normal and Hypervitaminotic A Chicks*

Age (days)	14		21		28	
Group	Hyper	Normal	Hyper	Normal	Hyper	Normal
No./group	3	3	4	4	5	5
R.B.C. 10^6/mm.^{3}	1·56	1·91	1·83	1·46	1·94	1·96
P.C.V. %	20	27	28	26	25	30
Hb g. %	6·2	7·5	7·5	6·2	7·2	8·6

haemoglobin estimations are given in Table IV. Consistent differences between the 2 groups were not found.

DISCUSSION

Our investigation of the chronic toxicity of vitamin A indicates that its effects on bone structure are much less marked in the chick than in the rat, in which bone resorption results in multiple fractures of the long bones. We have been unable to demonstrate marked resorption in the long bones of chicks even when large quantities of retinoic acid have been administered (Howell and Thompson, unpublished), a procedure which results in extremely severe bone fragility in rats (Thompson and Pitt, 1960).

Our findings support those of Wolbach and Hegsted (1952c) in that the administration of large doses of vitamin A does produce bone lesions in the chick but we cannot agree with these authors concerning the detail of these changes. The bones were shorter, narrower and lighter than those of the controls. Histologically there were 2 main abnormalities in the structure of the bones of hypervitaminotic birds; there appeared to be an inhibition of osteoblats (Fig. 1) and there was an increased amount of epiphyseal cartilage present (Fig. 3).

The more fundamental lesion appeared to be an inhibition of osteoblasts, few of these cells were seen and those present were inactive. Blood and bone alkaline phosphatase levels were lower in the hypervitaminotic birds than in the controls and this was thought to confirm the histological finding of a low osteoblastic activity. It would be interesting to see if complete inhibition of osteoblasts would be produced by the administration of a higher level of retinyl acetate than that given in these experiments. Wolbach and Hegsted (1952c) did not comment directly upon the action of hypervitaminosis A on osteoblasts but they recorded

that " the deep layer of the periosteum is less cellular than that of normal controls", and they recorded that the cortical bone was very dense and that compact bone seemed to replace cancellous bone more rapidly than in the controls.

Irving (1949) had concluded that the inhibition of osteoblastic activity was the important action of high levels of vitamin A in the rat. He found that osteoclasts were not directly affected and this would appear to be so in the chick. The importance of vitamin A in the control of osteoblastic activity has been reported by Mellanby (1944; 1950) and Irving (1949) for mammals and by Howell and Thompson (1967*a*, *b*), for birds. The results of the investigation reported here on hypervitaminosis A and of the experiments on vitamin A deficiency (Howell and Thompson, 1967*a*,*b*) lead us to the conclusion that in the chick as in the rat (Irving, 1949) vitamin A controls the activity of osteoblasts. While we would not subscribe to the view that the mechanisms underlying the abnormalities resulting from vitamin A deficiency and vitamin A excess are necessarily or obviously related to one another, it is true that vitamin A deficiency results in stimulation of the activity of osteoblasts and hypervitaminosis results in its suppression.

The failure to remove epiphyseal cartilage at the normal rate is at variance with the findings of Wolbach and Hegsted (1952*c*), who described a narrowing of this cartilage zone. Wolbach and Hegsted (1952*b*) and Howell and Thompson (1967*a*) found an increase in the thickness of epiphyseal cartilage and a reduction in the number of vascular tunnels in the long bones of vitamin A deficient chicks, and Carlton and Henderson (1964) had recorded similar changes in copper deficient chicks. Howell and Thompson (1967*a*) suggested that this lesion was associated with inanition, for the change appeared some days after the vitamin A deficient chicks had ceased to grow at the normal rate, and was also associated with a fibroblastic replacement of the haemopoietic tissue of the bone marrow. The results reported here would not contradict this hypothesis, although bone marrow fibrosis was not seen.

The cell damage and swelling seen in the central nervous system of some of the hypervitaminotic birds was thought to have been due to mechanical factors associated with the failure of bone formation. The skin lesions were restricted to the commissures of the beak, nose and eyes of the hypervitaminotic chicks. The histological appearance of the lesion was of a non-specific inflammatory response with degeneration and necrosis of the epithelium. In previous experiments (Howell and Thompson, unpublished) the vitamin A had been given by pipette into the mouth and some of this had run over the beak. In these birds the skin lesions were more severe and were also found on the feet. In the experiments reported here the vitamin A acetate was deposited into the oesophagus and only a small amount was ever present in the mouth. This reduced the severity and extent of the skin lesions, and we presume that they are a local response to irritation. The haematological findings do not support those of Poumeau-Delille (1943) and Walker, Eylenberg and Moore (1947) in the rat. The hypervitaminotic chicks in our experiments did not become anaemic.

SUMMARY

Hypervitaminosis A was induced in 15 chicks by giving daily 20 mg. of retinyl acetate/100 g. body weight. This was first given when the chicks were 7 days old and hypervitaminotic birds were killed together with an equivalent number of

controls when they were 14, 21 and 28 days old. All hypervitaminotic birds grew more slowly and had shorter, narrower, lighter bones than the controls. There was a pronounced effect on osteoblasts and their activity was severely inhibited. This was confirmed by low alkaline phosphatase levels in blood and bone. The significance of the changes in osteoblasts is discussed. The epiphyseal cartilage was abnormally thick and the vascular channels were fewer and wider than in the controls. This was thought to be due to inanition. Inflammatory lesions were present on the skin of the face and these were thought to have been a local response to irritation. The birds were not anaemic.

We wish to thank Professor D. L. Hughes and Professor R. A. Morton for encouragement and advice; Mrs. M. W. Harling, and Mrs. C. McLaughlin for technical assistance, and Mr. G. Weston and Mr. E. O'Neill, for the photographs. J. N. T. was a British Egg Marketing Board Fellow, and the work was supported by a grant from the British Egg Marketing Board.

REFERENCES

Carlton, W. W. and Henderson, W.—(1964) *Avian Dis.*, **8**, 48.
Grey, R. M., Nielsen, S. W., Rousseau, J. E., Jr., Calhoun, M. C. and Eaton, H. D.—(1965) *Path. Vet.*, **2**, 446.
Howell, J. McC. and Thompson, J. N.—(1967*a*) *Br. J. Nutr.* in press.—(1967*b*) *Br. J. exp. Path.*, **48**, 450
Irving, J. T.—(1949) *J. Physiol.*, **108**, 92.
Jeffree, G. M.—(1959) *J. Bone Jt. Surg.*, **41 B**, 401.
King, E. J. and Armstrong, A. R.—(1934) *Canad. med. Ass. J.*, **31**, 376.
Mellanby, E.—(1944) *Proc. roy. Soc. B.*, **132**, 28.—(1950) 'A Story of Nutritional Research', Baltimore (Williams and Wilkins).
Moore, T.—(1957) 'Vitamin A' (Elsevier).
Moore, T. and Wang, Y. L.—(1945) *Biochem. J.*, **39**, 222.
Persson, B., Tunell, R. and Ekengren, K.—(1965) *Acta Paed. Scand.*, **54**, 49.
Poumeau-Delille, G.—(1943) *C.R. Soc. Biol., Paris*, **137**, 604.
Rigdon, R. H., Rude, J. C. and Bieri, J. G.—(1951) *Archs Path.*, **52**, 299.
Thompson, J. N. and Pitt, G. A. J.—(1960) *Nature*, **188**, 672.
Walker, S. E., Eylenberg, E., Moore, T.—(1947) *Biochem. J.*, **41**, 575.
Wolbach, S. B.—(1947) *J. Bone Jt Surg.*, **29**, 171.
Wolbach, S. B. and Hegsted, D. M.—(1952*a*) *Archs Path.*, **54**, 1.—(1952*b*) *Archs Path.*, **54**, 13.—(1952*c*) *Archs Path.*, **54**, 548.—(1953) *Archs Path.*, **55**, 47.

Ann. Inst. Pasteur 110(4):487-496. 1966.

Bazin-'66
Bib. No. 665

Vitamin A

French publication, Annales de l'Institut Pasteur, Hypervitaminose A et collagene, pages 487-496

Influence of A hypervitaminosis on the constitution of the connective tissue and on the collagenolytic activity of normal or inflamed tissues (*)

by Susanne Bazin and Albert Delaunay
(with the technical collaboration of Nicole Briquelet and Jean-Claude Allain)
(C.N.R.S. and Pasteur Institute, Annexe de Garches (Hauts-de-Seine))

Introduction

We have shown, in the course of previous research /2,3/ that there was a certain collagenolytic activity in the normal, and particularly in the inflamed tissues. Where do the enzymes responsible for this activity originate? We thought of the lysosomes for three reasons: 1) The amount of enzymes that we can extract from an inflamed tissue varies as a function of the degree of evolution of the inflammation /2/. 2) The seat of optimum enzymatic activity is always in a zone of acid pH /1/. 3) Finally, three years ago Frankland and Wynn /12/ managed to localize, in the lysosomes, the collagenolytic enzyme which they themselves found in the liver cells of the rat.

But if we assume that the enzymes in question are actually localized in the lysosomes, a corrollary is implied: the collagenolytic activity of normal and inflamed tissues must be modified when the animals are placed under special conditions which are known to alter the permeability of the lysosomes, for example when they are treated with very large doses of vitamin A.

The demonstration of such a fact appeared to us to be important enough to justify a series of experiments. In the course of these (the results of which constitute the subject of the present paper), young rats were subjected to A hypervitaminosis. When the time came, they were sacrificed. Then we examined the composition of their connective tissue, and in addition we made a comparative study of the collagenolytic activity of their normal or inflamed tissues.

Equipment and techniques

1. Preparation of the animals A group of two lots, composed of 20 male and female albino rats each, aged 5 weeks and weighing 80 to 90 g, received daily oral doses (esophagian probe), of 60,000 units of vitamin A (1) (per 100 g of animal). A group of three control lots of 20 animals of the same age and weight as the preceding, were given neutralized olive oil, likewise per os; the volume corresponding to that in which was dissolved the dose of vitamin A administered to the animals in the first group.

Five days after the start of these treatments, the rats belonging to one lot in each group were given an injection of 0.25 ml of turpentine essence. The injection was made sub-cutaneously in the interscapular region.

All the animals were sacrificed on the 19th day, i.e. after 18 days of treatment with vitamin A (or olive oil) and 13 days after the injection of essence.

In the course of the treatment, the following observations were made:

a) Control animals The weight gain was 83.2% in those receiving only olive oil, and 58.5% in those also receiving an injection of turpentine.

b) Experimented animals (animals treated with vitamin A). In the case of these, growth was slowed down; the weight gain, in fact, was only 45 and 35% respectively. Comparison of these two figures indicates that local inflammation reinforced the general hampering effect of hypervitaminosis.

2) Obtention and treatment of tissues - Immediately after the sacrifice of the animals, we took samples of: the liver, the cartilege of the sternum and ears, and, according to cases, the inflammatory granuloma (animals tested with spirits of turpentine) or the normal subcutaneous tissue of the interscapular region (animals without inflammation). The samples of cartilege were taken to enable us to find in the rat, the modifications in the connective tissue that could be produced in the young rabbit by A hypervitaminosis

(Thomas and coll. /24/). In this animal there is loss of rigidity of the ears and, in the matrix of the cartileges, disappearance of metachromasia (by diminution of the rate of chondroitine sulphate).

When the samples were taken, the various tissues from a given lot of animals (liver, cartilege,granuloma or normal subcutaneous tissue) were chopped up, mixed, weighed and finally divided into three fractions.

The first fraction (0.50 to 3 g) was utilized for dosing the water; for this it was dried at 100° until a constant weight was obtained.

The second fraction (2 to 10 g) was dehydrated by the action of acetone, ground and finally delipidated by petroleum ether; it served for dosage of the total mucopolysaccharides and collagen.

From the third fraction, (remainder of the samples) finally, we extracted the collagenolytic enzymes, first by simple exhaustion in physiological water, then after action of saponin by means of a process which we have described previously /2/.

3. Dosages and measurements

a) The dosage of totalmucopolysaccharides was made on a tissue delipidated and hydrolyzed for 15 hours at 103°C in the presence of 2 N HCl. The hexosamines were isolated on amberlite columns according to the Partridge and Ellsden method /18/, then titered in the eluate by the Elson and Morgan method /6/, modified by Immers and Vasseur /14/ and Pearson /19/.

b) The collagen was dosed on a delipidated, hydrolyzed tissue for 24 hours at 105°C in the presence of 6N HCl. Hydroxyproline was isolated by means of chromatography on Amberlite column using the method of Partridge and Elsden /18/ then titered in the eluate by Stegemann's method /23/.

c) Collagenolytic activity This was evaluated from the action of our tissue extracts on an acid-soluble collagen, under conditions already indicated /1/.

Results

With regard to the liver and cartilege, the results obtained were comparable in the animals belonging to a given group, whether bearing an inflammation or not. We therefore give here only the averages of the results obtained with the two lots (bearers of inflammation or not) of a given group (control group or group treated with vitamins).

1. Rate of mucopolysaccharides

Our results in this case are shown in fig. 1. Examination of this figure shows that, in the animals treated with strong doses of vitamin A, the amount of mucopolysaccharides is, in the cartilege and the sub-cutaneous tissue, smaller than it is in the control animals. The diminution observed is 31% in the cartilege, 33% in normal sub-cutaneous tissue, 24% in the sub-cutaneous granuloma.

In the liver, on the contrary, the amount was larger than that found in the controls.

Fig. 1 page 490 Mucopolysaccharide content in tissues of normal rats and rats subjected to A hypervitaminosis

A - M P (in mg hexosamines)/g dry tissue; B - T = control rats. VA = rats treated with vitamin A; C - Cartilage; D - Sub-cutaneous tissue; E - Granuloma; F - Liver

---

2) Collagen

See Fig. 2 Examination of this figure shows that, in the animal under A hypervitaminosis, the collagen content of the tissues is scarcely different from a normal content. We did observe a rise of 12% in the sub-cutaneous tissue, but this difference is practically without statistical significance.

3) Value of the collagenolytic activity

The results of our measurements are given in fig. 3. Examination of this

figure leads to the following conclusions:

a) The collagenolytic activity is clearly greater, both in the normal sub-cutaneous tissue and in the granulomatous tissue, in the animals subjected to A hypervitaminosis. The increase is 24.5% in normal sub-cutaneous tissue; it is 33.5% in the granulomatous tissue.

b) The observed increase resides exclusively in the easily extractible fraction (the one obtained without application of saponin). The activity observed in the other fraction (obtained after action of saponin) was, in the case of the granuloma, less important in the animals treated with vitamin A than in the control animals.

c) We were able to make an analogous observation in regard to the liver. In this organ, as a matter of fact, although the total collagenolytic activity is substantially the same in the control animals and in those who received vitamin A (the diminution of 6.6% observed is not significant), the activity of the fraction recoverable only after action of saponin was lower in the latter.

Fig.2 page 491 Collagen of animal tissues of normal and animals subjected to A hypervitaminosis.

A - Collogen (in my of hydroxyproline)/ g dry tissue;

B - T = control animals; VA = animals treated with vitamin A;

C - Sub-cutaneous tissue; D - Granuloma; E - Liver

Fig. 3 Collagenolytic activity of tissues of normal animals and animals subjected to A hypervitaminosis.

A - Degraded collogen (in my hydroxyproline) per g of dry tissue; B - Fraction soluble in NaCl, 0.15 M; C - Fraction insoluble in NaCl 0.15 M;

E - Normal sub-cutaneous tissue; F - Granuloma; G - Liver

Discussion

1) The first fact which, in our opinion, ought to be brought out, relates to the drop in the MP content of the cartilage of rats placed under A hypervitaminosis. This drop corresponds to the one already noted in the case of other animals by different authors (Fell et coll./7, 8, 9, 10/, Thomas et coll. /24/, Dingle et coll. /5/). It thereby confirms the identity of action of the vitamin in the various animal species.

2) A new fact: we have observed a comparable drop in the MP content of normal sub-cutaneous tissue and in granulomatous tissue of animals treated with vitamin A. We may therefore assume that hypervitaminosis does not confine its action to the cartilage but also works on other connective tissues.

3) The connective tissue of the liver, however, appears to escape this rule. In its own case, as a matter of fact, the MP content does not diminish; on the contrary it increases. What reasons can be assigned to this pecularity? We propose the following. The liver is an organ which appears to be not very rich in connective tissue, if we compare it with sub-cutaneous tissue or cartilage. Moreover, it is not a place of storage of acid mucopolysaccharides; it is an organ forming circulating glycoproteins (20, 21, 22). We know that the latter are produced in excess in many reactions, whether local (inflammation), or general (hyperthermia) of the organism (27). Doubtless, the general trouble brought on by A hypervitaminosis(of which the retardation of growth is a test), is also capable of triggering hyperproduction of glycoproteins in the liver. In this connection we can refer to the observations of Weissmann (25), and Lasnitzki (16). These authors observed, in animals subjected to A hypervitaminosis, a strong hypersecretion of various mucuses (in the intestine, the esophagus, etc.), particularly rich in glycoproteins.

4) Now let us consider the question of collagen. According to our observations, its percentage, in the various tissues, is not modified by A hypervitaminosis. Such a result extends and confirms those of Houck and Patel (13),

they having reported the constancy of rate of collagen in the dermis of rats subjected to A hypervitaminosis.

Another remark: the collagen content having been found identical in the various granulomatous tissues studied, (in treated animals and in controls) we are inclined to think that A hypervitaminosis is not capable per se of substantially modifying the evolution of an inflammatory reaction.

5) Having said this, we believe we have come to the capital observation which is as follows: an A hypervitaminosis, although it does not always increase the total collagenolytic activity of a normal or inflamed tissue (the liver being an exception), it never fails to increase the said activity in the tissue fraction soluble in water. If, as a matter of fact, we strike the ratio between the latter, and the activity exerted by the fraction recoverable only after action by a detergent (saponin) we perceive that it is higher in every case. Thus it shifts from 0.81 to 1.45 in the sub-cutaneous tissue, from 0.52 tol in the liver, and from 0.64 to 3.7 in the granuloma. It appears merely from this that under the influence of Ahypervitaminosis,there is extracellular liberation of enzymes.

How is the hypervitaminosis supposed to work? The answer appears to us to have been provided by the works of Dingle (4), Fell et coll. (8), Weissmann and Thomas (26), Janoff and McCluskey (15), etc. A vitaminosis has the property both in vivo and in vitro, of altering the permeability of the lysosomes; for this reason it would provoke the liberation of the hydrolases (among which an active protease with acid pH has been characterized) contained in these organites. In the present state of our research, we think, therefore, that the enzymes responsible for the collagenolytic activity which we are studying, are to be classed with these hydrolases.

6. We now must try to find an answer to a hard question. How can we explain the fact that, in animals treated with vitamin A, while the free collagenolytic activity in their tissues increases, the collogen content in the

connective tissue is not substantially modified? Certainly we are aware that this activity is not very powerful /1/. But we would nevertheless expect to note a certain amount of action. The explanation probably lies in the fact that the overall chemical methods we use do not represent a method of analysis fine enough to detect, in the state of aggregation of the molecules of tropocollagen, the modifications that the liberation of enzymes could entrain. In this respect, an observation we have just made might perhaps be worth mentioning: in the granulomes of animals subjected to A hypervitaminosis, the amount of soluble collagens has risen 56% with respect to that which we find in the granulomas of the control animals.

7. A final point calls for our attention. It concerns the drop in the acid mucopolysaccharides in the cartilage and the sub-cutaneous tissue of animals treated with vitamin A. The authors who have studied this drop in the case of the cartilage, have assumed that it was due to the action of a protease. The latter, liberated by hypervitaminosis, would go and destroy a protein normally bonded to the molecules of chondroitine-sulphate, would thus dislocate the macromolecular aggregates and would finally permit partial elimination of the chondroitin-sulphate. It would be cathepsic in nature (17, 7, 4).

As for the drop in the amount of the same bodies in the normal or inflamed sub-cutaneous tissue, a drop which we have found to be real, would we be entitled to attribute an analogous mechanism? If so, could we not consider an intervention of the collagenolytic cathepsins which we are studying? This appears possible to us for two reasons:

a) First of all because we know that our enzymatic extracts are endowed with a general, non-specific proteolytic activity (1).

b) Secondly, because we were struck by the result of recent experiments (still unpublished). When we bring into contact, for 3 hours at 30°C with slight agitation, fragments of rabbit ear cartilage and our enzymatic extracts, there is passage, into the suspension liquid, of a quantity of hexosamines 56%

larger than that which diffuses into the liquid in which control fragments are immersed.

It would therefore not be impossible that the cathepsins detected by us do act on the non-fibrillary proteins of the connective tissue; in particular, they would be responsible for the secondary drop in the amount of MPs in the inflammed tissues, these bodies having accumulated in the first stages of formation of the granuloma. It is certain, however, that A hypervitaminosis liberates not only collagenolytic cathepsins but also other enzymes of the lyssomes. We will call on further experiments before issuing a true opinion.

Resume and conclusions

1. In young rats subjected to A hypervitaminosis, the amount of the mucopolysaccharides decreases by about 30% in normal sub-cutaneous tissue and in sub-cutaneous granulomas, as it decreases in the cartilaginous matrix.

2. At the same time, the amount of collagen does not change substantially.

3. The collagenolytic activity, in normal or inflamed tissues of animals subjected to the same hypervitaminosis, increases in the fraction soluble without prior action of a detergent. The phenomenon is obviously a release of enzymes from the cells. This release could be attributed to the action of vitamin A on the lysosomes. The cathepsins responsible for the collagenolytic activity may therefore have a lysosomic origin.

4. The influence of the cathepsins in question on the modifications in the composition of the connective tissue in vivo has been discussed as a function of the experimental results.

Footnote

(*) French Microbiological Society, session of October 7, 1965.

(Translated by Carl Demrick Associates, Inc/GCT/t)

Bazin-'66
Bib. No. 665

Ann. Inst. Pasteur 110(4):487-496. 1966.

INFLUENCE EXERCÉE PAR UNE HYPERVITAMINOSE A SUR LA CONSTITUTION DE LA TRAME CONJONCTIVE ET L'ACTIVITÉ COLLAGÉNOLYTIQUE DE TISSUS NORMAUX OU ENFLAMMÉS (*)

par Suzanne BAZIN et Albert DELAUNAY
(avec la collaboration technique de Nicole BRIQUELET et Jean-Claude ALLAIN)

(*C. N. R. S. et Institut Pasteur, Annexe de Garches [Hauts-de-Seine]*)

INTRODUCTION

Nous avons montré, au cours de recherches antérieures [**2, 3**], qu'il existait une certaine activité collagénolytique dans les tissus normaux et surtout enflammés. D'où peuvent venir les enzymes responsables de cette activité ? Nous avons pensé aux lysosomes pour trois raisons. 1° La quantité d'enzymes qu'on peut extraire d'un tissu enflammé varie en fonction du degré évolutif de l'inflammation [**2**]. 2° L'optimum d'activité enzymatique siège toujours dans une zone de pH acide [**1**]. 3° Enfin, il y a trois ans, Frankland et Wynn [**12**] sont parvenus à localiser dans les lysosomes l'enzyme collagénolytique qu'ils avaient eux-mêmes trouvée dans les cellules hépatiques du rat.

Cependant, admet-on que les enzymes en question sont localisées effectivement dans les lysosomes, un corollaire se trouve impliqué : l'activité collagénolytique des tissus normaux et enflammés doit être modifiée quand les animaux sont placés dans des conditions particulières qui sont connues pour altérer la perméabilité des lysosomes, par exemple quand ils sont traités par de très fortes doses de vitamine A.

La démonstration d'un tel fait nous a paru assez importante pour justifier la mise en route d'une série d'expériences. Au cours de celles-ci (dont les résultats font l'objet du présent mémoire), de jeunes rats ont été soumis à une hypervitaminose A. Le moment

(*) *Société Française de Microbiologie*, séance du 7 octobre 1965.

venu, ils ont été sacrifiés. Alors nous avons examiné la composition de leur trame conjonctive et, d'autre part, nous avons étudié comparativement l'activité collagénolytique de leurs tissus, normaux ou enflammés.

MATÉRIEL ET TECHNIQUES

1° Préparation des animaux. — Un groupe de deux lots, composés chacun de 20 rats albinos, mâles et femelles, âgés de 5 semaines et pesant de 80 à 90 g, a reçu chaque jour par voie buccale (au moyen d'une sonde œsophagienne) 60 000 unités de *vitamine A* (1) (pour 100 g d'animal). Le traitement a été poursuivi pendant dix-huit jours consécutifs. Un groupe de deux lots témoins de 20 animaux, de même âge et de même poids que les précédents, a reçu, également par voie buccale, de l'huile d'olive neutralisée : le volume correspondait à celui dans lequel avait été dissoute la dose de vitamine A administrée aux animaux du premier groupe.

Cinq jours après le début de ces traitements a été pratiquée, chez les rats appartenant à un lot de chaque groupe, une injection de 0,25 ml d'*essence de térébenthine*. L'injection était faite par voie sous-cutanée, dans la région interscapulaire.

Tous les animaux ont été sacrifiés au dix-neuvième jour, c'est-à-dire après dix-huit jours de traitement par la vitamine A (ou l'huile d'olive) et treize jours après l'injection d'essence.

En cours de traitement, les observations suivantes ont été faites :

a) *Animaux témoins.* L'augmentation de poids a été de 83,2 p. 100 chez ceux qui avaient reçu seulement de l'huile d'olive et de 58,5 p. 100 chez ceux qui avaient subi en outre une injection d'essence de térébenthine.

b) *Animaux en expérience* (animaux traités par la vitamine A). Chez ceux-ci, la croissance a été ralentie ; l'augmentation de poids, en effet, n'a été respectivement que de 45 et de 35 p. 100. La comparaison de ces deux chiffres indique que l'inflammation locale a renforcé l'action contrariante générale de l'hypervitaminose.

2° Obtention et traitement des tissus. — Aussitôt après le sacrifice des animaux, ont été prélevés : le foie, le cartilage du sternum et des oreilles et, selon les cas, le granulome inflammatoire (animaux éprouvés par l'essence de térébenthine) ou du tissu sous-cutané normal de la région interscapulaire (animaux sans inflammation). Les prélèvements de cartilage ont été faits pour nous donner la possibilité de retrouver chez le rat les modifications de la trame conjonctive que peut produire chez le jeune lapin une hypervitaminose A (Thomas et coll. [24]). Il y a, chez cet animal, perte de la rigidité des oreilles et,

(1) La vitamine A nous avait été aimablement fournie par les Etablissements Byla, que nous tenons à remercier.

dans la matrice des cartilages, disparition de la métachromasie (par diminution du taux de chondroïtine-sulfate).

Les prélèvements étant faits, les différents tissus provenant d'un même lot d'animaux (foie, cartilage, granulome ou tissu sous-cutané normal) ont été hachés, mélangés, pesés, enfin répartis en *trois fractions*.

La première fraction (de 0,50 g à 3 g) a été utilisée pour le *dosage de l'eau* ; pour cela, elle était desséchée à 100° jusqu'à obtention d'un poids constant.

La seconde fraction (de 2 à 10 g) a été déshydratée par l'acétone, broyée, enfin délipidée par l'éther de pétrole ; elle a servi aux *dosages des mucopolysaccharides totaux et du collagène*.

De la troisième fraction (reste des prélèvements), nous avons extrait enfin les *enzymes collagénolytiques*, d'abord par simple épuisement à l'eau physiologique, puis après action de la saponine, au moyen d'un procédé que nous avons précédemment décrit [2].

3° Dosages et mesures. — a) *Le dosage des mucopolysaccharides totaux* a été fait sur un tissu délipidé et hydrolysé pendant quinze heures à 105° en présence de HCl 2 N. Les hexosamines ont été isolées sur colonnes d'amberlite selon la méthode de Partridge et Elsden [18], puis titrées dans l'éluat par la méthode de Elson et Morgan [6], modifiée par Immers et Vasseur [14] et par Pearson [19].

b) *Le collagène* a été dosé sur un tissu délipidé, hydrolysé pendant vingt-quatre heures à 105° en présence de HCl 6 N. L'hydroxyproline a été isolée au moyen d'une chromatographie sur colonne d'Amberlite selon la méthode de Partridge et Elsden [18], puis titrée dans l'éluat par la méthode de Stegemann [23].

c) *Activité collagénolytique*. Elle a été évaluée d'après l'action de nos extraits tissulaires sur un collagène acido-soluble, dans des conditions déjà indiquées [1].

RÉSULTATS

En ce qui concerne le foie et le cartilage, les résultats obtenus ont été comparables chez les animaux appartenant à un même groupe, qu'ils fussent ou non porteurs d'une inflammation. Ne seront donc données ici que les moyennes des résultats obtenus avec les deux lots (porteurs ou non d'inflammation) d'un même groupe (groupe témoin ou groupe traité par la vitamine).

1° Taux des mucopolysaccharides.

Nos résultats, en ce cas, sont reportés sur la figure 1. L'examen de cette figure montre que, chez les animaux traités par de fortes doses de vitamine A, le taux des mucopolysaccharides est, dans le cartilage et dans le tissu sous-cutané, *inférieur* à ce qu'il est chez

les animaux témoins. La diminution observée est, dans le cartilage de 31 p. 100, dans le tissu sous-cutané normal de 33 p. 100, dans le granulome sous-cutané de 24 p. 100.

Dans le foie, au contraire, le taux a été supérieur à celui qui était trouvé chez les témoins.

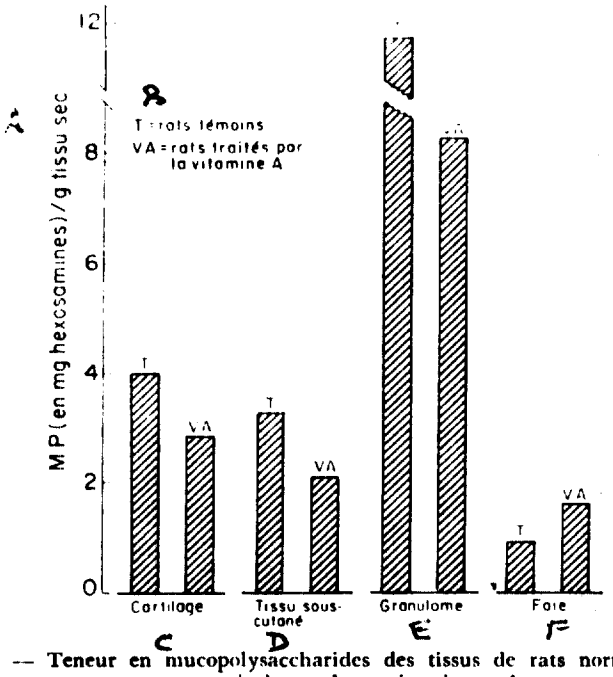

FIG. 1. — **Teneur en mucopolysaccharides des tissus de rats normaux et de rats soumis à une hypervitaminose A.**

2° TAUX DU COLLAGÈNE.

Se reporter à la figure 2. L'examen de cette figure montre que, chez le animaux en hypervitaminose A, la teneur en collagène des tissus n'est guère éloignée d'une teneur normale. Sans doute nous avons observé une augmentation de 12 p. 100 dans le tissu sous-cutané, mais cette différence est, pratiquement, sans signification statistique.

3° VALEUR DE L'ACTIVITÉ COLLAGÉNOLYTIQUE.

Les résultats de nos mesures sont inscrits cette fois sur la figure 3. L'examen de cette figure conduit aux conclusions suivante :

a) L'activité collagénolytique est nettement augmentée, tant dans le *tissu sous-cutané* normal que dans le tissu granulomateux, chez

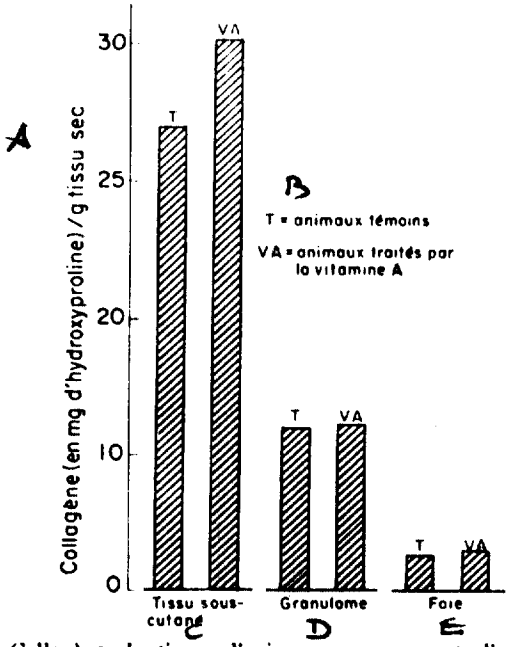

FIG. 2. — Collagène de tissus d'animaux normaux et d'animaux soumis à une hypervitaminose A.

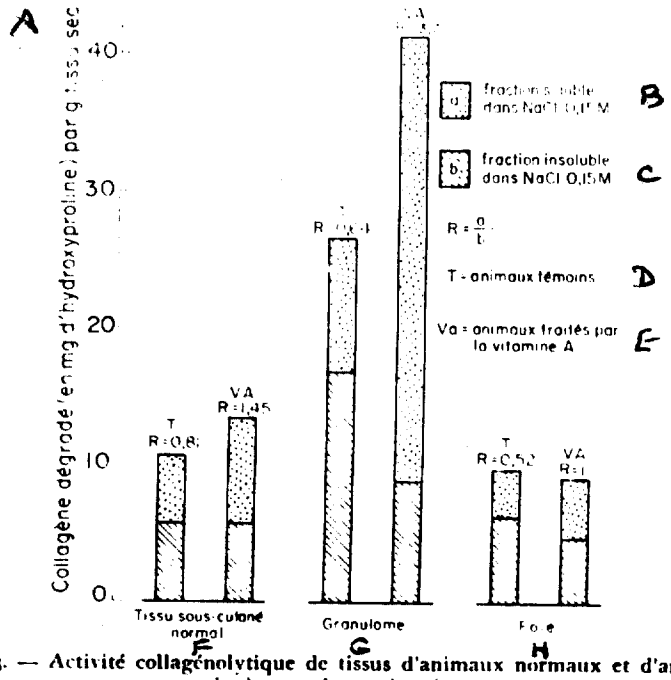

FIG. 3. — Activité collagénolytique de tissus d'animaux normaux et d'animaux soumis à une hypervitaminose A.

les animaux soumis à une hypervitaminose A. L'augmentation est de 24,5 p. 100 dans le tissu sous-cutané normal ; elle est de 33,5 p. 100 dans le tissu granulomateux.

b) L'augmentation observée réside exclusivement dans la fraction aisément extractible (celle qui est obtenue sans application de saponine). L'activité observée dans l'autre fraction (obtenue après action de la saponine) a été, dans le cas du granulome, moins importante chez les animaux traités par la vitamine A que chez les animaux témoins.

c) Nous avons pu faire une observation analogue à propos du *foie*. Dans cet organe, en effet, si l'activité collagénolytique totale est sensiblement la même chez les animaux témoins et chez ceux qui ont reçu la vitamine A (la diminution de 6,6 p. 100 observée n'est pas significative), l'activité de la fraction récupérable seulement après action de la saponine a été nettement plus faible chez ces derniers.

DISCUSSION

1° Le premier fait qui est, selon nous, à relever se rapporte à la *chute du taux des MP dans le cartilage des rats qui ont été placés en hypervitaminose A*. Cette chute correspond à celle qui a déjà été notée, chez d'autres animaux, par différents auteurs (Fell et coll. [**7**, **8**, **9**, **10**], Thomas et coll. [**24**], Dingle et coll. [**5**]). Elle confirme, par là, l'identité d'action de la vitamine dans les différentes espèces animales.

2° Fait nouveau : nous avons constaté une *chute comparable du taux des MP dans le tissu sous-cutané normal et dans le tissu granulomateux des animaux traités par la vitamine A*. On peut donc admettre que l'hypervitaminose ne borne pas son action au cartilage, qu'elle l'exerce encore sur d'autres tissus conjonctifs.

3° Le tissu conjonctif du *foie* paraît, cependant, échapper à cette règle. Dans son cas, en effet, le taux des MP ne diminue pas : au contraire, il augmente. Quelles raisons donner à cette particularité ? Nous proposons les suivantes. Le foie est un organe qui apparaît peu riche en trame conjonctive pour peu qu'on le compare au tissu sous-cutané ou au cartilage. D'autre part, il n'est pas un lieu de stockage de mucopolysaccharides acides : il est un organe formateur de glycoprotéines circulantes [**20**, **21**, **22**]. On sait que celles-ci sont produites en excès dans beaucoup de réactions, locales (inflammation) ou générales (hyperthermie), de l'organisme [**27**]. Sans doute, le trouble général apporté par l'hypervitaminose A (dont le ralentissement de croissance est un test) est-il capable, lui aussi, de déclencher une hyperproduction hépatique de glycoprotéines. A ce sujet, on peut rappeler les observations de Weissmann [**25**], de Lasnitzki [**16**]. Ces

auteurs ont observé, chez les animaux soumis à une hypervitaminose A, une forte hypersécrétion de mucus divers (dans l'intestin, l'œsophage, etc.) particulièrement riches en glycoprotéines.

4° Considérons maintenant ce qui a trait au *collagène*. D'après nos observations, sa teneur, dans les différents tissus, n'est pas modifiée par l'hypervitaminose A. Pareil résultat étend et confirme ceux de Houck et Patel [13], ceux-ci ayant signalé la constance du taux du collagène dans le derme de rats soumis à une hypervitaminose A.

Autre remarque : la teneur en collagène ayant été trouvée identique dans les divers tissus granulomateux étudiés (chez les animaux traités et chez les témoins), nous sommes enclins à penser que l'hypervitaminose A n'est pas capable, *per se*, de modifier sensiblement l'évolution d'une réaction inflammatoire.

5° Cela dit, nous pouvons en venir à l'observation capitale qui est la suivante : *une hypervitaminose A, si elle n'augmente pas toujours l'activité collagénolytique totale d'un tissu normal ou enflammé* (l'exception, ici, se rapporte au foie) *ne manque jamais d'augmenter la dite activité dans la fraction tissulaire soluble dans l'eau.* Fait-on en effet, le rapport entre celle-ci et l'activité exercée par la fraction seulement récupérable après action d'un détergent (saponine), on s'aperçoit qu'il est, dans tous les cas, plus élevé. C'est ainsi qu'il passe de 0,81 à 1,45 dans le tissu sous-cutané, de 0,52 à 1 dans le foie et 0,64 à 3,7 dans le granulome. Il apparaît, par là même, que, sous l'effet d'une hypervitaminose A, il y a *libération extracellulaire d'enzymes.*

Comment agirait l'hypervitaminose ? La réponse nous paraît avoir été apportée ici par les travaux de Dingle [4], Fell et coll. [8], Weissmann et Thomas [26], Janoff et McCluskey [15], etc. La vitamine A a la propriété, *in vivo* comme *in vitro*, d'altérer la perméabilité des lysosomes ; pour cette raison, elle provoquerait la mise en liberté des *hydrolases* (parmi lesquelles une protéase active à pH acide a pu être caractérisée) contenues dans ces organites. Dans l'état actuel de nos recherches, nous pensons donc que *les enzymes responsables de l'activité collagénolytique que nous étudions sont à mettre au nombre de ces hydrolases.*

6° Il nous faut essayer, maintenant, de répondre à une question difficile. Comment expliquer que, chez les animaux traités par la vitamine A, alors que l'activité collagénolytique libre de leurs tissus augmente, le taux de collagène, dans la trame conjonctive, n'est pas sensiblement modifié ? Certes, nous savons bien que cette activité n'est pas très puissante [1]. On se serait attendu, néanmoins, à constater une certaine action. L'explication tient peut-être au fait que les méthodes chimiques globales que nous utilisons ne représentent pas une méthode d'analyse assez fine pour déceler, dans l'état d'agrégation des molécules de tropocollagène, les modifications

que pourrait entraîner la libération d'enzymes. A cet égard, une observation que nous venons de faire mérite peut-être d'être signalée : dans les granulomes des animaux soumis à l'hypervitaminose A, le taux des collagènes solubles est augmenté de 56 p. 100 par rapport à celui qu'on trouve dans les granulomes des animaux témoins.

7° Un dernier point, enfin, appelle notre attention. Il concerne la chute du taux des mucopolysaccharides acides dans le cartilage et le tissu sous-cutané des animaux traités par la vitamine A. Les auteurs qui ont étudié cette chute *dans le cas du cartilage* ont admis qu'elle était due à l'action d'*une protéase*. Celle-ci libérée par l'hypervitaminose, irait détruire une protéine normalement liée aux molécules de chondroïtine-sulfate, disloquerait ainsi les agrégats macromoléculaires, permettrait finalement l'élimination partielle du chondroïtine-sulfate. Elle serait de nature cathepsique [17, 7, 4].

Pour ce qui est de la chute du taux des mêmes corps dans le *tissu sous-cutané normal ou enflammé*, chute dont nous avons découvert la réalité, aurait-on le droit de mettre en cause un mécanisme analogue ? Si oui, ne pourrait-on pas penser à une intervention des cathepsines collagénolytiques que nous étudions ? Cela nous paraît possible pour deux raisons :

a) D'abord, parce que nous savons que nos extraits enzymatiques sont doués d'une activité protéolytique générale non spécifique [1].

b) En second lieu, parce que nous avons été frappés par le résultat d'expériences récentes (et encore inédites). Quand on met en contact pendant trois heures à 30°, sous légère agitation, des fragments de cartilage de l'oreille de lapin et nos extraits enzymatiques, il y a passage, dans le liquide de suspension, d'une quantité d'hexosamines supérieure de 56 p. 100 à celle qui diffuse dans le liquide où baignent des fragments témoins.

Il ne serait donc pas impossible que les cathepsines détectées par nous agissent sur les protéines non fibrillaires de la trame conjonctive ; notamment, elles seraient les responsables de l'abaissement secondaire du taux des MP dans les tissus enflammés, ces corps s'étant accumulés aux premiers stades de la formation du granulome. Cependant, il est certain que l'hypervitaminose A met en liberté, non seulement des cathepsines collagénolytiques, mais encore d'autres enzymes des lysosomes. Aussi, ferons-nous appel à de nouvelles expériences avant d'énoncer une véritable opinion.

RÉSUMÉ ET CONCLUSIONS

1° Chez les jeunes rats soumis à une hypervitaminose A, le taux des mucopolysaccharides diminue d'environ 30 p. 100 dans le tissu sous-cutané normal et dans les granulomes sous-cutanés, comme il diminue dans la matrice cartilagineuse.

2° Au même moment, le taux du collagène ne change pas sensiblement.

3° L'activité collagénolytique, dans les tissus normaux ou enflammés des animaux soumis à la même hypervitaminose, augmente dans la fraction soluble sans action préalable d'un détergent. Le phénomène traduit certainement une libération d'enzymes hors des cellules. Cette libération pourrait être attribuée à l'action de la vitamine A sur les lysosomes. Les cathepsines responsables de l'activité collagénolytique auraient donc une origine lysosomique.

4° L'influence des cathepsines en question sur les modifications de la composition de la trame conjonctive *in vivo* a été discutée en fonction des résultats expérimentaux.

SUMMARY

Influence of A hypervitaminosis on the constitution of the connective tissue and on the collagenolytic activity of normal or inflamed tissues

In young rats, treated by excessive doses of vitamin A :

1. The amount of mucopolysaccharides is decreased in normal or inflamed subcutaneous tissue in the same ratio (about 30 %) as it is decreased in the cartilage matrix.

2. In the same animals, the collagen amount is not significantly modified.

3. In the normal or inflamed tissues of the hypervitaminic animals, the collagenolytic activity is increased in the fraction extracted without using detergent. This phenomenon is obviously a release of enzymes out of the cells : such a release might be due to the action of vitamin A on lysosomes. Thus the collagenolytic cathepsines might have their origin in lysosomes.

4. The influence of these cathepsines, *in vivo*, on the modifications of the chemical components of connective tissue is discussed according to the experimental data.

BIBLIOGRAPHIE

[1] Bazin (S.) et Delaunay (A.). *Ann. Inst. Pasteur*, 1966, **110**, 192.
[2] Bazin (S.) et Delaunay (A.). *Ann. Inst. Pasteur*, 1966, **110**, 347.
[3] Delaunay (A.) et Bazin (S.). *Année biolog.*, 1965, **4**, 83.
[4] Dingle (J. T.). *Bioch. J.*, 1961, **79**, 509.
[5] Dingle (J. T.), Lucy (J. A.) and Fell (H. B.). *Bioch. J.*, 1961, **79**, 497.
[6] Elson (L. A.) and Morgan (W. T. J.). *Bioch. J.*, 1933, **27**, 1824.

[7] FELL (H. B.) and DINGLE (J. T.). *Bioch. J.*, 1963, **87**, 403.
[8] FELL (H. B.), DINGLE (J. T.) and WEBB (M.). *Bioch. J.*, 1962, **83**, [illegible].
[9] FELL (H. B.) and MELLAMBY (E.). *J. Physiol.*, 1956, **127**, 427.
[10] FELL (H. B.), MELLAMBY (E.) and PELC (S. R.). *J. Physiol.*, 1956, **134**, 179.
[11] FELL (H. B.) and THOMAS (L. J.). *J. exp. Med.*, 1960, **111**, 719.
[12] FRANKLAND (D. M.) and WYNN (C. H.). *Bioch. J.*, 1962, **85**, 276.
[13] HOUCK (J. C.) and PATEL (Y. M.). *Amer. J. Path.*, 1964, **45**, 1043.
[14] IMMERS (J.) and VASSEUR (E.). *Acta Chem. Scand.*, 1952, **6**, 363.
[15] JANOFF (A.) and MC CLUSKEY (R. T.). *Biol. Med.*, 1962, **110**, 58.
[16] LASNITZKI (I.). *J. exp. Med.*, 1963, **118**, 1.
[17] LUCY (J. A.), DINGLE (J. T.) and FELL (H. B.). *Bioch. J.*, 1961, **79**, 500.
[18] PARTRIDGE (S. M.) and ELSEN (D. F.). *Bioch. J.*, 1961, **80**, 34 P.
[19] PEARSON (C. H.). *Bioch. J.*, 1963, **88**, 540.
[20] RICHMOND (J. E.). *Biochemistry*, 1963, **2**, 676.
[21] ROBINSON (G. B.), MOLNAR (J.) and WINZLER (R. J.). *J. biol. Chem.*, 1964, **239**, 1134.
[22] SARCIONE (E. J.). *Arch. Bioch. Bioph.*, 1963, **100**, 516.
[23] STEGEMANN (H.). *Z. physiol. Chem.*, 1958, **311**, 41.
[24] THOMAS (L.), MC CLUSKEY (R. T.), POTTER (J. L.) and WEISSMANN (G.). *J. exp. Med.*, 1960, **111**, 705.
[25] WEISSMANN (G.). *J. exp. Med.*, 1961, **114**, 581.
[26] WEISSMAN (G.) and THOMAS (L.). *J. clin. Invest.*, 1963, **42**, 661.
[27] WINZLER (R. J.). *Meth. Bioch. Anal.*, 1955, **2**, 279.

Becker-'63
Bib. No. 689

Am. J. Path. 43:1017-1030. 1963.

Reproduced by permission of the copyright owner

PATHOLOGIC FEATURES OF THE CHOROID PLEXUS

1. Cytochemical Effects of Hypervitaminosis A

Norwin H. Becker, M.D., and Carl H. Sutton, M.D.

From the Lucy and Henry Moses Research Laboratories of the Laboratory Division, Montefiore Hospital, New York, N.Y.

In spite of more than a century of inquiry into the formation and flow of the cerebrospinal fluid, the precise role played by the choroid plexus is still unclear.[1] The 19th century descriptions of numerous granules and vacuoles in the choroidal epithelium was interpreted as evidence of secretory activity. The administration of such drugs as ether or pilocarpine was said to increase the height of these cells and to cause watery swelling of their apical poles. However, more recent refined techniques of fixation suggest that most of these early observations represented artifact. Nevertheless, the presence in these cells of numerous vesicles, infoldings of the plasma membranes, and microvilli, as revealed by electron microscopy, coupled with high levels of enzyme activity, suggest that the choroid plexus is actively engaged in the formation of at least a portion of the cerebrospinal fluid.[2]

One of the most intriguing aspects of cerebrospinal fluid formation is the observation that both experimental hypo- and hypervitaminosis A are capable of producing hydrocephalus;[3-5] clinically, vitamin A overdosage in infants and adults has resulted in acute elevations of cerebrospinal fluid pressure and occasionally pseudotumor cerebri.[6-8] The mechanisms of these phenomena are not understood, but excess secretion of the cerebrospinal fluid has been postulated.

Conventional histologic examination of tissue in this area has been rather unrewarding, and it therefore seemed promising to restudy the problem with the aid of more recently developed cytochemical methods. The application of enzymatic staining techniques to the rat choroid plexus has provided useful markers for the various cytoplasmic organelles.[9,10] Thus acid phosphatase can be used to demonstrate lysosomes; "nucleoside diphosphatase(s)," with thiamine pyrophosphate or inosine diphosphate as substrate, for the Golgi apparatus and blood vessels; DPNH-diaphorase for mitochondria; nucleoside triphosphatase, with adenosine triphosphate as substrate, for plasma membranes and blood vessels, and alkaline phosphatase for blood vessels.

In the expectation that a better understanding of the cytochemical

Supported by grant NB 04525-01 of the United States Public Health Service.
Accepted for publication, July 18, 1963.

alterations of the choroid plexus might provide some insight into normal function, this report concerns the application of the aforementioned cytochemical techniques to a study of the choroid plexus in rats fed an excess of vitamin A.

Material and Methods

Adult and weanling rats of both sexes from a Wistar strain were used in all these studies. The adult rats ranged from 250 to 400 gm. in weight, while the weanling rats weighed 40 to 60 gm. The animals were studied in experimental groups of 6 to 10. The source of vitamin A was "Aquasol A" (U.S. Vitamin Corporation) containing 50,000 units of vitamin A palmitate per ml. in a Tween 80 vehicle. This was administered orally by gastric tube. The experiments were divided into "acute" and "chronic" studies.

In the acute studies, rats were fed one dose of 500,000 units of vitamin A per kg. of body weight and killed 18 to 24 hours or 48 hours after feeding. In the chronic studies they were fed 250,000 units of vitamin A per kg. per day for 7 days and killed 24 hours after the last feeding. In both studies food and water were allowed *ad libitum*.

Representative rats from both the acute and chronic studies were selected at random for the intravenous injection of horseradish peroxidase (Nutritional Biochemicals Corporation), 1.0 gm. per kg. dissolved in 0.25 ml. of physiologic saline, 1, 2 and 4 hours respectively prior to death. This was done in order to follow the transport of a histochemically demonstrable protein (i.e., peroxidase) across the choroid plexus.

In addition, a group of weanling rats from the acute group were given an intraperitoneal injection of 5 mg. per kg. of hydrocortisone immediately following, and at 6 and 12 hours after their vitamin A feeding. They were killed at 18 hours.

Normal rats of similar weight and rats fed an equal volume of the vitamin A vehicle (Tween 80) served as controls.

In all cases the rats were killed by crushing the cervico-thoracic spinal cord. The cranial vault was rapidly reflected and the brain removed *in toto*. Coronal sections, 3 to 4 mm. thick, chosen to include choroid plexus, were fixed in cold formol-calcium. After fixation at 2 to 4° C. for 18 to 24 hours, the blocks were rinsed 3 times in cold distilled water for a total of 2 hours and placed in ice-cold 1 per cent gum acacia in 0.88 M sucrose to facilitate sectioning and storage. Frozen sections 10 to 15 μ thick were cut with a freezing microtome into cold distilled water. These sections were incubated at 37° C. for acid phosphatase (30 minutes), alkaline phosphatase (45 minutes), adenosinetriphosphatase (20 minutes), and thiamine pyrophosphatase (20 minutes), using the modified Gomori lead procedures previously described.[9,10] DPNH-tetrazolium reductase (10 and 15 minute incubations) activity was demonstrated using Nitro-BT (Dajac Laboratories) as the tetrazolium salt.[9] Substrate controls consisting of tissue incubated in the absence of the enzyme substrates were also prepared. Peroxidase activity (5 minutes' incubation) was demonstrated, using a modified benzidine reaction,[11] by incubating in a mixture containing 95 ml. of a saturated aqueous solution of benzidine, 5 ml. of 1 per cent nickel ammonium sulfate, and 10 drops of fresh 3 per cent hydrogen peroxide.

Tissues from normal and control animals were incubated simultaneously with that of the experimental groups.

Results

Normal and Control Animals

Acid phosphatase activity in the choroid plexuses of both the weanling (31) and adult (15) rats was localized to acid phosphatase-rich

cytoplasmic bodies (lysosomes). In the choroidal cells, these varied in size from 0.2 to 0.8 μ in diameter. They were present in all zones but were most numerous in the basal vascular and perinuclear zones (Fig. 1). Some variation in activity was noted among the choroidal cells. Occasional macrophages with their classically large lysosomes and endothelial cells with a few small lysosomes were identified. In general the lysosomes in the adult rats were similar in size and distribution to those of the younger rats, although they frequently appeared fewer in number (Fig. 2). The lysosomes of the ependymal cells of both adult and weanling rats varied in diameter from 0.3 to 1.5 μ in diameter and maintained a predominantly apical (ventricular) polarization.

Thiamine pyrophosphatase activity was localized to the blood vessels and the Golgi lamellas of the choroidal and ependymal cells. In both weanling and adult rats, the Golgi lamellas were represented by delicate, frequently coalescing strands, localized predominantly to the apical perinuclear zones (Fig. 3). The Golgi lamellas of the ependymal cells were somewhat broader than those of the choroidal cells but maintained a similar polarization.

Adenosinetriphosphatase activity in the choroid plexus of weanling rats was limited to the blood vessels; the choroidal and ependymal cells were unstained. In adult rats, staining of the cytomembranes of the choroidal and the ependymal cells was noted (Fig. 4). Alkaline phosphatase activity in both age groups was limited to the blood vessels (Fig. 5).

DPNH-diaphorase activity was noted in the mitochondria of the cellular components of the choroid plexuses in both weanling and adult rats. The mitochondria could be identified in all zones of the choroidal and ependymal cells. They varied in size from 0.2 to 1.0 μ in diameter and showed some variation in number from cell to cell. If incubation times were prolonged, the cells were so heavily stained that no cytoplasmic detail was obtained (Fig. 6).

Following the injection of horseradish peroxidase into normal weanling rats (10), there was no uptake of peroxidase by the choroidal cells after 30 minutes. After 1 hour, a few peroxidase-positive granules were present within these cells. They were localized predominantly in the vascular and perinuclear portions of the cell (Fig. 7). The peroxidase-positive granules resembled lysosomes in size. After 2 hours, the peroxidase-positive granules were present most predominantly midway between the vascular and ventricular surfaces (Fig. 9). After 4 hours, many peroxidase-positive granules were present at the ventricular surface (Fig. 11). In adult rats (6), this progression of peroxidase-positive granules was similar to that of the weanling rats, but at all times they

were fewer in number. No peroxidase activity was present at any time in the ependymal cells of either weanling or adult rats.

Following both the acute and chronic feeding of the Tween 80 vitamin vehicle to both weanling (6) and adult (4) rats, no alterations were noted. In animals not injected with peroxidase, no endogenous peroxidase activity in the choroidal or ependymal cells was present. The blood vessels were stained (Pickworth stain).[12] Substrate controls of tissue, incubated in the absence of their respective enzyme substrates, were negative.

Acute Hypervitaminosis A

In weanling rats (40) killed 18 to 24 hours after vitamin A feeding, acid phosphatase staining revealed a significant increase in the number of lysosomes in the choroidal cells. Many lysosomes appeared somewhat larger than normal and were seen with greater frequency at the ventricular poles (Fig. 13). These lysosome changes were consistently noted in 38 of the 40 rats; they were unaltered in the remaining 2 animals. There was a moderate increase in the number and size of ependymal cell lysosomes in 30 of the 40 animals, but no alterations of polarization. Lysosomal changes similar to those in the 18 to 24 hour group were present in only 1 of 5 weanling rats permitted to survive 48 hours (Fig. 14).

Thiamine pyrophosphatase staining for the demonstration of the Golgi apparatus revealed alterations in the Golgi lamellas of the choroidal cells in 35 of 40 weanling animals. The normal pattern of reticular and linear lamellas was replaced by more rounded forms with an even more than usual perinuclear polarization (Fig. 15). These changes in the Golgi apparatus were most marked in those rats showing the greatest lysosomal changes (Fig. 16). The Golgi lamellas in 5 weanling rats were unaltered; this group included the 2 animals in which there were no lysosomal changes. In all 40 weanling rats the Golgi apparatus of the ependymal cells did not appear altered.

In all animals the blood vessels, demonstrated by virtue of their thiamine pyrophosphatase, adenosinetriphosphatase, and alkaline phosphatase activity, remained normal. Similarly the mitochondria, stained by virtue of their DPNH-diaphorase activity, remained unaltered.

In weanling rats injected with peroxidase (15), the uptake by choroidal cells after 1 hour resembled that of controls in their basal polarization. However, more peroxidase-positive granules were seen, and many of these appeared increased in size (Fig. 8). After 1 hour these granules became more rapidly dispersed throughout the cell than in the case of normal animals (Figs. 10 and 12). The granules again appeared at the

ventricular pole of these cells. The ependymal cells did not possess peroxidase activity.

Hydrocortisone, given to 6 experimental and 2 control weanling rats, did not alter in any way the normal or experimentally-produced enzyme patterns. In contrast to the response of weanling rats, adult rats (10) killed 24 hours after their dose of vitamin A demonstrated no alterations in the enzyme activities studied or in their uptake of peroxidase.

Chronic Hypervitaminosis A

In weanling rats (12) maintained on vitamin A for 7 days, no alterations in any of the enzyme activities were noted in the choroid plexus or ependyma. However, an increased uptake of injected peroxidase similar to but less impressive than that of the acute experiments was observed in 2 of 4 rats. In the case of adult rats (5), no alterations in either enzyme activity or peroxidase uptake was seen.

Discussion

The fact that both hypo- and hypervitaminosis A are capable of producing elevations in cerebrospinal fluid pressure is confusing. An extensive literature now exists dealing with the effects of vitamin A deficiency.[3,4] Nevertheless, the anatomic basis for the cerebrospinal fluid changes is not clear. While at first cerebrospinal fluid changes were felt to result from induced abnormalities of cranial ossification and the cerebral aqueduct, continued investigation has suggested that these were secondary to the primary condition of excessive cerebrospinal fluid formation. The problem of hydrocephalic newborn rabbits born of hypovitaminotic A dams has been restudied and reviewed by Carton, Pascal and Tennyson [4] whose findings appear to support the concept of cerebrospinal fluid overproduction. Light microscopic examination of the choroid plexuses from these hydrocephalic rabbits revealed only vascular engorgement. Tennyson and Pappas,[2] using the same colony, noted an increased dispersion of the endoplasmic reticulum as the only significant fine structural change. Witzel and Hunt,[13] using similar tissue, noted capillary leakage, intercellular cisternae, inclusion bodies, and an increase in the endoplasmic reticulum.

In the case of hypervitaminosis A, a description of the choroid plexus in the newborn rats exhibiting hydrocephalus as a part of their teratogenic response is lacking.[5] No choroid plexus has been examined in either the clinical cases or the puppies exhibiting increased cerebrospinal fluid pressure and bulging fontanelles associated with vitamin A intoxication.[6-8]

In neither hypo- nor hypervitaminosis A are cytochemical studies

available with which to compare our findings. It is nevertheless not surprising that the most profound response of the choroid plexus was the alteration in the number and polarization of the lysosomes. A prominent role has been assigned to these organelles in the processes of secretion and pinocytosis.[14] It has been proposed that the lysosomes arise from the Golgi apparatus and at some point fuse with the pinocytotic vacuoles. This has been demonstrated in the rat kidney following injection of peroxidase where pinocytotic granules containing peroxidase are at first devoid of, but later acquire, acid phosphatase activity.[15] In contrast to the neurons,[16,17] combined staining to demonstrate the lysosomes and the Golgi apparatus simultaneously suggest that in the choroidal and ependymal cells, most lysosomes are not closely associated with the Golgi lamellas.[18] Nevertheless, the alterations in the choroidal Golgi lamellas in the cases of profound lysosomal change confirm a close functional relationship. The limited enzyme response of the ependymal cells to vitamin A, coupled with their inability to take up intravascular peroxidase, suggest a functional difference between the choroidal and ependymal cells.

Other investigators have demonstrated the ability of the chick choroid plexuses *in vitro* to absorb and concentrate dye and fluorescent-labeled protein.[19,20] Tennyson and Pappas[2] demonstrated *in vivo* uptake of thorotrast from the cerebrospinal fluid by the choroidal cells of newborn rabbits. This ability was lost in the newborn with hypovitaminosis A. In neither case were they able to demonstrate a choroidal uptake from intravenously injected thorotrast. Observations of this kind have led to the hypothesis that the choroidal epithelium functions to reabsorb portions of the cerebrospinal fluid. The demonstration that an intravenously injected protein (i.e., peroxidase) can be taken up by the choroidal cells with transport toward the ventricular pole, and that this uptake is increased in hypervitaminosis A, provides anatomic evidence for a vascular-to-ventricular transport function as well.

The mechanism whereby excess vitamin A was able to affect the lysosomes and peroxidase transport remains unexplained. Recent studies (reviewed by Thomas[21]) have suggested that excess vitamin A is capable of compromising the integrity of lysosomes with release of their enzymes. In some cases, steroids have been able to protect lysosomes against this vitamin A effect. This vitamin A-lysosome relationship has thus far been studied predominantly on a biochemical level, and, to date, there are no published morphologic observations of the affected lysosomes. In our case many lysosomes appeared somewhat larger in size following administration of vitamin A. It is conceivable that more profound changes occur at the fine structure level. One must also consider the possibility that the changes observed in lysosomes re-

flected increased pinocytotic activity not directly related to the vitamin-lysosome effect but to some secondary effect of vitamin A (i.e., the increased congestion of the choroid plexus). This would at least explain the transient nature of the choroidal cell response, since, after chronic vitamin A intoxication, the choroidal cell lysosomes returned to normal. It would also explain the inability of hydrocortisone to abolish this effect of vitamin A. However, this failure of protection by steroids may be related to the resulting secondary release of vitamin A from the liver.[22]

The lack of response of the adult choroid plexus is perplexing but consistent with the observations of others who note an increased susceptibility to the toxic effects of excess vitamin A in young animals and children. This may be related to the fact that the adult choroid plexus is capable of less pinocytotic activity, as evidenced by fewer lysosomes and a decreased uptake of peroxidase, than in young animals. In addition, the adenosinetriphosphatase activity of the adult cell membranes may play an important role in controlling the pinocytotic process.

A further elucidation of the relationship of vitamin A, lysosomes, and pinocytosis in the choroid plexus must await histochemical studies at the level of fine structure.

Summary

The acute and chronic effects of hypervitaminosis A on the cytoplasmic organelles of the choroid plexus were studied in adult and weanling rats. In addition, the choroidal cell uptake of intravenously administered peroxidase was observed. The following structure-function correlations emerged: (1) The administration of vitamin A to weanling rats was followed in 24 hours by an increased number and repolarization of lysosomes and a reduction in the size and form of the Golgi apparatus in the choroidal cells. The remaining organelles were unaltered. (2) These changes were not observed in adult rats. (3) In both weanling and adult rats, peroxidase-positive granules were seen to migrate progressively toward the ventricular surface of the choroidal cells. In weanling rats, vitamin A resulted in an increased number of peroxidase granules.

It was concluded that the choroidal epithelium was capable of a vascular to ventricular protein transport which was increased in weanling rats by excess vitamin A. Lysosomes and the Golgi apparatus were related to this process.

References

1. Wolstenholme, G. E. W., and O'Connor, C. (eds.). The Cerebrospinal Fluid; Production, Circulation and Absorption. Ciba Foundation Symposium. Little, Brown & Co., Boston, 1958.

2. TENNYSON, V. M., and PAPPAS, G. D. Electron Microscopic Studies of the Developing Telencephalic Choroid Plexus in Normal and Hydrocephalic Rabbits. In: Disorders of the Developing Nervous System. FIELDS, W. S. and DESMOND, M. M. (eds.). Charles C Thomas, Springfield, Ill., 1961, pp. 267–325.

3. MILLEN, J. W., and WOOLLAM, D. H. M. Vitamins and the Cerebrospinal Fluid. In: The Cerebrospinal Fluid,[1] pp. 168–188.

4. CARTON, C. A.; PASCAL, R. R., and TENNYSON, V. M. Hydrocephalus and Vitamin-A-Deficiency in the Rabbit: General Considerations. In: Disorders of the Developing Nervous System. FIELDS, W. S., and DESMOND, M. M. (eds.) Charles C Thomas, Springfield, Ill., 1961, pp. 214–266.

5. COHLAN, S. Q. Congenital anomalies in the rat produced by excessive intake of vitamin A during pregnancy. *Pediatrics*, 1954, 13, 556–567.

6. MARIE, J., and SEE, G. Acute hypervitaminosis A of the infant; its clinical manifestations with benign acute hydrocephalus and pronounced bulge of the fontanel; clinical and biologic study. *Am. J. Dis. Child.*, 1954, 87, 731–736.

7. MORRICE, G., JR.; HAVENER, W. H., and KAPETANSKY, F. Vitamin A intoxication as a cause of pseudotumor cerebri. *J.A.M.A.*, 1960, 173, 1802–1803.

8. TURTZ, C. A., and TURTZ, A. I. Vitamin-A intoxication. *Am. J. Ophthalmol.*, 1960, 50, 165–166.

9. BECKER, N. H.; GOLDFISCHER, S.; SHIN, W. Y., and NOVIKOFF, A. B. The localization of enzyme activities in the rat brain. *J. Biophys. & Biochem. Cytol.*, 1960, 8, 649–663.

10. BECKER, N. H.; NOVIKOFF, A. B., and GOLDFISCHER, S. A cytochemical study of the neuronal Golgi apparatus. Experimental diphtheritic encephalitis in rats. *Arch. Neurol.*, 1961, 5, 497–503.

11. GOMORI, G. Microscopic Histochemistry: Principles and Practice. University of Chicago Press, Chicago, 1952, pp. 164–165.

12. PEARSE, A. G. E. Histochemistry, Theoretical and Applied. Little, Brown & Co., Boston, 1953, p. 481.

13. WITZEL, E. W., and HUNT, G. The ultrastructure of the choroid plexus in hydrocephalic offspring from vitamin A deficient rabbits. *J. Neuropath. & Exper. Neurol.*, 1962, 21, 250–262.

14. NOVIKOFF, A. Lysosomes and Related Particles. In: The Cell; Biochemistry, Physiology, Morphology. BRACHET, J., and MIRSKY, A. E. (eds.). Academic Press, Inc., New York, 1961, Vol. 2, pp. 423–288.

15. NOVIKOFF, A. B. The Rat Kidney: Cytochemical and Electron Microscopic Studies. In: Biology of Pyelonephritis. Henry Ford Hospital International Symposium. QUINN, E. L., and KASS, E. (eds.). Little, Brown & Co., Boston, 1960, pp. 113–144.

16. NOVIKOFF, A., and ESSNER, E. Pathological changes in cytoplasmic organelles. *Fed. Proc.*, 1962, 21, 1130–1142.

17. BARRON, K., and TUNCBAY, T. Histochemistry of acid phosphatase and thiamine pyrophosphatase during axon reaction. *Am. J. Path.*, 1962, 42, 637–652.

18. BECKER, N. Unpublished data.

19. LUMSDEN, C. Observations on the Choroid Plexus Maintained as an Organ in Tissue Culture. In: The Cerebrospinal Fluid,[1] pp. 97–123.

20. KLATZO, I. Personal communication.

21. THOMAS, L. Papain, vitamin A, lysosomes and endotoxin. An essay on useful irrelevancies in the study of tissue damage. *Arch. Int. Med.*, 1962, 110, 782–786.

22. WEISSMANN, G. Changes in connective tissue and intestine caused by vitamin A in amphibia and their acceleration by hydrocortisone. *J. Exper. Med.*, 1961. 114, 581–591.

[*Illustrations follow*]

LEGENDS FOR FIGURES

IG. 1. Choroid plexus, normal weanling rat. Most lysosomes are localized in the basal and perinuclear zones of the choroidal cells (arrows). Acid phosphatase stain. × 900.

IG. 2. Choroid plexus, normal adult rat. The adult choroidal cells contain fewer lysosomes than weanling rats. Acid phosphatase stain. × 900.

IG. 3. Choroid plexus, normal weanling rat. The Golgi lamellas (arrow) consist of linear perinuclear arrays. Thiamine pyrophosphatase stain. × 900.

IG. 4. Choroid plexus, normal adult rat. Activity in the apical cell membrane is noteworthy. Adenosinetriphosphatase stain. × 600.

IG. 5. Choroid plexus, normal weanling rat. Only the blood vessels are stained. The choroidal cells are inactive. Alkaline phosphatase stain. × 400.

IG. 6. Choroid plexus, normal weanling rat. The mitochondria (arrow) are scattered throughout the cells. In some zones, enzymatic activity is so high as to obliterate cytoplasmic detail. DPNH-diaphorase stain. × 700.

1
2
3
4
5
6

FIGS. 7 to 12. The choroidal cell uptake of intravenously administered horseradish peroxidase by normal weanling rats is compared with the uptake of weanling rats killed 24 hours after vitamin A feeding. Peroxidase activity. × 1,000.

FIG. 7. Normal rat, one hour after peroxidase. The peroxidase-positive granules (arrow) exhibit a basal localization.

FIG. 8. Experimental rat, one hour after peroxidase. Compare with Figure 7. The granules are still at the base but are increased in number (arrows).

FIG. 9. Normal rat, two hours after peroxidase. The granules are localized to the basal and midzonal portions of the choroidal cells (arrows).

FIG. 10. Experimental rat, two hours after peroxidase. Compare with Figure 9. Granules are increased in number and are more diffusely scattered throughout the cell (arrows).

FIG. 11. Normal rat, 4 hours after peroxidase. Many peroxidase positive granules have reached the ventricular surface (arrows).

FIG. 12. Experimental rat, 4 hours after peroxidase. In comparison to Figure 11, many more peroxidase-positive granules are evident (arrow).

7

9

11

FIG. 13. Choroid plexus, weanling rat, 24 hours after vitamin A. Increased numbers of lysosomes are manifest. Some are increased in size and many can be identified at the ventricular poles of the cells (arrow). Acid phosphatase stain. × 1,000.

FIG. 14. Choroid plexus, weanling rat, 48 hours after vitamin A. The lysosomes are still increased in size and number. At this time, apical polarization is less impressive. Acid phosphatase stain. × 1,000.

FIG. 15. Choroid plexus, weanling rat, 18 hours after vitamin A. While a few normal Golgi lamellas can be identified (N), enzyme activity in many cells is limited to perinuclear spheres (A). Thiamine pyrophosphatase stain. × 1,000.

FIG. 16. Choroid plexus, same rat shown in Figure 13. In rats with the most profound lysosomal alterations, most of the thiamine pyrophosphatase activity is limited to these rounded forms (arrows). BV, blood vessel. Thiamine pyrophosphatase stain. × 1,000.

Bell-'71
Bib. No. 720

Reproduced by permission
of the copyright owner

Methods, apparatus: new product research, process development and design

Separation of oil-soluble vitamins by partition chromatography on Sephadex LH20

by J. G. Bell

Laboratory of the Government Chemist, Stamford Street, London S.E.1

During the development of a gas-liquid chromatographic method for vitamin D in cod liver oil, it was found that a partition column of Sephadex LH20, with a stationary phase of aqueous methanol and a mobile phase of 2,2,4-trimethylpentane, gave complete separation of vitamins A and D in the residue after saponification and extraction of the oil. This convenient clean up procedure has several advantages over existing methods for the separation of oil-soluble vitamins from interfering substances present in food. Columns of Sephadex LH20 are easy to prepare and operate, and they can be regenerated repeatedly without difficulty by solvent washing. Elution characteristics of the columns are readily determined and any loss of stationary phase from the columns during elution does not interfere with subsequent operations, such as can occur with partition columns of polyethylene glycol on Celite. The process requires only simple equipment and provides improved separations of oil-soluble vitamins, especially vitamin A, from food in less than three hours. Results obtained with a mixture of pure vitamins are shown in Fig. 1.

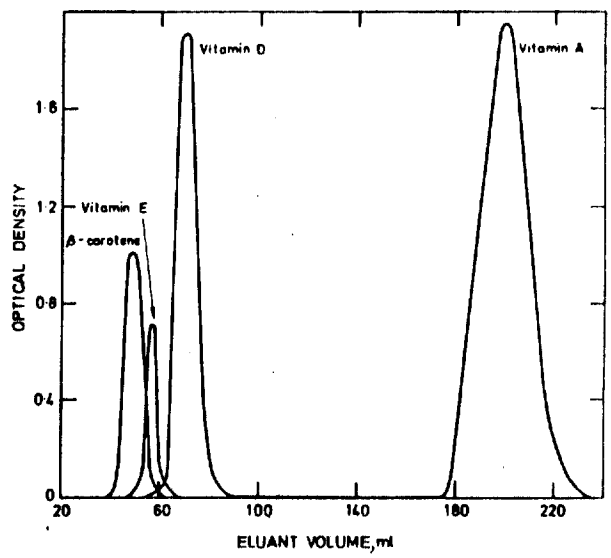

Fig. 1 *Separation of oil-soluble vitamins on Sephadex LH20 column (50cm): flow rate c. 1ml/min*

Apparatus and reagents

Glass columns (2cm diameter) fitted with discs (porosity 2) and glass impregnated PTFE stopcocks, have been found satisfactory. The column length may be 20, 25, 30 or 50cm, depending on the vitamins to be separated and the degree of separation required (*e.g.* a column of 25cm is adequate for the separation of vitamins A and D, whereas separation of β carotene and vitamins A, D and E requires a column of 50cm).

The solvents used are 2,2,4-trimethylpentane (mobile phase) and a 90:10 methanol water mixture (stationary phase) They are saturated with each other by shaking equal volumes together for one minute and are then stored separately.

Column preparation

To prepare a 25cm column, 50g of Sephadex LH20 is allowed to swell in aqueous methanol overnight. The slurry is poured into the column through an extension tube, allowed to settle and the Sephadex is compressed to the required height (*c.* 25cm) by means of a blowball connected to the top of the extension tube. At least one bed volume of 2,2,4-trimethylpentane is passed through the Sephadex after which the column is ready for use. The extension tube is removed for a sample addition and replaced for elution.

Determination of elution characteristics and regeneration of the column

2,2,4-trimethylpentane (2ml), containing 200μg of vitamin A,D or E is placed on the column and eluted with this solvent at *c.* 1ml/min. Eluant fractions of 5ml are collected. The fractions are scanned with an ultraviolet spectrophotometer to detect the vitamin D (at 265nm) and E (at 300nm), or alternatively the vitamin may be located by colorimetric tests. The elution position of β carotene on the column can be observed visually and the position of vitamin A by inspection with a low power ultraviolet lamp. The column is regenerated by passing two bed volumes of aqueous methanol through it followed by at least one bed volume of the mobile phase. Should any cracks appear in the Sephadex as a result of use, the column may be shaken thoroughly to disperse the Sephadex in aqueous methanol,

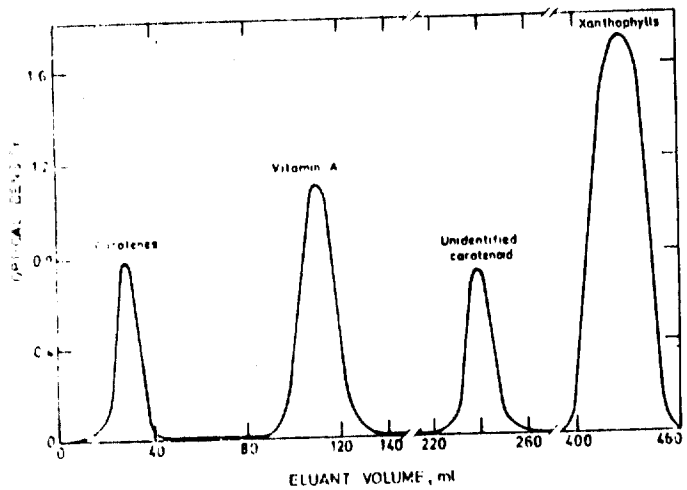

Fig. 2 *Separation on Sephadex LH20 of vitamin A in egg from carotenes and xanthophylls*

allowed to settle, and repressurised and regenerated as previously described. The Sephadex should always be maintained under liquid.

Applications: 1 *Margarine*

Columns of alumina and of polyethylene glycol on Celite have been used for many years to separate vitamin A in margarine from anhydrovitamin A and β carotene. Neither column has been entirely satisfactory and a partition column of Sephadex LH20 has been found to give much cleaner separations and be easier in operation. After saponification of margarine (10g) for 20min with alcoholic potassium hydroxide solution containing an anti-oxidant, the unsaponifiable matter is extracted with diethyl ether (250ml). The solvent is evaporated and the residue, dissolved in 2,2,4-trimethylpentane (2ml), is applied to a Sephadex column (20cm) prepared as previously described. During elution with 2,2,4-trimethylpentane at a rate of *c.* 1ml/min carotene travels with the solvent front, followed closely by anhydrovitamin A, if present. After elution with a further 40ml of solvent, vitamin A begins to appear well separated from all interfering substances.

2 *Eggs.* A Sephadex column has also been found useful for the separation of vitamin A from eggs. After saponification and extraction of the unsaponifiable matter from freeze dried egg (10g) most of the cholesterol is precipitated in aqueous methanol and removed by filtration. The filtrate is then evaporated, the residue dissolved in 2,2,4-trimethylpentane (2ml) and the solution applied to a Sephadex partition column (25cm). Elution with 2,2,4-trimethylpentane separates carotenes, vitamin A and xanthophylls (Fig. 2). Results of the vitamin A (retinol) content of eggs and the recovery of added retinol are shown in the Table.

Table

Vitamin A (retinol) content of freeze dried eggs

Separation on 25cm Sephadex column: measurement by UV spectrophotometry

Eggs purchased at supermarket	*Vitamin A (retinol) content of freeze dried eggs*		*Recovery of added (18 IU/g) vitamin A*	
	IU/g	*μg/g*	*IU/g*	*Per cent*
A	21·2	6·4	37·7	96·9
	20·7	6·2		
B	17·8	5·3		
	18·6	5·6		
C	18·4	5·5	36·1	99·0
	18·7	5·6		

3 *Other applications.* A similar technique has been successfully applied to the separation of vitamin D from A in cod liver oil and to the isolation of vitamin A from carotenoids and other interfering substances in freeze dried milk.

Received 25 *September* 1970

Berdjis-'58
Bib. No. 751
Reproduced by permission
of the copyright owner

Arch. Pathol. 66:278-281. 1958.

Late Effects of Hypervitaminosis A in the Rat

Disturbance and Retardation in the Normal Growth of Offspring

LIEUT. COL. CHARLES C. BERDJIS (MC), U. S. Army

The acute phase of excessive administration of vitamin A to experimental animals is well known (Takahashi et al.,[1] Wolbach and Bessey,[2] Rodahl,[3] and others).

Although Cohlan[4] reported congenital abnormalities in the offspring of rats treated with excessive doses of vitamin A and other authors[5,6] described bone resorption as a result of direct effect of vitamin A on bones in tissue culture, no mention was made of the protracted effects of vitamin A administration.

In spite of high mortality, severe congenital anomalies, and poor condition of premature rats of hypervitaminotic A mothers, some offspring survived.

It is the purpose of this paper to set forth the data related to these survivals after excessive doses of vitamin A administration to pregnant rats.

Materials and Methods

In order to determine the effects of heavy doses of vitamin A on pregnant rats, groups of rats were fed orally with a solution of crystalline vitamin A alcohol in corn oil, having a potency of 500,000 I. U. per gram, at a level of 100,000 I. U. per gram of body weight per day in addition to the standard laboratory diet. For this purpose three experiments were conducted: The rats were fed with excessive doses of vitamin A before, after, and during pregnancy, respectively. Twenty young healthy pregnant rats—15 for the experimental groups and 5 as controls—were used in these experiments. Offspring of these 20 pregnant rats, 123 newborn rats in all, averaging 30 in each group, were studied for a period of four months. Records of mortality and survivors were taken in both control and vitamin-treated animals during the experiments, as indicated in Table 1.

Submitted for publication March 3, 1958.

4th U. S. Army Medical Laboratory, Fort Sam Houston, Texas.

Results

In the first experiment, the rats of this group were fed vitamin A before pregnancy. Offspring of this group were healthy, and the vitamin A seemed to have no effects on them over a period of four months' observation.

In the second experiment, the rats were fed vitamin A after pregnancy and during the lactation. No significant difference was detectable in the rats of five litters followed about four months.

On examination, the rats of the third experiment, which received excessive doses

TABLE 1.—*Comparison of the Number of Animals and Litters in Each Group and Mortality During the Experiments*

	Number	Number Litter	Average No. Each Litter	Total No. Offspring at Birth	Offspring at End of Experiment No.	Mortality No.	Mortality %
Hypervitaminosis A *							
Group 1	5	5	6	30	24	6	20
Group 2	5	5	6½	33	28	5	15
Group 3	5	5	5	25	10	15	60
Controls	5	5	7	35	30	5	14

* Group 1 indicates animal fed with excessive doses of vitamin A before pregnancy; Group 2, after pregnancy; Group 3, during pregnancy.

TABLE 2.—*Comparison of Average Body Weight Between the Control and the Hypervitaminotic A Animals from Birth to Four Months* *

	Birth	1 Wk.	2 Wk.	3 Wk.	4 Wk.	2 Mo.	3 Mo.	4 Mo.
Hypervitaminosis A †–								
Group 1	6	14	20	35	60	150	175	215
Group 2	6 ½	15	20	35	65	150	185	220
Group 3	5	12	16	35	35	100	110	150
Controls	6 ½	15	21	35	60	150	180	225

* Body weight in grams.

† Group 1 indicates animal fed with excessive doses of vitamin A before pregnancy; Group 2, after pregnancy; Group 3, during pregnancy.

of vitamin A during the entire period of pregnancy, had premature and reduced number of litters (Table 1). Most of the offspring showed more or less severe congenital anomalies and died in a few days. The remainder, kept in observation for a period of four months, showed signs of retardation in growth and were markedly underweight (Table 2). Signs of retardation consisted of prolonged time of weaning subsequent to loss of appetite, possible retardation of development of the labial muscles, weight loss, dry skin, fragility and/or roughening of the hair, and diminished amount of subcutaneous adipose tissue. After weaning, these animals were kept in a separate cage under normal conditions and were fed the regular laboratory diet. Compared to the control rats of the same age and under the same conditions, they showed a retardation in their normal growth. At 4 months of age these rats appeared to be about one-half the size of the controls and were somewhat weaker (Fig. 1). Tables 1 and 2 show the number of animals in each litter, comparative mortality in each group, and the body weight during the experiment.

Fig. 1.—This figure shows two rats of the same age (4 months); one is normal (right), and the other (left), a subnormal offspring whose mother was fed excessive doses of vitamin A during pregnancy.

Histopathologic changes observed in hypervitaminosis A animals consisted of generalized but moderate lacunar fibro-osteoclasia of the entire bony system (Figs. 2 and 3), mild parathyroid hyperplasia, and deposits of calcium in the organs, especially in the kidneys. Detailed description of these changes will be reported elsewhere.[15]

Comment

According to the previous workers,[5,6] it is already established that vitamin A has the remarkable property of controlling the shape and texture of certain bones in young animals and has the function of controlling the position and intensity of activity of osteoclasts and osteoblasts.

Following the findings of Cohlan[4] (congenital anomalies), Giroud and Martinet[7] described considerable retardation of the growth and development of the cartilage bones in the fetuses of pregnant rats with hypervitaminosis A.

Herbertson[8] studied in tissue culture the direct action of vitamin A in chick bone and showed its reversibility in vitro. Such reversibility in vitro does not occur after

Fig. 2.—Photomicrograph showing section of normal femur in a control rat. Hematoxylin and eosin; × 60.

four months in our animals. Further study is required to determine whether or not this reversibility exists in vivo with a considerable retardation or whether vitamin A changes definitely the size of survival offspring.

Although Wolbach and his associates [9-11] in their studies of hypophysectomized, adrenalectomized, and parathyroidectomized hypervitaminotic A animals stated that the endocrine glands have no part in mediating the effects of excessive doses of vitamin A on the skeleton, other authors found evidence of changes in the endocrine glands.[12-15]

Nevertheless, the mechanism of the action of excessive doses of vitamin A in experimental animals could not be established with certainty. However, two factors seem to play a major role in hypervitaminosis A syndrome: (*a*) endocrine factor and (*b*) direct action of vitamin A on bones

Fig. 3.—Photomicrograph showing subperiosteal and cortical lacunar fibro-osteoclasis in the femur of a hypervitaminotic A rat. The arrows show the areas of fibro-osteoclasis. Hematoxylin and eosin; × 60.

(Fell and Mellanby,[5,6] Berdjis and Rinehart[15]).

The role of the endocrine glands certainly cannot be neglected because, as mentioned above, some authors found changes in the endocrine system. From analysis of the literature relative to action of vitamin A on bone in vivo and in vitro including tissue culture,[5,6,8,15] it is believed that vitamin A has a direct action on bone. Whether or not vitamin A acts directly or by intervention of the endocrine system to change the normal growth in the offspring of animals fed during pregnancy with excessive vitamin A, heavy doses of vitamin A create a complex syndrome in the body in which the first target appears to be the bony system.

Summary

Groups of rats were fed orally with excessive doses of vitamin A before, after, and during pregnancy. Compared with the control rats of the same age, no significant difference was detectable between the offspring of the first and second groups after four months.

The rats of the third group were premature, some died and/or showed congenital anomalies, and 40% survived. The survivors (Table 1), kept under observation for a period of four months, showed signs of weakness and retardation in growth (Fig. 1). They were all underweight (Table 2).

Conclusion

It is concluded that excessive intake of vitamin A during pregnancy decreases size of offspring in rats and causes disturbance of normal growth. In addition, congenital anomalies and prematurity were observed, as described by previous authors.[4,7]

Pathology Division, Headquarters 4th U. S. Army Medical Laboratory, Fort Sam Houston, Texas.

REFERENCES

1. Takahashi, K.; Nakamiya, Z.; Kawakimi, K., and Kitazato, T.: On the Physical and Chemical Properties of Biosterin and on Its Physiological Significance, Scient. Papers Inst. Phys. & Chem. Res., Tokyo 3:81, 1925.

2. Wolbach, S. B., and Bessey, O. A.: Tissue Changes in Vitamin Deficiencies, Physiol. Rev. 22:233, 1942.

3. Rodahl, K.: Hypervitaminosis A: A Study of the Effects of Vitamin A in Experimental Animals, Skrifter No. 95, Norsk Polarinstitutt, 1950.

4. Cohlan, S. Q.: Excessive Intake of Vitamin A as a Cause of Congenital Anomalies in the Rat, Science 117:535, 1953.

5. Fell, H. B., and Mellanby, E.: The Effect of Hypervitaminosis A on Embryonic Limb-Bones Cultivated in Vitro, J. Physiol. 116:320, 1952.

6. Fell, H. B.: Effects of Excess Vitamin A on Organized Tissues Cultivated in Vitro. Brit. M. Bull. 12:35, 1956.

7. Giroud, A., and Martinet, M.: Hypervitaminosis A and Abnormalities in Rat Fetuses, Internat. Ztschr. Vitaminforsch. Bern, 28:10, 1956.

8. Herbertson, 1955, cited by Fell.[6]

9. Wolbach, S. B.: Vitamin-A Deficiency and Excess in Relation to Skeletal Growth, J. Bone & Joint Surg. 29:171, 1947.

10. Wolbach, S. B., and Maddock, C. L.: Vitamin-A Acceleration of Bone Growth Sequences in Hypophysectomized Rats, A. M. A. Arch. Path. 53:273, 1952.

11. Wolbach, S. B.; Maddock, C. L., and Cohen, J.: The Hypervitaminosis-A Syndrome in Adrenalectomized Rats: Skeletal Changes in Weanling Rats With and Without Cortisone, A. M. A. Arch. Path. 60:130, 1955.

12. Cornil, L.; Chevallier, A.; Paillas, J. E., and Chouquet, T.: Modifications of the Pituitary Body in Hypervitaminosis and Hypovitaminosis A, Ann. Anat. path. 16:83, 1939.

13. Sadhu, D. P., and Brody, S.: Excess Vitamin A Ingestion, Thyroid Size and Energy Metabolism, Am. J. Physiol. 149:400, 1947.

14. Uotila, U.: Über die Schilddrüsenveränderungen bie A-, B-, C- und D-Avitaminosen, Arch. path. Anat. 301:535, 1938.

15. Berdjis, C. C., and Rinehart, J. F.: Fibro-Osteoclasia in the Rat and Guinea Pig Following Excessive Administration of Vitamin A, Acta vitaminol. 12:49, 1958.

Berdjis-'59
Bib. No. 752

AMA Arc Puthol 67:355-63. 1959

Hypervitaminosis A and Hyperparathyroidism

Comparative Study of the Effects of Vitamin A and Parathyroid on Bone in Vivo and in Vitro, with Special Reference to Parathyroid Glands in Hypervitaminosis A

MAJ. COL. CHARLES C. BERDJIS (MC), U. S. Army

Introduction

It has been reported for many years that an excessive intake of vitamin A can have toxic effects on laboratory animals. Hypervitaminosis A, described by several authors, creates a complex syndrome in the body, in which the first target appears to be the skeletal system. Congenital malformations, including gross anomalies in the development of the skull (Cohlan[1]) and retardation in the normal growth (Berdjis[2]), have also been described in young rats whose mothers had received excessive amounts of vitamin A during pregnancy.

Although excessive doses of vitamin A cause severe changes in the skeleton, the exact mechanism of the action of vitamin A remains obscure. Fell and Mellanby,[3-5] who studied the effects of vitamin A on bone in tissue culture, came to this conclusion—Whether the changes resulting from hypervitaminosis A are due to a direct action of vitamin A on the bone or to an indirect action through the endocrine glands is uncertain. However, direct action was elicited by these authors.

In a previous study,[6] it was concluded that the hypervitaminosis A syndrome in living animals is similar to that produced by parathyroid. The purpose of this paper is to compare the direct action of parathyroid and excessive intake of vitamin A on bones both in vivo (experimental animals) and in vitro (tissue culture). It is also the purpose of this paper to study the parathyroid changes in hypervitaminotic A animals.

Submitted for publication Aug. 28, 1958.

From the Division of Pathology, Fourth U. S. Army Medical Laboratory, Fort Sam Houston, Texas.

Materials and Methods

Most of the experiments in the present investigation were carried out with the use of rats, and the results described below were obtained with administration of excess vitamin A both in vivo and in tissue culture. In order to compare the effects of hypervitaminosis A and parathyroid hormone, an experimental hyperparathyroidism was produced in a series of rats and in the culture medium.

A solution of crystalline vitamin A alcohol in corn oil, having a potency of 500,000 I. U. per gram, was used to feed the animals orally, at a level of 100-300 I. U. per gram of body weight per day, in addition to the standard laboratory diet.

The detailed distribution of the animals used in these experiments was as follows:

In Vivo.—Ninety-five young rats, averaging 35 days of age, were used in the following experiments: (*a*) 40 controls, untreated and fed with the standard laboratory diet; (*b*) 40 rats, fed with excessive doses of vitamin A, as indicated above, in addition to the standard laboratory diet, and (*c*) 15 rats, given subcutaneous injections with 250 U. S. P. units of parathyroid, daily for three days.

In Vitro (Tissue Culture).—In these experiments, isolated long bone rudiments (tibia) of rat fetuses at birth were used. Twenty-five newborn

rats were killed under complete asepsis, and the tibiae were isolated for tissue culture. All of the material and instruments used were carefully sterilized to avoid secondary contamination.

(*a*) Explants: Twenty-five pairs of tibiae were isolated; soft tissue was removed, cleaned, and explanted, in an equal number, as follows: One of each pair of tibiae of the same animal was explanted in normal medium (see below), and the other in the same medium to which had been added one of these two solutions: 2,000 I. U. of vitamin A per 100 ml. and 300 U. S. P. units of parathyroid per 100 ml. The tibiae were fixed onto coverslips by a clot of chick embryo extract and chick plasma, about one drop of each. This was found sufficient to keep the tibiae fixed to the coverslips in the liquid medium for the duration of the experiment.

(*b*) Culture Medium: In order to prepare a complete medium, the following composition, a modification of Eagle medium * was used:

Solution	Concentration	Amount Required for 100 Ml., Cc.
Earle's BSS †	1×	35
Chick serum	1×	15
Eagle amino acid	5×	20
Eagle vitamins and glutamine	100×	1
Distilled water	Glass-distilled twice	25.5
$NaHCO_3$	4.4%	1.5
Penicillin	100,000 units/ml.	0.5
Streptomycin	100,000 units/ml.	0.5
Nystatin (Mycostatin)	5,000 units/ml.	1.0

To the complete medium (a liquid) glucose was added to bring the concentration of glucose up to 0.16%.

The phenol red was included in the media as a color indicator of the pH. The pH ranged between 7.2 and 7.4.

The liquid medium was chosen because it was felt that the feeding and maintenance of the bone cultures could be more easily handled in a liquid medium than in a solid medium, i. e., the clot medium.

Vitamin A Preparation.—The stock contains 1,500,000 I. U. of vitamin A alcohol crystalline per gram. One gram of this crystalline vitamin A was dissolved in 15 cc. of absolute alcohol, then diluted by means of normal medium to 2,000 I. U/100 cc., as required for this experiment. Alcohol concentration of the media was 0.2% and believed not to be harmful for tissue culture.

Parathyroid Preparation.—The stock contained 100 U. S. P. units per cubic centimeter. Three U. S. P. units per cubic centimeter was added to the normal medium so that the required concentration was 300 U. S. P. units per 100 cc.

Histological Technique.—All of the animals (Table 1) were killed. The entire bony system, including femur, tibia, humerus, vertebrae, jaws, skull, ribs, and parathyroid glands, was fixed in 10% formalin, embedded in paraffin, and sectioned approximately 6μ thick.

All bones, including the long bone rudiments (tibiae) from the tissue culture at 11 days, were first decalcified, then embedded in paraffin. All tissues were stained routinely by hematoxylin and eosin, unless special mention is made.

Results

The animals were killed, as scheduled in Table 1, at varying intervals (every week) during experiments. For each group, records were taken of bony changes and parathyroid modification. The following data were obtained in gross and microscopic examination.

TABLE 1.—*Schedule of Killing*

Animals	Week 1	2	3	4
Hypervitaminotic-A rats	10	10	10	10
Rats given parathyroid injections	--	--	15	--
Control rats	10	10	10	10

In Vivo.—Control Groups: The entire skeletal system and parathyroid glands of the control animals were examined, both grossly and histologically, and they showed no alterations.

Hypervitaminotic A Animals: Bones. Because of frequent and extensive hemorrhages and multiple spontaneous fractures in the first two weeks of experiments, the histologic pictures were somewhat confusing, and fibro-osteoclasia could not be described and isolated easily. Nevertheless in the living animals, hypervitaminosis A caused severe changes in the skeleton, which are summarized here. The maturation and degeneration of the cartilage cells and the

* Eagle, H. J.: *J. Exper. Med.* 102:595, 1955. Mr. Adrian Rake of the Virology Division, Fourth U. S. Army Medical Laboratory, helped in conducting the tissue culture for these experiments.

† A buffered isotonic balanced salt solution.



Fig. 1.—*A*, section of a long bone shaft of hypervitaminotic A rat, showing subperiosteal and subcortical lacunar fibro-osteoclasia. *B*, the same bone of a normal untreated rat. Hematoxylin and eosin; reduced 10% from mag. × 80.

replacement of cartilage by bone were greatly accelerated and resulted in the abnormally early closure of the epiphyses (Wolbach and Bessey [7,8]); rarefaction and reduced deposition of bone in the mandible (Irving [9]); retardation of osteogenesis, reduction of endochondral ossification, and a variable degree of osteoclasis in the region of the fractures (Strauss [10]) and elsewhere (Berdjis and Rinehart [6]). The fractures appeared to be due to the extensive loss of previously formed cortical bone before the newly deposited bone had acquired firmness sufficient to meet mechanical requirements (Wolbach [8]).

In the course of the third and fourth week after vitamin A administration, the skeleton underwent lacunar resorption con-

Fig. 2.—Section of a parathyroid gland in a normal untreated rat. Note the trabecular structure and two kinds of cells (rounded and elongated), equally distributed throughout the parenchyma. Hematoxylin and eosin; reduced 5% from mag. × 450.

TABLE 2.—*Parathyroid Size and Animal Weight in Normal and Hypervitaminotic-A Rats at Fifty-Five Days of Age*

Observations	Animal, No.	Animal Weight, Gm.		Parathyroid Glands			Ratio, Size/Weight
		Range	Average	No.	Size μ		
					Range	Average	
Hypervitaminosis A	10	35–60	50	20	180–435	300	$\frac{300}{50}=6$
Control	10	125–135	130	20	330–480	400	$\frac{400}{130}=3$

sistent with the early stage of generalized fibro-osteoclasia (Berdjis and Rinehart[6]).

Briefly, the total amount of bone matrix was reduced, and small, narrow, irregular, and delicate bony trabeculae were frequently encountered. About the trabeculae, and subcortical or subperiosteal regions as well, some fibrotic tissue, more or less rich in osteoclasts, indicating lacunar resorption, was present (Fig. 1). This lacunal resorption was more marked in the mandibular bone, femur, and vertebrae.

Parathyroids in Normal Rat (Fig. 2): Under normal conditions, a parathyroid gland is composed of closely packed trabeculae, lying in one or more relatively compact lobules and generally surrounded by a thin capsule. A tiny network of well-vascularized fibroconnective tissue, generally devoid of fat cells, forms the stroma. The parenchyma consists of two kinds of cells, rounded and elongated, which are usually equally distributed throughout the parenchyma. The nuclei are centrally placed, and the cytoplasm, usually ill-defined, is more or less acidophilic, without real boundaries. This histologic structure applies generally for both rat and mouse parathyroids.

Parathyroids in Hypervitaminotic-A Rat: In order to evaluate the size of the parathyroid glands, serial sections of each parathyroid were performed. Table 2 shows the average size of the parathyroids in normal and hypervitaminotic A rats. According to this Table, the parathyroid glands showed a relative increase in size in hypervitaminotic A animals. They were also moderately

Fig. 3.—A rat parathyroid gland three weeks after excessive administration of vitamin A. This photomicrograph shows closely packed round cells with clear cytoplasm and rounded nuclei. The number of elongated cells is markedly decreased. Hematoxylin and eosin; reduced about 10% from mag. ×450.

modified in histologic structure. The parathyroid glands become more compact, losing partially or entirely their trabecular architecture. Consequently, the stroma is scanty. The cells undergo two major changes: (*a*) The rounded or polyhedral cells predominate, replacing the elongated cells, and (*b*) the cytoplasm becomes spongy and clear, losing the major part of its acidophilia (Fig. 3).

Parathyroid Hormone: The rats that received parathyroid injections showed the classical picture of experimental fibro-osteoclasia, namely, lacunar resorption of the trabecular and subcortical regions, osteoclasts in the resorptive areas, and metastatic calcification (kidney, etc.). These findings were similar to those found in hypervitaminotic A animals by Berdjis and Rinehart.[8]

In Vitro (Tissue Culture).—When we take into consideration the above findings of in vivo hypervitaminosis A and experimental hyperparathyroidism with parathyroid hormone, it is interesting, first of all, to see whether the same would occur under the recent experimental conditions in vitro. The following data are obtained in vitro in order to compare the two categories of findings:

Explants in Normal Medium (Controls): The tibiae explanted in normal medium for 11 days grew in a normal way. The cartilage and the bone matrix were differentiated as in vivo. The diaphysis contained normal bone marrow but slightly reduced in amounts, and the cartilage ends grew with a normal relationship to the metaphysis. The periosteal bone was firm and formed a well-developed coat for the marrow cavity (Fig. 4). Comparing these explants with the normal bones of living animals at the same age, it appears that the rate of growth is not modified in the tissue culture.

Fig. 4. — This photomicrograph shows the tibia of a rat fetus, explanted in a normal medium. There is a normal growth of bone and cartilage. Hematoxylin and eosin; ×6.

Fig. 5.—Opposite tibia of the animal shown in Figure 4, explanted in a hypervitaminotic A medium. There are constriction, shrinkage, and cartilage atrophy. Hematoxylin and eosin; × 6.

Explants in Hypervitaminotic-A Medium: The rudiments grew normally for the first two to three days, then declined during the eight remaining days.‡ In general, the rate of elongation diminished, and the tibiae became shorter and more slender than in the controls. A few explants stopped growing and began to shrink. The terminal cartilage had resorbed, atrophied, and almost disappeared (Fig. 5). The diaphyseal bone underwent excessive resorption. There were several areas of diffuse or localized fibrosis in the subcortical and subperiosteal regions. A few slender trabeculae were found in the metaphysis, and they were fragile, fragmented, and more or less resorbed, disclosing varying numbers of osteoclasts.

This resorption led to constriction, and spontaneous fractures (Figs. 6, 7) generally occurred at the terminal part of the tibia. This constriction appeared in the zone of flattened cartilage cells (proliferating zone) just where the sheath of periosteal bone ended. This change was most conspicuous at the proximal end of the tibia. In some cases, however, the constriction appeared also at the distal end.

Explants in Medium with Parathyroid: Growth progressed normally at first, then declined. Parathyroid, however, did not stop entirely the normal growth of bone tibiae and did not affect the cartilage significantly. The rudiments underwent resorption; they became slender and shrunk-

‡ All explants, regardless of the medium in which they grew, remained under observation in tissue culture for a period of 10 to 11 days.

Fig. 6.—Constriction of the cartilage and cartilage atrophy in higher magnification. The cartilage cells are compressed, and some are degenerating. Hematoxylin and eosin; × 80.

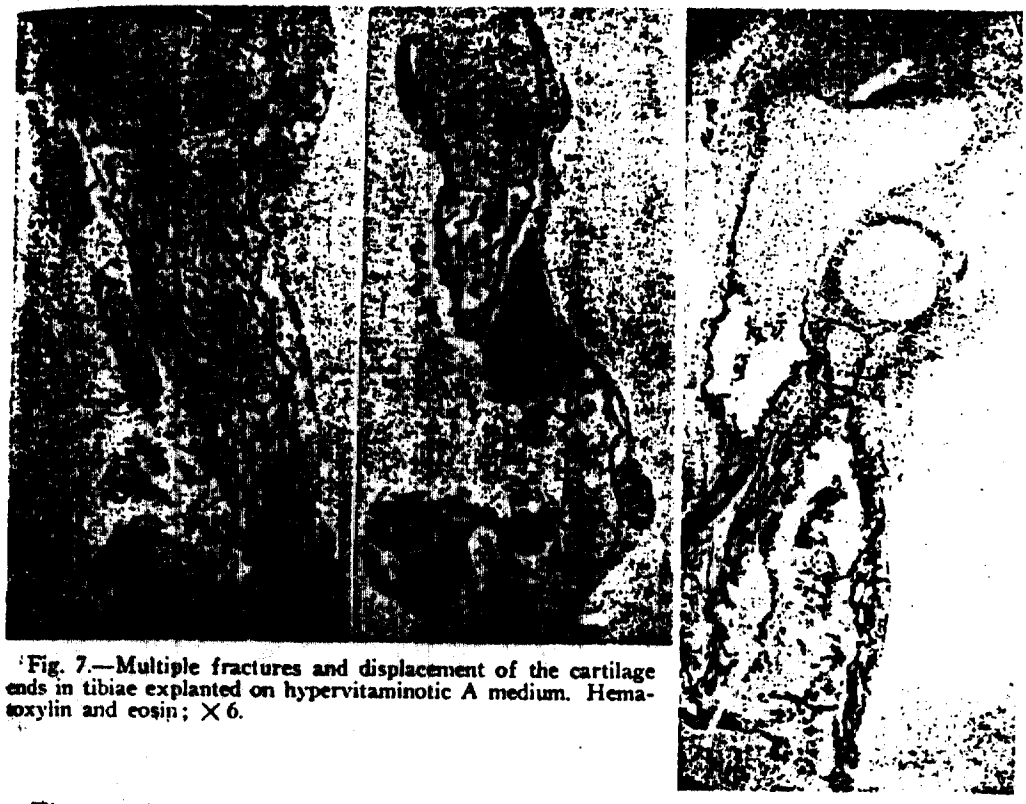

Fig. 7.—Multiple fractures and displacement of the cartilage ends in tibiae explanted on hypervitaminotic A medium. Hematoxylin and eosin; ×6.

en. The terminal cartilage grew normally in both distal and proximal ends. No constriction or spontaneous fractures were observed. The osteoclasts here, as in the hypervitaminosis A medium, were present in subcortical and subperiosteal regions and around the slender trabeculae.

Comment

In a previous study, Berdjis and Rinehart[6] pointed out that the effects of administration of excessive vitamin A on bone are comparable to those produced in rat by parathyroid hormone. In the present investigation, this study was extended in tissue culture and the changes were produced in bone both by vitamin A and parathyroid hormone.

From the analysis of histologic findings and the data summarized in Table 3, it seems that the vitamin A and parathyroid

TABLE 3.—*Comparative Study Between the Effect of Vitamin A and Parathyroid on Bone in Vivo and in Vitro*

Observations (Long Bones)	Living Animals (In Vivo)			Tissue Culture (In Vitro)		
	Vitamin A	Parathyroid	Control	Vitamin A	Parathyroid	Control
Size	Reduced	Reduced	Normal	Reduced	Reduced	Increased
Linear growth	Arrested	Reduced	Normal	Arrested	Reduced	Normal
Terminal cartilage	Disturbed	Almost normal	Normal	Atrophied	Almost normal	Normal
Differentiation of chondroblasts	Moderately accelerated	Normal	Normal	Not arrested	Normal	Normal
Maturation and calcification	Failure	Disturbed	Normal	Failure	Disturbed	Normal
Matrix formation	Reduced	Reduced	Normal	Dissolution	Reduced	Normal
Spontaneous fractures	Frequent	?	None	Frequent	?	None
Periosteal bone & shaft	Resorbed	Resorbed	Normal	Resorbed	Resorbed	Normal
Osteoclasia	Present	Present	Normal	Present	Present	Normal
Soft tissue surrounding bone	Normal growth	Normal growth	Normal growth	Normal growth	Normal growth	Normal growth

have a similar action on bones, namely, resorption and subsequent lacunar fibro-osteoclasia. Cartilage, however, reacts differently; while cartilage is greatly affected by heavy doses of vitamin A, the parathyroid seems to have no significant action on cartilage. Endochondral ossification, however, is highly reduced or arrested in both instances.

Although excessive doses of vitamin A cause severe changes in the skeleton, the exact mechanism of action of vitamin A remains obscure. In the living animals, hypervitaminosis A renders the bones fragile, and so they sometimes suffer spontaneous fractures. The fractures appear to be due to the extensive loss of previously formed cortical bone before the newly deposited bone has acquired firmness sufficient to meet mechanical requirements (Wolbach [8]). Nevertheless, the spontaneous fractures also occurred frequently in tissue culture rich in vitamin A. Whether the changes resulting from hypervitaminosis A are due to a direct action of vitamin A on the bone or to an indirect action through the endocrine glands is uncertain.[3-5,13]

Barnicott, in 1948,[12] showed direct local action of vitamin A on bone by implanting the bone fragments in the cerebral hemispheres of mice, in which he introduced the crystals of pure vitamin A. It is well known that the parathyroid fragments introduced into the skull, behind the parietal bone, reproduce the same effect, namely, resorption of bone and sometimes perforation.

Fell and Mellanby,[3-5] in a series of experiments, studied the direct action of vitamin A on bone by demonstrating both disintegration of cartilage matrix and resorption of bone in fetal mouse bones grown in tissue culture. Our own observations are in close agreement with the findings of these authors.

Berdjis and Rinehart [6] described frequent lacunar bony resorption in hypervitaminosis A animals, indicating direct action of vitamin A on bone in living animals. These authors also elicited a similarity of action on bone between vitamin A and parathyroid. In this study we confirmed previous reports [2,6,13] that endocrine glands, except parathyroid, have no part in hypervitaminosis A syndrome. The parathyroid glands, however, showed evidence of increasing volume and predominance of rounded cells with more compact parenchyma, interpreted as slight hyperplasia. It is more tentative than conclusive to say that the parathyroid changes are responsible for bone alterations. It may be suggested, according to a statement of Askanazy and Erdheim (Wernly and Berdjis [11]), that this slight parathyroid hyperplasia is the response of bone change rather than a cause. In the course of these experiments we found a close similarity between vitamin A and parathyroid action on bone in living animals and in tissue culture as well (Table 3). This implies that the interrelationship of vitamin A and bone is comparable to that of parathyroid and bone.

Summary

Hypervitaminosis A and hyperparathyroidism are produced in young rats, which are killed at regular intervals with the same number of control animals, as indicated in Table 1. Bones and parathyroid glands are systematically studied. In order to compare these findings with those produced in vitro, the tibiae of rat fetuses at birth are explanted in normal medium, hypervitaminotic A medium, and parathyroid medium for a period of 11 days.

Experimental hypervitaminosis A appears to be somewhat similar to experimental hyperparathyroidism both in living animals and in tissue culture.

The parathyroid glands in hypervitaminotic A animals undergo modification consistent with mild hyperplasia, which is believed to be due to bone alterations (fibro-osteoclasia).[6,11]

REFERENCES

1. Cohlan, S. Q.: Excessive Intake of Vitamin A as a Cause of Congenital Anomalies in the Rat. Science 117:535, 1953.

2. Berdjis, C. C.: Late Effects of Hypervitaminosis A in the Rat: Disturbance and Retardation in the Normal Growth of Offspring, A. M. A. Arch. Path. 66:278, 1958.

3. Fell, H. B., and Mellanby, E.: The Effects of Hypervitaminosis A on Foetal Mouse Bones; Cultivated in Vitro: Preliminary Communication, Brit. M. J. 2:535, 1950.

4. Fell, H. B., and Mellanby, E.: The Effect of Hypervitaminosis A on Embryonic Limb-Bones Cultivated in Vitro, J. Physiol. 116:320, 1952.

5. Fell, H. B.: Effects of Excess Vitamin A on Organized Tissue Cultivated in Vitro, Brit. M. Bull. 12:35, 1956.

6. Berdjis, C. C., and Rinehart, J. F.: Fibro-Osteoclasia in the Rat and Guinea Pig Following Excessive Administration of Vitamin A, Acta vitaminol. 2:49, 1958.

7. Wolbach, S. B., and Bessey, O. A.: Tissue Changes in Vitamin Deficiencies, Physiol. Rev. 22:233, 1942.

8. Wolbach, S. B.: Vitamin-A Deficiency and Excess in Relation to Skeletal Growth, J. Bone & Joint Surg. 29:171, 1947.

9. Irving, J. T.: Effects of Avitaminosis and Hypervitaminosis A upon Incisor Teeth and Incisal Alveolar Bone of Rats, J. Physiol. 108:92, 1949.

10. Strauss, K.: Beobachtungen bei hypervitaminose A, Beitr. path. Anat. 94:345, 1934.

11. Wernly, M., and Berdjis, C. C.: Human Parathyroids: Contribution to the Study of Adenomas and Hyperplasias, Helvet. med. acta (Supp. 19) 13:69, 1946.

12. Barnicot, N. A.: Local Action of Calciferol and Vitamin A on Bone, Nature, London 162:848, 1948.

13. Bracali, G.; Camera, A., and De Gaetani, G., Jr.: Sui complessi quadri anatomo ed istopatologici nella ipervitaminosi A: considerazioni e fattori patogenetici, Endocrinol. & sc. costit. 22:325, 1955.

Berdjis-'58
Bib. No. 753

Acta Vitaminologica 12:49-57. 1958.

Reproduced by permission
of the copyright owner

ACTA
VITAMINOLOGICA

ANNO DODICESIMO PUBBLICAZIONE BIMESTRALE - APRILE 1958 FASCICOLO 2

Fibro-osteoclasia in the rat and guinea pig following excessive administration of vitamin A (*)

CHARLES C. BERDJIS, M. D. (**) - JAMES F. RINEHART, M. D. (***)

The effects of excessive administration of vitamin A to experimental animals were first described by Takahashi and his associates (16) and later confirmed by a number of investigators. The manifestations of hypervitaminosis A consisted of loss of weight, superficial ulceration, bleeding, and crusting of the skin and eyelids, diarrhea, paralysis of the posterior extremities, visceral hemorrhages and fractures, and infections such as pneumonia, often resulting in death. In addition to these abnormalities some researchers have found evidence of many changes in the endocrine glands including:

1) increased activity of the thyroid gland (17) or reduced size of thyroid with depressed basal metabolism (15);

2) increase in the basophilic cells of the pituitary gland (7); and

3) hypertrophy of the islet tissue of the pancreas (6).

During the present investigation, in addition to fractures and visceral hemorrhages of the acute phase, we observed slight but generalized bony alterations indicating fibro-osteoclasia or progressive atrophy of bone, and some changes in the parathyroid glands with concomitant calcium deposition in the kidneys of the experimental animals. The purpose of this paper is to correlate these findings with excessive dosage of vitamin A.

MATERIALS AND METHODS

In order to determine the effects of heavy doses of vitamin A on rat and guinea pig tissues, two series of experiments were undertaken. Table I shows the details and distribution of the material used. In the first experiment both rat and guinea pig were used and in the second experiment only rats.

In addition, in order to compare the histologic findings in animals having hypervitaminosis A with those in animals that had received parathormone, two other groups of animals were used. In this last experiment four young guinea pigs (20 days old) and fourteen rats (40 days old) received 250 USP parathyroid Lilly, daily for 3 days by subcutaneous injection. They were sacrificed 24 hours after the last injection.

A solution of crystalline vitamin A alcohol in corn oil having a potency of 500,000 IU

(*) This work was initiated in the University of California, School of Medicine, San Francisco, California, and completed in the Fourth U.S. Army Medical Laboratory, Fort Sam Houston, Texas.

(**) Presently, Lt Col, MC Fourth U.S. Army Medical Laboratory, Fort Sam Houston, Texas.

(***) Late Professor of Pathology University of California, School of Medicine, San Francisco, California.

per gram was fed orally at a level of 100–700 IU per gram of body weight per day (table I) in addition to the standard laboratory diet.

The animals were autopsied immediately after death or were sacrificed, and the principal organs including the endocrine glands, kidneys, and bones (femur, tibia, vertebrae, skull, jaws, and ribs) were fixed in formalin. The tissues were imbedded in paraffin and stained with hematoxylin and eosin.

TABLE I

Details and distribution of animals and vitamin A

Group number	Animal number: Rat	Animal number: Guinea pig	Age	Vitamin A (daily) I. U. per gram of body weight
FIRST EXPERIMENT:				
I		10	5	700
Controls		5	5	0
II	8		40	350
		8	5	350
Controls	4	4	Same ages respectively	0
III	8		90	200
		5	70	200
Controls	4	4	Same ages respectively	0
IV	1		90	200
Basic study for another experiment (3)				
V	6		90	100–200
		6	70	100–200
Controls	3	3	Same ages respectively	0
VI	4		40	Parathormone (see text)
		4	20	
SECOND EXPERIMENT:				
	15	—	30–40	200–300
	5	—	90	200
	10	—	30–40	Parathormone
	10	—	30–40	Controls
	5	—	90	Controls

RESULTS

All of the animals in groups I and II (acute stage, table I) died or were sacrificed when moribund between 7 and 17 days after administration of vitamin A. The animals in the remaining groups were sacrificed between 22 and 100 days after the termination of the experiment.

One female rat from group IV was unique in that she was pregnant and received vitamin A during her entire pregnancy. This animal served as basic study for another experiment which could be published separately (3).

Experiment V, conducted to ascertain the late effects of hypervitaminosis A on rats and guinea pigs, revealed no significant gross alterations. The animals in this group were sacrificed between 100 and 200 days after the termination of the experiment. The late effects of vitamin A in adult animals appear to be reversible.

MICROSCOPIC EXAMINATION

The histologic study of the early, acute stage of hypervitaminosis A, groups I and II, characterized by hemorrhages, fractures, and acceleration of normal bone growth, has been omitted from this report. The descriptions which follow apply to both rats and guinea pigs, three or more weeks after vitamin administration.

BONES - Femur, tibia, fibula, vertebrae, jaws, skull, ribs, and knees were examined.

Microscopic examination showed fragmentary osseous trabeculae, some of which were surrounded by fibrotic tissue with occasional or numerous osteoclasts, indicating slight or marked lacunar resorption (figures 1, 3), in several areas outside the zones of fracture and hemorrhage if present. This lacunar resorption was more marked in the mandibular bone, femur, and vertebrae. The total amount of bone matrix was reduced, and small, narrow, irregular, and delicate bony trabeculae were frequently encountered. This rarefaction was a constant finding in every animal but not all bones were involved evenly. Sections of the femur and the upper end of the tibia showed erosion of older bone and of the bone recently laid down, with irregular contour lines and some fibrous tissue in subperiosteal bone. The trabeculae of the diaphyseal side of the epiphyseal disk was partly

resorbed, leaving some osteoclasts in their place. The skull showed variation in the appearance of its inner and outer tables in relation to the changes in the diploe, in which the bony trabeculae were partly replaced by fine fibrous tissue with little osteoclastic activity. Transverse sections of the bone also showed irregular contour lines and subsequent replacement of bone by fibrous tissue.

Fig. 1 - Section of femur of a normal untreated rat. H & E ×60.

In general, apart from fractures and calluses which were discarded from the material examined, the bone was chaotically arranged, with partial destruction of the spicules and signs of moderate osteoclastic activity or slight resorption, resembling experimental fibro-osteoclasia obtained by parathormone administration, or human moderate renal osteodystrophy or progressive atrophy of bone in early stages of evolution.

PARATHYROIDS - The parathyroids of the animals treated with vitamin A undergo modifications. They appeared to be enlarged and more compact. They will be describ elsewhere (2).

KIDNEYS - The kidneys appeared hyperem in all cases, with occasional subscapular h morrhage and infrequent red blood cells Bowman's space. Some convoluted tubul both proximal and distal, showed edem casts, or degeneration. Frequently som deposits of calcium, either as fine granules o large masses, were found in the cortex, and occasionally, in the medulla (figures 6, 7) This presumably metastatic calcification w mostly intratubular, occasionally intracellul and rarely present in interstitial tissue.

Other endocrine glands examined show no striking differences from those of the co trol animals. The islets of Langerhans appear to be enlarged and/or increased in numbe similar conditions may be encountered no mally. The adrenal glands of vitamin treate animals showed slight proliferation of th cortical cells. The thyroid glands, manifested



Fig. 2 - Section of femur of a rat treated with 300 I.U. of vitamin A/g of body weight daily for 12 days. Note subperiosteal fibro-osteoclasia with lacunar resorption (arrows), similar to human lacunar resorption. H & E × 80.

Fig. 3 - Sagittal section of upper jaw of a guinea pig given 250 I.U. vitamin A/g of body weight daily for 12 days, showing extensive areas of fibro-osteoclasia. H & E × 80.

more or less evenly distributed small follicles with pale or vacuolated colloid but were otherwise essentially normal. The follicles were composed of occasionally elongated or irregularly distributed epithelial cells. The basophilic cells of the anterior lobe of the pituitary gland were slightly increased, but the size and structure of the pituitary gland remained normal.

hemorrhage, fracture, or exacerbation of a natural resorption about the joints. Furthermore, fibro-osteoclasia was more frequent in the bones in which no fractures were observed and some sections showed evidence of decalcification and fragility, a condition similar to osteoporosis. It would be interesting to determine whether or not the excessive losses of vitamin A were responsible for these



Fig. 4 - Same section of a normal untreated guinea pig. H & E × 80.

The animals receiving parathormone showed at autopsy a general bone fragility. Microscopic examination revealed more or less small and diffuse lacunar resorption of the bony trabecular and subcortical regions. The fibrosis formation was mostly devoid of osteoclast. However, some resorptive areas showed one or two small and fusiform osteoclasts. The kidneys of the parathormone-treated animals showed a few small areas of granular calcification usually in the tubules.

DISCUSSION

Our analysis of histologic observations indicates that there was a moderate but generalized osteitis fibrosa in most of the bones examined three weeks or more after administration of vitamin A. We believe that this general osseus rarefaction is a condition apart from the bony alterations resulting from

alterations and whether the endocrine glands played a role (8, 10).

Although Rodahl (14) found small amounts of vitamin A in bone marrow, Barnicot (1) found that local application of vitamin A, like local application of the parathyroid gland (see McLean, 13) in the parietal bone of 10-day-old C-57 black mice caused intense osteoclastic bone resorption after 10 to 14 days. Wolbach and Bessey (22) first described the histological findings of hypervitaminosis A as decalcification and osteoporosis, accompanied by a large number of osteoclasts. They also reported the osteoporosis to be most marked in the regions where the remodeling of bone is a normal growth process. Fell and Mellanby (8, 10) who studied the direct action of vitamin A on the bone in tissue culture, found marked resorption in the presence of excess vitamin A. They stated that vitamin A had the remarkable

of the parathyroids was the cause of the fibro-osteoclasia observed, since vitamin A acts directly in bone. It may be suggested (according to a statement of Askanazy and Erdheim, see Wernly and Berdjis (18) that this parathyroid change is related to bony modifications. Frequent calcium deposits in the kidneys is similar to the metastatic calcification of experimental fibro-osteoclasia produced by parathormone. It is obvious that excessive doses of vitamin A create a complex syndrome in the body in which the first target appears to be the bony system.

If the other authors reported only the hemorrhages, fractures and acceleration of normal bone growth in hypervitaminotic A animals, this is because:

1) these lesions were more apparent;

2) the animals were studied usually in the early, acute phase of hypervitaminosis A; and

3) the parathyroid glands and entire bony system were not studied by a great number of authors; and

4) in one or two instances, in which the hormonal activities of the parathyroid glands have been evaluated, they remained unchanged or underwent slight modifications.

We did not evaluate the hormonal activities of the parathyroid in this study, the reason being that the results of such evaluation are generally uncertain when the parathyroids are secondarily affected. Furthermore, Wolbach and associates (4) found no significant changes in the serum calcium and phosphorus in hypervitaminotic A animals. Nevertheless, it is a curious fact that hypervitaminosis A, resulting in generalized fibro-osteoclasia and calcium deposits in the kidneys, is similar in syndrome to that produced by parathormone.

SUMMARY AND CONCLUSIONS

The effects of hypervitaminosis A were studied in guinea pigs and rats, both young and adult. Bony alterations were observed in all cases.

We have observed that the formation of small fibro-osteoclastic zones and/or lacunar resorption in the entire bony system of animals having hypervitaminosis A is as much a part of the classical picture of this condition as are fractures, hemorrhages, and acceleration of all processes of bone growth. This frequently observed phenomenon (small lacunar resorption) seemed to be independent of the hemorrhages and fractures, since direct application of vitamin A is shown to produce the same phenomenon.

The parathyroid glands also underwent modifications. Deposits of calcium were frequently present in the kidneys.

Our conclusions are:

1) slight experimental fibro-osteoclasia with concomitant parathyroid change and metastatic calcification in the kidneys has been caused by excessive administration of vitamin A to rats and guinea pigs.

2) this syndrome is revealed to be similar to that produced by parathormone;

3) late effects of hypervitaminosis A in adult animals appeared to be reversible.

SUMMARY

Groups of rats and guinea pigs were fed with heavy doses of crystalline vitamin A alcohol (Table I) and sacrificed three weeks or later after treatment. Excessive administration of vitamin A by direct action on bone caused generalized bony alterations (fibro-osteoclasia) with concomitant parathyroid changes and metastatic calcification in the kidneys. This syndrome was revealed to be similar to that produced by parathormone. Late effects of hypervitaminosis A in adult animals appeared to be somewhat reversible.

RIASSUNTO

Fibro-osteoclasia nel ratto e nella cavia in seguito a iperdosaggio di vitamina A.

Gruppi di ratti e di cavie sono stati alimentati con larghe dosi di vitamina A cristallizzata come alcool e sono stati sacrificati tre settimane o più dopo il trattamento. L'iperdosaggio di vitamina A ha provocato, per diretta azione sul tessuto osseo, alterazioni scheletriche generalizzate (fibro-osteoclasia), oltre a modificazioni delle paratiroidi ed a calcificazioni metastatiche nei reni. Questa sindrome si è dimostrata simile a quella provocata dal paratormone. Gli effetti tardivi dell'ipervitaminosi A negli animali adulti hanno mostrato un certo grado di reversibilità.

property of controlling the shape and texture of certain bones in young animals, and had the function of controlling the position and intensity of activity of osteoclasts and osteoblasts.

Fell and Mellanby (9) showed also that the effect produced on bone in tissue culture by vitamin A in high concentration is similar to that produced in hypervitaminotic A animals. More recently Fell (8) confirmed that the bones of young animals in tissue culture with high concentrations of vitamin A became increasingly rarefied. Herbertson (12) studied this direct action in chick-bone and showed its reversibility *in vitro*. Such possible reversibility *in vivo* was observed only in adult animals late after vitamin A administration (group V, table I). The result of this study will be reported elsewhere.

However, our own observations are in close agreement with those of Fell and Mellanby.

Therefore, it may be concluded that excessive intake of vitamin A has a direct action on bone. The data published by Wolbach and his associates (19, 21) seemed to confirm this direct effect. Although Wolbach and his coworkers in their studies of hypophysectomized (20), adrenalectomized (21), and parathyroidectomized (4) hypervitaminotic A animals stated that the endocrine glands have no part in mediating the effect of excessive doses of vitamin A on the skeleton, other authors (6, 7, 15, 17) found evidence of changes in the endocrine glands. However, we believe that these changes were inconstant and not sufficiently pronounced to be considered as hyperactivity. Although the islets of Langerhans appeared to be increased in volume and in number, the blood sugar tests in four animals were normal. Apart from the parathyroid glands which showed evidence of increasing volume and predominance of rounded cells with more compact parenchyma, interpreted as slight hyperplasia, the other endocrine glands appeared to be normal or slightly hypertrophied without real hyperfunction. The detailed observations in parathyroid changes will be published elsewhere (2). It can not be said that this slight hyperplasia



Fig. 5 - Sagittal section of vertebra of a vitamin A treated rat showing marked fibro-osteoclastic process. H & E × 80.



Fig. 6 - Widespread intratubular and interstitial metastatic calcification in kidney of a rat treated with 300 I.U. of vitamin A/g of body weight daily for 12 days. H & E ×80.



Fig. 7 - The same as in Figure 6, higher magnification. H & E ×475.

RÉSUMÉ

Fibro-ostéoclasie chez le rat et le cobaye, consécutive à un surdosage en vitamine A.

Des groupes de rats et de cobayes ont été alimentés avec des doses abondantes de vitamine A cristallisée sous forme d'alcool, et sacrifiés après une période de traitement de 3 semaines au minimum. Le surdosage en vitamine A a provoqué, par action directe sur le tissu osseux, non seulement des altérations osseuses généralisées (fibro-ostéoclasie), mais aussi des modifications des parathyroïdes et des calcifications métastatiques au niveau du rein. Ce syndrome s'est avéré semblable à celui provoqué par la parathyrine. Les effets tardifs de l'hypervitaminose A chez les animaux adultes ont montré un certain degré de réversibilité.

ZUSAMMENFASSUNG

Fibro-Osteoklasis in Ratten und Meerschweinchen in Folge einer Überdosierung an Vitamin A.

Gruppen von Ratten und Meerschweinchen wurden starke Dosen von kristallisiertem Vitamin A Alkohol verabreicht und wurden drei oder mehr Wochen nach der Behandlung geopfert. Überdosierung an Vitamin A verursachte, durch direkte Wirkung auf das Knochengewebe, verallgemeinerte Alterationen des Skelettes (Fibro-Osteoklasis), ausserdem Veränderungen der Epithelkörperchen und metastatische Verkalkungen in den Nieren. Das Gesamtbild wies sich dem von Parathormon hervorgerufenem ähnlich. Die Spätefekte der Hypervitaminose A erwiesen sich in erwachsenen Tieren etwas reversibel.

RESUMEN

Fibroosteoclasia en la rata y el cobayo, consecutiva a sobrecarga de vitamina A.

Grupos de ratas y cobayos han sido alimentados con grandes dosis de vitamina A cristalizada como alcohol y sacrificados a las tres y más semanas de tratamiento. La sobrecarga de vitamina A ha provocado, por acción directa sobre el tejido óseo, alteraciones esqueléticas generalizadas (fibro-osteoclasia), además de modificaciones en las paratiroides y de calcificaciones metastásicas en el riñón. Este síndrome se ha demostrado semejante al provocado por la paratirina. Los efectos tardíos de la hipervitaminosis A en los animales adultos se han demostrado en parte reversibles.

REFERENCES

(1) Barnicot N. A. - *Nature*, 1948, **162**, 848. - (2) Berdjis C. C. - *In preparation*. - (3) Berdjis C. C. - *Unpublished data*. - (4) Cohen J., Maddock C. L. and Wolbach S. B. - *A.M.A. Arch. of Path.*, 1955, **59**, 723. - (5) Cohlan S. Q. - *Science*, 1953, **117**, 30. - (6) Cornil L., Chevallier A. and Paillas J. E. - *Ann. d'Anat. Path.*, 1939, **16**, 74. - (7) Cornil L., Chevallier A., Paillas J. E. and Chouquet T. - *Ann. d'Anat. Path.*, 1939, **16**, 83. - (8) Fell H. B. - *Brit. Med. Bull.*, 1956, **12**, 35. - (9) Fell H. B. and Mellanby E. - *J. Physiol.*, 1952, **116**, 320. - (10) Fell H. B. and Mellanby E. - *Brit. Med. J.*, 1950, **2**, 535. - (11) Giroud A. and Martinet M. - *Int. Z.f. Vitaminf.*, 1956, **28**, 10. - (12) Herbertson M. A. - *Belgisch Tsjchr. Geneesk.*, 1955, **11**, 380 (Reported by Fell, 1956). - (13) Mc Lean F. C. - *J.A.M.A.*, 1941, **117**, 609. - (14) Rodahl, K. - Hypervitaminosis A. A study of the effects of vitamin A in experimental animals. Skrifter No. 95. Norsk Polarinstitutt, 1950. - (15) Sadhu D. P. and Brody S. - *Am. J. Physiol.*, 1947, **149**, 400. - (16) Takahashi K., Nakamiya Z., Kawakimi K. and Kitazato T. - *Sci. Pap., Inst. Phys. Chem. Tes., Tokyo*, 1925, **3**, 81. - (17) Uotila U. - *Virchows Arch. f. Path. Anat.*, 1938, **301**, 535. - (18) Wernly M. and Berdjis C. C. - *Helv. Med. Acta*, Suppl. XIX, 1946, **13**, *Benno Schwabe and Co., Ed. Bale*, 1946, p. 69. - (19) Wolbach S. B. - *J. Bone and Joint Surg.*, 1947, **29**, 171. - (20) Wolbach S. B. and Maddock C. L. - *A.M.A. Arch. Path.*, 1952, **53**, 273. - (21) Wolbach S. B. and Cohen J. - *A.M.A. Arch. Path.*, 1955, **60**, 130. - (22) Wolbach S. B. and Bessey O. A. - *Physiol. Rev.*, 1942, **22**, 233.

Bern-'55
Bib. No. 771

Am. J. Anat. 96:419-448. 1955.

THE INFLUENCE OF VITAMIN A ON THE EPIDERMIS [1]

HOWARD A. BERN, JOEL J. ELIAS, PATRICIA B. PICKETT, THOMAS R. POWERS AND MARY NISHI HARKNESS

Department of Zoology and its Cancer Research Genetics Laboratory, University of California, Berkeley

TWELVE FIGURES

Sabella, Bern and Kahn ('51) demonstrated that vitamin A dissolved in sesame oil, applied topically to the dorsal epidermis of castrated mature female rats for 10 days, resulted in a significant increase in thickness of the whole epidermis (less the stratum corneum) and of the stratum granulosum alone over both that of sesame oil-treated and of untreated controls. Effects on the stratum corneum were indicated, including occasional parakeratosis, but were not possible to quantify. It was concluded that topical vitamin A application resulted in acanthosis and that there was some evidence for interference with the normal keratinization process. Estrogen did not affect the epidermal picture when topically administered alone for the same period of time, nor did it alter the response to vitamin A when administered simultaneously with the latter.

These results are similar to those obtained by Swiss investigators (Studer and Frey, '49, '52; Studer, '53) who administered large quantities of the vitamin orally and topically to very young rats. However, they ('49) reported a maximal effect after 11–13 days of oral treatment and a regression to the normal thickness, despite continuation of treatment, after an additional 10 days. In addition to these studies, vitamin A has been shown to interfere with estrogen-induced vaginal

[1] Aided in part by Cancer Research Funds of the University of California.

cornification (cf. Kahn and Bern, '50; Kahn, '54a, b), and recent investigations by Flesch ('52, '53) and Flesch and Goldstone ('52) indicate a possible depilatory ("anti-keratinizing") action of vitamin A in pharmacologic dose levels. Furthermore, observations on integument grown in organ-culture by Fell and Mellanby ('53); Fell, Mellanby and Pelc ('54); and Weiss and James ('54) especially emphasize the role of vitamin A in epidermal differentiation. Vitamin A added to such cultures induces differentiation of a mucus-secreting epithelium in place of the usual keratin-forming stratified epithelium.

The present study was undertaken to extend our previous observations and to examine the following aspects of the vitamin A-epidermis relationship *in vivo:* (1) the effect of prolonged vitamin A treatment on the epidermis and the possibility of a local "adaptation" to continued topical treatment; (2) the possible existence of a dermal-epidermal barrier to vitamin A administered otherwise than by the topical route; (3) the effects, if any, of vitamin A on the formation of keratin; and (4) the evidence for any relation between vitamin A and estrogen in their effects on estrogen-sensitive epidermis. We have attempted to examine these aspects (1) by treating rats continuously with vitamin A for periods up to 60 days; (2) by comparing the effects of vitamin A administered locally by topical and by subcutaneous routes; (3) by the use of certain cytochemical reactions, the polarizing microscope, and the electron microscope; and (4) by the choice of the male guinea pig nipple as an established estrogen-sensitive epidermal region to compare the response to vitamin A and to estrogen. Some information on the nature of the keratohyalin granules of the stratum granulosum is also presented.

MATERIALS AND METHODS

Sixty-one male Long-Evans rats, two to three months of age at the beginning of the experiment, were employed in the study of the effects of prolonged vitamin A treatment on the epidermis. They were divided into 5 groups receiving treat-

ment as follows: (1) 13 untreated rats, (2) 11 rats with topical application of sesame oil, (3) 17 rats with topical application of vitamin A in sesame oil, (4) 8 rats with subcutaneous injection of sesame oil, (5) 12 rats with subcutaneous injection of vitamin A in sesame oil. These treatments were continued for 10, 20, 30 and 60 days, as indicated in table 1.

The animals were prepared as described previously (Sabella et al., '51): all rats, including the controls, bore a one-inch square felt pad over a shaved dorsal area between the scapulae. The pad was attached by a wide strip of adhesive tape bound around the thorax and over the pad. The bandages were changed occasionally as they became loosened. Topical applications were accomplished by daily injection into the pad of 0.3 ml of sesame oil or 0.3 ml of sesame oil containing 1000 units of vitamin A alcohol. Subcutaneous injections of similar amounts of materials were performed by use of a two-inch, 20-gauge hypodermic needle inserted at a distance from the felt pad to a point directly under the center of the skin area covered by the pad. Thus, topical contamination of the tested area was avoided.

The animals were killed by concussion, and the area of skin subjacent to the felt pad was removed, flattened on a piece of cardboard, and cut into several parallel strips. Portions of tissue were fixed while still attached to cardboard in Bouin's fluid for staining with alum-hematoxylin and eosin, with iron-hematoxylin, and with the periodic acid-Schiff (PAS) method for polysaccharides (McManus-Hotchkiss, cf. Lillie, '54), with and without diastase digestion; in Carnoy's fluid for the Azure B method for nucleic acids (Flax and Himes, '52), with and without ribonuclease digestion; in 1% trichloroacetic acid in 100% ethanol for protein-bound sulfhydryl (SH) and disulfide (S-S) groups (Barrnett and Seligman, '52, '54). In all cases paraffin sections were cut at 6 μ. The PAS sections were utilized for study with the polarizing microscope. Occasionally small pieces of skin were fixed in 1% osmic acid buffered at pH 7.4, sectioned after imbedding in methacrylate, and examined with the electron microscope. Further cytochemical

tests were performed on the aforementioned material, as well as on skin from additional vitamin A-treated and control rats and mice, with special attention to the reactions of keratohyalin granules: the Feulgen reaction for desoxyribonucleic acid (DNA) (Stowell, '45); the mercuric-bromphenol blue method (Mazia et al., '53) and the Millon reaction (Gomori, '52) for proteins, all on Carnoy-fixed material; Baker's acid-hematein method for phospholipids (Baker, '46, '47; Cain, '47) on material fixed in calcium-formol and in weak Bouin's solution (the latter to allow pyridine extraction), imbedding in paraffin as suggested by Rennels ('53). Cytochemical tests were not performed on the subcutaneously injected rats.

Epidermal thicknesses were measured from 5 different regions of each tissue stained with hematoxylin and eosin, using an ocular micrometer at 500 × magnification. Typical areas between hair follicles were selected. The thickness of the combined stratum germinativum(-spinosum)-granulosum is referred to as epidermal thickness. The generally disjoined state of the stratum corneum did not allow its inclusion in any measurements. The thickness of the stratum granulosum was measured separately.

For the nipple study, 20 male guinea pigs, two to three months of age, were used in a 10-day experiment. They were divided into the following groups: (1) 2 untreated controls, (2) 3 sesame oil-treated controls, (3) 4 estrogen-treated, (4) 5 vitamin A-treated, and (5) 6 estrogen + vitamin A-treated. A "band-aid" was placed over each nipple and attached around the pelvic region with adhesive tape. Estrogen-treated nipples received 200 I.U. estradiol benzoate in sesame oil daily; vitamin A-treated nipples received about 1500 units vitamin A alcohol or acetate in sesame oil daily; estrogen + vitamin A-treated nipples received the same doses as above simultaneously in a single solution. The oil solutions were injected into the gauze portion of the bandage once daily in a volume of 0.2 ml per nipple. The bandages were replaced if the gauze portion became detached from the adhesive tape owing to action of the oil.

After 10 days of treatment, the animals were sacrificed, and the length of each nipple was measured with a fine divider. A section of skin which included each nipple, its areola, and the circumareolar area posterior to the nipple was excised and fixed in Bouin's fluid. Paraffin sections were cut serially at 10 μ and stained with hematoxylin and eosin.

Epidermal and granulosum thicknesses were obtained as in the rat studies in the nipple, areolar, and circumareolar areas, using an ocular micrometer at 225 × magnification. The areola is the hair-free area surrounding the nipple; the circumareola refers to the hairy skin immediately peripheral to the areola. Measurements were made of areas which seemed most representative, and places where the epidermis was "irregular" (e.g., adjacent to hair follicles, to the orifice of the mammary duct, to epidermal pegs, etc.) were avoided. Each nipple was considered as a separate reactive area.

RESULTS

Figure 1 and table 1 summarize the data from vitamin A treatment of rat epidermis for periods of 10, 20, 30 and 60 days. The topical vitamin A resulted in an acanthotic response after all 4 treatment periods. Figures 3 and 4 allow comparison of the epidermis after 20 days of treatment with sesame oil and with vitamin A respectively. Topical sesame oil resulted in a moderate hyperplasia after treatment for 30 days, which was more evident after 60 days. In general, the stratum granulosum thickness paralleled the epidermal thickness, except for the 60-day vitamin A-treated group where keratohyalin granules were occasionally absent from the treated epidermis (fig. 5), making measurement of stratum granulosum thickness impossible for this group (see table 1). The subcutaneously administered vitamin and sesame oil resulted in no appreciable reaction in the overlying epidermis. Extensive "pools" of the oil solutions were evident in the subcutaneous tissues in most sections of skin from these groups.

For the most part, the *cytochemical tests* performed on skin sections from the untreated and topically treated rats revealed little difference among the three groups.

A diastase-resistant PAS-positive reaction (for mucopolysaccharides *inter alia)* was seen in the basement membrane region. A light coloration occurred in the cytoplasm of the epidermal cells, particularly demarcating the cell boundaries.

TABLE 1

Thickness of epidermis and of stratum granulosum of variously treated male rats

GROUP		LENGTH OF TREATMENT IN DAYS			
		10	20	30	[illegible]
Untreated	No.	3	3	4	[illegible]
	Epidermis [1]	27.2	24.5	26.4	2[illegible]
	Str. gran.[2]	7.9	6.4	8.8	[illegible]
Topical sesame oil	No.	2	2	3	[illegible]
	Epidermis	25.2	22.6	33.5	4[illegible]
	Str. gran.	7.0	4.9	9.0	11[illegible]
Topical vitamin A	No.	4	4	4	[illegible]
	Epidermis	43.0	45.0	52.8	78[illegible]
	Str. gran.	14.8	13.7	18.0	[illegible]
Subcutaneous sesame oil	No.	2	2	2	[illegible]
	Epidermis	19.8	28.3	30.7	19[illegible]
	Str. gran.	5.4	9.4	6.7	4[illegible]
Subcutaneous vitamin A	No.	3	3	3	[illegible]
	Epidermis	27.4	25.7	28.4	25[illegible]
	Str. gran.	9.4	8.3	7.4	5[illegible]

[1] Epidermal thickness, less stratum corneum, in microns.
[2] Thickness of stratum granulosum in microns.

The sesame oil-treated animals showed considerable sloughing debris which was retained on the surface undoubtedly owing to the adhesive action of the daily administered oil. This debris showed an intense PAS reaction, most of which was diastase-sensitive. In the vitamin A-treated animals, PAS-positive granules of two kinds were seen in the epidermal cells: (1) diastase-digestible granules, presumably glycogen, in epidermal cells generally bordering on hair follicles (as well as

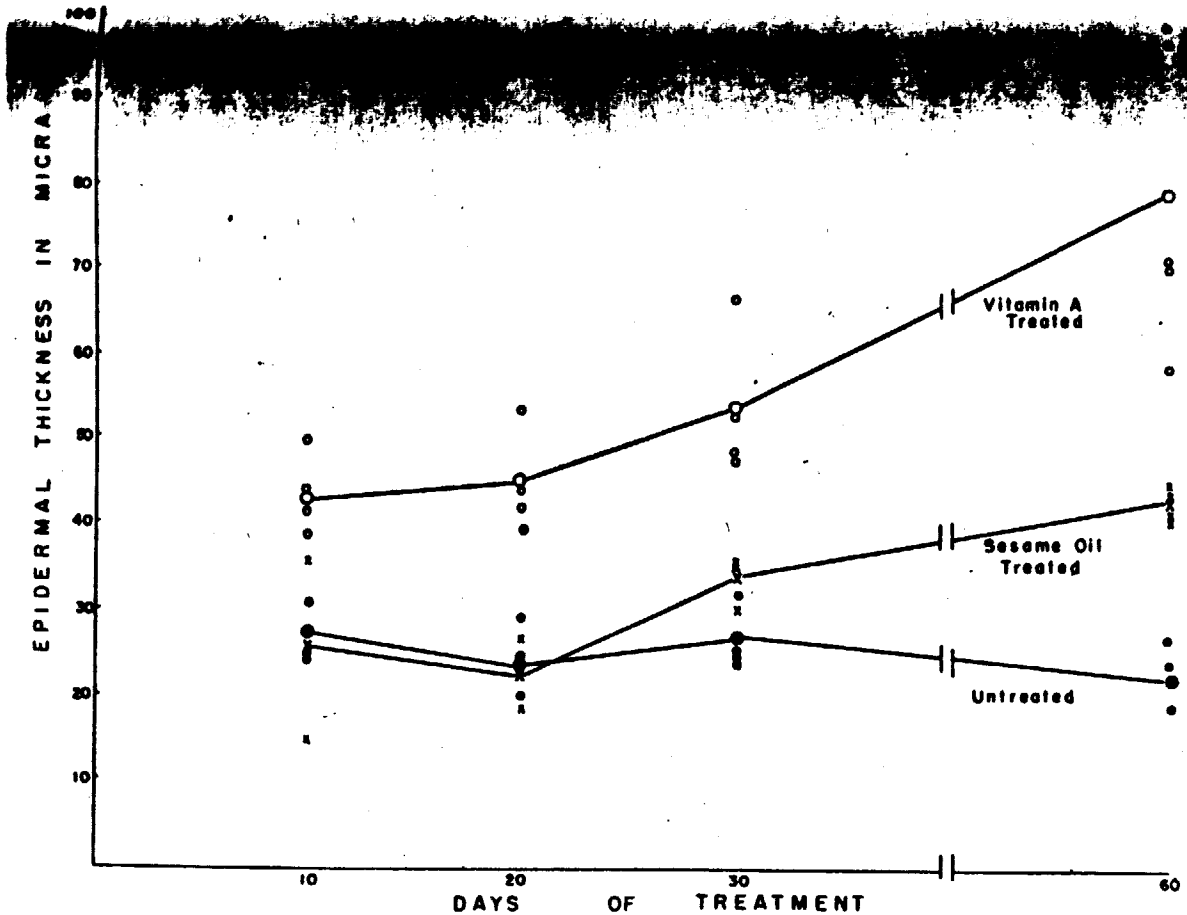

Fig. 1 Effect of topical treatment with vitamin A and with sesame oil for various periods of time on epidermal thickness of rat skin. Epidermal thickness herein indicated is exclusive of stratum corneum. ○ = values from individual vitamin A-treated rats; ● = values from untreated rats; X = values from sesame oil-treated rats. Larger symbols represent the mean values obtained for each group and each period of treatment.

in the hair follicles themselves), and (2) infrequent diastase-resistant material appearing as irregular granules in the superficial cells of the stratum spinosum (*not* keratohyalin). Glycogen granules were also seen occasionally in the sesame oil-treated epidermis, but never in the untreated tissues. The stratum granulosum region in all groups was consistently negative for PAS-positive materials, other than at the cell boundaries.

The reaction for protein-bound SH groups revealed a homogeneous distribution of these groups in the cytoplasm of the epidermal cells, frequently with a somewhat more intense reaction in the uppermost stratum granulosum and in the most basal layers of the stratum corneum (stratum lucidum?) than elsewhere. The intense reaction was particularly evident in vitamin A-treated animals (fig. 10). In rats treated for 60 days with vitamin A, occasional parakeratotic regions showed an especially intense SH reaction. The nucleoli of the stratum spinosum cells often showed definite coloration in contrast to the remainder of the nuclear contents; this was particularly evident in the acanthotic epidermis. The keratohyalin granules gave a completely negative reaction in all animals and were generally evident as clear areas in the cytoplasm.

The reliability of the method for disulfide (S-S) groups is open to some question, inasmuch as we noted that SH-blocking with iodoacetic acid and with n-ethyl maleimide was not always complete (cf. Goldblum et al., '54). The location of S-S groups was determined by comparing the sections supposedly treated for S-S alone with the SH-blocked slides treated for SH alone. In all animals a positive reaction for disulfide, as well as for SH, was obtained in the stratum corneum. With the S-S method, the stratum corneum showed a considerably weaker reaction than did the hair shafts; no SH reaction was obtained in the fully formed regions of the latter. The only notable point indicated by use of these methods, other than the absence of protein-bound SH and S-S groups from keratohyalin, was the existence of an intense reaction

for SH in the lowest layers of the stratum corneum in the vitamin A-treated epidermis, which was distinctly greater than in the control animals.

The Azure reaction for nucleic acids demonstrated considerable ribonucleic acid (RNA) in the basal layers of the epidermis with distinct fine RNA-containing granules in the upper layers of the stratum spinosum. Careful examination revealed, in addition, that the layers immediately beneath the stratum corneum contained variously-sized granules giving a light reaction for RNA which disappeared after ribonuclease digestion. These structures are identical with the keratohyalin granules, although it is to be emphasized that their RNA content, as visually judged, is not great (fig. 8). The morphology and distribution of these lightly azurophilic granules is best studied in the vitamin A-stimulated acanthotic epidermis wherein a multilayered stratum granulosum occurs. However, other than the increased number of cell layers showing these granules after vitamin A treatment, no appreciable difference in nucleic acid distribution was seen among the various animal groups. A comment should be made on the consistent bright-blue staining of the hard keratin of the hair shaft with the Azure method, which was not affected by ribonuclease treatment and is of unknown significance. The soft keratin of the stratum corneum was completely unreactive.

The cytochemical methods discussed above demonstrate that the keratohyalin granules contain no detectable SH or S-S groups and no PAS-positive glycogen or mucopolysaccharide component. In addition, they are Feulgen-negative. They do contain some RNA indicated by slight metachromatic Azure staining. Ribonuclease removes the azurophilic material, but does not at all affect the hematoxylin-staining of these granules, either after Carnoy's or Bouin's fixation. For this reason, further investigation of their chemical nature was conducted.

Baker's acid-hematein method for phospholipid demonstrated an intensely positive reaction on the part of kerato-

hyalin (fig. 6). This presumed phospholipid was absent after weak Bouin's fixation, whether or not tissues were subsequently treated with hot pyridine (fig. 7). The reactive material in the myelin sheaths of nerves in the dermis and in the subcutaneous tissues is partially preserved by the weak Bouin's fixation and is entirely extracted by pyridine treatment. The stratum granulosum in the untreated, sesame oil-treated, and vitamin A-treated epidermis of the rat and the distinct stratum granulosum induced by vitamin A in the mouse were similarly stained after calcium-formol fixation. A positive reaction was also seen in the lower layers of the stratum corneum, which however remained unchanged after pyridine treatment (fig. 7).

An interesting difference in the response of keratohyalin to two different cytochemical methods for proteins was seen. The Millon reaction and the mercuric-bromphenol blue method were employed on sections from the same Carnoy-fixed tissue blocks. (1) With the bromphenol blue method, an intense staining of the keratohyalin (fig. 9) was seen in all but the vitamin A-treated animals where the extensive stratum granulosum demonstrable with hematoxylin was only occasionally reactive. (2) With the Millon reagent as employed herein (prepared with trichloroacetic acid to prevent loss of histones from the tissue sections), no staining of the keratohyalin granules was seen; unstained "vacuoles" appeared in the stratum granulosum region. The bromphenol blue stained the soft keratin of the stratum corneum, but not the hard keratin of the hair shaft. On the other hand, the Millon reaction stained the hair shaft even more intensely than it stained the stratum corneum. The question of absolute specificity of both of these reactions for all protein is thus raised. With both methods a distinct protein-rich layer immediately beneath the stratum corneum was seen, presumably corresponding to the intensely SH-positive region described above.

Polarizing microscope studies of the PAS-treated sections demonstrated birefringence in the stratum corneum and in

the superficial layers of the cellular epidermis. Birefringence was evident also in the narrow columnar basal cells of the acanthotic epidermis; the extent of this birefringent region increased with the degree of hyperplastic response. However, birefringence appeared to be less in the superficial layers of the vitamin A-treated epidermis, as compared with the sesame oil-treated and untreated controls. This observation is suggestive of an anti-keratinizing action of the vitamin, but the difference is difficult to establish quantitatively.

The limited observations with the *electron microscope* are best considered in relation to the cytologic picture seen after staining with iron-hematoxylin. This latter stain clearly demonstrated the "intercellular" bridges (cf. Medawar, '53), with the nodes of Bizzozero-Ranvier appearing as darkly-staining granules. Reduction in the prominence of these structures was evident in the stratum spinosum cells after topical vitamin A treatment, although those of the basal cells remained exaggeratedly distinct until after 30 or more days of treatment. In general, after continued vitamin A treatment the spinous cells in section resemble pavement cells in their close application one to the other. Electron micrographs of the stratum spinosum after continued vitamin A treatment show that the intercellular bridges are reduced to desmosomes and that the intercellular "gaps" characteristic of the normal and sesame oil-treated epidermis are not seen (figs. 11, 12). Pease's ('51) micrographs of human hair follicle cells resemble the acanthotic stratum spinosum of the rat.

Previous electron microscope studies of normal human and laboratory mammal epidermis have revealed intercellular bridges connecting stratum spinosum cells separated by spaces of varying degrees of prominence (Adolph et al., '51; Pease, '51; Laden et al., '52, '53; Gray et al., '52; von Albertini, '53). Regardless of the interpretation of these bridges and spaces as intracellular or intercellular structures (Pease, '51; Medawar, '53), they reflect points of contact between

neighboring cells (Porter, '54). Von Albertini ('53) has shown that the morphology of these bridges is altered in the hyperplastic phase in the development of epidermal cancer.

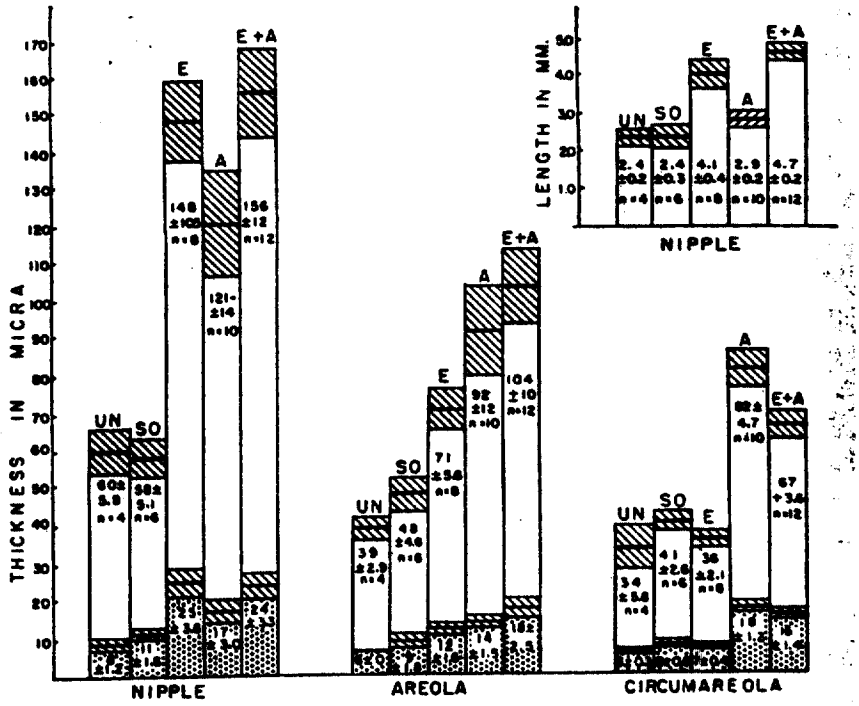

Fig. 2 Effect of topical treatment with various materials for 10 days on epidermal thickness in guinea pig nipple region. UN = untreated; SO = sesame oil-treated; E = estrogen-treated; A = vitamin A-treated; E + A = estrogen + vitamin A-treated. Line bisecting hatched area atop each block represents mean epidermal thickness, where hatched area is standard error of mean. Stippled area similarly represents thickness of stratum granulosum. Insert at upper right shows mean lengths of nipples and standard errors of means for each animal group. (n = number of nipples treated.)

The disappearance of the intercellular gaps — and the reduction of the bridges themselves to desmosomes — is fairly typical of the late stages of simple hyperplasia. These alterations also characterize vitamin A-induced acanthosis and are evident when cells of the stratum spinosum are ex-

amined with the electron microscope. Tonofibrils could be seen in all groups, with no evidence of any difference in prominence consequent to vitamin A treatment.

Figure 2 summarizes the response of the several areas of the male guinea pig nipple region to vitamin A and to estrogen. Estradiol benzoate, in the presence or absence of vitamin A, resulted in nipple hypertrophy indicated by a length of about twice normal. Estrogen caused an increase in thickness of nipple epidermis to about 2.5 times normal, accompanied by grossly evident hyperkeratosis. The effect on the areolar region was less (about two-fold hypertrophy), and no effect was seen in the circumareolar area. Vitamin A caused an increase in epidermal thickness similar to that seen in the rat in all areas examined: an increase to almost exactly twice the normal thickness. Where the vitamin and the hormone were administered simultaneously, the thickness obtained essentially represented the response to the more effective stimulant for each area. No evidence of any antagonism in the induction of acanthosis was seen, and the hyperkeratotic response to estrogen occurred in the presence of vitamin A. The thickness of the stratum granulosum was altered to the same extent as that of the entire epidermis (less the stratum corneum), and in general the stratum granulosum comprised about one-sixth of the total epidermis. The 10-day treatment with sesame oil alone did not result in any significant increase in thickness of any epidermal area.

The acanthosis owing to vitamin A administration involves an increase in the number of cell layers of the strata germinativum and granulosum and an increase in the size of cells composing these layers. The acanthosis induced by estrogen in the nipple region is indistinguishable histologically from that resulting from vitamin A administration. No definite effects of vitamin A on the stratum corneum could be discerned. Occasional parakeratotic areas were seen, but these occurred in members of all groups and may have resulted from the irritant effect of the overlying gauze bandage.

DISCUSSION

The effects of topical treatment of the epidermis for 10 days with sesame oil and vitamin A in the doses employed herein were essentially the same as those reported previously with larger doses (Sabella et al., '51), *viz.*, no effect of the sesame oil and an increase in thickness of the epidermis including the stratum granulosum resulting from vitamin A treatment to approximately twice the normal value. After treatment for 20 days, the effects are not appreciably different from those seen after 10 days. However, treatment for 30 days with sesame oil alone results in a mild acanthotic response of the epidermis, which is accentuated after 60 days of treatment. Thus, the apparent increase in response to vitamin A in sesame oil seen after 30 and 60 days may result in part from the non-specific action of sesame oil (fig. 1). In general, the acanthosis owing to the vitamin A is maintained even after 60 days of treatment with the vitamin. Evidence for an "adaptation" of the epidermis to vitamin A after 10–20 days of treatment, as claimed by Studer and Frey ('49) using an oral mode of administration, is not to be found in our observations with topically applied vitamin A.

Local subcutaneous injection of vitamin A did not result in any significant hyperplastic response of the overlying epidermis, even after 60 daily injections. This may indicate the existence of a subepidermal barrier preventing the uptake by the epidermis of vitamin A in quantities adequate to cause the response seen when the vitamin is applied on the surface and absorbed therefrom. The "barrier" could be the circulatory system itself which may take up much of the vitamin as it diffuses out from the subcutaneous oil pools.

Attempts to decide whether topically administered vitamin A interferes with keratinization were not successful. A stratum corneum is still present in all vitamin A-treated epidermis, except in the 60-day treatment group where some parakeratotic areas are seen, which are however often associated with evidence of local infection. No quantitative measure was devised which would allow determination of the extent of

keratinization. Polarizing microscope observations were suggestive, but also not conclusive, of a possible decrease in birefringence of the outer stratum spinosum after vitamin A treatment. Electron microscope observations substantiated cytologic observations and revealed no changes after vitamin A treatment other than those associated with simple hyperplasia. In particular, the tonofibril system appeared unaffected.

Montagna ('54) has recently criticised briefly some of the conclusions of Flesch and his co-workers ('52, '53) regarding the induction of depilation with vitamin A. Little evidence for a depilatory action was obtained in our studies, and we are in accord with Montagna's views. While no detailed observations on the effects of vitamin A on hair growth were made, hair follicles were seen even after 60 days of topical application (fig. 5). Furthermore, it was observed that a rapid growth of hair occurred during vitamin A treatment; the matted hair could eventually be removed *en masse* (owing to the adhesive effect of the oily solution), as would be expected at completion of the hair growth cycle. Removal of the hair was followed by a regrowth of hair apparently more rapid than normal. If the entire epidermis is stimulated by vitamin A, it is not surprising that hair follicles might also respond to such treatment and that acceleration of the hair cycle would result. An analysis of the hair cycle in the vitamin A-treated mouse based upon comparison with the normal cycle (cf. Chase, '54) would be desirable.

Cytochemical differences in the epidermis from untreated, sesame oil-treated, and vitamin A-treated rats are not great. The untreated epidermis was devoid of glycogen. The appearance of small amounts of glycogen in the stratum spinosum, primarily, after oil and vitamin-in-oil treatment has been observed also by Montagna ('54) in the vitamin A-treated guinea pig when fatty acids were employed as vehicles. He points out that the appearance of glycogen is a reflection of non-specific damage to the epidermis. Glycogen is not usually seen in the normal epidermis (Bradfield, '51; Ar-

gyris, '52; Patzelt, '54; Washburn, '54; and others), but is present in regenerating and embryonic epidermis. The reaction for protein-bound SH groups seems greater after vitamin A treatment in the stratum granulosum-"lucidum" region (cf. Mescon and Flesch, '52; Barrnett, '53; Goldblum et al., '54). Montagna et al. ('54) describe this zone in man as a reactive band between the stratum granulosum and stratum corneum, analogous to the "keratogenous zone" of hard keratinization (cf. Bern et al., '55). Mazia ('54) has commented that SH concentrations such as are revealed here cytochemically may reflect merely a high concentration of protein possessing average numbers of SH groups, rather than protein with large numbers of SH groups. Both cytochemical methods employed for protein give an intensely positive reaction in this region. However, recent radioautographic observations (Bern et al., '55) indicate that this subcorneal zone may be a region of cysteine incorporation into protein.

Regardless of the significance of this zone, its presence after vitamin A treatment indicates a different picture in the epidermis from that described by Kahn ('54a) in the vitamin A-treated rat vagina, where a diminution of histochemically detectable protein-bound SH seems to occur. Such a reduction in SH might be expected to occur if Flesch's ('52, '53) contention is correct that vitamin A or one of its conversion products binds free SH groups, owing to the presence of unsaturated groupings (-CH = CH-). In the superficial layers of vitamin A-induced parakeratotic areas, however, SH groups appear in even higher concentrations than in keratin-forming regions. This is to be expected, of course, if disulfide cross-linkages are limited, and has been reported in other parakeratotic epithelia (Eisen et al., '53). Attention is called to the appreciable concentration of free SH groups in the formed stratum corneum in all experimental animals, a cytochemical finding which has been reported previously (Rudall, '52; Mescon and Flesch, '52; Barrnett, '53), and which has been confirmed recently by chemical means (Van Scott and Flesch, '54a, b).

Although local application of vitamin A inhibits estrogen-induced cornification of the vagina *in vivo* (Kahn and Bern, '50; Kahn, '54a) and addition of vitamin A causes mucous metaplasia of epidermis *in vitro* (Fell and Mellanby, '53), no definite changes of this type are seen even after treatment with vitamin A for 60 days *in vivo*. If vitamin A is considered to have a reversible inductive action in epidermal differentiation (cf. Weiss and James, '54), as has been demonstrated *in vitro*, acanthosis and possibly occasional parakeratosis are the responses seen *in vivo*.

The data from our guinea pig experiments show, as has been reported by Montagna ('54), that the guinea pig epidermis responds to topical vitamin A application as does that of the rat and mouse. The acanthosis, including increase in granulosum thickness, after vitamin A treatment is indistinguishable from that after estrogen treatment. All epidermis — estrogen-sensitive and -insensitive — evidently responds to vitamin A treatment, whereas there is a gradient of response to estrogen which is greatest on the nipple and non-existent in the circumareolar skin. Estrogen induces obvious hyperkeratosis of the nipple epidermis (cf. Lansing and Opdyke, '50; Wheeler et al., '53), which was not qualitatively inhibited by the addition of vitamin A. In general, observations on the guinea pig, with or without estrogen treatment, failed to demonstrate any clear anti-keratinizing influence of vitamin A after 10 days of application.

For many decades the significance of keratohyalin granules has been debated (cf. Bern, '54; Rothman, '54). The classical picture of a transformation of keratohyalin to eleidin and thence to keratin is still presented in histology textbooks (e.g., Maximow and Bloom, '52) and elsewhere in more sophisticated fashion (e.g., Patzelt, '54). Summaries of the earlier literature pertinent to the status of keratohyalin in the process of keratinization can be found in Patzelt ('26), Weinmann ('40) and Montagna ('52). Carruthers and Suntzeff ('53) review some of the chemical properties of keratohyalin. Leuchtenberger and Lund ('51) demonstrated the presence of RNA

in these granules, the existence of small amounts of which we have confirmed. However, whereas they pointed out that ribonuclease treatment removed the granules from the sections, we would emphasize that despite the loss of the RNA component, their hematoxylin-staining is not affected by such enzyme digestion (cf. Smith and Parkhurst, '49). The small amount of RNA demonstrable presumably accounts for Blank's ('52) statement that RNA is absent from keratohyalin in man. Patzelt ('54) feels that keratohyalin contains a non-glycogen carbohydrate component; however, we find that they are always PAS-negative in our material. (In the guinea pig, Lansing and Opdyke, '50, reported occasional PAS-positive granules.) A protein component is clearly indicated by one protein stain (mercuric-bromphenol blue method of Mazia et al., '53), but a second protein stain (Millon reaction, employed according to Gomori, '52) shows no coloration of the granules whatsoever. With Baker's method, which presumably demonstrates phospholipid (Baker, '47; Cain, '47; Rennels, '53), the granules show a strong positive reaction which is not present after weak Bouin's fixation, even if the hot pyridine extraction is not performed. Pyridine extraction does not remove these granules (or myelin) after calcium-formol fixation. Some doubt must be raised as to the validity of the control in Baker's method wherein two different fixations are used. However, it is possible that the weak Bouin's fixative itself may serve as an extractive of the keratohyalin phospholipid. It is assumed that the hematein-staining material is protein-bound and, hence, not removed by the standard paraffin technic employed. The absence of SH and S-S groups from the granules (contrary to the earlier findings of Chèvremont and Frederic, '43) would indicate no relation of the granules to keratin formation, although the remainder of the cytoplasm of the cells of this region and of the lowest layers of the stratum corneum (= stratum lucidum?) often shows a high concentration of SH (cf. Montagna, '52; Eisen et al., '53; Barrnett and Seligman, '54). The significance of the keratohyalin granules could lie solely in their appearance

consequent to degenerative processes, rather than concomitant with keratin synthesis.

SUMMARY AND CONCLUSIONS

The epidermis of male rats treated with vitamin A in sesame oil for 10, 20, 30 and 60 days was compared with that of sesame oil-treated and untreated controls. Both topical and subcutaneous modes of application were employed. The following conclusions were drawn:

1. Acanthosis occurs after topical application of vitamin A, regardless of length of treatment, and no "adaptation" to the effects of the vitamin was seen. Occasional parakeratotic areas were present, particularly in the 60-day treatment group.
2. Subcutaneous administration of the vitamin was without effect on the overlying epidermis.
3. Cytologic observations and electron microscope studies reveal no changes in the tonofibril system, but eventual reduction of the "intercellular" bridges to desmosomes occurs, accompanying the hyperplasia induced by vitamin A treatment.
4. Cytochemical differences among the several groups were minor. No reduction in protein-bound SH groups was seen following vitamin A treatment, and in general, no definite evidence of interference with the keratinization process was obtained.

Vitamin A induced acanthosis in male guinea pig epidermis in the nipple region and did not interfere with the response of the nipple epidermis to estrogen.

The cytochemistry of keratohyalin granules was investigated. A RNA component is present, probably along with phospholipid bound to protein. The granules give a negative PAS reaction and contain no SH or S-S groups. No relation to keratinization is suggested, and it is conceivable that they may appear concomitant with cytoplasmic degeneration.

ACKNOWLEDGMENTS

We are indebted to Dr. P. L. Harris of Distillation Products, Inc., Rochester, N. Y., for the vitamin A alcohol and acetate and to Dr. G. K. Hawkins of Schering Corporation, Bloomfield, N. J., for the estradiol benzoate. We wish to express our appreciation to Mrs. Patricia Harris for initial work on the electron micrographs and to Mr. Victor Duran for the photomicrography.

LITERATURE CITED

ADOLPH, W. E., R. F. BAKER AND G. M. LEIBY 1951 Electron microscope study of epidermal fibers. Science, *113:* 685–686.

ARGYRIS, T. S. 1952 Glycogen in the epidermis of mice painted with methylcholanthrene. J. Nat. Cancer Inst., *12:* 1159–1165.

BAKER, J. R. 1946 The histochemical recognition of lipine. Quart. J. Micr. Sci., *87:* 441–471.

——— 1947 Further remarks on the histochemical recognition of lipine. Ibid., *88:* 463–465.

BARRNETT, R. J. 1953 The histochemical distribution of protein-bound sulfhydryl groups. J. Nat. Cancer Inst., *13:* 905–926.

BARRNETT, R. J., AND A. M. SELIGMAN 1952 Histochemical demonstration of protein-bound sulfhydryl groups. Science, *116:* 323–327.

——— 1954 Histochemical demonstration of sulfhydryl and disulfide groups of protein. J. Nat. Cancer Inst., *14:* 769–803.

BERN, H. A. 1954 Histology and chemistry of keratin formation. Nature, *174:* 509–511.

BERN, H. A., D. R. HARKNESS AND S. M. BLAIR 1955 Radioautographic studies of keratin formation. Proc. Nat. Acad. Sci. U.S., *41:* 55–60.

BLANK, H. 1952 Virus induced tumors of human skin. Ann. N.Y. Acad. Sci., *54:* 1226–1231.

BRADFIELD, J. R. G. 1951 Glycogen in vertebrate epidermis. Nature, *167:* 40–41.

CAIN, A. J. 1947 An examination of Baker's acid hematein test for phospholipines. Quart. J. Micr. Sci., *88:* 467–478.

CARRUTHERS, C., AND V. SUNTZEFF 1953 Biochemistry and physiology of epidermis. Physiol. Rev., *33:* 229–243.

CHASE, H. B. 1954 Growth of the hair. Physiol. Rev., *34:* 113–126.

CHÈVREMONT, M., AND J. FREDERIC 1943 Une nouvelle méthode histochimique de mise en évidence des substances à fonction sulfhydrile. Application à l'épiderme, au poil et à la levure. Arch. biol., *54:* 589–605.

EISEN, A. Z., W. MONTAGNA AND H. B. CHASE 1953 Sulfhydryl groups in the skin of the mouse and guinea pig. J. Nat. Cancer Inst., *14:* 341–354.

FELL, H. B., AND E. MELLANBY 1953 Metaplasia produced in cultures of chick ectoderm by high vitamin A. J. Physiol., *119:* 470–488.

FELL, H. B., E. MELLANBY AND S. R. PELC 1954 Influence of excess vitamin A on the sulphate metabolism of chick ectoderm grown *in vitro*. Brit. Med. J., *2:* 611.

FLAX, M. H., AND M. H. HIMES 1952 Microspectrophotometric analysis of metachromatic staining of nucleic acids. Physiol. Zool., *25:* 297–311.

FLESCH, P. 1952 Inhibition of keratin formation with unsaturated compounds. J. Invest. Derm., *19:* 353–363.

——— 1953 Studies on the mode of action of vitamin A. J. Invest. Derm., *21:* 421–434.

FLESCH, P., AND S. B. GOLDSTONE 1952 Local depilatory action of unsaturated compounds. The effect of human sebum on hair growth. J. Invest. Derm., *18:* 267–287.

GOLDBLUM, R. W., W. N. PIPER AND A. W. CAMPBELL 1954 A comparison of three histochemical stains for the demonstration of protein-bound sulfhydryl groups in normal human skin. J. Invest. Derm., *23:* 375–384.

GOMORI, G. 1952 Microscopic Histochemistry. University of Chicago Press, Chicago. P. 113.

GRAY, M., H. BLANK AND G. RAKE 1952 Electron microscopy of normal human skin. J. Invest. Derm., *19:* 449–458.

KAHN, R. H. 1954a Effect of locally applied vitamin A and estrogen on the rat vagina. Am. J. Anat., *95:* 309–336.

——— 1954b Effect of œstrogen and of vitamin A on vaginal cornification in tissue culture. Nature, *174:* 317.

KAHN, R. H., AND H. A. BERN 1950 Antifolliculoid activity of vitamin A. Science, *111:* 516–517.

LADEN, E. L., J. O. ERICKSON AND D. ARMEN 1952 Electron microscopic study of epidermal prickle cells. J. Invest. Derm., *19:* 211–216.

LADEN, E. L., J. LINDEN, J. O. ERICKSON AND D. ARMEN 1953 Electron microscope study of epidermal basal cells and epidermal dermal junction. J. Invest. Derm., *21:* 37–42.

LANSING, A. I., AND D. L. OPDYKE 1950 Histological and histochemical studies of the nipples of estrogen treated guinea pigs with special reference to keratohyalin granules. Anat. Rec., *107:* 379–397.

LEUCHTENBERGER, C., AND H. Z. LUND 1951 The chemical nature of the so-called keratohyaline granules of the stratum granulosum of the skin. Exp. Cell Research, *2:* 150–152.

LILLIE, R. D. 1954 Histopathologic Technic and Practical Histochemistry. Blakiston Co., New York and Toronto. Pp. 120–128.

MAXIMOW, A. A., AND W. BLOOM 1952 A Textbook of Histology. Sixth Ed. W. B. Saunders Co., Philadelphia and London. Pp. 313–314.

MAKIA, D. 1954 In discussion of R. J. Barrnett and A. M. Seligman: Histochemical experiments on sulfhydryls and disulfides. Glutathione. Ed. by S. Colowick et al. Academic Press, New York. Pp. 89–102.

MAKIA, D., P. A. BREWER AND M. ALPERT 1953 The cytochemical staining and measurement of protein with mercuric bromphenol blue. Biol. Bull., *104:* 57–67.

MEDAWAR, P. B. 1953 The micro-anatomy of the mammalian epidermis. Quart. J. Micr. Sci., *94:* 481–506.

MESCON, H., AND P. FLESCH 1952 Modification of Bennett's method for the histochemical demonstration of free sulfhydryl groups in skin. J. Invest. Derm., *18:* 261–266.

MONTAGNA, W. 1952 The cytology of mammalian epidermis and sebaceous glands. Internat. Rev. Cytol., *1:* 265–304.

——— 1954 Penetration and local effect of vitamin A on the skin of the guinea pig. Proc. Soc. Exp. Biol. Med., *86:* 668–672.

MONTAGNA, W., A. Z. EISEN, A. H. RADEMACHER AND H. B. CHASE 1954 Histology and cytochemistry of human skin. VI. The distribution of sulfhydryl and disulfide groups. J. Invest. Derm., *23:* 23–32.

PATZELT, V. 1926 Zum Bau der menschlichen Epidermis. Z. f. mikr. anat. Forsch., *5:* 371–462.

PATZELT, V. 1954 Über Tonofibrillen, Keratohyalin, Glykogen und Verhornung in der Epidermis. Acta anat., *21:* 349–356.

PEASE, D. C. 1951 Electron microscopy of human skin. Am. J. Anat., *89:* 469–497.

PORTER, K. R. 1954 Observations on the submicroscopic structure of animal epidermis. Anat. Rec., *118:* 433.

RENNELS, E. G. 1953 Localization of phospholipids in the rat hypophysis. Anat. Rec., *115:* 659–671.

ROTHMAN, S. 1954 Physiology and Biochemistry of the Skin. University of Chicago Press, Chicago. Pp. 375–376.

RUDALL, K. M. 1952 The proteins of the mammalian epidermis. Adv. Protein Chem., *7:* 253–290.

SABELLA, J. D., H. A. BERN AND R. H. KAHN 1951 Effect of locally applied vitamin A and estrogen on rat epidermis. Proc. Soc. Exp. Biol. Med., *76:* 499–503.

SMITH, C., AND H. T. PARKHURST 1949 Studies on the thymus of the mammal. II. A comparison of the staining properties of Hassall's corpuscles and of thick skin of the guinea pig. Anat. Rec., *103:* 649–673.

STOWELL, R. E. 1945 Feulgen reaction for thymonucleic acid. Stain Technol., *20:* 45–56.

STUDER, A. 1953 Zur Frage der Angriffsorte von Compound E (Cortison). Eine experimentelle Studie. Z. f. die ges. exper. Med., *121:* 287–418.

STUDER, A., AND J. R. FREY 1949 Ueber Hautveränderungen der Ratte nach grossen oralen Dosen von Vitamin A. Schweiz. med. Wchnschr., *79:* 382–384.

——— 1952 Wirkung von Cortison auf die ruhende und die mit Vitamin A oder Testosteronpropionat zur Proliferation gebrachte Epidermis der Ratte. Dermatologica, *104:* 1–18.

VAN SCOTT, E. J., AND P. FLESCH 1954a Sulfhydryl and disulfide in keratinization. Science, *119:* 70–71.

——— 1954b Sulfhydryl groups and disulfide linkages in normal and pathological keratinization. Arch. Derm. Syph., *70:* 141–154.

VON ALBERTINI, A. 1953 Electron microscopic study of epidermal carcinoma induced by methylcholanthrene in the mouse. J. Nat. Cancer Inst., *13:* 1473–1496.

WASHBURN, W. W., JR. 1954 Comparative histochemical observations on wound healing in adult rats and cultured adult epithelium. I. Methods and glycogen distribution. J. Invest. Derm., *23:* 97–112.

GOLDMANN, J. 1940 The keratinization of the human oral mucosa. J. Dental Res., *19:* 57–71.

[illegible], P., AND R. JAMES 1954 Vitamin A and skin keratinization *in vitro:* experimental dissociation of induction and realization phases in cytodifferentiation. Science, *119:* 587.

[illegible], C. E., E. P. CAWLEY AND A. C. CURTIS 1953 The effects of topically applied hormones on growth, pigmentation and keratinization of the nipple and areola. J. Invest. Derm., *20:* 385–399.

PLATE 1

EXPLANATION OF FIGURES

3 Skin from 75-day-old male rat treated topically for 20 days with sesame oil Bouin's, H. and E. × 110.

4 Skin from 75-day-old male rat treated topically for 20 days with vitamin A in sesame oil. Note increased epidermal thickness, prominence of stratum granulosum, persistence of stratum corneum and hair follicles. Bouin's, H. and E. × 110.

5 Skin from 5-month-old male rat treated topically for 60 days with vitamin A in sesame oil. Note increased epidermal thickness, variable appearance of stratum granulosum, parakeratotic region at right, persistence of hair follicles. Bouin's, H. and E. × 110.


3
4
5

PLATE 2

EXPLANATION OF FIGURES

6 Skin from 3-month-old untreated male rat to show positive reaction of keratohyalin granules for presumed phospholipid. Calcium-formol, Baker's acid-hematein. × 900.

7 Skin from 3-month-old untreated male rat to show absence of keratohyalin stainability after weak Bouin's fixation. In addition, this tissue was extracted with pyridine. Note retention of coloration by lower layers of stratum corneum. Weak Bouin's, Baker's acid-hematein. × 900.

8 Skin from 3-month-old untreated male rat to show azurophilic staining of keratohyalin. Granules and globules in superficial layers lose stainability (RNA) after ribonuclease treatment. Carnoy's, Azure B. × 900.

9 Skin from 65-day-old untreated male rat to show strong affinity of keratohyalin for protein stain. Carnoy's, mercuric-bromphenol blue. × 900.

10 Skin from 75-day-old male rat topically treated for 20 days with vitamin A in sesame oil. Note intense reaction for protein-bound sulfhydryls in most superficial zone (between stratum spinosum and disjoined stratum corneum); nucleoli are fairly prominent. 1% trichloroacetic acid in 80% ethanol, Barrnett-Seligman method. × 900.

6
7
8
9
10

PLATE 3

EXPLANATION OF FIGURES

11 Electron micrograph of cells from stratum spinosum of 3-month-old male rat treated for 30 days with sesame oil. Note prominent "intercellular" bridges, nodes and spaces. Osmic acid, methacrylate-imbedded. × 6000 approx.

12 Electron micrograph of cells from stratum spinosum of 3½-month-old male rat treated for 30 days with vitamin A in sesame oil. Note reduction of "intercellular" bridges to desmosomes and disappearance of "intercellular" spaces. This is the characteristic picture of simple epidermal hyperplasia. Prominent tono fibril system is present in center of figure. Osmic acid, methacrylate-imbedded. × 6000 approx.

11

12

5

Influence of Vitamin A on Keratinization*

HOWARD A. BERN AND DONALD J. LAWRENCE†
Department of Zoology and Its Cancer Research Genetics Laboratory, University of California, Berkeley

For many years a relationship between vitamin A and keratinization has been recognized (Mori, 1922; Evans and Bishop, 1922), but the nature of the influence of the vitamin on epithelia has not been well understood. However, new experimental findings are helping to clarify our view of the relationship; consequently, the present survey is focused on recent developments.

In conditions in which there is a *deficiency of vitamin A*, keratinization is somehow favored: many or all external areas of the mammal appear to be more heavily keratinized than normally, and most ectoderm-derived glands and "mucous membranes," as well as at least some epithelia of endodermal origin, appear to undergo keratinization (Wolbach and Bessey, 1942; Moore, 1957). The latter process of ectopic keratinization appears likely to be one of a local metaplastic alteration of the epithelium, although there is little experimental evidence to rule out other possible mechanisms, such as an ingrowth of normally keratinizing epithelium in areas adjacent to the orifices. The effects of vitamin A deficiency are discussed elsewhere in this symposium by Parnell and Sherman.

The converse of the vitamin A-epithelium relation, the effects on normal keratinization of an *excess of vitamin A*, has been investigated with less certain conclusions. It has been reasoned that if a

* Supported in part by cancer research funds of the University of California.
† Supported under U.S. Public Health Service Grant CRT-5045.

lack of the vitamin favors hyperkeratosis and keratinizing metaplasia, then an excess might inhibit normal keratinization. It is the latter possibility which concerns us here. Domagk and Dobeneck (1933) first described the epithelial changes produced by excess vitamin A. After large oral doses of the vitamin, the normally keratinizing epithelium of the rat forestomach showed a thinning of the stratum corneum and an increase both in total thickness and in number of the subcorneal cell layers. Similar changes in the oral epithelium of monkeys after large oral doses of vitamin A were reported by Ziskin *et al.* (1943).

Studer and Frey (1949) observed the effects of excess vitamin A on the epidermis. Large oral doses of the vitamin were administered to rats; after 3 days of such treatment, epidermal thickening, together with swelling and vacuolization of the Malpighian (suprabasal) cells, was observed. Proliferation did not appear to be prominent at this stage, although the mitotic index was not reported. Later, after 4 to 12 days of treatment, the epidermis became even thicker and showed a well-defined stratum granulosum as well as evidence of basal-cell proliferation. The authors pointed out a fact applicable to all conventional histologic studies of keratinizing epithelia: little can be said with assurance of the state of the stratum corneum, since the histologic technic employed often results in splitting off and partial loss of the more superficial layers. After several days of continued vitamin A treatment, epidermal alterations were reduced in degree, and finally disappeared altogether, to result in a normal-appearing epidermis. In a later paper, Studer and Frey (1952) reported a significant 33% increase in epidermal thickness after 4 days of vitamin A treatment; this thickening was accompanied by a 50% increase in colchicine-arrested mitoses. The epidermal thickening and hyperplasia produced by vitamin A were reduced strikingly by injections of cortisone.

The vaginal epithelium of the ovariectomized rat treated with estrogen undergoes a continuous typical keratinization with the production of a prominent stratum granulosum and a definite stratum corneum. Kahn and Bern (1950) found that application of large amounts of vitamin A locally to the keratinizing vagina dramatically modified the superficial layer of the vaginal mucosa. Figs

Am. Assoc. Adv. Sci. 70:95-112. 1962.

Bern-'62
Bib. No. 772

1–4) from one composed of keratinized, anucleate plaques to one composed of spheroidal, nucleated cells. The appearance of the altered cells suggested possible early mucification. Similar findings were reported also by Hohlweg (1951, 1952). In later studies by Kahn (1954a), even as little as 1 unit of vitamin A per day applied locally to the vaginal epithelium was found to have an antikeratinizing effect. Still later, Kahn (1954b, 1959) found that organ cultures of prepuberal rat vagina, exposed to vitamin A *in vitro*, showed inhibited (but not completely suppressed) keratinization. Lasnitzki (personal communication) now has established conclusively the *in vitro* inhibition of vaginal keratinization by vitamin A.

Local application of vitamin A to the skin of the rat (Sabella *et al.*, 1951; Bern *et al.*, 1955a), mouse (Lawrence and Bern, 1958), guinea pig (Montagna, 1954; Bern *et al.*, 1955a), and young chicken (Lawrence and Bern, unpublished) produces an epidermal thickening, with increased prominence of the stratum granulosum, after several days of treatment (Figs. 5–12). These changes are identical with those described earlier by Studer and Frey (1949) in the rat after oral administration for 4 to 12 days of massive amounts of vitamin A. However, the local application of the vitamin produces only local epidermal hypertrophy, with no changes evident in the skin at distant sites. Furthermore, no "adaptation" of the epidermis was observed even after local treatment for as long as 90 days (Bern *et al.*, 1955a).

Some criticism can be directed at earlier studies involving topical application, because (*a*) only massive amounts of the vitamin were employed; (*b*) the oily vehicles alone produced various degrees of epidermal damage, including thickening; (*c*) no control was provided for the influence of the hair cycle, which is known to influence not only epidermal thickness (Chase *et al.*, 1953) but also the degree and type of response of the epidermis to various chemical and physical agents (Chase and Montagna, 1951; Argyris, 1954; Argyris and Bell, 1959). In studies of the effect of local applications of vitamin A to mouse skin, Lawrence and Bern (1958) found that when a minimally "irritating" vehicle was employed, the following points became clear: (*a*) epidermal thickening as well as increase in mitotic index was roughly proportional to the amount of vitamin

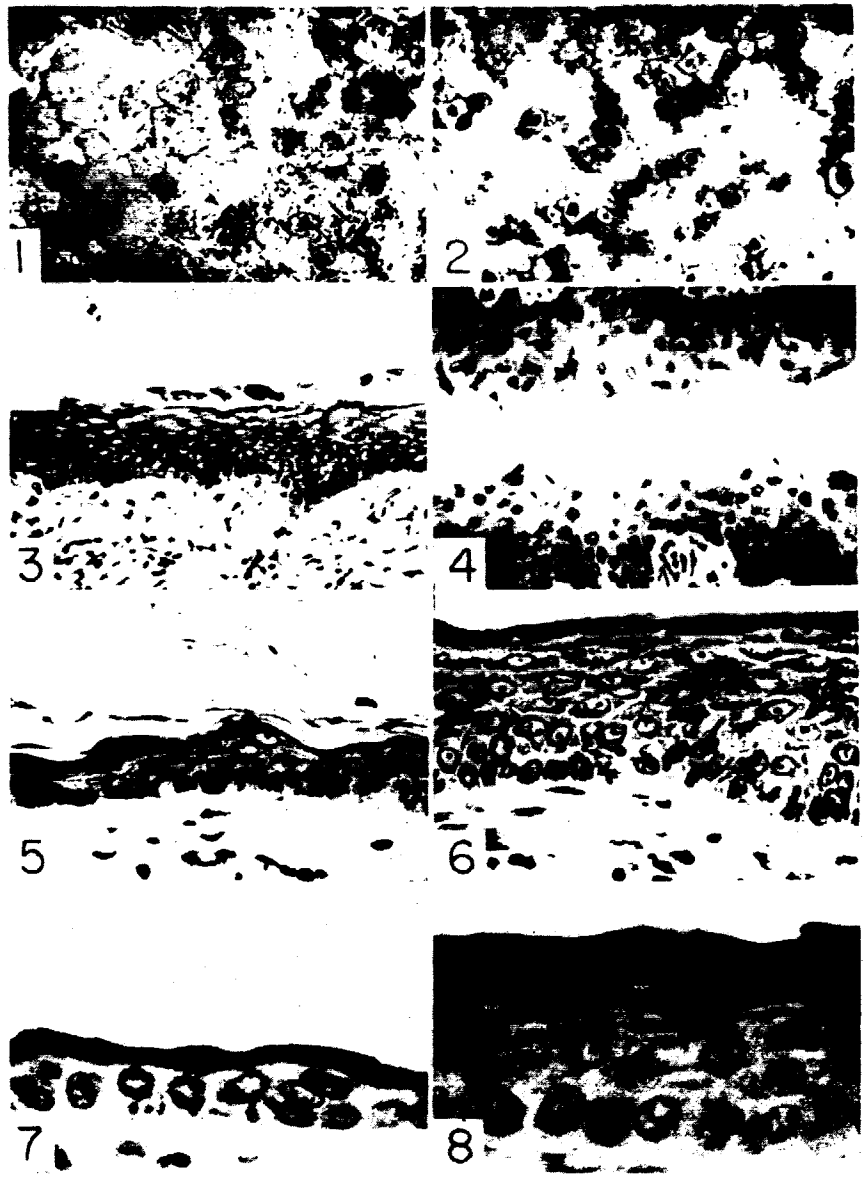

Figs. 1–8. The figures on the left represent various epithelia treated with control substances. The figures on the right represent corresponding epithelia after treatment with vitamin A.

A applied, and was seen even after small amounts of the vitamin (1 unit per day); (*b*) oleic acid, an effective "irritant" of rodent epidermis, produced no effect even at levels 300 times that of the minimally effective dose level of vitamin A employed; (*c*) the epidermal response to vitamin A at low dose levels was influenced only minimally by the stage of the hair cycle. These observations suggest a more-or-less "specific" hyperplastic effect of the vitamin upon rodent epidermis, but it was nevertheless not possible to establish any real effect of the vitamin on keratinization. In contrast to others (Setälä, 1960; Setälä *et al.*, 1960), we do not feel that epidermal thickening is proof of an altered differentiation rate. The increase in thickness could be accounted for solely by increased mitoses.

Local epidermal thickening with increased prominence of the

Fig. 1. Vaginal smear from ovariectomized, estrogen-treated rat after 6 daily topical applications of sesame oil control vehicle. Note large number of anucleate keratinized placques. Wright's stain, ×67 (Kahn and Bern, 1950; reprinted by permission).

Fig. 2. Vaginal smear from ovariectomized, estrogen-treated rat after 6 daily topical applications of 1500 units vitamin A per day in sesame oil. Note preponderance of nucleated spheroidal epithelial cells; cf. Fig. 1. Wright's stain, ×67 (Kahn and Bern, 1960; reprinted by permission).

Fig. 3. Vaginal epithelium from ovariectomized, estrogen-treated rat after 6 daily topical applications of sesame oil control vehicle. Note typically keratinized epithelium, presence of stratum granulosum. Hematoxylin-eosin, × approx. 150 (from R. H. Kahn, unpublished).

Fig. 4. Vaginal epithelium from ovariectomized, estrogen-treated rat after 6 daily topical applications of 1500 units vitamin A per day in sesame oil. Note absence of stratum corneum and stratum granulosum; cf. Fig. 3. Hematoxylin-eosin, × approx. 150 (from R. H. Kahn, unpublished).

Fig. 5. Rat epidermis after topical treatment with sesame oil control vehicle for 10 days. Hematoxylin-eosin, ×360 (Sabella *et al.*, 1951; reprinted by permission).

Fig. 6. Rat epidermis after topical treatment with vitamin A (3700 units/day) in sesame oil for 10 days. Note epidermal thickening, prominence of stratum granulosum; cf. Fig. 5. Hematoxylin-eosin, ×360 (Sabella *et al.*, 1951; reprinted by permission).

Fig. 7. Mouse epidermis after topical treatment with dilute Aquasol control vehicle for 10 days. Hematoxylin-eosin, ×725 (Lawrence and Bern, 1958; reprinted by permission).

Fig. 8. Mouse epidermis after topical treatment with vitamin A (100 units/day) in dilute Aquasol vehicle for 10 days. Note epidermal thickening, prominence of stratum granulosum; cf. Fig. 7. Hematoxylin-eosin, ×725 (Lawrence and Bern, 1958; reprinted by permission).

stratum granulosum has been reported after local injection of large amounts of vitamin A in the rabbit (Jewell *et al.*, 1957), man (Klauder, 1960), guinea pig and hamster (Gold *et al.*, 1960). However, local intermittent application of vitamin A has been reported to have no effect on the skin of man (Fisher and Herrmann, 1957) nor on the hamster cheek pouch (Gold *et al.*, 1960). In view of the definite effects observed in these same tissues after other means of application of the vitamin (Klauder, 1960; Lawrence *et al.*, 1960), it seems likely that the vehicle and mode of application may be of considerable importance.

The results of Studer and Frey (1952) and of Lawrence and Bern (1958) revealed a significant increase in mitotic index of epidermis under the influence of vitamin A. Furthermore, Sherman (1959) noted an early increase in mitotic index in both normal and A-deficient mouse epidermis, when these tissues are exposed *in vitro* to low levels of vitamin A; higher levels reduce the mitotic activity. The report by Jewell *et al.* (1957), describing epidermal thickening without increase in mitotic activity after a single local injection in the skin of the rabbit, is open to some question since colchicine was not used; the importance of the use of colchicine in mitotic studies of epidermis has been demonstrated by Bullough (1944) and others. Small amounts of vitamin A appear to stimulate cell division in normally keratinizing epidermis both *in vivo* and *in vitro* by a direct effect on the integument, and to a degree roughly proportional to the applied dose. The resulting hyperplasia, probably along with some cell hypertrophy, could account for the overall epidermal thickening (epidermal hypertrophy) observed in many species after repeated local application of the vitamin. When a large increase in mitotic activity is evident, it does not seem necessary to assume any decrease in rate of differentiation to account for epidermal thickening. Nevertheless, such a possible alteration in rate of differentiation may exist, and deserves critical examination, for example, by employing radioisotopes of more-or-less stable chemical constituents of the keratinizing cell (Downes and Lyne, 1959).

In a study of the response of guinea pig nipple epidermis to estrogen and to vitamin A, Bern *et al.* (1955a) observed a nearly

uniform response by epidermis from all regions of that area to vitamin A application. Estrogen, however, produced a marked response at the nipple, a reduced response in the areola, and no response in the circumareolar epidermis. With both agents, the response was one of epidermal thickening with increased prominence of the stratum granulosum. Estrogen, however, exhibited a degree of "organ specificity" not apparent with vitamin A. The vitamin apparently has a much more generalized influence on epithelia.

Perhaps the most striking effects of vitamin A have been demonstrated *in vitro* by Fell (Fell and Mellanby, 1953; Fell, 1957). Organ cultures of embryonic chick skin keratinize normally, but precociously, *in vitro*, the addition of high vitamin A to the medium produced a dramatic mucous metaplasia of the normally keratinizing ectoderm. Metaplastic cells are columnar, pseudostratified, and (under certain culture conditions) ciliated, and often contain intracellular periodic acid-Schiff (PAS)-positive, diastase-resistant material interpreted as mucin. After withdrawal of the vitamin A stimulus, the ectoderm reverts to normal keratinization: no new mucous cells are produced, and those mucous cells already present first appear to undergo a burst of synthetic activity, then later degenerate.

Organ and cell cultures of the adult skin of man and rat are maintained better in the presence of high vitamin A than in its absence (Szabó, 1959). Although atypical basal cells may appear in the presence of large amounts of the vitamin, no definite mucous metaplasia has yet been observed. Weiss and James (1955) reported that dissociated chick embryo skin exposed briefly *in vitro* to vitamin A, became reconstituted to form an epithelium no longer completely keratinizing, but with areas of secretory cells similar to those observed by Fell. Such cells seemed to persist after withdrawal of the high vitamin A stimulus, and consequently this process was termed an "induction," in the terms proposed by Weiss (1949).

The hamster cheek pouch is the first adult tissue reported to undergo [illegible] mucous metaplasia *in vivo* in response to vitamin A (Lawrence [illegible] 1960; Lawrence and Bern, 1960). In the golden

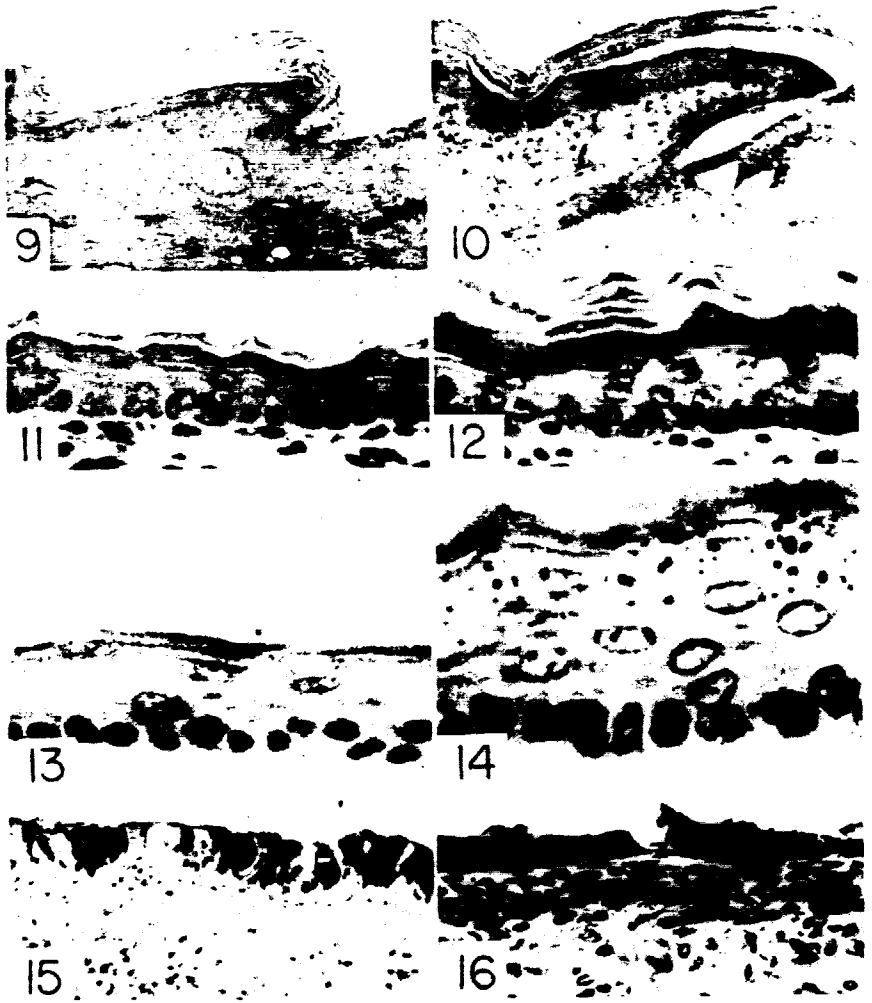

Figs. 9–16. The figures on the left represent various epithelia treated with control substances. The figures on the right represent corresponding epithelia after treatment with vitamin A.

Fig. 9. Mouse tail epidermis after topical application of dilute Aquasol control vehicle for 10 days. Note scales of harder keratin separated by regions of softer keratin. Hematoxylin-eosin, ×100 (Lawrence and Bern, 1958; reprinted by permission).

Fig. 10. Mouse tail epidermis after topical application of vitamin A (100 units/day) in dilute Aquasol vehicle for 10 days. Note lack of harder variety of keratin and continuity of stratum granulosum-containing keratinizing epithelium ("soft"); cf. Fig. 9. Hematoxylin-eosin, ×100 (Lawrence and Bern, 1958; reprinted by permission).

hamster, cheek pouch epithelium bears a strong resemblance to normal interfollicular epidermis except that it occasionally contains glycogen normally, and has no adnexae such as hair follicles, "rete pegs," or glands. Its lack of adnexae makes it an ideal test organ for studies of keratinization. Vitamin A, when applied in a paraffin pellet maintained in place continuously for several days, produced a variety of changes, depending on the amount of vitamin in the pellet. At lower dose levels, epithelial thickening and increased prominence of the stratum granulosum occurred (Fig. 14) in a manner identical with that previously observed in the epidermis of many species, and in degree roughly proportional to the applied dose level. At these lower dose levels, there were no clear-cut effects upon the stratum corneum except for a proportional increase in thickness. Intermediate dose levels produced a parakeratosis (i.e., stratified polyhedral cells containing nuclear remnants), as well as atypical cells in the lower layers similar to those reported after exposure of epidermis *in vitro* to high vitamin A (Szabó, 1959); keratohyalin granules also were present. No hyperplastic response was seen in cheek pouches exposed to paraffin pellets without the vitamin (Fig. 13).

Fig. 11. Epidermis from 12-day-old chicken after topical application of dilute Aquasol control vehicle for 10 days. Hematoxylin-eosin, ×525.

Fig. 12. Epidermis from 12-day-old chicken after topical application of vitamin A (100 units day) in dilute Aquasol vehicle for 10 days. Note epidermal thickening and increased prominence of stratum granulosum, cf. Fig. 11. Hematoxylin-eosin, ×525.

Fig. 13. Epithelium from cheek pouch of golden hamster after treatment for 10 days with control paraffin pellet. Hematoxylin-eosin, ×65[illegible] (Lawrence *et al.*, 1960; reprinted by permission).

Fig. 14. Epithelium from cheek pouch of golden hamster after treatment for 10 days with vitamin A (10[illegible] units) in paraffin pellet. Note epithelial thickening, prominent keratohyalin granules, stratum corneum, cf. Fig. 13. Hematoxylin-eosin, ×65[illegible] (Lawrence *et al.*, 19[illegible]; reprinted by permission).

Fig. 15. Mucous metaplasia of hamster cheek pouch epithelium after treatment for 20 days with paraffin pellet containing 50,000 units of vitamin A. Note columnar mucous-containing epithelial cells on surface of mucosa, cf. Fig. 13. Hematoxylin-eosin, ×185.

Fig. 16. Epithelium of cheek pouch from golden hamster 10 days after cessation of 15-day treatment with vitamin A. Note suggestion of early degenerative changes in overlying mucous cells and of reformation of squamous epithelium [illegible] Periodic acid-Schiff [illegible] with light hematoxylin [illegible]

High dose levels produced a mucous metaplasia (Fig. 15), apparently identical in every respect to that reported earlier *in vitro* by Fell, except that the cheek pouch epithelium exhibited no cilia. In addition, at some higher dose levels, epithelial downgrowths were observed; these were shown to consist of columns of undifferentiated cells (as well as some folds). These downgrowths occasionally included cystic structures. In regions where mucous metaplasia was evident in the surface epithelium, the cysts were lined by mucous cells; where the surface epithelium was parakeratotic, cysts were less frequent and were lined by a parakeratotic epithelium. These mucous cysts and tubular structures were termed "glands" because of their organized appearance; some communicated with the surface epithelium (Lawrence and Bern, 1960).

In another experiment (Lawrence and Bern, unpublished) the occurrence of mucous metaplasia was verified after treatment of cheek pouches for 15 days with vitamin A pellets; the pellets were then removed. After a subsequent 10-day period without treatment, mucous cells were large and swollen, and were frequent in number and widely distributed (Fig. 16). Often they appeared to be degenerating and occasionally were found to overlie regenerating squamous epithelium. These observations, made on a limited number of animals, appear to coincide with the early stages of reversion to a normally keratinizing epithelium observed by Fell *in vitro* after withdrawal of vitamin A.

Electron micrographs of metaplastic areas from the vitamin A-treated hamster cheek pouch (Fig. 17) reveal cells with a large number of complex cytoplasmic organelles, arranged in a manner suggestive of apical polarity, in contrast to the perinuclear arrangement of mitochondria and Golgi membranes in normally keratinizing cheek pouch cells. In addition, metaplastic cells show undifferentiated osmiophilic bodies similar to those reported by Nilsson (1958). Fingerlike microvilli project into the lumen from the free cell surface of the metaplastic cell. The smaller columnar cells shown in Fig. 17 are assumed to represent an early stage in the differentiation of mucous cells, since they are similar in every respect to the early mucous cells reported by Nilsson (1958) in the hormone-stimulated uterine epithelium.

hamster, cheek pouch epithelium bears a strong resemblance to normal interfollicular epidermis, except that it occasionally contains glycogen normally, and has no adnexae such as hair follicles, "rete pegs," or glands. Its lack of adnexae makes it an ideal test organ for studies of keratinization. Vitamin A, when applied in a paraffin pellet maintained in place continuously for several days, produced a variety of changes, depending on the amount of vitamin in the pellet. At lower dose levels, epithelial thickening and increased prominence of the stratum granulosum occurred (Fig. 14), in a manner identical with that previously observed in the epidermis of many species, and in degree roughly proportional to the applied dose level. At these lower dose levels, there were no clear-cut effects upon the stratum corneum except for a proportional increase in thickness. Intermediate dose levels produced a parakeratosis (i.e., stratified polyhedral cells containing nuclear remnants), as well as atypical cells in the lower layers similar to those reported after exposure of epidermis *in vitro* to high vitamin A (Szabó, 1959); keratohyalin granules also were present. No hyperplastic response was seen in cheek pouches exposed to paraffin pellets without the vitamin (Fig. 13).

Fig. 11. Epidermis from 12-day-old chicken after topical application of dilute Aquasol control vehicle for 10 days. Hematoxylin-eosin, ×525.

Fig. 12. Epidermis from 12-day-old chicken after topical application of vitamin A (100 units/day) in dilute Aquasol vehicle for 10 days. Note epidermal thickening and increased prominence of stratum granulosum; cf. Fig. 11. Hematoxylin-eosin, ×525.

Fig. 13. Epithelium from cheek pouch of golden hamster after treatment for 10 days with control paraffin pellet. Hematoxylin-eosin, ×650 (Lawrence *et al.*, 1960; reprinted by permission).

Fig. 14. Epithelium from cheek pouch of golden hamster after treatment for 10 days with vitamin A (100 units) in paraffin pellet. Note epithelial thickening, prominent keratohyalin granules, stratum corneum; cf. Fig. 13. Hematoxylin-eosin, ×650 (Lawrence *et al.*, 1960; reprinted by permission).

Fig. 15. Mucous metaplasia of hamster cheek pouch epithelium after treatment for 20 days with paraffin pellet containing 50,000 units of vitamin A. Note columnar, mucus-containing epithelial cells on surface of mucosa; cf. Fig. 13. Hematoxylin-eosin, ×185.

Fig. 16. Epithelium of cheek pouch from golden hamster 10 days after cessation of 15-day treatment with vitamin A. Note suggestion of early degenerative changes in overlying mucous cells and of reformation of squamous epithelium beneath mucous cells. Periodic acid-Schiff technique with light hematoxylin stain, ×260.

High dose levels produced a mucous metaplasia (Fig. 15), apparently identical in every respect to that reported earlier *in vitro* by Fell, except that the cheek pouch epithelium exhibited no cilia. In addition, at some higher dose levels, epithelial downgrowths were observed; these were shown to consist of columns of undifferentiated cells (as well as some folds). These downgrowths occasionally included cystic structures. In regions where mucous metaplasia was evident in the surface epithelium, the cysts were lined by mucous cells; where the surface epithelium was parakeratotic, cysts were less frequent and were lined by a parakeratotic epithelium. These mucous cysts and tubular structures were termed "glands" because of their organized appearance; some communicated with the surface epithelium (Lawrence and Bern, 1960).

In another experiment (Lawrence and Bern, unpublished) the occurrence of mucous metaplasia was verified after treatment of cheek pouches for 15 days with vitamin A pellets; the pellets were then removed. After a subsequent 10-day period without treatment, mucous cells were large and swollen, and were frequent in number and widely distributed (Fig. 16). Often they appeared to be degenerating and occasionally were found to overlie regenerating squamous epithelium. These observations, made on a limited number of animals, appear to coincide with the early stages of reversion to a normally keratinizing epithelium observed by Fell *in vitro* after withdrawal of vitamin A.

Electron micrographs of metaplastic areas from the vitamin A-treated hamster cheek pouch (Fig. 17) reveal cells with a large number of complex cytoplasmic organelles, arranged in a manner suggestive of apical polarity, in contrast to the perinuclear arrangement of mitochondria and Golgi membranes in normally keratinizing cheek pouch cells. In addition, metaplastic cells show undifferentiated osmiophilic bodies similar to those reported by Nilsson (1958). Fingerlike microvilli project into the lumen from the free cell surface of the metaplastic cell. The smaller columnar cells shown in Fig. 17 are assumed to represent an early stage in the differentiation of mucous cells, since they are similar in every respect to the early mucous cells reported by Nilsson (1958) in the hormone-stimulated uterine epithelium.

With the production of mucous metaplasia in the adult hamster cheek pouch *in situ* by vitamin A, it now appears certain that the original observations of the vitamin A-produced metaplasia *in vitro* by Fell and by Weiss and James were not indicative of a specialized property of embryonic tissue only nor a consequence of special *in vitro* conditions. Rather, the ability to undergo mucous metaplasia in response to vitamin A appears to be a fundamental property of keratinizing epithelia generally. The two instances of mucous metaplasia observed to date seem unlikely to result from an ingrowth of normal mucous cells from a nearby source; in the *in vitro* systems no such source is known to be present, and in the hamster cheek pouch the nearest source is located at some distance. Furthermore, in the cheek pouch, mucous cells are found in a number of apparently separate metaplastic foci.

The striking alterations in the cell surface structure and in the number and distribution of cytoplasmic organelles seen in electron micrographs of metaplastic epithelium suggest a profound alteration in the synthetic processes of the metaplastic cell compared with the normally keratinizing cell. Several such biochemical alterations have been documented by *in vitro* studies with chick ectoderm by Fell *et al.* (1954) and Pelc and Fell (1960): initially, the rapid uptake of S^{35}-cyst(e)ine seen in normally keratinizing ectoderm is depressed by vitamin A treatment; somewhat later, the uptake of S^{35}-sulfate is increased markedly. Such observations are profoundly significant (Fig. 18) in view of the known importance of cyst(e)ine in normal keratinization (Bern, 1954; Bern *et al.*, 1955b; Harkness and Bern, 1957; Ryder, 1958; Rogers, 1959) and of sulfate in mucus synthesis (cf. Fell *et al.*, 1954).

The mechanism and site of action of vitamin A on epithelia remain unknown. The point of action appears to be within the epithelial tissue, upon the basal epithelial cell; however, an effect could be mediated by immediately adjacent stroma. Tissue culture studies involving epithelial cells without stroma, or studies employing separated and recombined epithelium-stroma combinations (cf. Billingham *et al.*, 1951; Grobstein, 1956; Orr, 1958), may answer this question. The mechanism of action on epithelia, at the biochemical level, may involve some alteration of copper-catalyzed enzymes

Fig. 17. Electron micrograph of metaplastic hamster cheek pouch lining. Note columnar epithelial cells, polarization of cytoplasmic organelles toward luminal surface, mv, microvilli; ob, osmiophilic bodies; n, nucleus; m, mitochondria. × 6000.

(Marston, 1952; Balakhovsky and Drozdova, 1957; Burley *et al.*, 1959), perhaps located in mitochondria (Sheldon and Zetterqvist, 1956), or a relationship to SH-groups and a protein moiety as demonstrated in the retina by Wald and Brown (1952).

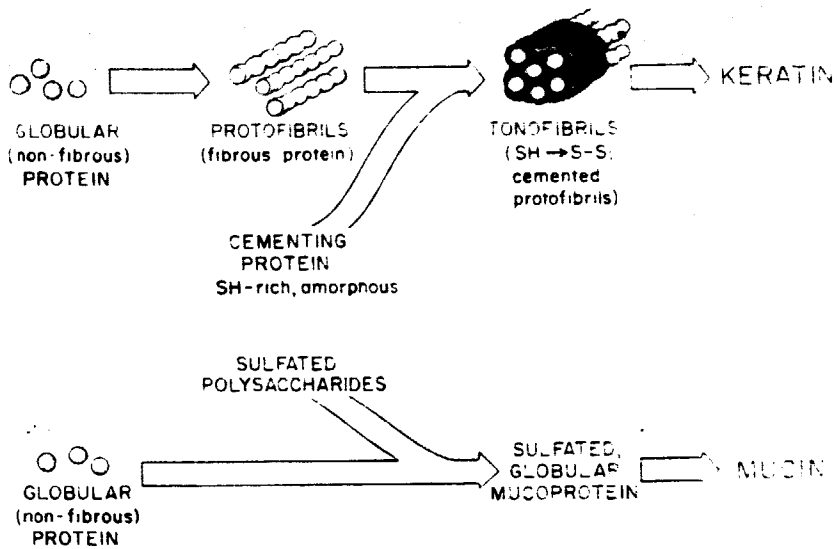

Fig. 18. Molecular aspects of epithelial metaplasia. Schematic representation of proposed mechanisms of major synthetic patterns in keratinization (above) and mucification (below). Based on the "two-component" hypothesis of keratin formation, as derived in part from the data of Rogers, Birbeck and Mercer, Ryder, Pelc and Fell, Bern and Harkness.

The current body of experimental evidence provides some rationale for the use of vitamin A therapy (Mulay and Urbach, 1958; Zegarelli *et al.*, 1959) in the treatment of leukoplakia, the keratinizing metaplasia of human mucous epithelium. Whether the epithelium of man is capable of expressing its presumed potential of mucous transformation, or even of a real inhibition of keratinization (by becoming parakeratotic) as a response to vitamin A, may depend on the employment of a suitable vehicle and mode of application. Adequate demonstration of any such effect must involve careful control for regional variations in keratinization within the oral cavity (cf. Weinmann and Meyer, 1959) as well as for the effects of the vehicle employed.

At dose levels below those which produce metaplasia, effects on the hamster cheek pouch were observed which are identical with those seen in the epidermis and oral epithelium of several mammalian and avian species. From these observations on the cheek pouch one can postulate a series of responses of keratinizing epithelia to excess vitamin A, depending on the dose level employed. At lower dose levels, hypertrophy is predominant, evidently as a result of increased mitotic rate. At moderate dose levels, parakeratosis is the major response; a marked change in differentiation now predominates over mitotic rate increase. At higher dose levels, mucous metaplasia ensues; accompanying this are changes in growth pattern of the epithelium, producing downgrowths, cysts, and gland-like structures. At still higher dose levels, death of the epithelium (Lawrence *et al.*, 1960) occurs.

Summary

The current body of experimental literature concerning the effects of excess vitamin A on keratinization is reviewed. It is concluded that the effect of excess vitamin A on keratinizing epithelia varies considerably with the dose level applied. At low dose levels, hyperplasia occurs. Intermediate dose levels result in a parakeratosis. High dose levels result in a mucous metaplasia, apparently reversible in time by removing the vitamin A stimulus. Massive dose levels produce death of the epithelium. There is evidence that these responses are generalized and may apply to all keratinizing epithelia.

Acknowledgments. We are indebted to Richard Nishioka for preparation of the electron micrograph reproduced herein and to Victor Duran for the photomicrography.

REFERENCES

Argyris, T. S. 1954. The relationship between the hair growth cycle and the response of mouse skin to x-irradiation. *Am. J. Anat.*, *94*: 439–471.

Argyris, T. S., and Bell, E. 1959. The physiologic activity of the skin and its response to ultrasound. *Anat. Record*, *134*: 153–169.

Balakhovsky, S. D., and Drozdova, N. N. 1957. A contribution to the study of the mechanism of the action of vitamin A (retinol). The

copper-polyene antagonism and keratinization of epithelial tissue. *J. Biochem. U.S.S.R.*, *22*: 330–335.

Bern, H. A. 1954. Histology and chemistry of keratin formation. *Nature*, *174*: 509–511.

Bern, H. A., Ancel, M., and Bladines, M. 1957. Cytochemical studies of keratin formation and of epithelial metaplasia in the rodent vagina and prostate. *J. Histochem. and Cytochem.*, *5*: 105–119.

Bern, H. A., Elias, J. J., Pickett, E. E., Powers, T. R., and Harkness, M. N. 1955a. The influence of vitamin A on the epidermis. *Am. J. Anat.*, *96*: 419–445.

Bern, H. A., Harkness, M. N., Elias, J. J., and Blackburn, M. 1955b. Radioautographic studies of keratinization. *Proc. Natl. Acad. Sci. U.S.*, *41*: 55–60.

Billingham, R. E., Orr, J. W., and Woodhouse, D. L. 1951. Transplantation of skin components during chemical carcinogenesis with 20-methylcholanthrene. *Brit. J. Cancer*, *5*: 417–432.

Bullough, H. F. 1944. Cyclical changes in the skin of the mouse during the oestrus cycle. *J. Endocrinol.*, *3*: 280–287.

Burley, R. W., and Hordern, E. W. A. 1959. Experiments on wool from copper-deficient sheep. *Nature*, *184*, suppl. *22*: 1725–1726.

Chase, H. B., and Montagna, W. 1951. Relation of hair proliferation to damage induced in the mouse skin. *Proc. Soc. Exptl. Biol. Med.*, *79*: 35–37.

Chase, H. B., Montagna, W., and Malone, J. D. 1953. Changes in the skin in relation to the hair growth cycle. *Anat. Record*, *116*: 75–92.

Domagk, G., and von Deshowitz, P. 1938. Ueber histologische Befunde bei der Ueberdosierung mit Vitamin a-Konzentrat. *Arch. pathol. Anat. u. Physiol. Virchows*, *299*: 385–395.

Downes, A. M., and Lyne, A. G. 1959. Measurement of the rate of growth of wool using cystine labelled with sulphur-35. *Nature*, *184*: 1834–1837.

Evans, H. M., and Bishop, K. S. 1922. On an invariable and characteristic disturbance of reproductive function in animals reared on a diet poor in fat soluble vitamin. *A. Anat. Record*, *23*: 17.

Fell, H. B. 1957. The effect of excess vitamin A on cultures of embryonic chicken skin explants at different stages of differentiation. *Proc. Roy. Soc. London, B*, *148*: 242–258.

Fell, H. B., and Mellanby, E. 1953. Metaplasia produced in cultures of chick ectoderm by high vitamin A. *J. Physiol. London*, *119*: 470–488.

Fell, H. B., Mellanby, E., and Pelc, S. R. 1954. Influence of excess vitamin A on the sulphate metabolism of chick ectoderm grown *in vitro*. *Brit. Med. J.*, *2*: 611.

Fischer, E., and Herrmann, F. 1957. Some effects of topical vitamin A upon human epidermis. *Arch. Dermatol.*, *75*: 667–675.

Gold, L., Morris, A. L., and Seligman, H. G. 1960. Skin and oral mucosal response to single vitamin A injection. *J. Dental Research*, *39*: 663.

Grobstein, C. 1956. Inductive tissue interaction in development. *Advances in Cancer Research*, *4*: 187–236.

Harkness, D. R., and Bern, H. A. 1957. Radioautographic studies of hair growth in the mouse. *Acta Anat.*, *31*: 35–45.

Hohlweg, W. 1951. Über die Hemmung der Oestrusreaktion durch Vitamin A-Überdosierung. *Klin. Wochschr.*, *29*: 193–195.

Hohlweg, W. 1952. Die Testierung von Vitamin A-Präparaten mit Hilfe der Antioestrusreaktion. *Pharmazie*, *5*: 280–284.

Jewell, H. A., Taube, H., Nicholls, M. E., and Lehman, R. A. 1957. Action of vitamin A on the skin following intracutaneous injection. *Proc. Soc. Exptl. Biol. Med.*, *96*: 162–165.

Kahn, R. H. 1954a. Effect of locally applied vitamin A and estrogen on the rat vagina. *Am. J. Anat.*, *95*: 309–335.

Kahn, R. H. 1954b. Effect of oestrogen and vitamin A on vaginal keratinization in tissue culture. *Nature*, *174*: 317.

Kahn, R. H. 1959. Vaginal keratinization *in vitro*. *Ann. N.Y. Acad. Sci.*, *83*: 347–355.

Kahn, R. H., and Bern, H. A. 1950. Antifolliculoid activity of vitamin A. *Science*, *111*: 516–517.

Klauder, J. V. 1960. Treatment of some dermatoses by local injection of vitamin A. *Arch. Dermatol.*, *81*: 253–259.

Lawrence, D. J., and Bern, H. A. 1958. On the specificity of the response of mouse epidermis to vitamin A. *J. Invest. Dermatol.*, *31*: 313–325.

Lawrence, D. J., and Bern, H. A. 1960. Mucous metaplasia and mucous gland formation in keratinized adult epithelium *in situ* treated with vitamin A. *Exptl. Cell Research*, *21*: 443–446.

Lawrence, D. J., Bern, H. A., and Steadman, M. G. 1960. Vitamin A and keratinization. Studies on the hamster cheekpouch. *Ann. Otol. Rhinol. & Laryngol.*, *69*: 645–661.

Marston, H. R. 1952. Cobalt, copper, and molybdenum in the nutrition of animals and plants. *Physiol. Revs.*, *32*: 66–121.

Montagna, W. 1954. Penetration and local effect of vitamin A on the skin of the guinea pig. *Proc. Soc. Exptl. Biol. Med.*, *86*: 668–672.

Moore, T. 1957. *Vitamin A*. Elsevier, Amsterdam.

Mori, S. 1922. Primary changes in eyes of rats which result from deficiency of fat soluble A in diet. *J. Am. Med. Assoc.*, *79*: 197–200.

Mulay, D. N., and Urbach, F. 1958. Local therapy of oral leukoplakia with vitamin A. *Arch. Dermatol.*, *78*: 637–638.

Nilsson, O. 1958. Ultrastructure of mouse uterine surface epithelium under different estrogenic influences. II. Early effect of estrogen administered to spayed rats. *J. Ultrastructure Research*, *2*: 73–95.

O[illegible], J. W. 1955. The mechanism of chemical carcinogenesis. *Brit. Med. Bull.*, 11: 9[illegible]-10[illegible].

Pe[illegible], S. E., and Fell, H. B. 1960. The effect of excess vitamin A on the uptake of labelled compounds by embryonic skin in organ cultures. *Expl. Cell Research*, 19: 99–115.

Rogers, G. E. 1959. Electron microscope studies of hair and wool. *Ann. N.Y. Acad. Sci.*, 83: 379–399.

Ryder, M. L. 1958. Nutritional factors influencing hair and wool growth. *The Biology of Hair Growth*, W. Montagna and R. A. Ellis, Editors. Academic Press, New York. Pp. 363–385.

Sabelli, J. D., Bern, H. A., and Ka[illegible], F. 1957. Effect of locally applied vitamin A and estrogen on rat epidermis. *Proc. Soc. Expl. Biol. Med.*, 76: 443–505.

Setälä, K. 1960. Progress in carcinogenesis. Tumor-enhancing factors. A bioassay of skin tumor formation. *Progr. Exp. Tumor Research*, 1: 225–278.

Setälä, K., Moreno[illegible], E., Stjernvall, L., and Nyhol[illegible], M. 1960. Mechanisms of experimental tumorigenesis. IV. Ultrastructure of interfollicular epidermis in normal adult mouse. *J. Nat. Cancer Inst.*, 25: 329–354.

Sheldon, H., and Zetterqvist, H. 1959. Experimental vitamin A changes in mitochondrial morphology. Vitamin A deficiency. *Expl. Cell Research*, 10: 225–228.

Sherman, B. S. 1959. The effect of vitamin A on normal and malignant mitoses in vitro. *Anat. Record*, 133: 429.

Studer, A., and Frey, J. R. 1949. Über Hautveränderungen der Ratte nach grossen oralen Dosen von Vitamin A. *Schweiz. med. Wochenschr.*, 79: 382–384.

Studer, A., and Frey, J. R. 1952. Wirkung von Cortison, auf die ruhende und die mit Vitamin A oder Testosteronpropionat zur Proliferation gebrachte Epidermis der Ratte. *Dermatologie*, 104: 1–18.

Szabó, G. 1959. Effect of vitamin A on tumors [illegible] vitro. *Excerpta Med. Sect. I*, 13: 211–212.

Wahl, G., and Brown, J. K. 1952. The [illegible] growth [illegible] the bleaching and synthesis of melanin [illegible]. *Cancer Research*, 12: 787–82[illegible].

Weinman, J. P., and Meyer, J. 1951. [illegible] of keratinization in the human gingiva. *Proc. Dermat. [illegible]*: 56–[illegible].

Weiss, E. 1941. The [illegible] in epidermal differentiation. *Proc. 1st Natl. Cancer Conf.*: Pp. 56–65.

Weiss, P., and James, E. 1955. Skin metaplasia induced by brief exposure to vitamin A. *Expl. Cell Research*, [illegible]: 384–394.

Wo[illegible], E., and Bess[illegible], O. A. 1942. Tissue changes in vitamin deficiencies. *Physiol. Rev.*, 22: 233–284.

Zegarelli, E. V., Kutscher, A. H., and Silvers, H. F. 1959. Keratotic lesions of the oral mucous membranes. Treatment with high dosage topical-systematic vitamin A. *N.Y. State Dental J.*, 25: 244–252.

Ziskin, D. E., Rosenstein, S. N., and Drucker, L. 1943. Interrelation of large parenteral doses of estrogen and vitamin A and their effect on the oral mucosa. *Am. J. Orthodontics Oral Surg.*, 29: 163–177.

Bernard-'68
Bib. No. 774

J. Gen. Physiol. 52(3):444-464. 1968

Taste Changes in Vitamin A Deficiency

RUDY A. BERNARD and BRUCE P. HALPERN

From The Rockefeller University, New York 10021 and the Department of Physiology and Section of Neurobiology and Behavior, Cornell University, Ithaca, New York 14850

ABSTRACT Taste preferences were studied in two groups of rats depleted of vitamin A by dietary restriction. One group received sufficient vitamin A acid supplement to maintain normal growth. The other group was repleted with vitamin A alcohol after the classical deficiency symptoms had appeared; this group gradually lost normal preferences for NaCl and aversion to quinine solutions during depletion. Vitamin A alcohol repletion tended to restore taste preferences to normal. In contrast, the group receiving vitamin A acid showed normal taste preferences throughout the depletion period. When the vitamin A acid supplement was removed taste preferences became abnormal and returned to normal when vitamin A acid was restored. Peripheral gustatory neural activity of depleted rats without any form of vitamin A was less than normal both at rest and when the tongue was stimulated with NaCl solutions. Histological examination showed keratin infiltrating the pores of the taste buds. Accessory glandular tissues were atrophied and debris filled the trenches of the papillae. It is concluded that vitamin A acid can provide the vitamin A required for normal taste, as contrasted with its inability to maintain visual function. It is suggested that the effect of vitamin A is exerted at the receptor level, as a result of its role in the biosynthesis of mucopolysaccharides, which have been recently identified in the pore area of taste buds, as well as being present in the various secretions of the oral cavity.

INTRODUCTION

Vitamin A depletion, in addition to the classically described symptoms, is accompanied by a gradual loss of normal taste preferences in rats. Repletion with vitamin A tends to restore normal taste preferences. The tongue shows increased keratinization of the lingual papillae including the pore area of the taste buds, adjacent epithelial and glandular tissues (Bernard, Halpern, and Kare, 1961, 1962).

Vitamin A acid can maintain normal growth and survival in vitamin A-deficient rats, but does not prevent the night blindness characteristic of vitamin A deficiency (Dowling and Wald, 1960). The visual effects, preceded by the depletion of liver and blood stores of vitamin A (alcohol and esters),

are accompanied by a decrease of the rhodopsin and finally of the opsin content of the retina. These biochemical changes are similar to those of classical vitamin A deficiency (Dowling and Wald, 1958). Histological study of the retina, however, showed that the structural changes were restricted to the visual cells. Vitamin A acid is not stored and its removal from the diet leads to an immediate interruption of growth and rapid appearance of the classical epithelial symptoms. The role of vitamin A in vision, filled by the alcohol form of vitamin A, can thus be dissociated from its more widespread role in other bodily tissues, which could be filled by vitamin A acid or alcohol.

The experiments reported here were undertaken to discover whether taste was comparable to vision in the requirement for vitamin A alcohol. Duncan (1964) reported that vitamin A acid maintained normal taste preferences in rats, and suggested that the taste loss in vitamin A deficiency was probably of central origin, associated with general debility. He made no direct test of the locus of the deficit.

The present study employed electrophysiological recordings of chorda tympani nerve activity and histological examination of the tongue in addition to preference tests of gustatory function, to assess the involvement of peripheral taste mechanisms in the behavioral deficits. Since vitamin A acid is not stored, it was possible to examine rapid onset of vitamin A deficiency in rats raised to adults on vitamin A acid.

METHODS AND PROCEDURE

Male CFN albino rats were started on the experiments as weanlings, with an average weight of 46 g. Standard vitamin A test diet (General Biochemicals, Chagrin Falls, Ohio), supplied with 100 mg chlortetracycline (Aureomycin)/kg, was fed to all the rats. Two experimental groups were employed, consisting of (*a*) a vitamin A-deficient group, which received only the test diet, unless otherwise noted, and (*b*) a vitamin A acid group, which received the test diet supplemented with 5 mg vitamin A acid/kg (Eastman Organic Chemicals, Rochester, N. Y.), unless otherwise noted. The controls were (*a*) a normal taste control group, which received the various solutions tested in the experiment, and (*b*) a H_2O–H_2O control group. Both control groups received the test diet supplemented with 2000 IU vitamin A/kg, unless otherwise noted. The diets were available ad libitum. Distilled water was used at all times. Reagent grade NaCl, USP quinine sulfate (QSO_4), sodium saccharin (Na sacch), and technical grade sucrose octa acetate (SOA) were used. The animals were weighed individually at regular intervals.

Preference Tests

The rats were housed in individual cages, fitted with two glass graduated drinking tubes. One contained water, the other, the solution being tested. The intake from each tube was measured once a day to the nearest milliliter and the tubes were washed

and filled with fresh solution every day. The amount of test solution drunk, expressed as a percentage of the total liquid consumed during 24 hr, is referred to as the per cent preference for that solution. In order to minimize the effect of reading error, preference was not calculated unless total intake exceeded 5 ml. The right left position of the tubes was varied once a day according to a restricted random schedule. The restriction ensured that test solutions would not appear more than twice in succession in the same position and that they would appear equally often in each position during a test period. Test period durations were 8 days in experiment I, 2 days in experiment II, and 4 days in experiment III.

PRELIMINARY TESTING During a single 8 day period, 52 rats were presented with 0.05 M and 0.02 M NaCl, and 20 μM and 10 μM QSO_4, each on 2 consecutive days in that order. Only those rats which showed greater than 50% preference for 0.02 M NaCl and less than 25% preference for 10 μM QSO_4 over the 2 days were randomly assigned to the three groups receiving taste solutions. Of the 52 rats tested, 40 met the criterion. 23 rats were assigned to the vitamin A–deficient group, 9 to the vitamin A acid group, and 8 to the normal, taste control group. 8 of the 12 rats that failed to meet the criterion were assigned to the fourth group, which received water in both tubes. This was the H_2O–H_2O control. The remaining four rats were not used. All four groups were tested in experiment I. The H_2O–H_2O control group was eliminated after experiment I. The vitamin A–deficient group was not tested after experiment II. Only the vitamin A acid group and the normal, taste control group were tested in experiment III.

EXPERIMENT I NaCl and QSO_4 solutions were offered during each of 20 consecutive 8 day periods, except for a water-water trial by all groups during the nineteenth period. The first period began at the end of the preliminary test. Each of the two solutions was offered four times per period, twice on each side. The reported preferences are the group means for the 4 days of each 8 day period. For the first four periods, 0.02 M NaCl and 10 μM QSO_4 were offered. During the fifth period the concentration was adjusted to 0.01 M NaCl and 30 μM QSO_4. From the sixth period to the end of the experiment concentration remained unchanged. During period 19 all groups were on a H_2O–H_2O choice.

At the beginning of period 15, seven rats of the vitamin A–deficient group were given orally 5,000-10,000 IU vitamin A alcohol in 0.5-1.0 ml of corn oil, thus forming a vitamin A repletion subgroup. This subgroup thereafter received the same diet as the two control groups. Vitamin A repletion continued through period 20, thus forming phase 2 of experiment I. Periods 1 through 14 form phase 1.

EXPERIMENT II This experiment expressly tested the recovery of the previously vitamin A deficient rats (experiment I) by exposing them to new taste stimuli. The vitamin A repletion subgroup was continued on repletion throughout this experiment. An ascending and then a descending series of concentrations of Na sacch and of SOA were presented for 8 and 10 consecutive 2 day periods, respectively. Each concentration was presented on 2 consecutive days and the preference values are the group means for each 2 day period. Concentrations ranged from 0.1 to 2.0 mM Na sacch

and from 0.01 to 1.0 mM SOA (Fig. 4). Between the Na sacch and the SOA series, all groups were on a H_2O H_2O choice for 12 days.

EXPERIMENT III This experiment tested the effect of removing and subsequently restoring vitamin A acid to the diet. Because of the expected rapidity of body weight changes, QSO_4 and NaCl solutions were studied in two separate phases, in 4 rather than 8 day periods.

Phase 1 Seven of the nine vitamin A acid animals were the experimental group. The other two members of the vitamin A acid group were maintained on vitamin A acid throughout phase 1. The test solution was 5 μM QSO_4. Vitamin A acid was withdrawn at the beginning of period 6, after preferences had stabilized. It was restored at the beginning of period 10, after statistically significant preference changes had occurred. Water was offered on a no choice basis during periods 14 and 15, and the QSO_4 solution was tested again in period 16, which concluded phase 1.

Phase 2 Water was offered on a no choice basis during period 17 and beginning with period 18 the test solution was 0.01 M NaCl. Vitamin A acid was withdrawn during period 24 when preferences were stable and not significantly different from the control. After significant changes had occurred, the rats were studied electrophysiologically and histologically. The two vitamin A acid rats that were not deprived in phase 1 were added to the three survivors of phase 1 to make up the experimental group of phase 2. The preference values are the group means for each 4 day period.

STATISTICAL ANALYSIS The Mann-Whitney U test, single-tailed, was applied to each period of experiments I and III. For experiment II, a two-tailed Mann-Whitney U test was applied to each concentration, while a χ^2 test was used on each full series (Siegel, 1956).

ELECTROPHYSIOLOGY Four vitamin A acid-deprived and three control rats were studied. The fifth deprived rat died upon being anesthetized. The exposure of the chorda tympani nerve and the recording electrodes (Halpern, Bernard, and Kare, 1962) as well as the electrical recording methods (Halpern, 1963) were previously described. At the time of electrophysiological study the four deficient rats had been deprived of vitamin A acid for from 18-24 days.

HISTOLOGY Six rats from the vitamin A-deficient group were taken for histological study, four at the end of period 14 and two at the end of period 17 of experiment I. One rat from the H_2O control group was also taken at the end of period 17 for the same purpose. Five deprived rats of the vitamin A acid group and three rats from the normal group were taken for histological study upon completion of the electrophysiological procedures that followed experiment III.

The animals were sacrificed, and the tongues were immediately removed and fixed in Bouin's fluid or in neutral, buffered formalin. The tongues were embedded in paraffin and serially sectioned at 5 μ in sagittal and coronal planes. Alternate sections were stained with hematoxylin and eosin and with Ladewig stain, which colors keratin a brownish red.

RESULTS

Preference Tests

EXPERIMENT I

Phase I Vitamin A depletion

The normal group consistently rejected 30 μM QSO_4, with preference values below 10%. The vitamin A acid group did not differ significantly from the normal group. (See Table I for these and subsequent *P* values.) The vitamin A-deficient group initially rejected the QSO_4 at the normal level, but gradually decreased its rejection until it reached a 31% preference level during period 14 (Fig. 1 A). Preference values were significantly different from normal group values during periods 13 and 14 and not significantly different from H_2O control group values during period 14.

TABLE I

P VALUES OF EXPERIMENT I, PHASE 1

Test period	Vitamin A deficiency vs taste control		Vitamin A deficiency vs. H_2O control		Vitamin A acid vs. taste control	
	QSO_4	NaCl	QSO_4	NaCl	QSO_4	NaCl
5 through 10*	>0.05‡	>0.05	<0.00005	<0.00007	≫0.05	≫0.05
11	0.088	0.021	<0.0003	<0.0005	≫0.05	≫0.05
12	0.187	0.003	<0.0002	0.038	≫0.05	≫0.05
13	0.018	<0.0003	<0.0001	0.443	≫0.05	≫0.05
14	<0.004	0.0003	≫0.05	0.415	≫0.05	≫0.05

* For QSO_4, period 5 not included.
‡ For period 9, $P = 0.043$.

A similar but mirror-image effect occurred with the NaCl solution (Fig. 1 B). The normal group consistently selected 0.01 M NaCl, with preferences above 82%. The vitamin A acid group did not differ significantly from the normal group. The vitamin A–deficient group initially selected the NaCl at the normal level, but gradually decreased its selection until a 50% level of intake was reached during period 14. Preference values differed significantly from those of the normal group for periods 11 through 14 and did not differ significantly from those of the H_2O control group during periods 13 and 14. The H_2O control group did not deviate significantly from an ideal 50% preference level during the entire experiment ($0.70 < P < 0.80$).

The changes in preference values began while the vitamin A–deficient group was in a plateau of its growth curve (Fig. 2). The first statistically significant preference change occurred during period 11, before the rats had

begun either to lose weight or to show grossly overt deficiency symptoms, viz. xerophthalmia, conjunctivitis, exudates around the eyes, etc. Of the 23 rats in the vitamin A–deficient group which started in experiment I, 4 died in the final periods of depletion and 4 were sacrificed for histological study during period 14.

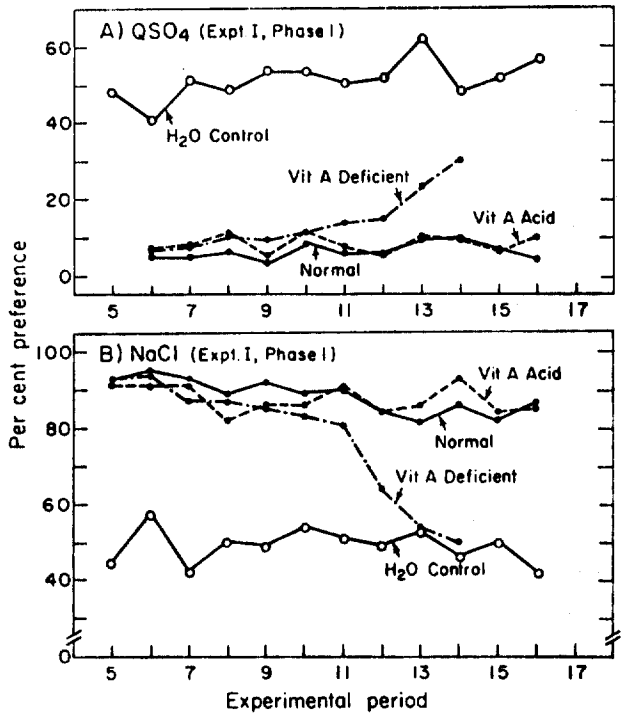

FIGURE 1 A. Preference functions of normal, vitamin A acid, and vitamin A–deficient rats for 30 μM quinine sulfate (QSO_4) solution. Here and in Fig. 3, each point represents the group mean per cent preference (milliliters of test solution drunk divided by milliliters of total liquid consumed, times 100) over 4 randomly alternating days of each 8 day period. (The H_2O control group received a water-water choice.) B. Preference functions of the same rats for 0.01 M NaCl solution.

Phase 2 Vitamin A repletion

Seven of the vitamin A–deficient rats which remained at the end of period 14 became the vitamin A repletion subgroup. One died during period 15, while the others rapidly gained weight and resumed a normal rate of growth (Fig. 2). The behavior of this repleted six rat subgroup during the preceding depletion phase had been similar to that of the whole vitamin A–deficient group. The repleted subgroup's preference values during depletion were excerpted from those of the whole deficient group and replotted for clearer

comparison (Fig. 3 A, B). During the first period of vitamin A repletion (period 15) rejection of the 30 μM QSO_4 solution by the vitamin A repletion subgroup abruptly shifted toward normal levels. Rejection continued to move closer toward normal in subsequent periods (Fig. 3 A). The QSO_4 preference values of the vitamin A–repleted subgroup did not significantly differ from those of the normal group from the first period of repletion onward (Table II).

The preference for 0.01 M NaCl reversed its downward trend in the first period of vitamin A repletion, but never fully returned to the normal level

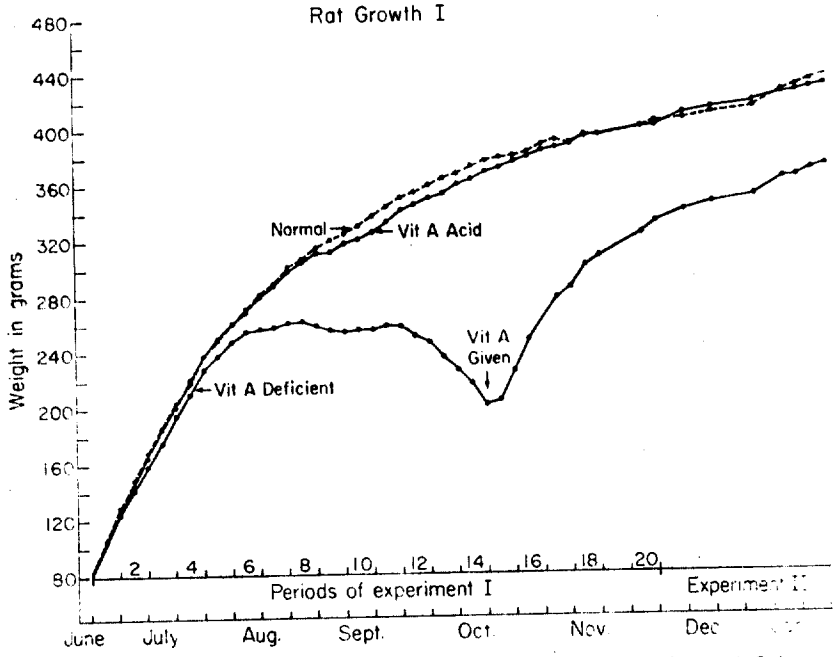

FIGURE 2. Growth curve of normal, vitamin A acid, and vitamin A–deficient rats.

(Fig. 3 B). The repleted subgroup's preference for NaCl was significantly different from the H_2O control levels, except during period 15. The vitamin A acid group remained indistinguishable from the normal group throughout the repletion phase of the experiment.

EXPERIMENT II. The vitamin A–repleted group did not differ significantly from the normal group at any of the concentrations of Na sacch which were tested, nor for the series as a whole (Table III). Preference values ranged from indifference at the lower concentrations to strong selection at the higher (Fig. 4 A). The vitamin A acid rats did not differ from the normal group for the concentration sequence as a whole, but showed a preference for 1.0 mM

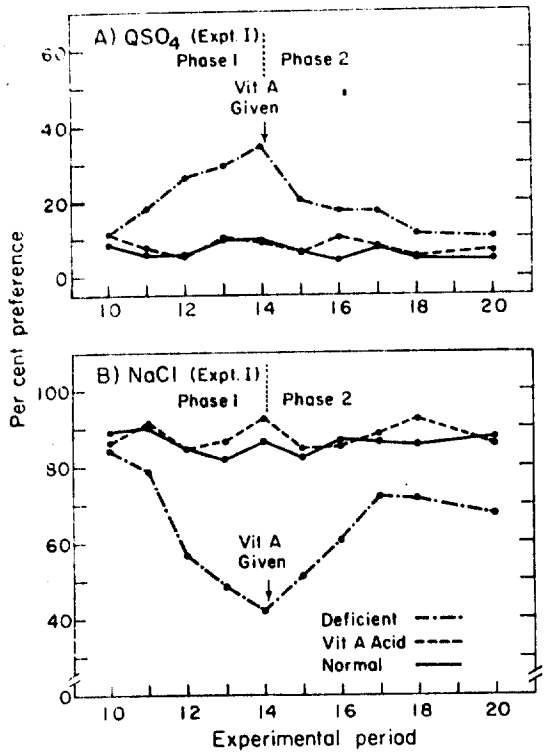

FIGURE 3 A. Preference functions of normal, vitamin A acid, and repleted vitamin A rats, before and after vitamin A repletion, for 30 μM QSO_4 solution. B. Preference functions of the same rats for 0.01 M NaCl.

Na sacch in the ascending concentration sequence that was statistically different from normal.

In the SOA series the vitamin A–repleted group differed significantly from the normal group for the series as a whole and at 0.1 mM in the descending concentration sequence. The preference values for the normal group ranged from weak selection (68%) to moderate rejection (23%) (Fig. 4 B). The repleted group showed no selection (56%) and much stronger rejection. The

TABLE II

P^a VALUES OF EXPERIMENT I, PHASE 2

	Repleted vitamin A vs. taste control		Repleted vitamin A vs. H_2O control		Vitamin A acid vs. taste control	
Test period	QSO_4	NaCl	QSO_4	NaCl	QSO_4	NaCl
15	0.17	0.002	0.004	0.33	$\gg 0.05$	$\gg 0.05$
16	0.33	0.006	0.001	0.015	> 0.05	$\gg 0.05$
17	0.50	0.03	0.001	0.001	$\gg 0.05$	$\gg 0.05$
18	0.48	0.23	0.004	0.004	$\gg 0.05$	$\gg 0.05$
20	0.31	0.02	—	—	$\gg 0.05$	$\gg 0.05$

vitamin A acid group showed stronger selection (83%) than the normal group but similar rejection (25%). The vitamin A acid group did not differ significantly from the normal one at any one concentration but did differ significantly for the SOA series as a whole. The preference values of the vitamin A acid group were almost always higher than those of the normal group. During this SOA series the growth rate of the vitamin A acid group began to taper off (Figs. 2 and 5).

TABLE III

P VALUES OF EXPERIMENT II

	Na sacch, *mM*								
	0.1	0.2	0.5	1.0	2.0	1.0	0.5	0.2	Entire series
Repleted vitamin A vs. taste control	0.34	0.75	0.70	1.0	0.95	0.95	0.34	0.66	>0.80
Vitamin A acid vs. taste control	>0.10	>0.10	>0.10	>0.05	>0.07	>0.10	>0.10	>0.10	>0.10

	SOA, *mM*									
	0.1	0.2	0.5	1.0	0.5	0.2	0.1	0.05	0.02	0.01
Repleted vitamin A vs. taste control	0.57	0.28	0.66	0.09	0.12	0.23	0.01	0.08	0.66	0.20
Vitamin A acid vs. taste control	0.07	>0.10	>0.10	>0.10	>0.10	>0.10	>0.10	>0.52	>0.10	>0.10

EXPERIMENT III. A 3-month period elapsed between the end of experiment II and the beginning of experiment III. During this time the growth rate of the vitamin A acid group markedly decreased. Increased amounts of vitamin A acid supplement did not have any effect. The rats began to lose weight slowly at first and then more rapidly. The downward trend was finally reversed with a fresh supply of vitamin A acid (Fig. 5). After 6 wk of growth at a restored normal rate experiment III was begun.

Phase 1 The vitamin A acid group did not differ significantly from the normal group in rejection of 5 μM QSO_4 solution for any of the first five periods (Table IV, Fig. 6 A). At the beginning of period 6 all but two of the original vitamin A acid group were completely deprived of the vitamin A acid supplement, thus forming a phase 1 vitamin A acid-depleted subgroup

The depleted subgroup's rejection of QSO_4 gradually decreased and became significantly less than normal during period 9. Restoration of vitamin A acid at the beginning of period 10, forming the phase I vitamin A acid repleted group, did not immediately restore rejection of QSO_4 to normal group levels, although the difference from normal was no longer statistically significant. In subsequent periods the rejection values returned to close to normal levels.

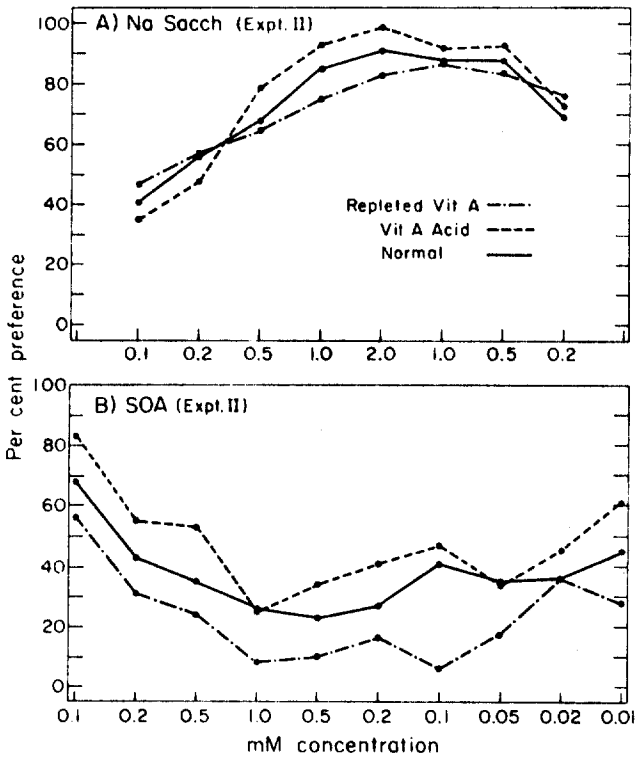

FIGURE 4 A. Preference functions of normal, vitamin A acid, and repleted vitamin A rats for an ascending and descending concentration series of Na saccharin solutions. Each point represents the group mean per cent preference over 2 consecutive days at each concentration. B. Preference functions of the same rats for an ascending and descending concentration series of sucrose octa acetate (SOA) solutions.

The phase I vitamin A acid-depleted group began to lose weight within days of the removal of vitamin A acid. The weight loss was slow at first and en became very rapid (Fig. 5). Restoration of vitamin A acid did not mediately reverse the weight loss, which continued through periods 10 d 11. Four of the seven vitamin A acid-repleted rats did not recover, dying t various times after the restoration of vitamin A acid.

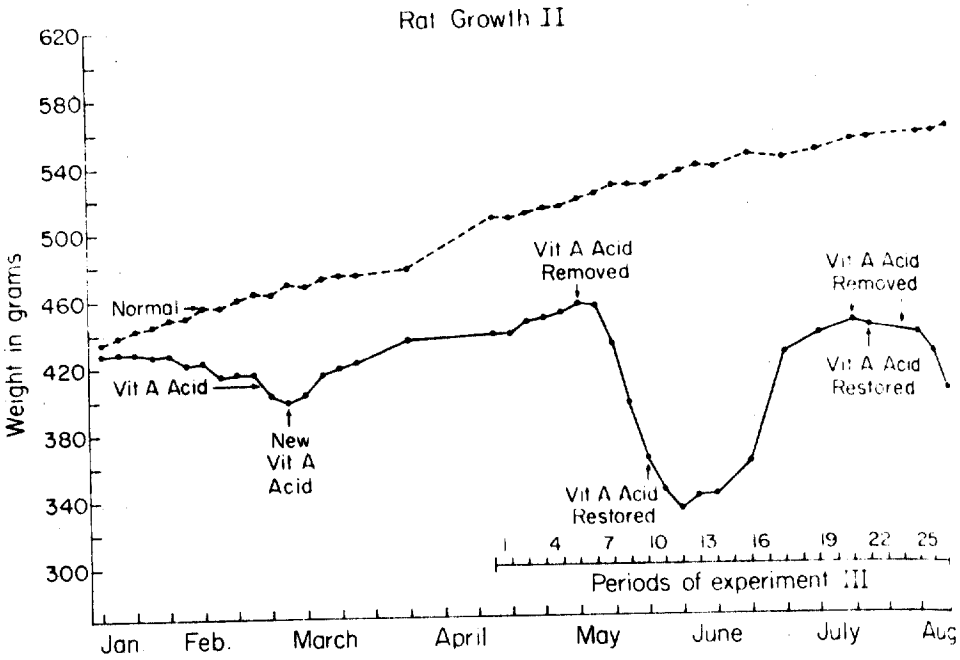

FIGURE 5. Continuation growth curve of normal and vitamin A acid rats.

Phase 2. This sequence was begun with the three surviving members of the phase 1 vitamin A acid repleted subgroup. Vitamin A acid was withdrawn at the beginning of period 21. Because of the small number of rats it was decided to enlarge the phase 2 depleted subgroup by adding the two vitamin A acid group rats that had not been deprived of vitamin A acid in

TABLE IV

P VALUES OF EXPERIMENT III

	Period No., Phase 1 (QSO)										
	1 5	6	7	8	9	10	11	12	13	14 15	16
Vitamin A acid vs. taste control	0.21	0.36	0.36	0.18	0.004	0.46	0.21	0.46	0.21		0.02

	Period No., Phase 2 (NaCl)							
	17	18	19	20	21	22 24	25	26
Vitamin A acid vs. taste control	—	0.12	0.14	0.50	0.46	—	0.27	0.04

phase 1 of experiment III. In order to have all members of the subgroup start from the same base line, testing was interrupted during period 22, before the phase 2 depleted rats had shown any preference changes. All five rats were now given the vitamin A acid diet for 1 wk, during which they were exposed to a 0.01 M NaCl H_2O choice, but no records of consumption were taken.

In calculating the results of phase 2, the data of the three survivors of the phase 1 depletion were pooled with those of the two rats that had not been

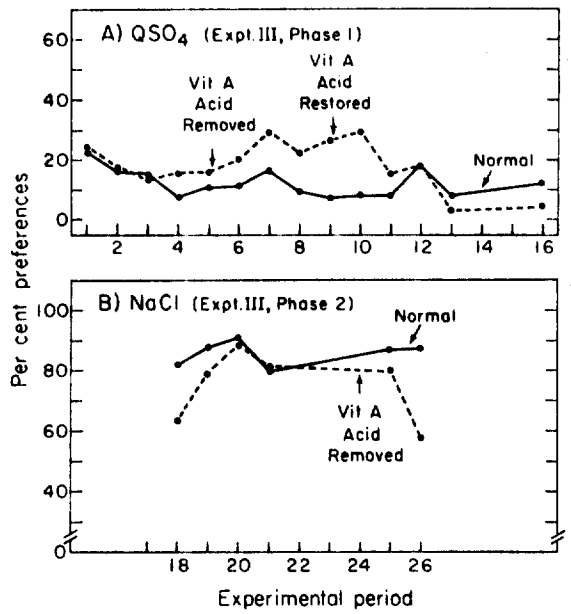

FIGURE 6 A. Preference functions of normal and vitamin A acid rats, before and after the withdrawal and restoration of vitamin A acid, for 5 μM QSO_4 solution. Each point represents the group mean per cent preference over 4 consecutive days of each 4 day period. B. Preference functions of the same rats, before and after a second withdrawal of vitamin A acid, for 0.01 M NaCl solution.

previously deprived of vitamin A acid, forming the phase 2 vitamin A acid group. Two periods were required before the phase 2 vitamin A acid group's preference for 0.01 M NaCl reached the normal group's level (Fig. 6 B), although the difference from normal was not statistically significant (Table IV). The low means of periods 18 and 19 were due primarily to the lower scores of the phase 1 survivors.

Deprivation of vitamin A acid began for all five rats during period 24, thus forming the phase 2 vitamin A acid-depleted group. Preference values were still at the normal level (80%) in period 25, but fell precipitously in period 26 (58%) when the difference from normal was statistically significant.

TABLE V

AMPLITUDE OF ELECTRICAL ACTIVITY OF RAT CHORDA TYMPANI UPON STIMULATION OF THE TONGUE WITH 0.1 M NaCl

Vitamin A status	Initial burst	End of flow
	μv	μv
Normal	49	43
Deficient	24*	17*

* $P < 0.004$, 1-tail (Mann-Whitney U test).

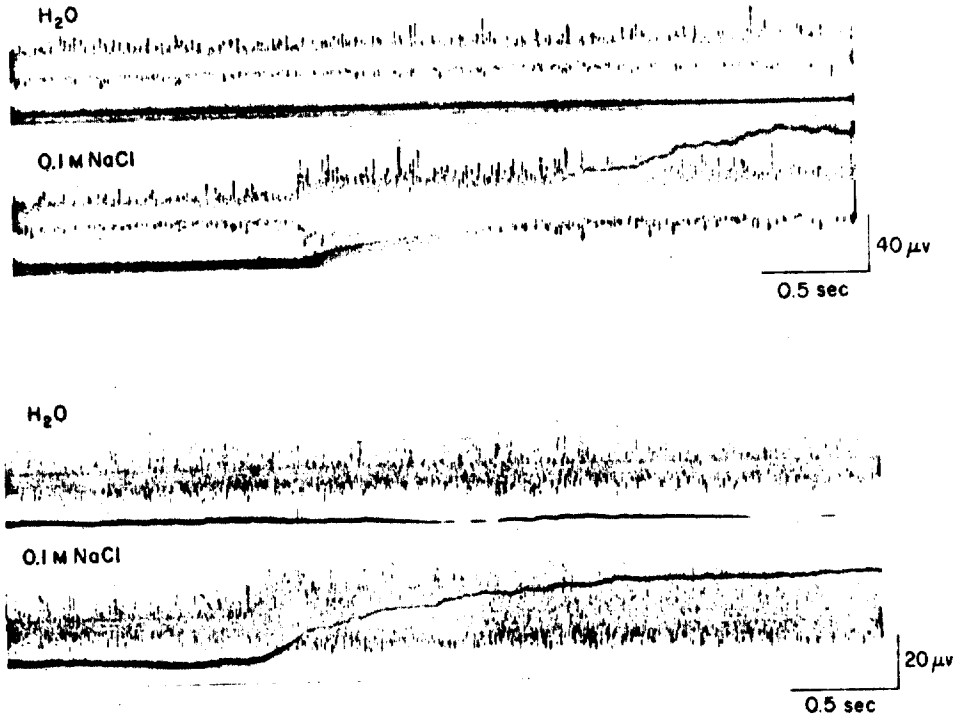

FIGURE 7 A. Oscilloscope records of the electrical activity in the chorda tympani nerve of a normal rat. The spikelike traces are the direct neural responses, the smooth traces are the same responses after passing through an electronic summator. Top records, H_2O flow started at the onset of the trace. A slight decrease in resting activity is seen. Bottom records, 0.1 M NaCl flow started at the onset of the trace. Response occurred as a sudden burst of neural activity. B. Similar records from a vitamin A-deficient rat after withdrawal of vitamin A acid for 23 days. Note that the amplification of the action potentials is two times greater than in A. Top records, H_2O flow started at the onset of the trace. A small decrease in resting activity occurred. Bottom records, 0.1 M NaCl flow started at the onset of the trace. Response amplitude is approximately half that of the control rat.

Weight losses of the phase 2 vitamin A acid–depleted group increased rapidly during this period (Fig. 5). The preference tests were terminated at the end of period 26 and followed by electrophysiological recordings.

Electrophysiology

The apparent absolute magnitude of the electrical activity of the chorda tympani nerve of the deficient rats was consistently less than that of the

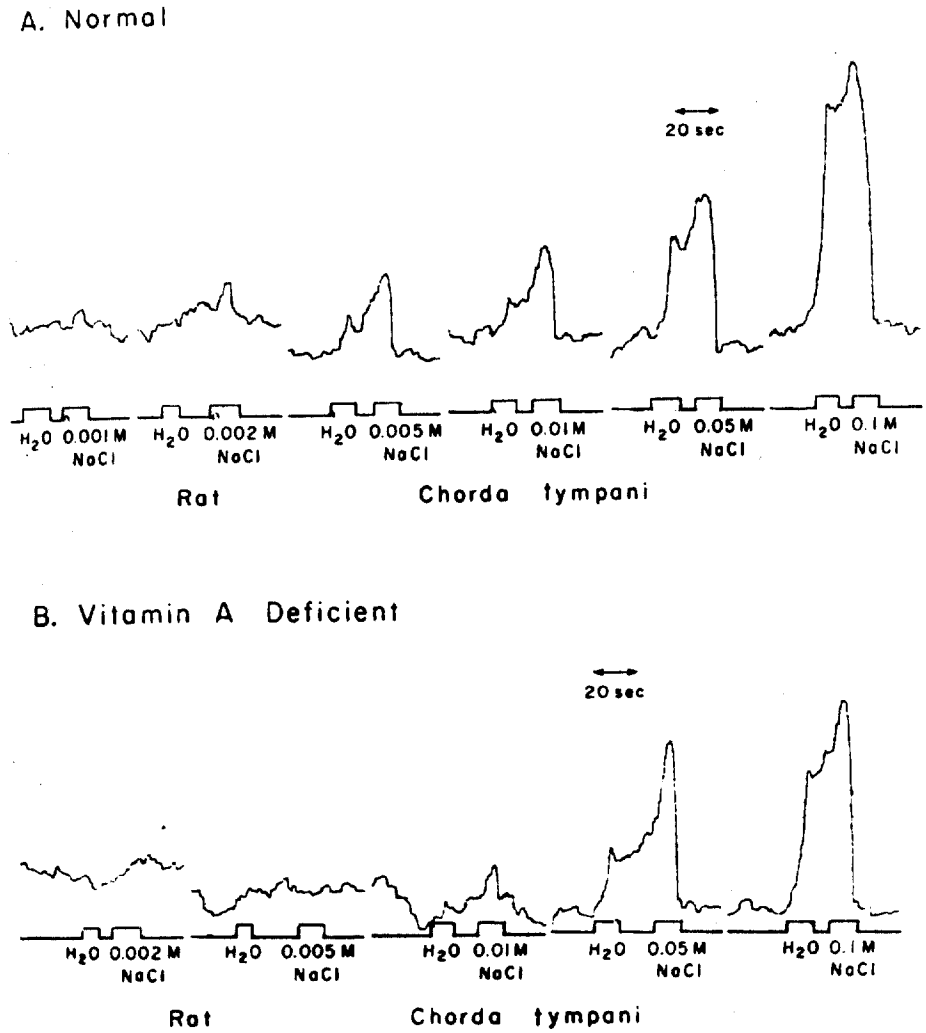

FIGURE 8. Summated chorda tympani responses to a series of NaCl solutions, obtained from the same rats as in Fig. 7. Records read from right to left. Solutions were presented in ascending order of concentration. A. Records from a normal rat. Responses can be seen starting at 0.001 M NaCl. B. Records from a deficient rat. Responses are smaller and become apparent only at 0.005 M NaCl.

controls. The response of the deficient rats to 0.1 M NaCl, which was used as the reference standard for all stimuli, was less than half of normal at both the onset and cessation of stimulus flow (Table V). A typical record of a whole nerve discharge from a deficient rat (Fig. 7) showed diminished amplitude for the tongue at rest and during water flow and diminished amplitude and a smaller number of action potentials in response to 0.1 M NaCl stimulation. Records of summated responses of a deficient rat (Fig. 8) also showed diminished amplitude throughout a concentration series of NaCl solutions. In the normal rat responses were obtained from 0.001 M NaCl to 0.1 M NaCl, whereas

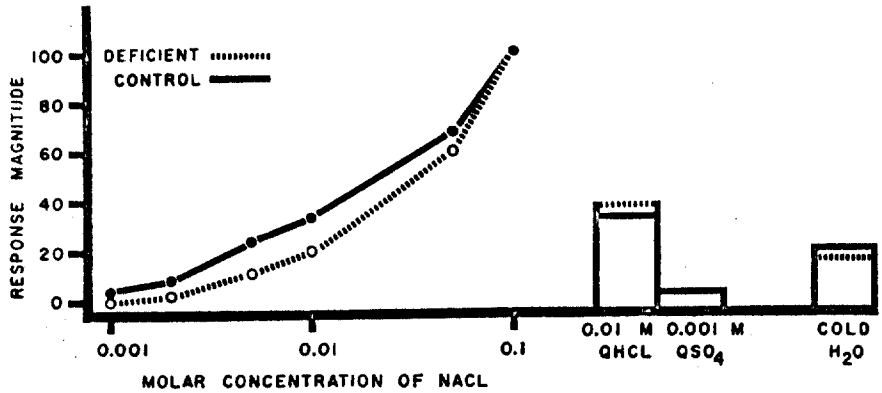

FIGURE 9. Median summated chorda tympani response magnitudes following stimulation of the anterior tongue of four vitamin A–deficient and three normal rats with NaCl, quinine hydrochloride (QHCl), and quinine sulfate (QSO_4) solutions and cold (4–14°C) distilled water. Ordinate represents magnitude of response in arbitrary units, adjusted to 100 units for the response to 0.1 M NaCl. Abscissa represents molar concentration, plotted logarithmically for NaCl.

responses from the deficient rats were perceptible only at 0.005 M NaCl. The stimulus-response relationships of the deficient rats were altered within the NaCl concentration series as well (Fig. 9). The response to 0.01 M NaCl by the deficient rats was a smaller fraction of the response to 0.1 M NaCl than in the normal rats. However, the relationship between 0.1 M NaCl and 0.01 M QHCl was altered in the direction of greater than normal sensitivity to the quinine. In relation to 0.1 M NaCl, the deficient rats were less sensitive to cold (4–14°C) water than the normal ones.

Histology

There were no apparent differences in deficiency symptoms between the rats of the vitamin A–deficient group (experiment I, phase 1) and the rats of the vitamin A acid group after the final withdrawal of vitamin A acid (experiment III, phase 2). All showed the classical gross symptoms of conjunctivitis,

xeropathalmia, exudate around the eyes, weight loss, etc. Histologically, there was increased keratinization of the dorsal surface of the tongue. The usual thin layer of keratin on the dorsal surface of the fungiform papillae (Figs. 10 A, 12), which in the rat contain a single taste bud, was thicker than normal and keratin was found to extend into the pore area of the taste buds

FIGURE 10 A. Section through the longitudinal axis of a normal rat fungiform papilla. B. Same as in A, but from vitamin A-deficient rat. Dark-staining keratin infiltrates taste bud pore. C. Section perpendicular to the longitudinal axis of a vitamin A deficient rat fungiform papilla. In upper half of photo the taste bud appears as a series of concentric rings surrounding dark-staining keratin in the pore. The smaller whorl-like structures are filiform papillae. In the lower left half of the photo is another taste bud at a level below the pore. Ladewig stain. × 253. Color excerpts in Fig. 12.

(Figs. 10 B, C, 12). Similar effects were found in the foliate and circumvallate papillae, where the taste buds lie along a groove-like depression (Figs. 11 A, 12). There was increased keratinization of the epithelial surface as well as keratin filling up the pore of the taste buds and a piling up of keratin and other debris in the groove (Figs. 11 B, 12). Although not visible in the photo-

graphs, the mucous and serous glands of the tongue were atrophied and the ducts leading into the foliate and circumvallate grooves were distended and filled with debris. There were also numerous abscesses at the base of the tongue. The taste buds did not appear atrophied or greatly diminished in number. The five deficient rats had an average of 143 (range: 51–201) taste buds in the circumvallate papilla while the one normal one in which the count was made had 181.



FIGURE 11 A. Section through normal rat circumvallate papilla. In the lower right quadrant are two taste buds whose pores are visible at the surface of the groove. The upper of the two pores is seen as an interruption in the thin keratin layer covering the groove at that point. Ladewig stain. × 450. B. Section through vitamin A-deficient rat circumvallate papilla. In the left half of the photo are three taste buds whose pores reach the surface of the groove. The pores are filled with tuftlike accumulations of keratin and the groove is filled with debris. At the top of the photo is the debris-filled duct of one of the accessory glands. Ladewig stain. × 249. Color excerpts in Fig. 12

DISCUSSION

Taste preference changes clearly occurred in conjunction with depletion of vitamin A reserves (experiment I, phase 1). These changes were in the direction of loss of discrimination. Both the normally selected and the normally rejected stimuli were brought close to a neutral level, not significantly different from that of water. It is hypothesized that these changes in preference behavior resulted from disruption of the receptors and were not due to general debility. The early appearance of a statistically significant change in NaCl

preference, which preceded weight loss or other deficiency symptoms, tends to rule out debility as an important factor in the observed behavioral changes.

The lack of complete recovery of NaCl preference may have been due to irreversible tissue damage. The return of normal levels of QSO_4 rejection but not of NaCl selection (experiment I, phase 2) may have resulted from

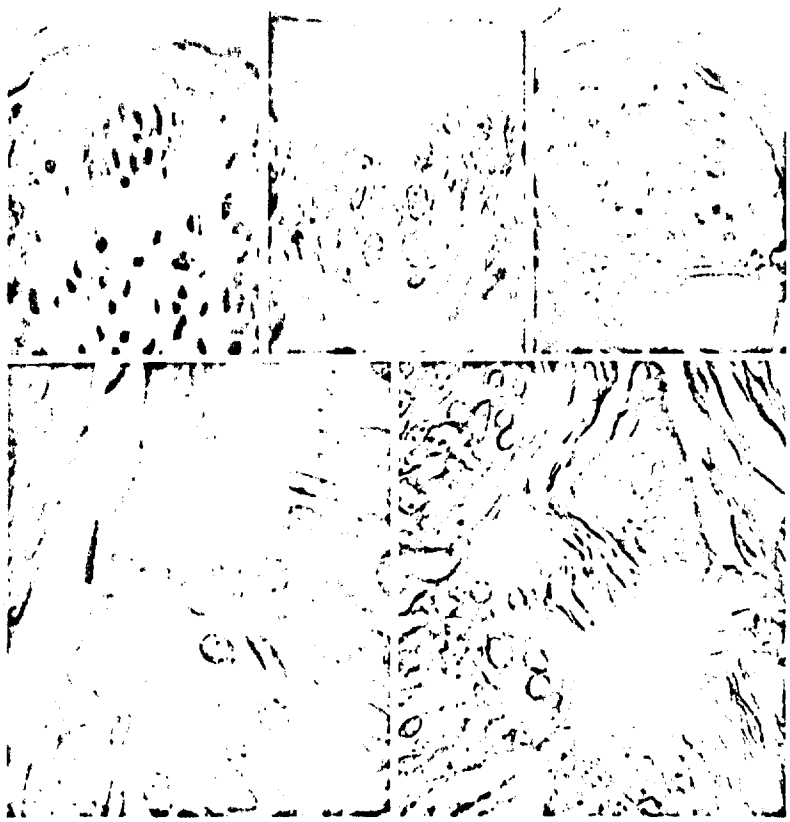

FIGURE 12. Top row, sections through normal and vitamin A deficient rat fungiform papilla corresponding to Fig. 10 A, B, and C. Bottom row, sections through normal and vitamin A deficient rat circumvallate papilla corresponding to Fig. 11 A and B. Magnifications (left to right): top row, × 253, × 450, × 253; bottom row, × 692, × 369.

0.01 M NaCl being closer to preference threshold than 30 μM QSO. (Pfaffmann, 1957). However, the recovered rats (vitamin A–repleted) reacted normally to a wide range of Na sacch concentrations but showed supranormal rejection of SOA (experiment II). The reason for this is unclear.

Although the vitamin A acid group did not differ from the normal group in its preference behavior towards NaCl and QSO_4 (experiment I), this experiment did not prove conclusively that vitamin A acid could maintain

normal taste preferences in the absence of vitamin A alcohol, since there was yet no direct evidence that the vitamin A acid group was actually depleted of vitamin A, as was the vitamin A deficient group. The accidental and unknown ingestion of the wrong diet on just one occasion would be enough to provide sufficient vitamin A for several weeks. This lack of direct evidence also seems to be true of Duncan's (1964) experiment.

The decreased aversion to SOA shown by the vitamin A acid rats in experiment II was unexpected. An explanation of this behavior was obtained when the same rats began to slow down in their growth toward the end of the experiment. As they continued to lose weight in spite of increased supplementation with vitamin A acid, it became clear that they were indeed depleted of vitamin A stores. The reversal of the weight loss by a fresh supply of vitamin A acid also showed that the original vitamin A acid had somehow lost its potency. Therefore, the decreased aversion to SOA could be explained both by the absence of vitamin A and an insufficient amount of vitamin A acid. Clarification of the role of vitamin A acid was obtained only in experiment III.

In experiment III the sudden weight loss following the complete withdrawal of vitamin A acid provided direct evidence that the experimental rats were now completely depleted of vitamin A alcohol. The normal taste preferences for quinine and NaCl in the periods immediately preceding the deprivation clearly demonstrated that vitamin A acid could maintain normal taste preferences in rats totally depleted of vitamin A alcohol. The reversible production of a taste deficit in the rats provided further evidence that the role of vitamin A in taste could be adequately filled by vitamin A acid. The role of vitamin A in taste is thus quite unlike its role in the visual system.

The delayed recovery of growth when vitamin A acid was restored to the diet indicated that this substance may not be as efficient as vitamin A alcohol in promoting growth. The return to normal quinine preference before growth was restored also suggests that vitamin A acid may have a more direct role in taste than in growth and/or that taste may have a greater priority in the utilization of available vitamin A. The restoration of normal preference while weight losses continued also tends to rule out debility or weight loss as the explanation for the taste deficits.

The electrophysiological and histological evidence clearly demonstrates that pronounced structural and functional changes at the periphery were involved in the behavioral taste deficits. The histological changes did not reveal atrophy and disappearance of the receptor cells, such as follow transection of the taste nerves of the rat (Guth, 1957). The persistence of the taste cells as well as the fact that the rats were fully grown when they developed the taste deficit in the last experiment tends to rule out constriction of the taste nerves by diminished bone growth as the cause. The reversibility of the taste changes in the earlier experiments also tends to rule out that explanation.

The diminished electrical activity of the chorda tympani nerve and the impaired behavior were most probably due to diminished activity of the receptors.

In addition to the taste buds, the adjacent epithelial and glandular tissues were also severely affected. The debris in the trenches of both the vallate and foliate papillae was probably due to the atrophy of the mucous and serous glands that normally irrigate these channels. The role of these glandular secretions in taste function is not known. It may be inferred that they at least keep the vallate and foliate grooves free and clear. How important this may be in taste reception is not clear but the malfunction of these glands undoubtedly contributed to the taste deficit. The massive infiltration of the taste bud pores by keratin, resulting in disruption of normal receptor stimulation, would seem to be the major factor responsible for the taste impairment.

The effects of keratinization lead to the conclusion that the role of vitamin A in taste is derived from its more general role of maintaining epithelial cell integrity. The ability of vitamin A acid to maintain normal taste clearly shows that vitamin A is not a specific requirement for taste as it is in vision, where the alcohol form alone can be utilized in a known biochemical reaction.

A biochemical basis for the epithelial role of vitamin A has been described by Wolf and Johnson (1960). They found that the vitamin was involved in the biosynthesis of mucopolysaccharides and postulated that in the presence of vitamin A epithelial cells were stimulated to produce mucus, and in the absence of the vitamin they formed keratin instead. This is of interest because histological and electron microscopic evidence indicates the presence of a mucoid substance in the pore of the taste bud (Farbman, 1965; Gray and Watkins, 1965; Scalzi, 1967). The histology of the deficient foliate and vallate taste bud (Figs. 11 B, 12) shows the keratin seemingly growing out of the taste bud. The keratin in the taste pore would not be due to excess production by adjacent epithelial cells but rather it would be the degenerative product of normal taste cell secretion, resulting from the absence of vitamin A. This suggests the hypothesis that the taste receptor cell secretes a mucoid substance that is involved in the chemoreceptive process. Scalzi (1967) identified this substance as a neutral mucopolysaccharide and suggests that it may act as an ion exchange resin. If this be so, it raises the possibility that the general epithelial role of vitamin A can take a very specialized form depending on the epithelial tissue involved.

Portions of this investigation were carried out at the College of Veterinary Medicine, Cornell University, and at the Upstate Medical Center, State University of New York, Syracuse.
We thank Dr. M. R. Kare for his support and encouragement.
The histology was performed under the direction of Dr. L. P. Krook at Cornell University.
This work was supported in part by the National Institutes of Health Grants NB-07143, NB-06945, NB-8896 and SO4-FR06002.

Received for publication 1 February 1968.

REFERENCES

1. BERNARD, R. A., B. P. HALPERN, and M. R. KARE. 1961. Effect of vitamin A deficiency on taste. *Proc. Soc. Exptl. Biol. Med.* **108**:784.
2. BERNARD, R. A., B. P. HALPERN, and M. R. KARE. 1962. The reversible effect of vitamin A deficiency on taste. *Federation Proc.* **21**:362.
3. DOWLING, J. E., and G. WALD. 1958. Vitamin A deficiency and night blindness. *Proc. Natl. Acad. Sci. U.S.* **44**:648.
4. DOWLING, J. E. and G. WALD. 1960. The biological function of vitamin A acid. *Proc. Natl. Acad. Sci. U.S.* **46**:587.
5. DUNCAN, C. J. 1964. The taste bud membrane and the role of vitamin A. *Inter. Z. Vitamin-forsch.* **34**:410.
6. FARBMAN, A. I. 1965. Fine structure of the taste bud. *J. Ultrastruct. Res.* **12**:328.
7. GRAY, E. G., and K. C. WATKINS. 1965. Electron microscopy of taste buds of the rat. *Z. Zellforsch. Mikroskop.* **66**:583.
8. GUTH, L. 1957. The effects of glossopharyngeal nerve transection on the circumvallate papilla of the rat. *Anat. Rec.* **128**:715.
9. HALPERN, B. P. 1963. Chemical coding in taste-temporal patterns. *In* Olfaction and Taste. Y. Zotterman, editor. Pergamon Press, New York. **1**:275.
10. HALPERN, B. P., R. A. BERNARD, and M. R. KARE. 1962. Amino acids as gustatory stimuli in the rat. *J. Gen. Physiol.* **45**:681.
11. PFAFFMANN, C. 1957. Taste mechanisms in preference behavior. *Am. J. Clin. Nutr.* **5**:142
12. SCALZI, H. A. 1967. The cytoarchitecture of gustatory receptors from the rabbit foliate papillae. *Z. Zellforsch. Mikroskop.* **80**:413.
13. SIEGEL, S. 1956. Nonparametric Statistics. McGraw-Hill Book Company, Inc., New York.
14. WOLF, G., and B. C. JOHNSON. 1960. Vitamin A and mucopolysaccharide biosynthesis. *Vitamins Hormones.* **18**:439.

Biswas-'65
Bib. No. 895

Endokrinologie Bd. 49:64-69. 1965.

From the Department of Physiology, University College of Science, Calcutta-9, India

Testicular Degeneration in Rats During Hypervitaminosis A

By Narendra Mohan Biswas and Chandicharan Deb

With 8 figures

The role of vitamin A on the reproductive organs has been discussed by a number of investigators. Chatterjee and Deb (2) have recently observed the disturbances in ovarian physiology in rats after excess vitamin A administration. Moddock et al. (16) have also reported testicular degeneration in weanling rats in the above condition. Opposed to these findings is the work of Weslaw et al. (24), and Poumean-Delille (21). These authors found a sort of hypertrophy of the reproductive organs in hypervitaminotic A rats.

The lack of agreement concerning the effect of excess vitamin A on testicular function prompted this investigation. In the present communication testicular activity has been studied both histologically and histochemically in hypervitaminotic A rats.

Materials and Methods

24 adult male rats, weighing about 90 gm. were used for the experiment. They were divided into three groups of equal number and kept under uniform laboratory conditions throughout the experimental period. All the rats were offered standard laboratory diet and a concentrated multivitamin drop every alternate day. The first

two groups were injected with 30,000 I.U. of vitamin A per animal per day through intramuscular route while the third group received a measured amount of oil injections as control. After six weeks of treatment, one experimental group of rats were killed by cerebral concussion along with the control group. Injection of vitamin A was withdrawn from the remaining group of experimental animals and they were killed after fifteen days of withdrawal. The testes of these animals were dissected and fixed for histological and histochemical studies.

For histological study the testes were fixed in carnoy and stained with hematoxylin and eosin. The following histochemical tests were applied in the testis of all the animals.

1. Neutral lipid [Kay and Whitehead (9)].
2. Plasmal [Hayes (8)].
3. Cholesterol [Lillie (13)].
4. Alkaline phosphatase [Gomori (5)].
5. Acid phosphatase [Gomori (6)].
6. Succinic dehydrogenase [Nachlas et al (19)].
7. Esterase [Malaty and Bourne (17)].

Observations

The histological picture of the testes from vitamin A treated rats revealed decreased spermatogenic activity, compared to controls. There was a great reduction in the diameter of the seminiferous tubules. The basement membrane of the tubules became much thickened and most of the tubules were lined by Sertoli cells without any sperm in the treated testis.

Histochemically a marked rise of neutral lipid, plasmal and cholesterol was noticed in the interstitial cells and Sertoli cells in hypervitaminotic A rats. These cells were found to contain lower quantities of sudan positive substances in the normal testis. The distribution of esterase activity was decreased in the testis of the treated rat. Succinic dehydrogenase, alkaline phosphatase and acid phosphatase reactions were demonstrated both in the interstitial cells and tubular cells of the normal testis. Excess vitamin A injection reduced these enzymatic activities. But acid phosphatase reaction was markedly increased in the interstitial cells of the treated testis. An atrophy of the accessory sex organs had been observed in the hypervitaminotic A rats (table 1). Withdrawal of vitamin A injection caused no return of spermatogenesis in 15 days.

Table 1

Effect of excess vitamin A on the weight of seminal vesicles and prostates

Group	No. of Rat.	Seminal vesicle mg/100 g body wt	Prostate mg/100 g body wt
Control	10	72.472 ± 3.96*	56.421 ± 2.77
Hyper A	10	21.545 ± 1.21	26.272 ± 2.20

* Mean ± standard error.



Fig. 1

Fig. 2

Fig. 1. Section of testes from control animal showing normal spermatogenesis. X9

Fig. 2. Section of testes from hypervitaminotic A rats indicating spermatogenic arres Compare with figure 1. X96

Discussion

Spermatogenesis was arrested in most of the vitamin A treated rat Degenerative lesions of the testis in immature rats [Maddock et al. (16) and the inhibition of estrous cycle in adult rats [Chatterjee and Deb (2) have been noted in the above condition. Histochemically sudanophilic material were increased significantly in the interstitial cells and the Sertoli cells

Fig. 3



Fig. 4

Fig. 3. Testes of normal rat stained with Sudan. X96

Fig. 4. Testes of vitamin A treated rat with Sudan. X96

Fig. 5

Fig. 6

Fig. 5. Acidphosphatase activity in normal rat. X96

Fig. 6. A rise of acid phosphatase in the interstitial cells but a fall in the tubular cell of vitamin A treated rats. X96

hypervitaminotic A rats. The importance of lipid in the spermatogenesis has been discussed by several workers [Roosen-Runge (22), Lacy (14) and Ambadkar et al. (1)]. Scott and Lynch (23) have suggested that the lipid content of the Sertoli cells is the source of nutritive materials for the spermatozoa. A marked accumulation of cholesterol, the precursor of androgen and plasmal, reflected the presence of ketosteroids, have been noted in the testis

Fig. 7



Fig. 8

Fig. 7. Distribution of succinic dehydrogenase in the normal testis. X96

Fig. 8. A fall of succinic dehydrogenase in the testes of vitamin A treated rats. X96

of vitamin A treated rats. Lipid accumulation has also been observed in the infertile human testis [Long and Engle (12)] and in the testis of hibernating toads [Mukherji and Deb (18)]. An increased accumulation of cholesterol and the atrophy of the accessory sex organs indicated disturbed biosynthesis of testosterone in the treated testis. A fall of alkaline phosphatase and the rise of acid phosphatase reactions in the interstitial cells of vitamin A treated rats was possibly due to cellular inactivity. The testicular phosphatases have been found to be related to testicular physiology [Kar (10)]. A possible relationship between the phosphatases and various hormones has been discussed by Mathies, Goodman and Palm (15) and Dempsey, Greep and Dean (3).

Deb et al. (4) have recently reported a rise of acid phosphatase and a fall of alkaline phosphatase in the interstitial cells of the degenerated testis of rat on psoraline treatment. The distribution of succinic dehydrogenase [Ambadkar et al. (1)] and esterase [Niemi et al.(20)], both in the Leydig cells as well as tubular cells have been noted previously. These findings were confirmed again in the present study, and it was expected that the localization of esterase, succinic dehydrogenase and lipids in the normal testis of rat may be present in a similar pattern. The role of succinic dehydrogenase [Kormano et al. (11)] and esterase [Huggins and Moulton (7)] in the testicular activity have been discussed by many workers. The changes of these enzymes might be due to the spermatogenic inhibition in vitamin A toxic rats. These collected observations can be taken to suggest that the functions of both the germinal epithelium and the Leydig cells were impaired in rats made hypervitaminotic A

Summary

The effect of excess vitamin A on the testicular activity of the rat has been studied both histologically and histochemically. Inhibition of spermatogenesis and the atrophy of the accessory sex organs have been noted in hypervitaminotic A rats. Distribution of phosphatases, succinic dehydrogenase, esterase and lipids have been demonstrated in normal and treated rat. A fall of alkaline and acid phosphatases, succinic dehydrogenase and esterase but a rise of neutral lipid, plasmal and cholesterol has been observed in vitamin A toxic rat. The acid phosphatase reaction was increased in the interstitial cells of the treated rat. The significance of all the above changes in the testicular physiology have been discussed.

References

1. Ambadkar, P. M., and J. C. George: J. Histochem. Cytochem. **12**, 586 (1964). — 2. Chatterjee, A., and C. Deb: Anat. Anz. In Press. — 3. Dempsey, E. W., R. O. Greep and H. W. Dean: Endocrinology **44**, 88 (1949). — 4. Deb, C., A. Chatterjee and D. P. Chakraborty: Endokrinologie **46**, 105 (1964). — 5. Gomori, G.: Amer. J. Clin. Path. **16**, 347 (1946). — 6. Ders.: Stain Technol. **25**, 81 (1950). — 7. Huggins, O., and S. H. Moulton: J. Exp. Med. **88**, 169 (1948). — 8. Hayes, E. R.: Stain Technol. **24**, 19 (1949). — 9. Kay, W. W., and R. Whitehead: J. Path. Bact. **53**, 279 (1941). — 10. Kar, A. B.: Proc. Nat. Inst. Sci. India **17**, 21 (1950). — 11. Kormano, M., M. Harkonen and E. Kontinen: Endocrinology **74**, 41 (1964). — 12. Long, E. M., and E. R. Engle: Ann. N. Y. Acad. Sci. **55**, 619 (1952). — 13. Lillie, R. D.: Histopathologie Technic and Practical Histochemistry, New York Toronto 1951. — 14. Lacy, D.: J. Roy. Micr. Soc. **79**, 209

1960). — 15. Mathies, J. C., E. D. Goodman and L. Palm: Amer. J. Physiol. **168**, 352 (1952). — 16. Moddock, C. L., J. Cohen and S. B. Wolbach: Arch. Path. **56**, 333 (1953). — 17. Malaty, H. A., and G. H. Bourne: Acta anat. **23**, 337 (1955). — 18. Mukherji, M., and C. Deb: J. Histochem. Cytochem. **8**, 242 (1960). — 19. Nachlas, M. M., K. C. Tsow, E. DeSouza, C. S. Cheng and A. M. Seligman: J. Histochem. Cytochem. **5**, 420 (1957). — 20. Niemi, M., M. Harkonen and A. Kokko: J. Histochem. Cytochem. **10**, 186 (1962). — 21. Poumeau-Delille, G.: Compt. rend. Soc. biol. **137**, 373 (1943). — 22. Roosen-Runge, E. C.: Biol. Rev. **37**, 343 (1962). — 23. Scott, W. W., and K. M. Lynch: In Studies on Testis and Ovary, Eggs and Sperm, Engle, E. T. ed. Thomas, Springfield, pp. 37 (1952). — 24. Westaw, W., B. Wronski, A. Wroblewski and B. Wroblewski: Klin. Wochschr. **17**, 777 (1938).

(Eingang bei der Redaktion 5. 4. 1965)

Anschr. d. Verf.:
Department of Physiology University
College of Science
Calcutta-9/India

Biswas-'68
Bib. No. 896

Anat. Anz. Bd. 123(5):337-341. 1968.

University College of Science and Technology
Calcutta-9, India.

Effect of Excess Vitamin A on Pituitary-Gonadal Axis in Rats

By NARENDRA MOHAN BISWAS[1]) and MRITUNJOY MUKHERJI[2])

With 6 figures

(Received February 13, 1968)

Introduction

In an earlier paper it has been shown that excess vitamin A can produce sterility in rats (BISWAS and DEB 1965). MODDOCK et al (1953) have observed that hypervitaminosis A caused testicular degeneration in weanling rats. In course of investigations in the mechanism of action of excess vitamin A, it has been found that inhibition of estrous cycles in hypervitaminotic A rats is due to fall in ascorbic acid level in the system (CHATTERJEE and DEB 1964). But recent studies on the action of vitamin A have suggested that the testicular damage was possibly due to lack of hypophyseal gonadotropin in hypervitaminotic A rats which was not corrected by vitamin C in high doses (BISWAS 1965).

In view of these conflicting reports we have studied the mode of action of excess vitamin A on the pituitary-gonadal axis of the male rats.

Experimental Procedure

20 male adult albino rats were selected for the experiments. The animals were fed a standard laboratory diet. One group of 10 rats was injected vitamin A (Roche) intramuscularly dialy 30,000 IU/100 100 g body weight, while rest of the animals received measured amount of oil injections as controls. After 8 weeks of treatment rats were killed by decapitation; testes were fixed in carnoy, the anterior pituitaries were fixed in sublimate-formol and 2.5% trichloroacetic acid (TCA) for 24 hours. TCA-placed pituitaries were refixed in sublimate-formol for 24 hours. The testes and pituitaries were embedded in paraffin, sectioned, stained with heamatoxylin and eosin for histological study, and PAS (periodic acid-Schiff) for identification of FSH (follicle stimulating hormone) and LH (luteinizing hormone) secreting cells of the anterior pituitary (PURVES and GRIL BACK 1954; BARRNETT LADMAN, McALLASTER and SIPERSTEIN 1956).

Results

Histological examination of the testes in vitamin A treated rats showed diminished spermatogenesis as indicated by the absence of spermatides and spermatozoa. There

1) Lecturer in Physiology, Ananda Mohan College, Calcutta, India.
2) Lecturer in Physiology, University College of Science, Calcutta, India.



Fig. 1. Testis of control rat showing normal spermatogenesis.

Fig. 2. Degenerative change in the testis of vitamin A treated rats.

Fig. 3. Distribution of FSH and LH secreting cells in the anterior pituitary of the control rat.

Fig. 4. Reduced FSH and LH secreting cells in the vitamin A treated rat.



Fig. 5. Distribution of LH secreting cells in the control rat.



Fig. 6. Decreased LH secreting cells in vitamin A treated rat.

was a marked degeneration of germinal epithelium and atrophy of the Leydig cells (Fig. 2). Histochemical reaction in the anterior pituitary of the control animals showed a normal distribution of coarsely granulated PAS-positive cells and finely granulated PAS-positive cells in peripheral and central region respectively (Fig. 3). But in vitamin A treated rats both the cells were decreased markedly (Fig. 4). The PAS-positive cells extracted with 2.5% TCA were also reduced in vitamin A treated rats as compared to that of control animals (Figs. 5, 6).

Discussion

The present study indicates that the testicular activity has been inhibited in hypervitaminotic A rats. These data confirm previous observation of gonadal dysfunction in the weanling (MODDOCK, COHEN and WOLBACH 1953) and adult rats (BISWAS and DEB 1965). In addition cytology of the anterior pituitary shows two types of basophils, which are markedly reduced in vitamin A treated rats. According to PURVES and GRIESBACH follicle stimulating hormone (FSH) is produced by coarsely granulated basophil cells situated peripherally and luteinising hormone (LH) is produced by finely granulated basophil cells situated centrally. BARRNETT et al (1956) have observed that PAS-positive cells of the anterior pituitary extracted in 2.5% TCA are the LH secreting cells. In the present investigation a decrease in FSH and LH secreting cells shows that gonadotropin secretion is inhibited in vitamin A treated rats.

Other investigators (AMES, SWANSON, RISLEY and HARRIS 1954) found hypertrophy and hyperfunction of the adrenal cortex in hypervitaminosis A. NOWELL and CHESTER JONES (1957) have noted a reduced gonadotropin production from anterior pituitary due to excessive ACTH release. The reduction of pituitary gonadotropin has also been observed in rats (STEIN and LISLE 1942) and rabbits (VANDYKE and CHEN 1946) after thyroidectomy. SADHU and TRUSCOTT (1948) have suggested that excess of vitamin A reduces TSH secretion. Although the present result do not permit any final conclusion, but it is felt that either an increased ACTH, or reduced TSH or a combination of both might be responsible for the decrease in gonadotropin formation as observed in hypervitaminotic A rats.

Acknowledgments

The authors wish to thank Dr. S. R. MAITRA, Head of the Department of Physiology, Calcutta University, and Prof. R. N. MITRA, Principal of Ananda Mohan College, for their constant encouragement. The authors are grateful to University Grants Commission, New Delhi, for a research grant.

Summary

The effect of excess vitamin A on testes and anterior pituitary gonadotrophes of rat has been studied. Inhibition of spermatogenesis and decrease in FSH and LH secreting basophils have been noted in vitamin A treated rats. Reason for all these changes has been discussed.

Literature

AMES, S. R., SWANSON, W. J., RISLEY, H. A., & HARRIS, P. L., Federation Proc. **13**, 174 (1954).
BARNETT, R. J., LADMAN, A. J., MCALLASTER, N. J., & SIPERSTEIN, E. R., Endocrinology. **59**, 398 (1956).
BISWAS, N. M., & DEB, C., Endokrinologie. **49**, 64 (1965).
D. Phil. Thesis (1965).
CHATTERJEE, A., & DEB, C., Anat. Anz. **115**, 1 (1964).
MODDOCK, C. L., & COHEN, J., & WOLBACH, S. B., Arch. Path. **56**, 333 (1953).
NOWELL, N. W., & CHESTER JONES, I., Acta endocr. **26**, 273 (1957).
PURVES, H. D., & GRIESBACH, W. E., Endocrinology. **55**, 785 (1954).
SADHU, D. P., & TRUSCOTT, B. L., Endocrinology. **43**, 120 (1948).
STILN, K. F., & LISLE, M., Endocrinology. **30**, 16 (1942).
VANDYKE, H. B., and CHEN, G., Proc. Soc. Exptl. Biol. N. Y. **31**, 327 (1946).

Author's adress: Dr. N. M. BISWAS and Dr. MRITUNJOY MUKHERJI, Department of Physiology, University of Science, 92 Acharya Prafulla Chandra Road, Calcutta 9 (India).

Z. Ges. Exptl. Med. 89:780-785. 1933.

Bomskov-'33
Bib. No. 1013

(Aus der Kieler Universitäts-Kinderklinik [Vorstand: Prof. *Rominger*].)

Über die Wirkung des A-Vitamins auf die Zusammensetzung des Blutes.

Von

Christian Bomskov und Günther Sievers.

Mit 1 Textabbildung.

(Eingegangen am 14. März 1933.)

Während wir durch zahlreiche Untersuchungen über die Wirkungen des A-Vitamins auf die morphologischen Bestandteile des Blutes weitgehend unterrichtet sind, liegen noch keine Untersuchungen vor, in denen ein Einfluß des A-Vitamins auf die chemische Zusammensetzung des Blutes festgestellt werden konnte. Es war deshalb von besonderem Interesse, namentlich im Hinblick auf die Untersuchungen von *Bomskov* und *Seemann*, die zeigten, daß hohe Dosen dieses Vitamins bei Ratten zu typischen Überdosierungserscheinungen und Entkalkung des Knochens führen, diese Frage erneut aufzugreifen, um so mehr, als wir im Vogan der I. G. Farbenindustrie über ein standardisiertes Vitamin A-Präparat verfügen.

Als Versuchstiere wählten wir Kaninchen, weil wir hier Blut in genügenden Mengen ohne Schwierigkeiten gewinnen konnten. Wir untersuchten zunächst die Blutzusammensetzung gesunder Tiere, dann das Blut derselben Tiere nachdem sie 10 ccm der öligen Vitaminlösung mit der Schlundsonde erhalten hatten. Endlich studierten wir den Einfluß einer A-Vitaminverabreichung auf die D-Hypervitaminose. In Vorversuchen stellten wir fest, daß eine Fütterung mit reinem Öl, wir wählten Oliven- und Erdnußöl, auf die Zusammensetzung des Blutes ohne jeden Einfluß ist.

1. Der Einfluß des A-Vitaminpräparats „Vogan" auf Blutgerinnung, Erythrocytenresistenz und Senkungsgeschwindigkeit.

Wir bestimmten zunächst bei gesunden Tieren Blutgerinnungszeit, Erythrocytenresistenz und Senkungsgeschwindigkeit und nahmen einige Tage später an denselben dieselben Untersuchungen vor, nachdem sie 48 Stunden vorher mit A-Vitamin gefüttert waren. Die Ergebnisse

gehen aus nebenstehender Tabelle hervor:

Wie ersichtlich hat das A-Vitamin in hohen Dosen weder auf Erythrocytenresistenz, noch auf die Senkungsgeschwindigkeit einen erkennbaren Einfluß. Was die Gerinnungszeit anbetrifft, so kann man vielleicht eine leichte Verkürzung feststellen. Dagegen ist deutlich, daß das A-Vitamin die gerinnungsfördernde Wirkung des D-Vitamins aufhebt.

Behandlung	Gerinnungszeit in Min.	Resistenz	Senkungsgeschwindigkeit nach 1 Std. mm	Senkungsgeschwindigkeit nach 24 Std. mm
Keine	3,5	0,45	0,2	24
	2,0	0,40	0,2	22
	4,0	0,45	0,3	32
	2,0	0,45	0,2	22
	4,5	0,40	0,2	28
	2,5	0,40	0,4	26
	3,5	0,40	—	—
Vogan 10 ccm	2,0	0,45	0,1	24
	2,0	0,45	0,1	18
	2,0	0,45	0,2	26
	2,3	0,45	0,3	24
Vigantol 10 ccm	1,5	0,50	0,1	28
	1,0	0,45	0,1	30
	1,7	0,50	0,2	26
Vogan 10 ccm + Vigantol 10 ccm	3,5	0,45	2,0	26
	2,5	0,40	4,0	36

2. Die Wirkung des A-Vitaminpräparats „Vogan" auf Bilirubin-, Zucker-, Kochsalz- und Reststickstoffgehalt des Blutserums.

In nachstehender Tabelle bringen wir die Ergebnisse der Bestimmungen der oben angeführten Blutbestandteile bei gesunden Tieren und bei solchen die mit A- oder D-Vitamin oder mit beiden gefüttert wurden.

Behandlung	Bilirubin	Blutzucker	Kochsalz	Reststickstoff
Keine	0,21	75	614	57
	0,61	90	585	49
	0,40	74	585	59
	0,39	81	599	55
	—	119	—	—
	—	94	—	—
	0,19	—	590	48
	0,19	119	579	52
	0,14	77	599	59
	0,14	—	585	60
Vogan 10 ccm	0,18	106	600	64
	0,28	120	570	60
	0,36	—	—	55
	0,16	—	—	56
Vigantol 10 ccm	0,21	141	585	65
	0,20	150	600	71
	0,16	—	—	66
Vogan 10 ccm + Vigantol 10 ccm	0,22	132	600	55
	0,26	150	585	58
	0,18	—	—	59

Wie ersichtlich werden obige Blutbestandteile durch Verabreichung des A-Vitamins in keiner Weise beeinflußt. Es scheint aber als ob das A-Vitamin, wenn es gleichzeitig mit dem D-Vitamin verabreicht wird, die Erhöhung des Reststickstoffs verhindert.

3. Der Einfluß des A-Vitaminpräparats „Vogan" auf den Gehalt des Blutserums an Calcium und Phosphor.

Die Ergebnisse dieser Untersuchungen gehen aus folgenden Tabellen hervor:

Blutkalk- und Phosphorwerte bei Kaninchen nach Verabreichung von 10 ccm Voganlösung. (Alle Werte in mg-%.)

Normalwert		Nach 24 Std.		Nach 48 Std.		Nach 4 Tagen		Nach 5 Tagen		Nach 6 Tagen		Nach 7 Tagen	
P	Ca	P	Ca	P	Ca	P	Ca	P	Ca	P	Ca	P	Ca
4,6	—	—	—	6,6	16,0	—	—	5,6	16,2	—	—	3,5	17,2
4,4	—	—	—	6,5	17,4	—	—	3,8	14,2	—	—	2,9	16,0
3,1	19,2	4,7	18,0	4,8	17,8	—	—	—	—	3,1	18,6	—	—
3,5	18,4	—	—	—	—	—	—	—	—	—	—	—	—
4,0	17,6	5,2	18,8	4,7	18,2	—	—	—	—	3,3	19,0	—	—
—	16,2	—	—	—	—	—	—	—	—	—	—	—	—
3,0	18,0	3,7	16,6	3,0	17,2	2,9	17,0	4,3	17,2	—	—	—	—
4,4	19,8	4,2	16,0	3,7	17,2	4,0	18,6	4,9	17,0	—	—	—	—
3,9	—	—	—	4,8	—		—	—	—	—	—	—	—
3,6	—	—	—	5,1	—		—	—	—	—	—	—	—
3,1	—	—	—	3,5	—	—	—	—	—	—	—	—	—
5,6	18,0	—	—	7,0	17,8	—	—	—	—	—	—	—	—
4,2	18,4	—	—	7,1	17,6	—	—	—	—	—	—	—	—
3,9	18,2			5,2	17,5	im Durchschnitt							

Tabelle 1 zeigt die Beeinflussung des Phosphor und Kalkspiegels nach Verabreichung von 10 ccm Vogan. Wie ersichtlich, steigt schon nach 24—48 Stunden der Phosphorspiegel um etwa 25% an, hält sich mehrere Tage auf dieser Höhe und fällt dann zur Norm ab. Der Kalkspiegel zeigt während dieser Zeit eher eine leichte Senkung.

Blutkalk- und Phosphorwerte nach Verabreichung von 10 ccm Vigantol.

Normalwert		Nach 48 Std.		
P	Ca	P	Ca	
2,9	19,6	2,9	15,6	
3,7	17,8	5,0	17,0	
2,8	19,2	5,3	14,6	
4,0	17,6	7,2	19,6	
3,1	20,0	4,5	16,8	
2,9	18,0	5,6	16,8	
2,1		3,7	—	
3,1	18,7	5,3	16,7	im Durchschnitt

Tabelle 2 zeigt den Anstieg des Phosphorspiegels bei der D-Hypervitaminose. Hier beträgt die Erhöhung des Phosphorspiegels etwa 65%, der Kalkspiegel ist ebenfalls leicht gesenkt.

Tabelle 3 zeigt die Versuche über die gegenseitige Beeinflussung der beiden Vitamine. Es zeigt sich, daß bei gleichzeitiger Verabreichung von Vogan und Vigantol der Phosphorspiegel zwar erhöht ist, aber nicht

Blutkalk- und Phosphorwerte nach Verabreichung von Vogan + Vigantol. (Alle Werte in mg-%.)

Normal			Nach 48 Std.		Nach 2 × 48 Std.		Nach 3 × 48 Std.		Nach 4 × 48 Std.		Nach 5 × 48 Std.	
P	Ca		P	Ca	P	Ca	P	Ca	P	Ca	P	Ca
3,7	16,6	10 ccm A 10 ccm D	5,5	19,4	5,9	17,8	6,2	18,4	4,9	18,2	5,7	18,2
3,0	18,0	10 ccm A 10 ccm D	4,2	19,2	5,1	18,8	5,8	18,4	4,4	18,0	4,6	17,6
3,7	17,8	10 ccm D	5,0	17,6	5,8	16,6	3,8	17,0				
4,0	17,6	10 ccm D	10 ccm A 7,2	19,6	7,9	15,8	3,5	15,2				
5,6	18,0	10 ccm A	10 ccm A 7,0	17,8	6,8	17,8	7,2	18,6	6,8	17,6	5,3	18,2
4,2	18,4	10 ccm A	10 ccm D 7,1	17,6	6,4	18,0	6,0	19,0	5,0	18,4	3,6	18,6
4,0	17,7		10 ccm D		5,8	17,5	im Durchschnitt					

in dem Maße, als wenn man die Einzelwirkungen zusammenaddieren würde. Die vorherige oder nachträgliche Verabreichung von Vogan scheint die D-Hypervitaminose nicht erheblich zu beeinflussen.

Das Diagramm zeigt einige sog. phosphatämische Kurven, die wir durch Verfolgung des Ablaufs der Phosphaterhöhung im Serum nach Injektion von sekundärem Natriumphosphat, einerseits bei mit Vogan behandelten Tieren, andererseits bei Tieren die mit Vigantol gefüttert waren, erhielten. Wie ersichtlich ist der sog. D-Wert der Kurve, die höchste Erhebung über den Ausgangswert, bei den Vigantoltieren etwa 6 mg-%, während er bei den Vogantieren nur 4 mg-% beträgt. Bei gesunden Tieren lag dieser Wert in unseren Versuchen um 3 mg-% herum. Wir sehen also bei Verfolgung dieser Kurven, daß das A-Vitamin, ebenso wie das D-Vitamin imstande ist, den D-Wert der phosphatämischen Kurve gegenüber der Norm zu erhöhen, wenn diese Erhöhung auch hinter der durch das Vigantol verursachten zurückbleibt.

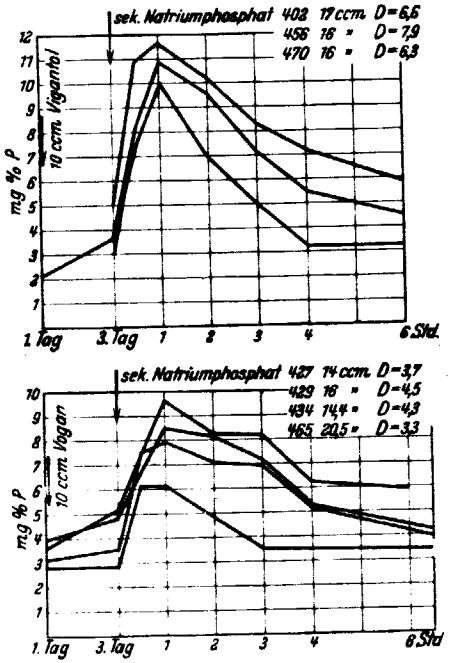

Abb. 1.

Ergebnisse.

Die Verabreichung großer Dosen A-Vitamin ist bei Kaninchen ohne Einfluß auf die Gerinnungszeit des Blutes, auf Resistenz und Senkungsgeschwindigkeit der Erythrocyten. Die durch große Dosen Vigantol beschleunigte Gerinnung des Blutes wird aber durch gleichzeitige Verabreichung von A-Vitamin verhindert.

Weiter wird festgestellt, daß das A-Vitaminpräparat „Vogan" in großen Dosen ohne Einfluß ist auf den Gehalt des Blutes an Bilirubin, Zucker, Kochsalz und Reststickstoff.

Demgegenüber führt aber die Verabreichung einer großen Dosis A-Vitamin in Form von „Vogan" beim Kaninchen schon nach 24 Stunden zu einer deutlich ausgeprägten Hyperphosphatämie, die mehrere Tage lang bestehen bleibt und dann langsam abklingt. Dabei ist der Phosphorspiegel um rund 25% gegenüber der Norm erhöht. Der Kalkspiegel ist leicht gesenkt. In diesem Falle sind also die Erscheinungen dieselben wie bei der D-Hypervitaminose. Das A-Vitaminpräparat „Vogan" verstärkt aber nicht die Erscheinungen der D-Hypervitaminose, wenn man es vorher gleichzeitig oder nach dem D-Vitamin verabreicht.

Überdosierung von A-Vitamin führt sowohl wie Überdosierung von D-Vitamin zu einer Erhöhung der phosphatämischen Kurve gegenüber der Norm, wobei aber ebenfalls das A-Vitamin in geringerem Grade wirkt.

Diese Versuche bestätigen also die Auffassung, daß das A-Vitaminpräparat „Vogan" einen bedeutsamen Einfluß auf den Mineralhaushalt besitzt, worauf ja schon die Untersuchungen von *Bomskov* und *Seemann*, die bei gesunden wachsenden Ratten durch Verabreichung von A-Vitamin eine Mineralverarmung der Knochen feststellten, hinwiesen.

Nach Angabe der Hersteller enthält das A-Vitaminpräparat „Vogan" pro Kubikzentimeter 40 000 Ratteneinheiten A-Vitamin und 3000 Ratteneinheiten D-Vitamin. Wir verabreichten also unseren Tieren 400 000 Einheiten A- und 30 000 Einheiten D-Vitamin. Es erhebt sich natürlich hier die Frage, ob dieser Gehalt des von uns benutzten Präparats an D-Vitamin nicht ausreicht, die von uns gefundenen Veränderungen zu erklären. Diese Frage glauben wir an Hand der Literaturergebnisse bejahen zu können. Rechnen wir die Dosis, die wir den Tieren an D-Vitamin gaben, auf Milligramm um, so sehen wir, daß diese 0,6 mg beträgt; das sind in Form von Vigantol 2 ccm.

Die bisher in der Literatur beschriebenen Dosen, die bei Kaninchen schädlich wirkten, liegen durchweg höher. So verabreichte *Pfannenstiel* 6 mg pro Tag, *Kreitmair* und *Moll* 2—10 mg. *Smith* und *Elvove* fanden für Kaninchen noch 1 mg pro Tag unschädlich. *Seel* behauptet, daß eine Einzeldosis von 50 mg bei Kaninchen ohne Wirkung bleibt, während *Pap* erst Dosen von 250—870 mg toxisch fand. *Warkany* sah in seinen Versuchen erst nach Verabreichung von 50—100 mg bestrahltem Ergosterin beim Kaninchen eine Hyperphosphatämie.

Bei der Auswertung dieser Ergebnisse ist aber zu berücksichtigen, daß die angegebenen Dosen in Milligramm sich nicht wie heute auf das krystallisierte D-Vitamin beziehen, daß stark verunreinigte Präparate vorlagen. Aus unseren Versuchen geht hervor, daß 10 ccm Vigantol = 3 mg krystallisiertes D-Vitamin eine Hyperphosphatämie verursacht, die nicht so ausgeprägt ist wie diejenige nach 10 ccm Vogan = 0,6 mg D-Vitamin. Da aber die Wirkungen nur quantitativ, nicht aber qualitativ verschieden sind, folgt daraus, daß in beiden Fällen als Ursache der Wirkung das D-Vitamin anzusehen ist.

Wir kommen also zu dem Schluß, daß die gefundene Hyperphosphatämie nach großen Dosen Vogan dem D-Vitamingehalt der Präparate zuzuschreiben ist. Danach besitzt das A-Vitamin, selbst in extremer Überdosierung, keine Wirkung auf die Zusammensetzung des Blutes.

Wir möchten hier weiter hervorheben, daß die Dosis die wir den Tieren verabreichten, auf die Verhältnisse beim Menschen umgerechnet, eine unvorstellbare große ist wie sie praktisch nie vorkommen kann. Trotz dieser Dosis waren die Tiere aber bei weitem nicht so schwer geschädigt wie bei der D-Hypervitaminose. Abmagerungen und Exitus haben wir nie beobachten können.

Zusammenfassung.

Die Verabreichung großer Dosen A-Vitamin in Form des Präparates „Vogan" führt am Kaninchen zu einer deutlich ausgeprägten Hyperphosphatämie, mit einer Erhöhung des Phosphorspiegels um etwa 25%, bei leicht gesenktem Kalkspiegel. Sonst ist dieses Vitamin auf die Blutzusammensetzung ohne Einfluß. Die gefundene Veränderung beruht wahrscheinlich auf dem Gehalt dieses Präparats an D-Vitamin.

Literaturverzeichnis.

Bomskov u. Seemann: Siehe vorstehende Arbeit.

Brusa & Testa-'53
Bib. No. 1266

Internatl. Zeitschr. Vitamin for sch. 25(1): 55-62, 1953.

Lesions in the Central Nernous System of Guinea Pigs with Hypervitaminosis A

by Dr. A Brusa and Dr. F. Testa

Reproduced by permission of the copyright owner

Received April 30, 1953

Many authors have studied the effects on the animal organism of experimentally produced hypervitaminosis A; of these, those prior to the year 1945 used vitamin by extraction while the authors after that date, which coincides with the publication of Moore and Wang, used the synthetically obtained product. With such synthetic products it was possible to demonstrate that the characteristic traits were due exclusively to this form of hypervitaminosis and not to substances which accompanied the extracted vitamin product.

It is not our invention to refer extensively to the vast literature existing on the question and concerning the lesions in the various organs and systems. For this, we refer to the fundamental work of Wolbach and coworkers (1945-1937-1949-1951-1952), Mouriquand (1948), Rodahl (1949-1950), Studer (1950), Matteini and Arcangeli (1951); we shall dwell more at length specifically on the alterations of the central nermous system. It is known that under hypervitaminosis A there exist, in the animals treated, serious neurological symptoms consisting of paresis of the limbs, spastic contractions, uncertain movement and signs of lack of motor coordination.

These observations were made by almost all the authors concerned with the question, but in contrast with what happened in the domain of avitaminosis A, the observations were limited to the study of the behavior of the animal and were not completed by accurate anatomical-histological research. As far as we were able to ascertain, only Collazo and Rodriguez (1933) observed thrombosis and hemorrhage type alterations involving cerebral vessels, as well as lesions in the nervous cells. From their work, however, it is not possible to have a precise idea concerning the nature and extent of such neurological lesions, inasmuch as the description made is quite brief, without photographic documentation.

Therefore we considered it fitting to institute research in that direction and we limited our observation to the study of the nervous system, while other research on the subject of hypervitaminosis A was done in our clinic by Zunin and Testa, who studied the passage of the vitamin from the mother to the fetus and the subsequent alterations of the fetus.

For our experiment we selected the guinea pig, which is an animal particularly sensitive to toxicity of strong doses of vitamin A. We used adult animals, whose body weight ranged between 350 and 600 grams; these received the normal diet of our laboratory, including also some fresh vegetables, and in addition they received, by mouth, synthetic vitamin A in the form of axerophtol palmitate containing 300,000 international units per cc dissolved in peanut oil.

The daily doses varied between 300 and 600 units per gram of body weight; death occurred in a period of time which ranged between 10 and 17 days. On the average every animal received altogether from 2.5 million to 3 million units of vitamin. The initial symptomatology consisted of a substantial loss of weight, loss of hair, weakness, loss of appetite; afterwards the animal exhibited a uncertain paretic spastic walk and considerable rigidity with marked curvature of the spine.

From each animal we removed the encephalon and the thoracic cervical section of spinal marrow. For the study of the cellular lesions, the material was fixed in 10% formalin and, after inclusion in paraffin, stained by the Gallego method, or with thiomine; for the study of the lesions of the myelin fibers we used the Marchi method. The observations were made on numerous transverse sections of the entire encephalic mass made at various levels from the frontal pole to the cerebellum.

For the evaluation of the findings of cellular lesions, in order to avoid easy errors due to the presence of cytological alterations caused by the

technique, we were always careful to refer to the pattern found in the normal animal. For this purpose we sacrificed animals of the same weight as those we used for the experiment, and their encephalon was treated in the identical manner.

In a first microscopic examination of the histological sections we observed evident hemorrhages of the pia mater and considerable basal hyperemia of the inside of the encephalic mass; the vascular formations of the choroid plexus and vessels of the oval center, of the cortex and of the basal gray formations as well as those of the cerebellum appeared dilated and filled with blood; red cells still preserved, or masses of hemosiderin, were present in great abundance throughout the nervous tissue. (See Figure 1)

Histopathological Description

Cerebral Cortex. The cortex was examined in various frontal, parietal occipital regions, and finally, in the hippocampus. Before we go into the topographical distribution of the lesions, we would like to give a brief description of them. They could be classified into two basic types: serious regressive facts involving cellular bodies and a certain degree of hyperplasia of the glial elements. Concerning the first type of alterations the nervous cells appeared particularly affected with edematous degeneration consisting of the appearance of many void spaces in the cytoplasm which gave the cellular element a spongy appearance, with the nucleus pushed to the periphery and pyknotic. Because of the much reduced affinity of the protoplasm for stains and of the process of tigrolysis, the element affected was barely visible among the other normally stained ones. In addition to this type of degeneration, other elements exhibited alterations similar to those described by Nissl as "serious degeneration" and consisting of pyknosis and other nuclear alterations, as well as a thickening of the tigroid substance in large strongly basophile clumps, pushed towards the periphery of the cellular body, outside of which could be

noted detritus of an also intensely basophile substance.

It is rather delicate to evaluate the "edematous degeneration," inasmuch as in the encephalon of even normal animals, it is quite easy to find a large number of cells with voids and having spots and alterations of their periphery. Even in our control preparations we observed this finding, involving especially the granular cells of the cerebral cortex. These alterations depend partially on causes inherent in the technique, and in part on a certain edematous state of the nerve elements, particularly in young animals. The feature which characterizes effective pathological alterations in the nerve cells is represented, however, in addition to swelling and voids, by the simultaneous presence of deep nuclear lesions, tygrolysis and evident alterations in the stainability and cellular form, and these characteristics were brought out in our treated animals, and in these only.

The distribution of the lesions was fairly extensive, involving the various regions of the cortex. Next to zones in which the nerve cells had an almost normal appearance, there were other areas, disseminated here and there, which exhibited decidedly altered cellular elements. As to the location of such lesions, we can say, taking account of the diverse structure of the cortex in the various regions examined, that these involved particularly the pyramidal elements of the upper and lower granular strata (strata 3 and 5 according to the Brodmann classification) (See Figs. 2 and 3). Minor lesions, that is extending to a much smaller number of cells, were found in the hippocampus.

Cerebral cortex. Already under superficial examination, while lesions appearing in the granular stratum were not brought out, it was possible to observe a considerable involvement in the layer of the Purkinje cells. The neurons in question all exhibited, although to a different degree, alterations similar to those of "grave degeneration" while facts of "edematous degeneration" were rarely observed.

Figs. 4 and 5 give a better idea than any description of the anatomic-pathological state found in these cells: From elements affected by simple chromatolysis with thickening of large blocks of tigroid towards the cellular membrane, we pass by degrees to the almost complete reduction of the cytoplasmic mass which is composed of irregular fragments around the single nucleus which appears pyknotic. The affinity for the dye is considerably reduced, the shape characteristics of the cellular body are lost, the entire cell, before complete disappearance, assumes that aspect observed and described by many authors as "Phanton cell." Around the cells so altered, there is scarce glial reaction.

Central Gray nuclei Transverse section made at various levels made it possible to study various cellular groupings forming the gray tele-encephalic and diencephalic masses. Without going into excessively fine topographic details, we merely point out the fact that in the thalamus as well as in the striated body we find many cellular elements affected by a serious edematous degeneration accompanied by glial hyperplasia. We found a normal appearance of the ependyma in the lateral ventricles, in the third, and in the aqueduct.

Mesencephalon, bridge and bulb The anatomic-pathological process did not spare the gray substance of these encephalic regions: inasmuch as no encephalon was cut in series, it was impossible in the preparation made by us with the common cellular stains, to locate with accuracy the various nuclei exhibiting affected cellular elements. We can only say that such alterations were universally distributed in the regions examined. The prevalent anatomic-pathological process was represented by various aspects of celluar swelling with consequent formation of voids and endematous degeneration as well as shrinkage and consequent atrophy. The alterations of the radicular neurons of the sixth and seventh pair were very evident. (See Fig. 6-7).

It was not possible to observe lesions in the nerve elements of the spinal

marrow or of the sensitive ganglions. The Marchi method did not bring out lesions of the myolinic fibers in the central nervous system; probably because death occurred in a period of time shorter than that required for the evaluation of the lesions by this technique.

Fig. 1 Vasal hyperemia and hematic extravasations of the cerebral substance.

Fig. 2 Cortical stratum of the large pyramidal cells in the normal animal.

Fig. 3 The Same animal treated

Fig. 4 Cerebral cortex of the normal animal

Fig. 5 Cerebral cortex in which we observe tygrolysis and atrophy in the Purkinje cells.

Figs. 6-7 Nucleus of the same pair. At left, in the normal animal; at the right, of the treated animal. In the treated animal, we observe the swelling and formations of voids in some of the neurongs, the shrinking and atrophy in others.

(Translated by Carl Demrick Associates,Inc/ARB/t)

Brusa & Testa-'53
Bib. No. 1266

Reproduced by per
of the copyright owner

Internatl. Zeitschr. Vitamin for sch. 25(1): 55-62, 1953.

Istituto di Clinica Pediatrica «G. Gaslini» dell'Università di Genova
Direttore: Prof. G. de Toni

Lesioni nel sistema nervoso centrale di cavie in ipervitaminosi A

Dott. A. Brusa e Dott. F. Testa

Ricevuto 30. IV. 1953

Molti sono gli Autori che si sono occupati degli effetti nell'organismo animale della ipervitaminosi A sperimentalmente provocata; di questi, quelli precedenti all'anno 1945 hanno usato vitamina estrattiva mentre quelli posteriori a tale data, che coincide con la pubblicazione di Moore e Wang, si sono valsi di prodotti ottenuti sinteticamente. Con tali prodotti sintetici è stato possibile dimostrare che il complesso quadro morboso caratteristico era dovuto esclusivamente a tale forma di ipervitaminosi e non a sostanze che accompagnavano il prodotto vitaminico estrattivo.

Non è nostra intenzione riferire per esteso sulla vasta letteratura esistente sull'argomento e riguardante le lesioni nei vari organi ed apparati: per essa rimandiamo ai fondamentali lavori di Wolbach e Coll. (1946—1947—1949—1951—1952), Mouriquand (1948), Rodahl (1949—1950), Studer (1950), Matteini e Arcangeli (1951); ci soffermeremo più a lungo su quanto riguarda più specificatamente le alterazioni del sistema nervoso centrale. E' noto come nella ipervitaminosi A esistano, negli animali trattati, gravi sintomi neurologici consistenti in paresi degli arti, contrazioni spastiche, deambulazione in certa e segni di incoordinazione motoria.

Tali rilievi sono stati effettuati da quasi tutti gli AA. che si sono occupati dell'argomento, ma le osservazioni, a differenza di quanto avvenne nel campo della avitaminosi A, si sono limitate allo studio del comportamento dell'animale e non sono state completate da una ricerca anatomo-istologica precisa. Per quanto ci è stato possibile appurare soltanto Collazo e Rodriguez (1933) osservarono alterazioni a tipo di trombosi ed emorragie a carico dei vasi cerebrali, nonchè lesioni delle cellule nervose: dal loro lavoro non è dato però avere una idea precisa sull'entità ed estensione di tali lesioni neurologiche in quanto chè la descrizione fattane è oltremodo succinta e priva di documentazione fotografica.

Abbiamo quindi creduto opportuno istituire delle ricerche in tal senso ed abbiamo limitato la nostra osservazione allo studio del

Fig. 1. Iperemia vasale e stravasi ematici nella sostanza cerebrale (238×).

Descrizione istopatologica

Corteccia cerebrale. La corteccia fu esaminata in varie regioni frontale, parietale, occipitale e infine nell'ippocampo. Prima di soffermarci sulla distribuzione topografica delle lesioni preferiamo darne una breve descrizione: esse si potevano raggruppare in due tipi fondamentali: gravi fatti regressivi a carico dei corpi cellulari e un certo grado di iperplasia di elementi gliali. Per quanto riguarda il primo tipo di alterazioni le cellule nervose ci sono parse colpite specialmente da «degenerazione edematosa» consistente nella comparsa nel citoplasma di numerosi vacuoli che conferivano all'elemento cellulare un aspetto spongioso con nucleo spinto alla periferia e picnotico. A causa dell'affinità protoplasmatica pei coloranti molto diminuita e del processo della tigrolisi, l'elemento colpito risulta appena visibile tra altri normalmente colorati. Oltre a questo tipo di degenerazione altri elementi presentano alterazioni simili a quelle descritte da Nissl come «degenerazione grave» e consistente in picnosi ed altre alterazioni nucleari, nonchè addensamento della sostanza tigroide in grosse zolle fortemente basofile spinte verso la periferia del corpo cellulare, all'esterno del quale si notano detriti di sostanza pur'essa intensamente basofila.

L'apprezzamento della «degenerazione edematosa» è piuttosto delicato, in quanto che è molto facile trovare nell'encefalo di animali anche normali, un gran numero di cellule vacuolizzate e presentanti intaccature ed alterazioni del loro contorno. Anche nei nostri preparati di controllo si notava questo reperto, interessante specialmente le cellule granulose della corteccia cerebrale. Queste

sistema nervoso, mentre altre richerche a proposito della ipervitaminosi A sono state eseguite nella nostra Clinica da Zunin e Testa che hanno studiato il passaggio della vitamina dalla madre al feto e le conseguenti alterazioni di questo.

Per le nostre esperienze abbiamo scelto la cavia, che è un animale particolarmente sensibile alla tossicità di forti dosi di vitamina A: abbiamo usato animali adulti, il cui peso oscillava dai 350 ai 600 grammi; essi ricevevano la normale dieta del nostro stabulario comprendente anche vegetali freschi e in più veniva loro somministrata per via orale vitamina A sintetica sotto forma di palmitato di axeroftolo contenente 300.000 unità internazionali per cc. sciolte in olio di arachide [1].

Le dosi giornaliere hanno variato fra le 300 e le 600 unità per grammo di peso; l'exitus è sopravvenuto in un periodo di tempo che oscillava tra i dieci e i diciasette giorni. In media ogni animale veniva a prendere complessivamente da due milioni e mezzo a tre milioni di unità di vitamina. La sintomatologia iniziale era costituita da notevole diminuzione di peso, perdita del pelo, astenia, anoressia; successivamente l'animale presentava andatura incerta paretico spastica e notevole rigidità con marcata curvatura della colonna vertebrale.

Da ogni animale venne prelevato l'encefalo e il tratto cervico toracico del midollo spinale. Per lo studio delle lesioni cellulari il materiale fu fissato in formalina al 10% e, dopo inclusione in paraffina, colorato secondo il metodo Gallego, oppure con tionina; per lo studio delle lesioni delle fibre mieliniche fu adottato il metodo di Marchi. Le osservazioni furono eseguite su numerose sezioni trasverse dell'intera massa encefalica praticate a varî livelli dal polo frontale al cervelletto.

Per la valutazione dei reperti delle lesioni cellulari, onde evitare facili errori dovuti alla presenza di alterazioni citologiche determinate dalla tecnica, abbiamo avuto cura di riferirci sempre al quadro riscontrabile nell'animale normale. A questo scopo abbiamo sacrificato animali dello stesso peso di quelli che erano serviti per l'esperienza, e il loro encefalo subì identico trattamento.

Ad un primo esame microscopico delle sezioni istologiche si potevano mettere in evidenza cospicue emorragie della pia madre e notevole iperemia vasale nell'interno della massa encefalica; le formazioni vascolari dei plessi coroidei e i vasi del centro ovale, della corteccia e delle formazioni grigie basali nonchè quelli del cervelletto, apparivano dilatati e ripieni di sangue; globuli rossi ancora conservati o ammassi di pigmento emosiderinico erano presenti in grande abbondanza sparsi nel tessuto nervoso. (V. fig. 1.)

* Ringraziamo la Prodotti Roche che ci ha fornito largamente l'Arovit.

alterazioni dipendono in parte da cause inerenti alla tecnica, in parte da un certo stato edematoso in cui si possono trovare gli elementi nervosi, specie in animali giovani. Il dato che caratterizza effettive alterazioni patologiche nelle cellule nervose è rappresentato però, oltre che dal rigonfiamento e dai vacuoli, dalla contemporanea presenza di profonde lesioni nucleari, tigrolisi e alterazioni evidenti della colorabilità e della forma cellulare e queste caratteristiche noi abbiamo potuto mettere in evidenza nei nostri animali trattati e soltanto in essi.

La distribuzione delle lesioni risultò abbastanza estesa interessando infatti le varie regioni della corteccia: accanto a zone in cui le cellule nervose avevano un aspetto pressochè normale, ve ne erano altre disseminate qua e là presentanti elementi cellulari decisamente alterati. Dal punto di vista della localizzazione di tali lesioni possiamo dire, tenuto conto della diversa struttura della corteccia nelle varie regioni esaminate, che esse interessavano specialmente gli elementi piramidali dello strato sopra e sotto granuloso (strati III° e V° secondo la classificazione di Brodmann) (V. figg. 2 e 3). Lesioni minori, estese cioè a un numero molto più limitato di cellule, furono riscontrate nell'ippocampo.



Fig. 2. Strato corticale delle grandi cellule piramidali nell'animale normale (640×).

Corteccia cerebellare. Già ad un primo superficiale esame, mentre non si mettevano in evidenza lesioni appariscenti nello strato dei granuli, era possibile notare una notevole compromissione nello strato delle cellule del Purkinje. I neuroni in questione presentavano tutti, quantunque in grado diverso, alterazioni simili a quelle della «degenerazione grave» mentre molto raramente



Fig. 3. Lo stesso nell'animale trattato (640×).

era possibile osservare fatti di «degenerazione edematosa».

Le figure n° 4—5 meglio di qualsiasi descrizione rendono l'idea del grave quadro anatomopatologico riscontrato a carico di queste cellule: da elementi in preda a semplice cromatolisi con addensamento di grossi blocchi di tigroide verso la membrana cellulare, si passa per gradi fino alla riduzione pressochè completa della massa citoplasmatica che risulta costituita da irregolari lem-

Fig. 4. Corteccia cerebellare di animale normale.

bi attorno al solo nucleo che appare picnotico. L'affinità per il colorante è molto ridotta, le caratteristiche di forma del corpo cellulare sono andate perdute, l'intera cellula, prima della scomparsa totale, assume quell'aspetto noto e descritto da numerosi AA., di «cellula fantasma». Intorno alle cellule in tal modo alterate esiste scarsa reazione gliale.



Fig. 5. Corteccia cerebellare in cui si nota tigrolisi ed atrofia nelle cellule di Purkinje (640×).

Nuclei grigi centrali. Le sezioni trasversali eseguite a vari livelli hanno permesso lo studio dei vari raggruppamenti cellulari costituenti le masse grigie telencefaliche e diencefaliche: senza addentrarci in dettagli topografici eccessivamente fini, a noi basta segnalare il fatto che sia nel talamo che nel corpo striato si repertavano numerosi elementi cellulari in preda a grave degenerazione edematosa accompagnata da iperplasia gliale. Normale risultò essere l'aspetto dell'ependima nei ventricoli laterali, nel terzo, nell'acquedotto.

Mesencefalo, ponte e bulbo. Il processo anatomopatologico non risparmiava la sostanza grigia di queste regioni encefaliche: dato che nessun encefalo fu tagliato in serie risultò impossibile localizzare con sicurezza, nei preparati con le comuni colorazioni cellulari da noi eseguite, i varî nuclei che presentavano elementi cellu-

lari lesi. Possiamo solo limitarci a dire che tali alterazioni erano ubiquitariamente distribuite nelle regioni esaminate: il processo anatomopatologico prevalente era rappresentato dai vari aspetti del rigonfiamento cellulare con successiva vacuolizzazione e degenerazione edematosa nonchè dal raggrinzimento e successiva atrofia. Molto evidenti risultarono essere le alterazioni nei neuroni radicolari del VI° e del VII° paio. (V. figg. 6 – 7.)



Fig. 6—7. Nucleo del sesto paio. A sinistra nell'animale normale, a destra nell'animale trattato. Si apprezzano, nel trattato, il rigonfiamento e la vacuolizzazione in alcuni neuroni, il raggrinzamento e l'atrofia in altri (640×).

Non è stato possibile osservare lesioni a carico degli elementi nervosi del midollo spinale o dei gangli sensitivi. Il metodo di Marchi non ha messo in evidenza lesioni delle fibre mieliniche nel sistema nervoso centrale; probabilmente perchè la morte sopravveniva in un periodo di tempo più breve di quello richiesto per l'apprezzamento di lesioni con tale tecnica.

Riassunto

Gli AA. hanno studiato l'effetto di forti dosi di vitamina A sul sistema nervoso centrale. Furono repertate gravi lesioni nella corteccia cerebrale e cerebellare, nei nuclei grigi centrali e in quelli del mesencefalo, ponte e bulbo.

ZUSAMMENFASSUNG

Schädigungen im zentralen Nervensystem des Meerschweinchens bei der Hypervitaminose A. Von A. Brusa und F. Testa.

Schwere Schädigungen sind gefunden worden in der Rinde des Gehirns und des Kleinhirns, im Thalamus und im Mesencephalon.

CONCLUSION

Des lésions dans le système nerveux central pendant l'hypervitaminose A. Par A. Brusa et F. Testa.

Des graves lésions ont été trouvées dans le cortex cérébral et cérébelleux, dans le noyau du thalamus, ainsi que dans le cerveau moyen.

SUMMARY

Lesions of the Central Nervous System in Guinea Pigs with Hypervitaminosis A. By A. Brusa and F. Testa.

Hypervitaminosis A was accompanied by severe damage in cerebral cortex, cerebellum, thalamus and mesencephalon of guinea-pigs.

Do not translate bibliography

BIBLIOGRAFIA

Collazo J. A. und J. S. Rodriguez: Klin. Wschr. 1933. *12*, 1732. — *Ibid.:* Klin. Wschr. 1933, *12*, 1768. — *Maddock C. L., S. B. Wolbach and S. Maddock:* J. Nutrit. 1949, *39*, 117. — *Matteini M. e P. Arcangeli:* Riv. Crit. Clin. Med. 1951, *51*, 281. — *Moore T. and Y. L. Wang:* Biochem J. 1945, *39*, 222. — *Mouriquand G.:* Presse Méd. 1948, *56*, 737. — *Rodahl K.:* Nature 1949, *164*, 531. — *Ibid.:* J. Nutrit. 1950, *41*, 399. — *Studer A.:* Schw. Z. Path. u. Bakt. 1950, *12*, 799. — *Wolbach S. B.:* Proc. Inst. Med. Chicago 1946. *16*, 116. — *Ibid.:* J. Bones and Joint Surg. 1947, *29*, 171. — *Wolbach S. B. and C. L. Maddock:* Proc. Soc. Exp. Biol. a. Med. 1951, *77*, 825. — *Wolbach S. B. and M. D. Hegsted:* Arch. of Path. 1952, *54*, 30. — *Zunin C. et F. Testa:* Comm. al III° Congresso Nazionale Soc. Ital. Pat. 26 marzo 1953, Siena.

Burn-'41
Bib. No. 1307

Yale J. Biol. & Med. 13(16):817-830. 1941.

CHANGES IN THE STRUCTURE OF THE DEVELOPING TOOTH IN RATS MAINTAINED ON A DIET DEFICIENT IN VITAMIN A*

CASPAR G. BURN, A. UNDERHILL ORTEN, AND ARTHUR H. SMITH

It has been shown that diets completely deficient in vitamin A influence the growing incisor teeth of animals. Both Shibata[9] and Simola[10] described changes occurring in most of the tooth structures and particularly in the odontoblasts and pulp cells. Wolbach and Howe[11] showed, however, that the effect of this diet is chiefly on the enamel organ of the incisor tooth of rats and guinea-pigs, with secondary involvement of the odontoblasts. Gross and histological changes in the molar teeth have been described by Marshal[5] and by Mellanby[6] in animals fed a diet deficient in vitamin A. None of these investigators has dealt with the effects of a chronic type of vitamin-A deficiency on the teeth and other tissues.

The difficulties encountered in producing and in maintaining a chronic deficiency are many; nevertheless, it has been possible to maintain rats for a year in a state of known chronic vitamin-A deficiency by feeding minimal quantities of vitamin A. The gross changes that were found to develop in the incisor teeth of the older rats while on this diet were bizarre and unusual. It is our purpose, therefore, to describe the sequence of the gross and histological changes found in the incisor and molar teeth of these rats and to compare them with those occurring in normal rats and in the animals fed a diet completely deficient in vitamin A.

Experimental method.

The rats used in these experiments were from the Connecticut Agricultural Experiment Station strain. At birth, each of the litters was reduced to eight and only young rats from litters of 6 to 8 at weaning were selected for the experiment.

The rats were placed in individual cages and the vitamin-A-free diet plus a vitamin supplement was fed to each rat. The diet was composed of dextrin 51 parts, with 18 of vitamin-A-free casein, 27 of Crisco, and 4 of the Osborne and Mendel salt mixture. The supplement consisted of 800 mg. of brewers' yeast and 30 I. U. of vitamin D as viosterol. Each rat consumed

* From the Departments of Pathology and Physiological Chemistry, Yale University School of Medicine. A contribution from the Dental Study Unit.

the entire amount of supplement daily. To hasten the depletion of vitamin A in the experimental animals, vitamin A was either partially or wholly removed from the diet of the mothers during the nursing period. This also served in obtaining a more uniform experimental animal.

When the first definite signs of vitamin-A deficiency appeared in the young rats, as manifested by a cessation of growth, a slight decline in weight, the development of photophobia, or a predominance over 4 days of cornified cells in vaginal smears, small known quantities of vitamin A (cod-liver oil) were given by mouth with care to assure a quantitative consumption of the oil. The amount of oil given daily to each rat was determined largely by its clinical appearance. A further description of the experimental procedure has been described in an earlier publication.[7] The rats on the diet completely deficient in vitamin A were litter mates of the A-low animals. They were allowed to develop the typical vitamin-A deficiency, inasmuch as they received no vitamin-A supplement at any time. The normal control rats were given the same diet, except that a daily dose of 300 I. U. of vitamin A as cod-liver oil was added.

Groups of five each of the experimental and control rats were anesthetized with ether and killed by bleeding from the heart at the ages of 15, 25, 40, 55, 70, 85, 100, 200, and 365 days, respectively. Each rat was autopsied and the tissues were preserved in 10 per cent formalin. The mandible and maxilla of each animal were carefully removed and the teeth, together with the supporting structures, were prepared for histological examination. The methods used in the decalcification and preparation of the teeth have been described previously by Arnim.[1] All blocks were serially sectioned and every tenth section was stained routinely with hematoxylin and eosin. An occasional section was stained by the Masson trichrome technic.

Serial sections of both the molar and incisor teeth of the upper and lower jaws were prepared; 74 rats in the A-low group and an equal number of animals in the control group were studied. The jaws obtained from 12 rats with acute vitamin-A deficiency were treated in the same manner. Tissue preparations were made of the viscera of many of the rats in all three groups.

Results

In general, the rats kept on the A-low diet were fairly well nourished and well developed. Some of the older animals showed a few external changes, such as tumor-like masses in the jaws, purulent discharge from the nares, and occasionally a discharging fistula in the lower abdominal region. The A-free rats, on the other hand, appeared in somewhat poorer physical condition, and showed nasal discharges, eye lesions, and greatly roughened coats. All of the normal rats were well developed and nourished with the exception

of an occasional rat of the year-old group that showed a slight serous discharge from the nares.

Gross and microscopic changes in the incisor teeth

The incisor teeth of rats killed at 15, 25, and 40 days of age showed the usual characteristic normal yellow translucency. The deep orange pigmentation became pale yellow and the teeth lost their translucency at 55 days, but at 70, 85, and 100 days the teeth became completely white and opaque. Ridging and irregularities of the lower incisors were first seen at autopsy in one of the 85-day rats, and a loosening of one of the upper incisors in a 100-day animal. Loss of an incisor tooth was found first in a 150-day rat. Bizarre shapes, twistings, irregularities in position, looseness, and loss of teeth were more frequently observed in rats 200, 300, and 365 days of age. Some of the incisors were both longitudinally and transversely ridged. Occasionally an extra incisor appeared at the side of the original tooth. A few of the teeth appeared sharply constricted at the gingival margin and were easily fractured post mortem. The edges of the teeth were irregular and jagged, and chipped readily. Pulp canals became exposed in animals between 100 and 365 days of age. Large, firm, non-sensitive tumor masses were found in the maxillae and mandibles of 9 mice of the 200- and 365-day groups. The teeth of the older rats varied in the extent of change from slight alterations in color and translucence to extreme bizarre twisted forms and even to loss of the teeth. The gross changes observed in the incisor teeth of rats fed the diet completely deficient in vitamin A consisted only of a loss of pigmentation and translucence. The incisor teeth of rats in the stock and in the A-adequate groups retained the deep orange pigmentation and normal luster.

The sequence of events in the development of the microscopic changes occurring in the rats fed the low vitamin-A diet for various lengths of time is given in the following descriptions.

15, 25, and 40 days. The enamel organs of these animals showed no apparent changes. Histologically, they were made up of an external layer of tall columnar ameloblasts and large epithelial cells of the papillary layers (Fig. 1). The external ameloblasts were regularly arranged and deeply pigmented and retained their normal appearance to within a few millimeters of the gingival margin. Odontoblasts of both the labial and lingual part of the incisor were regularly arranged and showed processes extending into the dentinal layers. The dentine was stained a homogeneous pink with

fine globular areas of calcification. The pulp consisted of embryonic fibrous connective tissue in which the capillaries were more prominent.

55 and 70 days. Evidence of histological change in the incisor teeth appeared in both the enamel organs and odontoblasts at 55 days. The change was manifested by multiple focal areas of atrophy and degeneration of the external and papillary ameloblastic cells (Fig. 2). The early lesions consisted of an irregularity in the arrangement of the columnar and papillary epithelial cells, which later showed atrophy and disintegration into amorphous material. Calcific, globular masses of enamel of varying sizes were present in these areas of degeneration. Changes were predominantly in the convexity and the posterior part of the incisor teeth, while the remaining ameloblasts were tall, columnar, and apparently unaffected.

The histological alterations of the pulp showed that the lingual odontoblasts were atrophic and their processes markedly shortened. Small, irregular, pale-staining osteo-dentinal structures appeared in the odontoblastic areas of the pulp tissue. In the 70-day-old rats, these cells appeared even more atrophic and sometimes completely absent, so that the connective tissue of the pulp was approximating the dentine. On the other hand, the odontoblasts of the labial portion of the incisor tooth appeared elongated and were hyperplastic. The dentine of the lingual portion of the tooth was decreased in width and showed many irregular borders of resorption. Inclusions of odontoblastic cells surrounding masses of dentine-like structures were found in the pulps of both the upper and lower incisor teeth in most of these rats. Other histological changes noted were the greatly engorged blood vessels situated between the connective tissue of the enamel organ and the bony trabeculae (Fig. 3). Large blood sinuses and cyst-like structures extended into and replaced parts of the enamel epithelium. Connective tissue adhesions between the enamel and the labial dentine resulted in the distortion of both these structures with osteo-dentinal structures.

85 and 100 days. The enamel organs in these two age groups showed a greater degree of localized degeneration and calcification than did those in the previous group. One rat showed evidence of a diffuse atrophy and metaplasia of the ameloblasts, which appeared more anteriorly in the enamel organ. The odontoblastic cell changes in the 85- and 100-day rats also were greatly increased and more severe than those of the previous groups. Atrophy and complete

absence of the odontoblasts in the lingual portion and thinning of the dentine in this area were the outstanding changes. In a few of the incisor teeth, the lingual dentine had been completely destroyed, so that areas varying in size intervened in which the connective tissue of the pulp was adjacent to the supporting structures of the maxilla or mandible. The labial odontoblasts were markedly hypertrophied and their processes extended into the thickened predentinal structures. The dentine of the labial part of the tooth was greatly widened with the formation of several coarse waves which were reflected in the enamel organs. Inclusions of odontoblasts and dentinoid structures were abundantly distributed throughout the connective tissue of the pulp. These histological changes of odontoblasts and pulp were even more marked in the lower incisor teeth of these two age groups.

200 days. Both focal and diffuse changes of the enamel organ occurred in the upper incisors at this age. A few rats showed the usual areas of focal degeneration and calcification in the enamel organ, while others showed a more diffuse change with conversion or replacement of the tall columnar cells by a stratified squamous epithelium. Irregular, calcified globules of enamel of various sizes were distributed throughout the basal connective tissue layers of the organ (Fig. 4). The ameloblasts of the lower incisors were less extensively involved; the changes consisted only of a few focal areas of degeneration. Odontoblasts in the upper and lower incisors showed extreme changes. The lingual odontoblastic cells were completely absent and the dentine was resorbed, leaving gaps in the tooth structure, thereby permitting the pulp connective tissue to grow without restraint into the surrounding structures of the mandible or maxilla. The labial odontoblastic cells were irregular in their arrangement and showed evidence of atrophy. The dentine of this portion of the tooth structure had greatly widened to four or five times the normal thickness. Furthermore, it had formed new dentine and osteo-dentinal structures. Several coarse curvatures of the enamel organ and of the labial part of the dentine were also observed in some of the teeth.

365 days. All the variations in the histological picture found in the incisor teeth of the previous animals were present with much greater intensity in the animals that had been maintained for one year in a state of chronic vitamin-A deficiency. The existing structure of the upper and lower incisor teeth in several of the rats consisted only of a greatly thickened labial dentine, with very coarse

curvatures, folds, and irregularities (Figs. 5 and 6). The lingual portions of the dentine had been destroyed and replaced by an overgrowth of connective tissue characteristic of the pulp. Histologically, in a few of the rats, the structure of the incisor teeth was completely destroyed (Fig. 7). Isolated germinal tooth follicles, developed from Hertwig's sheath, showed a tendency to form mature tooth structures in some instances (Fig. 8). Some of the teeth appeared narrowed and constricted at the gingival margin. The epithelium of the gingiva around some of the distorted teeth was necrotic, ulcerated, and infiltrated with numerous polymorphonuclear leukocytes. Although the pulp canals in a few of the incisor teeth were exposed to the oral cavity, histological evidence of a diffuse pulpitis occurred in only two of the rats. The engorged and dilated blood sinuses present at the base of the connective-tissue layer of the enamel organ in the younger rats were not seen in these year-old rats, since dense granulation tissue had developed within these areas. Stratified squamous epithelium lined the entire portion of the enamel organs of the incisor teeth.

Tumors. The earliest overgrowth of pulp tissue was seen in the teeth in which the lingual dentine had been partially destroyed (Fig. 9). It was through these spaces that the embryonic pulp tissue grew into the surrounding connective tissue structures of the maxilla or mandible. The tumor cells were long and spindle-shaped with pale blue cytoplasm and blue vesicular nuclei similar in appearance to the pulp cells (Fig. 10). Mitotic figures were occasionally seen, even in this very hyperplastic type of growth. The cells at first grew diffusely and without any order or arrangement throughout the soft tissues lying adjacent to the incisor teeth, while the more widespread tumor growth replaced the bony trabeculae and connective tissue within the maxilla and mandible. These were the enlargements of the maxillae observed grossly during the life of the rat. None of the growths penetrated into the sinuses or nares, but they did grow anteriorly and ulcerated the gingiva near the base of the tooth. In spite of the extensive polymorphonuclear infiltration of the surrounding tissues, other evidence of infection in these overgrowths was very unusual.

Tooth-like structures found in many of the tumor growths varied widely in the different rats. Some of the tumors were composed largely of embryonic connective-tissue cells of the pulp and resembled cellular fibroma. Others contained predominantly large dentinal and osteo-dentinal structures similar to those seen in the

pulp tissue of the younger rats. The majority of the tumors, however, contained odontoblastic and epithelial inclusions that surrounded newly formed predentine. Some of the aggregates of cells were composed of large, flat, indistinct epithelial cells which were surrounded by dentinal tissue, staining a pale pink, and at the periphery by odontoblastic cells, staining a deep blue. Other structures consisted of typical tooth germinal follicles and groups of flattened epithelial cells with central zones of keratin formation (Fig. 11). Masses of keratin and dentine were found frequently in the connective tissue of these tumors. The histological changes, therefore, revealed both a degenerative and a reparative process occurring in the new growths, thus resembling the effects known to occur after the administration of vitamin A to rats deficient in this vitamin.

Of the 74 rats of the A-low group in which the incisors were examined histologically, 27 (36 per cent) showed tumor growths; 32 per cent occurred in the upper jaw, and 28 per cent in the mandible. Fifteen (20 per cent) of the rats developed tumor growths in both the upper and lower jaws. Differences in the frequency of tumors between the right or left incisors could not be detected. The chief difference in the upper and lower incisors was the time of appearance of changes in the enamel organ. Focal areas of degeneration in the ameloblasts were recognized in the upper incisor as early as the 55th day, but they were not found in the lower incisors before 100 days. On the other hand, the odontoblasts showed histological change in both the upper and lower jaws at 70 days.

The relation of the duration of the feeding of the A-low diet to the severity of tissue change in the teeth is given in the following table:

TABLE I

RELATION OF TIME ON DIET TO SEVERITY OF LESIONS AND TUMOR FORMATION

Duration of feeding	*Total No. of rats*	*Negative for changes*	*Slight to moderate changes*	*Severe changes and tumor*		*Total No. with tumors*	
Days		*No.*	*No.*	*No.*	*%*		*%*
15, 25, and 40	9	9	0	0	....	0	....
55 and 85	11	0	8	3	27	0	....
100 and 150	11	0	5	6	54	4	36
200 and 250	14	0	7	7	50	5	35
300 and 365	29	0	11	16	58	18*	62

* Tumors diagnosed by biopsy from two rats.

The gross and histological changes in the incisor teeth of the rats fed on a diet completely free of vitamin A are as follows:

57 to 93 days. The incisor teeth were pale yellow or white at death. No irregularities or unusual gross changes were seen. The epithelium of the enamel organ in the majority of rats of this group showed focal areas of atrophy, degeneration, and calcification. A few of the rats, however, showed a more diffuse type of atrophy of the ameloblasts with a metaplasia to a squamous type of epithelium. These changes were chiefly found in the upper incisors, with very early focal degenerative processes beginning in the lower teeth. Odontoblasts of the labial portion of the incisors were not changed. The lingual odontoblasts of both the upper and lower teeth were decreased in size but did not entirely disappear. Inclusions of odontoblasts and dentinal structures were found in the pulp tissue of all the incisors. Some infoldings and irregularities were present at the basal formative end of the upper incisor teeth. None of the teeth showed complete loss of dentine or tumor growth. The blood vessels in the pulp and in the connective-tissue base of the enamel organ were greatly engorged. These histological changes are comparable, therefore, to those found in the rats fed the low vitamin-A diet for a period of about 85 to 100 days.

Histological examination of the teeth of the control rats of the same age groups showed no unusual tissue changes. The ameloblasts and odontoblasts of the teeth were well preserved and regularly arranged. The dentine was evenly calcified and showed a narrow predentinal area.

Gross and microscopic changes in molar teeth

Gross changes in the molar teeth of the control and experimental rats were not found, but there were two kinds of changes histologically in the A-low rats. The most frequent changes occurred in the second and third molars and were characterized by the intense deep blue staining of the enamel remains and of the underlying dentine. This alteration was found occasionally in the older rats of the control groups, and was consistently present in the A-low group of animals. Only two of the molar teeth were carious with resultant exposure of the pulp canal, necrosis of the pulp, and peri-apical abscesses. The cuticle was the only remaining part of the enamel in the preparations of the normal teeth. The ameloblasts of the

unerupted molars did not show any apparent histological change in the very young rats, inasmuch as the deficiency had not fully developed.

The most striking histological change found in the molar teeth was the focal resorption of the cementum and dentinal structures of the roots, with fibrous connective-tissue proliferation in these areas (Fig. 12). An increase in this lesion was shown in the rats that were kept on the A-low diet for a prolonged period. Early lesions of resorption were occasionally seen in the older rats of the normal control groups.

Of the 72 A-low rats in which the molar teeth were examined histologically, 59 (81 per cent) showed areas of resorption in the roots, and 53 (73 per cent) exhibited deeply stained enamel remains. The rats fed the diet free of vitamin A showed an increase in frequency of these blue-staining enamel remains, but only an occasional area of resorption was observed in the roots. Of the control rats, 11 (30 per cent) showed small focal areas of root resorption and 7 (19 per cent) showed enamel which stained a deep blue.

Changes in the peri-odontal tissue

Gingival tissues of the A-low rats showed only a slight degree of histological change, except in the areas near the fractured or unerupted incisors in which ulceration and superficial infection occurred. In a few animals this inflammatory process involved the epithelial attachments and extended along the peri-odontal tissues for a short distance. The gingival epithelium showed some increase in cornification.

Resorption and fibrosis of bone were present in the maxillae and mandibles of the A-low rats. There were areas of decalcification and many osteoclasts with fibrous connective-tissue proliferation replacing the bony trabeculae. The extent and degree of these changes depended on the survival time of the rats.

Changes in other tissues

Changes found in the mucous membranes and soft tissues of the rats fed the A-low diet may be described as an incomplete metaplasia of the epithelial cells of the lining mucous membrane together with the findings associated with a superimposed bacterial infection. The epithelial cells lining the sinuses, bladders, and renal pelves showed

atrophy and irregularity in arrangement of the cells and also a marked proliferation of the basal epithelium where cells showed many mitotic figures. Complete metaplasia into the keratinizing epithelium was seen occasionally in the year-old animals of the A-low group and was particularly noticeable in the sinus and bladder epithelium. On the other hand, the epithelial cells lining the salivary ducts, trachea, bronchioles, and intestinal tract of the A-low rats showed minimal alteration, except for an apparent increase in the goblet cells. Epithelial cells lining the viscera and the endocrine organs were not significantly altered. The vitamin-A-deficient rats showed complete metaplasia to the squamous epithelium in their sinuses, bladders, renal pelves, and salivary ducts. Inflammatory reaction dominated the picture in all of these A-free rats.

Gross and microscopic evidence in the A-low and A-free rats was found chiefly in the sinuses, middle ears, lungs, and pelvic organs. Even the normal rats showed purulent sinusitis, middle ear infections, and lung abscesses, particularly in the year-old group. Otitis media of the A-low group was bilateral in 11 and unilateral in 23 of the rats. One of the infected ears contained an otolith. Bladder stones were found in 23 per cent of the A-low rats and in 4 per cent of the kidney pelves. Infection of the pelvic region of these rats was manifested either by oöphoritis, vaginitis, or by peri-urethral abscesses. One animal developed a diffuse osteomyelitis involving the skull, sternum, and long bones. Only the rats fed the diet free of vitamin A showed xerophthalmia. Abscesses throughout the visceral organs, with exception of the lungs, were not found in either the A-low or A-free rats. The blood vessels failed to show any change.

An unusual tissue change, found only in the A-low rats, was the large number of mast cells in the connective tissue of the sinuses, mediastinum, submucosa of the intestine, stomach, and other mucosal surfaces. These cells were readily distinguished by the large basophilic granules that sometimes completely masked the nucleus and cytoplasm. There was, however, considerable variation in size and in number of the granules in the individual cells. Occasionally, these basophilic granules were liberated from the cell and were found free within the connective-tissue stroma. Some appeared to have entered the fibrous connective-tissue sheaths to form a chain of three or four cells. The first evidence of increase of these cells in the tissue appeared in the 70-day rats, and the greater the length of time they were on this diet, the more numerous were the cells.

Discussion

These studies show that there are histological changes in the incisor teeth of rats fed a diet poor in vitamin A that are indistinguishable from those observed in groups deprived of vitamin A. All of the changes in the teeth described by Wolbach and Howe[11] as typical of a complete vitamin-A deficiency were readily demonstrated in the chronic vitamin-A-deficient animals. However, further changes developed in the incisor teeth of the A-low group as a result of the prolonged chronic deficiency. The prolonged mild deficiency in these animals permitted a study of the development of the more extreme changes that might have occurred after a complete deficiency had the rats survived longer. Deformed and bizarre teeth, tumors in the jaws, and even supernumerary teeth were some of the end-results.

Whether the depletion of the tissues in vitamin A was the only factor in accounting for these changes in the incisor teeth of the A-low rats cannot be definitely stated. Some of the histological alterations observed in the pulp canals of the incisor and molar teeth of the chronic vitamin-A-deficient rats suggest that a vitamin-C deficiency may also have been present. The extreme sensitivity of the odontoblasts of the pulp to minimum quantities of vitamin C in the diet has been demonstrated by Höjer.[8] Other changes, such as atrophy and irregularity of growth of the odontoblasts in the molar teeth, pericemental resorption along the molar roots, varying degrees of bony change and fibrosis, and a tendency to a microscopical hemorrhagic diathesis as found in these A-low rats, point to a possible chronic vitamin-C deficiency. It is conceivable, therefore, that when rats are deprived partially or entirely of vitamin A, they will be unable to synthesize sufficient quantities of vitamin C to prevent the onset of a mild deficiency. It is of interest that Wolbach and Howe[11] found no changes in the odontoblasts of guinea-pigs on a vitamin-A-deficient diet in which there was an ample supply of vitamin C in the form of orange juice.

The formation of the tumor growths in the jaws of the A-low rats was associated with atrophy and disappearance of the lingual odontoblasts and with complete resorption of the dentine. This allowed the embryonic pulp connective tissue to grow freely into the surrounding supporting structures of the jaws. Although some of the growths were unusually cellular and invaded the adjacent tissues of the jaw in a disorderly manner, there was no evidence that

the tumor growths were malignant or even of neoplastic origin. They are autogenous transplants of pulp connective tissue with the potentialities of forming new germinal tooth centers and even mature tooth structures such as dentine and osteo-dentinal tissue. They differ from the autogenous transplants described by Huggins, McCarroll, and Dahlberg[3] inasmuch as the growth in our experiments is in direct connection with the original germinal center of the incisor teeth. It is probably the force exerted by the continuously growing embryonic pulp tissue, encased by a rigid and greatly thickened lobulated dentine, together with the complete resorption of the lingual dentine, that allows the herniation and growth of the pulp about the surrounding tissues of the mandible or maxilla. The frequent trauma to the incisors, losses of teeth, infection, exposure of pulp canals, and other factors, undoubtedly contribute to the development of abnormal growths of tooth structures.

None of these unusual changes occurred in the molar teeth of any of the chronic vitamin-A-deficient rats. These teeth had fully formed before the effects of the diet could influence their structures. Furthermore, it is questionable whether the intense staining of the enamel remains and of the dentine of the molar teeth and the focal absorption of the roots, best seen in the older animals of the chronic vitamin-A group, were primarily related to the diet poor in vitamin A. The influence of malocclusion resulting from the abnormal growth and loss of the incisor teeth must be considered as an important contributing factor in these molar changes. True caries was not found in the teeth of any of these A-low rats.

The other tissues of the rat showed changes chiefly in the epithelium of the mucosal surfaces. They consisted of acute and chronic inflammatory reactions, and of hyperplasia of the epithelium. Evidence of complete metaplasia of the mucosal epithelium was not demonstrated in the A-low rats even in year-old animals. The marked increase of the mast cells in the connective tissue of the mucous membranes and other structures of the body of the chronic vitamin-A rats suggests the absorption of toxic bacterial products from these heavily infected mucosal surfaces. Both Ringoen[8] and Levaditi[4] have been able to produce these cells in the tissues of animals that received repeated injections of foreign protein and bacterial toxins. Levaditi[4] obtained a 40 per cent mast cell leukocytosis following a single injection of toxin prepared from a strain of staphylococcus. It was this organism that was the predominant pathogen isolated from the mucous membranes of the A-low rats.

Restoration of vitamin A to the diet of the A-low group, particularly after the formation of abnormal teeth and tumor growth, was not undertaken in these experiments. It would have been of interest to ascertain the changes such bizarre teeth and tumor growths might have shown. The A-low rats that required larger quantities of the vitamin for survival seemed to have greater ability to form mature tooth structures within the tumor growths. There were many that had new germinal tooth centers and odontoblastic formation with predentinal and dentinal-like tissue, although ameloblasts and enamel formations were not found in these growths.

Summary

1. A mild, chronic vitamin-A deficiency was produced and successfully maintained in rats for periods as long as one year. This procedure served as an excellent means for following the gross and microscopic pathologic changes which develop as the result of insufficient dietary vitamin A.

2. Striking gross and microscopic changes were observed in the incisor teeth. There occurred progressively a loss of pigmentation and of translucency, twisting of the teeth, both transverse and longitudinal ridging, exposure of the pulps, and constrictions, and eventual exfoliation of the erupted portion of the tooth. The older animals developed large odontomas.

3. Microscopic changes occurred in the enamel organ and in the odontoblasts of the incisor teeth. Focal areas of degeneration of the ameloblasts developed, with a progressive, more diffuse change in the older animals. The lingual odontoblasts became atrophic and completely disappeared. The labial odontoblasts were regular, but enlarged and hyperplastic.

The lingual dentine was resorbed and eventually disappeared, thus permitting the embryonic pulp cells to grow unrestrained into the surrounding soft tissues of the jaw to form tumor masses. These odontomas occurred in 62 per cent of the animals of advanced age. Of these, 55 per cent had developed tumors in both jaws.

The odontoma was characterized by an embryonic type of connective tissue similar in appearance to that of the pulp tissue, with inclusions of odontoblasts, epithelial cells, keratin, dentinal formations, and newly formed tooth germinal centers. In a few cases supernumerary teeth developed.

4. The molar teeth showed no gross changes; microscopically, intensely staining dentine and enamel remains and also focal resorption of the cementum and roots, were observed.

5. Other gross abnormalities noted in the chronic vitamin-A-deficient animals include bladder and renal calculi, subcutaneous abscesses, infection in the upper respiratory tract and ears, and mucopurulent plugs in the trachea.

6. Histologically, changes observed in the tissues included incomplete metaplasia of the epithelial surfaces and an associated infection. Mast cells in increased number were present throughout the connective tissue.

References

1 Arnim, S. S.: A method for preparation of serial sections of teeth and surrounding structures of the rat. Anat. Rec., 1935, *62*, 321.

2 Höjer, A.: Method for determining the antiscorbutic value of a foodstuff by means of histological examination of teeth of young guinea pigs. Brit. J. Exper. Path., 1926, *7*, 356.

3 Huggins, C. B., McCarroll, H. R., and Dahlberg, A. A.: Transplantation of tooth germ elements and the experimental heterotopic formation of dentine and enamel. J. Exper. Med., 1934, *60*, 199.

4 Levaditi, R.: Contributions à l'étude des Mastzellen et de la Mastzellen leucocyte. Thése, Paris, 1902 (Cited by Ringoen).

5 Marshal, J. A.: Dental caries and pulp sequelae resulting from experimental diets. J. Am. Dental Asso., 1927, *14*, 3.

6 Mellanby, M.: The influence of diet on the structure of the teeth. Physiol. Rev., 1928, *8*, 545.

7 Orten, A. U., Burn, C. G., and Smith, A. H.: Effects of prolonged chronic vitamin A deficiency in the rat with special reference to odontomas. Proc. Soc. Exper. Biol. & Med., 1937, *36*, 82.

8 Ringoen, A. R.: The mast leucocytes in the adult guinea pig under experimental conditions. Am. J. Anat., 1923, *31*, 319.

9 Shibata, M.: Effects of lack of vitamins on development of teeth. Japan. J. Exper. Med., 1931, *9*, 21.

10 Simola, P. E.: Über die Knochen und Zahnveränderungen bei A-and B-Avitaminose. Biochem. Ztschr., 1932, *254*, 245.

11 Wolbach, S. B., and Howe, P. R.: The incisor teeth of albino rats and guinea pigs in vitamin-A deficiency and repair. Am. J. Path., 1933, *9*, 275.

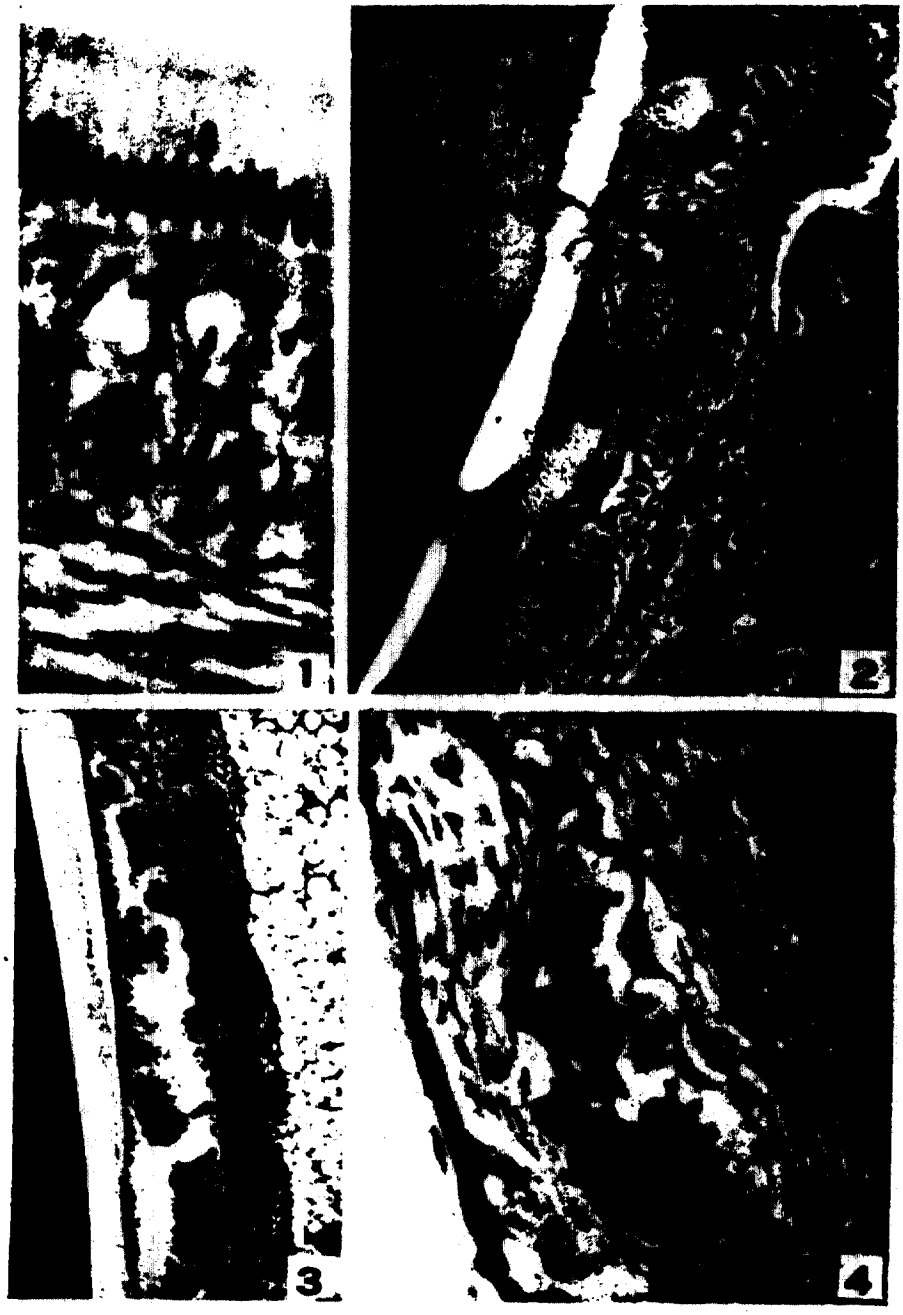

FIG. 1. Enamel organ of rat, on an adequate diet, showing normal ameloblasts and papillae. × 475.

FIG. 2. Focal changes in enamel organ of the vitamin-A-low rat. × 100.

FIG. 3. Blood sinus in enamel organ of 70-day-old vitamin-A-low rat showing metaplasia of ameloblasts. × 70.

FIG. 4. Metaplasia of ameloblasts and calcific globules in enamel organ of year-old, chronic vitamin-A-deficient rats. × 475.

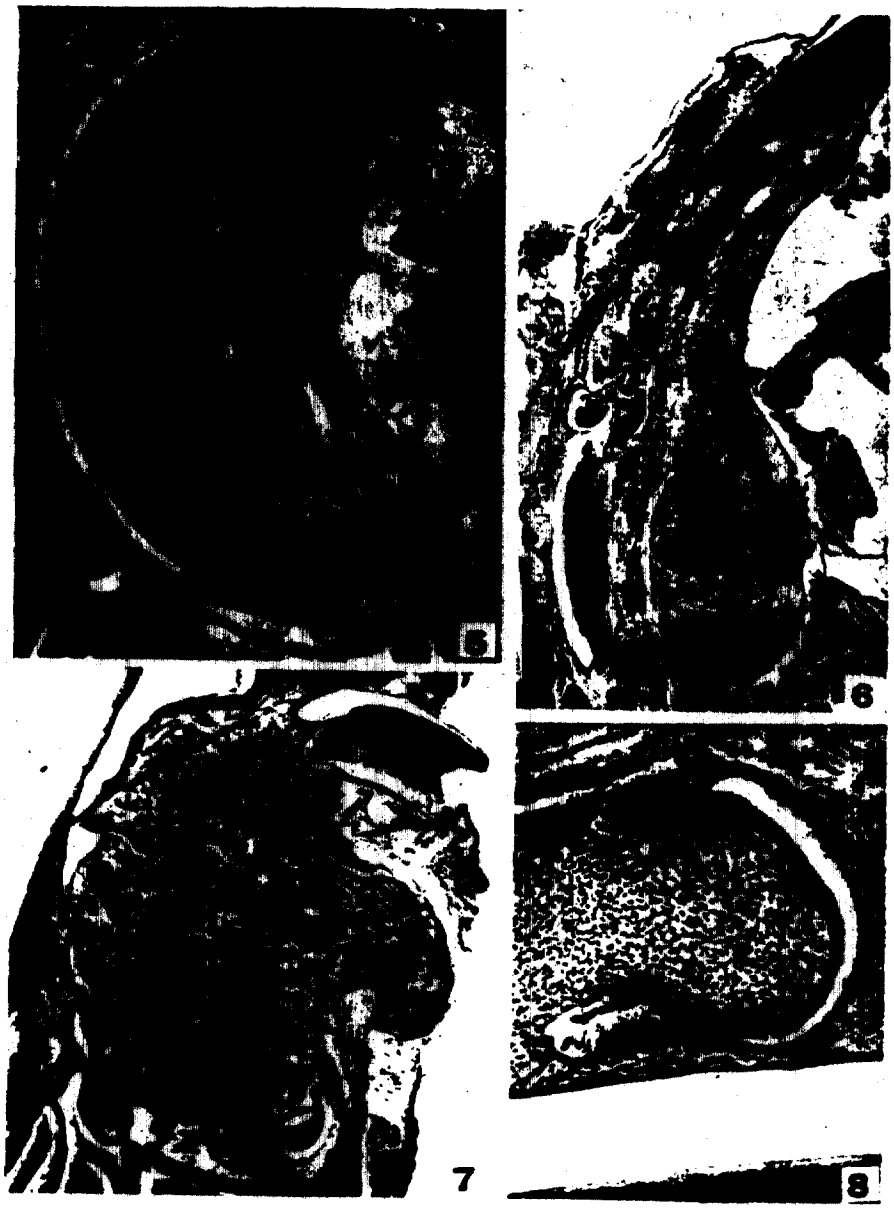

FIG. 5. Upper incisor of a year-old vitamin-A-low rat. Thickened lobule dentine, resorption of lingual dentine with overgrowth of pulp. × 10.

FIG. 6. Lower incisor of a year-old vitamin-A-low rat. Partial destruction of tooth with overgrowth of pulp tissue. 10.

FIG. 7. Upper incisor of year-old A-low rat with complete destruction of tooth by tumor growth. × 10.

FIG. 8. Isolated tooth germinal follicle in enamel organ of A-low rat. × 110.



FIG. 9. Upper incisor with resorption of dentine and unrestrained growth of pulp into maxilla. × 55.

FIG. 10. Section of tumor showing embryonic pulp cells. × 80.

FIG. 11. Upper incisor showing the formation of supernumerary teeth in vitamin-A-low rat. × 10.

FIG. 12. Resorption of fibrosis of molar root in a year-old vitamin-A-low rat. × 100.

Yale J. Biol. & Med. 14:89-99. 1941.

Burn-'41
Bib. No. 1308

THE INFLUENCE OF CHRONIC VITAMIN-A DEFICIENCY ON THE BACTERIAL FLORA OF RATS*

CASPAR G. BURN, A. UNDERHILL ORTEN, AND ARTHUR H. SMITH

Previous reports, reviewed in a recent symposium,[2] suggest that infection of the mucous membranes in vitamin-A-deficient animals is secondary to the well-known epithelial changes such animals display and that early in the course of this avitaminosis resistance to infection is reduced. A study[1, 7] designed primarily to follow pathologic changes associated with a prolonged, mild, chronic vitamin-A deficiency in rats afforded an opportunity to obtain further information on this question, as well as to determine the bacteriological changes which occur during the development and course of such a deficiency.

A detailed bacteriological examination of the mucosal surfaces and of the viscera of these rats was undertaken with the idea of ascertaining the value of this vitamin in infection. Furthermore, the prolongation of a mild vitamin-A deficiency would tend to establish a more chronic type of infection in the tissue and thereby give some additional information as to the nature of the immunological response elicited.

Methods

The following report deals with the bacteriological findings from the mucous membranes and viscera of 56 rats fed a diet poor in vitamin A, 95 litter-mates that were fed adequate amounts of vitamin A, and 10 rats whose diet had been entirely free of this vitamin.

Details regarding nutritional studies and feeding are presented in another report.[1] The rats were divided into four groups and designated as N-stock, the normal stock on a calf-meal diet; A-adequate, fed the synthetic diet with adequate vitamin A; A-low, those on the synthetic diet with maintenance doses of vitamin A; and A-free, those on the synthetic diet completely lacking in vitamin A.

The first rats to be sacrificed for bacteriological study were killed at 15 days, others were sacrificed after intervals of 25, 40, 70, 85, 100, 200, and 365 days. The animals in the A-free group died within 60 to 90 days.

*From the Departments of Pathology and Physiological Chemistry, Yale University School of Medicine. A contribution from the Dental Study Unit.

The routine bacteriological procedure follows: Immediately after death the rat was fastened to a board and the entire outside of the body bathed generously in lysol before removal of the skin. After the skin had been freed from the body, both the abdominal and chest cavities were exposed. Of the heart blood, procured with a sterile syringe and needle, 1 cc. was inoculated into a tube of Holman's meat medium and the remainder was retained for serological purposes. Portions of the lung, liver, spleen, and kidney were removed and placed in tubes of meat medium. Following examination of the viscera, the mucous membranes were exposed and scraped with a sterile platinum wire-loop. The bladder, vagina, upper portion of the jejunum, lower portion of the ileum, the colon, trachea, nasal sinuses, and middle ears were cultured. The sinuses and middle ears were approached by lifting the bony structure of the skull over the nose and ethmoidal sinuses. In addition to cultures, smears, stained by the Gram method, were made of all surface areas.

Surface blood agar plates were used for culturing the mucous membranes and the intestinal tract. This permitted a rough quantitative estimate of the predominating colonies grown from these sites. Identification and cultural studies of the organisms were made by the usual procedures.

Serological examination for the presence of agglutinins in the blood sera of the rats was made by a microscopic test. This was necessary because of the small amounts of sera available and because several bacterial strains were used, including *Bact. coli*, *Br. bronchisepticus*, *Staph. aureus*, *Ps. fluorescens*, and a *Strep. hemolyticus* procured from rat tissues.

The majority of the rats in the A-low, A-free, and N-stock groups were examined during the months of February to July of 1935. The rats in the A-adequate group were fed at a later period, and the majority were killed between November, 1935, and March, 1936. The colony of rats remained free of epidemics of respiratory or intestinal disease during the entire experimental period.

Samples of the diet mixtures and of the tap-water before and after feeding were taken for culturing in June, July, September, November, 1935, and January, 1936. Cod-liver oil and the yeast used in the diet were also examined bacteriologically.

Results

A marked increase in number and kinds of bacteria was found on the mucosal surfaces and in the viscera of the A-low and A-free rats.

The incidence of bacterial growth obtained from the mucosal surfaces of the sinuses, vagina, bladder, and middle ears of the experimental and control rats appears in Table 1.

TABLE 1

INCIDENCE OF BACTERIAL GROWTH ON MUCOUS MEMBRANES

Group of rats	Sinus		Vagina		Bladder		Ears	
	No.	% Pos.	No.	% Pos.	No.	% Pos.	No.	% Pos.
N-stock	47	73	40	90	41	27	40	12
A-adeq.	48	64	38	87	47	16	47	17
A-low	56	96	41	97	48	67	39	59
A-free	10	100	9	100	8	100	9	100

A significant increase in the frequency of bacterial growth for all four sites was encountered in the rats fed a diet either poor in or free from vitamin A. Bacterial cultures were also made from the tracheal mucosa, but were not included in these observations, since the method used in killing the animals caused aspiration of contaminated material from the nasopharynx into the trachea.

Although the incidence of growth obtained from the mucous membranes of the adequately fed vitamin-A rats was high, the number of colonies obtained on the surface blood agar plates indicated that the organisms were few. On the other hand, early in the course of feeding the vitamin-A-poor diet, a significant increase in the number of colonies was noted, until they became extremely numerous in the older animals. This increase in population on the mucosal surfaces was further substantiated by means of stained smears, as is evident from the data in Table 2.

TABLE 2

PER CENT FREQUENCY OF DEGREE OF GROWTH FROM THE MUCOUS MEMBRANES OF SINUS, BLADDER, AND VAGINA OF A-LOW AND NORMAL RATS

Age of rat (days)	A-low diet				Normal diet			
	No. of mucous membranes cultured	No growth	Colonies Few*	Colonies Many†	No. of rats	No growth	Colonies Few*	Colonies Many†
15	10	40	30	30	19	74	26	0
25	13	30	61	7	24	42	58	0
30	13	15	46	38	30	40	40	20
55	16	18	19	62	30	33	30	36
70	18	5	22	72	30	40	26	33
85	15	6	6	73	30	36	33	30
100	21	4	0	95	30	50	50	0
200	15	0	0	100	30	43	33	23
365	24	4	4	91	37	26	52	22

* Less than 50 colonies on plate.
† More than 50, to countless numbers on plate.

The variety of bacteria isolated from the two groups of rats als was distinctive. Whenever bacteria were grown from the mucos surfaces of the control animals, they included a large variety. The usually consisted of a few colonies of *Strep. viridans*, of Gram negative cocci, occasional *Staph. aureus* or *albus*, diphtheroids, an

TABLE 3

PER CENT FREQUENCY IN GROWTH OF PS. FLUORESCENS, STAPH. AUREUS, BR. BRONCHISEPTICUS, BACT. COLI, AND STREP. HEMOLYTICUS ON THE MUCOSAL SURFACE OF RATS FED A DIET ADEQUATE OR INADEQUATE IN VITAMIN A

Source of culture	*N-stock* (47)	*Adequate* (48)	*A-low* (56)	*A-fr* (10
	Ps. fluorescens			
Sinus	4	2	32	60
Vagina	17	2	56	66
Bladder	0	0	33	62
Intestine	29	4	39	60
Ear	0	0	12	55
	Staph. aureus			
Sinus	23	20	58	40
Vagina	10	18	36	11
Bladder	2	0	29	12
Intestine	27	33	50	40
Ear	2	1	13	11
	Br. bronchisepticus			
Sinus	40	37	41	40
Vagina	32	52	41	22
Bladder	0	0	14	12
Intestine	6	6	3	0
Ear	0	2	16	27
	Bact. coli			
Sinus	15	8	7	0
Vagina	67	50	31	0
Bladder	24	17	18	37
Intestine	100	100	89	100
Ear	0	0	2	0
	Strep. hemolyticus			
Sinus	0	10	5	0
Vagina	7	0	9	0
Bladder	0	0	8	0
Intestine	4	8	14	0
Ear	0	2	6	0

spore-forming aerobic bacilli; very infrequently some of the rats showed a few hemolytic streptococci. When present at all, the *Br. bronchisepticus* was the only organism occurring in significantly greater numbers. In contrast, the A-low and A-free groups of rats showed a dominance of one or two kinds of organisms, including *Staph. aureus*, *Ps. fluorescens*, and when present *Br. bronchisepticus*. Furthermore, when one mucosal surface showed a change in the bacterial flora, the others seemed to show a similar alteration.

The incidence of recovery of *Ps. fluorescens*, *Staph. aureus*, *Br. bronchisepticus*, *Bact. coli*, and *Strep. hemolyticus* from five of the mucosal surfaces of the rats of the control and experimental groups is presented in Table 3.

Bact. coli and *Strep. hemolyticus* were included in these observations for they demonstrated another type of bacteriological response to the diet. *Strep. hemolyticus*, although probably slightly increased in incidence, showed no evidence of numerical increase on the mucosal surfaces of either the A-low or A-free group of rats. *Bact. coli*, on the other hand, actually was decreased in incidence and number on all the mucous membranes, including the intestinal.

Further evidence to substantiate the decrease in incidence and number or organisms obtained from the mucosal surfaces is shown in Table 4.

TABLE 4

PER CENT FREQUENCY OF BACTERIAL STRAINS CULTIVATED FROM THE SMALL INTESTINE

Species of bacteria from intestine	*A-low diet (56)*		*Normal diet (94)*	
	No.	*%*	*No.*	*%*
Bact. coli	29	51	80	85
L. acidophilus	11	20	71	75
Ps. fluorescens	21	32	7	7
Staph. aureus	19	34	18	19

The table shows a significant decrease in the incidence and number of *Bact. coli* and *L. acidophilus* in the intestinal flora of rats fed a diet poor in vitamin A. *Staph. aureus* and *Ps. fluorescens* showed some increase in growth, but they were not found in very large numbers.

Cultures of the blood and viscera of the rats fed the diets inadequate in vitamin A also showed a greater incidence of bacteria than

did the control animals. The heart blood or viscera were positive in 67 per cent (38) of the rats in the chronic vitamin-A group, in 80 per cent (8) of the completely vitamin-A-deficient rats and in 28 per cent (29) of the control rats.

Table 5 shows the incidence of occurrence of *Ps. fluorescens*, *Staph. aureus*, *Br. bronchisepticus*, *Bact. coli*, and *Strep. hemolyticus* in the blood and organs of the four groups of rats.

TABLE 5

INCIDENCE OF BACTERIA IN BLOOD AND VISCERA

	A-low (38)	*N-stock and A-adequate* (29)	*A-free* (8)
Ps. fluorescens	14 (37%)	1 (3%)	5 (62%)
Staph. aureus	22 (57%)	4 (10%)	1 (12%)
Br. bronchisepticus	9 (23%)	6 (20%)	1 (12%)
Strep. hemolyticus	7 (18%)	3 (10%)	0
Bact. coli	4 (10%)	17 (58%)	2 (25%)

The bacteria that were found in the blood or viscera of the chronic and deficient vitamin-A animals were also present in large numbers on their mucosal surfaces. *Staph. aureus* and *Ps. fluorescens* were the predominant strains that invaded the tissues. *Br. bronchisepticus* and *Strep. hemolyticus* showed very little evidence of increased invasion. *Bact. coli* was markedly decreased in the viscera and paralleled the findings of other intestinal organisms.

The frequency of bacterial growth from the heart blood and viscera of the control and experimental rats is given in Table 6.

TABLE 6

INCIDENCE OF BACTERIAL GROWTH IN VISCERA

	No. of rats cultured	*Blood*		*Lung*		*Liver*		*Spleen*		*Kidney*	
		No.	*%*	*No.*	*%*	*No.*	*%*	*No.*	*%*	*No.*	*%*
N-stock	47	3	6	6	12	5	10	6	12	5	10
A-adeq.	48	1	2	9	18	5	10	7	14	7	14
A-low	56	3	5	18	32	18	32	15	26	27	48
A-free	10	3	30	6	60	5	50	3	30	6	60

The apparent difference between the A-low and A-free groups of rats becomes less significant when the rats of the A-low group, which are younger than 55 days, are removed from the analysis.

The only difference existing between these two groups is in the time required for maximum invasion to occur. Most of the A-free rats showed evidence of maximum bacterial invasion at the time of death at 55 to 90 days, while the chronic vitamin-A-deficient rats failed to show comparable findings until they had been on the diet for from 200 to 365 days.

Many tests were made to demonstrate in the sera of these rats agglutinins for *Ps. fluorescens*, *Br. bronchisepticus*, *Strep. hemolyticus*, and *Staph. aureus*. All were negative even though both stock and recently isolated strains of each organism were employed. On the other hand, antibodies for *Bact. coli* were readily demonstrated in the sera of 71 per cent of the chronic vitamin-A group, 66 per cent of the vitamin-A-deficient group, and 24 per cent of the controls. The antibodies were found first in the A-low rats at 55 days, while the controls failed to show them before 365 days.

Gross and microscopic evidence of inflammation of the mucous membranes of the sinuses, middle ears, and bladder was present in the majority of the rats on inadequate or deficient diets. Suppurative sinusitis was demonstrated in 38 (64 per cent) of those fed the A-poor diet and in all 10 of those on the completely deficient vitamin-A diet. None of the control animals showed gross suppuration in the sinuses, but 25 per cent exhibited histologically a definite acute inflammatory reaction in the mucous membranes. Similarly, 5 of the 18 rats of the A-low group showed evidence of an inflammatory reaction histologically. Although more than one kind of organism was isolated from the pus of the chronic and deficient vitamin-A rats, there seemed to be an apparent increase in the frequency of *Staph. aureus* with increasing evidence of suppuration.

Suppuration in the middle ears showed a significant increase in incidence for the A-low and A-free groups. Pus was found in one or both middle ears in 50 per cent of the chronic vitamin-A-deficient rats, 66 per cent of the A-free rats, and 22 per cent of the control animals. Cultures made from the pus of the middle ears in the control rats always contained a diphtheroid that had the cultural characteristics of *Corynebacterium murium*. Only occasionally were colonies of *Staph. aureus*, *Strep. hemolyticus*, and *Br. bronchisepticus* associated with the diphtheroid. The middle ears that were free of pus in these control rats failed to show bacterial growth. On the other hand, the cultures made from the pus found in the inadequately fed A rats showed *Ps. fluorescens*, *Staph. aureus*, and *Br.*

bronchisepticus, either in pure or mixed cultures. They were also present in ears grossly free of pus. *Corynebacterium murium* was found in only 33 per cent of the ears with pus, but this may have been the result of overgrowth by other organisms.

Table 7 shows the frequency of growth and kinds of bacteria isolated from the middle ears in the four groups of rats.

TABLE 7

PER CENT FREQUENCY OF GROWTH AND KINDS OF BACTERIA ISOLATED FROM MIDDLE EARS WITH AND WITHOUT SUPPURATION

Groups of rats	*Condition of middle ear*		*With growth*		*Kinds of bacteria in per cent*				
		No.	*No.*	*%*	*Ps. fluor.*	*Staph. aur.*	*Br. bron.*	*Strep. hem.*	*Diph.*
N-stock	Clear	67	1	2	0	0	0	0	100
	Pus	13	10	76	0	10	0	0	100
A-adeq.	Clear	70	0	0	0	0	0	0	0
	Pus	21	12	57	0	8	16	16	91
A-low	Clear	55	12	21	33	41	33	16	0
	Pus	28	26	92	23	23	38	11	30
A-free	Clear	9	7	77	57	42	42	0	2
	Pus	9	9	100	55	11	44	0	33

The only evidence of a toxemia from the heavily infected mucosal surfaces was the demonstration of mast cells in the tissues of the older A-low rats.

The possible origin of a few of the strains commonly isolated from the mucous membranes of the chronic and deficient vitamin-A rats is indicated by the kind of organisms that were recovered from the drinking water and from the diet mixture. Five bacteriological examinations of the water made at intervals of 4 to 8 weeks during the experiment showed *B. flavus* and *Ps. fluorescens* to be present in small numbers upon each examination. After the water, collected in a common distributing bottle, had been allocated to the individual cages, cultures were made from the water residue. It was found that an additional organism, namely, *Strep. hemolyticus* had been introduced during the procedure of watering the colony. Only rarely were staphylococci isolated from the water. The diet, which incidentally was mixed with the hands, contained predominantly a saprophyte, an aerobic Gram-positive spore-forming bacillus, probably *B. megatherium*. *Staph. aureus* was found consistently and

usually in fairly large numbers in the food. *Strep. hemolyticus*, yeast, molds, and several unidentified bacteria were obtained in small numbers upon each examination.

Discussion

These experiments reveal many similarities in the bacteriological findings from the chronic vitamin-A-deficient rats and the complete vitamin-A deficiency group. The A-low rats are of particular value for the study of the relation of vitamin A to infection, as the progression of the changes occurring on the mucosal surfaces and in the tissues is sufficiently retarded to suggest an association between bacterial alterations and animal resistance.

One of the important differences recognized between the A-low rats and the complete vitamin-A deficiency group was the absence of widespread suppuration in the tissues of the rats fed a diet poor in vitamin A. It has been the experience of most investigators that suppuration due to a pyogenic organism is the most frequent kind of spontaneous infection in vitamin-A-deficient rats. Green and Mellanby[5] have demonstrated widespread distribution of such lesions throughout the body of vitamin-A-deficient rats. Death invariably resulted from overwhelming infection unless a rich supply of vitamin A was added to the diet. If the infection had not become too widespread, the administration of vitamin A would apparently control the infection and the lesions would heal. The daily minute quantities of vitamin A given to our A-low rats not only controlled the infection, but prevented widespread distribution of the lesions. However, individual variations in response occurred both in the daily quantity of vitamins required and in the extent of the lesions.

It is believed that the *Ps. fluorescens* and *Br. bronchisepticus* were secondary invaders and that the organism of greatest importance as an etiological factor was the staphylococcus. The latter was the predominant organism in both the A-low and A-free groups of rats in these experiments and was found widely disseminated throughout the tissues of the A-low rats, particularly the older ones of the group. However, none of the organs in which these bacteria were found showed gross or microscopic evidence of suppuration. Only two of the A-low animals were known to have died as the result of an overwhelming septicemia. Another manifestation of

infection in the tissues of the A-low rats was the presence of mast cells, believed to be evidence of a toxemia. Increases of mast cells in the tissues and blood of rats have been produced experimentally by Levaditi[5] from a single injection of toxin from a known strain of staphylococcus.

The resistance induced in the A-low and A-free rats by the administration of vitamin A is believed not to be the result of specific action on the toxin or the invasive properties of the bacteria, but to be due to non-specific stimulation. The nature of this type of immunity is not known, but it is apparently capable of acting upon many kinds of experimentally produced infection in vitamin-A deficient animals. It is manifested in the tissues of the host by a tendency to localize the lesion. Only small quantities of vitamin are necessary to maintain this resistance and insure the survival of the animals. The disappearance of certain kinds of bacteria from the mucous membranes and tissues of the A-low rats may be the result of other chemical changes in the body initiated by the unbalanced vitamin-A diet. Both *Bact. coli* and *L. acidophilus* have been found to be significantly decreased in the intestinal flora of rats in other dietary conditions. Friedman[4] found *Bact. coli* to be decreased in rachitic rats, and Eppright, Valley, and Smith[3] found a similar decrease of *L. acidophilus* in rats kept on a low-salt diet. They found that calcium and phosphorus were important salt components for sustaining *L. acidophilus* in the intestinal flora. Histological examinations of the teeth and tissues of the A-low rats[1] indicate mild vitamin-C deficiency. It is apparent, therefore, that it is difficult to correlate infection with the lack of vitamin A until a more detailed analysis of the many chemical changes that occur in the A-low rats is carried out.

Summary

1. Bacteriological studies have been made on rats in which a mild chronic vitamin-A deficiency was produced and maintained for periods up to one year. The results have been compared with those obtained from control animals exhibiting the typical vitamin deficiency and from normal rats.

2. During the year the chronic deficient animals showed a progressive increase in the number of bacteria on the mucous membranes and in the tissues. Bacterial invasion into the organs and tissues change compatible with a toxemia were consistently found in the

older rats. At the end of a year, the bacteriological findings were indistinguishable from those of the acute vitamin-A-deficient animals.

3. There was a shift in the bacterial flora, from few colonies of a variety of organisms in the normal control animals to many colonies of *Staph. aureus* and *Ps. fluorescens* predominantly, both in the animals with the chronic deficiency and in those with the acute deficiency. In the latter animals there was also a marked decrease in *Bact. coli* in the intestinal flora and on all the mucous membranes. *Strep. hemolyticus* remained unaffected.

4. Suppurative lesions, chiefly in the sinuses and middle ear, were found in the majority of the older chronic vitamin-A-deficient rats. *Staph. aureus* is believed to be the organism of primary etiological importance, while *Ps. fluorescens*, *Br. bronchisepticus*, and other bacteria are considered to be secondary invaders.

5. The bacterial changes closely followed the changes induced in the epithelial lining of the mucosal surfaces by the low vitamin-A diet.

References

1 Burn, C. G., Orten, A. U., and Smith, A. H.: Yale J. Biol. & Med., 1940-41, *13*, 817.
2 Clawson, S. W.: J. Am. Med. Asso., 1938, *111*, 144.
3 Eppright, E. S., Valley, G., and Smith, A. H.: J. Bact., 1937, *34*, 81.
4 Friedman, H.: J. Nutrition, 1936, *12*, 165.
5 Green, H. N., and Mellanby, E.: Brit. Med. J., 1928, *ii*, 691.
6 Lewaditi: Thèse, Par., 1902 (cited by Ringoen: Am. J. Anat., 1923, *31*, 319).
7 Orten, A. U., Burn, C. G., and Smith, A. H.: Proc. Soc. Exper. Biol. & Med., 1937, *36*, 82.

Butler-'68
Bib. No. 1330

J. Reprod. Fert. (1968) **15**, 157–159

EFFECT OF SHORT-TERM VITAMIN A DEFICIENCY ON TESTICULAR LIPIDS IN THE RAT

W. R. BUTLER, A. D. JOHNSON* AND W. R. GOMES

Animal Reproduction Teaching and Research Center,†
Ohio State University, and Ohio Agricultural Research and
Development Center, Columbus, Ohio, U.S.A.

(*Received* 22*nd August* 1967)

In 1933, Mason reported that long-term vitamin A deficiency caused sloughing of seminiferous tubular elements of the rat testis. Since that time, several workers have reported testicular lesions caused by deficiency of the vitamin (Beaver, 1961; Coward, McHowell, Pitt & Thompson, 1966; Gamball, 1966). Gamball (1966) found changes in testicular phospholipid associated with sterility following vitamin A deficiency. Since other treatments which result in sterility also cause lipid changes in the testis (Fleeger, Bishop, Gomes & VanDemark, 1968; Johnson, VanDemark, Gomes, Butler & Hodgen, 1967), it is possible that testicular lipids reflect the status of the testis, even during early stages of degeneration following deleterious treatments. The present study was undertaken to determine whether testicular lipid levels are affected by short-term vitamin A deficiency and, if so, the nature of such changes.

Male Wistar rats, 30 days of age, and weighing about 100 g, were fed a commercially available (Nutritional Biochemicals Corporation, Cleveland, Ohio 44128) rat diet, purported to be vitamin A free, for 5 weeks. Control animals were supplemented with 12 i.u. retinol/g of feed to meet the vitamin A requirement. A body-weight plateau, considered the first sign of deficiency, was recorded for test animals after 4 weeks on the vitamin A free diet. Some animals showed initial signs of xerophthalmia and lack of coordination. At the end of the 5-week feeding period, testes were taken from twenty-four 'deficient' rats and eight control rats. Samples were taken for dry weight determination and histological examination. The remaining tissue was analysed for total lipid, cholesterol, lipid phosphorus and triglyceride levels according to the procedures reported by Fleeger *et al.* (1968).

Treated animals weighed an average of 246 ± 4 g, compared to 267 ± 10 g for control animals ($P < 0{\cdot}05$). Neither wet weight ($1{\cdot}58 \pm 0{\cdot}02$ g) nor dry weight (191 ± 3 mg) of testes from treated animals differed significantly from control values of $1{\cdot}58 \pm 0{\cdot}05$ g and 193 ± 6 mg, respectively. No differences were found between histological sections of testes from control and treated rats either in the tubules or the interstitium. Tubule size, seminiferous elements, Sertoli cells, interstitial mass and Leydig cells all appeared quantitatively and qualitatively normal in both control and treated groups. However, as shown in

* Present address: Department of Animal Science, University of Georgia, Athens, Georgia.
† 735 Stadium Drive, Columbus, Ohio 43210, U.S.A.

Table 1, the concentration of all lipid fractions, except free cholesterol, was higher in testes from treated animals.

The reasons for the increased lipid levels found in this study are not clear; however, other treatments which impair spermatogenesis also result in early increases in lipid levels (Fleeger *et al.*, 1968). Lack of lipid utilization by tubular elements after their destruction and an increasing ratio of interstitial to tubular elements have been suggested as possible reasons for these increases (see Fleeger *et al.*, 1968, for discussion) but the present data do not support these theories, since histological appearance was not affected by the short term treatment.

The known relationship between vitamin A and membrane lipids (Dingle, 1964) suggests that deficiency of the vitamin may affect cellular or lysozymal membranes. Coward *et al.* (1966) reported that retinoic acid would not prevent vitamin A deficiency lesions in the testis, but retinol was effective. Retinoic

TABLE 1

EFFECT OF SHORT-TERM VITAMIN A DEFICIENCY ON TESTICULAR LIPIDS IN THE RAT

	Control ($n = 8$)		*Deficient* ($n = 24$)	
	Mean	*S.E.*	*Mean*	*S.E.*
Lipid levels/g dry testis				
Total lipid (mg)	189	9	209*	5
Total cholesterol (mg)	19·8	0·6	21·7*	0·6
Free cholesterol (mg)	8·4	1·0	7·7	0·6
Esterified cholesterol (mg)	11·4	1·3	14·0*	0·8
Lipid phosphorus (mg)	3·6	0·2	4·6*	0·2
Triglyceride (μmoles)	67·7	6·4	84·5*	4·3

* Significantly different from control ($P<0·01$).

acid has also been reported to be ineffective in releasing proteolytic enzyme from lysozymes or in stabilizing cell membranes, whereas retinol and retinaldehyde have potent actions in these respects (Dingle, 1964).

These findings would suggest that deficiency of the vitamin alcohol might result in lesions of lipid layers of cell membranes and a failure of release of lysozyme-bound proteolytic or lipolytic enzymes. A short-term continuation of lipogenic activity, in conjunction with these events, followed by a later decline would satisfactorily explain the results reported here and those of Gamball (1966). It is possible that other treatments which impair spermatogenesis could also affect membrane stability or permeability and enzyme activities.

The above reasoning might not explain, however, the increased ratio of esterified to free cholesterol found in this and other studies (Fleeger *et al.*, 1968; Johnson *et al.*, 1967). This increased ratio has been associated with changes in interstitial mass, suggesting an effect of gonadotrophins on lipid levels in the testis (Butler, Johnson, Gomes & VanDemark, 1967; Gamball, 1966), but conflicting data have been reported (Coward *et al.*, 1966). To answer this question, hormone changes during the onset of testicular lesions should be measured.

REFERENCES

BLAVER, D. L. (1961) Vitamin A deficiency in the germ-free rat. *Am. J. Path.* **38**, 335.

BUTLER, W. R., JOHNSON, A. D., GOMES, W. R. & VANDEMARK, N. L. (1967) Testis lipids after stimulation or inhibition of testicular elements. *J. Dairy Sci.* **50**, 1003.

COWARD, W. A., MCHOWELL, J., PITT, G. A. J. & THOMPSON, J. N. (1966) Effects of hormones on reproduction in rats fed a diet deficient in retinol (Vitamin A alcohol), but containing methyl retinoate (Vitamin A acid methyl ester). *J. Reprod. Fert.* **12**, 309.

DINGLE, J. T. (1964) Penetration and stabilization of biological membranes by vitamin A. *Biochem. J.* **90**, 56P.

FLEROEN, J. L., BISHOP, J. P., GOMES, W. R. & VANDEMARK, N. L. (1968) Testicular lipids. I. Effect of unilateral cryptorchidism on lipid classes. *J. Reprod. Fert.* **15**, 1.

GAMBALL, D. (1966) Effects of hormones on the testicular lipids of vitamin A deficient rats. *J. Nutr.* **89**, 203.

JOHNSON, A. D., VANDEMARK, N. L., GOMES, W. R., BUTLER, W. R. & HODGEN, G. D. (1967) Effect of antispermatogenic and hormone treatments on testicular cholesterol. *Fedn Proc. Fedn Am. Socs exp. Biol.* **26**, 645.

MASON, K. E. (1933) Differences in testis injury and repair after vitamin A deficiency, vitamin E deficiency and inanition. *Am. J. Anat.* **52**, 153.

Pediatrics 5:672-688. 1950.

Caffey-'50
Bib. No. 1364

Reproduced by permission
of the copyright owner

CHRONIC POISONING DUE TO EXCESS OF VITAMIN A

Description of the Clinical and Roentgen Manifestations in Seven Infants and Young Children

By JOHN CAFFEY, M.D.
New York City

DURING 1945 the author observed a girl 25 months of age who had cortical hyperostoses in many sites of the skeleton. Her disease began when she was 19 months of age. She was described as a probable example of infantile cortical hyperostosis,[1] although at that time there was some question of the validity of including, in the syndrome of infantile cortical hyperostosis, patients such as this one who exhibited neither facial swellings nor mandibular hyperostoses and in whom the onset appeared after the first four months of life. Later it was learned that this patient had been taking one teaspoonful of oleum percomorphum daily for "several months" before the symptoms appeared. The author now has records of seven patients who ingested excessive amounts of vitamin concentrate A and D over long periods and who present similar clinical, roentgenographic and chemical findings. The subject of this report is a description of the toxic signs and symptoms in this group. The morbid anatomy of the lesions is unknown; there have been no biopsies or necropsies.

CASE REPORTS

Case 1. A. M., a girl 25 mo. of age, had complained of anorexia for 6 mo. and pain in the legs for 4 mo. She had been well until the 19th mo. when she became fussy, tired easily and began to refuse most of the food offered. During the 21st mo. the left shank and foot became swollen and painful; she refused to walk and the left shoe could not be worn because the foot was too large and tender. On several occasions she had heavy sweats at night.

Physical examination disclosed malnutrition, dry cracked lips, bilateral palpable clavicular swellings, and a tender firm swelling in front of the left tibia. These swellings were all deep, firm, not overly warm, not discolored and unattached to the skin. There was a similar swelling in the left foot. She refused to stand or to walk. Liver was not enlarged to palpation. She was and remained afebrile.

Hemogram and urinary examinations were normal. Blood proteins were present in normal concentrations (albumin 4.6 gm., globulin 2.3 gm./100 cc.), as were the serum calcium and phosphorus (10.6 mg. and 4.3 mg./100 cc., respectively). Blood NPN was 34 mg./100 cc. Serum phosphatase activity equaled 18 Bodansky units. ESR was 22 mm. in 1 hr. (Westergren). Blood serum gave a nonsyphilitic reaction to Kline's test. No serum agglutinins for the typhoid-dysentery-cholera group of bacteria were found in dilutions of 1:20 or higher.

Roentgen examination of the skeleton revealed cortical hyperostoses in both clavicles, in the right and left 7th ribs, both ulnas, right femur, left tibia, right fibula, and in all of the metatarsals in both feet, save the 1st metatarsals (Fig. 1). The mandible and the cranium were normal roentgenographically. There were no destructive changes anywhere in the skeleton and the bones unaffected by hyperostosis were all normal. Maturation of the skeleton was normal.

From the Department of Pediatrics, College of Physicians and Surgeons, Columbia University, and the Babies Hospital, New York City.

Read in summary at the Annual Meeting of the American Pediatric Society, Atlantic City, N.J., May 6, 1949.

(Received for publication June 21, 1949.)

The course in the hospital was uneventful. At first all food was refused and the patient was [illegible] apparently from painful pseudoparalysis associated with the tender swellings on the leg and feet. After a few days she was feeding herself and taking a normal diet in normal amounts. At the end of about 4 days, most of the pain and tenderness had subsided although the swellings persisted. A bone biopsy had been planned but this was cancelled owing to the rapidity of recovery.

During the 2nd wk. of hospital residence it was learned from the mother that she had voluntarily increased the dose of oleum percomorphum* several months before so that the child had been receiving daily approximately 150,000 u. vitamin A and 22,000 u. vitamin D. This dosage had been stopped on admission to the hospital and clinical improvement was almost immediate.

After 22 days of hospital residence the patient was discharged asymptomatic. In roentgen films made 3 mo. following discharge, the hyperostoses were still visible but were all smaller and more sclerotic than before. One year later the hyperostoses were invisible roentgenographically. She has had no recurrence of symptoms for 4 yr.

Case 2. B. K., a girl, was 21 mo. of age when she was first seen in consultation with her pediatrician who had made a diagnosis of infantile cortical hyperostosis. She had been well until the 19th mo. when she became restless and "whiny" and a painful tender lump appeared on her right shin. For 3 wk. she had been refusing food and was unwilling to walk. Penicillin intramuscularly did not modify these manifestations. At the same time she became hyperirritable, insomnia was marked and she sweated excessively at night. She screamed when the weight of the bed clothes was on her, and resisted attempts to dress her, put on her shoes or change the diaper. Two weeks before, tender swellings first made their appearance in the left forearm and on the dorsum of the right foot. One week prior to the consultation a large hard lump appeared over the occiput but there were no facial or mandibular swellings. The temperature never exceeded 37.8 °C.

In the physical examination the 21st mo., she was found to be exceedingly irritable and apprehensive of being touched. Photographs and roentgen films were made with great difficulty. The lips, especially the lower lip, were dry and cracked. Deep, firm, tender swellings were visible and palpable in the occipital region, in both forearms, on the ventral surface of the right shank, and in the lateral aspects of the dorsum of both feet (Fig. 2A and B). Liver was not enlarged and temperature was normal.

Hemogram and urinary findings were normal. ESR was 21 mm. after 1 hr. Multiple cortical hyperostoses were demonstrated by roentgenographic examination in both ulnas, left tibia and in both 5th metatarsals (Fig. 2C, D and E). Mandible was normal and there was no sign of bone production under the large swelling in the occipital region. The mother on being questioned in more detail about vitamin intake related that she had been giving the patient 1 teaspoonful of oleum percomorphum daily since the 12th mo. of life, which meant that this child had received 200,000 to 300,000 u. vitamin A daily over a period of about 9 mo. Blood withdrawn at this time showed a concentration of 330 u. of vitamin A/100 cc. plasma (normal 50-150); blood carotene was 70 gammas/100 cc. (normal 40-200 gammas).

Oleum percomorphum was stopped and within 4 days the patient was asymptomatic, although swellings were still present. She began to take normal amounts of food; the pain, tenderness and hyperirritability disappeared completely and sleep was undisturbed. The swellings gradually diminished in size so that they could not be detected after about 2 wk. In films, the hyperostoses in the 5th metatarsals were barely visible at the end of 6 wk. although, at the same time, the ulnar and tibial hyperostoses were only slightly diminished in size and much denser than earlier. At the end of 1 yr., all the hyperostoses were invisible save slight residual thickening in the cortical walls of the ulnas and the right tibia. The patient has thrived during the last 23 mo.

Case 3. H. A., a boy 12 mo. of age, was referred for roentgenographic examination with the clinical problem of soreness of the left shoulder and swelling and failure to use the left arm. These symptoms had been present for approximately 3 wk. The referring pediatrician suspected unrecognized traumatic injury to the left shoulder joint. There were no constitutional symptoms; the appetite had remained good and there had been no fever.

Roentgenographic examination disclosed ulnar hyperostoses (Fig. 3). Remainder of the skeleton,

---

* Oleum percomorphum (Mead Johnson) is made up of liver oils of the percomorph fishes, viosterol and other fish oils. It is standardized to contain not less than 60,000 u. vitamin A and 8,500 u. vitamin D/gm.

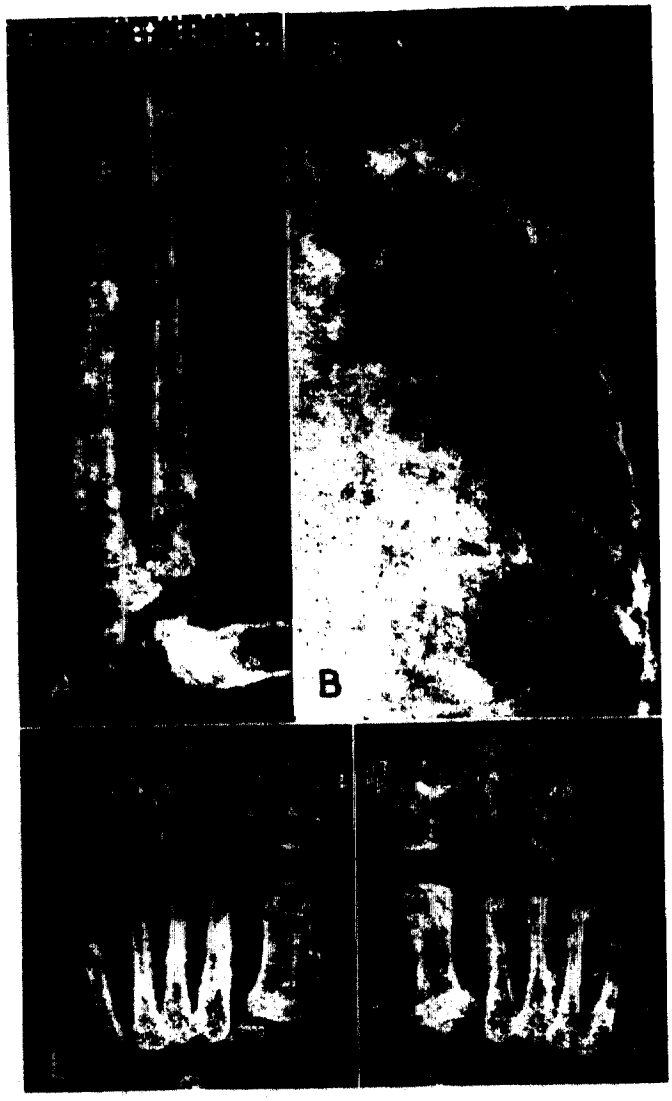

FIG. 1 (Case 1). Legend on page 675.

including the mandible and bones of the feet, were normal roentgenographically at this time. A presumptive roentgen diagnosis of hypervitaminosis A was made on the basis of the symmetric ulnar hyperostoses and, on direct questioning, the father stated that the infant had been receiving 2 teaspoonfuls of oleum percomorphum daily during the preceding 6 mo. (400,000 to 600,000 u. vitamin A/day). The family pediatrician later reported that the mistake in dosage was due to error in purchase at the drug store. The mother had supposed she was getting cod liver oil and the druggist was under the impression that she ordered oleum percomorphum.

Infant was well nourished, without pallor or fever. There were many large and small patches of erythema in the skin and in these areas numerous scratch marks were present. Pruritus had not been recognized by the parents. In the left forearm there was a long, poorly defined, firm tender swelling which was not discolored or especially warm. Liver was not enlarged.

Blood count and urinary findings were normal. ESR was 24 mm. after 1 hr. Serum calcium was 9.9

FIG. 1 (Case 1). Multiple cortical hyperostoses in A. ulna; B. L. clavicle and L. 7th rib; C. R. femur; D. L. tibia and R. fibula; E. 2nd, 3rd, 4th and 5th metatarsals in both feet. First metatarsals are not affected.

mg./100 cc.; phosphorus 4.8 mg./100 cc.; serum phosphatase activity equaled 15.2 Bodansky u. Kline's test on blood serum gave a nonsyphilitic reaction. Concentration of vitamin A in blood plasma was 1384 I.U./100 cc. (normal 50-150); total blood lipid was 840 mg./100 cc.; blood carotene concentration equaled 146 gammas/100 cc. (normal 40-200).

The ingestion of vitamin concentrate was stopped and pain and tenderness in the left arm disappeared after 4 days. The patient has remained asymptomatic. In films of the skeleton made 10 wk. later, the ulnar hyperostoses were still visible but were smaller and more sclerotic; in films of the feet, symmetric hyperostoses of the 2nd metatarsals were now visible although they had not been visible in the earlier films and the patient had never had signs or symptoms in the feet.

Case 4 (Dr. A. Ashley Weech, Children's Hospital, Cincinnati). W. K., a boy, was first seen at 32 mo. of age when he complained of painful feet of 3 wk. duration. Twelve days before, tender swellings appeared in the left hand, left arm and left shin. He became generally irritable but had no fever and retained a normal appetite. During the 10 days prior to admission, there had been several nosebleeds. On admission the parents stated that he had been receiving 2 teaspoonfuls of cod liver oil daily.

The boy was well nourished and mentally alert. Liver edge was at the costal margin. In the left forearm there was a long, hard, tender swelling over the ulna. The swelling was not overly warm or discolored. There were similar swellings on the left thumb, over the left 2nd metacarpal and over the left tibia. Regional lymph nodes were not enlarged. Both feet and one wrist were also slightly swollen. There was no reaction of the skin to tuberculin or histoplasmin.

Findings in the blood count and urine were normal. Kahn's test on the blood gave a nonsyphilitic reaction. Serum calcium was 10.7 mg./100 cc.; phosphorus 4.8 mg./100 cc.; serum phosphatase activity equaled 19 Bodansky u. Blood protein nitrogen was 30 mg./100 cc.

FIG. 2 (Case 2). Legend on page 677.

Roentgenographic examination of the skeleton disclosed hyperostoses in the 2nd left metacarpal (Fig. 4), both ulnas, both tibias and the fibula. In the feet both 4th metatarsals were thickened. The bones of the head and chest were normal roentgenographically and maturation of the skeleton was normal.

The course in hospital was uneventful. Before discharge it was learned that the mother had been giving the child oleum percomorphum instead of cod liver oil. Three years later the history was reviewed again with the mother. In review she stated that 10 drops of oleum percomorphum® were given daily from the 6th wk. until the 17th mo. of life. During the 17th mo., the child had a severe laryngotracheitis and the mother, deciding that more vitamins would be beneficial, increased the dose to 1 teaspoonful of oleum percomorphum daily. This dose had been continued during the 15 mo. which preceded admission to hospital.

Case 5 (Drs. S. Z. Levine and John Dale, Jr., New York Hospital, New York City). A. C., a boy 18½ mo. of age, was admitted with a chief complaint of pain in the bones of a few weeks' duration. Appetite had always been poor. Drisdol® with vitamin A,* a vitamin concentrate of A and D, had been started at 1 wk. of age when a "dropper-full" was given daily. After the 12th mo., the vitamin concentrate was increased to ½ and later ¾ teaspoonful daily, which provided about 125,000 u. vitamin A and 20,000 u. vitamin D. After the 13th mo., 1 teaspoonful of drisdol® with vitamin A (about 250,000 u. vitamin A and 40,000 u. vitamin D) was given daily. Two weeks before admission he was said to have bruised his leg in a fall and had had pain in his legs.

Examination disclosed that he was hyperirritable and afebrile. Both hands were swollen and tender. Liver edge was 2 cm. below the right costal margin. Left shank and both forearms were swollen and tender.

Hemogram and urinary findings were normal. ESR was 27 mm. after 1 hr. Serum calcium was 10.5 mg./100 cc.; serum phosphorus 3.6 mg./100 cc.; serum phosphatase activity equaled 9.7 Bodansky u. Vitamin A concentration in the blood plasma was 1395 u./100 cc. (normal 80-200); blood carotene was 73 gammas (normal 50). Vitamin C content of the leucocytes was 4.2 mg./100 cc. (low). The Mazzini blood test gave a nonsyphilitic reaction.

* Drisdol® with vitamin A is a solution in sesame oil of drisdol, vitamin D2 from ergosterol, and natural fish liver oils. Each gram contains 50,000 u. U.S.P. vitamin A and 10,000 u. vitamin D.

FIG. 2 (Case 2). Tender swellings and hyperostoses after 9 mo. of ingestion of excessive amounts of oleum percomorphum®. A. Ulnar swellings in forearms and fissuring of lips; B. symmetric swellings over 5th metatarsals and over R. tibia; C. long wavy cortical hyperostosis of ulna; D. symmetric thickenings of cortices of 5th metatarsals; E. long wavy cortical hyperostosis of R. tibia; striking absence of metaphyseal and epiphyseal changes.

FIG. 3 (Case 3). Bilateral ulnar hyperostoses, 3 wk. after onset of soreness in arms, and after 12 mo. of intake of 2 teaspoonfuls of oleum percomorphum daily. Remainder of skeleton was normal roentgenographically, including feet. However, 10 wk. later and 10 wk. after oleum percomorphum had been stopped, symmetric hyperostoses of 2nd metatarsals were demonstrated roentgenographically.

Roentgenographic examination of the skeleton disclosed cortical hyperostoses in both clavicles, 6th and 7th right ribs, both ulnas, right radius, left tibia, right fibula, 4th and 5th right metatarsals and both 4th metacarpals (Fig. 5). Mandible was normal, as was skeletal maturation.

In the hospital the daily vitamin intake was reduced to approximately 12,000 u. vitamin A, 1,800 u. of D and 50 mg. ascorbic acid. Clinical recovery was rapid. He became active and asymptomatic; after 6 wk., he had gained 0.5 kg. The plasma concentration of vitamin A fell to 700 I.U. on the 12th hospital day, 500 I.U. on the 20th hospital day, 400 I.U. on the 27th day and 360 I.U. on the 37th hospital day.

Case 6. R. B., a boy 24 mo. of age, complained of pain, tenderness and swellings of the extremities for about 2 mo. According to his mother, he had always been in good health prior to the present complaint and had been taking the "usual" amounts of vitamin concentrates. The first symptoms were pain and swellings in the forearms, especially on the right side. One month later his shanks and ankles became swollen. At this time roentgenographic examination had shown symmetric hyperostoses on the ulnas. The feet and ankles became so swollen and tender that he could not wear his shoes. Roentgenographic examination then disclosed no abnormal changes in the bones of the feet

FIG. 4 (Case 4). Cortical thickenings of 2nd metacarpal 3 wk. after appearance of tender swellings in hand. This patient had received 1 teaspoonful of oleum percomorphum daily for 15 mo.

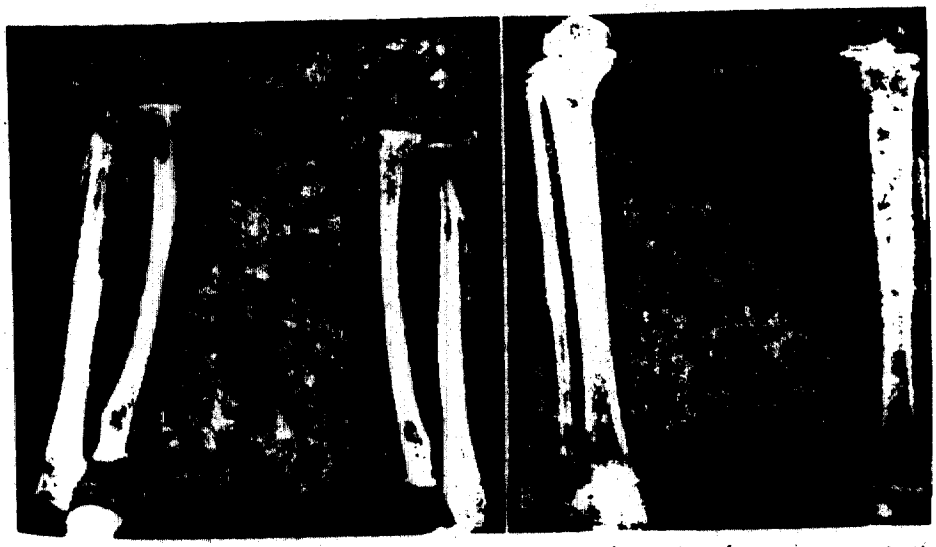

FIG. 5 (Case 5). Multiple cortical hyperostoses after 10 mo. of ingestion of excessive amounts of drisdol® with vitamin A, ½ to ¾ teaspoonful daily: A. in both ulnas and one radius. B. in L. tibia and R. fibula; arrow on right points to cortical defect not related to hypervitaminosis A.

or shanks. During the first weeks of the illness, fever occurred for shor[illegible]d then disappeared completely.

When examined by the author 2 mo. after onset, there were no abnormal physical signs. The swellings could not be identified clinically. In the roentgenographic examination, however, cortical thickenings were visible in both ulnas and in the 5th metatarsal (Fig. 6).

The family was requestioned 2 yr. later and it was then learned that the mother, who had given the original history, had had little to do with the care of the child during his 1st 2 yr. Actually he had lived with and been under the care of his grandmother. She stated that oleum percomorphum had been given daily since the first weeks of life, starting with a few drops daily with gradual in-

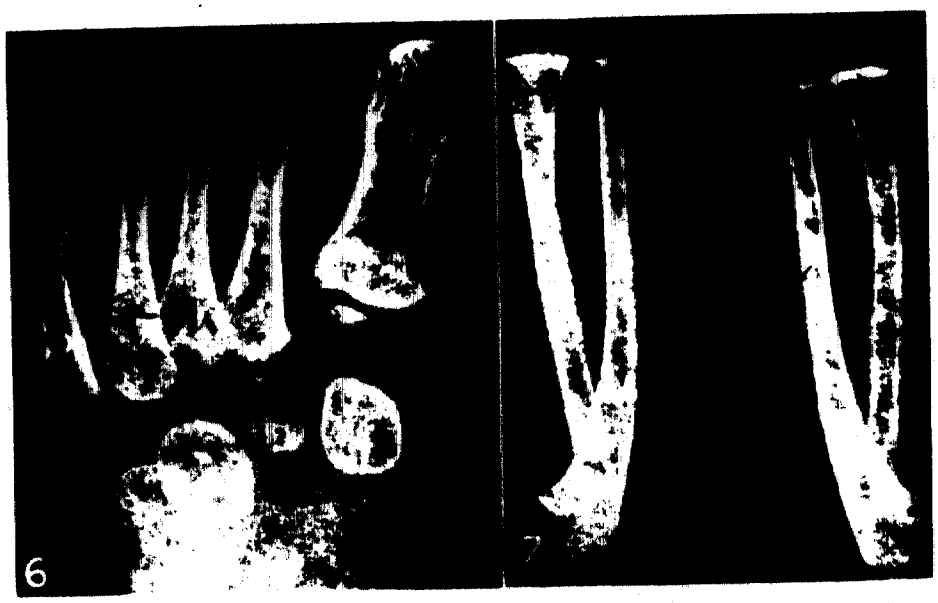

FIG. 6 (Case 6). Lamellated cortical hyperostosis of L. 5th metatarsal 9 mo. after beginning ingestion of ½ teaspoonful of oleum percomorphum daily. Two ulnas were only other bones affected.

FIG. 7 (Case 7). Symmetric, bilateral thin hyperostoses of ulnas after 15 mo. of ingestion of excessive amounts of navitol® in daily dosage of 1 teaspoonful, which provided approximately 200,000 u. vitamin A daily. Both clavicles were also thickened.

creases to ½ teaspoon daily. During the 7 mo. prior to onset of symptoms, the boy received approximately 100,000 u. vitamin A every day.

After a few days of hospital residence, the patient went to live with his mother and remained permanently asymptomatic.

Case 7 (Dr. Frederic N. Silverman, Children's Hospital, Cincinnati). R. B., a boy 37 mo. of age, had had a pruritic rash on his buttocks and back for 5 mo. His arms and legs had been tender for 2 mo. He frequently limped and refused to bend over owing to pain. He had been afebrile. His skin was dry and contained many scratch marks. The liver edge was 3 cm. below the right costal margin. He whined with pain when manual pressure was made on his legs and arms, especially when deep palpation was attempted. Blood count disclosed a mild anemia; there were 9 thousand leucocytes/cmm. with normal differential count. Serum calcium was 10.8 mg./100 cc.; serum phosphorus 5.2 mg./100 cc.; phosphatase activity of the serum equaled 22 Bodansky u. Roentgenographic examination of the skeleton disclosed cortical hyperostoses in both clavicles and both ulnas (Fig. 7). The bones of the feet were not filmed.

The cause of these clinical manifestations and roentgen changes remained unexplained until 4 yr. later when the mother was requestioned concerning the patient's intake of vitamin concentrates. The mother referred to the written records in her baby book and then stated for the first time

navitol®,* a concentrate of vitamins A and D, had been started on the 10th day of life and 10 drops daily had been given until the 20th mo. During the 20th mo., the child suffered from a respiratory infection and the mother increased the dosage of navitol® to 1 teaspoonful daily (200,000 to 300,000 u. daily vitamin A). This excessive intake had been continued for 17 mo. prior to admission to the hospital. The patient recovered quickly in the hospital and has remained well for the ensuing 4 yr.

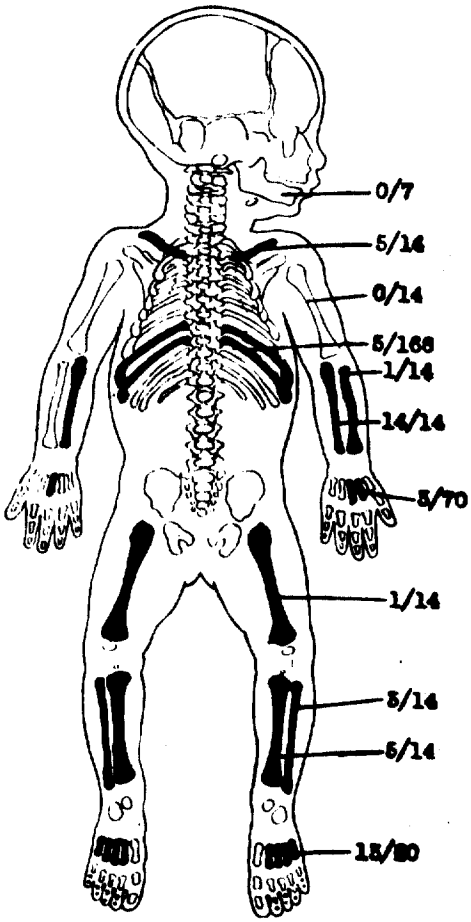

FIG. 8. Distribution of hyperostoses in 7 patients. Shaded bones were hyperostotic and numbers opposite each shaded bone indicate total number of such affected bones in all 7 patients on both sides of body. In every patient both ulnas were thickened and in every patient some of metatarsals were affected. First metatarsals, however, were not affected in any patient.

COMMENT

Acute poisoning due to the ingestion of large single doses of vitamin A is rare but has occurred occasionally when children have swallowed an entire (50 cc.) bottle of oleum percomorphum.[2] Under these circumstances, the only clinical manifestations have been transient nausea and vomiting. The toxicity of polar bear liver to Arctic travellers, Eskimos,

* A fish liver concentrate containing 65,000 u. U.S.P. vitamin A and 13,000 u. U.S.P. vitamin D/gm.

and their dogs has long been recognized; apparently it is due to the high content of vitamin A. Poisoning from this source is said to be characterized by headache and hyperirritability during the first 24 hours, followed by an irresistible desire to sleep. Desquamation of the skin begins at the mucocutaneous junctions of the lips during the second 24 hours, with rapid spreading until the entire skin peels in a few days. Several parties of Arctic explorers have been poisoned in this fashion and a number of deaths have been reported. Rodahl[3] found the vitamin A content in polar bear liver approximated 18,000 u./gm. He estimated that the ingestion of 0.5 kg. of polar bear liver represented an intake of approximately 8,000,000 u. of vitamin A.

Moore[3] found a wide variety of toxic manifestations in experimental vitamin A poison-

FIG. 9. Healing of ulnar hyperostosis in Case 2. A. Thin, wavy, shell-like cortical thickening during active phase of poisoning at admission. B. Four months after stoppage of vitamin concentrate; same hyperostosis is shrunken, smooth and more sclerotic.

ing in small animals. He observed roughening of the hair, alopecia, generalized seborrhea, enteritis, pneumonia, emaciation, softening and fractures of the long bones, and sudden profuse internal hemorrhage. Wolbach[4] and Maddoch, Wolbach and Maddoch[5] made comprehensive studies of the skeletal changes produced by excess vitamin A in small animals. They report that all features of skeletal maturation are accelerated: endochondral bone formation and subperiosteal appositional growth of the cortex. The rapid and excessive tubulation of rat bones resulted in tubular bones of smaller caliber than normal, in contrast to the swollen thickened shafts which have been observed in all the human examples of clinical vitamin A poisoning. Many of Wolbach's animals, especially the

younger growing ones, developed fractures after 6 to 10 days of high intake of vitamin A.

There are five examples of chronic vitamin A poisoning in infants and younger children reported in the literature. Josephs[6] first pointed out the dangers of high vitamin A intake in pediatric prophylactic practice and first demonstrated the value of the increased blood content of vitamin A in diagnosis of its poisoning. He described hypervitaminosis A in a boy 34 months of age who had received one teaspoonful of halibut liver oil (240,000 u. vitamin A) daily after the third month of life and occasionally drank the oil directly from the bottle. Toomey and Morrisette[7] first observed deep, hard, tender swellings in the extremities and were the first to describe cortical thickenings in tubular bones. Their patient was a boy 23 months of age who received one teaspoonful of oleum percomorphum daily from the second week until the 19th month and two teaspoonfuls from the 19th month until the 23rd month. After stoppage of oleum percomorphum and subsidence of clinical signs, Toomey and Morrisette reinduced the clinical signs by refeeding oleum percomorphum, and then a second time by feeding pure vitamin A.

Dickey and Bradley[8] reported tender swellings and cortical hyperostoses in a child 22 months of age who was poisoned by navitol® fed in daily dosage of three teaspoonfuls. Two patients of Rothman and Leon,[9] who were poisoned by excessive dosage of oleum percomorphum, exhibited tender swellings, cortical hyperostoses and high blood content of vitamin A. In all recorded cases, with the exception of the case of Josephs, rapid recovery followed the stoppage of ingestion of vitamin concentrate containing vitamin A.

In the group of seven patients reported here, the principal toxic manifestations were similar to those previously described; the roentgenographic observations are more complete and more detailed than those in earlier reports. Data in 12 cases now provide the opportunity for a more complete presentation of the clinical picture and a better insight into the differential diagnosis. Current findings in a comparatively large number of patients also make possible a comparison of hypervitaminosis A and infantile cortical hyperostosis, a syndrome with which vitamin A poisoning has been confused. It seems certain now that the two older patients described in 1946 (Caffey,[1] cases 2 and 5) as examples of infantile cortical hyperostosis actually suffered from excess vitamin A.

In all these patients, the excessive intake of vitamin A was unknown to their pediatrician and was not recorded in the original hospital histories. In three cases the history of overdosage was not obtained until two, three and four years after discharge from the hospital. Customarily, in history-taking, the interest in vitamin intake is directed exclusively at insufficiency of intake and the question of excessive intake is not raised. If overdosage is to be detected early from the history, the actual frequency of feeding and amounts of vitamin concentrate fed, the method of measuring the amount and the preparation used must all be sought for in detail. Apparently it is not an uncommon practice for mothers to stop measuring vitamin concentrate accurately, drop by drop, soon after they start its use; to save time the estimated dosage is poured directly from the bottle into a teaspoon. Under these circumstances the error of estimate appears to be invariably in the direction of overdosage. In one of the cases, the mother stated that she had been giving 20 drops of oleum percomorphum daily but, on further questioning, revealed that she had not been measuring each dose; actually she had been feeding the infant one bottle of 50 cc. of oleum percomorphum each month. The infant had received 60 to 70 drops each day instead of the 20 drops daily originally stated. Knowledge of the frequency and the amount of vitamin concentrate purchased may be more informative than the mother's statement of the unmeasured daily dose. The physician must also make certain that informants, especially fathers and grandmothers, actually know the details

of vitamin feeding. The possibility of confusion between oleum percomorphum and cod liver oil at the time of purchase should also be borne in mind.

All these parents were wholly ignorant of the harmful effects in higher doses of the vitamin concentrates recommended to them in small doses for prophylaxis. The parental reasons for giving toxic doses are interesting and important. In one case, the mother simply decided that, if a small amount of the concentrate was good for the baby's bones, a larger amount would be better. One grandmother increased the dosage to make sure that she was doing a better job at prophylaxis than the mother had been doing. In two cases the reason for higher dosage was never satisfactorily explained; apparently these mothers, ignorant of potential dangers, increased dosage in the blind belief that plenty of vitamins would promote the health of their children. In two instances dosage was increased and then toxic doses were continued in the hope of combatting and preventing upper respiratory infections. In another case, not reported in this group, the mother stated that her infant had developed such a fondness for oleum percomorphum that she had to feed one teaspoonful daily to keep the baby satisfied. In another instance the mother was unwittingly feeding oleum percomorphum instead of cod liver oil.

The estimated daily intake for these patients varied from about 75,000 to about 500,000 u. vitamin A. The data in this regard are difficult to evaluate precisely. In some cases the actual dosage was underestimated by the mother. On the other hand, such factors as incomplete filling of the teaspoon, spillage during feeding and spitting out of some of the concentrate by the infant may well have lessened the actual intake and absorption in comparison with the amount fed, as stated in the history. It should be emphasized that in no case was overdosage due to erroneous advice by a physician or erroneous labelling of the bottle by the manufacturer. It is equally true, however, that in no case did a manufacturer's label state the harmful effects of overdosage nor had any mother been so advised by her pediatrician. This failure to point out clearly the dangers of excess feeding of vitamin concentrates is a serious error of omission and should be corrected.

There are several possible toxic elements in the concentrates of vitamins A and D in fish oils, which presumably might have been the toxic agents in these patients. Vitamin D is an unlikely toxic factor because it had been used clinically in considerably higher dosages without toxic effect; also when children have been poisoned by massive administration of vitamin D, they have not exhibited signs and symptoms like those in this group. According to Debré,[10] the toxic manifestations of vitamin D poisoning in children include anorexia, polydypsia, renal damage, increased blood urea and blood calcium, and extraskeletal calcifications. There are some toxic proteins in several types of fish liver, notably halibut liver; supposedly, even minute traces of the liver proteins are removed from fish liver oils in the current methods of their extraction and processing.[11] Toomey and Morrissey[12] performed the crucial clinical experiment of feeding excess of vitamin A to their patient and reproduced the clinical picture of hypervitaminosis A. These facts all indicate that the toxic component of the vitamin concentrate fed to our patients was vitamin A.

There are several characteristic features in the clinical picture. In all cases, there was a long latent period of several months between the start of excessive dosage and the appearance of diagnostic clinical signs. The length of this latent period did not depend on the size of the overdose. The shortest latent period was six months; the longest was 15 months. The appearance of tender swellings has been used as the criterion for the

onset of the clinical disease. In some cases pruritus and anorexia preceded tender swellings by several weeks or months; anorexia and pruritus are so common in children who do not suffer from hypervitaminosis A that their significance in children poisoned by vitamin A is exceedingly difficult to evaluate from a causal standpoint. Since anorexia is a prominent feature of vitamin D poisoning, it is possible that vitamin D played a part in the causation of anorexia in these patients. In Case 3, however, appetite remained normal during a period of six months of excessive vitamin concentrate feeding and for three weeks after the appearance of tender swellings. Enlargement of the liver has been found by others in several patients; the liver was normal in size in all the patients examined personally.

Tender swellings, hyperirritability and limitation of motion all became evident at about the same time. Tender swellings were most common in the forearms but they were more conspicuous in the shanks and feet in some patients. Swellings were always deep and firmly attached to underlying structures, apparently the bones. The overlying skin in contrast was always freely movable over the deeper masses and was never edematous or discolored. Tenderness appeared to be moderate and local heat was not increased. All types of handling were feared and resisted. Large temporal and occipital swellings developed in two patients but the mandible and face were always normal in all patients. Lymph nodes, regional to the swellings, were not enlarged.

Hyperostoses in two or more of the long bones were identified roentgenographically in every patient; the distribution and frequency of involvement of different bones are shown in Figure 8. Hyperostoses were found under all of the soft tissue swellings which could be demonstrated clinically. All the 14 ulnas in seven patients were affected and in every patient one or more of the metatarsals were thickened. None of the 12 first metatarsals examined was involved. The high incidence of localization in the ulnas and metatarsals appears to be the most diagnostic feature of the skeletal lesions of poisoning due to excess vitamin A intake. In Case 3, metatarsal thickenings were not visible three weeks after onset when ulnar hyperostoses were demonstrated, but 10 weeks after the withdrawal of all vitamin A by mouth, both second metatarsals were found to be thickened. There is no satisfactory explanation for the high frequency in the ulnas and metatarsals; it is possible that trauma played some part in thickening these relatively exposed bones. The bones at the roots of the extremities, the femurs and humeruses, which are relatively well protected from trauma by heavy muscles were the least affected. Only one of the 14 femurs and none of the 14 humeruses showed cortical thickening. The mandibles and scapulas were normal in all patients. Five of 14 clavicles exhibited deep cortical hyperostoses.

The earliest roentgenographic observations were in Case 3 in which films showed cortical hyperostoses in the ulnas three weeks after the appearance of clinical swellings in the forearms. Early, the hyperostoses have a shell-like appearance with a zone of diminished density between the subperiosteal thin layer of bone and the external surface of the old cortex. After withdrawal of vitamin A this intermediate clear zone disappears, the hyperostoses then shrinks onto the old cortex and fuses with it (Fig. 9). These solid sclerotic cortical thickenings are in turn gradually resorbed from within but remain visible for many months after complete clinical recovery. During the reparative phase some of the hyperostoses became lamellated.

The amounts of vitamin A in the blood have been increased in all patients whose blood have been tested. The concentrations varied from 400 to 2000 u./100 cc. It is not [illegible]

tain how early blood vitamin A rises, or whether it is elevated during the long latent period prior to the appearance of clinical manifestations; it is possible, however, that an excess of vitamin A in the blood might point to the diagnosis while the patient was still asymptomatic. Following the stoppage of ingestion of excessive vitamin concentrate, vitamin A levels in the blood fell gradually and did not return to normal levels for several weeks (Case 5; Toomey,[7] Dickey[8] and Rothman[9]).

The rapid and complete clinical recovery of these patients after the stoppage of over dosage is one of the most distinct and convincing features of the syndrome. In patients observed personally, tenderness, pain, hyperirritability and anorexia have disappeared completely within one week. Recovery is comparable to the recovery in scurvy following the administration of vitamin C. In Case 1, recovery was so rapid after admission to the hospital that a bone biopsy which had been scheduled was cancelled.

As mentioned earlier, hypervitaminosis A has been confused by the author with infantile cortical hyperostosis. Personal communications from several sources indicate that this continues to be a not infrequent diagnostic error. Actually there are but two features which are common to both disorders; cortical hyperostoses and tender soft tissue swellings. In contrast, there are several outstanding differences which readily identify hypervitaminosis A and infantile cortical hyperostosis as separate entities. Infantile cortical hyperostosis has always made its appearance during the first four months of life and in one case was present on the first day of life; in hypervitaminosis A, on the other hand, diagnostic clinical signs have never been recognized prior to the 12th month of life. It is interesting that there is no recorded example of onset between the 5th and 11th months in either disorder. The face and jaw have been swollen and the mandible has been thickened in every case of infantile cortical hyperostosis; these structures have not been affected in a single case of hypervitaminosis A. Metatarsal hyperostoses have been present in every case of vitamin A poisoning in which the feet have been examined roentgenographically but have been demonstrated in only one case of infantile cortical hyperostosis. The blood vitamin A has been increased in hypervitaminosis A in every patient tested; blood vitamin A levels were normal in the only six patients with infantile cortical hyperostosis so tested. Fever is the rule in infantile cortical hyperostosis (15 of 17 cases); fever, other than transient fever due to respiratory infection, was absent in all cases of hypervitaminosis A.

Excessive intake of vitamin concentrate A and D preceded poisoning by vitamin A in all cases; vitamin intake has apparently not been excessive in any cases of infantile cortical hyperostosis. Also the feeding of excessive vitamin concentrate A and D during the first four months of life has not produced the manifestations of infantile cortical hyperostosis.[6,7,9] It seems likely that impaired absorption of vitamin A in oil during early life[12] is responsible for the absence of toxic symptoms in babies fed large amounts of oleum percomorphum during the first months of life. Recovery from vitamin A poisoning is dramatically rapid after admission to hospital and stoppage of the excessive ingestion of vitamin A; in contrast, the signs and symptoms of infantile cortical hyperostosis have continued and exacerbations have occurred weeks and months after hospital entry when it was certain that there was no excessive ingestion of vitamin A. Scapular lesions are unknown in vitamin A poisoning; they have been present in several cases of infantile cortical hyperostosis. Soft tissue swellings in the latter disease are usually much larger and more tender and the edges of the hyperostoses are much rougher than their counterparts in hypervitaminosis A.

Summary and Conclusions

The clinical manifestations, the roentgenographic changes in the skeleton and the elevation of blood vitamin A are reported in a group of seven infants and younger children poisoned by ingestion of excessive quantities of vitamin concentrates A and D over periods of several months.

The differential features of vitamin A poisoning and infantile cortical hyperostosis are discussed.

Three types of vitamin concentrate A and D, commonly used in routine pediatric prophylaxis, were found to be toxic when ingested in sufficiently large quantities over sufficiently long periods. The minimal preclinical latent period of vitamin A poisoning was about six months and the minimal toxic daily dose was about 75,000 units.

Excessive dosage was due to overenthusiasm for vitamins and ignorance of the dangers of high vitamin intake.

The hazards of vitamin A poisoning from the routine prophylactic feeding of vitamin concentrates A and D to healthy infants and children on good diets are considerably greater than the hazards of vitamin A deficiency in healthy infants and children not fed vitamin concentrates.

Addendum

Since this manuscript was submitted for publication, two additional cases of vitamin A poisoning have been described (Fried, C. T., and Grand, M. J. H., Hypervitaminosis A, Am. J. Dis. Child. 79:475, 1950). The clinical, chemical and roentgen findings are all similar to those in the other reports. A total of 14 cases of infantile and juvenile poisoning due to vitamin A have now been recorded.

References

1. Caffey, J., Infantile cortical hyperostoses, J. Pediat. **29**:341, 1946.
2. Bills, C. E., personal communication to the author.
3. Rodahl, K., and Moore, T., Vitamin A content of bear and seal liver, Biochem. J. **37**:166, 1933.
4. Wolbach, S. B., Vitamin A deficiency and excess in relation to skeletal growth, J. Bone & Joint Surg. **45**:171, 1947.
5. Maddoch, C. L., Wolbach, S. B., and Maddoch, S., Hypervitaminosis A in dog, J. Nutrition **39**:117, 1949.
6. Josephs, H. W., Hypervitaminosis A and carotinemia, Am. J. Dis. Child. **67**:33, 1944.
7. Toomey, J. H., and Morrisette, P. A., Hypervitaminosis A, Am. J. Dis. Child. **73**:473, 1947.
8. Dickey, L. B., and Bradley, E. J., Hypervitaminosis A: Case report, Stanford M. Bull. **6**:345, 1948.
9. Rothman, P. E., and Leon, E. E., Hypervitaminosis A: Report of 2 cases in infants, Radiology **51**:368, 1948.
10. Debré, R., Toxic effects of overdosage of vitamin D2 in children, Am. J. Dis. Child. **75**:787, 1948.
11. Cox, W. M., Jr., personal communication to the author.
12. Sobel, A. E., Bessman, L., and Kramer, B., Vitamin absorption in newborn, Am. J. Dis. Child. **77**:576, 1949.

Spanish Abstract

Envenenamiento Crónico Debido al Exceso de Vitamina A: Descripción de Manifestaciones Clínicas y de Roentgen en Siete Infantes y Niños Menores

Las manifestaciones clínicas, cambios roentgenográficos en el esqueleto, y la elevación vitamina A de sangre se reportan en un grupo de 7 infantes y niños menores envenenados por la ingestión de cantidades excesivas de concentrados de vitamina A y D por períodos de varios meses.

Se discuten las características diferenciales del envenenamiento de vitamina A y la hiperostosis cortical infantil.

Se encontró que tres tipos de concentrados de vitamina A y D, comunmente usados en la rutina pediatrica profilaxis, son tóxicos cuando ingeridos en cantidades suficientemente grandes durante períodos suficientemente largos. El período latente preclínico mínimo de envenenamiento de vitamina A fué de 6 meses y la dosis diaria tóxica mínima fué de poco más o menos 75,000 unidades.

La dosis excesiva fué debida al gran entusiasmo por vitaminas y a la ignorancia de los peligros de alta toma de vitaminas.

Los peligros del envenenamiento de vitamina A de la alimentación profilactica de rutina de concentrados de vitamina A y D a infantes y niños sanos que tienen buenos dietas son considerablemente más grandes que los peligros de la deficiencia de vitamina A en infantes y niños sanos que no estan alimentados con concentrados de vitamina.

622 West 168th Street

Calaustro-'68
Bib. No. 1367

J. Nutr. 95(4):517-525. 1968.

Reproduced by permission
of the copyright owner

Effects of Retinoic Acid and Progesterone on Reproductive Performance in Retinol-deficient Female Rats [1,2]

EDNA Q. CALAUSTRO AND IRA J. LICHTON
Division of Nutrition, University of Hawaii, Honolulu, Hawaii

ABSTRACT It was desired to determine whether administration of retinoic acid, or a combination of retinoic acid plus progesterone, could repair the defects in reproductive performance which occur in retinol-deficient female rats. A reliable degree of retinol deficiency was achieved in virgin female albino rats by feeding a retinol-replete diet from weaning until attainment of a body weight of 80 g, followed by a retinol-free diet until the rats reached 200 g and were mated. One group of 60 rats was fed an unsupplemented retinol-free diet, and two other groups of 48 and 60 rats, respectively, were additionally given all-*trans* retinoic acid by mixing it into the diet (10 μg/g) or by medicine dropper (375 μg/rat/week). Supplementation of the retinol-free diet with retinoic acid improved weight gains and restored regular estrous cycles in nonpregnant rats and also improved rates of mating and conception. Administration of retinoic acid by dropper was more effective than admixture in the diet. Neither retinoic acid alone nor in combination with 5 mg progesterone/rat/day from the day of conception prevented resorption or death of fetuses. Hemorrhage of the labyrinth and necrosis of the junctional zone of the placenta were characteristic antecedents of late fetal death. Although retinoic acid did not prevent resorption of fetuses in retinol-deficient dams, it supported formation of chorio-allantoic placentas and postponed the time of fetal resorption until approximately day 16 of gestation.

Considerable attention has been focused on the relationship between deficiency of vitamin A and reproductive failure in experimental animals (1–6). Mason's experiments in particular (3, 4) present a classic picture of reproductive failure in rats as characterized by fetal resorption, stillbirths, congenital malformations, prolonged labor, irregular estrous cycles, and cornification of the vagina which tends to obscure estrous cycles. It has been suggested that failure of reproduction might be a nonspecific resultant of general debility of the retinol-deficient animal (7) since deficiency of retinol is known to cause a variety of pathological disorders such as stunted or abnormal growth, decreased resistance to infection, lesions of the nervous system (8), keratinization of epithelial cells (9), and suppression of steroid hormone biosynthesis (10). This suggestion has been disputed on the ground that reproductive failures have resulted even when the animals have been fed retinoic acid, a substance known to correct the above abnormalities while not supporting vision and reproduction (11–20).

The earliest abnormality observed during pregnancy in retinol-deficient rats receiving retinoic acid is necrosis of the junctional zone of the placenta which later spreads to the labyrinth (14). That placental damage is associated with poor reproductive performance in retinol-deficient rats suggests that such rats may be suffering from insufficiency or imbalance of steroid hormones. This suggestion is supported by the fact that the fetal resorption occurring in retinol-deficient rats also occurs in reproductive failure caused by deficiency of ovarian progesterone (21–24) and that steroid hormone synthesis, especially conversion of pregnenolone to progesterone, is depressed in rats deficient in retinol (10).

Received for publication November 22, 1967.

[1] Published with the approval of the Director of the Hawaii Agricultural Experiment Station as Technical Paper no. 930.

[2] Based on a thesis submitted by Edna Q. Calaustro to the Graduate Division, University of Hawaii, in partial fulfillment of the requirements for the Master of Science degree in Nutrition, June 1967.

In the present work reproductive performance of retinol-deficient rats was examined with respect to rates of conception, formation of chorio-allantoic placentas, continued placental integrity, and delivery of live young. Retinoic acid was given to determine its effects upon the variables mentioned and to produce retinol-deficient rats not suffering from general growth suppression and debility. Progesterone was injected into retinol-deficient rats fed retinoic acid to determine whether this hormone could correct any remaining reproductive defects and permit the rats to carry gestation to a successful conclusion.

MATERIALS AND METHODS

A preliminary experiment was carried out with virgin, female albino rats of the Navy strain (raised in the Division of Nutrition) with the object of establishing standard conditions for the development of retinol deficiency and methods for the introduction of retinoic acid. A second experiment was conducted, under the established conditions, in which the effects of progesterone were studied in rats of the same strain fed a retinol-free diet supplemented with retinoic acid. All experiments were carried out in air conditioned animal quarters kept at 21 to 27°, with the females caged in pairs.

Preliminary experiment. One hundred and seven weanling females with initial weights ranging from 30 to 40 g were used. Daily records were kept of body weight and vaginal smears were recorded daily starting 2 weeks before the desired date of mating. The rats were fed a commercial laboratory ration[3] until they reached a body weight of approximately 80 g. Thereafter they were fed a retinol-free diet vitamin A test diet, USP.[4] Group 1 was continued with this retinol-free diet; group 2 was fed the retinol-free diet supplemented with crystalline all-*trans* retinoic acid,[5] 10 μg/g of diet (see table 1). No special care was taken to mix this diet at frequent intervals; unused retinoic acid was wrapped in light-proof foil and kept in an evacuated desiccator. Females of both groups were mated as soon as possible after they had been fed the retinol-free diet (with or without retinoic acid) for 75 days. The day on which sperm were found in the vaginal smear was designated as day zero of gestation.

Rats were killed with ether on day 10, 11, or 12 of gestation and at least six whole conceptuses from each animal were removed and examined grossly. Care was

[3] Purina Laboratory Chow Pellets, Ralston Purina Company, St. Louis.
[4] Diet composition: (in percent) USP salt mixture no. 2, 4; irradiated yeast, 8; starch, 65; vegetable oil, 5; vitamin-free casein, 18; viosterol, 0.0011.
[5] Eastman Organic Chemicals, Rochester, New York.

TABLE 1

Group designations of vitamin A-deficient rats in relation to diet and injection

Group	No. of rats	Diet	Daily injections
		Preliminary experiment	
1	59	Retinol-free diet	none
2	48	Retinol-free diet supplemented with all-*trans* retinoic acid; supplements were added by mixing 10 μg of retinoic acid/g of diet	none
		Progesterone experiment	
2-O	30	Same as group 1 diet but all-*trans* retinoic acid was dissolved in corn oil and administered through a medicine dropper 3 times weekly, each dose containing 125 μg, totaling 375 μg/rat/week	vehicle (corn oil) alone; intramuscular
2-P	30	Same as group 2-O	5 mg progesterone diluted in corn oil; intramuscular

taken to select only conceptuses that did not appear to be undergoing resorption. These were fixed in Bouin's solution for 3 to 4 days, sectioned at 7 μ, and stained with hematoxylin and eosin. At least 2 conceptuses from each dam were examined microscopically.

Progesterone experiment. Sixty females were fed the commercial laboratory ration until they reached a weight of approximately 80 g, and were then fed the retinol-free diet. All of these rats were given 375 μg of all-*trans* retinoic acid by medicine dropper in three weekly doses of 125 μg each. The retinoic acid was dissolved in a small amount of corn oil. This mode of administraton of retinoic acid was introduced to attain higher growth rates than could be obtained when retinoic acid was added to the diet. The rats were mated after 75 days of receiving this diet. Starting with day zero of gestation, 30 rats were injected intramuscularly with 0.2 ml corn oil (group 2-O) daily, and the remaining 30 rats (group 2-P) were injected intramuscularly with 5 mg progesterone in 0.2 ml of oil[6] daily. See table 1 for identification of groups of rats. Six rats from each of these groups were permitted to proceed to term and the others were killed on day 12, 14, 16, or 18 of gestation. Injections of vehicle or progesterone were stopped on day 20 of gestation for those rats that continued to term. Liver and blood serum were saved for analysis of vitamin A. Conceptuses were collected and examined as previously described. Placentas, rather than whole conceptuses, were collected from rats pregnant more than 12 days. Lipids were extracted from the liver (25), and both extracts and serum were analyzed for their content of retinol by a trifluoroacetic acid method (26). Serum and liver vitamin A concentrations were measured for rats fed laboratory chow and for rats fed the retinol-free diet with admixed retinoic acid for 75 days and rats fed the retinol-free diet and retinoic acid by medicine dropper for 75 to 100 days. Serum was prepared immediately after bleeding, and both serum samples and livers were stored frozen until ready for analysis 2 to 4 weeks later.

RESULTS

Weight gains and general appearance. Body weight gains are shown in figure 1. Rats fed the vitamin A-free diet (group 1) manifested most of the classic signs of deficiency of this vitamin. There was poor weight gain, followed by decline in body weight during the tenth week of feeding the retinol-free diet. Weight gains of group 2-O and 2-P rats were similar and were plotted as a single curve. This curve closely followed that for normal rats (those fed stock laboratory ration). However, the curve for rats of group 2, given retinoic acid in the diet, fell below the curves for normal rats and those given retinoic acid by dropper, more closely approached the curve for group 1. The weight gain curves for normal rats and those of groups 2-O

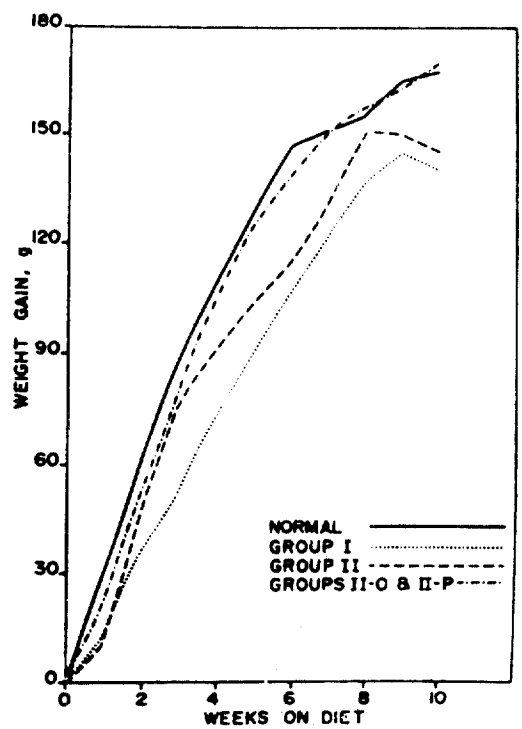

Fig. 1 Weight gains of female rats fed laboratory chow (normal), retinol-free diet (group 1), and retinol-free diet supplemented with retinoic acid, either mixed in the diet (group 2) or given by medicine dropper (groups 2-O and 2-P).

[6] Proluton, Schering Corporation, Bloomfield, New Jersey.

and 2-P continued to rise, whereas those for rats of groups 1 and 2 began to fall after the ninth week. The difference in weight gains of group 2 rats from those of groups 2-O and 2-P is ascribed to the difference in the mode of administration of the retinoic acid supplements. Administration by medicine dropper was more effective than admixture in the diet, possibly because retinoic acid in the diet was damaged by light. Skeletal deformities developed in some of group 1 rats. Such rats developed a hunchback appearance and peculiar gait as observed in dogs by Mellanby (27). Some of these rats had coughing spells, and others had convulsive seizures lasting up to 1 minute. These signs of vitamin A deficiency were completely absent in normal rats and those of groups 2, 2-O, and 2-P. No ocular changes were observed, possibly because the length of time during which the rats were fed the retinol-free diet was not sufficient for total depletion of vitamin A stores in the eye (28).

Estrous cycles and rates of conception. Estrous cycles of group 1 rats became irregular soon after the menarche. Later there was constant vaginal cornification, unrelated to any particular stage of the reproductive cycle, as evidenced by continuous presence of large numbers of cornified cells in the vaginal smears. Rates of conception, pseudopregnancy and failure to mate are shown in table 2. Rats were judged to have been pseudopregnant if they showed continued anestrus, gained weight to the same extent as pregnant animals, and displayed hyperemic ovaries and uteri, but no fetuses, at autopsy. Rats of group 1 showed the lowest rates of conception and the highest rates of pseudopregnancy and failure to mate. Administration of retinoic acid by dropper was slightly more effective than admixture in the diet in improving the rate of conception. Pseudopregnancies and failures to mate were rarer in rats given supplements of retinoic acid.

Microscopic examination. In examining conceptuses and placentas collected from rats fed the retinol-free diet, with or without retinoic acid, particular attention was paid to whether or not a true chorio-allantoic placenta had formed; and if so whether any pathological processes could be observed; and if so, at what time they appeared. The criterion adopted for the presence of a chorio-allantoic placenta was the formation of fetal blood channels within the labyrinth as identified by the presence within them of nucleated fetal erythrocytes. The number of rats that showed true chorio-allantoic placental formation are set forth in table 3. Dietary and especially oral administration of retinoic acid had a beneficial effect upon placental formation. Additional treatment with 5 mg progesterone/day gave no significant improvement beyond the result achieved with oral retinoic acid alone.

Placental lesions were seen in all groups of retinol-deficient rats. Hemorrhages of the junctional zone and within the labyrinth were commonly seen. At a later stage there was generalized necrosis of the junctional zone which led to gradual degeneration of the embryo. These findings are summarized in table 4.

Administration of retinoic acid in the diet tended to delay the onset of embryonic degeneration until about day 11 of gestation, whereas oral administration of this substance delayed the onset of most pathological changes until day 16. After this time, however, few if any conception sites

TABLE 2

Rates of conception, pseudopregnancy, and inability to mate in vitamin A-deficient rats

Group	Total no. of rats	Rats that conceived		Rats that became pseudopregnant		Rats that failed to mate	
		No.	%	No.	%	No.	%
1	59	18	30.5	32	54.3	9	15.2
2	48	34	70.8	14	29.2	0	
2-O	30	23	76.6	5	16.7	2	6.7
2-P	30	23	76.6	3	10.0	4	13.4

TABLE 3

Effect of dietary supplements of retinoic acid upon the development of chorio-allantoic placentas in vitamin A-deficient rats

Group	Retinoic acid fed	No. of days fed diet	No. of rats mated	No. of placental sites examined [1]	No. of sites where a chorio-allantoic placenta was:	
					Present [2]	Absent [2]
1	None	75–100	8	16	2	14
		100–125	3	6	—	6
		125–150	—	—	—	—
		150–175	1	2	1 [3]	1
2	10 μg/g diet	75–100	15	30	8	22
		100–125	6	12	2	10
		125–150	5	10	2	8
		150–175	2	4	—	—
2-O	375 μg/week by dropper	75–100	23	46	42	4
2-P	375 μg/week by dropper	75–100	23	46	44	2

[1] Sites were examined at autopsy on days 10 to 12 of gestation.
[2] See text for criterion of presence or absence of a chorio-allantoic placenta.
[3] Degenerating.

TABLE 4

Summary of pathological changes in vitamin A-deficient pregnant rats

Group	Day of gestation	No. of rats	No. of conceptuses examined	No. of conceptuses showing hemorrhagic junctional zone and labyrinth	No. of conceptuses showing necrosis of junctional zone	No. of conceptuses showing incipient embryonic degeneration
1	10	5	10	6	10	8
	11	5	10	9	10	3
	12	4	8	8	8	5
2	10	6	12	8	4	0
	11	9	18	14	18	4
	12	11	22	22	22	20
2-O	12	3	6	3	3	2
	14	6	12	4	4	2
	16	5	10	10	10	10
	18	6	12	12	12	12
2-P	12	1	2	1	1	0
	14	6	12	2	6	0
	16	6	12	8	8	8
	18	6	12	10	10	12

had escaped severe damage and embryos were destroyed. Administration of progesterone afforded extra protection to the embryo up to day 14 of gestation but not thereafter.

By day 16 of gestation, placental damage was extensive in rats of groups 2-O and 2-P, and nearly all embryos were degenerating. Placental damage at this time consisted mainly in loss of fetal blood channels and invasion of the former channels with maternal blood, which gave a hemorrhage-like appearance to the labyrinth. Figure 2 shows an 18-day placental labyrinth from a normal rat with intact fetal blood channels, and figure 3 shows the hemorrhagic appearance of an 18-day labyrinth from a rat of group 2-O fed the retinol-free diet supplemented with retinoic acid by medicine dropper.

In animals in which placental damage was extensive after day 16 of gestation, the fetuses were adversely affected among all groups of rats. Fetal degeneration was

Fig. 2 Labyrinth of 18-day placenta from a normal rat. × 235.

recognized by the fuzzy appearance of neural tubes and somites. Toward the end of gestation in all retinol-deficient rats given retinoic acid (groups 2, 2-O, and 2-P) the placental labyrinths became either empty or filled with blood. It appeared that maternal-fetal exchange of nutrients had stopped. No fetuses in any retinol-deficient group survived to full term, though one dam of group 2-P (progesterone-injected) delivered two dead, malformed pups.

Serum and liver concentrations of vitamin A. Concentrations of retinol in the serum and liver of rats fed a replete diet and of pregnant rats fed retinol-free diets are shown in table 5. After a 75- to 100-day period of depletion, the serum concentrations of retinol fell to values only one-third as high as those of replete rats. Liver stores in the pregnant, retinol-deficient rats were too low to be detected by the method used.

DISCUSSION

Newton (29) showed in 1938 that pregnant rats fed a vitamin A-free diet after they had attained a weight of 35 to 100 g with a replete diet failed to complete gestation because of fetal resorption. If the deficiency diet was fed from weaning, failure to mate was the most common defect. In the present work, weanling rats were brought to 80-g body weight with laboratory ration and then fed a retinol-free diet with or without supplements of retinoic acid. This procedure produced a reliable degree of retinol deficiency. Serum levels of vitamin A were consistently about one-third of normal, whereas liver stores were essentially depleted.



Fig. 3 Labyrinth of 18-day placenta from a retinol-deficient rat given retinoic acid by medicine dropper and injected with corn oil vehicle. While areas of maternal blood remain, no fetal red blood cells are seen. × 235.

TABLE 5

Serum concentrations and liver stores of vitamin A

Group	Diet	Injections	No. of days fed deficient diet	No. of rats	Vitamin A concn	
					Serum	Liver
					μg 100 ml	*μg/g*
Normal	Stock ration	none	—	6	33	3.0
1	Retinol-free	none	75	6	12	nd [1]
2-O	Retinol-free + oral retinoic acid	corn oil alone	75–100	30	10	nd
2-P	Retinol-free + oral retinoic acid	5 mg progesterone in corn oil; intramuscular	75–100	30	12	nd

[1] Not detected.

The present data demonstrate that retinoic acid in the absence of retinol provides nutritional support for improving weight gain, frequency of mating, and conception in the rat. A most striking effect of retinoic acid, in our hands, was its support of invasion of allantoic blood vessels into the labyrinth and thus formation of chorio-allantoic placentas. This effect was not further augmented by injection of 5 mg progesterone/day from conception.

Regardless of improvements in mating, conception, and formation of placentas, there was no success in obtaining live young from retinol-deficient dams even when both retinoic acid and progesterone were given. Failure to carry gestation to a successful conclusion was probably not ascribable to insufficient supply of retinoic acid, as the rats showed improved growth, mating and conception. These results are in accord with those of Juneja et al. (13), and of Thompson et al. (14, 30), who used either 10 μg of methyl retinoate/g diet or 700 μg/week of sodium retinoate in 2 doses of 350 μg mixed into the diet. In the present work one group of rats received 10 μg of crystalline all-*trans* retinoic acid/g diet (group 2). The overall food consumption of these rats averaged 5 g/day. Thus the weekly consumption of retinoic acid was 50 μg/day for 7 days, or 350 μg/week. This computation was used in selecting the dose of 375 μg/week by medicine dropper. This was only about half the dose of methyl retinoate used by Thompson and co-workers. Nevertheless, in neither study did retinoic acid support full-term gestation in the presence of a severe deficiency of retinol.

Other dietary manipulations are known to cause failure of gestation. The best-known example is that of vitamin E deficiency (31), but such failures also occur when the diet is lacking in pantothenic acid (32), pyridoxine (33), protein (34), or when there are multiple deficiencies of vitamins, minerals, and protein (35). It is notable that in all of these instances live young could be obtained if the dams had been given daily injections of progesterone in amounts up to 5 mg/day. Although injections of progesterone have been shown to be beneficial in vitamin A-deficient rabbits (36), neither progesterone alone as in the present study, or progesterone plus estrogen as used by Coward et al. (37), have led to birth of live young in retinol-deficient rats given retinoic acid. It is usually considered that a combination of 3 or 4 mg progesterone/day with 1 μg estrone/day will suffice to maintain pregnancy in rats ovariectomized in early pregnancy (23). In view of this maintenance requirement it is of interest that pregnancy apparently cannot be maintained in the retinol-deficient rat by similar doses of progesterone and estrogen, while these steroids have proved to be effective in rats deficient in other nutrients as listed above. The reason for these latter successes is not clear, especially in the absence of corroborating evidence that deficiency of pantothenic acid, pyridoxine, or protein leads to disturbed synthesis or removal of steroid hormones.

Although lack of retinol blocks the synthesis of progesterone from pregnenolone, this metabolic defect can be repaired under some conditions by retinoic acid (10). This finding emphasizes that fetal resorption or other features of reproductive failure in retinol-deficient rats are not necessarily caused by lack of specific steroid hormones or any other disturbances in hormone metabolism. The evidence reported here supports the concept of Thompson et al. (30) that there are three dissociable modes of action of vitamin A, namely, systemic, visual, and reproductive. It is evident that neither retinoic acid alone nor in combination with progesterone, in the doses used here can replace retinol in its specific action on reproduction. This action appears to be one of maintenance of the integrity of the conceptus from the time of formation of the chorio-allantoic placenta to term.

ACKNOWLEDGMENTS

The authors thank Dr. Vincent J. DeFeo for advice and Mary Jane Gooley for preparation of photographs.

LITERATURE CITED

1. Evans, H. 1928 The effects of inadequate vitamin A on the sexual physiology of the female. J. Biol. Chem., 77: 651.
2. Coward, K. 1929 The influence of vitamin A deficiency on the estrus cycle of the rat. J. Physiol., 67: 26.

3. Mason, K. E., and E. T. Ellison 1935 Changes in the vaginal epithelium of the rat after vitamin A deficiency. J. Nutr., *9:* 735.
4. Mason, K. E. 1935 Foetal death, prolonged gestation, and difficult parturition in the rat as a result of vitamin A deficiency. Amer. J. Anat., *57:* 303.
5. Kalter, H., and J. Warkany 1959 Experimental production of congenital malformation in mammals by metabolic procedure. Physiol. Rev., *39:* 69.
6. Lamming, G. E., G. W. Salisbury, R. L. Hays and K. A. Kendall 1954 The effect of incipient vitamin A deficiency on reproduction in the rabbit. J. Nutr., *52:* 227.
7. Parkes, A. S., and J. C. Drummond 1933 The effects of fat-soluble vitamin A deficiency on reproduction in the rat. Brit. J. Exp. Biol., *3:* 251.
8. Moore, T. 1957 Vitamin A. Elsevier, New York.
9. Wolbach, S. B., and P. R. Howe 1933 Epithelial repair in recovery from vitamin A deficiency. J. Exp. Med., *57:* 511.
10. Juneja, H. S., S. K. Murthy and J. Ganguly 1966 The effect of vitamin A deficiency on the biosynthesis of steroid hormones in rats. Biochem. J., *99:* 138.
11. Dowling, J. E., and G. Wald 1960 The biological function of vitamin A acid. Proc. Nat. Acad. Sci., *46:* 587.
12. Murray, T. K. 1962 Potency of vitamin A-acid in the vaginal smear assay. Proc. Soc. Exp. Biol. Med., *111:* 609.
13. Juneja, H. S., S. K. Murthy and J. Ganguly 1964 Effect of retinoic acid on the reproductive performances of male and female rats. Indian J. Exp. Biol., *2:* 153.
14. Howell, J. M., J. N. Thompson and G. A. J. Pitt 1964 Histology of the lesions produced in the reproductive tract of animals fed a diet deficient in vitamin A alcohol but containing vitamin A acid. II. The female rat. J. Reprod. Fert., *7:* 251.
15. Moore, L. A., and J. F. Skyes 1941 Terminal cerebrospinal fluid pressure values in vitamin A deficiency. Amer. J. Physiol., *134:* 436.
16. Arens, J. F., and D. A. van Dorp 1946 Activity of vitamin A acid in the rat. Nature, *158:* 662.
17. Wolf, G., W. R. Shreepad, R. A. van Dyke and B. C. Johnson 1958 The function of vitamin A in metabolism. J. Biol. Chem., *230:* 979.
18. Gloor, U., and O. Wiss 1959 Vitamin A and biosynthesis of cholesterol. Biochem. Biophys. Res. Commun., *1:* 182.
19. Van Dyke, R. A., G. Wolf and B. C. Johnson 1960 The functions of vitamin A in adrenal steroid metabolism. Biochem. Biophys. Res. Commun., *3:* 123.
20. Diplock, A. T., J. Green and J. Bunyan 1965 Vitamin A and isoprenoid synthesis in the rat. Biochem. J., *95:* 138.
21. Haterius, H. O. 1935 Reduction of litter size and maintenance of pregnancy in the oophorectomized rat: evidence concerning the endocrine role of the placenta. Amer. J. Physiol., *114:* 399.
22. Rothchild, I., and R. K. Meyer 1940 Maintenance of pregnancy in castrate rats by means of progesterone. Proc. Soc. Exp. Biol. Med., *44:* 402.
23. Lyons, W. R. 1943 Pregnancy maintenance in hypophysectomized-oophorectomized rats injected with estrone and progesterone. Proc. Soc. Exp. Biol. Med., *54:* 65.
24. Alexander, D., J. F. D. Frazer and J. Lee 1955 The effects of steroid on the maintenance of pregnancy in the spayed rat. J. Physiol., *130:* 148.
25. Diplock, A. T., J. Green and J. Bunyan 1963 The determination of vitamin A in animal tissues and its presence in the liver of the vitamin A deficient rat. Brit. J. Nutr., *17:* 199.
26. Neeld, B. J., and W. N. Pearson 1963 Macro- and micromethods for the determination of serum vitamin A using trifluoroacetic acid. J. Nutr., *79:* 454.
27. Mellanby, K. 1941 Skeletal changes affecting the nervous system produced in young dogs deficient in the vitamin A. J. Physiol., *99:* 467.
28. Popper, H. 1949 Histological demonstration of vitamin A in rats by means of fluorescence microscopy. Proc. Soc. Exp. Biol. Med., *43:* 133.
29. Newton, W. H. 1938 A note on the effects of vitamin A deficiency in pregnant rats. J. Physiol., *92:* 32.
30. Thompson, J. N., J. M. Howell and G. A. J. Pitt 1964 Vitamin A and reproduction in rats. Proc. Roy. Soc. London (series B), *159:* 510.
31. Moore, T. 1965 Nutritional factors affecting fertility: vitamin E and other nutrients. In: Agents Affecting Fertility, eds., G. R. Austin and J. S. Perry. Little, Brown and Company, Boston, pp. 34–36.
32. Nelson, M. M., and H. M. Evans 1946 Pantothenic acid deficiency and reproduction in the rat. J. Nutr., *31:* 497.
33. Nelson, M. M., W. R. Lyons and H. M. Evans 1951 Maintenance of pregnancy in pyridoxine-deficient rats when injected with estrone and progesterone. Endocrinology, *48:* 725.
34. Nelson, M. M., and H. M. Evans 1954 Maintenance of pregnancy in the absence of dietary protein with estrone and progesterone. Endocrinology, *55:* 543.
35. Kendall, K. A., and R. L. Hays 1960 Maintained pregnancy in the rat as associated with progesterone administration and multiple-nutrient deficiency. J. Nutr., *70:* 10.
36. Hays, R. L., and K. A. Kendall 1956 The beneficial effect of progesterone on pregnancy in the vitamin A-deficient rabbit. J. Nutr., *59:* 337.
37. Coward, W. A., J. M. Howell, G. A. J. Pitt and J. N. Thompson 1966 Effects of hormones on reproduction in rats fed a diet deficient in retinol (vitamin A alcohol) but containing methyl retinoate (vitamin A acid methyl ester). J. Reprod. Fert., *12:* 309.

Calhoun-'65
Bib. No. 1374

Reproduced by permission
of the copyright owner

J. Dairy Sci. 48:729-732. 1965.

CISTERNAL CEREBROSPINAL FLUID PRESSURE DURING DEVELOPMENT OF CHRONIC BOVINE HYPERVITAMINOSIS A[1]

M. C. CALHOUN, J. E. ROUSSEAU, JR., R. C. HALL, JR., AND H. D. EATON
Animal Industries Department

S. W. NIELSEN
Animal Diseases Department

AND

J. J. LUCAS[2]
Storrs (Conn.) Agricultural Experiment Station, Storrs

ABSTRACT

Twenty male Holstein calves, average age 94 ± 8 days and average plasma vitamin A 11.6 ± 1.2 μg/100 ml were fed one of three daily intakes of vitamin A (calculated as retinol), either 55, 8,800, or 26,400 μg per kilogram of live weight, for one of four durations, 3, 6, 12, or 24 days. The trend in cisternal cerebrospinal fluid (CSF) pressures, taken in left lateral recumbency under general anesthesia, with days fed vitamin A, did not differ significantly from zero for those calves fed either the 55- or 8,800-μg intakes. For those fed the 26,400-μg intake, there was a 1.4% decrease in pressure per day for the actual values and a decrease of 1.6% for the age-adjusted values. It is tentatively concluded that CSF pressures are not increased during the early stages of bovine chronic hypervitaminosis A.

Lowered cerebrospinal fluid (CSF) pressure, determined cisternally, has been a consistent finding in calves fed excessive amounts of vitamin A (4, 5). Obstruction or blockage, or both, between the ventricles and subarachnoid space was not the cause of the reduced pressure (4). The latter was in part due to an internal hydrocephalus ex vacuo, caused by failure of the internal bony plates of the frontal sinuses to form (3). Thus, there was more CSF space, due to a lack of bony separation of the brain from the frontal sinus. Based upon palpation of the frontal, lacrimal, and nasal bones, the bone changes apparently occurred as early as 4 wk in some of the calves fed 26,400 μg of vitamin A (retinol) per kilogram of live weight per day (4). In contrast to these findings, elevated CSF pressure has been a fairly consistent finding in clinical cases of acute and chronic hypervitaminosis A of humans (6, 8, 10, 11). On the basis of distention of the fontanel, a similar elevation of CSF pressure has been reported in acute hypervitaminosis A of the dog (7). Since it was recognized that CSF pressures could have initially been elevated in the calves during the feeding of excessive intakes of vitamin A (5), the present study reports measurements of CSF pressure during development of chronic hypervitaminosis A.

Received for publication December 30, 1964.

[1] Scientific contribution No. 119, Agricultural Experiment Station, University of Connecticut, Storrs. This study was supported in part by grant-in-aid funds provided by PHS research grant, NB-02108-06, from the National Institute of Neurological Diseases and Blindness, Public Health Service, and by Wirthmore Feeds, Inc., Waltham, Massachusetts.

[2] Station biometrician.

EXPERIMENTAL PROCEDURE

Twenty male Holstein one-day-old calves were obtained from various state institution herds during the period January through April, 1964. Upon arrival, each calf was placed in an individual sawdust-bedded tie-stall in a section of the Animal Nutrition Research barn where the environmental temperature was not regulated nor light limited to incandescent. Through the 63rd day of age each calf was raised on a ration consisting of limited whole milk, limited calf starter, and ad libitum chopped alfalfa hay (2). Thereafter, each received a vitamin A depletion ration (2) until its blood plasma level decreased to or less than 15 μg/100 ml. One seven-day period after this partial vitamin A depletion, it was then fed one of three daily intakes of vitamin A, calculated as retinol: 55, 8,800, or 26,400 μg per kilogram of live weight. The first intake which was fed to

four calves, was considered adequate with respect to vitamin A status and was anticipated to result in no adverse biological change. The second and third intakes, fed to eight calves each, were expected to result, respectively, in mild and severe chronic hypervitaminosis A. To preclude feed refusals and thereby eliminate feed intake as a source of variation, the vitamin A depletion ration allowance fed during supplementation with vitamin A was reduced to 60% of that previously fed to calves, to provide an anticipated seven-day increase in weight of approximately 4.5 kg (2).

Prior to the start of the experiment, each calf was randomly assigned to one of the three vitamin A intakes and to one of four durations: 3, 6, 12, or 24 days, of feeding vitamin A. Feed intakes were recorded daily. Live weights, cisternal CSF pressures after a 16- to 18-hr fast and blood plasma vitamin A concentrations, were measured (4, 5) for each calf prior to addition of vitamin A to the ration and at the assigned duration of vitamin A supplementation. The average minimum and maximum environmental temperatures with their SE's were 18.7 ± 0.2 and 25.5 ± 0.3 C, and light exposure 8.9 ± 1.8 ft-c. The chemical composition of the vitamin A depletion ration determined at successive 4-wk periods was essentially similar to that reported previously (2, 4, 5). The vitamin A supplement (Hoffmann-La Roche, dry vitamin A acetate beadlets, type 325-40, Lot no. 013113 and with a guaranteed potency of 325,000 USP units per gram), analyzed twice, contained 109.3 and 110.4 mg of vitamin A (as retinol) per gram.

RESULTS AND DISCUSSION

Feed intake was not affected in calves fed the 55- or 8,800-μg intakes, but was, in the case of two calves, fed the 26,400 μg intake (one in the three-day group which consumed 93% of the total amount offered and one in the 24-day group, 97.4%). Growth rate as indicated by live weight increase (Table 1), was only slightly less for the calves fed the 8,800-μg intake than for those fed the 55-μg, 0.4 versus 0.5 kg increase per day fed vitamin A (values adjusted by covariance). In contrast, live weight decreased over the 24-day period for calves fed the highest vitamin A intake of 26,400 μg, amounting to a daily decrease of 0.1 kg.

Plasma vitamin A concentrations increased, as was expected, with the level of vitamin A intake (Table 1), but did not vary consistently with days fed vitamin A. The average response for the 8,800-μg group of 88 μg of vitamin A per 100 ml of plasma is in agreement with averages, 87 and 86, obtained in previous experiments (4, 5), but the value 129, for calves fed the 26,400 μg intake, is higher than 106, as observed previously (4).

TABLE 1

Effect of excessive vitamin A intake on growth and plasma vitamin A concentrations of Holstein male calves

Vitamin A intakes[a]	Initial values[b]	Days fed vitamin A				SD per calf	
		3	6	12	24	Initial values	Comparison period values
No. of calves							
55 μg	4	1	1	1	1		
8,800 μg	8	2	2	2	2		
26,400 μg	8	2	2	2	2		
Age *(days)*							
55 μg	92	93	102	113	106		
8,800 μg	96	102	103	104	118	8	8
26,400 μg	95	98	103	102	122	8	8
Live weight *(kg)*							
55 μg	91	86(96)[c]	105(101)	102(105)	90(108)		
8,800 μg	104	103(98)	100(98)	106(102)	112(106)	6	5(3)
26,400 μg	98	96(96)	100(96)	87(95)	97(95)	6	5(3)
Plasma vitamin A *(μg/100 ml)*							
55 μg	10	24	21	23	23		21–24[d]
8,800 μg	14	84	108	75	86	1	73–134
26,400 μg	10	120	149	109	139	1	87–186

[a] Micrograms per kilogram of live weight per day.
[b] Prior to vitamin A supplementation.
[c] Adjusted by covariance for live weight prior to vitamin A supplementation.
[d] Range.

Clinical signs associated with hypervitaminosis A were seen in two calves of the 26,400-μg vitamin A intake group. Mild erythema of the inguinal skin and of the anal and nasal mucosa, accompanied by softening of the skull bones between the eyes and nares along the nasal ridge, was observed in one calf by the 13th day of supplementation and the above signs without softening of the skull bones were observed in a second calf by the 20th day.

The cisternal CSF pressures taken in left lateral recumbency under general anesthesia are given in Table 2. The amount of anesthetic employed for each calf averaged, for the measurements taken prior to vitamin A supplementation, 68 ml per 100 kg of live weight, with a SD of 7 and for those during vitamin A supplementation 68 with a SD of 3. In the case of the latter, neither level of vitamin A intake nor days fed vitamin A affected appreciably the amount of anesthetic necessary for abolishment of corneal reflex. The trend in CSF pressure with days fed vitamin A did not differ significantly from zero for those calves fed the 55- or 8,800-μg intakes. For those fed the 26,400-μg intake, there was a 1.4% decrease in pressure per day for the unadjusted values and a 1.6% decrease for the age-adjusted values. When the difference for each calf between the pressure measured prior to and during supplementation was calculated, no statistically significant time trends were present.

On the basis of the above data, it can be reasonably assumed that no elevation in CSF pressures occurred in growing calves fed excessive vitamin A intakes. In addition, based upon the evidence from the present experiment and others (4, 5), the decreases in CSF pressures occurring in calves fed toxic amounts of vitamin A probably resulted from a gradual decrease in pressure during the development of chronic hypervitaminosis A. Thus, it is tentatively concluded that this gradual decrease is a reflection of the concomitant changes taking place in the frontal, lacrimal, and nasal bones of the head and skull (3). In the present experiment, these changes were readily apparent, upon palpation, in one of the calves on the 26,400-μg intake after only 13 days of supplementation. This tentative hypothesis does not

TABLE 2

Cisternal cereprospinal fluid pressures of calves before and after feeding excessive vitamin A intakes

Vitamin A intakes[a]	Days fed vitamin A				SD per calf
	3	6	12	24	
	(mm saline)				
Prior to vitamin A supplementation					
Actual values					
55 μg	183	184	180	124	.....
8,800 μg	175	188	202	180	.....
26,400 μg	218	186	214	198	.....
Common logarithm					
55 μg	2.26	2.26	2.26	2.09	.....
8,800 μg	2.24	2.27	2.30	2.25	0.07
26,400 μg	2.34	2.26	2.33	2.29	0.07
Common logarithm, age-adjusted[b]					
55 μg	2.31	2.29	2.26	2.18	
8,800 μg	2.26	2.30	2.35	2.28	0.06
26,400 μg	2.37	2.30	2.38	2.32	0.06
After vitamin A supplementation					
Actual values					
55 μg	128	185	123	181	.....
8,800 μg	118	158	156	182	.....
26,400 μg	214	195	190	155	.....
Common logarithm					
55 μg	2.11	2.27	2.09	2.26	.....
8,800 μg	2.07	2.20	2.19	2.26	0.12
26,400 μg	2.30	2.29	2.28	2.17	0.12
Common logarithm, age-adjusted[b]					
55 μg	2.14	2.27	2.09	2.26	.....
8,800 μg	2.07	2.20	2.19	2.26	0.11
26,400 μg	2.32	2.31	2.28	2.17	0.11

[a] Micrograms per kilogram of live weight per day.

[b] Adjusted as follows: $y = a + 0.004(101 - x)\theta$, in which y = age-adjusted CSF pressure, a = observed pressure, x = days of age when pressure measurement was taken, and $\theta = 1$ when $x \leqslant 101$ and $\theta = 0$ when $x > 101$ (1).

exclude the possible involvement of other factors. For example, increased membrane permeability, decreased systemic venous pressure, and altered secretory activity of the choroid plexus might conceivably have the same or compounding effects. Finally, the results contained herein should be considered with caution, since many factors not included in the present experiment affect the results due to toxic vitamin A intake (9).

ACKNOWLEDGMENTS

The authors are grateful to B. A. Donohue and T. Watts for the care and feeding of the animals, to A. J. Hoza, P. N. Cote, H. D. Hurt, and Mrs. Mae Miller for technical assistance, and to Dr. H. J. Fisher, Connecticut Agricultural Experiment Station, for proximate analysis of the feeds. The vitamin A supplement was furnished by Hoffmann-La Roche, Inc., Nutley, N.J., through the courtesy of Drs. J. C. Bauernfeind and R. H. Bunnell.

REFERENCES

(1) CALHOUN, M. C., ROUSSEAU, J. E., JR., EATON, H. D., HALL, R. C., JR., AND LUCAS, J. J. 1965. Association Between Age and Cisternal Cerebrospinal Fluid Pressure in Holstein Male Calves. J. Dairy Sci., 48: 100.

(2) CALHOUN, M. C., WOELFEL, C. G., HALL, R. C., JR., ROUSSEAU, J. E., JR., EATON, H. D., AND LUCAS, J. J. 1964. Growth of Holstein Male Calves Fed an Enzyme Supplement, A Combination of Primary Fungal and Bacterial Fermentation Products, with Limited Milk Replacer and Starter and ad Libitum Hay, with Observations on Carotene Utilization. University of Connecticut, Coll. of Agr. Expt. Sta., Prog. Rpt. 56.

(3) GREY, R. M. 1964. The Pathology of Bone in Experimental Bovine Hypervitaminosis A. M.S. thesis, Graduate School, University of Connecticut, Storrs.

(4) GREY, R. M., CALHOUN, M. C., ROUSSEAU, J. E., JR., WOELFEL, C. G., HALL, R. C., JR., NIELSEN, S. W., EATON, H. D., AND LUCAS, J. J. 1964. Cisternal and Intraventricular Cerebrospinal Fluid Pressures in Chronic Bovine Hypervitaminosis A. J. Dairy Sci., 47: 783.

(5) HAZZARD, D. G., WOELFEL, C. G., CALHOUN, M. C., ROUSSEAU, J. E., JR., EATON, H. D., NIELSEN, S. W., GREY, R. M., AND LUCAS, J. J. 1964. Chronic Hypervitaminosis A in Holstein Male Calves. J. Dairy Sci., 47: 391.

(6) JEGHERS, H., AND MARRARO, H. 1958. Hypervitaminosis A: Its Broadening Spectrum. Am. J. Clin. Nutrition, 6: 335.

(7) MARIE, JULIEN, AND SEE, G. 1954. Acute Hypervitaminosis A in the Infant. Am. J. Diseases Children, 87: 731.

(8) MORRICE, G., JR., HAVENER, W. H., AND KAPETANSKY, F. 1960. Vitamin A Intoxication as a Cause of Pseudotumor Cerebri. J. Am. Med. Assoc., 173: 1802.

(9) NIEMAN, C., AND OBBINK, H. J. K. 1954. The Biochemistry and Pathology of Hypervitaminosis A. Vitamins and Hormones, 12: 69.

(10) OLIVER, T. K., AND HAVENER, W. H. 1958. Eye Manifestations of Chronic Vitamin A Intoxication. A.M.A. Arch. Ophthalmol., 60: 19.

(11) TURTZ, C. A., AND TURTZ, A. I. 1960. Vitamin A Intoxication. Am. J. Ophthalmol., 50: 165.

Callison-'45
Bib. No. 1379

Am. J. Physiol. 143(3):444-452. 1945.

LIVER RESERVES OF VITAMIN A AND THEIR RELATION TO THE SIGNS OF VITAMIN A DEFICIENCY IN THE ALBINO RAT[1]

ELIZABETH CROFTS CALLISON AND VIRGINIA H. KNOWLES

From the Bureau of Human Nutrition and Home Economics, Agricultural Research Administration, United States Department of Agriculture

Received for publication November 18, 1944

The several physiological signs of vitamin A deficiency in mammals are too well recognized to require further description. Failure of growth and paralysis of the hind limbs in the young and xerophthalmia in both young and adult animals occur only after a prolonged period of complete deprivation of the vitamin, while night blindness and continuously cornified cells in the vagina of the female are less obvious signs and occur earlier in the course of the deficiency.

Both the occurrence and accurate measurement of night blindness in humans have been subjected to extensive study and the results have been used for the evaluation of their vitamin A status and requirements. It is assumed in these studies that an elevated threshold for dim light is evidence of the exhaustion of the vitamin A reserves of the liver; the length of time on the deficient diet required to produce this hemeralopic condition is regarded as a rough measure of the previous vitamin A reserves of the subject. It is obviously impossible to test these assumptions experimentally in human beings, though it would be of great interest to be certain of these facts. For this reason albino rats were used to determine the amount of the hepatic stores of vitamin A in animals showing symptoms of night blindness and of xerophthalmia. In addition, growth rates, oestrus cycles in the females, scotopic visual thresholds and vitamin A content of the livers were studied in rats receiving cod liver oil at several different levels of vitamin A intake.

EXPERIMENTAL. *General plan of the experiment.* Albino rats, weaned at 21 to 25 days, when weighing 30 to 45 grams, were placed on a vitamin A-free diet, composed of 18 per cent extracted casein, 53 per cent cornstarch, 15 per cent brewer's yeast, 4 per cent Osborne-Mendel salt-mixture, 10 per cent cottonseed oil and irradiated ergosterol to supply three units of vitamin D value to each gram of diet. The experimental animals were offspring of mothers whose diet was somewhat limited in vitamin A content, thus insuring small vitamin A reserves in the young. From 3 to 6 animals were housed in a single large cage with raised screen bottom; the temperature of the room was relatively constant, varying from 76° to 80°F. Food and water were supplied ad libitum. The animals were divided into 4 groups of at least 20 rats each, males and females being equally represented. Litter-mates were distributed evenly throughout the groups. Each group received cod liver oil at a different level of vitamin A

[1] This research was supported by an appropriation from Bankhead-Jones funds (Bankhead-Jones Act of June 29, 1935). A preliminary report of this work was made before the Washington Chapter of the Society for Experimental Biology and Medicine in November 1941.

intake. Since the vitamin A requirement of animals shows a more nearly constant relation to weight than to any other bodily characteristic, the rats were weighed and the amount of vitamin A to be fed calculated on the basis of this weight once a week. Goss and Guilbert (1) have estimated that 18 to 22 units of vitamin A per kilogram of body weight per day will satisfy the rat's minimal needs for this dietary essential. This average minimal amount of 20 units per kilogram per day of vitamin A was given to one group and 30, 50, and 80 units, respectively, to the other three. The rats continued on this regimen until they were adult. As soon as the vagina opened, examinations were made at intervals on each female to determine whether the oestrus cycles were recurring normally. Several animals from each group were conditioned to respond to dim light and their visual thresholds measured. At approximately 275 days, when active growth had definitely ceased, some of the rats were killed and the amount of vitamin A in the livers measured. At this time the liver stores, even in animals on the higher levels of intake, were so meager that the remaining rats were kept to approximately 365 days of age, and at this time several of the animals that had been trained to respond to light were deprived of the vitamin A supplement and tested for hemeralopia at frequent intervals.

When the visual thresholds were abnormal beyond a doubt, some of these rats were killed and the livers analyzed. The remaining hemeralopic rats were continued on the vitamin A-free diet until xerophthalmia appeared before analyzing the livers. The untrained rats which remained were killed for liver analysis. Later, a second series of experiments was begun using three groups of animals which were given 10, 15, and 20 units of vitamin A per kilogram of body weight per day, respectively. The above procedure was followed except that no animals were depleted.

Preparation and feeding of supplement. U.S.P. reference cod liver oil no. 1 diluted with cottonseed oil containing 0.01 per cent hydroquinone, was used to supply the vitamin A supplements. Calculations of the amount of the reference oil fed were based on the assigned potency of 3000 international units per gram. Fresh dilutions of the stock oil were prepared every ten days and were stored at 0°C. between feedings.

Vaginal examinations. At intervals, beginning at the time of vaginal opening, the vaginal secretions of the female rats in this series were examined microscopically without staining.

Visual threshold measurements. It has been demonstrated by many investigators that responses based on brightness differentiation are easily acquired by the albino rat and that this particular kind of discrimination is fundamental for this species of animal. An apparatus very similar to that described by Slater and Mann (2) was built and used to determine the absolute threshold of the rat's dark-adapted eye.

The apparatus consisted, briefly, of a discrimination chamber whose floor sloped gently toward two stimulus patches separated by a narrow partition. The stimulus patches consisted of six-inch squares of flashed opal glass each of which could be illuminated separately from below. In front of the stimulus

patches was an electric grid through which a weak current, just sufficient to give a moderately unpleasant sensation to the feet of the rat, could be passed. Each of the stimulus patches formed the top of a light-tight box to the other end of which was fitted a slide carrying a seven watt Mazda lamp with an arrangement for placing filters and a diaphragm in front of it. The light was reflected upward through the glass plates by means of mirrors set at a 45° angle below them. The upper part of the apparatus was painted a dull black, while the inside of the light boxes was given several coats of white sphere paint which made an excellent surface for reflecting the light evenly over the entire plate. Tests made with the Macbeth illuminometer showed that the differences in brightness between the center and edges of the plate were negligible. The intensity of the light was varied by means of a series of decimal filters in combination with a calibrated diaphragm. The actual experimental lights used were of too small intensity to be measured directly. Instead, the lamp was calibrated without filters and with the diaphragm opened fully; the intensity of the experimental light was then calculated from the brightness of the lamp, the density of the filter, and the size of the aperture of the diaphragm.

The rat was trained to respond positively to light in the following way: He was presented with one stimulus patch light and the other dark. When he chose to go to the light side, there was a reward of food at the other end of the passage, but when the dark side was chosen, punishment followed in the form of a shock from the electric grid and food was withheld. After 100 to 200 trials, the rat would invariably choose the light and when he was responding with an accuracy of 100 per cent he was considered to be trained.

During the course of the tests the light was shifted from one side of the apparatus to the other in random order. The light patch was then reduced in intensity gradually until the point was reached at which the animal was responding with an accuracy of 80 per cent, but below which he was making many more errors. Each threshold reported here represents the average of 30 to 50 trials at the particular brightness on several days. Care was taken at all times to guard against all auditory or other cues which the animal might use in judging the correct response. If one persisted in presenting a light which was subliminal, the rat would finally refuse to run altogether or would indulge in aimless jumping. Morgan (3) has shown that the time required for complete dark adaptation is much longer for rats than for humans. For this reason, the rat was dark adapted for an hour before each test.

Liver analysis. The vitamin A content of the unsaponifiable fraction of the livers of the experimental animals was determined by means of the antimony trichloride reaction, using the Evelyn photoelectric colorimeter. The galvanometer readings were converted to vitamin A units by the use of a reference curve, derived from 20 analyses of the unsaponifiable fraction of reference cod liver oil no. 1. Complete absorption curves of a number of these unsaponifiable fractions were made by means of a Hilger constant wave length photoelectric spectrophotometer for comparison with the blue unit values.

RESULTS. *Growth and physiological condition of the animals.* It appeared

possible that a deficiency of dietary vitamin A might influence the weight gain of the rat at one particular period of growth more than at another. Accordingly for purposes of statistical analysis, weight gains made by the animals in each experimental group during 52 weeks of life have been divided according to five periods of time during each of which the rate of gain was relatively uniform, as shown by the characteristic slope of the growth curve at each period. The times studied represent weaning to 9 weeks, 9 to 13 weeks, 13 to 26 weeks, 26 to 36 weeks, and 36 to 52 weeks of age, respectively. A summary of the averages of these weight gains as well as of the occurrence of oestrus cycles in the females

TABLE 1

The relation of vitamin A intake to growth response, oestrus cycles and visual threshold in rats

VITAMIN A INTAKE, FED AS COD LIVER OIL	AVERAGE WEIGHT GAINS FOR SUCCESSIVE STAGES OF GROWTH, IN GRAMS PER WEEK, WITH STANDARD ERROR										OESTRUS CYCLES	VISUAL THRESHOLDS* LOG μμ LAMBERTS	
	Period I Weaning–9 wks.		Period II 9–13 wks.		Period III 13–26 wks.		Period IV 26–36 wks.		Period V 36–52 wks.				
	♂	♀	♂	♀	♂	♀	♂	♀	♂	♀	♀	♂	♀
units/kg/day													
10	17.0± 1.27	15.0± 0.67	11.2± 1.34	8.3± 0.64	6.0± 0.78	2.6± 0.12					100% continuous cornified cells	4.5 4.9	4.2 4.8
15	19.5± 0.64	15.9± 1.25	13.5± 0.64	9.1± 0.64	6.4± 0.49	3.7± 0.13					Some cornified cells in all smears	3.5 4.0	3.9 3.2 3.5
[illegible]	21.3± 0.98	15.6± 0.42	15.0± 0.70	8.7± 0.30	6.3± 0.43	3.3± 0.23	4.2± 0.45	2.4± 0.33	1.5± 0.21	0.90± 0.44	Normal	3.6 3.2 3.5	3.4 3.2 3.2
30	21.5± 0.36	15.6± 0.56	16.3± 0.72	9.3± 0.44	6.9± 0.30	3.4± 0.12	3.6± 0.38	2.0± 0.76	1.7± 0.90	0.90± 0.10	Normal	3.6 3.5 3.7	3.5 3.2
[illegible]	23.2± 0.93	17.6± 0.81	18.3± 1.11	9.9± 0.30	7.2± 0.30	3.5± 0.19	4.5± 0.40	2.5± 0.80	2.7± 0.22	1.6± 0.40	Normal	3.5 3.6 3.5	3.3 3.6 3.5
[illegible]	23.6± 1.21	18.1± 0.36	18.5± 1.34	9.4± 0.38	6.5± 0.39	3.3± 0.20	4.5± 0.48	2.0± 0.25	2.0± 0.61	1.3± 0.42	Normal	3.5 3.5 3.6	3.4 3.6 3.2

*Values given are for individual rats, since the number of individual animals it was feasible to train and test was necessarily limited.

and visual thresholds of the individual rats on which such determinations were made, is given in table 1.

Individual t-tests were applied at each level of vitamin A intake for each period of growth. From this analysis, the effect of increasing amounts of dietary vitamin A appeared to be limited entirely to the periods from weaning to 9 weeks and from 9 to 13 weeks of age, that is, the time of active growth.

During the 9 weeks immediately following weaning, growth was significantly retarded in both male and female animals by levels of 10 and 15 units per kilogram body weight, as compared with the higher levels of vitamin A intake. In

this period of most rapid growth, the male animals appeared to be less sensiti to increasing amounts of vitamin A above the 20-unit level than did the femal There was a significant increase in rate of weight gain only between the 20- an 80-unit levels in the males, while the females showed significant increases betwe both 30 to 50 and 30 to 80 units of vitamin A per kilogram body weight. Th difference in sensitivity between the sexes was reversed during the followin period, when growth was somewhat slower. At this time the male anima showed significant differences between all levels except the 50- to 80-unit inte vals while no significant differences between the several levels of intake we exhibited by the females.

Examination of the vaginal smears of female animals receiving vitamin at the 10-unit level showed large numbers of cornified cells at all times. In fac it was impossible to follow the oestrus cycles without staining. Those receivin 15 units exhibited some cornified cells in all smears, though not in sufficie numbers to obscure the normal cycles. Animals on the higher intakes we completely normal as far as vaginal contents were concerned, thus confirmin the work of Goss and Guilbert (1).

Under the conditions of this experiment, the normal scotopic visual thresho of the rat appeared to be slightly higher than that reported for human bein It is possible that the experimental procedure necessary to the determinatio in the rats has a tendency to give results which are somewhat high. Visu thresholds of animals on the two lowest levels of intake were elevated in relatio to those on the higher levels.

In connection with the question of general physical well-being, two furthe observations are of interest. The rats on the two lowest levels of vitamin A intake had rough hair and the teeth were chalky white, with no sign of the usual orange pigmentation. Wolbach and Howe (4) have described the same condi tion in their vitamin A-deficient rats and ascribe it to a loss of the enamel laye and a change in the composition of the dentine.

In addition, the incidence of middle ear disease, which we have observed to be somewhat higher in the stock animals receiving limited amounts of vitamin A for the purpose of breeding young for bioassay, than in the stock colony as a whole, decreased with the increase of vitamin A intake and was greater in the males than in the females in almost every group. With the intake of 10 units per kilogram per day, the proportion of the group succumbing to middle ear disease was 44 and 38 per cent; with 15 units, 25 and 40 per cent; with 20 units, 40 and 18 per cent; with 30 units, 21 and 8 per cent; with 50 units, 13 and 0 per cent; and with 80 units, 8 and 10 per cent for the males and females, respectively.

Vitamin A stores in the liver. In table 2 is presented a summary of vitamin A stores of the animals on the four higher levels of vitamin A intake. The amounts of vitamin A stored were extremely meager in the rats receiving the vitamin at the 20-, 30-, and 50-unit levels. It is well-known that the Carr-Price reaction is not specific for vitamin A, and it was found in these experiments that all of the complete absorption curves of the liver extracts with the exception of the ones derived from livers of rats in the 80-unit group, gave marked indication of the

presence of substances other than vitamin A absorbing strongly in the region of 328 mμ. For this reason little quantitative significance can be attached to the actual figures except at the 80-unit level, though such differences as occur are in the expected direction. At the 80-unit level, measurable reserves are accumulated, although even they appear small in comparison with the tens of thousands of units which the rat liver is capable of storing. Goss and Guilbert (1) have reported similar results from experiments extending over a shorter period of time and in which they used animals which were first depleted of their stores to the point of the appearance of cornified vaginal cells. Baumann, Riising, and Steenbock (5) have shown that a smaller percentage of a large single dose of vitamin A can be recovered from the livers of animals that have been depleted than from normal animals. It was for this reason that these experiments were begun with weanling rats having small reserves, rather than with depleted and

TABLE 2

The relation of vitamin A intake to vitamin A content of the livers of rats

Vitamin A intake fed as cod liver oil	Average vitamin A content of liver with standard error											
	Animals 275 days old						Animals 365 days old					
	No. of animals		Units/whole liver		Units/gram liver		No. of animals		Units/whole liver		Units/gram liver	
	♂	♀	♂	♀	♂	♀	♂	♀	♂	♀	♂	♀
units/kg/day												
[illegible]	3	2	3.6 ±0.19	4.8 ±0.40	0.36 ±0.016	0.76 ±0.059	4	6	6.5 ±0.28	8.5 ±0.11	0.76 ±0.042	1.2 ±0.25
[illegible]	6	5	4.3 ±0.47	4.9 ±0.67	0.46 ±0.060	0.75 ±0.100	5	7	5.9 ±0.87	7.0 ±0.67	0.61 ±0.070	1.01 ±0.078
[illegible]	7	4	8.4 ±1.46	5.7 ±1.02	0.81 ±0.12	0.87 ±0.092	5	6	14.2 ±2.78	17.4 ±4.37	1.19 ±0.15	2.51 ±0.82
[illegible]	5	3	45.5 ±42.6	62.4 ±30.0	4.65 ±2.64	12.2 ±6.20	5	6	98.4 ±34.2	104.6 ±41.6	9.0 ±4.10	15.9 ±6.12

therefore physiologically abnormal animals. Analyses of the combined livers of eight male weanling rats and of three females gave an average value of 22.3 units per gram or 22.0 units per liver for the males and 23.8 units per gram or 24.4 units per liver for the females. Thus, the amount of the vitamin A in the livers of the rats on the three lower levels of vitamin A actually decreased from the time they were weaned until they were killed.

From these results it appears that until four times the so-called "minimum" dose of vitamin A is present in the diet of the rat, no measurable reserves are accumulated in the liver. It also may be noted that in spite of their smaller body size and hence lower vitamin intake, and the smaller size of the liver, the amount of vitamin A stored is greater in the females than in the males, not only on a per gram but also on an absolute basis.

Depletion of vitamin A stores. In table 3 may be found a summary of the observations made on the selected animals transferred to the unsupplemented

vitamin A-free diet after 365 days on one of the four highest levels of vitamin A intake. Continuous cornification appeared in the vaginal smears of the female so depleted immediately after the occurrence of hemeralopia, and was followed considerably later by the appearance of xerophthalmia. It is of interest that although liver stores of vitamin A are considerably larger in the female than in the male, the female appears to deplete more quickly than does the male. Since the number of animals used in this portion of the experiment is small, the evidence is not conclusive; however, this result is not incompatible with the observation that the female is more sensitive to a relative deficiency of dietary vitamin A at an earlier period than is the male. The vitamin A content of the

TABLE 3

The relation of previous vitamin A intake and liver stores in depleted rats to the appearance of hemeralopia and xerophthalmia

EXPERIMENTAL ANIMAL AND VITAMIN A INTAKE	VISUAL THRESHOLDS		DEPLETION TIME REQUIRED TO PRODUCE:		VITAMIN A CONTENT OF LIVERS AT APPEARANCE OF	
	Normal	Hemeralopic	Hemeralopia	Xerophthalmia	Hemeralopia	Xerophthalmia
	log μμ lamberts	*log μμ lamberts*	*days*	*days*	*units/whole liver*	*units/whole liver*
20 units/kg./day						
6526 ♂	3.5	4.5	9	23		5.2
6772 ♂	2.6	4.3	10	34		5.8
7037 ♀	3.2	4.2	5	25		13.3
30 units/kg./day						
6535 ♀	2.6	3.9	10	50		7.8
6771 ♂	3.5	4.5	38		13.3	
50 units/kg./day						
6773 ♀	3.3	4.1	48		6.0	
6770 ♂	2.5	3.9	48		7.6	
80 units/kg./day						
6774 ♀	3.4	4.5	55		7.2	
6769 ♂	3.6	4.7	83	112		5.0

livers of animals in a condition of mild vitamin A deficiency differed little from that of animals with xerophthalmia and neither was different from values for liver stores found in apparently normal animals receiving up to 50 units of vitamin A per kilogram per day. The fact that the 30-unit and 50-unit levels of intake prolonged considerably the time necessary to produce physiological symptoms of vitamin A deficiency, although the liver stores were not significantly different from those of the animals receiving 20 units of vitamin A, leads one to the conclusion that the needs of the body tissues which must be satisfied before there is any excess vitamin A available for liver storage must be of considerable magnitude. It also suggests the possibility that lack of vitamin A may effect certain bodily changes, as yet undiscovered, which would serve as a still more

sensitive indicator of vitamin A deficiency than those we rely upon at present. With this idea in mind the brains, spinal cords, and some of the larger nerves of rats from each group were stained by the Marchi technique and examined for signs of degeneration, following the work of Wolbach and Bessey (6). However, no such signs appeared in any of the animals which had either been raised on the low levels of vitamin A or depleted after they were adult. Extensive degeneration, as described by these authors, could be demonstrated in rats depleted to the point of declining weight during the time just after weaning by a diet entirely devoid of vitamin A, i.e., as for bioassay.

CONCLUSIONS

Groups of weanling albino rats fed a vitamin A-deficient diet supplemented with 10, 15, 20, 30, 50, and 80 units of vitamin A per kilogram body weight, respectively, give evidence that growth is inhibited in both males and females at the two lowest levels. During the 9 weeks immediately following weaning, females show further significant improvement in growth rate when the intake is raised from 30 to 50 and from 50 to 80 units per kilogram, while males show a significant difference only when the intake is raised to the 80-unit level. In contrast, during the next period the females show no significant difference while the males give evidence of an enhanced growth rate at the higher levels of dietary vitamin A.

The scotopic visual threshold of normal albino rats, as determined by the brightness discrimination test used, lies between log 2.6 to 3.5 $\mu\mu$ lamberts. Hemeralopia appears as the first detectable sign of vitamin A deficiency, followed closely by continuous cornification of the vaginal contents of the females.

Female animals appear to deplete more rapidly than do the males in spite of larger liver reserves, and the vitamin A stores of the liver are practically exhausted before hemeralopia appears.

No quantitatively measurable stores of vitamin A can be demonstrated in the livers of rats fed less than 50 to 80 units of vitamin A per kilogram body weight per day. This is about four times the amount usually considered as the "minimum" requirement for the rat. Judging from the times necessary to produce the usual physiological signs of vitamin A depletion in the 4 groups of animals receiving vitamin A at 4 levels, it appears that some considerable need of the body must be met in an apparently normal animal before liver storage occurs. It also appears as a possibility that more sensitive physiological indicators of vitamin A deficiency remain to be discovered, and that the "minimum" vitamin A requirement may be somewhat higher than 20 units per kilogram body weight per day.

Acknowledgments. The authors wish to express their gratitude to Dr. Joseph Roe, Department of Biochemistry, George Washington University School of Medicine, for making it possible for them to use the Evelyn photoelectric colorimeter. We are also very much indebted to Dr. T. H. Tomlinson, Pathology Division, National Institute of Health, for the histological examinations of the tissues and to Mr. H. G. Wiseman, Bureau of Dairy Industry, Agricultural Research Administration, U. S. D. A., for the spectrographic analyses of the liver extracts and to Mrs. Sophie Marcuse of the Bureau of Human Nutrition and Home Economics, Agricultural Research Administration, U. S. D. A., for the statistical analysis of the growth rates.

REFERENCES

(1) Goss, H. and H. R. Guilbert. J. Nutrition 18: 169, 1939.
(2) Slater, J. E. and N. L. Munn. J. Comp. Psychol. 13: 273, 1932.
(3) Morgan, C. T. Psychol. Bull. 35: 718, 1938.
(4) Wolbach, S. B. and P. R. Howe. Am. J. Path. 9: 275, 1933.
(5) Baumann, C. A., B. M. Riising and H. Steenbock. J. Biol. Chem. 107: 705, 1934.
(6) Wolbach, S. B. and O. A. Bessey. Science 91: 599, 1940.

Cappellin-'50
Bib. No. 1414

Information Company of America 2204 Walnut Street, Philadelphia, Pa. 19103 215/569-9717

EFFECT OF VITAMIN A IN STRONG DOSES ON THE BONE SYSTEM IN THE ALBINO RAT [Azione della vitamina A in forti dosi sul sistema osseo del ratto albino]

by

M. Cappellin and P. Crepax

(Institute of Human Physiology and Orthopedic Clinic of the University of Bologna)

from

Bull. Soc. Ital. Biol. Sper. 26: 1495-1497 (1950).

Translation from the Italian JNMK/im

4792

1414

EFFECT OF VITAMIN A IN STRONG DOSES ON THE BONE SYSTEM IN THE ALBINO RAT

M. Cappellin and P. Crepax

Vitamin A in large doses may have a toxic effect. The objections raised against this thesis are discredited by the demonstration (Moore and Wang, 1) of morbid manifestations obtainable using the synthetic vitamin. Nevertheless, there is no doubt that the natural concentrates of the vitamin – i.e. the form in which it is predominantly used – may be toxic due to other substances contained in the concentrates (Yamamoto, 2; Yoshida, 3; Hamano, 4; Vedder and Rosenberg, 5).

Two points seem to merit particular attention today.

In the first place, the symptoms that are observed following the administration of strong doses of vitamin A are abundant and very inconsistent which – in accordance with the findings mentioned above – may simply be related to the varying degree of purity and the different animal and vegetable sources of the vitamin concentrates used. Now, experimentation with the pure vitamin should permit us to determine those phenomena that are really attributable to the effect of the vitamin.

In the second place, having distinguished these phenomena, it remains to discuss whether and within what limits they may by nature be considered as expressing the basic physiological action of the vitamin. In reality, the concept of hypervitaminosis – used to include without restriction any effect observable following the administration of large doses of any vitamin – seems to be necessarily limited to those phenomena which represent in any case the antithesis of those phenomena resulting from a vitamin deficiency*, excluding the other generally toxic phenomena lacking an

*The manifestations which may be observed following the administration of fairly high doses of vitamin D seem to meet these requisites.

obvious relation to the physiological action of the vitamin and probably attributable to the influence of aspecific defense mechanisms. Now, in the case of vitamin A, only the modifications observable in the bone system seem to meet the above requirements. Therefore, although these manifestations were already described many years ago (1932: Collazo and Rodriguez, 6), the importance of studying them is all the more necessary since their precise nature is still subject to discussion (Wolbach, 7; Irving, 8).

Our experiments were conducted on 97 albino rats of both sexes, ranging in weight between 50 and 100 g, to which daily doses of vitamin A* were administered through an esophageal catheter at doses varying between 10,000 and 50,000 I.U. per day and per animal.

The daily dosage of 10,000 I.U. was tolerated without harm for a period of more than three months. Starting with 20,000 I.U., it was not long before the general condition of the animals began to progressively decline, all the more rapidly and all the more conspicuously as the quantity of vitamin administered was higher: reduction in the body weight; alterations in the animals' coat, which was shaggy with a loss of hair, leaving large bald spots; inflammatory phenomena of the connective tissue, frequently with a hemorrhagic nature. Daily doses of 20,000 I.U. led to the death of animals weighing from 80 to 100 g within 25-30 days. Starting from the 15th day, or perhaps earlier, spontaneous and multiple bone fractures were observed, which frequently affected animals whose general condition was still good in every other way. These fractures affected the long bones (Figures 1 and 2) and were always symmetrical. In the animals treated with larger doses – although other phenomena were manifested that are difficult

---

*Axerophthol acetate produced synthetically, dissolved in olive oil in a proportion of 100,000 I.U. per ml. The control animals were given quantities corresponding to the excipient alone. We thank Biochimici Alfa di Bologna for kindly supplying us with the vitamin.

to observe at lesser doses (muscular dystrophy, phenomena of hemorrhagic diathesis) – it was possible for death to occur too quickly for the lesions to have time to develop completely. An anatomical examination of the animals demonstrated an accentuated anemia in all the viscera and conspicuous steatosis of the liver and the kidneys – with noticeable enlargement of the adrenals and atrophy of the thymus gland.

The microscopic study of the long bones showed – in addition to the formation of fairly abundant and fibrous calluses at the fracture sites – alterations in the connective cartilages, in the diaphyseal bone, and in the bone marrow. Normally rich in fat, the latter consisted completely of hematopoietic elements (Figure 3). The connective cartilages (Figure 6) were fairly thin (half of the normal size). In the area of the seriate cells, the arrangement of the chondrocytes was irregular, lacking the normal stacking in parallel columns with the result that there were rather extensive areas of acellular cartilage. The zone containing hypertrophic cells – fairly reduced in height – often consisted of two to three rows of cells, whose nuclei were fairly reduced in size with respect to the analogous nuclei in the control rat. The diaphyseal bone sheath, which in the untreated animals apparently consisted of compact bone tissue in which the very moderate osteoblastic activity was limited to the marginal zones, was made up (Figures 4 and 5) of a thin shell of fundamental substance, predominantly having the morphological characteristics of recently deposited bone. In this substance there were a large number of cells with abundant protoplasm, provided with a nucleus containing obvious nucleoli which, based on their appearance and their relationship with the surrounding substance, may be considered as cells of the osteoblastic type.

As was already mentioned, the effects of strong doses of vitamin A on the bone tissue have been variously described. While according to

Irving[8] "The osteoblasts were hardly affected.... The chief feature noticed was the cessation of action of the osteoblasts", Wolbach[7] describes the greatly accelerated depositing of the osteoid tissue, which is only slightly and poorly impregnated with calcium salts and is easily fractured. Our observations agree with the description of Wolbach, but the histogenesis of the alterations observed requires subsequent clarifications concerning their initial phases. Actually, in the stages which we studied, the pre-existent bone tissue is completely replaced by the tissue having the characteristics previously described – forming right after the administration of the vitamin – and it is precisely the phenomena according to which this substitution takes place which we propose to investigate in subsequent studies.

Legend to the Figures

Figure 1. - Radiogram of the upper limb in a rat having an initial weight of 85 g, treated for 24 days with 20,000 I.U. of vitamin A per day. Two fractures of the humerus and one fracture involving the radius and ulna are visible.

Figure 2. - Radiogram of the lower limb in the same animal as that shown in Figure 1: presence of a fracture in the tibia.

Figure 3. - Tibial bone marrow of a rat initially weighing 70 g treated for 28 days with 20,000 I.U. of vitamin A per day. The marrow consists almost exclusively of hemopoietic elements which have replaced the adipose tissue normally found here in abundance (magnification 100).

Figure 4. - Tibial diaphysis of a rat initially weighing 75 g, treated for 32 days with 20,000 I.U. of vitamin per day. Atypical bone tissue with intense signs of rearrangement; this is combined with a layer of osteoid tissue (magnification 200).

Figure 5. - Tibial diaphysis of a rat initially weighing 80 g, treated for 24 days with 40,000 I.U. of vitamin A per day. A layer of mature bone tissue is observed, bordered by a thick layer of osteoid tissue just deposited, rich in numerous osteoblastic type cells (magnification 200).

Figure 6. - Connective cartilage of the upper tibial epiphysis of a rat initially weighing 65 g, treated for 24 days with 20,000 I.U. of vitamin A per day. The greatly reduced thickness of the connective cartilage (150 μ) is observed, along with an irregularity in the areas with seriate cells, the presence of acellular areas, plus the numerical reduction and the peculiar appearance of the hypertrophic cartilaginous cells (magnification 100).

AZIONE DELLA VITAMINA A IN FORTI DOSI SUL SISTEMA OSSEO DEL RATTO ALBINO. — M. Cappellin e P. Crepax.

(Dall'Istituto di Fisiologia Umana e dalla Clinica Ortopedica dell'Univ. di Bologna).

Sezione di Bologna — Seduta del 6 novembre 1950.

La vitamina A in grandi dosi può esercitare azione tossica. Le obiezioni sollevate contro tale tesi cadono di fronte alla dimostrazione (Moore e Wang, 1) di manifestazioni morbose ottenibili usando vitamina sintetica. E' fuor di dubbio, tuttavia, che i concentrati naturali della vitamina, la forma cioè sotto cui essa venne in precedenza sempre impiegata, possono riuscire tossici a causa di altre sostanze in essi contenute (Yamamoto, 2; Yoshida, 3; Hamano, 4; Vedder e Rosenberg, 5).

Due punti sembrano oggi meritevoli di particolare attenzione.

In primo luogo, i sintomi che sono stati osservati in seguito alla somministrazione di forti dosi di vitamina A sono molti e molto incostanti, ciò che, in conformità con i rilievi sopra riferiti, può essere semplicemente in relazione con il diverso grado di purezza e le diverse fonti, animali e vegetali, dei concentrati vitaminici impiegati. Ora, la sperimentazione con vitamina pura dovrà dire quali siano i fenomeni realmente riferibili all'azione della vitamina.

In secondo luogo, individuati tali fenomeni, resterà da discutere se ed entro quali limiti la loro natura consenta di considerarli espressioni dell'azione fisiologica fondamentale della vitamina. In realtà la denominazione di ipervitaminosi, impiegata a comprendere, senza restrizione, ogni effetto osservabile in seguito all'apporto di forti dosi di alcune vitamine, sembra doversi riservare a quei fenomeni che rappresentino in qualche modo l'antitesi di quelli che conseguono a un deficiente apporto vitaminico (*), escludendone gli altri genericamente tossici, senza rapporto patente con l'azione fisiologica della vitamina e verosimilmente

(*) Le manifestazioni osservabili in seguito all'introduzione di dosi assai elevate di vitamina D sembrano rispondere a questi requisiti.

riferibili all'entrata in gioco di meccanismi di difesa aspecifici. Ora, nel caso della vitamina A, solo le modificazioni osservabili nel sistema osseo sembrano rispondere a tali requisiti: di qui l'interesse dello studio, tanto più necessario in quanto, sebbene messe in evidenza già parecchi anni or sono (1932: Collazo e Rodriguez, 6) la loro precisa natura è ancora oggetto di discussione (Wolbach, 7; Irving, 8).

I nostri esperimenti sono stati eseguiti su 97 ratti albini di entrambi i sessi, di peso compreso tra i 50 e i 100 g, a cui venivano somministrate giornalmente mediante sonda esofagea dosi di vitamina A (*) che variavano tra le 10.000 e le 50.000 U. I. per giorno e per animale.

La dose giornaliera di 10.000 U. I. è stata sopportata senza danno per un periodo di oltre tre mesi. A partire dalle 20.000 U. I. le condizioni generali degli animali non tardano a manifestare uno scadimento progressivo, tanto più precoce e tanto più accentuato quanto più grandi sono le quantità di vitamina somministrata: diminuzione del peso corporeo; alterazioni del pelame, che si presenta ispido e cade lasciando vaste aree alopeciche; fenomeni infiammatori delle congiuntive, spesso con carattere emorragico. Dosi giornaliere di 20.000 U. I. portano a morte animali di 80-100 g in 25-30 giorni; a partire dal quindicesimo giorno, talora più precocemente, si osservano fratture ossee spontanee e multiple, che colpiscono spesso animali, le cui condizioni generali sono ancora, per ogni altro verso, buone. Tali fratture colpiscono le ossa lunghe (figg. 1 e 2) e sono sempre simmetriche. Negli animali trattati con dosi più grandi, mentre si manifestano altri fenomeni difficilmente osservabili con dosi minori (distrofia muscolare, fenomeni di diatesi emorragica) la morte può occorrere in troppo breve tempo perchè le lesioni ossee abbiano modo di evolvere compiutamente. L'esame anatomico degli animali dimostra un'accentuata anemia di tutti i visceri, steatosi cospicua del fegato e dei reni, notevole ingrossamento dei surreni ed atrofia del timo.

Lo studio microscopico delle ossa lunghe dimostra, oltre alla formazione nelle sedi di frattura di calli assai esuberanti e fibrosi, alterazioni a carico delle cartilagini di coniugazione, dell'osso diafisario e del midollo osseo. Questo normalmente ricco di grasso, risulta interamente costituito da elementi emopoietici (fig. 3). La cartilagine di coniugazione (fig. 6) si presenta assai sottile (metà del normale). Nella zona delle cellule seriate, la disposizione dei condrociti è irregolare, venendo a mancare il normale impilamento in colonne parallele e risultandone aeree piuttosto estese di cartilagine acellulare. La zona a cellule ipertrofiche, di altezza assai ridotta, è costituita soltanto da due-tre file di cellule, i cui nuclei sono assai impiccioliti rispetto agli omologhi dei ratti controllo. L'astuccio osseo diafisario, che negli animali non trattati appare costituito da tessuto osseo compatto nel quale l'attività osteoblastica molto modesta è limitata alle zone marginali è formato (figg. 4 e 5) da un sottile guscio di sostanza fondamentale, avente in gran parte

(*) Acetato di axeroftolo prodotto sinteticamente, sciolto in olio di oliva nella proporzione di 100.000 U. I. per ml. Agli animali controllo venivano somministrate quantità corrispondenti del solo eccipiente. La vitamina ci è stata gentilmente fornita dalla Biochimici Alfa di Bologna, che ringraziamo.

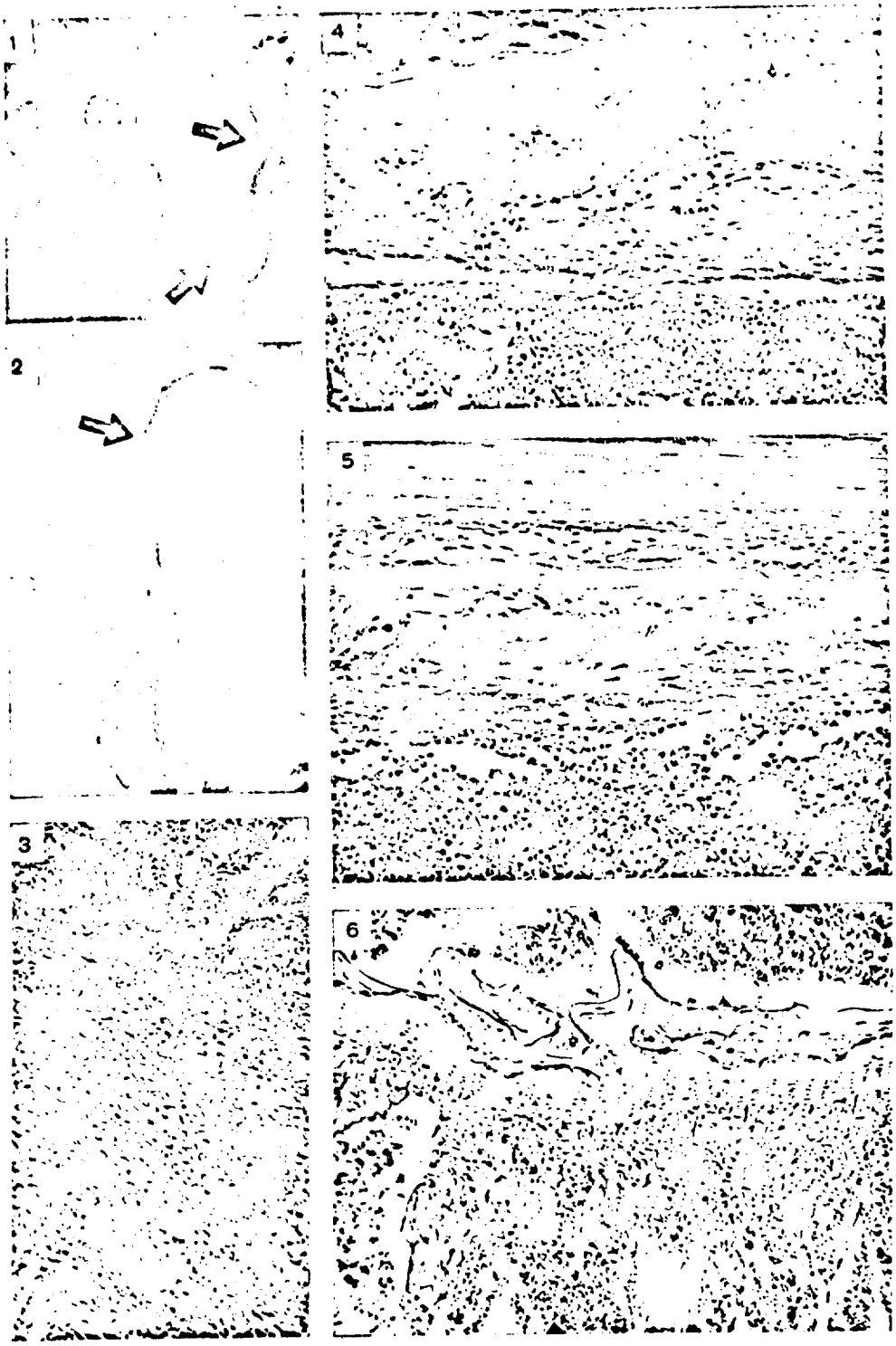

M. Cappellin e P. Crepax.
Azione della vitamina A in forti dosi sul sistema osseo del ratto albino.

i caratteri morfologici dell'osteide appena deposto; entro tale sostanza si trovano in gran numero cellule a protoplasma abbondante, provviste di nucleo con nucleoli evidenti, che per l'aspetto e per i rapporti con la sostanza che li circonda possono considerarsi cellule in funzione osteoblastica.

Come si è detto, gli effetti delle forti dosi di vitamina A sul tessuto osseo sono diversamente descritti; mentre secondo Irving (l. c. 8) « The osteoclasts were hardly affected... The chief feature noticed was the cessation of action of the osteoblasts », Wolbach (l. c. 7) descrive la deposizione grandemente accelerata di un tessuto osteoide, che s'impregna poco e male di sali di calcio e facilmente va incontro a fratture. Le nostre osservazioni si accordano con la descrizione di Wolbach, ma l'istogenesi delle alterazioni rilevate necessita di ulteriori delucidazioni relativamente alle sue prime fasi. Invero, negli stadi da noi studiati il tessuto osseo preesistente è completamente sostituito dal tessuto avente i caratteri prima descritti, formatosi in seguito alla somministrazione della vitamina, e sono appunto i fenomeni attraverso i quali tale sostituzione avviene che ci proponiamo di indagare con ulteriori ricerche.

---

(1) *Biochem. J.*, 1945, 39, 222. — (2) *Bull. Inst. phis. chem. Res. Japan.*, 1934, 13, 1. — (3) *J. agric. chem. Soc. Japan*, 1937, 13, 120. — (4) *Ibidem.*, 1935, 11, 341. — (5) *J. Nutrit.*, 1938, 16, 57. — (6) *Klin. W'schr.*, 1932, 12, 1732, 1768. — (7) *Proc. Inst. Med. Chicago*, 1946, 16, 118. — (8) *J. Physiol.*, 1949, 108, 92.

LEGGENDE DELLE FIGURE

Fig. 1. - Radiografia dell'arto superiore di un ratto del peso iniziale di 85 g, trattato per 24 giorni con 20.000 U.I. di vitamina A *pro die*. Sono visibili due fratture nell'omero ed una frattura che interessa radio ed ulna.

Fig. 2. - Radiografia dell'arto inferiore del medesimo animale di cui alla fig. 1: presenza di frattura nella tibia.

Fig. 3. - Midollo osseo tibiale di ratto del peso iniziale di 70 g trattato per 28 giorni con 20.000 U.I. di vitamina A *pro die*. Il midollo è costituito quasi esclusivamente da elementi emopoietici che sostituiscono il tessuto adiposo che normalmente vi abbonda (100 X).

Fig. 4. - Osso della diafisi tibiale di ratto del peso iniziale di 75 g, trattato per 32 giorni con 20.000 U.I. di vitamina *pro die*. Tessuto osseo atipico con segni intensi di rimaneggiamento; ad esso si affianca uno strato di tessuto osteoide (200 X).

Fig. 5. - Osso della diafisi tibiale di ratto del peso iniziale di 80 g, trattato per 24 giorni con 40.000 U.I. di vitamina A *pro die*. Si osserva una lamella di tessuto osseo maturo, fiancheggiata da uno spesso strato di tessuto osteoide appena deposto ricco di numerose cellule in funzione osteoblastica (200 X).

Fig. 6 - Cartilagine di coniugazione dell'epifisi tibiale superiore di un ratto, del peso iniziale di 65 g, trattato per 24 giorni con 20.000 U.I. di vitamina A *pro die*. Si notino lo spessore fortemente ridotto della cartilagine di coniugazione (150 μ) l'irregolarità della zona a cellule seriate, la presenza di aree acellulari, la riduzione numerica e l'aspetto particolare delle cellule cartilaginee ipertrofiche (100 X).

Chen-'63
Bib. No. 1576

Reproduced by permission of the copyright owner

Column Partition Chromatography of Vitamins A and D on Fluoropak 80

PHILIP S. CHEN, Jr., A. RAYMOND TEREPKA, and NANCY REMSEN
Department of Radiation Biology, University of Rochester, Rochester, N. Y.

▶ A reversed-phase column chromatographic system allowing the separation of vitamin D from vitamin A is described. The stationary phase consisted of Fluoropak 80 impregnated with iso-octane and the mobile phase was aqueous methanol. Advantages include the use of easily volatile non-u.v.-absorbing solvents which facilitate spectrophotometry and liquid scintillation counting of eluted fractions. Examples illustrating the use of this column are presented.

ALTHOUGH A LARGE VARIETY of techniques are available for partition chromatography of polar compounds, relatively few systems have been described for such separation of nonpolar materials—e.g., vitamins A and D (*4*). Most methods for the latter substances rely on the theoretically less desirable adsorption systems (*1*).

This report introduces the use of Fluoropak 80 impregnated with iso-octane as a stationary phase for the column partition chromatography of vitamin D. Use of this support eliminates a serious drawback of available partition methods, namely the difficulty of obtaining separated material free of the solvents used in chromatography. The mobile phase employed in most of these studies has been 90% methanol.

The column has been used mostly for evaluating the purity of and for purifying radioactivity-labeled vitamin D_3 which may then be used for physiological or biochemical studies. In the latter studies, the Fluoropak column has been used to separate radioactive vitamin D_3 from vitamin A in tissue extracts.

EXPERIMENTAL

Apparatus. A 3-foot glass column (12 mm. i.d.) with fritted glass disk and Teflon stopcock was used with the GME Model V 15² fraction collector. Ultraviolet absorption was measured either on the collected fractions with the Beckman DK-2 recording spectrophotometer or between the column and

fraction collector with the GME Model U.V. 265 I.F. recording attachment coupled to a Texas Instruments recorder. Radioactivity was counted in the TMC Model LP-1 liquid scintillation counter.

Reagents. Flouropak 80 (full range particle size) was purchased from the Fluorocarbon Co., 1206 East Ash Ave., Fullerton, Calif. Sieving revealed that practically all the particles were between 20 to 40 mesh, and material between these sizes was used. Iso-octane (2,2,4-trimethylpentane) was obtained from Phillips Petroleum Co., Bartlesville, Okla. The scintillator solution added to each sample for counting was 10 ml. of toluene containing 0.4% diphenyloxazole (DPO) and 0.01% 1,4-di[2-(5-phenyloxazolyl)]-benzene (POPOP).

Procedure. Equal volumes of iso-octane and 90% methanol were equilibrated. Some of the stationary liquid phase (iso-octane) was mixed with dry Fluoropak 80 to impregnate the solid support. The column was filled with iso-octane and the impregnated Fluoropak 80 added to a height of 80 cm. The solid support was then gently tamped with a glass rod until the column was 75 to 77 cm. The iso-octane level was lowered to the top of the Fluoropak and at least 100 ml. of mobile phase (90% methanol) was slowly run through and the sample applied in about 1 ml. of mobile phase. Several hundred μg. of unlabeled vitamin D_3 marker may be added to facilitate location to the vitamin D_3 zone when separating radioactive vitamin D_3 from tissue extracts. Elution was then begun and fractions of 5 or 10 ml. were collected. For radioactivity measurement, the test tube contents were transferred to a 10-dram glass vial, dried with air, dissolved in scintillator solution, and counted.

RESULTS AND DISCUSSION

Figure 1 shows a typical separation of vitamin A_1 and D_3 standards. Toluidine Blue 0, which partitions exclusively into the methanol phase, was added simply to illustrate the solvent front, peak of which was at 30 ml. With 90% methanol, vitamin A emerged very soon after the solvent front, while the peak of vitamin D_3 occurred at 220 ml. As evident from the figure, separation of these two vitamins was excellent.

Stability of vitamin D on the Fluoropak 80 column was checked by running paper chromatograms of pooled column eluates in the systems described by Kodicek (*2*). The paper chromatograms were heated to 80° C. in an oven after dipping through 25% antimony trichloride/$CHCl_3$ (*3*). No colored or fluorescent breakdown products were observed.

Recoveries of vitamin D_3 (as well as vitamin A) were essentially quantitative at 4° C. (column set up in walk-in refrigerator), as shown in Table I. At summer room temperatures, recoveries of the less stable vitamin A were not so good as at the lower temperature, but vitamin D_3 recoveries always exceeded 92%.

A primary application of the Fluoropak column has been to purify radioactively labeled vitamin D_3 for physiological or biochemical studies. An example is illustrated in Figure 2 where 1 mg. of vitamin D_3-7-H^3 was run. The radiochemical purity of the vitamin D_3 exceeded 97% and the non-vitamin D_3 radioactivity was present in u.v.-absorbing material more polar than the vitamin and eluted earlier from the column.

The radioactive contaminant present with the original labeled vitamin D_3-7-H^3 could have arisen from breakdown of the vitamin D_3 itself. A variety of experimental conditions can cause destruction of vitamin D. While it is not the purpose of the present paper to present extensive data on this point, it is necessary to indicate that the Fluoropak column effectively separates vitamin D from its more polar breakdown products produced by ultraviolet irradiation, exposure to oxygen, and dispersion into water. An illustration of this type of separation is shown in Figure 3, where the last mentioned

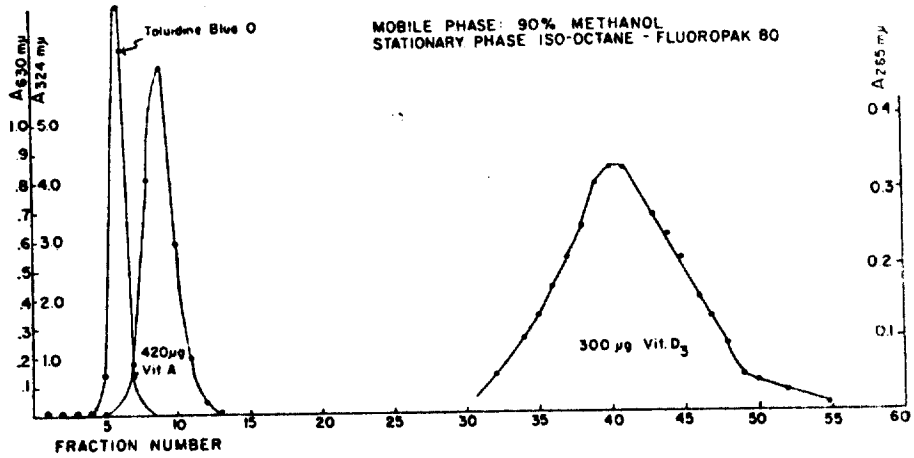

Figure 1. Separation of vitamins A and D_3 on Fluoropak 80

Table I. Recoveries of Vitamins A and D from Fluoropak 80 Column

Temperature	Sample	Added, μg.	Recovered, μg.	Recovered, %
4° C.	Vitamin D_3	300	295	98.3
	Vitamin D_3	3000	2985	99.6
	Vitamin A_1	420	412	98.2
25–30° C.	Vitamin D_3	1077	1007	93.5
	Vitamin D_3	1255	1155	92.0
	Vitamin D_3	940	896	95.4
	Vitamin A_1	2950	2150	73.0
	Vitamin D_2	400	388	97.2

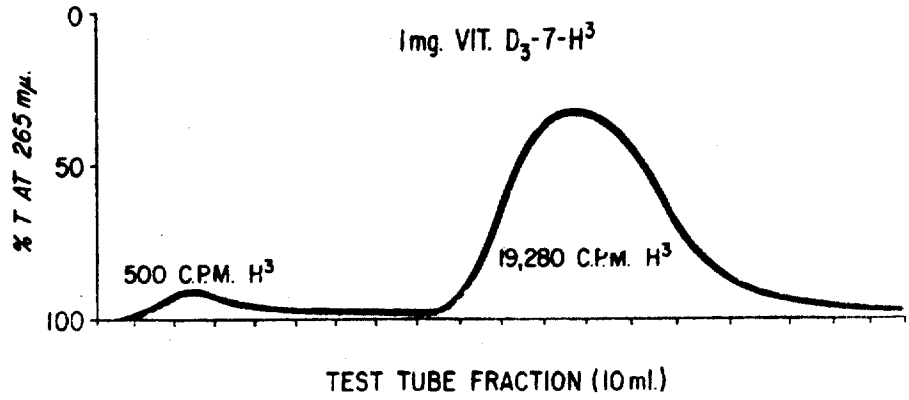

Figure 2. Vitamin D_3-7-H^3

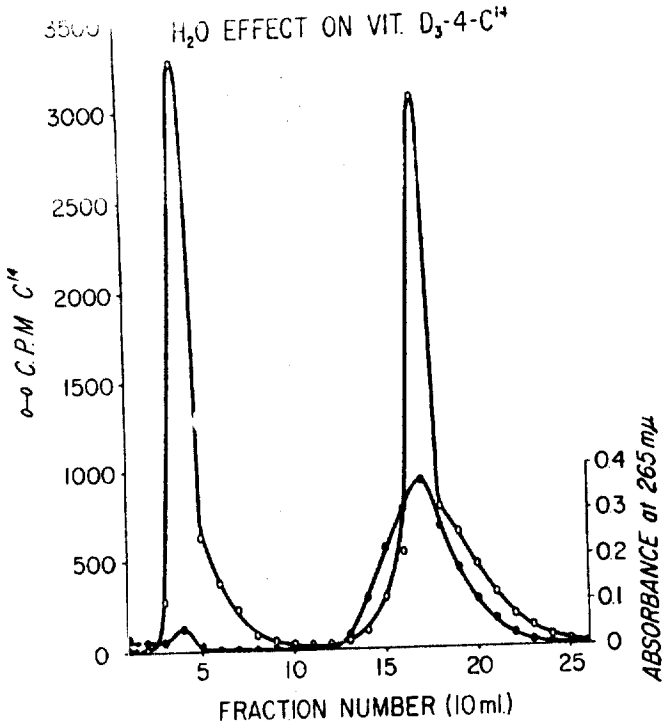

Figure 3. Effect of water on vitamin D_3-4-C^{14}

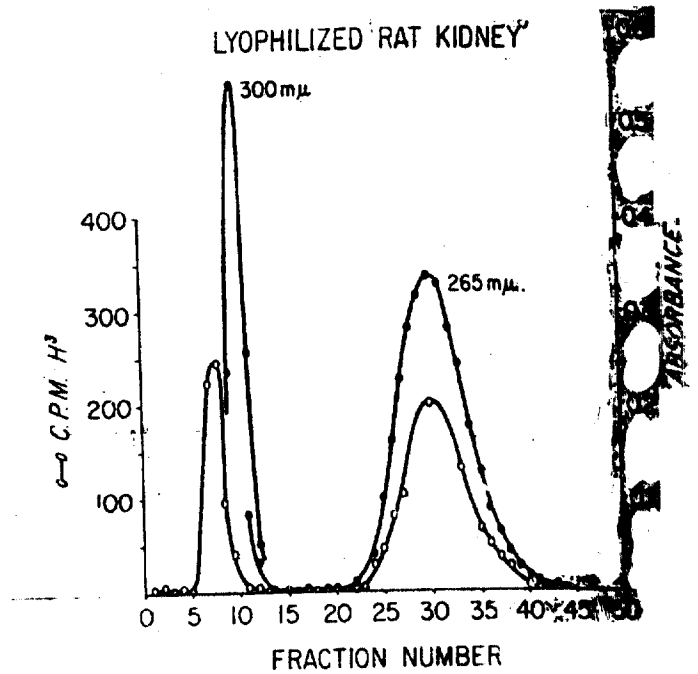

Figure 4. Lyophilized rat kidney with 400 μg. added vitamin D_3 marker

procedure was employed. Five μg. of vitamin D_3-4-C^{14} in 10 μl. of methanol was rapidly squirted into 25 ml. of water, the dispersion allowed to stand for 24 hours, dried under vacuum, and applied to the Fluoropak column. With concentrations of vitamin D large enough to be followed by u.v. absorption—e.g., 10 to 20 μg. per ml.—this breakdown could be observed as a loss in absorbance and shift in peak to longer wavelengths. Further details on studies of vitamin D stability will be reported elsewhere.

The Fluoropak column may also find application to physiological studies in the chromatography of tissue extracts. In preliminary experiments lyophilized or saponified rat tissues, extracted with chloroform (or dichloromethane) and ethyl acetate were used. Chromatographic eluates from liver extract prepared in the above manner exhibited an early peak of relatively polar u.v.-absorbing material running with and near vitamin A, as in Figure 4. Most of the absorbance was due to this vitamin or its breakdown products. In the region where vitamin D was eluted (130 to 250 ml.), practically no ultraviolet absorbance was evident with extracts of normal liver or other soft tissues. This indicated the futility of demonstrating normal tissue vitamin D levels by ultraviolet absorption alone but gave hope that more sensitive quantitation methods might be developed in the future for chemically estimating tissue vitamin D levels following a separation of this type.

Exhaustive surveys of either the stationary liquid phase or the mobile phase were not made, and perhaps other combinations of solvents can be developed for other purposes. The distribution ratio of vitamin D between 90% MeOH and iso-octane was about 0.22, rising to 0.5 at a concentration of 95% MeOH. Thus elution characteristics may be easily varied by altering the alcohol concentration of the mobile phase.

The liquid stationary phase was less amenable to changes. Without iso-octane, there must be some adsorption effects, for if methanol in concentrations of 70% or above was run over Fluoropak 80 powder, the sterols all remained in the alcohol. However, at 65% methanol separations between vitamins A and D were possible, although there was tailing and the solubilities of sterols in this concentration of methanol were poor.

The major advantages of the reversed-phase system described above are: the inert stationary support which does not decompose or otherwise contribute impurities to the eluates; use of solvents which are available in pure form at low cost and which are transparent in the visible and u.v. regions allowing direct absorbance measurements without evaporation or further purification; and use of solvents which are completely and readily volatile, facilitating the application of liquid scintillation counting or other analytical techniques to column eluates.

A disadvantage which may arise in attempting to chromatograph large amounts of crude extract is the necessity of dissolving the material in 90% methanol. Some extracts are rather poorly soluble in this solvent and may require preliminary purifications before running on Fluoropak 80.

LITERATURE CITED

(1) Heftmann, E., "Chromatography," Reinhold, New York, 1961.
(2) Kodicek, E., Ashby, D. R., *Biochem. J.* 57, xii (1954).
(3) Nield, C. H., Russell, W. C., Zimmerli, A., *J. Biol. Chem.* 136, 73 (1940)
(4) U.S.P. XVI, 910 (1960).

RECEIVED for review April 25, 1963. Accepted August 12, 1963. Pittsburgh Conference on Analytical Chemistry and Applied Spectroscopy, Pittsburgh, Pa., March 1963. Paper is based on work performed under contract with the United States Atomic Energy Commission at the University of Rochester Atomic Energy Project, Rochester, N. Y.

Proc. Soc. Exptl. Biol. Med. 115(3):631-633. 1964. Bib. No. 1686

Reproduced by permission of the copyright owner

Connective Tissue IX: Effects of Hypervitaminosis A upon Connective Tissue Chemistry.* (28989)

A. C. Chung and J. C. Houck

Surgical Research Metabolic Laboratory, Georgetown University Hospital, and Biochemical Research Laboratory, Children's Hospital, Washington, D.C.

Massive amounts of Vit. A have been shown by Fell and Mellanby(1) to effect the release of acid polysaccharides from cartilage *in vitro*. This effect of excess Vit. A has been explained by Lucy *et al*(2) to be a result of release of endogenous proteolytic enzymes from lysosomes. These enzymes degrade the protein-polysaccharide complex of the matrix of cartilage releasing the acid polysaccharides from the tissue(3).

To date the effect of hypervitaminosis A upon the soft connective tissue (dermis) of the whole animal has not been studied. This paper describes the effects of large amounts of this vitamin upon the chemistry of the skin *in vivo*.

Materials and methods. Five groups of 6 male Sprague-Dawley rats weighing 140-160 g each were used. One group of animals remained untreated as a control, the other groups received daily doses of 150,000 I.U. of Vit. A palmitate in corn oil (Nutritional Biochemical Co.) intraperitoneally. One group of 6 animals each was sacrificed after 1, 2, 3 and 4 days of Vit. A. The abdominal skin (about 3 g) from each sacrificed rat (including the controls) was shaven, removed and dissected free of adhering fat, fascia and muscle. Aliquots of each skin were hydrolyzed in 10 ml/g of 4 N HCl for 8½ hours at 100°C. The bulk of the tissue samples was pooled, aliquots removed for lipid determination, and the remaining tissue divided into 3 equal samples representing one group of animals from each day of sacrifice. These pools were then extracted sequentially in the cold with 0.15 M NaCl, 0.5 M NaCl and 0.5 M citrate buffer as has been described previously(4). These fractions have been shown to extract quantitatively the "ground substance," salt soluble collagens and acid soluble collagens respectively(4,5). Samples from each extract were hydrolyzed in HCl as described above, and the hydrolysates from both the whole skin and the various fractions were analyzed for their hexosamine (6), hydroxyproline(7) and nitrogen(4) contents. The unhydrolyzed extracts were analyzed for their fucose(8) and sialic acid(9) contents. Lipids were determined as described previously(10).

These results were expressed as the mean and standard deviation of triplicate analyses of triplicate extracts from each group of animals. Means differing by more than 2 standard deviations were found to be significantly different by the "t" test ($p<.05$). The standard deviation of each mean never exceeded 7% of that mean.

Results. The effects of daily Vit. A injection upon total dermal concentration of hexosamine, collagen (from hydroxyproline), cholesterol, phospholipid and triglyceride are shown in Table I. These results are expressed in mg/mmole of total dermal nitrogen to obviate variations in tissue water content. The data of this Table indicate that daily administration of massive doses of Vit. A palmitate were without effect upon total dermal concentrations of lipids and collagen. Total dermal concentration of hexosamine, however, was significantly reduced by administration of Vit. A.

The dermal concentrations of hexosamine, nitrogen, hydroxyproline, fucose and sialic acid soluble in isotonic saline of animals receiving various doses of Vit. A are expressed in Table II per mmole of total dermal nitrogen. These results indicate that concentration of hexosamine and hydroxyproline in the connective tissue was profoundly decreased with Vit. A administration. Moderate decreases of fucose and nitrogen in this fraction were also observed with repeated doses of Vit. A.

* Supported in part by a grant-in-aid from N.I.H., P.H.S., Bethesda, Md.

TABLE I. Total Dermal Lipid, Hexosamine and Collagen Contents in mg per mmole of Total Nitrogen of Skins from Rats Which Have Received Daily Doses of Vit A.

Dosage	Cholesterol	Phospholipid	Triglyceride	Hexosamine	Collagen†
0	.80	2.0	12	.48	35.4
1	.80	1.8	14	*.32	37.3
2	.81	1.8	12	*.29	34.5
3	.78	1.6	14	*.29	35.0
4	.71	1.4	11	*.27	36.0

* Significantly different from 0 ($p < .05$).
† 1 μmole of hydroxyproline = 1 mg of collagen(5).

The hexosamine, nitrogen and hydroxyproline contents of the 0.5 M NaCl and citrate extracts of the connective tissue from animals receiving various doses of Vit. A are presented in Table III per mmole of total dermal nitrogen. These results demonstrate that hypervitaminosis A resulted in a marked decrease in hexosamine content of the saline extract. This decrease was paralleled by moderate decrease in the nitrogen and hydroxyproline content of this fraction with repeated doses of Vit. A. The primary effect of hypervitaminosis A upon the chemistry of the citrate extract was to increase profoundly the hydroxyproline concentration of this fraction.

Subtraction of the sum of soluble components from the total dermal concentrations of hexosamine, nitrogen and hydroxyproline permits the calculation of the insoluble concentration of these materials remaining in the tissue. These results, expressed per mmole of total dermal nitrogen are presented in Table IV. This Table indicates that there is essentially no change in concentration of insoluble hexosamine, nitrogen and hydroxyproline with Vit. A administration.

Discussion. Hypervitaminosis A has been demonstrated to be without effect upon the lipid composition of the skin. Since all results were expressed per mmole of total dermal nitrogen, these results could not be affected by variations in the water and fat content of the skin. It is obvious from these results that the primary action of hypervitaminosis A upon the chemistry of the connective tissue was to produce a marked decrease in the amounts of hexosamine containing materials within this tissue. Since the major sources of hexosamine in the connective tissue are glycoproteins and acid mucopolysaccharides, it is these two substances then which are most profoundly affected by hypervitaminosis A. Since one dose of Vit. A was sufficient to effect the loss of over 60% of the hexosamine in the "ground substance," while no significant decrease in nitrogen content of this fraction was observed, it is suggested that this represents the loss of acid mucopolysaccharides rather than glycoproteins from the tissue. With further doses of Vit. A, decreases in the fucose and nitrogen contents of the "ground substance" were also observed. Presumably this represents the loss of fuco-glycoprotein from the tissue with

TABLE II. Amount of Dermal Hexosamine (Hex), Hydroxyproline (Hypro), Fucose and Sialic Acid (in μMoles/mMole Total Nitrogen) and Nitrogen (as % of Total) Soluble in 0.15 M NaCl from the Skin of Rats Receiving Various Amounts of Vit. A.

Dosage	Hex	Nitrogen (%)	Hypro	Fucose	Sialate
0	1.84	13	1.93	.60	.05
1	*.77	11	*1.10	*.48	.04
2	*.62	12	*.74	*.34	.04
3	*.50	*9.0	*.74	*.36	.05
4	*.39	*8.1	*.27	*.27	.06

* Significantly different from 0 ($p < .05$).

TABLE III. Amount of Dermal Hexosamine (Hex) and Hydroxyproline (Hypro) in μMoles/mMole Total Nitrogen and Nitrogen Soluble (as % of Total) in 0.5 M NaCl and Citrate Buffer (pH 3.0) from the Skin of Rats Receiving Various Doses of Vit. A.

	Saline			Citrate		
Dosage	Hex	N	Hypro	Hex	N	Hypro
0	.73	12	3.45	0	.22	2.60
1	*.18	11	3.05	0	.22	*9.25
2	*.14	*9.0	*2.72	0	*.16	*6.75
3	*.15	*9.0	*2.30	0	*.10	*5.30
4	*.13	*8.0	*1.62	0	*.16	*7.45

* Significantly different from 0 ($p < .05$).

TABLE IV. Insoluble Dermal Hexosamine (Hex) and Hydroxyproline (Hypro) in μMoles/mMole Total Nitrogen and Nitrogen as % of Total in the Skin of Rats Receiving Various Doses of Vit. A.

Dosage	Hex	Nitrogen	Hypro
0	.80	53	27
1	.79	57	24
2	.74	63	24
3	.76	62	24
4	.76	59	26

massive doses of Vit. A. Since the "ground substance" of rat skin contains only glucosamine and *no* galactosamine(11) the mucopolysaccharide disappearing from the "ground substance" must be hyaluronic acid and perhaps heparin. Similarly, decreases in concentration of hexosamine in the 0.5 M NaCl extract occurred initially without parallel losses of nitrogen and therefore presumably represent a loss of the mucopolysaccharide content of this fraction with Vit. A administration. Since this fraction has been shown to contain only galactosamine and no glucosamine(11), the mucopolysaccharides lost from this fraction presumably was chondroitin sulfate.

Associated with hypervitaminosis A was a marked increase in dermal concentration of citrate soluble hydroxyproline, or collagen. Despite this change in the concentration of soluble collagen, hypervitaminosis A was without significant effect upon the chemistry of the insoluble portion of the connective tissue.

Summary. In general, the initial primary effect of hypervitaminosis A upon the chemistry of the connective tissue appeared to be a marked loss of hyaluronic acid and chondroitin sulfate from the saline soluble components of the tissue. With further doses of Vit. A there appeared to be a significant decrease in the glycoprotein content of these fractions. To this degree these chemical studies essentially confirm the effects of Vit. A described by others for cartilage *in vitro,* upon the soft connective tissues *in vivo.*

1. Fell, H. B., Mellanby, E., *J. Physiol.,* 1952, v116, 320.

2. Lucy, J. A., Dingle, J. T., Fell, H. B., *Biochem. J.,* v79, 500.

3. Fell, H. B., Dingle, J. T., *ibid.,* 1963, v87, 403.

4. Houck, J. C., Jacob, R. A., PROC. SOC. EXP. BIOL. AND MED., 1960, v105, 324.

5. Houck, J. C., *Ann. N. Y. Acad. Sci.,* 1963, in press.

6. Blix, G., *Acta Chem. Scand.,* 1948, v2, 467.

7. Martin, C. J., Axelrod, A. E., PROC. SOC. EXP. BIOL. AND MED., 1953, v83, 461.

8. Dische, Z., Shettles, L. B., *J. Biol. Chem.,* 1951, v192, 579.

9. Warren, L., *ibid.,* 1959, v234, 1971.

10. Chung, A. C., Houck, J. C., PROC. SOC. EXP. BIOL. AND MED., 1962, v109, 454.

11. Houck, J. C., *Am. J. Path.,* 1962, v41, 365.

Received October 18, 1963. P.S.E.B.M., 1964, v115.

THE JOURNAL OF BIOLOGICAL CHEMISTRY
Vol. 239, No. 4, April 1964
Printed in U.S.A.

Reproduced by permission
of the copyright owner

Effects of Hypervitaminosis A and D on Skeletal Metabolism*

IRWIN CLARK† AND MARILYN R. SMITH

From the Departments of Orthopedic Surgery and Biochemistry, Columbia University College of Physicians and Surgeons, New York 32, New York

(Received for publication, August 19, 1963)

The feeding of excessive amounts of vitamin D to animals causes pathological changes in the skeleton and calcification of soft tissues (1–4). Hypervitaminosis A causes bone fragility. Spontaneous fractures occur in growing rats, whereas in the adult rat only rarefaction develops (5–8). Although excesses of each vitamin cause specific pathological changes, the concomitant feeding of toxic amounts of both vitamins prevents to a large extent soft tissue calcification and the skeletal changes that accompany hypervitaminosis D (9–10). The present investigation was undertaken to determine how vitamin A exerts its beneficial action in offsetting some of the pathological changes observed in hypervitaminosis D. A preliminary account of these studies has been reported (11).

EXPERIMENTAL PROCEDURE

Male albino rats of the Holtzman strain were used in all experiments except one (Table V), and in this experiment, female rats were used. During metabolic studies, animals were housed individually in metabolism cages designed to separate urine and feces. In Experiments IX (Table I), AJ (Tables II and III), and Q (Table IV), urines were collected for 24 hours, and immediately thereafter the animals were killed; their gastrointestinal tracts were removed and combined with their feces. In Experiments I (Table V) and W (Table VI), urines and feces were collected every 48 hours. Suitable aliquots of urine were plated out in stainless steel planchets for radioactive determinations. Feces and gastrointestinal tracts were ashed, dissolved in concentrated HNO_3, and diluted to suitable volumes, and aliquots were plated out in stainless steel planchets. The radioactivity of all samples was determined with a proportional gas flow counter containing a Micromil window, and the counting period was sufficient to ensure a statistical accuracy of at least 1%. Whenever necessary, corrections for background and decay were made. Phosphorus was determined by the method of King (12); calcium by the method of Berger (13); hydroxyproline by the method of Stegemann (14) and hexosamine by the method of Belcher, Nutten, and Sambrook (15). The marrow was removed from the long bones after the shaft was carefully split. The bones were then extracted three times with chloroform-methanol (2:1) to remove the lipids. Each extraction period was for 24 hours, and the bones were shaken frequently. The bones were dried in an oven at 100–105°. Ashing of samples was done in a muffle furnace at 650°. The loss of weight of the bones after ashing is expressed as the organic fraction of bone. Bone samples were hydrolyzed with 4 N HCl for 18 hours in sealed tubes at 110° before the estimation of hydroxyproline and hexosamine.

The vitamin A palmitate (Merck) used in these experiments was generously supplied by Merck, Sharp and Dohme Research Laboratories. The crystalline vitamin D_2 (calciferol) was kindly donated by Philips-Roxane Company. Purified sesame oil was used to dilute the vitamins and was fed to all control rats. The calciferol was dissolved in a minimum of ethyl alcohol before dilution. The vitamins were administered daily on a body weight basis by stomach tube. An analysis of variance was performed on each experiment.

RESULTS

Calcium and Phosphorus Absorption and Excretion in Adult and Young Rats—The smaller gain in weight observed in the adult rats fed 10,000 units of vitamin A per 100 g of body weight (Table I) indicates that this amount of vitamin A is slightly toxic. The same quantity of vitamin D is more toxic and caused a marked loss of weight. The administration of vitamins A and D together appears less toxic than vitamin D alone, since the animals fed the combination lost less weight than did those fed just vitamin D.

Comparison of the amounts of ^{45}Ca in the alimentary tract and feces of the control rats and those fed vitamin D (Table I) clearly shows the enhancement of calcium absorption in hypervitaminosis D; an effect which has been observed by others (16–18). Vitamin A had no effect on calcium absorption, and the combination of A and D did not alter the enhancing action of vitamin D on intestinal absorption of calcium. These results on absorption correlate well with the urinary data (Table I) which indicate greater spillage after increased absorption. Neither vitamin A nor vitamin D affected the absorption of phosphate from the gastrointestinal tract, although vitamin A did increase the urinary ^{32}P in this experiment.

In the rapidly growing young rat (Table II), vitamin A also diminished the toxicity of excessive amounts of vitamin D as measured by gains in body weight. Although the older animals lost weight when fed toxic amounts of vitamin D or the combination of vitamins A and D (Table I), these young animals continued to gain weight, although very slowly (Table II). Absorption of calcium or phosphorus was similar to that seen with the older rats in the previous experiment (Table I).

Analyses of 24-hour urine samples, collected at the end of the experiment, indicate (Table III) that in these young animals vitamin D increased calcium excretion, whereas vitamin A had no effect. The combination of vitamins A and D tended to lower the values observed after vitamin D alone, but the differences were not significant.

* Supported by United States Public Health Service Grant No. A-4071 and United States Atomic Energy Commission Grant No. AT (30-1)-2530.

† Recipient of a Career Development Award.

TABLE I

Calcium and phosphorus absorption by adult rats with hypervitaminosis A and D

Experiment IX: Each group contained 12 rats. The animals received 10,000 units of vitamin A, or 10,000 units of vitamin D, or a combination of 10,000 units of vitamin A and 10,000 units of vitamin D per 100 g of body weight. The animals were maintained on this regimen for 30 days. Each animal received 10 μc of ^{45}Ca or ^{32}P in 0.5 ml of milk *per os* 24 hours before being killed.

Treatment	Body weight		^{45}Ca			^{32}P		
	Initial	Final	Urine	Gastrointestinal tract and feces	Sum	Urine	Gastrointestinal tract and feces	Sum
	g		% dose			% dose		
Control	275	332	0.49	28.9	29.1	4.3	12.0	16.3
Vitamin A	275	297*	0.46	35.2	35.7	6.7*	20.2	26.9
Vitamin D	275	232*	10.6*	3.3*	13.9*	4.1	10.4	14.5
Vitamins A and D	275	255*	6.6*	6.1*	12.7*	5.0	20.0	25.0

* Statistically significant ($p < 0.01$) as compared to control values.

TABLE II

Calcium and phosphorus absorption by young rats with hypervitaminosis A and D

Experiment AJ: Each group contained 16 rats. The animals received 10,000 units of vitamin A, or 15,000 units of vitamin D, or a combination of 10,000 units of vitamin A, and 15,000 units of vitamin D per 100 g of body weight. The animals were maintained on this regimen for 24 days. Each animal received 10 μc of ^{45}Ca or ^{32}P in 0.5 ml of milk *per os* 24 hours before being killed.

Treatment	Body weight		^{45}Ca			^{32}P		
	Initial	Final	Urine	Gastrointestinal tract and feces	Sum	Urine	Gastrointestinal tract and feces	Sum
	g		% dose			% dose		
Control	85	190	0.88	31.2	32.1	10.9	11.5	22.4
Vitamin A	85	178*	1.06	36.1	37.2	12.3	9.5	21.8
Vitamin D	85	97*	7.9*	1.0*	8.9*	12.5	7.2	19.9
Vitamins A and D	85	120*	10.6*	1.4*	12.0*	13.4	7.0	20.4

* Statistically significant ($p < 0.01$) as compared to control values.

Vitamin D decreased phosphate excretion and vitamin A had no effect. When vitamin A was given with vitamin D, urinary phosphate values approached those of the controls. Although the administration of vitamin D increased calcium excretion, it decreased phosphate excretion, regardless of the method of calculation. Similar findings have been observed in acute experiments (19).

Increasing the amount of vitamin D to 60,000 units and of vitamin A to 30,000 units per 100 g of body weight caused a significant loss of weight in young growing rats, and the concomitant administration of vitamin A with this amount of vitamin D did not decrease significantly the loss in weight (Table IV), although it did decrease the mortality rate (10). In this experiment, the isotopes were administered parenterally and urinary labeled and unlabeled calcium again were significantly increased in the animals fed vitamin D or the combination of vitamin A and D. When calculated on a body weight basis, vitamin D alone or in combination with vitamin A increased urinary isotopic and unlabeled phosphorus. Urinary calcium or phosphate values of the rats treated with vitamin A did not differ significantly from those of the control animals.

Calcium and Phosphorus Excretion after Varied Levels of Vitamin A Intake—Vitamin A, 10,000 units per 100 g of body weight, again was toxic in these mature female rats, as evidenced by the greater loss in body weight (Table V). Despite this toxicity, the rats fed vitamin A excreted less unlabeled calcium and phosphate (urine and feces). Moreover, the decrease in unlabeled calcium excretion was accompanied by a significant increase in the elimination of radioactive calcium that had been deposited in the skeleton 120 days before.

TABLE III

Urinary values at 24 hours

Same legend as Table II.

	Calcium		Phosphorus	
	mg	mg/100 g body weight	mg	mg/100 g body weight
Control	0.47	0.23	11.4	6.0
Vitamin A	0.49	0.34	12.0	6.7
Vitamin D	3.76*	3.85*	4.5*	4.6*
Vitamins A and D	2.41*	1.98*	7.5*	6.3

* Statistically significant ($p < 0.01$) as compared to control values.

Increasing the level of vitamin A 10-fold (Table VI) resulted in an enhanced excretion of both labeled and unlabeled calcium and phosphorus.

Bone Composition of Hypervitaminotic A and D Rats—Analyses of two representative types of bones (Table VII), *i.e.* tibia and calvaria of the animals described in Table II, showed that the ash content was considerably reduced in the animals fed vitamin D. This loss of mineral was prevented to a large extent by the simultaneous administration of vitamin A. Vitamin A alone had no effect on the ash content of the bone.

TABLE IV

Urinary calcium and phosphorus values at hours after parenteral administration of nuclides

Experiment Q: Each group contained 7 rats. The animals received 30,000 units of vitamin A, 60,000 units of vitamin D, or a combination of 30,000 units of vitamin A and 60,000 units of vitamin D per 100 g of body weight. The animals were maintained on this regimen for 15 days before being killed. ^{45}Ca was administered as calcium acetate intraperitoneally and ^{32}P as Na_2HPO_4 subcutaneously.

Treatment	Body weight		Calcium			Phosphorus		
	Initial	Final	^{45}Ca	^{40}Ca	^{40}Ca	^{32}P	^{31}P	^{31}P
	g		total counts × 10^4	mg	mg/100 g body weight	total counts × 10^4	mg	mg/100 g body weight
Control	135	202	5.5	1.3	0.67	8.5	12.5	5.7
Vitamin A	135	167*	7.9	1.8	1.10	7.2	8.6*	5.2
Vitamin D	135	91*	40.8*	8.9*	9.9*	14.8*	8.9*	9.9*
Vitamins A and D	135	101*	36.4*	8.4*	8.5*	13.0*	9.2*	9.2*

* Statistically significant ($p < 0.01$) as compared to control values.

TABLE V

Total excretion values (12 days)

Experiment I: Each group consisted of 6 rats. The daily dosage of vitamin A was 10,000 units/100 g of body weight. Each rat received 100 μc of ^{45}Ca intraperitoneally and 200 μc of ^{32}P subcutaneously 120 days before the collection period. The amount of ^{32}P excreted after 120 days was too little to measure with any degree of accuracy.

Treatment	Body weight		Urine			Feces		
	Initial	Final	^{40}Ca	^{45}Ca	^{32}P	^{40}Ca	^{45}Ca	^{32}P
	g		mg	total counts	mg	mg	total counts	mg
Control	223	213	14.4	9,600	77.1	1,400	176,000	722
Vitamin A	223	189*	13.3	21,900*	57.3*	950*	354,000*	539*

* Statistically significant ($p < 0.01$) as compared to control values.

TABLE VI

Total excretion values (12 days)

Experiment W: Each group consisted of 8 rats. The daily dosage of vitamin A was 100,000 units/100 g of body weight. During the collection period and for 14 days before the animals were fed a diet low in calcium and phosphorus. Isotopes were administered intravenously 48 days before collection period.

Treatment	Body weight		^{40}Ca		$^{45}Ca^*$		^{32}P		$^{32}P^*$	
	Initial	Final	Urine	Feces	Urine	Feces	Urine	Feces	Urine	Feces
	g		mg		total count × 10^4		mg		total count × 10^4	
Control	212	213	7.1	21.1	2.0	21.6	210	57.5	12.2	0.7
Vitamin A	214	185*	19.3*	43.2*	22.7*	145.0*	205	112.7*	15.2*	1.3*

* Statistically significant ($p < 0.01$) as compared to control values.

TABLE VII

Bone analyses

Same legend as Table II.

Treatment	Dry, defatted weight of tibia	Ash		Hydroxyproline				Hexosamine			
		Calvaria	Tibia	Calvaria		Tibia		Calvaria		Tibia	
				Dry weight	Organic weight	Dry weight	Organic weight	Dry weight	Organic weight	Dry weight	Organic weight
	mg	%		%		%		%		%	
Control	212	60.7	59.4	2.93	7.2	2.63	6.48	0.20	0.54	0.47	1.14
Vitamin A	191	61.9	59.7	3.03	7.9	2.73	6.76	0.18	0.47	0.41	1.02
Vitamin D	146*	49.8*	47.9*	4.04*	7.7	3.71*	7.17*	0.27*	0.50	0.59*	1.13
Vitamins A and D	144	55.9*	54.0*	3.20	7.2	3.10	6.76	0.23	0.51	0.48	1.05

* Statistically significant ($p < 0.01$) as compared to control values.

TABLE VIII

Bone analyses

Same legend as Table IV.

Treatment	Dry, defatted weight of femur	Ash		Hydroxyproline				Hexosamine			
		Calvaria	Femur	Calvaria		Femur		Calvaria		Femur	
				Dry weight	Organic weight	Dry weight	Organic weight	Dry weight	Organic weight	Dry weight	Organic weight
	mg	%		%		%		%		%	
Control	299	64.0	60.9	2.25	6.20	2.43	6.12	0.137	0.40	0.44	1.13
Vitamin A	230*	63.8	62.3	2.20	5.55	2.12	5.82*	0.141	0.39	0.38*	0.99*
Vitamin D	212*	50.4*	51.0*	3.1	6.65	3.49*	7.16*	0.241*	0.49*	0.49*	0.97
Vitamins A and D	220*	54.1*	54.5*	2.7	5.90	3.19*	6.96*	0.205*	0.43	0.45	0.98*

* Statistically significant ($p < 0.01$) as compared to control values.

TABLE IX

Bone analyses

Same legend as Table VI.

Treatment	Control	Vitamin A
Dry, defatted weight (mg)		
Femori	353	328*
Humeri	166	131*
Ash (%)		
Calvaria	63.9	62.2
Femori	61.3	60.0
Humeri	63.0	62.0
Hydroxyproline		
Calvaria		
Dry, defatted weight (%)	2.94	2.84†
Organic weight (%)	8.2	7.9†
Humeri		
Dry, defatted weight (%)	2.57	2.31†
Organic weight (%)	7.03	6.31*
Hexosamine		
Calvaria		
Dry, defatted weight (%)	0.24	0.24
Organic weight (%)	0.67	0.62*
Humeri		
Dry, defatted weight (%)	0.55	0.53
Organic weight (%)	1.08	0.83*

* Statistically significant ($p < 0.01$) as compared to control values.

† Statistically significant ($p < 0.05$) as compared to control values.

Hydroxyproline values, used as a measure of collagen content, were elevated significantly in hypervitaminotic D animals, when calculated as a percentage of the weight of dry, defatted bone. When calculated as a percentage of the organic fraction bone, the hydroxyproline values were usually higher than control values, although the results were not always statistically significant. Administration of 10,000 units of vitamin A, alone or in combination with vitamin D, had no significant effect on the hydroxyproline content of the bone in this 24-day experiment.

Hexosamine content, although not very specific, was used as an index of mucopolysaccharide content. In this experiment (Table VII), vitamin D caused a relative increase in hexosamine content when calculated as a percentage of the dry, defatted weight of bone, but this increase was not significant when calculated as a percentage of the organic weight. Vitamin A tended to decrease the hexosamine content of bone and to prevent the increase observed with vitamin D alone regardless of the method of calculation.

When the dosages of vitamins A and D were increased 3- and 4-fold, respectively, essentially similar findings were observed (Table VIII). Vitamin D decreased significantly the ash content of both types of bones, while the combination of vitamins A and D prevented, to a large extent this loss of mineral. In this experiment, vitamin D increased the hydroxyproline content of femurs. The hydroxyproline values of the bones of the animals fed the combination of vitamins A and D were less, although not significantly different from those of the animals fed vitamin D alone.

Vitamin D increased the hexosamine content of the calvaria, regardless of the method of calculation, but the increase in hexosamine content of the femur was only relative. Vitamin A decreased significantly the hexosamine content of the femur but not of the calvaria. The combination of vitamin A and D again tended to prevent the increase caused by vitamin D alone.

Administration of 100,000 units of vitamin A for 12 days reduced the weight of the femurs and humeri significantly (Table IX). Despite this marked loss of osseous tissue, the percentage of ash was normal. The hydroxyproline content of the bones was significantly decreased regardless of the method of calculation. The hexosamine content was usually reduced in the animals fed the vitamin.

DISCUSSION

The administration of large amounts of vitamin A to rats causes increased excretion of calcium and phosphorus ((20, 21) and Table VI) and if continued long enough, extensive rarefaction of bone results ((5, 8) and Table IX). Despite these findings, the ash content of the bones appears to be normal ((8, 21) and Table IX). The present studies show that there is a loss of collagen and mucopolysaccharide from bone (Tables VIII and IX). Since the amounts of these substances in bone are small compared to the mineral content, small changes in their values would not be readily detected by gross measurement of ash content.

Tissue culture studies have shown that excessive amounts of vitamin A arrest the growth of bone and cause a disappearance of the matrix leaving behind apparently normal cartilage cells. In addition, resorption of bone occurred simultaneously with

normal soft tissue growth surrounding the explant (22, 23). The chemical data in these studies *in vivo* support the observations *in vitro*. Under the influence of large excesses of vitamin A, there is a decrease in the collagen content (as measured by hydroxyproline) and mucopolysaccharide content (as measured by hexosamine) of the skeleton (Tables VIII and IX).

Recent reports (24–27) have suggested that vitamin A may act at the cellular or subcellular level to liberate a protease which in turn may hydrolyze tissue proteins. Proteolysis of the non-collagenous protein of bone by such a protease may disrupt the collagen fibrils in such a manner as to render them vulnerable to attack by proteolytic enzymes. Another possibility may be the liberation of a collagenase by the stimulus of increased metabolic activity of bone during hypervitaminosis A since this condition results in acceleration of remodeling processes (28) which must involve removal of collagen. Although no collagenase has been isolated from mammalian tissue, recent studies have shown the production and liberation of a collagenase by amphibian tissues undergoing rapid remodeling (29). The loss of collagen from the bones of the rats with hypervitaminosis A (Tables VIII and IX) could be explained by such an action of vitamin A.

The isotopic data (Table V) support the histological observations of Wolbach (28) that excess vitamin A accelerates the remodeling process. In this experiment, the animals had received ^{45}Ca 120 days before the administration of vitamin A. The animals fed vitamin A excreted less unlabeled calcium and phosphate than the controls but excreted twice as much isotope, indicating a more rapid turnover or remodeling of bone that had been formed 3 months previously. Since no balance studies were done in this experiment, it is possible that the decreased excretion of unlabeled calcium and phosphate by the rats fed vitamin A may have resulted from a decreased food intake, since these animals did not gain as much weight as the control rats and may not have eaten as much.

Vitamin D intoxication in rats causes a thinning of bones accompanied by an accelerated bone production in the medullary cavities of the long bones with large quantities of osteoid about the original trabeculae. There also is increased deposition of new matrix (4, 10). These histological observations implied less ash and more organic matter and this was confirmed by the chemical analyses (Tables VII and VIII). The bones of these animals had less ash and more collagen and mucopolysaccharide than those of the normal animals. Whether this increased amount of matrix is the result of increased synthesis or decreased breakdown or both is not known.

The feeding of large amounts of vitamin A with toxic amounts of vitamin D prevents to a large extent the pathological changes of hypervitaminosis D on the skeleton (9–11). Chemical analyses of the bones of the animals treated with the combination of vitamins A and D (Tables VII and VIII) show that the ash, collagen, and mucopolysaccharide content approach the control values and in several instances are significantly different from the values of the bones of the rats with hypervitaminosis D. This improvement in the composition of the bone has also been observed histologically (10). The role of vitamin A may be either to prevent the action of vitamin D in increasing collagen and mucopolysaccharide synthesis or more likely as in hypervitaminosis A, to increase the rate of remodeling (28) to remove the excess mucopolysaccharide and protein (24–27) resulting in a more normal bone composition and structure. It is clear that vitamin A does not exert its beneficial action by decreasing the enhanced absorption of calcium (Tables I and II) which results from increased vitamin D intake (16–18). In these experiments, neither vitamin A nor vitamin D had any effect on the intestinal absorption of phosphate. Any beneficial effect of vitamin A on the renal handling of calcium and phosphate must also be discounted, since no differences in the elimination of parenterally administered ^{45}Ca and ^{32}P were observed between the vitamin D-treated rats and those treated with the combination of these vitamins.

It is conceivable that substances derived from bone as a result of the increased rate of remodeling seen in hypervitaminosis A may act to prevent soft tissue calcification (9, 10). The increased elimination of phosphorus caused by large amounts of vitamin A may in part tend to prevent renal calcification, since it has been shown that increasing phosphate in the diet tends to prevent kidney calculi (30). It is also possible that the increased breakdown products of mucopolysaccharide and collagen may prevent the precipitation of calcium-phosphate salts in the soft tissues.

SUMMARY

Increased bone mineral turnover has been observed with large amounts of vitamin A. Toxic amounts of vitamin A decrease mucopolysaccharide and collagen content of bone with no demonstrable changes in ash content. Toxic amounts of vitamin D decrease the ash while increasing the absolute amounts of mucopolysaccharide and collagen content. The combination of large amounts of vitamin A with vitamin D partially prevents the pathological changes observed in the skeleton in hypervitaminosis D. It is suggested that the beneficial effect of vitamin A results from increased mucopolysaccharide and collagen turnover. Vitamin A does not prevent the enhanced intestinal absorption of calcium resulting from an excessive intake of vitamin D.

REFERENCES

1. Gyorgy, P., *Klin. Wochschr.*, **9**, 102 (1930).
2. Harris, L. J., and Innes, J. R. M., *Biochem. J.*, **25**, 367 (1931).
3. Shohl, A. T., Goldblatt, H., and Brown, H. B., *J. Clin. Invest.*, **8**, 505 (1930).
4. Follis, R. H., *Transactions of the Second Conference on Metabolic Interrelations*, Josiah Macy, Jr. Foundation, New York, 1950, p. 221.
5. Collazo, J. A., and Rodriguez, J. S., *Klin. Wochschr.*, **12**, 1732, 1768 (1933).
6. Bomskov, C., and Seeman, G., *Z. ges. exptl. Med.*, **89**, 771 (1933).
7. Davies, A. W., and Moore, T., *Biochem. J.*, **28**, 288 (1934).
8. Moore, T., and Wang, Y. L., *Biochem. J.*, **39**, 222 (1945).
9. Clark, I., and Bassett, C. A. L., *Federation Proc.*, **19**, 412 (1960).
10. Clark, I., and Bassett, C. A. L., *J. Exptl. Med.*, **115**, 1[illegible] (1962).
11. Clark, I., and Smith, M. R., in N. Sissakian (Editor), *Abstracts of the Fifth International Biochemical Congress, Moscow, 1961*, Pergamon Press, Ltd., Oxford, 1963, p. [illegible]
12. King, E. J., *Micro-analysis in medical biochemistry*, J. & A. Churchill, Ltd., London, 1951, p. 68.
13. Berger, E., *Clin. Chem.*, **1**, 249 (1955).
14. Stegemann, H., *Z. Physiol. Chem.*, **311**, 41 (1958).
15. Belcher, R., Nutten, A. J., and Sambrook, C. M., *Analyst*, **79**, 201 (1954).
16. Nicolaysen, R., *Biochem. J.*, **31**, 107, 122, 1086 (1937).
17. Greenberg, D. M., *J. Biol. Chem.*, **157**, 99 (1945).
18. Migicovsky, B. B., and Nielson, A. M., *Arch. Biochem. Biophys.*, **34**, 105 (1951).

19. Clark, I., in R. O. Greep and R. V. Talmage (Editors), *The parathyroids*, Charles C Thomas, Springfield, Ill., 1961, p. 183.
20. Maddock, C. L., and Wolbach, S. B., *Federation Proc.*, **9**, 337 (1950).
21. Nerurker, M. K., and Sahasrabudhe, M. B., *Biochem. J.*, **63**, 344 (1956).
22. Fell, H. B., and Mellanby, E., *Brit. Med. J.*, **2**, 535 (1950).
23. Fell, H. B., and Mellanby, E., *J. Physiol., London*, **116**, 320 (1952).
24. Fell, H. B., Mellanby, E., and Pelc, S. R., *J. Physiol., London*, **134**, 179 (1956).
25. Fell, H. B., Lucy, J. A., and Dingle, J. T., *Biochem. J.*, **78**, 111 (1961).
26. Lucy, J. A., Dingle, J. T., and Fell, H. B., *Biochem. J.*, **79**, 500 (1961).
27. Dingle, J. T., *Biochem. J.*, **79**, 509 (1961).
28. Wolbach, S. B., *J. Bone and Joint Surg.*, **29**, 171 (1947).
29. Gross, J., and Lupiere, C. M., *Proc. Natl. Acad. Sci. U. S.*, **48**, 1014 (1962).
30. Howard, J. E., Thomas, W. C., Mukai, T., Johnston, R. A., and Pascoe, B. J., *Trans. Assoc. Am. Physicians*, **75**, 301 (1962).

Nature 217:1174-1176. 1968.

Reproduced by permission
of the copyright owner

Skeletal Abnormalities in the Hindlimbs of Young Cats as a result of Hypervitaminosis A

HYPERVITAMINOSIS A causes extensive confluent exostosis formation of the cervical spine in adult cats[1,2]. It was initially reported that no juvenile osteodystrophy occurred in this disease[1], but an abnormal hindquarter gait was described later in a group of young cats receiving large daily doses of vitamin A (ref. 2). No explanation of this abnormal gait was given and the condition was therefore studied further.

A litter of six healthy 8 week old kittens was divided randomly into two groups of three, whose diet consisted raw meat and milk. The first group received no vitamin A supplementation and each cat in the second group was supplemented for 4 weeks with a daily oral dose of 50,000 I.U. of vitamin A acetate in polyethylene glycol and isopropanol. To prevent rickets due to a possible interaction between vitamin A and vitamin D (ref. 3), all cats received calcium and vitamin D supplementation throughout the experiment.

From the beginning of vitamin A supplementation the cats showed a marked disinclination to walk and depression of appetite. Immediately after cessation of vitamin A dosing, appetite returned, but reluctance to walk remained. Two weeks later the cats had a distinctly abnormal hindlimb gait which became more severe with time and was not a result of weakness. Their limbs appeared disproportionately short, particularly the hindlimbs. During walking, extension of the stifle joints was restricted and the hocks projected laterally. One cat from each group was killed after a further 4 weeks. After another 6 weeks some toes of the remaining test cats were observed to be shortened (Fig. 1). These animals and the two remaining controls were killed in the seventeenth week of the experiment--13 weeks after the cessation of vitamin A supplementation.

The outstanding pathological findings in the test cats included the following. (1) A dramatic shortening of the long bones of the limbs. (2) Alteration in structure of the stifle joint. The tibial crest was prolonged dorsally so that the tubercle lay above the remainder of the proximal epiphysis and rested against the distal femoral articular surface (Fig. 2). The femoral condyles were enlarged and

Hind paws of one cat which had been dosed with vitamin A with hind paws of a control shown above.



Fig. 2. The right tibia from a control (left) and hypervitaminosis A cat. (Normal size.)

displaced proximally so that the trochlea was the most distal part of the femur. (3) Irregular shortening of the metatarsal bones.

The first two changes were bilaterally symmetrical in all three cats. The projection of the anterior proximal tibial diaphysis was longer and curved in a caudal direction in the cats killed at the later date. The third change was observed only in the latter two cats and was bilaterally symmetrical in one, affecting the third metatarsal bones. All four metatarsal bones were shortened in the right hind paw of the other cat, but only the fourth one was affected in the left. Histopathological examination of the distal ends of the metatarsal bones showed varying degrees of reduction of epiphyseal plates, sometimes with complete disappearance. In some bones, the medullary cavities of the epiphysis and diaphysis were continuous and a small piece of residual cartilage appeared free in the extended cavity, thus playing no part in the endochondral bone formation needed for longitudinal growth (Fig. 3).

It seems that after exposure to vitamin A for 4 weeks the growth of specific epiphyseal cartilages was arrested and as the bones continued to increase in diameter growth took place around the retarded epiphyseal cartilages and these were completely or partially resorbed.

These findings differ from those of Wolbach[4], using rats and guinea-pigs, who concluded that bone shortening in hypervitaminosis A was simply a result of premature closure of epiphyses caused by accelerated growth sequences. Our observations seem rather to support those of Fell and Thomas[5] and Thomas *et al.*[6], who found actual depletion of cartilage caused by dissolution of its matrix and loss of chondroitin sulphate in foetal mouse bones *in vitro* and in growing rats, respectively.

Fairbank[7] stated that the skeletal changes due to hypervitaminosis A in children resolved with no per-

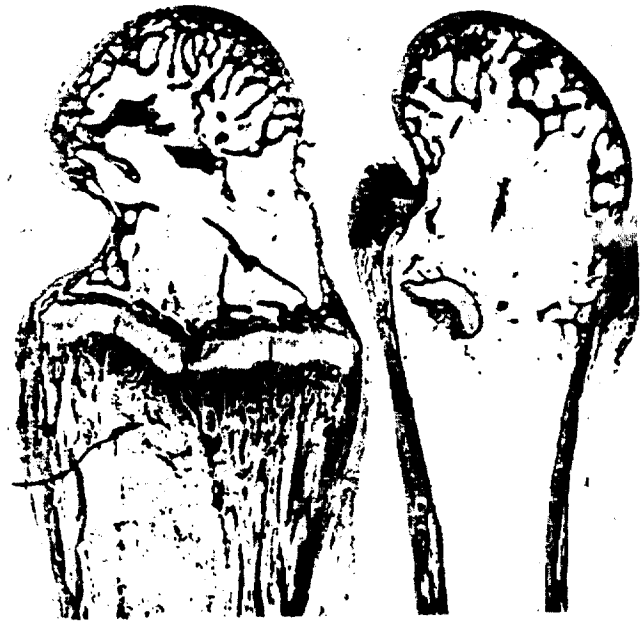

Fig. 3. Distal end of the right fourth metatarsal bone in a control (left) and hypervitaminosis A cat. (×8.)

sistence of bone lesions. Pease[8], however, reported permanent bone shortening in some children who suffered from hypervitaminosis A. The shortening of limbs was asymmetric and this was simply attributed to difference in weight bearing. The irregular nature of the shortening of metatarsal bones in young cats in this experiment is unlikely to have this explanation. The chief cause of the permanent gait abnormality in these cats was the bilaterally symmetrical prolongation of the anterior proximal tibia, making the extension of their stifle joints beyond ninety degrees mechanically impossible. Growth at the proximal end of the tibia takes place both at the cartilaginous epiphysis and also at an anterior fibro-osseous epiphysis[9,10]. The bone deformation observed in this study seems to be a result of restricted growth at the cartilaginous epiphyseal plate, while that at the anterior fibro-osseous region remained unrestricted, although probably modified by new stresses imposed by the changed stifle joint action.

High levels of vitamin A intake comparable with those in this experiment are possible for cats in natural conditions in Australia, where liver which is high in vitamin A content is readily available as pet food[11]. The osteodystrophy described here probably occurs in some kittens fed intensively for a short period on livers which are unusually high in vitamin A content.

L. [illegible]
A. A. [illegible]

Veterinary School,
University of Queensland.

Received November 20, 1967

[1] Seawright, A. A., English, P. B., and Gartner, R. J. W., [illegible] 171 (1967).
[2] Seawright, A. A., English, P. B., and Gartner, R. J. W., [illegible] 77, 29 (1967).
[3] Nielsen, C., and Klein Ostbirk, H. J., *Tidsskr. f. Veterinærmedicin* [illegible] (1954).
[4] Wolbach, S. B., *J. Bone Joint Surg.*, 29, 171 (1947).
[5] Fell, H. B., and Thomas, L., *J. Exp. Med.*, 111, 71[illegible] (1960).
[6] Thomas, L., McCloskey, R. T., Porter, J. L., and [illegible] *J. Exp. Med.*, 111, 705 (1960).
[7] Fairbank, T., *An Atlas of General Affections of the Skeleton*, 1st ed., 354 (E. and S. Livingstone Ltd., Edinburgh and London, 1951).
[8] Pease, C. N., *J. Amer. Med. Assoc.*, 182, 980 (1962).
[9] Lewis, O. J., *J. Anat.*, 92, 5-7 (1958).
[10] Smith, J. W., *J. Anat.*, 96, 299 (1962).

Clark-'70
Bib. No. 1710

THE EFFECT OF EXCESS VITAMIN A ON LONGBONE GROWTH IN KITTENS

By

Leigh Clark

Veterinary School, University of Queensland, Brisbane, Australia

INTRODUCTION

Spectacular and permanent alterations in longbone morphology have been described in kittens dosed with high levels of vitamin A for a short period after weaning and then allowed natural growth (Clark and Seawright, 1968; Clark, Seawright and Gartner, 1970). This paper describes longbone pathology in kittens destroyed immediately after a similar dosage period. Pair-fed controls were used to determine the part played by reduced food intake, which can occur in hypervitaminosis A (Rodahl, 1950).

MATERIALS AND METHODS

Animals and treatments. The experimental animals comprised 10 pairs of newly-weaned 6 to 8-week-old kittens. The kittens in each pair were litter mates of the same sex and similar weight. One of each pair was a test kitten (odd numbers) and the other a control (even numbers). The test kittens were given 50 to 100 μg./g. body weight of vitamin A daily by mouth for 21 or 30 days. The dose for each kitten was varied to ensure maximum intake of vitamin A without signs of acute toxicity and the shorter treatment was employed for the kittens most affected by the vitamin. The vitamin A preparation* was water miscible, contained 500,000 i.u. (approximately 170,000 μg.) of vitamin A acetate/ml., and was administered in gelatin capsules. Eight of the pairs of kittens (group A) were destroyed immediately after the dosage period, while 2 pairs (7 and 8, and 19 and 20), constituting Group B, were allowed to recover for some weeks on normal diets to confirm the development of longbone lesions previously described (Clark *et al.*, 1970). Details of treatment of the kittens are given in Table 1.

Throughout the experiment the daily food intake of each test kitten was measured and an identical amount was fed to its control the next day. The diet consisted of minced abattoir offals. To ensure that it was adequate in Ca and P and that the Ca/P ratio was optimal for growing kittens (Scott, 1965), $CaCO_3$ and $CaHPO_4$ were added so that 100 g. mince contained approximately 319 mg. Ca and 292 mg. P. Several analyses were done throughout the experiment to ensure that these levels remained fairly constant (Association of Official Agricultural Chemists, 1960). Each kitten also received one drop of a solution containing 65 mg. KI/100 ml. water per day to provide I, as recommended for kittens on meat diets by Scott (1965). The animals were kept indoors in individual cages except for an exercise period of 2 hours a day in the sunshine.

Post-mortem procedures. The kittens were destroyed by an intraperitoneal injection of barbiturate solution. Bones from the left limbs were fixed in buffered neutral

* E. R. Squibb Vitamin A W/M Oral.

formalin and decalcified by the formic acid-sodium citrate method (U.S. Armed Forces Institute of Pathology, 1949). With the exception of the proximal end of the femur, which was cut in the medio-lateral plane, the end of all bones were cut longitudinally in the sagittal plane. A transverse section was also taken through the midshaft of selected larger bones. Paraffin sections were stained with haematoxylin and eosin and toluidine blue. The humerus, radius, femur, tibia, metatarsals and the proximal phalanges of the hindpaws from all kittens were examined histologically. Frozen sections were made of selected decalcified bones and stained with oil red O for fat. Radiographs were made of the large longbones from the right limbs. Liver and kidney vitamin A levels were determined by the method of Gartner and Ryley (1956).

Bone measurements. The right humerus, radius, femur and tibia were measured in 6 of the 8 pairs of kittens destroyed at the end of dosing, and also in the 2 pairs which were allowed to recover. Using calipers, lengths were measured from the proximal to distal articular surfaces and midshaft diameter was measured cranio-caudally.

RESULTS

Clinical Observations

The average daily food intakes of the test kittens were depressed from 20 to 80 per cent. of their starting levels. Three animals whose initial weights were below 700 g. lost weight during the dosage period (Table 2). This effect was most extreme in kittens 1 and 3, and they would probably not have survived vitamin A administration beyond 21 days. In contrast, their respective controls gained weight and were healthy when destroyed. All test kittens were dull and reluctant to walk during treatment. The 2 which were allowed to recover became brighter, ate more and soon gained weight. In the following weeks, however, they developed a distinct abnormality of gait: their limbs appeared shorter than normal, particularly the hindlimbs; extension of the stifle joints was restricted and the hocks projected laterally.

TABLE 1

TREATMENT OF TEST KITTENS

Kitten	*Vitamin A dosage period (days)*	*Average daily dose vitamin A (μg.)*	*Day of necropsy*
1	21	50,781	21
3	21	39,314	21
5	21	57,333	21
7*	21	52,419	49
9	30	65,360	30
11	30	60,773	30
13	30	45,867	30
15	30	51,600	30
17	30	42,427	30
19*	30	64,213	82

* Kittens 7 and 19 were allowed to recover on normal diets for some weeks after dosage ceased.

TABLE 2

BODY WEIGHTS OF EXPERIMENTAL KITTENS

The start and end of the dosage period and average food intakes during the dosage period

Kitten	*Test or control*	*Body weight (g.)*		*Average food intake in dosage period (g./day)*
		Start of dosage period	*End of dosage period*	
1	T	650	510	33
2	C	650	800	33
3	T	600	435	20
4	C	600	770	20
5	T	775	820	105
6	C	675	1080	105
7	T	610	600	41
8	C	640	820	41
9	T	1040	1440	92
10	C	1025	1525	92
11	T	745	1125	99
12	C	645	1140	99
13	T	765	950	81
14	C	750	1100	81
15	T	765	1100	99
16	C	745	1260	99
17	T	830	910	66
18	C	780	1110	66
19	T	850	975	70
20	C	600	980	70

Gross Pathology and Radiographical Findings

Kittens destroyed immediately after the dosage period (group A). At necropsy the test kittens weighed less than their controls (Table 2), were dehydrated and had less subcutaneous fat.

The principal changes were in the bones which in the test animals were generally more brittle than those of the controls. Longbones were consistently shorter and narrower in shaft diameter (Fig. 1, Table 3). The epiphyses displayed a proportional reduction in size. Metaphyseal flaring was pronounced in the test bones. In addition, there were minor abnormalities in the modelling of the ends of some of the large longbones. The head of the humerus and the femoral condyles were flattened, the latter showing mild caudal and proximal rotation. In the tibia the tubercle was elevated due to a slight dorsal elongation of the crest. At the same time the tibial condyles were depressed and their caudal slope exaggerated.

Radiographs of the large longbones of the control kittens appeared normal. Besides confirming the overall features noted in the gross specimens, the radiographs of test bones showed thinner cortices and many cartilaginous epiphyseal plates were narrow, indistinct or absent. Radiographical density was similar in test and control groups.

Kittens allowed to recover on normal diets (group B). The test and control kittens in both pairs were in good nutritional condition when they came to necropsy. Certain differences were noted between the bones of group B kittens and those of group A. The differences in length between test and control bones had become more marked in the recovery period: in contrast the differences in shaft diameter were not consistent (Table 3). The slight morphological abnormalities at the extremities of some bones described above were much more pronounced and were similar to those previously described for kittens allowed to recover after dosing. In addition, the bone measurements were statistically compatable with those in the previous experiment (Clark *et al.*, 1970).

In contrast to the kittens destroyed immediately after the dosage period, radiographs of test and control bones revealed no significant differences in shaft thickness. Many epiphyseal plates were absent in the test animals. Again radiographical density was similar in both groups.

Microscopical Pathology (Group A)

In the test kittens both endochondral and appositional bone formation was abnormal.

Epiphyseal plates. Table 4 is an attempt to show the degree of the lesions encountered in the epiphyseal plates of various bones. Most plates were involved, but those most severely and consistently affected were found in the distal humerus,

TABLE 3

MEASUREMENTS OF BONES FROM EIGHT* PAIRS OF TEST AND CONTROL KITTENS

Kitten (test or control)	*Humerus*		*Radius*		*Femur*		*Tibia*	
	Length (cm.)	*Diameter (cm.)*	*Length (cm.)*	*Diameter (cm.)*	*Length (cm.)*	*Diameter (cm.)*	*Length (cm.)*	*Diameter (cm.)*
1(t)	5·91	0·50	4·80	0·20	6·24	0·45	6·10	0·30
2(c)	6·20	0·56	5·40	0·25	6·70	0·53	6·80	0·50
3(t)	5·43	0·50	4·65	0·20	5·90	0·50	5·79	0·41
4(c)	5·84	0·55	5·00	0·25	6·24	0·52	6·46	0·48
† 7(t)	5·56	0·57	4·60	0·23	5·97	0·54	5·76	0·46
8(c)	6·50	0·64	5·35	0·25	6·81	0·55	7·19	0·48
9(t)	7·20	0·59	5·99	0·28	7·89	0·62	7·83	0·46
10(c)	7·24	0·60	6·20	0·36	8·11	0·65	8·30	0·55
13(t)	6·26	0·47	4·97	0·19	6·39	0·45	6·19	0·40
14(c)	6·50	0·64	5·46	0·29	6·74	0·58	6·94	0·53
15(t)	6·53	0·45	5·36	0·20	6·77	0·46	6·57	0·43
16(c)	6·93	0·56	5·84	0·28	7·32	0·54	7·24	0·49
17(t)	6·37	0·56	5·30	0·23	7·00	0·57	6·79	0·49
18(c)	6·69	0·63	5·63	0·28	7·45	0·60	7·45	0·51
†19(t)	7·80	0·63	6·64	0·33	8·56	0·57	7·53	0·50
20(c)	7·82	0·67	6·88	0·28	8·83	0·57	9·16	0·58

* Measurements were not made of bones from kittens 5 and 6, and 11 and 12.
† Pairs 7 and 8, and 19 and 20 were allowed a recovery period after treatment.

TABLE 4

ASSESSMENT OF PATHOLOGICAL CHANGES IN THE EPIPHYSEAL PLATES OF THE TEST KITTENS

Kitten	*Humerus*		*Radius*		*Femur*			*Tibia*			*Metatarsals*				*Proximal phalanges (hindpaws)*			
	Proximal	*Distal*	*Proximal*	*Distal*	*Head*	*Trochanter major*	*Distal*	*Proximal*	*Tubercle*	*Distal*	*2*	*3*	*4*	*5*	*2*	*3*	*4*	*5*
1	1	1	1	2	1	1	3	2	–	3	1	1	1	1	1	1	1	1
3	2	1	1	2	1	1	3	2	–	2	1	1	1	1	1	1	1	1
5	2	1	1	–	–	–	2	3	2	3	–	–	–	–	–	–	–	–
7	3	3	2	3	1	–	3	3	–	3	3	3	3	3	3	3	3	3
9	–	3	2	–	2	3	2	2	–	–	–	–	–	–	1	1	1	1
11	2	3	1	1	1	1	3	3	–	1	–	–	–	–	1	2	1	1
13	3	3	2	2	2	1	3	3	–	3	3	3	3	3	3	3	3	3
15	–	2	1	1	–	–	3	3	2	3	1	3	1	1	3	3	3	3
17	3	3	1	3	1	1	3	3	2	3	2	1	3	2	3	3	3	3
19	1	3	1	1	1	–	–	3	–	3	–	–	–	–	–	–	–	–

1 = Plate reduced in depth, fewer and stouter pillars of calcified cartilage extending into the primary spongiosa.
2 = More severe damage to the plate including vascularisation, eosinophilic matrix and irregularities in depth.
3 = Discontinuity or fragmentation of the plate.
– = No abnormality detected.

distal femur and the proximal and distal tibia. Minimal involvement (score 1, Table 4) was characterised by a reduction in depth, with shorter irregular columns of chondrocytes. In some plates the intercellular matrix was less dense than normal, allowing its fibrillary nature to become more obvious. Sometimes this change had advanced to a degree to cause separation of the matrix in the form of clear elongated clefts either between cell columns (Fig. 2), or, less commonly, transversely across the plate. In all plates showing mild changes, the pillars of mineralised cartilage extending into the zone of provisional calcification were fewer and stouter than normal.

More severely affected epiphyseal plates (score 2, Table 4) were irregular in depth and were invaded by vascular connective tissue channels, which entered mainly from the epiphyseal side (Fig. 3). Haemorrhages were frequently seen in these channels and the cartilaginous matrix surrounding them was often eosinophilic and granular in appearance. The eosinophilic zones usually extended the full depth of the plate beneath the invading channels, tapering distally (Fig. 4), and the eosinophilic matrix showed distinct loss of metachromasia with toluidine blue stain. The few remaining chondrocytes in the altered cartilage were pale staining and some were elongated in the direction of the zone of provisional calcification. Other portions of the plates showed few or no multiplying chondrocytes between the zones of resting and degenerating cells, and both transverse and longitudinal clefts in the matrix were common. The few stout metaphyseal trabeculae being formed were covered by a layer of osteoid of normal thickness which usually extended along the diaphyseal margin of the plate (Fig. 3). The osteoblasts lining the trabeculae appeared to be normal.

The most severely affected epiphyseal plates (score 3, Table 4) were discontinuous and in some bones no plate remained. Discontinuity was often confined to narrow zones and was associated with vascular connective tissue invasion, eosinophilia and fragmentation of the cartilage. V-shaped cartilaginous remnants directed towards the metaphysis sometimes bridged the gap between the broken ends of the plate (Fig. 5), but more often the medullary cavities of diaphysis and epiphysis were confluent. Frequently there was a wide central gap with only the peripheral portions of the epiphyseal plates remaining. These were progressively reduced in depth towards their broken extremities due to fewer or no multiplying chondrocytes, so that the residues often consisted only of resting cartilage undergoing ossification. In most bones with discontinuous or absent epiphyseal plates bony trabeculae extended vertically to link diaphysis and epiphysis.

Diaphyses. The main change in the test kittens was a reduction in the quantity of bone tissue, or osteoporosis. In 2 pairs of kittens (1 and 2, and 3 and 4, both tests and controls had additional early changes of osteodystrophia fibrosa (Palmer, 1968). As the average daily food intake of these pairs was less than 35 g., their daily Ca and P intakes averaged less than 112 mg. and 102 mg. respectively, and skeletal disease could have been expected (Scott, 1965). The following description will therefore be restricted to lesions observed in those kittens which had an adequate food (and Ca and P) intake.

The compact bone of the shaft was always thinner in the test bones. The external shaft diameters were invariably narrower and the internal diameters

usually so. Periosteal cellularity appeared normal, but in the test kittens the cytoplasm of osteoblasts had slightly less affinity for basic stains.

Most bones from the hypervitaminosis A kittens contained more resorption tunnels than normal. These were imperfectly lined with osteogenic cells and frequently only marrow cells or fat globules could be identified in their lumens. Osteoclasts were present, but were not numerous. In all bones the resorption tunnels were most evident in the immediate submetaphyseal area, where they were often distributed across the whole shaft thickness. This zone of increased erosion then tapered towards the midshaft, becoming progressively more restricted to subendosteal bone. In the large limb bones an increased number of resorption tunnels was not a marked feature and the middle third of the shaft was seldom affected. Transverse sections through the midshaft showed fewer resorption tunnels than normal and more cartilaginous remnants. The periosteum was more regular and did not have the plentiful longitudinal ridges and grooves seen in the controls; there were fewer subperiosteal haversian canals and cement lines. A greenstick fracture had occurred in the distal tibial shaft of kitten 13, where a thick subperiosteal collar of woven bone had formed. An increased number of resorption tunnels was the most obvious pathological change in the metatarsal bones and the proximal phalanges. The numerous fat-filled tunnels had caused almost complete shaft erosion in some bones (Fig. 6), but no fractures were seen.

On the proximo-medial aspect of 4 of the 8 test radii (from kittens 1, 13, 15 and 17) there was a subperiosteal deposit of woven bone at the insertion of the brachialis muscle. The overlying periosteum was thickened, contained numerous neocapillaries, and in kitten 15, haemorrhagic foci. Similar deposits were seen in the metaphyseal region of some metatarsal bones.

Microscopical Pathology (Group B)

The damaged epiphyseal plates resembled those in animals destroyed immediately after dosing, but distortion of some diaphyses was superimposed where the damage to the plate was variable and uneven endochondral growth had ensued. There was no evidence of osteoporosis. In short, the changes were essentially similar to those previously described (Clark *et al.*, 1970).

Vitamin A in the Liver and the Kidney

The total amount of vitamin A administered, and the concentration of vitamin A in the liver and kidney of each kitten at necropsy, are shown in Table 5.

DISCUSSION

The administration of high levels of vitamin A to kittens for 21 or 30 days resulted in the following longbone changes: damage to many epiphyseal growth plates causing partial or complete cessation of endochondral ossification with reduction of longitudinal growth; marked osteoporosis of the diaphyses considered to be due to suppression of osteoblastic activity, and early exostosis formation in certain areas of muscle or ligament attachment.

TABLE 5

TOTAL AMOUNT OF VITAMIN A ADMINISTERED TO EACH KITTEN AND LIVER AND KIDNEY VITAMIN A LEVELS AT NECROPSY

Kitten	*Test or control*	*Total vitamin A administered (μg.)*	*Liver vitamin A (μg./g.)*	*Kidney vitamin A (μg./g.)*
1	T	1,066,400	10,905	861
2	C	—	30	65
3	T	825,600	5,111	375
4	C	—	41	117
5	T	1,204,000	5,461	414
6	C	—	449	93
7	T	1,100,800	5,731	260
8	C	—	2	112
9	T	1,960,800	5,250	236
10	C	—	479	94
11	T	1,823,200	7,297	944
12	C	—	630	135
13	T	1,376,000	5,582	944
14	C	—	325	80
15	T	1,548,000	4,704	774
16	C	—	203	60
17	T	1,272,800	5,328	1,690
18	C	—	139	172
19	T	1,926,400	4,125	233
20	C	—	27	107

Degenerative changes in cartilaginous epiphyseal plates resulting in reduction in longitudinal growth of longbones have been previously reported in hypervitaminosis A in the young rat and guinea pig (Wolbach, 1947), dog (Maddock, Wolbach and Maddock, 1949) calf (Grey, Nielsen, Rousseau, Calhoun and Eaton, 1965), pig (Wolke, Neilsen and Rousseau, 1968) and cat (Clark and Seawright, 1968; Clark *et al.*, 1970). In the present experiment it would appear that excess vitamin A inhibited the multiplication of chondroblasts in the epiphyseal plate. The cartilaginous matrix did not seem to be adequately maintained by the abnormal cells and was invaded by blood vessels, this step being followed by fragmentation and dissolution of the plate.

Reduction in bone formation through suppression of osteoblastic activity has been reported in hypervitaminosis A in some species (Wolbach, 1947; Irving, 1949; Rodahl, 1950; Grey *et al.*, 1965; Wolke *et al.*, 1968). In an earlier publication on hypervitaminosis A in the kitten Clark *et al.* (1970) stated that this lesion was not a prominent feature, but that a recovery period of several weeks may have obscured such an effect. In the present study, kittens destroyed immediately after the dosage period had much less compact diaphyseal bone than their pair-fed controls, with evidence of periosteal inactivity. Osteoporosis was accentuated in the submetaphyseal shafts of most bones, particularly the small bones of the paws, where resorption tunnels responsible for shaft remodelling were more

numerous than normal. Rather than being a result of increased osteoclasia, this appeared to be because the tunnels were poorly lined by osteogenic cells, which allowed little or no formation of new haversian systems. Further, osteoclastic activity was shown to be decreased in the midshaft zone of the large longbones, where resorption tunnels were fewer than normal. Thus no increase in osteoclast numbers was observed in any bone, and the present findings of decreased osteoblastic activity without increased osteoclasia are in agreement with those of Grey *et al.* (1965) and Wolke *et al.* (1968). In contrast the two kittens which were allowed to recover showed no evidence of osteoporosis, their diaphyses being as thick and as compact as those of the controls. This confirms the previous observation of Clark *et al.* (1970) and indicates that osteoblasts may rapidly recover from the effects of vitamin A toxicity. The increased metaphyseal flaring seen in the bones of all test kittens is a feature of hypervitaminosis A in man (Pease, 1962), calves (Grey *et al.*, 1965) and pigs (Wolke *et al.*, 1968). It was explained by Wolke *et al.* (1968) in terms of retarded bone growth with normal metaphyseal osteoclasia.

Periosteal exostoses are a manifestation of chronic hypervitaminosis A in man (Caffey, 1951; Fairbank, 1951) and the cat (Seawright, English and Gartner, 1965, 1967). Recently, Pryor, Seawright and McCosker (1969) reported exostoses in the pig after only 19 days of high vitamin A intake, which supports the present observation in kittens that these lesions may occur before the chronic stage of the disease is reached. It has been suggested by Riser, Brodey and Shirer (1968) that exostoses of cats receiving large amounts of pure vitamin A, or fed on liver rich in vitamin A, may be dependent on low calcium, high phosphorus rations. Such an explanation can be excluded in the present experiment because developing exostoses were present on the longbones of 3 kittens which, since weaning, had had an adequate daily intake of Ca and P in the optimal ratio, according to the criteria of Scott (1965), i.e. an average daily intake of 200 to 400 mg. of Ca and 150 to 400 mg. of P in a ratio which lies between 0·9 and 1.1. Exostoses were also observed in kittens which had an inadequate intake of Ca, but a correct Ca/P ratio.

The minced offal diet fed to kittens in this experiment must have been of satisfactory quality since all 6 controls which had an average daily intake of 70 g. or more made satisfactory weight gains, according to the figures of Jackson (1968). However, only 2 test kittens from the above pairs, on the same food intakes as their respective controls, made the satisfactory weight gain of 85 to 95 g. per week in the dosage period. This supports the work of Pryor *et al.* (1969) in pigs, who showed that high vitamin A rations caused a reduction in food utilization.

SUMMARY

Eight kittens were destroyed after receiving a high daily dose of vitamin A for 21 days or 30 days following weaning. Longbone pathology was studied in comparison with bones from pair-fed controls. Two kittens which had received similar treatment were returned to normal diets after the dosage period and destroyed some weeks later. In the kittens destroyed immediately after dosing the

main changes were reduction in endochondral bone growth due to damage to epiphyseal plates, and osteoporosis due to cessation or retardation of osteoid production in the diaphyses. Retarded endochondral bone growth was accentuated in the two kittens allowed to recover after dosing, while bone formation in the diaphyses had returned to normal.

ACKNOWLEDGMENTS

The author gratefully acknowledges the assistance of Drs. A. A. Seawright and T. H. Vickers. The animals were cared for by Mr. Gerd Pfotenhauer and the vitamin A, Ca and P analyses were done in the Department of Mr. R. J. W. Gartner, Animal Research Institute, Queensland.

REFERENCES

—— *Manual of Histologic and Special Staining Technics,* U.S. Armed Forces Institute of Pathology (1949), McGraw-Hill Book Company, Inc.; New York, Toronto and London.

—— *Methods of Analysis,* Association of Official Agricultural Chemists (1960), A.O.A.C.; Washington.

Caffey, J. (1951). *Amer. J. roentgenol. radium Therapy,* **65**, 12.

Clark, L., and Seawright, A. A. (1968). *Nature, Lond.,* **217**, 1174.

Clark, L., Seawright, A. A., and Gartner, R. J. W. (1970). *J. comp. Path.,* **80**, 113.

Fairbank, T. (1951). in *An Atlas of General Affections of the Skeleton,* E. and S. *Livingstone;* Edinburgh and London.

Gartner, R. J. W., and Ryley, J. W. (1956). *Q'ld. J. agric. Sci.,* **13**, 1.

Grey, R. M., Nielsen, S. W., Rousseau, J. E., Calhoun, M. C., and Eaton, H. D. (1965). *Path. vet.,* **2**, 446.

Irving, J. T. (1949). *J. Physiol.,* **108**, 92.

Jackson, O. F. (1968). *J.S. Afr. vet. med. Ass.,* **39**, 18.

Maddock, C. L., Wolbach, S. B., and Maddock, S. (1949). *J. Nutr.,* **39**, 117.

Palmer, N. C. (1968). *Aust. vet. J.,* **44**, 151.

Pease, C. N. (1962). *J. Amer. med. Ass.,* **182**, 980.

Pryor, W. J., Seawright, A. A., and McCosker, P. J. (1969). *Aust. vet. J.,* **45**, 563.

Riser, W. H., Brodey, R. S., and Shirer, J. F. (1968). *J. Amer. vet. Radiol. Soc.,* **9**, 37.

Rodahl, K. (1950). *Norsk Polarinstitutt Skrifter,* No. 95.

Scott, P. P. (1965). in *Canine and Feline Nutritional Requirements,* Pergamon Press; London.

Seawright, A. A., English, P. B., and Gartner, R. J. W. (1965). *Nature, Lond.,* **206**, 1117; (1967). *J. comp. Path.,* **77**, 29.

Wolbach, S. B. (1947). *J. Bone and Joint Surg.,* **29**, 171.

Wolke, R. E., Nielsen, S. W., and Rousseau, J. E. (1968). *Amer. J. vet. Res.,* 29, 1009.

[*Received for publication, March 5th,* 1970]

Fig. 1. Right humerus, radius, femur and tibia from test kitten 15 (on left) and control kitten 16. There is consistent shortening of the test bones, which are also narrower in midshaft diameter and have pronounced metaphyseal flaring. (Natural size.)

Fig. 2. Distal radial epiphyseal plate of kitten 13. There are fewer multiplying chondrocytes than normal in irregular columns. The matrix is divided by fine clefts. × 70.

Fig. 3. Proximal epiphyseal plate from the humerus of kitten 3. The plate is reduced in depth and contains mainly resting and degenerating chondrocytes. The metaphyseal trabeculae are fewer and stouter than normal, and osteoid has been laid down along the base of the plate between them. Vascular connective tissue channels have invaded the plate from the epiphyseal side. × 42.

Fig. 4. Distal femoral epiphyseal plate from kitten 1. A zone of eosinophilic matrix extends below an invading vascular channel. × 70.

Fig. 5. Discontinuous epiphyseal plate from the third metatarsal bone of kitten 15. V-shaped cartilaginous remnants bridge the gap between the broken ends, in the metaphyseal region. × 70.

Fig. 6. Longitudinal section through the submetaphyseal diaphyses of the third metatarsal bones from test kitten 15 (left) and control kitten 16. The test shaft is narrower and contains numerous resorption tunnels which are poorly lined by osteogenic cells and contain fat vacuoles. × 70.

To face page 634

Fig. 1.

2

3

4

5

Fig. 6.

J. Nutr. 70:272-277. 1960.

Coggeshall-'60
Bib. No. 1750

Reproduced by permission
of the copyright owner

Pathology of the Brain in Single and Mixed Deficiencies of Vitamins A and E in the Chick

R. E. COGGESHALL[1] AND J. G. BIERI
Laboratory of Neurophysiology, National Institute of Mental Health and the Laboratory of Nutrition and Endocrinology, National Institute of Arthritis and Metabolic Diseases, Public Health Service, U. S. Department of Health, Education and Welfare, Bethesda, Maryland

There is general agreement that the pathology of the central nervous system of the chick in vitamin E deficiency consists of large necrotic areas appearing usually in the cerebellum but occasionally in other areas of the brain (Pappenheimer and Goettsch, '31; Jungherr, '49). In the pathology of vitamin A deficiency, in contrast, the reports are conflicting. Wolbach ('54) stated that the symptomatology and pathology related to the central nervous system in the vitamin A-deficient chick is caused by compression of the central nervous system through the overgrowth of the bony structures surrounding it. Adamstone ('47) found small pinpoint lesions in the cerebellum and brainstem of vitamin A-deficient chicks. Rigdon ('52), however, found that the vitamin A-deficient duckling developed pyknotic, atrophic neurons in the spinal cord and vertebral ganglia.

In the course of studying the pathology of vitamin E deficiency in the chick, it became apparent that chicks exhibiting encephalomalacia frequently were simultaneously deficient in vitamin A. This raised the question as to the deficiency responsible for the observed pathology. For this reason, and because of the controversy in the literature about the effects of vitamin A deficiency on the central nervous system, the present experiments were undertaken to elucidate the pathology in uncomplicated deficiencies of vitamins A and E alone, and also as a combined deficiency.

EXPERIMENTAL

Day-old female New Hampshire chicks were fed purified diets deficient either in vitamin A or E. Basal diet C47 contained in per cent: purified soybean protein[2] 30; salt mix A (Briggs et al., '52) 6; DL-methionine 0.2; stripped lard[3] 4 to 25; and glucose to make 100. Adequate amounts of all B vitamins and vitamins D and K were added (Fox et al., '55). In addition, all diets contained 0.5 mg/kg of selenium as sodium selenite. This amount of selenium effectively prevents exudative diathesis but has no effect on the development of encephalomalacia. Diets were freshly prepared every two weeks. One jar of diet, sufficient for one week's feeding, was kept in the air-conditioned animal room (78°F.), whereas the second jar was kept refrigerated until used.

When chicks exhibited definite symptoms of deficiency, as described below, but before they were moribund, they were killed with pentobarbital sodium and perfused through the heart with neutralized 10% formalin. After macroscopic examination, the brains were embedded in celloidin and cut serially at 20 micra. Every 20th section was stained with cresyl violet for cells and the sections were mounted in the usual manner.

RESULTS

Vitamin A status of vitamin E-deficient chicks. When diets prepared to be deficient in only vitamin E and containing 10 to 25% of lard were used, analyses of

Received for publication August 31, 1959.

[1] Present address: Department of Medicine, Cook County Hospital, Chicago 12.

[2] Archer-Daniel Midland Company, Assay Protein.

[3] Distillation Products Industries.

the livers showed that the chicks were frequently simultaneously deficient in vitamin A. The vitamin A acetate in some experiments was given in the drinking water (Bieri, '57), in some it was added in ethanol directly to the diet at levels from 1.5 to 20 mg/kg, while in others 0.5 mg in water was given orally twice weekly. In all of these experiments, the majority of birds showing typical symptoms of encephalomalacia had no vitamin A in their livers when analyzed by the Carr-Price reaction. Furthermore, even when the vitamin A source and the vitamin E stress was 2% of fresh cod liver oil no vitamin A was detectable in the livers from chicks with encephalomalacia. Table 1 summarizes some of the analyses from various experiments. Although these chicks exhibited the characteristic symptoms of encephalomalacia, particularly the pedalling leg movements, apparently, biochemically, many of them may have had a deficiency of both vitamin A and E.

It was found that an adequate intake of vitamin A could be assured with the high lard diets by using a commercial stabilized dry vitamin A product.[4] When this was added at a level of 14 mg of vitamin A/kg of diet, the liver storage at 28 to 31 days of age amounted to 4 to 25 μg/gm in various series. The small amount of antioxidant in the stabilized product did not influence the onset of encephalomalacia.

These experiments vividly emphasized that chicks consuming vitamin E-free diets high in lard (10 to 25%) are extremely likely to be vitamin A-deficient also. Although this relationship between vitamins A and E had been known for a long time, a review of the literature suggests that in many studies of encephalomalacia the complication of vitamin A deficiency may have been present. In undertaking such studies it would appear imperative that analyses of the livers be performed routinely in order to assure investigators that vitamin A is adequate.

Vitamin A deficiency only. Chicks in this series were fed the purified diet containing 4% of lard with 100 mg of DL, α-tocopheryl acetate/kg. Analyses of livers for total tocopherols revealed 10 to 15 μg/gm. The ataxia of vitamin A deficiency appeared after 13 to 19 days and progressed rapidly during the next 18 to 48 hours. The picture was distinctly different from that of chicks deficient in vitamin E in that the "drunken" staggering and leg pedalling symptoms were absent.

Macroscopic examination of the brains and spinal cords of 9 chicks revealed no abnormalities. No herniation of the cerebellar tonsils was observed, pinching of spinal nerves, hydrocephalus nor other signs of increased intracranial pressure. Microscopically, 8 of the 9 brains showed only increased basophilia and pyknosis of scattered cells (fig. 1). These cells were especially common in the Purkinje cell layer of the cerebellum (fig. 2) and the inner layer of the optic tectum. One brain also had a few pinpoint lesions in the frontal lobes. This chick, in contrast to the others, was very emaciated and was

[4] Nopco Chemical Company.

TABLE 1

Liver storage of vitamin A in chicks fed purified vitamin E-free diets[1]

Vitamin A acetate added to diet	Amount and type of fat in diet	No. of chicks	Vitamin A in liver
mg/kg	%		μg/gm
1.5	lard, 25	3	0
5.0	lard, 25	5	0
10.0	lard, 25	6	2.6 ± 0.8
20.0	lard, 25	4	21.5 ± 3.8
14.0[2]	lard, 25	5	3.8 ± 1.0
0	cod liver oil, 1	1	0
0	cod liver oil, 2	4	0

[1] Chicks were killed between the 18th and 26th days when they exhibited classical symptoms of encephalomalacia.

[2] Vitamin A palmitate in the form of a dry, stabilized product.

killed more than 48 hours after the onset of symptoms.

Vitamin E deficiency only. The 13 chicks in this group received stabilized vitamin A in a diet containing 25% of lard and their livers were found to have adequate stores of vitamin A. The onset of symptoms occurred from 18 to 30 days of age and the typical picture was an inability of the chick to right itself even though it made frantic pedalling motions. Prostration, head retraction and emaciation eventually set in, ending in death.

Macroscopically, 4 of these brains exhibited dark red, soft areas in the cerebellum. Microscopically, large acellular necrotic areas were observed, usually in the cerebellum but occasionally in the optic lobes, frontal lobes and brain stem (fig. 3). No pinpoint lesions were seen, nor any vacuolar spaces surrounding vessels.

Combined deficiency of vitamins A and E. The 22 chicks in this category came from several series differing only in vitamin A intake. The diets contained 25% of lard, and as indicated above, vitamin A was added directly to the diet (1.5 and 3.0 mg/kg), put into the drinking water or given orally as described in the experimental section. No detectable vitamin A was found in the livers of these chicks. Analyses for vitamin E revealed a depleted level (Pollard and Bieri, '59). The symptoms, which appeared in 12 to 23 days, were characterized in some chicks by ataxia as seen in the group depleted of vitamin A only, whereas others were unable to stand. As the deficiency progressed, these birds became prostrate. Pedalling leg movements were observed in only a few of the chicks.

Macroscopically, the brains revealed no abnormalities. Microscopically, however, all brains exhibited pinpoint lesions to some extent (figs. 4 and 5). In sections showing only a few of these lesions (namely, in the early stage of deficiency), open areas (50 to 100 micra in diameter) always surrounded a blood vessel. The ground substances of the brain apparently had been pushed back from the blood vessel. In brains where large numbers of these pinpoint lesions were seen, a blood vessel could not always be detected in the center of the clear areas. These lesions were always seen in the frontal lobes and in a few instances they spread throughout the entire brain.

In addition to these findings, 8 chicks also had necrotic areas in their brains. These areas showed loss of architectural detail, fallout of all cellular elements and were sharply demarcated from the surrounding relatively normal brain. These large lesions, similar to those seen in chicks with encephalomalacia as described above, were all located in the cerebellum except for being in the frontal lobes in one chick.

DISCUSSION

The lesions found in the central nervous system of vitamin A deficient chicks were very limited. The pyknotic changes seen in these brains, however, are the same neuronal changes that Rigdon ('52) reported in the spinal cord and vertebral ganglia of the duckling. An interesting point about these vitamin A-deficiency changes is the lack of evidence indicating compression of the brain, increased cerebrospinal fluid pressure or bony overgrowth of the skull and vertebral column. This finding is contrary to that of Wolbach ('54) and Wolbach and Bessey ('41) and others who noted that the central nervous system was affected secondarily by compression from an overgrowth of the skull and vertebral column. A probable explanation for this disagreement may be found in the difference in time required to produce deficiency symptoms in different laboratories. The chicks in our study required less than 3 weeks to develop symptoms and undoubtedly were acutely deficient. This would be too short a time for a severe overgrowth of bone to take place.

The pinpoint lesions found in the combined deficiency of vitamins A and E are probably manifestations of edema from the small vessels of the brain. These lesions, though present in a somewhat different distribution, are similar to those described by Adamstone ('47) as being characteristic of the vitamin A-deficient chick. It appears highly probable that such lesions are a manifestation of a combined vitamin A and vitamin E deficiency. The observations of the difficulty of assuring an adequate intake of vitamin A when vitamin E-free diets with a high con-

tent of unsaturated fat, are used, emphasize the caution required in experimental nutrition studies.

The necrotic lesions found in pure vitamin E deficiency (encephalomalacia) and the large lesions in the combined deficiency of vitamins A and E, are similar to the characteristic lesions described by Jungherr ('49). It is significant, however, that many of these brains did not have gross pathology. Obviously, encephalomalacia cannot be diagnosed simply by the presence or absence of cranial hemorrhage.

SUMMARY

Day-old chicks were fed purified diets containing 4 to 25% of stripped lard. When the diets were made deficient in vitamin E, many chicks with encephalomalacia were found by chemical analyses to be simultaneously deficient in vitamin A. Special precautions had to be taken to assure an adequate intake of vitamin A. Histological comparisons of the central nervous systems revealed that brains from chicks deficient in vitamin A only had scattered pyknotic neurons, located most frequently in the optic tectum and Purkinje cell layer of the cerebellum. In vitamin E deficiency, large necrotic areas in the cerebellum and occasionally in other parts of the brain were seen. The combined deficiency of vitamins A and E resulted in many small acellular areas that were always found in the frontal lobes and occasionally in all parts of the brain.

ACKNOWLEDGMENT

The authors wish to thank Dr. Paul D. MacLean for providing the facilities for histological work.

LITERATURE CITED

Adamstone, F. B. 1947 Histologic comparison of the brains of vitamin A- and vitamin E-deficient chicks. Arch. Pathol., 43: 301.

Bieri, J. G. 1957 A simplified method for administering vitamin A to chicks fed purified diets. Poultry Sci., 36: 918.

Briggs, G. M., M. R. Spivey, J. C. Keresztesy and M. Silverman 1952 Activity of citrovorum factor for the chick. Proc. Soc. Exp. Biol. Med., 81:113.

Fox, M. R. Spivey, L. O. Ortiz and G. M. Briggs 1955 Toxicity of ethionine in the young chick. J. Agr. Food Chem., 3: 436.

Jungherr, E. 1949 Ten year incidence of field encephalomalacia in chicks with observations on its pathology. Ann. N. Y. Acad. Sci., 52: 83.

Pappenheimer, A. M., and M. Goettsch 1931 A cerebellar disorder in chicks, apparently of nutritional origin. J. Exp. Med., 53: 11.

Pollard, C. J., and J. G. Bieri 1959 Studies of the biological function of vitamin E. I. Tocopherol and reduced diphosphopyridine nucleotide-cytochrome c reductase. Biochim. Biophys. Acta, 34: 420.

Rigdon, R. H. 1952 Pathologic lesions in the nervous system of the duck fed a ration deficient in vitamin A. Arch. Pathol., 53: 239.

Wolbach, S. B. 1954 Effects of vitamin A deficiency and hypervitaminosis A in animals. In: The Vitamins: Chemistry, Physiology, Pathology. Vol. 1, Eds., W. H. Sebrell and R. S. Harris, Academic Press, Inc., New York.

Wolbach, S. B., and O. A. Bessey 1941 Vitamin A deficiency and the nervous system. Arch. Pathol., 32: 689.

PLATE 1

EXPLANATION OF FIGURES

1 Darkly staining, pyknotic neurons are shown in the optic tectum of a vitamin A-deficient chick. Next to these cells are larger, lighter staining, more normal appearing neurons. × 400.

2 Two shrunken and pyknotic Purkinje cells can be seen in the cerebellum of a vitamin A-deficient chick. × 285.

3 Large, acellular necrotic areas in the frontal lobes of a vitamin E deficient chick. × 20.

4 Pinpoint lesions are spread diffusely through the frontal lobes of a chick deficient in both vitamins A and E. × 10.

5 A higher magnification of the pinpoint lesions in figure 4 showing that the substance of the brain is spread and vacuolated leaving relatively acellular areas. × 185.







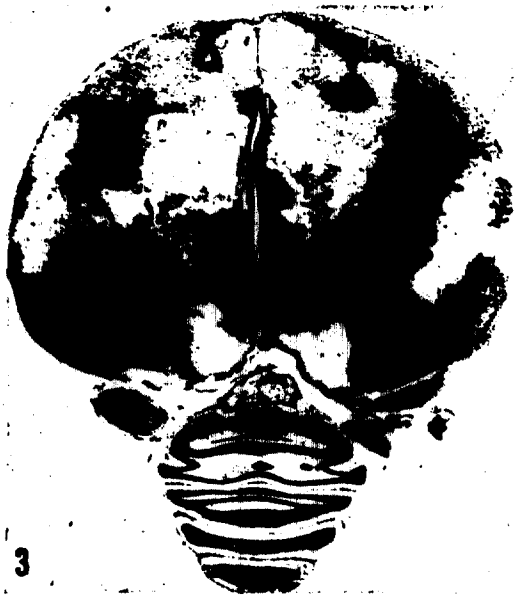

Cohlan-'54
Bib. No. 1757

Pediatrics 13:556-567. 1954.

Reproduced by permission
of the copyright owner

CONGENITAL ANOMALIES IN THE RAT PRODUCED BY EXCESSIVE INTAKE OF VITAMIN A DURING PREGNANCY

By SIDNEY Q. COHLAN, M.D.
New York City

CONGENITAL anomalies in the mammal had long been thought to be determined solely by hereditary genetic mechanisms. Many investigations in experimental embryology had demonstrated that a multitude of agents acting on fetal environment could evoke drastic teratologic changes in marine and lower form animals, but there was little knowledge or belief that the mammalian embryo could similarly be affected in view of the protection of the placenta and uterus which is not afforded lower forms of life. In the last two decades, however, experimental evidence has accumulated indicating that various specific disturbances of mammalian fetal environment will result in predictable congenital malformations. Following Hale's observation[1] in 1935 of anophthalmos and cleft palate in pigs whose maternal diet during pregnancy was deficient in vitamin A, Warkany, Wilson and co-workers[2-5] described a syndrome of congenital defects of the skeleton, eye, genitourinary tract, diaphragm, heart and aortic arches following maternal vitamin A-deficiency, as well as a pattern of skeletal anomalies following maternal riboflavin-deficiency[6] in the rat. Gregg[7] and Swan[8] observed that rubella occurring during pregnancy resulted in a high incidence of specific developmental defects suggesting that congenital anomalies in the human as well as in the experimental animal may be either acquired or inherited and gave great impetus to more recent studies in experimental teratology. Warkany[9] in 1947 reviewed the chemical, endocrine, dietary, actinic, mechanical and infectious factors known to induce congenital malformations. Subsequently, other teratogenic agents have been reported which include hypoxia,[10] administration of cortisone,[11,12] trypan blue,[13] alloxan,[14] enzyme inhibitors[4] (mepharsen, chlormercuribenzoate, iodosobenzoate), antimetabolites[15] (aminopterin), anticancer drugs (nitrogen mustard and TEM)[15] and atomic radiation.[16] Continuing study[13,17,18] of the effects on the fetus of ionizing radiation has resulted in a more detailed knowledge of its stage specificity in the production of developmental malformations.

The teratologic effect of maternal deficiency of specific nutrients may be due to the fact that the developing embryo requires these nutrients at critical developmental stages for the orderly progress of normal fetal differentiation. That excess of a nutritional element may likewise result in developmental malformations has not been previously reported. However, during the course of the author's investigations of the skeletal changes of hypervitaminosis A in mature rats, it was noted that several pregnant animals produced offspring with congenital malformations. Preliminary report of an investigation[19] undertaken to study this phenomenon revealed that excessive intake of vitamin A during pregnancy in the rat resulted in a high incidence of congenital malformations including exen-

From the Department of Pediatrics and Laboratories, Beth Israel Hospital, the Department of Pediatrics, New York University College of Medicine, and the Children's Medical Service, Bellevue Hospital, New York City.

Read, in part, before the 23d annual meeting of the Society for Pediatric Research, Atlantic City, May 5, 1953, and the Seventh International Congress of Pediatrics, Havana, October 13, 1953.

Supported by grants from the Loyal League Philanthropies, Inc., New York City; the Mead Johnson Company, Evansville, Ind., and the National Institutes of Health, United States Public Health Service.

(Received for publication Nov. 27, 1953.)

TABLE 1

LITTER RATE AND ANOMALY INCIDENCE IN EXPERIMENTAL* AND CONTROL GROUPS

	No. of Females Mated	No. of Litters Produced	Total No. of Offspring	Litter Rate	No. of Malformed Offspring
Experimental	210	25	148	12%	77 (52%)
Control	100	84	831	84%	0

* Pregnant animals fed 35,000 i.u. vitamin A daily from 2nd, 3rd, or 4th to 16th day of gestation.

ephaly, hydrocephalus, spina bifida, cleft palate, eye malformations and shortening of the mandible and maxilla. This report will present further data on gross anomalies following excessive vitamin A intake during pregnancy, as well as the results of an investigation into the critical developmental period of its action.

MATERIALS AND METHODS

Female rats of the CF Wistar strain weighing 150 to 200 gm. were mated to males of the same strain by exposure in the pre-estrous stage from 6 P.M. to 8 A.M. of the following morning. The date of the morning of exposure was considered the first day of gestation. Animals were fed the standard Rockland pellet diet with water ad lib. The experimental groups were fed an aqueous preparation of vitamin A (containing 50,000 i.u. of natural vitamin A dissolved in a sorethitan monolaurate and water diluent) in doses from 15,000 i.u. to 75,000 i.u. at varying periods in gestation ranging from single dose on one day to daily doses from the 2nd to 16th day inclusive. Controls were given equal volumes of the sorethitan monolaurate diluent. All feedings were by intubation. Pregnancy was allowed to proceed and in most instances the animals were killed on the 20th to 21st day, at or near term. Both uterine horns were removed and the uterine wall, amnion, placenta and fetus were examined and fixed in formalin. Representative samples of several experimental and control groups were used for vitamin A assay of the fetal embryo, the fetal liver and the placenta. These data, not yet complete, will be reported separately in a study of transplacental vitamin A. Because the maternal rat will destroy only abnormal or dead offspring, they were not allowed to deliver spontaneously except in carefully observed instances, the results of which will be described below.

1. Statistical Incidence

In the first series of experiments pregnant rats were fed 35,000 i.u. vitamin A daily from the 2nd, 3rd or 4th to the 16th day of gestation. Controls were fed an equal volume of diluent. As can be seen in table 1, of 100 control animals, 84 produced litters with a total of 831 apparently normal offspring, a successful pregnancy rate of 84%; whereas in the experimental group, of 210 mated females only 25 produced litters with a total of 148 newborn, a corrected successful pregnancy rate of 12%. This marked litter failure in the vitamin A-fed group was due to fetal death and resorption, various stages of which were observed in many uteri at autopsy. Of much greater significance, however, was the incidence of anomalies in the litters produced by the vitamin A-fed group. Of the 148 offspring obtained from 25 litters, 77 exhibited a gross anomaly of the skull and brain, an anomaly rate of 52%. Other anomalies, such as cleft palate, shortening of the mandible and maxilla, gross eye defects, and hydrocephalus, were also observed occurring either alone or associated with the major cranial deformity. In the 84 control litters with a total of 831 offspring no gross congenital abnormalities were seen. The incidence of gross cranial anomalies in each of the litters is summarized in table 2. Though the anomaly rate is seen to differ in each litter, none escaped without at least one malformed fetus, while in others all the young of a litter were defective.

There was moderate to marked vascular congestion of the uteri of the vitamin A-fed animals but no evidence of hemorrhage was noted. It was often possible, however, to recognize abnormal embryos in situ as their amniotic sacs were swollen with excess fluid which was occasionally blood-stained. It is noteworthy that

TABLE 2

INCIDENCE OF CONGENITAL CRANIAL ANOMALY (EXENCEPHALY) IN OFFSPRING OF PREGNANT RATS FED EXCESSIVE AMOUNTS OF VITAMIN A

Animal No.	No. of Offspring in Litter	No. with Congenital Cranial Anomaly	Gestation Days Fed 35,000 i.u. Vitamin A
14	10	4	2–16
30	6	4	4–16
35	6	4	4–16
39	6	1	4–16
59	9	5	3–16
62	11	3	3–16
79	9	9	2–16
90	2	2	2–16
93	5	5	2–16
100	8	2	2–16
104	9	3	2–16
116	5	1	2–16
128	6	1	2–16
129	5	5	2–16
141	4	2	3–16
153	6	1	3–16
161	2	2	3–16
177	5	3	2–16
179	9	5	2–16
184	11	3	4–16
189	4	4	4–16
193	7	3	4–16
198	3	2	4–16
201	3	2	4–16
207	7	1	4–16
Total	158	77	

polyhydraminios in humans is frequently associated with congenital malformation, particularly anencephaly.

2. Gross Developmental Malformations

Head Deformities.—The outstanding gross cranial anomaly was a protrusion of part or all of the forebrain through a variable sized defect in the upper part of the cranium involving the parietal and frontal bones which is best described as "exencephaly" (Figs. 1 and 2). A thin membrane covers the exposed brain mass which rises caplike over the surface of the head. In many instances the base of this conical cranial protrusion extends laterally to obscure gross examination of eye structure which in several dissected specimens was found either to be deformed or absent. This cranial defect is similar to the "pseudencephaly,"[13, 17, 20] "anencephaly"[10] and "extrakranielle Dysencephalie"[21] experimentally induced by other teratogenic agents. In several litters hydrocephalus was observed and was characterized by enlarged, dome-shaped fetal heads with increased transillumination. The microscopic anatomy of these anomalies awaits further study.

Though gross examination of the exencephalic young made it highly unlikely that any of these severely deformed animals would have survived if delivered spontaneously, 6 vitamin A-fed pregnant rats were allowed to deliver under close observation. A total yield of 41 offspring resulted, 18 of which exhibited the major cranial deformity and, as expected,

FIG. 1. A. Normal control 19 day fetus. B. Experimental fetus with exencephaly. Note extrusion of forebrain to surface of fetal head and foreshortening of mandible and maxilla with protrusion of tongue.

Fig. 2. Typical abnormal litter. Note varying degrees of cranial malformation. Maternal rat fed 25,000 i. u. vitamin A daily from 7th to 10th day gestation.

were promptly multilated by their mothers. None of the remaining 23 young exhibited gross abnormalities but, during the course of careful examination of fetal heads, small hematoma-like discolorations ranging from 1 to 3 mm. were observed in 12 young in the region of the anterior fontanelle. The entire surviving group was allowed to suckle (maternal animals were all placed on a normal diet after delivery), and then weaned to the standard diet and divided into 2 groups, those with, and those without, neonatal discoloration of the fontanelle. At 30 days of age one half of each group was killed (the remainder grew to maturity and were remated with normal rats of the same strain). Examination of the denuded skull of the 30 day rats revealed that those with the previously observed fontanelle "hematomas" now exhibited defects of varying degree in the bony continuity of the cranium. As can be seen in Fig. 3 there is a lacunar opening in the area of the fontanelle which is covered with a thickened dura. Casual observation of the behavior of the young with these skull defects did not differ from their controls. It is therefore evident that there is wide variation in the degree of cerebral deformity following excessive vitamin A intake.

Gross Eye Deformities.—In normal organogenesis[22] the primordium of the rat eye appearing between the 10th and 11th day differentiates rapidly so that by the 15th day

FIG. 3. Skull defect in rat killed at 30 days. Maternal animal fed 25,000 I. u. vitamin A daily from 7th to 10th day of gestation. (Spontaneous delivery.)

the double walled optic cup, lens and hyaloid vessels are formed. By the 18th day the retina shows active differentiation and the ciliary body and lids form. The lids remain approximated and do not normally open till 12 to 14 days after birth. Maternal vitamin A excess apparently influences eye development at various key stages of differentiation so that a wide variety of gross disturbances ranging from the "open eye" syndrome, exophthalmos, cataract and microphthalmia to unilateral or bilateral anophthalmia have been observed. These eye abnormalities have occurred either alone or associated with other abnormalities of the head. Figure 4 is a photograph of a control fetus and one exhibiting typical gross eye malformations consisting of separation of the lids, bulging of the globe and opacity of the cornea and lens. Defects of the retina and other structures of the eye chambers have been observed in the few specimens that have been sectioned but are still too small in number for inclusion in this report.

Cleft Palate.—The palates of only 50 offspring from vitamin A-fed mothers have been examined grossly since the distorting manipulation necessary for this observation interferes with future sectioning. Of those examined, 19 were found to have a triangular shaped palatal defect with its apex extending anteriorly to the incisive papilla but not involving the alveolar process or lips (Fig. 5). This anomaly appears identical to the defect described in the vitamin A deficiency syndrome[28] and is believed due to a lack of fusion of the palatine process of the maxilla and the horizontal process of the palatine bones. There were 2 severely deformed fetuses with marked exencephaly and

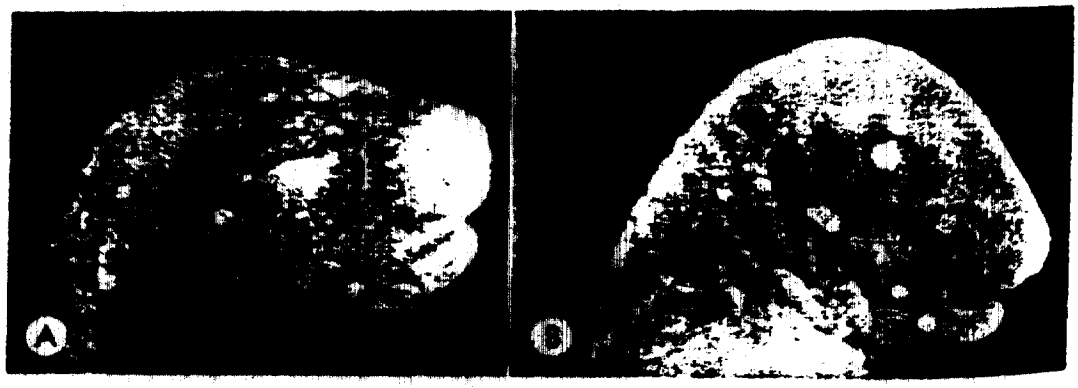

FIG. 4. A. Normal control. Eyelids closed. (Lids separate normally 12 to 14 days after birth.)
B. Abnormal eye. Note "open eye" with bulging of globe and corneal opacity.

palate with associated harelip.

Skeletal Defects.—Twenty fetuses from vitamin A-fed mothers were cleared and stained with alizarin red by the Dawson[24] technic and mounted in plastic for the study of skeletal malformations. The cranial defects were found to involve parts of the parietal and frontal bones. The defect varied in size in different specimens. Foreshortening of the mandible and maxilla which occurred in almost every instance of exencephaly was also observed. This malformation was usually due to shortening of the corpus mandibulae, the rami rarely being affected; a similar anomaly has been described in the vitamin A-deficiency syndrome.[22] The abnormal protrusion of the tongue seen in most instances of exencephaly, though first thought to represent macroglossia, is probably the result of extrusion of a normal tongue due to micrognathia.

Seven fetuses, the offspring of mothers fed 75,000 i.u. vitamin A as one dose on the 10th day of gestation, exhibited occult spina bifida with meningocele. As seen in Fig. 6, there is an open defect in the skin involving the lumbosacral region.

Miscellaneous Defects.—Moderate to marked edema of the entire fetus was observed in some of the experimental young. In 4 instances markedly dwarfed, shrivelled and pale white

Fig. 5. Cleft palate. Maternal animal fed 25,000 i.u. vitamin A daily from 8th to 11th day of gestation.

Fig. 6. Spina bifida with meningocele. Defect involves lower lumbar and entire sacral area. Maternal animal fed 75,000 i. u. vitamin A as single dose on 10th day of gestation.

offspring were obtained at various dose levels and were seemingly inconsistent with any critical stage sensitivity.

Critical Stage and Minimum Dose.—It is now an established fact that acquired anomalies are a function of the stage of development in which an injurious environmental agent is active. The minimal effective dose is also an important aspect of stage specificity as embryonal tissues will exhibit sensitivity at stages adjacent to that of maximal susceptibility when exposed to large doses of a teratologic agent thus leading to the overlapping of critical periods and a confusion of anomalies produced. The author therefore endeavored to

TABLE 3

TERATOLOGIC EFFECT OF VARYING DOSAGE AND PERIOD IN GESTATION OF ADMINISTRATION OF VITAMIN A

Vitamin A Intake (I.U.)	Gestation Days Fed	No. of Mated Rats	No. of Litters at Term	Litter Data		
				Abnormal	Normal	% Abnormal
35,000	2–16	210	25	77	71	52.0
35,000	8–16	14	4	16	20	44.0
25,000	6–10	10	6	16	22	42.1
25,000	7–10	18	8	21	49	30.0
75,000	8th*	15	11	10	50	16.0
75,000	10th*	6	3	7†	8	53.0
25,000	7–9	14	12	0	113	0.0
15,000	3–16	12	9	0	76	0.0

* Single dose administered on specific day.
† Spina bifida.

find the minimal dose and the fetal period critically sensitive to maternal excess of vitamin A.

The results obtained from experiments devised to investigate this problem are outlined in table 3. As previously noted the animals fed 35,000 i.u. vitamin A from the 2nd to 16th day of gestation experienced a marked reduction in litter rate and when litters were carried to term the incidence of cranial anomaly was 52%. Reducing the daily intake to 25,000 i.u. vitamin A daily and limiting the period of administration to the 6th to 10th day improved the litter rate but still yielded an anomaly rate of 42%. Reducing the daily intake further to 15,000 i.u. administered through either time period had no apparent adverse effect. The litter rate was 100% and there were no grossly abnormal young. A dosage lying somewhere between 15,000 i.u. and 25,000 i.u., therefore, would seem to be the minimal daily dose necessary to produce gross malformations (histologic sections may reveal malformations at lower dosage). The critical period of susceptibility at this dose level of vitamin A was between the 7th and 10th day of gestation. Control data at the different gestational periods are summarized in table 4.

Subsequent Matings.—Following weaning of their surviving young, 6 vitamin A-fed maternal rats that had delivered spontaneously were immediately mated with normal males of the same strain. Litters were produced by all 6 with a total yield of 58 offspring with no evidence of gross malformation, nor did their behaviour seem to differ from normal controls. It will be recalled that the surviving young of the first generation that had been spontaneously delivered were separated into 2 groups, one with and one without fontanelle hematomas. There was a chance distribution of 2 males and 4 females in the fontanelle hema-

TABLE 4

CONTROL DATA—EFFECT OF FEEDING VITAMIN A DILUENT TO PREGNANT RATS

Diluent Intake	Gestation Days Fed	No. of Mated Rats	No. of Litters at Term	Litter Data		
				Abnormal	Normal	% Abnormal
0.7 cc.	3–16	100	84	0	831	0
0.7 cc.	8–16	5	4	0	32	0
0.7 cc	6–10	10	7	0	64	0
0.7 cc.	7–0	35	29	0	274	0
Totals		150	124	0	1201	0

toma group and 3 males and 3 females in the other. When these animals were mated with normal controls of the same strain 108 normal offspring were obtained. These results indicate that hereditary genetic mechanisms are not involved in the malformations produced by vitamin A excess.

Discussion

In a classic monograph on hypervitaminosis A, Rodahl[25] describes several experiments in which 25,000, 50,000 and 100,000 i.u. of vitamin A in a whale oil concentrate were fed daily to four small groups of rats for several weeks prior to maturity and was continued throughout the entire gestational period in the three instances in which pregnancy supervened following mating. Two animals in the 50,000 unit group and one in the 25,000 unit group carried litters to term. There were no pregnancies in the 100,000 unit group. No gross anomalies were seen but microscopic examination of the fetus revealed hyperemia of the viscera, thickening of the alveolar walls of the lungs, slight degeneration of the kidney tubules and an increase in sudanophil droplets in the liver and adrenal. Failure to produce anomalies in these experiments was probably due to (1) the limited number of exposed animals; (2) the use of whale liver concentrate, an oily preparation which, as was previously shown,[26] is not as well absorbed or stored as aqueous preparations of vitamin A; (3) the feeding of large doses of vitamin A weeks prior to conception which markedly depresses fertility. However, attempts will be made in this laboratory to study more definitively the effects on the fetus of oily preparations of vitamin A. That aqueous preparations fed to pregnant rats do produce congenital malformations has been shown by the following results:

1. Pregnant rats fed excessive amounts of vitamin A produce a consistent high incidence of reproducible anomalies.

2. Control rats of the same strain maintained on a standard diet with added vitamin A diluent produce normal offspring.

3. Female rats that had previously produced abnormal offspring yield normal young in subsequent matings if maintained on the standard diet.

4. Abnormal offspring with minor anomalies compatible with survival produce normal young.

The question arises whether the teratologic effect of vitamin A (as well as that of the other environmental agents) is a function of disturbed maternal metabolism or is rather the result of direct injury to the developing fetus. Gilman[13] has produced anomalies in rats by maternal injection of trypan blue from 1 to 8 days prior to conception as well as by administration of the dye during the 7th to 8th gestational day. (The dye could be traced to the yolk sac but did not enter the fetus.) He is of the opinion that malformations may be mediated either by effects on the placenta which undergoes crucial differentiation during the critical period of fetal organogenesis or more likely through a disturbed maternal metabolism. The latter hypothesis, however, does not seem applicable to these results with vitamin A or with the description of its toxic effects in the mature animal. The pertinent pathology of hypervitaminosis A in the adult rat, described by Rodahl,[25] includes gross multiple fractures, skin and eye changes, visceral hyperemia and hemorrhage, as well as fatty changes in the liver and enlargement of the adrenals. Except for a decrease in serum ascorbic acid, chemical determinations on the blood were within normal limits. Wolbach[27] also observed enlargement of the adrenal in the hypervitaminotic animal but found no changes in the thyroid, pituitary or parathyroids. With the exception of adrenal pathology none of these manifestations of hypervitaminosis A in the maternal animal would seem organically critical or of enough severity to produce the profound fetal disturbances observed in these experiments. Furthermore, the hypothesis that teratogenic agents produce their effect by stress reactions mediated through the adrenal has been explored by Wilson,[28] who administered ML_{50} doses of CCl_4 as an agent of stress to pregnant rats. As expected, marked

liver pathology with some deaths resulted. Litters were resorbed in 50% of the animals surviving the drug, but there were no fetal abnormalities in those that did carry to term. Experimentally induced hemorrhagic anemia during pregnancy likewise caused fetal death and resorption without an appreciable anomaly incidence in the offspring that were obtained. These observations indicate that marked maternal stress alone does not result in developmental malformation. On the other hand, Fell and Mellanby[29,30] have demonstrated that when excess vitamin A is added to in vitro mouse embryo tibia-fibula cultures, destruction and dissolution of growing bone ensues and similar hypervitaminotic growth medium caused differentiation of ectoderm from the trunk and limbs into a mucous secreting membrane histologically similar to that of the nasal cavity. These findings suggest the possibility that excess vitamin A may perhaps exert its teratogenic effect by direct action on the developing embryo.

The relatively massive doses necessary to evoke malformations are attributed to the fact that vitamin A does not ordinarily cross the placental barrier. Lewis[31] has shown that, following administration of large amounts of vitamin A to the pregnant guinea pig near term, there was a marked rise in fetal liver storage though fetal blood levels were not appreciably increased, suggesting transplacental transmission with rapid withdrawal to the fetal liver. However, there was no demonstrable increase in liver storage following administration of physiologic or moderately increased amounts of vitamin A.

Preliminary studies in this laboratory of transplacental transfer of vitamin A in the rat (to be reported elsewhere) are for the most part in agreement with those of Rodahl[23] who found that the livers of fetal rats born to hypervitaminotic mothers contained 150 i.u./gm. as compared to 34 i.u./gm. in the control.

With advances in experimental teratology it has become increasingly evident that unrelated agents acting during pregnancy may produce the same developmental malformation depending upon the stage of development that the agent is active. Thus, the exencephaly produced by excessive intake of vitamin A during the 7th to 10th day of gestation is similar to the "extrakranielle Dysencephalie" produced by Kaven[21] following radiation of the maternal rat on the 7th and 8th day of gestation. More recently Russel[17] has observed "pseudencephaly" in the mouse following radiation on the 7th to 8th day, Warkany,[32] using larger R doses, on the 10th, 12th and 13th day, produced "encephalocele," Gilman[13] reported pseudencephaly following maternal injection of trypan blue and cranial malformations were produced by Ingalls[10] by maternal exposure on the 8th day to the hypoxia of 25,000 feet elevation for five hours. Similarly cleft palate in the experimental animal has been produced by maternal vitamin A deficiency,[23] x-ray,[32] hypoxia,[10] injections of trypan blue[13] and cortisone.[11,12] It is important to note that identical anomalies have been observed to occur as hereditary traits. Bonnevie[33] has described pseudencephaly in one strain of mice produced by the action of a recessive gene. Abnormal development was first observed in these animals in the 7th to 8th fetal day, manifested by a delay in separation of the chorda from the primitive brain. Hereditary cleft palate[34] and spina bifida[35] have likewise been reported. Abnormalities which can be induced either by genetic mechanisms or by environmental disturbances are called "phenocopies." Their existence makes it impossible to differentiate hereditary from environmental anomalies solely by study of the type of developmental defect produced.

The critical period (7th to 10th day) of fetal susceptibility for the production of exencephaly by vitamin A excess is, for the most part, in accord with the timetable of malformations in the rodent reported by Russel[17] following radiation and by Hicks following either radiation[15] or the administration of specific antienzymes or anti-

metabolites.[15] Hicks concludes that the fetal central nervous system is relatively insensitive to teratologic stimuli until the 8th to 9th day at which time the posterior part of the neural tube is still closing and rapid cellular changes occur characterized by differentiation from primitive neurectoderm to the neuroblast phase. Primitive neurectoderm is insensitive to x-ray whereas the neuroblast is susceptible to radiation. That the 8th to 9th fetal day is a critical period for the development of central nervous system anomalies is further evidenced by the exencephaly produced by exposure at this time to other agents such as hypoxia[10] and the administration of trypan blue.[13] The transition from insensitive neurectoderm to susceptible neuroblast continues throughout the fetal period as various parts of the central nervous system develop, thus, differentiation is still taking place in the cerebellum three weeks after birth. Hicks also proposes that mesenchyme and skeletal blastema similarly pass through an early phase of resistance and a later period of sensitivity. From these observations a time table for the production of anomalies has been evolved revealing that forebrain, eye and skeletal defects occur with greatest incidence following exposure from the 9th to 12th day, after which these anomalies markedly diminish or do not occur. However, since differentiation of the cerebellum begins late and continues into the neonatal period anomalies of this part of the brain follow environmental disturbances from the 18th gestational day to 3 weeks after birth. It is noteworthy from a clinical standpoint that the susceptible critical period of rapid differentiation sensitive to teratogenic agents in the rat corresponds to the second to sixth postconceptual week in the human. However, not in all instances do experimental anomalies conform to the predictable sensitivity based on the known facts of descriptive embryology.

The teratologic mechanism of excess vitamin A as well as that of the other anomaly producing agents is not well understood. The problem is complicated by the fact that anomalies may result not only from productive and destructive changes but also from the failure of regression of fetal structures whose persistence into adult life is abnormal. However, the sensitivity of the embryonal nervous system to such agents as chlormercuribenzoate and aminopterin suggests that one factor may be the dependence of developmental processes on sulfhydryl enzyme and other metabolic systems in the fetus. It may therefore not be improbable that specific nutrients (vitamin A, folic acid, riboflavin) are essential for the enzymatic and metabolic processes vital for normal differentiation, while an excess of one of these, vitamin A, may act at a critical developmental period as an antienzyme or antimetabolite to produce congenital malformations.

Though we certainly cannot, at present, relate the observations of the teratology of vitamin A excess to human malformations, the long-term results of these experiments with vitamin A as well as the projected investigation of the other vitamins, both singly and in multiple preparations, may dictate more caution in the indiscriminate use during pregnancy of vitamin supplementation far in excess of human requirements.

Summary

Excessive intake of vitamin A during pregnancy in the rat results in a marked litter failure. However, when litters are carried to term a variety of gross congenital anomalies are produced which include: encephaly, eye malformations, cleft palate, shortening of the mandible and maxilla, spina bifida with meningocele and hydrocephalus. Of 148 offspring of vitamin A-fed maternal rats, 77 exhibited gross malformations (an anomaly rate of 52%). There were no congenital anomalies observed in 1201 control young.

The 7th to 10th day of gestation was found to be the period critically susceptible to the teratogenic effect of vitamin A excess.

The stage specificity of various environ-

mental agents and the possible mechanism of action of the teratogenic effect of maternal vitamin A excess are discussed.

ACKNOWLEDGMENT

The technical assistance of Mr. Jay Fields is gratefully acknowledged.

REFERENCES

1. Hale, F., Relation of vitamin A to anopthalmos in pigs, Am. J. Opth. 18:1087, 1935.
2. Warkany, J., and Nelson, R. C., Appearance of skeletal abnormalities in offspring of rats reared on deficient diet, Science 92:383, 1940.
3. Warkany, J., and Schraffenberger, E., Congenital malformations induced in rats by maternal vitamin A deficiency. 1. Defects of eye, Arch. Opth. 35:150, 1946.
4. Wilson, J. G., and Warkany, J., Malformations in genitourinary tract induced by maternal vitamin A deficiency in fetal rats, Anat. Rec. (suppl.) 97:60, 1947.
5. Wilson, J. G., and Warkany, J., Aortic-arch and cardiac anomalies in offspring of vitamin A deficient rats, Am. J. Anat. 83:113, 1949.
6. Warkany, J., and Nelson, R. C., Skeletal abnormalities in offspring of rats reared on deficient diets, Anat. Rec. 79:83, 1941.
7. Gregg, N. M., Congenital cataract following german measles in mother, Tr. Opth. Soc. Australia 3:35, 1941.
8. Swan, C., and others, Congenital defects in infants following infectious disease, M. J. Australia 2:201, 1943.
9. Warkany, J., Etiology of congenital malformations, in Advances in Pediatrics, edited by S. Z. Levine and others, New York, Interscience Publishers, Inc., 1947, vol. 2, p. 1.
10. Ingalls, T. H., Curley, F. J., and Prindle, R. A., Anoxia as cause of fetal death and congenital defect in mouse, Am. J. Dis. Child. 80:34, 1950.
11. Baxter, H., and Fraser, F. C., Production of congenital defects in offspring of female mice treated with cortisone, McGill M. J. 19:245, 1950.
12. Glaubach, S., Antopol, W., and Graff, S., Excessive doses of cortisone in pregnant mice: Effect on development and survival of fetus and newborn and on maternal breast tissue, Bull. New York Acad. Med. 27:398, 1951.
13. Gilman, J., Gilbert, C., and Gilman, T., Preliminary report on hydrocephalus, spina bifida, and other congenital anomalies in rats produced by trypan blue, South African J. M. Sc. 13:67, 1938.
14. Ross, O. A., and Spector, S., Production of congenital anomalies in mice by alloxan, read before the Society for Pediatric Research, Old Point Comfort, Va., May 1952.
15. Hicks, S. P., Some effects of ionizing radiation and metabolic inhibition on developing mammalian nervous system, J. Pediat. 40:489, 1952.
16. Plummer, G., Anomalies occurring in children exposed in utero to atomic bomb in Hiroshima, PEDIATRICS 10:687, 1952.
17. Russel, L. B., X-ray induced developmental abnormalities in mouse and their use in analysis of embryological patterns, J. Exper. Zool. 114:545, 1950.
18. Hicks, S. P., Developmental malformations produced by radiation, Am. J. Roentgenol. 69:272, 1953.
19. Cohlan, S. Q., Excessive intake of vitamin A as cause of congenital anomalies in rat, Science 117:535, 1953.
20. Snell, G. Induction by roentgen rays of hereditary changes in mice, Radiology 36:189, 1941.
21. Kaven, A., Das Auftereten von Gehirnmissbildungen nach Röntgenbestrahlung von Mäuseembryonen, Ztschr. menschl. Vererb-u. Konstitutionslehre. 22:238, 1938.
22. Wilson, J. G., Roth, C. B., and Warkany, J., Analysis of syndrome of malformations induced by maternal vitamin A deficiency: Effects of restoration of vitamin A at various times during gestation, Am. J. Anat. 92:189, 1953.
23. Warkany, J., Nelson, R. C., and Schraffenberger, E., Congenital malformations induced in rats by maternal nutritional deficiency. IV. Cleft palate, Am. J. Dis. Child. 65:882, 1943.
24. Dawson, A. B., Stain technology note on staining of skeleton cleared specimens with alizarin red S., Stain Technology 1:23, 1926.
25. Rodahl, K., Hypervitaminosis A. Norsk Polarinstitutt, Skrifter Nr. 95:73, 1950.
26. Lewis, J. M., and Cohlan, S. Q., Comparative toxicity of aqueous and oily preparations of vitamin A, PEDIATRICS 9:5, 1952.
27. Wolbach, S. B., Vitamin A deficiency and excess in relation to skeletal growth.

J. Bone & Joint Surg. 29:171, 1947.
28. Wilson, J. G., Effects on offspring of altered physiologic states during pregnancy, read before the New York Academy of Science, New York City, January 1953.
29. Fell, H. B., and Mellanby, E., Effects of hypervitaminosis A on foetal mouse bones cultivated in vitro, Brit. M. J. 2:535, 1950.
30. Fell, H. B., and Mellanby, E., Metaplasia produced in cultures of chick ectoderm by high vitamin A, J. Physiol. 119:470, 1953.
31. Lewis, J. M., Bodansky, O., Lillienfeld, M.D., and Schneider, H., Supplements of vitamin A and carotene during pregnancy, Am. J. Dis. Child. 73:143, 1947.
32. Warkany, J., and Schraffenberger, E., Congenital malformations induced in rats by roentgen rays, Am. J. Roentgenol. 57:455, 1947.
33. Bonnevie, K., Pseudencephalie al spontane recessive Mutation bei der Häusmas. Skr. Norske Vidensk.—Akad., Oslo I. Math.—nat Kl., 9:39, 1936.
34. Steininger, F., Neue Beobachtungen an der erblichen Hasencharte der Mäus, Ztschr. F. menschl. Vererb.—u.—Konstitutionslehre 23:427, 1939.
35. Gluecksohn-Schoenheimer, S., Embryonic developments of mutants of Sd-strain in mice, Genetics 30:29, 1945.

SPANISH ABSTRACT

Anomalías Congénitas en la Rata Producidas por Ingestión exagerada de Vitamina A Durante el Embarazo

Las anomalías congénitas en los mamíferos se atribuyeron durante mucho tiempo únicamente a mecanismos genéticos hereditarios. Muchas investigaciones en embriologiá experimental habían demostrado la producción de cambios teratológicos en animales marinos y de baja escala con múltiples agentes que actuaban sobre el medio fetal, suponiéndose que en los mamíferos no se observaban estos cambios debido a la protección ofrecida por la placenta y la matriz. En los últimos años se han tenido pruebas experimentales de que la alteración del medio fetal en los mamíferos con factores específicos puede determinar malformaciones congénitas predecibles.

El efecto teratológico de las deficiencias maternas de elementos nutricionales específicos puede atribuirse a su necesidad en momentos críticos del desarrollo y la diferenciación fetal progresiva; hasta ahora no se han descrito malformaciones congénitas determinadas por el exceso de tales elementos nutricionales. Este informe presente los resultados de las observaciones de una ingstión exagerada de vitamina A proporcionada a ratas durante su embarazo, así como la relación del efecto tenido con el período crítico de desarrollo en que se administró.

Las observaciones fueron las siguientes: abortos frecuentes, pero cuando el embarazo llegaba a término los productos mostraban anomalías congénitas gruesas que incluían exencefalia, malformaciones oculares, paladar hendido, acortamiento de la mandíbula y de los maxilares, espina bífida con meningocele e hidrocefalia. De 148 productos obtenidos de ratas que recibieron vitamina A en exceso, 77 exhibieron tales malformaciones, dando un 52% de productos afectados. No se observaron anomalías congénitas en 1201 ratas control. El período críticamente susceptible al efecto teratogénico del exceso de la vitamina se extendió del séptimo al décimo día del embarazo.

El mecanismo teratológico con el exceso de vitamina A como con cualquier otro agente no puede explicarse todavía; el problema se complica aún más por el hecho de que las anomalías puede resultar no sólo en cambios productivos y destructivos sino también en ausencia de involución en estructuras fetales cuya persistencia en la vida adulta debe considerarse anormal. De estos experimentos los autores suponen que la vitamina A actúa en un período crítico del desarrollo embrionario como una anti-ezima o anti-metabolito para producir las malformaciones. No se atreven a aplicar en los seres humanos las observaciones teratológicas del exceso de vitamina A, pero en vista de existir hechos, así sean remotos, que sugieren cierto paralelismo de acción tóxica en las ratas y en los seres humanos (fontanela abombada e hidrocefalia temprana en niños con intoxicación aguda y trastornos esqueléticos en la rata y en los seres humanos con intoxicación crónica por vitamin A) se consideran obligados a proponer mayor cautela en el uso durante el embarazo, de factores vitamínicos más allá de lo que exigen los requerimientos humanos.

8 Gramercy Park

Cohlan-'61
Bib. No. 1758
Reproduced by permission
of the copyright owner

Biol. Neonat. 3: 330–342 (1961)

From the Department of Pediatrics, New York University Medical Center

Observations on the Effect of Experimental Endocrine Procedures on the Teratogenic Action of Hypervitaminosis A in the Rat[1]

Observations sur les effets de procédés endocrinologiques expérimentaux sur l'action tératogène de l'hypervitaminose A du rat

Beobachtungen über die Wirkung von experimentellen endokrinen Maßnahmen auf den teratogenen Einfluß der A-Hypervitaminose bei der Ratte

By SIDNEY Q. COHLAN and SHIRLEY M. STONE

In 1953 we demonstrated (1, 2) that a wide range of congenital malformations (exencephaly, cleft palate, spina bifida, hydrocephalus, "open eye" and anophthalmos) could be induced in the offspring of the pregnant rat by the administration of vitamin A excess during the 7th–10th day of gestation. These findings have been amply corroborated and extended by *Giroud and Martinet* (3, 4, 5) who have also produced developmental defects in the mouse, guinea pig and rabbit by maternal vitamin A excess. The mechanism of this extraordinary effect of vitamin A excess on mammalian fetal development is obscure.

The observation by *Selye* (6) that growth hormone protected the mature rat from the known skeletal changes of vitamin A toxicity, the reports of *Millen and Woollam* that cortisone (7, 8) and 4-methyl-2-thiouracil (9) potentiates and that insulin (10), thyroxin (11) and vitamin B complex (12) inhibits the teratogenic activity of hypervitaminosis A and the statement of *Berdjis* (13) tat "experimental hypervitaminosis A appears to be somewhat similar to hyperparathyroidism both in living animals and in tissue culture" prompted an investigation of the effect of various endocrines on the teratogenicity of hypervitaminosis A. In this paper we will report the results of experiments indicating that 1) Growth Hormone, 2) Parathyroidectomy, 3) Thymectomy, 4) Cortisone, 5) Insulin and 6) Adrenalectomy do not alter the incidence of vitamin A induced brain malformations.

[1] These studies supported by grant B-422 National Institute of Neurological Diseases and Blindness, N.I.H. U.S.P.H.S.

Material and Methods

Wistar strain rats from the same source were used in all experiments. Animals lived two in a cage and were allowed water and commercial pellets ad lib. The vitamin A used in all experiments, except, in part, in the cortisone and insulin investigation, was an aqueous preparation[1]) of vitamin A containing 50,000 i. u. natural vitamin A dispersed in sorethitan monolaurate and water. The oil preparation[2]) contained 120,000 i. u. vitamin A acetate per gram of peanut oil. The aqueous teratogenic dose administered daily via gastric tube from the 8th to 13th day of gestation was 25,000 i. u.; the oily dose was 60,000 i. u. Concurrent controls were observed in each experiment.

The day following the night of mating is considered day 1 of gestation. Rats were sacrificed on the 20th day of gestation, examined for gross malformations and fixed for sectioning. Details of each experiment follow:

1. *Growth Hormone.* Ninety pregnant rats were divided into two groups. One group was fed 25,000 i. u. vitamin A from the 8th–13th day of gestation. In addition this group received 4 mg. growth hormone (NIH-BGH-1, a highly purified bovine preparation kindly provided by the Endocrinology Study Section of the National Institutes of Health) in 0.4 ml. distilled water administered subcutaneously twice daily. Two groups served as controls; one received growth hormone, the other vitamin A.

2. *Parathyroidectomy.* Forty pregnant rats were parathyroidectomized under ether anesthesia on the third day of gestation and divided into two groups. One group was allowed to proceed to term, the other group received the usual challenge with vitamin A. A control group of 20 pregnant rats were fed vitamin A.

3. *Thymectomy.* Twenty-four pregnant rats were thymectomized under ether anesthesia on the third day of gestation and divided into two groups. One thymectomized group was otherwise untreated, the other, in addition, was fed the teratogenic dose of vitamin A. Twelve control rats were fed vitamin A.

4. *Cortisone and Insulin.* Two hundred and forty rats were divided into four groups of sixty each. Half the animals in each group

[1] Aquasol A (R) supplied by U. S. Vitamin Corp.
[2] Prepared and kindly supplied by Distillation Products, Rochester, N.Y.

received a teratogenic dose of aqueous vitamin A, the other half was fed the oily preparation. Group 1 served as controls. Group 2 received 20 mg. of cortisone subcutaneously, daily, from the 9th to 12th day of gestation. Group 3 in addition to cortisone received 1.5 u. protamine zinc insulin daily from the 9th–12th day of gestation. In group 4 the vitamin A fed pregnant rats were similarly injected with 1.5 u. of protamine zinc insulin but without cortisone.

5. *Adrenalectomy*. Fifty pregnant rats were subjected to bilateral adrenalectomy under ether anesthesia on the third day of gestation and divided into two groups. One group was allowed to proceed to term. The other group in addition was fed the teratogenic dose of vitamin A. A control group of twenty-five pregnant rats was fed vitamin A.



Fig. 1. Typical brain malformation. Deformed remnants of brain with almost total vascular replacement extruding through a congenital cranial defect.

Fig. 1. Malformation cérébrale typique. Restes cérébraux informes. Le cerveau est remplacé presque totalement par un bourgeon vasculaire en protrusion à travers une malformation cranienne congénitale.

Abb. 1. Typische cerebrale Mißbildungen. Der Rest des Gehirns ist deformiert, im übrigen ist es ersetzt durch Gefäße, wobei diese durch einen angeborenen cranialen Defekt austreten.

Results

1. *Growth hormone.* In table 1 the results following administration of growth hormone to 30 pregnant rats challenged with excess vitamin A are compared with 30 controls receiving vitamin A or growth hormone alone. Of 176 young obtained from the vitamin A fed-growth hormone treated pregnant rats, 58 exhibited the typical deformity (fig. 1) of the brain and calvarium (exencephaly), an anomaly rate of 33%. In the control vitamin A group there was a comparable brain malformation incidence of 37%. The growth hormone control group produced a yield of 171 young with no apparent gross changes, except for a slight increase in average fetal weight.

Comment: *Selye* has reported a protective effect of growth hormone on the known skeletal changes of vitamin A toxicity. The administration of 4 mg. of growth hormone prevented or diminished the gross and microscopic evidence of the characteristic bone resorption of vitamin A excess. Hemorrhages did not occur and the animals gained normally. *Selye* (6) concluded that growth hormone can "counteract both the inhibition of somatic growth and bone resorption that are characteristic of hypervitaminosis A".

Our results would indicate that growth hormone in doses adequate to inhibit the bone changes of hypervitaminosis A in the maturer at does not alter its teratogenic effect. An effect on fetal size of cruder

Table 1

Effect of growth hormone on the incidence of hypervitaminosis A brain malformations

Effet de l'hormone de croissance sur la fréquence des malformations cérébrales produites par l'hypervitaminose A

Einfluß des Wachstumshormons auf die Häufigkeit der Hirnmißbildungen bei A-Hypervitaminose

Treatment	No. of Rats at Term	Total No. of Young	No. of Malformed Young (%)
Growth hormone[1] vitamin A[2]	26/30	176	58 (33%)
Vitamin A[2] (control)	23/30	168	62 (37%)
Growth hormone[1] (control)	21/30	171	0

[1] 4 mg. growth hormone in 0.4 cc. distilled water administered subcu. b.i.d. from the 4th–20th day of gestation.

[2] 25,000 i.u. Vitamin A daily from the 8th–13th day of gestation.

rations of growth hormone has been reported by others (14, 16).

2. *Parathyroidectomy*. The results of vitamin A challenge in 20 parathyroidectomized pregnant rats compared to their controls are n in table 2. The incidence of brain malformations in the offspring the parathyroidectomized-vitamin A fed pregnant rats and their inal vitamin A fed controls was 40% and 34% respectively. There were no gross malformations in the offspring of otherwise untreated, athyroidectomized pregnant rats.

Comment: A relationship between hyperparathyroidism and hypervitaminosis A has been reported by *Berdjis* who has shown that the thyroid in hypervitaminotic A animals exhibits evidence of mild rplasia. In vivo and in vitro experiments lead *Berdjis* (13) to bude that "experimental hypervitaminosis A appears to be what similar to experimental hyperparathyroidism both in living als and tissue culture". Since we could demonstrate no difference in incidence of brain malformation in parathyroidectomized rats compared to their controls, it would appear that the parathyroid ne is not involved in the teratogenesis of vitamin A.

3. *Thymectomy*. Similar results were obtained with thymectomized pregnant rats. As seen in table 3 there was no difference in the incidence of brain anomaly in the experimental and control groups.

4. *Cortisone*. Table 4 summarizes the data on the effect of cortisone on the teratogenicity of vitamin A. The malformation rates following administration of aqueous or oily preparations of vitamin A were 31

Table 2

Effect of parathyroidectomy on the incidence of hypervitaminosis A brain malformations

Effet de la parathyroidectomie sur la fréquence des malformations cérébrales produites par l'hypervitaminose A

Einfluß der Parathyreoidektomie auf die Häufigkeit der Hirnmißbildungen bei A-Hypervitaminose

	No. of Rats at Term	Total No. of Young	No. of Malformed Young (%)
Parathyroidectomized[1]	18/20	117	0
Parathyroidectomized + vitamin A[2]	16/20	95	38 (40%)
Vitamin A[2]	17/20	128	43 (34%)

[1] Parathyroidectomized on third day of gestation.
[2] 25,000 I.U. vitamin A daily from 8th–13th day of gestation.

Table 3

Effect of thymectomy on the incidence of hypervitaminosis A brain malformations

Effet de la thymectomie sur la fréquence des malformations cérébrales produites par l'hypervitaminose A

Einfluß der Thymektomie auf die Häufigkeit der Hirnmißbildungen bei A-Hypervitaminose

	No. of Rats at Term	Total No. of Young	No. of Malformed Young (%)
Thymectomized[1]	10/12	94	0
Thymectomized vitamin A[2]	8/12	69	22 (31%)
Vitamin A[2]	9/12	57	20 (34%)

[1] Thymectomy on the third day of gestation.
[2] 25,000 i.u. vitamin A fed daily from 8th–13th day of gestation.

and 34% respectively. The control rates were 34 and 38% respectively. These data suggest that the administration of cortisone does not affect the incidence of brain malformation induced by either aqueous or oily preparations of vitamin A in CF *Wistar* rats.

Comment: *Millen and Woollam* (7) have reported that cortisone potentiates the teratogenic activity of hypervitaminosis A. They fed 12 pregnant *Wistar* rats 60,000 i. u. of vitamin A acetate in peanut oil from the 3th–13th day of gestation. A yield of 77 offspring was produced with a brain malformation rate of 7.8%. When 20 mg. of cortisone was administered subcutaneously to another group of 12 vitamin A challenged rats a yield of 41 young was obtained with a brain malformation rate of 36.6%. A malformation incidence in the vitamin A-cortisone treated rats of 36.6% is an impressive increase over a rate of 7.8% in the control vitamin A treated rats. However, a control rate of 7.8%, is far below the expected incidence of hypervitaminosis A brain malformations in most rat strains reported. In various experiments in our laboratory a total of 1012 *Wistar* rats have been exposed to vitamin A excess with an overall brain malformation rate of 36%. Similarly *Giroud and Martinet* (3) report an incidence of 50% brain malformations in the offspring of pregnant rats fed 60,000 i. u. of an oily preparation of vitamin A from the 8th–10th day of gestation.

(5) *Insulin.* The results of the subcutaneous administration of 1.5 μ. protamine zinc insulin from the 9th–12th day of gestation in pregnant rats treated with vitamin A or vitamin A and cortisone are summar-

Table 4

Effect of cortisone and insulin on the incidence of hypervitaminosis A brain malformations

Effet de la cortisone et de l'insuline sur la fréquence des malformations cérébrales produites par l'hypervitaminose A

Einfluß von Cortison und Insulin auf die Häufigkeit von Hirnmissbildungen bei A-Hypervitaminose

Treatment	Vitamin A Preparation	No. of Rats at Term	Total No. of Young	No. of Malformed Young (%)
Vitamin A	Aqueous[1]	31/30	222	76 (34%)
Vitamin A	Oil[2]	26/30	192	73 (38%)
Vitamin A	Aqueous	31/30	210	65 (31%)
Cortisone[3]	Oil	39/30	271	92 (34%)
Vitamin A Cortisone	Aqueous	22/30	132	38 (29%)
Insulin[4]	Oil	20/30	119	38 (32%)
Vitamin A	Aqueous	33/30	218	85 (39%)
[illegible]	Oil	25/30	181	42 (36%)

[1] 5,000 i.u. natural vitamin A in sorethitan monolaurate aqueous diluent fed daily [illegible] 13th day of gestation.

[2] 60,000 i.u. vitamin A in peanut oil fed daily from 8th-13th day of gestation.

[3] [illegible] mg. cortisone administered subcutaneously daily from 9th-12th day of gestation.

[4] [illegible].5 i.u. protamine zinc insulin administered subcutaneously daily from 9th-12th day of gestation.

ized on table 4. It is apparent that the malformation rates obtained from insulin treated vitamin A fed pregnant rats does not differ significantly from the vitamin A fed controls.

Comment: *Millen and Woollam* (10) have reported that insulin will protect the pregnant rat from the teratogenic effect of vitamin A excess. This suggestion is based on results of an experiment in which 1.2 μ protamine zinc insulin was administered subcutaneously daily from the 9th-12th day of gestation to two groups of 12 pregnant rats. One insulin treated group was fed 60,000 i. u. vitamin A in peanut oil from the 8th-13th day of gestation. the other insulin treated group was challenged with vitamin A and cortisone. The brain malformation rates recorded were 0 and 1.2% respectively. As can be seen on table 4 we were unable to similarly demonstrate that insulin protects the rat fetus from cranial defects following administration of a teratogenic dose of either aqueous vitamin A or vitamin A in peanut oil to pregnant [illegible] rats.

(6) *Adrenalectomy*. Only 20 of the 50 adrenalectomized pregnant rats carried litters to term. There were 9 post-operative deaths up to the 8th day of gestation. The litter yield and malformation rates are summarized on table 5. There were 33 malformed young in a yield of 82 offspring from 9 litters obtained from 21 surviving adrenalectomized-vitamin A fed rats. The malformation incidence of 41% is comparable to the incidence of 39% observed in the vitamin A fed controls. There were no gross malformations seen in 89 offspring from 11 litters produced by otherwise untreated adrenalectomized pregnant rats.

Table 5

Effect of bilateral adrenalectomy
on the incidence of hypervitaminosis A brain malformations
Effet de la surrénalectomie bilatérale
sur la fréquence des malformations cérébrales dues à l'hypervitaminose A
Einfluss der bilateralen Adrenalektomie
auf die Häufigkeit von Hirnmißbildungen bei A-Hypervitaminose

	No. of Rats at Term	Total No. of Young	No. of Malformed of Young (%)
Adrenalectomized[1])	11/25	89	0
Adrenalectomized Vitamin A[2])	9/25	82	33 (41%)
Vitamin A[2])	19/25	152	59 (39%)

[1]) Bilateral adrenalectomy on third day of gestation.
[2]) 25 000 i.u. Vitamin A daily from the 8th–13th day of gestation.

Comment: During the course of the cortisone-vitamin A experiments the question arose whether the absence of endogenous steroid would affect teratogenesis. The data presented on table 5 suggests that bilateral adrenalectomy on the 3rd day of gestation neither affects gross normal fetal development nor does it influence the incidence of hypervitaminosis A malformations in the rat. *Hoar* (17) however has recently presented evidence that adrenalectomy in the guinea pig before 18 hours of gestation results in a 29% incidence of fetal abnormalities (microphthalmia, myelomeningocele, cervical hematoma, sacral spina bifida, umbilical hernia and gastroschisis) in embryos removed at 30 days gestation. The over-all fetal resorption rate was 49%. Forty one per cent of the adrenalectomized pregnant guinea pigs died before the 30th day of gestation.

[illegible]

Depending on the animal species, time in [illegible] and dose employed, vitamin A excess has been [illegible] variety of [illegible] of the central nervous [illegible] the [illegible], cardio-vascular and [illegible]. Whether this phenomenon is [illegible] indirectly [illegible] of [illegible] metabolism or is a [illegible] of the [illegible] A excess [illegible] tissue is still unknown. From the reports of *Giroud* (18, 19) and [illegible] unpublished data it is apparent that though there is a twofold increase in total embryo vitamin A [illegible] following administration of 60,000 i. u. of vitamin A to the [illegible] animal, the quantitative amounts recovered in the embryo are not impressive. *Giroud* (18, 19) reported an [illegible] fetal vitamin A content of 4.18 i. u. The hypervitaminotic [illegible] content was 10.08 i. u. Our results were 3.8 i. u. and 5.9 i. u. [illegible]. These fetal concentrations subject to the technical error [illegible] low levels of vitamin A, are of such a small [illegible] that the hypothesis of a direct effect of vitamin A on the [illegible] is open to [illegible]. On the other hand *Fell and Mellanby* (20) [illegible] a direct action of vitamin A on fetal bone in vitro by demonstrating [illegible] of cartilage and resorption of bone [illegible] culture containing excess vitamin A. A possible [illegible] of this phenomenon, supporting the thesis of a direct effect on bone, has been presented by the more recent observations of [illegible] *Lucy and Fell* (21, 22, [illegible]) that vitamin A excess (vitamin [illegible]) may exert its influence on a cellular level. These authors have shown that vitamin A excess in vitro produces rupture of cell [illegible] with liberation of large amounts of hydrolytic enzymes which in turn disrupts cartilage and bone metabolism. Further [illegible] of these findings [illegible] significant advance [illegible] of the teratogenesis of vitamin A. There have also been [illegible] suggesting that vitamin A exerts its teratogenic effect by interfering in some way with carbohydrate metabolism. *Millen and Woollam* (11) [illegible] would seem justifiable to conclude, that vitamin [illegible] teratogenic powers by interfering in some way at [illegible] carbohydrate metabolism of mother, placenta of fetus. To support this thesis [illegible] experimental data suggesting [illegible] activity of vitamin [illegible]

insulin or vitamin B complex or be aggravated by cortisone or 4-methyl-2-thiouracil.

Clinically *Hoet, Gommers and Hoet* (24) have collected a series of 116 selected women (prediabetic or 'concealed" hypothyroid) with a previous history of 70% fetal wastage from 353 pregnancies. They present evidence that treatment with insulin or thyroid or both during 127 subsequent pregnancies in these same women reduced the fetal wastage to 8%. From their clinical data and the experimental evidence of *Millen* and *Woollam* they speculate that the disturbance of vitamin A metabolism caused by prediabetes or concealed hypothyroidism may be a cause of congenital malformations in the human.

It is indeed tempting, as *Millen and Woollam* suggest to interpret their results of endocrine and vitamin B modification of vitamin A induced malformations as support for the hypothesis that the teratogenic action of vitamin A is mediated through some, as yet undefined disturbance in carbohydrate metabolism. However, our inability to produce either the potentiating effect of cortisone or the protective effect of insulin on vitamin A induced brain malformations as well as the observation of *Giroud* that neither vitamin B complex or vitamin C influences the teratogenicity of vitamin A in his laboratory may imply that the effects of some "modifiers" may be related to strain and substrain differences. It has been previously shown (25, 26, 27) that the effects of certain teratogens vary with genetic strain differences. That there is a difference in experimental conditions is apparent from the fact that the control incidence of vitamin A induced cranial malformations reported by *Millen and Woollam* following administration of 60,000 i.u. of vitamin A in peanut oil from the 8th–13th day is 7.8% while our control rate using the same vitamin A preparation during the same gestational period is 36%. Similarly, *Giroud and Martinet* administering an oily preparation of 60,000 i. u. vitamin A from the 8th–10th day report a control incidence of 50%.

The exploration of teratogenic mechanism by attempts at experimental modification of the effects of known teratogens holds great promise. However, in view of the many complex variables implicit in such investigation experimental conclusions as to the metabolic mechanism of hypervitaminosis A, are, in our present state of knowledge, relatively hypothetical. Clinical inferences from these experimental hypotheses are certainly no less hypothetical.

Summary

1. The administration of purified bovine growth hormone in doses known to protect the mature rat from the bone changes of excess vitamin A exerts no influence on the brain malformation rate induced by hypervitaminosis.

2. Brain malformations in the rat fetus induced by hypervitaminosis A were not potentiated by cortisone or prevented by insulin.

3. Parathyroidectomy, thymectomy or bilateral adrenalectomy on the third day of gestation in the rat does not appear to alter gross normal fetal development or influence the incidence of hypervitaminosis A brain malformations.

Résumé

1° On a administré des doses d'hormone de croissance bovine purifiée connues comme protectrices chez le rat des effets osseux de l'hypervitaminose A: cette administration n'a pas d'influence sur la fréquence des malformations cérébrales produites par l'hypervitaminose A.

2° Les malformations cérébrales du fœtus du rat produites par l'hypervitaminose A n'ont pas été potentialisées par la cortisone ni prévenues par l'insuline.

3° La parathyroïdectomie, la thymectomie ou la surrénalectomie bilatérale au 3e jour de la gestation de la rate ne semblent pas causer de grosses anomalies du développement fœtal, ni influencer la fréquence des malformations cérébrales après hypervitaminose A.

Zusammenfassung

Gereinigtes bovines Wachstumshormon verhindert in Dosen, die bei der ausgewachsenen Ratte die durch Vitamin-A-Intoxikation ausgelöste Entstehung von typischen Knochenveränderungen hintanhalten, eine durch Vitamin A induzierte Hirnmißbildung beim Rattenfetus nicht. Ebensowenig wird die Vitamin-A-induzierte Hirnmißbildung durch Cortison verstärkt, noch durch Insulin gehemmt. Eine am 3. Tage der Gestation durchgeführte Parathyreoidektomie, Thymektomie oder bilaterale Adrenalektomie schien die normale fetale Entwicklung weder einschneidend zu stören noch die Vitamin-A-induzierte Hirnmißbildung zu beeinflussen.

ACKNOWLEDGEMENTS

Th[illegible]rchnical assistance of Mrs. *Charlotte Violin* and Dr. *Franklin Ward* is gratefully acknowledged.

BIBLIOGRAPHY

1. [illegible], S. *Q.*: Excessive intake of vitamin A as a cause of congenital malfor-[illegible]ns in the rat. Science *117:* 536 (1953).
2. [illegible]n, S. *Q.*: Congenital anomalies in the rat produced by excessive intake of [illegible]min A during pregnancy. Pediatrics *13:* 556 (1954).
3. [illegible]*oud, A. et Martinet, M.*: Malformations diverses du fœtus de rat suivant les [illegible]s d'administration de vitamine A en excès. C. R. Soc. Biol. *149:* 1088 (1955).
4. [illegible]*d. A. et Martinet, M.*: Tératogénèse par hautes doses de vitamines A en [illegible]ion des stades du développement. Arch. Anat. Micr. *45:* 77 (1956).
5. [illegible]*d. A. et Martinet, M.*: Tératogénèse par hypervitaminose A chez le rat, [illegible]is, le cobaye et le lapin. Arch. franç. Pédiat. *7:* 1 (1959).
6. [illegible] *H.*: Prevention of vitamin A overdosage by somatotrophic hormone. [illegible]locrin. *16:* 231 (1957).
7. [illegible]*llen, J. W. and Woollam, D. H. M.*: Influence of cortisone on teratogenic effects of hypervitaminosis A. Brit. Med. J. *2:* 196 (1957).
8. *Millen, J. W. and Woollam, D. H. M.*: Effect of cortisone on the incidence of cleft palate induced by experimental hypervitaminosis A. Brit. Med. J. *2:* 197 (1957).
9. *Woollam, D. H. M. and Millen, J. W.*: Influence of 4-methyl-2-thiouracil on the teratogenic activity of hypervitaminosis A. Nature, Lond. *181:* 99 (1958).
10. *Millen, J. W. and Woollam, D. H. M.*: Insulin-cortisone relationship in experimental teratogenesis. Nature, Lond. *181:* 418 (1958).
11. *Woollam, D. H. M. and Millen, J. W.*: The modification of the activity of certain agents exerting a deleterious effect on the development of the mammalian embryo. Congenital Malformations, Ciba. Found. Symp. p. 158 (Little, Brown Co., Boston 1960).
12. *Millen, J. W. and Woollam, D. H. M.*: Effect of vitamin B complex on the teratogenic activity of hypervitaminosis A. Nature, Lond. *182:* 940 (1958).
13. *Berdjis, C. C.*: Hypervitaminosis A and hyperparathyroidism. A.M.A. Arch. Path. *67:* 355 (1959).
14. *Engfeldt, B. and Hultquist, C. T.*: Administration of crystalline growth hormone to pregnant rats. Acta endocrin., Kbh. *14:* 181 (1953).
15. *Glass, L. C.*: Effects of injection of antuitrin G upon a strain of harelip mice. Am. Naturalist *74:* 566 (1940).
16. *Soniag, L. W. and Munson, P. L.*: The effect on the weight of the offspring of administration of Antuitrin G to the pregnant rat. Amer. J. Physiol. *108:* 593 (1934).
17. *Hoar, R. M.*: The production of congenital malformations in guinea pigs by adrenalectomy. Abst. First Annual Meeting (The Teratology Society, Cincinatti, May 26, 27, 1961).
18. *Giroud, A.; Gounelle, H. et Martinet, M.*: Concentration de la vitamine A chez la mère et le fœtus au cours de la tératogénèse par hypervitaminose A. C. R. Soc. Biol. *150:* 2064 (1956).
19. *Giroud, A.; Gounelle, H. et Martinet, M.*: Données quantitatives sur le taux de la vitamine A chez le rat lors d'expériences de tératogenèse par hypervitaminose A. Bull. Soc. Chim. biol. *39:* 331 (1957).

20. *Fell, H. and Mellanby, E.:* The effect of hypervitaminosis A on embryonic limb bones cultivated in vitro. J. Physiol., Lond. *116:* 320 (1952).
21. *Dingle, J. T.; Lucy, S. A. and Fell, H. B.:* Studies on the mode of action of excess of vitamin A: 1. Effect of excess of vitamin A on the metabolism and composition of embryonic chick-limb cartilage grown in tissue culture. Biochem. J. *79:* 497 (1961).
22. *Lucy, J. A.; Dingle, J. T. and Fell, H. B.:* Studies on the mode of action of excess of vitamin A: 2. A possible role of intracellular proteases in the degradation of cartilage matrix. Biochem. J. *79:* 500 (1961).
23. *Dingle, J. T.:* Studies on the mode of action of excess of vitamin A: 3. Release of a bound protease by the action of vitamin A. Biochem. J. *79:* 509 (1961).
24. *Hoet, J. P.; Gommers, A. and Hoet, J. H.:* Causes of congenital malformations: Role of prediabetes and hypothyroidism. Congenital Malformations, Ciba Found. Symp. p. 219 (Little, Brown Co., Boston 1960).
25. *Fraser, F. C. and Fainstat, T. D.:* Production of congenital defects in the offspring of pregnant mice treated with cortisone. Pediatrics *8:* 527 (1951).
26. *Kalter, H.:* Inheritance of susceptibility to the teratogenic action of cortisone in mice. Genetics *39:* 186 (1954).
27. *Gunberg, D. L.:* Variations in the teratogenic effects of trypan blue administered to pregnant rats of different strain and substrain origin (abst.). Anat. Rec. *130:* 310 (1958).

Authors' address: Sidney Q. Cohlan and Shirley M. Stone, Department of Pediatrics, New York University Medical Center, 550, First Avenue, New York, N.Y. (USA)

HYPERVITAMINOSIS A: The Symptomatology of Hypervitaminosis A in Young Rats Caused a Pure Vitamin A diet.

Klinische Wochenschrift 12(44): 1732-1734. 4 November 1933

by J.A. Collazo and J. Sanchez Rodriguez
From the Institute for Medical Pathology and the Provincial Laboratory (General Hospital) in Madrid. Spanish Original.

I. Introduction

The understanding of vitaminopathy caused by hypervitaminosis became possible through the discovery of the chemical composition of vitamins. Thus hypervitaminosis D was described on the basis of the discovery of the transformation of ergosterol into vitamin D by ultra-violet light, which changes the provitamin or inactive ergosterol into a less saturated isomeric or irradiated, active ergosterin. Today there exists an extensive literature which confirms the findings of KREITMAIR and MOLL and our own concurrent findings published together with MORELLI, VARELA and RUBINO.

With the discovery of Vitamin A, which was chemically identified as a doubling of the carotin molecule, hypervitaminosis A caused by large doses became a biological question of large scientific and practical interest.

Pathologic changes induced by over-doses of vitamin A were not reported with adequate exactness until the recently published work by DRIGALSKI. This author treats various remarkable facts in his article: the appearance of eye inflamations, weight loss and alopecia; we consider these findings remarkable because of the similarities with vitamin A deficiency symptoms. Drigalski's work, which was published on February 25, 1933, coincided with the beginning (March 2) of our studies.

Hypervitaminosis A, caused by a chemically pure preparation dissolved in an inactive oil, is not related to the pathological symptoms that were observed earlier after administration of large doses of fish liver oil or more or less pure concentrations of this vitamin; at that time, the antirachitic vitamin D and the growth vitamin A had not yet been definitively separated, so identification was based upon their different biological actions, and also pure vitamin A had not yet been extracted from the provitamin (carotin) or oranges, which contain a large quantity of it. The work of AGDUHR, BURSTROM, HOEJER, TAKAHASHI, HENRIKSEN, and HOGAWA belongs to this period.

We know that vitamin A is produced by a doubling of the carotin molecule in animal tissue. The following chemical formula was given to vitamin A on the basis of its physio-chemical and biological properties: $C_{20}H_{29}OH$.

Vitamin A is colorless and in oily solutions it appears the color of the solution, unlike the provitamin or carotin which has a deep red color. Pure vitamin A (Vogan, Merck and I. G. Farben) is obtained from the liver of fish and some mammals, whereas carotin is obtained almost solely from carrots.

The vitamin activity of pure vitamin A is parallel to its toxicity, since it contains no other elements which could account for it. In addition, the inactivation, that is the disappearance of the antixerophthalmic effect by hydration, through the action of light, sun, ultraviolet rays coincides with the destruction of the toxic effect in rats. The toxicity of carotin could not be proved because, due to its poor solubility, it always had to be administered along with large amounts of a solvent, which is not suitable for experiments on rats.

II. Experimental Conditions

Procedure: We used the preparation Vogan from the Merck Company, which contains vitamin A in high concentration (40,000 Rat Units per cm^3), in our experiments. A Rat Unit is the smallest amount that can prevent growth retardation and xerophthalmia in a young rat weighing 35-40 g for 4-8 weeks on a vitamin A free diet.

Because of the scarcity of the product, which was administered daily in doses of 20,000 RU, we had to limit our experiment to two rats. We intend to repeat our experiments with a larger number of subjects; nevertheless we did find a number of changes that allow us to assert that large doses of vitamin A induce a pathological state, not to be confused with other experimental vitaminopathic conditions, in the young rat.

Animals: From one litter of 8 rats we selected 2 and put them in a glass metabolism cage with a metal ceiling and floor which had a urine-collecting depression. Another rat from the same litter (i.e., of the same age, 26 days), was used as a control in a similar cage. The development of the remaining 5 rats, who stayed with their mother, was also observed. Unlike DRIGALSKI who used fully grown rats weighing more than 125 g, we prefer young animals because it is easier to observe their development and also because vitamin A is an important growth factor.

Diet: The laboratory bred rats are fed bread with milk, peeled potatoes and cabbage and exhibit good development, normal reproduction and complete health. The litter used in our experiments had already begun to supplement their milk diet with the usual food.

The two subjects to whom vitamin A was being administered received the usual diet supplemented with oat and corn meal. The food was left in the cage from early afternoon till the following morning, so that the rats could eat it all up.

In addition, a piece of hard bread of bread with milk and a small piece of cabbage was given to the rats in the morning. Whatever had not been consumed by afternoon was removed. As for vitamins, the rats received beer yeast in powder form (vitamin B_1 and B_2) and a drop of Vigantol (vitamin D) every 4 days. Even though the rats did not eat any vitamin C, probably because they synthesize it in their organism, the cabbage in their diet did contain small amounts of it. Water and food were given ad libitum.

During the experiments the rats were kept at a temperature 18-20°. Special attention was given to the temperature because the cages provided to protection (such as straw or cellulose) and the extreme sensitivity of such small rats to cold could result in errors. We collected the feces and uring of the rats with hypervitaminosis A for chemical examination and to determine if and how vitamin A is excreted.

At first, vitamin A was dripped into the rats' mouths with a serological pipette, but after the first few administrations they sucked the oil themselves. Between day 10 and 12 we ceased administering vitamin A in order to prolong the process of the disease, as the animals seemed near death. The majority of DRIGALSKI'S animals died after 5 days, a period which is insufficient to observe the whole disease process of hypervitaminosis A.

III. Clinical Picture

Appetite: After the first few days. when the rats had not yet adjusted to their new diet their appetite normalized again and they liked to eat the small helpings of vegetable and bread with milk as well as the meal supplement. Their digestion was excellent, as determined by the feces examination. The stool was well formed and normal in consistency and amount. The only difference in comparison to the controls was a somewhat lighter color of the feces.

Weight: The two rats weighed 48 g and 50 g at the start of the experiment. Weight remained roughly constant until around day 10 when the larger amount of vitamin A was no longer administered. From this point on, the rats gained about 7 g. The controls, on the other hand, continued to grow normally. They now weigh 127 g, that is more than twice as much as the rats with hypervitaminosis A.

Growth cessation and retardation of weight increase is one of the main symptoms of hypervitaminosis A in rats. Only 3 days of discontinuing vitamin A administration suffices to eliminate the metabolism symptoms which dominate the hypervitaminosis A picture. DRIGALSKI states that the weight of his rats, which weighed about 100 g at the start, remained constant or decreased. Since the rats retained their appetites, this weight loss may be attributed to a trophic inhibition of growth when the rats are young, a fact not mentioned by DRIGALSKI, who instead connects the lack of normal weight increase with emaciation.

Growth: The weight curve shows most clearly the almost total cessation of growth in the two subjects. In the first three months of the rat's life the weight curve is sufficient proof of growth. However, the total body size, the length and thickness of the tail, teething, the length of extremities must also be considered. The genital organs give an indication of age, by the macroscopic development in the males and by the spontaneous opening of the vagins in the females.

From the start of the vitamin A administration (20,000 RU per day) growth of the young, 4 week old rats ceases. This dwarfness is overall, in the head, the tail and the extremities, which are all much smaller than in the controls (ILLUSTRATION I).

ILL. 1: Two rats from the same litter. On left normal control, on right subject with hypervitaminosos A. Obvious difference in the growth and condition of the fur. This state can in no way be confused with simple weakness. When vitamin A over-dose administration is stopped on time, the rats begin to grow normally again. This renewed growth stops immediately, when the 20,000 RU daily dosage is continued again.

General Condition: The sick total impression of the subjects contrasts with their uneasiness, their maintained strength and normal movements. When they are herded together, they do not become scared, as is normally the case with animals that have chronic experimental lesions as for example with hypervitaminosis D, avitaminosis B etc. Outwardly the rats are dirty and their fur is moist. We repeat, however, that rats with hypervitaminosis A retain their ability to move lively. This ability does not disappear until about in week 2, when the high doses of vitamin A have broken the organism's resistance.

Trophic Changes of the Skin: One of the first signs is the mussed (shaggy) moist, colorless and dirty hair, changes which become more noticeable day by day. At the end of the first week the hair begins to fall out in bunches. This alopecia naturally begins at the edge of the furry parts and spreads gradually, forming bald patches. In other words, it starts from the snoot, moving into the eye region and up to the ears, and from the paws moving up to the belly (Ill. 2). The skin of the bald patches is as thin as silk and very pale, which may indicate strong anemia. The same condition appears on the tail as well as trophic changes in the form of ring-shaped crusts.

Gait: In the first week the animals run and move very well, and have no difficulty with the direction or regularity of their gait; i.e., they do not have ataxia. In week 2, however, spastic changes appear in one rat; it runs on closed paws and limps. In the other rat there is a strong contraction in the toes of the left back paw, so that when the rat runs, it lands on the back flat area of the paw. When such an animal is forced to run, a sudden limping on the other paw due to laming contractions appears, but disappears again when the animal is left alone and allowed to rest. The rigidity of the left back paw toes has already lasted 10 days.

We do not yet have enough indications to explain the pathology of this phenomenon. At this point it appears to be a purely functional nature. We suspect changes in the calcium metabolism and we are attempting to prove this.

Ill. 2. Rat with hypervitaminosis A. Exophthalmus, hair fall-out.

Changes in the Eyes (Exophthalmus): DRIGALSKI first called attention, to the changes that occur in the eye tissue after administration of large doses of vitamin A. They are inflammations without further symptoms except eyelid edema and red mucous membranes. According to the same author, nose mucous membrane inflammations with quite strong secretion also occurred.

We could confirm these findings with our subjects but we must add that, in addition, they exhibited pronounced bulging of the eyeballs, exophthalmus, with a tendency toward lid closure and total loss of eye lashes (see Ill. 2). The eye changes become very noticeable at the end of the first week, but improve upon cessation of the vitamin A administration.

Vitamin A Excretion: When several millograms of dried feces from a rat suffering from hypervitaminosis A are administered to another rat with xerophthalmia and growth retardation, an immediate healing of the avitaminosis can be observed. This leads us to the conclusion that vitamin A consumed in large doses is at least partially excreted through the intestines.

We intend to try this same experiment with the urine of hypervitaminotic rats, which differs from the urine of the controls by its dark yellow color.

We will publish our roentgenological and histological studies of hypervitaminosis A in a second article and the chemical metabolism changes in a third article.

IV. Reflections on Hypervitaminosis

The changes described above can only be attributed to the administration of large doses of vitamin A. The solvent (sesame oil) is not capable of inducing patholgical changes in the amount used for administration of the vitamin. On the contrary, plans oils are considered an excellent fat source for laboratory feeding of rats. Therefore, the hypervitaminosis A can only have resulted from the over-doses of pure vitamin A molecules.

When hypervitaminosis A caused by irradiated ergosterin was first discovered, several authors posed the question whether it was really a case of specific changes. Some even tended to assume, albiet without proof, the existence of other substances, which formed in the ergosterin by the action of ultraviolet light or by chemical changes in the solution. Other authors described the existence of commercial products without toxic effect but with a completely retained antirachitic effect.

Today it is considered a sufficiently experimentally proved fact that the antirachitic action of a pure vitamin D product given in over-doses causes excessive vitaminization (hypervitaminosis) of the organism (WINDAUS et al.). The lack of hypervitaminotic symptoms in such cases was only attributable to a considerable dilution of the product and the resulting mitigation of its antirachitic effect. When administered in equally massive antirachitic doses, all preparations cause hypervitaminosis (GIOERGY, LAQUEUR, SCHEUNER etc.) which means as one of us has shown, that there can be no doubt about the existence of hypervitaminosis D, which should be regarded as a physio-pathological phenomenon through an excess of the normal vitamin D functions.

Taking into consideration our knowledge today this definition is not yet accepted for hypervitaminosis A. Nevertheless, a comparison of the biological symptoms of these two types of hypervitaminosis is useful: Whereas in hypervitaminosis D hypermineralization (early and total calcification of the growth cartilage, hyperphosphatemia and hypercalcemia) appears, a process in opposition to hypovitaminosis D or rachitis (retardation of ossification, hyperphosphatemia and a tendancy toward hypocalcemia) in hypervitaminosis A observation of the described clinical picture reveals signs of hyperfunction of the physiological mechanism influenced by vitamin A. We believe that vitamin A encourages cholester in metabolism, as one of us has shown in a study in collaboration with HAMBURGER using raw Notwegian fish liver oil. Those experiments need to be repeated with pure vitamin A; they are being carried out now.

We found, suprisingly, that hypervitaminosis A induces growth retardation which in terms of degree and prematureoccurrence is very much like the growth retardation observed in rats fed a diet lacking vitamin A. Inflammation of the eyes also occurs noticeably in avitamonisos A without any perceptable transition to a suppurative process. The clinical picture of hypervitaminosis A does not exhibit any increase in functions normally controlled by vitamin A. If vitamin A acted the way vitamin D does in over-doses, we would have had to find signs of gigantism. Nevertheless, we want to call attention to the meager knowledge and unexact experimental proof of the functions of vitamin A in animal organisms. Therefore we must, for the time being, be very careful in the evaluation of our results. The growth phenomenon, the point of attack for vitamin A, can be sub-divided into a number of factors that are hard to prove. Nevertheless it is necessary to first study the metabolism whose normal functioning forms the trophic basis of growth in normal animals, i. e. animals without congenital dwarfism. On the other hand, we believe that hypervitaminosis is not a particular danger in vitamin consumption by man. In this first article, which has the character of a preliminary report, we have described the existence of hypervitaminosis character of a preliminary report, we have described the existence of hypervitaminosis A and hope to contribute to the clarification of the problems touched upon in future articles.

V. Conclusions

Large doses of pure vitamin A induce trophic skin changes, growth cessation, eye inflammation, and spastic contractions of the extremeties, which can lead to death in young, 3 week old rats. When the administration of vitamin A over-doses is stopped on time, growth resumes and the eyes improve.

The literature is listed at the end of the second article.

HYPERVITAMINOSE A.

Die Symptomatologie der durch Fütterung von reinem A-Vitamin an jungen Ratten hervorgerufenen Hypervitaminose A.

Von

J. A. COLLAZO und J. SÁNCHEZ RODRIGUEZ.

Aus dem Institut für medizinische Pathologie (Direktor: Prof. Dr. MARAÑON) und dem Provinzial-Laboratorium (Hospital General) in Madrid (Direktor: Prof. Dr. MOURIZ)

Aus dem Spanischen übersetzt von Dr. DOHMANN, Darmstadt.

I.

I. Einleitung.

Der Begriff der Vitaminopathie durch Hypervitaminose ist erst durch die Entdeckung der chemischen Konstitution der Vitamine möglich geworden. So wurde die Hypervitaminose D auf Grund der Entdeckung der Umwandlung des Ergosterols in Vitamin D durch das ultraviolette Licht, welches das Provitamin oder inaktive Ergosterol in ein weniger gesättigtes isomeres oder das bestrahlte, aktive Ergosterin umwandelt, beschrieben. Über die Hypervitaminose D ist heutzutage eine umfangreiche Literatur vorhanden, die die zuerst und zu gleicher Zeit von KREITMAIR und MOLL und von einem von uns mit MORELLI, VARELA und RUBINO beschriebenen Befunde bestätigt.

Mit der Entdeckung des A-Vitamins, das chemisch als eine Verdoppelung des Carotinmoleküls identifiziert wurde, ist die Frage der Hypervitaminose A durch Anwendung großer Dosen dieser Substanz als biologische Frage von großem wissenschaftlichen und praktischen Interesse aufgetaucht.

Pathologische Veränderungen durch Überdosierung von Vitamin A sind mit ausreichender Genauigkeit bis zu der kürzlich veröffentlichten Arbeit von DRIGALSKI nicht beschrieben worden. Dieser Autor beschreibt darin verschiedene merkwürdige Tatsachen: Auftreten von entzündlichen Veränderungen an den Augen, Gewichtsabnahme und Haarausfall; wir sagen, daß die Befunde merkwürdig sind, weil sie auffallend genau mit den Symptomen übereinstimmen, die man bei Vitamin A-Mangel beobachtet. Die Arbeit von DRIGALSKI, die am 25. II. 1933 erschien, fiel mit dem Beginn unserer Untersuchungen (2. III.) zusammen.

Die Hypervitaminose A, die durch ein chemisch reines, in einem unwirksamen Öl gelöstes Präparat hervorgerufen wird, hat keine Beziehungen zu den pathologischen Erscheinungen, wie sie früher bei Anwendung großer Dosen von Lebertran oder mit mehr oder weniger reinen Konzentraten dieses Vitamins beschrieben wurden, als nämlich das antirachitische D-Vitamin und das Wachstums-Vitamin A noch nicht definitiv voneinander getrennt vorlagen, und man sich auf ihre verschiedenen biologischen Wirkungen stützte, und ferner als das reine Vitamin A seinerseits noch nicht aus dem Provitamin (Carotin) oder aus den Organen, in denen es sich in großer Menge befindet, gewonnen war. In diese Zeit gehören die Arbeiten von AGDUHR, BJÖRSTROM, HOJER, TAKAHASHI, HENRIKSEN und HOGAWA.

Wir wissen heute, daß das A-Vitamin aus einer Verdoppelung des Carotinmolekuls im tierischen Gewebe entsteht, und man hat ihm daraufhin und auf Grund seiner physikalisch-chemischen und biologischen Eigenschaften folgende chemische Formel gegeben: $C_{20}H_{29}OH$



Das A-Vitamin ist farblos und erscheint in obigen Lösungen in der Farbe des Lösungsmittels im Gegensatz zu dem Provitamin oder Carotin, das eine intensiv ziegelrote Färbung aufweist. Das reine A-Vitamin (Vogan, Merck und I. G. Farben) wird aus der Leber von Fischen und gewissen Säugetieren, die sie in großen Mengen enthält, gewonnen. Das Carotin gewinnt man dagegen fast ausschließlich aus der Mohrrübe.

Die Vitaminaktivität des reinen A-Vitamins ist seiner Toxizität parallel, zumal es keine anderen Elemente enthält, auf die man diese zurückführen könnte. Außerdem geht die Inaktivierung, also das Verschwinden der antixerophthalmischen Wirkung durch Hydrierung, durch die Einwirkung von Licht, Sonne, ultravioletten Strahlen einher mit der Zerstörung der toxischen Wirkung für die Ratten. Die toxische Wirkung konnte bisher für das Carotin nicht bewiesen werden, weil es auf Grund seiner schlechten Löslichkeit immer mit großen Mengen Lösungsmittel gegeben werden muß, die für Experimente an Ratten ungeeignet sind.

II. Versuchsbedingungen.

Präparat: Wir benutzten für unsere Untersuchungen das Präparat Vogan der Firma Merck, das Vitamin A in hoher Konzentration (40000 RE. pro Kubikzentimeter) enthält. Wie man weiß, ist eine Ratteneinheit die kleinste Menge, die in der Lage ist, eine 4—8 Wochen hindurch einer Vitamin A freien Kost unterworfene, junge Ratte von 35—50 g Gewicht vor Wachstumsstillstand und Xerophthalmie zu bewahren.

Wegen der Knappheit des Präparates, das wir in Dosen von 20000 RE. täglich anzuwenden beschlossen, mußten wir den Versuch auf 2 Ratten beschränken. Trotzdem haben wir dabei eine Anzahl von Veränderungen gefunden, die, wenngleich wir natürlich beabsichtigen, unsere Versuche an einer größeren Anzahl von Versuchstieren zu wiederholen, uns gestatten zu behaupten, daß große Dosen von A-Vitamin bei der jungen Ratte ein mit anderen experimentellen, vitaminopathischen Zuständen nicht zu verwechselndes pathologisches Bild hervorrufen, das ausschließlich durch das Vitamin A hervorgerufen wird.

Tiere. Aus einem Wurfe von 8 Ratten von demselben Muttertier suchten wir 2 aus und setzten sie in einen ganz aus Glas bestehenden Stoffwechselkäfig mit Deckel und Boden aus Metall, in dem man den Urin in einer Vertiefung sammeln kann. Ein anderes Tier desselben Wurfes, also desselben Alters (26 Tage) wurde als Kontrolltier in einen ähnlichen Käfig gesetzt. Außerdem beobachteten wir die Entwicklung der übrigen 5 Tiere, die bei der Mutter verblieben. Im Gegensatz zu DRIGALSKI, der ausgewachsene Ratten von mehr als 125 g Gewicht verwendet, ziehen wir junge Tiere vor, weil sich an ihnen die Entwicklung besser beobachten läßt. Unser Interesse, junge Tiere zu untersuchen, ist um so eher verständlich, als das Vitamin A der wichtigste Faktor für das Wachstum ist.

Ernährung. Die Zuchttiere bekommen Brot mit Milch, geschälte Kartoffeln und Kohl und zeigen dabei eine gute Entwicklung, normale Fortpflanzung und vollständige Gesundheit. Der Wurf, den wir im Versuch genommen hatten, begann schon die Milch durch die übliche Nahrung zu ergänzen.

Den beiden Ratten, die das Vitamin A bekamen, wurde die übliche Kost gegeben unter Hinzufügung von Hafer- und Maismehl; die Kost wurde vom frühen Nachmittag bis zum folgenden Morgen im Käfig gelassen, damit die Tiere sie gänzlich auffressen konnten.

Am Morgen wurde dann noch hartes Brot oder Brot mit Milch und ein kleines Stückchen Kohl oder Kraut gegeben, und am Nachmittag wurde das, was inzwischen nicht verzehrt war, wieder herausgenommen. Von Vitaminen bekamen die Tiere Bierhefe als Pulver (Vitamin B 1 und B 2) und einen Tropfen Vigantol (Vitamin D) alle 4 Tage. Wenn auch die Ratten kein Vitamin C zu sich nahmen, wahrscheinlich weil sie es in ihrem Organismus synthetisieren, wurde es ihnen in Form von Kohl und Kraut, die es bekanntlich in kleinen Mengen enthalten, verabfolgt. Wasser und Nahrung wurde ad libitum gegeben.

Während des Versuches wurden die Tiere bei einer Temperatur von etwa 18—20° gehalten und diesem Punkt besondere Beachtung geschenkt, weil die Käfige ohne Schutz (Stroh oder Cellulose) wegen der großen Empfindlichkeit so kleiner Tiere gegen Abkühlung Veranlassung zu Irrtümern sein können.

Kot und Urin der Ratten mit A-Hypervitaminose sammelten wir für chemische Untersuchungen und um festzustellen, ob und wie das Vitamin A ausgeschieden wird.

Das Vitamin A wurde mit einer serologischen Pipette den Tieren in die Schnauze getraufelt; nach den ersten Verabreichungen saugten sie das Öl schon von selbst. Zwischen dem 10. und 12. Tage hörten wir mit der Vitamin A-Darreichung auf, um den Verlauf der Krankheit hinauszuziehen, zumal die Tiere schon den Eindruck machten, als ob das Ende nahe sei. Die Mehrzahl der Tiere von DRIGALSKI starb nach 5 Tagen, eine Zeit, die zur Beobachtung des ganzen Krankheitsbildes der A-Hypervitaminose unzureichend ist.

III. Klinisches Bild.

Appetit. Nach den ersten Tagen, an denen sich die Tiere noch nicht an den Wechsel der Kost gewöhnt hatten, wurde der Appetit

weder normal, sie nagten das harte Brot mit Vergnügen und fraßen die kleinen Portionen Gemüse und Brot mit Milch sowie den Zusatz von Mehl gerne. Die Verdauung war ausgezeichnet, wie aus der Stuhluntersuchung festgestellt wurde. Stuhl gut geformt, in Konsistenz und Menge normal; es fiel lediglich eine etwas hellere Färbung als einziger Unterschied gegenüber normalem Stuhl auf.

Gewicht. Die beiden Ratten wogen bei Beginn der Versuche 48 und 50 g. Das Gewicht blieb auf dieser Höhe, bis wir etwa 10 Tage die größere Menge von Vitamin A absetzten. Von da ab nahmen die Tiere etwa 7 g zu. Die Kontrolltiere wuchsen ihrem Alter entsprechend weiter. Die Kontrolltiere wiegen gegenwärtig 127 g, also mehr als das Doppelte als die mit A-Hypervitaminose.

Der Wachstumsstillstand und das Zurückbleiben im Gewicht der Tiere mit A-Hypervitaminose ist eines der Hauptsymptome. Es genügte, 3 Tage hindurch das Vitamin A abzusetzen, um die Stoffwechselsymptome, die das Bild der A-Hypervitaminose beherrschen, zu beseitigen. DRIGALSKI gibt an, daß bei seinen Ratten, die bei Beginn ungefähr 100 g wogen, das Gewicht stehen blieb oder absank. Da die Tiere ihren Appetit bewahren, bedeutet dieser Gewichtsverlust eine trophische Hemmung des Wachstums, wenn es sich um junge Tiere handelt, eine Tatsache, von der DRIGALSKI nicht spricht, der vielmehr das Stehenbleiben des Gewichts mit der Abmagerung in Zusammenhang bringt.

Wachstum.

Die Gewichtskurve zeigt am allerdeutlichsten das fast vollständige Aufhören des Wachstums bei den beiden Versuchsratten. In den ersten 3 Lebensmonaten ist die Gewichtskurve ein genügender Beweis für das Wachstum. Trotzdem muß man auch die Gesamtgröße des Tieres, die Länge und Dicke des Schwanzes, das Durchbrechen der Zähne, die Länge der Extremitäten usw. mit berücksichtigen. Die Genitalorgane geben durch ihre makroskopische Entwicklung bei den Männchen und durch die spontane Öffnung der Vagina bei den Weibchen Zeugnis von dem Alter der Tiere.

Von dem Moment an, wo die Verabreichung des A-Vitamins (20000 RE. pro Tag) beginnt, hört das Wachstum der jungen, 4 Wochen alten Ratten auf. Die Zwerghaftigkeit ist allgemein und betrifft die Gesamtgröße, den Kopf, den Schwanz und die Extremitäten, die viel kleiner sind als die der Kontrolltiere (Abb. 1).

Keinesfalls kann man den Zustand mit einfacher Schwäche verwechseln. Wenn man den Ratten rechtzeitig die übergroße Menge von Vitamin A entzieht, so beginnen sie wieder zu wachsen; das erneute Wachstum hört sofort auf, wenn man wieder 20000 RE. pro Tag gibt.

Allgemeinbefinden. Mit dem elenden Gesamteindruck der Tiere kontrastieren die Unruhe, die Erhaltung der Kraft und die normalen Bewegungen. Wenn man sie alle zusammentreibt, lassen sie sich nicht einschüchtern, wie es mit Tieren geschieht, die chronische

Abb. 1. Zwei Ratten desselben Wurfes. Links normales Tier, rechts mit A-Hypervitaminose. Deutlicher Unterschied in der Größe und Beschaffenheit des Felles.

experimentelle Läsionen haben, wie z. B. Hypervitaminose D, Avitaminose B usw. Äußerlich sind die Tiere schmutzig, und ihr Fell ist feucht. Wir wiederholen aber, daß die Ratten mit A-Hypervitaminose ihre Fähigkeit, sich lebhaft zu bewegen, behalten. Diese verschwindet erst ungefähr in der 2. Woche, wenn die hohen Vitamin A-Dosen den Widerstand des Organismus gebrochen haben.

Trophische Veränderungen der Haut. Eines der ersten Zeichen ist das strubbelige, feuchte, faltige und schmutzige Haar. Veränderungen, die sich von Tag zu Tag stärker bemerkbar machen. Am Ende der ersten Woche beginnt das Haar streckenweise auszufallen. Der Ausfall beginnt natürlich am Rande der behaarten Partien und breitet sich nach und nach unter Bildung von haarlosen Flecken aus, d. h. von der Schnauze ausgehend über die Augengegend bis zu den Ohren und von den Pfoten aufsteigend bis zum Bauch (Abb. 2). Die Haut ist an den kahlen Stellen so dünn wie Seide und hat eine sehr blasse Farbe, was auf eine starke Anämie hindeutet. Am Schwanz sieht man dasselbe und außerdem trophische Veränderungen in Form von ringförmigen Krusten.

Gang. In der ersten Woche laufen und bewegen sich die Tiere sehr gut und haben keine Schwierigkeiten in der Richtung und Regelmäßigkeit des Ganges, d. h. sie haben keine Ataxie. Von der 2. Woche ab treten jedoch bei einer Ratte spastische Veränderungen auf; sie läuft auf geschlossenen Pfoten und hinkt. Bei dem anderen Tier sieht man eine sehr starke Kontraktur der Zehen der linken Hinterpfote, so daß sie beim Laufen mit der Rückenfläche der Pfote auftritt. Wenn man zuweilen ein solches Tier zum Laufen zwingt, so sieht man auch plötzliches Hinken auf der anderen Pfote durch Lähmungskontraktur, die mit der Ruhe wieder verschwindet. Die Rigidität der Zehen der linken Hinterpfote dauert schon 10 Tage.

Abb. 2. Ratte mit Hypervitaminose A. Exophthalmus, Haarausfall.

Wir verfügen noch nicht über genügende Anhaltspunkte, um die Pathogenie dieser Veränderungen erklären zu können. Bis jetzt scheinen sie rein funktioneller Natur, und wir denken an Veränderungen des Kalkstoffwechsels, die zu beweisen wir uns bemühen.

Veränderungen an den Augen (Exophthalmus). DRIGALSKI hat zum erstenmal die Aufmerksamkeit auf die Veränderungen gelenkt, die sich nach Anwendung großer Dosen von A-Vitamin an dem Augengewebe abspielen. Es sind entzündliche Veränderungen ohne weitere Erscheinungen mit Ausnahme von Lidödem und Rötung der Schleimhäute. Nach Angaben desselben Autors treten auch Entzündungen der Nasenschleimhaut mit ziemlich starker Sekretion auf.

Bei unseren beiden Ratten konnten wir diese Feststellungen bestätigen, müssen aber hinzufügen, daß sie außerdem noch ein sehr ausgesprochenes Hervortreten des Augapfels, Exophthalmus, darboten, mit Tendenz zum Lidverschluß und vollständigem Ausfall der Wimpern (s. Abb. 2). Die Augenveränderungen machen sich am Ende der ersten Woche sehr deutlich bemerkbar, bessern sich aber, wenn das Vitamin A abgesetzt wird.

Ausscheidung des A-Vitamins. Wenn man einige Milligramm getrockneter Faeces der an Hypervitaminose A leidenden Ratten einer anderen Ratte mit Xerophthalmie und Wachstumsstillstand verabreicht, beobachtet man die sofortige Heilung des avitaminotischen Krankheitsbildes, was uns zu dem Schluß ermächtigt, daß das in großen Dosen eingenommene Vitamin A wenigstens zum Teil durch den Darm ausgeschieden wird.

Wir beabsichtigen, denselben Versuch mit dem Urin hypervitaminotischer Ratten zu machen, dessen Aussehen sich wesentlich von dem der Kontrolltiere, nämlich durch seine dunkelgelbe Farbe, unterscheidet.

In einer zweiten Arbeit werden wir unsere röntgenologischen und histologischen Untersuchungen der A-Hypervitaminose und in einer dritten die chemischen Stoffwechselveränderungen veröffentlichen.

IV. Betrachtungen über den Begriff der Hypervitaminose.

Die oben beschriebenen Veränderungen sind ausschließlich auf die Zufuhr großer Dosen von A-Vitamin zurückzuführen. Das Lösungsmittel, Sesamöl, ist nicht fähig, in den zur Anwendung gelangten Mengen irgendwelche pathologischen Veränderungen hervorzurufen. Die Pflanzenöle werden im Gegenteil bei der Rattenernährung von den Laboratorien als eine ausgezeichnete Fettquelle aufgefaßt, so daß also die Hypervitaminose A ätiologisch vollkommen auf die in übergroßer Menge verabfolgten, reinen A-Vitaminmoleküle zurückzuführen ist.

Als die Hypervitaminose D, durch bestrahltes Ergosterin hervorgerufen, entdeckt wurde, warfen einige Autoren die Frage auf, ob es sich wirklich dabei um spezifische Verände-

rungen handle, und manche von ihnen neigten dazu, allerdings ohne Beweise, als Grund das Vorhandensein von anderen Substanzen anzunehmen, die sich im Ergosterin durch die Wirkung des ultravioletten Lichtes oder durch chemische Veränderungen der Lösungsmittel gebildet haben sollten. Andere beschrieben das Vorhandensein von Handelspräparaten ohne toxische, aber mit voll erhaltener, antirachitischer Wirkung.

Heute gilt als experimentell genügend begründete Tatsache, daß die antirachitische Wirksamkeit eines reinen D-Vitaminpräparates, wenn es in zu hohen Dosen gegeben wird, eine exzessive Vitaminisierung (Hypervitaminose) des Organismus bedingt (WINDAUS und Mitarbeiter). Das Fehlen von hypervitaminotischen Erscheinungen in jenen Fällen war nur einer beträchtlichen Verdünnung des Präparates und dadurch bedingter Herabsetzung seiner antirachitischen Wirksamkeit zuzuschreiben. Bei Gleichheit massiver antirachitischer Dosen führen alle Präparate zu Hypervitaminose (GIÖRGY, LAQUEUR, SCHEUNER usw.), d. h. also, daß man, wie einer von uns gezeigt hat, nicht an der Existenz der D-Hypervitaminose zweifeln kann, die als ein physio-pathologisches Phänomen durch Übertreibung der normalen Funktionen des D-Vitamins zu betrachten ist.

Unter Berücksichtigung unserer heutigen Kenntnisse ist diese Definition aber vorerst noch nicht für die Hypervitaminose A anerkannt. Trotzdem ist der Vergleich der biologischen Symptome beider Arten nützlich: während sich bei der D-Hypervitaminose eine Vermehrung der Verknöcherung oder Hypermineralisation (frühzeitige und totale Verkalkung des Wachstumsknorpels, Hyperphosphatämie und Hypercalcämie) einstellt, die der Hypovitaminose D oder der Rachitis (Verzögerung der Ossifikation, Hypophosphatämie und Neigung zu Hypocalcämie) sich gegensätzlich verhält, findet man bei der Hypervitaminose A bei der Beobachtung des beschriebenen klinischen Bildes Zeichen einer Hyperfunktion der durch das Vitamin A beeinflußten physiologischen Mechanismen. Wir können nur vorausschicken, daß das Vitamin A den Cholesterinstoffwechsel fördert, wie einer von uns in gemeinsamen Untersuchungen mit HAMBURGER bei Gebrauch von rohem norwegischen Fischlebertran gezeigt hat. Diese Untersuchungen bedürfen jedoch der Wiederholung mit reinem A-Vitamin und werden zur Zeit durchgeführt.

Überraschenderweise haben wir festgestellt, daß die Hypervitaminose A einen Wachstumsstillstand macht, der in bezug auf Intensität und frühzeitigen Eintritt dem ähnelt, den man bei Vitamin A-arm ernährten Ratten beobachtet. Auch die entzündlichen Augenveränderungen bei der Avitaminose A treten deutlich auf, ohne daß man bisher einen Übergang in einen eitrigen Prozeß beobachtet hatte. Das klinische Bild der Hypervitaminose A läßt keine Vermehrung der Funktionen, die das Vitamin A normalerweise beherrscht, erkennen. Wenn sich das Vitamin A bei Überdosierung wie das Vitamin D verhielte, müßten wir Zeichen von Gigantismus gefunden haben. Trotzdem lenken wir nachdrücklich die Aufmerksamkeit auf die spärlichen Kenntnisse und auf den wenig genauen experimentellen Nachweis der Funktionen des A-Vitamins im tierischen Organismus. Wir müssen deswegen auch vorläufig bei der Auswertung unserer Resultate sehr vorsichtig sein. Das Wachstumsphänomen der Angriffspunkt des Vitamin A, kann sich in eine Menge von Faktoren aufteilen, die schwer zu beweisen sind. Trotzdem ist es notwendig, zunächst den Stoffwechsel zu studieren, dessen normale Funktion die trophische Basis des Wachstums bei normalen Tieren, d. h. solchen ohne kongenitalen Zwergwuchs, darstellt. Auf der anderen Seite glauben wir, daß in der Vitaminanwendung beim Menschen die Gefahr einer Hypervitaminose außerhalb der praktischen Reichweite liegt. In dieser ersten Arbeit, die den Charakter einer vorläufigen Mitteilung hat, haben wir das Vorhandensein der Hypervitaminose A beschrieben und hoffen in den folgenden Arbeiten zur Klärung der aufgerollten Probleme beitragen zu können.

V. *Schlußfolgerungen.*

Mit großen Dosen reinsten A-Vitamins lassen sich bei jungen, 3 Wochen alten Ratten trophische Hautveränderungen, Wachstumsstillstand, entzündliche Augenveränderungen und spastische Kontrakturen der Extremitäten hervorrufen, die den Tod der Tiere herbeiführen können. Wenn man rechtzeitig mit der Darreichung der übergroßen Mengen von Vitamin A aufhört, wachsen die Tiere wieder weiter, und die Augenveränderungen bessern sich.

Die Literatur befindet sich am Schluß der II. Mitteilung.

Compt. Rend. Soc. Biol. 161(1):151-154. 1967.

Effect of Semisynthetic Diets Enriched with Vitamin A on the Vaginal Cycle of the Rat

by C. Combescot, J. Demaret and D. Lemonnier

As we have already pointed out in our previous publications, the vaginal cycle of the rat can be disturbed by the administration of a semisynthetic artificial diet enriched simultaneously with lipids and proteins (1*). These initial results have led us to suspect the possible involvement of vitaminic factors.

The purpose of this paper is to describe our experiments on the effect of a balanced diet and a hyperlipidic diet, both with a high vitamin A content.

Ninety-three female rats of the Wistar C.F. strain were divided into two groups as soon as they were weaned. The 43 animals in the first group were fed a balanced semisynthetic diet containing 4.000 International Units of vitamin A per 100 grams. while the 50 animals in the second group received a semisynthetic diet during the same time and under the same conditions which was enriched with lipids (butter) and contained 4.040 International Units of vitamin A per 100 grams.* In the following, we have listed the characteristics and the exact composition of these diets (Tables I and II).

Table I Characteristics of the Diets Employed

Composition	Balanced Diet	Diets Enriched with Lipids
% Protein by weight		
% Lipids by weight		
% Glucides by weight		
Vitamin A per 100 grams		
Calories per 100 grams		

During the first eight months of the experiment, the animals living on the above diets were not subjected to any other treatment; then, in order to determine the length and the regularity of the cycles, vaginal smears were made daily for 87 days. The weight of the ingested food was recorded each day so that the amount of vitamin A absorbed by the animals could be ascer-

tained.

In the course of the experiments, each rat in Group 1 consumed an average of 14 grams of food daily, or 563 units of vitamin A. Among the 43 animals which also received a vitamin A enriched diet after weaning, but one which was balanced, only 5 exhibited normal cycles lasting 4 to 5 days; 17 others were in a state of permanent estrus, and platelets were observed almost daily in the smears; finally, in 21 rats the phases of estrus and diestrus alternated very irregularly; the average length of the cycles was often increased as well.

Hence, an increased quantity of vitamin A appears to have a harmful effect on the vaginal cycle when the diet is balanced. The behavior of the animals in Group 2 indicates that it is not the same when the diet contains a great many lipids. In fact, of the 50 rats who received a semisynthetic artificial diet since weaning and for a period of 8 months, enriched simultaneously with vitamin A and oils (butter), 41 exhibited vaginal cycles of normal length and the alternation of platelets and polynuclears in them was perfect. In six animals, the extrus was manifested in an irregular fashion while in three others the platelets were observed every day. It will be seen that the rats in this group took in an average of only 10 grams of food per day, representing 494 units of vitamin A, or 12% less than that eaten by the animals that were fed the balanced diet.

Table II - Composition of 100 grams of diet

Composition	Balanced Diet	Diet Enriched in Lipids
Casein		
Butter		
Bran		
Wheat Flour		
Vitamin mixture, L. M. (**)		
Mineral mixture (***)		

(* *)

Vitamin content of 2.2 grams of L. M. mixture;
Thiamin
Riboflavin
Pyridoxin
Niacin
Calcium Panothenate
Folic acid
Biotin
Vitamin B_{12}
Vitamin A
Vitamin D_3
DL-alpha-tocopherol
Meandione
Essential fatty acids
Paraaminobenzoic acid
Inositol
Choline chloride

(***) Composition of 1000 grams of mineral mixture (in grams):
Triosodium citrate
Tripotassium citrate
Bipotassium phosphate
Tricalcium phosphate
Magnesium carbonate
Calcium carbonate
Magnesium sulfate

We also found that the caloric content of the daily ingested ration is about 48.07 calories for the balanced diet and 52.8 calories for the hyperlipidic diet, so that the caloric content of the ration which was spontaneously absorbed each day was essentially the same for the balanced diet and the hyperlipidic diet, which confirms the result previously published by one of us (2)*.

These various observations are summarized in Table III

Table III

Key: a. Diet given
b - Average weight of the food ingested per day per animal
c - Vitamin A ingested per day per animal
d - Lipids ingested per day per animal
e - Duration of the experiment (in months)
f - Number of animals in the experiment
g - Vaginal cycles disturbed
h - Balanced diet
i - Hyperlipidic diet

Conclusions - Rats which received a semisynthetic balanced diet but one which contained 4.026 units of vitamin A per 100 grams exhibited modifications of the vaginal cycle which consisted either of an irregularity of the appearance of estrus phases or the daily presence of anuclear platelets.
A very slight reduction (12%) of this excess vitamin A combined with a very marked increase in the lipid ration suppresses these anomalies.

Thus, excess vitamin A can alter the vaginal cycle of the rat in the long run, but the disturbing role of this vitamin does not make itself felt if the diet is very rich in oils.

1*

C. Combescot, J. Demaret, F. N'Gore-Kassi and J. Tremolieres: Comptes Rendus, Soc. Biol., Vol. 159, P.965,1965

* The experimental semisynthetic diets were devised by the dietetic research department of Bichat Hospital.

*

D. Lemonnier, Doctoral Thesis, Third Cycle, Paris, 1965

(Translated by Carl Demrick Associates,Inc/WSG/t)

Combescot-'67
Bib. No. 1784

Compt. Rend. Soc. Biol. 161(1):151-154. 1967.

Endocrinologie.

Action sur le cycle vaginal de la Ratte de régimes alimentaires semi-synthétiques enrichis en vitamine A.

par C. Combescot, J. Demaret et D. Lemonnier.

Comme nous l'avons déjà signalé dans des publications antérieures, le cycle vaginal de la Ratte peut être perturbé par l'administration d'un régime semi-synthétique artificiel enrichi à la fois en lipides et

en protides (1*). Ces premiers résultats nous ont incités à envisager le rôle éventuel de facteurs vitaminiques.

Cette note se propose de relater notre expérimentation concernant l'action d'un régime équilibré et d'un régime hyperlipidique, l'un et l'autre à haute teneur en vitamine A.

Quatre-vingt-treize rats femelles de souche Wistar C.F. sont, au moment du sevrage, répartis en 2 lots. Les 43 animaux constituant le premier lot sont alimentés à l'aide d'un régime semi-synthétique équilibré comportant 4.026 U.I. de vitamine A pour 100 g, tandis que les 50 animaux du second lot reçoivent pendant le même temps et dans les mêmes conditions un régime semi-synthétique enrichi en lipides (beurre) et renfermant 4.940 U.I. de vitamine A pour 100 g (*). On trouvera ci-après les caractéristiques et la composition exacte de ces régimes (tableaux I et II).

Composition	Régime équilibré	Régime enrichi en lipides
% de protides en poids	28,5	28,5
% de lipides en poids	3,6	41,0
% de glucides en poids	49,0	11,0
Vitamine A pour 100 g	4.026 U.I.	4.940 U.I.
Calories pour 100 g	343	528

Tableau I. — Caractéristiques des régimes utilisés.

Pendant les 8 premiers mois de l'expérience, les animaux soumis à l'action des régimes précités ne subissent aucun autre traitement ; puis pendant 87 jours, afin d'apprécier la longueur et la régularité des cycles, des frottis vaginaux sont effectués quotidiennement. Le poids de nourriture ingérée est noté chaque jour ce qui permet de connaître la quantité de vitamine A absorbée par l'animal.

Au cours de l'expérience chaque ratte du 1er lot a consommé en moyenne 11 g de nourriture par jour soit 563 U.I. de vitamine A. Parmi les 43 animaux qui ont ainsi reçu depuis le sevrage une alimentation enrichie en vitamine A mais équilibrée : 5 seulement présentent des cycles normaux d'une durée de 4 à 5 jours ; 17 autres sont en état d'œstrus permanent, des placards étant observés presque quotidiennement dans les frottis ; enfin chez 21 rattes les phases d'œstrus et de diœstrus alternent très irrégulièrement, la longueur moyenne des cycles est aussi très souvent augmentée.

Un taux élevé de vitamine A paraît donc avoir une influence néfaste sur le cycle vaginal lorsque le régime alimentaire est équilibré. Le comportement des animaux du 2e lot révèle qu'il n'en est pas de même lorsque la ration alimentaire renferme une grande quantité de lipides. En effet parmi les 50 rattes qui ont reçu dès le sevrage et pendant

(1*) Ch. Combescot, J. Demaret, F. N'Gore-Kassi et J. Trémolières, *C. R. Soc. Biol.*, 1965, t. *159*, p. 965.

(*) Les régimes semi-synthétiques expérimentés ont été mis au point par l'Unité de Recherches de Diététique de l'Hôpital Bichat.

8 mois, un régime semi-synthétique artificiel enrichi à la fois en vitamine A et en graisses (beurre), 41 présentent des cycles vaginaux de longueur normale et la succession des placards et des polynucléaires dans les frottis est parfaite. Chez 6 animaux l'œstrus se manifeste d'une façon irrégulière tandis que pour 3 autres des placards sont observés chaque jour. On notera que les rattes de ce lot ont absorbé en moyenne 10 g seulement de nourriture par jour représentant 494 U.I. de vitamine A, soit 12 % de moins que celles alimentées avec le régime équilibré.

Composition	Régime équilibré	Régime enrichi en lipides
Caséine	26,5	31,8
Beurre	1,3	47,0
Farine de blé	64,0	13,0
Son	3,0	3,0
Mélange vitaminique L.M. (**)	2,2	2,2
Mélange minéral (***)	3,0	3,0

Tableau II. — Composition de 100 grammes de régime.

Nous avons par ailleurs constaté que le pouvoir calorique de la ration journalière ingérée est de 48,07 calories pour le régime équilibré et de 52.8 calories pour le régime hyperlipidique, ainsi le pouvoir calorique de la ration spontanément absorbée chaque jour est sensiblement le même qu'il s'agisse du régime équilibré ou du régime hyperlipidique, ce qui confirme les résultats déjà publiés par l'un d'entre nous (2*).

(**) Contenu en vitamines de 2,2 g de mélange L.M. :

Thiamine	1,5 mg
Riboflavine	1,5 mg
Pyridoxine	1 mg
Niacine	5 mg
Pantothénate de Ca	5 mg
Acide folique	0,2 mg
Biotine	0,1 mg
Vitamine B_{12}	0,005 mg
Vitamine A	1.000 U.I.
Vitamine D_3	1.000 U.I.
DL-α-tocophérol	30 mg
Ménadione	1 mg
Acides gras essentiels	280 mg
Acide para-amino-benzoïque	30 mg
Inositol	50 mg
Chlorure de choline	200 mg

(***) Composition de 1.000 g de mélange minéral (en g) :

Citrate trisodique	185,6
Citrate tripotassique	129
Phosphate bipotassique	286
Phosphate tricalcique	123
Carbonate de magnésium	33,3
Carbonate de calcium	218
Sulfate de magnésium	22

(2*) D. Lemonnier, Thèse de Doctorat du 3e cycle, Paris, 1965.

Ces différentes observations sont consignées dans le tableau III.

a Régime administré	b Poids moyen de nourriture ingérée par jour et par animal	c Vitamine A ingérée par jour et par animal	d Lipides ingérés par jour et par animal	e Durée de l'expérience (en mois)	f Nombre d'animaux en expérience	g Cycles vaginaux perturbés
Régime équilibré.....	14 g	563 U.I.	0,50 g	11	43	38
Régime hyperlipidique	10 g	494 U.I.	4,1 g	11	50	9

Tableau III.

Conclusion. — Des rattes, recevant dès le sevrage un régime alimentaire semi-synthétique équilibré mais contenant 4.026 U.I. de vitamine A pour 100 g, présentent des modifications du cycle vaginal consistant soit en une irrégularité dans l'apparition des phases d'œstrus, soit en la présence journalière de placards annucléés. Une réduction très faible (12 %) de cette surcharge en vitamine A conjointement à une très forte élévation de la ration lipidique supprime ces anomalies.

Ainsi, un excès de vitamine A peut à la longue altérer le cycle vaginal de la Ratte, mais le rôle perturbateur de cette vitamine ne se manifeste pas si l'alimentation est très riche en graisses.

(*Laboratoire de Zoologie et Parasitologie, Faculté de Médecine et de Pharmacie, Tours, et Unité de Recherches de Diététique, Hôpital Bichat, Paris*).

Endocrinologie.

Modifications de la sensibilité aux œstrogènes du récepteur vaginal de la Ratte castrée sous l'influence du régime alimentaire.

par C. Combescot, F. Reynoard-Brault et D. Lemonnier.

Dans le cadre de notre programme de recherches sur les lipides, nous avons montré que certains régimes alimentaires semi-synthétiques dans lesquels glucides, protides et lipides ne sont pas en proportion convenable perturbent le cycle vaginal de la Ratte. C'est ainsi qu'une alimentation très enrichie en protides et en lipides entraine,

au bout de quelques mois, d'importantes modifications dans la succession des phases d'œstrus et de diœstrus (1). Une surcharge en vitamine A peut aussi, même dans un régime équilibré, avoir des effets similaires, mais les perturbations n'apparaissent pas si le taux de lipides de la ration alimentaire est très élevé (2).

Par ailleurs l'un de nous a précédemment signalé qu'une dose de benzoate d'œstradiol, capable de maintenir en œstrus permanent des rattes castrées normalement nourries, devenait insuffisante si les animaux recevaient un régime artificiel comportant une forte proportion de graisses (3). Quel est dans ce cas le rôle de la Vitamine A ?

Cette note relate les effets sur le récepteur vaginal de la Ratte castrée d'un régime équilibré et d'un régime hyperlipidique tous deux enrichis en vitamine A.

Quatre-vingt-treize rats femelles de souche Wistar C.F. sont, au moment du sevrage, répartis en deux lots. Les 43 animaux constituant le premier lot sont alimentés à l'aide d'un régime semi-synthétique équilibré comportant 4.026 U.I. de vitamine A pour 100 g. Les 50 animaux du 2e lot reçoivent un régime semi-synthétique enrichi en lipides (beurre) et renfermant 4.940 U.I. de vitamine A pour 100 g. Les caractéristiques et la composition exacte de ces deux régimes ont été précisées dans la communication relative à « l'action sur le cycle vaginal de la Ratte de régimes alimentaires semi-synthétiques enrichis en vitamine A » (2).

Puis, dans le but d'annihiler toute production naturelle d'hormone œstrogénique, les rattes sont castrées à l'issue d'une période de 340 jours. Des frottis vaginaux journaliers sont alors pratiqués pendant une semaine afin de s'assurer de la validité de l'intervention.

Trente-huit jours après la castration, tandis que les animaux continuent à recevoir leurs régimes semi-synthétiques à l'exclusion de toute autre nourriture, débute la phase de l'expérimentation qui va permettre de tester la sensibilité aux œstrogènes du récepteur vaginal. Au cours de cette période qui va durer 58 jours, une quantité connue de benzoate d'œstradiol est injectée chaque jour à chaque animal, alors que les frottis vaginaux également quotidiens permettent de connaître la réponse du récepteur.

Le produit injecté est préparé à partir d'une solution mère obtenue en mélangeant 10 ml de « Benzo-Gynœstryl 1 » à 240 ml d'huile d'olive stérilisée et neutralisée. Cette solution mère est elle-même diluée dans de l'huile d'olive afin d'obtenir une solution huileuse de benzoate d'œstradiol renfermant 10 µg de produit actif par ml. Une telle concentration permet d'apprécier la quantité d'œstrogènes injectée à 0,25 µg près à condition d'utiliser une seringue à insuline graduée en 1/40 de ml. 1,5 µg de benzoate d'œstradiol est ainsi administré quotidiennement à chaque animal des 2 lots pendant les 7 premiers jours. A partir du 8e et jusqu'au 32e jour la quantité journalière injectée

(1) Ch. Combescot, J. Demaret, F. N'Gore-Kassi et J. Trémolières, *C. R. Soc. Biol.*, 1965, t. *159*, p. 965.

(2) Ch. Combescot, J. Demaret et D. Lemonnier, *C. R. Soc. Biol.*, 1967, t. *161*, p. 151.

(3) F. Reynouard-Brault, 84e Congrès de l'Association Française pour l'Avancement des Sciences. S.I.P. Tours, Edit., 1965, p. 89.

Cornfeld-'52
Bib. No. 1830

Pediatrics 10(1):33-39. 1952.

VITAMIN A DEFICIENCY: CASE REPORT

Unusual Manifestations in a 5½ Month Old Baby

By David Cornfeld, M.D.,* and Robert E. Cooke, M.D.
New Haven, Conn.

MOST of the signs of vitamin A deficiency noted in animals have been observed in humans. However, certain manifestations have been described either infrequently or not at all in man. Furthermore, avitaminosis A has been noted rarely in infancy because of the usual practice of feeding milk of animal origin, and the signs of deficiency at this age may be different from those noted in older children.

The following case report is that of a baby maintained on an artificial diet containing no fats of animal origin and to whom only crystalline vitamin D and ascorbic acid were regularly given as vitamin supplements. The infant presented certain signs of vitamin A deficiency which are classical in humans[1-4] and, in addition, signs hitherto observed only in experimental animals fed diets lacking vitamin A.[5-11]

Case Report

S. S. was a 5½ mo. old white female on the University Service of Grace-New Haven Community Hospital from Aug. 1 to 21, 1950. Mother had had 3 previous pregnancies. Each sibling had been slightly jaundiced after birth, but subsequent course of each was benign. Patient was born at a neighboring hospital after a pregnancy characterized by good health and excellent dietary intake. Delivery was normal and spontaneous and birth weight was 2.4 kg. About 1 hr. after delivery infant was noted to have respiratory distress and to be icteric. Blood examination revealed RBC 4.2 million/cmm. and Hgb. 15.0 gm./100 cc. Blood smear contained 410 nucleated RBC cells/100 WBC. Infant was transfused several times and seemed to improve slowly. Exact cause of the neonatal difficulty was not determined. It was not due to Rh incompatibility but may have been due to ABO isoimmunization.

Infant was fed a one-half skimmed milk and carbohydrate mixture but did not gain well, had 5 to 6 bulky stools daily and upon discharge from hospital at age of 1 mo., weighed only 2.5 kg.

At age of 5½ wk. she was readmitted because of explosive diarrhea and vomiting leading to severe dehydration. She was given parenteral fluid, blood, and penicillin and then fed a powdered protein milk mixture with a prompt recurrence of the diarrhea on resumption of milk feedings.

At age 2½ mo., after control of repeated attacks of diarrhea by starvation and parenteral alimentation, she was started on a feeding mixture containing a protein hydrolysate, vegetable fats and dextrimaltose (nutramigen®, Mead Johnson and Company) because of possibility that she might have an allergy to cow's milk. Diarrhea was controlled immediately with this synthetic feeding mixture and she began to gain weight slowly. Attempts were subsequently made to add other foods to diet but they always resulted in recurrence of diarrhea. For the following 2 mo. she was fed only nutramigen® and received the following dietary supplements daily:

(1) Crystalline vitamin D 750 u.
(2) Ascorbic acid 66 mg.
(3) Crude liver extract 1 cc. intramuscularly; stopped because of an urticarial reaction after 5 days.

From the Department of Pediatrics, Yale University School of Medicine, New Haven, Conn.
(Received for publication Aug. 17, 1951.)
* Present address: Children's Hospital, Philadelphia.

(4) Unknown amounts of folic acid given parenterally for 2 wk.
(5) Elemental iron 65 mg. in the form of ferrous sulfate.

Infant was discharged from hospital 9 days before admission to Grace-New Haven Community Hospital. During the previous 4 wk. the mother had noted increasing prominence of breasts without evidence of development of any other secondary sex characteristics. For about 2 to 3 wk. she had seen the development of a filmy opaque membrane over the bulbar conjunctivae, and for

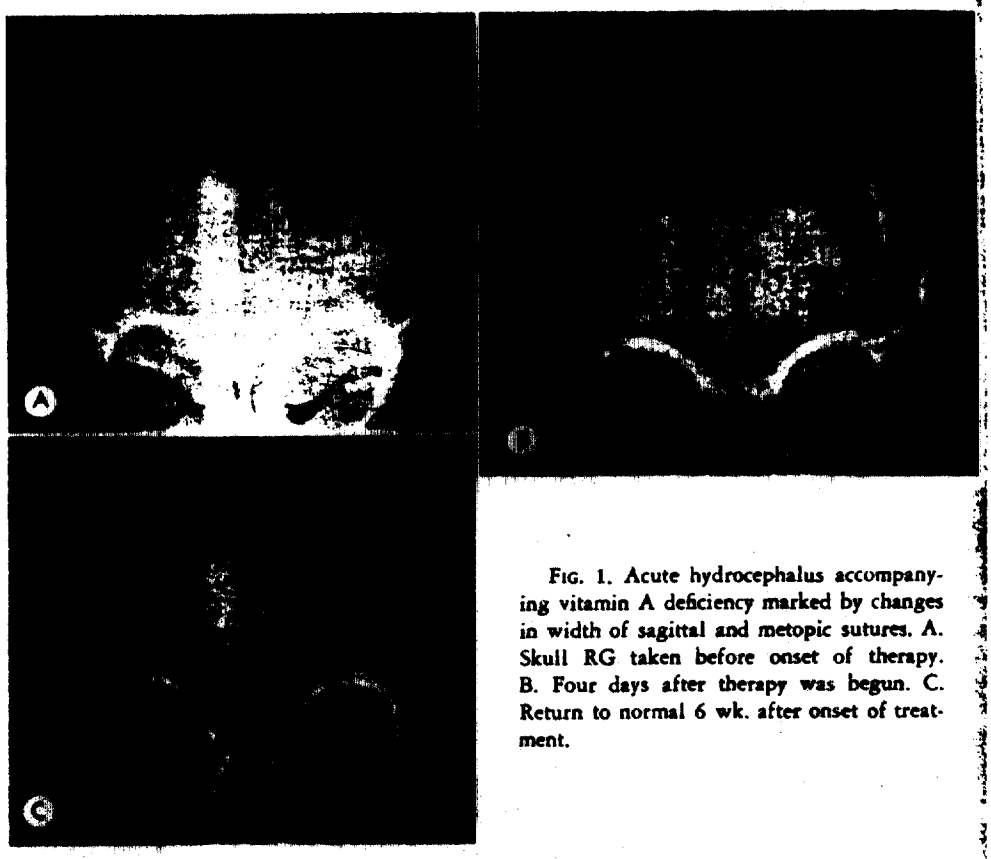

FIG. 1. Acute hydrocephalus accompanying vitamin A deficiency marked by changes in width of sagittal and metopic sutures. A. Skull RG taken before onset of therapy. B. Four days after therapy was begun. C. Return to normal 6 wk. after onset of treatment.

about 1 wk. she had noted asymmetry of face with mouth drawn to one side, as well as increasing frequency of bowel movements.

On specific questioning at the time of admission, the mother stated that the baby did not seem to be as alert as her other children, that she showed no interest in her environment and appeared to be retarded mentally as well as physically.

Physical examination: Patient was a thin, irritable, chronically ill-appearing baby, moderately dehydrated, who followed objects with her eyes but did not lift her head and would not roll over. Weight was 3.7 kg., fontanelle was slightly depressed but head contour was normal. There was facial asymmetry with evidence of a R nuclear 7th cranial nerve injury. The conjunctivae were dry and red with a grayish-white, dry and scaly opaque membrane involving bulbar conjunctivae of both eyes and spreading over the cornea. Eye changes appeared to be characteristic of xerophthalmia. There was marked enlargement of breasts of a firm, glandular rather than adipose nature. Heart and lungs were normal. Liver was palpable 4 cm. below costal margin and spleen palpable 2 cm. below costal margin. Genitalia appeared normal externally and no significant adenopathy was found. All reflexes were physiologic.

Laboratory Findings: Hemogram revealed RBC count 2.8 million/cmm., Hgb. 10.8 gm./100 cc., hematocrit 28%, with WBC count varying from 6 to 16 thousand/cmm. and a normal differential. Reticulocyte count 1.5% of total RBC count. Red blood cell fragility was normal and platelets were present in average numbers on smears of peripheral blood. Coomb's test and tests for presence of cold agglutinins were not remarkable. Bone marrow revealed presence of a normal myeloid series with slight erythroid suppression.

Urine was completely negative as were serologic tests for syphilis. Tests of liver function included a 3+ cephalin flocculation, 0.9% bromsulfalein retention in 45 min. after injection of dye (5 mg./kg. body weight), thymol turbidity 4.6 units, an alkaline phosphatase 17.4 Bodansky units; a total bilirubin 0.48 mg., an albumin of 3.3 and a globulin of 2.1 gm./100 cc.

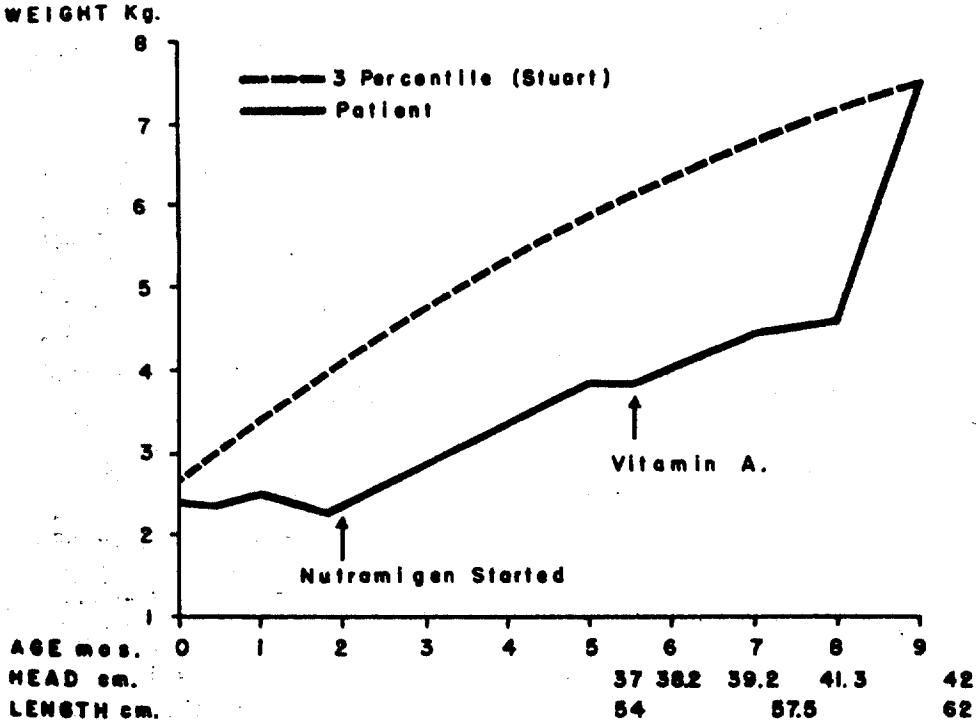

CHART 1. Growth curve demonstrating change in weight, length and head size after vitamin A therapy.

Analyses of serum revealed normal electrolyte concentrations; a galactose tolerance test and epinephrine tolerance test were within normal limits. ECG was normal and radiographs of the chest and abdomen were indeterminate. Culture of stool yielded only E. coli on several occasions and numerous stools in 1-100 dilution digested gelatin. A 4 day stool collection did not contain an excess amount of lipid. EEG was within normal limits. An attempt was made to collect a 24 hr. urine specimen for 17-ketosteroid determination but this was unsuccessful. Papanicolaou stains of vaginal secretions revealed a cornified vaginal mucosa with histologic appearance of vaginal epithelium of an adult female on 18th day of her menstrual cycle. Serum vitamin A concentration was determined by Dr. Augusta McCoord of University of Rochester School of Medicine and was reported to be 40 International U/100 cc.—a value definitely below normal level.

Course: On 3rd hospital day patient was noted to have a bulging fontanelle. Skull radiographs which had previously been normal showed increasing separation of sutures (Fig. 1). Lumbar puncture at this time revealed an increased cerebrospinal fluid pressure (280 mm. H_2O) with a normal protein concentration. Subdural taps bilaterally were negative. At this time she was given intra-

muscularly vitamin A, 100,000 u. daily for 3 days, and thereafter maintained on a multivitamin preparation. By 9th day xerophthalmia had cleared completely, breasts had diminished in size and liver and spleen were no longer considered to be enlarged. Right facial palsy began to disappear on 7th day of therapy and has cleared completely since. Bulging of fontanelle persisted, however, and an increase in head size of 2.2 cm. occurred during the following 4 wk.

Follow-up examinations have revealed a bright, healthy, alert, well-developed baby who has shown a marked increase in growth (chart 1), and is still being maintained on nutramigen® alone

TABLE 1

SIGNS OF VITAMIN A DEFICIENCY

Human Cases	Animals	Patient
Eye changes—xerosis to xerophthalmia	Xerosis to xerophthalmia	Xerophthalmia
Epithelial metaplasia	Epithelial metaplasia	Cornified vaginal epithelium
Failure of growth—degenerative changes of muscle, cessation of proliferation of epiphyseal cartilage	Failure of growth—degenerative changes of muscle, cessation of proliferation of epiphyseal cartilage	Retarded mental and physical growth
Lymphoid hypoplasia		
Diminished resistance to infection	Diminished resistance to infection	
Anemia—with atrophy of bone marrow		Anemia—resistant to iron, folic acid and liver; erythroid suppression in bone marrow
Hepatosplenomegaly—? due to hemosiderin deposition		Hepatosplenomegaly
Increased cerebrospinal fluid pressure	Increased cerebrospinal fluid pressure	Increased cerebrospinal fluid pressure
	Cranial nerve injury	Seventh cranial nerve injury
	Increased sensitivity of end-organs to estrogen effect	Gynecomastia
		Cornified vaginal epithelium

with added supplements of a multivitamin preparation and folic acid. Growth of head is now within normal limits. There is no evidence of physical or mental retardation at present time, 2½ mo. after beginning of a vitamin A therapy.

DISCUSSION

Bloch[1] first described in detail the signs and symptoms of vitamin A deficiency in humans from his studies of Danish children during World War I. In addition, subsequent clinical studies have revealed certain other changes in adults and children[2-4] (table 1). These manifestations include eye changes varying from xerosis to keratomalacia,

as well as epithelial metaplasia of the skin and mucous membranes of the trachea, bronchi, sinuses, pancreatic ducts and gastrointestinal and genitourinary tracts. Failure of growth has been described with degenerative changes of the muscle, consisting of swelling of the muscle fibers, loss of striation, and even complete degeneration, as well as changes in the bones with cessation of the proliferative activity of the epiphyseal cartilage resulting in a narrow band of atrophic cartilage. Lymphoid hypoplasia and anemia with atrophy of the bone marrow and possibly diminished resistance to infection as a result have all been noted. Diarrhea has been reported as a frequent symptom and may result from changes in the mucous membranes of the gastrointestinal tract. Hepatomegaly and splenomegaly have been reported by Sweet and K'ang[4] in approximately 50% of their cases. The pathogenesis of these lesions was not clear with the only consistent finding an increase in hemosiderin deposition. Blackfan and Wolbach[3] described the development of keratomalacia, cellular elements in the urine and hydrocephalus in a 3½ month old infant maintained on a synthetic diet because of an allergic diathesis.

Although many of the changes noted in experimental animals deficient in vitamin A resemble those found in deficient states in man, the findings are generally more widespread than those described in human cases (table 1).

Mellanby,[5,6] in young dogs, and Wolbach and Bessey,[7] in young rats, investigated the relation of vitamin A deficiency to certain neurologic disorders. The former postulated that a certain amount of vitamin A was necessary for normal bone growth. In deficiency states a controlling influence on growth is lost. The size of the bone increases (especially the cancellous bone of the skull) and causes compression of the overlying nerves with pressure necrosis and loss of function. Wolbach and Bessey postulated that neurologic lesions result when a normally growing central nervous system is compressed by bones whose rate of growth is retarded. As a result, the nerve roots herniate through the intervertebral foramina. Both theories attribute the cause of the neurologic signs to a disproportion between the size of the cranial vault and that of the central nervous system. The associated increased cerebrospinal fluid pressure which both groups of investigators observed was thought to be due to interference with absorption of the cerebrospinal fluid. Increase in cerebrospinal fluid pressure has also been produced in cows on a vitamin A-deficient diet[8] and has been reversed on adding vitamin A to the diet.

Both in castrated and noncastrated male rats, vitamin A deficiency increases the sensitivity to estrogen as measured by epithelial metaplasia and changes in the sex organs.[9] Other data[10] indicates that in rats which have a mild vitamin A deficiency the administration of growth hormone fails to stimulate growth but rather results in increased mortality, decreased length of survival, and frequently precipitates acute symptoms of vitamin A deficiency.

In the patient described, the facial palsy and the increased intracranial pressure may possibly be accounted for by the theory of Wolbach and Bessey. The rapid clearing after the institution of massive vitamin A therapy and the absence of any other likely cause make it probable that these signs were due to vitamin A deficiency. The possibility of a thiamine deficiency as a contributing factor in the neurologic disorder was considered unlikely in view of the complete absence of any signs of vitamin B_1 deficiency (cardiac enlargement, anasarca, constipation, oliguria, reflex changes).[12]

The explanation of the hypertrophy of the breasts is not as clear. It is possible, however, that the deficiency of vitamin A sensitized the mammary tissue so that it became hyper-

plastic under the stimulation of a concentration of estrogen which is usually ineffective. Again, the rapid disappearance of the gynecomastia after specific therapy is suggestive evidence as to its etiology.

The reason for the six week interval from onset of vitamin A therapy to great acceleration in weight gain remains obscure.

It is of interest that despite the fact that the infant did not increase her weight rapidly initially, she did show a prompt response in skeletal growth with addition of vitamin A to her diet (chart 1).

As a practical consideration it is worth emphasizing that serious vitamin A deficiency may occur in infants maintained on synthetic diets unless specific vitamin A therapy is included. The signs of vitamin A deficiency in young infants may resemble more closely the findings in experimental animals than would those in older patients. The rapid growth of young infants and laboratory animals may be the reason for this similarity.

Summary

A case of vitamin A deficiency in a 5½ mo. old infant is presented. The multiple manifestations of vitamin A deficiency as noted in this case clearly resemble the signs of deficiency described in experimental animals. The need for adequate supplementation of synthetic diets is re-emphasized.

Acknowledgment

The authors are indebted to Dr. William U. Gardner, Department of Anatomy, Yale University School of Medicine, for his suggestions regarding this patient.

References

1. Bloch, C. E., Clinical investigation of xerophthalmia and dystrophy in infants and young children (xerophthalmia et dystrophia alipogenetica), J. Hyg. **19**:3, 1921.
2. Eddy, W. H., and Dalldorf, G., Avitaminoses, ed. 3, Baltimore, Williams & Wilkins Company, 1944, chap. 16, p. 137.
3. Blackfan, K. D., and Wolbach, S. B., Vitamin A deficiency in infants: Clinical and pathological study, J. Pediat. **3**:679, 1933.
4. Sweet, L. K., and K'ang, N. J., Clinical and anatomic study of avitaminosis among Chinese, Am. J. Dis. Child. **50**:699, 1935.
5. Mellanby, E., Effect of bone dysplasia (overgrowth) on cranial nerves in vitamin A deficient animals, J. Physiol. **101**:408, 1943.
6. Mellanby, E., Skeletal changes affecting nervous system produced in young dogs by diets deficient in vitamin A, J. Physiol. **99**:467, 1941.
7. Wolbach, S. B., and Bessey, O. A., Vitamin A deficiency and nervous system, Arch. Path. **32**:689, 1941.
8. Moore, L. A., and Sykes, J. F., Cerebrospinal fluid pressure and avitaminosis A, Am. J. Physiol. **130**:684, 1940.
9. Hume, E. M., Burbank, R., and Korenchevsky, V., Some effects of administration of estrogens on organs of castrated and non-castrated female rats partially deprived of vitamin A, J. Path. & Bact. **49**:291, 1939.
10. Ershoff, B. H., and Deuell, H. J., Jr., Effect of growth hormone on vitamin A deficient rat, Endocrinology **36**:280, 1945.
11. Mason, K. E., Sex and Internal Secretions, ed. 2, Baltimore, Williams & Wilkins Company, 1939, chap. 3.
12. Williams, R. R., and Spies, T. D., Vitamin B_1 and Its Uses in Medicine, New York, The Macmillan Company, 1938, p. 135.

SPANISH ABSTRACT

Avitaminosis A: Caso de una niña de cinco y medio meses de edad con manifestaciones poco frecuentes

El interés de este caso de avitaminosis A depende de su edad pues la costumbre de la alimentación láctea de origen animal en esa época hace que los signos puedan ser distintos de los niños mas grandes.

Se trata de una niña a término, cuya madre se alimenta adecuadamente durante el embarazo, que se le administró un hidrolisado proteíco, grasas vegetales y dextromaltosa desde los 2½ meses de edad por padecer diarrea probablemente por alergia a la leche de vaca, suplementada con vitaminas D y C en cantidades adecuadas pero no con vitamina A. Al mes y medio de dicha dieta apreció aumento progresivo de los senos de la niña y una semana después la formación de una fina membrana, opaca, en la conjuntiva ocular, y finalmente una semana mas tarde la madre notó asimetría facial con desviación de la comisura bucal hacia un lado y evacuaciones frecuentes. Ademas, parecía estar física y mentalmente, retardada para su edad. La exploración física demostró desnutrición algo severa, fontanela deprimida, parálisis nuclear del nervio facial derecho, conjuntivas secas y rojas con una membrana blanco grisasea, seca y descamativa que las cubría totalmente y se extendía sobre la cornea, lesiones que fueron clasificadas como características de xeroftalmía. Tenía también hipertrofia glandular marcada de los senos, hígado palpable a 4 cm. abajo del reborde costal y el bazo a 2; sus órganos genitales externos eran normales y no había desarrollo de otros caracteres sexuales secundarios.

Los resultados de laboratorio comprobaron: anemia marcada, proteínas sanguíneas dentro de límites inferiores normales, presencia de mucosa vaginal cornificada por el método de tinción de Papanicolaou correspondiente a un epitelio vaginal de mujer adulta en el decimo octavo día de su ciclo menstrual y la dosificación de vitamina A en el suero sanguíneo de 40 unidades internacionales por 100 c.c.

En los días siguientes al ingreso al hospital con el cuadro clínico descrito, la fontanela presentó abombamiento y las radiografías de cráneo que habían sido normales mostraron separación de suturas y la presión del líquido cefalorraquídeo aumentó hasta 280 milímetros, momento en el cual se iniciaron 100.000 unidades de vitamina A diarias por vía intramuscular 3 días en total y se continuó con un preparado multivitamínico por vía oral. Nueve días después la xeroftalmía había desaparecido, los senos habían disminuido, y el hígado y bazo no eran palpables, la parálisis facial mejoró y solo el abombamiento de la fontanela persistió y a las 4 semanas la cabeza había aumentado 2.2. cm.

A los 2 ½ meses de iniciada la vitaminoterapia la niña estaba completamente curada, con edad mental y desarrollo físico correspondiente a su edad.

De acuerdo con los experimentos de avitaminosis A en animales, se suguiere que la hidrocefalia y la parálisis facial sean producidas por una desproporción entre el tamaño de la bóveda craneana y el del sistema nervioso central y el aumento de presión del líquido cefalorraquídeo a una interferencia en su absorción.

En cuanto a la hipertrofia mamaria es posible que una deficiencia de vitamina A sensibilice el tejido mamario y la acción de estrógenos en cantidades usualmente indiferentes determine su hipertrofia.

La rápida respuesta de estos síntomas a la vitamina A no deja lugar a duda acerca de su etiología avitaminósica.

La conclusión práctica es no olvidar nunca administrar vitamina A simultaneamente con las otras variedades de vitaminas.

789 *Howard Avenue*

Cousins-'69
Bib. No. 1849

J. Nutr. 97:409-418. 1969.

Reproduced by permission
of the copyright owner

Biochemical Constituents of the Dura Mater in Vitamin A Deficiency[1]

R. J. COUSINS,[2] H. D. EATON, J. E. ROUSSEAU, JR. AND R. C. HALL, JR.
Institute of Nutrition and Food Science, and Storrs Agricultural Experiment Station, University of Connecticut, Storrs, Connecticut

ABSTRACT Twenty-three male Holstein calves were fed a vitamin A-depletion ration, plus either 4, 12, 36 or 108 μg vitamin A/kg of live weight per day, for 16 consecutive weeks. Feed intake was not significantly different and growth was slightly less in those calves fed the 4 and 12 μg intakes. Cerebrospinal fluid (CSF) pressure of those animals fed the two lower intakes was elevated and inversely proportional to vitamin A intake. The tentorium cerebelli region of the dura mater, where arachnoid villi considered to be a site of CSF bulk absorption are abundant, was excised and analyzed. No significant differences were found in weight, dry matter or hydroxyproline content. Two distinct mucopolysaccharide-peptide complexes were isolated and separated on DEAE-Sephadex columns. The uronic acid content of both fractions was increased in dura tissue from the calves receiving the 4 and 12 μg intakes and inversely related to vitamin A intake. Total DNA content was not changed; however, total RNA and the ratio of RNA to DNA were greater in the tissue of those calves fed the two lower levels of vitamin A, and the magnitude of the response was inversely related to intake. It was postulated that the overproduction of the mucopolysaccharide moiety of the intercellular connective tissue matrix in the cerebral dura mater may be responsible either directly or indirectly for the increased resistance to bulk CSF absorption occurring in hypovitaminosis A.

Elevated cerebrospinal fluid (CSF) pressure in the bovine appears to be one of the first measurable physiological changes associated with vitamin A deficiency (1, 2). Recently, increased resistance to bulk CSF flow has been demonstrated in avitaminotic A-calves which also exhibited normal rates of CSF formation (3); therefore, the tissue(s) involved in the absorption process are of considerable interest. A route of CSF absorption occurs via valvular structures, arachnoid villi, situated in an intracranial connective tissue, the dura mater (4, 5). As demonstrated earlier in the dog (6), this tissue in the hypovitaminotic A-calf (7) appears to be considerably thickened. Therefore, the thickened dura might be responsible for the increased resistance to CSF flow. Because the metabolism of various connective tissue components has been postulated to be affected by vitamin A (8–10), this study was undertaken to ascertain whether some of the connective tissue constituents of the dura were affected in an uncomplicated deficiency of vitamin A.

EXPERIMENTAL

Animals and rations. Twenty-three male Holstein calves were obtained at 1 day of age from the State of Connecticut and private herds during September to December, 1967. Each animal was housed in an individual wood shaving-bedded tie stall where neither temperature nor light was controlled. Upon arrival, each calf received orally a gelatin capsule containing 34,000 μg vitamin A acetate and a 500 mg oblet of chlortetracycline,[3] the latter dose was repeated for 2 additional days. If a calf had not nursed its dam the first feeding consisted of 1.82 kg of colostrum from a frozen bank.

The experiment was divided into two periods, a growing period and a depletion-

Received for publication October 7 1968.

[1] Scientific Contribution no. 339, Storrs Agricultural Experiment Station, University of Connecticut, Storrs. Supported in part by National Institutes of Health Training Grant no. GM 1199 and Public Health Service Research Grant no. NB-02108 from the National Institute of Neurological Diseases and Blindness.

[2] Present address: Department of Biochemistry, University of Wisconsin, Madison, Wisconsin.

[3] Aureomycin, American Cyanamid Company, Princeton, N. J.

supplementation (comparison) period. During the initial growing period, 1 through 35 days of age (zero through experimental week 5), all animals received limited whole milk, limited calf starter plus chopped alfalfa hay and water ad libitum essentially as described previously (11).

Starting at 36 days of age and until the completion of the comparison period (experimental weeks 6 through 22) all animals received a vitamin A-depletion ration as described previously (11), at a rate calculated to produce a 7-day weight gain of 5%. In addition, the calves were randomly assigned, based on order of arrival, in sets of four (except the last three) to receive one of four intake levels of vitamin A: 4, 12, 36 or 108 μg retinol (fed as vitamin A acetate [4]) per kilogram live weight daily. Based on available data (12), the 4-μg and 12-μg intakes were considered, respectively, deficient and mildly deficient for maintenance of normal CSF pressure, and the 36- and 108-μg intakes, adequate. Calves designated to receive either 36 or 108 μg/kg live weight per day began supplementation on day 1 of their experimental week 6; those assigned to either 4 or 12 μg/kg live weight per day began supplementation only after the blood plasma vitamin A concentration of each animal had decreased to, or less than 5.0 μg/100 ml, for a 1-week period. In all cases, supplementation continued until day 6 of the last experimental week.

Observations. The amounts of feed fed and refused were weighed daily to the nearest 0.05 kg (table 1).

Each animal was weighed to the nearest 0.45 kg on day 7 of each experimental week. Height at withers was taken at the end of week 5 and week 21 of the experiment. Heart rate, respiration rate and rectal temperature were taken terminally during experimental week 21.

On the last day of week 5 and at weekly intervals through week 21, blood samples (30 ml citrated) were obtained via jugular puncture for plasma vitamin A and carotenoid determination (13).

Cisternal cerebrospinal fluid pressure was measured manometrically in the unanesthetized standing position (14, 15) once during experimental week 22.

Removal of tissues. After exsanguination, the head was skinned. Two cuts were made through both the frontal bone and adhering dura mater, lateral and 3 cm on either side of the frontal suture, from the naso-frontal suture to the occipital condyles, followed by two transverse cuts along a straight line from the base of the horn to the middle of supraorbital processes and lastly, one transversely at the occipital condyles. The defined section of bone with

[4] Dry vitamin A acetate beadlets, Type 325-m Hoffmann-LaRoche, Inc., Nutley, N. J., supplied through the generosity of Dr. R. H. Bunnell.

TABLE 1

Data for comparison period showing feed consumption and growth

	Vitamin A intake, μg/kg live wt per day				SD per calf
	4	12	36	108	
No. of animals	6	6	6	5	—
Duration of comparison period, week	16	16	16	16	—
Feed, kg/day					
Fed	2.62	2.60	2.57	2.42	0.11
Consumed	2.55	2.47	2.54	2.37	0.14
Live weight					
Initial, kg	59.9	59.4	57.6	51.7	4.3
Gain, kg/day	0.66	0.64	0.74	0.70	0.07
Height at withers					
Initial, cm	80.0	79.6	79.5	79.4	2.0
Gain, cm/day	0.149	0.147	0.153	0.163	0.025

adherent dura mater was lifted from the remainder of the skull. The tentorium cerebelli section of the dura, where arachnoid villi are abundant, was removed by cutting the dura through the suprapineal process at the tentorium apex, then posterior and outward along the base of the tentorium to, and then transversely along, the parieto-occipital suture. After lifting the tentorium cerebelli dura from the internal plate of the parietal bone, it was rinsed twice with ice-cold 0.9% sodium chloride solution, blotted dry and stored at −10° for 2 to 4 hours. Two separate homogenates (0.2 M sucrose and 0.05 M sodium acetate buffer, 0.005 M EDTA, 0.005 M cysteine·HCl, pH 5.5) were prepared from this tissue by dividing it bilaterally while still frozen, followed by homogenation[5] in a homogenizer[6] at 4° for 20 minutes.

A section of dura (3 cm by 3 cm) immediately anterior to the suprapineal process was taken for dry-matter determination. The adrenal glands, pituitary gland, kidneys, liver and brain were also removed at necropsy and weighed. Dura thickness was measured (table 5) to the nearest 0.01 mm with a precision thickness gauge.[7]

Determination of nitrogen, liver vitamin A and dry matter. Nitrogen content of the dura mater tissue was determined by the Kjeldahl method (16, 17) using an aliquot of the 0.25 M sucrose homogenate. Vitamin A concentration of the liver was measured by a modification of the Gallup-Hoefer procedure (18). Dry matter of dura and liver samples was determined by drying for 24 hours at 105° in a forced-draft oven.

Determination of hydroxyproline. Aliquots of the 0.25 M sucrose homogenate were hydrolyzed in 3 ml 12 N HCl with 2 ml of internal standard solution[8] or distilled water in sealed tubes at 124° for 24 hours. The hydroxyproline content of the hydrolysate was determined spectrophotometrically[9] by the method of Prockop and Udenfriend (19).

Determination of mucopolysaccharides. Isolation of mucopolysaccharide-peptide complexes was accomplished by the method of DeLuca and Wolf (20) utilizing the total 0.05 M acetate buffer homogenate. Separation of these complexes by ion exchange-gel filtration chromatography on columns (Sephadex Type K 15/30, 1.5 cm by 30 cm)[10] of DEAE-Sephadex (Type A-25, 40–120 μ)[11] followed the procedure of Schmidt (21). Assay of the uronic acid content of the eluted fractions followed the carbazole method of Bitter and Muir (22) using glucuronolactone[12] in benzoic acid-saturated distilled water as the standard, but utilizing the reagent volumes originally suggested by Dische (23). Identification of the eluted peaks was accomplished by comparison with elution patterns of standard hyaluronic acid and chondroitin sulfate.[13] Eluted fractions of the two peaks isolated by chromatography were concentrated by lyophilization and aliquots subjected to electrophoresis[14] (250 v, 30 minutes) on cellulose-acetate strips. Visualization was accomplished by the method of DeLuca and Wolf (20). Standard hyaluronic acid[15] and chondroitin sulfate[16] were used for identification of the separated bands.

Determination of nucleic acids. DNA and RNA contents of both dura and liver tissues were measured spectrophotometrically[17] on aliquots of the respective 0.2 M sucrose homogenates following the procedure of Schneider (24), as modified for DNA by Burton (25) and for RNA by Munro and Fleck (26). Adenosine-5′-monophosphate[18] served as the orcinol reaction standard, 1.0 mg assumed to equal 1.6 mg of calf dura mater RNA and 1.8 mg of calf liver RNA (27). Deoxyadenosine-5′-monophosphoric acid[19] served as the diphenylamine reaction standard, 1.0 mg assumed to equal 2.0 mg of calf dura mater and liver DNA (27). A deoxyadenosine-5′-monophosphoric acid[20] standard was used

[5] Cousins, R. J. 1968 Biochemical constituents of the dura mater in vitamin A deficiency. Ph.D. thesis, University of Connecticut, Storrs.
[6] Virtis model 45. Virtis Company, Inc., Gardiner, N. Y.
[7] Model 25M, B. C. Ames Company, Waltham, Mass.
[8] Crystalline *dl*-hydroxyproline, Calbiochem, Los Angeles, Calif.
[9] Beckman model DU spectrophotometer, Beckman Instruments Inc., Fullerton, Calif.
[10] Pharmacia Fine Chemicals, Inc., Piscataway, N. J.
[11] See footnote 10.
[12] K and K Laboratories, Inc., Plainview, N. Y.
[13] Sigma Chemical Company, St. Louis, Mo.
[14] Microzone System, model R-101, Beckman Instruments Inc., Fullerton, Calif.
[15] See footnote 13.
[16] See footnote 13.
[17] See footnote 9.
[18] See footnote 13.
[19] See footnote 13.
[20] See footnote 13.

to correct for the contribution of DNA to the orcinol reaction.

Statistical analyses. Data were first subjected to analysis of variance (28) to estimate the variability due to vitamin A intakes (treatments) and individual animals within vitamin A intake (error). The variability due to vitamin A intakes was further divided into three orthogonal single degree of freedom contrasts as follows: 4- and 12-μg intakes versus 36- and 108-μg intakes, 4-μg intake versus 12-μg intake and 36-μg intake versus 108-μg intake. When applicable, a broken-line regression equation (29) was calculated to estimate the vitamin A intake level below which various biochemical responses deviated in a linear manner from "normal" levels.

RESULTS

Animals. Actual age at the beginning of the comparison period, feed fed and consumed and growth are presented in table 1. Due to the method of feeding based on initial live weight, the amount fed was related to the initial weight of each group of calves. This influenced the amount of feed actually consumed, but the differences in feed consumed were not statistically significant. When feed consumed was expressed as a percentage of that fed (percentages transformed to arcsin $\sqrt{\%}$), there were no statistically significant differences at $P \leq 0.05$. Live weight increase was slightly less ($P \leq 0.05$) in those calves receiving the 4- and 12-μg intakes. Height at withers followed this same trend, but was without statistical significance.

Observations and general analyses. Average terminal heart rate equaled 10[illegible] beats/minute with a SD of 14, respiratory rate 24 cycles/minute with a SD of 7 and rectal temperature 39.08° and a SD of 0.22. No statistically significant differences among groups were found for any of these criteria. Cisternal cerebrospinal fluid pressure (table 2), as expected, was substantially higher in those calves receiving the lower vitamin A intakes. The common logarithm of CSF pressure, Y_1, was related to the log vitamin A intake in micrograms per kilogram live weight per day, X, as follows:

$$Y_1 = 1.76 - 0.6588\,(X - 1.682)\Theta, \text{ SD} \pm 0.17, \text{ where } \Theta = 0 \text{ when } X > 1.682 \text{ and } \Theta = 1 \text{ when } X \leq 1.682$$

Therefore, in this study cisternal CSF pressure was elevated at an estimated vitamin A intake of less than 48 μg/kg live weight per day. In evaluating these statistics, it is necessary to note that cisternal CSF pressure was successfully measured in only three of the six calves fed the lowest intake of vitamin A. As expected (30) high incidence of papilledema and convulsions were evident in the calves receiving the lowest intake of 4 μg (table 2).

Vitamin A concentrations in both plasma and liver are reported in table 3. Plasma concentrations increased with the common logarithm of vitamin A intake, and when the lowest intake of 4 μg was not included

TABLE 2

Effect of vitamin A intake upon cisternal cerebrospinal fluid pressure and incidence of convulsions and papilledema

	Vitamin A intake, μg/kg live wt per day				SD per calf
	4	12	36	108	
Cisternal cerebrospinal fluid pressure, mm of saline					
Actual	241 [1]	180	63 [2]	68 [3]	—
Log_{10}	2.38 [1]	2.25	1.78 [2]	1.76 [3]	0.17
No. of calves exhibiting convulsions	4	1	0	0	—
No. of calves exhibiting papilledema	6	2	0	0	—

[1] Based on three calves instead of six.
[2] Based on four calves instead of six.
[3] Based on four calves instead of five.

TABLE 3

Effect of vitamin A intake upon plasma and liver vitamin A concentration

	Vitamin A intake, μg/kg live wt per day				SD per calf
	4	12	36	108	
Plasma vitamin A, μg/100 ml					
Initial	13.0	14.6	12.2	10.6	3.6
Avg	4.2	8.6	19.3	32.3	1.9
Terminal	2.4	7.8	18.1	32.0	2.2
Liver vitamin A, μg/100 g					
Actual	2	47	932	6092	—
Log_{10}	0.03	1.63	2.95	3.78	0.34

TABLE 4

Effect of vitamin A intake upon the weight of brain, kidneys and pituitary gland

	Vitamin A intake, μg/kg live wt per day				SD per calf
	4	12	36	108	
Brain					
Total, g	315	338	343	346	22
Per unit live wt, g/kg	2.45	2.55	2.40	2.56	0.31
Kidney					
Left, g	298	263	246	226	41
Right, g	290	256	241	228	42
Total, g	588	519	487	454	80
Per unit live wt, g/kg	4.6	3.9	3.4	3.4	1.0
Pituitary, g	1.96	1.54	1.43	1.44	0.28

it increased in essentially a linear fashion. In the case of liver, the common logarithms of the vitamin A concentration followed essentially the same trends with the common logarithm of vitamin A intake as did plasma.

The left and right adrenal glands of the average calf weighed 7.8 g with a SD of 1.2, and the liver weighed 2365 g with a SD of 206. The kidneys and pituitary gland weights (table 4) were heavier in the group receiving the 4-μg intake of vitamin A. The brains in the lowest vitamin A-intake group were smaller, however, when expressed on a gram per kilogram of live weight basis; this difference was not observed. In four of the six calves of the 4-μg intake group pituitary cysts were observed, a condition reported previously (30), and were responsible for the greater average weight exhibited by this group.

Biochemical analyses of dura mater. Thickness measurements (table 5) reflected a dural thickening in the animals receiving the lowest vitamin A intake. Measurement no. 5 was suggestive of a progressive thickening process. The change in measurement no. 5, Y_5, was related to the log vitamin A intake in micrograms per kilogram live weight per day, X, as follows:

$$Y_5 = 0.33 - 0.2485\ (X - 1.442)\theta;\ SD \pm 0.18,$$
$$\text{with } \theta = 0 \text{ when } X > 1.442 \text{ and } \theta = 1 \text{ when } X \leq 1.442$$

The thickness of the dura at measurement no. 5 occurred at an estimated vitamin A intake of less than 28 μg/kg live weight per day. Sample weights of the excised tentorium cerebelli dural region averaged 6.4 g with a SD of 1.4. Only the dura tissue from the severely deficient animals fed the 4-μg intake had a slightly lower dry matter content.

Hydroxyproline concentration (milligrams per gram fresh tissue) appeared to be slightly greater in the dura tissue of the calves fed the 4-μg intake (table 5), but this difference was not of sufficient magnitude to be statistically significant. Express-

TABLE 5

Effect of vitamin A intake upon thickness, dry matter plus hydroxyproline and nitrogen concentrations of the dura mater

	Vitamin A intake, μg/kg live wt per day				SD per calf
	4	12	36	108	
Thickness, mm					
Measurement no. 1 [1]	1.22	0.54	0.44	0.66	0.32
Measurement no. 2 [2]	1.46	1.00	1.05	0.82	0.41
Measurement no. 3 [3]	0.69	0.43	0.36	0.41	0.20
Measurement no. 4 [4]	0.78	0.62	0.76	0.58	0.16
Measurement no. 5 [5]	0.54	0.42	0.34	0.33	0.18
Measurement no. 6 [6]	0.82	0.32	0.42	0.32	0.13
Dry matter, g/100 g	20.2 [7]	22.9	22.2	21.8 [8]	1.9
Hydroxyproline, mg/g	17.0	16.1	14.9	15.9	2.2
Nitrogen, mg/g	25.3	28.7	27.4	28.6	1.9

[1] Falx cerebelli, 5 cm anterior to the parieto-frontal suture on midline.
[2] Falx cerebelli, 6 cm anterior to the parieto-frontal suture on midline.
[3] Frontal bone dura, 1.5 cm anterior to the parieto-frontal suture and 1.0 cm lateral of midline.
[4] Basi-occipital bone dura, 1.0 cm anterior to posterior margin of basi-occipital bone and lateral to the bulky subdural venous system.
[5] Dura on 1st cervical vertebra, middorsally.
[6] Dura on sphenoid bone, 5 mm anterior to midline of optic foramina.
[7] Based on five calves instead of six.
[8] Based on four calves instead of five.

ing concentration on a dry matter basis accentuated this difference.

The concentrations (as micrograms uronic acid per gram fresh tissue) of total isolated mucopolysaccharides (peak I + peak II), as well as that of each separated fraction, peak I (hyaluronic acid) and peak II (chondroitin sulfate), were higher in those animals fed the 4- and 12-μg intakes of vitamin A (fig. 1). These differences in the uronic acid content of peak I, Y_3; peak II, Y_4; and the total (peaks I + II), Y_5; were related to the log vitamin A intake in micrograms per kilogram live weight per day, X, as follows:

$Y_3 = 43-31.9573\ (X-1.422)\theta$, SD $\pm$ 13, with $\theta = 0$ when $X > 1.422$ and $\theta = 1$ when $X \leq 1.422$

$Y_4 = 272-463.0879\ (X-1.222)\theta$, SD $\pm$ 63 with $\theta = 0$ when $X > 1.222$ and $\theta = 1$ when $X \leq 1.222$

$Y_5 = 316-498.2014\ (X-1.232)\theta$, SD $\pm$ 68 with $\theta = 0$ when $X > 1.232$ and $\theta = 1$ when $X \leq 1.232$

The changes in uronic acid content of peak I, peak II and total (peaks I + II) were affected at an estimated vitamin A intake of less than 26, 17 and 17 μg/kg live weight per day, respectively. When the uronic acid concentrations were calculated on a dry-matter basis, the same general trends were apparent.

Electrophoretic separation of the individual mucopolysaccharide-peptide complexes, obtained from the dura mater of one calf fed the 4-μg intake and one calf fed the 108-μg intake, appeared as individual bands. Peak I and peak II moved 2.2 cm and 3.5 cm, respectively, whereas standard hyaluronic acid and chondroitin sulfate moved 2.1 cm and 3.5 cm, respectively.

The concentration of deoxyribonucleic acid (DNA, milligrams per gram fresh tissue) was not significantly affected by vitamin A intake (fig. 2), whereas both ribonucleic acid (RNA, milligrams per gram fresh tissue) and the ratio of RNA to DNA were found to be elevated in the dural tissue of those calves receiving the two lower intakes of vitamin A. The differences in RNA, Y_6; and RNA/DNA, Y_7; were related to the log of vitamin A intake in micrograms per kilogram live weight per day, X, as follows:

$Y_6 = 1.14-0.2557\ (X-1.552)\theta$, SD $\pm$ 0.28, with $\theta = 0$ when $X > 1.552$ and $\theta = 1$ when $X \leq 1.552$

$Y_7 = 1.78-0.3347\ (X-1.712)\theta$, SD $\pm$ 0.23, with $\theta = 0$ when $X > 1.712$ and $\theta = 1$ when $X \leq 1.712$

The elevation in RNA content occurred at an estimated vitamin A intake of less than

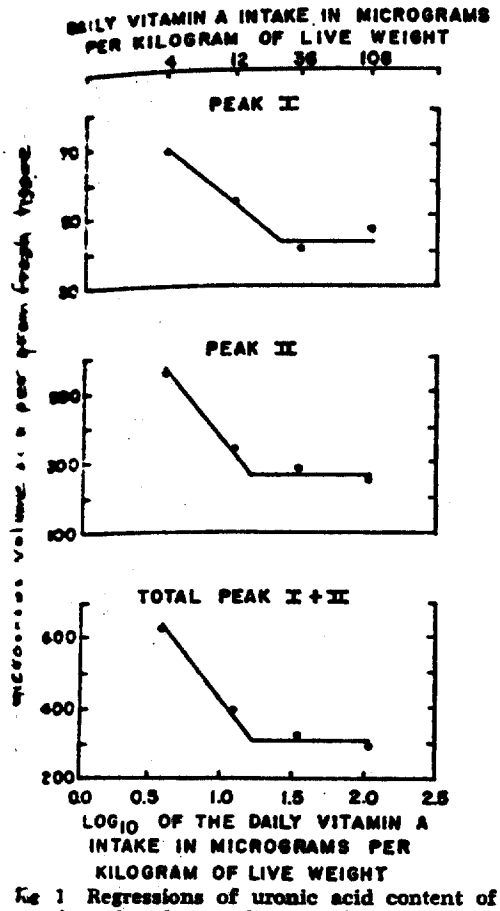

Fig. 1 Regressions of uronic acid content of mucopolysaccharide-peptide complexes isolated from the dura mater on vitamin A intake.

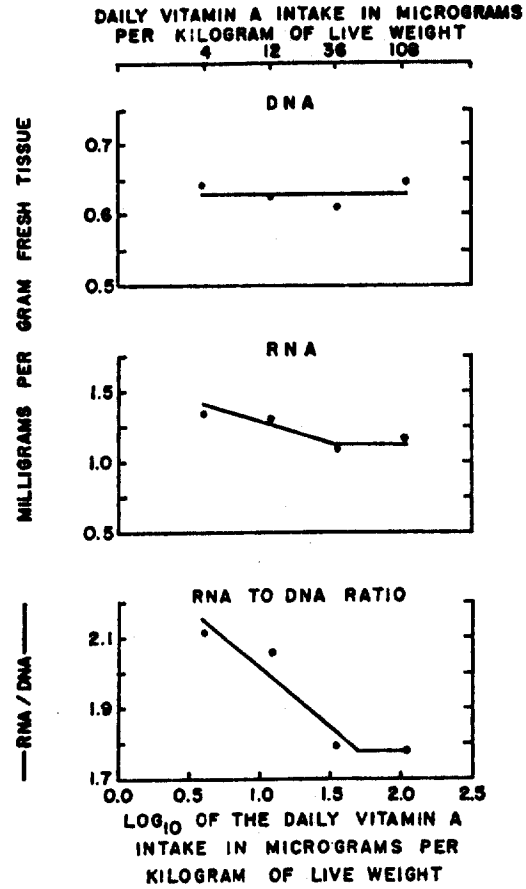

Fig. 2 Regressions on DNA and RNA content plus the RNA-to-DNA ratio of the dura mater on vitamin A intake.

μg/kg live weight per day; the increase in RNA DNA occurred at an estimated vitamin A intake of less than 52 μg/kg live weight per day.

No differences in dura mater total nitrogen content (milligrams per gram fresh tissue) were observed among the treatment groups (table 5).

When the concentration of DNA was calculated on a dry-matter basis, the dura mater from the most deficient calves, 4-μg intake, contained greater DNA, but this was not of sufficient magnitude to be of statistical significance at $P \leq 0.05$. When RNA was expressed on a dry-matter basis, the same general trend as found for the

TABLE 6

Effect of vitamin A intake upon the dry matter and nucleic acid content of the liver

	Vitamin A intake, μg/kg live wt per day				SD per calf
	4	12	36	108	
Dry matter, g/100 g	25.4	27.5	27.6	27.4	1.6
Ribonucleic acid, mg/g	5.62	5.38	5.38	5.33	0.37
Deoxyribonucleic acid, mg/g	3.40	3.07	2.95	3.02	0.42
Ribonucleic acid-to-deoxyribonucleic acid ratio	1.70	1.76	1.82	1.79	0.20

fresh tissue was present. Dura mater nitrogen content per unit of dry matter was elevated in the tissues of the calves fed the lowest vitamin A intake.

Biochemical analyses of liver. Liver dry matter of those calves fed the 4-μg intake was slightly less; RNA (milligrams per gram fresh tissue) slightly greater; DNA (milligrams per gram fresh tissue) slightly greater; and the ratio of RNA to DNA slightly less (table 6). Only the differences in the dry matter and RNA content per unit dry matter between the 4- and 12-μg intake groups were significant at $P \leq 0.05$.

DISCUSSION

The results on dura mater composition (table 5 and figs. 1 and 2) provide evidence that metabolic changes occur in dura mater connective tissue during vitamin A deficiency. The collagen component of the intercellular matrix, as measured by hydroxyproline content, was found not to be significantly changed. This is in agreement with Havivi and Wolf (10) who were unable to find a difference in epiphyseal bone-collagen hydroxyproline concentration in the vitamin A-deficient chick. Moreover, since it has been shown that peptide-bound proline hydroxylation necessary for collagen formation is ascorbic acid-dependent (31), the present data and those previously obtained on whole blood and plasma ascorbic acid concentrations in vitamin A-deficient calves (32) indirectly support the recent suggestion of Zile and DeLuca (33) that ascorbic acid biosynthesis is not affected by vitamin A deficiency.

In contrast to hydroxyproline content of the dura mater, there was a marked increase in mucopolysaccharide concentration of this tissue in the vitamin A-deficient calves fed the 4- and 12-μg vitamin A intakes, and the increase was related to the extent of the deficiency. Since this increase occurred in both isolated mucopolysaccharide-peptide fractions, which were tentatively identified as hyaluronic acid (peak I) and chondroitin sulfate (peak II) (fig. 1), it appears that the degree of enzymatic sulfation of polysaccharide precursors is probably not altered in the deficient animals, although this cannot be directly established from these data. The estimates establishing the intake level below which this increase occurs support the hypothesis that this change occurs relatively early in vitamin A deficiency; and that the magnitude of the change parallels the degree of the deficiency.

The above results are in agreement with those of Frape et al. (34) who reported increased "SO_4" uptake into bone, cartilage and lung tissue in avitaminotic A pigs; of DeLuca and Wolf (20) who found an increase in mucopolysaccharide content of lung tissue from pair-fed deficient rats; and of Havivi and Wolf (10) who reported a higher uronic acid content of epiphyseal bone matrix from deficient chicks. The latter report is of interest, since cerebral dura mater serves as the periosteum for at least a portion of the frontal bone (35). Hence, the excessive mucopolysaccharide content observed in the present study could well be the first step in altered cranial bone formation observed in avitaminotic A-calves (7).

The agreement of the present study with the above reports provides fairly firm biochemical evidence for a tissue change involving the mucopolysaccharide moiety. More latitude is necessary, however, to explain the elevated CSF pressure in relation to this tissue change. The model for connective tissue structure proposed by Mathews (36) is compatible with an accelerated rate of mucopolysaccharide synthesis. Mucopolysaccharide side chains extending from a central mucoprotein core impart a high degree of interaction with collagen fibrils and are responsible for maintaining intercellular matrix stability. It is easy to visualize how changes in the mucopolysaccharide moiety could drastically alter the structure, and hence, the properties of this highly ordered tissue matrix. Since arachnoid villi which are responsible for considerable CSF bulk absorption are embedded within the dura mater (4, 5), a modification of the macromolecular structure of the dura could indirectly alter the physiological function of these villi, which could in turn be responsible for the elevated CSF pressure observed in avitaminosis A.

A second possible explanation of the impaired CSF bulk absorption would involve the structural integrity of arachnoid villi. Since the arachnoid granulations, aggrega-

tions of individual villi, are believed rich in mucopolysaccharides (37), any change in these macromolecules could directly affect the integrity of the villi and thereby result in decreased functional ability. It needs to be noted here that Wolbach (38) reported herniations of the cerebellum and cerebrum into dural sinuses at sites of arachnoid villi, and attributed this to faulty connective tissue or bone growth. Lastly, the cells lining these structures, particularly those of the tubules (5), could also be modified and result in reduced clearance of CSF into the venous system.

The DNA content of the dura was very low as expected since all connective tissues are characteristically hypocellular. Moreover, the concentrations of DNA were not significantly different among vitamin A-intake levels employed in this study, providing evidence that the actual cell content was not affected by deficient intakes of the vitamin. In contrast to DNA, there was a progressive increase in RNA concentration with decreasing vitamin A intakes below an estimated intake of 36 μg, and consequently the RNA-to-DNA ratio (fig. 2) also increased. Since none of these criteria, when expressed on a fresh tissue basis, were significantly altered in the liver (table 6), some specificity of action of vitamin A on RNA synthesis in the dura may be present.

Though the response of RNA content may involve all major types of RNA, selective effects could not be detected by the methods employed, and would necessitate a different type of experiment. It is of interest that in 12 hypervitaminotic A calves, the ratio of RNA to DNA in dural tissue was less than in 12 control calves.[21] Although the significance of the nucleic acid change found in the present study is not known at present, one is reminded of the postulated regulatory function for vitamin A proposed by Olson (39).

ACKNOWLEDGMENTS

The authors are grateful to H. I. Frier and T. Dwyer for technical assistance; to Drs. A. M. Galina and K. C. Hayes for the dura measurements and clinical advice; to Dr. G. Wolf of the Massachusetts Institute of Technology for advice on the mucopolysaccharide isolation; to B. A. Donohue and T. Watts, Sr. for the care and feeding of the calves; to Dr. J. J. Lucas for advice on the regression computations; and to Mrs. Mae Miller for assistance in preparation of the manuscript.

LITERATURE CITED

1. Moore, L. A., and J. F. Sykes 1940 Cerebrospinal fluid pressure and vitamin A deficiency. Amer. J. Physiol., *130:* 684.
2. Eaton, H. D., J. E. Rousseau, Jr., C. G. Woelfel, M. C. Calhoun, S. W. Nielsen and J. J. Lucas 1964 A reevaluation of the minimum carotene requirement of Holstein male calves based upon elevated cerebrospinal fluid pressure. Univ. of Conn. Agr. Exp. Sta., Storrs, Bull. no. 383.
3. Calhoun, M. C., H. D. Hurt, H. D. Eaton, J. E. Rousseau, Jr. and R. C. Hall, Jr. 1967 Rates of formation and absorption of cerebrospinal fluid in bovine hypovitaminosis A. J. Dairy Sci., *50:* 1486.
4. Welch, K., and M. Pollay 1961 Perfusion of particles through arachnoid villi of the monkey. Amer. J. Physiol., *201:* 651.
5. Davson, H. 1967 Physiology of the Cerebrospinal Fluid. Little Brown and Company, Boston, p. 21.
6. Mellanby, E. 1950 A Story of Nutritional Research. Williams and Wilkins Company, Baltimore.
7. Hayes, K. C., S. W. Nielsen and H. D. Eaton 1968 Pathogenesis of the optic nerve lesion in vitamin A-deficient calves. Arch. Ophthalmol., *80:* 777.
8. Dingle, J. T., and J. A. Lucy 1965 Vitamin A, carotenoids and cell function. Biol. Rev., *40:* 422.
9. Danes, B. S., and A. G. Bearn 1966 Effect of retinol (vitamin A alcohol) on cellular mucopolysaccharides in cultured human skin fibroblasts. J. Exp. Med., *124:* 1181.
10. Havivi, E., and G. Wolf 1967 Vitamin A, sulfation and bone growth in the chick. J. Nutr., *92:* 467.
11. Calhoun, M. C., H. D. Hurt, H. D. Eaton, J. E. Rousseau, Jr. and R. C. Hall, Jr. 1967 Rates of formation and absorption of cerebrospinal fluid in Holstein male calves. Univ. of Conn. Agr. Exp. Sta., Storrs, Bull. no. 401.
12. Rousseau, J. E., Jr., H. D. Eaton, C. F. Helmboldt, E. L. Jungherr, S. A. Robrish, G. Beall and L. A. Moore 1954 Relative value of carotene from alfalfa and vitamin A from a dry carrier fed at minimum levels to Holstein calves. J. Dairy Sci., *37:* 829.
13. Kimble, M. S. 1939 The photocolorimetric determination of vitamin A and carotene in human plasma. J. Lab. Clin. Med., *24:* 1055.
14. Sykes, J. F., and L. A. Moore 1942 The normal cerebrospinal fluid pressure and a method for its determination in cattle. Amer. J. Vet. Res., *3:* 364.

[21] Cousins, R. J., H. D. Eaton and J. E. Rousseau, Jr., unpublished results.

15. Dehority, B. A., D. G. Hazzard, H. D. Eaton, A. P. Grifo, Jr., J. E. Rousseau, Jr., C. F. Helmboldt, E. L. Jungherr and D. G. Gosslee 1960 Some biochemical constituents in serum, cerebrospinal fluid and aqueous humor of vitamin A deficient Holstein calves. J. Dairy Sci., *43:* 630.
16. Association of Official Agricultural Chemists 1965 Official Methods of Analysis, ed. 10. Washington, D.C.
17. Peters, J. P., and D. D. Van Slyke 1956 Quantitative Clinical Chemistry, vol. 2. Williams and Wilkins Company, Baltimore.
18. Bunnell, R. H., J. E. Rousseau, Jr., H. D. Eaton and G. Beall 1954 Estimation of vitamin A and carotenoids in calf liver. J. Dairy Sci., *37:* 1473.
19. Prockop, D. J., and S. Udenfriend 1960 A specific method for the analysis of hydroxyproline in tissues and urine. Anal. Biochem., *1:* 228.
20. DeLuca, L., and G. Wolf 1968 The mucopolysaccharides of lung tissue and the effect of vitamin A thereon. Arch. Biochem. Biophys., *123:* 1.
21. Schmidt, M. 1962 Fractionation of acid mucopolysaccharides on DEAE-Sephadex anion exchanger. Biochim. Biophys. Acta, *63:* 364.
22. Bitter, T., and H. Muir 1962 A modified uronic acid carbazole reaction. Anal. Biochem., *4:* 330.
23. Dische, Z. 1947 A new specific color reaction of hexuronic acids. J. Biol. Chem., *167:* 189.
24. Schneider, W. C. 1957 Determination of nucleic acids in tissues by pentose analysis. In: Methods in Enzymology, vol. 3, eds., S. Colowick and N. O. Kaplan. Academic Press, New York, p. 680.
25. Burton, K. 1956 A study of the conditions and mechanism of the diphenylamine reaction for the colorimetric estimation of deoxyribonucleic acid. Biochem. J., *62:* 315.
26. Munro, H. N., and A. Fleck 1966 The determination of nucleic acids. In: Methods of Biochemical Analysis, vol. 14, ed., D. Glick. Interscience Publishers, New York, p. 113.
27. Chargaff, E., and J. N. Davidson 1955 The Nucleic Acids. Academic Press, New York.
28. Steel, R. C. D., and J. H. Torrie 1960 Principles and Procedures of Statistics. McGraw-Hill Book Company, New York.
29. Eaton, H. D., J. E. Rousseau, Jr. and H. W Norton 1961 Association between cerebrospinal fluid pressure and plasma vitamin A concentration of Holstein calves fed fixed intakes of carotene. J. Dairy Sci., *44:* 1368.
30. Mills, J. H. L., S. W. Nielsen, J. E. Rousseau, Jr., C. G. Woelfel and H. D. Eaton 19[illegible] Experimental pathology of dairy calves ingesting one-third the daily requirement of carotene. Acta Vet. Scand., *8:* 324.
31. Jeffery, J. J., and G. R. Mortin 1966 The role of ascorbic acid in the biosynthesis of collagen. Biochim. Biophys. Acta, *121:* 281.
32. Eaton, H. D., C. F. Helmboldt, J. E. Avampato, E. L. Jungherr and K. L. Dolge 19[illegible] Blood levels of ascorbic acid and vitamin A during vitamin A depletion and effect of administration of ascorbic acid during terminal vitamin A depletion in the dairy cow. J. Dairy Sci., *35:* 607.
33. Zile, M., and H. F. DeLuca 1968 Retinoic acid: Some aspects of growth promoting activity in the albino rat. J. Nutr., *94:* 302.
34. Frape, D. L., R. S. Allen, V. C. Speer, V. W Hays and D V. Catron 1959 Relationship of vitamin A to ^{35}S metabolism in the baby pig. J. Nutr., *68:* 189.
35. Ham, A. W. 1953 Histology, ed. 2. J. B. Lippincott Company, Philadelphia, p. 379.
36. Mathews, M. B. 1965 The interaction of collagen and acid mucopolysaccharides. Biochem. J., *96:* 710.
37. Friede, R. L. 1966 Topographic Brain Chemistry. Academic Press, New York, p. 447.
38. Wolbach, S. B. 1954 Effects of vitamin A deficiency and hypervitaminosis A in animals. In: The Vitamins, vol. 1, eds., W. H. Sebrell, Jr., and R. S. Harris. Academic Press, New York, p. 119.
39. Olson, R. E. 1965 The regulatory functions of the fat-soluble vitamins. Can. J. Biochem. *43:* 1565.

Brit. Med. J. (4329):435-436. 1942.

Coward-'42
Bib. No. 1876

Reproduced by permission of the copyright owner

THE RELATIVE NEEDS OF YOUNG MALE AND FEMALE RATS FOR VITAMIN A

BY

KATHARINE H. COWARD, D.Sc.Lond.

(*From the College of the Pharmaceutical Society of Great Britain*)

It has been shown (Coward *et al.*, 1931) that if young rats were given a diet deficient in vitamin A until their reserves of that factor had been exhausted, and were then given relatively small doses of vitamin A, the response of the male rats (increase in weight in five weeks) was less than that of the female rats. When the dose of vitamin A given was rather larger the responses of the two sexes were equal, and when larger still the response of the male rats was greater than that of the female rats. This was depicted graphically by drawing the curves of response of male and female rats respectively to five graded doses of cod-liver oil, the average increase in weight of each group of rats being plotted against the logarithm to base 10 of the dose of oil given. The curve of response of the male rats was steeper than that of the female rats, and the two lines crossed at the point where the increase in weight was 13.7 gm. and the daily dose of the sample of cod-liver oil given was about 1.2 mg. (equal to about 1.8 international units of vitamin A, as determined later). The smaller response of the male rats to low doses of vitamin A indicated that the male rat was more sensitive to a shortage of this factor than was the female rat.

All the tests of low doses of vitamin A which had up to that time been carried out in our laboratory were then examined for the number of male and female rats that had died in each group, every member of any one group having received the same dose of cod-liver oil. It was found that, in 23 groups, 57 out of 288 male rats and 37 out of 277 female rats had died. Dr. J. H. Gaddum supplied a calculation based on the numbers of groups in which more males than females and more females than males, respectively, had died. The numbers were 17 and 5, and 1 in which the mortalities of male and female rats were equal. His value of χ^2 was 6.26. The table of χ^2 shows that the probability of this value of χ^2 being due to chance is between 1/50 and 1/100 (Fisher and Yates, 1938). Hence it was concluded that there was a strong probability that young male rats are more sensitive to a shortage of vitamin A than young female rats.

Since the publication of that paper many more determinations of vitamin A have been carried out in this laboratory by the same method, and it seemed worth while to examine some of our recent work to obtain more information on this point. It happened that we had used a particular sample of cod-liver oil as a standard of reference for determining the vitamin A (carotene) content of a large number of fruits and vegetables, and the international standard of reference (carotene) for determining the vitamin A content of a large number of substances containing vitamin A of animal origin. Thus it was possible not only to obtain the further information required on the relative needs of male and female rats for vitamin A but also, by separating the groups given vitamin A of animal origin from those given vitamin A (β-carotene) of vegetable origin, to see whether this difference in response between male and female rats applied to both sources of the vitamin.

Calculations of tests which fell naturally into four groups have been made. They are summarized in Table I and also put out separately, for several results all supporting the same conclusion are often more convincing than one total result.

TABLE I.—*Relative Needs of Male and Female Rats for Vitamin A*

Tests	All Groups			Groups given Vitamin A of Animal Origin			Groups given Vitamin A (β-carotene) of Vegetable Origin		
	No. of Groups in which died:			No. of Groups in which died:			No. of Groups in which died:		
	More Males	More Females	χ^2	More Males	More Females	χ^2	More Males	More Females	χ^2
Fruits and vegetables from Ceylon compared with a sample of cod-liver oil (Z) as standard	78·0	46·0	8·26	29·5	16·5	3·67	48·5	29·5	4·63
Routine tests carried out under war conditions, mostly vegetable products compared with inter. standard	27·5	7·5	11·43	9·0	3·0	3·0	18·5	4·5	9·14
Research tests carried out under war conditions, mostly vegetable products compared with inter. standard	57·0	7·0	39·19	12·0	1·0	8·31	45·0	6·0	29·82
The last 200 groups in tests carried out before the war, mostly animal products compared with inter. standard	137·5	62·5	28·13	91·5	41·5	18·80	47·0	20·0	10·88
For all tests	300·0	123·0	74·06	142·0	62·0	31·37	159·0	60·0	44·75

The significance of the values of χ^2 found above may be judged from the following figures quoted from the χ^2 table. The probability that the difference between males and females in their need for vitamin A is due to chance is 0.10 when $\chi^2=2.706$; 0.05 when $\chi^2=3.841$; 0.02 when $\chi^2=5.412$; 0.01 when $\chi^2=6.635$; 0.001 when $\chi^2=10.027$.

A probability of 0.10 (or more) of the result being due to chance is generally considered a pretty good one, and no significance would be attached to a result giving this probability. A probability of 0.01 to 0.05 of the result being due to chance is not good, and the result would be accepted as fairly dependable. A probability of 0.001 of the result being due to chance is almost *nil*, and the result would be accepted as almost certainty. Most of our separate values are highly significant, and the values of the totals leave no room at all for doubt of the fact that young male rats are more sensitive to a shortage of vitamin A than young female rats. The further analysis of the results shows also the same difference between male and female behaviour whether the vitamin A is of animal or of vegetable origin. Hence young male and female rats seem to have equal ability to convert carotene into vitamin A.

TABLE II.—*Deaths under 1 Year per 1,000 Live Births*

Period	Deaths		Ratio M/F	Period	Deaths		Ratio M/F
	Males	Females			Males	Females	
1891	164	133	1·23	1915	123	96	1·28
2	162	132	1·23	6	102	80	1·28
3	173	143	1·21	7	108	85	1·27
4	150	124	1·21	8	108	86	1·26
5	176	144	1·22	9	100	78	1·28
6	161	134	1·20	1920	90	69	1·30
7	170	141	1·21	1	93	72	1·25
8	175	145	1·21	2	87	66	1·32
9	177	148	1·20	3	78	60	1·30
1900	169	139	1·22	4	85	65	1·31
1	166	136	1·22	5	84	66	1·27
2	147	118	1·25	6	79	61	1·30
3	145	118	1·23	7	79	60	1·32
4	159	131	1·21	8	74	56	1·32
5	141	115	1·23	9	83	65	1·28
6	145	120	1·21	1930	68	51	1·33
7	130	104	1·25	1	75	57	1·32
8	133	107	1·24	2	73	56	1·30
9	120	97	1·24	3	72	55	1·31
1910	116	94	1·23	4	65	51	1·28
1	142	117	1·21	5	64	50	1·28
2	106	84	1·26	6	66	50	1·32
3	120	96	1·25	7	65	50	1·30
4	116	93	1·25	8	60	46	1·30

It is tempting to speculate on the possibility that a low intake of vitamin A by human babies may have a greater influence on male infants than on female infants in their mortality from, say, 0 to 1 year of age. The numbers of deaths under 1 year of age per 1,000 live births of male and female infants published by the Registrar-General are shown in Table II together with the ratio male/female deaths for each year from 1891 to 1938. The numbers of deaths per 1,000 live births have fallen dramatically in that time for both males and females, and this fall must have been due to the influence of a very great many factors. One point, however, is of particular interest: the ratio of male/female deaths, already high in the 1890's, rose steadily from about 1900 to 1920, since when it has remained nearly constant. Assuming that all forms of extra care lavished on infants in the last fifty years have been given to male and female infants equally, is it possible (*a*) that the extra cod-liver oil given since prenatal and child clinics have been operating has been sufficient to bring about some improvement only, which, according to the rats, would be greater in the females than in the males; and (*b*) that by giving abundance of vitamin A, which would mean more cod-liver oil for boys than girls, the ratio of male/female deaths would be reduced to unity?

REFERENCES

Coward, K. H., Key, K. M., Dyer, F. J., and Morgan, B. G. E. (1931). *Biochem. J.*, 25, 551.
Fisher, R. A., and Yates, F. (1938). *Statistical Tables for Biological, Agricultural and Medical Research*, Oliver and Boyd, London.

Coward-'66
Bib. No. 1878

J. Repro. Fert. 12:309-317. 1966.

EFFECTS OF HORMONES ON REPRODUCTION IN RATS FED A DIET DEFICIENT IN RETINOL (VITAMIN A ALCOHOL) BUT CONTAINING METHYL RETINOATE (VITAMIN A ACID METHYL ESTER)

W. A. COWARD, J. McC. HOWELL, G. A. J. PITT AND J. N. THOMPSON

Departments of Biochemistry and Veterinary Pathology, University of Liverpool

(*Received* 18*th January* 1966)

Summary. The observations of Thompson, Howell & Pitt (1964), that male and female rats maintained on diet deficient in vitamin A but containing retinoic acid (vitamin A acid, see page 310) are unable to reproduce, have been confirmed. The development of the testicular lesions in male rats was not prevented by injections of FSH or testosterone propionate, and injections of oestrone and progesterone, alone or in combination, did not prevent resorptions in pregnant females. Small amounts of retinyl acetate (vitamin A acetate) prevented the development of reproductive lesions in both males and females. It seems unlikely that the failure of retinoic acid to support normal reproduction in the rat can be explained in terms of a known endocrine insufficiency.

INTRODUCTION

When rats reared on a vitamin A-free diet are given supplements of retinoic acid they do not suffer the overt and fatal effects of vitamin A deficiency: they grow well, have a normal life-span and appear to be healthy (Arens & van Dorp, 1946; Sharman, 1949; Redfearn, 1960). Retinoic acid, however, unlike the true vitamin, retinol (vitamin A alcohol) does not maintain vision (Dowling & Wald, 1960) or reproduction (Thompson, Howell & Pitt, 1961a, b, 1964; Juneja, Murthy & Ganguly, 1964; High, Moore, Collins & Frazier, 1964). It has been suggested that the lesions seen in the reproductive tract of rats maintained on a diet deficient in retinol but containing retinoic acid represent a specific effect of vitamin A deficiency on these structures (Howell, Thompson & Pitt, 1963, 1964).

Male rats maintained on vitamin A free diets containing retinoic acid develop testicular lesions 5 to 8 weeks after weaning, that is at a time when their body reserves of retinol and retinyl esters are exhausted. Spermatogenesis ceases, the cells of the seminiferous epithelium are sloughed and eventually the lumen of the tubules becomes obliterated by Sertoli cells (Howell *et al.*, 1963). Female rats reared on a similar diet have regular oestrous cycles and mate with normal males, but pregnancy is invariably terminated in foetal resorption. The

earliest detectable lesion was necrosis of cells at the edge of the placenta during the 15th or 16th day of pregnancy (Howell *et al.*, 1964).

Although the inability of the acid to function in reproduction has, as yet, no certain biochemical explanation, the good growth, the longevity and absence of metaplastic change in epithelia in animals fed retinoic acid permit investigation on the uncomplicated reproductive disorders. In completely deficient animals untreated with retinoic acid, other factors such as inanition and infection have complicated the lesions (Mason, 1939).

This paper reports experiments in which steroid and pituitary sex hormones were administered to rats fed a vitamin A-free diet supplemented with methyl retinoate. The results of these experiments indicate that the reproductive failure in animals maintained with methyl retinoate is unlikely to be a secondary manifestation of an abnormality in the endocrine system.

MATERIALS AND METHODS

Animals, diets and experimental techniques

Albino Sprague-Dawley rats were bought as 21-day-old weanlings weighing 40 to 60 g. They were fed from the outset the retinol-free Diet II described previously (Thompson *et al.*, 1964) either unsupplemented or containing methyl retinoate (3 μg/g diet) as indicated in the text. Supplements of retinyl acetate were dissolved in 0·2 ml arachis oil and were administered orally from a pipette; crystalline steroid hormones were injected subcutaneously in 0·2 ml arachis oil, and FSH (purchased from Nutritional Biochemical Corporation, Cleveland 28, Ohio) was injected subcutaneously in 0·2 ml physiological saline.

Female rats were mated with males of the same strain that had been reared on a normal laboratory diet. Vaginal smears were obtained daily throughout the mating periods and subsequent pregnancies. The first day of pregnancy was taken to be the day on which spermatozoa were found in the vaginal smear.

During mating three female rats were placed with each male. After individual females had mated they were removed from the male and caged in groups of three or four. If, by the 18th day of pregnancy their daily weight gain indicated that pregnancy had been maintained, they were caged individually with nesting materials.

Resorptions were characterized by an initial increase in weight followed by a sharp decrease preceded by vaginal bleeding which persisted for several days. Such animals did not abort and no foetuses were delivered.

In accordance with the rules for the nomenclature of vitamins approved by the Commission on the Nomenclature of Biological Chemistry of the International Union of Pure and Applied Chemistry (1960), vitamin A alcohol, vitamin A acid and vitamin A esters will be called retinol, retinoic acid and retinyl esters respectively. The term vitamin A will sometimes be employed in a more general nutritional sense.

Post-mortem and histology

Animals were killed by chloroform inhalation. Material for histological examination was fixed in Bouin's fluid as soon as possible after death. Testes

and seminal vesicles were weighed before fixation. Tissues were embedded in paraffin wax; sections were cut at 4 μ and stained with haematoxylin and eosin.

Administration of FSH *to male rats*

Fifty male rats were prepared for the experiment by rearing them from weaning on the basic diet supplemented with methyl retinoate. To establish the time at which the body stores of retinol acquired during lactation had been exhausted another five rats were simultaneously fed unsupplemented basic diet. The latter group of animals, group I, displayed typical signs of vitamin A deficiency (failure to gain weight and xerophthalmia) after 45 days on the diet. At this time they were killed together with ten rats, group II, from the main experimental group.

The remaining forty rats, which were growing well and appeared healthy, were separated into four groups of ten animals. One group of animals was left untreated, group III; two other groups, IV and V, were given 5 μg retinyl acetate daily; the rats in group V were also given 1 mg FSH each day, and rats in group VI were given FSH alone. After 30 days' treatment all the animals were killed and their testes and seminal vesicles were examined.

Administration of testosterone propionate to male rats

Forty male weanling rats were fed the basic diet and methyl retinoate. Six rats fed the unsupplemented diet, group VII, were killed when showing signs of vitamin A deficiency after 39 days on the diet. At this stage of the experiment the forty animals fed methyl retinoate were separated into four groups of ten. One group was left untreated, group VIII; animals in the other groups were given 5 μg retinyl acetate/day, group IX; or 5 μg retinyl acetate and 1 mg testosterone propionate/day, group X; or 1 mg testosterone propionate alone, group XI. After 28 days of treatment all the rats were killed and their testes and seminal vesicles were examined.

Administration of progesterone and oestrone to pregnant rats

One hundred and ten female rats were reared on the basic diet supplemented with methyl retinoate. Six rats, given unsupplemented diet, showed signs of vitamin A deficiency after 46 days on the diet indicating exhaustion of their body reserves of retinol and retinyl esters.

The rats, fed methyl retinoate, grew well and, when 4 months old, they were mated with normal males. Seven groups of ten mated rats were thus obtained. These rats were given retinyl acetate, steroid hormones or both, from the 8th to 20th days after mating. Details of the treatments are shown in Table 2.

RESULTS

The effects of FSH *and testosterone propionate on male rats*

The testes and seminal vesicle weights and the histological appearance of the seminiferous epithelium of these rats are summarized in Table 1. The testes were classified according to their histological appearance into five categories: A, B, C, D and E (see Table 1 and Pl. 1, Figs. 1 to 4).

TABLE 1

EFFECTS OF FSH TESTOSTERONE PROPIONATE AND RETINYL ACETATE ON WEIGHT AND HISTOLOGICAL APPEARANCE OF TESTES AND SEMINAL VESICLES OF RETINOL DEFICIENT RATS FED METHYL RETINOATE

Group	*Average body weight (g)*	*Histological classification*									
		A		*B*		*C*		*D*		*E*	
		Testes weight (mg)	*Seminal vesicle weight (mg)*	*Testes weight (mg)*	*Seminal vesicle weight (mg)*	*Testes weight (mg)*	*Seminal vesicle weight (mg)*	*Testes weight (mg)*	*Seminal vesicle weight (mg)*	*Testes weight (mg)*	*Seminal vesicle weight (mg)*
II. Rats killed after 45 days feeding on vitamin A-deficient diet supplemented with methyl retinoate	306	2589	634	2728	799	1547	1056				
		3067	897	2547	1018						
		2995	1135	3095	573						
		2985	987								
		3510	1121	2781	862						
Total		5		4		1					
III. Rats killed after 75 days feeding on vitamin A-deficient diet supplemented with methyl retinoate	326							1775	453	1347	1047
								1541	932	1320	987
										1324	844
										1593	742
										1415	409
										1753	465
										1069	1021
										1142	554
Total								2		8	
IV. Rats killed after 75 days feeding on vitamin A-deficient diet supplemented with methyl retinoate; they were also given 5 μg retinyl acetate each day after 45 days on the diet	366	3095	1758	3268	1587	1903	1421				
		2951	1467	1183	1077	1162	1207				
		2790	1073	2615	1250						
		2793	1193	2490	1231						
Total		4		4		2					
V. Rats killed after 75 days feeding on vitamin A-deficient diet supplemented with methyl retinoate; they were also given 5 μg retinyl acetate and 1 mg FSH each day after 45 days on the diet	379	3376	1584	2456	1447						
		3192	1250	2342	1152						
		3025	1211	2410	946						
		3406	1463	2280	1384						
				2607	1266						
Total		4		5							

VI. Rats killed after 75 days feeding on vitamin A-deficient diet supplemented with methyl retinoate; they were also given 1 mg rsu each day after 45 days on the diet	400				2294	1130	1483	1109	1725	1469
									1419	1405
									1744	1312
									1509	1369
									1536	1543
									2066	1666
									1493	1517
									1911	1656
Total					1		1		8	
VIII. Rats killed after 67 days feeding on vitamin A-deficient diet supplemented with methyl retinoate	285				2313	1286	1864	641	1688	613
							1663	756	1540	692
							1455	794	1659	829
							1386	1150	1152	545
									1432	1043
Total					1		4		5	
IX. Rats killed after 67 days feeding on vitamin A-deficient diet supplemented with methyl retinoate; they were also given 5 μg retinyl acetate each day after 39 days on the diet	326		2983	1133	1656	663				
			2578	977						
			2425	1484						
			2707	832						
			2494	1360						
			2785	679						
			2587	896						
			2654	1047						
			2000	1210						
Total			9		1					
X. Rats killed after 67 days feeding on vitamin A-deficient diet supplemented with methyl retinoate; they were also given 5 μg retinyl acetate and 1 mg testosterone propionate each day after 39 days on the diet	288		1783	2148	1640	2289				
			2068	2037	1067	2385				
			2378	2558	957	1594				
			2156	2080						
			2391	2177						
			2304	1737						
			1590	1642						
Total			7		3					
XI. Rats killed after 67 days feeding on vitamin A-deficient diet supplemented with methyl retinoate; they were also given 1 mg testosterone propionate each day after 39 days on the diet	298		2241	1715	1250	2202	1370	3432	771	2861
							1115	2868	895	1937
									774	1491
									1133	3215
									872	2056
									879	2055
Total			1		1		2		6	

At the beginning of the various treatments degenerative changes were at an early stage (group II, Table 1, and Howell *et al.*, 1964).

At the end of the experimental period rats receiving retinyl acetate had testes which, in size and histological structure, differed little from the normal. Neither FSH nor testosterone propionate prevented the development of testicular lesions in vitamin A-deficient rats receiving methyl retinoate.

Testosterone propionate had the expected effect in that it produced an increase in size of the seminal vesicles; FSH had a similar, but smaller effect, presumably due to contamination with LH.

The effect of oestrone and progesterone on female rats

The details of the pregnancies of the rats given various hormone treatments are given in Table 2.

Only rats receiving retinyl acetate (with or without the steroid hormones) delivered litters. Oestrone and progesterone, alone or together, neither allowed litters to be born nor affected the course of resorption in rats given the vitamin A-deficient diet and methyl retinoate.

DISCUSSION

The previous observations (Thompson *et al.*, 1961a, b, 1964), that rats fed a semi-synthetic diet, deficient in retinol but containing retinoic acid, were unable to reproduce, have been confirmed: male rats maintained with retinoic acid had testes with severely degenerate tubules (Howell *et al.*, 1963) and female rats invariably resorbed their foetuses during the last week of pregnancy (Howell *et al.*, 1964).

Degenerative changes in the seminiferous tubules of male rats maintained with methyl retinoate were not ameliorated by injections of testosterone propionate that stimulated over-development of the seminal vesicles (see Table 1)

EXPLANATION OF PLATE 1

CLASSIFICATION OF HISTOLOGICAL APPEARANCE OF TESTIS TUBULES

Type A: Complete spermatogenesis in all tubules.

Type B: Complete spermatogenesis in most tubules; a few tubules lacked spermatids and spermatocytes (Pl. 1, Fig. 1).

Type C: Many tubules showed complete spermatogenesis, some contained early spermatid stages and in a few there was a severe loss of germinal epithelium (Pl. 1, Fig. 2).

Type D: There was severe loss of germinal epithelium. Many tubules were lined by Sertoli cells and spermatogonia. In some tubules spermatocytes were numerous but few spermatids were present. Some tubules did not have a lumen and the cytoplasm lining many of the tubules was vacuolated (Pl. 1, Fig. 3).

Type E: Most of the tubules were lined by Sertoli cells and spermatogonia: spermatocytes were rare and spermatids absent. Some tubules did not have a lumen and the cytoplasmic lining of others was vacuolated (Pl. 1, Fig. 4).

FIG. 1. Section of a testis showing some spermatid and spermatocyte loss in three tubules; the others are normal. Type B in Table 1. H & E. ×70.

FIG. 2. Section of a testis showing severe loss of germinal epithelium in two of the tubules. Type C in Table 1. H & E. ×70.

FIG. 3. Section of a testis showing severe loss of germinal epithelium. Type D in Table 1. H & E. ×70.

FIG. 4. Section of a testis showing severe loss of germinal epithelium. Many of the tubules no longer have a lumen. Type E in Table 1. H & E. ×70.

PLATE I

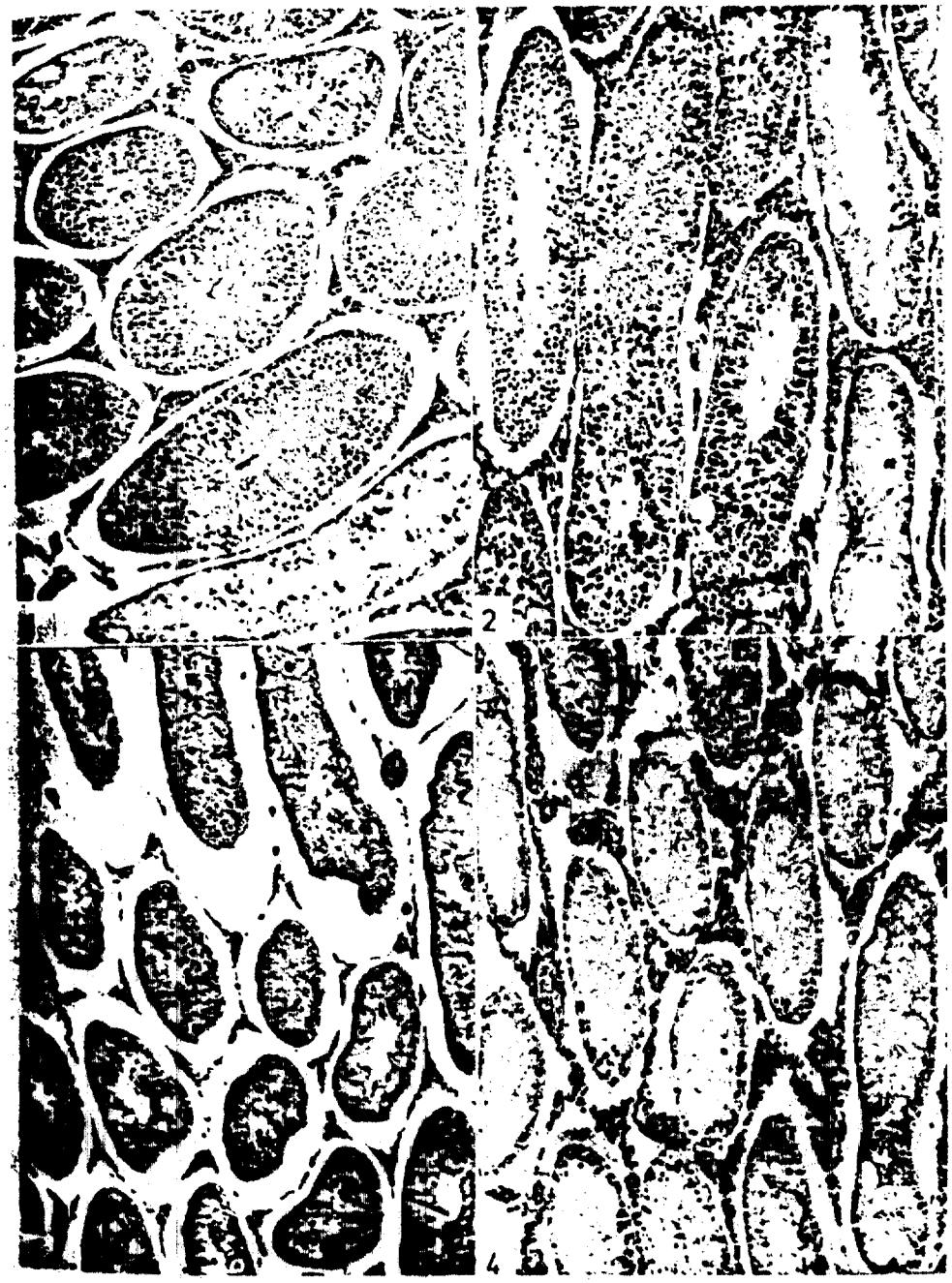

(Facing p. 314)

or by injections of FSH. The doses of both FSH and testosterone propionate were those sufficient to maintain spermatogenesis in hypophysectomized rats (Simpson, Li & Evans, 1951; Albert 1960).

Small amounts of retinol were effective in maintaining spermatogenesis in these rats. The absence of retinol cannot, therefore, affect the seminiferous epithelium indirectly by a reduction in the secretion of FSH by the pituitary or of androgen by the interstitial cells of the testis. The failure of spermatogenesis in retinol-deficient rats appears to be due to a more direct requirement for retinol.

TABLE 2

EFFECT OF INJECTIONS OF PROGESTERONE AND OESTRONE ON PREGNANCY IN VITAMIN A-DEFICIENT RATS MAINTAINED ON METHYL RETINOATE

Treatment (daily from 8th to 20th days after mating)	*No. of rats mated*	*No. of rats producing litters*	*No. of rats resorbing foetuses*	*No. of young in each litter*		
				Living	*Dead*	*Total*
5 μg retinyl acetate	10	6	0	0	2	2
				7	0	7
				10	1	11
				10	0	10
				9	0	9
				5	0	5
5 μg retinyl acetate 4 mg progesterone	10	7	0	3	2	5
				0	2	2
				7	0	7
				6	2	8
				8	0	8
				7	2	9
				5	3	8
4 mg progesterone	10	0	9	–	–	–
5 μg retinyl acetate 1 μg oestrone	10	6	0	5	0	5
				6	3	9
				7	0	7
				6	2	8
				6	0	6
				1	0	1
1 μg oestrone	10	0	7	–	–	–
1 μg oestrone 4 mg progesterone	10	0	5	–	–	–
No treatment	10	0	9	–	–	–

The existence of specific changes in the seminiferous epithelium of vitamin A-deficient rats was recognized by Mason (1939), who found that administration of pregnancy urine or implantation of pituitary tissue did not prevent the degeneration of the testes, although they did stimulate enlargement of the seminal vesicles. Similar observations on animals with orthodox vitamin A deficiency were made by van Os (1936) with pregnancy urine, Mayer & Truant (1949) with testosterone and Mayer & Goddard (1951) using chorionic gonadotrophin. The decreased size of the seminal vesicles and other accessory

organs in rats subjected to vitamin A deficiency has been ascribed to inanition (Mason, 1939) which reduces the level of circulating hypophysial gonadotrophins (Leathem, 1958). Our rats, maintained on methyl retinoate, had a normal food intake; thus the small size of the seminal vesicles in vitamin A deficiency cannot be ascribed entirely to inanition.

The reduction in size of the accessory sexual organs may be a consequence of the primary change in the germinal epithelium. Thus, in cryptorchid rats (Nelson, 1937) and in rats maintained with methyl retinoate, degeneration of the tubular epithelium is accompanied by atrophy of the seminal vesicles.

The gradual loss of vision in retinol-deficient rats maintained on retinoic acid (Dowling & Wald, 1960) may be a complicating factor. Browman (1940), using rats from which the eyes had been removed at birth, and Fiske (1941), using rats kept in constant darkness, showed that lack of visual stimulation resulted in a reduction in seminal vesicle size compared with normal controls.

Female rats, maintained with methyl retinoate, resorbed their foetuses even when the ovarian hormones, progesterone and oestrone, were injected together or separately. The quantities administered were those previously reported to maintain pregnancy in rats ovariectomized and hypophysectomized on the 8th day of pregnancy (Lyons, 1943). When small quantities of retinol were given, pregnancies were completed. Thus in the female rat, as in the male, retinol appears to have a specific and direct effect on reproduction which is not mediated through the endocrine system.

These results are compatible with the opinion of Thompson *et al.* (1964) that it is not possible to explain the salient features of the reproductive failure in terms of an obvious or simple endocrine insufficiency.

Our results contrast with the observations of Scott & Scott (1964) who reported a 'surge of meiotic divisions' in the seminiferous tubules of vitamin A deficient cats in response to gonadotrophins, and also with those of Hays & Kendall (1956) who found that pregnancy was maintained in vitamin A-deficient rabbits when progesterone was administered. These results do not necessarily indicate a species difference since the thoroughness of the vitamin A depletion and the specificity of the responses to the endocrine treatment are variously open to question. It is noteworthy that injections of ovarian hormones have been shown to be beneficial during pregnancy if given to pyridoxine-deficient rats (Nelson, Lyons & Evans, 1951); to rats fed diet low in protein (Nelson & Evans, 1954); and to rats fed sucrose only throughout pregnancy (Kendall & Hays, 1960).

It seems probable that unequivocal evidence for a specific function of retinol in the reproduction of higher animals will be obtained only by using rigorously defined diets completely free of retinol but containing retinoic acid.

ACKNOWLEDGMENTS

We wish to thank Professor D. L. Hughes and Professor R. A. Morton, F.R.S., for their encouragement and advice, Mrs M. W. Harling, A.I.M.L.T., and Miss P. McMahon for technical assistance, Mr G. Weston, F.I.M.L.T., and Mr E. O'Neil for the photographs and Dr O. Isler of F. Hoffmann-La Roche & Co.,

Basel, for gifts of retinoic acid. This work was supported in part by United States Public Health Service Grant AM-05282-02. W.A.C. is in receipt of an Agricultural Research Council Research Studentship and J.N.T. is a British Egg Marketing Board Fellow.

REFERENCES

ALBERT, A. (1960) *The mammalian testis.* Sex and Internal Secretions, 3rd edn. Ed. W. C. Young. Williams & Wilkins, Baltimore.

ARENS, J. F. & VAN DORP, D. A. (1946) Synthesis of some compounds possessing vitamin A activity. *Nature, Lond.* **157**, 190.

BROWMAN, L. G. (1940) The effect of optic enucleation in the male albino rat. *Anat. Rec.* **78**, 59.

DOWLING, J. E. & WALD, G. (1960) The biological function of vitamin A acid. *Proc. natn. Acad. Sci. U.S.A.* **46**, 587.

FISKE, V. M. (1941) Effect of light on sexual maturation, estrous cycles and anterior pituitary of rat. *Endocrinology*, **29**, 187.

HAYS, R. E. & KENDALL, K. A. (1956) The beneficial effect of progesterone on pregnancy in the vitamin A deficient rabbit. *J. Nutr.* **59**, 337.

HIGH, E. G., MOORE, Y. E., COLLINS, J. D. & FRAZIER, H. M. (1964) Effects of vitamin A acid on growth, reproduction and some tissues in the rat. *Fedn Proc. Fedn Am. Socs exp. Biol.* **23**, 294.

HOWELL, J. McC., THOMPSON, J. N. & PITT, G. A. J. (1963) Histology of the lesions produced in the reproductive tract of animals fed a diet deficient in vitamin A alcohol but containing vitamin A acid. I. The male rat. *J. Reprod. Fert.* **5**, 159.

HOWELL, J. McC., THOMPSON, J. N. & PITT, G. A. J. (1964) Histology of the lesions produced in the reproductive tract of animals fed a diet deficient in vitamin A alcohol but containing vitamin A acid. II. The female rat. *J. Reprod. Fert.* **7**, 251.

JUNEJA, H. S., MURTHY, S. K. & GANGULY, J. (1964) Effect of retinoic acid on the reproductive performance of male and female rats. *Indian J. exp. Biol.* **2**, 153.

KENDALL, K. A. & HAYS, R. L. (1960) Maintained pregnancy in the rat as associated with progesterone administration and multiple-nutrient deficiency. *J. Nutr.* **70**, 10.

LEATHEM, J. H. (1958) *Extragonadal factors in reproduction.* Recent Progress in the Endocrinology of Reproduction. Ed. C. W. Lloyd. Academic Press, New York.

LYONS, W. R. (1943) Pregnancy maintenance in hypophysectomized-öophorectomised rats injected with oestrone and progesterone. *Proc. Soc. exp. Biol. Med.* **54**, 65.

MASON, K. E. (1939) *Relation of the vitamins to the sex glands.* Sex and Internal Secretions, 2nd edn. Eds. E. Allen, C. H. Darnforth and E. A. Doisy. Williams & Wilkins, Baltimore.

MAYER, J. & GODDARD, J. W. (1951) Effects of administration of gonadotropic hormone on vitamin A-deficient rats. *Proc. Soc. exp. Biol. Med.* **76**, 149.

MAYER, J. & TRUANT, A. P. (1949) Effects of administration of testosterone on vitamin A-deficient rats. *Proc. Soc. exp. Biol. Med.* **72**, 436.

NELSON, M. N. & EVANS, H. M. (1954) Maintenance of pregnancy in the absence of dietary protein with oestrone and progesterone. *Endocrinology*, **55**, 543.

NELSON, M. N., LYONS, W. R. & EVANS, H. M. (1951) Maintenance of pregnancy in pyridoxine deficient rats injected with oestrone and progesterone. *Endocrinology*, **48**, 725.

NELSON, W. O. (1937) Some factors involved in the control of the gametogenic and endocrine functions of the testis. *Cold Spring Harb. Symp. quant. Biol.* **5**, 123.

OS, P. M. VAN (1936) The influence of the gonadotropic hormone from the urine on the testis with degenerated seminal tubules. *Acta brev. neerl. Physiol.* **6**, 151.

REDFEARN, F. R. (1960) The metabolism of vitamin A acid and its C_{25} homologue. *Archs Biochem. Biophys.* **91**, 226.

SCOTT, P. P. & SCOTT, M. G. (1964) Vitamin A and reproduction in the cat. *J. Reprod. Fert.* **8**, 270.

SHARMAN, I. M. (1949) The biological activity and metabolism of vitamin A acid. *J. Nutr.* **3**, viii.

SIMPSON, M. E., LI, C. H. & EVANS, H. M. (1951) Synergism between pituitary follicle stimulating hormone and human chorionic gonadotropin. *Endocrinology*, **48**, 370.

THOMPSON, J. N., HOWELL, J. McC. & PITT, G. A. J. (1961a) Vitamin A acid and reproduction in male rats. *Biochem. J.* **80**, 25P.

THOMPSON, J. N., HOWELL, J. McC. & PITT, G. A. J. (1961b) The inability of vitamin A acid to replace vitamin A in pregnant female rats. *Biochem. J.* **80**, 16P.

THOMPSON, J. N., HOWELL, J. McC. & PITT, G. A. J. (1964) Vitamin A and reproduction in rats. *Proc. R. Soc.* B, **159**, 510.

Cox-'57
Bib. No. 1889

Cox R. P., H. J. Deuel, and B. H. Ershoff: Exp. Med. Surg. *15*, 328–334, 1957.

Potentiating Effects of DPPD, Bile Salts and Sulfasuxadine on Hypervitaminosis A in the Rat[1]

By R. P. COX[2], H. J. DEUEL, Jr.[3], and B. H. ERSHOFF

From the Department of Biochemistry and Nutrition, University of Southern California, Los Angeles

Available data indicate that the prolonged ingestion of massive doses of vitamin A results in growth retardation, spontaneous leg fractures, paralysis and other toxic manifestations including death in the immature rat, the severity of symptoms and their rapidity of onset being proportional to the dosage of vitamin A administered (1, 2). A vitamin A intake of 10,000 to 12,500 U. S. P. units per day results in a significant retardation in growth; the dosage required to produce more severe symptoms (including leg fractures) in immature rats has generally been found to range from 25,000 to 50,000 U. S. P. units of vitamin A per day. In the present communication data are presented indicating that supplements of DPPD (di-phenyl-*p*-phenylenediamine), bile salts or sulfasuxadine significantly increased the toxic manifestations of hypervitaminosis A in immature rats fed massive but relatively non-toxic doses of this vitamin.

Procedure

The basal ration employed in these studies consisted of sucrose, 66%; casein[4], 24%; salt mixture[5], 5%; and cottonseed oil, 5%. To each kg. of the above diet were added the following vitamines: thiamine hydrochloride, 10 mg.; riboflavin, 10 mg.; pyridoxine hydrochloride, 10 mg.; calcium pantothenate, 60 mg.; nicotinic acid, 100 mg.; ascorbic

[1] Communication No. 437 from the Department of Biochemistry and Nutrition, University of Southern California.

[2] Research Fellow, Peterson Manufacturing Co., Los Angeles, Calif.

[3] Deceased, April 17, 1956.

[4] Vitamin-free Test Casein, General Biochemicals, Inc., Chagrin Falls, O.

[5] Wesson modification of Osborn and Mendel's Salt Mixture, Nutritional Biochemicals Corp., Cleveland, O.

acid, 200 mg.; biotin, 4 mg.; folic acid, 5 mg.; para-aminobenzoic acid, 400 mg.; inositol, 800 mg.; vitamin B_{12}, 150 μg.; 2-methyl-naphtoquinone, 5 mg.; choline chloride, 2 gm.; vitamin A acetate, 6000 U. S. P. units; vitamin D_2, 500 U. S. P. units; and alpha-tocopherol acetate, 100 mg. The vitamins and supplements to be tested were added in place of equal amounts of sucrose. The rats were housed in metal cages with raised screen bottoms (two or three animals per cage) and were provided with food and water *ad libitum*. Diets were made up weekly and stored under refrigeration in air- and light-tight containers. The animals were fed on alternate days and all food not consumed 48 hours after feeding was discarded. These measures were employed to minimize oxidative changes in the diet. The animals were weighed and examined for fractures weekly. Feeding was continued for 6 weeks or until death, whichever occurred first. In each of the following experiments rats of the University of Southern California strain were selected at 21 to 24 days of age and a body weight of 38 to 48 gm. In each experiment one group was fed the basal ration and the remaining groups were fed the basal ration with the supplements listed in Table 1. The vitamin A supplement was a liquid preparation containing 1 million U. S. P. units of vitamin A (synthetic vitamin A acetate in corn oil) per gm.[6]

Experiment 1. *Potentiating effects of DPPD on symptoms of hypervitaminosis A in the immature rat*

In agreement with earlier findings (1, 2), the ingestion of a purified ration containing 3 million U. S. P. units of vitamin A acetate per kg. of diet resulted in a significant retardation in growth and the occurrence of spontaneous leg fractures in the immature rat. These symptoms of hypervitaminosis A were accentuated by the concurrent feeding of DPPD at levels of 0.025 or 1% of the diet. This was evidenced by the following criteria: (a) the weight increment of rats fed DPPD in conjunction with the vitamin A supplement was significantly less than that of rats fed the vitamin A supplement alone, (b) 100% of the rats fed both the DPPD and vitamin A supplements developed leg fractures in contrast to an incidence of 50% or less in animals fed the vitamin A supplement alone, and (c) 50 to 100% of the rats fed DPPD in conjunction with the vitamin A supplement

[6] Vitamin A Acetate in Corn Oil (1 million U. S. P. units per g.), Hoffman-LaRoche, Inc., Nutley, N. J.

Table 1

Effects of DPPD and other Antioxidants, Sulfasuxadine and Bile Salts on Symptoms of Hypervitaminosis A in the Rat [1]

Supplements Fed with Basal Ration	Number of Animals	Initial Wt.	Gain in Body Wt. After Following Days of Feeding		% Surviving [2]	% of Rats with Fractures [3]
			21st	42nd		
		g.	g.	g.		
Experiment 1						
Male rats						
None	10	43	91 (10)	187 (10)	100	0
0.025% DPPD	10	41	82 (10)	172 (10)	100	0
1% DPPD	10	42	76 (10)	164 (10)	100	0
3 million U. S. P. units of vitamin A acetate per kg. of diet	20	41	80 (20)	130 (20)	100	10
3 million U. S. P. units of vitamin A acetate per kg. of diet plus the following supplements:						
0.025% DPPD	20	39	35 (20)	56 (6)	30	100
1% DPPD	20	40	31 (20)	48 (10)	50	100
Female rats						
None	10	43	84 (10)	142 (10)	100	0
0.025% DPPD	10	42	72 (10)	125 (10)	100	0
1% DPPD	10	42	63 (10)	113 (10)	100	0
3 million U. S. P. units of vitamin A acetate per kg. of diet	10	42	57 (10)	83 (10)	100	50
3 million U. S. P. units of vitamin A acetate per kg. of diet plus the following supplements:						
0.025% DPPD	10	43	34 (10)	—	0	100
1% DPPD	10	45	26 (10)	26 (5)	56	100

[1] The antioxidants employed in the present experiment were obtained from the following sources: DPPD, B. F. Goodrich Chemical Co., Cleveland, O.; Santoquin, Monsanto Chemical Co., St. Louis, Mo.; DBH, Distillation Products Industries, Rochester, N. Y.; BHT, Bowman Food Products, Inc., Holland, Mich.; Vitamin E, Type 4-50 Concentrate, Distillation Products Industries, Rochester, N. Y.

[2] Experimental period—6 weeks.

[3] Data were based only on animals with grossly detectable leg fractures sufficiently marked to result in dragging or disuse of the limb.

Table 1—Continued

Supplements Fed with Basal Ration	Number of Animals	Initial Wt.	Gain in Body Wt. After Following Days of Feeding		% Surviving[a]	% of Rats with fractures[b]
			21st	42nd		
		g.	g.	g.		
Experiment 2						
Female rats						
None	10	42	92 (10)	145 (10)	100	0
3 million U. S. P. units of vitamin A acetate per kg. of diet	10	44	70 (10)	83 (10)	100	20
3 million U. S. P. units of vitamin A acetate per kg. of diet plus the following supplements:						
0.005% DPPD	10	44	64 (10)	91 (10)	100	70
0.05% DPPD	10	39	39 (10)	74 (6)	60	100
0.05% Santoquin	20	40	56 (20)	81 (20)	100	40
0.05% DBH	20	40	63 (20)	97 (20)	100	20
0.05% BHT	20	40	70 (20)	102 (20)	100	0
0.05% tocopherol alcohols	10	45	68 (10)	111 (10)	100	0
0.05% alpha-tocopherol acetate	10	44	64 (10)	106 (10)	100	20
1% sulfasuxadine	10	42	40 (10)	68 (6)	60	100
0.25% bile salts[4]	10	40	8 (6)	—	0	100

The values in parenthese indicate the number of animals which survived and on which averages are based.

[4] Bacto Bile Salts, Difco Laboratories, Detroit, Mich.

succumbed during the 6 week experimental period in contrast to a 0% mortality in animals fed the vitamin A supplement alone. Similar findings were obtained with male and female rats (Table 1). When DPPD was incorporated in the basal ration (without the vitamin A supplement) at levels of 0.025 or 1% of the diet, no deleterious effects were observed in respect to gross appearance, incidence of fractures or per cent survival. Gain in body weight was slightly retarded, however, in animals fed the DPPD supplements, particularly at the 1% level.

Experiment 2. *Comparative effects of DPPD and other antioxidants on symptoms of hypervitaminosis A in the rat*

In agreement with the findings obtained in experiment 1, DPPD accentuated symptoms of hypervitaminosis A in the immature rat. In contrast to these results other antioxidants such as Santoquin (6-ethoxy-2, 2, 4-trimethyl-1, 2-dihydroquinoline), DBH (2, 5-di-tert-butylhydroquinone), BHT (2, 6-di-tert-butyl-*p*-cresol), or tocopherol alcohols were without significant effect on symptoms of hypervitaminosis A. Supplements of alpha-tocopherol acetate were also inactive in this regard. On the contrary the tocopherol supplements and BHT not only did not accentuate symptoms of hypervitaminosis A but actually counteracted in part the growth retardation obtained in rats fed the basal ration with the vitamin A supplement, Sulfasuxadine when fed at a 1% level in the diet and bile salts at a 0.25% level were also active in accentuating symptoms of hypervitaminosis A in the immature rat (Table 1). Experiments were subsequently conducted which were similar to the above except that vitamin A palmitate[7] replaced vitamin A acetate as the source of supplemental vitamin A. Findings under these conditions were similar in all respects to the above. Similar findings were also obtained when the vitamin A supplement was provided in the form of a dry powdered material[8]. It was also observed that sodium glycocholate or sodium taurocholate when fed at a 0.16% level in the diet was as active as a 0.25% level of bile salts in accentuating symptoms of hypervitaminosis A in the immature rat.

Discussion

Considerable data are available indicating that DPPD can affect the absorption and/or utilization of vitamin A. *Matterson* et al. (3) reported that DPPD increased plasma vitamin A and liver storage of vitamin A in chicks fed diets containing fish oil the source of vitamin A. *Teichmann* et al. (4) found that dairy cows not only used carotene more efficiently but that there was also a lowered incidence of oxidized milk flavors when DPPD was fed. *Potter* et al. (5) reported that DPPD increased the vitamin A and carotenoid content of blood plasma and liver of chicks fed either a purified or a practical type diet. *Monson* et al. (6) reported that DPPD significantly increased liver storage of

[7] Vitamin A Palmitate in Corn Oil (1 million U. S. P. units per g.), Hoffman-LaRoche, Inc., Nutley, N. J.

[8] Dry Vitamin A Acetate (500,000 U. S. P. units per g.), Hoffman-LaRoche, Inc., Nutley, N. J.

vitamin A in chicks fed diets containing vitamin A oil or graded levels of alfalfa as the only vitamin A sources. The latter authors suggest that the effect of DPPD may be indirect "by making available in the gut some factor(s) that is needed by the tissues to efficiently utilize vitamin A." Present findings indicating that DPPD accentuated symptoms of hypervitaminosis A in the immature rat are in accord with the above observations. Since similar effects could be obtained by feeding larger doses of vitamin A without DPPD (1, 7) it would appear that the effects obtained with the latter material may have been due to an increased absorption and/or utilization of vitamin A. That the effects obtained with DPPD were due to its antioxidant activity which prevented the destruction of vitamin A in the diet and hence left more of the vitamin present for absorption appears to be ruled out by chemical tests which indicate that no detectable destruction of vitamin A occurred in the purified basal diet supplemented with 3 million U. S. P. units of vitamin A per kg. of ration (either as the acetate or the palmitate) after 30 days of storage under refrigeration. Under conditions of the present experiment diets were made up at weekly intervals and were consumed within 10 days of the time they were made. In addition, no significant difference in response occurred between rats fed the above ration and animals fed an identical diet which was made up daily immediately before feeding. The possibility that DPPD was functioning as an antioxidant which protected vitamin A from destruction in the intestinal tract and/or the animals' tissues has not been excluded although other antioxidants such as Santoquin, DBH, BHT and tocopherol alcohols were without effect in accentuating symptoms of hypervitaminosis A. The possibility has not been ruled out that the effects obtained with DPPD may have been due to some property other than its antioxidant activity. The marked activity of sulfasuxadine and bile salts in accentuating symptoms of hypervitaminosis A indicate that properties other than antioxidant activity may be involved.

Summary

Immature rats were fed a purified ration containing a massive but relatively non-toxic dose of vitamin A. Supplements of DPPD when fed in conjunction with the above diet resulted in a significant potentiation of symptoms of hypervitaminosis A as judged by a more pronounced retardation in growth, a higher incidence of spontaneous leg fractures and a greater mortality than occurred in rats fed a similar diet with DPPD omitted. Other antioxidants such as Santoquin, DBH,

BHT and tocopherol alcohols were without significant activity in this regard. Sulfasuxadine and bile salts were also active in accentuating symptoms of hypervitaminosis A in the immature rat.

References

1. *Rodahl, K.*: Hypervitaminosis A in the rat. J. Nutrit. (Am.) *41*, 399, 1950.
2. *Nieman, C.*, and *H. J. Klein Obbink*: The biochemistry and pathology of hypervitaminosis A. Vitamins and Hormones *12*, 69, 1954.
3. *Matterson, L. D., R. H. Bunnel, L. D. Stinson, E. P. Singsen*, and *L. M. Potter*: The effect of incorporating diphenyl-*p*-phenylenediamine (DPPD) into a ration containing various levels of vitamin A from fish oils. Poultry Sci., *34*, 1080, 1955.
4. *Teichman, R., M. E. Morgan, H. D. Eaton*, and *P. MacLeod*: Effect of feeding DPPD to lactating cows on carotene utilization and incidence of oxidized milk flavor. J. Dairy Sci. *38*, 693, 1955.
5. *Potter, L. M., R. H. Bunnel, L. D. Matterson*, and *E. P. Singsen*: The effects of antioxidants and a vitamin B_{12} concentrate on the utilization of carotenoid pigments by the chick. Poultry Sci. *35*, 452, 1956.
6. *Monson, W. J., E. T. Gade, M. D. Lloyd*, and *A. C. Groschke*: Utilization of vitamin A activity from alfalfa or fish oil by chicks receiving diets with and without diphenyl-*p*-phenylenediamine (DPPD). Poultry Sci. *36*, 166, 1957.
7. *Ershoff, B. H., H. J. Hernandez*, and *J. M. Muckenthaler*: Potentiating effects of material of plant and animal origin on symptoms of hypervitaminosis A in the rat. J. Nutrit. (Am.), *62*, 527, 1957.

Cruess-'65
Bib. No. 1918

Reproduced by permission of the copyright owner

Biochem. J. (1965) **96**,

Alterations in the Lipids of Bone caused by Hypervitaminosis A and I

BY RICHARD L. CRUESS AND IRWIN CLARK
Department of Orthopaedic Surgery, Royal Victoria Hospital, Montreal, Quebec, Canada, and Department of Orthopaedic Surgery and Biochemistry, College of Physicians and Surgeons of Columbia University, New York, N.Y. 10032, U.S.A.

(*Received* 14 *December* 1964)

1918

1. The total lipid, phospholipid, total and free fatty acid, free and esterified cholesterol contents of the long bones of normal, hypervitaminotic A, D and A plus D rats were determined. 2. Toxic amounts of vitamin A decreased the total fatty content, whereas toxic amounts of vitamin D increased triglycerides, esterified cholesterol and in particular the phospholipids of bone. 3. An interaction occurred between toxic amounts of vitamins A and D, which prevented, to a large extent, the alterations in bone lipids that occur in hypervitaminosis D. 4. The studies suggest an involvement of vitamin D in lipid metabolism and tend to support the idea that lipids are involved in ossification.

Although there is considerable information about the collagen, mucopolysaccharide and mineral composition of bone (Bourne, 1956), very little is known about the lipids. Recent histochemical studies suggest that lipids may be involved in calcification (Johnson, 1960) and ossification (Irving, 1958). The following studies were undertaken to characterize the lipids of bones of normal rats and of rats given vitamins A and D, in quantities sufficient to alter other constituents of bone (Clark & Smith, 1964), in an attempt to ascertain whether lipids are involved in osteogenesis. A preliminary account of some of this work has been reported (Cruess & Clark, 1964).

METHODS

Albino male rats of the Holtzman strain, weighing about 150g., were fed on a complete synthetic laboratory diet containing sufficient amounts of vitamins A and D for adequate growth and maintenance. The vitamin A palmitate was generously supplied by Merck, Sharpe and Dohme Research Laboratories and the vitamin D_2 (calciferol) by the Roxane–Philips Co. The supplemental vitamins were administered daily by stomach tube/100g. body wt. Vitamin A palmitate was diluted with purified sesame oil. The control rats (group I) received sesame oil; group II received 15000i.u. of vitamin A; group III received 30000i.u. of vitamin D; group IV received 15000i.u. of vitamin A and 30000i.u. of vitamin D. Fifteen animals in each group were maintained on the above regimens for 44 days, during which time three of the animals from group III and one from group IV had died. The animals were decapitated and the femora, tibiae, humeri, radii and ulnae were removed after subperiosteal dissection of soft tissues. The epiphyseal ends of the bones were prised off and the remaining cartilage was trimmed by transection through the metaphyseal end of the bone close to the epiphyseal line, removing as little as possible of the metabolically active metaphysis. The marrow elements were removed by flushing the marrow cavity with a jet of distilled water through a 22-gauge hypodermic needle. The bones were frozen immediately with solid CO_2, freeze-dried at −50° and stored in a desiccator over P_2O_5 until used. The bones of each rat were pulverized in a mixer mill (model 5000; Spex Industries, New Jersey) for 2min., and the lipids were extracted and purified by the method of Folch, Lees & Sloane-Stanley (1957). The washed extract was stored under nitrogen in the cold until used.

Total lipid content was determined gravimetrically after evaporation of the solvent. Free cholesterol was determined on the dry residue by a modification of the Liebermann-Burchard reaction (Shaftel, 1944). Lipid phosphorus was determined on a 2ml. sample of extract by the method of King (1956), and the phospholipid content was calculated by multiplying P by 25 (Wittcoff, 1951). The fatty acids and total cholesterol were determined in a 10ml. sample of extract by the method of Albrink (1959), except that 5mM-sodium methoxide was used in place of 4mM-NaOH in the titration step. Free fatty acids were calculated by subtracting from the chemically determined total fatty acids the sum of the amounts found in phospholipids (with lecithin as a representative phospholipid), and in the triglycerides (with tristearin as a representative triglyceride), and in the cholesterol esters. The colorimetric procedure for total cholesterol was that of Abel, Levy, Brodie & Kendall (1952). The triglycerides were measured by the method of Van Handel, Zilversmit & Bowen (1957), except that the oxidation was stopped with sodium sulphite (0·5M).

Dried defatted weight was determined by drying 100mg. of extracted bone in an oven at 110° for 24hr. The ash content of the dried defatted bone was measured after ashing in a muffle furnace at 650° for 18hr. The organic content was calculated by subtracting the ash weight from the dried defatted weight.

Table 1. *Changes in the body and bone weights of rats receiving dietary vitamin supplements for 44 days*

Experimental details are given in the text. Values significantly different from control values are indicated by: $*P < 0.001$; $**P < 0.01$. Significant interaction between vitamins A and D is indicated by: $\dagger P < 0.001$; $\dagger\dagger P < 0.025$.

	Control	Vitamin A	Vitamin D	Vitamins A and D
Initial weight (g.)	149	152	151	150
Final weight (g.)	306	182*	176*	177†
Ash (%)	68·3	69·6**	58·9*	64·6††
Organic fraction (%)	31·7	30·4	41·1*	35·4††

The experimental design was that of a 2 × 2 factorial with unequal replications per group and an analysis of co-variance was performed on the data according to the method of Rao (1952).

RESULTS

Although the animals that received vitamin A failed to gain weight normally, the ash content of their bones was slightly, though significantly, elevated (Table 1). Rats treated with vitamin D also failed to gain weight as well as the control animals, but there was a marked decrease in the ash content of the bones of these animals. Although the gains in body weight of the rats given the combination of excess of vitamins A and D were about the same as those of the animals given vitamin A or vitamin D, calculation of an analysis of co-variance indicates that an interaction exists between these vitamins and that the gain in body weight after the combined administration is significantly greater than could be expected if these vitamins acted independently. Moreover, as has been reported by Clark & Smith (1964), the deviations in the values of the ash and organic content of the bones of the rats given the combination of vitamins A and D from those of the controls were not as great as those of the rats given just vitamin D, indicating an interaction between these vitamins with respect to bone ash and organic content.

The lipid analyses of the bones are shown in Table 2. Hypervitaminosis A did not change significantly the lipid values of the bones with the exception of total fatty acids, and this fraction only if expressed as mg./g. of bone. Toxic amounts of vitamin D, however, increased significantly the total lipid content and the individual components of the lipids when expressed as mg./g. of bone and, with the exception of free fatty acids and free cholesterol, they increased other lipids when expressed as percentage of organic matter. The lipid values of bones from animals that received vitamin A together with vitamin D were greater than those of the control but not as elevated as those of the bones of the hypervitaminotic D rats. However, significant interactions between the vitamins only were found in the phospholipids and total fatty acids when expressed as mg./g. of bone.

An examination of the proportion of the lipids (Table 2) shows that only total fatty acids were affected by hypervitaminosis A. Excess of vitamin D increased the percentage of phospholipids from 16 to 24, and although this increase was not statistically significant it is considered that this is a true increase since only two of the treated animals had values within the normal range. The increase in total fatty acids results from the fatty acids derived from the increased phospholipids.

DISCUSSION

The only lipid values of normal bone found in the literature were those of Leach (1958), who reported values considerably lower than those reported above. However, since his methods of extraction and analysis and also the type of bone and species of animal were different from ours, the variation in results is not surprising.

It has been shown that in bones of hypervitaminotic D rats the proportion of mineral to organic matrix differs from that of control bones (Follis, 1950; Clark & Smith, 1964). Consequently, when the results are expressed as mg./g., conclusions about the composition of the matrix are misleading. If the lipid values are calculated as a fraction of the organic matter, of which they are an integral part, it is evident (Table 2) that vitamin D increased the absolute amount of phospholipids, triglycerides and total cholesterol, and of their constituent fatty acids. Further, it appears that vitamin D increases the phospholipid fraction to a greater extent than the other components, indicating an altered lipid composition (Table 2). Whether these increases result from increased synthesis or decreased breakdown of the lipids is not apparent from these experiments. The persistence of the phospholipids in the bones of the hypervitaminotic D rats may in some way be associated with the failure of calcification, since it

Table 2. *Analyses of the bone lipids from rats receiving dietary vitamin supplements for 44 days*

Experimental details are given in the text. Values significantly different from control values are indicated by: $*P < 0{\cdot}001$; $**P < 0{\cdot}01$; $***P < 0{\cdot}025$. Significant interaction between vitamins A and D is indicated by: $\dagger P < 0{\cdot}001$; $\dagger\dagger P < 0{\cdot}025$.

	Control			Vitamin A			Vitamin D			Vitamins A and D		
	(mg./g.)	(% of organic fraction)	(% of total lipid)	(mg./g.)	(% of organic fraction)	(% of total lipid)	(mg./g.)	(% of organic fraction)	(% of total lipid)	(mg./g.)	(% of organic fraction)	(% of total lipid)
Total lipids	9·00	2·96	—	11·47	3·77	—	18·80*	4·58*	—	16·63	4·77	—
Phospholipids	1·54	0·46	16·4	1·93	0·63	17·2	4·42*	1·07*	23·8	2·85††	0·81	18·4
Total fatty acids	4·21	1·39	44·3	4·09**	1·35	37·1**	9·71*	2·37*	53·3	6·75†	1·94	40·7
Free fatty acids	2·21	0·69	24·0	2·11	0·70	19·4	4·15***	1·07	25·1	2·73	0·78	18·5
Triglycerides	1·05	0·31	10·0	0·99	0·32	8·7	2·13*	0·52**	11·6	1·55	0·44	9·4
Total cholesterol	0·51	0·15	5·3	0·52	0·17	4·7	0·87*	0·22*	4·9	0·80	0·23	5·1
Free cholesterol	0·17	0·05	1·9	0·24	0·08	2·1	0·32*	0·08	1·7	0·27	0·08	1·9
Total lipid recovered (%)	—	—	56·6	—	—	50·0	—	—	65·4	—	—	51·4

has been observed that phospholipids disappear just before calcification (Johnson, 1960). Also, it has been shown that the incorporation of [^{32}P]orthophosphate into the intestinal mucosa of vitamin D-deficient rats is approximately one-third that of control animals, indicating a relationship between phospholipid metabolism and vitamin D (Thompson & DeLuca, 1964). Although a relationship appears to exist between vitamin D and phospholipid metabolism, it is impossible, at present, to state with certainty whether the phospholipids are intimately involved in ossification. However, the absence of lipid-staining material in the epiphyseal cartilage of rachitic animals and its return on treatment with vitamin D (Irving, 1959) suggest a relation between vitamin D, lipids and ossification.

Excess of vitamin A alone or in combination with excess of vitamin D tended to lower the total fatty acids, the major fraction of the lipids, of bone. Vitamin A also has been shown to decrease the collagen and mucopolysaccharide contents of bone (Clark & Smith, 1964).

The administration of excess of vitamin A to rats along with excess of vitamin D has been shown to prevent, to a large extent, the histological changes of hypervitaminosis D (Clark & Bassett, 1962) as well as the chemical changes (Clark & Smith, 1964). The interaction of the vitamins also occurs with many of the lipid fractions. The mechanism of action of vitamin A in preventing the accumulation of excess of matrix in hypervitaminosis D is still obscure. Vitamin A has been shown to hasten both osseous maturation and remodelling of normal bone (Wolbach, 1947). The excess of vitamin A may be acting in a similar fashion on this abnormal matrix, possibly by liberating cellular proteases (Fell, Mellanby & Pelc, 1956; Fell, Lucy & Dingle, 1961; Lucy, Dingle & Fell, 1961; Dingle, 1961) capable of hydrolysing the macromolecules of bone.

Only 50–65% of the chloroform–methanol-extractable material could be accounted for by the phospholipids, free fatty acids, triglycerides and total cholesterol (Table 2). The identification of the remaining 35–50% is under investigation.

The authors extend their sincere appreciation to Mr George P. H. Styan of the Department of Mathematics Statistics, Columbia University, for the detailed statistical analyses performed on the data. This work was supported by a U.S. Atomic Energy Commission Contract no. AT(30-1)2530 and U.S. Public Health Grant AM-04071. I. C. is the holder of a U.S. Public Health Service Research Career Development Award no. 5-K3-AM-15 374-03.

REFERENCES

Abel, L. L., Levey, B. B., Brodie, B. B. & Kendall, R. I. (1952). *J. biol. Chem.* 195, 357.

Albrink, M. J. (1959). *Lipid Res.* 1, 53.

Bourne, G. H. (1956). In *The Biochemistry and Physiology of Bone*, p. 81. Ed. by Bourne, G. H. New York: Academic Press Inc.

Clark, I. & Bassett, C. A. L. (1962). *J. exp. Med.* **115**, 147.

Clark, I. & Smith, M. (1964). *J. biol. Chem.* **239**, 1266.

Crosse, R. L. & Clark, I. (1964). *Fed. Proc.* **23**, 375.

Dingle, J. T. (1961). *Biochem. J.* **79**, 509.

Fell, H. B., Lucy, J. A. & Dingle, J. T. (1961). *Biochem. J.* **78**, 11P.

Fell, H. B., Mellanby, E. & Pelc, S. R. (1956). *J. Physiol.* **134**, 179.

Folch, J., Lees, M. & Sloane-Stanley, G. H. (1957). *J. biol. Chem.* **226**, 497.

Follis, R. H. (1950). In *2nd Conf. Metabolic Interrelations*, p. 221. Ed. by Reifenstein, E. C., jun. New York: Josiah Macy, jun., Foundation.

Irving, J. R. (1958). *Nature, Lond.*, **181**, 704.

Irving, J. R. (1959). *Nature, Lond.*, **183**, 1734.

Johnson, L. C. (1960). *Publ. Amer. Ass. Advanc. Sci. no. 64: Calcification in Biological Systems*, p. 117.

King, E. J. (1956). *Microanalysis in Medical Biochemistry*, 3rd ed., p. 79. New York: Grune and Stratton.

Leach, A. A. (1958). *Biochem. J.* **69**, 429.

Lucy, J. A., Dingle, J. T. & Fell, H. B. (1961). *Biochem. J.* **79**, 500.

Rao, C. R. (1952). *Advanced Statistical Methods in Biometric Research*. New York: John Wiley and Sons Inc.

Shaftel, A. G. (1944). *J. Lab. clin. Med.* **29**, 875.

Thompson, V. W. & DeLuca, H. F. (1964). *J. biol. Chem.* **239**, 984.

Van Handel, Z., Zilversmit, D. B. & Bowen, K. (1957). *J. Lab. clin. Med.* **50**, 152.

Wittcoff, H. (1951). *The Phosphatides*, p. 162. New York: Reinhold Publishing Corp.

Wolbach, S. B. (1947). *J. Bone Surg.* **29**, 171.

J. Agr. Food Chem. 17(4):778-784. 1969.

Metabolism of Vitamins D and A

DeLuca-'69
Bib. No. 2093

Hector F. DeLuca

Reproduced by permission
of the copyright owner

Recent advances in the elucidation of the metabolism of vitamins A and D have been reviewed. Retinol and retinoic acid are metabolized to CO_2 and other excretion products by three pathways. Both in vivo and in vitro evidence has been obtained for all three. One pathway, traced to the microsomal fraction, involves oxidative decarboxylation of the terminal carbon to CO_2 with TPNH and O_2 as requirements. Vitamin D is metabolized to 11 metabolites, which are readily separated on silicic acid columns. An ester of vitamin D with long-chain fatty acids represents one metabolite fraction. Quantitatively most important is another metabolite which has been isolated and identified as 25-hydroxycholecalciferol. It probably represents the metabolically active form of vitamin D. Other metabolites are as yet unidentified.

Within the last ten years, new and revolutionary findings have injected into the field of the metabolism of fat-soluble vitamins a renewed interest in finding a detailed understanding of the metabolism and function of these compounds at the molecular level. This discussion of recent developments regards only two fat-soluble vitamins, A and D.

VITAMIN D

Recent advances in the study of the metabolism of vitamin D have been made possible by modern techniques of isotopic labeling, various chromatographic methods, and new methods of identification with only minute quantities—mass spectrometry and nuclear magnetic resonance spectrometry.

Although attempts were made in the last decade (Kodicek, 1958), it was not possible to examine the metabolism of vitamin D extensively because the specific activity of the labeled vitamins was too low to permit experiments with physiologic doses. It was shown, however, that absorption of vitamin D requires the presence of bile; the primary excretion of the end products of vitamin D is in the feces via the bile; and vitamin D is not excreted intact but is metabolized (Kodicek, 1956). However, the old methods and nonphysiologic doses led to incorrect conclusions or assumptions, not enumerated here.

It was only after the synthesis of radioactive vitamins D_2 (Imrie *et al.*, 1967), D_3 (Neville and DeLuca, 1966), and D_4 (DeLuca *et al.*, 1968) of sufficient radioactivity that progress became rapid. The methods of synthesis of radioactive D_3 and D_4 are shown in Figures 1 and 2, respectively.

Cholesteryl benzoate labeled in the 1,2 positions was brominated allylically with *N N'*-dibromodimethylhydantoin and then dehydrohalogenated to yield the 7-dehydrocholesteryl benzoate, which on irradiation with ultraviolet light after hydrolysis yielded 1,2-^{3}H vitamin D_3. The 22, 23 ^{3}H vitamin D_4 was prepared by reaction of the ergosteryl acetate with maleic anhydride followed by reduction of the side chain with tritium using palladium black as the catalyst. The maleic anhydride was removed by sublimation at 220°C. and following hydrolysis, the 22, 23 ^{3}H vitamin D_4 was prepared in the usual fashion. A radioactive vitamin D_2 of high specific activity was also obtained by a biosynthetic route (Imrie *et al.*, 1967).

Using physiologic quantities of radioactive vitamin D, it was possible to detect metabolites of vitamin D that had been

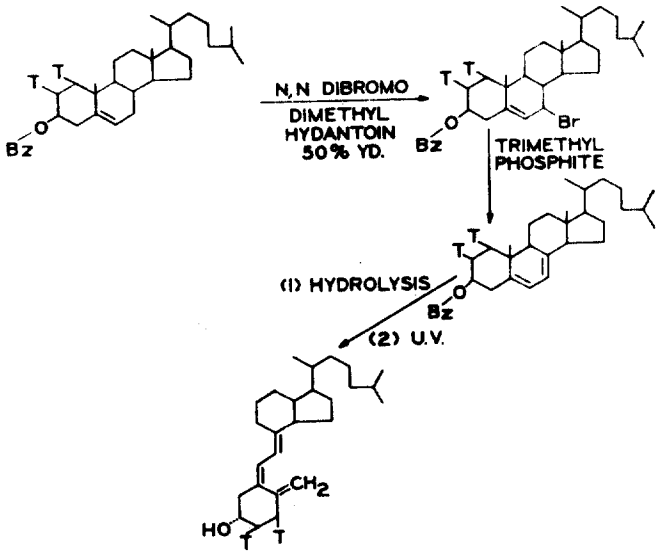

Figure 1. Synthesis of 1,2-^{3}H vitamin D_3 of high specific activity 26,000 d.m.p./I.U.

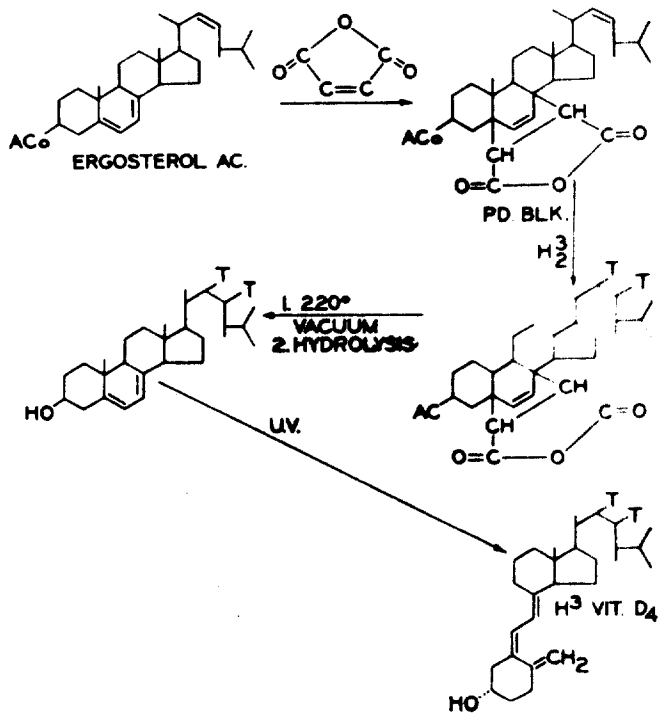

Figure 2. Synthesis of 22,23-^{3}H vitamin D_4 150,000 d.p.m./I.U.

Biochemistry Department, University of Wisconsin, Madison, Wis. 53706

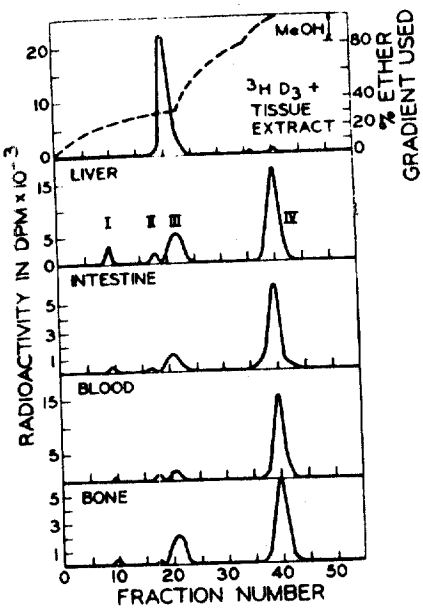

Figure 3. Silicic acid column chromatography of methanol-chloroform extracts of tissues from rats given 0.25 μg. of 1,2-^{3}H vitamin D$_3$ intravenously 12 hours previously

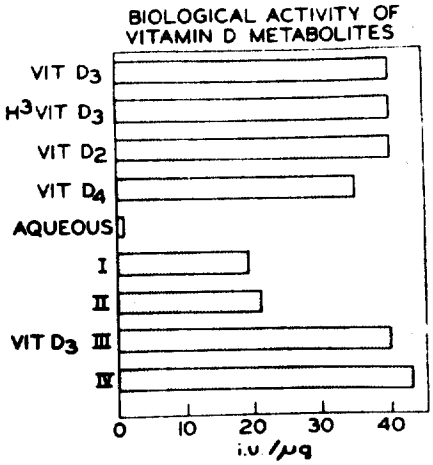

Figure 4. Biological activity of vitamin D$_3$ and its metabolite fractions

Biological activity assessed by line test assay method for vitamin D activity

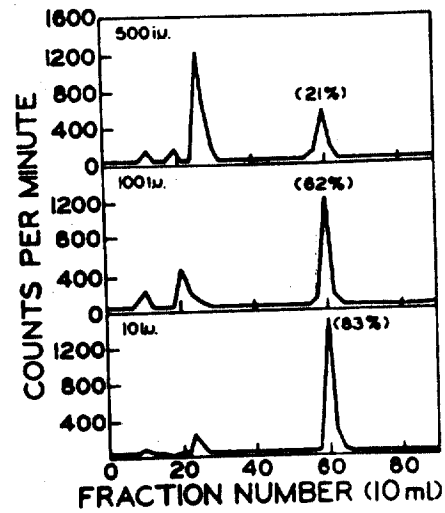

Figure 5. Effect of dose on distribution of ^{3}H among metabolite fractions after 1,2-^{3}H vitamin D$_3$

bypassed previously. After intravenous injection of radioactive vitamin D, tissues were removed and extracted by the methanol-chloroform procedure of Bligh and Dyer (1959). Some metabolic degradation products of vitamin D were readily apparent, in that some radioactivity was detected in the methanol-aqueous phase. These products were, however, biologically inactive and have not been studied further (Lund and DeLuca, 1966). However, chromatography of the $CHCl_3$ extract on silicic acid yielded four major radioactive components (Figure 3). Peak I was identified as an ester of vitamin D and long-chain fatty acids (Lund *et al.*, 1967), because on hydrolysis in base, the resulting radioactivity chromatographed as peak III which has been positively identified as unchanged vitamin D (Norman *et al.*, 1964). Furthermore, this substance gives full biological activity by the rickets cure test in rats (Lund *et al.*, 1966). Fraser and Kodicek (1965, 1968) also positively identified esters of vitamin D and provided evidence that the fatty acids are palmitic, linoleic, oleic, and steric. The ester fraction appears to have little physiologic significance in mammals, because their concentration remains small regardless of dose or time after dose (Lund *et al.*, 1966).

Peak II represents an unidentified metabolite which is approximately half as effective as vitamin D in curing rickets in rats. It does not appear to be either previtamin D or 5,6-*trans*-vitamin D. The quantity of this metabolite remains small regardless of dose or time after dose and is thus not considered of great significance. Peak III represents unchanged vitamin D$_3$ as determined by cochromatography and biological assay (Norman *et al.*, 1964). Of major interest is the peak IV metabolite fraction, since it probably represents the metabolically active form of the vitamin (DeLuca, 1967).

When bioassayed on the basis of radioactivity, this metabolite was at least as active as the parent vitamin in curing rickets in rats (Figure 4) (Lund and DeLuca, 1966). Furthermore, it produced all known physiologic effects of the vitamin, including bone mobilization and stimulation of intestinal transport of calcium. Surprisingly, however, it produced these effects more rapidly than vitamin D itself (Morii *et al.*, 1967).

When the dose of ^{3}H vitamin D$_3$ was reduced to physiologic doses—i.e., 10 I.U.—the proportion of radiaoctivity in this fraction greatly increased (Lund and DeLuca, 1966) (Figure 5). Efforts were also made to rule out artifactual production of this metabolite fraction. It soon became evident that the peak IV fraction was not a single radioactive substance and a more careful chromatographic procedure was developed (Ponchon and DeLuca, 1969) capable of separating peak IV into many fractions (Figure 6). When these fractions were biologically assayed for vitamin D activity, only that labeled as peak IV was biologically active.

The properties of the peak IV metabolite prompted an intensive effort in our laboratory to isolate and identify this metabolite. A method of isolation of the metabolite in pure form was devised (Blunt *et al.*, 1968a) (Figures 7 and 8). Hogs were chosen as the source of the material because preliminary experiments showed that large amounts of the metabolite could be induced in their blood by feeding large amounts of vitamin D (Blunt *et al.*, 1968a). Plasma was therefore obtained from four hogs fed for 26 days on 250,000 I.U. of D$_3$

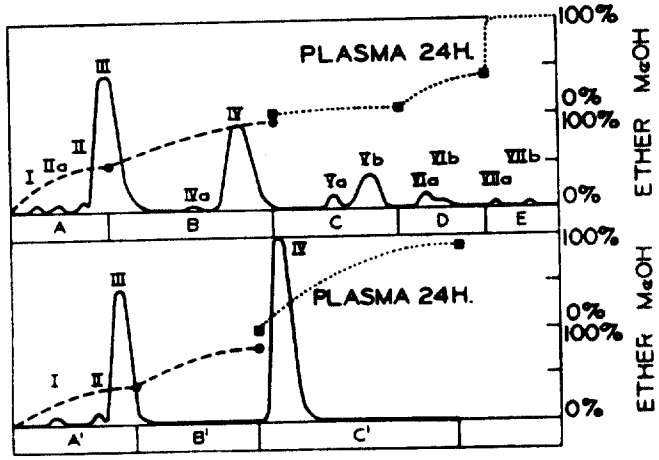

Figure 6. Chromatography of plasma extract on silicic acid using a refined gradient system

—— Radioactivity
- - - - - - - - - - Gradient
Vitamin D-deficient rats had received 0.25 μg. 1,2-^{3}H vitamin D$_3$ 24 hours before
A, *B*, *C*, etc. New system
A', *B'*, *C'*. Old chromatographic system

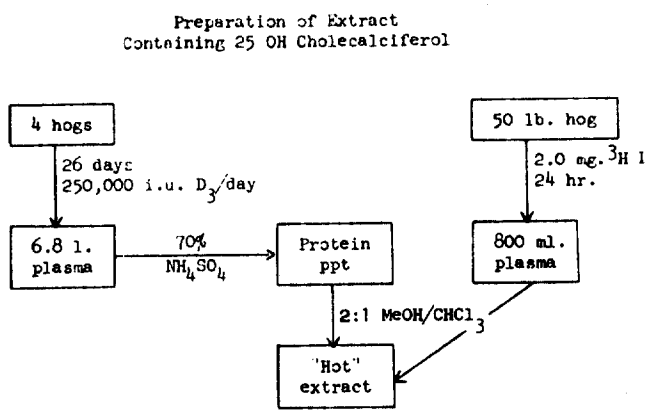

Figure 7. Preparation of extract for isolation of 25-hydroxycholecalciferol

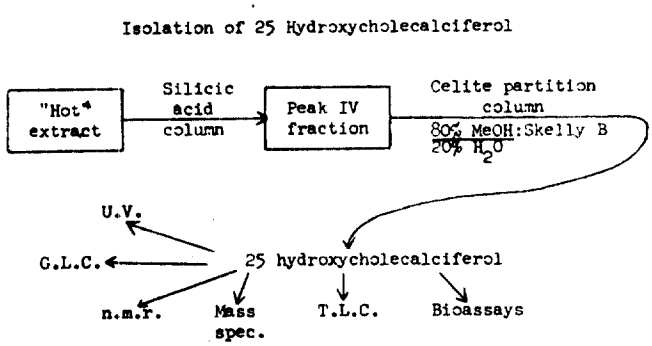

Figure 8. Flow diagram of isolation of 25-hydroxycholecalciferol from porcine plasma

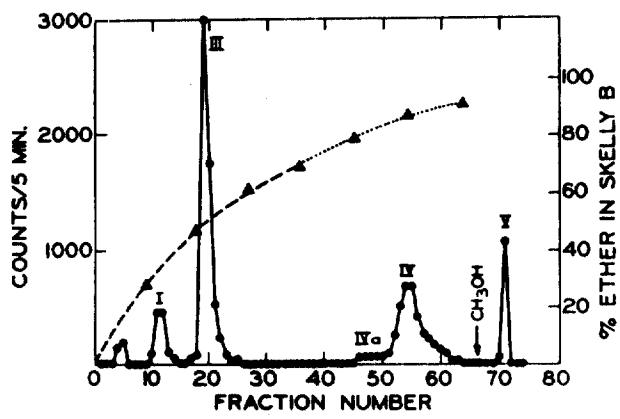

Figure 9. Silicic acid chromatography in isolation of 25-hydroxycholecalciferol from porcine plasma

per day. The protein of the plasma which binds the metabolite was precipitated out by means of 70% saturation with ammonium sulfate. The precipitate was then extracted with methanol and chloroform. A small pig was injected with ^{3}H vitamin D_3, the blood plasma was isolated and extracted, and the chloroform extract was combined with that obtained from the four pigs. The metabolite was isolated by silicic acid chromatography (Figure 9) followed by partition chromatography (Figure 10) to yield 1.3 mg. of pure metabolite (Blunt *et al.*, 1968a,b). The purity of the metabolite was established by TLC, GLC (Figure 11), and its ultraviolet spectrum (Figure 12). Its structure was unequivocally established as 25-hydroxycholecalciferol by a combination of techniques, including ultraviolet analysis, behavior on GLC to produce pyro and isopyro forms, mass spectra, and nuclear magnetic resonance spectra. Finally, it was synthesized by

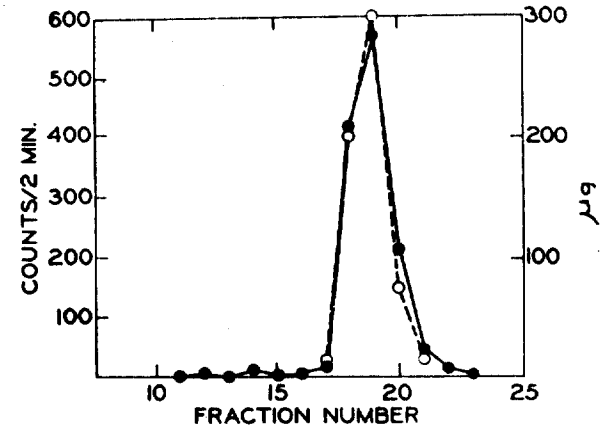

Figure 10. Partition chromatography of 25-hydroxycholecalciferol on Celite using 80% methanol, 20% water equilibrated with a petroleum fraction b.p. 65–67°C. ○ μg. 25 OH D_3 based on spectrum. ● Radioactivity

two independent methods (Blunt and DeLuca, 1969); the synthetic material is identical in all respects, including biological activity, to the isolated 25-hydroxycholecalciferol. Thus, its structure is firmly established (Figure 13).

The biological properties of 25-hydroxycholecalciferol provide strong evidence that it represents the metabolically active form of the vitamin (Blunt *et al.*, 1968). Table I shows that on a weight basis it is 1.4 times as active as cholecalciferol itself in curing rickets in rats. Results demonstrate a similar relationship in chicks. In a study of calcium transport by everted sacs of intestine, a 0.25-μg. intravenous dose of 25 OH D_3 produces a response in 3 hours while 6 to 10 hours are required for a similar response to vitamin D_3 (Figure 14). Likewise, a rise in serum calcium at the expense of bone occurs 4 hours after a 2.5-μg. dose of 25 OH D_3, while 12 hours is required for a similar response to 2.5 μg. of D_3 (Figure 15). Finally this substance induces bone resorption in culture at a concentration of 0.3 I.U. per ml., while as much as 500 I.U. per ml. of vitamin D_3 produces a questionable response (Trummel *et al.*, 1969). The resorption of "old" bone is considered an important physiologic action of vitamin D in vivo (DeLuca, 1967).

The 25-hydroxycholecalciferol is almost certain to be the metabolically active form of the vitamin, but only continued experiments with isolated systems will establish this important concept.

Finally the present study has shown that the nuclear membrane of intestinal mucosa accumulates a large amount of this metabolite, and in some way it initiates the transcription of a specific DNA into mRNA which codes for a calcium transport component (Stohs and DeLuca, 1967).

Table I. Comparative Effectiveness of 25-Hydroxycholecalciferol and Vitamin D_3 in the Cure of Rickets in Rats[a]

Type of Dosage[b]	25-OH D_3, I.U./μg.	Vit D, I.U. μg.
Oral (8)[b]	58 ± 5[c]	40 ± 4[c]
Oral (7)[b]	52 ± 3	38 ± 5
Intravenous (7)[b]	56 ± 2	41 ± 3

[a] Standard line test assay for vitamin D activity carried out as described in U. S. Pharmacopeia (1955).
[b] Number of rats per group.
[c] Standard deviation.

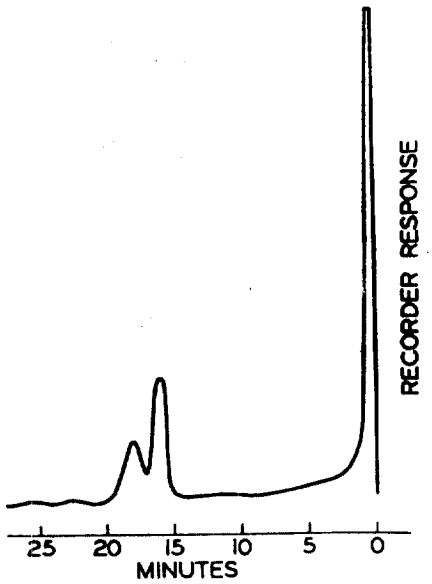

Figure 11. Gas-liquid chromatography of 25 - hydroxycholecalciferol demonstrating purity of isolated material from porcine plasma

Repeated attempts have not verified reports from another laboratory that the metabolite is found in the chromatin (Haussler *et al.*, 1968). Using high specific activity ^{3}H D_3 (160,000 d.p.m. per I.U.) or ^{3}H D_3 (26,000 d.p.m. per I.U.) which allows such an experiment to be carried out, no radioactivity could be found in intestinal chromatin isolated by the method of Marushige and Bonner (1966), a result which verifies our earlier failure to find radioactivity in deoxyribonucleoprotein isolated by the method of Zubay and Doty (1959).

The only other metabolite of vitamin D that has been reported is a sulfate ester in which the SO_4 is esterified to the 3-hydroxy group (Higaki *et al.*, 1965a,b). This has been shown to occur in homogenates of liver, using phosphoadenosylphosphosulfate as the sulfate donor. This substance is currently considered as an excretory product from massive amounts of vitamin D, but additional work must be carried out to establish its existence when physiologic amounts of vitamin D are given.

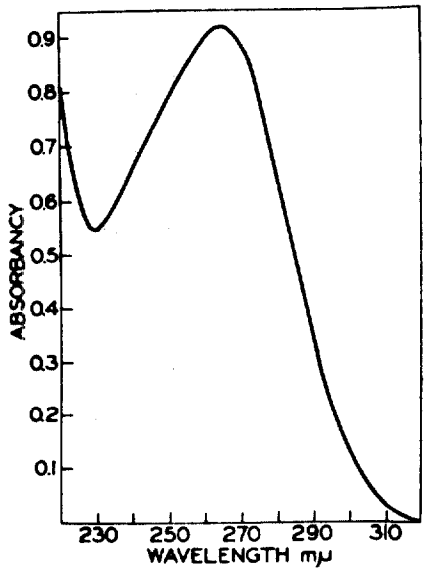

Figure 12. Ultraviolet spectrum of isolated 25-hydroxycholecalciferol in diethyl ether

Much work remains to be done on the metabolites of vitamin D. Many metabolites are as yet unidentified, and the enzymatic steps for virtually all reactions involving the vitamin D molecule also remain unknown. A start has been made, however, with the isolation and identification of the 25-hydroxycholecalciferol, which is probably the metabolically active form of vitamin D.

VITAMIN A

Virtually all the progress which has been made is the result of the synthesis of two specifically labeled vitamin A compounds by the Hoffman LaRoche group: 6,7-^{14}C retinoic

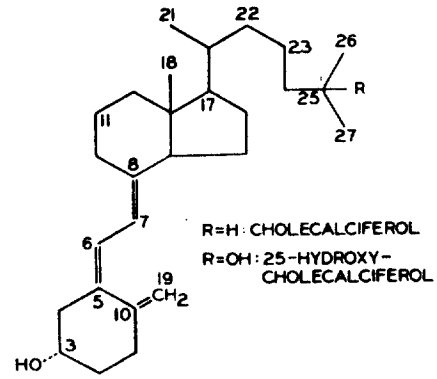

Figure 13. Structure of 25-hydroxycholecalciferol, believed to be metabolically active form of vitamin D_3

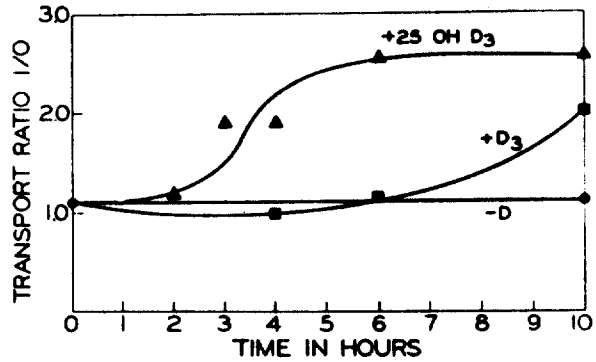

Figure 14. Response of calcium transport system of rats to 0.25 μg. intravenously of 25-hydroxycholecalciferol or vitamin D_3

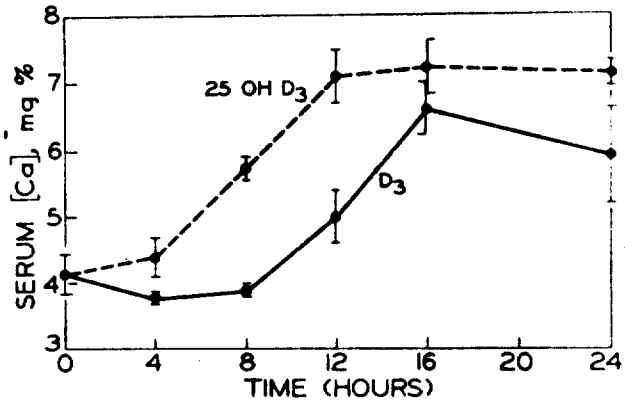

Figure 15. Serum calcium response of vitamin D-deficient rats on a low-calcium diet to 25-hydroxycholecalciferol or vitamin D_3

2.5 μg. of either compound in 0.02 ml. ethanol administered intravenously

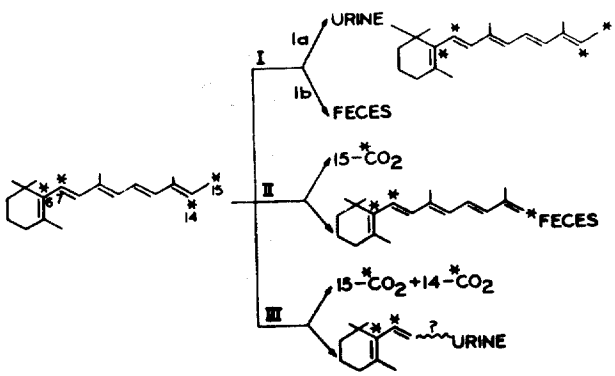

Figure 16. Proposed pathways of retinol or retinoic acid metabolism

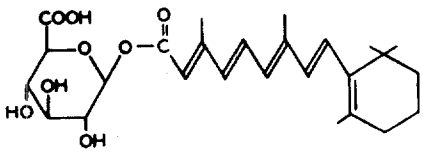

Figure 17. Retinoyl β-glucuronide

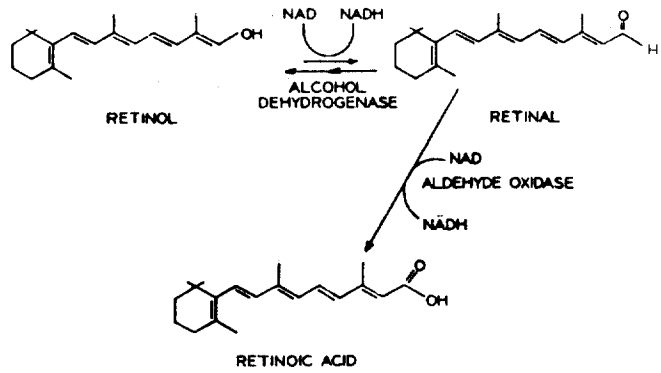

Figure 18. Conversion of retinol to retinoic acid

Table II. Recovery of ^{14}C from Rats Given Radioactive Retinoic Acid[a]

Fraction	Position of ^{14}C in Retinoic Acid (14.5 μg.) 6,7-^{14}C, % dose	14-^{14}C, % dose	15-^{14}C, % dose
Carbon dioxide	0.8 ± 0.4 (2)	18.9 ± 3.4 (3)	35.0 ± 4.5 (2)
Urine	38.0 ± 4.4 (4)	18.3 ± 0.3 (3)	19.9 ± 1.7 (5)
Feces	64.5 ± 1.3 (4)	61 (3)[b]	43.7 ± 3.0 (4)
Total recovery	103.3	98.2	98.6

[a] Means ± S.D. Number in parentheses indicates number of rats.
[b] Values obtained were all low, because of bacterial decomposition of radioactive products in feces. A plot of the three values obtained *vs.* time lapse from completion of experiment to time of combustion of samples was linear and extrapolated to 61% recovery of dose at zero time.

acid and retinol, and 15-^{14}C retinoic acid and retinol. In addition, 14-^{14}C vitamin A compounds are available commercially (Tracerlab, Inc.).

These compounds have made possible some insight into the degradation of the vitamin A molecule (Roberts and DeLuca, 1967). If physiologic amounts of ^{14}C retinoic acid (14.5 μg. per rat) are administered intravenously and the pathways of the resulting ^{14}C excretion products are examined, the following data are obtained (Table II): From the 6,7-^{14}C positions, no $^{14}CO_2$ arises, whereas both 14-C and 15-C positions yield $^{14}CO_2$. As much as 30% of the dose of 15-^{14}C is excreted as CO_2 which is interpreted as an oxidative decarboxylative pathway. The remainder of the dose appears in the feces and urine. The 14 position yields less $^{14}CO_2$ but, nevertheless, represents an oxidative side-chain degradation. If the assumption is made that the urinary and fecal excretion products labeled with 15-^{14}C from retinoic acid represent intact molecule products, some analysis can be made in regard to the retinoic acid chain. From the recovery data, the following pathways of retinoic acid metabolism can be postulated to account for the excretion data (Figure 16). Pathway I represents intact side-chain excretion products, probably in large measure the retinoyl β-glucuronide isolated and identified by Olson and his coworkers (Dunagin *et al.*, 1965, 1966) (Figure 17). Olson and coworkers (Lippel and Olson, 1968) have reported that 90% or more of administered retinoic acid is excreted by this route. However, not more than 60% of injected retinoic acid has been identified as this product. Bile duct cannulated rats continue to metabolize 30% of 15-^{14}C retinoic acid to $^{14}CO_2$ (Roberts and DeLuca, 1968b), making it unlikely that retinoyl-β-glucuronide represents 90% of the excretory products of retinoic acid. A glucuronide of retinol is probably the major excretion form of retinol (Lippel and Olson, 1968), although its identification is incomplete at the present time. Only small amounts of retinoyl glucuronide are formed from retinol (Emerick *et al.*, 1967). The oxidatively decarboxylated retinoic acid yields a metabolite shorter by one carbon, as shown in pathway II (Figure 16), with this product appearing in the feces via the bile. A third pathway (III) involves oxidation of the side chain to some point between the 7 and 14 positions. This pathway is shown in Figure 16 as pathway III, yielding urinary products.

Table III shows that data similar to those obtained with retinoic acid can be obtained with retinyl acetate. Thus, the pathways for retinol metabolism and excretion are apparently similar. The metabolism of retinyl acetate is much slower than retinoic acid—for example, the ^{14}C recovery from 14.5 μg. of retinoic acid was complete in 48 hours, while that

Table III. Recovery of ^{14}C from Rats Given Radioactive Retinyl Acetate[a]

Fraction	Position of ^{14}C in Retinyl Acetate: 6,7-^{14}C, (2.0 μg.) Recovery, % dose	Total,[b] %	2.0 μg. Recovery, % dose	Total,[b] %	(1.46 μg.) Recovery, % dose	Total,[b] %
Carbon dioxide	2.5 (2)	4.5	15 (2)	30.6	8.8 (2)	32.1
Urine	26.8 ± 2.8 (4)	48.2 ± 5.3	15.0 ± 2.0 (2)	30.6 ± 4.1	8.3 ± 0.8 (2)	30.3 ± 2.9
Feces	26.3 ± 5.0 (4)	47.3 ± 9.0	18.9 ± 2.6 (2)	38.6 ± 5.3	10.3 ± 2.5 (2)	37.6 ± 9.1
Total	55.6	100.0	48.9	100.0	27.4	100.00

[a] Values for urine and carbon dioxide represent radioactivity recovered after 4 days. Feces values represent 5-day collection to allow for time lag in elimination.
[b] Per cent of total amount of radioactivity recovered in 4 days.

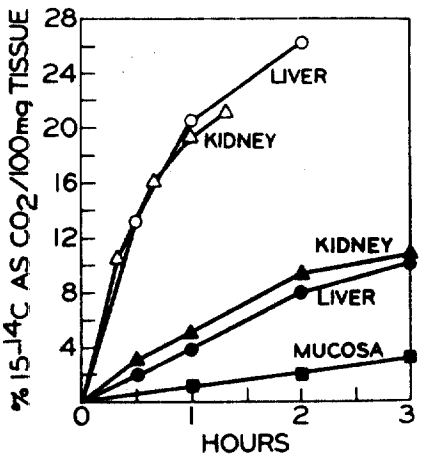

Figure 19. Rate of C-15 decarboxylation of retinoic acid by tissue slices

Each flask contained Krebs-Ringer phosphate and tissues from a retinol-deficient rat (●, ▲, ■) or Krebs-Ringer bicarbonate and tissue from a stock rat (○, △).

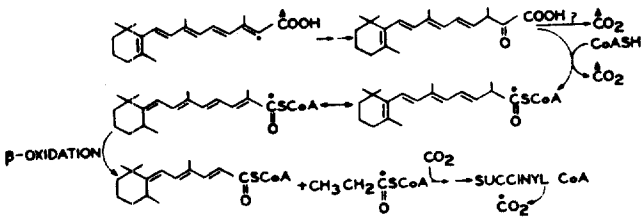

Figure 20. Proposed pathway of metabolism of 14-^{14}C retinoic acid in tissue slices

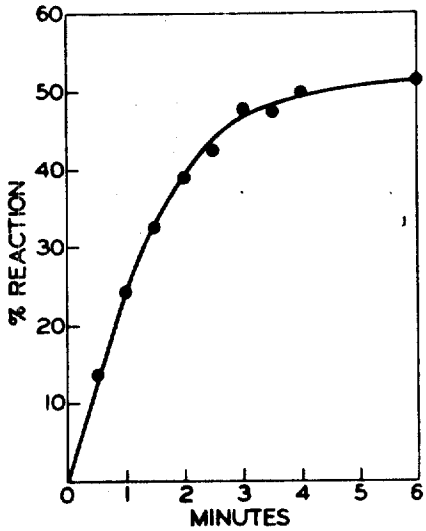

Figure 21. Rate of C-15 decarboxylation of retinoic acid by microsomes from rat liver

Reaction mixture as described in Table V

from 2.0 μg. of retinyl acetate was only 30% complete in 4 to 5 days. The pathway of retinol to retinoic acid is well known (Figure 18). Retinol is oxidized via a nonspecific alcohol dehydrogenase to retinal, requiring NAD (Futterman and Saslaw, 1961; Wald and Hubbard, 1950; Zachman and Olson, 1961). Retinal is also readily reduced to retinol by reversal of this reaction; thus the interconversion of retinol to retinal is not unexpected in vivo. Retinal is further oxidized to retinoic acid by the indicated reaction (Figure 18) (Dimitrovsky, 1961; Elder and Topper, 1962; Futterman, 1962; Mahadevan *et al.*, 1962). Furthermore, whether free retinoic acid is a significant intermediate in retinol metabolism is questionable, since only small amounts of retinoic acid as the glucuronide can be found in the bile after retinol administration (Dunagin *et al.*, 1964; Emerick *et al.*, 1967). That this reaction is irreversible in vivo is also well known, since retinoic acid cannot cure night blindness and reproductive failure due to retinol deficiency (Dowling and Wald, 1958, 1960; Thompson *et al.*, 1961a,b; Thompson, 1964). No storage of retinol in the liver results from even massive doses of retinoic acid (Arens and Van Dorp, 1964a,b; Sharman, 1949).

Table IV. Inhibitors of Retinoic Acid Metabolism to CO_2 by Kidney Slices[a]

Inhibitor	% Control $^{14}CO_2$ 15-^{14}C	14-^{14}C
$-O_2(N_2)$	46	..
+ malonate, $2 \times 10^{-2}M$	133	26
Fluoroacetate	98	18
Antimycin A 3, μg./ml.	110	22
DPPD $2 \times 10^{-7}M$	0	0

[a] Krebs-Ringer phosphate buffer used as medium. Incubations for 2 hours.

Table V. Requirements for Microsomal Oxidative Decarboxylation of Retinoic Acid[a]

Medium	% of Complete
Complete	100
$- Fe^{2+}$	59
– NADPH	12
$- PP_i$	65
– NADPH, Fe^{2+}, PP_i	12
– Microsomes	12
– NADPH, PP_i	12
$- Fe^{2+}$, PP_i	32

[a] Reaction mixture contained 3.6 m*M* of KCl, 5 m*M* $MgCl_2$, 5 m*M* phosphate buffer (pH 7.3); 88 m*M* NADPH, excess glucose 6-PO_4 dehydrogenase, 1 m*M* glucose-6-PO_4, 0.3 m*M* pyrophosphate (PP_i) and microsomes from liver.

Because of the irreversibility in vivo of retinoic acid to retinol, it has been postulated that an active metabolite of vitamin A must exist which is formed from either retinol or retinoic acid. A search for such a compound in several laboratories ensued with only 13-*cis*-retinoic acid (Zile *et al.*, 1967) and retinoyl glucuronide (Dunagin *et al.*, 1965, 1966) being positively identified as metabolites of retinoic acid. Many unidentified metabolites have been described, but no further information on these is available at the present time.

In this laboratory, work continued on the oxidative reactions of retinoic acid. It was possible to show that slices of liver and kidney can oxidatively decarboxylate retinoic acid in vitro (Figure 19) (Roberts and DeLuca, 1968a). Both the 15-^{14}C and 14-^{14}C labeled retinoic acids yielded $^{14}CO_2$. The production of $^{14}CO_2$ from 15-^{14}C retinoic acid was not inhibited by TCA cycle inhibitors (Table IV). The oxidation of 14-^{14}C retinoic acid was markedly inhibited by such things as fluoroacetate, malonate, or antimycin A. It is evident then that pathway II involves the scission of the retinoic acid side chain between the 7 and the 14 position. This piece of the side chain is then probably metabolized in some way via the TCA cycle (Figure 20).

The oxidative decarboxylation of the 15-^{14}C retinoic acid has now been traced to the microsomal fraction, as shown in Figure 21 (Roberts and DeLuca, 1968b). The reaction takes place in both liver and kidney microsomes and requires O_2, NADPH, Fe^{2+}, and a pyrophosphate moiety (Table V). The

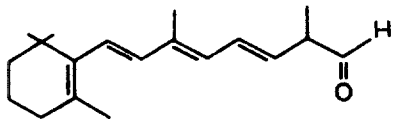

Figure 22. Proposed product of oxidative decarboxylation of retinoic acid

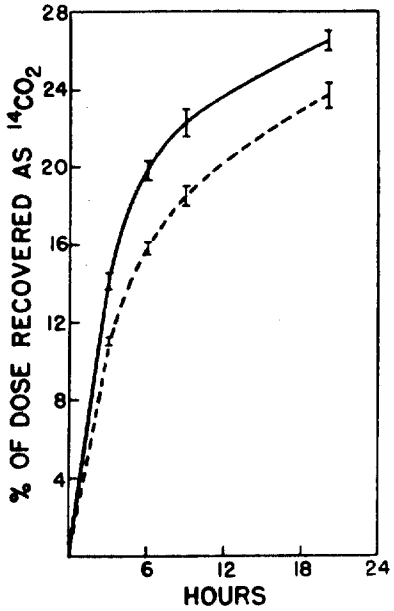

Figure 23. Effect of DPPD on in vivo decarboxylation of 15-^{14}C retinoic acid

Rats given 14.5-μg. intravenous injection of 15-^{14}C retinoic acid. One half the rats were fed a diet containing 0.01 to 0.05% DPPD and given an oral dose of 2 mg. DPPD on oil 3 hours before the experiment.
—— No DPPD
- - - +DPPD

pyrophosphate can be supplied by many nucleotides, including thiamine pyrophosphate, but is specific only for pyrophosphate. Boiled microsomes do not catalyze the reaction, while ascorbate plus boiled microsomes will. This reaction is inhibited by *p*-chloromercuribenzoate, $K_3Fe(CN)_6$, EDTA, phenozine methosulfate, and *N,N'*diphenyl-*p*-phenylenediamine (DPPD), but not by SKF-525 A, phenobarbital, and aminopyrine. In this regard the reaction resembles a lipid peroxidation system and probably involves a free radical mechanism. It does not appear to be a microsomal hydroxylation reaction. The reaction product has not yet been identified, although all evidence suggests that the first product is a 14-C aldehyde (Figure 22). Unfortunately, proof of this structure is lacking at the present time.

An attempt was made to assess the in vivo importance of the microsomal decarboxylation system by administering DPPD in vivo to rats and observing its effect on $^{14}CO_2$ production from 15-^{14}C retinoic acid (Roberts and DeLuca, 1969). The data show approximately a 20% inhibition by DPPD (Figure 23). Thus at least a portion of the in vivo decarboxylation of retinoic acid is related to the microsomal reaction.

LITERATURE CITED

Arens, J. F., Van Dorp, D. A., *Nature* **157**, 190 (1946a).
Arens, J. F., Van Dorp, D. A., *Nature* **158**, 522 (1946b).
Bligh, E. G., Dyer, W. J., *Can. J. Biochem. Physiol.* **37**, 911 (1959).
Blunt, J. W., DeLuca, H. F., *Biochemistry*, **8**, 671 (1969).
Blunt, J. W., DeLuca, H. F., Schnoes, H. K., *Biochemistry*, **7**, 3317 (1968a).
Blunt, J. W., DeLuca, H. F., Schnoes, H. K., *Chem. Commun.* **1968b** (14), 801.
Blunt, J. W., Tanaka, Y., DeLuca, H. F., *Proc. Natl. Acad. Sci.*, **61**, 1503 (1968).
DeLuca, H. F., *Vitamins Hormones*, **25**, 315 (1967).
DeLuca, H. F., Weller, M., Blunt, J. W., Neville, P. F., *Arch. Biochem. Biophys.* **124**, 122 (1968).
Dimitrovsky, A. A., *Biokhimiya*, **26**, 126 (1961).
Dowling, J. E., Wald, G., *Proc. Natl. Acad. Sci.* **44**, 648 (1958).
Dowling, J. E., Wald, G., *Proc. Natl. Acad. Sci.* **46**, 587 (1960).
Dunagin, P. E., Jr., Meadows, E. H., Jr., Olson, J. A., *Science* **148**, 86 (1965).
Dunagin, P. E., Jr., Zachman, R. D., Olson, J. A., *Biochim. Biophys. Acta* **90**, 432 (1964).
Dunagin, P. E., Jr., Zachman, R. D., Olson, J. A., *Biochim. Biophys. Acta* **124**, 71 (1966).
Elder, T. D., Topper, Y. J., *Biochim. Biophys. Acta* **64**, 430 (1962).
Emerick, R. J., Zile, M., DeLuca, H. F., *Biochem. J.* **102**, 606 (1967).
Fraser, D. R., Kodicek, E., *Biochem. J.* **96**, 59P (1965).
Fraser, D. R., Kodicek, E., *Biochem. J.* **106**, 485 (1968).
Futterman, S., *J. Biol. Chem.* **237**, 677 (1962).
Futterman, S., Saslaw, L. D., *J. Biol. Chem.* **236**, 1652 (1961).
Haussler, M. R., Myrtle, J. F., Norman, A. W., *J. Biol. Chem.* **243**, 4055 (1968).
Higaki, M., Takahashi, M., Suzuki, T., Sahashi, Y., *J. Vitaminol.* **11**, 261 (1965a).
Higaki, M., Takahashi, M., Suzuki, T., Sahashi, Y., *J. Vitaminol.* **11**, 266 (1965b).
Imrie, M. H., Neville, P. F., Snellgrove, A. W., DeLuca, H. F., *Arch. Biochem. Biophys.* **120**, 525 (1967).
Kodicek, E., "Ciba Foundation Symposium on Bone Structure and Metabolism," G. E. W. Wolstenholme and C. M. O'Conner, eds., pp. 161–74, Little, Brown and Co., Boston, Mass., 1956.
Kodicek, E., "Fourth International Congress of Biochemistry," Vol. XI, "Vitamin Metabolism," pp. 198–208, Pergamon Press, London, 1958.
Lippel, K., Olson, J. A., *J. Lipid Res.* **9**, 168 (1968).
Lund, J., DeLuca, H. F., *J. Lipid Res.* **7**, 739 (1966).
Lund, J., DeLuca, H. F., Horsting, M., *Arch. Biochem. Biophys.* **120**, 513 (1967).
Mahadevan, S. N., Murthy, S. K., Ganguly, J., *Biochem. J.* **85**, 326 (1962).
Marushige, K., Bonner, J., *J. Mol. Biol.* **15**, 160 (1966).
Morii, H., Lund, J., Neville, P., DeLuca, H. F., *Arch. Biochem. Biophys.* **120**, 508 (1967).
Neville, P., DeLuca, H. F., *Biochemistry* **5**, 2201 (1966).
Norman, A. W., Lund, J., DeLuca, H. F., *Arch. Biochem. Biophys.* **108**, 12 (1964).
Ponchon, G., DeLuca, H. F., *J. Nutr.* in press (1969).
Roberts, A., DeLuca, H. F., *Arch. Biochem. Biophys.* **123**, 279 (1968).
Roberts, A. B., DeLuca, H. F., *Biochem. J.* **102**, 600 (1967).
Roberts, A., DeLuca, H. F., *Arch. Biochem. Biophys.*, **129**, 290 (1969a).
Roberts, A., DeLuca, H. F., *J. Lipid Res.* **9**, 501 (1968b).
Sharman, I. M., *Brit. J. Nutr.* **3**, viii (1949).
Stohs, S. J., DeLuca, H. F., *Biochemistry* **6**, 3338 (1967).
Thompson, J. N., *Proc. Roy. Soc.* **159**, 510 (1964).
Thompson, J. N., Howell, J. M., Pitt, G. A. J., *Biochem. J.* **80**, 16P (1961a).
Thompson, J. N., Howell, J. M., Pitt, G. A. J., *Biochem. J.* **80**, 25P (1961b).
Trummel, C., Raisz, L. G., Blunt, J. W., DeLuca, H. F., *Science* **163**, 1450 (1969).
U. S. Pharmacopeia, Vol. XV, p. 889, Mack Publishing Co., Easton, Pa., 1955.
Wald, G., Hubbard, R., *Proc. Natl. Acad. Sci.* **36**, 92 (1950).
Zachman, R., Olson, J. A., *J. Biol. Chem.* **236**, 2309 (1961).
Zile, M., Emerick, R. J., DeLuca, H. F., *Biochim. Biophys. Acta* **141**, 639 (1967).
Zubay, G., Doty, P., *J. Mol. Biol.* **1**, 1 (1959).

Received for review September 6, 1968. Accepted January 10, 1969. Symposium on Recent Trends in Nutritional Chemistry, Division of Agricultural and Food Chemistry, 156th Meeting, ACS, Atlantic City, N. J., September 1968. Published with the approval of the director of the Wisconsin Agricultural Experiment Station. Work supported by the NIH (AMO-5800-07) and the NSF (GB5845).

Dingle-'61
Bib. No. 2196

Reproduced by permission
of the copyright owner

Biochem J
Biochem. J. (1961) 79, 497

Studies on the Mode of Action of Excess of Vitamin A

1. EFFECT OF EXCESS OF VITAMIN A ON THE METABOLISM AND COMPOSITION OF EMBRYONIC CHICK-LIMB CARTILAGE GROWN IN ORGAN CULTURE

By J. T. DINGLE, J. A. LUCY and HONOR B. FELL*
Strangeways Research Laboratory, Cambridge

(*Received* 8 *September* 1960)

Fell & Mellanby (1952) showed that in organ cultures the addition to the medium of excess of vitamin A (10–15 i.u./ml.) severely affects cartilaginous limb-bone rudiments from 6–7-day chick embryos. During 7–10 days' cultivation, the vitamin A-treated rudiments cease to grow, begin to shrink and become soft and gelatinous; the matrix no longer stains metachromatically with toluidine blue and the intercellular partitions become narrow and eventually disappear. These effects on the matrix are accompanied by cytological changes; the cartilage cells become smaller and less vacuolated and lose most of their glycogen (Fell & Thomas, 1960). They remain viable, however, and continue to multiply by mitosis. In experiments on foetal-mouse cartilage, it was shown that if the cells are killed by heating to 45° for 15 min., vitamin A has no effect on the explants (Fell & Mellanby, 1952).

In radioautographic experiments with labelled inorganic sulphate ($^{35}SO_4$), Fell, Mellanby & Pelc (1956) found that in the presence of the vitamin the explants first cease to take up sulphate and then lose that already incorporated; in the matrix the loss of $^{35}SO_4$ is accompanied by the disappearance of metachromasia. They concluded that vitamin A first inhibits the synthesis of new chondroitin sulphate and then causes the dissolution of that already formed. That these effects of vitamin A on cartilage matrix and cells are not peculiar to organ cultures has recently been demonstrated by Thomas, McCluskey, Potter & Weissmann (1960), who observed similar changes in the cartilage of young rabbits dosed with excess of vitamin A.

The object of the present investigation was to find what biochemical changes are associated with the morphological effects of excess of vitamin A on limb-bone rudiments in culture.

MATERIALS AND METHODS

Organ culture. The humeri, femora and tibiae of 7-day chick embryos were grown by the watch-glass method described by Fell & Mellanby (1952). Each watch glass contained a mixture of 15 drops of cock's blood plasma and 5 drops of embryo extract. The extract, which was made from 13- to 14-day chick embryos, was prepared by mixing equal parts of embryo pulp and Tyrode solution supplemented with 1% (w/v) of glucose; the mixture was centrifuged for 5 min.

Synthetic vitamin A alcohol (Roche Products, London) was dissolved in ethanol and added to the plasma; the same quantity (0·2%) of ethanol without the vitamin was added to the control plasma. The final medium contained 10 i.u. of vitamin A/ml. The rudiments from one side of each embryo were grown in vitamin A medium, and those from the opposite side in control medium. They were transplanted to fresh clots at 2-day intervals and were harvested for biochemical study after 6 days' cultivation.

Analyses. After incubation the bones were washed in iso-osmotic 0·9% NaCl soln., blotted dry on filter paper and weighed. The dry weights were obtained from the lipid-free material after extraction with ether. Ribonucleic acid (RNA) was estimated by the method of J. Biggers, K. Lawson, J. A. Lucy & M. Webb (unpublished), and deoxyribonucleicacid (DNA) by the method of Burton (1956). Results are expressed as μg. of nucleic acid phosphorus.

Bone rudiments and samples for hexosamine analysis were hydrolysed in 5N-HCl for 4 hr. at 100°. This procedure was always used in all analyses; no attempt was made to determine the hydrolysis conditions for optimum yields of hexosamine since the experiments were comparative and absolute quantities were not required. After hydrolysis, the samples were dried over phosphorus pentoxide *in vacuo*, and subsequently redissolved in 0·5N-HCl before analysis for total hexosamine content. Each sample was transferred to a 23 cm. column of Amberlite ion-exchange resin, CG-120 (II), washed in with 10 ml. of water and then eluted with 2N-HCl at room temperature to remove non-hexosamine components that interfere in the Elson–Morgan reaction (Boas, 1953). In experiments in which glucosamine and galactosamine were determined separately, the hydrolysed sample was redissolved in 0·3N-HCl and placed on a 60 cm. column of the same resin; elution was with 0·3N-HCl at room temperature (Gardell, 1953). The eluted hexosamines were estimated by the procedure of Rondle & Morgan (1955); four different concentrations of a standard solution of glucosamine hydrochloride were included with each batch of samples.

Metabolism. The oxygen uptake of the bones was measured by conventional Warburg techniques. Twelve bone rudiments were put into each flask. The vitamin-treated bones were each approx. 4–5 mm. in length and weighed about 2 mg. The control bones were about 6–7 mm. in length and weighed about 4 mg. The suspending medium

* Foulerton Research Fellow, Royal Society.

was Krebs–Ringer phosphate (Umbreit, Burris & Stauffer, 1957) containing 1·8 mg. of glucose/ml. and 10% of horse serum. To prevent the bicarbonate in the serum from altering the pH of the medium, the horse serum was pretreated by the method of Friend & Hastings (1940). The gas phase was air, and 20% sodium hydroxide was included in the centre well. All flasks had an equilibration period of 10 min. at 37°, after which incubation was continued for 90 min.; over this period the rate of oxygen uptake was linear. Agitation rate was 120 strokes/min. At the end of the incubation period 1 ml. of suspending fluid was removed, made up to 7 ml. and 1·5 ml. of 5% (w/v) $ZnSO_4,6H_2O$ and 1·5 ml. of approx. 0·3N-$Ba(OH)_2$ were added. Lactic acid was estimated by the method of Barker & Summerson (1941) and glucose by the method of Nelson (1944).

Clot lysis. At the end of the culture period the bone rudiments were removed from their supporting clot and washed in salt solution. The washings were returned to the culture medium and an equal volume of 10% trichloroacetic acid was added. The precipitate was spun off and washed twice with 5% trichloroacetic acid. The acid-insoluble material was dissolved in 5N-KOH and samples of this and of the acid-soluble material were estimated for nitrogen content by the micro-Kjeldahl method (Hawk, Oser & Summerson, 1952). The amount of clot digestion is expressed as the percentage of acid-soluble nitrogen.

RESULTS

Effect of vitamin A on the composition of bone rudiments. Cultivation of the bone rudiments in the presence of added vitamin A, under the conditions reported here, severely decreased the metachromatic staining reaction of the matrix with toluidene blue. This reaction is believed to be specific for sulphate esters of high-molecular-weight substances (Kent & Whitehouse, 1955) and it is probable therefore that the lack of metachromatic staining is related to the 50% loss of amino sugars (Table 1). There was some alteration in the ratio of glucosamine/galactosamine, since the vitamin A-treated explants lost slightly more galactosamine. The decrease in total hexosamine content of the vitamin A-treated rudiments was accompanied by a quantitatively similar decrease in the wet and dry weights; that these changes were not due simply to the presence of fewer cells in the vitamin A-treated explants is shown by the fact that the ratio dry weight/DNA, which gives an approximate measure of the ratio of total mass to cell number, was much lower in the vitamin A-treated rudiments.

Though there is little cellular degeneration in vitamin A-treated explants at the stage used in this work, the vitamin affects the ratio DNA/RNA (Table 2); DNA showed a drop of 20% as compared with the controls, whereas RNA was lowered by over 60%.

Metabolism. The presentation of metabolic results is made difficult by the changes in composition of the rudiments. The severe effect of vitamin A on both the wet and dry weights pre-

Table 1. *Weight and amino sugar composition of cartilaginous limb-bone rudiments grown in culture*

The wet-wt. and dry-wt. results are the means of four experiments; analyses were made of material from 12 rudiments. The material for the amino sugar analyses was obtained from 18 rudiments.

	Wet wt. (mg./bone)	Dry wt. (mg./bone)	Dry wt./DNA P	Total amino sugars (μg./bone)	Glucosamine (μg./bone)	Galactosamine (μg./bone)
Vitamin A explants	1·89	0·21	360	8·19	1·94	6·25
Control explants	4·21	0·41	570	16·92	2·92	14·0

Table 2. *Nucleic acid content of cultured limb-bone rudiments*

Results are the means of three experiments. In each experiment analyses were made of material from 12 bones.

	DNA P (μg./bone)	RNA P (μg./bone)	RNA P/DNA P
Vitamin A explants	0·60	0·69	1·15
Control explants	0·76	1·83	2·41

Table 3. *Aerobic metabolism of cultured limb-bone rudiments*

Results are the means of three experiments. In each experiment analyses of the suspending fluid were made after 90 min. incubation in Warburg flasks at 37°. Gas phase, air; medium, Krebs–Ringer phosphate containing 10% of neutralized horse serum. Glucose concentration, 1·8 mg./ml.

	Uptake of O_2		Production of lactic acid		Utilization of glucose	
	μl./hr. bone	μl. hr./μg. of DNA P	μg./hr./bone	μg./hr./μg. of DNA P	μg./hr./bone	μg./hr./μg. of DNA P
Vitamin A explants	1·00	1·76	16·5	27·6	24	37
Control explants	1·72	2·38	13·2	17·4	46	58

clude their use as a basis for expressing the metabolism of the rudiments. We have adopted two criteria: the DNA phosphorus to give a measure of the metabolism on a 'cellular' basis and the metabolism of the whole rudiment without taking into account any changes in composition. The oxygen uptake of the rudiments grown in the presence of the vitamin and expressed on either basis was depressed, but the rate of lactic acid formation was increased. Glucose utilization was less in the vitamin A-treated material than in the controls (Table 3).

Clot lysis. The bone rudiments are cultivated on a plasma : embryo extract clot and are transferred to fresh medium at 2-day intervals; during each 48 hr. period the explants become surrounded by a zone of lysis, which is very much larger in the vitamin A-treated cultures than in the controls. In an attempt to measure this lytic effect we estimated the amount of acid-soluble and acid-insoluble nitrogen in the medium at the end of the experiment. After 6 days' cultivation the percentage of acid-soluble nitrogen in the control cultures was 2·25 and in the vitamin A-treated cultures 5·40. It is known that the fibrin of plasma clots may contain adsorbed fibrinolysin (Bidwell, 1953) and it was possible that the action of the vitamin was to activate this enzyme. To test this possibility, culture dishes containing vitamin A or control medium without explants were prepared and incubated for 2 days; there was no apparent lysis and no difference in the ratio of acid-soluble to acid-insoluble nitrogen between the vitamin A clots and the controls.

DISCUSSION

Although the wet and dry weights of the vitamin A-treated explants are only 50 % of the control values (Table 1), the DNA content, which may be taken as an approximate measure of cell number, is 80 % of the controls (Table 2). This suggests that the severe inhibition of growth in length and weight is mainly due to a substantial reduction in the amount of intercellular material rather than in number of cells, an interpretation that is supported by the histological finding (Fell & Mellanby, 1952) that in the vitamin A-treated cartilage the intercellular partitions become narrow and lose their metachromasia. The histological changes in the matrix are probably correlated with the low amino sugar content of the vitamin A-treated cartilage as compared with that of the controls (Table 1).

Fell *et al.* (1956) have shown that the synthesis of new cartilage matrix is inhibited by excess of vitamin A. They suggested that, under the influence of excess of vitamin A, the cartilage cells may produce an enzyme which results in the liberation of sulphated mucopolysaccharide, and hence in the dissolution of existing matrix. That hydrolytic enzyme activity might be concerned in the changes produced in cartilage matrix under the influence of excess of vitamin A was further indicated by the similarity between the effects on the intercellular material of the vitamin and of papain protease; this was true whether the comparison were made on the cartilage of young rabbits *in vivo* (Thomas *et al.* 1960) or on limb-bone rudiments in organ culture (Fell & Thomas, 1960). As a tentative working hypothesis, Fell & Thomas (1960) suggested that 'vitamin A may enhance the activity of a number of cellular enzymes, one of which resembles papain in its effect; such an enhanced hydrolytic activity might be due to the activation of enzymes, to their greater production or to their increased liberation through an increased permeability of the cells or their organelles'.

Experiments which will be reported in the following paper (Lucy, Dingle & Fell, 1961) have shown that the cells of normal embryonic cartilage in fact contain a hydrolase which under appropriate conditions can remove from the matrix most of the amino sugars and the capacity for metachromatic staining. Another paper (Dingle, 1961) suggests that the vitamin acts by releasing enzymes from the lysosomes.

SUMMARY

1. After 6 days' cultivation in medium containing added vitamin A (10 i.u./ml.) the wet and dry weights and amino sugar content of cartilaginous limb-bone (chick) rudiments were half those of controls on normal medium.

2. Compared with the control cultures, the amount of deoxyribonucleic acid was 80 % and the amount of ribonucleic acid was 40 %.

3. The vitamin depressed the rate of oxygen uptake but increased that of lactic acid formation.

4. There was twice as much acid-soluble nitrogen in the used culture medium (plasma–embryo extract clot) of the vitamin A-treated explants as in that of the control, indicating a greater proteolytic activity in the presence of the vitamin.

One of us (J.T.D.) is in receipt of a grant from the British Empire Cancer Campaign. We are much indebted to Mr L. J. King for his assistance in the organ-culture work, and to Miss P. Carter and Mr R. J. Thomson for their help in the biochemical estimations.

REFERENCES

Barker, J. B. & Summerson, N. H. (1941). *J. biol. Chem.* **138**, 535.
Bidwell, E. (1953). *Biochem. J.* **55**, 497.
Boas, N. F. (1953). *J. biol. Chem.* **204**, 553.

Burton, K. (1956). *Biochem. J.* **62**, 315.
Dingle, J. T. (1961). *Biochem. J.* **79**, 509.
Fell, H. B. & Mellanby, E. (1952). *J. Physiol.* **116**, 320.
Fell, H. B., Mellanby, E. & Pelc, S. R. (1956). *J. Physiol.* **134**, 179.
Fell, H. B. & Thomas, L. C. (1960). *J. exp. Med.* **111**, 719.
Friend, D. G. & Hastings, A. B. (1940). *Proc. Soc. exp. Biol., N.Y.*, **45**, 137.
Gardell, S. (1953). *Acta chem. scand.* **7**, 207.
Hawk, P. B., Oser, B. L. & Summerson, W. H. (1952). *Practical Physiological Chemistry*, p. 820. London: J. and A. Churchill Ltd.
Kent, P. & Whitehouse, M. W. (1955). *Biochemistry of the Aminosugars*. London: Butterworths Scientific Publications.
Lucy, J. A., Dingle, J. T. & Fell, H. B. (1961). *Biochem. J.* **79**, 500.
Nelson, N. (1944). *J. biol. Chem.* **153**, 375.
Rondle, C. J. M. & Morgan, W. T. J. (1955). *Biochem. J.* **61**, 586.
Thomas, L., McCluskey, R. T., Potter, J. L. & Weissmann, G. (1960). *J. exp. Med.* **111**, 705.
Umbreit, W. W., Burris, R. H. & Stauffer, J. F. (1957). *Manometric Techniques*. Minneapolis: Burgess Publishing Co.

Dingle-'61
Bib. No. 2197

Reproduced by permission
of the copyright owner

Biochem. J. (1961) 79, 509

Studies on the Mode of Action of Excess of Vitamin A

3. RELEASE OF A BOUND PROTEASE BY THE ACTION OF VITAMIN A

By J. T. DINGLE
Strangeways Research Laboratory, Cambridge

(*Received* 8 *September* 1960)

In the two preceding papers (Dingle, Lucy & Fell, 1961; Lucy, Dingle & Fell, 1961) it was shown that excess of vitamin A causes changes in both the composition and metabolism of cartilage cells and extensive breakdown of extracellular material. Hypo-osmotic treatment of embryonic cartilage released a proteolytic enzyme and degraded the matrix in a manner that was very similar to the effects of excess of vitamin A.

It was suggested that some of the effects of vitamin A might be explained if the vitamin causes the lysosomes to release a protease which would split the protein–polysaccharide complex of the matrix.

This paper presents evidence for a direct action of vitamin A upon isolated particulate components of liver cells and demonstrates some of the conditions under which the vitamin may release a bound protease.

METHODS

Tissue fractionations. Material was obtained from the livers of young adult rats. The tissue was cooled in ice-cold 0·25M-sucrose, weighed and a suspension (1 g. in 10 ml.) made, an all-glass motor-driven homogenizer being used. Debris and nuclei were removed by centrifuging at 600*g* for 5 min. in a Serval Superspeed centrifuge. The supernatant was either centrifuged at 10 000*g* for 25 min. to sediment all mitochondria-like particles, or else submitted to a fraction procedure similar to that of Appelmans, Wattiaux & de Duve (1955). For the latter process the extract was first spun at 10 000*g* for 5 min. to give the 'heavy' fraction, the pellet was washed twice under the same conditions and the very loosely packed material removed. This, together with the first supernatant, was spun at 10 000*g* for 25 min. to form the 'light' fraction.

All manipulations were done in a cold room at 4°, and, provided that care was taken when using the homogenizer, negligible hydrolytic activity was released from the particles.

Enzyme assay. The free protease was assayed in 0·1M-sodium acetate buffer, pH 4, with 2% (w/v) haemoglobin as substrate. The hydrolysis of the protein, which was estimated by the method of Anson (1938), was at 37° for 20 min. Activity was expressed as μg. of acid-soluble 'tyrosine' released. The reaction was stopped by the addition of ice-cold trichloroacetic acid and the mixture kept cold until the addition of the alkali (Gianetto & de Duve, 1955). Under these conditions the presence of sucrose did not appreciably interfere with the estimation of tyrosine. 'Total' activity was measured after suspending the particles in glass-redistilled water (10 ml./g. of original tissue) and storing at 4° for 30 min.

Treatment with vitamin A. A 1:5 suspension of the particles was made in 0·25M-sucrose and crystalline vitamin A alcohol (Roche Products Ltd.) dissolved in ethanol was added. An equal amount of ethanol was added to the control tubes, though at the maximum concentration of ethanol used (1%, v/v) there was no appreciable effect upon enzyme release. The particles were then incubated, usually at 37° for 45 min. under nitrogen, and at the end of the reaction period the suspensions were spun at 15 000*g* for 20 min. in the cold. The enzyme released was measured in the clear supernatant fluid and the amount expressed as a percentage of the total activity released by hypo-osmotic treatment.

RESULTS

Rate of release of the protease. The effect of incubation of a 'mitochondrial' suspension with increasing amounts of vitamin A has been investigated (Fig. 1). The protease activity of the controls

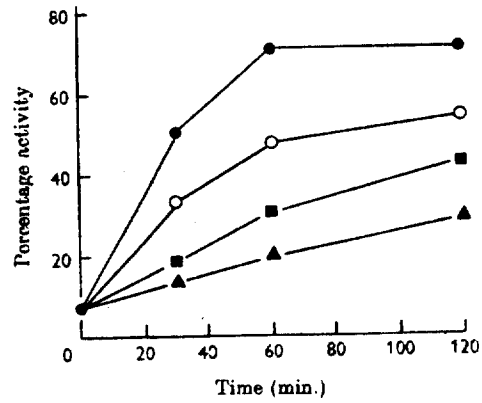

Fig. 1. Effect of vitamin A on the release of cathepsin from rat-liver lysosomes. 'Mitochondrial' fraction was suspended in 0·25M-sucrose and incubated at 37° under nitrogen, with varying concentrations of vitamin A. At the end of the incubation period the suspension was spun at 15 000*g* for 20 min. Proteolytic activity was measured in the supernatant and the amount is expressed as a percentage of the total activity released by hypo-osmotic treatment. ▲, Control; ■, 0·5 μg. of vitamin A/mg.; ○, 1·0 μg. of vitamin A/mg.; ●, 2·0 μg. of vitamin A/mg.

increased with time, but the vitamin caused a more rapid release of the enzyme. The experiment also demonstrates that the release of enzyme is related to the concentration of vitamin, and that the maximum rate of release is in the first hour of incubation.

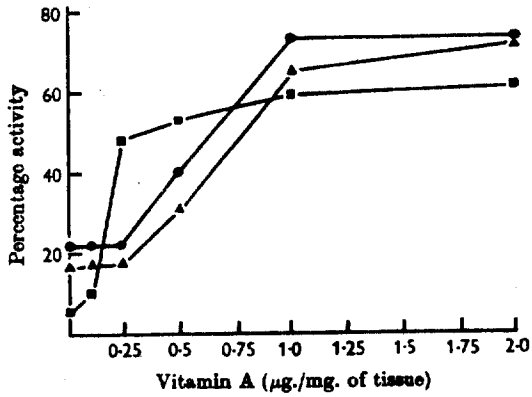

Fig. 2. Release of the protease from various mitochondrial fractions. Rat-liver mitochondria were fractionated in 0·25 M-sucrose as described in the text. The various fractions were incubated at 37° with vitamin A, for 45 min. under nitrogen. At the end of the incubation period the suspensions were spun at 15 000*g* for 20 min. and the proteolytic activity was estimated in the supernatant. ■, 'Light' mitochondrial fraction; ●, 'heavy' mitochondrial fraction; ▲, whole mitochondrial fraction.

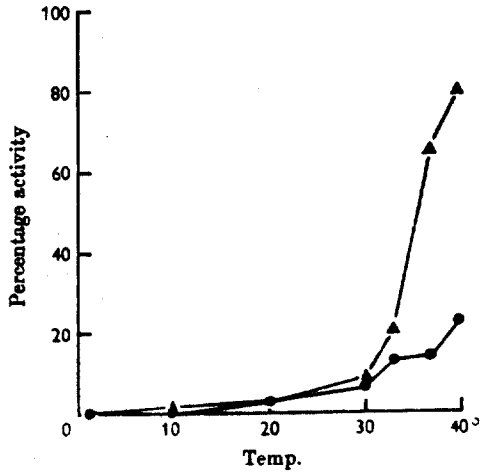

Fig. 3. Effect of temperature upon the release of cathepsin by vitamin A. Rat-liver mitochondria, suspended in 0·25 M-sucrose, were incubated for 45 min. under nitrogen with vitamin A (1 μg./mg. of tissue). At the end of the experimental period the suspensions were spun at 15 000*g* for 20 min. and proteolytic activity was measured in the supernatant. ▲, Vitamin A (1 μg./mg. of tissue); ●, control.

Release of the protease from various 'mitochondrial' fractions. The 'light' mitochondrial fraction that was obtained in this work appears to be more sensitive to the action of the vitamin than the 'heavy' or the whole fractions. 50 % of the total activity of the 'light' fraction is released by 0·25 μg. of vitamin A/mg. of original tissue after 45 min. at 37°, whereas three times this concentration is required to liberate 50 % of the activity of the whole fraction (Fig. 2). This difference may be due to higher ratios in the light fraction of lysosomal to non-lysosomal protein, or to lipoprotein, both of which may compete for the available vitamin.

Though all three preparations show an increasing release of protease with rising concentrations of vitamin A, the 'light' fraction exhibits a considerable release of enzyme over a narrow range of concentrations.

This rise in proteolytic activity under the influence of increasing amounts of the vitamin must be due to an increased liberation of the enzyme, since the vitamin has no effect upon the enzyme after it has been liberated under hypo-osmotic conditions.

Effect of temperature and pH *upon enzyme release.* The action of the vitamin upon the enzyme-containing particles is influenced by temperature (Fig. 3). Between 1° and 30° the vitamin has little or no effect, but above 30° there is an extremely rapid increase in the percentage activity released after incubation for 45 min. with 1 μg. of vitamin A/mg. of original tissue. At 40° there is also an increase in the thermal activation but this is small compared with the effect of the vitamin.

All the experiments so far reported have been performed by incubating the intracellular particles in 0·25 M-sucrose dissolved in glass-redistilled water of approximately neutral pH. Appelmans & de Duve (1955) reported that increase in acidity favoured the thermal activation of rat-liver lysosomes; it was therefore decided to compare the effects of different pH values on the thermal activation. The release of protease by the lysosomes was measured after incubation, with and without vitamin A, for 45 min. at 37° in 0·25 M-sucrose containing 0·02 M-sodium acetate buffers of differing pH values.

Below pH 5 (Fig. 4) there is a considerable increase in thermal activation and this is not appreciably altered by the presence of the vitamin. Above pH 5 the particles are stable in the absence of vitamin A, but the addition of the vitamin (1·0 μg./mg. of original tissue) is much more effective at neutral than at acid pH.

Effect of pH *upon the released enzyme.* Gianetto & de Duve (1955) reported that cathepsin released from rat-liver lysosomes by hypo-osmotic treat-

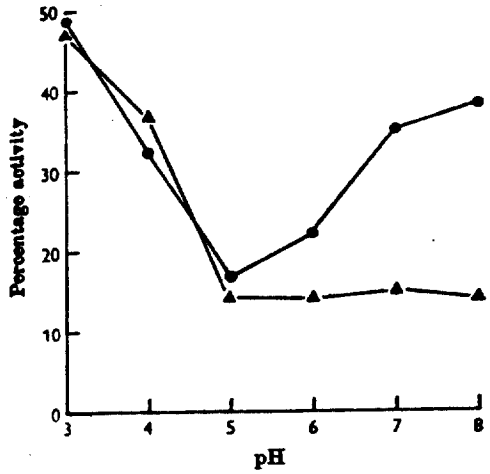

Fig. 4. Effect of pH upon the release of proteolytic activity from rat-liver lysosomes by vitamin A. 'Mitochondria' were suspended in 0·25M-sucrose containing 0·02M-sodium acetate buffer. The suspensions were incubated at 37° for 45 min. under nitrogen with 1 μg. of vitamin A/mg. of tissue. At the end of the incubation period the suspensions were spun at 15 000g for 20 min. and proteolytic activity was estimated in the supernatant. ●, Vitamin A (1 μg./mg. of tissue); ▲, control.

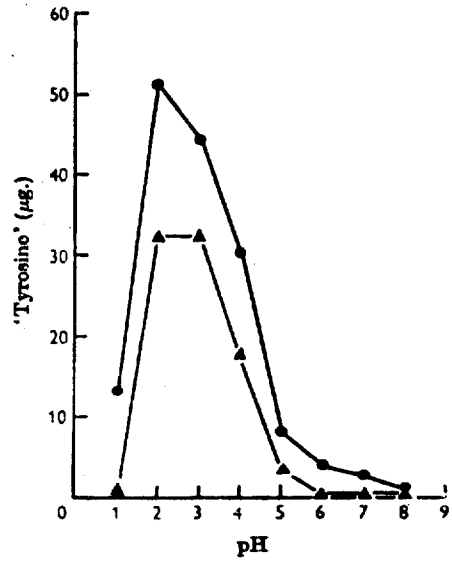

Fig. 5. Effect of pH upon the released enzyme. The cathepsin was released from rat-liver lysosomes by treatment with vitamin A (1 μg./mg. of tissue) and also by hypo-osmotic treatment. The enzyme solutions were incubated for 20 min. at 37° with 2% haemoglobin in 0·1M-sodium acetate buffers of different pH values. The acid-soluble tyrosine released was estimated as indicated in the text. ●, Enzyme released by vitamin A; ▲, enzyme released by hypo-osmotic treatment.

ment was more active at pH 3·6 than at pH 5·0; this is confirmed by the results of the present experiments (Fig. 5), which also show that the enzyme released by vitamin A has the same pH optimum against haemoglobin as that liberated by hypo-osmotic treatment.

DISCUSSION

In the preceding paper (Dingle *et al.* 1961) it was shown that the effects of vitamin A on cartilaginous limb-bone rudiments could be simulated by hypo-osmotic treatment, and also that the hypo-osmotic effects were probably due to the action of an intracellular protease, which was able to break some part of the protein–polysaccharide complex of the matrix. In order to relate this model system, in which the enzyme is released by hypo-osmotic treatment, to the action of the vitamin on living tissues an important step was to find if the vitamin was able to liberate a protease by the direct addition of the chemically pure compound to the enzyme-containing particulate components of the cells.

The results presented in this paper show that a proteolytic enzyme, with an acid pH optimum, similar to the enzyme liberated from the cartilaginous rudiments by hypo-osmotic treatment, is rapidly released by treatment of the 'mitochondrial' fraction of rat liver with vitamin A. Rat liver was used as a source of material as Gianetto & de Duve (1955) have shown that stable cathepsin-containing particles, the lysosomes, can easily be obtained from this tissue. Preliminary observations upon homogenates of embryonic cartilage indicate that the vitamin probably has a similar effect on the particulate components of this tissue also. Since no evidence could be found that the activity of the protease liberated from rat-liver lysosomes by hypo-osmotic treatment is affected by the presence of the vitamin, it is probable that the increased proteolytic activity of the supernatant is due to release of the bound enzyme under the influence of vitamin A. There is no direct evidence at present to indicate the way in which the vitamin alters the permeability of the particles, though the dependence of the vitamin A effect upon temperature and pH might perhaps suggest an enzymic mechanism.

The above results may indicate the mechanism by which the vitamin, acting at a subcellular level, is able to alter so drastically the composition of the extracellular material. Mainly because the breakdown of matrix was initially of greatest interest and also because of the ease of assay, this paper has dealt only with the release of a proteolytic enzyme from the particulate preparations. de Duve (1959) has demonstrated the presence of a number of

hydrolases in the particles he terms lysosomes. Besides a cathepsin, these include a ribonuclease, a deoxyribonuclease, a phosphatase, a glucuronidase and a sulphatase. As described in the first paper of this series, the action of the vitamin upon the cartilaginous rudiments grown in culture causes a complex series of changes, including loss of ribonucleic acid, amino sugars and dry weight. It seems very likely that the vitamin may release some, or all, of these bound hydrolases and that this complex of enzymes may cause many of the changes seen in the tissue treated with vitamin A.

SUMMARY

1. Particulate preparations from rat liver suspended in 0·25M-sucrose and treated with vitamin A release a proteolytic enzyme with an acid pH optimum.

2. The action of the vitamin on the particles is dependent upon temperature and pH.

3. The enzyme, after release by hypo-osmotic treatment, is not affected by the vitamin.

4. The relationship of this effect to the action of vitamin A on intact tissue is discussed.

The author is indebted to Dr H. B. Fell and Dr J. A. Lucy for helpful discussions and to Mr J. A. Thomson for technical assistance.

REFERENCES

Anson, M. L. (1938). *J. gen. Physiol.* 22, 79.

Appelmans, F. & de Duve, C. (1955). *Biochem. J.* 59, 426.

Appelmans, F., Wattiaux, R. & de Duve, C. (1955). *Biochem. J.* 59, 438.

de Duve, C. (1959). *Subcellular Particles*, p. 128. New York: The Ronald Press Co.

Dingle, J. T., Lucy, J. A. & Fell, H. B. (1961). *Biochem. J.* 79, 497.

Gianetto, R. & de Duve, C. (1955). *Biochem. J.* 59, 433.

Lucy, J. A., Dingle, J. T. & Fell, H. B. (1961). *Biochem. J.* 79, 500.

Dingle-' 62
Bib. No. 2198

Biochem. J. 84:611-621. 1962.

Reproduced by permission
of the copyright owner

Studies on the Mode of Action of Excess of Vitamin A

5. THE EFFECT OF VITAMIN A ON THE STABILITY OF THE ERYTHROCYTE MEMBRANE*

By J. T. DINGLE† and J. A. LUCY†
Strangeways Research Laboratory, Cambridge

(*Received* 5 *March* 1962)

On the basis of experiments in which the intracellular enzymes of cartilage were released by treatment with hypo-osmotic solutions (Lucy, Dingle & Fell, 1961), it was proposed by Fell, Lucy & Dingle (1961) that the effects of excess of vitamin A on embryonic chick cartilage cultivated *in vitro* (Fell & Mellanby, 1952; Dingle, Lucy & Fell, 1961) could be explained by the hypothesis that the vitamin alters the permeability of intracellular particles. The liberation of one or more proteolytic enzymes, possibly cathepsins, from the lysosomes of chondrocytes was thought to be responsible for the degradation of the protein moiety of the polysaccharide–protein complex in embryonic cartilage that occurs when the tissue is cultivated *in vitro* with excess of the vitamin. This view was supported by the fact that vitamin A releases a proteolytic enzyme with an acid pH optimum from rat-liver lysosomes (Dingle & Lucy, 1961; Dingle, 1961).

In an attempt to discover whether the action of vitamin A is confined to the membrane of lysosomes, or whether it has a similar action on other membrane structures, the effect of the vitamin on the stability of the erythrocyte membrane has been investigated. The present paper presents observations which demonstrate that vitamin A alters the permeability of the cell membrane of the erythrocyte on incubation *in vitro*. This provides additional evidence for the hypothesis that the site of action of vitamin A is at the lipoprotein membranes of cells and their organelles. A preliminary communication has been published (Lucy & Dingle, 1962).

EXPERIMENTAL

Materials

Vitamin A alcohol (Roche) was dissolved in ethanol to give a 100 mg./ml. solution. (For convenience, 'vitamin A alcohol' is referred to as 'vitamin A' throughout the paper.) This was stored under nitrogen in the cold, and was stable for at least 3 weeks in the dark. Dilutions were made immediately before use. 4-Apo-β-carotenal and 3-apo-3-carotenal were given by Dr John Glover and Professor R. A. Morton, F.R.S., of the University of Liverpool. 4-Apo-β-carotenol and 3-apo-β-carotenol were obtained by reduction of the corresponding aldehyde in ether solution with sodium borohydride (sodium tetrahydroborate) at 0°. The methyl ether of vitamin A, β-ionylidene ethanol, β-ionylidene acetaldehyde, vitamin A_2 (alcohol) and vitamin A_2 aldehyde were gifts from Dr Philip L. Harris of the Biochemistry Laboratories, Distillation Products, Rochester, N.Y.; vitamin A acid was a gift from Dr T. Moore of the Dunn Nutritional Laboratory, Cambridge. Vitamin A acetate (Roche), vitamin A palmitate (British Drug Houses Ltd.) and all-*trans* vitamin A aldehyde (Eastman Organic Chemicals) were commercial preparations and were used without further purification. The other derivatives of vitamin A and related compounds were prepared as described by Fell, Dingle & Webb (1962). All other materials used were commercial preparations of the highest purity available.

Lysolecithin was a gift from Dr R. M. C. Dawson, of the Agricultural Research Council Unit for Animal Physiology, Babraham. This sample, which was free from venom, was prepared from ovolecithin by means of cobra venom.

The non-ionic detergent BRIJ 35 (Atlas Powder Co., Wilmington, Delaware, U.S.A.), an ether of poly(ethylene glycol), was stored as a 1% (v/v) solution in glass-distilled water and was diluted immediately before use.

The rabbit erythrocytes were obtained from six young adult males (mean weight 5 lb.). The animals were bled from the ear and the blood was collected in an approximately equal volume of Alsever's solution (Bukantz, Rein & Kent, 1946). The cells were centrifuged and washed twice with approximately 10 vol. of 0·9% sodium chloride solution. The packed-cell volume was then determined by centrifuging the cells in a small quantity of iso-osmotic sodium chloride solution at 220*g* for 5 min. in an angle-head centrifuge. Finally, the cells were suspended in 0·9% sodium chloride solution to give 1 ml. of packed cells/40 ml. of suspension. This was the standard suspension used in all experiments unless otherwise stated.

Bovine and pig blood were obtained from the slaughterhouse and rat blood from adult laboratory animals. The same anticoagulant and washing procedures were used for each species. All suspensions were kept at 5° until required.

Methods

Since vitamin A and most of the other compounds tested were virtually insoluble in the suspending medium it was necessary to standardize the mode of addition of the test compound to the cells. Reproducible results were obtained when an ethanolic solution of the compound (0·05 ml.) was

* Part 4: Fell, Dingle & Webb (1962).

† Member of the external staff of the Medical Research Council.

pipetted into the bottom of a dry tube and then a measured volume (5 ml.) of the cell suspension added. An equal volume of ethanol was added in similar manner to the controls.

The suspension of erythrocytes in 0·9% sodium chloride solution was incubated with the test compound; the cold suspension of erythrocytes at 5° was placed directly in the water bath unless otherwise stated. At the end of the incubation period the suspension was immediately centrifuged for 4 min. and the supernatant removed. This was analysed for potassium with an EEL flame photometer, and the extinction at 500 mμ of the supernatant solution was determined as a measure of the release of haemoglobin. Total haemolysis was obtained by the addition of an excess of vitamin A (usually 1 mg./ml.).

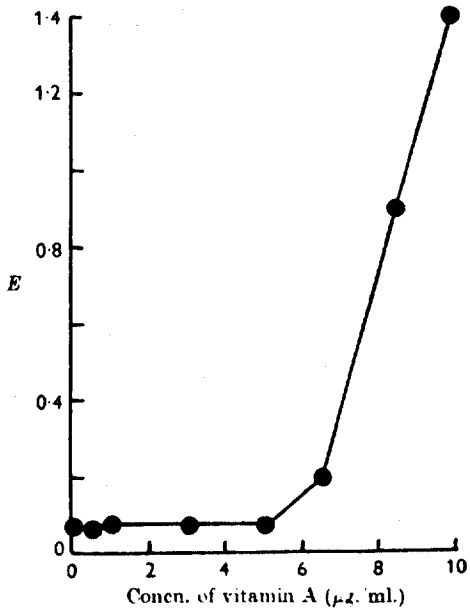

Fig. 1. Release of haemoglobin by vitamin A. The standard suspension of erythrocytes in 0·9% NaCl solution was incubated at 37° for 30 min. with the vitamin. The release of haemoglobin was followed by measurement of extinction at 500 mμ as described in the text.

RESULTS

Haemolysis by vitamin A. The addition of vitamin A to a suspension of rabbit erythrocytes in 0·9% sodium chloride solution caused rapid haemolysis. The degree of haemolysis was dependent on concentration, though changes in the extent of haemolysis in response to changes in concentration were found only over a very narrow range. Thus, under the conditions of the experiment shown in Fig. 1, 10 μg. of vitamin A/ml. caused extensive haemolysis, whereas half this concentration had no effect on the erythrocytes. (The E value for total haemolysis was 2·0.) The amount of vitamin per cell appeared to be the critical factor; thus, if the number of cells per unit volume of suspending medium was reduced, less vitamin A was required to give the same degree of lysis. If 50% lysis is taken as the standard, 2×10^8 cells required the addition of 7 μg. of vitamin A/ml. under the conditions of these experiments. If it is assumed that all the vitamin was taken up by the cells, a maximum of approx. 12×10^{-11} μmoles of vitamin A per cell is obtained.

The absence of the normal ionic constituents of serum from the iso-osmotic sodium chloride solution

Table 1. *Effect of vitamin A on the morphology of rabbit erythrocytes*

Erythrocytes were suspended in 0·9% NaCl solution, and 5 ml. of this suspension was mixed with 0·05 ml. of vitamin A dissolved in ethanol (final concn. 35 μM). 4-Apo-β-carotenal was added in the same way to give the same final concentration. Ethanol only was added to the controls. The suspension was kept at room temperature (about 19·5°) and samples were withdrawn at intervals. These were placed on a silicone-treated slide and covered with a silicone-treated coverslip. At the end of the experiment the number of intact erythrocytes were counted.

Time (min.)	Control	Vitamin A	4-Apo-β-carotenal
0	Smooth disks	Smooth disks	Smooth disks
1	Smooth disks	Marked crenation of many cells	Crenated disks
2–5	Smooth disks	Crenations more numerous; some crenated spheres present	—
5–11	Smooth disks; a few slightly crenated cells	Crenated spheres	Crenated disks
20	Smooth disks; a few slightly crenated cells	Smooth spheres	Crenated disks
25–30	Smooth disks; a few slightly crenated cells	Some prelytic spheres	Crenated disks
35	Smooth disks; a few slightly crenated cells	Prelytic spheres; some stroma	Crenated disks
64	Smooth disks; a few slightly crenated cells	Stroma; some prelytic spheres	Crenated disks
Cell count at end of experiment	141×10^6 cells/ml.	$1·3 \times 10^6$ cells/ml.	125×10^6 cells/ml.

used had no influence on lysis of erythrocytes by vitamin A, since rabbit erythrocytes suspended in Hanks's saline (Paul, 1959) at pH 6·8 were lysed by the vitamin to an equal extent.

Effect of vitamin A on the morphology of rabbit erythrocytes. We are indebted to Dr M. Daniel for the microscopic observation of the cells during treatment with vitamin A and 4-apo-β-carotenal.

The changes observed after treatment with vitamin A (Table 1) were very similar to those after the addition of saponin (Ponder, 1952). The appearance of crenation was very rapid under the conditions of these experiments and may have been related to uptake of the vitamin by the cells. 4-Apo-β-carotenal, which had no haemolytic activity, also caused some crenation. The cell counts emphasized the difference between the control and treated suspensions at the end of the experiments. Treatment with ethanol at the same concentration as that used for the addition of vitamin A had no effect on the cells under these conditions.

Effect of temperature on the release of haemoglobin. Since the release of protease from rat-liver lysosomes treated with vitamin A is much affected by temperature (Dingle, 1961), the temperature-dependence of erythrocyte lysis by vitamin A was investigated to see if this phenomenon shows similar characteristics to those of lysosomal breakdown under the influence of the vitamin.

The release of haemoglobin was affected by the temperature of incubation with vitamin A. During a short incubation period, little release of haemoglobin from rabbit erythrocytes occurred below 25° (Fig. 2). Experiments with incubation periods of 5, 10, 30 and 60 min., however, showed that, as the time of incubation with the vitamin was lengthened, loss of haemoglobin from the cells occurred at progressively lower temperatures. During a period of 60 min., haemolysis was nearly complete at 25° and some haemoglobin was released from the treated cells even at 5° (Fig. 3). The rapid release of haemoglobin that occurred at 37°, as compared with that at 5°, closely resembled the effect of temperature on release of lysosomal protease under the influence of vitamin A (Fig. 4).

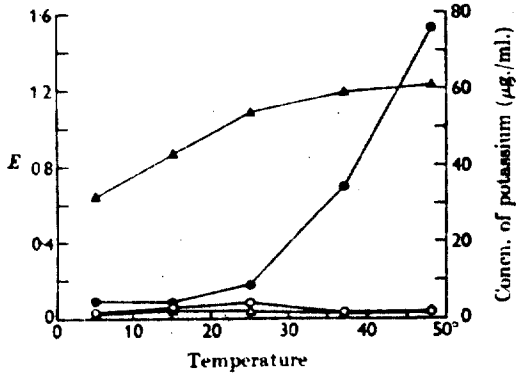

Fig. 2. Effect of temperature on haemolysis of erythrocytes by vitamin A (20 μg./ml.) during incubation for 5 min. ●, Release of haemoglobin by vitamin A; ○, release of haemoglobin by ethanol; ▲, release of potassium by vitamin A; △, release of potassium by ethanol.

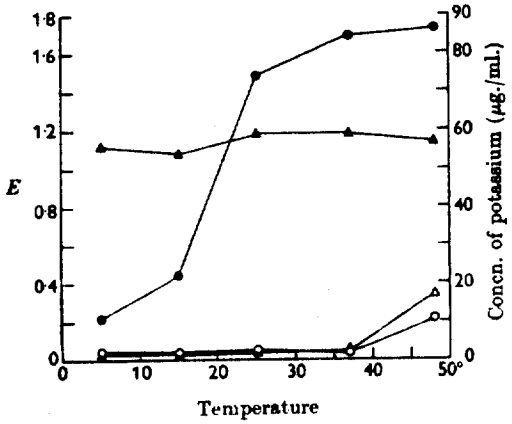

Fig. 3. Effect of temperature on haemolysis of erythrocytes by vitamin A (20 μg./ml.) during incubation for 60 min. ●, Release of haemoglobin by vitamin A; ○, release of haemoglobin by ethanol; ▲, release of potassium by vitamin A; △, release of potassium by ethanol.

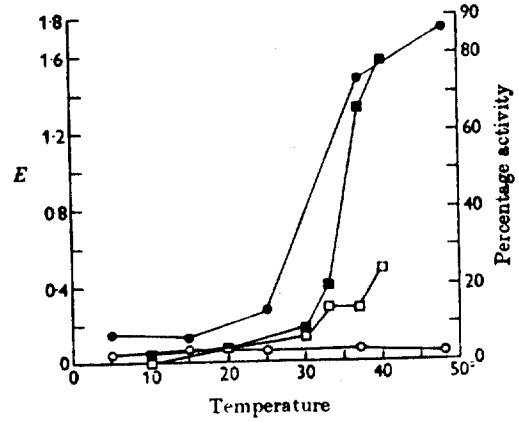

Fig. 4. Comparison of temperature characteristics of haemolysis and release of lysosomal protease by vitamin A. Erythrocytes were treated with vitamin A (20 μg./ml.) for 10 min. The results for the release of lysosomal protease are taken from Dingle (1961); the total activity was that obtained after suspending the lysosomal particles in water. ●, Release of haemoglobin by vitamin A; ○, release of haemoglobin by ethanol; ■, release of protease by vitamin A; □, release of protease by ethanol.

Rate of release of haemoglobin. Loss of haemoglobin from rabbit erythrocytes was rapid during treatment with vitamin A at 37°, and was virtually complete in 10 min. when the standard cell suspension was treated with 20 μg. of vitamin A/ml. When the same quantity of vitamin A was used at 25°, however, the kinetics of liberation could be followed easily since the release of haemoglobin occurred more slowly. Under these conditions, the rate of liberation of haemoglobin from the cells was linear with time during the first 60 min. (Fig. 5).

Release of potassium: kinetics and temperature-dependence. It was shown by Davson & Danielli (1938) that treatment of rabbit erythrocytes with subhaemolytic concentrations of pentanol or dihydric phenols caused loss of potassium from the cells. In our experiments with vitamin A, potassium was released much more rapidly than the haemoglobin. For example, at 25°, release of potassium reached a constant maximum value in 10 min.; during the same time haemoglobin was released only to the extent of 15–20% of the total amount that can be liberated by vitamin A (Fig. 5).

Loss of potassium from erythrocytes treated with vitamin A also occurred quite rapidly in the cold, unlike the loss of haemoglobin. On treatment of the standard cell suspension with 20 μg. of vitamin A/ml., approximately 50% of the total potassium was released from the cells in 5 min. at 5° when the release of haemoglobin was negligible (Fig. 2). Potassium loss, which was complete in 60 min. at 5° (Fig. 3), sometimes reached the maximum value in 30 min. under the same conditions.

Temperature-dependence of haemolysis by BRIJ 35 and by lysolecithin. Erythrocytes are easily lysed by a variety of chemical agents. It is of interest to know whether the lysis produced by other haemolysins has a temperature-dependence similar to that of vitamin A. The temperature-dependence of the lysis of rabbit erythrocytes by two other agents has therefore been investigated.

Rabbit erythrocytes were haemolysed by a neutral detergent, BRIJ 35. This was much less effective in producing lysis of the cells than vitamin A. For example, the standard suspension of cells was almost completely lysed in 10 min. by 20 μg. of vitamin A/ml. at 37°, whereas haemolysis was only 50% complete under the same conditions with 100 μg. of BRIJ 35/ml. The effect of temperature on the release of haemoglobin and potassium from rabbit erythrocytes by BRIJ 35 is shown in Fig. 6. No loss of either potassium or haemoglobin occurred at 15° or 5°; both potassium and haemoglobin were released most rapidly at about 32° and lysis was less at 37° and at 48° than at 32°. Haemolysis by BRIJ 35 resembled that produced by vitamin A in that no haemoglobin was released in the cold. Haemolysis with the detergent, however, differed markedly from that with the vitamin in that with BRIJ 35 there was no release of potassium in the cold and both potassium and haemoglobin showed optimum liberation at 32° instead of progressively greater release with increasing temperature up to 48° as occurred with vitamin A (Fig. 2).

Lysolecithin caused a rapid release of both potassium and haemoglobin in the cold from rabbit erythrocytes. Lysis at 48° was not much greater than at 5°. A small peak of increased haemolysis was observed at about 32° (Fig. 7). Haemolysis of rabbit erythrocytes by lysolecithin is therefore virtually independent of temperature, in contrast with the effect of temperature on lysis produced by vitamin A (Fig. 2).

Lysis of cells from different species. Initial experiments on the effect of vitamin A on erythro-

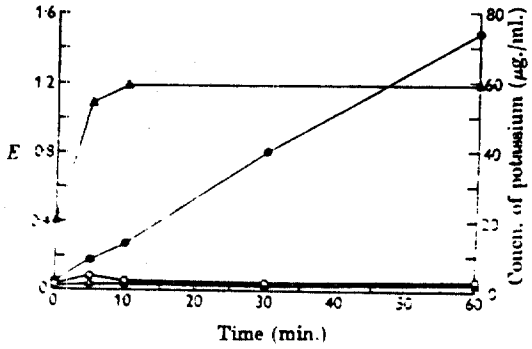

Fig. 5. Rate of haemolysis by vitamin A (20 μg. ml.) at 25°. ●, Release of haemoglobin by vitamin A; ○, release of haemoglobin by ethanol; ▲, release of potassium by vitamin A; △, release of potassium by ethanol.

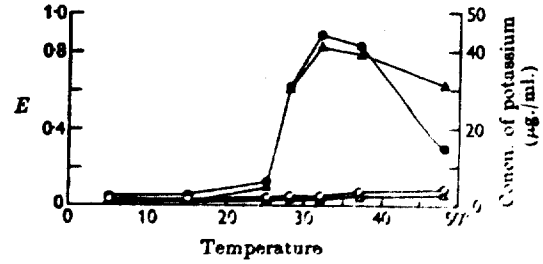

Fig. 6. Effect of temperature on haemolysis of erythrocytes by BRIJ 35 (100 μg. ml.) during incubation for 10 min. Cell suspension (5 ml.) was added to an aqueous solution of BRIJ 35 (0·05 ml.); the usual incubations with ethanol (0·05 ml.) were also carried out. ●, Release of haemoglobin by BRIJ 35; ○, release of haemoglobin by ethanol; ▲, release of potassium by BRIJ 35; △, release of potassium by ethanol.

cytes *in vitro* were done with cells from the rabbit. To determine whether the lysis of erythrocytes caused by vitamin A is peculiar to the rabbit, single samples of erythrocytes from a number of other species were tested. Erythrocytes from human, ox, pig and rat were lysed on incubation *in vitro* with vitamin A. The sensitivity of the single samples tested from the different species varied; that from the human was least and that from the rat most affected by a dose of 10 μg. of vitamin A/ml. of suspension.

The sensitivity of these cells to lysis by lysolecithin was also investigated; except for the rat, ease of lysis by lysolecithin occurred in the reverse order to that with vitamin A (Table 2).

Resistance of cells to haemolysis by vitamin A. The experiments with rabbit erythrocytes were all done with erythrocytes obtained from six rabbits that were bled in rotation at intervals for 3 months. At the end of this period, cells were occasionally found to be partially or wholly resistant to haemolysis by 10 μg. of vitamin A/ml. during incubation for 15 min. at 37°. In these instances, the cells were discarded. Treatment of 'resistant' cells with a slightly larger quantity of vitamin A (15 μg./ml.) caused extensive lysis during incubation for 15 min. at 37°. Incubation of 'resistant' cells for 30 min. at 37° before treatment with the vitamin frequently reduced the resistance of the cells to lysis by 10 μg. of vitamin A/ml.

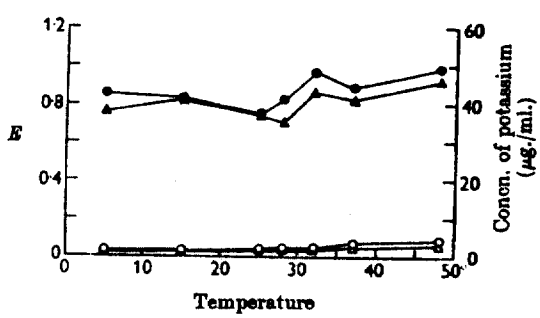

Fig. 7. Effect of temperature on haemolysis of erythrocytes by lysolecithin (35 μM) during incubation for 10 min. ●, Release of haemoglobin by lysolecithin; ○, release of haemoglobin by ethanol; ▲, release of potassium by lysolecithin; △, release of potassium by ethanol.

The phenomenon of resistance to haemolysis by vitamin A may be associated with the frequent repeated bleeding of animals, and the problem is being investigated further. Our observations may be related to the suggestion of Pollard & Bieri (1958) that reticulocytes are largely responsible for the destruction of vitamin A by haemolysed blood.

Inhibition of haemolysis by serum. No observations appear to have been recorded in the literature on the haemolysis of erythrocytes *in vivo* under conditions of hypervitaminosis A. This may indicate that the lysis of erythrocytes by excess of the vitamin is prevented *in vivo* by the presence of serum proteins that bind the vitamin and thereby render it inactive in lysing erythrocytes. The effect of treating erythrocytes with vitamin A *in vitro* in the presence of serum was therefore investigated to see if serum inhibits lysis under these conditions.

Vitamin A was added to a series of dilutions of rabbit serum immediately before the addition of a suspension of erythrocytes from the same animal. In a second experiment, the serum solutions were added to the cell suspensions before the addition of the cells to vitamin A. The cell suspensions were then incubated at 37° for 10 min. The presence of 2%, 8% and 17% of serum in the final volume of 6 ml. inhibits completely the release of haemoglobin from cells treated with 8·3 μg. of vitamin A/ml. of suspension. With 0·2% and 0·8% of serum, inhibition occurs but is not complete (Fig. 8). After the cells had been treated with vitamin A in the presence of 2% of serum and then removed, the supernatant solution contained only one-fifth of the quantity of potassium found when the cells were treated with vitamin A in the complete absence of serum. (The addition of larger quantities of serum, 8% and 17%, increased the final concentration of potassium by virtue of the potassium already present in the added serum, and caused a slight increase in the extinction of the supernatant solution.) These observations therefore demonstrate that the release of both potassium and haemoglobin from rabbit erythrocytes treated with vitamin A *in vitro* is inhibited by homologous serum.

Table 2. *Lysis of erythrocytes from different species by vitamin A (alcohol) and by lysolecithin*

The values represent percentage of total haemolysis.

Treatment	Human erythrocytes	Ox erythrocytes	Pig erythrocytes	Rabbit erythrocytes	Rat erythrocytes
Incubation for 10 min. at 37° with vitamin A (35 μM)	4	4	16	34	54
Incubation for 30 min. at 37° with vitamin A (35 μM)	13	13	22	47	63
Incubation for 15 min. at 37° with lysolecithin (35 μM)	82 84	80 73	49 56	21 23	65 47

Effect of preincubation on the release of haemoglobin. The release of haemoglobin from rabbit erythrocytes under the influence of vitamin A is much more rapid at 37° than at 5°. Temperature-dependence of this kind may indicate that an enzymic mechanism is involved in the action of vitamin A on the erythrocyte membrane. If this is so, preincubation and treatment of the cells with the vitamin at 48° might result in heat-inactivation of the enzyme system concerned.

To test this possibility, standard suspensions of rabbit erythrocytes were incubated at 48° and 37° for 30 min. before treatment with vitamin A at 48° and 37° respectively. Cells that had been preincubated at 37° for 30 min. and then incubated with vitamin A at 37° for 30 min. released the same quantity of haemoglobin as cells treated with the vitamin in the same way but not preincubated. Further, cells preincubated at 48° and treated with vitamin A at 48° released more haemoglobin than cells that were preincubated at 37° and then treated with the vitamin at 37°. It is thus unlikely that a heat-labile enzyme is involved in the action of vitamin A on the erythrocyte membrane, but the possibility that heat-insensitive enzymes may participate in the process is not excluded.

Molecular structure and biological activity. The structural requirements at the molecular level for the action of vitamin A in animals are highly specific, and this specificity was also found both in the action of the vitamin on chick-limb-bone rudiments in culture and on isolated rat-liver lysosomes (Fell *et al.* 1962). It was therefore desirable to compare these requirements with those for activity towards the rabbit erythrocyte. Table 3 shows that the action of the vitamin in releasing haemoglobin and potassium from the erythrocyte was closely dependent on molecular structure, and, with certain exceptions, this dependence was very similar to that observed in the systems *in vivo* and *in vitro* mentioned above. Of the substances tested, no compound without both a β-ionone ring and a conjugated double-bond system had any effect on the erythrocytes when used at a concentration of 35 μM. The chain length is of great importance since compounds having shorter or longer chains than vitamin A were much less active than the C_{20} vitamin A alcohol and aldehyde compounds (Table 4). β-Ionone and other low-molecular-weight terpenes were also without activity (Table 3).

The activity of the vitamin A molecule is greatly reduced in all systems after oxidation or hydrogenation. Oxidized vitamin A is without effect on animals, isolated lysosomes or erythrocytes, and has only a very slight effect upon the growth of chick-limb-bone rudiments. The hydrogenated form of the vitamin, though ineffective in the animal and on lysosomes, had a slight action both in organ culture and on the erythrocyte (Table 3). This action of hydrogenated vitamin A on erythrocytes had the same dependence on temperature as vitamin A itself.

The low activity in the erythrocyte system of anhydrovitamin A, the methyl ether of vitamin A, and the acetate and palmitate esters, would seem to indicate that the nature of the end of the side chain is of importance (Table 3). Vitamin A aldehyde is as effective in the lysis of erythrocytes as vitamin A, but vitamin A acid had only a slight action.

Effect of low ionic strength. In an attempt to obtain more information about the reason for the very different activities of vitamin A and vitamin A acid, the effect on haemolysis of replacing sodium chloride by sucrose, in a series of solutions ranging from 0·154 M-sodium chloride solution to 0·25 M-sucrose solution, was investigated. Equal quantities of cells were suspended in the different media and treated with vitamin A (10 μg./ml.) for 15 min. at 25°, or vitamin A acid (10 μg./ml.) for 15 min. at 37°.

The release of haemoglobin and potassium by vitamin A and by vitamin A acid was greater from cells suspended in media composed of equal parts of iso-osmotic sodium chloride solution and iso-osmotic sucrose than from cells suspended in iso-osmotic sodium chloride solution alone (Figs. 9 and 10). The stepwise increase in the release of haemoglobin by vitamin A acid on reducing the ionic strength was found to be reproducible. Cells

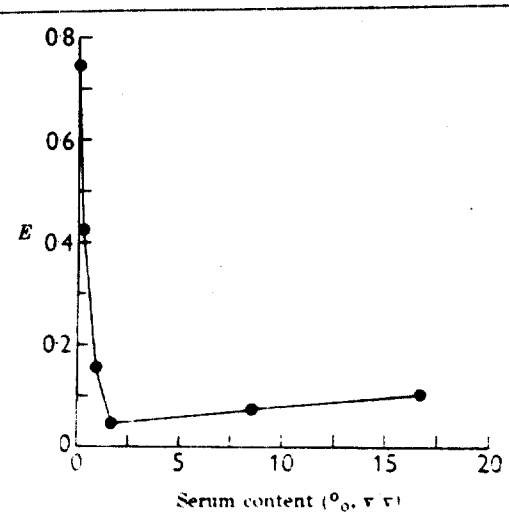

Fig. 8. Inhibition of haemolysis by homologous serum. Vitamin A (8·3 μg./ml.) was added to a series of dilutions of rabbit serum in 0·9% NaCl solution immediately before the addition of a suspension of erythrocytes from the same animal. The suspension was then incubated at 37° for 10 min.

Table 3. *Comparison of molecular structure and activity in various systems*

The percentage activity of each compound is expressed relative to that of vitamin A (alcohol). The effect on the growth of chick-limb-bone rudiments was measured as the difference in length between the treated and control cultures after 8 days in culture; test compounds were added to the media to give a final concentration of 10 μM. Isolated lysosomes were suspended in 0·25 M-sucrose made 0·7 mM with respect to each test compound for 40 min. at 37°; the released enzyme was measured in the supernatant fluid after centrifuging. Rabbit erythrocytes, suspended in 0·9% sodium chloride, were treated for 15 min. at 37°, centrifuged, and the released haemoglobin and potassium measured in the supernatant fluid; the test compounds were used at a final concentration of 35 μM.

	Molecular structure		Action on erythrocytes		Action on rat-liver lysosomes (Fell, Dingle & Webb, 1962)	Biological action: Growth of limb rudiments in organ culture (Fell, Dingle & Webb, 1962)	Biological action: In animals (Moore, 1957)
Compound	No. of conjugated double bonds	End group	Haemoglobin loss	K^+ loss			
Vitamin A (alcohol)	5	$—CH_2·OH$	100	100	100	100	100
Vitamin A aldehyde	5	—CHO	102	100	—	—	91
Vitamin A acid	5	$—CO_2H$	8	8	92	94	100*
Hydrogenated vitamin A	0	$—CH_2·OH$	10	16	0	25	0
Oxidized vitamin A alcohol	4 (?)	$—CH_2·OH$	1	1	0	11	0
Anhydrovitamin A	6	$=CH_2$	3	3	0	0	0·4
Vitamin A methyl ether	5	$—CH_2·O·CH_3$	2	4	—	—	100
Vitamin A acetate	5	$—CH_2·O·CO·CH_3$	1	6	11	—	100
Vitamin A palmitate	5	$—CH_2·O·CO·C_{15}H_{31}$	2	0	0	—	100
Vitamin A_2 alcohol	6	$—CH_2·OH$	9	22		—	40†
Vitamin A_2 aldehyde	6	—CHO	17	28		—	33‡
β-Ionone	3	$—CO·CH_3$	0	0	25	2	—
Geraniol	0	$—CH_2·OH$	0	0	27	—	—
Citral	0	—CHO	0	0	0	17	—
Phytol	0	$—CH_2·OH$	4	4	7	0	—
Dodecanol	0	$—CH_2·OH$	1	1	0	—	—
Ethanol	0	$—CH_2·OH$	0·4	0	0	0	—

* Inactive in the retina and reproductive tissues of the rat. † Shantz & Brinkman (1950).
‡ Sundaresan & Cama (1961).

Table 4. *Relative activity in haemolysis of vitamin A (alcohol) and vitamin A aldehyde, as compared with derivatives having side chains of differing length*

Compounds	No. of C atoms per molecule	Percentage activity
β-Ionylidene-ethanol	15	8
β-Ionylidene-acetaldehyde	15	3
Vitamin A (alcohol)	20	100
Vitamin A aldehyde	20	100
4-Apo-β-carotenol	25	49
4-Apo-β-carotenal	25	4
3-Apo-β-carotenol	27	7
3-Apo-β-carotenal	27	4

suspended in a solution of 6% (w/v) dextran containing 5% (w/v) of glucose were also lysed by vitamin A more readily than cells in 0·154 M-sodium chloride solution. In control incubations loss of haemoglobin from cells suspended in 0·25 M-sucrose (Figs. 9 and 10), or in dextran–glucose solution, and then treated with ethanol was negligible under the conditions of the experiments. Considerable loss of potassium occurred, however, when cells were incubated at 37° for

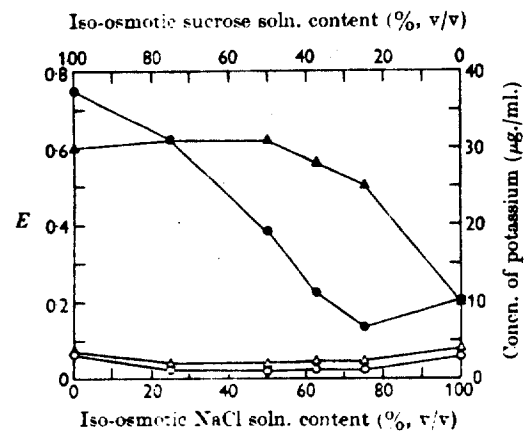

Fig. 9. Relationship of haemolysis of erythrocytes by vitamin A to the salt concentration of the iso-osmotic suspending medium. Erythrocytes were suspended in media composed of differing proportions of iso-osmotic NaCl solution and iso-osmotic sucrose solution. The cells were incubated with vitamin A (10 μg./ml.) for 15 min. at 37°. ●, Release of haemoglobin by vitamin A; ○, release of haemoglobin by ethanol; ▲, release of potassium by vitamin A; △, release of potassium by ethanol.

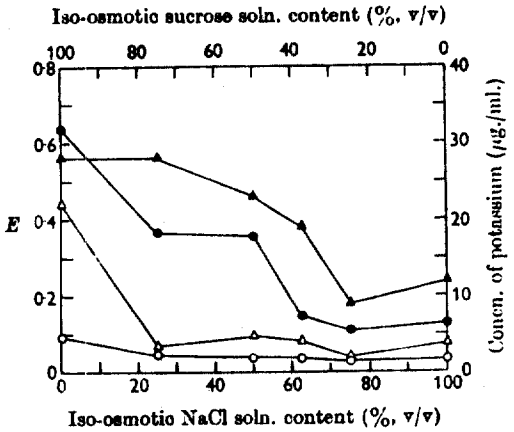

Fig. 10. Relationship of haemolysis of erythrocytes by vitamin A acid to the salt concentration of the iso-osmotic suspending medium. Erythrocytes were suspended in media composed of differing proportions of iso-osmotic NaCl solution and iso-osmotic sucrose solution. The cells were incubated with vitamin A acid (10 μg./ml.) for 15 min. at 37°. ●, Release of haemoglobin by vitamin A acid; ○, release of haemoglobin by ethanol; ▲, release of potassium by vitamin A acid; △, release of potassium by ethanol.

15 min. in iso-osmotic sucrose and in the presence of ethanol (Fig. 10), but this was not observed at 25° (Fig. 9).

DISCUSSION

The experiments reported in this paper show that vitamin A has a profound effect on the stability of the erythrocyte membrane when erythrocytes are incubated *in vitro* with the vitamin, and the cells are rapidly destroyed when treated at 37° with 10 μg. or less of vitamin A/ml. It is clear, therefore, that vitamin A can alter the permeability of a cell membrane as well as that of lysosomal subcellular particles.

Haemolysis of erythrocytes may be prevented in animals suffering from hypervitaminosis A by the protective action of serum proteins in the blood. Once the erythrocyte is removed from the influence of serum, however, it is readily lysed by the vitamin. Inhibitor systems of this kind may provide a means of protecting tissues and controlling the action of vitamin A. T. Moore & I. M. Sharman (personal communication) have recently found that erythrocytes from rats that had been treated with large doses of vitamin A were more sensitive to haemolysis by dialuric acid than erythrocytes from normal animals.

The quantity of vitamin A that will cause 50% haemolysis is related linearly to the number of erythrocytes in suspension. This finding indicates that the addition of the cell suspension to vitamin A dissolved in ethanol successfully overcomes the difficulty of bringing cells in contact with the fat-soluble vitamin.

The temperature-dependence of erythrocyte lysis, as measured by release of haemoglobin, is similar to that of the release of a proteolytic enzyme from lysosomes treated with vitamin A *in vitro* (Dingle, 1961). In both systems there is little release of protein in the cold as compared with that between 30° and 40°. One possible explanation of the observed kinetics and temperature characteristics of haemoglobin and potassium liberation from treated erythrocytes may be that the rates of release are determined by diffusion of the haemoglobin and potassium through a cell membrane that had been damaged or altered by the vitamin. The small K^+ ion might then be expected to be liberated from the cell more easily than the bulky haemoglobin molecule. Although there is no direct evidence to show that the effect of vitamin A on the surface of the lysosome is closely related to its effect on the membrane of the erythrocyte, the similarity of the temperature characteristics for release of protein in the two systems would be consistent with the operation of similar mechanisms. On the other hand, it seems reasonable to conclude that the mechanism of the lytic action of vitamin A on erythrocytes is different from that of either BRIJ 35 or lysolecithin, since the effect of temperature on haemoglobin release by vitamin A differs from the temperature characteristics of the lysis caused by the other two compounds. Confirmation of this hypothesis is provided, with lysolecithin, by the fact that the sensitivity of the samples of erythrocytes from human, ox, pig and rabbit towards lysis by vitamin A increased progressively on passing from human cells to rabbit cells, whereas the sensitivity to lysis by lysolecithin increased in the reverse order. The temperature-dependence of the action of vitamin A on erythrocytes is also different from that of the rapid phase of haemolysis produced by anionic detergents in which rising temperature decreases the rate of haemolysis (Rideal & Taylor, 1957).

At a concentration of 35 μM vitamin A acetate and vitamin A palmitate are unable to lyse erythrocytes. Similar observations have been made with these compounds in a study of the effect of vitamin A on the stability of rat-liver lysosomes (Fell *et al.* 1962). It is possible that the efficacy of the esters that is normally observed in nutritional experiments and with whole tissues may be dependent on esterase activity. This might apply to vitamin A acetate, for example, both under physiological conditions and in studies of the action of excess of vitamin A on skin made by Fell & Mellanby (1953) in which the acetate was used. Lysosome preparations from rat liver might be

unable to hydrolyse vitamin A acetate to the alcohol during short-term experiments. The inactivity of the esters towards rat-liver lysosomes may explain the fact that vitamin A is stored in the liver principally in an esterified form. The very specialized erythrocyte may not possess the required esterase. Although Krause & Alberghini (1950) reported hydrolysis of esterified vitamin A by blood, no hydrolysis could be demonstrated by the cellular elements of the blood. Vitamin A acetate may be inactive towards lysosomes and erythrocytes because of steric hindrance that occurs when the chain length of the molecule is increased by the addition of the acetate group. The absence of an alcohol or aldehyde end group in the acetate is thought to be a more likely reason for inactivity, however, since anhydrovitamin A is also inactive and this molecule, unlike the acetate, has a chain length similar to that of vitamin A and thus cannot be sterically hindered. The hypothesis that the nature of the end group is important for activity towards the erythrocyte membrane is also supported by the finding that the methyl ether of vitamin A, which is active *in vivo* (Moore, 1957), is inactive with erythrocytes.

Another requirement for activity concerns the properties of the chain. For the molecule to be active, the chain must apparently be rigid since hydrogenated vitamin A, which has a very flexible side chain, is only weakly active. An alternative explanation of the inactivity of the hydrogenated form may lie in the absence of the conjugated double-bond system. The weak activity of the hydrogenated vitamin A has the same dependence on temperature as the activity of vitamin A itself, despite the fact that the hydrogenated material used was completely free from vitamin A as shown by spectrophotometric measurements. The length of the side chain is also of great importance in determining the activity of the molecule as a haemolysin. Thus decreasing the number of carbon atoms in the side chain from 9 to 5 (excluding methyl groups), or increasing the number to 13, results in greatly decreased haemolytic activity. The reason for the greater activity of the C_{15} and C_{25} alcohols, as compared with the corresponding aldehydes, is at present unknown.

Although vitamin A acid is able to replace vitamin A in the functions of growth and general tissue maintenance, it cannot do so in the retina of the rat (Dowling & Wald, 1960) or in the reproductive processes of male and female rats (Thompson, Howell & Pitt, 1961*a*, *b*). In our experiments, vitamin A acid was relatively inactive in causing haemolysis of rabbit erythrocytes. It is possible that the rate of haemolysis is partly governed by interaction of the negative charge on the surface of the erythrocyte with the charge on the haemolysin. Bangham & Dawson (1962) showed that *Penicillium notatum* phospholipase requires lecithin micelles to possess a minimum net negative ζ-potential before activity begins, whereas phospholipase C of *Clostridium perfringens* hydrolyses lecithin only when it possesses a positive ζ-potential, achieved by adding long-chain bases. Ionization of vitamin A acid, with the production of a negative anion, might be responsible for its low activity as compared with the much more weakly ionized vitamin A alcohol. Although the presence of sugars has an inhibitory action on the lysis of erythrocytes by saponin (Ponder, 1952) and on the slow lysis by anionic detergents (Rideal & Taylor, 1957), the reduced concentration, or absence, of sodium chloride in the media of high sucrose concentration used in our experiments may have been the important factor in causing increased lysis of erythrocytes by both vitamin A alcohol and acid. Thus the increased lysis at low salt concentrations may be related to the decrease in the net negative electrokinetic charge density of the surface of the erythrocyte observed with decreasing ionic strength (Seaman & Heard, 1960). The finding that vitamin A acid is relatively inactive in lysing erythrocytes is significant, since it indicates that the membrane structure of the tissue concerned (retina, placenta, erythrocyte) may determine whether or not vitamin A acid is active.

Fell & Mellanby (1952) showed that excess of vitamin A has a drastic effect on the matrix of embryonic chick cartilage during cultivation *in vitro*. The changes produced in the matrix are similar to those observed in rabbits under conditions of hypervitaminosis A (Thomas, McCluskey, Potter & Weissmann, 1960). Lucy *et al.* (1961) demonstrated that an effect on normal cartilage similar to that of vitamin A can be produced by liberating the intracellular enzymes by treatment with hypo-osmotic solutions and then incubating the cartilage for 2 hr. at pH 3–5. In the light of these and other experiments (Dingle *et al.* 1961), it was suggested that vitamin A acts on chick cartilage by altering the permeability of the lysosomes of the chondrocytes, thereby liberating hydrolytic enzymes (Fell *et al.* 1961). This view was supported by the fact that vitamin A releases a proteolytic enzyme from isolated rat-liver lysosomes (Dingle & Lucy, 1961; Dingle, 1961). In speculations about the mechanism of action of excess of vitamin A on membranes, two possible modes of action of the vitamin are immediately apparent. First, the compound may activate enzyme systems which then attack the components of the membranes of cells and particles; degradation of the structural framework of the membrane in this way would then lead to release of the materials inside the cell or particle. On the other

hand, vitamin A may actually become attached to the structural components of membranes either in an addition reaction or in a displacement reaction whereby the normal molecular components of the membrane are displaced. The intrusion of vitamin A in this way may result in mechanical weakening of the membrane, or the vitamin may interfere with reactions that are essential to the maintenance of the membrane, with the result that the structure is no longer stable.

It may be thought that information obtained on the mechanism of action of vitamin A used in concentrations greater than the normal physiological level has little relation to the mechanism of action of the vitamin under physiological conditions. Experimental observations on the molecular structural requirements for degradation of cartilage *in vitro*, liberation of protease from lysosomes (Fell *et al.* 1962), and haemolysis of erythrocytes show, however, that, with certain exceptions discussed above, the relationships between structure and activity in these systems are the same as for the prevention of vitamin A deficiency in animals. Further, the present experiments have demonstrated that both vitamin A alcohol and aldehyde (C_{20}) are 10 times more effective in producing lysis of erythrocytes than the related C_{18} and C_{22} alcohols and aldehydes that have shorter and longer side chains respectively. Haemolytic activity is therefore a property of vitamin A alcohol and aldehyde which is possessed in only a small degree by quite closely related molecules. It it suggested, therefore, that alterations in the structure of cellular and intracellular membranes with concomitant changes in permeability may be a common feature underlying the differing actions of vitamin A in many different systems. This type of action of vitamin A on the membranes of cells and intracellular particles is probably not limited to vitamin A alone but may be characteristic of fat-soluble vitamins. For instance, vitamin E deficiency has been shown by Heard, Moore & Sharman (1952) to increase the ease of chemical lysis of erythrocytes, and there is evidence that this deficiency may also be associated with increased catheptic activity in muscle, probably of lysosomal origin (Zalkin, Tappel, Desai, Caldwell & Peterson, 1961). Vitamin D is important in maintaining the structure of mitochondria (DeLuca, Reiser, Steenbock & Kaesberg, 1960), though it has yet to be established if it plays a part in maintaining the structure of either the lysosome or the erythrocyte.

The function of vitamin A may be regarded as the control of membrane permeability, particularly in relation to large molecules, and it is possible that the behaviour of the vitamin under physiological conditions is similar to its action when present in excess except that the membranes affected become excessively unstable in the latter situation. Further, the effect of excess of vitamin A on the erythrocyte membrane may be regarded as a model of the way in which vitamin A may act on membrane structures in general.

SUMMARY

1. The addition of a suspension of erythrocytes from rabbit, pig, ox, rat or human to vitamin A alcohol, dissolved in ethanol, results in rapid lysis of the cells and production of erythrocyte stroma on incubation at 37°. Homologous serum inhibits lysis. Erythrocytes suspended in a medium containing sucrose and sodium chloride are more easily lysed than those in sodium chloride solution alone.

2. The temperature-dependence of the release of haemoglobin by vitamin A is similar to that of the release of protease from rat-liver lysosomes treated with the vitamin.

3. Haemolysis produced by vitamin A has been compared with that caused by a neutral detergent and by lysolecithin.

4. Only weak haemolytic activity is possessed by hydrogenated vitamin A, oxidized vitamin A, anhydrovitamin A, vitamin A_2 alcohol and vitamin A_2 aldehyde. β-Ionone, geraniol, citral, phytol and dodecanol are without activity at the concentrations tested.

5. Changes in the nature of the end group or the chain length of the molecule result in diminished haemolytic activity. The molecular specificity for lysis is similar to that for biological activity and for action on isolated lysosomes.

6. The hypothesis is presented that the site of action of the vitamin is at the lipoprotein membranes of cells and their organelles and that its function is the control of the permeability of biological membranes.

We thank Dr Honor B. Fell, F.R.S., for her encouragement and interest in this work, and for many stimulating discussions. We are most grateful to Professor R. A. Morton, F.R.S., Dr Philip L. Harris, Dr T. Moore and Dr R. M. C. Dawson for gifts of chemicals, and to Dr M. R. Daniel for observations on the effect of vitamin A on the morphology of erythrocytes. We are indebted to Miss J. Mizen and Miss P. Carter for skilful technical assistance.

REFERENCES

Bangham, A. D. & Dawson, R. M. C. (1962). *Biochim. biophys. Acta*, **59**, 103.

Bukantz, S. C., Rein, C. R. & Kent, S. F. (1946). *J. Lab. clin. Med.* **31**, 394.

Dawson, H. & Danielli, J. F. (1938). *Biochem. J.* **32**, 991.

DeLuca, H. F., Reiser, S., Steenbock, H. & Kaesberg, P. (1960). *Biochim. biophys. Acta*, **40**, 526.

Dingle, J. T. (1961). *Biochem. J.* **79**, 509.
Dingle, J. T. & Lucy, J. A. (1961). *Biochem. J.* **78**, 11P.
Dingle, J. T., Lucy, J. A. & Fell, H. B. (1961). *Biochem. J.* **79**, 497.
Dowling, J. E. & Wald, G. (1960). *Proc. nat. Acad. Sci., Wash.*, **46**, 587.
Fell, H. B., Dingle, J. T. & Webb, M. (1962). *Biochem. J.* **83**, 63.
Fell, H. B., Lucy, J. A. & Dingle, J. T. (1961). *Biochem. J.* **78**, 11P.
Fell, H. B. & Mellanby, E. (1952). *J. Physiol.* **116**, 320.
Fell, H. B. & Mellanby, E. (1953). *J. Physiol.* **119**, 470.
Heard, D. H., Moore, T. & Sharman, I. M. (1952). *Biochem. J.* **52**, i.
Krause, R. F. & Alberghini, C. (1950). *Arch. Biochem.* **25**, 396.
Lucy, J. A. & Dingle, J. T. (1962). *Biochem. J.* **82**, 31P.
Lucy, J. A., Dingle, J. T. & Fell, H. B. (1961). *Biochem. J.* **79**, 500.
Moore, T. (1957). *Vitamin A*. Amsterdam: Elsevier.
Paul, J. (1959). *Cell and Tissue Culture*. Edinburgh: Livingstone.
Pollard, C. J. & Bieri, J. G. (1958). *Brit. J. Nutr.* **12**, 359.
Ponder, E. (1952). *Haemolysis and Related Phenomena*. London: J. and A. Churchill Ltd.
Rideal, E. & Taylor, F. H. (1957). *Proc. Roy. Soc.* B. **146**, 225.
Seaman, G. V. F. & Heard, D. H. (1960). *J. gen. Physiol.* **44**, 251.
Shantz, E. M. & Brinkman, J. H. (1950). *J. biol. Chem.* **183**, 467.
Sundaresan, P. R. & Cama, H. R. (1961). *Brit. J. Nutr.* **15**, 225.
Thomas, L., McCluskey, R. T., Potter, J. L. & Weissmann, G. (1960). *J. exp. Med.* **111**, 705.
Thompson, J. N., Howell, J. McC. & Pitt, G. A. J. (1961*a*). *Biochem. J.* **80**, 16P.
Thompson, J. N., Howell, J. McC. & Pitt, G. A. J. (1961*b*). *Biochem. J.* **80**, 25P.
Zalkin, H., Tappel, A. L., Desai, I., Caldwell, K. & Peterson, D. W. (1961). *Fed. Proc.* **20**, 303.

Dowling-'58
Bib. No. 2276

Proc. Natl. Acad. Sci. U.S. 44:648-661. 1958.

Reproduced by permission
of the copyright owner

VITAMIN A DEFICIENCY AND NIGHT BLINDNESS

By John E. Dowling and George Wald*

BIOLOGICAL LABORATORIES OF HARVARD UNIVERSITY, CAMBRIDGE

Communicated May 16, 1958

One of the oldest diseases known to man is nutritional night blindness. Its descriptions go back to the ancient Egyptian medical papyri and are already accompanied by the correct prescription for its cure, the eating of liver. Toward the end of World War I the factor in liver which cures night blindness was identified with the then newly discovered vitamin A.[1]

Vitamin A is the precursor in the retina of the visual pigments of the rods and cones.[2] It seems reasonable to suppose that on a diet deficient in this factor the retina eventually synthesizes subnormal amounts of visual pigment, with the corresponding decline of visual sensitivity that constitutes night blindness.

Some of the first studies of experimental human night blindness seemed to reveal such a simple and direct relationship.[3] In two subjects deprived of vitamin A, the visual thresholds of both rods and cones began at once to rise, until a mild night blindness had been established.[4] On oral administration of vitamin A or carotene, the thresholds of both rod and cone vision returned to normal within 2–3 hours.

It looked for a time, therefore, as though this might be an exemplary instance of the origin and cure of a biochemical disease, all elements of which were well understood. Further studies, however, exposed two major discrepancies: (1) Though in some subjects placed on a vitamin A-deficient diet the visual threshold began at once to rise, in a larger number it remained unchanged for periods ranging from several months[5] to, in one instance, 2 years.[6] (2) Among the subjects who developed night blindness, some were completely cured within a few hours after receiving vitamin A, whereas others, though showing some immediate improvement, took months of vitamin A supplementation to return to normal.[7]

One might take a simple position with regard to the first of these discrepancies. The amounts of vitamin A stored in the livers of healthy human subjects are known to vary enormously.[8] In Britain, for example, Moore[6] found reserves in adults during 1941–44 ranging from about 7 to 750 μg/gm. If we take 1,500 gm. as the average weight of the adult liver and about 300 μg. (about 1,000 I.U.) as the daily drain upon stored vitamin A, the average Briton stores enough vitamin A in his liver—if used economically—to tide him over some 500 days of total deprival. An unusually well-supplied Briton—if we can disregard spoilage—might survive seven times as long, or almost 10 years! On the other hand, the most poorly supplied members of this group might have run through their stored vitamin A within 1–2 weeks. It is not difficult to understand, therefore, why most subjects taken from ordinary American or British environments fail to respond to vitamin A-deficient diets within months or even years. It is less clear why a fairly large proportion of them responded within a few days, even though in some instances highly supplemented with vitamin A for the preceding period.[3]

The second discrepancy—the great variability in the times required to cure night blindness—raises other issues. The visual pigments are composed of vitamin A

aldehyde (retinene) joined to specific proteins of the rods and cones called "opsins." The amounts of visual pigment that can be formed in the normal retina are limited, not by vitamin A, which is ordinarily present in excess, but by opsin. In thinking about night blindness, we have tended in the past to be too much preoccupied with vitamin A and have paid too little attention to the opsins.[2]

When one does consider the opsins, this at once suggests further relationships. The outer segment of a rod—and this must be true also of many cones—is composed in considerable part of visual pigment, that is, of opsin, since the retinene chromophore constitutes only about 1 per cent of these molecules. Opsin accounts for about 40 per cent of the dry weight of the outer segment of a frog rod and 14 per cent of that of a cattle rod.[2] It is an important structural constituent of the rods and probably of the cones; and any loss of this protein might be equivalent to the structural deterioration of the visual receptors.

Tansley[9] showed some years ago that in vitamin A–deficient rats and dogs, somewhat later than the decline in rhodopsin production that should have initiated night blindness, the outer segments of the rods deteriorated structurally. Johnson[10] confirmed and extended these observations in the rat; and recently similar changes have been observed in both rods and cones of the monkey.[11] According to Johnson, after 7–13 weeks of vitamin A deprivation in young rats, many outer segments have disappeared, and those that remain stain abnormally. As the deficiency progresses, the inner segments of the rods also degenerate, and then successively the external limiting membrane, the outer nuclear layer, and the inner nuclear layer. These changes occur sooner in central than in peripheral areas of the retina. The outer segments of rods which have deteriorated only slightly seem to repair considerably within 24 hours of feeding vitamin A. Even rods which have degenerated completely seem to be replaced within 10–18 weeks of vitamin A supplementation.

These observations suggest that the time required to cure night blindness may depend on the extent to which vitamin A deficiency has altered the retinal structure. Simple lack of vitamin A, through lowering the concentrations of visual pigments, might induce a night blindness that is cured as rapidly as vitamin A re-enters the retina; but the structural deterioration of the retina, heralded perhaps by the loss of opsin, might take much longer to repair.

For these reasons it seemed worthwhile to map the entire course of vitamin A deficiency and its cure in the rat. In single groups of animals we have measured simultaneously the vitamin A in the liver and blood, the retinal content of rhodopsin and opsin, the electroretinographic threshold, and the ERG's obtained over a wide range of light intensities. In key instances we have also examined the retinal histology.

Not all these things were done for the first time. We have already discussed the histological studies of Tansley and Johnson and should mention particularly also Tansley's fine study of rhodopsin synthesis in normal and vitamin A–deficient rats[12] and the measurements of liver, blood, and retinal vitamin A in normal and deficient rats by Lewis, Bodansky, Falk, and McGuire.[13]

Plan of the Experiments.—A number of experiments were performed, all of which yielded substantially the same pattern of results. We shall describe primarily the last such experiment, because it brings together all the procedures and represents most completely and typically all our observations.

Male albino rats of the highly inbred Harvard colony, 22–24 days old and weighing 36–66 gm., were divided into two groups, one kept on the complete laboratory ration, the other placed on the standard USP vitamin A test diet. The animals on the deficient diet continued to gain weight for about 5 weeks, though more slowly than normal. At this time they weighed an average of 112 gm. as compared with the control weight of 215 gm. but were altogether normal in appearance. In the fifth to seventh weeks their weights plateaued and thereafter declined rapidly. At the same time—in the seventh and eighth weeks— the classic overt signs of vitamin A deficiency appeared, and by the end of the eighth week all the animals not sacrificed in the experiments had died.

For electroretinography, animals that had been dark-adapted overnight were anesthetized with nembutal. The eye was held open with threads drawn through the lids. Cotton-wick electrodes were used, moistened with Ringer solution, one touching the side of the cornea, the other a shaved area on the cheek. The response was recorded with a capacity-coupled Grass P4 preamplifier and a Dumont oscilloscope with camera attachment. The stimuli were $^1/_{50}$-second flashes of white light, the intensity of which was controlled with neutral filters and photographic wedges. The absolute threshold was measured by starting with the light well below threshold and flashing it every few seconds at gradually increasing intensities until a response could be detected on the oscilloscope. This procedure was repeated until constant readings were obtained. Then the ERG was recorded over a wide range of intensities.

After dark-adapting overnight, the same animals were used next morning for the biochemical measurements. They were again anesthetized, the body cavity was opened, and 5–10 ml. of blood were taken from the heart with an oxalated syringe. The entire liver was removed and also both eyes. One eye of each animal was used to measure rhodopsin, the other to measure opsin; but, since each of these determinations requires 2 retinas, animals were paired, usually on the basis of having yielded comparable electroretinograms.

To determine blood vitamin A, the oxalated blood from one animal was centrifuged, and the clear plasma was mixed with an equal volume of ethyl alcohol and extracted three times with petroleum ether. This extract was transferred to 0.3 ml. of chloroform, and a micro-antimony chloride test was performed by mixing 0.25 ml. of the extract with 0.50 ml. of antimony chloride reagent, recording the absorption spectrum at once in a Cary recording spectrophotometer.

The livers, weighing 4–12 gm., were ground with anhydrous sodium sulfate to a fine powder and extracted by shaking with diethyl ether. An aliquot of this extract was transferred to chloroform, and its vitamin A content determined by the antimony chloride procedure.

To measure rhodopsin, two retinas were hardened in 4 per cent alum solution for 15–20 minutes, then washed with distilled water and buffer, and extracted overnight with 0.2 ml. of 2 per cent digitonin solution. After centrifuging, 0.01 ml. of 1 *M* hydroxylamine was added to the extract, and the absorption spectra recorded before and after bleaching. The change in extinction at 500 mμ measured rhodopsin.

Opsin was determined by measuring the capacity of retinas to regenerate rhodopsin when incubated with neo-*b* (11-*cis*) retinene.[11] We found that rat rhodopsin

in digitonin solution regenerates very little when bleached and incubated with neo-*b* retinene. For this reason whole retinas were exposed to bright light until wholly bleached. Then a large excess of neo-*b* retinene, dissolved in 0.025 ml. acetone, was added to the retinas suspended in buffer solution, the mixture was stirred periodically during 4–6 hours at room temperature and then left at 5° C. overnight. The rhodopsin which had formed was extracted and measured as described above. Control measurements showed that 70–80 per cent of rhodopsin originally present in a retina was regenerated and recovered by this procedure.

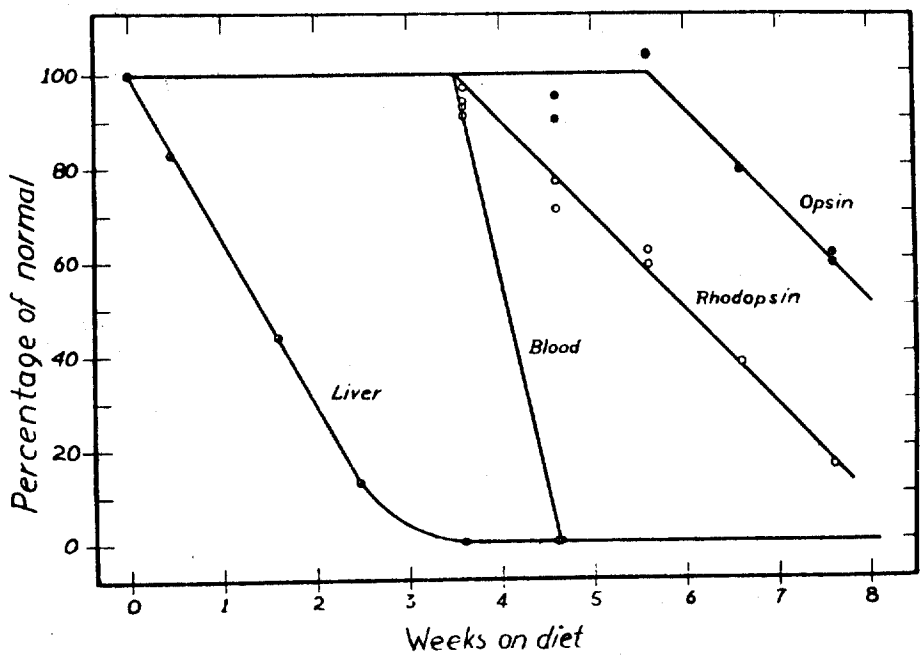

FIG. 1.—Biochemical changes in a group of white rats on a vitamin A–deficient diet. The animals were 22–24 days old when the diet was begun. The liver vitamin A began to fall at once and within 3 weeks had reached low values. Then within a week the blood level fell from normal to zero. With this, the rhodopsin content of the retina declined, marking the onset of night blindness. Later the opsin also declined, marking the beginning of the histological deterioration of the retina.

Vitamin A of Liver and Blood; Rhodopsin and Opsin.—Figure 1 shows in one group of animals the effects of the deficient diet on the vitamin A content of the liver, the vitamin A concentration in the blood, and the rhodopsin and opsin of the retina. The values are expressed as percentages of normal. For the liver this means the percentage remaining of the vitamin A present in control animals at the time the diet was begun. The blood vitamin A, rhodopsin, and opsin are expressed as percentages of the values found in control animals of the same age.

The liver vitamin A begins to fall as soon as the diet is begun and within 3 weeks has reached a very low value. This depletion proceeded at the average rate of 2–2.5 μg. daily, the withdrawal rate for animals of this age and weight. Meanwhile, the control animals on the complete diet increased their liver stores at an average rate of 45 μg. daily. It is this that makes the age at which the diet is

begun decisive for the course of the deficiency. Our control animals when 53 days old had livers weighing, on the average, 16 gm. and containing 1,360 μg. vitamin A; withdrawn at a daily rate of even 5 μg., this might have tided them over 9 months of a deficient diet.

The blood maintains its normal concentration of vitamin A (10.4 μg. per cent in the deprived animals, 11.2 μg. per cent in the controls) until the liver has been

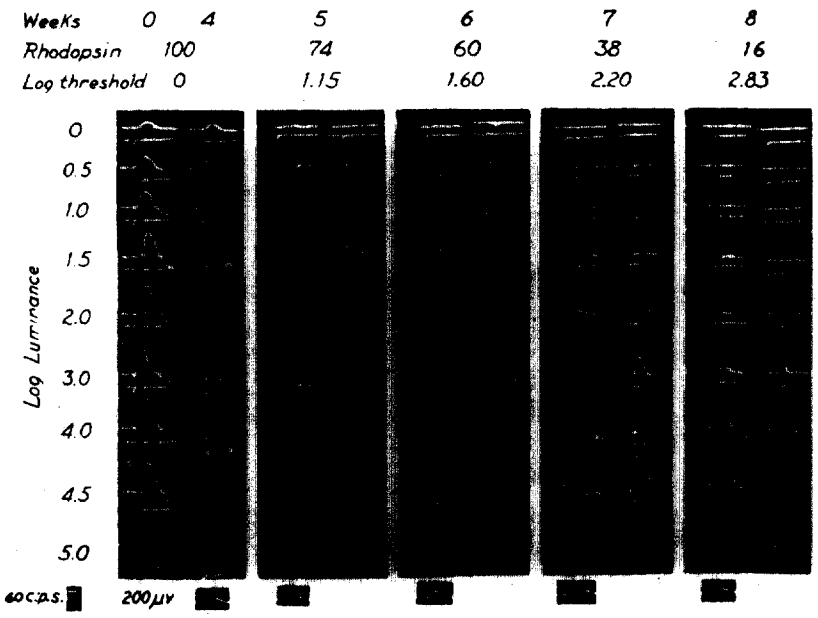

FIG. 2.—Effects of vitamin A deficiency on the electroretinogram (ERG). The top three lines show the number of weeks on the deficient diet, the rhodopsin content of the retinas as percentages of normal; and the logarithm of the luminance of light needed to evoke a just perceptible ERG, the average threshold of normal animals being set arbitrarily at 1 (log threshold = 0). ERG's are shown in response to a range of luminances of 5 log units, i.e., 1 to 100,000. Below each ERG, a marker shows the $^1/_{50}$-second flash. The small rectangles at the bottom show a trace of the 60-cycle A.C. to indicate the time scale, and weekly calibrations of the oscillographic response to a pulse of 200 microvolts. The first two vertical rows of ERG's show responses from a rat about to begin the diet and those from another after 4 weeks, when the vision is still normal. Thereafter, records are shown from a pair of animals each week. As the rhodopsin declines, the ERG threshold rises (night blindness), and the ERG displays characteristic changes: (*a*) the *b*-wave at each level of luminance declines; (*b*) the *a*-wave declines still more rapidly; and (*c*) an inflection on the downward sweep of the *b*-wave is delayed longer and longer until it appears as a separate positive wave.

emptied. Then in the space of a few days the blood vitamin A falls precipitately to zero.

Up to this time the rhodopsin content of the retina remains normal. The extract of two retinas in 0.21-ml. solution possesses an extinction at 500 mμ of 0.280, corresponding to a rhodopsin content of 7.24×10^{-4} μmoles per retina. This is equivalent to a vitamin A content of 0.21 μg. per retina. (Lewis *et al.*[12] found only one-fifth to one-third as much vitamin A in the rat retina; the description of their preparative procedure suggests that it may have involved large losses of rod outer segments.)

Now the rhodopsin also begins to fall and within 3 weeks has reached very low values. As we shall see, this marks the beginning of night blindness.

There is a curious interval of 2–3 weeks in which, though the rhodopsin content has declined, the opsin level is still normal. That is, with the liver and blood emptied of vitamin A, the retina contains opsin which can find no vitamin A with which to combine.

Then the opsin level, too, begins to fall, and this marks the beginning of the structural deterioration of the retina (see below). At this time also—the seventh and eight weeks of the diet—the classic signs of vitamin A deficiency appear. (In another of our experiments it took 10–11 weeks to reach this stage.) The

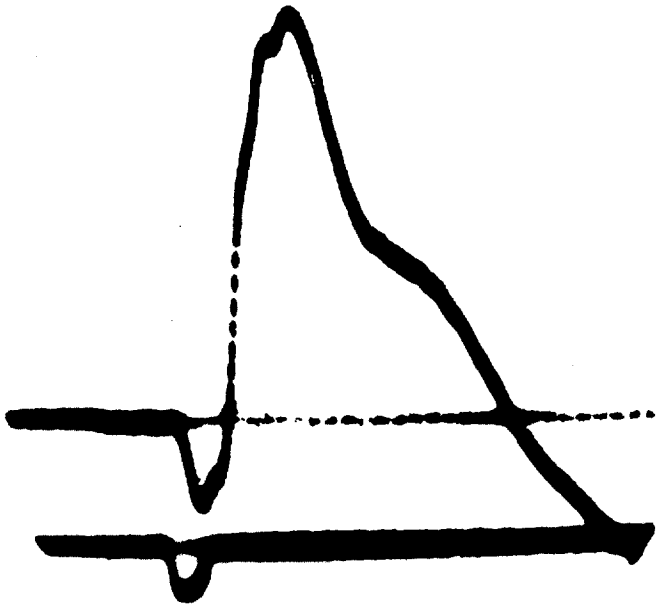

FIG. 3.—Form of the ERG. Both the *a*- and *b*-waves are two-cusped. This feature appears also in the human ERG, where the shorter-latency component in each wave is believed due to cone responses, the longer-latency component to rods. The strong inflection evident on the downward sweep of the *b*-wave is delayed longer and longer as night blindness develops. Below the ERG, a marker shows the $^1/_{50}$-second stimulating flash.

animals lose weight rapidly; and by the end of the eighth week all not already used in the experiments have died.[15]

Physiological Changes.—For the first 4 weeks on the diet, the animals appear to be physiologically normal. During this time, first the liver and then the blood is depleted of vitamin A. In the fifth week, as the rhodopsin level begins to fall, the visual threshold rises, marking the beginning of night blindness.

Figure 2 shows electroretinograms recorded in pairs of experimental animals. At the top of the figure are shown the number of weeks on the diet, and below this the average rhodopsin content of the retinas as percentages of the normal value. Below this is the logarithm of the threshold for a just perceptible retinogram; the normal threshold has been set arbitrarily at 1 (log threshold = 0), so that these

numbers represent the rise in log threshold over the normal value. The rat's eyes were exposed to $^1/_{50}$-second flashes at the log luminances shown on an arbitrary scale at the left. The figure shows a series of ERG's at various luminances for each of two rats each week. Since no changes occur in the first 4 weeks, the first pair of records involves one rat just about to begin the diet and another rat that had been 4 weeks on the diet.

At the end of the fourth week the ERG is entirely normal. In the fifth week, the rhodopsin level falls to 74 per cent, and the visual threshold rises 1.15 log unit, or about 14 times. In the succeeding weeks, as the rhodopsin level continues to

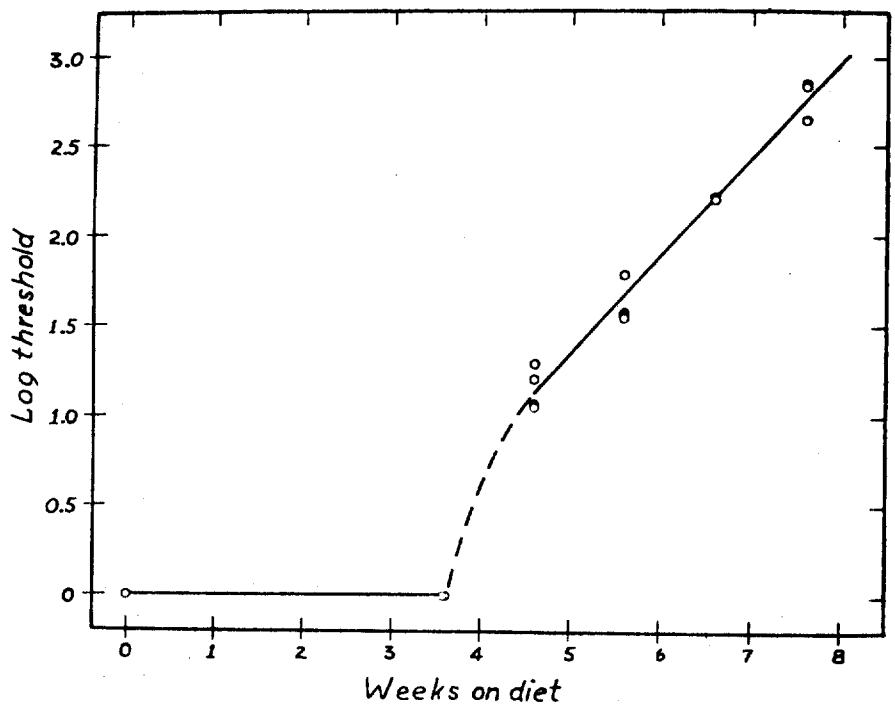

FIG. 4.—Development of night blindness with time on the vitamin A–deficient diet. Each point shows the logarithm of the ERG threshold of a single animal, the normal threshold being set arbitrarily at 1 (log threshold = 0). The log threshold rises linearly with time on the diet, following a more rapid initial rise.

decline, the threshold rises until, at the end of the eighth week, the rhodopsin is at 16 per cent, and the visual threshold has risen about 680 times.

Simultaneously, the ERG undergoes characteristic changes: (1) At all luminances but particularly at the lower ones, the height of the positive *b*-wave declines as the deficiency progresses. So, for example, at log luminance 3.0 the *b*-wave, nearly maximal at the end of the fourth week, has sunk to the just perceptible threshold level by the end of the eighth week. (2) The negative *a*-wave declines in amplitude still more rapidly. It is initially nearly as large as the *b*-wave at log luminance 5: but by the end of the eighth week it can hardly be elicited at all, even at this highest luminance. (3) A small positive inflection, which appears initially only as a hump on the downward sweep of the *b*-wave, is delayed longer and longer as the

deficiency progresses, until finally it has become a well-separated second positive wave, particularly evident at the higher luminances. The source of this delayed positive wave has not yet been identified. The possibility that it is an off-effect is not supported by our tests.

It may be noted in passing that some of the ERG's show clearly that both the *a*- and the *b*-waves are two-cusped. This is particularly evident in such records as those of the sixth week at log luminance 5. One of this pair of ERG's has been enlarged in Figure 3. Such two-cusped *a*- and *b*-waves have come to be associated in the human retinogram with the responses of cones and rods, the shorter latency component in each wave presumably representing the cone response.[16]

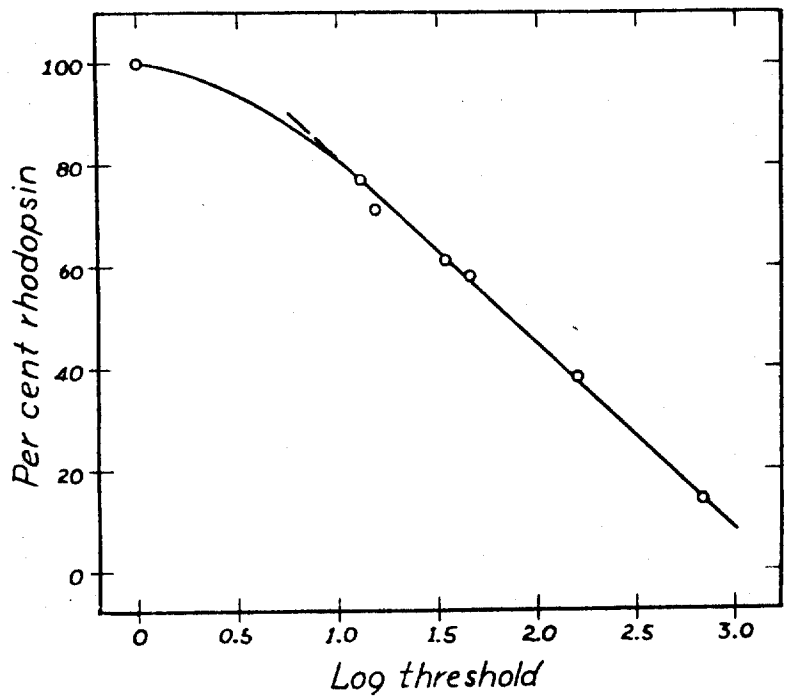

FIG. 5.—Rise of the ERG threshold with decline in rhodopsin content in the retinas of vitamin A–deficient rats. The normal log threshold is set at 0. Rhodopsin is expressed as the percentage of that found in control animals of the same age. Over most of its course the log threshold rises linearly as rhodopsin falls, following a disproportionately large rise of threshold with the first decline of rhodopsin.

It has frequently been asserted that rats possess only rods; yet Tansley[16] and Walls[17] state unequivocally that cones are present, and Sidman[18] has recently reported finding them in the approximate proportion 1 cone:10 rods. Since in the whole human retina the proportion of cones to rods is about 1:20, there may be as good anatomical basis in the rat as in man, for the two-cusped ERG's to represent cone and rod responses.

Figure 4 shows the relation between log threshold, and time on the deficient diet. After a somewhat abrupt start in the fifth week, the log threshold rises linearly. Similar behavior has been reported in man, the log threshold, rod and cone, rising linearly or nearly linearly for long periods on vitamin A–deficient diets.[3, 7]

Figure 5 shows the relation between the rhodopsin level of the retina and the logarithm of the visual threshold. Most of this relation again is linear, though distorted, as was Figure 4, by a somewhat disproportionate rise of threshold accompanying the first decline of rhodopsin. When the rhodopsin has fallen to half its normal content as the result of the deficiency, the threshold has risen about 100 times; when the rhodopsin is at 10 per cent, the threshold is up about 1,000 times. It would be interesting to determine whether in normal rats the bleaching of rhodopsin that accompanies light adaptation causes similar changes of threshold. It is now recognized that in the human eye the bleaching of a small fraction of rhodopsin raises the threshold enormously;[19] by one estimate, the bleaching of 0.6 per cent of the rhodopsin raises the threshold about 3,300 times.[20]

Histologic Changes.—The deterioration of retinal tissues in vitamin A-deficient rats has been described by Tansley[9] and by Johnson.[10] Our principal problem is

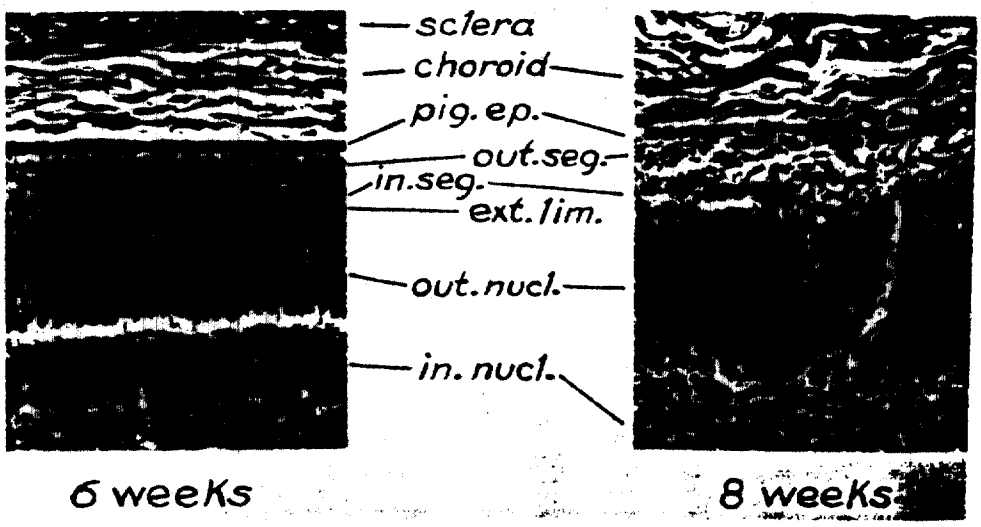

FIG. 6.—Effect of vitamin A deficiency on the structure of the rat retina. After 6 weeks on a vitamin A-deficient diet, the retina appears entirely normal. After 8 weeks it has deteriorated markedly: only traces remain of the pigment epithelium; the layer of rods, particularly the outer segments, is disintegrating; and the external limiting membrane has disappeared.

to orient these changes in the pattern of biochemical and physiological events that we have described.

After 6 weeks on the vitamin A-deficient diet, when the rhodopsin had fallen to about half its normal value but the opsin was still intact, the retinal histology of these animals appeared entirely normal (Fig. 6, *left*). After 8 weeks on the diet, however, when the opsin also had fallen to about half its normal value, the retinal tissues had deteriorated markedly (Fig. 6, *right*). The outer segments of the rods were attenuated, many had a gnawed appearance, and they were irregularly spaced. Only vestiges of the pigment epithelium remained. The sharp boundary that marked the external limiting membrane was gone; and the blood vessels of the choroid layer were frequently occluded.

Our supposition that, when opsin goes, the outer segments of the rods should deteriorate structurally has proved to be correct. By this time, however, the

animal is deteriorating generally. Not only are other retinal tissues affected as just described, but the superficial structures of the eye now begin to display the classic signs of vitamin A deficiency: corneal clouding, xerophthalmia, and secretion of a sticky red exudate about the eyes. The animal is losing weight rapidly, the coat is disarranged, some animals have developed an unsteady gait, some breathe with difficulty.

There is no compelling reason, therefore, to single out opsin among the animals' disabilities. To the degree that the loss of opsin is responsible for the histological decay of the outer segments of the rods, it may be only one of many proteins respon-



FIG. 7.—Recovery from night blindness on administration of vitamin A. Following intraperitoneal injection of a large dose of vitamin A, the ERG threshold returns within 64 hours to normal (log threshold = 0). During this interval the ERG retraces in reverse all the changes which had accompanied the development of night blindness.

sible for similar manifestations in many tissues. We shall have more to say of this below.

Recovery from Night Blindness.—A number of animals which have developed night blindness were "cured" by administering vitamin A. It was found that the vitamin could be supplied more effectively by intraperitoneal injection than orally. Oral administration yielded irregular results, successful in some deficient animals, not in others. It seemed as though some deficient animals had lost temporarily the capacity to take up vitamin A fed by mouth.

The effect of administering vitamin A to a night-blind animal is shown in Figure 7. At the beginning of the experiment this animal exhibited much the same ERG responses as did the animals of Figure 2 in the seventh week of the deficiency. Its ERG threshold was a little more than 100 times normal.

This animal was given a large dose of vitamin A—340 μg. dissolved in 1 ml. cottonseed oil, injected intraperitoneally. The ERG threshold slowly fell and within 64 hours had reached the normal level. Simultaneously, the ERG retraced in reverse all the changes that had accompanied the development of night blindness: the *a*- and *b*-waves increased to their former sizes, and the delayed positive wave was reincorporated into the *b*-wave.

Figure 8 shows the return of the ERG threshold to normal in a series of such recovery experiments. On the left are shown data from three deficient animals exhibiting various degrees of night blindness. Various amounts of vitamin A in cottonseed oil, ranging from 320 to 920 μg., were injected in 1–3 doses. In every

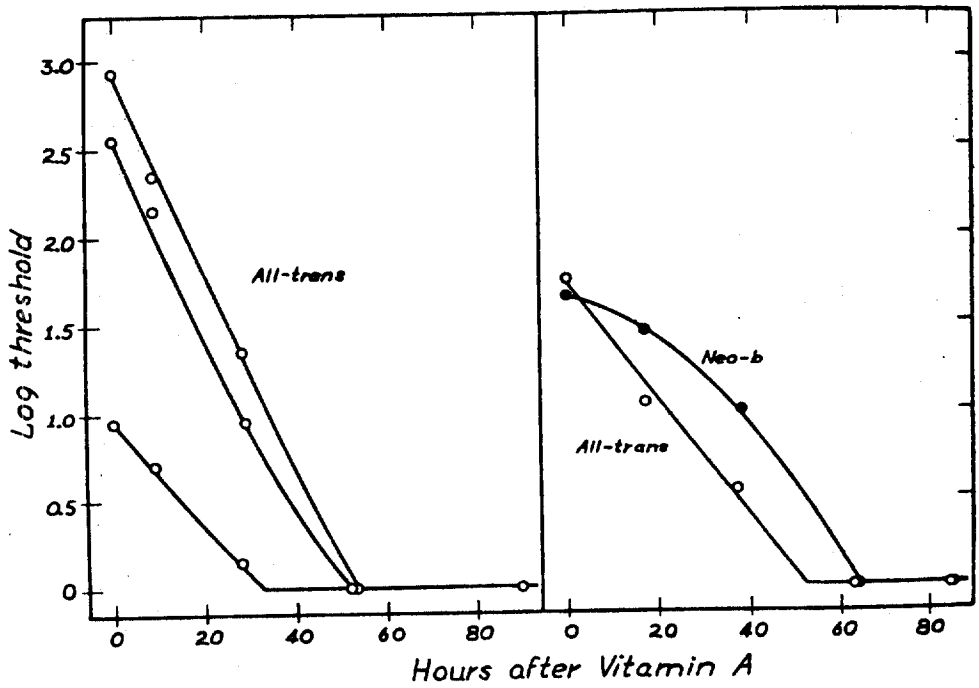

FIG. 8.—Recoveries from night blindness on administration of vitamin A. Log ERG thresholds measured at various times after intraperitoneal injection of large doses of all-*trans* vitamin A (*open circles*), or neo-*b* (11-*cis*) vitamin A (*closed circles*). After injection of the all-*trans* isomer, the log threshold falls almost linearly to the normal level; but with neo-*b* vitamin A there is a lag in recovery, caused apparently by the necessity to isomerize this configuration primarily to all-*trans* before it is used by the eye.

case the fall of log threshold to the normal level was approximately linear. The time for complete recovery depended primarily on the degree of night blindness, not the dosage level, at least within this range of high dosage.

In one instance two rats, closely matched in their degree of night blindness, were injected with equal amounts (*ca.* 1,000 μg.) of two geometric isomers of vitamin A: the all-*trans* form, which is most prevalent and which has been shown to be most effective in stimulating growth and liver storage in the rat,[21] and the hindered *cis* neo-*b* isomer (11-*cis*), which serves as precursor of the visual pigments. The result is shown at the right in Figure 8. The fall of log threshold on injection of all-*trans* vitamin A was, as usual, approximately linear; the neo-*b* isomer, however,

exhibited a distinct initial lag in its effect, though after 30–40 hours the responses to both isomers ran approximately parallel.

The vitamin A of the liver and blood was measured in these animals and in another pair which had been treated similarly. The animals injected with all-*trans* vitamin A had stored 71–87 μg. in the liver, in each case about 9 per cent of that injected, whereas those that received neo-*b* vitamin A had stored 32–39 μg., or about 4 per cent of that injected. Isomerization experiments conducted in both instances showed that none of the stored vitamin A was of the neo-*b* configuration. The blood levels after injection of either all-*trans* or neo-*b* vitamin A were normal (11.9 and 13.8 μg. per cent, respectively); again none of this was neo-*b*. Rhodopsin also was extracted from the retinas of the animals which yielded the data of Figure 8 (*right*). The extinctions at 500 mμ were 0.259 and 0.252, somewhat low, yet within the normal range.

It appears, therefore, that neo-*b* vitamin A, when injected intraperitoneally, is converted to other isomers, primarily all-*trans*, before entering the eye. It is presumably this process of isomerization that causes the observed delay in its action and may be responsible also for its relatively low effectiveness in growth and storage.[21]

Where this isomerization occurs is not yet known; but it appears to be a general feature of vitamin A metabolism, for surveys in our laboratory of representative tissues in fishes, rats, and cattle have failed to find the neo-*b* isomer anywhere but in the eye.[22] It seems likely that only other isomers of vitamin A are carried in the blood or stored in the liver and that the eye tissues themselves isomerize one or several of these to the neo-*b* configuration for the synthesis of visual pigments. The bleaching of the visual pigments by light, on the other hand, yields all-*trans* retinene and vitamin A; so that the visual processes include a continuous cycle of geometric isomerization between these two configurations.[14]

At the left of Figure 8 two recoveries are shown from states of night blindness involving 2.5–3 log units rise of threshold above normal. Figure 5 shows that this degree of night blindness corresponds to the decline of rhodopsin to 10–20 per cent of normal and Figure 1 that, by this time, opsin should have fallen to about 60 per cent of normal, with a corresponding disturbance of retinal histology. We cannot be certain that all these lesions occurred in the animals that yielded the data of Figure 8, but they were to be expected. The return of the threshold of these animals to normal 50 hours after administration of vitamin A implies that, within this interval, not only had neo-*b* vitamin A again been made available but that the retina had regained whatever opsin it had lost and had repaired whatever tissue deterioration had occurred. It should be said at once that these animals had been selected because their corneas were clear, since we wished to avoid the special complications of threshold measurement with cloudy corneas. The animals were, however, losing weight, and some of them exhibited the rough coats, red eye exudate, and postural imbalance already noted. In such instances, though a single large dose of vitamin A quickly brought the visual threshold back to normal, as shown in Figure 8, the external appearance was still poor. Several days elapsed before the weight began to increase, and it took several weeks before they again looked sleek, though no more vitamin A had been administered.

Conclusions.—These experiments reveal a simple and consistent series of changes

directly related to the availability of vitamin A. On being deprived of vitamin A, the rat exhausts its store of this substance in the liver at a regular rate, meanwhile maintaining the levels in the other tissues. With the liver emptied, the blood level falls, and shortly afterward evidences of tissue deprivation appear. The first of these is night blindness—the visual pigments lose their prosthetic group, vitamin A aldehyde. Later the protein components of the visual pigments, the opsins, also decline; but this is a secondary phenomenon accompanied by general signs of tissue disintegration in the eye and elsewhere in the organism. On administering vitamin A, all these changes are reversed.

For some years past we have had to face the embarrassment that the only function of vitamin A in the organism that we understand—that of supplying the chromophores of the visual pigments—plays only a trivial part in the whole complex of vitamin A deficiency. No animal dies of night blindness. Vitamin A must have some general and fundamental function in tissues all over the body, perhaps particularly in epithelia, so that in its absence the organism as a whole deteriorates and eventually succumbs. The nature of this general function is still unknown.

It has recently become increasingly evident that the protein opsin is stabilized chemically by its combination with retinene. Opsin, for example, is denatured much more readily than rhodopsin, by acids and alkalies[23] and by heat.[24] We have supposed that possibly for this reason opsin can be maintained in the rods and cones only through its opportunity to form visual pigments; and that, when this opportunity is lost, as in vitamin A deficiency, the opsins also might soon be lost. It is in part this consideration that led us to perform the present experiments.

They come out well in this regard. It is true, whether for this reason or another, that, shortly after opsin ceases to be saturated with retinene, it begins to leave the retina; and, since opsin is an important structural constituent of the outer segments of the rods, it is perhaps for this reason that the rods deteriorate anatomically. The important point is that these things do not happen alone but as part of a wide pattern of tissue disintegration all over the body. The outer segments of the rods are only one among many tissues, and opsin may be only one of many tissue proteins stabilized by the presence of vitamin A or its derivatives and doomed in its absence.

We should like, therefore, to suggest that opsin may behave here as a representative protein and that the mechanism of its stabilization in the rods and cones may be representative also. This would mean that many tissues contain structural proteins which are stabilized by direct combination with vitamin A or its derivatives and which are lost with the consequent anatomical disintegration of the tissues in the absence of vitamin A. In this sense opsin and the rod outer segments may provide a model for the general function of vitamin A in the tissues.

* This investigation was supported in part by funds from the Rockefeller Foundation and the Office of Naval Research. J. E. D. wishes to express his appreciation of a summer stipend provided by the National Science Foundation. We should also like to thank Dr. Toichiro Kuwabara of the Howe Laboratory of Ophthalmology and Dr. David G. Cogan, its director, for preparing the histologic sections used in this investigation.

[1] E. V. McCollum and N. Simmonds, *J. Biol. Chem.*, 32, 181, 1917; C. E. Bloch, *J. Hyg.*, 19, 283, 1920–21. It is important to distinguish the night blindness caused by vitamin A deficiency from various types of hereditary night blindness found in man and other animals (cf. Sir W. S. Duke-Elder, *Text-book of Ophthalmology* [St. Louis: C. V. Mosby, 1944], 1, 982). The latter seems

to correspond to a permanent congenital failure of rod function. We know of no adequate histologic studies in man. In certain mutant mice the layer of rods is missing, though the remainder of the retina appears normal (C. E. Keeler, *J. Exptl. Zool.*, **46**, 355, 1927). The present observations suggest that some forms of hereditary night blindness may possibly involve the failure to synthesize the specific protein of the rods—rod opsin; the comparable hereditary disease, day blindness, might similarly be caused by the failure to synthesize cone opsin.

[2] G. Wald, *Am. J. Ophthalmol.*, **40**, 18, 1955.

[3] G. Wald, H. Jeghers and J. Arminio, *Am. J. Physiol.*, **123**, 732, 1938; G. Wald and D. Steven, these PROCEEDINGS, **25**, 344, 1939.

[4] The first demonstration that night blindness associated with chronic liver disease involves cones as well as rods is due to C. Hess, *Arch. Augenheilk.*, **62**, 50, 1909; and to C. Haig, S. Hecht, and A. J. Patek, Jr., *Science*, **87**, 534, 1938.

[5] L. F. Steffens, H. L. Bair, and C. Sheard, *Proc. Staff Meetings Mayo Clinic*, **14**, 698, 1939; S. Hecht and J. Mandelbaum, *Am. J. Physiol.*, **130**, 651, 1940; S. Brenner and L. J. Roberts, *Fed. Proc.*, **1**, 188, 1942; G. Wald, L. Brouha, and R. E. Johnson, *Am. J. Physiol.*, **137**, 551, 1942.

[6] E. M. Hume and H. A. Krebs, *Vitamin A Requirements of Human Adults* (Med. Res. Council Spec. Rep. Ser., No. 264 [London: H.M. Stat. Office, 1949]).

[7] S. Heht and J. Mandelbaum, *Science*, **88**, 219, 1938; *J. Am. Med. Assoc.*, **112**, 1910, 1939; *Am. J. Physiol.*, **130**, 651, 1940.

[8] T. Moore, in R. M. Herriott (ed.), *Symposium on Nutrition* (Baltimore: Johns Hopkins Press, 1953), pp. 31–33.

[9] K. Tansley, *Proc. Roy. Soc. London, B*, **114**, 79, 1933; *Biochem. J.*, **30**, 839, 1936.

[10] M. L. Johnson, *Arch. Ophthalmol.*, **29**, 793, 1943.

[11] V. Ramingalaswami, E. H. Leach, and S. Sriramachari, *Quart. J. Exptl. Physiol.*, **40**, 337, 1955.

[12] K. Tansley, *J. Physiol.*, **71**, 442, 1931.

[13] J. M. Lewis, O. Bodansky, K. G. Falk, and G. McGuire, *J. Nutrition*, **23**, 351, 1942.

[14] R. Hubbard and G. Wald, *J. Gen. Physiol.*, **36**, 269, 1952–53; P. K. Brown and G. Wald, *J. Biol. Chem.*, **222**, 865, 1956.

[15] Tansley (*Proc. Roy. Soc. London, B*, **114**, 79, 1933) reported that weanling rats after 7–9 weeks on a vitamin A–deficient diet yielded little or no histological test for rhodopsin (staining with platinic chloride) and by then were losing weight and moribund.

[16] E. D. Adrian, *J. Physiol.*, **104**, 84, 1945; J. C. Armington, E. D. Johnson, and L. A. Riggs, *J. Physiol.*, **118**, 289, 1952; E. Auerbach and H. M. Burian, *Am. J. Ophthalmol.*, **40**, 42, 1955.

[17] G. L. Walls, *The Vertebrate Eye* (Bloomfield Hills, Mich.: Cranbrook Inst. of Science, 1942), p. 509.

[18] R. Sidman, in J. Wolken (ed.), *Symposium on Photoreception* (New York: New York Acad. Sci., 1958) (in press).

[19] W. A. H. Rushton and R. D. Cohen, *Nature*, **173**, 301, 1954.

[20] G. Wald, *Science*, **119**, 887, 1954.

[21] S. R. Ames, W. J. Swanson, and P. L. Harris (*J. Am. Chem. Soc.*, **77**, 4134, 1955) have reported that to promote growth and storage in the rat, neo-b vitamin A acetate is only about 23 per cent as effective as *trans* isomer.

[22] P. S. Brown, unpublished observations.

[23] C. M. Radding and G. Wald, *J. Gen. Physiol.*, **39**, 923, 1955–56.

[24] R. Hubbard, *J. Gen. Physiol.* (in press).

Bib. No. 2293

(Clinical Weekly)
Klinische Wochenschrift
v. 12, no. 8, 25 Feb. 1933
p. 308

Damage from Vitamin A

By Dr. Wolf v. Drigalski

From the Medical University - Poly Clinic, Koenigsberg in Prussia
(Director: Prof. Dr. O. BRUNS)

The question arises whether there exists the possibility of a harmful overdosage of vitamin A. Reasons for this are the extensive efforts in recent years for preparing very ~~strong~~ potent and pure vitamin A preparations, as well as the indications primarily from American laboratories, concerning the therapeutic use of vitamin A.

The scant literature references are so contradictory and, as DRUMMOND, in our view correctly indicates, the work was conducted with deficient methods, in order to derive a clear picture from them. We used as experimental animals, white rats of a strain, normally fed with bread, oats and water, weighing about 100g and divided the animals into 6 series.. We gave the animals of Series 1 and 3 as a supplement to their normal feeding the strongest vitamin A preparation available at the time: oily solution of vitamin A (Merck Co.), that Merck kindly placed at our disposal; 1 ccm contains 40,000 rat units, where 1 R.E. (R.U.) represents the lowest dosage capable of protecting rats from vitamin A-deficiency. The vitamin was introduced to the stomach through a probe just as were the control solutions; as probe, a tube of medium thickness connected to a syringe was used, over which the end piece of a urethral catheter was drawn. By this method we could give exact doses, and never experienced injuries.

6 animals (group 1) received daily 1 ccm, 2 animals (group 3) ½ ccm of this vitamin A solution. In order to be sure, that the phenomena which occurred were actually attributable to excess vitamin supply and not to the oily masses as such, which is conceivable with the large quantities used, controls were applied. As control mass the same vitamin A preparation was used after destroying its vitamin A content. The safest means to destroy vitamin A is ultra-violet radiation. In earlier experiments in the II. Medical Clinic of Charité (KAUFFMANN and v. DRIGALSKI, see preceding paper), we had established, that the vitamin A preparation used, when exposed as a thin layer to U.V.-radiation, loses its vitamin A content in about 6-8 hours. In this manner the content is reduced to no more than one-eighthundreth. The total loss of vitamin A content would only be biologically demonstrable; for our purposes this reduction was demonstrated by means of blue-reaction with arsenic trichloride. This reaction gives the original preparation still in dilution up to 1:800; the control preparation was now irradiated, until ~~it~~ undiluted, it no longer yielded a blue-reaction, ~~undiluted~~ and thus was reduced to atleast one-eighthundreth in vitamin A content. Harmful effects can no longer be attributable to such a low vitamin A content (GLANZMANN, KAUFFMANN- v. DRIGALSKI). The control mass, thus obtained, that practically no longer contains vitamin A, was given to the same number and same weight animals in equal amounts, at least as long as given the animals of groups 1 and 3. As 2nd control we used peanut oil, that was given in the same manner to groups 5 and 6.

All animals of group 1, that each received daily 1 ccm vitamin A, died. After 4-6 days, the animals showed shaggy fur, extensive emaciation and loss of weight. All animals of this group showed catarrhalic

symptoms in the sense of conjunctivitis, hemorrhagical rhinitis and diarrhea after 5-8 days. Longevity starting with the day on which the supplement was given, varied from 5-14 days with 1 ccm daily to 7-19 days with ½ ccm daily. The animals of group 3, fed with half doses, behaved the same in all respects, only the catarrhalic symptoms and the deterioration occurred later. Entirely different was the result of the experiment, in which the animals of groups 2 and 4 were fed analogously with the irradiated control mass. Of the 8 animals one animal died spontaneously after 11 days, the other 7 remained alive, hardly lost weight or none at all, and no catarrhalic symptoms occurred. The animals were killed, after they were given supplements at least 2 days longer than the longest vitamin A-fed animal, in order to be examined histologically as the other animals. Of the control groups 5-7, which analogously were fed with peanut oil, all animals remained alive, without showing any adverse symptoms.

Thus, it is certain that vitamin A in very large doses can have harmful to fatal effects on rats. The control experiments show that this effect actually is attributable to vitamin A, and not to any impurities.

Only extended histological examinations will provide information about the center of attack of the noxa; the organs of all animals are examined by Dr. LAUBMANN in the Pathological Institute of the University of Koenigsberg (Prof. KAISERLING). The result will be published in a detailed paper elsewhere.

References:.....

Table I.

	Type of Supplement	Amt. of daily supplement in ccm	Duration of supplement in days or amt. of supplement in ccm	Result of supplemental feeding
Group 1 5 animals a-f	Vit. A			Spontaneous death of all animals on day after last supplement.
Group 2 6 animals a-f	Irradiated control mass			2a spontaneous death after 11 days. The other animals remained alive, killed for histological examination on the day after last supplement.
Group 3 2 animals a-b	Vit. A			Spontaneous death of both animals on day after last supplement.
Group 4 2 animals a-b	Irradiated control mass			Both animals remained alive, killed on day after last supplement for histological examination.
Group 5 and 6 (4 animals)	Peanut oil		Like Group 4	Like Group 4
Group 7 2 animals	Peanut oil		Like Group 4	Like Group 4

Figure I.: Animals 1c and d from the series fed with vitamin A after 13 days supplement of 1 ccm vitamin A daily. Catarrhalic symptoms are clearly evident on eyes and nose.

Figure II.: Animals 2c and d from the series fed with irradiated control mass after 13 days supplement of 1 ccm daily.

Bib No. 2293

Klin. Wochenschrift 12(8):308-309.

ÜBER SCHÄDIGUNG DURCH VITAMIN A.

Von

Dr. WOLF v. DRIGALSKI.

Aus der Medizinischen Universitäts-Poliklinik Königsberg i. Pr.
(Direktor: Prof. Dr. O. BRUNS).

Die durch die umfangreichen Arbeiten der letzten Jahre auf dem Gebiet des Vitamins A geschaffene Möglichkeit zur Herstellung sehr starker und reiner Vitamin A-Präparate sowie die vor allem von amerikanischer Seite gegebenen Hinweise auf therapeutische Verwendung des Vitamins A lassen die Frage auftauchen, ob die Möglichkeit einer schädlichen Überdosierung besteht.

Die spärlichen Hinweise in der Literatur sind so widersprechend und, wie DRUMMOND, unserer Ansicht nach mit Recht, anführt, zum Teil mit unzureichenden Methoden angestellt, daß daraus ein klares Bild nicht zu gewinnen ist. Wir verwandten als Versuchstiere weiße Ratten einer Zucht, normal mit Brot, Hafer und Wasser ernährt, im Gewicht um 100 g und teilten die Tiere in 6 Serien ein. Wir gaben den Tieren der Serie 1 und 3 als Zulage zur Normalkost das zur Zeit stärkste Vitamin A-Präparat: ohne Lösung: von Vitamin A (Merck-I. G.), das uns von Merck freundlicherweise zur Verfügung gestellt wurde; 1 ccm enthält 40000 Ratteneinheiten, wobei 1 RE. die niedrigste die Ratte vor A-Mangel schützende Dosis darstellt. Das Vitamin wurde ebenso wie die Kontrollösungen durch eine Sonde in den Magen gegeben; als Sonde wurde eine an eine Rekordspritze angeschlossene Kanüle von mittlerer Dicke verwandt, über die das Endstück eines Urethralkatheters gezogen war. Wir konnten so exakt dosieren und erlebten niemals Verletzungen.

6 Tiere (Gruppe 1) bekamen tgl. 1 ccm, 2 Tiere (Gruppe 3) $^1/_2$ ccm dieser Vitamin A-Lösung. Um sicher zu gehen, daß die auftretenden Erscheinungen auch tatsächlich auf die übermäßige Zufuhr des Vitamins und nicht der öligen Masse als solcher zurückzuführen sind, was bei den großen verwandten Mengen denkbar wäre, wurden Kontrollen angesetzt. Als Kontrollmasse diente dasselbe A-Präparat nach Zerstörung seines A-Gehaltes. Das sicherste Mittel, um A zu zerstören, ist Ultraviolettbestrahlung. In früheren Versuchen in der II. Med. Klinik der Charité (KAUFFMANN und v. DRIGALSKI, siehe vorstehende Arbeit) hatten wir festgestellt, daß das verwandte A-Präparat, in dünner Schicht unter der Höhensonne bestrahlt, in etwa 6—8 Stunden seinen A-Gehalt verliert; zum mindesten wird er so weit reduziert, daß er höchstens den 800. Teil beträgt. Der totale Verlust des A-Gehaltes war nur biologisch nachzuweisen, für unsere Zwecke genügte der Nachweis dieser Reduktion mittels der zum A-Nachweis dienenden Blaureaktion mit Arsentrichlorid. Diese Reaktion gibt das Originalpräparat noch in Verdünnung bis 1 : 800; das Kontrollpräparat wurde nun so lange bestrahlt, bis es unverdünnt keine Blaureaktion mehr gab, also auf mindestens den 800. Teil im A-Gehalt reduziert war. Einem so geringen A-Gehalt kommen schädigende Wirkungen nicht mehr zu (GLANZMANN, KAUFFMANN-v. DRIGALSKI). Die so erhaltene Kontrollmasse, die praktisch kein A mehr enthält, wurde gleich vielen, gleich schweren Tieren in gleicher Menge mindestens ebensolange wie den Tieren der Gruppen 1 und 3 gegeben. Als 2. Kontrolle verwandten wir Erdnußöl, das in gleicher Weise an Gruppe 5 und 6 gegeben wurde.

Tabelle 1.

	Art der Zulage	Menge der täglichen Zulage in ccm	Dauer der Zulage in Tagen bzw. Menge der Zulage in ccm	Ergebnis der Zufütterung
Gruppe 1 6 Tiere a—f	Vit. A	1	1a: 5 1b: 5 1c: 14 1d: 14 1e: 14 1f: 8	Spontaner Tod aller Tiere am Tage nach der letzten Zulage
Gruppe 2 6 Tiere a—f	Bestr. Kontrollmasse	1	2a: 11 2b: 20 2c: 17 2d: 17 2e: 17 2f: 17	2a spontaner Tod n. 11 Tagen. Die übrigen Tiere blieben am Leben, zur histologischen Untersuchung am Tag nach der letzten Zulage getötet
Gruppe 3 2 Tiere a—b	Vit. A	$^1/_2$	3a: 19 3b: 7	Spontaner Tod beider Tiere am Tag nach der letzten Zulage
Gruppe 4 2 Tiere a—b	Bestr. Kontrollmasse	$^1/_2$	4a: 27 4b: 27	Beide Tiere blieben am Leben, zur histologischen Untersuchung am Tag nach der letzten Zulage getötet
Gruppe 5 u. 6 (4 T.)	Erdnußöl	1	Wie Gruppe 4	Wie Gruppe 4
Gruppe 7 2 Tiere	Erdnußöl	$^1/_2$	Wie Gruppe 4	Wie Gruppe 4

Sämtliche Tiere der Gruppe 1, die tgl. je 1 ccm A bekamen, gingen ein. Die Tiere zeigten nach 4—6 Tagen struppiges Fell, starke Abmagerung und Gewichtsverlust. Bei allen Tieren dieser Gruppe traten nach 5—8 Tagen katarrhalische Symptome im Sinne von Conjunctivitis, hämorrhagischer Rhinitis und Durchfällen auf. Die Lebensdauer vom Tage der Zulage ab schwankte bei 1 ccm tgl. von 5—14, bei $^1/_2$ ccm tgl. von 7—19 Tagen. Die Tiere der Gruppe 3, mit halben Dosen gefüttert verhielten sich in allem gleich, nur traten die katarrhalischen Erscheinungen und der Verfall später ein. Ganz



Abb. 1. Tiere 1c und d der mit Vitamin A gefütterten Serie nach 13tägiger Zulage von 1 ccm A täglich. An Augen und Nase sind deutlich katarrhalische Erscheinungen zu sehen.

anders fiel der Versuch aus bei den mit der bestrahlten Kontrollmasse analog gefütterten Tieren der Gruppen 2 und 4. Von den 8 Tieren starb ein Tier spontan nach 11 Tagen, die anderen 7 blieben am Leben, verloren kaum oder gar nicht an Gewicht, es traten keine katarrhalischen Erscheinungen auf. Die Tiere wurden getötet, nachdem sie mindestens 2 Tage länger als das am längsten mit A gefütterte Tier unter Zulage gestanden hatten, um ebenso wie die anderen Tiere histologisch



Abb. 2. Tiere 2c und d der mit der bestrahlten Kontrollmasse gefütterten Serie nach 13tägiger Zulage von 1 ccm täglich.

untersucht zu werden. Von den Kontrollgruppen 5—7, die analog mit Erdnußöl gefüttert wurden, blieben alle Tiere am Leben, ohne irgendwelche krankhaften Erscheinungen zu zeigen.

Damit steht fest, daß Vitamin A in sehr großen Dosen an Ratten schädigend bis tödlich wirken kann; aus den Kontrollversuchen geht hervor, daß diese Wirkung tatsächlich dem Vitamin A zukommt und nicht irgendwelchen Begleitstoffen.

Über den Angriffspunkt der Noxe können erst ausgedehnte histologische Untersuchungen Auskunft geben; die Organe sämtlicher Tiere werden im Pathologischen Institut der Universität Königsberg (Prof. KAISERLING) von Dr. LAUTMANN untersucht. Das Ergebnis wird im Rahmen der ausführlichen Arbeit an anderer Stelle veröffentlicht.

Literatur: DRUMMOND, Proc. Soc. exper. Biol. a. Med. 19, 6, 25, 26. — GLANZMANN, Jb. Kinderheilk. 133, H. 3/4 (1931). — HENRIKSEN, Acta paediatr. (Stockh.) 8, 397; 9, 154 (1929). — ITOGAWA, Trans. jap. path. Soc. 212, 15 (1930). — SUZAKI, ref. Ronas Ber. 37, 572 (1926). — TAKAHASHI u. INO, Jap. med. World 5, 1, 2 (1925).

Drill-'43
Bib. No. 2305

Physiol. Revs. 23:355-379. 1943.

INTERRELATIONS BETWEEN THYROID FUNCTION AND VITAMIN METABOLISM

VICTOR A. DRILL[1]

Department of Physiology, Northwestern University Medical School, Chicago

During the past fifteen years considerable literature has accumulated on the interrelationships between the function of the thyroid gland and vitamin metabolism. Most of these studies are experimental, although some clinical observations have been reported. The experimental observations can be divided into two main groups: 1, the effect of a specific vitamin deficiency on the thyroid gland; 2, the effect of administration of a vitamin on animals which were given desiccated thyroid, or injected with thyroxin, or with the thyrotropic hormone of the anterior pituitary gland.

Hyperthyroidism, both experimental and clinical, has been shown to increase the requirements for certain vitamins. This increased vitamin requirement should not imply an antithyrogenic effect, although the increased requirements for certain vitamins indicate that some of the symptoms of hyperthyroidism, previously seen in animals and man, may be due to a secondary deficiency of these vitamins. The administration of these vitamins in larger amounts will correct these secondary changes, as will be pointed out in certain cases. An actual antithyrogenic effect has only been definitely shown in a few cases, although other suggestive evidence is available, which awaits confirmation and elucidation.

THYROID GLAND AND VITAMIN A. *1. Effect of deficiency of vitamin A on the thyroid gland.* McCarrison (1931) found hypertrophy of the rat thyroid to occur during vitamin A deficiency. The thyroid gland of rats and guinea pigs has also been reported to be enlarged and inactive as a result of vitamin A deficiency (Mitzkewitsch, 1934; Uotila, 1938; Schulze and Hundhausen, 1939a). However, other authors were unable to find thyroid hypertrophy during vitamin A deficiency (Drennan, Malcolm and Cox, 1931; Sampson and Korenchevsky, 1932; Sure, 1938). Sampson and Korenchevsky did, however, observe hypertrophy of the thyroid gland when the diet was deficient in both vitamin A and iodine.

Coplan and Sampson (1935) have studied this problem in the greatest detail and with adequate control observations. Their studies show the important influence of sex, time interval and diet in studying such problems. They found that iodine deficiency alone produced thyroid hypertrophy in male and female rats, which persists longer in the female, and is followed by atrophy in both sexes. Vitamin A deficiency produced a definite hypertrophy in female, but consistent atrophy in male rats. Whereas iodine deficiency and vitamin A deficiency produced hyperplasia of the epithelial cells of the thyroid gland, vitamin A deficiency also produced degeneration of the epithelial cells, which the authors

[1] National Research Council Fellow, 1942-1943. Present address, Dept. of Pharmacology, College of Physicians and Surgeons, New York.

believe is a specific effect of vitamin A deficiency. A deficiency of both iodine and vitamin A produced hypertrophy in male and female rats followed by atrophy in the male. Harris and Remington (1939) observed that neither vitamin A nor carotene influenced the utilization of minimal amounts of iodine in the rat.

2. Effect of vitamin A administration on the thyroid gland. As early as 1923 McCarrison found that the administration of cod liver oil would delay the metamorphosis of tadpoles receiving a high iodine intake, and later carotene was reported to exert a similar effect in delaying the metamorphosis of axolotls (Rokhlina, 1936). It was also found that vitamin A would depress the accelerating effect of thyroxin on the metamorphosis of tadpoles (Eufinger and Gottleib, 1933, 1935) and of salamander larvae (Fleischmann and Kann, 1936). These results demonstrate an antagonistic relationship between vitamin A and the thyroid gland in amphibia.

Harvey (1927) found that feeding cod liver oil, which contained some iodine, to goats increased the amount of iodine in the milk more than an equivalent amount of iodine as potassium iodide. The administration of large amounts of vitamin A was reported by Sherwood, Toth and Carr (1934) to reduce the amount of colloid in the thyroid gland of rats, a similar but not as marked a result being obtained with caritol and haliver oil (Sherwood and Luckner, 1935). Uotila (1938) observed that an excess of vitamin A produced a diffuse hyperplasia of the thyroid. Collazo and Rodriguez (1933) also reported exophthalmos in rats receiving large doses of vitamin A. Schulze and Hundhausen (1939a) observed a decreased thyroid activity and decreased thyrotropic content of the anterior pituitary during hypervitaminosis A. According to Wegelin (1939) and Elmer, Giedosz and Scheps (1935) vitamin A does not materially alter the thyroid gland, although in some cases smaller follicles were observed. The addition of 1 per cent cod liver oil to the stock diet of young rats for 4 months significantly reduced the thyroid weight, when compared with rats on the stock diet alone (Freudenberger and Clausen, 1935).

Hypervitaminosis A can be produced in rats by administering 8,000 to 40,000 I.U. vitamin A per day (Drigalski, 1933; Drigalski and Laubmann, 1933; Moll et al., 1933). Fasold and Peters (1933) administered 1 cc. of Vogan[2] per day to rats and produced symptoms of hypervitaminosis A which they reported could be prevented, or cured before paralysis occurred, by administering thyroxin. However, Baumann and Moore (1939) and Weslaw and Wroblewski (1939) could not confirm these results in fact, they both found that the symptoms of hypervitaminosis A were enhanced by injections of thyroxin.

3. Effect of vitamin A on weight loss of hyperthyroid animals. In an extensive series of studies Abelin (1930a, 1930b; Abelin, Goldener and Kobori, 1926; Abelin, Knochel, and Spichtin, 1930) showed the beneficial effects of yeast, egg yolk, cod liver oil, high protein and high fat diets on the weight of rats fed thyroid gland. These authors were interested in finding a beneficial diet for use

[2] Vogan, used extensively in German literature; 1 cc. contains about 6 gamma of iodine, 40,000 rat units of vitamin A, vitamin D potency not stated.

during hyperthyroidism and not in the effect of any particular compound. Von Euler and Klussman (1932) found that rats injected with thyroxin lost weight less rapidly when carotene was administered each day. According to Loumos (1934) a daily dosage of 10,000 U. S. P. units of vitamin A administered to rats receiving 100 mgm. of thyroid gland per day had little effect on the loss of weight. An initial loss of weight was prevented for a few days after which time the loss of weight continued at about the same rate as control rats. Others have observed that vitamin A, administered in various forms, will affect the loss of weight of hyperthyroid animals to various degrees, either only partially or nearly completely preventing the loss of weight (Abelin, 1935; Schneider and Widmann, 1935; David, 1938; Steffan and Zois, 1938). Vitamin A in arachis oil, or arachis oil alone would prevent the toxic action of thyroxin (Fasold and Peters, 1933). These results also depend to a large degree on the dosage of thyroxin or thyroid gland employed, and the age and sex of the rats used. Rats weighing over 140 grams will rapidly lose weight when 100 mgm. of thyroid gland are fed per day, whereas rats averaging 100 grams will gain weight for a while. Also, 100 mgm. of thyroid gland per day will produce a more rapid loss of weight than will an injection of 100 gamma of thyroxin each day, and will thus offer a more rigorous method of testing the effect of vitamin A on weight loss. The sex differences in hyperthyroid rats can be seen from the data presented by Drill (1938b) and Logaras and Drummond (1938). The latter authors administered 19 doses of 100 gamma of thyroxin to rats over a period of 28 days. With thyroxin, and without vitamin A in the diet, their male rats lost an average of 11.0 grams in weight, and with 3000 I.U. of vitamin A per day the hyperthyroid male rats lost an average of 8.6 grams. In the meantime normal male rats receiving 3000 I.U. vitamin A per day gained an average of 21.0 grams. On the other hand, female rats injected with thyroxin without vitamin A in the diet lost only an average of 1.6 grams, whereas hyperthyroid female rats receiving 3000 I.U. vitamin A per day gained an average of 2.6 grams. Normal females receiving the same amount of vitamin A gained an average of 7.0 grams. Their other experiment with rats receiving 10 I.U. vitamin A per day showed a similar result. Although vitamin A may have some protective effect, under specific conditions, against the loss of weight of hyperthyroid animals, it is not as great as generally interpreted in the literature. The slight effect of vitamin A on weight reported by Logaras and Drummond was obtained by the use of small doses of thyroxin. Sure and Buchanan (1937b) showed an increased requirement for vitamin A during hyperthyroidism, as judged by the appearance of xerophthalmia, but did not obtain any effect of moderate doses of vitamin A on the loss of weight of the rats.

According to Weslaw and Wroblewski (1939) rats injected with thyroxin survived longer if vitamin A (as Vogan) was administered. However, they reported an equally good effect by administering sesame oil, the solvent for the vitamin A in Vogan. Thus the effect seems non-specific due to the administration of fat. In fact, the authors state the rats receiving sesame oil were in better condition, had better growth curves and survived longer than those fed the vitamin A supplement.

Wegelin (1939) found that whereas thyroxin increased the number of mitotic figures in the liver, this increase could be prevented by vitamin A. An excess of vitamin A is also reported to reduce the protective action of thyroxin against the toxicity of acetonitrile in the Reid-Hunt reaction in mice (Fleischmann and Kann, 1936). Greaves and Schmidt (1936) obtained evidence of an increased utilization of vitamin A in the hyperthyroid rat. In the thyroidectomized rat the requirement for vitamin A was decreased.

4. Thyroid activity and storage of vitamin A. Euler and Klussman (1932) obtained a reduction of vitamin A and carotene in the liver when thyroxin was administered. When guinea pigs were fed a vitamin A free diet, the administration of carotene led to the storage of vitamin A and carotene in the liver, but when both carotene and thyroxin were given the liver failed to show storage of vitamin A and carotene (Abelin, 1933; Fasold and Peters, 1933). Although Schneider and Widmann (1935) found no carotene and little vitamin A in the liver of hyperthyroid rats, they obtained an increase in liver carotene in thyroidectomized guinea pigs injected with thyroxin. If this report were confirmed it might mean that in the absence of the thyroid gland, even though thyroxin was injected, carotene could not be metabolized to vitamin A. According to Schneider and Widmann (1934) the injection of thyrotropic hormone will also lower the vitamin A stores in the liver of rats and guinea pigs. Logaras and Drummond (1938) found no reduction of hepatic vitamin A in rats injected with thyroxin, although the amount of thyroxin used was small. The administration of thyroxin to scorbutic animals did not cause a reduction of hepatic vitamin A (Balassa and Szanto, 1938). Also, feeding large doses of vitamin A, Baumann and Moore (1939) did not observe any reduction of vitamin A in the liver when thyroxin was injected.

In human cases of exophthalmic goiter normal values or an increase in hepatic stores of vitamin A have been reported. Wolff (1932) observed an increase in hepatic vitamin A in this disease, the mean value for 5 cases of exophthalmic goiter being 210 I.U. per gram, whereas in accidental death the value was 147 I.U. per gram. A similar result was obtained by Moore (1937), four exophthalmic patients showing an average of 304 I.U. per gram of liver, the values after accidental death being 210 I.U. per gram.

5. Effect of vitamin A on carbohydrate and protein metabolism in hyperthyroid animals. Abelin, Knochel and Spichtin (1930) reported that vitamins A and D would prevent the fall of muscle and liver glycogen of rats generally produced by thyroid feeding, and a similar result was obtained with carotene (Abelin, 1935). David (1938) also reported that vitamin A tended to reduce the carbohydrate changes of hyperthyroid animals to a minimum. Carotene was able to counteract the decrease of liver glycogen produced by thyrotropic hormone in guinea pigs but vitamin A did not prevent the disappearance of liver glycogen when thyroxin was administered (Schneider, 1934; Schneider and Widmann, 1934). Microscopically, Wegelin (1939) showed some effect of vitamin A on liver glycogen; whereas the liver glycogen decreased when both vitamin A and thyroxin were administered, it did not altogether disappear, as it did when thy-

roxin was administered alone. However Steffan and Zois (1938) and Fasold and Peters (1933) did not obtain any effect of vitamin A on the liver glycogen of hyperthyroid rats. It was also reported that carotene did not prevent the fall of liver glycogen of thyroidectomized guinea pigs injected with thyroxin (Schneider and Widmann, 1935).

Vitamin A has been shown to lessen the creatinuria seen during hyperthyroidism (Fischer and Oehme, 1933, 1937; De la Bernardie, 1939), and also to prevent the decrease of creatinine in heart and skeletal muscle (David, 1938), but one group of workers were unable to find any effect of vitamin A or carotene on the creatinuria (Steffan and Zois, 1938).

Török and Neufeld (1938) noted that the effect of thyroxin in lowering the serum lipase content of rabbit serum could be prevented by the simultaneous administration of large doses of vitamin A, but the effect was only temporary, for the serum lipase began to fall in a few days, even though the administration of vitamin A was continued.

6. Relation of thyroid function to carotene metabolism. This part of the review is not concerned with any antithyrogenic properties of carotene or vitamin A, but with the effect of thyroid gland function on the conversion of carotene to vitamin A. Noorden (1907) first suggested the association of carotenemia with metabolic disturbances. Since then various authors (Hess and Meyers, 1919; Head and Johnson, 1921; Stoner, 1928) have noted the appearance of carotenemia in certain individuals, and were unable to reproduce this condition by over-feeding of vegetables to control patients. In the meantime Kunde (1926) had noted the appearance of xerophthalmia in rabbits, on a diet that was adequate for normal rabbits, after they had been thyroidectomized for 8 to 12 months. Her result can only be interpreted now to show that in the absence of the thyroid gland a molecule of carotene was not converted into two molecules of vitamin A, with the resultant occurrence of xerophthalmia.

In 1932 Fellenberger and Grueter reported that the milk of thyroidectomized goats remained yellow, which was attributed to the presence of a lipochrome, probably carotene. A year later Fasold and Heidemann showed that thyroidectomy in goats decreased the vitamin A content of goat's milk and increased the carotene content, leading to the conclusion that the thyroid gland is necessary for the conversion of carotene to vitamin A. In the face of this evidence and the work of Kunde it seems certain that in the absence of the thyroid gland carotene is not metabolized to vitamin A, although the work of Kunde should be repeated using synthetic diets with carotene as the only source of vitamin A.

Wendt (1935a) also believes that the thyroid is necessary for the conversion of carotene to vitamin A and for the storage of vitamin A in the liver. Anderson and Soley (1938) reported 13 patients with carotenemia, 5 of which were hypothyroid, 1 hypothyroid case showed hepatic insufficiency, and three other cases showed abnormal liver function. Savy et al. (1938) observed 5 cases of carotenemia with liver damage, and later (1939) one case of carotenemia with hypothyroidism. By studying the dark adaption of hypothyroid patients Wohl and Feldman (1939) also obtained evidence that the conversion of carotene to vitamin

A was disturbed. Escamilla (1942) reported 7 cases and Mandelbaum et al. (1942) reported 1 case of hypothyroidism associated with carotenemia. As thyroid medication was instituted the blood carotene level fell.

Since carotene is a lipochrome its metabolism might be expected to follow the metabolism of other lipochromes during disease. Although carotenemia was observed in hypothyroid patients, some functioning thyroid tissue is still left in these patients. This then raises the question as to cause of the hepatic damage seen in some of these patients. Is it due to a long standing thyroid hypofunction or the effect of an excess of carotene on the liver? Since carotenemia was also seen in patients without evidence of hypothyroidism, but with hepatic damage, it is possible than an abnormal liver function alone may be the cause of the carotenemia. These problems still await experimental elucidation.

7. *Effect of vitamin A on metabolic rate during experimental hyperthyroidism.* There is a good deal of evidence to show that vitamin A partially counteracts the high oxygen consumption produced by thyroid feeding. Rappai and Rosenfeld (1935) increased oxygen consumption 42.4 per cent by injecting thyroxin, whereas a rise of only 13 per cent was obtained when both vitamin A and thyroxin were administered, and an increase of 10 per cent when carotene and thyroxin were given. Sesame oil had no effect on the B. M. R. Abelin (1935) obtained a similar increase of 50 per cent in oxygen consumption by administering thyroxin and only 20 per cent rise when vitamin A and thyroxin were administered to rats. These results were confirmed on rats by Logaras and Drummond (1938) and Belasco and Murlin (1940). In an acute study on cats, the injection of thyroxin for three days increased O_2 consumption 45.7 per cent, and with carotin and thyroxin the rise was only 25.4 per cent (Smith and Perman, 1940).

The R. Q. of hyperthyroid rats was not affected by vitamin A (Rappai and Rosenfeld, 1935), nor did carotene influence the R. Q. of cats injected with thyroxin for 3 days (Smith and Perman, 1940). This suggests that vitamin A did not selectively affect the metabolism of any particular foodstuff. Belasco and Murlin (1940) also reported that the increase in liver and kidney metabolism seen in hyperthyroidism was not changed by vitamin A.

Chevalier and Baert (1934) reported that vitamin A deficiency increased the B. M. R. of rats, and that large doses of vitamin A decreased the metabolic rate below normal. However, Sherwood, Toth and Carr (1934), Belasco and Murlin (1940) and Sheets and Struck (1942) did not find any affect of vitamin A on oxygen consumption of normal rats. The latter authors also found no significant change in thyroidectomized rats fed large doses of vitamin A. Rappai and Rosenfeld (1935) found that vitamin A lowered the B. M. R. of normal rats 4 to 12 per cent.

Sheets and Struck (1942) confirmed the above reports, finding that after premedication with vitamin A for 50 days thyroid feeding raised the B. M. R. of rats an average of 25.5 per cent, whereas other rats receiving only thyroid showed a rise of 58 per cent. However, after the B. M. R. of these rats had risen to 58 per cent treatment with vitamin A showed a tendency to lower the level, but did not produce any significant change. Thus, while the administration of thyroid

and vitamin A together will prevent the rise in oxygen consumption to the level produced by thyroid alone, there is no experimental evidence to show that treatment with vitamin A will reduce the high B. M. R., once it has been produced by thyroid feeding.

8. Thyrotropic hormone of the anterior pituitary gland and vitamin A. There are reports which indicate that vitamin A will partially prevent the histological changes produced in the thyroid gland of guinea pigs by injection of thyrotropic hormone (Schneider, 1934; Fellinger and Hochstaedt, 1936; Elmer, Giedosz and Scheps, 1935). Parhon and Werner (1935) have reported that thyroxin or thyrotropic hormone reduced the blood carotene in ducks. According to Schulze and Hundhausen (1939a) a lack of vitamin A leads to increased thyroid activity and increased thyrotropic potency of the pituitary gland, whereas hypervitaminosis A has the opposite effect.

9. Clinical studies on thyroid function and carotene and vitamin A metabolism. Mellanby and Mellanby reported (1921b) that patients with exophthalmic goiter receiving a diet high in cod liver oil and low in fat gained weight. Although no figures were given, the B. M. R. was also reported to be lowered. Others have also studied the effect of iodized fatty acid and vitamins A and D in the treatment of Graves' disease (Adamson and Cameron, 1928; Fraser and Cameron, 1929; Rabinowitch, 1929). Their results are complicated by the simultaneous administration of iodized fatty acids or of iodine contained in the cod liver oil.

Wendt (1935a, 1935b) observed that patients with Graves' disease had practically no serum vitamin A and had low serum carotene values. The administration of vitamin A to such patients caused less of a rise in plasma vitamin A than is seen in normal persons. These serum values were observed to increase after successful iodine treatment or surgery. He also found a low serum vitamin A value in cretins, which showed little change when carotene was administered orally. This confirms experimental work discussed above, where the thyroid gland was found to be necessary for the conversion of carotene to vitamin A. Clausen and McCoord (1938) observed two hyperthyroid patients with low plasma vitamin A and carotinoids. The majority of their hypothyroid patients showed a high plasma carotene value, and in all cases the vitamin A value was low. When several of the hypothyroid patients were studied, following thyroid therapy to elevate the B. M. R. and lower blood cholesterol, the carotene and vitamin A values tended to return to normal. Wendt (1935c) also reported that large doses of vitamin A (as Vogan[2]) increased the weight and lowered the B. M. R. from 46 per cent to 20.5 per cent in three hyperthyroid patients, and two other patients showed some improvement (cf. Wendt, 1936). Dietrich (1936) also found vitamin A to be beneficial in three of six hyperthyroid patients. Abelin (1936) advocates the use of vitamin A in conjunction with iodine and diiodotyrosine as an aid in controlling crisis and the temporary exacerbation that may occur under such treatment.

Studies on the dark adaptation of hyperthyroid patients also indicated a deficiency of vitamin A in hyperthyroid patients (Wohl and Feldman, 1939). Evidence was obtained which suggested that the administration of thyroid ex-

tract or a-dinitrophenol facilitates the utilization of vitamin A by the visual mechanism, representing an increase in the speed and extent of visual purple regeneration (Patek and Haig, 1941). Godtfredson (1941) found impaired dark adaptation and liver function in ten hyperthyroid patients. He suggests that the liver damage in hyperthyroidism disturbs vitamin A metabolism.

Fasold (1937) treated 7 girls with adolescent goiter, none showing any symptoms of hypo- or hyperthyroidism, with Vogan, administering 30 drops 3 times a day. After about one month of treatment the tumor had regressed, but recurred a few weeks after treatment was discontinued. The dose of Vogan used supplied about 3.6 gamma of iodine per day.

In 1938 Catel reported a case of hyperthyroidism in a child which was treated with vitamin A. The blood level of vitamin A was raised but the B. M. R. and other symptoms were not affected. Jacobi and Pomp (1938) studied 14 cases of hyperthyroidism, some treated by rest and diet, and others treated by rest, diet and the administration of vitamin A as Vogan. The criteria of improvement they used were decreased B. M. R. and pulse rate, increase in weight, and improvement of general condition, but they did not find any beneficial effects from the vitamin A supplement.

Although experimental evidence shows that vitamin A has some relation to thyroid function, the clinical results are as yet too few to draw any conclusions concerning the efficacy of this treatment, and such factors as hospitalization, diet and rest. It should also be borne in mind that plasma carotene and vitamin A will vary from the norm in diseases other than thyroid disorders (Clausen and McCoord, 1938; Moore, 1937).

Summary. A deficiency of vitamin A will produce thyroid hypertrophy, although a sex difference in response is present. An excess of vitamin A seems to decrease the amount of colloid in the thyroid gland, although this result is still controversial, as is the effect of thyroxin on hypervitaminosis A. In amphibia, however, a definite antagonism between thyroxin and vitamin A has been demonstrated.

Experimental hyperthyroidism in mammals increases the requirements for vitamin A. However, the degree to which the administration of vitamin A will prevent a loss of weight in such animals is not clear, especially as some authors have observed no effect of vitamin A on weight loss and others have obtained the same effect with the vehicle in which the vitamin A is dissolved. The effect of hyperthyroidism on the liver stores of vitamin A, and the effect of vitamin A on liver glycogen during hyperthyroidism still await further clarification, although vitamin A seems to decrease the creatinuria observed in such animals.

All of the evidence to date indicates that in the absence of the thyroid gland carotene is not metabolized to vitamin A. Various authors also agree that the simultaneous administration of vitamin A with thyroxin will partially prevent a rise in the B. M. R., this being the first definite antithyrogenic action of vitamin A to be demonstrated. However, there is no evidence to indicate that the treatment of hyperthyroid animals with vitamin A will lower the B. M. R. There is some evidence to indicate that vitamin A will partially prevent the histological changes in the thyroid produced by the thyrotropic hormone.

Clinically, hyperthyroidism increases the requirement for vitamin A, also lowering serum vitamin A and serum carotene. Although the administration of vitamin A to such patients will provide for the increased requirements, any other effect of vitamin A in such patients awaits further demonstration.

THYROID GLAND AND VITAMIN B_1. *Effect of deficiency of vitamin B_1 on the thyroid gland.* McCarrison (1914) first reported hyperplasia of the thyroid gland of pigeons fed a polished rice diet. Later Spence (1932, 1934) observed thyroid enlargement in rats, the diet however containing multiple deficiencies. There is also said to be a decreased amount of thyroid hormone in the thyroid gland during vitamin B deficiency (Verzar and Vasarhely, 1924) and Aalsmeer (1932) suggests that beriberi is associated with dysfunction of the thyroid gland. According to Fischer (1933) a deficiency of both iodine and vitamin B_1 will produce thyroid hypertrophy. However, iodine deficiency alone will produce thyroid hypertrophy and will reduce the amount of iodine in the thyroid gland.

A recent study by Sandburg and Holly (1933) revealed some interesting results. They fed rabbits an autoclaved diet of alfalfa hay and rolled oats and found that the thyroid increased in size and was very vascular in appearance. They then made the observation that the administration of either iodine or yeast had an effect on the Ca and P metabolism of rabbits with hyperplastic thyroids. Both the iodine and yeast caused a marked increase in Ca excretion, changing the ratio of Ca and P retention from Ca:P = 1:0.3 to Ca:P = 1:216. Presumably the effect of the yeast on the Ca and P metabolism of rabbits with hyperplastic thyroid glands was due to its vitamin B_1 content, as no effect was obtained with autoclaved yeast.

Other experiments on vitamin B deficiency have generally shown an increase in colloid, later, as the time of deficiency increased, followed by atrophy of the thyroid gland (cf. Meyer, 1937, for earlier references,—Schneider, 1938a; Hundhausen and Schultze, 1939). Sure (1938) reported an increase in thyroid weight in B_1 deficiency. No change in the size, iodine content, dry matter, or structure of the thyroid gland of rats on a vitamin B deficient diet has been observed by Carpenter and Sharpless (1937) and Harris and Remington (1939). Carpenter and Sharpless also concluded that the colloid goiter developed in rats by feeding a low iodine and a vitamin B_1 deficient diet could be prevented by feeding more iodine or vitamin B. Harris and Remington failed to confirm this observation. They found no difference between the effect of yeast or autoclaved yeast on the thyroids of rats fed a low iodine diet, and supplements of vitamin B_1 failed to prevent the picture of colloid goiter from appearing. A diminished food intake per se is reported to have no effect on the thyroid gland (Hundhausen, 1939).

Spence (1934) found no effect of a vitamin B extract on size or vascularity of the thyroid gland of rabbits fed fresh cabbage and rolled oats.

Baglioni (1940) reported that the administration of vitamin B_1 did not alter the histological appearance of the guinea pig thyroid, whereas Giedosz (1938a) has reported injections of vitamin B_1 in the guinea pig stimulate the thyroid gland.

2. *Effect of deficiency of other B vitamins on the thyroid gland.* Giedosz (1938b) observed stimulation of the thyroid in guinea pigs during a deficiency of vitamin

B_2, and Sure (1938) reported that 88 per cent of the rats showed an average increase of 42.8 per cent in thyroid weight during a vitamin B_2 deficiency. Sure also found a slight increase in thyroid weight during a deficiency of vitamin B_6, and also found that 65 per cent of the rats showed a 28 per cent increase in thyroid weight on a B complex free diet. Uotila (1938) reported that a deficiency of the vitamin B complex produced thyroid atrophy, the follicles being enlarged and filled with colloid.

3. Relation of B vitamins to calorie intake and weight during experimental hyperthyroidism. That a relationship exists between calorie intake and vitamin B_1 requirements has been demonstrated by many authors (cf. Cowgill, 1934). Himwich, Goldfarb and Cowgill (1932) first studied the relation of calorie intake to the B vitamins during hyperthyroidism. They found that normal dogs fed a yeast-free diet developed anorexia in an average of 32 days, whereas hyperthyroid dogs fed a yeast-free diet developed anorexia in an average of 17 days. These dogs started to regain their lost weight when 10 grams of a vitamin B concentrate was fed each day. Cowgill and Palmieri (1933) also found that the vitamin B requirement (as yeast) of pigeons was increased by feeding thyroid gland. This report has been amply confirmed (Capraro, 1937; Mouriquand, Morin and Czerszchowska, 1939; Morin and Czerszchowska, 1939).

It was then observed by Sure and Smith (1934) that a potent vitamin B concentrate protected rats receiving thyroxin from a loss of weight. With the advent of crystalline vitamin B_1 Sure and Buchanan (1937a) restudied the effectiveness of vitamin B_1 in *preventing* the loss of weight produced by hyperthyroidism. Their tables show that 7 rats fed diet 3080, containing 15 per cent autoclaved yeast, and receiving 0.2 mgm. of thyroxin (orally or parenterally?) per day gained 64 to 108 per cent of the weight of control rats when a supplement of 30 to 300 gamma of vitamin B_1 was administered each day. Rats on the same diet fed 0.5 gram of yeast per day plus 0.2 mgm. of thyroxin per day gained 52 to 132 per cent of the weight of control rats. The change in weight of untreated rats receiving the same diet and thyroxin is not stated.

Drill (1938b) studied the effect of vitamin B_1 and yeast on hyperthyroid rats that had lost weight, to determine if such treatment would enable them to regain their lost weight. When the rats had lost an average of 23 grams in weight they were injected with 500 gamma of vitamin B_1 per day. The vitamin B_1 stopped a further loss of weight, but the rats did not regain their lost weight until a rich source of the vitamin B_2 complex was administered. A sex difference in response was also observed. These results were confirmed and extended by Drill and Sherwood (1938). They reported that the effect of vitamin B_1 in stopping further loss of weight in hyperthyroid rats was due to the increased calorie intake which it produced. Although vitamin B_1 increased food intake and prevented a further loss of weight, the rats still did not regain their lost weight until a rich source of the vitamin B_2 complex was supplied. Thus in addition to vitamin B_1, some other factors in the B_2 complex are also required in larger amounts than normal. If the rats were limited to 13 grams of food per day the vitamin B_1 injections did not stop a further loss of weight. The effect of vitamin B_1 in pre-

venting a further loss of weight of hyperthyroid rats was confirmed by Peters and Rossiter (1939). It was later found that pyridoxine (vitamin B_6) and calcium pantothenate can effectively replace the B_2 complex addition to the diet of hyperthyroid rats, and the rats regained and maintained their lost weight while still receiving thyroid gland (Drill and Overman, 1942). Thus in addition to vitamin B_1, both pyridoxine and pantothenic acid are required in larger amounts during experimental hyperthyroidism.

When a small amount of yeast was fed to hyperthyroid dogs an initial increase in food intake was observed. The removal of the yeast from the diet after 4 to 9 weeks of thyroid feeding produced a sudden and marked drop in appetite to values below normal within a few days (Drill, 1941). The subcutaneous injection of 2 mgm. of vitamin B_1 restored the appetite to its previous hyperthyroid level within 24 to 48 hours. This suggests that anorexia is not a primary effect of hyperthyroidism but is a secondary symptom due to a deficiency of vitamin B_1.

Hyperthyroid dogs that lost weight, following the removal of the yeast from the diet, require increased amounts of vitamin B_1 and the vitamin B complex in order to regain their lost weight (Drill and Shaffer, 1942), confirming previous work on rats. By administering sufficient B vitamins from the start of thyroid feeding it was found possible to maintain the weight of 3 of 4 hyperthyroid dogs for as long as 112 days. The food intake of such dogs is above normal. A similar maintenance of body weight of thyroid fed rats receiving yeast concentrate was obtained over a period of 79 days (Drill, Overman and Leathem, 1943).

4. Effect of B vitamins on estrous cycle during hyperthyroidism. Earlier studies have shown that thyroid feeding soon produces a constant diestrus in rats. Hyperthyroid rats receiving vitamin B_1 and yeast supplements were observed to maintain normal estrous cycles (Drill and Sherwood, 1938). In further studies it was shown that hyperthyroid rats receiving a normal but small amount of yeast each day, had only two or three estrous cycles before entering complete diestrus. Besides a loss of weight, these rats also showed a fall in pituitary and ovarian weight, ovarian sections suggesting a lack of anterior pituitary hormone. Other rats received thyroid gland and yeast concentrate for 79 days with complete maintenance of weight and estrous cycles. The weights of the pituitary and ovaries were normal, as was ovarian histology (Drill, Overman and Leathem, 1943).

5. The B vitamins and liver function during experimental hyperthyroidism. Youmans and Warfield (1926), using the phenoltetrachlorphthalein test, did not detect hepatic damage in hyperthyroid dogs. With the use of more sensitive tests thyroid feeding was shown to produce an increase in bromsulphalein retention (Drill and Hays, 1940) and a rise in serum phosphatase (Drill and Shaffer, 1943). Drill and Hays (1940) fed thyroid gland to 5 dogs receiving a small but normal amount of yeast. Three of the dogs developed abnormal liver functions during the period of thyroid feeding, the dye retention being further increased by removing the yeast from the diet. The other two hyperthyroid dogs still

had a normal liver function during this period, and removing the yeast from their diet produced an abnormal dye retention within 24 hours. Although the deficiency of the B vitamins seems to bear a causal relationship to the production of hepatic damage in thyroid fed dogs, it does not mean that it is the only or the most important factor. Later studies on this problem were reported (Drill and Hays, 1942), showing that once an abnormal liver function had been produced in hyperthyroid dogs, treatment with large doses of vitamin B_1 and yeast concentrate did not improve the abnormal liver function. It was also shown that a yeast-free diet renders dogs extremely susceptible to the effects of thyroid feeding, an abnormal liver function being produced in an average of 22 days (Drill, Shaffer and Overman, 1943). Thyroid fed dogs receiving a small amount of yeast each day developed an abnormal liver function in an average of 45 days. When hyperthyroid dogs were fed a high B vitamin diet it took an average of 90 days before an abnormal liver function was observed. Thus, the amount of B vitamins fed has a direct relationship to the time elapsed before an abnormal liver develops. A high B vitamin diet will delay but will not prevent the appearance of an abnormal liver function in hyperthyroid dogs.

6. The B vitamins and pulse rate during experimental hyperthyroidism. The effects of diets deficient in vitamin B on the cardiovascular system of man and animals have been discussed by Weiss and Wilkins (1937) and Frazier and Ravdin (1938). In the dog and rat a deficiency of vitamin B_1 produces bradycardia, whereas in human beriberi bradycardia is rarely observed and tachycardia is common. Parade (1938b) reported that thyroid feeding during a deficiency of vitamin B_1 will retard the development of bradycardia and subnormal temperature. In experiments on dogs thyroid feeding produced a marked tachycardia of 150 to 160 beats per minute (Drill and Hays, 1942). The removal of the yeast from the diet of these dogs after 30 to 60 days caused a marked drop in pulse rate to values below 100 beats per minute, while still feeding thyroid gland. The injection of these dogs with vitamin B_1 raised the pulse rate to its previous hyperthyroid level within 24 to 48 hours. Thus, the action of an excess of thyroid gland in producing tachycardia in dogs depends in some manner on an adequate supply of vitamin B_1, possibly through an effect on food intake (Parade, 1937; 1938a).

Hyperthyroid dogs fed a yeast-free diet develop only a slight tachycardia which returns to normal within 10 days (Drill, Shaffer and Overman, 1943), and hyperthyroid dogs receiving a high B vitamin diet maintain a high pulse rate for only 80 to 100 days, after which time the pulse rate falls towards normal. The drop in pulse rate at this time seems to be associated with a compensatory hypertrophy of the heart.

7. The B vitamins and liver glycogen during hyperthyroidism. Abelin and coworkers first studied the effect of foodstuffs on liver glycogen during experimental hyperthyroidism (Abelin, 1930; Abelin, Knochel and Spichtin, 1930). Among other findings, discussed elsewhere in this paper, they found that yeast would prevent the fall in liver glycogen of rats fed thyroid gland for 5 to 6 days. This observation was confirmed by Drill (1937) who studied the liver glycogen of rats

injected with small amounts of thyroxin. Frazier, Brown, and Vars (1939) obtained a partial rise of liver glycogen in one of three groups of hyperthyroid rats treated with yeast and McIver and Winter (1941) obtained maintenance of liver glycogen in 4 of 6 hyperthyroid rats treated with yeast. Drill, Overman and Shaffer (1942) also found that yeast concentrate would maintain the weight and liver glycogen of rats fed thyroid gland for 86 days. Vitamin B_1 is also reported to diminish the creatinuria produced in rats by injecting thyroxin (De la Bernardia, 1939).

8. Effect of hyperthyroidism on vitamin B_1 content of tissues. Rats fed 100 mgm. of thyroid gland per day and 12 grams of a normal diet per day supplying 10.8 I.U. of vitamin B_1 per day showed a normal amount of vitamin B_1 in the spleen, a reduction in the kidney, and a marked reduction in the liver. The ability of hyperthyroid rats to store vitamin B_1 was studied in a similar group of rats injected with 500 gamma of vitamin B_1 during the last nine days of the experiment. When compared with control rats injected with vitamin B_1 the hyperthyroid rats showed a normal amount of vitamin B_1 in the spleen and muscle, a slightly raised content in the heart and a definite reduction in the kidney and liver. The storage in the whole liver was 35.7 per cent less than the controls (Drill, 1938a). Peters and Rossiter (1939) confirmed the above report using rats injected with thyroxin and the caatorulin test for vitamin B_1, and found a lowered amount of cocarboxylase in rat tissues, the greatest lowering again being observed in the liver. Hyperthyroidism in the rat does not increase the rate of absorption of vitamin B_1 from the intestine (Stockholm, Althausen and Borson, 1941).

Schneider and Burger (1938) found that control patients excreted 80 to 100 gamma of vitamin B_1 in the urine per day, being between 7 and 8 gamma per cent, with a serum value of 6.4 gamma per cent. Hyperthyroid patients excreted an average of 8.4 gamma per cent of vitamin B_1 in the urine but with a daily output averaging 224.8 gamma per day. Coincident with this large increase in B_1 excretion was a daily urine output averaging 2770 cc. After operation the urine output sank to an average of 1100 cc. with a normal value of 79.9 gamma of vitamin B_1 per day.

9. Vitamins of the B_2 complex and the thyroid gland. The effect of a deficiency of the vitamins of the B_2 complex on the thyroid gland has been discussed above. In 1926 Kunde reported that thyroidectomized rabbits, receiving the same diet as normal animals, developed pellagra-like lesions on the dorsum of the feet, the neck, mouth and nose, after 8 to 20 months of complete thyroidectomy. It is interesting that Greene (1938) observed two patients with myxedema and pellagra that showed a similarity of gastroenteric, neurologic, and psychic symptoms, and to a certain extent, similar dermatologic manifestations. Drill and Overman (1942), studying the weight changes of hyperthyroid rats, did not find any evidence of an increased requirement of riboflavin, above that supplied by the daily yeast supplement. The increased requirements of pyridoxine and pantothenic acid during hyperthyroidism have been reported above.

10. Thyrotropic hormone of the anterior pituitary gland and the B vitamins.

Elmer, Giedosz and Scheps (1937) did not find any antagonistic effect of vitamin B_1 on the thyroid stimulation produced in guinea pigs with the thyrotropic hormone. Similar results were obtained by Schneider (1936b). Cutting and Robson (1939) reported no effect of daily administration (length of administration?) of 40 I. U. of vitamin B_1 and 12 Sherman units of vitamin B_2 on the B. M. R. of two guinea pigs injected with thyrotropic hormone. Vitamin B_1 did not prevent the death of guinea pigs or lessen the reduction of liver glycogen of guinea pigs injected with large doses of thyrotropic hormone (Schneider, 1938b). Gentzen and Moire (1938) reported that premedication with vitamin B_1 lessens the effect of thyrotropic hormone on the B. M. R. of guinea pigs.

The thyroid gland of rats fed a B_1 deficient diet is said to respond normally to an injection of thyrotropic hormone (Schneider, 1938a), although extracts of the pituitaries of such rats, when tested on immature guinea pigs, were found to be less active than extracts from normal rats (Hundhausen and Schulze, 1939).

Elmer, Giedosz and Scheps (1938), Hoen and Oehme (1938), and Wahl (1939), showed that the administration of riboflavin (vitamin B_2) did not affect the B. M. R. or histological picture of the thyroid of normal guinea pigs, or of guinea pigs injected with thyrotropic hormone. Wahl (1939) reported that riboflavin augmented the increase in B. M. R. produced by thyrotropic hormone. Riboflavin deficiency does not affect the thyrotropic content of the pituitary (Schulze and Hundhausen, 1939).

11. Clinical studies on the B vitamins and thyroid activity. Shimazono (1931) reported that iodine and thyroid substance have a curative effect on the paralysis produced by vitamin B deficiency, but that these substances were not tolerated by patients with beriberi until the cardiac symptoms were first treated and relieved. In studying blood iodine, Takasugi (1931) found that in beriberi there was first an increase in blood iodine and B. M. R. both of which later dropped.

Means (1937) mentioned 3 hyperthyroid patients, studied by Lerman and Hertz, that gained weight when a high B vitamin diet was administered. In 1938 Frasier and Ravdin studied the effect of vitamin B_1 and yeast on the preoperative preparation of patients with Graves' disease. They found not only improved nutritional status, as judged by increased appetite and gain in weight, but also that "patients with severe hyperthyroidism can be adequately prepared for operation in a shorter time". The patients treated with the B vitamins also showed a larger preoperative fall in pulse rate than control patients. No influence of the supplement of B vitamins was found on the B. M. R. or on the severity of the post-operative reaction. Frazier and Ravdin administered about 2½ times the estimated daily requirement of vitamin B_1. Experimental work indicates that the requirement for vitamin B_1 during hyperthyroidism may be larger than this (Drill and Shaffer, 1942), suggesting that larger doses of the B vitamins might be more beneficial. Scrutinio (1939) also reported that administration of 1000 I. U. of vitamin B_1 increased the weight and decreased the B. M. R. of hyperthyroid patients. The author favors the use of vitamin B_1 in cases of hyperthyroidism with cardiac decompensation. Hertzler (1941) also uses vitamin B_1 in preoperative preparation of toxic patients, cardiotoxic

patients, and in thyroid crisis. Jacobi and Pomp (1938) reported on 14 cases of hyperthyroidism; some were treated by rest and diet, while others received the same regimen plus the administration of vitamin A, either alone or in combination with vitamin B_1. They reported no apparent beneficial effects from the administration of vitamin A, either alone or in combination with vitamin B_1. The increased urinary excretion of vitamin B_1 in patients with Graves' disease has been discussed in section 8 of this review.

Summary. As various results have been reported, no definite conclusion can be stated at this time, as to the effect of a vitamin B_1 deficiency of the thyroid gland. However, the experiments of Carpenter and Sharpless, and Harris and Remington show no effect of vitamin B_1 deficiency on the thyroid gland, and in other cases the possibility of an iodine deficiency must be ruled out. Hyperthyroidism increases the requirements for vitamin B_1, vitamin B_6 and pantothenic acid. The administration of sufficient yeast concentrate to thyroid-fed animals will prevent a loss of weight, or will allow hyperthyroid animals which have lost weight to regain their lost weight. The maintenance of body weight is due to the increase in food intake that occurs when the increased requirements for the B vitamins are met. Such animals will also maintain normal estrous cycles.

Experimental hyperthyroidism has been shown to produce hepatic damage, which is related in part to the amount of B vitamins supplied in the diet. Vitamin B_1 also shows a relation to the cardiovascular system in experimental hyperthyroidism, and yeast concentrate tends to maintain the liver glycogen of thyroid-fed animals.

Hyperthyroidism decreases the amount of vitamin B_1 in various rat tissues, and clinically there is an increased excretion of vitamin B_1. Vitamin B_1 does not appear to antagonize the administration of the thyrotropic hormone. Clinically most authors have reported a beneficial effect of vitamin B_1 and yeast in patients with Graves' disease, although one paper reported no effect when vitamin B_1 was administered.

THYROID GLAND AND VITAMIN C. *1. Effect of a deficiency of vitamin C on the thyroid gland.* In 1915 Rondoni and Montagnani observed hemorrhagic infiltration of the thyroid gland of guinea pigs on a vitamin C deficient diet. McCarrison (1920a, b) confirmed this finding and also noted an increase in thyroid weight of scorbutic guinea pigs, sometimes 2 or 3 times normal. An irregular enlargement of the thyroid was also observed by Bessesen (1923). However, Löwy (1923) did not find changes in the thyroid gland of guinea pigs during scurvy, and Meyer (1928) reported irregular changes in the thyroid of guinea pigs fed a vitamin C deficient diet for 30 days and concluded that no noteworthy changes took place.

Harris and Smith (1928) reported an increase in both the height of the follicular epithelium and number of inter-follicular cells, with a decrease in amount and an increase in the vacuolation of the colloid, after *chronic* scurvy lasting 97 days. They also suggested a possible influence of vitamin C on iodine metabolism. Abercrombie (1935) confirmed the findings of Harris and Smith, also observing hemorrhagic infiltration to a slight extent in normal animals, more so

in *acute* scurvy of 29 days' duration, and much more marked in 126 days of *chronic* scurvy. He further found that potassium iodide or thyroid gland, administered during acute or chronic scurvy, exerted their characteristic effect on the thyroid gland, without prolonging the life of the vitamin C deficient guinea pigs, and concluded that vitamin C is not concerned in iodine metabolism. Neither Rondoni and Montagnani, Löwy, Harris and Smith, nor Abercrombie found any effect of starvation on the histology of the guinea pig thyroid.

May (1937) also found that vitamin C deficiency in the guinea pig produced a marked hyperemia, somewhat increased activity, irregular structure, and the formation of utricles and vesicles without colloid. The therapeutic or prophylactic administration of vitamin C would prevent these changes. Other reports on vitamin C deficiency in the guinea pig have also shown hyperplasia and hypersecretion of the thyroid gland, which was more marked in chronic than acute cases (Schulze and Linnemann, 1938; Uotila, 1938). Vitamin C did not prevent the hyperplasia produced by feeding fresh cabbage to rabbits (Spence, 1934).

2. Increased requirements of vitamin C and effect of vitamin C during experimental hyperthyroidism. Whereas the administration of 0.5 mgm. of ascorbic acid per day would prevent the loss of weight of scorbutic guinea pigs, Demole and Ippen (1935) reported that 10 to 20 mgm. per day were required when the animals were injected with 0.1 mgm. of thyroxin per day. Fischback and Terbrüggen (1937b) found that thyroxin administration to scorbutic guinea pigs increased the loss of weight, but that if large doses of ascorbic acid were given before the thyroxin the loss of weight was less. Ray (1938) also reported that the requirements of thyroid-fed rabbits for vitamin C was increased. Vitamin C deficiency and hyperthyroidism are also said to produce the same blood picture in guinea pigs (Aszodi, 1937). Brandt (1937) observed that the effect of thyroid gland on the axolotl was less when vitamin C was also given. It is also reported that vitamin C will reduce the blood iodine of normal and hyperthyroid animals (Lohr, 1936).

3. Effect of vitamin C on carbohydrate and protein changes in hyperthyroid animals. Fischbach and Terbrüggen (1937a) found that the effect of thyrotropin in lowering liver glycogen was inhibited by large doses of vitamin C, but that vitamin C did not prevent the fall in liver glycogen when thyroxin was administered. Large doses of ascorbic acid were also reported to prevent a loss of muscle glycogen and partially prevent a fall of liver glycogen produced by thyroxin (Steffan and Zois, 1938), and would prevent or suppress the loss of muscle glycogen produced in guinea pigs by injecting thyrotropic hormone.

The creatinuria observed during hyperthyroidism has been found to be reduced by the administration of vitamin C (Fischer and Oehme, 1937; v. Plehwe, 1938; Steffan and Zois, 1938; De la Bernardia, 1939). Similar results have also been reported after the administration of thyrotropic hormone (Steffan and Zois, 1938).

Vitamin C will not prevent the fall in serum lipase induced in rabbits by thyroxin (Török and Neufeld, 1938).

4. Thyroid activity and tissue vitamin C. Many authors have reported a decrease of vitamin C in the adrenal during hyperthyroidism (Demole and Ippen, 1935; Mosonyi, 1935; Plaut and Bülow, 1935, Nespor, 1936; Farmer and Fribourg, 1942). Farmer and Fribourg believe that the effect of thyroid feeding in increasing the anaphylactic response of guinea pigs is due to the reduction of adrenal vitamin C, which in turn lowers the cortin content of the adrenal. This hypothesis, however, requires further testing as to the therapeutic administration of vitamin C in preventing the changes reported. Contrary to all of the above reports Paal and Brecht (1937) reported that the administration of thyroxin and thyrotropic hormone to guinea pigs increased the amount of vitamin C in the adrenal, and Ray (1938) observed no decrease in vitamin C in adrenals of thyroid-fed rabbits. Mosonyi (1936) found that the loss of vitamin C in the liver and adrenals of guinea pigs after thyroxin could be prevented by vitamin A. In dogs, hyperthyroidism also reduced the vitamin C content of the liver and adrenals, whereas thyroidectomy produced the opposite results (Thaddea and Runne, 1938). Sure and Theis (1939) observed that the reduction of vitamin C in various rat tissues produced by thyroxin was accentuated when a supplement of vitamin B_1 was not administered.

5. Effect of vitamin C on metabolic rate during experimental hyperthyroidism. Demole and Ippen (1935) and Oehme (1936) found that vitamin C would partially reduce the high B. M. R. seen in hyperthyroidism. This was confirmed by Belasco and Murlin (1940), who also reported that the increased metabolism of liver and kidney during hyperthyroidism was not influenced by vitamin C.

6. Thyrotropic hormone of the anterior pituitary gland and vitamin C. The administration of ascorbic acid is said to produce changes in the thyroid gland similar to that induced by thyrotropic hormone (Heyl, 1934). Schulze and Linnemann (1938) did not find an increase of thyrotropic hormone in the pituitary gland during vitamin C deficiency.

There is some evidence that vitamin C will partially inhibit the action of the thyrotropic hormone in the thyroid gland (Marine, Baumann and Rosen, 1934; Elmer, Giedosz and Scheps, 1935; Schulze and Linnemann, 1938). Other authors, however, did not obtain any effect of large doses of vitamin C on the thyroid hyperplasia produced by thyrotropic hormone (Spence and Scowen, 1935; Schäffer, 1936; Schöber, 1939). Fischback and Terbrüggen (1937a) reported that 20 mgm. of vitamin C per day did not prevent thyroid hypertrophy or loss of weight in animals injected with thyrotropic hormone. Also, the effect of thyrotropic hormone on tadpole metamorphosis was not lessened by vitamin C (Schäffer, 1936).

7. Clinical studies on vitamin C and hyperthyroidism. According to Löhr (1936) vitamin C will reduce the blood iodine in normal and hyperthyroid patients. He reports clinical improvement in Graves' disease, but often without the B. M. R. being altered. In 1938 Eitel observed a latent vitamin C deficiency in patients with hyperthyroidism. He concluded that the administration of vitamin C to hyperthyroid patients had a symptomatic effect but not a direct action on thyroid activity. At the same time Thaddea and Runne (1938) showed

that hyperthyroid patients had a subnormal excretion of vitamin C after a test dose was administered, while two patients with myxedema excreted large quantities of vitamin C. This was confirmed by Lewis (1938) who found that the vitamin C excretion of 5 hyperthyroid patients receiving a constant diet was below normal, but rose to normal in 4 of the 5 cases after thyroidectomy.

Summary. Vitamin C deficiency produces hemorrhagic infiltration and hyperplasia of the thyroid gland of scorbutic guinea pigs, the effect being more marked in chronic than acute scurvy. Experimental hyperthyroidism increases the requirements for vitamin C. The effect of vitamin C on the liver glycogen of hyperthyroid animals is not definite, but vitamin C will reduce the creatinuria found in hyperthyroid animals. Hyperthyroidism will also reduce the amount of tissue vitamin C. Vitamin C will partially reduce the B. M. R. of hyperthyroid animals, but its effect on thyroid stimulation produced by the thyrotropic hormone is still controversial. Clinical studies have also shown an increased requirement for vitamin C in hyperthyroidism.

THYROID GLAND AND VITAMIN D. *1. Effect of vitamin D deficiency on the thyroid gland.* In early studies on rickets thyroid hypertrophy and hyperplasia was observed (Mellanby and Mellanby, 1921a; Murray, 1923). Rats maintained on the Steenbock rachitogenic diet also show thyroid hypertrophy and hyperplasia, but the changes produced developed in the presence or absence of vitamin D (Clausen, 1928; Krause and Monroe, 1930; Thompson, 1932; Levine, Remington and v. Kolnitz, 1933). The latter authors definitely showed that the changes produced in the thyroid by Steenbock's rachitogenic diet were due to a deficiency of iodine. The administration of cod liver oil to such rats may supply the daily requirement of iodine. In a later report Remington and Levine (1936) found no effect of the presence or absence of vitamin D on the degree of goiter produced in rats. Drennan, Malcolm and Cox (1931) and Sure (1938) did not observe any effect of vitamin D deficiency on thyroid size. Changes in the thyroid gland reported by other authors (Nitschke, 1933; Bennholdt-Thompson and Wellman, 1934; Uotila, 1938) can be regarded as due to imbalanced diet. Similarly, the decrease of iodine in the thyroid gland during vitamin D deficiency is due to a low intake of iodine (Krause and Monroe, 1930; Levine, Remington and v. Kolnitz, 1933).

Although human rickets is said to reduce blood iodine (Nitschke and Doering, 1933; Nitschke, 1934) this observarion has not been confirmed (Fasold, 1934a, b; Toepfer, 1934a, b). According to Kunde and Williams (1926) rabbits thyroidectomized soon after birth developed changes in the bones resembling rickets.

2. Effect of vitamin D administration on the thyroid gland. Large doses of irradiated ergosterol were found to increase the B. M. R. (Reed, Thacker, Dillman and Welch, 1933; Nitschke, 1933; Reed, 1934). Elmer, Geidosz and Scheps (1935) did not observe any effect of vitamin D on the thyroid of guinea pigs. However, Lands and Stoland (1935) observed that while non toxic amounts of irradiated ergosterol had no effect on the thyroid of cats, larger doses increased the amount of colloid. Similar results were obtained by Nitzesco and Bratiano (1936), Bruman and Bromberg (1936), Kucera and Soos (1933) and Goormagh-

tigh and Handovsky (1935). Handovsky and Goormaghtigh (1937) reported that 40 to 60 gamma of vitamin D_2 will produce some increase in thyroid function in dogs, and that with 110 to 230 gamma per day the thyroid was histologically hyperplastic. Thyroparathyroidectomized dogs tolerated 600 gamma per day very well, whereas thyroidectomized dogs tolerated this dose very badly with severe damage to the aorta and large arteries. They concluded that the action of the thyroid tends to protect the aorta and large arteries, while the action of the parathyroid gland intensifies the injurious action of excessive vitamin D.

As parathyroid extract did not increase the B. M. R. of dogs, Steck, Reed and Miller (1934) decided that vitamin D did not produce its effect by this means. Later Deutsch, Reed and Struck (1936) administered vitamin D to 2 thyroparathyroidectomized dogs, and did not obtain any increase in metabolic rate as they had in normal dogs. Thus the effect of large doses of vitamin D on the metabolic rate depends on an intact thyroid gland. Unpublished results have shown that the calorigenic effect of vitamin D is mediated through the thyrotropic hormone of the anterior pituitary gland (cf. Reed, Struck and Steck, 1939).

Vitamin D has also been reported to stimulate the oxygen consumption of frog muscle (Gelfan, 1935). Elmer, Giedosz and Scheps (1935) found no effect of vitamin D on thyrotropic stimulation of the thyroid gland, and vitamin D did not produce involution of the thyroid of rabbits fed a cabbage diet (Spencer, 1934).

3. Experimental hyperthyroidism and vitamin D. It has been shown that the calcium balance during hyperthyroidism may become negative due to a large increase in fecal calcium. The administration of vitamin D to normal animals will decrease fecal calcium and simultaneously increase urinary calcium excretion, suggesting that the effect of vitamin D on calcium metabolism during hyperthyroidism should be studied. Thus Taylor and Weld (1932) reported that vitamin D decreased the fecal calcium output of hyperthyroid dogs and Pugsley and Anderson (1934a) obtained similar results on rats, although a positive calcium balance was not produced. It was then demonstrated that, with the proper dosage, vitamin D would produce a calcium balance in thyroid-fed rats (Pugsley and Anderson, 1934b).

4. Clinical studies on vitamin D and hyperthyroidism. Tibbets, McLean and Aub (1932) found no effect of vitamin D on calcium metabolism during hyperthyroidism, whereas Hansman and Wilson (1934) reported a beneficial effect of vitamin D on calcium balance.

Summary. A deficiency of vitamin D has no effect upon the thyroid gland. The administration of vitamin D to normal animals increases the B. M. R., probably through its effect on the thyroid gland. When given in experimental hyperthyroidism, vitamin D will counteract the increased calcium excretion, returning the calcium balance to normal. Further work is needed before the effect of vitamin D on calcium balance in Graves' disease can be ascertained.

THYROID GLAND AND VITAMIN E. *1. Effect of vitamin E deficiency on the*

thyroid gland. The reports of Paal and Kleine (1933), Singer (1936), Barrie (1937) and Bromskov and Schneider (1939) indicate that vitamin E deficiency in rats produces a picture of decreased thyroid activity. However Telford, Emerson and Evans (1938) did not find any evidence of thyroid hypoplasia in vitamin E deficient female rats, and Biddulph and Meyer (1941, 1942) reported an increase in thyroid activity during vitamin E deficiency. The latter authors found that vitamin E deficiency increased the thyroid weight and B. M. R. of male rats, producing no change in female rats. They also found that the E deficient animals were receiving only about one-fourth as much iodine as control rats on a stock diet. By the addition of iodine to the diet of E deficient males they were able to prevent the changes in the thyroid and the increase in B. M. R. from occurring. They conclude that the effect of vitamin E deficiency in increasing thyroid weight and the B. M. R. is due to a relative deficiency of iodine.

Bromskov and Schneider (1939) noted that the thyroid of vitamin E deficient rats resembled that of ovariectomized animals, and that the administration of follicular hormone restored the thyroid function of vitamin E deficient rats. Vitamin E would also restore the thyroid of the deficient animals to normal, but had no effect on the thyroid of deficient animals that were ovariectomized. They believe, therefore, that the effect of vitamin E on the thyroid is mediated through the ovary.

The administration of vitamin E had no effect on the thyroid of normal rats (Bromskov and Schneider, 1939) or guinea pigs (Giedosz, 1938c), although Paal and Kleine (1933) reported stimulation.

2. Thyrotropic hormone and vitamin E. Bromskov and Schneider (1939) reported that the administration of thyrotropic hormone would restore the thyroid of their vitamin E deficient animals to normal. They also found no reduction in the thyrotropic content of the pituitary of E deficient animals, and no change in the antithyrotropic function of the blood of such rats.

Summary. Further experiments are necessary to ascertain if the changes reported to occur in the thyroid gland during vitamin E deficiency are a result of this deficiency or are due to other dietary factors.

GENERAL SUMMARY

Certain general statements on the interrelations between thyroid function and vitamin metabolism may be made. While some vitamin deficiencies will affect the thyroid gland, a number of the reports emphasize the necessity of controlling such factors as the length of time a deficient diet is fed, the influence of sex difference and whether or not the deficiency is acute or chronic. Each of these variables will influence the results obtained. Also, if a given vitamin deficiency will produce a picture of thyroid hypo- or hyperfunction, it does not follow that overdoses of the same vitamin will produce the opposite effect. Further work is also needed to ascertain the relation of the pituitary gland to the changes produced in the thyroid gland by a vitamin deficiency or the administration of a vitamin.

It has been demonstrated that the requirements for vitamins A, B and C are

increased during hyperthyroidism, and if these increased requirements are not met a relative deficiency of the vitamins will ensue. Such a vitamin deficiency may produce changes previously ascribed to an effect of hyperthyroidism per se. Whereas the administration of the necessary vitamins will correct these changes, it should not imply an antithyrogenic action, unless such an effect is demonstrated by further experiments. Conversely, if a vitamin will antagonize certain effects of thyroid feeding, it does not follow that a deficiency of the vitamin alone will increase thyroid activity. In studying vitamin metabolism during experimental hyperthyroidism there is also a sex difference in response, at least in the rat, and a difference in the degree of hyperthyroidism produced by the commonly used doses of thyroxin or thyroid gland. Also, growing rats may gain weight for a considerable period on the same dose of thyroxin or thyroid gland that will produce a progressive loss of weight in adult rats. These factors are of importance in studying the effect of a given vitamin on hyperthyroid animals.

REFERENCES

AALSMEER, W. C. Klin. Wchnschr. **11**: 2111, 1932.

ABELIN, I. Biochem. Ztschr. **228**: 165, 1930a.
Biochem. Ztschr. **228**: 211, 1930b.
Ztschr. f. physiol. Chem. **217**: 109, 1933.
Ztschr. f. Vitaminforsch. **4**: 120, 1935.
Schweiz. med. Wchnschr. **66**: 1106, 1936.

ABELIN, I., E. GOLDENER AND B. KOBORI. Biochem. Ztschr. **174**: 232, 1926.

ABELIN, I., M. KNOCHEL AND W. SPICHTIN. Biochem. Ztschr. **228**: 189, 1930.

ABERCROMBIE, W. F. Am. J. Path. **11**: 469, 1935.

ADAMSON, G. L. AND A. T. CAMERON. Canad. M. A. J. **19**: 420, 1928.

ANDERSON, H. H. AND M. H. SOLEY. Am. J. Med. Sci. **195**: 313, 1938.

ASZODI, Z. Klin. Wchnschr. **16**: 715, 1937.

BAGLIONI, T. Boll. Soc. ital. biol. sper. **15**: 322, 1940.

BALASSA, G. AND G. SZANTO. Ztschr. f. Vitaminforsch. **8**: 233, 1938.

BARRIE, M. M. O. Nature **139**: 286, 1937.
Lancet **2**: 251, 1937.

BAUMANN, C. A. AND T. MOORE. Biochem. J. **33**: 1639, 1939.

BELASCO, I. J. AND J. R. MURLIN. J. Nutrition **20**: 577, 1940.

BENNHOLDT-THOMPSON, C. AND M. WELLMAN. Klin. Wchnschr. **13**: 800, 1934.

DE LA BERNARDIE, A. M. Compt. rend. soc. Biol. **208**: 1170, 1939.

BESSESEN, D. H. Am. J. Physiol. **63**: 245, 1923.

BIDDULPH, C. AND R. K. MEYER. Am. J. Physiol. **132**: 259, 1941.

BIDDULPH, C. AND R. K. MEYER. Endocrinol. **30**: 551, 1942.

BRANDT, W. Ztschr. ges. exper. Med. **100**: 205, 1937.

BROMSKOV, C. AND E. SCHNEIDER. Arch. exper. Path. u. Pharmakol. **191**: 715, 1939.

BRUMAN, F. AND A. BROMBERG. Ztschr. f. d. ges. exper. Med. **97**: 229, 1936.

CAPRARO, V. Atti accad. Lincei, Class sci. fis. **26**: 50, 1937.

CARPENTER, M. D. AND G. R. SHARPLESS. J. Nutrition **13**: 235, 1937.

CATEL, W. Klin. Wchnschr. **17**: 574, 1938.

CHEVALIER, A. AND H. BAERT. Compt. rend. soc. Biol. **116**: 1037, 1934.

CLAUSEN, E. M. L. Proc. Soc. Exper. Biol. and Med. **26**: 77, 1928.

CLAUSEN, S. W. AND A. B. MCCOORD. J. Pediat. **13**: 635, 1938.

COLLAZO, J. A. AND J. S. RODRIGUEZ. Klin. Wchnschr. **12**: 1732, 1933.

COPLAN, H. M. AND M. M. SAMPSON. J. Nutrition **9**: 469, 1935.

COWGILL, G. R. The vitamin B requirement of man. Yale Univ. Press, New Haven, 1934.

Cowgill, G. R. and M. L. Palmieri. Am. J. Physiol. **105**: 146, 1933.
Cutting, W. C. and G. B. Robson. J. Pharmacol. and Exper. Therap. **66**: 389, 1939.
David, C. Ztschr. ges. exper. Med. **104**: 397, 1938.
Demole, V. and F. Ippen. Ztschr. f. Physiol. Chem. **235**: 226, 1935.
Deutsch, H., C. I. Reed and H. C. Struck. Am. J. Physiol. **117**: 1, 1936.
Dietrich, H. E. München. med. Wchnschr. **83**: 313, 1936.
Drennan, A. M., J. Malcolm and G. A. Cox. Brit. J. Exper. Path. **12**: 430, 1931.
Drigalski, W. Klin. Wchnschr. **12**: 308, 1933.
Drigalski, W. and W. Laubmann. Klin. Wchnschr. **12**: 1171, 1933.
Drill, V. A. J. Nutrition **14**: 355, 1937.
Am. J. Physiol. **122**: 486, 1938a.
Proc. Soc. Exper. Biol. and Med. **39**: 313, 1938b.
Am. J. Physiol. **132**: 629, 1941.
Drill, V. A. and H. W. Hays. Proc. Soc. Exper. Biol. and Med. **43**: 450, 1940.
Am. J. Physiol. **136**: 762, 1942.
Drill, V. A. and R. Overman. Am. J. Physiol. **135**: 474, 1942.
Drill, V. A., R. Overman and J. H. Leathem. Endocrinol., **32**: 327, 1943.
Drill, V. A., R. Overman and C. B. Shaffer. Endocrinol. **31**: 245, 1942.
Drill, V. A. and C. B. Shaffer. Endocrinol. **31**: 567, 1942.
Gastroenterol. **1**: 308, 1943.
Drill, V. A., C. B. Shaffer and R. Overman. Am. J. Physiol. **138**: 370, 1943.
Drill, V. A. and C. R. Sherwood. Am. J. Physiol. **124**: 683, 1938.
Eitel, H. Ztschr. Vitaminforsch. **7**: 45, 1938.
Elmer, A. W., B. Giedosz and M. Scheps. Compt. rend. soc. de Biol. **120**: 560, 1935.
Compt. rend. soc. de Biol. **126**: 1037, 1937.
Compt. rend. soc. de Biol. **129**: 343, 1938.
Escamilla, R. F. J. Clin. Endocrinol. **2**: 33, 1942.
Eufinger, H. and J. Gottlieb. Klin. Wchnschr. **12**: 1397, 1933.
Monatschr. Geburtsh. u. Gynec. **98**: 257, 1935.
v. Euler, H. and E. R. Klussmann. Ztschr. f. Physiol. Chem. **213**: 21, 1932.
Farmer, L. and R. Fribourg. Proc. Soc. Exper. Biol. and Med. **50**: 208, 1942.
Fasold, H. Ztschr. f. Kinderheilk. **56**: 408, 1934a.
Ztschr. f. Kinderheilk. **56**: 695, 1934b.
Klin. Wchnschr. **16**: 90, 1937.
Fasold, H. and E. R. Heidemann. Ztschr. f. d. ges. exper. Med. **92**: 53, 1933.
Fasold, H. and H. Peters. Ztschr. f. d. ges. exper. Med. **92**: 57, 1933.
v. Fellenberger, T. and F. Greuter. Biochem. Ztschr. **253**: 42, 1932.
Fellinger, K. and O. Hochstaedt. Wien. klin. Wchnschr. **49**: 1339, 1936.
Fischbach, H. and A. Terbrüggen. Klin. Wchnschr. **16**: 1125, 1937a.
Arch. f. path. Anat. **301**: 186, 1937b.
Fischer, G. Schweiz. med. Wchnschr. **30**: 749, 1933.
Fischer, G. and C. Oehme. Klin. Wchnschr. **12**: 1397, 1933.
Klin. Wchnschr. **16**: 1453, 1937.
Fleischmann, W. and S. Kann. Wien. Klin. Wchnschr. **47**: 1488, 1936.
Fraser, R. H. and A. T. Cameron. Canad. M. A. J. **21**: 153, 1929.
Frazier, W. D., R. B. Brown and H. M. Vars. Trans. Am. Assn. Study of Goiter, p. 247, 1939.
Frasier, W. D. and I. S. Raydin. Surgery **4**: 680, 1938.
Freudenberger, C. B. and F. W. Clausen. J. Nutrition **10**: 549, 1935.
Gelfan, S. Am. J. Physiol. **113**: 464, 1935.
Gentzen, G. and T. Moir. Klin. Wchnschr. **17**: 1243, 1938.
Giedosz, B. Compt. rend. Soc. Biol. **129**: 333, 1938a.
Compt. rend. Soc. Biol. **129**: 335, 1938b.
Compt. rend. Soc. Biol. **129**: 342, 1938c.

GODTFREDSON, E. Nord. Med. **10**: 1765, 1941.
GOORMAGHTIGH, N. AND H. HANDOVSKY. Compt. rend. soc. Biol. **118**: 1616, 1935.
GREENE, J. A. Am. J. Med. Sci. **195**: 618, 1938.
GREEVES, J. D. AND C. L. A. SCHMIDT. Am. J. Physiol. **116**: 456, 1936.
HANDOVSKY, H. AND N. GOORMAGHTIGH. Arch. Internat. Pharmacodyn. **56**: 376, 1937.
HANSMAN, F. S. AND F. H. WILSON. Med. J. Australia **1**: 37, 1934.
HARRIS, P. L. AND R. E. REMINGTON. J. Biol. Chem. Proc. **128**: xl, 1939.
J. Nutrition **17**: 31, 1939.
HARRIS, K. D. AND E. A. SMITH. Am. J. Physiol. **84**: 599, 1928.
HARVEY, D. Biochem. J. **21**: 1268, 1927.
HEAD, G. D. AND R. A. JOHNSON. Arch. Int. Med. **28**: 268, 1921.
HESS, A. F. AND V. C. MEYERS. J. A. M. A. **73**: 1743, 1919.
HERTZLER, A. E. Diseases of the thyroid gland. Paul B. Hoeber, New York, 1941.
HEYL, J. G. Acta. brev. Neerland. **4**: 12, 1934.
HIMWICH, H. E., W. GOLDFARB AND G. R. COWGILL. Am. J. Physiol. **99**: 689, 1932.
HOEN, E. AND C. OEHME. Klin. Wchnschr. **17**: 452, 1938.
HUNDHAUSEN, G. Arch. Exper. Path. und Pharmakol. **192**: 634, 1939.
HUNDHAUSEN, G. AND E. SCHULZE. Arch. Exper. Path. und Pharmakol. **191**: 570, 1939.
JACOBI, J. AND H. POMP. Klin. Wchnschr. **17**: 873, 1938.
KRAUSE, W. E. AND C. F. MONROE. J. Biol. Chem. **89**: 581, 1930.
KUCERA, C. AND M. SOOS. Compt. rend. Soc. Biol. **113**: 619, 1933.
KUNDE, M. M. Proc. Soc. Exper. Biol. and Med. **23**: 812, 1926.
KUNDE, M. M. AND L. WILLIAMS. Proc. Soc. Exper. Biol. and Med. **23**: 812, 1926.
LANDS, H. M. AND O. O. STOLAND. Endocrinol. **19**: 701, 1935.
LEVINE, H., R. E. REMINGTON AND H. v. KOLNITZ. J. Nutrition **6**: 325, 1933.
LEWIS, R. A. Bull. Johns Hopkins Hosp. **63**: 31, 1938.
LOGARAS, G. AND J. C. DRUMMOND. Biochem. J. **32**: 964, 1938.
LOHR, H. Arch. f. exper. Path. u. Parmakol. **180**: 344, 1936.
LOUMOS, S. Proc. Soc. Exper. Biol. and Med. **31**: 895, 1934.
LÖWY, E. Ztschr. f. d. ges. exper. Med. **38**: 407, 1923.
MANDELBAUM, T., S. CANDEL AND S. MILLMAN. J. Clin. Endocrinol. **2**: 465, 1942.
MARINE, D., E. J. BAUMANN AND S. H. ROSEN. Proc. Soc. Exper. Biol. and Med. **31**: 870, 1934.
MAY, M. M. Ztschr. f. Vitaminforsch. **6**: 239, 1937.
MCCARRISON, R. Ind. J. Med. Res. **2**: 369, 1914.
Brit. Med. J. **2**: 236, 1920a.
Ind. J. Med. Res. **7**: 633, 1920b.
Ind. J. Med. Res. **11**: 1, 1923.
Brit. Med. J. **1**: 989, 1931.
MCIVER, M. A. AND E. A. WINTER. J. Clin. Investigation **21**: 191, 1942.
MEANS, J. H. The thyroid and its diseases. p. 378, J. B. Lippincott Co., 1937.
MELLANBY, E. AND M. MELLANBY. J. Physiol. **55**: vii, 1921a.
J. Physiol. **55**: x, 1921b.
MEYER, A. W. Stanford Univ. Publ., Univ. Series., Med. Sc. **2**: 173, 1928.
MEYER, A. Klin. Wchnschr. **16**: 1593, 1937.
MITZKEWITSCH, M. S. Arch. exper. Path. und Pharmakol. **174**: 339, 1934.
MOLL, T., O. DALMER, P. v. DOBENICK, G. DOMAGK AND F. LAQUER. Arch. f. exper. Path. und Pharmakol. **170**: 176, 1933.
MOORE, T. Biochem. J. **31**: 155, 1937.
MORIN, G. AND R. CZERSZCHOWSKA. Compt. rend. soc. Biol. **131**: 1070, 1939.
MOSONYI, J. Ztschr. f. physiol. Chem. **237**: 173, 1935.
MOURIQUAND, G., G. MORIN AND R. CZERSZCHOWSKA. Compt. rend. Soc. Biol. **131**: 1070, 1939.
MURRAY, I. Brit. J. Exper. Path. **4**: 335, 1923.

NESPOR, E. Compt. rend. soc. Biol. **122**: 427, 1936.
NITSCHKE, A. Klin. Wchnschr. **12**: 1793, 1933.
Ztschr. f. Kinderheilk. **56**: 690, 1934.
NITSCHKE, A. AND H. DOERING. Klin. Wchnschr. **12**: 1910, 1933.
NITZESCO, I. I. AND S. BRATIANO. Compt. rend. soc. Biol. **121**: 1533, 1936.
v. NOORDEN, C. Die Suckerblaubleit. 4th ed., Berlin, 1907.
OEHME, C. Klin. Wchnschr. **15**: 512, 1936.
PAAL, H. AND H. O. KLEINE. Beitr. z. all. Path. **91**: 322, 1933.
PAAL, H. AND K. BRECHT. Klin. Wchnschr. **16**: 261, 1937.
PARADE, G. W. Z. Vitaminforsch. **6**: 327, 1937.
Z. Vitaminforsch. **7**: 35, 1938a.
Z. Vitaminforsch. **7**: 40, 1938b.
PARHON, C. I. AND G. WERNER. Compt. rend. soc. Biol. **118**: 1659, 1935.
PATEK, A. J. AND C. HAIG. Proc. Soc. Exper. Biol. and Med. **46**: 180, 1941.
PETERS, R. A. AND R. J. ROSSITER. Biochem. J. **33**: 1140, 1939.
PLAUT, F. AND M. BULOW. Klin. Wchnschr. **14**: 1318, 1935.
v. PLEHWE, H. J. Deutsch. Arch. Klin. Med. **182**: 145, 1938.
PUGSLEY, L. I. AND E. ANDERSON. Biochem. J. **28**: 754, 1934a.
Biochem. J. **28**: 1313, 1934b.
RABINOWITCH, I. M. Canad. M. A. J. **21**: 156, 1929.
RAPPAI, S. AND P. ROSENFELD. Pflüger's Arch. **236**: 464, 1935.
RAY, S. N. J. Ind. Chem. Soc. **15**: 237, 1938.
REED, C. I. Proc. Soc. Exper. Biol. and Med. **32**: 274, 1934.
REED, C. I., H. C. STRUCK AND I. E. STECK. Vitamin D. p. 145, Chicago University Press, 1939.
REED, C. I., E. A. THACKER, L. M. DILLMAN AND J. W. WELCH. J. Nutrition **6**: 355, 1933.
REMINGTON, R. E. AND H. LEVINE. J. Nutrition **11**: 343, 1936.
ROKHLINA, M. L. Bull. biol. med. exp. U. R. S. S. **2**: 219, 1936.
RONDONI, P. AND M. MONTAGNANI. Sperimentale Arch. di biol. **69**: 659, 1915.
SAMPSON, M. M. AND V. KORENCHEVSKY. Biochem. J. **26**: 1322, 1932.
SANDBERG, M. AND O. M. HOLLY. J. Biol. Chem. **99**: 547, 1933.
SAVY, P., M. JEUNE AND J. LEDRU. J. de med. de Lyon **20**: 257, 1939.
SAVY, P., A. VACHON AND D. VINCENT. J. de med. de Lyon **19**: 245, 1938.
SCHÄFFER, A. Klin. Wchnschr. **15**: 406, 1936.
SCHNEIDER, E. Deutsch. Ztschr. f. Chir. **242**: 189, 1934.
Klin. Wchnschr. **17**: 542, 1938a.
Deutsch. Ztschr. f. Chir. **250**: 167, 1938b.
SCHNEIDER, E. AND A. BURGER. Klin. Wchnschr. **17**: 905, 1938.
SCHNEIDER, E. AND E. WIDMANN. Klin. Wchnschr. **14**: 1786, 1935.
Klin. Wchnschr. **13**: 1497, 1934.
SCHÖBER, M. Endokrinol. **22**: 24, 1939.
SCHULZE, E. AND G. HUNDHAUSEN. Arch. exper. Path. und Pharmakol. **192**: 43, 1939a.
Arch. exper. Path. und Pharmakol. **192**: 664, 1939b.
SCHULZE, E. AND H. LINNEMANN. Arch. exper. Path. und Pharmakol. **189**: 448, 1938.
SCRUTINIO, L. Boll. Soc. ital. Biol. sperim. **14**: 563, 1939.
SHEETS, R. F., JR. AND H. C. STRUCK. Science **96**: 408, 1942.
SHERWOOD, T. C. AND W. G. LUCKNER. J. Nutrition **9**: 123, 1935.
SHERWOOD, T. C., L. A. TOTH AND K. D. KARR. Endocrinology **18**: 254, 1934.
SHIMAZONO, J. Ergebn. d. inn. Med. u. Kinderheilk. **39**: 1, 1931.
SINGER, E. J. Physiol. **87**: 287, 1936.
SMITH, D. C. AND J. M. PERMAN. Endocrinology **27**: 110, 1940.
SPENCE, A. W. Brit. J. Exper. Path. **13**: 157, 1932.
St. Bartholomew Hosp. Rept. **67**: 201, 1934.

SPENCE, A. W. AND E. F. SCOWEN. Biochem. J. **29**: 562, 1935.
STECK, I. E., C. I. REED AND D. S. MILLER. Am. J. Physiol. **110**: 1, 1934.
STEFFAN, F. AND T. ZOIS. Arch. exper. Path. und Pharmakol. **189**: 75, 1938.
STOCKHOLM, M., T. L. ALTHAUSEN AND H. J. BORSON. Proc. Soc. Exper. Biol. and Med. **46**: 387, 1941.
STONER, W. C. Am. J. Med. Sc., **175**: 31, 1928.
SURE, B. Endocrinology **23**: 575, 1938.
SURE, B. AND K. S. BUCHANAN. J. Nutrition **13**: 513, 1937a.
J. Nutrition **13**: 521, 1937b.
SURE, B. AND M. E. SMITH. J. Nutrition **7**: 547, 1934.
SURE, B. AND R. M. THEIS. Endocrinology **24**: 672, 1939.
TAKASUGI, T. Jap. J. Med. Sci., Sect. VIII, **2**: 26 (Proc.), 1931.
TAYLOR, N. B. AND C. B. WELD. Brit. J. Exper. Path. **13**: 109, 1932.
TELFORD, I. R., G. A. EMERSON AND H. M. EVANS. Proc. Soc. Exper. Biol. and Med. **38**: 623, 1938.
THADDEA, S. AND H. J. RUNNE. Ztschr. ges. exper. Med. **103**: 283, 1938.
THOMPSON, J. J. Nutrition **5**: 359, 1932.
TIBBETS, D. M., R. MCLEAN AND J. C. AUB. J. Clin. Investigation **11**: 1273, 1932.
TOEPFER, D. Ztschr. f. Kinderheilk. **56**: 405, 1934a.
Ztschr. f. Kinderheilk. **56**: 693, 1934b.
TÖRÖK, G. AND L. NEUFELD. Ztschr. ges. exper. Med. **103**: 69, 1938.
UENO, J. Jap. J. Obstet. and Gynec. **17**: 267, 1934.
UOTILA, U. Virchow's Arch. **301**: 535, 1938.
VERZAR, F. AND B. VASARHELYI. Pflüger's Arch. **206**: 675, 1924.
WAHL, H. Klin. Wchnschr. **18**: 1363, 1939.
WEGELIN, C. West. J. Surg. Obstet. and Gynec. **47**: 147, 1939.
WEISS, S. AND R. W. WILKINS. Ann. Int. Med. **11**: 104, 1937.
WENDT. H. Klin. Wchnschr. **14**: 9, 1935a.
München. med. Wchnschr. **82**: 1160, 1935b.
München. med. Wchnschr. **82**: 1679, 1935c.
München. med. Wchnschr. **83**: 808, 1936.
WESLAW, W. AND B. WROBLEWSKI. Ztschr. ges. exper. Med. **105**: 497, 1939.
WOHL, M. G. AND J. B. FELDMAN. Endocrinology **24**: 389, 1939.
WOLFF, L. K. Lancet **2**: 617, 1932.
YOUMANS, J. B. AND L. M. WARFIELD. Arch. Int. Med. **37**: 1, 1926.

Drummond-'22
Bib. No. 2314

Analyst 47:235-246. 1922.

The Testing of Foodstuffs for Vitamins.

By J. C. DRUMMOND, D.Sc., F.I.C., and A. F. WATSON, M.Sc., A.I.C.

(*Read at the Meeting, November* 2, 1921.)

The advances which have been made in the field of vitamin research since Hopkins first described these substances (*J. Physiol.*, 1912, **44**, 425), only ten years ago, have been so rapid that to-day it may be said that the testing of foodstuffs for these important dietary principles may soon become part of the everyday work of the food chemist.

This aspect of food chemistry is of very great importance to Public Analysts, and the present paper has been brought forward to point out to them how foodstuffs are tested for vitamins at the present time, and to describe a few of the more important discoveries in this field, with their bearing on food in its relation to public health.

For those who wish to read an accurate summary of our knowledge concerning these remarkable substances, the official report of the Accessory Food Factors Committee of the Medical Research Council is recommended (Report No. 38, H.M. Stationery Office, 1919).*

Unfortunately, there are, at present, no chemical or physical methods available for the detection or estimation of these substances in foods, and we are obliged to utilise biological methods. It is, therefore, not surprising that the technique at present employed is liable to the errors associated with this type of test, and which are largely introduced by the individual variations of the test animals. In recent years, however, whilst unabating efforts to devise chemical or physical methods capable of accuracy have been made, the technique of conducting the feeding tests has been greatly improved so as to reduce these errors very considerably.

In the first place, it must be borne in mind that, to carry out a large number of routine vitamin tests of this nature, great care and attention must be devoted to the organisation of the laboratory for feeding experiments.

A special room or animal house must be available, and should be airy, light, and well ventilated, and, preferably, with walls and floors which may be washed

* This report is now slightly out of date owing to the rapid advance of knowledge of this subject. A new edition is being prepared by the Committee.

down or disinfected. Means of heating the room should be installed, for it is of primary importance to keep the experimental animals warm in cold weather.

For the majority of vitamin tests carried out in this laboratory rats are employed. The advantages of this species for the work have been alluded to many times by various workers (*cf.* Osborne and Mendel, "Experiments with Isolated Food Substances," Carnegie Publication, 156, 1911). Briefly stated, these are that the rat is cheap, easy to breed and rear, matures early, and has a life span of only two to three years. Further, it is omnivorous and will consume many substances which would be unpalatable to other species, whilst its food consumption is not high, a fact of no little importance when the high cost of preparing the purified basal dietary is considered. Moreover, the rat rapidly responds to a change in the nutritive value of the diet.

The animals are kept in small wire cages, 12 in. by 12 in. (see Figure), which are arranged in rows on racks constructed from ordinary gas piping.

The dimensions of the cage are 12 in. by 12 in. by 4 in. A galvanised iron tray containing a layer of sawdust ½-inch deep is placed at the bottom, and a small wooden nest-box is provided to ensure a place free from cross draughts. By releasing the pin the top may be raised to feed or handle the animal. A glass automatic drinking device hangs through the bar.*

It is preferable to utilise home bred stock for feeding experiments, and no great difficulties are presented by this task, if care is taken to select good breeding animals, to house them warmly, and feed them well.

THE TESTING OF FOODS FOR VITAMIN *A*.—The technique for this testing has been briefly described by Drummond and Coward (*Biochem. J.*, 1920, **14**, 661).

The first step is to feed young healthy rats of not more than 50 grms. body weight on a ration of purified foodstuffs from which all traces of the vitamin *A* have been removed.

This ration is compounded as given below:—

	Parts
Casein	20
Rice starch	50
Commercial yeast extract	5
Salt mixture	5
Lemon juice	5
Hardened refined vegetable oil	15

* These cages, which are cheap and convenient, may be obtained from Messrs. Mantica, Essex Road, London, N.1.

Of the constituents of this mixture, only one, namely, the caseinogen, is liable to be contaminated with traces of vitamin *A*, the commercial samples usually containing this impurity associated with the traces of milk fat retained by the protein. Formerly it was necessary to submit the components of artificial diets to lengthy and costly extraction with alcohol and ether, in order to purify them from the associated growth-promoting factor, but this procedure is no longer necessary now that we know that this substance, whatever its nature, is readily destroyed by oxidation. Accordingly, the commercial caseinogen is now submitted to an oxidation in which the protein is spread out in thin layers and exposed to a temperature of 110° C. for several hours in a current of air.*

The composition of the inorganic salt mixture is essentially that described by McCollum and Davis (*J. Biol. Chem.*, 1915, **20**, 161):—

	Grms.
Sodium chloride	5·2
Magnesium sulphate	8·0
Sodium dihydrogen phosphate	10·4
Dipotassium hydrogen phosphate	28·6
Calcium superphosphate, $CaH_4(PO_4)_2$	16·2
Calcium lactate	39·0
Ferric citrate	3·5
Potassium iodide	Trace.
Manganese sulphate	,,

This mixture must be compounded from the pure salts. The yeast extract (marmite) and the lemon juice supply the other two accessory factors, and do not contain any detectable traces of vitamin *A*, whilst the hardened fat (usually cottonseed or linseed) is equally pure in this respect.

We have, on more than one occasion, drawn attention to the importance of selecting a source of fat devoid of the vitamin *A* for the basal ration (*cf.* Drummond and Coward, *Biochem. J.*, 1920, **14**, 661), for many failures to get clear-cut results are to be attributed to the inclusion of fats of which the vitamin content may be uncertain. For this reason we refuse to use any untreated fat, such as lard (*cf.* references to technique in the *Vitamin Manual*, Eddy, 1921, Baltimore).

It is important to start the test animals on the basal diet before they are heavier than 70 grms. Young rats fed on this ration usually grow for a few days, presumably while they are utilising the vitamin *A* reserves present in their own bodies, but soon show a retardation and cessation of growth (Period 1, Curve 1). When they have shown no further increment of weight over a period of 14 days they may be considered fit for vitamin tests. It is of the greatest importance to be sure that the rats show this satisfactory phase of no growth before testing is begun. The substance to be tested is then administered in a daily ration of known weight. The supplement is always given to the animals before they receive their daily ration of food, so as to ensure that it is eaten. In the very few cases in which the nature of the supplement renders it unpalatable, it is necessary to

* The British Drug Houses now prepare this purified caseinogen for utilisation in vitamin tests.

incorporate it with a little of the basal diet before it will be consumed, and, with a little pains, all such difficulties may be surmounted. The value of the supplement as a source of vitamin *A* is judged from the changes in body weight of the animals which follow its administration. In Period 2, Curve 1, is shown the sharp recovery

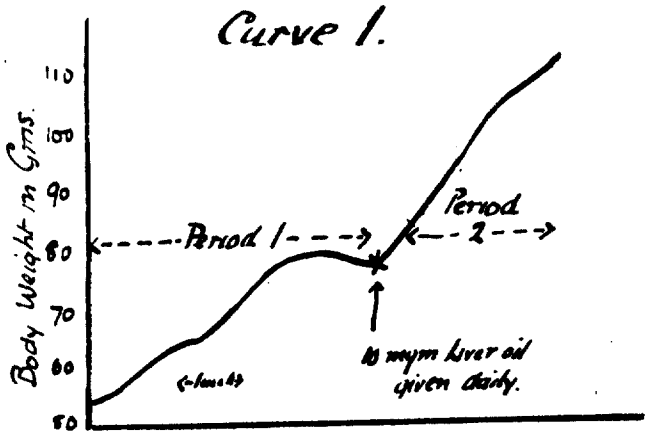

which follows the administration of a highly potent source of vitamin *A*, viz. 0·05 grm. daily of raw cod-liver oil.

By varying the "dosage" it is possible to compare, with a fair degree of accuracy, the value of a series of foodstuffs.*

Curve 2 shows the falling off of growth-promoting powers as the vitamin *A* present in a sample of coal-fish oil (liver oil) is destroyed by oxidation at high temperatures.

That this method may, in the hands of skilled persons, be capable of a useful degree of accuracy is well shown by a recent series of tests which one of us (J. C. D.) is carrying out in collaboration with Dr. S. S. Zilva, of the Lister Institute. Almost identical results were obtained in the two laboratories on the same samples of oil by following closely the same technique.

Very occasionally, as in the case of certain plant tissues, for example, the material to be tested contains constituents which are toxic to rats. In such cases it is useless to attempt direct administration, and we have found that the best course is to prepare from the material that fraction which resists saponification by alkalis. This fraction, if prepared under conditions which exclude oxidation, will contain all the vitamin *A* present in the original material. Such a procedure is, however, laborious, and, fortunately, not frequently necessary.

By employing such a technique as outlined above it has been possible to gain much important information concerning vitamin *A* in foodstuffs, of which the

* Some remarkably fine quantitative results are shown in a recent paper by Zilva and Miura (*Biochem. J.*, 1921, **15**, 654). They were obtained by a refinement of the method of measuring and administering the supplements to be tested.

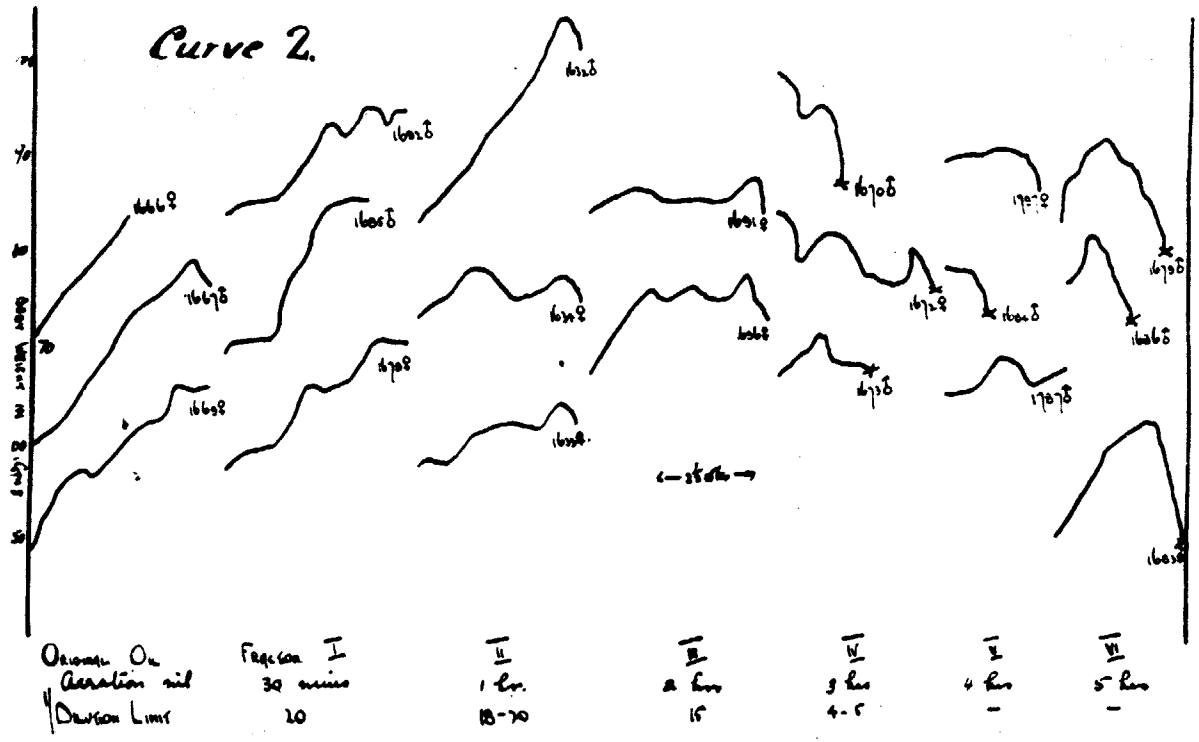

The Aeration at 100° C. of Acton Coal Fish Liver Oil.

These series of curves show the loss of growth-promoting power in a sample of coal-fish liver oil during aeration at 100° C. The preparatory period illustrating the initial growth and following cessations on the basal diet is in each case omitted for simplicity. The curves illustrate only the effect of the supplement of oil (3 rats in each case). Complete inactivation appears to occur between 2 and 3 hours. Dose in each case 7·0 mgrms. per day of oil.

following examples are chosen as being of particular interest to Public Analysts:

The superior nutritive value of butter and cod liver oil to that of other fats was early shown to be due to the presence of vitamin *A*, but, more recently, it has been found that samples of butter may vary very considerably in the amount of vitamin they contain. The vitamin is apparently synthesised by the actively assimilating green leaves of plants (Coward and Drummond, *Biochem. J.*, 1921, **15**, 530), and from that source passes into the tissues of animals. The vitamin content of butter may therefore depend very largely on the diet of the cow, and interesting experimental data on this point have been presented by Drummond, Coward and Watson (*Biochem. J.*, 1921, **15**, 540).

The significance of the vitamin question in determining the food value of butters and butter substitutes must be taken into account, for it is very far reaching. The majority of the important vegetable oils and the raw products from which they are derived have recently been examined by Dr. Zilva and one of us (J. C. D.) (*J. Soc. Chem. Ind.*, 1922), with the result that the earlier conclusions of Halliburton and Drummond (*J. Physiol.*, 1917, **51**, 235) have been confirmed. All these oils appear to be very much lower in vitamin *A* content than the average samples of animal oils and fats, but, as pointed out above, the latter vary considerably with the diet of the animal (Drummond and Coward, *Biochem. J.*, 1920, **14**, 668). This relationship has been emphasised by us in the case of lard (Drummond, Golding, Zilva and Coward, *Biochem. J.*, 1920, **14**, 742).

Of the other animal fats employed for margarine manufacture, oleo-oil also shows marked variation. A number of samples from N. America and the Argentine show a varying vitamin *A* content, which, from a study of the associated pigments and other evidence, appears to be a seasonal one, dependent on the state of the pasturage.

One important source of vitamin *A*, namely, cod-liver oil, is now being exhaustively studied by one of us (J. C. D.) in collaboration with Dr. S. S. Zilva. The extraordinary potency of this oil is well shown by the striking experiments of Zilva and Miura (*Lancet*, 1921, i., 323), who have shown that a daily ration of the order of 2 to 5 mgrms. is sufficient to produce nearly normal growth in a rat. When this is compared with the dose of an average sample of butter required to give the same result (from 0·2 to 0·4 grm.), the extraordinary efficacy of cod-liver oil is appreciated. It has recently been shown by Zilva and Drummond (*Lancet*, 1921, ii., 753) that other fish-liver oils may be of the same order of potency. To appreciate the minute amount of the physiologically active principle which is effective in stimulating growth, it is only necessary to consider that the whole of the vitamin *A* is present in the unsaponifiable matter of the oil. Taking the larger figure for the "dosage" of oil (5 mgrms.) and the approximate value for the unsaponifiable matter as 2 per cent., we find the activity of the oil is wholly in the 0·1 mgrm. of this fraction, of which probably 90 per cent. is composed of cholesterol, which is known to be inactive, leaving the remaining 0·01 mgrm. as the source of the active substance.

THE TESTING OF FOODS FOR VITAMIN *B*. The technique in this case is closely parallel to that described in the previous section. The basal diet is, however, one from which the vitamin *B* has been excluded. The composition of the mixture used in this laboratory is as follows:

	Parts
Purified caseinogen (preferably alcohol-extracted) ..	20
Rice starch	55
Butter fat	15
Salt mixture	5
Orange juice	5

On such a diet the young rats quickly cease growing, there being apparently little or no reserve supplies which may be mobilised from the tissues (Curve 3, Period 1). After they have been stationary in weight for at least 14 days they

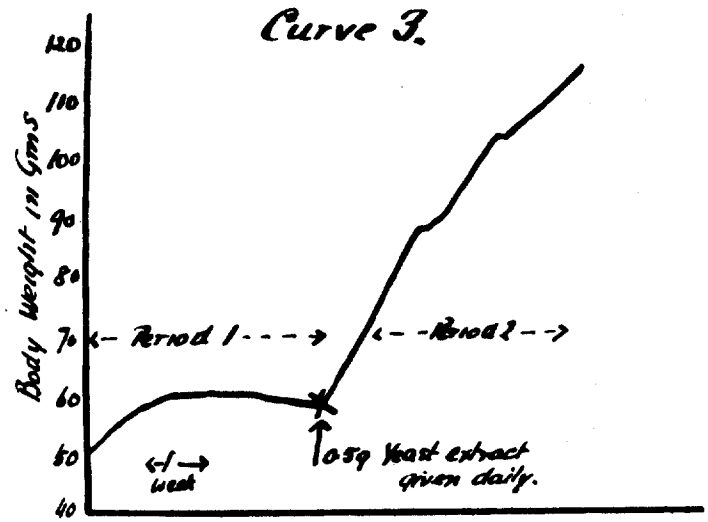

are ready for use. The supplement to be tested should be administered before the daily ration of basal diet, and there is seldom, if ever, any need to prepare an extract from the foodstuff under examination. The response in this test is very sharp (Curve 3, Period 2), and there is scarcely ever any doubt in interpreting the result.

Some investigators prefer to use the pigeon as a test animal for the vitamin *B*, taking, as the proof of its presence, the curative effect of the supplement on the pathological condition, termed incorrectly "avian polyneuritis," induced by a diet of polished rice. In our opinion, this method is very much less reliable than the tests on rats, which we find respond in a very sensitive manner to small supplements of foodstuffs containing vitamin *B*. By some, indeed, it has been questioned whether the same dietary factor is involved in the two cases, although the opinion of the chief workers in this country tends to regard them as identical (see *M. R. C. Report*).

More recently, in an attempt to introduce methods of estimating the vitamin content of foods which should be capable of a greater degree of accuracy than the animal-feeding tests, a number of American workers have turned their attention to the growth of yeast in pure cultures.

It may be remembered that, some years ago, Wilders, of Louvain, found that, to ensure the satisfactory growth of yeast cells in pure culture, a small amount of an organic complex, termed by him "bios," was necessary. Williams, in America, drew a parallel between "bios" and vitamin *B*, and, after investigation, suggested that the growth of yeast in artificial culture solutions might be standardised by extracts containing vitamin *B* (*J. Biol. Chem.*, 1919, **38**, 465; 1920, **42**, 259; 1921, **46**, 113).

At first the suggestion appeared most promising, and there are still investigators who advocate its use (Funk and Dubin, *J. Biol. Chem.*, 1920, **44**, 487; Bachmann, *J. Biol. Chem.*, 1919, **39**, 235), but the general tendency is to regard the method as unreliable, for the reason that the factors governing the rate of growth of yeast in such a test, in which miscellaneous extracts containing many constituents other than vitamin are added to the cultures, are very complex. This view has been strengthened by the discovery that yeast in pure culture can synthesise vitamin *B* (Nelson, Fulmer and Cessna, *J. Biol. Chem.*, 1921, **46**, 77; Harden and Zilva, *Biochem. J.*, 1921, **15**, 438).

Of the many interesting results concerning vitamin *B* which have recently been obtained, and which are of especial interest to Public Analysts, are those which show that the amount of vitamin *B* in milk depends entirely on the food of the cow (Dutcher, Kennedy and Eccles, *Science*, 1920, **52**, 588), and the observations that many commercial yeast extracts are almost the richest sources of the *B* factor which are available as foodstuffs. The latter point is of interest, when it is remembered that it is usual to test meat extracts for adulteration with yeast extracts. In future, it may be that adulteration of the more highly nutritive yeast extracts with less potent materials may be feared.

TESTING FOR VITAMIN *C*.—The testing for vitamin *C* presents more difficulties than either of the previous two techniques. This is due to the fact that the only two species of animal known to be suitable for the work are the guinea pig and the monkey. The latter is undoubtedly the ideal test animal, but it has the disadvantage of being very expensive. Moreover, it requires special housing and handling, and is somewhat delicate in this country. It also takes much longer to obtain a result with a monkey than with a guinea pig. The technique used with monkeys has been described by Harden and Zilva (*J. Path. and Bact.*, 1919, **22**, 246).

In most laboratories, however, guinea pigs are the only animals available, but this species also has its limitations. The guinea pig is entirely herbivorous, and normally consumes a bulky diet, largely composed of roots and leaves, for which its alimentary tract is especially suited. Many foodstuffs which it is wished to test for the antiscorbutic vitamin are such that they are not well tolerated by the digestive system of this animal, and it is frequently difficult to prepare the

food or an extract in a form which will be consumed and absorbed. This is particularly true when foodstuffs containing much fat, or when products of a sticky nature, as, for example, certain types of proprietary vitamin preparations, are to be tested.

The actual testing can be done either by determining the dose of foodstuff which will prevent the onset of the disease, or that necessary to effect a cure. By either method comparative figures are obtained. The basal diet which is usually employed to induce the scorbutic conditions is that originally used by Holst and Fröhlich (*Zeitsch. Hyg. und Infektionsk.*, 1912, **72**, 1), consisting of bran and oats. Improved modifications of this diet have been proposed by other workers, that employed by Chick, Hume and Skelton (***Biochem. J.***, 1918, **12**, **131**), in which the oats and bran are supplemented by autoclaved milk, being very good. More recently, American workers have employed more complex rations, such as that of La Mer, Campbell and Sherman (***Dissert.***, Columbia Univ., 1921), whose basal mixture is compounded as follows:

	Per Cent.
Skim milk powder heated in air to 110°C. for two hours	30
Butter fat	10
Ground whole oats	59
Sodium chloride	1

These workers claim that their results have a high degree of accuracy for this type of test.

The potency of the food supplement added is judged from the "dosage" necessary to prevent the onset of, or to cure established scurvy, as proved by the subsequent post-mortem examination. This method has been used with success in the testing of milk and milk products, and in estimating the anti-scorbutic value of fruit juices and other commercial extracts.

Amongst the many interesting results obtained may be mentioned the discovery that the antiscorbutic value of the milk is dependent on the diet of the animals, and the fact that lemon juice possesses a very much higher antiscorbutic potency than lime juice (Chick, Hume and Skelton, *Lancet*, 1918, II., 735).

CONCLUSIONS.—In conclusion we would again emphasise the point that the opening up of this wide new field of food chemistry is of considerable importance to the Public Analyst, and we may briefly specify one or two examples.

Much of the work in this branch will deal with dairy products, since it is now no longer possible to be satisfied with the ordinary routine chemical analysis of a sample of milk or butter, if the information as to the true food value of these products is desired. Indeed, it is not at all improbable that certain aspects of the relationships of butter to butter substitutes may be greatly changed within the next few years, although it is yet too early to indicate the lines along which these changes may be made.

The control of the vitamin value of antiscorbutic material for the artificial feeding of infants, for supply to ships or for polar or other exploration parties will sooner or later be a task which certain Public Analysts must be prepared to

undertake, whilst an active branch of their work will possibly be concerned with the routine examination of proprietary foodstuffs whether for human or animal consumption, of which so many have already appeared on the market. Of such products which we have from time to time examined a number are genuine, in that they do actually contain the three known vitamins. Where most, in fact nearly all of them fail, is in their claims to supply these food factors in a highly concentrated form. On the other hand, several preparations are quite fraudulent, being found to be inactive from a vitamin standpoint when tested.

A certain, and by no means small, proportion of the public always buy such articles for themselves, their children, or their farm animals, and there is opening a wide and promising field for the quack unless such preparations are guaranteed by controlled tests.

The importance of tests for vitamins is so far recognised by certain firms of high standing that more than one have established special biological testing stations where they may submit their preparations to periodical testing, and also carry out research in order to improve the food value of their products.

THE BIOCHEMICAL LABORATORIES,
INSTITUTE OF PHYSIOLOGY,
UNIVERSITY COLLEGE, LONDON.

DISCUSSION.

The PRESIDENT (Mr. A. Smetham) said that he was interested in the nutritive values of margarine and butter, and would like to know what became of the fats in the case of margarine, if they did not contain these vitamins. As they were digested, why did they not have a nutritive effect on the body?

Mr. A. E. PARKES hoped that the authors would bring forward some chemical methods of determining the presence of vitamins. He thought that vitamins must have some function in plants, and presumed it had something to do with growth. The question was: Were they of the nature of enzymes? He was much interested in the experiments with cows at different times of the year, and asked whether the question of the vitamins in hay had ever been discussed; had, for instance, the drying of hay the effect of destroying or preserving the vitamins?

Mr. C. A. MITCHELL said that enzymes apparently resembled vitamins in being a peculiar form of energy attached to a material substance associated with life, but the difference appeared to be that, whereas enzymes exerted a specific chemical action, the activity of vitamins appeared to be directed to the stimulation of a sum of chemical actions in vital processes. Following this line of thought, he enquired whether any experiments had ever been made to see whether the activity of individual enzymes could be stimulated *in vitro* by different vitamins. If, for example, the action of lipase were increased by the fat-soluble vitamin, a measure of vitaminic activity might be based on the differences in the lipolytic action with and without the presence of the vitamin. The recent work of Beszenoff, showing that certain vitaminic substances were associated with a substance of a

phenolic character would, if corroborated, mark an advance towards a chemical method of identification of, at all events, one of the vitamins.

Mr. E. HINKS said that he would be glad to know where the methods of preparing vitamin-free basal rations were recorded, and asked if any thing were known as to the effect of an excess of vitamins.

Mr. BOLTON drew attention to the experiment which the authors had demonstrated, with such marked effect, with mgrms. of cod-liver oil. He said that when one considered that there must have been 99 per cent. of glycerides and also unsaponifiable matter, all in the two mgrms., the actual weight of vitamins present was so small as to be hardly realisable. He deprecated the use of strong sulphuric acid as a distinguishing agent, in view of the striking colours it gave with so many organic substances. In his opinion the exact part played by (*a*) temperature, and (*b*) oxidation, in the destruction of vitamins was a matter of extreme importance, requiring particular investigation. Recent experiments seemed to show that oxidation was the main destructive factor, and that temperature played a far less important part.

Mr. COLLETT enquired whether the authors had ever tried any experiments on reducing the quantity of vitamins in these foods, to see if thereby they could acclimatise the animals to the complete absence of these growth-promoting factors.

Dr. MONIER-WILLIAMS asked whether the substance discovered by Professor Hopkins had ever been tried on rats.

Dr. J. A. VOELCKER remarked that it was quite clear that vitamins were going to play an important part in food examination, but it was a terrible thought that one might have to go on weighing the animals, to see if the vitamins had had any effect or not. It would be comparable, for instance, with milking a cow to see how the animal was getting on, instead of for the purpose for which cows were sent into the world. Knowledge was wanted as to the cause of the influences which destroyed the activity of vitamins. He asked whether the cooking of food, such as, for instance, the heating or sterilising of milk, had a destructive influence on vitamins. These were all factors which bore, not so much on animals, as on human beings.

Dr. DRUMMOND, replying, said that the determining factor of the difference in the nutritive value of margarine and butter was the absence of vitamin *A* from some margarines. Vegetable fats were very low in the scale in this particular vitamin, but this was not the case with most animal fats. As to digestibility, the majority of ordinary edible fats were equally well digested, but fats such as cod-liver oil and butter were merely carriers of the vitamin. With regard to the possibility of these substances being enzymes, he thought the available evidence was all against this view. As regards the milk from London cows, he knew cases of special cows which were fed for high milk production on a low vitamin diet, with the result that they gave a very large volume of milk, although the nutritive value of the milk was not so good as that from many cows fed on grass and living in the open air. He had no knowledge as to whether hay lost or retained its vitamins. As to Mr. Hinks' question of the vitamin-free basal

ration, full details would be given in the published paper, or might be obtained from the Medical Research Council's Report, which anyone might buy. Regarding an excess of vitamins, the cow appeared to store up in her body reserves of vitamin A, which she was able to call upon when desired. He agreed that the sulphuric acid test was not one upon which one could place much reliance. As to the hydrogenation of fats, it would appear that the substance was destroyed by reduction as well as by oxidation. He was not aware of any laboratory experiments that would answer Mr. Collett's question. There was little definite information available upon the cooking of foodstuffs, and the literature on the subject was somewhat confused, but it was now generally believed that relatively little damage to vitamin occurred in the usual processes. So far as he was aware, no work had been done on the lines suggested by Mr. Mitchell. The suggestion might be made the subject of an interesting series of experiments.

Dziewialkowski-'54
Bib. No. 2401

J. Exptl. Med. 100(1):11-24. 1954.

Reproduced by permission
of the copyright owner

VITAMIN A AND ENDOCHONDRAL OSSIFICATION IN THE RAT AS INDICATED BY THE USE OF SULFUR-35 AND PHOSPHORUS-32

By DOMINIC D. DZIEWIATKOWSKI, Ph.D.

(From the Hospital of The Rockefeller Institute for Medical Research)

Plates 3 and 4

(Received for publication, March 2, 1954)

Mellanby (1) expressed the opinion that vitamin A influences the activity of osteoblasts and osteoclasts. He focused attention on the deranged calcification in vitamin A deficiency. Wolbach (2), on the other hand, has shown that in vitamin A deficiency the epiphyseal cartilage cells cease to multiply and mature, except cells which have reached the vesicular stage; these latter cells continue to mature and finally disappear, with the result that the epiphyseal cartilage plates are narrower in vitamin A-deficient rats than in normal rats of the same age. The effects of an excessive intake of vitamin A on the skeletons of young rats can be ascribed to the acceleration of normal growth sequences of epiphyseal cartilage cells (2, 3).

The decreased proliferation of epiphyseal cartilage cells in vitamin A-deficient rats suggested that there might be a decreased turnover of the chondroitin sulfate in the cartilage. The results of the experiments described in this paper indicate this to be the case. In addition the experiments indicate that in vitamin A deficiency the mechanisms by which phosphate accumulates in the skeleton are depressed, and that this occurs even sooner than the reduction in uptake of sulfate by epiphyseal cartilage.

Procedure

In the first four sets of experiments, 38 albino rats of the Sherman strain were used. At 21 days of age each of 19 rats was given an intraperitoneal injection of 2 mg. of vitamin A[1] in 0.1 ml. of ethyl laurate, and each of the remaining 19 rats was given a similar injection of ethyl laurate alone. Immediately thereafter, 25 μc. of carrier-free sulfur-35 as sodium sulfate in water[2] was injected intraperitoneally into each rat. 4 to 6 representative animals from each group were sacrificed 7, 24, 48, and 72 hours later. Blood was drawn directly from the heart under deep ether anesthesia and allowed to clot. The serum was separated and stored at 0°C.

[1] This was a commercially available crystalline preparation; the molecular extinction coefficient at 325 to 327 mμ was found to be 46,500, using absolute ethanol as solvent. The value 60,000 at 328 mμ with 95 per cent ethanol as solvent for the vitamin A, has been reported by Holmes, H. N., and Corbet, R. E., *J. Am. Chem. Soc.*, 1937, 59, 2042.

[2] The sulfur-35 and phosphorus-32 used in this investigation were supplied by the Oak Ridge National Laboratory on allocation from the United States Atomic Energy Commission. The dosage used was calculated on the basis of the data available from the supplier.

until analyzed, usually the next day. For the collection of the urine, voided during the 24 hours immediately preceding sacrifice, the animals were kept in metabolism cages without food but with water. The urines were stored at 0°C until analyzed.

The sera and urines were analyzed as recently described (4).

The right femur was removed from each rat and stored in a "deep freeze" at about −25°C. until analyzed. For analysis the ends of each femur were separated from the shaft by cutting across the shaft with a pair of scissors, one cut being made just below the lesser trochanter and the other just above the patellar facet. The two ends and the shaft were weighed separately and then placed in porcelain evaporating dishes containing 5 ml. of 0.05 N sodium sulfate. Organic sulfur was oxidized to sulfate by the use of 5 ml. of Denis reagent (5), and then isolated as barium sulfate.

Both tibiae were removed from each rat: the proximal end of one of these was placed in a 3.7 per cent solution (w/v) of formaldehyde, and the corresponding end of the other was placed in a 3.7 per cent solution of formaldehyde which had been previously saturated with barium hydroxide. The bones were fixed for 48 hours at 25°C. and then dehydrated by passage through increasing concentrations of ethanol. After passage through xylol they were embedded in paraffin and sectioned at 7 μ. Radioautographs of the sections were prepared as previously described (6). The sections were subsequently stained with 0.1 per cent toluidine blue in 30 per cent ethanol. Additional sections from the tibiae which had been fixed in formaldehyde were also stained with alizarin red as recommended by Dahl (7).

In the second set of experiments, albino rats of the Sherman strain were fed a vitamin A-deficient diet[3] for 42 days, starting with the 28th day of life. On the 70th day of life each of 21 rats (treated) received a single intraperitoneal injection of 2 mg. of vitamin A in 0.1 ml. ethyl laurate, and each of the remaining 20 rats (untreated) received 0.1 ml. of ethyl laurate alone. Immediately thereafter, each of 14 treated and 14 untreated rats was given an intraperitoneal injection of carrier-free sulfur-35 as sodium sulfate in water (0.5 μc. per gm. of body weight). Under deep ether anesthesia, 4 rats from each of the two groups were sacrificed by exsanguination 24 hours later; 5 more from each group were sacrificed at 72 and at 120 hours after injection.

The remaining 6 untreated and 7 treated rats were given an intraperitoneal injection of carrier-free sulfur-35 as sodium sulfate (0.5 μc. per gm. of body weight) 72 hours after administration of ethyl laurate and vitamin A in ethyl laurate, respectively. These animals were sacrificed 24 hours later.

Sera, urines, femurs, and tibiae were taken for analysis as in the first set of experiments.

In the third set of experiments, 62 albino rats of the Sherman strain were maintained on the vitamin A-deficient diet for 42 days, starting with the 28th day of life. At the end of the depletion period, 34 of the rats were given 0.1 ml. of ethyl laurate by intraperitoneal injection, and the remaining 28 rats were given 2 mg. of vitamin A in 0.1 ml. of ethyl laurate. Thereafter, at intervals of time representative animals from each group received labelled sodium sulfate by intraperitoneal injection in a dose of 0.3 μc. of carrier-free sulfur-35 per gm. of body weight. The animals were sacrificed by exsanguination under deep ether anesthesia 12 hours after receiving the isotope. Urine specimens were collected during the 12 hours immediately preceding sacrifice.

Sera, urines, femurs, and tibiae were again analyzed as in the first set of experiments. In addition, after removing most of the musculature, the remainders of the skeletons from the animals in each subgroup were separately pooled. The pelts of the animals were similarly pooled. Separate pools were also formed of all the viscera of the untreated and treated rats.

The tissues in each pool were minced and added to about 10 times their weight of 95 per

[3] The vitamin A-deficient diet was purchased from General Biochemicals, Inc., Chagrin Falls, Ohio.

cent ethanol. This ethanol was replaced 24 hours later by an equal volume of fresh 95 per cent ethanol, which after an additional 24 hours was removed by filtration. A large Buchner funnel without filter paper was used. The pools of tissue were separately dried in air for 24 to 48 hours and then for 12 hours at 110°C. Each pool of dried skeletons and dried viscera was then further pulverized by grinding in a mortar with a pestle. Mucopolysaccharide samples were isolated from the tissue samples by an adaptation of the procedure described by Boström (8) for the preparation of chondroitin sulfate from rib cartilage of rats.

For the determination of sulfur-35 in the isolated samples of mucopolysaccharides, weighed portions (about 10 mg.) were each added to 5 ml. of 0.05 N sodium sulfate solution (carrier sulfate). A 10 ml. aliquot of 2.5 N hydrochloric acid and 100 ml. of water were added. The volume was reduced to about 10 ml. by gentle boiling on a hot plate. The water was replaced and boiled away two more times. Finally 200 ml. of water was added and the solution brought to a boil. The sulfate was precipitated by the slow addition of 5 ml. of a 10 per cent barium chloride solution. Gentle boiling was continued until the volume had been reduced to about 100 ml. The precipitate of barium sulfate was collected on a filter paper disk as previously described (9). The radioactivity of each sample was determined with a G-M tube having a mica end-window with a thickness of 1.5 mg./cm.^{2}. The distance from the sample to the end-window was about 2 mm. All values for radioactivity were corrected for decay and self absorption.

The sulfate-sulfur content of the mucopolysaccharide samples was determined after acid hydrolysis of 70 to 100 mg. of sample, the procedure being the same as above except that no carrier sulfate was added. Sulfate was precipitated as barium sulfate and isolated in tared Gooch crucibles. However, in the case of the pelts each pool yielded only 30 to 40 mg. of the mucopolysaccharide preparation; from each pool a 10 mg. portion was added to the same beaker to form a composite sample for sulfate analysis.

The nitrogen content of each mucopolysaccharide sample was determined by micro Kjeldahl analysis (10). The hexuronic acid content was estimated by the procedure described by Dische (11). After each sample had been hydrolyzed as recommended by Einbinder and Schubert (12), the hexosamine contents were determined according to Sørensen (13).

For comparison, 4 rats raised on a diet of Purina dog biscuits (stock diet) to the same age, namely 70 days, were given by intraperitoneal injection 0.3 μc. per gm. of body weight of carrier-free sulfur-35 as sodium sulfate. The animals were sacrificed 12 hours later and their tissues were analyzed as described above.

In the fourth set of experiments, forty albino rats of the Sherman strain were used. They were maintained on the vitamin A-deficient diet from the 28th to the 70th day of life. Each of 20 animals was then given 2 mg. of vitamin A in 0.1 ml. of ethyl laurate by intraperitoneal injection and each of the remaining 20 rats was similarly given ethyl laurate alone. At intervals of time, thereafter, 4 animals from each group received phosphorus-32 as disodium phosphate[2] in water by intraperitoneal injection. The dose was 1 μc. of carrier-free phosphorus-32 per gm. of body weight. 12 hours after administration of the isotope, the animals were sacrificed by exsanguination under deep ether anesthesia. Sera, urines, femurs, and tibiae were taken for analysis.

Proximal ends of the tibiae were placed in a 3.7 per cent solution of formaldehyde which had been previously saturated with magnesium carbonate. The bones were kept in the fixative for 48 hours at 25°C. and then were dehydrated in increasing concentrations of ethanol, starting with a 30 per cent concentration. The ethanol solutions were saturated with magnesium carbonate before use. After passage through two changes of xylol, the bones were imbedded in paraffin and sectioned at 7 μ. Radioautographs of the sections were prepared as previously described (6). The sections were subsequently stained with alizarin red as recommended by Dahl (7).

Each of 4 normal rats, 70 days old, previously maintained on a stock diet of Purina dog biscuits, was given 1 μc. of phosphorus-32, as disodium phosphate, per gm. of body weight by intraperitoneal injection, 12 hours before sacrifice. Sera, urines, femurs, and tibiae of these animals were analyzed as were those from the vitamin A-deficient rats.

For the determination of phosphorus-31 and phosphorus-32 contents, each femur was divided into ends and shafts as described above. The combined ends were weighed separately from the shaft. The samples were heated in 50 ml. pyrex beakers at 500°C. in a muffle furnace for 6 hours. To the cooled beaker, 2 ml. of 8 N nitric acid was added and evaporated with heat. The beaker was reheated at 400°C. for 15 minutes. After cooling, 1 ml. of concentrated hydrochloric acid was added and evaporated. The residue was dissolved in 10 ml. of 3 N hydrochloric acid and transferred to a 25 ml. volumetric flask. After diluting to volume with water, an aliquot, 2 ml. in the case of the femoral ends and 5 ml. in the case of the femoral shafts, was further diluted to 25 ml. with water. The phosphorus-32 contents of the solutions so prepared were determined with a dipping G-M tube and a scaler. All values were corrected for decay. The concentrations of total phosphorus in the solutions were determined by an adaptation of the method of Fiske and Subbarow (14). A procedure similar to the above has been used by McAuliffe (15) for the determination of phosphorus-32 in plant materials.

One ml. of each of the sera was added to 9 ml. of a 5 per cent solution of trichloracetic acid in a centrifuge tube. After mixing and centrifuging, a 1 ml. aliquot of the supernate was transferred to a calibrated digestion tube and digested as recommended by Fiske and Subbarow (14). The phosphorus-32 and total phosphorus concentrations were determined as described above.

The inorganic phosphorus concentration in each urine specimen was determined by an adaptation of the method of Fiske and Subbarow (14). The phosphorus-32 contents were assayed with the dipping G-M tube and scaler after suitable dilution of the urines with 0.1 N hydrochloric acid. Corrections for decay of radioactivity were made.

RESULTS

The Lack of Effect of Vitamin A When Given to Normal Weanling Rats on an Adequate Diet.—The 21-day-old stock rats, each of which received 2 mg. of vitamin A in ethyl laurate, apparently disposed of the concurrently administered sulfate as did their litter mates to whom only ethyl laurate was given. The sulfur-35 and inorganic sulfate levels in the sera, and the fractions of the dose of sulfur-35 which were excreted in the urines were similar. Vitamin A had no effect on the concentrations of sulfur-35 in the femurs, nor on the autographs produced by sections of tibiae. On microscopic examination of the tibial sections no effect of vitamin A on the epiphyseal cartilage was noted.

The Immediate Effects of Administering Vitamin A to Deficient Rats.— The sulfur-35 levels in the sera and the fractions of the dose of the isotope excreted in the urines in the second set of experiments were also similar whether the deficient animals were or were not given vitamin A. Between the 24th and 120th hour after administration of the vitamin, however, the concentration of inorganic sulfate-sulfur in the sera decreased from a value of about 2.5 mg. per cent to a value of about 1.8 mg. per cent. The value for the concentration of inorganic sulfate-sulfur in the sera of normal stock rats of the same age was found to be 2.0 $\pm$ 0.1 mg. per cent.

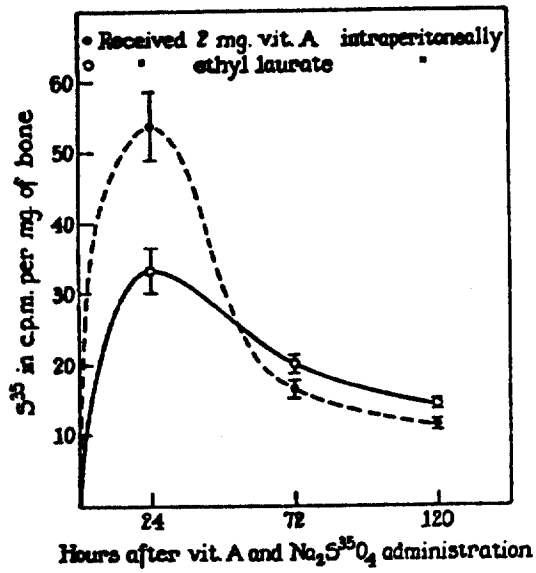

TEXT-FIG. 1. Effect of vitamin A on the disposition of sulfur-35 in the ends of femurs in vitamin A-deficient rats. Each rat received 0.5 μc. of carrier-free sulfur-35 as sodium sulfate per gm. of body weight at the same time that either ethyl laurate or 2 mg. of vitamin A in ethyl laurate were administered intraperitoneally. The standard deviation of each average value is indicated by a vertical bar.

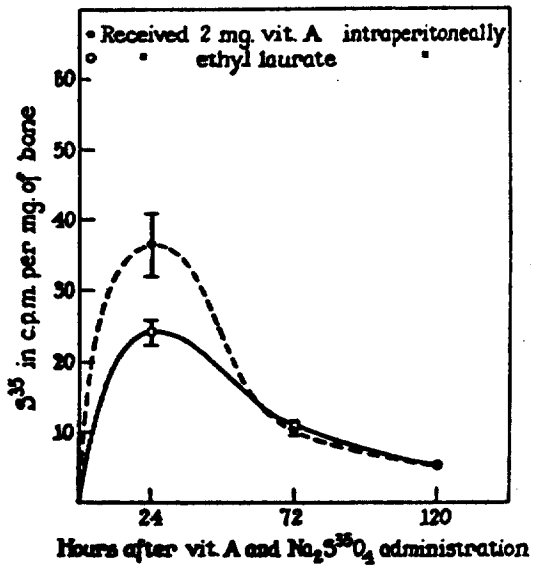

TEXT-FIG. 2. Effect of vitamin A on the disposition of sulfur-35 in the shafts of femurs in vitamin A-deficient rats. The legend under Text-fig. 1 also applies here.

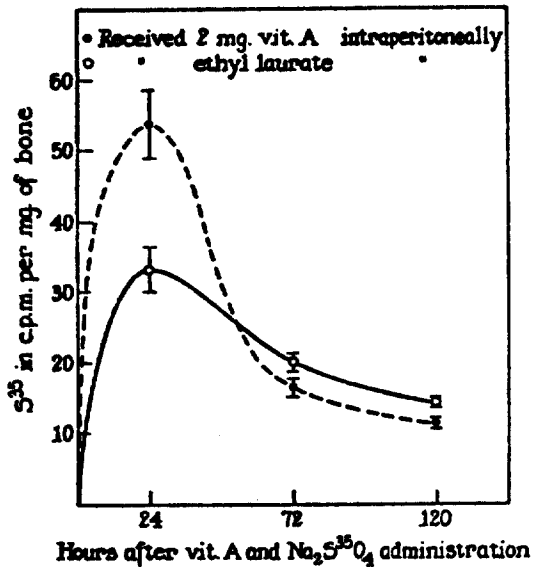

TEXT-FIG. 1. Effect of vitamin A on the disposition of sulfur-35 in the ends of femurs in vitamin A-deficient rats. Each rat received 0.5 μc. of carrier-free sulfur-35 as sodium sulfate per gm. of body weight at the same time that either ethyl laurate or 2 mg. of vitamin A in ethyl laurate were administered intraperitoneally. The standard deviation of each average value is indicated by a vertical bar.

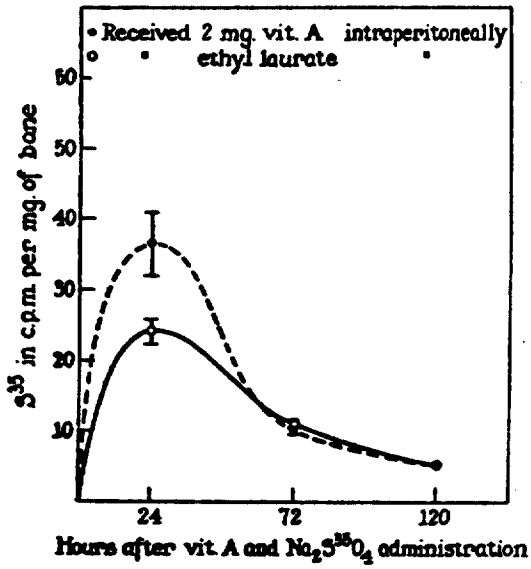

TEXT-FIG. 2. Effect of vitamin A on the disposition of sulfur-35 in the shafts of femurs in vitamin A-deficient rats. The legend under Text-fig. 1 also applies here.

The concentration of sulfur-35 in the femurs of vitamin A-treated rats was higher 24 hours after administration and subsequently decreased more rapidly than in the femurs of the untreated rats, Text-figs. 1 and 2.

In Table I are given the averaged concentrations of sulfur-35 found in the femoral ends and shafts of rats that received either vitamin A or only ethyl laurate 72 hours before administration of sulfur-35. It can be seen that in the 24 hours following injection of the isotope more of it was concentrated in the femurs of the rats pretreated with vitamin A than in the femurs of their untreated litter mates.

Radioautographs produced by sections of tibiae fixed in a solution of formaldehyde are shown as Figs. 1 through 8. It can be seen that the epiphyseal cartilage of the tibiae removed from rats 24 hours after the concurrent administration of vitamin A and sulfur-35, Fig. 1, elicited a stronger reaction on the photographic film than did the epiphyseal cartilage of the tibiae from the untreated rats, Fig. 5. The converse was observed in the case of the tibiae removed 72 and 120 hours after injection, compare Fig. 2 with 6 and Fig. 3 with 7, respectively. Similar results were obtained in radioautographs of the diaphyses.

TABLE I

Effect of Vitamin A on the Concentration of Sulfur-35, Administered as Sodium Sulfate, in Femurs of Vitamin A-deficient Rats

Tissue	A-deficient rats	A-deficient rats given vitamin A
	c.p.m./mg. of bone	*c.p.m./mg. of bone*
Femoral ends	36.9 ± 1.2	54.9 ± 2.4
Femoral shaft	29.3 ± 3.0	36.2 ± 2.4

After the rats had been maintained on a vitamin A-deficient diet for 42 days, some of the rats were given 2 mg. each of vitamin A in ethyl laurate and others were given ethyl laurate alone by intraperitoneal injection. 72 hours later each rat was given an intraperitoneal injection of carrier-free sulfur-35 as sodium sulfate in a dose of 0.5 μc. per gm. of body weight. The animals were sacrificed 24 hours later. The values in the table are averages and standard deviations for groups of 6 untreated and 7 treated rats.

It can also be seen that, in agreement with the data of Table I, the radioautographic image produced by sections of tibiae from rats given vitamin A 96 hours and sulfur-35 24 hours before sacrifice is darker, Fig. 4, than that produced by sections of tibiae from the untreated animals, Fig. 8. In addition, the epiphyseal plate of the tibiae was broader in those animals which had been given vitamin A.

Radioautographs produced by sections of tibiae fixed in a solution of formaldehyde saturated with barium hydroxide are shown as Figs. 9 through 16. In animals given vitamin A and labelled sulfate progressively more sulfur-35 was deposited at the epidiaphyseal junction than in the same region of the tibiae

from the untreated vitamin A-deficient rats, Figs. 9, 10, and 11 compared with Figs. 13, 14, and 15, respectively. The effect of vitamin A on the concentration of sulfur-35 in the tibiae is again indicated by a comparison of Fig. 12 with Fig. 16.

The Delayed Effects of a Single Dose of Vitamin A Given to Deficient Rats as Reflected in the Uptake of Sulfur-35.—Neither the level of total sulfur-35 in the sera nor the fraction of the dose of sulfur-35 excreted in the urine by the vitamin A-treated rats was strikingly different from the corresponding values for untreated rats. In contrast, the concentration of inorganic sulfate-sulfur in the serum was found to have decreased from an average of 2.5 mg. per cent to 1.9

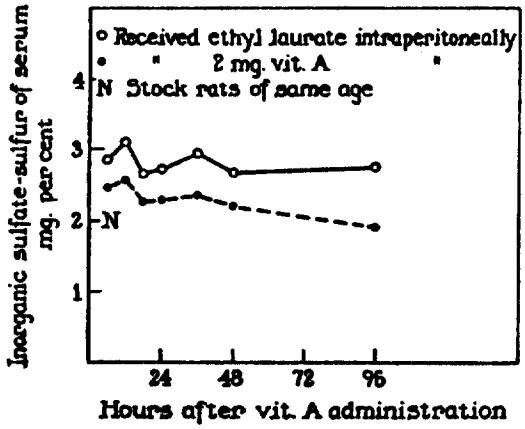

TEXT-FIG. 3. Effect of a single dose of vitamin A on the concentration of inorganic sulfate-sulfur in the sera of vitamin A-deficient rats. Each value is the average for a group of 4 or 5 rats. The abscissa indicates the time after vitamin A administration at which sulfur-35 was administered to the rats. For the purpose of obtaining data recorded in other figures the sera were collected 12 hours after injection of the isotope.

mg. per cent between the 18th and 108th hour after vitamin A administration, Text-fig. 3.

The concentration of sulfur-35 in the femoral ends but not in the femoral shafts was found to be affected by the prior administration of vitamin A, Text-figs. 4 and 5.

Radioautographs produced by sections of tibiae fixed in a solution of formaldehyde are shown as Figs. 17 through 24. It can be seen that sections of tibiae from the untreated animals produced radioautographs that were similar to those produced by sections of tibiae from vitamin A-treated animals if the animals were examined at the end of the 42 day depletion period, or shortly thereafter, compare Figs. 21 and 22 with Figs. 17 through 20. The magnitude of the radioautographic reaction was similar to that produced by sections of tibiae from normal stock rats of the same age. Continued maintenance of the untreated rats

on the deficient diet was reflected in the production by the epiphyseal cartilage plate of a radiographic image of diminished density and width, Figs. 23 and 24.

On examination of the radioautographs produced by the sections of tibiae fixed in a solution of formaldehyde saturated with barium hydroxide no difference was made out between those produced by the tibial sections from the vitamin A-treated or untreated rats.

The above data and those presented graphically in Text-fig. 6 show that the metabolism of chondroitin sulfate in the skeleton is under the influence of

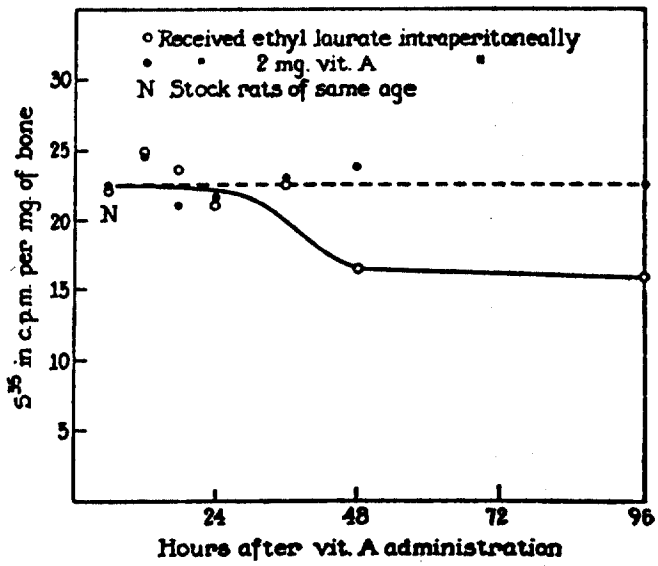

TEXT-FIG. 4. Effect of vitamin A on the concentration of sulfur-35 in the ends of femurs from vitamin A-deficient rats. Each rat received 0.3 μc. of carrier-free sulfur-35, as sodium sulfate, per gm. of body weight at intervals of time after the administration of vitamin A, (or of ethyl laurate only) as indicated on the abscissa. The animals were sacrificed 12 hours later. The values plotted are the averages obtained from 4 or 5 rats.

vitamin A, for the specific activity of the sulfur-35 in the chondroitin sulfate samples isolated from the skeletons is affected by the administration of this vitamin.

Vitamin A also exerts an influence on the metabolism of the sulfomucopolysaccharides of the rat skin as shown in Text-fig. 7, and it probably has an influence on the mucoitin sulfuric acid of the gastrointestinal tract since the respective specific activities of the samples isolated from the viscera of the untreated deficient rats, vitamin A-treated rats, and normal rats were found to be 85,300, 94,100, and 111,600-values which are significantly different.

The Delayed Effects of a Single Dose of Vitamin A Given to Deficient Rats as Shown in the Uptake of Phosphorus-32.—The concentrations of trichloracetic acid-soluble phosphorus and phosphorus-32 in the sera, and the values for the

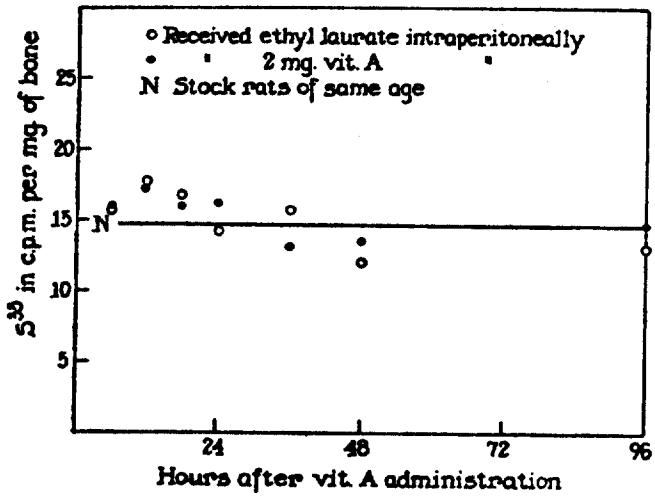

TEXT-FIG. 5. Effect of vitamin A on the concentration of sulfur-35 in the shafts of femurs from vitamin A-deficient rats. The legend under Text-fig. 4 also applies here.

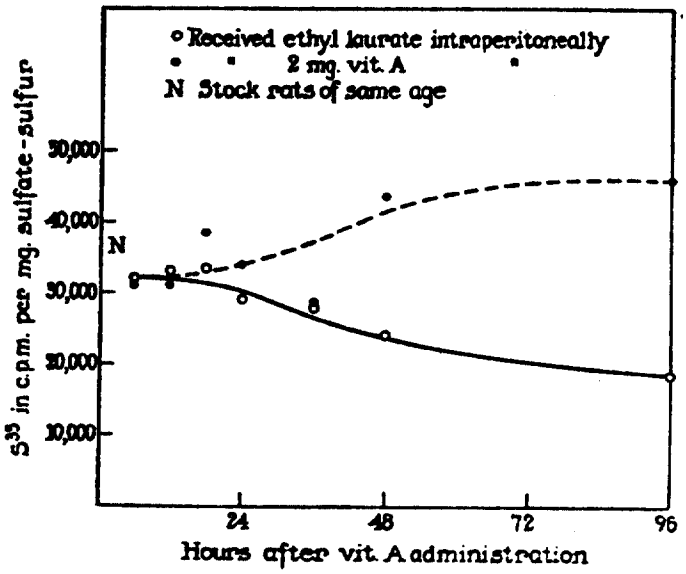

TEXT-FIG. 6. Concentration of sulfur-35 in chondroitin sulfate samples isolated from the skeletons of vitamin A-deficient rats. Each rat received by intraperitoneal injection 0.3 μc. of carrier-free sulfur-35, as sodium sulfate, per gm. of body weight at intervals of time after the administration of vitamin A (or of ethyl laurate only), as indicated on the abscissa. The animals were sacrificed 12 hours later. The isolated chondroitin sulfate samples resembled each other closely in composition. Their composition did, however, deviate from that usually ascribed to chondroitin sulfate. On analysis about 3 per cent of sulfate-sulfur, about 5 per cent of nitrogen, about 26 per cent of hexuronic acid, and about 30 per cent of hexosamine were found in these samples.

specific activity of the inorganic phosphorus fractions in the urines, were essentially the same in the deficient rats as in those which had been given vitamin A. The specific activity of the phosphorus-32 in the femoral ends and shafts of the rats given vitamin A 48 hours or more before administration of the labelled phosphate was found to be higher than that in the femurs of the untreated rats, Text-fig. 8, and approached the values found in the same regions of the femurs from normal rats of the same age on a stock diet, namely 10,000 and 4,200 C.P.M. per mg. of phosphorus in femoral ends and shafts, respectively. Not only

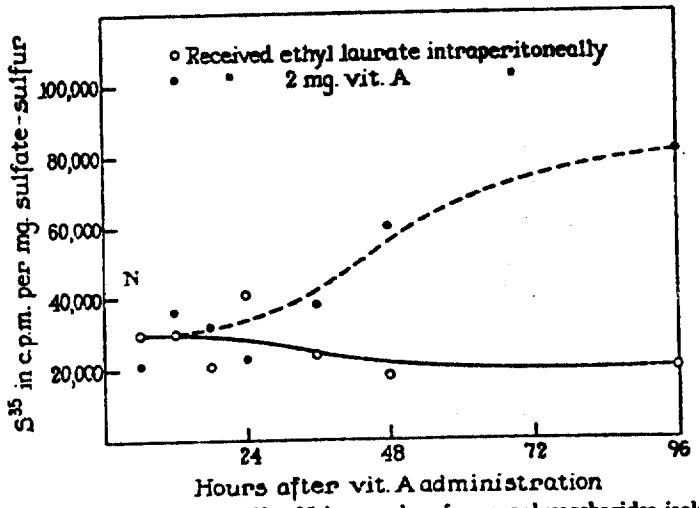

TEXT-FIG. 7. Concentration of sulfur-35 in samples of mucopolysaccharides isolated from the skins of vitamin A-deficient rats. Each rat received by intraperitoneal injection 0.3 μc. of carrier-free sulfur-35, as sodium sulfate, per gm. of body weight. The isotope was injected at intervals of time after the administration of vitamin A (or of ethyl laurate only). The time at which the isotope was administered is given on the abscissa. The animals were sacrificed 12 hours later. On analysis, the isolated mucopolysaccharide samples were shown to contain about 2 per cent of sulfate-sulfur, about 9 per cent of nitrogen, about 15 per cent of hexuronic acid, and about 18 per cent of hexosamine.

was more phosphorus-32 taken up by the femurs, the concentration of total phosphorus also rose: The concentrations of phosphorus in the femurs of the rats given vitamin A solution were found to be intermediate (4.50 and 6.75) between those of the vitamin A-deficient (3.70 and 6.10) and normal rats (5.42 and 8.02). The values are given as per cent of phosphorus in the ends and shafts, respectively, and in the case of the vitamin A-treated rats are the values found 108 hours after vitamin administration.

The radioautographic evidence for the effect of vitamin A on the deposition of phosphorus in the tibiae of vitamin A-deficient rats is reproduced in part in Figs. 25–32. It can be seen that sections of the tibiae removed from rats that had received the vitamin at least 48 hours before the labelled phosphate gave

more pronounced radioautographic reactions, Figs. 26 to 28, than did the sections of the tibiae either from animals given the phosphorus-32 sooner, Fig. 25, and from untreated vitamin A-deficient rats, Figs. 29 through 32.

The extent to which the sections stained with alizarin red was correlated with the density of the autographs they produced: an intense radioautographic reaction invariably accompanied a deep stain, particularly at the epidiaphyseal junction. It is of interest that in the third set of experiments an intensification of staining with alizarin red occurred also in the sections removed from the rats 36 to 48 hours after vitamin A administration.

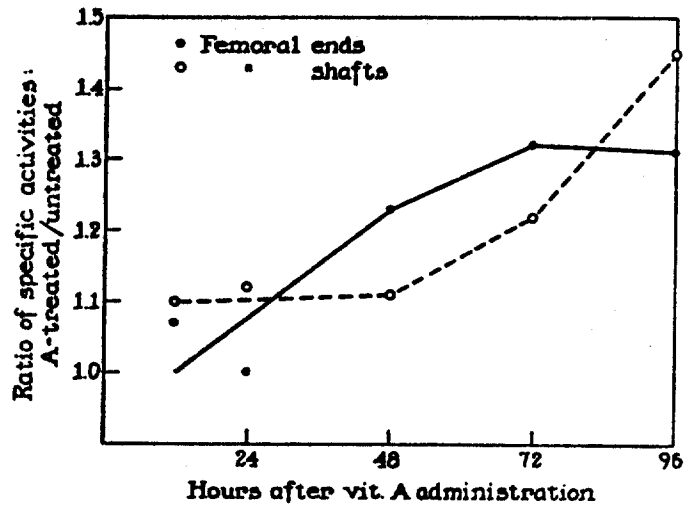

TEXT-FIG. 8. Effect of vitamin A on the concentration of phosphorus-32 in the femurs of vitamin A-deficient rats. Each rat received 1 μc. of carrier-free phosphorus-32, as disodium phosphate in water, per gm. of body weight. The isotope was injected intraperitoneally at intervals of time after the administration to each rat of 2 mg. of vitamin A in ethyl laurate (or of ethyl laurate only). The time at which the phosphorus-32 was administered is given on the abscissa. The animals were sacrificed 12 hours later. The concentrations of the phosphorus-32 in the femurs were calculated as specific activities (counts per minute per milligram of total phosphorus).

DISCUSSION

In regions where endochondral ossification occurs there is an arrangement of cartilage cells in rows parallel to the long axis of the bone. Prior to calcification the cartilage cells enlarge and then degenerate. The multiplication, maturation, and degeneration of the cells in the cartilage plate at epidiaphyseal junctions continues until growth in length of the bone is completed. Supposedly, a function of the cartilage cells is the elaboration of the matrix in which they are imbedded. Chondroitin sulfate is part of this matrix. Therefore, since there is in vitamin A deficiency, a characteristic arrest of this sequence of normal cellular maturation, one might find a decreased synthesis of chondroitin sulfate

in vitamin A-deficient animals as compared with that in normal or in deficient animals given vitamin A. The experiments detailed in this paper indicate that such a decreased synthesis of chondroitin sulfate actually occurs in vitamin A-deficient rats. Further, as a result of the administration of vitamin A the rate at which chondroitin sulfate is synthesized can be restored to, maintained at, or even increased above the rate of synthesis in normal rats. A depression in the synthetic mechanism was demonstrated only after the rats were unmistakably deficient, Text-figs. 4 and 6; at this stage the administration of vitamin A was promptly reflected in increased rate of uptake of S^{35}, (Text-fig. 2 and Figs. 1 and 5) presumably due to accelerated synthesis of chondroitin sulfate.

Vitamin A also influences the metabolism of phosphorus in the rat skeleton, Text-fig. 8 and Figs. 17 to 32. The uptake of phosphorus by femurs and tibiae of vitamin A-deficient rats was observed to be less than the uptake by these bones in normal rats. The administration of vitamin A to the animals was reflected in an unmistakably increased uptake of phosphorus in the skeleton, particularly in regions of most active calcification. This effect, however, was not apparent until about 48 hours after administration of the vitamin A.

One would like to compare the two sets of experiments in which sulfur-35 and phosphorus-32 were used under similar conditions. It would be of interest to know whether in the skeletons of animals deprived of vitamin A phosphorus metabolism is depressed before a decreased metabolism of sulfate occurs. The radioautographs reproduced in Figs. 17 to 32 and the radiochemical data, Text.-figs. 4 and 8, suggest that this is probably the case. The fact that the alizarin stained tibial sections from the third set of experiments resembled those in the fourth set gives further weight to this suggestion.

After the administration of vitamin A to deficient rats not only rate of synthesis but also the rate of degradation of chondroitin sulfate is accelerated, Text-figs. 1 and 2 and Figs. 1 to 16. In the photographs of Figs. 1 to 16 there is also a suggestion that the sulfur of chondroitin sulfate is deposited in the newly formed spongy bone as the latter replaces cartilage. The sulfur-35-containing material deposited in these recently calcified regions has not been identified; it is more soluble than chondroitin sulfate in a 3.7 per cent solution of formaldehyde but less soluble than the chondroitin sulfate in a 3.7 per cent solution of formaldehyde previously saturated with barium hydroxide.

Skin lesions have been reported as an early manifestation of vitamin A deficiency in experimental animals and in man (16–18). The sebaceous and sweat glands, the hair, and the nails are affected; the skin appears dry, scaly, and shrivelled. In this connection it is of interest that the rate at which sulfate-sulfur is incorporated into the sulfomucopolysaccharides of the skin of vitamin A-deficient rats is slightly lower than the rate of incorporation observed in normal rats, Text-fig. 7. Administration of vitamin A is followed by increase of the rate to that in normal rats or even to a rate above normal.

SUMMARY

The administration of vitamin A to vitamin A-deficient rats resulted in a decreased concentration of inorganic sulfate-sulfur in the serum from a value of 2.5 mg. per cent to 1.8 mg. per cent, the latter being close to the value of 2.0 mg. per cent found in normal rats of the same age.

The uptake of sulfate and phosphate by femurs and tibiae of vitamin A-deficient rats was less than that in normal rats of the same age. An increased uptake followed the administration of vitamin A: radioautography indicated that in the case of sulfate, its uptake was particularly increased in the epiphyseal cartilage; an increased uptake of phosphate was particularly evident in the diaphysis immediately adjacent to the epiphyseal cartilage plate.

The specific activity of the sulfate-sulfur in the chondroitin sulfate samples isolated from the skeletons of vitamin A-deficient rats fell progressively as the deficiency continued. Following administration of vitamin A, the specific activity approached and exceeded the value given by the sample from the skeletons of normal rats of the same age.

A substantial increase was found in the value of the specific activity of the sulfate-sulfur of sulfomucopolysaccharides isolated from skins of vitamin A-deficient rats that had been given vitamin A.

Following administration of vitamin A to rats deficient in this vitamin, an increased accumulation of some sulfur-containing material was found in regions of active calcification.

BIBLIOGRAPHY

1. Mellanby, E., *Proc. Roy. Soc. London, Series B*, 1945, **132**, 28.
2. Wolbach, S. B., *J. Bone and Joint Surg.*, 1947, **29**, 171.
3. Wolbach, S. B., and Maddock, C. L., *Proc. Soc. Exp. Biol. and Med.*, 1951, **77**, 825.
4. Dziewiatkowski, D. D., *J. Exp. Med.*, 1954, **99**, 283.
5. Denis, W., *J. Biol. Chem.*, 1910, **8**, 401.
6. Dziewiatkowski, D. D., *J. Exp. Med.*, 1951, **93**, 451.
7. Dahl, L. K., *Proc. Soc. Exp. Biol. and Med.*, 1952, **80**, 474.
8. Boström, H., *J. Biol. Chem.*, 1952, **196**, 477.
9. Dziewiatkowski, D. D., *J. Exp. Med.*, 1953, **98**, 119.
10. Methods for Medical Laboratory Technicians, TM 8-227-AFM 160-14, Washington, D. C., United States Government Printing Office, 1951, 212.
11. Dische, Z., *J. Biol. Chem.*, 1947, **167**, 189.
12. Einbinder, J., and Schubert, M., *J. Biol. Chem.*, 1950, **185**, 725.
13. Sörensen, M., *Compt.-rend. trav. Lab. Carlsberg, Chim.*, 1938, **22**, 487.
14. Fiske, C. H., and Subbarow, Y. P., *J. Biol. Chem.*, 1925, **66**, 375.
15. McAuliffe, C., *Anal. Chem.*, 1949, **21**, 1059.
16. Nicholls, L., *Indian Med. Gaz.*, 1933, **68**, 681.
17. Nicholls, L., *Indian Med. Gaz.*, 1934, **69**, 241.
18. Frazier, C. N., and Hu, C. K., *Arch. Dermatol. and Syphilol.*, 1936, **33**, 825.

EXPLANATION OF PLATES

PLATE 3

Radioautographs produced by sections of the proximal ends of tibiae fixed for 48 hours at 25°C. in a 3.7 per cent solution of formaldehyde (Figs. 1 through 8) or in a 3.7 per cent solution of formaldehyde previously saturated with barium hydroxide (Figs. 9 through 16). Kodak contrast process film was exposed to the sections for 2 and 4 weeks, respectively. Each of the rats received 0.5 μc. of sulfur-35 as sodium sulfate per gm. of body weight.

FIGS. 1, 2, and 3. Photographs of radioautographs produced by sections of tibiae removed from vitamin A-deficient rats 24, 72, and 120 hours after the concurrent intraperitoneal injection of 2 mg. of crystalline vitamin A in ethyl laurate and sulfur-35. × 3.7.

FIGS. 5, 6, and 7. To be compared with Figs. 1, 2, and 3, respectively. They are from vitamin A-deficient rats that received concurrently injections of ethyl laurate and sulfur-35. × 3.7.

FIGS. 4 and 8. Photographs of radioautographs produced by sections of tibiae from vitamin A-deficient rats 24 hours after the intraperitoneal injection of sulfur-35. In one case (Fig. 4) 2 mg. of vitamin A in ethyl laurate and in the other (Fig. 8) only ethyl laurate was injected 72 hours before administration of the isotope. × 3.7.

FIGS. 9, 10, and 11. Photographs of radioautographs produced by sections of tibiae removed from vitamin A-deficient rats 24, 72, and 120 hours after the concurrent intraperitoneal injection of 2 mg. of crystalline vitamin A in ethyl laurate and sulfur-35. × 3.7.

FIGS. 13, 14, and 15. To be compared with Figs. 9, 10, and 11, respectively. The former are from the vitamin A-deficient rats that were given ethyl laurate only and sulfur-35. × 3.7.

FIGS. 12 and 16. Photographs of radioautographs produced by sections of tibiae from vitamin A-deficient rats 24 hours after the intraperitoneal injection of sulfur-35. 2 mg. of vitamin A in ethyl laurate were given in one case (Fig. 12) and only the ethyl laurate in the other, 72 hours before administration of the isotope. × 3.7.

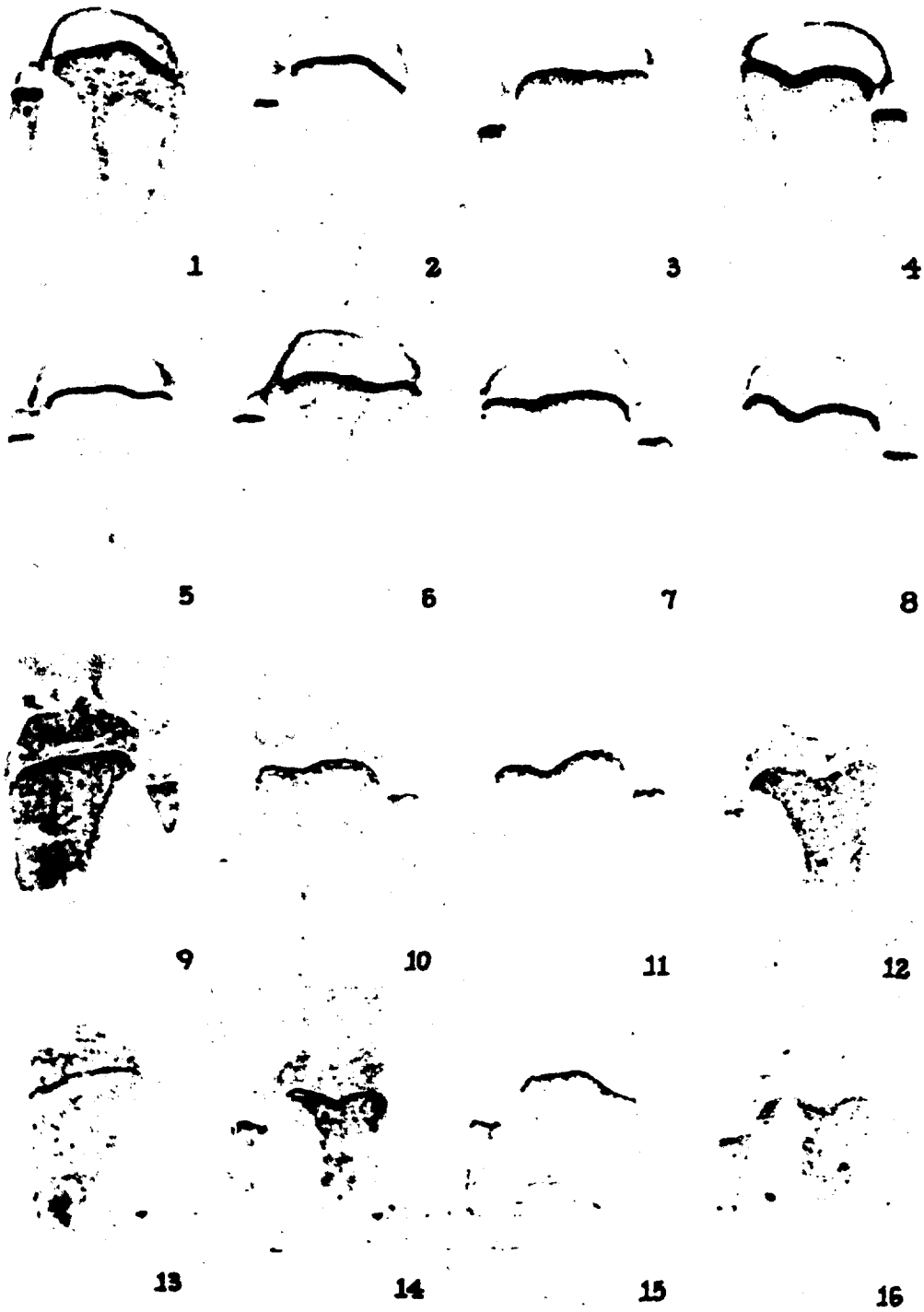

(Dziewiatkowski: Vitamin A and endochondral ossification)

Ershoff-57
Bib. No. 2554

Proc. Soc. Exp. Biol. Med. 95:660-664. 1957.

Reproduced by permission
of the copyright owner

Effects of Flavonoids on Response of Rats Fed Massive and Suboptimal Doses of Vit. A.* (23320)

BENJAMIN H. ERSHOFF
Department of Biochemistry and Nutrition, University of S. California, Los Angeles

Prolonged ingestion of massive doses of vit. A results in growth retardation, spontaneous leg fractures, paralysis and other toxic manifestations including death in the immature rat, the severity of symptoms and their rapidity of onset being proportional to dosage of vit. A administered(1-3). A vit. A intake of 10,000 to 12,500 U.S.P. units/day results in a significant retardation in growth; the dosage required to produce more severe symptoms (including leg fractures) in immature rats has generally been found to range from 25,000 to 50,000 U.S.P. units of vit. A/day. In the present communication data are presented indicating that administration of bioflavonoids significantly affects the physiologic response to massive but relatively non-toxic doses of vit. A in the immature rat.

Procedure. The basal flavonoid-free diet employed consisted of sucrose, 66%; casein,† 24%; salt mixture,‡ 5%; and corn oil, 5%. To each kg of above diet were added the following crystalline vitamins: thiamine hydrochloride, 10 mg; riboflavin, 10 mg; pyridoxine hydrochloride, 10 mg; calcium pantothenate, 60 mg; nicotinic acid, 100 mg; ascorbic acid, 200 mg; biotin, 4 mg; folic acid, 10 mg; para-aminobenzoic acid, 400 mg; inositol, 800 mg; vit. B_{12}, 150 μg; 2-methylnaphthoquinone, 5 mg; choline chloride, 2 g; vit. A, 5000 U.S.P. units; vit. D_2, 500 U.S.P. units; and alpha-tocopherol acetate, 100 mg. The vitamins and the various test additives were incorporated in the basal diet in place of an equal amount of sucrose. Diets were made up weekly and stored under refrigeration when not in use. The animals were fed daily and all food not consumed 24 hours after feeding was discarded. The rats were housed in metal cages with raised screen bottoms (2 or 3 animals/cage) and were provided with food and water *ad libitum*. Feeding was continued for 6 weeks or until death, whichever occurred sooner.

Results. Exp. 1. Two hundred and forty-seven female rats of the Holtzman strain were selected at an average weight of 49.2 g (range 44 to 52 g). Animals were divided into 26 comparable groups. One group was fed the basal diet; the remaining groups were fed the basal diet with supplements listed in Table I. The ingestion of a purified ration containing 3.75 million U.S.P. units of vit. A palmitate/kg of diet resulted in a significant retardation in growth and occurrence of spontaneous leg fractures in the immature rat. These symptoms of hypervitaminosis A were accentuated by the concurrent feeding of flavonoids (calcium flavonate glycoside, naringen, hesperidin complex, hesperidin methyl chalcone, lemon bioflavonoid complex or rutin) at levels of 0.5, 1 or 2% of diet. This was evidenced by the following criteria: (a) weight increment of rats fed the above flavonoids in conjunction with the vit. A supplement was significantly less than that of rats fed the vit. A supplement alone, (b) 90 to 100% of the rats fed both the flavonoid and vit. A supplements developed leg fractures in contrast to an incidence of 39% in animals fed the vit. A supplement alone, and (c) 50 to 100% of rats fed flavonoids in conjunction with the vit. A supplement succumbed during the 6 week experimental period in contrast to 0% mortality in animals fed the vit. A supplement alone. In general the effects of the flavonoids in accentuating symptoms of hypervitaminosis A were as marked when fed at a 0.5% level in the diet as when they were fed at higher levels. When the flavonoids were incorporated at 2% level in the basal diet (without the vit. A supple-

* Communication No. 432 from Department of Biochemistry and Nutrition, Univ. of So. California. This investigation was supported in part by grant-in-aid from Sunkist Growers, Ontario, Calif.

† Vitamin-free Test Casein, General Biochemicals, Chagrin Falls, O.

‡ Hubbel, Mendel and Wakeman Salt Mixtures, General Biochemicals, Chagrin Falls, O.

TABLE I. Effects of Flavonoids on Symptoms of Hypervitaminosis A in the Immature Rat.*

Supplements fed with basal diet	No. of animals	Initial wt (g)	Body wt (g) after following days of feeding† 21st	42nd	% of rats with fractures	% surviving	Avg survival time of decedents (days)
None	7	49.0	133 (7)	173 (7)	0	100	
1% calcium flavonate glycoside	7	49.2	115 (7)	160 (7)	0	100	
1% naringen	7	49.2	122 (7)	162 (7)	0	100	
1% hesperidin complex	7	49.2	131 (7)	172 (7)	0	100	
1% hesperidin methyl chalcone	7	49.2	123 (7)	167 (7)	0	100	
1% lemon bioflavonoid complex	7	49.0	132 (7)	167 (7)	0	100	
1% rutin	7	49.2	130 (7)	171 (7)	0	100	
1.75 million units vit. A palmitate/kg of diet	18	49.1	106 (18)	131 (18)	39	100	
Idem + following supplements:							
.5% calcium flavonate glycoside	10	49.2	76 (10)	83 (4)	100	40	31
1 % *Idem*	10	49.1	73 (10)	61 (2)	100	20	34
2 % "	10	49.0	78 (8)	72 (1)	100	10	30
.5% naringen	10	49.3	68 (7)		100	0	26
1 % "	10	49.4	73 (6)	81 (1)	100	10	25
2 % "	10	49.4	72 (5)	76 (1)	100	10	22
.5% hesperidin complex	10	49.3	77 (6)	84 (2)	90	20	26
1 % *Idem*	10	49.2	75 (8)	79 (2)	100	20	28
2 % "	10	49.2	78 (9)	81 (5)	100	50	32
.5% hesperidin methyl chalcone	10	49.2	67 (7)		100	0	27
1 % *Idem*	10	49.2	61 (8)		100	0	27
2 % "	10	49.3	61 (6)		100	0	22
.5% lemon bioflavonoid complex	10	49.3	64 (8)	52 (2)	100	20	25
1 % *Idem*	10	49.4	61 (8)		100	0	26
2 % "	10	49.3	67 (9)		100	0	25
.5% rutin	10	49.4	57 (7)		100	0	22
1 % "	10	49.4	49 (2)		100	0	19
2 % "	10	49.3	57 (9)		100	0	25

* The calcium flavonate glycoside, naringen, hesperidin complex, hesperidin methyl chalcone and lemon bioflavonoid complex employed were kindly provided by Mr. W. E. Baier of Sunkist Growers, Ontario, Calif. Vit. A supplement was Synthetic Vit. A Palmitate in Corn Oil (1 million U.S.P. units/g), obtained from Hoffmann-La Roche, Nutley, N. J.

† Values in parentheses indicate No. of animals which survived and on which averages are based.

ment). no deleterious effects were observed on any of the rations in respect to weight increment, gross appearance, incidence of fractures or per cent survival.

Exp. 2. In Exp. 1 data were obtained on the effects of flavonoids on the response of rats administered excessive amounts of vit. A. The following experiment was undertaken to determine the effects of flavonoids on vit. A-depleted rats fed suboptimal amounts of this vitamin. The animals employed were female rats of the Univ. of S. California strain in which the dietary regime of mother rats was such as to make the young rats satisfactory for bioassay studies for vit. A. The mother rats were maintained for at least 2 months previous to breeding and for 7 days after birth of the litter on Sherman diet B(4) without addition of supplementary lettuce or meat. Litters were reduced to 7 at 3 days of age, and on the 7th day mothers and litters were placed on vit. A-free, flavonoid-free diet identical to basal diet employed in Exp. 1 except that the vit. A was omitted from this ration. The young rats were weaned at 21 days of age and were continued on the above

diet until they were depleted of vit. A. The end of depletion period was set as 5th day on which rats on the vit. A-free, flavonoid-free diet showed stationary or decreasing weight. The average time of depletion was 21 days after weaning (range 18 to 23 days); and average body weight at time of depletion was 91 g (range 68 to 115 g). On the day of depletion animals were divided into 8 comparable groups of 10 rats each. Four groups were fed vit. A-free, flavonoid-free diet indicated above supplemented with (1) 0, (2) 100, (3) 250, and (4) 1000 U.S.P. units of vit. A palmitate/kg of diet. The remaining 4 groups were fed diets identical with the 4 rations indicated above but containing in addition 5 g of hesperidin complex and 5 g of lemon bioflavonoid complex/kg of diet. The flavonoids were added in place of an equal amount of sucrose. Animals were placed in metal cages with raised screen bottoms and were fed the above diets *ad libitum* for 28 days or until death, whichever occurred sooner.

All rats fed the vit. A-free diet either with or without the flavonoids succumbed after an average survival of 7 to 8 days (range 4 to 16 days). All rats fed vit. A-free diet supplemented with 100 U.S.P. units of vit. A palmitate/kg of diet either with or without the flavonoids also succumbed within 28 days. Average survival time on the non-flavonoid diet was 14 days, whereas average length of survival on the flavonoid-containing ration was 12 days. At higher levels of vit. A intake, however, the flavonoids exhibited a highly significant effect. Only 2 of the 10 rats fed the non-flavonoid ration supplemented with 250 U.S.P. units of vit. A/kg of ration survived the experimental period of 28 days (average weight increment of the 2 survivors was 29 g). In contrast 8 of the 10 rats fed the flavonoid-containing ration at the same level of vit. A supplementation survived (average weight increment of the 8 survivors was 25 g). Of the rats fed 1000 U.S.P. units of vit. A/kg of ration, 8 of the 10 rats in the non-flavonoid group survived with average weight increment of 47 ± 2.4 g.§ Of rats fed the same level of vit. A in presence of flavonoids, 9 out of 10 survived with average weight increment of 69.4 ± 5.0 g.§ It is apparent from these findings that supplements of hesperidin complex and lemon bioflavonoid complex when fed at 0.5% level in the diet were without significant effect when fed with rations containing 100 U.S.P. units of vit. A or less/kg of ration but significantly increased both the number of animals surviving and the average increment in body weight of vit. A-depleted rats fed diets containing 250 and 1000 U.S.P. units of vit. A respectively/kg of diet. It would seem from these findings that the above flavonoids were active in increasing absorption and/or utilization of vit. A not only when this vitamin was present in excess (Exp. 1) but under conditions of suboptimal intake as well.

Discussion. Present findings indicate that flavonoids can significantly affect the response of immature rats fed purified rations containing either excessive or suboptimal amounts of vit. A. When immature rats were fed flavonoid-free diets containing massive but relatively non-toxic doses of vit. A, supplements of calcium flavonate glycoside, naringen, hesperidin complex, hesperidin methyl chalcone, lemon bioflavonoid complex or rutin resulted in a striking accentuation of the symptoms of hypervitaminosis A. This was evidenced by a more pronounced retardation in growth, a higher incidence of spontaneous leg fractures and a significantly greater mortality in rats fed the flavonoid-containing rations than in those fed similar diets with the flavonoids omitted. These symptoms were identical in appearance, time of onset, severity and incidence to those of rats fed the flavonoid-free diet supplemented with amounts of vit. A considerably in excess of the amounts present in above rations. Supplements of hesperidin complex and lemon bioflavonoid complex also significantly increased both the number of animals surviving and the average increment in body weight of vit. A-depleted rats fed diets containing 250 and 1000 U.S.P. units of vit. A respectively/kg of diet. These find-

§ Including standard error of mean calculated as follows: $\sqrt{\frac{\Sigma d^2}{n}} / \sqrt{n}$ where "d" is deviation from the mean and "n" is number of observations.

ings suggest that the above flavonoids may have promoted an increased absorption and/or utilization of vit. A. That unidentified factors exist in natural foodstuffs which promote utilization of vit. A has been reported by a number of investigators. Palm kernel meal(5,6), coconut cake(5,6), acetone-extracted herring roe(5,6), soybean lecithin (7,8), yeast(9), fish solubles(10,11), alfalfa and other succulent plants(12), liver(12) and other substances including the tocopherols(13-15), xanthophyll(16), aureomycin(17,18) and DPPD(19,20) have all been shown to improve vit. A utilization as judged by various indices in experimental animals. Present findings indicate that the flavonoids also have significant activity in this regard and suggest that the activity of at least some of the natural foodstuffs indicated above may have been due, at least in part, to their flavonoid content.

No data are available to indicate the mechanism(s) whereby the flavonoids indicated above exert their physiologic effects. The possibility that the flavonoids are functioning as antioxidants that prevent destruction of vit. A in the diet and hence leave more vitamin present for absorption appears to be ruled out by chemical tests which indicate that no detectable destruction of vit. A occurred in the purified basal diet supplemented with 2.5 million U.S.P. units of vit. A palmitate/kg of ration after 30 days of refrigeration. Under conditions of our experiment, diets were made up at weekly intervals and were consumed within 10 days of the time they were made. In addition no significant difference in response occurred between rats fed the above ration and animals fed an identical diet which was made up daily immediately before feeding. Flavonoids, however, can function not only as *in vitro* antioxidants (21) but in the intact animal as well(22,23). Hence further studies are indicated to determine to what extent the effects of flavonoids in modifying the response to vit. A feeding under conditions of our experiment were due to their function as biological antioxidants which protected vit. A from destruction in the intestinal tract and/or the animals' own tissues. It must be emphasized that the effects of the flavonoids in accentuating symptoms of hypervitaminosis A in the rat occurred with diets containing approximately 2000 to 3000 times the amount of vit. A required for optimal growth, breeding and longevity as determined by Sherman and co-workers(24,25). Preliminary findings indicate that with diets containing smaller amounts of this nutrient (up to 1000 times the optimal vit. A intake) the flavonoids did not accentuate symptoms of hypervitaminosis A. In view of these findings the possibility that flavonoids might induce symptoms of hypervitaminosis A in man even when fed with large therapeutic doses of this nutrient would appear to be extremely remote. On the contrary present findings indicate that flavonoids may play an important role in the treatment of vit. A deficiency states, not only those arising from the ingestion of diets deficient in this vitamin but those resulting from impaired absorption or utilization of this nutrient as well.

Summary. Supplements of calcium flavonate glycoside, naringen, hesperidin complex, hesperidin methyl chalcone, lemon bioflavonoid complex or rutin at levels of 0.5 to 2% of the diet significantly increased the vit. A utilization of immature rats fed massive doses of this vitamin. Flavonoids also increased the apparent utilization of this nutrient in vitamin A-depleted rats fed suboptimal amounts of vit. A.

1. Rodahl, K., *Norsk Polarinstitutts Skrifter* No. 95, 1950.

2. Nieman, C., and Klein Obbink, H. J., *Vitamins and Hormones,* 1954, v12, 69.

3. Rodahl, K., *J. Nutrition,* 1950, v41, 399.

4. Sherman, H. C., and Campbell, H. L., *J. Biol. Chem.,* 1924, v60, 5.

5. Teinsh, P., and Wilkinson, H., *Chemistry and Industry,* 1939, v58, 1051.

6. Gridgeman, N. T., Lees, H., and Wilkinson, H., *J. Trans. Soc. Chem. Ind.,* 1940, v59, 120.

7. Slanetz, C. A., and Scharf, A., PROC. SOC. EXP. BIOL. AND MED., 1943, v53, 17.

8. ———, *J. Nutrition,* 1945, v30, 239.

9. Patrick, H., and Morgan, C. L., *Science,* 1943, v98, 434.

10. Harms, R. H., Camp, A. A., Reed, B. L., Grant, E. L., Creech, B. G., and Couch, J. R., *Poul-*

try Sci., 1956, v35, 285.

11. Harms, R. H., Reed, B. L., and Couch, J. R., *ibid.*, 1956, v35, 1254.

12. Ershoff, B. H., Hernandez, H. J., and Muckenthaler, J. M., *J. Nutrition,* 1957, v62, 527.

13. Moore, T., *Biochem. J.*, 1940, v34, ii, 1321.

14. Davies, A. W., and Moore, T., *Nature,* 1941, v147, 794.

15. Hickman, K. C. D., Kaley, M. W., and Harris, P. L., *J. Biol. Chem.*, 1944, v152, 303, 313, 321.

16. Sherman, W. C., *Fed. Proc.*, 1947, v6, 290.

17. Murray, T. K., and Campbell, J. A., *J. Nutrition,* 1955, v57, 89.

18. ———, *ibid.*, 1955, v57, 101.

19. Matterson, L. D., Bunnel, R. H., Stinson, L. D., Singsen, E. P., and Potter, L. M., *Poultry Sci.*, 1951, v34, 1080.

20. Monson, W. J., Gade, E. T., Lloyd, M. D., and Groschke, A. C., *ibid.*, 1957, v36, 166.

21. Clark, W. G., and Geissman, T. A., *Biological Antioxidants, Trans. of 3rd Conf. Josiah Macy, Jr. Fn.*, N. Y., 1948, 92.

22. Cruz-Coke, E., and Reyes, M. P., *Bull. Soc. biol. Santiago, Chile,* 1947, v4, 10.

23. ———, *Bull. Soc. chim. biol.*, 1947, v29, 573.

24. Sherman, H. C., and Campbell, H. L., *Proc. Nat. Acad. Sci. U. S.*, 1945, v31, 164.

25. Sherman, H. C., and Trupp, H. Y., *J. Nutrition,* 1949, v37, 467.

Received May 3, 1957. P.S.E.B.M., 1957, v98.

Fell-'52
Bib. No. 2675

Reproduced by permission
of the copyright owner

Reprinted with the
permission of the copyright owner,
Cambridge University Press

J. Physiol. (1952) 116, 320–349

THE EFFECT OF HYPERVITAMINOSIS A ON EMBRYONIC LIMB-BONES CULTIVATED *IN VITRO*

By HONOR B. FELL (Foulerton Research Fellow, Royal Society)
AND E. MELLANBY, F.R.S.

From the Strangeways Research Laboratory, University of Cambridge, and the Nutrition Building, National Institute for Medical Research, London, N.W. 7

(*Received* 10 *October* 1951)

Experiments on young animals have shown (Mellanby, 1938, 1939, 1944, 1947) that vitamin A determines the shape and texture of certain bones by controlling the position of the osteoblasts and osteoclasts of periosteal bone and the intensity of their activity. Both deficiency and excess of the vitamin cause severe changes in the skeleton, though the way in which the vitamin acts remains obscure.

Some years ago a method was developed for cultivating early bone rudiments *in vitro* (Fell & Robison, 1929; Fell, 1951); the explants grew and continued to differentiate *in vitro* in a surprisingly normal way. It occurred to Mellanby (1944) that such bone cultures might be used to study the action of vitamin A on skeletal tissue and especially to decide whether the action was a direct one. The method of cultivating organized tissues *in vitro* may be a valuable adjunct to animal experiments because of the great simplification of experimental conditions which it provides. *In vitro* there are no vascular or nervous systems, and the influence of other organs is completely eliminated; thus any effect produced by a chemical agent *in vitro* must be due to its direct action on the tissue. Also the experimental conditions can be widely varied at will and are more easily controlled in a tissue culture than in the body; the technique has the further advantage that the living explants can be observed under the microscope whenever desired. It was therefore decided to undertake experiments on the effects of hypervitaminosis A on embryonic long bones cultivated *in vitro* by the watch-glass method.

In the living animal, hypervitaminosis A renders the long bones fragile, so that they sometimes suffer spontaneous fracture. This has often been observed in young rats fed on a diet containing an excessive quantity of vitamin A

(Collazo & Rodriguez, 1933; Bomskov & Seemann, 1933; Davies & Moore, 1934; Strauss, 1934; Van Metre, 1947; and many others). The same effect may also be produced by large doses of pure vitamin A (Wolbach & Bessey, 1942; Moore & Wang, 1943, 1945; Herbst, Pavcek & Elvehjem, 1944; Pavcek, Herbst & Elvehjem, 1945).

These gross effects of hypervitaminosis A are associated with drastic histological changes. Strauss (1934) observed retardation of osteogenesis, reduction of endochondral ossification and a variable degree of osteoclasis in the region of the fractures. Irving (1949) described rarefaction and reduced deposition of bone in the mandible of young rats. Wolbach & Bessey (1942) and Wolbach (1947) showed that in the limb bones of young rats and guinea-pigs the maturation and degeneration of the cartilage cells and the replacement of cartilage by bone were greatly accelerated and resulted in the abnormally early closure of the epiphyses. The fractures appeared to be due to 'the extensive loss of previously formed cortical bone before the newly deposited bone has acquired firmness sufficient to meet mechanical requirements' (Wolbach, 1947).

Whether the changes resulting from hypervitaminosis A were due to a direct action of the vitamin on the bone or to an indirect action through the endocrine glands, was uncertain. Recently, Barnicot (1950) has approached this problem by grafting experiments. Fragments of crystalline vitamin A acetate were attached to small pieces of parietal bone from 10-day mice and the combination was inserted into the cerebral hemispheres of litter-mates. When the grafts were removed 7–14 days later, advanced absorption accompanied by many osteoclasts was found, sometimes causing perforation of the bone. In Barnicot's experiments a direct action of vitamin A on the bone seems to have been clearly demonstrated, but the conditions were not wholly comparable with those in a hypervitaminotic animal. In the grafts the bone was in direct contact with a solid mass of vitamin, whereas in the hypervitaminotic animal it is only exposed to the relatively minute concentration present in the blood stream.

The experiments described below were undertaken to see whether the vitamin in concentrations similar to those in the blood of animals suffering from hypervitaminosis A had a direct effect on skeletal tissues and, if so, to learn something about the nature of its action. Two groups of experiments were made, one on the limb-bone rudiments from 5- to 6-day chick embryos to study the effect of hypervitaminosis A on the differentiation of bone and cartilage, and the other on late foetal mouse bones, to investigate the effect on bones which were already highly differentiated at the time of explantation. A comparison was also made of the effects of 'artificial' hypervitaminosis A produced in the culture medium by adding vitamin A alcohol or acetate to normal plasma, and of 'natural' hypervitaminosis, obtained by using plasma

drawn from a fowl suffering from hypervitaminosis A. A short preliminary account of the experiments on mouse bones has already been published (Fell & Mellanby, 1950).

TECHNIQUE

The explants

Chick. Chick embryos were removed from the egg after 5–6 days' incubation and the limb buds cut from the trunk. In the younger embryos (Exp. 48, Table 1) individual bone rudiments were not yet distinguishable and the axial core of procartilage was isolated and explanted whole; in the older embryos, the humerus, radius and ulna from the wing and the femur and tibia from the leg were explanted separately.

Mouse. Mouse bones were obtained from foetuses of about 17–20 days' gestation. The radius, ulna, tibia and fibula were cultivated; the humerus and femur were too bulky.

The culture medium

Embryo extract. The extract was made from chick embryos of 12–14 days' incubation. By drastic mincing and grinding, the embryo was reduced to a very fine, slimy pulp which was mixed with an equal volume of a modified Tyrode's solution (see below) and centrifuged for not more than 5 min. This produced a yellowish, rather turbid, fluid which was freshly prepared for each subculture.

The modified Tyrode's solution, mentioned above, contained 0·2% calcium glycerophosphate and the glucose content was raised to 1% for the experiments on chick bones and for Exp. 51 on mouse bones, and to 4% for all the other experiments on mouse bones. In Exp. 2 the extract was made with ordinary Tyrode.

The vitamin A content of the embryo extract was estimated and found to be low, viz. 130 i.u./100 ml.

Preparation of plasma. The syringes were sterilized by heating in oil and were then cooled to 4° C. Three ml. of Ringer's solution containing 10 i.u. heparin/ml. was first drawn into the syringe after which blood was drawn from a wing vein so that the volume was 30 ml. The contents of the syringe were gently mixed and then centrifuged, giving about 20 ml. of plasma.

'Artificial' hypervitaminotic plasma (AH plasma). This description refers to fowl plasma to which vitamin A had been added directly. In some experiments vitamin A alcohol was used and in others vitamin A acetate.

When vitamin A alcohol was added, a sample of avoleum containing 1,500,000 i.u. vitamin A/g. was dissolved in absolute alcohol to give a solution containing about 20,000 i.u./ml. The alcoholic solution was then added to normal plasma to raise the vitamin A content to the desired amount. The strength of the alcoholic solution of vitamin A was such, that the final plasma contained about 1% ethanol in the earlier experiments and 0·2% or less in the rest. When vitamin A acetate was added, the crystalline substance was dissolved in absolute alcohol to give amounts similar to those obtained with vitamin A alcohol. In each experiment, the same quantity of ethanol was added to the normal (control) plasma as to the AH plasma.

'Natural' hypervitaminotic plasma (NH plasma). This denotes plasma obtained from a fowl suffering from hypervitaminosis A.

All fowls were given a diet containing much cabbage, together with pellets said to be sufficient for the normal feeding of these birds. In addition the hypervitaminosis A fowls were given 3 g. of avoleum by tube directly into their beaks (1 g. at each of the following times: 9 a.m., 2 p.m. and 5 p.m.) and 2 g. in the food. Each gram of avoleum contained 30,000 i.u. of vitamin A, so that each fowl was given 150,000 i.u. per diem.

At the end of a fortnight, or longer, the vitamin A supplement was stopped and the next morning the blood was withdrawn from the vein. In view of recent observations, the desired hypervitaminosis A might have been more rapidly obtained if the vitamin A oil had been first emulsified and it is also certain that a higher vitamin A content of the blood would have been obtained if it had been withdrawn on the same day as the last supplement of vitamin was given. The plasma of the normal bird contained about 200–400 i.u. of vitamin A and about 300 i.u. of

carotene per 100 ml., whereas that of the birds fed on large quantities of vitamin A contained about 1200–1500 i.u. of the vitamin and about 150 i.u. of carotene per 100 ml. Thus a high vitamin A diet usually lowered the carotene content of the plasma as compared with that of the normal bird, but raised its vitamin A content; a similar though less pronounced effect has been obtained in cattle (Walker, Thomson, Bartlett & Kon, 1949).

Estimation of vitamin A and carotene. The concentration of vitamin A and carotene in the plasma and embryo extract was estimated by a method closely similar to that of Yudkin (1941), a modification of Kimble's method (1939), and in detail was almost the same as that used by the Cambridge team in the investigation of the Medical Research Council (1949) on the vitamin A requirements of human adults. A sealed glass tube was used instead of a corked centrifuge tube when the plasma and alcohol mixture was extracted with petroleum ether. In the earlier experiments acetic anhydride was not added, as it was not necessary under the experimental conditions employed, but it was used in the later part of the work.

The final culture medium. The final culture medium consisted of 3 parts of fowl plasma mixed with 1 part of embryo extract. Thus the concentrations of calcium glycerophosphate and of glucose in the embryo extract were lowered to 25% of their original values; the final medium contained 0·05% of the former and 0·25% glucose in the chick experiments and in Exp. 51 on mouse bones, and 1% glucose in the other experiments on mouse bones. The high glucose content had a beneficial effect on the explants and reduced internal necrosis; the calcium glycerophosphate was added in the hope of improving ossification. It is probable that both these substances reached the interior of the bones in a much lower concentration than was present in the medium (cf. Trowell, 1952).

Since the vitamin A content of the embryo extract was low, the concentration of the vitamin in the final medium was about 25% less than in the plasma. In the following account, the concentrations given are those estimated in the original plasma samples, so that the final medium contained about 25% less vitamin A than the figure stated.

The vitamin A content of normal mouse plasma is only 20–60 i.u./100 ml., while that of fowl plasma is about 200–300 i.u./100 ml. Even the normal culture medium was therefore somewhat hypervitaminotic for the mouse bones.

Cultivation by the watch-glass method

In the watch-glass method (Fell & Robison, 1929; Fell, 1951) the culture vessel consisted of a watch-glass enclosed in a Petri dish which was carpeted with cotton-wool soaked with distilled water; a hole was cut in the cotton-wool to allow transillumination. First the plasma and then the embryo extract was dropped into the watch-glass, thoroughly mixed and spread with a fine glass rod and allowed to clot. The explants were placed in a drop of embryo extract made with ordinary Tyrode's solution, sucked into a pipette and deposited on the surface of the clot; all surplus fluid was removed from the tissue with a fine pipette. The watch-glass cultures were incubated on a strip of board, which prevented heavy condensation of water on the inner surface of the Petri dish lid.

The culture medium described above caused such rapid growth of the chick rudiments, that it was necessary to transplant them to freshly prepared watch-glasses four times a week; otherwise they exhausted the medium in their immediate neighbourhood and quite suddenly degenerated. For the same reason it was important to ensure that there was sufficient depth of medium beneath the rudiments; they were therefore explanted on 9 or 12 drops of medium, transferred to 15 drops at the first subculture and finally to 20 drops, the ratio of 3 parts plasma : 1 part embryo extract being maintained throughout. The modifications of culture medium and procedure adopted for the present experiments gave much better results than any previously obtained by H.B.F. when cultivating chick bone rudiments by the watch-glass technique.

The smaller and less actively growing mouse bones did well in 9–12 drops of culture medium and it was sufficient to transplant them three times a week. All the chick explants and the mouse bones in Exps. 51 and 52 were drawn with the aid of a camera lucida at the beginning of the experiment and at intervals during cultivation.

Histological technique

Most of the explants were fixed in acetic Zenker's fluid, embedded in paraffin wax and serially sectioned; in the later experiments with chick bone rudiments (section I) the bones were embedded in ester wax with very good results. The sections were usually stained with Delafield's haematoxylin and chromotrop 2 R. In the later experiments some sections were stained with 0·5% toluidine blue in 5% alcohol and van Gieson's stain preceded by celestine blue and Mayer's haemalum; in section III all the sections were stained with Nicolle's carbol thionin and counterstained with alcoholic eosin.

Some of the mouse bones were fixed in absolute alcohol and mounted whole in glycerin jelly, which gave a very clear general picture of their structure.

RESULTS

I. *The effect of cultivating the limb-bone rudiments of 5- to 6-day chick embryos in a medium containing excess vitamin A alcohol*

The object of these experiments was to study the effect of hypervitaminosis A on the differentiation of limb-bone rudiments which were at a very early stage of development when explanted.

The structure of the rudiments at the time of explantation. In the chick the rudiment of the limb skeleton is always slightly more developed in the leg than in the wing and the proximal elements are in advance of the more distal parts. The stage of differentiation may be clearly seen when the skeletal tissue is dissected under the binocular microscope.

There is considerable variation in the degree of development attained by embryos of the same age, and in the present study the embryos have been classified in four groups according to their stage of histogenesis:

Stage 1. The limb skeleton consisted of a continuous blastema of procartilage with no trace of a joint.

Stage 2. Individual bone rudiments were recognizable and were composed of very early cartilage in which chondroblastic hypertrophy had not yet appeared.

Stage 3. Chondroblastic hypertrophy was just distinguishable in the femur (Pl. 1, fig. 1) and humerus but not in the tibia, radius or ulna.

Stage 4. Chondroblastic hypertrophy was distinct in the femur and humerus, and had just appeared in the tibia, radius and ulna; a two-layered periosteum had differentiated round the middle segment of the shaft in the femur and humerus but the only sign of ossification was some fibres among the osteoblasts.

The behaviour of the rudiments in culture. The skeletal blastemas from limb buds at stage 1 (see above) were removed and cultivated entire, as the boundaries of individual bone rudiments were not yet distinguishable. The femur, tibia, humerus, radius and ulna of the older limbs were explanted separately.

Fifty-five pairs of explants were grown; one of each pair was cultivated in

normal medium and the other in the same medium to which excess vitamin A had been added. Explants were fixed and sectioned at intervals.

The results are summarized in Table 1. Only one experiment (Exp. 48) was done with blastemas at stage 1, a rather low concentration of vitamin A (1475 i.u./100 in plasma) being used. After 48 hr. growth, in both the control and experimental explants, the individual bone rudiments had become visible and the knee- and elbow-joints had appeared. In the two pairs of wing-buds, however, only the humerus developed well; it enlarged to several times its original length and acquired some semblance of its normal shape. There was little difference between the experimental and control humerus in the pair of wing explants fixed after 5 days; in both the cartilage differentiated into hypertrophic, proliferative and epiphysial zones and a thin layer of periosteal bone was deposited. In the 7-day pair, however, chondroblastic hypertrophy and ossification were much more advanced in the hypervitaminotic humerus than in the control. The radius and ulna in both pairs of wing blastemas grew much less than the humerus and underwent neither chondroblastic hypertrophy nor ossification.

The femur, tibia, fibula and part of the tarso-metatarsal region developed in the leg blastemas. The bones grown on the AH medium were rather more slender than those on the control medium. The femur, tibia and fibula of all four explants showed chondroblastic hypertrophy and ossification, but differentiation was more advanced in the hypervitaminotic rudiments than in the controls.

Control rudiments explanted at stages 2–4 grew and differentiated extremely well in cultures, sometimes increasing to more than four times their original length and assuming a surprisingly normal shape (Text-figs. 1 and 2). The soft tissue adhering to the cartilage proliferated rapidly and soon formed a capsule of organized connective tissue which often contained many muscle fibres and was permeated by a network of rather dilated endothelial channels. The zone of hypertrophic cartilage cells could be seen gradually spreading towards the ends of the diaphysis; the proliferative zone of flattened cells could be distinguished in life and the demarcation of this region from the epiphysis could also be observed. A yellowish layer of periosteal bone or osteoid was deposited on the surface of the hypertrophic cartilage, the structure of which it soon obscured. This layer became thicker and more opaque but it did not appear to become densely calcified. In the explants the cartilage enclosed by the bone was not excavated by ingrowing tissue as in normal development *in ovo*.

Sections of the control bones fixed after 9–11 days' cultivation in normal medium confirmed the observations on living cultures (Pl. 1, figs. 2, 4 and 6). The diaphysis consisted of hypertrophic cartilage enclosed by a thick sheath of periosteal bone; beyond the hypertrophic region was a broad proliferative zone of flattened cells which ended abruptly at the border of the small-celled

ABLE 1. The effect of vitamin A alcohol on the explanted limb-bone rudiments of 5- to 6-day chick embryos (AH, plasma with added vitamin A; N, normal plasma. Where two values are given for the vitamin A content, they refer to two samples of plasma used during the experiment.)

Exp.	Vitamin A (i.u./100 ml. plasma)	Stage of embryos (see p. 324)	Days in culture	No. pairs of bone rudiments	Effect of hypervitaminosis
49	AH: 902 1050 N: 232 410	2, 3	4	5: femora, tibiae, humeri, ulnae, radii	None; like controls in N medium
			11	5: femora, tibiae, humeri, ulnae, radii	Femur: smaller than control and cartilage matrix reduced. Tibia: looks normal but control lost. Humerus: like control. Ulna: much better developed than control. Radius: like control
48	AH: 1475 N: 334	1	5	6: femora, tibiae, fibulae, humeri, ulnae, radii	Femur, tibia, fibula: better developed than controls. Humerus, radius, ulna: like controls
			7	6: femora, tibiae, fibulae, humeri, ulnae, radii	Femur, tibia, fibula, humerus: better developed than controls. Radius, ulna: like controls
47	AH: 1640 1550 N: 325 450	4	7	5: femora, tibiae, humeri, ulnae, radii	Shorter and thinner than controls; constriction at one end of shaft in femur, tibia and humerus; in shaft cartilage matrix reduced and metachromasia less; good periosteal bone
			11	5: femora, tibiae, humeri, ulnae, radii	Smaller than controls, especially femur and humerus; constriction at both ends of shaft in femur and proximal end in humerus; metachromasia nearly gone from shaft; less periosteal bone than in controls. Note: in the control radius the metachromasia has gone from a short middle section of the shaft (only control to show this)
46	AH: 1980 1920 N: 231 167	2	7	2: femora, tibiae	Constriction at one end of tibia and both ends of femur; cartilage matrix losing basophilia in shaft; bone as good as in controls
			9	5: femora, tibiae, humeri, ulnae, radii	Proximal end of humerus severed; constriction of shaft at one end of tibia and both ends of femur; basophilia and metachromasia of cartilage matrix greatly reduced in shaft; thick periosteal bone
			11	3: humeri, ulnae, radii	Proximal end of humerus severed and displaced; metachromasia and basophilia gone from shaft; slightly less bone than in controls
43	AH: 2280 2154 N: 212 256	3	4	5: femora, tibiae, humeri, ulnae, radii	Constriction of shaft at both ends of femur and one end of tibia and humerus; cartilage matrix still basophilic except at margin of constrictions; rather more bone than in controls
			7	4: femora, tibiae, ulnae, radii	Femur: distal end severed, proximal end nearly gone; constriction at one end of tibia; basophilia nearly gone from shaft in femur and tibia, partly gone in ulna, unchanged in radius; rather less bone than in controls
50	AH: 2800 3247 N: 290 260	3	7	5: femora, tibiae, humeri, ulnae, radii	Constrictions at both ends of femur, tibia, humerus; basophilia and metachromasia lost from periphery of shaft; rather less bone than in controls
		2	11	5: femora, tibiae, humeri, ulnae, radii	Constrictions at both ends of all bones except tibia; basophilia and metachromasia gone except in interior of epiphyses; less bone than in controls

cartilage of the epiphysis. There were many mitotic figures in the epiphyses and proliferative zones. The cartilage matrix was densely basophilic when stained with Delafield's haematoxylin and acquired an intense metachromatic coloration with toluidine blue (Pl. 1, figs. 4, 10; Pl. 2, fig. 12); it remained almost colourless after van Gieson's stain. Especially in the humerus, there was sometimes an area of mucoid degeneration in the interior of the broad terminal regions of the shaft; the matrix was swollen, showed disintegration and the cells, though not dead, were widely separated by the swollen matrix. Such appearances were probably due to imperfect nutrition in the centre of the large, avascular explants.

The periosteal bone, which was vividly red after van Gieson's stain, was slightly metachromatic with toluidine blue. Where the ossified layer was very thick, small islets of cartilage were sometimes present, merging with the surrounding bone; in such specimens the histological picture somewhat resembled that of callus in which cartilage and bone are irregularly mingled. Metachromasia has been described in normal osteoid tissue by Follis & Berthrong (1949).

The hypervitaminotic explants of stages 2–4 were grown in concentrations of vitamin A ranging from 902 to 3247 i.u./100 ml. plasma. The lowest concentration (Exp. 49, Table 1) produced little change, and after 4 days' cultivation the experimental and control rudiments were indistinguishable. In the 11-day cultures the hypervitaminotic femur was considerably smaller than its control in normal medium, and sections showed that the intercellular partitions in the cartilage were much thinner. Chondroblastic hypertrophy and ossification were much more advanced in the hypervitaminotic ulna than in the control, the development of which was somewhat retarded. There was no obvious difference between the other experimental and control explants.

In concentrations of about 1550–3247 i.u. vitamin A/100 ml. of plasma (Text-figs. 1, 2), the rudiments grew normally for the first two days and did not differ from their controls. Then growth began to decline; the rate of elongation diminished and the shaft ceased to broaden, so that it became both shorter and more slender than in the controls. The epiphyses continued to enlarge but less than in the normal cultures. Eventually growth stopped and some of the explants even began to shrink. Periosteal ossification progressed and the differentiation of the hypertrophic cartilage, zones of flattened cells and epiphyses could be watched.

In some of the hypervitaminotic explants, at about the 7th day a constriction appeared in the zone of flattened cells (proliferating zone) just where the sheath of periosteal bone ended (Text-fig. 2). This was most conspicuous at the proximal end of the humerus and at the distal end of the femur; later a constriction usually appeared also at the proximal end of the femur and sometimes, though to a lesser degree, at the distal end of the tibia. The terminal

part of the rudiment beyond the constriction often became completely detached from the shaft and was sometimes displaced to one side (Text-fig. 2). In the highest concentration (Table 1, Exp. 50) by the 11th day a constriction had formed at both ends of all the bones except the tibia.

The consistency of the hypervitaminotic explants changed during cultivation. Instead of remaining firm and stiff like the controls, when transferred

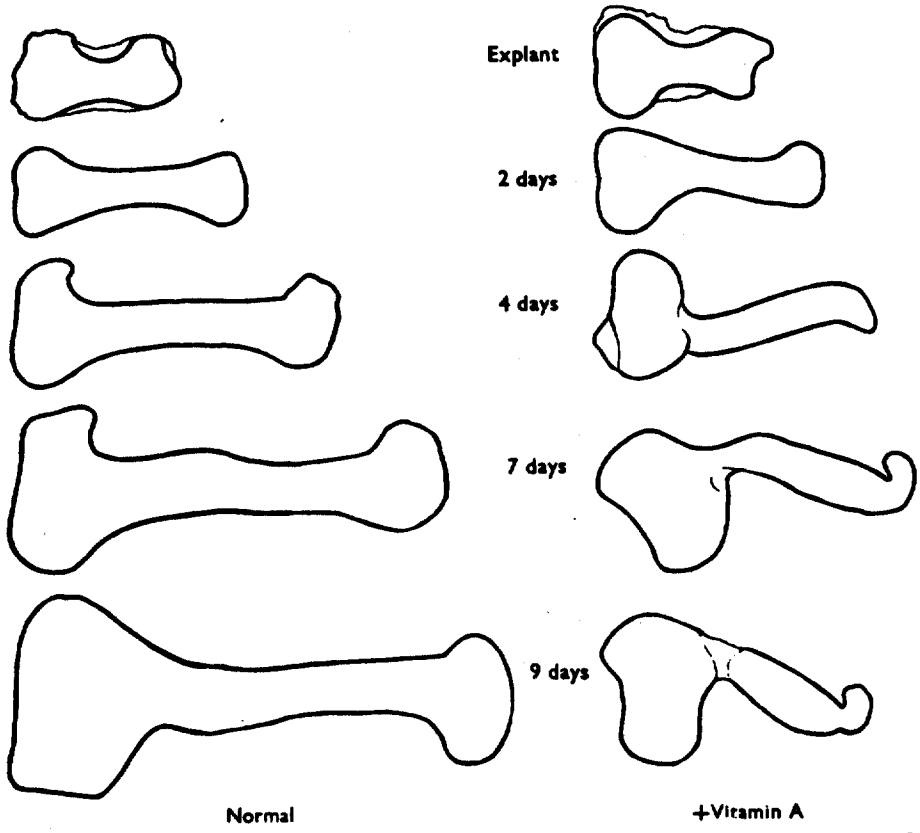

Text-fig. 1. Camera lucida drawings of a pair of living femora from a 6-day chick embryo (stage 2) one grown in normal and the other in AH medium (Exp. 46, Table 1). During 9 days' cultivation the femur in normal medium elongated from 1·6 to 5·2 mm. and showed no distortion. That in AH medium grew normally for the first 2 days; then growth rapidly declined, a constriction appeared in the distal part of the shaft and by the 9th day the condylar end was nearly detached from the diaphysis and the rudiment was shrunken and bent. Sections of these explants are shown in Pl. 1, figs. 2 and 3.

to fresh medium they were found to be soft and 'rubbery'. Throughout the culture period the cells surrounding the cartilage grew profusely, forming a thick capsule of connective and myogenic tissue around the skeletal rudiment.

Sections of the explants grown in the higher concentrations of vitamin A revealed some interesting histological abnormalities. The differentiation of the

cartilage into epiphyses, zones of flattened cells and hypertrophic region was at least as rapid as in the controls and in two explants (Exp. 49, ulna, and Exp. 50, radius) it was much more advanced. The layer of periosteal bone deposited on the surface of the cartilage was in some explants nearly or quite as thick as in the controls (Pl. 1, cf. figs. 4 and 5); in the highest concentration of vitamin A (Exp. 50) many of the osteoblasts in some of the larger rudiments were degenerate by the 11th day of cultivation, but in other explants the majority remained healthy throughout the culture period.

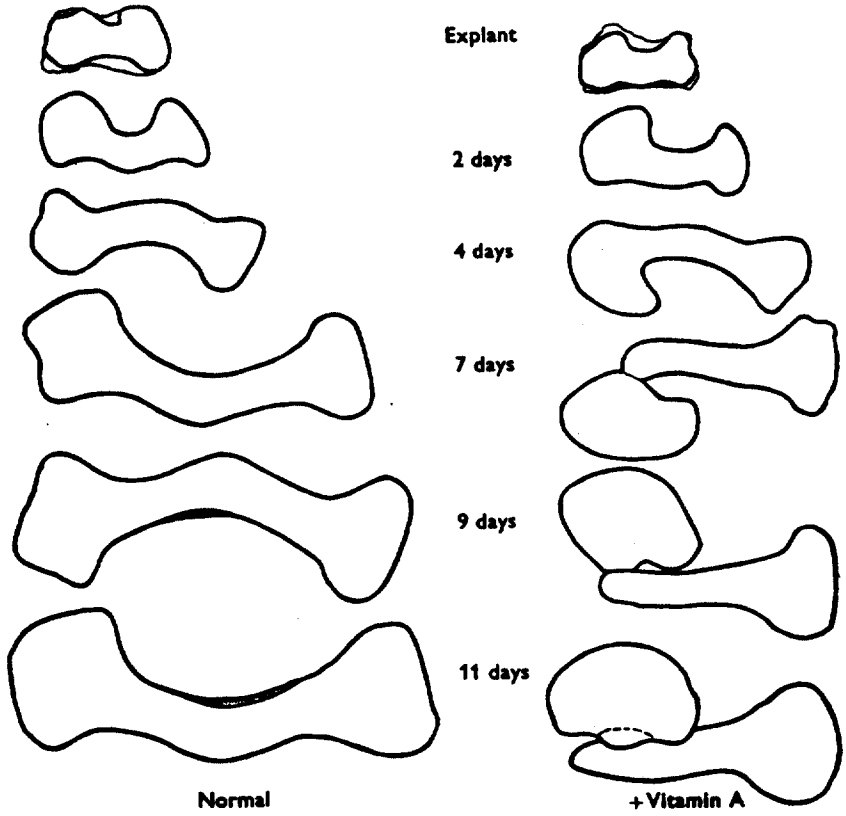

Text-fig. 2. Camera lucida drawings of living humeri from a 6-day chick embryo (stage 2), one grown in normal and the other in AH medium (Exp. 46, Table 1). During 11 days' cultivation, the humerus in normal medium elongated from 1·3 to 5·2 mm. and developed a fairly normal shape. That in AH medium also enlarged considerably, but a constriction appeared at the proximal end of the shaft and by the 9th day the proximal epiphysis had become completely detached from the diaphysis. Sections of these explants are shown in Pl. 1, figs. 6 and 7.

The most striking histological effect of the hypervitaminosis was on the cartilage matrix, and to this were due the severe changes described above in the living cultures. The intercellular partitions began first to narrow and then to lose their metachromasia (Pl. 2, cf. figs. 11 and 12); under high magnification the fibrous texture demonstrated by staining with toluidine blue was seen

to be looser than in the controls. The loss of metachromasia spread inwards from the periphery (Pl. 1, figs. 9 and 10) until by about the 11th day the matrix of the whole shaft was completely colourless when stained with Delafield's haematoxylin or toluidine blue (Pl. 1, cf. figs. 4 and 5; Pl. 2, fig. 13). When neighbouring sections of the same hypervitaminotic explant were stained with van Gieson's solution and with toluidine blue respectively, it was found that in those areas where the matrix had lost its metachromasia with toluidine blue, it stained a bright pink with van Gieson's solution; conversely, regions which still retained their metachromasia were nearly colourless after van Gieson's stain, as also was the cartilage of the controls grown in normal medium (Pl. 2, cf. figs. 13 and 14).

In only one of the fifty-four controls grown in normal medium was there a similar loss of metachromasia in the cartilage matrix. This was seen in a control radius after 11 days' cultivation (Exp. 47); a short segment in the middle of the shaft failed to stain metachromatically with toluidine blue; in the corresponding radius grown in AH medium the metachromasia had almost completely disappeared from the whole diaphysis.

The matrix of the epiphyses was less affected by the hypervitaminosis than that of the shaft, but after 11 days' cultivation in the highest concentration of vitamin A (Exp. 50), the metachromasia persisted only in small regions in the interior of the epiphyses and elsewhere had vanished completely (Pl. 2, fig. 13).

While these drastic changes were progressing in the matrix, the chondroblasts throughout most of the affected cartilage appeared healthy (Pl. 1, fig. 5 and Pl. 2, fig. 11), though in the hypertrophic region of the shaft they became smaller and less vacuolated than in the controls (Pl. 1, cf. figs. 4 and 5). In some of the 11-day explants grown in the highest concentration of vitamin A (Exp. 50), the intercellular partitions had disappeared completely in places, so that groups or nests of cells were often enclosed in one large capsule; in some explants it was surprising to find many of these cells in mitosis.

In those hypervitaminotic explants in which, as already mentioned, a constriction formed near the end of the diaphysis (Text-fig. 2), localized necrosis was always present at this site, where the following events took place. Immediately beyond the sheath of periosteal bone, the peripheral cartilage matrix lost its metachromasia, softened and shrank in the usual way; the chondroblasts became closely packed together and some degenerated, while the boundary between the cartilage and the surrounding connective tissue became indistinct. As the changes in the matrix spread inwards, a tract of cartilage extending right across the shaft began to show pressure effects (Pl. 1, fig. 8): the cells became greatly flattened and some degenerated, while the matrix was compressed into fibrillae staining brightly with van Gieson's stain or chromatrop and orientated at right angles to the long axis of the rudiment (Pl. 2, fig. 14). The pressure responsible for these changes was apparently exerted by the capsule of myogenic and connective tissue which enveloped

the cartilage and which seemed to contract when the tissue was removed from the clot. The zone of cartilage just beyond the periosteal bone was probably more susceptible to pressure than the rest of the rudiment, since it was presumably the weakest part; it was narrower than the terminal part of the diaphysis which broadened rapidly on approaching its junction with the epiphysis, and lacked the support of the stiff sheath of bone which reinforced the rest of the diaphysis.

The necrotic layer of cartilage produced in this way was sometimes invaded by the adjacent connective tissue cells, until the epiphysis and the wide terminal part of the zone of flattened cells was completely severed from the ossified shaft. Continuing pressure often bent the detached end to one side and occasionally forced it down alongside the shaft. The periosteal bone might grow over the broken end of the diaphysis and in one explant (Pl. 1, fig. 7) ossification spread diffusely into the surrounding connective tissue.

From these results it is concluded that:

(1) The cartilaginous long-bone rudiments of 5- to 6-day chick embryos differentiate at the normal rate into epiphyses, zones of flattened cells and hypertrophic region when cultivated in medium to which excess vitamin A has been added.

(2) Periosteal ossification of the long-bone rudiments is only slightly inhibited by hypervitaminosis A.

(3) Hypervitaminosis A produces drastic changes in the cartilage matrix of the explants, viz. shrinkage of the intercellular partitions, softening and loss of basophilia and metachromasia.

(4) These changes are not associated with degeneration of the chondroblasts.

II. *The effect of cultivating late foetal and early infant mouse bones in normal medium containing excess vitamin A acetate or alcohol*

These experiments were made to study the effect of hypervitaminosis A on bones that were already at an advanced stage of development when explanted.

The structure of the bones at the time of explantation. In every experiment on late *foetal mouse bones*, a fore- and hind-limb of one foetus from each litter was fixed and sectioned to show the approximate stage of development of the original explants. The late foetal bones were well developed (Pl. 2, fig. 15). Most of the shaft consisted of a tube of trabecular bone covered by a periosteum with an outer fibrous and an inner osteoblastic layer. The cartilage had been completely excavated from most of the diaphysis and replaced by marrow, permeated by trabeculae of endochondral bone, but the ends of the shaft (metaphyses) were largely occupied by hypertrophic cartilage undergoing endochondral ossification and separated from the round-celled epiphyses by broad tracts of flattened cells with the usual columnar arrangement; there was no sharp demarcation between the three zones of cartilage. The cartilage

matrix was intensely basophilic with Delafield's haematoxylin and strongly metachromatic with toluidine blue; both stains showed clearly the cartilaginous centres of the endochondral bone trabeculae.

The bones used for Exp. 51 (Table 2) were slightly younger than the rest. The marrow cavity occupied only about one-third of the length of the shaft, and the periosteal bone was more cellular and less abundant than in the older rudiments. Otherwise the histological structure was similar to that described above.

The normal bones of 3-*day infant mice* were not taken from the same litter as that which provided the explants. The periosteal bone was much less trabecular and more compact than in the foetal rudiments and little endochondral bone remained in the middle segment of the shaft. The strongly basophilic and metachromatic terminal cartilage occupied a smaller proportion of the shaft than in the late foetus, but otherwise was similar. The articular cartilage, however, was better developed; in some regions it was much less metachromatic with toluidine blue than the rest of the epiphysial cartilage and stained brightly red with van Gieson's solution.

The behaviour of the bones in culture. Fifty pairs of foetal bones and four pairs of infant mouse bones were used in these experiments. Of each pair, one was grown in medium to which an alcoholic solution of vitamin A acetate or alcohol had been added to give various concentrations, the other in the same medium containing the same quantity of ethanol but no added vitamin A.

During cultivation in normal medium, the control *foetal bones* elongated (Text-fig. 3), but much less than the early skeletal rudiments of the chick, and the cartilaginous ends broadened. The cells from the soft tissue attached to the bone wandered into the clotted medium and by the 3rd day had formed a broad zone of outgrowth which anchored the bone to the clot and thus resisted its further expansion; this sometimes forced the cartilaginous ends slightly out of alinement with the shaft in 7- to 10-day cultures.

In sections (Pl. 2, figs. 16 and 18), surprisingly little cell degeneration was seen in the controls even after 10 days in culture, the longest period for which the explants were maintained, but they showed certain abnormalities which were probably due partly to the lack of a vascular system and partly to the fact that, as mentioned above, normal fowl plasma is somewhat hypervitaminotic for mouse bones.

As in normal development, the periosteal bone was partially reorganized to become less trabecular and more compact (Pl. 2, cf. figs. 15 and 16). Sometimes layers of new bone were deposited on the outside of the diaphysis parallel with the surface, so that the wall of the shaft was thickened. In other explants, especially in those of Exp. 51 which were obtained from rather younger embryos than the rest, bone absorption slightly exceeded bone deposition; as will be seen later, the younger bones were more sensitive to the action of vitamin A than the older rudiments, so that this slight rarefaction of

TABLE 2. The effect of vitamin A acetate and alcohol on foetal mouse bones (AH, plasma with added vitamin A; N, normal plasma)

Exp.	Vitamin A (i.u./100 ml. plasma)	Days in culture	No. pairs of bone rudiments	Effect of hypervitaminosis
11	AH: 1000 (vit. A acetate)	7	2: radii, ulnae	Cartilage much reduced; matrix still basophilic; bone rarified
	N: 220	10	4: tibiae, fibulae, radii, ulnae	Cartilage nearly gone; little or no basophilia in matrix; bone very rarified and nearly gone in fibula
12	AH: 1060	3	2: tibiae, fibulae	Like controls
	960	7	2: radii, ulnae	Cartilage reduced; basophilia of matrix nearly gone; bone rarified
	(vit. A acetate)	10	2: radii, ulnae	Cartilage much reduced; very little basophilia in matrix; extensive bone absorption
	N: 382			
	400			
	AH: 1880	3	2: tibiae, fibulae	Cartilage reduced; partial loss of basophilia in matrix; bone unchanged
	1920	5	2: tibiae, fibulae	Cartilage much reduced, especially in fibula; bone much eroded in tibia, nearly gone in fibula
		7	2: radii, ulnae	Cartilage nearly (ulna) or completely gone (radius); great absorption of bone
	AH: 2640	3	2: tibiae, fibulae	Cartilage much reduced; partial loss of basophilia in matrix; some bone absorption
	2720	7	2: radii, ulnae	Cartilage gone; very great bone absorption
52	AH: 2845 (vit. A alc.)	4	4: tibiae, fibulae radii, ulnae	Cartilage much reduced; metachromasia nearly or completely gone; bone greatly rarified
	N: 261	7	4: tibiae, fibulae radii, ulnae	Cartilage nearly (tibia) or completely gone; great absorption of bone
51	AH: 2876 (vit. A alc.)	2	4: tibiae, fibulae, radii, ulnae	Cartilage much reduced; partial loss of metachromasia in matrix; extensive bone absorption with many osteoclasts
	N: 268	4	4: tibiae, fibulae, radii, ulnae	Cartilage greatly reduced; metachromasia almost or completely gone from matrix; bone nearly gone. Some rarefaction of bone in controls
7	AH: 4000 (approx.) (vit. A acetate)	7	2: tibiae, fibulae	Cartilage nearly gone; metachromasia gone in matrix; great bone absorption
	N: unknown	10	2: radii, ulnae	Cartilage gone; bone almost gone
2	AH: 8000 (approx.) (vit. A acetate)	5	2: radii, ulnae	Cartilage greatly reduced; basophilia gone from matrix; much bone absorption
	N: unknown	8	2: tibiae, fibulae	Cartilage greatly reduced (tibia) or gone (fibula); basophilia nearly gone from matrix in tibia; extensive bone absorption

the periosteal bone in the controls may have been due to the hypervitaminosis A of normal fowl medium for mouse bones. Relatively few osteoblasts and osteocytes were degenerate except in the innermost periosteal trabeculae of the larger bones (tibia and sometimes ulna) and in the endochondral spongy bone.

As in the normally developed limb bones, there was considerable absorption of the bone trabeculae in the marrow cavity, but in the explants endochondral ossification was almost arrested, so that the spongy bone of the metaphyses was not replaced as it is in normal development (Pl. 2, fig. 16). Instead, the hypertrophic cartilage was slowly invaded and excavated by cells from the marrow; erosion was sometimes very irregular and sometimes proceeded along a fairly straight front. In some explants a layer of osteoid tissue was deposited on the surface of the cartilage which was thus sealed from the marrow cavity, the histological picture somewhat resembling that of the terminal plate of bone formed on the surface of the epiphysial cartilage during arrested growth *in vivo*, e.g. in hypophysectomized young rats (Ray, Evans & Becks, 1942). This removal of the pre-existing spongy bone and failure to replace it by further endochondral ossification, weakened the metaphyses which, as described above, sometimes bent or crumpled slightly owing to the resistance to elongation caused by the outgrowth of cells into the clot; for the same reason the metaphyses often became abnormally narrow, so that the terminal cartilage bulged rather abruptly from the bony shaft.

The cartilage matrix continued to increase in amount and the intercellular partitions broadened. With Delafield's haematoxylin it was strongly basophilic; with toluidine blue (used in Exps. 51, 52 only) it was intensely metachromatic (Pl. 2, fig. 18), except in the near neighbourhood of the excavation at the marrow surface, where the staining capacity was lost or greatly reduced. After van Gieson's stain (Exps. 51, 52 only), the matrix of the hypertrophic cartilage was pale pink as in normal development; elsewhere in the explants of Exp. 52 it was nearly colourless and pale pink in those of Exp. 51 for which, as already mentioned, rather younger rudiments had been used.

The chondroblasts remained apparently healthy throughout, except in the hypertrophic cartilage most deeply situated in the bony shaft where, especially in the relatively large tibiae, many or all of the cells were dead by the 7th day: in normal development this region would already have been excavated by the ingrowing vessels and associated tissues. The proliferative zone showed signs of diminishing activity; the columnar arrangement of the chondroblasts became disorganized and the cells less flattened so that by the 10th day the zone could hardly be distinguished from the adjacent cartilage.

Most of the haemopoietic cells originally present in the marrow degenerated during the first few days in culture; their remains were phagocyted and, in the smaller bones, were often removed completely. After the destruction of

the original marrow, haemopoiesis continued, especially in the smaller explants, though on a greatly reduced scale; most of the marrow cavity was occupied by the reticulum, a loose tissue of irregularly arranged fibres and cells some of which were in mitosis; there was also a network of thin-walled vessels. A few osteoclasts were always found, they were more numerous in the controls of Exp. 51 than in the controls of the other experiments.

From the foregoing account, it will be seen that in normal fowl medium, the control foetal mouse bones survived with little necrosis for at least 10 days and underwent some further differentiation, but that their growth was at first greatly retarded and finally arrested by conditions *in vitro*.

The effect of hypervitaminosis A on the corresponding bone rudiments cultivated in medium containing excess vitamin A acetate or alcohol, was remarkable. It was most conspicuous in the explants of Exp. 51 (Table 2), for which younger embryos were used than for the other experiments. These rudiments were grown in a concentration of 2876 i.u. vitamin A/100 ml. plasma and after only 2 days *in vitro* they had shrunk considerably, while the controls had enlarged during this period. When the living cultures were examined under the dissecting binocular, the bone was seen to be greatly rarefied and the cartilaginous ends much reduced in size as compared with the corresponding controls. After 4 days, when the experiment was terminated, the bone had nearly disappeared from the hypervitaminotic rudiments, only a few small spicules remaining, while the cartilage had dwindled to a tiny nodule at either end of the original shaft region; the controls showed little change except that, as mentioned above, the diaphysial bone was rather less dense than at the beginning of the experiment. The soft tissue surrounding the rudiments grew with equal vigour in both series.

In the other experiments on rather more advanced bones, the cartilage disappeared more quickly than the shaft. Except at the highest concentrations (Exps. 2 and 7, Table 2), little difference was seen between the hypervitaminotic and control explants during the first 2 days in culture (Text-fig. 3), but after 4 days there was a marked contrast between them. The explants in excess vitamin A were much smaller than the controls; the terminal cartilage which looked rather opaque, was shrunken and often displaced at an angle to the bony shaft in which jagged holes had appeared.

The cartilage diminished very quickly and soon ceased to fit the diaphysial bone, from which it emerged like a small head and neck from a too large collar (Text-fig. 3); sometimes it was forced downwards into the marrow cavity by the pressure of the surrounding tissue. Meanwhile, the periosteal bone continued to be absorbed rapidly; by the 5th day it had a moth-eaten appearance and had become much shorter. Different rudiments reacted at different rates; the changes were most advanced in the fibula, less in the radius, less still in the ulna and least in the tibia.

During the later stages of cultivation the shaft became greatly disorganized (Text-fig. 3); by the 10th day the cartilage had often disappeared in the fibula and radius and the bone had disintegrated. All that remained of the original explant was an actively growing sheet of amoeboid cells in which were scattered a few spicules of bone. In the tibia small nodules of cartilage and a little bone persisted.

Histological examination of the foetal bones grown in AH medium showed that the disappearance of the cartilage was due to two causes: a progressive narrowing of the partitions of matrix between the chondroblasts and an abnormally fast excavation at the marrow surface. As in the chick rudiments,

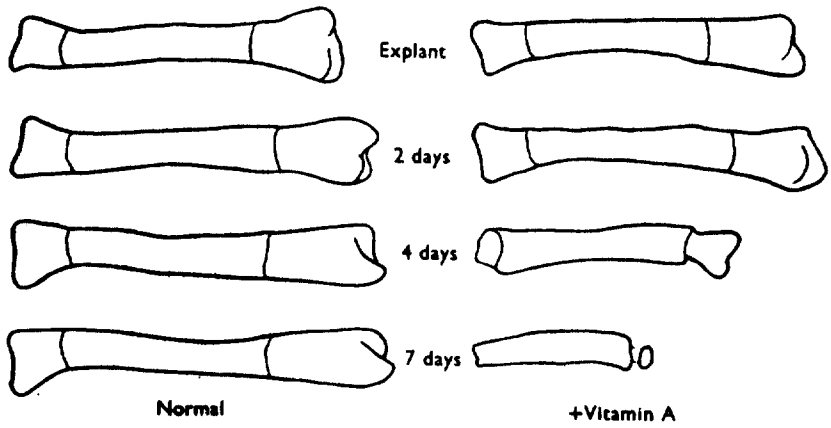

Text-fig. 3. Camera lucida drawings of living radii from a late mouse foetus, one grown in normal and the other in AH medium (Exp. 52, Table 2). During 7 days' cultivation the radius in normal medium enlarged somewhat and the bone and cartilage remained intact. That grown in AH medium also enlarged during the first 2 days, then suddenly the cartilage began to shrink and the bone to be absorbed; by the 4th day the cartilage had almost disappeared and the bone was much rarefied and reduced. Sections of these explants are shown in Pl. 2, figs. 15–19.

shrinkage of the matrix was accompanied by loss of basophilia and metachromasia, which began at the surface and spread inwards (Pl. 2, fig. 21), and those areas which had lost their metachromasia stained more brightly with van Gieson's solution.

During the original dissection, small superficial areas of cartilage were usually killed by pressure when the cataract knife was inserted between adjacent articular surfaces to isolate the bones. In the controls grown in normal medium, these little necrotic patches formed a negligible part of the terminal cartilage and were hardly noticeable. In the hypervitaminotic explants, however, they became increasingly conspicuous, as the matrix did not shrink and lose its basophilia in these killed regions nearly so fast as in the neighbouring undamaged cartilage where the cells were still alive; this indi-

cated that the chondroblasts were themselves concerned in the destruction of their intercellular material.

At the marrow surface large groups of liberated hypertrophic chondroblasts were sometimes seen during the first few days of cultivation.

How the bone was absorbed was not entirely clear from the sections. In Exp. 51 the number of osteoclasts was considerably greater in the hypervitaminotic bones, but in other experiments there seemed to be no more than in the controls, and the appearance suggested that the other cell types, e.g. macrophages, reticular cells, endothelial cells and possibly the osteoblasts and osteocytes, were responsible for the absorption.

There was little, if any, deposition of new osteoid tissue in the hypervitaminotic mouse bones, which in this respect differed from those of the 6-day chick embryos in which ossification was nearly as active as in the controls. Nevertheless, the osteoblasts in the hypervitaminotic mouse explants multiplied actively so that the tissue around the bone became much denser than in the controls (Pl. 2, cf. figs. 16 and 17) and contained many mitotic figures. It is possible that more growth-promoting material from the culture medium reached the interior of the shaft as the periosteal bone was eroded, and encouraged the cells to multiply; later the general shrinkage of the shaft probably compressed the cells and so further increased their density. The osteoblasts soon lost their characteristic appearance, however, and became transformed into spindle-shaped cells of the fibroblast type which continued to divide.

Sections showed that in the final stages of the explants' dissolution, the cartilage had shrunk to a compact mass of chondroblasts enclosed by very thin capsules which stained pink with van Gieson's solution or chromotrop. Eventually these capsules also disappeared, leaving the cells free. The subsequent fate of the chondroblasts depended on the amount of tissue by which they were surrounded. If tags of muscle and tendon had been left attached to the original cartilage, the cells proliferated and enveloped the cartilage by a fairly thick layer of connective tissue; when the matrix had gone, the soft mass of cartilage cells was compressed by this surrounding layer and degenerated. On the other hand, if the cartilage had been dissected clean, all but the innermost chondroblasts in the larger rudiments and nearly all those in the smaller explants survived the loss of their capsules and seemed to wander into the medium where they were lost (Pl. 2, fig. 22).

In Exp. 51 in which, as already described, the bone was absorbed with extraordinary speed, the osteoblasts which at first multiplied profusely and showed very active mitosis, became greatly compressed by the very rapid shrinkage of the diaphysis and most of them degenerated. The destruction of the shaft was more gradual in the explants from older foetuses and there was little degeneration among the cells of the marrow cavity; as the bone vanished,

these cells spread out on the medium and continued to multiply. Finally all that was left of the explants (Pl. 2, fig. 20) was a mass of fibroblasts and macrophages with a few shreds of bone and one or more of the small islets of dead cartilage mentioned above.

The rate at which the explanted foetal bones reacted to hypervitaminosis A depended on the concentration of the vitamin in the medium. Thus, as may be seen from Table 2, Exp. 12, after 3 days' cultivation, a tibia explanted in medium containing about 1000 i.u. vitamin A/100 ml. of plasma showed no change, in about 2000 i.u./100 ml. the cartilage had begun to shrink and lose its basophilia and in about 3000 i.u./100 ml. the cartilage was greatly reduced, had lost much of its basophilia and the bone was partly absorbed. Similarly, after 7 days' cultivation, a radius in medium containing about 1000 i.u. vitamin A/100 ml. plasma retained some cartilage which, however, was greatly reduced and had nearly lost its basophilia, and the shaft persisted, though much rarefied, while at a concentration of about 3000 i.u./100 ml. the rudiment had almost vanished.

The results of the experiment on radii and ulnae from 3-*day infant mice*, cultivated in medium containing 3316 and 3180 i.u. vitamin A/100 ml. plasma, were similar to but less drastic than those described above. The controls explanted in normal medium grew little and endochondral ossification was arrested; a terminal plate of bone, like that described on p. 334, was deposited on the surface of the hypertrophic cartilage at the proximal end of the radius. The marrow degenerated, but even after 10 days' cultivation there were few necrotic cells, in spite of the large size of the explants and the density of their intercellular material.

In the hypervitaminotic bones the cartilaginous ends showed severe changes after only 5 days' cultivation; they were much smaller than those of the controls and in the radius the matrix had lost all and in the ulna nearly all its basophilia with Delafield's haematoxylin. The chondroblasts appeared healthy. The diaphysial bone was thinner than in the controls and the osteoblasts were fewer and less well developed. After 10 days the cartilage had nearly gone and the periosteal bone was extensively absorbed, especially near the ends of the diaphysis.

It may be concluded that *in vitro*:

(1) Hypervitaminosis A causes the cartilage matrix to shrink, lose its basophilia and metachromasia and finally to disappear.

(2) The chondroblasts of the affected cartilage appear healthy.

(3) There is great absorption of bone.

(4) The younger the bone rudiment when explanted, the greater is its susceptibility.

III. *The effect of heating* (a) *the bones*, (b) *the plasma of the culture medium on the growth of foetal mouse bones in normal medium and in medium containing excess vitamin A alcohol*

In the previous section it was shown that areas of cartilage which had been killed by mechanical damage did not respond to hypervitaminosis A like the adjacent, living cartilage. The following experiments were made to see what relationship, if any, existed between the growth of bones *in vitro* and their response to hypervitaminosis A.

The effect of heating the embryos. Mouse embryos, after removal of one fore-paw, were placed in a tube containing about 20 ml. of Ringer's solution and a thermometer. The tube was then immersed in a bath at a temperature slightly higher than that desired for the heating of the embryo. When the required temperature of 60, 50, 45, 40 or 37° C. had been reached, it was maintained for 15 min., after which the tube was quickly cooled to room temperature. The radius and ulna were dissected out of both fore-paws and explanted on the culture medium in the usual way. The explants were transferred to fresh medium on the 2nd day and fixed on the 4th. To produce the hypervitaminotic medium about 2280 i.u. vitamin A alcohol/100 ml. was added to the plasma.

The reaction of the rudiments to different temperatures was found to be delicately balanced. Thus rudiments from embryos heated to 60, 50 and 45° C. respectively for 15 min. failed to grow on normal medium, and sections showed that after 4 days they were necrotic; at what stage the necrosis developed was uncertain. They also failed to respond to hypervitaminosis A when incubated on AH medium, although controls from the limb removed before the embryo was heated gave the characteristic reaction (Pl. 3, cf. figs. 23 and 24, and 25 and 26). On the other hand, preheating to 40° C. prevented neither growth in normal medium nor the typical response to hypervitaminosis A (Pl. 3, cf. figs. 27 and 28).

It is concluded that preheating the bones to a temperature that is just sufficient to inhibit growth, also inhibits the vitamin A reaction.

The effect of heating the plasma of the culture medium. Blood plasma was heated to 50° C. for 15 min. in a water-bath. To part of the plasma, about 2280 i.u. vitamin A/100 ml. was added before heating.

Heating the plasma affected neither the growth of the bones nor their response to hypervitaminosis A. From this it is concluded that nothing essential for either the growth of the bones or their reaction to hypervitaminosis A was destroyed.

IV. *A comparison of the effects on explanted foetal mouse bones of 'natural' and 'artificial' hypervitaminosis A*

In the experiments described in the preceding sections, the hypervitaminosis was 'artificially' induced by adding vitamin A acetate or alcohol to normal plasma. The following experiments were made to see whether the effect on explanted mouse bones of vitamin A, added to normal plasma in this way, was the same as that of a similar concentration of vitamin A introduced 'naturally' into the plasma by feeding the donor fowl on a diet rich in the vitamin.

Experiments were also undertaken to see whether there was any difference in the state of the vitamin in the plasma in 'artificial' and in 'natural' hypervitaminosis respectively.

The effect of 'natural' and 'artificial' hypervitaminosis A on late foetal mouse bones. Bone rudiments from mouse embryos near term, similar to those described in section II, were used. Three experiments were made (Exps. 16, 19 and 23, Table 3), in which the effects on the explants of plasma from a fowl having hypervitaminosis A (NH medium) was compared with that of normal plasma to which approximately the same quantity of vitamin A acetate or alcohol had been added (AH medium).

Since the 'artificial' hypervitaminosis had been produced in Exps. 16 and 19 by adding a solution of crystalline vitamin A acetate to the medium and in Exp. 23 by adding vitamin A alcohol extracted from avoleum (see p. 322), a fourth (control) experiment was made in which the effects of these two substances on explanted mouse bones were directly compared. Ten pairs of foetal mouse bones were grown as follows. Four pairs: one of each pair was cultivated in medium containing about 1500 i.u. of vitamin A acetate per 100 ml. and the other in normal medium; four pairs: one of each pair was grown in medium containing about 1500 i.u. of vitamin A alcohol from avoleum per 100 ml. plasma, and the other in normal medium; two pairs: one of each pair was grown in medium to which vitamin A acetate had been added and the other in medium containing vitamin A alcohol.

The results of the first three experiments are summarized in Table 3. In the first experiment (Exp. 16), even after 12 days' cultivation in the NH medium, the bones seemed unaffected when compared with their controls grown in normal medium. The only exceptions were the two fibulae in which there was more absorption and less deposition of bone than in the corresponding controls.

The 'natural' hypervitaminosis produced some effect in the second experiment (Exp. 19) but far less than did the equivalent 'artificial' hypervitaminosis. Apart from a slight rarefaction of the bone, the explants in NH medium showed little change during the first 7 days, but by the 12th day they had shrunk to about two-thirds the size of their normal controls, the bone was much eroded while the cartilaginous ends had dwindled and the matrix had

TABLE 3. Comparison of the effects of 'natural' and 'artificial' hypervitaminosis A on foetal mouse bones *in vitro*

(The foetuses used for Exp. 23 were younger than those used in Exps. 16 and 19. NH, plasma from a fowl with hypervitaminosis; AH, plasma with added vitamin A; N, normal plasma)

Exp.	Vitamin A (i.u./100 ml. plasma)	Days in culture	No. of explants	Effect of hypervitaminosis
16	NH: 1435	5	4: tibiae, fibulae, radius, ulna	No difference between NH and N except in fibula where shaft is rather disorganized in NH
	N: 487	5	4: tibiae, fibulae, radius, ulna	
	NH	12	4: tibiae, fibulae, radius, ulna	More absorption and less deposition of bone in fibula in NH than in N; otherwise no difference between NH and N
	N	12	4: tibiae, fibulae, radius, ulna	
19	NH: 1235 1545	7	4: 2 radii, 2 ulnae	NH: little or no difference between NH and N AH: very great reduction of cartilage; basophilia of matrix almost or completely lost; considerable absorption of bone
	AH: 1287 1460 (vit. A acetate)	7	4: 2 radii, 2 ulnae	
	N: 327 296	7	4: 2 radii, 2 ulnae	
	NH	12	4: 2 tibiae, 2 fibulae	NH: marked difference from N; cartilage greatly reduced; partial loss of basophilia; much bone absorption
	AH	12	4: 2 tibiae, 2 fibulae	
	N	12	4: 2 tibiae, 2 fibulae	AH: Cartilage nearly (tibiae) or completely gone (fibulae); basophilia quite gone from matrix; bone nearly (tibiae) or completely gone (fibulae)
23	NH: 1540 1800	4	4: 2 radii, 2 ulnae	NH: Cartilage slightly reduced as compared with N; slight loss of basophilia from matrix; much bone absorption
	AH: 1537 1760 (vit. A alc.)	4	4: 2 radii, 2 ulnae	AH: Cartilage greatly reduced; partial loss of basophilia from matrix; extensive absorption and partial disruption of bone
	N: 200 232	4	4: 2 radii, 2 ulnae	
	NH	7	4: 2 tibiae, 2 fibulae	NH: cartilage reduced; basophilia of matrix nearly or completely gone; bone partly absorbed
	AH	7	4: 2 tibiae, 2 fibulae	AH: much greater reduction of cartilage and absorption of bone than in NH
	N	7	4: 2 tibiae, 2 fibulae	N: slight rarefaction of bone, otherwise unchanged

begun to lose its basophilia (Pl. 3, cf. figs. 31 and 32). In similar bones grown for the same time in AH medium, the changes were much more advanced.

The greatest effect of 'natural' hypervitaminosis was obtained in the third experiment (Exp. 23), in which the concentration of vitamin A was slightly higher than in the two previous experiments (see Table 3) and the foetal bones were rather younger and therefore more susceptible to the action of the vitamin (see p. 335). There was, however, a great difference between the effects of the 'natural' and of the 'artificial' hypervitaminosis. By the 4th day, the bones had begun to shrink in response to both the 'natural' and the 'artificial' hypervitaminosis, but the shrinkage was far greater in the latter; similarly, while there was considerable bone absorption in the former, in the latter the shaft had largely disintegrated. The loss of basophilia from the cartilage matrix was always much more advanced in the 'artificial' than in the 'natural' hypervitaminosis.

In the fourth experiment in which the effects of vitamin A acetate and vitamin A alcohol were directly compared, the results showed little difference in the action of the two substances on explanted mouse bones, though if anything the vitamin A alcohol was slightly the more potent.

It is concluded that the effect of 'natural' hypervitaminosis A on explanted foetal mouse bones is similar to but much less drastic than an equivalent 'artificial' hypervitaminosis A.

The physical condition of vitamin A in the plasma in 'artificial' and 'natural' hypervitaminosis. Extraction experiments showed that by shaking the plasma with petrol ether, much of the vitamin A could be recovered from the AH plasma, whether it had been added as the acetate or the alcohol, but not from the NH plasma. On the other hand, if the NH plasma were first treated with 50% alcohol to denature the protein, the vitamin could then be extracted with petrol ether (Dzialoszynski, Mystkowski & Stewart, 1945). In the body it is probable that vitamin A is combined with a protein; if so, this combination may have to be broken down before the vitamin becomes soluble in petrol ether.

It may be concluded that the state of vitamin A added to plasma *in vitro* differs from that found in the fowl plasma as a result of hypervitaminosis A.

DISCUSSION

The first question to consider is how the effects of hypervitaminosis A on long-bone rudiments in culture compare with its effects on the long bones of young animals. Wolbach (1947) has recorded the following changes in the limb bones of young hypervitaminotic guinea-pigs and rats. For the cartilage: (1) rapid maturation of the cartilage cells, so that vesicular chondroblasts extend far towards the epiphysial line; (2) relative retardation of matrix-formation, causing compression of the maturing cells on the diaphysial side

of the cartilage plate; (3) cessation of cell division in the proliferative cartilage; (4) very deep and rapid penetration of the cartilage by capillaries; (5) concurrently rapid replacement of the cartilage by bone, resulting in premature closure of the epiphyses and arrest of linear growth. In the bone he observed: (1) acceleration of remodelling sequences, involving absorption by increased osteoclasis and appositional bone formation; absorption and deposition take place at the same sites as in normal bone development; (2) failure of the matrix of the newly formed bone to mature and to calcify completely; (3) fractures caused by excessive absorption of the old cortical bone and lack of firmness in the new bone. There is a quantitative relationship between the rate at which these changes appear in the long bones and the dose of vitamin A received by the animal.

Wolbach has shown that the changes produced in the limb bones *in vivo* by hypervitaminosis A are closely related to the normal growth pattern of the bones. Hence, when comparing the effects of excess vitamin A on the explanted bone rudiments *in vitro* and on the long bones of young animals, certain important differences between the growth patterns of the bones *in vitro* and *in vivo* must be borne in mind.

Limb-bone rudiments of 5- to 6-day chick embryos grown *in vitro* do not acquire a marrow cavity by excavation of the cartilage nor is the bone subjected to remodelling sequences by absorption and redeposition as in normal development *in ovo*. On the other hand, the young cartilage differentiates normally into hypertrophic region, zones of flattened cells and epiphyses, and a fairly thick single layer of bone is deposited on the surface. When hypervitaminosis A is imposed on this developmental picture, the result resembles somewhat that obtained *in vivo* in that linear growth is arrested, spontaneous fractures occur, differentiation of the chondroblasts is not retarded, though there is no conclusive evidence that it is accelerated, and ossification proceeds at almost the normal rate. The excavation of cartilage and the absorption of bone, processes which are omitted from the normal pattern of growth in these explants, are not induced by hypervitaminosis A, at least not during the culture periods of the present experiments. The most profound effect of the vitamin is on the cartilage matrix of chick explants. Whereas the spontaneous fractures which occur *in vivo* are due to the erosion of the old bone and the softness of the new, in the explants they are caused by softening of the intercellular material of the cartilage at its weakest point, i.e. just beyond the sheath of periosteal bone, so that it cannot withstand the pressure of the surrounding capsule of connective tissue. It is not clear whether the epiphysial cartilage is affected *in vivo* in any comparable way. Wolbach (1947) states that the formation of cartilage matrix in hypervitaminotic animals 'does not keep pace' with the rapid maturation of the cartilage cells 'and in consequence, there is compression of the maturing cells on the diaphysial side of the

cartilage plate'. This observation suggests that *in vivo* also, there may have been a slight softening and even reduction of the cartilage matrix, as well as retardation or inhibition of its production.

Late foetal mouse bones in culture present a different developmental pattern from that of the early chick rudiments. They are at an advanced stage of differentiation when explanted, with a marrow cavity, a stout shaft of bone and large cartilaginous ends. During cultivation they enlarge a little, but much less than do the chick rudiments. Their formative processes are greatly reduced *in vitro*, probably owing to the sudden abolition of a blood supply from such very vascular structures; endochondral ossification ceases and not much periosteal bone is formed. Excavation of the cartilage and absorption of bone continue, however, and most of the skeletal cells survive in a healthy condition, though in a state of depressed functional activity.

Hypervitaminosis A affects this histological picture rather differently from that of the chick explants. The absorption of cartilage and bone is enormously accelerated as *in vivo*, but the old bone is not replaced by new osteoid tissue as it is in the limb bones of the animal, so that in culture the shaft disappears altogether. The cartilage shows the same remarkable changes as appear in the hypervitaminotic chick rudiments, but in the mouse the dissolution of the matrix is so rapid and complete that in 7–10 days the intercellular material has gone entirely, leaving the chondroblasts naked.

It remains to consider why the vitamin should have a far more drastic effect on the explanted bone rudiments in our experiments than it has on the long bones of hypervitaminotic animals. There appear to be two main reasons, though other factors may also be concerned. In the first place, as shown in section IV, excess vitamin A introduced 'naturally' into the plasma by feeding the donor fowl has a much lower biological activity than when it is added to normal plasma, though its action on the explants is qualitatively similar in both cases. In the second place, the experiments in section II demonstrated that the bones of younger mouse embryos are much more susceptible to hypervitaminosis A than those of older foetuses, which in turn react more quickly than the bones of 3-day infant mice. It seems likely, therefore, that the bones of young weanling animals such as are used to study the action of hypervitaminosis A *in vivo*, would be still less sensitive to the vitamin.

The question arises as to why the bones of the younger foetuses should be more susceptible to hypervitaminosis A than those of older embryos and infant animals. It has been shown that cartilage killed by mechanical damage or by heating to a temperature (45° C.) just sufficient to kill the cells, fails to respond to vitamin A. From this we conclude that the effect of vitamin A is not directly on the intercellular material but depends on the activities of living cells. The younger the bone, the greater is the proportion of cellular to intercellular material, and the less are the hardness and density of the latter;

it is probably these factors which determine the degree of the effect of hypervitaminosis A.

Many aspects of this problem remain obscure. At present we do not know how the metabolism of the cells is altered by hypervitaminosis A, what chemical changes are produced in the cartilage matrix or how far the effects of the vitamin are reversible. Further studies are planned which we hope may shed light on these and other questions.

SUMMARY

1. Experiments were made to study the effect of hypervitaminosis A on embryonic long bones growing under the simplified environmental conditions provided by tissue culture.

2. Pairs of limb-bone rudiments from 5- to 6-day chick embryos and foetal mice near term, were cultivated by the watch-glass method. One of each pair was grown in hypervitaminotic and the other in normal medium.

3. In normal medium the chick rudiments sometimes grew to more than four times their original length, the cartilage differentiated into hypertrophic region, zones of flattened cells and epiphyses; a layer of periosteal bone was deposited but no marrow cavity was formed by excavation of the cartilage, as occurs *in vivo*.

4. In medium to which excess vitamin A alcohol had been added growth was arrested, but the cartilage differentiated at the normal rate and ossification was only slightly reduced. The cartilage matrix was greatly affected; it shrank, softened and lost its basophilia and metachromasia while its affinity for van Gieson's stain was much increased. There was no excavation of cartilage or absorption of bone. The surrounding soft tissue grew profusely.

5. These changes were not associated with cell degeneration.

6. The severity of the effect was correlated with the concentration of vitamin in the culture medium.

7. Late foetal mouse bones in normal medium enlarged, but much less than the chick rudiments; endochrondral ossification ceased, but a little more periosteal bone was formed in some explants. Excavation of the cartilage and absorption of the spongy bone continued *in vitro*; necrosis was usually slight.

8. The addition of vitamin A acetate or alcohol to the medium had a drastic effect on the mouse explants. The cartilage matrix rapidly dwindled, lost its metachromasia and finally disappeared, leaving the chondroblasts naked. The bone was quickly absorbed, though in most experiments few osteoclasts were present, it was not replaced by new osteoid tissue.

9. The younger the foetuses from which the long bones were obtained, the greater was the effect of the vitamin A.

10. The higher the concentration of added vitamin A in the medium, the more rapid was its effect on the explanted mouse bones.

11. Mechanically damaged cartilage, in which the cells were dead, did not respond to hypervitaminosis A like the adjacent living cartilage.

12. Heating the mouse bones to 45° C. prevented their growth in normal medium and their characteristic reaction to hypervitaminosis A; heating to 40° C. did not affect either their growth in normal medium or their response to hypervitaminosis A.

13. 'Natural' hypervitaminosis A obtained by using plasma from a hypervitaminotic fowl for the culture medium, had a qualitatively similar but far less drastic effect on explanted foetal mouse bones than 'artificial' hypervitaminosis A produced by adding the same quantity of vitamin A acetate or alcohol to normal plasma.

14. Extraction experiments showed that whereas much of the added vitamin A can be removed from the plasma by petrol ether, it cannot be extracted from the 'natural' hypervitaminotic plasma unless the protein has first been denatured with 50% alcohol.

15. It was concluded that: (*a*) vitamin A in concentrations similar to those produced in the blood of hypervitaminotic animals, has a direct action on cartilage and bone *in vitro*; (*b*) the severity of the effect depends on (1) the concentration of the vitamin in the culture medium and (2) the proportion of skeletal cells to intercellular material in the explanted rudiment; (*c*) the character of the vitamin A effect is correlated with the developmental pattern of the explant under normal conditions of culture, and is probably an exaggerated form of that produced in the bones of young animals by hypervitaminosis A; (*d*) vitamin A has a lower biological activity and is in a different state in the blood plasma of a hypervitaminotic animal than when it is added directly to normal plasma.

The authors wish to thank Mr L. J. King, technician at the Strangeways Research Laboratory, for his skilful help with the tissue culture, Mr R. J. C. Stewart, chief technician of the Nutrition Building, National Institute for Medical Research, for his valuable assistance in the preparation of the blood plasma, and Mr V. C. Norfield, head assistant at the Strangeways Research Laboratory, for photomicrography and the preparation of the plates. Their thanks are also due to the British Drug Houses Ltd. for the large supplies of Avoleum kindly provided.

REFERENCES

Barnicot, N. A. (1950). *J. Anat., Lond.*, **84**, 374.
Bomskov, C. & Seemann, G. (1933). *Z. ges. exp. Med.* **89**, 771.
Collazo, J. A. & Rodriguez, J. S. (1933). *Klin. Wschr.* **12**, 1732.
Davies, A. W. & Moore, T. (1934). *Biochem. J.* **28**, 288.
Dzialoszynski, L. M., Mystkowski, E. M. & Stewart, C. P. (1945). *Biochem. J.* **39**, 63.
Fell, H. B. (1951). *Methods in Medical Research*, **4**, 234. Chicago: Year Book Publishers.
Fell, H. B. & Mellanby, E. (1950). *Brit. Med. J.* ii, 535.
Fell, H. B. & Robison, R. (1929). *Biochem. J.* **23**, 767.
Follis, R. H. & Berthrong, M. (1949). *Johns Hopk. Hosp. Bull.* **85**, 281.
Herbst, E. J., Pavcek, P. L. & Elvehjem, C. A. (1944). *Science*, **100**, 338.
Irving, J. T. (1949). *J. Physiol.* **108**, 92.

Kimble, M. S. (1939). *J. Lab. clin. Med.* **24**, 1055.
Medical Research Council (1949). *Spec. Rep. Ser. med. Res. Coun., Lond.*, no. 264, p. 91.
Mellanby, E. (1938). *J. Physiol.* **94**, 380.
Mellanby, E. (1939). *J. Physiol.* **96**, 36*P*.
Mellanby, E. (1944). *Proc. Roy. Soc.* B, **132**, 28.
Mellanby, E. (1947). *J. Physiol.* **105**, 382.
Moore, T. & Wang, Y. L. (1943). *Biochem. J.* **37**, viii.
Moore, T. & Wang, Y. L. (1945). *Biochem. J.* **39**, 222.
Pavcek, P. L., Herbst, E. J. & Elvehjem, C. A. (1945). *J. Nutr.* **30**, 1.
Ray, R. D., Evans, H. M., & Becks, H. (1942). *Anat. Rec.* **82**, 67.
Strauss, K. S. (1934). *Beitr. path. Anat.* **94**, 345.
Trowell, O. A. (1952). *Exp. Cell Res.* (in the Press).
Van Metre, T. E. (1947). *Johns Hopk. Hosp. Bull.* **81**, 305.
Walker, D. M., Thomson, S. Y., Bartlett, S. & Kon, S. R. (1949). *XII Int. Dairy Congr.*, no. 83.
Wolbach, S. B. (1947). *J. Bone Jt Surg.* **29**, 171.
Wolbach, S. B. & Bessey, O. A. (1942). *Physiol. Rev.* **22**, 233.
Yudkin, S. (1941). *Biochem. J.* **35**, 551.

EXPLANATION OF PLATES

The photomicrographs were taken by Mr V. C. Norfield (Strangeways Research Laboratory), except figs. 23–28 which were the work of Mr R. J. C. Stewart (National Institute for Medical Research).

Abbreviations

dc	degenerate cells	*pb*	periosteal bone
ep	epiphysis	*pf*	pressure fibrils
m	metachromasia	*zfc*	zone of flattened cells
mdc	mechanically damaged cartilage	*zhc*	zone of hypertrophic cells

PLATE 1

Fig. 1. Femur from a 6-day chick embryo at stage 3 (see p. 324). Hypertrophy of the cartilage cells is just beginning in the middle segment of the shaft, but no bone has formed. ×19. (Delafield's haematoxylin, chromotrop.)

Fig. 2. Control femur (Exp. 46) explanted at a slightly earlier stage (stage 2) than that shown in fig. 1, and cultivated in normal medium for 9 days. (Camera lucida drawings of this femur in life are shown in Text-fig. 1). Note the great enlargement that has taken place *in vitro*, and the differentiation of the cartilage into hypertrophic region, zones of flattened cells and epiphyses. The cartilage matrix is strongly basophilic. ×19. (Delafield's haematoxylin, chromotrop.)

Fig. 3. Femur from the opposite side of the same chick as shown in Fig. 2, after 9 days' cultivation in AH medium (see Text-fig. 1). Note the small size of the explant and the loss of basophilia from the matrix; the condylar end is nearly detached from the shaft. ×19. (Delafield's haematoxylin, chromotrop.)

Fig. 4. Part of the diaphysial region of the section shown in fig. 2. Note the layer of periosteal bone which has been deposited on the surface of the cartilage, the vacuolated hypertrophic chondroblasts and the broad intercellular partitions of strongly basophilic matrix. ×400.

Fig. 5. Part of the diaphysial region of the section shown in fig. 3. Note the periosteal bone and the loss of basophilia from the cartilage matrix; the chondroblasts are smaller and less vacuolated than those of fig. 4, but have not degenerated. ×400.

Fig. 6. Proximal end of a control humerus (Exp. 46) from a chick embryo at stage 2, after 11 days' cultivation in normal medium (see Text-fig. 2). The three zones of cartilage are highly developed and a fairly thick layer of periosteal bone has been formed. ×37. (Delafield's haematoxylin, chromotrop.)

Fig. 7. Proximal end of the opposite humerus from the same embryo as that shown in fig. 6, after 11 days' cultivation in AH medium (see Text-fig. 2). The end of the humerus has become detached and displaced, the periosteal bone is spreading diffusely from the broken end of the shaft and the cartilage matrix of the hypertrophic region has lost much of its basophilia. ×37. (Delafield's haematoxylin, chromotrop.)

Fig. 8. Proximal end of a humerus (Exp. 43) from a chick embryo at stage 3, after 4 days in AH medium. This shows an early stage in the detachment of the end; the shaft is constricted just beyond the proximal limit of the periosteal bone, the cartilage cells are compressed and some are degenerate. ×52. (Delafield's haematoxylin, chromotrop.)

Fig. 9. Radius (Exp. 47) from a chick embryo at stage 4, after 7 days' cultivation in AH medium. Metachromasia has begun to disappear from the peripheral cartilage of the shaft. ×19. (Toluidine blue.)

Fig. 10. Control radius from the same embryo as that shown in fig. 9, after 7 days' cultivation in normal medium. Note the intense metachromasia of the cartilage matrix. ×19. (Toluidine blue.)

PLATE 2

Fig. 11. Part of the diaphysial region of the section shown in fig. 9. Note the narrow intercellular partitions in the cartilage, and the compact arrangement and healthy appearance of the chondroblasts. ×400.

Fig. 12. Part of the diaphysial region of the section shown in fig. 10. Note the broad, intensely staining metachromatic intercellular partitions; the shape of the chondroblasts is less regular than in the hypervitaminotic cartilage shown in fig. 11. ×400.

Fig. 13. Humerus (Exp. 50) from a chick embryo at stage 2, after 11 days' cultivation in AH medium. One end is completely and the other nearly detached and metachromasia has disappeared from the cartilage except in the interior of the two ends. Most of the cells in this explant appeared healthy. ×24. (Toluidine blue.)

Fig. 14. Section of the same humerus as that shown in fig. 13, stained with celestine blue, haematin and van Gieson's solution. All the cartilage stains bright pink with van Gieson's stain except the two regions which in the previous section retained their metachromasia; note the pressure fibrils in the cartilage at either end of the shaft. ×24.

Fig. 15. Normal radius (Exp. 52) from a late mouse foetus. Note the large terminal cartilages, stout shaft of bone and the marrow cavity permeated by endochondral bone trabeculae. ×23. (Celestine blue, haematin, van Gieson.)

Fig. 16. Control radius (Exp. 52) from a late mouse foetus after 7 days' cultivation in normal medium (see Text-fig. 3). The rudiment has enlarged slightly, much of the endochondral bone has been absorbed and endochondral ossification has ceased; the terminal cartilage is being invaded in an irregular way by tissue from the marrow cavity. ×23. (Celestine blue, haematin, van Gieson.)

Fig. 17. Opposite radius from the same foetus as the control shown in Fig. 16, after 7 days' cultivation in AH medium (see Text-fig. 3). Note the enormous shrinkage of the entire rudiment, the extensive absorption of the bone and the density of the marrow reticulum. ×23. (Celestine blue, haematin, van Gieson.)

Fig. 18. The same control as that seen in fig. 16, showing the large, metachromatic terminal cartilages. ×23. (Toluidine blue.)

Fig. 19. The same hypervitaminotic radius as that shown in fig. 17. The terminal cartilage has disappeared. ×23. (Toluidine blue.)

Fig. 20. Radius of foetal mouse (Exp. 7) after 10 days' cultivation in AH medium. Nothing of the original rudiment remains except a nodule of mechanically damaged cartilage and a few spicules of bone. ×82. (Delafield's haematoxylin, chromotrop.)

Fig. 21. Terminal cartilage of foetal mouse radius (Exp. 52) after 4 days' cultivation in AH medium. The cartilage matrix has almost completely lost its metachromasia which persists only in a small internal area and in the remains of the hypertrophic zone. ×72. (Toluidine blue.)

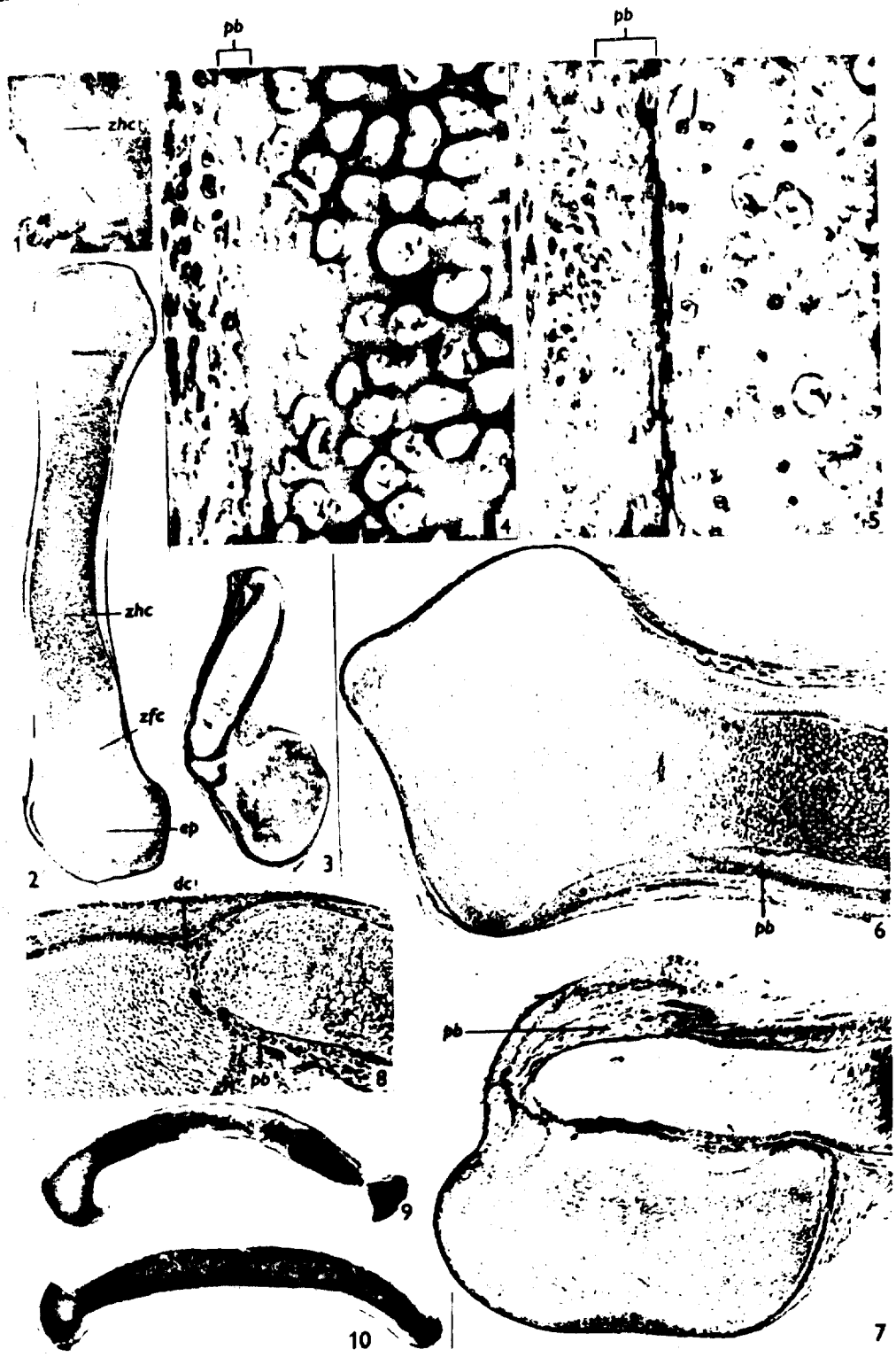

To face p. 348

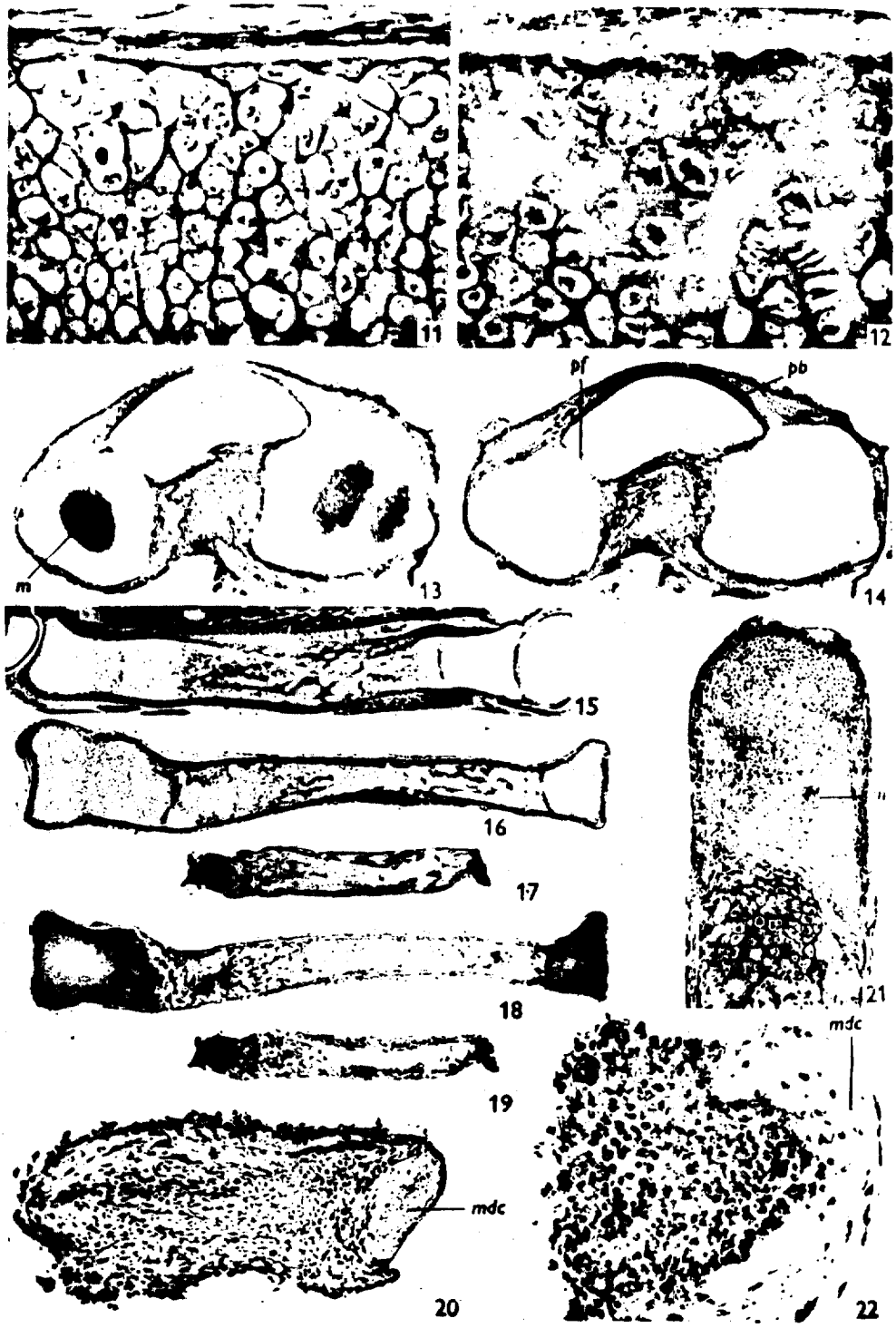
11
12
pf
pb
m
13
14
15
16
17
18
21
mdc
19
mdc
20
22


23


24


25


27

28


26

31

32


29


30

Fig. 22. Terminal cartilage of foetal mouse radius (Exp. 51) after 4 days' cultivation in AH medium. Except in a crescent of mechanically damaged cartilage on the right, the matrix has completely disappeared and the liberated chondroblasts, which appear healthy, seem to be wandering away from the surface of the explant. × 220. (Toluidine blue.)

PLATE 3

Fig. 23. Unheated radius of foetal mouse cultivated in AH medium for 4 days. The cartilage has nearly gone and the bone is much eroded. × 34. (Thionine, eosin.)

Fig. 24. Radius from the opposite side of the same mouse, heated at 45° C. for 15 min. and then cultivated for 4 days in AH medium. This explant did not grow and failed to respond to the hypervitaminosis A. × 34. (Thionine, eosin.)

Fig. 25. An area of cartilage in the section shown in fig. 23. The matrix has almost disappeared, but the chondroblasts look healthy. × 565.

Fig. 26. An area of cartilage in the section shown in fig. 24. There is no loss of matrix, but the chondroblasts are necrotic. × 565.

Fig. 27. Unheated radius of foetal mouse cultivated in AH medium for 4 days. The rudiment shows the characteristic response to hypervitaminosis A. × 34. (Thionine, eosin.)

Fig. 28. Radius from the opposite side of the same foetus, heated at 40° C. for 15 min. and cultivated in AH medium for 4 days. Heating at 40° C. has not affected the response of the explant to hypervitaminosis A. × 34. (Thionine, eosin.)

Fig. 29. Radius from a mouse foetus (Exp. 19) after 7 days' cultivation in 'artificial' hypervitaminosis. The explant shows the usual response to excess vitamin A added to the medium. × 23. (Delafield's haematoxylin, chromotrop.)

Fig. 30. Radius from the same foetus after 7 days' cultivation in 'natural' hypervitaminosis. Although the medium contained approximately the same quantity of vitamin A as was added to the AH medium, the rudiment appears unaffected. × 23. (Delafield's haematoxylin, chromotrop.)

Fig. 31. Distal end of a control tibia of a mouse foetus from the same experiment (Exp. 19) as the explants shown in the two preceding figures. The explant was grown in normal medium for 12 days. Note the large terminal cartilage with strongly basophilic matrix. × 35. (Delafield's haematoxylin, chromotrop.)

Fig. 32. Distal end of the opposite tibia of the same foetus as that shown in fig. 31, after 12 days' cultivation in NH medium. Note the greatly reduced cartilage, the matrix of which is beginning to lose its basophilia near the margin. × 35. (Delafield's haematoxylin, chromotrop.)

Fell - '56
Bib. No. 2681

J. Physiol. (1956) 134, 179–188

INFLUENCE OF EXCESS VITAMIN A ON THE SULPHATE METABOLISM OF BONE RUDIMENTS GROWN *IN VITRO*

BY H. B. FELL, THE LATE E. MELLANBY AND S. R. PELC*

From the Strangeways Research Laboratory, Cambridge; The Nutrition Building, National Institute for Medical Research; the Medical Research Council, Experimental Radiopathology Research Unit, London

(*Received* 30 *May* 1956)

In organ culture experiments, Fell & Mellanby (1952) found that when vitamin A was added to the culture medium (+A medium) of long-bone rudiments from chick and mouse embryos, the intercellular material of the cartilage rapidly lost its capacity for metachromatic staining, shrank and finally disintegrated: the chondroblasts usually appeared healthy throughout this process. Later, the effect of excess vitamin A on the differentiation *in vitro* of the early embryonic epidermis of the chick was investigated (Fell & Mellanby, 1953); in normal medium the ectoderm formed squamous, keratinizing epithelium, but in +A medium keratinization was suppressed and the epithelium developed into a mucus-secreting, often ciliated membrane resembling the normal nasal mucosa.

The transformation of the epidermis into a mucous instead of a keratinizing epithelium was accompanied by a profound alteration in the sulphate metabolism (Fell, Mellanby & Pelc, 1954). This was shown by treating ectodermal explants, grown in +A and in normal medium respectively, with labelled sodium sulphate ($Na_2{}^{35}SO_4$) and studying the distribution of the isotope by means of autoradiographs (ARG). In the present investigation similar experiments were made to elucidate the sulphate metabolism of long-bone rudiments grown in normal and in +A medium. For comparison, the *in vivo* uptake of sulphate in the long bones of chick embryos was studied.

MATERIALS AND METHODS

Femora and tibiae from 6-day chick embryos were grown by the watch glass method (Fell & Robison, 1929; Fell & Mellanby, 1952) in a mixture of 3 parts of fowl plasma and 1 part of chick embryo extract. This mixture was supplemented with approximately 0·2% of glucose. Normal medium contained 250–300 i.u. of vitamin A/100 ml., and +A medium 2800–3000 i.u./100 ml. The rudiments were transferred to fresh medium every 2 days. Labelled sulphate was obtained

from the Radiochemical Centre, Amersham, England. One drop of Tyrode solution containing 200 μc $Na_2{}^{35}SO_4$ ml. was deposited on each explant and the remaining liquid pipetted off after 30 sec.

The explants were fixed in acetic acid alcohol (1:3; 30 min) followed by formol saline (60 min), embedded in paraffin wax and serially sectioned. This method of fixation has been used successfully in previous investigations and has the advantage of combining good preservation of the cells with freedom from artifacts in autoradiography. It has the disadvantage that flattening does not eliminate folds from sections of cartilage fixed in this way. Autoradiographs of the sections were prepared by the stripping film technique (Doniach & Pelc, 1950). One slide of each bone was exposed for 7–9 days and, after photographic processing, stained with toluidine blue. The slide was then treated with 10% acetic alcohol, which largely decolorized the photographic film but not the underlying sections; after being washed in tap water, it was passed through the increasing concentrations of ethanol to xylene and mounted in DPX. The second slide was exposed for 19–25 days and left unstained; the ARG was sufficiently heavy for observation with a pair of projection microscopes, which facilitated comparison of sections.

Expt. in vivo. Eggs were injected with 200 μc $Na_2{}^{35}SO_4$ per egg after 7, 9 or 13 days' incubation, opened after 4 or 24 hr, and ARG's of the long bones prepared.

Expt. no. 1. After 4 days' growth in normal or + A medium, explanted bones were treated with $Na_2{}^{35}SO_4$ and fixed 2, 4, 24 or 48 hr later.

Expt. no. 2. After 4 days in normal or + A medium, $Na_2{}^{35}SO_4$ was applied; 24 hr later the explants were transferred to non-radioactive medium for 4, 24 or 48 hr and fixed.

Expt. no. 3. After 2, 4, 6, 8 or 10 days in normal or + A medium, $Na_2{}^{35}SO_4$ was applied; 4 hr later some of the explants were fixed, while others were washed in dilute embryo extract and transferred to non-radioactive medium for 24 or 48 hr and then fixed.

Expt. no. 4. Explants were grown for 4 or 6 days in normal medium, then for 4 days in + A medium; after this $Na_2{}^{35}SO_4$ was applied for 30 sec, then soaked off and 4 hr later one half of the bones were fixed. The other half were transferred to unlabelled + A medium and fixed 2 days later. For an equal number of explants the procedure was reversed, i.e. the explants were grown for 4 or 6 days in + A medium followed by 4 days in normal medium, then treated with $Na_2{}^{35}SO_4$ for 4 hr; half the number were fixed immediately, and the rest after 2 days in normal unlabelled medium.

Altogether 168 explants were used in the experiments.

RESULTS

Experiment in vivo. In bones fixed 4 hr after injection, the $^{35}SO_4$ is concentrated in the cells (Pl. 1, fig. 1): after 24 hr an appreciable concentration is found in the matrix as well (Pl. 1, fig. 2), confirming results of previous experiments on the renewal of chondroitin sulphate in the cartilage of adult mice (Pelc & Glücksmann, 1955). It can be concluded that in normal cartilage $^{35}SO_4$ is bound in an organic substance or substances first within the cartilage cells; this material, which is probably chondroitin sulphate, or a precursor which is not removed by fixation, etc., then passes into the matrix.

The bone rudiments from eggs injected after 7 days' incubation show almost uniform incorporation of $^{35}SO_4$ (Pl. 1, fig. 3) throughout the cartilage, which at this stage is still continuous in all the long bones, as the marrow cavity is not yet formed. The ARG is weaker above the hypertrophic cells in the middle portion of the shaft.

After 9 days' incubation the first signs of the marrow cavity have appeared in the middle of the shaft of the femur, humerus and tibia, but not in the ulna and radius. After 4 hr contact with $^{35}SO_4$ the uptake of the isotope is confined to the epiphyses, to the zones of flat, proliferating cells, young hypertrophic cells (cf. Amprino, 1954) and to a relatively narrow zone in the middle of the shaft (Pl. 1, fig. 4), in which the cells are more tightly packed than in the adjacent regions of mature hypertrophic cartilage which show no ARG. This narrow zone of ARG coincides with the part of the cartilage which is destined to disappear first when the marrow cavity begins to be excavated. The bones from eggs injected after 9 days' incubation and fixed 24 hr later have well-developed marrow cavities (Pl. 1, fig. 5). $^{35}SO_4$ is still found where it was at 4 hr but, as would be expected, the ARG is much heavier, since 24 hr instead of 4 hr were available for incorporation. The cells in the newly formed marrow cavity are weakly labelled; the periosteal bone is also labelled. The bones from embryos incubated for 13 days show essentially the same uptake as after 9 days; some cells in the marrow cavity give a strong ARG (cf. Lajtha, Ellis & Oliver, 1953).

Control explants in normal medium. Two and four hours after the application of the $^{35}SO_4$ (Expts 1, 3), in all rudiments the sulphate is concentrated more in the cells than in the matrix. In the 2-day explants (Expt. 3), which are at an early stage of differentiation, are still growing actively and are forming matrix throughout their length, the sulphate is taken up intensely by the whole rudiment, though uptake is greatest in the zones of flattened cells and in the epiphyses. In the 4-day (Pl. 2, fig. 6) and still more in the 6-day explants (Pl. 2, fig. 7), however, in which development is more advanced, the heaviest ARG is over the young hypertrophic cells in the distal parts of the shaft where matrix-formation is probably maximal; the ARG is also dense over the small-celled epiphyses and in the two proliferative zones of flattened cells. As hypertrophy increases, the uptake in the middle segment of the shaft, where chondrogenesis is rapidly coming to an end, becomes progressively less with age, although a small proportion of cells continue to bind $^{35}SO_4$ (Pl. 2, fig. 7): this diminution begins in the interior of the hypertrophic zone, i.e. in the oldest cartilage, and spreads to the surface. The young periosteum maintains synthesis, however, and a weak ARG is seen over the newly formed sheath of bone on the surface of the hypertrophic cartilage.

When the explants are transferred after 4 hr in labelled medium to non-radioactive medium for 24 hr (Expt. 3), the $^{35}SO_4$, though still plentiful in the cells, is more evenly diffused throughout the cartilage. The intensity of the ARG, as seen by low power, seems diminished in the epiphyses, but the total content of $^{35}SO_4$ is about the same in the young hypertrophic cells and in the middle segment of the shaft. To some extent it has merely become more dispersed as a result of the expansion of the growing rudiment. Incubation

on non-radioactive medium for a further 24 hr produces a still greater diffusion of the ARG, the matrix often containing much more $^{35}SO_4$ than the cells.

The rudiments grown continuously for 24–48 hr in labelled medium (Expt. 1) show the same trend, but results are less clear-cut because labelled sulphate is available for up to 2 days. For this reason the difference between cells and matrix is less pronounced. Similarly, explants grown in labelled medium for 24 hr and then transferred (Expt. 2) give the same result as those of Expt. 3, but the situation is more complicated because some sulphate is already concentrated in the matrix at the time of transfer to non-labelled medium.

+A explants. As in the controls, 4 hr after the application of the $^{35}SO_4$ more sulphate is present in the cells than in the matrix. Throughout the series, the femur is more affected by the +A than the tibia. After 2 days in +A medium, the matrix of the femur shows a slightly weakened metachromatic stain in the peripheral regions of the epiphyses and of the proliferative zones of flattened cells, but no histological change can be detected in the tibia. The regions of reduced metachromasia have taken up rather less sulphate than the rest of the femur and throughout both rudiments the uptake seems to be somewhat lower than in the corresponding controls. After 4 days' growth, the loss of metachromatic stain from the peripheral matrix of the zones of flattened cells is more pronounced in the femur and has now appeared in the tibia also; the uptake of $^{35}SO_4$ is greatly reduced in the matrix that fails to stain with toluidine blue, but elsewhere is only slightly less dense than in the controls (Pl. 2, fig. 8). In the 6-day +A explants, the zones of flattened cells show similar but more extensive areas of nearly unstained matrix with greatly diminished uptake, but in addition peripheral regions of the hypertrophic zone, though still staining with almost normal intensity, take up much less $^{35}SO_4$ than in the controls. In some rudiments at this stage the changes are more advanced; in the middle segment of the shaft the matrix has almost completely lost its affinity for toluidine blue and the ARG is very sparse.

Twenty-four hours after transfer to non-radioactive +A medium, the ARG in the +A explants, as in the controls, is less concentrated in the cells and more evenly distributed between the cells and matrix. The 2-day explants show a slight loss of metachromasia and less ARG at the periphery of the zones of flattened cells when examined 24 and 48 hr after transfer, but otherwise do not differ from the controls. A greater change appears in the 4-day explants when grown for a further 24–48 hr on non-radioactive +A medium. In the femur fixed 48 hr after transfer, the matrix of a large part of the zone of flattened cells has lost its affinity for toluidine blue, is much reduced in amount and has almost completely lost its ARG, although some remains in the cells; metachromasia and $^{35}SO_4$ have almost disappeared from the shaft. The tibiae fixed after

24 and 48 hr on non-radioactive +A medium show similar but usually less pronounced changes.

The femora cultivated for 6 days in +A medium are drastically affected after further growth on non-radioactive +A medium. Twenty-four hours after transfer there is much peripheral loss of metachromasia from the zones of flattened and young hypertrophic cells, and while some ^{35}S remains in the cells, it has almost completely gone from the intercellular material; other parts of the rudiment also show such peripheral changes, though to a lesser degree.

TABLE 1. (Expt. 3.) Comparison of autoradiograph and metachromatic staining of the shafts of bones grown in +A and in normal medium

		Normal medium						+A medium					
Days before SO_4		2, 4	4	4	6	6	6	2, 4	4	4	6	6	6
Days after SO_4		0	1	2	0	1	2	0	1	2	0	1	2
Femora	M	4	4	4	4	4	4	4	4	3	4	1	0
	ARG	4	3	3	3	4	3	4	3	0	0	0	0
Tibiae	M	4	4	4	4	4	4	4	4	4	4	3	3
	ARG	4	3	4	3	4	3	4	3	3	3	0	0

M, metachromatic stain: 0, none; 1, slight; 3, strong; 4, very strong.
ARG: 0, none; 3, strong; 4, very strong.

After 48 hr (Pl. 2, fig. 9), the matrix has almost disappeared from some zones of flattened cells, and the $^{35}SO_4$ is greatly reduced in both cells and matrix; the peripheral matrix of the epiphyses has lost its characteristic staining and most of its $^{35}SO_4$, but the interior still stains normally and has an intense ARG. There is no uptake of $^{35}SO_4$ in the mature hypertrophic cells of the shaft, even in regions which still show metachromasia. Relative values for the intensity of metachromatic staining and ARG in the shaft are given in Table 1 (Expt. 3). In tibiae cultivated for 6 days the changes are similar but less advanced.

A time-lag between the disappearance of $^{35}SO_4$ and of metachromasia can be seen in Table 1. Metachromatic staining in the shaft of the femora is intense up to the 6th day of cultivation in +A medium and then diminishes rapidly. All the $^{35}SO_4$ which was taken up in the shafts of the 4-day explants has disappeared 2 days later, and subsequently the cells cease to utilize $^{35}SO_4$. A similar effect appears about 2 days later in the tibiae. The connexion between intensity of metachromatic staining and concentration of chondroitin sulphate is not known, and further, since staining was not standardized in our experiments and our estimate of the intensity of the stain is subjective, we cannot state what loss of chondroitin sulphate is equivalent to a given change in the staining reaction. It can be assumed, however, that a drop from our grade 4 to grade 0 represents almost complete disappearance of chondroitin sulphate. For the ARG's a quantitative estimate of the change is easier, and a drop from grade 4 to grade 0 is equivalent to a loss of 95% or more of the isotope. It can

be concluded that the time-lag between the disappearance of $^{35}SO_4$ and of metachromasia is a real difference.

Mixed treatment (*Expt.* 4). Pl. 2, figs. 10–12, show stained sections and ARG of explants which were cultivated either first in normal medium and then in +A medium, or first in +A and then in normal medium. It is seen that rudiments grown first in +A medium are much more affected than those which were first cultivated on normal medium. For example, the rudiment shown in Pl. 2, fig. 10 (4 days normal + 4 days +A) is only bent, and the centre of the shaft is well stained, whilst that in Pl. 2, fig. 12 (4 days +A +4 days normal) is broken and distorted. Two days later (Pl. 2, fig. 11, 4 days normal + 6 days +A) the middle of the shaft is severely affected and bent sharply. These rudiments grown first in normal medium thus differ in an important respect from those continuously grown in +A medium, which show a constriction in the zone of proliferating cells before the shaft is drastically altered (Fell & Mellanby, 1952). Conversely, the region of proliferating cells is much less affected than in rudiments grown only in +A medium. The sequence of damage in rudiments first grown in +A medium and then in normal seems to follow the pattern of continuous growth in +A medium. All the explants are severely damaged: the epiphysis has been detached from the shaft, the remains of which are relatively straight. As far as the experiments overlap, these results agree with Herbertson's findings (1955).

DISCUSSION

The uptake of $^{35}SO_4$ by the control explants in normal medium is very similar to that of the normal long-bone rudiments in the embryo. In both, the sulphate is first concentrated in the cells and then appears in the matrix; the ARG is most intense over the epiphyses, the proliferative regions and the newly formed distal hypertrophic cartilage; as development proceeds it becomes progressively less in the old hypertrophic cartilage in the middle of the shaft, indicating that the synthesis of matrix is diminishing in this region. The main difference between the normal long bone in the chick and the control explants is the presence in the former of a narrow zone of ARG over an area of closely packed cartilage cells in the middle of the shaft (Pl. 1, fig. 4*b*). This region is the first to be eroded when the narrow cavity is formed, and it is absent in the control explants *in vitro* in which no marrow cavity develops; this uptake of $^{35}SO_4$ suggests that the area may be the site of catabolic processes preceding dissolution.

When the control explants are compared with those grown in +A medium the following facts emerge: (1) in explants grown in normal medium, the cartilage of the shaft retains all or most of the $^{35}SO_4$ once it has been incorporated; (2) in the explants grown for 4 days in +A medium, $^{35}SO_4$ is taken up, but after a further 2 days in unlabelled +A medium much of the sulphate is lost, especially from the middle of the shaft and the periphery; (3) after abo

[illegible] growth in +A medium, the peripheral cartilage and the middle segment of the diaphysis cease to incorporate $^{35}SO_4$; (4) explants grown first in +A and then in normal medium are more severely damaged than those grown first in normal and then in +A medium.

Our experiments indicate, therefore, that vitamin A both inhibits the synthesis of new cartilage matrix and causes the dissolution of that already formed. These results could be explained, at least in part, by the following hypothesis: (a) excess vitamin A causes cells either to elaborate a new enzyme which converts chondroitin sulphate to a more soluble form, or to produce excessive amounts of an enzyme which is already present in the tissue: (b) this enzyme diffuses into the matrix, and (c) once cells have begun to produce this enzyme, they continue to do so. Chondroitin sulphate in normal adult cartilage is continuously broken down in the matrix and replenished by the cells (Pelc & Gluckson, 1955). It is therefore likely that an enzyme which hydrolyses chondroitin sulphate is normally present.

Under the influence of excess vitamin A the concentration of this hypothetical enzyme will at first be high in the cells, but when sufficient quantities have been secreted into the matrix the existing chondroitin sulphate will be affected. There will therefore be a time-lag between the production of this soluble sulphated compound and the dissolution of old matrix. This would account for the time-lag between the disappearance of bound $^{35}SO_4$ and that of metachromatic staining (see Table 1). It is hoped to test this hypothesis by experiments on the uptake of ^{14}C-labelled vitamin A and by comparing the enzymic action of extracts of vitamin-A-treated and untreated explants.

As described above, the effect of vitamin A is not uniform throughout the rudiment. Thus the loss of metachromatic staining and of sulphate uptake begins near the surface and spreads inwards: this may be correlated with the inward diffusion of the vitamin from the culture medium. In addition, the old hypertrophic cartilage of the shaft is more rapidly and severely affected than the distal cartilage. It has been shown that normally the synthesis of matrix is waning in the middle of the shaft while it is still active distally; it might be expected that this natural decline in the synthetic processes would be hastened by the vitamin, so that matrix formation would be arrested in this region before it ceased in other parts of the rudiment.

Dziewiatkowsky (1954) has investigated the effect of vitamin A on the sulphate metabolism of vitamin-A-deficient rats. He found that the administration of vitamin A causes a higher uptake of sulphate in the mucopolysaccharide of the cartilage of the femur and in the skin after a delay of about 48 hr. This increased uptake (Dziewiatkowsky, 1954, text-figs. 1, 2) is probably due to unbound sulphate since it does not appear in the series where the unbound sulphate has been removed (Dziewiatkowsky, 1954, text-fig. 4). This author's autoradiographs also indicate a quicker release of bound sulphate from the epiphysial

cartilage after vitamin A was given to deficient animals. Dziewiatkowsky's results are thus comparable to ours, which show very little effect of excess vitamin A on explanted limb-bone rudiments during the first 2 days in +A medium, but a rapid disappearance of the ^{35}S after more prolonged exposure to the vitamin.

SUMMARY

1. The influence of excess vitamin A, on the sulphate metabolism ($Na_2{}^{35}SO_4$) of chick long-bone rudiments grown *in vitro* by the watch-glass method, was investigated by means of autoradiography.

2. The normal medium used for the controls (3 parts fowl plasma +1 part chick embryo extract +0·2% added glucose) contained 250–300 i.u. of vitamin A/100 ml., and the +A medium 2800–3000 i.u./100 ml. One drop of Tyrode solution containing 200μc $Na_2{}^{35}SO_4$/ml. was deposited on each explant and was pipetted off after 30 sec.

3. Some explants were fixed after 2, 4, 24 or 48 hours in labelled medium; others were transferred after 4 hours to unlabelled medium and fixed 24 or 48 hours later.

4. For comparison, eggs were injected with 200μc $Na_2{}^{35}SO_4$ after 7, 9 and 13 days' incubation, the long bones were fixed 4 or 24 hours later and serial sections were cut from which autoradiographs were made.

5. In all the bones, both normal and explanted, fixed 2 and 4 hours after labelling, sulphate was mainly concentrated in the cells; later, considerable quantities were found in the matrix, confirming earlier results on the sulphate metabolism of cartilage in mice.

6. In the rudiments from normal embryos, uptake was almost uniform throughout the cartilage in 7-day chicks; after 9 days' incubation it was confined to the epiphyses, the proliferative zones and a narrow region in the middle of the shaft; in 13-day rudiments the narrow zone of uptake in the middle of the shaft had been replaced by the invading marrow.

7. Control explants grown in normal medium showed essentially the same uptake as the embryonic rudiments labelled *in ovo*; when the control explants were transferred from labelled to unlabelled medium for 2 days little bound sulphate was lost.

8. In +A medium uptake diminished in the peripheral regions of the epiphyses and of the shaft. Two days after transfer to unlabelled medium there was an appreciable loss in the periphery of the shaft; this preceded the disappearance of metachromasia from the matrix, after which the cells were unable to bind sulphate.

9. If explants were first grown for 4–6 days in +A medium and then transplanted to normal medium for 4 days, the changes were similar to those produced by continuous culture in +A medium, but if normal medium were followed by +A medium, the effect was much less drastic.

10. It is tentatively suggested that, under the influence of vitamin A, the cartilage cells may produce an enzyme which results in the formation of a soluble sulphated mucopolysaccharide, instead of the normal chondroitin sulphate, and in the dissolution of existing matrix.

The authors wish to thank Lady Mellanby and Dr G. Popjak for helpful and constructive criticism of the manuscript; Mr R. J. C. Stewart, who made the cultures and contributed in many other ways to this work, for his skilful and enthusiastic help; and Mr V. C. Norfield, who printed the photographs and prepared the plates.

REFERENCES

Amprino, R. (1954). Differenziazione e accrescimento della cartilagine di abbozzi scheletrici studiati con l'impiego del radiosolfo. *R.C. Accad. Lincei*, Ser. 8, **16**, 781–785.

Doniach, I. & Pelc, S. R. (1950). Autoradiograph technique. *Brit. J. Radiol.* **23**, 184–192.

Dziewiatkowsky, D. D. (1954). Vitamin A and endochondral ossification in the rat as indicated by the use of Sulfur-35 and Phosphorus-32. *J. exp. Med.* **100**, 10–24.

Fell, H. B. & Mellanby, E. (1952). The effect of hypervitaminosis A on embryonic limb-bones cultivated *in vitro*. *J. Physiol.* **116**, 320–349.

Fell, H. B. & Mellanby, E. (1953). Metaplasia produced in cultures of chick ectoderm by high vitamin A. *J. Physiol.* **119**, 470–488.

Fell, H. B., Mellanby, E. & Pelc, S. R. (1954). Influence of excess vitamin A on the sulphate metabolism of chick ectoderm grown *in vitro*. *Brit. med. J.* ii, 611–612.

Fell, H. B. & Robison, R. (1929). The growth, development and phosphatase activity of embryonic avian femora and limb-buds cultivated *in vitro*. *Biochem. J.* **23**, 767–784.

Herbertson, M. A. (1955). The reversibility of the effect of hypervitaminosis A on embryonic limb bones cultivated *in vitro*. *J. Embryol. exp. Morph.* **3**, 355–365.

Lajtha, L. G., Ellis, F. & Oliver, R. (1953). Isotope uptake of individual cells: uptake of S^{35} sulphate by human bone-marrow cells *in vitro*. *Brit. J. Cancer*, **7**, 401–406.

Pelc, S. R. & Glücksmann, A. (1955). Sulphate metabolism in the cartilage of the trachea, pinna and xiphoid process of the adult mouse as indicated by autoradiographs. *Exp. Cell. Res.* **8**, 336–344.

EXPLANATION OF PLATES

ep	epiphysis	*ohc*	old hypertrophic cartilage
hc	hypertrophic cartilage	*yhc*	young hypertrophic cartilage
mc	marrow cavity	*zfc*	zone of flattened cells

Plate 1

Photographs of limb bones of normal embryos, from eggs into which $Na_2{}^{35}SO_4$ had been injected (*in vivo* experiment). Figures 3–5 are all to the same magnification.

Fig. 1. Hypertrophic cartilage from the femur of a 9-day embryo, fixed 4 hr after injection of $Na_2{}^{35}SO_4$. The ARG is mainly concentrated above the cells; slide exposed for 7 days, stained with toluidine blue.

Fig. 2. Hypertrophic cartilage from the femur of a 9-day embryo, fixed 24 hr after injection of $Na_2{}^{35}SO_4$. The ARG is now profuse over the matrix as well as over the cells; slide exposed for 7 days, stained with toluidine blue.

Fig. 3. Humerus from a 7 day embryo, 4 hr after injection of $Na_2{}^{35}SO_4$. The ARG is weak above the hypertrophic cells in the centre of the shaft; elsewhere the incorporation of the $^{35}SO_4$ is fairly uniform. (*a*), slide exposed for 7 days, stained with toluidine blue; (*b*) 21 days' exposure, unstained.

Fig. 4. Humerus from a 9-day embryo, 4 hr after injection of $Na_2{}^{35}SO_4$. The uptake of $^{35}SO_4$ is now confined to the distal parts of the bone, except for a narrow zone of ARG (marked with an arrow) in the middle of the shaft; (*a*) and (*b*) as for fig. 3.

Fig. 5. Humerus from a 10-day embryo, 24 hr after injection of $Na_2{}^{35}SO_4$. Excavation of the marrow cavity has begun in the middle of the shaft. (*a*) and (*b*) as before; the dark appearance in (*a*) is partly due to the heavy autoradiograph.

Plate 2

Photographs of explanted femora and tibiae (Expt. 1, figs. 6–9; Expt. 4, figs. 10–12). Figs. 6, 7, 9 and 10–12 are to the same magnification.

Fig. 6. Tibia; 4 days in normal medium; $Na_2{}^{35}SO_4$, 4 hr. The ARG is heaviest over the young (distal and peripheral) hypertrophic cartilage and weakest over the oldest hypertrophic cartilage in the interior of the shaft; it is also dense over the epiphysis and zone of flattened cells. Slide exposed 19 days, unstained.

Fig. 7. Femur; 6 days in normal medium; $Na_2{}^{35}SO_4$, 4 hr. The ARG is very sparse over the old hypertrophic cartilage. (*a*) Slide exposed 7 days, stained with toluidine blue; (*b*) 19 day exposure, unstained.

Fig. 8. Tibia; 4 days in +A medium; $Na_2{}^{35}SO_4$, 4 hr. Peripheral area in the zone of flattened cells; both the ARG and the coloration of the matrix progressively diminish towards the surface of the cartilage; the arrow indicates the long axis of the rudiment. 7 days' exposure, stained with toluidine blue.

Fig. 9. Femur; 6 days in +A medium; $Na_2{}^{35}SO_4$, 4 hr. The rudiment is greatly distorted, the peripheral matrix of the epiphysis has begun to lose its staining capacity and shows a diminished ARG, while, except in the interior, the shaft has lost both its affinity for toluidine blue and its capacity to take up $^{35}SO_4$ (*a*) and (*b*) as fig. 7.

Fig. 10. Femur; 6 days in normal medium + 4 days in +A medium; $Na_2{}^{35}SO_4$, 4 hr. The matrix in the middle segment of the shaft has not lost all its staining capacity, and the rudiment has preserved a fairly normal shape. (*a*) and (*b*) as fig. 7.

Fig. 11. Femur; 6 days in normal medium + 6 days in +A medium; $Na_2{}^{35}SO_4$, 4 hr. The shaft is more severely affected than in the explant shown in fig. 10. (*a*) and (*b*) as in fig. 7.

Fig. 12. Femur; 4 days in +A medium + 4 days in normal medium; $Na_2{}^{35}SO_4$, 4 hr. The explant is much more drastically altered than those grown first in normal and then in +A medium (figs. 10, 11). (*a*) and (*b*) as in fig. 7.


1
2
50μ
hc
3a
3b
5a
5b
1 mm
ep
zfc
yhc
ohc
4a
4b

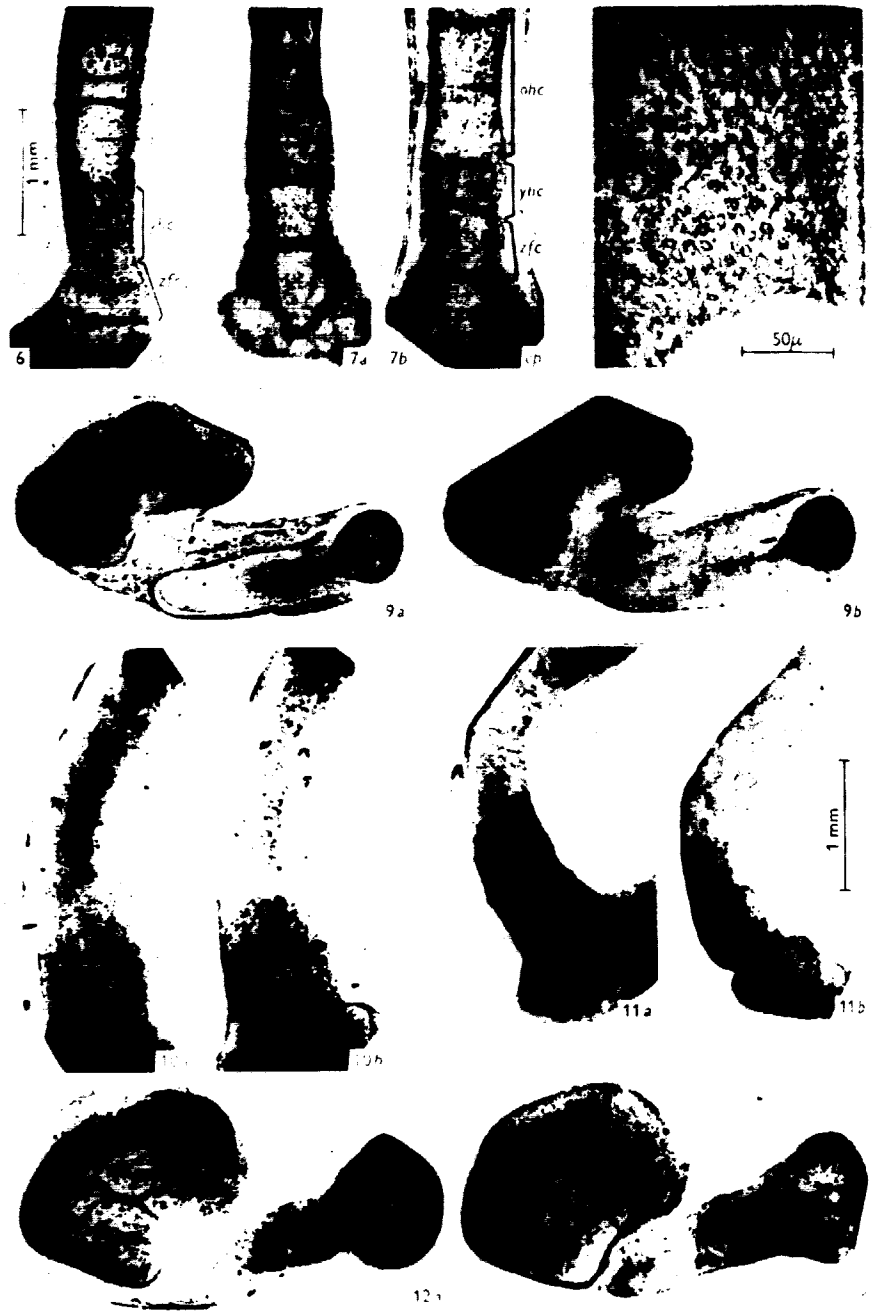
1 mm
6
7a
7b
ohc
yhc
zfc
50μ
9a
9b
11a
11b
1 mm
12a

Fell - '60
Bib. No. 2684

COMPARISON OF THE EFFECTS OF PAPAIN AND VITAMIN A ON CARTILAGE

II. The Effects on Organ Cultures of Embryonic Skeletal Tissue

By HONOR B. FELL,* and LEWIS THOMAS,‡ M.D.

(From the Strangeways Research Laboratory, Cambridge, England, and the Department of Medicine, New York University-Bellevue Medical Center, New York)

Plates 58 to 62

(Received for publication, January 12, 1960)

When embryonic cartilage is grown in medium containing excess vitamin A, the most conspicuous effect of the vitamin is the disappearance of metachromatic material from the matrix (Fell and Mellanby, 1952). Autoradiographic studies, in which the explants were treated with labeled inorganic sulfate, $S^{35}O_4$, showed that this loss of metachromasia is preceded by an inability of the cartilage to fix sulfate, and is accompanied by a loss of the sulfate already present (Fell, Mellanby, and Pelc, 1956). It was not known whether this effect on chondroitin sulfate was the fundamental action of the vitamin on embryonic skeletal tissue in culture, or whether it would account for all the changes observed, including the quick resorption of fetal mouse bone (Fell and Mellanby, 1952).

Thomas (1956) found that crude papain injected into young rabbits caused a rapid loss of chondroitin sulfate from all the cartilage of the body. This was dramatically seen in the collapse of the ears which, 18 hours after injection, drooped like those of a spaniel. Histological examination of the affected cartilage showed that the intercellular partitions were much reduced and had lost their normal basophilia. The general picture was strikingly reminiscent of that seen in fetal mouse bones grown in medium containing excess vitamin A. Later it was found that this effect of the crude papain could be reproduced by the protease component (McCluskey and Thomas, 1958).

Since both papain and vitamin A removed the chondroitin sulfate from living cartilage, it seemed desirable to compare the effects of these two agents on the same material under the same experimental conditions; if the structural changes produced by the vitamin were due primarily to the removal of chondroitin sulfate from the tissue, they should be almost identical with those

* Royal Society Foulerton Research Fellow.
‡ Work done during tenure of a Fellowship awarded by the Commonwealth Fund.

produced by papain protease. In the preceding paper (Thomas, McCluskey, Potter, and Weissmann, 1960) experiments were described in which the effects of papain and vitamin A on the cartilage of young rabbits were compared; it was shown that the administration of large doses of vitamin A caused partial collapse of the ears and release of chondroitin sulfate from the cartilage matrix. The present paper deals with experiments in which limb bone rudiments from embryonic chicks and late fetal mice were grown as organ cultures and exposed to papain, or vitamin A, or to both substances simultaneously.

Material and Methods

Material.—Bone rudiments were dissected from the limbs of 7- and 13-day chick embryos, and of mouse fetuses near term.

Culture Methods.—The standard watch-glass method was used (Fell and Robison 1929; Fell and Mellanby, 1952). The culture medium consisted of 15 drops of cock plasma mixed with 5 drops of embryo extract, and the bones were transplanted to fresh medium every 2 days. For each subculture, 2 extracts were prepared from 13-day chick embryos, as described by Fell and Mellanby (1955). The extract for the culture medium was made of equal parts of tissue mince and Tyrode supplemented with 1 per cent (w/v) glucose for chick explants and 4 per cent glucose for mouse bones; a more dilute extract, in which the rudiments were finally washed before being explanted, was composed of 1 part of mince and 2 parts of Tyrode without extra glucose.

Addition of Papain Protease and Vitamin A to the Medium.—Crystalline papain protease was obtained from Nutritional Biochemicals Corporation, Cleveland. It was received as a non-sterile solution containing 0.03 M cysteine; in some experiments the cysteine was removed by dialysis. To obtain a sufficiently high concentration of the enzyme without diluting the medium too much, the following procedure was adopted. A measured amount of the papain solution was placed in a 6.5 × 2 cm. centrifuge tube and dried in a vacuum desiccator; absolute ethanol was added to sterilize the dried material, which was ground with a sterile glass rod until it formed a fine suspension in the ethanol. The alcohol was then evaporated in the desiccator. A measured volume of plasma was introduced into the tube, well mixed with the dry powder and transferred to a sterile wax tube to prevent clotting. The plasma containing the papain was allowed to stand at 4°C. for 2 days before use, during which time most of the powder dissolved. At the beginning of the investigation, irregular results were obtained because the plasma was used immediately or very soon after addition of the papain. Solid as yet undissolved material rapidly sank to the bottom of the pipettes and watch-glasses, so that the explants received variable doses. These experiments were rejected. However, the procedure indicated above proved satisfactory and gave reproducible results. Except in Experiments 252, 270 (Table I), 251 (Table II), and 253 (Table IV) the solution of papain protease also contained cysteine.

Synthetic vitamin A alcohol (Roche Products, Ltd., London) was used and was stored under nitrogen (at −20°C.). To introduce it into the plasma, a weighed quantity was dissolved in absolute ethanol; the strength of the alcoholic solution was adjusted so that the addition of 0.2 per cent to the plasma produced the required concentration of vitamin A. Since ethanol is not a biologically inert substance, 0.2 per cent was added to the plasma of all the culture media whose effects were to be compared with those of the media containing vitamin A.

Measurement.—In most experiments the explants were drawn with the aid of a camera lucida at the beginning of the experiment and thereafter at 2-day intervals. Each drawing was measured along its midline by means of a piece of string infiltrated with paraffin wax, which served as a flexible ruler (Fell and Mellanby, 1952)

Design of Experiments.—The designs of the individual experiments and the number of explants in each are recorded in Tables I to IV. To compare the effects of 2 media, the bone rudiments from one side of each embryo (set *a*) were explanted in one medium and those from opposite side (see *b*) in the other. Thus in Table II, the first line indicates that in Exp. 251, 2 pairs of humeri, femora, and tibiae (*i.e.* 12 rudiments) were explanted; the rudiments from one side of each chick were grown in medium containing 75 micrograms/ml. of papain without cysteine, those from the opposite side in normal (control) medium, and the explants were cultivated *in vitro* for 2 days.

Histology.—For histological study the explants were fixed for 30 minutes in 3 per cent acetic Zenker's fluid which was then replaced by Zenker's fluid without acetic acid. After a further hour's fixation, the rudiments were washed in several changes of tap water for 2 to 3 hours; they were left overnight in 70 per cent ethanol, then stained in bulk with eosin in 95 per cent ethanol to facilitate subsequent orientation, dehydrated, and cleared in 3 changes of cedar wood oil. The explants were infiltrated overnight with paraffin wax of m.p. 38°C. in an oven kept at 45°C., and transferred for 5 to 6 hours to paraffin wax of m.p. 56°C. containing a trace of beeswax (one change). For the study of glycogen (Exps. 265, 266, 267, 269) the explants were fixed in Rossmann's fluid; this, like other alcoholic fixatives, has the disadvantage of causing serious folding in the cartilage when the sections are flattened.

Serial sections (7 μ) were cut and stained with toluidine blue, with celestine blue, Mayer's acid hemalum, and Van Gieson's stain, or with Delafield's hematoxylin and chromotrop. For the demonstration of glycogen, sections were stained by the periodic acid–Schiff method (PAS); control sections from the same block were digested with diastase before staining.

RESULTS

A. The Effect of Single Exposure of Limb-Bone Rudiments from 7-Day Chick Embryos to Papain or Vitamin A

The experimental procedure is summarised in Table I. The femora, tibiae, humeri, and in one experiment (270) the radii and ulnae were used. At the time of explantation the rudiments consisted of a cartilaginous rod differentiated into the usual 3 zones: a middle segment of hypertrophic cartilage merging on either side with a relatively broad proliferative zone of flattened cells which in turn was continuous with the small-celled epiphyseal cartilage. A thin layer of periosteal bone covered the hypertrophic region.

Nine rudiments were incubated for 30 minutes (Exps. 237, 254) and 7 for 1 hour (Exps. 268, 270) in Tyrode medium containing 200 micrograms/ml. of papain with cysteine and were histologically examined. Metachromasia had largely or completely disappeared from the matrix of those incubated for 30 minutes and had entirely gone from all of those incubated for 1 hour (Fig. 1 b); many mitoses in all phases were present in the cartilage.

Six rudiments fixed after 30 minutes' incubation in Tyrode containing 200 micrograms/ml. of papain without cysteine (Exp. 252) were much less affected than those incubated for 30 minutes in papain and cysteine; and metachromasia had disappeared from the terminal cartilage only. Five rudiments incubated for 1 hour in papain without cysteine (Exp. 270) all contained some metachromatic material, though less than those fixed after the shorter period.

The eight rudiments fixed after 1 hour's incubation in Tyrode containing 100 I.U./ml. of vitamin A (Exps. 268, 270) were unchanged, as were the 8 controls incubated in Tyrode alone (Exps. 268, 270) (Fig. 1 a) and the 5 rudiments in Tyrode-containing cysteine (Exp. 270).

In 2 experiments, 8 pairs of rudiments were incubated in Tyrode containing papain and

cysteine for 30 minutes (Exps. 254) or 1 hour (Exp. 268); one of each pair was fixed immediately after incubation (Fig. 1 b) (see above) and the other was transferred to normal medium and cultivated for 2 or 4 days before fixation (Fig. 1 c).

TABLE I

Experiments on a Single Exposure of 7-Day Chick Bone Rudiments to Papain and/or Vitamin A in Various Solutions in Tyrode Solution

Experiment	No. pairs	Incubation			Subsequent treatment		
		Solution		Incubation period	Immediate fixation	Cultivated	Culture period
		Set a	Set b				days
237	1 H, F, T.	PP + CSH	Tyrode	30 min.	a, b	—	—
240	1 H, F, T, R, U.	" "		"	a	—	—
252	1 H, F, T.	PP − CHS	PP − CSH	"	a	b	2
	"	" "	" "	"	"	"	4
254	"	PP + CSH	PP + CSH	"	a	b	2
	"	" "	" "	"	"	"	4
268	1 H, T.	" "	" "	1 hr.	a	b	"
	1, H, F, T.	APP + CSH	APP + CSH	"	"	"	"
	"	A	A	"	"	"	"
	"	Tyrode	Tyrode	"	"	"	"
270	1 H, F, T, R, U.	PP + CSH	PP − CSH	"	a, b	—	—
	"	APP − CSH	A	"	"	—	—
	"	Tyrode + CSH	Tyrode	"	"	—	—

H, humerus; F, femur; T, tibia; R, radius, U, ulna. PP, papain protease, 200 γ/ml.; CSH cysteine, A, vitamin A, 100 I.U. ml.; APP, papain protease + vitamin A; set a and set b, rudiments from opposite sides of the same embryo.

The papain-treated rudiments rapidly recovered in culture; by the end of the 2nd day the metachromatic material had been largely restored, and after 4 days the matrix appeared normal and the explants had more than doubled their original length. In rudiments treated with papain without cysteine and then grown for 2 days (Exp. 252) the terminal cartilage recovered all or most of its metachromasia. Explants pretreated with vitamin A or Tyrode (Exp. 268) behaved normally during subsequent cultivation.

TABLE II

Experiments on 7-Day Chick Bone Rudiments Grown in Medium Containing Papain (γ/ML.), Vitamin A (I.U./ML.) or both

Experiment	No. pairs	Culture medium: Set a	Culture medium: Set b	Culture period	Subsequent treatment: Immediate fixation	Subsequent treatment: To normal medium	Subsequent treatment: Culture period
				days			*days*
251	2 HFT	PP, 150 γ	Control	2	a, b	—	—
257	1 "	A, 15 I.U.	"	6	a, b	—	—
261	1 "	A, 10 I.U.	"	4	a, b	—	—
	1 "	" " "	"	6	" "	—	—
262	2 "	PP, 150 γ	"	8	a, b	—	—
	2 "	A, 15 I.U.	A, 15 I.U. + PP, 150 γ	8	" "	—	—
265	2 "	A, 10 I.U.	Control	8	a, b	—	—
	2 "	PP, 75 γ	A, 10 I.U. + PP, 75 γ	8	" "	—	—
267	2 "	PP, 75 γ	Control	8	a, b	—	—
	2 "	A, 10 I.U.	A, 10 I.U. + PP, 75 γ	8	" "	—	—
269	2 "	PP, 150 γ	PP, 150 γ	6	a	b	6
	2 "	A, 15 I.U. + PP, 150 γ	A, 15 I.U. + PP, 150 γ	6	a	b	6
277	2 "	PP, 15 γ	Control	8	a, b	—	—
	2 "	PP, 1.5 γ	"	8	"		

Lettering as for Table I. Papain protease + cysteine was used for all experiments except No. 251 in which cysteine was omitted.

B. Comparison of the Effects on Limb Bone Rudiments of Cultivation in Media Containing Papain and Excess Vitamin A

1. Seven-Day Chick Rudiments (Table II). The femur, tibia, and humerus were cultivated; their structure at explantation has been described in section A. Camera lucida drawings were made at 2-day intervals of all the explants except in Exps. 257, 261.

The 33 controls grown in normal medium enlarged rapidly (Text-figs. 1 and 2); by the 2nd day they had elongated by about 50 per cent and had nearly trebled their length by the 8th

day. There was a corresponding increase in the width of the epiphyses. When examined under the dissecting microscope they appeared transparent and very refractile, and the thin layer of periosteal bone originally present in most of the explants had thickened considerably during cultivation. The cartilage was enclosed in a capsule of organized connective tissue from the margin of which there was a diffuse outgrowth of ameboid fibroblasts and macrophages.

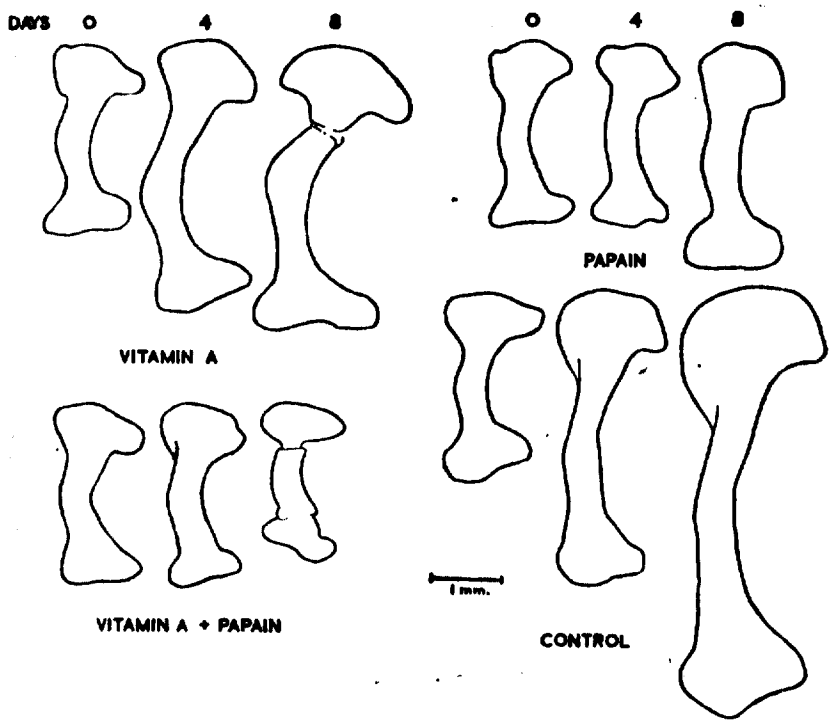

TEXT-FIG. 1. Serial camera lucida drawings of 4 living humeri in culture, from Exp. 262. Explants from 7-day chick embryos. Doses: 15 I.U./ml. of vitamin A; 150 γ/ml. of papain; control grown in normal medium. Vitamin A, the humerus is smaller than the control and there is a fracture at the proximal end of the shaft. Papain, the protease has inhibited growth more than vitamin A, but its effect is uniform throughout the rudiment. Vitamin A and papain, the two agents have a potent additive effect; there is a fracture at both ends of the shaft, and the explant is much smaller than either the vitamin A- or papain-treated rudiments.

When examined histologically after 8 days in culture, the controls appeared healthy (Fig. 2). They showed the normal differentiation into small-celled epiphyses each separated by a zone of flattened cells from the region of vacuolated, hypertrophic cells composing the middle segment of the shaft. In sections stained with toluidine blue, the cells were separated by broad partitions of intensely metachromatic matrix. On the surface of the hypertrophic cartilage there was a thick layer of young periosteal bone which also stained metachromatically in varying degrees, though far less intensely than the cartilage. In sections stained with PAS, the

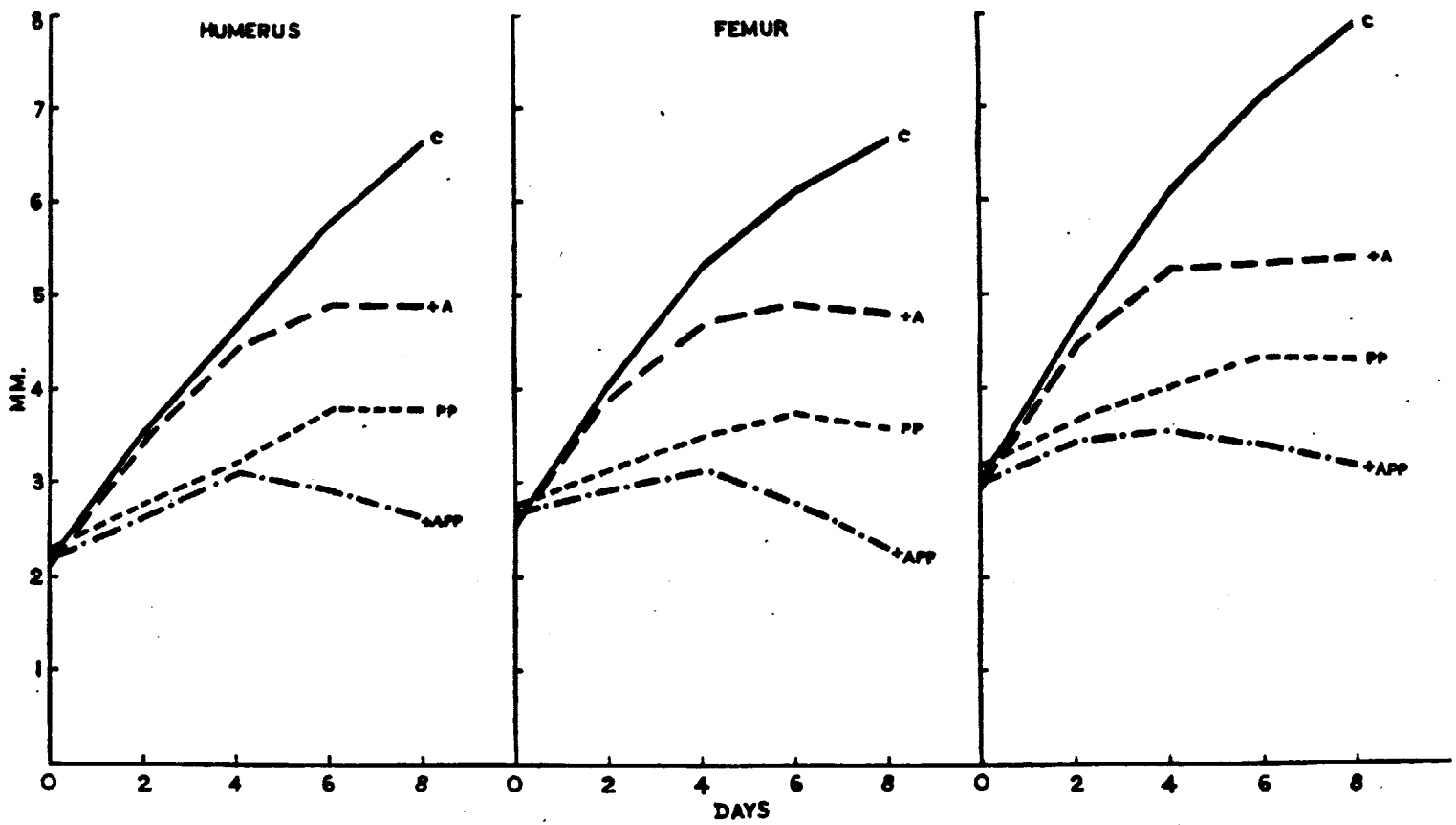

TEXT-FIG. 2. Curves showing the effects of vitamin A, papain, and vitamin A with papain on the growth in length of the humerus, femur, and tibia in culture (Exps. 265, 267). Explants from 7-day chick embryos. Doses, 10 I.U./ml. of vitamin A; 75 γ/ml. of papain; controls in normal medium.

Each of the 12 curves represents the average growth of 4 explants. Papain reduces growth more than vitamin A, and vitamin A and papain more than either agent alone.

matrix was pale pink; with Van Gieson's stain it was almost colorless and the bone a vivid scarlet.

There were striking differences between the control rudiments grown in normal medium, and those taken from the opposite side of the same embryos and cultivated for 8 days in medium containing papain (Exps. 262, 267, 277) (Text-figs. 1 and 2). Some of the 18 rudiments grown in the presence of 150 micrograms/ml. of papain with cysteine (Exps. 262, 269) enlarged slightly during 6 to 8 days in culture, but others remained almost the same size or even diminished a little. The 12 explants in medium containing 75 micrograms/ml. of papain with cysteine (Exps. 265, 267) enlarged slowly until the 6th day when growth ceased. When the living cultures were observed at daily intervals under the dissecting microscope, a gradual change in the cartilage was noted. It became less refractile, the epiphyses acquired a yellowish tinge by direct illumination, the diaphysis appeared increasingly grey and opaque, and the chondroblasts more closely packed together. The humeri were the least and the tibiae the most affected by the enzyme. After each subculture, the soft tissue attached to the rudiments formed a broad zone of outgrowth. Changes seen in the 6 explants exposed to papain without cysteine (Exp. 251) were similar but much less pronounced; this was at least partly owing to the fact that the rudiments were fixed after only 2 days in culture.

The histological structure of the explants grown for 8 days in medium containing papain with cysteine presented a great contrast to that of the corresponding controls in normal medium (*cf.* Figs. 2 and 3). In the papain-treated rudiments (Fig. 9 a) there were no zones of flattened cells as in the controls, so that the hypertrophic cartilage of the shaft merged gradually with the small-celled epiphyses. The hypertrophic cells had the same vacuolated structure as in the controls but a more regular, rounded outline. The amount of intercellular material was drastically reduced throughout the rudiments, the chondroblasts being separated by extremely thin partitions which were particularly tenuous in the hypertrophic region. In sections stained with toluidine blue, metachromasia had almost disappeared from the cartilage matrix and had completely gone from the fairly thick layer of periosteal bone. In adjacent sections stained with PAS, however, the delicate intercellular septa were a deeper red than the matrix of the controls, and with Van Gieson's stain a similar but even greater difference was seen. This result showed that one component of the matrix was not removed by the enzyme and probably became compressed by the general shrinkage of the rudiment caused by the removal of other materials. The glycogen content of the cells of the papain-treated cartilage was similar to that in the controls.

Six explants were grown in medium containing 75 micrograms/ml. of papain without cysteine (Exp. 251). Although the rudiments were cultivated for 2 days only, a definite effect was observed; the intercellular partitions were much narrower than in the controls grown in normal medium, and metachromasia though still present was reduced, showing that the addition of cysteine was not necessary for the reaction.

One experiment (Exp. 277) was made with far lower concentrations of papain. With 15 micrograms/ml. of medium the explants were considerably smaller than their controls and the intercellular partitions were much narrower, so that the cartilage cells were more closely packed together; even after 8 days' cultivation, however, the matrix remained metachromatic although the staining was less intense than in the controls. A concentration of 1.5 micrograms/ml. produced no obvious effect.

The capacity of the rudiments to recover from the effects of papain was tested in Exp. 269.

Six pairs of explants were grown for 6 days in medium containing 150 micrograms/ml. of papain with cysteine after which one from each pair was fixed and sectioned and the other

transferred to normal medium for a further 6 days. During the period in the medium with papain, there was little increase in size and the rudiments examined after 6 days in culture showed almost complete loss of metachromasia and close approximation of the chondroblasts (Fig. 9 a). As soon as the rudiments were transferred to normal medium they began to enlarge (Text-fig. 3); the shaft did not grow very much but the ends increased to several times their previous size and the cartilage resumed its normal, glassy appearance. The rudiments became surrounded by a curious thick, rather hyaline capsule which felt hard when touched with the knife.

When these explants were studied histologically (Fig. 9 b), broad intensely metachromatic intercellular partitions were seen throughout the rudiment. An unexpected result was the spread into, and sometimes throughout the connective tissue capsule, of typical cartilage and of a strange diffuse, highly metachromatic chondroid tissue. In some explants the inner osteoblastic layer of the periosteum had been completely transformed into hypertrophic cartilage and the outerfibroblastic coat into the metachromatic chondroid tissues mentioned above. There was profuse mitosis throughout the capsule. This remarkable histological picture is not understood and is being investigated further.

The 27 explants grown in medium to which excess vitamin A had been added (Exps. 257, 261, 262, 265), behaved differently in several respects from those treated with papain. (Text-Figs. 1 and 2).

During the first 2 days the vitamin A-treated rudiments grew much more rapidly than did those exposed to papain, but thereafter growth declined and by the 6th day many had begun to shrink; at the end of the culture period they were much smaller than the controls in normal medium but still considerably larger than rudiments exposed to papain in the same experiment. The vitamin A–treated explants, unlike those grown in medium containing papain, usually became bent and distorted, and as previously described (Fell and Mellanby, 1952) most of them developed spontaneous fractures near one or both ends of the shaft. The surrounding soft tissue grew copiously to form a broad outgrowth round the cartilage.

Histological comparison revealed interesting resemblances and differences in structure between the vitamin A and the papain-treated explants. Both showed loss of metachromasia from the cartilage, but whereas in the papain-treated rudiments the matrix was affected fairly evenly throughout, in those cultured in excess vitamin A (Fig. 4), some areas were always altered earlier and more drastically than others; this explained why the shape of the explants which remained almost normal in the medium containing papain was much distorted in the presence of excess vitamin A. As noted in earlier work, (Fell and Mellanby 1952; Fell, Mellanby and Pelc, 1956), the most sensitive part of the bone-rudiment is the region where the zone of flattened cells is becoming transformed into hypertrophic cartilage. There, the metachromasia rapidly disappeared and usually the cells became closely squashed together, very flattened, and separated only by fibers which stained bright red with PAS and Van Gieson. Meanwhile the 2 ends of the rudiment continued to enlarge, the interior of the epiphyses remaining metachromatic for some days although metachromasia continued to disappear from an ever widening peripheral zone. As a result of this continued terminal expansion, the strongly affected, rapidly shrinking region of young hypertrophic cartilage was first distorted and then disrupted so that the end was broken off the shaft; this process was usually assisted by invasion of the proliferative zone by connective tissue cells.

In the older hypertrophic cartilage in the vitamin A-treated explants, the matrix underwent changes very similar to those produced by papain; *i.e.*, the intercellular partitions became very narrow, lost metachromasia, and acquired an increased staining reaction with Van Gieson and PAS; the effect progressed from the surface inwards. The behavior of the hypertrophic cells,

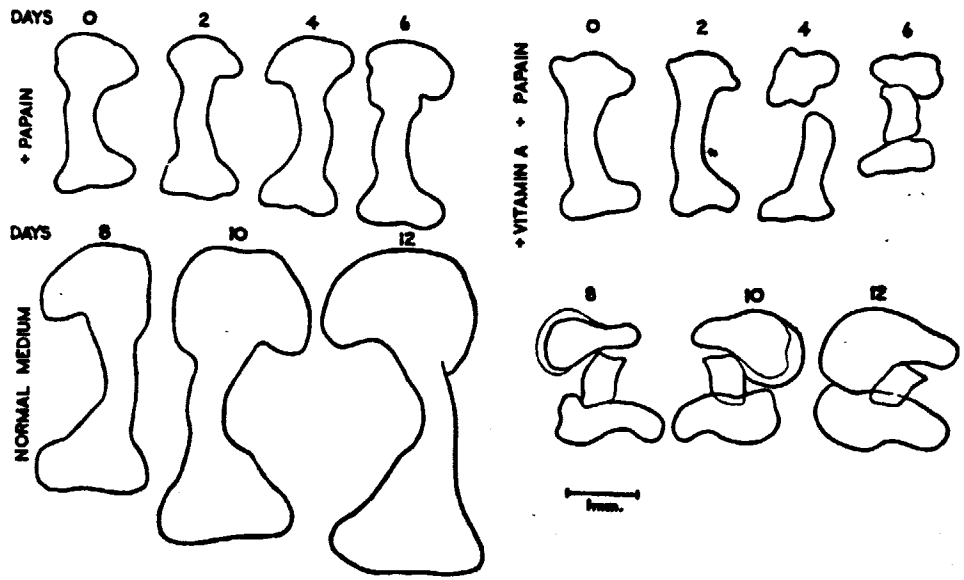

TEXT-FIG. 3. Serial camera lucida drawings of 2 living humeri in culture, from Exp. 269. Explants from 7-day chick embryos. Doses: 15 I.U./ml. of vitamin A; 150 γ/ml. of papain.

One explant was grown for 6 days in papain medium and then transferred to normal medium for a further 6 days; in the absence of papain, the explant immediately began to enlarge.

The other rudiment was cultivated for 6 days in medium containing both vitamin A and papain, and was then transplanted to normal medium for a further 6 days; after transfer the ends enlarged, but the shaft did not recover.

however, differed from that seen in the papain-treated cultures, in which the cells remained swollen and vacuolated as in the controls. With vitamin A, however, the cells lost their vacuolated appearance and diminished in size; the cytoplasm became basophilic and very irregular in outline and, as already recorded, mitotic figures were seen (Fell and Mellanby, 1952; Herbertson, 1955). Mitosis is extremely rare in normal hypertrophic cartilage and was not observed in that of papain-treated explants.

Another striking difference between the rudiments cultured in excess vitamin A and those grown in medium with or without papain was the almost complete disappearance of glycogen from the cells.

TABLE III

Experiments on 13-Day Chick Bone Rudiments Grown in Medium Containing Papain (γ/ml.), Vitamin A (i.e./ml), or Both

Experiment	No. pairs	Culture medium		Culture period
		Set a	Set b	
				days
248	3 MT; 1 D2; P 1, 2, 3, 4; 1 U; R; MC 2	PP, 150 γ	Control	6
257	" ; " ; "	A, 15 I.U.	Control	8
261	3 MT 1 D2; P 1, 2, 3, 4; 1 U; R; MC 2	A, 10 I.U. ", " "	Control "	6 8
263	1 D2; P 1, 2, 3, 4; 1 U; R; MC 2–3. "	A, 15 I.U. PP, 150 γ	Control A, 15 I.U. + PP, 150 γ	" "

Papain protease + cysteine was used for all experiments. MT, metatarsal; D 2, 2nd digit of foot; P 1, 2, 3, 4, 1st to 4th phalanges of 3rd digit of foot. U, ulna; R, radius; MC 2–3, 2nd and 3rd metacarpals. Lettering as for Table I.

2. Thirteen-Day Chick Rudiments (Table III). The following bones were grown:

Hind-limb: the 2nd, 3rd, and 4th metatarsals, the 2nd digit less the terminal phalanx, all 4 phalanges (separated) of the 3rd digit; fore-limb: radius, ulna, 2nd and 3rd metacarpals.

At explantation the larger bones, *i.e.* the ulna, radius, metacarpals, and metatarsals, consisted of small-celled terminal cartilage (either epiphyses, or fused tarsal, or carpal elements), a proliferative zone, and hypertrophic cartilage. A thick tube of trabecular periosteal bone had been formed and the cartilage had been cleanly excavated from the middle segment of the bony shaft and replaced by marrow (there is no endochondral ossification in chicken bones at this stage). In the phalanges of the foot, erosion of the cartilage had usually begun in the 2nd digit and in the 2 proximal phalanges of the 3rd, but a continuous narrow cavity had not yet been formed within the sheath of periosteal bone. In all the rudiments the cartilage matrix was much denser and more plentiful than at the 7th day, and the intercellular partitions were much wider.

The controls in normal medium enlarged considerably, Camera lucida drawings made in Exp. 263 showed that during 8 days' cultivation the explants increased in length as follows: ulna, 31 per cent; radius, 38 per cent; 2nd and 3rd metacarpals, 35 per cent; 2nd digit (2 phalanges), 45 per cent; and the 4 isolated phalanges of the 3rd digit by 38, 73, 43, and 24 per cent respectively; there was a corresponding increase in width.

The 14 controls histologically examined after 6 days' cultivation (Exps. 248, 261) appeared quite healthy, although in the larger bones the hemopoietic elements had degenerated and the marrow cavity was occupied by a network of reticulum cells. The cartilage matrix was very dense and intensely metachromatic. The bone was usually healthy and periosteal ossification was progressing actively. The larger of the 28 control bones fixed after 8 days in culture (Exps. 257, 261, 263) displayed more internal degeneration than those grown for 6 days only, but some of the smaller rudiments, *e.g.* the metacarpal (Fig. 6) remained in very good condition.

The 20 explants grown on medium containing 150 micrograms/ml. of papain (Exps. 248, 263) did not elongate during 6 to 8 days' cultivation, and measurements of camera lucida drawings (Exp. 263) showed they either remained the same length or diminished slightly; the width of the cartilaginous ends also changed little. In sections stained with toluidine blue (Fig. 7), the metachromatic material was seen to have been almost completely removed from the cartilage matrix. Although the intercellular partitions were much narrower than in the corresponding controls, they were much broader than in the papain-treated 7-day rudiments; they stained a brighter red with PAS and Van Gieson than those of the controls. As in the preceding experiments, the effect of the papain was produced evenly throughout the cartilage, and the flattened cells were much less compressed than in the controls, so that the proliferative zones were not clearly demarcated from either the epiphyses on the one side or the hypertrophic cartilage on the other. In the explants fixed after 6 days, most of the cartilage cells appeared normal, but, as in the controls, there was more degeneration after 8 days.

Although the chondroblasts and the fibroblasts of the surrounding connective tissue seemed unaffected by the papain during the period of the experiment, there was degeneration of many osteoblasts and little sign of osteogenic activity. There was no obvious effect on the existing bone.

From the camera lucida drawings of Exp. 263, it was seen that the bones in medium containing vitamin A elongated slightly during the first 2 days; growth then ceased and soon the bones began to diminish in both length and width, though the shrinkage was not great.

Unlike the 7-day rudiments in excess vitamin A, the 13-day bones did not become distorted in form, so that the histological changes produced by the vitamin A were very clear in sections.

Of the 20 explants treated with 15 I.U./ml. of the vitamin (Exps. 257, 263), 12 showed the following effect (Fig. 8). Metachromasia had disappeared from a peripheral zone of the epiphyses, but though much reduced it persisted in the interior. Where each zone of flattened cells merged with the hypertrophic cartilage, a broad band of matrix had completely lost its metachromasia, acquired a fibrillar structure and a capacity for staining brightly with PAS and Van Gieson, while the cells were extremely compressed; this appearance contrasted with that of the papain-treated rudiments in which the cells of this region had largely lost their normal flattened structure. Most of the metachromasia had gone from the hypertrophic cartilage except inside the capsules of the chondroblasts where the strands of intercellular material bridging the gap between the cytoplasm and the capsular wall had broken down into deeply stained, granular debris. The hypertrophic cells, unlike those in the papain-treated explants, lost their vacuolated structure and became increasingly irregular in outline. The existing bone was not greatly affected, but there was little or no osteogenesis in progress. The 3rd metacarpal, per-

haps because of its small size, showed the most severe effect, and in one epiphysis the matrix had almost gone, leaving a dense mass of naked chondroblasts.

In 5 rudiments, metachromasia had disappeared from the epiphyses; there was no broad band of metachromatically negative matrix at the junctions of the proliferative and hypertrophic zones, but metachromasia had begun to disappear from the periphery of these regions. The 3 metatarsals and one ulna remained metachromatic throughout, but the amount and the staining capacity of the matrix were less than in the control.

Of the 11 rudiments exposed to 10 I.U./ml. of vitamin A (Exp. 261), 4 showed the first pattern of effect described above, and in the other 7 the amount of cartilage matrix was diminished, but there were no areas free from metachromasia.

3. Late Fetal Mouse Bones (*Table IV*). The radius, ulna, and tibia were cultivated, and all were drawn at 2-day intervals with the aid of a camera lucida.

At explantation the bones consisted of large, intensely metachromatic cartilaginous ends, each comprising an epiphysis, a proliferative zone of flattened cells, and a hypertrophic region, and a stout shaft of trabecular bone surrounding a narrow cavity; in the hypertrophic cartilage adjoining the marrow cavity, endochondral ossification was in progress and the marrow contained spicules of endochondral bone enclosing the highly metachromatic remains of the cartilage matrix on which it had been deposited.

Forty-eight controls were grown in normal medium. They elongated by 12 to 15 per cent during a 6- to 8-day culture period and the ends increased in width by a similar amount (Text-figs. 4 and 5). In general, the shape of the bones was well preserved, but by the 6th or 8th day the terminal cartilage had sometimes become slightly bent at an angle to the shaft. Sections (Fig. 10) showed that during cultivation the cartilage matrix increased, and the periosteal bone was thickened by the deposition of new bone by the osteoblastic layer of the periosteum. Endochondral ossification, however, did not advance although excavation of the cartilage continued; this weakened the rudiment at the junction of the cartilage and the marrow cavity and probably accounted for the slight displacement of the cartilaginous ends referred to above. Throughout the cartilage, the chondroblasts were extremely vacuolated (Fig. 14). In preparations of 4-day explants stained with PAS, these vacuoles were found to contain glycogen in the epiphyses and proliferative zones, but some of those in the hypertrophic region were clear; glycogen was also plentiful in the osteoblasts, fibroblasts, and reticulum cells, and much lay freely in the marrow cavity. It was less abundant in the 6-day explants.

The 30 bones grown in the presence of 75 and 150 micrograms/ml. of papain all behaved in essentially the same way. In Exp. 253, 6 bones (one radius, ulna, and tibia from each of 2 embryos) were cultivated in medium to which had been added 150 micrograms/ml. of papain without cysteine and 6 in medium containing 75 micrograms/ml.; the effect of the higher dose was only slightly greater than that of the lower. In Exps. 259 and 264, 75 micrograms/ml. of papain with cysteine was used. The fetuses used in Exp. 253 were slightly younger than those in Exps. 259 and 264, and their bones correspondingly smaller. As these differences in dosage and size of explant, and the presence or absence of cysteine did not materially affect the results, the bones of all 3 experiments will be described together.

Measurement of the camera lucida drawings (Text-fig. 5) showed that after 2 days the papain-treated bones were about the same size as when explanted, although the controls had already begun to elongate, and when viewed under a dissecting microscope the cartilage appeared more opaque than in the normal cultures. After 4 days (Text-fig. 4) the length had sometimes diminished slightly while the terminal cartilage had shrunk somewhat and increased in opacity. These changes progressed slowly until the explants were fixed on the 6th or 8th day,

but even with a dose of 150 micrograms/ml. of papain the length only declined by about 8 per cent. This diminution was due entirely to shrinkage of the cartilage and the bone seemed little affected by the enzyme. The unorganized outgrowth from the surrounding soft tissue was often increased as compared with that in the controls.

TABLE IV

Experiments on Late Fetal Mouse Bones Grown in Medium Containing Papain (γ/ml.), Vitamin A (I.U./ml.) or Both

Experiment	No. pairs	Culture medium		Culture period	Subsequent treatment		
		Set a	Set b		Immediate fixation	To normal medium	Culture period
				days			*days*
253	1 R, U, T	PP, 75 γ	Control	4	a, b	—	—
	1 "	" "	"	6	" "	—	—
	1 "	PP, 150 γ	"	4	" "	—	—
	1 "	" "	"	6	" "	—	—
259	1 "	PP, 75 γ	"	4	a, b	—	—
	1 "	" "	"	8	" "	—	—
	1 "	A, 10 I.U.	"	4	" "	—	—
	1 "	" " "	"	8	" "	—	—
264	1 "	" " "	"	4	a, b	—	—
	1 "	" " "	"	6	" "	—	—
	1 "	PP, 75 γ	A, 10 I.U. + PP, 75 γ	4	" "	—	—
	1 "	" "	" "	6	" "	—	—
266	1 "	A, 10 I.U.	A, 10 I.U. + PP, 75 γ	4	a, b	—	—
	1 "	" "	" "	6	" "	—	—
	1 "	PP, 75 γ	Control	4	" "	—	—
	1 "	" "	"	6	" "	—	—
270	2 "	PP, 15 γ	Control	6	a, b	—	—
	2 "	1, 5 γ	"	6	" "	—	—

Papain protease + cysteine was used for all experiments except No. 253 from which the cysteine was omitted. Lettering as for Table I.

When the bones were examined histologically after 4 days in culture, the intercellular partitions of the cartilage were seen to be greatly reduced in both width and metachromasia, whereas their staining capacity with Van Gieson was greater than in the controls and with PAS was about the same as in the untreated explants. In the articular cartilage and in the proliferative and hypertrophic zones of the papain-treated rudiments, metachromasia had completely disappeared but a little remained in the interior of the epiphyses; the columnar arrangement of the cells of the growing zone, characteristic of mammalian ossifying cartilage,

was much less distinct than in the bones grown in normal medium. The chondroblasts appeared almost unaffected, although those in the interior of the cartilage contained rather less glycogen than in the controls. The periosteal bone also seemed unchanged except that the metachromatic staining sometimes present in the distal part of the shaft of the controls was

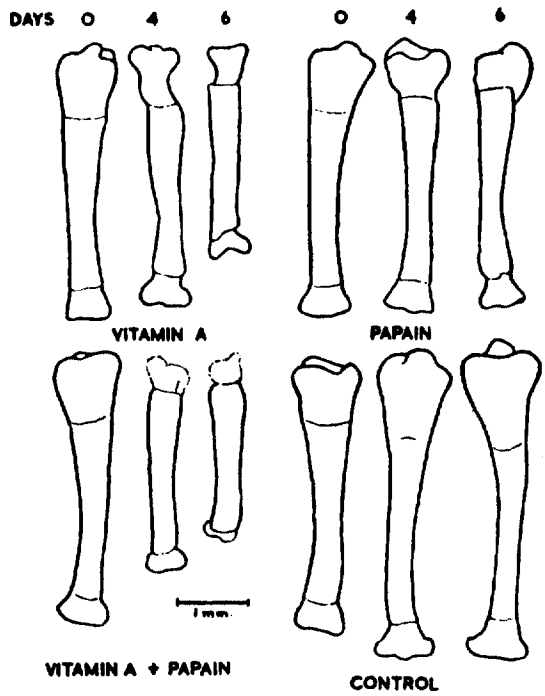

TEXT-FIG. 4. Serial camera lucida drawings of 4 living radii in culture, from Exp. 264. Explants from mouse fetuses near term. Doses: 10 I.U./ml. of vitamin A; 75 γ/ml. of papain; control in normal medium. Vitamin A, the terminal cartilage shrinks greatly and the bony shaft becomes shorter (there was also extensive rarifaction of the bone, but this is not shown in the outline drawing). Papain shrinkage of the cartilage is less than with A, and there is no obvious effect on the bony shaft. Vitamin A and papain: there is a marked additive effect of the two agents on the terminal cartilage, but the effect of vitamin A on the bony shaft is not appreciably enhanced by papain.

absent, but there was no evidence of increased resorption; the osteocytes and osteoblasts contained plenty of glycogen, many of the osteoblasts were in mitosis and osteogenesis was in progress beneath the periosteum. In the region of endochondral ossification within the marrow cavity, the metachromatic staining inside the spicules of endochrondral bone was completely unchanged by papain, so that the spicules were strikingly conspicuous in preparations stained with toluidine blue whereas the rest of the skeletal tissue was almost colourless. That this absence of effect was not due to the presence of an impermeable layer of bone deposited on the surface of the cartilaginous core, was shown by the fact that the metachromasia was equally

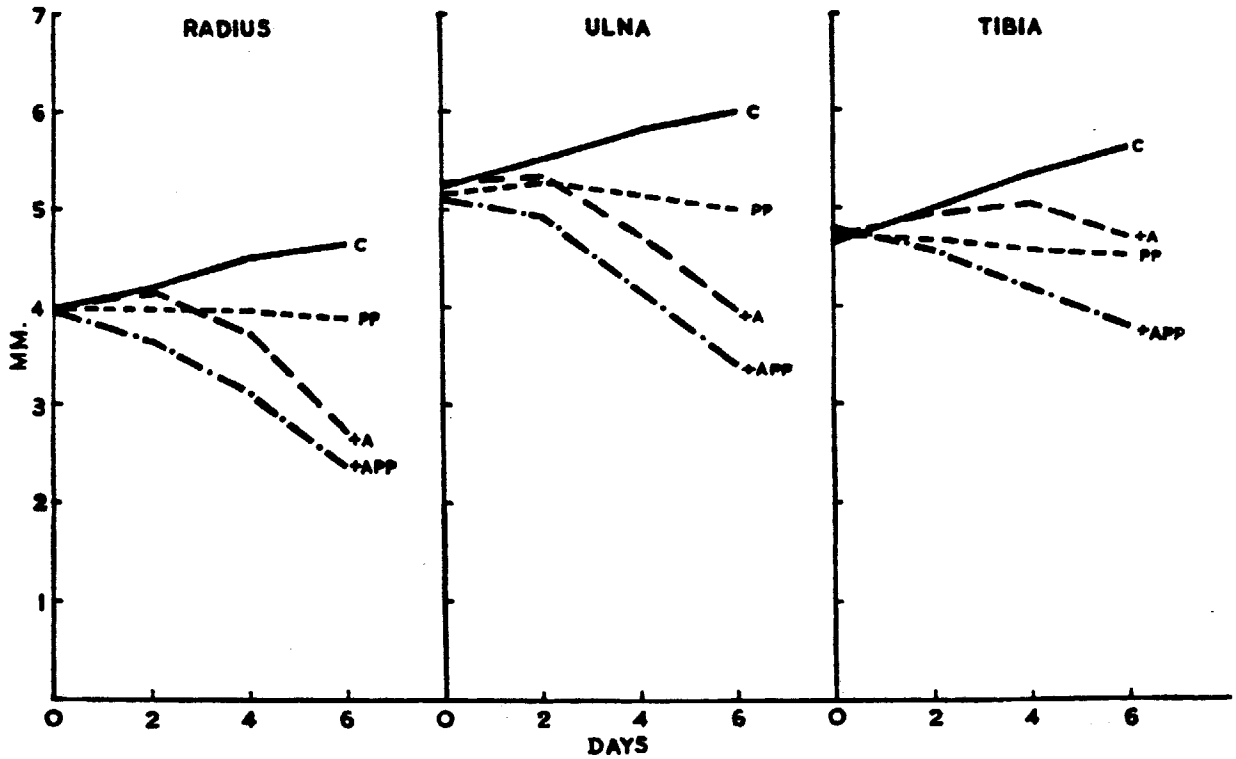

TEXT-FIG. 5. Curves showing the effects of vitamin A, papain, and vitamin A with papain on the growth in length of the radius, ulna, and tibia in culture (Exps. 264 and 266). Explants from late mouse fetuses. Doses: 10 I.U./ml. of vitamin A; γ/ml. of papain; controls in normal medium.

Each curve represents the average growth of 4 bones up to the 4th day when half the number of bones were fixed. Vitamin A: there is a rapid shrinkage of the radius and ulna, due partly to diminution of the cartilage and partly to resorption of bone. This effect appears more slowly in the larger and stouter tibia. Papain: the lengths of the radius and ulna are reduced much less than with vitamin A. At first the effect on the tibia is greater than that of vitamin A, but by the 6th day the vitamin A–treated tibia are shrinking at a faster rate. Vitamin A and papain: the two agents together are more effective than either alone, but the difference between the effects of vitamin A and of vitamin A and papain is relatively much less than in the wholly cartilaginous chick rudiments (*cf.* Text-fig. 2); this is because papain acts on cartilage but not appreciably on bone, whereas vitamin A affects both.

intense in spicules from which the bone had been resorbed and where cells were in direct contact with the metachromatic material.

In the older 6- to 8-day papain-treated explants (Figs. 12 and 15) the remaining metachromasia of the epiphysical matrix had almost gone, although that of the endochondral bone was still normal. The general appearance of the explants had not greatly changed.

One experiment (Exp. 276) was made with much lower concentrations of papain: 15 and 1.5 micrograms/ml. of culture medium respectively. The changes produced by 15 micrograms/ml. differed little from those described above for the higher concentrations. The effect on the cartilage of 1.5 micrograms/ml. was also quite severe, and qualitatively resembled that of the larger doses; the changes appeared more slowly, however, and after 6 days, removal of the metachromatic material was more incomplete than with the higher levels of protease.

There was a striking difference in behaviour between the mouse bones grown in medium containing 10 I.U./ml. (Exps. 259, 264, 266) of added vitamin A and those treated with papain.

When the living cultures were observed after 4 days in medium containing excess vitamin A (Text-figs. 4 and 5) the cartilage was seen to have shrunk considerably more than in the papain-treated explants and there were areas of resorption in the bone. As previously described (Fell and Mellanby, 1952), the diameter of the dwindling proliferative zone became less than that of the bony shaft, so that the cartilaginous end looked like a head and neck protruding from a too large collar; in the cultures in papain this effect was either very slight or absent. These changes progressed rapidly, and by the 6th day only a small nodule of cartilage remained at either end and the bone had a very "moth-eaten" appearance. After 8 days' cultivation (Exp. 259) little remained of the vitamin A–treated rudiments, whereas in the papain-treated explants, the bony shaft was almost unaffected and the cartilaginous ends, though reduced in size, were still intact. In the bones cultured in vitamin A, there was a profuse outgrowth of cells from the surrounding soft tissue.

In histological preparations, the fetal mouse bones, like those of the embryonic chick, showed a pronounced regional effect of vitamin A (Figs. 11 and 16). Thus in the cartilage of bones fixed after 4 days, there was a steep gradient of change from the surface inwards, unlike a more evenly distributed effect of papain. In the interior of the cartilage of the vitamin A–treated explants, there was usually an area of strongly metachromatic matrix, while at the surface there was a compact layer of chondroblasts which, even in sections stained with PAS or Van Gieson, appeared completely devoid of intercellular material. Between these two extremes was a broad zone in which the matrix resembled that of the papain-treated rudiments: the intercellular partitions had become narrow and lost their metachromasia but stained bright red with Van Gieson or PAS. The cells of this zone, however, differed from those of the explants exposed to papain. In the latter, the vacuolated cells were almost indistinguishable from those of the controls and contained much glycogen, but in the chondroblasts of the cultures in vitamin A the large vacuoles had gone and the cytoplasm had become smaller, more basophilic and had lost nearly all its glycogen; the basophilia increased towards the surface and was intense in the layer of free chondroblasts. The cells in the still metachromatic interior retained their normal appearance and high glycogen content.

The intense metachromasia inside the endochondral bone trabeculae was unaffected by the vitamin as it was by papain, even in areas where the trabeculae were being actively resorbed. The marrow cavity was much more thickly populated with cells, many of which were dividing, than in either the corresponding controls or the papain-treated cultures, and usually more osteoclasts were present. The periosteal bone was fragmentary, but the osteoblasts were abundant, healthy, and many were in mitosis. All the cells of the shaft contained much less glyco-

gen than did those of the controls or the papain-treated explants, but there was plenty of free glycogen in the marrow cavity.

After 6 days in the presence of excess vitamin A, most of the cartilage had disintegrated into a mass of free chondroblasts; some matrix remained in the interior of these masses, however, although greatly reduced both in amount and metachromatic staining. The glycogen content of the cells remained much lower than in control and papain-treated explants of the same age. Three bones were fixed after 8 days (Exp. 259); in these the cartilage had disappeared completely from the ulna and radius, but a little remained at one end of the tibia; only spicules of bone persisted in the now almost completely cellular shaft.

C. The Combined Effects of Papain and Vitamin A

1. Seven-Day Chick Rudiments.—(*a*) Effects of a single exposure to papain and vitamin A. (Table I, Exp. 270). As described above, when 7-day rudiments were incubated for 1 hour in a solution of papain in Tyrode without the addition of cysteine, the metachromatic material was incompletely removed from the matrix. An experiment was made to determine whether the effect of the papain could be increased by the addition of vitamin A.

Five rudiments (femur, tibia, humerus, radius, and ulna) were incubated for 1 hour in Tyrode containing 200 micrograms/ml. of papain without cysteine and 100 I.U./ml. of vitamin A; they were then fixed and sectioned.

A comparison of the histological preparations with those of similar rudiments incubated in papain without either cysteine or vitamin A, showed that the vitamin had not enhanced the effect of the enzyme.

(*b*) Cultivation in medium containing both vitamin A and papain (Table II). The two agents together had a pronounced additive effect (Exps. 262, 265, 267, 269).

Before the 2nd day the rudiments so treated were usually indistinguishable from those grown in the presence of papain alone, though they were much smaller than the explants in excess vitamin A. After this stage, however, they became shorter and narrower than the papain-treated rudiments (Text-figs. 1 and 2) and by the 6th day a fracture developed at one or both ends at the junction of the proliferative and hypertrophic zones, as described above in the vitamin A-treated cultures; rudiments from smaller embryos sometimes showed this effect as early as the 4th day. During further cultivation the explants became fragmentary and much distorted. There was a profuse outgrowth of the surrounding soft tissue throughout the period of culture.

Explants fixed and sectioned after 6 to 8 days in medium containing vitamin A and papain showed much greater histological changes than those exposed to either agent alone (Figs. 5 and 18 a). There was a thin film of slightly metachromatic matrix over the chondroblasts in the interior of the epiphyses, but towards the surface the intercellular substance had vanished; in some explants the epiphyses consisted almost entirely of a compact mass of naked chondroblasts. Metachromasia had completely gone from the shaft which was separated from the epiphyses by a dense mass of cells with no intercellular partitions; the hypertrophic chondroblasts had undergone the changes typical of vitamin A described above and many were in mitosis. In Exp. 262 cell division was very active throughout the explants. Like the vitamin A treated explants, the rudiments grown in the presence of vitamin A and papain contained much less glycogen than those grown in papain alone, but it was curious that in 3 explants

(Exp. 269) in which the cartilage matrix had almost completely disintegrated the chondroblasts contained more glycogen than was seen in any of the cultures in vitamin A.

An experiment (269) was made to see how far the explants were capable of recovery following culture in medium containing papain and vitamin A.

Six pairs of rudiments were grown in medium containing 150 micrograms/ml. papain and 15 I.U./ml. of vitamin A; after 6 days one of each pair was fixed and sectioned and the other transferred to normal medium for a further 6 days (Fig. 18). The terminal cartilage soon began to enlarge (Text-fig. 3) and to resume its normal hyaline appearance, but the detached fragment of shaft remained unaltered. As in the papain-treated cultures, the capsule of connective tissue surrounding the cartilage became organized and refractile and helped to obscure the already confusing morphology of the explants.

On histological examination, it was found that as in the papain cultures transferred to normal medium, the terminal cartilage had regenerated large quantities of metachromatic matrix, but the matrix of the shafts, unlike that in papain cultures, remained unchanged. In some explants the shaft fragment was compressed between the expanding terminal cartilage and enclosed by dense capsular tissue so that it was largely degenerate, but in others the now basophil cells appeared healthy although they had failed to synthesize chondroitin sulfate. The connective tissue capsule presented a chaotic mixture of true cartilage, sometimes both small-celled and hypertrophic, diffuse chondroid tissue like that seen in the regenerating papain treated rudiments, and in several explants large areas of osteoid tissue spreading outwards from the shaft fragment. Glycogen was plentiful in both terminal cartilage and capsular cells, but none was seen in the cells of the shaft. There was profuse mitosis throughout the explants.

2. Thirteen-Day Chick Bones. (Table III).

Nine bones from a 13-day embryo were grown for 8 days in medium containing 150 micrograms/ml. of papain and 15 I.U./ml. of vitamin A, and compared with similar rudiments cultivated on a clot containing papain or vitamin A only (Exp. 263). At first there was little difference between either group of explants, though both were considerably smaller than the controls. Of the larger bones, the ulna changed little throughout the culture period, but by the 8th day the terminal cartilages of the radius and of the 2nd metacarpal had greatly diminished in size as compared with those of the corresponding bones treated with papain or vitamin A. They had also acquired well marked constrictions at the junctions of the epiphyses and proliferative zones; in the slender 3rd metacarpal this effect was seen as early as the 4th day and by the 8th day one end had almost disintegrated. Similar constrictions appeared on the 8th day at one or both ends of the phalangeal explants from the 2nd and 3rd digit of the foot, and were accompanied by a greater shrinkage of the cartilage than was seen in either the papain or vitamin A rudiments.

The histological changes were more advanced than in the papain or vitamin A-treated bones. All the rudiments had completely lost their metachromasia with toluidine blue. Near the articular surfaces and in the constrictions described above, the matrix had entirely disappeared, leaving a dense mass of free chondroblasts; this was particularly conspicuous in the 3rd metacarpal and the phalanges. The hypertrophic cartilage cells had the irregular shape and very basophilic cytoplasm characteristic of these cells in the explants in vitamin A or papain of the previous experiments; sometimes several cells occupied one capsule and mitotic figures were found amongst them. The periosteal bone was largely necrotic but there was no evidence that it was being resorbed, and there was no deposition of new bone.

3. Late Fetal Mouse Bones (Table IV, Exps. 264, 266).—

Twelve fetal mouse bones were grown on a clot containing 75 micrograms/ml. of papain and 10 I.U./ml. of vitamin A; 6 were fixed after 4 days', and 6 after 6 days', cultivation.

The combined effects of the two agents on the terminal cartilage was much greater than that of either alone (Text-figs. 4 and 5). As early as the 2nd day the ends of the rudiments treated with both papain and vitamin A were smaller than those of the corresponding explants grown in either agent alone, and by the 6th day the cartilage had almost completely disappeared in the radius and ulna and was much reduced in the larger tibia. There was no evidence, however, that the drastic effect of vitamin A on the bone was significantly increased by the presence of papain.

In histological preparations of the explants fixed after 4 days, a very faint metachromasia sometimes remained in the interior of the cartilage but the matrix had completely gone from the peripheral region, liberating the chondroblasts, some of which were in mitosis. Metachromasia remained intense within the spicules of endochondral bone. By the 6th day (Figs. 13 and 17) the cartilage had almost and sometimes entirely disappeared. There was intense resorption of the periosteal bone, but the sections confirmed the observations on the living cultures, and indicated that resorption was no greater than in the explants grown in vitamin A alone.

DISCUSSION

Before the implications of these results are discussed, it is necessary to consider how the changes produced by vitamin A in explanted skeletal tissue *in vitro* compare with those produced in the intact skeleton of young animals.

The administration of large amounts of vitamin A to young rats or guinea pigs results in bony abnormalities characterized by spontaneous fractures, remodelling of bone, excessive osteoclasis and ossification of the epiphyseal plates (Wolbach, 1947). These changes have been interpreted by Wolbach to be the result of acceleration of all phases of normal bone growth, but this concept is not supported by any direct evidence, and does not adequately explain the observed changes in bone.

The changes produced by excess vitamin A in the fetal mouse bones in culture are similar to but more severe than those seen in the skeleton of a hypervitaminotic animal. Both *in vitro* and *in vivo*, vitamin A causes an abnormally rapid erosion of epiphyseal plate cartilage from the diaphyseal surface, and intense resorption of bone (*cf.* Wolbach, 1947; Barnicot and Datta, 1956). In the rabbit loss of the cartilage matrix in epiphyseal, articular and tracheal cartilage also occurs (Thomas, McCluskey, Potter, and Weissmann, 1960). In the explants, however, these processes end in the complete dissolution of both cartilage and bone, an extreme effect that could not occur *in vivo* because the animal would die before this stage was reached. It is probable that the greater speed of the resorptive processes in the cultures is correlated with the age of the bones. *In vivo* the younger the animal, the more susceptible is its skeleton to excess vitamin A (Moore, 1957) and in the present study the explants were obtained from late fetuses; in earlier organ-culture experiments

(Fell and Mellanby, 1952) it was found that bone rudiments from younger embryos disappeared more rapidly in vitamin A–containing medium than did those from fetuses near term. There may be other contributory factors to the rapid destruction of the mouse bones in culture. Thus vitamin A added directly to the plasma of the culture medium is more potent than the same concentration of vitamin A introduced "naturally" into the plasma by feeding the donor cock on a high vitamin A diet (Fell and Mellanby, 1952); it is possible that the vitamin is more readily available to bones by direct contact with a medium high in vitamin A, than it is *via* the circulation of an animal with hypervitaminosis A.

It is less easy to compare the effects of excess vitamin A on the cartilaginous rudiments from 7-day chick embryos with those produced in the limb skeleton of young hatched chicks (Wolbach and Hegsted, 1952), because the normal histological structure of the earlier embryonic limb skeleton is so different from that of the hatched chick. The changes caused by vitamin A in the hypertrophic chondroblasts of both the 7- and 13-day explants seem to be very similar to those described by Wolbach and Hegsted in the postembryonic chick bones, although these authors do not record mitosis in the hypertrophic cells of vitamin A–treated chicks. Loss of metachromasia from the cartilage matrix of the rudiments occurred in culture; metachromasia was not studied by Wolbach and Hegsted in the cartilage of the hypervitaminotic chicks. In the 13-day rudiments, which possess trabecular periosteal bone enclosing a marrow cavity, the bone does not undergo rapid resorption in medium containing excess vitamin A, unlike fetal mouse bones. Wolbach and Hegsted (1952) found, however, that the bones of young chicks also differed from those of mammals in their response to excess vitamin A; instead of becoming rarified and developing fractures, the cortical bone rapidly became "exceedingly dense" owing to the speedy replacement of cancellous by compact bone.

A comparison of the effects of papain and of vitamin A on the explants reveals interesting similarities and differences. Both agents remove chondroitin sulfate from the cartilage matrix, but whereas papain does so fairly uniformly, vitamin A has a well marked regional effect. In the explants, treated with vitamin A, loss of metachromasia occurs first and is most advanced in the peripheral cartilage (mouse and chick rudiments) and in the proliferative zones of flattened cells (chick).

Mouse cartilage is more susceptible to papain than that of the 7-day chick; thus, a low concentration of papain (1.5 microgram/ml.) produces a distinct effect in the mouse cartilage but no visible change in the 7-day chick rudiments. This is probably due to the fact that the rate of synthesis of chondroitin sulfate in culture is greater in 7-day chick cartilage than in fetal mouse cartilage, so that a small depletion is readily made good in the former but not in the latter. Experiments with minimal concentrations of vitamin A have not been made,

but with those used (10 and 15 I.U./ml.) a more rapid and drastic effect is produced on the mouse than on the chick cartilage.

Histologically, papain appears to affect only the matrix, and produces no obvious change in the chondroblasts, whereas in the rudiments treated with vitamin A the-cartilage cells show disappearance of glycogen, reduction of cytoplasmic vacuoles and consequently of size, increased basophilia, and the presence of mitosis in the altered hypertrophic chrondroblasts. In the intact rabbit, however, the changes seen in cartilage cells following administration of papain or of vitamin A were similar and consisted of slight shrinkage, and loss of PAS-positive material and basophilia.

The effects of vitamin A and papain in combination on embryonic chick and mouse cartilage are very striking. In the 7-day chick rudiments, the rapid, uniform removal of metachromasia characteristic of papain is seen, but this is associated with the regional action of vitamin A as evinced by the early dissolution of the zones of proliferative cells, which usually causes a double fracture, and the complete disappearance of the peripheral matrix from the epiphyseal cartilage; the result of the combined action is a spectacular shrinkage of the whole rudiment. The cellular changes (loss of vacuoles and glycogen, and presence of mitosis in the hypertrophic cells) are those seen in vitamin A-treated cartilage. As described above, these severe effects are reversible in the epiphyses but not in the diaphyses.

It is interesting that papain preparations from which cysteine has been removed by dialysis were nearly or quite as effective as fully activated preparations when added to the culture medium in the more prolonged experiments. This was not so when the rudiments were incubated in papain solutions in Tyrode for periods of only 30 minutes or 1 hour; under these conditions the papain without cysteine produced much less change than the activated enzyme, which removed all or most of the metachromasia from the cartilage. The effect of papain without cysteine was not enhanced by the addition of a large concentration of vitamin A to the solution in these short term experiments.

A major question to be considered is whether papain and vitamin A produce their effects on cartilage matrix by a similar mechanism. Theoretically, vitamin A might cause chondroitin sulfate to disappear in two ways: (*a*) by inhibiting synthesis, so that chrondroitin sulfate lost from the matrix during the normal turnover would not be replaced and (*b*) by the active breakdown of one or more components of the matrix. It is very unlikely, however, that the disappearance of the chondroitin sulfate is due to lack of synthesis alone. Thus in the rabbit experiments, Thomas, McCluskey, Potter, and Weissmann (1960) showed that S^{35} previously incorporated in the cartilage was released after treatment with vitamin A, but not in the controls receiving corn oil; further, increased levels of chrondroitin sulfate appeared in the blood coincidently with the decrease of this component in the cartilage matrix. In autoradiographic

studies on organ cultures (Fell, Mellanby and Pelc, 1956), the limb bone rudiments of 6-day chick embryos were grown either in normal medium or in medium containing excess vitamin A and were treated with $S^{35}O_4$ at various stages. In the medium with excess vitamin A, the cartilage first failed to incorporate new sulfate, indicating that synthesis of chrondroitin sulfate had been inhibited, and when the explants were grown for a further period in medium containing excess vitamin A and no S^{35}, the radioactive material already present in the matrix was lost at the same time as the metachromasia disappeared. Since under the same conditions S^{35} remained in the matrix of labelled controls transferred to unlabelled normal medium for the same length of time, its loss from the vitamin A–treated cartilage could not be due solely to ordinary turnover in the absence of synthesis. The effects of excess vitamin A on cartilage *in vivo* and in culture are compatible with a hydrolytic action on chondromucoprotein similar to that of papain. It is possible that chondroitin sulfate can also be removed from the matrix of living cartilage by enzymes other than proteases. Thus Paff and Seifter (1950) report the loss of basophilia and diminution of intercellular material in embryonic chick limb cartilage incubated in a solution of hyaluronidase in Tyrode.

Despite the similarities of the effects of papain and vitamin A on cartilage, these two agents differ considerably in their action on fetal mouse bone in culture, in that the bone is almost or completely unaffected by the protease, but disintegrates with remarkable speed in the presence of excess vitamin A. This indicates that the bony changes produced by vitamin A are not simply the result of activation of a proteolytic enzyme resembling papain. However, it cannot be assumed that all of the effects of hypervitaminosis A are mediated by a single mechanism.

As a tentative working hypothesis it is suggested that vitamin A may enhance the activity of a number of cellular enzymes, one of which resembles papain in its effect; such an enhanced hydrolytic activity might be due to the activation of enzymes, to their greater production or to their increased liberation through an increased permeability of the cells or their organelles.

SUMMARY

The effects of papain protease and of vitamin A on explanted limb bone rudiments from 7- and 13-day chick embryos and fetal mice have been studied and compared.

The incubation of cartilaginous rudiments from 7-day chick embryos in a solution containing papain and cysteine resulted in complete loss of the metachromasia of the cartilage matrix within 1 hour; explants treated in this fashion recovered normal metachromatic staining properties when grown in normal medium for 4 days.

The incubation of 7-day chick cartilage rudiments in a solution containing

embryonic avian femora and limb-buds cultivated *in vitro*, *Biochem. J.*, 1929, **23**, 767.

Herbertson, M. A., The reversibility of the effect of hypervitaminosis A on embryonic limb bones cultivated *in vitro*, *J. Embryol. and Exp. Morphol.*, 1955, **3**, 355.

McCluskey, R. T., and Thomas, L., The removal of cartilage matrix, *in vivo*, by papain. Identification of crystalline papain protease as the cause of the phenomenon, *J. Exp. Med.*, 1958, **108**, 371.

Moore, T., Vitamin A, Amsterdam, Elsevier Publishing Company, 1957.

Paff, G. H., and Seifter, J., The effect of hyaluronidase on bone growth *in vitro*, *Anat. Rec.*, 1950, **106**, 525.

Thomas, L., Reversible collapse of rabbit ears after intravenous papain and prevention of recovery by cortisone, *J. Exp. Med.*, 1956, **104**, 245.

Thomas, L., McCluskey, R. T., Potter, J. L., and Weissmann, G., Comparison of the effects of papain and vitamin A on cartilage and bone. I. The effects in rabbits, *J. Exp. Med.*, 1960, 111, 705.

Wolbach, S. R., Vitamin A deficiency and excess in relation to skeletal growth, *J. Bone and Joint Surg.*, 1947, **29**, 171.

Wolbach, S. B., and Hegsted, D. M., Hypervitaminosis A and the skeleton of growing chicks, *Arch. Path.*, 1952, **54**, 30.

EXPLANATION OF PLATES

Photography by Mr. V. C. Norfield, Strangeways Research Laboratory. All sections were stained with toluidine blue.

PLATE 58

FIG. 1. Three humeri from 7-day chick embryos (Exp. 268). Fig. 1 a, control fixed after 1 hour's incubation in Tyrode. Fig. 1 b, humerus fixed after 1 hour's incubation in Tyrode containing 200 γ/ml. of papain + cysteine; the metachromatic material has been completely removed (*cf.* Fig. 1 a). Fig. 1 c, opposite humerus from the same chick as in Fig. 1 b incubated for 1 hr. in Tyrode + 200 γ/ml. of papain and cysteine and then cultivated for 4 days on a normal plasma: embryo extract clot; the metachromatic material has been restored. × 15.

FIG. 2. Control femur from a 7-day chick embryo grown for 8 days on a normal plasma: embryo extract clot (Exp. 262). × 15.

FIG. 3. Similar femur grown for 8 days in medium containing 150 γ/ml. of papain (exp. 262). The cartilage is uniformly devoid of metachromatic material; note the thick layer of periosteal bone on the surface of the cartilaginous shaft. × 15.

FIG. 4. Femur from 7-day chick embryo grown for 8 days in medium containing 15 I.U./ml. of vitamin A (Exp. 262). The condylar end is fractured, and metachromasia has disappeared from the periphery of the rudiment and is reduced throughout the cartilage. × 15.

FIG. 5. Femur from the same chick as the explant shown in Fig. 3, fixed after 8 days' cultivation in medium containing both vitamin A (15 I.U./ml.) and papain (150 γ/ml.) (Exp. 262). Both ends are detached from the shaft. Metachromasia has almost gone and the rudiment is far smaller than the femur treated with either papain (Fig. 3) or vitamin A (Fig. 4 alone). × 15.

FIG. 6. Control 2nd metacarpal from a 13-day embryo grown for 8 days on a normal plasma: embryo extract clot. (Exp. 263). A thick layer of trabecular bone and a small marrow cavity are present. × 15.

FIG. 7. Second metacarpal from the same experiment (Exp. 263) as the preceding bone, fixed after 8 days' growth in medium containing 150 γ/ml. of papain. Note the uniform disappearance of metachromasia throughout the cartilage. × 15.

FIG. 8. The opposite 2nd metacarpal from the same 13-day embryo as the explant shown in Fig. 6, after 8 days' cultivation in medium containing 15 I.U./ml. of vitamin A. (Exp. 263). The explant is much smaller than its control in Fig. 6 and metachromasia has disappeared from the proliferative zones of flattened cells and from the periphery of the epiphyses. × 15.

Fell-'61
Bib. No. 2686

J. Exp. Med. 114:343. 1961.

Reproduced by permission
of the copyright owner

THE INFLUENCE OF HYDROCORTISONE ON THE ACTION OF EXCESS VITAMIN A ON LIMB BONE RUDIMENTS IN CULTURE

By HONOR B. FELL,* D.Sc., and LEWIS THOMAS, M.D.

(From the Strangeways Research Laboratory, Cambridge, England, and the Department of Medicine, New York University Bellevue Medical Center, New York)

Plates 34 and 35

(Received for publication, May 1, 1961)

It is well known that large doses of cortisone retard fibroplasia in animals (for a review of the literature see Pintar, 1960).

It affects the skeleton by inhibiting its growth in young animals (Follis, 1951) and greatly delays the healing of fractures (Blunt *et al.*, 1950). Cortisone also much reduces the growth rate in culture of the cartilaginous limb bone rudiments from 6- to 7-day-old chick embryos (Buno and Goyena, 1955; Sobel and Freund, 1958). Recently Whitehouse and Lash (1961) have studied the effect of cortisone, hydrocortisone, and related compounds on chondrogenesis induced in somites cultivated *in vitro*, and found that the hormones greatly reduced the amount of cartilage formed; this seemed to be due to inhibited sulfation of chondroitin.

Excess vitamin A causes rarifaction of bone *in vivo* (Wolbach, 1947) and in culture (Fell and Mellanby, 1952; Fell and Thomas, 1960). It also accelerates the resorption of cartilage *in vivo* and in culture (Wolbach 1947; Fell and Mellanby, 1952) and removes the metachromatic material from the matrix (Thomas *et al*, 1960; Fell and Mellanby, 1952; Fell and Thomas, 1960).

Selye (1958) found that the simultaneous administration of cortisone and excess vitamin A to rats produced extensive resorption of bone by the 20th day of treatment, a stage at which no effect is seen in animals given either agent alone; from this result he concluded that there is a "sensitisation of the skeleton to vitamin A overdosage by cortisol." In animal experiments, however, it is seldom possible to determine whether a given effect is produced by the direct action of an agent on a particular tissue, or whether it is due to indirect systemic reactions.

To investigate this question, we have studied the influence of hydrocortisone on limb bone rudiments from chick and mouse embryos, grown in medium with and without added vitamin A. Our results show that in culture the hormone retards the effect of the vitamin on skeletal tissue. This suggests that the remarkable potentiation of the effect observed by Selye (1958) in animals treated with both agents together may have been due to systemic factors that are eliminated in organ culture.

* Foulerton Research Fellow, Royal Society.

After this investigation had been begun, H. B. Fell found some notes by the late Sir Edward Mellanby, dated November 26, 1951, in which he described preliminary experiments on the effects of cortisone alone and in conjunction with vitamin A, on late fetal mouse bones in culture; his results, like ours with hydrocortisone, showed that the simultaneous addition of cortisone to the medium delayed but did not arrest the effect of the vitamin. Mellanby did not pursue this study further and his observation remained unpublished.

Material and Methods

Material.—Limb bone rudiments were removed from 7-day-old chick embryos and mouse fetuses near term.

Culture Methods.—The standard watch glass method was used, the procedure being the same as that described in the previous paper (Fell and Thomas, 1960). For the mouse bones, the embryo extract was made with Tyrode supplemented with 2 per cent (*w/v*) glucose instead of 4 per cent as in the earlier experiments.

Addition of Hydrocortisone and Vitamin A to the Medium.—Hydrocortisone sodium succinate (solu-cortef, Upjohn Co., Kalamazoo) was dissolved in sterile distilled water and added to the plasma to give a concentration in the final medium of either 7.5 μg or 75.0 μg/ml of clot.

Vitamin A alcohol (Roche Products, Ltd., London) was dissolved in ethanol and added to the plasma exactly as described by Fell and Thomas (1960). The final medium contained 10 I.U. vitamin A/ml of clot.

The different media whose effects were to be compared all contained the same quantity of water and/or ethanol, in order to make the experimental conditions as nearly uniform as possible.

Measurement.—In all experiments the explants were drawn at 2-day intervals with the aid of a camera lucida, and their lengths measured with string infiltrated with paraffin wax (see Fell and Mellanby, 1952).

Design of Experiments.—The designs of the various experiments and the number of explants used in each are shown in Tables I and II. To compare the effects of two experimental treatments the bone rudiments from one side of each embryo (set a) were exposed to one treatment and those from the opposite side of the same embryo (set b), to the other treatment.

Histology.—The explants were fixed in Zenker's fluid, washed, dehydrated, cleared, and embedded as described by Fell and Thomas (1960).

Serial sections were cut and stained with toluidine blue (0.5 per cent in 5 per cent ethanol), or with celestine blue, Mayer's acid hemalum and van Gieson's stain.

RESULTS

A. Experiments on Chick Limb Bone Rudiments (Table I)

1. Controls in Normal Medium.—The long bones of 7-day embryos vary somewhat in their size and stage of development according to the time of year and other factors. They consist of a cartilaginous rod with small celled epiphyses each separated by a broad proliferative zone of flattened cells from the middle region of hypertrophic chondrocytes. On the surface of the hypertrophic cartilage there is a layer of periosteal bone which varies in thickness and degree of calcification in different embryos. The bone is covered by a periosteum composed of an outer fibroblastic and an inner osteoblastic layer. The explants

used in these experiments included the cartilage, bone, periosteum, and a little attached muscle.

During 8 days' cultivation in normal medium (Experiments 311, 319) the controls (24 explants) enlarged 2 to 2½ times their original length; the layer

TABLE I

Experiments on 7-Day Chick Bone Rudiments Grown in Medium Containing Hydrocortisone (μg/ml of Medium), Vitamin A (10 I.U./ml) or Both Agents

Experiment	No. pairs	Culture medium		Culture period	Subsequent treatment			
		Set *a*	Set *b*		Immediate fixation	To normal medium	To HC medium	Culture period
				days				*days*
311	2 HFT	HC 7.5 μg	Control	8	*a*, *b*	—	—	—
	2 "	" 75.0 μg	"	8	", "	—	—	—
319	2 "	" 7.5 μg	"	8	", "	—	—	—
	2 "	" 75.0 μg	"	8	", "	—	—	—
281	1 "	A + HC 7.5 μg	A	8	", "	—	—	—
	1 "	"	"	8	—	*a*, *b*	—	4
	1 "	A + HC 75.0 μg	"	8	*a*, *b*	—	—	—
	1 "	"	"	8	—	*a*, *b*	—	4
285	1 "	A + HC 7.5 μg	"	8	*a*, *b*	—	—	—
	1 "	"	"	8	—	*a*, *b*	—	4
	1 "	A + HC 75.0 μg	"	8	*a*, *b*	—	—	—
	1 "	"	"	8	—	*a*, *b*	—	4
288	1 "	A + HC 7.5 μg	"	8	*a*, *b*	—	—	—
	1 "	"	"	8	—	*a*, *b*	—	4
	1 "	A + HC 75.0 μg	"	8	*a*, *b*	—	—	—
	1 "	"	"	8	—	*a*, *b*	—	—
300	2 "	A + HC 7.5 μg	HC 7.5 μg	8	*a*, *b*	—	—	—
	2 "	A + HC 75.0 μg	HC 75.0 μg	8	", "	—	—	—
308	2 "	A + HC 7.5 μg	A + HC 7.5 μg	8	—	*a*	*b* 7.5 μg	4
	2 "	A + HC 75.0 μg	A + HC 75.0 μg	8	—	*a*	*b* 75.0 μg	4
290	2 "	A	A	6	—	*a*	*b* 7.5 μg	6
	2 "	A	A	6	—	*a*	*b* 75.0 μg	6
321	4 "	A	A	4	—	*a*	*b* 7.5 μg	4

H, humerus; F, femur; T, tibia; HC, hydrocortisone; A, vitamin A. Set *a* and Set *b*, rudiments from opposite sides of the same embryo.

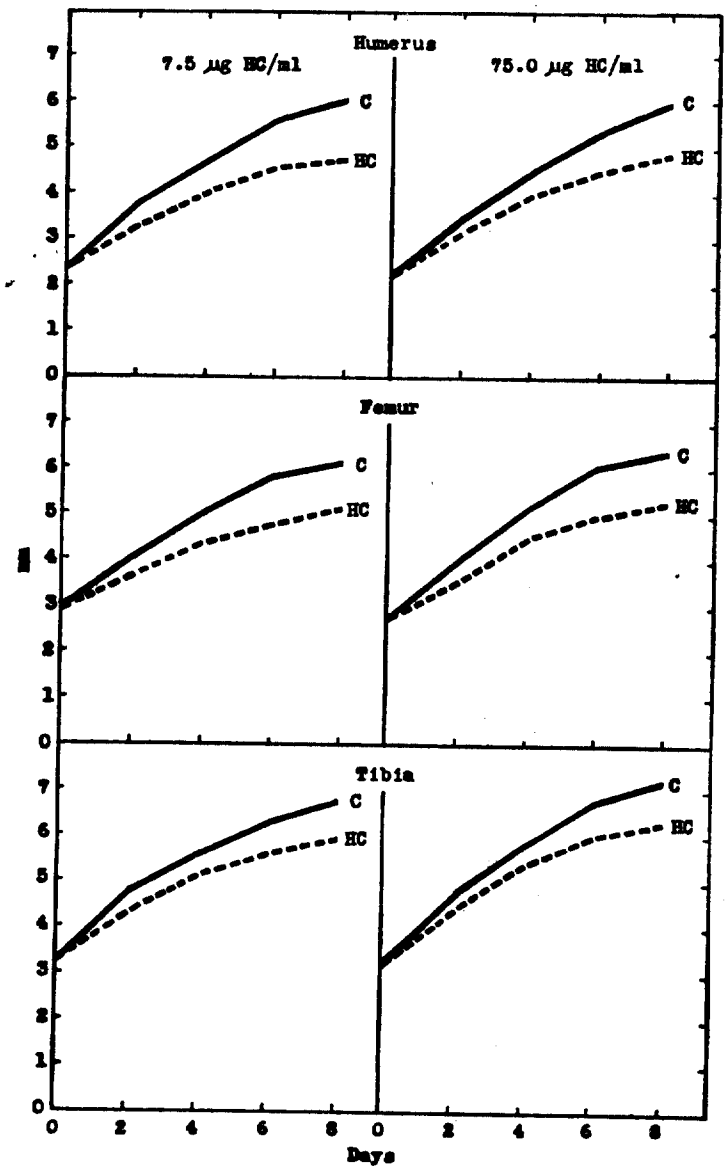

TEXT-FIG. 1. Curves showing the effect of hydrocortisone (HC) on the growth in length of the humerus, femur, and tibia in culture (Experiments 311, 319). Explants from 7-day chick embryos. Each curve represents the average growth of 8 explants.

Both doses of hydrocortisone (HC) reduce the growth rate to about the same extent as compared with that of the controls (C) in normal medium.

of periosteal bone became much thicker, the three cellular zones of the cartilage continued to differentiate fairly normally, and the amount of matrix greatly increased. The structure and behavior of such explants have been described in more detail elsewhere (Fell and Mellanby, 1952).

2. The Effect of Hydrocortisone Alone.—No significant difference could be detected between the effects of 7.5 μg/ml (12 explants) and 75.0 μg/ml (12 explants), respectively, so the two series will be described together.

The hydrocortisone-treated rudiments (Experiments 311, 319) grew more slowly than their controls (Text-fig. 1) (*cf.* Buno and Goyena, 1955; Sobel and Freund, 1958), but appeared healthy and preserved their normal shape during 8 days' cultivation. On histological examination after 8 days' growth, the cells of both epiphyses and diaphysis were found to be smaller than in the controls (Fig. 1*a*, and 1*b*) (*cf.* Sobel and Freund, 1958) and in the epiphyses the intercellular partitions were narrower and gave a more intense metachromatic stain with toluidine blue.

3. The Effect of Vitamin A Alone.—The 36 explants treated with vitamin A alone and fixed after 8 days (Experiments 281, 285, 288) showed the characteristics previously recorded (Fell and Mellanby, 1952; Fell and Thomas, 1960), *viz.* shrinkage, distortion, and, in sections stained with toluidine blue, loss of metachromasia from the cartilage matrix.

In the present experiments the humeri which were the least affected of the rudiments, had doubled their average length by the 6th day after which they suddenly began to shrink (Text-figs. 2 and 4). The femora and tibiae, which grew less rapidly than the humeri, also reached their maximum average length by the 6th day and then began to diminish. As previously noted (Fell and Mellanby, 1952; Fell and Thomas, 1960), the regions most sensitive to the action of vitamin A were those where the cells of the proliferative zones were becoming transformed into the young hypertrophic chondrocytes; here there was an early reduction and rapid disappearance of metachromasia and extreme compression of the cells. The softened cartilage was often invaded by connective tissue cells which sometimes completely detached the terminal cartilage from the shaft. The camera lucida drawings of the living rudiments (Text-fig. 3) showed that by the 8th day, this sensitive region had collapsed at one or both ends in 32 of the 36 vitamin A-treated explants; this phenomenon was largely responsible for the sudden decrease in length between the 6th and 8th day. There was also loss of metachromatic material throughout the cartilage, especially from the shaft and from the periphery of the epiphyses.

As stated above, embryos of the same age vary in their degree of development; vitamin A affected the rudiments from earlier embryos more drastically than those from more advanced chicks.

4. The Effect of Vitamin A + Hydrocortisone.—Observations on the living explants during 8 days' cultivation (Experiments 281, 285, 288, 300, 308,

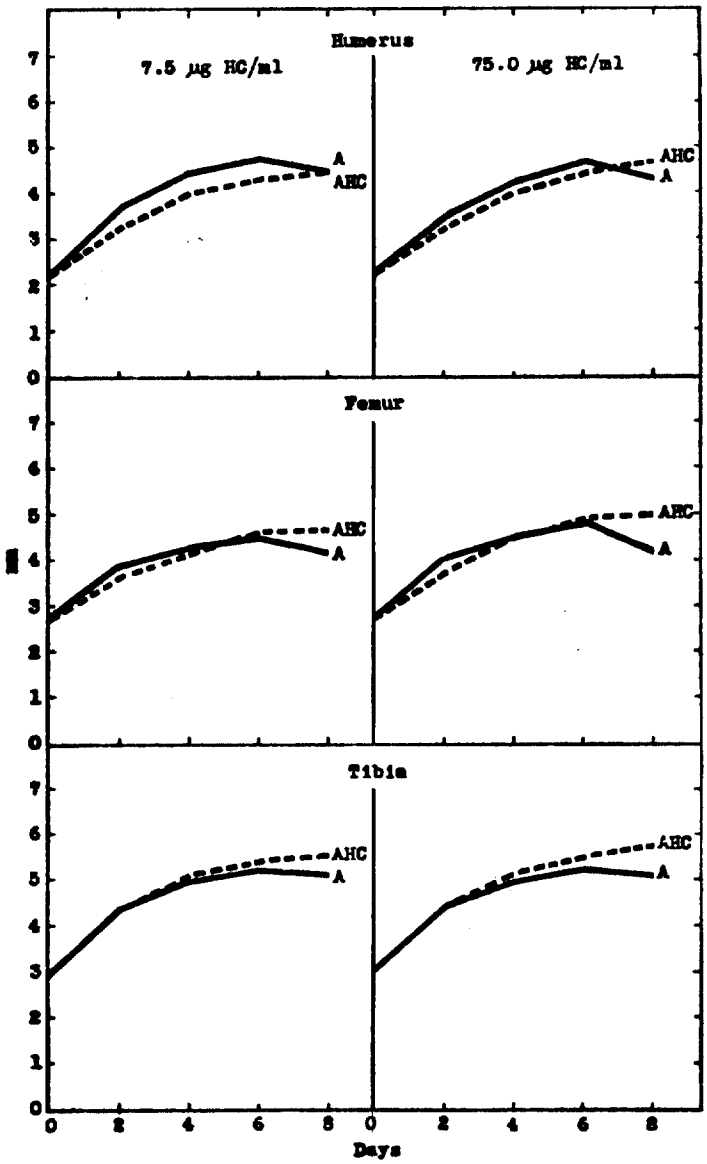

TEXT-FIG. 2. Curves showing the effect of vitamin A alone (A) as compared with that of vitamin A + hydrocortisone (AHC) on the growth in length of the humerus, femur, and tibia of 7-day chick embryos. (Experiments 281, 285, 288). Each curve represents the average growth of 6 explants.

Between the 6th and 8th day the growth curve of the vitamin A-treated explants is deflected downwards owing to shrinkage of the cartilage, whereas that of the rudiments exposed to vitamin A + hydrocortisone continues to rise slowly.

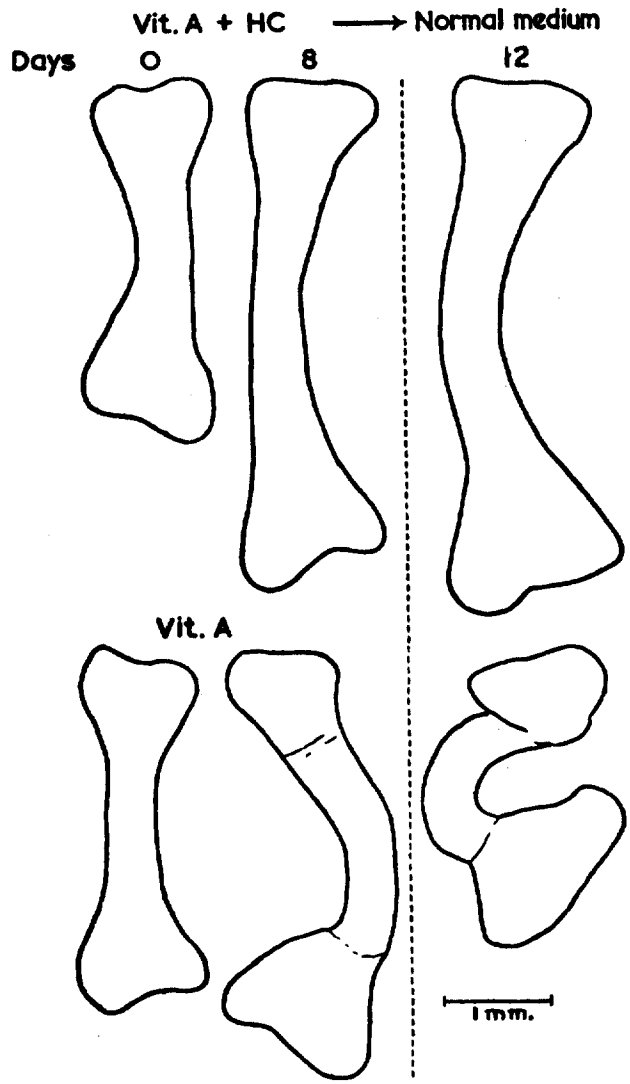

TEXT-FIG. 3. Camera lucida drawings of a pair of femora from the same 7-day chick embryo (Experiment 285). One explant was grown for 8 days in medium containing both vitamin A (10 I.U./ml) and hydrocortisone (7.5 μg/ml) and the other in medium to which only vitamin A had been added. After 8 days, both explants were transferred to normal medium for a further 4 days.

The explant pretreated with vitamin A only is much more severely affected than that pretreated with both agents.

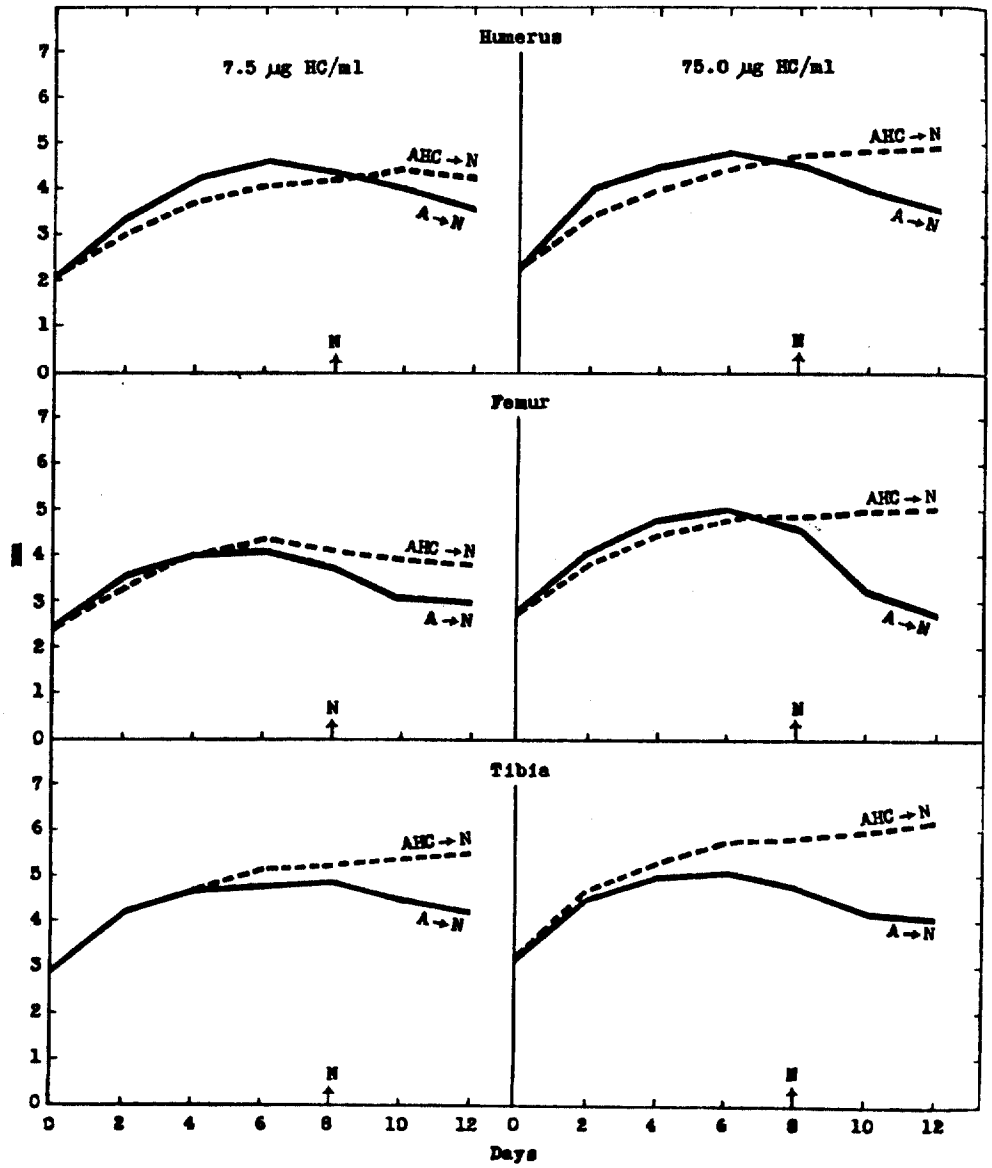

TEXT-FIG. 4. Curves showing the growth in length of paired humeri, femora, and tibiae from 7-day chick embryos, grown first for 8 days either in medium to which only vitamin A had been added or in medium containing both the vitamin and hydrocortisone, and then transferred to normal medium for 4 days (Experiments 281, 285, 288). Each curve represents the average growth of 3 rudiments.

The explants pretreated with hydrocortisone as well as vitamin A, are less severely affected than those exposed to vitamin A alone.

showed that in 70 out of 72 rudiments grown in medium containing both vitamin A and hydrocortisone, vitamin A failed to produce the collapse of the sensitive region at the junction of the proliferative and hypertrophic zones, so that the explants treated with both agents remained intact with little or no distortion during this period. (Text-fig. 3). There was little difference in the growth rates (Text-fig. 4) of the vitamin A- and vitamin A + hydrocortisone–treated rudiments during the first 6 days, but when the sensitive region in the explants exposed to the vitamin alone began to collapse, the average growth curve was deflected downwards whereas that of the series treated with both the hormone and the vitamin continued slowly to rise.

Histological examination after 8 days' cultivation revealed a striking contrast between the vitamin A- and the vitamin A + hydrocortisone-treated rudiments. In paired explants from the same embryo (Experiments 281, 285, 288), the rudiment grown in medium containing both agents was without exception much less affected by the vitamin than the corresponding rudiment grown in the presence of the vitamin alone. In many of the pairs (Fig. 2b) the member exposed to vitamin A + hydrocortisone appeared almost normal in sections stained with toluidine blue; there was usually diminished metachromasia at the margin of the sensitive region mentioned above, and in a narrow peripheral zone of the epiphyses, but elsewhere the metachromatic staining was intense. In the vitamin A–treated member on the other hand (Fig. 2a) the metachromasia was greatly reduced throughout and had almost completely gone from the shaft, while the cartilage of the sensitive region was greatly compressed and sometimes disintegrating. Some of the explants given vitamin A + hydrocortisone showed a more advanced vitamin A effect than that described above, but their vitamin A–treated controls were altered to a correspondingly greater degree. The higher dose of the hormone (75 μg/ml) gave a slightly better protection against the action of the vitamin than the lower concentration, but the difference was not great.

In one experiment (300) the effect of the two agents together was directly compared with that of hydrocortisone alone. The two humeri treated with 7.5 hydrocortisone + vitamin A grew at about the same rate as the opposite rudiments treated with the hormone alone, but in the remaining 10 pairs of explants, the rudiments exposed to both compounds were much shorter than those treated with hydrocortisone only, especially in the 6 pairs of femora and tibiae. The explants in vitamin A + hydrocortisone medium displayed a moderate vitamin A change on histological examination; as before, the higher dose of hydrocortisone gave a slightly better protection than the lower. In sections stained with toluidine blue, the matrix was much more intensely metachromatic in the series treated with hydrocortisone than in that treated with both compounds.

These experiments showed that the effect of vitamin A was much retarded but not arrested by the simultaneous addition of hydrocortisone to the medium.

5. *The Effect of Transferring Vitamin A- and Vitamin A + Hydrocortisone-Treated Explants to Normal Medium.*—In 18 pairs of rudiments (Experiments 281, 285, 288), one member of each pair was grown for 8 days in medium containing the vitamin only and the other in medium to which both the vitamin and hydrocortisone had been added (7.5 or 75.0 μg hydrocortisone/ml); both were then transferred to normal medium for a further 4 days. After transfer, the vitamin A change progressed in both series, but far more rapidly in the vitamin A-treated than in the corresponding vitamin A + hydrocortisone-treated explants (Text-figs. 3 and 4), so that by the end of the culture period the former were much more shrunken and distorted than the latter; histological examination confirmed the difference seen in the living cultures. After transfer to normal medium there was no obvious difference in behaviour between explants previously grown in the presence of vitamin A + 7.5 μg hydrocortisone/ml and those in vitamin A + 75.0 μg hydrocortisone/ml.

6. *The Effect of Transferring Explants from Medium Containing Vitamin A + Hydrocortisone to Medium with Hydrocortisone Only.*—In one experiment (308) an attempt was made to see if the vitamin A changes could be completely arrested by transferring vitamin A + hydrocortisone-treated explants (12 pairs) to medium containing hydrocortisone alone. Both members of each pair were grown in medium with vitamin A + hydrocortisone (7.5 or 75.0 μg hydrocortisone/ml) for 8 days; one rudiment was then transferred to normal medium and the other to medium containing hydrocortisone only (7.5 or 75.0 μg/ml). Transfer to medium with hydrocortisone failed to arrest the vitamin A changes in any of the explants. The 6 rudiments transferred to medium containing 7.5 μg hydrocortisone/ml were less severely altered than the opposite rudiments transplanted to normal medium, but there was no difference between those in 75.0 μg hydrocortisone/ml and in normal medium. This suggests that under these conditions the lower dose of the hormone was more effective in retarding the vitamin A effect than the higher, but more experiments with a wider dose range and longer culture period would be required to settle this point.

7. *The Effect of Transferring Vitamin A-Treated Explants to Medium Containing Hydrocortisone.*—In two experiments (290, 321), paired rudiments were grown in vitamin A medium for 6 (Experiment 290) or 4 days (Experiment 321); one of each pair was then transferred to a normal clot and the other to one containing hydrocortisone for a further 6 (Experiment 290) or 4 days (Experiment 321). The object of these experiments was to see whether treatment with hydrocortisone would hasten recovery from the vitamin A effect which, as described above, progresses for some days after withdrawal of the added vitamin.

In the living cultures there was little difference in appearance or growth rate between the explants transferred to normal and to hydrocortisone medium respectively. In sections stained with toluidine blue, the cartilage matrix was rather more intensely metachromatic in the hydrocortisone-treated rudiments than in those transplanted to the normal clot, but otherwise the two series were similar.

These results provided no evidence of accelerated recovery in response to treatment with hydrocortisone following exposure to excess vitamin A.

TABLE II

Experiments on Late Fetal Mouse Bones Grown in Medium Containing Hydrocortisone (μg/ml of Medium), Vitamin A (10 I.U./ml) or Both Agents

Experiment	No. pairs	Culture medium		Culture period	Subsequent treatment			
		Set *a*	Set *b*		Immediate fixation	To normal medium	To HC medium	Culture Period
				days				*days*
316	4 R, U, T	HC 7.5 μg	Control	6	*a*, *b*	—	—	—
318	4 ", ", "	" " "	"	6	", "	—	—	—
298	2 ", ", "	A + HC 7.5 μg	A	6	", "	—	—	—
	2 ", ", "	A + HC 75.0 μg	"	6	", "	—	—	—
317	4 ", ", "	A + HC 7.5 μg	"	6	", "	—	—	—
320	4 ", ", "	A	"	4	—	*a*	*b* 7.5 μg	6

R, radius; U, ulna; other lettering as for Table I.

B. Experiments on Limb Bones from Late Fetal Mice (Table II)

1. Controls in Normal Medium.—The limb bones from late fetal mice are at a much more advanced stage of development than those of 7-day chick embryos. A mouse bone at this stage consists of a bony shaft covered by the usual two-layered periosteum and enclosing a marrow cavity. Each end of the shaft is occupied by a partially eroded mass of hypertrophic cartilage; this merges with the proliferative zone of flattened cells beyond which is the cartilaginous epiphysis where hypertrophy of the chondrocytes has not yet begun. Of the three bones studied, the radius is the smallest, the ulna the longest, and the tibia the stoutest.

Twenty-four explants (Experiments 316, 318) were cultivated for 6 days in normal medium. During this period they elongated very little, unlike the actively growing chick rudiments, but the terminal cartilage enlarged somewhat. Histological examination showed that the cells were healthy except in some areas of the old hypertrophic cartilage, and mitosis was abundant especially among the osteoblasts and marrow reticulum cells. There were large erosion bays in the hypertrophic cartilage (Figs. 3a and 5a) both at the surface next

to the marrow, and laterally as a result of invasion from the periosteum; most of the cells lining these bays were osteoblasts and marrow reticulum cells but a few osteoclasts were present. In sections stained with toluidine blue, areas of matrix adjacent to erosion cavities had often lost their metachromasia, which suggested that digestion of the matrix was in progress (*cf.* Fell and Thomas, 1960). In places new bone was being deposited by the periosteum.

2. *The Effect of Hydrocortisone Alone.*—During 6 days' cultivation, the growth of the mouse bones (24 explants) exposed to hydrocortisone (Experiments 316, 318) was similar to that of the corresponding controls in normal medium; in this respect the slowly growing mouse bones differed in their response from the rapidly growing chick rudiments treated with the same dose (7.5 μg/ml) of hydrocortisone.

The chief histological difference between the hydrocortisone-treated and control explants, was the arrest of cartilage excavation in the former (Figs. 3, and 5). The resorption bays that were so conspicuous in the controls, were small or absent in the bones exposed to the hormone and the surface of the hypertrophic cartilage next to the marrow appeared almost straight in longitudinal section. After toluidine-blue staining, the zone of colourless matrix often seen in the controls in regions of active resorption, were rarely observed in the bones grown in the presence of hydrocortisone.

3. *The Effect of Vitamin A Alone.*—The effect of vitamin A on late fetal mouse bones has been described in detail elsewhere (Fell and Mellanby, 1952; Fell and Thomas, 1960). In the present experiments (298, 317), the 24 bones grown for 6 days in vitamin A medium showed the usual response *viz.* rapid shrinkage and resorption of the cartilage with loss of metachromasia, and speedy dissolution of the bone (Figs. 4 and 6), so that by the 6th day the explants had largely disintegrated (Text-fig. 5). Most of the cells, however, remained healthy and active except in some places in the interior of the explant where the cells had become densely packed owing to the collapse of the bone and cartilage; mitosis was abundant among the osteoblasts and marrow reticulum cells, and quite common among the chondrocytes of the dwindling cartilage.

The radius, being the smallest rudiment, was the most affected by the vitamin; the relatively stout tibia was the least changed and though greatly reduced in size by the 6th day, it had largely preserved its original shape.

4. *The Effect of Vitamin A + Hydrocortisone.*—All the 18 bones grown in the presence of both vitamin A and 7.5 μg hydrocortisone/ml, differed strikingly from the corresponding explants cultivated in medium to which only vitamin A had been added (Experiments 298, 317). The effect of the vitamin was much retarded by hydrocortisone (Text-fig. 5; Fig. 4), so that after 6 days in culture the explants treated with both agents had shrunk very little and in life appeared almost normal, whereas those in vitamin A medium were either fragmentary (radius and ulna) or greatly reduced (tibia). The contrast between

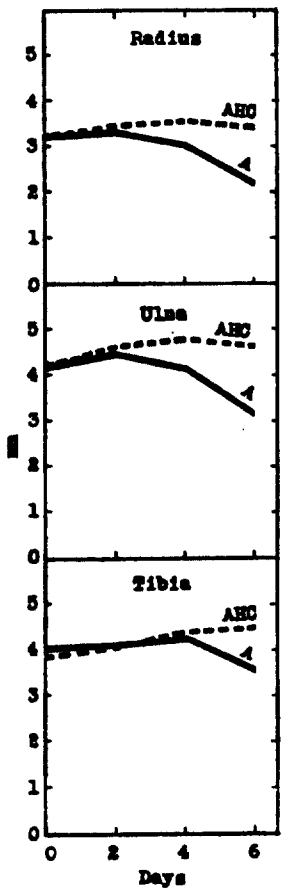

TEXT-FIG. 5.

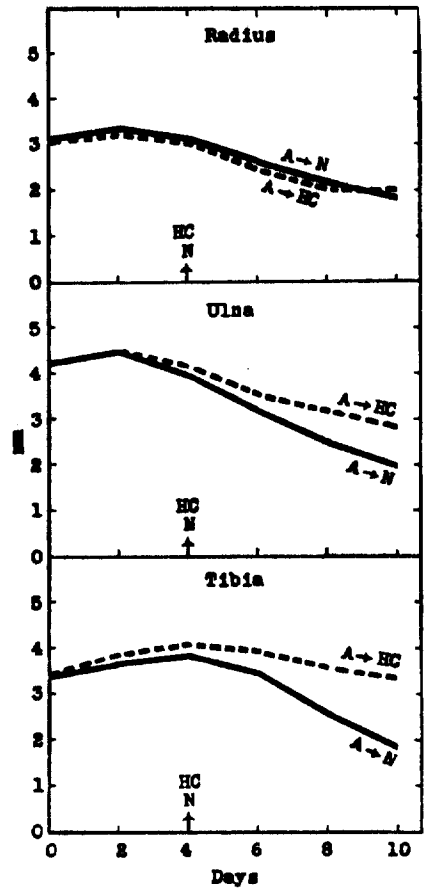

TEXT-FIG. 6.

TEXT-FIG. 5. Curves showing the effect of vitamin A (A) on the length of the radius, ulna, and tibia from late fetal mice as compared with that of vitamin A + hydrocortisone (7.5 μg/ml) (AHC) (Experiments 317, 298). Each curve represents the average change in length of 6 bones.

Vitamin A alone produces a severe shrinkage which does not appear when hydrocortisone also is present in the medium.

TEXT-FIG. 6. Paired radii, ulnae, and tibiae of late fetal mice were grown for 4 days in medium containing 10 I.U. vitamin A/ml; one of each pair was then transferred to normal medium and the other to medium containing 7.5 μg hydrocortisone/ml (Experiment 320). Each curve shows the average change in length of 4 bones.

Hydrocortisone had no effect on the shrinkage of the radii, but retarded the vitamin A effect on the larger ulnae and tibiae.

the bones exposed to both vitamin A and hydrocortisone and those treated with the vitamin only, was greater in the radii and ulnae than in the tibiae; as stated above, of the three bones used the tibia is the most resistant to the action of the vitamin.

Although the effect of vitamin A was greatly retarded by hydrocortisone it was not arrested. In histological preparations (Fig. 6b), the terminal cartilage of the bones treated with both agents showed loss of metachromasia from the peripheral matrix, and resorption of both bone and cartilage was greater than in rudiments grown in normal medium.

Six bones were grown in medium containing 75 μg hydrocortisone/ml + vitamin A (Experiment 298); they were similar to the explants grown with the vitamin + 7.5 μg hydrocortisone/ml.

5. *The Effect of Transferring Explants from Medium Containing Vitamin A to Medium with Hydrocortisone.*—Twelve pairs of bones (Experiment 320) were grown for 4 days in vitamin A medium. One of each pair was then transferred to medium with hydrocortisone (7.5 μg/ml) and the other to a normal clot; after a further 6 days' cultivation, they were fixed for histological study.

In the living cultures, the usual vitamin A changes were observed during the first 4 days (Text-figs. 6 and 7). After transfer to normal medium, the radii and ulnae continued to disintegrate and were fragmentary by the 8th day. The tibia fared rather better. Both the bony and the cartilaginous parts of the shaft rapidly shortened, until finally the broad end of the terminal cartilage was sitting squarely on a short tube of periosteal bone (Text-fig. 7); in three of the tibiae, this residual cartilage continued to enlarge at the proximal end of the bone and in all 4 explants it acquired a curious bilobed shape.

The radii and ulnae transferred to normal medium, showed all the histological changes characteristic of exposure to excess vitamin A. The cartilage had almost gone, and the interior of the dilapidated bony shaft was filled with cells which seemed to be mainly osteoblasts and narrow reticulum cells; mitosis was plentiful and even occurred in the shrunken remnants of the cartilage. In the tibiae, the surviving terminal cartilage was quite strongly metachromatic; the chondrocytes were nearly all in the early hypertrophic stage and represented the epiphysial ossification centre, but the small celled articular cartilage that normally covers the centre, had almost completely disappeared. In all four explants, bone was being deposited on the articular surfaces of the hypertrophic cartilage.

The radii transferred to medium with hydrocortisone did not differ significantly from those placed in normal medium (Text-fig. 6), and retardation of the vitamin A effect was seen in only one explant, the largest of the 4. In all the ulnae, however, hydrocortisone considerably retarded the vitamin A changes. The greatest inhibitory effect of the hormone was in the tibiae all of which were much larger at the end of the culture period than the corresponding rudiments transferred to a normal clot.

Histological examination confirmed the observations on the living cultures treated with hydrocortisone. The sections also showed evidence of diffuse ossification in the very cellular marrow cavity, and bone was being deposited on the articular surfaces of the tibiae.

From these results it was clear that after 4 days' exposure to vitamin A, the

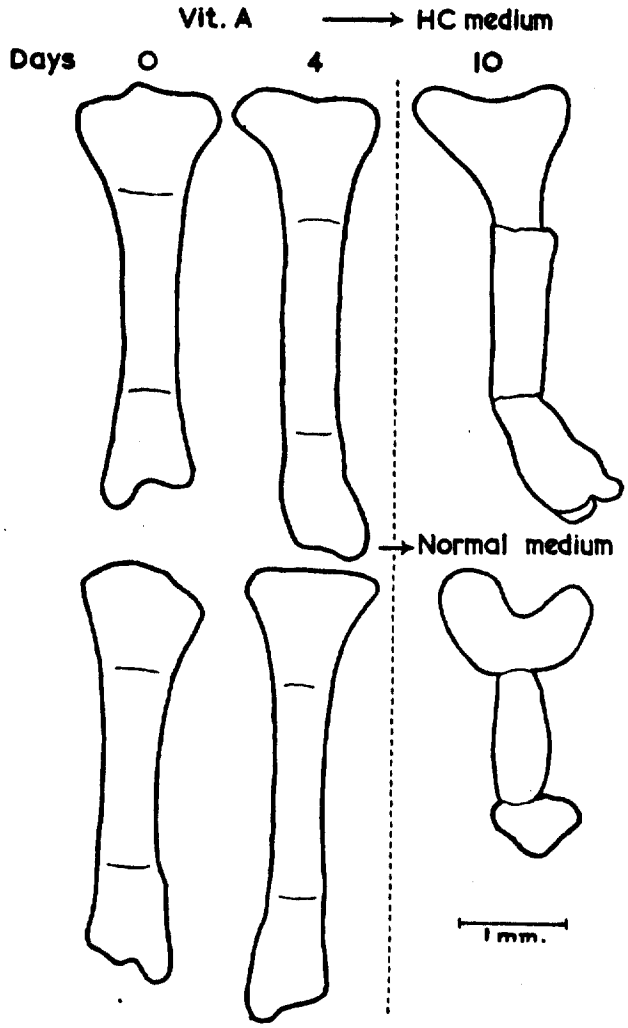

TEXT-FIG. 7. Camera lucida drawings of a pair of tibiae from a late fetal mouse (Experiment 320). Both bones were grown for 4 days in medium containing 10 I.U. vitamin A/ml; one was then transferred for a further 6 days to medium to which hydrocortisone (7.5 μg/ml) had been added and the other to normal medium.

The hydrocortisone has retarded the progress of the vitamin A effect.

relatively stout tibia which is the most vitamin A–resistant of the three bones, gave the best response to hydrocortisone, that the small highly susceptible radius was unaffected by the hormone, and that the medium-sized ulna gave an intermediate reaction. Although the vitamin A changes were much retarded in the ulna and tibia, however, they were not arrested by hydrocortisone.

DISCUSSION

In our experiments, hydrocortisone alone severely inhibited the growth of the cartilaginous limb bone rudiments from 7-day chick embryos; these results confirmed previous work on the action of cortisone and hydrocortisone on embryonic chick cartilage in culture (Buno and Goyena, 1955; Sobel and Freund, 1958; Whitehouse and Lash, 1961). Neither Buno and Goyena nor Sobel and Freund record any difference in the matrix between hydrocortisone-treated and control explants. On the other hand Whitehouse and Lash found that the synthesis of matrix was much inhibited by cortisone and hydrocortisone during chondrogenesis induced in somite cultures; our results agree with these findings, since the intercellular partitions of the epiphysial matrix were considerably narrower in the hydrocortisone-treated rudiments than in the controls. Rather to our surprise, however, in sections stained with toluidine blue, the metachromasia was more intense in the hydrocortisone-treated cartilage; the significance of this is not known. In our explants, as in those of Sobel and Freund, the diaphysial cartilage cells were smaller in the rudiments grown in medium with hydrocortisone.

The question arises as to what factors are responsible for the reduced growth of chick cartilage cultivated in the presence of hydrocortisone or cortisone. Buno and Goyena attribute the reduced growth rate to diminished cell division. Whitehouse and Lash, however, found that the increase in deoxyribonucleic acid (DNA) was the same in both treated and control explants, and state that "the effects of hydrocortisone cannot therefore be simply explained as an inhibition of cell multiplication and loss of viability"; their results suggest that the lowered growth rate is due to depressed synthesis of matrix. In our material also, diminished synthesis of matrix must account at least partly for the growth inhibition, but it is probable that the failure of the diaphysial chondroblasts to hypertrophy normally is a contributory factor; we have no information about the DNA content of the hydrocortisone-treated and control explants. Retardation of skeletal growth has also been described by Moscona and Karnofsky (1960) in chick embryos treated *in vivo*.

The explants of the well developed but slowly growing mouse bones, displayed another effect of hydrocortisone *viz.* an inhibition of cartilage resorption of the cells of the marrow cavity; this effect also is mentioned by Mellanby in his unpublished notes. A similar inhibition of the excavation of cartilage has been observed *in vivo*. Follis (1951), who investigated the effect of cortisone on the growing bones of young rats, found that "a dense zone composed of spicules

of calcified cartilaginous matrix encased in bone appears at the growing ends of the bone," and he concludes that "there is an inhibition or retardation in normal osteolytic sequences." Moscona and Karnofsky (1960) record a similar phenomenon in the limb bones of chick embryos treated with cortisone *in vivo*; at a stage when the cartilage had been excavated from the shafts of the long bones in the controls, in the hydrocortisone-treated chicks "the shaft consisted of a continuous core of cartilage surrounded by perichondral bone." The arrested resorption of the terminal cartilage in the fetal mouse bones exposed to hydrocortisone in culture, shows that this "retardation in normal osteolytic sequences" is due to a direct action of the hormone on the tissue.

Thus hydrocortisone or cortisone has essentially the same effect on skeletal tissues in culture as it has on the growing skeleton of the intact animal, and inhibits normal growth and resorption both *in vitro* and *in vivo*. The combined action of hydrocortisone or cortisone and vitamin A, however, is strikingly different in culture from that in the body: in the former the hormone retards and in the latter it accelerates the action of the vitamin on skeletal tissue. The accelerating influence of the hormone on the effect of the vitamin was first shown by Selye (1958) in rats, and in the Strangeways Laboratory similar results (unpublished) have recently been obtained by G. Weissmann on *Xenopus* larvae.

In view of the fact that skeletal resorption is inhibited by hydrocortisone alone, both *in vivo* and in organ culture, it might have been expected that the processes of skeletal dissolution set in motion by excess vitamin A, would be retarded *in vivo* as they are in organ culture, and the apparent additive effect of the two agents in the body is puzzling. *In vivo*, however, systemic factors operate that are excluded from cultures *in vitro*. Thus Clark and Colburn (1955) showed that in rats put on a vitamin A–deficient diet, the administration of cortisone reduced the amount of vitamin A stored in the liver to 20 per cent of its original value in 13 days, whereas there was no measurable depletion in the controls during this brief period. G. Weissmann (personal communication) observed a striking additive effect of the two agents on the histological structure of the liver in *Xenopus* larvae; either compound alone produced little change, but both together caused partial atrophy. Moreover Jackson and his colleagues (Wang, Glass, Goldenburg, Stearns, Kelly, and Jackson, 1954) found that the administration of pituitary corticotropin to patients with rheumatic fever raised the level of vitamin A in the blood stream. These observations suggest that *in vivo* the hormone may hasten the action of the vitamin by preventing it from being stored in the liver, so that a high concentration is rapidly produced in the blood. It should be emphasized that under the conditions of our experiments, hydrocortisone merely delays but never arrests the action of the vitamin, and there is little difference in protective action between a dose of 7.5 and one of 75.0 μg hydrocortisone/ml.

As yet nothing is known of the mechanism whereby hydrocortisone retards

the effect of excess vitamin A on skeletal rudiments in culture. Recent work (Fell and Thomas, 1960; Dingle, Lucy, and Fell, 1961; Lucy, Dingle, and Fell, 1961; Dingle, 1961) indicates that vitamin A increases the proteolytic activity of the chondrocytes, and that the degradation of the cartilage matrix may be due to the liberation of a protease (with other enzymes) from the lysosomes (Dingle, 1961). If this view is correct, it is possible that hydrocortisone may partially inhibit the activity, the synthesis or the release of the protease. Further experiments on animals and organ cultures should resolve the discrepancy between the results obtained *in vivo* and *in vitro*.

SUMMARY

The effect of hydrocortisone has been studied in organ cultures of the cartilaginous long bone rudiments from 7-day chick embryos and of the well ossified limb bones from late fetal mice. In the chick rudiments, which grow rapidly in culture, the growth rate was much reduced by hydrocortisone, less intercellular material was formed, and the hypertrophic cells of the shaft were much smaller than in the controls in normal medium. In the late fetal mouse bones, which grow very little in culture, hydrocortisone had no obvious effect on growth but arrested resorption of the cartilage. These effects resemble those described by others in the skeleton of animals treated with cortisone or hydrocortisone.

The influence of hydrocortisone on the response of the chick and mouse explants to excess vitamin A was investigated. In the presence of excess vitamin A, cartilage (chick, mouse) and bone (mouse) rapidly disintegrated, but when hydrocortisone also was added to the medium, this dissolution of the intercellular material was much retarded, though not suppressed.

The retardative action of hydrocortisone on the changes produced by excess vitamin A in skeletal tissue in culture, contrasts sharply with the strongly additive effect of the two agents on the skeleton in the intact animal (Selye, 1958). It is suggested that this discrepancy between the results obtained *in vitro* and *in vivo* is probably due to systemic factors that operate in the body but are eliminated in organ cultures.

The authors wish to thank Mr. L. J. King for his skillful technical assistance throughout the work, and Mr. V. C. Norfield for drawing the graphs. They are indebted to Mr. J. C. Dingle for valuable suggestions and to Dr. T. Moore and Dr. I. M. Sharman of the Dunn Nutritional Laboratory, Cambridge, for kindly reading the manuscript.

BIBLIOGRAPHY

Blunt, J. W., Plotz, C. M., Lattes, R., Howes, E. H., Meyer, K., and Ragan, C., Effect of cortisone on experimental fractures in the rabbit, *Proc. Soc. Exp. Biol. and Med.*, 1950, **73**, 678.

Buno, W., and Goyena, H., Effect of cortisone upon growth *in vitro* of femur of the chick embryo, *Proc. Soc. Exp. Biol. and Med.*, 1955, **89**, 622.

Clark, I., and Colburn, R. W., A relationship between vitamin A metabolism and cortisone, Endocrinology, 1955, **56**, 232.

Dingle, J. T., Studies on the mode of action of vitamin A. III. The release of a bound protease by the action of vitamin A, *Biochem. J.*, 1961, **79**, 509.

Dingle, J. T., Lucy, J. A., and Fell, H. B., Studies on the mode of action of vitamin A. I. The effect of excess vitamin A on the metabolism and composition of embryonic chick limb-cartilage grown in organ culture, *Biochem. J.*, 1961, **79**, 497.

Fell, H. B., and Mellanby, E., The effect of hypervitaminosis A on embryonic limb-bones cultivated *in vitro*, *J. Physiol.*, 1952, **116**, 320.

Fell, H. B., and Thomas, I., Comparison of the effects of papain and vitamin A on cartilage. II. The effects on organ cultures of embryonic skeletal tissue, *J. Exp. Med.*, 1960, **111**, 719.

Follis, R. H., Effect of cortisone on growing bones of rat, *Proc. Soc. Exp. Biol. and Med.*, 1951, **76**, 722.

Lucy, J. A., Dingle, J. T., and Fell, H. B., Studies on the mode of action of vitamin A. II. A possible role of intracellular proteases in the degradation of cartilage matrix, *Biochem. J.*, 1961, **79**, 500.

Moscona, M. H., and Karnofsky, D. A., Cortisone induced modifications in the development of the chick embryo, Endocrinology, 1960, **66**, 533.

Pintar, K., The influence of adrenal cortico-steroids on fibrous tissue formation, *Am. J. Med. Sc.*, 1960, **240**, 361.

Selye, H., Sensitisation of the skeleton to vitamin-A overdosage by cortisol, *Arthritis and Rheumatism*, 1958, **1**, 87.

Sobel, H., and Freund, O., The action of cortisone on the embryonic cartilage and muscle *in vitro*, Experientia, 1958, **14**, 421.

Thomas, L., McCluskey, R. T., Potter, J. L., and Weissmann, G., Comparison of the effects of papain and vitamin A on cartilage. I. The effects in rabbits, *J. Exp. Med.*, 1960, **111**, 705.

Wang, P., Glass, H. L., Goldenburg, L., Stearns, G., Kelly, H. G., and Jackson, R. L., Serum vitamin A and carotene levels in children with rheumatic fever, *Am. J. Dis. Child.*, 1954, **87**, 659.

Whitehouse, M. W., and Lash, J. W., Effect of cortisone and related compounds on the biogenesis of cartilage, *Nature*, 1961, in press.

Wolbach, S. B., Vitamin A deficiency and excess in relation to skeletal growth, *J. Bone and Joint Surg.*, 1947, **29**, 171.

EXPLANATION OF PLATES

The photographs in Fig. 4 are by Mr. V. C. Norfield and the remaining photographs by Mr. M. F. Applin.

PLATE 34

FIG. 1. Hypertrophic cartilage in humeri from a 7-day chick embryo, after 8 days' cultivation in control medium (Fig. 1 *a*) and medium containing 7.5 μg of added hydrocortisone Fig. 1 *b* (Experiment 311). The cells are much smaller in Fig. 1 *b* than in Fig. 1 *a*. Toluidine blue. × 1300.

FIG. 2. The proximal ends of femora from a 7-day chick embryo, grown for 8 days in medium containing 10 I.U./ml of added vitamin A alcohol (Fig. 2 *a*) and in medium to which had been added both the vitamin and 7.5 μg/ml of hydrocortisone (Fig. 2 *b*) (Experiment 285). The severe loss of metachromasia from the cartilage matrix of Fig. 2 *a* has been inhibited in Fig. 2 *b* by the hormone. Toluidine blue. × 20.

FIG. 3. Fig. 3 *a*, distal ends of the ulnae of a mouse fetus near term after 6 days' cultivation in control medium (Fig. 3 *a*) and medium containing 7.5 μg of added hydrocortisone Fig. 3 *b* (Experiment 316). Note the active invasion and resorption of the cartilage in 3 *a*; these processes are arrested in 3 *b*. Mayer's acid hemalum, celestine blue, and van Gieson's stain. × 335.

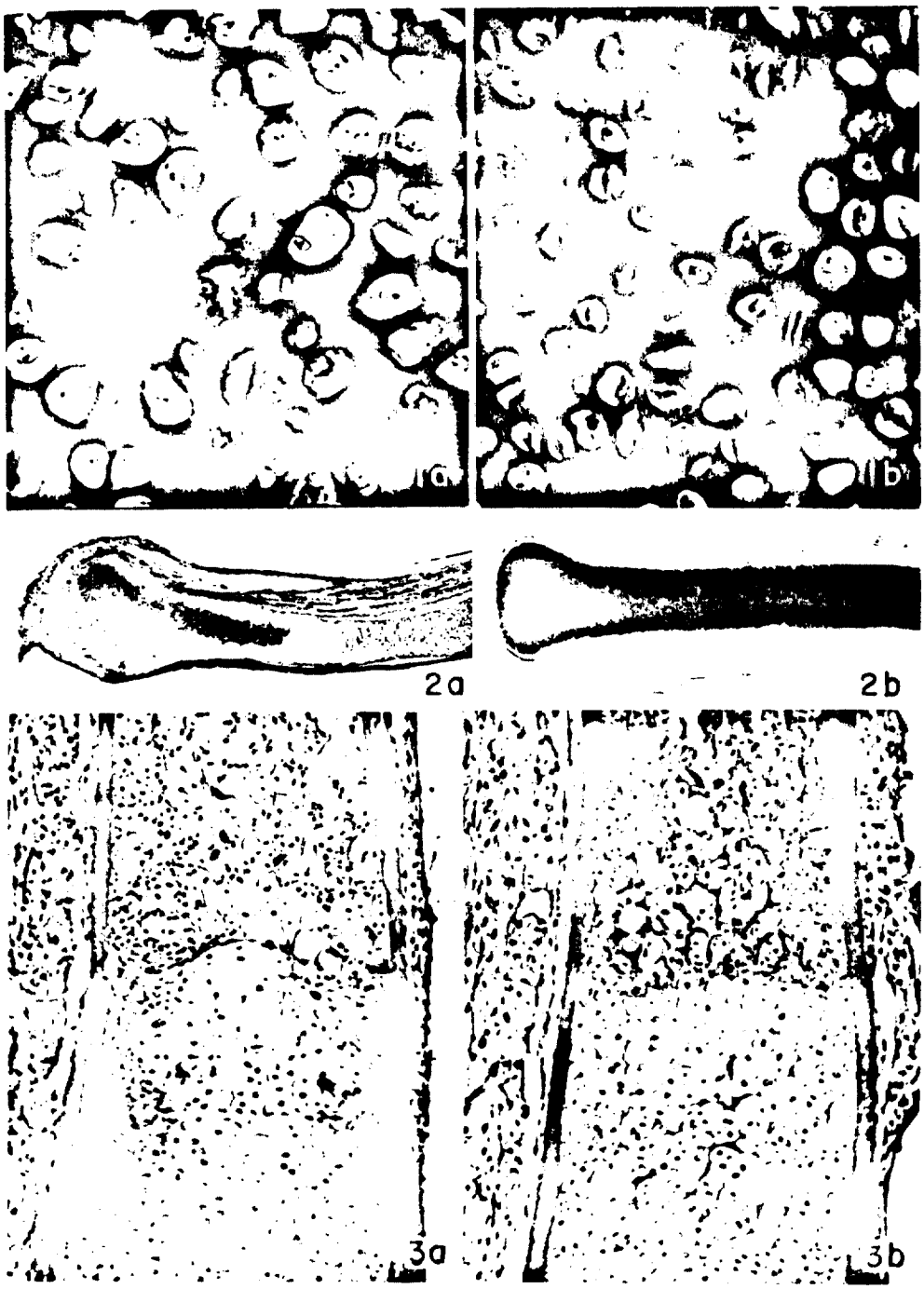

Fell and Thomas: Hyperisoneans and isoneurudiments

PLATE 35

All the explants shown in this plate are from fetal mice near term.

FIG. 4. Three pairs of living bone rudiments from the same fetus photographed after 6 days' cultivation (Experiment 317). One of each pair (*A*) was grown in medium to which 10 I.U./ml of vitamin A had been added, and the other (*AHC*) in medium containing both the vitamin and 7.5 μg/ml of hydrocortisone. In all three pairs the hydrocortisone has greatly retarded the action of the vitamin. Fig. 4 *a* ulnae; Fig. 4 *b* radii; Fig. 4 *c* tibiae. × 15.

FIG. 5. Radii from the same fetus after 6 days' growth in control medium (Fig. 5 *a*) and medium containing 7.5 μg/ml of hydrocortisone (Fig. 5 *b*) (Experiment 316). Note the extensive invasion and resorption of the distal cartilage in Fig. 5 *a*; these processes are arrested in Fig. 5 *b*. Toluidine blue. × 20.

FIG. 6. Radii from the same foetus after 6 days' growth in medium to which had been added 10 I.U./ml of vitamin A of (Fig. 6 *a*) and both the vitamin and 7.5 μg/ml of hydrocortisone (Fig. 6 *b*). The dissolution of the cartilage and bone which is advanced in Fig. 6 *a* is greatly retarded though not arrested in Fig. 6 *b*; note some loss of metachromasia from the distal cartilage in Fig. 6 *b* as compared with the control shown in Fig. 5 *a*. Toluidine blue. × 20.

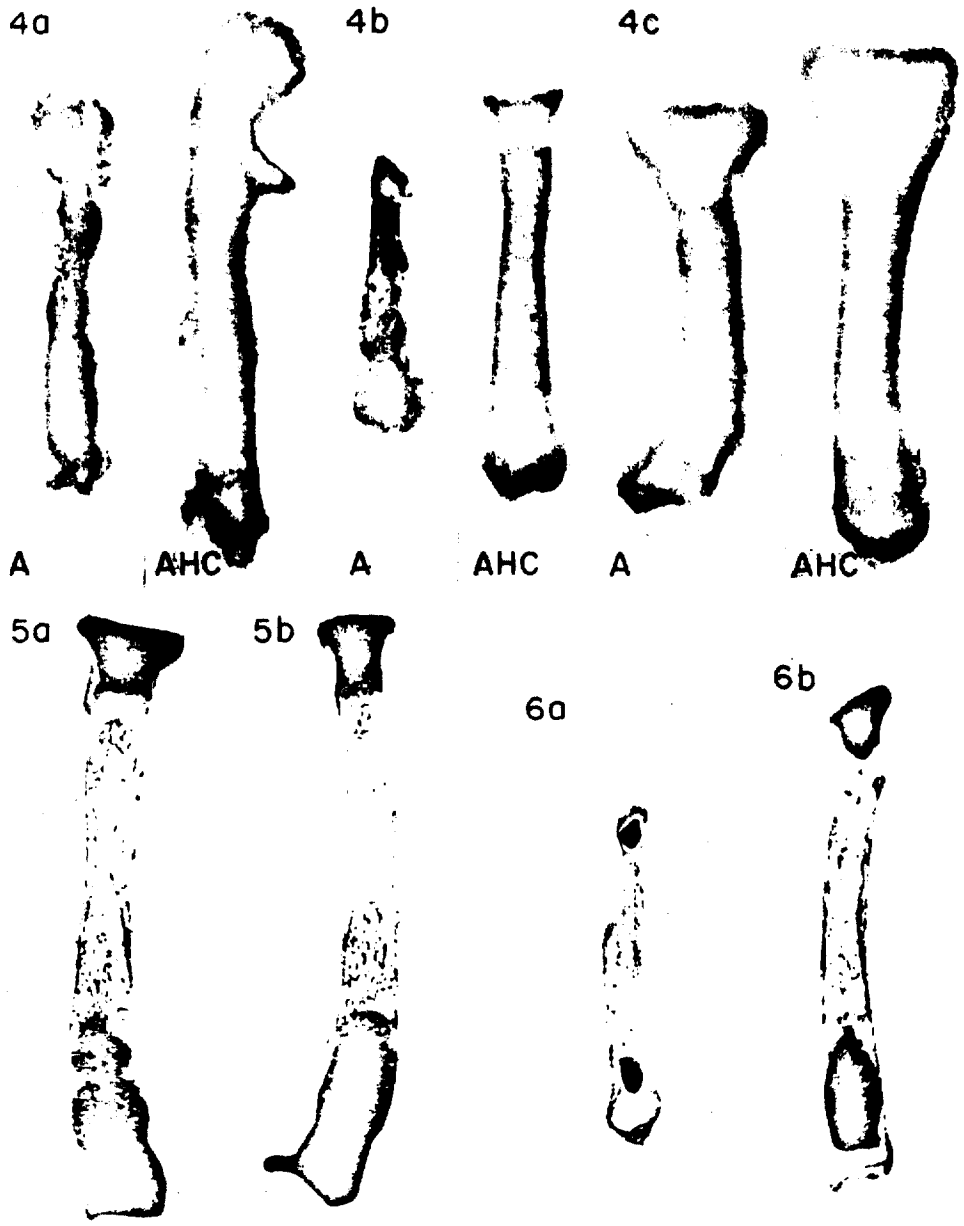

Fell and Thomas: Hydrocortisone and limb-bone rudiments

Fell-'62
Bib No. 2688

Reproduced by permission
of the copyright owner

Biochem. J. 83:63-69. 1962.

Biochem. J. (1962) 83, 63

Studies on the Mode of Action of Excess of Vitamin A

4. THE SPECIFICITY OF THE EFFECT ON EMBRYONIC CHICK-LIMB CARTILAGE IN CULTURE AND ON ISOLATED RAT-LIVER LYSOSOMES*

BY HONOR B. FELL†, J. T. DINGLE AND M. WEBB‡
Strangeways Research Laboratory, Cambridge

(*Received* 11 *August* 1961)

Previous work has shown that when embryonic cartilage is grown in medium containing an excess of vitamin A, metachromatic material is progressively lost from the matrix, which rapidly disintegrates (Fell & Mellanby, 1952; Fell & Thomas, 1960); metachromatic material also disappears from the cartilage of young rabbits fed with excessive amounts of the vitamin (Thomas, McLuskey, Potter & Weissmann, 1960). This previous work suggested that the degradation of the cartilage matrix under the influence of hypervitaminosis A might be due to an enhanced proteolytic activity of the chondroblasts; recent results (Dingle, Lucy & Fell, 1961; Lucy, Dingle & Fell, 1961) have confirmed this view and indicated that the degradation is associated with the release of protease from the lysosomes (Dingle, 1961).

The present experiments were undertaken to determine whether the action of vitamin A on cartilage in culture and on isolated lysosomes is specific, or whether a similar effect can be produced by other chemically-related compounds. The

* Part 3: Dingle (1961).

† Royal Society Fullerton Research Fellow.

‡ Member of the External Staff, Medical Research Council.

results indicate that the effect of the vitamin is highly specific on cartilage in culture and also at low concentrations on the isolated lysosomes.

MATERIALS AND METHODS

Compounds tested

Vitamin A (alcohol). A commercial preparation (Roche) was dissolved in ethanol (100 mg./ml.) and stored under nitrogen. Dilutions were made immediately before use. If the dilute solution showed a yellow colour indicative of oxidation a fresh preparation was used.

Vitamin A acid. This compound was a gift from Dr T. Moore of the Dunn Nutritional Laboratory, Cambridge. The sodium salt was obtained by neutralization of an ethanolic solution of the acid with the calculated amount of sodium hydroxide. The water-soluble preparation was dissolved in 0·02 M-sodium acetate in 0·25 M-sucrose and the pH adjusted to 7.

Vitamin A acetate and palmitate. These derivatives were commercial preparations (British Drug Houses Ltd.).

Vitamin A epoxide. This was prepared by oxidation of vitamin A (alcohol) (1 g.) according to the method of Karrer & Jucker (1947). The product (100 mg.) from the oxidation moved as a single band when rechromatographed on alumina with anhydrous benzene as the mobile phase, and had absorption maxima at 238 mμ ($E^{1\%}_{1cm.}$ 337) and 281 mμ ($E^{1\%}_{1cm.}$ 282), as found by Vinet & Meunier (1947), but not at 275 mμ as reported by Karrer & Jucker (1947).

Hydrogenated vitamin A. Vitamin A (alcohol) in ethanol (1 g./20 ml.) was hydrogenated at a pressure slightly greater than atmospheric and at room temperature (18°) in the presence of Adams catalyst (23·5 mg.). Uptake of hydrogen ceased when the theoretical amount for the saturation of four double bonds/molecule had been absorbed. The solution was filtered in nitrogen to remove the catalyst, diluted to 50 ml. with ethanol and stored under nitrogen. A portion of the solution was evaporated to dryness *in vacuo* and the residue dissolved in light petroleum (b.p. 80–100°). This solution (50 μg./ml.) had an absorption maximum below the limit of the spectrophotometer (200 mμ), and exhibited no absorption above 300 mμ.

Anhydrovitamin A. This derivative was prepared in 70–75% yield by the method of Edisburg, Gillam, Heilbron & Morton (1932), and isolated by chromatography in light petroleum (b.p. 60–80°) solution on alumina (Shantz, Cawley & Embyal, 1943). Evaporation of the eluate in nitrogen under reduced pressure gave a yellow syrup which crystallized slowly at room temperature.

In light petroleum (b.p. 80–100°) solution the compound exhibited three sharp absorption bands in the range 300–400 mμ with maxima at 351, 369 and 392 mμ. At 369 mμ $E^{1\%}_{1cm}$ for different preparations varied from 2560 to 3010. Although the compound could be crystallized as deep-yellow prisms (m.p. 78–79°) from either light petroleum (b.p. 60–80°) (Shantz *et al.* 1943) or ethanol solutions at low temperature, its concentrated solutions were extremely susceptible to oxidation by traces of air, and it was difficult to avoid the formation of an insoluble resinous material during the separation of the crystals. Preparations for the biological experiments, therefore, were used without recrystallization. Under the conditions of storage in these experiments, the absorption of a solution of the compound at 369 mμ decreased by 12·8% over a period of 70 days; the proportions of the $E^{1\%}_{1cm.}$ values at 350, 369 and 391 mμ changed from 1:1·40:1·23 to 1:1·43:1·18.

β-Ionone. The commercial preparation ('perfumery quality', British Drug Houses Ltd.) was purified as described by Tiemann (1898). The intermediate semicarbazone was recrystallized from ethanol to constant m.p. (148°), the crude compound being dissolved initially in an excess of the solvent to remove less-soluble impurities. The β-ionone (b.p. 134°/14 mm., 130–131°/12 mm.; *d*, 0·946), obtained by hydrolysis of the semicarbazone, was stored in sealed ampoules under nitrogen.

Brij 35. This neutral detergent (Atlas Powder Co., Wilmington, Del., U.S.A.), an ether of polyethylene glycol, was kept as a 1% (w/v) solution in glass-distilled water.

Other chemicals. Other compounds tested were commercial products of the highest purity available.

Organ-culture experiments

The rudiments of the humerus, ulna, femur and tibia of 7-day-old chick embryos were used. At this stage the bones consist of a cartilaginous rod differentiated into the usual small-celled epiphyseal regions, proliferative zones of flattened cells and middle zone of hypertrophic cells; the hypertrophic cartilage is usually covered by a thin layer of periosteal bone. In sections, the cartilage matrix stains metachromatically with toluidine blue and appears a deep reddish-purple.

The following compounds were tested and their effects compared: vitamin A (alcohol), vitamin A acid, hydrogenated vitamin A, anhydrovitamin A, β-ionone and phytol.

The technique of organ culture was the same as that already described (Dingle *et al.* 1961). Eight pairs of bone rudiments, namely the humeri, ulnae, femora and tibiae from two embryos, were used for each test. The lengths of the explants were measured at the beginning of the experiment and at 2-day intervals during cultivation by the method described by Fell & Mellanby (1952). The results are expressed as the mean of the lengths of the eight rudiments in each group. Length was measured on camera lucida drawings in arbitrary units, 2·6 units being equal to 1 mm.

After eight days' growth, the explants were fixed in Zenker's fluid plus 3% (v/v) acetic acid for 30 min., followed by Zenker's fluid without acetic acid for 1½ hr. Serial sections were cut and stained with 0·5% toluidine blue (G. T. Gurr Ltd., London) in 5% ethanol for 30 min.

In the first series of experiments, all seven compounds, dissolved in ethanol, were tested against vitamin A (alcohol). Each compound was added to the plasma so as to give a concentration of 0·01 μmole/ml. in the final medium (plasma–embryo-extract clot). The rudiments from one side of each chick were grown in medium containing the substance being tested, and those from the opposite side were cultivated in medium to which an equimolar concentration of vitamin A (alcohol) had been added. In the second series of experiments, the action of hydrogenated vitamin A, anhydrovitamin A, β-ionone and phytol in a tenfold concentration (0·1 μmole/ml.) was investigated, and the treated rudiments were compared with controls grown in normal medium to which only ethanol had been added. All the media in both series contained the same amount of solvent (0·2% ethanol).

Table 1. *Effect of vitamin A and related compounds on the matrix and growth in length of chick-cartilaginous-limb-bone rudiments in culture*

The compounds were added to the culture as ethanolic solutions at a final concentration of 0·01 μmole/ml. An equal amount of ethanol was added to the control. The bone rudiments of 7-day-old chick embryos were grown in organ culture for eight days. The mean length at the end of the culture period is given ± the standard error. The figures in parentheses are the number of bone rudiments. The effect on metachromasia is indicated by the following symbols: ±, rather less matrix in hypertrophic cartilage of some explants; +, rather less matrix in hypertrophic cartilage; + + + +, metachromasia nearly gone, drastic effect.

Addition to medium	Effect on matrix	Mean length after 8 days in culture (arbitrary units)
None (control)	–	15·66 ± 0·282 (8)
Phytol	–	16·31 ± 0·405 (8)
Anhydrovitamin A	–	15·79 ± 0·443 (8)
β-Ionone	–	15·51 ± 0·423 (8)
Vitamin A epoxide	–	14·96 ± 0·252 (8)
Citral	–	14·64 ± 0·268 (8)
Hydrogenated vitamin A	–	14·10 ± 0·307 (8)
Vitamin A acid	+ + + +	9·88 ± 0·394 (8)
Vitamin A (alcohol)	+ + + +	9·48 ± 0·244 (64)

Lysosome experiments

Lysosome suspensions in 0·25 M-sucrose were prepared as previously described (Dingle, 1961). No attempt was made to separate the lysosomes from the mitochondria in this work. To test the action of the compounds upon the lysosomes, each substance, dissolved in ethanol, was added to a suspension of particles in 0·25 M-sucrose; the suspension was then incubated at 37° for 40 min., after which it was centrifuged in the cold for 20 min. at 15 000*g*. The free protease was measured in the supernatant fluid as described in earlier work (Dingle, 1961). Haemoglobin (2%, w/v) dissolved in 0·1 M-acetate buffer, pH 4·0, was used as enzyme substrate, and acid-soluble tyrosine was measured after incubation for 20 min. at 37°. In each experiment a standard concentration of vitamin A (alcohol) (0·7 μmole/ml.) was tested, and the activity of the test compounds in releasing enzyme activity was expressed as a percentage of that released by the standard concentration of the vitamin.

RESULTS

Organ culture experiments

Series 1. At a concentration of 0·01 μmole/ml. none of the agents tested had a significant effect on the explants except vitamin A acid [Table 1; Figs. 1 and 2; Plate 1, (*a*)–(*d*)]; this compound produced the typical vitamin A response, i.e. softening, shrinkage and distortion of the cartilage and, in sections, loss of metachromatic material from the matrix. Hydrogenated vitamin A may have slightly retarded growth in length (Table 1) but no histological effects were seen.

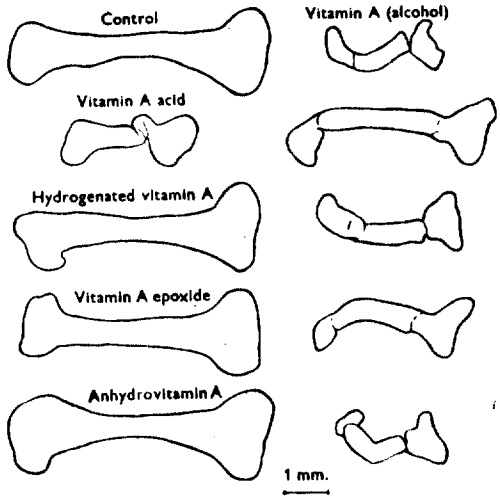

Fig. 1. Camera lucida drawings of five pairs of living femora after cultivation for 8 days. All the explants on the right were grown in medium containing 0·01 μmole of vitamin A (alcohol)/ml.; the corresponding rudiments on the left were grown either in normal medium (top) or in the presence of 0·01 μmole of an analogue of vitamin A/ml. Of the test compounds only vitamin A acid produced the same effect as vitamin A.

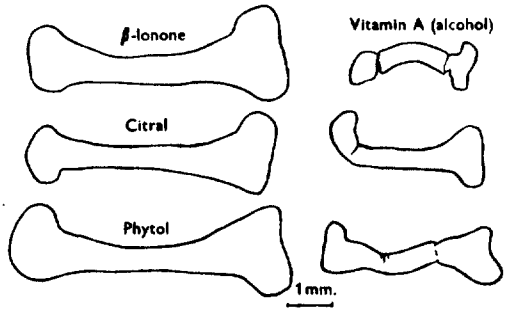

Fig. 2. Camera lucida drawings of three pairs of living femora after cultivation for 8 days. The explants on the right were grown in medium containing 0·01 μmole of vitamin A (alcohol)/ml., those on the left in medium with the same concentration of a test compound. None of the test compounds produced an effect comparable with that of vitamin A.

The controls treated with vitamin A (alcohol) underwent all the characteristic changes previously described (Fell & Mellanby, 1952; Fell & Thomas, 1960). There was some variation in the degree of effect in different experiments; this was probably due both to variation in the degree of development of different embryos and to partial oxidation of the vitamin during storage, the rapidity of this process not being fully appreciated at first.

Table 2. *Effect of some related compounds on the growth of chick-limb-bone rudiments in culture*

Cultural conditions were as described in Table 1; the compounds were added in tenfold concentration (0·1 μ-mole/ml.). Each compound was tested against controls in normal medium by the paired limb-bone technique. The standard deviation of the difference and the *P* values for the difference being ascribed to chance are shown. The figures in parentheses are the number of bone rudiments. The symbols for effect on the matrix are defined in Table 1.

	Effect on metachromasia	Mean length (arbitrary units)	S.D. of diff.	
Control	−	16·75 (8)	0·415	$P < 0·001$
Hydrogenated vitamin A	+	15·53 (8)		
Control	−	17·50 (8)	0·578	$P < 0·001$
β-Ionone	±	15·86 (8)		
Control	−	17·73 (8)	1·256	$P = 0·07$
Anhydrovitamin A	±	16·70 (8)		
Control	−	16·37 (8)	0·548	$P > 0·9$
Phytol	−	16·22 (8)		

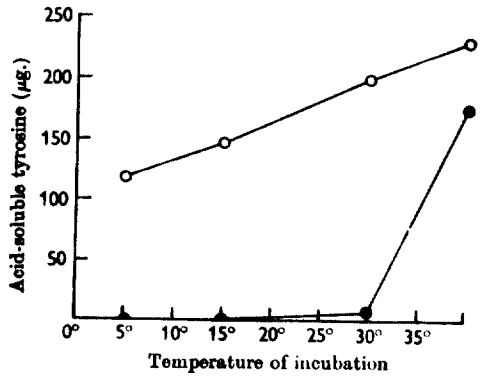

Fig. 3. Comparison of the action of vitamin A and a non-ionic detergent (Brij 35) on isolated rat-liver lysosomes. The action of the compounds was tested by addition to a suspension of particles in 0·25 M-sucrose. The suspensions were then incubated at various temperatures for 45 min., after which they were centrifuged in the cold at 15 000*g* for 20 min. and the activity of the released protease was measured in the supernatant fluids. Vitamin A (●) was used at a final concentration of 0·15 mg./ml. and Brij 35 (○) at 1·0 mg./ml. Enzyme activity is expressed as the acid-soluble tyrosine (μg.) liberated ml. of supernatant fraction from a 2% haemoglobin substrate in 20 min. at 37°.

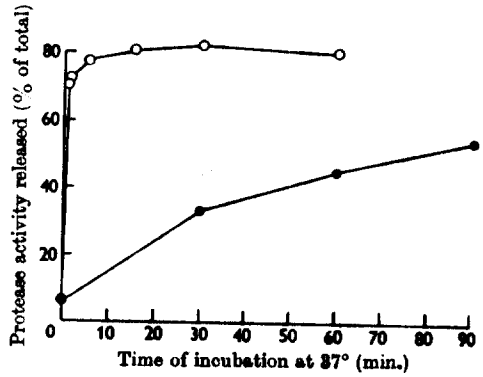

Fig. 4. Release of enzyme from rat-liver lysosomes by the action of vitamin A and of Brij 35. The action of the compounds was tested by addition to a suspension of particles in 0·25 M-sucrose. The suspensions were then incubated at 37° for various periods. After incubation the suspensions were centrifuged in the cold at 15 000*g* for 20 min. and the released enzyme was measured in the supernatant. Vitamin A (●) was used at a final concentration of 0·2 mg./ml. and Brij 35 (○) at 1·0 mg./ml. The activity of the enzyme liberated is expressed as a percentage of the total activity released by hypo-osmotic treatment (Dingle, 1961).

Series 2 of the four compounds tested at the higher concentration (0·1 μ-mole/ml.) (Table 2), phytol had no effect on either growth in length or histology, as compared with controls in normal medium. The remaining three agents all caused a slight reduction in growth, which was statistically significant only for hydrogenated vitamin A and β-ionone, but very little histological change was produced. In section the matrix of some of the treated explants was rather less intensely stained with toluidine blue, and the intercellular partitions in the hypertrophic cartilage were narrower than in the corresponding controls in normal medium; these effects were greatest in the bones, femora and tibiae exposed to hydrogenated vitamin A [Plate 1, (*e*)].

Protease release from lysosomes

Comparison of vitamin A and Brij 35. Previous work has shown that the release of protease from isolated lysosomes by vitamin A is temperature-dependent (Dingle, 1961). This observation has been confirmed and the action of the vitamin at various temperatures compared with that of the detergent (Fig. 3). The latter was effective at

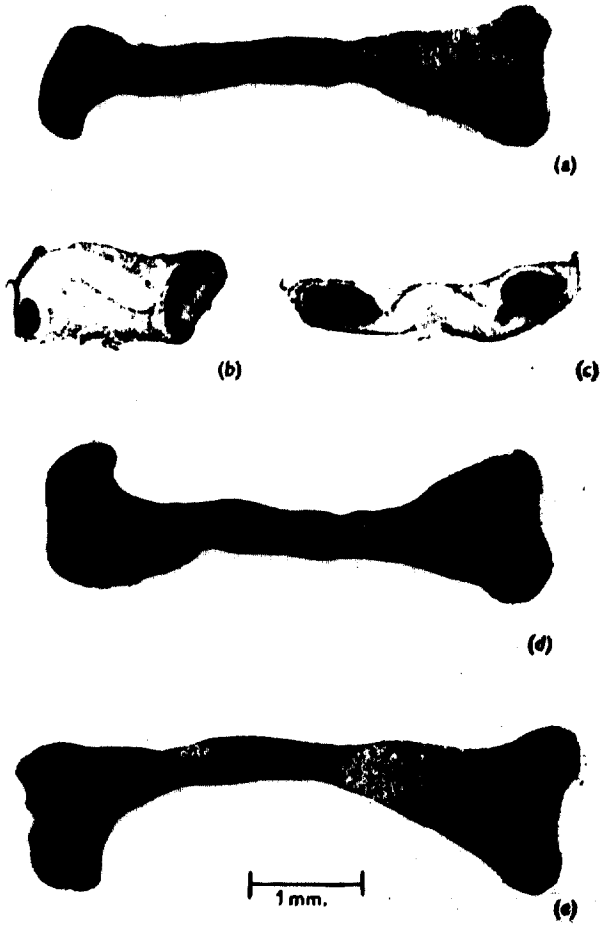

All the explants are from 7-day-old chick embryos and were grown in culture for eight days. Sections were stained with toluidine blue.

(a) Control femur grown in normal medium.

(b) Opposite femur from the same embryo grown in medium containing 0·01 μmole of vitamin A (alcohol). Note shrinkage, distortion and loss of metachromasia from all but the interior of the epiphyses.

(c) Femur grown in an equimolar concentration of vitamin A acid. The effect is the same as that of vitamin A.

(d) Femur grown in an equimolar concentration of phytol. No effect is apparent (cf. *a*).

(e) Femur grown in medium containing β-ionone at ten times the previous molar concentration. There is a slight inction in the amount of matrix in the young hypertrophic cartilage, but otherwise no effect.

Table 3. *Action of derivatives of vitamin A and other compounds on isolated rat-liver lysosomes*

The particles, isolated at 15 000*g* from rat liver, were suspended in 0·25 M-sucrose at a concentration equivalent to 1 g. of original tissue/5 ml. The compounds, dissolved in ethanol, were added to the sucrose suspensions which were then incubated for 40 min. at 37°. At the end of the incubation period the suspensions were centrifuged at 15 000*g* for 20 min. and the released enzyme was measured in the supernatant fractions. The results are expressed as a percentage of the activity released by 0·7 μmole of vitamin A (alcohol)/ml. The vitamin A acid (sodium salt) was tested in 0·02 M-sodium acetate–0·25 M-sucrose solution at pH 7·0.

	0·7 μmole/ml.	3·5 μmoles/ml.	7·0 μmoles/ml.
Vitamin A (alcohol)	100	157	189
Vitamin A acid (Na salt)	7	62	—
Vitamin A acid (free)	92	—	—
Vitamin A acetate	11	22	—
Vitamin A palmitate	0	—	—
Vitamin A oxidized in air	25	—	—
Vitamin A epoxide	0	115	165
Hydrogenated vitamin A	0	17	76
Anhydrovitamin A	0	0	0
Isoprene	7	12	28
Citral	0	85	164
Geraniol	27	98	92
α-Ionone	21	92	110
β-Ionone	25	—	—
p-Cymene	20	—	98
Pinene	24	80	170
Phytol	7	3	3
Dodecanol	0	0	0
Octanol	0	—	—
Glycerol trioleate			0
Glycerol			3
Isobutanol			15
2-Methylbutan-2-ol			0
Ethanol	0	0	0
Toluene	—	—	9
Acetone	—	—	7
Cysteine	—	—	22
Calciferol	—	—	17

temperatures at which no action of the vitamin could be detected, but to release about the same amount of enzyme at 40° it was necessary to add approximately seven times as much detergent (by weight) as vitamin A. The action of the detergent was also extremely rapid, most of the proteolytic activity being released within a few seconds of its addition, unlike the action of the vitamin, which required incubation (Fig. 4).

Action of derivatives of vitamin A. The effect of vitamin A derivatives on isolated lysosomes is shown in Table 3. The concentration of vitamin used as the standard (0·7 μmole/ml.) was sufficient to liberate approximately two-thirds of the bound enzyme under the conditions of assay in these experiments. At this concentration, only vitamin A acid had an effect comparable with that of vitamin A (alcohol); the water-soluble sodium salt of vitamin A acid in the buffered medium was not active.

Oxidation of the vitamin by bubbling a stream of oxygen through an alcoholic solution reduced the activity by approximately 75%. This reduction in activity was related to changes in the ultraviolet absorption which indicated a 70% loss of the vitamin. Inactivation of the vitamin by oxidation was confirmed by studies with the epoxide, which was ineffective at the standard concentration; at five times this concentration the activity was still less than that of the vitamin.

Hydrogenated vitamin A had very little effect on the isolated lysosomes. Anhydrovitamin A showed no activity at any of the concentrations tested, but this may have been partly due to the rapidity with which this compound polymerized when exposed to air.

Action of terpenes and related compounds. At the standard concentration most of the terpenes tested had about one-fifth of the activity of vitamin A, but isoprene and citral were ineffective. At the higher concentrations, however, all of these compounds, except isoprene, were active, though in varying degrees.

Action of long-chain alcohols and other compounds. The C_{20}-alcohol phytol resembles the basic skeleton of the vitamin A molecule, but lacks the conjugated double bonds that are characteristic of vitamin A and the terpenes. It is possible, at least in theory, to derive vitamin A from phytol by dehydrogenation and ring closure. In spite of this similarity in

structure, however, phytol, when tested in seven experiments on various occasions, exhibited only minimal activity against the lysosomes, even at the highest concentration. All the other alcohols tested, from dodecanol down to ethanol, had little effect.

DISCUSSION

Vitamin A appears to act as specifically on cartilage in organ culture as it does in reversing hypovitaminosis-A changes in animals [see Moore (1957) for review]. The concentration of vitamin A (alcohol) (10 i.u./ml.) used as the standard dose in the culture experiments is comparable with that found in the plasma of hypervitaminotic patients; in such cases Gribetz, Silverman & Sobel (1951) found levels of 20–30 i.u./ml., of which as much as 70% was present as the free alcohol. Our results have shown that at this concentration relatively small modifications of the vitamin A molecule can completely abolish its action on chick-limb-bone rudiments in culture. Increasing the dose tenfold, however, gives a statistically significant inhibition of growth by both the hydrogenated vitamin and β-ionone; at this dose these compounds may also have a very slight histological effect on the matrix of the rudiments.

The use of these high doses in the organ-culture experiments was suggested by the results obtained with the isolated lysosomes. In the latter system the specificity of the vitamin was high at a concentration that released approximately two-thirds of the enzymic activity; at this concentration anhydrovitamin A, hydrogenated vitamin A and vitamin A epoxide were ineffective, as also was isoprene, and the terpenes gave only about 25% of the activity of the vitamin. A five- or ten-fold increase in the dose, however, diminished the specificity (see Table 3). It would appear that, both in culture and on the isolated lysosomes, vitamin A (alcohol) is active at concentrations at which none of the other compounds tested produce much effect.

Vitamin A acid has recently been shown to cause marked resorption in the skeleton of young rats (Thompson & Pitt, 1961), and we have found it to be at least as potent as the free alcohol on cartilage in culture. In the lysosome system, too, it is about as active as the free alcohol, provided that it is added to the sucrose suspension as an ethanolic solution. If, however, the water-soluble sodium salt is used at neutral pH, very little activity is found. Thus this derivative acts only when it is in a lipid-soluble form, presumably owing to the 'lipoprotein' structure of the lysosomal membrane. The activity of the vitamin A derivatives cannot be explained solely in terms of lipid-solubility, however, since both vitamin A acetate and palmitate had a negligible effect (see Table 3).

The non-ionic detergent Brij 35 probably acts in a different manner from the vitamin, since its effect is far more rapid and is not altered greatly by temperature (Fig. 4). It is also significant that, weight for weight, only about one-seventh of the amount of vitamin is required to give approximately the same amount of release as that given by the detergent; in fact the amount of vitamin is probably much smaller than this, since a considerable proportion is lost as an insoluble precipitate when the ethanolic solution is added to the sucrose suspension. It is thus unlikely that the action of the vitamin resembles that of this surface-active agent.

The degree of specificity reported in this work both in organ culture and on the isolated lysosomes lends further support to the hypothesis (Dingle, 1961; Lucy *et al.* 1961) that the effect of excess of vitamin A is due at least in part to an action on the intracellular particles.

SUMMARY

1. A number of compounds, including derivatives of vitamin A, terpenes and alcohols, have been examined for ability to reproduce the effects of vitamin A on embryonic chick-limb cartilage in culture and on the release of cathepsin from isolated lysosomes.

2. In the organ cultures at a concentration of 0·01 μmole/ml. none of the compounds examined, except vitamin A acid, had a significant effect on the explants; the effects of this derivative were indistinguishable from those produced by vitamin A. At a concentration of 0·1 μmole/ml. hydrogenated vitamin A and β-ionone slightly reduced the growth in length of the explants, but caused little histological change.

3. Approximately two-thirds of the bound protease was released from isolated rat-liver lysosomes by 0·7 μmole of vitamin A/ml. Of the compounds studied at this concentration and under the same conditions, only vitamin A acid had an effect comparable with that of the vitamin; other derivatives of vitamin A were inactive, and most of the terpenes had about 25% of the activity of the vitamin. At higher concentrations the specificity of the vitamin was reduced.

4. The results indicate that the action of vitamin A is highly specific on cartilage in culture and also at low concentrations on the isolated lysosomes.

The authors are indebted to Professor R. A. Morton, F.R.S., for helpful information; they express their grateful thanks to Mr L. J. King and Miss P. A. Carter for their skilful technical assistance and to Mr M. Applin for preparing the photographs. The work was supported by the Medical Research Council and the British Empire Cancer Campaign.

REFERENCES

Dingle, J. T. (1961). *Biochem. J.* **79**, 509.

Dingle, J. T., Lucy, J. A. & Fell, H. B. (1961). *Biochem. J.* **79**, 497.

Edisburg, J. R., Gillam, A. E., Heilbron, I. M. & Morton, R. A. (1932). *Biochem. J.* **26**, 1164.

Fell, H. B. & Mellanby, (1952). *J. Physiol.* **116**, 320.

Fell, H. B. & Thomas, L. (1960). *J. exp. Med.* **111**, 719.

Gribetz, D., Silverman, S. H. & Sobel, A. E. (1951). *Pediatrics*, **7**, 372.

Karrer, P. & Jucker, E. (1947). *Helv. chim. acta*, **30**, 559.

Lucy, J. A., Dingle, J. T. & Fell, H. B. (1961). *Biochem. J.* **79**, 500.

Moore, T. (1957). *Vitamin A.* Amsterdam: Elsevier Publishing Co.

Shantz, E. M., Cawley, J. D. & Embval, N. D. (1943). *J. Amer. chem. Soc.* **65**, 901.

Thomas, L., McLusky, R. T., Potter, J. L. & Weissmann, G. (1960). *J. exp. Med.* **111**, 705.

Thompson, J. N. & Pitt, G. A. J. (1961). *Biochem. J.* **79**, 33P.

Tiemann, F. (1898). *Ber. dtsch. chem. Ges.* **31**, 867.

Vinet, A. & Meunier, P. (1947). *Bull. Soc. Chim. biol.* **29**, 25.

Fell-'63
Bib. No. 2690

Reproduced by permission
of the copyright owner

Biochem. J. (1963) 87, 403

Studies on the Mode of Action of Excess of Vitamin A

6. LYSOSOMAL PROTEASE AND THE DEGRADATION OF CARTILAGE MATRIX*

By H. B. FELL and J. T. DINGLE
Strangeways Research Laboratory, Cambridge

(*Received* 9 *November* 1962)

Changes in the matrix of cartilaginous limb-bone rudiments after cultivation *in vitro* in the presence of excess of vitamin A were first demonstrated by Fell & Mellanby (1952). The possible relationship of these changes, which include cellular alterations as well as loss of extracellular material, to the liberation of lysosomal enzymes was postulated by Lucy, Dingle & Fell (1961) and by Dingle (1961). It was considered that release of a proteolytic enzyme from the lysosomal particles was responsible for the degradation of the protein polysaccharide complex of the matrix, and that liberation of other lysosomal hydrolytic enzymes might cause the cellular changes observed in cartilage cultivated in the presence of the vitamin; this hypothesis was supported by observations on the specificity of the action of the vitamin, both in organ culture and on the isolated lysosomes (Fell, Dingle & Webb, 1962). Recent experiments on the effect of the vitamin on the cell membrane of erythrocytes (Dingle & Lucy, 1962), and on mitochondria (J. A. Lucy, M. Luscombe & J. T. Dingle, unpublished work), provide further evidence that one site of vitamin A action is at the lipoprotein membranes of cells and their organelles.

Though the evidence so far obtained favoured this hypothesis concerning the mode of action of vitamin A on cartilage, three important pieces of information were still lacking. (1) Although normal cartilaginous rudiments had been found to contain a protease, with an acid pH optimum, that when freed by treatment with hypo-osmotic solutions can degrade the matrix (Lucy *et al.* 1961), and though there was increased lysis of the plasma clot by cartilaginous rudiments grown in the presence of excess of vitamin A (Dingle, Lucy & Fell, 1961), the liberation of an acid protease by the vitamin A-treated explants had not been clearly demonstrated. (2) It was not known whether the vitamin could release the enzymes from intracellular particles isolated from cartilage, though it had been shown to liberate a protease from lysosomes isolated from rat liver (Dingle, 1961). (3) It was not known whether acid hydrolases from isolated intracellular particles could degrade cartilage rudiments. These three points have now been investigated.

* Part 5: Dingle & Lucy (1962).

MATERIAL AND METHODS

Experiments in organ culture. The humeri, femora and tibiae of 6- and 7-day-old chick embryos were grown by the watch-glass method (Fell & Mellanby, 1952); the medium and conditions of culture were those described by Dingle *et al.* (1961). Vitamin A (10 i.u. or 3·3 μg./ml.) dissolved in ethanol was added to the plasma; the controls received ethanol alone. At the end of the cultivation period the rudiments with their surrounding capsule of connective tissue were removed from the plasma clot, washed twice in Tyrode's solution, once in synthetic medium, and then placed on a grid in a watch-glass containing 1·6 ml. of synthetic medium. The explants were incubated for up to 29 hr. at 38° under an atmosphere of oxygen + nitrogen + carbon dioxide (20:75:5). The rudiments were then removed from the watch-glass and weighed.

The following chemically defined media were used: for experiments on the rate of enzyme release from vitamin A-treated explants, medium BGJ (Biggers, Gwatkin & Heyner, 1961); for Expts. 358, 359 and 362, medium BL1 (Biggers & Lucy, 1960); for Expt. 377, Eagle's (1959) medium, without tyrosine; for Expts. 360 and 373, Parker 199 medium (Morgan, Morton & Parker, 1950).

Protease assay. The cartilaginous rudiments were homogenized in 2 ml. of a solution of a neutral detergent, 0·1% BRIJ 35 (Atlas Powder Co., Wilmington, Del., U.S.A.), a motor-driven homogenizer being used (Aldridge, Emery & Street, 1960), and the suspension was kept at 5° until it was assayed. Immediately before assay, 0·5 ml. of the homogenate was diluted with 0·5 ml. of 0·1 M-acetate buffer, pH 4·0. The synthetic culture medium (1·6 ml.) was adjusted to pH 4·0 with 0·5 N-HCl and then diluted to 4·0 ml. by the addition of 0·1 M-acetate buffer, pH 4·0. Samples (1·0 ml.) of both the solutions to be assayed were added to 1·0 ml. of 4·0% (w/v) haemoglobin dissolved in 0·1 M-acetate buffer, pH 4·0, and incubated at 37° for 60 min. in stoppered tubes. A duplicate sample of each solution was prepared and 5·0 ml. of ice-cold 4·7% (w/v) trichloroacetic acid added immediately without incubation. At the end of the incubation period the reaction was stopped by the addition of trichloroacetic acid, and the acid-soluble 'tyrosine' was measured in the filtrate by the method of Anson (1938). The proteolytic activity is expressed as the increase in μg. of acid-soluble 'tyrosine'/hr.

Preparation of a particulate fraction from embryonic cartilage. Cartilage was obtained from limb-bone rudiments from 10-day-old chick embryos and also from two 59-day-old bovine embryos. The cartilaginous rudiments were dissected in the usual way, but it was necessary to remove the area of calcification that was present in the middle of the shaft of the long bones from the bovine embryos.

The cartilage was homogenized in 0·25 M-sucrose, centrifuged at 600*g* for 5 min. to remove debris, and then at 10 000*g* for 20 min. Protease activity was determined in the supernatant fluid and in the particulate fractions. The 'free activity' is expressed as a percentage of free to total activity [free × 100/(free + bound)]. The action of vitamin A was tested as described for rat-liver lysosomes by Dingle (1961). The enzyme activity released by the vitamin is expressed as a percentage of the bound activity.

Preparation of a crude protease from a particulate fraction of rat liver. All manipulations were done in the cold room at 4°. A portion (50 g.) of rat liver was homogenized in 500 ml. of 0·25 M-sucrose, the nuclei and debris were removed by centrifuging at 600*g* for 5 min., and the mitochondrial and lysosomal pellet was obtained after centrifuging at 10 000*g* for 20 min. The pellet was resuspended in 100 ml. of 0·1% BRIJ 35, allowed to stand in the cold for 30 min. and then recentrifuged. The pellet was washed twice with BRIJ 35 and the washings were added to the first supernatant. Sodium chloride was added to give a final concentration of 0·9% and the pH was adjusted to pH 4·6. The solution was allowed to stand in the cold for 30 min. and the precipitate removed by centrifuging. Saturated ammonium sulphate (5 vol.) was then added and the solution kept in the cold room for 3 hr. The precipitate was removed by centrifuging and dissolved in about 25 ml. of water. This solution was dialysed overnight against water, the precipitate removed by centrifuging and the solution freeze-dried. The yield was 280 mg. of dry powder with a proteolytic activity under the above conditions of assay of 17 400 μg. of 'tyrosine' hr. This crude protease preparation was dissolved in 10 ml. of 0·9% sodium chloride.

Action of the protease preparation on limb-bone rudiments from chick embryos. The femora from 9-day-old chick embryos were dissected free from muscle and connective tissue and were kept at room temperature, in a mixture of equal parts of 0·9% sodium chloride and amniotic fluid, until the beginning of the experiment. The rudiments were washed in 0·9% sodium chloride and then placed in Hanks solution (Hanks & Wallace, 1949), or in 0·9% sodium chloride made 0·1 M with respect to phosphate buffer of the required pH. The enzyme, dissolved in 0·9% sodium chloride, was added and the rudiments were incubated at 37°. In some experiments an equal amount of enzyme that had been inactivated by heating at 100° for 3 min. was added to the controls, and in other experiments the controls received an albumin solution. Single rudiments were removed at intervals and fixed for histological observation, and samples of the suspending fluid taken for the determination of polysaccharide by the turbidimetric method of Di Ferranti (1956).

Histology. The limb-bone rudiments were fixed in Zenker's fluid containing 3% (w/v) of acetic acid for 30 min., followed by Zenker's fluid without acetic acid for not less than 1 hr. After being washed for some hours in tap water, the rudiments were dehydrated, cleared in cedar-wood oil and embedded in paraffin wax. Sections were stained for 30 min. in toluidine blue [0·5% (w/v) in 5% (v/v) ethanol] and mounted in Depex (G. T. Gurr Ltd., London).

RESULTS

Release of a protease from vitamin A-treated limb-bone rudiments. Previous observations on the lysis of the plasma clot during the growth of limb-bone rudiments *in vitro* indicated the possible release of proteolytic enzymes during cultivation in the presence of vitamin A (Dingle *et al.* 1961). Initially, therefore, attempts were made to determine the proteolytic activity of the 'natural' medium (embryo extract–plasma clot). Though this proved possible and though the vitamin-treated cultures usually showed a higher proteolytic activity than the controls, the results were variable and difficult to reproduce. At the beginning of the culture period there was substantial proteolytic activity in the medium, probably originating in the embryo extract, and this activity decreased during incubation. The presence of this unstable enzyme made it difficult to obtain an accurate measure of enzyme liberation from the explants. It was advisable therefore to grow the rudiments on natural medium until the desired degree of the vitamin A effect had been obtained, as shown by microscopic observations of the living explants, and then to transfer the rudiments to a fully synthetic medium to study the liberation of protease. Since vitamin A rapidly breaks down in the absence of protein, it was not added to the chemically defined medium.

The first experiment was made to investigate the influence of the 6 days' pretreatment with vitamin A on the rate of release of protease into the chemically defined medium; the result was expressed as a percentage of the activity liberated by paired control rudiments grown for the same period in normal medium. After 4 hr. in synthetic medium, the vitamin A-treated explants released 60% more protease than the controls, and after 29 hr. 275% more (Fig. 1).

For reasons that are not properly understood, the rate at which the vitamin acted varied in different experiments. The release of enzyme, however, was correlated with the severity of the morphological changes produced: the more severe the gross anatomical effect and the more numerous the fractures in the treated explants, the greater was the liberation of enzyme (Table 1). For example, in Expt. 358, in which the rudiments were cultured for 4 days on natural medium before transfer to synthetic medium, there was only a slight action of the vitamin and no increase in enzyme release could be found in the vitamin A-treated cultures as compared with the controls. On the other hand, in Expt. 339, which was also of 4 days' duration, there was a marked effect of the vitamin and an increased liberation of protease into the medium. The greatest effect as indicated by the number of bones fractured and the difference in weight between the hypervitaminotic explants and their controls was seen in Expt. 362 (Table 1): in this experiment the liberation of enzyme was about 7 times the control value.

The total amount of protease present in the

control cultures (explant plus medium) after 4 days in culture (i.e. 4 days on natural medium followed by 1 day on synthetic medium) was sufficient to liberate 137–139 μg. of 'tyrosine'/hr. in each of three experiments. Prolonging the culture period in natural medium to 6 or 8 days (Expts. 360 and 362) caused a small increase in the total amount of enzyme in the controls (156–159 μg./hr.), but a substantial increase in the total enzyme content of the severely affected vitamin A-treated cultures (187–257 μg./hr.).

Although more enzyme was released into the medium from the vitamin-treated cartilage, the treated rudiments themselves contained at least as much as, and often more than, the controls at the end of the experimental period.

The pH optimum, with haemoglobin as substrate, of the protease liberated into the synthetic medium by the vitamin-treated explants was very similar to that of the enzyme in an aqueous extract of normal embryonic cartilage, and to that of the enzymes released from a particular fraction of the normal rudiments (Fig. 2).

Action of the vitamin on intracellular particles. The centrifuging of homogenates of bovine and avian embryonic cartilage yielded a particulate fraction containing an acid protease. Protease activity was also found in the supernatant fraction; the percentage of free activity in the mammalian cartilage

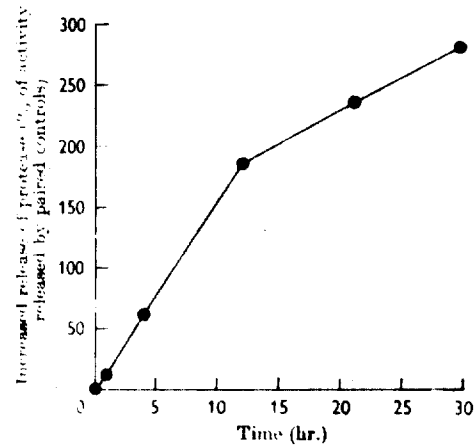

Fig. 1. Release of protease from vitamin A-treated chick-limb-bone rudiments. Sixteen rudiments were grown on natural medium in the presence of 10 i.u. of vitamin A for 6 days and then transferred to a synthetic medium. Control paired rudiments were treated in a similar manner. Samples of the synthetic medium were removed and their proteolytic activity was measured. The effect of the vitamin on enzyme release is expressed as a percentage of the enzyme activity released by the controls at each time.

Table 1. *Release of protease from vitamin A-treated chick-limb-bone rudiments*

In each experiment 16 rudiments (12 in Expt. 373) were grown on natural medium containing 10 i.u. of vitamin A/ml. for 4–8 days, then transferred to synthetic medium for 21–23 hr. at 38°. The gas phase was $O_2 - N_2 + CO_2$ (20:75:5). At the end of the incubation period the rudiments were removed, weighed and homogenized in 0·1% BRIJ 35, and the protease activity was measured. Control cultures were treated in the same manner. The protease was also measured in the medium.

Expt. no.	Treatment	Time in natural medium (days)	No. of rudiments with fractures	Time in synthetic medium (hr.)	Total wet wt. (mg.)	Protease activity (μg. of 'tyrosine'/hr.) In medium	Protease activity (μg. of 'tyrosine'/hr.) In rudiments	Protease activity (μg. of 'tyrosine'/hr.) Total	Sp. activity of total protease (μg. of 'tyrosine'/hr./mg. wet wt. of tissue)
358	Vitamin A	4	0/16	21	—	6·4	123·2	129·6	—
	Control	4	0/16	21	—	14·8	121·9	136·7	—
362	Vitamin A	4	0/16	23	33·5	21·2	171·7	192·9	5·8
	Control	4	0/16	23	40·9	9·5	128·3	137·8	2·8
373	Vitamin A	8	1/12	21	34·4	41·3	72·3	113·6	3·3
	Control	8	0/12	21	77·2	23·4	97·6	121·0	1·6
359	Vitamin A	4	8/16	21	—	62·6	143·6	206·2	—
	Control	4	0/16	21	—	39·2	100·7	138·9	—
360	Vitamin A	6	11/16	23	24·3	38·2	148·4	186·6	7·5
	Control	6	0/16	23	61·1	21·2	134·6	155·8	2·5
362	Vitamin A	8	16/16	23	35·0	103·9	152·6	256·5	10·3
	Control	8	0/16	23	104·9	14·8	144·2	159·0	1·4

(46 %) was similar to that in the avian (49 %). The high activity in the supernatant fraction from the mammalian tissue may have been due to an unavoidable delay of about 2 hr. between the killing of the animal and the homogenization of the dissected cartilage. The release of bound proteolytic activity by vitamin A (100 μg. ml.) added *in vitro* was greater with the particles isolated from bovine (61 %) than from chick cartilage (40 %).

Degradation of normal cartilage matrix by lysosomal protease. Experiments were made on the disappearance of metachromatic material from limb-bone rudiments, from 9-day-old chick embryos, incubated for 6 hr. in phosphate-buffered 0·9 % sodium chloride containing lysosomal protease obtained from rat liver. Fig. 3 shows the action of the enzyme on normal rudiments at both pH 6 and pH 7. At pH 7 the metachromasia was greatly decreased, whereas at pH 6·0 it was entirely absent; the controls showed little loss of metachromasia. This experiment indicated that the crude enzyme preparation was active in degrading the matrix of the cartilaginous rudiments and that it was effective at neutral pH.

Further experiments indicated that this disappearance of metachromasia was associated with considerable loss of polymeric chondroitin sulphate from the rudiments (Fig. 4). The controls, which in this experiment had been treated with enzyme that had been heated to 100° for 3 min., lost some polysaccharide; since this heating of the enzyme solution destroyed about 95 % of its activity, it seems probable that the loss of chondroitin sulphate in the controls was due to the release of intracellular enzymes in the cartilage itself. This action of the lysosomal extract in liberating chondroitin sulphate and causing disappearance of metachromasia was dependent on temperature (Table 2). Thus although there was rapid loss of chondroitin sulphate and of metachromasia at 37° there was little or none at 5°.

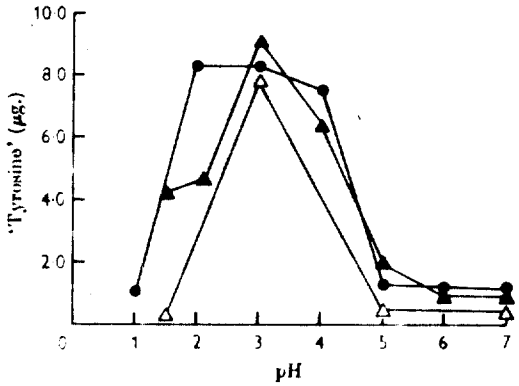

Fig. 2. Effect of pH on the protease from chick and bovine rudiments. The enzyme was extracted from a particulate fraction obtained after centrifuging an homogenate of the rudiments (10 mg. in 20 ml.) on treatment with 0·1 % SRH 35. The enzyme liberated into the synthetic medium was incubated after adjustment of the pH with HCl to approximately the correct value; each sample was then diluted with an equal volume of 0·1 M-acetate buffer of the appropriate pH. The rudiments were treated with glass-distilled water at 4° for 1 hr. to obtain the aqueous extract. The measurements of protease activity were made with haemoglobin (2 %, w/v) as substrate, and acid soluble 'tyrosine' was measured as indicated in the text. ●, Aqueous extract of rudiments; ▲, synthetic medium; △, particulate fraction of rudiments.



Fig. 3. Normal cartilaginous long bone rudiments from a 9-day chick embryo, incubated for 6 hr. in phosphate-buffered 0·9 % sodium chloride with and without the addition of lysosomal extract. Sections were stained with toluidine blue. Magnification × 12. (*a*) (i) Control femur incubated at pH 7·0: little or no effect on metachromasia. (ii) femur incubated at pH 7·0 in the presence of lysosomal extract: metachromasia is greatly reduced, but some remains. (*b*) (i) Control tibia incubated in buffer at pH 6·0 without lysosomal extract: little or no effect on metachromasia; (ii) tibia incubated at pH 6·0 in the presence of lysosomal extract: metachromasia is absent.

DISCUSSION

The present studies show that, after cultivation in the presence of excess of vitamin A (3·3 μg./ml.), the cartilaginous limb-bone rudiments from chick embryos release an acid protease into the culture medium. The control rudiments also liberate some proteolytic enzyme into the medium, but much less than explants showing advanced resorption in response to vitamin A. The significance of the enzymic activity liberated by the controls is not yet [illegible] possibly connected with digestion of the maternal medium, it may provide a clue concerning the physiological function of the lysosomal protease. Carrel & Baker (1926) demonstrated a proteolytic enzyme, in embryo extract, that was ineffective at neutral pH but became increasingly active between pH 6·2 and 5·0. They suggested that this enzyme, acting at the cell surface, might hydrolyse proteins to proteases which would then be absorbed and utilized by the tissues.

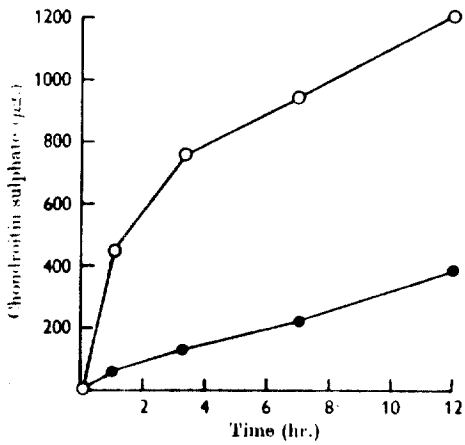

Fig. 4. Release of chondroitin sulphate from chick-limb-bone rudiments by lysosomal protease. Normal rudiments from 10-day-old chick embryos were incubated at 37° in 0·1 M-phosphate buffer, pH 7·0, containing the lysosomal extract. The controls contained enzyme that had been heated at 100° for 3 min. The liberation of polysaccharide was measured by the method of Di Ferranti (1956) on samples taken at intervals. ○, Treated with enzyme; ●, treated with boiled enzyme (control).

Since the amount of enzyme present in the vitamin A-treated explants at the end of the experimental period was often higher than in the larger control rudiments, the increased release of protease appears to be correlated with either an increased synthesis or an activation of the enzyme. This is especially striking in Expt. 362, in which the morphological changes were severe; the wet weight was only 25% of the controls and yet the total enzyme content was almost twice that of the controls.

The optimum pH of the protease released by the explants is similar to that of the enzyme liberated from normal rudiments by treatment with hypo-osmotic solutions (Lucy *et al.* 1961) and also to that released by vitamin A from particles isolated from homogenates of normal cartilage in the present experiments. It seems likely, therefore, that the same protease, or group of proteases, is involved in all three experimental systems, and hence that the proteolytic enzymes of chick cartilage are present in the cell in a particle-bound form. Though it is probable that the protease is situated in lysosomal granules, further experiments are needed to see whether it is associated with other typical lysosomal enzymes (de Duve, 1959) before a firm conclusion can be reached.

The crude preparation of protease from rat-liver lysosomes proved to be very effective in degrading

Table 2. *Loss of metachromasia and chondroitin sulphate from enzyme-treated chick-limb-bone rudiments*

Normal rudiments were incubated at 5° and 37° in a lysosomal extract buffered at pH 7·0 with 0·1 M-phosphate buffer. Samples of the solution were taken at intervals for measurement of polysaccharide and single rudiments were removed and fixed for histological observation. Histological changes are indicated as follows: –, no change; ±, some loss of metachromasia from superficial cartilage of epiphyses; +, substantial loss from epiphyses; + +, substantial loss from epiphyses and zone of flattened cells; + + +, substantial loss from whole rudiments.

	Temperature of incubation			
	5°		37°	
Incubation period (min.)	Metachromasia loss	Chondroitin sulphate released (μg.)	Metachromasia loss	Chondroitin sulphate released (μg.)
30	–	100	±	140
60	–	155	+	220
100	–	170		400
180	–	180	+ +	540
270	±	220	+ + +	1040

the extracellular material of the cartilage even at neutral pH. In previous work on cartilaginous rudiments (pretreated with hypo-osmotic solutions) incubated in buffer at acid pH for 2 hr., the loss of metachromasia from the matrix was paralleled by the loss of polymeric chondroitin sulphate and by degradation of protein (Lucy *et al.* 1961). In the present experiments with the lysosomal protease of rat liver, the disappearance of metachromasia was again correlated with a release of chondroitin sulphate. It would have been preferable to have prepared the enzyme from particles obtained from chick cartilage, but since the limb-bone rudiments weighed only 2–3 mg. (wet wt.) it was impossible to obtain enough enzyme from this material. The results show, however, that a protease with an acid pH optimum, similar to that released by vitamin A from chick cartilage, can break down cartilage matrix at a neutral pH, though more slowly than at the acid optimum pH.

On the basis of a comparison of the effect of the proteolytic enzyme papain and of vitamin A on embryonic skeletal tissues, Fell & Thomas (1960) proposed, as a tentative working hypothesis, that vitamin A might enhance the activity of a number of cellular enzymes, one of which resembled papain in its effects. They further suggested that such an enhanced hydrolytic activity might be due to activation of the enzymes, to their greater production, or to their increased liberation through an increased permeability of cells or their organelles; this theory was supported by the observation by Dingle (1961) that isolated lysosomal particles released a bound proteolytic enzyme on the addition of vitamin A. The present results provide further evidence that the vitamin, when added in excess of normal requirements, causes a change in the permeability or stability of intracellular particles. It is possible that all the effects of vitamin A observed in cartilage, including the changes in metabolism, tissue composition (Dingle *et al.* 1961) and degradation of the extracellular material (Lucy *et al.* 1961), were due to alterations in the composition or stability of the membrane systems of the cells and their organelles, including lysosomes and mitochondria. This view is supported by the work of Dingle & Lucy (1962) on the instability of the erythrocyte membrane under the influence of the vitamin.

In all these systems, including the erythrocytes, the lysosomes and the cartilaginous explants, the specificity for the action of the vitamin is the same as that for reversing the effect of hypovitaminosis A in the intact animal. It may well be that one of the physiological actions of vitamin A is the control of membrane structure; if this were so it would help to explain the wide range of biological effects produced by both hypo- and hyper-vitaminosis A.

SUMMARY

1. Cartilaginous rudiments grown in the presence of 3·3 μg. of vitamin A/ml. release an acid protease into the culture medium. The pH optimum of this enzyme is similar to that of a protease obtained from a particulate fraction of the rudiments.

2. A crude protease preparation derived from rat-liver lysosomes proved to be effective in degrading the extracellular material of cartilage, even at neutral pH.

3. Vitamin A released a protease from a particulate preparation obtained from bovine and chick cartilage.

4. The relationship of these studies to the physiological action of vitamin A in tissues is discussed.

The authors thank Mr L. J. King for his skilful technical assistance and Mr M. Applin for the photographs. The authors also thank Dr H. M. Dott of the Agricultural Research Council Unit of Reproductive Physiology for the provision of bovine embryos. H.B.F. is a Foulerton Research Fellow (the Royal Society) and J.T.D. a member of the external staff of the Medical Research Council.

REFERENCES

Aldridge, W. M., Emery, R. C. & Street, B. W. (1960). *Biochem. J.* **77**, 326.
Anson, M. L. (1938). *J. gen. Physiol.* **22**, 79.
Biggers, J. D., Gwatkin, R. B. L. & Heyner, S. (1961). *Exp. Cell Res.* **25**, 41.
Biggers, J. D. & Lucy, J. A. (1960). *J. exp. Zool.* **144**, 253.
Carrel, A. & Baker, L. E. (1926). *J. exp. Med.* **44**, 503.
de Duve, C. (1959). *Subcellular Particles*, p. 128. New York: The Ronald Press Co.
Di Ferranti, N. (1956). *J. biol. Chem.* **220**, 303.
Dingle, J. T. (1961). *Biochem. J.* **79**, 509.
Dingle, J. T. & Lucy, J. A. (1962). *Biochem. J.* **84**, 611
Dingle, J. T., Lucy, J. A. & Fell, H. B. (1961). *Biochem. J.* **79**, 497.
Eagle, H. (1959). *Science*, **130**, 432.
Fell, H. B., Dingle, J. T. & Webb, M. (1962). *Biochem. J.* **83**, 63.
Fell, H. B. & Mellanby, E. (1952). *J. Physiol.* **116**, 320.
Fell, H. B. & Thomas, L. (1960). *J. exp. Med.* **111**, 719.
Hanks, J. H. & Wallace, R. E. (1949). *Proc. Soc. exp. Biol., N.Y.*, **71**, 196.
Lucy, J. A., Dingle, J. T. & Fell, H. B. (1961). *Biochem. J.* **79**, 500.
Morgan, J. F., Morton, H. J. & Parker, R. C. (1950). *Proc. Soc. exp. Biol., N.Y.*, **73**, 1.

Fell-'65
Bib. No. 2692

Proc. Nutr. Soc. 24:166-170. 1965.

Reproduced by permission
of the copyright owner

Reprinted with the
permission of the copyright owner,
Cambridge University Press

The effect of vitamin A on the breakdown and synthesis of intercellular material in skeletal tissue in organ culture

By HONOR B. FELL (ROYAL SOCIETY RESEARCH PROFESSOR), *Strangeways Research Laboratory, Cambridge*

In a previous talk to the Society in 1959, I gave an account of our studies of the direct action of vitamin A on tissue structure (Fell, 1960); the present paper deals with the sequel to this early work.

My interest in the action of vitamin A was aroused by the late Sir Edward Mellanby. It is known that, when animals are fed on a diet containing excess of vitamin A, their bones undergo severe resorption often accompanied by spontaneous

fractures. How did vitamin A produce this effect? At the Strangeways we had developed a technique for growing entire bones from chick and mouse embryos, in small dishes of nutritive medium (Fell & Robison, 1929). Mellanby thought that this method of cultivating whole bones in vitro might shed light on the mechanism through which the vitamin acted on the tissue. The object of these initial experiments was merely to discover whether vitamin A had a direct action on skeletal tissue, as this was quite uncertain at that period and many people thought that the resorption of bone and cartilage in hypervitaminosis A was mediated through the parathyroid or some other endocrine system.

Obviously, if vitamin A produced an effect on bone and cartilage grown as an organ culture in vitro, this could only mean that the vitamin has a direct action on the tissue, because all systemic reactions are, of course, eliminated in a culture. We were delighted to find that the addition of vitamin A to the culture medium had a very drastic effect on the explants, and caused a rapid dissolution of the intercellular material (Fell & Mellanby, 1952). These changes in bone and cartilage were not necrotic, and the healthier and more active the cells, the more rapid was the breakdown of intercellular substance. Later work (Fell, Dingle & Webb, 1962) showed that this action of the vitamin had a high degree of molecular specificity.

The main object of our recent work has been to discover the cellular mechanism of this dissolution of intercellular material in response to excess of vitamin A. My biochemical colleagues, J. T. Dingle and J. A. Lucy, and I decided to investigate some of the biochemical effects of the vitamin on the cartilaginous limb-bone rudiments from 7-day embryos (Dingle, Lucy & Fell, 1961). The oxygen consumption of the vitamin A-treated rudiments was depressed as compared with that of their controls, the wet and dry weights and hexosamine content of the vitamin A-treated explants were half those of the paired controls, but their DNA content was only 20% less.

For a long time I had noticed that any tissue grown on a semi-solid medium composed of blood plasma and embryo extract, and containing added vitamin A, liquefied the clot more than controls in normal medium. This led me to suspect that the vitamin was increasing the proteolytic activity of the explants; in particular I wondered whether the acid proteases known as cathepsins were involved. The idea that a protease might be responsible for the dissolution of cartilage matrix in response to vitamin A received some encouragement from Thomas's (1956) observation that, when the vegetable protease, papain was injected into rabbits, it caused a rapid loss of cartilage matrix in the living animal. In joint work (Fell & Thomas, 1960), Thomas and I found that papain protease added to the culture medium of cartilaginous explants produced an effect on the matrix that closely resembled that caused by excess of vitamin A.

Dingle and I examined the effect of vitamin A on the proteolytic activity of cartilaginous limb-bone rudiments from 7-day chick embryos, grown in organ culture (Fell & Dingle, 1963). We were able to show that in 24 h the cartilage grown in the presence of vitamin A released into the culture medium up to seven times as much acid protease as the paired controls in normal medium. But when we examined the cartilage itself, we found that it still retained at least as much proteolytic activity as

the control, and sometimes more. So we concluded from this that the increased release of enzyme in response to vitamin A was compensated by an increased synthesis.

In other experiments (Dingle *et al.* 1961; Fell & Dingle, 1963) we found that acid protease acts on the matrix by breaking down the protein moiety of the protein-mucopolysaccharide complex, and in this way liberates polymeric chondroitin sulphate from the tissue. We also found (Fell & Dingle, 1963) that, although the pH optimum of the enzyme is around 5·0, it nevertheless actively degrades cartilage matrix at a neutral pH, though more slowly.

Just recently we have obtained further evidence that the breakdown of the cartilage is due to the acid protease. Ali (1964) has shown that ε-aminocaproic acid, which inhibits the enzyme plasmin, also inhibits the acid protease of cartilage. Stimulated by this work, we added this inhibitor to the culture medium along with the vitamin A, and found that the protease inhibitor largely prevented the action of the vitamin on the cartilage matrix.

de Duve and his colleagues (de Duve, Pressman, Gianetto, Wattiaux & Appelmans, 1955) have shown that a similar acid protease is localized in a bound form, in certain cytoplasmic granules which they have termed 'lysosomes'. These granules, which were discovered in tissue fractionation studies on the rat liver, contain about a dozen acid hydrolases (de Duve, 1963) which can be released from the particles in vitro by hypotonicity, detergents and other destructive agents.

Dingle wondered whether the increased proteolytic activity of cartilage grown in the presence of excess of vitamin A might be due to an effect on the lysosomes of the chondrocytes. It seemed possible that the vitamin might alter the permeability of the lipoprotein membranes of these organelles, and thus release the cathepsin, along with other enzymes. He therefore isolated the lysosomal granule fraction from rat liver (Dingle, 1961), embryonic chick cartilage (Fell & Dingle, 1963) and other tissues and treated it in vitro with vitamin A. The vitamin rapidly released the hydrolytic enzymes that the lysosomes contained; this observation of Dingle's gave us the key to the effect of hypervitaminosis A on skeletal tissue. The effect was dose-dependent and temperature-dependent (Dingle 1961) and had a high degree of molecular specificity (Fell *et al.* 1962), which in general corresponded to that for preventing vitamin A deficiency in animals.

From all these results, we concluded that vitamin A activates the lysosomes of the chondrocytes and thus releases the lysosomal hydrolases including the cathepsin; this protease then digests the protein moiety of the mucopolysaccharide complex of the matrix which consequently disintegrates; release of the enzyme is compensated by an increase in its synthesis.

It is probable that a lysosomal mechanism is also responsible for the breakdown of bone matrix, though at present there is no direct proof of this. It is known, however, that foetal bone contains lysosomal enzymes (Vaes, 1964), and that these can be released from particulate preparations in vitro by the addition of vitamin A (Fell & Dingle, quoted by Fell, 1961); cytochemical studies by several authors have shown that osteoclasts are filled with lysosomal granules. Moreover, the resorption

of bone grown in the presence of excess of vitamin A can be much reduced by simultaneous addition to the medium of the cathepsin inhibitor, ε-aminocaproic acid (Fell & Dingle, unpublished).

Change in lysosomal stability in response to excess of vitamin A is not confined to in vitro systems, but also takes place in the intact animal (Dingle, Sharman & Moore, 1963; Weissmann, Uhr & Thomas, 1963).

The effect of vitamin A on bone and cartilage in culture can be greatly retarded by adding hydrocortisone to the medium (Fell & Thomas, 1961); this hormone has been shown to stabilize lysosomal and other membrane systems (de Duve, Wattiaux & Wibo, 1962; Weissmann & Dingle, 1961; Weissmann & Thomas, 1963).

Recently we have investigated the effect of vitamin A on the synthesis of the components of cartilage matrix. The vitamin causes the breakdown of the fully formed matrix, but it was not known whether the chondrocytes continue to synthesize the components of the matrix, but merely release the products into the culture medium because the increased proteolytic activity prevents them from being built into intercellular material.

To answer this question, Dingle, Lucy and I (unpublished) grew 7-day chick limb-bone rudiments in a chemically defined fluid medium. Every 2 days the old medium was sucked off with a pipette and collected, and at the end of the culture period of 8 days the bone explants also were harvested. My colleagues then estimated the amount of hexosamine and hydroxyproline in both the medium and the tissue, as these substances are two of the main constituents of cartilage matrix. We found that the vitamin A-treated explants synthesize much more hydroxyproline and hexosamine than would appear from examination of the cartilage alone, but they liberate relatively more into the medium than the controls do. If the effect of the vitamin is not too severe, the total amount of hydroxyproline and hexosamine synthesized may be almost as great as in the controls, but usually it is rather less.

At present we have no idea whether the well-known effects of the vitamin on epithelia are mediated through the same cytological mechanism as its action on bone and cartilage. On the whole, we incline to the view that, in epithelia, changes in the endoplasmic reticulum and the ribosomes may be primarily concerned, but this is a mere guess, and in the end we may find that the lysosomes are implicated here also.

The lysosomal membranes are not the only membrane systems to be affected by vitamin A, as Dingle & Lucy (1965) will show in the next paper.

REFERENCES

Ali, S. Y. (1964). *Biochem. J.* **93**, 611.

de Duve, C. (1963). *Lysosomes. Ciba Found. Symp.* p. 1.

de Duve, C., Pressman, B. C., Gianetto, R., Wattiaux, R. & Appelmans, F. (1955). *Biochem. J.* **60**, 604.

de Duve, C., Wattiaux, R. & Wibo, M. (1962). *Biochem. Pharmac.* **8**, 30.

Dingle, J. T. (1961). *Biochem. J.* **79**, 509.

Dingle, J. T. & Lucy, J. A. (1965). *Proc. Nutr. Soc.* **24**, 170.

Dingle, J. T., Lucy, J. A. & Fell, H. B. (1961). *Biochem. J.* **79**, 497.

Dingle, J. T., Sharman, I. M. & Moore, T. (1963). *Proc. Nutr. Soc.* **22**, x.

Fell, H. B. (1960). *Proc. Nutr. Soc.* **19**, 50.

Fell, H. B. (1964). In *Bone and Teeth. Proceedings of the First European Symposium*, p. 311. [H. J. J. Blackwood, editor.] London: Pergamon Press.

Fell, H. B. & Dingle, J. T. (1963). *Biochem. J.* **87**, 403.
Fell, H. B., Dingle, J. T. & Webb, M. (1962). *Biochem. J.* **83**, 63.
Fell, H. B. & Mellanby, E. (1952). *J. Physiol.* **116**, 320.
Fell, H. B. & Robison, R. (1929). *Biochem. J.* **23**, 767.
Fell, H. B. & Thomas, L. (1960). *J. exp. Med.* **111**, 719.
Fell, H. B. & Thomas, L. (1961). *J. exp. Med.* **114**, 343.
Thomas, L. (1956). *J. exp. Med.* **104**, 245.
Vaes, G. (1964). *Abstr. Fed. Europ. biochem. Socs*, **1**, 83.
Weissmann, G. & Dingle, J. (1961). *Exp. Cell Res.* **25**, 207.
Weissmann, G. & Thomas, L. (1963). *J. clin. Invest.* **42**, 661.
Weissmann, G., Uhr, J. W. & Thomas, L. (1963). *Proc. Soc. exp. Biol., N.Y.*, **112**, 284.

Ferm-'67
Bib. No. 2709

Life Science 6:493-497. 1967.

Reproduced by permission
of the copyright owner

Reprinted with the
permission of the copyright owner,
Pergamon Press, Inc.

POTENTIATION OF THE TERATOGENIC EFFECT OF VITAMIN A WITH EXPOSURE TO LOW ENVIRONMENTAL TEMPERATURE*

Vergil H. Ferm

Department of Anatomy/Cytology, Dartmouth Medical School, Hanover, N. H.

(Received 7 November 1966; in final form 13 December 1966)

EXTENSIVE investigations on the teratogenic effect of Vitamin A on embryos of the golden hamster have provided data on the frequency of specific malformations induced by this agent (1). Within 6 hours after the administration of Vitamin A to pregnant hamsters on the 8th day of gestation, shrinkage and necrosis of the embryonic mesenchyme, followed by necrosis of embryonic somites, is noted. The malformations induced by this technique include exencephaly, spina bifida, rib defects, microphthalmia, lip and palate clefts, and limb abnormalities.

One of the more severe malformations noted were 2 cases of conjoined twins (2) found in 2 different litters. In an attempt to increase the incidence of this twinning phenomenon, pregnant hamsters were treated with oral Vitamin A, and, borrowing from the experience of Stockard (3) in twinning experiments in trout, the pregnant animals were confined to a cold temperature of 0° to 2°C for a period of 48 hours during critical stages of development. Although no new cases of abnormal twinning were discovered, a different spectrum of malformations was noted in the surviving embryos as compared to embryos exposed only to Vitamin A. Some of these malformations bear close resemblance to complex human malformations.

Materials and Methods

Virgin female golden hamsters were bred to males under direct observation

* Supported by USPHS Grant GM 10210

and the day following the evening of breeding was considered to be the first day of pregnancy. All of the animals were maintained in individual cages on laboratory chow and water ad libitum. At 8:00 a.m. on the 7th day of gestation, the pregnant hamsters were placed in a cold room in which the temperature was maintained at 0°C to +2°C. One group of females was fed 20,000 units of Vitamin A by stomach tube at 4:00 p.m. on the 7th day of gestation. The second group of animals was fed the same amount of Vitamin A at 8:00 a.m. on the 8th day of gestation. A third group of animals received no Vitamin A. All animals had free access to food and water. At 8:00 a.m. on the 9th day of gestation, the animals were removed from the cold room and returned to normal temperatures in the animal room. Between the 9th and 12th days of gestation, the animals were sacrificed and the fetuses recovered. Resorption sites and maternal weight changes were noted. All fetuses were examined carefully for gross external malformations and representative specimens photographed. Serial histological sections were made from the areas of spina bifida in animals with the typical defect described.

Results

The confinement of the pregnant hamster during early gestation to cold temperature without Vitamin A treatment did not increase the number of embryonic deaths for the embryonic survival rate was the same as untreated animals kept at normal room temperature. No developmental malformations were noted in this group of animals. The incidence of embryonic resorption in the Vitamin A-cold animals was markedly increased as shown in Table 1. This was especially marked when the animals were treated with Vitamin A on Day 7. In addition to this, several litters had fetuses with major malformations not previously seen in litters from mothers treated with Vitamin A alone. Three cases of sympodia or fusion of the lower extremities were found in three separate litters. More commonly, however, was the combination of a severe lumbosacral spina bifida (FIG. 1) associated with eventration of the anterior abdominal wall and marked

exencephaly.

TABLE 1

	Number of Mothers Treated	Total Number of Embryos Recovered	Total Number of Resorptions	Total Number Abnormal
COLD-VITAMIN A				
8:00 A.M., Day 8				
Embryos recovered days 12-13	15	58	129	49
Embryos recovered days 9-10	6	74	1	45
VITAMIN A-NO COLD				
8:00 A.M., Day 8				
Embryos recovered day 13	10	89	78	34
COLD-VITAMIN A				
4:00 P.M., Day 7				
Embryos recovered days 12-13	6	1	77	1
COLD-NO VITAMIN A				
Embryos recovered days 12-13	5	54	2	0

Discussion

Embryonic development in lower forms including fish (3) has been known to be affected by hypothermic treatment. Little is known, however, concerning the effect of hypothermia in mammalian development where intrauterine development serves to protect the embryo from extreme environmental conditions. Smith (4) has reviewed the brief literature, and in addition, has utilized the golden hamster as the subject of investigations into the effect of super-cooling in pregnancy. In these experiments he has described malformations in litters from mothers who were subjected to super-cooling for short intervals at selected times during early gestation.

The interaction of various environmental stimuli in the production of congenital malformations has been demonstrated by various means. Two teratogenic agents may have an additive or synteratogenic effect on the developing embryo. Thus, Landauer et al. (5) have demonstrated this synteratogenic effect

utilizing insulin and other agents on the developing chick embryo, and Kalter (6) described an additive teratogenic effect with the combined use of cortisone and hypocaloric diets in mice.

FIG. 1

Dorsal view of 12-day old littermate embryos removed from mother who was treated with 20,000 units of Vitamin A on day 8 of gestation and also subjected to hypothermic conditions. All demonstrate the same type and degree of exencephaly, spina bifida and anterior abdominal hernia. X5.

On the other hand, a single teratogenic agent may be potentiated by some simultaneous treatment which, in itself, is non-teratogenic. These are the so-called proteratogens of Landauer (7). The detection and influence of these proteratogenic stimuli in human mal-development as well as in experimental teratology are much more difficult to determine, and certain unrecognized subtle environmental factors may be the most important of these proteratogens.

With respect to the present experiments, the maintenance of pregnant hamsters in the cold environment without additional treatment resulted in no increase in the embryonic resorption rate nor in any evidence of congenital malformations.

One explanation for the teratogenic effect of Vitamin A (1,8) is that

Vitamin A directly affects the embryonic mesenchyme including a shrinkage of these cells, followed by necrosis of these cells. Cordier and Piery (9) noted that the absorption of glucose from the gut wall was increased following exposure of rats to hypothermia and postulated that this may be due to increased thyroid activity. Data on the absorption of Vitamin A under hypothermic conditions is not available and it is possible that the proteratogenic effect of hypothermia may be due to increased or simply perhaps prolonged levels of Vitamin A in the maternal system with the consequent effect on the developing embryo. Beaudoin and Roberts (10) have suggested that the thyroid stimulating hormone is teratogenic in rats and that it appears to potentiate the anomaly-producing effect of trypan blue.

The possibility exists that the potentiation of the teratogenic effect of Vitamin A may be due to the hypersecretion of adrenal hormones resulting from the cold stress. Cortisone and ACTH do have a teratogenic effect in certain inbred strains of mice but neither is a consistent teratogen (11). Further efforts are needed to identify other proteratogenic stimuli and their mechanisms in experimental teratology.

References

1. M. MARIN-PADILLA and V. H. FERM, J. Emb. exp. Morph., 13, 1 (1965).
2. V. H. FERM, Lab. Invest., 14, 1500 (1965).
3. C. R. STOCKARD, Am. J. Anat., 28, 115 (1921).
4. A. U. SMITH, J. Emb. exp. Morph., 5, 311 (1957).
5. W. LANDAUER and E. M. CLARK, J. Exp. Zoo., 151, 253 (1962).
6. E. KALTER, Proc. Soc. Exp. Biol. & Med., 104, 518 (1960).
7. W. LANDAUER and E. M. CLARK, J. Exp. Zoo., 151, 245 (1962).
8. M. MARIN-PADILLA, J. Embryol. exp. Morph., 15, 261 (1966).
9. D. CORDIER and Y. PIERY, C. rend. Soc. biol., Par., 144, 1521 (1950).
10. A. R. BEAUDOIN and J. M. ROBERTS, J. Emb. exp. Morph., 15, 281 (1966).
11. F. C. FRASER, E. KALTER, B. E. WALKER and T. D. FAINSTAT, J. Cell. and Comp. Physiol., 43, 237 (1954).

Ferm- 06
Bib. No. 2710

Arch Environ Health 19: 353-357, 1968.

Reproduced by permission
of the copyright owner

Conjoined Twinning in Mammalian Teratology

Vergil H. Ferm, MD, PhD, Hanover, NH

Three cases of conjoined twinning have been found in the golden hamster following treatment of the mothers with three different known teratogens: vitamin A, dimethyl sulfoxide (DMSO), and urethan. The twinning impetus which results in monozygous (MZ) twinning may thought of as an abnormal phenomenon in itself. This form of twinning in many cases is associated with a high intrauterine mortality, a high rate of situs inversus viscerum, severe developmental malformations associated with placental vascular abnormalities, discordance in organ development, and conjoined twinning.

IN THE COURSE of investigations of the teratogenic effects of various drugs in embryonic development in the golden hamster, three sets of conjoined twins have been found. All of these sets resulted from the treatment of the pregnant mother with known potent teratogens: vitamin A, dimethyl sulfoxide (DMSO), and urethan. The teratogenic effects of vitamin A,[1] dimethyl sulfoxide,[2] and urethan[3] in the golden hamster have been reported. One previous case of spontaneous incomplete twinning in the hamster has been recorded.[4] Bodemann[5] has described one set of uniovular twin embryos, out of 1,500 studied, in an eight-day mouse gestation sac. These twins were from a mating in which the male's father had received an unspecified amount of irradiation. A single set of conjoined twins in rabbit embryos following maternal treatment with thalidomide,[6] and a single set of conjoined rat twins following maternal treatment with the chlorhydrate of N, N-dimethylbiguanide[7] have been reported.

The instances of twinning reported here may not be the direct result of a teratogenic insult, but no other cases of spontaneous twinning have been found in any of the several hundred control litters (10,000+ embryos) in this laboratory. Approximately 650 embryos from mothers receiving vitamin A, 500 from those receiving dimethyl sulfoxide and 350 following maternal administration of urethan have been studied. Not all of these have been recovered early in gestation, and it is impossible, therefore, to predict what the monozygous MZ twinning incidence might be under these experimental conditions. This severe malformation would likely result in early fetal resorption, and this would account for the relative infrequency of the description of this phenomenon. This is supported by the invariably early embryonic deaths and resorption reported for the genetically determined MZ twinning phenomenon in mice.[8] Only recently we have begun to utilize methods for the earlier detection of the teratogenic effects of drugs in the golden hamster.[9] Within 24 hours of the treatment of pregnant hamsters with known teratogens, severe developmental malformations can be detected grossly. Twinning may be just such a malformation and might only be discovered if searched for earlier in gestation rather than following the more conventional teratogenic studies done at or near term.

Materials and Methods

Virgin female hamsters weighing 100 to 125 gm were bred to healthy males during the early evening hours. They were left with the males overnight and then separated and maintained in individual cages on regular laboratory feed. The day following the evening of breeding was considered to be the first day of pregnancy. On the eighth day of pregnancy the animals were either injected with 25 mg of urethan intraperitoneally, fed 20,000 units of vitamin A by gavage, or injected with 1,250 mg/kg dimethyl sulfoxide intravenously. Twin set 1 (vitamin A) was recovered from its mother on the ninth day of gestation, twin set 2 (urethan) was recovered from its mother on the 11th day of gestation, and twin set 3 (dimethyl sulfoxide) was recovered on the 11th day of gestation. All specimens were fixed on Bouin's fluid and photographed. Twin set 3 was serially sectioned. The placenta from each of the sets was fixed, examined grossly, and then sectioned for histological study.

Submitted for publication Aug 1, 1968; accepted Aug 12.

From the Department of Anatomy/Cytology, Dartmouth Medical School, Hanover, NH.

Reprint requests to the Department of Anatomy/Cytology, Dartmouth Medical School, Hanover, NH 03755 (Dr. Ferm).

Fig 1.—Nine-day-old hamster twins joined at thorax. Mother had received 20,000 units of vitamin A 24 hours previously (× 21 approx).

Fig 3.—Anterior view of eleven-day-old conjoined hamster embryos. Note exencephaly. Mother had received urethan intraperitoneally 72 hours previously (× 8 approx).

Fig 2.—Eleven-day-old hamster embryos joined at head. Mother had received intravenous dimethyl sulfoxide 72 hours previously (× 6 approx).

Fig 4.—Posterior view of same twins as in Fig 3.

Fig 5.—Section through mandible and double neural tube just below exencephaly of conjoined twins shown in Fig 3 and 4 (× 12 approx).

Results

One set of twins resulting from each of the three different teratogenic stimuli are shown in Fig 1 to 4. The extraembryonic membranes were ruptured during the removal of these specimens from their gestation sacs, and no statements can be made concerning the arrangement of the amniotic membranes or of the yolk sac placentas. However, careful histological examination of the chorioallantoic placentas of each set revealed no unusual findings, and there appeared to be only one placental mass of normal size. Each of the sets of twins showed some degree of failure of closure of the anterior neural tube. There is remarkable external symmetry in these specimens, and each twin appears to be the same size as its co-twin. Those treated with vitamin A (Fig 1) were somewhat delayed in development, appearing to be about half a day behind in developmental age. The growth of the other sets appeared to be normal for their developmental age.

Figure 5 shows a cross section through the head region of twin set 3. Two distinct closed neural tubes are present at this level which is just below the exencephalic abnormality shown in Fig 3 and 4. Further studies on the complex cardiovascular pattern in these conjoined twins are in progress.

Comment

The phenomenon of MZ twinning is associated with so many abnormalities of development that this form of twinning may in itself be considered a manifestation of a developmental malformation. Certainly, the relatively high rate of embryonic, fetal, and perinatal deaths associated with this phenomenon in humans reflects major developmental problems in these twins.[10] Naeye[11] has emphasized the marked growth and developmental differences in certain organs between twins of MZ origin in the human parabiotic syndrome. Also, the greater discordance of separate MZ human twins as compared to binovular twins has been described.[12-14] The high incidence of single umbilical arteries and vélamentous insertion of the umbilical cord into the placenta in MZ twins has also been reported.[15]

A variety of forms of conjoined twins have been reported in many lower forms.[16] In mammalian development MZ twinning is a relatively rare event. In certain armadillos, MZ polyembryony is a regular phenomenon.[17]

Sporadic reports of MZ twinning have been reported in other mammalian species. About 10% of all like-sexed twins in cattle are probably of MZ origin.[18] Other reports have been based on the fortuitous histological observation of twinning in early blastocysts such as in the sheep,[19] ferret,[20] or in the polyembryonic opossum blastocyst described by Patterson and Hartman.[21] In other species, MZ twinning is definitely known to occur only by the reported observations of various forms of conjoined twins. These have been recorded for the calf,[22] lamb,[23,24] horse,[25] pig,[26] cat,[27,28] and dog.[29]

The phenomenon of MZ twinning has been much more actively investigated in man where genetic, skin grafting, and placental membrane studies have been utilized to identify these pairs. In man, MZ twinning occurs in approximately one third of twin births or about once in 260 term births. The actual incidence of MZ twinning is probably much greater because the higher intrauterine mortality associated with twinning throughout gestation permits fewer to reach term. A greater incidence of situs inversus viscerum in human conjoined twins (73%), as compared to separate MZ twins (22%), has been observed.[30] In addition, several authors have noted a more marked physical dissimilarity in human

conjoined twins as compared to separate MZ twins.[30,31] Nielsen[32] has reviewed the surprisingly high frequency of chromosomal abnormalities in one or both members of human monozygotic twin pairs, a phenomenon which could contribute to the discordance previously described.

The obvious developmental implications of the anatomico-physiological parabiosis of conjoined twins may be extended to separate MZ twins where placental vascular anastomoses likely contribute to severe developmental malformations such as acardia, acephalus, hemicardia, or even other less severe malformations in one of the twins. However, the ultimate cause of the marked discordance for severe malformations in separate MZ twinning is not known, and further studies are needed to determine if this discordance is due to a physiological parabiosis or a postzygotic chromosomal aberration.

Two hypotheses have been suggested as explanations for conjoined twinning. The first of these is the fusion of two originally separate embryonic axes which arose from a single blastocyst which, in turn, was derived from a single zygote. In this context, Assheton[19] has suggested that the twinning event may be the result of the irregular distribution of the inner cell mass during the time of the transformation of the morula to the blastocyst stage. The complete separation of the embryonic masses and the maintenance of this separation results in the formation of separate MZ twins.

The second hypothesis suggests a fission of a single embryonic axis probably at some point in gastrulation. Newman,[33] emphasizing the bilaterality of the embryonic disk, suggested that the two halves of this embryonic axis may separate just at the time of gastrulation due to some, as yet, undefined twinning impetus. This could explain many of the variety of forms that conjoined twins exhibit as well as the high incidence of situs inversus viscerum in the resulting twins. Arey,[34] in a study of the high frequency of MZ twinning in human tubal pregnancies, concludes also that fission of the embryonic axis occurs and results in double gastrulation at the primitive streak stage.

The fusion of two mouse blastocysts to produce chimeras[35] suggests the possibility that conjoined twins might arise in the same manner. This cannot be the case for those conjoined twins in fish, amphibia, reptiles, or birds where the developing blastocysts may be kept separate. This possibility, however remote, must still be considered in mammalian conjoined twinning and only blood grouping, sex concordance, chromosome, and genetic studies would positively rule it out.

Newman and Patterson[36] have postulated that the twinning impetus, especially in armadillos, is related to the delayed implantation of the blastocyst in this species. Thus, the armadillo blastocyst undergoes "periods of quiescence" as well as a "discontinuous mode of development" with twinning resulting. Stockard[37] has experimentally induced conjoined twinning in trout embryos by the retardation of development following lowered environmental temperatures. The mode of teratogenic action of vitamin A or dimethyl sulfoxide is not yet known for certain, although both of these agents appear to affect the embryonic mesenchyma.[38] Urethan is known to inhibit mitosis in embryonic tissues[39] and is a potent teratogen in the hamster.[3] Whether these types of stimuli are sufficient to provoke a twinning impetus is not known although the hamster embyro is at an early primitive streak stage at the time of the teratogenic insult used in these experiments.[9,40] Benirschke[41] has formulated a time scale in human development devised to show the intervals at which a twinning impetus would result in various arrangements of the placental membranes as well as conjoined twinning. This scale suggests that the twinning impetus which results in conjoined twins is a relatively late event in human development. This adds further credence to the fission theory of the origin of conjoined twins. While the development and relationship of the extraembryonic fetal membranes in MZ twins in the human and armadillo have been well studied, more attention should be devoted to these membranes in MZ twinning in other species.

Whatever the twinning impetus may be, if it results in the formation of two closely related axial centers, especially at the primitive streak stage, it is likely to result in

conjoined twins, for it is at this time that the two axial centers of development will not easily separate. These two centers, which lie side by side, remain fused at some particular level. Thus, in these hamster embryos, one set (Fig 1) is fused at the thoracic level (thoracopagus), while both of the other sets (Fig 2 and 3) shared a common head (syncephalus).

This investigation was supported by Public Health Service research grants GM-10210 and HD-02616.

Technical assistance was rendered by Kate Faulkner

Figure 1 is reproduced with permission from *Laboratory Investigation* (14:1500-1505 [Aug] 1965).

Generic and Trade Names of Drugs

Dimethyl sulfoxide—*Dromisol.*
Thalidomide—*Kevadon.*

References

1. Marin-Padilla, M., and Ferm, V.H.: Somite Necrosis and Developmental Malformations Induced by Vitamin A in the Golden Hamster, *J Embryol Exp Morph* 13:1-8 (Feb, pt 1) 1965.

2. Ferm, V.H.: Congenital Malformations Induced by Dimethyl Sulphoxide in the Golden Hamster, *J Embryol Exp Morph* 16:49-54 (Aug) 1966.

3. Ferm, V.H.: Severe Developmental Malformations, *Arch Path* 81:174-177 (Feb) 1966.

4. Boyer, C.C.: A Case of Incomplete Twinning in the Hamster, *Anat Rec* 99:1-5 (Sept) 1947.

5. Bodemann, E.: A Case of Uniovular Twins in the Mouse, *Anat Rec* 62:291-294 (June) 1935.

6. Hay, M.F.: Effects of Thalidomide on Pregnancy in the Rabbit, *J Reprod Fertil* 8:59-76 (Aug) 1964.

7. Tuchmann-Duplessis, H., and Mercier-Parot, L.: Répercussions sur la gestation et le développement foetal du rat d'un hypoglycemiant, le chlorhydrate de N,N-dimethylbiguanide, *C R Acad Sci* 253:321-323 (July) 1961.

8. Gluecksohn-Schoenheimer, S.: The Effects of a Lethal Mutation Responsible for Duplications and Twinning in Mouse Embryos, *J Exp Zool* 110:47-76 (Feb) 1949.

9. Ferm, V.H.: The Rapid Detection of Teratogenic Activity, *Lab Invest* 14:1500-1505 (Aug) 1965.

10. Benirschke, K.: Twin Placenta in Perinatal Mortality, *New York J Med* 61:1499-1508 (May 1) 1961.

11. Naeye, R.L.: Organ Abnormalities in a Human Parabiotic Syndrome, *Amer J Path* 46:829-842 (May) 1965.

12. Gruenwald, P., and Mayberger, H.W.: Differences in Abnormal Development of Monozygotic Twins, *Arch Path* 70:685-695 (Dec) 1960.

13. Klein, D.E., and Friedman, S.: Occurrence of a Cardiac Anomaly in One of Symmetrical Conjoined Twins, *New Eng J Med* 271:249-251 (July 29) 1964.

14. Forel, B.J.; Nitowsky, H.M.; and Gruenwald, P.: Discordant Abnormalities in Monozygotic Twins, *J Pediat* 66:64-72 (Jan) 1965.

15. Benirschke, K., and Driscoll, S.G.: "Placenta," in *Handbuch der Speziellen Pathologischen Anatomie und Histologie*, Berlin: Springer-Verlag, 1967, Band 5, pp 187-275.

16. Newman, H.H.: *The Physiology of Twinning*, Chicago: University of Chicago Press, 1923.

17. Patterson, J.T.: Polyembryonic Development in Tatusia Novemcincta, *J Morph* 24:559-682 (Dec) 1913.

18. Hancock, J.: Monozygotic Twins in Cattle, *Advances Genet* 6:141-181, 1954.

19. Assheton, R.: An Account of a Blastodermic Vesicle of the Sheep of the Seventh Day, with Twin Germinal Areas, *J Anat Physiol* 32:363-373 (April) 1898.

20. Assheton, R.: *Fission of the Embryonal Area in Mammals*, Ninth International Congress of Zoology, series 3, Rennes, France: Imprimbie Oberthur, 1913, pp 415-421.

21. Patterson, J.T., and Hartman, C.G.: A Polyembryonic Blastocyst in the Opossum, *Anat Rec* 13:87-95 (July) 1917.

22. Smallwood, W.M.: Notes on a Two-Headed Calf, *Anat Rec* 22:27-32 (Aug) 1921.

23. Reese, A.M.: The Anatomy of a Two-Headed Lamb, *Anat Rec* 13:179-197 (Sept) 1917.

24. Arthur, G.H.: Conjoined Twins—the Veterinary Aspect, *Vet Rec* 68:389-393 (June) 1956.

25. Gurlt, E.F.: Die neuere literatur über menschliche und thierische missgeburten, *Virch Arch* 74:503-527 (Dec) 1878.

26. Carey, E.: The Anatomy of a Double Pig, Syncephalus Thoracopagus, With Especial Consideration of the Genetic Significance of the Circulatory Apparatus, *Anat Rec* 12:177-192 (Feb, pt 1) 1917.

27. McIntosh, W.C.: Notes on the Structure of a Monstrous Kitten, *J Anat Physiol* 2:366-373, 1968.

28. Reese, A.M.: The Anatomy of a Double Cat, *Anat Rec* 5:383-390 (Aug) 1911.

29. Pilcher, L.S.: Double Monsters, *Ann Anat Surg Soc* 2:19-37, 1880.

30. Aird, I.: The Conjoined Twins of Kano, *Brit Med J* 1:831-837 (April 10) 1954.

31. Newman, H.H., and Quisenberry, W.B.: One-Egg Twins With Spina Bifida and Polydactyly, *J Hered* 35:309-314 (Oct) 1944.

32. Nielsen, J.: Inheritance in Monozygotic Twins, *Lancet* 2:717-718 (Sept 30) 1967.

33. Newman, H.H.: *The Biology of Twins*, Chicago: University of Chicago Press, 1917.

34. Arey, L.B.: Direct Proof of the Monozygotic Origin of Human Identical Twins, *Anat Rec* 23:245-252 (April) 1922.

35. Mintz, B.: Experimental Study of the Developing Mammalian Egg: Removal of the Zona Pellucida, *Science* 138:594-595 (Nov 2) 1962.

36. Newman, H.H., and Patterson, J.T.: The Development of the Nine-Banded Armadillo From Primitive Streak Stage to Birth; With Especial Reference to the Question of Specific Polyembryony, *J Morph* 21:359-424 (Oct) 1910.

37. Stockard, C.R.: Developmental Rate and Structural Expression, *Amer J Anat* 28:155-277 (Jan) 1921.

38. Marin-Padilla, M.: Mesodermal Alterations Induced by Dimethyl Sulfoxide, *Proc Soc Exp Biol Med* 122:717-720 (July) 1966.

39. Sinclair, J.G.: Specific Transplacental Effect of Urethane in Mice, *Tex Rep Biol Med* 8:[illegible] (winter) 1950.

40. Ferm, V.H.: The Use of the Golden Hamster in Experimental Teratology, *Lab Anim Care* 17:452-462 (Oct) 1967.

41. Benirschke, K.: Major Pathologic Features of the Placenta, Cord and Membranes, Proceedings from the Symposium on the Placenta, Its Form and Functions, *Birth Defects Orig Art Ser* 1:52-63 (April) 1965.

Fidge-'68
Bib. No. 2732

J. of Lipid Res. 9:103-109. 1968.

J. of Lipid Research 9:103-109. 1968.

Reproduced by permission
of the copyright owner

Pathways of absorption of retinal and retinoic acid in the rat

NOEL H. FIDGE, TATSUJI SHIRATORI, JAGANNATH GANGULY, and DEWITT S. GOODMAN

Department of Medicine, Columbia University College of Physicians and Surgeons, New York 10032

ABSTRACT The chemical and anatomical pathways of absorption of dietary retinal, retinoic acid, and retinol were examined in rats containing lymph, bile, and duodenal cannulae. The experiments were designed to maintain physiological conditions to the greatest possible extent. In each rat an uninterrupted flow of bile into the duodenum was maintained by connecting the duodenal cannula to the bile duct of a second rat.

Labeled vitamin A compounds were introduced into the duodenum in very small amounts (7–14 μg) in the form of a bile–lipid mixture resembling normal intestinal contents. Under these conditions, most (70–80%) of the radioactivity recovered after the feeding of labeled retinol or retinal was found in the lymph, predominantly in saturated retinyl esters. In contrast, 92–95% of the radioactivity recovered after the feeding of labeled retinoic acid was found in the bile, and was contained in a mixture of polar metabolites, most of them more polar than free retinoic acid. Two-thirds of the small amount of radioactivity found in lymph after retinoic acid-^{14}C feeding was in the form of free retinoic acid.

The results indicate that under normal conditions the major pathway of retinal absorption involves its reduction to retinol, which is then esterified and transported via the lymphatics in a manner similar to that of dietary retinol. A small proportion of retinal is apparently normally oxidized, and is then transported via the portal vein and excreted in the bile in a manner similar to that of dietary retinoic acid. The relative importance, in quantitative terms, of these two pathways of retinal metabolism can vary, depending on the status of the animal.

KEY WORDS vitamin A · retinal · retinoic acid · retinol · retinyl esters · rat · absorption · metabolism · intestine · lymphatics · portal vein · bile · reduction · oxidation

RECENT STUDIES on the biosynthesis of vitamin A from β-carotene have demonstrated that the initial reaction in this biosynthetic sequence involves the central cleavage of β-carotene into two molecules of retinal (1–4). This reaction occurs during the intestinal absorption of β-carotene and is catalyzed by a soluble mucosal enzyme (1–4). Some uncertainty exists, however, as to the events that occur during the subsequent metabolism of the mucosal retinal. On the one hand, studies in vivo, both in the rat (5) and in man (6), have demonstrated that vitamin A, newly formed from dietary β-carotene, is mainly transported in the lymph in the form of retinyl esters. These studies suggest that newly-formed retinal is reduced to retinol, and subsequently esterified, in the intestinal mucosa. Reduction of retinal to retinol is catalyzed by a soluble mucosal aldehyde reductase which requires NADH or NADPH as cofactor (7). On the other hand, it is known that intestinal mucosa also contains an enzyme capable of oxidizing retinal to retinoic acid (8, 9), and it has recently been suggested that a significant portion of mucosal retinal is oxidized to retinoic acid and absorbed via the portal vein (9). There is some evidence suggesting that retinoic acid, if absorbed, would not accumulate in tissues, but would be largely excreted in the bile in the form of polar metabolites (10–12). Thus, large amounts of radioactivity were found in the bile of rats after the intraportal injection of labeled retinoic acid (10, 11). Two possible pathways of retinal metabolism hence exist: (*a*) reduction to retinol and transport as retinyl esters via the lymphatics; (*b*) oxidation to retinoic acid and transport via the portal vein. The relative importance of these alternative pathways under normal conditions is not clear.

In the experiments described below, this question was examined by comparing the intestinal absorption and metabolism of dietary retinal, retinoic acid, and retinol in rats containing both lymph and bile fistulae. The ex-

This paper is number 7 in the series "Vitamin A and Carotenoids" from the laboratory of DeW. S. Goodman.

periments were designed to maintain conditions as nearly physiological as possible. Thus, in each experiment, bile was continuously replaced via a duodenal cannula connected to the bile duct of a second, donor rat. Furthermore, all vitamin A compounds were administered in very small amounts in the form of a bile–lipid mixture resembling normal intestinal contents. The results demonstrate that under normal conditions retinal is mainly reduced to retinol and absorbed via the lymphatic route.

METHODS AND MATERIALS

Labeled Substrates

Retinyl-6,7-^{14}C acetate (specific radioactivity 6.83 μc/μmole) was a generous gift from Hoffmann-La Roche, Basel, Switzerland.

Retinol-6,7-^{14}C was prepared by saponification of the retinyl acetate-^{14}C (see below for details). The nonsaponifiable fraction was extracted with hexane, and the ^{14}C-labeled retinol was isolated by chromatography on a column of alumina (5).

Retinal-6,7-^{14}C was prepared by oxidation of retinol-6,7-^{14}C with MnO_2 (13), and the retinal was also purified by alumina chromatography (5).

Retinoic acid-6,7-^{14}C was prepared by the enzymic oxidation of retinal-6,7-^{14}C as described previously (1).

Unlabeled Substrates

Unlabeled retinal, retinol, and retinoic acid were purchased from Eastman Kodak (Rochester, N.Y.). Unlabeled retinyl palmitate, oleate, and linoleate were synthesized by reaction of retinol with the appropriate acyl chloride as described previously (5).

Feeding Mixtures

In each study, approximately 32 μg (0.7–0.8 μc) of the labeled vitamin A compound was dissolved in 25 μl of acetone. To this was added 0.1 ml of a mixture of oleic acid and monoolein (2:1, v/v); freshly collected rat bile was then added to a final volume of 2 ml. The mixture was agitated with a Vortex mixer to provide a relatively stable emulsion.

Surgical Procedures

Lymph and bile duct cannulations were performed on the same rat. Polyethylene tubing (Intramedic, Clay-Adams, Inc. New York Cat. No. PE 50) was implanted into the thoracic duct below the diaphragm by a modification of the method of Bollman, Cain, and Grindlay (14). The bile duct was severed 2–3 cm above its point of entrance into the duodenum. Cannulae of polyethylene tubing (PE 10) were inserted into both ends of the severed bile duct. One tube was inserted towards the liver for the collection of bile, and the second tube was inserted through the lower portion of the bile duct into the duodenum. The external ends of these two tubes were then connected, so as to provide an uninterrupted flow of bile from the liver into the duodenum.

The animals were kept in restraining cages and allowed access to a solution of 5% glucose in 0.45% saline. Studies were begun 12–24 hr after the completion of surgery. At the start of each experiment the duodenal and bile cannulae were separated from each other, and the animal was tested for its ability to absorb fat as follows. Through the duodenal cannula was fed a test meal of 0.2 ml of the oleic acid–monoolein mixture 2:1, emulsified with 0.3 ml of bile. When fat absorption and the formation of chylomicrons was evinced by the milky appearance of the chyle, 0.5 ml of the appropriate ^{14}C-labeled vitamin A feeding mixture was fed through the duodenal cannula. This (duodenal) cannula was then connected to the bile duct of a second (bile donor) rat, so that the uninterrupted flow of bile into the duodenum was continued for the remainder of the experiment. Lymph and bile were collected in amber graduated cylinders kept in ice. After 24 hr of collection the rats were killed; at this time the livers were excised, rinsed in saline, blotted, and weighed.

Extraction Procedure

Lymph, bile, and liver samples were extracted with 20 volumes of chloroform–methanol 2:1. A mixture of nonradioactive carrier vitamin A compounds, containing 100 μg each of retinal, retinol, a mixture of retinyl esters, and retinoic acid, was added to the chloroform–methanol extract. The total extract was filtered, and a portion was taken for radioassay. The remainder was split into two phases by addition of 0.01 N H_2SO_4 (5). One-tenth of each chloroform and of each methanol–water phase was taken for radioassay and the rest was saved for chromatographic and other analyses.

Column and Thin-Layer Chromatography

Chromatography was performed on alumina columns as described previously (5).

The composition of the labeled retinyl esters eluted in fraction 2 (see Table 3) from the alumina columns was determined by chromatography on thin-layer plates of Alumina Gel G impregnated with silver nitrate, as described previously (5). Approximately 100 μg each of retinyl palmitate, oleate, and linoleate were added to the samples before chromatography. After development, the separated bands were viewed under UV light and scraped onto filter funnels, and the esters were eluted with chloroform.

Other Procedures

Saponification was carried out in amber tubes under N_2 with 2 N KOH in 70% ethanol. The samples were heated at 60–70°C for 1.5 hr, and the nonsaponifiable fraction was extracted with light petroleum ether (bp 39–53°C) or hexane. The saponifiable fraction was similarly extracted after acidification.

In some samples, acidic and nonacidic lipids were separated by extraction of a hexane solution of the lipids with 0.1 N NaOH in 50% ethanol (15). The nonacidic lipids remained in the hexane phase, which was removed; the acidic lipids were subsequently recovered by acidification of the ethanolic NaOH and extraction with hexane.

Radioassay

Samples were dissolved in 12 ml of the scintillation mixture described by Bray (16) and assayed in a Packard Tri-Carb scintillation counter at an efficiency of 78%. Corrections were made for quenching, where necessary, by the addition of toluene-^{14}C as internal standard.

RESULTS

The percentage recovery and distribution of radioactivity in the lymph, bile, and liver, after the feeding of the various ^{14}C-labeled vitamin A compounds to rats, is shown in Table 1. Most of the radioactivity recovered after feeding ^{14}C-labeled retinol or retinal was found in the lymph, while 15–20% was present in the bile. In sharp contrast, after feeding of retinoic acid-^{14}C, 90–95% of the recovered radioactivity was found in the bile. The liver contained 5–10% of the recovered ^{14}C after labeled retinal had been fed, but only 0.1–0.6% after labeled retinol or retinoic acid.

The distribution of radioactivity between the chloroform (lipid) and the methanol–water (nonlipid) phases is shown in Table 2. Nearly all of the radioactivity from all the lymph extracts was found in the lipid (chloroform) fraction. In contrast, 28–53% of the radioactivity in the bile extracts was found in the nonlipid (methanol–water) phase. Most of the radioactivity of the liver extracts was found in the lipid fraction, although 14–38% was recovered in the methanol–water phase after the feeding of retinol-^{14}C or retinoic acid.

Table 3 shows the distribution of radioactivity observed after chromatography of the lipid extracts of lymph, bile, and liver on alumina columns. Most of the radioactivity present in the lymph and liver extracts of rats fed retinol-^{14}C or retinal was found in the retinyl ester fraction. Most of the radioactivity in the bile lipid extracts, however, remained on the column, presumably

TABLE 1 Recovery and Distribution of Radioactivity after the Feeding of ^{14}C-Labeled Retinol, Retinoic Acid, and Retinal to Rats

Rat No.	Labeled Compound Fed	Amount Fed		Total ^{14}C Recovered*	Distribution of Recovered ^{14}C		
					Lymph	Bile	Liver
		μg	μc	% of ^{14}C fed		%	
1	Retinol	14	0.29	47.5	79.8	20.1	0.1
2	Retinoic acid	7	0.19	50.7	5.3	94.3	0.4
3	Retinoic acid	7	0.19	37.5	6.7	92.7	0.6
4A†	Retinal	8	0.19	41.5	79.8	20.2	—†
4B†	Retinal	8	0.19	44.0	70.3	19.4	10.3
5	Retinal	8	0.19	64.2	78.3	15.6	6.1

* Recovered in lymph, bile, and liver. It is presumed that the recovery of ^{14}C in these samples also represents the percentage absorption of the labeled substrate.

† Rat No. 4 was fed twice. At the end of the second experiment (4B), the liver was removed and extracted.

TABLE 2 Partition of Recovered ^{14}C between Lipid and Nonlipid Phases

Rat No.	Labeled Compound Fed	Lymph		Bile		Liver	
		C*	M*	C	M	C	M
				%			
1	Retinol	98.4	1.6	47	53	86	14
2	Retinoic acid	85.9	14.1	72	28	62	38
3	Retinoic acid	97.8	2.2	65	35	81	19
4A	Retinal	99.9	0.1	55	45	—†	—†
4B	Retinal	99.9	0.1	54	46	99	1
5	Retinal	99.9	0.1	66	34	99	1

* C, chloroform (lipid) phase; M, methanol–water (nonlipid) phase.

† Rat No. 4 was fed twice. At the end of the second experiment (4B), the liver was removed and extracted.

TABLE 3 Distribution and Recovery of ^{14}C after Chromatography on Alumina Columns

Labeled Compound Fed:	Retinol		Retinoic Acid		Retinal		
Lipid Extract of:	Lymph	Bile	Lymph†	Bile†	Lymph‡	Bile‡	Liver‡
Total ^{14}C Recovered from Column* (%):	101	36	70	27	92	20	90
Column Fraction			*% distribution of recovered ^{14}C*				
1 (β-carotene)	6	0.2	3	3	9	1	4
2 (retinyl esters)	77	2	22	35	82	6	79
3 (retinal)	6	2	5	3	4	10	5
4 (retinol)	8	23	3	17	3	17	3
5 (polar; nonacidic)	3	27	2	11	1	20	2
6 (polar; acidic§)	1	45	65	32	2	45	7

* Per cent of applied ^{14}C recovered in the sum of the six fractions collected.

† Mean of two experiments. Each sample was analyzed separately, with good agreement obtained between the individual samples. The results were, therefore, averaged for presentation here.

‡ Mean of three experiments, with good agreement between individual samples. The results were averaged for presentation here.

§ Including retinoic acid.

because of the retention of very polar labeled compounds by the column.

The composition of the labeled retinyl esters isolated from the lymph and liver extracts of rats fed ^{14}C-labeled retinal is shown in Table 4. Labeled saturated esters predominated in all samples. Portions of the retinyl ester fractions from the lymph of rat No. 5 and from the liver of rat No. 4 were saponified. After saponification the radioactivity was recovered in the nonsaponifiable fraction, and was subsequently recovered in the retinol fraction (fraction 4) after alumina column chromatography. These procedures established that the ^{14}C found in the retinyl ester fraction (fraction 2) after column chromatography actually resided in esters of labeled retinol.

Portions of the lipid extracts of the lymph and bile samples from the rats fed retinoic acid-^{14}C (rats No. 2 and 3) were separated into acidic and nonacidic lipids by solvent partition. 65% and 76%, respectively, of the lymph-^{14}C was found in acidic lipids. These values were almost identical with the percentage of lymph ^{14}C recovered in the retinoic acid fraction (fraction 6) after alumina column chromatography (Table 3). This suggests that approximately two-thirds of the small amount of radioactivity in the lymph of these rats resided in free retinoic acid. The recovery of lymph ^{14}C after solvent partition was 87% and 90% in these two rats. In contrast, only 57% and 60% of the ^{14}C in the lipid extracts of the bile of these rats was recovered after solvent partition. The acidic fraction contained 35% and 13%, respectively, of the recovered ^{14}C. These data indicate that only a very small portion (maximum 5-15%) of the ^{14}C in the bile of these rats could possibly have been present as free retinoic acid.

Of the small amount of ^{14}C found in the lymph of the rats fed retinoic acid-^{14}C, 22% was recovered in the retinyl ester fraction (fraction 2, Table 3). After saponification of this fraction, 75% of the ^{14}C was found as labeled saponifiable lipid. This suggests the presence of an ester of labeled retinoic acid in the lymph of these rats. This ester would have to be a monoester, such as a cholesteryl ester, since triglycerides (tri-esters) are eluted mainly in column fraction 3, rather than in fraction 2.

In all the experiments so far described, the lymph became chylous after the test meal, and the vitamin A compounds were fed in small amounts. In two experiments, however, (rats No. 6 and 7, Table 5) the lymph remained clear before and after test meals containing retinal-^{14}C. In these rats, more of the ^{14}C recovered was found in the bile than in the lymph. In addition, in two experiments (rats No. 6 and 8, Table 5) retinal was fed in large amounts (0.9 mg). In these experiments, despite the large amount fed, both rats absorbed a substantial percentage of the retinal-^{14}C. As already discussed, the lymph of one of these rats (No. 6) did not become chylous, and most of the absorbed ^{14}C was found in the bile. In contrast, the lymph of rat No. 8 did become chylous after the test meal, and much more ^{14}C was recovered in the lymph than in the bile. In addition, 30% of the ^{14}C re-

TABLE 4 Labeled Retinyl Ester Compositions in Lymph and Liver of Rats after the Feeding of ^{14}C-Labeled Retinal

		% Distribution of Labeled Retinyl Ester		
Rat No.	Sample	Saturated	Mono-unsaturated	Di-unsaturated
4A	Lymph	58	31	11
4B	Lymph	59	33	8
4B	Liver	82	11	8
5	Lymph	67	23	11
5	Liver	81	12	7

TABLE 5 EFFECT OF ABNORMAL PHYSIOLOGICAL CONDITIONS ON THE ROUTE OF ABSORPTION OF RETINAL-^{14}C

Rat No.	Amount Fed		Total ^{14}C Recovered	Distribution of Recovered ^{14}C		
				Lymph	Bile	Liver
	μg	μc	% of ^{14}C fed		%	
6*	900	0.07	41	3	78	19
7†	6	0.14	8	21	73	6
8‡	900	0.12	15	49	21	30

* Rat No. 6 was fed a large amount of retinal; after the labeled compound had been fed in a mixture containing fat (see text), the lymph remained clear.

† Rat No. 7. As with rat No. 6, the lymph remained clear and gave no evidence of chylomicron formation. This animal did not receive bile continuously from a donor rat.

‡ Rat No. 8 was fed, as indicated in the table, a large amount of retinal. The lymph did become chylous.

covered from this rat was found in the liver. Most (78%) of this liver ^{14}C resided in retinyl esters, which suggests that the hepatic radioactivity was derived from labeled retinyl esters absorbed via aberrant lymphatic pathways (the normal pathways lead to the cannula).

In addition to the above experiments with triply cannulated rats, a study was conducted to examine the absorption of retinal-^{14}C in a rat containing only one cannula, in its thoracic duct. 22 hr after cannulation, this rat was fed via gastric intubation 0.3 ml of triolein containing 350 μg of retinal-^{14}C. Lymph was collected for 24 hr and the rat was then fed 0.3 ml of trilinolein containing 350 μg of retinal-^{14}C. The rat was killed 24 hr later and the liver was extracted. The recovery of fed ^{14}C in the lymph was 19% after the first feeding and 23% after the second. The liver contained 3–4% of the total amount of fed ^{14}C. Centrifugal flotation of the chylomicrons in the first lymph sample demonstrated that 77% of the lymph ^{14}C was present in lymph chylomicrons. Analysis by alumina column chromatography demonstrated that most of the label in the lymph and liver samples resided in labeled retinyl esters. The composition of the labeled retinyl esters in the lymph and liver samples was determined by TLC on $AgNO_3$-impregnated alumina gel, and is shown in Table 6. Saturated esters predominated in all three samples. A small effect of the fatty acid composition of the diet was seen, in that relatively more monoenoic than diunsaturated esters were found after the feeding of triolein, whereas the reverse was found after trilinolein had been fed.

DISCUSSION

The studies reported here were designed to elucidate the anatomical and chemical pathways of absorption of several vitamin A compounds. In order to obtain physiologically valid information, we attempted to maintain nearly physiological conditions. To this end, an uninterrupted flow of bile into the duodenum was maintained, and the labeled substrates were fed in very small amounts in the form of emulsions resembling normal intraluminal contents during fat absorption. The feeding mixtures contained monoolein and oleic acid in a ratio of 1:2 (v/v), rather than normal fat (triglyceride), because of the possibility that bile duct cannulation might have interfered with the flow of pancreatic juice into the intestine. It is well known that intraluminal lipolysis is dependent on the action of pancreatic lipase, and that the major products of lipolysis are monoglyceride and free fatty acid (17). The physiological status of each rat was assessed by examining its ability to absorb fat and to form lymph chylomicrons. Animals were used only if it was certain that they could still absorb fat in this form. In some preparations, lymph and bile flows were obviously impaired, or the lymph did not become chylous after fat administration; these rats were not used, except as indicated in the results to demonstrate a particular effect.

When nearly physiological conditions were achieved, as described above, most of the radioactivity recovered after the feeding of labeled retinol or retinal was found in the lymph. When labeled retinoic acid was fed, however, nearly all the radioactivity recovered was found in the bile. In the study with retinol-^{14}C, 80% of the absorbed radioactivity was recovered in the lymph. This finding was expected, since numerous published studies, carried

TABLE 6 EFFECT OF DIETARY FAT COMPOSITION ON THE COMPOSITION OF RETINYL ESTERS AFTER THE FEEDING OF ^{14}C-LABELED RETINAL TO RATS

Sample	% Distribution of Labeled Retinyl Ester		
	Saturated	Mono-unsaturated	Di-unsaturated
Lymph*	56	37	7
Lymph†	59	19	22
Liver	68	23	8

Feeding mixture contained:
* 350 μg of retinal-^{14}C in 0.3 ml of triolein.
† 350 μg of retinal-^{14}C in 0.3 ml of trilinolein.

out with a number of species, have demonstrated that retinol absorption mainly occurs via the lymphatic route (18–21). The fact that 20% of the radioactivity recovered was found in the bile suggests that under normal conditions some dietary retinol may be oxidized to retinoic acid in the intestinal mucosa and absorbed via the portal vein. Portal vein transport of dietary vitamin A may be even more significant under abnormal conditions, since it has been reported that ligation of the thoracic duct does not prevent the absorption of vitamin A in rats (22). In the present studies, after labeled retinal had been fed the results observed were almost identical with those obtained after the feeding of labeled retinol. Thus, in the three physiological experiments reported in Table 1, 70–80% of the radioactivity recovered after feeding retinal-^{14}C was found in the lymph, and 15–20% in the bile.

In striking contrast to the results observed with retinol and retinal, feeding labeled retinoic acid gave only 5–7% of the absorbed radioactivity in the lymph, whereas 92–95% was found in the bile. These findings establish that absorption of retinoic acid occurs via the portal venous route, and are consistent with the finding of Zachman, Dunagin, and Olson (10, 11) that retinoic acid, injected into the portal vein, was rapidly metabolized and excreted in the bile. The labeled compounds found in the bile consisted of a mixture of polar metabolites, most of which were more polar than free retinoic acid. Only very small portions (5–15%) of the ^{14}C in the bile of these rats could possibly have been present as free retinoic acid. These findings are consistent with the observations of Zachman et al. (11), that retinoic acid injected into the portal vein of rats was largely excreted in the bile in the form of more polar metabolites of retinoic acid. The major metabolite in rat bile has been tentatively identified as retinoyl β-glucuronide (12).

Since samples of portal blood were not analyzed in the present studies, no direct information is available about the chemical form in which retinoic acid was absorbed via the portal vein. It is possible, for example, that retinoic acid was absorbed as the free acid, perhaps in the form of its carboxylate anion bound to serum albumin. The similarities between the properties of the biliary metabolites observed here and those observed after intraportal injection of free retinoic acid (11) are consistent with this suggestion. It is also possible that retinoic acid was converted to its glucuronide conjugate in the intestinal mucosa, and then transported in portal blood in this form.

It is interesting to speculate why retinoic acid, a 20-carbon carboxylic acid, is not absorbed via the lymphatics as are the usual long-chain fatty acids. Perhaps, because of substrate specificity on the part of the enzymes involved in fatty acid activation and in glyceride ester bond formation, retinoic acid is unable to be converted into glyceride esters. In this regard it should be noted that two-thirds of the small amount of radioactivity found in lymph after administration of retinoic acid-^{14}C was found as free retinoic acid. Most of the remaining radioactivity in lymph was tentatively identified as a monoester of labeled retinoic acid. We can, therefore, hypothesize that retinoic acid might be unable to be incorporated into glyceride esters, but instead can be converted into water-soluble derivatives or can be bound to (and hence "solubilized" by) serum albumin. Since portal blood flow greatly exceeds that of intestinal lymph, the absorption of retinoic acid via the portal route can thus be explained. Only 0.5% of the radioactivity recovered after labeled retinoic acid had been fed was found in the livers of the rats. Previous workers (23–25) have found no accumulation of retinoic acid in the tissues, including the intestinal mucosa itself, after the feeding of this compound to animals, despite the fact that many symptoms of vitamin A deficiency can be relieved by administration of retinoic acid (26).

Almost all of the radioactivity recovered in the lymph after the feeding of labeled retinal (and retinol) was found in lipid-soluble compounds, mainly in retinyl esters. These studies hence demonstrate that, under physiological conditions (i.e., when the animal was able to absorb fat), absorption of retinal occurred mainly via the lymph, in the form of retinyl esters. Under these conditions, therefore, the major pathway of retinal absorption involved its reduction to retinol, which was then esterified and transported in a manner similar to that of dietary preformed retinol. Since this seems to be the main "physiological" pathway, it is likely that retinal newly formed from β-carotene in the intestinal mucosa would also be metabolized predominantly via this pathway. Saturated retinyl esters predominated in the lymph after administration of retinal, regardless of the fatty acid composition of the diet. This finding is similar to that observed after the feeding of labeled retinol or β-carotene, both in the rat (5) and in man (6). The capacity of the rat intestine to reduce retinal and then to transport the retinol via the lymph greatly exceeded the small physiological daily requirement for vitamin A. Thus, when large amounts (350 or 900 μg) of retinal were fed, a considerable amount of the total radioactivity was absorbed via the lymphatic route.

Under physiological conditions as defined above, in addition to the ^{14}C found in the lymph, 15–20% of the radioactivity recovered after retinal-^{14}C feeding was found in the bile. Furthermore, when fat absorption was impaired, as indicated by the failure of the lymph to become chylous, most of the absorbed ^{14}C (from retinal-^{14}C) was found in the bile, rather than in the lymph. These results may explain the findings of Crain, Lotspeich, and

Krause (9), who injected large doses (1 mg) of labeled retinal, emulsified with Tween-80, into ligated intestinal loops of rats, and found 30–40% of the absorbed radioactivity in portal blood collected via an exchange transfusion technique. In our experiments, the labeled compounds in bile consisted of a mixture of polar metabolites, grossly similar to those observed after the feeding of retinoic acid-^{14}C. These data suggest that, under normal conditions, a small portion of dietary (or newly biosynthesized) retinal is oxidized to retinoic acid, which is then transported and metabolized in a manner similar to that of dietary preformed retinoic acid. The results also suggest that the relative importance, in quantitative terms, of the two pathways of retinal metabolism can vary, depending on the status of the animal.

We are grateful to Miss Elizabeth Miller for expert technical assistance, and to Hoffmann-La Roche, Basel, Switzerland, for the generous gift of retinyl-6,7-^{14}C acetate.

This work was supported by PHS Research Grant AM-05968 from the National Institutes of Health.

N.H.F. was an Overseas Research Fellow of the Life Insurance Medical Research Fund of Australia and New Zealand, and J.G. was a Visiting Professor at the Institute of Nutrition Sciences, Columbia University, during the conduct of this work. J.G. was on leave of absence from the Indian Institute of Science, Bangalore, India, and gratefully acknowledges support from the U.S. Educational Foundation in India and the Whitehall Foundation in New York. D.S.G. is a Career Scientist of the Health Research Council of the City of New York under Contract 1-399.

Manuscript received 4 August 1967; accepted 6 October 1967.

References

1. Goodman, DeW. S., H. S. Huang, and T. Shiratori. 1966. *J. Biol. Chem.* **241:** 1929.
2. Olson, J. A., and O. Hayaishi. 1965. *Proc. Natl. Acad. Sci. U. S.* **54:** 1364.
3. Goodman, DeW. S. and H. S. Huang. 1965. *Science.* **149:** 879.
4. Goodman, DeW. S., H. S. Huang, M. Kanai, and T. Shiratori. 1967. *J. Biol. Chem.* **242:** 3543.
5. Huang, H. S., and DeW. S. Goodman. 1965. *J. Biol. Chem.* **240:** 2839.
6. Goodman, DeW. S., R. Blomstrand, B. Werner, H. S. Huang, and T. Shiratori. 1966. *J. Clin. Invest.* **45:** 1615.
7. Fidge, N. H., and DeW. S. Goodman. 1967. *Federation Proc.* **26:** 849. (Abstr.)
8. Mahadevan, S., S. K. Murthy, and J. Ganguly. 1962. *Biochem. J.* **85:** 326.
9. Crain, F. D., F. J. Lotspeich, and R. F. Krause. 1967. *J. Lipid Res.* **8:** 249.
10. Zachman, R. D., and J. A. Olson. 1965. *J. Lipid Res.* **6:** 2[illegible].
11. Zachman, R. D., P. E. Dunagin, Jr., and J. A. Olson. 1966. *J. Lipid Res.* **7:** 3.
12. Dunagin, P. E., Jr., E. H. Meadows, Jr., and J. A. Olson. 1965. *Science.* **148:** 86.
13. Ball, S., T. W. Goodwin, and R. A. Morton. 1948. *Biochem. J.* **42:** 516.
14. Bollman, J. L., J. C. Cain, and J. H. Grindlay. 1948. *J. Lab. Clin. Med.* **33:** 1349.
15. Borgström, B. 1952. *Acta Physiol. Scand.* **25:** 111.
16. Bray, G. A. 1960. *Anal. Biochem.* **1:** 279.
17. Mattson, F. H., and R. A. Volpenhein. 1964. *J. Biol. Chem.* **239:** 2772.
18. Drummond, J. C., M. E. Bell, and E. T. Palmer. 1935. *Brit. Med. J.* **1:** 1208.
19. Ganguly, J. 1960. *Vitamins Hormones.* **18:** 387.
20. Moore, T. 1957. *In* Vitamin A. Elsevier Publishing Co., Amsterdam. 192.
21. Deuel, H. J., Jr. 1957. *In* The Lipids. Interscience Publishers, Inc., New York. **3:** 454.
22. Murray, T. K., and H. C. Grice. 1961. *Can. J. Biochem. Physiol.* **39:** 1103.
23. Dowling, J. E., and G. Wald. 1960. *Proc. Intern. Congr. Biochem., 4th, Vienna.* **11:** 185.
24. Redfearn, E. R. 1960. *Arch. Biochem. Biophys.* **91:** 22[illegible].
25. Krishnamurthy, S., J. G. Bieri, and E. L. Andrews. 1963. *J. Nutr.* **79:** 503.
26. Dowling, J. E., and G. Wald. 1960. *Vitamins Hormones.* **18:** 515.

Firschein-'70
Bib. No. 2758

AMERICAN JOURNAL OF PHYSIOLOGY
Vol. 219, No. 5, November 1970 Printed in U.S.A.

Reproduced by permission
of the copyright owner

Collagen and mineral accretion rates in bone during vitamin A deficiency

H. E. FIRSCHEIN
Bone Research Laboratory, Division of Orthopedic Surgery, Department of Surgery, University of California at Los Angeles, School of Medicine, Los Angeles, California 90024

FIRSCHEIN, H. E. *Collagen and mineral accretion rates in bone during vitamin A deficiency.* Am. J. Physiol. 219(5): 1183–1187. 1970.—Vitamin A deficiency decreases the growth rate in rats. This model system can be used to test the validity of the Bauer, Carlsson, and Lindquist equations for calculating the mineral accretion rate. Vitamin A-deficient rats (and their controls) were injected with ^{85}Sr and L-proline-^{14}C. The rats were sacrificed at 2, 6, 18, and 24 hr after injection, and the rates of mineral formation and collagen synthesis were measured. The relative rates of collagen synthesis were estimated from the extent of the conversion of proline to hydroxyproline. Vitamin A deficiency decreased the ash, calcium, and hydroxyproline content of the bones. There was no change in the mineral:collagen ratio in the bones or in the serum calcium level. Vitamin A deficiency decreased the mineral accretion rate in the proximal end of the tibia and calvaria by 48.7 and 20.6%, respectively, and the rates of collagen synthesis by 39.8 and 19.9% in the same bones. Thus in this particular case, a close correlation was observed between the mineral accretion rate and the rate of synthesis of the collagen.

bone; collagen synthesis; hydroxyproline

THE DEVELOPMENT of methods for the measurement of the rate of calcium accretion in bone by Bauer, Carlsson, and Lindquist (2), Heaney and Whedon (10) and Aubert and Milhaud (1) has led to important advances in our present state of knowledge of bone metabolism. These methods involve the administration of a radioactive bone-seeking element, such as ^{47}Ca, or ^{85}Sr, and the subsequent measurement of the serum specific activity and the total radioactivity of specific bones (or the entire skeleton) at different time intervals after injection. From this data, it is possible to calculate an "accretion rate" in terms of milligrams Ca per hour. Jowsey (11), however, maintains that the uptake of mineral tracer by the skeleton is not a valid measurement of bone formation because of long-term exchange and secondary mineralization. This problem has been thoroughly studied by Lee, Marshall, and Sissons (12). These investigators showed that in areas of bone undergoing rapid growth or remodeling, the error due to the uptake of isotope by exchange into the diffuse component is small, and under these conditions the calcium accretion rate is a valid measurement of bone formation (as determined by tetracycline labeling).

One of the basic assumptions made by many investigators in this field is that studies of the calcium accretion rate reflect the metabolism of the organic phase of bone as well (7). The development of methods for the measurement of the rate of collagen synthesis in bone by Firschein (8, 9) affords us an opportunity to directly compare collagen and mineral accretion rates in the same bones. The procedure for the measurement of the rate of collagen synthesis is based upon the fact that collagen is the only protein found in bone that contains an appreciable amount of hydroxyproline, and the precursor of the hydroxyproline is actually proline (17, 18). The extent of conversion of proline to hydroxyproline is therefore a measure of the rate of collagen synthesis. Relative rates of collagen synthesis may be calculated from the percent of the injected dose of labeled proline that is converted to hydroxyproline.

In order to provide a test system in which one would expect to find a change in either the calcium accretion rate or the collagen accretion rate, the vitamin A-deficient rat was employed. Vitamin A deficiency is well known to result in an impaired growth rate (13), and any general inhibition of growth will be reflected in a decreased bone formation rate.

The histological changes in bone resulting from a deficiency of vitamin A have been described by Wolbach (20) and Mellanby (15). Dziewiatkowski (5) has reported that the uptake of both sulfate and phosphate by the bones of vitamin A-deficient rats was less than in normal rats and also has observed a decreased synthesis of chondroitin sulfate. It is difficult to extrapolate the effects of excess quantities of vitamin A upon bone resorption in tissue culture to a physiological, in vivo situation (6). The present studies were also undertaken in order to determine if vitamin A plays a role in the regulation of collagen and mineral metabolism in bone under physiological conditions.

METHODS

Weanling male rats (Sprague-Dawley strain) were fed either a vitamin A-deficient diet (Nutritional Biochemicals Corp.) or the same diet to which 40 units of vitamin A (as vitamin A acetate, gelatin-coated) per gram of diet had been added. A third group of rats were fed a normal diet (Purina Laboratory Chow). The animals were not pair fed. The vitamin A test diet contained 0.36% calcium and 0.46% inorganic phosphate (P) (fresh-weight basis) as compared with 1.1% calcium and 0.54% P for the normal diet. The rats were given distilled water to drink in order to avoid any possible effects of fluoride, which was present in the local water supply.

After 6 weeks on the vitamin A test diet, the animals were given simultaneous intraperitoneal injections of 5 μc of $^{85}Sr(NO_3)_2$ (specific activity 2,340 mc/g) and with 25 μc of L-proline-^{14}C (specific activity 8.8 mc/μmole), in isotonic saline, per 100 g of body weight. The animals on the normal diet did not receive any injections of isotopes and were just used for chemical analyses of the serum and bones. Cohn and Gusmano (4) have demonstrated that ^{85}Sr is a valid tracer for calcium in studies of bone metabolism, and this isotope has been used in numerous investigations for this purpose.

The rats were sacrificed by decapitation at periods of 2, 6, 18, and 24 hr after injection of the tracers, the blood was collected, and the femurs, tibias, and calvaria were removed. The proximal 20% of the tibia was measured and saved for subsequent analyses; the remainder of the tibia was discarded. Four animals were used at each time interval.

The femurs were dried at 110 C, weighed, and then ashed in a muffle furnace at 600 C. The proximal end of the tibias and the calvaria were dried, and then each bone sample was individually hydrolyzed in a sealed ampoule with 4 ml of 6 N HCl for 18 hr at 125 C. The hydrolysates were analyzed for their total calcium and hydroxyproline content and then counted in a scintillation well counter in order to determine ^{85}Sr radioactivity. A diluted aliquot of the solution used for injection was also counted at the same time as the bone hydrolysates and the results were expressed as a percentage of the injected dose. The serum samples were also counted for ^{85}Sr and analyzed for their calcium content. Hydroxyproline was isolated from the bone hydrolysates by chromatography on columns of Dowex 50W-X8, employing two different solvent systems. The isolated samples of hydroxyproline-^{14}C were then reanalyzed, and counted in a liquid scintillation counter. The results were corrected for quenching (3) and expressed as a percentage of the injected dose of proline-^{14}C.

Calcium was determined by atomic absorption (19), and hydroxyproline by oxidation with chloramine-T and coupling with Ehrlich's reagent (9). These methods have recently been reviewed in detail (8).

RESULTS

The rats placed on the vitamin A-deficient diet grew much more slowly than the rats fed the same diet containing added vitamin A. After 5 weeks on their respective diets, the average weight of the vitamin-deficient rats was 177 g, as compared with 216 g for the animals which had been fed the same diet with added vitamin A and 245 g for the animals on the normal diet. By the 6th week a number of the vitamin-deficient animals had failed to show any weight gain, and some had actually lost weight. At this point the animals were injected with the radioactive tracers.

The results of the chemical analyses on the serum and bones are shown in Table 1. The ash content of the femurs of the vitamin-deficient animals decreased by 12.4%, and the calcium content of the proximal end of the tibia and the calvaria decreased by 15.8 and 5.6%, respectively. These changes were all highly significant statistically and were not accompanied by any decrease in the serum calcium level. The hydroxyproline (hypro) content of the bones also decreased in the vitamin-deficient animals: 13.5% in the proximal end of the tibia and 9.6% in the calvaria. Although differences in the calcium and hydroxyproline content in the bones of the rats on the normal diet as compared with the rats on the vitamin A test diet with added vitamin A were observed, these changes were not consistent and are difficult to interpret.

In the proximal end of the tibia of the vitamin-deficient animals, where the changes in the calcium and hydroxyproline content were greatest, there was no change in the proportion of the mineral to the collagen (calcium:hydroxyproline ratio), and only a barely significant increase in this ratio of 4.6% in the calvaria.

The clearance of ^{85}Sr from the serum is shown in Fig. 1. The rate of removal of the tracer from the serum was much slower in the vitamin-deficient animals. Twenty-four hours after injection, there was a 57.4% difference in the serum specific activity values.

The difference in the rate of removal of mineral tracer from the serum is reflected in the radioactivity data for the proximal end of the tibia (Fig. 2). At all time intervals studied, the total radioactivity, when expressed as a percentage of the injected dose, was lower in the bones obtained from the vitamin-deficient animals. In the calvaria, however, exactly the opposite results were observed; the total radioactivity was higher in the calvaria obtained from the vitamin-deficient animals (Fig. 3).

It should be emphasized at this point that the animals were injected with the radioactive isotopes on a weight basis and that also these results are expressed as a percentage of the radioactivity actually injected into each animal. The

TABLE 1. *Chemical composition of serum and bone during vitamin A deficiency*

	Control Diet	Vitamin A Test Diet Plus A	Vitamin A Deficient Diet	P Values (−A vs. +A)
Serum, mg %	11.36 ± 0.08 (10)	10.96 ± 0.13 (15)	10.78 ± 0.06 (15)	NS
Femur, % ash	59.71 ± 0.22 (12)	59.22 ± 0.18 (12)	51.90 ± 0.54 (12)	<0.001
Proximal tibia, % Ca	19.17 ± 0.16 (22)	18.39 ± 0.16 (32)	15.90 ± 0.27 (32)	<0.001
Calvaria, % Ca	24.01 ± 0.47 (11)	22.39 ± 0.23 (16)	21.13 ± 0.39 (16)	<0.01
Proximal tibia, % hypro	2.74 ± 0.03 (22)	2.60 ± 0.03 (32)	2.25 ± 0.03 (32)	<0.001
Calvaria, % hypro	3.30 ± 0.08 (11)	3.22 ± 0.02 (16)	2.91 ± 0.03 (16)	<0.001
Proximal tibia, Ca/hypro	7.01 ± 0.08 (22)	7.31 ± 0.11 (32)	7.08 ± 0.12 (32)	NS
Calvaria, Ca/hypro	7.23 ± 0.05 (11)	6.95 ± 0.08 (16)	7.27 ± 0.12 (16)	<0.05

The chemical composition of the bones was calculated as a percentage of the dry weight. Values shown are means ± SE. Number in parentheses equals number of samples analyzed. P values were calculated by means of the t test. Hypro = hydroxyproline; NS = not significant.

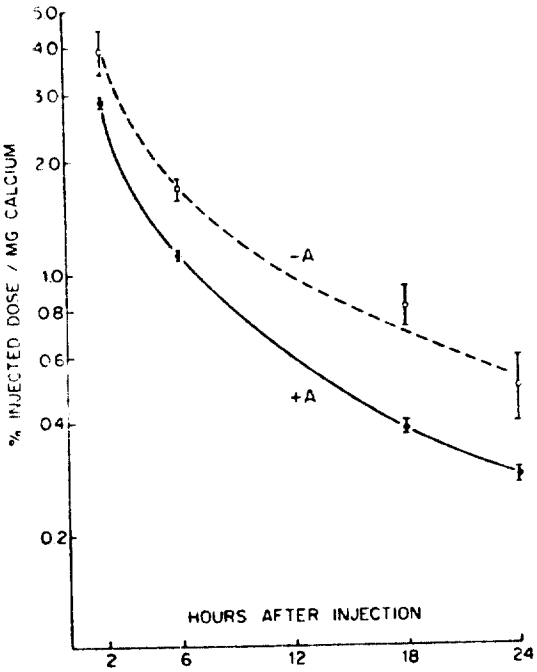

FIG. 1. Serum levels of ^{85}Sr in control and vitamin A-deficient rats.

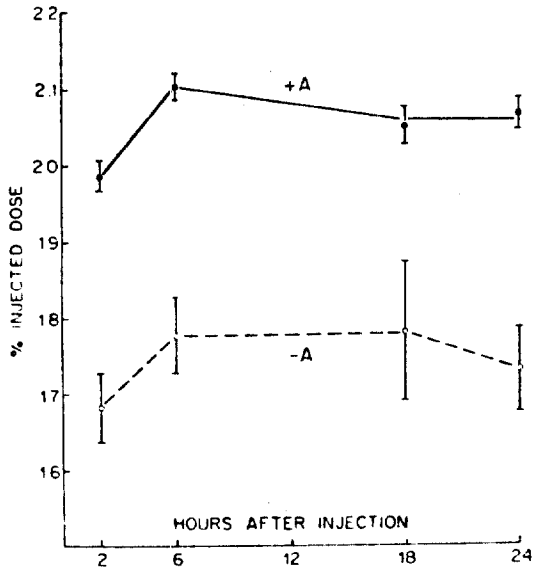

FIG. 2. Levels of ^{85}Sr in proximal end of tibias in control and vitamin A-deficient rats.

number of samples obtained for analysis is indicated in Table 1.

Part of the uptake of mineral tracer from the serum is due to accretion, and part is due to exchange. From the data shown above, the rates of calcium accretion and the size of the exchangeable calcium pool were calculated using the equations derived by Bauer, Carlsson, and Lindquist (2). The calculated values for the calcium accretion rate (A) and the exchangeable calcium pool (E) are shown in Table 2.

In both the proximal end of the tibia and the calvaria, vitamin A deficiency resulted in a decrease in the calcium accretion rate. In the proximal end of the tibia this decrease amounted to 48.7%, and 20.6% in the case of the calvaria.

The exchangeable calcium pool was calculated at both 6 and 18 hr after injection of the isotopes. For both the proximal end of the tibia and the calvaria, these values were identical at both time intervals. However, in the case of the proximal end of the tibia, vitamin A deficiency resulted in a decrease in the size of the exchangeable calcium pool of 29.4% but caused an increase of 43.3% in the calvaria.

In the proximal end of the tibia, the decrease in the exchangeable calcium pool in the vitamin-deficient rats paralleled the decrease in the calcium content. Thus, the exchangeable calcium pool constituted 4.13% of the total calcium in the case of the vitamin A-fed controls, and 3.79% in the case of the vitamin-deficient rats. In the calvaria, however, the situation was quite different. In this bone, the exchangeable calcium pool amounted to only 0.66% of the total calcium in the vitamin A-fed controls, but this value increased to 1.07% in the vitamin-deficient animals. This represents an increase in the proportion of exchangeable calcium of 62.1%.

The relative rates of collagen synthesis were calculated from the percent of the injected dose of proline-^{14}C that was converted to hydroxyproline-^{14}C (Figs. 4 and 5). The values (percent of the injected dose) obtained for both the proximal end of the tibia and the calvaria 2 hr after injection seem

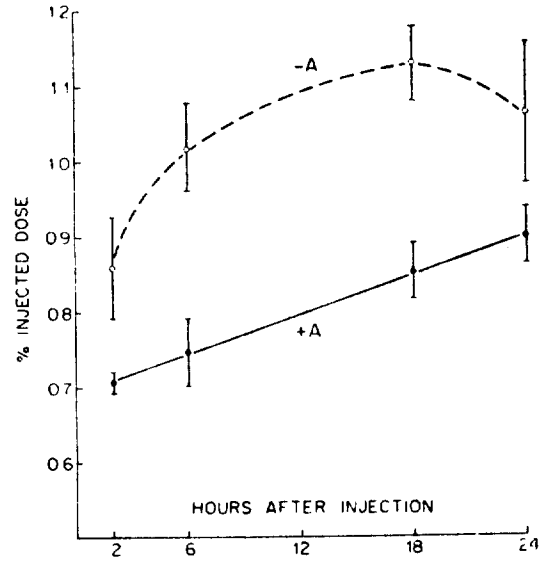

FIG. 3. Levels of ^{85}Sr in calvaria of control and vitamin A-deficient rats.

TABLE 2. *Calcium kinetics during vitamin A deficiency*

	Test Diet	
	(+) Vitamin A	(−) Vitamin A
Proximal Tibia		
Accretion rate (A), mg Ca/hr	0.076	0.039
Exchangeable Ca (E), mg Ca		
6-hr values	0.822	0.580
18-hr values	0.824	0.580
Calvaria		
Accretion rate (A), mg Ca/hr	0.034	0.027
Exchangeable Ca (E), mg Ca		
6-hr values	0.194	0.278
18-hr values	0.194	0.278

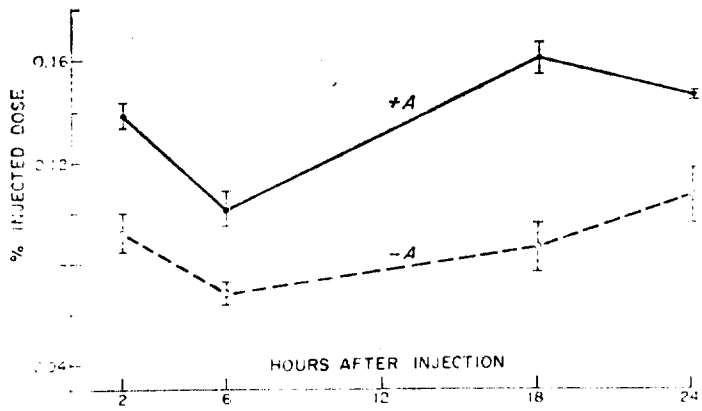

FIG. 4. Levels of hydroxyproline-^{14}C in proximal end of tibias in control and vitamin A-deficient rats.

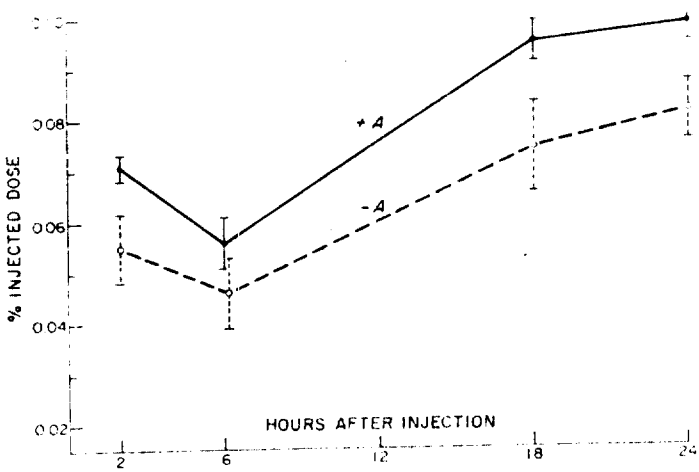

FIG. 5. Levels of hydroxyproline-^{14}C in calvaria of control and vitamin A-deficient rats.

TABLE 3. *Comparison of collagen and mineral accretion rates, percent decrease during vitamin A deficiency*

	Proximal Tibia	Calvaria
Mineral	48.7	20.6
Collagen	39.8	19.9

much too high and may be erroneous. Alternatively, this may also indicate that a certain fraction of the injected proline was rapidly converted to hydroxyproline, without incorporation into structural bone collagen, and may have been transported out of the bone rather quickly, while the synthesis of structural bone collagen proceeded at a somewhat slower pace. This combination of events could have resulted in the biphasic curves which were observed. It is not known which of these two possibilities is correct.

However, at all time intervals studied (including the 2-hr periods) less proline was converted to hydroxyproline in both the proximal end of the tibia and the calvaria in the vitamin-deficient animals. Using both the 6- and 18-hr values, the same time intervals that were used in the calculation of the calcium accretion rates, collagen synthesis was found to have decreased by an average of 39.8% in the proximal end of the tibia, and 19.9% in the calvaria. No attempt was made to isolate different collagen fractions from bone. These results therefore, just reflect an average rate of synthesis.

DISCUSSION

A direct comparison of the rates of collagen and mineral accretion in bone is shown in Table 3. Vitamin A deficiency depressed the mineral accretion rate by 48.7% in the proximal end of the tibia and 20.6% in the calvaria. The corresponding figures for the collagen are 39.8% in the proximal tibia and 19.9% in the calvaria. Since these were young growing animals, the error in calculating the calcium accretion rate due to the uptake of mineral tracer by exchange into the diffuse component must have been small (12). Thus under the conditions of this experiment, a close correlation was observed between the mineral accretion rate and the collagen accretion rate. This comparison is based upon the assumption that the size of the proline pool was the same in both groups of animals and that the total quantity of labeled hydroxyproline in the two groups is a valid measurement of the relative amounts of collagen synthesized.

In addition to the experiment reported here, two other experiments have been carried out in which the collagen and mineral accretion rates have been compared. All three of these experiments have yielded essentially the same results. In the first experiment (16), a comparison of the specific activity ratios of ^{47}Ca to hydroxyproline-^{14}C in various bone segments obtained 24 hr after the simultaneous injection of the radioactive tracers was made. In spite of the fact that the calcium accretion rate was obviously different in these bone segments, the specific activity ratios were identical, demonstrating that a close correlation exists between the collagen and mineral accretion rates. In the second experiment (8), the specific activity ratios (accretion ratio) obtained 24 hr after the simultaneous injection of the radioactive tracers into normal and phosphate-depleted rats were compared. Although the specific activity of both the mineral and the hydroxyproline was higher in the bones of the phosphate-depleted animals, the accretion ratios were identical, again demonstrating that a close correlation exists between the rates of collagen and mineral accretion under these experimental conditions.

Under these experimental conditions, a change in the collagen content of bone was followed by a change of similar magnitude in the mineral content. Although both the calcium and hydroxyproline content of the bones decreased due to vitamin A deficiency, there was no change in the calcium:hydroxyproline ratio. Such parallel changes in the collagen and mineral content of bone do not always occur. It was shown previously that the calcium:hydroxyproline ratio in the proximal end of the tibia decreased by 19% ($P < 0.001$) in phosphate-depleted rats (8). However, when the mineral:collagen ratio is changing, such as in a healing fracture, one may not observe any correlation between the mineral and collagen accretion rates (16). Thus caution is advised when attempts are made to extrapolate these results to other experimental or pathological conditions. In a given situation, where the mineral:collagen ratio is changing, a close correlation between the mineral and collagen accre

tion rates may still be observed, if the change in bone composition is due to altered resorption rates and not to altered accretion rates.

The calculated value for the calcium accretion rate observed in the proximal end of the tibia in the vitamin A-fed controls was 0.076 mg Ca/hr. This compares with a value of 0.193 in normal control rats observed by Lindquist et al. (14). In this latter study, the animals were fed a stock diet presumably similar to the control diet (Purina Laboratory Chow) used in this experiment. It was noted above that the rate of growth of the rats on the test diet with added vitamin A was less than the rate of growth of the rats on the normal stock diet. This could account for the difference in the accretion rate found in this study and that by Lindquist and coworkers (14).

The size of the exchangeable calcium pool, calculated from the experimental values obtained at either 6 or 18 hr after injection, showed very good agreement with each other (Table 2). In the proximal end of the tibia of the vitamin A-fed rats, the exchangeable calcium pool amounted to 4.13% of the total calcium. This compares with a value of 6.98% obtained by Lindquist et al. (14), 3.03% for the entire tibia, and 4.70% for the pooled ends (2). Thus the values obtained in this experiment for the calcium accretion rate and the size of the exchangeable calcium pool are reasonably close to the values obtained by other investigators.

The depression of the bone formation rate (collagen and mineral) observed during vitamin A deficiency does not necessarily indicate a specific effect of vitamin A upon bone. These differences could simply be due to a general depression of the rate of growth caused by a lowered dietary intake. However, one cannot explain the decrease in the calcium and hydroxyproline content, when expressed as a percentage of the dry weight, which was observed in the bones of the vitamin-deficient rats, upon the basis of a decreased growth rate. This might represent an effect of vitamin A upon bone, which would be in accord with the findings reported by other investigators (5, 6, 15, 20). These results must be repeated using pair-fed animals before any definite conclusion can be drawn.

The total evidence, both from this study, the work of Dziewiatkowski (5), and Fell (6), suggests that vitamin A may play an important role in regulating mucopolysaccharide, collagen, and mineral metabolism in bone.

This investigation was supported, in part, by Grants AM08978, AM14056, and Research Career Development Award K3AM21720 from the National Institute of Arthritis and Metabolic Diseases.

Received for publication 2 January 1970.

REFERENCES

1. Aubert, J. P., and G. Milhaud. Methode de mesure des principales voies du metabolisme calcique chez l'homme. *Biochim. Biophys. Acta* 39: 122–139, 1960.
2. Bauer, G. C. H., A. Carlsson, and B. Lindquist. Evaluation of accretion, resorption, and exchange reactions in the skeleton. *Kgl. Fysiograf. Sallskap. Lund. Forh.* 25: 1–16, 1955.
3. Bush, E. T. General applicability of the channels ratio method of measuring liquid scintillation counting efficiencies. *Anal. Chem.* 35: 1024–1029, 1963.
4. Cohn, S. H., and E. A. Gusmano. Kinetics of strontium and calcium skeletal metabolism in the rat. *Proc. Soc. Exptl. Biol. Med.* 126: 79–83, 1967.
5. Dziewiatkowski, D. D. Vitamin A and endochondral ossification in the rat as indicated by the use of sulfur-35 and phosphorus-32. *J. Exptl. Med.* 100: 11–24, 1954.
6. Fell, H. B. Some factors in the regulation of cell physiology in skeletal tissues. In: *Bone Biodynamics*, edited by H. M. Frost. Boston: Little, Brown, 1964, p. 189–207.
7. Firschein, H. E. Collagen turnover in calcified tissues. *Arch. Biochem. Biophys.* 119: 119–123, 1967.
8. Firschein, H. E. Collagen and mineral dynamics in bone. *Clin. Orthoped. Rel. Res.* 66: 212–225, 1969.
9. Firschein, H. E., and J. P. Shill. The determination of total hydroxyproline in urine and bone extracts. *Anal. Biochem.* 14: 296–304, 1966.
10. Heaney, R. P., and G. D. Whedon. Radiocalcium studies of bone formation rate in human metabolic bone disease. *J. Clin. Endocrinol. Metab.* 18: 1246–1267, 1958.
11. Jowsey, J., W. Lafferty, and J. Rabinowitz. Analysis of distribution of Ca^{45} in dog bone by a quantitative autoradiographic method. *J. Bone Joint Surg.* 47A: 359–370, 1965.
12. Lee, W. R., J. H. Marshall, and H. A. Sissons. Calcium accretion and bone formation in dogs. *J. Bone Joint Surg.* 47B: 157–180, 1965.
13. Lewis, J. M., O. Bodansky, K. G. Falk, and G. McGuire. Vitamin A requirements in the rat. The relation of vitamin A intake to growth and to concentration of vitamin A in the blood plasma, liver and retina. *J. Nutr.* 23: 351–363, 1942.
14. Lindquist, B., A. M. Budy, F. C. McLean, and J. L. Howard. Skeletal metabolism in estrogen-treated rats studied by means of Ca^{45}. *Endocrinology* 66: 100–111, 1960.
15. Mellanby, E. Skeletal changes affecting the nervous system produced in young dogs by diets deficient in vitamin A. *J. Physiol., London* 99: 467–486, 1941.
16. Shtacher, G., and H. E. Firschein. Collagen and mineral kinetics in bone after fracture. *Am. J. Physiol.* 213: 863–866, 1967.
17. Stetten, M. R. Some aspects of the metabolism of hydroxyproline, studied with the aid of isotopic nitrogen. *J. Biol. Chem.* 181: 31–37, 1949.
18. Stetten, M. R., and R. Schoenheimer. The metabolism of l(−)-proline studied with the aid of deuterium and isotopic nitrogen. *J. Biol. Chem.* 153: 113–132, 1944.
19. Willis, J. B. Determination of metals in blood serum by atomic absorption spectroscopy. I. Calcium. *Spectrochim. Acta* 16: 259–272, 1960.
20. Wolbach, S. B. Vitamin A deficiency and excess in relation to skeletal growth. *J. Bone Joint Surg.* 29: 171–192, 1947.

J. Dairy Sci. 53:1051-1057. 1970.

Frier-'70
Bib. No. 2924
Reproduced by permission
of the copyright owner

Rates of Formation and Absorption of Cerebrospinal Fluid in Mild Chronic Bovine Hypervitaminosis A[1]

H. I. FRIER, J. E. ROUSSEAU, JR., A. M. GALLINA,[2]
H. D. EATON, and R. C. HALL, JR.
Animal Nutrition, Animal Industries Department
George C. White Building and Institute of Nutrition and Food Science
University of Connecticut, Storrs 06268

Abstract

Ventriculocisternal perfusion was performed in 12 control calves and 12 calves fed a mildly toxic dose of vitamin A for 12 weeks. The average intraventricular cerebrospinal fluid pressures of these two groups of calves were, respectively, 48 and −14 mm of synthetic cerebrospinal fluid, with corresponding plasma vitamin A concentrations of 35.6 and 96.8 μg/100 ml. Linear regressions of bulk flow, Y, in grams per minute on the imposed ventriculocisternal perfusion pressure (either 0 or +200 mm of the initially determined intraventricular pressure in millimeters of synthetic cerebrospinal fluid), X, were for the control and hypervitaminotic A calves, respectively; $Y = -0.002 - 0.00177X$ and $Y = -0.004 - 0.00266X$, SD = 0.059 and bulk absorption, Y, in grams per minute, $Y = 0.25 + 0.00194X$ and $Y = 0.38 + 0.00239X$, SD = 0.07. Rates of formation of cerebrospinal fluid were greater in the hypervitaminotic A calves, 0.37 g/min versus 0.25 g/min in the controls, with a SD of 0.06, and were unaffected by the imposed ventriculocisternal perfusion pressure. The lower cerebrospinal fluid pressure occurring in relatively mild chronic hypervitaminosis A is, therefore, associated with greater bulk absorption of cerebrospinal fluid and decreased resistance to bulk absorption.

Received for publication October 31, 1969.

[1] Scientific Contribution no. 392, Storrs Agricultural Experiment Station, University of Connecticut, Storrs. This research was supported in part by Public Health Service Research Grant no. NB-02108 from The National Institute of Neurological Diseases and Stroke and by Training Grant no. GM 1199 from The National Institutes of Health.

[2] Present address: School of Veterinary Science and Medicine, Purdue University, Lafayette, Indiana 47907.

Introduction

Elevated cerebrospinal fluid (CSF) pressure occurs in the infant and adult ingesting excessive intakes of vitamin A (6). In contrast, lower CSF pressure has been reported in the calf, dog, and pig chronically fed hypervitaminotic A intakes (6). Hurt et al. (10) attributed the lower CSF pressure of the calf to a lowered rate of formation of CSF and possibly to decreased resistance to CSF absorption. The hypervitaminotic A calves in the latter experiment were fed 10,800 μg of vitamin A per kilogram of live weight per day which resulted in a relatively severe hypervitaminosis A. Of 12 calves fed the hypervitaminotic A intake, two succumbed prior to completion of the experiment apparently from congestive heart failure and accumulation of fluids within the pleural and abdominal cavities, and data were not obtained from another four due to respiratory arrest during ventriculocisternal perfusion.

This study was designed to produce a milder toxicosis with all the clinical signs indicative of vitamin A toxicity, including that of a decreased CSF pressure, but without the debilitative condition present in hypervitaminotic A calves of the experiment reported by Hurt et al. (10), and to estimate rates of formation and absorption of CSF by ventriculocisternal perfusion (1, 5) of these calves.

Experimental Procedure

Animals. From May, 1967, through November, 1968, 24 one-day-old Holstein male calves were obtained from various institutional and private herds in Connecticut. Each calf was subjected to a 21-week experimental period consisting of an initial growing period (0 through the 5th experimental week), a standardization period (6th through the 9th experimental week), and a comparison period (10th through the 21st experimental week). All animals in the experiment were maintained and fed as previously (10), except that at the beginning of the 10th experimental week each

calf, according to a random allotment, was fed per kilogram of live weight per day either a control intake of vitamin A acetate equivalent to 108 μg of vitamin A alchohol or a hypervitaminotic A intake of 8,800 μg. Also, feed offered was anticipated to produce a 5% gain in live weight each 7 days (1), instead of 60% of this amount as was offered in the experiment of Hurt et al. (10). Based on the statistics of Hazzard et al. (9), the hypervitaminotic A intake was anticipated to produce clinical signs of hypervitaminosis A but not the debilitation observed by Hurt et al. (10). Also, feed consumption was not anticipated to be affected by the hypervitaminotic A intake.

Ventriculocisternal perfusion, VCP. On either the 2nd or 4th day of the 21st experimental week, each animal was anesthetized with sodium pentobarbital (Norden Laboratories, Anesthesal, containing 64 mg/ml sodium pentobarbital diluted 1:1 with physiological, 0.85% NaCl, saline) via jugular puncture and was subjected to VCP at either the calf's initially determined lateral intraventricular CSF pressure or 200 mm synthetic CSF greater than the initially determined pressure. VCP of the calves was conducted as previously reported (10). Exceptions were the placement of a cannula into the rumen to eliminate any effects that intraruminal pressure might have on the CSF pressure of the calf, and an additional 10-minute effluent sample was collected.

Other observations and analyses. On the last day of the 10th experimental week and for the remaining weeks of the experiment, each animal was observed for various clinical signs of hypervitaminosis A.

Feed composition, feed consumption, growth measurements, plasma vitamin A levels, and pre- and post VCP serum osmolalities were measured as in previous experiments (1, 2, 10).

Average daily minimum and maximum barn temperatures for the comparison period were 22.5 and 27.6 C, with respective SE-s of 1.2 and 1.2 C. Light exposure, determined every four weeks for each animal during the comparison period, averaged 74 ± 10 lux.

Statistical analyses of criteria unrelated to actual VCP included estimation of variability between the control and hypervitaminotic A calves and calves within treatments (error) by analysis of variance. In regard to VCP data, the variability between controls and hypervitaminotic A calves, imposed pressures within each treatment group and calves within treatments (error) were also estimated by analysis of variance. Linear regressions, wherever applicable, were calculated for the response of VCP parameters on imposed VCP pressures (13).

Results

Comparison period. The statistics of the comparison period, the 10th through the 21st week, including feed offered, feed consumed and growth, are presented in Table 1. Growth gain in live weight (kg/day) and gain in height at withers (cm/day) was less ($P \leq 0.05$ and

TABLE 1. Feed consumption and growth for the comparison period.

Criteria	Vitamin A status: Control calves	Vitamin A status: Hypervitaminotic A calves	SD per calf
Animals (number)	12	12	–
Duration of comparison period (weeks)	12	12	–
Vitamin A intake (μg/kg live wt day)	108	8,800	–
Actual age, start of comparison period (days)	63	63	3
Feed (kg day)			
Offered	2.83	2.85	0.18
Consumed	2.80	2.77	0.25
Growth			
Live wt			
Start of comparison period (kg)	77	76	9
Gain (kg day)	0.83	0.67	0.07
Height at withers			
Start of comparison period (cm)	84.4	84.1	3.2
Gain (cm/day)	0.172	0.144	0.027

$P \leq 0.01$, respectively) in the hypervitaminotic A group. No significant difference was noted for feed consumption.

Additional statistics for the comparison period, including initial and terminal heart rates and rectal temperatures, are presented in Table 2. Although a trend was present for a greater mean terminal heart rate for the hypervitaminotic A group, the difference was of insufficient magnitude to be statistically significant at $P \leq 0.05$. A higher ($P \leq 0.01$) terminal rectal temperature was present for the group fed the toxic level of vitamin A. The initial, the comparison period, and the terminal plasma vitamin A concentrations are also presented in this table, the latter two with their respective ranges. The greater concentrations for the hypervitaminotic A group are indicative of vitamin A toxicity (10).

Clinical signs consisted of varying degrees of hyperemia of the anal, the inguinal, and the nasal mucosal areas and were observed in the hypervitaminotic A calves as early as the third week of the comparison period. The lesions became more pronounced as the comparison period progressed. Mild lameness and abnormal stance were evident late in the comparison period, not being observed until the 9th week. By the 12th week of the comparison period all 12 hypervitaminotic A calves exhibited retarded horn growth. These clinical signs were less severe than those of the calves in the previous experiment (10).

Ventriculocisternal perfusion. The statistics for the day of VCP of the control and hypervitaminotic A calves at their respective perfused pressures (either 0 or 200 mm of synthetic CSF greater than their initially determined lateral intraventricular pressure) are summarized in Table 3. Live weight on the day of VCP and the averages of the common logarithm of the intraventricular CSF pressure plus 100 were lower ($P \leq 0.01$) for the hypervitaminotic A group. The initial amounts of anesthetic required, calculated from live weight, for endotracheal intubation (induction) were less ($P \leq 0.01$) for the hypervitaminotic A calves, whereas the amounts of anesthetic required for maintenance of anesthesia (absence of corneal reflex) were not significantly different. Anesthesia time, respiratory rate, and respiratory tidal volume did not exhibit any statistically significant differences among treatments. The smaller tidal volumes for the hypervitaminotic A calves were a consequence of their lower live weight. The hypervitaminotic A group had a lower ($P \leq 0.01$) heart rate. Post-VCP serum osmolality was higher ($P \leq 0.01$) in the hypervitaminotic A calves.

Linear regressions with their respective standard deviations for outflow volume minus inflow volume ($\dot{V}_o - \dot{V}_i$) and clearance of inulin (C_{In}) expressed in grams per minute, Y, on the imposed VCP pressure, X, (at either 0 or 200 mm plus the initially determined lateral intraventricular CSF pressure, expressed in mm of synthetic CSF) and rates of formation, Y, in grams per minute are presented in Figure 1. Each point on this graph is representative of the individual calf's mean values for 60 through

TABLE 2. Heart rate, rectal temperature, and plasma vitamin A concentrations for comparison period.

Criteria	Vitamin A status: Control calves	Vitamin A status: Hypervitaminotic A calves	SD per calf
Heart rate (beats/min)			
Initial	106	99	26
Terminal	106	115	19
Rectal temperature (C)			
Initial	39.1	39.0	0.4
Terminal	38.7	39.2	0.4
Plasma vitamin A (μg/100 ml)			
Initial	30.9	30.1	5.2
Comparison period average	33.0 (28.9–38.4)[a]	93.0 (72.7–125.0)[a]	–
Terminal	35.6 (27.9–43.2)[a]	96.8 (42.4–124.8)[a]	–

[a] Range.

TABLE 3. Statistics for calves the day of ventriculocisternal perfusion.

Criteria	Control calves VCP pressure 0	Control calves VCP pressure +200	Hyper-A calves VCP pressure 0	Hyper-A calves VCP pressure +200	SD per calf
Animals (number)	6	6	6	6	–
Actual age (days)	149	148	150	143	4
Live wt day of VCP (kg)	149	147	128	128	12
Intraventricular cannula depth (mm)	45	47	42	42	2
Intraventricular CSF pressure (mm synthetic CSF)					
Actual	48	47	−3	−25	–
Log_{10} (mm +100)	2.17	2.12	1.94	1.86	0.18
Anesthetic required					
Induction (ml)	107	105	92	90	9
Maintenance (ml)	53	48	57	54	14
Total dose per unit live wt per unit time (ml/kg live wt/hr)	0.29	0.30	0.32	0.28	0.03
Time under anesthesia (hr)	3.8	3.5	3.7	4.0	0.25
Heart rate (beats/min)	154	152	129	126	16
Respiratory rate (cycles/min)	17	17	15	17	3
Respiratory pump tidal volume (ml)	1357	1267	1272	1214	231
Serum osmolality (mOsm/kg H_2O)					
Before VCP	289	290	291	290	3
After VCP	288	288	296	291	4

100 minutes of VCP with tracers and is representative of the steady state. $\dot{V}_o - \dot{V}_i$ was not significantly different between the two groups of calves at the 0-mm imposed VCP pressure. However, the response to the imposed VCP pressure of 200 mm of synthetic CSF was greater ($P \leq 0.01$) in the hypervitaminotic A calves. C_{In}, which is a measure of bulk CSF absorption, was greater ($P \leq 0.01$) in the hypervitaminotic A group. Although there was a greater positive slope in the hypervitaminotic A group with increasing VCP pressure, the difference between slopes was not of sufficient magnitude to be statistically significant ($P \leq 0.20$). The rate of CSF formation ($\dot{V}_f$) was greater ($P \leq 0.01$) in the hypervitaminotic A group.

Figure 2 represents the linear regressions for total creatine clearance ($C_{Cr,t}$), Y, in grams per minute on the imposed VCP pressure, X, and ventriculocisternal creatinine clearance ($C_{Cr,vc}$), Y, in grams per minute and ventriculocisternal distribution volume of inulin (VD_{In}), Y, in grams. The latter two VCP parameters were not related to imposed VCP pressure. Values for $C_{Cr,vc}$ and VD_{In} were not significantly different between the two groups of calves. Total creatinine clearances were greater ($P \leq 0.01$) and had a greater degree of positive slope ($P \leq 0.10$) for the hypervitaminotic A group.

Discussion

The lowered CSF pressure of the mild chronic hypervitaminotic A calf apparently can be attributed to alterations in bulk absorption of CSF. When the calves were perfused at their respective initially determined lateral intraventricular pressure (0 mm imposed CSF pressure), rates of formation of CSF ($\dot{V}_f$) for the control calves averaged 0.25 g/min and for the hypervitaminotic A calves 0.37 g/min. Rates of bulk absorption of CSF (C_{In}) averaged 0.25 g/min and 0.38 g/min, respectively. Thus, the increased rate of formation of CSF occurring in the hypervitaminotic A calves was equalled by a comparable increase in the rate of bulk absorption of CSF. When CSF pressure was elevated, as represented by the +200 mm VCP imposed pressure, the bulk absorption of CSF was increased for the control calves 0.00194 ± 0.00020 g/min/mm of synthetic CSF

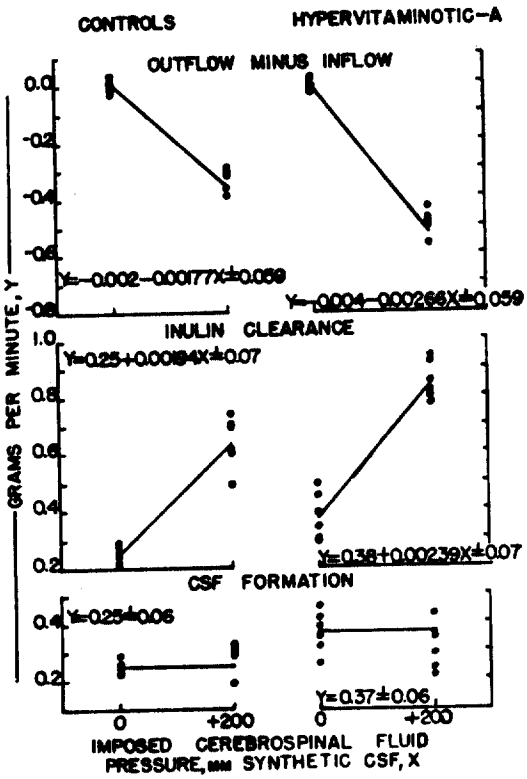

FIG. 1. Linear regressions of outflow volume minus inflow volume ($\dot{V}_o - \dot{V}_i$) and clearances of inulin (C_{in}) on imposed ventriculocisternal perfusion pressure and rates of formation ($\dot{V}_f$) of control and hypervitaminotic A calves.

and for the hypervitaminotic A calves 0.00239 ± 0.00020. Thus, the lower CSF pressure in mild hypervitaminosis A is attributed to the increased bulk absorption of CSF and to decreased resistance to bulk absorption. The results for the lowered resistance to bulk absorption agree with those of Hurt et al. (10), who fed hypervitaminotic A intakes which resulted in a more severe bovine hypervitaminosis A than that in our experiment.

The factors responsible for the increased bulk CSF absorption in hypervitaminosis A remain unknown. In the reverse situation, hypovitaminosis A, the increased CSF pressures have been attributed to increased resistance to bulk absorption (2). Cousins et al. (3) found in the vitamin A-deficient calf dura tissue, from the region of the tentorium cerebelli where arachnoid villi are abundant, greater concentrations of mucopolysaccharides and total RNA. These workers postulated that the greater mucopolysaccharide content of the intercellular connective tissue matrix in the dura mater was responsible directly (arachnoid villi) or indirectly (dura mater surrounding arachnoid granulations) for the increased resistance to CSF absorption in hypovitaminosis A. Employing electron microscopy, Hayes and McCombs (8) have attributed the defect to increased periodic acid-Schiff and toluidine blue-positive substances (presumably mucopolysaccharides) in arachnoid epithelial cells. If toxic intakes of vitamin A have an effect opposite to those of deficient intakes, then possibly a reduction of the mucopolysaccharide content in the arachnoid granulations or dura mater closely associated with these structures may be present. In addition, the dura mater itself may be physically thinner. These factors may, in part, provide information on direct cause (s) of the decreased CSF pressure in the hypervitaminotic A calf.

Of additional importance, Thomas and Pasternak (15) were unable to demonstrate a direct involvement of vitamin A in the synthesis of mucopolysaccharides. However, vitamin A may be involved in the degradation and turnover of mucopolysaccharides from cells. In fact, Danes

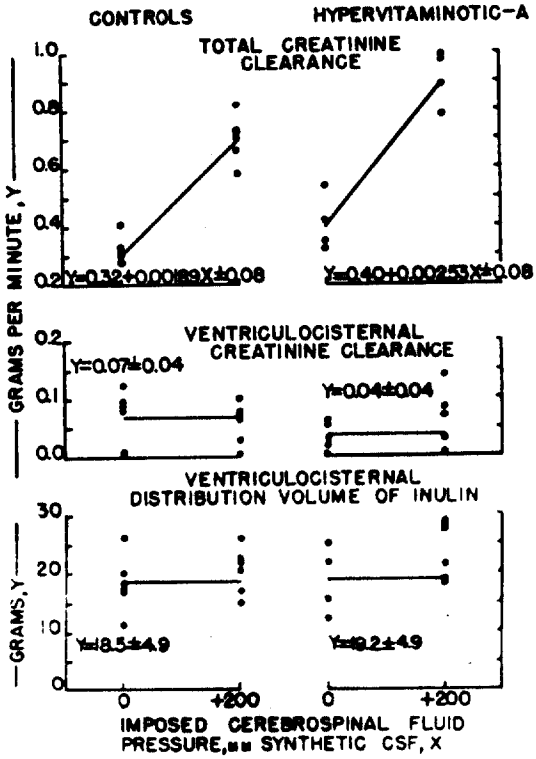

FIG. 2. Linear regressions of total creatinine clearances ($C_{cr,t}$) on imposed ventriculocisternal perfusion pressure and ventriculocisternal creatinine clearances ($C_{cr,vc}$) and ventriculocisternal distribution volume of inulin (VD_{in}) of control and hypervitaminotic A calves.

and Bearn (4) have postulated such and provided evidence for an increased urinary mucopolysaccharide excretion by administration of vitamin A to humans exhibiting the Hurler syndrome.

The greater values for rates of formation in the hypervitaminotic A group were opposite to those reported previously (10). This possible discrepancy may be explained by the effect that large intakes of vitamin A may have on CSF production. For example, the cardiac glycoside, ouabain, can inhibit (high doses) and stimulate (low doses) both the magnesium-dependent, sodium-potassium-activated ATPase enzyme system in the brain choroid plexuses of the cat and the rates of formation of cerebrospinal fluid (12, 16). Although the biphasic mechanisms involved in these responses (12) are not fully understood, there is a direct association between activities of the enzyme system and CSF production (12, 16). Since ATPase activities in brain, liver, heart, and lungs (14) and in erythrocyte ghosts (11) are affected by excessive vitamin A, and other enzyme systems (5) associated with CSF production also may be affected, the difference in rates of formation between the present experiment and the previous one (10) possibly may be explained by their differing levels of toxicity. In addition to these considerations, the restriction of feed intake by Hurt et al. (10) to 60% of that in our experiment may have altered the metabolic rate to such an extent that the animal's ability to detoxify the excess vitamin A fed was considerably less than that of the calves in our experiment. Plasma vitamin A levels of the hypervitaminotic A calves in the experiment of Hurt et al. (10) were approximately 25% greater than those of the calves of the present experiment. Such an increase would not be expected from a previous regression estimate of plasma vitamin A response to $\log_{10}$ vitamin A intake of calves fed a ration intake (9) similar to that of the present experiment.

The purpose for including creatinine as a tracer in the synthetic CSF was to provide information as to the possible effect of mild vitamin A toxicity on the passive diffusion across the ependyma of the ventricles (1). No statistically significant difference was observed in the ventriculocisternal creatinine clearances ($C_{cr,vc}$); therefore, permeability of the ventricular ependyma remains unaffected in mild chronic hypervitaminosis A. The magnitude of the increasing positive slopes for total creatinine clearances ($C_{cr,t}$) of the control and hypervitaminotic A calves followed the same trend as for C_{In} and supports the observation of an increased bulk absorption of CSF in the hypervitaminotic A calf.

No evidence was provided in this study for the presence of dilated ventricles. Although the ventriculocisternal distribution volumes of inulin were slightly greater in the hypervitaminotic A group, no significant differences were present. The difference between these observations and those of previous studies (7, 10) can be attributed to the mild hypervitaminosis A of the present study and the severe hypervitaminosis A of the previous ones (7, 10).

Acknowledgments

The authors are indebted to B. A. Donohue and T. Watts, Sr. for diligent care of the calves, to T. M. Dwyer, Susan Donoghue, and Mrs. Mae Miller for excellent technical assistance, to Dr. R. H. Bunnell of Hoffmann-La Roche, Nutley, New Jersey, for the vitamin A supplement, and to the Clinton Corn Processing Co., a Division of Standard Brands Inc., Clinton, Iowa, for the irradiated dry yeast used in the vitamin A depletion ration. H. D. Hurt made helpful suggestions during preparation of the manuscript.

References

(1) Calhoun, M. C., H. D. Hurt, H. D. Eaton, J. E. Rousseau, Jr., and R. C. Hall, Jr. 1967. Rates of formation and absorption of cerebrospinal fluid in Holstein male calves. University of Connecticut Agr. Exp. Sta., Bull. 401.

(2) Calhoun, M. C., H. D. Hurt, H. D. Eaton, J. E. Rousseau, Jr., and R. C. Hall, Jr. 1967. Rates of formation and absorption of cerebrospinal fluid in bovine hypovitaminosis A. J. Dairy Sci., 50:1486.

(3) Cousins, R. J., H. D. Eaton, J. E. Rousseau, Jr., and R. C. Hall, Jr. 1969. Biochemical constituents of the dura mater in vitamin A deficiency. J. Nutrition, 97:409.

(4) Danes, B. S., and A. G. Bearn. 1967. The effect of retinol (vitamin-A alcohol) on the urinary excretion of mucopolysaccharides in the Hurler syndrome. Lancet, 1:1029.

(5) Davson, H. 1967. Physiology of the Cerebrospinal Fluid. Chap. 6. Little, Brown and Company, Boston.

(6) Eaton, H. D. 1969. Chronic bovine hypo- and hypervitaminosis A and cerebrospinal fluid pressure. Amer. J. Clin. Nutrition, 22:1070.

(7) Grey, R. M., S. W. Nielsen, J. E. Rousseau, Jr., M. C. Calhoun, and H. D. Eaton. 1965. Pathology of skull, radius and rib in hypervitaminosis A of young calves. Pathol. Vet., 2:446.

(8) Hayes, K. C., and H. L. McCombs. 1969. Fine structure of the arachnoid granula-

tions in vitamin A deficiency. (Abstr.) Federation Proc., 28:489.

(9) Hazzard, D. G., C. G. Woelfel, M. C. Calhoun, J. E. Rousseau, Jr., H. D. Eaton, S. W. Nielsen, R. M. Grey, and J. J. Lucas. 1964. Chronic hypervitaminosis A in Holstein male calves. J. Dairy Sci., 47:391.

(10) Hurt, H. D., H. D. Eaton, J. E. Rousseau, Jr., and R. C. Hall, Jr. 1967. Rates of formation and absorption of cerebrospinal fluid in chronic bovine hypervitaminosis A. J. Dairy Sci., 50:1941.

(11) Kameyama, N. 1967. Inhibitory effect of excess vitamin A on membrane ATPase. J. Fac. Sci. Univ. Tokyo, Sect. IV, 11:181. [Chem. Abstr., 71:1201u, 1969.]

(12) Oppelt, W. W., and R. F. Palmer. 1966. Stimulation of cerebrospinal fluid production by low doses of intraventricular ouabain. J. Pharm. Exptl. Therapy, 154: 581.

(13) Ostle, B. 1964. Statistics in Research. 2nd ed. The Iowa State University Press, Ames.

(14) Ostolovskii, E. M. 1969. Adenosinetriphosphatase activity in rat organs following massive doses of vitamin A and nicotinic acid. Vop. P. Tan. 28:27. [Chem. Abstr., 70:85411c, 1969.]

(15) Thomas, D. B., and C. A. Pasternak. 1969. Vitamin A and the biosynthesis of sulphated mucopolysaccharides. Biochem. J., 111:407.

(16) Vates, T. S., S. L. Bonting, and W. W. Oppelt. 1964. Na-K activating ATPase and formation of cerebrospinal fluid in the cat. Amer. J. Physiol., 206:1165.

Ganguly-'69
Bib. No. 3047

Reproduced by permission
of the copyright owner

THE AMERICAN JOURNAL OF CLINICAL NUTRITION
Vol. 22, No. 7, July, 1969, pp. 923-933
Printed in U.S.A.

Absorption of Vitamin A

JAGANNATH GANGULY[1]

THE PRESENT AUTHOR had summarized earlier work on absorption of vitamin A at the "International Symposium on Vitamin A and Metabolism" held in Burgenstock in 1960 (1). All that could be said at that time was that the dietary retinyl esters undergo extensive hydrolysis in the lumen of the small intestine of rats and other species of animals and that vitamin A is absorbed through the lymphatic system, as its esters. Since then, considerable progress has been made regarding several aspects of absorption of vitamin A. In the past, absorption of vitamin A meant absorption of retinol and its esters, but now it includes absorption of retinal and retinoic acid also. Moreover, later work has shown that vitamin A is not absorbed through the lymphatic system alone, significant amounts of it being absorbed through the portal route also, which is quite contrary to the well-established concepts of absorption of vitamin A. During our work on absorption of vitamin A, we have often tried to compare it with that of cholesterol, and, in doing so, we have come across several significant points of difference in this respect. Attempts will be made here to summarize relevant information regarding these points and bring them up to date.

HYDROLYSIS AND SYNTHESIS OF RETINYL ESTERS, DURING ABSORPTION

As already stated, it was generally known that during absorption dietary retinyl esters undergo extensive hydrolysis in the lumen of the small intestine. But it used to be the general belief that this reaction was carried out by the pancreatic lipase. However, it was eventually shown that rat pancreas secreted highly active enzymes, retinyl ester hydrolase and cholesteryl ester hydrolase, which were responsible for the hydrolysis of the dietary retinyl esters and cholesteryl esters, respectively. These enzymes were found to be distinct from each other and from the pancreatic lipase. Similarly, the pancreatic retinyl ester synthetase was shown to be different from the cholesteryl ester synthetase (2).

Our work further showed that rat intestinal mucosa also contained these enzymes and that the mucosal enzymes were not of pancreatic origin. During the course of our work, when everted intestinal sacs of rats were incubated with retinyl esters or with retinol plus fatty acids, rapid hydrolysis, but no synthesis, of retinyl esters took place in the medium. Inclusion of compounds like TEPP (tetraethylpyrophosphate) or DFP (di-isopropylfluorophosphate), which are powerful inhibitors for retinyl ester hydrolase, led to almost complete inhibition of hydrolysis of the medium esters (3). Similarly, when cholesteryl oleate or cholesterol plus oleic acid was included in the incubation medium, rapid hydrolysis, but no synthesis, of the steryl ester took place (4).

These observations led us to the tentative conclusion that the hydrolases are situated on the outer surface of the mucosal cell membrane. In the meantime a method for the isolation of the brush border of the mucosal cell of hamster intestine was described by Miller and Crane (5). When the brush border of rat intestine was isolated by employment of this pro-

[1] Professor of Biochemistry, Indian Institute of Science, Bangalore, India.

cedure, it was found to contain virtually all of the cholesteryl ester hydrolase and the bulk of the retinyl ester hydrolase of the whole mucosal cell. It contained significant amounts of the two synthetase activities also; the rest of all these activities were located in the interior of the cell (4, 6). Therefore, it appears that the two hydrolases of the brush border are situated on its outer surface and are oriented in such a way that they can come into direct contact with their substrates. The two synthetases of the brush border, on the other hand, must be oriented towards the interior of the cell (4). The significance of these observations will be discussed later on.

ABSORPTION OF VITAMIN A

Retinol and Retinyl Esters

At the initial stages of our work, when rats and chickens were fed retinol, its acetate or palmitate esters, extensive hydrolysis of the fed esters and certain amounts of esterification of retinol were found to take place in the lumen of the small intestine of both species. However, irrespective of whether retinol or retinyl palmitate was fed, the bulk of the vitamin A of the intestinal mucosa was in the esterified state, and on fractionation of the mucosal cell most of the esters were localized in the supernatant fraction (7). Later on, rats were fed retinyl acetate, after which the retinyl esters isolated from various tissues were resolved by reverse-phase chromatography into the higher and lower esters of retinol. Excepting the intestinal mucosa, all tissues analyzed contained only higher esters of retinol. In addition to containing large amounts of higher esters of retinol, the mucosa contained small amounts of retinyl acetate also, and it was suggested by us that probably the acetate is adsorbed on the outer surface of the mucosal cell (8). At about the same time Kaiser and Kagan (9) also showed that the retinyl esters in animal body are composed of higher fatty acids. Therefore, there was some evidence that, during absorption, at least retinyl acetate is hydrolyzed and that the retinol formed is reesterified with higher fatty acids. The higher ester was eventually identified to be mostly palmitate (10).

In later experiments (11), rats were fed acetate, stearate, laurate, palmitate, and linoleate esters of retinol dissolved in groundnut oil, after which, at the time of active absorption, the ester fraction of the mucosa was resolved into various higher esters of retinol. In all cases, irrespective of the type of ester fed, palmitate was the most abundant of all esters in the mucosa. Here also, it was not possible to detect more than trace amounts of the fed ester in the mucosa. Therefore, here we had further evidence that other esters also are similarly hydrolyzed before absorption into the mucosal cell.

In another series of experiments, where rats were given retinol dissolved in carriers of different fatty acid composition, resolution of the higher esters of retinol of the intestinal mucosa, at the time of active absorption, showed that in all cases it contained largely retinyl palmitate, with appreciable amounts of other esters, that reflected the fatty acid composition of the carrier used. However, when the carrier did not contain any exogenous fatty acids, e.g., colloidal dispersions, considerable amounts of retinyl esters were always present in the mucosal cell, but here the bulk of the esters was invariably palmitate (10). Obviously, the fatty acids readily available in the mucosa are utilized for reesterification, while the palmitic acid is probably donated by the triglycerides and phospholipids of the mucosal cell.

That retinyl esters are not absorbed into the mucosal cells, unless they are hydrolyzed, was further proved by using everted intestinal sacs of rats. When such sacs were incubated in dispersions containing retinol or retinyl esters in the medium,

TABLE I

Effect of tetraethylpyrophosphate and di-isopropylfluorophosphate on the uptake of different forms of vitamin A by everted intestinal sacs of rats

Form of vitamin A in medium	Incubation medium vitamin A, μg		Intestinal mucosa vitamin A, μg					
			Particulate fraction			Supernatant fracton		
	ME	AL	ME	P	AL	ME	P	AL
Retinol								
Without TEPP	32	3,300	0	40	214	0	78	37
With TEPP	20	3,300	0	38	222	0	66	39
Retinyl acetate								
Without TEPP	2,300	785	28	41	256	13	94	41
With TEPP	2,100	30	150	2	18	53	10	13
Retinyl stearate								
Without TEPP	2,800	253	0	9	63	7	48	4
With TEPP	3,000	240	10	8	58	6	53	7
Without DFP	2,900	260	3	10	65	7	57	7
With DFP	3,100	25	93	2	6	13	6	2

ME = medium ester; P = retinyl palmitate, AL = retinol, TEPP = tetraethylpyrophosphate, and DFP = di-isopropylfluorophosphate. Adapted from Mahadevan et al. (3).

there was not only rapid hydrolysis of the medium ester, but also in both cases considerable amounts of retinol and its esters appeared in the sac. When organophosphorus compounds, like TEPP or DFP, which powerfully inhibit retinyl ester hydrolase, were introduced into the incubation medium containing retinyl esters, the result was the appearance of very little retinol in the medium as well as in the sac, and as a consequence, very little retinol or retinyl palmitate appeared in the cell. However, when retinol was used, its uptake and conversion into palmitate remained unaffected by the presence or absence of these inhibitors (3). The results of these experiments, as summarized in Table I, therefore, confirmed that the retinyl ester hydrolase of the mucosa is exposed to the lumen of the small intestine, so that it comes into direct contact with its substrates as well as inhibitors. It should be obvious that these results also showed that hydrolysis of the retinyl esters was a prerequisite for their absorption into the cell.

In yet another set of experiments (11) rats were fed retinol or its acetate, laurate, stearate, palmitate, or linoleate esters, after which, at the time of active absorption, the mucosa was fractionated into the particulate and supernatant fractions. In all cases, the particulate fraction was found to contain the bulk of the retinol, while the supernatant contained most of the esters, the bulk of which was palmitate (Table II). Similar fractionation of the mucosal cell, following incubation of everted intestinal sacs with retinol or retinyl esters in the medium, led to a recovery of most of the retinol of the cell in the particulate fraction, while a major portion of the esters was concentrated in the supernatant fraction, mostly in the form of palmitate (Table III) (3).

At the time this work was being carried out no satisfactory method for the isolation of the brush border was available, and, during the fractionation of the whole mucosa, as carried out in the above experiments, this outermost structure of the mucosal cell sedimented along with the particulate materials. Although in recent years electron microscopy has revealed

TABLE II

Distribution of retinol and its esters between particulate and supernatant fractions of ho[illegible] nates of intestinal mucosa of rats 2–3 hr after feeding retinol or its esters in groundnut[illegible]

Form of vitamin A fed	Particulate fraction						Supernatant fraction					
	Ester, μg					Alcohol, μg	Ester, μg					Alc[illegible]
	A	S	P	M	L		A	S	P	M	L	
Alcohol	0	6	25	15	3	284	0	4	90	5	3	[illegible]
Acetate	24	2	22	5	1	252	14	1	73	2	0	[illegible]
Laurate	0	1	26	4	10	145	0	0	71	1	3	[illegible]
Stearate	0	9	17	2	3	135	0	4	62	2	1	[illegible]
Palmitate	0	3	19	1	2	142	0	3	74	2	1	[illegible]
Linoleate	0	2	28	8	2	129	0	2	68	3	0	[illegible]

A = acetate, S = stearate, P = palmitate, M = myristate, and L = laurate est[illegible] retinol. Adapted from Mahadevan et al. (11).

the existence of a well-organized ultrastructure of the brush border on the mucosal cell, due to the nonavailability of a suitable method of isolation, its precise role in absorption in general had remained unknown. As has been mentioned already, very recently such a method has been described by Miller and Crane (5), which made it possible for us to investigate its role in absorption of cholesterol and vitamin A; it also has been discussed that the brush border isolated from rat intestine was found to contain virtually all of the cholesteryl ester hydrolase and significant amounts of the retinyl ester hydrolase of the whole mucosa, while at the same time it also contained certain amounts of the two synthetase activities.

At about the same time a rather unique concept in the intraluminal phase of absorption of lipids was introduced by Hofmann and Börgstrom (12). Thus, it was shown by these workers that during intraluminal digestion triglycerides are mostly hydrolyzed by the pancreatic lipase to the 2-monoglyceride stage. The monoglyceride then forms a water-clear micellar solution with bile salts and free fatty acids, and from such a micellar solution the products of lipolysis diffuse into the mucosa to be reesterified into triglycerides on the endoplasmic reticulum of the cell. This eleg[illegible] work immediately gave a new orientat[illegible] to our thinking, because it appeared to[illegible] that probably all lipids are similarly m[illegible] water soluble before they can be absorb[illegible] into the mucosal cell. In the light of th[illegible] new developments a fresh approach to o[illegible] work was made, and in planning our e[illegible]periments we chose to use both cholesteryl and retinyl esters, because it was know[illegible] that both compounds are absorbed into th[illegible]

TABLE III

Uptake of retinol and its esters by e[illegible] intestinal sacs of rats

Vitamin A introduced	Medium vitamin A, μg			Vitamin A in muc[illegible]			
				Particulate			Sup[illegible] nat[illegible]
	ME	P	AL	ME	P	AL	M[illegible]
Alcohol		10	2,205		38	200	[illegible]
Acetate	1,125	16	630	27	26	225	1.[illegible]
Laurate	2,997	9	293	10	4	57	6.[illegible]
Stearate	3,015	7	245	6	6	66	7.[illegible]
Linoleate	3,125	4	277	5	6	45	7.[illegible]
Palmitate		2,925	255		8	62	[illegible]

ME = ester of incubation medium, P = ret[illegible] palmitate, and AL = retinol. Adapted [illegible] Mahadevan et al. (3).

TABLE IV

Distribution of cholesterol and vitamin A in contents and brush border of small intestine of rats fed 4-^{14}C-cholesteryl oleate and retinyl acetate

	Cholesterol		Vitamin A, μg	
	Unesterified	Esterified	Retinol	Retinyl esters
Intestinal contents				
Fat layer	555[a] (0.100)[b]	1,150 (0.200)	20	28
Micelle	790 (0.340)	Nil	26	14
Brush border	320 (2.01)	Nil	45	20
Nonparticulate supernatant			9.1	21

Adapted from David and Ganguly (6). [a] Counts per minute. [b] Chemically determined cholesterol in milligrams.

TABLE V

Retinyl ester composition of intestinal contents, brush border, and nonparticulate fraction of intestinal mucosa of rats fed 3 mg retinyl acetate

	30 min		120 min	
	Acetate, μg	Higher esters, μg	Acetate, μg	Higher esters, μg
Intestinal contents				
Fat layer	68	14	53	76
Micelle	10	10	22	18
Brush border	25	Nil	20	10
Nonparticulate supernatant	Nil	10	Nil	20

Adapted from David and Ganguly (6).

mucosal cell only after they are totally deesterified.

Rats were fed free or esterified cholesterol, after which, at the time of active absorption, the brush border was separated from the rest of the mucosal cell. Subsequent analysis showed that the brush border contained large amounts of cholesterol, in the unesterified state, with no traces of steryl esters being present there, while the rest of the cell contained some esters, although most of the cholesterol was in the unesterified state (4). In later experiments (6) rats were fed retinyl acetate and 4-^{14}C-cholesteryl oleate, after which, at the time of active absorption the intestinal contents were separated into the micellar and fat phases, while at the same time the brush border was separated from the rest of the mucosal cell. The cholesterol fraction was resolved into esterified and unesterified sterol, while the vitamin A was resolved into retinol, retinyl acetate, and higher esters of retinol. It is shown in Table IV that, in the intestinal contents, the micellar phase contained large amounts of unesterified cholesterol with absolutely no traces of ester cholesterol, while in contrast, both retinol and retinyl esters were present there. The fat layer, on the other hand, contained both esterified and unesterified cholesterol, as also both retinol and its esters. The brush border isolated from these rats showed total absence of esterified cholesterol, although the labeled sterol rapidly appeared there, in the unesterified state. In sharp contrast, the brush border was not only rich in retinol, but it contained some amounts of retinyl esters also; at 30 min after the dose it contained only retinyl acetate, while at 120 min both acetate and higher esters of retinol were present there. The particulate free supernatant fraction of the cell, on the other hand, never contained acetate, but always had higher esters of retinol. These results are assembled in Table V.

These results thus not only clearly showed the importance of micellar solubilization of these two lipids in their absorption, but they also suggested some important role of the brush border in this respect. The sequence of events in the absorption of the two lipids, therefore, appears to be as follows.

The dietary cholesteryl esters are hydrolyzed by the powerful pancreatic choles-

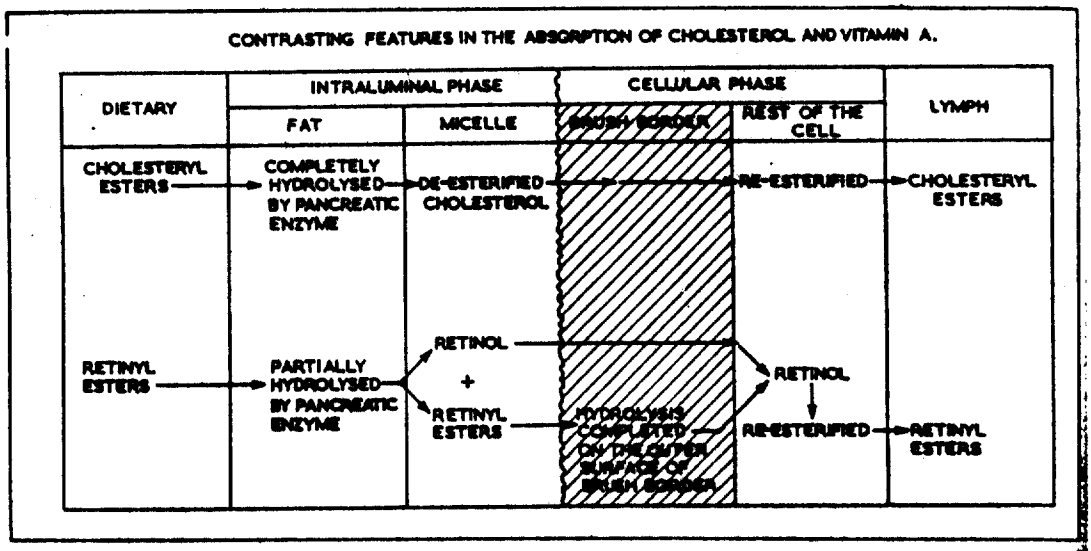

FIG. 1.

teryl ester hydrolase, while they are in the fat phase, after which the deesterified sterol appears in micellar solution. From such micellar solution the brush border rapidly picks up the sterol and transfers it inside the cell, where it is reesterified for eventual transport through the lymph. In contrast, the dietary retinyl esters are partially hydrolyzed by the pancreatic hydrolase, while they are in the fat phase, after which both retinol and its esters appear in micellar solution. From the micelle the brush border readily picks up both retinol and its esters; the retinol is directly admitted into the cell, while its esters are hydrolyzed by the hydrolase situated on the outer surface of the brush border, after which the retinol is transferred inside the cell. Here also, the alcohol is reesterified inside the cell to be eventually transported through the lymph. This is schematically presented in Fig. 1.

It should, however, be mentioned here that the mechanism outlined above operates in the living rat under normal conditions. Thus, our very recent work has shown that at 0 C, a temperature at which the retinyl ester hydrolase and synthetase become less active, large amounts of retinyl acetate can cross the brush border and enter the mucosal cell unchanged. In these experiments everted intestinal sacs of rats were incubated for 30 min at 0 C in a dispersion containing retinyl acetate, after which the sacs were thoroughly washed with buffer and reincubated in the buffer at 0 C for another 30 min. When the cells of these sacs were fractionated into the brush border and "the rest of the cell" fractions, most of the vitamin A was found in the latter cell fraction and was still in the form of retinyl acetate. In contrast, when the reincubation was carried out at 37 C for 30 min, most of the retinyl acetate of the cell was converted into the palmitate. Therefore, it appears that, in the living animal, soon after the retinyl acetate is picked up by the mucosal cell, the powerful hydrolase of the brush border hydrolyzes it and thereby does not allow it to enter the cell unchanged.

Also, a certain amount of species difference seems to exist in the general functioning of the above mechanism, because it has been reported that chicks can absorb small amounts of retinyl acetate, without prior hydrolysis (13). Our unpublished observations also have indicated that, when

TABLE VI

Absorption of 5 mg of retinal in rats

Time, min	Intestine			Blood, μg/5 ml	Liver, μg/organ
	Contents, μg	Mucosa, μg	Muscles, μg		
30					
Retinol + esters	8.0	31.5	9.5	47.0	54.0
Retinal	270	147	17.7	11.0	1.5
150					
Retinol + esters	5.0	56.2	16.0	73.0	201
Retinal	257	182	18.0	25.0	4.0

Adapted from Deshmukh et al. (15).

TABLE VII

Intracellular distribution of vitamin A in rat mucosa at 2 hr after feeding 5 mg of retinal

Mucosal fraction	Retinyl esters, μg	Retinol, μg	Retinal, μg
Nuclear + mitochondrial	7.5	2.5	72.0
Microsomal	5.0	2.5	43.0
Supernatant	35.0	2.0	67.0

Adapted from Deshmukh et al. (15).

retinyl acetate is fed to chickens, small amounts of the acetate can be found in several tissues of this species.

Retinal

While significant progress has been made regarding absorption of retinol and its esters, not much work seems to have been done on the absorption of retinal. Probably the only significant report on absorption of retinal was by Glover et al. (14), who had claimed that, following oral administration of retinal, it could not be detected in the intestinal wall, blood, and liver of rats, while large amounts of retinol and its esters were found in these tissues. It was, therefore, suggested by these workers that the aldehyde is not absorbed unchanged and that during absorption it is reduced to the alcohol form in the intestinal wall.

Since this work of Glover et al. (14), great advances have been made in the techniques of purification of small amounts of retinol derivatives in the presence of large quantities of lipid impurities. Thus, introduction of reverse-phase and thin-layer chromatography has greatly improved our ability to purify and characterize small amounts of these compounds, when extracted from biological materials.

In our experiments (15), rats were fed retinal, after which their tissues were analyzed for various retinol derivatives, using these newer techniques. It is shown in Table VI that not only appreciable amounts of retinol and its esters appeared in the mucosal cell, but large amounts of retinal also appeared there, and that, compared to retinol and its esters, the concentrations of retinal were much higher. It will also be seen that retinal was not only absorbed into the mucosal cell, but significant amounts of it were also found in the intestinal muscles, blood, and liver of the rats, which obviously proved that certain proportions of it are absorbed into the body in the unchanged form. That the compound is retinal was conclusively proved on the basis of its behavior during reverse-phase and thin-layer chromatography, and from its spectral properties.

We had previously shown that rat liver contains highly active retinol dehydrogenase and retinal oxidase (16). Later on, we demonstrated the presence of these enzymes in the intestinal mucosa of rats (17). Yet, in the above experiments, following feeding of retinal, we could never demonstrate the presence of retinoic acid in the intestine of rats, although large amounts of retinal, and of retinol and its esters were found there. Investigations on the intracellular distribution of the retinal of the mucosa, as presented in Table VII, clearly showed that the bulk of the retinal of the

mucosa had actually entered the cell. Therefore, we were confronted with the situation that the mucosal cell contains rather active retinal oxidase, and yet, apparently it was not active against its substrate in these experiments with the living animals. Moreover, as will be seen from Table VIII, when everted intestinal sacs of rats were incubated with retinal in the medium, large amounts of retinol, retinyl esters, and retinoic acid were formed (17).

The results of Table VIII are quite interesting for several reasons. They demonstrate the presence of both retinal oxidase and reductase in the mucosal cell and both of them seem to be about equally active. It will also be seen from the table that, while both retinol and retinoic acid were present both in the medium and in the sac, no retinyl ester could be found in the medium, all of it being present in the sac. This work, therefore, further showed that both the alcohol and the acid can readily diffuse out of the cell, while the ester cannot. It has already been discussed that retinol, and not its esters, can cross the mucosal brush border. Therefore, these observations with the isolated system confirmed our earlier conclusions with the living animal, that reesterification of retinol, during absorption, takes place inside the cell. It is rather tempting to speculate that esterification serves as a trapping mechanism in preventing the retinol from diffusing out of the cell. It is also possible that it protects the retinol against attack of the enzymes like retinol dehydrogenase of the mucosa.

Retinoic Acid

The Dutch workers, Arens and Van Dorp (18), who had synthesized retinoic acid, could find no retinoic acid, retinol, or retinyl esters in the tissues of rats that were given massive doses of the acid. Several years later, Wald (19) showed that, when retinoic acid is included in a vitamin

TABLE VIII

Oxidation and reduction of 2 μmoles of retinal by everted intestinal sacs of rats

	Weight of sac, g	Retinyl esters, mμmoles	Retinol, mμmoles	Retinoic acid, mμmoles	Retinal mμmoles
Medium		Nil	57.4	89.76	793.5
Sac	1.5	84.35	73.85	103.6	149.8

Adapted from Deshmukh and Ganguly (17).

A-free diet, rats grow well (but become blind); but soon after the acid supplementation was withdrawn, they started to lose weight. Also, retinoic acid has never been detected in the tissues of normal animals. All this accumulated evidence went to contribute to the firm belief that retinoic acid is neither absorbed by animals, nor stored in their tissues.

On the other hand, there were several indications that retinoic acid is absorbed by several species of animals. Thus, Jurkowitz (20) had claimed to have detected retinoic acid in the blood of humans 3 hr after a dose of the acid. Krishnamurthy et al. (21) reported that, within 3 hr after feeding ^{14}C-labeled retinoic acid to chicks, they could detect the radioactivity in the intestinal wall, blood, and liver, but after 18 hr it seemed to have disappeared from these tissues. At about the same time, in our laboratory, during our work on the biopotency of retinoic acid, we noticed that a single dose of 500 μg of the acid can sustain the growth of vitamin A-deficient rats for nearly 28 days (22). Therefore, here we had definite indications that the acid is absorbed by rats, and that its effects persisted for a considerable length of time. The question of absorption of retinoic acid by rats was, therefore, reinvestigated, and soon it was shown by us that the acid was indeed rapidly absorbed by rats, but the absorbed acid rapidly disappeared from the tissues (23). It will be seen from Table IX that, within 1 hr after an oral dose of

TABLE IX

Intestinal absorption of retinoic acid in rats

	1 Hr	2 Hr	3 Hr	4 Hr	6 Hr	24 Hr	48 Hr
Stomach	1,240	1,100	1,024	1,074	488	186	5.5
Intestine							
Contents	333	118	98.7	58.8	22.5	5.0	4.5[a]
Mucosa	81.4	42.0	67.0	59.5	9.6	3.75	1.1[a]
Muscles	22.7	28.7	41.7	37.2	11.0	1.5[a]	1.5[a]
Blood	18.6	16.3	14.7	13.4	6.07	2.53[a]	2.81[a]
Liver	50.0	44.0	47.2	54.7	12.0	3.4[a]	2.70[a]

[a] Apparent values of retinoic acid as calculated from Carr-Price color reaction. Adapted from Deshmukh et al. (23).

5 mg sodium retinoate, considerable amounts of it could be found in the intestinal wall, blood, and liver of the rats, while only traces of it could be detected in these tissues after 24 hr. That we were dealing with the unchanged acid, and not with any artifacts or metabolites derived from it, was established by the spectroscopic and chromatographic properties of the compound isolated. It was thus clearly established that the acid is rapidly absorbed by rats, but it was also clear that after absorption it rapidly disappears from animal tissues. In the meantime, Professor J. A. Olson (24) made the interesting observation that retinoic acid is excreted through the bile as a glucuronide conjugate. Therefore, it began to appear that the rapid disappearance of the acid may be due to its excretion through the bile.

It has already been discussed that rapid oxidation of retinal to retinoic acid could be demonstrated both with mucosal homogenates and with everted intestinal sacs of rats, and yet, when retinal was fed, no retinoic acid could ever be detected in rat intestine. This was even more puzzling, because, as already shown in Table VII, after an oral dose of retinal, large amounts of it did enter the mucosal cell. It was, therefore, suggested by us (17) that during absorption some amounts of retinal are oxidized to retinoic acid in the mucosa and that the acid thus formed is either rapidly absorbed or quickly destroyed.

Soon an opportunity presented itself for testing this hypothesis. During a recent visit to Columbia University in New York I had occasion to do some collaborative work with Professor DeWitt S. Goodman on these aspects (25). Lymph and bile cannulas were introduced into a rat, whose normal bile supply was maintained by the bile flowing from a donor rat through another bile cannula. Rats with such double cannulas were separately fed ^{14}C-labeled retinol, retinal, or retinoic acid, after which the lymph and bile were collected at various time intervals and analyzed for different retinol derivatives. It will be seen from Table X that, after retinoic acid was fed, virtually no radioactivity appeared in the lymph, which immediately suggested that the acid was not absorbed through the lymphatic system and that all of it was absorbed through the portal route. In contrast, when the labeled alcohol or aldehyde was fed, while large amounts of radioactivity were recovered from the lymph, significant proportions of it appeared in the bile also. Analysis of the compounds in the lymph and bile revealed that most of the radioactivity in the bile was associated with retinoic acid, while that in the lymph was with retinol and its esters. Independently and simultaneously, Crain et al. (26) have claimed that, following intraduodenal injection of 1 mg of 15-^{14}C retinal, 39% of the administered radioactivity appeared in the portal blood

TABLE X

Recovery and distribution of radioactivity after feeding retinol (6–7-^{14}C), retinoic acid (15-^{14}C), or retinal (15-^{14}C) to rats

Compound fed	Amount fed		Total ^{14}C recovered (% of amount fed)	Distribution of recovered ^{14}C, %		
	μg	μCi		Lymph	Bile	Liver
Retinol	14.0	0.29	47.5	79.8	20.1	0.1
Retinoic acid	7.0	0.19	50.7	5.3	94.3	0.4
Retinal	8.0	0.19	44.0	70.3	19.4	10.3

Adapted from Fidge et al. (25).

of rats. When the portal blood extract was chromatographed through alumina columns, the radioactivity resolved into fractions corresponding to retinyl esters, retinal, retinol, and retinoic acid. Although the compounds in these fractions were not properly identified, this work has certainly produced additional evidence in support of portal absorption of vitamin A.

Conclusions

A number of far-reaching conclusions can be drawn from this work. First of all, it has been well established that higher fatty acids are mostly absorbed through the lymphatic system, and as esters. Retinoic acid is a higher fatty acid with 20 carbons (no doubt it is an unusual fatty acid having one β-ionone ring and several conjugated double bonds), but it is not absorbed through the lymphatic system; all of it is apparently absorbed through the portal circulation and excreted through the bile. The reasons for such behavior of retinoic acid are not quite clear. It is possible that it is conjugated in the intestine with glucuronic acid, which mechanism might well prevent its acylation with glycerol or other alcohols, and consequently, its transport through the lymphatic system. Alternatively, it is also possible that the enzyme systems necessary for its acylation with such alcohols do not exist in the intestine, and, therefore, it travels through the portal route.

A more significant point to note here is the portal absorption of vitamin A. Ever since our work at Reading (27), where we had demonstrated, by establishing lymph cannulas in rats and pigs, that vitamin A is absorbed through the lymphatic system and in the esterified state, it has been universally accepted that this vitamin is absorbed through the lymphatic route, as retinyl esters. But this latest work has clearly demonstrated that significant proportions of fed retinol and retinal are absorbed through the portal route and are excreted through the bile. Our experiments certainly did not prove that the dietary retinol and retinal are oxidized in the mucosa. But these enzymes are present in these cells, which should make it possible to argue that at least some portions of these compounds are oxidized to the acid, which in turn travels to the liver through the portal route and is excreted through the bile. It is also equally probable that some of the dietary retinol and retinal are absorbed through the portal route into the liver, where they are oxidized to the acid, which in turn is excreted through the bile. Be that as it may, this work has certainly demonstrated that, contrary to the current concepts of route of absorption of vitamin A, lymph is not the only route for its absorption.

Finally, it should now be possible to explain the failure of earlier investigators to demonstrate the absorption of retinoic acid, or its formation in the intestine from fed retinol or retinal. It is obvious that retinoic acid is rapidly absorbed through the portal route and is equally rapidly excreated through the bile. Earlier workers had analyzed the tissues of rats long after these animals were given retinoic acid, and, therefore, by the time the analysis was carried out the rats would have excreted the absorbed acid through the bile. Similarly, if certain proportions of the fed retinol or retinal are oxidized to the acid in the intestine, the acid thus formed would be immediately removed through

the portal route, and thus there would be no accumulation of the acid in the intestine.

Most of this work was supported by continuous grants from the Indian Council of Medical Research, New Delhi, and very recently by a PL 480 Project 514905 from the National Institutes of Health. The author also wishes to acknowledge grants for equipment from the Rockefeller Foundation, New York and the Wellcome Trust, London.

REFERENCES

1. GANGULY, J. Absorption, transport and storage of vitamin A. *Vitamins Hormones* 18: 387, 1960.
2. MURTHY, S. K., AND J. GANGULY. Studies on cholesterol esterases of the small intestine and pancreas of rats. *Biochem. J.* 83: 460, 1962.
3. MAHADEVAN, S., P. SESHADRI SASTRY AND J. GANGULY. Studies on metabolism of vitamin A: [illegible] Studies on the mode of absorption of vitamin A by rat intestine *in vitro*. *Biochem. J.* 88: 534, 1963.
4. DAVID, J. S. K., P. MALATHI AND J. GANGULY. Role of the intestinal brush border in the absorption of cholesterol in rats. *Biochem. J.* 98: [illegible], 1966.
5. MILLER, D., AND R. K. CRANE. The digestive function of the epithelium of the small intestine: [illegible] Localisation of disaccharide hydrolysis in the [illegible]ated brush border portion of intestinal epi[illegible]ial cells. *Biochim. Biophys. Acta* 52: 293, [illegible]
6. [illegible]VID, J. S. K., AND J. GANGULY. Further studies [illegible] the mechanism of absorption of vitamin A [illegible] cholesterol. *Indian J. Biochem.* 4: 14, 1967.
7. [illegible]NGULY, J., S. KRISHNAMURTHY AND S. MAHADE[illegible] The transport of carotenoids, vitamin A [illegible] cholesterol across the intestines of rats and [illegible]ckens. *Biochem. J.* 71: 756, 1959.
8. [illegible]HADEVAN, S., S. KRISHNAMURTHY AND J. [illegible]NGULY. The mode of absorption of vitamin A [illegible] the intestine of rats. *Arch. Biochem. Bio*[illegible] 83: 371, 1959.
9. [illegible]ER, E., AND B. M. KAGAN. Separation of vita[illegible] A alcohol and vitamin A esters by paper [illegible]matography. *Arch. Biochem. Biophys.* 63: [illegible] 1956.
10. [illegible]HADEVAN, S., AND J. GANGULY. Further studies [illegible] the absorption of vitamin A. *Biochem. J.* [illegible]83, 1961.
11. [illegible]HADEVAN, S., P. SESHADRI SASTRY AND J. [illegible]NGULY. Studies on the metabolism of vitamin [illegible] The mode of absorption of vitamin A esters [illegible] the living rat. *Biochem. J.* 88: 531, 1963.
12. HOFMANN, A. F., AND B. BORGSTROM. Physicochemical state of lipids in intestinal content during their digestion and absorption. *Federation Proc.* 21: 43, 1962.
13. BRAEKKAN, O. R. Studies on the absorption of different forms of vitamin A in young chicks. *Intern. Z. Vitaminforsch.* 33: 234, 1963.
14. GLOVER, J., T. W. GOODWIN AND R. A. MORTON. Studies in vitamin A: 6. Conversion *in vivo* of vitamin A aldehyde (Retinene$_1$) to vitamin A$_1$. *Biochem. J.* 43: 109, 1948.
15. DESHMUKH, D. S., S. K. MURTHY, S. MAHADEVAN AND J. GANGULY. Studies on metabolism of vitamin A: Absorption of retinal (vitamin A aldehyde) in rats. *Biochem. J.* 96: 377, 1965.
16. MAHADEVAN, S., S. K. MURTHY AND J. GANGULY. Enzymatic oxidation of vitamin A aldehyde to vitamin A acid by rat liver. *Biochem. J.* 85: 326, 1962.
17. DESHMUKH, D. S., AND J. GANGULY. Demonstration of oxidation and reduction of retinal in rat intestine. *Indian J. Biochem.* 4: 18, 1967.
18. ARENS, J. F., AND D. A. VAN DORP. Activity of vitamin A acid in the rat. *Nature* 158: 622, 1946.
19. DOWLING, J. E., AND G. WALD. The role of vitamin A acid. *Vitamins Hormones* 18: 515, 1960.
20. JURKOWITZ, L. Determination of vitamin A acid in human plasma after oral administration. *Arch. Biochem. Biophys.* 98: 337, 1962.
21. KRISHNAMURTHY, S., J. G. BIERI AND E. L. ANDREWS. Metabolism and biological activity of vitamin A acid in the chick. *J. Nutr.* 79: 503, 1963.
22. MALATHI, P., K. SUBBA RAO, P. SESHADRI SASTRY AND J. GANGULY. Studies on metabolism of vitamin A: 1. The biological activity of vitamin A acid in rats. *Biochem. J.* 87: 305, 1963.
23. DESHMUKH, D. S., P. MALATHI, K. SUBBA RAO AND J. GANGULY. Absorption of retinoic acid (vitamin A acid) in rats. *Indian J. Biochem.* 1: 164, 1964.
24. DUNAGIN, P. E., JR., E. H. MEADOWS, JR. AND J. A. OLSON. Retinoyl beta-glucuronic acid: A major metabolite of vitamin A in rat bile. *Science* 148: 86, 1965.
25. FIDGE, N. H., T. SHIRATORI, J. GANGULY AND D. S. GOODMAN. Pathways of absorption of retinal and retinoic acid in the rat. *J. Lipid Res.* 9: 103, 1968.
26. CRAIN, F. D., F. J. LOTSPEICH AND R. F. KRAUSE. Biosynthesis of retinoic acid by intestinal enzymes of the rat. *J. Lipid Res.* 8: 249, 1967.
27. THOMPSON, S. Y., R. BRAUDE, M. E. COATES, A. T. COWIE, J. GANGULY AND S. K. KON. Further studies of the conversion of β-carotene to vitamin A in the intestine. *Brit. J. Nutr.* 4: 398, 1950.

Gaylor-'64
Bib. No. 3078

New York State J. Med. 64:905-906. 1964.

Nutrition Excerpts

Prepared under the auspices of the Graduate School of Nutrition, Cornell University, Ithaca, New York

DAPHNE A. ROE, M.D., Editor

Possible Role of Vitamin A in Metabolism of Mucopolysaccharides

J. L. Gaylor, PH. D.
Ithaca, New York

The CONVERSIONS of water-soluble vitamins coenzymes and the functions of these cofactors were summarized recently in this Journal by McCormick.[1] Apart from quiet on the elucidation of the role of Vitamin A in the visual process, there are four examples of functions of fat-soluble vitamins as coenzymes.

The secretion of mucus by epithelial impaired in animals that are deficient in vitamin A. Excessive doses of Vitamin A lead to mucous metaplasia of certain epithelial tissues and the inhibition of the processes of normal keratinization.[2] For results of recent studies on the effects of Vitamin A on the metabolism of MPS polysaccharides) now permit some of possible functions of vitamin A with respect to the observed changes in epithelia in states of deficiency and hypervitamin A. A few of these studies are summarized in this brief review.

Wolf and Phil[3] observed that vitamin A deficiency decreases the incorporation of carbonate, ammonia, acetate, and sulfate into MPS by enzymes from cell-free preparations of rat colon. Synthesis was restored to the normal rate by the addition of vitamin A to the cell-free preparation. Further study demonstrated that the metabolic defect in the absence of vitamin A was associated with the incorporation of sulfate into MPS. 3′-Phosphoadenosine-5′-phosphosulfate (active sulfate) is the normal, activated donor of sulfate residues to form MPS. The rate of formation of active sulfate by cell-free preparations of colon from vitamin A-deficient rats was substantially slower than the rate of formation of active sulfate by tissue from normal rats or by tissue from deficient rats to which vitamin A was added during the incubation.[4] These results led to the conclusion that vitamin A may be required metabolically to obtain a normal rate of biosynthesis of active sulfate. A decreased rate of formation of active sulfate may limit the subsequent rate of formation of MPS.

These studies do not suggest that vitamin A may affect the biosynthesis of active sulfate in other tissues. The coexistent keratomalacia and xerophthalmia of severe vitamin A deficiency suggested a field of investigation related to the pathologic keratinization of the cornea. Accordingly, Pasternak, Humphries, and Pirie[5] studied the formation of active sulfate by cell-free preparations of corneal tissue from vitamin A-deficient rats and rabbits. In all cases, deficiency did not reduce markedly the rate of formation of active sulfate. When some inhibition was observed, the rate was not restored to normal by the addition of vitamin A to the incubation mixture. Similarly, one might expect a decreased formation of lipid sulfates from active sulfate in the brains of animals that are deficient in vitamin A. Severe lesions of brain tissue that

may be predicted by such an impaired synthesis were not observed histologically by Coggeshall and Bieri.[6]

After high-speed centrifugation of the cell-free system of rat colon homogenate that was used by Wolf, Bergan, and Sundaresan[7] in their previous studies, activity was not restored by the addition of vitamin A to the system. Activity was restored by a metabolite of vitamin A acid that was isolated from intestine following administration of the acid. Therefore, the role of vitamin A in the biosynthesis of MPS may not be a direct effect but rather mediated through a metabolite. Possibly, this metabolite of vitamin A was formed in the crude homogenate that was used previously.

The effect of excessive doses of vitamin A on the secretion of MPS is not attributed solely to excessive amounts of MPS that are formed during hypervitaminosis A. The work of Wolf, Bergan, and Sundaresan[7] suggested that vitamin A may be required for maximal rates of formation of active sulfate, but there was no indication that an excess of vitamin A may promote either the formation of excessive amounts of active sulfate or the formation of excessive amounts of MPS.

The continued studies of Fell[2] offer a plausible explanation for the metabolic effect of vitamin A on keratinizing tissue. Explants of chicken skin, grown in tissue culture, incorporate sulfate from the medium; the uptake of sulfate is enhanced by vitamin A. Normal keratinization of skin apparently results in a slower biosynthesis of MPS, and vitamin A administration promotes mucous secretion in place of keratin formation. Embryonic cartilage grown in tissue culture is particularly susceptible to doses of vitamin A. The results of studies by Fell, Dingle, and Webb[8] suggest that vitamin A enhances the release of proteolytic enzymes from cartilage. The proteolytic enzymes catalyze the hydrolysis of the protein moiety of the protein-MPS matrix to yield nonprotein-bound MPS. Accordingly, these results indicate that excessive amounts of vitamin A increase the secretion of MPS by promoting a more rapid breakdown of the MPS-protein matrix and not because of excessive rates of formation of MPS.

The same group has demonstrated that a specific interaction of vitamin A and protein is required for the effect.[8] Liver lysosomes release proteolytic activity on treatment with vitamin A, although the lipoprotein membrane of the lysosome remains unaltered. By using cold lysis of erythrocytes by vitamin A as a model system of Vitamin A lipoprotein membrane interaction Luca and Dingle[9] suggest that a protein-vitamin A interaction may be required for the MPS activity.

Comment

Studies on the metabolism of MPS states of vitamin A deficiency and hypervitaminosis A suggest that the latter is not a metabolic exaggeration of recovery of the deficiency state. The two effects can be differentiated. In severe Vitamin A deficiency, less MPS is formed, and epithelia undergo keratinization. In severe hypervitaminosis A some excess of MPS may be formed, but excessive rates of hydrolysis of the protein moiety of the MPS protein complex cause the integrity of the complex to be lost, and the MPS is liberated. These studies illustrate the need for independent approaches to problems of inadequacy and hypervitaminosis to the extent that mechanisms for an explanation of gross changes in either state may not be related.

References

1. McCormick, D. B.: Biochemical advances in [illegible] research. Partial replacement and interference of [illegible] functions by pseudovitamins, New York State J. Med. [illegible] 2842 (Sept. 1) 1962.
2. Fell, H. B.: The effect of vitamin A on [illegible] ture, Proc. Nutrition Soc. 19: 50 (1960).
3. Wolf, G., and Phil, D.: Vitamin A in adrenal [illegible] and mucopolysaccharide biosynthesis, Am. J. Clin. [illegible] (pt. 2): 36 (July-Aug.) 1961.
4. Varandani, P. T., Wolf, G., and Johnson, B. C.: [illegible] tion of vitamin A in the synthesis of 3'-phosphoadenosine [illegible] phosphosulfate, Biochem. biophys. Res. Commun. [illegible] (July) 1960.
5. Pasternak, C. A., Humphries, S. K., and [illegible] The activation of sulfate by extracts of cornea and [illegible] mucosa from normal and vitamin A-deficient animals. [illegible] chem. J. 86: 382 (Feb.) 1963.
6. Coggeshall, R. E., and Bieri, J. G.: Pathology of [illegible] brain in single and mixed deficiencies of vitamins A and [illegible] the chick, J. Nutrition 70: 272 (Feb.) 1960.
7. Wolf, G., Bergan, J. G., and Sundaresan, P. R.: [illegible] min A and mucopolysaccharide biosynthesis by cell-free [illegible] ticle suspensions, Fed. Proc. 21: 171 (Mar.-Apr.) 1962.
8. Fell, H. B., Dingle, J. T., and Webb, M.: Studies [illegible] the mode of action of excess of vitamin A. 4. The specificity of the effect on embryonic chick-limb cartilage in culture [illegible] on isolated rat-liver lysosomes, Biochem. J. 83: [illegible] 1962.
9. Lucy, J. A., and Dingle, J. T.: Vitamin A and [illegible] brane systems. 2. Membrane stability and protein-[illegible] min A-lipid interactions, ibid. 84: 76p (Sept.) 1962.

Bib. No. 3154

Reproduced by permission
of the copyright owner

Vitamin A Requirement of the Guinea Pig

A. GIL,[1] G. M. BRIGGS, J. TYPPO[2] AND G. MACKINNEY
Department of Nutritional Sciences, University of California, Berkeley, California

ABSTRACT This study was undertaken to establish the dietary level of vitamin A best adapted to the growth and maintenance of the young guinea pig. Growth records were kept and plasma and livers were analyzed for vitamin A. Histological examinations of tissues of the eye, trachea, kidney and liver were made. Optimal growth occurred when the level of vitamin A was between 1.67 and 9.9 mg/kg of diet. Significant storage of the vitamin in the liver began at a level between 6 and 7 mg/kg of diet, and the quantity stored increased rapidly with further increase in the level of vitamin A in the diet. No such pattern was found in the levels of vitamin A in the plasma. Levels of 1.67 and 3.3 mg of vitamin A/kg, although maintaining normal growth, did not prevent metaplasia of epithelial tissue in all animals.

This study was undertaken to establish the vitamin A requirement of the growing guinea pig and also, to describe the results of a dietary insufficiency and excess of this vitamin. Committee reports of the National Research Council (1) and the Canadian Department of Agriculture (2) indicate little new work on this subject since that of Bentley and Morgan (3) in 1945, which showed that a daily intake of 0.2 mg of vitamin A was the minimum level to allow its detection in the liver. The control diet formulated by Reid and Briggs (4) contains 6.0 mg/kg which means, if we assume a daily food consumption of about 30 g, an intake of 0.18 mg/day. From all indications, this level appears satisfactory for the guinea pig for growth and optimal health.

Recently, Howell et al. (5) studied changes in tissues of guinea pigs on diets containing methyl retinoate, with one set of controls on a diet free from vitamin A or its derivatives, and another set to which retinyl acetate (0.5 mg/animal) was administered in oil by pipet twice weekly. In view of their detailed report a relatively brief note indicating our different objectives and conclusions will suffice here. We are in general agreement where comparisons are relevant.

Our first experiment was designed to answer four main questions: 1) The time needed to deplete young animals of the vitamin A reserve that might have been built up prior to weaning; 2) to look for symptoms useful in assessing progressive stages of vitamin A deficiency; 3) to determine the relative efficiencies of different levels of vitamin A (retinol) to restore growth; and 4) to determine whether a relationship exists between liver and plasma levels and dietary intake.

In a second experiment, several groups of guinea pigs were compared for their ability to thrive on graded intakes of the vitamin, with doses ranging from zero to toxic levels in the diets.

EXPERIMENTAL

Animals. Male short-hair albino guinea pigs of the Hartley strain, were received from Fort Detrick, Maryland. They were reared individually in wire-bottomed cages and given food and water ad libitum. To avoid weight losses, they were fed a commercial ration[3] the first day, with increasing proportions of the experimental diet mixed with the ground ration in succeeding days. In this way, they adjusted to the diet change in the course of a week without setbacks of any consequence. It meant however that whereas Howell et al. (5) began with weanling guinea pigs with an average weight of about 200 g, ours were appreciably bigger before the experiment could be started. This undoubtedly is responsible for certain differences which exist between the two sets of findings. Ours

Received for publication February 26, 1968.

[1] Faculty of Chemistry and Chemical Engineering, National University of Colombia, Bogotá, Colombia.
[2] School of Home Economics, University of Missouri, Columbia, Missouri 65201.

[3] Purina Chow for guinea pigs, Ralston Purina Company, St. Louis.

began with a total liver storage of about 90 μg of vitamin A (average for 3 animals) with individual levels of 8.4, 7.2 and 7.6 μg of vitamin A/g liver. Under natural conditions, it appears that liver storage in the guinea pig may be low, about 3 μg/g of moist liver (see 6).

Diets. The vitamin A-free diet was a modification of the diet of Reid and Briggs (4). It contained, in grams per kilograms of diet: vitamin-free casein, 300; powdered sucrose, 246; glucose-hydrate, 170; cellulose (powdered cellophane), 150; mineral mixture (7), 75; corn oil, 50 (containing the fat-soluble vitamins); L-arginine·HCl, 3; ascorbic acid, 2; choline chloride, 2; and inositol, 2. In addition, fat-soluble (in corn oil) and B vitamins (in glucose-hydrate) were added at the levels used by Liu et al. (7), with 16 mg thiamine·HCl/kg present. The corn oil used was analyzed for carotene and none was found. Crystalline retinyl palmitate in corn oil was used as the source of vitamin A in these experiments.

Another group of animals received the commercial ration[3] as an additional control.

Vitamin A assays. The quantity of vitamin A in the diet was estimated from the stated potency of the oil and checked by spectrophotometry. In liver and plasma it was estimated by use of trifluoroacetic acid in chloroform at 620 mμ, essentially by the method of Neeld and Pearson (8). Because of very low levels in the plasma, certain modifications were necessary. As much blood as possible was obtained by heart puncture before autopsy. After centrifugation, the serum was mixed with ethanol and exhaustively extracted with petroleum ether. This could then be concentrated to a small volume, and an aliquot taken for the determination.

RESULTS

Growth experiments. In the first experiment there were 20 animals. Three were killed at the start, 10 were placed on the vitamin A-free diet, and 7 received a diet containing 6 mg vitamin A/kg diet. The initial weights averaged 360 g. Until day 27 there was no noticeable difference in growth rates, after which those on the vitamin A-free diet lagged behind, and after day 41 weight losses became more apparent. Thus, on day 46 the average had fallen from 595 to 565 g, whereas those receiving vitamin A continued to gain, weighing an average of 650 g on day 46. Growth was resumed by animals after 40 days on the vitamin A-free diet when placed on diets containing 3.3 to 33 mg of the vitamin/kg diet, but at levels of 66 mg/kg and above there was loss of weight.

In animals kept on the deficient diet for 7 to 8 weeks, few external symptoms of deficiency were discerned. The hair was slightly more unkempt, and some developed scales on the ears and on the dorsal surface of the feet. So far as could be detected, vision was unimpaired and this was confirmed by subsequent histological examination of the retinas.

In the second experiment, groups of 5 animals each were placed on diets containing 1.67, 3.3, 6.6, 9.9, 16.5, 165 and 330 mg retinol/kg diet. Starting weights averaged 258 g. Growth ceased after 21 days at zero intake and remained unchanged for the next 18 days, after which losses in weight were noted. Growth averages for all animals in each group are given in footnote 2, table 1. At dietary levels of 1.67 and 3.3 mg/kg the range of averages was from 516 to 537 g with no clear-cut evidence to favor one intake over another. At zero and toxic (330 mg vitamin A/kg diet) levels, the averages were 364 and 425 g, respectively.

Plasma levels. The plasma from 23 animals was analyzed for vitamin A. Levels of 0.05 to 0.10 μg of vitamin A/ml plasma were found in 4 out of 15 fed diets containing from zero to 6.6 mg vitamin A/kg diet. In 6 out of 8 animals on diets containing 9.9 mg/kg diet or above, the plasma levels were 0.08 to 0.4 μg/ml.

Liver storage. It appears worthwhile to show the individual analyses (table 1) to indicate not only the variation within a group, but to show also that storage of vitamin A in the liver becomes significant only when the vitamin concentration is 6.6 mg/kg or higher. In fact, at the optimal level for growth, it is not evident that significant storage has occurred.

Hematology. Normal red blood cell counts, hematocrit and hemoglobin were

TABLE 1

Vitamin A content of individual guinea pig livers, as affected by intake

Diet content	Approximate daily intake	Days on diet	Vitamin A content	
mg/kg	*mg*		*μg/g* liver	*μg* total
After adapting to diet		0 [1]	8.1 [2]	89.3
			7.2	82.0
			7.6	94.0
0		40	0 [3]	—
1.67	0.05	40	0.18	4.8
		40	0.10	2.1
		49	0.20	5.1
		49	0.30	6.7
		56	0.20	4.0
3.3	0.10	40	0.71	9.8
		40	0.26	4.7
		49	0.55	13.1
		49	0.57	17.0
		56	1.4	25.2
6.6	0.20	40	5.6	147.0
		40	1.4	32.5
		49	2.5	65.0
		56	17.0	289.0
9.9	0.30	40	22.1	590
		40	26.0	592
		49	33.5	880
		49	20.0	544
		56	9.0	238
330.0	10.0	40	2,000.0	26,000
		40	2,060.0	35,000
		56	1,094.0	19,700
		56	1,590.0	28,600
		60	2,030.0	39,000
(—) [4]	Commercial ration	40	12.1	242 [5]
		40	6.4	128
		40	8.0	160
		56	15.0	300
		56	9.0	180

[1] Seven days were allowed after receipt of the animals for adaptation to the diet.
[2] Values for individual animals are listed to show the degree of variability. Growth averages at day 40 were: 364 ± 23.9, 516 ± 17, 537 ± 30.4, 527 ± 18.8, 425 ± 24.3, and 555 ± 12.8 for dietary levels of zero, 1.67, 3.3, 6.6, 9.9 and 330 mg of vitamin A/kg, and for the commercial ration (Purina Chow).
[3] For all 5 animals.
[4] Contained 12 IU/g vitamin A (presumably as carotene in the alfalfa).
[5] An arbitrary figure was set here for liver weight. The actual weights were apparently not recorded for this group.

found in the deficient animals. Though the diet is adequate in all respects except for vitamin A, it is possibly not surprising that no abnormality should be observed in this respect.

Histology. Tissues to be examined were excised and samples were fixed in 5% formalin. These included: a small ring of trachea at the bifurcation point; a gram of liver from the lower edge of a lobe; the left kidney, sliced through the midlongitudinal plane to cut open the calyx end of the ureter; the left eye, exorbitated by excision of the optic nerve, and tearing of the external muscles, and fixed as such.

Slide mounts were made from paraffin and from frozen sections, and stained.[4] Findings may be summarized as follows:

Eye. The scleral and corneal mucous membranes, known to become keratinized

[4] Department of Pathology, University of California Medical Center, San Francisco, California.

during vitamin A deficiency in rats still appeared normal.

Tracheal epithelium revealed squamous metaplasia, severe in the deficient animals, and detectable at dietary levels of 1.67 and even 3.3 mg vitamin A/kg diet.

Kidney. Metastatic calcinosis was clearly evident at the toxic level only. Hyperplastic epithelium of the collecting tubules and degeneration were evident in deficient animals, and in one animal at the toxic level. The pelvic mucous membrane was replaced by a flattened nonfunctional thin layer of cells in deficient animals and signs of derangement could be detected when the diets contained low and toxic levels of the vitamin, namely 3.3 and 330 mg, respectively, per kilogram diet.

Liver. Atrophy, as revealed by reduced cytoplasmic content, and increased mitosis usually appear together. The atrophy was severe at zero and toxic levels, and was detected in one animal on the diet containing 3.3 mg of vitamin A/kg. Metastatic calcinosis was found only at the toxic level. Fat infiltration was strongly marked in deficient animals, and was detected also at the toxic level.

DISCUSSION

These tests show that levels of vitamin A ranging from 1.67 to 9.9 mg/kg diet maintained normal growth. There was no advantage, in terms of growth response, to levels above 6.6 mg/kg, although they resulted in a marked increase in storage of vitamin A in the liver. Significant growth impairment of animals occurred at deficient and toxic levels, and this is a manifestation of pathological disturbance.

In the deficient animals, there was marked metaplasia of epithelial cells, atrophy of liver cells and fatty degeneration of the liver. Even dietary levels of 1.67 and 3.3 mg vitamin A/kg did not invariably suffice to preserve fully the integrity of tissues such as secretory epithelia and liver cells.

It may be concluded that a diet containing between 6 and 7 mg of vitamin A/kg meets the requirement of the growing guinea pig for this vitamin. On the basis of 30 g of food consumed daily, this is equivalent to 0.2 mg of vitamin A, and is in agreement with the recommendations of Reid and Briggs (4).

LITERATURE CITED

1. Nutrient Requirements of Laboratory Animals 1962 National Research Council Publ. 990. National Academy of Sciences — National Research Council, Washington, D. C.
2. Report of the National Committee on Animal Nutrition 1966 Biological values of provitamins A for man, domestic animals and birds. Publication 1238, p. 72, Canada Dept. Agr., Ottawa, Canada.
3. Bentley, L., and A. F. Morgan 1945 Vitamin A and carotene in the guinea pig. J. Nutr., *30*: 159.
4. Reid, M. E., and G. M. Briggs 1953 Development of a semisynthetic diet for young guinea pigs. J. Nutr., *51*: 341.
5. Howell, J. M., J. N. Thompson and G. A. J. Pitt 1967 Changes in the tissues of guinea pigs fed on a diet free from vitamin A, but containing methyl retinoate. Brit. J. Nutr., *21*: 37.
6. Biochemists' Handbook, ed., C. Long. 1961 E. and F. N. Spon, London, England.
7. Liu, K. C., J. T. Typpo, J. Y. Lu and G. M. Briggs 1967 Thiamine requirement of the guinea pig and the effect of salt mixtures in the diet of thiamine stability. J. Nutr., *93*: 480.
8. Neeld, J. B., and W. N. Pearson 1963 Macro- and micromethods for the determination of serum vitamin A using trifluoroacetic acid. J. Nutr., *79*: 454.

Archives d'Anatomie Micro, 45: 77-98, 1956.

Giroud-'56
Bib. No. 3192

Teratogenesis by high doses of vitamin A as a function of the stages of development

A. Giroud M. Martinet Laboratory of Embryology, Faculty of Medicine Paris

I Introduction

It is known that vitamin A deficiency causes development of malformations in the embryo.

Hale (1935)was the first to demonstrate in the piglet that cleft palate, harelip, microphthalamia and renal abnormalities, including horseshoe kidney, that appeared in the stock were due to a deficiency of vitamin A. These deformations were produced before the 60th day of pregnancy because after this date the administration of vitamin A had no result.

Andersen (1941) had noted diaphragmatic hernias in the rat, following experimental deficiency of this vitamin.

Warkany and Schraffenberger (1946), Warkany, Roth and Wilson (1948), had also observed a number of malformations: ocular anomalies, cardiovascular anomalies, pulmonary anomalies, renal anomalies including horseshoe kidney and abnormal development of the male genital organs.

Excess vitamin A was also found to be teratogenic.

Cohlan (1953-1954), in fact, saw after administration of large doses of vitamin A, exencephalies, malformations of the eyes, spinabifida, cleft palate, meningoceles, hydrocephalies, and finally cataracts.

We ourselves (1954) confirmed these facts and extended these observations. In an initial test, we administered 35,000 international units of vitamin A for twelve days from the second to the fourteenth day of pregnancy. We obtained total abortions in 90% of the cases. In our second series of experiments, we gave only 20,000 international units. Under these conditions, we obtained a certain number of resorptions, but nevertheless a number

Reproduced by permission of the copyright owner

of abnormal embryos was able to develop. Among these embryos, there were many malformations of the encephalon, generally serious enough to merit the name of anencephalies. In addition, we quite frequently found ocular malformations, 25%; anophthalmia or microphthalmia, Likewise, we found numerous cases of cleft palate (25%). Finally, there were cataracts. The internal organs appeared normal.

The multiplicity of anomalies observed would indicate that the excess of the vitamin acted at different stages. It was therefore appropriate to determine what the influence of the embryonal stage was in which malformations developed that were of such considerable variety. Moreover, the question was worthy of study because in many instances the question of the stage in which certain anomalies are formed is still being debated. For example, certain authors feel that anencephalia or exencephalia may be the result of hyperplasia and a secondary opening of the encephalon: in this case, they came after the stage of closure of the encephalic tube.

II - Techniques

Our experiments were performed on Wistar rats which were raised in the normal manner and placed with the males on a specific day. Their state of pregnancy was confirmed by the presence of spermatozoa in the vagina and the persistence of diestrus. We then gave them (orally) vitamin A in an oil solution (acetate or palmitate) at a concentration of one million units per gram. These animals were sacrificed on the 21st day of pregnancy.

In order to perform these tests, we increased our initial daily doses by giving 60,000 units. We gave these doses for only three days, covering the entire period of pregnancy in stages. These steps were broken down as follows: 5 to the 7th day inclusive, 8th to the 10th day, and so on.

The animals were sacrificed on the 21st day, dissected and studied histologically. The study was performed on 90 rats and allowed 615 embryos

to be examined.

We complemented it on a small scale by treatments which likewise lasted three days but alternated with the first treatments. We will refer to this in particular when we come to study the various anomalies.

III - Experimental Results

First of all, our studies showed that the frequency of total abortions decreases as action is taken at increasingly later times.

Table I

Percentage of total resorptions as a function of the date of the start of the administration of Vitamin A

The results concerning the deformations as a function of the date of treatment are as follows:

5th to 7th day We found many total reabsorptions (43%). Among the fetuses that were found on the 21st day, 20% were dead. Of the survivors, 80% were normal. Several abnormal ones were anencephalic or anophthalmic.

8th to 10th days We essentially found anencephalic, anophthalmic, or microphthalmic fetuses, some of which showed spina bifida.

10th or 12th day In addition to cleft palate, we found median fissures of the lower jaw; some deformations of the ear were also observed.

11th to 13th days We found cleft palate, aplasias of the eyelids ("open eyes") and malformations of the limbs, (micromelia and syndactyly).

14th to 16 days Only cleft palate was produced.

18th to 20th days Only cataracts were observed.

Figure 1 shows this distribution of the various deformations and their frequency.

In order to interpret these results, it is necessary to recall certain facts concerning the development of vitamin A in the organism. This substance diffuses naturally in the mother and secondarily reaches the embryo. Dann

(1932) in various species and Wendt (1936) in man found that vitamin A passes from the mother to the fetus, albeit with difficulty. Recently, Zunin and Testa (1953) gave high doses of A to the pregnant rabbit. Examining the liver of a fetus from a treated mother in comparison to one from a fetus from a normal mother, these authors found 2723 units in the first and only 3 units in the second.

We also know that vitamin A is stored in the organism, in contrast to water-soluble vitamins which may be easily eliminated. From this we can conclude that while it is possible to ascertain the beginning of the action of the vitamin, it is more difficult to determine the cessation of its action. The quantity of the vitamin can therefore remain sufficiently high to explain malformations following the cessation of treatment: presence of an anomaly following early treatment, therefore, does not allow a definite conclusion to be drawn. This possibility of delayed reaction, however, may not be very important, because among the survivors of very early treatment (5th to 8th days) we found a very high number of normal fetuses. The gradual disappearance of the malformations. Following later and later treatments, is very revealing.

Fig.1 Diagram of the distribution of malformations as a function of the dates of administration of vitamin A.

a Types of anomalies according to date of treatment
b Anencephalia
c anophthalmia and microphthalmies
d spina bifida
e cleft palate
f aplasia of the eyelids
g micromella syndactyly
h cataracts
i day

Fig. 2 Anencephalic and anophthalmic rat embryo(treated on the 8th to 10th day)

Figure 3 Section of the brain of the anencephalic embryo. Nearly complete destruction. Only the Gasserian ganglia remain. One neuroblastic layer remains on the left, clearly continuous with the epidermis. There are several choroid plexuses and a tremendous development of the menigeal vessels.

The results will now be studied in detail, anomaly by anomaly.

The anencephalic malformations are generally very intensive; they deserve the name of anencephalia, as it is understood in human pathology. They correspond to the acleiencephalia of Angel (1955), in other words, the absence of closure of the nerve tube.

The vault of the cranium and the tegument are missing. The rhombencephalon is generally intact. The mesencephalon and the prosencephalon on the other hand, are highly abnormal; the cavities open to the exterior and their walls are continuous with the epidermis. At certain points, there are abundant choroid plexuses; some anencephalic portions are recognizable, but a great deal of the tissue is necrotic (figure 3). Note that in addition to the serious malformations, there are also more benigh ones but of the same type.

This anencephalia appears with the administration of vitamin A from the 5th to the 8th days, but in a small number of individuals. The maximum was found in the tests from the 8th to the 11th days (53%). They are not found when treatment is given after the 10th day. They do not occur after this, which appears to indicate that they donot result from a secondary process but correspond rather to an arrest of the closure of the anencephalic tube.

We know that it is on the 9th day that the development of the chordomesoblast is completed and consequently nervous induction begins. After 11 days and 6 hours (13 somites), according to Schwind (1928), in other words the 12th day, the anencephalic nerve tube would be completely closed.

In fact, Hicks (1953) observed anencephalia following irradiation on the 9th to the 10th day, while other malformations of the nervous system are more delayed: Wilson (1953) has also confirmed the same fact.

The anencephalic embryos very often show a foreshortening of the superior facial structure and this malformation, which does not exist in the pure state, likewise disappears in anencephalia, thus representing a secondary malformation. It would appear to be related to a lack of cranio-caudal development of the skull.

Figure 4 Spinabifida accompanying an anencephaly (8-10 days)

The spinabifida which we observed were all lumbar. The marrow is exposed and the two edges are continuous with the epidermis. Except for this, the structure can be normal and the spinal ganglia well-developed. However, in several cases the nerve tissue may be in a state of degeneration. Spinabifida is never found when treatment is given on the 5th to 7th days. It does occur after such treatments on the 8th to 10th days. It ultimately disappears in those of the 11th to 13th days. It does develop a little later than the anencephalia however, since it does not occur when treatments are given earlier: the neural tube being completely closed on the 12th day, it would result in a suspension of its closure.

In fact, Hicks (1953) notes that the medullary malformations follow irradiation on the 10th and 11th days, while anencephaly is obtained in those irradiated on the 9th to the 10th days.

Figure 5 Section of spinabifida

Figure 6 Section in the region of the orbit of an embryo with unilateral anophthalmia. The presence of the ocular adnexa can be seen.

Anencephalia and microcephalia are quite characteristic. In the case of anencephalia, the adnexa oculi (lids, palpebral chamber, ocular muscles, lacrymal glands) are present (Figure 6). On the whole, microcephalia appears as follows. The optic cup is generally represented by two adjacent but undifferentiated epithelial layers. More rarely, a portion of the internal layer has undergone retinal differentiation. The crystalline lens is small, and usually composed of a continuous epithalial layer which resembles the interior epithelium, covering a mass of cells which are chemically differentiated, but not transformed into fibers (Figure 7). Sometimes there is a portion of the epithelium which has been transformed into fibers. These anomalies are found in treatments extending from the 5th to the 11th day. They disappear in treatments from the 11th to the 13th day.

Figure 7 Microphthalmia. The optic cup is represented by two undifferentiated epithelial layers. The crystalline lens has not undergone evolution into fibers: Some cells have accumulated in the lens vesicle, whose cells have all retained their epithelial appearance. The adnexa oculi, on the other hand, are normal. (8-10 days).

This corresponds to the evolution of the eye. It is on or about the 10th day that the optical primordium begins and the optic vesicle is well formed on the 11th day.

The arrest of the development of the eyelids, constituting the state called "open eye," is found in the later experiments after treatment on the 11th to the 13th day (Figure 8). It is no longer found in those from the 14th to the 16th day. We know that normally the eyelids close toward the end of the 18th day and open only a few days after birth. We know that this anomaly has been found in vitamin A deficiency (Warkany et al. 1948) and that Cohlan (1954) found it in the case of vitamin A hypervitaminosis.

The cleft palates are slits limited to the secondary palate usually they are total but they may be limited to the posterior area. In some cases, the opening is located in the anterior portion and appears as an orifice that opens at the rear of the anterior palate and consequently at the level of the nasopalatine canals. There are never any slits in the anterior palate, i.e., harelip. On the 21st day, the abnormal palatine processes are characterized by their ventral inflection and especially their underdevelopment (Figures 10 and 11). These palatine slits appear after treatments on the 11th and 16th days. We obtain 92% by operating from the 11th to the 13th. They no longer are found after the 16th day.

—

Figure 8 Embryo with aplasia of the eyelids. Simultaneously, the external ear is missing and there is an auricular appendage (10-12 days).

—

Figure 9 Section through an eye whose eyelids are incompletely developed. The eye itself is normal

—

Figure 10 Palatine fissure viewed from below. Note the healthy condition of the anterior palate (11-13 days).

—

Figure 11 Section through the head of an embryo showing a cleft palate. The palatine processes appear short, as does the nasal septum.

—

Warkany and Schraffenberger (1947) have obtained this by irradiation from the 10 to the 16h day with a maximum on the 15th day. We know that the palate develops by rotation and confrontation between the palatine processes and the nasal septum which takes place towards the end of the 16h day. Reabsorption of the joined epithelium takes place only later, and it is not complete by the 17th day so that some epithelial residue still remains on the 18th. A secondary disjunction is therefore theoretically possible, but it is unlikely after the date of the teratogenic action. The arrangement

of the palatine plates, which are often started downwards, is less favorable for this interpretation. We also know that such a disjunction could be produced in the anterior palate, creating harelip, in the mouse (Steiniger, 1941) and according to us, in the rat as well, as we have seen following folic acid deficiency.

The median fissures of the lower jaw were found after administration from the 10th to the 12th days. They were very deep, cutting through the jawbone and the buccal floor. Hence, the anterior portion of the tongue is bifidal (figure 12 and 13).

Shrinking of the buccal orifice by adhesion of the commissuralabiorium was also found under the same conditions.

Figure 12 Embryo with median fissure of the mandible and doubling of the anterior portion of the tongue (10 - 12 days).

Figure 13 Sections showing fissuring of the mandible and the tongue

---

Malformation of the ear were found on several occasions under identical conditions (administrations from the 10th to the 12th days). The external ear (pinna and external auditory canal) is absent (Figure 14). On the other hand, we can see the presence of auricular apendages with cartilaginous skeletons in the malar region; from one to three are found (see figures 8 and 15). The middle ear is less developed or not developed at all. It may be reduced to a simple indifferentiated diverticulum: in other cases, there may be a Eustachian tube and a tympanic cavity, but very reduced, (Figure 16), and the ossicles are missing.

It can therefore be considered that we are dealing only with anomalies of development of the branchial apparatus; the inner ear, however, seems to tolerate some of the effects of these anomalies.

Figure 14 Right: a normal ear; left: same region, without the external ear (10-12 days)

Figure 15 Section through the mandibular region showing an auricular appendage jutting out under the skin. It has an cartilaginous axis attached to the skeleton. At the same time one can see the irregularity of the lower jaw (10-12 days). At the right, control animal.

Malformations of the limbs were found following treatment on the 11-12th days. They include micromelia and syndactyly (figures 17 and 18). They resemble those obtained by B^2 avitaminosis (Warkany and Schraffenberger, 1944; Giroud and Lefebvres, 1947) or by x-rays (Warkany and Schraffenberger, 1947). The anomalies develop on the 13th day, according to Warkany and Schraffenberger, that is, at a stage when the rudementary skeleton is formed with the appearance of mesenchymatous, condensations; the limb at this stage is already quite well structured and its first rudiments have begun on the 11th day but the chondrification does not begin until the 11th day.

Figure 16 Under development of the middle ear, On the one hand, there is a rudimentary tympanic cavity; on the other hand, the Eustachian tube is reduced to a small diverticulum (10-12 days). At the top, control animal.

Figure 17 Syndactyly on the left; and normal foot on the right (11-12 days)

Figure 18 Syndactaly: fusion of the metatarsia

Finally, there are some tissue changes in the cataracts (figure 19). They correspond to a nearly total destruction of the fibers, involving only the zonal cells. They only develop after delayed reaction from the 18th to the 21st days. They are not found in earlier treatments.

Haven found the same thing in the mouse by irradiation on the 18th and

10th days. It is known to be found after treatment of the mother with thyroxin (Giroud and Martinet, 1953), but this sensitivity disappears shortly after birth (Tusques, 1955). It will be recalled that in man they are found in rubella beginning in the first or second month. Note that Nelson et al (1955) obtained them at all stages with folic antivitamin.

As we can see, it clearly follows from these experiments that the embryonic state at which high doses of vitamin A are administered is extremely important: there are several particularly sensitive times and hence malformations are most likely to develop at these times.

Figure 19 Eye with cataract (18-20 days)

IV General Conclusion

It should first be noted that, according to our experimental results, in the stages preceding implantation and the beginning of gastrulation, vitamin A hypervitaminosis causes no malformations. However, there is a period when the embryo appears to be less resistant, as indicated both by the high mortality and by the gradual regression of total abortions throughout pregnancy (table 1).

This finding is completely in agreement with observations made following the action of X-rays at various stages of development. Indeed, Russel and Russel (1953) report that in the pre-implantation stages there are many deaths, but only a few malformations among the survivors.

Furthermore, all the results show that several stages are much more sensitive than others and that certain embryogenetic processes may be disturbed more easily than others: cleft palate can appear in 92% of cases, and anencephalia in 53%, and other malformations with frequencies that are much lower. This sensitivity is probably the explanation for the high freqency of malformations of an anencephalic nature, called spontaneous, noted in man

(Murphy, 1947) as well as in birds (Angel, 1950).

It is possible that anencephalia, like anophthalmia, results from disturbances of the inductive processes. After the stages in which excess vitamin A causes anencephalia, it is possible that there is an early perturbation which does not allow closure of the encephalic tube.

Other anomalies appear to result from problems with specific growth: cleft palates would be the result of an insufficient growth of the palatine processes. One can conclude that after the stages of action of vitamin A, there is an absence of fusion and not of secondary dehiscence.

Finally, we have seen that there may be simple tissue alterations. These include the case of cataracts which develop later.

The variations in the malformations caused by an excess of vitamin A, according to stages, is not an isolated fact.but a well-known idea. In the past, Stockard (1921) in his experiments with poisons of the fish Fundulus, had suggested that the type of malformation obtained depends essentially on the stage at which it is applied.

Angel (1950) has clearly shown this fact in the chicken. During the 24 first hours of incubation anencephalia can be produced by different substances; on the second day, anuria and malformations of the limbs; on the fourth day, celosomia and achondroplasia. In certain cases, these facts are particularly evident. With sodium cacodylate Angel (1950) obtained anurias and malformations by early injection then at the 72nd hour, malformations of the limbs only; Landauer (1947), using insulin, observed anuria only up to the 72nd hour and micromelia by the 120th hour. Ingalls et al (1950) produced anencephalia in the mouse by anoxia on the 8th day and cleft palate on the 13th day. Ohsaamen (1951) in the chicken, initially obtained anencephalia and later malformations of the eyes, limbs and tail.

With an infection such as rubella, Carruthers (1945), Aycok and Ingalls

(1943), and Bourquin (1948) also observed that the malformations vary according to whether the disease occurs early or late in pregnancy.

Certain cases of sudden deficiency are also instructive, such as those of Nelson, Wright, Asling and Evans (1955), caused by brief administration of folic antivitamin methyl folic acid. Between the 7th and 9th days, they obtained cerebral, cardiovascular and urogenital anomalies. From the 9th to the 11th day, anomalies of the skeleton, cleft palate, and gastroschisis; from the 10th to the 11th days, anomalies of the skeleton with polydactyly and facial fissures; from the 10th to the 13th day, anomalies of the skeleton, cleft palate, harelip, vascular and urogenital anomalies; from the 11th to the 14th days, anomalies of the skeleton and the cleft palate only. In all of these series cataracts were found. The results led these authors to view the stage as playing the most critical role.

The cessation of vitamin A deficiency at different times reveals that this deficiency acts quite late but at different stages (Wilson, Roth, Warkany, 1953). The cardiac malformations disappear when the administration takes place before the 10th day, and horseshoe kidney disappears when the treatment is given before the 14th day. It is a curious fact that diaphragmatic hernia, which was on the right, switches to the left after vitamin administration on the 12th to the 15th days.

The clearest demonstrations of the importance of the stage result from experiments with x-rays whose action can easily be pinpointed in time.

Job, Leirold, Fitz-Maurice (1935) in the rat, on the 9th day obtained hydrocephalia;on the 10th day, ocular anomalies and on the 11th day anomalies of the jaws.

Raven(1938) obtained dysencephalia and meningoceles in the mouse on the 8th day; from the 9th to the 13th day, anomalies of the tail; from the 15th to the 17th, changes in the testicle; from the 18th to the 19thdays, cataracts.

Warkany (1947) obtained anomalies of the head in the rat from the 10th to the 13th days and on the 15th day cleft palate and still later malformations of the limbs.

More recently, Russel (1954) and Hicks (1954) further specified facts of the same nature. On the 9th day, Hicks obtains anencephalia; on the 10th day, anomalies of the forebrain, mesencephalon and the medulla, anophthalmia and malformations of the bone structure of the head; on the 11th day phydrocephalia, encephalocle and anomalies of the mdeulla; on the 12th day, microcephalia and porencephalia, and anomalies of the skeleton; on the 13th and 15th days, microcephalia and limited anomalies of the encephalone; finally, before and after birth anomalies of the cerebellum. This influence of time does not prevent Hicks from recognizing the importance of the very nature of the teratogenic agent, as indicated by his experiments with various substances in which he attempted to reproduce the results produced by irradiation.

The significance of the stage at which treatment is made is therefore quite clear, but we must not underestimate the specific nature of the teratogenic element.

Certain observations by Landauer (1952) are very suggestive in this regard of the complexity of the method of action of the teratogenic factor. They show that the same substance can give different effects depending on the stage. Thus, by administering boric acid to the chicken, Landauer, working at early stages, causes anuria and when working at late stages, malformations of the limbs and beak. Thus the addition of riboflavin is capable of inhibiting these later changes but not the first, and Landauer concluded from this that the chemical mechanisms which are disturbed are distinct in these two cases.

In the past, some good examples have been found in certain experiments performed at the same stage on batrachians: using lithium chloride, anderwal-

opment of the nervous system has been obtained, Lehman (1938); using potassium sulfocyanide, Ranzi (1945) on the other hand observed hyperplasias.

Angel (1950), having studied about 100 substances at different stages, was able to show that there is a definite specificity of action: one substance can cause a malformation and not another. Thus, eserine sulfate causes brachymelia with tibia-tarsus bending which is something that no other substance, except certain sulfamides, can produce. Colchicine causes strophosmia. Trypaflavin slows down the development of the amnion. Disodium methyl arsinate has been found to be the most active substance for preventing development of the budding cauda. Quinine sulfate has caused malformations of the limbs and the budding cauda by localized hemorrhages. At a low dose level, this is always the case; however, Angel points out that at a stronger dose level these substances can lose their specificity and produce certain other malformations.

The observations of Wolff and Ginglinger (1935) as well as those of Jost (1950) with male and female hormones and their opposite results are also very demonstrative.

Deficiencies also reveal the importance of the very nature of the deficient substance. Folic acid deficiency such as we obtained by a deficient diet (Giroud and Lefebvres, 1951) appears to be quite specific; it is much less so when obtained by an anti-vitamin, as was done by Nelson, Wright, Asling and Evans (1955). With riboflavin deficiency, regardless of the date on which the deficiency begins and consequently regardless of the time when the deficiency reaches a certain point, only two malformations are observed; cleft palate and micromelia with syndactyly (Warkany and Schraffenberger, 1944; Giroud and Lefebvres, 1947; Bologna and Piccioni, 1950.) The use of antivitamin by Baird, Nelson, Monie, Wright and Evans caused cardiovascular malformations to develop. However, we might propose one hypothesis, among others of whether the intensity of the action thus obtained causes the

specificity to disappear.

The anomalies of vitamin A deficiency involve the eye, the cardiovascular system, the kidney and the genital organs; (Warkany and Schraffenberger, 1948; Wilson, Roth and Warkany, 1953). This very special picture induced by vitamin A hypovitaminosis, is very different from that which we obtain following vitamin A hypervitaminosis. Pantothenic acid deficiency is also quite characteristic: it involves the brain and eye and is accompanied by vascular changes followed by ectrodactylia (Lefebvres; 1951; Giroud and Lefebvres, 1955).

In amino acid deficiency we also find facts that favor specificity. The deficiencies produced by using analogues of amino acids prove this: antiphenylalarine causes malformations of the nervous system, antileucine prevents segmentation of the mesoblast (Herrman, 1953). With ethionine, the antagonist of methionine, we obtain difficulties in the development of the initial embryo and the nervous system (Feldman and Waddington, 1955).

Even in the case when the results with distinct teratogenic agents appear to be comparable, detailed analysis reveals differences, as was pointed out by Warkany (1953) and Landauer (1953). Thus,according to Warkany, irradiation on the 13th through 14th days does not produce exactly the same results as riboflavin deficiency. Analysis of the malformations of the limbs, obtained by various substances, thus leads Landauer to conclude that they have a specific action.

All of these facts therefore indicate that the results produced by a teratogenic factor are also dependent upon their own nature. The same is true for vitamin A hypervitaminosis; while its results vary with the stages of pregnancy they also produce a picture which is quite specific.

Giroud-'56
Bib. No. 3192

Reproduced by permission
of the copyright owner

Archives d'Anatomie Micro, 45: 77-98, 1956.

TÉRATOGENÈSE PAR HAUTES DOSES DE VITAMINE A EN FONCTION DES STADES DU DÉVELOPPEMENT

Par A. GIROUD et M. MARTINET
(Laboratoire d'Embryologie de la Faculté de Médecine de Paris.)

SOMMAIRE

I. — *Introduction* 77
II. — *Technique* 78
III. — *Résultats* 79
IV. — *Considérations générales* 91
Résumé 95

I. — *INTRODUCTION*

On sait que la carence A entraîne l'apparition de malformations chez l'embryon.

HALE (1935), le premier, avait démontré chez le porcelet que des fissures palatines, des becs-de-lièvre, des microphtalmies et des anomalies rénales, dont le rein en fer à cheval, apparues dans des élevages étaient dues à une carence en vitamine A. Ces malformations se produiraient avant le 60e jour de la gestation, car à partir de cette date l'administration de vitamine A ne modifie pas les résultats.

ANDERSEN (1941) avait noté chez le Rat, à la suite d'une carence expérimentale en cette vitamine, des hernies diaphragmatiques.

WARKANY et SCHRAFFENBERGER (1946), WARKANY, ROTH et WILSON (1948), avaient observé toute une série de malformations : anomalies oculaires, anomalies cardio-vasculaires, anomalies pulmonaires, ano-

malies rénales y compris le rein en fer à cheval, développement anormal de l'appareil génital mâle.

L'excès de vitamine A s'est aussi révélé tératogène.

Comlan (1953-1954) a vu en effet, après administration de grandes doses de vitamine A, des exencéphalies, des malformations des yeux, des spina-bifida, des fentes du palais, des méningocèles, des hydrocéphalies et, enfin, des cataractes.

Nous avons confirmé nous-mêmes (1954) ces faits et étendu ces observations. Dans un premier essai, nous avions donné 35 000 U. I. de vitamine A pendant 12 jours, du 2e au 14e jour de la gestation. Nous avions obtenu des avortements totaux dans 90 % des cas. Dans une deuxième série d'expériences, nous avions donné seulement 20 000 U. I. Dans ces conditions, nous avions obtenu un certain nombre de résorptions, mais néanmoins une série d'embryons anormaux ont pu se développer. Parmi ces embryons, il y a eu beaucoup de malformations de l'encéphale, en général assez graves pour mériter le nom d'anencéphalies. On trouve aussi très fréquemment des malformations oculaires, 25 % : anophtalmies ou microphtalmies. On rencontre également de nombreuses fentes palatines 25 %. Enfin, il y a eu des cataractes. Les organes internes ont paru normaux.

La multiplicité des anomalies observées faisait prévoir que l'excès de vitamine agit à des stades différents. Il y avait donc lieu de voir quelle était l'influence du stade embryonnaire où se formaient des malformations aussi variées. De plus, la question méritait d'attirer l'attention, car, dans bien des cas, on discute encore sur le stade où se forment certaines anomalies : par exemple certains auteurs pensent que les anencéphalies ou exencéphalies pourraient résulter d'une hyperplasie et d'une ouverture secondaire de l'encéphale; elles seraient, dans ce cas, postérieures au stade de fermeture du tube encéphalique.

II. — *TECHNIQUE*

Nos expériences ont été faites sur des rates Wistar qui étaient au régime normal d'élevage et qui ont été mises au mâle à jour fixe. Leur état de gestation a été vérifié par la présence de spermatozoïdes dans le vagin et par la persistance du diœstrus. Nous leur avons alors administré, par voie orale, de la vitamine A en solution huileuse (acétate ou palmitate), à la concentration de 1 000 000 U. I. par gramme. Ces animaux ont été sacrifiés le 21e jour de la gestation.

Pour réaliser ces essais, nous avons augmenté nos premières doses journalières en donnant 60 000 U. I. Nous avons donné ces doses pendant 3 jours seulement, en couvrant ainsi, par étapes, toute la durée de la gestation.

Ces étapes se répartissaient ainsi : 5 au 7e jour inclus, 8 au 10e jour, etc.

Les animaux ont été sacrifiés au 21e jour, disséqués et étudiés histologiquement. Cette étude a porté sur 90 rates et a permis d'examiner 615 embryons.

Nous l'avons complétée sur une petite échelle par des traitements également de 3 jours, mais alternant avec les premiers. Nous y ferons surtout allusion à l'occasion de l'étude des diverses anomalies.

III. — *RÉSULTATS EXPÉRIMENTAUX*

Notre étude a d'abord montré que la fréquence des avortements totaux diminuait au fur et à mesure qu'on agissait plus tardivement

TABLEAU I

POURCENTAGE DES RÉSORPTIONS TOTALES EN FONCTION DE LA DATE DU DÉBUT DE L'ADMINISTRATION DE VITAMINE A

5e jour	43 %	12e jour	0 %
8e jour	35 %	14e jour	0 %
11e jour	10 %	18e jour	0 %

Les résultats concernant les malformations en fonction de la date du traitement ont été les suivants :

5e au 7e jour. Nous avons eu beaucoup de résorptions totales 43 %. Parmi les fœtus trouvés au 21e jour, 20 % étaient morts. Des survivants, 80 % étaient normaux. Les quelques anormaux étaient anencéphales ou anophtalmes.

8e au 10e jour. On trouve essentiellement des anencéphalies, des anophtalmies ou microphtalmies, des spina-bifida.

10e ou 12e jour. On a trouvé, outre des fentes palatines, des fissures médianes de la mâchoire inférieure; des malformations de l'oreille s'observent aussi.

11e au 13e jour. Nous avons rencontré des fentes palatines, des aplasies des paupières « yeux ouverts », des malformations des membres (micromélie et syndactylie).

14e au 16e jour. On obtient seulement des fentes du palais.

18e au 20e jour. On observe seulement des cataractes.

La figure 1 met en évidence cette distribution des diverses malformations et leur fréquence.

Pour interpréter ces résultats, il faut se rappeler certains faits concernant l'évolution de la vitamine A dans l'organisme. Celle-ci diffuse naturellement dans la mère et, secondairement, atteint l'embryon. DANN (1932), chez diverses espèces, et WENDT (1936), chez l'homme, ont constaté que la vitamine A passe de la mère au fœtus, quoique diffici-

lement. Récemment, ZUNIN et TESTA (1953) ont donné à la Lapine gestante de hautes doses de vitamine A. En dosant le foie du fœtus de mère traitée par rapport à celui du fœtus de mère normale, ces auteurs ont trouvé 2 723 U. I. dans le premier et seulement 3 U. I. dans le second.

On sait par ailleurs que la vitamine A s'accumule dans l'organisme,

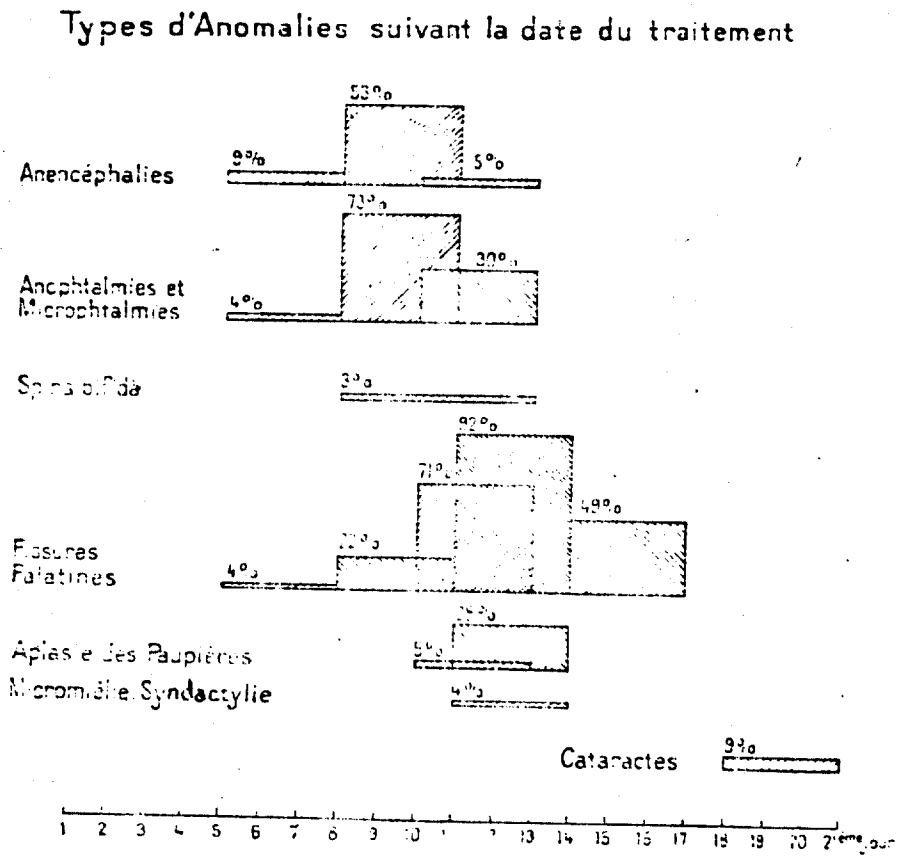

FIG. 1. — Schéma de la répartition des malformations en fonction des dates de l'administration de la vitamine A.

à l'inverse des vitamines hydrosolubles qui peuvent être facilement éliminées. On peut en conclure que, s'il est possible de préciser le début de l'action de la vitamine, il est plus difficile de préciser la disparition de son action. Le taux de la vitamine peut donc rester assez élevé pour expliquer des malformations après la cessation du traitement : la présence d'une anomalie à la suite d'un traitement précoce ne permet donc pas de conclusion certaine. Cette possibilité d'action retardée n'est

peut-être cependant pas très importante, car parmi les survivants des traitements très précoces (5e au 8e jour) on a observé un nombre très notable de fœtus normaux. La disparition progressive de malformations, à la suite de traitements de plus en plus tardifs, est très révélatrice.

L'examen des résultats mérite maintenant d'être étudié en détail : anomalie par anomalie.

Les malformations encéphaliques sont généralement très intenses : elles méritent le nom d'anencéphalie tel qu'il est entendu en pathologie humaine. Elles correspondent à l'acleiencéphalie de Angel (1955), c'est-à-dire à l'absence de fermeture du tube nerveux.



Fig. 2. — Embryon de Rat anencéphale et anophtalme (traité du 8-10e jour).

La voûte du crâne manque ainsi que le tégument. Le rhombencéphale est en général intact. Le mésencéphale et le prosencéphale sont, par contre, très anormaux; leur cavité s'ouvre à l'extérieur et leur paroi vient se continuer avec l'épiderme. En certains points, il y a d'abondants plexus choroïdes, quelques portions encéphaliques sont reconnaissables, mais une grande

Fig. 3. — Coupe d'un cerveau d'anencéphale. Destruction presque complète. Seuls persistent les ganglions de Gasser. Un feuillet neuroblastique persistant, à gauche, se continue nettement avec l'épiderme. On note quelques plexus choroïdes et l'énorme développement des vaisseaux méninges.

partie des tissus est nécrotique (fig. 3). Notons qu'à côté de ces graves malformations, on peut en trouver de plus bénignes, mais de même nature.

Ces anencéphalies apparaissent avec les administrations de vitamine A, du 5e au 8e jour, mais en petit nombre. Le maximum a été trouvé dans les essais du 8e au 11e jour, 53 %. Elles ne se retrouvent plus avec un traitement postérieur au 10e jour. Elles ne se produisent plus au-delà, ce qui semble indiquer qu'elles ne résultent pas d'un processus secondaire, mais correspondent bien à un arrêt de la fermeture du tube encéphalique.



Fig. 4.
Spina-bifida accompagnant une anencéphalie (8-10e).

On sait en effet que c'est au 9e jour qu'apparait la mise en place du chordo-mésoblaste et, par suite, le début de l'induction nerveuse. Après 11 jours et 6 heures (13 somites), d'après Schwind (1928), c'est-à-dire le 12e jour, le tube nerveux encéphalique serait complètement fermé.

De fait, Hicks (1953) observe l'anencéphalie après irradiation au 9e-10e jour, tandis que d'autres malformations du système nerveux sont plus tardives : Wilson (1953) a constaté aussi le même fait.

Les embryons anencéphales présentent très souvent un raccourcissement du massif facial supérieur, cette malformation, qui n'existe pas à l'état pur, disparait également avec l'anencéphalie, elle représente donc une malformation secondaire. Elle serait corrélative à une insuffisance de développement cranio-caudal du crâne.

Les spina-bifida que nous avons observés sont tous lombaires. La moelle est ouverte et les deux bords viennent se continuer avec l'épiderme. A part cela, sa structure peut être normale et les ganglions rachidiens bien développés. Dans quelques cas cependant, le tissu nerveux peut être en dégénérescence. Les spina-bifida ne se rencontrent jamais avec les traitements du 5e au 7e jour. Ils sont présents après ceux du 8e au 10e jour. Ils disparaissent ultérieurement dans ceux du 11e au 13e jour. Ils se développent donc un peu plus tardivement que les anencéphalies, puisqu'ils n'apparaissent pas dans les traitements les plus précoces : le tube nerveux étant complètement fermé au 12e jour, ils résulteraient bien d'un arrêt de sa fermeture.

De fait, Hicks (1953) note que les malformations médullaires suivent

les irradiations du 10e au 11e jour, alors qu'il obtenait l'anencéphalie avec celles du 9e-10e jour.



Fig. 5. — Coupe de spina-bifida.

Les anophtalmies et les microphtalmies sont bien caractéristiques. Dans les cas d'anophtalmies, les annexes de l'œil : paupières, chambre

Fig. 6. — Coupe, dans la région de l'orbite, d'un embryon présentant une anophtalmie unilatérale.
On note la présence des annexes de l'œil.

palpébrale, muscles oculaires, glandes lacrymales, sont présentes (fig. 6). Les microphtalmies sont, dans l'ensemble, constituées de la façon suivante. La cupule optique est généralement représentée par deux feuillets

épithéliaux adjacents, mais non différenciés. Plus rarement, une portion du feuillet interne a subi une différenciation rétinienne. Le cristallin est petit, le plus souvent il est constitué d'une couche épithéliale continue rappelant l'épithélium antérieur, recouvrant une masse de cellules différenciées chimiquement, mais non transformées en fibres (fig. 7). Quelquefois, il y a cependant une portion de l'épithélium transformé en fibres. Ces anomalies se rencontrent dans les traitements s'étendant du 5e au 11e jour. Elles disparaissent dans les traitements du 11e au 13e.



FIG. 7.

Microphtalmie. La cupule optique est représentée par deux feuillets épithéliaux indifférenciés. Le cristallin n'a pas subi son évolution en fibres : des cellules sont accumulées dans la vésicule cristallinienne dont les cellules ont toutes gardé l'aspect épithélial. Les annexes de l'œil sont, par contre, normales (8-10e).

Cela correspond à l'évolution de l'œil. C'est vers le 10e jour que débute l'ébauche optique et la vésicule optique est bien formée au 11e jour.

L'arrêt du développement des paupières, constituant l'état dit « œil ouvert », se rencontre dans les expériences plus tardives, après traitement du 11e au 13e jour (fig. 8). On n'en trouve plus dans celles du 14e au 16e. On sait que, normalement, les paupières se ferment vers la fin du 18e jour, et ne s'ouvriront que quelques jours après la naissance. On sait que cette anomalie a pu être rencontrée dans la carence A (WARKANY et coll., 1948) et que COHLAN (1954) l'avait déjà signalée avec l'hypervitaminose A.

Les fissures palatines sont des fentes limitées au palais secondaire. Le plus souvent, elles sont totales, mais elles peuvent être limitées à sa partie postérieure. Dans quelques cas, l'ouverture est située à la partie

antérieure et se présente comme un orifice béant en arrière du palais antérieur et, par suite, au niveau des canaux nasopalatins. Jamais il n'y



Fig. 8.

Embryon avec aplasie des paupières. Simultanément, l'oreille externe fait défaut et il existe un appendice auriculaire (10-12e).

a de fentes du palais antérieur, c'est-à-dire de bec-de-lièvre. Au 21e jour, les processus palatins anormaux sont caractérisés par leur inflexion

Fig. 9.

Coupe d'un œil dont les paupières se sont incomplètement développées. L'œil lui-même est normal.

ventrale, et surtout leur sous-développement (fig. 10 et 11). Ces fentes palatines se manifestent après les traitements du 11e au 16e jour. Nous en

avons obtenu 92 % en opérant du 11e au 13e. Elles ne se rencontrent plus après le 16e jour.

WARKANY et SCHRAFFENBERGER (1947) en ont obtenu par irradiation du 10e-16e jour avec un maximum au 15e jour. On sait que le palais doit se développer par rotation et affrontement des processus palatins et du septum nasal, cela s'effectuerait vers la fin du 16e jour. La résorption des épithéliums soudés n'est effectuée que plus tardivement, elle n'est pas



FIG. 10.

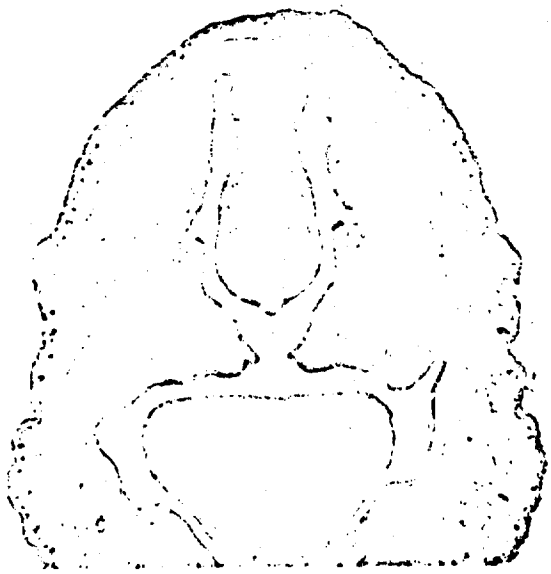

FIG. 11.

FIG. 10. — Fissure palatine vue par dessous. Noter l'intégrité du palais antérieur (11-13e).

FIG. 11. — Coupe d'une tête d'embryon présentant une fissure palatine. Les processus palatins apparaissent courts ainsi que le septum nasal.

faite le 17e jour et il reste encore des résidus épithéliaux le 18e. Une disjonction secondaire est donc théoriquement possible, mais elle est peu probable d'après la date de l'action tératogène. La disposition des lames palatines, qui restent souvent inclinées vers le bas, est peu favorable à cette interprétation. On sait par ailleurs qu'une telle disjonction pourrait se produire au niveau du palais antérieur, créant le bec-de-lièvre chez la Souris (STEINIGER, 1941) et, d'après nous, aussi chez le Rat, comme nous l'avons vu à la suite de la carence en acide folique.

Des fissures médianes de la mâchoire inférieure ont été trouvées après les administrations du 10e au 12e jour. Elles étaient très profondes, sec-

tionnant le maxillaire et le plancher buccal. De ce fait la partie antérieure de la langue était bifide (fig. 12 et 13).

Des rétrécissements de l'orifice buccal par soudure des commissures labiales ont été également constatés dans les mêmes conditions.



Fig. 12.

Fig. 13.

Fig. 12. — Embryon atteint de fissure médiane de la mandibule et dédoublement de la partie antérieure de la langue (10-12e).

Fig. 13. — Coupe montrant la fissuration de la mandibule et de la langue.

Des malformations de l'oreille ont été constatées plusieurs fois dans des conditions identiques (administration du 10e au 12e jour). L'oreille externe (pavillon et canal auditif externe) est absente (fig. 14). On note, par contre, la présence d'appendices auriculaires à squelette cartilagineux dans la région de la joue : on en rencontre de un à trois (voir fig. 8 et 15). L'oreille moyenne est peu ou pas développée. Elle peut être réduite à un simple diverticule indifférencié; dans d'autres cas, on peut reconnaître une trompe et une cavité tympanique, mais très réduite (fig. 16), et les osselets font défaut.

On peut donc considérer qu'il s'agit seulement d'anomalies d'évolutions de l'appareil branchial; l'oreille interne semble cependant en supporter certaines répercussions.

Fig. 14. — A droite, une oreille normale;
à gauche, même région dépourvue d'oreille externe (10-12e).

Fig. 15. — Coupe de la région mandibulaire montrant un appendice auriculaire faisant saillie sous la peau. Il présente un axe cartilagineux fixé au squelette. On note, simultanément, l'irrégularité du maxillaire inférieur (10-12e). A droite, témoin.

Des malformations des membres ont été trouvées à la suite du traitement du 11e au 13e jour. Elles comprenaient une micromélie et une syn-

dactylie (fig. 17 et 18). Elles rappellent celles obtenues par l'avitaminose B² (WARKANY et SCHRAFFENBERGER, 1944; GIROUD et LEFEBVRES, 1947) ou par les rayons X (WARKANY et SCHRAFFENBERGER, 1947). Les anomalies



FIG. 16.

Insuffisance de développement de l'oreille moyenne. D'un côté, la cavité rudimentaire de la caisse du tympan ; de l'autre, la trompe d'Eustache est réduite à un petit diverticule (10-12). En haut, témoin.

se produiraient vers le 13ᵉ jour, selon WARKANY et SCHRAFFENBERGER, c'est-à-dire à un stade où les ébauches squelettiques se forment sous l'aspect de condensations mésenchymateuses; le membre, à ce stade, est déjà bien ébauché, ses premiers rudiments ayant débuté au 11ᵉ jour, mais la chondrification ne débute qu'au 11ᵉ jour.

Fig. 17.
Syndactylie à gauche et pied normal à droite (11-13e).

Enfin, il existe des altérations tissulaires, des cataractes (fig. 19). Elles correspondent à une destruction presque totale des fibres ne respectant que les cellules zonales. Elles ne se manifestent seulement qu'après les

Fig. 18. — Syndactylie : fusion des métatarsiens.

actions tardives, du 18e au 21e jour. Elles ne se rencontrent pas dans les traitements plus précoces.

Kyvrs en a obtenu, chez la Souris, par irradiation vers le 18e-19e jour. On sait que l'on peut en observer après traitement de la mère par thy-

roxine (GIROUD et MARTINET, 1953), mais que cette sensibilité disparait peu après la naissance (TUSQUES, 1955). On se rappelle que, chez l'homme, elle se rencontre dans les rubéoles débutant au 1er ou au 2e mois. Signalons que NELSON et coll. (1955) l'auraient obtenue à tous les stades avec l'antivitamine folique.

Comme on le voit, il résulte manifestement de ces expériences que le

FIG. 19. — Œil avec cataracte (18-20e).

stade embryonnaire où est effectué l'administration de hautes doses de vitamine A est très important : il y a plusieurs moments particulièrement sensibles et, de ce fait, la possibilité d'apparition de malformations bien distinctes.

IV. — *CONSIDÉRATIONS GÉNÉRALES*

On note donc d'abord, d'après nos résultats expérimentaux, que dans les stades précédant l'implantation et le début de la gastrulation l'hypervitaminose A ne provoque pas de malformation. Cependant, c'est une période où l'embryon semble peu résistant, comme le prouve la grande mortalité, d'une part, et la régression progressive des avortements totaux tout au long de la gestation, d'autre part (tableau I).

Cette constatation est tout à fait en accord avec les observations faites

après l'action des rayons X à divers stades du développement. RUSSEL et RUSSEL (1953) signalent en effet que, dans les stades de préimplantation, il y a beaucoup de morts, mais peu de malformations chez les survivants.

Par ailleurs, nos résultats montrent que plusieurs stades sont beaucoup plus sensibles que d'autres et que certains processus embryogénétiques peuvent être perturbés bien plus facilement que d'autres : les fentes du palais peuvent apparaître dans 92 % des cas, les anencéphalies dans 53 %, et d'autres malformations avec des fréquences beaucoup plus faibles. Cette sensibilité est probablement l'explication de la grande fréquence des malformations encéphaliques, dites spontanées, notées chez l'homme (MURPHY, 1947) comme chez les Oiseaux (ANCEL, 1950).

Il est possible que les anencéphalies, comme les anophtalmies, résultent de perturbations dans les processus inductifs. D'après les stades où l'excès de vitamine A provoque l'anencéphalie, on peut envisager qu'il s'agit d'une perturbation primitive n'ayant pas permis la fermeture du tube encéphalique.

D'autres anomalies paraissent résulter de troubles de croissance spécifique : les fentes palatines seraient de la sorte le résultat d'une croissance insuffisante des processus palatins. On peut conclure en effet ici, d'après les stades d'action de la vitamine A, qu'il s'agit d'une absence de fusion et non d'une déhiscence secondaire.

Enfin, on a vu qu'il peut se produire de simples altérations tissulaires : tel serait le cas des cataractes qui se produisent tardivement.

Les variations des malformations que provoquent l'excès de vitamine A selon les stades n'est pas un fait particulier.

C'est une notion bien connue. Déjà, STOCKARD (1921), dans ses expériences avec des toxiques sur le poisson Fundulus, avait avancé que le type de malformation obtenu dépendait essentiellement du stade de leur application.

ANCEL (1950) a bien montré le fait chez le Poulet. Pendant les 24 premières heures de l'incubation, on provoque, avec diverses substances, des anencéphalies; le 2e jour, de l'anourie et des malformations des membres; le 4e jour, de la cœlosomie et de l'achondroplasie. Les faits sont, dans certains cas, particulièrement évidents. Avec le cacodylate de soude, ANCEL (1950) obtient, par injection précoce, des anouries et des malformations des membres, puis, à la 72e heure, uniquement des malformations des membres; LANDAUER (1917), avec l'insuline, observe des anouries jusqu'à la 72e heure et, à la 120e heure, des micromélies. INGALLS et ses collaborateurs (1950) provoquent chez la Souris, par anoxie, au 8e jour, des anencéphalies et, au 13e jour, des fentes du palais. RUBNAMEN (1951), chez le Poulet, obtient d'abord des anencéphalies et, plus tardivement, des malformations des yeux, des membres et de la queue.

Avec une infection comme la rubéole, CARRUTHERS (1945), AYCOK et INGALLS (1946), BOURQUIN (1948), ont noté aussi que les malformations varient suivant que la maladie correspond à des dates plus ou moins avancées de la gestation.

Certains cas de carence brusques sont aussi instructifs, tels sont ceux de NELSON, WRIGHT, ASLING et EVANS (1955), provoqués par une administration courte d'antivitamine folique, l'acide méthylfolique. Du 7e-9e jour, ils obtiennent des anomalies cérébrales et cardio-vasculaires, et urogénitales. Du 9-11e, des anomalies du squelette, des fentes du palais, des gastroschisis; du 10-11e, des anomalies du squelette avec polydactylisme, des fissures faciales; du 10-13e, des anomalies du squelette, des fentes du palais, des becs-de-lièvre, des anomalies vasculaires et urogénitales; du 11e au 14e, uniquement des anomalies du squelette et des fentes palatines. Dans toutes les séries, ils trouvent des cataractes. Ces résultats ont amené ces auteurs à envisager le rôle primordial du stade.

L'arrêt de la carence A à des moments divers révèle que cette carence agit assez tardivement, mais à divers stades (WILSON, ROTH, WARKANY, 1953). Les malformations cardiaques disparaissent lorsque l'administration a lieu avant le 10e jour, le rein en fer à cheval disparait lorsque le traitement a lieu avant le 14e jour. Fait curieux, la hernie diaphragmatique qui était droite devient gauche après vitaminisation du 12e au 15e jour.

Les démonstrations les plus manifestes de l'importance du stade résultent des expériences avec les rayons X dont l'action peut être facilement localisée dans le temps.

JOB, LEIBOLD, FITZ-MAURICE (1935), chez le Rat, ont obtenu, au 9e jour, des hydrocéphalies; au 10e jour, des anomalies oculaires et, au 11e, des anomalies des mâchoires.

KAVEN (1938), chez la Souris, avait obtenu, au 8e jour, des dysencéphalies et des méningocèles; du 9e au 13e, des anomalies de la queue; du 15e au 17e, des altérations du testicule; du 18e au 19e jour, des cataractes.

WARKANY (1947), chez le Rat, avait obtenu, du 10e au 13e jour, des anomalies de la tête, ensuite, du 15e jour, des fentes du palais et, plus tardivement encore, des malformations des membres.

Plus récemment, RUSSEL (1951) et HICKS (1954) ont précisé des faits du même ordre. HICKS obtient, au 9e jour, de l'anencéphalie ; au 10e jour, des anomalies du cerveau antérieur, du mésencéphale et de la moelle, de l'anophtalmie, des malformations du squelette de la tête; au 11e jour, de l'hydrocéphalie, des encéphalocèles, des anomalies de la moelle; au 12e jour, de la microcéphalie et de la porencéphalie, des anomalies du squelette; au 13e jour, ainsi qu'au 15e, de la microcéphalie et des anomalies limitées de l'encéphale; enfin, avant et après la naissance, des anomalies du cervelet. Cette influence du temps n'empêche pas d'ailleurs HICKS de reconnaître l'importance de la nature même de

l'agent tératogène, comme le lui ont montré ses expériences avec diverses substances où il cherchait à reproduire les résultats provoqués par l'irradiation.

Le rôle du stade où se fait l'intervention est donc des plus manifestes, mais il ne faudrait pas sous-estimer la nature spécifique de l'élément tératogène.

Certaines observations de LANDAUER (1952) sont, à cet égard, très suggestives de la complexité du mode d'action du facteur tératogène. Elles montrent qu'une même substance a un mode d'action différent selon les stades. Ainsi, par administration d'acide borique chez le poulet, LANDAUER obtient, en agissant précocement, de l'anourie et, à des stades tardifs, des malformations des membres et du bec. Or, l'addition de riboflavine est capable d'inhiber ces dernières malformations, mais pas la première, et LANDAUER en conclut que les mécanismes chimiques perturbés sont distincts dans les deux cas.

Déjà, on en trouve de beaux exemples dans certaines expériences effectuées au même stade sur les batraciens : avec le chlorure de lithium, on obtient des sous-développements du système nerveux, LEHMAN (1938); avec le sulfocyanure de potassium, RANZI (1945) a observé, au contraire, des hyperplasies.

ANGEL (1950), ayant étudié une centaine de substances et à divers stades, a pu mettre en évidence qu'il existe une indiscutable spécificité d'action : une substance pouvant provoquer une malformation et non une autre. Ainsi, le sulfate d'ésérine provoque la brachymélie avec coudure du tibia-tarse, ce qu'aucune autre substance, sauf certains sulfamides, n'a fait apparaître. La colchicine détermine la strophosomie. La trypaflavine empêche le développement de l'amnios. Le méthylarsinate disodique s'est révélé la substance la plus active pour empêcher le développement du bourgeon caudal. Le sulfate de quinine a produit des malformations des membres et du bourgeon caudal par hémorragies localisées. A faible dose, il en est toujours ainsi ; cependant, note ANGEL, à dose plus forte ces substances peuvent perdre leur spécificité et produire quelques autres malformations.

Les observations de WOLFF et GINGLINGER (1935), de JOST (1950), avec les hormones mâles et femelles et leurs résultats opposés, sont tout aussi démonstratives.

Les carences révèlent aussi l'importance de la nature même de la substance déficiente. La carence en acide folique, telle que nous l'avons obtenue par régime déficient (GIROUD et LEFEBVRES, 1951), paraît assez spécifique; elle l'est beaucoup moins quand elle est obtenue par une antivitamine, comme l'ont fait NELSON, WRIGHT, ASLING et EVANS (1955). La carence en riboflavine, quelle que soit la date de début des carences et, par suite, quels que soient les moments où la carence atteint un certain degré, on observe seulement deux malformations : des fentes

du palais et des micromélies avec syndactylies (WARKANY et SCHRAFFENBERGER, 1944; GIROUD et LEFEBVRES, 1947; BOLOGNA et PICCIONI, 1950). L'usage d'une antivitamine par BAIRD, NELSON, MONIÉ, WRIGHT et EVANS, fait apparaître des malformations cardio-vasculaires. Cependant, on peut se demander, entre autres hypothèses, si l'intensité d'action ainsi obtenue ne fait pas disparaître la spécificité.

Les anomalies de la carence A portent sur l'œil, l'appareil cardio-vasculaire, le rein et l'appareil génital (WARKANY et SCHRAFFENBERGER, 1948; WILSON, ROTH et WARKANY, 1953). Ce tableau bien spécial, réalisé par l'hypovitaminose A, est très différent de celui que nous venons d'observer à la suite de l'hypervitaminose A. La carence en acide pantothénique est aussi bien caractéristique, elle porte sur le cerveau, l'œil et s'accompagne d'altérations vasculaires suivies d'ectrodactylies (LEFEBVRES, 1951; GIROUD et LEFEBVRES, 1955).

Pour les carences en acides aminés, on retrouve également des faits en faveur de la spécificité. Les carences obtenues en utilisant des analogues des acides aminés le prouvent : l'antiphénylalanine provoque des malformations du système nerveux, l'antileucine empêche la segmentation du mésoblaste (HERRMAN, 1953). Avec l'éthionine antagoniste de la méthionine, on obtient des troubles de développement de l'ébauche embryonnaire et du système nerveux (FELDMAN et WADDINGTON, 1955).

Même dans les cas où les résultats avec des agents tératogènes distincts semblent comparables, l'analyse détaillée révèle des différences, comme l'ont noté WARKANY (1953), LANDAUER (1953). Ainsi, selon WARKANY, l'irradiation au 13-14e jour ne donne pas exactement les mêmes résultats que la carence en riboflavine. L'analyse des malformations des membres, obtenue par diverses subsfances, conduit aussi LANDAUER à penser à leur action spécifique.

Tous ces faits révèlent donc que les résultats provoqués par un facteur tératogène sont aussi fonction de leur nature propre. Il en est de même pour l'hypervitaminose A : ses résultats varient avec les stades de la gestation, mais ils réalisent, d'autre part, un tableau d'ensemble assez particulier.

RÉSUMÉ

Un excès de vitamine A se révèle tératogène et ses manifestations sont multiples sur l'embryon : elles comprennent des malformations correspondant à divers processus embryogénétiques.

Administrée à des stades divers de l'embryogénèse, l'excès de vitamine A produit des résultats ou des malformations bien distinctes.

Au fur et à mesure que progresse le développement, la résistance vitale des embryons devient de plus en plus grande. Pendant la période précédant la gastrulation, l'administration de vitamine A provoque en

effet beaucoup de résorptions. Théoriquement, il ne doit pas y avoir d'action tératogène.

Dans la suite, l'excès de vitamine produit des anomalies variant suivant le stade.

Du 8e au 10e jour, on obtient surtout des anencéphalies, des anophtalmies, des microphtalmies et des spina-bifida; ces anomalies ne se rencontrent plus avec les traitements débutant à partir du 11e jour.

Du 11e au 16e jour, on obtient des fentes palatines avec un maximum du 11e au 13e jour.

Des micromélies avec syndactylies ne s'observent que du 11e au 13e jour.

Des altérations de l'appareil branchial, avec arrêt du développement de l'oreille moyenne, absence d'oreille externe et présence d'appendices auriculaires, se constatent après traitement, du 10e au 12e jour.

Tardivement, on rencontre seulement des cataractes.

Le facteur temps est donc très important dans l'hypervitaminose A. Néanmoins, dans ce cas comme dans beaucoup d'autres, il n'éclipse pas l'influence de la nature propre de l'agent tératogène.

BIBLIOGRAPHIE

ANDREL (P.), 1950. — La chimiotératogenèse chez les vertébrés. Doin, Paris.

— 1955. — Malformations déterminées par des injections de substances chimiques localisées à la tête d'embryons de Poule. *Journ. of Embryol. and Exper. Morph.*, **3**, déc. 1955, part 4, 335-354.

ANDERSEN (D. H.), 1941. — Incidence of congenital diaphragmatic hernia in the young of rats bred on a diet deficient in vitamine A. *Am. J. Dis. Child.*, **62**, 888-889.

AYCOK (W. L.) et INGALLS (T. H.), 1946. — Maternal disease as a principe in the epidemiology of congenital anomalies. *Am. J. Med. Sci.*, **212**, 366-379.

BAIRD (C. D. G.), NELSON (M. N.), MONIF, WRIGHT (L. W.) et EVANS (H.), 1955. — Congenital cardiovascular anomalies produced with the riboflavin antimetabolite galactoflavin in the rat. *Fed Proc.*, **14**, 428.

BOLOGNA (V.) et PICCIONI (V.), 1950. — Effets de l'hypovitaminose B2 sur la gestation et sur les nouveau-nés chez le Rat albinos. *Boll. soc. Ital. Biol. Sper.*, **26**, 2, 219-221.

BOURQUIN (J. B.), 1948. — Les malformations du nouveau-né causées par les viroses de la grossesse, et plus particulièrement de la rubéole. Le François, Paris, 1948.

CHAMBERLAIN (D. G.), 1945. — Congenital deaf mutism as a sequel of a rubella like maternal infection during pregnancy. *Med. J. of Austral.*, **1**, 315-320.

COHEN (S.), 1952. — Excessive intake of vitamin A as a cause of congenital anomalies in the rat. *Science*, **117**, 553-556.

— 1954. — Congenital anomalies in the rat produced by excessive intake of vitamin A during pregnancy. *Pediatrics*, **13**, 6, 555-567.

DANN (W. J.), 1952. — The transmission of vitamin A from parents to young in mammals. *Biochem. Jour.*, **23**, 1072.

FELDMANN et WADDINGTON, 1955. — The uptake of methionine S 35 by the chick embryo and its inhibition by ethionine. *Journ. of Embryol.*, **3**, 44-58.

FITZ (H. B.), 1953. — The effect of excess vitamine A on the differentiation of chick ectoderm in culture. *Acta anat. a experim. Morphol.*, **1**, 287-288.

GIROUD (A.) et MARTINET (M.), 1953. — Cataractes fœtales par thyroxine chez diverses souches de Rats. *C. R. S. B.*, **127**, 997-998.

— 1955. — Malformations embryonnaires par hypervitaminose A. *Arch. fr. Pédiat.*, **12**, 3, 292-300.

GIROUD (A.) et LEFEBVRES (J.), 1947. — Répercussions de l'avitaminose B2 sur l'embryon de Rat. *Arch. fr. Pédiat.*, **4**, 317-327.

— 1951. — Influence tératogène de la carence en acide folique. *C. R. Soc. de Biol.*, **145**, 526-527.

GIROUD (A.), LEFEBVRES (J.) et DUPUIS (R.), 1952. — Répercussion sur l'embryon de la carence en acide folique. *Rev. internat. de Vitamin.*, **24**, 420-429.

GIROUD (A.), LEFEBVRES (J.), PHOST (H.) et DUPUIS (R.), 1955. — Malformations des membres dues à des lésions vasculaires chez le fœtus de Rat déficient en acide pantothénique. *J. of Embryol. a. exper. Morphol.*, **3**, 1-12.

HALE (F.), 1935. — The relation of vitamin A to anophtalmos in pigs. *Am. J. Ophtalm.*, **18**, 1087-1093.

HERRMAN (H.), 1953. — Interference of amino acid analogues with normal embryonic development. *J. of Embryol. a. exper. Morphol.*, **1**, 291-295.

HICKS (S. P.), 1953. — Developmental Malformations Produced by radiations : A Timetable of their development. *Am. J. Roent.*, **69**, 272-293.

— 1954. — Effects of radiation, Hormones and Enzyme inhibitors on the developing Embryonic Nervous system. *J. Comp. a. Cell. Physiol.*, suppl., 1 vol., **43**, 151-178.

INGALLS, 1950. — Anoxia as a cause of fetal death and congenital defect in the mouse. *Am. J. Dis. Child.*, **80**, 34-45.

JOB, LEIBOLD, FITZ, MAURICE, 1935. — Biological effects of roentgen rays; The determination of critical periodes in mammalian development with X rays. *Am. J. Anat.*, **56**, 97-117.

JOST (A.), 1950. — Sur le contrôle hormonal de la différenciation sexuelle du lapin. *Arch. Anat. Microsc. et Morph. exp.*, **39**, 4, 577-607.

KAHEN (A.), 1938. — Das Auftreten von Gehirnmissbildungen nach Rœntgenbestrahlung von Mäusembryonen. *Ztschr. f. menschl. Vererb u. Konstitutionslehre*, **22**, 247-257.

— 1952. — Malformations of chicken embryo produced by boric acid and the probable role of riboflavin in their origin. *J. exp. Zool.*, **120**, 469-508.

LANDAUER (W.), 1947. — Insulin-induced abnormalities of beak, extremities and eyes in chickens. *J. Exp. Zool.*, **105**, 145-172.

LEFEBVRES (J.), 1951. — Rôle tératogène de la déficience en acide pantothénique chez le Rat. *Ann. Méd.*, **52**, 227-298.

LEHMANN (F. E.), 1938. — Regionale Verschiedenheiten des Organisators von Triton insbesonder in der vorderer und hinteren Kopfregion nach-gewiesen durch phasenspecifische Erzeugung von Lithium bedingten und operativ bedingten Regionaldefekten. *Arch. f. Entw. Mech.*, **138**, 104.

MURPHY (D.), 1947. — Congenital malformations. Lippincott Comp., édit., London.

NELSON (M. N.), WRIGHT (H. V.), ASLING (C. W.) et EVANS (H. M.), 1955. — Multiple Congenital abnormalities résulting from transitory deficiency of pteroylglutamic acid during gestation in the rat. *The Journ. of Nutr.*, **56**, 349-370.

REED (S. C.), 1933. — An embryological study of harelip in mice. *Anat. Rec.*, **56**, 101-110.

RANZI (S.), TANDINI (E.) et STORCHI-OFFER (E.), 1945. — Alterazioni dello sviluppo embrionale di anfibi prodotte da solfocianoto e da altre sostanze. *Rendiconti cl. di scienze*, **79**, 1, 161-197.

RUBSAMEN (H.), 1951. — Die beeinflussung der Kiemenentwicklung von Triton in experimentellen Sauerstoffmangel. *Beitr. pathol. anat.*, **111**, 2, 236-244.

RUSSELL (E. S.) et RUSSEL (W. L.), 1954. — An analysis of the changing radiation response of the developing mouse embryo. *J. Cell Comp. Physiol.*, **43**, 103-115.

SCHWIND, 1928. — The development of the hypophysis of the albino Rat. *Am. J. of Anat.*, **41**, 295-320.

STEINGER (F.), 1940. — Ueber die experimentelle beeinflussung der Ausbilding [illegible] der Maus. *Ztschr. f. Menschl. Vererb. u. Konstitutionslehre*, **24**, 1-12.

STOCKARD (C. R.), 1921. — Developmental rate and structural expression : an experimental study of twins « double-monsters » and single deformities. *Am. J. Anat.*, **28**, 115-278.

TUSQUES (J.), 1955. — Effet toxique (cataracte) sans effet morphogénétique de la thyroxine injectée *in utero*, chez les fœtus de Rat blanc, avant le développement des sensibles localés. *C. R. Soc. de Biol.*, **149**, 1170-1173.

WARKANY (J.), 1947. — Etiology of congenital malformations. Advances in Pediatrics, vol. 2. Interscience Publishers Inc., New-York, 1-63.

— 1952-1953. — Congenital malformations induced by maternal dietary deficiency. Experiments and their interpretations. *The Harvey Lectures*, **48**, 89-109.

WARKANY (J.) et SCHRAFFENBERGER (E.), 1944. — Congenital malformations induced in rats by maternal nutritional deficiency. VI. The preventive factor. *The Journ. of Nutrit.*, **27**, 477-484.

— 1946. — Congenital malformations induced in rats by maternal vitamin A deficiency. I. Defects of the eye. *Arch. of Ophtalm.*, **33**, 150-169.

— 1947. — Congenital malformations induced in rats by rœntgen rays. *Am. J. Dis. Ch.*, **57**, 455-463.

WARKANY (J.), ROTH (C. B.) et WILSON (G.), 1948. — Multiple congenital malformations : a consideration of etiologic factors. *Pediatrics*, **3**, 462-471.

WENDT (H.), 1935. — Ueber den Carotin. Vitamin A. Stoffwechsel des menschlichen Fetus. *Klin. Wschr.*, **15**, 222-225.

WILSON (J.), 1954. — Differentiation and the reaction of rat embryos to radiation. *Journ. of Cellular and Comp. Physiolog.*, **43**, 11-37.

WILSON (J.), ROTH (C.) et WARKANY (J.), 1953. — An analysis of the syndrome of malformations induced by maternal vitamin A deficiency. Effect of restoration of vitamin A at various times during gestation. *Am. Journ. of Anat.*, **92**, 2, 189-217.

WOLFF (E.) et GINGLINGER (A.), 1935. — Sur la transformation des poulets mâles en intersexués par injection d'hormone femelle (folliculine) aux embryons. *Arch. Anat. Hist. et Embryol.*, **20**, 219-278.

ZUSIN (C.) et TESTA (F.), 1953. — L'effetto di dosi massive di vitamine A sui figli con la somministrazione alle madri in gravidanza. *Atti. Soc. Ita. di pathol.*, **3**, 637-641.

Archives D'Anatomie Microscopique 46:3. 1957.

Giroud-'57
Bib. No. 3195

Reproduced by permission
of the copyright owner

Morphogenesis of Anencephalia

A. Giroud and M. Martinet

I - Introduction

The characteristics of anencephalia in man are well known. The tegument and the vault of the cranium show defects. In contact with an angiomatous tissue, we find in the portion corresponding to the anterior region of the anencephalon some nerve tissue debris which is frequently necrotic and composed of neuroglial elements, as well as nerves, especially the optic nerves with the eyes. At the near, the formations derived from the rhombencephalon generally persist. Morphogenesis of anencephalia is little understood and it has been described in only a small number of anencephalic embryos, often not either very young embryos or those in a perfect state of preservation.

Frazer (1921) studied a 17 mm embryo reconstructed by Mann (1937) in which the anterior portion of the brain was lacking.

De Wrete (1924) has described a 7 week embryo with craniorachischisis. De Vries (1927) published a similar document on an embryo 23 mm long.

Bohmig (1927) has likewise described the case of an embryo (2 months) with an extension of the anomaly to the medulla. Groth (1928) published a report on a case of craniorachischisis (14 mm) and Spanner (1928) described another (37 mm).

Dodds (1937) reports on a 16.5 mm embryo that had achieved anencephalia. Stroer and W. Derzwan (1939) described another, 18 mm long, with complications of rachischisis.

Van Der Zwan (1951) has described 3 interesting human embryos (18 to 22 mm). In one of them (22 mm), which also exhibited rachischisis, the anencephalon formed an enormous mass above the base of the cranium, protruding at the front and back. The entire surface was formed by the diencephalon, mesencephalon and rhombencephalon which were exposed. The ependymal layer was continuous with the epidermis. In the thickness of the nerve septum, one

could make out a germ layer, a mantle and a marginal zone. One could recognize the corpora striata, an optical recess and an infundibular recess. Several choroid plexuses were found at the level of the foramen of Monro, as well as along the edges of the diencephalon, at the junction of the epidermis. They were also found in the same region, at the level of the fourth ventricle. (this description largely corresponds to that of our 17 day embryos). The other two embryos also exhibited rachischisis. In all cases, beneath the cerebrospinal axis, there was loose, very vascular connective tissue. Without being more specific, Van Der Zwan pointed out that these malformations have a very early origin and suggested that the nervous degeneration was caused by circulatory difficulties.

Erskine (1955) studied two anencephalic human embryos; in one 18 mm. embryo, the base of the cranium was covered by a loose mesenchyma, which was cystic, vascular and edematous and covered a fine fibrous cuticle. Below this, one could find only a few masses of neuroblasts. The eye and the optic nerve were present. One could make out the 5th, 7th, 8th and 9th nerves, as well as fragments of the 3rd,4th, 6th and 12th. In one 14 mm, embryo, the same edematous mesenchyma was observed, in which debris from the diencephalon and perhaps the hemisphere could be found, as well as sensory and motor nerves, except for the 3rd. Erskine supposes that the neural tube did not close originally and was nevertheless covered later by the mesenchyma.

Bivetti (1954) has described, under the name of pseudoenoephalia, 3 embryos ranging in size from 14 to 30 mm. in which the mesenchymatous cranium showed interruptions by or coming from portions of the encephalon. In one, the rhombencephalon alone was present, which indicates that this embryo was anencephalic.

Recently, Ford (1956) has studied an anencephalic, 33.5 mm. long, in which the entire anterior portion of the brain was missing up to the root

of the 5th. The eyes and the optic nerves, as well as fragments of the 3rd, were present. This destruction could have resulted from a change in the cerebral arteries. He initially suggests a lack of closure of the neural groove.

Experimentally, the data seem to be more complete. In the mouse, the existence of strains that showed malformations of the anencephalon, a little less serious than typical anencephalia, had made it possible for several authors, among them Snell and Picken (1935), as well as Bonnevie (1936) to study the development of this anomaly. As we will see, their conclusions do not agree.

Two fundamental interpretations of anencephalia have been devised. In the first the anomaly results in persistence of the neural groove, which does not close and develops in this form. In the second, the anomaly results from a secondary rupture of an originally closed brain.

We have tried to take advantage of the circumstances in which we found ourselves for studying the morphogenesis of anencephalia. In the course of our experiments with teratogeneses caused by vitamin A hypervitaminosis, we obtained a great many cases of anencephalia.

Cohlan (1953) mentioned that by administering 20,000 units of vitamin A to a pregnant rat on the 2nd, 3rd and 4th to 16th days, he was able to produce various anomalies in the embryo. We repeated these experiments (1954) and showed (1955) that distinct malformations are produced by intervening at various stages. To do this, we gave only 50,000 units of the vitamin for three days in a row. Under these conditions, with treatments on the 8th, 9th and 10th days, we obtained 52% anencephalia.

We have therefore continued this research, this time studying the embryos at various stages of pregnancy.

II - Technique

These experiments were carried out on Wistar rats weighing 250 grams whose reproductive cycle was followed by examining vaginal smears. They were mated at estrus and impregnation was monitored.

On the 8th, 9th and 10th days of pregnancy, i.e. 3 days in a row, 50,000 units of vitamin A were given orally in the form of an oil solution.

These females were eventually sacrificed, beginning on the 11th day, until the 21st day of pregnancy.

The embryos were photographed, fixed in Bouin's solution and studied by using ordinary histological techniques. The smallest embryos were fixed in the uterus and were not removed until later. In certain cases the embryos were even sectioned in the uterus, using classical planes.

We therefore studied more than 200 anencephalic embryos at various stages.

III - Observations

As we shall see, the encephalic tube does not close but remains open. Nevertheless, pronounced organogenesis takes place: hemispheres form and develop. There is therefore a quite significant encephalic structure which forms a voluminous mass above the base of the cranium. Secondarily, everything degenerates and only the remains of these formations are left behind.

At 12 o'clock on the 11th day, when the encephalon should have completed its closure, it was always open in the entire prosencephalic region as well as in the mesencephalic region. Beginning at the septa of the open telencephalon, lateral evaginations form which give rise to the hemisphere. Probably, by virtue of the union of the diencephalic septum with the ectoderm, the development of the hemisphere is slightly modified. It's flattened primordium extends from top to bottom and toward the rear, and remains adjacent to the everted septa of the diencephalon. The diencephalon is open at

the top and widens gradually, with its walls diverging to the right and left. In its ventral portion, on the other hand, it retains a normal appearance and has a flattened sagittal cavity. Two optical primordia can be distinguished. Frequently they appear in the immediate vacinity of the primordia of the hemispheras; it seems that there is some telescoping between the telencephalic and diencephalic formations. The mesencephalon is located in a wide open groove. The rhombencephalon is generally closed for its entire length.

Fig. 1 Embryo on the 11th day, 12 o'clock The prosencephalon is open and one can see the continuity of the neural layer with the epidermis. The evagination of the hemispheres is beginning at the right and left. At the front, one can see the closed rhombencephalon.

On the 12th day, the encephalon, which should be completely closed, remains open except in the rhombencephalic region. As far as the depth is concerned, the hemispheres are well developed: the corpora striata have already formed. The diencephalon in the open condition presents an optical formation which is quite developed but abnormal, because in our embryos there were frequently cases of microphthalmia. The primordium of the neurohypophysis has opened.

On the thirteenth day, the encephalon is always largely open in the entire anterior region as far as the rhomb-encephalon. Ventrally, one can see that this opening terminates at a certain distance from the point where the anterior neuropore is located; this is a fact that demonstrates that closure does take place in this region and even a little above it. Beginning at this point, the telencephalon (or what remains of it) diencephalon and mesencephalon are open.

The entire anterior portion of the telencephalon is nearly completely incorporated in the hemispheres. The latter, which cannot develop upward

and forward, have plunged ventrally, in the form of laterally flattened sacs and are directed downward and blakward.

On their internal walls, the primordia of the corpora striata are quite developed and one can see them extending forward in what remains of the telencephalic cavity. By virtue of their presence they transform the foramina of Monro into simple slits which one can see from the outside.

Figure 2 Embryo,12 days, 12 o'clock

A. Sections showing the telencephalon open at the front, with eversion of the neuroblastic layer on one side. To the fight and left, formation of the hemispheres. At the rear, rhombencephalon.

B. Section a bit lower, One can see the hemispheres on the septum from which the corpora striata have developed.

C. Section still lower From the diencephalon come the optical primordia. At the rear, rhombencephalon with auditory vesicles.

The diencephalon in its lower portion is a transversely flattened cavity; the optical reduncles separate at the front from an infundibulum whence the neurohypophysis comes. Dorsally, the open cavity of the diencephalon widens and continues in a wide groove toward the mesencephalon. It is beneath these everted diencephalic layers that the hemispheres develop.

The mesencephalon is located in a very wide-open groove at its two extremities. In its middle region, this arrangement extends to receive a projecting plate at the point where the vertex would be located. The mesencephalon is continuous, with the rhombencephalon generally closed.

Figure 3 14-day embryo External view One can see the groove on the surface of the diencephalon and the mesencephalon, exposed and projecting.

Figure 4 14 day embryo

A. Sections showing the open diencephalon with eversion of its wall.

to the right and left, hemispheres

B. Lower section, passing through the vicinity of the foramina of Monro.

Note the folding of the walls of the hemispheres

C. Still lower section passing through the level of the optic primordia and located beneath the opening of the prosencephalon.

Figure 5 16-day embryo

Section with high magnification. At the right, one can see the bottom of the diencephalon. To the left, one can see the everted wall of the diencephalon. In the depths, the hemisphere: One can see the beginning of the differentiation of the cortex.

At this stage, the several walls of the encephalon have already thickened but they still enclose only the three classic layers: the germ zone or subependymal layer, the mantle and the marginal zone. They have their normal arrangement with the germ layer inside at the level of the hemisphere and the base of the diencephalon; however, at the level of the everted walls, due to the eversion, the ependymis with its germ layer appears at the surface.

In the entire open region of the encephalon, the thick neuroblastic layer is directly continuous with the very thin epidermis.

On the 14th day, the various organogeneses are more advanced. Due to their growth, the walls of the hemispheres are folded. The corpa striata are massive. The ocular primordium may be well developed. The structures of the encephalic walls are always of a primitive type.

By the 15th and 16th days, the encephalon has undergone considerable development. Among the important modifications on the 16h day we could mention the appearance of the choroid plexuses which are located particularly near the orifices of the hemispheres and which one can see from the outside. One can

see the initial differentiations of the cortex at the level of the walls of the hemispheres.

On the 17th day the encephalon literally forms a considerable mass above the base of the cranium. It forms a projection in the anterior region above the nasal region but it also extends backward above the rhombencephalic region. This large mass, when viewed laterally, shows a form of dorso-ventral sill which bounds the diencephalic region at the front and the mesencephalic region at the back.

As viewed from the front, one can see at the level of the anterior opening of the encephalon two flattened orifices (foramina of Monro) which open into the hemispheres. These orifices are overhung by large globular projections composed of the corpora striata. Aside from these projections, and running along the wall of the hemisphere, one can see to the right and the left formations with a wavy appearance; these are the choroid plexuses.

Figure 6 17 day embryos. Considerable development of the encephalic mass above the base of the cranium in embryos from the same litter.

At this time, the hemispheres located lower down are subjacent to the everted edges of both the diencephalon and the mesencephalon. They have undergone considerable development and their walls are therefore irregularly folded. Olfatory lobes can be distinguished at their bases.

A histogenetic differentiation, which has already begun on the 16th day has taken place in their walls. Some neuroblasts from the germ layer and the mantle have accumulated in the marginal zone, in other words, at the surface; hence, there is now a primordium of the cortex. At the level of the olfactory lobes, histogenesis has also commenced.

The diencephalon now has rather thick walls, Lower down, there is a flattened cavity. From the infundibulum, a well-differentiated neurohypophysis has separated. Its upper walls, turned back at the exterior, are

elevated by the hemispheres and their ventrally recurved edges are continuous with the epidermis. We have not observed any epiphyseal primordium.

The mesencephalon has considerable thickness; one can see significant fibrous formations. It is loose on the outside and only a simple median furrow remains as a trace of tis location in the groove; it has even become convex , and its lateral edges have recurved ventrally. Under these mesencephalic layers,to the right and left, are the posterior portions of the hemispheres.

Figure 7 17-day embryo One can see the slit-like opening of the hemispheres and at the top the globular projection of the corpora striata. The choroid plexus is also visible. At the bottom, the everted wall of the diencephalon, then the mesencephalon, can be seen.

Further back, the encephalon generally has a nearly normal structure.

The choroid plexuses at this stage are highly developed at the front, at the level of the orifice of the hemisphere. They are detached from the external layer of the hemisphere. Others occur laterally which correspond to the everted edges of the diencephalon.

The connections of the neural masses with the epidermis occur through the intermediary of a neuroblast layer which is quite thick and only slightly differentiated.

In the diencephalic region, a zone of dark cuboid cells with choroid significance is located between the neuroblast layer and the epidermis in three layers, and it is this which can develop into small plexuses.

In the mesencephalic region, the neuroblast plate becomes thinner quite rapidly and is directly continuous with the epidermis.

On the 18th day, the structures are only slightly different except that their sections are a little larger. The whole always forms an enormous

cerebral mass.

On the 19th day, distinct processes of degeneration begin. In the middle region of the diencephalon or mesencephalon, one can see on the surface a slight edema, dissociating the cells, and pyknoses can be observed.

Fig. 8 17-day embryo

A. Transverse section through the extreme front region. One can see the orifice of the hemispheres with the choroid plexus. In the middle one can see the projections formed by the corpora striata.

B. Transverse section passing through the hemispheres which, at the top and below, give rise to the olfactory bulbs. The whole is covered by the spread out diencephalon.

On the 20th day, significant necroses can be found in the superficial regions of the encephalon. Below the cerebrospinal axis, there are already signs of tissue with an angiomatous appearance.

On the 21st day, the appearance is that of a human, anencephalic at birth.

Outwardly; one can see only a reddish mass of tissue with an irregular shape above the base of the cranium. Most of the anterior structures have necrosed and disappeared. Only their remains can be found in the lower regions (mainly fragments of the hemispheres, some debris from the bottom of the diencephalon, as well as some nerves.) The remains of the neuroblast layer, more or less altered, still persist and are continuous with the epidermis, this time in a well-differentiated form.

Figure 9 17-day embryo

A. Transverse section, more posterior than in the previous figure: Particular interest surrounds the subjacent hemispheres in the spread-out diencephalon. One can already see the significant differentiation of the cortex. A ventral

portion of the cavity of the diencephalon can be seen in the middle of this section. At the point where the wall of the diencephalon meets the epidermis, a choroid plexus can be seen at the left.

B. Transverse section, very much to the rear. The upper wall is composed of the open mesencephalon whose edges are continuous with the epidermis. To the left, the mesencephalic wall covers the posterior extremity of the hemisphere. In the center is the tangential section of the protuberance.

Figure 10 Encephalon of 17 day embryo

The section shows the left side, where the lateral extremity of the everted diencephalon, the neuroblast layer (thick), the simple choroid epithelium and finally the epidermis occur from top to bottom.

Figure 11 18-day embryo

The encephalon always constitutes a voluminous mass. One can see the rearward projection of the everted mesencephalon above the rhombencephalon. The choroid plexuses are visible in front of the everted diencephalon. The small formation which one sees at the top corresponds to the projection of a corpus striatum.

The choroid plexuses, on the other hand, show considerable development.

One can see them at the front and at the side, generally in the vicinity of the junction with the epidermis. The epithelial wall of these plexuses is composed of a layer of clear cells, with functional appearance already evident in 17-day embryos. Let us recall that we have mentioned in all cases of anencephalia the coexistence of a hydramnion: the quantity of amniotic fluid in this case is essentially 10 times greater than normal. This fact has led us to suggest that the increase in the volume of amniotic fluid was due to the increased secretion of cerebrospinal fluid.

Figure 12 19-day embryo

Considerably magnified. Beginning of degeneration at the surface of the wall of the diencephalon

---

Figure 13 Anencephalic fetus, 21 days. The encephalic structures have disappeared; one can see only a few richly vascularized formations on the surface of the base of the cranium.

In contact with the base of the cranium, there is a highly developed angiomatous tissue: certain dilated vessels contain erythrocytes, while others which are still more dilated still seem to contain plasma.

Figure 14 21-day fetus

A. Sections showing that only a few fragments of the hemispheres remain. The choroid plexuses remain numerous. In contact with the base of the cranium: angiomatous tissues.

B. Section considerably to the rear, passing through the level of the hypophysis. Nothing remains of the encephalon except the choroid plexus and at the left, a fragment of the neuroblast layer. Enormous angiomatous formation with depth.

IV - Discussion

The fragmentary data for man allow us to draw hardly any conclusions concerning the morphogenesis of anencephalia.

According to Spanner (1929) and Sternberg (1929) there was originally a failure of the telencephalon and the diencephalon to close, and the mesencephalon, considerably distorted by the growth of the bulb, has ruptured. According to Spanner, the continuity of the neural layer and the epidermis would be the proof of failure to close.

This opinion was shared by Baxter and Boyd (1937) after studying two cases of anencephalia in the pig.

Stroer and Van Der Zwan (1939) have also admitted that the non-closure of the encephalic groove would be the main direct cause of anencephalia. However, they have considered that in certain cases it could be the consequence of hydrocephalia.

Andre Thomas (1950), who has studied a great many anencephalic children, on the basis of the presence of nerve residue and notably the optic nerves and eyes, concludes that more or less normal organogenesis must have occurred initially and that there was a secondary cataclysm which caused degeneration of the larger elements of the encephalon.

Van der Zwan (1951) concludes that origin is very early and simply points out that the degeneration that has been found was due to circulatory problems.

Mann (1937) together with Frazer (1921) supposed that anencephalia results from a secondary rupture caused by accumulation of cerebrospinal fluid. The continuous growth of the bulb pushes the anterior portion of the mesencephalon forward, causing the rupture of the carotids and the nerves.

Patten (1952) has suggested that the exaggerated growth of the encephalon could cause rupture of the thin subjacent membranes and lead encephalocele or secondary openings of the cerebrospinal axis.

Bivetti (1954) supposed that secondary anomalies were involved in the case of a properly closed brain that was normally segmented.

The data on animals correspond to later studies.

Snell and Picken (1935) studied cerebral malformations referred to as pseudoencephalias which occurred following chromosomal shifts produced in mice by x-rays. They described them as being the result of absence of closure of the encephalic groove and recognized that cerebral organogenesis also took place normally.

Bonnevie (1936) also studied a cerebral malformation in the mouse that

was very similar in nature and of genetic origin, pseudoencephalia in which the brain is more or less exposed, naked and forms a projection of the base of the cranium. According to this author, the neural tube initially closes normally. Various curves of the medulla in the cervical region cause tension in the neural tube which exaggerates the rapid development of the mesencephalon and the pontic curvature. The roof of the mesencephalon, which would be the point of least resistance, yields under this pressure. Tension caused by certain nerves would cause eversion of the diencephalon and ventral inflection of the hemispheres. The basic structures would thus be of mechanical origin and themselves linked to an insufficiency of development of mesodermal structures adjacent to the cerebrospinal axis. According to this author, the cord is attached to the cerebrospinal axis in these young abnormal embryos; in certain cases, there are even abnormal conditions of separation of the layers which would lead to premature death. Nevertheless, Bonnevie observes that perhaps following the encephalic flexures, the mesencephalon is not entirely closed or insufficiently resistant and it is there that a secondary opening that grows larger and larger originates.

According to Grunewald (1947) one could mention, by way of supporting the hypothesis of a secondary opening, the observations of Paff (1939) who obtained dyeraphia in the chicken with colchicine after 48 hours of incubation; in other words, when the neural tubes should have been closed.

The possibility of a secondary opening, while not the rule, can not be excluded completely.

Wilson, Brent and Gordan (1952) following irradiation on the 7th day, observed evaginations of the cerebrospinal axis which could come in contact with the epidermis, destroy it and open it outward. Certain of their figures are quite demonstrative of this process.

We ourselves have seen some facts of this kind in anomalies that resulted from pantothenic deficiency (Giroud, Delmas, Frost and Lefebvres (1953).

Our own observations allow the question to be made more specific.

I. The development of anencephalia begins with the non-closure of the encephalic groove. Perhaps it closes at the level of the neuropore and a little beyond. But most of the telencephalic region, the entire diencephalic region and the mesencephalic region remain open. Depending on the case, the rhombencephalic region is affected more or less.

II. This does not block organogenesis or histogenesis on the whole. At selected points, the hemispheres develop considerably and possess corpora striata while the olfactory bulbs form. The differentiation of the germ, pallial and marginal layers then takes place and finally a cortex develops as in normal cases.

A fact that clearly shows the development of well-defined territories is the appearance of the choroid plexuses. The latter form at the level of the wall of the hemisphere, especially in the vicinity of their exterior opening. They also form along the border of the everted diencephalic plates in the vicinity of the epidermis. This corresponds to regions which must have been located at the vault of the normal diencephalon in order to form the plexus of the third ventricle.

These organs and structures therefore develop in a quasi-normal fashion and it would seem even in great abundance.

III. A little later, necrotic processes appear. They begin in the outermost parts, in other words, opposite the adjacent mesenchyma. They extend downward and soon everything has been destroyed. Nothing remains except a little debris and a few nerves that survive.

Anencephalia therefore involves organogenesis and histogenesis of a quasi-normal nature in a brain that remains open, but all this is followed by a process of degeneration.

At least, this is what happens in the anencephalics that we have caused and which correspond to these in man. The existence of young human embryos

that could be superimposed on some of our stages appears to indicate that the same process is probably involved in both instances.

Administration of vitamin A in large doses on the 8th, 9th and 10th days of pregnancy in the rat causes the development of a great many anencephalics. We studied their development from the 11th day until the 21st day of pregnancy.

The encephalic tube does not close for the entire length of the prosencephalon and the mesencephalon. Generally the rhombencephalon is normal.

In this open encephalon, a nearly normal organogenesis nevertheless takes place. The hemispheres form laterally, which will be covered by the everted walls of the diencephalon and the mesencephalon. Olfactry bulbs develop. Corpora striata can be seen as well as choroid plexuses, and normal histogenesis takes place with the appearance of a cortex. A comparable development occurs at the level of the diencephalon and the mesencephalon. In addition, an open encephalon with large dimenstions forms, constituting a considerable mass above the base of the skull.

Secondarily, necrotic processes destroy all of these structures and nothing remains at birth except a few remainders, especially choroid plexuses and nerves.

Anencephalia is therefore the result of degeneration of an encephalon which has remained open but has nevertheless been subject to highly advanced organogenesis.

Giroud-'57
Bib. No. 3195

Archives D'Anatomie Microscopique 46:3. 1957.

Reproduced by permission
of the copyright owner

ARCHIVES
D'ANATOMIE MICROSCOPIQUE
ET DE
MORPHOLOGIE EXPÉRIMENTALE

TOME 46 *N° 3* *1957*

MORPHOGENÈSE DE L'ANENCÉPHALIE

A. GIROUD et M. MARTINET
(Laboratoire d'Embryologie de la Faculté de Médecine de Paris.)

SOMMAIRE

I. — *Introduction* 247
II. — *Technique* 249
III. — *Observations* 250
IV. — *Discussion* 260
Résumé 263

I. — *INTRODUCTION*

On connaît les dispositions de l'anencéphalie chez l'homme. Le tégument, la voûte du crâne, font défaut. Au contact d'un tissu angiomateux, on trouve dans la partie correspondant à la région antérieure de l'encéphale des débris de tissus nerveux souvent nécrotiques ou constitués d'éléments névrogliques, ainsi que des nerfs, notamment les nerfs optiques avec des yeux. En arrière, les formations dérivées du rhombencéphale persistent généralement.

La morphogenèse de l'anencéphalie est peu connue, on a décrit seulement un petit nombre d'embryons humains anencéphales et souvent il s'agissait ni d'embryons très jeunes, ni en parfait état de conservation.

Frazer (1921) a étudié un embryon de 17 mm reconstruit par Mass (1937), dans lequel la partie antérieure du cerveau manquait.

De Wrete (1924) a décrit un embryon de 7 semaines avec craniorachischisis. De Vries (1927) en a publié un analogue de 23 mm.

Bohmig (1927) a décrit également le cas d'un embryon de 2 mois avec extension de l'anomalie à la moelle. Groth (1928) a publié un cas de craniorachischisis de 14 mm et Spanner (1928) un autre de 37 mm.

Dodds (1937) a fait connaître un embryon de 16,5 mm atteint d'anencéphalie. Stroer et V. Derzwan (1939) en ont décrit un autre de 18 mm compliqué de rachischisis.

Van der Zwan (1951) a décrit trois embryons humains intéressants (de 18 à 22 mm). Chez l'un d'eux (22 mm), qui présentait aussi un rachischisis, l'encéphale formait une énorme masse au-dessus de la base du crâne, débordant en avant et en arrière. La surface entière était formée par le diencéphale, le mésencéphale et le rhombencéphale ouverts : la couche épendymaire se continuant avec l'épiderme. Dans l'épaisseur de la paroi nerveuse, on distinguait une zone germinative, un manteau et une zone marginale. On reconnaissait des corps striés, un recessus optique et un recessus infundibulaire. Des plexus choroïdes s'observaient au niveau des trous de Monro, ainsi que le long des bords du diencéphale, à la jonction de l'épiderme. On en retrouvait également dans la même région au niveau du IVe ventricule (cette description correspond assez à celle de nos embryons du 17e jour). Les deux autres embryons présentaient plutôt des rachischisis. Dans tous les cas, sous le névraxe, il y avait un tissu conjonctif lâche, très vasculaire. Van der Zwan a envisagé, sans plus préciser, que ces malformations avaient une origine très précoce et a suggéré que les dégénérescences nerveuses étaient dues à des troubles circulatoires.

Erskine (1955) a étudié deux embryons humains anencéphales; sur un embryon de 18 mm, la base du crâne était recouverte d'un mésenchyme lâche, kystique, vasculaire et œdémateux que recouvrait une fine cuticule fibreuse. Au-dessous, on trouvait seulement quelques amas de neuroblastes. L'œil et le nerf optique étaient présents. On reconnaissait les nerfs V, VII, VIII, X, ainsi que des fragments du III, IV, VI, XII. Sur un embryon de 14 mm, on rencontrait le même mésenchyme œdémateux dans lequel on retrouvait des débris du diencéphale et peut-être de l'hémisphère, ainsi que des nerfs sensitifs et des nerfs moteurs, sauf le III. Erskine suppose que le tube nerveux ne se serait pas fermé et se serait, secondairement, recouvert néanmoins de mésenchyme.

Bivetti (1954) a décrit, sous le titre de pseudo-encéphalie, 6 embryons de 14 à 30 mm chez lesquels le crâne mésenchymateux présentait des interruptions par où passaient des portions d'encéphale. Chez l'un d'eux, le rhombencéphale persistait seul, ce qui permettait de considérer cet embryon comme anencéphale.

Récemment Ford (1956) a étudié un anencéphale de 33,5 mm chez lequel toute la partie antérieure du cerveau faisait défaut jusqu'à la racine du V. Les yeux et les nerfs optiques, ainsi que des fragments du III, étaient présents. Ces destructions pourraient résulter d'une altération des

artères cérébrales. Il envisage, au début, une absence de fermeture de la gouttière nerveuse.

Expérimentalement, les données seraient plus complètes. Chez la souris, l'existence de lignées présentant des malformations de l'encéphale, un peu moins graves que l'anencéphalie typique, ont permis à plusieurs auteurs, entre autres SNELL et PICKEN (1935), BONNEVIE (1936), d'étudier l'évolution de cette anomalie. Comme on le verra, leurs conclusions ne sont pas concordantes.

Deux interprétations fondamentales de l'anencéphalie ont été envisagées. Dans la première, l'anomalie résulterait de la persistance de la gouttière nerveuse qui ne se fermerait pas et évoluerait sous cette forme. Dans la seconde, l'anomalie résulterait d'une rupture secondaire d'un cerveau primitivement fermé.

Nous avons voulu profiter des circonstances où nous nous sommes trouvés pour étudier la morphogenèse de l'anencéphalie. En effet, au cours d'expériences de tératogenèse par hypervitaminose A, nous avions obtenu un grand nombre de cas d'anencéphalie.

COHLAN (1953) avait signalé qu'en administrant à la rate gestante 20 000 U. I. de vitamine A du 2e, 3e, 4e au 16e jour, on pouvait obtenir diverses anomalies chez l'embryon. Nous avions repris ces expériences (1954) et nous avons montré (1955) que l'on obtient des malformations distinctes en agissant à des stades divers. Pour cela, nous donnions seulement pendant 3 jours de suite 50 000 U. I. de vitamine. Dans ces conditions, avec des traitements aux 8e, 9e, 10e jours, nous avons obtenu 52 % d'anencéphalies.

Nous avons donc poursuivi ces recherches en étudiant cette fois les embryons aux divers stades de la gestation.

II. — *TECHNIQUE*

Ces expériences ont été réalisées sur des rates Wistar de 250 g, dont le cycle génital était suivi par examen des frottis vaginaux. Elles étaient accouplées au moment de l'œstrus et on contrôlait la fécondation.

Les 8, 9, 10e jours de la gestation, c'est-à-dire 3 jours de suite, on administrait par voie orale 50 000 U. I. de vitamine A sous forme de solution huileuse.

Ces femelles étaient enfin sacrifiées à partir du 11e jour jusqu'au 21e jour de gestation.

Les embryons étaient photographiés, fixés au Bouin et étudiés par les techniques histologiques courantes. Les plus petits étaient fixés dans l'utérus et n'étaient isolés que secondairement. Dans certains cas même, les embryons étaient sectionnés dans l'utérus selon les plans classiques.

Nous avons ainsi étudié plus de 200 anencéphales à divers stades.

III. — OBSERVATIONS

Comme on va le voir, le tube encéphalique ne se ferme pas, il reste ouvert. Néanmoins, une organogenèse poussée se produit : des hémisphères se forment et évoluent. Il se produit ainsi une édification encéphalique fort importante formant une masse volumineuse au-dessus de la base du crâne. Secondairement, tout dégénère, il ne reste que des résidus de ces formations.

Au 11e jour, 12 heures, alors que l'encéphale devrait terminer sa fermeture, il est toujours ouvert dans toute la région prosencéphalique et mésencéphalique. A partir des parois du télencéphale ouvert se forment des évaginations latérales qui donnent naissance aux hémisphères. Probablement,

FIG. 1.
Embryon du 11e jour, 12 heures. Le prosencéphale est ouvert et l'on voit la continuité du feuillet nerveux avec l'épiderme. A droite et à gauche débute l'évagination des hémisphères. En arrière, on voit le rhombencéphale fermé.

du fait de l'union de la paroi diencéphalique avec l'ectoderme, l'évolution de l'hémisphère est un peu modifiée. Son ébauche aplatie se dirige de haut en bas et en arrière, et reste sous-jacente aux parois éversées du diencéphale. Le diencéphale est ouvert en haut et s'évase progressivement, ses parois s'éversant à droite et à gauche. Dans sa partie ventrale, au contraire, il conserve une disposition normale et se présente avec une cavité sagittale aplatie. Des ébauches optiques s'en dégagent. Souvent elles apparaissent au voisinage immédiat des ébauches des hémisphères; il semble qu'il y ait, en effet, des processus de télescopage entre formations télencéphaliques et diencéphaliques. Le mésencéphale est disposé en une gouttière largement ouverte. Le rhombencéphale est généralement fermé dans toute son étendue.

Au 12e jour, l'encéphale, qui devrait être complètement fermé, reste ouvert, sauf dans la région rhombencéphalique. En profondeur, les hémisphères sont bien développés : les corps striés y sont déjà ébauchés. Le diencéphale ouvert présente une ébauche optique assez développée, mais anormale, car chez nos embryons il y a souvent de la microphtalmie. L'ébauche du lobe nerveux de l'hypophyse est apparue.

Au 13e jour, l'encéphale est toujours très largement ouvert dans toute la région antérieure jusqu'au rhombencéphale. Ventralement, on peut

reconnaître que cette ouverture s'arrête cependant à une certaine distance du point où était le neuropore antérieur : fait qui démontre qu'une fermeture s'est produite dans cette région et même un peu au-dessus. A partir de là, télencéphale ou ce qui en reste, diencéphale, mésencéphale, sont ouverts.

La partie toute antérieure télencéphalique est presque toute incorporée dans les hémisphères. Ceux-ci, qui ne peuvent se développer en haut et en avant, ont plongé ventralement sous forme de sacs aplatis latéralement et se dirigent en bas et en arrière. Sur leur paroi interne, les ébauches de corps striés sont assez développées et on les aperçoit

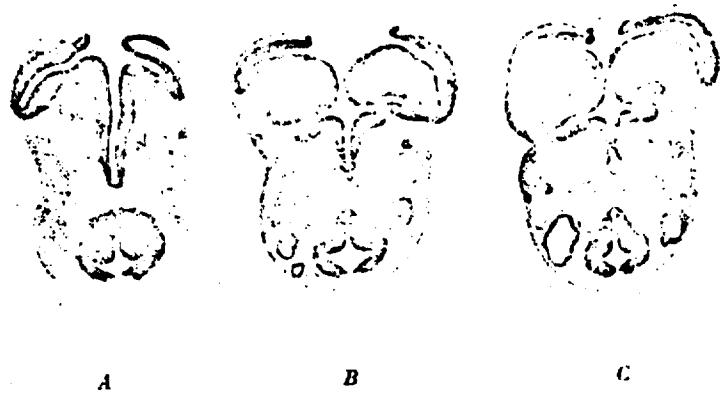

FIG. 2. — Embryon du 12e jour, 12 heures.

A. Coupe montrant le télencéphale ouvert en avant, avec, d'un côté, éversion du feuillet neuroblastique. A droite et à gauche, formation des hémisphères. En arrière, rhombencéphale.

B. Coupe un peu inférieure. On voit les hémisphères sur la paroi desquels se sont développés les corps striés.

C. Coupe encore plus inférieure. Du diencéphale partent les ébauches optiques. En arrière, rhombencéphale avec vésicules auditives.

venant faire saillie en avant dans ce qui reste de la cavité télencéphalique. Ce sont eux qui, par leur présence, transforment les trous de Monro en simples fentes que l'on aperçoit de l'extérieur.

Le diencéphale, dans sa partie inférieure, présente une cavité aplatie transversalement; des pédoncules optiques s'en dégagent en avant d'un infundibulum d'où part l'ébauche nerveuse de l'hypophyse. Dorsalement, la cavité ouverte du diencéphale s'évase et se continue en une large gouttière vers le mésencéphale. C'est sous ces lames diencéphaliques éversées que se sont développés les hémisphères.

Le mésencéphale est disposé en une gouttière très largement ouverte



FIG. 3.
Embryon du 14e jour. Vue extérieure. On voit la gouttière à la surface du diencéphale et du mésencéphale étalés et saillants.

A B C

FIG. 4. - Embryon du 14e jour.

A. Coupe montrant le diencéphale ouvert avec éversion de sa paroi. A droite et à gauche, hémisphères.

B. Coupe plus inférieure passant au voisinage des trous de Monro. Noter le plissement de la paroi des hémisphères.

C. Coupe encore plus inférieure passant au niveau des ébauches optiques et située au-dessous de l'ouverture du prosencéphale.

à ses deux extrémités. Dans sa région moyenne, cette disposition s'atténue pour prendre celle d'une plaque saillante au point où se serait situé le vertex. Le mésencéphale se continue avec le rhombencéphale généralement fermé.

A ce stade, les diverses parois de l'encéphale sont déjà épaisses, elles ne comprennent cependant encore que les trois couches classiques : zone germinative ou couche sous-épendymaire, manteau et zone marginale. Elles ont leur disposition normale avec couche germinative en dedans, au niveau de l'hémisphère et de la base du diencéphale; mais au niveau



Fig. 5.
Embryon du 16e jour. Coupe à fort grossissement. A droite, on aperçoit le fond du diencéphale. A gauche, on voit la paroi éversée du diencéphale. En profondeur, l'hémisphère : on y voit le début de la différenciation du cortex.

des parois éversées, du fait de l'éversion, l'épendyme avec sa couche germinative apparaissent en surface.

Dans toute la région ouverte de l'encéphale, le feuillet neuroblastique épais vient se continuer directement avec l'épiderme très mince.

Au 14e jour, les diverses organogenèses sont plus avancées. Du fait de leur croissance, les parois des hémisphères sont plissées. Les corps striés sont plus massifs. L'ébauche oculaire peut être bien développée. Les structures des parois encéphaliques sont toujours du type primitif.

Au 15-16e jour, l'encéphale a pris un très grand développement. Parmi les modifications importantes signalons, au 16e jour, l'apparition des plexus choroïdes qui se trouvent surtout vers les orifices des hémisphères et que l'on peut apercevoir de l'extérieur. On peut noter les premières différenciations du cortex au niveau des parois des hémisphères.

Au 17e jour, l'encéphale forme véritablement une masse considérable au-dessus de la base du crâne. Il vient faire une saillie dans la région antérieure au-dessus de la région nasale, mais il s'étend aussi en arrière au-dessus de la région rhombencéphalique. Cette masse exubérante présente latéralement une sorte de sillon dorso-ventral qui délimiterait une

région diencéphalique en avant et une région mésencéphalique en arrière.

Vu de face, on reconnait au niveau de l'ouverture antérieure de l'encéphale deux orifices aplatis (trous de Monro) qui s'ouvrent dans les hémisphères. Ces orifices sont surplombés par de grosses saillies globuleuses constituées par les corps striés. En dehors de ces saillies se prolongeant avec la paroi de l'hémisphère, on voit, à droite et à gauche, des formations d'aspect frisé, ce sont les plexus choroïdes.

A ce moment, les hémisphères situés en profondeur sont sous-jacents



Fig. 6. — Embryons du 17e jour.
Développement considérable de la masse encéphalique au-dessus de la base du crâne dans les embryons d'une même portée.

aux bords éversés non seulement du diencéphale, mais aussi du mésencéphale. Ils ont pris un grand développement et, de ce fait, leur paroi est irrégulièrement plissée. De leurs bases se sont individualisés des lobes olfactifs.

Une différenciation histogénétique, qui s'était déjà amorcée au 16e jour, s'est produite dans leur paroi. De la couche germinative et du manteau, des neuroblastes sont venus s'accumuler dans la zone marginale, c'est-à-dire en surface : il y a donc maintenant une ébauche du cortex. Au niveau des lobes olfactifs, l'histogenèse est aussi commencée.

Le diencéphale a maintenant des parois assez épaisses. Inférieurement,

il présente une cavité aplatie. De l'infundibulum se détache une neurohypophyse bien différenciée. Ses parois supérieures retournées extérieurement sont soulevées par les hémisphères, ses bords recourbés ventralement sont en continuité avec l'épiderme. Nous n'avons pas reconnu d'ébauche épiphysaire.

Le mésencéphale présente une épaisseur considérable; on y note d'importantes formations fibreuses. Il est extrêmement étalé et seule une simple rainure médiane persiste comme trace de sa disposition en gouttière, il est même devenu convexe et ses bords latéraux viennent se recourber ventralement. Sous ces lames mésencéphaliques se trouvent, à droite et à gauche, la partie postérieure des hémisphères.



FIG. 7.
Embryon du 17e jour. On voit l'ouverture en fente des hémisphères et au-dessus la saillie globuleuse des corps striés. En dehors, on aperçoit les plexus choroïdes. En arrière, on voit la paroi éversée du diencéphale, puis du mésencéphale.

Plus en arrière, l'encéphale se présente généralement avec des dispositions presque normales.

Les plexus choroïdes sont, à ce stade, très développés en avant au niveau de l'orifice des hémisphères; ils se détachent du feuillet externe de l'hémisphère. On en trouve d'autres, latéralement, qui correspondent aux bords éversés du diencéphale.

Les connexions des masses nerveuses avec l'épiderme se font par l'intermédiaire d'une lame neuroblastique assez épaisse et peu différenciée.

Dans la région diencéphalique, une zone de cellules cubiques sombres, de valeur choroïdienne, s'interpose entre le feuillet neuroblastique et l'épiderme à 3 couches, c'est elle qui peut évoluer en petits plexus.

Dans la région mésencéphalique, la lame neuroblastique s'amincit assez brusquement et vient directement se continuer avec l'épiderme.

Au 18e jour, les structures sont peu différentes, seules leurs tailles

sont un peu plus grandes. L'ensemble forme toujours une masse cérébrale énorme.

Au 19e jour débutent de discrets processus de dégénérescence. Sur la région moyenne du diencéphale ou du mésencéphale, on voit en effet en surface un léger œdème dissociant les cellules et on observe des pycnoses.

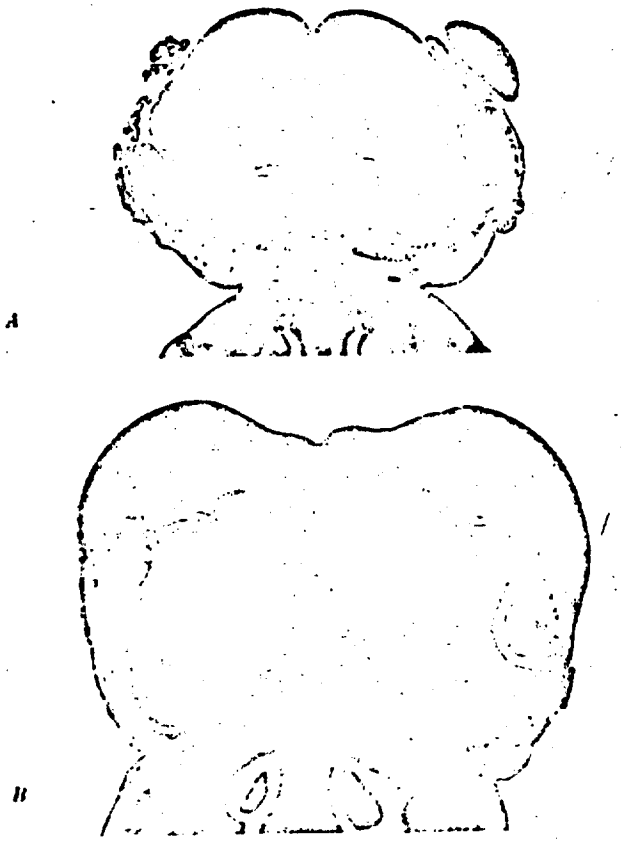

Fig. 8. — Embryon du 17e jour.

A. Coupe transversale de la région toute antérieure. On voit l'orifice des hémisphères avec des plexus choroïdes. Au milieu se trouvent les saillies formées par les corps striés.

B. Coupe transversale passant par les hémisphères qui, en bas et en dedans, donnent naissance aux bulbes olfactifs. Le tout est recouvert par le diencéphale étalé.

Au 20e jour, des nécroses importantes peuvent être trouvées dans les régions superficielles de l'encéphale. Au-dessous du névraxe se trouve manifestement déjà un tissu d'aspect angiomateux.

Au 21e jour, les dispositions sont celles que l'on rencontre chez l'anencéphale humain à la naissance.

Extérieurement, on ne voit plus au-dessus de la base du crâne qu'une masse tissulaire rougeâtre, d'aspect irrégulier. La plus grande partie des édifications antérieures se sont nécrosées et ont disparu. On en trouve

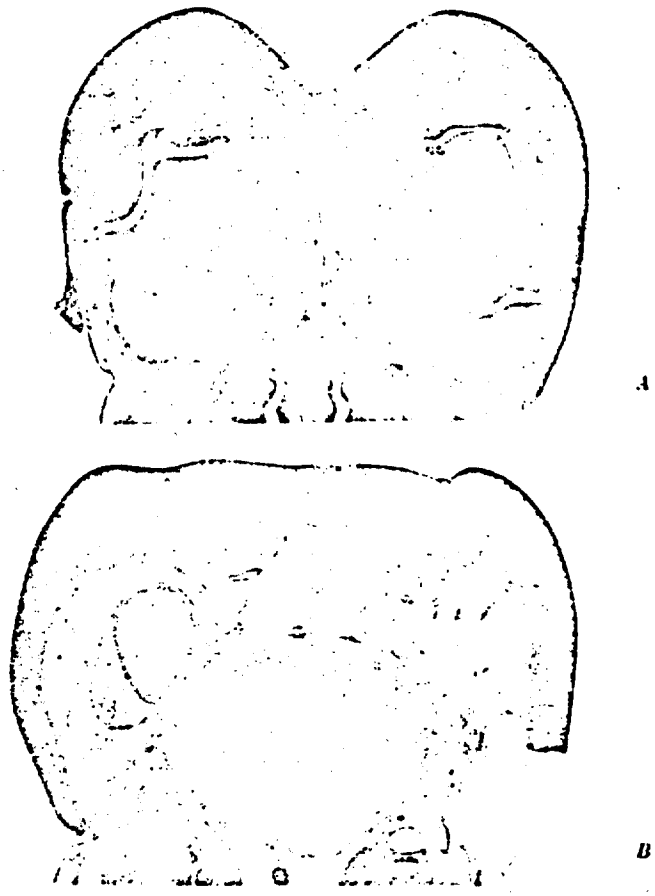

Fig. 9. — Embryon du 17e jour.

A. Coupe transversale plus postérieure que dans la figure précédente, intéressant les hémisphères sous-jacents au diencéphale étalé. On peut noter déjà une différenciation importante du cortex. Une portion ventrale de la cavité du diencéphale se voit au milieu de la coupe. Au point de raccord de la paroi du diencéphale avec l'épiderme, on note à gauche un plexus choroïde.

B. Coupe transversale très postérieure. La paroi supérieure est constituée par le mésencéphale ouvert dont les bords viennent se continuer avec l'épiderme. A gauche, la paroi mésencéphalique recouvre l'extrémité postérieure de l'hémisphère. Au milieu, section tangentielle de la protubérance.

seulement des résidus appartenant aux parties profondes : notamment des fragments d'hémisphères, des débris du fond du diencéphale, ainsi que des nerfs. Des restes du feuillet neuroblastique plus ou moins altérés persistent encore et viennent se continuer avec l'épiderme, cette fois bien différencié.

Les plexus choroïdes présentent, par contre, un grand développement.

Fig. 10.



Fig. 11.

Fig. 10. — Encéphale d'embryon au 17e jour. Coupe intéressant le côté gauche, montrant de haut en bas l'extrémité latérale du diencéphale éversé, la couche neuroblastique (épaisse), l'épithélium simple choroïdien et, enfin, l'épiderme.

Fig. 11. — Embryon du 18e jour. L'encéphale constitue toujours une masse volumineuse. On peut noter la projection en arrière du mésencéphale éversé au-dessus du rhombencéphale. Les plexus choroïdes sont visibles en avant du diencéphale éversé. La petite formation que l'on aperçoit au-dessus correspond à la saillie d'un corps strié.

On en trouve en avant et latéralement, généralement au voisinage de la continuité avec l'épiderme. La paroi épithéliale de ces plexus est constituée d'une couche de cellules claires, d'aspect fonctionnel déjà réalisé sur les embryons du 17e jour. Rappelons que nous avons signalé, dans tous les cas d'anencéphalie, la coexistence d'un hydramnios : la quantité

de liquide amniotique étant en effet, dans ces cas, 10 fois supérieure à la normale. Ce fait nous avait permis d'avancer que l'augmentation de



Fig. 12. — Embryon du 19e jour. Fort grossissement.
Début de dégénérescence à la surface de la paroi du diencéphale.

volume du liquide amniotique était due à la sécrétion surajoutée du liquide céphalo-rachidien.

Fig. 13.
Fœtus anencéphale au 21e jour. Les structures encéphaliques ont disparu. On note seulement quelques formations richement vascularisées à la surface de la base du crâne.

Au contact avec la base du crâne, il existe un tissu angiomateux extrêmement développé : certains vaisseaux dilatés contiennent des hématies, d'autres plus dilatés encore semblent surtout contenir du plasma.

Fig. 14. — Fœtus du 21e jour.

A. Coupe montrant que seuls persistent quelques fragments des hémisphères. Les plexus choroïdes sont très nombreux. Au contact de la base du crâne, tissus angiomateux.

B. Coupe assez postérieure passant au niveau de l'hypophyse. Il ne reste rien de l'encéphale, sauf des plexus choroïdes et, à gauche, un fragment de lame neuroblastique. Enorme formation angiomateuse en profondeur.

IV. — *DISCUSSION*

Les données fragmentaires, chez l'homme, ne permettent guère de conclusions concernant la morphogenèse de l'anencéphalie.

Selon Spanner (1928), Sternberg (1929), il y aurait à l'origine une absence de fermeture du télencéphale et du diencéphale, le mésencéphale fortement tordu par la croissance du bulbe se rompt. Selon Spanner, la

continuité du feuillet neural et de l'épiderme serait la preuve de l'absence de fermeture.

C'est à cette opinion que se rallient BAXTER et BOYD (1937), après étude des 2 cas d'anencéphalie chez le porc.

STROER et VAN DER ZWAN (1939) ont admis également que la non-fermeture de la gouttière encéphalique serait la cause immédiate essentielle de l'anencéphalie. Cependant, ils ont envisagé que certains cas pourraient être la conséquence d'une hydrocéphalie.

ANDRÉ THOMAS (1950), qui a étudié beaucoup d'enfants anencéphales, se basant sur la présence de résidus nerveux et notamment des nerfs optiques et des yeux, conclut qu'une organogenèse plus ou moins normale a dû d'abord être réalisée et que secondairement un cataclysme a entraîné la dégénérescence des éléments nobles de l'encéphale.

VAN DER ZWAN (1951) conclut à une origine très précoce et précise seulement que les dégénérescences constatées sont dues à des troubles circulatoires.

MANN (1937) a supposé, avec FRAZER (1921), que l'anencéphalie résultait d'une rupture secondaire par accumulation de liquide céphalo-rachidien. La croissance continue du bulbe repousserait en avant la partie antérieure du mésencéphale, entraînant la rupture des carotides et des nerfs.

PATTEN (1952) a avancé que des croissances exagérées de l'encéphale pourraient provoquer la rupture des minces membranes sus-jacentes et déterminer des encéphalocèles ou des ouvertures secondaires du névraxe.

BIVETTI (1954) a supposé qu'il s'agissait d'anomalies secondaires portant sur un cerveau bien fermé et normalement segmenté.

Les données sur l'animal correspondent à des études plus sériées.

SNELL et PICKEN (1935) ont étudié des malformations cérébrales, désignées sous le nom de pseudo-encéphalie, apparues à la suite de translocations chomosomiques produites chez la souris par des rayons X. Ils les décrivent comme résultant de l'absence de soudure de la gouttière encéphalique et ils reconnaissent que l'organogenèse cérébrale s'est, par ailleurs, assez normalement développée.

BONNEVIE (1936) a étudié également, chez la souris, une malformation cérébrale très voisine d'origine génétique, la pseudo-encéphalie, dans laquelle le cerveau plus ou moins ouvert est à nu et forme une saillie au-dessus de la base du crâne. Selon cet auteur, le tube nerveux se fermerait d'abord normalement. Diverses courbures de la moelle dans la région cervicale entrainerait une tension dans le tube neural qu'exagérerait le rapide développement du mésencéphale et de la courbure pontique. Le toit du mésencéphale, qui serait un point de moindre résistance, céderait sous cette pression. Des tractions dues à certains nerfs entraineraient l'éversion du diencéphale et l'inflexion ventrale des hémisphères. Les dispositions fondamentales seraient donc d'origine mécanique et liées elles-mêmes à une insuffisance de développement des structures mésoder-

miques adjacentes au névraxe. Selon cet auteur, la chorde serait attachée au névraxe chez ces jeunes embryons anormaux; il y aurait même, chez certains, des anomalies de séparation des feuillets, ce qui les conduirait à une mort précoce. Néanmoins, BONNEVIE fait observer que, peut-être lors des flexions encéphaliques, le mésencéphale n'est pas entièrement fermé ou insuffisamment résistant, et c'est là que débuterait une ouverture secondaire de plus en plus grande.

Selon GRÜNEWALD (1947), on pourrait citer en faveur de l'hypothèse d'une ouverture secondaire les observations de PAFF (1939), qui aurait obtenu avec la colchicine des dysraphies chez le poulet, après 48 heures d'incubation, c'est-à-dire alors que le tube nerveux devait être fermé.

La possibilité d'ouverture secondaire, si elle n'est pas la règle, ne doit pas être absolument exclue.

WILSON, BRENT et JORDAN (1952), à la suite d'irradiation au 9e jour, ont observé des évaginations du névraxe qui pourraient venir en contact de l'épiderme, le détruire et venir s'ouvrir en dehors. Certaines de leurs figures sont assez démonstratives de ce processus.

Nous avons vu nous-mêmes des faits de cet ordre dans des anomalies consécutives à la carence pantothénique (GIROUD, DELMAS, PROST et LEFEBVRES (1956).

Nos observations actuelles permettent de préciser la question.

I. — L'évolution de l'anencéphalie débute par la non-fermeture de la gouttière encéphalique. Peut-être se ferme-t-elle au niveau du neuropore et un peu au-delà. Mais toute la plus grande partie de la région télencéphalique, la totalité de la région diencéphalique et mésencéphalique, restent ouvertes. Selon les cas, la région rhombencéphalique est plus ou moins atteinte.

II. — Cela n'empêche pas l'organogenèse ni l'histogenèse dans leur ensemble. Aux points voulus s'édifient notamment les hémisphères et ceux-ci possèdent des corps striés, des bulbes olfactifs s'y forment. La différenciation des couches germinative, palléale, marginale, s'effectue, puis, pour finir, il apparaît un cortex, comme normalement.

Un fait qui met bien en évidence l'évolution de territoires bien définis, c'est l'apparition des plexus choroïdes. Ceux-ci se forment au niveau de la paroi de l'hémisphère, spécialement au voisinage de leur orifice extérieur. Ils s'en forment aussi en bordure des lames diencéphaliques éversées au voisinage de l'épiderme. Cela correspond aux régions qui auraient dû se trouver à la voûte du diencéphale normal pour former les plexus du IIIe ventricule.

Ces organes et ces structures s'édifient ainsi quasi normalement et même, semble-t-il, avec une grande exubérance.

III. — Un peu plus tard, des processus de nécrose apparaissent. Ils débutent dans les parties les plus extérieures, c'est-à-dire à l'opposé du mésenchyme adjacent. Ils s'étendent en profondeur et bientôt tout est détruit. Il ne reste plus que quelques débris et quelques nerfs qui survivent.

L'anencéphalie comporterait donc une organogenèse et une histogenèse quasi normales sur un cerveau resté ouvert, mais le tout serait suivi de processus de dégénérescence.

Du moins, c'est ce qui se passe dans les anencéphalies que nous avons provoquées et qui correspondent à celles de l'homme. L'existence de jeunes embryons humains, superposables à certains de nos stades, semble indiquer qu'il doit bien s'agir du même processus dans les deux cas.

RÉSUMÉ

L'administration de vitamine A à haute dose aux 8, 9, 10e jours de la gestation, chez la rate, entraîne l'apparition d'un grand nombre d'anencéphales. Nous avons étudié leur évolution depuis le 11e jour jusqu'au 21e jour de la gestation.

Le tube encéphalique ne se ferme pas dans toute l'étendue du prosencéphale et du mésencéphale. Généralement, le rhombencéphale est normal.

Sur cet encéphale ouvert, une organogenèse presque normale s'effectue néanmoins. Il se forme latéralement des hémisphères qui seront recouverts par les parois éversées du diencéphale et du mésencéphale. Des bulbes olfactifs s'y développent. Des corps striés se différencient ainsi que des plexus choroïdes, une histogenèse normale s'effectue avec apparition d'un cortex. Une évolution comparable se produit au niveau du diencéphale et du mésencéphale. Ainsi se forme un encéphale ouvert de grandes dimensions, constituant une masse considérable au-dessus de la base du crâne.

Secondairement, des processus de nécrose détruiront toutes ces édifications dont il ne reste au moment de la naissance que quelques résidus, notamment des plexus choroïdes et des nerfs.

L'anencéphalie est donc le résultat de la dégénérescence d'un encéphale resté ouvert et ayant subi néanmoins une organogenèse très poussée.

BIBLIOGRAPHIE

Ancel (P.), 1954. — Sur la réalisation expérimentale de deux *malformations du* crâne et de l'encephale : cléiencéphalie et acléiencéphalie. *C. R. Acad. Sc.*, **239**, 1330-1332.

André-Thomas (A.), 1950. — L'anencéphalie est-elle primitive ou secondaire ? *Presse méd.*, 58-82, 1425-1429.

Bantin (J. B.) et Boyd (J. D.), 1937. — Abnormal development of the brain in an 8 mm pig embryo. *Journ. of Anatomy*, vol. **72**, 3e partie, 422-429.

Bivetti (J. M.), 1954. — Ein Beitrag zur Frage der Entstehung der Pseudenkephalie. *Schweiz. Arch. Neurol. Psychiat.* **73**, 1, 19-56.

BOHMIG (R.), 1927. — Ueber das primodialcranium eines menslichen Embryos aus dem Zweitem Monat mit cranio-rachischisis. *Zeit. f. ges. anat.*, **65**, 570-591.

BONNEVIE (K.), 1936. — Vererbbare Missbildungen und Bewegungsstorungen auf Embryonale Gehirnanomalien zuruckfuhrbar-*Erbarzt. Beit. z. Dtsch. Aerztebl.*, **42**, 2, 145-150.

COHLAN (S.), 1953. — Excessive intake of vitamin A as a cause of congenital anomalies in the rat. *Science*, **117**, 535 556.

DODDS (G. S.), 1937. — An anencephalic human embryo 16,5 mm long. *Anat. Record*, **67**, 499-505.

ERSKINE (C. A.), 1955. — Human anencephaly in early developmental stages. *Acta Anatomica*, **23**, 251-258.

FORD (E. H. R.), 1956. — An anencephalic embryo of 35,5 mm. *Acta Anatomica*, **28**, 149-155.

FRAZER (J. E.), 1921. — Report on an anencephalic embryo, *J. of Anatomy*, **56**, 12.

GIROUD (A.), DELMAS (A.), PROST (H.) et LEFEBVRES (J.), 1957. — Malformations encephaliques par carence en acide pantothénique et leur interprétation. *Acta Anatomica*, **29**, 209-227.

GIROUD (A.) et MARTINET (M.), 1954. — Fentes du palais chez l'embryon de rat par hypervitaminose A. *C. R. S. B.*, **148**, 1742-1743.

— 1955 *a*. — Hypervitaminose A et anomalies chez le fœtus de rat. *Rev. Intern. de Vitaminologie*, **26**, 10-18.

— 1955 *b*. — Hydramnios et anencéphalie. *Gyn. et Obst.*, **54**, 391-399.

— 1956. — Tératogenèse par hautes doses de vitamine A en fonction des stades du développement. *Arch. Anat. micr. Morph. exp.*, **45**, 2, 77-98.

GROTH (K. E.), 1928. — Ein fall von Anencephalie mit rachischisis bei einem 14 mm longen menslichen Embryo rekonstruktiv untersucht. *Zeit. f. Mik. anat. Forsch.*, **14**, 183-510.

GRUENWALD (P.), 1947. — Mechanisms of abnormal development. II. Embryonic development of malformations. *Arch. of Pathology*, **44**, 495-559.

MALL (E. P.), 1900. — A contribution to the study of the pathology of early human embryos. *Johns Hopkins Hosp. Rep.*, **9**, 1-68.

MANN (I. C.), 1937. — Developmental abnormalities of the eye. Cambridge Univ. Press.

PAFF (G. H.), 1939. — The action of colchicine upon the 48 hour chick embryo. *Am. J. of Anatomy*, **64**, 331-339.

PATTEN (B. M.), 1952. — Overgrowth of the neural tube in young human embryos. *Anat. Rec.*, **113**, 4, 381-393.

POLITZER (G.), 1955. — Ueber spaltbildung des Gehirns und Rückenmarks menslicher Embryonen und ihre unterscheidung von Verletzung. *Wiener Zeits. f. Nervenheilk.*, **10**, 18 34.

SPANNER (R.), 1928. — Untersuchungen zur genese der Rachischisis anterior und posterior mit Berüksichtigung der Craniorachischisis. *Zeit. f. Ges. Anat.*, **83**, 323-362.

SNELL (G. D.) et PICKEN (D.), 1935. — Abnormal development in the mouse caused by chromosome unbalance. *J. of Genetics*, **31**, 213 235.

STERNBERG (H.), 1929. — Ueber Spaltbildungen des Medullarrohres bei jungen menschlichen Embryonen ein Beitrag zur Entstehung der Anencephalie und der Rachischisis. *Virchows Archiv für Path. Anatomie*, 272.

STROEH (W. F. H.), VAN DER ZWAN (A.), 1939. — Anencephaly and rachischisis posterior, with the description of a human hemicephalus of 18 mm. *J. of Anatomy*, **73**, 111, 441-450.

VRIES (E. DE), 1927. — Description of a young anencephalic and amyelic embryo. *Anat. Rec.*, **36**, 293-317.

WILSON (J. G.), BRENT (R. L.), JORDAN (CH.), 1952. — Neoplasia induced in rat embryos by roentgen irradiation. *Cancer Res.*, **12**, 3, 222-228.

WULTE (M.), 1924. — Ein fall von Enzephalomyeloschisis totalis bei einem menslichen Embryo in der 7. Woche. *Zeit. mikr. Anat. Forsch.*, **1**, 563-606.

VAN DER ZWAN (A.), 1951. — Anencephaly and rachischisis. Case description, pathology and etiology. *Folia psychiatr., neurol. et neurochirurgica neerlandica*, **54**, 2, 147-156.

Giroud-'58
Bib. No. 3198

Compt. Rend. Soc. Biol. 152:931-932. 1958.

Reproduced by permission of the copyright owner

Repercussions of Vitamin A Hypervitaminoses in the Rabbit Embryo

A. Giroud and M. Martinet

We asked ourselves whether the experimental malformation produced by vitamin hypervitaminosis which were obtained in large numbers in the rat might not also occur in a number of species belonging to separate groups.

Deficiency of this vitamin has already been shown to be teratogenic and occurs in many species. Hale (1935) was the first to demonstrate cleft palate, harelip and microphthalmia, following vitamin A deficiency. Warkany and Schraffenberger (1946), Warkany, Roth and Wilson (1948) observed a number of ocular, cardiovascular and renal malformations in the rat including horseshoe kidney. In the sheep, Moore (1935) observed microphthalmia which was also a function of vitamin A deficiency in the mother.

We have shown that giving excess vitamin A to rats during pregnancy causes numerous anomalies in the embryo; anencephalia, encephalocele, meningocele, anophthalmia, microphthalmia, cleft palate, malformations of the ear, fissures of the jaw and tongue, urohydronephrosis, syndactyly and cataracts.

Note also that the disturbing influence of excess vitamin A on the development of tissue was noted by Fell and Melamby. These authors observed in a culture (in the chicken) in the presence of excess vitamin A, that the ectoderm does not undergo normal evolution into keratinized stratified epithelium, but is transformed into ciliar epithelium with mucus cells.

We performed studies to determine whether maternal hypervitaminosis could turn out to be teratogenic in other species of mammals. We dealt with rabbits and guinea pigs in other words, two species of rodents, very different from the rat. We shall discuss here only the results with the former.

We used rabbits weighing 2 kg. Impregnation took place on a specific day, taking into account the congestive state of the vagina before putting

them with the males. On each occasion the rabbits were full without exception. We treated them between the 5th and 14th days of pregnancy, giving them vitamin A three days in a row. We used doses of 500,000 units, 240,000 units or only 125,000 units. At the high doses, corresponding to 160,000 per kg, we obtained only total abortions. At the moderate doses that corresponded to 80,000 units per kg., we obtained 50% partial abortions and certain malformations (partial exencephalia, one anuria and one case of renal agenesis as well as a complex case of microstomy).

If we compare these doses with those which we gave the rats and which yielded a large number of abortions, we will see that the latter are much higher since they correspond to 280,000 units per kg. per day. The rabbits were much more sensitive than the rats. On the other hand, resistance to teratogenic action was much more pronounced than in the rats; in the latter with 50% abortions, we obtained a very large number of abnormal specimens while we obtained only a few in the rabbit.

In a series in which we used still lower doses, 41,000 units per kg. of rabbit, we had several abnormal individuals. In one litter, all of the embryos were edematous; in addition, they showed atrophy of the lower jaw and a lateral contraction of the face. They were afflicted with considerable exophthalmy with hemorrhages between the two retinal layers as well as in the interior of the crystalline lens. In addition, they had cleft palates and ectrodactyly. The origin of all of these malformations is doubtful.

If we assume that these various malformations were due to vitamin A hypervitaminoses, we must conclude that the percentage of anomalies obtained is quite low.

In the rabbit, experimentation is more delicate than in the rat, because these animals appear to be much more sensitive to the toxic effect that the rat, as indicated by the case with which abortions were induced.

We studied the teratogenic action of excess vitamin A in the rabbit. Under conditions where 50% abortions were obtained, we found only a few malformations, while under the same conditions in the rat, a large number could be obtained. These results demonstrate that while vitamin A hypervitaminosis is highly teratogenic in the rat, it is not equally so in the rabbit. On the contrary, the latter is much more sensitive to the abortive effects.

Giroud-'58
Bib. No. 3198

Reproduced by permission
of the copyright owner

Compt. Rend. Soc. Biol. 152:931-932. 1958.

SÉANCE DU 28 JUIN 1958.

Présidence de M. A. Lacassagne.

Répercussions de l'hypervitaminose A chez l'embryon de Lapin.

par A. Giroud et M. Martinet.

Nous nous sommes demandé si les malformations expérimentales par hypervitaminose A, que nous avons obtenues en grand nombre chez le Rat, ne pourraient pas se retrouver chez toute une série d'espèces appartenant à des groupes distincts.

Déjà la carence en cette vitamine s'était revélée tératogène et se retrouvait chez plusieurs espèces. Hale (1935) avait démontré le premier des fissures palatines, des becs-de-lièvre, des microphtalmies à la suite d'une carence en vitamine A. Warkany et Schraffenberger (1946), Warkany, Roth et Wilson (1948) avaient observé chez le Rat toute une série de malformations oculaires, cardio-vasculaires et rénales, y compris le rein en fer à cheval. Chez le veau, Moore (1935) avait observé des microphtalmies qui dépendaient aussi d'une déficience en vitamine A chez la mère.

Nous avons montré ici même qu'un excès de vitamine A administré à la ratte au cours de la gestation, provoque de multiples anomalies chez l'embryon : anencéphalies, encéphalocèles, méningocèles, anophtalmies, microphtalmies, fissures palatines, malformations de l'oreille, fissures du maxillaire et de la langue, uro-hydronephrose, syndactylies ainsi que des cataractes.

Notons de suite que l'influence perturbatrice d'un excès de vitamine A sur l'évolution d'un tissu avait été notée par Fell et Melamby. Ces auteurs ont observé en culture, chez le Poulet, en présence d'un excès de vitamine A, que l'ectoderme ne subit pas son évolution normale en épithélium stratifié kératinisé, mais se transforme en épithélium cilié à cellules muqueuses.

Nous avons recherché si une hypervitaminose maternelle pouvait se montrer tératogène chez d'autres espèces de Mammifères. Nous nous sommes adressés à des lapins et à des cobayes, c'est-à-dire à deux espèces de Rongeurs très différentes du Rat. Nous n'insisterons que sur le cas des premiers.

Nous avons pris des lapines pesant 3 kg. La fécondation a été faite à jour fixe en tenant compte, pour la mise au mâle, de l'état conges-

tif du vagin : chaque fois les lapines ont été pleines sans exception. Nous avons traité du 5e au 14e jour de la gestation, trois jours de suite, avec la vitamine A. Nous avons utilisé des doses soit de 500.000 U.I., soit de 240.000 U.I., soit de 125.000 U.I. seulement. Avec les hautes doses, ce qui correspond à 160.000 U.I. par kilog, nous n'avons eu que des avortements totaux. Avec des doses moyennes qui correspondent à 80.000 U.I. par kilog nous avons obtenu 50 % d'avortements partiels et quelques malformations (une exencéphalie partielle, une anourie et une agénésie rénale et un cas complexe de microstomie).

Si nous comparons ces doses à celles que nous administrons aux rats, et qui donnent aussi un grand nombre d'avortements, nous voyons que ces dernières sont beaucoup plus élevées puisqu'elles correspondent à 280.000 U.I. par kilog par jour. Les lapins sont donc beaucoup plus sensibles que les rats. Par contre la résistance à l'action tératogène est bien plus marquée que chez le Rat : chez ce dernier, avec 50 % d'avortements, nous avons obtenu un très grand nombre d'anormaux, tandis que nous n'en obtenons que quelques-uns chez le Lapin.

Dans la série où nous avons utilisé des doses encore plus faibles, soit 41.000 U.I./kilog de Lapin, nous avons eu quelques anormaux. Dans une portée tous les embryons étaient œdémateux ; surtout ils présentaient une atrophie du maxillaire inférieur et un rétrécissement latéral de la face. Ils étaient atteints d'exophtalmies considérables avec hémorragies entre les deux feuillets rétiniens ainsi qu'à l'intérieur du cristallin. De plus, ils présentaient des fissures palatines et des ectrodactylies. L'origine de toutes ces malformations peut être discutée.

Si l'on admet que ces diverses malformations doivent être attribuées à l'hypervitaminose A on est, en tout cas, amené à conclure que le pourcentage des anomalies obtenues est assez faible.

Chez le Lapin, l'expérimentation est plus délicate que chez le Rat, car ces animaux semblent bien plus sensibles à l'action toxique que le Rat, ainsi que le démontre la facilité des avortements.

Résumé. — On a recherché l'action tératogène d'un excès de vitamine A chez le Lapin. Dans des conditions où il se produit 50 % d'avortements, nous avons constaté seulement quelques malformations, alors que dans les mêmes conditions chez le Rat on peut en obtenir un grand nombre. Ces résultats démontrent que si l'hypervitaminose A est très tératogène chez le Rat, il n'en est pas de même chez le Lapin. Par contre ce dernier est beaucoup plus sensible à l'action abortive.

Giroud-'59
Bib. No. 3201

Reproduced by permission
of the copyright owner

Compt. Rend. Soc. Biol. 153:201-202. 1959.

Vitamin A

French publication, Societe de Biologie, Seance du February 14, 1959

pages 201-202

Extension to several species of mammals, of embryonic malformations due to A hypervitaminosis

by A. Giroud and M. Martinet

We have shown in this same place that vitamin Aadministered in large doses to the gestating rat, provoked manifold anomalies in the embryo (1'). We attempted to find out whether a maternal hypervitamonosis could be demonstrated to be teratogenic in other species of mammals. To do this we turned to cavies, rabbits and mice.

To gestating cavies we gave 50,00 IU of vitamin A on the 12th to 14th day of gestation. We noted a high percentage of total abortions. In other pregnancies, with embryos undergoing resorption, we found embryos alive, some of them abnormal. In particular, we observed a case of total fissure of the inferior maxillary with anterior doubling of the tongue.

In rabbits weighing 3 kg, we administered decreasing doses of vitamin A from the 5th to the 10th day of gestation. With the largest doses we noted only abortions. With the dose of 125,000 IU, given per os for 6 consecutive days (5th to 10th day), we obtained either total abortions or births in which a part of the embryos remained alive and on some of these we noted a series of anomalies. We saw one embryo with considerable malformation of the face, microstomia and synotia. We observed a case of exencephalia limited to the rhombencephalus. In one birth we obtained 5 embryos in resorption and 6 live ones with multiple malformations. There was no normal embryo, and all had the same anomalies. There was a contraction of the fact, palatine fissures, atrophies of the limbs with reduction of the number of fingers. They were also suffering from ocular malformations: there were colobomas accompanying

severe intra-ocular hemmorhages, entraining exophthalmias of a more or less marked character.

Finally, we directed our tests to mice. For this we used a Swiss Webster stock. Females weighing 25 to 26 grams were mated with the male on a fixed date after verification of estrus by vaginal smears. From the 8th to the 10th day of gestation we administered 5,000 IU of vitamin A by means of an oily concentrate. All were sacrificed on the 18th day. We observed only abortions. We therefore reduced this dose several times, but these secondary attempts were again followed by abortions.

However, on giving only 3,0000 IU of vitamin A for three consecutive days, (8th-10th day) we then obtained, aside from resorbed embryos and embryos undergoing resorption, living embryos suffering from grave anomalies. Thus in a liter of 10 embryos, we had three very characteristic anencephalies. The whole brain was replaced by angiomatous tissue in which there several vestiges of encephalic formations with choroid plexus. We find the same continuity between the epidermis and the remainders of neural epithalium as would be expected in a case of an encephalus remaining open. These embryos also had a certain uni- or bilateral exophthalmia with a few alterations of the crystalline. We therefore observe, in this case, the same encephalic malformations as those we found in the rat after administration of vitamin A on the 8th to the 10th day of gestation, i.e. at a stage corresponding to the appearance of the neural plaque. Owing to the date of the treatment, there were, naturally, no palatine fissures.

These facts demonstrate that vitamin A in strong doses is not only teratogenic in the rat; it is so in the cavy, the rabbit and the mouse as well, i.e. although to different degrees, in all the species of the mammal on which we tested the treatment. This is, then, not an exceptional fact but, on the contrary, a fact capable of generalization.

Resume Having originally shown the teratogenic role of A hyper vitaminosis in the rat, we sought to find out whether we would also find this in other species of mammals. We were able to provoke anomalies in the cavy, the rabbit and the mouse in the same way.

Giroud-'59
Bib. No. 3201

Reproduced by permission
of the copyright owner

Compt. Rend. Soc. Biol. 153:201-202. 1959.

Extension à plusieurs espèces de Mammifères des malformations embryonnaires par hypervitaminose A.

par A. Giroud et M. Martinet.

Nous avons montré ici même que la vitamine A administrée à hautes doses à la Ratte gestante provoquait de multiples anomalies chez l'embryon (1*). Nous avons recherché si une hypervitaminose maternelle pouvait se montrer tératogène chez d'autres espèces de Mammifères. Nous nous sommes adressés pour cela à des Cobayes, des Lapins et des Souris.

A des cobayes gestantes nous avons donné 50.000 U.I. de vitamine A du 12e au 14e jour de la gestation. Nous avons constaté un grand pourcentage d'avortements totaux. Dans d'autres portées, avec des embryons en voie de résorption, nous avons vu des embryons vivants dont certains étaient anormaux. Notamment nous avons observé un cas de fissure totale du maxillaire inférieur avec dédoublement antérieur de la langue.

Sur des lapines de 3 kg nous avons administré des doses décroissantes de vitamine A du 5e au 10e jour de la gestation. Avec les doses les plus fortes nous avons constaté uniquement des avortements. Avec une dose de 125.000 U.I. donnée oralement 6 jours consécutifs (5e au 10e jour), nous avons obtenu soit des avortements totaux, soit des portées dont une partie des embryons étaient restés vivants et sur certains nous avons pu noter une série d'anomalies. Nous avons vu un embryon présentant une malformation considérable de la face avec

(5) P. Buser, *J. de Physiol.*, 1957, t. *49*, p. 589.
(6) R. W. Doty, *J. Neurophysiol.*, 1958, t. *21*, p. 437.
(7) A. Fourment, G. Lelord, J. Calvet et J. Scherrer, *C. R. Soc. Biol.*, 1958, t. *152*, p. 1680.
(1*) A. Giroud et M. Martinet, *C. R. Soc. Biol.*, 1955, t. *149*, p. 1088.

microstomie et synotie. Nous avons observé un cas d'exencéphalie limitée au rhombencéphale. Dans une portée nous avons obtenu 5 embryons en résorption et 6 vivants atteints de malformations multiples. Il n'y avait aucun embryon normal et tous présentaient les mêmes anomalies. Ils avaient un rétrécissement de la face, des fissures palatines, des atrophies des membres avec réduction du nombre des doigts. De plus ils étaient atteints de malformations oculaires : il s'agissait de colobomes qu'accompagnaient de grosses hémorragies intra-oculaires, entrainant des exophtalmies plus ou moins marquées.

Nous avons enfin porté nos essais sur des souris. Nous avons pour cela utilisé une souche Swiss Webster. Des femelles de 25 à 26 grammes ont été mises au mâle à jour fixe après vérification de l'œstrus par des frottis vaginaux. Du 8e au 10e jour de la gestation nous avons administré 5.000 U.I. de vitamine A au moyen d'un concentré huileux. Toutes ont été sacrifiées le 18e jour. Nous n'avons constaté que des avortements. Nous avons donc diminué cette dose à plusieurs reprises, mais ces tentatives secondaires ont encore été suivies d'avortements.

Cependant en ne donnant que 3.000 U.I. de vitamine A trois jours consécutifs (8e-10e jours) nous avons alors obtenu, à côté d'embryons résorbés et en voie de résorption des embryons vivants atteints d'anomalies graves. Ainsi, dans une portée de 10 embryons, nous avons eu trois anencéphales bien caractéristiques. Tout leur cerveau était remplacé par un tissu angiomateux dans lequel se trouvaient quelques vestiges des formations encéphaliques avec des plexus choroïdes. On y trouve la même continuité entre l'épiderme et les restes de l'épithélium neural comme il fallait s'y attendre dans le cas d'un encéphale resté ouvert. Ces embryons présentaient, de plus, une certaine exophtalmie uni- ou bi-latérale avec quelques altérations du cristallin. Nous observons donc dans ce cas les mêmes malformations encéphaliques que celles que nous avions trouvées chez le Rat après administration de vitamine A du 8e au 10e jour de la gestation, c'est-à-dire à un stade correspondant à l'apparition de la plaque neurale. Du fait de la date du traitement, il n'y avait naturellement pas de fissures palatines.

Ces faits démontrent que la vitamine A à hautes doses n'est pas seulement tératogène chez le Rat ; elle l'est également chez le Cobaye, le Lapin et la Souris, c'est-à-dire, quoique à des degrés divers, chez toutes les espèces de Mammifères sur lesquelles nous avons essayé le traitement. Il ne s'agit donc pas d'un fait exceptionnel, mais au contraire d'un fait susceptible de généralisation.

Résumé. — Ayant primitivement montré le rôle tératogène de l'hypervitaminose A chez le Rat, nous avons cherché à savoir si on le retrouvait aussi chez d'autres espèces de Mammifères. Nous avons pu provoquer de la même façon des anomalies chez le Cobaye, le Lapin et la Souris.

Compt. Rend. Seances, Soc. Biol. (Paris) 156: 449-490, 1962.

Giroud-'62
Bib. No. 3206

Reproduced by permission of the copyright owner

Vitamin A

Societe de Biologie, Seance du 24 Mars 1962, pages 449-450

Smallness of teratogenic doses of vitamin A

by A. Giroud and M. Martinet

Teratogenic agents generally have no repercussions on adult organisms themselves. In a small dose or at low intensity, however, they easily act on the embryo and disturb its development. Tuchmann-Duplessis and Mercier-Parot have even reported an anti-tumoral substance, actinomycin, which is teratogenic at doses ten times as small as those used in therapy. Among the numerous substances which Murphy used, she noted only two exceptions to this rule.

The teratogenic action of vitamin A, first of all, could appear to be an exception to this rule. In his experiments, as a matter of fact, Cohlan used, in the rat, 35,000 I.U. of vitamin A from the 2nd to the 16th day of gestation. In our case, with this animal, we administered to this animal, orally, 50,000 I.U. of vitamin A for three consecutive days at various stages of gestation. Subsequently, we extended our experiments in teratogenesis to the mouse, using doses on the same order. Thus we gave 3,000 I.U. of vitamin A for three consecutive days from the 8th to the 10th day of gestation.

There was occasion to know whether smaller doses would not entrain the same accidents. We therefore investigated, in this animal, whether much smaller doses would not provoke still more malformations. Immediately going below 1,000 I.U., we tested doses of 500, 250 and 100 I.U.

With 500 I.U. for three days (8th-10th) on 53 mice, we obtained the following results: total abortions, 11%; resorptions, 2%; anencephalies, 10%; miscellaneous malformations, 36%.

With 250 I.U. for 3 days (8th-10th) on 10 mice, we obtained the following results; total abortions, 28%, deaths or resorptions, 63%; anencephalies, 19%; malformations of the face, 18%.

With 100 I.U. for 3 days (8th-10th) on31 mice, we obtained the following results: total abortions, 9.9%; deaths and resorptions, 7.5%; miscellaneous malformations, 0%.

Another test made with this same dose, 100 I.U., per day, 5 consecutive days, from the 7th to the 11th, gave us 30% total abortions, and 7.5 living embryos per litter, but no malformation.

As we can see, doses of 250 I.U. are still very teratogenic, since we

obtained 37% malformations. But the doses of 100 I.U. although they do not seem to be teratogenic, still provoked abortions.

The estimation of these doses per kg of animal seems interesting, if only to permit comparison with those used in the clinic. Per kg, the doses which we employed are, as a matter of fact, respectively: with 500 I.U. per day and per mouse, 12,500 I.U. per kg; with 250 I.U. per day per mouse, 6,250 I.U.; with 100 I.U. per day per mouse, 2,500 I.U. per kg. It should be noted that these doses are close to those given currently in therapy, which are 2,500 to 3,000 I.U./kg. We have even given women, in a single dose, 350,000 I.U., representing 7,000 I.U. per kilogram; our doses are now smaller.

We may conclude that it is not necessary to give large doses of vitamin A in order to obtain malformations in the embryo. This vitamin remains teratogenic at relatively small doses. The case of vitamin A as teratogenic agent does not, therefore, constitute an exception to the general rule: smallness or slightness of these agents. Note, moreover, that vitamin A is always teratogenic, in the vicinity of, or at the doses used in therapy.

(Laboratory of Embryology, Faculty of Medicine, Paris)

Giroud-'62
Bib. No. 3206

Reproduced by permission
of the copyright owner

Compt. Rend. Seances, Soc. Biol. (Paris) 156: 449-490, 1962.

Légèreté de la dose tératogène de la vitamine A.

par A. Giroud et M. Martinet.

Des agents tératogènes restent généralement sans répercussions sur les organismes adultes eux-mêmes. A faible dose ou à légère intensité ils agissent au contraire facilement sur l'embryon en perturbant son développement. Tuchmann-Duplessis et Mercier-Parot ont même signalé une substance anti-tumorale, l'actinomycine, qui est tératogène à des doses dix fois inférieures à celles utilisées en thérapeutique. Parmi les nombreuses substances que M. Murphy a employées, elle n'a noté que deux exceptions à cette règle.

L'action tératogène de la vitamine A pourrait paraître, au premier abord, une exception à cette règle. Dans ses expériences Cohlan en effet utilisait chez le Rat 35.000 U.I. de vitamine A du 2e au 16e jour de la gestation. Nous-mêmes, chez cet animal, avons administré oralement 50.000 U.I. de vitamine A trois jours consécutifs à divers stades de la gestation. Depuis nous avons étendu nos expériences de tératogénèse à la Souris en utilisant des doses du même ordre. Ainsi nous donnions 3.000 U.I. de vitamine A trois jours consécutifs du 8e au 10e jour de la gestation.

Il y avait lieu de savoir si des doses plus faibles n'entraineraient pas les mêmes accidents. Nous avons donc recherché, chez cet animal, si des doses beaucoup moins fortes ne provoqueraient pas encore des malformations. Passant de suite au-dessous de 1.000 U.I., nous avons testé des doses de 500 U.I., 250 U.I. et 100 U.I.

Avec 500 U.I. pendant 3 jours (8e-10e) sur 53 souris, nous avons obtenu les résultats suivants : avortements totaux, 11 % ; résorptions, 2 %, anencéphalies, 10 % ; malformations diverses, 36 %.

Avec 250 U.I. pendant 3 jours (8e-10e) sur 10 souris, nous avons obtenu les résultats suivants : avortements totaux, 28 % ; morts ou

résorptions, 63 % ; anencéphalies, 19 % ; malformations de la face : 18 %.

Avec 100 U.I. pendant 3 jours (8e-10e), sur 31 souris, nous avons eu les résultats suivants : avortements totaux, 9,9 % ; morts et résorptions, 7,5 % ; malformations diverses, 0 %.

Un autre essai fait avec cette même dose, soit 100 U.I. par jour, 5 jours consécutifs, du 7e au 11e, nous a donné 30 % d'avortements totaux et 7,5 embryons vivants par portée, mais aucune malformation.

Comme on le voit, les doses de 250 U.I. sont encore très tératogènes puisque nous avons obtenu 37 % de malformations. Par contre les doses de 100 U.I., si elles ne semblent pas tératogènes, ont néanmoins provoqué des avortements.

L'estimation de ces doses par kg d'animal semble intéressante, ne serait-ce que pour permettre la comparaison avec celles utilisées en clinique. Par kg les doses que nous avons employées sont en effet respectivement : avec 500 U.I. par jour et par souris de 12.500 U.I. par kg ; avec 250 U.I. par jour et par souris de 6.250 U.I. par kg ; avec 100 U.I. par jour et par souris de 2.500 U.I. par kg. Il y a lieu de remarquer que ces doses sont voisines de celles que l'on donne couramment en thérapeutique qui sont de 2.500 à 3.000 U.I./kg. On a même donné, chez la femme, en une seule fois, 350.000 U.I., ce qui représente 7.000 U.I. par kilog ; nos doses sont alors inférieures.

Nous pouvons conclure qu'il n'est pas nécessaire de donner de hautes doses de vitamine A pour obtenir des malformations chez l'embryon. Cette vitamine reste tératogène à des doses relativement petites. Le cas de la vitamine A, comme agent tératogène, ne constitue donc pas une exception à la règle générale : petitesse ou légèreté de ces agents. Par ailleurs notons que la vitamine A est toujours tératogène au voisinage ou aux doses utilisées en thérapeutique.

(*Laboratoire d'Embryologie, Faculté de Médecine, Paris*).

Glauert-'63
Bib. No. 3217

J. Cell Biol. 17:111-121. 1963.

STUDIES ON THE MODE OF ACTION OF EXCESS OF VITAMIN A

VII. Changes in the Fine Structure of Erythrocytes during Haemolysis by Vitamin A

AUDREY M. GLAUERT, MARY R. DANIEL, M.D., J. A. LUCY, Ph.D., and J. T. DINGLE

From the Strangeways Research Laboratory, Cambridge, England

ABSTRACT

Rabbit erythrocytes have been haemolysed by treatment with vitamin A alcohol and the sequence of changes in the fine structure of the cells during lysis has been investigated by phase contrast microscopy of intact cells and electron microscopy of thin sections. The initial effect of the vitamin, which occurs within 1 minute, is the production of cells of bizarre appearance which have a greatly increased surface area relative to untreated cells. Large indentations appear in the surfaces of the cells, and vacuoles are formed from the indentations by a process that resembles micropinocytosis. The cells then become spherical and loss of haemoglobin begins as breaks appear in the membranes of some cells; finally, ghosts are produced that are no longer spherical but still contain numerous vacuoles. These observations support the thesis that one site of action of vitamin A is at lipoprotein membranes.

INTRODUCTION

It has previously been reported that the addition of a suspension of erythrocytes to vitamin A dissolved in ethanol results in the rapid lysis of the cells upon incubation at 37°C (Dingle and Lucy, 1962). The molecular specificity for lysis of red cells was found to be similar to that for the prevention of vitamin A deficiency in animals and for the action of the vitamin on isolated lysosomes from rat liver. For example, the hydrogenated and anhydro forms of the vitamin and related terpenes show little activity in any of these systems. On the basis of these observations, it was suggested that the site of action of vitamin A is at the lipoprotein membranes of cells and their organelles, and that its function is to control the permeability of biological membranes, which become unstable in the presence of excess of the vitamin.

Earlier observations with the light microscope on erythrocytes treated with vitamin A showed that the cells become first crenated and then spherical, and that finally red cell ghosts are produced (Dingle and Lucy, 1962). These observations have now been extended in a study of the effect of the vitamin on the fine structure of rabbit red cells by electron microscopy of thin sections. It has been found that treatment with the vitamin causes a reproducible series of changes in the morphology of the red cell, and these are described in this paper. A preliminary communication has been published (Dingle, Glauert, Daniel, and Lucy, 1962).

MATERIALS AND METHODS

[illegible]

Rabbit erythrocytes were obtained from young adult male animals. The rabbits were bled from the marginal ear vein and the blood was collected in an approximately equal volume of Alsever's solution (DeGowin, Hardin, and Alsever, 1949). The cells were centrifuged and washed twice with approximately 10 volumes of 0.9 per cent sodium chloride solution. The packed-cell volume was then determined by centrifuging the cells in a small quantity of 0.9 per cent sodium chloride solution at 220 *g* for 5 minutes in an angle-head centrifuge. Finally, the cells were suspended in 0.9 per cent sodium chloride solution to give 1 ml of packed cells per 40 ml of suspension. This was the standard suspension that had been used in the previous biochemical experiments (Dingle and Lucy, 1962) and was, therefore, used here.

Vitamin A

Vitamin A alcohol (Roche) was dissolved in ethanol to give a 100 mg/ml solution; for convenience, "vitamin A alcohol" is referred to as "vitamin A" throughout the paper. The solution was stored under nitrogen in the cold; dilutions were made immediately before use. Since vitamin A is virtually insoluble in saline, it was necessary to standardize the mode of addition of the vitamin to the cells. Reproducible results were obtained when an ethanolic solution of the vitamin (0.05 ml) was pipetted into the bottom of a dry tube and then a measured volume (5 ml) of the cell suspension added. An equal volume of ethanol was added in a similar manner to cells in control experiments.

Phase Contrast Microscopy

A small chamber was made by Mr. Ross Munro by forming a thin rim of Araldite (type one natural) around four sides of a 1-inch square on a thin microscope slide. After hardening, the Araldite was filed down until the surface was smooth and the layer was only a few thousands of an inch thick. A small drop of the suspension of cells to be observed was placed in the centre of the square and the chamber sealed with a 1-inch square No. 0 coverslip. Observations were made with a Cooke, Troughton, and Simms phase contrast microscope, with a Point-o-Lite source, green filter, heat filter, × 95 oil immersion objective, and × 10 eyepiece.

Stained Preparations

Sections 1 to 2 μ thick were cut from the methacrylate blocks (see below) and stained overnight with G. T. Gurr's "R 66" Giemsa stain without removing the embedding medium. Photographic recordings were made with a Leitz Ortholux [illegible] with a × [illegible] apochromatic oil immersion objective and × [illegible] eyepiece.

Electron Microscopy

Normal and treated suspensions of red cells in [illegible] per cent NaCl solution were centrifuged at 130 [illegible] 7 minutes and the pellets were fixed by the addition of 1.0 ml of buffered osmium tetroxide fixative at [illegible] 7.0 (Zetterqvist, 1956). To study changes occurring only a few seconds after the addition of the cells to the vitamin, 1.0 ml of fixative was added to 1.0 ml of the treated cells in saline; the mixture was centrifuged immediately and the pellet resuspended in 1.0 ml of the fixative in the usual way. After fixation for 1 to [illegible] hours, the cells were centrifuged and resuspended in 50 per cent ethanol in water; after at least 30 minutes in the cold, they were centrifuged again and resuspended in 70 per cent ethanol in water. The cells were left in 70 per cent ethanol for 1 hour, or overnight, and were then centrifuged to produce a firm pellet. This pellet was cut into small pieces with a sharp razor blade and these pieces were passed through the subsequent dehydrating and embedding solutions. The cells were embedded in partially prepolymerized methacrylate.

Thin sections, 500 to 800 A thick, were cut with an A. F. Huxley microtome and collected on grids coated with collodion and carbon films. Some sections were stained by floating the grids on a solution of uranyl acetate in water or ethanol. The sections were examined in a Siemens Elmiskop I electron microscope operating at 60 kV, and photographed at instrumental magnifications of 6,000 to 14,000.

RESULTS

Phase Contrast Microscopy

Living rabbit erythrocytes suspended in 0.9 per cent sodium chloride solution appear uniformly dense and many of the cells have irregular "prickly" outlines (Fig. 1). Bessis and Bricka (1950) have shown that this appearance is a common result of suspending red cells in saline and that these spherical "sea urchin" forms return to the biconcave shape in normal plasma.

The addition of ethanol to the suspensions in the control preparations has no effect on the appearance of the cells, and no haemolysis is seen during 1 hour at room temperature.

Treatment with vitamin A (20 μg/ml) has an immediate effect on the morphology of the red cells; large indentations appear in their surfaces and they assume various bizarre forms (Fig. 2



FIGURES 1 TO 3

Phase contrast photographs of living rabbit erythrocytes in 0.9 per cent NaCl solution. The scale marks represent 10 microns. × 2,500.

FIGURE 1

Normal rabbit red cells in saline appear uniformly dense with "prickly" outlines.

FIGURE 2

After treatment with vitamin A (20 μg/ml) for 20 minutes at room temperature; there are deep indentations in the red cells.

FIGURE 3

At a later stage of treatment with vitamin A (20 μg/ml) at room temperature; thin channels are present in the cells.

FIGURE 4

Light microscope photograph of a section stained with Giemsa. 30 seconds after the addition of the cells to vitamin A (10 μg/ml) at 25°C; bizarre forms are present. The scale mark represents 10 microns. × 1,800.

The two sides of the indentation then approach each other so that only a thin channel remains (Fig. 3), and at the same time many small vacuoles appear within the red cell just beneath the surface of the indentations. The channels eventually vanish, the red cell becomes spherical, and the vacuoles are now peripheral. Soon after this some of the red cells rapidly become less dense and ghosts are formed; this final rapid fading and production of ghosts occurs in 2 or 3 seconds. The peripheral vacuoles are still present and appear as dark dots at the surface of the ghost. At lower concentrations of vitamin A (10 μg/ml) many of the red cells do not lyse within an hour under the conditions of observation in the chamber, and there are considerable variations in the rate of lysis of the individual cells. At higher concentrations (40 μg/ml) all the red cells lyse but

the process of haemolysis is so rapid that it is not possible to distinguish the sequence of morphological changes.

Light Microscopy of Stained Preparations

The red cells are too thick for clear photographic recordings to be made with the phase contrast microscope, and consequently the observations on living cells were confirmed by a study of sections, 1 to 2 μ thick, cut from the methacrylate blocks and stained with Giemsa (Fig. 4).

The cells do not all respond to treatment with the vitamin at the same rate, although the majority are in the same stage of haemolysis at any one time. It is possible that the vitamin does not reach all the cells at exactly the same moment. The sequence of changes in the morphology of the cells is shown in diagrammatic form in [illegible] which was constructed from a set of tracing[illegible] the outlines of cells as seen in the sections [illegible] sequence was deduced from the observation[illegible] living cells with the phase contrast micro[illegible] and from the series of stained preparations [illegible]tained by treating the red cells with diffe[illegible] concentrations of vitamin A at different temp[illegible]tures for different times.

ELECTRON MICROSCOPY

Normal Red Cells Suspended in Saline

The cells have various irregular shapes [illegible]pending on the plane in which they are section[illegible] the familiar outline of a biconcave disc is [illegible] only when the cell is sectioned in a plane at ri[illegible]

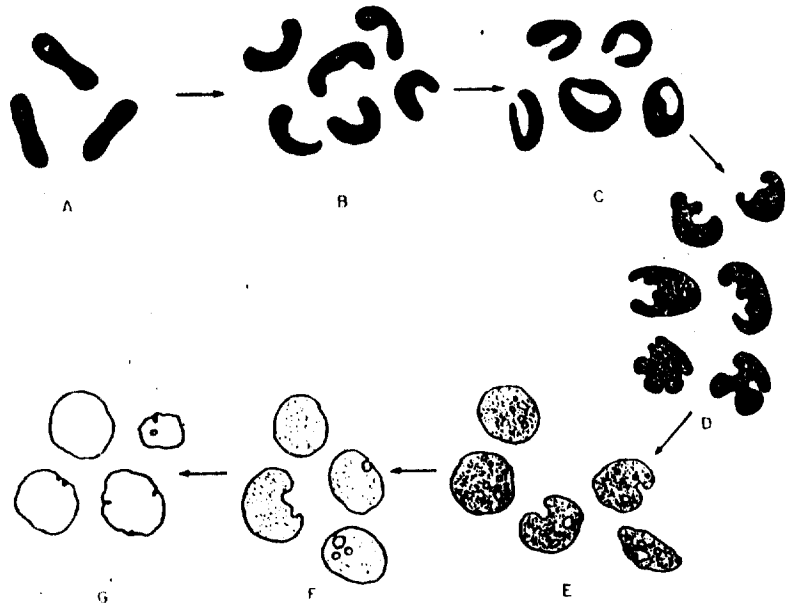

FIGURE 5

Diagram of the sequence of changes during haemolysis of red cells by vitamin A.

A. Untreated cells.

B. Large indentations appear in the cell surfaces.

C. The indentations enlarge.

D. The indentations begin to close up. Smaller indentations appear on the surfaces of the large ones and small vacuoles are formed. Loss of haemoglobin begins.

E. Loss of haemoglobin continues. The cells are becoming spherical and the small vacuoles move to the periphery of the cell.

F. Further loss of haemoglobin occurs.

G. Red cell ghosts are formed. The small vacuoles are still present.



FIGURES 6 TO 16

Electron micrographs of thin sections of rabbit erythrocytes. The scale marks represent 1 micron.

FIGURE 6

Normal red cells suspended in saline. In favourable sections the outline of a biconcave disc is seen (arrow). × 15,000.

...les to the plane of the disc (Fig. 6, arrow). ...e cells no longer have the "prickly" appearance ...n in the phase contrast microscope, having ...umably returned to the disc form during the ...ation and embedding procedures. The interior ...the cell appears uniformly dense at low mag...cation (Fig. 6) although a pattern of coarse ...fine granules is seen in thinner sections at ...ger magnification (Fig. 7). The red cell is ...nded by a dense peripheral layer which ap...ars as a thin line about 55 A thick at places ...ere the edge of the cell is accurately perpen...ular to the plane of the section (Fig. 7, arrows). ...esumably, this dense layer represents the mem...ane of the red cell.

The dense outer layers of two adjacent red cells are always separated by a gap. The width of the gap depends upon the conditions of centrifugation during the preparation of the pellet of cells, but is rarely less than 500 A and usually much greater.

In the control experiments, incubation of suspensions of red cells in saline in the presence of 1 per cent ethanol for 15 minutes at 25°C has no effect on the fine structure of the cells (Fig. 8).

Initial Effects of Vitamin A

Electron micrographs of thin sections of red cells fixed immediately (30 to 45 seconds) after the addition of the cells to vitamin A in ethanol show the same bizarre forms that are seen in the



FIGURE 7

The surface of the red cell is bounded by a thin dense line about 55 A thick (arrows). × 66,000.

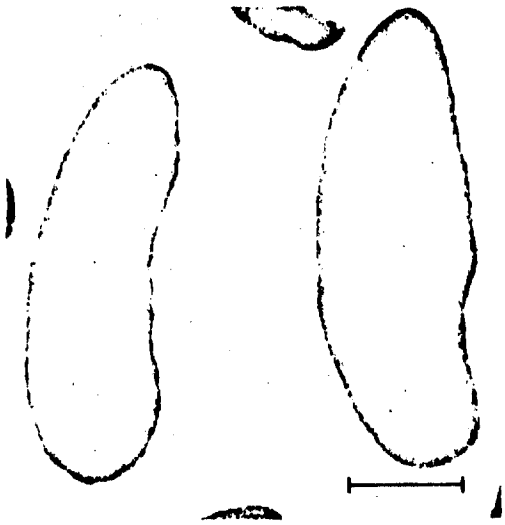

FIGURE 8

Red cells incubated with 1 per cent ethanol for 15 minutes at 25°C show no observable change in fine structure. × 15,000.

preparations viewed in the light microscope (*cf.* Figs. 4 and 9). Initially, the vitamin has no effect on the density of the interior of the cells or on the appearance of the dense peripheral layer. The cell surface is deeply infolded so that its area is greatly increased but the dense line bounding the cell is still about 55 A thick. An alteration in the surface properties of the cells occurs, however, since some adjacent cells are now observed to be in close contact (Fig. 10).

Small vacuoles are often observed inside the cells near the surfaces of the indentations (Figs. 10 and 11, arrows) and presumably correspond to those seen at this stage in the living cells with the phase contrast microscope.

In preparations centrifuged before the addi of the fixative the majority of the cells are alre assuming a spherical form (Fig. 12); some app still uniformly dense but most have lighter cen regions. Many small vacuoles, often in grou are present in the peripheral regions of the c (Fig. 12). The vacuoles appear empty and bounded by a thin dense line (Fig. 13) which n represent a membrane similar to the limi membrane of the cell. This limiting membra becomes more clearly defined as the contents the cell become less dense; it still appears as thin line about 55 A thick.

Later Stages in the Lysis of Red Cells by Vitamin A

The progressive haemolysis of the red cells accompanied by a gradual loss of density duri which light areas appear in the matrix of haem globin (Fig. 14). Some of the cells lose their sphe ical shape at this stage; the peripheral vacuo are still present (Fig. 14). Discontinuities a visible in the membranes of the red cells and, an extreme example, the membrane appears break simultaneously at many places around th periphery (Fig. 15).

Finally almost completely empty ghosts a formed (Fig. 16). Breaks are present in the mem branes of the ghosts (Fig. 16, arrows) but th peripheral vacuoles remain. The cell membran do not appear as clean lines and it seems th haemoglobin is easily adsorbed onto the inn and outer surfaces under these conditions.

DISCUSSION

In previous experiments (Dingle and Lucy, 196 it was observed that the extent of haemolysis b vitamin A was dependent both upon the concen



FIGURES 9 TO 11

Sections stained with uranyl acetate.

FIGURE 9

40 seconds after the addition of the cells to vitamin A (10 μg/ml) at 25°C. Deep indentations are seen in the cell surfaces. × 15,000.

FIGURE 10

At a slightly later stage small vacuoles (arrow) are formed at the surface of an indentation. Adjacent red cells are in close contact. × 15,000.



FIGURE 11

After 5 minutes incubation with 10 μg/ml vitamin A at 20°C the cells have begun to lose haemoglobin. Many small vacuoles have formed and one is budding off (arrow) from the surface of the large indentation seen in transverse section in the centre of the red cell. × 15,000.

tration of the vitamin relative to the numbe red cells, and upon the temperature of incubat These two parameters have, therefore, been u to obtain red cells in various stages of partial for study with the electron microscope. In ral, the degree of lysis, as measured by the re of haemoglobin, was paralleled by the exte damage and loss of density of the erythrocy revealed by the electron microscope.



FIGURE 12

The same stage as in Fig. 11; most of the cells now spherical and some have lighter central gions. × 15,000.

The appearance of the surfaces of rabbit cells in our electron micrographs of thin sectio after osmium tetroxide fixation confirms the o servations of Chalfin (1956) who described a m brane 60 to 70 A thick. Katchalsky, Danon, Nevo (1959) used a similar technique in a of human erythrocytes, and assumed that thin dense line at the surface of the cell represe the cell membrane; in their cells this line about 60 A thick, in good agreement with value of 55 A for rabbit red cells. Hiller Hoffman (1953) estimated that the membra

FIGURE 13

The vacuoles are bounded by thin dense lines similar to the limiting membrane of the red cell. × 66,000.

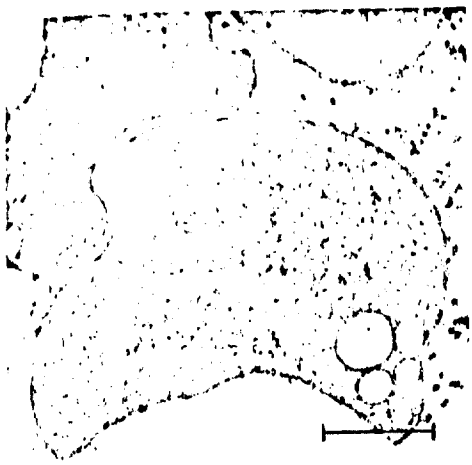

FIGURE 14

After 15 minutes incubation with 20 μg/ml vitamin A at 25°C, holes appear in the matrix of haemoglobin, and free haemoglobin is present outside the cells. The peripheral vacuoles are still present. × 15,000.



FIGURE 15

The membrane of a red cell has broken simultaneously at many points. × 10,000.

red cell ghosts from a number of species were about 50 Å thick. In the present experiments there was no detectable alteration in the thickness of the cell membrane during haemolysis.

The initial effect of vitamin A on rabbit red cells is the production of a large increase in surface area of the cells without any accompanying change in volume. In consequence, deep indentations are formed in the surfaces of the cells, which assume a variety of unusual shapes. The subsequent development of small vacuoles at the surfaces of the indentations may represent a further increase in total surface area, but at this stage the membrane appears to become unstable, the cells become spherical, and the loss of haemoglobin begins. The early stages of indentation and vacuole formation have features in common with the process of pinocytosis in amoebae where small vacuoles are pinched off from tube-like invaginations of the cell surface (Holter, 1959).

Once the small vacuoles have been formed, they appear to be comparatively stable and persist during the haemolysis of the red cell and the formation of a ghost. The numerous breaks that are visible in the membrane of the ghost suggest that most of the haemoglobin is lost at these points.

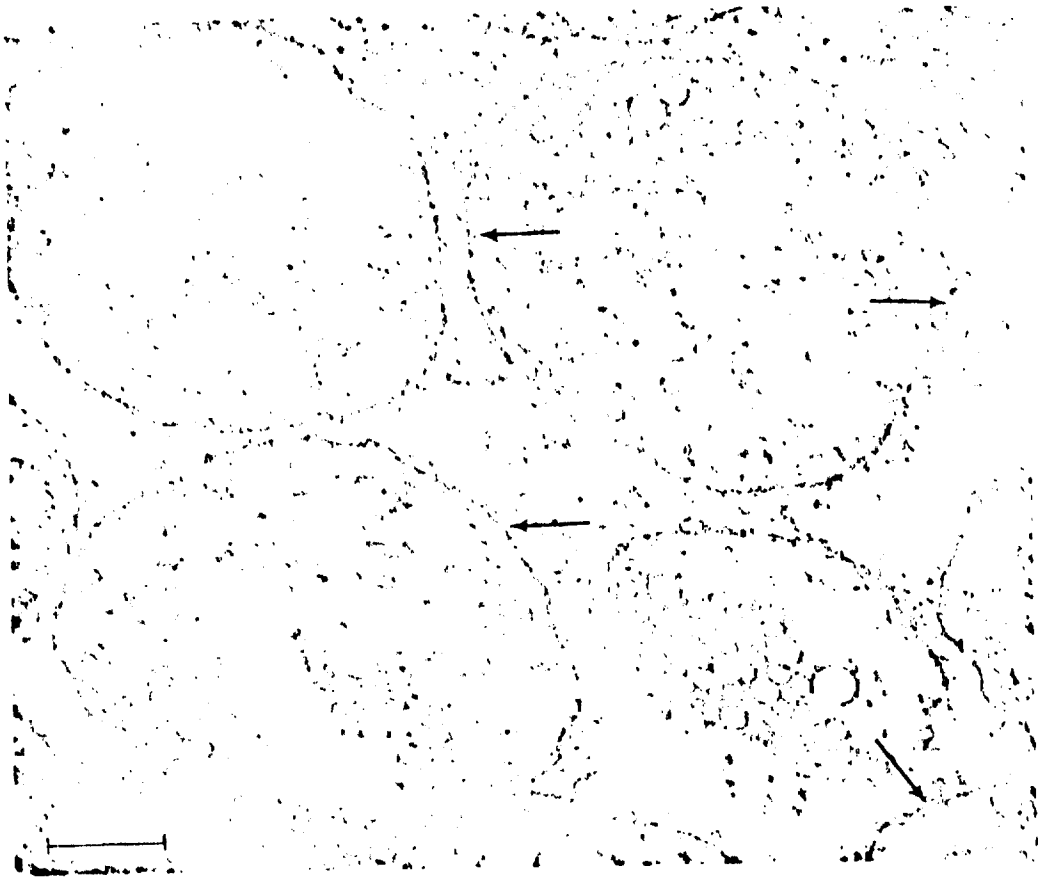

FIGURE 16

After incubation for 15 minutes with 20 μg/ml vitamin A at 37°C red cell ghosts have been formed. Breaks are visible in the membranes of the ghosts (arrows). The peripheral vacuoles are still present and haemoglobin is adsorbed onto the ghost membranes. × 15,000.

Presumably, the action of the vitamin causes local instabilities in the cell membrane.

The changes produced in the red cell membrane by excess vitamin A are reflected not only in the great increase in the surface area of the membrane and its subsequent instability, but also in the changes in surface properties which cause the treated cells to stick together. Also the membrane of the ghosts formed by vitamin A has the ability to bind haemoglobin since haemoglobin is found to be attached to the inner and outer surfaces of the membrane.

In previous experiments, it was shown that the molecular structural requirements for activity in haemolysis by vitamin A were, with certain exceptions, similar to those for prevention of vitamin A deficiency in animals (Dingle and Lucy, 1962). It was suggested, therefore, that the site of act of vitamin A is at the lipoprotein membrane the cells and their organelles, and that the funct of the vitamin may be to control membra permeability. The present study with phase c trast and electron microscopes provides supp for the thesis that one site of action of vitamin is at lipoprotein membranes. Since the im effect of vitamin A on the red cell is to produc large increase in the surface area of the cell would appear that the vitamin is incorpora in the membrane which expands in order to commodate the additional molecules. This crease in surface area may be associated with rapid loss of potassium, which precedes loss haemoglobin on treatment of erythrocytes w vitamin A (Dingle and Lucy, 1962). The ini

[illegible]tion of the membrane is consistent with [illegible] experiments which have demonstrated [illegible] vitamin A possesses the ability to penetrate [illegible] expand a monolayer of lecithin and cholesterol at an air-water interface (A. D. Bangham, [illegible] J. Dingle, and J. A. Lucy, unpublished observations). The exact mode of subsequent haemolysis is not yet clear. Lysis may arise from mechanical weakening or reorientation of the structure of the membrane, or other mechanisms may be involved.

We thank Dr. Honor B. Fell, F.R.S., for her encouragement and interest in this work, and for many stimulating discussions. We are also grateful for the skilled technical assistance of Miss J. A. Mizen and Mr. R. A. Parker.

Miss Glauert is a Sir Halley Stewart Research Fellow. Dr. Daniel works under the auspices of the British Empire Cancer Campaign. Dr. Lucy and Mr. Dingle are members of the external staff of the Medical Research Council.

Received for publication, September 1, 1962.

REFERENCES

[illegible]AS, M., and BRICKA, M., Études au microscope électronique sur l'hémolyse, l'agglutination, la forme et la structure des globules rouge, *Rev. Hématol.*, 1950, **5**, 396.

[illegible]HALLIS, D., Differences between young and mature rabbit erythrocytes, *J. Cell. and Comp. Physiol.*, 1956, **47**, 215.

[illegible]GOWIN, E. L., HARDIN, R. C., and ALSEVER, J. B., Blood Transfusion, Philadelphia and London, W. B. Saunders Co., 1949, 330.

DINGLE, J. T., GLAUERT, A. M., DANIEL, M., and LUCY, J. A., Vitamin A and membrane systems. I. The action of the vitamin on the membranes of cells and intracellular particles, *Biochem. J.*, 1962, **84**, 76P.

DINGLE, J. T., and LUCY, J. A., Studies on the mode of action of excess of vitamin A. 5. The effect of vitamin A on the stability of the erythrocyte membrane, *Biochem. J.*, 1962, **84**, 611.

HILLIER, J., and HOFFMAN, J. F., On the ultrastructure of the plasma membrane as determined by the electron microscope, *J. Cell. and Comp. Physiol.*, 1953, **42**, 203.

HOLTER, H., Pinocytosis, *Internat. Rev. Cytol.*, 1959, **8**, 481.

KATCHALSKY, A., DANON, D., and NEVO, A., Interactions of basic polyelectrolytes with the red blood cell. II. Agglutination of red blood cells by polymeric bases, *Biochim. et Biophysica Acta*, 1959, **33**, 120.

ZETTERQVIST, H., The ultrastructural organisation of the columnar absorbing cells of the mouse jejunum, Thesis, University of Stockholm, 1956.

Goodman-'66
Bib. No. 3296

Reproduced by permission
of the copyright owner

Journal of Clinical Investigation
Vol. 45, No. 10, 1966

The Intestinal Absorption and Metabolism of Vitamin A and β-Carotene in Man *

DEWITT S. GOODMAN,† ROLF BLOMSTRAND, BENGT WERNER, HELEN S. HUANG,‡ AND TATSUJI SHIRATORI

(From the Department of Medicine, Columbia University College of Physicians & Surgeons, New York, N. Y., and the Departments of Clinical Chemistry and Surgery at Serafimerlasarettet, Karolinska Institutet, Stockholm, Sweden)

The fact that vitamin A is absorbed via the lymphatic route was first demonstrated by Drummond, Bell, and Palmer in 1935, in studies carried out in a patient with chylothorax (2). Since then this finding has been confirmed and amplified by studies with other animal species. It has been well established that retinol [1] is largely esterified during its intestinal absorption, and partial information about the processes of absorption and esterification has been available from the studies of Ganguly and his associates (3–5) and Pollard and Bieri (6). In contrast to retinol, however, much less detailed information has been available concerning the intestinal absorption and metabolism of the provitamin A, β-carotene.

Detailed studies of the events occurring during the intestinal absorption of β-carotene and retinol in the rat were recently reported by Huang and Goodman (7). Radioactive β-carotene or retinol was dissolved in oil and fed to rats containing cannulae implanted in the thoracic duct. Absorption of radioactivity occurred entirely via the lymphatic route, mainly in the form of lymph chylomicrons. Retinyl esters were the predominant labeled compounds in all samples of lymph and contained an average of 89% of the radioactivity absorbed after the administration of either labeled retinol or labeled purified β-carotene. There was virtually no absorption of unchanged labeled β-carotene into the lymph. The composition of the lymph retinyl esters was remarkably constant, regardless of the fatty acid composition of the diet and regardless of whether the retinyl esters were derived from dietary retinol or from β-carotene. Retinyl palmitate was the predominant ester in lymph, and saturated esters (retinyl palmitate plus stearate, in a ratio of approximately 2 to 1) consistently comprised two-thirds to three-fourths of the retinyl esters.

The studies reported here were designed to define the events occurring during the intestinal absorption of β-carotene and vitamin A in man. These studies represent both an extension, to man, of the studies carried out in the rat, and a continuation of earlier investigations on the transport of lipids via the thoracic duct in man (8).

Methods

Labeled compounds.[2] Retinol-15-^{14}C (specific radioactivity, 29.6 μc per mg) and retinyl-15-^{3}H acetate (specific radioactivity, 100 μc per mg) were stored under argon in sealed vials until used and were used without further purification. Previous assay of a different vial

* Submitted for publication April 25, 1966; accepted July 7, 1966.

This work was supported by research grants AM-05968, HE-05741, and HE-07663 from the National Institutes of Health, Bethesda, Md., and by grants from the Swedish Medical Research Council, the Scientific Council of the Swedish Dairies Association, and Svenska Margarinindustriens förening för Näringsfysiologisk forskning.

Parts of this work were presented at the Fifty-seventh Annual Meeting of the American Society for Clinical Investigation in Atlantic City, N. J., May 1965 (1), and at the Second International Symposium on Drugs Affecting Lipid Metabolism in Milan, Italy, September 1965. The preceding paper in this series is reference 9; this is paper no. 5 in the series.

† Recipient of Career Scientist Award from the Health Research Council of the City of New York under contract I-399.

Address requests for reprints to Dr. DeWitt S. Goodman, Dept. of Medicine, Columbia University College of Physicians & Surgeons, 630 W. 168th St., New York, N. Y. 10032.

‡ Trainee in Metabolism and Endocrinology under grant T1-AM-5397 from the National Institutes of Health.

[1] The terms retinol, retinal, retinoic acid, and retinyl ester refer, respectively, to vitamin A alcohol, aldehyde, acid, and ester.

[2] The labeled compounds used in these studies were the generous gift of Dr. U. Gloor of Hoffmann-La Roche, Basel, Switzerland.

from the same preparation of retinol-15-^{14}C had indicated that at least 98% of the radioactivity chromatographed with unlabeled retinol on alumina column chromatography (7). β-Carotene-15,15′-^{3}H (specific activity, 1.09 μc per mg) was chromatographed on a column of deactivated alumina (7) just before use. Further information about this preparation of labeled β-carotene has been provided elsewhere (9).

Subjects and collection of samples. Four studies were carried out in three subjects. In all subjects, polyethylene cannulae were implanted in the thoracic duct in the neck by the procedure described by Werner (10). Lymph was drained directly into containers kept in a small closed refrigerator, thus ensuring that the samples remained cold and in the dark during the time of collection.

Subject AW (study I) was a 61-year-old man who presented with a 2-month history of bilateral supraclavicular swellings. Past history included the presence of an esophageal diverticulum and of gallstones. Biopsy revealed the swellings in the neck to consist of lipomas. Lymph duct cannulation was performed at the time of surgical exploration of the swelling in the left supraclavicular region. At the time of cannulation the serum cholesterol concentration was 266 mg per 100 ml, and the lymph cholesterol in the fasting subject was 182 mg per 100 ml. On the day after cannulation the patient was fed a formula meal containing 52 μc β-carotene-^{3}H (47 μg) dissolved in 2 ml olive oil and emulsified with 50 ml skim milk. Lymph samples were collected at 1- to 2-hour intervals for 22 hours. The lymph flow was in the range of 15 to 25 ml per hour for most of the collection period. The patient was not fed during the collection period, but was allowed to drink water ad libitum.

Subject IC (studies II and III) was a 58-year-old housewife who presented with a lump in the left breast of 1 year's duration. Past history revealed a 1-year history of hypertension and mild congestive heart failure, treated with digitalis and chlorothiazide. Needle aspiration biopsy of the left breast showed the presence of malignant cells. Chest and skeletal X rays revealed no visible metastases. There was no history of gastrointestinal symptoms or abnormalities. Cannulation of the thoracic duct in the neck was performed at the time of scalene node biopsy, which was done to exclude the possibility of cervical node metastases. The serum cholesterol concentration was 310 mg per 100 ml, and the fasting lymph cholesterol was 158. One hour after cannulation the patient was given a formula meal containing 50 μc (46 μg) β-carotene-^{3}H, 91 μg unlabeled β-carotene, and 2 mg α-tocopherol, all dissolved in 2 ml of a polyunsaturated commercial vegetable oil [3] and emulsified with 50 ml skim milk. Lymph was collected at 1- to 2-hour intervals for the next 44 hours. A second formula feeding, consisting of 20 μc (0.68 mg) retinol-15-^{14}C plus 2 mg α-tocopherol dissolved in 2 ml of Kronolja and emulsified with 50 ml skim milk, was administered 23 hours after the first formula. The lymph flow was in the range of 15 to 30 ml per hour during most of the first collection period (study II) and in the range of 25 to 35 ml per hour during the second collection period (study III). The patient remained fasting for at least 10 hours after each of the two formula feedings, but was then allowed to drink milk (study II) or to eat a small meal (study III).

Subject HD (study IV) was a 52-year-old male engineer admitted for resection of a gastric carcinoma. A weight loss of 7 kg had occurred during the preceding year. The serum cholesterol concentration was 268 mg per 100 ml. At the time of total gastrectomy the liver appeared free of metastases, but regional lymph nodes contained metastatic tumor. The pathological diagnosis of the resected specimen was anaplastic carcinoma. Two hours before the start of gastrectomy, lymph duct cannulation was performed in the neck, in connection with a study of the appearance of malignant cells in lymph during and after gastric surgery. Four hours before lymph duct cannulation the patient was fed 50 ml of olive oil containing 194 μc (1.94 mg) of retinyl-^{3}H acetate. Lymph samples were collected at short time intervals (15 to 30 minutes) during the first 2 hours after cannulation, followed by infrequent collections thereafter.

Extraction and chromatography. In each study, the time course of the absorption of radioactivity was determined by extracting 0.5 ml of each lymph sample with 10 ml $CHCl_3$:MeOH (2:1, vol:vol), followed by radioassay of the total lipid extract so obtained. The lymph samples containing the main peak of absorbed radioactivity were then pooled for subsequent analyses. Portions of the pooled lymph were layered under an equal volume of isotonic saline and centrifuged for 45 to 60 minutes at 15,000 × *g* to 20,000 × *g*. The top, creamy zone of packed chylomicrons and the clear, chylomicron-free bottom fraction were separately collected and extracted with 20 vol of $CHCl_3$:MeOH (2:1, vol:vol), followed by the addition of 5 vol of 0.01 N H_2SO_4. A mixture of unlabeled carriers, consisting of 250 μg of retinol plus 100 μg each of β-carotene, retinal, retinoic acid, and of each of four retinyl esters (palmitate, stearate, oleate, and linoleate) was added to each sample at the time of extraction. The lower, chloroform phase was collected and evaporated to dryness. The total lipid extract was weighed, dissolved in benzene, and stored under argon at −15° C.

In study IV the lymph samples obtained during the first 3 hours of collection were all found to contain approximately 25,000 dpm of ^{3}H per ml. The lymph samples were pooled, and the total lipid of whole lymph was extracted as described.

Portions of each lipid extract were chromatographed on columns of deactivated alumina [4] as described previously (7). The order of elution and volume of eluent per 5 g of alumina were as follows: fraction 1, β-carotene (20 ml of *n*-hexane); fraction 2, retinyl esters (20 ml of benzene-hexane, 3:17); fraction 3, retinal (20 ml of

[3] The Swedish trade name of the vegetable oil is Kronolja. It consists mainly of soybean oil and contains a high proportion of linoleic acid.

[4] Woelm, grade III.

benzene-hexane, 1:1); fraction 4, retinol (50 ml of benzene); fraction 5, more polar but nonacidic compounds (20 ml methanol); and fraction 6, acids including retinoic acid (20 ml methanol:25% acetic acid, 3:1). Portions of each column fraction, and of each total lipid extract, were assayed for radioactivity.

Composition of retinyl esters. The composition of the labeled retinyl esters in each column fraction 2 was determined by a combination of two different chromatographic separations, as described in detail previously (7). A carrier mixture of unlabeled retinyl esters, comprising 30 μg each of retinyl palmitate, stearate, oleate, and linoleate, was added to each sample just before chromatography. Separation of the retinyl esters on the basis of the degree of unsaturation of the fatty acid component was first accomplished by thin-layer chromatography on alumina gel G impregnated with silver nitrate. The saturated, and other, esters were then separated according to fatty acid chain length by reversed phase chromatography on silicone-impregnated paper. The retinyl ester composition of each sample was calculated after expressing the results of each chromatographic separation as the percentage distribution of recovered radioactivity in the different esters.

Identification procedures. Radioactivity in column fraction 2 from the chylomicron samples of studies I and II (after feeding β-carotene-^{3}H) was established to reside in retinyl esters by the procedures described previously (7). These procedures included saponification to form labeled retinol, followed by acetylation to form labeled retinyl acetate (which was identified by column and thin layer chromatography). The material present in each column fraction 2 was also subjected to thin layer chromatography on alumina gel G, together with appropriate carriers, so as to separate long chain fatty acid esters of retinol from short chain esters (such as retinyl acetate) and from cholesterol esters (7). Elution and radioassay of the separated compounds indicated that in every sample, in all four studies, virtually all of the radioactivity in column fraction 2 resided in long chain retinyl esters.

Other procedures. The fatty acid composition of the total lipid extract of each sample was determined by gas-liquid chromatography of the fatty acid methyl esters, as described previously (7).

Pure lecithin was isolated from two of the samples and was subjected to hydrolysis with phospholipase A, as described elsewhere (11). The compositions of the fatty acids attached to the β and to the α′ positions of lecithin were then separately determined by gas-liquid chromatography.

Radioassay (for ^{3}H or ^{14}C or both) was carried out by dissolving samples in 15 ml of 0.5% diphenyloxazole in toluene, followed by assay with a Packard Tri-Carb liquid scintillation counter. Significant quenching was not observed.

The sources of all materials and compounds used in this study were described previously (7).

Results

The time course of the absorption of radioactivity into the lymph, in the two subjects fed β-carotene-^{3}H, is shown in Figure 1. In both subjects

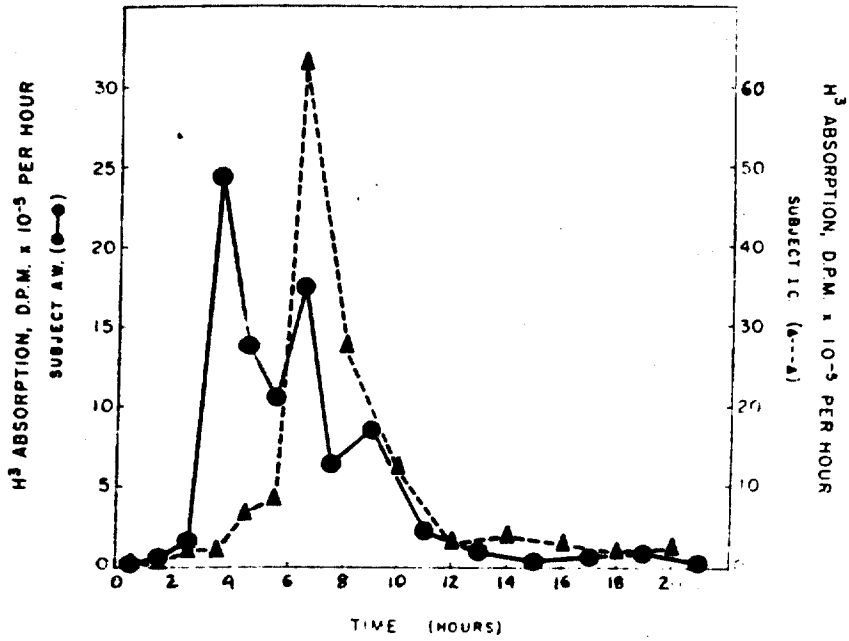

FIG. 1. THE TIME COURSE OF THE ABSORPTION OF RADIOACTIVITY INTO THORACIC DUCT LYMPH IN TWO HUMAN SUBJECTS FED β-CAROTENE-15,15′-^{3}H.

TABLE I

Distribution of radioactivity in human lymph after β-carotene-15,15'-^{3}H

Alumina column fraction	Percentage distribution of absorbed ^{3}H			
	Study I		Study II	
	Chylomicrons	Bottom fraction*	Chylomicrons	Bottom fraction*
1. β-Carotene	23	22	30	27
2. Retinyl esters	67	71	61	65
3. Retinal	3	2	3	2
4. Retinol	3	3	3	3
5+6. Polar; acids	4	2	3	3

* Lymph from which chylomicrons had been removed by centrifugation.

radioactivity was absorbed in a fairly sharp peak, which coincided with the peak of fat absorption into the lymph (as determined qualitatively by the degree of visible lactescence of the lymph samples). In study I (subject AW) the main peak of absorption occurred between 3 and 4 hours, and 88% of the absorbed ^{3}H appeared in the lymph between 3 and 10 hours. The apparent second peak of absorption seen in this study immediately after the main peak probably reflects irregular gastric emptying of the formula meal containing the labeled β-carotene. In study II (subject 1C) the main peak of absorption occurred between 6 and 7 hours, and 81% of the recovered ^{3}H was absorbed between 5 and 11 hours. In both studies the absorption of radioactivity was virtually complete by 12 hours. The total amount of radioactivity recovered in thoracic duct lymph during the entire period shown in Figure 1 comprised 8.74% of the fed radioactivity in study I and 16.76% of the fed radioactivity in study II.

A similar time course of absorption of radioactivity was seen after feeding retinol-^{14}C. Thus, in study III the main peak of absorption of ^{14}C occurred between 3 and 5 hours, and 78% of the radioactivity absorbed into the lymph was absorbed between 2 and 8 hours. A total of 21.5% of the fed radioactivity was recovered in the lymph during a period of 20 hours.

Chylomicrons, isolated as described from the pooled samples representing the main peak of absorption of radioactivity, contained 70% of the absorbed radioactivity in study I and 80% of the absorbed radioactivity in study III. The relative amount of lymph radioactivity contained within lymph chylomicrons was not precisely determined in studies II or IV.

Table I summarizes the distribution of radioactivity in the chylomicron and the nonchylomicron ("bottom") portions of lymph in the two subjects given β-carotene-^{3}H (studies I and II). In all samples, most of the radioactivity was found in the retinyl ester fraction (fraction 2), which contained 61 to 71% of the radioactivity absorbed into the lymph. Analysis of a portion of the retinyl ester fraction from each chylomicron sample demonstrated that the radioactivity in this column fraction definitely resided in long chain fatty acid esters of retinol (see above, under *Identification procedures*). Significant amounts of radioactivity were also recovered in the β-carotene fractions (fraction 1's), which contained 22 to 30% of the absorbed radioactivity. To determine whether this radioactivity resided in unchanged β-carotene, we added unlabeled pure β-carotene (250 μg) to a portion of each fraction 1 and serially crystallized the β-carotene two or three times, to constant specific radioactivity. Most (81 to 85%) of the ^{3}H in each fraction 1 was established to reside in β-carotene by this procedure.

Comparable data for the distribution of radioactivity in lymph, in the two subjects fed labeled preformed vitamin A, are presented in Table II. In both subjects, most of the radioactivity absorbed into the lymph was found in the retinyl ester fraction, which contained 86 to 88% of the absorbed radioactivity in study III and 80% of the absorbed radioactivity in study IV. Further analysis showed that all of the radioactivity in these retinyl ester fractions resided in long chain fatty acid esters of retinol. This indicated that, in study

TABLE II

Distribution of radioactivity in human lymph after radioactive vitamin A

Alumina column fraction	Percentage distribution of absorbed label		
	Study III (retinol-^{14}C)		Study IV (retinyl-^{3}H acetate)
	Chylomicrons	Bottom fraction	Whole lymph
1. β-Carotene	1	2	5
2. Retinyl esters	88	86	80
3. Retinal	6	5	6
4. Retinol	3	3	6
5+6. Polar; acids	2	4	3

TABLE III

Fatty acid compositions of the total lipid of human lymph

Study; oil in test meal	Sample analyzed	Percentage distribution of fatty acid mass					
		Palmitate (16:0)*	Palmitoleate (16:1)	Stearate (18:0)	Oleate (18:1)	Linoleate (18:2)	Arachidonate (20:4)
I. Olive oil	Chylomicrons	27	3	10	43	11	Trace
	Bottom	27	3	11	35	15	Trace
II. Kronolja	Chylomicrons	14	1	6	24	38	8
	Bottom	19	2	9	26	33	6
III. Kronolja	Chylomicrons	13	1	4	24	40	8
	Bottom	18	2	8	25	33	6
IV. Olive oil	Whole lymph	19	2	3	53	22	Trace

* Number of carbon atoms: number of double bonds. Only the major component fatty acids have been listed in this table. A number of minor components, comprising together less than 10% of the total fatty acid mass, were observed in each sample.

IV, the dietary retinyl acetate had been hydrolyzed completely before or during absorption, followed by a re-esterification of the released retinol with long chain fatty acids. Small amounts of radioactivity were also recovered in all of the other column fractions. Most of this latter radioactivity probably represented artifactual chromatographic "smearing" secondary to oxidation or other alterations occurring during the processing of the samples. Similar slight smearing of radioactivity is commonly observed during the handling of pure labeled retinyl esters or retinol. Attempts to identify the radioactive material recovered in column fraction 4 [see (7)] demonstrated that only about one-third to one-half the radioactivity in the several fraction 4's definitely resided in retinol.

The fatty acid composition of the total lipid extract of each lymph sample studied is summarized in Table III. Since triglycerides constitute the major lipid in both the chylomicron and nonchylomicron portions of lymph, the compositions listed in Table III largely represent the triglyceride compositions of the several samples. As expected, the fatty acid composition reflected the composition of the dietary fat in all samples. Thus, linoleic acid predominated in lymph after test meals containing the polyunsaturated vegetable oil (Kronolja) (studies II and III), and oleic acid predominated after test meals containing olive oil. Furthermore, the degree of predominance of oleic acid was greater in study IV, in which 50 ml of olive oil had been fed, than in study I, in which only 2 ml of olive oil had been fed.

The composition of the labeled retinyl esters present in the retinyl ester fraction of each sample studied, for all four studies, is presented in Table IV. All samples contained a mixture of four retinyl esters: retinyl palmitate, stearate, oleate,

TABLE IV

Labeled retinyl ester compositions in human lymph

Study; labeled compound fed	Oil in test meal	Sample analyzed	Percentage distribution of labeled retinyl esters			
			Palmitate	Stearate	Oleate	Linoleate
I. β-Carotene-^{3}H	Olive oil	Chylomicrons	57	25	12	6
		Bottom	54	25	14	7
II. β-Carotene-^{3}H	Kronolja	Chylomicrons	53	27	13	7
		Bottom	57	26	12	5
III. Retinol-^{14}C	Kronolja	Chylomicrons	60	22	10	8
		Bottom	60	24	10	6
IV. Retinyl-^{3}H acetate	Olive oil	Whole lymph	56	19	16	9

TABLE V

Fatty acid compositions of chylomicron lecithin

Study, oil in test meal	Fatty acid position on lecithin	Percentage distribution of fatty acid mass					
		Palmitate	Palmitoleate	Stearate	Oleate	Linoleate	Arachidonate
I. Olive oil	α′	45.5	0.8	34.8	11.8	5.0	Trace
III. Kronolja	α′	42.8	1.2	31.2	9.9	9.4	3.8
I. Olive oil	β	3.7	1.4	1.2	18.3	58.5	11.2
III. Kronolja	β	3.2	1.6	2.0	14.4	64.5	13.6

and linoleate; there was no evidence for the presence of polyunsaturated retinyl esters containing more than two double bonds in the fatty acid moiety.[5] Retinyl palmitate was the predominant retinyl ester in all samples, and the two saturated esters, retinyl palmitate and stearate, together comprised 75 to 84% (average 79%) of the total retinyl esters in all samples. The ratio of retinyl palmitate to stearate was relatively constant ranging from 2.0 to 2.9 (average 2.4) in the seven samples listed in Table IV. The composition of the labeled retinyl esters bore no resemblance to the composition of the dietary fat or of the lymph total lipid (Table III). Furthermore, the retinyl ester composition was relatively constant regardless of whether the retinyl esters were derived from preformed vitamin A or from β-carotene and regardless of whether the chylomicron or the nonchylomicron portion of lymph was analyzed.

Analyses were also carried out to determine the fatty acid composition of the lecithin present in the chylomicron samples of studies I and III. It is known that lecithin comprises the major phospholipid in rat (12) and human (13) lymph and that the composition of lymph lecithin is relatively fixed, regardless of the composition of the diet (11–13). Furthermore, it has been pointed out (7) that, in the rat, the composition of the fatty acids attached to the α′ position of lymph lecithin strongly resembles the fatty acid composition of newly absorbed lymph retinyl esters.

Table V summarizes the composition of the fatty acids attached to both the α′ and the β positions of chylomicron lecithin for the two samples studied. Similar compositions were found in both lecithin samples. Saturated fatty acids predominated at the α′ position, comprising 74 to 80% of the fatty acids in the two samples. Linoleic acid predominated at the β position. The ratio of palmitate to stearate, at the α′ position, was 1.31 and 1.37 in the two samples. These results are in accord with previously reported observations on the fatty acid distribution in human lymph lecithin (13).

Discussion

The studies reported here demonstrate that during the intestinal absorption of dietary preformed vitamin A, in man, the vitamin A is almost completely esterified with long chain fatty acids, and the retinyl esters are then transported via the lymphatic route mainly in association with lymph chylomicrons. During the absorption of dietary β-carotene, the carotene is largely converted to vitamin A, and the newly synthesized vitamin A is then esterified and transported in the lymph in the same fashion as dietary retinol. The composition of the lymph retinyl esters was remarkably constant in all the present studies, regardless of the fatty acid composition of the diet, regardless of whether the retinyl esters were derived from preformed vitamin A or from β-carotene, and regardless of whether the chylomicron or the nonchylomicron portion of lymph was analyzed. Retinyl palmitate predominated in all samples, and saturated esters (retinyl palmitate plus stearate, in an average ratio of 2.4 to 1) consistently comprised approximately 80% of the labeled esters.

These results indicate that the events occurring during the intestinal absorption of β-carotene and vitamin A in man are very similar to those occurring

[5] Although small amounts of radioactivity (5 to 11% of the total retinyl ester radioactivity) were consistently found at or just above the origin (below the linoleate zone) after thin layer chromatography, this radioactivity apparently resided in oxidation products formed during chromatography. Thus, after elution from the thin layer plate and rechromatography on an alumina column, less than 10% of this radioactivity was recovered in the retinyl ester fraction (column fraction 2).

ring in the rat. Thus, labeled retinyl esters predominated in rat lymph after the feeding of either labeled retinol or labeled β-carotene (7). Furthermore, the composition of the labeled retinyl esters found in rat lymph after a wide range of test meals was remarkably constant and was similar to the retinyl ester composition found here in human lymph. One difference was, however, observed between man and the rat: Man is capable of absorbing small but significant amounts of unchanged dietary β-carotene into the lymph, whereas virtually no dietary β-carotene can be absorbed intact into rat lymph. The quantitative difference in the ability of these two species to absorb intact β-carotene is, however, not very great, since most of the radioactivity absorbed into human lymph after feeding β-carotene-^{3}H was found in retinyl esters, and not in unchanged β-carotene. The human intestine therefore possesses only an extremely limited capacity for the absorption of unchanged dietary β-carotene.

Since the labeled β-carotene employed in these studies was labeled with tritium at the central two carbon atoms (C-15 and 15′), the question should be raised as to whether some ^{3}H label might not be lost during the metabolism of this β-carotene, particularly during its conversion to vitamin A. Recent studies with rat intestinal mucosa have demonstrated that the reaction mechanism of vitamin A biosynthesis consists of the central cleavage of β-carotene into two molecules of retinal, and that the hydrogen atoms attached to the central two carbon atoms of β-carotene are completely retained during this reaction (9, 14). β-Carotene-15,15′-^{3}H hence should be a suitable compound to use in studies of the metabolism of β-carotene. Because of its location the ^{3}H label would, of course, be lost during the conversion of newly formed retinal into retinoic acid, so that the present studies would not have detected the formation of retinoic acid had it occurred during absorption and metabolism of the β-carotene-^{3}H. Significant amounts of retinoic acid were not detected in rat lymph, however, in previous studies with ^{14}C-labeled β-carotene (7), and retinoic acid was not detected in human lymph, in the present study, after feeding retinol-^{14}C. The conversion of β-carotene into two molecules of retinal appears to be a dioxygenase reaction involving a direct reaction between molecular oxygen and the central carbon atoms of β-carotene (9). The newly formed retinal is then reduced to retinol (14), which in turn is esterified and transported via the lymph in the manner described herein.

The composition of the retinyl esters found in human and in rat lymph may be compared with the composition of the retinyl esters recently reported for a number of rat tissues (15). The composition of the labeled retinyl esters in each of six rat tissues was determined at several time intervals after the intravenous injection of chylomicrons containing newly absorbed labeled vitamin A (15). The retinyl ester compositions were remarkable in showing a consistent predominance of saturated esters in all tissues. Large differences were, however, seen in the relative amounts of labeled retinyl palmitate and stearate in different tissues. Thus, retinyl palmitate markedly predominated in liver, whereas similar amounts of retinyl palmitate and stearate were found in kidneys, and retinyl stearate predominated in adrenal glands. A marked predominance of retinyl palmitate in rat liver has also been reported by Futterman and Andrews (16). In addition, these workers determined the composition of the retinyl esters formed during incubation *in vitro* of homogenized retinas in the light (17): in four mammalian species the composition of the newly formed retinyl esters was similar to the retinyl ester composition observed here in lymph.

In a previous publication (7) it was pointed out that the fatty acid composition of retinyl esters in rat lymph is similar to the composition of the fatty acids present at the α′ position of lymph lecithin. It was also pointed out (15) that, since lecithin from practically all sources shows a striking predominance of saturated fatty acids at the α′ position, the predominance of saturated retinyl esters in all tissues extends the comparison between the fatty acid composition of retinyl esters and that of the α′ position of lecithin. In the present study, direct analysis of the fatty acid composition of lecithin from two of the chylomicron samples showed that, as with the retinyl esters, the composition of lecithin was relatively fixed and was hardly influenced by the composition of the test meal. The composition of the fatty acids attached to the α′ position of lecithin resembled the composition of the retinyl esters in being largely saturated; the ratio of palmitate to stearate at the

α' position of lecithin was, however, distinctly lower than that seen in the retinyl esters. Despite considerable similarities, therefore, the fatty acid compositions of retinyl esters and of the α' position of lecithin are certainly not identical.

The reason for the remarkably constant composition of the retinyl esters found in human and rat lymph is not known. It has been suggested (7) that retinol esterification during absorption may involve the direct reaction of retinol with a fatty acyl donor of composition similar to that seen in lymph retinyl esters. It has also been pointed out (7) that the similarity between the fatty acid composition of the α' position of lymph lecithin and that of retinyl esters suggests that retinyl ester fatty acids may derive either from the α' position of lecithin or from the precursor pool of the fatty acids of this position of lecithin. Some selectivity would, of course, have to exist to account for the different ratio of palmitate to stearate in retinyl esters and in lecithin. Further definition of the mechanism of retinol esterification during absorption will be required to decide between these and other, alternative possibilities.

Summary

β-Carotene-15,15'-^{3}H, vitamin A alcohol-15-^{14}C, and vitamin A-15-^{3}H acetate were fed to patients in whom polyethylene cannulae had been inserted in the thoracic duct in the neck. Serial samples of lymph were collected, and the lipid was extracted and chromatographed on columns and on thin layer plates of alumina. Absorption of radioactivity into the lymph mainly occurred between 3 and 10 hours. During this time washed chylomicrons contained 70 to 80% of the absorbed radioactivity. Labeled vitamin A esters predominated in all lymph samples, representing 80 to 90% of the absorbed radioactivity after the feeding of labeled preformed vitamin A, and 60 to 70% after β-carotene. The fatty acid composition of the vitamin A esters in lymph bore no resemblance to the composition of the diet and was remarkably constant, regardless of the fatty acid composition of the diet, regardless of whether the vitamin A esters were derived from dietary vitamin A or from β-carotene, and regardless of whether chylomicron or nonchylomicron lipid was analyzed. Vitamin A palmitate predominated in all samples, and saturated esters (vitamin A palmitate plus stearate, in an average ratio of 2.4 to 1) consistently comprised 75 to 85% of the labeled esters. Small amounts of vitamin A oleate and linoleate were also found in all samples. Unchanged labeled β-carotene comprised only 20 to 30% of the absorbed radioactivity, after ingestion of β-carotene-^{3}H. The human intestine possesses only an extremely limited ability to absorb unchanged dietary β-carotene into the lymph. The fatty acid composition of the lymph vitamin A esters was similar to but not identical with that of the α' position of lymph lecithin.

Acknowledgments

We are grateful for the expert technical assistance of Mrs. Joan Vormbaum, Mrs. Lena Zimmerman, and Miss Barbro Aurell. We wish to thank Dr. U. Gloor of Hoffmann-La Roche, Basel, for the labeled compounds used in these studies.

References

1. Goodman, DeW. S., R. Blomstrand, B. Werner, H. S. Huang, and T. Shiratori. Absorption and metabolism of radioactive β-carotene and vitamin A in man (abstract). J. clin. Invest. 1965, **44**, 1054.
2. Drummond, J. C., M. E. Bell, and E. T. Palmer. Observations on the absorption of carotene and vitamin A. Brit. med. J. 1935, **1**, 1208.
3. Mahadevan, S., and J. Ganguly. Further studies on the absorption of vitamin A. Biochem. J. 1961, **81**, 53.
4. Murthy, S. K., S. Mahadevan, P. Seshadri Sastry, and J. Ganguly. Fatty acid specificity for the esterification of vitamin A and cholesterol by intestinal and pancreatic enzymes in rats. Nature (Lond.) 1961, **189**, 482.
5. Mahadevan, S., P. Seshadri Sastry, and J. Ganguly. Studies on metabolism of vitamin A. 3. The mode of absorption of vitamin A esters in the living rat. Biochem. J. 1963, **88**, 531.
6. Pollard, C. J., and J. G. Bieri. Esterification of vitamin A by an acetone powder from pancreas. Arch. Biochem. 1960, **87**, 9.
7. Huang, H. S., and DeW. S. Goodman. Vitamin A and carotenoids. I. Intestinal absorption and metabolism of ^{14}C-labeled vitamin A alcohol and β-carotene in the rat. J. biol. Chem. 1965, **240**, 2839.
8. Blomstrand, R., C. Franksson, and B. Werner. The Transport of Lymph in Man. Uppsala, Sweden, Appelberg, 1965.
9. Goodman, DeW. S., H. S. Huang, and T. Shiratori. Mechanism of the biosynthesis of vitamin A from β-carotene. J. biol. Chem. 1966, **241**, 1929.

10. Werner, B. Thoracic duct cannulation in man. I. Surgical technique and a clinical study on 79 patients. Acta chir. scand. 1965 (suppl. 353), 5.

11. Whyte, M., DeW. S. Goodman, and A. Karmen. Fatty acid esterification and chylomicron formation during fat absorption in rat: III. Positional relations in triglycerides and lecithin. J. Lipid Res. 1965, 6, 233.

12. Whyte, M., A. Karmen, and DeW. S. Goodman. Fatty acid esterification and chylomicron formation during fat absorption: 2. Phospholipids. J. Lipid Res. 1963, 4, 322.

13. Blomstrand, R., and O. Dahlbäck. The fatty acid composition of human thoracic duct lymph lipids. J. clin. Invest. 1960, 39, 1185.

14. Goodman, DeW. S., and H. S. Huang. Biosynthesis of vitamin A with rat intestinal enzymes. Science 1965, 149, 879.

15. Goodman, DeW. S., H. S. Huang, and T. Shiratori. Tissue distribution and metabolism of newly absorbed vitamin A in the rat. J. Lipid Res. 1965, 6, 390.

16. Futterman, S., and J. S. Andrews. The composition of liver vitamin A ester and the synthesis of vitamin A ester by liver microsomes. J. biol. Chem. 1964, 239, 4077.

17. Futterman, S., and J. S. Andrews. Metabolism of the retina. IV. The composition of vitamin A ester synthesized by the retina. J. biol. Chem. 1964, 239, 81.

Goodwin-'58
Bib. No. 3304

MORTALITY OF NEW-BORN PIGS ASSOCIATED WITH A MATERNAL DEFICIENCY OF VITAMIN A

By

R. F. W. Goodwin and A. R. Jennings

School of Veterinary Medicine, University of Cambridge

INTRODUCTION

Although it is over twenty years since Hale (1933, 1935) described the birth of blind and deformed piglets from gilts fed a diet deficient in vitamin A, there is still debate in Britain on the extent to which avitaminosis A might be concerned in the neonatal pathology of the pig (Harding and Done, 1956; Watt and Barlow, 1956b). During 1956 we were asked to examine four herds in which piglets were dying shortly after birth or, although viable, were suffering from microphthalmia. In all these herds a diagnosis of avitaminosis A was reached and the object of this paper is to describe the clinical and pathological features of the field condition. In particular, we refer to one herd, the first examined, where the disease as first presented suggested an infective aetiology. The four herds are referred to as herds A, B, C and D, and their respective histories are given in an appendix. The main text contains an integrated account of the condition based on all the material examined.

MATERIALS AND METHODS

Estimation of vitamin A. For liver analyses the method of Davies (1933) was used and for serum levels a modification of the method of Kimble (1939).

Post-mortem examinations. All post-mortem examinations were made within 36 hours of death, but in many instances the interval was less than 18 hours. Several piglets were killed by cutting the throat vessels in the laboratory and examined at once. Tissues for histological examination were fixed in 10 per cent formol saline or Zenker's fluid; paraffin, frozen or celloidin sections were then prepared. The stains used were haematoxylin and eosin, van Gieson, Sudan III, Lendrum's phloxine tartrazine, Giemsa, Mann's eosin methyl blue and Marchi. The tissues examined were as follows: pituitary gland, parotid gland and duct, submaxillary gland, adrenal, colon, small intestine, stomach, eye, thyroid gland, spinal cord, lung, liver, heart, testis, cervix, ovary, skin including mammary gland, pancreas, kidney, spleen, rib junction and jaw bone with developing teeth.

GENERAL OBSERVATIONS

Aetiology

The conclusion that a deficiency of vitamin A was the primary cause of the abnormalities described derives from evidence of three main types—circumstantial, analytical and experimental. The circumstantial evidence is based on the diets fed during pregnancy

to the affected sows and in herds A, B and C these were grossly deficient in vitamin A; furthermore, in these same three herds the animals that were fed vitamin A, either concurrently or at a later date, gave birth to normal litters. The effect of improving the diet was particularly instructive in herd A; for whereas many litters had been born dead before vitamin A was incorporated, a succession of blind, but otherwise healthy piglets was born during the period immediately following the dietary change, and it was not until later that completely normal piglets were produced.

The analytical evidence depends mainly on the figures for the concentration of vitamin A in the livers of the piglets at birth. In herd A only one litter was so examined and this, unfortunately, was not until the piglets were being born viable but blind. However, the values of between 4 and 5 i.u. per g. in this instance support the general conclusion. In herd B, three piglets were examined from two litters and seven piglets from a third. All these animals had died shortly after birth and in none was there any appreciable concentration of vitamin A in the liver.

The experimental results, obtained with the four affected sows of herd B, were unequivocal. The animals were moved to Cambridge and re-mated to our boars after two of them had received over a short period vitamin A palmitate in arachis oil. All four sows were fed the same diet that had produced non-viable or blind piglets on the home farm and the treated pair continued to receive vitamin A throughout gestation. The litters born from the treated sows were vigorous and apparently normal, whereas no piglet survived from the litters of the deficient sows. One piglet was sacrificed from each of the normal litters and both livers were well-stocked with vitamin A. By comparison, the piglets out of the untreated sows had no vitamin A in their liver (Table I, appendix).

Clinical Signs

The clinical signs can be conveniently classified into three groups that accord with the severity of the condition. In the most severe form the piglets were born at full-term but were either still-born or moribund. In such litters some piglets were under-developed, but an insufficient number of litters has been seen to say whether this lack of development might be more common than in the piglet population generally. Some of the still-born piglets showed severe ascites. The piglets that lived for only a few hours were listless and very weak; they had little interest in suckling and commonly crawled well away from the sow. There was a marked tendency on the part of slightly stronger piglets to burrow as deeply as possible into the bedding. None had the strength to walk normally and many lay on their sides around the hindquarters of the sow until they died. In the latter instance it was usual for the piglet to make slow paddling movements with the legs while squawking intermittently. Such plaintive squawking by many pigs in an

affected litter is particularly characteristic. Another very common feature in those piglets that died shortly after birth was a lack of tone and colour in the skin, so that flakes of membrane continued to adhere to the body (Fig. 1). Sometimes the presence of subcutaneous oedema gave the animals a rounded appearance. In the litters where the disease was naturally-occurring, and where the necessary examination was made, all the moribund piglets had eye defects, usually with either marked entropion (Fig. 2) or exophthalmos. The lids were often gummed together with a brown wax-like material that also caused the eyelashes to be stuck together in groups; this material tended to accumulate at the inner canthus of the eye (Fig. 3). The contents of the orbit were commonly sunken owing to the existence of microphthalmia and vestigial eyeballs (Fig. 4). Corneal opacity was seen (Fig. 5) and in one animal the lids were firmly fused to the cornea. In the two affected litters that were produced experimentally, however, there were no eye abnormalities of any type; this fact is of special interest and is discussed later. Our cases do not permit any discussion of the more severe forms of the condition where the litter might be aborted or resorbed.

When the condition was less severe the pigs were more vigorous at birth and they appeared normal except for gross eye defects similar to those seen in the still-born pigs. In the third and mildest form of the disease the only obvious defects were again in the eye, but there was now no involvement of the lids and the eyeball was of normal shape and size: the defects were mainly in the position and extent of the iris so that the sclera was either too extensive (Fig. 3) or unusually restricted. Piglets that were vigorous at birth were usually reared, but there were some cases in herd A where the deficiency appeared to worsen by about 3 weeks of age. These animals developed nervous signs and posterior paralysis, and they were probably similar to the cases produced by Nordfeldt (1945).

It is noteworthy that of the sows examined none that farrowed affected piglets showed any obvious clinical abnormalities, not even the two sows of herd B that lost two successive litters each. Some of the gilts of herd C became weak in the hindquarters early in gestation and such signs could have been referable to avitaminosis A, but these particular animals were slaughtered before the herd was first examined.

Gross Pathology

Twenty-seven piglets were examined from herds A and B, and of these ten were still-born. On opening the carcases of both still-born and live animals the subcutaneous tissues, particularly the axillary and submaxillary regions, were seen to be infiltrated with a yellow, gelatinous fluid. The musculature was moist and an unusual, very light-brown colour. The body cavities, and especially the pericardial sac, contained large quantities of a sero-fibrinous straw-coloured fluid, which also permeated and thickened the

mesentery. Occasionally the volume of fluid in the cavities was sufficient to produce obvious distension. The hearts appeared larger than normal and had a pale, slightly-boiled appearance. The epicardium showed petechial haemorrhages, most marked on the fat and in the coronary grooves. The gall bladders were distended with a dark, viscous bile and the walls were oedematous. Fibrin was often present on the peritoneal surface of the liver, usually in a network but sometimes as a solid sheet. In piglets that had not suckled, the stomach contained a glairy mucus; this was sometimes abundant and then it was more fluid. The spleens were enlarged and turgid from venous congestion. The mesentery of the colon often contained a gelatinous, semi-solid material similar to that seen in cases of so-called bowel oedema of older pigs, and there was also oedema beneath the peritoneal coat of the intestines. On longitudinal section both the medulla and cortex of the kidneys frequently contained cysts that varied greatly in size. In a few piglets there was no obvious renal medulla and a somewhat gelatinous tissue was present instead. Numerous subcapsular haemorrhages were present but these are normally seen in the kidney of the new-born pig. The kidneys were absent in one still-born pig and vestigial in two live-born animals. There were no gross changes in the central nervous system, the skin or the skeletal system.

In the still-born piglets the lungs, which were a deep-bluish colour, were collapsed and small, and in three cases there was marked hypoplasia of the left lung, which was completely collapsed and only about a third of the normal size. One piglet had a diaphragmatic hernia, a portion of the liver being in the thorax. Striking changes were present in the livers, which were yellowish-grey in colour and mottled by large darker areas and small subcapsular haemorrhages.

In contrast to the still-born animals, the piglets that breathed did not show striking liver changes, but the liver was usually very congested and oozed blood when cut. The chests of the live-born animals also contained fluid, but only parts of the lungs were collapsed. In many cases there was obvious pulmonary oedema and sometimes congestion with petechiae. The small bowel in two live-born pigs showed widespread venous congestion and was a deep plum-colour.

The experimental cases were generally similar to those received from the field, but the extensive oedema was now much more a feature of the disease. In the still-born animals the livers, which were mottled as before, contained haemorrhages and these were most obvious at the edges of the lobes.

Histopathology

Lungs. A number of different changes were seen in the lungs, often within a single litter. In the still-born animals the lungs were collapsed,

the alveolar walls being in close apposition. Usually there was evidence of venous congestion and pulmonary oedema, which was sometimes striking (Fig. 6). The alveolar spaces and smaller bronchioles were distended with an eosinophilic material that was granular in appearance. In all the piglets the bronchial epithelium showed some degree of change. There was invariably vacuolation of the cells, together with a proliferation of epithelial layers which produced heaped up areas of cells (Fig. 7). The epithelial cells were irregular in shape and in some the nuclei had disappeared or seemed to be undergoing change. In no case, however, was there a distinct metaplasia to a squamous epithelium. In some animals the bronchial epithelium had desquamated and the bronchial lumen contained debris; these changes were associated with a foetal pneumonia (Fig. 8), with plugs of cells in the alveoli and bronchioles, and thickening of the alveolar walls. Mononuclear cells were prominent in these sections but polymorphonuclear leucocytes were not common.

Liver. The histology of the liver was quite different in still-born and live-born piglets. In the former, the changes were those of decomposition, so that in many areas the liver architecture had been lost and there remained only an indistinct stroma filled with red cells. In less advanced cases there was extensive fatty change and marked venous congestion. In the animals that breathed, however, venous congestion was a fairly constant finding, the sinusoids being prominent and engorged with red cells. In many instances there was an increase, sometimes very marked, in the numbers of round cells around the small bile ducts (Fig. 9). The liver cells contained glycogen vacuoles resembling fat spaces but although fat droplets could be demonstrated in frozen sections stained with Sudan III, fatty changes were not marked. It had been observed previously that the liver of the new-born pig does not show lobulation and this finding was confirmed in both the affected and the control animals.

Myocardium. The only consistent change was some slight degree of separation of the muscle bundles by oedema fluid.

Pancreas and salivary glands. Generally there was some lymphocytic infiltration around the ducts of all these glands; it varied in degree, but was always more pronounced than in the two control piglets. The duct epithelium was vacuolated and in places several layers deep, but no metaplasia was noted (Fig. 10). The pancreas seemed slightly deficient in stroma, and the acini were separated by clear spaces. These probably represented oedema spaces. The islets of Langerhans were not easy to find, but they were no more obvious in the control piglets.

Kidneys. Developmental abnormalities were common. The vestigial kidneys were small and probably non-functional. The cortex was fairly well developed, with many glomeruli, but the medulla was not well-defined and the renal tubules were scanty. This medullary hypoplasia was best seen in kidneys where the medulla consisted of two or three cystic spaces with the rest a mixture of myxomatous and fibrous tissue (Fig. 11). Cystic kidneys showed varying degrees of hypoplasia. The cysts, which appeared to have arisen from both Bowman's capsule and from the proximal convoluted tubule, were most frequent in the cortex (Fig. 12) and they were so common in some areas that the kidney had a multilocular appearance. There were very obvious changes in the epithelium of the renal pelvis: the transitional epithelium was vacuolated

and, in parts, undergoing degeneration; in some areas there had been proliferation into papilliform ingrowths. Generally throughout the kidneys there was slight interstitial round-cell infiltration. There was an impression that the foetal lobulation was more marked than in the control piglets. Venous congestion was present and there were free red cells in both the cortex and medulla.

Gastro-intestinal tract. There were no consistent changes in the alimentary tract except for an engorgement of the vessels and a very prominent separation and distension of the mesentery by oedema fluid. Fluid was also present beneath the serous coat of the intestine.

Genital tract. The epithelium of the cervix showed slight vacuolation and an increase in thickness. There were no consistent changes in the ovaries and testes.

Endocrine glands. No abnormalities were seen.

Teeth and skeletal system. Unfortunately, the bones and teeth of only one control and one deficient piglet were examined, so that definite conclusions cannot be drawn. No differences were found in the bones. In the teeth of the deficient piglet there was some disorganization of the odontoblasts, and the ameloblasts were difficult to distinguish.

Eyes. All stages of aplasia and hypoplasia (Figs. 13 and 14) were present. When there was no recognizable eyeball, the orbit contained a fibro-cellular and fatty tissue, within which were a few bundles of muscle fibres. In two piglets, this mass of fibro-fatty tissue contained small, irregularly arranged, islands of pigmented epithelial tissue. The upper and lower lids were sometimes continuous and in one case the lids were fused to the cornea. The sclera, when present, was poorly developed and tended to thin out and disappear towards the back of the eye. In many piglets the anterior chamber, the iris, the ciliary body and the posterior chamber could not be identified from a mass of jumbled tissues. The vitreous humour was replaced by fibrous tissue that was myxomatous in places and also vascularized, the network of vessels probably representing the hyaloid artery (Fig. 15). In eyes that were better differentiated, the choroid and the retina were folded. The choroid in particular was ridged and varied in thickness, especially in the region of the ciliary processes, and its epithelial layers showed irregularities. The lens in these cases was poorly developed, the capsule being ill-defined and the so-called lens epithelium apparently absent. The retina showed folding and was separated in places into two not well-defined areas of cells. In some parts of the retina the optic nerve cells were not very numerous and spaces were present in this layer. The rods and cones appeared normal, except in a few areas where they were reduced in number.

Nervous system. Examination of the brain and cord of two piglets failed to reveal any evidence of developmental or other abnormality, such as demyelination. On the other hand, the older pig with posterior paralysis (herd A) showed demyelination in the cord, particularly in the lumbar area, and also slight demyelination in the cerebellar peduncles. There was, however, no histological evidence of an encephalomyelitis.

Skin. There was separation of the collagen fibres with oedema fluid but no other changes, such as hyperkeratosis.

DISCUSSION

In the four herds examined, at least twenty-one litters were a

complete loss or suffered heavy mortality, and a further eleven or more litters contained piglets that lived, but showed a variety of eye defects. Taking all these cases together several general points emerge. In the three herds where the dietary history was known with certainty the basic meal was home-mixed and, as mentioned by Watt and Barlow (1956a), there is always more chance of an unbalanced ration arising under these circumstances than when meal is purchased from a commercial supplier. In the herd where the losses were most serious, vitamin A deficiency was not suspected at once because the basic meal was fortified with a proprietary concentrate and the owner was unaware that this concentrate contained no vitamin A. In a somewhat similar way it is possible to be misled by a superficial account of the management during pregnancy; for in three herds it was stated initially that the affected animals had been at free range, whereas further enquiry established that very little herbage was available at the critical period in each case. Thus the first herd examined (herd A) was of this type and as the early piglets showed severe liver damage, excess pericardial, pleural and peritoneal fluid, together with petechial haemorrhages on the heart, we suspected at the outset that an infective agent was involved. Consequently, transmission experiments were carried out by inoculating a pregnant sow and a litter of new-born pigs with material from the dead piglets. Although, as would now be expected, these inoculations proved harmless, they are quoted to emphasize how the condition may not always be immediately apparent.

Most of the affected litters were from gilts and usually they had been kept housed for most of the time between birth and early pregnancy. From the work of Braude, Kon, Mitchell and Thompson (1951) it appears that older sows can accumulate reserves of vitamin A sufficient to tide them over periods of temporary deficiency, such as when the grazing is poor. However, in contradistinction to the findings of Braude *et al.* (1951), which suggested that in order to produce severely affected piglets the dam had to be brought near to collapse, all the sows and gilts examined in this study were found to be normal in appearance and vigour. This observation could be of importance in field diagnosis. The clinical appearance of the affected piglets was not particularly striking and it is interesting that in all four herds it was the recognition of eye defects which first suggested a known entity. Thus pigs that were viable, yet blind, commanded more attention than those that died shortly after birth; for often in the latter instances the closed lids at death were not so obviously different from those of piglets dead from a variety of other causes. It is also noteworthy that in none of the piglets were there any marked deformities such as the accessory ears, subcutaneous cysts, cleft palate and hare-lip described by Hale (1935).

Herd A appeared to demonstrate the effects of varying degrees

of vitamin deficiency and the findings in all four herds support the conclusion that as the deficiency is ameliorated the changes seen clinically tend to be confined to the eye. Circumstantial evidence from the dietary histories is compatible with the view that a deficiency for only the first month of pregnancy, may still result in blindness (Hale, 1935). Such a view, however, as also the comparable finding in rats (Warkany, 1954), is based on experimental work where an absolute deficiency early in gestation is subsequently corrected and it is more difficult to devise experiments to demonstrate either the effects of a continuing but very low vitamin transfer to the foetus, or a level that is just sufficient only during the first part of gestation. Even so, it is questionable whether information of this type would explain the absence of blindness in the second (experimental) litters from the four sows of herd B. At the first visit to this herd all the survivors from the first three farrowings had eye defects and the fourth gilt, which was seen to farrow, also had piglets with defective eyes. It is known with certainty, therefore, that both the gilts that were left untreated during their second pregnancy had produced blind piglets previously. Furthermore, it was said that the first dead piglets examined by us in this herd came from the same two gilts, and the livers of these piglets were found to be devoid of vitamin A. Having produced piglets that were blind, moribund and depleted of vitamin A, therefore, the two untreated gilts continued on the same ration. Yet, although the second litters died shortly after birth and were still completely deficient of vitamin A, the eyes had developed normally. There is no ready explanation for this unexpected result, but it is fortunate that it occurred because we had come to the view that if piglets could be born viable but blind, then piglets that were moribund at birth could not be expected to have normal eyes. The logical result of this argument would have been to examine the eyes in any litter that died shortly after birth to see whether avitaminosis A should be suspected, but on the basis of the present finding this procedure is probably unsound. It would be interesting to speculate on the mechanisms by which a litter could be moribund at birth but not blind, even though, with the same maternal diet, the litter that immediately preceded it exhibited microphthalmia; but before invoking complicating factors such as the influence of other vitamins and their concentration in the foetus relative to that of vitamin A, it must be recognized that the experimental animals under discussion were not always in our possession. There was a period of 11 days between the last farrowing on the farm and the arrival of the four sows in Cambridge, and although extraordinary precautions were taken to ensure that the untreated sows received no source of vitamin A in Cambridge, it cannot be stated categorically that they could not have gained access to a small amount of carotene during the short unsupervised period.

The main gross pathological changes were the abnormalities

of the eye and the severe oedema. The eye lesions have been described by others, but the marked outpouring of fluid, although seen under comparable conditions in other species, does not appear to have been the subject of previous comment in the pig. In the severely affected animals there was evidence of a very poor circulation and it is probably this and the consequent anoxia which bring about the oedema. The existence of fluid in the body cavities, the pulmonary oedema and the venous congestion of all the organs support the concept of a failing circulation, but no detailed examination was made of the heart and great vessels in order to determine a more precise cause and the primary disturbance might have been elsewhere in the body or even in the placenta. The hearts of many of the piglets were probably dilated, but this is a difficult point to confirm. The presence of tissue anoxia was further substantiated by the histological changes and such anoxia may be significant in the development of the eye lesions.

Two other changes require further comment: those of the kidney and the epithelial surfaces. Congenital kidney lesions are common in piglets and it may be that one of the causes of these abnormalities is a partial maternal deficiency of vitamin A. Gross changes comprising various degrees of aplasia were not uncommon, but microscopic changes were more frequent. The latter were most marked in the renal pelvis and were part of the general pattern of epithelial tissue disorganization. Wolbach and Bessey (1942) epitomized the pathogenesis of the epithelial lesions as 'atrophy of the epithelium concerned, reparative proliferation of basal cells, and growth and differentiation of the new products into a stratified keratinizing epithelium'. In the present study, many of the epithelial surfaces showed changes that ranged from vacuolation to proliferation and accumulation of cells, but nowhere had these changes progressed to the third stage above—the differentiation seen in the adult.

Congenital abnormalities may arise from causes other than vitamin deficiencies, such as by irradiation and mutant genes. Following upon the observations of Young (1952), however, interest has recently centred on the effect of virus infection of the sow during pregnancy as a cause of congenital abnormalities and foetal death. As abnormalities produced by different means may tend to show a common pattern, there is a need for caution in diagnosis. Indeed, the cases of cleft palate, subcutaneous oedema and microphthalmia recently produced in piglets after maternal infection (Harding and Done, 1956) are somewhat reminiscent of the earliest cases ascribed to avitaminosis A. However, given the opportunity to obtain a complete herd history and examine affected piglets, it should be simpler to determine whether the foetus has suffered from a deficiency of vitamin A, than to establish that there has been a maternal infection in early pregnancy, particularly as in the latter instance viruses other than the swine fever virus might be involved.

CONCLUSIONS

Four herds are described in which many piglets died shortly after birth or, if viable, were born blind. At least twenty-one litters suffered heavy mortality and a further eleven or more litters contained piglets that showed a variety of eye defects.

It was concluded that a maternal deficiency of vitamin A was the common cause. In three herds with reliable histories the diet of the affected dams was grossly deficient in vitamin A and in two herds where the analyses were made there was little or no vitamin A in the piglets' livers at birth. In one herd, dosing two pregnant sows with vitamin A palmitate prevented the condition, while two sows left untreated continued to lose their litters.

The dams of affected litters appeared normal and, apart from blindness, the clinical signs in the piglets were not striking. Litters that were moribund at birth were born at full term but showed extreme weakness. Viable piglets showed eye defects, but externally there were no other deformities.

Internally, there were gross abnormalities of the kidney and lung, and one of the most striking features was the generalized oedema. Histologically, there was proliferation and vacuolation, but no metaplasia of epithelial surfaces. The eyes showed a great variety of changes ranging from complete disorganization to near normality.

ACKNOWLEDGMENTS

We are grateful to Miss E. A. Robb and Mr. P. J. D. V. Brett for general laboratory assistance. Most of the vitamin A analyses were carried out in the Dunn Nutritional Laboratory by Miss P. J. Holder and Miss M. C. Anable. The vitamin A palmitate was kindly supplied by Dr. M. D. Wright of Vitamins Limited. The work was assisted financially by a grant to one of us (R.F.W.G.) from the Agricultural Research Council.

REFERENCES

Braude, R., Kon, S.K., Mitchell, K. G., and Thompson, S. Y. (1951). *Vet. Rec.*, **63**, 671.
Davies, A. W. (1933). *Biochem. J.*, **27**, 1770.
Hale, F. (1933). *J. Hered.*, **24**, 105; (1935). *Amer. J. Ophthal.*, **18**, 1087.
Harding, J. D. J., and Done, J. T. (1956). *Vet. Rec.*, **68**, 865.
Kimble, M. S. (1939). *J. Lab. clin. Med.*, **24**, 1055.
Nordfeldt, S. (1945). *LantbrHögsk. Ann.*, **12**, 204.
Warkany, J. (1954). *J. cell. comp. Physiol.*, **43**, Supplement 1, 207.
Watt, J. A., and Barlow, R. M. (1956a). *Vet. Rec.*, **68**, 780; (1956b). *Ibid.*, 1059.
Wolbach, S. B., and Bessey, O. A. (1942). *Physiol. Rev.*, **22**, 233.
Young, G. A. (1952). *J. Amer. vet. med. Ass.*, **121**, 394.

APPENDIX

Herd A

Clinical history. This herd of about twenty Essex sows and a Large White boar had been self-contained, except for boars, for many years. Eight first-cross gilts were retained for breeding in 1955 and they farrowed in 1956, from early February onwards. During February and March six of the gilts, together with four sows, lost their entire litter. It was said that the piglets were listless at birth, with no desire to suckle. During this same period five other sows kept their litters for a week or more, but one of these litters died off from 3 weeks of age, showing signs described as fits with posterior paralysis in some cases. At this stage the problem was referred to us and at the first visit to the farm two survivors from the last-mentioned litter were seen. One of these piglets moved on its abdomen, dragging its hind legs, and it was killed to allow further examination.

The next gilt to farrow was brought to Cambridge on March 29th and the farrowing on April 14th was attended. Although the gilt appeared to be in excellent condition, of the nine pigs born five did not breathe; two of these still-born pigs had grossly distended abdomens. The four live-born pigs were all abnormal in that they were listless, weak and disinterested in suckling. Three were particularly so and these animals did not dry off properly after birth: their skins remained pale and clammy so that skin-like flakes of membrane adhered to them. Their eye-lids remained closed. The remaining live-born pig dried off almost normally and it could just walk. Its eye-lids were open and it lived for between 48 and 60 hours, although it was never seen to suckle well. At about the same time a sow had farrowed ten piglets on the farm. Six of the litter were found dead the morning after farrowing and the remainder, which died during the second night, were received for examination.

The management and feeding can now be described, as the problem was alleviated by a change in the diet. The farm conditions were poor, the sows and gilts running in a small field surrounding a group of sheds that served as a food store and housing. In summer the ground was virtually devoid of grass, and in winter it became a quagmire. The original ration consisted of a mixture of flaked maize, wheat germ, wheatfeed, barley meal, bean meal and minerals. To this was added a proprietary concentrate containing no vitamin A, at the rate of 10 per cent, but this concentrate was replaced on April 30th by one containing 52 million i.u. of vitamin A per ton. Unfortunately, the date of substitution cannot be relied upon precisely. However, although no litters farrowed after this date were lost, there was a period before the advent of completely normal litters, when the piglets were born with a variety of eye defects. Thus a litter of six born on June 2nd included two animals with seemingly normal eyes and four with defects. The next litter of eight, born on June 13th, were normal but for one animal where one eye only was defective. A third litter of ten, born on June 17th, contained three pigs with defective eyes. These abnormalities, in eight piglets altogether, were not examined until July 6th, when it was seen that they were mainly in the sclera and pupil so that the eyeball appeared to be largely white, with only a small pigmented area usually displaced dorsally. Alternatively, the eyeball was all coloured and covered with a grey film. In two piglets there was a unilateral, severe entropion.

One of the original eight gilts, which had lost all its first litter, was served on February 28th and before receiving vitamin A in its ration it was moved to Cambridge on April 17th, it then being 7 weeks in-pig. Thereafter it was fed at 7 lb. per day a meal containing about 4½ million i.u. of vitamin A per ton until it farrowed on June 21st. In general, the litter of nine live pigs (two more were still-born) lacked vitality, but most of them dried off well and kept suckling. Only one pig showed no interest in suckling and this animal moved about on its abdomen, constantly burrowing into the straw in the manner of the fourth litter in herd B. The whole litter was blind, exhibiting either severe entropion (Fig. 2) or a bulging of the eyeball behind closed lids. The eyelids could usually be opened only with difficulty and in some cases the cornea was hyperaemic or coated with a bluish-grey film. Three pigs were soon overlain and two more were killed on the second day for vitamin A analyses. Their livers contained between 4 and 5 i.u. of vitamin A per g. One more pig was found dead at 5 weeks and hence three pigs were weaned. Two of these animals were kept until they were 8 months old, when they were slaughtered and examined. The orbits of both pigs contained a fibro-fatty tissue within which was pigmented epithelium and cartilaginous tissue (Fig. 4).

Herd B

Clinical history. Four breeding gilts, retained for breeding from two foundation sows, had been kept indoors since birth without any access to green food. The basic meal was ground on the farm after mixing two sacks of barley with four sacks of oats, one sack of wheat and one sack of maple peas. This mixture was then fed as two parts

of the diet with one part of middlings. In June gilt 1 farrowed ten very weak pigs and nine soon died. It was stated that all the litter had either bulging eyes or severe entropion, and the one survivor seen at 3 weeks of age showed bilateral entropion. Gilt 2 farrowed nine pigs the day after gilt 1. Eight survived, although all but two showed eye abnormalities as in herd A, with the added feature in some cases of a bladder-like structure in place of a normal eyeball. Gilt 3 farrowed twelve weak pigs on the same day as gilt 2: only five survived and all these had abnormal eyes as before. Three of the dead pigs from gilts 1 and 3 (not individually identifiable) were received for examination; they were blind and no vitamin A could be detected in their livers. Gilt 4 pigged early in July and the farrowing on the farm was attended. Thirteen pigs were born and all were very weak. Clinically, their behaviour was identical with that of the first litter farrowed in Cambridge from herd A: they moved listlessly on their abdomens, burrowing under the straw and scattering to the corners of the box away from the sow. All were blind: some showed entropion and one piglet possessed a fibro-fatty structure similar to that seen in the two mature pigs from herd A. By 12 hours after farrowing only five pigs remained alive; these were killed and in each the liver contained no appreciable amount of vitamin A.

At this visit to the farm the four sows were bled for serum and the vitamin A levels were 44 (sow 1), 52 (sow 2), 90 (sow 3) and 25 (sow 4) i.u. per 100 ml.

The four sows were then moved to Cambridge for a controlled experiment in which numbers 2 and 4 received vitamin A palmitate (in arachis oil) as a dietary supplement. All four animals were fed the same basic ration as before, it being ground on the farm and sent to Cambridge. Dosing commenced on July 26th and continued twice-weekly until farrowing. The oil was freshly mixed in a little meal on the day of dosing and then fed from a hand-bowl. Approximately 200,000 i.u. of vitamin A was given to the two treated animals by August 8th and thereafter the standard weekly dose was approximately 80,000 i.u. until the end of gestation. No bedding was available until October, when wood chips and a little straw were provided. None was mated until the treated group had had time to re-establish their vitamin A reserves. There was little difficulty in getting the sows in-pig; sows 4 and 2 conceived to their first service on August 21st and October 10th respectively. Sow 3 did not show signs of oestrus and so she was housed with the boar from September 16th onwards: from the farrowing date she had conceived within a few days of this date. Sow 1 was served on September 22nd but returned to conceive on October 13th.

Sow 4 farrowed ten very robust and normal pigs, one of which was killed for examination before suckling, on December 11th, 1956. The liver vitamin A concentration in this latter piglet was 16 i.u. per g. Sow 2 farrowed fourteen pigs, including two that were still-born, on January 31st, 1957. The litter was completely normal and vigorous, and the liver vitamin A concentration in one piglet that was killed on the second day was 26 i.u. per g. In contrast, the litters of both the untreated sows were grossly abnormal and the neonatal livers contained no vitamin A. Sow 3 farrowed fourteen pigs on January 12th, and it is of interest that with an average weight of nearly 2·5 lb. they were not undersized. Sow 1 farrowed on February 4th. Eight pigs were seen but more could have been born later in the night and then eaten. This litter was individually smaller, the average weight being just under 2 lb. Both litters were clinically similar in that the piglets were either born dead or so weak that they could hardly crawl. The live-born animals lay about on their sides in a hunched posture making weak cries, while they often paddled slowly with their legs. As in other litters they were frequently covered with large flakes of membrane (Fig. 1). There was, however, an important difference from earlier litters: for despite the complete absence of vitamin A in all the neonatal livers examined, in no case was there any abnormality of the eyes. These experimental findings are summarized in Table 1.

TABLE 1

EXPERIMENTAL LITTERS FROM HERD B

Sow	Remarks	Piglets born	Vit. A (i.u. g. neonatal liver)	Litters
1	Untreated controls	8 or more	Zero	Piglets born dead or moribund
3		14	Zero	
2	Dietary supplement of vitamin A	14	26	Piglets normal and vigorous
4		10	16	

Herd C

Clinical history. This herd of about fifty breeding sows farrowed indoors, going out with their litters 5 days after farrowing and returning indoors when the litters were 4 or 5 weeks old. In general, the in-pig sows ran at pasture until about a week or so before term, but twelve gilts born in August, 1955, were yarded after weaning and kept indoors until they were served. Although born at pasture, it is probable that little grass was by then available and after weaning they were fed a home-mixed ration of barley, oats, middlings, fish meal, soya bean meal and minerals. The animals with which we were later concerned farrowed between July 8th and 30th, 1956, and hence their service dates would have been between about March 16th and April 7th. Shortly after service several of the gilts became very weak on their hind legs, as did the boar that was running with them. One gilt aborted, and this, along with some of the paralysed gilts, was slaughtered. Five survivors were then turned out to pasture and although the date of turning-out is not known exactly, it was thought to be the beginning of May. It is possible, therefore, that gilt 32 was 6 weeks in-pig and gilt 41, the last to farrow, about 4 weeks in-pig at this time. It is also probable that with the abnormally dry spring, little grass may have been available at first. All the gilts remained at grass until a week before farrowing and the farrowing histories can be considered, together with those of the older sows that farrowed concurrently, in tabular form (Table 2).

TABLE 2

FARROWING HISTORIES FROM HERD C

Dam	*Farrowed*	*Boar*	*Litter*
Gilt 32	8.7.56	A	All died during the first week.
Sow 42	9.7.56	A	Nine born alive; none blind.
Sow 49	10.7.56	B	Fifteen born alive and one dead; none blind.
Gilt 33	11.7.56	A	Eight born, seven examined. Six bilateral entropion; one unilateral entropion with exophthalmos other eye.
Sow 39	20.7.56	A	Fifteen born alive; three dead none blind).
Gilt 35	22.7.56	A	Eight born alive. Four survivors examined: one bilateral exophthalmos: two unilateral exophthalmos with entropion other eye; one bilateral entropion.
Gilt 48	23.7.56	A	Seven born alive. Three survivors seen: all severe entropion.
Sow 5	27.7.56	B	Thirteen born alive; none blind.
Gilt 41	30.7.56	A	Eight born alive. Seven examined: all variety of eye defects but not as severe as above; more like the malformations of the later litters in herd A, i.e. only three showed entropion (unilateral).

The above affected litters were examined for the first time on August 14th. It was stated that the litter that died from gilt 32 was weak and unable to suckle strongly; the pigs that died from gilts 35 and 48 were observed to behave similarly.

No histopathological studies were made in this herd.

Plate I



To face page 94

Plate II



Plate III

Plate IV

13

14

15

Herd D

Clinical history. In this case the records were unsatisfactory and more doubt arises. However, the findings warrant a brief report.

Seven gilts were purchased in November, 1955, and kept housed until after they were served between January and March, 1956. Two animals stayed indoors until they farrowed and five went out to grass, most probably in early April. None of the gilts was numbered, but it is known that the one that lost its litter had been housed continuously. Farrowing took place between May 18th and July 10th. One litter of ten pigs was entirely blind and died during the first week. Three other litters were completely blind, mainly with severe entropion, and of a total of twenty-eight pigs, ten died before 4 weeks of age. A further litter of nine pigs was clinically normal but for one blind animal, and the remaining two litters were also normal. The blindness was comparable with that seen before in herds A, B and C. The owner stated that he had been feeding a locally-ground meal throughout pregnancy. Private enquiry at the mill, however, showed that whereas this meal contained 2½ per cent dried grass, none had been supplied to the farm before May, 1956.

Once more, no histopathological observations were made.

[*Received for publication, March 28th,* 1957]

LEGENDS TO ILLUSTRATIONS

Fig. 1. Piglets moribund at birth. Dried amniotic flakes and rounded appearance due to anasarca.

Fig. 2. Viable new-born piglet with microphthalmia.

Fig. 3. Eye of piglet 4 weeks old. Abnormal iris, eyelashes stuck together and entropion.

Fig. 4. Vestigial eyes removed from mature pigs: fusion of lids to the eyes. X 4.

Fig. 5. Eye showing keratitis in piglet 4 weeks old.

Fig. 6. Section through lung to show pulmonary oedema. X 100.

Fig. 7. Section of bronchial wall to show vacuolation and proliferation of the epithelium. X 100.

Fig. 8. Section of lung to show bronchiole containing desquamated material and mononuclear reaction in the alveoli. X 50.

Fig. 9. Section of liver to show the peri-ductal round-cell infiltration and associated slight oedema. X 100.

Fig. 10. Section through main duct of pancreas to show the peri-ductal round-cell infiltration and oedema. The lining epithelium is vacuolated and becoming multi-layered. X 100.

Fig. 11. Kidney: absence of medulla.

Fig. 12. Cortex of kidney showing cysts. X 100.

Fig. 13. Section through eye to show complete lack of organization. The upper lid is fused to the conjunctiva. The choroid and retina are rudimentary and irregular. There is a fibrous structure from the lens capsule to the optic nerve. X 12.

Fig. 14. Section through eye to show disorganization. The retina is small and folded, as is the choroid. The lens appears to be relatively large and the ciliary processes are vestigial. X 12.

Fig. 15. Section through a vestigial eye to show islets of pigmented, folded epithelium in a stroma of vascular, cellular, fibrous tissue. X 50.

Gorlin-'59
Bib. No. 3323

J. Dent. Res. 38:1008. 1959.

THE EFFECT OF HYPERVITAMINOSIS A UPON THE INCISOR AND MOLAR TEETH, THE ALVEOLAR BONE, AND TEMPOROMANDIBULAR JOINT OF WEANLING RATS

ROBERT J. GORLIN AND ANAND P. CHAUDHRY

Division of Oral Pathology, School of Dentistry, University of Minnesota, Minneapolis, Minn.

BECAUSE of the divergence of opinions available on the effect of hypervitaminosis A upon the teeth, periodontium, and temporomandibular joint, the authors thought it worth while to investigate this problem. Irving[1] in 1949 indicated that this vitamin had a minimal effect upon the teeth of rats. No change was observed in the incisor enamel, but the rate of dentin apposition due to odontoblastic atrophy and the amount of interfibrillar cementing substances were reduced. This effect on the mesodermal tissues was also reflected in the lingual alveolar bone where the rate of formation was pronouncedly slowed and a marked decrease in the number of osteoblasts was observed.

Rodahl[4] observed marked hyperemia or hemorrhage in the incisor pulp, as well as in the vacuoles and calcium deposits. An irregular arrangement and occasional degeneration of the odontoblastic layer were noted. The pulpal (inner) dentin manifested amorphous calcification.

On the other hand, Pohto[7] found no changes in the teeth and Wolbach[2] indicated that histopathologic changes in the teeth were inapparent, insofar as remodeling did not occur.

Wolbach[2] in 1947, Maddock and colleagues[5] in 1949, and Rodahl[4] in 1950 performed extensive studies on the general pathologic changes wrought by hypervitaminosis A in the rat, mouse, dog, and other laboratory animals. The most outstanding effects were observed in bone, resulting from the accelerated maturation rate of the skeleton.

Fractures of the long bones were thought to be predicated upon premature closure of the epiphyses and on accelerated substitution of compact for cancellous bone. Anorexia, hemorrhagic diatheses and hypoprothrombinemia, alopecia and exophthalmos were commonly observed. An excellent review of earlier work is that of Rodahl.[4]

Several investigators observed that the bones of younger animals were more rapidly affected[1, 2] and Rodahl[4] noted a difference in "acute" and "chronic intoxication" due to vitamin A, the latter producing the far more serious signs.

Received for publication April 15, 1959

He indicated that the absence of normal weight gain was one of the first signs following ingestion of large doses of the vitamin. He attributed this to loss of appetite. In young rats, having a gross consumption of from 500,000 to 1,000,000 I.U., fractures of long bones were manifest from the twentieth to the fortieth day, subsequent to stiffness and limping seen early in the experiment.

MATERIALS AND METHODS

Sixty (60) Sprague-Dawley male rats of weanling age were divided into two groups of 40 experimental and 20 control animals. They were isolated for a week and individually caged. Their initial weights were then recorded. Vitamin A concentrate in corn oil (150,000 I.U. per gram)* was administered daily at a level of 600 I.U. per gram of body weight to the experimental animals and a corresponding amount of corn oil was given to the controls by mouth per syringe. Body weights and clinical data, such as hemorrhage, paralysis, limping, alopecia, and/or diarrhea, were recorded every 3 days. All animals were kept on an ad libitum diet of Purina laboratory chow throughout.

When animals appeared to be terminally ill they were killed by chloroform anesthesia and autopsied. A long bone, costochondral junction, and complete head were placed in 10 per cent formalin for pathologic study. Care was taken to inspect for gross hemarthrosis and subperiosteal hemorrhage at the time of leg removal. The jaws were propped open with applicator sticks for greater ease of penetration of formalin solution.

The bones and teeth were decalcified by the formic acid-sodium citrate method, the skull split longitudinally and returned for further decalcification, and the tissues finally imbedded in paraffin. Specimens were orientated in preparation for sectioning through the long axis of the molar teeth. The incisor tooth preparation was made from the other half of the head. Both longitudinal and cross sections were prepared. All were stained with hematoxylin and eosin by the rapid method.[5]

CLINICAL OBSERVATIONS

By the ninth day, most of the experimental animals were weak and scrubby looking. Perioral alopecia and edema about the eyes were common. Some had frank exophthalmos. Loss of appetite was quite apparent. An abnormal posture with marked bending of the spine was seen. Limping was observed about the twelfth to fourteenth day (in some, by the ninth day) and fractures were apparent in one or more limb bones, usually the hind legs, by the sixteenth to nineteenth day, with hemorrhage about the fracture evident externally. This produced a clinical "paralysis" of the hind limbs.

PATHOLOGIC AND HISTOPATHOLOGIC FINDINGS

The experimental group was considerably smaller than the control animals as may be seen from Fig. 1. Their coat was usually matted and unkempt.

*Supplied by Hoffmann-La Roche, Inc., Nutley, N. J., as synthetic vitamin A palmitate the concentration of 150,000 units per gram in corn oil. Dilution was made with additional corn oil under nitrogen.

Upon opening the chest and abdominal cavity, injection of lungs and intestinal viscera became apparent. Hemorrhage both intramuscularly and subperiosteally was noted in nearly all animals (Fig. 2).

Fig. 1.—Picture of typical rat on hypervitaminosis A regimen for 12 days. Note size, appearance of coat and eyes. Control littermate is on the right.

Fig. 2. Subperiosteal hemorrhage adjacent to temporomandibular joint. Hemorrhage was noted beneath periosteum of most long bones. (Orig. mag. ×105.)

In the epiphyseal cartilage of the long bones, the number of cells was reduced, the width of the plate becoming markedly narrower (Figs. 3 and 4). The rate of enchondral bone formation beneath the plate was enhanced, as

manifested by increased depth of calcified cartilage trabeculae. Increased remodeling, demonstrated by large amounts of new endosteal bone and resorption of peripheral bone, was evident. Increased osteoblastic activity was seen,

Fig. 3 Epiphyseal plate of tibia-control animal. Compare this with Fig. 4 taken at same magnification.

Fig. 4 Epiphyseal plate of tibia—hypervitaminosis A rat—12 days. Note the reduction in both size and number of cartilage cells. There is evidence of initial closure of the epiphyses. (Orig. mag. 105.)

especially about the cortical bone of periosteal origin. Animals that were on the vitamin A regimen for a longer time appeared to have an epiphyseal change that indicated closure, as both sides tended to become sealed off with calcified cartilage matrix.

Changes in the incisor teeth were not marked. There was a significant reduction in the thickness of dentin but alteration in the quality of the dentin was not apparent. The odontoblastic layer was reduced in thickness. Increased vascularity and edema of both the pulp and the periodontal ligament were noted, as well as a reduction in the amount of collagen. The thickness of the alveolar bone was significantly reduced (Figs. 5 and 7).

Fig. 5.—Longitudinal section through maxillary incisor—control animal. Compare this with Fig. 6 at same magnification and at same distance from labial alveolar crest.



Fig. 6. Longitudinal section through maxillary incisor—hypervitaminosis A animal. Note decrease in width of dentin, some decrease in the number of odontoblasts. There is a widening of the periodontal ligament. Increased vascularity is apparent both in the pulp and periodontal tissues as well as edema and a paucity of collagen fibers. The entire thickness of the alveolar bone is apparent.

Fig. 7. Pulp of molar tooth of hypervitaminosis A rat. Note marked edema and vascularity of pulp. Odontoblastic layer is intact, however. (×150.)

Fig. 8. Temporomandibular joint condyle head. Compare this view in the control rat with Fig. 9, taken at the same magnification, ×150.

Fig. 9.—Temporomandibular joint—condyle head—hypervitaminosis A rat. Note marked reduction in size, absence of cartilage cap, numerous fractures of bony trabeculae. Both this and Fig. 7 were made at the same magnification.

Fig. 10. Callus adjacent to pathologic fracture of ramus of mandible of hypervitaminosis A rat.

The molar teeth showed similar vascular and degenerative changes in the pulp (Fig. 7). There was, however, no apparent alteration in the odontoblastic layer. Cementum deposition was also reduced.

The most marked changes were apparent in the temporomandibular joint. The condylar head was greatly reduced in size and its architecture altered. Subperiosteal hemorrhage was present in 78 per cent of the experimental group.

The cartilage cap was not present and numerous fractures of bony trabeculae were noted (Figs. 8 and 9). In one animal, complete pathologic fracture of the ramus was noted with resultant callus formation. No difference was noted in the thickness of the gingival epithelium of the two groups.

DISCUSSION

Hypervitaminosis A has far less effect upon the teeth than upon the bone. Loss of appetite is part of the toxic reaction induced by the large amount of vitamin A. As is true in many induced single vitamin "deficiencies," loss of appetite results in deprivation of not only other vitamins and minerals but protein as well. Changes in the joints, the teeth, and the periodontium in starvation and in protein deficiency have been studied by several investigators and serve as a base line.[9-12] Most of the changes seen in the bones and teeth in hypervitaminosis A may be predicted upon protein deficiency. Increased vascularity and edema of both the pulp and periodontal ligament seem to be the only *specific changes* seen in this condition.

SUMMARY

Hypervitaminosis A had severe effect upon the temporomandibular joint but minimal effect upon the teeth. Reduction in the amount of dentin, the odontoblastic changes, and the decrease in collagen of the periodontal ligament can be due to loss of appetite. Marked vascularity of both the pulp and periodontal ligament appeared to be the only specific changes in this condition.

REFERENCES

1. Irving, J. T.: The Effects of Avitaminosis and Hypervitaminosis A Upon the Incisor Teeth and Incisal Alveolar Bone of Rats, *J. Physiol.* **108**: 92, 1949.
2. Wolbach, S. B.: Vitamin A Deficiency and Excess in Relation to Skeletal Growth, *J. Bone & Joint Surg.* **29**: 171, 1947.
3. Maddock, C. L., Wolbach, S. B., and Maddock, S.: Hypervitaminosis A in the Dog, *J. Nutrit.* **39**: 117, 1949.
4. Rodahl, K.: Hypervitaminosis A in the Rat, *J. Nutrit.* **41**: 399, 1950.
5. Moore, T., and Wang, Y. L.: Hypervitaminosis A, *Biochem. J.* **39**: 222, 1945.
6. Walker, S. E., Eylenburg, E., and Moore, T.: The Action of Vitamin K in Hypervitaminosis A, *Biochem. J.* **41**: 575, 1947.
7. [illegible], M.: Mikroskopische Untersuchungen über die Schneidezähne der Ratten bei der A Avitaminose, der Heilung [illegible] und der A Hypervitaminose, Helsinki, The University, 1938.
8. Clark, H., and Gorlin, R. J.: On the Use of a Modified Fifteen-Minute Hematoxylin and Eosin Tissue Stain, *Oral Surg., Oral Med. & Oral Path.* **11**: 431, 1958.
9. Chawla, T. N., and Glickman, I.: Protein Depreciation and the Periodontal Structures of the Albino Rat, *Oral Surg., Oral Med. & Oral Path.* **4**: 578, 1951.
10. Glickman, I., Morse, A., and Robinson, L.: The Systemic Influences Upon Bones in Periodontoclasia, *J. I. D. A.* **31**: 1435, 1944.
11. Stein, G., and Ziskin, D.: The Effect of Protein Free Diet on the Teeth and the Periodontium of the Albino Rat, *J. D. Res.* **28**: 529, 1944.
12. Hunter, H. A.: Hypoproteinemia in Relation to Dental Tissues, *J. D. Res.* **29**: 72, 1950.

Grey-'64
Bib. No. 3455

J. Dairy Sci. 47:783. 1964.

Reproduced by permission of the copyright owner

CISTERNAL AND INTRAVENTRICULAR CEREBROSPINAL FLUID PRESSURES IN CHRONIC BOVINE HYPERVITAMINOSIS A[1]

R. M. GREY, M. C. CALHOUN, J. E. ROUSSEAU, JR., C. G. WOELFEL, R. C. HALL, JR., S. W. NIELSEN, H. D. EATON, AND J. J. LUCAS[2]

Animal Industries and Animal Diseases Departments, Storrs (Conn.) Agricultural Experiment Station, Storrs

SUMMARY

Eighteen Holstein male calves, average age 96 days and average plasma vitamin A 6.4 μg per 100 ml, were fed daily vitamin A intakes of either 18, 54, 4,000, or 12,000 μg per 454 g of live weight for 12 wk. Feed intake and growth were less in calves fed the two higher intakes. Clinical signs of hypervitaminosis A were observed in calves fed the 12,000 intake, but only hyperemia of the inguinal skin in calves fed 4,000. Total weight as well as weight per unit of live weight of the adrenals were greater in calves fed the two highest intakes. Cisternal and intraventricular cerebrospinal fluid pressures were lower in calves fed the two higher intakes, but within the individual calves the pressures at the two sites were not appreciably different. It is tentatively concluded that the lower pressures observed in the hypervitaminotic A calves were not due to obstruction or blockage, or both, between the ventricles and the cisternal subarachnoid space.

Contrary to expectation (1), calves fed high intakes of vitamin A for a period of 12 wk exhibited decreased cisternal cerebrospinal fluid (CSF) pressures with the decrease being linearly related to the level of excess intake of the vitamin (7). One of the possible causes of this might have been obstruction or blockage in the ventricles, aqueducts or foramina, or both, leading to the subarachnoid space. Since the major site of formation of CSF is the lateral ventricles (3), the presence or absence of obstruction or blockage might be ascertained by measuring the CSF pressure both in the ventricles and at the cisterna magna, which is below the foramina leading to the subarachnoid space. The present study reports such measurements in normal and in chronic hypervitaminotic-A calves.

EXPERIMENTAL PROCEDURE

During the period November, 1962, through January, 1963, 18 Holstein male calves of one day of age were obtained from various state institution herds. Feeding and management were as described before (7), except that a commercial milk replacer (0.15 part of milk replacer plus 0.85 part of water, w/w) was fed in place of whole milk and the milk-starter-hay period was not followed by a standardizing period during which the vitamin A depletion ration was fed with a constant low level of vitamin A intake. The percentage composition of the depletion ration was 33.35 beet pulp, 15.196 ground barley, 16.7 crimped oats, 16.7 wheat bran, five expeller processed linseed oil meal, five solvent extracted soybean oil meal, 6.65 cane molasses, 0.7 iodized salt, 0.7 steamed bone meal, and 0.004 irradiated yeast guaranteed to contain 64 times 10^6 units of vitamin D per gram.

At an average age of 96 days with a SD of 10, and one seven-day period after each calf's blood plasma vitamin A had decreased to or less than 12.0 μg per 100 ml on the basis of consecutive seven-day bleedings, each calf was then fed one of four daily intakes of vitamin A, either 18, 54, 4,000, or 12,000 μg (calculated on an alcohol basis) per 454 g of live weight, from the same source as before (7) for 12 consecutive weeks. With the exception of the highest vitamin A intake, each intake was fed to four calves. In the case of the highest intake, six calves were used so as to insure sufficient numbers if death occurred prior to the completion of the experiment. Based on pre-

Received for publication April 29, 1964.

[1]Scientific contribution No. 82, Agricultural Experiment Station, University of Connecticut, Storrs. This study was supported in part by grant-in-aid funds provided by a PHS research grant, NB-02168-05, from the National Institute of Neurological Diseases and Blindness, Public Health Service, and by Wirthmore Feeds, Inc., Waltham, Massachusetts.

[2]Station biometrician.

vious statistics (7), the first two intakes represented those which would result in no adverse biological effects, and the third and fourth to result, respectively, in mild and severe chronic hypervitaminosis A. Three days after completion of 12 wk of vitamin supplementation (comparison period), during which each calf continued to receive its designated vitamin A intake, each calf was slaughtered.

Feed intake and growth were measured as previously (7), as was sampling of the feeds for chemical analysis. During the comparison period, the average minimum and maximum temperature of the barn (temperature was not maintained at a minimum and light not limited to incandescent) with their SE's were, respectively, 56.9 ± 0.4 and 67.4 ± 0.5 F, and light exposure 6.9 ± 1.6 foot-candles.

Blood samples in which citrate was used as an anticoagulant were obtained by jugular puncture the day prior to the comparison period and at consecutive 28-day periods thereafter for the determination of the plasma concentration of carotenoids and vitamin A.

Initial cisternal CSF pressures were determined manometrically on all calves the week prior to vitamin A supplementation. Terminal cisternal and intraventricular pressures were measured either seven days prior to or one day after completion of the comparison period. Within a vitamin A intake grouping, site and time of measurement were balanced. Pressures were determined manometrically under anesthesia, employing the same anesthetic and dosage as before (8), except that administration was by means of an infusion pump (Harvard Apparatus Co., No. 600-950V). The rate per minute of administration of the first one-half of the dose was 14.8 ml, the remainder of the dose at 7.4, and additional amounts as required at 3.7. Depth of anesthesia in the case of cisternal CSF pressure was judged sufficient when the corneal reflex was abolished and in the case of intraventricular CSF pressure when there was no corneal reflex plus sluggishness of the palpebral reflex. Immediately upon entry of the needle into either the subarachnoid or ventricular space, the hub was connected to a saline manometer (4) and pressure readings recorded every one-half minute for 10 min. Essentially constant pressures were obtained for the period 6 to 10 min and these were, therefore, averaged. At the termination of the 10-min period, the jugular vein was occluded to verify the puncture of either space, as evidenced by a rapid rise in pressure which returned to the reading observed prior to occlusion within 1 min in the majority of calves.

The procedure for the intraventricular tap was to clip the frontal surface of the head (Oster clipper, Model 82, blade No. 30) followed by cleaning the area with 70% ethanol. The following procedure was carried out in order to establish the proper landmark: A line was drawn through the frontal eminence at right angles to the frontal suture with a red china marking pencil. A second line was drawn across the frontal suture at the level of the anterior borders of the supraorbital processes. Midway between these two lines a third line was drawn across the frontal suture. On this third line, 5 mm from the median line (frontal suture), was the point of entry into the cranium. After establishing the landmark and again scrubbing with ethanol, a small incision, approximately 9 mm long and paralleling the frontal suture, was made through the skin to the external surface of the frontal bone with a surgical blade (No. 10 Bard-Parker). At the site of the incision, a 1/16-in. twist drill attached to a small hand-held electric drill (Dremel Moto-Tool) was used to penetrate the external plate and the internal plate of the frontal bone into the subarachnoid space. Care was taken to insure that the drill entered perpendicularly to the frontal surface, since the hole was used as a guide for proper direction of the needle into the lateral ventricle. Slight pressure was applied during drilling and penetration into the cranial vault was evident by a sudden decrease in resistance. An 18-gauge Quincke spinal needle (90 mm length to the hub) with stilet in place was introduced into the drill hole. Infrequently, some difficulty was encountered in inserting the needle through the hole in the internal plate of the frontal bone; however, if the drilling had been perpendicular to the frontal surface, this was minimal. The needle was gently and slowly pushed through the cerebral hemisphere until the lateral ventricle was entered, which for the calves of the present experiment was a distance of ca. 35 mm. That the needle had penetrated through the corpus callosum into the ventricle was determined by an almost imperceptible decrease in resistance. The stilet was removed to check if the needle was in the ventricle as evidenced by flow of CSF. If the needle was not in the ventricle, the stilet was replaced, the needle moved very slightly, and then checked again for proper puncture. Once entry into the ventricle was established, the needle was firmly pressed against the drill hole to stabilize it, and the manometer tubing attached to the needle hub. At the end of the pressure readings, the stilet was replaced, the needle slowly removed, and

the skin wound closed with Michel wound clips. The clips were removed in eight days. The puncture of the right lateral ventricle was attempted initially, but if this was unsuccessful, the procedure was repeated into the left ventricle. Unsuccessful measurement was experienced with two calves, one due to hemorrhage in the ventricles and the other to loss of copious amounts of fluid at the drill hole.

Immediately following euthanasia, the adrenals, heart, kidney, and liver were weighed. As before (7), samples of the above tissues as well as others were obtained, processed, and stored for biochemical analysis (liver for carotenoids and vitamin A), or histological or radiographic examination (bone). The biochemical analyses of the feeds fed, blood, and liver were similar to those reported previously (7). The vitamin A supplement contained 73.8 ± 1.4 mg of vitamin A (as alcohol) per gram. The chemical composition of the vitamin A depletion ration was 90.3 ± 0.8% dry matter, 15.9 ± 0.1 crude protein, 1.9 ± 0.2 ether extract, 11.8 ± 0.2 crude fiber, 63.5 ± 0.3 nitrogen-free extract, and 6.9 ± 0.1 ash, with a carotene concentration of 0.20 ± 0.02 mg/kg of ration as fed.

In the analysis of variance, variation due to vitamin A intakes and calves within vitamin A intakes (error) was isolated. The variation among vitamin A intakes was subdivided into comparisons between the two lower and the two higher intakes and between the two higher intakes.

RESULTS AND DISCUSSION

Feed consumption and growth and plasma and liver concentrations of vitamin A are presented in Tables 1 and 2. The statistics on ration intake and growth are essentially in agreement as to trend with those of the initial study (7), in that the 4,000 μg vitamin A intake caused slight adverse effects, whereas the 12,000 μg intake produced marked effects. The rates of change of terminal plasma, or liver (logarithmic basis) concentrations of vitamin A with an increase in the vitamin A intake (logarithmic basis) were less at the two higher intakes than at the lower intakes. Concentrations of carotenoids in plasma and liver were not affected by dietary vitamin A intake and averaged for the comparison period 3 μg per 100 ml of plasma, with a SD of one or terminally two with a SD of one and for liver 0.99 log unit per 100 g with a SD of 0.13 (arithmetic mean equalled ten).

Scours was not a problem in this experiment, since only one calf fed the 54 μg vitamin A intake exhibited scours. Clinical signs and their chronological appearance in calves fed excessive vitamin A intakes of equal to or greater than 8,000 μg in the initial experiment (7) were essentially the same in the calves of the present study fed the highest vitamin A intake. Calves fed the 4,000 μg intake of vitamin A exhibited only hyperemia of the inguinal skin which appeared in two calves the

TABLE 1

Effect of excessive intakes of vitamin A upon feed consumption and growth

	Daily vitamin A intake [a]				SD per calf
	18	54	4,000	12,000	
Days free of feed refusals					
%	99.1	99.4	89.0	59.5	
Arcsin $\sqrt{\%}$	87	88	74	51	10
Ration consumed					
%	99.8	100.0	97.3	92.2	
Arcsin $\sqrt{\%}$	88	90	82	74	4
Growth					
Liveweight *(kg)*					
Initial [b]	102	97	97	99	19
Gain [c]	76	76	59	29	6
Height at withers *(cm)*					
Initial	89.2	89.7	87.8	92.1	1.8
Gain	13.0	13.7	11.1	8.7	2.3
Heart girth *(cm)*					
Initial	102	102	101	103	4
Gain	22	22	19	10	5
Girth of paunch *(cm)*					
Initial	119	116	121	117	6
Gain	24	24	20	14	4

[a] μg of vitamin A per 454 g of live weight with averages representing the four calves for 18, 54, and 4,000 intakes and six calves for the 12,000 intake.

[b] The day prior to vitamin A supplementation.

[c] Increase during the 12-wk vitamin A supplementation (comparison) period.

TABLE 2

Effect of excessive intakes of vitamin A upon plasma and liver concentrations of vitamin A

	Daily vitamin A intake [a]				SD per calf
	18	54	4,000	12,000	
Plasma vitamin A *(μg/100 ml)*					
Initial [b]	7.6	5.9	5.7	6.5	2.0
Average [c]	26	34	90	106	12
Terminal [d]	28	39	86	80	26
Liver, terminal					
Vitamin A					
Concentration *(μg/100 g)*					
Actual	1,038	5,698	51,250	104,969	....
Log	2.99	3.75	4.66	5.01	0.16
Total *(μg)*					
Actual	35,105	173,030	1,556,297	2,954,207	....
Log	4.52	5.23	6.14	6.45	0.18
Per unit live wt *(μg/kg)*					
Actual	195	1,005	9,972	22,868	....
Log	2.27	3.00	3.94	4.34	0.17

[a] μg of vitamin A per 454 g of live weight with averages representing four calves for the 18, 54, and 4,000 intakes and six calves for the 12,000 intake.
[b] The day prior to vitamin A supplementation.
[c] Average for the 12-wk vitamin A supplementation (comparison) period.
[d] At the completion of the comparison period.

5th wk of vitamin A supplementation and in the two remaining calves of this intake grouping, the 7th wk. Not previously observed in chronic hypervitaminosis A (7) was a softening of the frontal, lacrimal, and nasal bones in calves fed the 12,000 μg intake. This was clinically determined by palpation and occurred in three calves the 4th wk of vitamin A supplementation and in the three remaining calves the 6th, 7th, and 8th wk, respectively.

The total fresh weights determined at slaughter of adrenals, heart, liver, and kidneys of calves fed the excessive vitamin A intake of 4,000 or 12,000 μg tended to be greater for adrenals and less for heart and liver than those of calves fed the lower two intakes, with the kidneys showing inappreciable difference among dietary groups. These averaged in order of increasing vitamin A intakes 10.2, 9.4, 10.8, and 12.2 g for adrenals with a SD of 1.9; 0.93, 0.94, 0.80, and 0.74 kg for heart with a SD of 0.09; 3.36, 3.08, 2.99, and 2.79 kg for liver with a SD of 0.34; and 0.60, 0.63, 0.58, and 0.60 kg for kidneys with a SD of 0.10. When expressed per unit of live weight the trend was for greater weight per unit of live weight for adrenals, expressed in milligrams per kilogram of live weight, as evidenced by the following values in increasing order of vitamin A intake of 56, 55, 69, and 96 with a SD of ten and for heart, liver, and kidneys in grams per kilograms of live weight, respectively, of 5.2, 5.5, 5.1, and 6.0, SD of 0.6; 18.9, 17.8, 19.1, and 21.6, SD of 1.6; and 3.3, 3.6, 3.7, and 4.8, SD of 0.5. Thus, these statistics support the previous findings (7) that the heart, liver, and kidneys are enlarged in relation to live weight in chronic hypervitaminotic-A calves as well as the adrenal glands.

Cisternal CSF pressures determined initially the day prior to vitamin A supplementation averaged 2.31 log units of millimeters of saline with a SD of 0.09 (arithmetic mean equalled 210). Total anesthetic used per calf was 79 ml with a SD of 19, or milliliters per 100 kg of live weight 80, with a SD of 18. Cisternal and intraventricular CSF pressures determined terminally during vitamin A supplementation with amounts of anesthetic used are given in Table 3. Similar to the results of the initial study (7), calves fed the 4,000 μg intake had slightly lower CSF pressures. In calves fed the highest vitamin A intake of 12,000 μg, pressures were considerably less than in those fed the two lower vitamin A intakes of 18 and 54 μg. In the case of the two lower intakes, the cisternal CSF pressures are in essential agreement with those reported for normal cattle (5, 6) in lateral recumbency and under general anesthesia. The greater amount of anesthetic used for intraventricular measurements was expected, since the depth of anesthesia was judged on the basis of the absence of the corneal reflex plus sluggishness of the palpebral reflex, whereas in the case of cisternal pressures the former reflex was used as the criterion. The lower requirement for anesthetic of the calves fed the two higher vitamin A intakes, particularly the 12,000 μg vitamin A intake calves, was due to their emaciated condition.

TABLE 3

Effect of excessive vitamin A intakes upon terminal cisternal and intraventricular CSF pressures

	Daily vitamin A intake [a]				SD per calf
	18	54	4,000	12,000	
CSF pressures *(mm of saline)* [b]					
Cisternal					
Actual	227	221	164	140	....
Log	2.35	2.34	2.19	2.13	0.12
Intraventricular					
Actual	269	253 [c]	168 [c]	126	....
Log	2.42	2.39 [c]	2.18 [c]	2.09	0.14
Amounts of anesthetic					
Cisternal					
Total *(ml)*	134	150	118	87	24
Per unit live wt *(ml/100 kg)*	76	88	77	68	13
Intraventricular					
Total *(ml)*	190	204 [c]	140 [c]	124	37
Per unit live wt *(ml/100 kg)*	133	120 [c]	87 [c]	96	23

[a] μg of vitamin A per 454 g of live weight with the averages unless otherwise indicated representing four calves for the 18, 54, and 4,000 intakes and six calves for the 12,000 intake.

[b] Either seven days subsequent to or one day after the completion of the 12-wk vitamin A supplementation period, but balanced within a vitamin A intake grouping with respect to time of measurement for cisternal or intraventricular pressures.

[c] Averages represent three calves instead of four.

To determine whether cisternal CSF pressures were different from intraventricular, these were plotted on an individual calf basis, Figure 1. As can be seen by reference to this graph, good agreement existed between CSF pressures determined at the two sites of measurement. The determined regression coefficient of log intraventricular CSF pressure in millimeters of saline, Y, on log cisternal CSF pressure in millimeter of saline, X, equalled 1.005 with a SE of 0.013. This coefficient was not different from unity. In addition, the introduction of an intercept term other than Y equal to zero when X equals zero in the model resulted in an intercept not significantly different from zero. While the statistics may be questioned because of errors in measurement of both variables (2), it would appear reasonable to tentatively conclude that because CSF pressures measured at both sites did not differ, there was not present in mild or severe chronic hypervitaminotic-A calves of this age group obstruction between the lateral ventricles, aqueducts, or foramina leading to the cisternal subarachnoid space. Additional evidence supporting this was that withdrawal via cisternal puncture of 3.0 ml of CSF from one-half of the calves of each intake group (except 54 μg intake) immediately after the 10-min intraventricular pressure measurement (one day after completion of the comparison period) resulted in an immediate drop in the intraventricular pressure. Upon replacing the 3.0 ml of CSF via the cisternal puncture, the intraventricular pressure returned in about 1 min to essentially the same pressure observed prior to the removal of CSF.

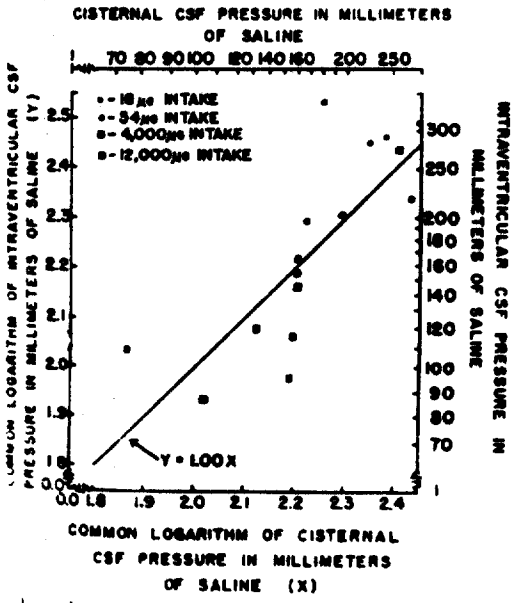

Fig. 1. Association between cisternal and intraventricular cerebrospinal fluid (CSF) pressures in [illegible] 18 or 54 μg vitamin A intakes, and hypervitaminotic-A, 4,000 or 12,000 μg vitamin A [illegible] calves.

ACKNOWLEDGMENTS

The authors appreciate the assistance of B. A. Donohue and T. Watts for the care and feeding

of the calves, of A. Hoza and Mrs. Mae Miller for technical assistance, and of Dr. H. J. Fisher, Connecticut Agricultural Experiment Station, for chemical analysis of the feeds. The Nopco Chemical Co., Harrison, N.J., through the assistance of C. M. Ely, supplied a portion of the vitamin A supplement, and the American Cyanamid Co., Princeton, N.J., through the cooperation of Dr. R. E. Messersmith, D.V.M., the chlortetracycline used in the prevention of diarrhea and sulfamethazine for its treatment. Lastly, we are indebted to Station staff members who made helpful suggestions in the preparation of the manuscript.

REFERENCES

(1) BASS, M. H. The Relation of Vitamin A Intake to Cerebrospinal Fluid Pressure: A Review. J. Mount Sinai Hosp., N.Y., 24: 713. 1957.

(2) DAVIES, O. L. Statistical Methods in Research and Production. Chap. 7, 3rd ed. rev. Hafner Publishing Co., New York. 1957.

(3) DAVSON, H. Physiology of the Ocular and Cerebrospinal Fluids. Little, Brown and Co., Boston. 1956.

(4) DEHORITY, B. A., HAZZARD, D. G., EATON, H. D., GRIFO, A. P., JR., ROUSSEAU, J. E., JR., HELMBOLDT, C. F., JUNGHERR, E. L., AND GOSSLEE, D. G. Some Biochemical Constituents in Serum, Cerebrospinal Fluid, and Aqueous Humor of Vitamin A Deficient Holstein Calves. J. Dairy Sci., 43: 630. 1960.

(5) DOLLAHON, J. C., OWENS, K. G., KOGER, M., HENTGES, J. F., JR., AND WARNICK, A. C. Cerebrospinal Fluid Pressures of Snorter Dwarf-Carrier and Non-Carrier Cattle. J. Am. Vet. Med. Assoc., 135: 109. 1959.

(6) FANKHAUSER, R. The Cerebrospinal Fluid. Chap. III, Comparative Neuropathology. Innes, J. R. M. and Saunders, L. Z. Academic Press, New York. 1962.

(7) HAZZARD, D. G., WOELFEL, C. G., CALHOUN, M. C., ROUSSEAU, J. E., JR., EATON, H. D., NIELSEN, S. W., GREY, R. M., AND LUCAS, J. J. Chronic Hypervitaminosis A in Holstein Male Calves. J. Dairy Sci., 47: 391. 1964.

(8) WOELFEL, C. G., ROUSSEAU, J. E., JR., KERSTING, E. J., NIELSEN, S. W., AND LUCAS, J. J. Intraocular Pressure of Vitamin A Deficient Holstein Male Calves. J. Dairy Sci., 47: 655. 1964.

Grey-'65
Bib. No. 3456

Reproduced by permission
of the copyright owner

Path. vet. 2: 446–467 (1965)

From the Department of Animal Diseases and the Animal Nutrition Section
University of Connecticut, Storrs, Conn.

Pathology of Skull, Radius and Rib in Hypervitaminosis A of Young Calves

R.M. Grey, S.W. Nielsen, J.E. Rousseau, Jr.,
M.C. Calhoun and H.D. Eaton

Contradictory observations have been reported by various workers on the effects of excessive vitamin A on skeletal bone in the rat, mouse, dog, chicken, duck, mink and man. There is considerable difference of opinion as to which signs and lesions are specific for hypervitaminosis A. These conflicting reports, as well as the complete lack of information on the bone changes in the bovine species, leave many questions unanswered as to the effects of excessive amounts of vitamin A in the diets of domestic animals.

With major feed companies supplementing commercial rations with vitamin A by automation, and the lay use of vitamin A for the treatment of ringworm[9] and other maladies, accidental overdosage of vitamin A by overzealous treatment is as possible in animals as it has been in man.

The purpose of this study was to determine the toxic effects of excessive vitamin A on the skeletal system of growing dairy calves by means of radiographic and pathologic examination of selected bones in 22 Holstein calves at 5 graded levels of vitamin A intake.

Review of Literature

The earliest indication of hypervitaminosis A probably belongs in the realm of folklore or superstition as it has been known for centuries among Eskimos and Arctic travelers that the eating of polar bear liver by man and dogs causes severe illness. Eskimos never eat it and consider the liver of all bears dangerous; even gulls, ravens and other scavenger birds leave the livers alone[25].

Rats

The first published report on the toxic effects of vitamin A was by TAKAHA-I et al.[34], using a crude vitamin A concentrate 'biosterin' fed orally. The rats d after periods of a few days to several weeks, with loss of hair, emaciation d paralysis of the hind legs.

Skeletal lesions were first reported by COLLAZO and RODRIGUEZ[10] who bserved that the long bones of rats, fed an excess of vitamin A concentrate, ecame fragile and prone to fractures. MOORE and WANG[26] also produced skeletal esions using purified crystalline vitamin A acetate. WOLBACH[37], using rats and guinea pigs, showed that growth sequences of bone are accelerated, and that the rate of change is quantitatively related to the amounts of vitamin A administered. Bone which does not require remodeling for maintenance of the normal growth pattern, was not responsive to the large amounts of vitamin A administered.

RODAHL[31] found that the average vitamin A content of polar bear liver was approximately 7000 μg/g, of bearded seal liver 6000 μg/g and of Greenland fox liver approximately 4000 μg/g. Radiographic examination of the long bones of rats fed polar bear liver revealed that the bones became thin and the cortical shadow was absent at both ends of the bones. On necropsy only spongy bone was found in the long bones and the epiphysis was of normal width. He concluded that vitamin A was the toxic agent in polar bear livers, which was later confirmed by using a purified oily solution of the crystalline vitamin A acetate[32].

IRVING[19] described rarefaction and reduced deposition of bone in the mandibles of young rats given excess vitamin A. GORLIN and CHAUDHRY[13] found that in hypervitaminotic rats, the lingual alveolar bone formed at a much slower rate and that a marked decrease in the number of osteoblasts occurred. In the epiphyseal cartilage of the long bones, the number of cells was reduced and the width of the epiphyseal plate became markedly narrower.

Mice

YPSILANTI[41] failed to produce bone changes in mice by the subcutaneous injection of vitamin A concentrates, but RODAHL[32] did obtain skeletal lesions similar to those of the rat. BARNICOT[4] attached crystalline vitamin A to small pieces of parietal bone from 10-day-old mice and then inserted the graft into littermates. When the grafts were removed 7–10 days later, advanced absorption ccompanied by many osteoclasts, which sometimes produced a perforation of the one, was observed.

Rabbits

THOMAS et al[35] found skeletal changes in rabbits due to excessive amounts of vitamin A. The normal basophilic, metachromatic and alcian blue staining properties of the matrix were lost especially in the articular and epiphyseal cartilage. The cartilage cells remained intact but were reduced in size.

Dogs

MADDOCK and co-workers[22] described bone changes in dogs similar to those described in the rat and guinea pig[37], and they concluded that the dog responds to excessive doses of vitamin A as do other laboratory animals.

Mink

HELGEBOSTAD[17] briefly described decalcification and spontaneous fracture of the long bones of mink fed excessive amounts of vitamin A.

Chickens

RODAHL[32] did not record skeletal changes in chickens but WOLBACH and HEGSTED[38] found that the skeletal responses to hypervitaminosis A in young chickens are of the same nature as those in mammals, in that vitamin A accelerates all histologic sequences of bone growth compatible with normal growth patterns.

Ducks

RIGDON et al.[29] found no significant pathologic or roentgenographic changes in the bones of ducks fed 'large amounts' of vitamin A and decided that this species reacted differently from those previously mentioned. However, on the contrary from controlled experiments, WOLBACH and HEGSTED[38] concluded that ducks behave as other avian and mammalian species in response to large amounts of vitamin A.

Man

Chronic Intoxication, Children

The first case of chronic hypervitaminosis A in children was reported by JOSEPHS[20] in a 34-month-old boy who had received 80,000 I.U. of vitamin A daily in the form of halibut liver oil since the third month of age, and who occasionally drank oil directly from the bottle. TOOMEY and MORISETTE[36] described a 23-month-old boy who had been given excessive amounts of vitamin A since 2 weeks of age, resulting in hard, tender swellings in the extremities and cortical thickening in the tubular bones. Vitamin A toxicity in children has also been reported by CAFFEY[6] who had excellent roentgenographic studies; by RINEBERG and GROSS[30] who described the first bone biopsy; by BAIR[3] who first reported skull bone lesions and, more recently, by WOODARD et al.[40] who described bone destruction and delayed ossification of the parietal bone. PEASE[28] reported on growing children in which he found focal retardation and arrest of bone growth

Chronic Intoxication, Adults

The first case of chronic vitamin A intoxication in adults was reported by SULZBERGER and LAZAR[33] who described a 44-year-old woman who had taken 600,000 units of vitamin A daily for 18 months in an attempt to prevent 'colds'. There was joint and bone pain, but the radiographic appearance of the bones was normal. Later GERBER et al.[12] reported on vitamin A toxicity in a woman who had been in 6 hospitals over a period of 9 years suffering from crippling bone and joint pains. Extensive calcification of cartilage, ligaments and subperiosteal tissues was present.

Acute Intoxication

The first acute changes were reported by MARIE and SÉE [23], and occurred in infants from a single large dose of vitamin A. A striking clinical sign was a bulging fontanel, which disappeared in all cases in 24–48 h. Careful questioning revealed that each child had received 350,000 I.U. vitamin A and 300,000 I.U. vitamin D_2 in one dose. In order to eliminate the role that supplementary vitamin D might have played in the disorder, 350,000 I.U. of vitamin A alone were administered orally to infants and in 3 out of 6 of them produced an acute benign hydrocephalus. Therefore, vitamin A alone was believed responsible for this syndrome. The disease was subsequently produced by them in puppies and the syndrome of hypervitaminosis A now carries their name (Marie and Sée syndrome).

BRESLAU[5] gives a comprehensive discussion of several aspects of vitamin A intoxication in both the acute and chronic stages. He makes a plea for wider recognition of mild or border-line hypervitaminosis A and states that the indiscriminate use of vitamin A by the layman and medical practitioner is to be deplored. He also suggests that the manufacturers of vitamin A preparations should point out the danger of high potency concentrates and that non-prescription concentrates be held to low level potencies.

Materials and Methods

Since it seemed desirable to determine the effect of experimental hypervitaminosis A in an experimental animal whose size and weight would approximately produce the stresses found in bone of human beings, Holstein calves were chosen because of their large size and fast growth rate. They are readily available, of low cost and sufficient base line data are known for food consumption, growth rate, clinical behaviour and biochemistry[7, 14, 16].

Twenty-two, 1-day-old Holstein calves were fed and managed as previously described[14]. On the 64th day each calf received a vitamin A depletion ration and when the blood plasma vitamin A concentration had decreased to 10 μg/100 ml, each calf was then fed either 18, 54, 4000, 12,000 or 16,000 μg of vitamin A per pound of live weight per day for a period of either 8 or 12 weeks (Table 1).

The level of feeding[8] of the basal ration (Table II) provided a weekly weight gain of 10 pounds or approximately 5% in the control calves; this is equal to

Table 1. Age, Sex, Duration and Clinical Signs of 22 Holstein Calves Fed 5 Levels of Vitamin A

Number	Sex	Duration (weeks)	Age at necropsy (months)	Vitamin A intake (μg/lb)	Skull softening (week observed)
E4902	M	12	6	18	–
E4909	M	12	6	18	–
E4916	M	12	6	18	–
E4924	M	12	6	18	–
E4901	M	12	6	54	–
E4911	M	12	6	54	–
E4914	M	12	6	54	–
E4922	M	12	6	54	–
E1172	F	8	5	54	–
E4906	M	12	6	4000	–
E4908	M	12	6	4000	–
E4917	M	12	6	4000	–
E4921	M	12	6	4000	–
E4905	M	12	6	12,000	4
E4907	M	12	6	12,000	6
E4915	M	12	6	12,000	8
E4923	M	12	6	12,000	4
E4925	M	12	6	12,000	4
E4928	M	12	6	12,000	7
E1170	F	8	5	16,000	4
E1171	F	8	5	16,000	4
E1173	F	8	5	16,000	4

current U.S. Department of Agriculture growth standards[24]. Calves receiving 4000, 12,000 or 16,000 μg intakes consumed from 10 to 30% less of the allotted feed allowance. By careful consideration of our previous data[15, 27], in which feed intake was restricted to 60% of that offered to the calves of the present study, it was found that no pathologic changes occurred due to the imposed feed restr[illegible]n. In addition, similar results due to excessive vitamin A intakes are being ob[illegible] in current studies with calves where differences in feed intake were elim[illegible]

The number of calves at each level was 4 at 18, 5 at 54, 4 at 4000, 6 at [illegible] and 3 at 16,000 μg. The vitamin A fed was a dry, stabilized form, Nopco [illegible] Type I.*. The experimental feeding period was 12 weeks, except for the [illegible] on the 16,000 μg and 1 control calf fed the 54 μg intake. This latter [illegible] group was made up of 4 female calves 5 months of age, while all othe[illegible] were males and 6 months of age when necropsied. The 9 calves at the [illegible]

* Nopco Chemical Company, Newark, New Jersey.

Table II. Composition of Basal Ration* Fed 22 Holstein Calves

	Per cent
Beet pulp	33.35
Ground barley	15.196
Crimped oats	16.7
Wheat bran	16.7
Expeller processed linseed oil meal	5.0
Solvent extracted soybean oil meal	5.0
Cane molasses	6.65
Iodized salt	0.7
Steamed bone meal	0.7
Irradiated yeast, guaranteed to contain 64 million I.U. of vitamin D per pound	0.004

* Chemical composition according to A.O.A.C. procedures[18] was 90.3±0.8% dry matter and of this dry matter the following: 15.9±0.1 crude protein; 1.9±0.2 ether extract; 11.8±0.2 crude fiber; 63.5±0.3 nitrogen-free extract; and 6.9±0.1 ash with a carotene concentration of 0.20±0.02 mg/kg of ration as fed. With the exception of vitamin A, this ration met the NAS-NRC Subcommittee on Dairy Cattle Nutrition nutrient requirement of rations for normal growth[21].

54 μg intake levels of vitamin A served as controls since 54 μg is considered to be within normal and 18 μg mildly deficient[15, 27].

The radii of the calves at the 16,000 μg level were radiographed at the start of the experiment and thereafter at 1-week intervals. The radii and skulls of all calves were radiographed at necropsy after removing skin and muscle. (The X-ray machine was a Picker 200 ma mobile unit. The film was Kodak Royal Blue and the casettes had Dupont Hi-Speed intensifying screens. Films were processed in Kodak Developer and Fixer according to the manufacturer's directions.) The radii were radiographed at 100 ma × 0.1 sec. using 55 kv.p.'s for a 7.0 cm thickness of part (measured through the thickest part of the carpus in an antero-posterior direction). For each increase or decrease in thickness of part of the base, ±2 kv.p.'s were used for each cm change. The exposures used for necropsy bone specimens were 100 ma × 0.1 sec. at 53 kv.p.'s for a 3.0 cm radius and 50 kv.p.'s for a 7.0 cm hemisection of skull.

At the completion of the experimental period each calf was killed by decapitation and exsanguinated. The right radius, right 9th rib, right half of the skull and samples of all organs were fixed in 10% buffered formalin. After fixation, the bones were decalcified in Decal®,* processed by standard histologic methods and stained with hematoxylin and eosin.

* Fisher Scientific Company, Medford, Massachusetts.

Results

Radiography

Radius

At the distal end of the radius no changes were noted in the control animals (18 and 54 μg/lb levels) while mild changes were evident at the 4000 μg/lb vitamin A intake level. The diaphyseal cortical shadow of these calves was thin and the diameter of the diaphyseal shaft as it joins the metaphysis was reduced. Instead of the normal gentle slope of the cortex at the diaphyseal-metaphyseal junction, a rather sharp angle resulted, which produced a flaring, referred to as a 'trumpet' or 'pagoda' effect. The amount of spongious bone was considerably reduced in 3 of the 4 animals, the length of the radius was shorter than the control by 1.0 cm in one and 2.0 cm in the others. Shortening of the radius did not occur in the 4th animal.

The calves at the 12,000 μg/lb level of vitamin A intake had essentially the same changes as the 4000 μg/lb calves and to approximately the same degree except that 3 of the 6 calves showed a more acute flaring of the diaphyseal-metaphyseal junction and less spongious bone (Fig. 1).

Serial radiographs of the calves at the 16,000 μg/lb level of vitamin A intake were taken at 1-week intervals. Two weeks after the start of increased vitamin A intake, a slight flaring of the metaphysis and a slight decrease in the amount of spongious bone could be noted. The thickness of the cortical bone at the diaphysis and metaphysis was less than that of the control animals. At 3 weeks the same changes were observed and to about the same degree except that the flaring was more pronounced. At 4 weeks the flaring was marked, the cortical bone was thinner in the region of the metaphysis and the spongious bone of less amount than in the controls. The diameter of the diaphyseal shaft was decreased. At 5 weeks the cortical bone in the diaphysis was thinner and the flaring more pronounced with a decided slowing of the remodeling process in the metaphyseal region. The width of the metaphysis was narrower than in the controls. At 6 weeks all the changes were more pronounced. In one animal, remodeling was so retarded that the diameter of the tubular bone at the diaphysis was approximately that of the metaphysis, resulting in a pronounced 'pagoda' effect (Fig. 2). At 7 and 8 weeks, the defect in tubulation was

Radiograph of normal radius (calf E4911) at left (N) and of 3 calves (D, E and F) fed 12,000 μg vitamin A for 12 weeks. The latter 3 are shorter and have decreased diameters of the shafts.

Röntgenbild eines normalen Radius (Kalb E4911) links (N) und der Radii von drei Kälbern (D, E und F), die 12 Wochen lang 12 000 μg Vitamin A erhalten hatten. Letztere drei sind kürzer und haben kleinere Schaftdurchmesser.

more pronounced and the radii were 2.0 to 3.0 cm shorter in length than in the controls.

In summary, radiographic changes in the distal end of the radius occurred in calves at the 4000, 12,000 and 16,000 μg/lb levels of vitamin A intake. The changes were similar at all levels, increasing in severity as the vitamin A level increased: (1) Thinning of the cortical bone in the diaphysis with a decrease in the diameter of the shaft and a

Fig. 2. Radius of control calves E1172 (left) and E1170 (right) after feedi 16,000 μg vitamin A for 6 weeks. Changes are increased osteopor and metaphyseal flaring [pagoda effect] (arrow).

Abb. 2. Radius von Kontrollkalb E1172 (links) und E1170 (rechts) nach 6wöch Verfütterung von 16 000 μg Vitamin A. Veränderungen in Form sta Osteoporose und trichterartiger Metaphysenerweiterung (Pagoden E (Pfeil).

lecrease in length; (2) termination of cortical shadow at a greater listance from the epiphyseal disc; (3) a slowing of remodeling at the iaphyseal-metaphyseal junction resulting in flaring; (4) a decrease in idth and in spongious bone of the metaphysis.

Skull

The area surveyed for changes in the skull was the frontal bone. so abnormalities were noted in the control animals. Extreme thinning f the external and internal plates of the frontal bones which enclosed he frontal sinus was evident at the 3 highest levels of vitamin A intake. The thinning increased as the vitamin A level increased, and it reached such a degree of osteoporosis that the external plates could be easily depressed with the thumb in the live animal. This occurred at the 12,000 μg level at the 4th week of intake in 3 animals, and at the 6th, 7th and 8th weeks in the remaining 3 calves. The frontal external plates of all calves at the 16,000 μg level could be depressed at 4 weeks. The skulls were smaller than in the controls and the radiographic density was considerably less. Particularly noticeable was the rounding off and greatly decreased bone mass of the occipital bone.

Pathology

Gross Changes

The changes observed in animals at all levels generally correlated well with the radiographic changes.

Radius. In calves fed at the 4000 μg level of vitamin A, 3 of 4 calves had radii shorter and thinner than controls. There was thinning of the cortical bone at the diaphysis and a decrease in diameter of the shaft. Spongious bone of the metaphyseal region was less than in the controls, while the epiphyseal disc was of the same thickness.

Calves fed 12,000 and 16,000 μg of vitamin A had changes in the e areas but to a more marked degree. Particularly apparent was the ked decrease in spongious bone and the pronounced flaring in the iphysis (Fig. 3).

Ribs. No abnormalities were noted in the control animals. In es fed at the levels of 4000, 12,000 and 16,000 μg of vitamin A,

a reduction in the width of the costochondral junction was noted, the ribs of all calves were brittle and easily fractured, and again the decrease in size was relative to the increasing doses of vitamin A (Fig. 4).

Skull. No abnormalities were noted in the control animals. At the 4000 μg level of vitamin A, the size of the skull was decreased and all the flat bones were thin, particularly the internal and external plates of the frontal bones.

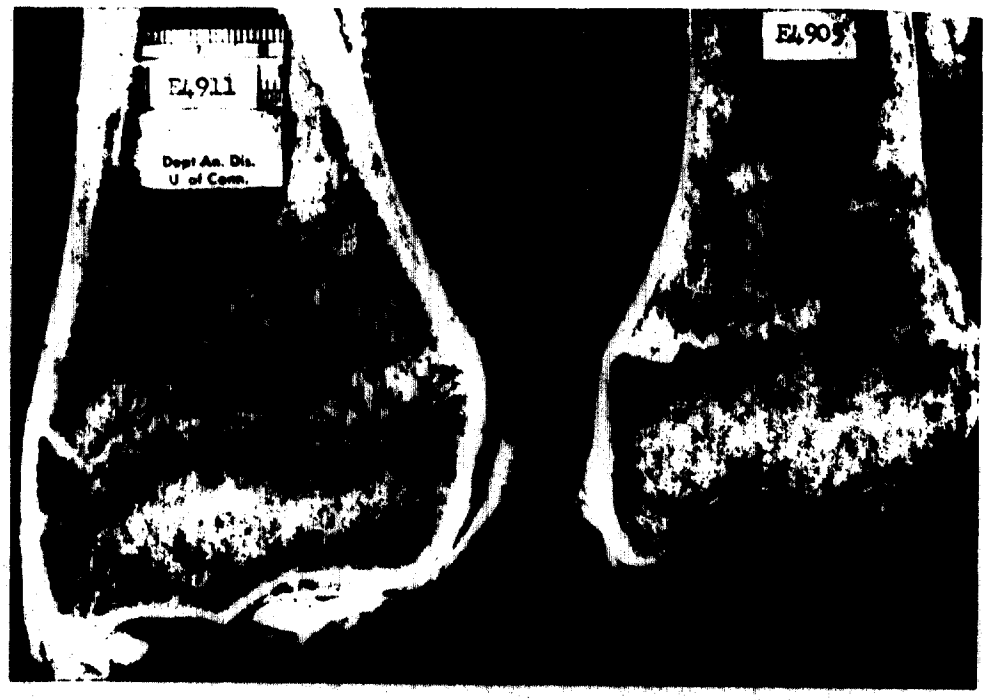

Fig. 3. Sagittal sections of the radius of calves E4911 (control) and E4905 after 12 weeks at level of 12,000 μg vitamin A. There is a decrease in overall length and width with less spongious bone. The cortical bone of the diaphysis is thinner and does not extend as far towards the epiphysis.

Abb. 3. Sagittalschnitte des Radius von Kalb E4911 (Kontrollkalb) und E490[illegible] nach 12wöchiger Gabe von 12 000 μg Vitamin A. Verkürzung der Gesamtlänge und -breite und Verminderung der Substantia spongiosa. D[illegible] Knochenrinde der Diaphyse ist dünner und reicht nicht so weit an d[illegible] Epiphyse heran.

Abb. 4. Sagittal sections of rib at the costochondral junction of normal calf E4911 and 5 calves fed 12,000 μg/lb vitamin A for 12 weeks. In the latter 5 there is a marked decrease in the diameter of the rib.

Abb. 4. Sagittalschnitte einer Rippe an der knorplig-knöchernen Verbindung von einem normalen Kalb (E4911) sowie von 5 Kälbern, denen 12 Wochen lang 12 000 μg/Pfund Vitamin A verabreicht wurde. Der Rippendurchmesser bei diesen 5 Kälbern ist erheblich verkleinert.

At the 12,000 and 16,000 μg levels, the skulls were much smaller than the controls. The external plates of the frontal bones were very thin and the internal plates had failed to form. The brain was separated from the frontal sinuses only by the dura mater (Fig. 5). Hydrocephalus was present at the 3 highest levels, but was more severe at the 12,000 and 16,000 μg levels with distended cerebral hemispheres protruding into the frontal sinuses, forming a bilateral meningo-encephalocele.

Fig. 5. Transverse sections through the same plane of the frontal sinus of a normal calf (E4911) and 2 calves (E4905 and E4928) fed 12,000 μg vitamin A for 12 weeks. In the latter two, the internal place of the frontal bone failed to form. There is a decrease in the size of the frontal sinus, with only the dura mater separating the brain from the sinus.

Abb. 5. Querschnitte durch dieselbe Ebene der Stirnhöhle von einem normalen Kalb (E 4911) sowie von 2 Kälbern (E4905 und E4928) nach 12wöchiger Gabe von 12 000 μg Vitamin A. Bei diesen beiden Kälbern blieb die Bildung der Stirnbeininnenplatte aus. Die Stirnhöhle ist verkleinert und das Gehirn nur durch die Dura mater von der Stirnhöhle getrennt.

. 6. Distal epiphyseal disc (diaphysis towards bottom) of radius from calf (E1170) after 8 weeks feeding of 16,000 μg vitamin A. There is distortion of the columnar alignment of chondroblasts, absence of vascular buds in hypertrophied cartilage cells and the chondroid lattice is not covered with osteoid. H & E, ×375.

. 6. Distale Epiphysenscheibe (Diaphyse unten) des Radius von Kalb E1170 nach 8wöchiger Verabreichung von 16 000 μg Vitamin A. Die zylindrische Anordnung der Chondroblasten ist gestört; die Gefässanlagen fehlen in hypertrophischen Knorpelzellen und das Knorpelgitter ist nicht mit Osteoid bedeckt.

Microscopic Pathology

Radius. The sections of the radius were taken at the distal epiphyl seal disc. No changes from the normal were noted in the control animals.

At the 4000 μg level, endochondral ossification appeared to be normal except for a deranged zone of proliferating cartilage and the zone of provisional calcification being wider than normal. There appeared to be a delay in the differentiation of the mesenchymal cells into osteoblasts. The marrow spaces between the trabeculae in the metaphysis were slightly larger than normal.

At the 12,000 μg level, changes were more pronounced than in the previous group with a reduction in the width of the epiphyseal disc, a wider zone of provisional calcification not covered by osteoid, and delay in osteoblastic differentiation. Spicules covered by osteoid contained much unresolved lattice.

At the 16,000 μg level, the epiphyseal disc was extremely thin and irregular, and the endochondral ossification had nearly stopped, as no osteoblasts could be seen lining the spicules of cartilage (Fig. 6). The rows of hypertrophied cartilage cells were irregular and not being penetrated by the mesenchymal vascular buds. Practically no resting or proliferating chondroblasts were present.

No evidence of increased osteoclasts was seen in these sections at any level of vitamin A.

Ribs. Sections of the rib, taken from the costochondral junction in the two control groups, were of normal histologic appearance.

At the 4000 μg level, endochondral ossification was proceeding at a nearly normal rate. However, in the zone of provisional calcification the osteoblasts were fewer in number. As a result, osteoid forma-

---

Fig. 7. Internal plate of the frontal bone of control calf (E1172) showing normal thickness and well developed Haversian canals. The dura mater has been stripped off below and the mucous membrane of the frontal sinus is seen on top. H & E, ×130.

Fig. 8. Internal plate of frontal bone of calf (E1171) fed 16,000 μg vitamin A, demonstrating a thinning of bone, with only a few Haversian canals. The dura mater is below and the sinus mucous membrane at the top H & E, ×130.

Abb. 7. Innenplatte des Stirnbeins von Kontrollkalb E1172 mit normaler Dicke und gut entwickelten Haversschen Knochenkanälchen. Unten ist die Dura mater abgetrennt und oben ist die Stirnhöhlenmukosa zu sehen.

7

8

8. Stirnbeininnenplatte von Kalb E1171, das 16 000 μg Vitamin A erhielt; Verdünnung des Knochens und nur wenige Haverssche Knochenkanälchen. Dura mater (unten) und Stirnhöhlenmukosa (oben).

tion began further away from the zone of provisional calcification than normal.

At the 12,000 μg level, the costochondral junction was very irregular in contrast to the nearly straight line formed in the control animals. In 2 of the calves, the cartilage cells were maturing normally and the chondroid lattice was being formed, but only a few osteoblasts were seen. In the other 4 calves, the chondroid lattice was very rudimentary. The spicules were thinner than normal, irregular in outline, sparsely covered with osteoblasts and contained unresorbed chondroid lattice. Lamellation was poor, some of the spicules having a fibrous character without Haversian systems.

At the 16,000 μg level, the costochondral junction was extremely irregular. The cartilage cells were nearly all resting cells with only a small zone of hypertrophied cartilage cells which was not penetrated by the vascular buds. The chondroid lattice was entirely lacking, thus there was no zone of provisional calcification. Between the cartilage and the spicules of the spongy bone was a wide band of fibrous connective tissue which extended between the spicules filling the marrow cavity.

Skull. Section of the frontal bones were taken from the angle between the external wall of the frontal sinus and the internal wall which lies against the dura mater. The control calves had thick membranous bone with well developed Haversian systems (Fig. 7).

At the 4000 μg level, the bony plates were thinner than normal.

At the 12,000 μg level, intramembranous ossification had nearly stopped and the plates were thinner than those at the 4000 μg level. The compacta was thin and lamellation was less dense with poorly formed Haversian systems. The internal plates thinned rapidly, changed to fibrous tissue and then disappeared.

At the 16,000 μg level, the plates were so thin that only rudimentary bone fragments were present with poorly formed Haversian systems (Fig. 8).

Parathyroid. No evidence of hyperplasia or other change was seen.

Discussion

Excessive amounts of vitamin A fed to young calves produced severe changes in skeletal bone manifested by decreased linear growth of the long bones, diminished size of the skull and ribs seen as thinning of the cortical bone and decreased amounts of spongious bone

n general, these findings agreed with the lesions seen in other species f experimental animals[1, 10, 11, 13, 31, 32]. The overall result was one of steoporosis due to a retardation of bone formation and remodeling hich could be demonstrated radiographically, grossly and microopically.

Radiographically, a decrease in size, a thinning of the cortex, and a ecrease in the amount of spongiosa resulted in radiolucency. The flaring observed at the metaphyseal-diaphyseal junction was an indication a slow remodeling which failed to keep pace with the linear growth.

Microscopically, the cortical thinning with decreased osteoblastic ctivity on both periosteal and endosteal surfaces, the widened marrow spaces and fewer osteoblasts on the spongiosa spicules resulted in a retarded bone formation. In many areas the osteoblasts did not attain their characteristic ovoid shape and had the appearance of spindle-shaped cells resembling fibroblasts, possibly indicating incomplete differentiation from mesenchymal cells. FELL and MELLANBY[11] also found little deposition of osteoid by the same type of primitive osteoblasts. Another mechanism producing a decrease in bone mass is the incomplete mineralization of osteoid occurring in rickets and osteomalacia. However, in a previous study of ours[16] the hypervitaminotic A calves had more bone ash than control calves. The exact mechanism whereby vitamin A exerts its effect is unknown, but on the basis of the morphologic observations, it appeared that the osteoblasts remained undifferentiated and thus were incapable of producing osteoid matrix, resulting in osteoporosis[1, 2].

As reported elsewhere[14], calves fed 4000 and 12,000 μg of vitamin A exhibited decreased cisternal and intraventricular cerebrospinal fluid (CSF) pressures. The pressures at the two sites were not appreciably different within individual calves indicating that obstruction was not the cause of the diluted cerebral ventricles. Since the internal plates of the frontal bone failed to form, a possible explanation for the low CSF pressure is the fact that the meninges and brain merely extended into the frontal sinus limited only by the dura mater and not by bony partition as in the normal calf.

Summary

n an experiment to produce hypervitaminosis A, twenty-two Holstein 3 months of age and with a plasma vitamin A of 10 μg/100 ml or less, d vitamin A levels of 18, 54, 4000, 12,000 or 16,000 μg/lb of body weight

per day for a 12-week period, except for the 16,000 μg group which was terminated in 8 weeks. The long bones and skulls were examined by X-rays and histologically.

The roentgenologic changes were a slowing of growth and remodeling processes in all calves on the 3 highest levels resulting in diminution of the overall size, thinning of the cortical bone and a marked decrease in the amount of spongious bone. Serial radiographs at weekly intervals of the radii of the calves on the highest level of vitamin A demonstrated changes as early as 2 weeks after administration of the vitamin supplement was begun.

The gross pathologic changes correlated well with the radiographic findings, except that failure of the internal bony plates of the frontal sinuses to form was not detected in the radiographs. The lack of bony separation of the brain from the frontal sinuses and the expansion of the cerebrum into these sinuses may explain the decreased cerebrospinal fluid pressure which accompanied the dilated cerebral ventricles.

Histologically, the essential change was retarded osteogenesis with poor differentiation of the mesenchymal cells into osteoblasts. As a result, the compacta was thin, osteoporotic and, at the 2 higher levels of vitamin A administration, contained large amounts of fibrous bone. As demonstrated in calves, the effect of excessive vitamin A on bone appears to be retardation of bone growth due to a defect in osteoid production resulting in osteoporosis.

Zusammenfassung

Bei einem Versuch A-Hypervitaminose zu erzeugen, erhielten 22 drei Monate alte Holsteinkälber, deren Vitamin-A-Gehalt im Blutplasma 10 μg/100 ml oder weniger betrug, täglich Vitamin A in Mengen von 18, 54, 4000, 12 000 und 16 000 μg pro Pfund Körpergewicht während 12, bzw. bei Gabe von 16 000 μg, 8 Wochen. Die Röhren- und Schädelknochen wurden röntgenologisch sowie histologisch untersucht.

Die röntgenologischen Veränderungen bestanden aus Wachstumsverzögerungen und Umwandlungsprozessen bei allen Kälbern mit den drei höchsten Vitamingaben und äusserten sich in Verminderung der Gesamtgrösse, Verdünnung der Knochenrinde und erheblichem Schwund der schwammigen Knochensubstanz. Wöchentlich durchgeführte Serienröntgenbilder des Radius von Kälbern, die die höchste Vitamin-A-Gabe erhielten, wiesen bereits 2 Wochen nach Verabreichung des Vitaminzusatzes Veränderungen auf.

Die makroskopischen Veränderungen entsprachen den röntgenologisch[illegible] Befunden, jedoch konnte den Röntgenbildern nicht entnommen werden, dass [illegible] Bildung der inneren Knochenplatten der Stirnbeinhöhlen ausgeblieben [illegible] Das Ausbleiben der knöchernen Trennung des Gehirns von den Stirnbeinhöh[illegible] und die Ausdehnung des Gehirns in diese Höhlen mag den verminderten Liq[illegible] druck erklären, der mit der Hirnkammererweiterung einherging.

Histologisch bestand die wesentliche Veränderung in verzögerter Oste[illegible] nese mit schlechter Differenzierung der mesenchymalen Zellen zu Osteobla[illegible] Als Folge war die Kompakta dünn, osteoporotisch und enthielt bei den Käl[illegible] mit den beiden höheren Vitamin-A-Gaben grosse Mengen fibröser Knoc[illegible]

substanz. Wie bei den Kälbern gezeigt wurde, wirkt sich übermässiges Vitamin A scheinbar auf die Knochen in Form von Verzögerung des Knochenwachstums durch gestörte Osteoidproduktion aus und führt zu Osteoporose.

Acknowledgments

This project was supported by Pathology Training Grant 5TIGM 98501-02 and Research Grant NB-02108-06 from the National Institute of Neurological Diseases and Blindness.

References

1. Aegerter, E. and Kirkpatrick, J.A.: Orthopedic Diseases (W.B. Saunders, Philadelphia 1963).
2. Albright, F.: Original not seen. Cited by: Aegerter, E. and Kirkpatrick, J.A.[1].
3. Bair, G.: Chronic vitamin A poisoning. *J. amer. med. Ass. 146:* 1573–1574 (1951).
4. Barnicot, N.A.: Local action of vitamin A on bones. *J. Anat. 84:* 374–387 (1950).
5. Breslau, R.C.: Hypervitaminosis A. *Arch. Pediat. 74:* 139–152, 178–197 (1957).
6. Caffey, J.: Chronic poisoning due to excess vitamin A. *Amer. J. Roentgenol. 65:* 12–26 (1951).
7. Calhoun, M.C.; Rousseau, J.E.; Eaton, H.D.; Hall, R.C. and Lucas, J.J.: Association between age and cisternal cerebrospinal fluid pressure in Holstein male calves. *J. dairy Sci. 48:* 100–102 (1965).
8. Calhoun, M.C.; Woelfel, C.G.; Hall, R.C.; Rousseau, J.E.; Eaton, H. D. and Lucas, J.J.: Growth of Holstein male calves fed an enzyme supplement, a combination of primary fungal and bacterial fermentation products, with limited milk replacer and starter and *ad libitum* hay, with observations on carotene utilization. *Storrs (Conn.) Agricultural Experiment Station, Progress Report No. 56* (1964).
9. Campbell, J.R.: Ringworm stopped with vitamin A. *Hoard's Dairyman 108:* 709, 713 (1963).
10. Collazo, J.A. and Rodriguez, J.A.: Hypervitaminosis A. *Klin. Wschr. 12:* 1732–1734 (1934).
11. Fell, H.B. and Mellanby, E.: The effect of hypervitaminosis A on embryonic limb-bones cultivated *in vitro. J. Physiol. 116:* 320–349 (1952).
12. Gerber, A.; Raab, A.P. and Sobel, A.E.: Vitamin A poisoning in adults: With a description of a case. *Amer. J. Med. 16:* 729–745 (1954).
13. Gorlin, R.J. and Chaudhry, A.P.: The effect of hypervitaminosis A upon the incisor and molar teeth, the alveolar bone, and temperomandibular joint of weanling rats. *J. dent. Res. 38:* 1008–1015 (1959).
14. Grey, R.M.; Calhoun, M.C.; Rousseau, J.E.; Woelfel, C.G.; Hall, R. C.; Nielsen, S.W.; Eaton, H.D. and Lucas, J.J.: Cisternal and intraventri-

cular cerebrospinal fluid pressures in chronic bovine hypervitaminosis A. *J. dairy Sci. 47:* 783–788 (1964).

15. HAZZARD, D.G.; GRIFO, A.P.; ROUSSEAU, J.E.; WOELFEL, C.G.; EATON, H.D.; NIELSEN, S.W. and GOSSLEE, D.G.: Effect of level of ration intake and duration of vitamin A deficiency upon some biochemical constituents in serum, cerebrospinal fluid, and aqueous humor of Holstein calves fed fixed carotene intakes. *J. dairy Sci. 45:* 91–104 (1962).
16. HAZZARD, D.G.; WOELFEL, C.G.; CALHOUN, M.C.; ROUSSEAU, J.E.; EATON, H.D.; NIELSEN, S.W.; GREY, R.M. and LUCAS, J.J.: Chronic hypervitaminosis A in Holstein male calves. *J. dairy Sci. 47:* 391–401 (1964).
17. HELGEBOSTAD, A.: Experimentally induced vitaminosis A in furred animals. *Nord. Vet. Med. 7:* 297–301 (1955).
18. HORWITZ, W.: Official Methods of Analysis of the Association of Official Agricultural Chemists, 9th ed. (Association of Official Agricultural Chemists, Washington, D.C. 1960).
19. IRVING, J.T.: Effect of avitaminosis and hypervitaminosis A upon incisor teeth and incisal alveolar bone of rats. *J. Physiol. 108:* 92–101 (1949).
20. JOSEPHS, H.W.: Hypervitaminosis A and carotenemia. *Amer. J. Dis. Child. 67:* 33–34 (1944).
21. LOOSLI, J.K.; BECKER, R.B.; HUFFMAN, C.F.; PHILLIPS, P.H. and SHAW, J.C.: Nutrient Requirements of Domestic Animals. III. Nutrient Requirements of Dairy Cattle, revised ed. (National Academy of Sciences, National Research Council, Publication No. 464, Washington D.C. 1958).
22. MADDOCK, S.L.; WOLBACH, S. and MADDOCK, S.: Hypervitaminosis A in the dog. *J. Nutr. 39:* 117–138 (1949).
23. MARIE, J. and SÉE, G.: Acute hypervitaminosis A of the infant: Its clinical manifestations with benign acute hydrocephalus and pronounced bulge of the fontanel. *Amer. J. Dis. Child. 87:* 731–736 (1954).
24. MATTHEWS, C.A. and FOHRMAN, M.H.: Beltsville Growth Standards for Holstein Cattle. U.S. Dept. Agriculture Technical Bulletin 1099 (1954).
25. MOORE, T.: Vitamin A., pp. 453–454 (Elsevier, New York 1957).
26. MOORE, T. and WANG, Y.L.: Hypervitaminosis A. *Biochem. J. 39:* 222–228 (1945).
27. NIELSEN, S.W.; MILLS, J.H.L.; ROUSSEAU, J.E. and WOELFEL, C.G.: Parotid duct metaplasia in marginal bovine vitamin A deficiency. *Amer. J. vet. Res.* In press (1965).
28. PEASE, C.N.: Focal retardation and arrestment of growth or bones due to vitamin A intoxication. *J. amer. med. Ass. 182:* 980–985 (1962).
29. RIGDON, R.H.; RUDE, J.C. and BIERI, J.C.: The effect of hypervitaminosis A and hypovitaminosis A on the skeleton of a duck. *A.M.A. Arch. Path. 32:* 299–314 (1951).
30. RINEBERG, I.E. and GROSS, R.J.: Hypervitaminosis A with infantile cortical hyperostosis. *J. amer. med. Ass. 146:* 1222–1225 (1951).
31. RODAHL, K.: The toxic effect of polar bear liver. *Skrifter No. 92, Norsk Polarinstitutt*, Oslo, Norway (1949).
32. RODAHL, K.: Hypervitaminosis A – A study of the effect of vitamin A in experimental animals. *Skrifter No. 95, Norsk Polarinstitutt*, Oslo Norway (1950).

33. SULZBERGER, M.B. and LAZAR, M.P.: Hypervitaminosis A: Report of a case in an adult. *J. amer. med. Ass. 146:* 788–793 (1951).
34. TAKAHASHI, K.; NAKAMIYA, Z.; KAWAKIMI, K. and KITASATO, T.: Physical and chemical properties of biosterin (fat-soluble vitamin A) and its physiological significance. *Inst. Physical Chem. Res. (Tokyo) 3:* 81–148 (1925).
35. THOMAS, L.; MCCLUSKEY, R.T.; POTTER, J.L. and WEISSMAN, G.: Comparison of the effects of papain and vitamin A on cartilage. I. The effect in rabbits. *J. exp. Med. 111:* 705–718 (1960).
36. TOOMEY, J.A. and MORISSETTE, R.A.: Hypervitaminosis A. *Amer. J. Dis. Child. 73:* 473–480 (1947).
37. WOLBACH, S.B.: Vitamin A deficiency and excess in relation to skeletal growth. *J. Bone Jt Surg. 29:* 171–192 (1947).
38. WOLBACH, S.B. and HEGSTED, D.M.: Hypervitaminosis A and the skeleton of growing chicks. *A.M.A. Arch. Path. 54:* 30–38 (1952).
39. WOLBACH, S.B. and HEGSTED, D.M.: Hypervitaminosis in young ducks. *A.M.A. Arch. Path. 55:* 47–54 (1953).
40. WOODARD, W.K.; MILLER, L.J. and LEGART, O.: Acute and chronic hypervitaminosis A in a 4-month-old infant. *J. Pediat. 59:* 260–264 (1961).
41. YPSILANTI, H.: Über den Einfluss des Vitamin A auf die weisse Maus. *Klin. Wschr. 14:* 90–91 (1935) [Original not seen. Cited by: BARNICOT, N.A. and DATTA, S.: Vitamin A and bone. *In:* Biochemistry and Physiology of Bone (G.H. BOURNE, ed.) pp. 507–538 (Academic Press, New York 1956)].

Author's address: Dr. R.M. GREY, Institute of Comparative Medicine, College of Physicians and Surgeons, Columbia University, *New York 32*, N.Y. (U.S.A.).