MONOGRAPH

ON

VITAMIN A

C32

#78 vol. VI

C 32

M O N O G R A P H

O N

V I T A M I N A

Volume 6

TR-72-1552-65

Submitted Under:
Contract No. FDA 74-104

January 31, 1975

INFORMATICS INC.
6000 Executive Boulevard
Rockville, Maryland 20852

Ahuja-'73
Bib No. 10188

Reproduced by permission
of the copyright owner

EFFECT OF HYPERVITAMINOSIS A ON BRAIN PHOSPHOLIPIDS

H. C. Ahuja and U. K. Misra

Department of Radioisotopes and Biochemistry
Vallabhbhai Patel Chest Institute
University of Delhi, Delhi, India

ABSTRACT

The quantitative response of adult brain phospholipids to oral administration of 33 mg of retinol daily for nine days has been studied. The amounts of brain total phospholipids were not affected. However, individual components viz. phosphatidyl choline, phosphatidyl ethanolamine, phosphatidyl serine, phosphatidyl inositol, phosphatidic acid, polyglycerol phosphatide and sphingomyelin showed an initial decrease which continued for a period of 4-5 days after retinol administration, and thereafter showed a peak concentration between 5-7 days, which then decreased.

INTRODUCTION

It has long been known that excessive intake of vitamin A for prolonged periods produces various toxic symptoms and effects lipid metabolism of various organs (1-3). One of the characteristic symptoms of vitamin A toxicity in experimental animals is increased cerebrospinal fluid pressure (4,5). However, no studies on the effect of hypervitaminosis A on brain phospholipids have been made. This communication presents the results on the effects of oral feeding of retinol from one to nine days on brain phospholipids of rats.

MATERIALS AND METHODS

Male rats of the Wistar strain weighing 110 g from our Institute maintained colony were divided in two groups of 18 (group A) and 54 (group B) rats each. To group B animals 33 mg of retinol (Hoffman La Roche, Bombay) in groundnut oil was given orally daily for a period of nine days. Rats of group A served as controls and were given only the vehicle solution. Six rats in group A were killed on the 2nd, 5th and 9th day of the experimental period. Six rats in group B were killed daily from the 2nd to 9th day. Immediately after the sacrifice, the brain was removed, dipped in ice cold saline, wiped lightly and weighed. Total lipids from brain were isolated and purified as described earlier (2,3). The final solutions of brain lipids were made in a known volume of chloroform and stored at -20° C until used for analysis. Brain lipids were assayed for total lipids (gravimetrically), total cholesterol (6), retinol (7)

and phospholipids (8). The fractionation of brain phospholipids into individual fractions was achieved by thin layer chromatography (TLC)(9).

RESULTS AND DISCUSSION

Oral administration of 33 mg of retinol daily for nine days did not affect the total brain weight, total lipids, total cholesterol, phospholipids and glycerides on a unit wet weight basis as compared to controls. These data are collected in Table I. However, changes are observed in these constituents when results are expressed on a body weight basis. These changes can be attributed to a drastic reduction in the body weight of rats during the course of retinol feeding. The results further show that the effects of experimental manipulations on brain lipids are less pronounced after the process of brain maturation is nearly complete. Though brain total phospholipids did not show any significant change during the course of feeding retinol, the brain phospholipid components viz. phosphatidyl choline (PC), phosphatidyl ethanolamine (PE), phosphatidyl serine (PS), sphingomyelin (SPH), phosphatidyl inositol (PI) and phosphatidic acid (PA) and polyglycerol phosphatide (PGP) showed marked changes (Figures 1-3). Both phosphatidyl choline and phosphatidyl ethanolamine increased on the 2nd day after retinol feeding, then gradually decreased till the 5th day and thereafter both PC and PE showed an increase which reached a peak on the 7th day and than again their amounts decreased reaching the control values. Similar trends were observed in the amounts of PS, SPH, PI and PA+PGP. However, the period of peak attainment of these phospholipids was different viz. the 5th day for SPH, the 6th day for PS and PI and the 7th day for PA + PGP after retinol feeding.

The effects of various experimental manipulations on brain lipids have been shown to be related to its stages of maturation (10). Thus these effects would be more pronounced during the developmental stages of brain, i.e. during the first 23 days after birth, when the metabolic reactions in brain are at a peak; thereafter, the brain lipids should not be affected by such experimental manipulations. Therefore, the results obtained on the above reported behavior of major phospholipids of adult brain in response to administration of toxic doses of retinol are interesting but remain unexplained. The principal components of myelin sheath are plasmalogens, sphingomyelin, cerebrosides, sulphatides,diphosphoinositides, non-esterified cholesterol and proteolipids (10,11). Myelin is produced by Schwann cells, since in nerve degeneration, there is a rapid proliferation of Schwann cells which is also accompanied by rapid labelling of phospholipids and cholesterol from their respective labelled precursors (12). There is sufficient experimental evidence to show that once deposited in myelin, the myelin lipids are metabolically inert. However, on the basis of metabolic turnover it seems likely that the lipids of the nervous system may be divided

Table I

EFFECT OF FEEDING 33 mg OF RETINOL DAILY FOR NINE DAYS ON BRAIN LIPIDS OF RATS

	No. of Animals	Brain Weight	Total Lipids	Total Phospholipids	Total Cholesterol	Total Glycerides
				mg/g wet tissue		
Group A (control)	18	1.41 ± 0.026	67.97 ± 1.45	47.56 ± 0.78	12.25 ± 0.27	9.11 ± 1.06
Group B (days of retinol feeding) 2 days	6	1.39 ± 0.08	69.22 ± 3.21	50.59 ± 0.42	11.90 ± 0.52	10.99 ± 1.10
3 days	6	1.32 ± 0.06	68.02 ± 4.91	47.84 ± 4.43	12.21 ± 1.50	13.38 ± 1.20
4 days	6	1.37 ± 0.01	67.25 ± 0.67	45.10 ± 0.65	11.19 ± 0.17	10.92 ± 0.35
5 days	6	1.25 ±0.08	70.11 ± 1.53	46.65 ± 1.53	11.03 ± 0.40	12.44 ± 1.90
6 days	6	1.38 ± 0.01	66.36 ±10.79	47.01 ± 4.86	11.69 ± 0.86	10.87 ± 2.39
7 days	6	1.39 ± 0.04	68.69 ± 0.27	47.73 ± 0.13	11.70 ± 0.80	9.19 ± 0.20
8 days	6	1.42 ± 0.03	67.23 ± 0.24	47.61 ± 0.41	11.92 ± 0.13	7.65 ± 0.60
9 days	6	1.31 ± 0.07	67.95 ± 0.35	44.71 ± 1.22	11.64 ± 0.30	11.10 ± 0.65

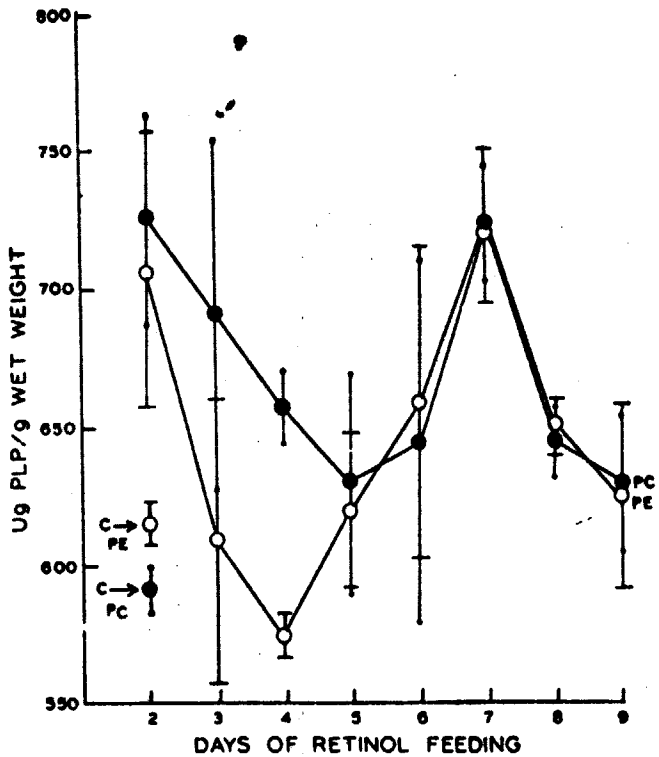

Figure 1. Effect of retinal feeding on some brain phospholipid components. PC = phosphatidyl choline; PE = phosphatidyl ethanolamine.

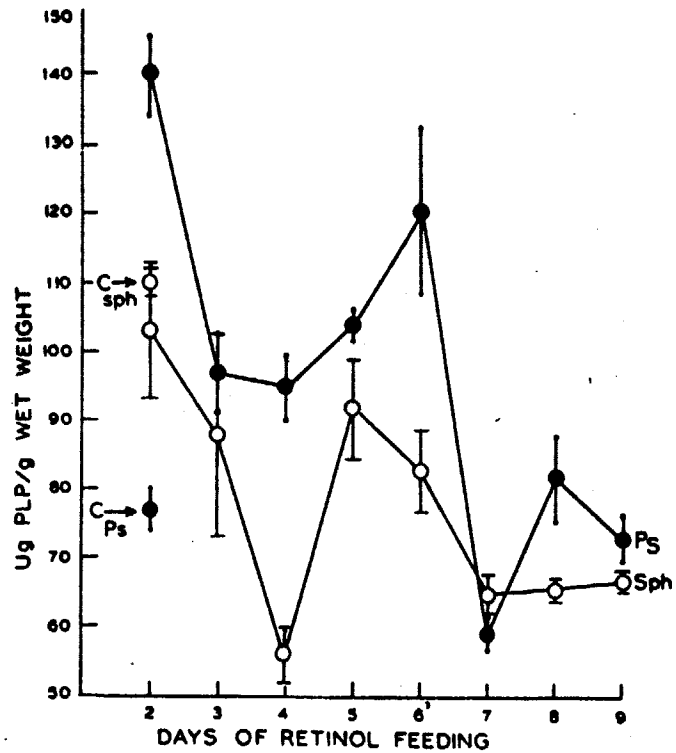

Figure 2. Effect of retinal feeding on some brain phospholipid components. Sph = sphingomyelin; PS = phosphatidyl serine.

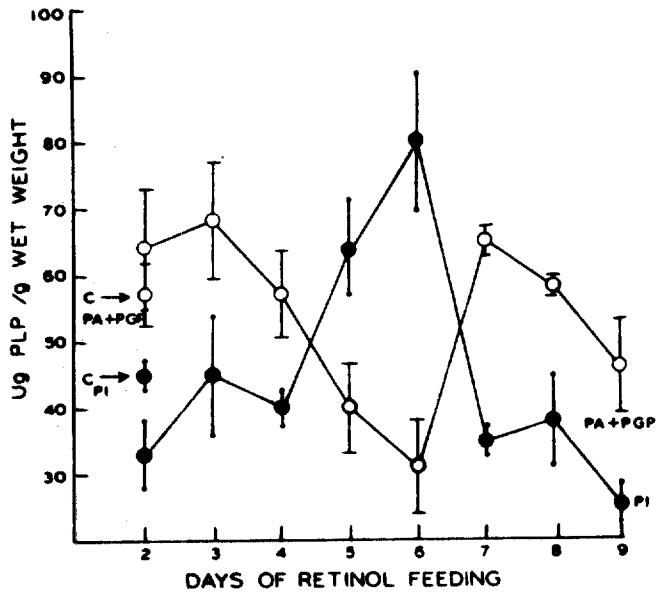

Figure 3. Effect of retinal feeding on some brain phospholipid components. PA + PGP = phosphatidic acid + polyglycerol phosphatide; PI = phosphatidyl inositol.

into two components : one located largely in the white matter of brain, spinal cord and peripheral nerve that is relatively inert except during the period of myelination and one located largely in the grey matter of brain that has appreciable metabolic turnover (13). It is the latter component that is responsible for most of the lipid metabolism of adult brain. Since brain was not fractionated into various components, it is difficult to assign the exact locale of these changes, but it is very likely that these changes are occurring in the slowly turning over pool of brain lipids. The different periods of attainment of peak concentration after initial fall in their amounts of the phospholipids after retinol administration perhaps represent their different metabolic turnover rates. Further experiments are in progress to elucidate the metabolism of brain phospholipids of rats given toxic amounts of retinol.

ACKNOWLEDGEMENTS

The work was supported in part by the United States Department of Agriculture, Washington, D.C. (Grant No. A7-HN-22, project No. FG-In-357). We gratefully acknowledge the generosity of M/s Hoffman La Roche, Bombay, India for supplying the retinol used in this investigation.

REFERENCES

1. Misra, U.K., Lipid Metabolism in Hypervitaminosis A. Nature (London), 209, 910 (1966).

2. Misra, U.K., Liver Lipids of Rats Administered Excessive Amounts of Retinol. Canad. J. Biochem. 46, 697 (1968).

3. Misra, U.K., Effect of Intramuscular Administration of Retinol on Plasma Lipids of Rats. Agri. Biol. Chem. 32, 707 (1968).

4. Marie, J. and See, G. Acute Hypervitaminosis A of the Infant. Am. J. Dis. Child. 87, 731 (1954).

5. Morice, G. Jr., Havener, W.H. and Kapetansky, F. Vitamin A Intoxication as a Cause of Pseudotumor Cerebri. J. Am. Med. Assoc. 173, 1802 (1960).

6. Hanel, H.K. and Dam, H. Determination of Small Amounts of Total Cholesterol by the Tschugaeff Reaction With a Note on the Determination of Lanosterol. Acta. Chem. Scand. 9, 677 (1955).

7. Carr, F.H. and Price, E.A. Colour Reactions Attributed to Vitamin A. Biochem. J. 20, 497 (1926).

8. Marinetti, G.V., Chromatographic Separation, Identification and Analysis of Phosphatides. J. Lipid Res., 3, 1 (1962).

9. Misra, U.K. A Note on the Phospholipid Estimation by Thin Layer Chromatography. Biochem. Biol. Sper. 8, 125 (1969).

10. Smith, M.E. The Metabolism of Myelin Lipids. Adv. Lipid Res. 5, 241 (1967).

11. McIlwain, H. Chemical and Enzymic MakeUp of the Brain During Development in Biochemistry of the Central Nervous System, J.A. Churchill, Ltd., London, p. 186-204 (1959).

12. Rossiter, R.J. The Chemistry of Wallerian Degeneration in Chemical Pathology of the Nervous System. (J. Folch, editor) Pergamon Press, London, p. 207-228 (1961).

13. Davidson, A. N. and Dobbing, J. Phospholipid Metabolism in Nervous Tissue. Biochem. J. 75, 565 (1960).

Received for publication: February 23, 1973.

J. of the Mount Sinai Hosp. 24:713-719. 1957.

Bass-'57
Bib No. 10233

THE RELATION OF VITAMIN A INTAKE TO CEREBROSPINAL FLUID PRESSURE: A REVIEW

MURRAY H. BASS, M.D.
New York, N. Y.

In this brief review I wish to call attention to the peculiar relationship between the intake of vitamin A and the cerebrospinal fluid pressure. Clinically this relationship is of particular interest to pediatricians as the condition of the fontanelle in the infant is so simple a guide in estimating intracranial fluid pressure, whereas in older individuals this pathological condition may be entirely overlooked. What makes a study of this relationship very fascinating is that increased pressure of the cerebrospinal fluid may appear both as a result of the intake of excessive amounts of vitamin A and also as a symptom of vitamin A deficiency.

INCREASED CEREBROSPINAL FLUID PRESSURE IN VITAMIN A DEFICIENCY

Vitamin A deficiency is not a commonly encountered condition in this country where the average diet includes milk which contains enough of the vitamin, rendering supplementation unnecessary. However, with the increasing frequency of the diagnosis "milk allergy," many infants are kept on vitamin A free diets, and if vitamin addition is neglected, the symptoms of avitaminosis A may appear. These symptoms result in a bizarre clinical syndrome including the following signs:

Retardation of mental and physical growth.
Anemia with or without splenomegaly.
Tendency to infection (skin and respiratory tract).
Epithelial metaplasia
- In the eye: xerophthalmia and keratomalacia.
- In the urinary tract: hematuria.
- In the vagina: cornified epithelium.
- In the digestive and respiratory tracts.

Endocrine disturbance: gynecomastia.
Increased cerebrospinal pressure with markedly bulging fontanelle.
Cranial nerve injury: facial paralysis.

As long ago as 1933 Blackfan and Wolbach (1) in a clinical and pathologic study of vitamin A deficiency described a 6½ month infant, allergic to cow's milk, on a diet containing no vitamin A, who showed marked apathy and keratomalacia. "The neck was retracted and the sutures of the skull showed some separation." With vitamin A therapy, the infant recovered but remained blind. This is the first description of a human infant showing evidence of increased cerebrospinal fluid pressure due to vitamin A deficiency.

Cornfeld and Cooke (2) in 1952 and Bass and Caplan (3) in 1955 published cases of vitamin A deficiency including symptoms of markedly increased cere-

From the Department of Pediatrics, The Mount Sinai Hospital, New York, N. Y.

brospinal fluid pressure. The following is a brief summary of Bass and Caplan's case:

A previously healthy infant at the age of a month developed severe generalized eczema for which he was put on a soy bean preparation, receiving in addition vitamin D (Drisdol) and vitamin C. He developed slowly so that at five months he weighed only 11¾ pounds. At seven months in the course of a mild upper respiratory infection with slight fever, he developed hematuria, for which he was hospitalized. Examination revealed severe anemia (hemoglobin 6.7 gms.), numerous minute corneal ulcerations, lethargy and complete anorexia. On the eleventh day extreme bulging of the fontanelle was noted with nuchal rigidity and rise in temperature to 104.2 degrees. Lumbar tap revealed normal fluid which rapidly reaccumulated. Skull X-ray, subdural and intraventricular taps proved negative.

The combination of anemia, corneal ulcers, hematuria and acute hydrocephalus led to the diagnosis of vitamin A deficiency. It was learned that the child had had no other food but Mull Soy, banana, peaches and rice. Vitamin A in large doses was given by intramuscular injection with dramatic results. The symptoms rapidly disappeared and the child made an uneventful recovery and has remained well.

The publication of this case led to the discovery a few months later of a similar one in New Jersey in a colored infant, also on a soy bean milk without added vitamin A. Beside malnutrition and xerophthalmia there was present a markedly bulging fontanelle with radiographic evidence of wide separation of the cranial sutures such as one sees in hydrocephalus. The blood level of vitamin A was zero. As in the above mentioned case, the administration of vitamin A resulted in rapid recovery.

Bass and Caplan (4) also described the sudden appearance of a markedly bulging fontanelle in a deeply icteric infant with avitaminosis A due to proven congenital absence of the bile ducts. When vitamin A was given by intramuscular injection, the distention of the fontanelle disappeared.

It has long been known that in experimental animals a diet deficient in vitamin A may give rise to definite changes in the nervous system including increased cerebrospinal pressure and hydrocephalus. These changes were blamed on faulty bone formation with resultant pressure on nerve trunks or on the brain itself. Thus Wolbach and Bessie (5) reporting on experiments on young mammals in 1941 say "The nervous lesions of vitamin A deficiency are wholly of mechanical origin, the genesis of which is a disproportionate growth of the central nervous system in relation to the bone which surround it." Again in 1955 Wolbach & Hagsted (6) investigating the same subject in young chicks conclude that "The neurologic disturbances of vitamin A deficiency in the chick are the result wholly of compression of the central nervous system produced by retardation of growth of vertebrae and bones of the cranium."

Sir Edward Mellanby (7) whose researches on this subject began as long ago as 1926, reviewed his findings in 1950. He was not quite as dogmatic about the neurologic disturbances, concluding that most of the degeneration could be ascribed to the fact that "a function of the vitamin A moiety was to control the activity of osteoblasts and osteoclasts, so that in its absence from the body, the bones were thickened and altered in shape, and that the incoordination was in fact, due largely, if not entirely, to the pressure on the nervous system of the thickened bone."

However, some investigators dealing with animals, long ago suspected that defects in bone growth might not be the sole cause of neurological disturbance. Moore (8) and his collaborators working with calves, wrote in 1935 "It seems doubtful that vitamin A could be concerned with such bone malformations as in the cases reported in this paper, but such an explanation might be plausible if the absence of vitamin A in some indirect way, raised the intracranial pressure." Again in 1939 he states "Vitamin A may possibly function to regulate intracranial pressure," and in 1940 (10) he concludes from further studies "A deficiency of vitamin A in the ration of the young bovine produces an increased cerebrospinal fluid pressure."

Recently considerable light has been thrown on this subject by the carefully controlled work of Millen (11) and his collaborators in England. Their papers deal directly with hydrocephalus due to experimental hypovitaminosis A. They have produced hydrocephalus in a very large percentage of the offspring of female rabbits kept for a long period on vitamin A free diet. The longer the animal was kept on this diet, the greater was the number of offspring with hydrocephalus. Their work shows that in the rabbit the increased intracranial pressure is definitely not dependent on abnormal bone formation. They say "The hypothesis that the primary factor in the pathogenesis of the condition is an overproduction of cerebrospinal fluid (Millen and others, 1954) receives additional corroboration from the result of the present experiments." They quote experiments by others in which increased pressure in vitamin A deficient animals rapidly falls after the restoration of the vitamin. "Indeed so sensitive to vitamin A deficiency is the cerebrospinal pressure that Sorensen (12) and others (1954) suggest it may be used as a guide to the onset of deficiency."

The same conclusion is reached by Rokkones (13) who in 1955 published studies on the offspring of vitamin A deficient rats. He concludes that "A rise in the cerebrospinal pressure appears to be the most characteristic and sensible symptom of the disease. It is demonstrable already before the occurrence of hydrocephalus and before the animals show visible symptoms."

The results of these recent animal experiments account very well for the findings in the vitamin deficient infants, for it would be impossible to explain the rapid disappearance of symptoms and signs of increased cerebrospinal fluid pressure when vitamin A was given, if they were due entirely to defective bone formation.

INCREASED INTRACRANIAL PRESSURE AND ACUTE HYPERVITAMINOSIS A

In 1951 Julien Marie and Georges See (14) published a report of three infants who, after the ingestion of a single huge dose of vitamins A and D, responded after twelve hours with extreme bulging of the fontanelle, lasting twelve to twenty-four hours. The vitamins were in the form of a preparation known as Vitadone forte which contained 350,000 units of vitamin A and 300,000 units of vitamin D. The infants twelve to twenty-four hours after ingestion usually vomited and showed restlessness, discomfort, insomnia or drowsiness. Believing that these symptoms were due to the vitamin A and not to vitamin D, authors gave a number of infants large doses of vitamin A alone (350,000 units) and were

able to reproduce this transitory bulging fontanelle in three of six infants. Spinal tap in these cases showed an increase in fluid pressure. The cytology and chemistry of the fluid was normal. Blood pressure remained normal. Vitamin A content of the blood rose to many times the normal but then fell rapidly as the symptoms disappeared. No vitamin A was demonstrable in the spinal fluid. They were unable to produce the syndrome when synthetic vitamin A was used instead of the natural vitamin, nor could they reproduce it with the subcutaneous injection of 60,000–90,000 units of natural vitamin A. The authors were able to reproduce the bulging fontanelle in some of the young puppies used as experimental animals.

Their conclusion reads (15) "Our clinical observations and our work on infants and animals convinces us that the acute hydrocephalus, with intensive bulge of the fontanelle, produced by the rapid absorption of vitamin A is a transitory and harmless disorder in both its immediate and its remote prognosis."

In the past five years this syndrome in infants has been reported by numerous authors from different countries. In one case it resulted from a preparation of vitamin A used as nose drops.

In this connection it is of interest to note that, especially in the Arctic regions, acute vitamin A poisoning in adults is not unknown. It occurs from ingestion of seal or polar bear liver which contains enormous quantities of the vitamin. One of the chief complaints in this illness is particularly violent headache accompanied by dizziness and somnolence. As pointed out by Knudsen and Rothman, (16) these symptoms may very well be due to increased intracranial pressure.

In contradistinction to acute poisoning from single large doses of vitamin A, there are now many reports of chronic hypervitaminosis A due to the prolonged use of excessive amounts of the vitamin. Such cases usually reveal symptoms due to lesions in the osseous system and only very rarely present neurological manifestations. However, two cases have been reported where infants with chronic poisoning showed signs of increased intracranial pressure (Gribetz (17) and Arena (18)).

A curious case was reported by Ehrengut (19) in 1955:

A five month old infant who had been on a soy bean milk without vitamin supplement since the age of three weeks developed keratomalacia, pustular skin lesions and gynecomastia. Avitaminosis A was diagnosed and 187,000 units of vitamin A was given in two days. This was followed by the appearance of very marked bulging of the fontanelle. Spinal fluid was found to be normal but under very high pressure. Vitamin A was stopped and the fontanelle returned to normal. Several days later 44,000 units of vitamin A was given by mouth with return of the bulging fontanelle. When the vitamin was discontinued the fontanelle again returned to normal in two days. The author considers the case one of acute hypervitaminosis A (Marie-See Syndrome) resulting from excessive intake of vitamin in attempting to cure symptoms due to prolonged vitamin A deficiency.

Just as we have seen hydrocephalus produced experimentally in litters of animals kept on a vitamin A deficient diet, so, curiously enough, hydrocephalus has also been produced in the offspring of rats fed *excessive* amounts of the same

vitamin (Cohlan-20). In other words hydrocephalus may result in experimental animals and in human infants both in *hypo* and *hyper*vitaminosis A.

Apparently this paradox may also be found in symptoms referable to the eyes of pigeons. Under the title "Avitaminose et hypervitaminose A du pigeon. Identité de leur semeiologie oculaire," Mouriquand (21) and his collaborators point out that the pigeon needs very little vitamin A in contradistinction to the rat, which very early shows signs of deprivation. In pigeons even as long as 300 or 400 days of deprivation, symptoms disappear very quickly when small doses are given. Both the loss of periocular feathers, resulting in the so-called "spectacle" appearance and changes in the eye itself occur in both hypo and hypervitaminosis A.

DISCUSSION

From the foregoing I believe we can definitely state that increased cerebrospinal pressure may occur both in overdosage as well as deficiency of vitamin A in infants and young animals. There is apparently in both conditions a defect in the production or absorption of cerebrospinal fluid. There are more published reports of human infants with bulging fontanelles due to acute hypervitaminosis A than to vitamin A deficiency. Most, though not all have been on some form of soy bean preparation. Mellanby (21) in 1931 postulated from work on puppies that vitamin A might be important in preventing damage to the nervous system by toxins derived from cereal grains fed to the animals. One can only speculate as to whether such a relationship might exist in some of the human infants deprived of vitamin A and fed on preparations made from soy bean.

That the ingestion of certain chemical substances may result in increased cerebrospinal pressure is emphasized by the recent observation of Gellis that "A bulging fontanelle may accompany antibiotic therapy. In these instances the bulging fontanelle was apparently directly related to antibiotic therapy and not to infection present; subsequently when the same children were tested with the same antibiotics at times when they were free of infection, the fontanelle could again be made to bulge during course of therapy and would promptly subside within twenty-four hours after antibiotics were discontinued. This has been seen most frequently with aureomycin." (23)

It is also strange that in reports in vitamin A deficient children in China, where this condition is common, no mention is made of hydrocephalus as one of its symptoms. Thus Sweet and K'Ang (24), in 1935 published a clinical and anatomical study of avitaminosis A in 203 Chinese infants, with seventeen autopsies and twenty two biopsies. No mention is made of the finding of hydrocephalus either clinically or at post-mortem. However, the authors do mention headache as a late symptom in cases with severe ocular lesions. The headache was "Sharp, piercing and difficult to control." There were also convulsions in four cases but no lesions were found in any of the cases to explain them.

It remains hard to explain why we see hydrocephalus in vitamin A deficiency in America and not in China where dietary deficiency is so widespread. The possibility of a second factor must be kept in mind.

Bicknell and Prescott (25) in their book on "The Vitamins in Medicine" make this relevant comment. "In man no neurological symptoms are generally associated with those conditions, such as keratomalacia, where they would be expected if the central nervous system were affected by vitamin A. There is however, the possibility that in man, as in animals, the degeneration gives such tardy symptoms that they seldom occur before the deficiency has been remedied or death occurs, unless degeneration is accompanied by a second deficiency."

To sum up we can only say that up to the present time we have no adequate explanation for our clinical findings in infants. Symptoms referable to the nervous system in vitamin A deficiency are more common than has been previously believed and the pediatrician should keep this condition in mind when signs of unexplained acute hydrocephalus are encountered.

The problem of the cause of hydrocephalus in hypo and hypervitaminosis A is a challenging one and its solution awaits further clinical and laboratory investigation.

ACKNOWLEDGMENT

We are indebted to Dr. David Adlersberg of The Mount Sinai Hospital in New York City, for the vitamin A determination.

REFERENCES

1. Blackfan, K. D., and Wolbach, S. B.: Vitamin A Deficiency in Infants: Clinical and Pathological Study. J. Pediatr. 3: 679, 1933.
2. Cornfeld, David, and Cooke, Robert E.: Vitamin A Deficiency: Case report: Unusual Manifestations in a 5½ month old Baby. Pediatrics. 10: 33, 1952.
3. Bass, M. H., and Caplan, J.: Vitamin A Deficiency in Infancy: J. Pediat. 47: 690, 1955.
4. Loc. cit.
5. Wolbach, S. B., and Bessie, O. A.: Vitamin A deficiency and the Nervous System. Arch. Path. 32: 689, 1941.
6. Wolbach, S. B., and Hagsted, D. Mark: Vitamin A Deficiency in the Chick. Arch. Path. 54: 13, 1952.
7. Mellanby, Sir Edward: A story of nutritional research: The Effect of some Dietary Factors on Bones and the Nervous System. Baltimore, 1950, Williams and Wilkens Co.
8. Moore, L. A., Huffman, C. F. and Duncan, C. W.: J. Nutrition. 9: 533, 1935.
9. Moore, L. A.: J. Nutrition. 17: 443, 1939.
10. Moore, L. A., and Sykes, J. F.: Cerebrospinal Fluid Pressure and Vitamin A Deficiency. Amer. J. Physiol. 130: 684, 1940.
11. Millen, J. W., Woollam, D. H. M. and Lanning, G. E.: Hydrocephalus associated with Deficiency of Vitamin A: Lancet II: 1234, 1953, and II: 679, 1954.
12. Sorensen, D. K., Kowalczyk, T. and Hentges, J. F.: Amer. J. Veterah Res. 15: 258, 1954.
13. Rokkonks, T.: Experimental Hydrocephalus in young Rats: Internationale Zeitschr. fur Vitaminforschung. XXVI: 1, 1955.
14. Marie, J., and See, G.: Hydrocephalie aigue benigne du nourrisson après digestion d'une dose massive et unique de vitamines A et D.: Arch. Français Pediat. 8: 563, 1951.
15. Marie, J., and See, G.: Acute Vitaminosis A of the Infant., Amer. J. Dis. Child. 87: 731, 1954.

16. Knudsen, A. G., and Rothman, P. E.: Hypervitaminosis A.: Amer. J. Dis. Child. 85: 316, 1953.

17. Gribetz, D., Silverman, S. H. and Sobel, A. E.: Vitamin A Poisoning., Pediatrics. 7: 372, 1951.

18. Arena, J. M., Sarazen, P. and Baylin, G. J.: Hypervitaminosis A.: Report of an Unusual Case with Marked Craniotabes. Pediatrics. 8: 788, 1951.

19. Ehrengut, W.: Akuter benigner Hydrocephalus durch Hypervitaminosis A (Syndrome Marie See) bei Keratomalacie. Zeitschr. fur Kinderheil. 77: 468, 1955.

20. Cohlan, S. Q.: Congenital Anomalies in the Rat Produced by Excessive Intake of Vitamin A during Pregnancy. Pediatrics. 13: 556, 1954.

21. Mourquand, G., Roblet, J., Edel, V. and Chighozola, R.: Avitaminose et Hypervitaminose A du pigeon. Identite de leur semeiologie oculaire: Comptes Rend. des Seances Acad. Sc. 241: 348, 1955.

22. Mellanby, Sir Edward: The Experimental Production and Prevention of Degeneration in the Spinal Cord. Brain. 54: 247, 1931.

23. Gellis, S.: Personal communication.

24. Sweet, L. K., and K'ang, H. J.: Clinical and Anatomic Study of Avitaminosis A among the Chinese. Amer. J. Dis. Child. 50: 699, 1935.

25. Bicknell, F., and Prescott, F.: The Vitamins in Medicine. 3rd. edition, London, W. Heineman, 1953. p. 75.

From the Pathological Institute of the University of Munich
Director: Professor Dr. M. Eder

Bayerle-'73
Bib No. 10238
Reproduced by permission of the copyright owner

FINDINGS IN SERUM AND LIVER FOLLOWING MEGADOSES OF VITAMIN A

By H. Bayerle, P. Meister and H. Wolff

The therapeutic application of vitamin A in very high quantities has recently caused considerable sensation and lively discussions. The application took place, primarily in malignomes, especially in plate epithelial carcinomas, and moreover in dermatoses, for example psoriasis - and ichthiosis cases (1,2,3). The dosages applied with these indications, exceed the individual dosages used to date. For this reason the designations "maximum dosage", "megadoses", "sub-toxic quantities" are also used here. It is known that 50,000 I.U. per day in adults are also dispensed over a longer period. In experiments by Hoefer-Janker and co-workers (1), Ahumada (2) and Luger (3) daily doses, for example, beginning with 150,000 I.U., and increasing to 900,000 I.U. are proposed, or are distributed over 10 days up to 20 million I.U. In older literature (4) one finds references to biochemical changes caused by vitamin A which effect the lipid metabolism. They were evaluated as hypervitaminoses A. Relationships resulted between vitamin administration and lipid content of livers and other organs, and moreover between plasma cholesterol from arterial sclerosis and vitamin A administration. It could not be explained, whether the vitamin influences the lipid metabolism directly or through non- specific reactions. The therapy results, that undoubtedly could be evaluated as positive on the one hand, but on the other hand not excluding the undesired side effects, were indicative, to seek pharmacodynamic effects in animal experiments on rats from the point of view of quantitative relations between serum-chemical and organ changes.

Material and Methods

Female rats of the Sprague-Dawley strain with average weights of 280 g were treated with emulsified vitamin A- palmitate in maximum dosages, using a probang, and were examined at differential time intervals following the last administration. A commercial preparation was used as a vitamin preparation. Plant oils serve as emulsifiers in this preparation and as gum-arabic stabilizer. It could be shown that the vitamin in this preparation is more resorbable even in greater amounts. After administration even of maximum doses (maximum up to ca. 2 mill. I.U.) our animals were inconspicuous in their vitality and external appearance. Especially no changes appeared in their fur and no spontaneous fractures appeared.

The animals were anesthesized with ether for obtaining serum and in the shortest possible time sufficient quantities of blood were taken from the vena cava inferior near the junction of the vena renalis, and were subsequently drained of blood. After killing, the organs were examined, and the liver, which microscopically appeared changed macroscopically in the sense of fat accumulation, was examined histologically. Fat staining, H-E- and van Gieson staining were undertaken. First the livers were weighed and the total weight of the animals was determined. Untreated animals were examined for comparison, ~~moreover~~ as well as those ~~emulsions~~ animals which were administered emulsions without vitamin A.

The following chemical investigations were undertaken:

Arzneim-Forsch. (Drug Res.) 23, Nr. 8 (1973) Bayerle et al - Vitamin A
p 1082-85

1. Ferments for liver function tests specifically : GOT, GPT, LDH, lipase and LAP. The ferment determinations followed according to the usual routine methods.
2. Lipid status in serum.
   Total lipids: method by Zoellner and Kirsch (5)
   Total cholesterol: method by Watson, Leffler and Zak (6)
   Neutral fats: method by Eggstein, Kreutz, and Schmidt (7)
   Phosphatides: method by Zoellner and Eberhagen (8)
   β- Lipoprotides: method by Watson (9)
   Free fatty acids: method by Duncombe (10)
3. Albumin electrophoresis and total albumin. Electrophoresis with acetate foil at 200 V - running time 2 hrs., albumin by Biuret.
4. In some animal series, the clotting status was also determined, namely fibrin, trypsin, fibrinolis (as euglobulinlysis test), recalcification time, whole blood clotting time and retraction. The experimental data are mentioned in the text.

Results

With respect to lipid status, which showed results that deviated maximally from the standard, the following may be concluded:

a) A pronounced hyperlipemia that lasts several weeks, even after settling of the administrations. The values of individual (single) components, eg. of β- lipoprotides run parallel. Here it is to be considered, that the stored vitamin A is involved in the quantity increase of the total lipids. However, the vitamin - A content of the serum is not determined in the method of lipid determination used here.
b) A hyperlipemia, around 3-5 times that of the standard, which is still clearly pronounced at least one month later. A proteolitical ferment mixture administered simultaneously with the vitamin A, effects a decrease of the triglyceride level.
c) A significant hyperphosphatidemia is likewise demonstrable for a longer period after settling of the preparation.
d) A hypercholesteremia, that first of all is not yet clearly pronounced, i.e. on examination immediately after administration, and which first becomes marked 4 weeks after the last administration.
e) The free fatty acids show a characteristic exception in contrast to the just described increases of the individual substances. A decrease in the level in the treated animals is clearly pronounced in every case in comparison to the standard values.

In ferments the SGOT shows a doubling of the activity in chronic administration. After administration of maximum doses for short periods, the activity increase is less pronounced. Indications may be present here pointing to low-grade parenchymal changes. Due to technical reasons only the SGOT could be tested systematically. A valuation is difficult for LDH in conjunction with the treatment, since in the case of rats, the standard values are greatly scattered according to our experiences. We could only undertake SGPT - determinations in a series of animals, that were treated with neutral emulsions (blank value). It was asserted elsewhere, that also the administration of vitamin A- free neutral emulsions show serum changes. Other enzyme investigations, as e.g. the triglyceride lipase or the plasma trypsin and the LAP (leucinamino-peptidase) show no deviation from the standard in the experimental stages chosen by us; clotting status, as measured on recalcification- and native blood clotting time also did not show deviation from the average. This, however, does not prove, that in the range of the tissue-bound enzymes, changes are not to be counted on.

The total albumin of the serum was clearly decreased even if not considerably decreased, after administration of the maximum amount of vitamin

A according to examination undetaken immediately. Here, too, the return to the standard follows slowly. In chronic administration of small individual doses, corresponding however, to the maximum when totaled, no changes are noticed. The fibrinogen is subjected to fluctuations in its amount, that cannot be related to treatment. In the albumin electrophoreses, shifts in the α_1 - fraction showed; ~~that~~ percentwise increases considerably. This fraction is noticeably higher in our rats in the average case, than in humans. The gamma fraction might also be included in the shift.

Organ Findings

From the organs of animals treated with vitamin A, the liver is clearly enlarged in weight and volume. The weight increase concerns water-content and material contents. The livers are more or less clay-colored. A fragility, that is shown even in the histological-technical preparation is also noteworthy. To date, we have not systematically undertaken a chemical analysis of the changed livers. After preliminary experiments especially deviations are to be expected in the lipid sector, but also the enzymatic activity of the organ extracts may also be changed in the acute stage. We are in the process of working on appropriate questions. In the histological valuation it was attempted to recognize quantitative relationships between serum-chemical reactions and the degree of liver change. An inventory is involved, in which the condition of the liver after maximum dosage, following chronic administration of the total amount and standardization of the chemical serum values, is described.

The result of the histological investigations can be summarized as follows: (Figures 11 and 12)

a) In all experimental series vacuolar fatty changes of hepatocytes and Kupffer cells ranging from the very finest to the small are generally shown as the first form of reaction of the liver.
b) The percentage component of the number of fatty hepatocytes increases with increasing dose.
c) In the livers of animal series, that were investigated after a short, treatment-free interval, the greater increase of the component of fatty Kupffer cells in comparison to the fatty hepatocytes is impressive.
d) The percentage component of the number of fatty hepatocytes decreases with increasing treatment-free interval.
e) The percentage increase of the number of fatty Kupffer cells is not so obviously dose-dependent. Here the total time which elapsed since start of treatment, appears to be of greater significance.
f) The development of sinusoidal collage fibers as a possible expression of toxic-nutritive liver damage was generally small. It was most frequent and clearest in the series with high vitamin A dose and after longer treatment-free interval.
g) Necrotic ranges or changes in the liver structure were not observed. The Kupffer cells are frequently enlarged. The bile passages show no changes.
h) No changes are recognized in the animals treated with neutral emulsion. A more detailed presentation is given in the dissertation by H. Wolff.

Discussion

These investigations give indications to pharmaco-dynamic effects of vitamin A, but permit only explanations with reference to therapy results in dermatoses and malignomas. The temporarily demonstrable lipid storage, or vacuolar fatty changes in hepatocytes and Kupffer cells and lipid diffusion in serum are presumably an expression for mobilization of the lipids and/or for a disturbed relationship of lipid synthesis and decomposition.

It is assumed, that as a result of the maximum dose of vitamin A, changes in cell membranes result, and as a consequence thereof diffusion of lysosomal ferments, as a consequence of which damaged tissue decomposes. Papers by Dingle and co-workers (11), Riecker, Goessner and Pearce (12) discuss this. On the other hand, notions exist on relationships with cellular-immunological processes. It will be important and interesting, to set up a material balance of the livers of vitamin A treated animals and to place them in relation to the serum findings with simultaneous coordination with histology. One question is the suitability of the animal species. Side effects, other than the ones described were not found in our experiments with rats. On the other hand analogies to human results exist, because in the serum of treated patients, lipid-factors and transaminases activity can be reversibly raised (3). With respect to the therapy experiments, the observation that, in the experimental animal, fibroses as a permanent condition were not recognizable, and thus certain risk factors are excluded, may be of great significance. The therapy experiments in humans ~~are~~ certainly do not eliminate simple vitamin deficiency phenomena; this is why it was correct, when in general medical practice, misgivings existed against their application. However, since these in the mean time have apparently been widely limited (13), it is justifiable to continue serious experiments in the treatment of conditions, difficult to cure, even when undesired side effects influence treatment.

Figure 1: triglycerides
Figure 2: total lipids
Figure 3: β- lipoprotides
Figure 4: cholesterol
Figure 5: free fatty acids
Figure 6: phosphatides
Figure 7: total albumin
Figure 8: liver weight in % of total weight
Figure 9: GOT
Figure 1o: GPT

=N =L =1 =2 =3 =4

explanation of N,L, and 1-4 (see legend).

Figure 1-10: Every bar corresponds to specific kind of treatment and contains the average values of the respective animal series of the analyses data obtained. N: normal rats. L: neutral emulsion. 1: 5 X 100,000 I.U. vitamin A: administered daily; total amount: 500,000 I.U.; immediately examined subsequently. 2: 51 X 30,000 I.U. vitamin A; administered every second day; total amount: 1.53 mill. I.U.; immediately examined subsequently. 3: 10 X 30,000 I.U. vitamin A; administered daily; then 45 X 30,000 I.U.; administered every 2nd day; total amount; 1.65 mill. I.U. ; immediately examined subsequently. (From time to time additional 200 mg α proteolytic ferment mixture was administered in this experiment) /trademark "Wobe"/ 4: 5 X 100,000 I.U. vitamin A and 20 X 50,000 I.U. vitamin A; administered daily; total amount: 1.5 mill. I.U.; examined 42 days after the last administration.

Figure 11: (liver) After administration of 500,000 I.U. vitaminA - 100,000 I.U. administered daily- investigated immediately. Moderate fat deposits (sudanophillic material in black) primarily in the Kupffer cells. Enlargement: 250 X -- Sudan stain.

Figure 12: (liver) After administration of 2 mill. I.U. vitamin A - 27 X 75,000 I.U. administered - one month suspension. Pronounced fat deposit in Kupffer-and-liver cells. Enlargement: 250 X -- Sudan stain.

Bayerle-'73
Bib No. 10238
Reproduced by permission
of the copyright owner

Ar zneim. -Forsch. 23(8);1082-1085. 1973.

Aus dem Pathologischen Institut der Universität München; Direktor: Professor Dr. M. Eder

Serum- und Leberbefunde bei Vitamin A-Megadosen

Von H. Bayerle, P. Meister und H. Wolff

Die therapeutische Anwendung von Vitamin A in sehr hohen Mengen hat in letzter Zeit beträchtliches Aufsehen erregt und lebhafte Diskussionen ausgelöst. Die Anwendung erfolgte vor allem bei Malignomen, besonders bei Plattenepithelkarzinomen, ferner bei Dermatosen, z. B. Psoriasis- und Ichthiosisfällen [1, 2, 3]. Die bei diesen Indikationen verwendeten Dosierungen gehen weit über die bisher bekannten Einzeldosierungen hinaus. Aus diesem Grunde wird auch hier von „Höchstdosierung", „Megadosen", „subtoxischen Mengen" gesprochen. So ist bekannt, daß 50 000 I.E. pro Tag bei erwachsenen Menschen auch über längere Zeit verabreicht werden. Bei Versuchen [illegible] Mitarb. [1], Ahumada [2] und Lugo [illegible] dosen, beginnend mit [illegible]

vorgeschlagen, bzw. bis 20 Mill. I.E. auf 10 Tage verteilt. In [illegible] Literatur [4] findet man Hinweise auf biochemische, [illegible] betreffende Veränderungen durch Vit[illegible] als A-Hypervitaminosen bewertet. Es [illegible] zwischen Vitaminverabrei[illegible] Lipidgehalt der Leber und anderer Organe, [illegible] Plasmacholesterin bei Arteriosklerose und [illegible] A-Verabreichung. Es konnte nicht geklärt werden, [illegible] Vitamin den Lipidmetabolismus auf direktem Weg [illegible] durch unspezifische Reaktionen. Die zweifel[illegible] bewertbaren Therapieergebnisse einerseits, aber [illegible] nicht [illegible] unerwünschte Nebenwirkungen [illegible] angezeigt sein, in Tierversuchen an Rat[illegible] Wirkungen, unter dem Ge[illegible] quantitativer Beziehungen zwischen serumchemi[illegible] Organveränderungen zu suchen.

[illegible] über die serumchemischen Befunde und über [illegible] Zustand der Leber der Versuchstiere.

Material und Methoden

[illegible] Ratten der Sprague-Dawley-Rasse mit Durchschnitts[illegible] von 200 g wurden mit Schlundsonde mit emulgiertem [illegible] A-Palmitat in Höchstdosierung, in unterschiedlicher Zeit[illegible] und in unterschiedlichen Zeitintervallen nach der [illegible] Verabreichung untersucht. Als Vitaminpräparat verwendeten wir ein Handelspräparat. Bei diesem Präparat dienen als Emulgierungsmittel pflanzliche Öle und als Stabilisator Gummiarabicum. Es konnte gezeigt werden, daß das Vitamin in dieser Zubereitung auch in größeren Mengen besser resorbierbar ist. Nach Verabreichung auch höchster Dosen (maximal bis ca. 2 Mill. I.E.) waren unsere Tiere in ihrer Vitalität und äußeren Erscheinung unauffällig. Insbesondere zeigten sich keine Veränderungen am Fell und keine Spontanfrakturen.

Zur Serumgewinnung wurden die Tiere mit Äther narkotisiert und in der kürzest möglichen Zeit aus der vena cava inferior in Nähe der Einmündung der vena renalis Blut in ausreichender Menge entnommen und schließlich entblutet. Nach Tötung wurden die Organe inspiziert und die Leber, die makroskopisch im Sinne einer Verfettung verändert schien, histologisch untersucht. Es wurden Fettfärbung, HE- und van Gieson-Färbungen durchgeführt. Vorher wurden die Lebern gewogen und das Gesamtgewicht der Tiere festgestellt. Es wurden unbehandelte Tiere zum Vergleich untersucht, ferner solche, denen Leeremulsionen, [illegible] ohne Vitamin A verabreicht wurden.

Folgende chemische Untersuchungen wurden durchgeführt:

1. Fermente zur Leberfunktionsprüfung und zwar:
GOT, GPT, LDH, Lipase und LAP.
Die Fermentbestimmungen erfolgten nach den [illegible] methoden.

2. Lipidstatus im Serum
Gesamtlipide: Methode nach Zöllner u. Kirsch [illegible]
Gesamtcholesterin: Methode nach [illegible]

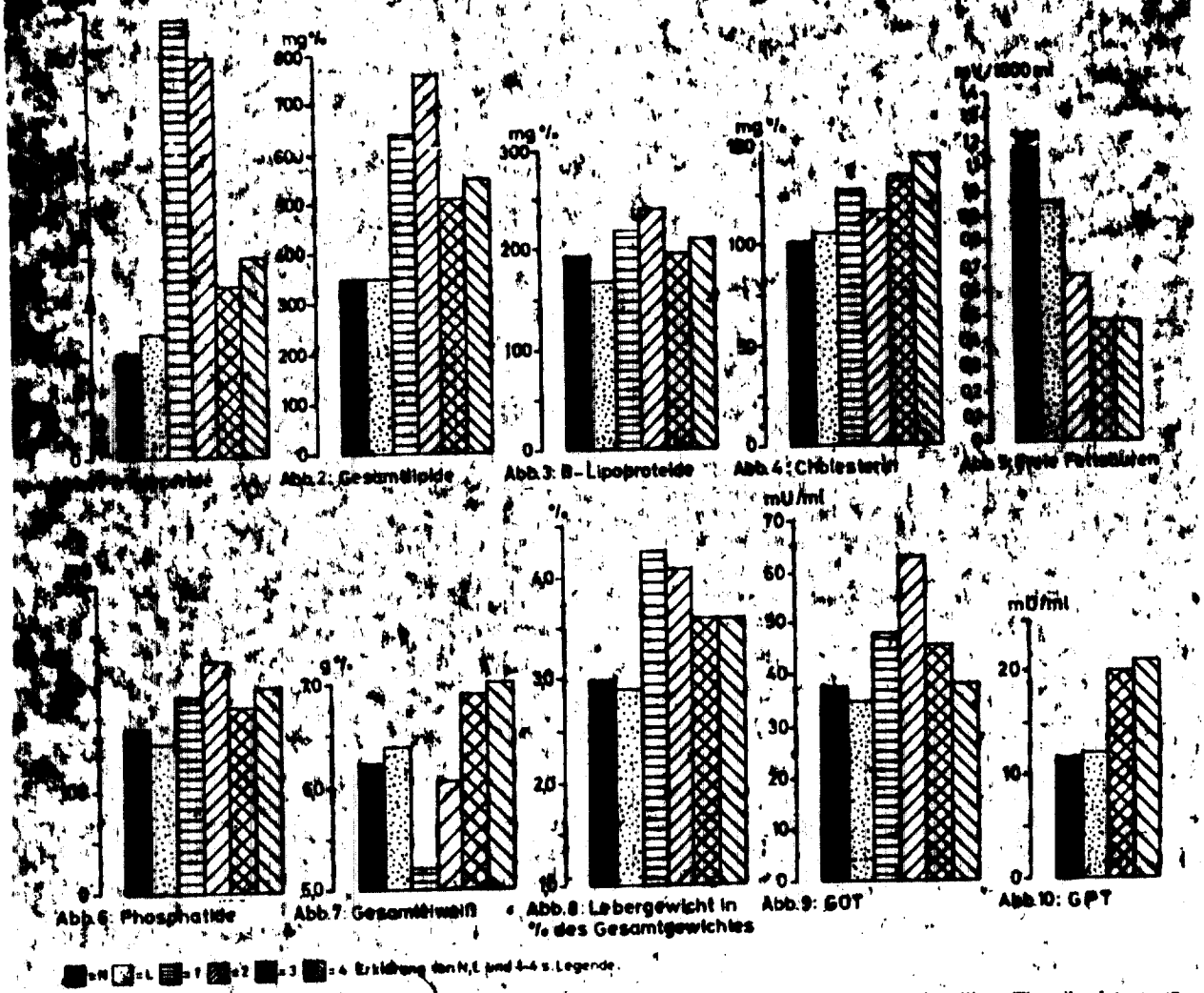

Abb. 2: Gesamtlipide
Abb. 3: B-Lipoproteide
Abb. 4: Cholesterin
Abb. 5: Freie Fettsäuren
Abb. 6: Phosphatide
Abb. 7: Gesamteiweiß
Abb. 8: Lebergewicht in % des Gesamtgewichtes
Abb. 9: GOT
Abb. 10: GPT

= N = L = 1 = 2 = 3 = 4 Erklärung von N, L und 1–4 s. Legende.

Abb. 1—10: Jede Säule entspricht einer bestimmten Behandlungsart und enthält die Mittelwerte bei der jeweiligen Tierreihe der gewonnenen Analysendaten. N: Normalratten. L: Leeremulsion. 1: 5×100 000 I.E. Vit. A; tgl. verabreicht; Gesamtmenge: 500 000 I.E.; anschließend sofort untersucht. 2: 51×30 000 I.E. Vit. A; jeden 2. Tag verabreicht; Gesamtmenge: 1,53 Mill. I.E.; anschließend sofort untersucht. 3: 10×30 000 I.E. Vit. A; tgl. verabreicht; dann 45×30 000 I.E.; jeden 2. Tag verabreicht; Gesamtmenge: 1,65 Mill. I.E.; anschließend sofort untersucht. (Es wurden bei diesem Versuch zusätzlich jeweils 200 mg proteolytisches Fermentgemisch (Firmenbezeichnung „Wobe") verabreicht.) 4: 5×100 000 I.E. Vit. A und 20×50 000 I.E. Vit. A; tgl. verabreicht; Gesamtmenge: 1,5 Mill. I.E.; 42 Tage nach letzter Verabreichung untersucht.

Neutralfette: Methode nach Eggstein, Kreutz u. Schmidt [7]
Phosphatide: Methode nach Zöllner u. Eberhagen [8]
β-Lipoproteide: Methode nach Watson [9]
Freie Fettsäuren: Methode nach Duncombe [10].

3. Eiweißelektrophorese und Gesamteiweiß
Elektrophorese mit Acetatfolie bei 200 V — Laufzeit 2 h, Eiweiß nach Biuret.

4. Bei einigen Tierserien wurden auch Bestimmungen zum Gerinnungsstatus durchgeführt, nämlich Fibrin, Trypsin, Fibrinolyse (als Euglobulinlysisteil), Rekalzifizierungszeit, Vollblutgerinnungszeit und Retraktion. Die Versuchsdaten finden im Text Erwähnung.

Ergebnisse

Hinsichtlich des Lipidstatus, der die von der Norm am meisten abweichenden Ergebnisse zeigte, kann festgestellt werden:

a) Eine ausgeprägte Hyperlipidämie, die mehrere Wochen anhält, auch nach Absetzen der Verabreichungen. Die Werte von Einzelkomponenten, z. B. der β-Lipoproteide laufen dabei parallel. Es ist hier zu bedenken, daß das gespeicherte Vitamin A an der Quantitätserhöhung der Gesamtlipide beteiligt ist. Es wird aber bei der hier angewendeten Methode der Lipidbestimmung der Vitamin A-Gehalt des Serums nicht miterfaßt.

b) Eine Hyperlipämie um das Drei- bis Fünffache der Norm, die mindestens einen Monat später noch deutlich ausgeprägt ist. Ein gleichzeitig mit dem Vitamin A verabreichtes proteolytisches Fermentgemisch bewirkt eine Senkung des Triglyceridspiegels.

c) Desgleichen eine signifikante Hyperphosphatidämie, ebenfalls länger nachweisbar nach Absetzen des Präparates.

d) Eine Hypercholesterinämie, die zunächst, d. h. bei Untersuchung unmittelbar nach Verabreichung, noch nicht deutlich ausgeprägt ist, und erst markant wird vier Wochen nach der letzten Verabreichung.

e) Eine charakteristische Ausnahme gegenüber den eben beschriebenen Erhöhungen der Einzelsubstanzen zeigen die freien Fettsäuren. Hier ist in jedem Fall im Vergleich zu den Normalwerten eine Absenkung des Spiegels bei den behandelten Tieren deutlich ausgeprägt.

Bei den Fermenten zeigt die SGOT eine Verdoppelung der Aktivität bei chronischer Verabreichung. Nach kurzfristig verabreichten Maximaldosen ist die Aktivitätssteigerung weniger ausgeprägt. Hier könnten Hinweise auf geringgradige Parenchymveränderungen vorliegen. Aus technischen Gründen konnte nur die SGOT systematisch geprüft werden. Bei der LDH ist im Zusammenhang mit der Behandlung eine Beurteilung insofern schwierig, als bei Ratten nach unseren Erfahrungen die Normalwerte stärker streuen. SGPT-Bestimmungen konnten wir lediglich durchführen bei einer Serie von Tieren, die mit Leeremulsionen (Blindwert) behandelt wurden. Es wurde nämlich an anderer Stelle behauptet, daß auch die Verabreichung Vitamin A-freier Leeremulsionen Serumveränderungen zeigen. Sonstige Enzymuntersuchungen, wie z. B. die Triglyceridlipase oder das Plasmatrypsin und die LAP (Leucinaminopeptidase) zeigten bei den von uns gewählten Versuchsstadien keine Abweichung von der Norm; desgleichen auch nicht der Gerinnungsstatus, gemessen an Rekalzifizierungs- und Nativblutgerinnungszeit. Damit ist aber nicht erwiesen, daß im Bereich der gewebsgebundenen Enzyme nicht mit Veränderungen zu rechnen ist.

Das Gesamteiweiß des Serums war nach der Verabreichung der Höchstmenge Vitamin A bei unmittelbar anschließender Untersuchung deutlich, wenn auch nicht erheblich vermindert. Auch hier erfolgt die Rückkehr zur Norm langsam. Bei chronischer Verabreichung kleiner Einzeldosen, jedoch summarisch der Maximalmenge entsprechend, sind keine Veränderungen zu erkennen. Das Fibrinogen ist in seiner Menge Schwankungen unterworfen, die nicht in bezug zur Behandlung gesetzt werden können.

Bei den Eiweißelektrophoresen zeigten sich Verschiebungen bei der α_1-Fraktion, die prozentual erheblich ansteigt. Übrigens ist bei unseren Ratten schon im Normalfall diese Fraktion auffallend höher als beim Menschen. Auch die γ-Fraktion kann in die Verschiebung einbezogen sein.

Organbefunde

Von den Organen der mit Vitamin A behandelten Tiere ist die Leber an Gewicht und Volumen deutlich vergrößert. Die Gewichtserhöhung betrifft Wassergehalt und Inhaltsstoffe. Die

Abb. 11: (Leber) Nach Verabreichung von 360 000 I.E. Vit. A — tgl. 100 000 I.E. verabreicht — sofort untersucht. Mäßige Fettablagerung (sudanophiles Material = schwarz) vor allem in den k. T. gewucherten Kupfferzellen. Vergr.: 250fach — Sudanfärbung.



Abb.12: (Leber) Nach Verabreichung von [illegible] I.E. Vit. A — 27×75 000 I.E. verabreicht — 1 Monat [illegible] Fettablagerung in Kupffer- und Leberzellen. Vergr.: [illegible]fach — Sudanfärbung.

Lebern sind mehr oder minder lehmfarben. [illegible] eine Fragilität, die sich auch bei der histologisch-[illegible] Aufarbeitung zeigt. Eine chemische Analyse der veränderten Lebern haben wir bisher nicht systematisch durchgeführt. Nach Vorversuchen sind insbesondere Abweichungen auf dem Lipidsektor zu erwarten, aber auch die enzymatische Aktivität der Organextrakte dürfte im akuten Stadium verändert sein. Wir sind damit beschäftigt, einschlägige Fragen zu bearbeiten. Bei der histologischen Beurteilung wurde versucht, quantitative Beziehungen zwischen serumchemischen Reaktionen und dem Grad der Leberveränderung zu erkennen. Es handelt sich zunächst um eine Bestandsaufnahme, indem der Zustand der Leber nach Höchstdosierung, nach chronischer Verabreichung der Gesamtmenge und nach Normalisierung der chemischen Serumwerte beschrieben wird.

Das Ergebnis der histologischen Untersuchungen kann wie folgt zusammengefaßt werden: (Abb. 11 u. 12)

a) In sämtlichen Versuchsreihen zeigt sich allgemein eine feinst- bis kleintropfige Verfettung der Hepatozyten und der Kupfferzellen als erste Reaktionsform der Leber.

b) Der prozentuale Anteil der Zahl der verfetteten Hepatozyten steigt mit zunehmender Dosis.

c) Bei den Lebern der Tierreihen, die nach kurzem behandlungsfreiem Intervall zur Untersuchung kamen, imponiert das stärkere Ansteigen des Anteils der verfetteten Kupfferzellen im Vergleich zu den verfetteten Hepatozyten.

d) Der prozentuale Anteil der Zahl der verfetteten Hepatozyten fällt mit zunehmendem behandlungsfreiem Intervall.

e) Der prozentuale Anstieg der Zahl der verfetteten Kupfferzellen ist nicht so offensichtlich dosisabhängig. [illegible] scheint von größerer Bedeutung die Gesamtzeit, die seit Beginn der Behandlung verstrichen ist.

f) Die Ausbildung von sinusoidalen [illegible] licher Ausdruck einer toxisch-[illegible] im allgemeinen gering, [illegible]

deutlichsten bei den Reihen mit hoher Vitamin A-Gabe und nach längerem behandlungsfreiem Intervall.

Nekrotische Bereiche oder Veränderungen in der Leber [illegible] sind nicht zu beobachten. Die Kupfferzellen sind [illegible]. Die Gallengänge zeigen keinerlei Verän[illegible]

[illegible] sind zu erkennen bei den mit Leer[illegible] behandelten Tieren.

[illegible] ausführlichere Darstellung erfolgt in der Dissertation [illegible].

Diskussion

[illegible]genden Untersuchungen geben Hinweise auf phar[illegible]mische Effekte des Vitamins A, erlauben aber nur [illegible] im Hinblick auf Therapieerfolge bei Dermatosen [illegible]machen. Die vorübergehend nachweisbare Lipid[illegible]ung bzw. tropfige Verfettung in Hepatozyten und [illegible] und die Lipidausschüttung in das Serum sind [illegible] ein Ausdruck für eine Mobilisierung der Lipide [illegible], oder für ein gestörtes Verhältnis von Lipidsyn[illegible] und -abbau. Es wird angenommen, daß durch die [illegible]ös von Vitamin A Veränderungen an Zellmembra[illegible] erfolgen und als Folge davon eine Ausschüttung lysoso[illegible] Fermente, wodurch geschädigtes Gewebe dem Abbau [illegible]fällt. Hierzu liegen Veröffentlichungen von Dingle u. [illegible] [11], Riecker, Gössner u. Pearce [12] vor. Andererseits bestehen auch Vorstellungen über Zusammenhänge mit [illegible]-immunologischen Vorgängen. Es wird wichtig und [illegible] sein, eine Stoffbilanz von Lebern Vitamin A-be[illegible]ter Tiere aufzustellen und sie in Beziehung zu den [illegible]befunden zu setzen bei gleichzeitiger Koordination mit [illegible] Histologie. Eine Frage ist die Eignung der Tierspezies. [illegible]erscheinungen, außer den beschriebenen, sind bei un[illegible] Versuchen mit Ratten nicht erkennbar gewesen. Andererseits liegen Analogien mit Ergebnissen beim Menschen [illegible] im Serum behandelter Patienten Lipidfaktoren und [illegible]aktivität reversibel erhöht sein können [3]. [illegible] Hinblick auf die Therapieversuche dürfte die Beobach[illegible] von großer Bedeutung sein, daß beim Versuchstier Fi[illegible]rungen als Dauerzustand nicht erkennbar waren, und [illegible] Risikofaktoren entfallen. Die Therapieversuche [illegible] Menschen sind sicher keine Behebung von einfachen [illegible]mangelerscheinungen; darum war es richtig, wenn [illegible] Anwendung in einer ärztlichen Allgemeinpraxis [illegible] bestanden. Da diese aber anscheinend inzwischen [illegible] eingeschränkt werden konnten [13], ist es ver[illegible] praktische Versuche der Behandlung schwer heilbarer [illegible] fortzusetzen, auch wenn unerwünschte Nebenwir[illegible] das Behandlungsbild beeindrucken.

Zusammenfassung

Nach oraler Verabreichung von hohen Dosen („Megadosen", z. B. 1—2 Mill. I.E.) von Vitamin A-Ester in emulgierter Form an Ratten zeigten sich serumchemische Veränderungen und morphologische Veränderungen an der Leber. Die serumchemischen Veränderungen betrafen vorwiegend den Lipidstatus, gemessen an Gesamtlipiden, Triglyceriden, Phosphatiden, Cholesterin und freien Fettsäuren. Bei den untersuchten Enzymaktivitäten zeigte sich die GOT erhöht. Beim Serumeiweiß war die Erhöhung der α_1-Fraktion bemerkenswert. Die Organveränderungen bestanden in einer feinst- bis kleintropfigen Verfettung von Hepatozyten und Kupfferzellen, deren prozentualer Anteil in Abhängigkeit von Dosierung und Zeitpunkt der Untersuchung abgeschätzt wurde. Eine völlige Normalisierung der Serumwerte und der Organe nach Unterbrechung der Verabreichung war nach mehreren Wochen erreicht, wobei jedoch keine Parallelität zwischen Serumwerten und Organnormalisierung vorzuliegen scheint. Spätfolgen waren an den Organen nicht zu erkennen.

Summary

Findings in Serum and Liver Following Megadoses of Vitamin A

After high doses of enterally given emulsified vitamin A ("megadoses", of e.g. 1—2 million I.U.) chemical changes in the serum and morphological changes in the liver could be shown in rats. The serum changes mainly concerned the lipids; total lipids, triglycerides, phosphatides, cholesterol and free fatty acids were determined. Among enzymes an increase of SGOT was found. As to proteins, an increase of the α_1-fraction was remarkable. The anatomic-pathological changes consisted of small vacuolar fatty changes of hepatocytes and Kupffer cells, which were semiquantitatively compared with dose and duration of vitamin A administration. Complete remission of serum and organ changes was found weeks after the vitamin was stopped; the remissions of serum and organ changes apparently did not run parallel to each other. All complications induced by vitamin A will be temporary and completely reversible.

Literatur

[1] Hoefer-Janker, Khazne, P., Scheef, W., Krebsarzt 24, 203 (1968) — [2] Alumada, F., Z. Haut-Geschl.Kr. 46, (24) 839—854 (1971) — [3] Luger, A., Till, R., Zips, A., Z. Haut-Geschl.Kr. 46, (5) 133—148 (1971) — [4] Ray, Sadhu, D. P., Nature 184, 1323 (1959) — Pallotata, Krause, Amer. J. Clin. Nutrit. 18, 201 (1963) — van Bruggen, Straumfiord, J. Lab. Clin. Med. 88, 67 (1948) — Misra, U. K., Nature 209, 910 (1966) — [5] Zöllner, N., Kirsch, K., Z. ges. exp. Med. 135, 545 (1962) — [6] Watson, D., Clin. chim. Acta 5, 637 (1960) — Zak, B. et al., Amer. J. clin. Path. 24, 1307 (1954) — Leffler, H. H., Amer. J. clin. Path. 31, 310 (1959) — [7] Eggstein, M., Kreutz, F. H., Klin. Wschr. 44, 262 (1966) — Eggstein, M., Klin. Wschr. 44, 267 (1966); Med. Welt 18, 843 (1967) — Schmidt, S. H., Dahl, K., Z. klin. Chem. 6, 156 (1968) — [8] Zöllner, N., Eberhagen, D., Us. d. Lip. im Blut, Springer Verlag, S. 261 und 393 (1965) — [9] Watson, D., Chin. chim. Acta 9, 637 (1960) — [10] Duncombe, W. G., Clin. chim. Acta 9, 122 (1964) — [11] Dingle, I., Biochem. J. 79, 509 (1961) — Dingle, I., Glauert, A. M., Daniel, M., Lucy, I. A., Bioch. J. 84, 76 (1962) — [12] Riecker, E. O., Gössner, W., Pearse, A. G. E., Histochemie 8, 22 (1967) — [13] Zecert, H., Österr. Chirurg. Kongreß, Krems 1972 (Vortrag) — Wrba, H., Vitamin-A-Symposium, Salzburg 1972 (Vortrag)

Für die Verf.: Dr. phil. Dr. med. H. Bayerle und Privatdozent Dr. med. P. Meister, Pathologisches Institut der Universität, 8 München 2, Thalkirchener Str. 36

Bethea-'62
Bib No. 10252

Reproduced by permission
of the copyright owner

Separation of vitamins A_1, A_2 and allied substances by reverse phase paper chromatography

The characterization of mixtures of vitamin A_1 and its derivatives by reverse phase paper chromatography has the drawback of complicated procedures and imperfect resolutions[1-6]. Furthermore, separation of vitamin A_2 and allied compounds has not been hitherto effected.

Irrigation (4–5 h), of circular paper chromatograms[7] (Whatman No. 1) im-

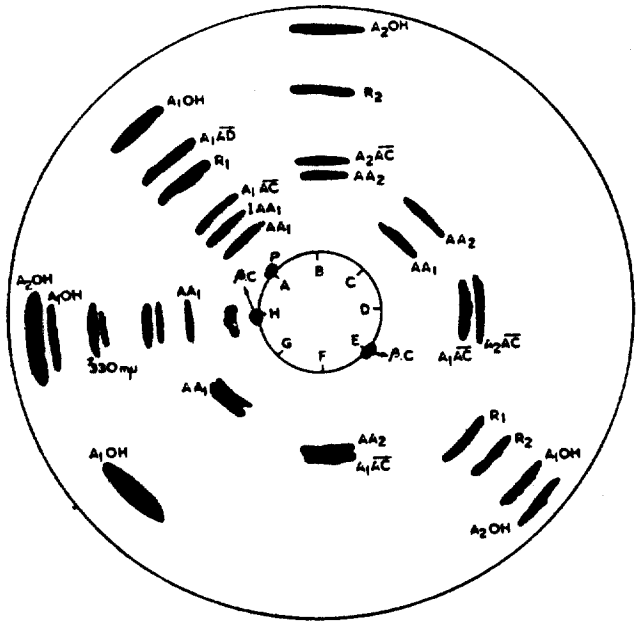

Fig. 1. Schematic representation of the separation of vitamins A_1, A_2 and their derivatives on 3% vaseline coated paper using 90% methanol. Unsaponifiable fraction of liver oil from: (G) *Zygena* species, (H) *Wallago attu*. P = Vitamin A_1 palmitate; AA_1 = Anhydrovitamin A_1; IAA_1 = Isoanhydrovitamin A_1; $A_1\overline{AC}$ = Vitamin A_1 acetate; R_1 = Vitamin A_1 aldehyde; $A_1\overline{AD}$ = Vitamin A_1 acid; A_1OH = Vitamin A_1 alcohol; AA_2 = Anhydrovitamin A_2; $A_2\overline{AC}$ = Vitamin A_2 acetate; R_2 = Vitamin A_2 aldehyde; A_2OH = Vitamin A_2 alcohol; β-C = β-Carotene; 330 mμ = Component X.

pregnated with 3% vaseline (snow-white petroleum, Stanvac, India), by 90% methanol effects their clear-cut separation (see Table I and Fig. 1). The absorption spectra of the substances eluted with ether–petrol ether (1:1) from bands located under ultraviolet light have been recorded.

Following this procedure, the constituents of marine and freshwater fish liver oils have been characterized. The resolution of the constituents of two representative fish liver oils (*Zygena* species and *Wallago attu*) after saponification is illustrated in Fig. 1. While vitamin A_1 alcohol together with anhydrovitamin A_1 and an uncharacterized component (R_F 0.15) seem to be characteristic of the marine sample, the *Wallago attu* oil, in agreement with the results of column chromatography[8],

due to the higher temperature during the linear temperature programmed portion of each run. The result is a chromatogram of evenly spaced, sharp peaks, Fig. 3. The optimum operating conditions, as determined by the "box" method of data collection, are a 10 min isothermal period at 40° followed by linear temperature programming

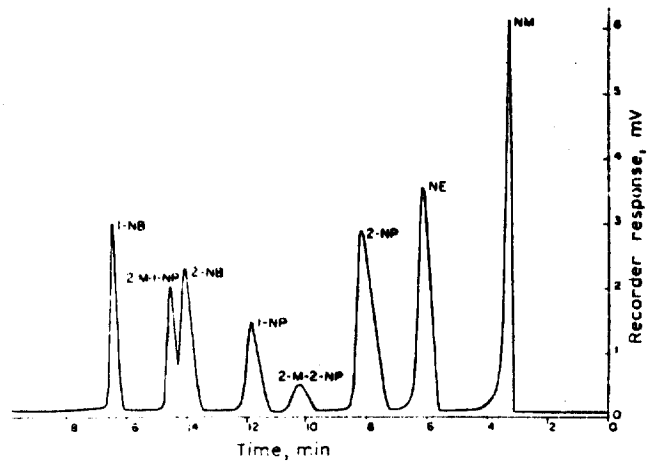

Fig. 3. Optimum ramp function separation of the C_1 to C_4 nitroparaffins. Conditions: 40° for 10 min followed by linear temperature programming at 11°/min; 60 ml H_2/min.

at a heating rate of 11°/min. Under these conditions, both the accuracy and precision of the analyses were ± 0.5 wt. % as determined from multiple replicate runs using known, gravimetrically prepared samples of the pure nitroparaffins. The oxygenated compounds were then added gravimetrically with the N–P mixture and tested in a similar fashion. Under the optimum conditions, values of R_{45} and R_{67} were, respectively, 1.80 and 0.73. It is concluded that the use of ramp function temperature programming for the analysis of the C_1 to C_4 nitroparaffins increases the resolution, R_{67}, by almost 15 % with an increase in the analysis time from the best conditions previously obtained of less than 2 min.

Chemical Engineering Department, Iowa State University, Ames, Iowa — R. M. BETHEA

and

Miami Valley Laboratories, Procter and Gamble Company, Cincinnati, Ohio (U.S.A.) — F. S. ADAMS, JR.

[1] R. M. BETHEA AND F. S. ADAMS, *Anal. Chem.*, 33 (1961) 532.
[2] W. L. JONES AND R. KESSELRA, *Anal. Chem.*, 30 (1958) 1500.

Received January 5th, 1962

Carpenter-'56
Bib No. 10297

Anat. Rec. 124:391.

Reproduced by permission
of the copyright owner

The effect of excess vitamin A in the diet on the thyroid gland of young female albino rats. Esther CARPENTER[1] and Myra M. SAMPSON[1], Zoology Department, Smith College.

In each of 7 sets of three litter mate female rats of Sprague-Dawley strain, one animal was given approximately 25,000 I.U. of vitamin A daily the first week in addition to a basal diet with vitamin supplements. In succeeding weeks the amount of vitamin A was doubled or tripled. Each set contained one pair-fed and one unlimited control. Experiments varied in length from 16 to 31 days depending on when the rat receiving excess vitamin A showed progressive loss of weight. Within 24 hours of the termination of the experiment, 5 of the sets were injected subcutaneously with equal tracer doses of I-131. Rats were etherized and the thyroids removed and fixed immediately.

The histological appearance of the thyroids of all rats given excessive amounts of vitamin A was consistently different from that of the controls. The majority of the follicles were smaller, highly irregular in shape and contained relatively little colloid. Follicular cells were hypertrophied and frequently contained PAS-stained droplets in the cytoplasm. Mitoses appeared occasionally. Autoradiographs of sections were distinctly darker than those of the controls. The blackening was particularly intense over the smaller follicles.

[1] Aided by grants from the Massachusetts Branch of the American Cancer Society and the American Cancer Society (Committee on Growth). Technical assistance of Roland Wight.

Chiou & Moorhatch-'73
Bib. No. 10311

Reproduced by permission
of the copyright owner

J.A.M.A. 223(8):328. 1973.

Interaction Between Vitamin A and Plastic Intravenous Fluid Bags

To the Editor.—Since the introduction of the flexible plastic intravenous fluid bags (Viaflex, marketed by Travenol Laboratories, Inc., Morton Grove, Ill) in 1971, their use in this country has received wide acceptance. There are some advantages of these bags over the traditional glass counterparts such as being lighter in weight, easier to store, and relatively unbreakable. However, their potential clinical problems such as sorption of drugs and leaching of chemicals from the bags do not appear to have been critically evaluated and reported in the literature. In our preliminary study on the sorption of some commonly used vitamins onto the bags, we were surprised to find that vitamin A (in the form of retinol acetate), at concentrations within the clinically used range, was strongly sorbed onto the bags. For example, 78% of 200 ml aqueous solution (with an initial concentration of 3μg per ml solubilized in 0.01% polysorbate 80) contained in 250 ml capacity Viaflex containers (Lot No. 2B8012) was found to be retained by the bags after 24 hours of storage at 25 C under only a gentle degree of shaking. The concentrations of vitamin A were analyzed spectrophotometrically at a wavelength of 330 mμ. During the study, the bags were protected from the light (the vitamin is sensitive to light) by wrapping with aluminum foil, and the controlled study was also performed by using Pyrex volumetric flasks as containers. It must be noted that the extent of sorption was found to be a function of storage time. They were only 10% and 31% sorbed after one and two hours of storage. Furthermore, our preliminary study indicated that the sorption process continued for at least 48 hours. The surfactant, polysorbate 80, and its strength used in this study are commonly employed in the parenteral dosage forms containing fat-soluble vitamins.

The type of solvents used was also found to influence the degree of sorption. For example, the sorption was increased by approximately 10% in the normal saline and 20% in the 5% dextrose solution. These striking results clearly indicate that vitamin A should not be administered to patients from plastic intravenous fluid bags, especially when the contact period between the drug and bag is more than one hour. The results of detailed study of the interactions of commonly parenterally administered drugs and the bags will be reported in the future.

Wis L. Chiou, PhD
Pat Moorhatch, Phar B
University of Illinois
College of Pharmacy
Chicago

Clark, L. -'71
Bib. No. 10318

Reproduced by permission
of the copyright owner

MID-DIAPHYSEAL BONE TURNOVER DURING AND AFTER VITAMIN A TOXICOSIS IN KITTENS:

A Fluorescent Labelling and Microradiographic Study

By

Leigh Clark

Veterinary School, University of Queensland, Brisbane, Australia

INTRODUCTION

Hypervitaminosis A in growing animals causes decreased appositional bone formation due to suppression of osteoblastic activity (Strauss, 1934; Irving, 1949, 1957; Grey, Nielsen, Rousseau, Calhoun and Eaton, 1965; Wolke, Nielsen and Rousseau, 1968; Clark, 1970). Further, rapid recovery of this process occurs when high vitamin A intakes ceases (Collazo and Rodriguez, 1933; Clark, 1970). Disagreement exists, however, as to the action, if any, of high levels of vitamin A on osteoclasts. Wolbach (1947) and Rodahl (1950) observed increased osteoclasia in hypervitaminosis A, while Irving (1949, 1957), Grey *et al.* (1965), Wolke *et al.* (1968) and Clark (1970) found no increase in this activity.

In a previous experiment on the effect of excess vitamin A on longbone growth in kittens (Clark, 1970) there was evidence of greatly reduced appositional bone formation by the periosteum and there were more resorption tunnels than normal in the juxta-metaphyseal areas of longbone diaphyses. Because the resorption tunnels were poorly lined by osteoblasts it was concluded that the intraosseous porosis resulted from retardation of bone formation rather than from increased resorption. Further, osteoclasia was apparently decreased in mid-diaphyseal areas of the same bones, because in this location there were fewer resorption tunnels than in pair-fed controls. In kittens allowed to recover for some weeks after vitamin A treatment both bone formation and resorption in diaphyses had returned to normal.

This paper describes an experiment designed to investigate further the activity of osteoblasts and osteoclasts both during and after a short period of vitamin A intoxication. Undecalcified sections from the mid-diaphyseal region of tibias from growing kittens were studied by means of in vivo labelling with fluorescent dyes (Frost, Roth, Villanueva and Stanisavljevic, 1961; Suzuki and Mathews, 1966) and microradiography (Sissons, Jowsey and Stewart, 1960).

MATERIALS AND METHODS

Animals and treatments. The experimental animals were divided into 2 groups, each comprising 4 pairs of newly-weaned 6 to 8-week-old kittens. The kittens in each pair were litter mates of the same sex and similar weight. One of each pair was a

test kitten (odd numbers) and the other a control (even numbers). The test kittens were given 20 to 60 μg./g. body weight of vitamin A daily by mouth for 30 days. The dose for each kitten was varied to ensure maximum intake of vitamin A without signs of acute toxicity. The vitamin A preparation* was water miscible, contained 500,000 i.u. (approximately 172,000 μg.) of vitamin A acetate/ml., and was administered in gelatin capsules. Four of the pairs of kittens (group A) were destroyed immediately after the dosage period, while the other 4 pairs (group B) were allowed to recover for 30 days without further vitamin A treatment.

All kittens in group A were injected intramuscularly with oxytetracycline hydrochloride† (terramycin) at the rate of 25 mg./kg. on day 15 and intraperitoneally with an alkaline solution of fluorescein –3, 3'– bimethyliminodiacetic acid‡ (calcein) at the same dose rate on day 25. The kittens in group B were injected during the second 30-day (recovery) period, with terramycin on day 45 and calcein on day 55, at the same dose rates. The composition of the diet and the food intake was described in a previous article (Clark, 1970).

Post-mortem procedures. The kittens were destroyed by an intraperitoneal injection of barbiturate solution. Livers and kidneys were removed, and their vitamin A content estimated by the method of Gartner and Ryley (1956). Transverse undecalcified sections were made from the midshaft area of the right tibia from each kitten. The tibia was chosen for this study because this bone was known to be severely affected in vitamin A toxicosis (Clark, 1970) and because the characteristic shape of transverse midshaft sections allows easy orientation. Unstained ground sections 100 μ thick were made by the method of Frost (1958), mounted on glass slides with a non-fluorescent mountant and examined under ultraviolet light. The light source was a 200-watt mercury vapour lamp with heat absorbing, red excluding, and ultraviolet filters. The microscope was fitted with a bright field condenser. Sections for microradiography were embedded in polyester resin, cut at 100 μ, mounted on plastic slides, and high resolution films were made of their X-ray diffraction.

RESULTS

Clinical Observations

During the dosage period the average daily food intakes of the test kittens were depressed. However, in the succeeding 30-day period, the food intakes of the 4 test kittens, allowed to recover, approximately doubled. Although there was equalised food intake for each pair of kittens, weight gains were greater in the controls during the dosage period. In the recovery period, however, although growth rates of both tests and controls increased markedly, they were relatively greater in 3 of the 4 test kittens. Food intake and weight gain data are presented in Table 1. All test kittens were dull and reluctant to walk during treatment, but rapidly regained normal behaviour after dosing ceased.

Microscopical Pathology and Microradiography (Group A)

Undecalcified transverse sections from the mid-diaphyseal region of tibias from the test kittens showed reduction in external, and sometimes internal, shaft diameters. Shaft thickness was reduced, and periosteal and endosteal surfaces were smoother and more regular than in the controls. The test bones were also markedly less porous.

* E. R. Squibb Vitamin A W/M Oral

† Pfizer Terramycin

‡ Hopkin and Williams Ltd. Calcein

TABLE 1

BODY WEIGHTS

Initial weights with weights at the end of dosage and recovery periods and average food intakes during dosage and recovery periods

Group	*Kitten (test or control)*	*Initial weight (g.)*	*Weight at day 30 (g.)*	*Average daily food intake days 1–30 (g.)*	*Weight at day 60 (g.)*	*Average daily food intake days 31–60 (g.)*
A (Destroyed after dosage period)	1t	765	950	81		
	2c	750	1100	81		
	3t	765	1100	99		
	4c	745	1260	99		
	5t	830	910	66		
	6c	780	1110	66		
	7t	695	1060	88		
	8c	670	1115	88		
B (Destroyed after recovery period)	1t	720	1000	84	1820	134
	2c	700	1000	84	1740	134
	3t	760	1265	90	1900	144
	4c	780	1350	90	2090	144
	5t	740	930	62	1820	150
	6c	760	1000	62	1800	150
	7t	750	885	62	2100	175
	8c	680	975	62	2130	175

TABLE 2

RELATIVE NUMBERS OF RESORPTION TUNNELS AND GROWING SECONDARY OSTEONES

In transverse midshaft sections from tibias of experimental animals

Group	*Kittens*	**Resorption tunnels*		**Growing secondary osteones*	
		Tests	*Controls*	*Tests*	*Controls*
A (Destroyed after dosage period)	1t & 2c	0	18	22	15
	3t & 4c	2	34	21	30
	5t & 6c	4	9	16	3
	7t & 8c	0	20	7	20
	TOTAL	6	81	66	68
Statistical significance		0.05>	p>0·01	NS	
B (Destroyed after recovery period)	1t & 2c	25	32	0	29
	3t & 4c	28	13	4	30
	5t & 6c	31	29	10	46
	7t & 8c	34	16	4	11
	TOTAL	118	90	18	116
Statistical significance		NS		0·05>	p>0·01

* Spaces with both resorption and formation surfaces were classified according to the process occupying the maximal surface length.

Examination of ground sections from control and test bones using fluorescent microscopy revealed a marked difference in growth patterns. In the controls, yellow (terramycin) and green (calcein) bands, indicating areas of bone deposition during the experimental period, were present in subperiosteal and subendosteal bone and in newly formed secondary osteones. The most concentrated labelling occurred in subperiosteal bone, particularly in anterior and lateral regions. Due to the formation of irregular folds and numerous primary osteones by the periosteum, the yellow and green bands were rarely parallel (Fig. 1b), and thus measurement of distances between them would not have been satisfactory. Bone formation on the endosteal surface was more regular, and in most bones parallel yellow and green bands extended almost all the way around, being absent only posteriorly. Irregular spaces without surrounding fluorescent bands, resorption tunnels, were numerous and, except anteriorly where they extended outwards towards the region of subperiosteal labelling, tended to be restricted to subendosteal bone. Spaces circumscribed by fluorescent bands, growing secondary osteones, were only slightly less numerous than resorption tunnels (Table 2).

The most striking difference in the test bones was a lack of, or reduction in, subperiosteal labelling with the fluorescent dyes. Sections from 3 of the 4 test bones showed no significant subperiosteal labelling (Fig. 1a); the fourth bone, from kitten 7, was labelled with both yellow and green dyes, but the 2 bands were closer together than in the controls and were regular and concentric. A second marked difference from normal in the test bones was that they contained few or no resorption tunnels (Fig. 1a, Table 2). On the other hand, subendosteal fluorescent labelling was not appreciably different from the controls, and the test bones contained approximately the same number of growing secondary osteones (Table 2).

Microradiographs demonstrated that there was no significant difference in mineralization between bones from test and control groups (Fig. 2a, b). However the control bones contained more newly formed bone which was slightly less dense, particularly in the subperiosteal location. Resorption tunnels were recognized by their highly calcified surfaces which were usually rough and uneven, and growing secondary osteones by their smooth surfaces and surrounding bone of lower mineral density. Although the relative numbers of resorption tunnels and forming secondary osteones tended to confirm the results obtained by fluorescent labelling, differences between the 2 kinds of cavities were not as obvious in the microradiographs and accurate counts were, therefore, not attempted. The circumference of the control bones presented a lace-work appearance in contrast to the almost smooth, uniform periphery of the tests. In addition, the controls had more cement lines than the test bones; moreover, cement lines between circumferential lamellae in the tests were not parallel and were often incomplete (Fig. 3a, b).

Microscopical Pathology and Microradiography (Group B)

The tibias of recovery test kittens were comparable in midshaft thickness and diameter to those of the controls. Porosity, although increased in this group, was still less than that of the controls.

Fluorescence microscopy revealed that subperiosteal bone formation was even greater in the test bones than in the controls, the thickness of the labelled zone often being twice that of the controls (Fig. 1c, d). In both test and control kittens subperiosteal bone formation was extremely irregular, with the formation of numerous primary osteones. In contrast to group A, group B showed more resorption tunnels but far fewer growing secondary osteones than the controls (Table 2). Endosteal bone formation was again comparable in both groups. The group B controls showed increased subperiosteal bone formation and more numerous resorption tunnels and growing secondary osteones than their group A counterparts (Fig. 1b, d).

Microradiographs again supported the findings of fluorescent microscopy, illustrating that the test bones had a more irregular periosteal surface, a wider zone of newly-formed subperiosteal bone and a greater proportion of resorption tunnels than growing secondary osteones (Figs. 2 and 3c, d).

Vitamin A in the Liver and Kidney

The total amount of vitamin A administered, and the concentration of the vitamin in the liver and kidney of each kitten at necropsy, are shown in Table 3. Although group B test kittens received less total vitamin A than group A, their liver levels tended to be higher at necropsy. As the livers from group B controls also contained more vitamin A than those from group A, although the experimental diet was low in the vitamin, it can only be assumed that the kittens in group B started the experiment with higher vitamin A reserves.

TABLE 3

TOTAL AMOUNT OF VITAMIN A ADMINISTERED TO EACH KITTEN AND LIVER AND KIDNEY VITAMIN A LEVELS AT NECROPSY

Group	*Kitten (test or control)*	*Total vitamin A administered (mg.)*	*Liver vitamin A (mg./g.)*	*Kidney vitamin A (mg./g.)*
A (Destroyed after dosage period)	1t	1377	5.6	0·9
	2c	—	0·3	0·1
	3t	1548	4·7	0·7
	4c	—	0·2	0·1
	5t	1273	5·3	1·7
	6c	—	0·1	0·2
	7t	1083	4·5	0·5
	8c	—	0·7	0·2
B (Destroyed after recovery period)	1t	1290	5·5	0·5
	2c	—	2·6	0·2
	3t	1050	9·4	0·4
	4c	—	3·9	0·3
	5t	765	8·2	0·4
	6c	—	3·2	0·4
	7t	618	5·2	0·3
	8c	—	3·0	0·2

DISCUSSION

Kittens dosed with high levels of vitamin A showed a reduction or a cessation of periosteal bone formation in the tibial midshaft, as demonstrated by in vivo labelling with fluorescent dyes and microradiography. Bone formation by the endosteum and in secondary osteones was similar, however, to that in pair-fed controls. Osteoclastic activity must have been decreased as the test bones were less porous due to significantly fewer resorption tunnels. These findings are consistent with those described in kittens using normal histological methods (Clark, 1970). Wolke, Eaton, Nielsen and Hemboldt (1969) described similar results of decreased periosteal bone growth and fewer resorption spaces in the middle thirds of longbone shafts in experimental hypervitaminosis A in growing pigs.

Recovery from osteoporosis due to vitamin A toxicosis has been observed clinically in rats by Collazo and Rodriguez (1933) and in man by Persson, Tunell and Ekergren (1965). Jowsey and Riggs (1968) studied microradiographs of rib bone biopsies from an 18-year-old woman immediately after several months of high vitamin A intake and again after a 7-week recovery period. They found that in hypervitaminosis A there was an increase in the extent of bone resorbing surfaces and formation surfaces were on the low side of a wide normal range. Recovery was characterised by a great increase in bone forming surfaces while resorption surfaces had almost returned to normal levels. These findings are consistent with those described histologically for the juxta-metaphyseal areas of longbone diaphyses, particularly those of the small paw bones, in kittens (Clark, 1970).

The present experiment clearly demonstrated that in the midshaft area of the tibia bone formation by the periosteum is increased above normal for a period after vitamin A intoxication ceases. At the same time there is a sudden resumption in osteoclastic activity, resulting in a greatly increased number of resorption tunnels. It is probable that few growing secondary osteones were seen in sections from kittens recovering from hypervitaminosis A because reduction in bone resorption during the dosage period resulted in few or no immediately available spaces for new bone formation. The fact that bone growth was greater in group B controls than in their group A counterparts was probably due to the increase in appetite in group B tests after dosing ceased, allowing their controls a less restricted food intake (Table 1). However, as these kittens were approximately 30 days older when examined, age may have been another factor influencing their bone formation rate.

It appears that in hypervitaminosis A osteoblasts in the longbones of growing kittens are not affected similarly in different locations. In the periosteum they appear to be present in normal numbers, but their activity is decreased (Clark, 1970); in the poorly lined resorption tunnels of the juxta-metaphyseal shafts they are greatly reduced in number (Clark, 1970), and the present experiment has shown that in the endosteal location, in midshaft areas at least, they are relatively unaffected. The effect of excess vitamin A on osteoclasts may be less complex: it seems possible that the vitamin has no direct effect on these cells, and they continue to grow normally unless or until they are inhibited by mechanisms

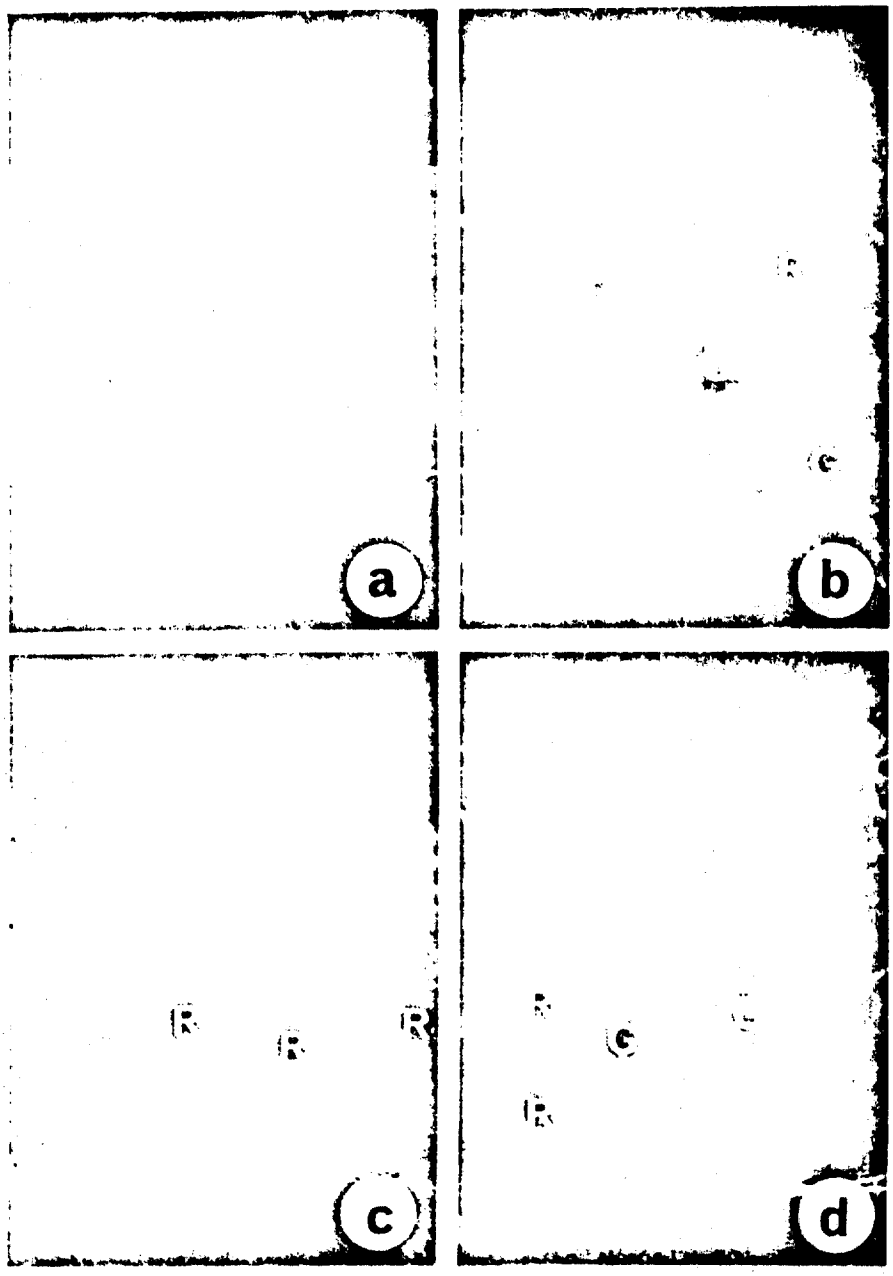

Fig. 1. Undecalcified transverse sections through the anterior midshaft region of right tibias. (a) group A, test kitten; (b) group A, pair-fed control; (c) group B, test kitten; (d) group B, pair-fed control. Yellow bands represent terramycin, and green bands calcein. R = resorption tunnel. G = growing secondary osteone. Unstained sections viewed under ultraviolet light. ×52.

To face page 370

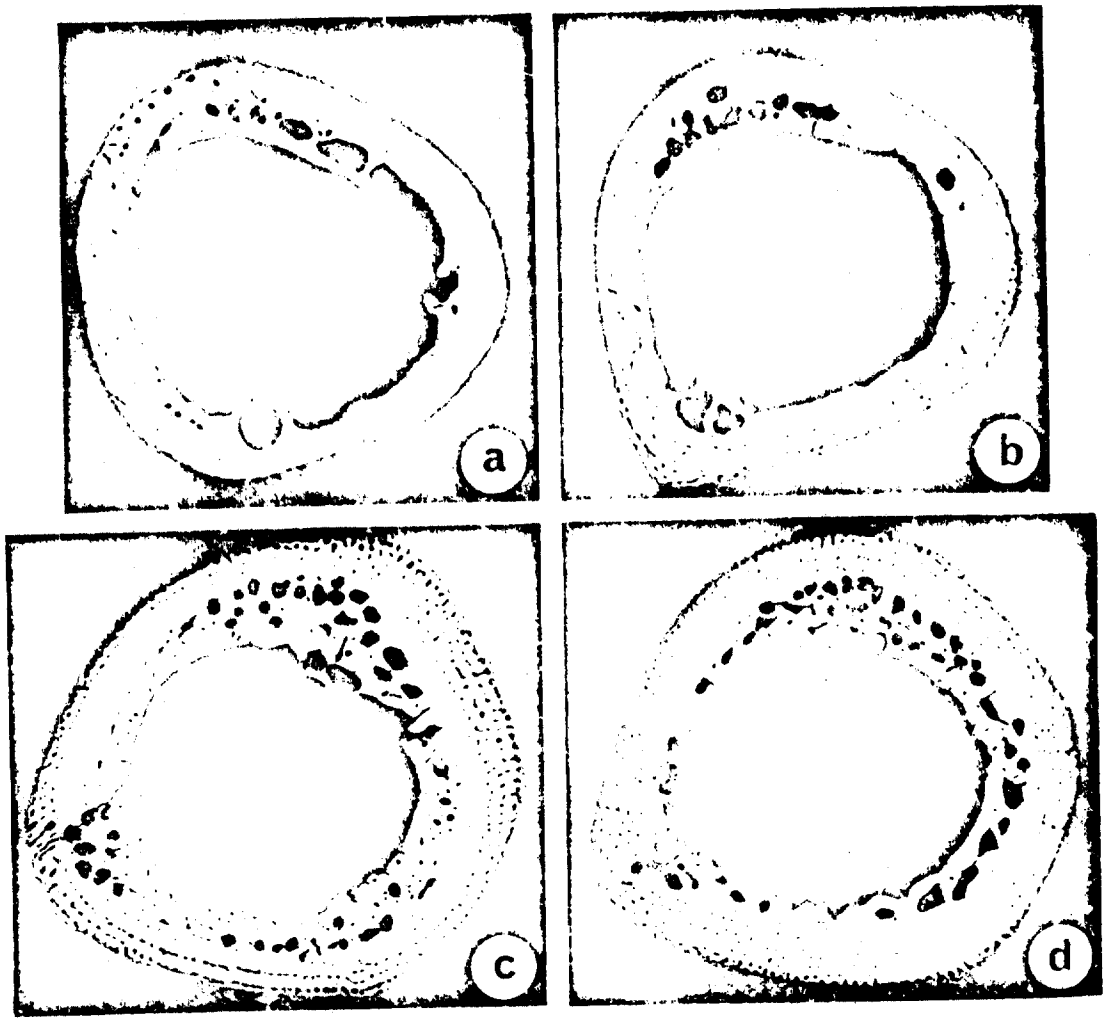

Fig. 2. Microradiographs of transverse midshaft tibial sections from group A test and control (a and b) and group B test and control (c and d) kittens.

a and b. The test bone has a thinner shaft, a more regular periosteal surface and is less porous. c and d. The test bone is comparable in thickness and porosity to its control but has a more irregular periosteal surface.

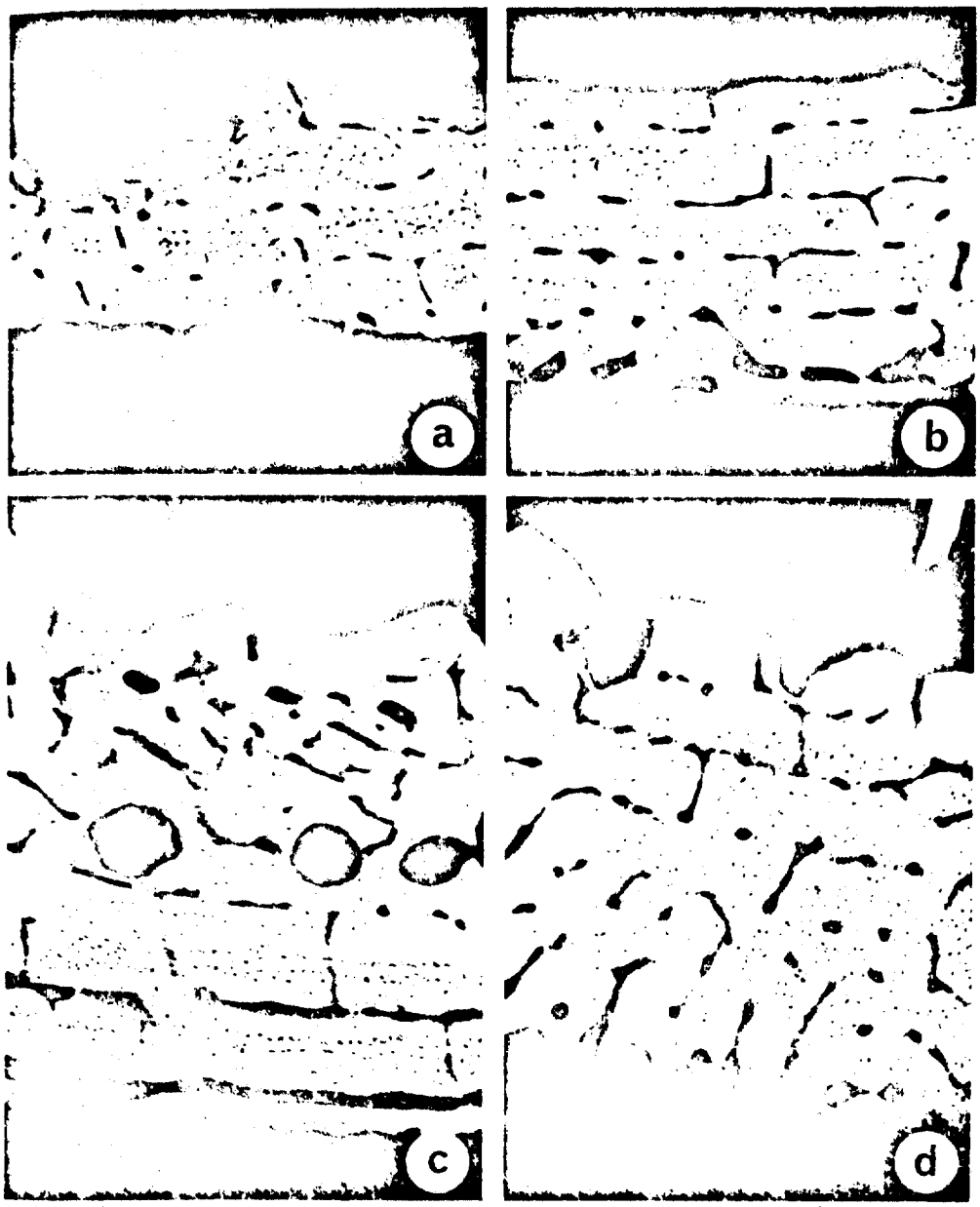

Fig. 3. Higher magnification of microradiographs from the posterior aspect of the same tibias as in Fig. 2. ×62.

activated by increased stresses in bones weakened by reduction in appositional bone formation.

SUMMARY

Undecalcified transverse sections through the midshaft of tibias from kittens dosed with high levels of vitamin A, and from kittens recovering from such treatment, were examined by in vivo labelling with fluorescent dyes and by microradiography. During treatment subperiosteal bone deposition was retarded while intraosseous and subendosteal bone formation were relatively unaffected; normal bone resorption, responsible for shaft remodelling, was also inhibited. In kittens labelled during the recovery period, both formation of bone by the periosteum and resorption of the original compacta were greater than normal. These results illustrate that rapid compensatory activity occurs in bones following vitamin A toxicosis.

ACKNOWLEDGMENTS

The author wishes to thank Drs. A. A. Seawright and T. H. Vickers for their encouragement and advice. The vitamin A analyses were done in the Department of Mr. R. J. W. Gartner, Animal Research Institute, Queensland. Mrs. Jana Hrdlicka, of the Queensland Veterinary School Toxicology Unit, performed the Ca and P estimations. The microradiography was done with the assistance of staff from the Queensland Dental School.

REFERENCES

Clark, L. (1970). *J. comp. Path.*, **80**, 625.
Collazo, J. A., and Rodriguez, J. S. (1933). *Klin. Wschr.*, **12**, 1732.
Frost, H. M. (1958). *Tech.*, **33**, 273.
Frost, H. M., Roth, H., Villanueva, A. R., and Stanisavijevic, S. (1961). *Henry Ford Hosp. Med. Bull.*, **9**, 312.
Gartner, R. J. W., and Ryley, J. W. (1956). *Q'ld. J. agric Sci.*, **13**, 1.
Grey, R. M., Nielsen, S. W., Rousseau, J. E., Calhoun, M. C., and Eaton, H. D. (1965). *Path. vet.*, **2**, 446.
Irving, J. T. (1949). *J. Physiol.*, **108**, 92.
Irving, J. T. (1957). *Vitamins and Hormones*, **15**, 291.
Jowsey, J., and Riggs, B. L. (1968). *J. Clin. Endocrin. Metab.*, **28**, 1833.
Persson, B., Tunell, R., and Ekengren, K. (1965). *Acta Paediat. Scand.*, **54**, 49.
Rodahl, K. (1950). *Norsk. Polarinstitutt Skrifter*, No. 95.
Sissons, H. A., Jowsey, J., and Stewart, L. (1960). in *Proc. Second Int. Symp. on X-ray Microscopy and X-ray Microanalysis*, Stockholm.
Strauss, K. S. (1934). *Beitr. path. Anat.*, **94**, 345.
Suzuki, H. K., and Mathews, A. (1966). *Tech.*, **41**, 57.
Wolbach, S. B. (1947). *J. Bone and Joint Surg.*, **29**, 171.
Wolke, R. E., Nielsen, S. W., and Rousseau, J. E. (1968). *Amer. J. vet. Res.*, **29**, 1009.
Wolke, R. E., Eaton, H. D., Nielsen, S. W., and Hemboldt, C. F. (1969). *J. Path.*, **97**, 677.

[*Received for publication, August 24th*, 1970]

Clark, L. - 15
Bib. No. 10320

Reproduced by permission
of the copyright owner

J. Comp. Path. 1973. Vol. 83. 447-46 Oct 1973

GROWTH RATES OF EPIPHYSEAL PLATES IN NORMAL KITTENS AND IN KITTENS FED EXCESS VITAMIN A*

A Fluorescent Labelling and Histological Study

By

Leigh Clark

Veterinary School, University of Queensland, Brisbane, Australia

INTRODUCTION

When excess vitamin A is administered to growing animals it has a specific effect on epiphyseal plates which results in a reduction of the longitudinal growth of longbones (Strauss, 1934; Wolbach, 1947; Wolke, Nielsen and Rousseau, 1968). In kittens dosed with vitamin A for 21 to 30 days epiphyseal plates are variably damaged, the more severely affected ones showing discontinuity and sometimes fragmentation (Clark and Seawright, 1968; Clark, Seawright and Gartner, 1970; Clark, 1970). Some plates, such as those of the distal femur and the proximal tibia, are consistently affected more than others, and the changes tend to be similar in left and right limbs.

The following experiment was designed to determine whether an excess of vitamin A has an unequal effect on different epiphyseal plates in kittens from the onset of intoxication.

MATERIALS AND METHODS

The growth of several epiphyseal plates was measured in both untreated kittens and in their litter-mates which were dosed with vitamin A for a short period. For these measurements the technique of in vivo labelling with a fluorescent dye was employed (Hulth and Olerud, 1962; Tapp, 1966; Hansson, 1967). In an attempt to explain differences in growth rate in terms of cellular changes, counts of the numbers of cells in the cartilage columns of the plates and measurements of cartilage cell size were also made (Sissons, 1956). For technical reasons it was necessary to use the epiphyseal plates from one limb of each kitten for growth rate measurements, and those from the opposite limb for the measurement of the cellular parameters outlined above. In considering growth rate measurements in conjunction with cellular changes it was assumed that opposite epiphyseal plates in kittens are affected equally in hypervitaminosis A.

Animals and treatments. The experimental animals comprised 4 pairs of newly weaned 6 to 8-week-old kittens. The kittens in each pair were litter-mates, not necessarily of the same sex, but of similar weights (Table 1). One of each pair was a test kitten (odd numbers) and the other a control (even numbers). The experiment lasted 7 days and the animals were killed on the eighth day. A 7-day experimental period was chosen because it was thought that all epiphyseal plates would grow a measurable distance in this time, without metaphyseal remodelling removing significant amounts of the label. On day 1 all kittens were injected i.m. with oxytetracycline

* Work performed in partial fulfilment of the requirements for the M.Sc. degree from the University of London.

hydrochloride* at a dose rate of 25 mg./kg. The test animal in each pair was given approximately 69 000 μg. of water-miscible vitamin A concentrate† orally in gelatin capsules on each of days 1 to 7.

The diet consisted of minced abattoir offals with calcium carbonate ($CaCO_3$) and calcium hydrogen orthophosphate ($CaHPO_4$) added as previously described (Clark, 1970) to ensure that the levels and balance of calcium and phosphorus were optimal for growing kittens (Scott, 1965): in addition, milk was fed. Pair-feeding was not employed because the reduced food intake which occurs in hypervitaminosis A (Rodahl, 1950; Clark *et al.*, 1970) would not be expected to affect bone growth in such a short period (Smith, 1931). Further, previous work has shown a marked difference in longitudinal bone growth between kittens fed an excess of vitamin A and pair-fed controls (Clark, 1970).

Necropsy procedures. The kittens were killed by an overdose of barbiturate solution. Portions of liver and kidney for vitamin A analysis were removed immediately and stored at −20 °C. The right humerus, radius, ulna, femur and tibia from each kitten were selected for undecalcified work and were fixed in 10 per cent. buffered neutral formalin. From the left hindlimbs, the distal femur and proximal tibia were taken for detailed histological study of the epiphyseal plates. These bone-ends were sawn longitudinally in the midplane and were fixed in Lillie's solution at 4 °C. in an attempt to preserve as much metachromasia as possible (Pearse, 1960).

Preparation of undecalcified sections. The fixed bones were sawn longitudinally, slightly lateral to their midsagittal plane, and transversely across the shaft adjacent to each metaphysis. The portions for embedding consisted of the medial half of each bone-end, which included the epiphysis, the epiphyseal plate and the metaphysis. The bones were dehydrated through alcohols, cleared in chloroform and embedded in polyester resin.‡ Sections were cut at approximately 140 μm on an Adcock and Shipley milling machine and then ground to 100±10 μm. The unstained sections were mounted on glass slides with a non-fluorescent mountant.§

Preparation of decalcified sections. Bones were decalcified by the formic acid–sodium citrate method (U.S. Armed Forces Institute of Pathology, 1960), processed by alcohol dehydration and xylol clearing and embedded in paraffin wax. Sections were cut at 7 μm and stained with haematoxylin and eosin and azure A.

Measurement procedures. All measurements were made with an eyepiece calibrated for each objective with a stage millimetre scale. Correction was made for an estimated shrinkage of 12·5 per cent. in the case of paraffin sections (Sissons, personal communication).

The undecalcified sections were examined under ultraviolet light, and 3 measurements were made between the base of the epiphyseal plate and the start of the transverse zone of oxytetracycline fluorescence in the metaphysis. The first of these measurements was made from the midpoint of the base of the plate. Two others, equidistant between the middle of the base of the plate and the periphery, were made on either side of the first. The average of the 3 measurements was taken to be the growth of that particular epiphyseal plate in the interval between the injection of oxytetracycline and the death of the animal.

Several series of measurements were made on the epiphyseal plates in decalcified sections. For each plate the length of columns of chondrocytes was measured in 3 places and an average taken. The number of cells was counted in several columns of chondrocytes to arrive at a figure for the mean number of cells per column: in addition, the longitudinal diameters of 20 of the largest hypertrophic chondrocytes seen at the bottom of the cell columns, or the spaces left by them, were measured. The largest cells were selected for measurement because not all would be cut in the plane displaying maximum size. An average of these measurements was taken as an estimate of the mean size of chondrocytes undergoing degeneration.

* Pfizer Terramycin.
† E.R. Squibb Vitamin A W/M Oral.
‡ A. C. Hatrick Chemicals Pty. Ltd. Polylite 61–209.
§ G. T. Gurr Uvinert.

For each epiphyseal plate from the control kittens the daily rate of cell formation per column of chondrocytes was obtained by dividing the average daily growth rate of the plate (obtained from oxytetracycline labelling) by the mean cell size. Similarly, mean cell life was calculated by dividing the mean number of cells per column by the rate of cell formation per column (Sissons, 1956).

Vitamin A determinations. The vitamin A content of the liver and kidney samples was estimated by the Carr–Price antimony trichloride reaction (Carr and Price, 1926), as modified by Gartner and Ryley (1956).

RESULTS

Body Weights and Liver and Kidney Vitamin A Levels

The sex of each experimental animal, its weights at the beginning and end of the experiment, and its liver and kidney vitamin A levels at necropsy are presented in Table 1. The weight gain of all the control kittens was satisfactory, but was slight in 3 of the 4 test kittens, the fourth losing weight during the dosage period.

Predictably, the administration of vitamin A caused an appreciable uptake by the liver and kidneys, concentrations of the vitamin in the organs of the test kittens always being over 10 times those in their respective controls.

TABLE I

SEX OF KITTENS IN EACH TEST AND CONTROL PAIR, WEIGHTS AT THE BEGINNING AND END OF THE EXPERIMENT, AND LIVER AND KIDNEY VITAMIN A LEVELS AT NECROPSY

Kitten (test or control)	*Sex*	*Weight (g.)* *Day 1*	*Day 8 (necropsy)*	*Vitamin A at necropsy (μg./g.)* *Liver*	*Kidney*
1T	F	900	800	3218	*
2C	M	950	1150	257	*
3T	F	720	760	2681	1587
4C	F	640	840	209	112
5T	M	870	900	3486	1630
6C	M	870	1080	209	112
7T	M	770	820	2145	897
8C	F	690	810	193	80

* Analysis not done.

Fluorescent Labelling

The growth of epiphyseal plates was invariably retarded in the test kittens, although the degree of retardation varied considerably between animals (Table 2 and Fig. 1). The relative growth rates of the different epiphyseal plates followed a similar pattern in animals from both control and test groups, and the percentage contribution to growth of the proximal and distal epiphyseal plates of bones from the test and control kittens was not markedly different (Table 3).



Fig. 1 Undecalcified unstained section of the distal radius from (a) kitten 1 (test) and (b) kitten 2 (control) viewed under ultraviolet light. The arrow between the base of the epiphyseal plate (EP) and the oxytetracycline labelling (OTC) in the metaphysis (M) is longer in the control, indicating increased longitudinal growth over the experimental period. Some oxytetracycline fluorescence is also present above the epiphyseal plate, in the epiphysis (E). ×62.

TABLE 2

GROWTH OF EPIPHYSEAL PLATES IN THE FOUR PAIRS OF TEST AND CONTROL KITTENS IN 7 DAYS

Growth reduction in the plates of the test kittens expressed as a percentage of the growth of those of their controls

Kitten (test or control)	*Humerus*		*Radius*		*Ulna*		*Femur*		*Tibia*	
	Proximal (mm.)	*Distal (mm.)*	*Proximal (mm.)*	*Distal (mm.)*	*Proximal (mm.)*	*Distal (mm.)*	*Proximal (mm.)*	*Distal (mm.)*	*Proximal (mm.)*	*Distal (mm.)*
1T	0·409	0·123	0·150	0·455	0·104	0·786	0·364	0·455	0·441	0·486
2C	1·241	0·486	0·241	1·486	0·214	1·695	0·786	1·636	1·241	1·168
	67%	75%	38%	69%	57%	54%	54%	72%	64%	58%
3T	1·486	0·668	0·455	1·332	0·241	1·818	1·014	1·514	1·409	1·123
4C	1·741	0·864	0·559	2·091	0·332	2·775	1·364	1·877	1·955	1·741
	15%	23%	19%	36%	27%	34%	26%	19%	28%	35%
5T	1·136	0·486	0·455	1·000	0·305	1·741	1·136	1·241	1·332	1·105
6C	1·713	0·877	0·636	1·850	0·364	2·986	1·334	2·182	2·195	1·686
	34%	45%	28%	54%	16%	42%	15%	43%	30%	38%
7T	1·332	0·623	0·441	1·532	0·305	2·241	1·077	1·286	1·486	1·395
8C	1·941	0·864	0·532	1·895	0·377	2·559	1·182	1·895	1·877	1·759
	31%	28%	17%	19%	19%	12%	9%	32%	21%	21%
Average tests	1·091	0·475	0·375	1·080	0·239	1·646	0·898	1·124	1·217	1·027
Average controls	1·659	0·773	0·492	1·830	0·322	2·504	1·166	1·897	1·817	1·613
	34%	39%	24%	41%	26%	34%	23%	41%	33%	36%

TABLE 3

PERCENTAGE CONTRIBUTION TO GROWTH OF PROXIMAL AND DISTAL EPIPHYSEAL PLATES OF BONES FROM TEST AND CONTROL KITTENS

Kitten (test or control)	*Humerus*		*Radius*		*Ulna*		*Femur*		*Tibia*	
	Proximal	*Distal*	*Proximal*	*Distal*	*Proximal*	*Distal*	*Proximal*	*Distal*	*Proximal*	*Distal*
1T	77	23	25	75	12	88	44	56	48	52
2C	71	29	14	86	11	89	32	68	52	48
3T	69	31	25	75	11	89	40	60	56	44
4C	67	33	21	79	11	89	42	58	53	47
5T	70	30	31	69	15	85	48	52	58	42
6C	66	34	26	74	11	89	38	62	55	45
7T	68	32	22	78	12	88	46	54	52	48
8C	69	31	22	78	12	88	38	62	52	48
Average tests	70	30	26	74	13	87	44	56	54	46
Average controls	68	32	21	79	11	89	38	62	53	47

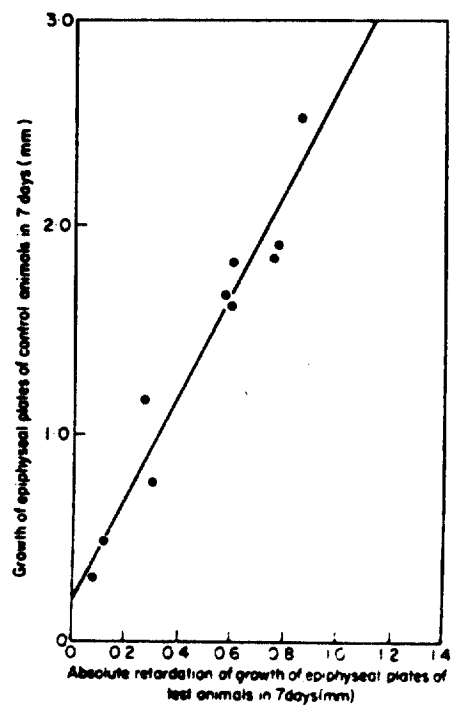

Fig. 2 Absolute retardation of growth of 10 epiphyseal plates of the test animals (x) and growth on the corresponding epiphyseal plates of the controls (y) in 7 days. The regression line linking these 2 variables has the equation $y = 2{\cdot}44x + 0{\cdot}21$. The values from which the equation was calculated are indicated by dots.

In order to ascertain whether or not there was a relationship between the normal rate of growth of an epiphyseal plate and the degree to which it was affected by an excess of vitamin A, the figures for absolute reduction in the growth of 10 epiphyseal plates in the test kittens were tested for correlation with the growth of the corresponding 10 plates in the control animals (average figures from Table 2). The correlation coefficient obtained ($r = 0{\cdot}97$) was highly significant ($P = 0{\cdot}001$) and the calculated regression line corresponding to the equation linking these 2 variables is shown in Fig. 2.

Histopathology

The epiphyseal plates of the test kittens were thinner than those of their controls, with shorter, irregular columns of chondrocytes (Table 4 and Fig. 3). Sections stained HE showed a generalized loss of basophilia, while sections stained with azure A were less metachromatic than the controls. In addition, some epiphyseal plates from the test animals showed localized areas with a grossly abnormal architecture and a staining reaction associated with vascular invasion from the epiphyseal face.

TABLE 4

EPIPHYSEAL PLATES OF KITTENS

Mean length of cell columns in 2 plates of each kitten, with mean number of cells per column, mean longitudinal diameter of last cells in columns, growth of plate per day, rate of cell formation per column per day and mean cell life

Kitten (test or control)	*Epiphyseal plate*	*Mean length cell cols. (μm.)*	*Mean no. cells/col.*	*Mean dia. last cells/col. (μm.)*	*Growth plate day (μm.)*	*Rate cell formation/ col./day*	*Mean cell life (days)*
1T	Distal	310	23·34	25·60	65·00	—	—
2C	femur	425	34·00	44·40	234·00	5·27	6·451
3T	Distal	98	13·00	28·80	216·00	—	—
4C	femur	371	35·34	45·80	268·00	5·85	6·041
5T	Distal	170	18·67	31·20	177·00	—	—
6C	femur	528	35·34	44·70	312·00	6·98	5·063
7T	Distal	377	27·34	32·30	184·00	—	—
8C	femur	488	42·00	42·30	271·00	6·41	6·552
Average tests	Distal	239	20·59	29·47	160·50	—	—
Average controls	femur	453	36·67	44·30	271·25	6·13	5·982
1T	Proximal	367	31·34	26·10	63·00	—	—
2C	tibia	589	44·34	31·00	177·00	5·71	7·765
3T	Proximal	165	14·00	29·60	201·00	—	—
4C	tibia	300	34·67	38·20	279·00	7·30	4·749
5T	Proximal	337	24·67	25·80	219·00	—	—
6C	tibia	458	41·67	41·50	314·00	7·57	5·505
7T	Proximal	438	33·00	40·40	212·00	—	—
8C	tibia	450	36·00	41·50	258·00	6·46	5·573
Average tests	Proximal	327	25·75	30·47	173·75	—	—
Average controls	tibia	449	39·17	38·05	259·50	6·76	5·794

The zones of proliferating and hypertrophic chondrocytes were reduced in thickness in the epiphyseal plates from the kittens with excess vitamin A. Moreover, the hypertrophic cells were smaller and had less vacuolated cytoplasm than normal (Fig. 4). Their nuclei were also smaller, and stained more weakly basophilic and less distinctly than those in the control plates. The lacunar borders of the abnormal hypertrophic chondrocytes were indistinct and sometimes irregular. In some areas of the hypertrophic cell zones in the test plates chondrocytes were separated by more matrix than normal, while in other areas cells were closely and irregularly packed at the base of the plate. Vascular invasion from the metaphysis was consequently irregular, and the trabeculae of the primary spongiosa were fewer and stouter than normal.

Fig. 3 Central portion of the proximal tibial epiphyseal plate of (a) kitten 1 (test) and (b) kitten 2 (control). The plate of the test kitten shows a diffuse loss of metachromasia compared with the control and is reduced in depth. The chondrocyte columns contain fewer cells than normal and are shorter and irregular. There is vascular invasion of the plate, and the trabeculae of the primary spongiosa are irregular, fewer and stouter than normal. Azure A ×62.

The matrix of epiphyseal plates from the test kittens gave the impression of being less dense than normal. Firstly, it stained more weakly than that of the controls and secondly, longitudinal fibrillation was often more distinct, the fibrils being widely separated (Fig. 5). These changes were accentuated beneath invading vascular connective tissue channels, often containing haemorrhages, which extended from the epiphyseal face deep into the plate. In the

most severe lesions longitudinal clefts in the matrix extended nearly the full depth of the plate. Areas of marked matrix rarefaction contained few chondrocytes, and cells bordering such areas exhibited pyknotic nuclei and very vacuolated cytoplasm (Fig. 5).

Fig. 4 Base of the hypertrophic cell zone of the proximal tibial epiphyseal plate of (a) kitten 1 (test) and (b) kitten 2 (control). The longitudinal diameters of the cells of the test kitten (marked by arrows) are less than the control and the cell boundaries are indistinct. In the test kitten there is increased intercellular matrix, which shows fibrillation and blood vessel invasion from the metaphysis is irregular. H.E. × 660.

Fig. 5 Portion of the proximal tibial epiphyseal plate of kitten 1 (test) at the level of the zone of proliferating chondrocytes. The chondrocytes show pyknotic nuclei and pathological vacuolation. In addition there is marked matrix rarefaction associated with abnormally distinct longitudinal fibrillation. H.E. 400.

Cellular Parameters

Measurements of the mean length of chondrocyte columns, the mean number of cells per column and the mean longitudinal diameter of the last cells in the columns were made on the distal femoral and the proximal tibial epiphyseal plates of all 8 kittens. They are presented in Table 4 which also shows the average daily growth of these plates over the experimental period, directly derived from the fluorescent labelling measurements on bones from the opposite limbs of each kitten. Calculated figures for the rate of cell formation per column per day and the mean cell life are presented for the plates from the control animals, but not for those from the treated animals for reasons to be outlined in the discussion.

In the plates of the control kittens the above parameters were fairly constant. For both the distal femoral and the proximal tibial epiphyseal plates it was estimated from the figures for daily growth that between 6 and 7 cells were being formed per column per day, and that each cell had a life expectancy of between 5 and 6 days. The epiphyseal plates of the kittens which had been dosed with vitamin A showed marked quantitative differences from those of their litter-mate controls. The mean length of the chondrocyte columns was less, there were fewer cells per column and the maximum diameter reached by the hypertrophic cells was less.

DISCUSSION

Wolbach (1947) was the first to present a detailed study of the changes in epiphyseal plates in hypervitaminosis A. Microscopically he observed that there were fewer mitoses than normal and "vesicular" cells extended far towards the epiphyseal side of an affected plate. Affected plates were thinner than normal, and were rapidly and deeply penetrated by capillaries. Their conversion to bone was abnormally fast. In the light of his own observations, it is difficult to understand how Wolbach (1947) interpreted these changes in terms of accelerated growth sequences. To explain the association of a thin epiphyseal plate with the alleged acceleration of growth processes Wolbach advocated an acceleration of maturation and degeneration of cartilage cells and their replacement by bone, resulting in complete "consumption" of the cartilage in 10 to 15 days. He drew attention to the fact that epiphyseal plates affected by excess vitamin A have a histological appearance which is similar to that of plates at the end of the growth period.

A number of authors including Becks, Simpson and Evans (1945) and Fahmy (1956) have described the histological changes associated with the reduction in thickness of an epiphyseal plate with increasing age. The main changes they observed for rats are a reduction in the thickness of the epiphyseal plate which is shared by both proliferative and hypertrophic layers; a relative increase in the amount of intercellular matrix, which shows areas of degeneration; and fewer and stouter metaphyseal trabeculae. These changes are strikingly similar to those seen in epiphyseal plates moderately affected by an excess of vitamin A. Fahmy (1956) suggested that the changes in hypervitaminosis A reflect only a reduced growth rate of the animal as a whole and are, presumably, a consequence of the reduction in food intake which occurs in this condition (Rodahl, 1950).

Although it must be admitted that the histological evidence for the above argument is good, there are now reasons for doubting its validity. For example Fell and Mellanby (1952) showed conclusively that excess vitamin A has a specific effect on cartilage when foetal mouse limb-rudiments are cultured in vitro, while Clark (1970) working on hypervitaminosis A in kittens employing pair-feeding, showed that epiphyseal plate lesions did not occur in the control animals. In the present experiment, the growth of all the epiphyseal plates, as measured by fluorescent labelling, was retarded after dosing the test kittens for 7 days with an excess of vitamin A. Taking into account the almost standard dose rate of vitamin A employed and the similar liver concentrations of the

vitamin in the test animals at necropsy, there was a marked individual variation in the susceptibility of the 4 test animals to epiphyseal plate damage. As the duration of dosing was short, it is not surprising that all the epiphyseal plates in the test kittens were still complete, although reduced in depth, and did not show the discontinuity or fragmentation which characterizes epiphyseal plate lesions in kittens dosed with vitamin A for longer periods (Clark, 1970).

Sissons (1956) was the first to point out that longitudinal bone growth is equal to the rate of production of new cells per cartilage column in an epiphyseal plate multiplied by the maximum size of the hypertrophic cells. If the rate of formation of new cells in a column is n per day, and a period of t days elapses between the formation and replacement of individual cells, then longitudinal growth rate $= nD$, (where D is the eventual longitudinal diameter of the cells), and the number of cells in column $= nt$. Sissons(1956)measured longitudinal growth rate radiographically, while the size and number of cartilage cells in the columns were determined from histological sections. The rate of production of new cells depends on the number of cells in the proliferating pool and on their average rate of division (Kember, 1971).

In the control kittens of the present study estimates of the rate of cell formation and the mean cell life were fairly constant between animals and for both epiphyseal plates examined. The figures of a cell formation rate of 6 to 7 per day, and a mean cell life of from 5 to 6 days, show little variation from those presented by Sissons (1956) for the proximal tibial epiphyseal plate in young growing rabbits.

While calculations of rate of cell formation and mean cell life can reasonably be applied to the epiphyseal plates from the control animals where growth rate can be expected to be uniform during the 7 day experimental period, this does not hold for those from the kittens with an excess of vitamin A. The epiphyseal plates in the latter became much thinner in the same length of time and it is evident that their growth progressively decreased over the 7 day dosage period. Thus figures obtained for growth over the total period could not be applied to represent the activity of the plates studied and measured at the end of the 7 day period, by which time their growth rates would be less than the mean value obtained.

Although it is well known from the literature that there are fewer chondrocytes per column in the epiphyseal plates of growing animals with hypervitaminosis A, the marked reduction of final cell size reported here has not received similar attention. Reduction in chondrocyte size in the hypertrophic cell zone was, however, observed by Fell and Mellanby (1952) in their well known in vitro experiments with embryonic limb-bone rudiments treated with excess vitamin A in organ culture.

It is obvious from the work of Sissons (1956) and Kember (1971) and from the figures presented in our paper, that reduction in cell size alone could account for a large proportion of the reduction in growth of epiphyseal plates affected by an excess of vitamin A observed in the present experiment. However, Kember (1971, 1972) feels that, in general, reduction in size of hypertrophic cells may be secondary to a reduction in the growth rate of an epiphyseal plate. This arises because the cells in a slowly growing plate may be invaded

from the metaphysis before they have increased to the maximum size observed in rapidly growing plates. Furthermore, as the epiphyseal plates in the test kittens in the present experiment were reduced in depth, it is unlikely that an increased cell life span is a cause of reduction in growth rate. It seems reasonable, therefore, to assume that a reduction in chondrocyte proliferation is the factor responsible in large measure for the reduction in growth rates of epiphyseal plates in hypervitaminosis A.

The absolute retardation of growth of epiphyseal plates in the test animals was directly proportional to their normal rates of growth as measured in the control animals and the findings have a high degree of statistical significance. Thus in short-term vitamin A toxicity the phenomenon of "amplification" (Rubin, 1964), i.e. that when epiphyseal plates are damaged equally retardation of growth is accentuated in relation to the rest of the skeleton in those bones which normally grow most in length, is applicable. Thus the differential damage to particular epiphyseal plates, including the complete cessation of growth and disappearance of certain plates, which occurs under more prolonged administration of vitamin A (Clark and Seawright, 1968; Clark *et al.*, 1970; Clark, 1970), is probably due to a secondary factor or factors.

Epiphyseal plates affected by excess vitamin A are thinner than normal and have serious matrix defects. Both the loss of metachromasia and the distinct fibrillation demonstrated in the abnormal matrix suggest a loss of mucopolysaccharide ground substance. This is a well known effect of an excess of vitamin A on cartilage (Fell and Mellanby, 1952; Thomas, McCluskey, Potter and Weissmann, 1960; Dingle, Lucy and Fell, 1961). Such plates are clearly poorly adapted to withstand the compressive stresses acting on them. Further, the stresses acting on different epiphyseal plates would vary in degree, which may be a major factor in determining the differential susceptibility to an excess of vitamin A of the various epiphyseal plates in the kitten. As the cat is notably an animal which uses its hindquarters for springing and jumping, one would expect, too, that the epiphyseal plates subject to the most stress would be those of the stifle joint.

In conclusion, it is suggested that in the early stages of vitamin A intoxication in the cat, as described here, growth retardation of individual epiphyseal plates is directly proportional to their normal rates of growth. In longer-term experiments such as those described previously (Clark and Seawright, 1968; Clark *et al.*, 1970; Clark, 1970), as the plates become progressively weakened due to pathological changes in both chondrocytes and their matrix, those subject to the greatest compressive forces collapse, thus becoming discontinuous or fragmented.

SUMMARY

The growth and structure of epiphyseal plates was studied in normal kittens, and in kittens given an excess of vitamin A for 7 days prior to necropsy. Growth measurements were made on 10 different epiphyseal plates from each animal by means of in vivo labelling with a fluorescent dye. It was found that the growth of all plates was retarded in kittens which had received an excess of vitamin A.

The absolute retardation of growth of each plate was directly proportional to its normal rate of growth as assessed in the control animals.

The opposite limbs of each kitten were used for the study of histopathological changes and the measurement of various cellular parameters. Epiphyseal plates from the test animals were reduced in depth, contained fewer chondrocytes arranged in shorter, irregular columns and the hypertrophic cells were smaller. The cartilaginous matrix exhibited a diffuse loss of basophilia and of metachromasia, and coarse fibrillation.

Measurements of growth rate and various cellular parameters were used to calculate the rate of cell formation per column and the average cell life span in epiphyseal plates from the control animals. Owing to the rapid development of pathological changes upsetting the state of dynamic equilibrium in the test plates, similar estimations in these would not have been valid. However, arguments are presented to suggest that an excess of vitamin A retards the growth of epiphyseal plates by affecting the rate of formation of new chondrocytes and, either directly or indirectly, the maximum size reached by the chondrocytes in the hypertrophic cell zone.

It was further concluded that, although differential susceptibility of certain epiphyseal plates to an excess of vitamin A has been reported in kittens dosed for longer periods, it is most likely that vitamin A primarily affects epiphyseal plates in proportion to their normal rates of growth. With increasing time secondary factors probably act on the abnormal plates, accounting for differences in the severity of lesions exhibited by them. Reasons are put forward to suggest that the stress of weight bearing may well be the most important factor involved in this process.

ACKNOWLEDGMENTS

The author wishes to thank Professor H. A. Sissons (Institute of Orthopaedics, London) for his expert advice. Mrs Jana Hrdlicka (University of Queensland Veterinary School, Australia) carried out the vitamin A analyses, and members of the technical staff of the Department of Morbid Anatomy, Institute of Orthopaedics, London, assisted with other work.

REFERENCES

—— (1960). In *Manual of Histologic and Special Staining Technics*, U.S. Armed Forces Institute of Pathology, 2nd Edit. The Blakiston Division, McGraw-Hill Book Co. Inc.; New York, Toronto and London.

Becks, H., Simpson, M. E., and Evans, H. M. (1945). *Anat. Rec.*, **92**, 109.

Carr, F. H., and Price, E. A. (1926). *Biochem. J.*, **20**, 497.

Clark, L., and Seawright, A. A. (1968). *Nature, Lond.*, **217**, 1174.

Clark, L., Seawright, A. A., and Gartner, R. J. W. (1970). *J. comp. Path.*, **80**, 113.

Clark, L. (1970). *Ibid.*, 625.

Dingle, J. T., Lucy, J. A., and Fell, H. B. (1961). *Biochem. J.*, **79**, 497.

Fahmy, A. (1956). *An Experimental Study of some Factors affecting Bone Growth*, Ph.D. Thesis; Univ. London.

Fell, H. B., and Mellanby, E. (1952). *J. Physiol.*, **116**, 320.

Gartner, R. J. W., and Ryley, J. W. (1956). *Q'ld. J. agric. Sci.*, **13**, 1.

Hansson, L. I. (1967). *Acta Orthop. Scand.*, Suppl. 101, 1.

Hulth, A., and Olerud, S. (1962). *Acta Soc. Med. Upsalien.*, **67**, 219.

Kember, N. F. (1971). *Clin. Orthop. and Rel. Res.*, **76**, 213; (1972). *J. Anat.*, **111**, 137.
Pearse, A. G. E. (1960). In *Histochemistry*, 2nd. Edit., J. & A. Churchill Ltd.; London.
Rodahl, K. (1950). *Norsk. Polarinstitutt, Skrifter No.* 95, Oslo, Norway.
Rubin, P. (1964). In *Dynamic Classification of Bone Dysplasias*, Year Book Medical Publishers Inc.; Chicago.
Scott, P. P. (1965). In *Canine and Feline Nutritional Requirements*, (Proceedings of a symposium organized by the British Small Animal Veterinary Association), pp. 75–90, Edit. by Graham-Jones, O. Pergamon Press; Oxford.
Sissons, H. A. (1956). In *Progress in Radiobiology*, Proc. 4th Internat. Conf. on Radiobiology, Cambridge 1955, pp. 436–448, Edit. J. S. Mitchell, B. E. Holmes and C. L. Smith, 1956
Smith, A. H. (1931). *J. Nutr.*, **4**, 427.
Strauss, K. S. (1934). *Beitr. path. Anat.*, **94**, 345.
Tapp, E. (1966). *J. Bone Jt Surg.*, **48B**, 517.
Thomas, L., McCluskey, R. T., Potter, J. L., and Weissmann, G. (1960). *J. exp. Med.*, **111**, 705.
Wolbach, S. B. (1947). *J. Bone Jt Surg.*, **29A**, 171.
Wolke, R. E., Nielsen, S. W., and Rousseau, J. E. (1968). *Amer. J. vet. Res.*, **29**, 1009.

[*Received for publication, November 9th*, 1972]

Clark-'70
Bib. No. 10345

Reproduced by permission
of the copyright owner

LONGBONE ABNORMALITIES IN KITTENS FOLLOWING VITAMIN A ADMINISTRATION

By

Leigh Clark and A. A. Seawright

Veterinary School, University of Queensland, Brisbane, Australia

and

R. J. W. Gartner

Animal Research Institute, Queensland Department of Primary Industries, Brisbane, Australia

INTRODUCTION

Chronic hypervitaminosis A causes extensive confluent exostoses of the cervical spine in adult cats fed whole liver diets, and has been produced experimentally by daily vitamin A administration for several months (Seawright, English and Gartner, 1965, 1967). Recently, spectacular and permanent alterations in long bone morphology were produced in kittens dosed with high levels of vitamin A for a short period at the time of their most active bone growth (Clark and Seawright, 1968). These preliminary observations have been extended and the composite results are presented in this paper.

MATERIALS AND METHODS

Animals and treatments. Each of 4 litters of healthy kittens, 15 animals in all, was divided into control (7 animals) and test groups (8 animals). The test animals were given vitamin A for 4 or 5 weeks at a level adjusted daily to depress appetite and playfulness but to avoid acute toxicity. This ranged from approximately 40 to 100 μg./g. body weight. They received no further doses of vitamin A before they were destroyed from 6 to 15 weeks later. Details of experimental animals and treatment are presented in Table 1.

The vitamin A preparation used* was water-miscible and contained 500,000 i.u. (approx. 172,000 μg.) of vitamin A acetate/ml. It was administered in gelatin capsules†. In addition, both control and test kittens received subcutaneously twice weekly 0·5 ml. of "Calci-ostelin"‡ containing 5,000 i.u. of vitamin D and 0·5 mg. colloidal calcium/ml., to prevent rickets due to a possible interaction between vitamin A and vitamin D (Niemen and Klein Obbink, 1954). The diet of the kittens consisted of milk ad lib and raw beef. Periodically throughout the experiment several radiographs were taken of all kittens in litter 1.

Post-mortem procedures. The kittens were destroyed by barbiturate given intraperitoneally. Selected bones were cut longitudinally in the mid-sagittal plane, fixed in buffered neutral formalin and decalcified by the formic acid—sodium citrate method (U.S. Armed Forces Institute of Pathology, 1949). Paraffin sections were stained with Mayer's haematoxylin and eosin and van Gieson. Other bones were

* E. R. Squibb Vitamin A W/M oral
† Parke, Davis
‡ Glaxo

macerated in cold water, defatted in chloroform and bleached in 2 per cent. hydrogen peroxide. Liver and kidney levels of vitamin A were determined by the method of Gartner and Ryley (1956).

Bone measurements. In each litter the bones of a control kitten were compared with those of a test kitten of the same sex, i.e. kittens 1 and 6, 7 and 10, 11 and 12, 13 and 14. The following macerated bones were weighed and measured: pelvis, right femur, tibia, humerus, radius and scapula. Long bone lengths were taken between proximal and distal articular surfaces. Mid-shaft diameter was measured cranio-caudally. Each scapula was measured in its longest dimension from the glenoid cavity. Pelvic length between the tuber coxae and the tuber ischii of the right side was recorded. The differences between control and test groups of kittens were tested for significance using Student's t test.

RESULTS

Clinical Observations

The 8 test kittens showed dullness and reluctance to walk throughout the experiment. Their food intake was depressed to approximately 20 to 40 per cent. of that of the controls from the end of the first week until vitamin A dosing ceased: thereafter, the appetites of the test kittens gradually improved. The

TABLE 1

EXPERIMENTAL ANIMALS AND VITAMIN A TREATMENTS

Kitten and sex	*Litter**	*Dosage period (weeks*	*Mean daily dose of vitamin A (μg.)*
1(F), 2(M), 3(F)	1	—	—
4(M), 5(F), 6(F)	1	4	34,000
7(F), 8(F)	2	—	—
9(M), 10(F)	2	5	69,763
11(F)	3	—	—
12(F)	3	5	61,920
13(M)	4	—	—
14(M), 15(F)	4	4	41,762 (14) 49,192 (15)

* Litter 1, kittens 2 and 5 killed at 10 weeks and kittens 1, 3, 4 and 6 at 17 weeks; litter 2, killed at 18 weeks; litters 3 and 4 killed at 19 weeks.
Dosage commenced when the kittens were 8 weeks old. The first week of dosage was week 1 of the experiment.

weight gains of control and test kittens relative to one another were similar in each litter and are shown in Fig. 1. Peeling of the epithelium of the pads and frequent blinking were observed in the test kittens during the period of dosing.

The test kittens showed a distinct gait abnormality by the 10th week and this became more marked with time. The limbs were short, and the hind limbs appeared especially so. There was restricted movement of the stifle joints and the hocks projected laterally. Some toes in the hind paws of all test kittens were shorter than normal by the 16th week. In some paws all toes were involved.

Fig. 1.

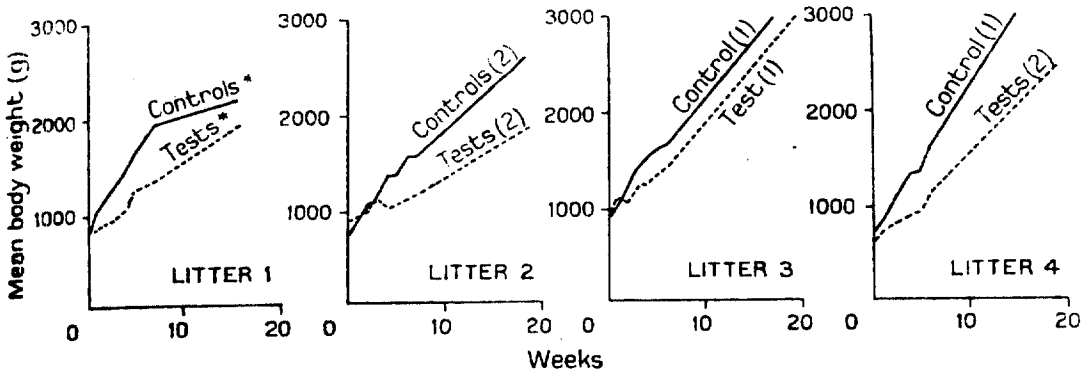

Relative weight gains of control and test kittens in each litter, for the duration of the experiment.
* To the 10th week there were 3 control and 3 test kittens in litter 1. Subsequently there were 2 kittens in each group.

Radiographic Findings

The controls showed normal bone development and density. In the test kittens the degree of mineralisation appeared normal throughout the experiment, but abnormalities in shape first appeared during the 8th week and became more marked subsequently. The large long bones of the limbs had indistinct epiphyseal lines and were shorter than normal with a slightly narrower shaft. The epiphyses, however, were as large as those of the controls. The crest of each tibia was elongated dorsally and caused the tibial tuberosity to extend beyond the tibial condyles and impinge on the femoral trochlea (Fig. 2). At the same time, the femoral condyles were displaced caudally. Fig. 3 allows a radiographic comparison of macerated control and test femurs and tibias. In the 16th week radiographs were taken of the hind paws of the four remaining kittens in litter 1. Some metatarsal bones in the kittens which had received vitamin A were shorter than normal, and in these bones the distal epiphyseal lines were absent (Fig. 4).

Gross Pathology

The principal gross changes were in the bones and varied between test kittens only in degree. Comparative bone measurements of control and test kittens are presented in Table 2, together with significant differences. The weights of all long bones were significantly less in the test kittens than in the controls. The large long bones of the limbs were considerably shorter in the kittens which had received vitamin A. The reduction in length was due to shortening of the diaphyses. Mid-shaft diameter was not significantly reduced except in the radius, but most long bones showed slight metaphyseal flaring. In spite of the marked reduction in length of the long bones, the epiphyses were of approximately normal size, although some showed characteristic alterations in shape.

TABLE 2

MEASUREMENTS OF BONES

Four pairs of control and test kittens of the same sex with significance of differences

Kitten	*Femur* Weight (g.)	*Femur* Length (cm.)	*Femur* Diameter (cm.)	*Tibia* Weight (g.)	*Tibia* Length (cm.)	*Tibia* Diameter (cm.)
1(c)	3·71	9·20	0·65	3·39	9·70	0·60
6(t)	2·31	5·87	0·70	1·83	5·60	0·57
7(c)	3·82	9·27	0·69	4·01	9·60	0·65
10(t)	2·85	7·40	0·65	2·58	6·88	0·65
11(c)	4·33	9·96	0·68	4·04	10·09	0·66
12(t)	3·47	9·60	0·60	3·44	8·42	0·56
13(c)	5·21	10·50	0·74	5·62	10·30	0·76
14(t)	3·19	9·64	0·67	3·08	7·00	0·60
	***	*	NS	**	***	NS
	Humerus			*Radius*		
1(c)	3·11	7·93	0·70	0·39	6·98	0·30
6(t)	1·99	5·66	0·70	0·63	4·56	0·30
7(c)	3·43	8·16	0·81	1·22	7·46	0·30
10(t)	2·24	6·37	0·65	0·76	5·36	0·30
11(c)	3·61	8·28	0·78	1·43	7·80	0·36
12(t)	3·31	8·26	0·76	1·20	7·48	0·30
13(c)	4·32	8·90	0·88	1·90	8·17	0·40
14(t)	3·21	8·17	0·84	1·15	7·28	0·36
	**	*	NS	**	*	*
	Scapula			*Pelvis*		
1(c)	0·92	5·27		2·99	6·50	
6(t)	1·01	5·49		2·51	6·25	
7(c)	1·18	5·60		4·05	6·64	
10(t)	1·00	5·10		3·24	6·37	
11(c)	1·55	6·29		4·37	7·08	
12(t)	1·36	6·09		3·59	7·00	
13(c)	2·08	6·55		5·21	7·46	
14(t)	1·34	5·57		3·02	6·60	
	NS	NS		*	NS	

* $p = 0·05$ or $p < 0·05$
** $p = 0·025$ or $p < 0·025$
*** $p = 0·01$

NS No statistical significance
(c) = control
(t) = test (dosed)

As determined radiologically, the main change in the tibia was a dorsal elongation of the crest, which continued the curvature of the crest proximally and caudally, carrying the tuberosity with it. In tibias showing the most advanced change the tuberosity had been rotated through one hundred and eighty degrees (Fig. 2). The proximal articular surfaces of the tibial condyles were slightly concave and sloped downwards from the cranial margins. The medial condyle was slightly more depressed than the lateral one. No prominence resembling a spine remained. The cranial distal diaphysis of the femur was elongated, causing the epiphysis to be rotated caudally and dorsally. In femurs showing the most advanced change the position of the condyles was dorsal to the trochlea. At the same time, the epiphysis tended to be flattened, resulting in a wider intercondyloid

fossa and a shallow trochlea. The lateral condyle was always larger than the medial one. Changes in the morhphology of the humerus resembled those in the tibia, but were less marked. The cranio-dorsal aspect of the diaphysis was elongated above the articular surface of the head, carrying the greater tuberosity with it. Consequently the intertuberal groove was deeper and the head of the humerus less rounded than normal. Apart from being shorter, with flaring at the metaphyses, the appearance of the radius was not significantly altered.

The scapula and pelvis were comparable in length and shape in the control and test groups. Both bones weighed less in the test animals, but this was only statistically significant for the pelvis.

Microscopic Pathology

The proximal end of the tibia and the distal ends of the radius and metatarsal bones were studied. The principal changes were in the cartilaginous epiphyseal plates of the tibia and radius. Some metatarsal bones in each kitten were similarly affected.

Normally, the major portion of the proximal tibial epiphyseal plate lies at right angles to the long axis of the diaphysis. Anteriorly, this plate diverges obliquely to extend below the secondary ossifying centre of the tibial tuberosity, which is separated from the rest of the proximal epiphysis by a band of cartilage which extends dorsally from the area of the junction of straight and oblique portions of the epiphyseal plate. The cranial oblique portion of the epiphyseal plate merges cranially with dense collagenous fibres, which form part of the attachment of the patellar ligament to the bone of the diaphysis (Fig. 5). In the test kittens it was found that the major straight portion of the proximal tibial epiphyseal plate had wholly or partially disappeared, whilst its cranial oblique portion, as well as the cartilaginous band extending above the tuberosity, remained. The cranial portion of the epiphyseal plate in these animals extended obliquely upwards rather than downwards due to a relative elongation of the crest with dorsal displacement of the tuberosity (Fig. 6). In bones with advanced changes the dorsal extension of the tibial crest was more marked and the tuberosity displaced caudally so that the fibro-osseous attachment of the patellar ligament was uppermost (Fig. 7).

The distal cartilaginous epiphyseal plates of several of the radii and metatarsals examined also showed partial or complete disappearance. In the least affected bones the epiphyseal plates were not straight, but were depressed centrally into the medullary cavity of the diaphysis. Most of the plates showing this change were discontinuous in the centre. In many instances continuous trabeculae of spongy bone extended through the central gap to link diaphysis with epiphysis. At the periphery these epiphyseal plates were usually normal in structure, but they became progressively reduced in width with disorganised cell columns centrally. Next to the broken edges no distinct columns remained and there was a marked reduction in multiplying and degenerating chondrocytes and endochondral bone formation. In bones showing more advanced lesions the central gap in the epiphyseal plate was wider and sometimes only fragments of the plate remained, mainly at the periphery of the extended medullary cavity. Ocassionally there was no remnant of an epiphyseal plate and only a few

trabeculae of spongy bone remained in the medullary cavity linking the epiphysis and diaphysis. In all the metatarsal bones where epiphyseal plates were reduced or absent, there was marked sub-periosteal proliferation of new woven bone from the metaphyseal region. In some bones the proliferation extended to form a collar around the neck of the epiphysis (Fig. 8).

The pattern of disappearance of epiphyseal cartilage differed in one cat in that the plates of the metatarsals were reduced in depth across their whole diameter and chondrocytes were greatly reduced in number and were not arranged in rows. Coarse trabeculae of spongy bone were being formed on both diaphyseal and epiphyseal surfaces and had almost completely replaced the remaining cartilage which did not show a central discontinuity (Fig. 9). In one bone, however, the cartilage was completely replaced by a thin bony bridge separating epiphysis from diaphysis. The pathological changes in the epiphyseal plates of the tibia and radius of this kitten were as in the other test animals.

In all sections examined there were no marked differences in the width or porosity of diaphyseal compact bone between control and test animals. There were no inflammatory or degenerative changes in articular cartilages or synovial membranes.

Vitamin A in Liver and Kidney

The concentration and total vitamin A in liver and kidney, and the mean intake of vitamin A for all kittens are shown in Table 3. The liver levels in the control kittens from litters 2, 3 and 4 were low, whereas the ingestion of liver for a week by the remaining kittens in litter 1 markedly increased hepatic reserves. Predictably, the administration of vitamin A caused appreciable storage in the livers and kidneys, but the number of animals available was insufficient and the range of dose rates too narrow to examine relative storage.

TABLE 3

TOTAL AMOUNT OF VITAMIN A ADMINISTERED TO EACH KITTEN AND LIVER AND KIDNEY VITAMIN A LEVELS AT POST MORTEM

Kitten	*Total vitamin A administered* (μg.)	*Liver vitamin A* (μg./g.)	*Total liver vitamin A* (μg.)	*Kidney vitamin A* (μg./g.)	*Total kidney vitamin A* (μg.)
1	—	1,218*	N.A.	N.A.	N.A.
2	—	58	,,	,,	,,
3	—	1,524*	,,	,,	,,
4	952,000	5,053	,,	,,	,,
5	,,	6,960	,,	,,	,,
6	,,	4,356	,,	,,	,,
7	—	<1	<80	95	1,520
8	—	7	553	145	2,755
9	2,441,705	7,840	627,200	242	4,114
10	,,	5,936	451,136	255	3,315
11	—	3	273	46	920
12	2,167,200	3,868	335,856	245	4,900
13	—	3	336	34	850
14	1,169,336	3,006	309,613	140	3,080
15	1,377,376	3,119	265,115	160	3,200

* Control kittens 1 and 3 had higher liver levels of vitamin A than kitten 2 because in the 16th week they were fed on ox liver in lieu of the regular meat diet.

DISCUSSION

High levels of vitamin A cause dissolution and destruction of cartilage matrix both in vitro (Fell and Mellanby, 1950) and in vivo (Thomas, McCluskey, Potter and Weissman, 1960). Degenerative changes in cartilaginous epiphyseal plates resulting in reduction in longitudinal growth of long bones through failure of endochondral ossification have been previously reported in hypervitaminosis A in the young rat and guinea pig (Wolbach, 1947), the dog (Maddock, Wolbach and Maddock, 1949), the calf (Grey, Neilsen, Rousseau, Calhoun and Eaton, 1965) and the pig (Wolke, Neilsen and Rousseau, 1968). Reduction in intramembranous ossification in some bones through suppression of osteoblastic activity has also been reported in hypervitaminosis A in some species (Wolbach, 1947; Irving, 1949; Rodahl, 1950; Grey *et al.*, 1965; Wolke *et al.*, 1968). This effect of excess vitamin A does not appear to be a prominent feature of the bone lesions in the kitten, but the relatively long period after dosing that elapsed before the animals were destroyed probably obscured such an effect in the present study. There do not appear to be other reports of similar experiments in which young animals have been given high doses of vitamin A for a short period and then allowed to continue growing on a diet low in the vitamin. However, irregular growth of the legs due to irreparable damage to some epiphyseal plates has been reported in children during recovery from acute hypervitaminosis A (Pease, 1962).

The consistent marked alteration in the morphology of the stifle joint took place in the recovery period. It was observed in all tibias that there was selective destruction of the major caudal portion of the proximal epiphyseal plate, while that of the tuberosity continued to grow. It would appear that the caudal part of the distal femoral epiphyseal plate was also selectively damaged. The pattern of disproportionate growth of the cranial proximal diaphysis of the tibia and the cranial distal diaphysis of the femur was probably modified by new stresses set up by an altered stifle joint action. The shape of the epiphyses in the stifle joint would also have been influenced by this factor. There must have been adequate compensatory and complementary development of muscles, tendons and ligaments, as in no joint was there evidence of developing osteoarthritis, which might have been expected with such deformity. Conformational modifications in the limbs of cats with such stifle joints are currently being studied.

Periosteal exostoses are a manifestation of chronic hypervitaminosis A in man (Caffey, 1951; Fairbank, 1951) and the cat (Seawright *et al.*, 1965, 1967). Early lesions have also been described in the pig, and occurred after 5 weeks feeding on an experimental ration high in vitamin A (Wolke *et al.*, 1968). In adult cats a high intake of vitamin A is necessary for several months before cervical exostoses develop, and trauma is thought to be a contributing factor in their pathogenesis, due to constant movement of the neck in coat cleaning (Seawright *et al.*, 1965, 1967). Lesions resembling early exostoses occurred in the kittens studied here in the metatarsal bones with reduced or absent epiphyseal plates. These shortened bones were probably subject to unusual trauma in the region of ligament or joint capsule attachments. The directional growth of the periosteal proliferation around the neck of the epiphysis would tend to support this suggestion. It would appear, in the cat at least, that high blood levels of vitamin A for a short period

are sufficient to cause destruction of cartilaginous epiphyseal plates, while exostoses develop after a more prolonged exposure and are associated with higher liver levels of the vitamin.

SUMMARY

High levels of vitamin A were administered daily to 8 kittens for 4 or 5 weeks after weaning, and they were destroyed after a further 6 to 15 weeks. At necropsy, most of the long bones were considerably shorter than those of litter mate controls and some showed abnormal morphology due to an altered growth pattern in the post-dosage period. Histopathologically there was variable damage to epiphyseal growth plates and in some long bones no remnant of an epiphyseal plate remained.

ACKNOWLEDGMENTS

The authors are indebted to Dr. T. H. Vickers for his valuable advice, and to Professor J. Francis for providing the facilities for this study.

REFERENCES

—— (1949). in *Manual of Histologic and Special Staining Technics,* U.S. Armed Forces Institute of Pathology, McGraw-Hill Book Company, Inc.; New York, Toronto and London.

Caffey, J. (1951). *Amer. J. roentgenol. radium Therapy,* **65,** 12.

Clark, L., and Seawright, A. A. (1968). *Nature, Lond.,* **217,** 1174.

Fairbank, T. (1951). in *An Atlas of General Affections of the Skeleton,* E. and S. Livingstone; Edinburgh and London.

Fell, H. B., and Mellanby, E. (1950). *Brit. med. J., ii,* 535.

Gartner, R. J. W., and Ryley, J. W. (1956). *Q'ld. J. agric. Sci.,* **13,** 1.

Grey, R. M., Nielsen, S. W., Rousseau, J. E., Calhoun, M. C., and Eaton, H. D. (1965). *Path. vet.,* **2,** 446.

Irving, J. T. (1949). *J. Physiol.,* **108,** 92.

Maddock, C. L., Wolbach, S. B., and Maddock, S. (1949). *J. Nutr.,* **39,** 117.

Nieman, C., and Klein Obbink, H. J. (1954). *Vitamins and Hormones,* **12,** 69.

Pease, C. N. (1962). *J. Amer. med. Ass.,* **182,** 980.

Rodahl, K. (1950). *Norsk Polarinstitutt Skrifter,* No. 95.

Seawright, A. A., English, P. B., and Gartner, R. J. W. (1965). *Nature, Lond.,* **206,** 1171; (1967). *J. comp. Path.,* **77,** 29.

Thomas, L., McCluskey, R. T., Potter, S. L., and Weissman, G. (1960). *J. exp. Med.,* **111,** 705.

Wolbach, S. B. (1947). *J. bone and joint Surg.,* **29,** 171.

Wolke, R. E., Nielsen, S. W., and Rousseau, J. E. (1968). *Amer. J. vet. Res.,* **29,** 1009.

[*Received for publication, May 19th,* 1969]



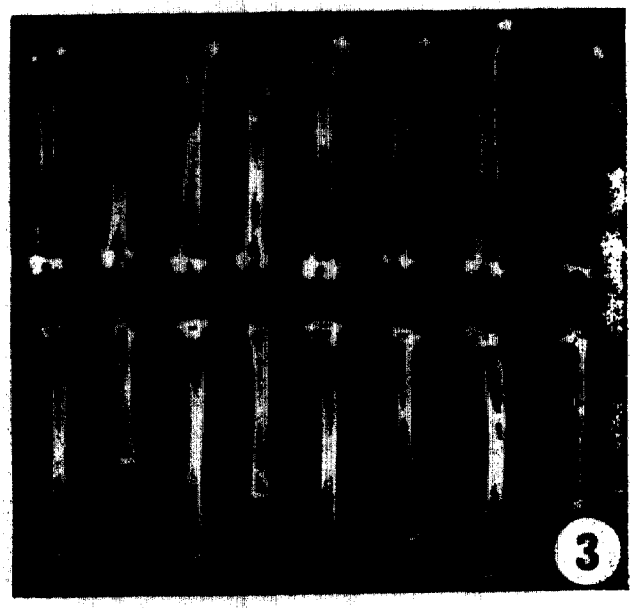



To face page 120

DeLuca-'69
Bib. No. 10372

THE AMERICAN JOURNAL OF CLINICAL NUTRITION
Vol. 22, No. 8, August, 1969, pp. 1050-1062
Printed in U.S.A.

Vitamin A and Protein Synthesis in Mucous Membranes[1]

L. DE LUCA AND G. WOLF

THE PRESENT SYMPOSIUM on vitamin A has made abundantly clear that four physiologically distinct effects of vitamin A deficiency can now be defined: *a*) degeneration of the retina; *b*) degeneration of the reproductive organs (seminiferous tubules) in the male and resorption of the fetus in the female animal; *c*) bone malformation, due possibly to a lack of osteoclastic activity, with continuing osteoblastic activity during remodeling of bone (1), which can lead to nervous lesions, caused by pressure on the central nervous system due to bone overgrowth (2); *d*) degeneration of mucus-secreting membranes and their subsequent keratinization; and, generally, keratinization of most ectoderm-derived glands. This last named symptom of vitamin A deficiency seems to be the decisive one in causing the death of animals in a normal (germ-infected) environment. Vitamin A, therefore, is needed for normal maintenance of the retina and reproductive functions, normal bone remodeling, and most importantly, maintenance of mucus-secreting epithelia.

Basal cells of epithelium have two pathways of cytodifferentiation open to them; they normally have the property of keratinization, but can be directed by the presence of excess vitamin A to form columnar, mucus-secreting cells (3). It seems as though different tissues have different thresholds to vitamin A action (4), the tissue with the lowest being the epithelial lining of the gastrointestinal tract. In the presence of normal levels of vitamin A, its basal cells produce mucus-secreting (goblet) cells; in the absence of vitamin A, these cells degenerate. The next highest threshold is the columnar epithelium of the trachea (4), which changes to a stratified, squamous type of tissue in vitamin A deficiency. A tissue with higher threshold is cornea epithelium, which, normally consisting of stratified, squamous cells, in vitamin A deficiency begins to keratinize. Finally, there is the epidermis. This tissue, even under normal, vitamin A-sufficient conditions, synthesizes keratin but increases this production during deficiency. As Fell (3) showed, if embryonic epidermis in tissue culture is exposed to massive doses of the vitamin, even this tissue can be directed to become mucus secreting. Electron microscopic studies by Jackson and Fell (5) have demonstrated that this transformation originates in the basal cells. Upon withdrawal of the vitamin from the medium on which these cells grow, tightly packed bundles of filaments appear rapidly around the nuclei of the basal cells. These filaments represent the earliest stage of keratinization. In some way, therefore, the absence of vitamin A directs the protein-synthesizing machinery of the cell to produce keratin; the presence of vitamin A stimulates the production of glycoprotein, which is the principal constituent of mucus.

We found in our laboratory that the behavior of intestinal mucosa towards vitamin A deficiency is similar to the behavior of chick embryo skin explants when trans-

From the Department of Nutrition and Food Science, Massachusetts Institute of Technology, Cambridge, Massachusetts.

ferred from a vitamin A-rich to a vitamin A-free medium; the mucus-secreting cells degenerate and are shed. Histologically, we found only about one-half the number of goblet cells in the intestinal wall of deficient rats (6), although there is no evidence of subsequent keratinization.

We regard the intestinal mucosa as a model for mucous membranes and are investigating the effect of vitamin A deficiency thereon.

We attempted to study this tissue on the assumption that the action of vitamin A on its differentiation must occur at some point along the pathway of gene expression: DNA→RNA→protein. Whereas various research groups are investigating the earlier stages of this pathway, we decided to begin with a study of protein synthesis and work backwards through protein, glycoprotein, cytoplasmic RNA, and so on (6). In particular, we attempted to determine the locus of the action of vitamin A in glycoprotein synthesis. We first concentrated on the protein core and studied in vitro protein synthesis in subcellular fractions from the small intestine of pair-fed normal and vitamin A-deficient rats.

In order to analyze the elements of the protein-synthesizing mechanism of mucosal cells, we began by sucrose gradient analysis of the polyribosomes. Surprisingly, the preparation from vitamin A-deficient mucosa showed a pattern resembling that obtainable from liver, with heavy polyribosomes (10 ribosomes or more) predominating, whereas normal mucosa yielded predominantly small aggregates of 2–4 ribosomes. The recent work of Alpers and Isselbacher (7) suggested that ligation of the common bile duct would result in preservation of polyribosomes with larger numbers of ribosomes. When ligation was performed 18 hr prior to the killing of the animals, identical polyribosome patterns from deficient and normal rat mucosa were obtained. Both consisted mainly of heavy aggregates of 10 or more ribosomes. From this point on, all animals used in this work were subjected to ligation of the common bile duct 18 hr before use.

The protein-synthesizing activity of the free polyribosomes was then tested.

The kinetics of incorporation of a labeled amino acid into protein by polyribosomes shows a slight decrease (about 12%) in deficient polyribosomes. Upon repeating this experiment several times, however, this decrease often disappeared. We concluded that the rate of protein synthesis on polyribosomes is not affected by vitamin A deficiency. We next attempted to determine whether protein synthesis on rough endoplasmic reticulum (RER) was affected by vitamin A deficiency.

For protein synthesis to proceed, not only the RER but also an enzyme fraction from the cell sap was needed (pH 5 fraction). The protein-synthesizing capacity of deficient was found to be markedly lower than of normal RER. Next, RER from deficient animals was incubated with pH 5 fraction from normals and vice versa. Such crossing-over experiments showed that the lesion produced by the vitamin deficiency was located in the pH 5 fraction and not in the RER. Such lesions were detected in animals even at the plateau stage. Finally, the beginning of a difference between deficient and normal animals was detected before the weight-plateau stage had been reached, in other words, before any overt symptoms of vitamin A deficiency had appeared.

A control experiment was necessary to demonstrate that the observed lesion did not occur in the livers of vitamin A-deficient rats. As had already been observed by Wolbach and Howe (8), the parenchymal cells of the liver are not affected by vitamin A deficiency. In fact, the difference in protein synthesis observed in liver RER and pH 5 fraction was slight. Actually, the protein-synthesizing system from liver of deficient rats showed higher incorporating activity than that from normal rats.

The results demonstrate that protein synthesis by membrane-bound but not by the polyribosomes of intestinal mucosa is depressed under conditions of vitamin A deficiency. Therefore, vitamin A in intestinal mucosa and by extension most probably in other mucous membranes, functions at some point in the process of protein synthesis, directly or indirectly at the level of "translation." Since this effect is only apparent with membrane-bound polyribosomes, it is clear that the vitamin is needed for the synthesis of a protein that is made on the RER. This result immediately suggests a glycoprotein. We have, in fact, obtained evidence to show that one of the glycoproteins of intestinal mucosa is not synthesized in vitamin A deficiency.

When labeled glucosamine was injected into deficient and pair-fed normal rats, the glycoprotein fraction of intestinal mucosa could be isolated and, after digestion of the protein moiety, separated into five different glycopeptides from the normal animal and four from the deficient, by chromatography on DEAE-Sephadex columns. Peak 3 is missing in the deficient intestine. In the normal, it was found to be high in hexoses, glucosamine, and glucuronic acid and low in sialic acid. Peak 5, which appeared both in the normal and deficient intestines and had a similar composition, was more than twice as large in the deficient, suggesting a precursor-product relation between these two glycoproteins in vivo.

There certainly is, then, a lesion in the synthesis of one of the intestinal glycoproteins caused by the vitamin deficiency. From what we now know about the locus of the synthesis of this type of protein, it would not seem surprising, then, that the depression in protein synthesis can be shown only with membrane-bound polyribosomes, not with the free kind. However, the crossing-over experiments mentioned earlier demonstrated that the actual effect resides in the pH 5 fraction. This fraction, obtained by precipitation from the cytoplasm, consists in the main of transfer RNA and the aminoacyl tRNA synthetases. Using the pH 5 fraction only, together with labeled amino acids, it was possible to demonstrate that the transfer of amino acids to tRNA was greatly depressed in the deficient system. When keeping the protein concentration constant, but increasing the concentration of homologous tRNA added to the system, we were able to show that the difference between deficient and normal pH 5 fraction was maintained, however high the concentration of tRNA, thus pointing to an effect of the vitamin deficiency on the aminoacyl tRNA synthetase enzymes. We are now attempting to determine whether this is an effect on the activity or the synthesis of these enzymes.

What kind of hypothesis can be formulated to account for these results? There is a growing body of work (e.g., Strehler et al. (9)) that points towards translational control of differentiation. More than one kind of tRNA exists for a number of amino acids investigated, and, therefore, presumably also more than one type of synthetase. One could speculate that, to change the type of protein to be translated, a new set of synthetases has to be activated or made to match a change in the tRNA that can recognize a change in the messenger RNA. Perhaps the vitamin can influence the type of aminoacyl tRNA synthetase activity or biosynthesis in mucosal cells, thereby controlling cell differentiation.

REFERENCES

1. Hayes, K. C., S. W. Nielsen and H. D. Eaton. Pathogenesis of the optic nerve lesion in vitamin A-deficient calves. *Arch. Ophthalmol.* 80: 777, 1968.
2. Howell, J. M., and J. N. Thompson. Changes in the central nervous system of vitamin A deficient chickens. *Brit. J. Exptl. Pathol.* 46: 18, 1965.
3. Fell, H. B. The effect of excess vitamin A on cultures of embryonic chicken skin explanted

at different stages of differentiation. *Proc. Roy. Soc., London, Ser. B.* 146: 212, 1957.

4. PARNELL, J. P., AND B. S. SHERMAN. Effects of vitamin A on keratinization in the A-deficient rat. In: *Fundamentals of Keratinization*, edited by F. O. Butcher and R. F. Sognnaes. Washington, D.C.: Am. Assoc. Advan. Sci., 1962, p. 113.
5. JACKSON, S. F., AND H. B. FELL. Epidermal fine structure in embryonic chicken skin during atypical differentiation induced by vitamin A in culture. *Develop. Biol.* 7: 396, 1963.
6. DE LUCA, L., E. P. LITTLE AND G. WOLF. Vitamin A and protein synthesis by rat intestinal mucosa. *J. Biol. Chem.* 244: 701, 1969.
7. ALPERS, D. H., AND K. J. ISSELBACHER. Protein synthesis by rat intestinal mucosa. *J. Biol. Chem.* 242: 5617, 1967.
8. WOLBACH, S. B., AND P. R. HOWE. Tissue changes following deprivation of fat-soluble A vitamin. *J. Exptl. Med.* 47: 753, 1925.
9. STREHLER, B. L., D. D. HENDLEY AND G. P. HIRSCH. Evidence on a codon restriction hypothesis of cellular differentiation: Multiplicity of mammalian leucyl-sRNA-specific synthetases and tissue-specific deficiency in an alanyl-sRNA synthetase. *Proc. Natl. Acad. Sci., U. S.* 57: 1751, 1967.

DeLuca-'69
Bib. No. 10373

THE JOURNAL OF BIOLOGICAL CHEMISTRY
Vol. 244, No. 3, Issue of February 10, pp. 701-708, 1969
Printed in U.S.A.

Vitamin A and Protein Synthesis by Rat Intestinal Mucosa*

(Received for publication, June 10, 1968)

LUIGI DE LUCA, E. PAYSON LITTLE, AND GEORGE WOLF
From the Department of Nutrition and Food Science, Massachusetts Institute of Technology, Cambridge, Massachusetts 02139

SUMMARY

Vitamin A deficiency caused a marked decrease in the number of goblet cells in the small intestine of the rat but no other morphological changes were revealed by electron microscopy. RNA and protein concentrations remained unaffected. Large polyribosomes could be isolated from the mucosa after the common bile duct was ligated. No differences were found in polyribosome stability or the protein-synthesizing activity of free polyribosomes from mucosa of vitamin A-deficient or pair fed normal rats. Rough endoplasmic reticulum, on the other hand, showed a decrease in uptake of a labeled amino acid into protein (to less than one-half of the normal level) under conditions of vitamin A deficiency. The lesion was located in the pH 5 fraction by "crossing-over" experiments, that is, by incubating normal rough endoplasmic reticulum with deficient pH 5 fraction and deficient rough endoplasmic reticulum with normal pH 5 fraction. The mucosal lesion occurs at a very early stage of the deficiency, before the weight plateau stage; however, it was not observable in liver. It is concluded that protein synthesis by membrane-bound but not by free polyribosomes of intestinal mucosa is depressed under conditions of vitamin A deficiency and that the vitamin is therefore involved, directly or indirectly, in protein synthesis at the translational level.

The successful elucidation of the metabolic function of the water-soluble vitamins as coenzymes has focused attention on a similar function for the fat-soluble vitamins. The usual technique in the investigation of vitamin function has been to make an animal vitamin-deficient and then to search for the decrease in activity of that enzyme for which the vitamin is the supposed coenzyme.

This method has been applied to the vitamin A problem in many laboratories and a number of enzymes have been reported to have decreased activity: gulonolactone oxidase (1), codeine demethylase,[1] squalene cyclodehydrase,[2] ATP-sulfurylase (2) and sulfate transferase (3). However, no clear-cut coenzymatic function with any of these enzymes has been established for vitamin A and the suspicion has arisen that these effects may be secondary.

In order to find a possible common, underlying, and primary lesion, we investigated the effect of vitamin A deficiency on the elements of the protein-synthesizing mechanism of intestinal mucosa. The work of Fell on the action of excess vitamin A on chick embryo skin explants *in vitro* (4) first suggested that vitamin A might affect the synthesis rather than the activity of an enzyme. In her work, the presence or absence of the vitamin controlled differentiation of the explant into mucus-secreting or keratinizing tissue. The hypothesis that vitamin A controls the differentiation of a specific tissue has given rise to the idea that this vitamin may function at the level of RNA or protein synthesis rather than of enzyme activity (5).

The choice of intestinal mucosa as the tissue to be examined offered several advantages: the mucosa is affected by vitamin A deficiency (6), whereas liver acts merely as a storehouse for the vitamin. While in other tissues the mucus-secreting cells disappear and become replaced by squamous keratinizing epithelium, the vitamin deficiency in intestinal mucosa results only in degeneration of mucus-secreting cells and in no change in differentiation. Thus, it should be possible to observe the first consequence of the deficiency in isolation.

This report describes an investigation of the protein-synthesizing activity of free polyribosomes and membrane-bound polyribosomes in vitamin A-normal and vitamin A-deficient rats.

EXPERIMENTAL PROCEDURE

Preparation of Animals—Weanling (50 g) Holtzman strain albino rats were made vitamin A-deficient; pair fed normal control animals received the deficient diet (7) plus 2,000 i.u. of vitamin A acetate per week. The common bile duct was ligated (8) 18 hours prior to killing the animals by decapitation. No food was given during this time.

Preparation of Cell Fractions—Polyribosomes were prepared as reported by Alpers and Isselbacher (8). The small intestine was dissected from the ligament of Treitz to the caecum and immediately rinsed with 100 ml of cold 0.9% NaCl solution con-

* This work was supported by the National Institutes of Health, Grant AM 08732. This paper is Contribution 1333 from the Department of Nutrition and Food Science, Massachusetts Institute of Technology, Cambridge, Massachusetts 02139.

[1] YONEMOTO, T., AND JOHNSON, B. C., *Fed. Proc.*, **26**, 635 (1967).
[2] SUBBA RAO, K., AND OLSON, R. E., *Fed. Proc.*, **26**, 635 (1967).

taining 1% bentonite. It was then cut open on a glass plate and the mucosa (epithelial cells and lamina propria) was scraped with a microscope slide. The mucosa was homogenized in 6 volumes of ice-cold Medium A of Littlefield and Keller (9) containing 1% bentonite in a Dounce tissue homogenizer with eight strokes of the loose pestle and six strokes of the tight pestle. Intact cells, cell debris, nuclei, and mitochondria were removed by centrifugation at 7,600 × *g* for 10 min. The supernatant fraction was used for the preparation of the polysomes as described by Wettstein, Staehelin, and Noll (10). The 7,600 × *g* supernatant fraction was layered on top of a discontinuous sucrose gradient consisting of 3.1 ml of 0.5 M sucrose on top of 2.3 ml of 2.0 M sucrose and centrifuged at 105,000 × *g* for 3 hours in the R-40 rotor of a Beckman model L ultracentrifuge.

The material at the interface of the 2.0 and 0.5 M sucrose was removed, diluted 1:1 with buffer consisting of Tris (0.05 M), $MgCl_2$ (5×10^{-3} M), KCl (0.025 M, pH 7.6) (Buffer TMK), and recentrifuged at 105,000 × *g* for 1 hour to pellet the membrane-bound polysomes used for RNA and protein estimation. The translucent pellet obtained from the discontinuous gradient was used for studying protein synthesis on free polysomes after thorough resuspension in the standard incubation mixture (see "Analytical Techniques" for composition and concentrations).

Polyribosome patterns were obtained by the method of Britten and Roberts (11) with a linear 15 to 30% sucrose gradient. After centrifugation at 115,000 × *g* for 75 min in a SW 50 rotor, the gradients were analyzed at 260 mμ by forcing them through a continuous flow cell of the Gilford model 2000 spectrophotometer.

Preparation of pH 5 and Microsome Fractions—A portion of the 7,600 × *g* supernatant fraction (postmitochondrial supernatant fraction) was centrifuged at 105,000 × *g* for 2 hours to yield a microsomal pellet and a supernatant fraction from which the pH 5 enzymes were precipitated by lowering the pH to 5 with a few drops of 1 N acetic acid and continuous stirring (12). The precipitate was collected by centrifugation at 15,000 × *g* for 10 min and redissolved in the incubation mixture. The resulting solution was designated as the pH 5 fraction for use in the studies *in vitro*.

Preparation of the Rough Endoplasmic Reticulum Fraction—The method of Moulé, Rouiller, and Chauveau (13) was used as described for rat liver. The mucosal scrapings were homogenized in 6 volumes of 0.88 M sucrose in Buffer TMK containing 1% bentonite. The homogenate was centrifuged at 20,000 × *g* for 20 min to remove cells, nuclei, and mitochondria, and the resulting supernatant was centrifuged for 1 hour at 82,000 × *g* to yield a pellet of rough endoplasmic reticulum and a supernatant fraction. This last named fraction was used to prepare the pH 5 fraction either by immediate precipitation at pH 5 or upon removal of free polysomes and smooth endoplasmic reticulum by dilution with Buffer TMK to 0.44 M sucrose, centrifugation at 105,000 × *g* for 2 hours, and subsequent precipitation at pH 5.

Analytical Techniques—Ribonuclease activity was examined as described by Utsunomiya and Roth (14). RNA content was determined by the method of Schneider (15) and protein by the method of Lowry *et al.* (16). Amino acid incorporation into protein, both on free and membrane-bound polyribosomes, was studied with the system of Maxwell (17). The standard incubation mixture contained, in a volume of 0.5 ml: 0.5 mg of ribosomal or rough endoplasmic reticulum protein, 1 mg of pH 5 fraction protein, 5 μmoles of P-enolpyruvate, 125 μmoles of sucrose, 1 μmole of ATP, 0.1 μmole of GTP, 20 μg of crystalline pyruvate kinase, 25 μmoles of Tris, 5 μmoles of $MgCl_2$, 30 μmoles of KCl, 1 μmole of mercaptoethanol, and 0.05 μmole of each of the 19 L-amino acids (minus leucine, cysteine) and uniformly labeled L-leucine-^{14}C (0.5 μC; specific activity, 250 mC per mmole). When rough endoplasmic reticulum preparations were used for the amino acid-incorporating study, 0.5 μmole of UDP-*N*-acetylglucosamine was added. Reaction mixtures were incubated at 37° for 45 min. Proteins were precipitated with an equal volume of 10% trichloracetic acid and the aminoacyl tRNA was solubilized at 90° for 15 min. The precipitated protein was collected on filter discs (0.45 μ pore size) and dried. The discs were then suspended in toluene 2,5-diphenyloxazole (PPO) (0.3%) scintillation medium and counted in a Nuclear Chicago liquid scintillation counter. When samples with more than 0.15 mg of protein were counted, NCS was used as a dissolving medium and Bray's (or Bruno's) solution was used for counting.

Materials—ATP, GTP, phosphoenolpyruvate, and phosphoenolpyruvate kinase were purchased from Sigma. Uniformly labeled L-leucine-^{14}C was obtained from New England Nuclear. Bentonite (U. S. P.) was purchased from Fisher. Rats were obtained from Holtzman. The vitamin A-deficient diet was obtained from General Biochemicals, and prepared according to the method of Wolf, Lane, and Johnson (7). All deficient animals were used 2 days after the end of the weight plateau stage, unless indicated otherwise.

RESULTS

Fig. 1, *A* and *B*, shows the sharp decrease, caused by the vitamin A deficiency, in the number of goblet cells in the crypts of the intestinal mucosal epithelium at the level of the common bile duct. The figure shows a standardized area, with crypt areas approximately equal in control and experimental animals. No difference in height of epithelium was found in a series of random measurements. A count of goblet cells per crypt in 100 crypts was made for a normal (17.3 ± 1.3) and a deficient (11.0 ± 1.0) animal (difference statistically significant at the level $P < 0.01$).[3]

It should be noted that in all experiments reported in this work the normal control rats were pair fed to the vitamin A-deficient rats such that food intake of the two groups was at all times the same. The histological appearance suggests that the tissue is quite unaffected by the vitamin deficiency, except in the severe reduction in the number of mucus-secreting cells. This conclusion was confirmed by electron microscopy of the tissue. This showed no morphological changes in vitamin A-deficient cells. Subcellular structures were unchanged. The amount of rough endoplasmic reticulum was about the same in normal (Fig. 2*A*) and deficient (Fig. 2*B*) mucosal cells. The deficient goblet cells, although fewer in number than normal goblet cells (Fig. 3*A*), were as richly endowed with rough endoplasmic reticulum (Fig. 3*B*).[4]

Analysis of the RNA and protein concentrations in the cell fractions involved in protein and glycoprotein synthesis again showed no differences in mucosal tissue from normal and deficient animals (Table I).

[3] The authors are grateful to Dr. P. M. Newberne, Department of Nutrition and Food Science, Massachusetts Institute of Technology, for preparing the histological sections shown and for performing the counts of goblet cells.

[4] The authors are grateful to Dr. G. Millonig, Department of Biology, Massachusetts Institute of Technology, for preparation of the electron micrographs.

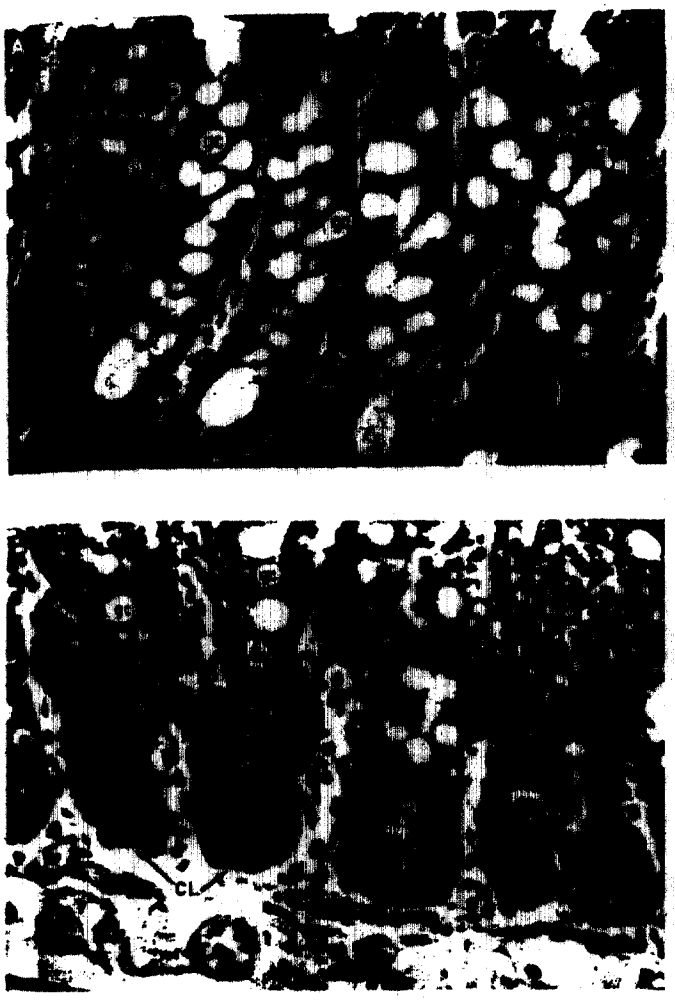

FIG. 1. Section of duodenum of normal, pair fed control (*A*), and vitamin A-deficient (*B*) rats showing crypts of Lieberkühn, stained with hematoxylin and eosin. Unstained areas are goblet cells. *CL*, crypt of Lieberkühn; *gc*, goblet cell. *A*, × 1400. *B*, × 1470.

In order to make an analysis of the elements of the protein-synthesizing mechanism of mucosal cells, we began by sucrose gradient analysis of the polyribosomes. The method included bentonite addition to inhibit destruction of the aggregates by ribonuclease. Surprisingly, the preparation from vitamin A-deficient mucosa showed a pattern resembling that obtainable from liver (Fig. 4*b*), with heavy polyribosomes (10 ribosomes or more) predominating, whereas normal mucosa yielded predominantly small aggregates of two to four ribosomes (Fig. 4*a*). The recent work of Alpers and Isselbacher (8)[5] suggested that ligation of the common bile duct would result in preservation of polyribosomes with larger numbers of ribosomes. When ligation was performed 18 hours prior to the killing of the animals, identical polyribosome patterns from deficient and normal rat mucosa (Fig. 4, *c* and *d*) were obtained. Both consisted mainly of heavy aggregates of 10 ribosomes or more. From this point

[5] The authors are grateful to Dr. D. H. Alpers for permission to peruse his manuscript prior to its publication.



FIG. 2. Electron micrographs of normal (*A*) and vitamin A-deficient (*B*) rat intestine. The tissue was fixed in 3% glutaraldehyde in 0.1 M sodium phosphate buffer (pH 7.5) and 5% sucrose overnight, rinsed in 5% sucrose with 1% osmium tetroxide and 0.5% NaCl in 0.1 M sodium phosphate buffer (pH 7.5) for 1½ hours, and rinsed again in 0.5% NaCl. The standard dehydration and Epon embedding technique was used (18). Sectioning was done on a Porter-Blum MT-2 ultramicrotome with a diamond knife and staining by the method of Millonig (19). Tissue preparations were examined in the Hitachi HU-11A electron microscope. *mv*, microvilli; *cm*, cell membrane; *m*, mitochondria; *rer*, rough endoplasmic reticulum. *A*, × 21,000. *B*, × 13,000.

FIG. 3. Electron micrograph of goblet cells in normal (*A*) and vitamin A-deficient (*B*) rat intestine. Tissue prepared as in Fig. 2. *mv*, microvilli; *gc*, goblet cell; *mu*, mucin; *Ga*, Golgi apparatus; *rer*, rough endoplasmic reticulum; *n*, nucleus. *A*, × 3500. *B*, × 6780.

on, all animals used in this work had their common bile duct ligated 18 hours before use.

The protein-synthesizing activity of the free polyribosomes was then tested. The requirements for protein synthesis were found to be the same as those described by Alpers and Isselbacher (8). However, it was necessary to determine the optimum amount of pH 5 fraction needed per incubation for incorporation of labeled amino acids into protein, since this amount might differ for polyribosomes from deficient and normal tissues. Fig. 5 shows a titration of polyribosomes against pH 5 fraction. No difference was found, at least for the optimum value, although for higher amounts of pH 5 fractions the activity of the normal polyribosomes declined while that of the deficient appeared to plateau.

The kinetics of incorporation of a labeled amino acid into protein by polyribosomes is shown in Fig. 6: a slight decrease (about 12%) in deficient polyribosomes was found. Upon repeating this experiment several times, however, this decrease often disappeared, and in no case was it found to be greater than that shown in Fig. 6. We concluded that the rate of protein synthesis on polyribosomes is not affected by vitamin A deficiency.

We next attempted to determine whether protein synthesis on microsomes was affected by vitamin A deficiency. Microsomes were prepared as described (17). A decrease in activity was occasionally observed with microsomes from deficient animals, but the results were variable; frequently, no such difference was found. With the technique for microsome preparation used it was obviously not possible to obtain precise and reproducible control of the proportions of free and membrane-bound polyribosomes constituting "microsomes." As shown above, protein synthesis on free polyribosomes is not affected by the vitamin A status and an uncontrolled increase in the amount of free polyribosomes in the mixture obscures the effect seen with membrane-bound polyribosomes.

The use of microsomes, prepared as described, was therefore deemed unsatisfactory. In consequence, the same experiments were performed with "clean" rough endoplasmic reticulum, prepared according to the method of Moulé *et al.* (13). The cofactor requirements were the same as for free polyribosomes. We found a partial requirement for UDP-*N*-acetylglucosamine in experiments with microsomes, but none for rough endoplasmic reticulum. Nonetheless, the compound was added to all incubations with rough endoplasmic reticulum because occasionally an improved level of incorporation of amino acid into protein could be observed in the presence of UDP-*N*-acetylglucosamine both for deficient and normal systems.

The optimum amount of pH 5 fraction remained to be determined (Fig. 7). The difference in protein-synthesizing capacity between deficient and normal rough endoplasmic reticulum was marked. The results of crossing-over experiments are shown in Fig. 8 for a normal and a deficient animal at the stage of deficiency 3 days beyond the weight plateau stage (severe deficiency). Similar results were found for animals at a stage of deficiency before they had begun to lose weight (2 days at the weight plateau stage) (Fig. 9). In all cases, the lesion produced by the vitamin deficiency was located in the pH 5 fraction and not in the rough endoplasmic reticulum. Finally, the beginning of a difference between deficient and normal animals was detected before the weight plateau stage had been reached, in other words, before any overt symptoms of vitamin A deficiency had appeared (Fig. 10). This was done by making the usual group of 10 rats vitamin A-deficient from weaning and killing those to be used for the experiment while they were still gaining in weight, at a time when the first two animals of the group had reached the plateau

TABLE I

RNA and protein content and ratios in various cell fractions from vitamin A-deficient and normal rat intestinal mucosa

The cell fractions were prepared as described under "Experimental Procedure." RNA and protein estimation on the pellets was done after suspension in Buffer TMK.

Cell fraction	Normal control			Vitamin A-deficient			RNA
	RNA	Protein	RNA/protein	RNA	Protein	RNA/protein	
	mg/g, wet tissue			*mg/g, wet tissue*			*% total*
Whole homogenate	3.50	64.54	0.054	2.39	54.32	0.04	100
6000 × *g* supernatant	1.12	22.57	0.050	1.18	27.83	0.042	33
6000 × *g* pellet	2.30	39.30	0.058	1.66	36.87	0.045	67
9000 × *g* supernatant	0.81	16.57	0.048	1.27	22.09	0.057	85[a]
Free polysomes	0.40	0.57	0.693, 0.707[b]	0.53	1.02	0.521, 0.666	49
Interface (RER + SER[c])	0.34	1.12	0.213, 0.140	0.40	2.38	0.167, 0.157	42

[a] Per cent of 6000 × *g* supernatant fraction.
[b] Duplicate figures represent results from a second experiment.
[c] RER, rough endoplasmic reticulum; SER, smooth endoplasmic reticulum.

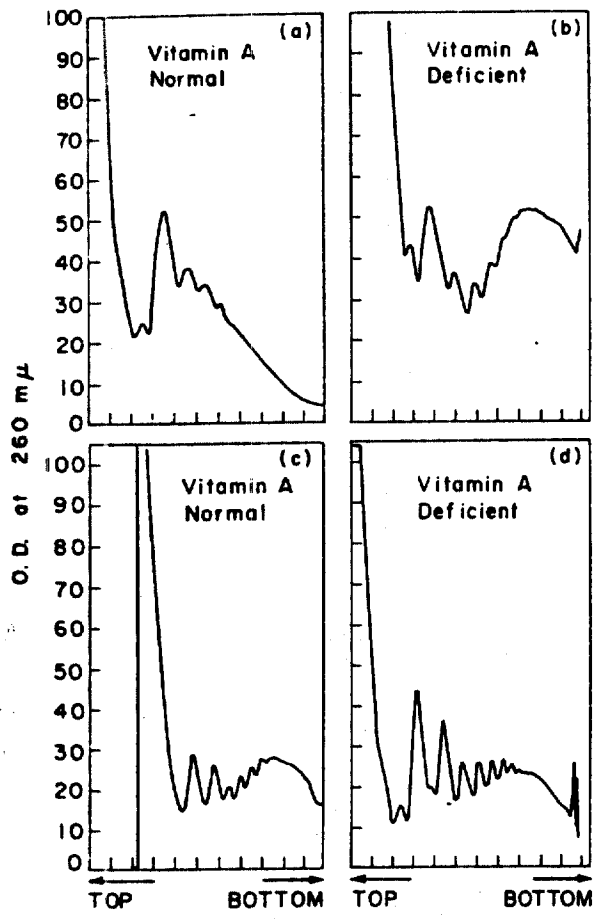

FIG. 4. Polysome profiles from normal (*a*) and vitamin A-deficient (*b*) rat intestinal mucosa. Postmitochondrial supernatant fraction was prepared without bentonite and layered on a 5-ml linear sucrose gradient as described under "Experimental Procedure." Polysome profiles from normal (*c*) and vitamin A-deficient (*d*) intestinal mucosa were prepared 18 hours after ligation of the common bile duct, with 1% bentonite in the rinse-NaCl solution and homogenizing mediums.

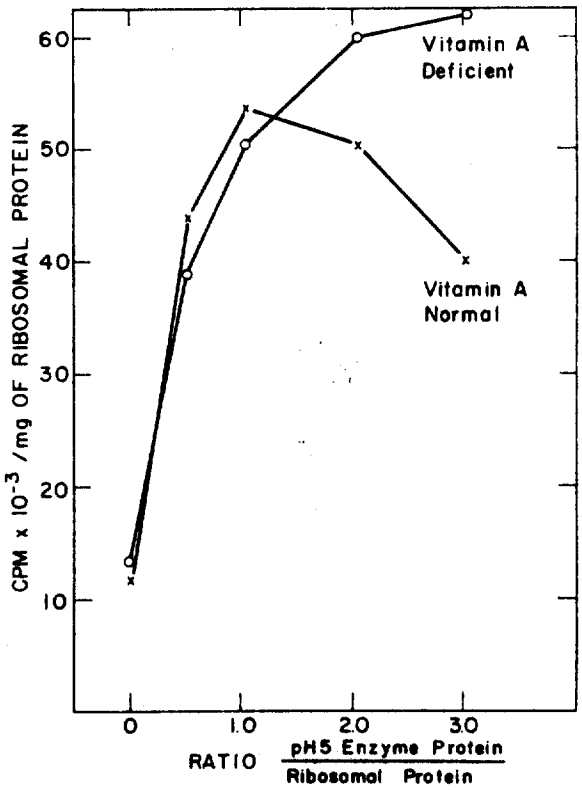

FIG. 5. Uptake of uniformly labeled L-leucine-^{14}C into protein with a changing ratio of ribosomal to pH 5 fraction protein. The polysome and pH 5 fractions were prepared as described under "Experimental Procedure," with their ratio varying as noted in the graph. Incubation and precipitation of aliquots were carried out as described in the text. Both vitamin A normal and deficient polysomes were incubated with normal and deficient pH 5 fractions, respectively.

stage. It had previously been observed that 2 to 3 days after the first animal in a group reaches the plateau stage of deficiency, all others follow. One can therefore safely assume that those animals whose protein-synthesizing capability of intestinal

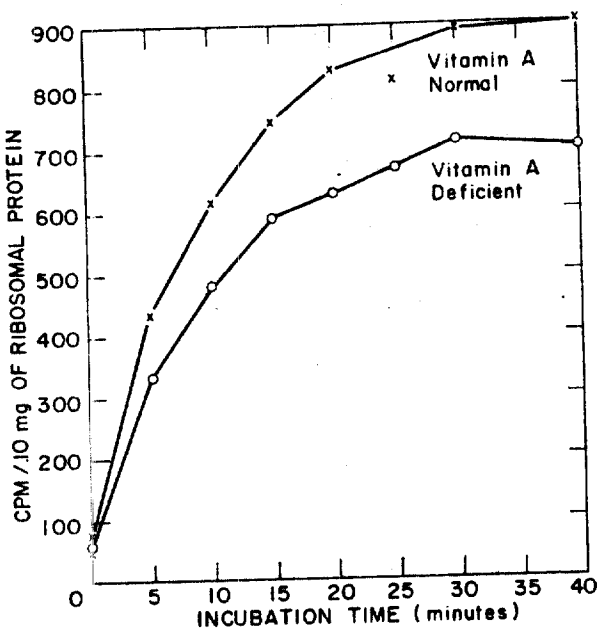

FIG. 6. Kinetics of uniformly labeled L-leucine-^{14}C uptake into protein by polysomes. Membrane-free polysomes and pH 5 fractions were prepared as described under "Experimental Procedure" and incubated with leucine-^{14}C. Incubation and precipitation of aliquots were as described under "Experimental Procedure."

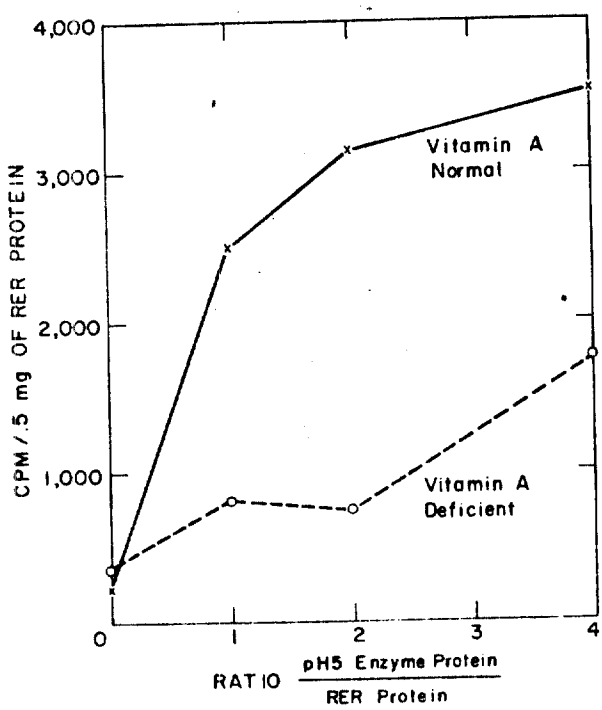

FIG. 7. Rough endoplasmic reticulum (*RER*), prepared according to Moulé *et al.* (13), and pH 5 fractions (prepared as described under "Experimental Procedure") were incubated with varying protein ratios to determine the optimum ratio of rough endoplasmic reticulum to pH 5 fraction protein.

rough endoplasmic reticulum is illustrated in Fig. 10 were at a stage of vitamin A deficiency 2 to 3 days before the plateau stage.

A control experiment was necessary to show that the observed

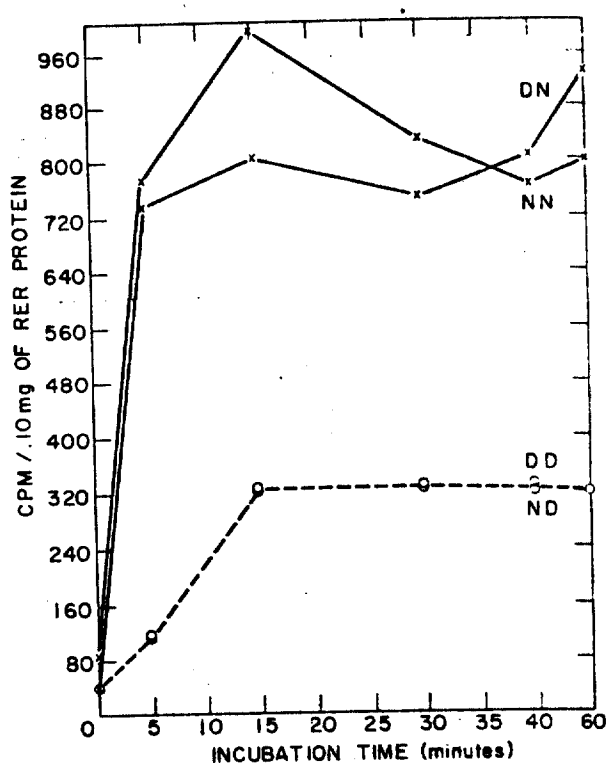

FIG. 8. Crossing-over experiment with rough endoplasmic reticulum (*RER*) prepared according to Moulé *et al.* (13). *ND*, normal rough endoplasmic reticulum, deficient pH 5 fraction; *NN*, normal rough endoplasmic reticulum, normal pH 5 fraction; *DN*, deficient rough endoplasmic reticulum, normal pH 5 fraction; *DD*, deficient rough endoplasmic reticulum, deficient pH 5 fraction.

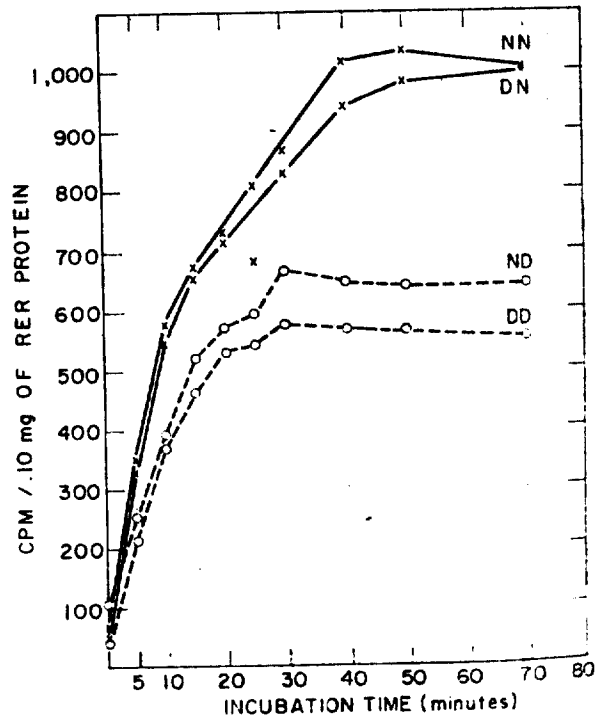

FIG. 9. Crossing-over experiment as in Fig. 8, with animals 2 days at the weight plateau stage of deficiency. Designations are the same as in Fig. 8. *RER*, rough endoplasmic reticulum.

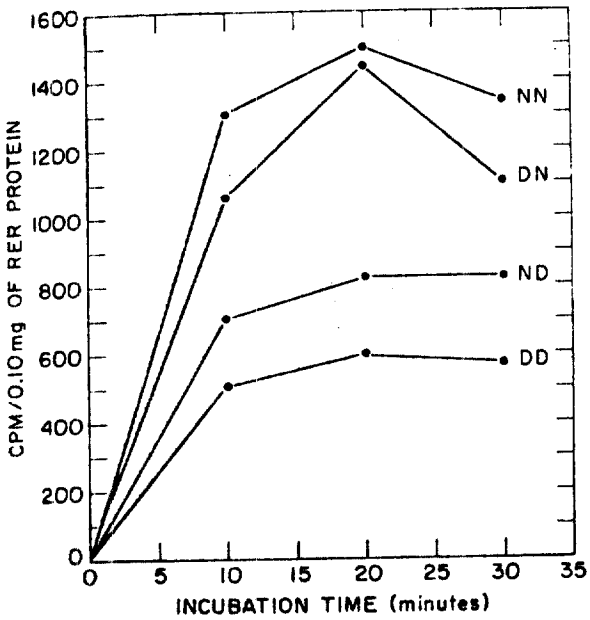

FIG. 10. Experiment as in Fig. 9, with animals before the onset of the plateau stage of deficiency, as described under "Results." Designations are the same as in Fig. 8. A similar experiment at an even earlier stage of deficiency gave 1100 cpm/0.1 mg of protein for the normal preparation and 900 cpm/0.1 mg of protein for the deficient preparation after 30 min of incubation. *RER*, rough endoplasmic reticulum.

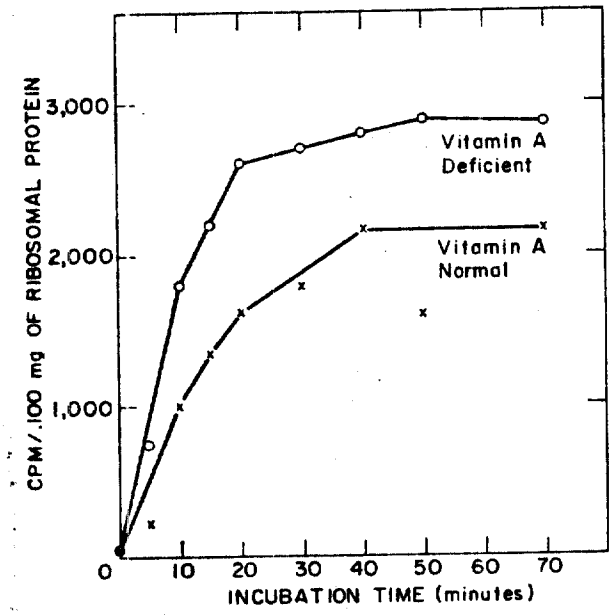

FIG. 11. Uniformly labeled L-leucine-^{14}C incorporation into proteins with a system identical with that described under "Experimental Procedure" for intestinal cell fractions, except with liver rough endoplasmic reticulum and pH 5 fractions.

sion did not occur in the livers of vitamin A-deficient rats. As has already been observed by Wolbach and Howe (20), the parenchymal cells of the liver are not affected by vitamin A deficiency. In fact, as shown in Fig. 11, the difference in protein synthesis observed with liver rough endoplasmic reticulum and pH 5 fraction was slight. Actually, the protein-synthesizing system from liver of deficient rats showed higher incorporating activity than that from normal rats.

DISCUSSION

The results show that protein synthesis by membrane-bound but not by free polyribosomes of intestinal mucosa is depressed under conditions of vitamin A deficiency. Therefore, vitamin A is involved, directly or indirectly, in the translation process, at least in intestinal mucosa. The lesion caused by the deficiency is located in the pH 5 fraction, and could be present in the tRNA, the amino acid-activating enzymes, or other enzymes involved in protein synthesis. tRNA and amino acid-activating enzymes have both been suggested as being implicated in the control of differentiation at the translational level (21, 22).

It is important to note that, apart from the effect on the mucus-secreting cells, the deficient mucosa cells are histologically and biochemically like normal cells. The same amount of rough endoplasmic reticulum is seen by electron microscopy, and even the goblet cells, although much fewer in number, are in appearance identical with normal goblet cells. Protein and RNA concentrations are not affected by vitamin A deficiency, and free polyribosomes show no differences with respect to intactness of pattern and function.

The technique of ligation of the common bile duct to obtain large aggregates of ribosomes similar to those found in liver preparations was introduced by Alpers and Isselbacher (8). Unlike these workers, we could not use bentonite in place of ligation to obtain improved polyribosome patterns. While they state that "very large polyribosomes (*i.e.* greater than 10) were not observed," we could obtain very large polyribosomes (Fig. 4*c*) provided that ligation was done 18 hours prior to the killing of the animals.

The stability of the large polyribosomes isolated from intestinal mucosa of vitamin A-deficient rats (Fig. 4*b*) deserves some comment. It is most probably a result of the atrophy of pancreatic glands or keratinization of pancreatic ducts, or both, which occur in vitamin A deficiency, as described by Wolbach and Howe (20). In consequence, there is less secretion of pancreatic ribonuclease into the intestine. Alpers and Isselbacher (8) showed that polyribosome instability in normal intestinal mucosa was due to pancreatic ribonuclease. On the other hand, although we assayed ribonuclease of intestinal mucosal homogenates and confirmed the high value found by Alpers and Isselbacher (10), we found no difference between vitamin A-deficient and normal animals.

As pointed out above, the control animals in all experiments reported were pair fed. As discussed in detail in an earlier report (23), pair feeding of a normal (20%) protein diet to normal and vitamin A-deficient rats results in depression of protein intake in the pair fed normal control animal, since in severe deficiency its food intake is depressed, being limited to that of the vitamin-deficient rat. The comparison, therefore, between a pair fed normal control and a vitamin A-deficient rat is somewhat obscured by the superimposition of the effect of depressed food levels, and especially of depressed protein intake. It was therefore gratifying to find the lesion due to vitamin A deficiency detectable at the plateau stage of deficiency (Fig. 9), that is, before food intake had declined severely, and even more so to find it detectable at the preplateau stage (Fig. 10), when food intake was still normal.

This study also shows a specificity of the action of the vitamin

on protein synthesis with respect to tissue through the fact that protein synthesis on liver rough endoplasmic reticulum with pH 5 fraction showed no decrease in deficiency.

Acknowledgment—The authors are grateful to Mr. William L. Klein and Mr. Christopher M. Roth for excellent technical assistance.

REFERENCES

1. Ganguly, J., *J. Sci. Ind. Res.*, **26**, 110 (1967).
2. Subba Rao, K., Seshadri Sastry, P., and Ganguly, J., *Biochem. J.*, **87**, 312 (1963).
3. Carroll, J., and Spencer, B., *Biochem. J.*, **96**, 79P (1965).
4. Fell, H. B., *Proc. Roy. Soc. (London), Ser. B*, **146**, 926 (1957).
5. Olson, R. E., *Science*, **145**, 926 (1964).
6. Manville, I. A., *Science*, **85**, 44 (1937).
7. Wolf, G., Lane, M. D., and Johnson, B. C., *J. Biol. Chem.*, **225**, 995 (1957).
8. Alpers, D. H., and Isselbacher, K. J., *J. Biol. Chem.*, **242**, 5617 (1967).
9. Littlefield, J. W., and Keller, E. B., *J. Biol. Chem.*, **224**, 13 (1957).
10. Wettstein, F. O., Staehelin, T., and Noll, H., *Nature*, **197**, 430 (1963).
11. Britten, R. J., and Roberts, R. B., *Science*, **131**, 32 (1960).
12. Keller, E. B., and Zamecnik, P. C., *J. Biol. Chem.*, **221**, 45 (1956).
13. Moulé, Y., Rouiller, C., and Chauveau, J., *J. Biophys. Biochem. Cytol.*, **7**, 547 (1960).
14. Utsunomiya, T., and Roth, J. S., *J. Cell Biol.*, **29**, 395 (1966).
15. Schneider, W. C., in S. P. Colowick and N. O. Kaplan (Editors), *Methods in enzymology, Vol. III*, Academic Press, New York, 1957, p. 680.
16. Lowry, O. H., Rosebrough, N. J., Farr, A. L., and Randall, R. J., *J. Biol. Chem.*, **193**, 265 (1951).
17. Maxwell, E. S., *Proc. Nat. Acad. Sci. U. S. A.*, **48**, 1639 (1962).
18. Luft, J. H., *J. Biophys. Biochem. Cytol.*, **9**, 409 (1961).
19. Millonig, G., *J. Biophys. Biochem. Cytol.*, **11**, 736 (1961).
20. Wolbach, S. B., and Howe, P. R., *J. Exp. Med.*, **47**, 753 (1925).
21. Sueoka, N., Kano-Sueoka, T., and Gartland, W. J., *Cold Spring Harbor Symp. Quant. Biol.*, **31**, 571 (1966).
22. Strehler, B. L., Hendley, D. D., and Hirsch, G. P., *Proc. Nat. Acad. Sci. U. S. A.*, **57**, 1751 (1967).
23. Levi, A. S., Geller, S., Root, D. M., and Wolf, G., *Biochem. J.*, **109**, 69 (1968).

Proc. Nutr. Soc. 22:X, 1963.

Dingle-'63
Bib. No. 10433

Reproduced by permission of the copyright owner

The influence of vitamin A status on the proteolytic activity of lysosomes from the livers and kidneys of rats. By J. T. DINGLE, *Strangeways Research Laboratory, Cambridge*, and I. M. SHARMAN and T. MOORE, *Dunn Nutritional Laboratory, University of Cambridge and Medical Research Council*

Treatment of lysosomes in vitro with vitamin A causes the liberation of their proteolytic enzymes (Dingle, Lucy & Fell, 1961; Dingle, 1961). Release of lysosomal enzymes could explain the loss of mucopolysaccharides, and cellular changes, seen by Fell & Mellanby (1952) in cartilaginous limb-bone rudiments cultured in the presence of excess vitamin A. To investigate whether the proteolytic activity of lysosomes is influenced by vitamin A reaching the cells in vivo by the normal routes of absorption and distribution, studies were made on homogenates and subcellular fractions from groups of rats given (1) no vitamin A, and (2) marginal, (3) adequate, (4) excessive (toxic) supplements of vitamin A. Portions of liver and kidney tissues were homogenized in 0·25 M-sucrose in a Potter homogenizer. Total cathepsin activity (μg tyrosine 20 min g wet weight of tissue) was measured in a portion of the original homogenate after lysis by detergent. The homogenate was then spun at 600 g for 5 min and the pellet rejected. The supernatant was next re-spun at 15 000 g for 20 min and free activity determined in the resulting supernatant. Lysosomally bound activity was measured after resuspending the pellet and lysing with detergent.

Means of bound activities for liver preparations showed only slight variation between groups in the first experiment. The mean free activity, however, was significantly higher in the group given excessive intakes of vitamin A (200) than in the other groups (39, 72, 65 for the deficient, marginal and adequate groups respectively). The total activity in the excessive group was also higher (1400) than in the other groups (990, 1050, 790, respectively). Catheptic activities in the kidney were little affected by vitamin A status.

To confirm these results on the liver the experiment was repeated with improvements in technique, particularly homogenization, as recommended by Aldridge, Emery & Street (1960), but the 'adequate' group was omitted. Again, free activity was higher in the group given excessive vitamin A (450) than in the other groups (250, 80). Total activity (1460) was also higher in this group, than in the others (1140, 820). An unexpected finding was a higher mean for free activity in the 'deficient' group (250) compared with the 'marginal' group (80). Again, bound activity varied little between groups.

Chemical estimation of vitamin A indicated that the total amounts of vitamin A in the livers were in agreement with the dietary intakes but no evidence was obtained of a higher concentration of vitamin A in the lysosomes compared with other subcellular fractions.

Experiments were also performed in collaboration with M. G. Stanton, to investigate the influence of vitamin E status on proteolytic activities. A pronounced release of lysosomal cathepsin was observed in the kidney, whereas little effect was detectable in the liver.

REFERENCES

Aldridge, W. N., Emery, R. C. & Street, B. W. (1960). *Biochem. J.* **77**, 326.
Dingle, J. T. (1961). *Biochem. J.* **79**, 509.
Dingle, J. T., Lucy, J. A. & Fell, H. B. (1961). *Biochem. J.* **79**, 497.
Fell, H. B. & Mellanby, E. (1952). *J. Physiol.* **116**, 320.

JOHN W. ERDMAN JR., SHU-HUI F. HOU and PAUL A. LACHANCE
Dept. of Food Science, Rutgers University, New Brunswick, NJ 08903

Food Sci. 38(3):447-449. 1973

Reproduced by permission
of the copyright owner

Erdman-'73
Bib. No. 10465

FLUOROMETRIC DETERMINATION OF VITAMIN A IN FOODS

INTRODUCTION

THE OFFICIAL AOAC method for vitamin A analysis is the colorimetric Carr-Price reaction. This method has been termed insensitive and nonspecific by Maynard and Loosli (1969) and De Ritter (1967). The use of other colorimetric reagents have been suggested, such as trifluoroacetic acid (Neeld and Pearson, 1963), trichloroacetic acid (Bayfield, 1971) and other Lewis acids (Dugan et al., 1964) but all the colorimetric reactions generally add large errors because of the difficulty in the detection of the end point, and insensitivity. Derse (1971) further maintains that sterols interfere with the colorimetric procedures.

Sobotka et al. (1943) first reported a procedure utilizing vitamin A's fluorescent characteristics for the analysis of fish liver oils. Fujita and Aoyama (1951), De (1955) and others followed with other fluorometric procedures, but these methods have not been commonly used, probably due to interference from carotenes and vitamin D (Gyorgy and Pearson, 1967), and from phytofluene (Thompson et al. 1971). The work of Thompson et al. with blood and liver vitamin A has shown that when the fluorescence of phytofluene is corrected for, the fluorometric assay is superior to the Carr-Price and other procedures in convenience, sensitivity, specificity and accuracy. Garry et al. (1970) also reported the presence of an interfering compound in plasma and serum extracts which they had not identified, but which they say may be the compound phytofluene, identified by Thompson's group.

We have adapted and modified the Thompson et al. (1971) procedure to the analysis of vitamin A in food.

MATERIALS & METHODS

THIS PROCEDURE for vitamin A analysis utilizes the characteristic fluorescence of vitamin A at 480 nm for quantitative measurement of the vitamin in different foods. A correction formula is applied to the raw fluorescent readings to correct for the phytofluene. Pure retinol and phytofluene are needed to obtain constants for this formula. Retinol was obtained from Hoffmann-LaRoche, Inc., Nutley, N.J., and the phytofluene was extracted from tomato paste.

Extraction of phytofluene

Fancy tomato paste (46% solids, West Coast Canners, Inc., courtesy of the Campbell Soup Company) was extracted following the procedure based on Koe and Zechmeister (1952) and revised by Thompson. 2 kg of tomato paste were adjusted to pH 8 with KOH and stirred with an equal volume of methanol. After standing overnight, the mixture was filtered through several layers of cheesecloth and squeezed dry. The remaining solid was stirred with 1.5 liters of a 1:1 mixture of carbon tetrachloride and methanol, and again filtered with cheesecloth. This extraction was repeated with another liter of the solvent mixture, and the filtrates were combined and washed several times with water. The deep red filtrate was dried with sodium sulfate and evaporated under reduced pressure. A portion of the oily residue was dissolved in petroleum ether and chromatographed on a column of 100g alumina (2% water). The principle fluorescent band was detected with an ultraviolet lamp and this band was eluted with 2% diethyl ether in petrol. (Caution must be taken to use an all glass apparatus and to shield the column from light and the excessive use of the ultraviolet lamp.) The elutant can be further purified by placing an aliquot into a silicic acid column. Phytofluene can be separated from two yellow pigments with petroleum ether. The phytofluene band is colorless, but highly fluorescent, and it elutes between the two yellow layers.

Vitamin A correction formula

Thompson's group developed a formula for calculating the fluorescence due to vitamin A in a blood or liver extract. This correction formula is based on the difference between the excitation spectrum of vitamin A and phytofluene. By taking two readings on each sample at different excitation wavelengths, one can calculate the proportion of fluorescence due to vitamin A.

This correction formula is shown below. The fluorescence at 330 nm excitation due to vitamin A is calculated by:

$$\alpha = \frac{P}{P-A}\left[\frac{Q_1}{q_1}(x - B_1)\right] - \frac{1}{P-A}\left[\frac{Q_2}{q_2}(y - B_2)\right]$$

where A and P are constants obtained from measurements of the ratio of the fluorescence of pure retinol and phytofluene, at 360 and 330 nm excitation and 480 nm emission, respectively, x and y are sample fluorescences at 330 nm and 360 nm, and Q_1 and Q_2 are readings of quinine sulfate in 0.1N H_2SO_4 at 330 nm and 360 nm. The quinine solution is used as a standard to correct for daily variations in sensitivity of the instrument if a spectrophotofluorometer is used for analysis. A, P, Q_1 and Q_2 were all calculated at the same time, being cautious not to change any instrument adjustments. q_1, q_2 and B_1, B_2 are quinine sulfate and blank readings at each subsequent analysis at 330 and 360 nm.

Having determined α, then the concentration of vitamin A in I.U. per gram food is obtained as follows:

$$\text{I.U. Vitamin A/g food} = \left(\frac{\alpha}{\text{g of food tested}}\right)\left(\frac{\text{I.U. retinol}}{\text{Fluorescence unit at 330 nm excitation}}\right)(\text{dilution factor})$$

The term "I.U. retinol/fluorescent unit at 330 nm excitation" is the same as the slope of the standard curve for retinol at 330 nm, and it is obtained, after conversion of μg to International Units, from Figure 1. The dilution factor is determined by the volume of the hexane extract vs. the volume of the hexane aliquot tested.

The standard curves of fluorescence of retinol in hexane and quinine sulfate in 0.1N H_2SO_4 at 330 nm and 360 nm are shown in Figure 1.

The fluorescent spectra of hexane extracts of saponified instant breakfast powder (both fortified with retinyl palmitate, and nonfortified) at 330 nm and 360 nm excitation are shown in Figures 2 and 3.

An Amico Keirs (Silver Springs, Md.) spectrophosphorimeter was used to obtain these spectra. The spectra show flattened peaks at

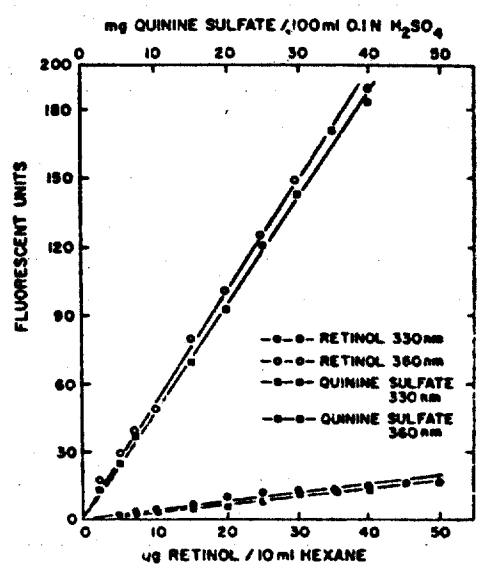

Fig. 1—Standard curves of fluorescence of retinol and quinine sulfate.

480 nm emission that are not interrupted by any other fluorescent maximum. It can be seen from our model system of instant breakfast extract that vitamin A can be quantified without interferences that would add error to the fluorescent analysis.

For the food analysis, reported in this paper, a Coleman Electronic Photofluorometer Model 12C with primary and secondary filters, manufactured by Perkin-Elmer, Coleman Instrument Div., Maywood, Ill., was used.

Extraction of vitamin A from foods

All vitamin A determinations are performed upon the unsaponifiable fraction of food samples. Varied saponification and separation steps are utilized for different food types because some foods require modified saponification procedure and/or further separation before fluorometric analysis. Three different extraction procedures are discussed below.

Table 1–Fluorometric determinations of vitamin A in fortified foods

Type of food	Vitamin claim µg/g	Average % of claim
Instant breakfast powder	30.23	116
Dry cereal (puffed wheat)	47.10	124
Dry cereal (puffed corn)	47.10	120
Fortified donut	15.06	137
Sponge cake	11.25	129
Devil's food cake	11.25	136
Peanut butter pastry	11.75	147
Chocolate bar	16.80	105
Freeze dried beef casserole	41.70	164
Margarine	33.20	102
Butter	33.20	131

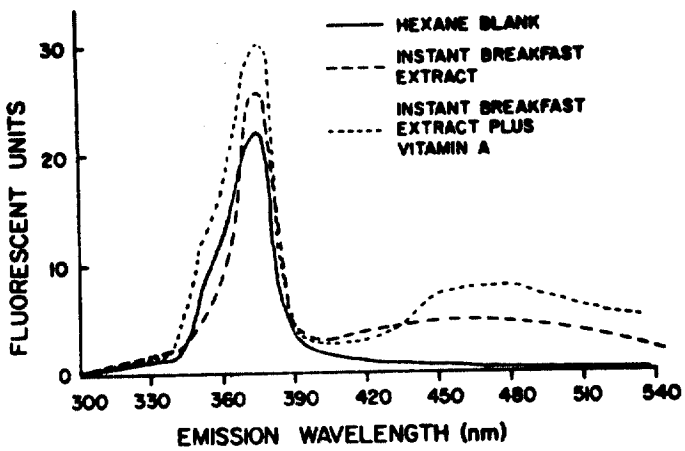

Fig. 2–Fluorescent scans at 330 nm excitation wavelength.

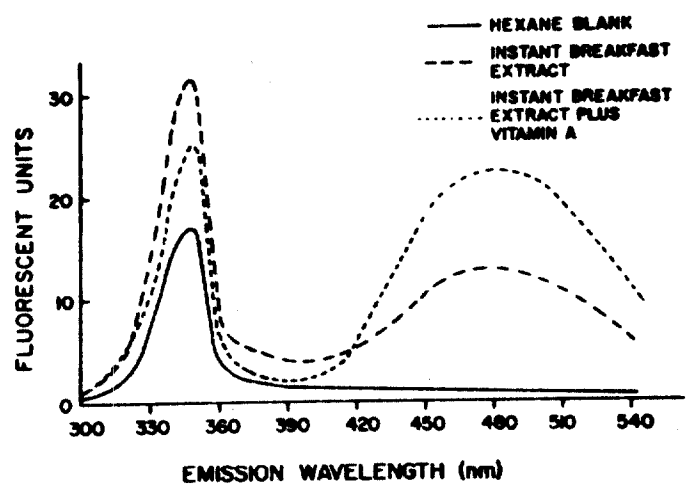

Fig. 3–Fluorescent scans at 360 nm excitation wavelength.

Low-fat, low-carotenoid foods

Convenience foods such as instant breakfast, most cereals and most prepared foods can be assayed for vitamin A content by saponifying 5g of homogenized sample (cereals should be finely ground) in 8 ml of 1% ethanolic pyrogallol and 4 ml of 60% aqueous KOH at a temperature between 85–90°C for 30 min. 5 ml of water is added to each sample at the 15 min mark. The resultant saponified material is homogenized and extracted twice with a 50 ml hexane using a tissue homogenizer (Inframo #8-111, Wayne, N.J.). 10 ml of this hexane extract is used directly for fluorometric measurements.

Care must be taken during saponification to avoid excessive boiling, exposure of the food sample to air, or exposure to light. Adjustment of water bath temperature, sample size and the covering of glassware with aluminum foil will limit the degradation of vitamin A.

High-fat foods

Foods with high fat content such as butter, margarine and ice cream, may not be completely saponified. Therefore, one should limit the sample size so that no more than 1g of fat is present. For example, samples of 1.5g or less of margarine can be saponified following the method previously described for low-fat foods.

High carotenoid foods

Fortified vegetable entrees, some margarines and other foods containing large amount of carotenoids, give very high fluorescent readings at the 360 nm excitation (y) wavelength, occasionally leading to negative result for (α). This is due to interference from carotenoids (other than phytofluene). In these cases the hexane extract can be further purified by a procedure described by Olson (1961). 10 ml of hexane extract is placed on a 1 × 15 cm column of 10g of deactivated alumina. The carotenoids are eluted first with 40 ml of hexane; then 80 ml of hexane with 2% benzene, 65 ml hexane with 2% acetone, and 40 ml of 10% acetone in hexane are eluted through the column. Retinol is eluted in the last 10% acetone portion. 10 ml of this extract is read directly in the photofluorometer, and the necessary dilution adjustments are made in the formula.

The final ethanol-water balance in the saponified material is crucial for complete hexane extraction. If improper separation occurs when hexane is added, the addition of a few ml of ethanol can be used to break the emulsion (Freed, 1966).

RESULTS & DISCUSSION

THE FLUORESCENCE of vitamin A is sufficiently intense to permit detection of quantities well below the microgram level (Udenfriend, 1962). As with all fluorometric assays, however, the researcher must work in ranges where Beer's Law applies. We have found in our laboratory that the best results with our instruments are obtained with foods containing 25–85 I.U. vitamin A per gram of sample. (This is equivalent to 12.5–42.5 I.U. per 10 ml extract.)

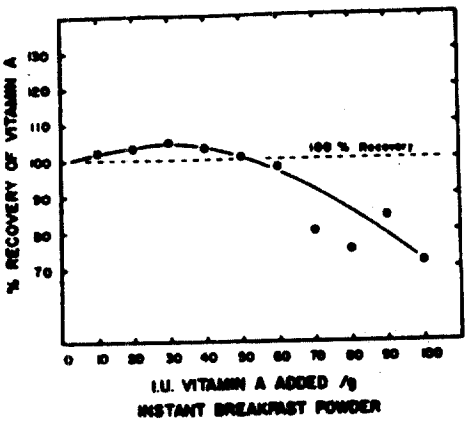

Fig. 4—Percent recovery of vitamin A palmitate when incremental additions are made to instant breakfast powder.

Figure 4 shows the % recovery of vitamin A palmitate when incremental additions are made to instant breakfast powder. The retinyl palmitate was added dry before saponification and a % recovery was observed for additions, as high as 60 I.U. per gram of powder. The results indicate a recovery of 100% ± 5% up to 60 I.U. per gram of powder for a total linear recovery range of 35–95 I.U. per gram food.

Utilizing the procedures described in this paper, vitamin A in several types of foods were investigated. Table 1 includes a list of fortified foods along with their respective claimed fortification and the % recovery of that claim. Most commercial operations add additional quantities of vitamin A (above what is claimed of the label) as an "overage" to assure compliance with the label claim and to allow for losses during storage and cooking. In all cases, a recovery greater than the claim (taken at 100%) was found indicating the presence of such "overage."

Six determinations of butter and seven determinations of wheat cereal were taken in order to demonstrate the precision which may be obtained with this analytical method. The results indicate that butter had an average content of 43.5 μg of vitamin A with a standard deviation of 1.2 μg, and the wheat cereal averaged 57.5 ± 2.8 μg. Much higher standard deviations are found in products such as the freeze dried casserole, where there is inherent vitamin A variability due to variations in product formulation and quality control thereof.

It is very difficult to satisfactorily compare the results of the fluorescent method to those from the Carr-Price method, particularly because of inherent errors in the latter method (Thompson et al. 1971). The accuracy of the fluorescent method is clearly demonstrated, however, in Figure 4 as 100 ± 5% of vitamin A is recovered from standard additions of the vitamin to instant breakfast powder.

Since the presention and submission of this manuscript, Thompson's group has published a paper describing a rapid fluorometric method for the determination of vitamin A in milk, butter, cheese and ice cream (Thompson et al., 1972). Our work, therefore confirms and extends the applicability of the method to food systems.

CONCLUSIONS

WHEN CARE is taken to shield all extraction steps from light, the fluorometric method for food analysis is accurate. For best results, investigators should use a spectrophotofluorometer with narrow band widths. Since this method is simple to perform and very rapid, we suggest that this fluorometric procedure be considered in lieu of the Carr-Price and other colorimetric methods for the analysis of vitamin A in food.

REFERENCES

Bayfield, R.F. 1971. Colorimetric determination of vitamin A with trichloroacetic acid. ANA. Biochem. 39: 282.

De, N.K. 1955. A fluorometric method for vitamin A assay. Indian J. Med. Res. 43: 391.

DeRitter, E. 1967. Newer analytical techniques—Vitamins. Assoc. Food & Drug Off. 31(2): 94.

Derse, P.H. 1971. Analytical problems associated with determining content and biological availability of vitamins and minerals in processed foods. In "AMS Symposium On Vitamins And Minerals In Processed Foods," p. 133.

Dugan, R.E., Frigerio, N.A. and Siebert, J.M. 1964. Colorimetric determination of vitamin A and its derivatives with trifluoroacetic acid. Ana. Chem. 36: 114.

Freed, M., Ed. 1966. "Methods Of Vitamin Assay," 3rd ed, p. 74. Interscience.

Fujita, A. and Aoyama, M. 1951. Fluorometric determination of vitamin A. J. Biochem. (Tokyo) 38: 271.

Garry, P.J., Pollack, J.D. and Owen, G.M. 1970. Plasma vitamin A assay by fluorometry and use of a silicic acid column technique. Clin. Chem. 16: 766.

Gyorgy, P. and Pearson, W.N. Ed. 1967. "The Vitamins," 2nd ed., 6: 158. Academic Press, New York.

Koe, B.K. and Zechmeister, L. 1952. Preparation and spectral characteristics of all-trans and a all-cis-phytofluene. Arch. Biochem. Biophys. 46: 100.

Maynard, L.A. and Loosli, J.K. 1969. "Animal Nutrition," p. 245. McGraw Hill, New York.

Neeld, J.B. Jr. and Pearson, W.N. 1963. Macro and micro methods for the determination of serum vitamin A using trifluoroacetic acid. J. Nutr. 79: 454.

Olson, J.A. 1961. The conversion of radioactive β-carotene into vitamin A by the rat intestine in vivo. J. Biol. Chem. 238: 349.

Sobotka, H., Kann, S. and Lowenstein, J. 1943. The fluorescence of vitamin A. J. Am. Chem. Soc. 65: 1959.

Thompson, J.N., Erdody, P., Brien, R. and Murray, T.K. 1971. Fluorometric determination of vitamin A in human blood and liver. Biochem. Med. 5: 67.

Thompson, J.N., Erdody, P., Maxwell, W.B. and Murray, T.K. 1972. Fluorometric determination of vitamin A in dairy products. J. Dairy Sci. 55: 1077.

Udenfriend, S. 1962. "Fluorescence Assay in Biology and Medicine," p. 232. Academic Press, New York.

Ms received 8/19/72; revised 10/21/72; accepted 10/25/72.

Presented at the 32nd Annual Meeting of the Institute of Food Technologists in Minneapolis.

Research supported by Office of Economic Opportunity Grant CG 2305 A/o and U.S. Dept. of Agriculture, Food & Nutrition Service Contract No. 12-35-600-8.

The authors acknowledge the assistance and advice of Dr. David H. Strumeyer and Dr. Stanley E. Katz from the Dept. of Biochemistry & Microbiology, Rutgers University, and Miss Eunyong Chung from the Dept. of Nutrition, Rutgers University.

Geelen-'72
Bib. No. 10507

Reproduced by permission
of the copyright owner

The Localization of Vitamin A in the Pregnant Rat by Means of Fluorescence Microscopy

J. A. G. GEELEN
Psychopathological and Neurophysiological Laboratory, Department of Neurology, University of Nijmegen, The Netherlands

ABSTRACT Pregnant Wistar rats were administered 50,000 IU of vitamin A palmitate orally on each of the 7th, 8th, and 9th days of gestation. Fluorescence microscopy of serial sections of 10th-, 11th-, and 12th-day embryos revealed a fading, bright green color indicative of vitamin A. The fluorescence was located in the decidua capsularis, decidua basilaris, Reichert's membrane, parietal yolk-sac epithelium, giant cells, and uterine musculature but not in the visceral yolk-sac epithelium or embryo. The thyroid, adrenal, and kidney of experimental pregnant females showed an increase of vitamin A fluorescence.

Past studies of the teratogenic action of vitamin A concentrated on the malformations produced, the interaction with other substances, and the embryology of some of the anomalies (Kalter, '68). Research has also been done on the influence of vitamin A on tissues *in vitro*, which showed the noxious effect of this substance on the membranes of various cell organelles (Dingle and Lucy, '65). Integration of the results of the experimental teratology and tissue culture experiments becomes feasible when it is possible to locate vitamin A in the embryo and its adnexa, and when the concentration in the tissues is high enough to produce a deleterious effect in the cell organelles.

Since the chemical tests for this vitamin are not sufficiently sensitive the concentration has only been measured in whole rat fetuses (Giroud et al., '57). After 60,000 international units (IU) vitamin A palmitate on days 12, 13, and 14 there were a twofold increase of the vitamin in fetuses and a relation between the concentration in the maternal liver and in the fetuses. Giroud et al. ('57) concluded that there was placental transmission of vitamin A and that it had a direct teratogenic action on the embryo. Zunin and Testa ('53, cited by Giroud et al., '57) found an increased concentration in the placenta of the hypervitaminotic rat. Cohlan and Stone ('61) found a slight increase in fetuses after excess vitamin A, but their results cannot be evaluated because not much information about the experiment was given. They emphasized the unreliability of the chemical measurements at low concentrations of vitamin A.

Some authors (Dann, '32; Baumann et al., '34; Henry et al., '49, cited by Moore, '57) found that there was a small amount of vitamin A in the neonatal rat liver even when the maternal liver contained much of it. Moore ('57, p. 237) concluded that in man the dietary intake affects the placental transmission of vitamin A more than in some other species including the rat. The above-quoted studies concerned the placenta at term, and not the early placenta which is much more important in the genesis of most malformations.

We know of two teratogens that do not reach the embryo: trypan blue (Wilson, '55; Wilson et al., '63), and mouse anti-kidney antiserum (Slotnick and Brent, '66; Gebhardt et al., '70; Brent et al., '71).

In the present investigation we wished to learn whether vitamin A has a direct or an indirect action on the rat embryo and where it would be localized if administered on different days of pregnancy.

MATERIAL AND METHODS

The technique of locating vitamin A in sections described by Popper ('41, '44) was used. When this substance is irradi-

Received Nov. 1, '71. Accepted Jan. 28, '72.

ated with ultraviolet light it exhibits a bright-green fluorescence, which fades rapidly (5 sec–about 1 min, depending on the amount and concentration present). Popper found that fluorescence was visible in droplets of an emulsion of oil in water if the oil contained more than 20 μg/g vitamin A and thus concluded that the vitamin A concentration of a fluorescing structure would be above this level.

Female (2–3-month-old virgins) and male Wistar rats (T.N.O. Holland) were put together from 6 PM to 8 AM. In the morning vaginal smears were made and examined for sperm. The day on which sperm was found was called the 1st day of pregnancy. Females were placed in groups of three in plastic cages and given food (Hope Farms, Woerden) and water ad libitum. At approximately 10 AM on each of the 7th, 8th, and 9th days of pregnancy 50,000 IU vitamin A (fat-soluble vitamin A palmitate, Arovit, Roche) was administered by oral intubation to a group of six animals. A control group of females that received no vitamin A were studied in the same way.

Females were killed at 9 AM on the 10th, 11th, and 12th days by exsanguination under ether anesthesia. After the number of implantation sites had been counted, two implantations, chosen at random, were cut away from each female and frozen in liquid nitrogen. Resorptions, noticeable by the blood on the cut surface, were not used. The tissue was serially sectioned at 16 μ on a cryostat, and stained immediately with hematoxylin; then the slices were mounted using glycerine as mounting medium.

The sections were studied with a Zeiss fluorescence microscope using a HB 200 mercury lamp (Philips CS 200W/4) with UG-1 and BG-38 filters. In the ocular the light was filtered so that only light with wavelengths above 410 mμ passed. Photographs were made on Kodak Tri-X film (exposure time 5 sec).

RESULTS

10th day

Control. Every other section was mounted, and thus 20 sections containing the embryo from every implantation were

TABLE 1

Vitamin A distribution [1] in hypervitaminotic rats

	Decidua basalis	Decidua capsularis	Ectoplacental cone	Area surrounding the basal part of the ectoplacental cone and early placenta	Cone of cell debris in the decidua capsularis	Embryo and visceral yolk sac	Parietal yolk sac	Reichert's membrane	Giant cells	Endometrium	Musculature of the uterus
10th day	+ +	+ + +	±	+ +	±	–	+	+	+ +	+	+ +
11th day	+ +	+ +	±	+ +		–	+	+	±	+	+ +
12th day	±	±	–	+ +		–	+	+	±	+	+

+ + +, bright fluorescence in many large granules.
+ +, bright fluorescence, but in smaller granules that were more scattered in the tissue.
+, small granules, exhibiting dull fluorescence that faded within a few seconds.
±, slight fluorescence observed in just a few sections.
–, no fluorescence observed.



Fig. 1 Section through a 10th-day experimental pregnant uterus. Giant cell showing vitamin A fluorescence in the cytoplasm; Reichert's membrane (RM) and the parietal yolk-sac epithelium (PY) have less fluorescence; the cells of the embryo (E) show no fluorescence.



Fig. 2 Section through a 10th-day experimental pregnant uterus. Decidua capsularis (DC) exhibits strong vitamin A fluorescence; the cone (C) consisting of cell debris shows slight fluorescence; the embryo (E) shows no fluorescence.

studied. The only structure that showed any fluorescence (weak, granular, and rapidly fading) was the decidua capsularis.

At this stage there was a cone consisting of maternal cell debris at the antimesometrial part of the egg cylinder. A small blood vessel passed through this cone. In one series of sections a strong vitamin A fluorescence was seen in the wall of this vessel.

Fig. 3 Section through the small vessel in the cone of cell debris in an experimental decidua capsularis, showing strong vitamin A fluorescence.



Fig. 4 Section through a 10th-day experimental pregnant uterus. Notice the difference in vitamin A fluorescence between the muscular layers of the uterus (U) and the decidua capsularis (DC).

Treated. The results are summarized in table 1. The embryos and the visceral yolk-sac epithelium contained no fluorescence (fig. 1), whereas the decidua capsularis showed strong fluorescence (fig. 2). The fluorescence in the decidua basilaris was located in the walls of the capillaries. In one series there was strong fluorescence in the small blood vessel in the cone of maternal cell debris (fig. 3). The fluores-

Fig. 5 Section through a 10th-day experimental pregnant uterus. Notice the fluorescence due to vitamin A in the basal part of the endometrial cells.

cence in the muscular layers of the uterus and in the endometrium is illustrated in figures 4 and 5.

11th day

Control. Every third section was mounted; 20 sections from each implantation were studied. There was occasional vitamin A fluorescence in the decidua capsularis.

Treated. The vitamin A fluorescence was slightly decreased in all structures in comparison with the 10th-day stage (table 1). In some sections fluorescence was seen in the fold connecting the visceral and parietal yolk-sac epithelia.

12th day

Control. Fifteen sections from each implantation were studied. A kidney, an adrenal gland, and the thyroid gland of each female were also sectioned. No vitamin A fluorescence was found in the implantations. The kidney showed a slight, granular fluorescence in the medulla but none in the cortex. The thyroid gland had no vitamin A fluorescence. The adrenal cortex contained much fluorescence in the zona fasciculata and reticularis but not in the zona glomerulosa (fig. 6). The medulla showed no fluorescence due to vitamin A.

Treated. Thirty sections of each implantation were studied (table 1). The vitamin A fluorescence was considerably reduced in comparison with the 11th day. The decidua capsularis showed less fluorescence than the decidua basilaris. The musculature of the uterus exhibited stronger fluorescence than the decidua. The fluorescence at the basal side of the chorioallantoic placenta is illustrated in figure 7. The kidney contained fluorescence in the cortex and in the medulla between the tubules. The glomeruli showed no fluorescence. In the thyroid gland a moderate fluorescence was found in the stroma and sometimes in the follicular cells but not in the colloid. The adrenal cortex contained more fluorescence in the zona fasciculata and reticularis than the control adrenals. The zona glomerulosa and the medulla showed a moderate fluorescence (fig. 8).

DISCUSSION

There is an abundant literature (sum-



Fig. 6 Section through the adrenal cortex (zona glomerulosa: ZG: zona fasciculata: ZF) of a control animal. The zona glomerulosa is devoid of vitamin A. The zona fasciculata shows strong vitamin A fluorescence.



Fig. 7 Section through the early chorioallantoic placenta of a hypervitaminotic mother on the 12th day of pregnancy. Beneath the placenta (P) there is a strong vitamin A fluorescence. The decidua basalis (DB) is devoid of vitamin A. The giant cells (GC) show a slight fluorescence.

Fig. 8 Section through the zona glomerulosa and zona fasciculata of the adrenal cortex of an experimental female on the 12th day of gestation. In comparison with figure 6 there is an increase in vitamin A fluorescence in the zona fasciculata. In the zona glomerulosa there is a little fluorescence visible.

marized by Popper, '44) showing that a rapidly fading, green fluorescence is characteristic for vitamin A. Our results supported this because we found much more fluorescence in experimental than in control animals.

A disadvantage of the staining procedure is that the embryos and the visceral yolk-sac epithelium were often disrupted, so that the cells were scattered in the cavity surrounded by the parietal yolk-sac epithelium. In experiments in the future we would try to use a fixative that does not affect the vitamin A fluorescence, so that the delicate structures remain intact.

As seen with fluorescence microscopy vitamin A appeared to penetrate only the giant cells, Reichert's membrane, and the parietal yolk-sac epithelium, but not the embryo and the visceral yolk-sac epithelium, when administered on the 7th, 8th, and 9th days of gestation.

Thus its teratogenic action is probably not exerted directly on the embryo, but possibly by interfering with the absorption of nutrients from the maternal organism. This influence on the yolk-sac placenta may be explained in two ways. 1. The vitamin could have a deleterious influence on the cell organelles (e.g., mitochondria) causing decreased cellular activity. It has been shown by Beck et al. ('67) that trypan blue causes an inhibition of the lysosomal enzymes in the visceral yolk-sac epithelium of near-term rat fetuses. They suggested that inhibition of the nutrition of the embryo might have a teratogenic effect. 2. The resorptive capacities of the yolk-sac placenta might be overstrained because of the excess of vitamin A, so that the nutritive function is diminished.

When the distribution of vitamin A is compared with that of trypan blue (Wilson et al., '63) it appears that vitamin A did not reach the yolk-sac and the visceral yolk-sac epithelium; the greatest accumulation of trypan blue was in the visceral yolk-sac epithelium, whereas vitamin A was especially concentrated in the decidua capsularis and in the decidua basalis bordering the chorioallantoic placenta. Therefore disturbance of the nutritive function of the decidua may also be involved in early teratogenesis by hypervitaminosis A.

On one occasion we found (unpublished) vitamin A fluorescence in the liver of a 16th-day rat fetus after administration of

50,000 IU vitamin A palmitate (Arovit) on the 7th, 8th, 9th, and 10th days of gestation. Thus it is possible that the early teratogenic action, producing, e.g., exencephaly, myeloschisis, and cleft palate (Giroud and Martinet, '56), is indirect; whereas late teratogenic effects such as phocomelia (Giroud and Martinet, '56) and disturbance of the development of the cerebral cortex (Langman and Welch, '67) might be direct, because the chorioallantoic placenta gradually takes over the function of the yolk-sac placenta, and becomes permeable to vitamin A. In further experiments we will try to demonstrate this phenomenon by locating vitamin A on the 13th, 14th, and 15th days of gestation.

Our investigation of some maternal organs revealed that they were overloaded with vitamin A after administration of large doses. However, as revealed by the study of successive stages of the pregnant uterus, the fluorescence gradually decreased. The most rapid decline was found in the decidua capsularis, which degenerated and disappeared during the 11th and 12th days of pregnancy.

The increase of the number of fat droplets in the adrenal cortex found by Takekoshi ('64) could have been due simply to a larger amount of vitamin A being stored and not to increased hormone production; and his finding of a hypofunction of the thyroid gland might have been caused by the high concentration of vitamin A in the stroma and follicular cells, inhibiting the release of thyroxine from the colloid. This could account for the rather uncommon increase of ^{131}I-uptake accompanied by a decreased PBI.

ACKNOWLEDGMENTS

The advice and encouragement of Dr. D. O. E. Gebhardt and Dr. H. H. J. Jaspar are very much appreciated. I would like to thank the assistants of the Psychopathological and Neurophysiological Laboratory for their enthusiastic and skilled help with the technical and photographical procedures and during the preparation of the manuscript.

LITERATURE CITED

Baumann, C. A., B. M. Riising and H. Steenbock 1934 The absorption and storage of vitamin A in the rat. J. Biol. Chem., *107*: 705–715.

Beck, F., J. B. Lloyd and A. Griffiths 1967 Lysosomal enzyme inhibition by trypan blue: a theory of teratogenesis. Science, *157*: 1180–1182.

Brent, R. L., A. J. Johnson and M. Jensen 1971 The production of congenital malformations using tissue antisera. VII. Yolk-sac antiserum. Teratology, *4*: 255–275.

Cohlan, S. Q., and S. M. Stone 1961 Observations on the effect of experimental endocrine procedures on the teratogenic action of hypervitaminosis A in the rat. Biol. Neonat., *3*: 330–342.

Dann, W. J. 1932 The transmission of vitamin A from parents to young in mammals. Biochem. J., *26*: 1072–1080.

Dingle, J. T., and J. A. Lucy 1965 Vitamin A, caretenoids and cell function. Biol. Rev., *40*: 422–461.

Gebhardt, D. O. E., E. H. Baart de la Faille-Kuyper and J. Nagel 1970 Embryolethality and localization of antikidney serum in the pregnant mouse, *Mus musculus*. Teratology, *3*: 143–151.

Giroud, A., and M. Martinet 1956 Tératogénèse par hautes doses de vitamine A en fonction des stades du développement. Arch. Anat. Micr. Morph. Exp., *45*: 77–98.

Giroud, A., H. Gounelle and M. Martinet 1957 Données quantitatives sur le taux de la vitamine A chez le rat lors d'expériences de tératogénèse par hypervitaminose A. Bull. Soc. Chim. Biol., *39*: 331–336.

Kalter, H. 1968 Teratology of the Central Nervous System. Univ. of Chicago Press, Chicago.

Langman, J., and G. W. Welch 1967 Excess vitamin A and development of the cerebral cortex. J. Comp. Neur., *131*: 15–26.

Moore, T. 1957 Vitamin A. Elsevier, Amsterdam.

Popper, H. 1941 Histologic distribution of vitamin A in human organs under normal and pathological conditions. Arch. Path., *31*: 766–801.

——— 1944 Distribution of vitamin A in tissue as visualized by fluorescence microscopy. Physiol. Rev., *24*: 205–224.

Slotnick, V., and R. L. Brent 1966 The production of congenital malformations using tissue antisera. V. Fluorescent localization of teratogenic antisera in the maternal and fetal tissues of the rat. J. Immun., *96*: 606–610.

Takekoshi, S. 1964 The mechanism of vitamin A induced teratogenesis. J. Embryol. Exp. Morph., *12*: 263–271.

Wilson, J. G. 1955 Teratogenic activity of several azo dyes chemically related to trypan blue. Anat. Rec., *123*: 313–333.

Wilson, J. G., T. H. Shepard and J. F. Gennaro 1963 Studies on the site of teratogenic action of C^{14}-labeled trypan blue. Anat. Rec., *145*: 300 (abst.).

Germain-'73
Bib. No. 10509

Reproduced by permission
of the copyright owner

Reprinted with the
permission of the copyright owner,
Pergamon Press, Inc.

Arch. oral Biol. Vol. 18, pp. 729–733, 1973. Pergamon Press. Printed in Great Britain.

THE EFFECTS OF VITAMIN A AND TETRACYCLINE ON A MOUSE TOOTH ANOMALY

JOCELYN GERMAIN and C. L. BERRY

Department of Pathology, Guy's Hospital Medical School, London, SE1 9RT

Summary—The effects of vitamin A and tetracycline on a polygenically determined mouse tooth anomaly have been examined. Transient hypervitaminosis A is associated with a significant increase in mean tooth size, tetracycline has no significant effect. The results suggest that these two teratogens do not exhibit their effects on the earliest stages of development of calcified structures.

INTRODUCTION

WE HAVE previously discussed the advantages of a polygenically determined tooth anomaly as a teratological screening system (BERRY and GERMAIN, 1972). Absence of the third molar of the CBA mouse is a threshold characteristic, a discontinuous variant which occurs at the lower end of the continuous variation in size shown by this tooth. The interaction of many gene loci in determining tooth size and the superimposition of a threshold are aspects of the anomaly that indicate that it is determined in a manner that resembles the determination of many malformations in man (CARTER, 1969).

This study concerns the use of this experimental model in an assessment of the role of vitamin A and tetracycline in teratogenesis. Both compounds cause malformations in mice, notably cleft palate, which may be associated with tooth anomalies and limb shortening (FILIPPI and MELA, 1957). The work of LANGMAN and WELCH (1966; 1967) has demonstrated that there is prolonged cell generation time in neuroepithelial cells in animals with hypervitaminosis A, and NANDA (1971) proposed that the teratological effect of this compound was due to interference with DNA synthesis. A comparable hypothesis was proposed by LOVE and VICKERS (1971), who suggested "failure of growth" as a cause of the limb defects. Our model is known to be sensitive to inhibition of DNA synthesis (BERRY and GERMAIN, 1972), and we hoped to find evidence which might support this work.

Tetracycline has well defined effects in inducing enamel hypoplasia (WITKOP and WOLF, 1963) and is a true teratogen in mice (FILIPPI, 1967). Its mode of action is uncertain, although induced maternal vitamin B deficiency has been suggested as a possible explanation of the malformations found (FILIPPI, 1967). Other hypothesis depend on the demonstration of growth inhibition (BEVELANDER and COHLAN, 1962), an inhibitory effect on collagen biosynthesis (HALME and AER, 1968), and a direct effect on the formation of bone marrow crystals (ILKKA *et al.*, 1970). It was considered that early tooth formation might be affected if any of these processes were involved.

MATERIALS AND METHODS

CBA mice were maintained under standard animal house conditions, as a closed colony with random breeding, and were given Oxoid breeding diet and water *ad libitum*. The day of birth of any litter was designated day 0. One group of mothers were given 2500 IU vitamin A, in 0·1 ml as an aqueous solution (Rovomix A300-W, Roche Products Ltd.) on day 3. This was administered by gastric tube under light anaesthesia. Other mothers were given 25 mg/100 ml tetracycline in drinking water, from day 0 to 14. The control litters and both experimental groups were killed at 5 weeks.

Vitamin A levels in serum were determined in a pilot study in which 14 adult mice were given 2500 I.U. vitamin A as described above. Blood was taken from seven of these animals 24 hr after administration of the vitamin and from the remaining seven at 48 hr. A number of control animals were used for determinations of normal vitamin A levels. In order to demonstrate the passage of tetracycline into the suckling mice, the mothers were given the antibiotic as described above. At 7 days the mice were killed, their heads cut in half and snap frozen. Cryostat sections were cut at 10 μm, mounted in "Univert" (aqueous mountant) and then were observed by ultraviolet light to localize tetracycline by fluorescence.

After death the third molar tooth from each jaw was examined and measured using a dissecting microscope; the maximum bucco-lingual and mesio-distal dimensions were noted and multiplied to give the "area" of the tooth. Previous experiments have shown no statistically significant difference between the size of left and right-sided teeth, and therefore the two sides have been combined in the results.

RESULTS

Administration of both compounds to mothers resulted in an increase in the numbers of litter mice which died between day 1 and 5 weeks. For controls the mortality rate was 4·6 per cent, for tetracycline-treated animals 11·8 per cent and for animals given vitamin A 28·5 per cent. Absence of the teeth occurred at the frequencies shown in Table 1 where the figures shown represent the number of teeth missing from the theoretical maximum, i.e. 100 mice have 400 expected teeth and 10 missing third molars represents a rate of 2·5 per cent. None of the differences shown are significant.

TABLE 1. NUMBER AND PER CENT THIRD MOLARS MISSING

		Maximum possible number of 3rd molars	Number missing 3rd molars	Percentage missing 3rd molars
Control	M	200	8	4·0
	F	228	6	2·6
Vitamin A	M	124	3	2·4
	F	107	2	1·8
Tetracycline	M	87	6	6·8
	F	94	4	4·2

Mean tooth area, together with range of sizes, the standard error of the mean and the number of teeth examined, are shown in Table 2. The teeth of vitamin A treated animals were significantly larger than those of controls; there were no other significant differences at the 5 per cent level (comparison of the standard errors of the means).

Fluorescence microscopy confirmed that tetracycline had reached the suckling mice, bright fluorescence was seen in the dentine of the first and second molars and of the incisor teeth in animals killed on day 7. Serum vitamin A levels in control females gave a mean of 16 IU/100 ml. 24 hr after the administration of vitamin A this figure was 1790 IU/100 ml. and 48 hr later 40 IU/100 ml.

TABLE 2. MEAN TOOTH AREA OF THE THIRD MOLAR TOOTH

		Male	n	Range of observations	Female	n	Range of observations
Controls	U	0·193(0·004)	58	0·133–0·249	0·195(0·004)	62	0·130–0·280
	L	0·144(0·004)	55	0·100–0·267	0·145(0·003)	56	0·089–0·213
Vitamin A	U	0·215(0·005)	62	0·106–0·311	0·215(0·007)	52	0·111–0·302
	L	0·160(0·007)	59	0·044–0·320	0·191(0·007)	53	0·035–0·284
Tetracycline	U	0·176(0·004)	45	0·073–0·249	0·187(0·006)	47	0·089–0·320
	L	0·145(0·005)	38	0·038–0·187	0·150(0·004)	43	0·044–0·249

The figures in parentheses denote the standard error of the mean, and *n* the number of teeth examined. U and L refer to the upper and lower teeth.

DISCUSSION

These results lend no support to the hypothesis that vitamin A is a teratogen by virtue of its effect on DNA synthesis. The experimental model is susceptible to such effects; we have previously reported the results of an 8 hr period of methotrexate, induced inhibition of DNA synthesis, with reduction in tooth size and increase in the frequency of missing teeth (BERRY and GERMAIN, 1972). Since our animals had very high blood vitamin A levels for a period in excess of 24 hr and since MOORE (1971) has shown that vitamin A transfer occurs freely during lactation, it seems likely that they were exposed to high concentrations of the vitamin as the mortality rate suggested. Our results, which showed a slight increase in the size of the third molars following transient hypervitaminosis A during early development seem to conflict with the decreased size (or absence) of limbs observed in rats subjected to a more sustained period of hypervitaminosis (LOVE and VICKERS, 1971). These differences can be accounted for if the limb defects result from disturbance of a later phase of development of calcified tissues, as Love and Vickers suggest. It seems unlikely that the death of animals with small teeth has occurred selectively. The suckling mice that died were not drawn from large litters. Increased litter size was accompanied by reduction in size of both the whole mouse and the third molar.

Tetracycline treatment also increased mortality and was associated with an insignificant increase in the frequency of missing teeth; mean tooth size was reduced, but not significantly. Fluorescence studies demonstrated that the drug had been transmitted to the suckling mice. It seemed unlikely that the teratogenic effects of tetracycline can be manifest in those stages of development which preceded the deposition of mineral crystals. The work of ILKKA *et al.* (1970) demonstrates that tetracycline may have a direct effect on the formation of bone mineral crystals, but at high concentrations the antibiotic may inhibit collagen biosynthesis (see also HALME and AER, 1968). This effect may be responsible for the reduced size of long bones in premature infants whose mothers have received tetracycline (COHLAN, BEVELANDER and TIAMSIS, 1963).

In both test groups, teeth smaller than those seen in controls were found. This alteration in the apparent "threshold" for tooth disappearance has been found following inhibition of DNA synthesis and after alterations in trace element metabolism (BERRY and GERMAIN, 1972; GERMAIN, unpublished observations). This suggests

that environmental factors may vary this threshold considerably. It is noteworthy that these small teeth usually occurred in animals with one or more teeth missing.

Factors which act on tooth size and the expression of the tooth defect must act between the third and seventh day of tooth development at the "cap" and "bell" stages, when the critical size threshold of the tooth which determines its presence or absence has to be reached (GREWAL, 1969; BERRY and GERMAIN, 1972). Tetracycline and vitamin A do not apparently affect the third molar to any great extent during its early development. From other experiments, it is evident that inhibition of DNA synthesis and large doses of fluoride will do so, and that the model is a sensitive one. The teratogenic effects of hypervitaminosis A and tetracycline are probably manifest as a result of interference with mineral formation, and possible collagen biosynthesis in developing teeth and bones, rather than an earlier effect on the relevant anlage.

Acknowledgements—This work is supported by Action for the Crippled Child.

Résumé—On a examiné les effets de la vitamine A et de la tétracycline sur une anomalie de la dent de souris déterminée polygéniquement. La hypervitaminose A transitoire est associée avec une croissance significative de la dimension moyenne de la dent; la tétracycline n'a pas un effet significatif. Les résultats suggèrent que ces deux tératogènes n'exhibent pas leurs effets dans les premiers stades du développement des structures calcifiées.

Zusammenfassung—Es ist die Wirkung von Vitamin A und Tetracyclin auf eine polygenetisch festgestellte Zahnanomalie einer Maus untersucht worden. Vorübergehende Hypervitaminose A wird mit einem bedeutenden Anwachsen der mittleren Zahngrösse in Verbindung gebracht, Tetracyclin übt keine bezeichnende Wirkung aus. Die Ergebnisse legen nahe, dass diese zwei Missgeburten hervorrufenden Stoffe ihre Auswirkungen in den frühesten Stadien der Entwicklung von Verkalkungsstrukturen nicht zum Ausdruck bringen.

REFERENCES

BERRY, C. L. and GERMAIN, J. 1972. Absence of the third molar tooth in the mouse: its relevance to human malformation *J. Path.* **108**, 35–45.

BEVELANDER, G. and COHLAN, S. Q. 1962. The effect on the rat fetus of transplacentally acquired tetracycline. *Biologia. Neonat.* **4**, 365–370.

CARTER, C. O. 1969. Genetics of common disorders. *Br. med. Bull.* **25**, 52–57.

COHLAN, S. Q., BEVELANDER, G. and TIAMSIS, T. 1963. Growth inhibition of prematures receiving tetracycline. *Am. J. Dis. Child.* **105**, 453–461.

FILIPPI, B. 1967. Antibiotics and congenital malformations: evaluation of the teratogenicity of antibiotics. In: *Advances in Teratology* (edited by WOOLLAM, D. H. M.), pp. 239–255. Logos Press.

FILIPPI, B. and MELA, V. 1957. Malformazioni congenite facciali et degli arti da tetraciclina. *Minerva. chir.* **12**, 1106–1110.

GREWAL, M. S. 1962. The development of an inherited tooth defect in the mouse. *J. Embryol. exp. Morph.* **10**, 202–211.

HALME, J. E. and AER, J. 1968. Effect of tetracycline on synthesis of collagen and incorporation of ^{45}calcium into bone in foetal and pregnant rats. *Biochem. Pharmac.* **17**, 1479.

ILKKA, K., WORTIOVAARA, J., OSSI, L. and SAXEN, L. 1970. The inhibitory effect of tetracycline on osteogenesis in organ culture. *J. Embryol. exp. Morphol.* **23**, 185–211.

LANGMAN, J. and WELCH, G. W. 1966. Effect of Vitamin A and development of the central nervous system. *J. comp. Neurol.* **128**, 1–15.

LANGMAN, J. and WELCH, G. W. 1967. Excess Vitamin A and development of the cerebral cortex. *J. comp. Neurol.* **131**, 15–26.

LOVE, A. M. and VICKERS, T. H. 1971. Hypervitaminosis A dymelia in rats. *Br. J. exp. Path.* **52**, 656–668.

MOORE, T. 1971. Vitamin A transfer from mother to offspring in mice and rats. *Internat. J. Vit. Nutr. Res.* **41**, 301–306.

NANDA, R. 1971. Tritiated thymidine labelling of the palatal processes of rat embryos with cleft palate induced by hypervitaminosis A. *Archs oral Biol.* **16**, 435–444.

WITKOP, C. J. and WOLF, R. O. 1963. Hypoplasia and intrinsic staining of enamel following tetracycline therapy. *J. Am. med. Ass.* **185**, 1008–1011.

Hall-'68
Bib. No. 10560

Univ. Conn. Agr. Exptl. Sta. Bull. 409. 1968.

November 1968
Bulletin 409

REVERSAL OF CHRONIC BOVINE HYPERVITAMINOSIS A

U. S. DEPT. OF AGRICULTURE
NATIONAL AGRICULTURAL LIBRARY
JAN 20 1970
CURRENT SERIAL RECORDS

By

R. C. Hall, Jr.
J. E. Rousseau, Jr.
M. C. Calhoun
H. D. Hurt
H. D. Eaton
T. W. Swerczek
J. J. Lucas

Storrs Agricultural Experiment Station
College of Agriculture
The University of Connecticut, Storrs

CONTENTS

Introduction 3

Experimental Procedure 4
Animals and Feeding 4
Observations 4

Results 6
Clinical Signs 6
Feed Consumption, Growth and Some Physiological Criteria, Table 1 7
Plasma and Liver Vitamin A, Table 2 7
Serum and Cerebrospinal Fluid, Tables 3, 4 and 5 9
Weights of Adrenals, Heart, Kidneys and Liver with Ascorbic Acid and Nitrogen Contents of Right Adrenals, Table 6 12
Metacarpus (Bone) Measurements and Ash Contents, Table 7 13

Discussion 15

Summary 16

References 17

ACKNOWLEDGMENTS

The authors are grateful to B. A. Donohue and T. Watts, Sr. for the care and feeding of the animals, to Mrs. Mae Miller, M. L. Diffendaffer and T. M. Dwyer for technical assistance and to Dr. H. J. Fisher, Connecticut Agricultural Experiment Station in New Haven, for proximate analysis of the feeds. The vitamin A supplement was furnished by Hoffmann – La Roche, Inc., Nutley, New Jersey, through the courtesy of Drs. J. C. Bauernfeind and R. H. Bunnell.

Received for publication March 26, 1968. (RP 1M)

REVERSAL OF CHRONIC BOVINE HYPERVITAMINOSIS A[1]

By R. C. Hall, Jr., J. E. Rousseau, Jr., M. C. Calhoun
H. D. Hurt, H. D. Eaton, T. W. Swerczek
and J. J. Lucas[2]

The number of abnormalities due to feeding excessive amounts of reformed vitamin A to calves for an extended period of time (7, 8) are ite remarkable. While there appears to be a paucity of literature with spect to experimental nutritional studies on reversal of chronic hyper-taminosis A, based upon clinical cases in man, T. Moore, (10) stated in 57 that it is "usually readily curable." This is essentially in agreement ith more recent clinical findings (5, 12, 14). An exception was the report Pease (13) who observed that bone changes were not cured in children ½ to 14 years following chronic vitamin A intoxication.

The present paper reports the effects of withdrawal of vitamin A from lves previously fed excessive amounts of the vitamin, and provides con-

---

This bulletin is based upon studies undertaken as part of Storrs Agricultural Experiment Station Project (A.I. 300) The Role of the Fat Soluble Vitamins and Their Interrelationships in the Bovine. It was supported in part by funds provided by a PHS research grant, NB-02108 from the National Institutes of Neurological Diseases and Blindness, Public Health Service and by Agway, Inc.. Syracuse, New York; Wirthmore Feeds, Inc., Waltham, Massachusetts; and Hoffman - La Roche, Inc., Nutley, New Jersey. Support for T. W. Swerczek, D.V.M. was provided by a National Institute of Health Pathology Training Grant STIGM 98501.

The first author is a Research Assistant in Animal Nutrition, and second and fifth Associate and Professor of Animal Nutrition, respectively, and sixth Research Assistant in Animal Diseases (Pathology), and the last is Professor of Biometrics, all of The University of Connecticut's College of Agriculture. M. C. Calhoun and H. D. Hurt were formerly Research Assistants in Animal Nutrition and their present addresses are, respectively, Animal Science and Agricultural Biochemistry Department, University of Delaware, Newark and Animal Science Department, Cornell University, Ithaca.

trol calves so that the possible withdrawal effects might be evaluat simultaneously. In addition, this research provided the opportunity f detailed histological examination of soft tissues from calves after th withdrawal of excess dietary vitamin A (19).

EXPERIMENTAL PROCEDURE

Animals and Feeding.

Each of 20 male Holstein 1-day-old calves, was raised on a die consisting of limited whole milk, limited starter and ad libitum chopped alfalfa hay to 9 weeks of age. Subsequently, each was fed a vitamin A depletion ration at a rate to provide a 5% increase in live weight p 7 days until one 7-day period after the plasma vitamin A concentratio had decreased to or less than 15 μg/100 ml. Thereafter, according to rando allotment, each calf received, in addition to the vitamin A depletion rati (fed at 60% of the above mentioned amount to preclude, insofar possible, feed refusals) vitamin A acetate equivalent to retinol intakes 55, 8,800 or 26,400 μg per kilogram of live weight per day. Four calv fed the 55 μg intake were controls and 8 calves fed the 8,800 μg inta and 8 the 26,400 μg intake were designated, respectively, mild and seve chronic hypervitaminotic A animals. Information or reference to th above procedures has been reported (4). The feeding of the abo designated vitamin A levels continued for 12 consecutive 7-day period induction period, IP. Then, vitamin A was withdrawn according random allotment from 4 calves of each of the hypervitaminotic A grou and all calves continued on experiment for an additional 13 consecuti 7-day periods, withdrawal period, WP. The experiment was terminat for each calf by slaughter the morning following the completion of t 13th week of the WP.

Observations.

At 7-day intervals during both the IP and WP, each calf was carefu observed and examined for clinical signs. All feed fed and refused weighed daily to the nearest 0.05 kg. Live weights were taken at succe 7-day periods and linear growth measurements recorded the day p to and the final day of both the IP and WP. The average minimum maximum barn temperatures with SE's during the IP were 17.9 ± 0.2 24.7 ± 0.3 C and light exposure 78 ± 12 lux. Similar values for W were 15.0 ± 0.4 C and 15.0 ± 0.3 C and 45 ± 22 lux.

Heart rate by auscultation of the right thoracic wall and rectal mperature were determined once during the 7 days immediately prior and the last 7 days of the WP. Cisternal cerebrospinal fluid pressure CSFP) was measured under general anesthesia in a left lateral recumbent osition (6) during 7 days prior to and the last 7 days of the WP. After ich CSFP measurement, a minimum of 30 ml of cerebrospinal fluid (CSF) as withdrawn for subsequent determination of protein concentration and actionation by procedures cited previously (8).

Venous blood samples, citrated to prevent clotting, were withdrawn jugular puncture from each calf the day prior to and at successive 8-day intervals during the IP and at 7-day intervals during the WP for bsequent determination of plasma vitamin A concentration. Whole ood samples were obtained every 28 days during the WP for serum paration and subsequent analyses of the serum for protein concentration d fractionation, enzymatic (glutamic-oxalacetic and glutamic-pyruvic nsaminase and alkaline phosphatase and acid phosphatase) activities. ethods employed were similar to those cited previously (8), except kaline phosphatase was determined by the method of Klein *et al.* (9) and d phosphatase as described by Babson and Read (2).

At slaughter, tissue samples were taken for histologic examination 9). The adrenals, heart, kidneys and liver as well as the right and left etacarpal bones were obtained, adhering tissue removed, weighed and ored at -18 C. Adrenal gland ascorbic acid and nitrogen were determined a the homogenized tissue (1, 16). The vitamin A concentration of the ver was determined by a modified Gallup-Hoefer procedure (3) after ne maceration in a food chopper. Weight and various linear measure-ents of the metacarpal bones were taken. The entire left bone was cut ngitudinally with a band saw, washed free of marrow, and sectioned nto small cubes (ca 1 cm on a side); while the right was cut into epiphyseal a a 2 cm cross section containing the distal epiphyseal margin) and id-shaft (ca 5 cm cross section of the mid-shaft) sections. The cut pieces bone, respectively, from the entire left metacarpus from the epiphyseal gion of the right and from the mid-shaft region of the right were sprayed th a tap water jet in a screened container to remove adhering blood d marrow. They were then placed in gauze bags in a Soxhlet extractor, tracted for 16 hr with ethanol and for 3 hr with petroleum ether P 30-60 C), and then ground in a micro Wiley mill. A 1 g sample was ied at 105 C for 1 hr prior to ashing at 525 C in a muffle furnace for hr.

As before (4, 8), the chemical composition of all feed fed was termined at successive 4-week periods during the experiment. However, e the composition differed little from the previous statistics (6, 8), it

will not be reported here. The vitamin A supplement as described in t companion paper to this one (4) contained 111,009 ± 658 μg of vitam A (retinol) per gram (average of two samples).

In the statistical analyses (18), variation attributable to vitamin intakes (treatments) and calves within vitamin A intake groupings (erro was calculated. The control calves' (55 μg intake group) response w compared with the response for each of the other vitamin A intake grou using Dunnett's one-sided comparison (18).

RESULTS

Clinical Signs.

Just prior to the withdrawal of vitamin A (WP), 3 of the 4 calv fed the 8,800 μg intake for the induction period (IP) and designated receive no vitamin A during the WP, exhibited mild erythema of t inguinal, anal and nostril skin and 1 calf, moderate lameness. Up withdrawal of vitamin A from the ration, remittance of the erythe occurred in 1 calf during the second week of the WP and in the ot 2 calves the fourth week while lameness was corrected by the fifth week.

In the group of 4 calves fed the 8,800 μg intake for both the IP a WP, clinical signs became progressively severe. All calves exhibited erythe as described above and lameness occurred in all 4 calves by the seven week of WP as well as softening of the frontal, lacrimal and nasal bo in all calves by the fifth week of WP. One calf, because of extreme lamen and general debilitation, had to be removed from the experiment in t ninth week of the WP.

Of the 4 calves designated to be fed the 26,400 μg intake for o the IP, all exhibited by the sixth week of this period erythema of the sk lameness, softening of the skull bones, skin abrasions of the feet and abnormal stance, alopecia, and ocular discharges. These outward cha became progressively worse so that by the completion of the 12-week only 2 of the 4 calves had survived. When the vitamin A was withd from these 2 surviving calves at the completion of the IP, erythe the skin and lameness had apparently disappeared by the sixth week WP. The skull bones had hardened by the sixth week, the skin abr and alopecia had largely been alleviated by the fifth and fourth respectively, and the ocular discharges by the fourth week. One o calves fell and broke its right femur as it was being led the seventh of the WP, and thus, had to be removed from the experiment.

Essentially, a similar clinical history as reported immediately above s observed in the 4 calves designated to be fed the 26,400 μg intake for th the IP and WP. By the fourth week of the WP, 1 calf had died and alves were removed from the experiment because of lameness, inability stand and anorexia.

ed Consumption, Growth and Some Physiological Criteria, Table 1.

During the IP, with the exception of calves fed the highest vitamin A nake, 26,400 μg, feed consumption was 100% of that offered except r 1 calf fed the 8,800 μg intake and its consumption was 99.4%. During IP, feed consumption was less in those animals remaining on the middle nake of vitamin A, 8,800 μg.

The actual growth measurements, the day prior to the WP, with the eption of the calf fed the highest vitamin A intake, 26,400 μg, during , were essentially similar. During the WP, the live weight increases re markedly less for the calves which continued to receive the 8,800 μg amin A intake. The increases in height at withers during WP were eater for the calves which did not continue to receive the 8,800 μg and arkedly less in the 1 calf which did not continue to receive the 26,400 μg take.

Heart rate and rectal temperatures were greater and cerebrospinal aid pressure less the week prior to WP (initial values) in those calves d either the mild or severe chronic hypervitaminotic A intakes during . At the termination of WP (terminal values), values for calves fed the 00 μg intake during IP but none during WP were similar to the values the control calves fed the 55 μg intake during both IP and WP.

asma and Liver Vitamin A, Table 2.

Within a 7-day period upon withdrawal of vitamin A from the ration the calves fed the mild hypervitaminotic A intake of 8,800 μg, plasma amin A concentrations decreased markedly, approaching the magnitude the values of the control calves fed the 55 μg intake during both IP and P. Liver vitamin A values at the termination of the WP were essentially same for the two above mentioned groups of calves. Plasma vitamin A ncentration of the calves, which continued to be fed the 8,800 μg intake ring WP, declined during WP but, on the average, were maintained considerably higher level than values for the control calves. Terminal er vitamin A values for this group of calves were significantly greater n the values for the control calves.

Table 1.—Effect of withdrawal of vitamin A (WP) from the ration calves previously fed excessive amounts of the vitamin (I) on feed consumption, growth and some physiological criter.

Period	Vitamin A intake, μg/kg live weight/day				SD per calf
IP	55	8,800	8,800	26,400[a]	
WP	55	0	8,800	0	
Feed consumption[b]					
Days consuming ration allowance					
% of total days	100.0	99.7	62.20	86.9	
Arcsin $\sqrt{\%}$	90	88	52**	69	4
Amount of ration consumed					
% of total fed	100.0	100.0	91.2	97.6	
Arcsin $\sqrt{\%}$	90	90	73**	81	2
Total consumption, kg	223.8	234.5	199.8	216.8	22.0
Growth					
Live weight, kg					
Initial-WP	134	134	134	92	10
Increase-WP	50.3	59.0	16.3**	54.9	8.[illegible]
Height at withers, cm					
Initial-WP	97.3	100.0	98.4	92.7	1.6
Increase-WP	8.2	14.0*	9.3	1.9	3.6
Heart girth, cm					
Initial-WP	116	117	115	107	4
Increase-WP	14.4	16.7	13.5	10.2	3.7
Girth of paunch, cm					
Initial-WP	136	140	140	125	8
Increase-WP	18.1	16.8	18.4	29.8	5.9
Heart rate, beats/min					
Initial-WP	69	84*	84*	104	9
Terminal-WP	74	77	98*	110	13
Rectal temperature, C					
Initial-WP	38.5	39.0*	38.8	39.2	[illegible]
Terminal-WP	38.6	38.8	38.8	38.7	[illegible]
Cerebrospinal fluid pressure, mm of saline					
Initial-WP					
Actual	190	163	177	162	[illegible]
Log_{10}	2.28	2.21	2.24	2.21	[illegible]
Terminal-WP					
Actual	259	222	199	308	
Log_{10}	2.41	2.34	2.30**	2.49	

a Since this treatment group contained only 1 calf instead of 4 as in the other groups, therefore, did not contribute to the SD per calf, no assessment of the statistical significance of this calf's values was made.

b Statistics for the first 12 of the 13 weeks of the withdrawal period, WP.

* Significantly different at $P \leq 0.05$ from control group fed 55 μg intake for both IP and WP.

** Significantly different at $P \leq 0.01$ from control group fed 55 μg intake for both IP and WP.

ıble 2.—Effect of withdrawal of vitamin A (WP) from the ration of calves previously fed excessive amounts of the vitamin (IP) on plasma and liver vitamin A.

Period	Vitamin A intake, μg/kg live weight/day				SD
IP	55	8,800	8,800	26,400[a]	per
WP	55	0	8,800	0	calf
ısma vitamin A, μg/100 ml					
Initial-WP	29.1 (23-37)[b]	92.5 (71-120)	109.8 (104-123)	169.8	-
1-wk-WP	29.4 (22-37)	31.0 (28-33)	92.0 (70-113)	42.3	-
2-wk-WP	29.0 (22-37)	33.7 (30-38)	81.9 (58-108)	38.0	-
3-wk-WP	26.0 (18-33)	30.6 (30-31)	89.7 (71-100)	49.6	-
4-wk-WP	27.2 (18-34)	30.2 (28-33)	97.4 (82-116)	45.0	-
8-wk-WP	27.7 (19-34)	28.6 (23-33)	74.7 (50-113)	27.2	-
12-wk-WP	28.2 (21-34)	31.8 (26-42)	54.3 (34-78)	21.8	-
ver vitamin A, terminal-WP					
Concentration, μg/100 g					
Actual	7,230	7,399	78,813	670	-
Log_{10}	3.48	3.84	4.87**	2.82	0.33
Total, μg					
Actual	195,307	209,642	1,508,295	16,556	-
Log_{10}	5.16	5.28	6.16**	4.22	0.31
Concentration per unit live weight, μg/kg live weight					
Actual	1,058	1,036	10,436	112	-
Log_{10}	2.88	2.98	4.00**	2.05	0.32

[a] See Table 1.
[b] Range.
[c] See Table 1.

ırum and Cerebrospinal Fluid, Tables 3, 4 and 5.

Prior to the start of the withdrawal period (Initial-WP values), ılves fed the mild or severe hypervitaminotic A intakes had, in most cases, rum protein distributions and albumin and total globulin concentrations ıfferent than the control calves. By the 12th week of WP, calves fed the ·00 μg intake only during IP, had values similar to those of the control ·lves. In the case of the calves continuing to receive the 8,800 μg intake ıring WP, the serum protein distribution and albumin and globulin ncentration values were significantly different from the values of the ·ntrol calves. During WP, total serum protein concentrations for the

Table 3.—Effect of withdrawal of vitamin A (WP) from the ration of calves previously fed excessive amounts of the vitamin (IP) on serum protein distribution and concentration.

Period	Vitamin A intake, μg/kg live weight/day				SD per calf
IP	55	8,800	8,800	26,400[a]	
WP	55	0	8,800	0	
Distribution					
Albumin, %					
Initial-WP	69.5	58.2*	64.7	36.2	6.0
4-wk-WP	71.6	63.9*	59.0**	52.0	3.6
8-wk-WP	72.9	69.0	58.6**	60.6	2.6
12-wk-WP	69.5	68.4	59.0**	65.5	2.9
Total globulin, %					
Initial-WP	30.5	41.8*	35.3	63.8	6.0
4-wk-WP	28.4	36.1*	41.0**	48.0	3.6
8-wk-WP	27.1	31.0	41.4**	39.4	2.6
12-wk-WP	30.5	31.6	41.0**	34.5	2.9
Albumin to globulin ratio					
Initial-WP	2.3	1.5*	1.9	0.6	0.4
4-wk-WP	2.5	1.8**	1.5**	1.1	0.3
8-wk-WP	2.7	2.2*	1.4**	1.5	0.3
12-wk-WP	2.3	2.2	1.4**	1.9	0.3
Concentration, g/100 ml					
Total					
Initial-WP	7.1	6.6	6.6	5.6	0.4
4-wk-WP	7.1	6.7	6.9	6.4	0.4
8-wk-WP	6.9	7.1	6.8	6.5	0.4
12-wk-WP	6.9	6.9	6.9	6.9	0.3
Albumin					
Initial-WP	4.9	3.9*	4.3	2.0	0.6
4-wk-WP	5.1	4.3**	4.0**	3.3	0.3
8-wk-WP	5.0	4.9	4.0**	4.0	0.1
12-wk-WP	4.8	4.7	4.1*	4.5	0.5
Total globulins					
Initial-WP	2.2	2.7*	2.3	3.6	0.3
4-wk-WP	2.0	2.4	2.9**	3.1	0.3
8-wk-WP	1.9	2.2	2.8**	2.5	0.2
12-wk-WP	2.1	2.2	2.8**	2.4	0.[illegible]

[a] See Table 1.
* See Table 1.
** See Table 1.

two groups fed the mild hypervitaminotic A intake of 8,800 μg for IP, were not significantly different from the control calves fed the 55 intake.

Except for the glutamic-pyruvic transaminase activity, the statistical differences in serum enzymatic activities were essentially the same as the

ıble 4.—Effect of withdrawal of vitamin A (WP) from the ration of calves previously fed excessive amounts of the vitamin (IP) on some serum enzymatic activities.

	Period	Vitamin A intake, μg/kg live weight/day				SD
	IP	55	8,800	8,800	26,400[a]	per
	WP	55	0	8,800	0	calf
ansaminases, units/ml[b]						
Glutamic-oxalacetic						
Initial-WP		55 (1.73)[d]	100 (2.00)**	100 (2.00)**	179	— (0.07)
4-wk-WP		46 (1.66)	69 (1.84)**	123 (2.08)**	137	— (0.06)
8-wk-WP		50 (1.70)	65 (1.80)	168 (2.15)**	94	— (0.16)
12-wk-WP		67 (1.79)	54 (1.72)	173 (2.15)	84	— (0.22)
Glutamic-pyruvic						
Initial-WP		18 (1.22)[d]	16 (1.21)	16 (1.18)	22	— (0.14)
4-wk-WP		12 (1.07)	12 (1.08)	16 (1.18)	15	— (0.13)
8-wk-WP		13 (1.12)	13 (1.11)	35 (1.35)	11	— (0.23)
12-wk-WP		13 (1.12)	13 (1.09)	23 (1.30)	12	— (0.18)
hosphatases, units/100 ml[c]						
Alkaline						
Initial-WP		5.0	14.0**	10.8*	26.0	3.5
4-wk-WP		5.6	9.8	15.4*	21.6	5.4
8-wk-WP		6.0	6.2	15.4**	12.8	3.5
12-wk-WP		7.6	6.2	12.0	8.2	3.8
Acid						
Initial-WP		1.3	3.2**	2.8**	4.3	0.5
4-wk-WP		2.3	1.9	2.9	3.0	0.6
8-wk-WP		1.6	1.7	2.6**	2.0	0.4
12-wk-WP		1.8	1.6	2.2	1.5	0.4

[a] See Table 1.
[b] A unit (sigma-Frankel) is a measure of the enzymatic activity that will form 4.82 x 10—4 M glutamate/minute at a pH of 7.5 and at 25 C resulting in a decrease in optical density at 340 mμ of 0.001/min/ml per centimeter of light path of serum.
[c] A unit (Klein-Babson-Read) is the amount of enzyme that will liberate 1.0 mg phenolphthalein in 30 minutes at 37 C.
[d] Log_{10} of units/ml.
[e] See Table 1.
[f] See Table 1.

or serum protein distribution and albumin and total globulin concentrations. While none of the averages of serum glutamic-pyruvic ansaminase activities of the groups fed the mild hypervitaminotic A intake 8,800 μg were significantly different from those of the group fed the ontrol intake, it was of interest that the 8- and 12-week WP values of the roup on continuous 8,800 μg intake during WP were considerably greater an the values for the control calves.

The statistical differences in cerebrospinal fluid protein distribution

Table 5.—Effect of withdrawal of vitamin A (WP) from the ration of calves previously fed excessive amounts of the vitamin (IP) on cerebrospinal fluid protein distribution and concentration.

Period	Vitamin A intake, μg/kg live weight/day				SD per calf
IP	55	8,800	8,800	26,400[a]	
WP	55	0	8,800	0	
Distribution					
Albumin, %					
Initial-WP	57.2[b]	39.0**	43.3**	17.8	5.4
Terminal-WP	55.1	52.2[b]	40.2**	-	3.9
Total globulin %					
Initial-WP	42.8[b]	61.0**	56.7**	82.2	5.4
Terminal-WP	44.9[b]	47.8[b]	59.8**	-	3.9
Albumin to globulin ratio					
Initial-WP	1.35[b]	0.65**	0.77**	0.22	0.18
Terminal-WP	1.26[b]	1.09[b]	0.68**	-	0.19
Concentration, mg/100 ml					
Total					
Initial-WP	25[b]	19**	26	20	3
Terminal-WP	28[b]	26[b]	23**	35	1
Albumin					
Initial-WP	14[b]	8**	11	4	2
Terminal-WP	16[b]	14[b]*	9**	-	2
Total globulins					
Initial-WP	11[b]	11	15**	16	2
Terminal-WP	12[b]	12[b]	14**	-	1

[a] See Table 1.
[b] Statistic based on 3 calves instead of 4.
* See Table 1.
** See Table 1.

and albumin and total globulin concentrations were essentially the same as those for serum.

Weights of Adrenals, Heart, Kidneys and Liver with Ascorbic Acid and Nitrogen Contents of Right Adrenals, Table 6.

In terms of total weight, the adrenal glands, heart and kidneys from calves, fed the 8,800 μg only during IP, tended to be heavier than the same organ weights of the controls. For calves fed continuously the 8,800 intake, the adrenal glands weighed more and the liver less than those of the control calves. When expressed as weight per unit live weight, the values for the adrenals, heart and kidneys from calves fed the 8,800 intake during both IP and WP were significantly greater than the values of the control calves. Ascorbic acid and nitrogen concentrations of the

ıble 6.—Effect of withdrawal of vitamin A (WP) from the ration of calves previously fed excessive amounts of the vitamin (IP) on adrenal and some organ weights and adrenal composition.

	Period	Vitamin A intake, μg/kg live weight/day				SD
	IP	55	8,800	8,800	26.400[a]	per
	WP	55	0	8,800	0	calf
ırenal						
Right, g		4.0	5.1*	6.3**	5.8	0.6
Left, g		4.4	5.1	7.1**	5.2	0.7
Total weight per unit live weight, mg/kg		44	50	92**	74	5
ırt						
Weight, g		810	871	785	885	81
Weight per unit live weight, g/kg		4.3	4.3	5.4**	6.0	0.4
dney						
Right, g		257	312	266	289	56
Left, g		271	310	310	289	71
Total weight per unit live weight, g/kg		2.8	3.1	3.9*	3.9	0.6
ver						
Weight, g		2,683	2,732	2,006*	2,510	375
Weight, per unit live weight, g/kg		14.2	13.6	13.7	17.0	1.6
corbic acid and nitrogen in ht adrenal						
Ascorbic acid						
Concentration, mg/100 g		101	107	84	103	13
Total, mg		4.0	5.4	5.3	5.9	1.0
Nitrogen						
Concentration, mg/g		25.3	25.0	24.3	24.3	0.7
Total, mg		100	126*	153**	140	13
Ascorbic acid per unit nitrogen, mg/g		40	43	34	42	5

[a] See Table 1.
[b] See Table 1.
[c] See Table 1.

ght adrenal gland were not significantly different. The total amounts these constituents were greater in both groups of calves fed the mild pervitaminotic A intake during IP and during IP and WP and were e to the relatively greater weight of this gland.

etacarpus (Bone) Measurements and Ash Contents, Table 7.

Weight and linear dimensions of the metacarpus from calves fed

Table 7.—Effect of withdrawal of vitamin A (WP) from the ration of calves previously fed excessive amounts of the vitamin (IP) on metacarpus.

Period	Vitamin A intake, μg/kg live weight/day				SD
IP	55	8,800	8,800	26,400[a]	pooled
WP	55	0	8,800	0	
Weight, g					
Right	264	290	250	236	19
Left	264	292*	256	228	18
Length					
Overall, proximal ridge to distal condylar ridges, cm					
Right metacarpus	20.5	21.3*	20.3	20.4	0.4
Left metacarpus	20.3	21.3**	20.3	19.8	0.4
From proximal ridge to margin of distal epiphysis, cm					
Right metacarpus	16.9	17.7**	16.7	16.8	0.3
Left metacarpus	17.0	17.7	16.8	16.5	0.5
Midshaft circumference, cm					
Right metacarpus	9.3	9.7	9.4	9.2	0.5
Left metacarpus	9.3	9.8	9.2	9.0	0.5
Midshaft cortical thickness of posterior surface, mm					
Left metacarpus	3.4	3.4	3.2	4.0	0.4
Incidence of exostoses on metacarpal tuberosity, no. of calves					
Right metcarpus	0	3	4	1	·
Left metacarpus	0	3	4	1	·
Ash, g/100 g[b]					
Entire bone[c]	66.2	66.6	67.2*	65.8	0.6
Mid-shaft[d]	70.2	68.7	70.0	68.3	1.1
Epiphyseal region[d]	63.3	62.6	64.0	62.0	1.1
Ratio of ash to organic matter, g/g[b]					
Entire bone[c]	1.96	1.99	2.05*	1.92	0.[illegible]
Mid-shaft[d]	2.38	2.20	2.34	2.16	0.1[illegible]
Epiphyseal region[d]	1.73	1.68	1.78	1.63	0.[illegible]

[a] See Table 1.
[b] Fat-free and moisture-free basis.
[c] Left metacarpus.
[d] Right metacarpus.
* See Table 1.
** See Table 1.

8,800 μg intake during IP but not during WP were greater than th[illegible] for the control calves fed 55 μg of vitamin A throughout IP and WP. [illegible] the calves fed 8,800 μg during IP and WP, the values were slightly

ın the controls, but they were not statistically significant. Exostoses curred frequently in all groups receiving excessive vitamin A, but were x seen in the control calves. Ash content and ratio of ash to organic atter of the entire metacarpus from calves fed the 8,800 μg intake for oth IP and WP were significantly greater than similar values of the ontrol calves.

DISCUSSION

The results of the present study with the young growing calf were sentially the same as those of clinical reports in which relatively rapid leviation of most of the hypervitaminotic A signs and blood and tissue anges occurred upon withdrawal of the vitamin from the diet (5, 12, 5, 17). On the other hand, enlarged adrenal glands, greater metacarpus e and exostoses on the metacarpal tuberosities were present in the lves even after 13 weeks of withdrawal of a mild hypervitaminotic A take. Therefore, some permanent damage may exist in growing animals eviously fed excessive amounts of vitamin A. The exostoses observed the present experiment agree with the report of Pease (13) who found perostoses of long bones in children previously fed toxic intakes of the tamin. Considerably longer periods of withdrawal of toxic intakes the vitamin will probably have to be employed in experimental animals fore the question of permanent bone damage can be definitively certained. In support of longer withdrawal periods, Pratt and McCance 5), in studies on porcine undernutrition, reported that complete rebilitation required in the case of certain animals took as many as 40 eks. This is at least three times greater than the 13-week period employed the present experiment with calves.

While the statistics of the present experiment agree with previous udies at this Station (4, 6, 7, 8), the general applicability of the statistics eds to be considered with caution. This is because species, age of the imal, carrier and mode of administration of the vitamin, level of feed take (restricted in the present study in order to preclude nutritive ake as an uncontrolled experimental variable) and others as outlined Nieman and Obbink (11) can affect the results. The differences in clinical reports on bone damage illustrate well the apparent effect of on the response to toxic intakes of the vitamin. For example, Persson al. (14) found no permanent damage in children whose range in age ing vitamin A overdosing was 3 to 51½ months. Pease (13) reported manent damage due to toxic intakes of the vitamin in children more

than a year of age. Silverman *et al.* (17) could not detect significant ferences in calcium and phosphorus metabolism and strontium kin between a period of feeding high doses of the vitamin to adult hum and a following period of withdrawal of the vitamin. Thus, the very yo child and the adult apparently may suffer no permanent damage fr toxic intakes, whereas, the rapidly growing child of more than a year age may well suffer permanent damage.

SUMMARY

Three-month-old Holstein male calves were fed for a 12-week perio either a control intake of the vitamin (4 calves), a mild chronic hy vitaminotic A intake (8 calves) or a severe chronic hypervitaminoti intake (8 calves). In a subsequent 13-week period, the 4 control cal continued on the same intake, whereas, the vitamin was complet withdrawn from the ration of 4 of the 8 calves in each of the hypervitaminotic A groups.

Upon withdrawal of the mild hypervitaminotic A intake, relativ rapid alleviation of clinical signs characteristic of the hypervitamin A syndrome occurred. Plasma vitamin A concentrations decreased wit one week to values essentially equal to those of the calves fed the cont vitamin A intake and remained at these levels throughout the remain of the vitamin withdrawal period. During or by the 13th week of the wit drawal period, physiological measurements, such as heart rate, re temperature and cisternal cerebrospinal fluid pressure, biochemical crite such as serum and cerebrospinal fluid protein distribution and albu and total globulin concentrations, and serum transaminase and phosphat activities, had all returned to values comparable to those of the controls. the completion of the vitamin A withdrawal period, the total weight the adrenal glands, heart and kidneys were heavier than the same or from control calves. Total weight and various linear measurements of metacarpus were greater than the controls. Exostoses on the metac tuberosities occurred in 3 out of 4 calves, but not in the control calves.

In the case of the 4 calves which continued receiving the chronic hypervitaminotic A intake throughout the experiment, cli signs became worse. In most of the physiological and biochemical cri the differences between this group of calves and the controls increase magnitude during the last 13 weeks of the experiment.

Only 1 of 4 calves fed the severe chronic hypervitaminotic A in for the initial 12 weeks survived the entire experimental period.

REFERENCES

) Association of Official Agricultural Chemists. 1965. Official Methods of Analysis. 10th ed., Washington, D. C.

Babson, A. L. and Read, P. A. 1959. A New Assay for Serum Prostatic Acid Phosphatase. *Tech. Bull. Reg. Med. Technol.*, 29:82.

) Bunnell, R. H., Rousseau, J. E., Jr., Eaton, H. D., and Bell, G. 1954. Estimation of Vitamin A and Carotenoids in Calf Liver. *J. Dairy Sci.*, 37:1473.

) Calhoun, M. C., Rousseau, J. E., Jr., Hall, R. C., Jr., Eaton, H. D., Nielson, S. W., and Lucas, J. J. 1965. Cisternal Cerebrospinal Fluid Pressure During Development of Chronic Bovine Hypervitaminosis A. *J. Dairy Sci.*, 48:729.

) Di Benedetto, R. J. 1967. Chronic Hypervitaminosis A in an Adult. *J. Am. Med. Assoc.*, 201:700.

) Grey, R. M., Calhoun, M. C., Rousseau, J. E., Jr., Woelfel, C. G., Hall, R. C., Jr., Nielsen, S. W., Eaton, H. D., and Lucas, J. J. 1964. Cisternal and Intraventricular Cerebrospinal Fluid Pressures in Chronic Bovine Hypervitaminosis A. *J. Dairy Sci.*, 47:783.

) Grey, R. M., Nielsen, S. W., Rousseau, J. E., Jr., Calhoun, M. C., and Eaton, H. D. 1965. Pathology of Skull, Radius and Rib in Hypervitaminosis A of Young Calves. *Path. Vet.*, 2:446.

) Hazzard, D. G., Woelfel, C. G., Calhoun, M. C., Rousseau, J. E., Jr., Eaton, H. D., Nielsen, S. W., Grey, R. M., and Lucas, J. J. 1964. Chronic Hypervitaminosis A in Holstein Male Calves. *J. Dairy Sci.*, 47:391.

) Klein, B., Read, P. A., and Babson, A. L. 1960. Rapid Method for the Quantitative Determination of Serum Alkaline Phosphatase. *Clin. Chem.*, 6:269.

) Moore, T. 1957. *Vitamin A*. Elsevier Publ. Co., New York.

) Nieman, C., and Obbink, H. J. K. 1954. The Biochemistry and Pathology of Hypervitaminosis A. *Vitamins and Hormones*, 12:69.

) Ostwald, Rosemarie and Briggs, G. M. 1966. Toxicity of the Vitamins. *In Toxicants Occurring Naturally in Foods*. NAS-NRC Publ., 1354.

) Pease, C. N. 1962. Focal Retardation and Arrestment of Growth of Bones Due to Vitamin A Intoxication. *J. Am. Med. Assoc.*, 182:980.

) Persson, B., Tunell, R., and Ekengren, K. 1965. Chronic Vitamin A Intoxication During the First Half Year of Life. *Acta Paediatrica Scand.*, 54:49.

) Pratt, C. W. M., and McCance, R. A. 1964. Severe Undernutrition in Growing and Adult Animals. 14. The Shafts of the Long Bones in Pigs. *Brit. J. Nutrition*, 18:613.

) Roe, J. H. 1954. Chemical Determination of Ascorbic, Dehydroascorbic and Diketogulonic Acids, Part III. *Methods of Biochem. Anal.*, 1:115.

) Silverman, S., Jr., Eisenberg, E., and Renstrup, G. 1965. A Study of the Effects of High Doses of Vitamin A on Oral Leukoplakia (Hyperkeratosis), Including Toxicity, Liver Function and Skeletal Metabolism. *J. Oral Therap. Pharmacol.*, 2:9.

Steel, R. G. D., and Torrie, J. H. 1960. *Principles and Procedures of Statistics*. McGraw-Hill Book Co., Inc., New York.

Swerczek, T. W. 1966. The Pathology of Soft Tissue in Calves During Vitamin A Excess and Reversal. M. S. Thesis. Graduate School, University of Connecticut, Storrs.

Hayes-'73
Bib No. 10567

SECOND EDITION

TOXICANTS OCCURRING NATURALLY IN FOODS

Committee on Food Protection
Food and Nutrition Board
National Research Council

NAS-NAE
NOV 6 1973
LIBRARY

NATIONAL ACADEMY OF SCIENCES
Washington, D.C. 1973

qualify as toxic emphasizes the need for rational decisions regarding the amounts of toxicants that may be allowed in the food supply. At the same time it should be recognized that relatively concentrated vitamin preparations are available in the marketplace and are promoted for their health benefits.

FAT-SOLUBLE VITAMINS

Vitamin A

Vitamin A active substances are consumed by man in two forms from either plant or animal sources. Plants contain the ultimate source in the form of the carotenoid pigments, particularly β-carotene, which can be cleaved in the intestinal mucosa to form two molecules of vitamin A (retinol).[6] Cleavage and conversion by man are poor, however, amounting to 20–30% efficiency. Vitamin A is stored in the liver and fat of animals as the palmitate ester; this ester provides a sizable component of man's vitamin A when meat, milk, and eggs are dietary staples. Vitamin A is also synthesized commercially and is supplied as the palmitate or acetate ester in vitamin supplements.

Although the literature contains approximately 200 reports of vitamin A toxicity in man, toxicity rarely results from ingestion of natural foodstuffs. Those exceptions result from the consumption of polar-bear liver by Arctic explorers, or from ingestion of fish livers from those large fishes (shark, halibut, cod) capable of storing high concentrations.[7] The usual cause of toxicity is the prolonged consumption of large vitamin supplements, often initiated for dermatologic reasons. There is no evidence that carotenoids are toxic, as massive oral loading does not result in elevated serum vitamin A[8] and may even depress circulating levels.[9] Children may develop a yellow pigmentation of the skin (xanthosis) when consuming pureed baby foods rich in carotenoids. Pigmentation slowly disappears when the dietary source of pigment is removed.[10]

Acute toxicity in the adult requires a dose in the range of 2–5 million IU or above[11,12] and ingestion of as much as 30 million IU has been reported.[7] Such cases occur after ingestion of polar-bear or fish livers, the latter of which contain up to 100,000 IU/g.[7,11] Ingestion of a comparable amount in vitamin capsules would be unlikely. In the infant, doses as low as 75,000 to 300,000 IU can precipitate acute toxic signs generally following an accidental overdose or unwitting supplementation by an overzealous mother.[11,13,14]

Chronic toxicity developing in a few months is most commonly encountered in infants and children,[15-18] whereas chronic toxicity in adults may take several months or even years (up to 8) to develop.[19-22] Although the chronic dose necessary to induce toxicity varies with the individual for reasons yet to be defined, reported cases of toxicity would indicate that chronic intakes in excess of 1,000 μg (approximately 3,000 IU)/kg body weight/day are likely to produce toxicity in man. Reports range from 18,000 to 60,000 IU/day for infants less than 1 yr old, and from 80,000 to 500,000 IU/day for the 1–5-yr-old age group.[15,22-25] Consumption of 100,000 IU or more per day has generally been associated with toxicity in man, whereas one half this intake apparently did not induce toxicity during 17 yr in an adult male.[24]

Signs of acute toxicity in adults have developed in 6–8 h following ingestion of vitamin A; these include severe headache centered in the forehead and eyes, dizziness, drowsiness, and nausea with vomiting followed in 12–20 h by redness and erythematous swelling of the skin, which eventually begins to peel. These changes may become most severe where the epidermis is thickest, in the palms of the hands and soles of the feet, and may persist for several weeks before returning to normal.[7] In infants, bulging fontanelles, anorexia, hyperirritability, and vomiting generally occur in 12 h, followed in a few days by a fine cutaneous desquamation.[11,13]

Chronic toxicity in man results in anorexia, headache, blurred vision, muscle soreness after exercise, hair loss, maculoerythematous eruptions on the shoulders and back, and general drying and flaking of the skin with pruritis, cracking and bleeding of lips, reddened gingiva, and nosebleeds. The liver and spleen may be palpably enlarged, and anemia may be present.[19,20] Often painful subcutaneous swelling and cortical hyperostoses are present in the regions of muscle attachments on long bones.[14] An increased angle of metaphyseal flare (pagoda effect) has been described in growing bones of children.[18,25] Increased cerebrospinal fluid pressure or pseudotumor cerebri with papilledema[26,27] seem to be symptomatic of chronic intake in somewhat less than half the cases reported in adults, whereas this syndrome in infants is generally diagnosed on the basis of bulging fontanelles.

Interestingly, there are no recorded deaths unequivocally ascribed to vitamin A excess, perhaps the most serious implied sequelae to toxicity being irreparable damage to the liver, resulting in cell death, fibrosis, and cirrhosis[19,20] or permanent stunting of bone growth due to cell death in the growing endochondral plate.[23,25] In essentially all cases, complete withdrawal of vitamin A results in regression of signs and symptoms in a matter of days, with no apparent changes remaining in a few weeks.

Diagnosis is best established by estimating the vitamin A concentration in plasma or serum from a fasting blood sample utilizing a colorimetric procedure, or more accurately by microfluorometry utilizing the natural fluorescence of the vitamin. Values in excess of 100 μg/100 ml (normal 20–60) can be considered suspect with values appreciably greater than that indicative of toxicity.

Vitamin A intoxication has been extensively studied in animals but almost exclusively in the young. Ability to induce toxicity varies widely with species, the calf[28] and pig[29] being in a range of susceptibility comparable to man (approximately 1,000–3,000 μg/kg body weight/day), whereas the rat[30] and carnivores such as the dog,[29,31] cat,[32] and probably the polar bear and seal can tolerate extremely large (20,000–60,000 μg/kg) daily doses before being clinically affected. Systemic toxicity probably reflects liver saturation and overflow into the general circulation, which would indicate that herbivores and, to a lesser extent, omnivores are less well equipped for handling the large doses of preformed retinol and retinyl esters that carnivorous species consume. In adult monkeys the rise in plasma vitamin A associated with toxic intake was not accompanied by an equal rise in the carrier, retinol-binding protein (RBP),[33] suggesting that "unbound" retinol or excessive retinyl esters may be the damaging agent in toxicity.

Toxicity in animals results in anorexia, weight loss, and cessation of growth, including bone, which becomes thin and brittle with a tendency to fracture.[30,34,35] Skin changes include hair loss, erythema, eczema of the axillary region and groin, with drying and desquamation of skin in the more exposed areas.[29,30,33,34] Bleeding from small hemorrhages subcutaneously and in the viscera may result in death.[30] Massive parenteral doses of a water-miscible form of vitamin A have produced calcification of arteries in rats.[36] Teratogenic changes, including cleft palate, spina bifida, deformities of the brain, and anomalies of other organ systems, can be induced when toxic doses are administered to the pregnant animal during critical periods of fetal development.[37] The developing mesenchymal cell seems particularly prone to toxicity.[38] Interestingly, in contrast to human beings, chronic toxicity has not resulted in elevated cerebrospinal fluid pressure in those animals studied experimentally,[39] with the possible exception of fetal rats affected *in utero*.[40]

The mechanism of *in vivo* toxicity is undefined, although it would appear to be related to the membrane-labilizing potential of retinol demonstrated to damage cell organelles and cause excessive release of hydrolytic enzymes.[41,42] Such changes are disruptive to the point of cell death, especially in mesenchymal cells normally containing hydrolytic enzymes. The likelihood that this is a pharmacologic effect related

to the physical characteristics of the vitamin is emphasized by the fact that α-retinol, an isomer of retinol, produces bone changes characteristic of toxicity in rats but has almost no physiological potential for promoting growth.[43]

An important aspect of the toxicity of fat-soluble vitamins, which has not been considered in most studies or case reports, is the interrelationship demonstrated to exist between them. Vitamins A and D diminish the toxic effects of each other,[44,45,46] which may explain why toxicity imposed by cod-liver oil can require a long induction period and why the observed toxicity may not be due clearly to either vitamin A or D as the relative concentrations of each may vary. Vitamin E also spares the toxic effect of vitamin A[47]; conversely, muscle weakness and degeneration described in vitamin A or D toxicity may reflect a relative vitamin E deficiency.[28,48] Similarly, nosebleeds, hemorrhagic diatheses, and prolongation of prothrombin time associated with vitamin A toxicity respond to vitamin K.[49,50] These may reflect competitive absorption and bulk displacement by the excessive vitamin, although this is not firmly established.

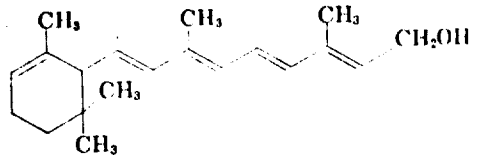

α-Retinol

Vitamin D

Unlike other vitamins, vitamin D can be made in the body where it is formed in the skin by the conversion of biologically synthesized 7-dehydrocholesterol to cholecalciferol (D_3). Ultraviolet irradiation from sunlight provides energy for this conversion, making this sterol-vitamin a sunlight-dependent hormone. Garments of civilized man, a cloistered life, or existence in northern latitudes, especially in cities, have necessitated an exogenous source of this vitamin supplied commercially by the irradiation of yeast ergosterol to form ergocalciferol (D_2). Vitamin D_2 can also be formed by irradiation of food. Vitamin D is also found in fish-liver oil, which was the original source of the antirachitic vitamin and still is incriminated as a source of toxicity. There are no recorded cases of vitamin D toxicity from overexposure to sunlight. Extensive exposure has evolved a means of protection by increasing the skin pigmentation, thereby filtering large amounts of ultraviolet irradiation.[51] By this means negroid populations seem to have established higher re-

erally relied upon in the diagnosis of vitamin B_{12} deficiency) and therefore can result in severe neurologic damage. For these reasons, excessive intake of folic acid is to be avoided.[121,122] Intravenous injection of 500 mg/kg body weight of folic acid in rats decreased renal filtration, increased kidney size, and produced epithelial degeneration in the proximal convoluted tubules.[123]

Thiamine

No toxic effects of thiamine have been reported following oral dosing; this is probably due to the fact that 5 mg is the maximum quantity that can be absorbed from a given dose.[124] Parenteral administration is indicated only when deficiency is evident, because repeated injections at levels of 10–100 mg may produce anaphylactic shock with vasodilation, nausea, tachycardia, and dyspnea.[125]

REFERENCES

1. H. Mohtor and G. Emerson, Vitamins as pharmacologic agents. Vitam. Horm. 6:69 (1948).
2. F. A. Robinson, The vitamin B complex. Wiley, New York (1951). P. 62.
3. W. Sebrell and R. Harris (eds.), The vitamins, chemistry, physiology, pathology. Academic Press, New York (1954).
4. T. Spies, R. Hillman, S. Cohlan, B. Kramer, and A. Kanof, Vitamins and avitaminoses. In Diseases of metabolism, G. Duncan (ed.). Saunders, Philadelphia (1959).
5. R. Ostwald and G. M. Briggs, Toxicity of the vitamins. In Toxicants occurring naturally in foods. National Research Council. National Academy of Sciences, Washington, D.C. (1966).
6. D. S. Goodman and H. S. Huang, Biosynthesis of vitamin A with rat intestinal enzymes. Science *149*:879 (1965).
7. J. P. Nater and H. M. G. Doeglas, Halibut liver poisoning in 11 fishermen. Acta Derm. *50*:109 (1970).
8. R. Greenberg, T. Cornbleet, and A. I. Jeffay, Accumulation and excretion of vitamin A-like fluorescent material by sebaceous glands after oral feeding of various carotenoids. J. Invest. Dermatol. *32*:599 (1959).
9. M. Dawadu and J. Gillman, Hypercarotenaemia in Ghanaians. Lancet *ii*:532 (1963).
10. H. W. Josephs, Hypervitaminosis A and carotenemia. Am. J. Dis. Child. *67*:33 (1944).
11. A. G. Knudson and P. E. Rothman, Hypervitaminosis A. A review with a discussion of vitamin A. Am. J. Dis. Child. *85*:315 (1953).
12. A. Gerber, A. Riab, and A. Sobel, Vitamin A poisoning in adults: Description of a case. Am. J. Med. *16*:729 (1954).

13. J. Marie and G. See, Acute hypervitaminosis of the infant. Am. J. Dis. Child. *87*:731 (1954).
14. W. K. Woodard, L. J. Miller, and O. Legant, Acute and chronic hypervitaminosis A in a 4-month old infant. J. Pediatr. *59*:260 (1961).
15. B. Persson, R. Tunell, and K. Ekengren, Chronic vitamin A intoxication during the first half year of life. Description of 5 cases. Acta Paediatr. Scand. *54*:49 (1965).
16. R. C. Breslau, Hypervitaminosis A. Arch Pediatr. *74*:139 (1957).
17. T. K. Oliver, Jr., Chronic vitamin A intoxication. Report of a case in an older child and review of the literature. Am. J. Dis. Child. *95*:57 (1958).
18. G. Bartolozzi, G. Bernini, L. Marianelli, and E. Corvaglia, Chronic vitamin A excess in infants and children. Description of 2 cases and a critical review of the literature. Riv. Clin. Pediatr. *80*:231 (1967).
19. M. D. Muenter, H. O. Perry, and J. Ludwig, Chronic vitamin A intoxication in adults. Am. J. Med. *50*:129 (1971).
20. E. Kubin, A. L. Florman, T. Degnan, and J. Diaz, Hepatic injury in chronic hypervitaminosis A. Am. J. Dis. Child. *119*:132 (1970).
21. J. W. Smit and D. P. Hofstede, Vitamin A poisoning in adults. Ned. Tijdschr. Geneeskd. *110*:10 (1966).
22. R. J. DiBenedetto, Chronic hypervitaminosis A in an adult. J. Am. Med. Assoc. *201*:700 (1967).
23. P. Ammann, K. Herwig, and T. Baumann, Vitamin A excess. Helv. Paediatr. Acta *23*:137 (1968).
24. R. F. Krause, Liver lipids in a case of hypervitaminosis A. Am. J. Clin. Nutr. *16*:455 (1965).
25. C. N. Pease, Focal retardation and arrestment of growth of bones due to vitamin A intoxication. J. Am. Med. Assoc. *182*:980 (1962).
26. A. D. Lascari and W. E. Bell, Pseudotumor cerebri due to hypervitaminosis A. Clin. Pediatr. *9*:627 (1970).
27. M. H. Feldman and N. S. Schlezinger, Benign intracranial hypertension associated with hypervitaminosis A. Arch. Neurol. *22*:1 (1970).
28. D. G. Hazzard, C. G. Woelfel, M. C. Calhoun, J. E. Rousseau, Jr., H. D. Eaton, S. W. Nielsen, R. M. Grey, and J. J. Lucas, Chronic hypervitaminosis A in Holstein male calves. J. Dairy Sci. *47*:391 (1964).
29. H. D. Hurt, R. C. Hall, Jr., M. C. Calhoun, J. E. Rousseau, Jr., H. D. Eaton, K. E. Wolke, and J. J. Lucas, Chronic hypervitaminosis A in weanling pigs. Univ. Corn. Agric. Exp. Stn. Bull. 400 (1966).
30. K. Rodahl, Hypervitaminosis A in the rat. J. Nutr. *41*:399 (1950).
31. C. L. Maddock, S. B. Wolbach, and S. Maddock, Hypervitaminosis A in the dog. J. Nutr. *39*:117 (1949).
32. A. A. Seawright, P. B. English, and R. J. W. Gartner, Hypervitaminosis A and deforming cervical spondylosis of the cat. J. Comp. Pathol. *77*:29 (1967).
33. K. C. Hayes and D. S. Goodman, Unpublished data.
34. K. E. Wolke, S. W. Nielsen, and J. E. Rousseau, Jr., Bone lesions of hypervitaminosis A in the pig. Am. J. Vet. Res. *29*:1009 (1968).
35. A. Khogali, Bone strength and calcium retention of rats in hypervitaminosis-A. Q. J. Exp. Physiol. *51*:120 (1966).
36. R. L. Strebel, R. J. Girerd, and B. M. Wagner, Cardiovascular calcification in rats with hypervitaminosis A. Arch. Pathol. *87*:290 (1969).

37. J. Langman and G. W. Welsh, Effect of vitamin A on development of the central nervous system. J. Comp. Neurol. *128*.
38. M. Marin-Padilla, Mesodermal alterations induced by hypervitaminosis A. J. Embryol. Exp. Morphol. *15*:261 (1960).
39. H. D. Eaton, Chronic bovine hypo- and hypervitaminosis A and cerebrospinal fluid pressure. Am. J. Clin. Nutr. *22*:1070 (1969).
40. M. H. Bass, The relation of vitamin A intake to cerebrospinal fluid pressure: A review. J. Mount Sinai Hosp., N.Y. *24*:713 (1957).
41. J. T. Dingle and J. A. Lucy, Vitamin A, carotenoids, and cell function. Biol. Rev. *40*:422 (1965).
42. S. Bazin and A. Delaunay, Influence of vitamin A excess on the constitution of the connective tissue and on the collagenolytic activity of normal or inflamed tissues. Ann. Inst. Pasteur *110*:487 (1966).
43. G. A. J. Pitt, Comments. In International symposium on the metabolic function of vitamin A, G. Wolf (ed.). Am. J. Clin. Nutr. *22*:1045 (1969).
44. T. G. Taylor, K. M. L. Morris, and J. Kirkley, Effects of dietary excesses of vitamins A and D on some constituents of the blood of chicks. Br. J. Nutr. *22*:713 (1968).
45. I. Clark and C. A. L. Bassett, The amelioration of hypervitaminosis D in rats with vitamin A. J. Exp. Med. *115*:147 (1962).
46. A. Ballitteri and Y. Raoul, Antagonism between vitamins A and D in mitochondria and lysosomes. C. R. Soc. Biol. *159*:1919 (1965).
47. I. W. McCuaig and I. Motzok, Excessive dietary vitamin E: Its alleviation of hypervitaminosis A and lack of toxicity. Poult. Sci. *49*:1050 (1970).
48. L. V. Kijukova, I. I. Ulasevic, and V. S. Medvedskaja, Interrelation of vitamins A and E in the live animal. Bjull. Eksp. Biol. Med. *6*:59 (1969); Nutr. Abstr. Rev. *40*:448 (1970).
49. J. T. Matschiner and E. A. Doisy, Jr., Role of vitamin A in induction of vitamin K deficiency in the rat, Proc. Soc. Exp. Biol. Med. *109*:139 (1962).
50. P. Griminger, Vitamin K activity in chickens: Phylloquinone and menadione in the presence of stress agents. J. Nutr. *87*:337 (1965).
51. W. F. Loomis, Skin-pigment regulation of vitamin D biosynthesis in man. Science *157*:501 (1967).
52. M. S. Seelig, Vitamin D and cardiovascular, renal, and brain damage in infancy and childhood. Ann. N.Y. Acad. Sci. *147*:537 (1969).
53. Committee on Nutrition, The prophylactic requirement and the toxicity of vitamin D. Pediatrics *31*:512 (1963).
54. R. S. Harris, B. D. Ross, and J. W. M. Bunker, Histological study of hypervitaminosis D. The relative toxicity of the vitamin D of irradiated ergosterol and tuna liver oil. Am. J. Dig. Dis. *6*:81 (1939).
55. H. Burgisser, C. Jacomet, and M. Leuenberger, Vitamin D poisoning in the pig. Schweiz. Arch. Tierheilkd. *106*:714 (1964).
56. R. D. Hunt, F. G. Garcia, and D. M. Hegsted, Hypervitaminosis D in new world monkeys. Am. J. Clin. Nutr. *22*:358 (1969).
57. J. J. Lewis, Clinical experience with crystalline vitamin D: The influence of the menstruum on the effectiveness of antirachitic factor. J. Pediatr. *6*:326 (1935).
58. M. I. Sevlagina, N. I. Gulinova, R. I. Gordon, I. M. Rasina, and A. S. Pigeo, Vitamin D excess in adults. Klin. Med. Moscow *46*:31 (1968). Nutr. Abstr. Rev. *39*:567 (1969).

Hurt-'66
Bib. No. 10586

December 1966
Bulletin 400

Chronic Hypervitaminosis A in Weanling Pigs

U. S. DEPT. OF AGRICULTURE
NATIONAL AGRICULTURAL LIBRARY
JUN 8 - 1967
CURRENT SERIAL RECORDS

By

H. D. Hurt
R. C. Hall, Jr.
M. C. Calhoun
J. E. Rousseau, Jr.
H. D. Eaton
R. E. Wolke
J. J. Lucas

AGRICULTURAL EXPERIMENT STATION
THE UNIVERSITY OF CONNECTICUT, STORRS

Chronic Hypervitaminosis A in Weanling Pigs[1]

By H. D. Hurt, R. C. Hall, Jr., M. C. Calhoun, J. E. Rousseau, Jr., H. D. Eaton, R. E. Wolke, and J. J. Lucas[2]

The toxicity of excessive intakes of preformed vitamin A has been well described for many species of laboratory animals (25, 27). However, with the exception of the dog and poultry, feeding of high levels of vitamin A to domestic animals has received little attention. Recently at this Station chronic hypervitaminosis A of the young bovine has been studied (8, 17, 19) and the results were essentially the same as reported in the aforementioned studies. One effect in opposition to previous reports for other species was a consistently lower cerebrospinal fluid pressure. Shortly after the initiation of the present study, the Iowa Agricultural Experiment Station reported on vitamin A toxicity in young swine (1). However, the measurement of cerebrospinal fluid pressure was not included.

Received for publication September 28, 1966. (RP 1100 — 12/66)

1 This bulletin is based upon studies undertaken as part of Storrs Agricultural Experiment Station Project (A.I. 360) The Role of the Fat Soluble Vitamins and Their Interrelationships in the Bovine. It was supported in part by funds from by PHS research grant, NB-02168-05 from the National Institutes of Neurological Diseases and Blindness, Public Health Service and by Agway, Inc., Syracuse, New York; Wirthmore Feeds, Inc., Waltham, Massachusetts; and Hoffman - La Roche Inc., Nutley, New Jersey. Support for R. E. Wolke, D.V.M. was provided by National Institute of Health Pathology Training Grant STIGM 98501-01.

2 The first, second and third authors are Research Assistants in Animal Nutrition and fourth and fifth Associate and Professor of Animal Nutrition, respectively; sixth Research Assistant in Animal Diseases (Pathology), and the last is Professor of Biometrics.

In present day intensive agricultural practices, swine are raised under confinement and are fed complete rations. While this practice results in fewer nutritional deficiencies, the use of high potency vitamin premixes increases the possibility of swine being fed excessive amounts of vitamin A. The present study was, therefore, undertaken to provide information on clinical signs, growth rate, biochemical and physiological changes of the chronic hypervitaminotic A young pig with particular interest in the response of the cerebrospinal fluid pressure to prolonged intakes of toxic levels of vitamin A. A preliminary report of these data have been presented (20). In addition, the study provided the opportunity for detailed histological examination of tissues from chronic hypervitaminotic A weanling pigs (33).

Experimental Procedure

Animals and feeding

Twenty-four male weanling crossbred (Hampshire-Yorkshire) pigs were obtained in six sets of four littermates from November 1964 to October 1965. The animals were housed in the Station's animal nutrition research barn in individual sawdust bedded concrete pens with a floor space of 1.7 square meters. Environmental temperature was maintained at a minimum of 10° C with radiant ceiling heat and light exposure limited to incandescent for 12 hours daily (Appendix Table I).

Upon arrival at the barn, each pig was fed a vitamin A depletion ration (Appendix Tables II and III) at a daily rate of 4 percent of the average live weight of its set of four littermates. In subsequent weeks this was increased 0.09 kg per day. In addition to the depletion ration, whole milk was offered (0.9 kg) in decreasing amounts for the first 12 to 20 days. Starting the third week for three of the sets of littermates (I, III, and V) and the fourth week for the remaining sets (II, IV, and VI), 39.7 γ of retinol (as vitamin A acetate) per kg of the next week's

$$\text{(Current 7th day live wt)} + \frac{\text{(Current 7th day live wt} - \text{two week previous live wt)}}{4}$$

anticipated average live weight[3] was incorporated into a portion kg) of the total daily ration. After this was consumed the remainder the day's feed allowance was offered.

After the above mentioned three or four weeks (standardi period), the pigs were fed, according to a random allotment wi each set of four, one of four levels of vitamin A intake; 39.7, 11 6,614 or 19,842 γ of vitamin A per kg of live weight per day. B upon unpublished pilot studies with weanling pigs (Appendix T VII) and dogs (Appendix Table VIII) as well as experience with ca (8, 17, 19), it was expected that the vitamin A intake of 19,842 γ w produce a severe and the 6,614 γ intake a mild hypervitaminot syndrome. The 39.7 γ and 119.0 γ intakes were anticipated to result no adverse biological effects and thus were considered as control intak To minimize differences in feed intake during the period when t treatment levels of vitamin A were fed (comparison period), the da feed allowance of a littermate set was based upon the average da consumption of the pig consuming the least amount during the p vious week. The duration of the comparison period, five weeks, w determined by the time required for the control pigs to double t live weight. On the third morning after completion of the five w comparison period during which the above mentioned dietary regi was continued, each pig was anesthetized and exsanguinated.

Observations and analyses

The daily allotments of feed fed and feed refused, the latter minimum of seven hours after feeding, were recorded to the near 0.04 kg. Live weight of each pig was recorded at 7-day periods to t nearest 0.04 kg before the day's feeding. Terminal live weights w taken just prior to slaughter. On the sixth day of each week of comparison period, each pig was observed for clinical signs of hy vitaminosis A.

The day before and the last day of the comparison period b samples, 15 ml citrated for plasma and 15 ml for serum, were ob by puncture of the anterior vena cava. Vitamin A concentration in plasma was determined by the Kimble method (22). Serum an included total protein concentration by the Gornall *et al.* pro (16), protein fractionation by paper electrophoresis as cited by D *et al.*, (10), glutamic-oxalacetic (SGOT) and glutamic-pyruvic (SG

acid transaminase activities according to the Reitman-Frankel method (28)[4] and alkaline and acid phosphatase activities by the Klein *et al.* (23) and Babson and Read (3) methods,[5] respectively.

On the day following the completion of the five week comparison period, each pig was anesthetized with pentobarbital sodium (64 mg per cc contained in 10% ethanol, 40% propyleneglycol in aqueous base)[6] via anterior vena cava injection. Cisternal cerebrospinal fluid pressure was measured in the lateral recumbent position with the procedure for puncture of the cisternal space as described by Fankhauser (13). Measurement of the cerebrospinal fluid pressure (CSFP) was with a saline manometer, Sykes and Moore (31), with dimensions as described by Dehority *et al.* (10). An additional rack and pinion drive equipped with a sighting device facilitated the leveling of the manometer.

At necropsy, the adrenal glands, heart, kidneys, liver, and right supraspinatus were removed and weighed. Ascorbic acid and nitrogen concentration of the right adrenal gland were determined, respectively, by the Roe (29) and the Kjehldahl (2) methods. Vitamin A concentration of the liver was determined by a modification of the Gallup-Hoefer procedure (7) In addition to the above, the right and left radii were obtained. All adhering tissue, except the periosteum, was removed and both bones measured. Measurements included weight, length (distal to proximal end), distance between epiphyseal margins, and shaft area (left radius, mid shaft). The left radius was separated into epiphyseal and diaphyseal portions by cross-sectional cuts 5 mm below the epiphyseal margins and prepared for ash analysis as outlined by Dehority *et al.* (11). The right radius and other tissues not mentioned above were reserved for additional histologic and radiographic study with the results reported elsewhere (33).

Analysis of the data (30) included isolating the variation due to replicates (sets of littermates), treatments (levels of vitamin A intake) and the interaction of these (error). As was previously stated, 39.7 and 119.0 γ levels of vitamin A supplementation were regarded as the controls and 6,614 and 19,842 γ as the mild and severe hypervitaminotic A intakes, respectively. Therefore, a set of orthogonal comparisons, controls *versus* hypervitaminotic A and within each of these, were employed for further isolation of the variation due to treatments. Also, when applicable, two types of regression functions, as discussed by Hazzard *et al.* (19) were fitted to the data.

---

[4] Substrate reagent preparation from Sigma Chemical Co., St. Louis, Missouri.

[5] Substrate reagent preparations from Warner-Chilcott Labs., Morris Plains, New Jersey.

[6] Anesthesal, Norden Labs., Lincoln, Nebraska.

Results

In spite of weekly adjustments of feed allotments, less total feed consumption occurred during the comparison period for the pigs receiving the highest vitamin A intake.[7] In addition, total weight gain and feed efficiency was less for this group. The mildly hypervitaminotic A pigs did not show any differences in feed consumption, total gain or feed to gain ratio when compared to the controls (Table 1).

Table 1.—Effect of excessive vitamin A intake upon feed intake, live weight increase feed efficiency, and cerebrospinal fluid pressure of weanling pigs.

	Control		Hypervitaminotic-A		SD per animal
			Mild	Severe	
	Vitamin A intake, γ/kg live wt/day				
	39.7	119.0	6,614	19,842	
Feed, kg[a]					
Total fed	23.3	23.4	23.4	23.3	0.2
Total consumed	23.3	23.2	23.4	19.7	1.2
Live weight, kg[a]					
Initial	10.1	10.3	11.2	9.9	1.4
Total gain	11.5 (11.3)[c]	10.9 (10.9)	10.8 (11.2)	6.8 (6.5)	1.4 (1.4)
Feed required per unit live weight gain, kg/kg[a]	2.06	2.14	2.18	3.14	0.62
Cerebrospinal fluid pressures, mm saline[b]					
Actual	45[d]	53	15[e]	17	—
Log_{10}	1.61[f]	1.67	1.15[f]	1.22	0.16
Amount of anesthesia[b]					
Total, ml	8.6[f]	8.7	8.4[g]	6.2	0.7
Per unit of live weight, ml/kg	0.40[f]	0.41	0.40[g]	0.37	0.04

[a] Statistics for the 5 week comparison period.
[b] Statistics for the day following the 5 week comparison period.
[c] Adjusted by covariance for initial value.
[d] Mean based on 5 values instead of 6.
[e] Mean based on 4 values instead of 6.
[f] Mean includes one calculated missing value.
[g] Mean includes two calculated missing values.

With the exception of one animal exhibiting slight hyperemia in the last week of the comparison period, no clinical signs characteristic of hypervitaminosis A or other outward changes occurred in the mildly hypervitaminotic A pigs during the five weeks of vitamin A supplementation. The pigs receiving the 19,842 γ/kg live weight/day exhibited

[7] Range of total feed fed 21.0 - 25.1 kg per litter.

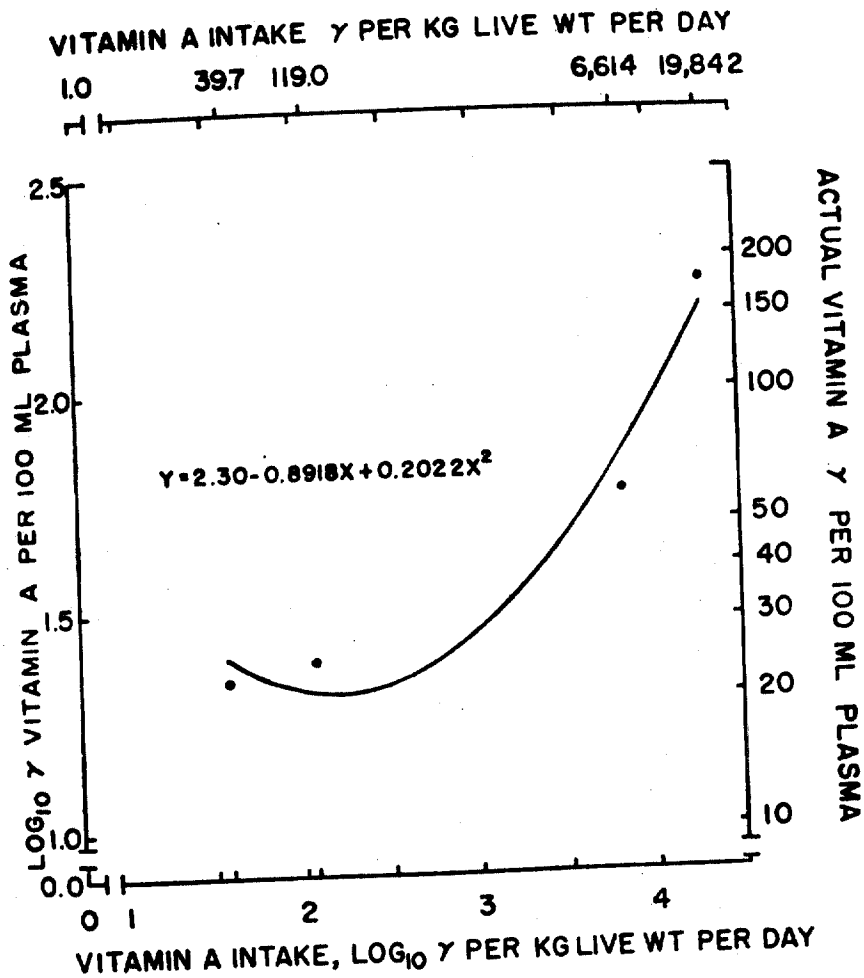

Figure 1.—The effect of excessive intake of vitamin A on plasma vitamin A concentration.

marked changes with hyperemia of the ventral portion of the body initially appearing by the second to the fourth week. Abnormal stance with varying degrees of lameness, from slight to severe hind limb immobilization was observed the second week and became well developed by the third week. At this time the pigs were unable to stand without assistance and appeared to be extremely sensitive to movement or handling. Upon completion of the comparison period they were extremely weak and moribund.

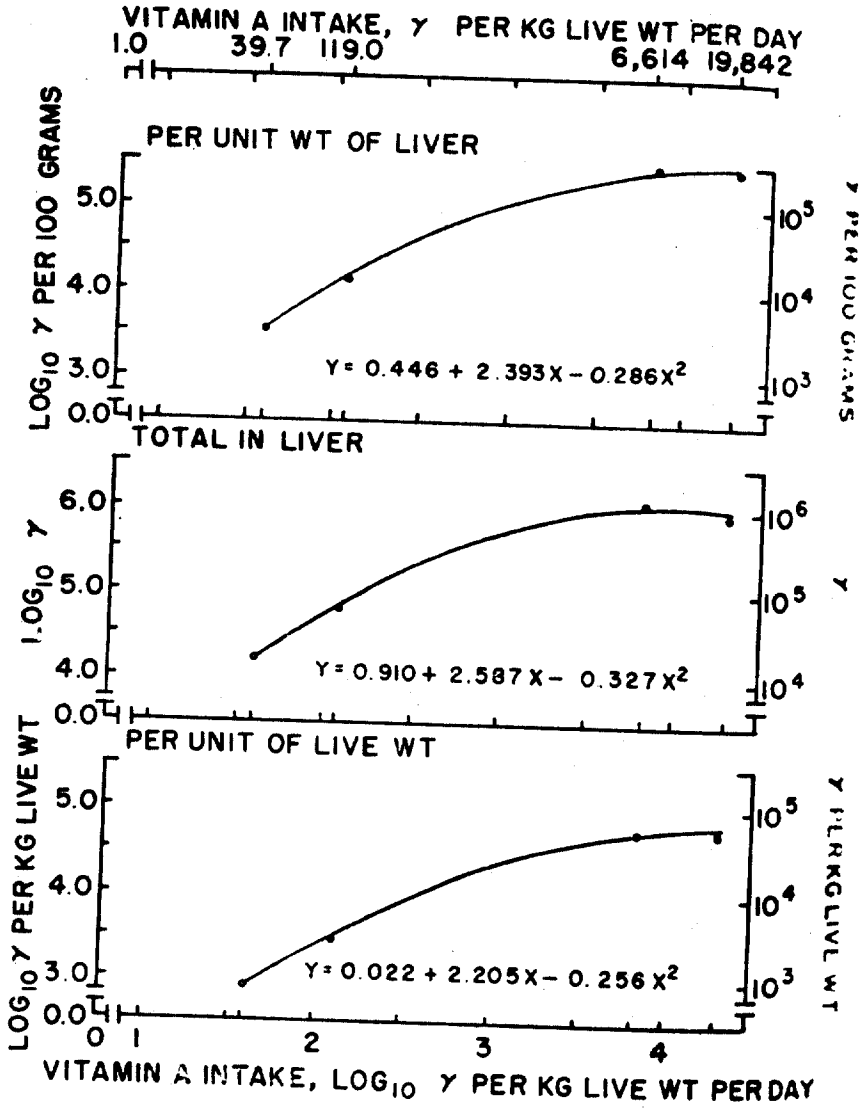

Figure 2.—The effect of excessive intake of vitamin A on liver vitamin A concentration.

Cisternal cerebrospinal fluid pressures were lower in those receiving the 6,614 γ and the 19,842 γ treatments. The dose of anesthetic required to achieve the desired plane of anesthesia prior to CSFP determination was similar for all treatments when expressed on a per unit body weight basis (Table 1).

Plasma vitamin A levels were only slightly elevated when the vitamin A intake was increased from 39.7 γ to 119.0 γ/kg live weight/day, whereas marked increases occurred in the pigs fed the mild and the severe hypervitaminotic A levels, (Figure 1 and Appendix Table IV).

Liver stores of vitamin A increased across all treatments when expressed as concentration per unit liver weight (γ/100g), total concentration (γ), or concentration per unit live weight (γ/kg) to maximum values at calculated vitamin A intakes of 15,520 γ, 9,016 γ, and 19,960 γ/kg live weight/day, respectively, (Figure 2 and Appendix Table IV). The last estimated maximum value is out of the range of intakes fed and thus should be viewed with caution.

Total serum protein concentration (g/100 ml) was not affected by the level of vitamin A supplementation (Appendix Table V). The concentration of the albumin fraction was lower with corresponding greater concentrations of alpha globulin, beta globulin, and gamma globulin for the severely hypervitaminotic A pigs. The lower albumin and greater globulin fraction concentrations resulted from a smaller percentage change, in the relative distribution of these, with time for the highest intake group (Appendix Table VI). The changes in the percentage of albumin, y_1; and the total globulins, y_2; of the total serum protein were related to the log daily vitamin A intake in γ/kg live weight/day, x as follows (Figure 3):

$y_1 = 7.710 - 4.270\,(x - 3.099)\,\theta$, SD $\pm$ 3.03, with $\theta = 0$ when $x \leq 3.099$ and $\theta = 1$ when $x > 3.099$.

$y_2 = -7.710 + 4.270\,(x - 3.099)\,\theta$, SD $\pm$ 3.03, with $\theta = 0$ when $x \leq 3.099$ and $\theta = 1$ when $x > 3.099$.

The magnitude of the change in the distribution of the albumin and total globulin fractions was affected at estimated vitamin A intakes above 1256 γ/kg live weight/day. The resulting albumin to total globulin ratio, y_3; was related to the log daily vitamin A intake in γ/kg live weight/day, x, as follows (Figure 3):

$y_3 = 0.495 - 0.376\,(x - 3.169)\,\theta$, SD $\pm$ 0.24, with $\theta = 0$ when $x \leq 3.169$ and $\theta = 1$ when $x > 3.169$.

A lower ratio of the two fractions occurred at estimated vitamin A intakes greater than 1476 γ/kg live weight/day.

Changes during the comparison period in SGOT activity were minimal for the two controls and the mildly hypervitaminotic A pigs, with a significant increase in SGOT activity for the severely hypervitaminotic A group (Table 2). SGPT activity was increased for all treatments with the highest intake group having the greatest change in activity during the comparison period. Small but consistent decreases in alkaline and acid phosphatase activities with time for all treatments were noted.

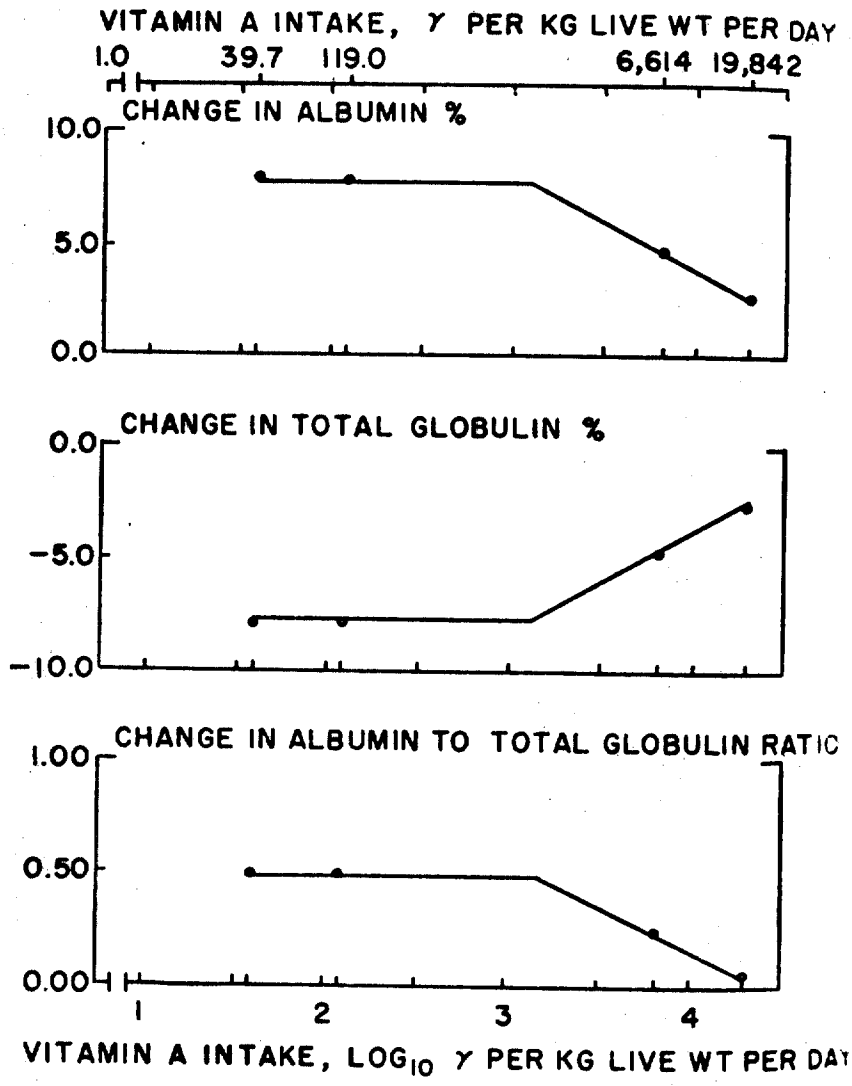

Figure 3.—The effect of excessive intake of vitamin A on changes in serum protein distribution.

As reported in Table 3, the adrenal and kidney weights of the [illegible] receiving the 19,842 γ intake were heavier than the controls [illegible] mildly hypervitaminotic A pigs when expressed as total weight or [illegible] of live weight. Actual heart weight did not appear to be different [illegible] ever, when expressed as per kg of live weight the hearts of the 19 [illegible] intake group were heavier. Conversely, the actual supraspinatus [illegible] and liver weight (Appendix Table IV) were less for the 19 [illegible]

Table 2.—Effect of excessive vitamin A intake upon some enzymatic activities in the serum of weanling pigs.

	Control		Hypervitaminotic-A		SD per animal
			Mild	Severe	
	Vitamin A intake, γ/kg live wt/day				
	39.7	119.0	6,614	19,842	
Transaminases, Sigma-Frankel unit/ml[a]					
Glutamic-oxalacetic					
Initial	41	46	31	31[c]	11
Terminal	30	34	36	73[c]	15
Change	—11 (—7)	—12 (—3)	5 (—1)	42 (35)	18 (17)
Glutamic-pyruvic					
Initial	19	19	17	16	2
Terminal	24	24	19	33	6
Change	5 (7)[d]	5 (6)	2 (2)	17 (15)	7 (6)
Phosphatases, Klein-Babson-Read unit/100 ml[b]					
Alkaline					
Initial	25	22	20	17	7
Terminal	14	12	10	12	3
Change	—11 (—7)[d]	—10 (—9)	—10 (—11)	—5 (—9)	7 (4)
Acid					
Initial	18	15	19	19	4
Terminal	16	14	17	18	3
Change	—2 (—2)[d]	—1 (—4)	—2 (—1)	—1 (0)	5 (3)

[a] A Sigma-Frankel unit is a measure of the enzymatic activity that will form 4.82 x 10^{-4}M glutamate/minute at a pH of 7.5 and at 25°C resulting in a decrease in the optical density at 340 mu of 0.001/min/ml per centimeter of light path of serum.
[b] A Klein-Babson-Read unit is the amount of enzyme that will liberate 1.0 mg phenolphthalein in 30 minutes at 37°C.
[c] Mean includes one calculated missing value.
[d] Adjusted by covariance for initial values.

intake group, with no differences noted when expressed per kg of live weight. Ascorbic acid concentration per unit of adrenal tissue, γ/g and ascorbic acid per unit of adrenal nitrogen, mg/mg were less in the highest intake group.

Bone growth (Table 4) was affected by excessive levels of vitamin A. The weight, gms, y_4; and mid shaft area, mm², y_5; were related to the log daily intake of vitamin A, x, as follows:

$y_4 = 28.252 - 20.494\,(x - 3.749)\,\theta$, SD $\pm$ 1.6, with $\theta = 0$ when $x \leq 3.749$ and $\theta = 1$ when $x > 3.749$.

$y_5 = 62.498 - 54.402\,(x - 3.719)\,\theta$, SD $\pm$ 7, with $\theta = 0$ when $x \leq 3.719$ and $\theta = 1$ when $x > 3.719$.

Above estimated daily vitamin A intakes of 5,610 γ/kg live weight/day and 5,236 γ/kg live weight/day, a decrease was observed in radius weight and mid-shaft area, respectively. (Figure 1). Overall length of the radius was decreased in the 19,842 γ intake group. Epiphyseal ash, g/100 g, y_6; organic matter, g/100 g, y_7; and ash to organic matter, ratio, y_8; were related to the log daily intake of vitamin A, x, as follows:

Table 3.—Effect of excessive vitamin A intake upon adrenal gland composition and weights of tissues of weanling pigs.

	Control		Hypervitaminotic-A		
			Mild	Severe	
	Vitamin A intake, γ/kg live wt/day				
	39.7	119.0	6,614	19,842	[illegible]
Adrenal					
Weight, g					
Right	0.90	0.88	0.88	1.18	0.
Left	0.90	0.84	0.87	1.23	0.
Total	1.80	1.72	1.75	2.41	0.
Per unit live weight, mg/kg	82 (67-109)[b]	79 (56-108)	78 (58-100)	155 (90-260)	—
Ascorbic acid, mg[a]					
Concentration per g	1.65	1.50	1.63	1.10	0.3
Total	1.46	1.32	1.44	1.32	0.3
Nitgrogen, mg[a]					
Concentration per g	27.4	28.7	28.4	26.2	1.4
Total	25	25	25	31	4
Ascorbic acid per unit nitogren, mg/mg[a]	0.060	0.052	0.057	0.042	0.0
Heart					
Weight, g	110	112	106	101	10
Per unit live weight, g/kg	5.0	5.1	4.7	6.4	0.4
Kidneys					
Weight, g					
Right	43	38	42	55	7
Left	42	40	43	55	7
Total	85	78	85	110	15
Per unit live weight, g/kg	3.9	3.6	3.8	7.0	0.8
Supraspinatus					
Weight, g	113	118	115	71	19
Per unit live weight, g/kg	5.1	5.4	5.1	4.5	0.9

[a] Statistics for right adrenal gland.
[b] Range.

$y_6 = 53.857 + 7.162\,(x-3.649)\,\theta$, SD $\pm$ 2.1, with $\theta = 0$ when $x \leq 3.649$ and $\theta = 1$ when $x > 3.649$.

$y_7 = 46.143 - 7.162\,(x-3.649)\,\theta$, SD $\pm$ 2.1, with $\theta = 0$ when $x \leq 3.649$ and $\theta = 1$ when $x > 3.649$.

$y_8 = 1.170 + 0.398\,(x-3.669)\,\theta$, SD $\pm$ 0.11, with $\theta = 0$ when $x \leq 3.669$ and $\theta = 1$ when $x > 3.669$.

Above an estimated daily vitamin A intake of 4,457 γ/kg live weight/day ash concentration increased with a corresponding decre in organic matter. The resulting ash to organic matter ratio was increased above an estimated daily intake of 4,661 γ/kg live weight/d (Figure 4). Diaphyseal ash was greater with a corresponding reduction in organic matter resulting in an increase in ash to organic ratio in the 19,842 γ/kg live weight/day group (Table 4).

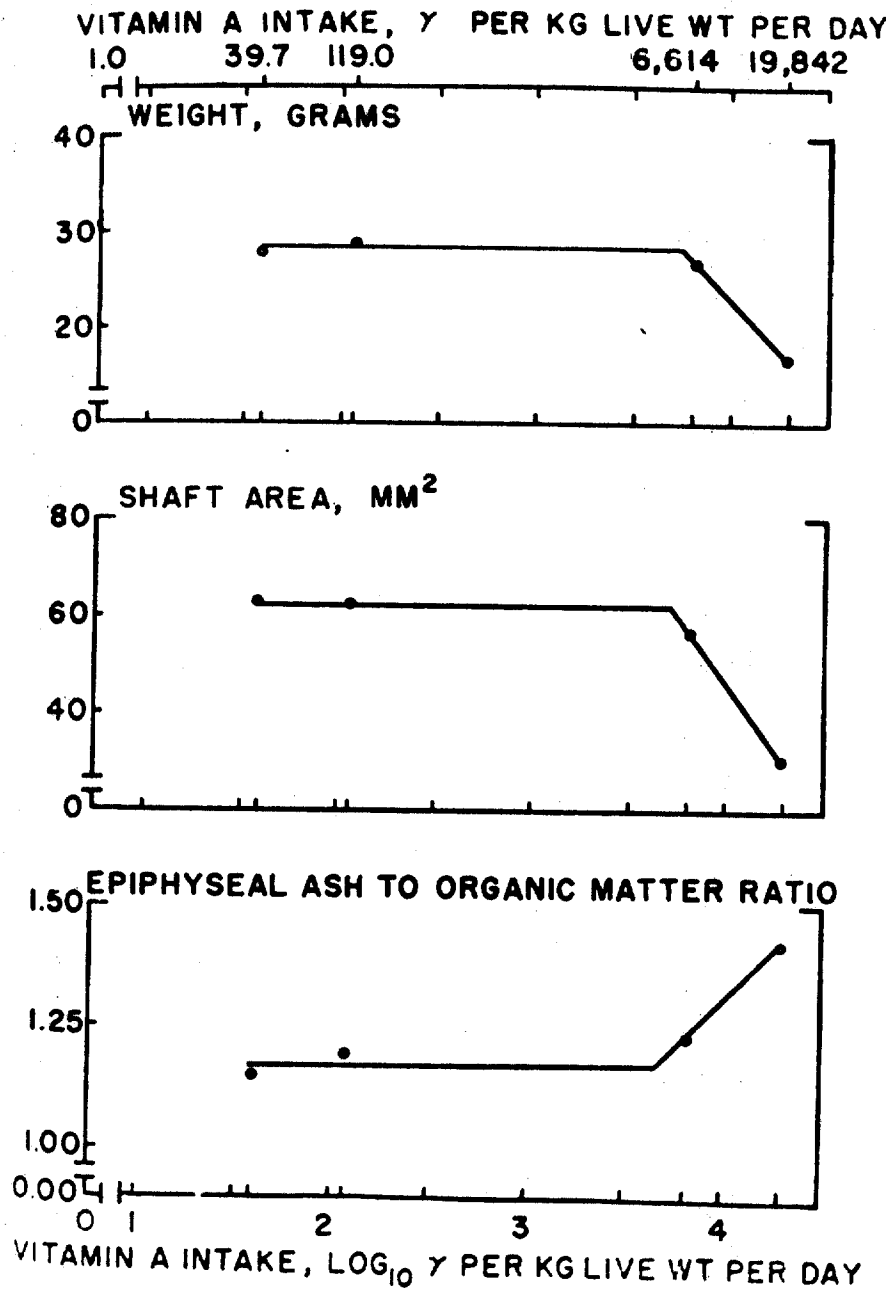

Figure 4.—The effect of excessive intake of vitamin A on bone growth.

Table 4.—Effect of excessive vitamin A intake upon the radius of weanling pigs.

	Control		Hypervitaminotic-A		
			Mild	Severe	
	Vitamin A intake, γ/kg live wt/day				
	39.7	119.0	6,614	19,842	[illegible]
Weight, g					
Right	28.4	29.8	27.2	17.5	[illegible]
Left	26.8	28.1	26.5	16.4	[illegible]
Avg	27.6	28.9	26.8	17.0	[illegible]
Length, cm					
Overall					
Right	9.0	9.0	9.3	8.2	[illegible]
Left	9.0	9.0	9.3	8.2	[illegible]
Avg	9.0	9.0	9.3	8.2	[illegible]
Between epiphyseal margins					
Right	6.3	6.4	6.6	6.3	[illegible]
Left	6.3	6.3	6.6	6.2	[illegible]
Avg	6.3	6.4	6.6	6.2	[illegible]
Shaft area, mm²					
Left	63	62	57	31	7
Ash, g/100 g[a]					
Epiphyses	53.5	54.2	55.1	58.5	[illegible]
Diaphysis	65.1	64.4	65.0	66.3	[illegible]
Organic matter, g/100 g[a]					
Epiphyses	46.5	45.8	44.9	41.5	[illegible]
Diaphysis	34.9	35.6	35.0	33.7	[illegible]
Ratio of ash to organic matter[a]					
Epiphyses	1.15	1.19	1.23	1.42	[illegible]
Diaphysis	1.87	1.81	1.86	1.97	[illegible]

[a] Statistics for left bone, fat-free and moisture-free basis.

Discussion

The decreased cisternal cerebrospinal fluid pressures (CSFP) observed in the chronic hypervitaminotic A weanling pigs are in agreement with previous studies at this Station with chronic hypervitaminotic A calves (8, 17, 19) and dogs (34). The lowered CSFP observed under controlled experimental procedures appear to be in opposition to clinical reports of elevated CSFP associated with vitamin A toxicosis (21). The decreased CSFP may be due in part to the rarification of the frontal and occipital bones of the skull (33) resulting in a [illegible] CSF space. Similar changes in the hypervitaminotic A calves and dogs (34) displaying decreased CSFP were observed. It is also recognized that the lowered pressures may be due in part to a decrease in the secretory activity of the choroid plexus (6) which is regarded as the main site of CSF formation and/or an increase in the rate of absorption of CSF (4).

The equalization of feed intake was intended to minimize any confounding effects of the toxic levels of vitamin A with the amount of feed consumed. In the study of Anderson (1) on porcine hypervitaminosis A, neither individual feed consumption nor the level of vitamin A intake per unit live weight was fixed, which may account for the major discrepancies between the two studies.

The clinical signs of hypervitaminosis A in the pigs receiving the highest vitamin A intake were essentially in agreement with the changes previously noted for other species (25, 27). The lack of visual changes but the presence of slight biochemical changes accompanied with decreased CSFP in the group fed the mild hypervitaminotic A intake may indicate that detection by visual examination may be difficult in the early stages of mild chronic hypervitaminosis A of young pigs.

Increases in plasma vitamin A levels with increasing intakes of vitamin A were expected in light of the response noted for other species (19, 25). Liver stores of vitamin A responded to increasing levels of intake but were noted to plateau below the 19,842 γ level when expressed as either concentration per unit weight of liver or as total content. This was interpreted that, although absorption of vitamin A continued with increasing intake of the vitamin, liver storage became maximal.

The changes in the concentration and distribution of the serum protein fractions, lowered albumin to total globulin ratio, were expected in light of experience with chronic hypervitaminotic A young calves (19) and dogs (34). Similar shifts in the protein distribution, possibly due to endocrine activity (5), have been noted for other nutritional deficiences and excesses. Thus vitamin A per se may not be directly responsible.

The presence of musculature and liver cellular damage as evidenced by elevated SGOT and SGPT enzymatic activities (9) in the pigs fed the highest vitamin A intake are in agreement with data previously presented (19, 34). Whether this is due to a tocopherol deficiency induced by the high levels of vitamin A (19), or to the toxic effect of vitamin A per se on the cell itself (12), is not known. The lack of elevated alkaline and acid phosphatase activities in the serum of the pigs receiving the highest intake were unexpected in light of the observed change in skeletal growth of these animals. The lack of response in enzymatic activities might be attributed to the slower rate of growth resulting from the decreased feed intake by this group, hence confounding any changes caused by vitamin A toxicity (24).

Enlargement of the heart, kidneys, and adrenal glands per unit of body weight of the pigs fed the highest intake of vitamin A was in agreement with reports on other chronic hypervitaminotic A animals

(25). The increased size of these organs may have reflected compensatory activity in order to overcome metabolic insult resulting from the toxic effects of the vitamin A (32). The greater weight and decreased ascorbic acid concentration of the adrenal glands were probably a result of increased activity of the hypophysis (15, 26).

With respect to the differences in the bone composition of the hypervitaminotic A pigs, the changes were essentially similar to those obtained in the calf (19). In addition, the effects of excess vitamin A were found to be more pronounced in the growing portions (epiphyseal area) of the bones. A detailed discussion of the alterations in bone growth resulting from hypervitaminosis A appears elsewhere (33).

It may be ascertained from this study that prolonged excessive intakes of vitamin A are toxic to the weanling pig. As previously mentioned, the direction of response of many of the criteria to toxic intakes of vitamin A was similar for the weanling pig and the young calf (19). A direct comparison was not possible between the two species in regards to the level of vitamin A supplementation tolerated before toxicity occurred. This was due to the similarity in response of the mildly hypervitaminotic A and two control groups of pigs which precluded the fitting of the broken-line regression equations used in the calf study. However, with the calf, changes were observed in many of the criteria (weight gain, serum transaminase and phosphatase activities, protein distribution, and tissue weight per unit body weight) at estimated vitamin A intakes below that received by the mildly hypervitaminotic A pig for which no response was observed. Thus, it may be concluded tentatively that the young ruminant was slightly more susceptible to vitamin A toxicity than the weanling pig. It should be recognized that many of the experimental procedures of the two studies were different and thus any comparisons made should be done with reservation.

Summary

Six sets of four littermate crossbred boar weanling pigs were fed a maize starch, maize oil, soybean meal, vitamin and mineral fortified ration at a rate determined by the pig consuming the least amount of feed in each littermate set. Each pig received vitamin A acetate equivalent to one of four retinol intakes: 39.7, 119.0, 6614 or 19812 [illegible] live weight day for five weeks. Signs characteristic of hypervitaminosis A were observed by the second week in the pigs receiving the 19812 intake. Also, this group had less weight gain and feed efficiency

sternal cerebrospinal fluid pressures were lower in the pigs fed the 14 and 19,842 γ intakes. Plasma vitamin A levels increased across treatments with liver vitamin A stores reaching maximum concentration at an estimated intake of 15,520 γ. Total serum protein concentrations were not affected. However, a lower albumin to globulin ratio was observed in the pigs fed 6,614 and 19,842 γ intakes. Serum transaminase (GOT, GPT) activities were elevated at the highest intake, whereas alkaline and acid phosphatase were not affected. The adrenal glands, heart, and kidneys weighed more per unit live weight in those receiving the highest intake. Ascorbic acid content per unit of adrenal nitrogen was slightly lower in the pigs fed the highest intake. Weight and shaft area of the radius were less above estimated intakes of 5,610 γ and 5,236 γ, respectively, with epiphyseal ash to organic matter ratio greater above an estimated intake of 4,664 γ.

References

(1) Anderson, M. D. 1964. The Effect of Hypervitaminosis A and Other Dietary Factors on the Young Pig. Ph.D. Thesis, Graduate School, Iowa State University of Science and Technology, Ames.

(2) Association of Official Agricultural Chemists. 1965. Official Methods of Analysis. Ed. Horwitz, W. Washington, D.C.

(3) Babson, A. L., and Read, P. A. 1959. A New Method for Prostatic Acid Phosphatase in Serum. Am. J. Clin. Path., 32:88.

(4) Bass, M. H. 1957. The Relation of Vitamin A Intake to Cerebrospinal Fluid Pressure: A Review. J. Mount Sinai Hosp., New York, 24:713.

(5) Beardwood, C., Gilbert, Christine, and Gillman, J. 1962. Endocrine Control of the Plasma Albumin/Globulin Ratio. Nature, 195:710.

(6) Becker, N. H., and Sutton, C. H. 1963. Pathologic Features of the Choroid Plexus. Am. J. Path., 43:1017.

(7) Bunnell, R. H., Rousseau, J. E., Jr., Eaton, H. D., and Bear, G. 1954. Estimation of Vitamin A and Carotenoids in Calf Liver. J. Dairy Sci., [illegible]

(8) Calhoun, M. C., Rousseau, J. E., Jr., Hall, R. C., Jr., Eaton, H. D., Nielsen, S. W., and Lucas, J. J. 1965. Cisternal Cerebrospinal Fluid Pressure During Development of Chronic Bovine Hypervitaminosis A. J. Dairy Sci., 48:720.

(9) Cornelius, C. E. 1963. Clinical Biochemistry of Domestic Animals. Ed., C. E. Cornelius and J. J. Kaneko. Academic Press, New York.

(10) Dehority, B. A., Hazzard, D. G., Eaton, H. D., Grifo, A. P., Jr., Rousseau, J. E., Jr., Helmboldt, C. F., Jungherr, E. L., and Gosslee, D. G. 1960. Some Biochemical Constituents in Serum, Cerebrospinal Fluid, and Aqueous Humor of Vitamin A Deficient Holstein Calves. J. Dairy Sci., 43:630.

(11) Dehority, B. A., Rousseau, J. E., Jr., Eaton, H.D., Myers, G. S., Jr., Grifo, A. P., Jr., Dicks, Martha W., Hazzard, D. G., Helmboldt, C. F., Gosslee, D. G., Thomas, J. W., Sykes, J. F., and Moore, L. A. 1961. Effects of Addition of Magnesium, Tocopherol, and Cod Liver Oil to a Whole Milk Diet on Some Biochemical Constituents in Serum, Soft Tissue, and Bones of Calves. J. Dairy Sci., 44:58.

(12) Dingle, J. T., and Lucy, J. A. 1965. Vitamin A, Carotenoids and Cell Function. Biol. Rev., 40:422.

(13) Fankhauser, R. 1962. The Cerebrospinal Fluid. Chap. III. Comparative Neuropathology. Ed. Innes, J. R. M., and Sanders, L. Z. Academic Press, New York.

(14) Fell, H. B., and Dingle, J. T. 1963. Studies on the Mode of Action of Excess Vitamin A. 6. Lysosomal Protease and the Degradation of Cartilage Matrix. Biochem. J., 87:403.

(15) Fortier, C. 1963. Hypothalamic Control of Anterior Pituitary. Chap. I. Comparative Endocrinology. Ed. von Euler, U. S., and Heller, H. Academic Press, New York.

(16) Gornall, A. G., Bardawill, C. J., and David, M. M. 1949. Determination of Serum Proteins by Means of the Biuret Reaction. J. Biol. Chem., 177:751.

(17) Grey, R. M., Calhoun, M. C., Rousseau, J. E., Jr., Woelfel, C. G., Hall, R. C., Jr., Nielsen, S. W., Eaton, H. D., and Lucas, J. J. 1964. Cisternal and Intraventricular Cerebrospinal Fluid Pressures in Chronic Bovine Hypervitaminosis A. J. Dairy Sci., 47:783.

(18) Grey, R. M., Nielsen, S. W., Rousseau, J. E., Jr., Calhoun, M. C., Eaton, H. D. 1965. Pathology of Skull Radius and Rib in Hypervitaminosis A of Young Calves. Path. Vet. 2:446.

(19) Hazzard, D. G., Woelfel, C. G., Calhoun, M. C., Rousseau, J. E., Jr., Eaton, H. D., Nielsen, S. W., Grey, R. M., and Lucas, J. J. 1964. Chronic Hypervitaminosis A in Holstein Male Calves. J. Dairy Sci., 47:391.

(20) Hurt, H. D., Hall, R. C., Jr., Calhoun, M. C., Rousseau, J. E., Jr., Eaton, H. D., Wolke, R. E., and Lucas, J. J. 1966. Chronic Hypervitaminosis A in Weanling Pigs. J. Animal Sci., 25:891. (Abst.).

(21) Jeghers, H., and Marraro, H. 1958. Hypervitaminosis A: Its Broadening Spectrum. Am. J. Clin. Nut., 6:335.

(22) Kimble, M. S. 1939. The Photocolorimetric Determination of Vitamin A and Carotene in Human Plasma. J. Lab. Clin. Med., 24:1055.

(23) Klein, B., Read, P. A., and Babson, A. L. 1960. Rapid Method for the Quantitative Determination of Serum Alkaline Phosphatase. Clin. Chem., 6:269.

(24) Miller, E. R., Ullrey, D. E., Zutaut, C. L., Baltzer, Betty V., Schmidt, D. A., Hoefer, J. A., and Luecke, R. W. 1964. Phosphorous Requirements of the Baby Pig. J. Nut., 82:34.

Moore, T. 1957. Vitamin A. Elsevier Publ. Co., New York.

Natanson, A. O., Mitashova, N. I., and Chuvaev, A. V. 1966. Role of Hypophysis in Development of Adrenal Hypertrophy in Rats with Hypervitaminosis A. Fed. Proc. Trans. Suppl., 25:T59.

Nieman, C., and Obbink, H. J. K. 1954. The Biochemistry and Pathology of Hypervitaminosis A. Vits. and Hormones, 12:69.

Reitman, S., and Frankel, S. 1957. A Colorimetric Method for the Determination of Serum Glutamic Oxaloacetic and Glutamic Pyruvic Transaminases. Am. J. Clin. Path., 28:56.

Roe, J. H. 1957. Methods of Biochemical Analysis. 1:127. Ed., David Glick. Interscience Publishers, Inc., New York.

Steel, R. G. D., and Torrie, J. H. 1960. Principles and Procedures of Statistics. McGraw Hill Book Co., Inc., New York.

Sykes, J. F., and Moore, L. A. 1942. The Normal Cerebrospinal Fluid Pressure and a Method for Its Determination in Cattle. Am. J. Vet. Res., 3:364.

Thomson, R. Y., and Halliburton, I. W. 1966. The Effect of Diet on Composition of the Kidney. Biochem. J., 99 (3):44P.

Wolke, R. E. 1966. The Osseous Pathology of Porcine Hypervitaminosis A. M. S. Thesis, Graduate School, University of Connecticut, Storrs.

Wolke, R. E., Calhoun, M. C., Hurt, H. D., Hall, R. C., Jr., Rousseau, J. E., Jr., and Eaton, H. D. 1965. Unpublished.

Appendix Table I.—Animals[a] and Environmental Control.[b]

[illegible]er	Birth date	Arrival at research barn	Days of age at start of comparison period	Barn Temperature, °C		Light exposure, foot-candles
				Minimum	Maximum	
[illegible]	10-10-64	11-10-64	52	16 ± 0.1[c]	19 ± 0.1[c]	2.8 1.0-5.2[d]
[illegible]	10- 3-64	11-10-64	67	16 ± 0.1	19 ± 0.1	4.2 2.0-7.0
[illegible]	3- 1-65	3-24-65	44	19 ± 0.3	23 ± 0.3	2.8 1.0-6.0
[illegible]	3- 6-65	3-24-65	46	19 ± 0.3	23 ± 0.3	4.4 2.0-6.5
[illegible]	9- 2-65	9-28-65	48	18 ± 0.2	21 ± 0.2	3.3 1.0-5.0
[illegible]	9- 4-65	9-28-65	53	18 ± 0.2	21 ± 0.2	4.0 2.0-6.0

[a] [illegible]mpshire-Yorkshire crossbred male pigs obtained from Meadow City Farms, Hadley, [illegible]ssachusetts.
[b] [illegible]ring comparison period.
[c] [illegible]andard error of mean.
[d] [illegible]nge.

Appendix Table II.—Composition of ration.

Ingredient[a]	Kil[illegible]
Soybean, seed, solv-extd grnd, 50 prot mx (52)	2[illegible]
Maize, starch, wet-mil dehy grnd (40)	5[illegible]
Maize, oil	2.[illegible]
Beet, sugar, pulp extd res, dehy (10)	2.[illegible]
Trace mineral mixture[b]	2.[illegible]
Dicalcium phosphate	2.[illegible]
Calcium carbonate	0.[illegible]
Iodized salt	0.[illegible]
DL-Methionine	0.[illegible]
Vitamin mixture[c]	2.[illegible]
Total	100.[illegible]

[a] Nomenclature from NAS NRC **Publ.**, 1232, 1964.
[b] Contributed the following mineral elements from feed grade sources (g/100 k[illegible] ration): Fe, 14.40; Zn, 2.29; Cu, 0.66; Mn, 1.61; and Co, 0.31 in a maize starch pr[illegible]
[c] Contributed the following vitamins (mg/100 kg of ration): thiamine (M.N., USP), riboflavin (USP), 330; niacin (USP), 2200; Ca-DL-pantothenate (USP), 2640; pyri[illegible] HCl (USP), 132; choline chloride (70%), 125,400; cyanocobalamin (0.1% in ca[illegible] phosphate), 2.2; d-α-tocopheryl acetate, 660; menadione sodium bisulfite, 55; chlor[illegible] cycline (97.9%), 5500; and vitamin D_2 in a maize starch premix 44,000 IU.

Appendix Table III.—Proximate composition of basal ration and Vitamin A supplem[illegible] as fed.

Constituents	Basal ration	Vitamin A supple[illegible]
	(%)	
Moisture	11.26 ± 0.36[a]	8.69 ± 0.72[b]
Crude protein	16.78 ± 0.71	51.35 ± 0.39
Ether extract	2.91 ± 0.10	0.76 ± 0.11
Crude fibre	1.65 ± 0.10	0.32 ± 0.05
Nitogren-free extract	63.33 ± 0.94	37.72 ± 0.61
Ash	4.07 ± 0.15	1.16 ± 0.15
	(γ/kg)	
Carotene	154.4 ±22.0	— —
	(γ/g)	
Vitamin A acetate	—	[illegible] ± [illegible]

[a] Standard error of mean based on 11 samples.
[b] Standard error of mean based on 10 samples.
[c] Standard error of mean based on 4 samples.

Appendix Table IV.—Effect of excessive vitamin A intake upon plasma and liver vitamin A concentrations of weanling pigs.

	Control		Hypervitaminotic-A		SD per animal
			Mild	Severe	
	Vitamin A intakes, γ/kg live wt/day				
	39.7	119.0	6,614	19,842	
Plasma vitamin A, γ/100 ml					
Initial	20	23	20	22	4
Terminal					
Actual	23 (14-27)[a]	25 (19-32)	62 (39-87)	190 (98-297)	—
Log_{10}	1.35	1.39	1.78	2.24	0.11
Terminal liver					
Weight, g	495	460	423	338	46
Per unit live weight, g/kg	22.4	21.0	18.8	21.1	2.6
Liver vitamin A					
Concentration, γ/100 g					
Actual	4,376	18,982	298,533	291,910	—
Log_{10}	3.57	4.14	5.46	5.43	0.22
Total, γ					
Actual	21,321	88,572	1,289,156	996,918	—
Log_{10}	4.25	4.80	6.09	5.94	0.22
Per unit live weight, γ/kg					
Actual	975	3,973	57,385	58,818	—
Log_{10}	2.91	3.46	4.73	4.74	0.22

[a] Range.

Appendix Table V.—Effect of excessive vitamin A intake upon serum protein concentration of weanling pigs.

	Control		Hypervitaminotic-A		SD per animal
			Mild	Severe	
	Vitamin A intake, γ/kg live wt/day				
	39.7	119.0	6,614	19,842[a]	
Concentration, g/100 ml					
Total					
Initial	6.36	6.27	5.74	6.10	0.33
Terminal	6.83	6.94	6.60	6.92	0.31
Change	0.47 (0.81)[b]	0.67 (0.88)	0.86 (0.33)	0.82 (0.80)	0.54 (0.32)
Albumin					
Initial	3.59	3.62	3.14	3.36	0.30
Terminal	4.35	4.45	3.96	4.02	0.19
Change	0.76 (0.90)	0.83 (1.00)	0.82 (0.57)	0.66 (0.60)	0.30 (0.22)
Alpha-globulin					
Initial	1.20	1.10	1.10	1.10	0.10
Terminal	0.87	0.79	0.88	1.01	0.17
Change	—0.33	—0.31	—0.22	—0.09	0.16
Beta-globulin					
Initial	0.86	0.91	0.99	1.01	0.15
Terminal	0.87	0.93	0.99	1.05	0.07
Change	—0.09 (—0.07)	—0.01 (—0.04)	0.10 (0.05)	0.04 (0.10)	0.15 (0.03)
Gamma-globulin					
Initial	0.60	0.64	0.60	0.67	0.11
Terminal	0.74	0.80	0.76	0.87	0.16
Change	0.14	0.16	0.16	0.20	0.17

[a] Data include one calculated missing value.
[b] Adjusted by covariance for initial values.

Appendix Table VI.—Effect of excessive vitamin A intake upon serum protein distribution of weanling pigs.

	Control		Hypervitaminotic -A		
			Mild	Severe	
	Vitamin A intake, γ/kg live wt/day				
	39.7	119.0	6,614	19,842[a]	
Distribution, %					
Albumin					
Initial	56.42	57.66	54.84	54.20	3.50
Terminal	63.74	64.02	60.12	57.88	3.01
Change	7.32 (7.76)[b]	6.36 (7.66)	5.28 (4.63)	3.68 (2.59)	3.71 (
Alpha-globulin					
Initial	19.13	17.61	19.27	18.27	1.63
Terminal	12.63 (12.13)	11.42 (12.28)	13.41 (12.78)	14.48 (14.75)	2.14 (1
Change	—6.50	—6.19	—5.86	—3.79	1.56
Beta-globulin					
Initial	15.01	14.57	15.51	16.52	2.19
Terminal	12.76	12.93	14.93	15.13	0.90
Change	—2.25 (—1.90)	—1.64 (—0.90)	—0.58 (—0.67)	—1.39 (—2.40)	2.15 (0
Gamma-globulin					
Initial	9.44	10.16	10.38	11.01	1.81
Terminal	10.87	11.63	11.54	12.51	2.01
Change	1.43	1.47	1.16	1.50	2.06
Total-globulins, %					
Initial	43.58	42.34	45.16	45.80	3.50
Terminal	36.26	35.98	39.88	42.12	3.01
Change	—7.32 (—7.76)	—6.36 (—7.66)	—5.28 (—4.63)	—3.68 (—2.59)	3.71 (3.
Ratio of albumin to globulin					
Initial	1.36	1.44	1.25	1.24	0.19
Terminal	1.83	1.87	1.54	1.36	0.24
Change	0.47 (0.49)	0.43 (0.50)	0.29 (0.25)	0.12 (0.07)	0.25 (0

[a] Means include one calculated missing value.
[b] Adjusted by covariance for initial values.

Appendix Table VII.—Effect of excessive vitamin A intakes upon weanlings pigs — Preliminary study.[a]

	— Vitamin A intakes γ/kg live wt /day —		
	55.1	8,820	26,460[b]
Feed, kg			
Total fed	25.5	25.8	23.0
Total consumed	25.4	25.8	19.5
Weight gain	11.9	9.9	2.8
Feed consumed/unit wt gain, kg/kg	2.14	2.74	6.69
Serum vitamin A γ/100 ml	34.6	111.0	315.0
Terminal liver			
Weight, g	356	355	298
Wt/unit live wt, g/kg	19.6	17.78	25.56
Vitamin A concentration per unit live wt, γ/kg	16,746	73,222	149,735
Serum protein distribution, %			
Albumin	51.60	52.50	51.24
Total globulin	48.40	47.50	48.76
Albumin to total globulin ratio	1.07	1.10	1.05
Serum protein concentration, g/100 ml			
Total protein	6.46	6.56	7.25
Albumin	3.34	3.44	3.72
Total globulin	3.12	3.12	3.53
Serum transaminase activity, Sigma-Frankel units/ml			
Glutamic-oxaloacetic	34	64	50
Glutamic-pyruvic	36	49	33
Organ weight, g			
Heart	75.5	83.6	75.4
Kidneys	53.3	75.2	95.8
Adrenals	1.04	1.35	1.82
Supraspinatus	95.0	91.2	57.5

[a] Preliminary study of 6 weeks duration for 3 male, 3 female 7 week old Yorkshire pigs.

[b] Blood values for the 26,460 γ intake reported are from data of one pig only.

Appendix Table VIII.—Effect of excess vitamin A intakes upon the young canine. Preliminary study.[a]

	Vitamin A intake γ/kg live wt/day		
	55.1	8,820	26,46[illegible]
Feed, kg			
Total fed	25.1	26.7	2[illegible]
Total consumed	24.6	26.4	2[illegible]
Weight gain	2.3	2.7	[illegible]
Feed consumed/unit wt gain, kg/kg	10.7	9.8	45.[illegible]
Plasma vitamin A, γ/100 ml	107.1	2,011.0	7,391.[illegible]
Cerebrospinal fluid pressure, mm saline	52	55	29
Terminal liver			
Weight, g	232	265	167
Wt/unit live wt, g/kg	32	37	36
Vitamin A concentration, γ/g	14	11,661	23,468
Conc./unit live wt, γ/kg	451	429,190	851,990
Serum protein distribution, %			
Albumin	62.95	59.74	55.[illegible]
Total globulin	37.05	40.26	44.[illegible]
Albumin to total globulin ratio	1.71	1.48	1.2[illegible]
Serum protein concentration, g/100 ml			
Total protein	6.2	6.2	6.[illegible]
Albumin	4.0	3.7	3.4
Total globulin	2.3	2.5	2.7
Serum enzymatic activity			
Glutamic-oxaloacetic transaminase	38	32	61
Glutamic-pyruvic transaminase	16	14	35
Alkaline phosphatase	6.1	7.7	6.9
Tissue weight, g			
Heart	55.6	55.7	30.9
Kidney	36.2	34.7	29.2
Adrenals	0.90	0.75	0.8[illegible]
Supraspinatus	19.4	20.0	11.7
Tibia	18.6	17.3	10.1

[a] 14 weeks duration for eight 10 week old Beagles, 1 male and 1 female receiving the 55.1 γ intake and 3 females each assigned to the 8,820 and 26,460 γ intake.

Acknowledgments

The authors are grateful to B. A. Donohue and T. Watts, Sr. for the care and feeding of the animals; Mrs. Mae Miller and T. M. Dwyer for technical assistance in preparation of this manuscript; W. W. Pierce, Wirthmore Feeds, Inc., Waltham, Mass., for help with the formulation and mixing of the basal ration; and Dr. H. J. Fisher, Connecticut Agricultural Experiment Station for proximate analysis of the feeds. The vitamin A supplement was furnished by Hoffman - La Roche, Inc., Nutley, New Jersey, through the courtesy of Drs. J. C. Bauernfeind and R. H. Bunnell.

Iwanowska-'67
Bib. No. 10596

ACTA PHYSIOLOGICA POLONICA
Vol. XVIII, No. 6, 1967

JANINA IWANOWSKA AND KRYSTYNA PĄCZEK

EFFECT OF ESSENTIAL UNSATURATED FATTY ACIDS ON VITAMIN A METABOLISM

Department of Biochemistry, Institute of Drugs, Warsaw
Head: Doctor *J. Iwanowska*

IWANOWSKA J., PĄCZEK K.: *Effect of Essential Unsaturated Fatty Acids on Vitamin A Metabolism*. Acta Physiol. Polon. 18 (6): 963—972, 1967. — The influence of several unsaturated fatty acids and their mixtures on the vitamin A content was investigated in rats, divided into three experimental groups. In the first experimentation procedure, basing on somatic symptoms, occurring in animals, it was stated that unsaturated fatty acids inhibited the negative effects of excessive vitamine A content in the body, stimulated the animals growth and prevented the overdosage. Second experimentation showed unsaturated fatty acids to be necessary for the process of vitamin A assimilation in the organism. In third experimentation the excretion of vitamin A in feces and their storage in the liver was examinated. The unsaturated fatty acids were found to induce lower vitamin A level in the liver and higher vitamin A excretion in feces. Basing on the results obtained it may be supposed that unsaturated fatty acids, which decrease vitamin A level in the liver and increase its excretion in feces may prevent the symptoms of A hypervitaminosis, but may also induce the A hypovitaminosis.

Several years ago the essential unsaturated fatty acids — linolic acid and linolenic acid — were classified as vitamin F and in that connection their interrelation with first of all vitamins of group B was studied. As reported by *Hogan* and *Richardson*, *Bierch* and *Gyorgy*, and *Salmon*, the deficiency of both pyridoxine, pantothenic acid, and the essential unsaturated fatty acids may be the cause to skin inflammatory states which withdraw when these vitamins as well as the acids are given in food.

According to *Medes et al.* there is a synergism of pyridoxine and the essential unsaturated fatty acids as can be inferred from the fact that deficiency symptoms disappear when only one of these compounds is administered. An antagonism of oleic acid and pyridoxine is indicated by data reported by *Sarm et al.*

No data could be found in the available literature concerning an interrelation of the essential unsaturated fatty acids and vitamin A. The problem seems to be topical for vitamin A is present in oil solutions used in

the therapy and in the fish oil together with unsaturated fatty acids: they both penetrate into the organism. In the animal organism the vitamin is assimilated and stored as esters of these acids [6, 7]. These data, as well as the authors' observation that rats fed fat-less diet after several weeks develop clear symptoms of A avitaminosis, were a basis for the present experiments on the effect of the essential unsaturated fatty acids — linolic and linolenic — as well as oleic acid on somatic changes and certain functions of the rat organism.

METHODS

Three experiments were performed:

I. Determination of the effect of the essential unsaturated fatty acids and oleic acid on the appearance of hypervitaminosis A upon administration of excessive doses of axerophthol.

II. Determination of the effect of the essential unsaturated fatty acids and oleic acid on the assimilation of vitamin A.

III. Determination of the effect of unsaturated fatty acids on excretion and storage of vitamin A administered in doses 10.000 times exceeding daily requirements of the animals.

Following materials were used:

1. male albino rats, 150—250 g of weight;
2. vitamin A concentrated to 100,000 i. u. per g; the concentration was tested by spectrophotometry;
3. oleic acid chromatographically pure;
4. linolic acid (Fluka, Buchs) chromatographically pure;
5. linolenic acid (BDH, Mann) chromatographically pure;
6. Linomag liq. (manufactured by Ziololek, Poznań) containing dehydrogenated fatty acids; it was tested by chromatography and found to contain linolic and linolenic acids 1 : 2;
7. refined soybean oil containing, according to the literature data, 29 percent of oleic acid, 51 percent of linolic acid, and 7 percent of linolenic acid.

Vitamin A was determined in the liver and feces as follows:

a) Vitamin A determination in feces. Daily portion of feces was weighed and ground with anhydrous sodium sulfate, then it was saponified with, potassium lye in a hot water bath for 30 min: 5 ml of 15 percent alcohol solution of potassium hydroxide and 5 ml of ethyl ether were used for gram of feces. After saponification the fluid was cooled and decanted into a separatory funnel. The residue was twice washed with ether, the washings being joined with the fluid in the funnel. After removing alcohol-water layer, the ether layer was washed with water until a neutral reaction of phenolphthalein disappeared, then it was filtered through anhydrous sodium sulfate, ether was evaporized at 40°C under reduced pressure and in carbon dioxide stream. The residue was dissolved in 10 ml of isopropanol and diluted to make a concentration of 10—15 i. u. of vitamin A per ml. In this solution the absorption maximum was determined and vitamin A content per g of feces was calculated from the formula:

$$\frac{A \cdot 1900}{b} R \cdot 1000$$

where A — absorption at 325 mμ, b — weight of daily portion of feces in g, R — dilution, and 1900 — calculation coefficient for vitamin A.

b) Vitamin A determination in the liver. The prepared organs were weighed and saponified in hot water bath for 45—60 min with 15 percent alcohol solution of potassium hydroxide, 5 ml of the solution and equal amount of ethyl ether per g of the liver. Further procedure was as above. Vitamin A contents in the liver were calculated from the above formula in which b — weight of the liver.

Rats in experiments I and III were fed breeding diet:

oats	22 percent	dry barm	6 percent
wheat	20 percent	sodium chloride	1 percent
rye	10 percent	calcium carbonate	0·5 percent
barley	10 percent	powdered milk	6 percent
corn	10 percent	fish oil	1 percent
casein	3·5 percent	margarine	6 percent
bone dust	5 percent		

In experiment II the animals received fat-less diet:

sugar	84 percent	calcium lactate	1·5 percent
defatted		ferrum citrate	0·01 percent
casein		magnesium sulfate	0·05 percent
	12 percent	sodium chloride	0·02 percent
sodium phosphate	1·3 percent		
calcium phosphate	0·5 percent		
potassium phosphate	0·1 percent		

The diet was supplemented with following vitamins:

carotene	0·4 g/kg of food
vitamin E	0·25 g/kg ,,
group B vitamins (defatted yeast)	6·5 g/kg ,,
calciferol	0·5 g/kg ,,
choline	0·286 g/kg ,,

All animals received water *ad libitum*. In all experiments vitamin A and unsaturated fatty acids were given orally by a syringe and a needle with a ball at its end. The needle was put into the esophagus, thus rendering possible quantitative dosage of the solution.

RESULTS

Experiment I. *Effect of the essential unsaturated fatty acids and oleic acid on the appearance of hypervitaminosis A upon administration of excessive doses of axerophthol.*

The rats were divided into three groups, six animals in each. During six weeks rats of group I received vitamin A 30.000 i. u. daily per animal, those of group 2 — 30,000 i. u. of vitamin A and 0·2 ml of

unsaturated fatty acids in the form of Linomag, and those of group 3 — 0·2 ml of Linomag. In each group the animals were weighed the every 14 days, changes in weight being recorded.

Clear symptoms of hypervitaminosis A were observed in rats of group 1, namely loss of body weight, yellow-colored hair, and general bad condition.

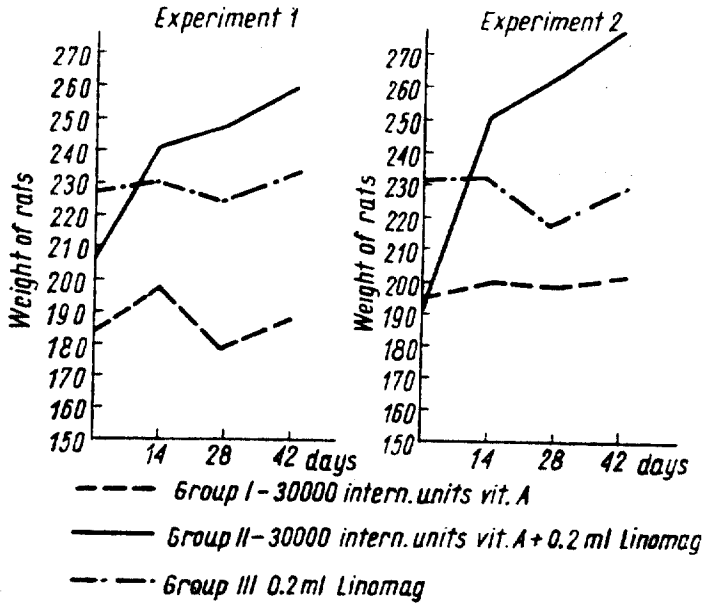

Fig. 1. **Changes in the body weight during administration of vitamin A, unsaturated fatty acids and a mixture of vitamin A and unsaturated fatty acids.**

In group 2 the rats clearly gained in weight and showed good condition.

In group 3 gain in weight was not observed, though condition of the animals was quite good.

Changes in body weight of animals in this experiment are illustrated in Fig. 1.

Experiment II. *Effect of the essential unsaturated fatty acids and oleic acid on the assimilation of vitamin A.*

The animals were divided into three groups six animals in each, and received for six weeks: in group 1 — vitamin A in an amount covering daily requirement of the animal (3 i. u.), in group 2 — vitamin A in the same amount and 0·1 ml of Linomag (corresponding to about

0·066 ml of linolenic acid and 0·33 of linolic acid), and in group 3 — vitamin A in the same amount and 0·5 ml of soybean oil (corresponding to 0·25 ml of linolic acid, 0·035 of linolenic acid, and 0·15 ml of oleic acid). The animals were weighed the every 14 days, changes in weight being recorded.

Loss of weight and bad condition of the animals were observed in group 1, the rats were clumsy, dull and after 5 weeks they lost a part of hair.

In group 2 the condition of rats was good, they gained in weight.

In group 3 gain in weight was only slight, but the rats were active and their condition was satisfactory.

Experiment III. *Effect of unsaturated fatty acids on excretion and storage of vitamin A administered in doses 10,000 times exceeeding daily requirement.*

The animals were divided into four groups 6 rats in each, and put into the metabolic cases. Once a day at a defined time they received breeding diet in the form of 15-g granules. The rats when fed were transferred for one hour into other cases. In that period feces were collected from the metabolic cases, separately from each. After one hour the animals were again put into the metabolic cases. To prevent coprophagy, the cases were supplied with double bottom: a net with large mesh through feces fell on another one with fine mesh.

Vitamin A and unsaturated fatty acids were given for 10 days, once a day after feeding. In group 1 the animals received daily 30,000 i. u. of vitamin A, in group 2 — vitamin A in the same amount and 0·2 ml of unsaturated fatty acids, in group 3 — 0·2 ml of unsaturated fatty acids, and group 4 was control. In consecutive experiments animals of group 2 and 3 were given:

1. oleic acid,
2. linolic acid,
3. a mixture of oleic and linolic acid 1 : 1,
4. a mixture of linolic and linolenic acid 1 : 2 (Linomag),
5. a mixture of oleic, linolic, and linolenic acids 1 : 1 : 1,
6. a mixture of oleic and linolenic acid 1 : 1.

The collected feces were weighed and vitamin A was determined in it and calculated per gram. The results are illustrated by graphs 2 a—b.

The every 5 days, starting from the beginning of the administration of vitamin A and fatty acids, in each group 2 rats were killed (the last two were killed on the 5th day after the end of the administration). The liver was prepared and vitamin A was determined in it and calculated per 100 g of tissue.

DISCUSSION

The results of experiment I indicate that unsaturated fatty acids first of all prevented vitamin A overdosage. A synergism of vitamin A and unsaturated fatty acids could also be observed; they together markedly

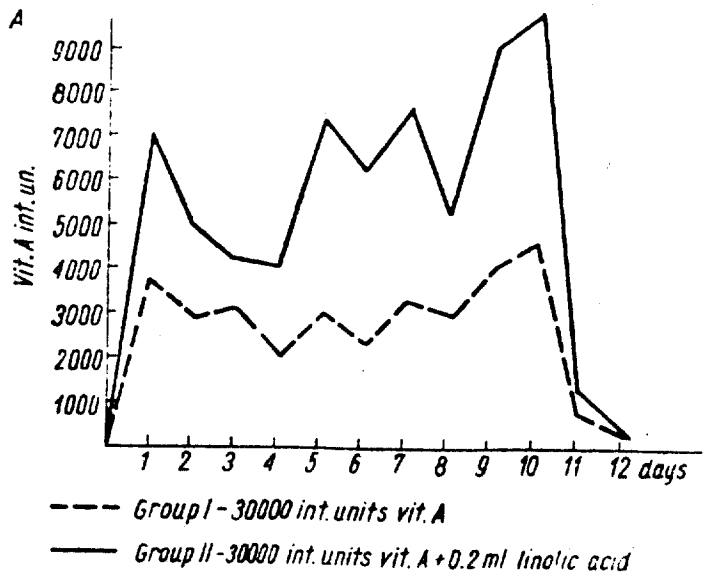

Fig. 2 a.

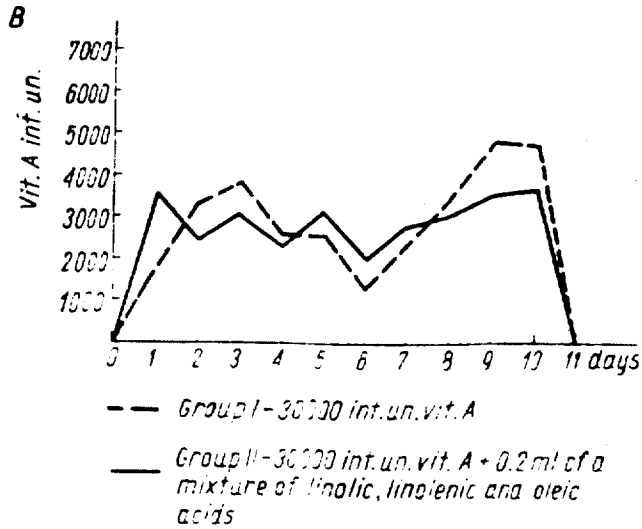

Fig. 2 b.

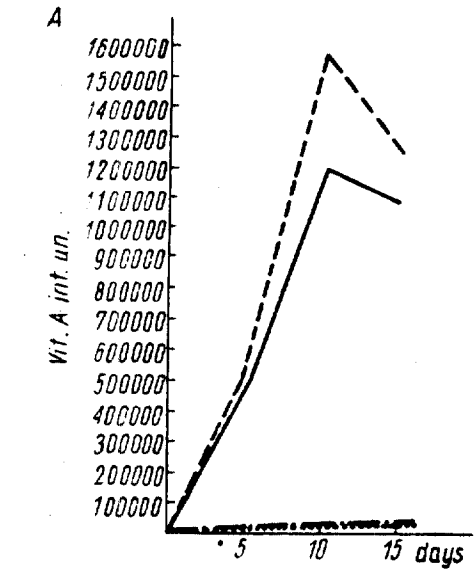

— — Group I - 30000 int. un. vit. A

—— Group II - 30000 int. un. vit. A + 0.2 ml oleic acid

—·— Group III - 0.2 ml oleic acid

---- Group IV - controls

Fig. 3 b.

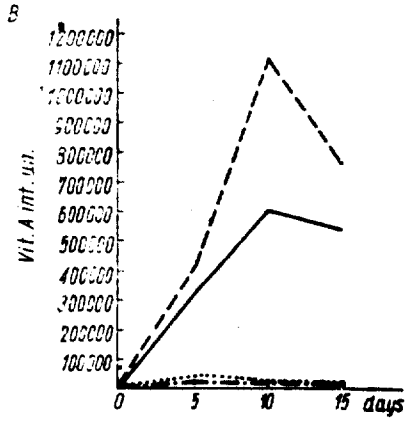

— — Group I - 30000 int. un. vit. A

—— Group II - 30000 int. un. vit. A + 0.2 ml of a mixture of linolic, linolenic and oleic acids

—·— Group III - 0.2 ml of a mixture of linolic, linolenic and oleic acids

---- Group IV - controls

Fig. 3 a.

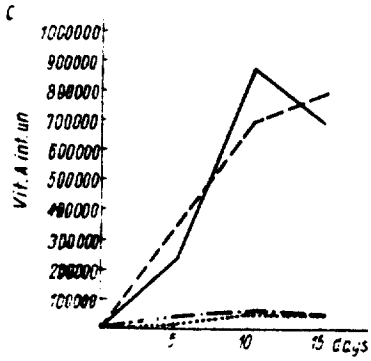

— — Group I - 30000 int. un. vit. A

—— Group II - 30000 int. un. vit. A + 0.2 ml of a mixture of linolic and oleic acids

—·— Group III - 0.2 ml of a mixture of linolic and oleic acids

------ Group IV controls

Fig. 3 c.

stimulated growth of the animals, while vitamin A alone as well as the acids did not so to such a high degree.

Experiment II clearly showed unsaturated fatty acids to have an effect on the assimilation of vitamin A. Their deficiency in diet induced symptoms of avitaminosis A in spite that axerophthol was administered in an amount covering daily requirement.

In experiment III linolic and linolenic acids were found to induce higher vitamin A excretion in feces; the excretion was higher when linolic acid was given (Fig. 2 a), while oleic acid and mixtures of the unsaturated acids tested showed no effect on the excretion of axerophthol in feces (Fig. 2 b).

Both the individual unsaturated fatty acids and mixtures of them decreased vitamin A level in the liver (Fig. 3 a, b); the decrease was high especially when acid mixtures were administered.

Higher vitamin A level in the liver after administration of oleic-linolic acid mixture and a mixture of oleic acid and linolenic acid (Fig. 3 c) remains to be inexplained. It may be supposed that unsaturated fatty acids, which decrease vitamin A level in the liver and increase its excretion in feces, prevent overdosage of the vitamin and may also induce its deficiency.

Technical assistance of Miss *H. Żukowska*, Mr. *A. Kuszyński*, and Mr. *S. Smolug* is greatly acknowledged.

REFERENCES

1. *Hogan A. G., Richardson L. R.:* Nature 1935, 136, 136.
2. *Bierch C. W., Gyorgy P.:* Bioch. J., 1936, 30, 304.
3. *Salamon W. D.:* J. Biol. Chem., 1941, 140.
4. *Medes G., Keller D. C., Rurkjian A.:* Arch. Bioch., 1947, 15, 19.
5. *Sarma P. S., Snell E. E., Elvehjem J.:* Nutrition 1947, 33, 121.
6. *Kunitaro Imaichi:* Am. J. Clin. Nutr., 1963, 13, 152.
7. *Fragner J.:* Vitamine. Chemie und Biochemie. Jena 1964.

Author's address: Department of Biochemistry, Institute of Drugs, Długa Str. No. 16, Warsaw (Poland).

Kochhar-'73
Bib. No. 10644

Reproduced by permission
of the copyright owner

Limb Development in Mouse Embryos

I. ANALYSIS OF TERATOGENIC EFFECTS OF RETINOIC ACID[1]

D. M. KOCHHAR
Department of Anatomy, School of Medicine, University of Virginia, Charlottesville, Virginia 22901

ABSTRACT Retinoic (vitamin A) acid produced phocomelia and micromelia in DBA/2J fetuses when administered to pregnant mice on the 12th or 13th day of gestation. The incidence of forelimb defects was higher after 12th- (in embryos having 33–41 somite pairs) than 13th-day treatment (40–51 somite pairs), the reverse was true for hindlimb defects. Hindlimb digits continued to be highly susceptible on the 14th day. Limb defects were not accompanied by body growth retardation or other skeletal malformations except cleft palate. The type and severity of limb defects depended on the average developmental stage of the limb bud at the time of treatment. From the beginning of the period of limb susceptibility, the 12th day, the ontogenetic sequence in which the long bones were rendered abnormal was: radius-ulna, humerus, fibula, tibia, femur or tibia-femur. The sequence in which the long bones lost their susceptibility to retinoic acid was: humerus, femur, ulna, radius, tibia-fibula. The radius appeared to be susceptible in some embryos at a time when the other long bones had escaped injury. An analysis of the shape of the same bone affected at different periods of prenatal development led to the following proposal. At earlier stages retinoic acid disrupts cellular activities that normally lead to the spatial organization of the mesenchymal cell condensations, resulting in a modified shape of the cartilage models; at later stages it prevents the enlargement of the condensations that have already appeared, resulting in smaller than normal models.

The objective of the study reported here was to induce congenital defects of the appendicular skeleton selectively and consistently. Retinoic (vitamin A) acid produces a number of congenital malformations in rats and mice that are similar to those produced by other forms of vitamin A (Kochhar, '67). However, retinoic acid, unlike other forms of vitamin A, is rapidly eliminated from the injected animal (DeLuca and Roberts, '69), and hence may be an agent of choice to demonstrate and analyze the embryonic-stage dependency of selected congenital malformations. Recent reports (Kochhar, '69, '70; Shenefelt, '72) indicated, in fact, that peak incidences of individual defects, which otherwise comprise a syndrome in fetuses of vitamin A-treated females, were obtained after retinoic acid treatment.

The results of the present investigation showed (1) that limb defects were specifically produced by retinoic acid treatment on chosen days in virtually all embryos, unaccompanied by any significant growth retardation or any other external or skeletal malformations except cleft palate, and (2) that the type and severity of reduction anomalies in fore- and hindlimbs depended on the developmental stage of the embryonic limb bud at the time of treatment.

MATERIALS AND METHODS

Timed-pregnant DBA/2J mice were obtained from the Jackson Laboratory (Bar Harbor, Maine) during the first week of gestation. The females were considered to be in the 1st day of pregnancy on the day a vaginal plug was discovered. On arrival in our laboratory the animals were distributed in cages and provided with food (Purina) and water ad libitum.

All-trans retinoic acid (Sigma Chemical Company, St. Louis, Missouri) was suspended in cottonseed oil to give a concentration of 20 mg/ml of oil. At 10 AM on

Received Nov. 6, '72. Accepted Feb. 1, '73.
[1] Supported by NIH grants HD04556 and HD06550.

one of the 10th–16th days of gestation each experimental animal was given by oral intubation a single dose of 80 mg/kg retinoic acid in 0.1 ml oil. Control animals were untreated or given 0.1 ml cottonseed oil by oral intubation.

All animals were killed by cervical dislocation on the 18th day of gestation, and the fetuses removed, weighed, and examined for external malformations. Two fetuses from each litter were fixed in Bouin's for subsequent histological study and examination by razor-blade sectioning (Wilson, '64), and the remaining ones were fixed in 95% ethanol and their skeletons cleared and stained by the following quick method. After 6–24 h in ethanol the fetuses were immersed without evisceration in 2% KOH until the bones were clearly visible. They were then put into a dilute solution of alizarin red S (Matheson) prepared by the addition of a few drops of a saturated alcoholic solution of the dye to 1% KOH. A period of 12–24 h was sufficient to give desired intensity of staining. The stained skeletons were then stored and photographed in a 1:1 mixture of absolute ethanol and glycerin. This staining method allowed the fetal skeleton to be examined within 3 days.

RESULTS

Seventeen percent of the implantation sites in the control animals were resorbed (table 1). The onset of resorption must have occurred early in gestation since the size of these sites was extremely small and gross dissection did not reveal the presence of any embryonic vestige. This apparently high rate of resorption was not due to the cottonseed oil alone since such an effect also occurred in untreated animals. Since the pregnant animals were in their first week of gestation during airshipment from the Jackson Laboratory it is possible that some resorptions occurred because of the handling involved and consequent stress. In experimental litters the resorption rate varied from 15–40% (table 1).

The mean weight (±SD) of control fetuses on the 18th day was 670 ± 53 mg (fig. 1). Treated fetuses weighed significantly less than this only after treatment on the 10th and 11th days (587 ± 45, and 582 ± 39 mg, respectively). The weights of fetuses treated on other days were within the control range (fig. 1).

There were no malformations in the surviving control fetuses. The types and frequencies of skeletal malformations produced in the experimental fetuses are given in table 1.

Limb defects

Limb defects occurred after treatment on the 12th day, and all fetuses were affected (table 1). This was a sudden peak since no long-bone defects were produced by treatment on the 10th or 11th day. After treatment on the 13th day the incidence of limb defects was still high (84%) but some fetuses with normal limbs were obtained. The incidence of limb defects

TABLE 1

Incidence of congenital defects in DBA/2J fetuses after retinoic acid administration on different days of gestation

	Number of litters	Number of implantation sites	% Sites resorbed	Number of living fetuses	% Limb defects	% Long bone defects only		% Cleft palate
						Forelimb	Hindlimb	
Control	28	196	17	163	0	0	0	0
Retinoic acid [1]								
10th day	6	50	26	37	3 [2]	0	0	68
11th day	8	60	17	50	0	0	0	22
12th day	22	136	33	92	100	100	62	96
13th day	9	62	40	38	84	50	81	57
14th day	3	37	15	32	61 [2]	0	0	58
15th day	6	33	23	24	0	0	0	50
16th day	6	42	14	37	0	0	0	0

[1] 80 mg/kg orally.
[2] Only digital defects.

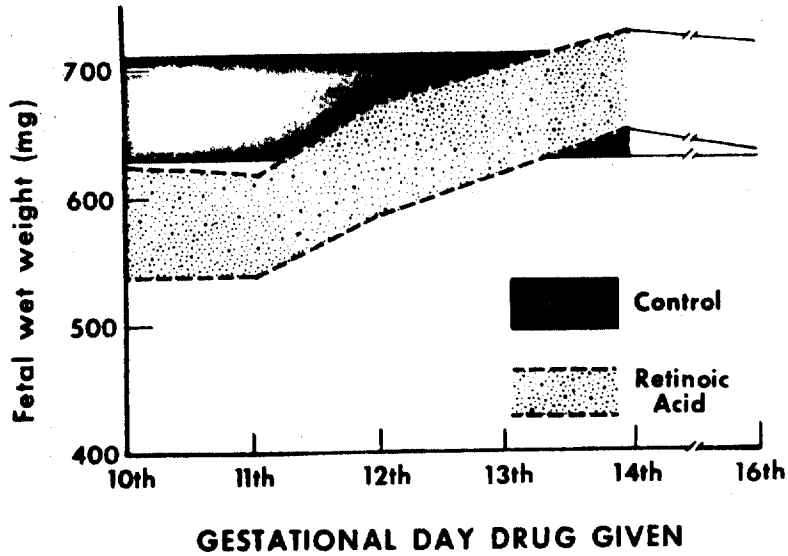

Fig. 1 Comparison of wet weights of freshly delivered 18th day control fetuses with fetuses obtained from mothers treated with 80 mg/kg retinoic acid on one of the 10th through 16th days of gestation. The width of the bars represent mean fetal weight ± standard deviation.

fell to 61% after treatment on the 14th day; these defects, however, were not long-bone defects and involved only digits. No limb defects of any sort were produced by treatment on the 15th or 16th day.

Forelimbs were more sensitive on the 12th day than the 13th day. Although no embryo escaped forelimb malformation on the 12th day, only 50% were affected on the 13th day. Conversely, the hindlimbs escaped malformation in 38% of the embryos on the 12th day, whereas 81% showed defects on the 13th day (table 1).

Types of limb defects. All limb defects to be described were bilateral. Fetuses treated on any one day had a range of mild to severe changes; variation even occurred among the members of the same litter.

12th day. The most severe malformation of the forelimb produced at this time, called phocomelia, consisted of a very short limb containing an extremely small, ectopic, triangular bone replacing the humerus, radius, and ulna; three metacarpals; and 2–4 digits (fig. 3). A slightly milder malformation, found in about 50% of the fetuses, was classified as micromelia. Present in such limbs were a small, misshapened humerus, a radius-ulna, represented by an osteogenic spot, and 2–4 metacarpals and digits (fig. 2). The scapula was normal in all these cases.

The hindlimb defects that accompanied these abnormalities of the forelimb helped delimit the beginning of susceptibility of the forelimb. Fetuses with forelimb micromelia were usually the smallest in the litter; a high percentage of them had completely normal hindlimbs (fig. 2). These offspring were perhaps the youngest in the litter at the time of retinoic acid treatment. Slightly larger fetuses had total forelimb phocomelia accompanied by various degrees of hindlimb defects (figs. 3, 4). The fibula was the first bone to be affected and was either short or absent; the tibia was only slightly shortened; the femur was normal in such cases. In fetuses that also had an abnormal femur, the tibia was stout, short, and curved (fig. 3). In the most severely malformed fetuses in this group, i.e., those with total forelimb phocomelia, the femur and tibia were misshapen and short (fig. 4). After treatment at this time only a few fetuses had a reduced number of hindlimb digits, although the metatarsals appeared longer than normal.

In summary, the sequence in which the limb bones were rendered abnormal, from

the onset of susceptibility to teratogenesis was: radius-ulna, humerus, fibula, tibia, femur or tibia-femur.

13th day. Treatment at this time never produced total phocomelia of either limb. The humerus and femur were always normal in length and shape (figs. 5–7); the ulna was rarely, and then only slightly, affected (fig. 7). The radius was the only bone in the forelimb that was frequently malformed by treatment on the 13th day; it was either missing or variably reduced in length in about half the fetuses (fig. 7). The tibia and fibula were affected in 80%; in about half of them they were completely absent (fig. 6) and in the other half they were variably reduced in length (fig. 5).

In summary, the radius was the last of the forelimb bones to lose its susceptibility to malformations. It is interesting to note that the radius appeared to be susceptible even in cases where the tibia and fibula escaped injury (fig. 7). The femur was the first of the hindlimb bones to lose its susceptibility to the drug. The tibia and fibula lost their susceptibilities gradually and simultaneously.

Digital defects. The frequencies of digital defects after treatment on the 10th–14th days are given in figure 8. Preaxial polydactyly was present in only one fetus. Most of the phocomelic and micromelic fetuses exposed on the 12th and 13th days had only four digits, occasionally two or three digits. Phalanges were normal in number but distorted in form. The degree of effect on forefeet digits was greater than on hindfeet digits on the 12th day, and vice versa on the 13th day (fig. 8). Treatment on the 14th day still produced severe malformations of hindfeet digits while forefeet digits were minimally affected (fig. 8). Most fetuses exposed on this day had no distal phalanges, resulting in stubby digits. If forefeet digits showed this malformation, hindfeet digits were also similarly affected, but the reverse was rarely true.

Cleft palate and other malformations

Cleft palate (without cleft lip) occurred in two peaks, after treatment on the 10th and 12th days separated by a less sensitive period on the 11th day (table 1). Only 22% of fetuses examined after treatment on the 11th day showed cleft palate; consistently, however, they had a stumpy tail with missing tail vertebrae.

Fifty percent of the fetuses exposed on the 10th day had a syndrome of malformations described previously (Kochhar, '67), which consisted of markedly shortened trunk, extreme exophthalmia, microcephaly, astomia, rudimentary or missing mandible, tail stump, no genital opening, malformed sternum and ribs, and missing vertebrae. Hindlimbs were malpositioned because of the shortened trunk, otherwise the long bones were normal.

DISCUSSION

Limb malformations

The purpose of this report was not merely to document the limb malformations induced by retinoic acid, but to relate them to particular embryonic stages. Limb deformities encountered after treatment during the susceptible period, the 12th and 13th days, were classified as phocomelia and micromelia. Analysis of them demonstrated a cephalocaudal and proximodistal gradient of factors sensitive to retinoic acid, resulting in distinct patterns of individual long-bone defects. These conclusions were drawn, not from offspring treated with retinoic acid at several closely spaced intervals, but from only two groups treated at 10 AM on the 12th or 13th day of pregnancy. Although the former approach would be ideal, e.g., in studies with the chick embryo, the two time intervals were relied on because of the following reason. Parallel studies (Kochhar and Aydelotte, '71) revealed that at 10 AM on the 12th day DBA/2J embryos attained a relatively consistent developmental stage, with the number of somites ranging from 33–41 pairs in different litters. A slight degree of asynchrony in development also occurred within litters. Because of this reason treatment of embryos at only limited time intervals was considered satisfactory for our purposes.

From the data presented we can assume that at the 33-somite stage the forelimb bud was only partially sensitive to retinoic acid, leading to micromelia but not phocomelia; the hindlimb showed no susceptibility at that stage. Total phocomelia of the

forelimb was obtained in embryos slightly older than the 33-somite stage, at which time the hindlimbs also began to show an effect. The long bones were malformed or reduced by exposure of 12th-day embryos in the following sequence: radio-ulna, humerus, fibula, tibia, femur or tibia-femur. The number of digits on malformed limbs ranged from 2–4.

The pattern of malformation changed on the 13th day. At 10 AM on the 13th day the oldest embryos attained 51 somite pairs (Kochhar and Aydelotte, '71). The radius was the only bone in the forelimb still susceptible to retinoic acid, being either completely missing or considerably shortened. The humerus and ulna were almost always normal. Although the hindlimb was severely malformed, it never showed total phocomelia and the femur appeared completely normal in all fetuses.

It is apparent that to investigate the cellular basis for the origin of limb bone defects, the study of 33–41-somite embryos may be most instructive. This developmental period in the mouse embryo (stages 23–25, Witschi, '62) corresponds in limb ontogeny to stages 21–23 of chick embryos (Hamburger and Hamilton, '51), and to 7–8-mm human embryos of Horizons XIV–XV (age 30–31 days, as summarized by Sledge, '66). At the beginning of this period the limb swellings are already present, the forelimb being more elongated than the hindlimb; the axial condensation in the mesenchymal core of the bud, reflecting the first step towards chondrogenesis, occurs only at the end of this period (see general summary by Sledge, '66).

That the sensitivity of the forelimb bones precedes that of the hindlimb bones was reported previously (Murakami and Kamevama, '65); it reflects the established fact that the hindlimb goes through its initial developmental sequence several hours to a day behind the forelimb.

One interesting finding concerned the differences in the appearance of tibia and fibula between fetuses exposed on the 12th and 13th days (figs. 3, 5). After treatment on the earlier day the two bones were represented by a single, thick, curved bone. On the 13th day, however, they were either absent or were present as separate bones variably reduced in size. From what is known of the histogenesis of these bones (Kochhar, '70), these observations lead us to propose that retinoic acid treatment in the earlier stages alters the cellular activities so as to interfere with the attainment of proper shape by the mesenchymal cell condensations resulting in displacement and gross misshapening of the cartilage models. In the later stages, when the condensations have already appeared, retinoic acid affects the further growth and addition of cells to the condensate resulting in smaller cartilage models and smaller but normal bones.

Grüneberg ('63) describing the early histogenesis of several skeletal mutants, stated that abnormalities of the osseous skeleton were already present in the cartilaginous models and that the gene action was traceable to an even earlier stage of mesenchymal blastemata. Commonly the mesenchymal condensations were reduced in size, and chondrogenesis did not occur in the condensation, which was reduced below a certain critical level. The growth of the mesenchymal condensations was correlated with the growth of the surrounding structures. The mutant gene action which is related to the growth characteristics of the embryonic tissues may thus secondarily result in bone abnormalities. In the light of our results (fig. 1) an unspecific effect of retinoic acid on general embryonic growth in the presence of limb malformations can be ruled out. There was, however, a specific effect on the growth processes within the limb bud, and also a definite effect on the mesenchymal blastemata of bones.

As far as the origin of chondrogenic and myogenic cell types in the limb is concerned, evidence does not support the presence of individual, mutually exclusive progenitor cell populations (Searls, '65; Zwilling, '66). Differences between cell populations are usually sought at the level of biosynthetic properties of the progenitor cells. Cellular properties that set cell types apart from each other may be more advantageously investigated with the use of teratogenic agents. Such studies (Caplan, '70, '72) have extended the previous investigations on the teratogenic properties of nicotinamide-sensitive teratogenic agents on chick limb development (Landauer and Clark, '62). Caplan ('70) re-

ported that the introduction of 3-acetylpyridine, a nicotinamide-antagonist, into a culture of chick limb cells inhibits myogenesis while potentiating chondrogenic expression. In the present study the major effect of retinoic acid was on the limb bones. Although muscle masses were disoriented because of the absence or reduction of bones, they formed thicker than normal sleeves surrounding the deformed bones. However, because of the lack of detailed examination minor effects on muscle development could not be ruled out.

It has become obvious that in order to answer several questions raised in this investigation, the use of an organ culture system will be helpful. Such a system has been devised and is being reported elsewhere (Kochhar and Aydelotte, '73).

Cleft palate

Cleft palate incidence had two peaks, the first after treatment on the 10th day when 68% of the fetuses had the deformity, and the second on the 12th day when virtually all embryos were affected. Based on previous work (Kochhar and Johnson, '65; Kochhar, '68) it is our opinion that the developmental changes responsible for cleft palate on the 10th day differed from those leading to cleft palate on the 12th–15th days. It is conceivable that the earlier-produced type resulted only secondarily to the growth retardation (fig. 1) and other orofacial malformations comprising part of a syndrome. When the heads of these fetuses were examined in coronal sections, the palatal shelves were always hypoplastic and arrested in a vertical position lateral to the tongue. Cleft palate produced by treatment on the 12th–15th days was of a different nature. Facial development and body size were normal except for cleft palate and phocomelia, as has been mentioned above. Although palatal shelves were either vertical (if treated on 12th or 13th day) or horizontal (if treated on 14th or 15th day), they were of normal size. No other gross orofacial anomalies were present. It is thus concluded that this cleft palate was produced as a primary effect on some factor residing in the palatal shelves themselves, such as changes in the intra- or extracellular components of the mesenchymal or epithelial tissues comprising the shelves. Of course, our observation did not rule out any unidentifiable effect on other organs of the oral cavity that may hinder the shelves from approaching each other.

ACKNOWLEDGMENTS

The skillful technical assistance of Mrs. Cleve Mohler, Miss Sharon Bucher, Miss Suzanne Riebe, and Mrs. Jane Svenson is gratefully acknowledged.

LITERATURE CITED

Caplan, A. I. 1970 Effects of the nicotinamide-sensitive teratogen 3-acetylpyridine on chick limb cells in culture. Exp. Cell Res., 62: 341–355.

——— 1972 The effects of the nicotinamide-sensitive teratogen 6-aminonicotinamide on chick limb cells in culture. Exp. Cell Res., 70: 185–195.

DeLuca, H. F., and A. B. Roberts 1969 Pathways of retinoic acid and retinol metabolism. Am. J. Clin. Nutr., 22: 945–952.

Grüneberg, H. 1963 The pathology of development. A study of inherited skeletal disorders in animals. Blackwell, Oxford.

Hamburger, V., and H. L. Hamilton 1951 A series of normal stages in the development of the chick embryo. J. Morph., 88: 49–92.

Kochhar, D. M. 1967 Teratogenic activity of retinoic acid. Acta Path. Micr. Scand., 70: 398–404.

——— 1968 Studies of vitamin A-induced teratogenesis. Effects on embryonic mesenchyme and epithelium, and on incorporation of thymidine-^{3}H. Teratology, 1: 299–310.

——— 1969 Localized factors responsible for teratogenic response of appendicular skeleton. Teratology, 2: 263 (abst.).

——— 1970 The role of altered metabolism of glycosaminoglycans in the production of experimentally produced congenital malformations. In: Symposium on Metabolic Pathways in Mammalian Embryos During Organogenesis and its Modification by Drugs. Free University Press, Berlin.

Kochhar, D. M., and M. B. Aydelotte 1971 Limb development in organ culture after transplacental exposure of mouse embryos to retinoic acid. Teratology, 4: 233–234 (abst.).

——— 1973 Limb development in mouse embryos. II. Experimental phocomelia and micromelia in organ culture after transplacental exposure to retinoic acid. Dev. Biol. in press.

Kochhar, D. M., and E. M. Johnson 1965 Morphological and autoradiographic studies of cleft palate induced in rat embryos by maternal hypervitaminosis A. J. Embryol. Exp. Morph., 14: 223–238.

Landauer, W., and E. M. Clark 1962 The interaction in teratogenic activity of the two niacin analogs 3-acetylpyridine and 6-aminonicotinamide. J. Exp. Zool., 151: 253–258.

Murakami, U., and Y. Kameyama 1965 Malformations of the mouse fetus caused by hyper

vitaminosis-A of the mother during pregnancy. Arch. Env. Hlth., *10*: 732–741.

Searls, R. L. 1965 An autoradiographic study of the uptake of ^{35}S-sulfate during the differentiation of limb bud cartilage. Dev. Biol., *11*: 155–168.

Shenefelt, R. E. 1972 Morphogenesis of malformations in hamsters caused by retinoic acid. Relation to dose and stage of treatment. Teratology, *5*: 103–118.

Sledge, C. B. 1966 Some morphologic and experimental aspects of limb development. Clin. Orthop., *44*: 241–264.

Wilson, J. G. 1964 Embryological considerations in teratology. In: Teratology: Principles and Techniques. J. G. Wilson and J. Warkany, eds. Univ. of Chicago Press, Chicago.

Witschi, E. 1962 Development: rat. II. Tissues and organs. In: Growth, Including Reproduction and Morphological Development. P. L. Altman and S. Dittmer, eds. Federation of American Societies For Experimental Biology, Washington, D. C., 306–313.

Zwilling, E. 1966 Cartilage formation from so-called myogenic tissue of chick embryo limb buds. Ann. Med. Exp. Biol. Fenn., *44*: 134–319.

PLATE 1

EXPLANATION OF FIGURES

2–7 Alizarin red-S stained representative right limbs from retinoic acid-treated animals. In each figure the forelimb is on the left and the hindlimb of the same embryo on the right. × 5.

2–4 Retinoic acid treatment on 12th day. Limbs go through a less reactive stage (2, forelimb micromelic and hindlimb normal) to a very susceptible stage (3, 4, forelimb phocomelic and hindlimb increasingly reactive).

5–7 Retinoic acid treatment on 13th day. Forelimbs almost normal but hindlimb variably defective (5, 6). Radius susceptible even at later stages when hindlimb bones lose their susceptibility (7).



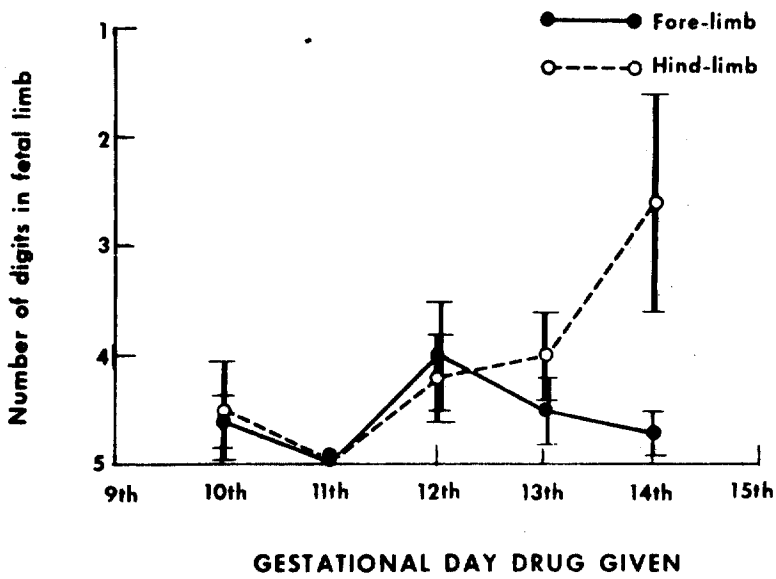

Fig. 8 Variations in the reduction anomalies of the digits after retinoic acid-treatment on different days of gestation. Standard deviations on each day are indicated by the vertical bars.

Krasits ka- 71
Bib. No. 10655

Farm. Zh. (Kiev), 26(6): 71-72, 1971.

TERATOGENICITY OF HYPERVITAMINOSIS AND HYDROCORTISONE UNDER CONDITIONS OF EXPERIMENTAL HYPOTHYREOSIS OF THE MATERNAL ORGANISM

O. P. Krasits'ka, L'vov Medical Institute

In the medical literature, pharmacology is widely discussed, concerning the organism, for such biologically active substances as vitamin A and hydrocortisone. Then there are such isolated studies as those investigating the joint action of vitamin A and hydrocortisone on the development of pregnancy (2-4, 8). Pharmacological preparations are indicated which are not harmful to the maternal organism, but they may destroy normal embrye development. Therefore, it evokes certain interest to explain the effect of vitamin A together with hydrocortisone (as teratogenic factors) on the development of breeding animals. It is likewise evident that hormonal discorrelations of the thyroid gland in the pregnant organism unfavorably affect embryogenesis (1, 5-7). However we could find no data in the literature available to us on the sensitivity of embryos which develop under conditions of decreased concentrations of the thyroidal hormone in the maternal organism. We did a study on the effect of hydrocortisone with vitamin A on the development of the palate in breeding animals during the course of a normal pregnancy, and also during experimental hypothyreosis in the maternal organism.

The objects chosen for the study were sexually mature, female, white, non-strain rats. 10 rats were chosen for every series of the studies. The state of hypothyreosis was created by daily administration of 6-methyl-thiouracil in doses of 15 mg per 100 g animal weight for 10 days before coupling and every day of the pregnancy. Vitamin A was administered at 75,000 osmotic pressure until the appearance of an oily solution in the stomach, observed using a probe, in the 13th and 14th days of pregnancy. Hydrocortisone was administered subcutaneously in 2.5-ml doses on the same day of pregnancy. The control was animals of the same species which did not differ in weight or age from the experimental animals. All the animals were kept under the same conditions and received the standard ration. The results of the study were calculated over 20 days of pregnancy. Then the breeders were weighed, and the upper jaw was removed and studied in detail using MBS-1 equipment.

In all, four series of studies were done. In the first series, the effect of hypothyreosis in the pregnant animal on embryogenesis was studied. Animals in the second series, except for those receiving 6-methyl-thiouracil daily, received vitamin A and hydrocortisone in the higher indicated dosages on the 13th and 14th days of pregnancy. The rats on which the third series of studies was done received the same dosages of vitamin A and hydrocortisone on the same day. The fourth group of animals remained intact.

For the state of hypothyreosis, conclusions were drawn on the basis of variations in base exchange, structural studies, and the histopathology of the thyroid gland. In the control group of animals, base exchange gradually increased up to the 7th day of pregnancy, i.e. up until the moment of implantation. Maximum increase in base exchange at that moment was 12%, in comparison to the 1st day. Up to the 11th day, base exchange decreased, but it did not reach the level of the 1st day. Another sharp increase was observed on the 15th day of pregnancy, i.e. at the moment of the completion of placentation,

it was 16.5%. On every one of the remaining days of pregnancy, base exchange gradually decreased.

In the animals which received vitamin A and hydrocortisone, there were no changes in the dynamics of base exchange in comparison to the control group.

In the course of the whole pregnancy in the hypothyroid animals which received vitamin A along with hydrocortisone, base exchange increased. The maximum increase in oxygen absorption at the moment of implantation was 18.3%, and at the moment of placentation 27%.

Cleft palate was found in 28% of the breeding animals, in mothers which received vitamin A and hydrocortisone. In animals which received vitamin A and hydrocortisone against a background of experimental hypothyreosis, clefts were found in 84%. In the controls and in the animals which received only 6-methyl-thiouracil, no local defects of the palate occurred.

In the animals under study, the weight of the thyroid gland was indicated. The mean weight of the gland in animals which received 6-methyl-thiouracil was 79 g vs. 15.4 g in the controls. In animals which received 6-methyl-thiouracil and vitamin A along with hydrocortisone, the weight of the thyroid gland increased to 36.7 g.

The mean number of breeding animals in the intact and hypothyroid groups was 8.2. In rats which received teratogenic agents, the average number of breeders was a little less, at 7.5. Differences in the weights of the control breeders and breeders with innate cleft palate did not occur.

Conclusions

1. Administration of vitamin A and hydrocortisone to white rats on the 13th and 14th days of pregnancy causes disruption in the formation of the palate in breeding animals.

2. Teratogenicity of vitamin A and hydrocortisone against a background of experimental hypothyreosis of the maternal organism is expressed significantly more strongly, and it is lower in animals with normal function of the thyroid gland.

Literature Cited

1. Detyuk, E. S., Diss., L'vov (1966).
2. Keval', A. V., Stomatologiya, No. 6 (1966), 31.
3. Letosh, E. A., Ibid., No. 5 (1965), 30.
4. Ibid., No. 2 (1966), 89.
5. Palenkova, N. G., Byulleten' Eksperimental'noy Biologii i Meditsiny, 35, No. 7 (1962), 111.
6. Teresa, S. I., Ibid., 7, No. 6 (1939), 556.
7. Yankova, M. F., Problemy Endokrinologii i Gormonoterapii, 7, No. 3 (1961), 84.
8. Abramonovich, A., F. C. Devoto, Rev. Soc. Argent. Biol., 43, Nos. 5-8 (1967), 121.

Krasits'ka-'71
Bib. No. 10655

Farm. Zh. (Kiev), 26(6): 71-72, 1971.

УДК 616.441-008.61.08+615.357+616.391.01

ТЕРАТОГЕННА ДІЯ ГІПЕРВІТАМІНОЗУ А І ГІДРОКОРТИЗОНУ В УМОВАХ ЕКСПЕРИМЕНТАЛЬНОГО ГІПОТИРЕОЗУ МАТЕРИНСЬКОГО ОРГАНІЗМУ

О. П. КРАСИЦЬКА
Львівський медичний інститут

В медичній літературі широко висвітлюється фармакологічна дія на організм таких біологічно активних речовин, як вітамін А і гідрокортизон. Проте зустрічаються тільки поодинокі дослідження, які присвячені вивченню сумісної дії вітаміну А і гідрокортизону на перебіг вагітності (2—4, 8). Вказані фармакологічні препарати є малошкідливими для організму матері, але вони можуть порушувати нормальний ембріональний розвиток. Тому певну зацікавленість викликає вияснення впливу вітаміну А з гідрокортизоном (як тератогенних факторів) на розвиток плодів. Відомо також, що гормональні дискореляції щитовидної залози в організмі вагітної несприятливо впливають на ембріогенез (1, 5—7). Проте в доступній нам літературі даних про чутливість ембріонів, які розвиваються в умовах пониженої концентрації тиреоїдного гормону в материнському організмі, знайти не вдалося. Тому нами зроблена спроба вивчити вплив гідрокортизону з вітаміном А на розвиток піднебіння плодів при нормальному протіканні вагітності, а також при експериментальному гіпотиреозі материнського організму.

Об'єктом досліджень вибрані статевозрілі самки білих нелінійних щурів. Для кожної серії дослідів взято по 10 щурів. Стан гіпотиреозу створювався щоденним введенням 6 МТУ в дозі 15 *мг* на 100 *г* ваги тварини за 10 днів до злучки і під час всіх днів вагітності. Вітамін А вводили по 75 000 ОД у вигляді масляного розчину в шлунок зондом на 13 і 14 день вагітності. Гідрокортизон вводили підшкірно по 2,5 *мл* в ці ж самі дні вагітності. Контролем були тварини аналогічного виду, які не відрізнялися за вагою і віком від експериментальних тварин. Всі тварини перебували в однакових умовах, одержували повноцінний корм. Результати досліджень враховували на 20 день вагітності. При цьому плоди зважували, верхні щелепи відділяли і детально вивчали за допомогою «МБС-1».

Усього поставлено 4 серії дослідів. В 1 серії вивчався вплив гіпотиреозу вагітної тварини на ембріогенез. Тваринам 2 серії, крім щоденного введення 6 МТУ, вводили вітамін А і гідрокортизон у вищевказаних дозах на 13 і 14 день вагітності. Щури, на яких провадилась 3 серія досліджень, одержували в ці ж дні і в цих же дозах вітамін А з гідрокортизоном. 4 група тварин була інтактною.

Про стан гіпотиреозу робили висновок на основі змін основного обміну, вивчення структури і гістофізіології щитовидної залози. У контрольної групи тварин основний обмін поступово зростав до 7-го дня вагітності, тобто до моменту імплантації. Максимальне збільшення основного обміну в цей момент в порівнянні з першим днем становило 12 %. До 11-го дня основний обмін знижувався, але не досягав рівня першого дня. Друге різке підвищення спостерігалося на 15-й день вагітності, тобто в момент завершення плацентації, і становило 16,5%. В усі останні дні вагітності основний обмін поступово знижувався.

У тварин, які одержували вітамін А і гідрокортизон, ніяких змін в динаміці основного обміну в порівнянні з контрольною групою не було.

На протязі всієї вагітності у гіпотиреоїдних тварин, які одержували вітамін А з гідрокортизоном, основний обмін підвищувався. Максимальне збільшення споживання кисню в момент імплантації дорівнювало 18,3%, а в момент плацентації — 27%.

Розщілини були знайдені в 28% плодів, матерям яких вводили

вітамін А і гідрокортизон. У тварин, яким вводили вітамін А і гідрокортизон на фоні експериментального гіпотиреозу, розщілини були знайдені у 84%. У контролі і у тварин, які одержували тільки 6 МТУ, ніяких локальних дефектів піднебіння не виявлено.

У піддослідних тварин визначали вагу щитовидної залози. Середня вага залози у тварин, які одержували 6 МТУ, була 79 *г* при 15,4 *г* в контролі. У тварин, які одержували 6 МТУ і вітамін А з гідрокортизоном, вага щитовидної залози збільшувалася до 36,7 *г*.

Середня кількість плодів в інтактній і гіпотиреоїдній групах становила 8,2. В щурів, які одержували тератогенні агенти, кількість плодів була дещо меншою і становила 7,5. Різниці у вазі контрольних плодів і плодів з вродженими розщілинами піднебіння не було виявлено.

ВИСНОВКИ

1. Введення вітаміну А і гідрокортизону на 13 і 14 дні вагітності білим щурам супроводжується порушенням формування піднебіння у плодів.

2. Тератогенна дія вітаміну А і гідрокортизону на фоні експериментального гіпотиреозу материнського організму виражена значно сильніше, ніж у тварин з нормальною функцією щитовидної залози.

ЛІТЕРАТУРА

1. Детюк Е. С., Дисс., Львов, 1966.— 2. Коваль А. В., Стоматология, 1966, № 6, 31.— 3. Лотош Е. А., там же, 1965, № 5, 30.— 4. Лотош Е. А., там же, 1966, № 2, 89 — 5. Паленкова Н. Г., Бюллетень экспериментальной биологии и медицины, 1962, 53, 7, 111.— 6. Тереза С. И., там же, 1939, 7, 6, 556.— 7. Янкова М. Ф., Проблемы эндокринологии и гормонотерапии, 1961, 7, 3, 84.

8. Abramonivich A., Devoto F. C., Rev. Soc argent. biol., 1967, 43, 5—8, 121.

Надійшло 15.IX 1971 р.

Arch, Pathol. 96(1):5-9, 1973

Leelapeute'73
Bib. No. 10677

Reproduced by permission
of the copyright owner

Hypervitaminosis A in Rats

Varying Responses Due to Different Forms, Doses, and Routes of Administration

Vichade Leelaprute, DDS, MS, Vijitr Boonpucknavig, MD; Natth Bhamarapravati, MD, DSc; Waranut Weerapradist, DDS, MS, Bangkok, Thailand

A study made on rats after excessive vitamin A treatment showed that the mortality, bone lesions, and calcification of organs are related to at least three factors, ie, forms of vitamin A (vitamin A palmitate or vitamin A alcohol), doses (25,000, 50,000, and 75,000 international units (IU)/rat/day), and routes of administration (intraperitoneal or oral). In rats that received vitamin A palmitate by intraperitoneal route, there was no clinical toxicity, no bone lesion, nor soft tissue calcification, but oral administration of vitamin A palmitate of the same dose produced clinical toxicity with bone lesion and soft tissue calcification. Clinical toxicity, bone damage, and tissue calcification developed in animals that received vitamin A alcohol by both routes. The intraperitoneal administration produced more toxicity and more tissue damage in rats than the oral administration.

Chronic hypervitaminosis A intoxication in infants and young children has been reported by Caffey[1] and Gribetz et al[2] and in adults by Gerber et al.[3] The minimal preclinical period of vitamin A poisoning was about six months and the minimal toxic daily dose was about 75,000 units.[1] Acute poisoning in man due to the ingestion of a large single dose of vitamin A is rare. In vitro experimental studies have shown that vitamin A has a direct action on membrane permeability of organelles such as rat liver lysosomes[4] or rat liver mitochondria[5,6] and on cultured bone tissue.[7,8] In vivo experimental studies of hypervitaminosis A have been made by several investigators.[9-11]

In order to define the factors involving the mechanism of injury in hypervitaminosis A, the present study was designed to evaluate the effect of different forms of vitamin A in rats, using different routes of administration and different doses. The severity of clinical toxicity and tissue changes reported by different investigators were compared.

Fig 1.—Hypervitaminosis A rat (group five). X-ray films of whole rat. Multiple foci of radiolucency of bones. Note resorption of fibula (arrows).



Accepted for publication Jan 31, 1973.

From the Department of Pathobiology, Faculty of Science and Department of Pathology, Faculty of Medicine, Ramathibodi Hospital, Mahidol University, Bangkok, Thailand. Dr. Leelaprute is now at the Department of Dental Pathology, Faculty of Dentistry, Chulalongkorn University, Bangkok, Thailand.

Reprint requests to Department of Pathology, Faculty of Medicine, Ramathibodi Hospital, Rama VI Rd, Bangkok, Thailand (Dr Bhamarapravati).

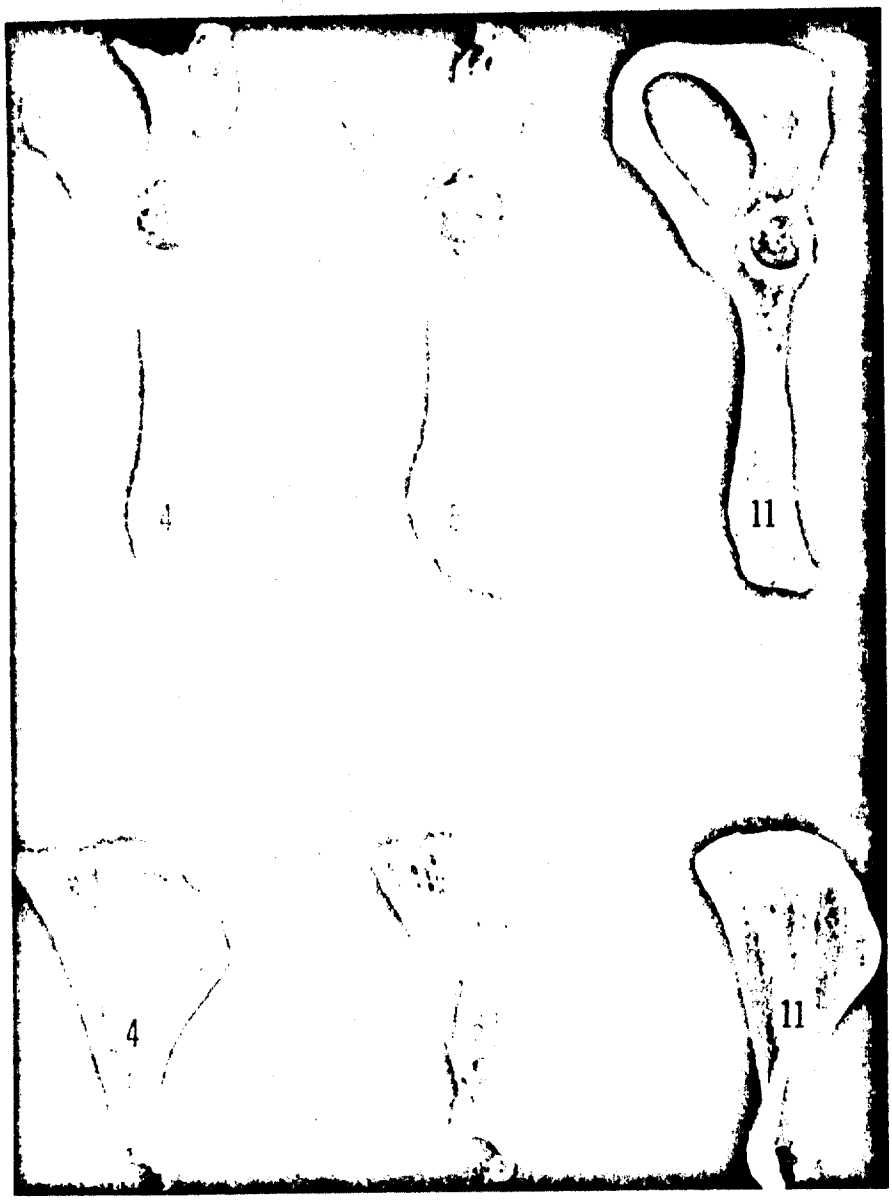

Fig 2. – Scapulae and pelvic bones show varying degree of osteoporosis and resorption. Most severe damage occurs in animal group five (intraperitoneal, vitamin A alcohol). Numbers indicate experimental group.

Group	Form of Vitamin A	Route†	Dose IU/Rat
1	Palmitate	IP	50,000
2	Palmitate	IP	75,000
3	Palmitate	O	50,000
4	Palmitate	O	75,000
5	Alcohol	IP	25,000
6	Alcohol	IP	50,000
7	Alcohol	O	25,000
8	Alcohol	O	50,000
9	Alcohol	O	75,000
10	Corn oil	IP	0.5 ml r.
11	Control	Untreated	. .

Fig 3. – Cross section through diaphyseal cortex of tibia shows osteoporosis and erosion of periosteal surface. Group five (hematoxylin-eosin, original magnification × 100).

Materials and Methods

Female albino rats, with an average initial body weight of 146.5 gm (range, 108 to 185 gm), were used in this experimental series. All of the rats were divided randomly into 11 groups of ten animals each. Because vitamin A palmitate is dissolved in corn oil at a very high concentration, we further diluted the preparation with corn oil to make the final concentration of 100,000 units of vitamin A palmitate/1 ml. Vitamin A alcohol (retinol) was obtained from a pharmaceutical company. The experimental grouping is shown in the Table. The last two groups served as control groups. The tenth group received corn oil intraperitoneally in the dose of 0.5 ml/rat/day for 16 consecutive days. The 11th group was the untreated control group. All of the rats were weighed individually on the beginning day of the experiment and on the 17th day or on the day the rats were killed. The animals were housed in individual steel cages and were maintained on commercial laboratory chow and tap water ad libitum. On the last day of the vitamin A treatment, all surviving rats were housed in individual metabolic cages for collection of urine for calcium determination by the calcium edetic acid tritration method.[12] On the day following the last day of vitamin A treatment, all surviving rats were killed with (anesthetic) ether. Blood was taken from the heart for the determination of serum calcium by the method of Bett and Fraser.[12] Total serum protein was examined by refractometer and serum albumin was determined by cellulose acetate electrophoresis. X-ray films were taken of all animals that were killed or had died. Scapulae, humerus, femurs, tibias, and pelvic girdles were dissected, evaluated grossly, and fixed in Zenker-formaldehyde solution

Comparison and Summary of the Results*

ortal-ity	Body Weight (% Change)	Microscopic Calcification of Organs				Gross Bone Changes	Serum†			Urine Calcium, mg/100 ml
		Kidneys	Heart	Lungs	Liver		Protein, gm/100 ml	Albumin, gm/100 ml	Calcium, mg/100 ml	
0/10	+37.47	0/10	0/10	0/10	0/10	0/10	6.97 (7)	2.60 (7)	8.91 (7)	9.16 (7)
0/10	+40.16	0/10	0/10	0/10	0/10	0/10	7.08	3.67	9.59	10.17
0/10	− 0.11	0/10	0/10	0/10	0/10	0/10	5.25	1.75	6.87	58.18
6/10	−18.08	4/10	1/7	3/10	0/10	10/10	4.7	1.11	5.87	68.2
5/10	−36.79	6/10	2/10	2/10	0/10	10/10	5.7 (4)	1.3 (4)	18.88 (4)	ND
0/10	−25.2	10/10	1/7	3/7	1/10	10/10	ND§	ND§	ND§	ND
0/10	− 2.02	0/10	0/10	0/10	0/10	0/10	4.45	1.26	8.66	10.06
7/10	−15.18	1/10	1/10	1/10	7/10	5/10	3.36 (4)	0.73 (4)	10.07 (4)	12.33 (4)
8/10	−22.15	2/10	2/10	0/10	9/10	7/10	3.2 (4)	0.4 (4)	9.01 (4)	19.00 (4)
0/10	−12.29	0/10	0/10	0/10	0/10	0/10	6.76	2.65	8.91	13.27
0/10	+24.6	0/10	0/10	0/10	0/10	0/10	6.79	2.42	8.51	9.69 (5)

*All rats were killed on the 17th day. Data include both living and dead rats.
†IP indicates intraperitoneal administration; O, oral administration.
‡Number in parentheses indicates the number of samples used.
§ND indicates not done because of hemolysis of blood samples.
¶ND indicates not done because urine could not be obtained.

for histologic examination. Tissues from heart, lung, liver, and kidney were fixed in 10% buffered formaldehyde solution, embedded in paraffin, sectioned and stained with hematoxylin-eosin, and by the von Kossa method for calcium deposits in the soft tissues.

Results

The toxic effects of different forms of vitamin A given at different doses and by different routes are shown in the Table. The rats of groups three, four, five, six, eight, and nine developed signs of vitamin A toxicity such as epilation, bent and limping posture, and bleeding around the nose and eyes, while animals in groups one, two, and seven exhibited only some inactivity. Most of the animals receiving vitamin A alcohol intraperitoneally developed severe oliguria (group five) and anuria (group six).

X-ray Film Findings.—Osseous lesions are not observed radiographically in the control rats, in the rats given corn oil intraperitoneally (group six), nor in the experimental animal groups one, two, and seven. The other experimental animals manifested radiolucency and thinning of long bones of extremities, pelvic girdles, scapulae, and spinal bones. The almost complete resorption of the fibula was demonstrable in animal groups four, five, and 6 (Fig 1).

Fig 4.—Kidney shows calcification of tubular epithelial cells with calcium concretion in tubular lumens. Group four (von Kossa stain, original magnification × 100).

Gross Findings of Bones.—The scapula, pelvic girdle, tibiofibula, and humerus of the animals in groups three, four, five, six, eight, and nine showed moderate to severe osteoporosis and thinning of bones. Resorption of parts of pelvic bones, fibulae, and scapulae were seen in animals in groups four, five, and six (Fig 2). There was no gross lesion of bone in untreated control rats, in the rats that received corn oil intraperitoneally, nor in group one experimental animals.

Microscopic Findings.—The general appearances of the bones (scapula, humerus, femur, and tibia), kidney, heart, lung, and liver of the animals in groups one, two, seven, and ten are not different from those of normal control (untreated) animals. The numbers of the animals that had calcification of the internal organs are

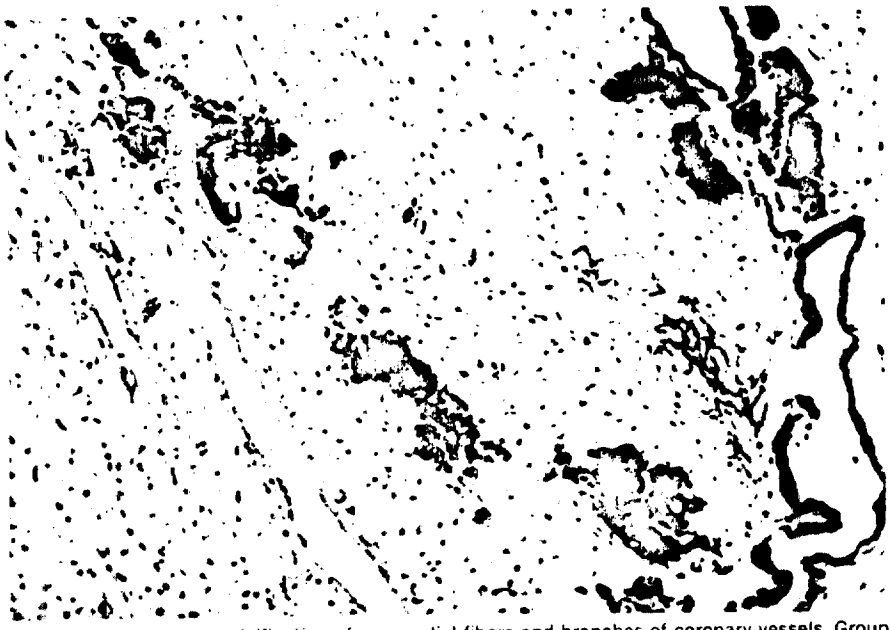

Fig 5.—Heart shows calcification of myocardial fibers and branches of coronary vessels. Group four (von Kossa stain, original magnification × 100).



Fig 6.—Lung shows calcification in alveolar walls. Group four (von Kossa stain, original magnification × 100).

shown in the Table.

Bone.—Cross and longitudinal sections were taken through the epiphyseal, metaphyseal, and diaphyseal areas of long bones (humerus, femur, and tibia) and pelvic girdles. The inner surface of the diaphyseal cortex become more attenuated by enlargement of the haversian canals until they appear spongiotic (Fig 3). The periosteal surface is irregularly eroded by demineralization. Typical findings of the epiphyseal line and subepiphyseal metaphyses are characterized by thinning of the epiphyses with irregularity of the line of ossification. The cancellous tissue of the metaphyses is demineralized, thin, and fragmented. There is no increase in the number of osteoclasts.

Kidneys.—The deposition of calcium in the tubules in association with tubular epithelial cell damage is more severe in animal groups five and six (vitamin A alcohol, intraperitoneally) than in animal groups three, four, eight, and nine (vitamin A palmitate or alcohol, orally). The calcification either appears as coarse calcific granules in proximal tubular epithelial cells or as concretions in the lumen (Fig 4). They sometimes appear as linear deposition along the basement membrane of the Bowman capsule or the basement membrane of the proximal tubules. Some collecting tubules of both cortical and medullary portions contained calcific concretions. Calcification of the wall of renal vessels is not present. In addition to the calcification of the renal parenchym, severe necrosis of the renal cortical tubules occurs in animals in groups five and six (vitamin A alcohol, intraperitoneally).

Heart.—The degree of calcification and degeneration of myocardium and its vasculature varies between two affected groups. Animals receiving vitamin A alcohol intraperitoneally (groups five and six) show more severe changes than animals receiving vitamin A palmitate orally (group four). The calcified myocardial fibers are noted around or near the dilated, calcified wall of the coronary veins (Fig 5).

Lungs.—Calcification occurs in animal groups three, four, five, and six in varying degrees. The animals that received vitamin A alcohol intraperitoneally show more calcification than animals that received vitamin A palmitate orally. The calcium granules are mainly located in the alveolar walls (Fig 6), and there is no obvious lesion in the parenchymal tissue. Some alveolar spaces contain clusters of calcium granules and edematous fluid. No calcification of walls of vascular structures is demonstrated.

Liver.—There is severe calcification of the liver in animals of groups eight and nine (vitamin A alcohol, orally) and to a lesser extent in one animal of group six (vitamin A alcohol, intraperitoneally). Coarse granules of calcium are confined mainly in the sinusoids. Calcified and necrotic Kupffer cells are seen throughout the involved area (Fig 7).

Comment

This study indicates that rats can be rendered toxic, and show damage and calcification of tissue by either forms of vitamin A, should the doses

or route of administration, or both, be adjusted accordingly. Vitamin A palmitate given intraperitoneally (groups one and two) produced neither clinical toxicity nor bone damage nor soft tissue calcification, while oral administration of the same form of the vitamin (groups three and four) resulted in clinical toxicity, bone rarefaction, and calcification of organs. Vitamin A alcohol given either orally or intraperitoneally produced toxicity, bone lesions, and tissue calcification. The severity of toxicity and tissue damage was dose-dependent in rats that received the same form of vitamin A and by the same route.

The transformation and transportation of vitamin A palmitate has been well established.[13-15] By oral route, vitamin A palmitate is hydrolyzed and re-esterified in the intestine and transported via lymphatic or venous systems in esterified form to the liver. In the liver, it is further hydrolyzed to alcohol form and transported to other organs by the blood stream. In groups one and two (vitamin A palmitate, intraperitoneal), the levels of serum calcium and urinary calcium are slightly higher than in the control group. This suggests the possibility that the relatively smaller amount of vitamin A palmitate given via the peritoneal route may be absorbed and transported to the liver and transformed into active form. This small amount of active form would affect the release of calcium from bone into the serum, but the level of serum calcium may not be high enough to cause tissue calcification, and, consequently, this elevated amount of calcium is excreted into the urine.

It is known that a major portion of the calcium in plasma is bound to protein, especially albumin.[16] Low calcium in serum and high calcium in urine of animal groups three and four may be explained by the low level of total serum protein due to the low dietary intake as reflected by the loss of body weight.

Our conclusion appears to be different from that of Strebel et al.[11] They reported that animals receiving vitamin A palmitate, intraperitoneally or orally, manifested similar bone damage, but only animals that received vitamin A palmitate by intraperitoneal route showed renal and cardiovascular calcification. They concluded that excessive dose of vitamin A palmitate, given by intraperitoneal route, acted directly on heart, vessels, and kidneys.



Fig 7.—Liver shows calcification of Kupffer cells and deposition of calcium granules in sinusoids. Group two (von Kossa stain, original magnification × 252).

It is still not possible to explain the difference in predilection for calcification in different organs. The cardiovascular calcification could be affected by either route of administration. Calcification in the liver occurred only in animals receiving vitamin A alcohol and was particularly severe in animals receiving this form of vitamin orally. Our findings concerning vitamin A palmitate are somewhat similar to those of Thomas et al.[10] They concluded that parenteral administration of vitamin A palmitate was less effective than was oral administration.

This investigation was supported by a Rockefeller Foundation training grant given to the Faculty of Science, and by a Graduate Fellowship of the Faculty of Graduate Studies of Mahidol University, Bangkok, Thailand.

A part of this work was used as a dissertation by Dr. Leelaprute in partial fulfillment for the requirement for a master of science degree in Experimental Pathology of Mahidol University.

References

1. Caffey J. Chronic poisoning due to excess of vitamin A. *Am J Roentgenol Radium Ther Nucl Med* 65:12-26, 1951.

2. Gribetz D, Silverman S, Sobel AE: Vitamin A poisoning. *Pediatrics* 7:372-385, 1951.

3. Gerber A, Raab AD, Sobel AE: Vitamin A poisoning in adults. *Am J Med* 16:729-745, 1954.

4. Dingle JT, Lucy JA: Studies on the mode of action of vitamin A: II. The release of a bound protease by the action of vitamin A, abstracted. *Biochem J* 78:11, 1961.

5. Dingle JT: Studies on the mode of action of vitamin A: III. Release of a bound protease by the action of vitamin A. *Biochem J* 79:509-512, 1961.

6. Lucy JA, Luscombe M, Dingle JT: Study on the mode of action of excess vitamin A. VIII. Mitochondrial swelling. *Biochem J* 89:419-425, 1963.

7. Fell HB, Mellanby E: The effect of hypervitaminosis A on embryonic limb-bones cultivated in vitro. *J Physiol* 116:320-349, 1952.

8. Fell HB, Lucy JA, Dingle JT: Studies on the mode of action of vitamin A: I. The metabolism, composition and degradation of chick-limb cartilage in vitro, abstracted. *Biochem J* 78:11, 1961.

9. Clark I, Basset CAL: The amelioration of hypervitaminosis D in rats with vitamin A. *J Exp Med* 115:147-155, 1962.

10. Thomas L et al. Comparison of the effects of papain and vitamin A on cartilage: I. The effects in rabbits. *J Exp Med* 111:705-718, 1960.

11. Strebel RF, Girerd RJ, Wagner BM: Cardiovascular calcification in rats with hypervitaminosis A. *Arch Pathol* 87:290-297, 1969.

12. Bett IM, Fraser GP: A rapid micro method for determining serum calcium, abstracted. *Biochem J* 68:13, 1958.

13. Lawrence CW et al: Absorption, transport and storage of retinyl-15-^{14}C palmitate-9, 10-^{3}H in the rat. *J Lipid Res* 7:226-229, 1966.

14. John KV, Lakshmanan MR, Canal HR: Absorption, storage and distribution of 3,4-dehydrovitamin A in the rat. *Biochem J* 99:312-316, 1966.

15. Plack AC: Occurrence, absorption, and distribution of vitamin A: Symposium of the Nutrition Society on vitamin A, March 12, 1965. *Proc Nutr Soc* 24:146-153, 1965.

16. Fourman P, Roger P: *Calcium Metabolism and the Bone*. Oxford, Blackwell Scientific Publications, 1968, pp 3-64.

Bib. No. 10698

Byull. Eksp. Biol. Med. 62: 1297-1299, 1966.

HYPERVITAMINOSIS A IN PREGNANT MICE OF LINE C3HA AND DEVELOPMENTAL ANOMALIES OF THE PALATE AND JAWS IN THEIR OFFSPRING

E. A. Lotosh

UDC 616.315+616.716.8]-007.2-053.1-056.716:616.391.01:577.161.11

Cohlan [1] reported that administration of large doses of vitamin A to pregnant rats leads to the development of cleft palates and anomalies of the upper jaw in some of the surviving embryos. In subsequent investigations [2, 3, 6] it was found that administration of large doses of vitamin A to pregnant rats and mice by mouth for several days or as a single dose causes various anomalies of the facial skull in the embryos, especially cleft palates. Although several investigations have revealed the teratogenic action of vitamin A on the primitive palate and jaws, the periods of development at which the primitive palate and jaws are maximally vulnerable to this agent have not been sufficiently studied.

The object of the present investigation was to determine the periods of development of the primitive palate and jaws of mouse embryos of line C3HA with maximal vulnerability during hypervitaminosis A.

EXPERIMENTAL METHOD

The beginning of pregnancy was determined from the appearance of a vaginal plug. From the 7th to the 14th day of pregnancy a vitamin A concentrate was given by mouth in a single dose of 35,000 i.u. The results were read on the 17th day of development. Under ether anesthesia, the fetuses were extracted from the uterus and studied while alive. The embryos were fixed with Bouin's fluid and then transferred to 70° alcohol. To determine the incidence of cleft palate in the embryos, the lower jaw and tongue were removed, so that the state of the palate could be examined. Altogether 57 mice (567 fetuses) were used as experimental animals and 20 mice (177 fetuses) as controls.

EXPERIMENTAL RESULTS

After administration of vitamin A in a single dose of 35,000 i.u. to the pregnant females, 66.8% of the embryos were found to have cleft palates, 14% anomalies of the upper jaw, and 60.3% anomalies of the lower jaw. All the embryos died after administration of vitamin A on the 7th day of development. After its administration on the 8th day of development 98.5% of the embryos died, and one survivor had developmental anomalies of the jaws and cleft palate. After administration of vitamin A on the 9th day of development cleft palate and developmental anomalies of the lower jaw were found in 88.8% of the surviving embryos and developmental anomalies of the upper jaw in 100%. When vitamin A was given on the 10th day, two types of cleft palate were found in 36 of the 50 surviving embryos: in 16% the palate was cleft throughout its length and in 56% the cleft was in its posterior part (see figure, c). Clefts of the palate situated in its posterior part were segregated as a special type of developmental anomaly in accordance with the data of Warkany and co-workers [7]. Developmental anomalies of the upper jaw were found in 38% of the living embryos, and anomalies of the lower jaw (see figure, d) in 72%; in some of them the lower jaw was absent or was almost vestigial. When vitamin A was given on the 11th day of development, cleft palates were found in 83.5% of the living embryos (see figure, b) and developmental anomalies of the lower jaw in 72.5%. After administration on the 12th day of development, cleft palate was found in 95.6% of the living embryos and was combined in every case with developmental anomalies of the lower jaw. Administration of a single dose of 35,000 i.u. vitamin A to the pregnant female on the 13th day caused development of cleft palate in 25.4% of the living embryos and developmental anomalies of the lower jaw in 7.2%. After administration of vitamin A on the 14th day of development, cleft palate was present in 12.5% of the living embryos.

Division of Embryology, Institute of Experimental Medicine, Academy of Medical Sciences of the USSR, Moscow (Presented by Active Member of the Academy of Medical Sciences of the USSR D. A. Biryukov). Translated from Byulleten' Éksperimental'noi Biologii i Meditsiny, Vol. 62, No. 11, pp. 96-98, November, 1966. Original article submitted June 7, 1965.

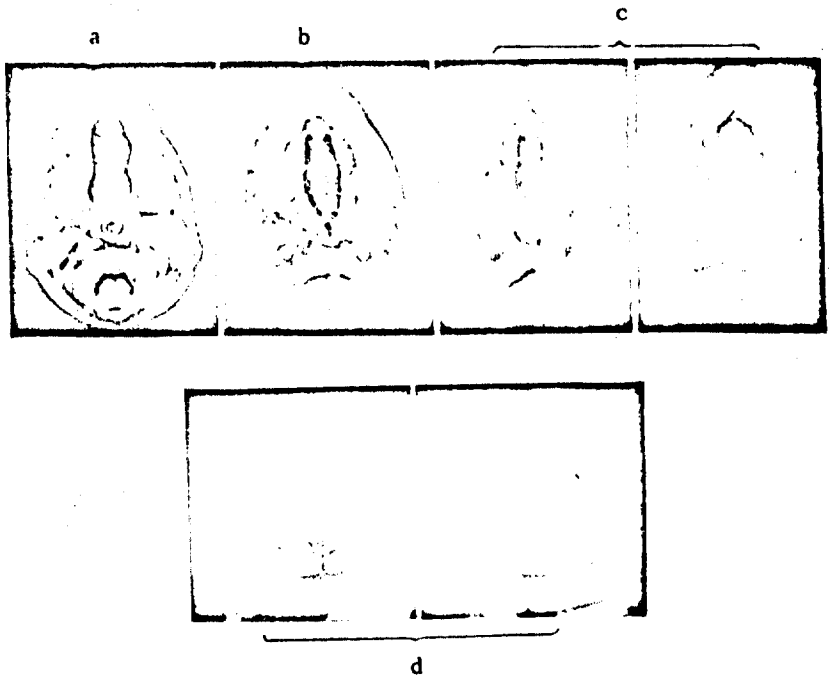

Character of lesion of the palate and lower jaw in 17 day embryos of mothers with hypervitaminosis A. a) Normal palate; b) cleft palate in an embryo after administration on 11th day of development; c) posterior cleft of palate in embryos after administration on 10th day of development; d) partial reduction of lower jaw after administration of vitamin A on 10th day of development (on the left—normal embryo).

It may be concluded from these results that the period of development of the primitive upper jaw of mouse embryos of line C3HA at which they are most vulnerable is on the 9th day, when the maximal number of developmental anomalies of the jaw was observed.

Because the incidence of developmental anomalies of the lower jaw was high from the 9th until the 12th days of development, it was impossible to determine the day of maximal vulnerability of its anlage.

To explain the high frequency of cleft palate after administration of vitamin A on the 9th day of development it should be pointed out that the cleft palate in the embryos treated on this day of development was combined in every case with developmental anomalies of the upper and lower jaws.

As regards the cleft of the posterior part of the palate observed on the 10th day of development, it was suggested that an important role in their pathogenesis was played by mechanical obstructions preventing the closure of the palatal laminae in their posterior parts. This suggestion is in agreement with results obtained by several authors [4, 5] indicating that the tongue may prevent the normal closure of the palate when this anomaly is combined with micrognathia and agnathia. In the present experiment on the 10th day a posterior cleft of the palate was always combined with absence or marked reduction of the lower jaw; in cases of this type of cleft palate the embryo's head was pressed against the thorax. This means that the development of a posterior cleft of the palate on the 10th day of development was not due to injury of the palatal anlagen, but to mechanical obstacles. It may accordingly be concluded that only 16% of cleft palates running along the whole length can be counted as resulting from injury to the palatal anlage itself; consequently, in hypervitaminosis A the sensitivity of the palatal anlage to this agent is reduced on the 10th day of development.

On the 11th and 12th days of development the incidence of cleft palate in the embryos after administration of vitamin A again rose temporarily. The appearance of cleft palate on the 11th-12th and 9th days of development was evidently due to different causes. Throughout the 9th day the whole complex of the facial skull was injured, along with the anlagen of the palate and jaws, which had not yet differentiated at this period. It may be concluded from the results obtained that the differentiation of the palate into a separate anlage as a physiological unit takes place after the 9th day of development; the period of development with maximal vulnerability of the palatal anlage to the action of vitamin A in a dose of 35,000 i.u. occurs on the 11th-12th day.

LITERATURE CITED

1. S. Q. Cohlan, Science, Vol. 117 (1963), p. 535.
2. A. Girond and M. Martinet, Rev. Stomat. (Paris), Vol. 57 (1956), p. 454.
3. H. Kalter and J. Warkany, Am. J. Path., Vol. 38 (1961), p. 1.
4. K. S. Larsson, Acta odont. scand., Vol. 20, Suppl. 31 (1962), p. 1.
5. B. E. Walker and F. C. Fraser, J. Embryol. exp. Morph., Vol. 5 (1957), p. 201.
6. B. E. Walker and B. Crain, Jr., Am. J. Anat., Vol. 107 (1960), p. 49.
7. J. Warkany, R. C. Nelson, and E. Schraffenberger, Am. J. Dis. Child., Vol. 65 (1943), p. 882.

Maddux'74
Bib. No. 10707

Reproduced by permission
of the copyright owner

J. Nutr. 104(4):478. 1974.

Effect of Vitamin A Intoxication on Intracranial Pressure and Brain Water in Rats[1]

GEORGIA W. MADDUX, FLOYD M. FOLTZ AND STANLEY R. NELSON
Departments of Anatomy and Pharmacology, Kansas University Medical Center, Kansas City, Kansas 66103

ABSTRACT Increased intracranial pressure occurs in both acute and chronic hypervitaminosis A in man, but a decreased cerebrospinal fluid (CSF) pressure has been reported in various laboratory animals treated chronically with vitamin A. In order to clarify this difference in findings, measurements of brain water and CSF pressure were made in immature and mature rats treated with high doses of vitamin A. No pressure or brain water changes were observed in the acutely treated mature rats, but those treated chronically for 6 to 8 days had a 93% decrease in CSF pressure. Brain edema was also present in the treated animals; brain volume increased 2.0% in immature rats and 4.8% in mature rats. When the CSF pressure of chronically treated mature rats was raised to a normal CSF pressure by the addition of artificial CSF, their pressures dropped to near their opening pressure within 24 minutes. These data suggest that the decreased CSF pressure in rats given vitamin A is associated with an increased bulk absorption of CSF, probably due to pathological membrane or connective tissue changes. J. Nutr. *104:* 478–482, 1974.

INDEXING KEY WORDS vitamin A · intracranial pressure · brain water

Increased intracranial pressure has been reported in patients intoxicated with vitamin A (1), but the results from animal studies indicate low cerebrospinal fluid (CSF) pressures are present during intoxication with this vitamin (2–5). Decreased production of CSF (3), decreased resistance to CSF outflow and increased bulk absorption (4, 5) have been suggested as causes for the low CSF pressure in animals.

The increase in CSF pressure in humans intoxicated with vitamin A suggests brain edema is present. However, CSF pressure measurement may be an unreliable measure of brain edema and no reports on the measurement of brain water in vitamin A intoxicated man or animal were found.

This study was done to help clarify the effects of high doses of vitamin A on animal brain. The CSF pressure in both acute and chronically treated rats was measured and changes in brain water were determined from specific gravity (sp. gr.) determinations. In addition, studies were done to determine the mechanism responsible for CSF pressure changes.

MATERIALS AND METHODS

Male Sprague-Dawley rats, both immature (45 to 125 g) and mature, (180 to 400 g) were used in this study. The animals were separated into groups in order to evaluate the effect of acute and chronic vitamin A treatment on: (A) the CSF pressure, (B) the possible change in the rate of absorption of the CSF into the venous system, and (C) the production of cerebral edema.

Vitamin A[2] in the form of retinol was administered through a polyethylene catheter inserted into the esophagus of anesthetized or nonanesthetized rats.

The rats were housed in our laboratory at room temperature with the lights off at 5:00 PM, and free access was allowed to food and water. The animals were fed commercial laboratory food[3] with the experi-

Received for publication October 1, 1973.
[1] Supported in part by an institutional general research grant, RR05373, from the National Institutes of Health.
[2] USV—Aquasol A. 0.3 μg retinol per unit. USV Pharmaceutical Corp., New York, N. Y. 10017.
[3] Purina Laboratory Chow, Ralston Purina Co., St. Louis, Mo.

mental rats receiving the following dosages of vitamin A as retinol. In the acute group, the immature rats received one dose of 15 mg of vitamin A and the mature rats 30 mg of vitamin A. The chronic immature rats were given vitamin A at 7.5 mg/day for 3 to 8 days while the chronic mature rats received 15 mg/day for 7 or 8 days. The acute dose was greater than that used by Marie and See (6) in their animal experiments. The chronic dose in the immature rats (7.5 mg/day) was reported as the chronic lethal dose (7).

A. Cerebrospinal fluid pressure measurement. The rats were anesthetized with ethyl carbamate,[4] 1 g/kg injected intraperitoneally. The posterior atlantooccipital membrane was exposed and the animal was secured in a stereotaxic instrument. The CSF pressure was obtained using a short-beveled, 24 gauge needle, which was attached to a stereotaxic micrometer-driven electrode carrier. The needle was inclined at a 45° angle and the needle tip advanced through the membrane, into the cisterna magna.

The CSF pressure was measured either using a low pressure Statham transducer[5] and a Sanborn recorder[6] or by a method using a glass capillary tube (1 mm diameter) attached to the 24 gauge needle by polyethylene tubing. The capillary tube was sealed at one end and the tubing and the proximal half of the capillary tube were filled with water. The capillary tube, in a small water jacket for temperature control, was attached to the stage of a binocular microscope which had a micrometer disc in one ocular. When the needle was advanced into the cisterna magna, the transmitted CSF pressure caused the meniscus to move against the trapped air in the capillary tube. Pulsations of the fluid meniscus corresponding to the animal's respiration were evidence of a good communication between the CSF and the capillary tube. The micrometer disc readings were calibrated during the experiments by switching measured columns of H_2O into the circuit with a three-way stopcock. Since small movements of liquid in the tube were used to measure CSF pressure, there was no appreciable removal of CSF during the procedure. No leakage was observed at any time around the needle.

B. Altered resistance to bulk absorption of CSF. An experiment similar to that of Katzman and Hussey (8) was conducted to determine the integrity of the membranes responsible for CSF clearance. Seven mature rats were used, three control and four chronically treated; the chronically treated rats were given 15 mg of vitamin A per day for 7 or 8 days. The opening CSF pressures of the control and experimental rats were obtained using a low pressure Statham transducer. The control rats had an average opening pressure of 44 mm H_2O; the pressure was brought to zero gravimetrically by allowing fluid to escape by way of an outflow catheter connected to a side arm on the needle hub. Then the CSF pressure was raised to an arbitrary control level of 46 mm H_2O by introducing a small amount of artificial CSF from a connecting reservoir. The reservoir was then closed to the animal and six pressure measurements were taken during the next 24 minutes. The four chronically treated rats had opening pressures of less than 5 mm H_2O and the CSF pressure in these animals was raised to 46 mm H_2O and again six pressure measurements were taken over the next 24 minutes.

C. Determination of cerebral edema. To test for the presence of cerebral edema, the specific gravity of small pieces of cortical gray matter was determined by the procedure outlined by Nelson et al. (9). Four small cortical samples (10 to 15 mg) were taken from the posterior portion of the parietal lobe of each rat. Student's t test was used to determine the significance of mean differences.

RESULTS

A. Cerebrospinal fluid pressure. Acute vitamin A intoxication in immature rats did not alter the CSF pressure (table 1). However, chronic treatment in immature rats was associated with a 73% decrease in pressure at 3 to 5 days and a further decrease of 93% at 6 to 8 days (table 1). Similarly, the mature rats in the acute treatment group had normal CSF pressures, but in the chronic treatment group, CSF

[4] Urethane, Matheson Coleman and Bell, Kansas City, Mo.
[5] Model no. P-37. Volume displacement = 12×10^{-4} mm³/mm Hg.
[6] Model no. 127, Sanborn Co., Cambridge, Mass.

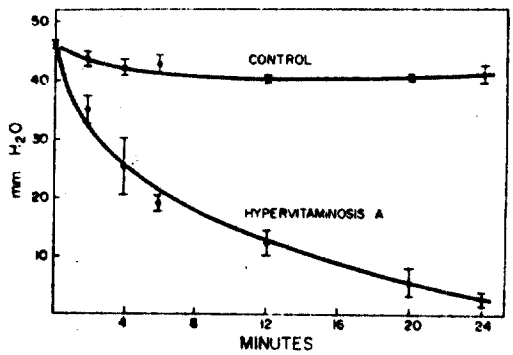

Fig. 1 CSF pressure changes following perfusion of artificial CSF into the cisterna magna of control and experimental rats. CSF pressures were measured at intervals after the pressure was adjusted to 46 mm H_2O in urethane-anesthetized rats. Each dot represents the mean CSF pressure for three (control) or four (experimental) rats. The SE is represented by a vertical line.
* Three animals were used.

pressure was less than 1 mm H_2O at the end of 7 or 8 days (table 2).

B. Bulk absorption of CSF. The integrity of the system providing resistance to CSF outflow was studied by measuring the rate of pressure drop when control and experimental animal CSF pressures were initially raised to the same level.

The CSF pressure in the chronically treated rats dropped quickly after the 46 mm H_2O control level was produced; the CSF pressure was less than 5 mm H_2O at 24 minutes and the half-time for the rate of pressure drop was about 4 minutes (fig. 1). After the first 2 minutes there was little change in the CSF pressure in the control group of rats.

C. Cerebral edema. The brain cortex of immature rats treated acutely with vitamin A had a density similar to that of the control rats (table 1). The cortex sp. gr. of the chronically treated rats (6 to 8 days) was slightly less than control values ($P < 0.05$). This mean difference in sp. gr. of 0.0009 is about a 2.0% increase in brain volume as calculated from the following equation:

$$[(\text{sp.gr.}-1)\ \text{cont.} - (\text{sp.gr.}-1)\ \text{exp.}/(\text{sp.gr.}-1)\ \text{exp.}] \times 100 = \%\ \text{vol. increase}$$

In the mature animals, acute treatment caused an increase in brain density, but chronic treatment was associated with a specific gravity decrease of 0.0021 (table 2). This latter decrease in cortex density corresponds to a 4.8% increase in brain volume.

DISCUSSION

The level of CSF pressure during vitamin A intoxication appears dependent upon the duration of vitamin A ingestion (table 1). The single dose, acute intoxication studies indicated no change in CSF pressure and brain specific gravity. After 1 week of high vitamin A intake, the rats had CSF pressures of less than 10 mm H_2O and brain edema was present. The problem is whether this loss of CSF pressure is primarily due to a reduced level of CSF production or a loss of resistance to CSF outflow. In the present study in which the CSF pressure was elevated to 46 mm H_2O in the chronically treated rats and then followed for 24 minutes, the CSF system

TABLE 1

The effect of hypervitaminosis A on CSF pressure and brain specific gravity in immature rats

Experimental group	CSF Pressure	Brain sp. gr.
	mm H_2O	
Control	59.6 ±4.8[1] (16)	1.0455 ±0.0002 (15)
Acute hypervit. A	62.9 ±7.3 (25)	1.0453 ±0.0002 (11)
Chronic hypervit. A (3-5 days)	16.0 ±4.0[2] (6)	1.0457 ±0.0002 (5)
Chronic hypervit. A (6-8 days)	3.9 ±2.0[2] (8)	1.0446 ±0.0003[3] (10)

Immature rats were treated acutely (15 mg vitamin A in one dose) or chronically (7.5 mg vit. A daily from 3 to 8 days). CSF pressure and sp. gr. measurements were made 14 hours (acute group) or 24 hours (chronic group) after animals were given their last dose of vitamin A.
[1] Each value is the mean ±SE for the number of animals given in parentheses. [2] Mean differs significantly from control, $P < 0.001$. [3] Mean differs significantly from control, $P < 0.05$.

TABLE 2

The effect of hypervitaminosis A on CSF pressure and brain specific gravity in mature rats

Experimental group	CSF Pressure	Brain sp. gr.
	mm H_2O	
Control	36.0 ±2.0[1] (19)	1.0456 ±0.0002 (22)
Acute hypervit. A	36.2 ±3.0 (4)	1.0464 ±0.0001[2] (4)
Chronic hypervit. A	<1 (16)	1.0437 ±0.0005[2] (21)

Mature rats were treated acutely with vitamin A (30 mg in one dose) or chronically (15 mg daily for 7 or 8 days). CSF pressure and sp. gr. measurements were made 14 hours (acute group) or 24 hours (chronic group) after animals were given their last dose of vitamin A.
[1] Each value is the mean ±SE for the number of animals given in parentheses. [2] Mean differs significantly from control at $P < 0.02$.

could not maintain a normal pressure for even 4 minutes; and more important, the pressure at the end of the 24-minute period was below the initial opening pressure (10 mm H_2O). Although either reduced CSF formation or loss of resistance to outflow could produce these findings, we believe the major factor to be the latter, since there is evidence that there is a critical resistance pressure to normal CSF outflow. The report of Welch and Friedman (10) demonstrated in vitro that monkey arachnoid granulations act only as one-way valves and have a critical opening pressure in the range of 20 to 50 mm H_2O. Cutler et al. (11) observed that CSF absorption in normal patients begins at an intraventricular pressure of 68 mm of CSF.

There are also a number of reports indicating that vitamin A has a disruptive effect on cell membranes and various cell organelle membranes in vitro (12, 13). Dingle (14) and Lucy (15) have proposed that the release of lysosomal enzymes, caused by hypervitaminosis A, is due to the retinol causing the fusion of the lysosomal membrane with the plasma membrane. High doses of vitamin A also decrease the amount of mucopolysaccharides of ground substance in connective tissue (16, 17). Thus the dura mater and arachnoid mater may be thinner, permitting a more rapid movement of fluid into the venous system, which is the conclusion reached by Frier et al. (5). Calhoun et al. (4) assumed a greater permeability of tissues surrounding the ventriculocisternal space in calves treated with high doses of vitamin A. Gorgacz et al. (18) studying the tentorium cerebelli, found that hypervitaminosis A decreases the dry weight of this dural reflection as well as decreasing total mucopolysaccharides, particularly the chondroitin sulfate fraction. Conversely, in vitamin A deficiency, there is an increase in the mucopolysaccharide content of the dura mater (19).

The generalization that can be proposed is that during vitamin A intoxication, capillary permeability is altered which results in the formation of brain edema. The increased brain volume, as edema, is not reflected in an elevation of CSF pressure because the drug has also reduced the resistance to CSF outflow. This coupled with the possible reduction of CSF formation becomes so great that after 7 days of high vitamin A ingestion, a rat is unable to maintain a CSF pressure greater than 10 mm H_2O.

LITERATURE CITED

1. Feldman, M. H. & Schlezinger, N. S. (1970) Benign intracranial hypertension associated with hypervitaminosis A. Arch. of Neurol. *2*, 1–7.
2. Hurt, H. D., Hall, R. C., Calhoun, M. C., Rousseau, J. E., Eaton, H. D., Wolke, R. E. & Lucas, J. J. (1966) Chronic hypervitaminosis A in weanling pigs. Conn. Agr. Exp. Sta. Bull., Storrs *400*, 1–24.
3. Hurt, H. D., Eaton, H. D. & Rousseau, J. E. (1967) Rates of formation and absorption of CSF in chronic bovine hypervitaminosis A. J. Dairy Sci. *50*, 1941–1947.
4. Calhoun, M. C., Rousseau, J. E., Hall, R. C., Eaton, H. D., Nielsen, S. W. & Lucas, J. J. (1965) Cisternal CSF pressure during the development of chronic bovine hypervitaminosis A. J. Dairy Sci. *48*, 729–732.
5. Frier, H. I., Rousseau, J. E., Gallina, A. M., Eaton, H. D. & Hall, R. C. (1970) Rates of formation and absorption of CSF in mild chronic bovine hypervitaminosis A. J. Dairy Sci. *53*, 1051–1057.
6. Marie, J. & Sée, G. (1954) Acute hypervitaminosis A of the infant. Amer. J. Dis. Child. *87*, 731–736.
7. Nieman, C. & Obbink, H. K. (1954) The biochemistry and pathology of hypervitaminosis A. Vitamins Hormones *12*, 69–99.
8. Katzman, R. & Hussey, F. (1970) A simple constant-infusion manometric test for measurement of CSF absorption. Neurology *20*, 534–544.
9. Nelson, S. R., Mantz, M. L. & Maxwell, J. A. (1971) Use of specific gravity in the measurement of cerebral edema. J. Appl. Physiol. *30*, 268–271.
10. Welch, K. & Friedman, V. (1960) The cerebrospinal fluid valves. Brain *83*, 454–469.
11. Cutler, R. P., Page, L., Galicich, J. & Water, G. V. (1968) Formation and absorption of CSF in man. Brain *91*, 707–720.
12. Dingle, J. T., Lucy, J. A. & Fell, H. B. (1961) Studies on the mode of action of excess of vitamin A. Biochem. J. *79*, 497–512.
13. Dingle, J. T. & Lucy, J. A. (1965) Vitamin A, carotenoids and cell function. Biol. Rev. *40*, 422–461.

14. Dingle, J. T. (1968) Vacuoles, vesicles and lysosomes. Brit. Med. Bull. *24*, 141–145.
15. Lucy, J. A. (1969) Some possible roles for vitamin A in membranes: micelle formation and electron transfer. Amer. J. Clin. Nutr. *22*, 1033–1044.
16. Fell, H. B. & Mellanby, E. (1952) The effect of hypervitaminosis A on embryonic limb-bones cultivated in vitro. J. Physiol. *116*, 320–349.
17. Wolf, G. & Johnson, B. C. (1960) Vitamin A and mucopolysaccharide biosynthesis. Vitamins Hormones *18*, 439–455.
18. Gorgacz, E. J., Rousseau, J. E., Frier, H. I., Hall, R. C. & Eaton, H. D. (1971) Composition of the dura mater in chronic bovine hypervitaminosis A. J. Nutr. *101*, 1541–1546.
19. Cousins, R. J., Eaton, H. D., Rousseau, J. E. & Hall, R. C. (1969) Biochemical constituents of the dura mater in vitamin A deficiency. J. Nutr. *97*, 409–418.

Monie'73
Bib. No. 10739

Reproduced by permission
of the copyright owi

Teratology 7(2):135-141. 1973.

Absent and Abnormal Umbilical Arteries

I. W. MONIE AND M. KHEMMANI
University of California San Francisco, San Francisco, California 94122 and Faculty of Medicine, Chulalongkorn Hospital, Bangkok, Thailand

ABSTRACT Umbilical arteries were not found in some fetuses from female rats given retinoic (vitamin A) acid by gavage on day 10 of gestation. It was felt that fetomaternal exchange in them must have been maintained either by the vitelline placenta alone, or by the allantoic placenta supplied by branches of the vitelline artery. In control rat embryos the vitelline and umbilical arteries communicated until day 11 after which the two circulations became separate. In young from females given retinoic acid during gestation, however, this communication (vitelloumbilical anastomosis) persisted and the definitive umbilical arteries failed to develop completely. This resulted in the normally formed single umbilical artery of the cord and its branches to the allantoic placenta receiving blood from the aorta through the vitelline or superior mesenteric artery. Thus, although the intra-abdominal portions of the umbilical arteries were missing, the allantoic placental circulation was maintained. The vitelline placental circulation was normal. In other experimental embryos persistent primary umbilical arteries were frequently seen alone or accompanied by definitive umbilical arteries. In normal human embryos a vitelloumbilical anastomosis apparently does not form and the single umbilical artery seen in fetuses with symmelia is most likely a persistent primary umbilical artery, as suggested by Dawson. However, the possibility of a vitelloumbilical anastomosis occasionally arising as an abnormality in human embryos cannot be overlooked.

Absence of the umbilical arteries has been reported in mouse young as a result of hypervitaminosis A (Kalter and Warkany, '61) and in rat fetuses following the administration of retinoic (vitamin A) acid to females during pregnancy (Khemmani, '67). In such cases no umbilical arteries are visible in the abdominal or pelvic cavities and the only vessel entering the cord is the vitelline (omphalomesenteric) artery; on the other hand, the umbilical and vitelline veins are present and course normally.

How the placental circulation is maintained under such circumstances is not clear but it has been suggested that fetomaternal exchange is accomplished either by the vitelline (yolk-sac) placenta alone, or by the allantoic placenta supplied by branches of the vitelline artery.

A somewhat similar question concerning the nature of the placental circulation is raised by human fetuses with symmelia (sympodia) where the umbilical arteries are replaced by a single artery arising from the aorta or the superior mesenteric artery. Some have considered such a vessel to be a vitelline artery (Ballantyne, 1898; Kampmeier, '27; Gisel, '38; Davies et al., '71) and it has been suggested that the placenta in such cases is of vitelline, rather than of allantoic, origin (Ballantyne, 1898). Dawson ('22), however, felt that the single artery in question was a true umbilical artery which pursued an abnormal course. Unfortunately, many accounts of human symmelia are incomplete, being based on examination of the fetus or placenta alone.

In view of these conflicting opinions it was decided to study the early development of the umbilical and vitelline vessels of the rat in control embryos, and in embryos from females given retinoic acid during gestation, in the hope that mechanisms producing abnormalities in them would be uncovered. The findings shed some light on the origin of abnormalities of the umbilical arteries in the rat and possibly in man as well.

MATERIALS AND METHODS

Long-Evans female rats aged 85 to 115

Received Oct. 12, '72. Accepted Nov. 21, '72.

days and ranging in weight from 185 to 260 g were given 30 mg retinoic acid in 1 ml peanut oil by gavage on day 10 of gestation (day of finding sperm in the vagina was designated day 0). Control animals received peanut oil only.

Young of 10 to 20 days' gestational age were collected, inspected, and fixed in Bouin's solution. A total of 43 experimental and 22 control embryos were embedded in paraffin, serially sectioned at 7–10 μ, stained with HE, and examined microscopically. Specimens from early gestation included the cord and the placenta; in the case of older fetuses about one-third of the proximal end of the cord was retained.

RESULTS

Embryos from females given retinoic acid during gestation were always smaller than corresponding controls and many presented malformations such as microstomia, "open eye," spina bifida, hydronephrosis, stunted hindlimbs, and short or absent tail. Control embryos were indistinguishable from normal young of the same age.

Normal development of the umbilical arteries. Examination of control rat embryos showed three distinct stages in the development of the umbilical arteries. During the first of these a single umbilical artery formed in the body stalk; in the second the primary umbilical arteries, which joined the former vessel, were replaced by definitive umbilical arteries; and in the third one of the latter vessels atrophied. The details of each stage were as follows.

Stage I. On day 10 the caudal portions of the paired aortae united ventral to the gut to form a single vitelline artery which, after running cranially for a short distance, left the embryo and entered the body stalk (figs. 1a, 4a,b). A single umbilical artery appeared at about day 10½ arising from the commencement of the recently formed vitelline artery; it immediately entered the body stalk and passed to the chorion (fig. 1b). About the same time the cranial portion of the single vitelline artery was joined by a vessel from each aorta; of these two arteries the right one soon disappeared while the left one enlarged to become the superior mesenteric artery. For a short time the vitelline and umbilical arteries communicated through the proximal portion of the former vessel, now referred to as the vitelloumbilical anastomosis (fig. 4d), but this channel disappeared about day 11 (fig. 1c). The dorsal aortae were now united except for their most distal portions which had become the primary umbilical arteries.

Stage II. About day 11½ definitive umbilical arteries appeared lateral to their predecessors (fig. 2a) and were well established by day 12 (fig. 2b). Each mesonephric (Wolffian) duct now advanced towards the cloaca and gave off a ureteric bud just caudal to the latter vessel. A sciatic artery grew out from each definitive umbilical artery and entered the adjacent hindlimb

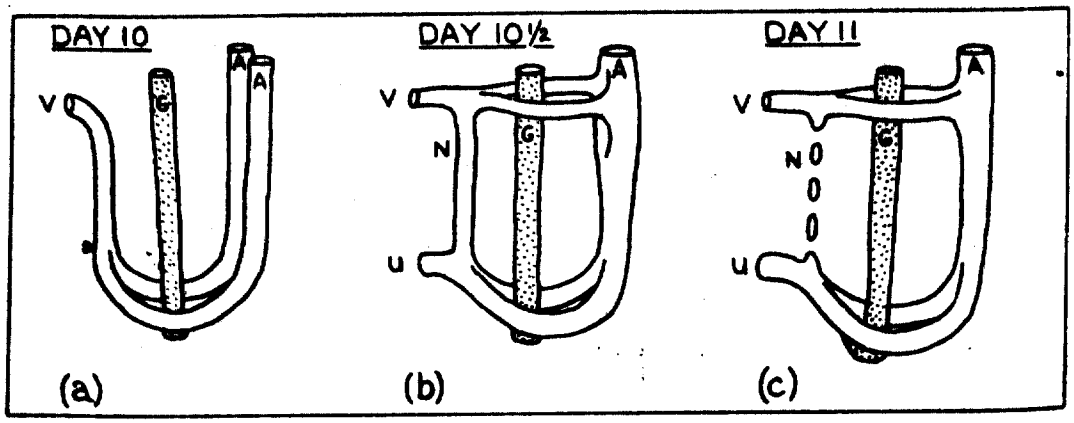

Fig. 1 Development of the umbilical and vitelline arteries from day 10 to 11. Key: A, aorta; G, gut; N, vitelloumbilical anastomosis; U, umbilical artery; V, vitelline artery.

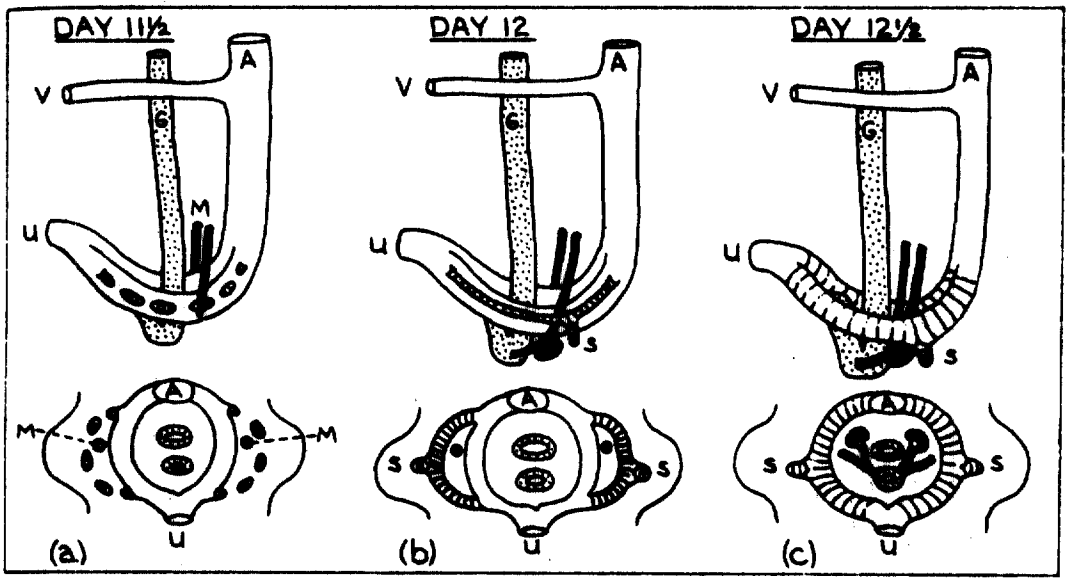

Fig. 2 Development of the umbilical and vitelline arteries from day 11½ to 12½. Key: M, mesonephric duct; S, sciatic artery. Rest of key as in figure 1. The definitive umbilical arteries are crossbarred.

bud. By day 12½ the primary umbilical arteries had mostly disappeared (fig. 2c).

Stage III. About day 14 one of the two umbilical arteries within the embryo, most often that of the left side, began to atrophy so that only one umbilical artery remained by day 17.

External iliac arteries were first distinguishable at about day 14 arising from the portion of the umbilical artery that later became the common iliac artery; the internal iliac artery appeared about the same time, the sciatic artery forming one of its branches. By day 15 the femoral artery, the continuation of the external iliac, was the main supplier of blood to the hindlimb.

Abnormal development of the umbilical arteries. Abnormalities of the vascular system were seen only in young from females given retinoic acid during gestation. They were first noted in day 11-embryos, five out of six of which still had a sizable vitelloumbilical anastomosis.

By day 12 vascular malformations were more evident. Of 12 embryos of this age, one resembled day 10½ controls except that the secondary connection of the vitelline artery with the aorta was absent (fig. 3a), four were similar to the day 11 or 11½ controls, and two showed primary umbilical arteries of varied size and incomplete formation of the definitive umbilical arteries (fig. 3b).

Of seven day 13-embryos, three exhibited abnormal vascular patterns. In one (fig. 3c) the distal portions of the definitive umbilical arteries were missing beyond the origins of the sciatic arteries, and a persistent primary umbilical artery (X) with a double origin from the aorta connected with the umbilical and vitelline arteries. In another (fig. 3d) a persistent primary umbilical artery (Y) connected the aorta to the umbilical artery as the latter entered the cord; while in the third embryo the right primary umbilical artery had failed to atrophy (fig. 3e).

Of nine day 14 embryos, five were normal, and two others were normal except that in each the left umbilical artery was of greater caliber than its fellow of the opposite side. Of the remaining two, one had only one umbilical artery, which arose from the vitelline artery (fig. 3f); the other had a small accessory vessel springing from the aorta near the origin of the inferior mesenteric artery, which joined the umbilical artery as the latter entered the cord.

There were nine embryos aged 15 to 19 days. Two members of this group, each

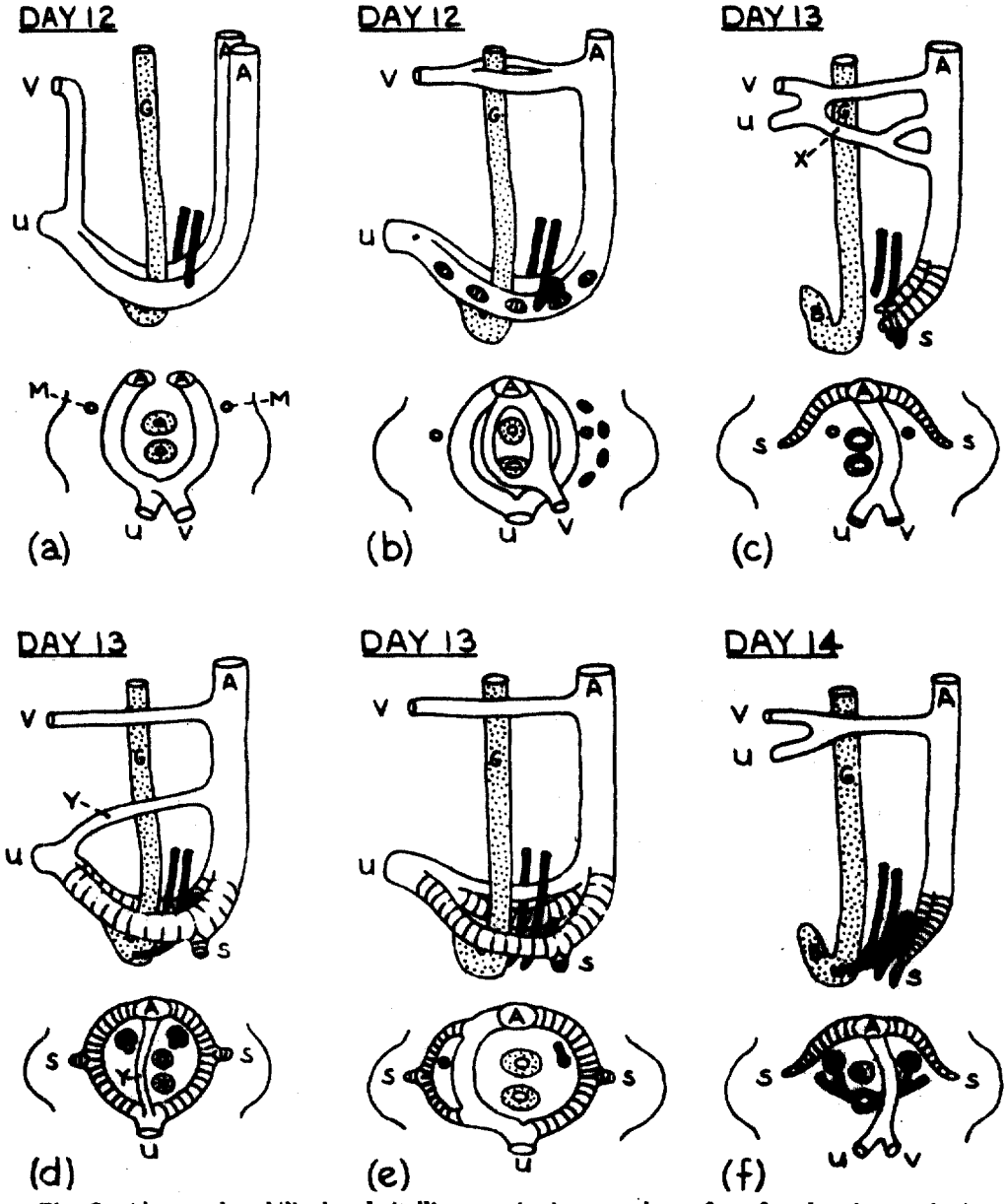

Fig. 3 Abnormal umbilical and vitelline arteries in rat embryos from females given retinoic acid during pregnancy. Key: X and Y, persistent primary umbilical arteries. Rest of key as in figures 1 and 2.

aged 17 days, contained a single umbilical artery arising from the vitelline artery as in figure 3f. The others resembled controls of corresponding age except for minor variations.

It was noted that in embryos in which the umbilical artery arose from the vitelline or the superior mesenteric artery the aorta tended to narrow beyond the origin of the latter vessel; in such cases, however, the pattern of the blood supply to the hindlimbs appeared normal.

Although anomalies of the umbilical arteries were often accompanied by abnor-

Fig. 4 Transverse sections of normal rat embryos. Compare with figures 1a and 1b. Day 10: A. Vitelline artery passing to body stalk; B. Vitelline artery ventral to gut. Section located caudal to A. × 225. Day 10½: C. Vitelline artery about to enter body stalk. It is joined by vessels (m,n) from aortae; D. Vitelloumbilical anastomosis ventral to gut. Umbilical artery in body wall. Section located caudal to C. Key: a, vitelloumbilical anastomosis; g, gut; m, transient branch of right aorta to vitelline artery; n, branch of left aorta to vitelline artery which later forms the superior mesenteric artery; u, umbilical artery; v, vitelline artery. × 113.

malities of other systems, no consistent combination was observed.

Development of the vitelline and umbilical veins. In day 10 control embryos the vitelline vein traversed the body stalk, then divided into right and left veins which terminated in the sinus venosus. By day 11 connections had formed between these veins from which the portal vein evolved 1 day later.

The umbilical vein was recognizable at day 10½ and, like the vitelline vein, on reaching the embryo it divided into right and left components which passed to the sinus venosus. The right umbilical vein was the larger of the two vessels up to day 12 but thereafter rapidly disappeared.

Except for a persistent right umbilical vein in one day 19 experimental embryo, no abnormalities of the venous system were encountered.

DISCUSSION

Absence of the umbilical arteries. The key factor in the genesis of this abnormality is failure of the vitelloumbilical anastomosis to disappear at about day 11 (fig. 1c). This, in association with lack of development of the distal portion of each definitive umbilical artery, results in the anastomosis becoming the sole channel by which blood from the aorta reaches the umbilical artery in the cord after the primary umbilical arteries have atrophied. As the embryo grows, the vitelloumbilical anastomosis is carried for a short distance into the cord. Since the umbilical artery distal

to the anastomosis forms in a normal way the abnormality perhaps would be better called *absence of the intra-abdominal umbilical arteries*. There is no apparent hindrance to the flow of blood to either the vitelline or the allantoic placentas in such cases.

The narrowing of the aorta observed in some experimental embryos with a persistent vitelloumbilical anastomosis might be explained by the diversion of blood from it through the latter channel. On the other hand a slower rate of development of the caudal end of the body with reduced demands on blood supply might favor persistence of the anastomosis.

The connection between the vitelline and umbilical arteries described in this study was reported by Ravn (1894) in mouse and rat embryos. It was said to be absent in other mammals, and in the chick, but Evans ('12) observed it in the pig. It probably occurs in most mammals in which the vitelline circulation is established prior to the umbilical (chorioallantoic) circulation.

Abnormal umbilical arteries. Besides so-called absence of the umbilical arteries, a number of our experimental embryos contained one or more umbilical arteries that followed abnormal paths within the pelvis or abdomen. Such vessels were apparently persistent primary umbilical arteries and resulted in various bizarre vascular patterns (figs. 3c,d,e). In one (fig. 3c), the primary umbilical artery retained its connection with the vitelloumbilical anastomosis.

Abnormalities of other systems. In rat fetuses with missing or abnormal umbilical arteries the caudal advance of the mesonephric ducts was usually delayed. Since these ducts must pass between the primary and definitive umbilical arteries to reach the cloaca persistence or delayed atrophy of the former vessels may interfere with their progress. In an earlier study in which chlorambucil was used as a teratogen (Monie, '61) it was noted that where development of the umbilical arteries of rat embryos was disturbed there was a greater incidence of abnormalities of the mesonephric ducts, ureters, and kidneys. The findings of the present investigation agree with that observation.

Spina bifida was especially common in the experimental embryos and was not always accompanied by vascular malformation. Indeed, it was seen in one day-12 embryo before formation of the umbilical arteries was complete, suggesting that it forms independently of the vascular pattern in its vicinity.

Abnormalities of the umbilical arteries in man. The developmental pattern of the human umbilical arteries generally resembles that of the rat but there are notable differences. Thus, whereas in the rat the single umbilical artery formed in the body stalk persists throughout gestation, in man it is reduced to the anastomosis between the umbilical arteries near the junction of the cord and the placenta. Another difference is that in human embryos there is no vitelloumbilical anastomosis of the type seen in the rat perhaps because in man the umbilical circulation is established in advance of the vitelline circulation. Again, in human fetuses both umbilical arteries remain functional throughout gestation whereas in the rat one of them disappears.

A single umbilical artery (SUA) in the human subject is of clinical interest since it may be accompanied by severe malformations. Its genesis has been attributed to either aplasia (Little, '61) or atrophy (Benirschke et al., '64) of one umbilical artery. It is possible, however, that it may also arise from persistence of the transitory single artery in the body stalk with subsequent atrophy of one intra-abdominal umbilical artery as normally occurs in the rat (Monie, '70). In SUA the portion of the umbilical artery within the fetus is derived from the definitive umbilical artery.

In human symmelia the single artery often seen crossing the abdominal cavity in a mesentery before entering the cord, has been considered by most observers to be a vitelline artery. Dawson ('22), however, believed it to be a persistent primary umbilical artery and the findings of this study of rat embryos lend support to his view. Even where such a vessel arises from the superior mesenteric artery it is conceivable that a persistent primary umbilical artery might be carried there by differential growth since in some rat embryos high-rising arteries of this type were seen quite close to the origin of that vessel.

Although a vitelloumbilical anastomosis

does not seem to form in normal human embryos, the possibility that it may occasionally arise as an abnormality cannot be excluded entirely. This would then permit an umbilical artery to spring directly from the superior mesenteric or vitelline artery in the same manner as that seen in some of the experimental rat embryos.

ACKNOWLEDGMENTS

Gratitude is expressed to J. Morgan, M. Freeman, E. Calaustro and S. Scott for technical assistance. The study was supported by NIH grant HD00419.

LITERATURE CITED

Ballantyne, J. W. 1898 The occurrence of a non-allantoic or vitelline placenta in the human subject. Tr. Edin. Obst. Soc., 23: 54–80.

Benirschke, K., M. M. Sullivan and M. Marin-Padilla 1964 Size and number of umbilical vessels. Obst. Gyn., 24: 819–834.

Davies, J., E. Chazen and W. E. Nance 1971 Symmelia in one of monozygotic twins. Teratology, 4: 367–378.

Dawson, A. B. 1922 The origin and occurrence of the single umbilical artery in normal and abnormal human fetuses. Anat. Rec., 24: 321–343.

Evans, H. M. 1912 The development of the vascular system. In: Keibel and Mall, Manual of Human Embryology. Vol. 2, Lippincott, Philadelphia.

Gisel, A. 1938 Persistenz der Arteria omphalomesaraica und Fehlen der Nabelarterien bei einer Neugeborenen. Z. Anat. Entwickl., 108: 686–694.

Kalter, H., and J. Warkany 1961 Experimental production of congenital malformations in strains of inbred mice by maternal treatment with hypervitaminosis A. Am. J. Path., 38: 1–21.

Kampmeier, O. F. 1927 On sireniform monsters with a consideration of the causation and the predominance of the male sex among them. Anat. Rec., 34: 365–389.

Khemmani, M. 1967 Facial and other malformations induced in fetal rats by retinoic acid. M.A. Thesis, Univ. of California, San Francisco.

Little, W. A. 1961 Umbilical artery aplasia. Obst. Gyn., 17: 696–700.

Monie, I. W. 1961 Chlorambucil-induced abnormalities of the urogenital system of rat fetuses. Anat. Rec., 139: 145–154.

——— 1970 Genesis of single umbilical artery. Am. J. Obst. Gyn., 108: 400–405.

Ravn, E. 1894 Ueber die Arteria omphalo-mesaraica der Ratten und Mäuse. Anat. Anz., 9: 420–424.

Moore'71
Bib. No. 10741

Reproduced by permission
of the copyright owner

Internat. J. Vit. Res. 41:301-306. 1971.

Internat. J. Vit. Nutr. Res. *41* (1971)
Received for publication
April 27, 1971

Vitamin A (retinol)
Concentration in
- Maternal liver
- Foetal liver
- Colostrum
- Milk
Maternal supply

Maternal / foetal ratio
Production of retinol deficient offspring
Mechanism of passage
- Gestation
- Lactation
Retinol binding protein

Vitamin A Transfer from Mother to Offspring in Mice and Rats

T. Moore

Strangeways Research Laboratory, Cambridge (England)

Summary: The transfer of vitamin A from mother to offspring was studied in mice and rats, under conditions in which the mother was given either liberal or restricted supplies of retinol. With a liberal maternal supply the proportion of the vitamin passed to the offspring before parturition was small, as expected from previous research. Larger amounts were transferred during lactation. With a restricted maternal retinol supply the amounts passed to the offspring were only slightly less than with a liberal supply, with the effect that the proportion of the maternal supply transferred was much higher. It appears therefore, that retinol is not only restricted from passage to the offspring when the maternal supply is high, but mobilised for transfer to the offspring when the maternal supply is low. Probably the mechanism controlling the passage of retinol to the offspring, at least before parturition, is closely connected with that known to control the release of retinol from the liver into the blood stream, which allows constant blood level to be maintained until the liver reserves are almost exhausted.

Introduction

Dann (1932, 1934) found in rats that the amounts of vitamin A transferred from mother to offspring were small in relation to the maternal liver reserve, and were not readily increased by raising the dietary intake of the vitamin. Observations by many workers on different species subsequently gave similar results (Moore, 1957). In foetal lambs nearing term, for example, Eder (1946) found mean reserves of only about 3 µg of vitamin A (retinol) per g of liver, as

compared with 320 μg in their mothers. Eventually massive dietary intakes of retinol were found capable of substantially increasing the liver reserves of offspring (Henry, Kon, Mawson, Stanier and Thompson (1949), but the corresponding increases in the maternal reserves maintained the disparity between mother and offspring. Dann (1933) found that bovine colostrum was much richer in retinol than the subsequent milk, and in all species this rich *post-partum* source of the vitamin appears to compensate for the small transfer *in utero*. Even after normal lactation, however, the retinol reserves in weanlings, under normal nutritional conditions, remain much lower than in the mother.

This paper reports studies on the transfer of retinol from mice and rats to their offspring in experiments carried out for two purposes [1] to find the point at which breeding females, previously fed upon a stock diet rich in retinol, should be changed to a diet low in the vitamin so as to ensure that their offspring should have only low retinol reserves at weaning [2] to explore whether the vitamin A intakes of mothers can be so adjusted as to allow them to produce viable, normally formed offspring, which can nevertheless be made deficient in the vitamin within the first ten days after parturition. For this second purpose the mothers were reared on a diet deficient in vitamin A, and were mated after the administration of small doses of retinol.

Experimental

Diets. Before transfer from the breeding colony mice and rats received the same pelleted stock diet, with ground wheat and ground barley as its main constituents. Retinol was included at the level 2.4 μg/g and also 5% of dried grass meal, providing unestimated amounts of carotene. With the help of Mr. P. D. Holmes, of Spillers Research and Technology Centre, Cambridge a pelleted diet deficient in vitamin A was made up from white bread flour 80%, casein (low vitamin content) 5%, dried yeast 10% and arachis oil (fortified with vitamins E and D_2) 5%. Further details of these diets, and of the routine production of vitamin A deficiency in the mice and rats, will be reported elsewhere.

Retinol estimations. Retinol was estimated in livers from mothers and offspring by a micro-adaptation of the method of Davies (1933). For matching the blue colour in the antimony trichloride reaction a Lovibond Tintometer was used. Undoubtedly this instrument lacks the precision of modern photoelectric absorptiometers. It has the advantage, however, that the blue colours produced in small volumes or reaction mixture are clearly seen by the naked eye. This avoids the danger, always present when minute amounts of retinol have to be estimated, of confusion arising from minor variations in the blank reading.

Results

Mice. Table 1 (expts. 1–4) gives results for the transfer of retinol to their offspring by mother mice reared on a stock diet. The maternal reserves were

Tab. 1: Retinol transfer to their offspring by mother mice reared on a stock diet, rich in retinol.

Expt. No.	Reproductive Stage	Diet	Liver retinol, µg				
			Maternal		Offspring		
			per g	Total	per g	Total for mouse	Total for litter
1	Parturition	Stock	200	400	5	0.4	2.5
2	After 28 days lactation	Stock	300	500	40	20	160
3	After 27 days lactation	Stock until parturition, then A-free diet	–	–	6	2	(12)[1]
4			–	–	12	4	20[2]

[1] From estimations of 3 weanlings, with the number in the litter unrecorded, but taken as 6.
[2] From estimations on 2 weanlings out of a litter of 5.

high (200 and 300 µg/g) but offspring killed soon after parturition had only low reserves (5 µg/g). After lactation, with the mother still receiving the stock diet, the reserves of the offspring were higher (40 µg/g). Again after lactation, but with the mothers receiving diet deficient in vitamin A during this period, the reserves of offspring were 6 and 12 µg/g in the two litters examined.

Table 2 (expts. 5, 6) gives results for experiments aimed at the production of 10-day old mice, deficient in vitamin A, for use in biochemical experiments by a colleague, Dr. J. Reynolds. The mother mice had been reared up to the age of 3 months on a diet deficient in vitamin A, and had then been given a single, substantial dose of retinyl acetate before mating. When mother and offspring were killed 10 days after parturition retinol estimations indicated concentrations

Tab. 2: Retinol transfer to their offspring by mother mice reared on a diet deficient in vitamin A, and given limited doses of retinyl acetate (100 µg once only) before mating.

Expt. No.	Reproductive Stage	Diet	Liver retinol, µg				
			Maternal		Offspring		
			per g	Total	per g	Total for mouse	Total for litter
5	After 10 days lactation	A-free for 3 months	1.4	2.2	2.5	0.4	2
6			0.4[1]	0.5	1	0.2	0.5

[1] Colour in $SbCl_3$ reaction faint and dull.

of 1.4 and 0.4 μg/g in the maternal livers, as compared with 2.6 and 1μg in the sucklings. In the mother giving the result 0.4 μg/g the colour produced with $SbCl_3$ was too faint and dull for recognition as the clear, bright blue typical of retinol, but in all other instances clear blue colours were seen. In agreement with the presence of these small, but definite concentrations of retinol in the livers of the sucklings Dr. Reynolds could detect no abnormality in the biochemical reaction in which he was interested.

Rats. The findings in experiments 5 and 6 indicated that the concentrations of retinol in the livers of the suckling mice were somewhat higher than in the maternal livers. The question remained open, however, whether most of this retinol was acquired *in utero* or during lactation. Experiments were therefore made on rats, similarly treated to the mice in experiments 5 and 6, but with pregnancy terminated by killing the mothers shortly before term. Rats were used in place of mice primarily because a change to this species had been made in the preparation of vitamin A deficient animals for use in other experiments. They had the advantage that the dissection out of the foetal livers was easier than in mice.

The results are given in table 3 (expts 7, 8). As expected only low retinol concentrations (3.4 and 4.8 μg/g) were found in the maternal livers. In the foetal livers the concentrations were of the same order (3.2 and 2.4 μg/g).

Tab. 3: Retinol transfer to their foetuses by rats reared on a diet deficient in vitamin A, then given limited doses of retinyl acetate (400 μg total in divided doses) and mated.

Expt. No.	Reproductive Stage	Diet	Liver retinol, μg				
			Maternal		Offspring		
			per g	per g	Per g	Total for mouse	Total for litter
7	Nearing	A-free for	3.4	28	3.2	.85	9.3
8	full term	4 months	4.8	38	2.4	.85	5.8

Discussion

In those of the above experiments in which the mother had been reared on a stock diet, rich in retinol, the findings obtained confirmed the wellknown wide disparity between the retinol concentrations in the maternal and foetal livers. So little retinol is passed to the foetus that it seems unnecessary, for the routine production of vitamin A deficiency in partially grown offspring, to restrict the

mother to a deficient diet before parturition. During lactation, however, the retinol content of the diet seems to have a greater effect in increasing transfer to the offspring than during gestation. For the production of vitamin A deficient offspring transfer of the mother to a deficient diet immediately after parturition is therefore recommended.

In contrast little difference was found between the liver retinol concentrations between mother and offspring when the maternal concentrations were low. Whereas a maternal/foetal ratio of 30:1 might be taken as typical when the mother has a high retinol reserve, 1:1 might be typical when the maternal reserve is low. It appears therefore that the retinol supply to the offspring is both restricted when the maternal supply is high and facilitated when the maternal supply is low.

This two-way control of the passage of retinol to the offspring is probably connected with the mechanisms for its storage in the liver and mobilisation as required into the blood stream. Thus DOWLING and WALD (1958) found that when rats with high retinol reserves were restricted to a deficient diet the level of retinol in the blood was maintained over a long period at a constant level, until a sharp fall when the liver reserves were almost completely exhausted. Presumably it is the blood concentration, rather than the liver concentration, that determines the amount transferred to the foetus. It seems inevitable that RBP (retinol binding protein), the specific carrier of retinol in the blood stream (KANNAI, RAZ and GOODMAN, 1968) must influence not only the mobilisation of the vitamin into the blood but also its transfer to the foetus.

To some extent the mechanisms concerned with the transport of retinol in the blood stream must also influence its concentrations in colostrum and milk. The factors controlling the permeability of the placenta to the passage of retinol, however, cannot be identical with those affecting its secretion by the mammary glands. As far as can be judged from the observations reported here on mice, and from the more extensive work by HENRY *et al.* (1949) on rats, retinol is passed to the offspring more freely during lactation than *in utero*.

In the present work the attempt to produce suckling mice deficient in vitamin A failed. Clearly it is difficult to avoid dosage with retinol either so low as to cause resorption of the foetuses or the production of deformed young or so high as to result in normal young. ROGERS and BIERI (1969), however, succeeded in choosing the right conditions for the production of avitaminosis A in preweanling rats.

References

1. Dann, W. J.: Biochem. J. 26, 1072 (1932). – 2. Dann, W. J.: Biochem. J. 27, 1998 (1933). – 3. Dann, W. J.: Biochem. J. 28, 634 (1934). – 4. Davies, A. W.: Biochem. J. 27, 1770 (1933). – 5. Dowling, J. E. and Wald, G.: Proc. natl. Acad. Sci. U. S. 44, 648 (1958). – 6. Eden, E.: Unpublished data, see Moore. 1957 (1946). – 7. Henry, K. M., Kon, S. K., Mawson, E. H., Stanier, J. E. and Thompson, S. Y.: Brit. J. Nutr. 3, 301 (1949). – 8. Kanai, K. M., Rae, A. and Goodman, D. S.: J. Clin. Invest. 47, 2025 (1968). – 9. Moore, T.: Vitamin A, pp. 238–242, Amsterdam, Elsevier (1957). – 10. Rogers, W. E. and Biers, J. G.: Proc. Soc. exp. Biol. Med. 132, 622 (1969).

Dr T. Moore, Strangeways Research Laboratory, Cambridge, England

Morriss'73
Bib. No. 10746

J. Embryol. exp. Morph. Vol. 30, 1, pp. 219–242, 1973
Printed in Great Britain

The ultrastructural effects of excess maternal vitamin A on the primitive streak stage rat embryo

By GILLIAN M. MORRISS[1]
From the Department of Anatomy, University of Cambridge

SUMMARY

1. A single injection of 100000 i.u. vitamin A palmitate was administered to pregnant female rats on one of the days 0–14 of pregnancy. The litters were examined for malformations and prenatal death. On the basis of the results of this preliminary investigation, treatment on day 8 was selected for detailed study.

2. Day-8 embryos were examined with the electron microscope from 2 to 24 h after maternal vitamin A administration. Ultrastructural abnormalities were: membrane swelling (cytoplasmic vacuoles, 'budding', nuclear membrane irregularities, general swelling leading to cell death); changes in the extra- to intracellular fluid ratio; increase in the number of lipid droplets; autophagic vacuoles; condensed and swollen mitochondria.

3. These changes were not equally distributed among the different cell types. It is suggested that this differential effect leads to a loss of synchrony between the development of structures from the different germ layers, in addition to a general retardation. Loss of contact between mesoderm cells may delay normal migratory movements and induction of neural plate. The general retardation is related to the lower birthweights of treated embryos versus controls, and the differential effects to the subsequent abnormal morphogenesis.

INTRODUCTION

The effects of excess maternal vitamin A on embryonic development were discovered by Cohlan (1953). Daily doses of 35000 i.u. administered from before implantation to the 16th day of gestation caused severe malformations, including exencephaly, cleft palate and eye defects. Giroud & Martinet (1955) found that the types of malformations produced depended on the stage of embryonic development at which the vitamin was administered.

Little attention has been paid to the mechanism of action of excess vitamin A in this situation. Woollam & Millen (1960) were able to modify its teratogenic activity by the administration of certain hormones, e.g. cortisone. However, if the abnormal development is due to direct action of the vitamin on the embryos their results may simply reflect changes in its availability.

Present understanding of the mechanism of action of excess vitamin A on cells, tissues and organs has come mainly from *in vitro* studies (reviewed in Fell

[1] *Author's address:* Department of Anatomy, Downing Street, Cambridge CB2 3DY, U.K.

& Rinaldini, 1965). Ultrastructural studies have suggested that the primary site of action of vitamin A is within membranes (Glauert, Daniel, Lucy & Dingle, 1963; Jackson & Fell, 1963; Daniel, Dingle, Glauert & Lucy, 1966). The present study of the ultrastructure of rat embryos following maternal vitamin A administration was undertaken in order to discover (1) whether the teratogenesis was brought about by a direct action of vitamin A on the embryonic cells, (2) whether this action, if detectable, was comparable to that in the *in vitro* studies, and (3) to elucidate the cellular origin of the subsequent abnormal development. Treatment on day 8 was selected for detailed study because severe malformations were produced in 100% of the young without a significant increase in the rate of resorptions over the control level.

MATERIALS AND METHODS

The rats used in this study were albino Wistar-derived stock bred in the Cambridge University Department of Anatomy, kept in conditions of natural lighting. Nulliparous females were housed two to a cage with a male, and vaginal smears taken in the morning. The day on which sperm were present in the smear was designated day 0 of pregnancy.

The vitamin A was supplied by Roche Products Ltd, and consisted of a suspension of 100000 i.u. retinyl palmitate in 1 ml water.

Examination of day-20 foetuses

Vitamin A, 100000 i.u., was administered as a single subcutaneous injection to pregnant female rats on one of the days 0–14 of pregnancy. Four control rats were injected with the diluent on day 8 of pregnancy and 8 were untreated. There was no difference between the litter data derived from the two groups of controls; they were therefore treated as one group as a basis for comparison with the experimental data. The dams were killed on the afternoon of day 20 and the young removed alive from the uterus. Malformations were assessed by external examination of whole live embryos, and by alizarin-staining of the skeleton. The internal soft parts were not examined.

Electron microscopy

The experimental dams were given a single subcutaneous injection of 100000 i.u. vitamin A palmitate between 09.00 and 09.30 a.m. on day 8 of pregnancy. They were killed after 2–24 h. '*X* hours after maternal vitamin A administration' refers to the time of killing of the dam; fixation of the embryos was about 30 min later. Control rats received no treatment; their embryos were prepared at the same time as the various batches from treated mothers. The uterus was placed in Tyrode saline and the embryos were dissected free of the decidual tissue. Only turgid, undamaged embryos with an intact Reichert's membrane were selected. These were fixed in 4% glutaraldehyde in phosphate buffer and

Table 1. *Mean values of the litter data from dams injected on different days of pregnancy*

(Individual pup weights for each group were compared with controls by Dunnett's 't' statistic, and the results are shown on the table: $^{*}P < 0{\cdot}005$; $^{**}P < 0{\cdot}05$. The number of resorptions per litter were compared with control values by χ^2 test: $^{\dagger}P < 0{\cdot}001$.)

Day of injection	No. of dams	Mean no. implant-ations	Mean no. live young	Mean no. resorp-tions	Mean litter weight (in g)	Mean pup weight (in g)
0	6	11·2	11·0	0·2	40·9	3·72
1	5	9·6	9·2	0·4	35·2	3·83
2	6	10·8	10·7	0·2	37·0	3·47*
3	7	11·0	10·1	0·9	33·6	3·31*
4	6	12·2	12·2	0	43·0	3·53*
5	8	11·8	10·8	1·0	34·1	3·18*
6	8	12·5	9·6	2·9†	31·9	3·32*
7	6	11·3	9·0	2·3†	29·1	3·23*
8	12	12·8	11·8	1·0	38·8	3·28*
9	9	10·3	9·9	0·4	36·5	3·69
10	9	13·7	13·6	0·1	49·1	3·62**
11	7	12·6	12·3	0·3	47·8	3·89*
12	6	12·5	12·3	0·3	45·2	3·67
13	6	12·0	11·8	0·2	43·2	3·65
14	6	11·8	11·7	0·17	44·1	3·78
Control	12	11·3	10·9	0·3	40·6	3·72

post-fixed in osmic acid. After flat embedding they were reorientated so that sections were cut in the sagittal plane. Sections for light microscopy of 1 μm were stained with toluidine blue; thin sections were stained with uranyl acetate and lead citrate, and viewed in a Philips EM300 electron microscope.

OBSERVATIONS

A. Examination of day-20 foetuses

The results are summarized in Table 1 and in Figs. 1 and 2.

Malformations of the central nervous system included exencephaly, meningo-encephalocoele, and meningocoele. Eye malformations included exophthalmos, ablepharia, microphthalmos and cataract. Cleft palate occurred either alone or in association with facial malformations. Facial malformations included micro-stomia, short snout, absence of the external ear. Limb malformations were short radius, syndactyly, missing claws. The abnormalities were used only as indicators of the effects of the teratogen on development following the different times of administration, and were not graded according to severity.

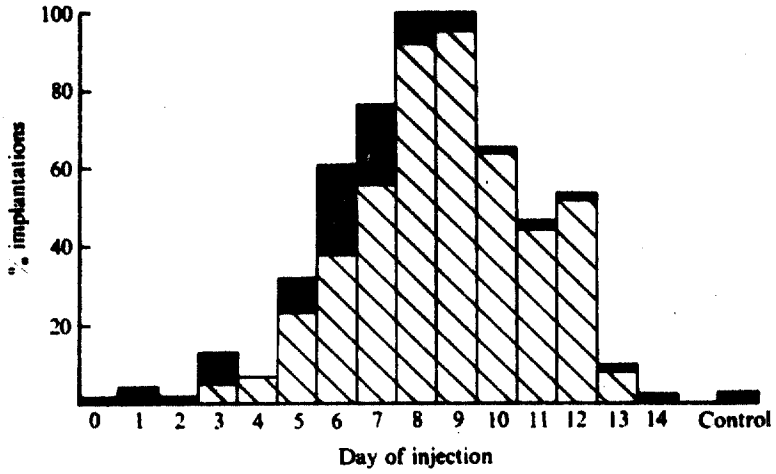

Fig. 1. Percentage implantations resorbed (black), abnormal (cross-hatched) and normal (remainder), according to the day of maternal vitamin A administration.

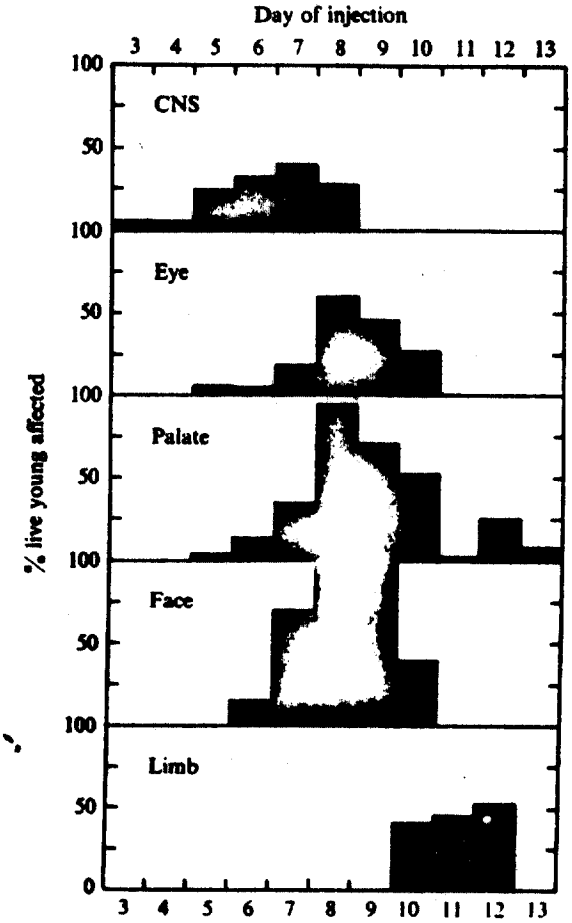

Fig. 2. Types of malformation according to the day of maternal vitamin A administration.

B. Ultrastructural observations

Normal embryos

The whole embryo (egg cylinder) consists of three regions: the ectoplacental cone, the extra-embryonic region and the embryo proper (Fig. 3). The last two are surrounded by Reichert's membrane and consist of an inner ectoderm layer and an outer endoderm layer. Between them is situated a small amount of mesoderm whose cells migrate from the primitive streak region of the ectoderm. The central cavity is called the pro-amniotic cavity in the embryonic region, since the amnion forms across the cavity to separate the embryonic and extra-embryonic regions during the following 24 h.

The thickness of Reichert's membrane varied between 0·3 and 0·5 μm in the sections examined. It is a many-layered structure made up of parallel lamellae which resemble basement membranes. Parietal endoderm cells adhere to its inner surface (Fig. 4); in no place were two of these cells seen to be in contact. They are irregular in shape, with irregular nuclei. The major cytoplasmic constituent is rough endoplasmic reticulum: some cells also contain large numbers of lipid droplets of moderate electron density. Parietal endoderm cells were occasionally observed in contact with proximal endoderm, but the function of this was not clear. The way in which the embryos were removed from the decidual tissue may have caused the separation of most of such attachments.

The endoderm of approximately the lower half of the embryo proper consists of a single layer of cells which are flat in section (Fig. 4), except when rounded for division. The nuclei are irregular, and the cytoplasm contains many electron-dense lipid droplets 0·5–1·5 μm in diameter. There is a considerable amount of rough endoplasmic reticulum. The mitochondria are rounded in shape, and contain more cristae than those of the ectoderm and mesoderm.

The extra-embryonic (future yolk-sac) endoderm differs from the lower embryonic endoderm in that the cells are columnar in shape, with an orientation along the radial axes of the egg cylinder (Fig. 7). The components of the cytoplasm are similar, except that there are more and larger electron-dense lipid droplets and the mitochondria are more variable in shape. The transition between the two types of endoderm involves only a few cells, and occurs in the mid-embryonic region.

All the endoderm cells have microvilli on the outer surface. These are relatively sparse in the squamous embryonic endoderm, and longer and more prolific in the columnar cells. Large numbers of pinocytotic vesicles may be seen forming at the bases of the microvilli and also on non-microvillous areas of the outer surface of the cells.

The embryonic ectoderm consists of a pseudostratified layer of columnar cells with regular ovate nuclei, each containing a distinct nucleolus (Figs. 4, 5). The cytoplasm contains large numbers of polyribosomes. The mitochondria are

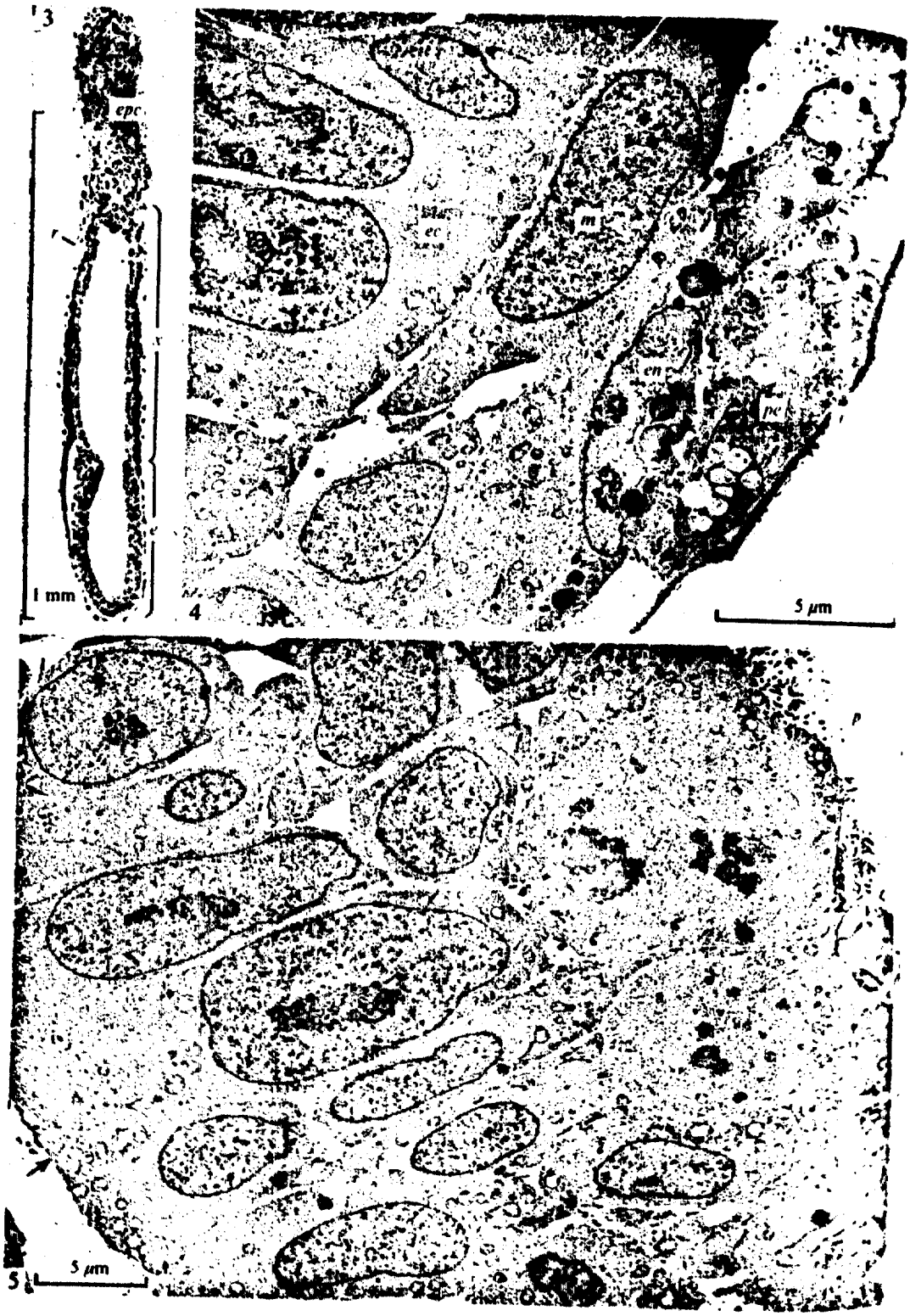
3
epc
1 mm
4
m
en
pc
5 μm
5
5 μm

spherical or ovate in shape, with few cristae; there is only a small amount of rough endoplasmic reticulum and Golgi bodies.

Each cell has an apical non-nuclear area bordering the pro-amniotic cavity. The main body of the cell may be joined to this area by a narrow neck, such as the one extending between the two dividing cells in Fig. 5. The pro-amniotic borders of the cells are joined to each other by long terminal bars, as opposed to the small focal tight junctions or close junctions between other parts of the cell surfaces. Cells in mitosis are always found adjacent to the cavity, having apparently lost their contact with the basement membrane. The basement membrane covers the outer aspect of the ectoderm cells, becoming discontinuous in the primitive streak region.

The inner surface of the ectoderm cells is thrown into small microvilli similar to those of the outer surface of the squamous embryonic endoderm; small pinocytotic vesicles may be seen forming at their bases.

Extra-embryonic ectoderm cells differ from those of the embryonic region in having a lower density of polyribosomes in the cytoplasm and a larger number of lipid droplets. The nuclei also differ in being irregular in outline. These differences give a clear indication of the embryonic/extra-embryonic junction, which is not given by the endoderm or mesoderm.

The amount of mesoderm differs between embryos, even differing quite markedly between embryos of the same litter. The cells are of a similar appearance to embryonic ectoderm cells, except for being irregular in outline and having larger intercellular spaces (Fig. 6). The nuclei are less regular than those of the embryonic ectoderm cells, but are still smooth in outline.

Mesoderm cells are joined by focal tight junctions and close junctions. These are sometimes at the ends of cytoplasmic extensions (filopodia), although every cell is joined to its neighbours by several junctions in any one plane of section. Contacts were observed between the surfaces of mesoderm cells and the ectodermal basement membrane, and with the inner surface of the endoderm.

FIGURES 3–5

Fig. 3. Day-8 embryo, sagittal section, Araldite/toluidine blue. *epc*, Ectoplacental cone; *r*, Reichert's membrane; *x*, extra-embryonic region; *e*, embryo proper. The inner layer is ectoderm, the outer is endoderm. Mesoderm arising from the primitive-streak region lies between these two layers at the embryonic/extra-embryonic junction on the left side of the section.

Fig. 4. Embryonic region showing Reichert's membrane (*r*), parietal (*pe*) and proximal (*en*) endoderm, mesoderm (*m*) and ectoderm (*ec*).

Fig. 5. Embryonic ectoderm. The bases of the cells are attached to a basement membrane (arrowed), and the apices bordering the pro-amniotic cavity (*p*) are joined by terminal bar-type junctional complexes. Spherical dividing cells lie beneath the apical region, having lost their contact with the basement membrane.

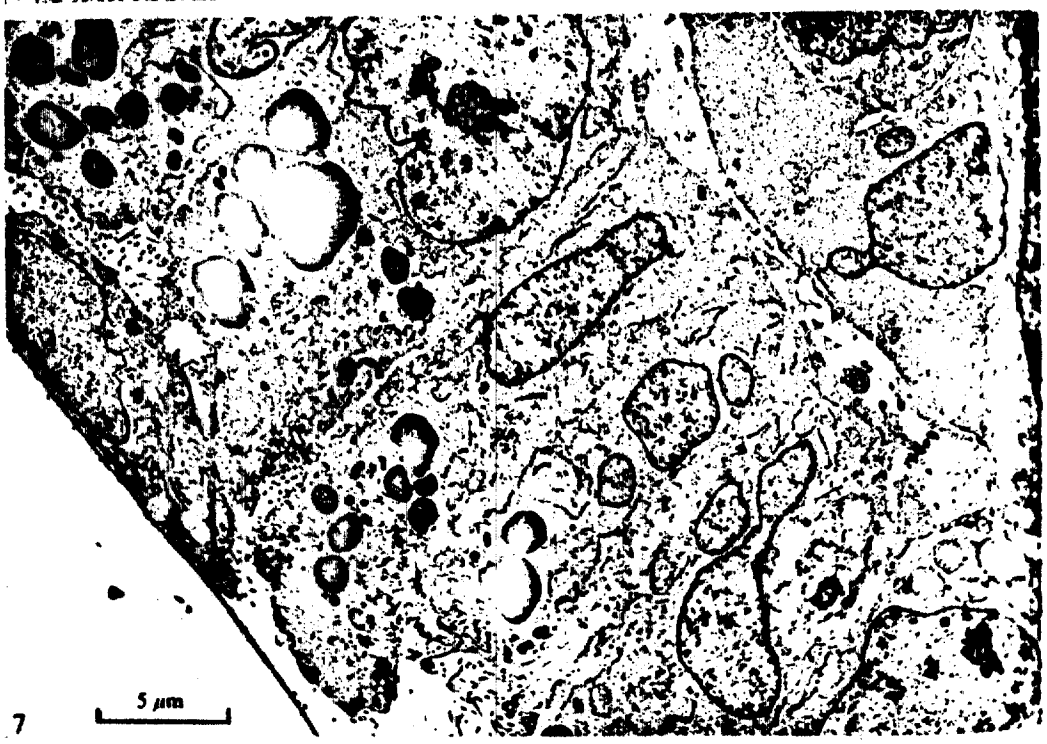

Fig. 6. Mesoderm (primary mesenchyme), including a cell in mitosis (upper left).

Fig. 7. Extra-embryonic endoderm: high columnar cells with large osmiophilic lipid droplets.

Embryos from vitamin A treated dams

The abnormal features observed in electron micrographs of embryos from dams given vitamin A may be grouped into the following categories: (1) membrane changes, (2) changes in the fluid balance of the embryo, (3) increase in the number of lipid droplets, (4) autophagic vacuoles, (5) mitochondrial changes. More than one of these features was frequently present in any single cell.

(1) *Membrane changes*

(*a*) *Vacuoles and buds*. Many of the abnormal ultrastructural features were associated with an increase in the surface area of the plasma and intracellular membranes. From 4 h after maternal vitamin A administration onwards small cytoplasmic vacuoles were visible just beneath the plasma membrane (Fig. 8). Some of these were attached to the plasma membrane (not illustrated) and all of them appeared to be derived from it. Within the same time range, larger vacuoles appeared deeper in the cytoplasm. These were sometimes recognizable as swollen mitochondria and contained flocculent material (Fig. 9). The largest vacuoles were found in the outer aspect of the endoderm cells and contained flocculent material of various densities (Figs. 11, 16). They resembled normal electron-dense lipid droplets in size, shape and position.

Swelling of the plasma membrane was also associated with the 'budding' of cells (Fig. 10). Portions of cytoplasm containing mainly ribosomes, and completely surrounded by plasma membrane, appeared to separate themselves from the parent cell. The bud illustrated in Fig. 13 was derived from an ectoderm cell, having pushed through the basement membrane to lie alongside the dying mesodermal cells. These structures, being deficient in nuclei and other organelles, are unlikely to survive for long. Rounded membranous 'ghosts' of a similar size to the buds were a common feature in embryos from dams killed 7 h or more after vitamin A administration (Fig. 20).

(*b*) *Cell death associated with membrane swelling*. Dead cells were present in all embryos from 7 h onwards (Figs. 11–13). These cells had lost most of their polyribosomes, and much of the nuclear material had also disappeared, leaving a membranous 'ghost'. The mitochondria were also swollen and the nuclear membrane was frequently vacuolated. In parietal endoderm cells, some of which showed this characteristic swelling as early as 4 h after the maternal injection, the endoplasmic reticulum formed a number of vesicles, and the nuclei became pyknotic (Fig. 11). The endoplasmic reticulum of mesoderm (Fig. 13) and ectoderm cells also formed vacuoles, but that of proximal endoderm appeared relatively normal (Fig. 12). Dead or dying mesoderm cells appeared to have lost their attachments to adjacent cells. Dead ectoderm cells were only seen loose in the preamniotic cavity, into which they appeared to have been expelled.

Many of the features seen in the 'ghost' cells were also observed in cells which appeared to be in early stages of the process of membrane swelling leading to

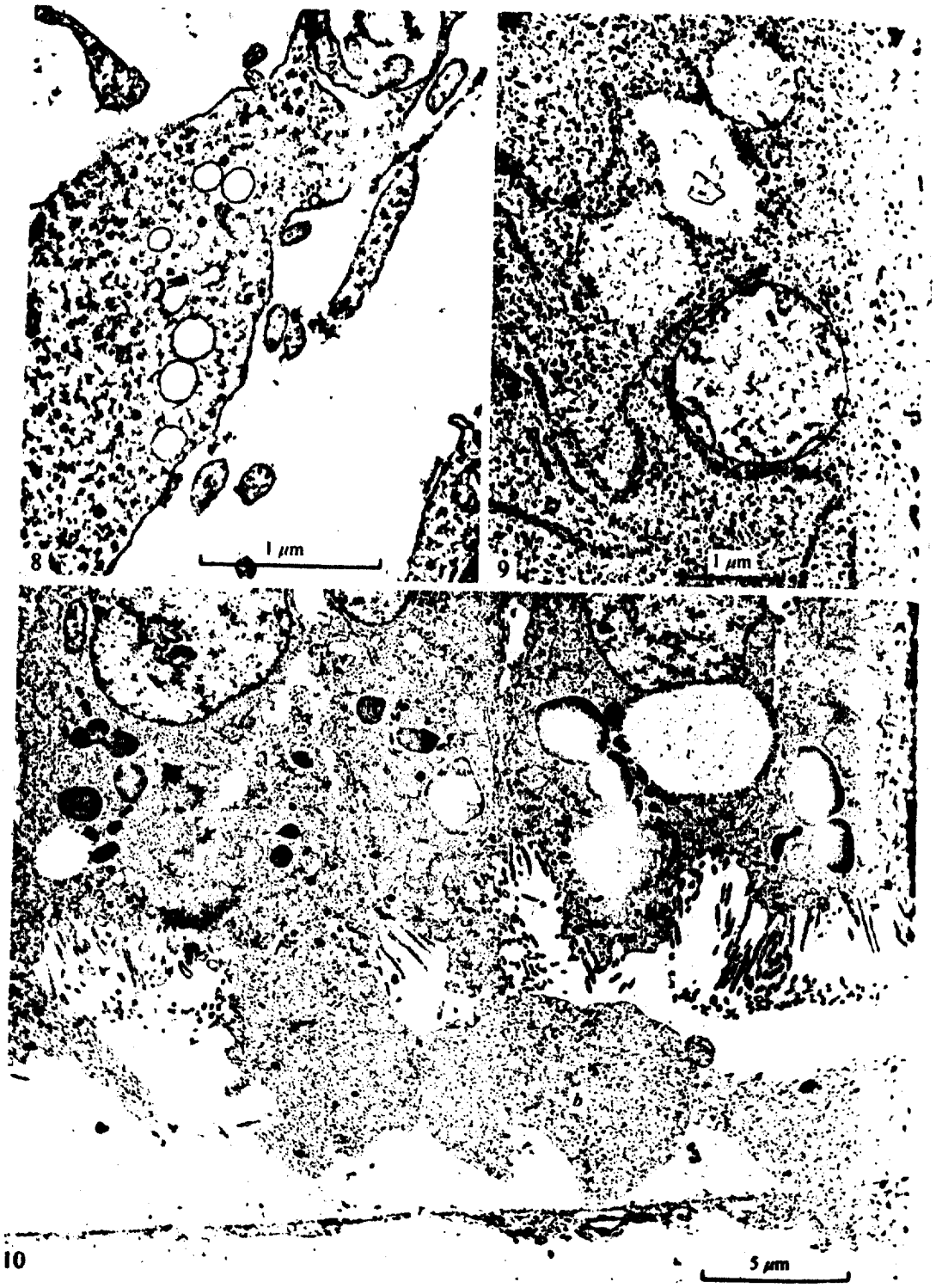
8
1 μm
9
1 μm
10
5 μm

cell death (Fig. 13). Small areas of plasma membrane swelling without vacuolation were common (Figs. 15, 20).

(c) *Nuclear irregularities.* Two embryos from a dam killed 6 h after vitamin A administration, and one after 8 h, showed striking irregularities of the normally ovate embryonic ectodermal nuclei (Figs. 14, 15). Minor nuclear membrane irregularities were seen in most embryos from 6 h onwards. These consisted of intuckings of the inner membrane and gross abnormalities of shape.

(2) *Changes in the fluid balance of the embryo*

In many embryos, or parts of embryos, an increase in the ratio of extracellular to intracellular fluid was observed. In the mesoderm at least, this increase was too large to be accounted for simply by movement of fluid out of the cells, and must have involved actual uptake of fluid by the embryo as a whole. The earliest example of altered fluid balance was in the endoderm of embryos from dams killed 4 h after vitamin A. Fig. 16 shows embryonic endoderm 6 h after vitamin A. The cells are more widely separated than controls, but the junctions appear to have remained firm, causing extensions to be drawn out between the cells at these points. The ectoderm behaved in a similar way (Fig. 17), although the earliest observations of this were in embryos prepared 2 h later than those showing the effect in the endoderm. In some instances the amount of separation of mesodermal cells was such that the density of cells in a given area of section was a half to one-third of that in the controls (Fig. 19). In this case fine long filaments were drawn out between the cells.

These changes in spacing of the cells were associated with an increase in their surface area, allowing the stretching between the junctions to occur. The fluid changes in the ectoderm and endoderm were temporary, in that cells which had once been widely separated later resumed their normal spacing. Such cells were still recognizable by the filaments which had previously been drawn out and now lay between them (Fig. 20). On resuming a more normal shape they made new junctions at the bases of the filaments. Fig. 18 shows a zonula adhaerens at the base of a filament which also contacts the adjacent cell by a close junction near its tip. [These types of junction have also been observed in early chick embryos (Hay, 1968).] Unaffected, widely separated, and previously separated

---

FIGURES 8–10

Fig. 8. Four hours after maternal vitamin A administration. Small vacuoles close to the plasma membrane. Embryonic endoderm.

Fig. 9. Four hours after maternal vitamin A administration. Extra-embryonic endoderm cell containing vacuoles apparently derived from swollen mitochondria.

Fig. 10. Five hours after maternal vitamin A administration. Extra-embryonic endoderm with large vacuoles (*v*). Parts of the cells (*b*), containing mainly ribosomes, appear to be budding off between the endoderm and Reichert's membrane (*r*).

11

12

13

cells could sometimes be found in different areas of the embryonic ectoderm of a single embryo 7–9 h after vitamin A.

Mesoderm cells appeared to regain their normal spacing more slowly. In embryos at 11 and 12 h some regrouping was apparent, but there were still large spaces between the cells. At 24 h the spacing was still not normal in all areas of the mesoderm, and there were large fluid-filled areas between the mesoderm and the other two layers in some areas.

(3) *Lipid droplets*

In control embryos, lipid droplets of moderate electron density [i.e. semi-saturated lipid (Fawcett, 1966)] were common in extra-embryonic ectoderm but relatively uncommon in embryonic ectoderm and mesoderm. Following maternal vitamin A administration their numbers were greatly increased in the embryonic ectoderm (Fig. 20). There was also an increase in this type of lipid in the endoderm: in this case it was frequently in the form of very large droplets, up to 9 μm in diameter, which caused some distortion of the cells. This phenomenon was commonly associated with some of the previously described membrane effects, such as 'budding', mitochondrial swelling (Fig. 21), cell filaments and plasma membrane swelling (Fig. 20). Very occasionally, lipid droplets were observed in the intercellular fluid between the proximal endoderm and Reichert's membrane (Fig. 21).

In three embryos at 4, 7 and 8 h after maternal vitamin A administration (Fig. 22), lipid droplets surrounded by a double membrane were observed in embryonic and extra-embryonic ectoderm. Some of these showed a mass of small vacuoles which also contained lipid, instead of the inner membrane. The origin of these structures was not clear, but their shape, size, and position in the cell suggested that they may have been of mitochondrial origin.

(4) *Autophagic vacuoles*

The term 'autophagic vacuole' is used here to describe an apparently degenerating area in a cell which is separated from the rest of the cytoplasm by a limiting membrane and which appears to be of intracellular origin. Such

---

FIGURES 11–13

Fig. 11. Five hours after maternal vitamin A administration. Parietal endoderm cell with swollen rough endoplasmic reticulum and pyknotic nucleus.

Fig. 12. Eight hours after maternal vitamin A administration. Extra-embryonic endoderm. Loss of ground cytoplasm; swollen mitochondria; vacuoles (*v*), probably derived from the plasma membrane; large lipid droplet (*l*); heterophagic vacuole (*h*) containing part of a dead cell.

Fig. 13. Seven hours after maternal vitamin A administration. Dying (left) and dead (right) mesoderm cells, showing vacuole formation from plasma and nuclear membranes, and loss of polyribosomes from cytoplasm. *b*, 'Bud' from adjacent ectoderm cell.

Figs. 14, 15. Six hours after maternal vitamin A administration. Abnormal nuclei in extra-embryonic ectoderm. In Fig. 15 the cytoplasm has separated from the plasma membrane in one place (s), either by cytoplasmic shrinkage or membrane swelling.

Fig. 16. Six hours after maternal vitamin A administration. Transitional embryonic endoderm: widely spaced cells, with vacuoles (v) containing flocculent material. pe, Parietal endoderm cell (in mitosis); r, Reichert's membrane.

Fig. 17. Seven hours after vitamin A administration. Whole width of embryonic ectoderm, with widely spaced cells. *p*, Pro-amniotic cavity; *bm*, basement membrane.

Fig. 18. Six hours after maternal vitamin A administration. New junctions formed between previously widely separated ectoderm cells.

Fig. 19. Seven hours after maternal vitamin A administration. Widely spaced mesoderm cells.

structures were extremely rare in control embryos. From 6 h after maternal vitamin A administration onwards they were a common feature, although the number per section varied greatly between embryos.

Early stages in the formation of autophagic vacuoles were not identified with certainty. In their 'mature' state they contained recognizable degenerating cell components such as mitochondria and nuclei (Fig. 23). Where the nucleus was normal, as was frequently the case, there was no justification for designating cells containing autophagic vacuoles as dying cells. However, dead cells containing autophagic vacuoles were occasionally observed. These were most common in the mesoderm, or as former ectoderm cells floating freely in the pro-amniotic cavity (Fig. 24).

(5) *Mitochondrial changes*

The occurrence of swollen mitochondria has already been referred to in connexion with cytoplasmic vacuoles, cell death, and lipid. Condensed, strongly electron-dense mitochondria were a much more common phenomenon, and were present in well over half the cells of all embryos from 6 to 12 h after maternal vitamin A administration, and in many cells at 24 h. They were commonly curved in shape, sometimes forming a complete ring surrounding a core of cytoplasm (Fig. 25). One mesoderm cell (at 9 h) contained a swollen, damaged mitochondrion adjacent to a ring-shaped condensed mitochondrion.

DISCUSSION

Many of the ultrastructural abnormalities observed in embryonic cells following maternal vitamin A administration may be classified as membrane effects (Figs. 3–10). These bear a striking resemblance to some of the effects seen after the treatment of cells and tissues with excess vitamin A *in vitro*. Daniel *et al.* (1966) treated a monolayer of rat dermal fibroblasts with vitamin A in buffered saline: electron microscopy showed damage to the plasma membrane and to the membranes of mitochondria, endoplasmic reticulum, and nuclei. Dingle & Lucy (1965) described the plasma membrane effect as a 'swelling and vacuolation' phenomenon. The swelling of mitochondria and nuclear membranes was

FIGURES 20–22

Fig. 20. Seven hours after maternal vitamin A administration. Cytoplasmic extensions between embryonic ectoderm cells bordering the pro-amniotic cavity. Large number of lipid droplets; two 'ghosts' in pro-amniotic cavity. Arrows: swollen areas of plasma membrane.

Fig. 21. Eight hours after maternal vitamin A administration. Dying cell between two parietal endoderm cells, containing lipid droplet and swollen mitochondria. Another large lipid droplet lies in the extracellular fluid.

Fig. 22. Eight hours after maternal vitamin A administration. Embryonic ectoderm. Structures of a similar size to mitochondria, containing lipid and having a double limiting membrane. Some of them also contain a lipid-filled mass of vesicles.

22

observed in embryonic cells as part of the process leading to cell death (Fig. 8). Further similarities to these dying embryonic cells and to the plasma membrane vacuolation shown in Fig. 3, are provided by Glauert *et al.* (1963) in electron micrographs showing the changes undergone by erythrocytes in the presence of 10 μg/ml vitamin A alcohol.

The membrane effects observed in the present study, like those in the earlier *in vitro* work, all represent an increase in the surface area of the membranes. Bangham, Dingle & Lucy (1964) demonstrated that retinol will permeate a monolayer of lecithin and cholesterol at an air/water interface and cause its expansion. Retinoic acid did not expand this monolayer: in combination with the observations in embryonic cells, this negative result provides circumstantial evidence against the suggestion of Wilson (quoted in Lloyd & Beck, 1969) that, since retinoic acid is a more potent teratogen than retinol, the teratogenicity of the latter might result from its oxidation to the acid form.

The presence of retinol in a membrane also increases its permeability, thus altering the distribution of water and small ions (Lucy & Dingle, 1964). The increase in extracellular fluid volume (Figs. 11–14) is difficult to explain on this basis, since it appears to represent an increase in the fluid:cell ratio of the whole embryo. Reichert's membrane consists of mucoprotein (Mukerjee, Ram & Pierce, 1965), so it is unlikely to be affected by vitamin A in the same way as lipoprotein membranes. In an ultrastructural study of embryonic chicken skin cultured in the presence of excess vitamin A, Jackson & Fell (1963) described an increase in extracellular fluid in the basal and lower spinosum regions. This phenomenon has also been observed by light microscopy in the mesoderm of hamster embryos (Marin-Padilla & Ferm, 1965; Marin-Padilla, 1966) and rat embryos (Morriss, 1972*b*) following maternal vitamin A administration.

Increase in lipid droplets

It is not clear whether the increase in lipid droplets of medium electron density (Figs. 15–17) was related to the other effects of whether it has any effect on subsequent abnormal development. In preliminary work for the present study (unpublished), similar droplets were seen in the Kupffer and hepatic cells of the maternal liver 30–60 min after the injection of vitamin A. They were also

FIGURES 23–25

Fig. 23. Seven hours after maternal vitamin A administration. Embryonic ectoderm. Cell containing three autophagic vacuoles, one of which appears to contain degenerating mitochondria. The other two, and the one in the cell on the left, appear to be nuclear in origin.

Fig. 24. Seven hours after vitamin A administration. Dead cell in pro-amniotic cavity resembling the cell in Fig. 18 without the plasma membrane and ground cytoplasm.

Fig. 25. Six hours after maternal vitamin A administration. Condensed mitochondria, elongated, curved and signet-ring-shaped, in an embryonic ectoderm cell.

2 μm
2 μm
1 μm
25

observed in the blood space around Reichert's membrane, along with debris from damaged cells, 5 h after the maternal injections (Morriss, 1973). Geelen (1972) demonstrated that lipid droplets in the decidual tissue following maternal vitamin A administration showed the characteristic vitamin A fluorescence in ultraviolet light. It may be that these droplets consist of, or contain, unconverted retinyl palmitate. This substance is not membrane-active (Fell, Dingle & Webb, 1962), but may be converted to retinol or retinoic acid by enzymes within the embryonic cells. The normal hydrolysis occurs in the maternal liver (Mahadevan, Ayyoub & Roels, 1966), and retinol is transported in the plasma attached to 'retinol binding protein' (Raz, Kanai & Goodman, 1968). In the bound form retinol is not membrane-active (Dingle, Fell & Goodman, 1972). Both the hydrolysing capacity of the liver and the RBP capacity of the blood would be exceeded following an injection of as much as 100000 i.u., so it appears likely that both free retinol and retinyl palmitate reach the embryo.

Autophagic vacuoles

Autophagic vacuoles may be described morphologically as degenerating cell components surrounded by a membrane. They have been observed as part of the normal physiological process of differentiation, and following a variety of pathological treatments (Ashford & Porter, 1962; Novikoff & Essner, 1962; Ericsson, 1964, 1969; Menkes, Sandor & Ilies, 1970).

De Duve (1963) described the formation of autophagic vacuoles as a process of the cell screening off a portion of its own cytoplasm and digesting this by a process which is kept localized by the membrane. The membrane-delimited structures probably fuse secondarily with primary lysosomes, so that lysosomal enzymes are released into the vacuole (Novikoff, 1963). Scheib (1965) suggested that lysosomes may be activated by toxic substances, the cell responding to this by delimiting them from the cytoplasm by membranous structures, including, by chance, other organelles. Alternatively, the toxic substance may affect cytoplasmic organelles, and the cell may delimit them by structures possessing a lytic enzyme activity. De Duve stressed that cell death is not normally caused by the lysosomes, and that they are involved only in the breakdown of already dead cell components. Swift & Hruban (1964) described autophagia as a response of the living cell, which leads to cell death only if the processes of inclusion formation and subsequent digestion cannot ultimately cope with the toxic stimulus. That this may indeed occur in the case of embryos subjected to maternal hypervitaminosis A is indicated by the occurrence of some dead cells containing autophagic vacuoles; however, many of these structures were found within otherwise healthy cells, while most cell death appeared to result from membrane swelling to form 'ghosts'. The two kinds of dead cells were easily distinguishable (Figs. 13, 24).

In the present situation a possible explanation for the autophagy is that the vitamin A causes sufficient damage to the membranes of the organelles to

stimulate the cell to partition them off from the unaffected components of the cytoplasm.

Heterophagic vacuoles occurred only in the endoderm, where healthy cells engulfed parts of nearby dead cells.

Mitochondrial changes

Excess vitamin A causes the swelling of mitochondria in a variety of *in vitro* situations. De Luca & Dingle (unpublished results: quoted in Fell & Rinaldini, 1965) found that excess vitamin A depressed the oxygen uptake of isolated mitochondria in the presence of hexokinase and glucose. Lucy, Luscombe & Dingle (1963) thought that this alteration in metabolism was associated with the swelling, and that the action site was within the membranes. Seward, Vaughan & Hove (1966) and Seward, Mitchell & Hove (1969) found that excess vitamin A lowered the endogenous oxidative phosphorylation of isolated rat liver mitochondria.

Glücksmann (1951) stated that 'in cells exposed to injurious agents mitochondria often show early and irreversible changes indicative of processes leading to subsequent cell death'. Bellairs (1961) observed condensed mitochondria, often becoming ring-shaped, in electron microscopy of necrotic areas in normal chick blastoderm, and considered that this appearance indicated an early stage in the process of cell death. In the present study a high proportion of cells contained condensed mitochondria, whereas the resorption rate following the same treatment was not significantly greater than that in the controls. Thus this phenomenon must be regarded as a response to the maternal hypervitaminosis which may have a detrimental effect on subsequent development but is not necessarily lethal, either to individual cells or to the embryo.

Daniel *et al.* (1966) observed a rapid decline in the respiratory activity of rat dermal fibroblasts after exposure to retinol for 6 h. They concluded that the membrane alterations brought about by the vitamin affected the functions of mitochondria and endoplasmic reticulum. In embryos subjected to excess vitamin A *in vivo*, a temporary fall in the respiratory activity of the cells would cause a retardation of overall growth. Retardation of development was in fact observed within 24 h of the maternal injection (Morriss, 1972*a*, *b*).

Possible origins of the malformations

The ultrastructural abnormalities, with the exception of the lipid increase, may be divided into three components in terms of interference with the normal function of the embryo as a unit. These are (1) cellular malfunction (the loss of parts of cells by budding, changes in membrane permeability, swelling and condensation of mitochondria, appearance of autophagic vacuoles), (2) cell death (resulting from membrane changes and from the cause of autophagic vacuole formation), and (3) the breakdown of normal relationships between cells (extracellular fluid volume increase).

Possible cell malfunction associated with the observed changes has already been discussed, and it is suggested that the overall effect may be to cause a general retardation in growth. By analogy with the mechanism of action of excess vitamin A on cartilage *in vitro* (Fell & Rinaldini, 1965) there may be chemical changes in the extracellular material resulting from lysosomal discharge. However, Schulz (1969) was unable to detect any changes in lysosomal stability in 12-day-old rat embryos, yolk sac, or placenta after the maternal injection of teratogenic doses of vitamin A.

Dead cells were not observed in control 8-day-old embryos although they are quite normal at later stages of development as a sculpturing device. In the experimental 8-day embryos dead cells were found in all parts of the embryo, but were less common in the endoderm than in the other two germ layers. Changes in the fluid balance of the embryo led to an alteration in the normal intercellular relationships, the mesoderm being more severely affected than the other two germ layers. Cell contacts may be important for the exchange of information between cells (Weiss, 1970) and for normal migration and organization of mesenchyme (Abercrombie, 1970). The chordamesoderm is responsible for initiating the neuralization of the overlying ectoderm (Spemann, 1918), and also determines its subsequent regional differentiation (Toivonen, 1967). This function of the mesoderm may be inhibited or retarded in the present experimental situation: in a study of the abnormal morphogenesis following maternal vitamin A administration on day 8, Morriss (1972*b*) found that neural tube formation was late in relation to foregut development, and that there was a paucity of cephalic mesoderm. This loss of synchrony between the development of structures derived from the three germ layers appears to have its origin in their different responses to the teratogen, to their different requirements for normal function, and to the important role of the primary mesenchyme in the differentiation of the neural plate.

This work was supported by the Wellcome Trust. I am grateful to Dr D. H. M. Woollam for advice, to Professor R. J. Harrison for the provision of laboratory facilities, to Mr J. F. Crane and his staff for assistance with photography, to Dr N. T. Pollitt of Roche Products Ltd for supplying the vitamin A, and to the Royal Society for providing a grant to purchase a diamond knife.

REFFERENCES

Abercrombie, M. (1970). Cellular Interactions. In *Congenital Malformations* (ed. F. C. Fraser and V. A. McKusick), pp. 111–114. Amsterdam, New York: Excerpta Medica.

Ashford, T. P. & Porter, K. R. (1962). Cytoplasmic components in hepatic cell lysosomes. *J. Cell Biol.* **12**, 198–202.

Bangham, A. D., Dingle, J. T. & Lucy, J. A. (1964). Studies on the mode of action of excess of vitamin A. 9. Penetration of lipid monolayers by compounds in the vitamin A series. *Biochem. J.* **90**, 133–140.

Bellairs, R. (1961). Cell death in chick embryos as studied by electron microscopy. *J. Anat.* **95**, 54–60.

Cohlan, S. Q. (1953). Excessive intake of vitamin A as a cause of congenital anomalies in the rat. *Science, N.Y.* **117**, 535–536.

DANIEL, M. R., DINGLE, J. T., GLAUERT, A. M. & LUCY, J. A. (1966). The action of excess vitamin A alcohol on the fine structure of rat dermal fibroblasts. *J. Cell Biol.* **30**, 465–475.

DE DUVE, C. (1963). The lysosome concept. In *Ciba Fdn Symp. Lysosomes* (ed. A. V. S. De Reuck and M. P. Cameron), pp. 1–31. Boston: Little, Brown.

DINGLE, J. T., FELL, H. B. & GOODMAN, D. S. (1972). The effect of retinol and of retinol-binding protein on embryonic skeletal tissue in organ culture. *J. Cell Sci.* **11**, 393–402.

DINGLE, J. T. & LUCY, J. A. (1965). Vitamin A, carotenoids, and cell function. *Biol. Rev.* **40**, 422–461.

ERICSSON, J. L. E. (1964). Absorption and decomposition of homologous hemoglobin in renal proximal tubular cells. *Acta path. microbiol. scand.* Suppl. no. 168.

ERICSSON, J. L. E. (1969). Mechanisms of cellular autophagy. In *Lysosomes in Biology and Pathology*, vol. II (ed. J. T. Dingle and H. B. Fell), pp. 345–394. Amsterdam: North Holland.

FAWCETT, D. W. (1966). *The Cell.* Philadelphia: W. B. Saunders.

FELL, H. B., DINGLE, J. T. & WEBB, M. (1962). Studies on the mode of action of excess of vitamin A. 4. The specificity of the effect on embryonic chick-limb cartilage in culture and on isolated rat liver lysosomes. *Biochem. J.* **83**, 63–69.

FELL, H. B. & RINALDINI, L. M. (1965). The effects of vitamins A and C on cells and tissues in culture. In *Cells and Tissues in Culture*, vol. I (ed. E. N. Wilmer), pp. 659–699. New York: Academic Press.

GEELEN, J. A. C. (1972). The localisation of vitamin A in the pregnant rat by means of fluorescence microscopy. *Teratology* **6**, 19.

GIROUD, A. & MARTINET, M. (1955). Malformations diverses du foetus de Rat suivant les stades d'administration de vitamin A en excès. *C. r. Séanc. Soc. Biol.* **149**, 1088–1090.

GLAUERT, A. M., DANIEL, M. R., LUCY, J. A. & DINGLE, J. T. (1963). Studies on the mode of action of excess of vitamin A. VII. Changes in the fine structure of erythrocytes during haemolysis. *J. Cell Biol.* **17**, 111–121.

GLÜCKSMANN, A. (1951). Cell death in normal vertebrate ontogeny. *Biol. Rev.* **26**, 59–86.

HAY, E. D. (1968). Organization and fibre structure of epithelium and mesenchyme in the developing chick embryo. In: *Epithelial-Mesenchymal Interactions* (ed. R. Fleischmajer & R. E. Billingham), pp. 31–55. Baltimore: Williams and Wilkins.

JACKSON, S. F. & FELL, H. B. (1963). Epidermal fine structure in embryonic chicken skin during atypical differentiation induced by vitamin A in cultures. *Devl Biol.* **7**, 394–419.

LUCY, J. A. & DINGLE, J. T. (1964). Fat-soluble vitamins and biological membranes. *Nature, Lond.* **204**, 156–160.

LUCY, J. A., LUSCOMBE, M. & DINGLE, J. T. (1963). Studies on the mode of action of excess of vitamin A. 8. Mitochondrial swelling. *Biochem. J.* **89**, 419–425.

LLOYD, J. B. & BECK, F. (1969). Teratogenesis. In *Lysosomes in Biology and Pathology*, vol. I (ed. J. T. Dingle and H. B. Fell), pp. 433–449. Amsterdam: North Holland.

MAHADEVAN, S., AYYOUB, N. I. & ROELS, O. A. (1966). Hydrolysis of retinol palmitate by rat liver. *J. biol. Chem.* **241**, 57–64.

MARIN-PADILLA, M. (1966). Mesodermal alterations induced by hypervitaminosis A. *J. Embryol. exp. Morph.* **15**, 261–269.

MARIN-PADILLA, M. & FERM, V. H. (1965). Somite necrosis and developmental malformations induced by vitamin A in the golden hamster. *J. Embryol. exp. Morph.* **13**, 1–8.

MENKES, B., SANDOR, S. & ILIES, A. (1970). Cell death in teratogenesis. *Adv. Terat.* **4**, pp. 169–215.

MORRISS, G. M. (1972*a*). *The Teratogenesis of Hypervitaminosis A.* Ph.D. Thesis, University of Cambridge.

MORRISS, G. M. (1972*b*). Morphogenesis of the malformations induced in rat embryos by maternal hypervitaminosis A. *J. Anat.* **113**, 241–250.

MORRISS, G. M. (1973). An electron microscopic study of the effects of hypervitaminosis A on the maternal-embryonic relationship of the rat at 8 days of pregnancy. *J. Reprod. Fert.* **33**, no. 2 (in the Press).

MUKERJEE, H., RAM, J. S. & PIERCE, G. B. J. (1965). Basement membranes. V. Chemical composition of neoplastic basement membrane mucoprotein. *Am. J. Path.* **46**, 49–57.

NOVIKOFF, A. B. (1963). Lysosomes in the physiology and pathology of cells: contributions of staining methods. In *Ciba Fdn Symp. Lysosomes* (ed. A. V. S. De Reuck and M. P. Cameron), pp. 36–73. London: J. and A. Churchill.

NOVIKOFF, A. B. & ESSNER, E. (1962). Cytolysomes and mitochondrial degeneration. *J. Cell. Biol.* **15**, 140–146.

RAZ, A., KANAI, A. & GOODMAN, DE W. S. (1968). Retinol binding protein (RBP): a newly recognized plasma lipoprotein. *Fedn Proc. Fedn Am. Socs exp. Biol.* **27**, 594 (Abstr.).

SCHEIB, D. (1965). Sur la régression du canal de Müller mâle de l'embryon de poulet: localisation de la phosphatase acide au microscope éléctronique. *C. r. hebd. Séanc. Acad. Sci., Paris* **261**, 5219.

SCHULZ, R. L. (1969). Effects of ovariectomy and hypervitaminosis A on lysosomes of the rat conceptus. *Teratology* **2**, 283–296.

SEWARD, C. R., MITCHELL, G. V. & HOVE, E. L. (1969). Some aspects of vitamin A deficiency or toxicity in intermediary metabolism. *Am. J. clin. Nutr.* **22**, 1014–1016.

SEWARD, C. R., VAUGHAN, G. & HOVE, E. L. (1966). Effect of vitamin A deficiency or excess on the oxidative phosphorylation by rat liver mitochondria. *J. biol. Chem.* **241**, 1229–1232.

SPEMANN, H. (1918). Über die Determination der ersten Organanlagen des Amphibienembryos. I–IV. *Wilhelm Roux Arch. EntwMech. Org.* **43**, 448–555.

SWIFT, H. & HRUBAN, Z. (1964). Focal degeneration as a biological process. *Fedn Proc. Fedn Am. Socs exp. Biol.* **23**, 1026–1037.

TOIVONEN, S. (1967). Mechanism of primary embryonic induction. In *Primary Embryonic Induction*, vol. I (ed. E. Hagen, W. Wechsler and F. Zilliken), pp. 1–7. Exp. Biol. Med. Basel/New York: S. Karger.

WEISS, L. (1970). Some biophysical mechanisms of morphogenesis. In *Congenital Malformations* (ed. F. C. Fraser and V. A. McKusick), pp. 106–110. Amsterdam, New York: Excerpta Medica.

WOOLLAM, D. H. K. & MILLEN, J. W. (1960). The modification of the activity of certain agents exerting a deleterious effect on the development of the mammalian embryo. In *Ciba Fdn Symp. Congenital Malformations* (ed. G. E. W. Wolstenholme and H. O'Connor), pp. 158–172. London: J. and A. Churchill.

(*Received 18 December 1972, revised 20 February 1973*)

Morriss'73
Bib. No. 10747

J. Reprod. Fert. (1973) 33, 451–456

AN ELECTRON MICROSCOPIC STUDY OF THE EFFECTS OF HYPERVITAMINOSIS A ON THE MATERNAL–EMBRYONIC RELATIONSHIP OF THE RAT AT 8 DAYS OF PREGNANCY

GILLIAN M. MORRISS

Department of Anatomy, University of Cambridge, Cambridge, England

(*Received* 15*th May* 1972)

Summary. The decidual and trophoblastic tissue of the rat 5 hr after the maternal administration of 100,000 i.u. vitamin A palmitate has been studied using light and electron microscopy.

The experimental tissue showed an increase in the surface area of membranes comparable to that previously described in cultures in the presence of excess vitamin A. Lipid droplets which may consist of vitamin A were seen in the blood, and most of the membrane damage was close to the capillaries. Vacuolated and distorted blood cells were observed, and cell débris was present in the blood space around the embryo. Decreased oxygen-carrying capacity and increased peripheral resistance were suggested as maternal vascular factors which may complement the direct embryotoxic effect of vitamin A in the teratogenic mechanism.

INTRODUCTION

The teratogenicity of hypervitaminosis A was discovered by Cohlan (1953). Giroud, Gounelle & Martinet (1957) reported that the levels of vitamin A in 14-day embryos from female rats given 60,000 i.u. on Days 11, 12 and 13 were higher than the levels in 14-day control embryos, thus suggesting a direct teratogenic effect. Woollam & Millen (1960) combined the administration of vitamin A with other substances. They reported that the teratogenic activity was accentuated by cortisone and methylthiouracil, and that a protective effect was exerted by the B-group vitamins, insulin and, most markedly, by thyroxine. From these results, they postulated that the teratogenic mechanism was an interference with the carbohydrate metabolism of the mother, placenta or fetus. Their results were challenged by Cohlan & Stone (1961) but supported by Takekoshi (1964), who suggested that the fall in blood thyroxine levels caused by excess vitamin A was an important factor in the teratogenic mechanism and the reason for the potentiating effect of methylthiouracil.

Examination of the early effects on the embryo itself was made in the golden hamster by Marin-Padilla & Ferm (1965) and Marin-Padilla (1966). Using light microscopy, they noted early alterations in the mesoderm, and interpreted these as the cause of the abnormal development of the central nervous system.

Morriss (1972), using electron microscopy, studied the early changes in the cells of 8-day rat embryos following excess maternal vitamin A. She confirmed and extended the results of Marin-Padilla (1966). The ultrastructural changes were comparable to those described in various *in-vitro* situations of hypervitaminosis A (e.g. Jackson & Fell, 1963). It seems likely, therefore, that the teratogen has a direct effect on the embryo. The present paper describes the ultrastructural appearance of the decidual, trophoblastic and blood cells 5 hr after maternal vitamin A administration. These have been studied in order to determine whether any effects observable in this way might be implicated as maternal components of the teratogenic mechanism.

EXPLANATION OF PLATES

All micrographs show sections of 8-day pregnant rat tissues. Key to symbols: B, blood space; C, capillary; Co, collagen; D, decidual tissue; DCS, distorted cell surfaces; E, embryo; En, endoderm; ER, endoplasmic reticulum; L, lipid droplet; R, Reichert's membrane; SM, swollen mitochondria; T, trophoblast.

PLATE 1

Light micrographs

FIG. 1. Transverse section of the uterus of a control 8-day pregnant rat. Paraffin-wax-embedded section, stained H. & E. × 17.

FIG. 2. Control embryo, trophoblast and maternal tissues. Embryo (left) cut tangentially. In Araldite section, stained with toluidine blue. × 215.

FIG. 3. Transverse section of a control embryo (top), and the surrounding tissues. Araldite section, toluidine blue. × 860.

FIG. 4. Decidual tissue 5 hr after vitamin A administration. Lipid droplets in a capillary are arrowed. Araldite section, toluidine blue. × 860.

PLATE 2

Electron micrographs

FIG. 5. Controls: decidual tissue. The granular endoplasmic reticulum forms a mass of vacuoles varying in size from cell to cell. × 2260.

FIG. 6. Part of a decidual cell to illustrate the form of the endoplasmic reticulum. × 11,240.

FIG. 7. Decidual tissue, trophoblast, blood space and embryo. × 2230.

PLATE 3

FIG. 8. Section taken 5 hr after vitamin A administration: decidual tissue with capillary. Swollen mitochondria in endothelial cell and adjacent area of decidual cell; distorted cell surface; leucocyte with vacuoles (arrowed). × 8380.

FIG. 9. Part of a decidual cell containing swollen mitochondria, and having a greatly distorted cell surface. × 6700.

FIG. 10. Trophoblast with capillary containing several erythrocytes with vacuoles (arrowed). × 8400.

PLATE 4

FIG. 11. Trophoblast, blood space and embryo. Degenerating cells and cell components lie in the blood space in a disorganized manner, along with the maternal erythrocytes. × 1120.

FIG. 12. Swollen endoplasmic reticulum, mitochondria, ribosomes, lipid droplets and vacuolated and distorted erythrocytes in the blood space. Abnormal microvilli and cytoplasmic budding in the extraembryonic endoderm of the embryo. × 13,400.

PLATE 5

FIG. 13. Ectoplacental cone. Control section. Erythrocytes in various stages of phagocytosis and lysis by the trophoblast cells. × 3760.

FIG. 14. Section taken 5 hr after maternal vitamin A administration. Vacuolated erythrocytes; trophoblast cells with abnormal cytoplasm and pycnotic nuclei, showing no evidence of phagocytosis; large amount of collagen-like material. × 5550. Inset: collagen-like material. × 16,500.

PLATE 1

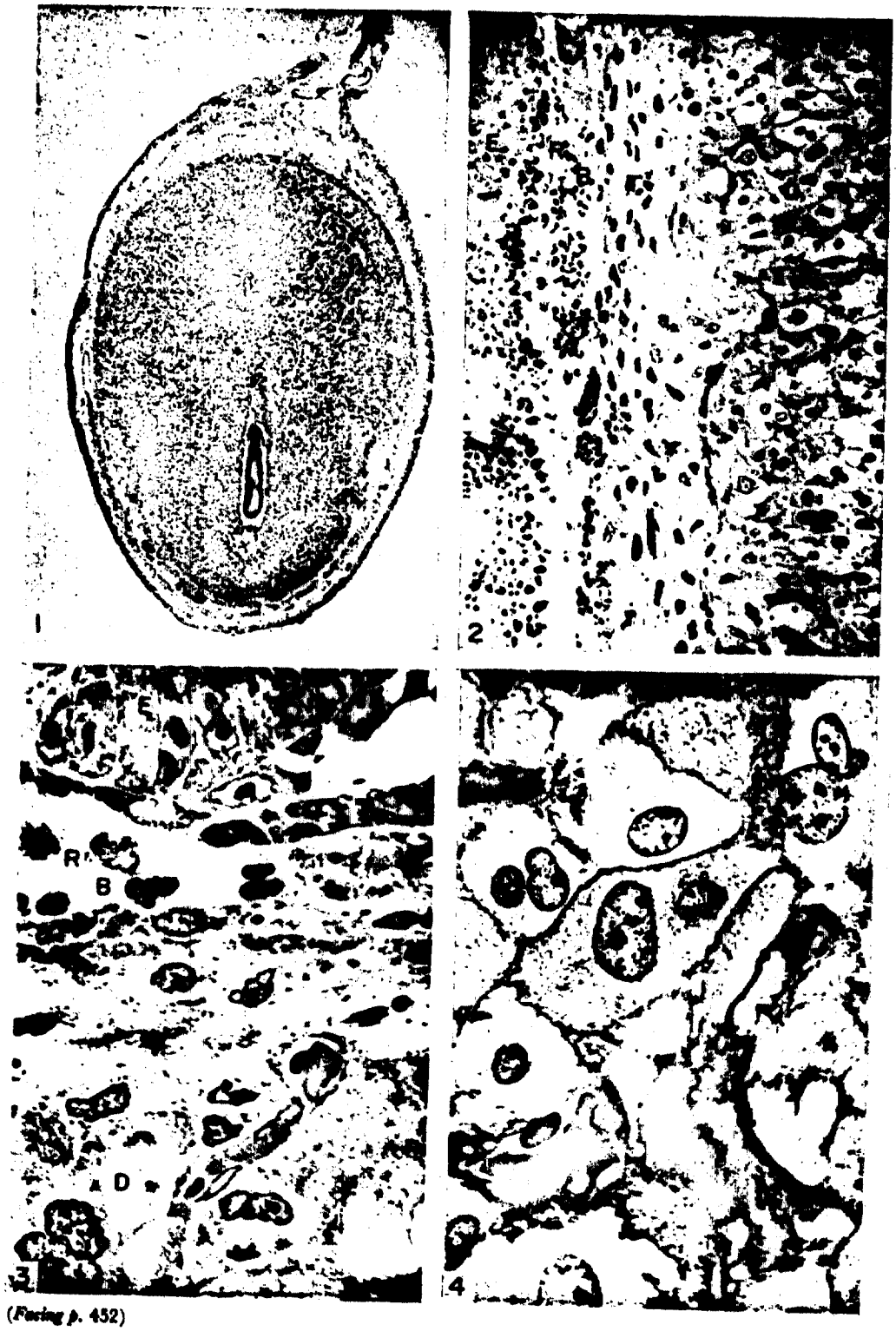

(*Facing p.* 452)

PLATE 2

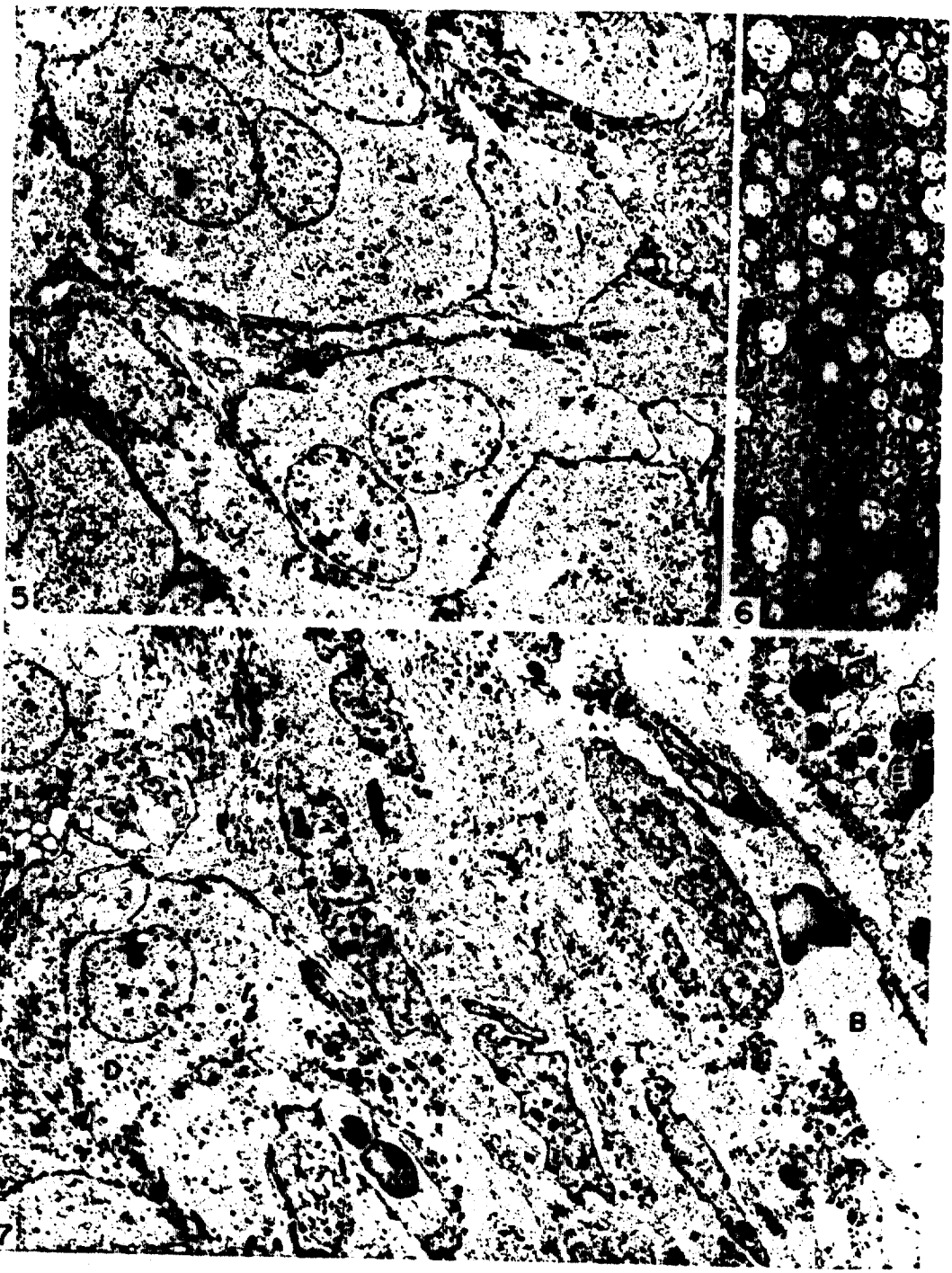

PLATE 3

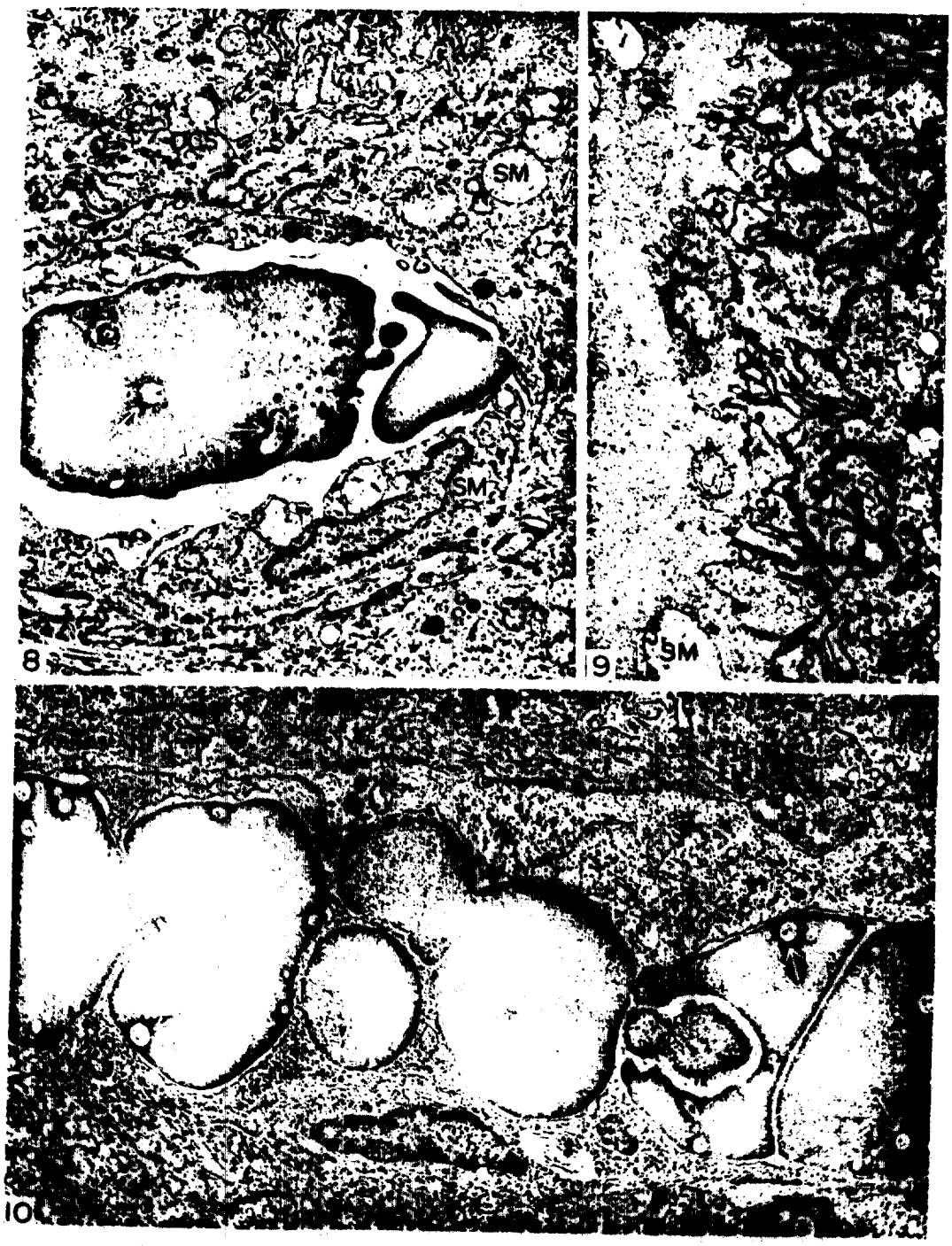

PLATE 4

PLATE 5

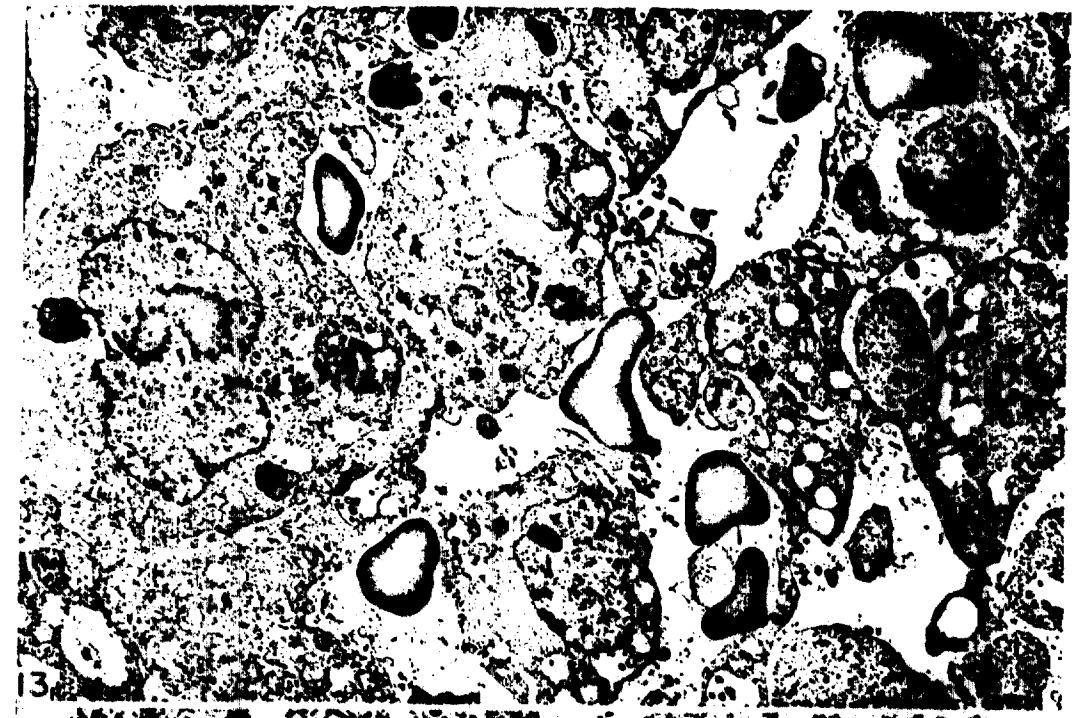

13

14

MATERIALS AND METHODS

Decidual tissue from 8-day pregnant rats was prepared as follows: after being removed from the uterus and placed in Tyrode saline, the pear-shaped decidua was trimmed to within 0·5 mm of the embryo on all sides. The trimmed tissue pieces containing embryos were fixed in 4% phosphate-buffered glutaraldehyde. They were then cut with a razor blade into pieces approximately 1 mm^3 in size. These were post-fixed in phosphate-buffered osmium tetroxide, dehydrated and embedded in Araldite. The final embedding was made directly in polythene capsules shaped ready for cutting, so that the orientation of the sections was a matter of chance. Suitable areas (cutting through embryo or ectoplacental cone in addition to decidual tissue) were found by the examination of thick sections with the light microscope. From these areas, thin sections were cut, double-stained in uranyl acetate and lead citrate, and viewed with a Philips EM 300 electron microscope.

Three control and four vitamin A-treated Wistar-derived rats were used. The day on which spermatozoa were found in the vaginal smear was designated Day 0 of pregnancy. The vitamin A preparation used was an aqueous suspension of vitamin A palmitate (Roche Products Ltd); it was administered subcutaneously between 09.00 and 09.30 hours on Day 8 of pregnancy.

OBSERVATIONS

The rat embryo on Day 8 of pregnancy is embedded in a mass of spongy decidual tissue which almost completely occludes the lumen of the uterus (Pl. 1, Fig. 1). Maternal blood from the uterine artery traverses the decidua by means of many small capillaries which open into the blood space surrounding the embryo (Pl. 1, Figs 2 and 3). Similar capillaries return the blood to the uterine vein. The embryo is thus surrounded by flowing maternal blood, from which it is separated only by Reichert's membrane. At the light microscope level, decidual tissue from rats killed 5 hr after vitamin A administration was indistinguishable from control tissue, except for groups of lipid droplets which were frequently observed within capillaries (Pl. 1, Fig. 4).

Electron microscopy of decidual tissue from control rats showed that the cells were irregular in shape and densely packed (Pl. 2, Fig. 5). The nuclei were rounded in section, and were frequently either U-shaped or two to the cell. The rough endoplasmic reticulum cisternae formed, to a greater or lesser degree in the different cells, a mass of vacuoles (Pl. 2, Fig. 6). The trophoblastic cells situated between the decidual cells and the embryo or blood space were flattened in shape, and contained irregular nuclei (Pl. 2, Fig. 7). By 5 hr after vitamin A administration, the cell surfaces were frequently observed to be greatly increased in area, being thrown into a mass of folds and protuberances. This was especially common close to the capillaries (Pl. 3, Figs 8 and 9), and swollen mitochondria were also common in these regions. The erythrocytes and leucocytes were frequently distorted or vacuolated (Pl. 3, Figs 8 and 10). In the blood space around the embryo, degenerating cells and cell components were present (Pl. 4, Fig. 11). Lipid droplets of moderate electron density were com-

mon, often in groups. Plate 4, Fig. 12 illustrates the close relationship between lipid droplets and vacuolated erythrocytes on one side of Reichert's membrane with an irregular appearance of the endodermal microvilli on the other.

Trophoblast cells from the ectoplacental cones of control rats formed a loose network in the meshes of which were many maternal erythrocytes and thrombocytes (Pl. 5, Fig. 13). These maternal cells were apparently engulfed by the trophoblast cells, undergoing subsequent degeneration by the formation of heterophagic vacuoles. In ectoplacental cone tissue from rats killed 5 hr after vitamin A administration, the cells appeared to be very irregular, both in shape and internal organization, compared with the controls (Pl. 5, Fig. 14). Clumping of material appeared to have taken place both in the cytoplasm and the nuclei. There was a large amount of collagen-like material between the cells. Fewer erythrocytes were seen within the cells, and those outside them were frequently vacuolated.

DISCUSSION

Within 30 min of a subcutaneous injection of vitamin A palmitate in the rat, electron microscopy of the maternal liver showed that large numbers of lipid droplets began to arrive in the sinusoids, from where they were engulfed by the Kupffer and hepatic cells; at the same time, an increase in the vitamin A content of these cells was demonstrable by fluorescence microscopy (G. M. Morriss, unpublished preliminary work for the present study). Geelen (1972) has shown a strong vitamin A fluorescence in the decidual cells of 9-day rat embryos following maternal injections of 50,000 i.u. vitamin A palmitate on 3 consecutive days. The fluorescence was concentrated around the capillaries and outside Reichert's membrane. The lipid droplets observed electron microscopically in the decidual capillaries and blood space in the present study are identical to those seen in the liver; the coincidence of the fluorescence in both situations provides additional evidence that they may consist of vitamin A. Further, vitamin A is a semi-saturated lipid and would be expected to have a moderate electron density, as is the case here. Such lipid droplets were also observed in the embryonic cells (Pl. 4, Fig. 11). Ganguly (1969) stated that vitamin A palmitate in the small intestine is hydrolysed to retinol before absorption by the mucosal cells, and re-esterified before passing into the lymph. A similar process may be involved in its transfer across Reichert's membrane.

The ultrastructural effects of excess vitamin A have previously been described in a number of situations *in vitro*: rat dermal fibroblasts (Dingle & Lucy, 1965; Daniel, Dingle, Glauert & Lucy, 1966); embryonic chicken skin (Jackson & Fell, 1963); erythrocytes (Glauert, Daniel, Lucy & Dingle, 1963). The effects were mainly on membranes, causing irregularities of the plasma membrane of the fibroblasts, swelling of mitochondria, vacuolation of the erythrocyte membranes, and an uptake of fluid by both chick epidermal cells and erythrocytes which suggested a change in membrane permeability. Vitamin A has also been shown to bring about an increase in the surface area of an 'artificial membrane', i.e. a lecithin/cholesterol monolayer (Bangham, Dingle & Lucy, 1964). Dingle & Lucy (1962) proposed that membranes might be a physiological site of the vitamin.

MARIN-PADILLA, M. (1966) Mesodermal alterations induced by hypervitaminosis A. *J. Embryol. exp. Morph.* 15, 261.

MARIN-PADILLA, M. & FERM, V. H. (1965) Somite necrosis and developmental malformations induced by vitamin A in the golden hamster. *J. Embryol. exp. Morph.* 13, 1.

MORRISS, G. M. (1972) *The teratogenesis of hypervitaminosis A.* Ph.D. thesis, University of Cambridge.

TAKEKOSHI, S. (1964) The mechanism of vitamin A induced teratogenesis. *J. Embryol. exp. Morph.* 12, 263.

WOOLLAM, D. H. M. & MILLEN, J. W. (1960) *The modification of the activity of certain agents exerting a deleterious effect on the development of the mammalian embryo.* In: Congenital Malformations, p. 158. Eds. G. E. W. Wolstenholme and M. O'Connor. Churchill, London.

NAS/NRC-'72
Bib No. 10763

INTEROFFICE CORRESPONDENCE

March 16, 1951

TO: Dr. E. L. Sevringhaus

FROM: L. O. Randall

RE: Chronic Toxicity of Synthetic Vitamin A (palmitate) in Rats and Dogs

The effects of synthetic vitamin A on the growth and blood picture of rats and dogs have been studied. Three preparations of vitamin A (1) Pure Vitamin A Palmitate, (2) Pharmaceutical Vitamin A Palmitate and (3) By-product Concentrate of Vitamin A Palmitate were used. These preparations have been fed five days per week to rats and dogs for ten months. The rats have been fed at three dose levels: (1) 10,000 units/kgm, (2) 25,000 units/kgm and (3) 50,000 units/kgm. The dogs have been fed at dose levels of (1) 1,000 units/kgm, (2) 5,000 units/kgm and (3) 25,000 units/kgm.

These doses were chosen to correspond to the tolerated human dose of vitamin A. The tolerated human dose is about 250 times the recommended daily allowance. The recommended daily allowance for good nutrition in human subjects is about 100 units/kgm of vitamin A (1,500 to 6,000 units from infancy to adulthood — National Research Council, 1948). Children can tolerate doses up to 25,000 units/kgm for a year but doses of 50,000 units/kgm are toxic (Josephs, Am. J. Dis. Child. 67:33, 1944; Toomey, Am. J. Dis. Child. 73:473, 1947).

Materials

Preparation	Lot No.	Potency units/gm.	Months fed to Rats	Months fed to Dogs
Pure Vitamin A Palmitate	CP 2	1,749,000	10	10
	CP 6	1,720,000	2	2
Pharmaceutical Vitamin A Palmitate	97	1,051,000	10	10
	92650	980,000	2	2
By-products Concentrate of Vitamin A Palmitate	40350	490,000	6	6
	92650	360,000	6	6

The various preparations of vitamin A palmitate were received from Dr. Surmatis. The pure vitamin A palmitate was about 95 per cent vitamin A; the pharmaceutical vitamin A palmitate was about 56 per cent

vitamin A; and the by-products concentrate of vitamin A palmitate was about 27 and 20 per cent vitamin A for the two preparations. These materials were assayed by Mr. DeWitter. The materials were then ampuled by Mr. Botticelli. Each ampul contained approximately one million units. The ampuls were kept in a refrigerator until needed. Stock solutions were prepared from the ampuls by measuring the oily material into purified corn oil. As antioxidants, Tocopherol (No. 2271X72-B) was added to the oil at a concentration of 10 mgm/million units of vitamin A and lecithin at 50 mgm/million units of vitamin A. These stock solutions were then diluted with corn oil to various concentrations which were necessary for dosing the animals.

Rats

Ten, weanling, male, Sprague-Dawley rats were fed on each dose of each vitamin A preparation and 30 rats were kept as controls. The rats were fed on Friskies dog chow. The vitamin A preparations were administered orally five days a week. The rats were weighed at weekly intervals.

The weight at the beginning of each week was used to calculate the dose for each animal for the week. The vitamin A preparations were diluted so that the dose per animal was contained in 0.1 cc. The rats were fed the vitamin materials by syringe five days per week.

The average weights of the rats are plotted against the weeks on experiment in Figure 1. The rats fed pure vitamin A palmitate (CP vitamin A palmitate) at 10,000, 25,000 and 50,000 units per kgm showed the same average growth rates as the control rats. The rats fed the pharmaceutical vitamin A palmitate (commercial vitamin A palmitate) at 10,000, 25,000 and 50,000 units per kgm showed the same average growth rate as the controls. The rats fed the by-products concentrate of vitamin A palmitate (vitamin A palmitate residue) at 50,000 units per kgm showed practically the same average growth rate as the controls. The rats fed 25,000 units per kgm had the same growth rate for 16 weeks and then showed a slightly smaller weight gain than the controls. The rats fed the lowest dose, 10,000 units per kgm, showed a falling off of the growth curve by the sixth week and the curve became flat after the 16th week. Since this effect occurred with the smallest dose, it is probably not a toxic effect of the vitamin A.

The blood counts on the rats were taken before beginning treatment and after 18 and 35 weeks of treatment. These average blood counts are given in Table 1. The white cell counts appear to be higher in the rats treated with vitamin A than the controls at both the 18 week period and the 35 week period. The rise in white count is not related to the preparation of vitamin A or to the dose. Since 10,000 units per kgm of vitamin A is already quite a high dose, it is not surprising that it should have the same effect as 50,000 units per kgm. The by-product concentrate shows no greater effect than the pure vitamin A. The red counts increased with age of the rats but the vitamin A itself appeared to have no effect. The red counts of the control rats apparently decreased between the 18th and 35th week while those of the treated animals

remained high. Hemoglobin values were normal throughout.

Table 2 shows the record of the sickness and death in the rats after various periods of treatment. A large number of the rats became sick with symptoms of colds during the experiment. The sickness rate did not seem to be related to the preparation of vitamin A fed on the dose level and occurred in the controls about as frequently as in the treated rats. The possibly higher number of sick rats in the group treated with the low dose of by-products concentrate may account for the poor growth rate in this group. The death rate seems slightly higher in the two groups treated with the lower doses of by-products concentrate.

Dogs

Mongrel beagle dogs were maintained on Friskies dog chow. The three vitamin A preparations were fed at dose levels of 1,000 units per kgm, 5000 units per kgm and 25,000 units per kgm to three dogs for each dose. The vitamin preparations were administered orally to each dog five days per week. The animals were weighed at weekly intervals. The weights at monthly intervals are given in Table 3. Dogs Nos. 1 and 21 died from pneumonia early in the experiment and Dog No. 7 died accidentally from choking on food. Most of the dogs added weight during the experimental period. Only two dogs on the pure vitamin A palmitate had about the same weight at the end as at the beginning of the experiment. Several dogs lost weight early in the experiment and then regained their weight but this was not related to the vitamin A intake. The various vitamin A preparations had no adverse effect on growth in the dogs.

Blood studies were made on the dogs at intervals of about 10 weeks. Red and white cell counts, hemoglobin and differential counts were measured. Inorganic phosphorus of serum was measured by the method of Fiske and Subbarow. Prothrombin times on oxalated plasma were measured by Quick's method. These results are summarized in Table 4. These data show no changes in hematology which can be attributed to vitamin A. The variations in red and white cell counts, hemoglobin, differential counts, inorganic phosphorus or prothrombin time were not related to the various preparations of vitamin A used nor to the various dose levels of vitamin A.

The plasma vitamin A levels in the dogs after six months of treatment were determined by the Carr-Price method. The values in Table 5 were obtained by Mr. DeRitter. The blood samples were taken in the morning 24 hours after the previous dose of vitamin A and again four hours after a dose of the vitamin.

The results show that all of the treated dogs have higher vitamin A plasma levels than the control dogs. There is a fair relation of the dose of vitamin A fed to the level found in the blood but there is considerable overlapping of the values. The vitamin A levels seem to be maintained throughout 24 hours since there is no consistent difference between the 4 hour and 24 hour levels. The three vitamin A preparations

produced about the same elevation of blood levels at the respective dose levels.

Summary

The oral chronic toxicity of three preparations of synthetic vitamin A palmitate, (1) Pure, (2) Pharmaceutical and (3) By-products Concentrate, has been studied at three dose levels in rats and dogs.

Rats have been fed the three preparations at dose levels of 10,000, 25,000 and 50,000 units per kgm for 10 months. Ten rats were treated at each dose level and 30 rats were fed the oil diluent alone. The pure vitamin A palmitate and pharmaceutical vitamin A palmitate had no adverse effect on growth, hematology or death rate. The by-product concentrate of vitamin A palmitate had no adverse effect at the highest dose level. The lower growth rate and higher incidence of death at the lowest dose of this preparation is probably not a toxic effect of the vitamin A preparation.

Dogs have been fed the three preparations at dose levels of 1,000, 5,000 and 25,000 units per kgm for 10 months. Three dogs were treated at each dose level and six were kept as controls. The plasma levels of vitamin A were elevated in proportion to the dose. The various vitamin A preparation had no adverse effect on growth or hematology in the dogs.

Lowell O. Randall

Lowell O. Randall

Workers:

M. Roe
R. Engelberg
P. Stofko

LOR:dec

Table 1

Average Values Obtained for Periodic Blood Counts of Rats Treated with Vitamin A

No. of Weeks on Expt.	Type of Vit. A Administered	Dose units/kgm	No. of Animals	WBC in Thousands	RBC in Millions	Hemoglobin gms/100 ml
0	Pure Vitamin A Palmitate	10,000	5	14.8	5.0	11.0
		25,000	5	14.5	5.1	11.0
		50,000	5	15.7	5.1	11.1
0	Pharmaceutical Vitamin A Palmitate	10,000	5	14.6	5.0	11.1
		25,000	5	15.4	5.0	10.8
		50,000	5	15.4	4.9	11.0
0	By-product Vitamin A Palmitate	10,000	5	14.4	5.1	11.1
		25,000	5	14.5	4.9	10.8
		50,000	5	15.7	5.0	11.3
0	Controls	—	15	14.4	5.2	11.7
18	Pure Vitamin A Palmitate	10,000	5	19.0	8.6	15.3
		25,000	5	18.2	7.9	14.4
		50,000	5	21.3	8.3	14.3
18	Pharmaceutical Vitamin A Palmitate	10,000	5	18.4	8.2	15.1
		25,000	4	22.9	8.1	15.1
		50,000	5	19.4	8.2	14.0
18	By-product Vitamin A Palmitate	10,000	5	16.8	8.7	14.9
		25,000	5	21.9	8.6	14.3
		50,000	5	26.6	8.2	14.2
18	Controls	—	15	12.7	8.5	15.5
35	Pure Vitamin A Palmitate	10,000	5	15.6	7.3	14.1
		25,000	5	16.5	7.1	13.9
		50,000	4	19.4	8.2	14.3
35	Pharmaceutical Vitamin A Palmitate	10,000	5	17.5	7.6	14.6
		25,000	4	15.7	7.7	13.8
		50,000	5	16.2	8.1	14.3
35	By-product Vitamin A Palmitate	10,000	4	18.0	9.1	15.1
		25,000	3	17.2	8.4	15.4
		50,000	5	18.2	8.4	14.9
35	Controls	—	15	13.9	6.9	14.9

Table 2

Record of Sickness and Death in Rats Treated with Vitamin A

Product Administered	Dose units/kgm	No. of Animals in Group	After 6 Wks. Treatment		After 12 Wks. Treatment		After 24 Wks. Treatment		After 45 Wks. Treatment		Per Cent	
			No. Sick	No. Dead	No. Sick	No. Dead	No. Sick	No. Dead	No. Sick	No. Dead	Sick	Dead
Pure Vitamin A Palmitate	10,000	10	-	-	-	-	1	-	3	-	30	-
	25,000	10	-	-	-	-	1	-	1	-	20	-
	50,000	10	4	-	1	-	1	-	1	-	40	20
Pharmaceutical Vitamin A Palmitate	10,000	10	3	-	-	-	1	-	3	-	50	-
	25,000	10	1	-	-	1	1	-	1	1	20	20
	50,000	10	-	-	-	-	-	-	2	-	20	-
By-product Concentrate of Vitamin A Palmitate	10,000	10	2	-	2	-	2	-	3	3	60	30
	25,000	10	1	-	1	-	2	-	2	4	40	40
	50,000	10	-	-	2	-	4	-	2	1	50	10
Controls	-	30	-	-	1	-	3	-	11	3	40	10

The symptoms noted in most of the sick rats, both treated and control animals, were: a mucous discharge from the nose, a slight bloody discharge from the nose or eye sometimes accompanied by wheezing and diarrhea. Occasionally the animals recovered, but many grew progressively worse, ate little, lost weight and finally died. Three rats listed as dead, one on the 50,000 unit dose of pure vitamin A and two controls, were sacrificed because they appeared moribund. The gross pathology observed in the animals that died or were sacrificed because they appeared to be dying, generally included a mucous-like exudate in the trachea, consolidation of a considerable portion of the lung sometimes accompanied by hemorrhagic areas or abscesses. Some rats have also shown hyperemic or hemorrhagic areas in the gastrointestinal tract, slight loss of hair or very small spleens.

Table 3

Weights of Dogs on Vitamin A Chronic Toxicity

Treatment	Dose units/kgm	Dog No.	MONTHS 1	2	3	4	5	6	7	8	9	10
Pure Vitamin A Palmitate	1,000	19	8.6	9.8	9.3	9.4	8.9	9.1	10.2	10.2	10.6	9.8
	"	20	5.6	6.8	7.9	7.6	7.3	7.7	8.2	8.6	9.3	8.2
	"	21	5.1	5.7	6.0	Died 8/11/50	-	-	-	-	-	-
	5,000	22	8.1	7.9	7.4	6.8	7.4	7.9	9.0	9.1	10.6	9.7
	"	23	9.3	9.0	9.2	8.7	8.3	8.6	8.1	8.5	9.8	8.6
	"	24	7.7	9.0	8.9	10.3	9.6	8.1	9.0	9.3	10.5	10.3
	25,000	25	6.8	8.4	9.5	9.4	9.7	9.7	9.3	9.0	10.6	11.3
	"	26	5.5	6.2	8.4	8.0	8.6	9.0	9.2	9.1	10.3	9.3
	"	27	7.3	6.8	6.7	6.2	6.0	7.3	7.0	7.7	7.8	7.6
Pharmaceutical Vitamin A	1,000	10	9.4	9.9	9.2	9.0	9.2	9.8	9.5	9.7	10.6	10.6
	"	11	6.8	7.4	7.4	7.3	7.4	8.7	9.2	9.5	9.1	8.4
	"	12	7.8	7.0	7.6	7.3	7.3	7.7	8.6	9.0	9.3	8.7
	5,000	13	5.3	6.5	6.3	5.8	5.8	6.1	7.3	7.4	9.0	8.9
	"	14	6.7	6.5	7.2	7.2	6.8	7.8	7.8	7.7	8.1	7.9
	"	15	5.8	6.5	7.1	6.5	6.6	6.6	7.5	7.2	8.0	9.0
	25,000	16	9.4	10.0	10.0	10.6	9.5	9.3	9.1	9.0	12.9	12.4
	"	17	9.4	10.0	10.5	10.1	9.8	9.4	9.1	9.0	12.2	12.3
	"	18	7.0	6.4	7.0	6.7	7.5	7.7	7.3	7.8	8.7	9.3
By-product Vitamin A	1,000	1	4.7	4.6	4.8	Died 8/21/50	-	-	-	-	-	-
	"	2	6.9	6.4	8.8	8.7	8.3	8.7	8.4	8.7	9.0	9.3
	"	3	7.2	7.8	7.1	9.2	9.5	9.3	10.2	10.9	12.4	11.2
	5,000	4	6.1	6.1	7.0	7.5	7.0	8.4	9.6	9.3	10.2	9.6
	"	5	5.9	5.9	6.5	6.2	6.0	7.3	7.6	7.7	9.2	8.1
	"	6	7.0	7.7	8.0	7.2	6.9	7.0	7.8	7.4	9.9	10.6
	25,000	7	8.6	7.9	8.1	8.3	8.3	8.0	8.3	Died 11/30/50	-	-
	"	8	5.2	6.4	8.2	8.1	7.9	7.9	9.4	9.6	10.7	10.5
	"	9	9.4	10.0	9.7	9.4	9.5	9.6	10.7	10.6	11.1	12.0
Controls		28	8.2	8.5	8.4	8.9	8.9	8.9	9.3	9.1	9.5	
		29	7.3	7.7	7.9	8.1	8.0	8.4	9.0	8.8	8.2	
		30	8.8	8.9	9.0	8.7	8.3	8.0	10.0	10.1	9.8	
		31	6.9	7.1	7.[illegible]	7.4	7.[illegible]	7.7	9.1	9.0	9.0	
		32	6.5	6.[illegible]	7.[illegible]	7.7	7.[illegible]	7.9	8.1	8.7	8.8	
		33	6.5	6.4	6.[illegible]	7.1	7.2	7.2	9.0	9.1	9.1	

Table 4

Hematology of Dogs Treated with Vitamin A

Dog No.	No. of Weeks	RBC in Millions	WBC in Thousands	Hemoglobin gms/100 ml.	Differential P	N	E	B	M	L	Inorganic Phosphorus mgm/100 ml.	Prothrombin Time
			Pure Vitamin A Palmitate 1000 units/kgm									
19	0	5.52	18.200	15.0	70	5	3	-	8	14	-	10.8"
	8	5.87	16.600	13.1	71	2	4	-	6	17	-	10.3"
	18	5.88	7.750	16.7	53	2	5	-	11	28	-	-
	28	6.44	9.350	16.1	55	4	10	-	4	27	4.37	-
	38	6.11	11.950	16.8	61	6	5	-	7	20	-	-
20	0	5.39	11.450	12.8	86	2	1	-	4	7	-	13.0"
	8	6.35	20.000	15.1	41	8	20	-	10	21	-	12.5"
	18	7.21	10.000	18.6	60	4	14	-	9	12	-	-
	28	7.14	7.900	16.9	61	4	14	1	6	14	3.00	-
	38	7.82	6.700	17.5	39	2	13	-	16	27	-	-
21	0	5.54	15.100	13.0	75	3	3	-	4	14	-	12.4"
	8	6.44	8.100	14.7	62	5	13	-	4	15	-	-
				Died								
			Pure Vitamin A Palmitate 5000 units/kgm									
22	0	6.23	35.100	14.6	80	-	2	-	9	9	-	11.4"
	8	5.68	41.200	12.6	64	2	8	1	8	15	-	8.3"
	18	5.96	14.600	14.7	51	5	8	-	20	16	-	-
	28	7.06	17.850	16.9	43	2	22	2	16	15	-	-
	38	6.91	18.650	16.9	41	2	26	-	15	16	-	-
23	0	6.54	11.400	14.2	61	2	5	-	10	21	-	12.0"
	8	5.07	12.600	13.0	53	6	8	1	8	24	5.0	-
	18	5.95	14.850	14.1	59	7	11	-	10	13	4.5	-
	28	6.92	11.950	14.1	61	1	5	-	10	23	3.0	-
	38	7.00	22.000	14.0	64	11	5	-	6	14	-	-

Table 4 (cont'd.)

Hematology of Dogs Treated with Vitamin A

Dog No.	No. of Weeks	RBC in Millions	WBC in Thousands	Hemoglobin gms/100 ml.	Differential P	N	E	B	M	L	Inorganic Phosphorus mgm/100 ml.	Prothrombin Time
24	0	6.52	7.650	16.0	74	7	2	-	9	8	-	12.1*
	8	4.85	27.200	10.3	75	3	4	-	4	13	4.4	11.8*
	18	5.11	13.550	13.0	69	7	6	-	11	5	4.0	-
	28	5.51	22.100	13.9	71	7	8	-	6	7	-	12.5*
	38	5.85	17.500	12.8	67	4	10	-	9	10	-	-
				Pure Vitamin A Palmitate 25,000 units/kgm								
25	0	7.00	10.800	17.3	56	2	6	-	12	23	-	11.5*
	8	4.66	10.500	12.0	68	7	8	-	5	10	-	-
	18	5.57	11.450	15.0	70	10	6	-	6	8	-	-
	28	7.31	10.250	16.8	58	6	9	-	11	15	3.64	-
	38	5.73	12.350	14.3	62	15	8	-	9	6	-	-
26	0	5.11	5.750	12.8	45	4	7	-	14	30	-	12.2*
	8	4.66	15.750	11.0	63	4	7	-	8	15	4.8	-
	18	5.68	20.100	13.1	74	3	8	-	3	12	6.4	-
	28	5.73	14.450	13.7	63	11	10	-	3	12	-	-
	38	7.00	13.950	14.0	58	5	21	-	11	5	-	-
27	0	5.73	6.850	12.5	63	2	9	-	5	20	-	13.0*
	8	5.24	17.000	12.4	70	1	12	-	6	11	4.7	-
	18	5.6	10.950	12.6	73	1	8	-	5	13	5.6	-
	28	4.75	40.700	12.8	83	2	1	-	9	5	3.73	-
	38	6.71	12.050	14.9	65	2	11	-	7	15	-	-

Table 4 (cont'd.)

Hematology of Dogs Treated with Vitamin A

Dog No.	No. of Weeks	RBC in Millions	WBC in Thousands	Hemoglobin gms/100 ml.	Differential P	N	E	B	M	L	Inorganic Phosphorus mgm/100 ml.	Prothrombin Time
			Pharmaceutical Vitamin A Palmitate 1000 units/kgm									
10	0	6.86	14.800	16.8	59	2	12	2	10	15	-	11.2"
	8	7.16	13.650	16.1	49	10	6	-	14	21	-	11.0"
	18	6.92	18.450	16.8	38	4	16	1	8	33	-	12.5"
	28	6.34	18.150	15.3	42	4	12	1	12	29	-	10.1"
	38	7.10	20.550	16.6	48	4	16	0	7	25	-	-
11	0	5.69	11.800	14.5	56	11	3	1	14	14	-	13.7"
	8	5.07	19.650	12.6	49	8	8	1	8	25	-	12.5"
	18	5.47	21.250	14.6	50	6	7	-	10	27	-	13.4"
	28	6.09	12.150	14.3	60	13	3	1	7	16	4.16	-
	38	5.90	15.400	16.6	59	6	-	7	10	24	-	-
12	0	5.82	20.600	12.8	69	2	5	1	5	18	-	11.5"
	8	6.65	19.650	14.4	56	3	6	-	10	22	-	12.0"
	18	6.27	13.000	14.2	47	6	10	-	6	30	-	-
	28	6.61	18.350	15.2	50	7	2	1	11	29	-	9.9"
	38	7.22	15.600	15.1	56	6	8	2	11	17	-	-
			Pharmaceutical Vitamin A Palmitate 5000 units/kgm									
13	0	6.10	15.200	13.6	59	4	10	-	4	23	-	12.0"
	8	5.68	20.250	13.0	54	6	10	-	5	25	-	-
	18	5.99	14.800	15.3	54	5	12	-	7	22	-	-
	28	5.54	13.100	15.0	59	5	3	-	10	23	-	12.3"
	38	6.48	13.500	14.9	47	10	5	3	11	22	-	-
14	0	6.0	8.650	13.6	55	4	-	-	2	39	-	12.3"
	8	7.19	18.350	15.1	50	9	3	1	5	31	-	10.0"
	18	6.60	11.050	15.9	53	9	3	1	10	22	-	-
	28	6.23	14.650	16.0	56	9	6	-	8	21	-	-
	38	5.94	24.000	14.9	70	6	2	-	9	13	-	-

Table 4 (cont'd.)

Hematology of Dogs Treated with Vitamin A

Dog No.	No. of Weeks	RBC in Millions	WBC in Thousands	Hemoglobin gms/100 ml.	Differential P	N	E	B	M	L	Inorganic Phosphorus mgm/100 ml.	Prothrombin Time
15	0	5.40	20.000	13.9	73	7	2	-	10	8	-	11.6*
	8	5.02	21.000	13.1	63	13	6	-	7	11	-	11.0*
	18	6.64	11.800	15.0	55	9	7	1	8	20	-	-
	28	5.05	27.500	13.5	65	13	3	1	10	8	4.55	-
	38	6.44	22.850	14.7	53	15	3	-	18	11	-	-
			Pharmaceutical Vitamin A Palmitate 25,000 units/kgm									
16	0	5.34	21.000	12.1	60	12	3	-	10	14	-	11.7*
	8	5.59	13.250	13.1	42	11	8	-	9	29	-	11.2*
	18	6.26	14.750	14.9	54	11	15	-	7	13	-	-
	28	6.49	14.950	15.1	57	5	13	-	6	19	-	10.2*
	38	7.33	12.200	16.0	49	10	12	-	9	20	-	-
17	0	6.64	28.150	13.1	73	6	5	-	2	14	-	11.0*
	8	5.58	16.700	12.9	68	7	9	-	9	7	-	9.6*
	18	6.55	12.900	15.9	44	9	13	-	12	22	-	-
	28	6.05	13.850	14.9	64	7	15	-	4	10	3.84	-
	38	7.00	14.500	15.1	56	8	12	-	8	15	-	-
18	0	7.45	24.800	19.2	70	6	1	-	7	16	-	12.3*
	8	5.27	11.400	12.9	64	8	5	-	4	15	-	-
	18	6.06	6.050	16.3	64	12	4	-	7	12	-	-
	28	5.9	16.600	15.0	65	11	6	-	8	8	-	11.2*
	38	7.00	12.600	14.8	56	9	3	-	11	20	-	-

Table 4 (cont'd.)

Hematology of Dogs Treated with Vitamin A

Dog No.	No. of Weeks	RBC in Millions	WBC in Thousands	Hemoglobin gms/100 ml.	Differential P	N	E	B	M	L	Inorganic Phosphorus mgm/100 ml.	Prothrombin Time
By-product Vitamin A 1000 units/kgm												
1	0	4.72	10.400	10.9	64	2	4	-	7	23	-	14.2*
	8	6.66	20.550	13.2	69	4	2	-	4	19	-	13.5*
				Died								
2	0	5.43	9.300	13.0	67	11	3	-	6	13	-	13.0*
	8	4.37	35.400	10.5	63	13	3	1	14	6	-	10.2*
	18	5.55	9.000	13.5	46	2	-	-	9	43	-	10.7*
	28	4.58	11.950	11.7	61	7	2	-	7	23	-	11.5*
	38	5.38	8.400	12.8	62	6	3	-	14	15	-	11.2*
3	0	5.21	8.000	12.5	67	2	10	-	11	10	-	12.0*
	8	5.01	12.350	11.4	53	-	16	1	4	23	-	11.8*
	18	5.05	5.700	14.7	66	3	4	1	10	16	-	10.8*
	28	6.25	10.200	14.8	65	1	8	-	11	14	-	11.5*
	38	5.29	11.950	13.9	68	2	15	-	5	10	-	15.0*
By-product Vitamin A 5000 units/kgm												
4	0	5.31	9.000	13.1	51	5	8	-	15	21	-	12.3*
	8	5.63	28.450	13.2	65	2	4	-	13	14	-	-
	18	5.85	11.900	14.7	50	13	14	-	16	7	-	13.4*
	28	5.71	18.950	14.1	54	9	6	-	9	20	-	12.5*
	38	6.51	9.150	15.1	59	8	2	-	11	18	-	11.5*
5	0	4.22	4.800	10.3	61	6	2	-	14	17	-	13.7*
	8	4.87	14.700	9.5	72	3	8	-	10	6	-	-
	18	5.23	8.600	11.4	56	9	2	-	19	14	-	13.5*
	23	6.9	12.400	14.0	53	7	2	-	21	17	-	13.1*
	38	7.00	18.050	16.8	65	7	11	-	6	10	-	11.4*

Table 4 (cont'd.)

Hematology of Dogs Treated with Vitamin A

Dog No.	No. of Weeks	RBC in Millions	WBC in Thousands	Hemoglobin gms/100 ml.	Differential P	N	E	B	M	L	Inorganic Phosphorus mgm/100 ml.	Prothrombin Time
6	0	6.8	13.300	16.3	79	5	2	-	6	8	-	11.9"
	8	4.16	8.900	15.5	56	2	12	-	7	22	-	12.5"
	18	6.18	16.850	13.4	67	1	7	2	8	15	-	10.9"
	28	6.29	22.600	15.9	60	4	9	-	11	16	-	12.9"
	38	5.97	16.950	15.1	53	6	10	-	13	17	-	10.9"
By-product Vitamin A 25,000 units/kgm												
7	0	4.61	9.950	11.7	80	1	2	-	6	8	-	14.1"
	8	5.83	10.700	12.8	65	2	3	-	9	20	-	14.0"
	18	6.9	11.300	16.2	44	8	9	-	10	29	-	13.0"
				Died								
8	0	5.46	7.900	13.4	66	3	1	-	6	24	-	14.0"
	8	5.60	20.450	12.6	74	4	3	-	6	12	-	11.0"
	18	7.36	10.250	16.8	61	4	9	-	13	13	-	12.5"
	28	6.95	13.600	15.1	57	4	9	-	10	20	-	-
	38	7.50	14.100	15.9	58	3	10	-	8	20	-	-
9	0	6.07	13.100	15.0	67	13	2	-	6	12	-	11.0"
	8	6.90	11.250	16.8	60	2	6	-	4	2	-	10.6"
	18	6.29	13.150	14.8	55	7	1	-	14	20	-	11.8"
	28	6.05	13.300	15.1	54	4	5	-	5	30	-	13.7"
	38	6.69	9.150	15.7	52	2	5	-	11	30	-	-

Table 4 (cont'd.)

Hematology of Dogs Treated with Vitamin A

Dog No.	No. of Weeks	RBC in Millions	WBC in Thousands	Hemoglobin gms/100 ml.	Differential P	W	E	B	M	L	Inorganic Phosphorus mgm/100 ml.	Prothrombin Time
					Controls							
28	0	4.94	17.550	12.4	60	2	5	-	12	21	4.8	12.8"
	8	6.16	12.400	16.0	62	10	2	-	8	18	-	-
	18	6.17	8.450	15.9	63	17	3	-	7	10	-	12.7"
	28	5.39	13.050	13.1	70	8	1	-	13	7	-	-
29	0	7.43	9.050	17.1	49	4	4	-	10	33	-	12.3"
	8	5.62	11.050	13.1	71	1	5	-	8	15	3.7	-
	18	5.57	16.900	14.1	67	4	6	-	6	15	-	-
30	0	5.51	16.900	14.5	34	12	9	-	14	31	-	-
31	0	5.51	24.900	14.7	65	9	2	-	11	12	-	-
32	0	6.49	15.650	17.0	66	14	4	-	8	8	-	-
	8	6.98	8.550	16.3	74	3	5	-	6	11	-	11.0"
	18	7.20	10.900	15.5	63	6	4	-	14	12	4.16	-
33	0	6.17	15.700	15.0	43	11	8	-	13	24	-	-
	8	6.44	7.100	17.1	55	3	11	-	6	23	-	10.7"
	18	6.89	15.250	14.3	72	4	4	-	7	12	-	-

Table 5

Plasma Vitamin A Levels in Dogs After Six Months of Treatment

Dog No.	Treatment	Plasma Vitamin A units/cc 24 hr.	4 hr.
	Pure Vitamin A Palmitate		
19	1,000 units/kgm	16.7	17.3
20	" "	20.6	24.3
21	" "	-	-
22	5,000 units/kgm	27.7	31
23	" "	70	63
24	" "	29.3	31
25	25,000 units/kgm	139	155
26	" "	175	159
27	" "	146	119
	Pharmaceutical Vitamin A Palmitate		
10	1,000 units/kgm	34	27.8
11	" "	44	31
12	" "	21.3	26.2
13	5,000 units/kgm	20.8	24.3
14	" "	46	66
15	" "	90	104
16	25,000 units/kgm	66	105
17	" "	96	118
18	" "	97	106
	By-product Vitamin A Palmitate		
1	1,000 units/kgm	-	-
2	" "	19.7	27.1
3	" "	22.8	29.6
4	5,000 units/kgm	18.0	23.8
5	" "	45	67
6	" "	48	45
7	25,000 units/kgm	50	38
8	" "	118	92
9	" "	114	88
28	Control	7.5	8.3
29	"	2.94	2.94
30	"	4.3	4.3
31	"	2.66	2.50
32	"	6.6	6.4
33	"	5.1	4.2

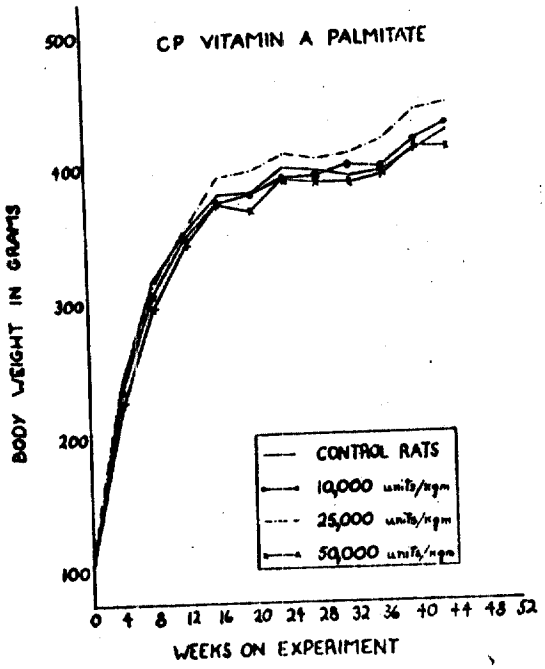

Figure 1A

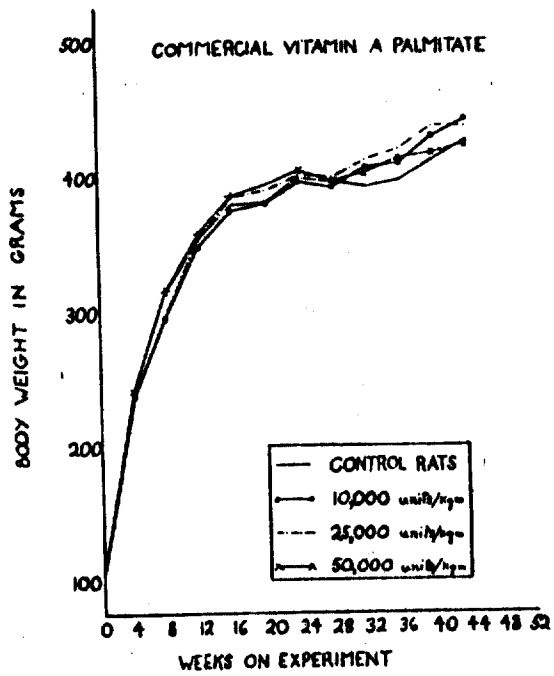

Figure 1B

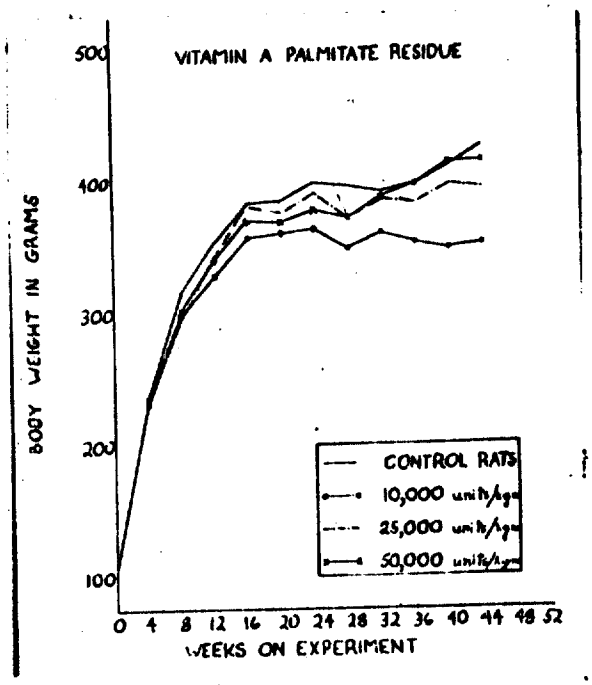

Figure 1C

NAS/NRC-'72
Bib No. 10763

Hypervitaminosis A -
Its Effect on the Incisor of the White Rat

Ph. Conne, L.-J. Baume, W.F. Kerner and H. Weiser

Hypervitamosis A - It's Effect on the Incisors of the White Rat

Works on the effects of hypervitaminosis A on dental tissue are few in number. Irving (1949) describes a reduction in the formation of the alvcolar bone, a decreased affixing of the dentin of the rat's incisor as well as thinning of the predentin layer. The odontoblast cells become wasted away principally on the lingual wall. According to Gorlin and Chaudhry (1959), atrophy of the odontoblast cells and the reduced dental affixture might have been due to the loss of appetite. For these authors, the increase of vascularization of pulp and periodontium is the only change specific to hypervitaminosis A at the dental tissue level. Studying in vitro the effects of an excess of vitamin A on the roots of rats' molars, Holloway and Mellanby (1961) observed a delayed development particularly at the cuspid level. The histodifferentiation of the enamel part is severely affected.

The aim of this work is to study the effects of hypervitaminosis A on the incisor of the white rat by means of radiography, histology, and microradiography, and to compare them with recent data concerning the effects of hypovitaminosis A on the same tissue (Conne, Korner and Baume, 1968, 1969; Baume, Conne and Korner, 1969; Conne and Baume, 1969).

Material and Method

Female Wistar rats received a diet containing 100 I.U. of vitamin A per week (Conne et al. 1968) from the time they were 30 days old (about 75 g. weight). After the castration of the animals at 42-43 days old, the same diet was continued. When they reached a weight of 150 g. the animals were divided into two groups. Seven among them (group 1) then additionally received 25'000 I.U. of vitamin A each day by mouth (water y dispersion; Arovit drops) for two weeks. The six other animals (group 2) served as control. During these 14 days, in the group 1 animals an evident hypervitaminosis A appeared; they were sacrificed at 54-55 days old. The six control rats were sacrificed between 70 and 124 days old.

After decapitation, the heads had been radiographed dorsally, then cut sagittally according to a slightly paramedian axis. Each half-head was radiographed in turn. The half-heads having a nasal septum were fixed in a 10% formaldehyde solution, then decalcified in a Rychlo solution. They had then been covered with either paraffin or celloidin. The sections had been stained with HE, PAS, Mallory, alcian blue and Hale. The incisive block of the other half-head had been taken out with its alveolar bone and covered with methyl methacrylate. The eroded sagittal sections were made, then microradiographed by means of a Hilger HRX diffractograph. The details concerning the covering, the eroded sections, and the microradiography had been given in a preceding report (Conne, Korner and Baume, 1968).

Results

1. Clinical aspect. The hypervitaminosis rats were in a complete state of marasm (Fig. 1 and 2). Their size and their weight represented about half of that of the control rats* at the end of the experiment. They were moribund; two of them died spontaneously the day before the date they were to be sacrificed.

2. Radiography aspect. The half-head of a control rat radiographed is presented as figure 3. The cephalogram of a hypervitaminosis rat shows a weaker density of bony structures (Fig. 4). The size of the incisors is reduced, their dentinal wall is thin.

3. Histology aspect. Concerning the general morphology of the incisor, a sagittal section of the control rat's upper incisor shows slight deterioration which could have been due to either the synthetic diet or to the gonadectomy. The labial contour is undulated and the dentinal structure is irregular (Fig. 5).

---

* Their skins were dirty and had the appearance of "damp fur".

The incisor of the hypervitaminosis rat is of reduced size (Fig. 6). The bloody congestion of the pulp and the desmodont is the predominant symptom. The dentinal walls are thin while the pulpal and desmodontal spaces are enlarged. The fibrodentin plug enclosing the pulp at the incisor edge is reduced.

The dorsal cervical loop of the control rat's incisor is formed by the external and internal adamantine epithelia between which is found the stratum intermedium (Fig. 7). This organ, in the hypervitaminosis rat, is rendered voluminous by the enlargement of the stratum intermedium (Fig. 8). The boundary between the epithelial tissues and the pulpal mesenchyme is clearly marked by a dense basal membrane.

The adamantine epithelium of a control rat and the matrix formation of the enamel in its initial calcification process are presented as figure 9. The same area in a hypervitaminosis rat is shown as figure 10. The prismatic structure of the enamel is regular. At the adamantine epithelium level the ameloblasts and the papillary layer are regular and well differentiated.

A part of the labial dentin wall is visible on the same section (Fig. 9 and 10). One notices between the odontoblasts and the calcified dentin a thin band representing the predentin. In the hypervitimanosis rat this predentin is narrower (Fig. 10). The dentinal structure appears to be more regular than in the control rat.

4. Microradiographic aspect. The microradiographic data are in accord with the histologic observations. The size of the incisor is reduced, the dentinal walls are thin (Fig. 11). The fibrodentin plugs badly enclose the pulp. The enamel presents some irregularities at the calcification level (Fig. 12). The dentin is regularly calcified. The dentin-predentin border is a clear and straight line.

Discussion

The radiographic, histologic and microradiographic observations of the incisor of the white rat with hypervitaminosis A, compared with recent data on hypovitaminosis A (Conne, Korner and Baume, 1968 & 1969; Baume, Conne and Korner, 1969; Conne and Baume, 1969), contribute some exact data concerning the effects of vitamin A on dentinogenetic and amelogenetic tissue.

Dentinagenesis.

In agreement with the observations of Irving (1949) and Gorlin and Chaudhry (1959), a reduction of the dentinal affixing on all the walls of the hypervitaminosis rat's incisor is noticed. The pulp and the desmodont are strongly vascularized and hyperemic. It is to be noticed that the thinning down of the dentinal walls takes place on the whole circumference of the teeth, contrary to that which is seen in the hypovitaminosis rat. In the latter, only the wall recovered with cement becomes thin whereas the wall recovered with enamel becomes thick (Wolbach & Howe, 1933; Schour, Hoffmann, and Smith, 1941; Irving, 1949; Conne, Korner, and Baume, 1968, 1969). The hypothesis of a compensation thickening of the labial wall described by Schour, Hoffmann and Smith (1941) and Sessle (1966) in the hypovitaminosis rat does not appear valid in the hypervitaminosis rat. This phenomenon is probably due to a greater rigidity of the incisor thanks to a better amount of calcification in the hypervitaminosis rat. In effect, the influence of hypervitaminosis A on the dentinogenesis is only noticable by the thinness of the predentin. The calcification is very regular. On the other hand, in the hypovitaminosis rat, all the authors agree in seeing a delay in the calcification which, in addition, is irregular and takes place at the formation of interglobular dentin.

Amelogenesis.

The cervical loop of the hypervitaminosis rat is dilated by the swelling of the stratum intermedium. The basal membrane separating the adamantine epithelium from the pulpal mesenchyme is clear and dense. The phenomenom inversed had been observed in a hypovitaminosis case (Conne, Korner, and Baume, 1969) in which is noticed a decrease in volume of the stratum intermedium and intermittent effacement of the basal membrane. The identical variations of the basal membrane had been observed with the gingival epithelium of the hypovitaminosis and hypervitaminosis rat (Franquin, Korner, Weiser and Baume, 1969).

Contrary to hypovitaminosis A, hypervitaminosis appeared to have a protective effect on the formation of the papillary layer and the matrix of the enamel. With the exception of some little important irregularities, visible in the mineralization zone of the enamel and probably due to some changes of the matrix, the amount of enamel calcification seems normal, except increased.

The data of this study confirm that it is necessary to look for the point of attack of vitamin A at the stratum intermedium level.

Conclusions

The boundary between the specific effects and the secondary effects of hypervitaminosis A on the incisor of the white rat is difficult to destinguish. For Gorlin and Chaudhry, only an increase in vascularization would be a specific effect of hypervitaminosis A.

It seems however that the intervening changes at the stratum intermedium level of the hypervitaminosis rat as much as the hypovitaminosis rat were due to a direct action of vitamin A.

As for the incidence of hypervitaminosis A on the calcification processes, experiments associating hypervitaminosis A and the calcium deficiency in the rat (Moore, 1965), have shown little importance at the bone level. Concerning the dentin, which does not undergo bone changes, the regularity of its structure and its calcification would seem to confirm this thesis. Quantitative mineral analysis has however revealed a higher amount of Ca and P in the incisor of the hypervitaminosis rat (Leaver and Trifitt, 1964)

It is interesting to note that in spite of the advanced state of marasm of the experimental animals, the dental lesions, macroscopic as well as histologic were not very important. In the hypovitaminosis rat, on the contrary, the serious dental lesions had been observed in animals whose general state was only a little affected (Conne, Korner, and Baume, 1968, 1969; Baume, Conne and Korner, 1969; Conne and Baume, 1969).

SUMMARY

HYPERVITAMINOSIS A - EFFECTS ON THE RAT INCISOR

Of 13 white castrated female Wistar rats 7 rats received from the 150 gr weight stage on during 2 weeks a daily dose of 25'000 I.U. of Vitamin A while 6 littermates received the control diet described previously. The upper incisors were studied radiographically, histologically and microradiographically.

The experimental rats aged 54 - 55 days were in a terminal state of marasm. The principal observation made in the incisor concuring with the few data reported in the literature, was an accrued vascularization of pulp and periodontium, accompagnied by a generally reduced thickness of dentin.

In the enamel organ an increase in bulk of the stratum intermedium was particularly obvious at the cervical loop. In view of the opposite effect observed in the deficiency state, Vitamin A seems to influence specifically this particular layer of enamel epithelium.

Matrix formation of enamel and dentin was regular as far as its structure was concerned, but it was reduced in width.

The calcification process in enamel and dentin contrary to the deficiency state seemed little disturbed leading to rather hypercalcified dental tissues such as also known of bones which, however, are susceptible to spontaneous fractures.

LEGENDS

Fig. 1 Control rats before sacrifice at the age of 55 days are shown.

Fig. 2 Experimental rats before sacrifice at the age of 54 days are shown.

Fig. 3 The lateral cephalogram of a bisected control rat aged 74 days is shown. 2 x.

Fig. 4 The lateral cephalogram of a bisected hypervitaminotic rat aged 53 days is shown. 2 x.

Figs 5 - 6 Midsagittal histologic section of the upper incisor is seen. H.E., 7,5 x.

Fig. 5 The aspect of a control rat aged 74 days is given.

Fig. 6 The aspect of an experimental rat aged 55 days is given.

Figs 7 - 8 Midsagittal sections of the cervical loop of the odontogenic epithelium are seen. H.E., 150 x.

Fig. 7 The aspect in a control rat aged 70 days is seen.

Fig. 8 In the experimental rat aged 54 days the stratum intermedium is markedly enlarged.

Figs 9 - 10 Midsagittal sections of the labial portion of the incisor in the region of initial enamel calcification are shown. H.E., 250 x.

Fig. 9 The aspect of a control rat aged 70 days is given.

Fig. 10 The aspect of an experimental rat aged 54 days is given.

Fig. 11 Microradiogram of a midsagittal groundsection of the upper incisor of an experimental rat aged 55 days is presented. 7,5 x.

Fig. 12 Higher magnification of the portion indicated in Fig. 11. 250 x.

BIBLIOGRAPHIE

BAUME, L.J./ CONNE, Ph./ KÖRNER, W.F.

Progressive atrophy and elimination of the upper rat incisor after prolonged vitamin A deficiency.

J.dent.Res. 48 : 330; 1969.

CONNE, Ph./ KÖRNER, W.F./ BAUME, L.J.

Les effets d'une hypovitaminose et d'une avitaminose A de plus en plus prolongées sur l'incisive du rat blanc.

I. Données radiographiques et microradiographiques qualitatives.

Rev.mens.suisse Odonto-stomatol. 78 : 1061; 1968.

CONNE, Ph./ KÖRNER, W.F./ BAUME, L.J.

Les effets d'une hypovitaminose et d'une avitaminose A de plus en plus prolongées sur l'incisive du rat blanc.

II. Données histologiques.

Rev.mens.Suisse Odonto-stomatol. 79 : 667; 1969.

CONNE, Ph./ BAUME, L.J.

Calcification de l'émail et de la dentine de l'incisive du rat blanc carencé en vitamine A.

Etude comparative histologique et microradiographique.

J.Canad.dent.Ass. (sous presse).

FRANQUIN, J.-C./ KÖRNER, W.F./ WEISER, H./ BAUME, L.J.

L'épithélium gingival du rat blanc soumis à une carence en vitamine A et à une hypervitaminose A.

I. Etude morphologique.

Rev.mens.Suisse Odonto-stomatol. 79 : 926, 1969.

GORLIN, R.J./ CHAUDHRY, A.P. The effect of hypervitaminosis A upon the incisor and molar teeth, the alveolar bone and temporomandibular joint of weanling rats.
J.dent.Res. 38 : 1008; 1959.

HOLLOWAY, P.J./ MELLANBY, M. The effect of hypervitaminosis A on the development of rat tooth germs in tissue culture.
Archs.oral Biol. 5 : 190; 1961.

IRVING, J.T. The effects of avitaminosis and hypervitaminosis A upon the incisor teeth and incisal alveolar bone of rats.
J.Physiol.(London) 108 : 92; 1949.

LEAVER, A.G./ TRIFFITT, J.T. Certain effects of hypervitaminosis A on the composition of the rat femur and incisor.
J.dent.Res. 43 : 957; 1964.

MOORE, T. Vitamin A deficiency and excess.
Proc.Nutr.Soc.(Engl.,Scot.) 24 : 129; 1965.

SCHOUR, I./ HOFFMANN, M.M./ SMITH, M.C.
Changes in the incisor teeth of albino rats with Vitamin A deficiency and the effect of replacement therapy.
Amer.J.Path. 17 : 529; 1941.

SESSLE, B.J. Retorded incisor eruption, general characteristics of the vitamin A deficient rat.
J.oral Ther.Pharmacol. 3 : 223; 1966.

WOLBACH, S.B./ HOWE, P.R. The incisor teeth of albino rats and guinea pigs in vitamin A deficiency.
Amer.J.Path. 9 : 275; 1933.

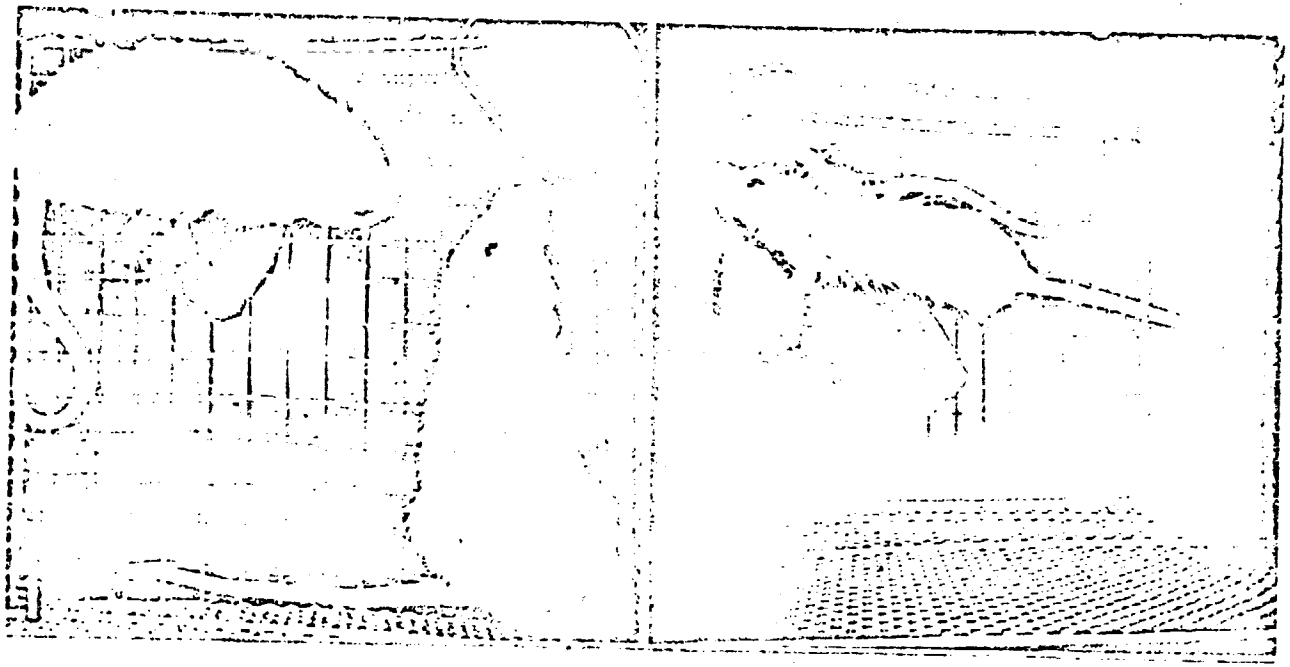



3 1cm



4 1cm

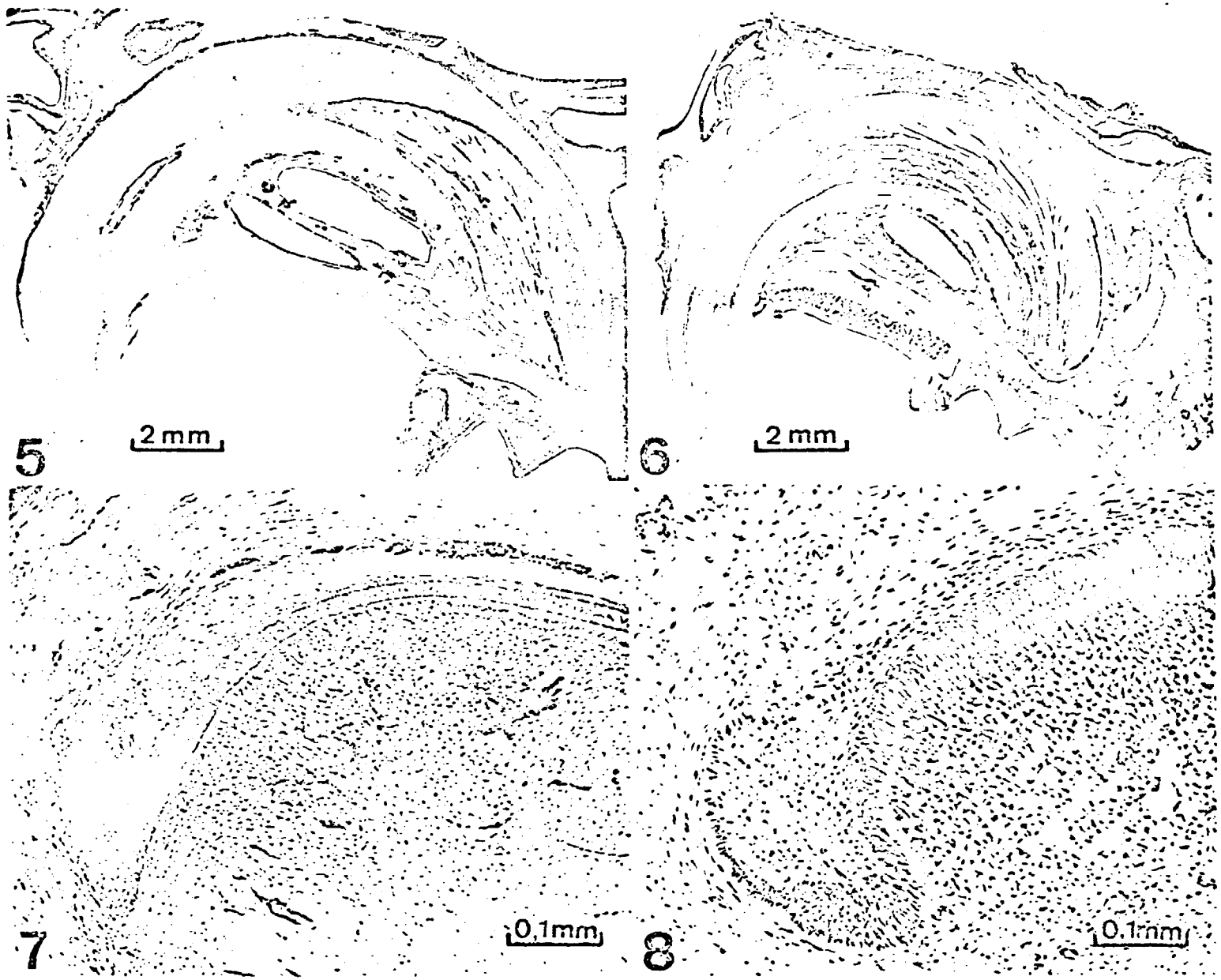
5
2 mm
6
2 mm
7
0,1mm
8
0,1mm


9
60 μ
10
60 μ
11
d
60 μ
12

NAS/NRC-'72
Bib No. 10763

L'HYPERVITAMINOSE A -
SON EFFET SUR L'INCISIVE DU RAT BLANC

Ph. CONNE*, L.-J. BAUME*, W.F. KÖRNER** et H. WEISER**

Ecole de Médecine dentaire de l'Université de Genève, Service des Traitements dentaires conservateurs (Directeur: Prof. L.-J. Baume)*

et

Département de Recherches sur les Vitamines et la Nutrition, F. Hoffmann-La Roche & Cie SA, Bâle (Directeur: Prof. O. Wiss)**

◇ Ce travail a bénéficié du subside No 3860 du Fonds National Suisse.

RESUME

13 rats blancs Wistar ont été utilisés; 7 ont reçu de hautes doses de vitamine A, tandis que 6 rats ont servi de contrôle. Les incisives supérieures de chacun de ces animaux ont été observées au moyen de la radiographie, l'histologie et la microradiographie.

Les animaux expérimentaux ont présenté un état de nanisme avancé. Les observations au niveau de l'incisive ont confirmé les données, peu nombreuses, rapportées dans la littérature : il a été remarqué une augmentation de la vascularisation de la pulpe et du parodonte et une réduction de l'épaisseur des parois de dentine.

Au niveau de l'organe de l'émail, une augmentation du volume du stratum intermedium s'est fait remarquer particulièrement dans la boucle cervicale. Cela a fait penser, à la lumière des données sur l'hypovitaminose A, à une action directe de la vitamine A sur cette couche épithéliale hautement spécialisée.

La formation des matrices de l'émail et de la dentine s'est révélée régulière en ce qui concernait leur structure. Leur épaisseur était cependant réduite.

L'hypervitaminose A a montré une faible influence sur le processus de calcification de l'émail et de la dentine qui paraissaient cependant légèrement hyperminéralisés. Ce phénomène a déjà été observé au niveau de l'os. L'hypovitaminose A au contraire a un effet important sur la calcification des tissus dentaires.

INTRODUCTION

Peu nombreux sont les travaux concernant les effets d'une hypervitaminose A sur les tissus dentaires. IRVING (1949) décrit une réduction de la formation de l'os alvéolaire, une apposition diminuée de la dentine de l'incisive du rat ainsi qu'un amincissement de la couche de prédentine. Les odontoblastes s'atrophient, principalement sur la paroi linguale. Selon GORLIN et CHAUDHRY (1959) l'atrophie des odontoblastes et l'apposition dentinaire réduite pourraient être dues à la perte de l'appétit. Pour ces auteurs, l'augmentation de la vascularisation pulpaire et périodontale est le seul changement spécifique de l'hypervitaminose A au niveau des tissus dentaires. Etudiant in vitro les effets d'un excès de vitamine A sur des germes de molaires de rats, HOLLOWAY et MELLANBY (1961) remarquent un développement retardé, particulièrement au niveau des cuspides. L'histodifférentiation de l'organe de l'émail est sévèrement affectée.

Le but de ce travail est d'étudier les effets de l'hypervitaminose A sur l'incisive du rat blanc au moyen de la radiographie, l'histologie et la microradiographie, et de les comparer aux récentes données concernant les effets de l'hypovitaminose A sur les mêmes tissus (CONNE, KÖRNER et BAUME, 1968, 1969; BAUME, CONNE et KÖRNER, 1969; CONNE et BAUME, 1969).

MATERIEL ET METHODE

Rats WISTAR femelles reçurent un régime contenant 100 UI de vitamine A par semaine (CONNE et al. 1968) à partir de l'âge de 30 jours (poids environ 75 g). Après la castration des animaux à l'âge de 42-43 jours on a continué le même régime. Lorsqu'ils atteignirent le poids de 150 g les animaux furent divisés en deux groupes. Sept d'entre eux (groupe 1) reçurent alors additionnellement 25'000 UI de vitamine A par jour per os (dispersion aqueuse; [illegible])

pendant deux semaines; les six autres animaux (groupe 2) servirent de contrôle. Au cours de ces 14 jours chez les animaux du groupe 1 une hypervitaminose A marquée apparut; ils furent sacrifiés à l'âge de 54-55 jours. Les six rats de contrôle furent sacrifiés entre 70 et 124 jours.

Après décapitation, les têtes ont été radiographiées dorsalement, puis coupées sagittalement selon un axe légèrement paramédian. Chaque hémitête a été radiographiée à son tour. Les hémitêtes possédant la cloison nasale ont été fixées dans le formol 10 % puis décalcifiées dans la solution de Rychlo. Elles ont ensuite été enrobées soit dans la paraffine soit dans la celloïdine. Les coupes ont été colorées à l'HE, au PAS, au Mallory, au bleu alcian et au Hale. Le bloc incisif de l'autre hémitête a été prélevé avec son os alvéolaire et enrobé dans le méthacrylate de méthyl. Des coupes sagittales par usure ont été faites puis microradiographiées au moyen du diffractographe de Hilger HRX. Les détails concernant l'enrobage, les coupes par usure et la microradiographie ont été donnés dans un précédent rapport (CONNE, KÖRNER et BAUME, 1968).

RESULTATS

1. Aspect clinique. Les rats hypervitaminosés étaient dans un profond marasme (Fig. 1 et 2). Leur taille et leur poids représentaient environ la moitié de ceux des rats de contrôle. Leur pelage était sale et avait l'aspect de la "fourrure mouillée". A la fin de l'expérience ils étaient moribonds; deux même sont morts spontanément la veille de la date prévue pour leur sacrifice.

2. Aspect radiographique. L'hémitête radiographiée d'un rat de contrôle est présentée par la figure 3. Le céphalogramme d'un rat hypervitaminosé montre une densité des structures osseuses plus faible (Fig. 4). La taille des incisives est réduite, leurs parois dentinaires sont minces.

3. Aspect histologique. En ce qui concerne la morphologie générale de l'incisive, une coupe sagittale de l'incisive supérieure d'un rat de contrôle montre de légères altérations qui pourraient être dues soit au régime synthétique soit à la gonadectomie. Le contour labial est ondulé, la structure dentinaire est irrégulière (Fig. 5).

L'incisive du rat hyperviteminosé est de taille réduite (Fig. 6). La congestion sanguine de la pulpe et du desmodonte est le signe prédominant. Les parois dentinaires sont minces tandis que les espaces pulpaire et desmodontal sont élargis. Le bouchon de fibrodentine fermant la pulpe au bord incisif est réduit.

La boucle cervicale dorsale de l'incisive du rat de contrôle est formée par les épithélia adamantins externe et interne entre lesquels se trouve le stratum intermedium (Fig. 7). Cet organe, chez le rat hypervitaminosé, est rendu volumineux par le grossissement du stratum intermedium (Fig. 8). La limite entre les tissus épithéliaux et le mésenchyme pulpaire est nettement marquée par une membrane basale dense.

L'épithélium adamantin d'un rat de contrôle et la matrice de l'émail au niveau de sa calcification initiale sont présentés sur la figure 9. La même zone chez un rat hypervitaminosé est montrée sur la figure 10. La structure prismatique de l'émail est régulière. Au niveau de l'épithélium adamantin les améloblastes et la couche papillaire sont réguliers et bien différentiés.

Une partie de la paroi de dentine labiale est visible sur les mêmes coupes (Fig. 9 et 10). On remarque entre les odontoblastes et la dentine calcifiée une bande claire représentant la prédentine. Chez le rat hypervitaminosé cette prédentine est plus étroite (Fig. 10). La structure dentinaire paraît être plus régulière que chez le rat de contrôle.

4. Aspect microradiographique. Les données microradiographiques sont en accord avec les observations histologiques. La taille de l'incisive est réduite, les parois dentinaires sont minces (Fig. 11). Le bouchon de fibrodentine ferme mal la pulpe. L'émail peut présenter quelques irrégularités au niveau de la zone de calcification (Fig. 12). La dentine est régulièrement calcifiée. La limite dentine-prédentine est droite et nette.

DISCUSSION

Les observations radiographiques, histologiques et microradiographiques de l'incisive du rat blanc en hypervitaminose A, comparées aux récentes données sur l'hypovitaminose A (CONNE, KÖRNER et BAUME, 1968 et 1969; BAUME, CONNE et KÖRNER, 1969; CONNE et BAUME, 1969), apportent quelques précisions concernant les effets de la vitamine A sur les tissus dentinogénétique et amélogénétique.

Dentinogenèse. En accord avec les observations de IRVING (1949) et GORLIN et CHAUDHRY (1959), une réduction de l'apposition dentinaire sur toutes les parois de l'incisive du rat hypervitaminosé est remarquée. La pulpe et le desmodonte sont fortement vascularisés et hyperémiés. Il est à remarquer que l'amincissement des parois dentinaires se fait sur tout le pourtour de la dent, contrairement à ce que l'on voit chez le rat hypovitaminosé. Chez ce dernier, seule la paroi

recouverte de cément s'amincit alors que la paroi recouverte d'émail s'épaissit (WOLBACH et HOWE, 1933; SCHOUR, HOFFMANN et SMITH, 1941; IRVING, 1949; CONNE, KÖRNER et BAUME, 1966, 1969). L'hypothèse d'un épaississement de compensation de la paroi labiale décrit par SCHOUR, HOFFMANN et SMITH (1941) et SESSLE (1966) chez le rat hypovitaminosé, ne paraît pas valable chez le rat hypervitaminosé. Ce phénomène est probablement dû à une rigidité plus grande de l'incisive grâce à un taux de calcification meilleur chez le rat hypervitaminosé. En effet, l'influence de l'hypervitaminose A sur la dentinogenèse ne se fait remarquer que par la minceur de la prédentine. La calcification est très régulière. En revanche, chez le rat hypovitaminosé, tous les auteurs s'accordent à voir un retard de la calcification qui, de plus, est irrégulière et donne lieu à la formation de dentine interglobulaire.

Améloganèse. La boucle cervicale du rat hypervitaminosé est dilatée par le grossissement du stratum intermedium. La membrane basale séparant l'épithélium adamantin du mésenchyme pulpaire est nette et dense. Le phénomène inverse a été observé en cas d'hypovitaminose (CONNE, KÖRNER et BAUME, 1969) dans lequel on remarque une diminution du volume du stratum intermedium et un effacement intermittent de la membrane basale. Des variations identiques de la membrane basale ont été observées au niveau de l'épithélium gingival du rat hypovitaminosé et hypervitaminosé (FRANQUIN, KÖRNER, WEISER et BAUME, 1969).

Contrairement à l'hypovitaminose A, l'hypervitaminose paraît avoir un effet protecteur sur la formation de la couche papillaire et de la matrice de l'émail. A l'exception de quelques irrégularités peu importantes, visibles dans la zone de minéralisation de l'émail et probablement dues à des altérations de la matrice, le taux de calcification de l'émail semble normal, sinon augmenté.

Les données de cette étude confirment qu'il faut chercher le point d'attaque de la vitamine A au niveau du stratum intermedium.

CONCLUSIONS

La limite entre les effets spécifiques et les effets secondaires de l'hypervitaminose A sur l'incisive du rat blanc est difficile à distinguer. Pour GORLIN et CHAUDHRY, seule l'augmentation de la vascularisation serait un effet spécifique de l'hypervitaminose A.

Il semble cependant que les changements intervenant au niveau du stratum intermedium du rat hypervitaminosé comme du rat hypovitaminosé soient dus à une action directe de la vitamine A.

Quant à l'incidence de l'hypervitaminose A sur les processus de calcification, des expériences associant l'hypervitaminose A et la déficience en calcium chez le rat (MOORE, 1965), ont montré son peu d'importance au niveau de l'os. En ce qui concerne la dentine, qui ne subit pas les remaniements de l'os, la régularité de sa structure et de sa calcification semblerait confirmer cette thèse. L'analyse minérale quantitative a cependant révélé un taux de Ca et de P plus élevé dans l'incisive du rat hypervitaminosé (LEAVER et TRIFFITT, 1964).

Il est intéressant de noter que, malgré l'état de marasme avancé des animaux expérimentaux, les lésions dentaires, tant macroscopiques qu'histologiques, étaient peu importantes. Chez le rat hypovitaminosé, au contraire, des lésions dentaires graves ont été observées chez des animaux dont l'état général n'était que peu touché (CONNE, KÖRNER et BAUME, 1968, 1969; BAUME, CONNE et KÖRNER, 1969; CONNE et BAUME, 1969).

NAS/NRC-'72
BIB No. 10763

EFFECTS OF VITAMIN A DEFICIENCY AFTER PROGRESSIVELY LONGER PERIODS AND OF EXCESS OF VITAMIN A ON THE DEVELOPMENT OF THE TIBIA OF THE WHITE RAT

*) School of Dental Medicine of the University of Geneva
Department of preventive, restorative and perodontal dentistry

**) Department of research on vitamins and nutrition,
F. Hoffman - La Roche and Cie S.A., Bale

INTRODUCTION

The influence of vitamin A on the skeletal development was studied principally on the laboratory animal, by means of appropriate dietetic experiments. The effects of vitamin A deficiency on osteogenesis has been described in a dog by MELLANBY (1944, 1950), a rat, a guinea pig, a duck, and chicken by WOLBACH (1954) and WOLBACH and BESSEY (1941) and in a rabbit by PERLMAN (1947). Concerning enchondral ossification in long bones, observations are infrequent. WOLBACH (1947) points out a decrease of the mitotic index in the epiphysary cartilage of the dog; this observation is confirmed by WOLBACH and HEGSTED (1952 a and b) in the chicken and the duck. The erosion of the cartilage was slower and enchondral ossification retarded. Concurrent with MELLANBY (1950), FRANDSEN and BECKS (1962) show a slackening of osteoblastic and osteoclastic activities in the tibia of the rat.

Concerning the consequences of an excess of vitamin A, WOLBACH (1947), WOLBACH and MADDOCK (1951), studying the skeletal modifications of the rat, the guinea pig, the dog, and the chicken, describe an acceleration of chondrogenesis and osteogenesis as well as some processes of modelling resorption, causing a friability of the bone and spontaneous fractures.

The goal of this study is to observe, in a like colony of white rats, the effects of a deficiency and of an excess of vitamin A on the cartilage of the proximal epiphysis of the tibia.

MATERIAL AND METHOD

Material. 51 weaned female Wister rats aged 29-30 days, recieved a standard diet with varying vitamin A levels. After eliminating secondary hormonal effects, these rats were castrated at the age of 42-44 days. Following the duration and nature of the diet, they were divided into 6 groups:

Group I	11 rats hypovitaminized during a short period; duration of diet from 39 to 146 days; average age at time of exam was 120 days.
Group II	9 rats avitaminized; duration of diet from 39 to 140 days; average age 132 days.
Group III	12 rats having recieved a standard diet and serving as the control for groups I and II; average afe 131 days.
Group IV	7 rats hypovitaminized during an extended period; duration of diet from 196 to 378 days; average age 304 days.
Group V	5 rats having recieved a standard diet and serving as the control for group IV; average age 330 days.
Group VI	7 rats having recieved during 14 days an excess of vitamin A (25.000 I.U. in aqueous solution; AROVIT administered orally daily); age at time of exam 54-55 days.

The experimental results concerning the first five groups was described in an earlier study (CONNE, KORNER, and BAUME, 1968), and that of group VI in the work of CONNE et al (1969).

Method. The posterior limb of each rat was seperated from the trunk at the coxo-femoral joint, then x-rayed. The tibia was taken by dissection of the articulary capsule of the knee, as well as that of the ankle, then x-rayed again; the length was measured by x-ray. After decalcification in Rychlo solution, the proximal epiphysis was dissected, coated with parafin and cut transversally in sections of 6/u thickness. The sections were stained with hematoxyline-eosine, PAS and toludine blue.

RESULTS

Radiometric results. It appears from the measurements that the growth in length of the tibias of the rats with vitamin A deficiency appear slower but seem little by little to catch up with age (Table 1). Nvertheless, note that the statistical tests (t test and parellelism test between the two lines of

regression) showed the relativity of the significance of these results on account of the insufficient sample.

The rats having recieved an excess of vitamin A were stunted; the dissection of tibias was delicate because of their extreme fragility. Some spontaneous fractures could be observed.

Morphologic Results. The proximal epiphysis of the tibia of a young control rat is presented in figure 1. Notice a thick patch of cartilage in which the length spreads over the width of the diaphysary neck. One notes a strong trabeculation arranged in lengthwise spicules more or less parallel. In the rats of the same age with vitamin A deficiency (Fig. 2), the size of the epiphysis is unchanged, but the neck is "inflated". The cartilage appears thickened whereas the trabecules are reduced in number and length. In the rats who recieved an excess of vitamin A (Fig. 3), the external part of the neck is very incurvated. The thickness of cartilage is augmented as well as the number of osseous fibers, whereas the external cortical is slight.

Histological Results.

Deficiency of short duration and analogous controls. The cartilage of proximal conjugation of the tibia of the young control rats (Fig. 4) shows an important activity of three interesting processes in enchondral ossification: chondrogenesis, erosion, osteogenesis. In rats of the same age with vitamin A deficiency (Fig. 5), an enlargement of the seriated zone results in a thickening of the cartilage; the intercellular substance appears augmented. A decresse in the number of vascular granules attests to a slower erosion. The osseous fibers are more sparse than in the control rats, indicating osteogenetic inhibition.

Deficiency of average duration and analogous controls. In the epiphysary cartilage of control rats more than 100 days old (Fig. 6), chondrogenesis

and erosion are attenuated. The isogenic groups are less regular and reduced in length. The osseous modification is nevertheless important; the fibers are thickened and spaced. The cartilage of rats of the same age with vitamin A deficiency remains thick (Fig. 7). A reduced number of capillary granules affect the hypertrophied chondrocytes. The osseous fibers, sparse, indicate a decline in osteogenesis.

Deficiency of long duration and analogous controls. The three processes responsible for the enchondral activity have practically ceased in the aged control rats; the cartilage is reduced in thickness (Fig. 8). A band of hypercalcified cartilage demarcates an entirely aplastic diaphysary medulla.

In the rat deprived of vitamin A for an extended period of time, signs of certain chondroblastic and chondroclastic activity are evident (Fig. 9). The cartilage is larger than that of the controls. Note an abundance of intercellular substances and, in places, important structural defects. The osteogenesis and the osseous transformation are however severely hindered.

Excess of vitamin A. The three process responsible for enchondral ossification are accelerated, particularly chondrogenesis (Fig. 10 and 11). Although the erosion and osteogenesis appear very active, the thickening of the cartilage is increased. The modification of the trabeculary bone is distinctly retarded, causing a dense trabeculation. The lamellary bone remains equally immature.

DISCUSSION

The effects of vitamin A on the epiphysary cartilage. The deficiency of vitamin A seems to provoke a dimunition of chondrogenesis and to hinder erosion and osteogenesis. The enchondral ossification remains active longer than in the control rat, in the manner of epiphysary cartilage of a thyroidectomized rat (ASLING and EVANS, 1956).

The measurement of the tibia effectively indicated a slackening of the growth which however eventually caught up (Table 1). The inhibition of the trabeculary modification and of the modelling resorption responsible for an "inflation" of the diaphysary neck, could confirm the secondary thyroidal insufficiency due to hypovitaminosis A, as was suggested by BAUMANN and MOORE (1939).

An excess of vitamin A engenders in return an acceleration of the three processes of enchondral ossification, particularly that of chondrogenesis. These observations agree with those of WOLBACH (1947) and WOLBACH and MADDOCK (1951). It was interesting to note a thickening of layers of seriated and hypertrophied chondrocytes, as much after hypovitaminosis as after hypervitaminosis. In the case of deficiency, this enlargement is probably due to a slowdown of erosion, whereas in the case of excess of vitamin A, it would be due to an acceleration of the maturation of chondrocytes.

Table 2 summarizes the effects of the different diets on the process of enchondral ossification in the epiphysary and condylary cartilages.

Differentiated responses of cartilage to growth. A comparison of results obtained from a recent study of effects of vitamin A on the condylary cartilage (BAUME et al, 1970) with those obtained on the epiphysary cartilage reveal an astonishing disparity of reactions (Table 2). Whereas with condyle the vitamin A deficiency causes a rejuvenation of chondrogenesis and osteogenesis, and the excess of vitamin A a precocious aging, the material was opposite is true for epiphysis. Given that the same experimental used in the two studies, the operative technique is outside of cause in this differentiated response of the two cartilages. One finds moreover its homologue in endocrinal experiments (BAUME, 1961), which supposes that the different embryonic origin of these two cartilages would be the principal cause. The epiphyses are derived from primordal hyalin cartilage; the condylary fibrocartilage is a neoformation appearing late in fetal development (BAUME, 1968).

The mode of action of vitamin A on the skeletal development is still, according to BARNICOT and DATTA (1956) not well understood. Three mechanisms can be considered:

a) A direct action on the osteogenetic process has been described (MELLANBY, 1944; WOLBACH, 1947; IRVING, 1949). The experiments in vitro of FELL and MELLANBY (1952) and in situ of BARNICOT (1950) seem to confirm this thesis. The corresponding changes observed in osteogenesis, as much in epiphyses as in condyles -- in contrast with those noted in the cartilage -- would be due to this direct action.

b) A hormonal interaction is suggested by some images resembling certain reactions obtained during endocrinal experiments (BAUME, BECKS and EVANS, 1953). The direct action of vitamin A on the surrenal glands has been established by SELYE (1958), ERSHOFF (1952), GIROUD and RATSIMANANGA (1960), BALKE et al (1964) and NICOL et al (1964). WOLBACH et al (1955), using adrenalectomized rats recieving vitamin A or cortisone, or both at the same time, showed the double action, direct and indirect, through the action of the surrenals, of vitamin A on the enchondral ossification. The same findings could be valid for the thyroid (BAUMANN and MOORE, 1939) and the hypophysis (WOLBACH and MADDOCK, 1952; SELYE, 1957). The differentiated response of the epiphisary and condylary cartilages to different diets of vitamin A can be explained by such hormonal action.

c) A direct influence of vitamin A on the metabolism of sulfate and hexosamine in the synthesis of amino glucides entering into the composition of the basic substance has been proved in many biochemical studies (Nutrition Reviews, 1966). Concerning the cartilage, vitamin A seems bound to certain basic changes of chondroitine sulfate. This interaction would be the source of changes found in the epiphysary cartilage after a long period of vitamin A deficiency.

SUMMARY

EFFECTS OF VITAMIN A DEFICIENCY AFTER PROGRESSIVELY LONGER PERIODS AND OF EXCESS OF VITAMIN A ON THE DEVELOPMENT OF THE TIBIA OF THE WHITE RAT

1. 51 castrated female Wistar rats, after weaning, received a standard diet with varying vitamin A levels, to produce extreme conditions of vitamin A deficiency and excess of vitamin A. The proximal epiphysis of the tibia was studied histologically.

2. Vitamin A deficiency caused retardation of chondrogenesis, erosion and ostoegenesis; cartilage activity, however, persisted longer than in the controls (Table 1).

3. Excess of vitamin A, on the contrary, accelerated endochondral activity, except modelling bone resorption, thus rendering the bone vulnerable to spontaneous fracture.

4. The action of vitamin A was discussed by comparing its effects on endochondral ossification in tibia and condyle of the same experimental rats (Table 2). Diametrically opposing responses of these two skeletal growth centers became evident. Similarities to conditions seen in endocrine experiments suggested a secondary interaction of vitamin A on endochondral ossification by the mediation of endocrine glands (adrenals, thyroid, pituitary) on the one hand. On the other hand, a direct action on cartilage ground substance and osteoblasts was implied by the changes common to both types of bones.

BIBLIOGRAPHIE

ASLING, C.W./EVANS, H.M.: Anterior pituitary regulation of skeletal development.
In: The Biochemistry and Physiology of Bone.
Edited by Bourne G.H., p. 671.
Academic Press Inc., New York, 1956.

BALKE, E./BOGUTH, W./STAUDINGER, Hj.: Die Nebennieren in der Aktivität der weissen Ratte im Vitamin A-Mangel.
Z.ges.exp.Med.133: 131 , 1964.

BARNICOT, N.A.: The local action of vitamin A on bone.
J.Anat. (Lond.) 84: 374, 1950.

BARNICOT, N.A./DATTA, S.P.: Vitamin A and Bone.
In: The Biochemistry and Physiology of Bone.
Edited by Bourne G.H., p. 507.
Academic Press Inc., New York, 1956.

BAUMANN, C.A./MOORE, T.: Thyroxine and hypervitaminosis A.
Biochem.J.33: 1639, 1939.

BAUME, L.J.: Principles of cephalofacial development revealed by experimental biology.
Amer.J.Orthodont.47: 881, 1961.

BAUME, L.J.: Embryogenesis of the human temporomandibular joint.
Science, 138: 904, 1962.

BAUME, L.J.: Patterns of cephalofacial growth and development.
A comparative study of the basicranial centers in rat and man.
Int.dent.J.13: 489, 1963

BAUME, L.J./BECKS, H./EVANS, H.M.: Growth and transformation of the mandibular joint in the rat thyroidectomized at birth.
Amer.J.Orthodont.39: 623, 1953.

BAUME, L.J./CONNE, Ph./HOLZ, J./KORNER, W.F.: L'articulation mandibulaire du rat soumis à une carence en vitamine A de plus en plus prolongée et à une hypervitaminose A.
Rev.Stomat. (Paris)71: 17, 1970.

CONNE, Ph./KORNER, W.F./BAUME, L.J.: Les effets d'une hypovitaminose et d'une avitaminose A de plus en plus prolongée sur l'incisive du rat blanc.
Rev.mens.suisse Odonto-stomat.78: 1061, 1968.

CONNE, Ph./BAUME, L.J./KORNER, W.F./WEISER, H.: L'hypervitaminose A - son effet sur l'incisive du rat blanc.
Helv.odont.Acta 13: 100, 1969.

ERSHOFF, B.H.: Nutrition and the anterior pituitary with special reference to the general adaptation syndrome.
Vitam. and Horm.10: 79, 1952.

FRANDSEN, A.M./BECKS, H.: The effect of hypovitaminosis A on bone healing and endochondral ossification in rats.
Oral Surg.15: 474, 1962.

FELL, H.B./MELLANBY, E.: The effects of hypervitaminosis A on embryonic limb-bones cultivated in vitro
J.Physiol.(Lond.)116: 320, 1952.

GIROUD, A./RATSIMANANGA, A.R.: Cortico-surrénale et déficiences vitaminiques Compte-rendu du Congrès "Nutrition et glandes endocrines" Paris, Centre National de la Recherche Scientifique,
B 105 - B 132, 26-29 octobre, 1960.

IRVING, J.T.: The effects of avitaminosis and hypervitaminosis A upon the incisor teeth and incisor alveolar bone of rats.
J.Physiol.(Lond.)108: 92, 1949.

MELLANBY, E.: Croonian Lecture: Nutrition in relation to bone growth and the nervous system.
Proc.roy.Soc.B.132: 28, 1944.

MELLANBY, E: The effect of some dietary factors on bones and the nervous system.
Baltimore: Williams and Wilkings Comp.,1950

NICOL, M./LE GALL, M./GRANGAUD, R.: Vitamine A et sécrétion surrénalienne. Activité des stimulines hypophysaires in vitro
C.r.Soc.Biol.(Paris)158: 1270 (1964)

N.N.: The influence of vitamin A on sulfate and hexosamine metabolism.
Nutr.Rev.24: 204, 1966.

PERLMAN, H.B.: Effect on the ear of vitamin A feeding after severe depletion.
Arch.Otolaryngol.50: 20, 1949.

SELYE, H.: Prevention of vitamin A overdosage by somatotrophic hormone.
J.Endocr.16: 231, 1957.

SELYE, H.: Sensitation of the skeleton to vitamin A overdosage by cortisol.
Arthr. and Rheum.1: 97, 1958.

WOLBACH, S.B.: Vitamin A deficiency and excess in relation to skeletal growth.
J.Bone Jt.Surg.29: 171, 1947.

WOLBACH, S.B.: Effects of vitamin A deficiency and hypervitaminosis A in animals. In: W.H.SEBRELL and R.S.HARRIS:
The Vitamins.Vol.I,New York:Academic Press Inc., Publishers, 1954, p.116-119

WOLBACH, S.B./BESSEY, D.A.: Vitamin A deficiency and the nervous system.
Arch.Path.32: 689, 1941.

WOLBACH, S.B./MADDOCK, C.L.: Hypervitaminosis A. An adjunct to present methods of vitamin A identification.
Proc.Soc.exp.Biol.(N.Y.)77, 825, 1951.

WOLBACH, S.B./MADDOCK, C.L.: Vitamin A acceleration of bone growth sequences in hypophysectomized rats.
Arch.Path.53: 273, 1952.

WOLBACH, S.B./MADDOCK, C.L./COHEN, J.: The hypervitaminosis A syndrome in adrenalectomized rats. Skeletal changes in weanling rats with and without cortisone.
Arch.Path.60: 130, 1955.

Table 1

Lines of regression of the length of the tibias by logarithmic function of age

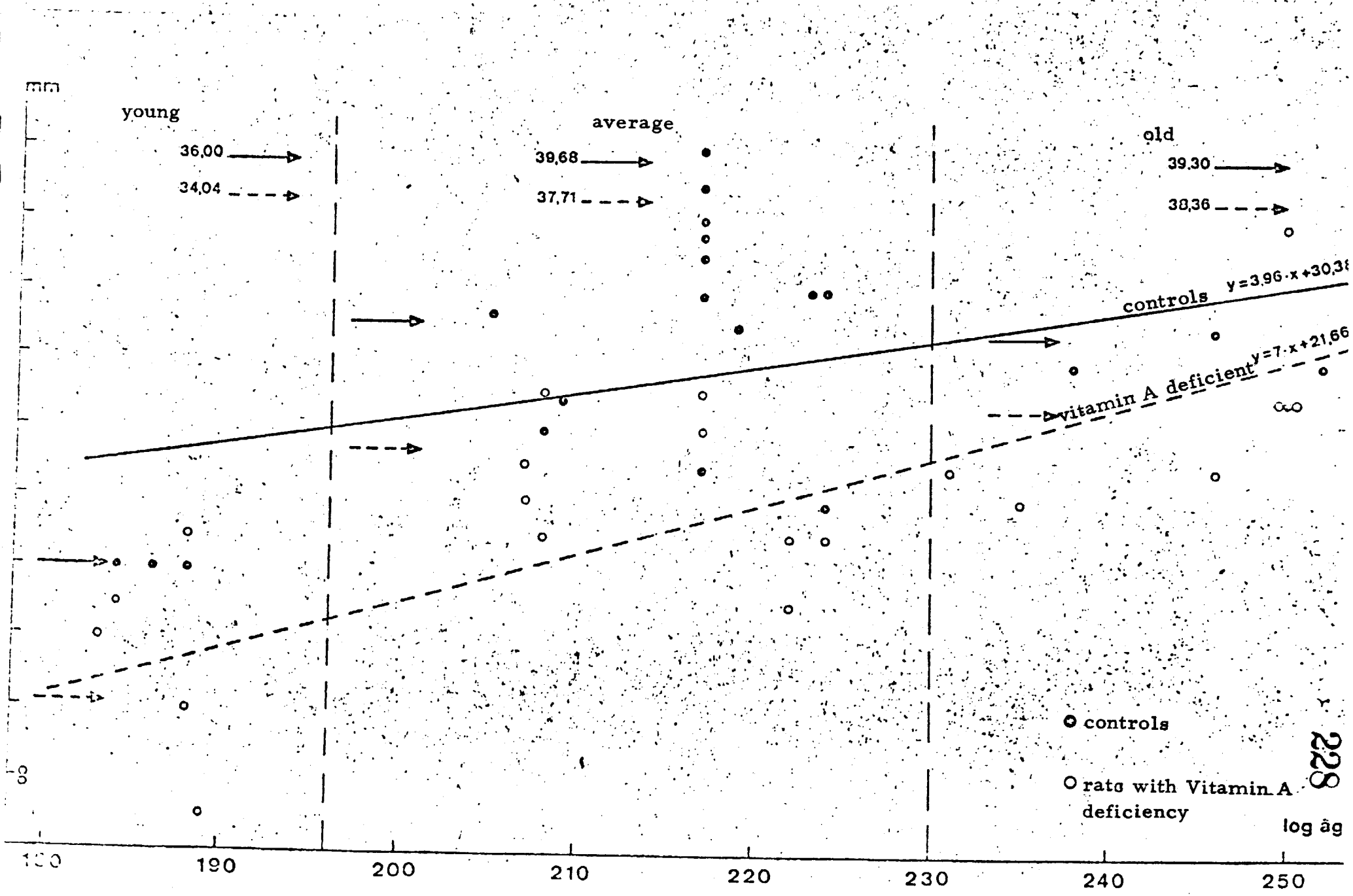

Table 2

EFFETS DE LA CARENCE ET DE L'EXCES DE VITAMINE A SUR L'OSSIFICATION ENCHONDRALE

EFFECTS OF DEFICIENCY AND EXCESS OF VITAMIN A ON ENCHONDRAL OSSIFICATION

Type de cartilage Type of cartilage	Chondrogenesis Chondrogenèse		Cartilage Erosion Erosion cartilagineuse		Trabeculary Ossification Ossification trabéculaire		Osseous Transformatic Transformation osseu	
	Carence deficiency	Excès excess	Carence deficiency	Excès excess	Carence deficiency	Excès excess	Carence deficiency	Exc excess
épiphysaire epipyisary	diminished diminuée prolongée prolonged	accelerated accélérée	retarded retardée	accelerated accélérée	diminished diminuée	n	inhibited inhibée	retarded retardé
condylaire* condylary	accelerated accélérés limitée limited	stopped arrêtée atrophiée atrophied	n	n	diminished diminuée	augmented augmentée	n	accelerated accélér

n = peu de différence avec les rats de contrôle
n= little difference with the control rats

*) BAUME et al., 1970

LEGEND

Fig. 1 - 3	General view of transversal sections of the center of the proximal epiphyses of the tibia. H. E. 18x.
Fig. 1	Control rat, 77 days old.
Fig. 2	Rat with vitamin A deficiency, 76 days old.
Fig. 3	Rat having recieved an excess of vitamin A, 55 days old.
Fig. 4 - 10	Histological aspects of conjugal cartilage of the proximal epiphysis of the tibia of 6 rats, 70 to 337 days old. H. E. 100x.
Fig. 4	Control rat, 70 days old. z. e. = embryonic zone z. s. = seriated zone z. h. = hypertrophied chondrocytes l. e. = line of erosion
Fig. 5	Rat deprived of vitamin A for a short period, 76 days old.
Fig. 6	Control rat, 150 days old.
Fig. 7	Rat deprived of vitamin A for an average length of time, 149 days old.
Fig. 8	Control rat, 337 days old.
Fig. 9	Rat deprived of vitamin A for extended period of time, 323 days old.
Fig. 10	Rat having recieved an excess of vitamin A, 55 days old.
Fig. 11	Enlargement of figure 10. H. E. 200x.

1
1 mm

2
1 mm

3
1 mm

control rats
rats de contrôle

rats with vitamin A deficiency
rats carencés

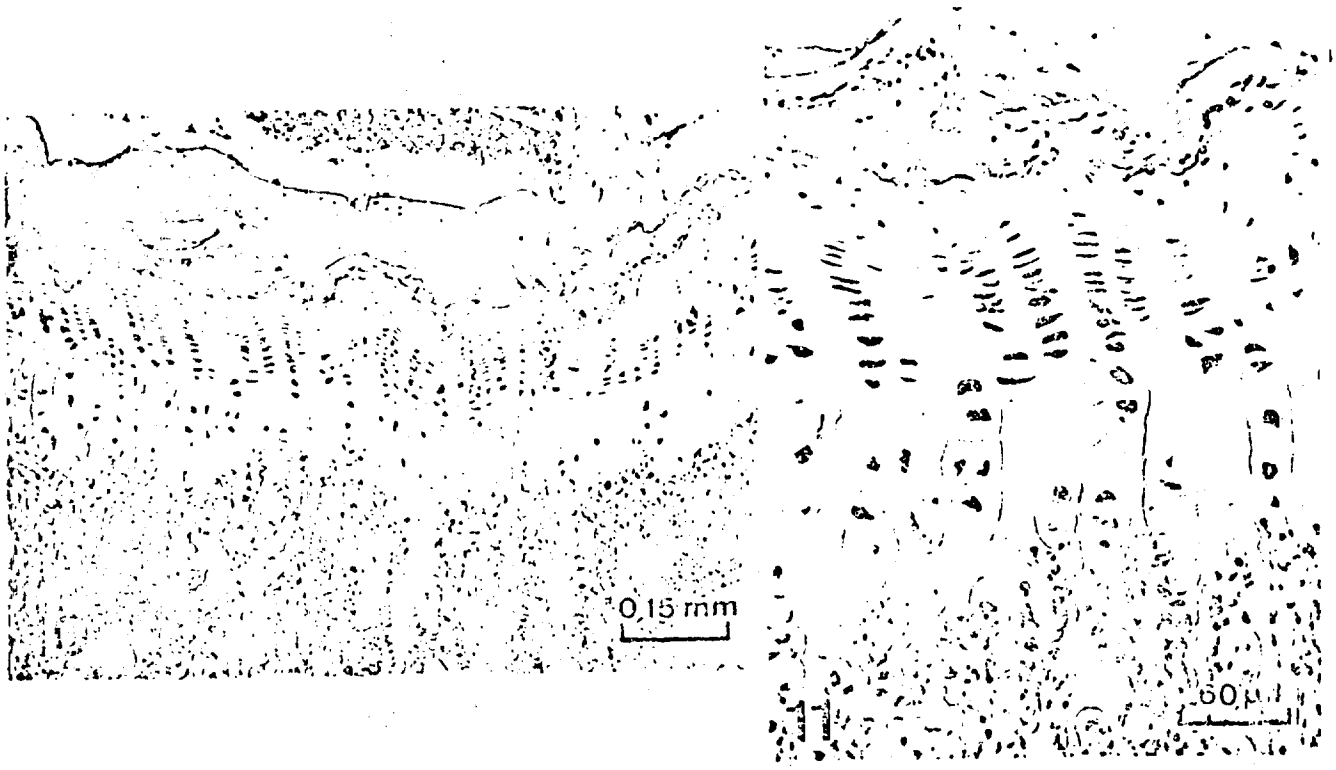
0,15 mm
60 µ

NAS/NRC-'72
BIB No. 10763

LES EFFETS D'UNE CARENCE EN VITAMINE A DE PLUS EN PLUS PROLONGEE ET D'UN EXCES DE VITAMINE A SUR LE DEVELOPPEMENT DU TIBIA DU RAT BLANC

L. J. BAUME*/ Ph. CONNE*/ W. F. KÖRNER**

*) Ecole de Médecine dentaire de l'Université de Genève
Département de médecine dentaire préventive, restauratrice et de parodontie.

**)Département de recherches sur les vitamines et la nutrition,
F. Hoffmann-La Roche & Cie S.A., Bâle.

Ce travail a bénéficié du subside no 3868 du Fonds National Suisse.

RESUME

1. 51 rats femelles Wistar castrés ont été soumis, dès leur sevrage, à un régime commun dont la teneur en vitamine A a subi d'importantes variations, provoquant des états allant de l'avitaminose à l'hypervitaminose.

2. La carence en vitamine A engendre un ralentissement des processus chondrogénétique, chondroclastique et ostéogénétique, dont les activités cartilagineuses semblent cependant se prolonger davantage que chez le rat de contrôle (Tableau 1).

3. L'excès de vitamine A, au contraire, accélère les processus intéressés dans l'ossification enchondrale, à l'exception du remaniement osseux, jusqu'à développer un os susceptible de se fracturer spontanément.

4. Le rôle de la vitamine A est discuté à la lumière d'une comparaison des effets sur l'ossification enchondrale observés au niveau des cartilages épiphysaire et condylaire, dans le même matériel expérimental (Tableau 2). Il en ressort une réponse diamétralement opposée des deux centres de croissance squelettique . La similitude de ces images avec celles obtenues dans des expériences endocriniennes laisse supposer, d'une part, une action secondaire de la vitamine A sur l'ossification enchondrale, par l'entremise des glandes endocrines (surrénales, thyroide, pituitaire). D'autre part, les perturbations osseuses communes aux deux types d'os étudiés suggèrent une action directe de la vitamine A sur le métabolisme de la substance fondamentale du cartilage et sur les ostéoblastes.

Key words: Vitamin A - Enchondral ossification.

INTRODUCTION

L'influence de la vitamine A sur le développement du squelette a été étudiée principalement sur l'animal de laboratoire , au moyen d'expériences diététiques appropriées. Les effets de la carence en vitamine A sur l'ostéogenèse ont été décrits du chien par MELLANBY (1944,1950), du rat,du cobaye, du canard et de la poule par WOLBACH (1954) et WOLBACH et BESSEY (1941) et du lapin par PERLMAN (1947). En ce qui concerne l'ossification enchondrale au niveau des os longs, les observations sont peu nombreuses. WOLBACH (1947) signale une baisse de l'index mitotique dans le cartilage épiphysaire du chien, observation confirmée par WOLBACH et HEGSTED (1952 a et b) chez la poule et le canard. L'érosion cartilagineuse serait plus faible et l'ossification enchondrale retardée. En accordance avec MELLANBY (1950), FRANDSEN et BECKS (1962) montrent un ralentissement des activités ostéoblastique et ostéoclastique au niveau du tibia du rat.

En ce qui concerne les suites d'un excès de vitamine A, WOLBACH (1947), WOLBACH et MADDOCK (1951), étudiant les modifications du squelette du rat, du cobaye, du chien et de la poule, décrivent une accélération des processus chondrogénétique et ostéogénétique ainsi que des processus de résorption modelante, causant une friabilité de l'os et des fractures spontanées.

Le but de ce travail est d'observer, au sein d'une même colonie de rats blancs, les effets soit d'une carence, soit d'un excès de vitamine A sur le cartilage de la plaque épiphysaire proximale du tibia.

MATERIEL ET METHODE

Matériel. 51 rats femelles de souche Wistar ont été soumis, dès leur sevrage, à l'âge de 29-30 jours, à un régime commun dont la teneur en vitamine A a subi d'importantes variations. Afin d'éliminer les effets hormonaux secondaires, ces rats ont été castrés à l'âge de 42-44 jours. Suivant la durée et la nature du régime, ils ont été répartis en 6 groupes :

Groupe I — 11 rats hypovitaminosés pendant une courte durée; durée du régime de 39 à 146 jours; âge moyen au moment de l'examen 120 jours.

Groupe II — 9 rats avitaminosés; durée du régime de 39 à 140 jours; âge moyen 132 jours.

Groupe III — 12 rats ayant reçu un régime standard et servant de contrôle pour les groupes I et II; âge moyen 131 jours.

Groupe IV — 7 rats hypovitaminosés pendant une longue durée; durée du régime de 196 à 378 jours; âge moyen 304 jours.

Groupe V — 5 rats ayant reçu un régime standard et servant de contrôle pour le groupe IV; âge moyen 330 jours.

Groupe VI — 7 rats ayant reçu pendant 14 jours un excès de vitamine A (25.000 U.I. sous forme de dispersion aqueuse; AROVIT gouttes par jour per os); âge au moment de l'examen 54-55 jours.

Le détail complet des données expérimentales concernant les 5 premiers groupes a été décrit dans une étude précédente (CONNE, KÖRNER et BAUME, 1968), et celui du groupe VI dans le travail de CONNE et coll.(1969).

Méthode. Le membre postérieur de chaque rat a été séparé du tronc au niveau de l'articulation coxo-fémorale, puis radiographié. Le tibia a été prélevé par dissection de la capsule articulaire du genou ainsi que celle de la cheville, puis radiographié à nouveau; la longueur a été mesurée sur radiographie. Après décalcification dans la solution de Rychlo, l'épiphyse proximale a été disséquée, enrobée dans la paraffine et débitée transversalement en coupes de 6 μ d'épaisseur. Les coupes ont été colorées à l'hématoxyline-éosine, au PAS et au bleu de toluidine.

RESULTATS

Données radiométriques. Il ressort des mesures que la croissance en longueur des tibias des rats carencés paraît ralentie mais semble petit à petit combler son retard avec l'âge (Tableau 1). Il est cependant à noter que les tests statistiques (test de "t" et test du parallélisme entre les 2 droites de régression) ont montré la relativité de la signification de ces résultats en raison de l'insuffisance de l'échantillon.

Les rats ayant reçu un excès de vitamine étaient de très petite taille; la dissection des tibias fut rendue délicate du fait de leur grande friabilité. Des fractures spontanées ont pu être observées.

Données morphologiques. L'épiphyse proximale du tibia d'un rat de contrôle jeune est présentée par la figure 1. On remarque une plaque de cartilage épaisse dont la longueur déborde sur la largeur du collet diaphysaire. On note une forte trabéculation arrangée en longues spicules plus ou moins parallèles. Chez les rats carencés du même âge (Fig.2), la taille de l'épiphyse est inchangée, mais le collet est "gonflé". Le cartilage paraît épaissi tandis que les trabécules sont réduites en nombre et en longueur. Chez les rats qui ont reçu un excès de vitamine A (Fig.3), la partie externe du collet est très incurvée.

L'épaisseur du cartilage est augmentée aussi bien que le nombre des travées osseuses, tandis que la corticale externe est mince.

Données histologiques.

Carence de courte durée et contrôles correspondants. Le cartilage de conjugaison proximal du tibia des rats de contrôle jeunes (Fig.4) montre une importante activité des 3 processus intéressés dans l'ossification enchondrale: chondrogenèse, érosion, ostéogenèse. Chez les rats carencés d'âge correspondant (Fig.5), l'élargissement de la zone sériée a pour résultat un épaississement du cartilage; la substance intercellulaire paraît augmentée. La diminution du nombre des bourgeons vasculaires atteste d'une érosion plus faible. Les travées osseuses sont plus rares que chez les rats de contrôle, indiquant une inhibition de l'ostéogenèse.

Carence de moyenne durée et contrôles correspondants. Dans le cartilage épiphysaire des rats de contrôle âgés de plus de 100 jours (Fig.6), l'activité chondrogénétique et l'érosion sont atténuées. Les groupes isogéniques sont moins réguliers et réduits en longueur. Le remaniement osseux est cependant important; les travées sont épaisses et espacées. Le cartilage des rats carencés d'âge correspondant reste épais (Fig.7). Un nombre réduit de bourgeons capillaires s'attaquent aux chondrocytes hypertrophiés. Les travées osseuses, rares, indiquent un ralentissement de l'ostéogenèse.

Carence de longue durée et contrôles correspondants. Les 3 processus responsables de l'activité enchondrale ont pratiquement cessé chez les rats de contrôle âgés; le cartilage est réduit en épaisseur (Fig.8). Une bande de cartilage hypercalcifiée délimite une moelle diaphysaire entièrement aplastique.

Chez les rats carencés de longue durée, les signes d'une certaine activité chondroblastique et chondroclastique sont évidents (Fig.9). Le cartilage est plus large que celui des contrôles. On note une abondance de sub-

stances intercellulaires et, par endroit, des défauts importants de structure. L'ostéogenèse et la transformation osseuse sont cependant sévèrement entravées.

Excès de vitamine A. Les trois processus responsables de l'ossification enchondrale sont accélérés, particulièrement la chondrogenèse (Fig.10 et 11). Bien que l'érosion et l'ostéogenèse paraissent très actives, l'épaisseur du cartilage est augmentée. Le remaniement de l'os trabéculaire est nettement retardé, provoquant une dense trabéculation. L'os lamellaire reste également en état d'immaturité.

DISCUSSION

Les effets de la vitamine A sur le cartilage épiphysaire. La carence en vitamine A semble provoquer une diminution de l'activité chondrogénétique et entraver l'érosion et l'ostéogenèse. L'ossification enchondrale reste active plus longtemps que chez le rat de contrôle, à l'instar du cartilage épiphysaire du rat thyroïdectomisé (ASLING et EVANS, 1956).

La mensuration du tibia indiquerait effectivement un ralentissement de la croissance qui finirait cependant par combler son retard (Tableau 1). L'inhibition du remaniement trabéculaire et de la résorption modelante, responsable d'un "gonflement" du collet diaphysaire, pourrait confirmer l'insuffisance secondaire thyroïdienne due à l'hypovitaminose A, comme l'ont suggéré BAUMANN et MOORE (1939).

L'excès de vitamine A engendre en revanche une accélération des trois processus intéressant l'ossification enchondrale, particulièrement celui de la chondrogenèse. Ces observations sont en accord avec celles de WOLBACH (1947) et WOLBACH et MADDOCK (1951). Il était intéressant de noter un épaississement des couches des chondrocytes sériés et hypertrophiés, tant après hypovitaminose qu'après hypervitaminose. En cas de carence, cet élargissement est probablement

dû à un ralentissement de l'érosion, tandis que dans le cas d'excès de vitamine A, il serait dû à une accélération de la maturation des chondrocytes.

Le tableau 2 résume les effets des différents régimes sur les processus intéressant l'ossification enchondrale au niveau des cartilages épiphysaire et condylaire.

Réponses différenciées des cartilages de croissance. La comparaison des données recueillies lors d'une récente étude des effets de la vitamine A sur le cartilage condylaire (BAUME et coll., 1970) avec celles obtenues sur le cartilage épiphysaire révèle une étonnante disparité des réactions (Tableau 2). Tandis qu'au niveau du condyle, la carence en vitamine A provoque un rajeunissement des processus chondrogénétique et ostéogénétique, et l'excès de vitamine A un vieillissement précoce, le contraire se produit au niveau de l'epiphyse. Etant donné que le même matériel expérimental a été utilisé dans les deux études, la technique opératoire est hors de cause dans cette réponse différenciée des deux cartilages. Elle a trouvé d'ailleurs son homologue dans des expériences endocriniennes (BAUME, 1961), ce qui a laissé supposer que l'origine embryonnaire différente de ces deux cartilages en serait la cause principale. Les épiphyses sont des dérivés du cartilage hyalin primordial; le fibrocartilage condylaire est une néoformation dite secondaire survenant tardivement dans le développement foetal (BAUME, 1968).

Le mode d'action de la vitamine A sur le développement du squelette est encore, selon BARNICOT et DATTA (1956) mal connu. Trois mécanismes peuvent être considérés:

a) Une action directe sur le processus ostéogène a été décrite (MELLANBY, 1944; WOLBACH, 1947 ; IRVING, 1949). Des expériences in vitro de FELL et MELLANBY (1952) et in situ de BARNICOT (1950) semblent confirmer cette thèse. Les changements correspondants observés dans l'ostéogenèse, tant au niveau des épi-

physes qu'au niveau des condyles - en contraste avec ceux notés dans le cartilage - seraient dûs à cette action directe.

b) Une interaction hormonale est suggérée par des images ressemblant à certaines réactions obtenues au cours d'expériences endocriniennes (BAUME, BECKS et EVANS, 1953). L'action directe de la vitamine A sur les glandes surrénales a été établie par SELYE (1958), ERSHOFF (1952), GIROUD et RATSIMANANGA (1960), BALKE et al (1964) et NICOL et al (1964). WOLBACH et coll. (1955), utilisant des rats adrénalectomisés recevant de la vitamine A ou de la cortisone, ou les deux à la fois, ont montré la double action directe et indirecte, par l'entremise des surrénales, de la vitamine A sur l'ossification enchondrale. La même constatation pourrait être valable pour la thyroïde (BAUMANN et MOORE, 1939) et l'hypophyse (WOLBACH et MADDOCK, 1952; SELYE, 1957). La réponse différenciée des cartilages épiphysaire et condylaire aux différents régimes de vitamine A trouverait son explication dans une telle action hormonale.

c) Une influence directe de la vitamine A sur le métabolisme du sulfate et de l'hexosamine dans la synthèse des glucides aminés entrant dans la composition de la substance fondamentale a été mise en évidence dans un grand nombre d'études biochimiques (NUTRITION REVIEWS, 1966). En ce qui concerne le cartilage, la vitamine A semble liée à certains changements au sein de la chondroïtine sulfate. Cette interaction serait à l'origine des altérations constatées dans le cartilage épiphysaire après une carence de longue durée.

NAS/NRC-'72
BIB No. 10763

The Gingival Epithelium of the White Rat Subjected to a Vitamin A Deficiency and Hypervitaminosis A

1. Morphological Study

By
Franquin J.C., Korner W.F., Baume L.J. and Weiser

The Gingival Epithelium of the White Rat Subjected to a Deficiency of Vitamin A and Hypervitaminosis

1. Morphological Study

The relationship between vitamin A and keratinization have been known for several decades (Mori, 1922; Evans & Bishop, 1922). The insufficiency, as well as the excess of vitamin A provokes changes in the epithelial tissue.

In 1925, Wolback and Howe had already established that vitamin A deficiency leads to a keratinization metaplasia of all the epithelia tissue. In the first studies carried out on the paradontium, Boyle (1938), King (1948), and Mellambry (1941) concluded that this deficiency leads to gingivial lesions. But in their more recent works, Burn, Orten & Schmidt (1941), Boyle (1947), Glickman & Stoller (1948) have not observed any change of the gingival structures with the absence of local irritations.

Hypervitaminosis A, on the contrary, hinders keratinization of the epithelial tissues (Domack & Dobeneck, 1933). Bern & Laurence (1958) have shown that this inhibition was suitable to the doses of vitamin A used. Hypervitaminosis A will provoke, according to Ziskin, Rosenstein & Drucker (1943), a lessening of the keratin layer and a thickening of the gingival epithelial structures.

In a series of experiments carried out on the gingival epithelium of the rat, we proposed to study successively the morphological, histological, histochemical and enzymatic changes provoked by either a more and more prolonged deficiency of vitamin A, or by hypervitaminosis A. This first work will deal with the basic morphological and histological changes happening at the gingival epithelium level.

Material & Methods

1. Material

51 captured female Wistar rats were reared on a stock diet containing different amounts of vitamin A at 29-30 days old (weight from 60-63 g.) In order to eliminate secondary hormonal effects, these rats were castrated at 42-44 days old (weight 100-120 g.).

These animals were distributed into six groups according to the duration and the nature of their treatment. Groups 1-5: Table 1 summarizes the average data concerning the first five groups. Details of the treatment and the preparation of these groups 1-5 were previously communicated (Conne, Körner, & Baume, 1968).

Group 6: 7 hypervitaminosis rats received, at age 30 days, the same treatment as the rats in groups 1-5, with 2 weekly suppliments of 50 I. U. of vitamin A (peanut oil). The highest serum concentration of vitamin A was obtained when these animals had reached a weight of 150 g. The rats then received for 14 days, 25,000 U.I. of vitamin A each day, by mouth. The average age at the autopsy was 55 days.

2. Methods

After deep narcosis, the rats were decapitated. The ring of buccal mucous around the three molars right or left of the lower maxillary had been instantaneously lifted out after dissection with a bistoury and fixed in a neutral 10% solution.

After dehydration, these rings were imbedded in solid paraffin in such a way that the surface of the cut was situated in a vestibule lingual direction, perpendicular to the bony implantation base of the ring.

Each piece was cut in a series to 7μ which permitted the selection for each animal of the sections possessing the necessary orientation.

In order to conserve the exact relationship of this gingival ring with the surrounding dental tissue, other sections of cuts were obtained from the mandible decalicified in the Rychlo solution.

The gingival epithelium of the rat was studied at the lower molar level in the three following gingival regions: alveolar, attached, and free (Sicher, 1962).

1) The epithelium of the alveolar gum was studied from the vestibular side as well as the lingual side, in consideration of their clear histological differences.

2) The epithelium of the attached vestibular gum was examined in its continuity with the free marginal gum. Their keratin layer was defined by the disappearance of cellular nucleus. Its thickness was measured with the help of dividers on the sections projected on an enlarged focusing screen (Hirsch, Cimasoni & Held, 1967). The measuring had been carried out on two sliced sections, at the top, the middle part, and the base of the selected papilla (Fig. 1). The number indicated for each papilla represents the sum of six measurings.

3) The epithelium of the gingivo-dental ridge was examined on one side in the marginal vestibular region and on the other side at the intermolar papilla level. For each of these three regions, the morphological and histological aspect of the gingival epithelium was examined successively in the control rat, the deficiencied animal and the hypervitaminosis animal.

Results

1. In the Control rat, the amount of keratinization of the alveolar gum is less important at the vestibular side (Fig. 2) than at the lingual side (Fig. 3). On both sides, the cellular membranes of the keratinized layer are still visible. The epithelium shows a granular and clearly differentiated layer, of several cellular layers, with visible kerato-hyaline granules. The cellules of the basal layer are hexagonal, with large nuclei.

1.1 In the dfficiencied rat, the epithelium of the alveolar gum shows an increase in thickness of the keratin layer. This hyperkeratinization is visible from the vestibular side (Fig. 4) in the deficiencied rat for 49 days (group 2), as well as from the lingual side (Fig. 5) in a hypovitaminosis rat for 291 days (group 4).

In the latter, the cornea layer occupies a thickness equal to that of the rest of the epithelium. The adhesion of the cornified cellules remains complete up to the surface. If the granular layer has the same importance as in the control rat, many of the kerato-hyaline granules are of lower growth and are smaller in size. The basal membrane disappears and the separation between the epithelium and the connective tissue becomes blurred in rats having been subjected to a long deficiency. It does not seem that hyperkeratinization is accompanied by an increased total thickening of the tissue.

1.2 In the hypervitaminosis A rat, the cornea layer becomes thinner. Cellular structure is no longer visible there. Through the granular layer, the keratohyaline granules are distributed irregularly and the size of some of these granules is considerably increased. One can observe a vacuolization and a swelling of the cellules in the spinose layer (Fig. 6).

The basal cellules lose their hexagonal shape in order to take a fusiform appearance and give the impression of increased volume (Fig. 7). The basal membrane is thickened and the demarcation of the tissue is very clear.

2. The epithelium of the attached gum and marginal on the vestibular side in the control rat is characterized by a keratinized layer more condensed and more clearly differentiated than that of the alveolar gum. The granular layer is non-existent or reduced to a single cellular layer (Fig. 8). One notices a topographical variation of the epithelial digitations (Fig. 1).

2.1 In the deficiencied rat, this epithelium shows a clear thickening of the keratin layer (Fig. 9). This hyperkeratinization is neither accompanied with an increase in the total thickness of the tissue, nor an increase in thickness of the granular layer (Fig. 10), even in the rat deficiencied for 378 days.

Table 2 gives the results of measurements concerning the Keratin layer of the vestibular epithelium in the first 4 groups.

The comparison of averages obtained show that the growth of the keratin layer is a function of the length of the deficiency diet. This growth is not linear, but decreases with time and tends toward a limit which is no longer possible to exceed, even in prolonging the duration of the vitamin A deficiency (table 3).

Statistical analysis (t test) made in comparing the average value obtained for the control group (group 3) and the hypervitaminosis group (group 4), indicates that the difference is, from a statistical point of view, very significant. There is in effect less than 1 chance in a thousand that such probability could be due to chance (t=5.1).

Statistical analysis made in comparing the average value obtained for the control group and for all the deficiencied rats indicate that the difference observed is still, from a statistical point of view, strongly enough significant (0.02 - t - 0.01).

2.2 In the hypervitaminosis animal, one observes at the vestibular gingival epithelium level an increase in the total thickening of the epithelium (Fig. 11). The thickness of the cornea layer is decreased and could not be measured satisfactorily. The structure of the cellular membranes of the cornea layer disappears. The desquamed cellules are able to present the nuclear residue. The granular layer clearly differentiated, possesses a thickening of several cellular layers. The kerato-hyaline granules are well visible and spread through all the cellular cytoplasm. The cellules of the basal layer, fusiforms, present numerous metotic figures. The epithelial tissue is distinctly marked with connective tissue.

3. The histological aspect of the gingivo-dental ridge varies according to its localization either in the vestibular marginal region, or at the level of intermolar papilla.

3.1 In the vestibular marginal region in the control rat (Fig. 8), the gingival side is recovered with a pavement epithelium of ten to twelve cellular layers. These oral type of epithelium does not have a granular layer, but may have a thin keratinized layer. It rejoins in the deepness of the ridge, an epithelium in the course of degeneration, expanding on the dental side. The bottom of the cul-de-sac is intra-epithelial. The epithelium of the dental side is composed of fusiform cellules with clear cytoplasm, which keep their nucleus up to the superficial layers; it is probably of adamantin origin. At the junction of these two epithelia, one notices in the underlying connective tissue, the presence of some inflammed cellules.

In a rat from group 2, deficiencied for 94 days (Fig. 9), the oral epithelium presents at the top of the ridge a keratinized layer clearly differentiated. The thickness of this increases proportionally to the duration of the deficiency. On the dental side, an adamantin type epithelium reduced to two cellular layers is found. The joining of these two epithelia close the bottom of the gingivo-dental ridge.

In a rat from group 4 (Fig. 10), deficiencied for 263 days, the oral epithelium of the gingival side is somewhat enlarged and proliferated in thickness. The accumulated layer of keratin is emphasized by a granular layer. The intraepithelial gingivo-dental ridge does not seem to be deepened. It is bordered on its dental side by an adamantin-type epithelium and is made up of two non-keratinized cellular layers. In the bottom of the ridge, the two epithelia unite and destinction between them becomes difficult.

In the hypervitaminosis rat (Fig. 11), the covering of the free gum on the total thickness of the ridge, is assured by an adamantin-type epithelium, only possessing a cellular layer. The connective underlying tissues does not show any trace of inflammation.

3.2 In the intermolar papillar region, the gingivo-dental epithelium in the control rat (Fig. 12) includes a very reduced number of fusiform cellules. This stratified epithelium doesn't possess either a granular layer or a keratinized layer, and the superficial cellules have all their nucleus; it is probably of adamantin origin. There is never proliferation of this epithelium beyond the cement-enamel junction, even in a rat of 408 days.

In the deficiencied rat the histological aspect varies according to the duration of the deprevation. In an avitaminosis rat, deficienced for a short duration (25 days, group 2), the cellular structures of the intermolar papillar epithelium seem more condensed (Fig. 13). In a hypervitaminosis rat of long duration deficiencied for 378 days (group 4), the papillar covering is composed of an oral-type of pavement epithelium. The superficial cellules bordering the ridge are keratinized, while those at the bottom proliferate in depth along the cement as well as in thickness in the connective tissue of the papilla. The epithelial attachment always remains, however, fixed to the dentin-enamel junction. The latter includes some inflammatory infiltrations (Fig. 14).

In the hypervitaminosis rat, the protection of the connective tissue is only assured by one to two layers of fusiform cellules. The attachment of this adamantin-type epithelium stops at the junction of the cement-enamel. The underlying connective tissue is more vascularized than in the control rat and contains some inflammatory cellules (Fig. 15).

4. Discussion

According to the results obtained, the vitamin A deficiency and the hypervitaminosis A in the rat, modify the evolution of the keratinization of the oral epithelium and the involution of the adamantin epithelium, without however causing parodental lesions.

The study of the gingival region, in the experimental rats as in the control rats, must pay attention to the sample zone and the type of epithelium considered.

The regional differences in the thickness of the keratin layer at the gum level is sufficiently important so that all comparative measure must be made at identical places.

In the gingival region, one distinguishes two types of epithelia: oral epithelium and adamantin epithelium. The latter can persist at the gingivo-dental ridge and in the intermolar region. It is characterized by its incapacity to form keratin and by its weak mitotic index (Franquin & Baume, 1962).

4.1 The deficiency in vitamin A provokes, at the oral epithelium level, a gingival hyperkeratimization, proportional to the duration of the deficiency. However, in the present study, one has not been able to confirm either the increase of the total thickness of the epithelium reported by King (1940), Mellanby (1941), Glickman & Stoller (1948), Miglani (1949), Frandsen (1963), or the gingival inflammation described by King (1940) & Mellanbry (1941). It is worth noting the absence of parodental lesion, even in rats deficiencied more than 300 days. These contradictory results may be due to a difference in experimentation methods. It is, in effect, in 1957 only that Clarke and Todd established, for avitaminosis A, experimental criteria based on the study of the vaginal smear in the female castrated rat. The adding, in this work, of supplemental precautions based on the examination of the bloody formula, allowed avoidance, with an almost certain fashion, of the occurence of changes connected to other additional troubles.

The vitamin A deficiency accelerates, in the region of the gingivo-dental ridge, the degeneration of the adamantin epithelium and its replacement by the oral epithelium. The epithelial attachment always remains situated at the cement-enamel junction. The early disappearance of the adamantin epithelium had been equally observed by Baume & Becks (1952) in rats having been subjected to a thyroid-ectomy, and by Conne, Körner & Baume (1968) in the incisors of rats with avitaminosis A. According to these authors, the atrophy of the enamel organ started at the intermedium stratum level and was followed by an early degeneration of the ameloblastic level.

4.2 Observations made at the gingival epithelium of the hypervitaminosis A rat are in accord with those described by Ziskin, Rosenstein, and Drucker (1943) in the monkey, after administration of 10,000 I.U. by mouth. Hypervitaminosis A provokes an increase of the total thickness of the epithelium, an enlargement of the granular layer, an increase in Kerato-hyaline granules, and a diminution of the cornea layer. On the other hand, Bern, Laurence and Steadman (1960) (on the rat), and Bern and Laurence (1962) (on the epithelium of the hamster jaw), have provoked by topical application of vitamin A, a metaplasia of pavement epithelium and cylindrical epithelium. The action of vitamin A seems to be different according to whether it is applied generally or topically.

The thickening of the basal membrane evident in the hypervitaminosis A animals confirms that this membrane is subjected to important modifications, sutiable to the amount of vitamin A. A histochemical study of the changes of this structure in deficiencied rats as well as hypervitaminosis rats, is being completed (Franquin & Baume).

Hypervitaminosis A, according to Sherman (1959) & Parnell & Sherman (1962), is accompanied with an increase of mitotic activity. The thickening observed at the gingival epithelium level could equally be due to this cellular growth. Nevertheless, the swelling of the thorny cellules, the enlargement of the Kerato-hyaline granules and the modifications of the basal membrane represent the existence of a profound changing of the cellular metabolism. The increase of the mitotic index might be a reporative effect of it.

The adamentin epithelium in the hypervitaminosis A rat persists on the gingival side of the intermolar and vestibular free gum. It does not present any sign of degeneration and the basal layer remains active.

Observations made outside of this study confirm that vitamin A plays a substantial role of protection and balance in the gingival epithelium of the rat. However, neither vitamin A deficiency nor hypervitaminosis A have produced, in the absence of local irritation, a deepening of the gingivo-dental ridge. The epithelial changes due to different diets have not lead to ~~state of~~ periodontal lesions in spite of ~~deficiency or strong hypervitaminosis.~~ the seriousness of the rats' general state of deficiency or strong hypervitaminosis.

Legend

Fig. 1 Histological aspect of a papilla of the vestibular gingival region. The arrows indicate the three places where the thickness of the Keratin layer has been measured. Control rats aged 408 days. H. E. x 100

Fig. 2-7 The figures on the left concern the epithelium of the alveolar gum of the vestibular side; the figures on the right show the epithelium of the alveolar gum situated on the lingual side. H. E. x 400

Fig. 2 Control rat aged 124 days (Group 3)

Fig. 3 Control rat aged 114 days (Group 3).

Fig. 4 Avitmainosis rat aged 79 days, deficiencied for 49 days (Group 2). The cornea layer is thick, the Kerato-hyaline granules diminish in volume and the distinction between the epithelium and the connective tissue becomes less clear.

Fig. 5 Hypovitaminosis rat aged 320 days, deficiencies for 291 days (Group 4). The cornea layer occupies by itself, half of the total thickness of the epithelium and the basal membrane becomes blurred.

Fig. 6&7 Hypervitaminosis rats aged 56 days (Group 6). The thickness and the condensation of the cornea layer diminishes. The kerato-hyaline granules and the cellules of the granular layer increase in volume. The cellules of the basal layer take a fusiform aspect; the basal layer becomes very clear and distinct from the connective tissue.

Fig. 8-11 Epithelium of the attached gum and the gingivo-dental ridge of the vestibular marginal region. H. E. x 250

Fig. 8 Control rat aged 167 days (Group 3).

Fig. 9 Avitaminosis rat aged 123 days and deficiencied for 94 days (Group 1). The Keratin layer becomes thick on the whole surface of the oral epithelium, principally on the gingival side of the gingivo-dental ridge.

Fig. 10 Hypovitaminosis rat aged 290 days and deficiencied for 263 days (Group 4). The Keratin layer is still thick on the whole surface of the oral epithelium, principally at the gingivo-dental ridge level where it is underlined with a granular layer.

Fig. 11 Hypervitaminosis rat aged 55 days (Group 6). The epithelium as well as the granular layer are considerably enlarged. The covering of the gingivo-dental ridge is of the adamantin type.

Fig. 12-15 Epithelia of the gingivo-dental ridge of the intermolar papilla region. H. E. x 400

Fig. 12 Control rat aged 408 days (Group 3).

Fig. 13 Avitaminosis rat, aged 76 days and deficiencied for 46 days (Group 2). The epithelium of adamantin type stops at the cement-enamel function.

Fig. 14 Hypovitaminosis rat, aged 407 days and deficiencied for 378 days. The oral type epithelium proliferated along the cement. The epithelial attachment stands, nevertheless, at the cement-enamel junction. The superficial cellules bordering the gingivo-dental ridge are keratinized.

Fig. 15 Hypervitaminosis rats aged 55 days. The covering bordering the gingivo-dental ridge is of adamentin type.

SUMMARY

1. The objective of this study was to assess histologically the effects of prolonged vitamin A deficiency and severe hypervitaminosis A upon the gingival epithelium of the white rat.

51 castrated females after weaning were reared on a stock diet containing different amounts of vitamin A : Group I consisted of rats deficient in vitamin A for appr. 100 days, Group II were completely deprived of vitamin A at the end of this period, Group III was the pair fed control; the Group IV rats were deficient during more than 200 days for which group V was the control, and group VI received during 14 days 25'000 I.U. of this vitamin.

The epithelia of the attached, marginal and papillary gingivae were studied.

2. Vitamin A deficiency induced hyperkeratinization of oral epithelium, rarefaction of kerato-hyalin granules and obliteration of the basement membrane. There was a proportional relation between the increase of the hornified layer (measured at the vestibular attached gingiva) and the duration of A deprivation.

Enamel epithelium which never keratinized, showed precocious degeneration. It was rapidly replaced by a keratinizing oral epithelium which remaind attached to the cemento enamel junction.

3. Hypervitaminosis A effected a general increase in size of oral epithelium, a marked reduction of the hornified layer, increment of the granular layer, enlargement of the kerato-hyalin granules and reinforcement of the basement membrane.

The enamel epithelium remaind in an active state at the creviculer, marginal and papillar sites.

4. Evidence tended to show that vitamin A above all acted as a protective substance maintaining tissular equilibrium. Neither prolonged hypovitaminosis nor severe hypervitaminosis produced by itself pathologic pocket formation. Epithelial pathosis in spite of the critical general condition of some experimental rats was not associated with periodontoclastic changes.

BIBLIOGRAPHIE

1. BAUME, L.J. et BECKS, H. T he effect of thyroid hormone on dental and paradental structures. Paradentologie 3, 89-109, 1952.

2. BAUME, L.J. et FRANDSEN, A.M. Phase constrast microscope study of oral epithelium of normal and vitamin A - deficient rats. Proc.of the Soc.for Experim.Biol.and Med. 83, 356-360,1953.

3. BERN, A.H. et LAWRENCE, D.J. Influence of vitamin A on keratinization. In: Fundamentals of Keratinization. Butcher, E.O. & Sognnaes, R.F., Edit., Washington, Chap. 5, 95-112, 1962.

4. BERN, A.H. et LAWRENCE, D.J. On the specificity of the response of mouse epidermis to vitamin A. J.Invest.Dermatol. 31, 313-325, 1958.

5. BOYLE, P.E. Dietary deficiencies as a factor in the etiology of diffuse alveolar atrophy. J.Amer.dent.Ass. 28, 1788-1793, 1938.

6. BOYLE, P.E. Effects of vitamin A deficiency on the periodontal tissues. Amer.J.orthod.oral surg. 33, 744-748, 1947.

7. BURN, C.G., ORTEN, A.V. et SMITH, A.H. Changes in the structures of the developpint teeth in rats maintained on a diet deficient in vitamin A. Yale J.Biol.Med. 13, 817-830, 1941.

8. CLARKE, P.M. et TODD, P.E. Some observations on the biological assays of vitamin A and its precursors by vaginal smear method.
Brit.J.Nutrition 11, 173-184, 1957.

9. COWNE, Ph., KÖRNER, W.F. et BAUME, L.J. Les effets d'une hypovitaminose et d'une avitaminose A de plus en plus prolongées sur l'incisive du rat blanc.
Rev.mens.suisse odonto-stomatol. 5, 667-684, 1969.

10. DOMAGK, G. et von DODENECK, P. Ueber histologische B efunde bei der Ueberdosierung mit Vitamin A - Konzentrat.
Arch.Pathol.Anat. & Physiol.Virchow's 290, 385-395, 1933.

11. EVANS, H.M. et BISHOP. K.S. On an invariable and characteristic disturbance of reproductive function in animals reared on a diet poor in fat soluble vitamins A.
Anat.Record 23, 17-18, 1922.

12. FRANDSEN, A.M. Periodontal tissue changes in vitamin A deficient young rats.
Acta Odont.Scand. 21, 19-35, 1963.

13. FRANQUIN, J.C. et BAUME, L.J. La kératinisation au niveau de la papille interdentaire.
Rev.mens.suisse odonto-stomatol. 72, 682-709,1962.

14. GLICKMAN, I. et STOLLER, D.H. The periodontal tissues of the albino rat in vitamin A deficiency.
J.dent.Res. 27, 758-762, 1948.

15. HIRSCH, C., CINASONI, G. et HELD, A.J.
Kératinisation et brossage : Etude histologique.
Parodont.& Acad.Review 1, 32-44, 1967.

16. KING, J.D.
Abnormalities in the gingival and subgingival tissues due to diets deficient in vitamin A and carotene.
Brit.dent.J. 68, 349-360, 1940.

17. LAWRENCE, D.J., BERN, A.H. et STEADMAN, M.G.
Vitamin A and keratinization. Studies on the Hamster cheekpouch.
Ann.otol.rhinol.and laryngol. 69, 645-661, 1960.

18. MELLANBY, H.
The effect of maternal dietary deficiency of vitamin A on dental tissues in rats.
J.dent.Res. 20, 489-509, 1941.

19. MIGLANI, D.C.
Effect of vitamin A deficiency on periodontal structures of rats molars with emphasis on cementum resorption.
Oral Surg. 12, 1372-1376, 1959.

20. MORI, S.
Primary changes in eyes of rats which result from deficiency of fat soluble vitamin A in diet.
J.Amer.Med.Assoc. 79, 197-200, 1922.

21. PARNELL, J.P. et SHERMAN, D.S. Effect of vitamin A on keratinization in the A-deficient rat.
In : Fundamentals of Keratinization.
Butcher, E.O. & Sognnaes, R.F. Edit., Washington, Chap. 6, 113-131, 1962.

22. SCHNEIDER, H.G. Vitaminmangel und sein Einfluss auf das Organum dentale.
Deutsch.Zahnärztl.Z. 9, 989-1000, 1966.

23. SICHER, H. Orban's Oral Histology and Embryology.
5th Edition, Chap. IX, p.233, 1962.

24. SHERMAN, D.S. The effect of vitamin A on epithelial mitoses in vitro.
Anat.Record 132, 429-439, 1959.

25. WOLBACH, S.B. et HOWE, P.R. Tissue changes following deprivation of fat soluble vitamin A.
J.exp.Med. 42, 753, 1925.

26. ZISKIN, D.E., ROSENSTEIN, S.N. et DRUCKER, L. Interrelation of larger parenteral doses of estrogen and vitamin A and their effects on the oral mucosa.
J.Orthodont.and Oral Surg. 29, 163-169, 1943.

Adresse des auteurs : Institut de Médecine dentaire,
Université de Genève
30, rue Lombard, CH - 1205 Genève,
et F. Hoffmann-La Roche & Cie S.A.,
4002 Bâle.

Experimental Data
~~Données expérimentales~~

Group no ~~Numéro du groupe~~ ~~Nombre d'animaux (n)~~ Number of animals (n)	Age at the beginning of treatment ~~Age au commencement du régime~~ ~~sans~~ without vitamine A days ~~(jours)~~ $\bar{x}$	Duration of treatment ~~Durée du régime~~ ~~sans~~ without vitamine A days ~~(jours)~~ $\bar{x}$	Age at the appearance of the deficiency ~~Age à l'apparition de la carence~~ days ~~(jours)~~ $\bar{x}$	Duration of the deficiency after the appearance of the first symptoms ~~Durée de la carence après l'apparition des premiers symptômes~~ days ~~(jours)~~	Age/wt. at the end of the experiment ~~Age/poids à la fin de l'expérience~~ (days/g) ~~(jours/g)~~
I n = 11	29,5	91	119,4	2	120,4 / 224,0
II n = 9	29,8	102	114,8	21,2	131,8 / 247,2
III n = 12	29,5	102	Bi-weekly supplement of 50 I.U. ~~Supplément bihebdomadaire de 50 U.I.~~ of ~~de~~ vitamine A per os		131,2 / 276,5
IV n = 7	29,7	274	Supplément de survie de 10 à 25 U.I. de vitamine A ttes les 2 weeks ~~semaines~~ 151,9	152,3	304,1 / 280,0
V n = 5	29,8	300	Bi-weekly supplement of 50 I.U. ~~Supplément bihebdomadaire de 50 U.I.~~ de vitamine A per os		330,0 / 406,0

au niveau de la ~~gencive marginale vestibulaire~~ Layer at the vestibular marginal Gum.

Groupe I	n = 8		~~Hypovitaminose courte~~ Hypovitaminosis Short		$\bar{x}_1$ = 26,4			
N° du rat	232	236	240	242	243	245	438	440
~~Base~~ Base	8,5	9	9	9	9	11	8	10
~~Milieu~~ middle	8,5	7,5	10	7,5	8	10	8	8,5
~~Sommet~~ Top	11,5	7,5	9	7,5	8,5	7,5	7	11
Total	28,5	24	28	24	25,5	28,5	23	29,5

Groupe II	n = 8		Avitaminose courte Avitaminosis Short		$\bar{x}_2$ = 28,2			
N° du rat	234	235	239	241	244	246	443	499
Base	11	12	7,5	9	9	8	10	13,5
Milieu	7,5	10	5	8,5	8,5	7,5	8,5	10
Sommet	10	11	9	9	9	11	13	8
Total	28,5	33	21,5	26,5	26,5	26,5	31,5	31,5

Groupe III	n = 8		~~Contrôle~~ Control		$\bar{x}_3$ = 20			
N° du rat	249	250	251	252	253	257	449	494
Base	3	8	6	5	8	8	6	11,5
Milieu	5	5	7	6,5	8	8	6,5	8
Sommet	7	7	5	6	5	8	5	7
Total	15	20	18	17,5	21	24	17,5	26,5

Groupe IV	n = 8		~~Hypovitaminose longue~~ Hypovitaminosis long		$\bar{x}_4$ = 34,5			
N° du rat	414	415	418	419	425	425	426	427
Base	10	15	12	10	13	11	9,5	11
Milieu	14	12	12	9	10	9,5	11,5	10
Sommet	18	12	12	11	10	11	11,5	11
Total	42	39	36	30	33	31,5	32,5	32

Each figure represents the sum of two measurings expressed in millimeters
Chaque chiffre représente la somme de deux mensurations exprimées en millimètres.
Le groupe V n'a pas été utilisé, car les [illegible]

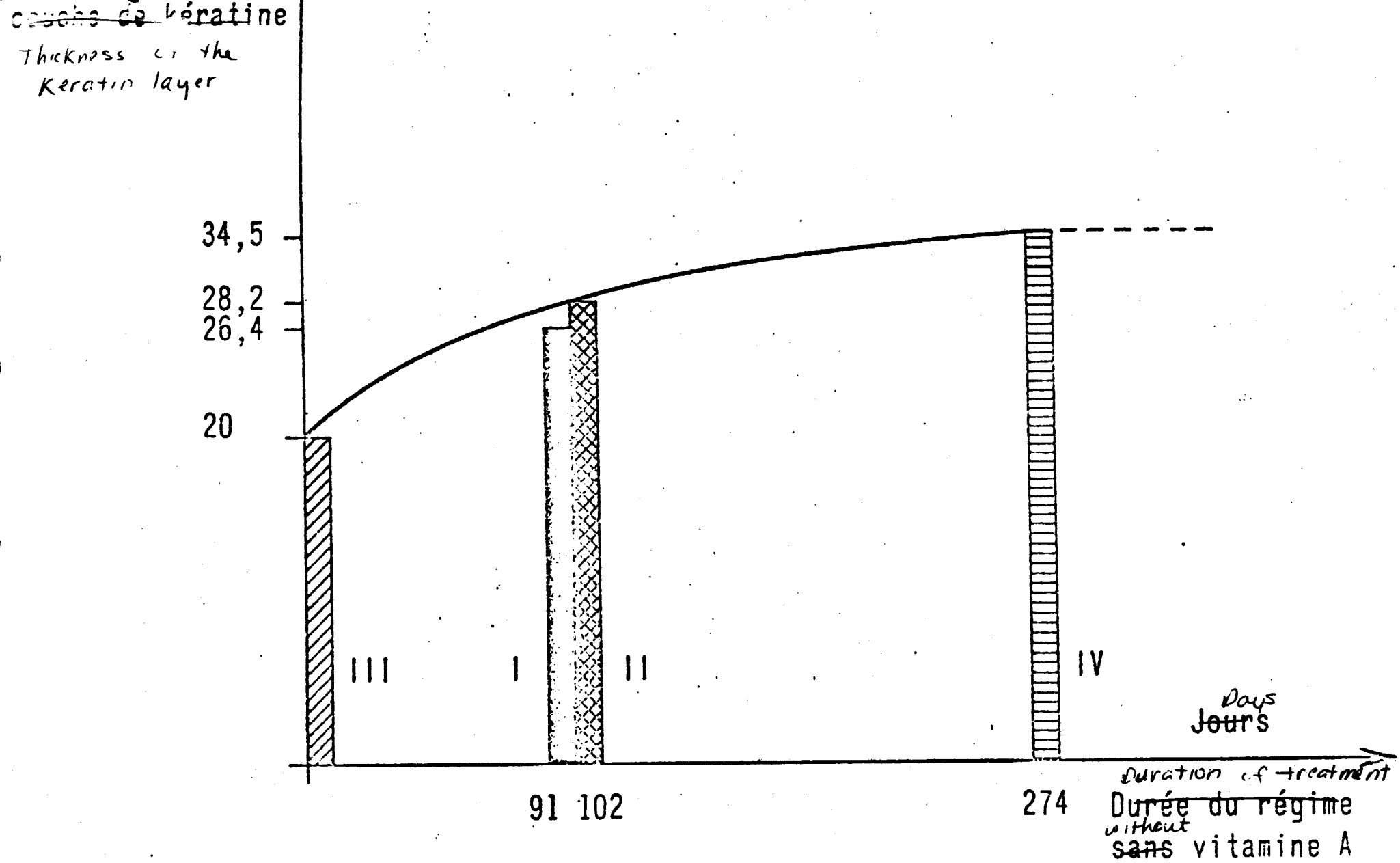

Diagram representing the evolution of the thickening of the Keratin layer as a function of the duration of ~~de~~ treatment without vitamin A

~~Diagramme représentant l'évolution de l'épaisseur de la couche de kératine en fonction de la durée du régime sans vitamine A~~

(III = control group ~~groupe de contrôle~~)

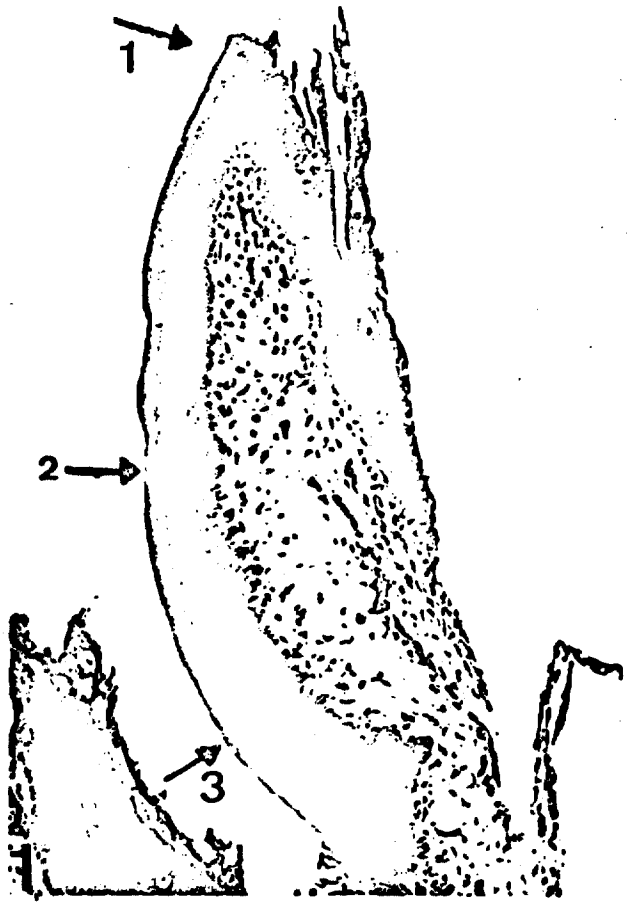
1
2
3

2
3
4
5
6
7

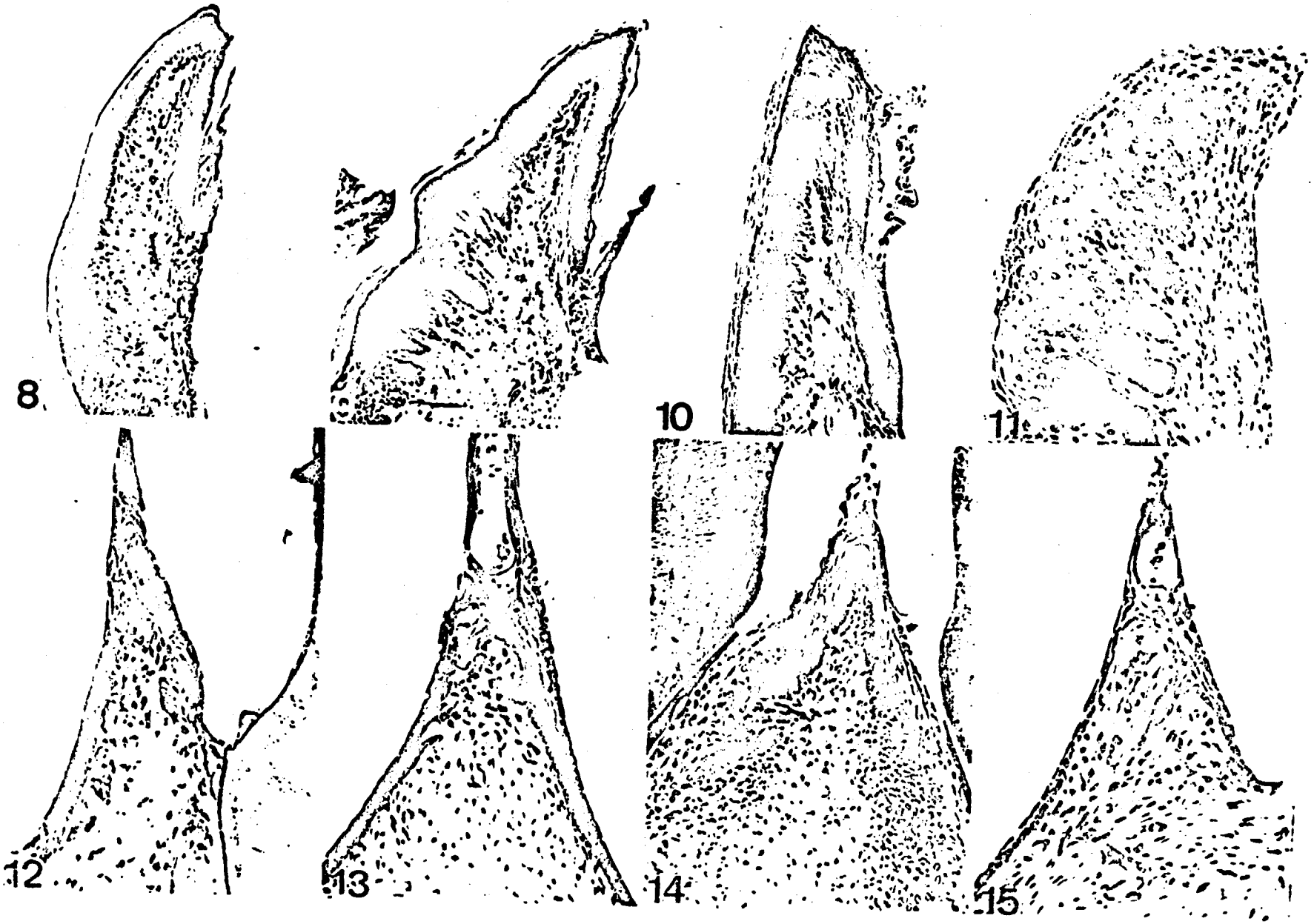
8
10
11
12
13
14
15

Institut de Médecine dentaire de l'Université de Genève, Service des traitements dentaires conservateurs (Directeur: Prof. L.J. Baume)

et

Département de Recherches sur les Vitamines et la Nutrition, F. Hoffmann-La Roche & Cie SA, Bâle (Directeur: Prof. O. Wiss)

NAS/NRC -'72
BIB No. 10763

L'EPITHELIUM GINGIVAL DU RAT BLANC SOUMIS A UNE CARENCE EN VITAMINE A ET UNE HYPERVITAMINOSE A*

I. Etude morphologique

par

Franquin J.-C., Körner W.F., Baume L.J. et H. Weiser

*) Ce travail a bénéficié du subside no [illegible] du Fonds National [illegible]

Les relations entre vitamine A et kératinisation sont connues depuis plusieurs décades (MORI, 1922; EVANS & BISHOP, 1922). L'insuffisance, comme l'excès de vitamine A, provoque des altérations au niveau des tissus épithéliaux.

Déjà en 1925, WOLBACH & HOWE ont établi que la carence en vitamine A entraîne une métaplasie kératinisante de l'ensemble des tissus épithéliaux. Dans les premières études portant sur le parodonte, BOYLE (1938), KING (1940) et MULLANBY (1941) ont conclu que cette carence induisait des lésions gingivales. Mais dans leurs travaux plus récents, BURN, ORTEN & SCHMIDT (1941), BOYLE (1947), GLICKMAN & STOLLER (1948) n'ont pas observé d'altération des structures gingivales, en l'absence d'irritations locales.

L'hypervitaminose A, par contre, entrave la kératinisation des tissus épithéliaux (DOMAGK & DOMENECK, 1933). BERN & LAWRENCE (1958) ont montré que cette inhibition était en rapport avec les doses de vitamine A utilisées. L'hypervitaminose A provoquerait, d'après ZISKIN, ROSENSTEIN & DRUCKER (1943), une diminution de la couche de kératine et un épaississement des structures épithéliales gingivales.

Dans une série d'expériences portant sur l'épithélium gingival du rat, nous nous sommes proposés d'étudier successivement les altérations morphologiques, histologiques, histochimiques et enzymatiques provoquées soit par une carence de plus en plus prolongée en vitamine A, soit par une hypervitaminose A. Ce premier travail portera sur les altérations morphologiques et histologiques essentielles survenant au niveau de l'épithélium gingival.

MATERIEL ET METHODES

1. Matériel

51 rats femelles de souche Wistar provenant de l'élevage A. Sprich (Biel, BL) ont été soumis dès leur sevrage, à l'âge de 29 à 30 jours (poids de 60 à 63 g), à un régime commun dont la teneur en vitamine A a subi d'importantes variations. Afin d'éliminer les effets hormonaux secondaires, ces rats ont été castrés à l'âge de 42-44 jours (poids de 100 à 120 g).

Ces animaux ont été répartis en six groupes suivant la durée et la nature de leur régime :

- Groupes I à V : Le tableau 1 résume les données moyennes concernant les cinq premiers groupes. Les détails du régime et de la préparation de ces groupes I à V ont été communiqués antérieurement (CONNE, KÖRNER et BAUME, 1960).

Tableau 1

- Groupe VI : 7 rats hypervitaminosés ont reçu, à l'âge de 30 jours, le même régime que les rats des groupes I à V, avec deux suppléments hebdomadaires de 50 U.I. de vitamine A (huile d'arachide). La plus haute concentration sérique en vitamine A a été obtenue lorsque ces animaux avaient atteint un poids de 150 g. Les rats ont alors reçu pendant 14 jours 25.000 U.I. de vitamine A par jour, per os. L'âge moyen à l'autopsie était de 55 jours.

2. Méthodes

Après narcose profonde, les rats ont été décapités.

La collerette de muqueuse buccale entourant les trois molaires droites ou gauches du maxillaire inférieur, a été instantanément prélevée après dissection au bistouri et fixée au formol neutre à 10%.

Après deshydratation, ces collerettes ont été incluses en paraffine de telle façon que le plan de coupe soit situé dans une direction vestibulo-linguale et perpendiculaire à la base d'implantation osseuse de la collerette.

Chaque pièce a été coupée en série à 7 µ, ce qui a permis la sélection pour chaque animal des coupes possédant l'orientation requise.

Afin de conserver les rapports exacts de cette collerette gingivale avec les tissus dentaires environnants, d'autres séries de coupes ont été obtenues à partir de mandibules décalcifiées dans la solution de Rychlo.

L'épithélium gingival du rat a été étudié au niveau des molaires inférieures, dans les trois régions gingivales suivantes : alvéolaire, attachée et libre (SICHER, 1962).

1) L'épithélium de la gencive alvéolaire a été étudié tant du côté vestibulaire que du côté lingual, en considération de leurs différences histologiques nettes.

2) L'épithélium de la gencive attachée vestibulaire a été examiné dans sa continuité avec l'épithélium de la gencive marginale libre. Leur couche de kératine a été définie par la disparition des noyaux cellulaires. Son épaisseur a été mesurée à l'aide d'un compas à pointes sèches sur des coupes projetées sur un verre dépoli avec un grossissement constant (HIRSCH, CIMASONI et HELD, 1967). Les mensurations ont été effectuées sur deux coupes par lame, au sommet, à la partie moyenne et à la base des papilles choisies (Fig. 1). Le chiffre indiqué pour chaque papille représente donc la somme de six mensurations.

3) L'épithélium du sillon gingivo-dentaire a été examiné d'une part dans la région marginale vestibulaire et d'autre part au niveau des papilles intermolaires. Pour chacune de ces trois régions, l'aspect morphologique et histologique de l'épithélium gingival a été examiné successivement chez le rat de contrôle, chez l'animal carencé et chez l'animal en hypervitaminose.

RESULTATS

1. Chez le rat de contrôle, le taux de la kératinisation au niveau de la gencive alvéolaire est moins important du côté vestibulaire (Fig. 2) que du côté lingual (Fig. 3). Sur les deux côtés, les membranes cellulaires de la couche kératinisée sont encore visibles. L'épithélium présente une couche granuleuse et nettement différenciée, de plusieurs assises cellulaires, avec des granules kérato-hyalins bien visibles. Les cellules de la couche basale sont hexagonales, à gros noyaux.

1.1. Chez le rat carencé, l'épithélium de la gencive alvéolaire montre une augmentation de l'épaisseur de la couche de kératine. Cette hyperkératinisation est visible tant du côté vestibulaire (Fig. 4), chez un rat carencé depuis 49 jours (groupe II), que du côté lingual (Fig. 5) chez un rat en hypovitaminose pendant 291 jours (groupe IV). Chez ce dernier, la couche cornée occupe une épaisseur égale à celle du reste de l'épithélium. L'adhésion des cellules cornifiées reste complète jusqu'à la surface. Si la couche granuleuse possède la même importance que chez le rat de contrôle, les granules kérato-hyalins sont en nombre moins élevé et de plus petite taille. La membrane basale s'efface, et la séparation entre l'épithélium et le tissu conjonctif devient floue, chez les rats ayant subi une longue carence. Il ne semble pas que l'hyperkératinisation s'accompagne d'une augmentation de l'épaisseur totale du tissu.

1.2. Chez le rat en hypervitaminose A, la couche cornée s'amincit. Aucune structure cellulaire n'y est plus discernable. Les liaisons intercellulaires sont lâches et la desquamation est rapide. A travers la couche granuleuse, les granules kérato-hyalins sont répartis de façon irrégulière et la grosseur de certains de ces granules est considérablement augmentée. On peut observer une vacuolisation et un gonflement

des cellules de la couche épineuse (Fig. 6). Les cellules basales perdent leur forme hexagonale pour prendre un aspect fusiforme et donnent l'impression d'un volume accru (Fig. 7). La membrane basale est épaissie et la délimitation des tissus très nette.

2. L'épithélium de la gencive attachée et marginale sur le versant vestibulaire chez le rat de contrôle est caractérisé par une couche kératinisée plus condensée et plus nettement différenciée que celle de la gencive alvéolaire. La couche granuleuse est inexistante ou réduite à une seule assise cellulaire (Fig. 8). On observe une variation topographique des digitations épithéliales (Fig. 1).

2.1. Chez le rat carencé, cet épithélium montre un net épaississement de la couche de kératine (Fig. 9). Cette hyperkératinisation ne s'accompagne ni d'une augmentation de l'épaisseur totale du tissu ni d'une augmentation de l'épaisseur de la couche granuleuse (Fig. 10), même chez un rat carencé pendant 378 jours.

Le tableau 2 donne les résultats des mensurations concernant la couche de kératine de l'épithélium vestibulaire dans les quatre premiers groupes.

La comparaison des moyennes obtenues montre que l'accroissement de la couche de kératine est fonction de la durée du régime carencé. Cette augmentation n'est pas linéaire, mais décroît avec le temps et tend vers une limite qu'il n'est plus possible de dépasser, même en prolongeant la durée de la carence en vitamine A (tableau 3).

L'analyse statistique (t test) faite en comparant les valeurs moyennes obtenues pour le groupe de contrôle (groupe III) et le groupe d'hypovitaminose longue (groupe IV) indique que la différence est, du point de vue statistique, très significative. Il y a en effet moins d'une chance sur mille pour qu'une telle probabilité soit due au hasard (t = 5,1).

L'analyse statistique faite en comparant les valeurs moyennes obtenues pour le groupe de contrôle et pour l'ensemble des rats carencés indique que la différence observée est encore, du point de vue statistique, assez fortement significative (0,02 - t - 0,01).

2.2. Chez l'animal en hypervitaminose, on observe au niveau de l'épithélium gingival vestibulaire une augmentation de l'épaisseur totale de l'épithélium (Fig.11). L'épaisseur de la couche cornée est diminuée et n'a pu être mesurée de façon satisfaisante. La structure des membranes cellulaires de la couche cornée disparaissent. Les cellules desquamées peuvent présenter des restes nucléaires. La couche granuleuse nettement différenciée possède une épaisseur de plusieurs couches cellulaires. Les granules kérato-hyalins sont bien visibles et répartis à travers tout le cytoplasme cellulaire. Les cellules de la couche basale, fusiformes, présentent de nombreuses figures de mitoses. Le tissu épithélial est distinctement délimité du tissu conjonctif.

3. L'aspect histologique de l'épithélium du sillon gingivo-dentaire varie selon sa localisation, soit dans la région marginale vestibulaire, soit au niveau des papilles intermolaires.

3.1. Dans la région marginale vestibulaire, chez le rat de contrôle (Fig. 8), le versant gingival est recouvert d'un épithélium pavimenteux de dix à douze assises cellulaires. Cet épithélium de type oral n'a pas de couche granuleuse, mais peut avoir une mince couche kératinisée. Il rejoint, dans la profondeur du sillon, un épithélium en voie de dégénérescence, s'étendant sur le versant dentaire. Le fond du cul-de-sac est intraépithélial. L'épithélium du versant dentaire est composé de cellules fusiformes au cytoplasme clair, qui gardent leur noyau jusqu'aux

couches superficielles; il est probablement d'origine adamantine. Au niveau de la jonction de ces deux épithélia, on note, dans le tissu conjonctif sous-jacent, la présence de quelques cellules inflammatoires.

Chez un rat du groupe II, carencé pendant 94 jours (Fig. 9), l'épithélium oral présente, sur toute la hauteur du sillon, une couche kératinisée nettement différenciée. L'épaisseur de celle-ci augmente proportionnellement à la durée de la carence. Sur le versant dentaire, se trouve un épithélium de type adamantin réduit à deux couches cellulaires. La jonction de ces deux épithélia ferme le fond du sillon gingivo-dentaire.

Chez un rat du groupe IV (Fig. 10) carencé pendant 263 jours, l'épithélium oral du versant gingival s'est quelque peu élargi et a proliféré en profondeur. La couche accrue de kératine est soulignée par une couche granuleuse. Le sillon gingivo-dentaire, intraépithélial, ne paraît pas être approfondi. Il est bordé sur son versant dentaire par un épithélium de type adamantin et constitué de deux assises cellulaires non kératinisées. Dans le fond du sillon, les deux épithélia fusionnent et leur distinction devient difficile.

Chez le rat hypervitaminosé (Fig. 11), le revêtement de la gencive libre sur toute la profondeur du sillon, est assuré par un épithélium de type adamantin, ne possédant qu'une couche cellulaire. Le tissu conjonctif sous-jacent ne présente pas de trace d'inflammation.

3.2. Dans la région papillaire intermolaire, l'épithélium gingivo-dentaire, chez le rat de contrôle (Fig. 12) comprend un nombre très réduit de cellules fusiformes. Cet épithélium stratifié ne possède ni couche granuleuse ni couche kératinisée, et les cellules superficielles possèdent toutes leur noyau; il est vraisemblablement d'origine adamantine. Il n'y a jamais prolifération de cet épithélium au-delà de

la jonction cément-émail, même chez un rat de 408 jours.

Chez le rat carencé l'aspect histologique varie selon la durée de la dépri-vation. Chez un rat en avitaminose, carencé pendant une courte durée (25 jours, groupe II), les structures cellulaires de l'épithélium papillaire intermolaire semblent plus condensées (Fig. 13). Chez un rat en hypovitaminose de longue durée, carencé pendant 378 jours (groupe IV), le revêtement papillaire est composé d'un épithélium pavimenteux de type oral. Les cellules superficielles bordant le sillon sont kératinisées, tandis que celles du fond ont proliféré aussi bien en profondeur le long du cément que en épaisseur dans le tissu conjonctif de la papille. L'atta-chement épithélial reste cependant toujours fixé à la jonction dentine-émail. Celui-ci comprend quelques infiltrations inflammatoires (Fig. 14).

Chez le rat hypervitaminosé, la protection du tissu conjonctif n'est assurée que par une à deux assises de cellules fusiformes. L'attachement de cet épithélium de type adamantin s'arrête au niveau de la jonction cément-émail. Le tissu conjonctif sous-jacent est plus vascularisé que chez le rat de contrôle et contient quelques cellules inflammatoires (Fig. 15).

4. DISCUSSION

D'après les résultats obtenus, la carence en vitamine A et l'hypervitaminose A chez le rat, modifient l'évolution de la kératinisation de l'épithélium oral et l'involution de l'épithélium adamantin, sans pourtant engendrer des lésions parodontales.

L'étude de la région gingivale, chez les rats expérimentaux comme chez les rats de contrôle, doit tenir compte de la zone du prélèvement et du type d'épithélium considéré.

Les différences régionales dans l'épaisseur de la couche de kératine au niveau de la gencive sont suffisamment importantes pour que toute mesure comparative doive être effectuée à des endroits identiques.

Dans la région gingivale, on distingue deux types d'épithélia : l'épithélium oral et l'épithélium adamantin. Ce dernier peut persister au niveau du sillon gingivo-dentaire et dans la région intermolaire. Il est caractérisé par son incapacité à former de la kératine et par son faible index mitotique (FRANQUIN et BAUME, 1962).

4.1. La carence en vitamine A provoque, au niveau de l'épithélium oral, une hyperkératinisation gingivale, proportionnelle à la durée de la carence. Cependant, dans la présente étude, on n'a pu confirmer ni l'augmentation de l'épaisseur totale de l'épithélium rapporté par KING (1940), MELLANBY (1941), GLICKMAN et STOLLER (1948), MIGLANI (1949), FRANDSEN (1963), ni l'inflammation gingivale décrite par KING (1940) et MELLANBY (1941). Il est remarquable de noter l'absence de lésion parodontale, même chez des rats carencés pendant plus de trois cent jours. Ces résultats contradictoires peuvent être dûs à une différence dans les méthodes d'expérimentation. C'est en effet en 1957 seulement que CLARKE et TODD ont établi, pour l'avitaminose A, des critères d'expérience basés sur l'étude des frottis vaginaux chez le rat femelle castré. L'adjonction, dans ce travail, de précautions supplémentaires basées sur l'examen de la formule sanguine a permis d'éviter, d'une façon presque certaine, la présence d'altérations liées à d'autres troubles surajoutés.

La carence en vitamine A accélère, dans la région du sillon gingivo-dentaire, la dégénérescence de l'épithélium adamantin et son remplacement par l'épithélium oral. L'attachement épithélial reste toutefois situé au niveau de la jonction cément-émail. La disparition précoce de l'épithélium adamantin a également été observée par BAUME et BECKS (1952) sur des rats ayant subi une thyroïdectomie, et par CONNE, KÜRNER et BAUME (1958) au niveau de l'incisive de rats en avitaminose A. Selon ces auteurs,

l'atrophie de l'organe de l'émail débuterait au niveau du stratum intermedium et serait suivi d'une dégénérescence précoce de la couche améloblastique.

4.2. Les observations faites au niveau de l'épithélium gingival du rat en hypervitaminose A, sont en accord avec celles qu'avaient décrites ZISKIN, ROSENSTEIN et BRUCKER (1943) chez le singe, après l'administration de 10.000 unités internationales par voie orale. L'hypervitaminose A provoque une augmentation de l'épaisseur totale de l'épithélium, un élargissement de la couche granuleuse, un agrandissement des granules kératohyalins et une diminution de la couche cornée. Par contre, BERN, LAWRENCE et STEADMAN (1960) sur le rat, et BERN et LAWRENCE (1962) sur l'épithélium de la joue du hamster, ont provoqué, par l'application topique de vitamine A aux doses utilisées, une métaplasie de l'épithélium pavimenteux en un épithélium cylindrique. L'action de la vitamine A semble être différente selon qu'elle s'applique par voie générale ou en application topique.

L'épaississement de la membrane basale mis en évidence sur les animaux en hypervitaminose A confirme que cette membrane subit d'importantes modifications, en rapport avec le taux de vitamine A. Une étude histochimique des altérations de cette structure, tant les rats carencés que chez les rats en hypervitaminose, est en cours d'achèvement (FRANQUIN et BAUME).

L'hypervitaminose A, selon SHERMAN (1959) et PARNELL et SHERMAN (1962), s'accompagne d'une augmentation de l'activité mitotique. L'épaississement observé au niveau de l'épithélium gingival pourrait également être dû à cet accroissement cellulaire. Toutefois, le gonflement des cellules épineuses, l'élargissement des granules kérato-hyalins et les modifications de la membrane basale traduisent l'existence d'un changement profond du métabolisme cellulaire. L'augmentation de l'index mitotique pourrait n'en être qu'une conséquence réparatrice.

11.

L'épithélium adamantin, chez le rat en hypervitaminose A, persiste sur le versant gingival de la gencive libre vestibulaire et intermolaire. Il ne présente pas de signe de dégénérescence et la couche basale reste active.

Les observations faites lors de cette étude confirment que la vitamine A joue un rôle de substance de protection et d'équilibre au niveau de l'épithélium gingival du rat. Toutefois, ni la carence en vitamine A ni l'hypervitaminose A n'ont engendré, en l'absence d'irritation locale, un approfondissement du sillon gingivo-dentaire. Les altérations épithéliales dues aux différentes diètes n'ont pas entraîné de lésions parodontales, malgré la gravité de l'état général des rats longuement carencés ou fortement hypervitaminosés.

RESUME

1. Ce travail a pour but d'étudier histologiquement les effets d'une hypo-vitaminose A de plus en plus prolongée et d'une hypervitaminose A sur l'épithélium gingival du rat.

51 rats femelles Wistar ont été soumis, dès leur sevrage, à un régime commun dont la teneur en vitamine A a subi d'importantes variations. Les animaux ont été répartis en 6 groupes suivant la durée et la nature de leur régime. Les groupes I et II reçurent un régime sans vitamine A, provoquant une hypovitaminose dans le groupe I et une avitaminose dans le groupe II. Les animaux du groupe IV reçurent le même régime déficient pendant plus de 200 jours. Les groupes III et V servirent de contrôle, respectivement pour les groupes I et II d'une part et pour le groupe IV d'autre part. Les rats du groupe VI reçurent un supplément de 25.000 U.I. de vitamine A par jour pendant 14 jours, ce qui les conduisit à un état de sévère hypervitaminose.

L'épithélium gingival du rat a été étudié au niveau des molaires inférieures, dans les régions attachée, marginale et papillaire.

2. La carence en vitamine A provoque au niveau de l'épithélium oral une hyperkératinisation, une réduction des granules kérato-hyalins et un effacement de la membrane basale. L'accroissement de la couche cornée a été mesuré au niveau de l'épithélium vestibulaire. Il est proportionnel à la durée durégime.

L'épithélium adamantin sans être kératinisé/ dégénère précocement. Son remplacement rapide par l'épithélium oral laisse l'attachement épithélial à la jonction émail-cément.

3. L'hypervitaminose A induit au niveau de l'épithélium oral une augmentation de l'épaisseur totale de l'épithélium, une diminution de la couche cornée, un élargissement de la couche granuleuse, un agrandissement des granules kératohyalins et un renforcement de la membrane basale.

L'épithélium adamantin, chez les rats hypervitaminosés, subsiste en état d'activité au niveau du sillon gingivo-dentaire, dans la région marginale vestibulaire et dans la région papillaire interrolaire, sans trace de kératinisation.

4. Les observations faites lors de cette étude confirment que la vitamine A joue un rôle de protection et d'équilibre au niveau de l'épithélium gingival. Toutefois, ni la carence en vitamine A ni l'hypervitaminose A n'ont engendré, en l'absence d'irritations locales, un approfondissement du sillon gingivo-dentaire. Les altérations épithéliales dues aux différentes diètes n'ont pas entraîné de lésions parodontales, malgré la gravité de l'état général des rats longuement carencés ou fortement hypervitaminosés.

Regezi'72
Bib. No. 10841

Reprinted with the
permission of the copyright owner,
Pergamon Press, Inc.

Archs oral Biol. Vol. 17, pp. 1609–1618, 1972. Pergamon Press. Printed in Great Britain.

MORPHOLOGIC EFFECTS OF HYPERVITAMINOSIS A ON RAT SUBMANDIBULAR GLAND

J. A. REGEZI and N. H. ROWE

Departments of Oral Pathology, David Grant USAF Medical Center, Travis Air Force Base, California, 94535, and University of Michigan School of Dentistry, Ann Arbor, Michigan, 48104, U.S.A.

Summary—Young male Sprague–Dawley rats were fed oral supplements of vitamin A; either a subtoxic dose of 5000 i.u./day for 16 weeks (10 animals), or a toxic dose of 15,000 i.u./day for 16 days (5 animals). High-dose animals exhibited signs of acute toxicity; low-dose animals demonstrated only less weight gain than controls. Vitamin A sera and liver levels evidenced intoxication. Light and electron microscopy were conducted upon acini, intercalated ducts, and striated-granular ducts of the submandibular gland. Acinar cells evidenced rough endoplasmic reticulum clefting and hyperplasia of both rough endoplasmic reticulum and Golgi apparatus similar to changes produced by pilocarpine or isoproterenol and interpreted as hyperactivity. Also increased were the number of degenerating acinar cells. Striated-granular duct cells were similar to controls except for increased cellular degeneration. Intercalated ducts appeared unaffected. Abnormalities were more pronounced in short-term, toxic hypervitaminosis A than long-term, subtoxic hypervitaminosis A.

INTRODUCTION

VITAMIN A has several dose-dependent effects on epithelial cells. Deficient levels cause cells that normally produce mucin to form keratin (NIELSEN *et al.*, 1966; PARNELL and SHERMAN, 1962; WOLBACH and HOWE, 1925). Excess vitamin A has an antikeratinizing effect on epithelial cells, and in sufficiently high doses causes mucous metaplasia of keratinizing epithelium (BERN *et al.*, 1955; BERN and LAWRENCE, 1962; HARDY, 1968; JACKSON and FELL, 1963; LAWRENCE and BERN, 1961; NEW, 1963). Increase as well as decrease of mitotic activity in epithelia has been reported to be vitamin A dependent (LAWRENCE and BERN, 1958; SHERMAN, 1961).

Previous studies of the effect of vitamin A upon salivary gland epithelia have been limited to deficiency. As in other epithelia, squamous metaplasia with keratin production by ductal cells was demonstrated (HAYES, MCCOMBS and FAHERTY, 1970; PARNELL and SHERMAN, 1962; TROWBRIDGE, 1969). Also in vitamin A deficiency, potentiation of chemically induced salivary gland neoplasia has been described (ROWE *et al.*, 1970). What effect excess vitamin A might have on cells of salivary gland tissue has not been reported.

MATERIALS AND METHODS

In the first of 2 investigations, long-term, subtoxic doses of vitamin A were used to produce hypervitaminosis. Twenty male Sprague–Dawley rats weighing 81 ± 2 g were separated into 2 equal groups (A and B). Group A rats were fed 10,000 i.u. of vitamin A (Aquasol A USV Pharmaceutica) orally once every 2 days; group B served as controls. All were fed Purina laboratory chow and water

ad libitum and weighed bi-weekly. Animals, 6 per cage, were maintained in a constant temperature and humidity environment. Animals were terminated after an experimental period of 16 weeks.

In the second investigation, short-term, toxic doses of vitamin A were used. Ten male Sprague–Dawley rats weighing 110 ± 4 g were randomly separated into 2 equal groups (C and D). Group C rats were fed 50,000 i.u. of vitamin A orally per day; group D rats served as controls. Diets and environmental conditions were otherwise identical to those for groups A and B. Animals were weighed every 4 days and terminated at the end of 16 days.

At termination, the submandibular glands of experimental and control animals were exposed through a ventral incision. The posterior half of the left gland was excised and immediately placed in fresh 3 per cent glutaraldehyde and fixed for 2 hr at 4°C. Tissue was rinsed in phosphate buffer, post-fixed in 1 per cent osmium tetroxide in veronal buffer, washed with distilled water, dehydrated in a graded series of ethanol, and embedded in Epon 811. Sections of 600–900 nm thickness were cut with glass knives on a Sorvall Porter-Blum MT-w ultra-microtome, double-stained with 7·6 per cent uranyl acetate in distilled water and Millonig's lead stain, examined and photographed in a Zeiss 9 S electron microscope (PEASE, 1964).

Thick sections for light microscopy were also cut from the Epon blocks for purposes of orientation and correlation. Sections 0·5–1·0 μm thick were mounted on glass slides and stained with a 1 per cent solution of toluidine blue, saturated with sodium borate.

The right and the remaining halves of the left submandibular glands were fixed in 10 per cent formalin and processed by standard histologic techniques for light microscopy.

Livers from 3 rats in each group were removed, pooled, and frozen for laboratory analysis of vitamin A (Younger Laboratories, 123 Cliff Cave Road, St. Louis, Missouri). Also for each group, 3 ml of blood from each of 3 rats was obtained by intracardiac aspiration, pooled, and serum vitamin A determined (Bio-Science Laboratories, 7600 Tyrone Avenue, Van Nuys, California).

RESULTS

Biochemical determinations

Serum vitamin A determinations were made using the method of SOBEL and SNOW (1947). Groups A and B sera showed no difference in vitamin A levels, while group C was more than 16 times that of group D.

Liver determinations of vitamin A were made using the method of DANN and EVELYN (1938). The experimental groups A and C showed remarkably high levels of vitamin A compared to their respective controls (Table 1).

TABLE 1. LABORATORY ANALYSIS FOR VITAMIN A

Group	Serum (i.u. A/100 ml)	Liver (i.u. A/g)
A	15	14,310
B	15	36
C	5097	39,861
D	311	621

Gross observations

Rats of group A showed less weight gain per unit time than controls, and began to lose weight at the fourteenth experimental week. The difference in mean weights between groups A and B was not statistically significant until the sixteenth week ($p < 0·01$).

Rats of group C (Short-term, toxic hypervitaminosis) initially showed arrested growth followed by progressive weight loss. A significant difference in mean weights was apparent by day 6 ($p < 0·01$). Controls exhibited a steady rapid weight gain.

Rats of group A appeared only slightly smaller in size than the group B rats by the end of the sixteenth week. Animals from groups A and B were normal in appearance and behaviour. Group C rats appeared lethargic, inactive, and smaller than controls. Hair loss occurred primarily around the mouth and continued caudally along the ventral surface. Elsewhere, fur was dull, matted, and shaggy.

Microscopic observations

Intralobular parenchyma (acini, intercalated ducts, and striated-granular ducts) were studied. Submandibular glands of control rats appeared as described in the literature (JACOBY and LEESON, 1959; LEESON and JACOBY, 1959; SCOTT and PEASE, 1959; TAMARIN and SREEBNY, 1965).

Frequent "washed out" appearing or degenerating acinar cells were seen in the submandibular glands of group A. Similar cells were also apparent in group C, but were less frequent. These cells, with light microscopy, exhibited dark fibrillar material set in a lighter cytoplasmic background (Fig. 1). Ultrastructurally they contained damaged rough endoplasmic reticulum, some evidence of residual Golgi vesicles, and a few irregularly shaped mucin granules. The disrupted organelles were found in a light-staining cytoplasm that was the same electron density as the acinar lumina (Fig. 2). Desmosomal attachments could be seen between these and normal neighbouring cells. Degenerating cells were infrequently seen in controls. A few striated-granular duct cells showed features of degeneration in the form of dilated rough endoplasmic reticulum cisternae, distorted organelles, and shrunken, irregular nuclei (Fig. 3).

Except for degenerative changes, acini of group C consistently exhibited more exaggerated alterations than group A. Acinar cells demonstrated enlarged ergastoplasmic areas. These areas appeared thickened and widened across the base and had many spindle-shaped, parallel clefts, evident to some degree in all cells (Fig. 4). Many acinar nuclei appeared larger than normal with prominent nucleoli and dense peripheral chromatin rings. Ultrastructurally, acinar cells displayed hyperplastic rough endoplasmic reticulum and clefting (Figs. 5 and 6). Acinar lumina and intercellular canaliculi were readily found due to dilatation and relative electron-lucency when compared to adjacent mucin granules (Fig. 7).

Intercalated duct cells were similar to controls. Granular duct cells were comparable to controls, except for some cells in group C which had a few small zymogen granules indicating immaturity. Striated ducts resembled controls except for the occasional degenerating ductal cells previously noted.

There was no evidence of mucous metaplasia in the intralobular ductal epithelium of either experimental group. Also, there was no change in the appearance of the mucin granules in the acinar cells in either treatment group.

DISCUSSION

Differences in animal age, route of administration, and type of vitamin A (i.e. mammal liver, emulsions, synthetic) are unimportant in the production of hypervitaminosis A (RODAHL, 1950). What remains for clarification are the time-dose

relationships. Vitamin A levels used in this study were based on previously reported studies (BRENNER and BROOKS, 1942; LEWIS *et al.*, 1942; MISRA, 1968; RODAHL, 1950).

Confirmation that hypervitaminosis A occurred was made by serum and liver Vitamin A determinations. Values reported elsewhere as normal for vitamin A content range from 8·5 to 112 i.u./100 ml of serum, and from 27 to 113 i.u./g of liver (BRENNER and BROOKS, 1942; GLOVER, GOODWIN and MORTON, 1947; LEWIS *et al.*, 1942). Although both groups A (long-term, subtoxic hypervitaminosis) and B (control) had similar normal serum values, liver values differed significantly, which indicated that group A rats were hypervitaminotic. The modest transient elevations of serum vitamin A over the 16-week experimental period had resulted in storage of excess vitamin A. Both serum and liver vitamin A in group C (short-term, toxic hypervitaminosis) were markedly elevated. The more frequent higher doses administered to animals in this group had resulted in incomplete serum clearance despite increased liver storage of absorbed vitamin A. It has been shown that normally the serum level of vitamin A is maintained relatively constant and does not reflect the liver store (BRENNER and BROOKS, 1942; GLOVER *et al.*, 1947). Also no direct relationship has been demonstrated between severity of clinical symptoms and serum levels (RODAHL, 1950). Thus, liver values rather than serum content provide the better indicator of vitamin A deficiency or intoxication.

The observed alterations (hyperplastic and hypertrophied Golgi apparatus and rough endoplasmic reticulum, clefting of rough endoplasmic reticulum, premature granule formation, and dilated, electron-lucent acinar luminal spaces) are interpreted to indicate acinar hyperactivity. Catecholamines administered to rats resulted in salivary gland enlargement due to hypertrophy and hyperplasia of acinar cells and their ergastoplasm; features indicative of increased protein synthesis (POHTO, 1966). Ultrastructural changes in the submandibular gland of the rat following isoproterenol administration included hypertrophic rough endoplasmic reticulum and Golgi apparatus, increased numbers of ribosomes, dilatation of secretory canaliculi, swollen nuclei and enlarged nucleoli (KANDA, MAYFIELD and GHIDONI, 1968; TAKAHAMA and BARKA, 1967). It was concluded that isoproterenol stimulated salivary secretions, DNA synthesis and mitotic activity. Pilocarpine administration increased both PAS staining and salivation (BIXLER, WEBSTER and MUHLER, 1958). Increased secretory activity was obtained in another study by the techniques of fasting-refeeding, pilocarpine, and electrical stimulation. Results, most dramatic to pilocarpine, were hyperplasia and hypertrophy of acinar RER and Golgi apparatus. Whorls and cisternal dilatations of rough endoplasmic reticulum were also seen (SCOTT and PEASE, 1964).

The degenerating acinar cells and disrupted ductal cells observed in both experimental groups contained fragmented and disoriented organelles. Similar-appearing cells have been reported in the pancreas following injections of ethionine (FITZGERALD and HERMAN, 1965). Rough endoplasmic reticulum disruption, acinar vacuolization, loss of ribosomes from rough endoplasmic reticulum, and cytoplasmic debris were observed. These features were interpreted as degenerative changes. Similar changes have been reported in liver cells following treatment with carbon tetrachloride (CHRIS-

TIE, 1968), Aflatoxin B_1 (BUTLER, 1966) and other toxins (BUTLER, 1968). The most consistent features were disruption of rough endoplasmic reticulum, dilatation of rough endoplasmic reticulum cisternae and Golgi apparatus, and mitochondrial swelling. Increased incidence of degenerating cells in a hyperactive gland suggest premature cell death from overwork or exhaustion. It is also possible that degeneration was due to an intracellular action of vitamin A. It is known that excess vitamin A causes increased cell and organelle membrane permeability (BELANGER and CLARK, 1967; DINGLE, 1961; DINGLE, LUCY and FELL, 1961). This could have been responsible for release of lysomal enzymes with subsequent autolysis.

Vitamin A does not produce morphologic evidence of altered protein metabolism in ductal cells. It can, however, be added to the list of agents that cause acinar hyperactivity. It was not determined whether the submandibular gland was directly or indirectly affected by vitamin A, nor what effect its administration had on other organs. The possibility must be considered that the alterations observed were a reflection of injury to, or stress upon, another organ or organs which secondarily affected cells of the submandibular gland.

Acknowledgement—This project was supported through funds from the NIH undef NIDR training grant DE00013, 040450. We are indebted to Dr. D. BAIC, Dept. of Zoology, University of Michigan for his assistance and the use of his laboratory. The opinions contained in this paper are those of the authors and are not to be construed as official or reflecting the view of the Department of the Air Force or of the Air Force Medical Service at large.

Résumé—De jeunes rats mâles Sprague–Dawley ont reçu per os de la vitamine A, soit une dose sub-toxique de 5000 i.u./jour pendant 16 semaines (10 animaux), soit une dose toxique de 15.000 i.u./pendant 16 jours (5 animaux). Ces derniers présentent des signes d'intoxication aigue: alors que le premier groupe ne présente qu'une perte de poids par rapport aux témoins. Les taux en vitamine A du sérum et du foie témoignent de l'intoxication. Des examens de microscopie classique et électronique ont été réalisés au niveau des acini, des canalicules intercalaires et des canalicules striés et granulaires de la glande sous-maxillaire. Les cellules acineuses présentent des ruptures de l'ergastoplasme ainsi qu'une hyperplasie de ce dernier et de l'appareil de Golgi. Ces lésions, identiques à celles provoquées par la pilocarpine ou l'isoproténerol, témoignent d'une hyperactivité. Le nombre des cellules acineuses dégénérées est aussi augmentée. Les cellules des canalicules striés et granulaires paraissent intactes. Les anomalies sont plus apparentes au cours de l'hypervitaminose A toxique, provoquée rapidement que par hypervitaminose A prolongée avec des doses sub-toxiques.

Zusammenfassung—Junge Sprague–Dawley Ratten, männlichen Geschlechts, erhielten mit ihrer Nahrung einen Zusatz an Vitamin A: einerseits eine subtoxische Dosis von 5000 i.u./Tag, während 16 Wochen (10 Tiere), andererseits eine toxische Dosis von 15.000 i.u./Tag, während 16 Tagen (5 Tiere). Bei den letzteren treten akute Vergiftungserscheinungen auf, während die erste Gruppe nur einen Gewichtsverlust, gegenüber den Test-Tieren zu verzeichnen hat. Der Gehalt an Vitamin A, von Serum und Leber kann als Beweis für die Vergiftung betrachtet werden. Am klassischen und elektronischen Mikroskop, werden über die Acini, die Zwischenkanälchen, die striierten und granular Kanaälchen der Unterkieferspeicheldrüse Untersuchungen vorgenommen. Die Zellen der Acinus lassen Zerreissungen des endoplasmatischen Retikulums erkennen, sowie eine Hyperplasie derselben und auch des Golgi Apparates. Die Gewebsveränderungen,

die identisch sind mit denen die durch Pilocarpin oder Isoproteneroi entstehen, sind der Beweis einer Überaktivität. Die Anzahl der degenerierten Zellen der Acinis ist auch erhöht, während diejenigen der striierten und granular Kanälchen intakt zu sein scheinen. Die aufgetretenen Anomalien kommen offensichtlicher zum Vorschein im Verlauf der schnell provozierten toxischen Hypervitaminose A, als bei der, auf längerer Sicht, hervorgerufenen sub-toxischen Hypervitaminose A.

REFERENCES

BELANGER, L. and CLARK, I. 1967. Alpharadiographic and histological observations on the skeletal effects of hypervitaminosis A and D in the rat. *Anat. Rec.* **158**, 443–451.

BERN, H. A., ELIAS, R., PICKETT, L., POWERS, G. and HARKNESS, H. 1955. The influence of vitamin A on the epidermis. *Am. J. Anat.* **96**, 419–447.

BERN, H. A. and LAWRENCE, D. J. 1962. *Fundamentals of Keratinization, a Symposium* (edited by BUTCHER, E. O. and SOGNNAES, R. F.), Pub. No. 70, pp. 95–112. Am. Ass. Adv. Science, Wash., D.Cl

BIXLER, D., WEBSTER, R. and MUHLER, J. C. 1958. The effect of pilocarpin on the submaxillary gland of the rat. *J. dent. Res.* **37**, 649–653.

BRENNER, S. and BROOKS, M. C. 1942. The relation of liver stores to the occurrence of early signs of vitamin A deficiency in the white rat. *J. Nut.* **23**, 459–456.

BUTLER, W. H. 1966. Early hepatic parenchyma changes induced in the rat by aflatoxin B1. *Am. J. Path.* **49**, 113–128.

BUTLER, W. H. 1968. Early electron microscopic changes in the course of liver injury. *New Zeal. med. J.* **67**, 18–25.

CHRISTIE, G. S. 1968. Some aspects of carbon tetrachloride hepatotoxicity. *New Zeal. Med. J.* **67**, 80–87.

DANN, W. J. and EVELYN, K. A. 1938. The determination of vitamin A with photo-electric colorimeter. *Biochem. J.* **32**, 1008–1017.

DINGLE, J. T. 1961. Studies on the mode of action of excess of vitamin A: release of bound protease by action of vitamin A. *Biochem. J.* **79**, 509–512.

DINGLE, J. T., LUCY, J. A. and FELL, H. B. 1961. Studies on the mode of action of excess vitamin A: effect of excess vitamin A on metabolism and composition of embryonic chick limb cartilage grown in organ culture. *Biochem. J.* **79**, 497–500.

FITZGERALD, P. J. and HERMAN, L. 1965. Degeneration and regeneration of pancreas. *Bull. N.Y. Acad. Med.* **41**, 804–810.

GLOVER, J., GOODWIN, T. W. and MORTON, R. A. 1947. Studies in vitamin A: the relationship between blood vitamin A levels and liver stores in rats. *Biochem. J.* **41**, 97–99.

HARDY, M. H. 1968. Glandular metaplasia of hair follicles and other responses to vitamin A excess in cultures of rodent skin. *J. Embryol. exp. Morph.* **19**, 157–180.

HAYES, K. C., MCCOMBS, H. L. and FAHERTY, T. P. 1970. The fine structure of vitamin A deficiency: parotid duct metaplasia. *Lab. Invest.* **22**, 81–89.

JACKSON, S. F. and FELL, H. B. 1963. Epidermal fine structure in embryonic chick skin during atypical differentiation induced by vitamin A in culture. *Dev. Biol.* **7**, 394–419.

JACOBY, F. and LEESON, C. R. 1959. The postnatal development of the rat submaxillary gland. *J. Anat.* **93**, 201–216.

KANDA, T., MAYFIELD, E. and GHIDONI, J. J. 1968. Ultrastructural alterations in the submaxillary acinar cells following isoproterenol administration: a new form of secretion granule. *Exp. molec. Path.* **9**, 189–196.

LAWRENCE, D. J. and BERN, H. A. 1961. Mucous metaplasia and mucous gland formation in keratinized adult epithelium *in situ* treated with vitamin A. *Exp. Cell Res.* **21**, 443–446.

LAWRENCE, D. and BERN, H. 1958. On the specificity of the response of mouse epidermis to vitamin A. *J. invest. Derm.* **31**, 313–325.

LEESON, C. R. and JACOBY, F. 1959. An electron microscopic study of the rat submaxillary gland during its postnatal development and in the adult. *J. Anat.* **93**, 287–295.

LEWIS, J. M., BODANSKY, O., FALK, K. G. and MCGUIRE, G. 1942. Vitamin A requirements in the rat. *J. Nut.* **23**, 351–363.

MISRA, U. K. 1968. Effect of hypervitaminosis A on rats: observations on growth and liver storage of vitamin A. *Br. J. Nut.* **22**, 461–464.

NEW, D. A. 1963. Effects of excess vitamin A on cultures of skin and buccal epithelium of embryonic rat and mouse. *Br. J. Derm.* **75**, 320–325.

NIELSEN, S. W., MILLS, J., ROUSSEAU, H. and WOLFEL, H. 1966. Parotid duct metaplasia in marginal bovine vitamin A deficiency. *Am. J. Vit. Res.* **27**, 223–233.

PARNELL, J. P. and SHERMAN, B. S. 1962. *Fundamentals of Keratinization, a Symposium* (edited by BUTCHER, E. O. and SOGNNAES, R. F.), Pub. No. 70, pp. 113–131. Am. Ass. Adv. Science, Wash., D.C.

PEASE, D. C. 1964. *Histological Techniques for Electron Microscopy*. Academic Press, New York.

POHTO, P. 1966. Catecholamine induced salivary gland enlargement in rats. *Acta odont. scand.* **24**, suppl. 45, 7–73.

RODAHL, K. 1950. Hypervitaminosis A in the rat. *J. Nut.* **41**, 399–421.

ROWE, N. H., GRAMMER, F. C., WATSON, F. R. and NICKERSON, N. H. 1970. A study of environmental influence upon salivary gland neoplasia in rats. *Cancer* **26**, 436–444.

SCOTT, B. L. and PEASE, D. 1959. Electron microscopy of salivary and lacrimal glands of the rat. *Am. J. Anat.* **104**, 115–161.

SCOTT, B. L. and PEASE, D. 1964. In: *Salivary Glands and their Secretions* (edited by SREEBNY, L. M. and MEYER, J.), pp. 13–44. MacMillan, New York.

SHERMAN, B. S. 1961. The effect of vitamin A on epithelial mitosis *in vitro* and *in vivo*. *J. invest. Derm.* **37**, 469–480.

SOBEL, H. and SNOW, G. 1947. The estimation of serum vitamin A with activated glycerol dichlorohydrin. *J. biol. Chem.* **171**, 617–632.

TAKAHAMA, M. and BARKA, T. 1967. Electron microscopic alterations of submaxillary gland produced by isoproterenol. *J. ultrastruct. Res.* **17**, 452–474.

TAMARIN, A. and SREEBNY, L. 1965. The rat submaxillary gland: a correlative study by light and electron microscopy. *J. Morph.* **117**, 295–352.

TROWBRIDGE, H. O. 1969. Salivary gland changes in vitamin A deficient rats. *Archs oral Biol.* **14**, 891–900.

WOLBACH, S. B. and HOWE, P. R. 1925. Tissue changes following deprivation of fat soluble vitamin A. *J. exp. Med.* **42**, 753–778.

PLATES 1–3 OVERLEAF

PLATE 1

FIG. 1. Epon-embedded section of submandibular gland acinus with a nucleated degenerating acinar cell. Toluidine blue. ×1000

FIG. 2. Electron micrograph of cytoplasm of degenerating acinar cell showing damaged rough endoplasmic reticulum (R), Golgi apparatus (G), and mucin granules. Note acinar lumen with associated desmosomes (upper left corner). ×8000

FIG. 3. Electron micrograph of degenerating striated-granular duct cell. Note damaged organelles. ×8000

PLATE 1
A.O.B. f.p. 1616

PLATE 2

FIG. 4. Epon-embedded section of submandibular gland from short-term, toxic hypervitaminosis A rats. Note acinar cells with clefting of hyperplastic ergastoplasm, large nucleoli, enlarged acinar lumen (middle right) and degenerating acinar cell (middle left). ×1000

FIG. 5. Electron-micrograph of short-term toxic hypervitaminosis A acinar cell. Note clefting of hyperplastic rough endoplasmic reticulum. ×12,000

Plate 2

PLATE 3

FIG. 6. High magnification electron-micrograph of hyperplastic acinar rough endoplasmic reticulum. Note clefting and Golgi apparatus (lower right) and nucleus (lower left). ×34,000

FIG. 7. Electron-micrograph of acinus with enlarged electron lucent lumen and intercellular canaliculus (upper right). Note clefting of rough endoplasmic reticulum and prominent Golgi apparatus. ×7000

PLATE 3
A.O.B. f.p. 1618

Sampson'56
Bib. No. 10860

Reproduced by permission
of the copyright owner

Fed. Proc. 15:571. 1956.

1861. Effects of excess vitamin A palmitate in paired feeding experiments on albino rats. MYRA M. SAMPSON, ESTHER CARPENTER* AND ROLAND WIGHT.* *Zoology Dept., Smith College, Northampton, Mass.*

Seven sets of 3 litter-mate female rats of the Sprague-Dawley strain were used. Initial weights varied from 126 to 150 gm and ages from 43 to 52 days. All rats were given a purified diet plus powdered yeast and biweekly supplements of vitamins A, C, D and E. The experimental rat in each group was given approximately 25,000 IU of vitamin A by mouth daily during the 1st wk. and twice or three times that amount in succeeding weeks. The pair-fed control was given the amount of food eaten by the experimental rat on the previous day. The other control was allowed to eat ad libitum. Each set was killed when the weight of the excess A rat continued to fall. The first consistent and progressive indication of hypervitaminosis A was a reduction in efficiency of food utilization which became apparent during the 2nd week. The total ratio of weight gain to food intake in one of the hypervitaminotic rats went as low as 13% of that of the intake paired control. In addition to the usual symptoms of toxic hypervitaminosis A, there should be mentioned a copious yellowish discharge in the urethral region and a marked thinning of the skeletal muscles. Changes in the thyroid gland will be reported elsewhere. (Supported in part by grants from the American Cancer Society and the Massachusetts Branch of the same.)

Shenefelt, -'72
Bib. No. 1089

Reproduced by permission
of the copyright owner

Am. J. Pathol. 66(3):589-592. 1972.

ANIMAL MODEL FOR HUMAN DISEASE

Gross Congenital Malformations

Animal Model: Treatment of Various Species with a Large Dose of Vitamin A at Known Stages in Pregnancy

Contributed by Ray E. Shenefelt, MD, Children's Hospital Research Foundation, Cincinnati, Ohio 45229.

Biologic Features

Large doses of vitamin A given to pregnant mammals produce many types of gross structural malformation in high incidence. This is true in the rat, mouse, golden hamster, guinea pig, and rabbit, and in limited experiments on monkeys, pigs, and dogs. The types and incidence of malformations depend on stage of pregnancy and dose, and to a lesser extent on species and strain. Doses used are hundreds of times the daily requirement. Most investigators use multiple treatments, but it is now clear that a single administration is just as effective if time and dose are chosen carefully. This model was discovered in 1953, and there are 167 papers on hypervitaminosis A teratogenesis in mammals *in vivo* (a bibliography is available from the author).

Comparisons with Human Disease

Malformations produced by hypervitaminosis A mimic human malformations of genetic, environmental and unknown causes. Malformation types can usually be divided into subtypes that vary in details of morphology and morphogenesis, and it is not possible at present to draw exact parallels between subtypes of most human malformations and experimentally produced malformations. More than 70 types of malformation are produced by hypervitaminosis A. In the hamster, 18 types could be produced at more than 90% incidence, and 28 types at 10–90%.[1] Some of these are shown in Figures 1 and 2.

Publication sponsored by the Registry of Comparative Pathology, under the auspices of the Universities Associated for Research and Education in Pathology, Inc., and supported by grant RR00301 from the US Public Health Service, Division of Research Resources.



Fig 1—*Left*, normal near-term hamster fetus. *Right*, hamster fetus after retinoic acid (vitamin A_1 acid) at 22–26 somite stage shows cleft lip, digit reduction, no tail. *Middle*, 4-week-old hamster after retinoic acid at presomite stage shows *situs inversus*.

Fig 2—A litter of hamster fetuses after retinoic acid at 5–9 somite stage. Multiple malformations include sympodia, exencephaly and omphalocele.

Structures affected (and analogs of some human malformations) include the following: brain (anencephaly), spinal cord (spina bifida), face (cleft lip, cleft palate, micrognathia), eye (microphthalmia), all parts of the ear, teeth, salivary glands, aortic arch (malformations of several types), heart (ventricular septal defect), lungs, gastrointestinal tract (imperforate anus, omphalocele), liver and gallbladder, urinary system (renal "agenesis," hydronephrosis), genitalia, pituitary, thyroid, thymus, skull, vertebrae, ribs, extremities (phocomelia, digit malformations), muscles, and *situs inversus.*

Usefulness of Model

A potential use of the model is the study of sequential stages in the morphogenesis of malformations. Alternative routes of morphogenesis are readily conceivable for most malformations, and have been demonstrated for some. Sequential studies have been done on a number of hereditary malformations. There are surprisingly few studies of the morphogenesis of malformations after treatment with a teratogen. The malformations produced by hypervitaminosis A that have been sequentially studied are microphthalmia,[2] inner-ear malformations,[3] anencephaly,[4] hydronephrosis[5] and cleft palate.[6] The high incidence and known time of treatment are advantages in these studies; simultaneous effects on other organs with possible secondary effects are disadvantageous. The multiplicity of effects is an advantage in studying relationships of malformations. The biochemical basis is not known for the toxicity of vitamin A, or indeed for most of its physiologic functions, so other models are better at present for studying biochemical bases of teratogenesis. Necrosis[8] and prolongation of cell generation time[7] have been described in treated embryos, but the relationship of these and other changes of cell behavior to malformations have not been clarified. Some newborns with malformations from hypervitaminosis A can be raised but this has not been systematically explored.

References

1. Shenefelt RE: Morphogenesis of malformations in hamsters caused by retinoic acid: relation to dose and stage at treatment. Teratology (in press)
2. Baba T, Kotani S: Morphogenesis of malformation due to excessive vitamin A. III. Morphogenesis of an- or microphthalmus. J Osaka City Med Center 5:135–140, 1959
3. Baba T, Kuzukawa S: Morphogenesis of malformation due to excessive vitamin A. V. Embryological studies on the inner ear malformation of rats due to excessive vitamin A. J Osaka City Med Center 8:105–119, 1962
4. Giroud A: Causes and morphogenesis of anencephaly, CIBA Foundation Symposium on Congenital Malformations. Edited by G. Wolstenholme. Boston, Little, Brown, Brown and Company, 1960, pp 199–218
5. Giroud A, Martinet M, Roux C: Urétérohydronéphrose expérimentale chez l'embryon par hypervitaminose A. Arch Fr Pediatr 15:540–551, 1958

6. Kochhar D, Johnson E: Morphological and autoradiographic studies of cleft palate induced in rat embryos by maternal hypervitaminosis A. J Embryol Exp Morphol 14:223–238, 1965
7. Langman J, Welch G: Excess vitamin A and development of the cerebral cortex. J Comp Neurol 131:15–26, 1967
8. Marin-Padilla M, Ferm V: Somite necrosis and developmental malformations induced by vitamin A in the golden hamster. J Embryol Exp Morphol 13:1–8, 1965

J. Am. Oil Chem. Soc. 49(11):619-633, 1972.

Gas Chromatography of the Fat-Soluble Vitamins: A Rev

A.J. SHEPPARD, A.R. PROSSER and W.D. HUBBARD, Division of Nutrition, Food and Drug Administration, Washington, D.C. 20204

Sheppard-'7
Bib. No. 10892

Reproduced by permission of the copyright owner

ABSTRACT

The application of gas liquid chromatography (GLC) as an analytical tool for the determination of the fat-soluble vitamins A, D, E and K has yet to be utilized to its full potential. A review of the published work of many researchers in this field is presented. GLC methods to measure the vitamin A isomers have not been developed to any appreciable practical extent. Liquid liquid chromatography might well be the technique of choice. In the field of vitamin D there are indications that a practical GLC analysis is feasible for pharmaceutical preparations. The GLC applications for vitamin E are diverse, well defined and generally widely accepted in research laboratory situations and for regulatory and quality control usage. Vitamins K_1 and K_2 have been measured with limited success in a few research laboratories, but the GLC methods have not developed on a practical basis. However GLC is used for measuring vitamin K_3 (menadione and menadione sodium bisulfite) on a fairly routine basis in quality control laboratories.

INTRODUCTION

Gas liquid chromatography (GLC) is a powerful analytical tool, but like all analytical instrumentation, it must be regarded as another means to be used in situations where it is superior to other instruments. In short, it must not be accepted *carte blanche* for every analytical problem.

Many research groups have attempted, with varying degrees of success, to use GLC as a means of identifying and quantitatively measuring the fat-soluble vitamins A, D, E and K. GLC has been most successfully applied on a practical basis to vitamin E. The overall success of GLC for analysis of vitamin A has been the least satisfactory of all the vitamins of the fat-soluble series.

Two papers appeared in December 1960 that signaled the advent of GLC as a possible means of determining the fat-soluble vitamins. Nicolaides (1) observed that α-tocopherol could be resolved partially from γ-tocopherol on a 5% silicone-gum rubber column packing during a study to determine the possible use of silicone-gum rubber as an immobile phase for GLC separation of lipids. Simultaneously Ziffer et al. (2) published their work aimed specifically at the GLC of vitamin D.

Ironically these early workers did not follow up their early advantage and leadership. It was left to others to develop GLC methods and applications for the fat-soluble vitamins. Eleven years after the initial reports, much remains to be done in completing the development of entirely suitable GLC applications to the fat-soluble vitamins. Despite this, however, there are areas of application where tremendous success has been achieved.

VITAMIN A

The term vitamin A, as used in this discussion, includes retinol, retinene, retinoic acid, retinyl acetate and retinyl palmitate. During 1963, Sheppard and Libby (unpublished results, 1963) attempted to develop a GLC method for the aforementioned vitamin A compounds. Stationary phases of 2.5% and 5% XE-60 and 1% and 5% SE-30 were tried together with column temperatures ranging from 170 C to 215 C. The palmitate derivative produced a single peak on the 5% SE-30 column at 215 C, but at ca. 200 C two peaks occurred with a shoulder appearing on the trailing edge of the second peak. Retinol produced multiple peaks on both SE-30 and XE-60 immobile phases, irrespective of [illegible] coating and temperature. The acetate derivative p[illegible] well defined symmetrical peaks at 170 C on the [illegible] column and produced a single peak exhibiting [illegible] edge on the back side of the peak, typical of an ad[illegible] isotherm, on the 2.5% XE-60 column.

Japanese workers (3) reported in 1963 that retinol, retinyl acetate and retinyl palmitate undergo dehydration to form anhydro retinol during conventional GLC operating conditions. Their conclusions were supported adequately by IR, UV and thin layer analysis of collected fractions from GLC. Carroll and Herting (4) attempted to chromatograph all-*trans* retinol with little success. The all-*trans* retinol produced a large broad-based response, with several well defined apexes indicative of severe alteration of the parent compound, during the GLC analysis on a 3% SE-30 column maintained at 181 C.

Dunagin and Olson (5) confirmed the finding of Ninomiya et al. (3), who analyzed collected GLC fractions by UV analysis, that retinol and retinyl acetate were completely converted to anhydro retinol. This is no doubt the reason why previous workers had observed that the various analogs of vitamin A yielded multiple peaks during attempts to chromatograph them. However Dunagin and Olson developed the first technique to overcome the decomposition of vitamin A to anhydro retinol. To chromatograph retinol or retinyl acetate with a minimum of dehydration, solutions of β-carotene or hydroquinone were injected onto the column and the treated columns were conditioned at 250 C for several hours. Both reagents worked well as protective agents on glass bead columns, but only the β-carotene worked on the Gas-Chrom P columns. The β-carotene treatment was generally adequate for 3 days, whereas the hydroquinone lost its protective activity within 2-3 hr. Glass columns, 35 cm x 4 mm ID, packed with 0.1% or 1.0% SE-30 coated on 60-80 mesh Gas-Chrom P were used. Retinol and retinyl acetate were completely resolved (Fig. 1) with ca. 6% decomposition, which appeared as two minor peaks occurring within 2 min after sample injection with the following operating parameters: column, 150 C; detector, 165 C; injector, 230-250 C; flow rate, 880 ml/min. The method was usable down to <0.05-0.2 μg of retinol or its derivatives with a β-argon ionization detector, or both. Following the work of Dunagin and Olson, the efforts by American researchers to develop GLC methods for vitamin A have subsided.

Walle et al. (6) observed that if vitamin A was converted to trimethylsilyl ether, it would not interfere with GLC determination of calciferol in preparations containing vitamin A. Macek and Vanecek (7) developed and applied a GLC scheme to follow the production of the possible intermediates in the synthesis of pseudoionone, isophytol and vitamin A. A 20% SE-30 column was used isothermally at 170 C or temperature-programed from 160 to 190 C to determine all the intermediates except those formed during the last stages in the synthesis of vitamin A.

Vecchi and coworkers (8) made practical use of GLC in measuring vitamin A forms by using the trimethylsilyl ethers of vitamin A and its isomers as a means of monitoring a synthesis process on a manufacturing scale on 5% silicon QF-1 columns. Their operating parameters were as follows: column, glass, 2 m x 2.3 mm ID at 160 C, flash heater, 245-250 C; carrier gas, helium, 70 ml/min; column

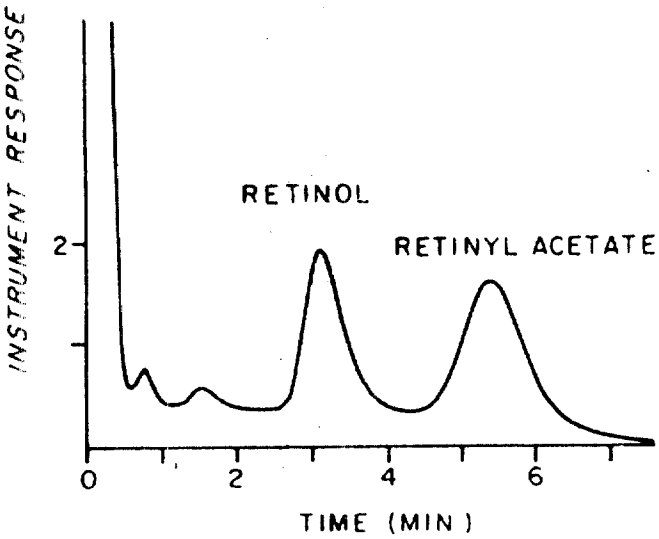

FIG. 1. Separation of retinol and retinyl acetate on β-carotene treated Gas-Chrom P (5).

packing, 5% silicon QF-1 coated on 80-100 mesh Gas-Chrom Q; detector, flame ionization presumably operated at approximately the same temperature as the flash heater. They were able to achieve complete resolution of 13-*cis*-vitamin A and all-*trans* vitamin A. The relative retention times based on all-*trans* vitamin A as 1.00 were as follows: 13-*cis*-vitamin A, 0.64; 11, 13-di-*cis*-vitamin A, 0.28; *retro*-vitamin A, 0.72 and 1.00. The analysis time was 25 min. The identification of the various GLC fractions was verified by mass spectrometry. The reproducibility of the method, based on 95% statistical certainty, was found to be 3.5% for all-*trans*-vitamin A and 13-*cis*-vitamin A and 3% for *retro*-vitamin A.

Hata and Hata (9) developed a GLC method to assay the vitamin A content of fish livers. The extracts were dissolved in benzene, and crystalline *p*-toluenesulfonic acid was added as a catalyst. The released fatty acids were esterified with diazomethane and determined by GLC. It was established that the catalyst did not alter the freed vitamin A fatty acids and that the wax esters and cholesterol esters did not release any fatty acids in the presence of the catalyst. Anhydrovitamin A was formed when the catalyst was used to release the fatty acids. The liver oil of bonito *(Katsuwonus pelamis)* was analyzed as an example. Based on the fatty acid analysis, the quantity of vitamin A present was calculated.

Shapira et al. (10) used GLC to study the intermediates in vitamin A production. At least one of the intermediates, *cis*-3-methyl-2-penten-4-yn-1-ol, underwent partial decomposition at temperatures exceeding 120 C. Their analyses for impurities in the intermediates were carried out on 12% polyethylene glycol 4000 or 12% polyethylene glycol adipate coated on 80-100 mesh Celite 545. These investigators did not devote any efforts toward the GLC analysis of vitamin A itself. A similar type of application previously was reported by Macek et al. (11).

Janecke and Voege (12) are often quoted in literature reviews regarding their studies of vitamin A. The cited report is a very short communication containing no research data per se, and indicates only that the fat-soluble vitamins can be determined on a 3% SE-30 column temperature programed from 100 to 270 C and on a 2.5% SE-30 column at 250 C.

VITAMIN D

The provitamins, the inactive precursors of the D vitamins, are cyclopentanophenanthrene derivatives. The main derivatives that occur in nature are ergosterol (provitamin D_2) and 7-dehydrocholesterol (provitamin D_3). Ergosterol is found in plants and 7-dehydrocholesterol in animals. This discussion is limited to the irradiation products of the provitamins, i.e., vitamins D_2 and D_3. Vitamin D_2 encompasses the terms calciferol, activated ergosterol, irradiated ergocalciferol and viosterol; vitamin D_3 is synonymous with cholecalciferol and activated 7-dehydrocholesterol. These terms are broadly used throughout the literature.

Interest in the development of GLC methods for vitamins has been caused by: (a) the inability of chemical methods to distinguish between vitamins D_2 and D_3; (b) the laborious clean-up procedures necessary to eliminate interferences from vitamin A and other substances during chemical analysis; (c) inability of the rat bioassay to distinguish between vitamins D_2 and D_3; and (d) the cost, labor and time required for bioassays.

Ziffer and coworkers (2) in 1960 were the first to report studies of the GLC behavior of the D vitamins. They used 0.75% SE-30 and 0.75% neopentyl glycol succinate (NPGS) immobile phases coated on 100-140 mesh Gas-Chrom P. The SE-30 columns (6 ft x 4 mm ID) were operated at 222 C and the NPGS columns (6 ft x 3 mm ID) at 210 C. Vitamins D_2 and D_3 yielded two GLC peaks each. UV and IR spectra of samples collected from the columns indicated that cyclization had occurred and that "pyro" and "isopyro" compounds were formed. They also observed that the "pyro" and "isopyro" compounds of the two vitamins do not occur naturally and that the relative retention times are quite distinct from those of the provitamins; thus GLC might be useful in studying irradiation mixtures. The relative retention time data reveals that, if both vitamins D_2 and D_3 were present in a sample, peaks would overlap and quantitation would be difficult under their GLC conditions. The influence of injector temperature on cyclization was investigated, and it was found that the ratio of products is only slightly dependent on injector temperature.

In 1963 Ninomiya et al. (3) reported their GLC experiences with vitamin D. The three columns evaluated were 1% Craig's polyester succinate on 80-100 mesh Anakrom A (silanized), 1% SE-30 on 80-100 mesh Anakrom A (silanized) and 1% (assumed) FS-1265 (QF-1) on 80-100 mesh Chromosorb W or Anakrom A. The glass columns were 200 cm x 0.6 cm ID. The formation of the "pyro" and "isopyro" cyclization compounds of vitamins D_2 and D_3 observed during GLC analysis by Ziffer et al. (2) was verified. It is evident from the retention time data with the three immobile phases that, at column temperatures sufficient to elute usable peaks (about 200 C or higher), vitamins D_2 and D_3 in a mixture would not be sufficiently resolved for quantitative analysis. On every column used α-tocopherol would interfere, and with the Craig's polyester succinate column α-tocopheryl acetate would also interfere with vitamin D analysis. It was evident that vitamin A eluted at temperatures significantly lower than vitamin D, especially on the Craig's polyester succinate and FS-1265 columns, and thus should not interfere with vitamin D analysis at 200 C or higher, even with the SE-30 column.

Concurrently in our laboratory (unpublished results, 1963-63), we were attempting to develop a GLC method for vitamins D_2 and D_3. Using 3 and 5% SE-30 on 100-120 mesh Gas-Chrom P (silanized) packed in glass columns (6 and 8 ft x 4 mm ID), we were never able to achieve a complete resolution of the two vitamin D forms. The isopyrovitamin D_3 and the pyrovitamin D_2 peaks overlapped sufficiently to circumvent proper quantitative analysis. We were able to duplicate the results of Ziffer et al. (2) using the 0.75% SE-30 packing, but we were never able to duplicate their efforts with 0.75% neopentyl glycol succinate columns.

Vessman and Ahlen (13) were first to report using a derivative (trimethylsilyl ether [TMS]) of vitamin D for

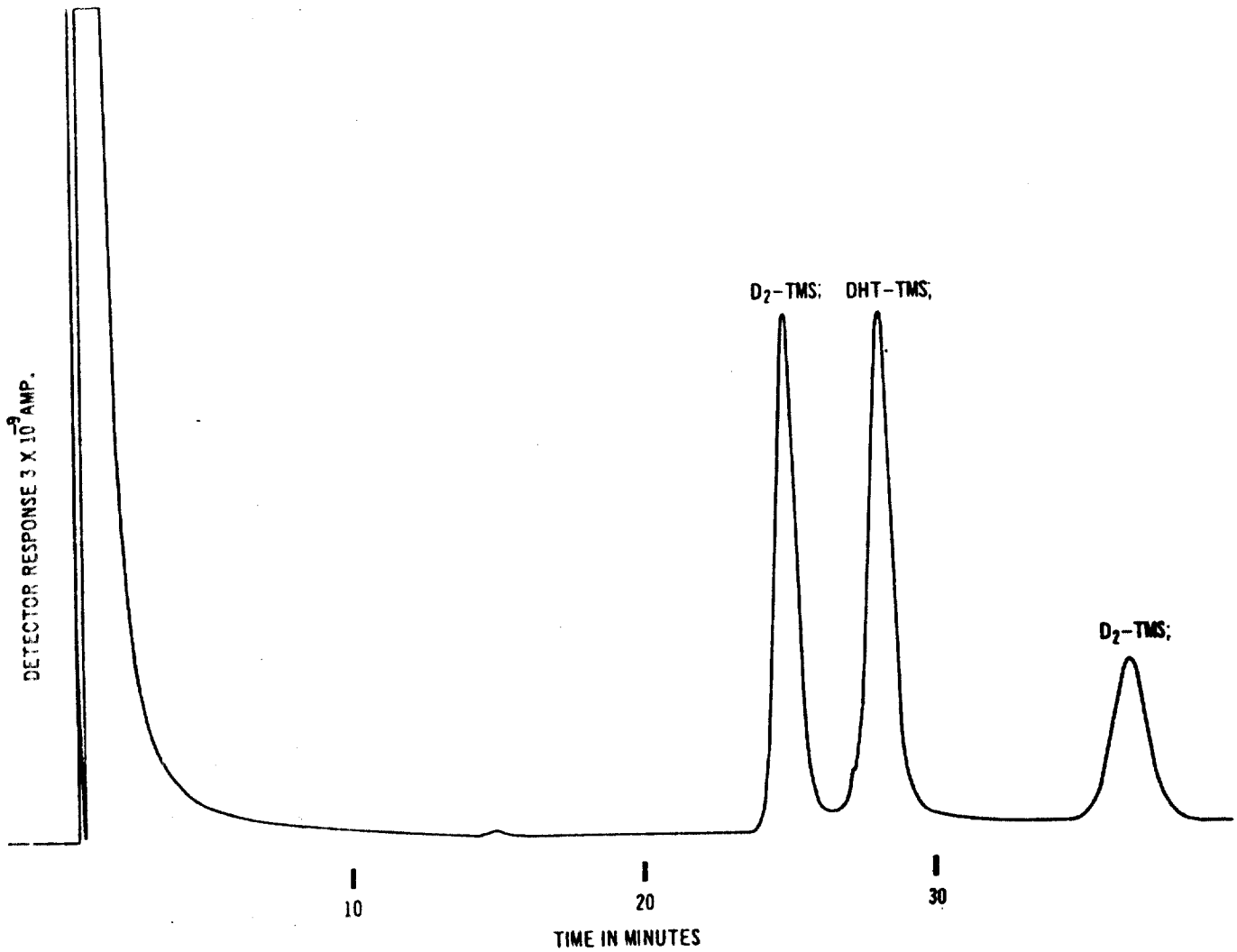

FIG. 2. Gas chromatographic separation of vitamin D_2 and dihydrotachysterol as trimethylsilyl ethers (14).

GLC analysis. They were also first to report efforts to exploit GLC specifically for quantitative analysis of vitamin D. They had concluded from the work of Ninomiya et al. (3) that on certain immobile phases vitamin A eluted at temperatures significantly lower than vitamin D, and they selected their immobile phases accordingly. They tried SE-30 and butanediol succinate (Craig's polyester succinate) stationary phases. The SE-30 immobile phase gave unsatisfactory resolution of pyro- and isopyrovitamin D_2 derivatives, but the polyester phase performed well, and they selected 3.4% butanediol succinate on Gas-Chrom P (glass column, 150 cm x 1/8 in. OD) operated at 210 C for the quantitative analysis of vitamin D_2. Cholesterol was used as an internal standard. The TMS derivative was formed, and the relationship between the area of the cholesteryl-TMS peak and that of the pyrovitamin D_2 derivative peak was used for quantitative calculations. Vitamin A palmitate eluted either with or in close proximity to the solvent peak. The TMS ether of cholesterol appeared intermediate between pyro- and isopyrovitamin D_2. However the resolution between the cyclization products and cholesteryl-TMS ether was sufficient for adequate quantitative analysis. From an inspection of their retention data, it is apparent that vitamin D_3 could have been measured effectively by the method, but the quantitative analysis would be difficult or impossible with mixtures of D_2 and D_3. If the ratio of vitamin A palmitate to vitamin D_2 was 30 or higher, the palmitate produced tailing that made measurements of the pyrovitamin D_2-TMS ether peak area more difficult. When 3 μg of vitamin D_2 per injection was used, a standard deviation of 1.5% was achieved and lower amounts gave diminished precision.

Nair et al. (14) reported the first successful attempt to measure the D vitamins in biological tissue by GLC. The provitamins and cholesterol were precipitated as the digitonides, and column chromatography was used for further purifying the extracts before GLC analysis. Studies were carried out in which the vitamin D was measured unreacted, as the trifluoroacetate (TFA), and as the trimethylsilyl ether (TMS). The GLC procedures were worked out for SE-52 and SE-52/β-cyanoethylmethylpolysiloxane (949) coated on the same inert support. Glass columns 6 ft x 5 mm ID were used routinely. The SE-52 columns were maintained at 213 C and the biphase columns at 225 C. It was reported that the structural alterations during GLC analysis of vitamins D_2 and D_3 are not affected by changes in temperature of the flash heater. GLC recoveries of 80-105% were obtained from blood and liver samples with the biphase column. Dihydrocholesterol and its TFA and TMS derivatives did not undergo cyclization upon GLC analysis. Typical chromatograms of TMS derivatives and the biphase column reproduced from their report are shown in Figures 2 and 3. The method was used routinely with 1-2 μg of vitamin injected onto the column. Much smaller samples could be analyzed at higher instrument sensitivity settings than those used routinely.

Murray et al. (15) recorded in a preliminary report the first attempt to avoid the formation of cyclization products of the D vitamins during GLC analysis by treating the

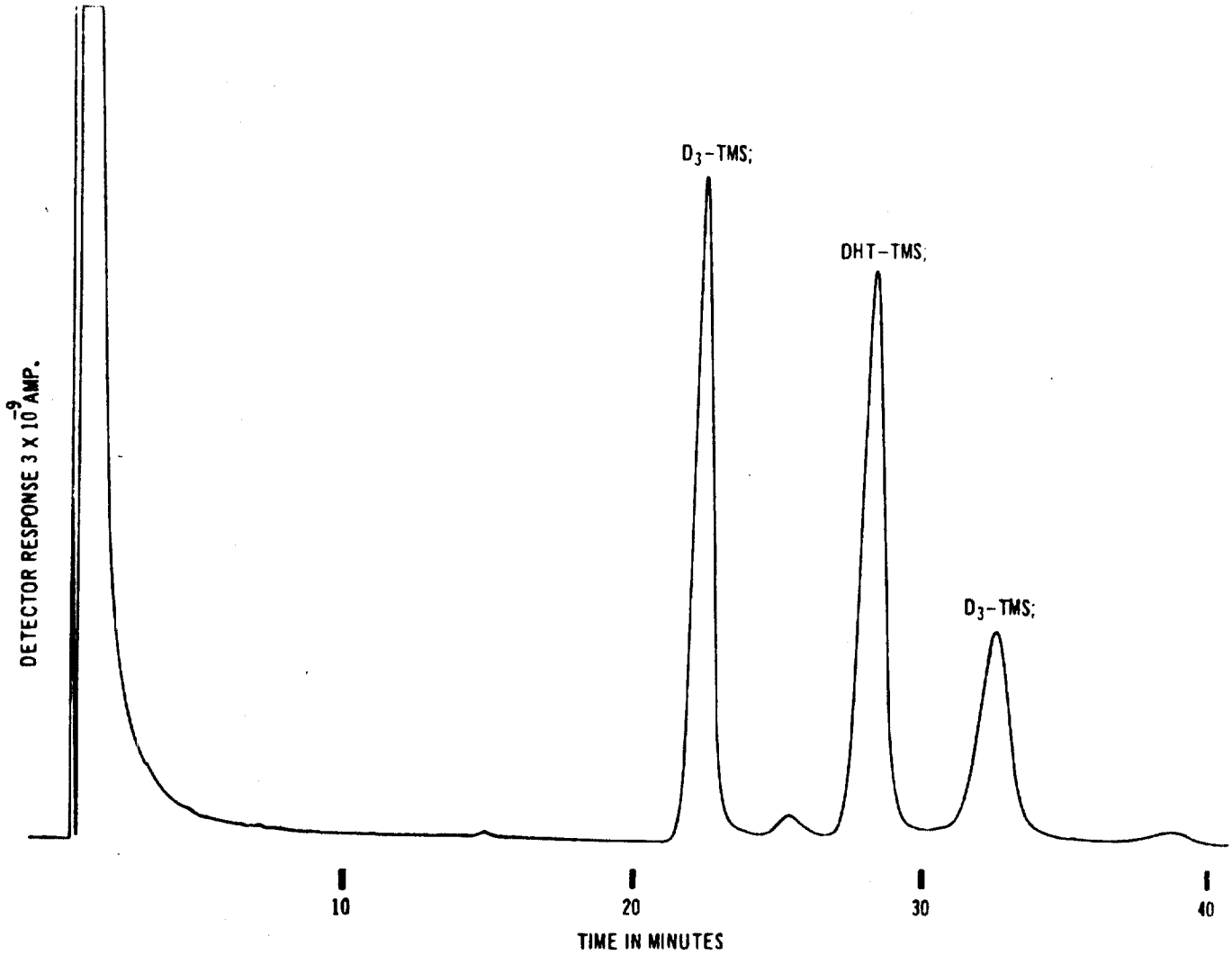

FIG. 3. Gas chromatographic separation of vitamin D_3 and dihydrotachysterol as trimethylsilyl ethers (14).

vitamin with antimony trichloride. The resulting compound was found to be stable during GLC, and it appeared to be isovitamin D based on UV spectra. Quantities down to 0.20 μg could be measured. GLC recoveries of 101% ± 2% were achieved for vitamin D_2 added to livers of deficient rats. A 4 ft glass column packed with 3% silicone oil on Celite maintained at 230 C and a flow rate of 60 ml/min was used. The sensitivity of this method is somewhat better than that reported by Nair et al. (14). Vitamin D_2 was used as the internal standard for vitamin D_3, and vice versa.

In 1966 Murray et al. (16) expanded their 1965 preliminary report (15) and included considerable detail about the sample extract clean-up procedures required. Two thin layer chromatographic steps—conversion of vitamin A to anhydrovitamin A and precipitation of sterols—were needed in addition to the key reaction of vitamin D with antimony trichloride. UV spectral data were presented in support of their contention that the provitamin was formed by the reaction of the D vitamins with antimony trichloride. The GLC resolution of the reacted vitamin D_2 and D_3 was not complete but was sufficient for analytical measurement.

Nair (17) reviewed the work of Ziffer et al. (2) in depth and showed the relationship among their studies, work in his own laboratory (14,18) and the chemistry of cyclization and derivative chemistry. This excellent review treats the specific aspects of the earlier research just cited in greater depth than does the present review. Nair and Bucana (19) successfully studied the intracellular distribution of vitamin D in rat liver, using the GLC method employing the trifluoroacetate and trimethylsilyl ether derivatives as discussed previously (14,17).

The study of Vessman and Ahlen (13) was expanded by Walle et al. (20) to include a closer study of vitamin D_2 rearrangement, which was found to be influenced by the presence of vitamin A among other factors. Stainless steel columns, 150 cm x 1/8 in. OD, packed with 1-3 butanediol succinate polyester on Gas-Chrom P (100-120 mesh) were operated isothermally at 200 C and temperature-programed at 2 C/min from 160 to 200 C, after which the temperature was maintained isothermally at 200 C. It was found that the separation of vitamin D derivatives was improved if vitamin A was present as the trimethylsilyl ether. The tailing of vitamin A palmitate was a problem during both isothermal and temperature programed analysis, whereas it was greatly reduced with the TMS derivative. The separation of the pyro- and isopyrovitamin D TMS ether derivatives from vitamin A TMS ether could be performed isothermally, but when the concentration ratio of vitamin A to vitamin D_2 exceeded 90, better precision was obtained by temperature programing. It was also found that measurements based on the sum of the pyro- and isopyrovitamin D_2 peaks gave somewhat lower values than measurements of the pyrovitamin D_2 peak alone. It was observed that, if large amounts of vitamin A were present in the test sample, rearrangement of vitamin D_2 was facilitated. Carrier gases, such as helium, which has a large thermal conductivity, gave more complete rearrangement than either argon or nitrogen, which have lower thermal conductivity. It was postulated that the differences ob-

tained with glass and metal GLC apparatus might be due partially to the different thermal conductivity of these materials. Only metal injectors gave a complete thermal rearrangement.

Avioli and Lee (21) described a GLC method capable of detecting 5 ng quantities from human serum. Sample extract clean-up procedures included precipitation of the sterols as digitonides and silicic acid column chromatography. No derivatives of vitamin D were used. The overall recovery of vitamin D added to serum by the clean-up procedures was 99.7% ± 2.4%. Sample size had little effect on the ratio of the artificial thermal products, thus confirming the observations of Nair et al. (14). Glass columns (4 ft x 3/16 in. OD) packed with 3.8% SE-30 on 80-100 mesh Diatoport S maintained at 215 C were used. The retention times relative to cholestane were: (a) pyrovitamin D_3, 1.68; (b) isopyrovitamin D_3 1.91; (c) pyrovitamin D_2, 1.87; and (d) isopyrovitamin D_2, 2.21. The sensitivity of this method was reported to be about a 40-fold increase over that reported by Murray et al. (16).

De Ritter (22) briefly discussed the work of Nair et al. (14) and the early work of Murray et al. (16) in his review of newer analytical techniques for vitamins during 1967.

The mechanism of thermal cyclization was investigated by Nair and deLeon (23). It was found that the 5,6-*cis* configuration favors the formation of thermal isomers during GLC, whereas the 5,6-*trans* configuration does not. However, when the vitamin D-trifluoroacetate (TFA) derivative was dissolved in *n*-hexane, I_2 added, and the solution irradiated with UV light (black light), the 5,6-*trans*-vitamin D-TFA configuration was produced. Another interesting aspect of this study was the observation that inclusion of ubiquinone in the stationary phase produced a distinct improvement in the shape of the GLC peaks. It was concluded that column sites having a high affinity for double bonds are apparently saturated. The biphase column used in the previous studies of Nair et al. (14) was used in this study, except that 2.0 mg of ubiquinone$_{50}$ per 25 g of inert support was added.

Blondin et al. (24) observed that the 5,8-peroxides of ergosterol and 7-dehydrocholesterol gave a characteristic pattern of pyrolysis products in contrast to other sterols, which gave single peaks on 0.92% XE-60 columns. The 6 ft column was packed with 0.92% XE-60 on 90-100 mesh Anakrom AB maintained isothermally at ca. 230 C, when not temperature-programed.

Kobayashi (25-29) wrote a series of papers that have an important bearing on the theory and use of chemical isomerization of vitamin D_2 as a means of preventing thermal cyclization during GLC analysis. It was clearly established that vitamin D_2 in ethylene dichloride was readily isomerized to isotachysterol$_2$ by acetyl chloride (29). A GLC method was developed for the identification of vitamin D_2, 5,6-*trans*-vitamin D_2, isovitamin D_2, isotachysterol$_2$, tachysterol$_2$, lumisterol$_2$ and ergosterol (27,28). The column was stainless steel (75 cm x 0.4 cm OD) packed with 1.5% SE-30 coated on 60-80 mesh Gas-Chrom P (silanized) maintained at 220 C and a flow rate of 90-120 ml/min. The relative times for vitamin D_2, 5,6-*trans*-vitamin D_2, isocalciferol, isotachysterol$_2$, tachysterol, lumisterol$_2$, ergosterol and squalene were 1.59/1.86, 2.45, 2.45, 2.84, 2.77, 1.68, 2.05 and 1.0, respectively.

We were able to verify the work of Kobayashi and extended our studies to include vitamin D_3 in addition to vitamin D_2 (30). The isomerization reaction is shown in Figure 4. The column was glass, 8 ft x 4 mm ID, packed with 3% JXR on 100-120 mesh Gas-Chrom Q maintained at 265 C and a flow rate of 32 ml/min. Typical separations obtained are shown in Figure 5. With the flame ionization detector, we have been able to achieve peaks large enough for quantitative analysis with 0.15 μg quantities

Nicolaides et al. (31) have found dihydrocholesterol

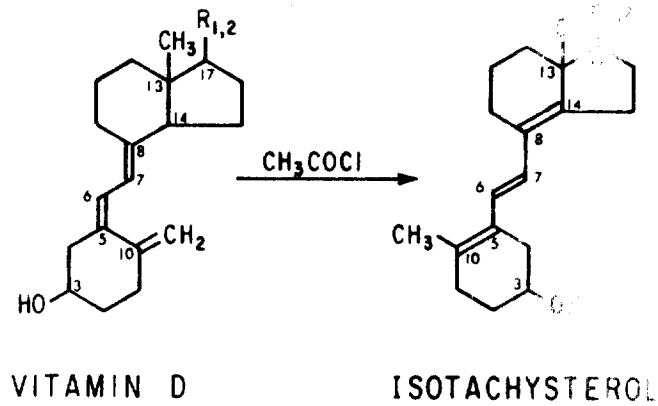

R_1 – $CH(CH_3)-CH=CH-CH(CH_3)-CH(CH_3)_2$

R_2 – $CH(CH_3)-(CH_2)_3-CH(CH_3)_2$

FIG. 4. Isomerization of vitamin D to isotachysterol; R_1: $CH(CH_3)$-CH=CH-$CH(CH)_3$-$CH(CH_3)_2$ and R_2: $CH(CH_3)$-$(CH_2)_3$-$CH(CH_3)_2$ (30).

present in the sterol ester fraction of human skin surface lipid. Its metabolic significance has not been elucidated. A 3% JXR column was used in the identification study.

Stereochemical studies on the microquantitative detection have been made by Nair and deLeon (32), extending their previous study (23). It was confirmed that the 9,10-secosterols having a 5,6-*cis* configuration contribute to the structural features favoring cyclization at elevated GLC temperatures. In the previous study it was established that the 5,6-*trans*-vitamin D was obtained by the iodine-catalyzed photoisomerization of vitamin D (5,6-*cis*) and did not exhibit any evidence of thermal cyclization under GLC conditions. However in the present study it was found that 5,6-*trans*-vitamin D undergoes double-bond rearrangement to the corresponding isotachysterol at high GLC temperatures. Thus the 5,6-*trans*-vitamin D analysis is in reality an isotachysterol analysis. The isotachysterols are stable under GLC temperatures, a fact established previously by Kobayashi (25,26) and in our own laboratory (30). However Nair and deLeon went a step further and formed isotachysteryl$_2$ and isotachysteryl$_3$ heptafluorobutyrates. A microquantitative method for the isotachysteryl esters was developed in which acyl or perfluoroacyl chlorides and vitamin D were used in the presence of ethylene dichloride as a solvent. Nanogram amounts of the vitamins D were detected as their isotachysteryl heptafluorobutyrates with a ^{63}Ni high temperature electron capture detector and a biphase column of 8% SE-52, 8% XE-60, and 4% coenzyme Q_{10} coated on 80-100 mesh Gas-Chrom P and maintained at 215 C was used. The glass columns were 6 ft x 5 mm ID. Coenzyme Q_{10} was included in the preparation of the column packing because highly symmetrical peaks could be obtained similar to those from older columns subjected to biological extracts. This effect was attributed to coenzyme Q_{10} which is retained on the column for an indefinite period, thus saturating sites having a high affinity for similar compounds possessing double bonds.

Blunt et al. (33) have used GLC analysis as one link in the identification of a biologically active metabolite of vitamin D_3 as 25-hydroxy-cholecalciferol. The column was glass, 4 ft x 0.25 in., packed with 3% W-98 on 80-100 mesh Diatoport S maintained at 240 C and a flow rate of 70 ml/min. The metabolite peak appeared in ca. 16 min. Vitamin D_3 occurred as two peaks at ca. 10 and 12 min.

Murray et al. (34) have adapted the method of Murray and coworkers (16) for the assay of vitamin D in multivitamin preparations. Column and thin layer chro-

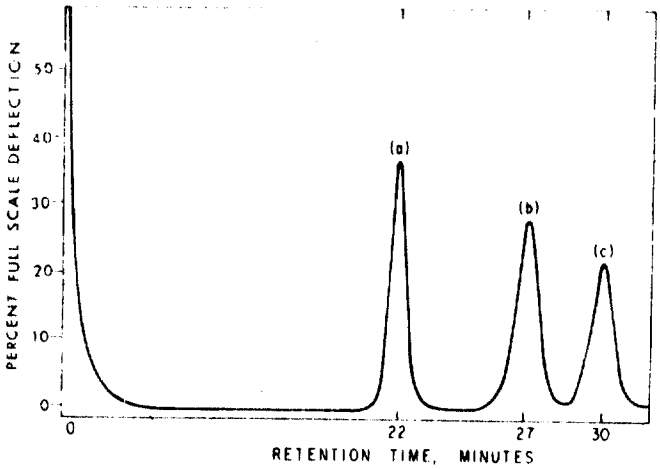

FIG. 5. Gas chromatogram of 2 μg each of (a) dihydrotachysterol D_2; (b) isotachysterol D_3; and (c) isotachysterol D_2 (30).

matographic procedures are used to remove vitamin A and other interfering compounds from the extracts. Recoveries of vitamin D_3 by the method were 100.5 ± 5.2% when vitamin A was not present in the vitamin preparation and 99.5 ± 5.2% in the presence of vitamin A. Vitamin A could be tolerated in the final test solutions in a ratio of 1:1 with vitamin D. When the method was used for the assay of multivitamin preparations, the coefficient of variation was 3.2%. Figure 6 is their published chromatogram representing 0.5 μg each of vitamins D_2 and D_3.

Wilson et al. (35) published GLC results utilizing the isotachysterol heptafluorobutyrate esters, as did Nair and deLeon (32), using a ^{63}Ni electron capture detector. The esters were prepared from heptafluorobutyric anhydride. The GLC column was not a biphase column as used by Nair and deLeon but rather a monophase column of 3.8% methyl silicone gum rubber W-98 on 80-100 mesh Diatoport S. The glass columns were 4 ft x 3 mm ID, maintained at 220 C and a flow rate of 60 ml/min. The increased sensitivity reported for the heptafluorobutyrate esters allowed for the estimation of at least 10 ng of vitamins D_2 and D_3. It appears that the usable sensitivity of the methods of Nair and deLeon (32) and Wilson and coworkers (35) using the isotachysteryl heptafluorobutyrate esters are similar: between 1 and 10 ng with a ^{63}Ni electron capture detector.

Petrova (36) reviewed the literature on vitamin D analysis in pharmaceutical preparations. The review includes chemical, biological and chromatographic methods. The chromatographic methods include paper, thin layer and GLC.

Edlund and Anfinsen (37) used GLC to determine vitamin D_2 in multiple-vitamin tablets and raw materials. Sample preparation was found to require saponification before extraction. Regisil (Regis Chemical Co.), Regisil-TMCS and trimethylsilylimidazole were about equally effective as silylating agents. The method utilizes an "internal-external" standard ratio procedure. The method is not effective for multiple vitamin preparations containing vitamin E or other materials that elute major peaks with the same retention time as silylated pyrovitamin D_2 and D_3 peaks. As the method is currently constituted, the multiple vitamin placebo must be available for preparation of the standard solution, unless the contribution of the placebo to the analysis has been previously established. The column used was glass, 6 ft x 0.08 in. packed with 3% OV-210 on 80-100 mesh Chromosorb W maintained at 250 C. A number of raw materials and tablets were analyzed by both the GLC and USP chemical methods. The GLC method had greater speed, precision and accuracy than the chemical method.

Canadian Food and Drug Directorate [illegible] extended the application of the GLC method [illegible] water-dispersible preparations (38), to fortified [illegible] dried milk (39) and to a more diverse range of pharmaceutical preparations (40). Panalaks (38) has reported that the previously required cleanup steps can be eliminated if the method is to be applied to water-dispersible preparations containing only vitamin D and a mixture of preservatives. This simplified version of the method has been used to study the stability of vitamin D in water [illegible] Total analysis time for vitamin D analysis of [illegible] nonfat dried milk products by GLC was ca. 7 [illegible] recovery of vitamin D added to the nonfat dri[illegible] 104%. The method was effective for both vitamins D_2 and D_3 added to the nonfat milk products. With the introduction of micro columns of silicic acid as a substitute [illegible] thin layer chromatography plates during sample extract clean-up, the GLC method was extended to a wider variety of pharmaceutical preparations (40).

The most recent GLC assay for vitamins D_2 and D_3 has been published by Feeter et al. (41). They have been able to accomplish satisfactory analysis in the presence of the tocopherols and vitamin A by treating the extracts with propionic anhydride to esterify all alcohols to their corresponding propionates. Trioctanoin was used as an internal standard. The solid support, 80-100 mesh Diatoport S, was propionated with propionic anhydride before the stationary phase was applied. Vitamin D_2 analysis was carried out on SE-52 columns, and vitamin D_3 was analyzed on SE-30 columns. The propionate derivatives underwent pyrolysis, forming the "pyro" and "isopyro" thermal rearrangement products. High sample levels of vitamin A were overcome by using higher levels of internal standard, which permitted use of higher attenuations in the vitamin D portion of the analysis with a consequent reduction of the magnitude of the solvent and vitamin A front. It was necessary to discard the chromatogram of the initial injection each day because its value was sometimes erroneous. Sample preparation procedures for this method are greatly simplified compared to previous methods. Glass columns 2.44 m x 0.63 cm were used for both vitamins D_2 and D_3. The SE-52 columns were maintained at 270 C, and the SE-30 columns were operated at 240-250 C. Carrier flow rate was 75 ml/min for both columns. The percentage of stationary phase was not determined by solvent stripping of the prepared packings but was based on the chemical ingredients used to prepare the columns initially; the immobile phase percentages would be 12% SE-52 and 4[illegible] SE-30. This is based on the assumption that all of the immobile phase in solution ended up on the inert support, a situation that normally does not occur. Nevertheless the method was quite successful and deserves consideration by investigators desiring to determine vitamin D_2 or D_3 in pharmaceutical products.

A recent article summarized the GLC methods and their application in our laboratory (42) for analysis of pharmaceuticals.

VITAMIN E

The discussion in this section is limited to the tocol series of the tocopherols, more specifically to those tocols commonly referred to as vitamin E. The various vitamin E analogs will be referred to by their Greek symbols in this review. More knowledge has probably been accumulated about the gas chromatographic characteristics of vitamin E and its subsequent analysis than for any other vitamin.

The indication that vitamin E might be amenable to GLC analysis was reported by Nicolaides (1) in 1960, when α-tocopherol was partially resolved from γ-tocopherol on a 5% silicone-gum rubber column in a study of low level silicone gum rubber columns for high temperature GLC of lipids.

The classic paper of Wilson et al. (43) was the first report solely devoted to GLC separation of the various vitamin E analogs. Their findings set the precedent for much of the subsequent work on the GLC analysis of vitamin E. Three immobile phases were tested: namely, 4% SE-30, 5% QF-1 and 4% polyethylene glycol adipate (PEGA), encompassing nonpolar to polar stationary phase characteristics. All columns were glass, 4 ft x 4 mm ID. Siliconized 100-120 mesh Celite was used as the inert support. The column temperatures were 250 C, 240 C and 250 C with flow rates of 40 ml/min, 50 ml/min and 50 ml/min, respectively, for SE-30, QF-1 and PEGA. The retention time for α-tocopherol, calculated from their data, was ca. 30.5, 13.1 and 16.0 min, respectively, for SE-30, QF-1 and PEGA columns. β- and γ-tocopherols were not resolved by any of the immobile phases tested. Tocopheryl acetates were prepared, and their gas chromatograms were characterized. Again the β and γ analogs could not be resolved from each other. The QF-1 packing gave a difference of 0.12 in relative retention volumes between the β- and γ-acetate derivatives; indicating that a highly polar column might possibly resolve these two analogs. No acetate derivative work using the PEGA column was reported.

Kofler et al. (44) evaluated 5% SE-30 and 5% Apiezon N stationary phases for the separation of the vitamin E analogs. The SE-30 column separated the groups of tri-, di- and monomethylated tocols and unsubstituted tocol. However, for the separation of the individual isomers, e.g., β-, γ- and δ_2-tocopherol, SE-30 as a stationary phase was not selective enough. Using SE-30, they were able to achieve almost a complete separation of α-tocopherol from α-tocopheryl acetate. The 5% Apiezon N stationary phase gave a separation of all tocols. The resolution of the two isomers β- and γ-tocopherol was partial. The retention times relative to the hydrocarbon n-$C_{28}H_{58}$ were 1.76 and 1.68 for γ- and β-tocopherol, respectively. Also of interest is that the α-tocopherol peak was the last peak to appear in the tocopherol series on the Apiezon N column. When a 5 m 5% Apiezon N column was used, α-tocopherol appeared in ca. 8 hr. However, on a 2 m column at 260 C, α-tocopherol appeared at slightly more than 2 hr. It was also found that the Apiezon N stationary phase would not separate α-tocopherol from α-tocopheryl acetate. The Apiezon N stationary phase used by these investigators appears to have excellent properties for the separation of the various natural vitamin E isomers but would not be so useful for pharmaceutical preparations. There was no indication of vitamin E alteration during GLC analysis.

Nair and Turner (45) reported their GLC experiences with vitamin E and vitamin K at the 36th AOCS Fall Meeting. The column was glass, 183 cm x 5 mm, packed with a stationary biphase of 2.5 mole % SE-52 and 2.5 mole % XE-60 coated on 60-80 mesh siliconized Gas-Chrom P. The operating parameters were: column, 228 C; detector, 250 C; flash heater, not specified but presumably approximately the same temperature as the detector; carrier gas flow rate, 75 ml/min; electrometer output, 3 x 10^{-8} amp; detector type, β-argon ionization with Sr_{90} foil. The biphase column did not separate β and γ-tocopherol isomers. The relative retention times with respect to α-tocopherol were 0.92, 0.92, 0.81, 0.49 and 0.28, respectively, for γ-tocopherol, β-tocopherol, Δ-tocopherol, Simon's metabolite and squalene. The α-tocopherol peak appeared at 32 min. The technique was applied successfully to the vitamin E isomers and closely related compounds in crude extracts from mammalian tissues. TMS ethers of the tocopherols were also used successfully. The elution times of the TMS derivatives of the various tocopherols were somewhat shorter than those for the unreacted tocopherols.

Schudel et al. (46) studied the synthesis of all-*trans*-δ_1-and- ε-tocopherol and the corresponding natural specimens in wheat bran. A GLC column of Apiezon N was used to help establish that the all-*trans* configuration of the side chain existed in nature.

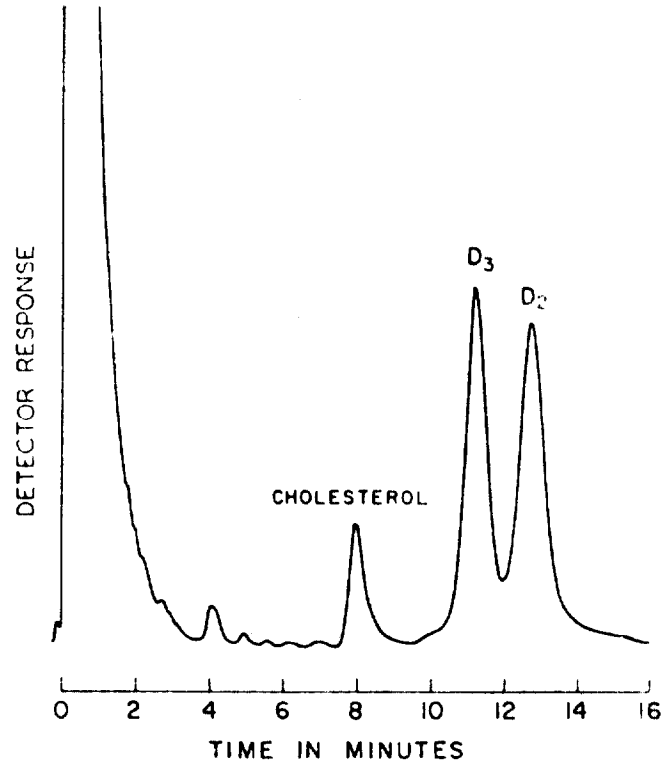

FIG. 6. Gas liquid chromatographic tracing of cholesterol, vitamin D_3 and vitamin D_2 (34).

An extensive study of the determination of α-tocopherol in animal tissues by GLC was carried out by Bieri and Andrews (47). The stationary phase SE-30 was evaluated by using concentrations of .75-7% coated on 80-100 mesh Chromosorb W in columns of 4 and 6 mm ID. Initial studies with *dl*-α-tocopherol indicated that the compound was not changed during GLC and that response deviated slightly from linearity in the 1-6 μg range with the β-argon ionization detector. Effective measurements were made in the range of 0.25-1.0 μg on a 1% SE-30 column. Detectable peaks were obtained at the 0.1 μg level, and 0.5 μg amounts gave a 67% full scale response. Calibration was achieved by comparing the response of an amount of standard α-tocopherol estimated to be close to the amount in the unknown. A DC cell voltage of 900 was found satisfactory for the tocopherols. The α-, γ- and δ-tocopherols were separated easily with relative retention times of 1.00, 0.83 and 0.68, respectively. It was found that α-tocopheryl quinone, which is of biological interest, came through the SE-30 column with a retention time only slightly different from that of α-tocopherol. On most columns tested, i.e., various percentages of SE-30, the separation of these latter two compounds generally resulted in a bicuspid peak. The 1% SE-30 packing proved to be the most satisfactory immobile phase. The retention times relative to cholestane on the 1% SE-30 column were 1.96, 2.11, 2.20, 2.27, 2.66 and 2.78, respectively, for cholesterol, *d*-α-tocopheryl quinone, *d*-α-tocopheryl acetate and cholesteryl acetate. The column was maintained at 230 C with an inlet pressure of 25 psi. This column was used to measure the tocopherol compounds in tissue extracts following extensive sample clean-up procedures, involving saponification and an alumina and zinc carbonate column. Extensive data indicated the advantage of the GLC measurements over those obtained by the ferric chloride-bipyridyl chemical method (Emmerie-Engel).

Ninomiya et al. (3) included *dl*-α-tocopherol and *dl*-α-

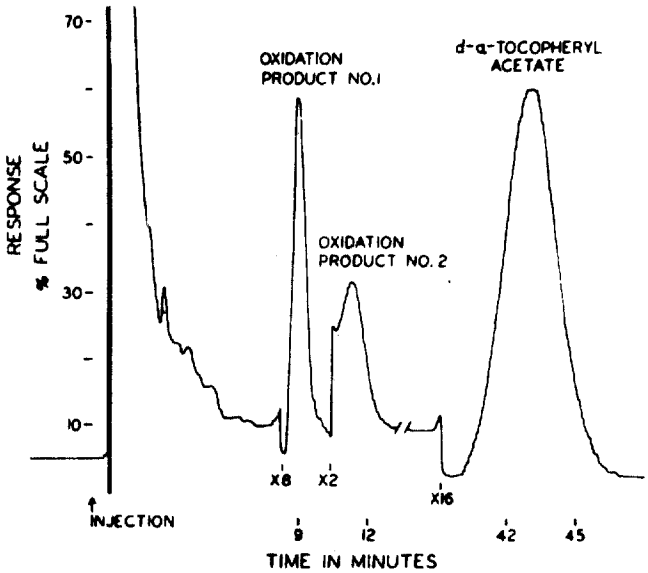

FIG. 7. Gas chromatogram on 5% SE-30 at 235 C of breakdown products from α-tocopheryl acetate when distilled above 160 C (Sheppard, Prosser and Strother, unpublished data).

tocopheryl acetate in their early studies on the GLC of the fat-soluble vitamins, previously discussed under vitamins A and D above. Excellent separation of the two α isomers was achieved by using SE-30 and FS-1265 (QF-1), but with Craig's polyester succinate the separation was nominal.

Conditions for the determination of the GLC relative retention volumes for the compounds occurring in a 14-stage vitamin E synthesis process have been reported by Yanotovski (48). The log relative retention volume vs. the number of carbon atoms in a homologous series was found to be linear. A column 120 cm long, packed with Apiezon L coated on Celite 545, was used. The column was maintained at 200 C with a carrier gas flow of 75 ml/min. Analysis time was 150 min.

Carroll and Herting (4) found that the *d*-isomers of monomethyl-, dimethyl- and trimethyltocols emerged in that order and were readily separated at 205 C on a 3% SE-30 immobile phase coated on silanized Gas Chrom P packed in a 6 ft x 1/8 in. glass column. The *d*-β-, *d*-γ and *dl*-δ_2-tocopherols were not effectively resolved from each other on the SE-30 column. The optical isomers of *dl*-δ_2-tocopherol and of *dl*-α-tocopherol appeared to have identical retention times. With a 3% QF-1-0065 column at 195 C (other column specifications same as the SE-30 column), δ-, β- and α-tocopherols were separated but not as well as on SE-30. The order of elution of γ- and β-tocopherol was reversed on QF-1-0065, but their retention times were almost identical. α-Tocopheryl acetate exhibited a greater relative retention time than the nonacetates on both immobile phases.

Libby and Sheppard (49) evaluated column loadings of 1-5% SE-30, 2.5-5% XE-60 and 5% SE-52. A 5% SE-30 on 100-140 mesh siliconized Gas Chrom P column was selected as most desirable, based on a number of factors such as resolution, sensitivity, reproducibility and analysis time. A glass column 8 ft x 3 mm ID was operated at 260 C. It was found that the column required saturation with 50 μg of each tocopherol on each assay day until a constant response was obtained. Heavy emphasis was placed on the necessity of calibration for each tocopherol analog in the sample size range as a part of GLC quantitative analysis. Linear response over a wide concentration range for each vitamin E analog was observed, but it was discovered that this resulted in specific response plots for each analog rather than a general response plot for the tocopherols.

Sheppard et al. (50) evaluated a vacuum distillation procedure for vitamin E isolation that had been recently designed for fatty acid work (51). α-Tocopheryl [illegible] carbon-14 labeled in the methyl group at the [illegible] was used to determine the stability and recovery of the vitamin during vacuum distillation. Recovery of 20 mg of pure standards was 97%. Recovery of 0.5 mg or less of the labeled compound added to "stripped" lard was 98% and recovery of the compound when 0.1 mg or less was added to butter was 82%. These recoveries were obtained at 140-160 C, 0.020 mm Hg and 60 min. Results of differential carbon-14 counting techniques indicated that the ester decreased in stability as temperature was [illegible] much beyond 160 C. GLC analysis revealed two [illegible] fied breakdown products. An unpublished GLC analysis showing the breakdown products is presented in Figure 7 (Sheppard, Prosser and Strother, unpublished data, 1965). This sublimation unit has the advantage over previous units in that it can be completely disassembled for cleaning, has greaseless seals and can be stored in a laboratory desk drawer.

Ishikawa and Katsui (52) and Ishikawa et al. (53) developed a satisfactory GLC analysis for the tocopherols in soybean oil. The two reports refer to essentially the same procedure with the same general type of results. In the first study, mixtures extracted from soybean oil were found to contain no *d*-β-compound; thus the usual combined β-γ peak could be considered entirely due to *d*-γ-tocopherol. It was also noted that the use of trimethylsilyl esters brought the retention time close to that of squalene so that it could not be used as the internal standard. However they found that acetylating the tocopherols was superior to using the unreacted tocopherols themselves, and squalene could be used as an internal standard. The most important contribution of their second paper is the sample extract clean-up procedure using a Florisil column after saponification. In both reports a 1.5% SE-30 immobile phase coated on 60-80 mesh Chromosorb W packing was used. Stainless steel columns 225 x 0.4 cm and 450 x 0.4 cm were maintained at 250 C and a carrier gas flow rate of 80-100 ml/min. Excellent recoveries and analysis data were achieved. The practical application of the GLC method for tocopherol analysis of soybean oils is well defined and relatively simple to follow.

Bruschi (54) successfully applied simultaneous GLC analysis to vitamin E acetate and methyl testosterone content of pharmaceutical products containing both. Excellent results were achieved for both compounds. A silicone column, 2 m x 2.7 mm ID, was maintained at 250 C and a flow rate of 30 ml/min. Unfortunately the percentage of silicone immobile phase used was not established. Testosterone acetate was used as an internal standard. The sequence of elution following sample injection was solvent, methyltestosterone, testosterone acetate and vitamin E acetate. All compounds were separated completely.

Eisner et al. (55) studied the unsaponifiable matter in butter and 12 vegetable oils. The unsaponifiable matter was fractionated on a Florisil column. A third fraction contained the tocopherols in addition to high molecular weight alcohols and triterpenoid alcohols. A 6 ft x 1/4 in. ID glass column packed with 1.5% SE-52 on silanized 100-120 mesh Gas Chrom P was operated at 210 C with an inlet pressure of 12 psi. The order of tocopherol elution was δ β or γ and α. They eluted in ca. 10-18 min. The presence of α- and δ-tocopherols was not definitely detected in the soybean oils examined. α-Tocopherol eluted with C_{28} normal alcohol under the GLC conditions imposed.

Nair et al. (56) achieved microquantitative separation of isomeric dimethyltocols with the SE-52/XE-60 biphase column used by Nair and Turner (45) as discussed above. γ-Tocopherol was separated from β-tocopherol as the paraquinones. The tocopherols react with ferric chloride, the reaction mixture is dissolved in α,α'-dipyridyl solution and the mixture is heated. This reaction appeared to be the

Emmerie-Engel reaction carried out on a microscale. The separation of the two isomers was complete under the GLC conditions used. The results reported for the separation of β and γ-tocopherols are better than any other attempts reported in the literature. β-Tocopherol could not be separated from the synthetic isomer 5,7-dimethyltocol. When TMS derivatives were used, the 5,7-dimethyltocol could be separated distinctly from the γ- and β-tocopherol combined peak.

In a follow-up paper, Nair and Machiz (57) were able to obtain a complete separation of the isomeric monomethyltocols on the biphase column. Conversion of the monomethyltocols to the corresponding trimethylsilyl derivatives resolved all three positional isomers, including the 7- and 8-methyl isomers, which remained indistinguishable from each other both in the unaltered and *p*-quinone forms on the biphase column. Acetate, trifluoroacetate and pentafluoropropionate derivatives were also studied. Irrespective of the mode of preparation of the silyl ethers, using either bis(trimethylsilyl) acetamide or hexamethyldisilazane, the tocopherols were completely converted to the corresponding derivatives, as evidenced by the complete absence of the characteristic hydroxy band at 2.7 μ in the IR band.

GLC identification and estimation of tocopherols in wheat germ oil, soybean oil, whole wheat flour and corn meal has been studied extensively by Slover et al. (58). The tocopherols were converted to their TMS ethers. The separations were made at 235 C on 15 ft x 0.08 in. ID silanized columns packed with either 0.5% Apiezon L or 2% SE-30 on 110-120 mesh Anakrom (acid- and base-washed and silanized). Kovats Retention Indices were determined for tocol, tocoltrienol and all 14 possible methylated tocols and tocotrienols. Considerable effort was expended with various mixtures to ascertain that the method is capable of a high degree of accuracy and precision. A partial resolution of β- and γ-tocopherol TMS ethers was achieved on the 0.5% Apiezon N column with a total analysis time of ca. 80 min. When a 2% SE-30 column was used, the analysis time exceeded 60 min and the separation of β- and γ-tocopherol TMS ethers was exhibited as a doublet in which the apex of each compound was barely delineated. It was indicated that some tocopherol decomposition undoubtedly occurred during these analyses due to the long residual time on the column and the high column temperatures required. The conditions used were a compromise to give the best resolution with the decomposition held to a minimum. Attempts to separate the free tocopherols on Apiezon L were not completely successful because of variable sample loss on the column and tailing peaks.

Bunnel (59) published an excellent review of the early GLC applications for vitamin E analysis. A large table of retention times and column data is provided. This article should be reviewed by investigators entering the field of GLC analysis of vitamin E for the many valuable suggestions offered.

Pillsbury et al. (60) adapted the earlier work of Libby and Sheppard (49) to the analysis of the vitamin E content of pharmaceutical products. Recoveries of 100.0 ± 8.9% of known amounts of α-tocopheryl acetate and α-tocopheryl succinate added to vitamin E-free tablets were obtained. An extremely simple extraction system was perfected. Then 24 different samples of pharmaceutical products were analyzed. The samples included tablets, capsules, baby drops and injectables. The GLC results were compared with results obtained by the Emmerie-Engel chemical method. The overall mean percentage recoveries of label claim (± standard deviation) were 103.7 ± 11.7 and 95.0 ± 21.4, respectively, for the GLC method and the chemical method. Some of the products having label claims of α-tocopheryl acetate were shown not to be entirely α-tocopheryl acetate but a mixture of α-tocopheryl acetate and α-tocopherol. The strength of the method is in its overall speed of analysis and analog specificity.

A collaborative study was carried out by Sheppard et al. (61) in 1968 under the auspices of the Association of Official Analytical Chemists, in which three GLC methods and the Emmerie-Engel chemical method were compared for the determination of the vitamin E content of pharmaceutical products. One was the method of Pillsbury et al. (60), discussed above. The other two methods were basically variations of Pillsbury's method designed to increase the rapidity of analysis. Of the three GLC methods, that of Pillsbury et al. exhibited the highest precision and was the method of choice. The mean composite coefficient of variation obtained for all analysts and all laboratories was 10.2. In evaluating the GLC methods, all of which outperformed the chemical method, it was concluded that the precision achieved with the method of Pillsbury et al. outweighed the few minutes' reduction in total analysis time gained by the more rapid GLC methods. The mean composite coefficient of variation exhibited by the chemical method was 28.6%. The study included seven pharmaceutical formulations containing either α-tocopheryl acetate or α-tocopheryl succinate that were analyzed by nine collaborating laboratories. A means of identifying α-tocopheryl succinate was included in the study, since α-tocopherol and α-tocopheryl succinate had a relative retention time of 0.9 with respect to α-tocopheryl acetate. An acetylation reaction was attempted on the sample following an initial chromatographic analysis, if the peak observed exhibited a relative retention time of 0.9. The sample was then rechromatographed. If the peak shifted to the α-tocopheryl acetate, the sample contained the alcohol; if it did not shift, the sample contained α-tocopheryl succinate. All collaborators successfully used the test. The method was adopted by the Association of Official Analytical Chemists as an "official first action" method (62). The "official" method is included in the 11th Edition, *Official Methods of Analysis of the AOAC* (63).

Mahn and coworkers (64) determined the vitamin E in multivitamin products by GLC on a copper column 121.9 cm x 3 mm ID packed with 10% SE-30 on 100-120 mesh Aeropak 30 maintained at 245 C with a flow rate of 40 ml/min. α-Tocopheryl acetate appeared at 25.5 min. The method was successful for the analysis of tablets, capsules, injectables and creams. An extensive sample extract clean-up procedure was developed that is suitable for a wide variety of pharmaceutical products extending beyond the usual multivitamin products administered orally or by injection. The relative retention times were 0.85, 0.71, 0.75, 0.68 and 1.00, respectively, for α-tocopheryl acetate, α-tocopherol, α-tocopheryl succinate, vitamin D_2 and dotriacontane. The outstanding features of this method are the successful use of copper columns, the introduction of dotriacontane as an internal standard and a sample clean-up procedure suitable for extending the GLC method beyond the usual tablets and liquids to include specialized products such as multivitamin creams. A precision of ±2-3% was achieved.

Bowman and West (65) have developed a GLC assay for α-tocopheryl acetate in multivitamin products using a 3% SE-30 column. The column used was 2 m x 3 mm ID packed with 3% SE-30 on 100-120 mesh Gas Chrom Q maintained at 235 C with a flow rate of 50 ml/min. The internal standard technique was developed for the assay, using 3-(*p*-methoxyphenyl)-2,4,5-triphenylcyclopentadieneone. The sample preparation is more involved than that in the AOAC method (66) but less involved than that of Mahn et al. (64). It was estimated that one analyst with two gas chromatographs could handle 20 assays per day, whereas an experienced analyst was able to complete 3-5 chemical assays per day depending on the procedure followed. Assay precision was determined for each type of formulation by replicate assay of a single lot. In every case

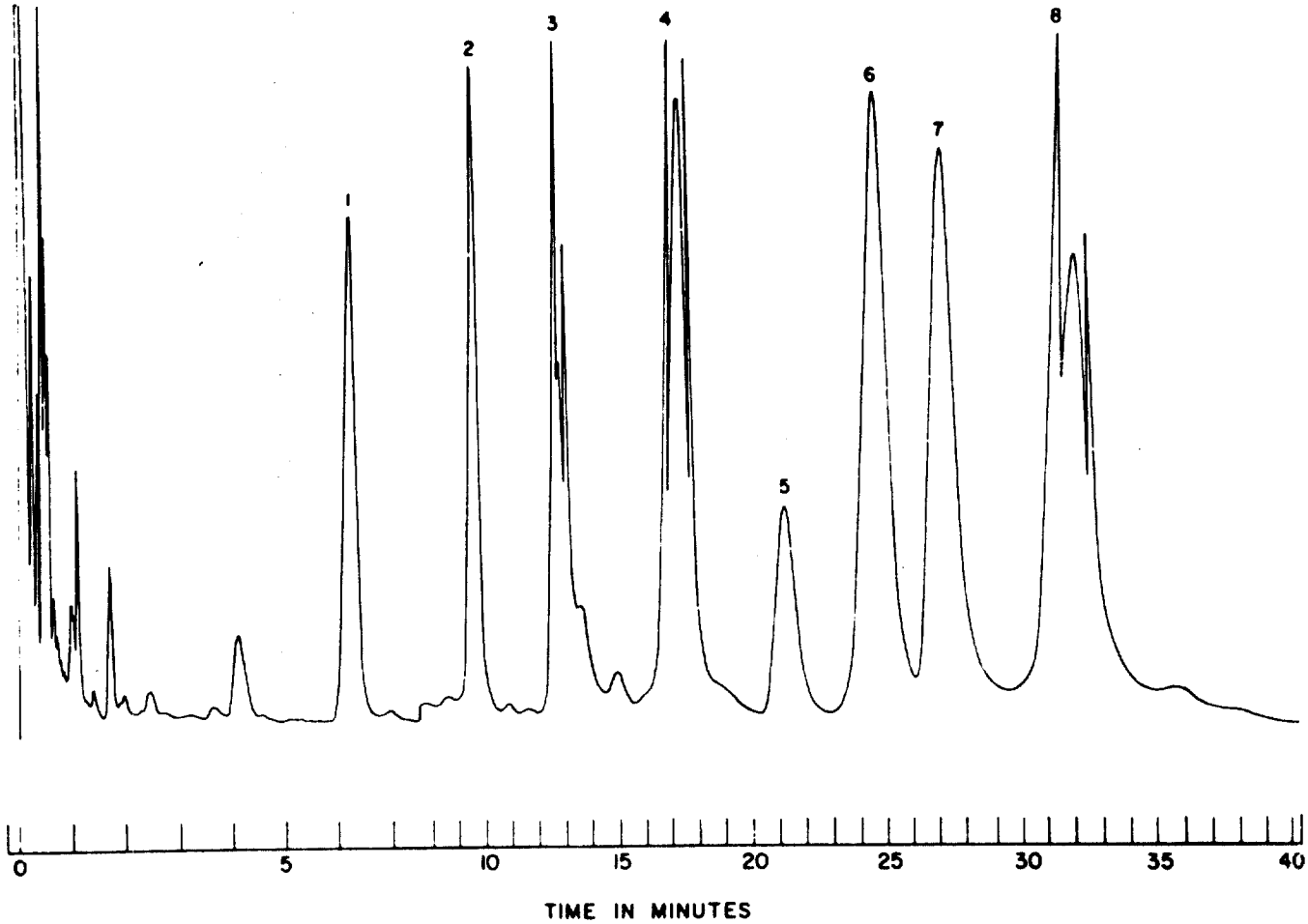

FIG. 8. Gas chromatogram of soya sludge unsaponifiables. Peak identification: (1) squalane; (2) squalene; (3) Δ-tocopherol; (4) β + γ-tocopherol; (5) α-tocopherol; (6) campesterol; (7) stigmasterol; and (8) sitosterol (70).

the coefficient of variation was less than 1.2%. When GLC assay results were compared with chemical assay results, the GLC values were consistently higher. A total of 20 samples encompassing a variety of pharmaceutical products were analyzed. The calculations and overall procedures used in this method and that of Mahn et al. (64) are similar. The outstanding feature of the method is the introduction of 3-(*p*-methoxyphenyl)-2,4,5-triphenylcyclopentadieneone as an internal standard in the GLC assay procedure.

Slover et al. (66) extended their previous study (60) and studied the validation of predicted retention data. Lipid from latex was extracted for its tocotrienol content. It was found that the predicted retention data and the peak identifications reported previously (58) were valid.

Hall and Laidman (67) have developed an improved analytical procedure to study the distribution of the tocopherols and of ubiquinone in ungerminated wheat grain. A comparison was made of several extraction procedures. Gradient elution column chromatography on acid-washed alumina columns efficiently separated the isoprenoid quinones and tocopherols into groups. The tocopherols were determined quantitatively by GLC analysis. Siliconized glass columns 5 ft x 4 mm packed with 4% SE-30 or 4% SE-301 on silicone-treated 100-120 mesh Gas-Chrom Z were used at 250 C with a carrier flow of 40 ml/min. The retention times of the tocopherols, tocotrienols and their acetates relative to that of α-tocopherol were similar to those reported by Wilson, Kodicek and Booth (43). Each tocopherol exhibited an individual nonlinear calibration curve, and the values were reproducible within ±4%. Quantities of tocopherol ranging from 0.2 to 1.0 μg could be determined conveniently by the hydrogen flame ionization detector.

Nair and Luna (68) have studied the identification of α-tocopherol from tissues by combined GLC, mass spectrometry and IR spectroscopy. The GLC vitamin E analysis was that previously reported from Nair's laboratory (45,56,57) in which the binary mixture of SE-52 and XE-60 was used. α-Tocopherol isolated from heart muscle was characterized by the combined system. The purpose of the study was to describe the identification procedures of α-tocopherol which form the basis of future biological studies.

Janecke and Voege (69) have developed a GLC quality control method for multivitamin preparations that purportedly assays both vitamin E and vitamin A in a single analysis. The vitamins react with N,O-bis(trimethylsilyl) acetamide. The column is programed from 100 to 270 C. It is indicated that the water-soluble vitamins can be determined by this method also.

GLC has been used to determine the tocopherol and sterol content in soya sludges and residues by Nelson and Milun (70). The method involves saponification of the sample followed by GLC analysis of the unsaponifiables. A glass column 6 ft x 3.5 mm ID packed with ca. 3% SE-30 coated on Gas Chrom Q was used. The column was maintained at 225 C with a carrier gas flow of 150 ml/min. Squalane was used as an internal standard. The relative retention times with respect to squalane were 3.40, 2.22, 2.05, 2.76, 3.90, 4.32 and 5.10, respectively, for α-tocopherol, β-tocopherol, Δ-tocopherol, campesterol, stigmasterol and sitosterol. A typical chromatographic separation of the unsaponifiables from sludge is shown in Figure 8. The β- and γ-tocopherols were not resolved. Compound identifications were confirmed by trapping GLC fractions and subsequent IR and mass spectral analysis. The non-

saponifiables were extracted by ether in a separatory funnel. Recovery data indicated that the method was very effective. The overall approach of the method was one of simplicity. The Nelson and Milun method is quite good and deserves consideration as a method of choice by investigators working in the area of legume oilseed products and byproducts who are seeking progress in their methodology.

A GLC method has been described by Siedenstrücker (71) for the identification and quantitative estimation of tertiary terpene alcohols occurring as intermediates in the syntheses of vitamins A and E. A 50 m x 0.25 mm steel capillary column coated with Apiezon L was used. Alcohols with molecular weights ≤224 were separated without preliminary reaction. The thermally unstable terpene alcohols with molecular weights >224 were silylated. It was observed that quantitative results may be lost when too much SiO_2, formed during combustion in the hydrogen flame ionization detector, deposits at the electrode.

Petrova (72) has recently reviewed the general area of vitamin E analysis. A section of the review is devoted to GLC analysis. Weglicki, Luna and Nair (73) used the GLC techniques previously developed in their laboratory (56,68) to study the sex and tissue differences in concentrations of α-tocopherol in mature and senescent rats. The biphase SE-30/XE-60 column was used to quantitate the α-tocopherol from the nonsaponifiable fraction. The α-tocopherol was measured as the trifluoroacetate derivative. In another study from the same laboratory that appeared in print at about the same time, Olweira et al. (74) reported data on the distribution of α-tocopherol in beef heart mitochondria. The α-tocopherol was identified by several independent procedures, one of which involved GLC. The GLC method was that of Nair et al. (56), previously discussed.

In the vitamin K work of Dialameh and Olson (75) α-tocopherol was used as an internal standard. On the 3.8% SE-30 column used, α-tocopherol appeared in 7 min. Prevot and Barbati (76) conducted a study of the analysis of hydroxyl compounds by GLC. They found the preparation of the TMS derivatives of the tocopherols to be very rapid and simple. The GLC method for the sterols was effective for measurement of the tocopherols. A 1.5 m column packed with 3% SE-30 coated on 60-80 mesh Chromosorb W HMDS and maintained at 255 C was used.

Slover et al. (77) have applied their previously discussed GLC techniques (58,66) to analyze the tocopherol content of foods. A wide variety of seeds, fats and oils were tested. Detailed procedures are described for extraction, saponification and partial purification by thin layer chromatography. The individual tocols and tocotrienols were identified and estimated as their trimethylsilyl ethers by GLC on SE-30 or Apiezon L columns maintained at 235 C. In a concurrent paper, Slover et al. extended their application of the GLC method (78) to determine the tocopherol content of 11 wheats, the flours from them and products made from the flours. In addition, 10 pooled consumer product samples from each of 10 U.S. cities were analyzed. These studies are of excellent analytical quality and represent the application of GLC to a very practical problem. Slover (79) presented a summary and discussion of the recent literature on the tocopherols in natural, processed and prepared foods at the 1970 AOCS-ISF World Congress. The discussion is centered around the literature appearing since 1964. A wide variety of foods and fat data has been compiled from a large number of sources. Although a considerable amount of the tabulated data was obtained by GLC analysis, it is not a methods paper.

Nelson et al. (80) have made some improvements in their previously published method for GLC analysis of tocopherol and sterol content of soya sludges and residues (70). The major modification was the conversion of the tocopherols and sterols to butyrate esters prior to GLC, whereas in their previous report no derivative was formed. The use

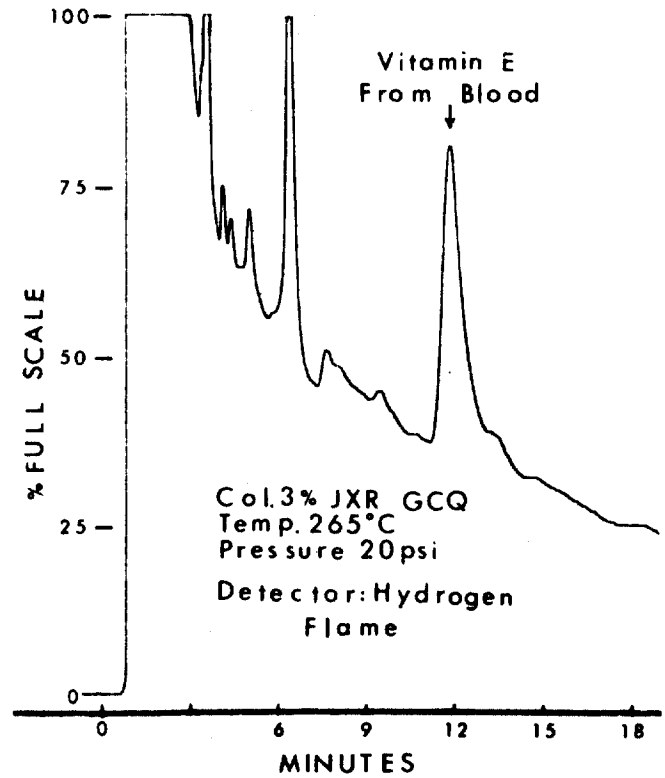

FIG. 9. Gas chromatogram of α-tocopherol in blood samples (Sheppard, Quaife and Friedman, unpublished results, 1969).

of the butyrate esters eliminated interference from materials encountered in the sludges and residues during GLC analysis. It was found that derivatization of the tocopherols to the acetate, propionate and the dimethyl or trimethylsilyl ethers did not succeed in eliminating these interferences. Also, the SE-30 immobile phase was reduced to 1%. The GLC conditions were revised slightly to column temperature of 235 C and a carrier gas flow of 170 ml/min. Cholesteryl isovalerate was used as an internal standard, whereas squalane has been used previously. The retention times relative to cholesteryl isovalerate were 0.46, 0.61, and 0.75, respectively, for δ-tocopheryl butyrate and β- and γ-tocopheryl butyrate. The new method exhibited improved precision over the previous method: coefficients of variation were 1.0% and 3.3%, respectively, for total tocopherol in soya sludge.

Bieri et al. (81) have used the gas chromatograph to determine the α-tocopherol in human erythrocytes. The α-tocopherol was oxidized to α-tocopherylquinone prior to GLC analysis. The columns used were glass, 180 cm x 3 mm ID, packed with 3% QF-1 on 80-100 mesh silanized Supelcoport maintained at 230 C and a carrier gas flow rate of 50-70 ml/min. The α-tocopherylquinone peak appeared in 7-8 min under these GLC conditions. It was necessary to prime the column at the start of the day with overloads of α-tocopherylquinone to saturate the active sites. Linearity of response was observed over the range of 0.025 to 0.25 μg of α-tocopherylquinone. Carbon disulfide was used as the carrier solvent. Sample preparation included thin layer chromatographic clean-up procedures. Two samples required a full day for total processing, but eight samples were easily completed in a 2 day period. No attempt was made to determine the presence of other tocopherols in erythrocytes. The retention times relative to α-tocopherylquinone for β-, γ- and δ-tocopherylquinones were 0.91, 1.09 and 1.00, respectively.

Kovensky and Day (82) have used GLC for individual determination of α-tocopherol, α-tocopheryl acetate or α-tocopheryl acid succinate in vitamin E capsule preparations. The column used was glass, 5 ft x 2 mm ID, packed

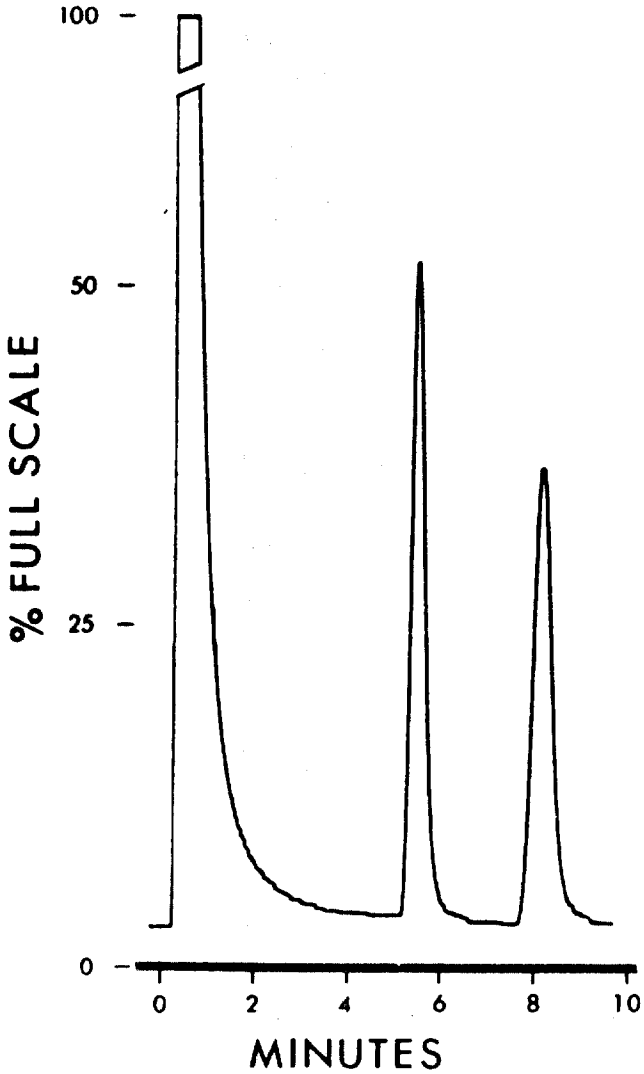

FIG. 10. Chromatogram of 0.5 μg/μl of menadione (ca. 6 min) and butylated hydroxy anisole (BHA, ca. 9 min) in *n*-hexane on a 1% neopentyl glycol succinate column at 145 C (98).

with 3% OV-1 on 60-80 mesh Chromosorb W acid-washed maintained at 260 C with a carrier gas flow of 54 ml/min. Hexadecyl palmitate was used as an internal standard. The average retention times for tocopherol, tocopheryl acetate, tocopheryl acid succinate and hexadecyl palmitate were 2.48, 2.85, 2.64 and 4.85 min, respectively. When the relative retention times are taken into consideration, this method is extremely limited in that only one analog of vitamin E can be measured in a given GLC analysis. Also, since the retention times are so closely grouped, analog identification by the method would be tenuous. Of interest in this method is the introduction of OV-1 immobile phase into the vitamin E field. For applications in pharmaceutical analysis, the time required for analysis is extremely rapid. Recovery rates of 101.5 ± 3.0% were reported. The analytical data presented indicated that the method has excellent precision ranging from ca. 1% for α-tocopherol to 2% for the α-tocopheryl acetate.

Lehmann and Slover (83) have recently described a GLC method for the determination of the tocopherols present in plasma. This method is a modification and adaptation of their previously discussed method for separation and identification of tocopherols in foods (77). The glass columns, 15 ft x 0.125 in. OD, were silanized and then packed with 0.5% Apiezon L on 100-125 mesh Gas Chrom Q and operated isothermally at 250 C with a carrier gas flow rate of ca. 25 ml/min. The method includes 5,7-dimethyltocol as an internal standard. Only α- and γ-tocopherols were detected in human plasma. A comparison of methods was carried out. The chemical method generally gave higher answers than the GLC, which were attributed to other reducing substances in plasma. The applicability of the GLC method was tested with blood from a series of human donors.

We have recently published an extensive review of our GLC methods for vitamin E measurements in a variety of items, i.e., pharmaceuticals and biologicals (84). This method was used to obtain the blood tocopherol measurements reported by Quaife and Friedman (85). Figure 9 is a typical gas chromatogram of α-tocopherol in these blood samples (Sheppard, Quaife and Friedman, unpublished results, 1969).

VITAMIN K

Vitamin K in this discussion includes 2-methyl-3-phytyl-1,4-naphthoquinone (K_1), 2-methyl-3-difarnesyl-1,4-naphthoquinone (K_2), 2-methyl-1,4-naphthoquinone (menadione or K_3), 2-methyl-1,4-naphthoquinone sodium bisulfite (menadione sodium bisulfite), 2-methyl-1,4-naphthoquinone diphosphoric acid ester tetrasodium salt (menadione diphosphate), 2-methyl-1,4-naphthohydroquinone diacetate (K_4) and 2-methyl-1,4-amino-1-naphthol hydrochloride (K_5). The common names in parentheses will be used throughout this discussion.

The initial report indicating the possibility of GLC analysis of vitamin K_1 was published by Nair and Turner (45). Their data showed very clearly that vitamin K_1 can be resolved from a mixture of tocopherol metabolites, tocopherols and vitamin K_1. The biphase column and operating parameters used were the same as for vitamin E. Under those conditions, vitamin K_1 appeared 53.2 min after sample injection. The relative retention time of vitamin K_1 was found to be 1.66 relative to α-tocopherol. It can be calculated from their data that the retention time is 6.05 relative to squalene, which is currently used by some workers as an internal standard in performing GLC analysis of fat-soluble materials, especially in the vitamin field. They also discovered that vitamin K_1 would not react with a mixture of hexamethyldisilazone and trimethylchlorosilane in chloroform to form the silyl ether. Carroll and Herting (4) and Libby et al. (86) subsequently verified that on the silicone polymer type of columns vitamin K_1 follows the vitamin E series as reported originally by Nair and Turner.

Ninomiya and coworkers (3) reported their evaluation of three column packings (1% SE-30 on 80-100 mesh silanized Anakrom A, 1% Craig's polyester succinate on 80-100 mesh silanized Anakrom A and 1% FS-1265 on 80-100 mesh Chromosorb W) for GLC separation of the fat-soluble vitamins including vitamins K_1-, K_3- and K_4-diacetate. On these columns vitamin K_1 required 200-220 C, vitamin K_4-diacetate required 150-180 C and vitamin K_3 required 90-130 C depending on the column packing and flow rates. Their chromatogram of vitamin K_1 on SE-30 was characterized by a broad peak preceding the main peak which had enough disturbance on its leading edge to suggest a possible breakdown product and distinct indications of two peaks intermeshed with the trailing edge. Unfortunately they did not provide chromatograms of vitamin K_1 on Craig's polyester succinate and FS-1265. One very surprising aspect of their experience with vitamin K_3 is that on all three stationary phases tested, two distinct peaks appeared that were not completely resolved. This is the only report found in the literature that indicates anything other than a single well defined peak for vitamin K_3. The vitamin K_4-diacetate peaks were excellent. This is the only known GLC work on this particular vitamin K analog.

Carroll and Herting (4) found that vitamin K_1 yielded two peaks, 8.6 min apart, having a 4:1 area ratio, on the 3% SE-30 column previously described under vitamin E. The

first peak occurred at 41.7 min. Vitamin K_1 gave a single peak on QF-1-0065 immobile phase at 195 C (previously described under vitamin E) in 27.8 min.

Dugan and Lundgren (87) developed a GLC vitamin K_3 method to detect the presence of menadione in extracts of *F. ferooxidans* obtained while studying coenzyme Q_6. One peak in the extract was tentatively identified as menadione based on retention time. They were unsuccessful in obtaining chromatograms for vitamin K_1. Their 5 ft x 1/8 in. OD glass columns were packed with 5% Dow silicone immobile phase coated on 60-80 mesh Chromosorb W and operated at 180 and 205 C. Vitamin K_3 appeared in 1 min at 205 C and in ca. 1.7 min at 180 C column temperatures. An electron capture detector was used since it "takes advantage of the electron capture system in that 'extensive' procedures are eliminated because of the inability of the detection system to sense most naturally occurring substances in low concentrations, i.e., alcohols, aldehydes, acids" (87). No preparation of halogenated derivatives was indicated.

Libby and Sheppard (88) carried out experiments to determine what column packing was most useful on a practical basis for menadione. Five stationary phases were evaluated: SE-30, XE-60, neopentyl glycol succinate (NPGS), neopentyl glycol adipate (NPGA) and neopentyl glycol sebacate (NPG Seb). The ideal column, in terms of peak confirmation and compound sensitivity, was a 6 ft x 4 mm ID glass column packed with 1% NPGS stationary phase coated on silanized 100-140 mesh Gas-Chrom P. As little as 4 ng of menadione could be detected with the hydrogen flame and 20-40 ng could be detected with the β-argon (^{226}Ra-foil) ionization detectors. Water-soluble derivatives could be analyzed by converting them to menadione. The GLC response to increasing quantities of menadione was found to be linear through 40 μg with the upper limit of linearity not established.

Cornelius and Yang (89) developed a GLC method to measure vitamin K_5 content of dried carrots. Vitamin K_5 was studied in foods because of its possible use as a food preservative and as a sensitizing agent for microorganisms subjected to ionizing radiation. Two approaches were tried, one to determine vitamin K_5 as its trimethylsilyl ether (TMS) derivative and the second to determine it as vitamin K_3. A 5 ft x 1/8 in. glass column packed with 3% OV-1 (STAP, Varian Aerograph) coated on 100-120 mesh AW-DMCX Chromsorb W was used with a 25 ml/min carrier gas flow rate at 175 C. A chart speed of 25 in./hr was used to obtain retention times of 16 mm for vitamin K_5 TMS, 132 mm for vitamin K_5 and 5.4 mm for vitamin K_3 which, when converted to a time scale, were 2.5, 20.8 and 8.5 min, respectively. Vitamin K_5 decomposed in the presence of water with time; thus it was necessary to determine both compounds on the food extracts. The vitamin K_3 peak occurred well before the solvent front was completely eluted and the instrument returned to the baseline.

Libby et al. (88) studied the GLC characteristics of vitamin K_1 and K_2. Four stationary phases were tested: SE-30, XE-60, QF-1 and a binary mixture of SE-30 and QF-1. All of these immobile phases produced satisfactory peaks for vitamin K_1 under similar operating conditions. However SE-30 was selected for the majority of the research primarily because vitamin K_1 could be chromatographed in combinations with the tocopherols without interference. It was found that the same extraction procedure could be used for both vitamins; thus being able to resolve vitamin K_1 from the tocopherols has practical merit. The columns used for the majority of the study were glass, 6 ft x 4 mm ID, packed with 1% SE-30 coated on silanized, 100-120 mesh Gas-Chrom P operated at 250-255 C. When small quantities of vitamin K_1 were measured, the peak had a small shoulder on the ascending slope. It was observed during this study that, when the columns were allowed to cool after use or were stored, they became unreliable for further vitamin K_1 analysis. Reproducibility was lost and multiple peaks were observed, thus the column had to be discarded and a new one prepared. The method has been applied successfully to a few regulatory samples of injectables to verify chemical results. GLC responses with 0.5 μg of vitamin K_1 were sufficiently large for quantitative analysis. When carrying out the original study, we were equipped with 0-5 mv strip chart recorders, but using newer instrumentation equipped with better electrometers and 0-1 mv recorders we have been able to achieve vitamin K_1 detection at 1-2 ng levels. Quantitative analysis requires at least 5 ng and is far superior at 15-20 ng, considering electrometer noise and chart measurements. Our results with vitamin $K_{2(35)}$ have been unsatisfactory to date. On the basis of molecular weights and differences in the side chain, it would normally be expected that vitamin K_1 and $K_{2(35)}$ could be resolved from each other under the same GLC conditions. Unfortunately vitamin $K_{2(35)}$ did not resolve as a single peak. There is always the possibility that the particular batch of vitamin $K_{2(35)}$ that was used was not pure, but in view of some of the problems noted with vitamin K_1 the GLC behavior of vitamin $K_{2(35)}$ is not too surprising.

Vetter and coworkers (90) obtained excellent vitamin K_1, vitamin $K_{2(35)}$ and vitamin $K_{2(45)}$ peaks by chromatographing the TMS derivatives of the dihydrovitamin. The structure and purity of the derivatives were confirmed by both GLC and mass spectrographic data. They were able to achieve a complete resolution of *cis*- and *trans*-TMS-dihydrovitamin $K_{1(20)}$. For vitamin $K_{1(20)}$ and TMS-dihydrovitamin $K_{1(20)}$, 5% Apiezon L or 10% UCW-98 immobile phase coated on 80-100 mesh Gas-Chrom Q was packed in a glass 2 m x 2.2 mm column operated at 250 C for UCW-98 and 275 C for Apiezon L. Vitamin $K_{1(20)}$ exhibited two peaks, whereas the TMS-dihydrovitamin $K_{1(20)}$ exhibited a single peak. A similar column packing of 3% silicon UCW 98 produced peaks of excellent chromatographic quality at 280 C for the TMS derivatives of both vitamins $K_{2(25)}$ and $K_{2(45)}$. It was further determined that the TMS ethers of the reduced vitamins K_1 and K_2 were well suited to GLC analysis. The problems of thermal conversion were attributed to the formation of chromenols and chromanols.

Russian workers have published their experiences (91,92) with GLC of a series of vitamins K and ubiquinones. Two stationary phases, SE-30 and Apiezon, were used as 10% coating on 100-120 mesh Celite 545 in 1.2 m x 6 mm ID columns at a variety of isothermal temperatures between 150 and 250 C. A dependency of the log of retention time on the number of isoprene units in a molecule was observed. It was postulated that a series of vitamin K and ubiquinones could be identified by means of plots of the retention time vs. the number of isoprene units. There were no indications that thermal conversion of the quinones to chromenols and chromanols occurred under their operating conditions.

Silvestri and Staibono (93) and Hubbard and Sheppard (94) published reports devoted to the analysis of vitamin K_3. Silvestri and Staibono were concerned with water-soluble vitamin K_3 in the form disodium disulfate. The GLC analysis was a determination of menadione following hydrolysis and oxidation of the water-soluble forms. Menadione appeared in 12 min on a glass column, 6 ft x 1/8 in., packed with 1.5% SE-30 on Chromosorb W-HMDS, maintained at 130 C and a carrier gas flow of 25 ml/min. A wide variety of dosage forms was tested with analytical errors of less than ±5%. The paper by Hubbard and Sheppard (94) reported the application of the Libby and Sheppard method (88) to the measurement of menadione and menadione sodium bisulfite content of pharmaceutical products. The GLC method was compared to the National

Formulary chemical method (95). Nine capsules, tablets and injectable types were analyzed. A comparison study of the data revealed no significant differences between the results; thus the GLC method was equivalent to the NF method. However the GLC had a distinct advantage over the NF methods, in that sample processing and analysis time was reduced by approximately half. Menadione sodium bisulfite was converted to menadione, which was determined by GLC. When NF menadione standard was added to samples containing a known amount of menadione, the mean recovery and standard deviation were 98 ± 3%. The samples ranged in potency from 0.1 mg per tablet to 7.2 mg per milliliter, indicating that the GLC method has a good practical range of application. The recovery of claim for all samples was 109 ± 2.2% for the NF methods and 113 ± 3.6% for the GLC method.

Dialameh and Olson (96) have described a GLC method for the identification and quantitation of 2-tocopherol, phytyl-ubiquinone, vitamin K_1 and homologs of the vitamin K_2 (menaquinone) family. Samples used for quantitative determinations were in the range of 0.02 to 1.0 μg. This is an excellent achievement considering that they not only worked with pure compounds but also obtained samples from liver that had to undergo a series of isolation steps. Glass columns, 122 cm x 3 mm ID, packed with 3.8% silicone gum rubber (SGR UC-W-982) coated on 80-100 mesh Diatoport S were used. The columns were used under a variety of temperatures, depending on the compound(s) to be analyzed, ranging from 235 to 295 C with a carrier gas flow rate of 25 ml/min. Relative tetention times of 1.00, 1.10, 1.62 and 1.95, respectively, were obtained for 2-tocopherol, phytyl ubiquinone, phylloquinone and menaquinone at 260 C on their 3.8% silicone gum rubber column. They did not encounter the problems of thermal conversion of the quinones to chromenols and chromanols as reported by Vetter and coworkers (90). The TMS-ether of phylloquinone was not found useful because of the susceptibility of the TMS-ether derivative to hydrolysis and of the resulting hydroquinone to oxidation. Furthermore TMS-ether derivatives did not appreciably improve the usefulness of the GLC analysis of lipophilic quinones. Their method is predicated on the direct GLC of the menaquinone series without resorting to formation of derivatives as the method of choice. A position that they justified scientifically by their data is that, unless there is a decided analytical advantage to using a derivative, the analysis should be done directly. Another important aspect of their work, especially for biological studies, is that they were able to use the system on a preparative scale to collect samples for subsequent chemical investigations.

The original vitamin K_3 study of Libby and Sheppard (88) has been developed into a routine GLC assay of menadione and menadione sodium bisulfite content of pharmaceutical products (97). Ten laboratories collaboratively studied the method and compared it with the NF methods (95). The data obtained indicated that overall the NF analysis is subject to a larger variation than the GLC analysis. There was no statistically demonstrable difference ($P>0.05$) between the average results by the two methods for the three pairs of samples used in the study. There was no statistically demonstrable difference ($P>0.05$) in the precision of the two methods for products containing 1,5 and 10 mg. The analytical time for the GLC method, including sample preparation, was considerably shorter than for the NF method. This basic method is currently used by some industrial quality control laboratories. Following the collaborative study report, attempts have been made to reduce the variation of the GLC method still further (98) by the evaluation of a number of compounds for possible use as an internal standard in the GLC method for menadione and menadione sodium bisulfite. Butylated hydroxy anisole (BHA) was found a most satisfactory compound for use as an internal standard. The relative time for BHA is ca. 9 min when the menadione peak appears at 6 min. The inclusion of BHA in future collaborative studies is expected to reduce the between laboratory variation. Figure 10 is a typical menadione-BHA GLC chromatogram.

Two articles have appeared recently that summarize the earlier attempts to analyze vitamin K and our efforts toward solution of the GLC analytical problems involved (99,100). However these articles are not full reviews of the subject in general and are methods for the application of GLC vitamin K analysis to practical problems as used in our laboratory.

REFERENCES

1. Nicolaides, N., J. Chromatogr. 4:496 (1960).
2. Ziffer, H., W.J.A. Vanden Heuvel, E.O.A. Haahti and E.C. Horning, J. Amer. Chem. Soc. 82:6411 (1960).
3. Ninomiya, T., K. Kidokoro, M. Horiguchi and N. Higosaki, Vitamins (Kyoto) 27:349 (1963).
4. Carroll, K.K., and D.C. Herting, JAOCS 41:473 (1964).
5. Dunagin, P.E., and J.A. Olson, Anal. Chem. 36:756 (1964).
6. Walle, T., G. Schill and J. Vessman, Acta Pharm. Suec. 3:167 (1966).
7. Macek, K., and S. Vanecek, J. Chromatogr. 22:71 (1966).
8. Vecchi, M., W. Vetter, W. Walther, S.F. Jermstad and G.W. Schutt, Helv. Chim. Acta 50:1243 (1967).
9. Hata, M., and M. Hata, Tohoku J. Agr. Res. 18:225 (1968).
10. Shapira, B.I., I.N. Tsabashova and M.Ts. Yanotovskii, Khim. Farm. Zh. 2:23 (1968).
11. Macek, K., S. Vanecek and J. Stanislavova, Sci. Pharm. Proc., 25th, 2:123 (1965); Chem. Abstr. 70:14452 (1969).
12. Janecke, H., and H. Voege, Naturwissenschaften 55:447 (1968).
13. Vessman, J., and G. Ahlen, Acta Pharm. Suec. 1:209 (1964)
14. Nair, P.P., C. Bucana, S. deLeon and D.A. Turner, Anal Chem. 37:631 (1965).
15. Murray, T.K., K.C. Day and E. Kodicek, Biochem. J. 96:291 (1965).
16. Murray, T.K., K.C. Day and E. Kodicek, Ibid. 98:293 (1965)
17. Nair, P.P., in "Advances in Lipid Research," Vol. 4, Edited by R. Paoletti and D. Kritchevsky, Academic Press, New York, 1966, p. 227.
18. Nair, P.P., and S. deLeon, Proc. 2nd Int. Symp. Drugs Affecting Lipid Metab., Milan, September 1965, S. Karger, Basel.
19. Nair, P.P., and C. Bucana, Biochim. Biophys. Acta 124:254 (1966).
20. Walle, T., G. Schill and J. Vessman, Acta Pharm. Suec. 3:167 (1966).
21. Avioli, L.V., and S.W. Lee, Anal. Biochem. 16:193 (1966).
22. DeRitter, E., Ass. Food Drug Offic. U.S., Quart. Bull. 31:94 (1967).
23. Nair, P.P., and S. deLeon, Prog. Biochem. Pharmacol. 3:498 (1967).
24. Blondin, G.A., B.D. Kulkarni, J.P. John, R.T. Van Aller, R.T. Russell and W.R. Nes, Anal. Chem. 39:36 (1967).
25. Kobayashi, T., Vitamins (Kyoto) 34:473 (1966).
26. Kobayashi, T., J. Vitaminol. (Osaka) 13:255 (1967).
27. Kobayashi, T., Ibid. 13:258 (1967).
28. Kobayashi, T., Ibid. 13:265 (1967).
29. Kobayashi, T., Ibid. 13:268 (1967).
30. Sheppard, A.J., D.E. LaCroix and A.R. Prosser, J. Ass. Off. Anal. Chem. 51:835 (1968).
31. Nicolaides, N., P.P. Nair and S. deLeon, Lipids 3:458 (1968).
32. Nair, P.P., and S. deLeon, Arch. Biochem. Biophys. 128:663 (1968).
33. Blunt, J.W., H.F. Deluca and H.K. Schnoes, Biochemistry 7:3317 (1968).
34. Murray, T.K., P. Erdody and T. Panalaks, J. Ass. Off. Anal. Chem. 51:839 (1968).
35. Wilson, P.W., D.E.M. Lawson and E. Kodicek, J. Chromatogr. 39:75 (1969).
36. Petrova, E.A., Farmatsiya (Moscow) 18:79 (1969).
37. Edlund, D.O., and J.R. Anfinsen, J. Ass. Off. Anal. Chem. 53:287 (1970).
38. Panalaks, T., Int. Z. Vitaminforsch. 39:426 (1970).
39. Panalaks, T., Analyst 95:862 (1970).
40. Erdody, P., and T.K. Murray, J. Ass. Off. Chem. 53:189 (1970).
41. Feeter, D.K., M.F. Jacobs and H.W. Rawlings, J. Pharm. Sci. 60:913 (1971).
42. Sheppard, A.J., and W.D. Hubbard, in "Vitamins and Coenzymes," Edited by D.B. McCormick and L.D. Wright, Vol. 18C of "Methods in Enzymology," Edited by S.P. Colowick

and N.O. Kaplan, Academic Press, New York, 1971, p. 733.
43. Wilson, P.W., E. Kodicek and V.H. Booth, Biochem. J. 84:524 (1962).
44. Kofler, M., P.F. Sommer, H.R. Bollinger, B. Schmidli and M. Vecchi, in "Vitamins and Hormones," Vol. 20, Edited by R.S. Harris and I.G. Wool, Academic Press, New York and London, 1962, p. 430.
45. Nair, P.P., and D.A. Turner, JAOCS 40:353 (1963).
46. Schudel, P., H. Mayer, J. Metzger, R. Rüegg and O. Isler, Helv. Chim. Acta 46:2517 (1963).
47. Bieri, J.G., and E.L. Andrews, Iowa State J. Sci. 38:3 (1963).
48. Yanotovski, M.T., Med. Prom. SSSR 18:47 (1964).
49. Libby, D.A., and A.J. Sheppard, J. Ass. Off. Anal. Chem. 47:371 (1964).
50. Sheppard, A.J., L.A. Ford, J.W. Boehne and D.A. Libby, Ibid. 48:977 (1965).
51. Sheppard, A.J., and L.A. Ford, Ibid. 46:947 (1963).
52. Ishikawa, S., and G. Katsui, J. Vitaminol. (Kyoto) 12:106 (1966).
53. Ishikawa, S., M. Sawada and G. Katsui, Vitamins (Kyoto) 34:185 (1966).
54. Bruschi, F., Boll. Chim. Farm. 105:237 (1966).
55. Eisner, J., J.L. Iverson and D. Firestone, J. Ass. Off. Anal. Chem. 49:580 (1966).
56. Nair, P.P., I. Sarlos and J. Machiz, Arch. Biochem. Biophys. 114:488 (1966).
57. Nair, P.P., and J. Machiz, Biochim. Biophys. Acta 144:446 (1967).
58. Slover, H.T., L.M. Shelley and T.L. Burks, JAOCS 44:161 (1967).
59. Bunnell, R.H., in "The Vitamins," Second Edition, Vol. VI, Edited by P. Gyorgy and W.N. Pearson, Academic Press, New York, 1967, p. 261.
60. Pillsbury, H.C., A.J. Sheppard and D.A. Libby, J. Ass. Off. Anal. Chem. 50:809 (1967).
61. Sheppard, A.J., W.D. Hubbard and A.R. Prosser, Ibid. 52:442 (1969).
62. Boehne, J.W., Ibid. 52:364 (1969).
63. "Official Methods of Analysis," 11th Edition, Association of Official Analytical Chemists, Washington, D.C., 1970, Methods 39.063-39.070, p. 779.
64. Malm, E.P., V. Viswanathan, C. Plinton, A. Menyharth and B.Z. Senkowski, J. Pharm. Sci. 57:2149 (1968).
65. Bowman, P.B., and W.E. West, Ibid. 57:470 (1968).
66. Slover, H.T., R.J. Valis and J. Lehmann, JAOCS 45:580 (1968).
67. Hall, J.S., and D.L. Laidman, Biochem. J. 108:465 (1968).
68. Nair, P.P., and Z. Luna, Arch. Biochem. Biophys. 127:413 (1968).
69. Janecke, H., and H. Voege, Naturwissenschaften 55:447 (1968); Chem. Abstr. 69:99440 (1968).
70. Nelson, J.P., and A.J. Milun, JAOCS 45:848 (1968).
71. Seidenstrucker, W., Z. Anal. Chem. 237:280 (1968).
72. Petrova, E.A., Farmatsiya (Moscow) 18:79 (1969).
73. Weglicki, W.B., Z. Luna and P.P. Nair, Nature 221(5176):185 (1969).
74. Olweira, M.M., W.B. Weglicki, A. Nason and P.P. Nair, Biochim. Biophys. Acta 180:98 (1969).
75. Dialameh, G.H., and R.E. Olson, Anal. Biochem. 32:263 (1969).
76. Prevot, A., and C. Barbati, Rev. Franc. Corps Gras 15:157 (1968).
77. Slover, H.T., J. Lehmann and R.J. Valis, JAOCS 46:417 (1969).
78. Slover, H.T., J. Lehmann and R.J. Valis, Cereal Chem. 46:638 (1969).
79. Slover, H.T., Lipids 6:291 (1971).
80. Nelson, J.P., A.J. Milun and H.D. Fisher, JAOCS 47:259 (1970).
81. Bieri, J.G., R.K.H. Poukka and E.L. Prival, J. Lipid Res. 11:118 (1970).
82. Kovensky, B.J., and R.I. Day, J. Chromatogr. Sci. 9:442 (1971).
83. Lehmann, J., and H.T. Slover, Lipids 6:35 (1971).
84. Sheppard, A.J., A.R. Prosser and W.D. Hubbard, in "Vitamins and Coenzymes," Edited by D.B. McCormick and L.D. Wright, Vol. 18C of "Methods in Enzymology," Edited by S.P. Colowick and N.O. Kaplan, Academic Press, New York, 1971, p. 356.
85. Quaife, M.L., and L. Friedman, Proc. Soc. Exp. Biol. Med. 133:849 (1970).
86. Libby, D.A., A.R. Prosser and A.J. Sheppard, J. Ass. Off. Anal. Chem. 50:806 (1967).
87. Dugan, P., and D. Lundgren, Anal. Biochem. 8:312 (1964).
88. Libby, D.A., and A.J. Sheppard, J. Ass. Off. Anal. Chem. 48:973 (1965).
89. Cornelius, J., and H.Y. Yang, J. Gas Chromatogr. 5:327 (1967).
90. Vetter, W., M. Vecchi, H. Gutmann, R. Rucegg, W. Walther and P. Meyer, Helv. Chim. Acta 50:1866 (1967).
91. Yanotovskii, M.Ts., E.I. Kozlov, E.A. Obol'nikova, O.I. Volkova and G.I. Samokhvalov, Dokl. Akad. Nauk SSSR 179:733 (1968).
92. Yanotovskii, M.Ts., E.I. Kozlov, E.A. Obol'nikova, O.I. Volkova and G.I. Samokhvalov, J. Gas Chromatogr. 6:520 (1968).
93. Silvestri, S., and J. Staibano, Farmaco Ed. Prat. 23:613 (1968).
94. Hubbard, W.D., and A.J. Sheppard, J. Ass. Off. Anal. Chem. 51:15 (1968).
95. National Formulary, 12th Edition, Mack Printing Co., Easton, Pa., 1965, p. 230.
96. Dialameh, J.H., and R.E. Olson, Anal. Biochem. 32:263 (1969).
97. Sheppard, A.J., and W.D. Hubbard, J. Ass. Off. Anal. Chem. 53:1093 (1970).
98. Sheppard, A.J., W.D. Hubbard and A.R. Prosser, Ibid., in press.
99. Sheppard, A.J., in "Vitamins and Coenzymes," Edited by D.B. McCormick and L.D. Wright, Vol. 18C of "Methods in Enzymology," Edited by S.P. Colwick and N.O. Kaplan, Academic Press, New York, 1971, p. 461.
100. Sheppard, A.J., and W.D. Hubbard, Ibid., p. 465.

[Received March 1, 1972]

Soliman-'72
Bib No. 10915

R[illegible] permission
of the copyright owner

Internat. Z. Vit.-Ern.-Forschung 42
Intl. Journal for Vit.-Nutrition-Research, Vol. 42
(1972)
Eingegangen am 27. Mai, 1972.
Received on May 27, 1972.

Hypervitaminosis A and coagulation factors, blood constituents and vitamin A overdosages, α-tocopherol and hypervitaminosis A.

Vitamin A Overdose

II. Cytological and biochemical changes in the blood of rats treated with high vitamin A or α-tocopherol doses.

M.K. Soliman

Schoubra Human Medical Laboratory
(Ass. Prof. Dr. M.K. Soliman)
and Physiological Institute of the Veterinary Medicine Faculty
Cairo U.A.R. (Prof. Dr. H. Nasr)

Summary:

1. Blood studies, chemical constituents as well as the coagulation factors in the blood of female rats, that were treated with high doses of Vitamin A or α-tocopherol, were investigated.
2. Rats, that were treated with high vitamin A doses, showed a decrease in thrombocytes, erythrocytes, hemoglobin and haematocrites content, whereas in the leucocytes no deviation from the normal physiological values was determined. Moreover, a prolongation of the coagulation-Quick-as well as partialthromboplastin-time (PTT) occurred. The percentage concentration of coagulation factors II., V., VII. and X is reduced with an overdosage of vitamin A.
3. α-tocopherol with vitamin A-palmitate yielded a delayed restoration of the initial erythrocytes-, hemoglobin- and haematocrite-values. The coagulation changes are not only normalized, but increased.

A close relation between vitamin A and E concentration exists in the body. The α-tocopherol concentration is reduced in A hypervitaminosis of rats (DIPLOCK and co-workers, 1961; EDWIN and co-workers, 1962) and in cows (DICKS and co-workers, 1959). Vitamin A is autooxydized rapidly and is protected y vitamin E (Green, 1962). Erythrocytes of rats, fed with high doses of vitamin A, also show increased dialuric acid sensitivity (LUCY and DINGLE, 1964) as due vitamin E deficient erythrocytes. In another study (SOLIMAN, 1972) it was found, that high vitamin A additions in pregnant rats lead to the most varied malformations in offspring, which were restricted with α-tocopherol application. The antihaemolytical effect of vitamin K during hypervitaminosis A also shows a close relation between vitamin A and K (UNYAN and co-workers, 1960; MATSCHINER and DOISY, 1962).

This paper treats cytological, biochemical as well as blood coagulation changes in hypervitaminosis A of rats with and without α-tocopherol addition.

Experimental Arrangement and Methods

An experimental series consisted of:

1. Normal rats (controls) fed with standard diet (LATZ).
2. Rats, that received during the 8-10th day after copulation 250,000 U vitamin A-palmitate/kg body weight.
3. Others, that received 2 x 0.1 g α-tocopherol S/K in olive oil in addition to vitamin A.
   On the 20th day the mother rats were killed by draining blood under chloroform anesthetic and, their blood was replaced with citrate (3.6%, 1:9).

Erythrocytes and leucocytes were counted (SCHALM, 1965). The haematocrite value (Vol %) was photometrically (Zeiss, 1961) determined in Wintrobe-haematrocrite-glass tubes and the Hb-content (g/100 ml blood) as hemoglobin-cyanide. The average volumes (Vol_e) of the individual erthrocytes in um^3, the average Hb-content (hb_e) of the individual erythrocytes in mg and the average Hb-concentration (Hb-Konz) in the individual erythrocytes were calculated in % (Wintrobe 1966). The thrombocytes were counted according to FONIO (1952). The blood coagulation time was determined with microglass tubes (DUKES, 1970) and the prothrombin time according to the modified Quick-method (MONTIGEL, 1952). Factors II., V., VII., and X were determined according to the ROCHE method (1959). The partial thrombo-plastin time - (PTT) and thrombin time determinations were made according to the methods of SCHWICK and STORKIO (1966). The plasma-cholesterol measurements followed immediately with aid of color test-combinations (BOEHRINGER). The Ca-, K- and Na-content in serum was measured flame-photometrically according to the method indicated by the manufacturer (NETHELER and HINZ-Hamburg). The serum-P-concentration was determined photo-metrically according to WEILMAL-HERBE and GREEN (1956) and the Mg-values spectrophotometrically according to HAURY and NAUMENN (1965).

Results

The results are shown in tables 1-3. After addition of vitamin A per osoru S/K, certain hematological changes were noticed in the female rats.

After oral administration of 3 x 250,000 U vitamin A-palmitate, a significant decrease of thrombocytes, of erythrocytes-, hemoglobin- and haematocrite-content, as well as increased serum-K-concentration were established in the treated rats (Tab. 1). The leucocyte values remained normal. Also no essential differences showed in the Ca-, Na-, P-, Mg- and cholesterin-concentrations (Tab. 2).

The percentage concentration of coagulation factors II, V., VII. and X is decreased with overdosage of Vitamin A, accordingly, the coagulation-, Quick (prothrombin)- as well as PTT-time is prolonged. α-tocopherol with vitamin A caused a delayed normalization of the initial erythrocytes-, hemaglobin-, and haematocrite-values as well as of the K-concentration.

Discussion

Vitamin A or its metabolites are significant in the membrane physiology (DINGLE and LUCY, 1965). The stabilizing effect of small quantities of vitamin A was tested with humans-, rabbits-, rats-, sheep- and chicken-erthrocytes (LUCY and DINGLE, 1962) and is supported in all cases by tocopherol acetate.

Vitamin-A-OH influences monomolecular films from cholesterol and lecithin on water (BANGHAM and co-workers, 1964). Many biological effects are attributed to this effect; the attack by vitamin A probably takes place on the cell membrane (COHLAN, 1954). High vitamin A doses decrease the stability of the lipoprotide boundary layer and erythrocyte cell organelles. Haemolysis and anemia can therefore occur as a result (Tab. 1.) The lysosomal membrane of the cells can be damaged by overdosages of vitamin A, upon which the emerging enzymes effect an autolysis of the cell and its surroundings.

If one treats rabbit erythrocytes with A-OH, then one observes irregularities on the border of the erythrocytes, and after 15 minutes most of the erythrocytes are lysated (LUCY and GLAUBERT, 1964). This explains the increased K-content of the serum of vitamin A-treated rats (Tab. 2.). If the erythrocytes are simultaneously treated with 50g γ-tocopherol acetate, all cells are still intact after 15 minutes. After treatment with 10g, 65% α-tocopherol acetate still prevents the escape of hemoglobin, but not that of potassium. DINGLE and LUCY (1963) observed, that complete haemolysis occurs in the K-loss.

With the addition of α-tocopherol and vitamin A, the blood values in rats are quite normal. Several investigations also show, that vitamin E is of great significance for blood albumin-synthesis (ROELS and co-workers, 1964), especially for DNA-synthesis (DINNING, 1962). Moreover, vitamin E has an albumin-saving effect (HOVE and HARDIN, 1951). The muscular dystrophy occurring through vitamin E-deficiency can only be alleviated by vitamin E, possible in conjunction with sulphur-containing amino acids (SCOTT, 1962). Moreover, influences of vitamin E on the structure of serumlipoprotein synthesis (OPPENHEIMER and co-workers, 1958), on Hb-synthesis in vitamin E-deficient rats (BENZE, and co-workers, 1966) as well as on new cell development after particular liver removal (MAROS and co-workers, 1966), and on collagen synthesis (BROWN and co-workers, 1967) were established.

The addition of high vitamin A doses with and without vitamin E leads to a significant thrombopeny as well as to a strong percentage decrease in factors II, V., VII., and X. As a result, the prothrombin-, PTT- and coagulation time are prolonged. GERVASONI and VANNOTTI (1956) observed fetal hemorrhaging in the internal organs of the rat in hypervitaminosis A. Other authors established, that hypervitaminosis A has a secondary anti-vitamin K-effect (WOSTMAN and co-workers, 1963). Smaller doses have no effect (WOSTMAN and KNIGHT, 1965). GREEN (1966) on the other hand, believes that this effect is not triggered by the disturbance from vitamin K-synthesis, and other authors reported, that A-avitaminosis leads to gradual decrease of the platlet number (WEICKER and BIGHARDI, 1953) and hemorrhages.

GLOOR and WISS (1959) found, that through hypervitaminosis A the blood cholesterol values are increased. WOOD, (1960), on the other hand, reports low cholesterol values. The present work shows, that the cholesterol concentration is unchanged in hypervitaminosis A. α-tocopherol-treatment in hypervitaminosis A shows no significant differences (Tab. 3). Vitamin E appears above all to maintain the vitamin A reserves and to impede indirectly synthesis of the endogenous cholesterol (SIMIC and co-workers, 1963).

TABLE 1

Blood Values	Normal Controls
Ery.	
Hb	
Hkt	
Vol. U	
HbU	
Hb-concentration	

$\pm$ Mean error of mean value.

+ Significant value based on control group.

TABLE 2

Plasma Values	Normal (Controls)	Vitamin A Treated	Vitamin A & E Treated
Na			
K			
Ca			
Inorganic P			
Na: K-ratio			
Ca: P-ratio			
Mg			
Ca: Mo-ratio			

+ Mean error of mean value
—

+ Significant value based on control group

+ Same

For the conversion of mg/100 ml to mg/1 plasma, the values were multiplied by 0.500 for Ca., O.555 for P, P.435 for Na, 0.256 for K and 0.840 for Mg.

TABLE 3

Coagulation Values	Normal (Controls)	Vitamin A Treated	Vitamin A & E Treated
Cholesterol			
Thrombocytes			
Coagulation Time			
Prothrombin Time (sec.)			
Prothrombin %			
Thrombin Time (sec.)			
Factor II - %			
Factor V - %			
Factor VII - %			
Factor X - %			
PTT-time (sec.)			

$\pm$ Mean error of mean value

$\pm$ Significant value based on control group

++ Same

Soliman-'72
Bib No. 10915

Reproduced by permission
of the copyright owner

Internat. Z. Vit.-Ern.-Forschung 42
(1972)
Eingegangen am
27. Mai 1972

Hypervitaminose A und
Gerinnungsfaktoren
Blutbestandteile und
Vitamin A-Überdosierungen
α-Tocopherol und
Hypervitaminose A

Vitamin-A-Überdosierung

II. Zytologische und biochemische Veränderungen im Blut von mit hohen Dosen Vitamin A bzw. α-Tocopherol behandelten Ratten

M. K. Soliman

Schoubra Humanmedizinisches Labor (Ass. Prof. Dr. M. K. Soliman) und Physiologisches Institut der Veterinärmedizinischen Fakultät Kairo V. A. R. (Prof. Dr. H. Nasr)

Zusammenfassung:

1. *Blutbild, chemische Bestandteile sowie die Gerinnungsfaktoren im Blut weiblicher Ratten, die mit hohen Dosen von Vitamin A bzw. α-Tocopherol behandelt waren, wurden untersucht.*
2. *Ratten, die mit hohen Vitamin-A-Dosen behandelt wurden, zeigten eine Abnahme des Thrombozyten-, Erythrozyten-, Hämoglobin- und Hämatokrit-Gehaltes, während sich bei den Leukozyten keine Abweichung von den normalen physiologischen Werten nachweisen liess. Ferner kam es zu einer Verlängerung der Gerinnungs-, Quick- sowie PTT-Zeit. Der prozentuale Anteil an Gerinnungsfaktoren II, V, VII und X ist bei Überdosierung von Vitamin A herabgesetzt.*
3. *α-Tocopherol mit Vitamin-A-Palmitat rief eine verzögerte Wiederherstellung der initialen Erythrocyten-, Hämoglobin- und Hämatokrit-Werte hervor. Die Gerinnungsveränderungen sind nicht nur normalisiert, sondern verstärkt.*

Es besteht eine enge Beziehung zwischen der Vitamin-A- und -E-Konzentration im Körper. Die α-Tocopherolkonzentration ist bei A-Hypervitaminose der Ratten (Diplock und Mit., 1961; Edwin und Mit., 1962) und Kühen (Dicks und Mit., 1959) herabgesetzt. Vitamin A ist schnell autooxydiert und wird von Vitamin E geschützt (Green, 1962). Erythrozyten von Ratten, die mit hohen Dosen Vitamin A gefüttert werden, zeigen ebenso wie Vitamin-E-Mangelerythrozyten erhöhte Dialursäureempfindlichkeit (Lucy und Dingle, 1964). In einer anderen

Studie (SOLIMAN, 1972) wurde gefunden, dass hohe Vitamin-A-Zugabe bei trächtigen Ratten zu den verschiedensten Missbildungen bei den Nachkommen führt, die bei α-Tocopherolapplikation gehemmt wurden. Die antihämolytische Wirkung von Vitamin K während der Hypervitaminose A zeigt auch eine enge Beziehung zwischen Vitamin A und K (BUNYAN und Mit., 1960; MATSCHINER und DOISY, 1962).

Diese Arbeit beschäftigt sich mit zytologischen, biochemischen sowie Blutgerinnungsveränderungen bei Hypervitaminose A der Ratten ohne und mit α-Tocopherolzusatz.

Versuchsanordnung und Methoden

Eine Versuchsserie bestand jeweils aus:

1. Normalratten (Kontrollen) gefüttert mit Standarddiät (LATZ).
2. Ratten, die während dem 8.–10. Tag nach dem Decken 250 000 E Vitamin-A-Palmitat/kg Körpergewicht bekamen.
3. Anderen, die neben Vitamin A 2 × 0.1 g α-Tocopherol S/K in Olivenöl erhielten.

Am 20. Tag wurden die Muttertiere durch Entbluten in Chloroformnarkose getötet, ihr Blut wurde mit Zitrat (3,6 %, 1:9) versetzt.

Erythrozyten und Leukozyten wurden gezählt (SCHALM, 1965). Der Hämatokritwert (Vol. %) wurde in Wintrobe-Hämatokrit-Glasröhrchen und der Hb-Gehalt (g 100 ml Blut) als Hämiglobinzyanid photometrisch (ZEISS, 1961) bestimmt. Das mittlere Volumen (Vol_E) der einzelnen Erythrozyten in μm^3, der mittlere Hb-Gehalt (hb_E) der einzelnen Erythrozyten in µg und die mittlere Hb-Konzentration (Hb-Konz.) in den einzelnen Erythrozyten in % wurden errechnet (WINTROBE 1966).

Die Thrombozyten wurden nach FONIO (1952) gezählt. Die Blutgerinnungszeit ist mit Mikroglasröhrchen (DUKES, 1970) und die Prothrombinzeit nach der modifizierten Quick-Methode (MONTIGEL, 1952) bestimmt worden. Die Faktoren II, V, VII und X wurden nach der ROCHE-Methode (1959) bestimmt. Die partielle Thromboplastinzeit- (PTT) und Thrombinzeitbestimmungen erfolgten nach den Methoden von SCHWICK und STORKIO (1966). Die Plasmacholesterinmessungen erfolgten unmittelbar anschliessend mit Hilfe der Farbtest-Kombinationen (BOEHRINGER). Der Ca-, K- und Na-Gehalt im Serum wurde flammenphotometrisch nach der vom Hersteller (NETHELER und HINZ-Hamburg) angegebenen Methode gemessen. Die Serum-P-Konzentration haben wir photometrisch nach WEIL-MALHERBE und GREEN (1951) und die Mg-Werte spektrophotometrisch nach HAURY und NAUMENN (1965) bestimmt.

Ergebnisse

Die Ergebnisse sind in Tabellen 1–3 aufgeführt. Nach Zugabe von Vitamin A per os bzw. E S K liessen sich bei den weiblichen Ratten gewisse hämatologische Veränderungen wahrnehmen.

Nach oraler Gabe von 3 × 250 000 E Vitamin-A-Palmitat, liessen sich bei den behandelten Ratten eine signifikante Abnahme der Thrombozyten, des Erythrozyten-, Hämoglobin- und Hämatokrit-Gehaltes sowie erhöhte Serum-K-Konzen-

tration feststellen (Tab. 1). Die Leukozytenwerte blieben normal. Auch zeigten sich keine wesentlichen Unterschiede in den Ca-, Na-, P-, Mg- und Cholesterinkonzentrationen (Tab. 2).

Tab. 1

Blutwerte	Normal (Kontrollen)	250 000 E Vitamin A	Vitamin A + 2 × 0.1 g α-Tocopherol
Ery. (10^6/mm³)	9.66 ± 0.03	6.94 ± 0.16*	7.42 ± 0.25*
Hb (g/100 ml)	17.67 ± 0.13	7.56 ± 0.21*	12.01 ± 0.29*
Hkt (Vol. %)	49.87 ± 0.69	37.50 ± 0.83*	42.00 ± 0.89*
Vol_E (µm³)	51.63 ± 0.90	54.03 ± 1.01	56.60 ± 0.89
Hb_E (µg)	18.28 ± 0.22	10.89 ± 0.39*	16.17 ± 0.40*
Hb-Konz. (%)	35.43 ± 0.81	20.16 ± 0.44*	28.60 ± 0.50*

± Mittlere Fehler des Mittelwertes
* Signifikanz bezogen auf Kontrollgruppe (P = 0.01)

Tab. 2

Plasma-Werte	Normal (Kontrollen)	Vitamin-A-behandelt	Vitamin-A- und -E-behandelt
Na (mg/100 ml)	353.50 ± 3.76	325.00 ± 6.00*	343.00 ± 3.71
K (mg/100 ml)	18.90 ± 0.32	21.13 ± 0.32*	20.50 ± 0.42**
Ca (mg/100 ml)	10.50 ± 0.37	11.29 ± 0.06	10.77 ± 0.10
Anorg. P (mg/100 ml)	5.08 ± 0.25	4.77 ± 0.20	4.67 ± 0.22
Na : K-Verhältnis	18.70	15.38	16.75
Ca : P-Verhältnis	2.06	2.37	2.31
Mg (mg/100 ml)	2.66 ± 0.06	2.47 ± 0.06	2.71 ± 0.04
Ca : Mo-Verhältnis	3.94	4.57	3.97

± Mittlere Fehler des Mittelwertes
* Signifikanz bezogen auf Kontrollgruppe (P = 0.01)
** Signifikanz bezogen auf Kontrollgruppe (P = 0.05)
Für das Umrechnen von mg/100 ml zum mEg/l Plasma wurden die Werte multipliziert mit: 0.500 für Ca, 0.555 für P, 0.435 für Na, 0.256 für K und 0.810 für Mg.

Der prozentuale Anteil an Gerinnungsfaktoren II, V, VII und X ist bei Überdosierung von Vitamin A herabgesetzt, demzufolge ist die Gerinnungs-, Quick (Prothrombin)- sowie PTT-Zeit verlängert.

α-Tocopherol mit Vitamin A verursachte eine verzögerte Normalisierung der initialen Erythrozyten-, Hämoglobin- und Hämatokrit-Werte sowie der K-Konzentration.

Tab. 3

Gerinnungswerte	Normal (Kontrollen)	Vitamin-A-behandelt	Vitamin-A- und -E-behandelt
Cholesterin (mg %)	62.60 ± 2.87	56.12 ± 3.37	59.71 ± 3.59
Thrombozyten (10^3/mm³)	583.00 ± 1.03	495.00 ± 1.20*	396.50 ± 0.56*
Gerinnungszeit (min)	3.22 ± 0.06	4.10 ± 1.33*	5.16 ± 0.21*
Prothrombinzeit (sek)	17.16 ± 1.72	21.28 ± 0.23*	27.37 ± 1.00**
Prothrombin %	76.50 ± 12.35	48.00 ± 3.60*	27.37 ± 2.24**
Thrombinzeit (sek)	23.20 ± 0.90	25.50 ± 1.61	25.67 ± 1.02
Faktor II %	100.83 ± 1.27	81.83 ± 4.27*	70.17 ± 4.58*
Faktor V %	95.83 ± 1.10	72.50 ± 3.82*	62.50 ± 3.55*
Faktor VII %	99.40 ± 1.58	81.17 ± 2.24*	65.70 ± 2.72*
Faktor X %	100.50 ± 2.40	79.80 ± 2.76*	59.83 ± 1.55*
PTT-Zeit (sek)	25.60 ± 0.55	39.33 ± 1.84*	44.33 ± 1.79*

± Mittlere Fehler des Mittelwertes
* Signifikanz bezogen auf Kontrollgruppe (P = 0.01)
** Signifikanz bezogen auf Kontrollgruppe (P = 0.05)

Diskussion

Vitamin A oder seine Metaboliten spielen eine Rolle in der Membranphysiologie (DINGLE und LUCY, 1965). Die stabilisierende Wirkung geringer Mengen Vitamin A wurde mit Menschen-, Kaninchen-, Ratten-, Schaf- und Hühnererythrozyten (LUCY und DINGLE, 1962) geprüft und wird in allen Fällen durch Tocopherolazetat unterstützt.

Vitamin-A-OH beeinflusst monomolekulare Filme aus Cholesterin und Lezithin auf Wasser (BANGHAM und Mit., 1964). Viele biologische Wirkungen werden auf diesen Effekt zurückgeführt, der Angriff von Vitamin A erfolgt dabei wahrscheinlich auf die Zellmembran (COHLAN, 1954). Hohe Vitamin-A-Dosen setzen die Stabilität der Lipoproteidgrenzschicht und Erythrozytenzellorganellen herab. Dadurch können Hämolyse und Anämie auftreten (Tab. 1). Bei Überdosierungen von Vitamin A kann die Lysosomenmembran der Zellen beschädigt werden, worauf die austretenden Enzyme eine Autolyse der Zelle und deren Umgebung bewirken.

Behandelt man Kaninchenerythrozyten mit A-OH, dann beobachtet man Unregelmässigkeiten am Erythrozytenrand, und nach 15 Minuten sind die meisten Erythrozyten lysiert (LUCY und GLAUERT, 1964). Dies erklärt den erhöhten K-Gehalt des Serums von Vitamin-A-behandelten Ratten (Tab. 2). Werden die Erythrozyten gleichzeitig mit 50 g α-Tocopherolazetat behandelt, sind nach 15

Minuten noch alle Zellen intakt, nach Behandlung mit 10 g noch 65%. α-Tocopherolazetat verhindert den Austritt von Hämoglobin, aber nicht den von Kalium. Dingle und Lucy (1963) beobachteten, dass im K-Verlust vollständig Hämolyse eintritt.

Bei Zufuhr von α-Tocopherol und Vitamin A sind die Blutwerte bei Ratten ziemlich normal. Es zeigt sich auch in mehreren Untersuchungen, dass Vitamin E für die Blut-Eiweiss-Synthese von grosser Bedeutung ist (Roels und Mit., 1964), besonders für die DNA-Synthese (Dinning, 1962). Vitamin E hat ferner eine eiweisssparende Wirkung (Hove und Hardin, 1951). Die bei Vitamin-E-Mangel auftretende Muskeldystrophie kann nur durch Vitamin E evtl. in Verbindung mit schwefelhaltigen Aminosäuren behoben werden (Scott, 1962). Ferner sind Einflüsse von Vitamin E auf den Aufbau der Serumlipoprotein-Synthese (Oppenheimer und Mit., 1958), auf die Hb-Synthese bei Vitamin-E-Mangelratten (Bencze und Mit., 1966) sowie auf die Zellneubildung nach partieller Leberentfernung (Maros und Mit., 1966) und die Collagensynthese (Brown und Mit., 1967) festgestellt worden.

Die Zugabe von hohen Vitamin-A-Dosen mit und ohne Vitamin E führt zu einer signifikanten Thrombopenie sowie einer starken prozentualen Verminderung der Faktoren II, V, VII und X. Demzufolge ist die Prothrombin-, PTT- und Gerinnungszeit verlängert. Gervasoni und Vannotti (1956) beobachteten fötale Blutungen in den inneren Organen der Ratte bei Hypervitaminose A. Andere Autoren stellten fest, dass Hypervitaminose A eine sekundäre Antivitamin-K-Wirkung hat (Wostman und Mit., 1963). Kleinere Dosen besitzen keine Wirkung (Wostman und Knight, 1965). Green (1966) meinte dagegen, dass dieser Effekt nicht durch die Störung der Vitamin-K-Synthese ausgelöst wird, und andere Autoren berichteten, dass die A-Avitaminose zum langsamen Absinken der Plättchenzahl (Weicker und Bighardi, 1953) und zu Hämorrhagien führt.

Gloor und Wiss (1959) fanden, dass bei Hypervitaminose A die Blutcholesterinwerte erhöht werden. Wood (1960) berichtet dagegen über niedrige Cholesterinwerte. Aus vorliegender Arbeit ist ersichtlich, dass die Cholesterinkonzentration bei Hypervitaminose A unverändert ist. Die α-Tocopherol-Behandlung bei Hypervitaminose A zeigt keine signifikanten Unterschiede (Tab. 3). Vitamin E scheint vor allem als Antioxydans die Vitamin-A-Reserven aufrecht zu erhalten und indirekt die Synthese des endogenen Cholesterins zu hemmen (Simić und Mit., 1963).

Summary:

1. *The blood picture, chemical constituents as well as the coagulation factors were determined in female rats given higher doses of vitamin A with and without α-tocopherol administration.*
2. *Rats given higher vitamin A doses presented a significant decrease in the Erythrocyte, Hemoglobin, Hematokrit and Thrombocyte values. The Leucocytic count showed no deviation from the normal physiological values. These animals exhibited also a significant decrease in the concentration of coagulation factors II, V, VII and X with a consequent prolongation in the coagulation-, Quick- and partial thromboplastin times.*
3. *Hypervitaminotic A rats given α-tocopherol in addition exhibited rather normal erythrocytic values. However, the coagulation changes are not only normalised but increased to a certain extent.*

Literatur

1. Bangham, A. D., Dingle, J. T. und Lucy, J. A.: Biochem. J. *90*, 133 (1964). – 2. Bencze, B., Gerloczy, F., Ugrai, E. und Knfiszl, F.: Int. Z. f. Vit. forsch. *36*, 24 (1966). – 3. Brown, R. G., Button, G. M. und Smith, J. T.: J. Nutr. *91*, 99 (1967). – 4. Bunyan, J., Green, J., Edwin, E. E. und Diplock, A. T.: Biochem. J. *75*, 460, 476 (1960). – 5. Cohlan, S. Q.: Pediatrics *13*, 556 (1954). – 6. Dicks, M. W., Rousseau, J. E. Jr., Eaton, H. D., Teichman, R., Grifo, A. P. und Kemmerer, H. A.: Dairy Sci. *92*, 501 (1959). – 7. Dingle, J. T. und Lucy, J. A.: Biochem. J. *86*, 15 P (1963). – 8. Dingle, J. T. und Lucy, J. A.: Biol. Rev. *40*, 422 (1965 a). – 9. Dinning, J. S.: Vit. u. Horm. *20*, 511 (1962). – 10. Diplock, A. T., Edwin, E. E., Bunyan, J. und Green, J.: Brit. J. Nutr. *15*, 425 (1961). – 11. Dukes, H. H.: The Physiology of Domestic Animals. 8 ed. Comstock Publ. Co., Ithaca N. Y. (1970). – 12. Fonio, A.: Acta hämat. *8*, 363 (1952). – 13. Gervasoni, E. A. und Vanotti, A.: Schw. med. Wschr. *86*, 708 (1956). – 14. Gloor, U. und Wiss, O.: Bioch. Biophys. Res. Commun. *1*, 182 (1959). – 15. Green, J.: Vit. u. Horm. *20*, 485 (1962). – 16. Green, J.: Ibid. *24*, 619 (1966). – 17. Haury, H. und Naumann, E.: Arzneimittelforsch. *15*, 579 (1965). – 18. Hove, E. L. und Hardin, J. O.: Proc. Soc. exp. Biol. Med. *78*, 858 (1951). – 19. Lucy, J. A. und Dingle, J. T.: Biochem. J. *84*, 76 P (1962). – 20. Lucy, J. A. und Dingle, J. T.: Nature *204*, 156 (1964). – 21. Lucy, J. A. und Glauert, A. M.: J. Mol. Biol. *8*, 727 (1964). – 22. Maros, T. N., Fodor, G. P., Kovacs, V. V. und Katonai, B.: J. Nutr. *90*, 219 (1966). – 23. Matschiner, J. T. und Doisy, E. A.: Proc. soc. exp. Biol. Med. *109*, 139 (1962). – 24. Montigel, C.: Ther. Umschau *9*, 17 (1952). – 25. Oppenheimer, H., Shulman, S., Roberts, S. und Milhorat, A. T.: Proc. soc. Biol. Med. *97*, 882 (1958). – 26. Roche: Einführung in die Methodik der Blutgerinnungsbestimmung. Grenzach-Baden 1969. – 27. Rofs, O. A., Morrill, C. C., Norton, H. W. und Rhoads, H. E.: J. Nutr. *58*, 19 (1964). – 28. Schalm, O. W.: Veterinary Hematology, 2nd ed. Lea & Febiger, Philadelphia 1965. – 29. Schwick, H. G. und Storkio, K.: Beiträge zur Diagnostik von Gerinnungsstörungen. Lab. blätter f. die med. Diagnostik 1. Behringwerke AG, Marburg 1966. – 30. Scott, M. L.: Vit. u. Horm. *20*, 621 (1962). – 31. Simić, B. S., Sibalić, S., Naumović, M., Simić, A., Marković, R., Raković, V. und Todorović, P.: Int. Z. f. Vit. forsch. *33*, 48 (1963). – 32. Soliman, M. K.: Ibid. *42*, 389 (1972). – 33. Weicker, H. und Bichardi, P.: Z. f. Kinderheilk. *72*, 532 (1953). – 34. Weil-Malherbe, H. und Green, R. H.: Biochem. J. *49*, 256 (1951). – 35. Wintrobe, M. M.: Clinical

Hematology. 5th ed. Lea & Febiger, Philadelphia. – 36. Wood, J. D.: Canad. J. Biochem. Physiol. *38*, 879 (1960). – 37. Wostman, B. S. und Knight, P. L.: J. Nutr. *87*, 155 (1965). – 38. Wostman, B. S., Knight, P. L., Keely, L. L. und Kan, D. F.: Fed. Proc. *1*, 120 (1963). – 39. Zeiss, C.: Photometrische Analysen Medizin. Zeiss-Oberkochen 1961.

Ass. Prof. Dr. M. K. Soliman, Institut für Physiologie, Vet. Med. Fakultät, Giza V. A. R.

Bib. No. 10934

J. Sci. Ind. Res. 31(12):581-592. 1972.

Recent Advances in the Metabolism of Vitamin A

P. R. SUNDARESAN

Lipids Laboratory, Research Institute, St Joseph Hospital, Lancaster, Pennsylvania, USA

CONTENTS

Introduction	581
Chemistry of Retinol	581
Metabolism of Retinol	581
Conversion of β-carotene to retinol	581
Absorption of retinol, retinal and retinoic acid	582
Transport of retinol	582
Distribution and storage of retinol	583
Active metabolites of retinol	584
Excretion of retinol and its metabolites	585
Physiological Actions of Retinol	586
Vision	586
Growth	587
Reproduction	587
Biochemical Role of Retinol	587
Sulphate activation	587
Protein synthesis	588
Role of retinol in membranes	588
Retinol and Protein Malnutrition	589
Concluding Remarks	590
Summary	590
References	590

Introduction

DURING the past few years our understanding of the metabolism of retinol has progressed to a considerable degree. The present article reviews critically the more important recent researches in the field.

Retinol* is unique among the vitamins in having a very specialized role in vision but only a general role associated with the normal functioning of the epithelial cells. The chemistry of retinol and its metabolites has been well delineated. Its biosynthesis, absorption, transport and storage have been studied in detail in recent years. It has now been accepted that a molecule of β-carotene is cleaved centrally by an oxygenase to yield two molecules of retinal. New insights into the transport of retinol have demonstrated that the well-established retinol binding protein exists in at least four molecular forms. Exciting findings on the storage of retinol in different cell types of liver have led to the re-evaluation of some of the earlier concepts in this area. Thus, the parenchymal cells of the liver assume more importance in storage mechanisms than the Kupffer cells which are now considered to be involved in the transport of retinol only. The metabolism of retinol has been a subject of great interest and the current thought is that retinol must be converted to an 'active' form before it exerts its effect. The role of retinol in vision has been defined at the molecular level. However, our knowledge of its roles in growth and reproduction is still fragmentary. Although retinol may not serve a coenzymic function, its role in biological sulphurylation seems confirmed. Retinol has been implicated in the synthesis of steroid hormones as well as in the control of membrane permeability. Recently, retinol has been shown to stimulate the protein synthetic mechanism of the intestinal cells, especially the synthesis of a fucose-containing glycopeptide in the goblet cells. Finally, the interrelationship of retinol and protein malnutrition has demonstrated the increasingly important aspect of retinol status not only in underdeveloped countries but also in well-nourished populations of the world.

*In accordance with suggestions by the International Union of Pure & Applied Chemistry Commission on Biochemical Nomenclature (1960), vitamin A alcohol, vitamin A aldehyde, vitamin A acid and vitamin A ester are now referred to as retinol, retinal, retinoic acid and retinyl ester respectively and the numbering system is that shown in Fig. 1.

Chemistry of Retinol

Though retinol was discovered as early as 1915 by McCollum and Davis[1,2], it was not until 1931 that Karrer *et al.*[3] proposed the correct structural formula for retinol. Later, Isler *et al.*[4] achieved the first chemical synthesis of retinol. The structures of retinol, retinal, retinoic acid and β-carotene are given in Fig. 1.

Retinol exists in nature predominantly as the all-*trans* form. However, other isomers of retinol have also been isolated and characterized. Of these, 11-*cis* retinal is important in that it functions as the prosthetic group of the visual pigments in the retina. Recent findings on the chemistry of retinol have been reviewed in detail by Schwieter and Isler[5] and should serve as a key to previous literature in this area.

Metabolism of Retinol

Conversion of β-carotene to retinol — The site of conversion of carotene to retinol *in vivo* was

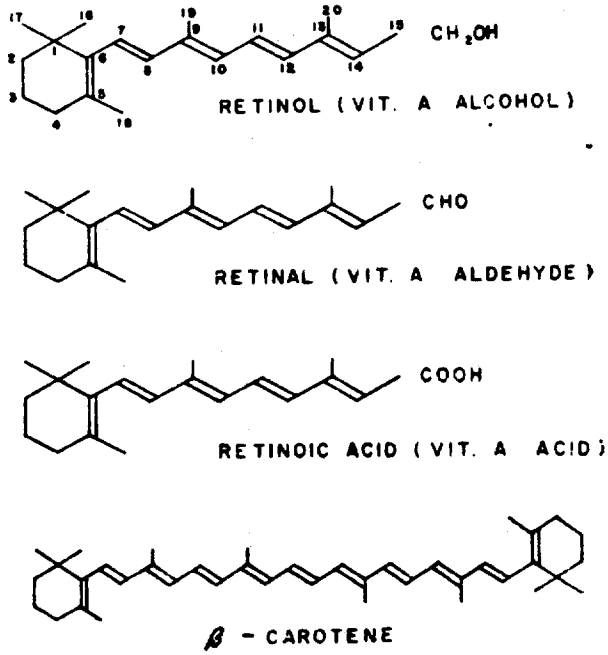

Fig. 1 — Structures of retinol and related compounds

originally thought to be the liver. However, subsequent work showed conclusively that the conversion takes place in the intestinal wall[6]. Both tissues have now been found to be active *in vitro* in the conversion of carotene to retinol.

Two pathways have been suggested for the formation of retinol: (i) cleavage at the 15,15′-double bond of β-carotene to yield two molecules of retinal; and (ii) stepwise degradation from one end of the trimethyl cyclohexene ring to yield one molecule of retinol. Evidence for the second pathway was obtained through biological tests on β-apocarotenals which were found to be converted to retinol *in vivo*[7]. The isolation of a soluble enzyme from both the intestine and the liver which cleaved β-carotene to two molecules of retinal conclusively provided evidence for the first pathway[8,9]. The enzyme, designated β-carotene 15,15′-oxygenase, was presumed to function through a dioxygenative mechanism in which molecular oxygen reacted with two carbons of β-carotene to yield two molecules of retinal. The retinal formed was rapidly converted to retinol in the intestine[10,11] and the reaction was catalysed by a NADH- or NADPH-activated soluble enzyme[12].

Absorption of retinol, retinal and retinoic acid — In an earlier review[13] it has been concluded that dietary retinyl esters undergo extensive hydrolysis during absorption. This hydrolysis was shown to be catalysed by a pancreatic retinyl ester hydrolase[14]. It was suggested that free retinol was then absorbed into the mucosal cell of the intestine, esterified with palmitic acid and transferred to the lymph. However, it was subsequently found that the intestinal mucosa itself contained the retinyl ester hydrolase in the brush border of the cells, probably on the outer surface and oriented in such a manner as to be in contact with the substrates. In contrast, the retinyl ester synthetase of the brush border region appears to be oriented towards the interior of the cell[15].

When rats were fed retinyl acetate, both retinol and retinyl esters were present in the fat layer and micellar phase of the intestinal contents. The brush border contained only retinyl acetate at 30 min after the dose, while at 120 min both the acetate and the higher esters of retinol were present[16]. These results provide evidence for the hypothesis that the retinyl esters are not absorbed into the mucosal cells before they are hydrolysed. Thus, the absorption of retinol is believed to proceed as follows. Partial hydrolysis of dietary retinyl esters to retinol while still present in the lipid phase, uptake of both retinol and retinyl esters from the micellar phase by the brush border after which retinol is transferred to inside of the cell, while its esters are hydrolysed by the hydrolase located on the outer surface. Retinol is then re-esterified inside the cell and transported via the lymph. While this mechanism may be operative under normal conditions in the rat, there appears to be a certain degree of species specificity. Thus, retinyl acetate was shown to be absorbed in small amounts in the chick without prior hydrolysis[17]. Furthermore, retro-retinyl acetate was found to be absorbed from the intestine without hydrolysis and appeared in the liver[13].

The intestinal absorption of retinol is considered as an active process in the rat and the human. It is greatly enhanced by ATP, whereas metabolic inhibitors and lack of oxygen prevent its accumulation and transport across the cell wall[19,20].

Irrespective of the forms of retinyl ester fed, the ester found in the intestinal mucosa is mainly retinyl palmitate[21]. Lawrence *et al.*[22] suggested that absorptive routes other than the lymphatic system might exist in regard to the transport of retinyl esters. Recent work has independently confirmed the partial absorption of 6,7-[$^{14}C_2$]retinol and [15-^{14}C]retinol to a significant degree[23].

Retinal and 3-dehydroretinal are readily absorbed as such, although they are mainly reduced to retinol by retinaldehyde reductase in the intestinal mucosa and esterified prior to absorption[24,25]. After an oral dose of retinal, no retinoic acid was detected, though it was found in *in vitro* experiments with everted intestinal sacs[26].

Earlier work of Arens and Van Dorp[27] and Dowling and Wald[28] had contributed to the belief that retinoic acid was neither absorbed from the intestine nor stored in the liver. Subsequent work, however, showed that retinoic acid was rapidly absorbed by rats[29] and equally rapidly excreted in the bile. The reason for the rapid disappearance of retinoic acid is due to its conjugation with glucuronic acid and excretion in the bile[30]. Further work indicated that when [^{14}C]retinoic acid was fed to rats, about 95% of the radioactivity was recovered from the bile, while insignificant amounts appeared in the lymph and the liver[23]. These studies clearly show that retinoic acid is absorbed rapidly through the portal route.

Transport of retinol — It has been known for some time that retinol is transported by a high density plasma protein[31,32]. This protein has been reported to differ from serum albumin in man in that it has either α_1-mobility[33] or α_2-mobility[34]. Furthermore, it has been suggested that this protein may be identical with the tryptophan-rich prealbumin in human serum[35]. In the latter study, the characteristic fluorescence of retinol was used as a marker in the isolation of a fraction from human plasma, which was successively purified by Sephadex G-200, DEAE-Sephadex and paper electrophoresis. However, in a subsequent study, it was shown that retinol in plasma was not linked to tryptophan-rich prealbumin but to an immunologically related protein[36].

It has been recently established that retinol circulates in the plasma, bound to a specific transport protein, retinol binding protein (RBP). The RBP was isolated from human plasma by the sequential use of DEAE-Sephadex chromatography, gel filtration and preparative polyacrylamide gel electrophoresis[37,38]. The protein has been purified 1500- to 2000-fold. Purified RBP has the mobility of α_1-globulin and a molecular weight of 21,000. In aqueous solution, the RBP has absorption maxima at 330 and 280 nm. The amino acid composition of RBP is unusual in that it has a very high content of aromatic amino acids with eight residues of tyrosine and four residues of tryptophan/molecule. It has also 10-11 residues of phenylalanine/molecule. The concentration of RBP in plasma is approximately 4-5 mg/100 ml. The protein binds one mole of retinol/mole of protein. In plasma, the RBP circulates as a complex, in combination with another larger protein, which has a mobility of

prealbumin on electrophoresis. This complex dissociates during gel electrophoresis, but it is again formed when solutions of RBP and prealbumin are mixed together. The transport of retinol in plasma is a process involving lipid-protein and protein-protein interactions.

The plasma prealbumin which binds RBP and the prealbumin which binds thyroxine appear to be identical. Also, the binding capacity and affinity of prealbumin for thyroxine are not affected by the presence or absence of RBP. Similarly, the interaction of prealbumin with RBP is not affected by thyroxine binding to prealbumin. Thus, the interaction of prealbumin with thyroxine is independent of prealbumin-RBP interaction[38]. Recent studies revealed distinct features involved in protein-protein interaction in retinol transport in plasma; for example, the RBP-prealbumin complex was dissociated in the presence of 6*M* urea, whereas the retinol-RBP complex remained intact. The effect of urea on this interaction was found to be completely reversible[39,40].

In a series of papers, Peterson and Berggard[41] and Peterson[42,43] have shown that the RBP isolated from biological fluids, such as serum and urine, especially from the urine of patients with tubular proteinuria, is similar to that described earlier by Kanai *et al.*[37]. Serious difficulties were involved in the isolation of RBP and Vahlquist *et al.*[44] reported a novel procedure for the isolation of RBP from serum and urine by affinity chromatography on prealbumin coupled to sepharose. This method helped in providing new insights into the mechanism of transport of retinol as RBP-prealbumin complex. Retinol transport is now considered to proceed via dissociation of RBP from prealbumin after the stabilization of RBP-prealbumin under physiological conditions, followed by extrusion of retinol from RBP, deposition of retinol in a target cell and excretion of free RBP in urine. This attractive hypothesis to explain one possible mode of action of retinol has gained support from the recent findings of the occurrence of small amounts of free RBP in serum and of the lower binding of free urinary RBP to prealbumin than RBP prepared from the RBP-prealbumin complex of serum[41].

Distribution and storage of retinol — It is well known that liver is the principal storage site for retinol in mammals. However, in certain species, such as the birds and the fish, the concentration of retinol in the intestine may exceed that in the liver. Earlier, Davies and Moore[45] observed traces of retinol in the pancreas, thymus and spleen and an appreciable amount in the adrenals after feeding large doses of retinol. It has been demonstrated that retinyl palmitate is by far the predominant form of retinyl ester present in the liver[21]. However, Futterman and Andrews[46] have recently indicated that other esters, such as stearate and oleate are also present in the liver in reasonably significant amounts.

The distribution of retinol was studied several years ago by fluorescence microscopy by Popper and Greenberg[47]. Their studies indicated that retinol was probably stored in the Kupffer cells. Subsequent studies by Krishnamurthy and Ganguly[48] demonstrated that retinyl esters were stored in reduced amounts in rats injected repeatedly with India ink to block the reticuloendothelial system of the liver. However, injection of India ink a day before the experiment did not affect the uptake, esterification and storage of [^{14}C]retinol by the perfused liver[49]. Further, it appears that the parenchymal cells of the liver are the main storage cells for intravenously administered chylomicra containing retinyl esters, whereas the Kupffer cells take up readily suspensions of retinyl esters in gelatin or phospholipids[50]. Thus, some uncertainty exists regarding the cells involved in the storage of retinyl esters in the liver. This problem has been clarified a great deal by the recent work of Linder *et al.*[51], who prepared relatively pure Kupffer cells, free of hepatocytes, and determined their retinol content by the trifluoroacetic acid method of Neeld and Pearson[52]. The Kupffer cells were prepared by pronase digestion, which seemed to preferentially digest the hepatocytes, leaving the Kupffer cells morphologically intact. Their results have clearly demonstrated that only 4% of the total retinol in the liver is present in Kupffer cells, while the remainder (about 96%) is stored in the hepatocytes. Their observations are supported by the findings that retinol is not destroyed during the process of isolation of the Kupffer cells and that the distribution of [^{14}C]retinol in different liver cell populations is similar to that found with unlabelled retinol.

In view of these provocative findings[51], it is necessary to re-examine some of the earlier results on the distribution of retinol in the liver. It appears that the conclusions arrived at by Popper and Greenberg[47] were subject to limitations in their experimental techniques. Firstly, the Kupffer cells tend to concentrate such substances as retinol into granules, thus making the vitamin more easily visible than the hepatocytes. Secondly, the light microscopic-fluorescent method may not have been sensitive enough to detect the vitamin in a more diffused form in the hepatocytes. After feeding 15,000 units of retinol per day, Popper and Greenberg[47] found that the Kupffer cells contained large amounts of fluorescent material, while the increase in the hepatocyte fluorescence was not appreciable. The observations of Krishnamurthy and Ganguly[48] that the reduced liver stores of retinyl esters after injections of India ink did not preclude the possibility of reduced function of the parenchymal cells in addition to the Kupffer cells, though under such conditions, the latter would be mainly affected in their phagocytic and storage functions. Thus, the interpretation of their results that retinol and its esters are stored in parenchymal and Kupffer cells[53] respectively seems erroneous. However, it is still possible that retinyl esters and retinol are associated with different types of lipoproteins of the liver.

One question which remains unanswered in the investigations cited earlier[51] is the actual form in which retinol is stored in the different cells. It has been shown that retinol is stored in the liver as retinyl ester to the extent of 90-95% of the total. Thus, 5-10% of total retinol is stored in the free form. The investigations of Linder *et al.*[51] have shown that 4% of the total retinol is stored in the Kupffer cells, while 96% of the total is present in the hepatocytes. Thus, it is quite conceivable that most of the total retinol is present in the parenchymal cells as retinyl esters, while that present in the Kupffer cells may be in the alcohol form.

Further work along these lines is necessary to support this hypothesis.

The work of Linder *et al.*[51] supported the hypothesis put forward by the previous workers[47] that Kupffer cells participate in the transfer of retinol from the blood to the parenchymal cells. In fact, the observation of 7-fold increase in retinol concentration of the Kupffer cell and 50-fold increase in that of the hepatocyte[51], as a result of increase in dietary retinol level from 13 to 100 IU/g, clearly indicates that Kupffer cells strictly function to transport the vitamin.

The intracellular distribution of retinol in rat liver suggested the possibility of retinyl ester being present in the supernatant fraction in association with low density lipoprotein fractions[54]. Earlier work had demonstrated that retinyl ester was present in the 'creamy' centrifugal layer of the homogenate which accounted for 86% of the total retinyl esters recovered[55]. Recently, it was found that the Golgi apparatus, among the membrane fractions from rat liver studied, had the highest concentration of retinol as retinyl esters. The amount of retinol present in the Golgi apparatus varied with retinol status. Thus, in female rats, the concentration of retinol in the Golgi apparatus reached about 8 μg/mg protein, whereas in males, the concentration of retinol was only 2·5 μg/mg protein. Further, starvation caused an almost twofold increase in the concentration of retinol in Golgi apparatus[56]. A possible role for the Golgi apparatus in the mobilization and transport of retinol compounds has thus been suggested.

Retinyl esterases are present in different tissues of the rat and the chick. For many years, the hydrolysis of retinyl palmitate, the main storage form of retinol, in liver could not be demonstrated. Thus, it was assumed that retinyl palmitate was hydrolysed in extrahepatic tissues and released into the blood stream as retinol. Mahadevan *et al.*[57] isolated retinyl palmitate hydrolase from rat liver and purified it 20-fold. The enzyme was primarily located in the nuclear and mitochondrial fractions. They claimed that the enzyme was probably associated with the membrane rather than with the nucleus. Though the enzyme preparation was mostly specific for retinyl palmitate, it also rapidly hydrolysed retinyl acetate. These data, which provided a reasonable explanation for the hydrolysis of retinyl palmitate and its subsequent release into the plasma as retinol[57], have recently been questioned by Yeung and Veen-Baigent[58] who were unable to demonstrate retinyl palmitate hydrolase in either homogenates or the acetone-dried powders of rat liver. In support of the work of Mahadevan *et al.*[57], Kishore *et al.*[59] demonstrated the presence of retinyl palmitate hydrolase activity in rat liver nuclear fractions. Although it is possible that the differences reported in these studies could be due to strain differences in rats, the observations of Yeung and Veen-Baigent[58] favour the original theory of extra-hepatic hydrolysis of retinyl palmitate. Further work on the activity of liver retinyl palmitate hydrolase, especially under conditions of retinol deficiency in which it is reportedly increased[60], should be interesting.

Active metabolites of retinol — The possibility that retinol itself may not be the 'active' form of the vitamin has interested investigators for several years. For instance, the liver reserves of retinol disappear long before the deficiency symptoms are noted, and much more retinol seems to be required for storage than for growth. When single doses of retinol are administered to deficient rats, at least 100 IU of retinol disappear before measurable storage in the liver begins[61]. These findings suggest that retinol is first transformed to an 'active' metabolite, which is utilized for growth and tissue maintenance. When this metabolite reaches saturation level, retinol itself appears in the blood and is finally stored in the liver. Moore[62] has discussed excellently the subject of the hidden forms of retinol in his treatise on retinol.

The aspect of 'active' metabolites of retinol has been reviewed in detail[63]. The all-*trans* isomer is most active biologically, while the *cis* isomers have 23-75% of the biological activity of the all-*trans* isomer[64]. Retinal, formed by the oxidation of retinol, retains most of the biological activity of the all-*trans* isomer. Its isomers are also biologically active. 3-Dehydroretinol and 3-dehydroretinal have 33-40% of the systemic activity of retinol[65,66].

Retinol readily oxidizes to retinal in several tissues and the conversion of retinal into retinoic acid is irreversible both *in vitro* and *in vivo*[67-70]. Recently, Moffa *et al.*[71] reported the isolation of a retinal-oxidizing enzyme from rat intestinal mucosa. Its activity was enhanced by Fe^{2+}, glutathione and FAD or NAD and inhibited by NADH. Retinoic acid was first reported by Arens and Van Dorp[27] to have biological activity equal to that of retinol; yet no retinol was deposited in the liver despite the large amounts of retinoic acid administered. This led Moore[72] to suggest that retinoic acid might not be able to function as a precursor of the visual pigments which need retinol or retinal for their synthesis. Subsequent studies by Dowling and Wald[73] clearly demonstrated that rats fed retinoic acid grew well and appeared normal except that they were extremely night blind. The lack of formation of the visual pigment had also specific effects on the visual cells. Thus, the outer segments of the visual cells deteriorated and subsequently all except a few of the cells were lost, leaving the retina normal. In addition, retinoic acid was shown to be ineffective in reproduction[74]. It has been suggested that the functions of retinol other than those concerned with vision and reproduction would require conversion of retinol to retinal and of retinal to retinoic acid[73]. Thus, the current hypothesis is that either retinoic acid itself or a precursor of it is the systemically 'active' form of retinol.

Many investigators supported the 'active' form hypothesis. It has been shown that retinoic acid is a normal metabolite of retinal[75,76] and retinol metabolism[77,78] and that it is absorbed by rats[29], but is rapidly eliminated from the liver and the intestine by conjugation with glucuronic acid and excretion in the bile as retinoyl β-glucuronide[30]. The requirement for retinoic acid has been shown to increase 20-fold in chronic cold exposure[79], which is in support of the 'active' form hypothesis. However, retinoic acid has been designated 'partial vitamin A'[80] because of its inability to maintain vision and reproduction. In addition, Morgan and Thompson[81] have argued that retinol itself may

be the 'active' form, since retinoic acid is found in various tissues in smaller quantity than retinol under similar experimental conditions, when retinol-deficient adult rats are fed physiological amounts of either retinol or retinoic acid.

On the assumption that a compound derived from retinoic acid may be the 'active' form of retinol, several investigators have studied the metabolism of retinoic acid in rats and chicks[82-85]. Several active metabolites have been obtained, although none is identical with retinoic acid. The biologically active metabolite obtained after the administration of [6,7-$^{14}C_2$]retinoic acid, which was referred to as fraction E-1 in their earlier studies, has been identified as 13-*cis* retinoic acid[86]. Fraction C obtained from chicken liver and intestine after the administration of retinoic acid[83] may be retinoyl glucuronide, since both have been shown to possess biological activity at high doses[87]. After intraportal injection of [15-^{14}C]retinoic acid into rats, all-*trans* methyl retinoate, *cis* methyl retinoate and retinoyl β-glucuronide were isolated from rat bile[88]. Of these, methyl retinoate, retinoyl β-glucurono-γ-lactone and retinoic acid have now been shown to arise through the hydrolysis and trans-esterification of the glucuronide during treatment of bile with methanol in the presence of an anion-exchange resin. Retinoyl β-glucuronide has been recognized as the only major metabolite of retinoic acid in rat bile[88].

Yagishita *et al.*[84] postulated that a derivative of retinoic acid may be the 'active' form of the vitamin on the basis of the isolation of a biologically active acidic metabolite (compound 5) derived from retinoic acid or retinol *in vivo*, with the loss of at least one carbon atom (C-15). On partial characterization this compound was found to be a carboxylic acid containing two double bonds in conjugation with the carboxyl group and a hydroxyl group. Although this metabolite has been suggested to be similar to retinoic acid on thin layer chromatography[88], this compound has been distinguished from retinoic acid chromatographically using several solvent systems. It is unlikely that compound 5 is identical with retinoic acid, since it lacks at least in C-15. The isolation and further characterization of this acidic metabolite are being pursued (Sundaresan, P. R. & Marquez, G. B., unpublished work).

The epoxides of retinol constitute a separate class of compounds in that they have been recently found to possess considerable biological activity[89,90]. The preparation and physico-chemical characterization of the crystalline epoxy derivatives have been reported. The preparation involves treatment of all-*trans* retinyl acetate or all-*trans* methyl retinoate with monoperphthalic acid in peroxide-free ether. The yields of 5,6-epoxy derivatives were about 25% of the starting material[90-92]. The 5,8-epoxy derivatives of retinol are formed when the 5,6-epoxy derivatives are treated with dilute acid. The 5,8-epoxy derivatives are considerably less active in biological tests.

The metabolism of 5,6-epoxy or 5,8-epoxy derivatives of retinol follows the same pathway as the corresponding retinol derivatives. Thus, 5,6-epoxy retinal is either reduced to the alcohol and esterified or oxidized to epoxy retinoic acid[89]. In addition, methyl 5,6-epoxy retinoate has been shown to be hydrolysed to the free acid[90]. When the epoxy derivatives are incubated with cattle opsin, new pigments with absorption maxima at 460 nm and 411 nm appear[93].

Pitt[94] observed that 5,6-epoxy retinal did not have high biological activity. On reinvestigation[95] the biopotency of 5,6-epoxy retinal was found to be only 7% of that of retinyl acetate when administered orally, and 40%, when given by the intraperitoneal route. 5,6-Epoxy retinoic acid showed a biological potency of 80% of that of retinoic acid. However, rats administered either 5,6-epoxy retinal or 5,6-epoxy retinoic acid lost weight after the test period of four weeks.

In the light of these new findings, the epoxy derivatives of retinol should be considered as having only slight biological activity. It appears that the 5,6-double bond is as essential for growth promoting activity as the conjugated side chain of the retinol molecule and any structural manipulation of the double bond in the β-ionone ring may affect its biological activity[95].

Excretion of retinol and its metabolites — The metabolites of retinol were shown to be excreted in the feces to an extent of 20% of the injected dose in the rat[63,96]. About 5% of the total radioactivity was recovered in expired CO_2 and 5-12% in the urine during the initial 24 hr. When chylomicra labelled with [15-^{14}C]retinyl ester was injected intravenously, only 4% of the radioactivity appeared in urine during 24 hr[97].

After intracardial administration of radioactive derivatives of retinol, the metabolites of retinol appeared in the feces of rats after a lag of 6-24 hr. Thus, 65% of the administered dose was excreted when [6,7-$^{14}C_2$]retinoic acid was employed. The percentages of dose excreted for [14-^{14}C]retinoic acid and [15-^{14}C]retinoic acid were 50 and 38 respectively. However, when [6,7-$^{14}C_2$]retinyl acetate and [15-^{14}C]retinyl acetate were employed, the percentage excretion in the feces was much less in both the cases[98]. In a separate study[87], it was reported that 65% of a dose of [15-^{14}C]retinoic acid was excreted in the feces. Fecal retinoyl β-glucuronide could account for only 30% of the total radioactivity in the feces. The fecal metabolites were partially hydrolysed by enteric bacteria, which possess β-glucuronidase, during their passage through the intestine[87].

Although it has been demonstrated that the metabolites of retinol are excreted mainly in the feces, another important route for the excretion of metabolites is the urine. By using differentially labelled retinoic acid in physiological doses, a considerably greater percentage of the injected dose was found to be excreted in the urine with [6,7-$^{14}C_2$]retinoic acid than with [14-^{14}C] or [15-^{14}C] retinoic acid (Table 1). These results are in accordance with those of the previously reported studies on rapid decarboxylation of retinoic acid[98,99]. On fractionation of the urine into ether-soluble, acidic and water-soluble fractions (Table 1), the possibility of the presence of at least six metabolites of retinoic acid in the urine was indicated[100]. This number was based on the assumption that the radioactivity appearing in urine from [15-^{14}C]retinoic acid represented a molecule with an intact side chain and a substituted cyclohexene ring. On this basis, the nature of the metabolites was represented as

TABLE 1 — DISTRIBUTION OF METABOLITES OF [^{14}C]RETINOIC ACID IN THE URINE*

Label	Dose (μC)	Percentage of radioactive dose excreted			
		Ether-soluble	Acidic	Water-soluble	Total
15-^{14}C	0·1467	3·23 ± 0·5	9·39 ± 0·8	7·41 ± 0·4	21·14 ± 1·3
14-^{14}C	0·1926	5·70 ± 0·9	15·34 ± 0·8	12·13 ± 0·6	33·84 ± 1·2
6,7-$^{14}C_2$	0·1520	5·63 ± 0·4	12·24 ± 0·3	30·00 ± 2·3	49·89 ± 2·1

*Adapted from Sundaresan and Bhagavan[100]. Each rat received 10 μg of labelled retinoic acid intraperitoneally. 'Total' values were obtained by direct radioactivity determination. The results are given as means ± SEM for four animals in each group.

follows: (i) ether-soluble (possibly common to all three labels), 3-6% of the injected dose; (ii) acidic (having C-15, C-14, C-6 and C-7), 9·4% of the dose; (iii) acidic (having only C-14, C-6 and C-7), 3-6% of the dose; (iv) water-soluble (having an intact side chain), 7·4% of the dose; (v) only water-soluble (having only C-14, C-6 and C-7), 4·5% of the dose; and (vi) water-soluble (having C-6 and C-7), 18% of the dose. From these results, it is apparent that the water-soluble metabolite without C-14 and C-15 might be the major metabolite(s) of retinoic acid. In addition, it was found that enzymic or alkaline hydrolysis of acidic and water-soluble fractions did not release any retinoic acid, thus indicating that retinoyl β-glucuronide was not present in the urine in significant amounts[100].

In continuation of this study, the distribution of radioactivity in the ether-soluble, acidic and water-soluble fractions of urine was studied in rats injected [11,12-$^3H_2$] and differentially labelled [^{14}C]-retinoic acid. Preliminary results on the $^{14}C/^3H$ ratios indicated that the acidic and water-soluble fractions had ratios markedly different from those for the injected material[101], due to the possible hydroxylation of the side chain.

During a preliminary study on the minimum daily requirements for retinol in humans, the excretion of radioactivity in urine, feces and expired CO_2 after intravenous injection of 10-15 mg of [15-^{14}C]retinyl acetate in seven subjects was investigated[102]. It was found that 21 days after the initial labelling, an average of 34% of the administered dose was excreted via the three routes and of the excreted radioactivity, about 50% was found in the urine and 25% in both feces and CO_2. This was in contrast to the situation in the rat where more radioactivity was found in the feces than in the urine[98]. It appears that there may be a species difference for this apparent divergence in the excretory pattern of radioactivity in humans.

Recently, it has been established that retinoic acid undergoes oxidative decarboxylation at the terminal carbon of the side chain[98,99]. The production *in vivo* of CO_2 after the administration of [15-^{14}C]retinoic acid was rapid, with the peak occurring at 30 min after administration and thereafter declining rapidly[99]. Only 1·4% of the total dose was recovered as CO_2 from [6,7-$^{14}C_2$]retinyl acetate, whereas 9 and 10% of the total dose were oxidized to CO_2 when [14-^{14}C] and [15-^{14}C] retinyl acetate were employed. When [6,7-$^{14}C_2$], [14-^{14}C] and [15-^{14}C]retinoic acids were administered intracardially, the percentages of the dose recovered as CO_2 were 1, 18 and 35 (48 hr) respectively[98]. In an earlier study, where the dosages were 15-27 times more than the physiological dose, a similar relationship between the position of the label on the retinoic acid molecule and the production of CO_2 was observed[99].

It is appropriate here to discuss certain features of enterohepatic circulation of retinol derivatives. It has been known for some time that conjugated bile acids and cholesterol recycle between the liver and the gut in an enterohepatic circulation. Retinol derivatives also have been shown to circulate between the liver and the gut in a similar manner[103]. With radioactive retinol, retinal and retinoic acid in tween dispersions injected intraportally, the percentage of the administered dose excreted in the bile within 27 hr was 25, 35 and 60 respectively[104]. When whole bile or part of it was placed in a duodenal loop *in vivo*, radioactive derivatives of retinol disappeared from the gut and reappeared in the bile[103]. After the administration of retinoic acid, the major polar metabolite of the bile was retinoyl β-glucuronide. When retinol was administered, the formation of retinyl β-glucuronide was found to be appreciable[88].

The physiological significance of the enterohepatic circulation of retinol metabolites is not clearly understood. Olson[105] postulated that the enterohepatic circulation of glucuronides of retinol seems to result from a lack of specificity in intestinal absorption and portal transport rather than from a physiological conserving mechanism. Recently, it has been reported that substantial recycling of retinol metabolites occurs in sheep[106]. These authors believe that a conservation mechanism as postulated by Olson[105] may be operative during periods of retinol deprivation[106].

Physiological Actions of Retinol

Retinol is essential for vision, growth and reproduction. In the absence of retinol, animals suffer from retarded growth, impairments in vision and reproduction, increased susceptibility to infection and finally death. The mode of action of retinol in either growth or reproduction with the exception of vision is not well understood.

Vision — Wald[107] has lucidly presented the retinol-protein interactions that take place before visual excitation. The molecular mechanisms involved in the synthesis of rhodopsin in the rods and of iodopsin in the cones of the retina have been reviewed in detail[108]. The site of attachment of 11-*cis* retinal to opsin has been a subject of active interest and has been shown to be an ε-amino group of lysine[109-112]. Recently, 11-*cis* retinal in native rhodopsin has been claimed as bound to the lipid phosphatidylethanolamine through a Schiff base linkage[113], thus assigning a role for the lipid in vision. Recent aspects of visual pigment research

have been reviewed exhaustively[114]. The methodology of retinol and visual pigments has been discussed in detail[115] and should be a useful guide to workers in the field.

Several theories have been proposed to explain the mechanism by which the breakdown of rhodopsin leads to neural excitation. Among these, the enzyme hypothesis for rhodopsin claims that rhodopsin may function as a proenzyme[116] or an ATPase[117]. The ionic hypothesis proposes that the breakdown of rhodopsin may lead to cation movement resembling that in a stimulated nerve[118,119]. However, all hypotheses on the nature of visual excitation must await further developments in the structure of the membranes in the rod discs of which little is known at present.

Growth — Animals on a retinol-deficient diet exhibit retardation of growth, accompanied by degeneration of mucous-secreting membranes and their subsequent keratinization. The latter symptom of retinol deficiency normally causes death in a normal environment. In germ-free conditions, animals on a retinol-deficient diet survive for long time[120]. These animals die from intestinal strangulation and urinary blockage.

The decrease in appetite in retinol-deficient animals has been attributed to the loss of taste preferences and this can be reversed by the administration of either retinol or retinoic acid[121]. Thus, the taste impairment in retinol deficiency may not be due to general debility and retinol may play a role in the peripheral taste mechanisms.

Reproduction — It has been known for some time that retinol is essential for normal reproduction. In retinol-deficient male rats, degeneration of the seminiferous epithelium and impairment in spermatogenesis are observed. Retinol-deficient female rats conceive when mated to normal rats, but fetuses are resorbed or born dead[122]. Though the retinoic acid-supplemented male rats grow normally, they show lesions in testes[123]. In the female rats receiving retinoic acid supplementation, although there are no changes in the ovaries[124,125], the corpora lutea are poorly developed and the activity of Δ^5-3β-hydroxysteroid dehydrogenase is lowered not only in retinoic acid-fed pregnant female rats but also during compensatory ovarian hypertrophy in non-pregnant rats treated with retinoic acid.

Attempts to prevent the resorption of fetus in retinoic acid-treated rats by the administration of progesterone[126] or progesterone and estrone[127] have been unsuccessful. However, injection of pregnenolone or 17 β-estradiol prevented fetal resorption in retinoic acid-fed rats[125]. Injection of progesterone is ineffective. The lowered rate of secretion of progesterone and 20-α-hydroxypregn-4-en-3-one has been suggested as a possible cause for fetal resorption in retinoate-fed females[128]. Further, the contents of pregnenolone, progesterone, and 20-α-hydroxy-preg-4-en-3-one have been found to be low in the ovaries of retinoic acid-fed rats[129]. Thus, the possibility of insufficient production of pregnenolone in addition to lowered synthesis and secretion of progesterone and 20-α-hydroxypregn-4-en-3-one may be responsible for fetal resorption in retinoate-fed female rats.

The involvement of retinol in the activity of Δ^5-3β-hydroxysteroid dehydrogenase has been controversial. Thus, no difference in the enzyme activity of adrenals between pair-fed control and deficient animals has been found by Rogers and Bieri[130], while Granguad *et al.*[131] have found lowered enzyme activity. The results of the latter study have been corroborated by Juneja *et al.*[125]. While strain differences in rats cannot be ruled out, further clarification regarding the involvement of retinol in steroid synthesis is certainly needed.

Biochemical Role of Retinol

Among the biochemical functions of retinol, the involvement of retinol in sulphate activation and its participation in steroid biosynthesis have been areas of intense investigation. Recent aspects of the latter subject have been discussed under the head 'Reproduction'. The importance of retinol in biological sulphurylation appears confirmed, although retinol may not have a coenzymic function.

Sulphate activation — A metabolic function for retinol has been the subject of several recent investigations. Since it has been known that water-soluble vitamins function as coenzymes in a variety of metabolic pathways, it has been assumed that retinol may have a similar coenzyme function. The approach usually is to render the animals retinol-deficient and to look for enzymes whose activity decreases under conditions of deficiency. There are many enzymes which have been found to decrease in retinol deficiency, viz. gulonolactone oxidase[132], codeine demethylase[133], Δ^5-3β-hydroxysteroid dehydrogenase[125], squalene cyclohydrase[134], ATP-sulphurylase[135-137] and sulphotransferase[138]. Among these, the enzymes ATP-sulphurylase and sulphotransferase have been studied in detail, but only ATP-sulphurylase is dealt with here.

Robbins and Lipmann[139] demonstrated that sulphate existed in the activated form as PAPS (3′-phosphoadenosine 5′-phosphosulphate) and this compound was formed in two stages through the catalytic action of ATP-sulphurylase (ATP: sulphate 3′-phosphotransferase). On the basis of several experiments, it was postulated that retinol might activate the first step in the formation of PAPS, the reaction of inorganic sulphate with ATP to form APS[136]. This investigation had arisen from the earlier observations of Wolf and Varandani[140], who found decreased incorporation of inorganic sulphate into mucopolysaccharides in retinol deficiency, and of Fell and Mellanby[141], who showed that in hypervitaminosis A, the normal keratinization of the skin of embryo chicks was completely suppressed and the ectoderm differentiated into mucus-secreting epithelium, whereas in normal medium, the epidermis developed into a keratinizing epithelium.

Several subsequent reports have confirmed the decrease in the activities of sulphate activating enzymes in retinol deficiency[138,142-145], while other studies have contradicted such effects of retinol deficiency[146-149]. In a careful study, Levi *et al.*[150] confirmed the decrease in liver of ATP-sulphurylase activity in retinol-deficient animals compared to pair-fed controls. While no difference was found in ATP-sulphurylase activity between pair-fed control and deficient animals two weeks after weaning on a 20% protein diet, pair-fed animals on 80% protein diet showed significantly higher enzyme activities in liver than the deficient animals. This investigation points to the complexity of

the problem and many of the inconsistencies cited earlier could have arisen from factors such as the nutritional status of the animals[142,146], the sex[147,151], the organ studied[143], and the technique of pair-feeding[149,150].

It may be appropriate here to examine objectively the divergent results from different laboratories on the involvement of retinol in sulphate activation. Among the factors which influence the sulphate-activating enzymes, the effect of food intake in retinol-deficient animals needs further consideration. The lowered ATP-sulphurylase activity in retinol-deficient animals as compared to *ad libitum* controls has been attributed to their reduced food intake. In support of this view, pair-feeding has been shown to negate the effect of retinol deficiency on ATP-sulphurylase. However, the pattern of food consumption of a pair-fed control animal is entirely different from that of a retinol-deficient animal which consumes its food throughout the experimental period. Moreover, the pair-fed animal is subject to many metabolic alterations. These aspects have been completely ignored in many investigations mentioned earlier. Pair-fed animals are useful to a limited extent, but they are not adequate controls to the deficient animals. Thus, conclusions based on data from pair-fed animals should be interpreted with caution.

In vitro effects of retinol and its metabolites on the activity of ATP-sulphurylase have also been reported[136,142]. However, highly active ATP-sulphurylase without radioactivity has been isolated from [^{14}C]retinol administered rats[152]. While retinol may not function as a coenzyme, a stabilizer role for retinol, among other possibilities, cannot be ruled out and further investigation along this line would be interesting.

Protein synthesis — The speculation that retinol might act in some manner at the level of RNA or protein synthesis[153] has given impetus to the study of protein synthesis in retinol deficiency in recent years. DeLuca *et al.*[154] investigated the effect of retinol deficiency on *in vitro* protein synthesis in subcellular fractions from the small intestine of pair-fed control and deficient rats. The intestinal mucosa was the tissue of choice, since it is not only affected in retinol deficiency, probably due to impaired glycoprotein synthesis[155], but it is also a tissue in which only degeneration of the mucus secreting cells takes place without any change in differentiation. No differences were noticed in the protein synthesizing capacity of the free polyribosomes of retinol-deficient and pair-fed control rats. However, protein synthesis by rough endoplasmic reticulum was depressed in retinol deficiency, the uptake of ^{3} labelled amino acid into protein being less than one-half of the normal level. The lesion due to the deficiency was located in the *p*H 5 fraction. This fraction contains transfer ribonucleic acid (tRNA) and the enzymes which activate amino acids (aminoacyl tRNA synthetases). Earlier work had indicated that tRNA and amino acid activating enzymes might be concerned in cell differentiation at the translational level[156]. Thus, the translational processes in the intestinal cell may have been affected in retinol deficiency.

Further, retinol deficiency has been shown to cause a reduction in the number of mucus-secreting goblet cells in the small intestine[151]. In continuation of this study, the glycopeptide synthesis in retinol deficiency both *in vivo* and *in vitro* was examined[157]. With radioactive glucosamine as precursor, no difference was found in the total incorporation between retinol-treated and deficient animals. However, a specific fucose-containing glycopeptide was noticeably less in retinol-deficient animals. Synthesis of this fucose-containing glycopeptide *in vitro* using [1-^{14}C]uridine-diphosphate-N-acetyl-D-glucosamine and [^{3}H]serine was then investigated. The incorporation of the labels into the fucose-glycopeptide by rough endoplasmic reticulum from the deficient animals showed a two- to threefold decrease as compared to control animals. In another study, the presence of retinol-dependent fucose-glycopeptide in the goblet cell of the rat small intestine was demonstrated by indirect immuno-fluorescence technique[158]. An antiserum against the fucose-glycopeptide was prepared in chickens and it was used to localize the fucose-glycopeptide. Fucose-glycopeptide was found only in the goblet cells.

The demonstration of a lipid intermediate in the biosynthesis of glycoproteins containing mannose[159] led to a study of the role of retinol in the formation of glycoproteins[160]. In the presence of [15-^{14}C]retinol and GDP [^{14}C]mannose, a mannolipid was synthesized by a membrane-rich fraction of rat liver. The mannolipid contained a polar metabolite of [^{14}C]retinol, distinctly different from retinol or retinoic acid, and of [^{14}C]mannose. The formation of a mannolipid containing a retinol derivative was also demonstrated *in vivo* by the administration of [15-^{14}C]retinol to retinol-deficient rats and isolation of the mannolipid containing [^{14}C]mannose and [^{14}C]-labelled metabolite of retinol[160].

In addition to its function at the level of translation in intestinal protein synthesis[154,157], retinol has been implicated at transcription level as well. Thus, Zachman[161] reported that RNA synthesis was stimulated by retinol both *in vivo* and *in vitro* in rat intestinal mucosa. In line with these observations are the data reported by Johnson *et al.*[162], who found a twofold stimulation in the rapidly labelled nuclear RNA of both the intestinal mucosa and liver after the administration of low doses of potassium retinoate. Additional evidence was reported by Zile and DeLuca[163]. They found two- to threefold stimulation of RNA synthesis of colon and small intestinal mucosa of retinol-deficient rats after the administration of retinol. In all these studies, however, the effects of precursor pool sizes on the incorporation of the label into RNA were not determined and thus these results might not represent a true difference between the control and retinol-deficient rats. For this reason, DeLuca *et al.*[164] used rats whose bile ducts were ligated, thus reducing the effect of ribonuclease. The current speculation is that the primary action of retinol is at the level of the biosynthesis of specific glycopeptides, which in turn act on RNA synthesis and cell differentiation. Further work along these lines will be awaited with interest.

Role of retinol in membranes — In recent years, the search for a metabolic role of retinol has led investigators to examine the effects of retinol on membranes. In this regard, studies have been conducted on hypervitaminosis A with the basic

assumption that some of the features of hypervitaminosis A may represent exaggerations of the normal activity of retinol.

In the presence of excess retinol, the cartilaginous bone rudiments from chick embryos, cultivated in tissue culture, caused the release of an acid protease from the lysosomes[165]. The protease was identified as cathepsin D[166]. The addition of excess retinol also caused the erythrocytes to expand, the mitochondria to swell and the bacterial membranes to show distinct changes[167]. There was relatively high molecular specificity with regard to the ability of retinol to penetrate and expand a monolayer of lecithin-cholesterol at an air-water interface. The biologically less active anhydroretinol and inactive hydrogenated retinol were much less surface active than retinol[168]. On the basis of these experiments, it was suggested that the ability to penetrate lipid films as well as to control permeability within membranes might explain the molecular specificity of retinol in different biological functions[169].

There is also considerable evidence *in vivo* to support the *in vitro* actions of excess retinol. Thus, the erythrocytic membrane was found to be altered in hypervitaminosis A and bound ATPase was more readily released[170]. Earlier work on rabbits had shown that dissolution of cartilage matrix resulted from hypervitaminosis A with consequent high serum levels of chondroitin sulphate[171]. The possible role of retinol in micelle formation and electron transfer has been reviewed[172]. It was suggested that a retinol-mediated process of fusion of lysosomal and plasma membranes might be occurring under physiological conditions, which in turn might control the cellular metabolism and function. Furthermore, on the basis of its chemical properties, retinol might be involved in electron-transfer reactions and this might be responsible for its activity towards membranes.

The work on hypervitaminosis A described above has validity with regard to retinol function only if the hypervitaminotic phenomena are exaggerations of the true actions of retinol at physiological levels. To test this validity, Pitt and coworkers synthesized α-retinol, which differs from retinol only in the position of the double bond in the ring, and studied its action both *in vitro* and *in vivo*[173]. α-Retinol resembled retinol in its *in vitro* actions, such as the hemolysis of cattle erythrocytes, the release of protease from rat liver lysosomes and the swelling of rat liver mitochondria. *In vivo*, α-retinol was as effective as retinol in causing bone damage. However, it had only 2·1% of the biological activity of retinol. Further, it was not as potent as retinol in inducing metaplasia in hamster cheek pouch epithelium. The electron donating properties of α-retinol to TCNQ (7,7,8,8-tetracyanoquinodimethane) and chloranil (tetrachloro-1,4-benzoquinone) were investigated and it was found that α-retinol was a much weaker electron donor than retinol (Pitt, G. A. J., personal communication). These studies, while not contradicting the interaction of retinol with membranes, do raise questions regarding the physiological significance of membrane effects of retinol. α-Retinol can be very useful in deciding which effects of hypervitaminosis A represent the true functions of retinol and which reflect the pharmacological effects.

Retinol and Protein Malnutrition

Because of the increasing importance of the interrelationship between retinol and protein malnutrition in recent years, a brief review of the literature in this field is presented below.

Early work on the effect of protein deficiency on absorption, transport, storage and metabolism of retinol as well as the intestinal conversion of β-carotene to retinol has been reviewed in detail[13]. Protein deficiency markedly affects the intestinal conversion of β-carotene to retinol and it appears that protein is essential for the efficient absorption and storage of retinol[174]. Protein deficiency also affects the transport of retinol[175]. In severe protein deficiency, several liver enzymes are affected, which are restored to normal levels on retinol administration[176]. In a situation analogous to protein malnutrition in humans, it was found in rats that the albumin fraction was lowered very markedly in retinol deficiency superimposed with protein deficiency, with consequent change in the albumin-globulin ratio[177].

The data obtained on experimental animals have relevance to the situations one sees in the human populations. Thus, in protein malnutrition, the absorption of dietary retinol from the intestinal tract was impaired and serum retinol levels, which were low to begin with, were not raised[178]. However, when adequate dietary proteins were given, the serum retinol levels rose to normal without retinol administration, provided the liver reserves were adequate.

Retinol deficiency mainly affects children between one and six years of age[179]. Kwashiorkor and protein-calorie malnutrition were shown to aggravate symptoms of retinol deficiency[180]. Oral administration of single massive doses of retinol to prevent retinol deficiency in this vulnerable age group has been tried with considerable success[181].

Recently, Arroyave[182] has explored the feasibility of fortifying table sugar with water-miscible retinyl palmitate. Taste, acceptability and stability trials were found to be favourable. Retinol levels in rats administered retinol-coated sugar were also determined in order to test the biological effectiveness of the material. Similar pilot trials with retinyl palmitate-fortified sugar should be worth while in countries such as India and Indonesia where retinol deficiency has been found to be widespread and where sugar is a common dietary constituent.

Murray[183] pointed out that 20-30% of North Americans of all age groups did not consume the recommended daily allowance of retinol and they did not have enough liver reserves of retinol. It was also found that a good number of children had blood levels below 30 μg/100 ml, while a much smaller number had a level less than 20 μg/100 ml.

In a study carried out on human beings for the determination of minimal requirements, Hodges[184] noted that while 75 μg of retinol was necessary to correct impaired dark adaptation, even larger amounts were needed to correct the impairment of taste, smell and vestibular function. It is possible that different tissues have varied requirements for retinol. It has been shown, for instance, with respect to keratinization, that the tissue with the lowest threshold for retinol is the epithelial lining of the intestinal tract[185] The columnar epithelium

of the trachea has the next higher threshold. Next higher in threshold is the corneal epithelium and finally the epidermis has the highest threshold for retinol.

Rueda-Williamson[186] presented clinical, biochemical and dietary data on retinol malnutrition in Latin America and the Caribbean. There is an urgent need for a simple and sensitive method for determining retinol status in man. It should be possible to employ urinary excretion of retinol metabolites as an indicator of retinol status[187]. In addition, conditions to improve the existing electroretinogram method to assess visual sensitivity during dark adaptation should be explored. For example, the use of a bright flash in the 495-505 nm region of the visible spectrum may be of interest[187].

Concluding Remarks

In recent years, our understanding of the physiology and metabolism of retinol has rapidly increased. However, our knowledge of its role in growth and differentiation is still fragmentary. The controversy regarding the mechanism of cleavage of β-carotene *in vivo* seems settled with the demonstration in the intestine and liver of a cytoplasmic enzyme, which cleaves β-carotene into two molecules of retinal. Retinol is mainly transported via the lymph, but a significant portion is oxidized and transported via the portal blood. The disappearance of retinoic acid after injection into animals has now been attributed to its conjugation with glucuronic acid and excretion in the bile as retinoyl β-glucuronide. It has been demonstrated unequivocally that retinol is not stored in Kupffer cells of the liver to a great extent but rather it is present in the hepatocytes.

The metabolism of retinol and retinoic acid has been vigorously pursued and the current hypothesis is that retinol must be converted to an 'active' form and that retinoic acid is itself, or is a precursor of the 'active' form of retinol. The decarboxylation of retinol and retinoic acid has assumed more importance than considered hitherto. There is reasonable evidence to show that the decarboxylated products of retinoic acid are mainly excreted in the urine, while the feces may contain the compounds which have the intact isoprenoid side chain. By the use of differentially labelled retinoic acid, it has been postulated that there are at least six metabolites in the urine. Of these, the major metabolite seems to be the one without the carbon-14 or carbon-15 of retinoic acid.

The role of retinol in biological sulphurylation seems to have been confirmed, though it may not have a coenzymic function. However, its function in reproduction is still not understood. Evidence has been forthcoming to explain the failure of retinoic acid to maintain reproduction. Retinol has been implicated in the synthesis of steroid hormones and more recently in the glycopeptide synthesis in the intestinal mucosal cell. This is a fascinating and challenging problem and further developments in this area will be awaited with interest. The importance of retinol in protein malnutrition has been discussed and recent developments in this field have been reviewed.

The recent advances in the metabolism of retinol are reviewed, the main aspects covered being its chemistry, biosynthesis, physiological actions and its relationship to protein malnutrition. Several important aspects of the metabolism and function of retinol, viz. (i) the involvement of retinol in carbohydrate and lipid metabolism, (ii) biological assay and chemical methods; and (iii) physiological aspects of vision, have not been considered, since they have been covered in some recent reviews[105,188,189] and treatises[62,190]. The proceedings of the symposia on 'Metabolic function of vitamin A'[191] and 'Fat-soluble vitamins'[192] provide additional information on the metabolism of retinol.

Summary

The current concepts on the metabolism and physiological functions of retinol are reviewed. The biochemical role of retinol in sulphate activation, protein synthesis and in the control of cell membrane permeability is discussed. Recent studies on the interrelationship of retinol and protein malnutrition, which demonstrate the increasingly important aspect of retinol nutriture in humans, are also discussed.

Acknowledgement

The author thanks Dr H. N. Bhagavan for going through the manuscript, Gloria B. Marquez for her expert technical assistance in the investigations and Dr David B. Coursin for his keen interest and encouragement. His thanks are also due to Drs G. Arroyave, T. K. Murray, L. DeLuca and M. Linder for permitting the author to peruse their manuscripts before publication and to the American Medical Association and the Council of Foods for permission to quote from the unpublished proceedings of the Western Hemisphere Nutrition Congress. The research by the author referred to here is supported by the National Institutes of Health (Grants AM-13557 and RR-05657).

References

1. McCollum, E. V. & Davis, M., *J. biol. Chem.*, **15** (1913), 167.
2. McCollum, E. V. & Davis, M., *J. biol. Chem.*, **23** (1915), 181.
3. Karrer, P., Morf, R. & Schopp, K., *Helv. chim. Acta*, **14** (1931), 1036, 1431.
4. Isler, O., Huber, W., Ronco, A. & Kofler, M., *Helv. chim. Acta*, **30** (1947), 1911.
5. Schwieter, U. & Isler, O., cited in *The vitamins*, Vol. I, edited by W. H. Sebrell (Jr) & R. S. Harris (Academic Press Inc., New York), 1967, 5.
6. Thompson, S. Y., Braude, R., Coates, M. E., Cowie, A. T., Ganguly, J. & Kon, S. K., *Br. J. Nutr.*, **4** (1950), 398.
7. Glover, J. & Redfearn, E. R., *Biochem. J.*, **58** (1954), 15p.
8. Goodman, D. S. & Huang, H. S., *Science, N.Y.*, **149** (1965), 879.
9. Olson, J. A. & Hayaishi, O., *Proc. natn. Acad. Sci., U.S.A.*, **54** (1965), 1364.
10. Huang, H. S. & Goodman, D. S., *J. biol. Chem.*, **240** (1965), 2839.
11. Goodman, D. S., Blomstrand, R., Werner, B., Huang, H. S. & Shiratori, T., *J. clin. Invest.*, **44** (1965), 1054.
12. Fidge, N. H. & Goodman, D. S., *J. biol. Chem.*, **243** (1968), 4372.
13. Ganguly, J., *J. scient. ind. Res.*, **26** (1967), 110.
14. Murthy, S. K. & Ganguly, J., *Biochem. J.*, **83** (1962), 460.
15. David, J. S. K., Malathi, P. & Ganguly, J., *Biochem. J.*, **98** (1966), 662.

16. David, J. S. K. & Ganguly, J., *Indian J. Biochem.*, **4** (1967), 14.
17. Braekkan, O. R., *Int. Z. Vitam. Forsch.*, **33** (1963), 234.
18. Murray, T. K. & Erdody, P., *Biochim. biophys. Acta*, **124** (1966), 190.
19. Loran, M. R. & Althausen, T. L., *Am. J. Physiol.*, **197** (1959), 1333.
20. Skala, I. & Hruba, F., *Am. J. Physiol.*, **206** (1964), 458.
21. Mahadevan, S. & Ganguly, J., *Biochem. J.*, **81** (1961), 53.
22. Lawrence, C. W., Crain, F. D., Lotspeich, F. J. & Krause, R. F., *J. Lipid Res.*, **7** (1966), 226.
23. Fidge, N. H., Shiratori, T., Ganguly, J. & Goodman, D. S., *J. Lipid Res.*, **9** (1968), 103.
24. Deshmukh, D. S., Murthy, S. K., Mahadevan, S. & Ganguly, J., *Biochem. J.*, **96** (1965), 377.
25. John, K. V., Lakshmanan, M. R. & Cama, H. R., *Biochem. J.*, **99** (1966), 312.
26. Deshmukh, D. S. & Ganguly, J., *Indian J. Biochem.*, **4** (1967), 18.
27. Arens, J. F. & Van Dorp, D. A., *Nature, Lond.*, **158** (1946), 622.
28. Dowling, J. E. & Wald, G., *Vitam. Horm. Lpz.*, **18** (1960), 515.
29. Deshmukh, D. S., Malathi, P., Subba Rao, K. & Ganguly, J., *Indian J. Biochem.*, **1** (1964), 164.
30. Dunagin (Jr), P. E., Meadows (Jr), E. H., & Olson, J. A., *Science, N.Y.*, **148** (1965), 86.
31. Krinsky, N. I., Cornwell, D. G. & Oncley, J. L., *Archs Biochem. Biophys.*, **73** (1958), 233.
32. Cornwell, D. G., Kruger, F. A. & Robinson, H. B., *J. Lipid Res.*, **3** (1962), 65.
33. Garbers, C. F., Gillman, J. & Peisach, M., *Biochem. J.*, **75** (1960), 124.
34. Glover, J. & Walker, R. J., *Expl Eye Res.*, **3** (1964), 327.
35. Alvasaker, J. O., Haugli, F. B. & Laland, S. G., *Biochem. J.*, **102** (1967), 362.
36. Johannessen, S., Alvasaker, J. O. & Laland, S. G., *FEBS Lett.*, **2** (1969), 146.
37. Kanai, M., Raz, A. & Goodman, D. S., *J. clin. Invest.*, **47** (1968), 20.
38. Raz, A. & Goodman, D. S., *J. biol. Chem.*, **244** (1969), 3230.
39. Raz, A., Shiratori, T. & Goodman, D. S., *J. biol. Chem.*, **245** (1970), 1903.
40. Goodman, D. S., cited in *The fat-soluble vitamins*, edited by H. F. DeLuca & J. W. Suttie (University of Wisconsin Press, Madison), 1969, 203.
41. Peterson, P. A. & Berggard, I., *J. biol. Chem.*, **246** (1971), 25.
42. Peterson, P. A., *J. biol. Chem.*, **246** (1971), 44.
43. Peterson, P. A., *J. biol. Chem.*, **246** (1971), 34.
44. Vahlquist, A., Nilsson, S. F. & Peterson, P. A., *Eur. J. Biochem.*, **20** (1971), 160.
45. Davies, A. W. & Moore, T., *Biochem. J.*, **28** (1934), 288.
46. Futterman, S. & Andrews, J. S., *J. biol. Chem.*, **239** (1964), 4077.
47. Popper, H. & Greenberg, R., *Archs Path.*, **32** (1941), 11.
48. Krishnamurthy, S. & Ganguly, J., *Nature, Lond.*, **177** (1956), 575.
49. Zachman, R. D. & Olson, J. A., *J. Lipid Res.*, **6** (1965), 27.
50. Demovsky, R. & Greenberg, R., *Proc. Soc. exp. Biol. Med.*, **118** (1965), 158.
51. Linder, M., Anderson, G. H. & Ascarelli, I., *J. biol. Chem.*, **246** (1971), 5538.
52. Neeld, J. B. & Pearson, W. N., *J. Nutr.*, **79** (1963), 454.
53. Ganguly, J., *Vitam. Horm. Lpz.*, **18** (1960), 387.
54. Krishnamurthy, S., Mahadevan, S. & Ganguly, J., *J. biol. Chem.*, **233** (1958), 32.
55. Krinsky, N. I. & Ganguly, J., *J. biol. Chem.*, **202** (1953), 227.
56. Nyquist, N. E., Crane, F. L. & Morre, D. J., *Science, N.Y.*, **173** (1971), 939.
57. Mahadevan, S., Ayyouib, N. I. & Roels, O. A., *J. biol. Chem.*, **241** (1966), 57.
58. Yeung, D. L. & Veen-Baigent, M. J., *Am. J. clin. Nutr.*, **24** (1971), 172.
59. Kishore, G. S., Perumal, A. S. & Cama, H. R., *Int. J. Vitam. Nutr. Res.*, **41** (1971), 171.
60. Roels, O. A., cited by J. A. Olson in *Vitam. Horm. Lpz.*, **26** (1968), 26.
61. Davies, A. W. & Moore, T., *Biochem. J.*, **42** (1948), xiii.
62. Moore, T., *Vitamin A* (Elsevier Publishing Co., Amsterdam), 1957.
63. Wolf, G. & Johnson, B. C., *Vitam. Horm. Lpz.*, **18** (1960), 403.
64. Ames, S. R., *A. Rev. Biochem.*, **27** (1958), 271.
65. Shantz, E. M. & Brinkman, J. H., *J. biol. Chem.*, **183** (1950), 467.
66. Sundaresan, P. R. & Cama, H. R., *Br. J. Nutr.*, **15** (1961), 225.
67. Dmitrovskii, A. A., *Biokhimiya*, **26** (1961), 126.
68. Futterman, S., *J. biol. Chem.*, **237** (1962), 677.
69. Elder, T. D. & Topper, Y. J., *Biochim. biophys. Acta*, **64** (1962), 430.
70. Bamji, M. S., Mahadevan, S., Lakshmanan, M. R. & Murthy, S. K., *Nature, Lond.*, **196** (1962), 672.
71. Moffa, D. J., Lotspeich, F. J. & Krause, R. F., *J. biol. Chem.*, **245** (1970), 439
72. Moore, T., cited in *Symposium on nutrition*, edited by R. M. Herriott (John Hopkins Press Inc., Baltimore), 1953, 28.
73. Dowling, J. E. & Wald, G., *Proc. natn. Acad. Sci., U.S.A.*, **46** (1960), 587.
74. Thompson, J. N., Howell, J. M. & Pitt, G. A. J., *Proc. R. Soc.*, **159B** (1964), 510.
75. Deshmukh, D. S., Malathi, P. & Ganguly, J., *Biochim. biophys. Acta*, **107** (1965), 120.
76. Dunagin (Jr), P. E., Zachman, R. D. & Olson, J. A., *Biochim. biophys. Acta*, **124** (1966), 71.
77. Emerick, R. J., Zile, M. & DeLuca, H. F., *Biochem. J.*, **102** (1967), 606.
78. Bossaler, A. K. & DeLuca, H. F., *Archs Biochem. Biophys.*, **142** (1971), 371.
79. Sundaresan, P. R., Winters, V. G. & Therriault, D. G., *J. Nutr.*, **92** (1967), 474.
80. Pitt, G. A. J., *Proc. Nutr. Soc.*, **24** (1965), 158.
81. Morgan, B. & Thompson, J. N., *Biochem. J.*, **103** (1967), 35P.
82. Zile, M. H. & DeLuca, H. F., *Biochem. J.*, **97** (1965), 180.
83. Krishnamurthy, S., Bieri, J. G. & Andrews, E. L., *J. Nutr.*, **79** (1963), 503.
84. Yagishita, K., Sundaresan, P. R. & Wolf, G., *Nature, Lond.*, **203** (1964), 210.
85. Wolf, G., Bergan, J. G. & Sundaresan, P. R., *Biochim. biophys. Acta*, **69** (1963), 524.
86. Zile, M. H., Emerick, R. J. & DeLuca, H. F., *Biochim. biophys. Acta*, **141** (1967), 639.
87. Nath, K. & Olson, J. A., *J. Nutr.*, **93** (1967), 461.
88. Lippel, K. & Olson, J. A., *J. Lipid Res.*, **9** (1968), 580.
89. Lakshmanan, M. R., Jungalwala, F. B. & Cama, H. R., *Biochem. J.*, **95** (1965), 27.
90. John, K. V., Lakshmanan, M. R. & Cama, H. R., *Biochem. J.*, **103** (1967), 539.
91. Jungalwala, F. B. & Cama, H. R., *Biochem. J.*, **95** (1965), 17.
92. Morgan, B. & Thompson, J. N., *Biochem. J.*, **101** (1966), 835.
93. Lewin, D. R. & Thompson, J. N., *Biochem. J.*, **103** (1967), 36P.
94. Pitt, G. A. J., *Am. J. clin. Nutr.*, **22** (1969), 967.
95. Krishna Mallia, A., John, J., John, K. V., Lakshmanan, M. R., Jungalwala, F. B. & Cama, H. R., *Indian J. Biochem.*, **7** (1970), 102.
96. Wolf, G., Kahn, S. G. & Johnson, B. C., *J. Am. chem. Soc.*, **79** (1957), 1208.
97. Goodman, D. S., Huang, H. S. & Shiratori, T., *J. Lipid Res.*, **6** (1965), 390.
98. Roberts, A. B. & DeLuca, H. F., *Biochem. J.*, **102** (1967), 600.
99. Sundaresan, P. R. & Therriault, D. G., *Biochim. biophys. Acta*, **158** (1968), 92.
100. Sundaresan, P. R. & Bhagavan, H. N., *Biochem. J.*, **122** (1971), 1.
101. Sundaresan, P. R. & Marquez, G. B., *Fedn Proc. Fedn Am. Socs exp. Biol.*, **30** (1971), 583.
102. Wallace, D. L., Baker, E. M., Canham, J. E., Raica, N., Sauberlich, H. E. & Hodges, R. E., *Fedn Proc. Fedn Am. Socs exp. Biol.*, **30** (1971), 584.
103. Zachman, R. D., Dunagin (Jr), P. E., & Olson, J. A., *J. Lipid Res.*, **7** (1966), 3.
104. Zachman, R. D. & Olson, J. A., *Nature, Lond.*, **201** (1964), 1222.
105. Olson, J. A., *Vitam. Horm. Lpz.*, **26** (1968), 1.

106. HUME, J. D., MITCHELL, G. E. & TUCKER, R. E., *J. Nutr.*, **101** (1971), 1169.
107. WALD, G., *Nature, Lond.*, **219** (1968), 800.
108. WALD, G., *Vitam. Horm. Lpz.*, **18** (1960), 417.
109. BOWNDS, D. & WALD, G., *Nature, Lond.*, **205** (1965), 254.
110. BOWNDS, D., *Nature, Lond.*, **216** (1967), 1178.
111. AKHTAR, M., BLOSSE, P. T. & DEWHURST, P. B., *Life Sci.*, **4** (1965), 1221.
112. AKHTAR, M., BLOSSE, P. T. & DEWHURST, P. B., *Chem. Commun.*, **13** (1967), 631.
113. POINCELOT, R. P., MILLAR, P. G., KIMBEL, R. L. & ABRAHAMSON, E. W., *Nature, Lond.*, **221** (1969), 5177.
114. MORTON, R. A. & PITT, G. A. J., *Adv. Enzymol.*, **32** (1969), 97.
115. HUBBARD, R., BROWN, P. K. & BOWNDS, D., cited in *Methods in enzymology*, Vol. 18, edited by D. B. McCormick & L. D. Wright (Academic Press Inc., New York), 1971, 615.
116. WALD, G., *Science, N.Y.*, **150** (1965), 1028.
117. MCCONNELL, D. G. & SCARPELLI, G. D., *Science, N.Y.*, **139** (1963), 848.
118. BONTING, S. L., CARAVAGGIO, L. L. & CANADY, M. R., *Expl Eye Res.*, **3** (1964), 47.
119. BONTING, S. L. & BANGHAM, A. D., *Expl Eye Res.*, **6** (1967), 400.
120. BIERI, J. G., MCDANIEL, E. G. & ROGERS, W. E., *Science, N.Y.*, **163** (1969), 574.
121. BERNARD, R. A. & HALPERN, B. P., *J. gen. Physiol.*, **52** (1968), 444.
122. MASON, K. E., *Am. J. Anat.*, **57** (1935), 303.
123. HOWELL, J. M., THOMPSON, J. N. & PITT, G. A. J., *J. Reprod. Fert.*, **5** (1963), 159.
124. HOWELL, J. M., THOMPSON, J. N. & PITT, G. A. J., *J. Reprod. Fert.*, **7** (1964), 251.
125. JUNEJA, H. S., MOUDGAL, N. R. & GANGULY, J., *Biochem. J.*, **111** (1969), 97.
126. CALUSTRO, E. Q. & LICHTON, I. J., *J. Nutr.*, **95** (1968), 517.
127. COWARD, W. A., HOWELL, J. M., PITT, G. A. J. & THOMPSON, J. N., *J. Reprod. Fert.*, **12** (1966), 309.
128. GANGULY, J., EDWARDS-WEBB, J. D. & WAYNFORTH, H. B., *Biochem. J.*, **122** (1971), 235.
129. GANGULY, J., POPE, G. S., THOMPSON, S. Y., TOOTHHILL, J., EDWARDS-WEBB, J. D. & WAYNFORTH, H. B., *Biochem. J.*, **123** (1971), 669.
130. ROGERS, W. E. & BIERI, J. G., *J. biol. Chem.*, **243** (1968), 3404.
131. GRANGUAD, R., NICOL, M. & DESPLANQUES, D., *Am. J. clin. Nutr.*, **22** (1969), 991.
132. SESHADRI SASTRY, P., MALATHI, P., SUBBA RAO, K. & GANGULY, J., *Nature, Lond.*, **193** (1962), 1080.
133. YONEMOTO, T. & JOHNSON, B. C., *Fedn Proc. Fedn Am. Socs exp. Biol.*, **26** (1967), 635.
134. SUBBA RAO, K. & OLSON, R. E., *Fedn Proc. Fedn Am. Socs exp. Biol.*, **26** (1967), 635.
135. SUNDARESAN, P. R. & WOLF, G., *Fedn Proc. Fedn Am. Socs exp. Biol.*, **22** (1963), 293.
136. SUNDARESAN, P. R., *Biochim. biophys. Acta*, **113** (1966), 95.
137. SUBBA RAO, K., SESHADRI SASTRY, P. & GANGULY, J., *Biochem. J.*, **87** (1963), 312.
138. CARROLL, J. & SPENCER, B., *Biochem. J.*, **96** (1965), 79P.
139. ROBBINS, P. W. & LIPMANN, F., *J. biol. Chem.*, **233** (1958), 681.
140. WOLF, G. & VARANDANI, P. T., *Biochim. biophys. Acta*, **43** (1960), 501.
141. FELL, H. B. & MELLANBY, E., *J. Physiol.*, **119** (1953), 470.
142. SUBBA RAO, K. & GANGULY, J., *Biochem. J.*, **90** (1964), 104.
143. HALL, M. O. & STRATTSMA, B. R., *Biochim. biophys. Acta*, **124** (1966), 246.
144. PERUMAL, A. S. & CAMA, H. R., *Indian J. Biochem.*, **4** (1967), 152.
145. CLAUSEN, J., *Eur. J. Biochem.*, **7** (1969), 575.
146. PASTERNAK, C. A., HUMPHRIES, S. K. & PIRIE, A., *Biochem. J.*, **86** (1963), 382.
147. MUKHERJI, B. & BACHHAWAT, B. K., *Biochem. J.*, **104** (1967), 318.
148. GEISON, R. L. & ROGERS, W. E. & JOHNSON, B. C., *Biochim. biophys. Acta*, **165** (1968), 448.
149. ROGERS, W. E., *Am. J. clin. Nutr.*, **22** (1969), 1003.
150. LEVI, A. S., GELLER, S., ROOT, D. M. & WOLF, G., *Biochem. J.*, **109** (1968), 69.
151. PERUMAL, A. S., ANANTHASAMY, T. S., LAKSHMANAN, M. R., JUNGALWALA, F. B. & RAMA RAO, P. B., *Biochim. biophys. Acta*, **124** (1966), 95.
152. LEVI, A. S. & WOLF, G., *Biochim. biophys. Acta*, **178** (1969), 262.
153. OLSON, R. E., *Science, N.Y.*, **145** (1964), 926.
154. DELUCA, L., LITTLE, E. P. & WOLF, G., *J. biol. Chem.*, **244** (1969), 701.
155. MORETTI, A. & WOLF, G., *Biochim. biophys. Acta*, **53** (1961), 263.
156. STREHLER, B. L., HENDLEY, D. D. & HIRSCH, G. P., *Proc. natn. Acad. Sci., U.S.A.*, **57** (1967), 1751.
157. DELUCA, L., SCHUMACHER, M. & WOLF, G., *J. biol. Chem.*, **245** (1970), 4551.
158. DELUCA, L., SCHUMACHER, M. & NELSON, D., *J. biol. Chem.*, **246** (1971), 5733.
159. CACCAM, J. F., JACKSON, J. J. & EYLAR, E. H., *Biochem. biophys. Res. Commun.*, **35** (1969), 505.
160. DELUCA, L., ROSSO, G. & WOLF, G., *Biochem. biophys. Res. Commun.*, **412** (1970), 615.
161. ZACHMAN, R. D., *Life Sci.*, **6** (1967), 2207.
162. JOHNSON, B. C., KENNEDY, M. & CHIBA, N., *Am. J. clin. Nutr.*, **22** (1969), 1048.
163. ZILE, M. & DELUCA, H. F., *Archs Biochem. Biophys.*, **140** (1970), 210.
164. DELUCA, L., KLEINSMAN, H. K. & WOLF, G., *Archs Biochem. Biophys.*, **145** (1971), 332.
165. FELL, H. B. & DINGLE, J. T., *Biochem. J.*, **87** (1963), 403.
166. WESTON, P. D., BARRETT, A. J. & DINGLE, J. T., *Nature, Lond.*, **222** (1969), 285.
167. DINGLE, J. T. & LUCY, J. A., *Biol. Rev.*, **40** (1965), 422.
168. BANGHAM, A. D., DINGLE, J. T. & LUCY, J. A., *Biochem. J.*, **90** (1964), 133.
169. LUCY, J. A. & DINGLE, J. T., *Nature, Lond.*, **204** (1964), 156.
170. ANDERSON, O. R., PFISTER, R. & ROELS, O. A., *Nature, Lond.*, **213** (1967), 47.
171. THOMAS, L., MCCLUSKEY, R. T., POLTER, J. L. & WEISSMANN, G., *J. exp. Med.*, **111** (1960), 705.
172. LUCY, J. A., *Am. J. clin. Nutr.*, **22** (1969), 1033.
173. PITT, G. A. J., *Am. J. clin. Nutr.*, **22** (1969), 1045.
174. DESHMUKH, D. S., MALATHI, P. & GANGLUY, J., *Biochem. J.*, **90** (1964), 95.
175. VEEN, M. J. & BEATON, G. H., *Can. J. Physiol. Pharmacol.*, **44** (1966), 521.
176. ESH, G. C. & BHATTACHARYA, R. K., *Ann. Biochem. exp. Med.*, **22** (1962), 83.
177. VAKIL, U., ROELS, O. A. & TROUT, M., *Br. J. Nutr.*, **18** (1964), 217.
178. ARROYAVE, G., VITERI, F., BEHAR, M. & SCRIMSHAW, N. S., *Am. J. clin. Nutr.*, **7** (1959), 185.
179. OOMEN, H. A. P., MCLAREN, D. S. & ESCAPINI, H., *Trop. Geogr. Med.*, **16** (1964), 271.
180. GOPALAN, C., VENKATACHALAM, P. S. & BHAVANI, B., *Am. J. clin Nutr.*, **8** (1960), 833.
181. SRIKANTIA, S. G. & REDDY, V., *Am. J. clin. Nutr.*, **23** (1970), 114.
182. ARROYAVE, G., *Proceedings (AMA) Western Hemisphere Nutrition Congress*, edited by P. L. White, 1971, 68.
183. MURRAY, T. K., *Proceedings (AMA) Western Hemisphere Nutrition Congress*, edited by P. L. White, 1971, 63.
184. HODGES, R. E., *Proceedings (AMA) Western Hemisphere Nutrition Congress*, edited by P. L. White, 1971, 67.
185. PARNELL, J. P. & SHERMAN, B. S., cited in *Fundamentals of keratinization*, edited by E. O. Butcher & R. F. Sognnaes (American Association for the Advancement of Science, Washington), 1962, 113.
186. RUEDA-WILLIAMSON, R., *Proceedings (AMA) Western Hemisphere Nutrition Congress*, edited by P. L. White, 1971, 56.
187. SUNDARESAN, P. R., *Proceedings (AMA) Western Hemisphere Nutrition Congress*, edited by P. L. White, 1971, 80.
188. WASSERMAN, R. H. & CORRADINO, R. A., *A. Rev. Biochem.*, **40** (1971), 501.
189. ADHIKARI, H. R., VAKIL, U. K. & SREENIVASAN, A., *J. scient. ind. Res.*, **29** (1970), 364.
190. SEBRELL (Jr), W. H. & HARRIS, R. S., *The vitamins*, Vol. I (Academic Press Inc., New York), 1967.
191. WOLF, G., *Am. J. clin. Nutr.*, **22** (1969), 903.
192. DELUCA, H. F. & SUTTIE, J. W., *The fat-soluble vitamins* (University of Wisconsin Press, Madison), 1969.

Bib. No. 10955

Reproduced by permission of the copyright owner

J. Dairy Sci. 55(8):1077-1080. 1972.

Fluorometric Determination of Vitamin A in Dairy Products

J. N. THOMPSON, PAULA ERDODY, W. B. MAXWELL, and T. K. MURRAY
Research Laboratories,
Health Protection Branch,
Department of National Health and Welfare,
Ottawa, Canada

Abstract

A rapid method has been devised for the determination of vitamin A (retinol) in milk, artificially fortified milk, butter, cheese and ice cream. Samples (1 ml or 1 g) were saponified and extracted with petroleum ether in stoppered centrifuge tubes. Retinol content of extracts was measured fluorometrically. Chromatography of the unsaponifiable lipids on columns of alumina and hydroxyalkoxypropyl Sephadex demonstrated that retinol was responsible for almost all of the measured fluorescence. Retinol amounts are reported for Canadian whole milk, 2% fat-milk and fortified 2% fat-milk. Samples were obtained monthly between March and November 1971. Mean retinol (μg/100 ml$\pm$SE) in whole milk was low in March (28.3$\pm$3.0) and November (32.1$\pm$1.5) and maximal in September (45.8$\pm$2.3). A similar cycle was observed in the values for 2% fat-milk which invariably were approximately two-thirds those of whole milk. Sixteen out of 18 fortified milks met their label claims but two had only 19 and 22 μg retinol/100 ml.

Introduction

Dairy products are important sources of vitamin A (1). The vitamin A content of milk however varies with the seasons (2) and it is markedly reduced when milk is skimmed. As skimmed milk is sometimes artificially fortified with vitamin A a need has arisen for an analytical method to permit routine monitoring.

Analytical methods used hitherto for the estimation of retinol in milk have had to contend with interference from various classes of lipids including carotenoids. Usually lipids have been extracted, saponified, and chromatographed and then retinol has been measured spectrophotometrically or colorimetrically (3, 4). Recently, it was found that retinol could be measured fluorometrically in hexane extracts of blood serum and in unsaponifiable lipids from liver providing that interference from a fluorescent carotenoid, phytofluene, was eliminated (5). However, in preliminary investigations phytofluene was not detected in milk and thus a simple direct fluorometric determination of vitamin A appeared feasible. Details of such a method and tests of its validity are described, together with results of its application to various types of milk sold in Canada. The method was also applied to other dairy products.

Received for publication February 4, 1972.

Procedures

Instrumentation, solvents and reagents. Absorption spectra were recorded with a Beckman DB-G spectrophotometer. Fluorescence was measured with a Hitachi Perkin Elmer MPF3 fluorescence spectrophotometer. Hexane (glass distilled, Burdick and Jackson Laboratories, Inc) and ethyl acetate (spectroquality, Matheson, Coleman and Bell) were used as obtained. Petroleum ether (bp 30 to 60, Mallinckrodt analytical grade) and benzene (toxigraphic grade, Anachemia Chemicals) were distilled. Ethanol was distilled from KOH pellets. Alumina was washed as described (5) and hydroxyalkoxypropyl Sephadex (HAPS) was prepared from Sephadex G-25 superfine and Nedox 1114 (6). Retinyl acetate was from USP vitamin A reference capsules.

Calibration of fluorescence spectrophotometer. Although retinol standards can be assayed with each set of samples this is tedious in practice. It was more convenient in the present method to calibrate the instrument less frequently and make day-to-day adjustments of the sensitivity with a standard solution of quinine sulphate as a reference. It is emphasized that retinol is unstable and that the accuracy of fluorometric and other determinations can be seriously impaired if standards are not carefully prepared.

The method used to calibrate the MPF3 was as follows. The contents of a capsule of retinyl acetate concentrate were squeezed into a 15 ml centrifuge tube and heated for 20 min in a boiling water bath with 1 ml water and .5 g

KOH. Water (1 ml) and hexane (5 ml) were added and the contents shaken.

An aliquot (2 ml) of the hexane layer was chromatographed on a 1 cm diameter column of 5 g alumina weakened with .2 ml water. The column was eluted successively with 50 ml portions of petroleum ether, 10% diethyl ether in petroleum ether and 50% diethyl ether in petroleum ether. The position of retinol on the column was followed from the fluorescence elicited with a manual ultraviolet lamp. Purified retinol was eluted in the last fraction and evaporated to .5 ml in a stream of nitrogen. This solution was diluted in hexane until the absorbance at 325 mμ was approximately .2. The concentration was calculated using a coefficient E 1 cm 1% of 1,830, and diluting the solution twentyfold to produce a standard of known concentration containing approximately .05 μg retinol/ml. The fluorometer was set at 330 mμ excitation and 480 mμ emission with both slits at 8 mμ band pass. The retinol solution was inserted and the sensitivity was adjusted until 50 scale units corresponded to .05 μg retinol/ml. Hexane was then inserted and a blank reading (1 unit) was measured with the same settings. The retinol solution was replaced and the sensitivity was readjusted so that .05 μg retinol/ml corresponded to 50 plus the reading of the hexane blank. Without further adjustment, a standard solution of quinine sulphate (.01 μg quinine/ml) in .1N H_2SO_4 was read in the instrument. In subsequent analysis the instrument sensitivity controls were set so that the quinine solution gave the same reading as when the instrument was calibrated.

The fluorescence of retinol is linearly related to concentration until self-absorption becomes significant (.25 μg/ml). However, it is cautioned that in some fluorometers, the factors between coarse settings change and are often not precisely as indicated on the dial. Therefore the coarse sensitivity switch should be calibrated or, if possible as with the MPF3, adjusted before linearity is assumed over the full range of the instrument.

Examination of milk lipids. Aliquots of milk (1 ml) were homogenized with 1 ml ethanol and 10 ml petroleum ether. Fluorescence measurements were made on the separated petroleum ether extracts.

Analysis of vitamin A in milk (recommended procedure). Milk (1 ml) was saponified in a 15 ml stoppered centrifuge tube by adding 5 pellets (.5 g) KOH and 2 ml 1% ethanolic pyrogallol and heating for 20 min in a bath of boiling water. Water (2 ml) was added and the digest was extracted twice with 5 ml portions of petroleum ether. The extracts, which were removed after centrifugation, were combined and their total volume was adjusted to 10 ml. The fluorescence of this solution was measured at 330 mμ excitation and 480 mμ emission with both slits set at 8 mμ band pass. Blank trials were made with water instead of milk. The blank reading was subtracted from the sample readings and using the calibration procedure described, the retinol content of the milk was given directly in μg/100 ml.

Analyses of vitamin A in butter, cheese, and ice cream (recommended procedure). Butter (1 g) was shaken with hexane (5 ml) and centrifuged. An aliquot of the clear supernatant (1 ml) was evaporated in a tared flask and the fat was weighed. A second aliquot (1 ml) was evaporated under nitrogen in a 15 ml stoppered centrifuge tube. Water (1 ml) was added and the lipid was saponified and analyzed according to the protocol for milk, modified in that the digest was extracted with four portions of petroleum ether which were combined and evaporated under nitrogen to 10 ml. Portions of cheese and ice cream were analyzed similarly.

Tests applied to the method. The efficiency of extraction of retinol from the saponification digest was examined by extracting test samples six times with 10 ml portions of petroleum ether. The fluorescence of each extract was measured.

Specificity of the determination was verified by chromatography of the saponified lipids from 1 ml and 5 ml of milk on columns of alumina (5). Four fractions were collected (petroleum ether, 2, 10 and 50% diethyl ether in petroleum ether) and on each the excitation spectrum of the 480 mμ fluorescence emission was recorded.

Specificity of the method was also tested by chromatographing saponified lipids from milk (1 ml), butter (.2 g), cheese (.1 g) and ice cream (.5 g) on a column of HAPS. Details of the chromatographic system for analysis of tocopherols will be published elsewhere (7). In this procedure a 25 cm x .5 cm diameter column of HAPS was eluted continuously with a mixture of ethyl acetate, benzene and hexane (3:30:67) and the effluent was passed through a flow cell in an Aminco Bowman spectrophotofluorometer. The fluorescence emission at 475 mμ with 320 mμ excitation was monitored with a Beckman 25.4 cm recorder set at a slow chart speed (2.54 mm per min).

To test the procedure, milk samples were purchased for analysis once a month for nine consecutive months in Halifax, Montreal, Toronto, Winnipeg and Vancouver. Two to four samples of both whole and 2% fat-milk were obtained from each city on each occasion. Fortified 2% fat-milk was also purchased in Halifax (17 samples) and Montreal (3 samples). A sample of 2% fat-milk was fortified in our laboratory with a commercially available dispersible preparation of vitamin A (Palma-Sperse Type 250A, Hoffmann-La-Roche Ltd.) and serial dilutions in the same milk were prepared for analysis. Fresh milk was also obtained in September from Guernsey cows which had been grazing during the summer.

Results and Discussion

It was not possible to estimate vitamin A fluorometrically in crude lipid extracts of milk. In these extracts the fluorescence of retinol was completely masked by relatively intense fluorescence from an unidentified substance. The latter had maximum emission at 415 mμ and its excitation spectrum had peaks at 290, 302 and 316 mμ (Fig. 1). This interfering substance was removed by saponification of the lipids. Its other properties have not been investigated.

The unsaponifiable lipids from milk, cheese, ice cream, and butter had fluorescence excitation and emission spectra similar in shape to those of retinol (Fig. 1). Chromatography confirmed that retinol was responsible for most of this fluorescence. Thus fluorescence was recovered in only the 50% diethyl ether in petroleum ether fraction when unsaponifiable lipids from milk were chromatographed on alumina: this is the fraction in which retinol is normally found (5). Supporting evidence that retinol was the dominant fluorescent substance in the unsaponifiable lipids was obtained by chromatography on HAPS. The latter is more suitable for identifying sources of fluorescence than conventional chromatography materials such as alumina because it can be thoroughly washed and it is inert: thus it neither generates nor releases fluorescent artifacts. The solvent system chosen for the tests eluted phytofluene after 10 min, retinyl esters after 13 min and retinol after approximately 40 minutes (Fig. 2). When unsaponifiable lipids from milk, butter and cheese were chromatographed, with the fluorometer monochrometers set at 330 mμ excitation and 480 mμ emission, a single peak was obtained after 40 min. Otherwise, the charts had only barely detectable ripples, most of which occurred during the first 20 min of the chromatography (Fig. 2). There was no evidence of significant amounts of phytofluene in milk. It was not even detected in summer Guernsey milk which is especially rich in carotenoids (1).

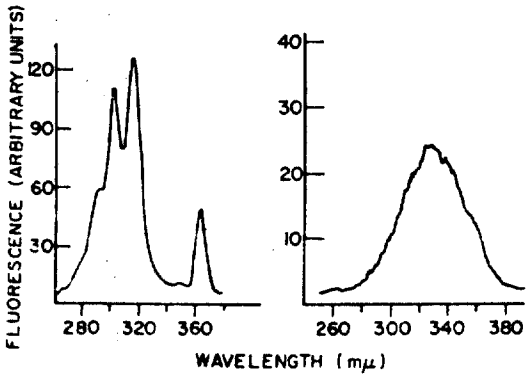

FIG. 1. Excitation spectra of hexane extracts of milk before (left) and after (right) saponification. Lipids from 1 ml milk were dissolved in 10 ml hexane. The excitation slit was set at 3 mμ and the emission slit at 10 mμ. The emissions were measured at 407 mμ (left) and 480 mμ (right).

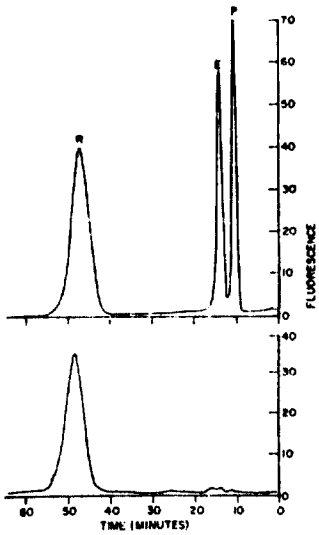

FIG. 2. Fluorescence (475 mμ emission, 320 mμ excitation) of eluates from hydroxyalkoxypropyl Sephadex column. The upper chromatogram was of a mixture of standards: retinol (R), retinyl acetate (E) and phytofluene (P). The lower chromatogram was of a sample of saponified milk lipid.

When saponified milk samples were extracted repeatedly with petroleum ether, only the first and second extracts contained fluorescence typical of retinol. However, with other dairy products, such as butter, fluorescence was

measurable in the first four extracts. Therefore in the recommended procedures, two extracts were combined in the analysis of milk, whereas four extracts were pooled in the analysis of other dairy products.

TABLE 1. Recovery of retinol from 2% fat-milk fortified with vitamin A.

Retinol added[a]	Total retinol found
(μg/100 ml)	(μg/100 ml)
0	32
30	62
60	94
90	122
120	152
150	185

[a] Added as retinyl palmitate, Palma-Sperse Type 250-S, Hoffmann-LaRoche Ltd.

Recovery of vitamin A added to 2% milk was essentially quantitative (Table 1).

The results of the monthly analyses of milk samples are in Figure 3. On each occasion the samples from different cities proved similar, and therefore the results have been combined. The values are similar to those found previously in other countries in that a seasonal cycle is clearly evident (1, 2). Whole milk at all times contained approximately one and one half times as much retinol as 2% fat-milk. Most of the artificially fortified 2% fat-milks tested (18 samples) met label claims. These samples contained 72 ± 9.3 μg retinol/100 ml (mean ± SD) which ranks them as a better source of vitamin A than fresh whole milk. However, two samples were discovered with 19 and 22 μg/100 ml which indicates that they had not been properly fortified.

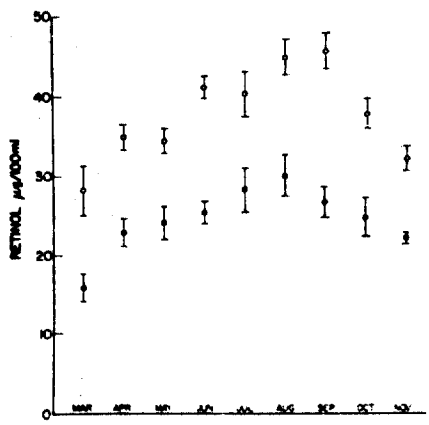

FIG. 3. Means of vitamin A in whole milk (open circles) and 2% fat-milk (filled circles) from 5 Canadian cities during 1971. Vertical bars show standard error.

The fluorometric method does not measure the carotenoid provitamins. However it is envisaged that most routine monitoring will be applied to fortified skimmed milks in which the carotenoids make a relatively small contribution to the total vitamin A activity.

Acknowledgments

We thank the Regional Field Staff of the Health Protection Branch for collecting milk samples and the Canada Department of Agriculture, Ottawa, for providing samples of Guernsey Milk.

References

(1) Hartman, A. M., and L. P. Dryden. 1965. Vitamins in Milk and Milk Products. Publ. Amer. Dairy Sci. Ass., Champaign, Illinois.

(2) Moore, T. 1957. Vitamin A. Elsevier, Amsterdam.

(3) Thompson, S. Y. 1968. Reviews of the progress of dairy science Section D, Nutritive value of milk and milk products. Fat soluble vitamins in milk and milk products. J. Dairy Res., 35:149.

(4) Strohecker, R., and H. M. Henning. 1965. Vitamin Assay. Verlag Chemie Gmb. H. Weinheim Bergstr.

(5) Thompson, J. N., P. Erdody, R. Brien, and T. K. Murray. 1971. Fluorometric determination of vitamin A in human blood and liver. Bioch. Med., 5:67.

(6) Ellingboe, J., E. Nystrom, and J. Sjovall. 1970. Liquid-gel chromatography on lipophylic-hydrophobic Sephadex derivatives. J. Lipid Res., 11:266.

(7) Thompson. J. N., P. Erdody, and W. B. Maxwell. Unpublished results.

Bib. No. 10994

Reproduced by permission of the copyright owner

Q. Jl exp. Physiol. (1971) 56, 147–155

ACTION POTENTIAL MODIFICATIONS IN RAT MYOCARDIAL CELLS INDUCED BY HYPERVITAMINOSIS A.

By U. Ventura, T. Ceriani, F. Zelaschi and G. Rindi. From the Institute of Human Physiology of the University of Pavia, Pavia (Italy).

(*Received for publication* 21*st November* 1970)

Ventricular cell action potentials were measured *in situ* using intracellular microelectrodes in the hearts of hypervitaminotic A rats, both at the spontaneous rate and at rates externally increased to various higher levels. The action potentials were much modified (decrease in amplitude, in depolarization rate, in fast and slow repolarization rate, and increase in partial and total duration). Excess of vitamin A also appeared to bring about a rise in spontaneous heart rate. Ion fluxes in myocardial cells at high levels of vitamin A seemed to be somewhat uncoupled from cardiac metabolism. The results obtained indicate that the changes in cardiac electrogenesis may be specifically related to the effects of an excess of vitamin A on cell membrane structure and consequently on permeability and ion fluxes through the membranes.

The results of a previous investigation [Rindi, Ventura, Ceriani and Zelaschi, 1970], involving the recording of intracellular action potentials from vitamin A deficient rat hearts *in situ*, suggested that vitamin A may affect the permeability of myocardial cell membranes, which is known to be a fundamental factor in cardiac electrogenesis. However, the metabolic and energetic processes of the heart did not appear to suffer from the lack of vitamin A.

We therefore felt it would be interesting to study the effect of hypervitaminosis A *in vivo* on intracellular action potentials in the heart, with a view to eliciting further information on the function of vitamin A in cardiac membranes and electrogenesis.

Materials and Methods

Animals and Diet. 6–8 weeks old Wistar strain male albino rats were used having an initial weight of 90–100 g. They were individually housed and fed on the Randoin and Causeret [1947] pellet diet, supplied by Piccioni (Brescia).

The rats were divided into two groups of nine animals each. Group 1 acted as control and was pair-fed with Group 2, the treated animals. Group 2 received a daily oral dose of 500 I.U./g of body weight of vitamin A palmitate ('Arovit', Roche, Basel) dissolved in 0·15–0·30 ml. of groundnut oil. Group 1 received the solvent only. The dose of vitamin A used to obtain the excess was of the same order as that employed by other investigators [Moore and Wang, 1943; Rodahl, 1950]. Hypervitaminosis A appeared within 3–4 weeks as described in the literature [Moore and Wang, 1943; Rodahl, 1950], being identified by a fall in the body weight to 10 g less than the maximum reached and being characterized by spontaneous limb fractures and oral and nasal haemorrhages.

Vitamin A content in heart and liver. This was determined by a method using the Carr–Price reaction [Association of Vitamin Chemists, 1966] in some treated and control rats and also in some normal Wistar rats of a similar age to the controls, which had been fed *ad libitum* on the Randoin and Causeret [1947] diet.

Measurement of intracellular heart action potentials 'in situ'. The rats were anaesthetized with urethane (80 mg/100 g of body weight). The chest and pericardial sac

were opened to expose the heart. Respiration was maintained by a respiratory pump connected to a cannula in the trachea.

The myocardial ventricular cells were impaled according to the Benoit technique (1962) using glass microelectrodes supported by a flexible mount as described by Rindi and Rapuzzi [1966]. The intracellular action potentials picked up by the microelectrodes were displayed via a cathode follower on the screen of a cathode ray oscilloscope (Tektronix, type 502 A) and photographed.

Cardiac rate was increased by applying electric pulses (0·1 msec duration and about 20 V intensity) to the right atrium through two platinum electrodes connected to a pulse generator set (Tektronix, type 160).

Ventricular intracellular action potentials were recorded at spontaneous heart rate and at heart rates increased successively to 460, 500 and 600 beats/min. The electrode was left in the same cell at each frequency. Cardiac rate was maintained at each frequency for about 10 sec and allowed to revert to the spontaneous rate for about 30 sec before being raised to the next highest frequency. All the microelectrodes used had an electrical resistance of 10–14 MΩ, with an apex certainly less than 1 μm, as judged by microscopical observation. Often the same microelectrode was used for both control and treated rats.

The heart rate and the potential parameters were measured on enlargements of the original photographs as described in a previous paper [Rindi *et al.*, 1970].

Results

Measured in six rats in each case, the vitamin A liver content (8·49 ± S.E. 1·16 mg/g) was 150–300 times higher in treated rats than in the controls (50·21 ± 7·20 μg/g) and in the normal animals (25·31 ± 2·48 μg/g). Prolonged treatment with vitamin A, therefore, raised the liver reserves of the vitamin to levels similar to those observed by Moore [1957]. Only traces of vitamin A were found in the hearts of the normal and control animals, and these were difficult to evaluate when using the Carr–Price reaction [Moore, 1931; Davies and Moore,

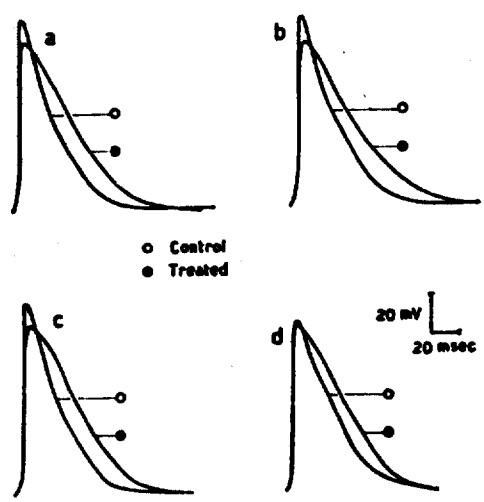

Fig. 1. Intracellular action potentials of ventricular myocardial cells of hypervitaminotic A rats (treated) and pair-fed controls, drawn up and superimposed after enlargement of the original photographs. Heart rate: a, spontaneous. b, c, d: 460, 500, 600 beats/min, respectively.

TABLE I. *Action potentials in ventricular myocardial cells recorded at various heart rates in hypervitaminotic A rats and pair-fed controls.* Means ± s.e.

Animals	No. of rats	No. of impaled cells	Heart rate, beats/min	Amplitude, mV	Rate (V/sec) of: Depolarization	Repolarization fast	Repolarization slow	Duration (msec) partial	Duration (msec) total
Hypervitaminotic A rats	9	36	S 434 ± 4·36	91·33 ± 0·97*	73·94 ± 2·23*	1·52 ± 0·02*	0·52 ± 0·01*	66·36 ± 1·12*	87·54 ± 1·06*
	3	6	I 460	91·83 ± 2·20*	77·93 ± 2·45*	1·55 ± 0·05*	0·55 ± 0·02	66·67 ± 1·59*	87·38 ± 3·20*
	3	6	I 500	91·33 ± 1·97	75·45 ± 3·79	1·52 ± 0·04*	0·50 ± 0·02*	67·71 ± 1·43*	85·96 ± 2·06*
	2	5	I 600	90·28 ± 2·19	71·82 ± 4·77	1·47 ± 0·14*	0·55 ± 0·01	69·47 ± 2·07*	84·46 ± 1·00*
Pair-fed controls	9	57	S 417 ± 5·74	97·60 ± 0·60	91·82 ± 3·40	2·36 ± 0·05	0·57 ± 0·01	46·07 ± 1·13	77·76 ± 3·12
	7	31	I 460	96·26 ± 0·83	83·81 ± 1·78	2·22 ± 0·09	0·55 ± 0·01	47·65 ± 1·71	75·96 ± 1·13
	7	25	I 500	93·95 ± 1·21	78·52 ± 2·75	2·06 ± 0·09	0·55 ± 0·01	50·21 ± 1·87	76·06 ± 1·24
	7	24	I 600	92·44 ± 1·37	73·97 ± 3·06	1·83 ± 0·09	0·56 ± 0·01	56·27 ± 2·00	76·47 ± 1·15

S = spontaneous heart rate. I = heart rate externally increased to levels indicated.
* Values which differ significantly ($P < 0·05$, Student's t test) from those of respective controls.

1934]. However, vitamin A content in the hypervitaminotic hearts was very high (55·20 ± 17·09 μg/g, average of six rats).

In Fig. 1 some examples of intracellular myocardial action potentials at spontaneous and increased heart rate in control and treated rats are superimposed. The differences in their overall configuration are evident.

Table I gives the values of the cardiac intracellular action potentials in hypervitaminotic A rats and in their respective controls at the spontaneous and increased heart rates. Chronic treatment with high doses of vitamin A brought about the following changes in the myocardial cell action potential: (*a*) decrease in amplitude; (*b*) decrease in depolarization rate; (*c*) decrease in fast and slow repolarization rate; and (*d*) increase in partial and total duration.

It will be seen from Table I that none of the increases in cardiac rate changed the differences in fast repolarization and partial and total duration between treated and control rats. However, the highest frequencies (500 and 600 beats/min) tended to eliminate the differences in amplitude, depolarization and slow repolarization rates, although the overall configuration of action potential in the hypervitaminotic A and control rats remained quite different (Fig. 1).

TABLE II. *Heart rate and systole and diastole duration recorded in hypervitaminotic A rats and respective pair-fed controls.* Means ± s.e.

Animals	Heart rate, beats/min	No. of rats	Duration (msec) systole	Duration (msec) diastole
Hypervitaminotic A rats	S 434 ± 4·36	9	87·54 ± 1·06*	51·01 ± 1·47*
	I 460	3	87·38 ± 3·20*	40·92 ± 3·31*
	I 500	3	85·96 ± 2·08*	33·36 ± 1·79*
	I 600	2	84·46 ± 1·00*	17·98 ± 0·85*
Pair-fed controls	S 417 ± 5·74	9	77·96 ± 3·12	67·68 ± 2·31
	I 460	7	75·96 ± 1·13	52·48 ± 1·12
	I 500	7	76·06 ± 1·24	44·56 ± 1·31
	I 600	7	76·47 ± 1·15	25·93 ± 1·18

S = spontaneous heart rate. I = heart rate externally increased to levels indicated.
* Values which differ significantly ($P < 0·05$, Student's *t* test) from those of respective controls.

Table II shows that heart rate and systole duration in hypervitaminotic A rats appear to increase in comparison with the controls, whereas diastole duration decreases. Raising the heart rate to over 460 beats/min did not eliminate these differences.

DISCUSSION

Hypervitaminosis A (Table I) caused very considerable changes in the cardiac intracellular action potential, as indicated in (*a*), (*b*), (*c*) and (*d*) above. In addition, as stated previously, hypervitaminotic A rats showed an increase in spontaneous heart rate and systole duration and a decrease in diastole duration (Table II).

None of the alterations in action potential (Table I) found at an average

spontaneous rate of 434 beats/min were modified when cardiac rate was increased to 460 beats/min, since this increase caused similar changes in the treated and control animals. When cardiac rate was raised further to 500 beats/min, or more, the differences remained, with the exception of amplitude, depolarization and slow repolarization rates, which did not change in hypervitaminotic A rats, but rather fell in the controls to levels comparable with those in the treated rats. Actually amplitude, depolarization and slow repolarization rate in treated animals changed little over the whole range of rates examined.

Ion fluxes in the myocardial cell at high levels of vitamin A did not seem greatly dependent on the metabolic requirements of increased rate, but were apparently uncoupled from them. It should be noted that the increase of cardiac rate could be obtained in only one-third of the treated animals, since the heart often stopped.

The main changes in intracellular action potential of hearts with a very high vitamin A content seem to be linked with myocardial cell permeability, which is known to be a basic factor in heart action potential. The 7 per cent decrease in amplitude and the 14 per cent reduction in depolarization rate in spontaneously beating hearts might be ascribed to a change in myocardial cell membrane structure caused by excess of vitamin A, as occurs both *in vitro* [Glauert, Daniel, Lucy and Dingle, 1963; Dingle, Glauert, Daniel and Lucy, 1962; Daniel, Dingle, Glauert and Lucy, 1965; Lucy, Luscombe and Dingle, 1963; Dingle, 1961] and *in vivo* [Dingle, Moore and Sharman, 1963; Dingle, 1963] in other cellular membranes. Indeed some investigators hold that vitamin A is a normal component of many cellular and subcellular membranes [Lui and Roels, 1969], acting as a link between the protein and lipid layers and contributing to the stability of the membrane structure [Dingle and Lucy, 1962; Lucy and Dingle, 1964; Lui and Roels, 1969]. An excess of vitamin A [Dingle and Lucy, 1965; Daniel, Dingle, Glauert and Lucy, 1966] is believed to be a cause of modifications in membrane structure, and thus of functional changes.

So it is conceivable that the possible structural modification caused by continued excess of vitamin A in the myocardial cell could give rise to a lessened ionic permeability, which is in turn responsible for the decrease in amplitude and depolarization rate.

The behaviour of these two parameters with both excess and lack of vitamin A suggests that vitamin A has some specific effect on the myocardial cell membrane, since lack [Rindi *et al.*, 1970] brought about an increase in amplitude and depolarization rate, but excess the reverse (Fig. 2). Increase of heart rate tended to reduce (hypervitaminosis A) or enhance (avitaminosis A) these differences. Actually, when the heart rate was increased, amplitude and depolarization rate, as stated above, were reduced more in control than in treated animals. Nevertheless, if the amplitude and depolarization rate recorded at each increased heart rate are compared to those of controls, they continued to be higher in avitaminosis A and lower in hypervitaminosis A than they had been at the spontaneous heart rate. In other words, the modified ionic permeability of the myocardial cells found either in avitaminotic or hypervitaminotic A rats

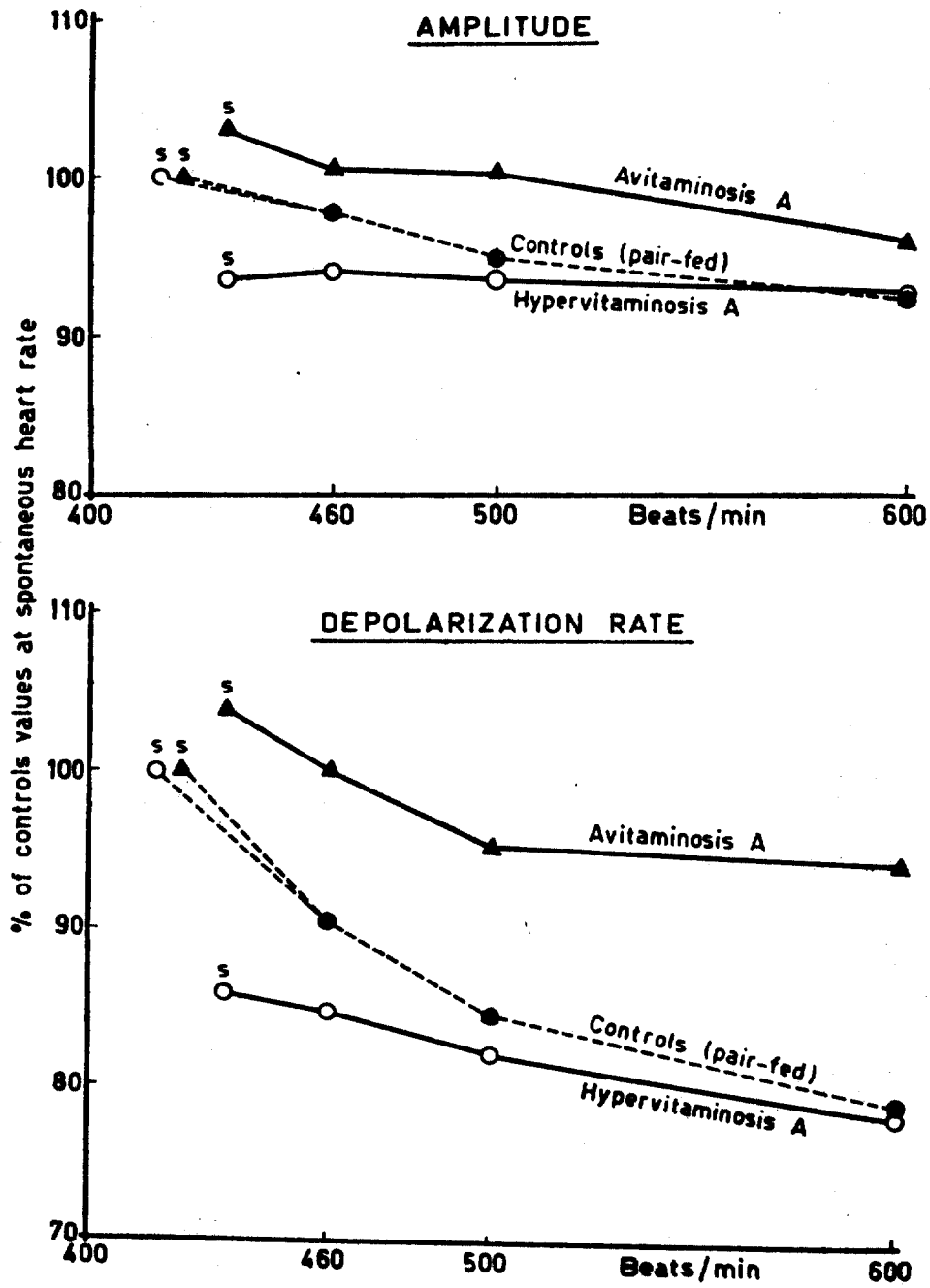

FIG. 2. Effects of hypervitaminosis A and avitaminosis A on amplitude and depolarization rate of intracellular myocardial action potential of rats at various heart rates. The data referring to avitaminosis A were taken from Rindi *et al.*, 1970.
±, avitaminosis A: - - - - controls;——treated rats.
○, hypervitaminosis A: - - - - controls;——treated rats.
S, spontaneous heart rate.

appeared to be a quite stable and highly peculiar membrane feature, independent of the externally increased heart rate.

Here it is interesting to note that Dingle and Lucy [1965] and Seward, Mitchell and Hove [1969] have speculated that cell membrane permeability largely depends on the presence of an optimum quantity of vitamin A in the membranes.

The substantial decrease (Table I) in the fast repolarization rate (−36 per cent) and the somewhat smaller reduction in the slow repolarization rate (−10 per cent), followed by increases in partial and total duration of the action potential and systole (Table II), may indicate that an excess of vitamin A is also able to change the processes underlying electrical recovery of the myocardial cell [Hoffman and Cranefield, 1960].

The fact that heart rate (Table I) was higher in hypervitaminotic A rats than in controls is somewhat surprising as this change was accompanied by considerable negative alterations in the action potential. One might indeed expect that heart rate would decrease to offset reduced electrogenesis, as usually occurs.

Assuming that one discounts vitamin A having any direct action on the cardiac pacemaker, one possible interpretation of the higher rate might be that hyperthyroidism occurs in hypervitaminotic A rats, as has been shown by several investigators [Uotila, 1938; Collazo and Rodriguez, 1933; Wheeler, 1945; Sadhu and Truscott, 1947]. By bringing about an increase in heart rate, hyperfunction of the thyroid gland could prevent any possible compensatory slowing of the heart and consequent overload of heart electrogenesis.

As a whole, the results we have obtained show that an excess of vitamin A causes considerable changes in heart electrogenesis, mainly as a result of alterations in myocardial cell membrane permeability, on which vitamin A seems to exert a specific action. Since both a lack and an excess of vitamin A cause modifications in heart electrogenesis, it is conceivable that the relative concentration of vitamin A in myocardial cells could have a critical effect on cell permeability and consequently on cell electrogenesis.

However, it cannot be disproved that vitamin A may have some action on the permeability of myocardial cells apart from its supposed function of normal component of biomembranes. Indeed vitamin A could be involved with some processes ongoing in the membranes, such as sulphate activation in their mucopolysaccharide synthesis (Clause, 1969). Recent findings of De Luca and Wolf [1970] have strengthened the possibility that vitamin A could function in the cellular membranes of certain tissues (lung, intestine) as an intermediate in the biosynthesis of glycoproteins. Our results obtained in the heart do not exclude that either high or low contents of vitamin A could alter the mucopolysaccharide component of myocardial cell membranes, and consequently cardiac ionic permeability

ACKNOWLEDGMENTS

This work was supported in part by a grant from Consiglio Nazionale delle Ricerche, Rome.

We are grateful to Professor G. Rapuzzi for his invaluable advice and criticism of the manuscript, and to Mr D. Bonizzoni for his skilful technical assistance.

We wish to thank Prodotti Roche of Milan for the generous supply of 'Arovit'.

REFERENCES

Ass. Vitamin Chemists (1966). *Methods of Vitamin Assay*, 3rd edn., p. 70. New York: Interscience Publ. Inc.

Benoit, L. M. (1962). 'Montage souple de microélectrodes intracellulaires, pour l'étude des tissus contractiles.' *C. r. Séanc. Soc. Biol.* **156**, 1465–1466.

Clausen, J. (1969). 'The effect of vitamin A deficiency on myelination in the central nervous system of the rat.' *Eur. J. Biochem.* **7**, 575–582.

Collazo, J. A. and Rodriguez, J. S. (1933). 'Hypervitaminose A. Die Symptomatologier der durch Fütterung von reinem A-vitamin an jungen Ratten hervorgerufenen Hypervitaminose A.' *Klin. Wschr.* **12**, 1732–1734.

Daniel, M. R., Dingle, J. T., Glauert, A. M. and Lucy, J. A. (1965). Quoted by Dingle, J. T. and Lucy, J. A. (1965). 'Vitamin A, carotenoids and cell function.' *Biol. Rev.* **40**, 422–461.

Daniel, M. R., Dingle, J. T., Glauert, A. M. and Lucy, J. A. (1966). 'The action of excess of vitamin A alcohol on the fine structure of rat dermal fibroblasts.' *J. Cell Biol.* **30**, 465–475.

Davies, A. V. and Moore, T. (1934). Vitamin A and carotene. XI. The distribution of vitamin A in the organs of the normal and hypervitaminotic rat.' *Biochem. J.* **28**, 288–295.

De Luca, L. and Wolf, G. (1970). 'Vitamin A and mucus secretion.' *Int. Z. Vitam. Forsch.* **40**, 284–290.

Dingle, J. T. (1961). 'Studies on the mode of action of excess of vitamin A. 3. Release of a bound protease by the action of vitamin A.' *Biochem. J.* **79**, 509–512.

Dingle, J. T. (1963). *Action of vitamin A on the stability of lysosomes "in vivo" and "in vitro"*. Ciba Foundation Symposium on Lysosomes, pp. 384–398, London: Ed. de Renck, A. V. S. and Cameron, M. L. London: Churchill, Ltd.

Dingle, J. T., Glauert, A. M., Daniel, M. R. and Lucy, J. A. (1962). 'Vitamin A and membrane systems. 1. The action of vitamin on the membranes of cells and intracellular particles.' *Biochem. J.* **84**, 76P.

Dingle, J. T. and Lucy, J. A. (1962). 'Studies on the mode of action of excess of vitamin A. 5. The effect of vitamin A on the stability of the erythrocyte membrane.' *Biochem. J.* **84**, 611–621.

Dingle, J. T. and Lucy, J. A. (1965). 'Vitamin A, carotenoids and cell function.' *Biol. Rev.* **40**, 422–461.

Dingle, J. T., Moore, T. and Sharman, I. M. (1963). 'The influence of vitamin A status on the proteolytic activity of lysosomes from the livers and kidneys of rats.' *Proc. Nutr. Soc.* **22**, X.

Glauert, A. M., Daniel, M. R., Lucy, J. A. and Dingle, J. T. (1963). 'Studies on the mode of action of excess of vitamin A. VII. Changes in the fine structure of erythrocytes during haemolysis by vitamin A.' *J. cell Biol.* **17**, 111–121.

Hoffman, B. F. and Cranefield, P. F. (1960). *Electrophysiology of the Heart*. New York: McGraw-Hill Book Co., Inc.

Lucy, J. A. and Dingle, J. T. (1964). 'Fat-soluble vitamins and biological membranes.' *Nature*, **204**, 156–160.

Lucy, J. A., Luscombe, M. and Dingle, J. T. (1963). 'Studies on the mode of action of excess of vitamin A. 8. Mitochondrial swelling.' *Biochem. J.* **89**, 419–425.

Lui, N. S. T. and Roels, O. A. (1969). 'Occurrence of retinol in biological membranes.' *Fedn Proc.* **28**, 490.

Moore, T. (1931). 'Vitamin A and carotene. VII. The distribution of vitamin A and carotene in the body of the rat.' *Biochem. J.* **25**, 275–286.

Moore, T. (1957). *Vitamin A*, p. 210. Amsterdam: Elsevier Publ. Co.

Moore, T. and Wang, Y. L. (1943). 'The toxicity of pure vitamin A.' *Biochem. J.* **37**, VIII–IX.

Randoin, L. and Causeret, J. (1947). 'Constitution d'un régime alimentaire équilibré pour les jeunes rats blancs destinés au dosage des vitamines A et D par les méthodes biologiques.' *Bull. Soc. scient. Hyg. aliment.* **35**, 14–22.

RINDI, G. and RAPUZZI, G. (1966). 'The action potential of cardiac ventricular fibre cells during thiamine deficiency.' *Quart. Jl exp. Physiol.* **51**, 249–255.

RINDI, G., VENTURA, U., CERIANI, T. and ZELASCHI, F. (1970). 'Action potential modifications in rat myocardial cells during vitamin A deficiency.' *Quart. Jl exp. Physiol.* **55**, 329–337.

RODHAL, K. (1950). 'Hypervitaminosis A in the rat.' *J. Nutrition.* **41**, 399–422.

SADHU, D. P. and TRUSCOTT, B. L. (1948). 'Hypervitaminosis A and the distribution of body iodine.' *Endocrinology.* **43**, 120–123.

SEWARD, C. R., MITCHELL, G. V. and HOVE, E. L. (1969). 'Some aspects of vitamin A deficiency or toxicity in intermediary metabolism.' *Am. J. clin. Nutrition.* **22**, 1014–1016.

UOTILA, U. (1938). 'Über die Schilddrüsenväranderungen bei A-, B-, C- und D-avitaminosen.' *Virchow's Archiv für pathologische Anatomie und Physiologie und für Klinische Medizin.* **301**, 535–546.

WHEELER, H. H. (1945). 'Effect of high vitamin A in the diet of domestic and non-domestic animals.' *Nature.* **156**, 238.