GLUTAMATES VOL 3 #39
COPIES OF ARTICLES CITED IN
MONOGRAPH SUMMARY PART I

Glutamates-Volume 3 #39 2/8/74

VOLUME 3

GRAS MONOGRAPH SERIES

GLUTAMATES

COPIES OF ARTICLES CITED IN MONOGRAPH SUMMARY (PART 1)

prepared for

THE FOOD AND DRUG ADMINISTRATION
DEPARTMENT OF HEALTH, EDUCATION
AND WELFARE

APRIL 30, 1973

prepared by

Tracor Jitco, Inc.

EXPERIMENTAL AND MOLECULAR PATHOLOGY 15, 43–60 (1971)

The Response of the Hypothalamus to High Doses of Monosodium Glutamate in Mice and Monkeys

Cytochemistry and Ultrastructural Study of Lysosomal Changes

R. ABRAHAM, W. DOUGHERTY, L. GOLBERG, AND F. COULSTON

Institute of Experimental Pathology and Toxicology, Albany Medical College, Albany, New York 12208

Received March 9, 1971

Administration of high doses (4 or 1 gm/kg) of monosodium-L-glutamate (MSG) in aqueous solution subcutaneously in 100 mice 5–7 days old produced changes in the arcuate nuclei and median eminence of the hypothalamus in 60% of treated mice given 4 gm/kg and in 42% of those receiving 1 gm/kg. The remaining mice appeared to be unaffected. The action of MSG was directed against both neuronal and glial cells. Corresponding doses of MSG given orally to 95 mice elicited a predominantly glial reaction in 28%. When four monkeys were given MSG (4 gm/kg) at 4 days of age, no distinction could be drawn between the appearance of the arcuate nuclei, median eminence, or ependymal cells in treated animals and the same structures in untreated controls. This species difference in susceptibility, as well as individual disparities among the mice, is probably attributable to the dissimilar degree of myelination of the central nervous system present at birth.

Cytochemical and ultrastructural studies on the hypothalamus of the affected mice demonstrated a significant increase in the number of lysosomes, with appearance of numerous myeloid bodies. The presumptive intermediate stage of autophagic vacuole formation was not seen. The lysosomal effects observed have served to delineate hitherto unsuspected changes in the cell cytoplasm in affected animals.

INTRODUCTION

There is a long-standing interest in the effects of amino acids as food additives. Amino acids are used to raise the nutritional value of foods and also to improve their palatability. Recently, much attention has been given to monosodium glutamate (MSG), a nonessential amino acid food additive that is used extensively as a flavor enhancer. A number of studies have produced contradictory information about the toxic effects in human adults as manifested by the "Chinese Restaurant Syndrome" (Schaumberg and Byck, 1968), and the production of lesions of the hypothalamus in newborn mice and monkeys (Olney, 1969b; Olney and Sharpe, 1969). Parenteral treatment of the neonatal mouse or rat with large doses of MSG readily induces degenerative changes in the retina (Lucas and Newhouse, 1957; Olney, 1969a).

As a result of these studies, the present investigation was undertaken in order to study the way in which MSG brings about its untoward effects. The production, by means of a chemical agent, of a selective lesion in the hypothalamus is

of considerable interest, particularly in view of the fact that this region of the brain controls the production of neurohypophyseal hormones, and releasing and inhibiting factors, that regulate the secretion of adenohypophyseal hormones (Kobayashi *et al.*, 1970).

The aim of the present investigation was twofold: first, to establish the facts concerning the relationship between dose of MSG, route of administration, and species of neonatal recipient of the material, secondly, to investigate in detail the nature and extent of the hypothalamic changes by cytochemical and ultrastructural methods. In pursuing this latter objective, it soon became evident that lysosomal effects were particularly worthy of attention, since they served to delineate the presence of subtle changes in cell cytoplasm that might otherwise have gone unrecognized.

MATERIALS AND METHODS

An aqueous solution (4% w/v) of monosodium-L-glutamate was administered to mice (5–7 days old, Swiss albino and C57BL strains) and rhesus monkeys (*M. mulatta*, 4 days old). The doses used were 4 gm/kg for monkeys and 4 gm/kg or 1 gm/kg for mice, given orally by stomach tube or by subcutaneous injection in the interscapular region. Control animals were given an equivalent amount of distilled water. The numbers of animals used are given in Table I. Groups of mice were decapitated at intervals ranging from 1 to 3 hours, 12, and 24 hours after administration of MSG. The brains were removed quickly and fixed for 6–24 hours in cold Zenker–formalin, formol–sucrose, or 5% glutaraldehyde in 0.1 *M* Sorensen buffer, pH 7.4.

Six monkeys were used for this study; two were given MSG orally by stomach tube; two received MSG by subcutaneous injection in the interscapular region. Of the two control monkeys, one was given an equivalent amount of distilled water by stomach tube, and the other subcutaneously. The animals were killed at 3 or 24 hours after treatment.

The hypothalami fixed in Zenker–formalin for light microscopy were, after dehydration, embedded in paraffin wax and sectioned at 5 μ thickness. Representative areas of the hypothalamus were stained by one of the following procedures: hematoxylin and eosin, gallocyanin, periodic acid–Schiff (McManus).

Frozen sections (15 μ) of hypothalamus that had been fixed in formol–sucrose were cut on a freezing microtome, and free-floating sections were used for histochemical staining. Acid phosphatase activity was demonstrated using both the technique of Gomori (1952) with β-glycerophosphate as substrate and the Barka and Anderson (1962) hexazotised pararosaniline method with naphthol AS-BT phosphate (Sigma). For the demonstration of β-glucuronidase, the medium of Hayashi *et al.* (1964) was employed, with naphthol AS-BI β-D-glucuronic acid (Sigma). The reaction was carried out by simultaneous coupling in the presence of hexazonium pararosaniline (pH 5.2) for 30 minutes.

In all instances, control sections were incubated in substrate-free media. Heat-inactivated sections (90° C for 5 minutes) incubated in complete media, were also used for controls.

For electron microscopy, small pieces of glutaraldehyde-fixed tissue from the

hypothalamic area were postfixed in a 1% solution of osmium tetroxide buffered with Sorensen's phosphate at pH 7.4, rapidly dehydrated in alcohol, and embedded in Epon 812. For histological and topographical comparisons by the light microscope, thicker sections (1–2 μ) were stained with toluidine blue. Thin sections from representative areas of the hypothalamus were examined in a RCA-EMU 4 electron microscope.

Acid phosphatase was demonstrated by the method of Holt and Hicks (1961) using tissue fixed in formol-sucrose. Frozen sections, 50 μ thick were cut on a freezing microtome, collected in cold 7.5% sucrose, and incubated for 15 minutes at 37° C in a Gomori medium.

RESULTS

Light Microscopy

The incidence of lesions produced by MSG is summarized in Table I. In mice given 4 gm/kg, the nature and severity of the histological changes seen in the area of the arcuate nuclei of the hypothalamus were found to depend on the route of administration. Thus an increase in microglial cells was seen in the arcuate nuclei of 28% of mice given MSG orally, but visible damage to neurones was minimal (Fig. 1). Within 3 hours of administration by the subcutaneous route, MSG produced pyknosis or necrosis of neuronal nuclei, associated with total loss of Nissl substance from necrotic cells. By 12–24 hours the neurones making up the arcuate nuclei were for the most part no longer visible; in 60% of the mice these neurones appeared to be replaced by infiltrating macrophages and microgliacytes (Fig. 2). Despite a thorough search, no effect of MSG was detected in the remaining 40% of treated mice. In 26% of mice given 1 gm/kg orally, damage was restricted to one to four neuronal cells of the arcuate nuclei (Fig. 3). The remaining mice of this group appeared to be completely unaffected by MSG.

TABLE I

OBSERVATIONS ON MICE AND MONKEYS GIVEN MSG

Species	Administration of MSG		Number of animals	
	Dose (gm/kg)	Route	Treated	Showing hypothalamic changes
Mouse	0	Oral	100	0
	0	Subcutaneous	100	0
	4	Oral	95	27
	4	Subcutaneous	60	36
	1	Oral	61	16
	1	Subcutaneous	26	11
Monkey	0	Oral	1	0
	0	Subcutaneous	1	0
	1	Oral	2	0
	1	Subcutaneous	2	0

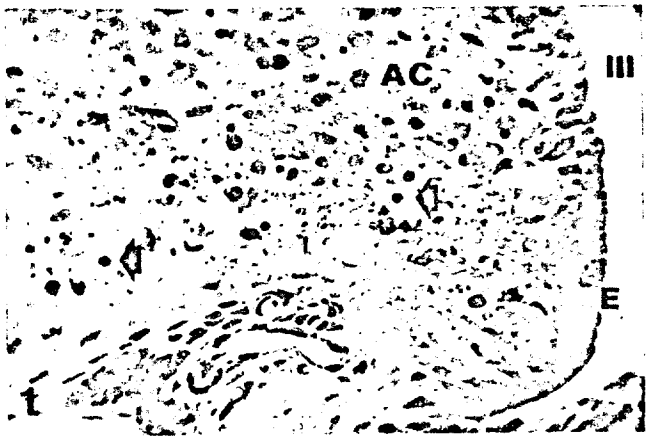

Note: Abbreviations used in figures: III, third ventricle; E, ependymal cells; AC, arcuate nucleus; ME, median eminence.

FIG. 1. Section of hypothalamus from mouse 3 hours after 4 gm/kg MSG given orally. There is an increase in glial cells, together with damaged neuronal cells (arrow). (Epon embedded, toluidine blue; ×480.)



FIG. 2. Section of hypothalamus from a mouse 24 hours after 4 gm/kg MSG given subcutaneously. A number of necrotic neuronal cells are visible in the area of the arcuate nucleus. (Epon embedded, toluidine blue; ×480.)

Enzyme Studies. The distinction between the glial effect of orally-administered MSG and the neuronal damage consequent upon subcutaneous injection of the same dose was clarified by histochemical study of acid phosphatase and β-glucuronidase activity. In the arcuate nuclei of the hypothalamus most of this enzyme activity is localized in the perikaryon in the form of perinuclear granules (Fig. 4). After oral administration of MSG (4 gm/kg), subtle changes were seen in lysosomal distribution; these alterations were restricted to a small area immediately adjacent to the third ventricle, in the arcuate nuclei close to the median eminence. In some neurones, only a slight loss of enzyme staining was seen, while



FIG. 3. Section of hypothalamus from mouse 3 hours after 1 gm/kg MSG given orally. The hypothalamus is normal, except for one or two damaged cells (arrow). (Epon embedded, toluidine blue; ×480.)

elsewhere aggregates of lysosomes formed in cells which appeared to be glial in origin (Fig. 5). Within 1–3 hours of subcutaneous injection of MSG (4 gm/kg), the loss of particulate acid phosphatase activity and appearance of diffuse enzyme staining suggested a striking labilization of lysosomal membranes. At 12 and 24 hours following subcutaneous administration, large aggregates of intensely-staining lysosomes were visible in glial cells, in regions formerly occupied by neuronal elements of the arcuate nuclei (Fig. 6).

In evaluating the effects of MSG on the hypothalamus of the monkey, careful attention was given to the method of dissection, fixation, and preparation of specimens for light microscopy. Thus, buffered formalin and Zenker-formalin was used for a special study of cell structure and Nissl substance in the neuronal and glial cells in paraffin-embedded sections. Formol-calcium was used to study the distribution of lysosomal acid phosphatase staining in fresh-frozen sections. Light-microscopic examination of the hypothalamus of the treated animals failed to show any adverse effect of MSG on the lateral preoptic nuclei, arcuate nuclei or median eminence (Fig. 7).

Electron Microscopy

Mice. The ultrastructure of the median eminence has been studied in the mouse (Oota, 1963) and rat (Scott and Knigge, 1970). In Fig. 8 is seen an example of a group of ependymal cells that line the third ventricle. These cells



FIG. 4. Section of hypothalamus from untreated mouse. Dark-stained granules (lysosomes) are seen in the perikaryon, distributed in close proximity to the cell nuclei. (Gomori's acid phosphatase; ×480.)



FIG. 5. Section of hypothalamus from mouse 3 hours after 4 gm/kg MSG given orally. The presence of small aggregates of lysosomes are visible in cells which are probably glial in origin. (Gomori's acid phosphatase; ×480.)

exhibit apical microvilli, tight junctions, and intercellular membranous interdigitation. Their cytoplasm is filled with arrays of rough endoplasmic reticulum and mitochondria. Following MSG treatment, membrane-delimited bodies containing amorphous material and lamellae accumulated in some of the ependymal cells (Fig. 9).



FIG. 6. Section of hypothalamus from mouse 24 hours after 4 gm kg MSG given subcutaneously. The pattern of lysosomal staining is drastically altered, with formation of numerous large aggregates in damaged neurones. (Gomori's acid phosphatase; ×480.)



FIG. 7. Section of hypothalamus from a monkey 24 hours after 4 gm kg MSG given orally. The region of the arcuate nucleus shows no sign of damage resulting from administration of MSG. A similar picture is seen after subcutaneous administration of MSG. (Hematoxylin and eosin; ×480.)

The arcuate nucleus in control mice contains clear and dark neurones, an observation made previously in rats by Jaim Etcheverry and Pellegrino de Iraldi (1968), and by Zambrano and de Robertis (1968). A clear neurone is shown in Fig. 10. Typical of such neurones is the large nucleus, with sparsely scattered

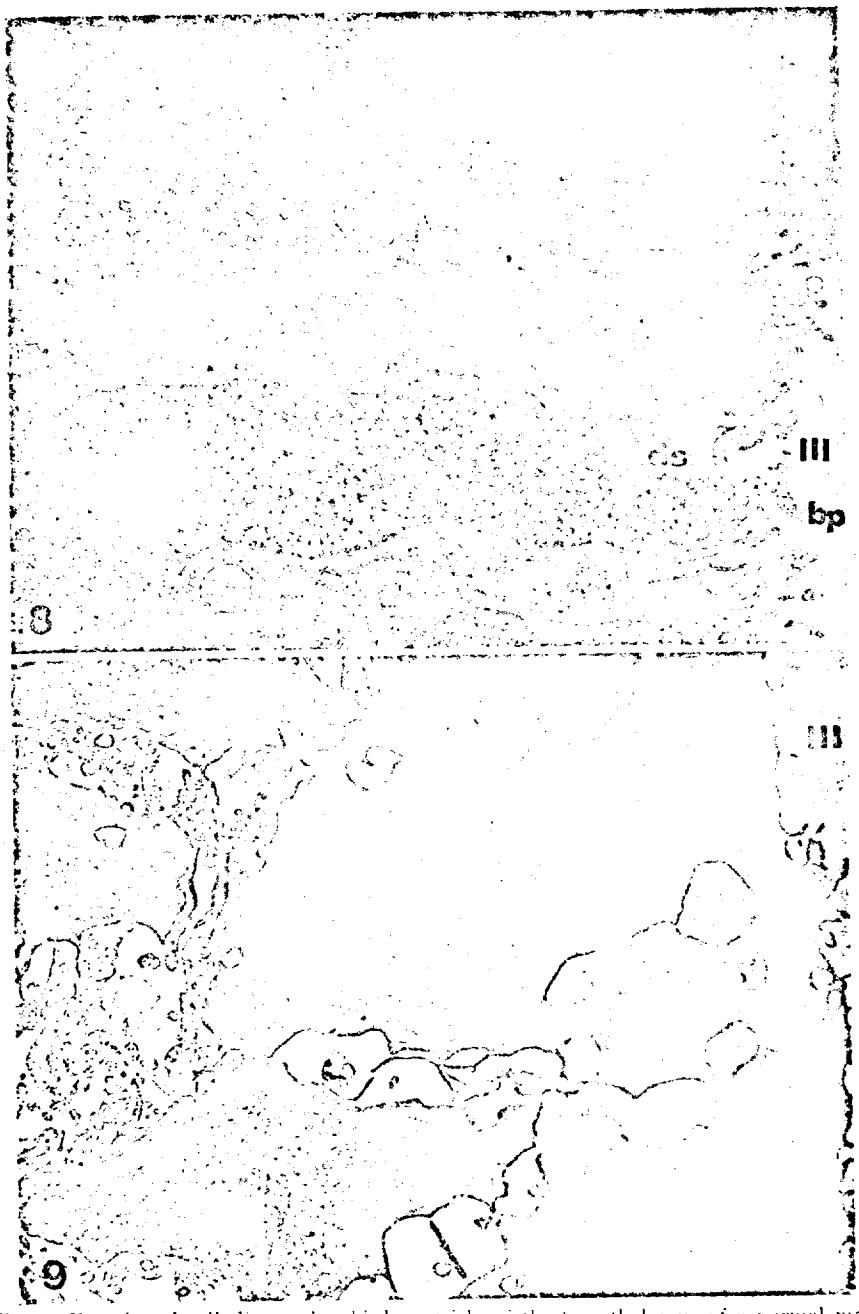

FIG. 8. Ependymal cells lining the third ventricle of the hypothalamus of a normal mouse. Numerous bulbous protrusions (BP) with small vesicles at the base, mitochondria (M), and desmosomes (DS) are seen. (×7400)

FIG. 9. Electronmicrograph of a similar area as in Fig. 8, but taken from an MSG-treated mouse. Note the membrane-delineated bodies (arrow) in the cytoplasm of ependymal cells. (×7400)

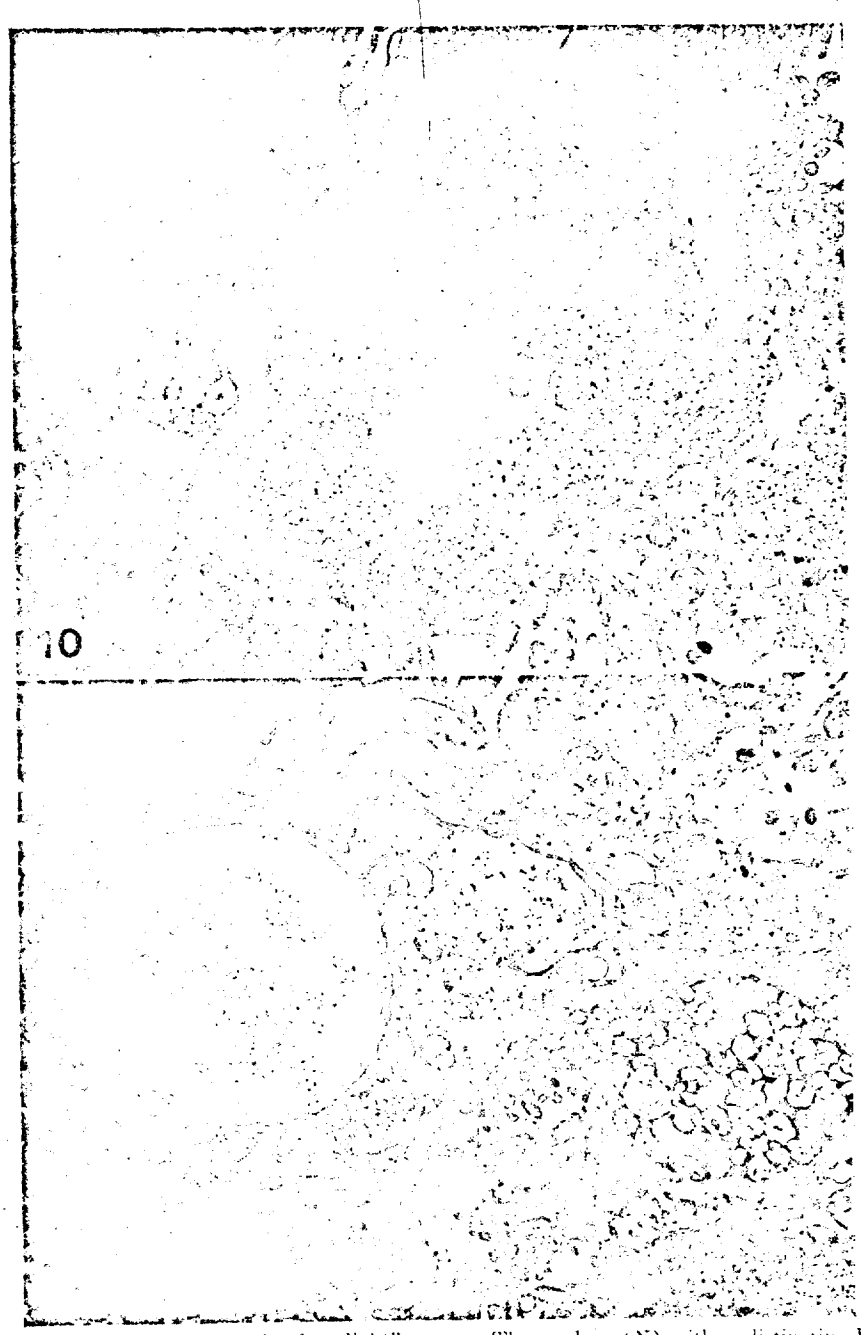

FIG. 10. Electronmicrograph of a "light" neuron. The nucleus (N) with a distinctive large nucleolus (NU), numerous mitochondria, and some dense bodies are seen. (×7400)

FIG. 11. Neuron from the arcuate nucleus of the hypothalamic region of an MSG treated mouse. Note the marked alteration of the arrangement of nuclear chromatin; together with lysis and destruction of almost all cellular structures. (×7400)

chromatin particles in the nuclear karyoplasm. The nucleus is distinguished by a conspicuous large spherical nucleolus. The cytoplasm is rich in ribosomes, either free or attached to the cisternae of endoplasmic reticulum. Numerous mitochondria and a few structures with the morphological characteristics of lysosomes are also observed.

Neurones and glial cells were damaged after MSG treatment. Ultrastructurally, as under the light microscope, a close correlation existed between the dose of MSG administered and the number of cells affected. The nuclei of damaged cells demonstrated marked alterations in the arrangement of nuclear chromatin. The cytoplasm was bare, reflecting lysis and destruction of almost all cellular structures (Fig. 11).

Electron Microscopic Cytochemistry

Numerous dense bodies containing the acid phosphatase or arylsulfatase reaction product have been observed in nerve cells (Holtzman, 1969). In experiments reported here, the acid phosphatase reaction product was sharply localized in dense bodies (lysosomes) and in the Golgi zone of both the ependymal and neuronal cells in control and experimental animals (Figs. 12, 13, and 16). Many myeloid bodies were observed in animals of the experimental group only, with the reaction product localized along the limiting membrane and also within the matrix (Figs. 13, 15, 17, and 18). The myeloid bodies contained cytomembranes, degenerating organelles whose origin was unrecognizable, and light and dense material. In spite of very careful observations at various time intervals after treatment, no definite autophagic vacuole (i.e., a lysosome containing a recognizable organelle) was seen.

Monkey. Alternate thick and ultrathin frontal sections of the hypothalamus were examined; these sections included the arcuate nuclei and median eminence. Thin sections were used for observations under the electron microscope; thick sections were stained by toluidine blue for light microscopy, and fresh-frozen sections were stained for lysosomal acid phosphatase. Meticulous examination of preparations obtained by these various techniques demonstrated that the hypothalamus in MSG-treated monkeys was normal and did not differ in any way from the hypothalamus in control monkeys.

DISCUSSION

Nature of Lesions Observed

The effect of MSG on the hypothalamus has been the subject of many recent experimental studies (Olney, 1969b; Olney and Sharpe, 1969; Olney and Ho, 1970; Adamo and Ratner, 1970; Arees and Mayer, 1970). Olney *et al.* have described a lesion in the arcuate nuclei and median eminence of the hypothalamus, produced in infant mice and in one newborn monkey. The damage was present in neuronal cells but not in glial cells. Olney (1969a) had suggested that MSG induced retinal degeneration in neonatal mice through a primary effect on the vasculature, leading to ischemic necrosis with marked alterations in mitochondrial structure. The evolution of the lesion was similar to that described by Shakib and Ashton

FIGS. 12–18. Material obtained from normal or MSG-treated mice, fixed in cold formol-sucrose, and incubated for acid phosphatase activity as described in the text.

FIG. 12. Electronmicrograph of ependymal cells from a normal mouse. Enzyme activity is present in lysosomes and Golgi elements in some of the ependymal cells. Partial staining of one or two of the nuclear membranes is nonspecific. (×5300)

(1966), who produced retinal ischemia by microembolization of the retinal vessels of the pig by means of glass spheres. Further evidence of an ischemic, rather than a direct retinotoxic action in the retinae of MSG-treated mice was provided by Deichman *et al.* (1971). The lesion in the hypothalamus, however, seems not to involve a primary action on the vascular components.

In contrast to the results in mice, Adamo and Ratner (1970) reported that they observed no adverse effect of MSG on the hypothalamus of infant rats. Arees and Mayer (1970), working with both adult and infant albino mice treated



FIG. 13 Ependymal cells from MSG-treated mouse display a variety of lysosomes, some of which have inclusions. (× 5300)

with MSG, found that the lesion in the hypothalamus involved primarily microglial cells, with no effect on the perikarya of neurones. These authors also proposed that the degenerating microglial cells were not the direct target sites of MSG, but may have infiltrated into the hypothalamus from some hitherto unrecognized site of damage in the nervous system.

The results reported here indicate that MSG did produce a lesion in the arcuate nuclei of the hypothalamus, in a proportion of mice given relatively large doses of MSG by the oral or subcutaneous route. The incidence of the lesion was much higher in the subcutaneously-treated group, and the effect was predominantly on neurones, whereas MSG by the oral route elicited a brisk response of infiltrating microglial cells. Electron-microscopic examination revealed severe

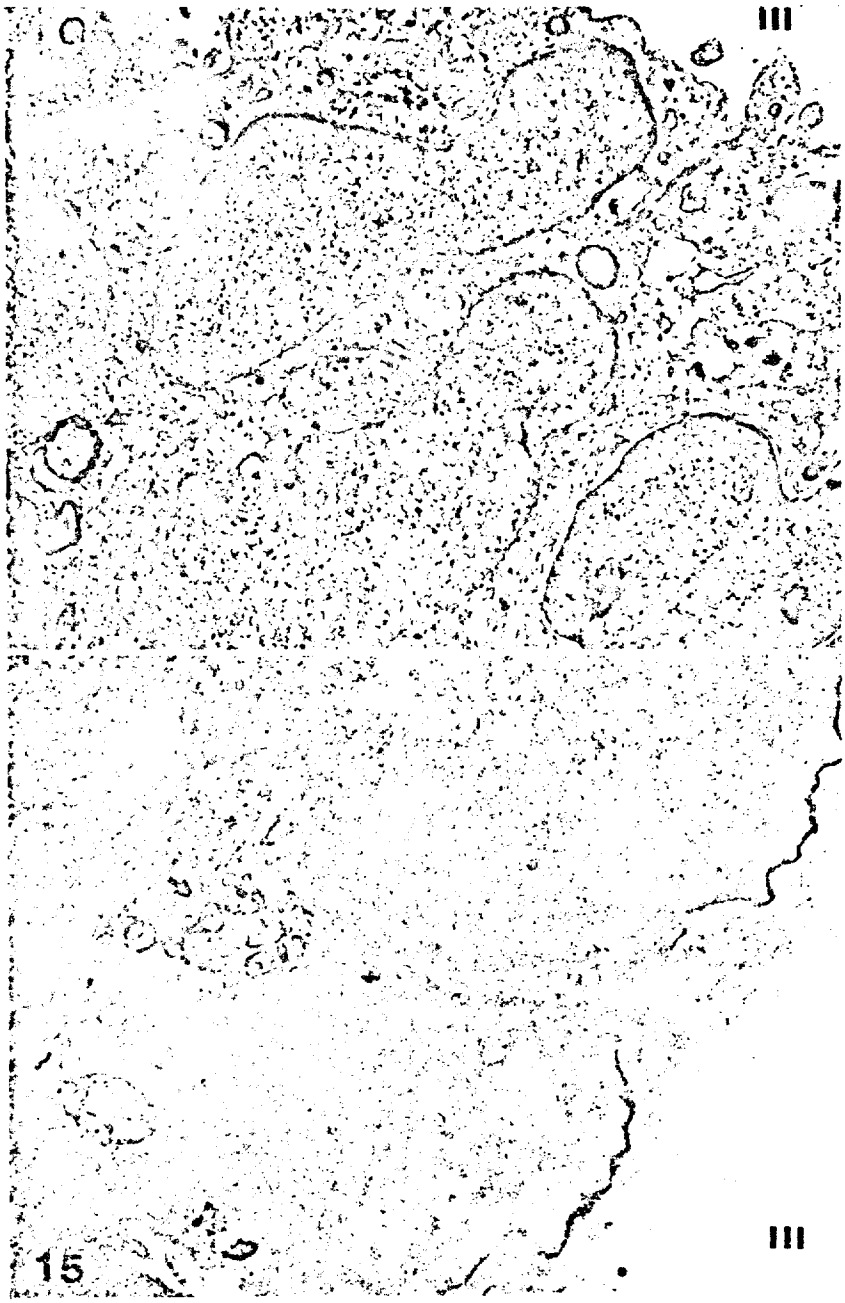

FIGS. 14 and 15. A high-power view of the types of myeloid bodies (arrows) seen in the cytoplasm of ependymal cells in close proximity to the third ventricle from different MSG-treated mice; staining of the Golgi elements is also observed. (×7400)

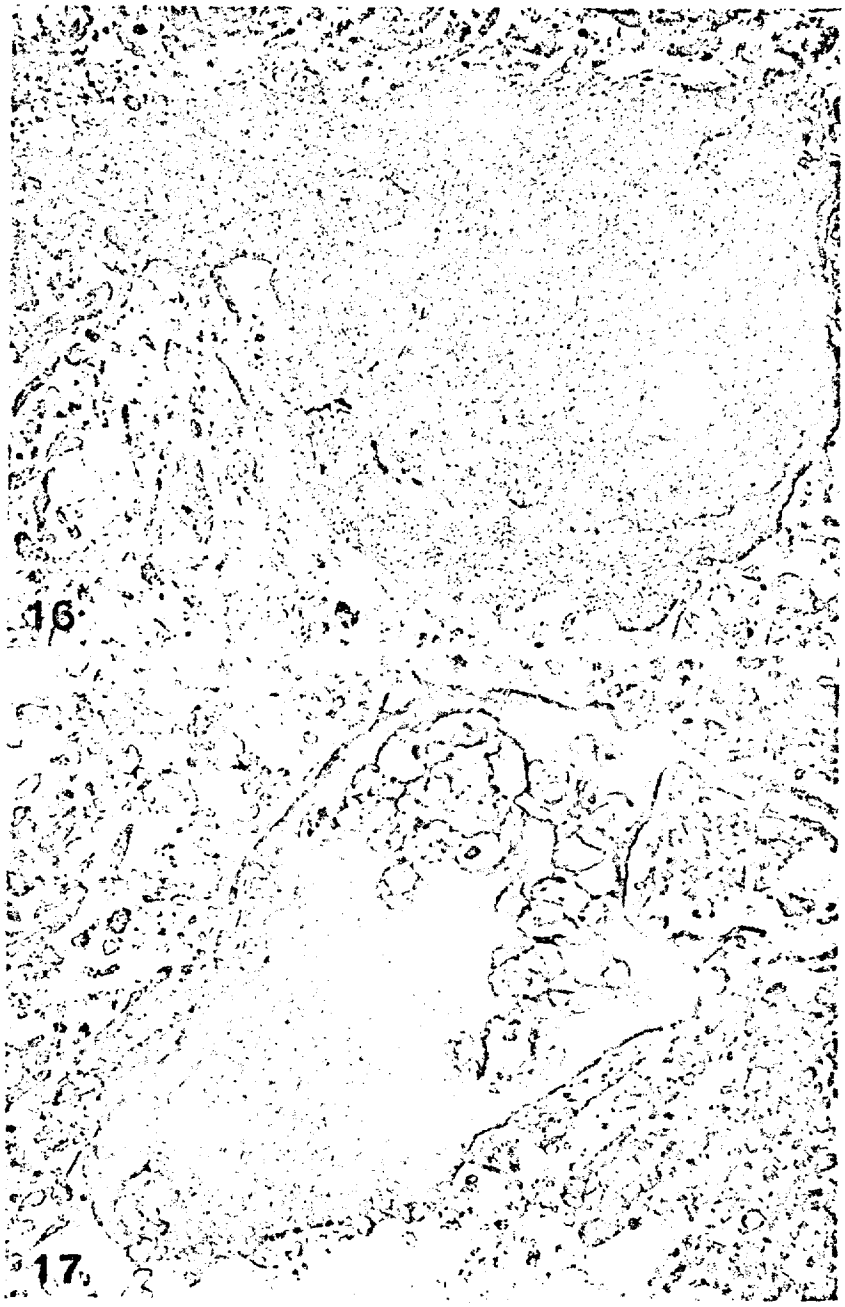

FIG. 16. A neuronal cell obtained from the arcuate nucleus of the hypothalamus of a normal mouse. Enzyme staining is mostly restricted to the Golgi region and an occasional dense body. (×7400)

FIG. 17. A neuronal cell taken from a similar area as in Fig. 16, but obtained from an MSG-treated mouse. The cytoplasm of this cell is strongly stained. Many vacuoles have membranous inclusions and stain for acid phosphatase. (×7400)



FIG. 18. A group of neuronal cells from the arcuate nucleus of the hypothalamus of an MSG treated mouse. Two of the neurones are damaged, as reflected by the increase in acid phosphatase staining of their cytoplasm. Numerous vesicles and membranous inclusions also show faint staining for this enzyme. (×5000)

damage to neuronal cells with loss of Nissl substance. Formation of membranous inclusions occurred both in neuronal cells and in microglial cells. The distinction between these two types of cells is difficult to draw under the electron microscope, even more so after damage has been induced; but cytochemical observations make it clear that marked alterations occurred in the lysosomes of both neuronal and glial cells in the hypothalamus.

The lack of MSG effect on the hypothalamus of the monkey is at variance with the observations of Olney and Sharpe (1969). These authors based their report on findings in one premature infant monkey, but our studies, supported by

cytochemical observations at both the light and ultrastructural level, do not indicate any difference between the control and experimental monkeys.

Possible Basis for Species Differences

The key to understanding the varied effects of MSG on mice and monkeys appears to be the permeability of the blood-brain barrier, consequent upon the disparate degrees of myelination of the central nervous system attained at birth. In rats, rabbits, and mice, myelination starts 10–15 days after birth, whereas in the higher animals and man the myelination process begins *in utero* and its rate reaches a maximum just before birth (Davison and Dobbing, 1966). In view of the incomplete state of myelination in newborn rodents, glutamate might be expected to cross the blood-brain barrier readily. Well-developed myelination in newborn monkeys and human neonates (Davison and Dobbing, 1966) may effectively protect them from the adverse consequences of large doses of MSG.

The very different effects of oral and parenteral administration of massive amounts of MSG may be related to the rates of entry of glutamate (and possibly alanine) into the central nervous system. Thus the tissue responses reflect a summation of factors such as rate of intestinal absorption, transamination within the intestinal epithelium, and rates of movement across the blood-brain barrier (McLaughlan *et al.*, 1970).

Effects on Lysosomes

The lysosomal changes observed in the affected mice were dramatic. One hour after the administration of monosodium glutamate, many myeloid bodies were observed in the ependymal, glial, and neuronal cells of the hypothalamus of the mice, together with loss of acid phosphatase staining. The observation that MSG affects all the cell types in the arcuate nucleus of the hypothalamus is not in accordance with the electron microscopic observations of Arees and Mayer (1970). These authors reported that the lesions involved primarily microglial cells, whose cytoplasm had an increased number of lysosomes and myeloid bodies, with no effect on the perikarya of neurones.

Neuronal cells subjected to mechanical injury or exposed to drugs, such as chlorpromazine and chloroquine, accumulate myeloid bodies in their perikarya (Holtzman *et al.*, 1967; Brosnan *et al.*, 1970; Abraham and Hendy, 1970). In all these instances the formation of myeloid bodies is preceded by the appearance of autophagic vacuoles. Careful observation of the hypothalamic cells did not reveal autophagic vacuoles during the course of the experiment. The sequence of events in lysosomes leading to the formation of myeloid bodies after treatment with monosodium glutamate is, therefore, not clear. It is likely that myeloid bodies result through changes occurring in the multivesicular bodies. It has been suggested by Smith and Farquhar (1966), and Holtzman and Dominitz (1968), that multivesicular bodies in the cells of the pituitary and adrenal medulla correspond to autophagic vacuoles occurring in other tissues. Another explanation given by Pick (1965) is that myeloid bodies arise *de novo* or by direct transformation of preexisting dense bodies.

It is not clear from our experiments whether monosodium glutamate has a direct or indirect effect on lysosomal membranes. Excess of dietary amino acids, particularly phenylalanine, leads to a decrease in brain weight and in formation of brain lipids and sulfatides in infant rats (Chase and O'Brien, 1970). If these effects are mediated by changes in the structure or function of cellular membranes, it seems likely that such altered or damaged membranes would then be sequestrated by lysosomes, resulting in the formation of myeloid bodies.

Our experiments demonstrated that administration of large amounts of MSG produced myeloid bodies in neuronal and glial cells of the hypothalamus. The significance of the formation of these myeloid bodies is not known. It has been suggested (Holtzman *et al.*, 1967) that increased numbers of lysosomes and their derivatives in nerve cells play a role in the metabolism of nucleoproteins and other macromolecules during adaptive changes in cells. It is also likely that these myeloid bodies might be expected to be more fragile than the primary lysosomes, and could release their enzymes with consequent destruction of cell cytoplasm, an event associated with the disappearance of neurones noted in histological sections.

ACKNOWLEDGMENTS

We thank Dr. A. G. Ebert of International Minerals and Chemical Corporation for providing the MSG and for his valuable cooperation. This research was supported by Research Grant *P*-01-ES-226-02 from the National Institute of Environmental Health Sciences, NIH, USPHS, by the National Institutes of Health Training Grant 5T01-ES 000103-03, and by the P.M.A. Foundation. We wish to thank Mrs. Margaret Colley and Mr. Jan Swart for excellent technical assistance.

REFERENCES

Abraham, R., and Hendy, R. J. (1970). Irreversible lysosomal damage induced by chloroquine in the retinae of pigmented and albino rats. *Exp. Mol. Pathol.* **12,** 185–200.

Adamo, N. J., and Ratner, A. (1970). Monosodium glutamate: Lack of effects on brain and reproductive function in rats. *Science* **169,** 673–674.

Arees, E. A., and Mayer, J. (1970). Monosodium glutamate-induced brain lesions: Electron microscopic examination. *Science* **170,** 549–550.

Barka, T., and Anderson, P. J. (1962). Histochemical methods for acid phosphatase using hexazonium pararosaniline as coupler. *J. Histochem. Cytochem.* **10,** 741–753.

Brosnan, C. F., Bunge, M. B., and Murray, M. R. (1970). The response in cultured neurons to chlorpromazine. *J. Neuropathol. Exp. Neurol.* **29,** 337–353.

Chase, H. P., and O'Brien, D. (1970). Effect of excess phenylalanine and of other amino acids on brain development in the infant rat. *Pediat. Res.* **4,** 96–102.

Davison, A. N., and Dobbing, J. (1966). Myelination as a vulnerable period in brain development. *Brit. Med. Bull.* **22,** 40–44.

Deichman, C., Smith, R. S., and Abraham, R. (1971). Effects of monosodium glutamate on retinal vasculogenesis. *Association for Research in Ophthalmology*, Sarasota, Florida.

Etcheverry, G. J., and de Iraldi, A. P. (1968). Ultrastructure of neurons in the arcuate nucleus of the rat. *Anat. Rec.* **160,** 239–254.

Gomori, G. (1952). "Microscopic Histochemistry: Principles and Practice." University of Chicago Press, Chicago, Illinois.

Hayashi, M., Nakajima, Y., and Fishman, W. H. (1964). The cytologic demonstration of β-glucuronidase employing naphthol AS-BI glucuronide and hexazonium pararosaniline: A preliminary report. *J. Histochem. Cytochem.* **12,** 293–297.

HOLT, S. J., and HICKS, R. M. (1961). The localization of acid phosphatase in rat liver cells as revealed by combined cytochemical staining and electron microscopy. *J. Biophys. Biochem. Cytol.* **11**, 47–66.

HOLTZMAN, E. (1969). Lysosomes in the physiology and pathology of neurons. *In* "Lysosomes in Biology and Pathology" (J. T. Dingle and H. B. Fell, eds.), Vol. 1, pp. 192–216. North-Holland Publishing Company, Amsterdam.

HOLTZMAN, E., and DOMINITZ, R. (1958). Cytochemical studies of lysosomes, golgi apparatus, and endoplasmic reticulum in secretion and protein uptake by adrenal medulla cells of the rat. *J. Histochem. Cytochem.* **16**, 320–336.

HOLTZMAN, E., NOVIKOFF, A. B., and VILLAVERDE, H. (1967). Lysosomes and Golgi in normal and chromatolytic neurons of the rat ganglion nodosum. *J. Cell Biol.* **33**, 419–436.

KOBAYASHI, H., MATSUI, T., and ISHII, S. (1970). Functional electron microscopy of the hypothalamic median eminence. In "International Review of Cytology" (G. H. Bourne and J. F. Danielli, eds.), Vol. 29, pp. 281–381. Academic Press, New York.

LUCAS, D. R., and NEWHOUSE, J. P. (1957). The toxic effect of sodium-L-glutamate on the inner layers of the retina. *Arch. Ophthal.* **58**, 193–201.

MCLAUGHLAN, J. M., NOEL, F. J., BETTING, H. G., and KNIPFEL, J. E. (1970). Blood and brain levels of glutamic acid in young rats given monosodium glutamate. *Nut. Rep. Int.* **1**, 131–138.

OLNEY, J. W. (1969a). Glutamate-induced retinal degeneration in neonatal mice. Electron microscopy of the acutely evolving lesion. *J. Neuropathol. Exp. Neurol.* **28**, 455–474.

OLNEY, J. W. (1969b). Brain lesions, obesity, and other disturbances in mice treated with monosodium glutamate. *Science* **164**, 719–721.

OLNEY, J. W., and HO, OI-LAN (1970). Brain damage in infant mice following oral intake of glutamate, aspartate or cysteine. *Nature (London)* **227**, 609–610.

OLNEY, J. W., and SHARPE, L. G. (1969). Brain lesions in an infant rhesus monkey treated with monosodium glutamate. *Science* **166**, 386–388.

OOTA, Y. (1963). Fine structure of the median eminence and pars nervosa of the mouse. *J. Fac. Sci. Univ. Tokyo.* **10**, 155–168.

PICK, J. (1965). The fine structure of sympathetic neurons in x-irradiated frogs. *J. Cell Biol.* **26**, 335–351.

SCHAUMBERG, H. H., and BYCK, R. (1968). Sin Cibo-Syc: Accent on glutamate. *New Engl. J. Med.* **279**, 105.

SCOTT, D. E., and KNIGGE, K. M. (1970). Ultrastructural changes in the median eminence of the rat following deafferentation of the basal hypothalamus. *Z. Zellforsch.* **105**, 1–32.

SHAKIB, M., and ASHTON, N. (1966). Part II. Ultrastructural changes in focal retinal ischaemia. *Brit. J. Ophthalmol.* **50**, 325–384.

SMITH, R. E., and FARQUHAR, M. G. (1966). Lysosome function in the regulation of secretory process in cells of the anterior pituitary gland. *J. Cell Biol.* **31**, 319–347.

ZAMBRANO, D., and DE ROBERTIS, E. (1968). The effect of castration upon the ultrastructure of the rat hypothalamus. II. Arcuate nucleus and outer zone of the median eminence. *Z. Zellforsch.* **87**, 409–421.

50

Monosodium Glutamate: Lack of Effects on Brain and Reproductive Function in Rats

Abstract. *Monosodium glutamate was injected subcutaneously in infant rats both sexes. The lateral preoptic and arcuate nuclei and median eminence were mined by light and electron microscopy for possible monosodium glutamate cts. As adults, treated animals showed no adverse monosodium glutamate cts on the reproductive system and neural morphology.*

lney (*1*) reported that a single sub- aneous injection of monosodium tamate (MSG) in newborn mice (2 9 days of age) induced acute neu- al necrosis in several brain areas in- ding the preoptic and arcuate nuclei median eminence region. Newborn e which received a series of injec- s of MSG, when adult showed a drome which suggested a compli- d neuroendocrine disturbance. e mice exhibited skeletal stunting, ked obesity, and female sterility. ale brain damage was also found in wborn rhesus monkey after a single ministration of MSG (*2*). This report concerned with both the acute and g-range effects of MSG upon the de- pment of the brain and reproductive ction of male and female rats after gle injection of MSG into newborn mals. The rat was chosen for these es because Olney (*1*) and Olney Sharpe (*2*) stated that acute hypo- amic lesions also are produced in and also because injections of hor- nes (*3*) and drugs (*4*) at a "critical e" of neonatal development can tically effect hypothalamic control chanisms as related to reproduction sexual behavior.

Male and female rats of the Wistar an (Simonson Laboratories, Califor- 3 to 4 days old, received a single taneous injection of MSG. The G (Mann Research Laboratories) jected subcutaneously in a volume ml: the total dose was 4 mg per of body weight. This concentra- approximately four times greater than the minimum dosage which produced hypothalamic lesions in newborn mice (*1*) and a newborn monkey (*2*). Control rats were injected with an equal volume of saline. In experiments concerned with the acute effects of MSG on the brain, the animals were killed 3 hours posttreatment. To determine long-range effects of MSG, uniform litters (eight pups per mother) were kept in an environmentally controlled room until weaned. The experiment was terminated at 68 days posttreatment for males and 88 days posttreatment for females. Relative reproductive organ weights were recorded (organ weight per unit body weight). The anesthetized rats were perfused intracardially with normal saline followed by either 10 percent buffered formalin or Flickinger's fixative (*p*H 7.2). Brains perfused with formalin were paraffin embedded, sectioned, and stained with cresyl violet for light microscopy. Brains perfused with Flickinger's modification of Karnovsky's fixative (*5*) were sectioned transversely, and the preoptic nucleus, median eminence, and arcuate nucleus were dissected out. The tissue was washed in 0.2*M* cacodylate buffer (*p*H 7.2), postfixed in 1 percent cacodylate-buffered osmium tetroxide for 1 hour, dehydrated in graded alcohols, and embedded in Epon 812. Silver and gray sections were stained with uranyl acetate followed by lead citrate and examined in a Hitachi HS-7S electron microscope.

Light microscopic examination of the

Table 1. Effect of monosodium glutamate (MSG) injection in infant rats on adult reproductive organ weights. Organ values are the mean ratios of organ weight (in milligrams or grams, as noted below) to body weight (in hundreds of grams), plus or minus the standard error of the mean.

Group	Females			Males			
	No. of rats	Ovaries (mg/100 g)	Uterus (mg/100 g)	No. of rats	Testes (g/100 g)	Seminal vesicles (mg/100 g)	Prostate (mg/100 g)
Control	7	34.7 ± 0.9	162.9 ± 9.4	8	1.02 ± .03	244.9 ± 17.0	120.7 ± 9.9
MSG-treated	8	29.3 ± 1.4*	179.8 ± 10.8	6	1.06 ± .06	287.0 ± 16.8	118.3 ± 3.5

* The difference from the value for the control group is significant at the $P < .01$ level.

Fig. 1. Neuron (*N*) and neuropil of the lateral preoptic nucleus in an MSG-treated adult rat. *Ax*, axon terminal; *D*, dendrite; *M*, mitochondrion; *My*, myelinated axon (× 16,300).

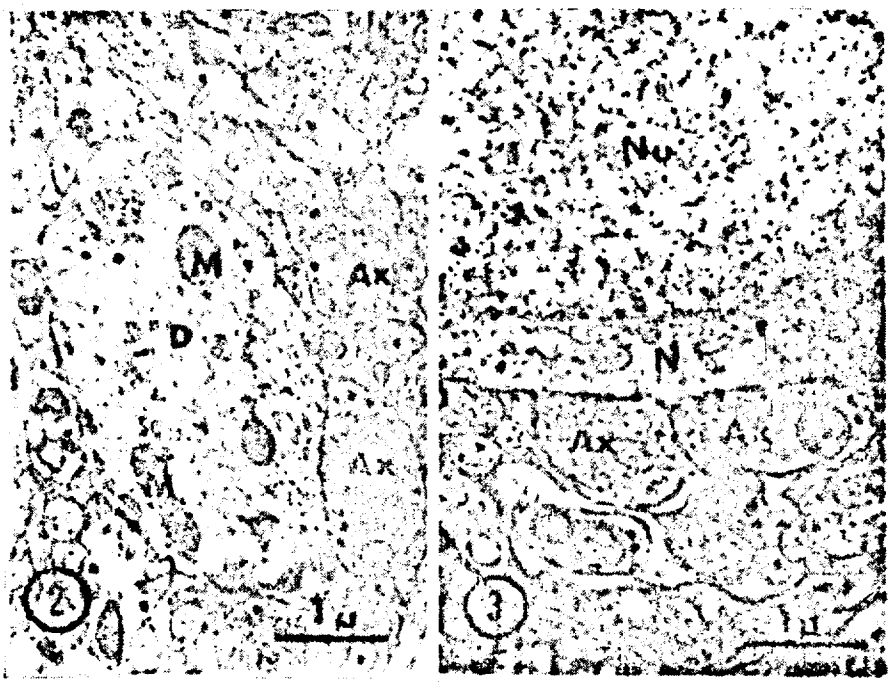

Fig. 2. Dendrite (*D*) in neuropil of m dian eminence of an MSG-treated ad rat. *Ax*, axon terminal; *M*, mitochondri (× 15,000). Fig. 3. Neuron neuropil in the arcuate nucleus of MSG-treated adult rat. *Ax*, axon termi *M*, mitochondrion; *Nu*, nucleus 16,300).

brains of the infant rats killed 3 hours after a single injection of MSG failed to reveal any effects upon the lateral preoptic nucleus, arcuate nucleus, and median eminence. The possibility still existed that the single injection of MSG could have produced effects which were not obvious with the light microscope; therefore, the same neural regions from male and female adult rats were examined with the electron microscope. Electron microscopic observations of the lateral preoptic nucleus, arcuate nucleus, and median eminence region did not show any edematous swelling or disintegration of organelles in neurons or neuronal processes such as was illustrated by Olney (*2*) in the infant monkey. There was no indication that such damage had ever occurred (Figs. 1–3). These areas were also examined with respect to distribution of neurons and glia, distribution and size of axon terminals and dendrites, nucleolar size, and distribution of dense-core and clear vesicles. No differences were observed between MSG-treated and control animals.

Not only were no morphological lesions of the brain detectable after MSG treatment, but adult animals also did not manifest any pronounced disturbances with respect to reproductive function. The lack of MSG effect was determined by the following criteria: (i) adult MSG-treated females cycled normally and were capable of mating and producing normal litters; (ii) although the relative ovarian weights were significantly less than the controls (34.7 ± 0.9 versus 29.3 ± 1.4, $P < .01$), no differences were noted when the ovaries were examined histologically; (iii) the relative uterine weights were not significantly different; and (iv) no significant differences were observed in the weights of testes, seminal vesicles, and prostates of MSG-treated males compared to controls (Table 1).

These results fail to duplicate the findings reported in mice and monkey by Olney (*1*) and Olney and Sharpe (Since the experimental approaches u in the present study and reported Olney are very similar, it is difficult determine the cause of the discrepan at this time. However, the possibl exists that the differences may be du variation in species susceptibility.

N. J. Ad
A. Rat

Departments of Anatomy and Physiology, University of New Me School of Medicine, Albuquerque

References and Notes

1. J. W. Olney, *Science* **164**, 719 (1969).
2. ——— and L. G. Sharpe, *ibid.* **166**, 386 (19
3. C. A. Barraclough, in *Neuroendocrinolog* Martini and W. F. Ganong, Eds. (Acade Press, New York, 1967), p. 61; ——— R. A. Gorski, *J. Endocrinol.* **25**, 175 (196
4. A. Corbin, F. Fraschini, A Carraro, L. M tini, *Program of the 46th Meeting of Endocrine Society*, San Francisco, p. 24 (19
5. C. J. Flickinger, *Z. Zellforsch. Mikros Anat.* **78**, 92 (1967).
6. Supported by a research grant from the N tional Institute of Neurological Diseases Stroke (5 R01 NS07557-02) to N.J.A. and N grant GB 8084 to A.R.

11 May 1970

Science
169: 673-4
Aug. 14 1970

168

UDC 612.64.046:615.739.6+591.392.1

STUDY OF THE TERATOGENIC ACTIVITY OF SOME AMINO ACIDS IN EXPERIMENTS ON CHICKEN EMBRYOS

P.N. Aleksandrov, V.A. Bogdanova, A.M. Chernukh

Department of Chemotherapy (Head -- Prof. A.M. Chernukh), Institute of Pharmacology and Chemotherapy (Director -- Prof. V.V. Zakusov, member AMS USSR) AMS USSR, Moscow

Data exist on the effect of certain amino acids and their analogs on chicken-embryo development. For example, glycocoll suppresses the development of the embryo, while methionine, injected simultaneously with ethionine, prevents completely the affection caused by the ethionine by blocking the processes of growth and differentiation [5].

It has been shown by experiments in vitro that phenylalanine also inhibits the indicated operation of ethionine [10]. Other works disclose that the analogs of the aromatic amino acids β-2-thionilalanine and β-0-phenylalanine cause retardation of growth accompanied by pathological changes of the nerve tube and somites. Phenylalanine suppresses the influence of β-2-thionilalanine on restraining growth but does not inhibit the effect produced by β-0-phenylalanine [6, 8]. The absence of such amino acids as threonine, arginine, and tryptophan in an artificial nutritive medium inhibits the growth of tibial and femoral bones of 6-7-day chicken embryos [4].

Pathol. Fiziol. Eksp. Ter. 10 (6): 53-56 (1966

At the same time, we did not find any data on the teratogenic influence of amino acids on chicken embryos. In studying the teratogenic activity of intermediate products of thalidomide synthesis, however, we discovered that glutamic acid in intravitelline administration causes defects in the development of chicken embryos.

We studied in this connection the influence of certain interchangeable and noninterchangeable amino acids on teratogenic activity.

The experiments were carried out with fertilized chicken eggs. We used DL-glutamic acid, glycocoll, L-cysteine, L-cysteine hydrochloride, DL-α-aminobutyric acid, DL-tryptophan, DL-methionine, and L-β-phenyl-α-alanine. All these amino acids were administered once intravitellinely prior to incubation in a dose of 1 mg in a 0.1 ml physiological solution. The fertilized eggs were incubated at 38°C and 60 percent relative humidity. Observation of the developing embryo with the help of an ovoscope was continued from the 3rd to the 14th day of incubation. Dead embryos were removed and studied for macroscopic changes.

Visual disclosure was made of defects in the development of the brain, eyes, beak, abdominal and internal organs, spine, and extremities. Irregular extrusions of its various divisions were found in the brain. The beak was either smaller in its entirety or its upper or lower parts were observed to be retarded in development. Nonclosure of the

the abdominal wall and protrusion of organs of the thoracic and abdominal cavities were frequently observed. Developmental defects of the extremities were manifested in the form of twisting and shortening. Imperfect development of the spine produced twisting and shortening of the body of the embryo.

The figure shows several embryos with developmental defects that arose following administration of the amino acids. In the wake of introduction of glycocoll, defects were noted of the beak, absence of both eyes, shortening of the spine, nonclosure of the abdominal wall, and evisceration. The administration of DL-L-aminobutyric acid produce defects of the brain, eyes, beak, nonclosure of the abdominal cavity, and evisceration. The injection of L-β-phenyl-α-alanine is accompanied by disrupted development of the brain, eyes, and twisting of the body axis of the embryo.

The embryos shown in the drawing do not reflect the entire diversity of developmental disturbances. More detailed data are presented in the table, from which it can be seen that the controls show 3.6 percent of the embryos to have defects and that those injected with physiological solution disclosed that 7 percent were afflicted. The greatest number of defects in embryos were found following administration of DL-tryptophan, glycocoll, and DL-glutamic acid, amounting to 17, 20, and 25 percent respectively.

The table gives the number of embryos with defects as well as the total number of defects. The relation of the

Table.

(1) Введенное вещество	(2) Число эмбрионов в опыте	(3) Число эмбрионов с дефектами: (4) до 5-го дня инкубации	(5) после 5-го дня инкубации	(6) % эмбрионов с дефектами	(7) Число дефектов развития (визуально) в различных органах: (8) производные эктодермы: (10) мозг	(11) глаз	(12) клюв	(9) производные мезодермы: (13) брюшная стенка	(14) конечности	(15) тело	(16) всего дефектов	(17) КИ	(18) КС
(19) Контроль	110		4	3,6	2	1	1	1	3	2	10	2,5	0,7
(20) Физиологический раствор	57		4	7	1	1	1	2	2	1	8	2,0	0,6
(21) l-цистин	40	2	2	10	2	1	1			3	8	4,0	1,0
(22) l-β-фенил-α-аланин	40	1	4	12	4	3	1			1	9	2,2	0,8
(23) dl-метионин	40		5	12	3	1	1	2	1		8	1,6	1,7
(24) dl-α-аминомасляная кислота	40	2	3	12	5	2	1	2	1	3	14	4,7	1,3
(25) l-цистеинхлоргидрат	40	1	5	15	4	2	4	3	2	5	20	4,0	1,8
(26) dl-триптофан	40	3	4	17	4	4	2	3	2		15	3,7	2,0
(27) гликокол	40	1	7	20	5	6	2	1	1	3	18	2,6	2,6
(28) dl-глютаминовая кислота	43		11	25	7	7	4	4	5	4	31	2,8	1,4

(1) Injected substance

(2) Number of embryos in experiment

(3) Number of embryos with defects

(4) Up to the 5th day of incubation

(5) After the 5th day of incubation

(6) Percentage of embryos with defects

(7) Number of developmental defects (visually) in different organs

(8) Derived from the ectoderm

(9) Derived from the mesoderm

(10) Brain

(11) Eye

(12) Beak

(13) Abdominal wall

(14) Extremities

(15) Body

(16) Total defects

(17) CI

(18) CS

(19) Control

(20) Physiological solution

(21) L-cystine

(22) L-β-phenyl-α-alanine

(23) DL-methionine

(24) DL-α-aminobutyric acid

(25) L-cysteine hydrochloride

(26) DL-tryptophan

(27) Glycocoll

(28) DL-glutamic acid

second quantity (number of defects) to the first (number of embryos with defects) constitutes the coefficient characterizing the degree of deformness in one embryo. This coefficient was called arbitrarily the coefficient of intensity (CI). The bigger the CI, the greater the disruption of development. As can be seen from the table, the most numerous defects of development occur in embryos following the administration of DL-α-aminobutyric acid (CI = 4.7), L-cystine and L-cysteine (CI = 4.0), and DL-tryptophan (CI = 3.7).

Figure. The influence of a 1-mg dose of amino acids on an egg on the development of chicken embryos (scale not adhered to).

a - control, 11-day embryo; b - injection of glycocoll, 12-day embryo; c - injection of L-cystine, 9-day embryo; d - injection of DL-α-aminobutyric acid, 7-day embryo; e - injection of L-β-phenyl--α-alanine, 5-day embryo.

[See page 54 of text.]

The table also contains a coefficient of the relation of defects of ectodermal origin to defects of mesodermal origin. This coefficient, which we arbitrarily call the coefficient of specificity (CS), characterizes the primary suppression of embryos of ecto- and mesodermal origin by the investigated compounds.

The CS in the control is 0.7. Clearly, among the spontaneously occurring defects, developmental disturbances of embryos of mesodermal origin are predominant.

The administration of L-cystine and L-cysteine resulted in an identical number of defects of ecto- and mesodermal origin (CS + 1.0). With the administration of the remaining amino acids, a predominance of defects of ectodermal origin was observed (CS = 1.3-2.6). This was especially noticeable in the case of L-β-phenyl-α-alanine (CS = 8.0).

The amino acids that we investigated in intravitelline injection of 1 mg per egg produced various developmental defects in 10-25 percent of the chick embryos.

Together with quantitative differences in the action of the amino acids, their qualitative similarity was observed, that is our data confirmed Stockard's thesis [9] that different influences on one phase of development of the embryo may be exerted by monotype changes.

Inasmuch as in poultry embryogenesis a mesodermal rudiment (layer) originates from an ectodermal as the result of intensified multiplication and migration of ectodermal cells [3], it may be assumed that the latter is subjected directly to the influence of the amino acids primarily and the mesoderm secondarily. Since we injected the amino acids prior to incubation, a basis exists for considering that their action precedes the formation of the initial stria characterizing heightened sensitivity to the damaging agents [2]. The injected amino acids can probably interfere in the processes of cellular division, since it has been proved in the culture of chicken fibroblasts that the absence of tryptophan results

in an abrupt retardation of cellular division and the absence of glutamic acid in a decrease in the number of anaphases and telophases. It should also be noted that their optimal correlation is essential to the normal mitosis of certain inadequately present amino acids [7].

On the basis of what has been described, it may be assumed that the observed defects occur at the earliest stages of development under the influence of the injected amino acids as a result of changes in the optimal proportions of their concentration necessary for normal cellular division. The possibility of such an influence on cellular division has been shown for antibiotics following their intravitelline injection prior to the incubation of the chick embryo [1]. A change in the intensity of cellular division (inhibition or stimulation) obviously may be due either to slowing down or acceleration of growth, which can lead to developmental defects.

Conclusions

1. Glycocoll, L-cysteine, L-β-phenyl-α-alanine, DL-α--aminobutyric acid, DL-tryptophan, DL-methionine, DL-glutamic acid, following injection of 1 mg per egg produce various developmental defects in 10-25 percent of chicken embryos.

2. Together with quantitative differences in the action of the amino acids, a qualitative similarity is observed.

3. The disclosed developmental defects are of ectodermal (primarily) and mesodermal origin.

LITERATURE

1. Aleksandrov, P.N. and Yekimovskiy, A.P., Pat. Fiziol., No. 4, 1964, p 67.

2. Ivanov, P.P., Obshchaya i Sravnitel'naya Embriologiya [General and Comparative Embryology]. Moscow-Leningrad, 1937, p 743.

3. Khlopin, N. B.M.E. [Bol'shaya Medical Encyclopedia]. Moscow, 1960, vol 17, p 892.

4. Biggers, I.D., Webb, M., Parker, C., et al., Nature, 1957, vol 180, p 825.

5. Dessi, P., Rizzoli, C., Cestari, A., Ricerca Sci., 1959, vol 29, p 14446.

6. Herrmann, H., J. Embryol. Exp. Morphol., 1953, vol 1, p 291.

7. Kieler, J., Acta Path. Microbiol. Scand., 1954, vol 34, p 11.

8. Rothfels, U., J. Exptl. Zool., 1954, vol 125, p 17.

9. Stockard, C.R., Am. J. Anat., 1921, vol 25, p 115.

10. Waddington, C.H. and Perry M., I. Embryol. Exp. Morphol., 1958, v 6, p 365.

Received 7 September 1965.

gac

УДК 612.64.046:615.739.6+591.392.1

ИЗУЧЕНИЕ ТЕРАТОГЕННОЙ АКТИВНОСТИ НЕКОТОРЫХ АМИНОКИСЛОТ В ОПЫТАХ НА КУРИНЫХ ЭМБРИОНАХ

П. Н. Александров, В. А. Богданова, А. М. Чернух

Отдел химиотерапии (зав. — проф. А. М. Чернух) Института фармакологии и химиотерапии (дир. — действ. член АМН СССР проф. В. В. Закусов) АМН СССР, Москва

Имеются данные о действии некоторых аминокислот и их аналогов на развитие куриного эмбриона. Например, гликокол подавляет развитие зародыша, а метионин, введенный одновременно с этионином, блокирующим процессы роста и дифференциации, полностью предотвращает поражения, вызываемые этионином [5].

В опытах in vitro показано, что фенилаланин также препятствует указанному действию этионина [10]. В других работах обнаружено, что аналоги ароматических аминокислот β-2-тиенилаланин и β-0-фенилаланин вызывают замедление роста, сопровождающееся патологическими изменениями нервной трубки и сомитов. Фенилаланин подавляет влияние β-2-тиенилаланина на задержку роста, но не тормозит действия, вызываемого β-0-фенилаланином [6, 8]. Отсутствие в искусственной питательной среде таких аминокислот, как треонин, аргинин, триптофан, тормозит рост берцовых и бедренных костей 6—7-дневных куриных эмбрионов [4].

Вместе с тем мы не нашли данных о тератогенном влиянии аминокислот на куриный эмбрион. Однако при изучении тератогенной активности промежуточных продуктов синтеза талидомида мы обнаружили, что глютаминовая кислота при внутрижелточном введении вызывает дефекты развития у куриных эмбрионов.

В связи с этим мы изучали влияние некоторых заменимых и незаменимых аминокислот на тератогенную активность.

Опыты проведены на оплодотворенных куриных яйцах. Использовали dl-глютаминовую кислоту, гликокол, l-цистин, l-цистеинхлоргидрат, dl-α-аминомасляную кислоту, dl-триптофан, dl-метионин и l-β-фенил-α-аланин. Все эти аминокислоты вводили однократно до инкубации внутрижелточно в дозе 1 мг в 0,1 мл физиологического раствора. Оплодотворенные яйца инкубировали при 38° и 60% относительной влажности. Наблюдение за развивающимся эмбрионом при помощи овоскопа продолжалось с 3-го до 14-го дня инкубации. Погибших эмбрионов извлекали и отмечали макроскопические изменения.

Визуально обнаружены дефекты развития мозга, глаз, клюва, брюшной стенки и внутренних органов, позвоночника и конечностей. В мозгу найдены беспорядочные выбухания его различных отделов. Клюв был весь уменьшен или наблюдалось отставание развития верхней или нижней его части. Нередко отмечалось незаращение брюшной стенки и выпячивание органов грудной и брюшной полости. Дефекты развития конечностей выражались в их искривлении и укорочении. Нарушение развития позвоночника проявлялось в искривлении и укорочении тела эмбриона.

На рисунке показаны некоторые эмбрионы с дефектами развития, возникшими после введения аминокислот. После введения гликокола отмечены дефекты клюва, отсутствие обоих глаз, укорочение позвоночника, незаращение брюшной стенки, эвисцерация. Под влиянием l-цистина нарушается развитие мозга, глаз и клюва. Введение dl-l-аминомасляной кислоты приводит к возникновению дефектов мозга, глаз, клюва, к незаращению брюшной стенки и эвисцерации. Введение l-β-фенил-α-аланина сопровождается нарушением развития мозга, глаз, искривлением оси тела эмбриона.

Представленные на рисунке эмбрионы не отражают всего многообразия нарушений развития. Более подробные данные приведены в таблице, из которой видно, что в контроле обнаружено до 3,6% эмбрионов с дефектами, а при введении физиологического раствора — 7%. Наиболь-

шее число эмбрионов с дефектами выявлено при введении dl-триптофана, гликокола и dl-глютаминовой кислоты — соответственно 17, 20 и 25%.

В таблице указано число эмбрионов с дефектами, а также общее количество дефектов. Отношение второй величины (число дефектов) к первой (число эмбрионов с дефектами) составляет коэффициент, характеризующий степень нарушений у одного эмбриона. Этот коэффициент мы условно назвали коэффициентом интенсивности (КИ). Чем больше КИ, тем сильнее нарушено развитие. Как следует из таблицы, самые множественные дефекты развития возникают у эмбрионов при введении



Влияние аминокислот в дозе 1 *мг* на 1 яйцо на развитие куриных эмбрионов (масштаб не выдержан).

а — контроль, 11-дневный эмбрион; *б* — введение гликокола, 12-дневный эмбрион; *в* — введение l-цистина, 9-дневный эмбрион; *г* — введение dl-α-аминомасляной кислоты, 7-дневный эмбрион; *д* — введение l-β-фенил-α-аланина, 5-дневный эмбрион.

dl-α-аминомасляной кислоты (КИ = 4,7), l-цистина и l-цистеина (КИ = =4,0) и dl-триптофана (КИ=3,7).

В таблице приведен также коэффициент, представляющий собой отношение дефектов эктодермального происхождения к дефектам мезодермального происхождения. Этот коэффициент, названный нами условно коэффициентом специфичности (КС), характеризует преимущественное угнетение исследуемыми соединениями зачатков экто- и мезодермального происхождения.

Введенное вещество	Число эмбрионов в опыте	Число эмбрионов с дефектами		% эмбрионов с дефектами	Число дефектов развития (визуально) в различных органах								
		до 5-го дня инкубации	после 5-го дня инкубации		производные эктодермы			производные мезодермы			всего дефектов	КИ	КС
					мозг	глаз	клюв	брюшная стенка	конечности	тело			
Контроль	110		4	3,6	2	1	1	1	3	2	10	2,5	0,7
Физиологический раствор	57		4	7	1	1	1	2	2	1	8	2,0	0,5
l-цистин	40	2	2	10	2	1	1			3	8	4,0	1,0
l-β-фенил-α-аланин	40	1	4	12	4	3	1			1	9	2,2	8,0
dl-метионин	40		5	12	3	1	1	2	1		8	1,6	1,7
dl-α-аминомасляная кислота	40	2	3	12	5	2	1	2	1	3	14	4,7	1,5
l-цистеинхлоргидрат	40	1	5	15	4	2	4	3	2	5	20	4,0	1,0
dl-триптофан	40	3	4	17	4	4	2	3	2		15	3,7	2,0
гликокол	40	1	7	20	5	6	2	1	1	3	18	2,6	2,6
dl-глютаминовая кислота	43		11	25	7	7	4	4	5	4	31	2,8	1,4

В контроле КС составляет 0,7. Очевидно, среди спонтанно возникающих дефектов преобладают нарушения развития зачатков мезодермального происхождения.

При введении l-цистина и l-цистеина число дефектов экто- и мезодермального происхождения одинаково (КС=1,0). При введении остальных аминокислот отмечено преобладание дефектов эктодермального происхождения (КС=1,3—2,6). Особенно резко это выражено у l-β-фенил-α-аланина (КС=8,0).

Исследованные нами аминокислоты при внутрижелточном введении в дозе 1 мг на 1 яйцо вызывали различные дефекты развития у 10—25% куриных эмбрионов.

Наряду с количественными различиями в действии аминокислот отмечено их качественное сходство, т. е. наши данные подтвердили положение Stockard [9], что разные воздействия на одной фазе развития эмбриона могут вызывать однотипные изменения.

Так как в эмбриогенезе птиц мезодермальный зачаток (слой) возникает из эктодермального в результате усиленного размножения и миграции клеток эктодермы [3], можно предположить, что последняя подвергается непосредственному влиянию аминокислот первично, а мезодерма — вторично. Поскольку мы вводили аминокислоты до инкубации, есть все основания считать, что их действие предшествует формированию первичной полоски, характеризующейся повышенной чувствительностью к повреждающим агентам [2]. Введенные аминокислоты могут, вероятно, вмешиваться в процессы клеточного деления, так как в культуре куриных фибробластов показано, что отсутствие триптофана приводит к резкому замедлению деления клеток, а отсутствие глютаминовой кислоты — к уменьшению числа анафаз и телофаз. Следует также заметить, что для нормального митоза недостаточно присутствия определенных аминокислот — необходимо их оптимальное соотношение [7].

На основании изложенного можно предполагать, что наблюдаемые дефекты возникают на самых ранних этапах развития под влиянием введенных аминокислот вследствие изменения оптимальных соотношений их концентрации, необходимых для нормального деления клеток. Возможность такого влияния на клеточное деление была показана для антибиотиков при внутрижелточном введении их до инкубации куриным эмбрионам [1]. Изменением интенсивности клеточного деления (торможение или стимуляция), очевидно, может быть обусловлено как замедление, так и ускорение роста, что может привести к дефектам развития.

Выводы

1. Гликокол, l-цистеин, l-β-фенил-α-аланин, dl-α-аминомасляная кислота, dl-триптофан, dl-метионин, dl-глютаминовая кислота при введении в дозе 1 мг на1 яйцо вызывают различные дефекты развития у 10—25% куриных эмбрионов.

2. Наряду с количественными различиями в действии аминокислот отмечается качественное сходство.

3. Обнаруженные дефекты развития имеют эктодермальное (преимущественно) и мезодермальное происхождение.

ЛИТЕРАТУРА

1. Александров П. Н., Екимовский А. П. Пат. физиол., 1964, № 4, с. 67.— 2. Иванов П. П. Общая и сравнительная эмбриология. М. — Л., 1937, с. 743.— 3. Хлопин Н. Б. М. Э. М., 1960, т. 17, с. 892. — 4. Biggers I. D., Webb M., Parker C. et al., Nature, 1957, v. 180, p. 825. — 5. Dessi P., Rizzoli C., Cestari A., Ricerca Sci., 1959, v. 29, p. 1446. — 6. Herrmann H., J. Embryol. exp. Morphol., 1953, v. 1, p. 291. — 7. Kieler J., Acta Path. microbiol. scand., 1954, v. 34, p. 11. — 8. Roth-

fels U., J. exptl. Zool. 1954, v. 125, p. 17. — 9. Stockard C. R., Am. J. Anat., 1921, v. 28, p. 115. — 10. Waddington C. H., Perry M., I. Embryol. exp. Morphol., 1958, v. 6, p. 365.

Поступила 7/IX 1965 г.

A STUDY OF TERATOGENIC ACTIVITY OF SOME AMINO ACIDS IN EXPERIMENTS ON CHICK EMBRYOS

P. N. Alexandrov, V. A. Bogdanova, A. M. Chernukh

The amino acids investigated induced various developmental defects in 10—25% of chick embryos when injected in a dose of 1 mg/egg. Along with quantitative differences in the amino acid action a qualitative similarity was noted. The defects revealed were of ectodermal (chiefly) and of mesodermal origin.

196

To the Editor: The unusual symptoms experienced by some persons after they have eaten in a Chinese restaurant, which has been called the "Chinese-restaurant syndrome" and discussed in a letter from Dr. R. H. M. Kwok in the April 4 issue, is of interest to us. During an elective period in our course in pharmacology we investigated this condition as a special project, and we can answer some of the questions raised in Dr. Kwok's letter.

The symptoms definitely are due to monosodium glutamate. They can be reproduced faithfully in susceptible persons by feeding of this substance in tomato juice or in dilute broth. As controls, the same persons received the vehicle alone, at another time. Sensitive people were able to distinguish the control from monosodium glutamate samples since they had symptoms only after eating the latter preparations.

The symptoms, as mentioned by Dr. Kwok, are usually a tingling and sensation of weakness in the facial and temporal regions, over the upper back, neck and arms, and often a feeling of warmth over the same areas. Most subjects observed the onset of symptoms 10 to 20 minutes after ingestion, and symptoms were clearly evident by 45 minutes if they occurred at all. The number of subjects we have tested is small but there seems to be a lower frequency of highly sensitive males (one strong and six moderate reactions out of 15) than females (nine strong and two mild out of 20). A dose of only two teaspoons of monosodium glutamate per 6-ounce glass of tomato juice was needed to provoke symptoms in the susceptible females, whereas twice this dose was found optimal to detect susceptible males. Further quantitative studies in males and females must be made to establish the threshold, but there is definitely a higher threshold in males.

Our studies will continue on the frequency of the reactivity to monosodium glutamate. Family studies are also planned to determine whether this sensitivity is an inherited trait, like the taste sensitivity of phenylthiourea.

It may be of interest to point out that although this reaction has not been described in the medical literature, as far as we know, it has been recognized by certain persons and within some families.

We have heard of one family with several sensitive members that has, by trial and error, composed a list of "safe" Chinese restaurants in town and a list of those that must be avoided. Apparently, Chinese cooks vary considerably in how liberally they use monosodium glutamate.

MARJORIE AMBOS
NANCY R. LEAVITT
LYNNE MARMOREK
SUSAN B. WOLSCHINA
Second-Year Students
Department of Pharmacology
New York University
School of Medicine
New York, N.Y.

Neuropathology

520 *Pathology*

CHANGES IN WALLS OF ARTERIES OF BRAIN ASSOCIATED WITH RUPTURED SACCULAR ANEURYSMS. L. W. McDonald* and L. W. Conway*. (SPON: B. H. Ruebner). Univ. of Calif., Davis, Calif. 95616.

In an histological analysis of the intradural arteries in five cases of subarachnoid hemorrhage due to ruptured saccular aneurysm, granulation tissue was found causing marked and widespread intimal thickening in two cases. This change was most marked in the sections taken 0.5 cm proximal and 0.5 to 2 cm distal to the aneurysm. These same two cases had more abundant hemosiderin filled macrophages and hematoidin pigment in the adventitia than was found in the other three cases. Changes attributed to edema were also more marked in the media of these two cases. The opposite middle cerebral arteries in the two cases also served as controls and did not show the intimal granulation, adventitial pigmentation or media edema seen in the vicinity of the aneurysms. Clinically, "vasospasm" with ischemic infarction was marked in these two cases, and relatively minor in the other three cases. From these results, it would appear that some of the prolonged delayed "vasospasm" in arteriograms may instead be due to vessel wall thickening produced by granulation tissue in the intima and edema of the media.

(Supported in part by GRS Grant RR-05684-02 from GRS Branch, Div. of Res. Resources, NIH).

521 *Physiology*

MONOSODIUM GLUTAMATE-INDUCED OPTIC PATHWAY LESIONS IN INFANT MICE FOLLOWING SUBCUTANEOUS INJECTION. Edward A. Arees*, Barry Sandrew* and Jean Mayer, Dept. of Nutrition, Harvard School of Public Health, Boston, Mass. 02115.

Seven-day old albino mice were given single, subcutaneous injections of monosodium glutamate in concentration corresponding to 3 mg/g body wt. The 18 mice studied were killed at various times ranging from 30 min to 7 days after treatment. Brains were removed, formalin fixed, frozen sectioned, and selected sections were stained either with a cresyl violet Nissl stain or the Fink-Heimer stain for degenerating boutons. At 24-hr survival time, terminal degeneration was seen both in the dorsal and ventral lateral geniculate nucleus indicating degeneration of the optic pathway. Argyrophilic cells were stained in the arcuate nucleus of hypothalamus but no efferent fiber degenerating pathways could be traced from this region. Both fiber and terminal degeneration was also seen in the area of the subiculum. The basis for extrapolating the equivalence of high doses injected in small animals (mice) with a high rate of metabolism to doses ingested by large animals (men) with a lower rate of metabolism is too uncertain to permit any conclusion at this time. (Supported in part by the Fund for Research and Teaching, Nutrition Dept., Harvard University.)

522 *Pathology*

FINE STRUCTURE OF MYELINATED NERVE FIBERS IN TRANSITORY TRAUMATIC PARAPLEGIA. George J. Dohrmann*, Franklin C. Wagner, Jr.* and Paul C. Bucy* (SPON. D.W.E. Smith). Departments of Pathology and Surgery (Neurosurgery), Northwestern University Medical School and Department of Neurosurgery, Chicago Wesley Memorial Hospital, Chicago, Illinois 60611.

A 300 gm-cm force, applied to the T10 level of the exposed spinal cord, has been shown to create a transitory paraplegia in the monkey (Macaca mulatta). Recovery from the complete sensory and motor deficit occurred by 1 to 2 weeks following trauma. The monkeys were perfused with a glutaraldehyde solution 5 minutes, 15 minutes, 30 minutes, 1 hour and 4 hours post-contusion while the control group was perfused in the same manner and at identical time intervals following completion of the laminectomy. At 5 minutes after injury, myelinated nerve fibers in the gray matter had a slightly increased periaxonal space and at 15 minutes selected nerve fibers in the white matter showed the same alteration. By 30 minutes and 1 hour after contusion, scattered nerve fibers within both the gray and white matter exhibited moderately enlarged periaxonal spaces and apparent attenuation of the surrounding myelin, while the axonal morphology was not altered. Some myelin sheaths were broken and/or collapsed and partially denuded axons were present. 4 hours post-contusion numerous nerve fibers within the white matter had markedly dilated peri-axonal spaces and associated axonal degeneration. (Supported in part by Grant NS 08970 and Neurosurgical Training Grant No. 5408 from the NINDS.)

523 *Pathology*

[illegible] IN ALLERGIC [illegible]. [illegible] Doehne, M. D. VA Hospital, [illegible] College of Medicine and [illegible]

[illegible] is preceded by [illegible] (Lab. Inv., 1973, 2, p. 199). This [illegible] S.J.L.J. mice, while [illegible] respectively to allergic [illegible] were [illegible] with [illegible] mouse brain in [illegible] activity in the ventricular angle of [illegible] 14, 17, 22 and [illegible]. In [illegible] were after day 14 resulting [illegible] while AA failed to show [illegible] mice, AA activity was quantitatively [illegible] AA activity remained [illegible]. Only BSUS mice showed [illegible] of inflammation. Splenic and thymic [illegible] activity in brain BRVR whereas [illegible] in brain BSUS significantly. [illegible] Administration, Washington, D. C.

524 *Pathology*

PREPARATION OF MICROTUBULAR PROTEIN ANTIBODY FROM VINBLASTINE-PRECIPITATED SUPERNATANTS. W. W. Schlaepfer* and W. Gray* (SPON: P. E. Lacy). Washington Univ. Med. Sch., St. Louis, Mo. 63110.

Microtubular protein was isolated from the supernatant of rat brain and spinal cord homogenates by precipitation with 5×10^{-3} M vinblastine sulfate (Olmsted, et al., Proc. Nat. Acad. Sci., 1970). Rabbits were twice injected intradermally with resuspended protein incorporated into complete Freund's adjuvant. Whole rabbit serum and globulin concentrates reacted with vinblastine-precipitated supernatant but not vinblastine controls. Immunoprecipitations could also be demonstrated against rat brain homogenates, 105,000 g supernatants and fraction I (39-49%) of ammonium sulfate precipitate. Colchicine-binding protein fractions from DEAE-Sephadex and Sephadex G-100 gel filtrations also precipitated with the globulin concentrates. Additional antigenic components were noted in fractions I and III and in supernatants of rat liver homogenates. Purification of microtubular protein antibody from immunized sera was undertaken by sepharose gel filtration using colchicine-binding protein from DEAE-Sephadex as immunoadsorbent (Rennies, et al., Immunochem., 1967). (Supported by USPHS Grant No09620-01).

525 *Pathology*

SEQUENTIAL STUDY OF GLUCOSE METABOLISM IN ADIPOSE TISSUE AND LIVER OF RATS WITH VENTROMEDIAL (VMN) HYPOTHALAMIC LESIONS. W. Roy Slaunwhite* and Jack K. Goldman* (SPON: L.L.Bernardis). Depts. of Path. and Med., SUNY at Buffalo and V.A. Hospital, Buffalo, N.Y. 14215

In vitro U-C^{14}-glucose metabolism of adipose tissue and liver was studied at various time intervals after electrolytic destruction of the VMN in weanling rats. Food intake, carcass fat, body weight and glucose oxidation and incorporation into lipids and adipose tissue glycogen were measured. In both tissues from VMN rats glucose incorporation into lipids was increased by the 4th day after lesioning, glucose oxidation by the 9th, and adipose tissue glycogen by the 13th day. The VMN adipose tissue glucose utilization rose linearly with time while liver glucose oxidation rose out plateaued, paralleling the rate in control rats. Food intake and body weight gains were lower in VMN rats until the 9th day although carcass fat showed steady gains and was significantly elevated by the 9th day. The results show: 1) increased glucose utilization especially for lipogenesis soon after VMN destruction despite a period of hypophagia; 2) not all pathways of glucose oxidation are affected equally and simultaneously; 3) the change in metabolism which favors increased glucose oxidation and incorporation into lipid is more marked in adipose tissue than in the liver. (Supported by NIH #AM-11746, V.A. Clinical Investigatorship (JKG), and NIGMS #GM 01500.)

3: 0307

Monosodium Glutamate–Induced Brain Lesions: Electron Microscopic Examination

Abstract. *Albino mice injected with monosodium glutamate developed brain lesions in the arcuate nucleus of the hypothalamus. Lesions involved primarily microglial cells with no effect to the perikarya of neurons. Distal neuronal processes were only slightly affected.*

Neuronal degeneration in the retina of mice after a single parenteral injection of monosodium glutamate (MSG) has been described (*1, 2*). Further, after subcutaneous injection of MSG, neuronal degeneration was described in the arcuate nucleus, preoptic area, and median eminence of the hypothalamus in the mouse, rat, and monkey (*3, 4*). With the C57BL/6 strain of mice, albino rats, and one infant rhesus monkey (*Macaca mulata*), the neuronal lesion was most pronounced 3 to 5 hours after injection in doses ranging from 0.5 to 5 mg/g.

Fig. 1. Necrotic region (arrows) just rostral to arcuate nucleus of hypothalamus 3 hours after injection of MSG. Note normal staining cells within affected area (× 253).

We were consistently able to produce lesions in the brains of Swiss albino mice (Charles River; CD-1) with single doses of MSG administered either subcutaneously or intraperitoneally. However, our lesion sites were smaller than those previously reported (*2–4*) and, within the time period studied, involved primarily, if not exclusively, microglial cells with only slight damage to distal portions of neuronal processes and no degeneration to the perikarya of neurons.

Infant Swiss albino mice (CD-1) ($N = 75$) (3 to 10 days old) were given single subcutaneous injections of MSG in concentrations equal to either 2 or 4 mg/g (0.1 ml by volume in distilled water). Another group of 50 adult mice (CD-1) were injected either subcutaneously or intraperitoneally with MSG in doses varying from 6 to 10 mg/g (1 ml by volume). Also, ten untreated mice and five control mice injected with sodium chloride (8 mg/g; 1 ml by volume) were studied by both light and electron microscopy.

Mice in both groups were killed between 3 and 72 hours after injection. Brain sections from 20 mice randomly selected from each age group of the two groups injected with MSG were examined with the electron microscope. All of the ten untreated ones and the five injected with sodium chloride were similarly examined. These mice were killed by perfusion with a solution of formalin and glutaraldehyde; their brains were removed and fixed in glutaraldehyde; they were then fixed in osmium tetroxide and embedded in Epon. Silver-reflecting thin sections were collected on 200-mesh copper grids and stained with uranyl acetate and lead citrate before examination. The remaining mice were studied with the light microscope. These animals were perfused in the left ventricle with physiological saline followed by a neutralized 10 percent formalin solution. Brains were removed from the skull and fixed in a 10 percent formalin solution for approximately 1 week; they were then fixed for 3 days in a solution of sucrose and formalin (30 percent). Brains were sectioned in a frontal plane at a thickness of 25 μm on a cryostat, and for cytological examination, selected sections were stained with the Nissl method (*5*).

Results with the light microscope showed no difference between control and MSG-treated animals in staining Nissl bodies of neurons located in the hypothalamus. Also no reduction in the number of neurons was observed in the hypothalamus between treated and control mice. The only pathological finding seen by light microscopy was small, sparsely appearing necrotic areas immediately lateral to the base of the third ventricle extending from the preoptic area caudally through the arcuate

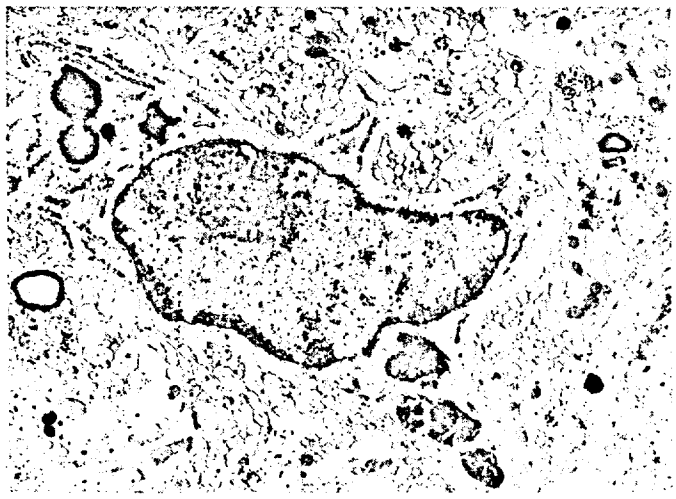

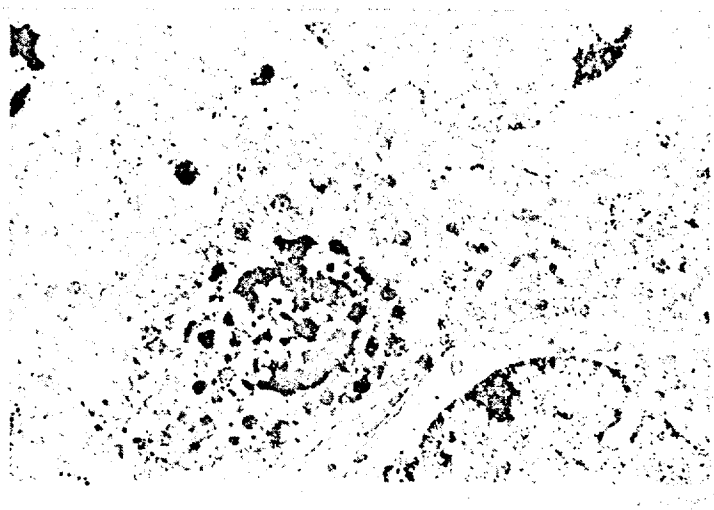

Fig. 2 (left). Glial cell showing lysosomes, lipofuscin granules, and other debris in the cytoplasm 3 hours after injection of MSG (× 5000). Fig. 3 (right). Glial cell showing pyknotic nucleus with damaged nuclear membrane 24 hours after injection of MSG (× 5000). Notice adjacent normal appearing neuron.

Science, 170(3957): 549-550 1970

nucleus to the level of the median eminence (Fig. 1). Of the 83 mice studied with the light microscope, this pathologic condition was found in all but three infants and two adult mice. With electron microscopy, it was possible to identify the small necrotic areas as degenerating microglial cells (*6*). At 3 hours after the MSG injection, there was a significant increase over control conditions in the number of lysosomes, myelin figures, and dense bodies within the cytoplasm of microglial cells (Fig. 2). This occurred in all mice studied within this time period. Also the lesion was very specific to these glial cells and apparently did not involve either the perikarya of neurons or the neuropil within the arcuate region. Further, the cytoplasm of astrocytes and oligodendrocytes was not affected. The possibility does exist that various changes may have been taking place within cells other than microglia, but were not made apparent at this time period (3 hours) either with light or electron microscopic study. At 24 hours after the injection there was a breakdown of the nuclear membrane with a marked increase in debris within the cytoplasm of microglial cells. Mitochondria appear markedly swollen, often with broken membranes, and the nuclei are completely pyknotic (Fig. 3). At this time after injection, myelin figures are occasionally seen in distal portions of few axons and dendrites within this area, but in general the entire neuropil appears normal. Also, there is a large increase in glycogen in normal-appearing glial processes in the lesioned area. No further spread of degeneration was seen at 72 hours after injection.

Regardless of the method of injection or the concentration of MSG given, the location of all lesions and the extent of damage was similar. Approximately 95 percent of all injected animals developed these lesions. Within the time period studied, the perikarya of all neurons within the arcuate nucleus and median eminence appeared normal. No evidence of any intracellular edema was seen. We have considered the possibility that the degenerating microglial cells were not the direct target sites for MSG or glutamic acid but were responding to other damage in the nervous system. The affected microglial cells may be invaders to the arcuate region of the hypothalamus and could be acting as phagocytes rather than being directly involved in the lesion. However, there appears to be no significant difference between the number of microglial cells in our control and MSG-treated animals (*7*). L-Glutamic acid decarboxylase has been found both in human glial cells grown in culture and in gliomas (*8*). Whether this finding can be construed as suggesting an affinity of glial cells for MSG remains to be determined. Olney (*2, 3*) and Olney and Sharpe (*4*) have shown that large, markedly swollen dendrites also were present in the area, but this may have been due to poor fixation rather than to experimental treatment. Often in electron microscopic study we have demonstrated this effect in poorly fixed samples from control animals. It seems that among other areas, dendrites and synaptic endings within the arcuate nucleus show more marked reaction to poor fixation than other regions of the nervous system. However, since MSG-treated mice showed more swollen dendritic processes within the area studied than did control mice, the possibility exists that poor fixation may have resulted from an occlusion of the blood vessels in the lesioned site due to MSG treatment. Reduction in blood flow to the ventromedial region of the hypothalamus has been demonstrated after the administration of gold thioglucose (*9*).

The doses injected in this study are large, in milligrams per gram, as compared to doses consumed by humans, and do not indicate what pathology results when comparable doses are administered by mouth either singly or in a series, or when lower amounts of MSG are consumed with food (*10*).

EDWARD A. AREES
JEAN MAYER
Department of Nutrition, Harvard University, School of Public Health, Boston, Massachusetts 02115

References and Notes

1. D. R. Lucas and J. P. Newhouse, *Arch. Opthalmol.* **58**, 193 (1957).
2. J. W. Olney, *J. Neuropathol. Exp. Neurol.* **28**, 455 (1969).
3. ———, *Science* **164**, 719 (1969).
4. ——— and L. G. Sharpe, *ibid.* **166**, 386 (1969).
5. M. M. Powers and G. Clark, *Stain Technol.* **30**, 83 (1955).
6. A. Peters, S. L. Palay, H. de F. Webster, *The Fine Structure of the Nervous System* (Harper & Row, New York, 1970), pp. 129–131.
7. J. Brawer and S. Palay, personal communication.
8. B. Haber, K. Kuriyama, E. Roberts, *Science* **168**, 598 (1970).
9. E. A. Arees and J. Mayer, *Exp. Neurol.* **25**, 410 (1969).
10. Since this paper was submitted, additional data have been obtained in our laboratory which show that adult albino rats injected with 5 mg of MSG per gram of body weight developed lesions in the arcuate nucleus of the hypothalamus similar to those described in this study. This finding is contrary to that of N. J. Adams and A. Ratner [*Science* **169**, 673 (1970)].
11. Supported in part by NIH grant NB 01941-12. We thank Miss J. Hamilton, H. Patterson, and P. Gustafson for their technical assistance.

14 July 1970; revised 28 August 1970

Antibody to Nuclear Material Eluted from Isolated Spleen Vessels in Systemic Lupus Erythematosus

Abstract. *Splenic blood vessels were isolated from surrounding cells by treatment with trypsin and the use of ultrasound. This procedure retained vascular-bound immunoglobulins which were recovered by acid elution of vessels isolated from a patient with systemic lupus erythematosus. These eluted immunoglobulins reacted with material from cell nuclei as demonstrated by immunofluorescence.*

Inflammation of blood vessels and deposits of γ-globulin and complement in vessel walls are common pathologic features of systemic lupus (*1*). Other investigators have eluted antinuclear antibodies from isolated renal glomeruli with acid, or deoxyribonuclease, or both (*2*), but results of eluting larger blood vessels have not been reported. Comparative studies of the amounts of vascular-bound γ-globulins in various organs of lupus patients have shown that protein deposition is often most pronounced in vessels of spleen (*3*). We now report a method of isolating blood vessels from spleen with the preservation of vascular-bound proteins and the successful elution of antibodies to nuclear material from splenic vessels isolated from a systemic lupus patient.

Whole spleen tissue was obtained at autopsy from patient K.R., a 17-year-old female who died of lupus nephritis,

Table 1. Immunoglobulin composition of deposits in K.R. splenic vessels and antinuclear antibodies in serum and eluate of K.R. spleen vessels; H ab, antibody showing homogeneous pattern of staining; Sp ab, antibody giving speckled type of nuclear reactivity. Protein bound to vessels is graded 1 to 4+ on the basis of intensity of fluorescence.

Class	Protein bound to vessels	Antibodies (reciprocal of titers)		
		Eluate H ab	Serum H ab	Serum Sp ab
γG	4+	64	128	256
γM	3+	16	64	64
γA	2+	2	32	Neg.

581

Monosodium Glutamate: Feeding of Large Amounts in Man and Gerbils

Abstract. *Oral administration of large amounts of glutamic acid to adult humans and animals in a formula diet appeared to cause no clinical pathological changes. The only biochemically demonstrable effect was a decrease in serum cholesterol and associated beta lipoproteins.*

Interest in the toxicity of monosodium glutamate (MSG) as a food additive has increased greatly in the past year because of the association of this compound with both the Chinese-restaurant syndrome in humans (*1*) and a lesion of the hypothalamus in newborn mice and monkeys (*2*, *3*). The burning sensation and, most probably, the headache in the Chinese-restaurant syndrome appear to be of vascular origin and represent a chemical idiosyncrasy (*1*). A discrete brain lesion is unlikely in this syndrome since the symptoms are transient and since sensitive individuals need only avoid exceeding their tolerance threshold in order to prevent a recurrence. No permanent neurological lesions have been observed. On the other hand, the brain lesions induced in newborn mice and monkeys by parenteral or oral administration of glutamate are characterized by a degeneration of dendritic processes and cell bodies of hypothalamic neurons (*3*, *4*). Associated with these lesions is a complex syndrome of metabolic, nutritional, and reproductive abnormalities visible in newborn mice for a 9-month period. These discoveries have given rise to concern about the safety of sodium glutamate when added to foods ingested by pregnant women and by infants. We report the harmless effects of large amounts of monosodium glutamate given to both animals and man by mouth. This project had its origin in a study of the hypocholesterolemic effects of glutamic acid when it was fed as a sole source of

Table 1. Effects of glutamate feeding in human subjects. Δ-Cholesterol represents the difference in concentrations of plasma cholesterol from those in subjects on the control diet (AAF). None of the subjects showed any clinical effects.

Subject	Time (days)	Dose (g/day)	Δ-Cholesterol (mg/100 ml)
J.B.	34	147	−27
R.S.	28	88	−82
R.M.	27	147	−16
J.M.	21	137	−46
P.B.	21	137	−40
P.K.	21	147	−55
J.A.*	14	25	−16
	14	50	− 7
	21	100	+ 3
S.S.†	22	131	− 5
R.M.	21	133	−23
M.E.†	21	126	−20
M.E.	21	68	−41
	21	137	−42
G.R.	28	137	−29
W.B.	42	137	−75
D.M.	21	147	−40

* Monosodium glutamate was added to a house diet. † Monosodium glutamate was added to a low protein (25 g) diet.

Table 2. Effects of various diets on mature male Mongolian gerbils. Observations on test diets were recorded at the end of 1 week. Weight is reported as the mean ± standard error (S.E.) of the mean. Food control diet (FCD) was Purina laboratory chow for small animals; 20 of the gerbils received FCD with 1 percent (by weight) of cholesterol added. See text for casein diet; 26 of the gerbils on this diet received 30 percent casein with 1 percent (by weight) of cholesterol added. (Δ-Cholesterol represents the difference in concentration of cholesterol from that in animals on the preceding diet ± S.E. of the difference.) Amino acid formula (AAF) was fed to 56 gerbils, 28 of which received AAF with 1 percent (by weight) of cholesterol added. For animals fed amino acid formula with glutamate (AAFG), the statistical evaluation is limited to the AAF-AAFG interaction ($P < .005$). (Δ-Cholesterol represents the difference in concentration of cholesterol from that in animals on the preceding diet ± S.E. of the difference.) Twenty-eight of these gerbils received AAFG with 1 percent (by weight) of cholesterol added.

Diet	Animals (No.)	Weight (g)	Δ-Cholesterol (mg/100 ml)	Observations
FCD	110	72 ± 1.0		Hair is smooth; occasional convulsions during handling
Casein (30%)	49	72 ± 1.1	−8 ± 7.8	Hair loss; increased number of convulsions; increased mortality rate
AAF control	56	60 ± 1.2		Hair ruffled with occasional hair loss; rare hyperactivity, ataxia without additional convulsions
AAFG experimental	56	65 ± 1.0	−53 ± 14.0	As above

Science 169(3951) 1208-1209 (1970)

nonessential nitrogen in amino acid formula (AAF) diets (*5*). Subsequently related studies were carried out on gerbils (*6*), in which a similar hypocholesterolemic effect was noted.

A chemically defined diet [amino acid formula with glutamate (AAFG)] supplying all of the essential amino acids in optimum amounts, 16.0 g of total nitrogen including 137 g of glutamic acid as the sole source of nonessential nitrogen, and calories to maintain body weight has been fed to 11 adult male subjects for periods ranging from 14 to 42 days. Lesser amounts were fed to three other subjects. All subjects tolerated the regime well, showed no changes in neurologic or hepatic function, and demonstrated a reduction in serum cholesterol and lipoproteins of 25 to 40 percent of control levels. None developed the Chinese restaurant syndrome. Substitution of glycine plus ammonium ion for glutamate (AAF) abolished the hypocholesterolemic effect. Supplements of glutamate of as much as 100 g/day to an ordinary diet were ineffective in lowering the serum lipids but showed no toxic manifestations. Table 1 shows the effects of feeding from 25 to 147 g of MSG per day to adult human subjects. No changes in weight, irritability, appetite, or mentation were noted. The average fall in plasma cholesterol was 42 mg (± 5.8 standard error of the mean) per 100 ml.

When these same diets (*6*) were fed to gerbils, with animals fed a 30 percent casein diet and a chow diet as controls, it was observed that AAF was less effective in maintaining body weight than the casein diet but more effective than AAF. Nevertheless, casein, AAF, and AAFG did not differ in their effects upon hair coat and general neurological status. When AAFG was replaced by food control diet (FCD) changes in body weight, hair appearance, and serum cholesterol concentration were significantly, if not completely, reversed within 1 week. No increase or decrease in neurological activity was noted during the feeding of AAFG. More specifically, there was no evidence of alteration of visual acuity or change in frequency of convulsion. A summary of these results is shown in Table 2. Animals on the glutamate diet were more tranquil than those on casein or chow diets. The oral doses employed in the study of gerbils (30 g per kilogram of body weight per day) should approximate the effect of the parenteral doses employed by others in animal studies [Lucas and Newhouse (*7*), Potts *et al.* (*8*), Freedman and Potts (*9*), Olney (*2*), and Olney and Sharpe (*3*)], who administered MSG in the range of 2 to 10 g per kilogram of body weight. In their latest report, Olney and Sharpe (*4*) reported effects of 1 g/kg, by feeding tube, in newborn mice.

Mayer-Gross and Walker (*10*) demonstrated a transient toxic effect (vomiting) after intravenous administration of 20 g of sodium glutamate to normal adults, while this dose produced a favorable metabolic effect (arousal) in comatose, hypoglycemic patients. To our knowledge, then, no permanent neurotoxic effect for glutamate has been definitely reported for adult humans.

Rapid utilization of MSG would prevent the accumulation of free amino acid in the plasma and would reduce the danger of damage to susceptible tissue. Oral MSG is well utilized by human subjects, as indicated by no significant alterations in concentrations of plasma glutamic acid plus glutamine 12 hours after thrice daily feeding of glutamate formulas. The subjects also were at constant body weight and in nitrogen balance (*11*).

Clearly, glutamate produced metabolic effects consisting of decrease in serum cholesterol, phospholipids, and β-lipoproteins without alterations of body weight, nitrogen balance, liver function, or neurological activity (*12*, *13*).

The question of MSG toxicity appears, therefore, to center around the permeability of the blood-brain barrier to glutamic acid. How much of the fed or injected glutamate does actually reach the brain? It is obvious that significant amounts reach the brain in newborn animals and possibly infants. Himwich *et al.* (*14*) have reported ready access of glutamate to the brain at birth but exclusion of it with establishment of a blood-brain barrier by the 10th day. In view of this finding, it is likely that even with parenteral administration of large doses of MSG only small amounts of it would reach the adult brain. In newborn mice and monkeys prior to the establishment of this barrier, the brain could be susceptible to the toxic effects of MSG described by Olney (*2*, *3*).

We conclude from our studies that very high oral doses of glutamate (147 g/day) are tolerated, with no neurological changes, by adult gerbils and humans. The problem of determining the age of transition from susceptibility to tolerance for MSG in human subjects remains open.

GAETANO BAZZANO
JOHN A. D'ELIA, ROBERT E. OLSON
Departments of Biochemistry and Internal Medicine, St. Louis University School of Medicine, St. Louis, Missouri

References and Notes

1. H. H. Schaumburg, R. Byck, R. Gerstl, J. H. Mashman, *Science* **163**, 826 (1969).
2. J. W. Olney, *ibid.* **164**, 719 (1969).
3. ——— and L. G. Sharpe, *ibid.* **166**, 386 (1969).
4. ———, *ibid.* **167**, 1017 (1970).
5. R. E. Olson, M. Z. Nichaman, J. Nittka, L. Dorman, *J. Clin. Invest.* **43**, 1233 (1964).
6. G. Bazzano, *Proc. Soc. Exp. Biol. Med.* **131**, 1463 (1969).
7. D. R. Lucas and J. P. Newhouse, *Arch. Ophthalmol.* **58**, 193 (1957).
8. A. M. Potts, R. W. Modrell, C. Kingsbury, *Amer. J. Ophthalmol.* **50**, 900 (1960).
9. J. K. Freedman and A. M. Potts, *Invest. Ophthalmol.* **1**, 118 (1962).
10. W. Mayer-Gross and J. W. Walker, *Biochem. J.* **44**, 92 (1949).
11. J. D. Garlich, G. Bazzano, R. E. Olson, *Amer. J. Clin. Nutr.*, in press.
12. R. E. Olson, *Proceedings of the Seventh International Congress of Nutrition* (Vieweg, Braunschweig, West Germany, 1966), vol. 2.
13. G. Bazzano and R. E. Olson, *Amer. J. Clin. Nutr.* **22**, 667 (1969).
14. W. A. Himwich, J. C. Peterson, M. L. Allen, *Neurology* **7**, 705 (1957).
15. Supported in part by PHS grants R01 AM 09732-03 and HE 5672-05. We thank Mrs. Linda Graham for technical assistance.

22 June 1970

J. Biol. Chem. 175, 817, 1948

THE ABSORPTION OF GLUTAMIC ACID AND GLUTAMINE*

By S. P. BESSMAN,† J. MAGNES,‡ PAULA SCHWERIN, AND HEINRICH WAELSCH

(*From the Departments of Biochemistry, New York State Psychiatric Institute and the College of Physicians and Surgeons, Columbia University, New York*)

(Received for publication, April 15, 1948)

The occurrence of free glutamine in plant tissue extracts has been recognized for a considerable time, but its presence in the protein-free filtrates of mammalian tissues was established only recently (1). The functional significance of the free amide in tissues cannot be appreciated without a knowledge of its quantitative relationship to glutamic acid and of the biological mechanisms regulating the interconversions of the two compounds. A study of these questions was made possible by the development of a chemical micromethod for the determination of glutamic acid and glutamine, each in the presence of a large excess of the other (2, 3). The method was applied in studies of the absorption of glutamic acid, glutamine, and glutathione from the gut of the cat by analysis of the portal blood, and of the concentration changes of glutamic acid and glutamine in peripheral blood after oral administration of glutamic acid to human subjects. The analytical procedure was simplified and extended to permit the complete removal of glutathione. This modification became necessary not only for the use of the method in the experiments in which intestinal absorption of glutathione was studied, but also for its application to tissue analysis, which will be the subject of subsequent reports.

EXPERIMENTAL

Determination of Glutamic Acid and Glutamine—In the previous study on the glutamic acid and glutamine content of blood plasma and serum the glutamine concentration was calculated as the difference between total glutamic acid determined after acid hydrolysis in one sample and free glutamic acid determined in another. The method has been simplified, with a saving of material, by the direct determination of glutamine in the filtrate from the adsorption column. The filtrate (2 ml.) of the solution containing glutamic acid and glutamine and the wash water (2 ml.) were

* Supported by grants from the Rockefeller Foundation, the New York Foundation, and the Williams-Waterman Fund of the Research Corporation.

† Fellow of the Children's Hospital Research Foundation, Washington, D. C.

‡ On leave from the Department of Physiology, The Hebrew University, Jerusalem.

collected in a 10 ml. volumetric flask and hydrolyzed with 2 ml. of 6 N HCl for 1 hour. The hydrolysate was neutralized and diluted to 10 ml. as described previously. 2 ml. of the neutralized solution were taken for the glutamine determination. In pure solution and in the absence of asparagine the glutamic acid may be determined directly without further adsorption on a second column. Under such conditions the hydrolyzed solution was neutralized, 5 mM of acetic acid were added, and the solution was diluted to 10 ml. with water. 4 ml. of this solution were treated with ninhydrin. In all determinations on tissue filtrates the hydrolyzed solution, containing glutamic acid originating from glutamine, was passed through a second column. The recovery of glutamine alone or in solutions containing glutamic acid and amide, as obtained in the above procedure, amounted to 95 to 105 per cent.

Removal of Glutathione—In glutathione-containing solutions, cysteine and glutamic acid, equivalent to approximately 20 per cent of the tripeptide when expressed as glutamic acid, were liberated under the conditions employed for glutamine hydrolysis. The removal of glutathione by precipitation with metal salts (copper, cadmium, lead) led to considerable losses of glutamic acid. A nearly complete removal of glutathione or cysteine without loss of glutamic acid was accomplished by adsorbing the sulfhydryl compound on lead carbonate introduced on top of the aluminum oxide column. 1 mg. of lead carbonate ($2PbCO_3 \cdot Pb(OH)_2$) suspended in 0.5 ml. of water was superimposed on the aluminum oxide column under gentle suction. By this modification of the column, glutathione and any cysteine were removed to the extent of at least 99 per cent (Table I). The last two glutathione experiments show that glutathione does not interfere with the direct determination of glutamine after glutamic acid adsorption. Glutathione in the amounts known to occur in mammalian tissue (4) can be successfully eliminated by this procedure.

Determination and Removal of Keto Acids—In the course of the investigation it became desirable to determine the keto acids formed after the intraintestinal administration of glutamic acid and glutamine. It was noted that high concentrations of keto acids, equivalent to more than 5 mg. of pyruvic acid per 100 ml. of plasma, lowered the glutamic acid recovery after acid hydrolysis of samples for the determination of total glutamic acid (glutamic acid plus glutamine) by the original method (3). No interference was experienced when the filtrates from glutamic acid adsorption, containing only glutamine, were submitted to acid hydrolysis, since most of the keto acid was retained in the column. If total glutamic acid is to be determined by the original procedure, the keto acids may be removed as the 2,4-dinitrophenylhydrazones, and they may be estimated by the same procedure.

In the experiments with blood plasma filtrates, 2 ml. of 0.1 per cent 2,4-dinitrophenylhydrazone in 2 N HCl were added to 1 ml. of the trichloroacetic acid filtrate. After 25 minutes the hydrazone was extracted with eight 4 ml. portions of benzene. The hydrazone was extracted from the benzene solution with three 2 ml. portions of a 10 per cent solution of sodium bicarbonate, the color was developed by the addition of 5 ml. of 2 N NaOH to 5 ml. of the extract, and read after 5 minutes in the Coleman junior spectrophotometer at wave-lengths 420 and 520 mμ in order to

TABLE I

Determination of Glutamic Acid and Glutamine in Presence of SH Compounds

SH compound added		In sample		Found	
		Glutamic acid	Glutamine	Glutamic acid	Glutamine
γ		γ	γ	γ	γ
Glutathione	604			4.7	
	1808			8.3	
	3012			14.9	
	564	41.4		41.8	
	600	37.3		37.3	
	1800	37.3		41.2	
	2400	37.3		45.8	
	1114	20.8	234*	21.9†	236
	2228	41.6	468*	45.1†	438
Cysteine	21.2	41.4		41.8	

* Corrected for a content of 92.5 per cent of glutamine.

† Corrected for retention of 1 per cent of glutamine as glutamic acid (2).

determine ketoglutaric acid and pyruvic acid. Sodium pyruvate served as the standard (5, 6).

For the determination of the total glutamic acid content after the removal of keto acids, 1 ml. of the extracted trichloroacetic acid filtrate was hydrolyzed with 0.5 ml. of 6 N HCl at 100° for 1 hour, neutralized, and diluted to 5 ml. with water. 2 ml. aliquots were taken for the duplicate determinations.

Absorption Experiments. Cats—A cannula was introduced into the trachea of a cat (4 to 5 kilos) under diallylbarbituric acid[1] anesthesia, and heparin[1] was injected intravenously. After ligation of the gastrosplenic vein, a 2-way cannula with a side arm was introduced into the portal vein. Thus the portal blood flow was not obstructed. A blood sample (8 ml.) was removed before the injection into the small intestine of 5 ml. of saline

[1] We are indebted to Ciba Pharmaceutical Products, Inc., for a gift of diallylbarbituric acid and to Roche-Organon for a generous supply of heparin.

containing glutamic acid, glutamine, or glutathione, adjusted to pH 7.3. Two further blood samples were taken 15 and 30 minutes later. The cell volume was determined in all blood samples.

Man—Venous blood was taken from human subjects at least 18 hours after the last meal. Two further blood samples were removed 1 and 2 hours after the intake of 1 gm. of glutamic acid per 10 kilos of body weight. The whole amount of glutamic acid was suspended in 100 ml. of water.

RESULTS AND DISCUSSION

The analysis of the blood of the portal vein after the intraintestinal administration of glutamic acid or glutamine showed that both compounds

TABLE II

Concentration of Free Glutamic Acid and Glutamine in Blood Plasma of Portal Vein after Intraintestinal Administration of Glutamic Acid, Glutamine, and Glutathione

Values expressed as mg. per 100 ml. of plasma.*

Time after administration	Cat 1		Cat 2		Cat 3		Cat 4		Cat 5		Cat 6	
	Acid	Amide	Acid	Amide	Acid	Amide	Acid	Amide	Acid	Amide	Acid	Amide
min.												
0	2.8	10.7	1.7	10.4	2.5	6.4	1.6	5.9	1.9	5.0	2.1	5.0
	100 mg. glutamic acid administered				100 mg. glutamine administered				205 mg glutathione administered			
15	12.9	4.2	6.6	8.3	3.9	12.7	1.9	12.3	1.9	5.0	1.8	5.6
30	14.8	13.0	1.0	15.5	3.1	25.8	1.6	8.8	1.7	5.0	2.3	5.4

* Per cent blood cells: Cat 1, 44, 36, 35; Cat 6, 49, 42, 41; Cats 2 to 5, change in blood cell volume less than 3 per cent.

passed the intestinal wall without any significant interconversion (Table II). A considerable increase of the administered compound occurred 15 minutes after administration, with only a small change in the level of the other. Simultaneously with the large increase in the glutamic acid concentration in the plasma after the administration of this amino acid (Cats 1 and 2) there was found, after 15 minutes, a decrease in the glutamine values. The increase of the glutamine concentration at 30 minutes may be interpreted as a release from the tissues of glutamine either formed from the administered glutamic acid or mobilized as a result of the increased glutamic acid concentration. Both phenomena, the decrease of the glutamine concentration and the following increase, have also been found in the peripheral blood plasma of human subjects after the ingestion of glutamic acid. The effect of an increased glutamic acid concentration in plasma in decreasing

the glutamine level appears to be part of a general mechanism since a lowering of the concentrations of glutamine, glycine, and residual amino nitrogen has been found under similar conditions in dogs (7).

In the glutamine experiments, there was found a small increase of glutamic acid, which is apparently not related to the glutamine concentration, and may therefore be due to a release of glutamic acid originating from the increased glutamine concentration in the tissue.

Glutamic acid and glutamine are apparently not converted into each other during the passage through the intestinal wall, and there seems to be no extensive deamination during this process. Only insignificant increases in the keto acid concentration were found and the optical absorption ratios of the hydrazones at 420 and 520 mμ varied between 1.2 and 1.4, a result which indicates that the relative concentration of ketoglutaric acid did not change significantly, either during the absorption of glutamine or the parent amino acid.

After the intraintestinal administration of an equivalent amount of glutathione, there was no change in the glutamic acid or glutamine concentration of the plasma of portal blood during the experimental period comparable with that found during the absorption of the amino acid and its amide. It has been pointed out in the experimental part that glutathione, if not removed, contributed to the glutamine fraction after acid hydrolysis about 20 per cent of its concentration in glutamic acid equivalents. Values obtained for glutamine in the glutathione experiments with and without the modification developed for the removal of glutathione agreed within the error of the method. It appears therefore that the tripeptide, if absorbed during the experimental period, is taken up rapidly by the cells or that it is not metabolized during passage through the intestinal wall to glutamic acid or glutamine to any considerable degree.

The direct evidence (8, 9) for the occurrence of glutamine and asparagine in proteins is based on the isolation of the amides from enzymatic hydrolysates. If changes in the glutamine content of the food proteins due to storage and preparation of the food are disregarded for the present, our experiments suggest the possibility that glutamic acid and glutamine are absorbed in about the ratio in which they occur in the original protein. Depending on the composition of the proteins ingested, varying amounts of the two compounds will therefore be absorbed and the organism, by enzymatic mechanisms, will have to adjust the amounts to the specific ratios of the tissues.

The oral administration of glutamic acid to human subjects led always to an increase of varying degree in the glutamic acid concentration of the peripheral blood (Table III). Two types of responses to the elevation of the blood glutamic acid may be distinguished. A small increase of the

glutamic acid concentration appeared to be accompanied by a considerable increase in the glutamine concentration, which may be interpreted as the return of the amidated amino acid from the tissue or a mobilization of tissue glutamine. A high glutamic acid concentration in the blood appeared to lead to a considerable decrease in the glutamine values 1 hour after the administration. In the experiments with cats, both the decrease and the increase in glutamine concentration were found in the portal blood of the same animal as a response to an elevated glutamic acid concentration. These findings are an additional demonstration of the influence of the blood concentration of one amino acid on that of another. These experiments do not permit any prediction as to the glutamic acid and glutamine levels in blood to be expected if glutamic acid is administered in combination with other amino acids, as in hydrolysates or whole protein.

Beneficial effects of the oral administration of glutamic acid to epileptics

TABLE III

Concentration of Free Glutamic Acid and Glutamine after Oral Administration of Glutamic Acid to Human Subjects (1 Gm. per 10 Kilos)

Values expressed as mg. per 100 ml. of plasma.

Time after administration	Subject 1		Subject 2		Subject 3		Subject 4	
	Acid	Amide	Acid	Amide	Acid	Amide	Acid	Amide
hrs.								
0	0.6	8.4	0.6	10.6	1.2	8.4	0.8	10.3
1	1.0	10.3	1.2	14.0	5.0	5.8	9.5	8.3
2	1.0	8.9	0.8	11.3	0.7	6.3	1.0	10.0

and mental defectives have been reported (10, 11). It had been difficult to understand why a daily administration of only 10 to 20 gm. of glutamic acid could have any effect in view of the large amounts of glutamic acid ordinarily ingested with protein. The absorption experiments with the cat show that glutamine and glutamic acid may pass the intestinal tract without interconversion. Therefore, depending on the glutamine-glutamic acid ratio in the protein, a small amount of additional glutamic acid may considerably increase the relative intake of this amino acid. Our experiments with human subjects show that the ingestion of 2 or 3 times the therapeutic amount of glutamic acid leads to a significant increase in the blood glutamic acid level and to alterations in the metabolism of glutamine.

SUMMARY

A simplified modification of the method for the determination of glutamic acid and glutamine is described. Glutamine and glutamic acid are ab-

sorbed from the gut of the cat without interconversion. The elevated glutamic acid level in the portal blood is accompanied by a decrease in the glutamine level, followed by an increase. The oral administration of glutamic acid to human subjects leads to an increase of the glutamic acid level in the peripheral blood, with a simultaneous decrease or increase in the glutamine concentration.

BIBLIOGRAPHY

1. Archibald, R. M., *Chem. Rev.*, **37**, 161 (1945).
2. Prescott, B. A., and Waelsch, H., *J. Biol. Chem.*, **164**, 331 (1946).
3. Prescott, B. A., and Waelsch, H., *J. Biol. Chem.*, **167**, 855 (1947).
4. Schroeder, E. F., and Woodward, G. E., *J. Biol. Chem.*, **129**, 283 (1939).
5. Friedemann, T. E., and Haugen, G. E., *J. Biol. Chem.*, **147**, 415 (1943).
6. Waelsch, H., and Miller, H. K., *J. Biol. Chem.*, **145**, 1 (1942).
7. Christensen, H. N., Streicher, J. A., and Elbinger, R. L., *J. Biol. Chem.*, **172**, 515 (1948).
8. Damodaran, M., *Biochem. J.*, **26**, 235 (1932).
9. Damodaran, M., Jaaback, G., and Chibnall, A. C., *Biochem. J.*, **26**, 1704 (1932).
10. Waelsch, H., and Price, J. C., *Arch. Neurol. and Psychiat.*, **51**, 393 (1944).
11. Albert, K., Hoch, P., and Waelsch, H., *J. Nerv. and Ment. Dis.*, **104**, 263 (1946).

Lethal Amounts of Casein, Casein Salts and Hydrolyzed Casein Given Orally to Albino Rats [1]

6D010 600

ELDON M. BOYD, C. J. KRIJNEN AND JOSEF M. PETERS
Department of Pharmacology, Queen's University, Kingston, Ontario, Canada

ABSTRACT The lethal dose of casein given as an aqueous suspension intragastrically to albino rats was estimated to be well over 1000 g/kg administered over a period of 2 weeks but could not be definitely established because deaths were due in part to distilled water in the suspension. The LD_{50} of the water-soluble sodium and calcium salts of casein was estimated to be some 400–500 g/kg given over a 5-day period, the intoxication being due mainly to salt effects. The $LD_{50} \pm SE$ of pancreatin-hydrolyzed casein was found to be 26.0 ± 1.6 g/kg, death occurred at 2 to 4 hours and was due to a violent gastroenteritis, blood and tissue dehydration, widespread capillary-venous congestion, coma and respiratory failure. Survivors of the latter group recovered clinically in 2 to 3 days but some changes in organ weights were significantly abnormal at 2 weeks and even at 1 month. The results indicate it is almost impossible to administer lethal amounts of casein orally to albino rats but that toxic effects can be produced by water-soluble salts of casein and particularly by the amino acids and polypeptides of hydrolyzed casein.

During the course of studies on the toxicity of drugs given to adult albino rats fed various purified vitamin-deficient diets, evidence was obtained which suggested that toxicity may be associated with the presence of large amounts of certain foods in the diets (1). As a corollary it should be possible to demonstrate toxic and lethal doses of such foods. Certain preparations of casein were found to produce toxicity and death when given orally in sufficient amounts to albino rats. The amount required to produce death was far in excess of that likely to be fed or eaten except in the instance of hydrolyzed casein.

Hydrolyzed casein is produced in the digestion of casein with, for example, pancreatin (2). It is present in certain proprietary infant food formulas (3) and is used in the therapy of babies with special feeding problems (4) such as allergenic sensitivity to intact proteins, pancreatic deficiencies and tube feeding (it is water-soluble). The results of the present study suggest that if casein hydrolysate were fed to infants in amounts somewhat greater than the recommended 5 g/kg per day (4), it might produce toxic signs which could resemble the disease being treated. Rats may eat some 15 to 30 g/kg per day of casein (1) and these amounts of casein hydrolysate can produce lethal reactions if given to rats at one administration. The results of the present study, therefore, have important implications in the fields of animal and human nutrition.

MATERIALS AND METHODS

Techniques. Seven preparations of casein were given by intragastric cannula to overnight-starved, young, male, albino rats [2] weighing 150 to 200 g, in increasing amounts until death occurred. The animals were housed in metabolism cages, one rat per cage, and were offered laboratory ration [3] and water ad libitum. Clinical signs of toxicity were noted daily (or at shorter intervals if indicated) until the syndrome had subsided. At intervals of 24 hours measurements were made of body weight in grams, food consumption in grams per kilogram of body weight per day, water intake in milliliters per kilogram per day, colonic temperature, urinary volume in milliliters per kilogram per day, urinary

Received for publication June 12, 1967.
[1] This research was supported by a grant from the Medical Research Council of Canada.
[2] The animals were a Wistar strain obtained from Canadian Breeding Laboratories of St. Constant, Quebec, Canada.
[3] Purina Laboratory Chow Checkers, Ralston Purina Company, Limited, Woodstock, Ontario, Canada.

protein and glucose output semi-quantitated in milligrams per kilogram per day, and urinary pH on a 24-hour sample. The last 3 measurements were made with the use of Ames Combistix[4] and colonic temperature was recorded by a Thermistemp Telethermometer[5] with the probe inserted into the descending colon. Other measurements were made as indicated and as noted below.

Premortem signs were recorded in detail when possible and following death the gross and microscopic appearance of the organs listed in table 1 were noted. Histopathologic studies were made of blocks of tissue fixed in Lillie's buffered formalin and sections were stained with hematoxylin-phloxine-saffron. In addition, the wet weight[6] and water content of the organs listed in table 1 were measured at death and in survivors at 2 weeks and at one month following administration of enzymatic casein hydrolysate.[7] Autopsies were performed within one hour of death to avoid the postmortem shifts in weight and water content described by Boyd and Knight (5). The contents of the lumen of the gastrointestinal organs were removed by a standardized washing and milking before weighing. The sample of muscle was the right half of the ventral abdominal wall muscle layer. The medulla oblongata was included in dissection of the brain. Water content was determined upon organs dried to constant weight at 95° in a forced-draft isotemp oven.[8] Aliquots from the dorsolumbar region of skin and from residual homogenized carcass were used for measuring water content.

Mean differences from controls were subjected to the *t* test for statistical significance (6). The $LD_{50} \pm SE$ was calculated by the linear regression method of Boyd (7).

Preparations of casein. Casein certified Fisher[9] was administered as a 30% (w/v) suspension in a 0.12% solution of ammonium hydroxide in distilled water as suggested from the data of Davies (8). Following pilot tests with lesser volumes, it was finally given warmed to body temperature in a volume of 100 ml/kg which volume appeared feasible from the report of Boyd et al. (9). This was repeated at hourly intervals to yield doses of 30, 60, 90, 120 and 150 g/kg with controls given the same volumes of 0.12% ammonium hydroxide solution, each dose of casein and of vehicle to 10 rats.

Following preliminary trials, high protein casein[10] and vitamin-free test casein[11] were administered in a dose of 50 ml/kg of a 15% (w/v) suspension at 5 successive hourly intervals each day (= 37.5 g/kg per day) for 3 days and then the dose was gradually increased to 9 administrations per day until death occurred or for 3 weeks, whichever occurred first, each preparation to 20 rats. Following similar pilot studies, sodium caseinate,[12] casein sodium and casein calcium[13] were each given as 50 ml/kg of a 15% (w/v) solution in distilled water at 10 successive intervals of 0.5 hours (= 75 g/kg per day) each day until the animals died or for one week, whichever occurred first, each preparation to 10 rats.

Enzymatic casein hydrolysate was dissolved in distilled water at body temperature and administered in a volume of 100 ml/kg in doses of 10, 20, 22.5, 24, 25, 26,

---

[4] Manufactured by the Ames Company of Canada Limited, Rexdale, Ontario, Canada.

[5] Purchased from the Fisher Scientific Company Limited, Don Mills, Ontario, Canada.

[6] Organs were weighed to 0.1 mg on a 1-911X3 Mettler semi-micro gramatic balance, except skin and residual carcass which were weighed on a Mettler K-5T precision balance, both balances purchased from Fisher Scientific Company Limited, Don Mills, Ontario, Canada.

[7] Enzymatic casein hydrolysate is produced by treating casein with pancreatin which converts casein into its amino acids and peptides. General Biochemicals, Chagrin Falls, Ohio, from whom it was purchased, state that it is edible and that the degree of hydrolysis is "acceptable to the American Medical Association." The preparation was found to be soluble to 60% (w/v) in distilled water at body temperature.

[8] See footnote 5.

[9] See footnote 5.

[10] High protein casein was obtained from General Biochemicals, Chagrin Falls, Ohio, who reported that it was produced by the controlled lactic acid fermentation of pure skim milk and contained 85% protein, 11% water, 1.9% ash, 1.5% milk fat and small amounts of thiamine, riboflavin, niacin, pyridoxine, pantothenic acid, biotin, folic acid, cyanocobalamin, copper, iron, zinc and iodine.

[11] Vitamin-Free Test Casein was obtained from General Biochemicals, Chagrin Falls, Ohio, who reported that it is prepared by controlled multiple extractions with hot alcohol and vacuum drying and contains 89.0% protein, 8.0% water, 2.0% ash and 0.5% fat. Alcohol extraction removes some 75% (35 to 100) of the vitamins contained in high protein casein so that it is not "vitamin-free" but may be considered such for most biological purposes.

[12] Sodium caseinate was obtained from General Biochemicals, Chagrin Falls, Ohio, who reported that it contained 92.5–94.5% protein, 4.0% ash (1.3% sodium) and 1.5% fat. It was found soluble to 20% in water at body temperature.

[13] Casein sodium and casein calcium were obtained from Nutritional Biochemicals Corporation, Cleveland. Casein sodium was found soluble in water to 25% and casein calcium to 15% at body temperature.

27.5, 29, 30, 40, and 50 g/kg each dose to 16 to 20 rats with 31 controls given 100 ml/kg of distilled water only.

RESULTS

Casein. Suspensions of casein Fisher gradually coagulated into particles of various sizes on standing and also in the rat's stomach. A dose of 30 g/kg killed 30% of the rats by regurgitation and aspiration into the lungs where it produced death from aspiration asphyxia, usually within 30 minutes, or from gastric rupture with death at 6 to 14 hours later. The LD_{50} of ammonium hydroxide, given in solution to the controls, was found to be 0.45 g/kg; death followed convulsoins at 0.5 to 4 hours and was accompanied by a violent gastritis. The LD_{50} of ammonium hydroxide is similar to that reported previously in cats by Spector (10).

High protein and vitamin-free test casein suspensions produced 40% deaths from stomach rupture after administration of 37.5 g/kg (day 1). There were no further deaths until the eighth day when daily administrations had increased to seven, or 52.5 g/kg per day, and a total of 345 g/kg of casein had been given — at which point 50% of rats had died of gastric rupture. Twenty percent of the rats survived 9 administrations or 67.5 g/kg per day for one week following the fourteenth day when this daily dose was reached. The clinical signs in these 8 rats were inhibition of growth, anorexia, a marked diuresis due largely to daily administration of large volumes of water, proteinuria, aciduria, and listlessness. These signs were accentuated premortally in 3 rats that died apparently of protein intoxication and at least not from gastric rupture or from regurgitation asphyxia.

Ability to survive large amounts of "natural" casein (high protein casein, vitamin-free test casein, and casein Fisher) appeared to be related mainly to ability of the stomach to accommodate the necessary large bulk. In survivors there was some capillary-venous congestion of the lamina propria and submucosa of the stomach, small bowel, cecum and colon. There was some evidence of systemic damage. The liver was congested and occasionally there were scattered areas of necrosis in the lobules. There was mild-to-moderate capillary-venous congestion of the brain, lungs, heart and kidneys and atrophic changes in the myofibrils of skeletal muscle and in the thymus gland. These changes were accentuated in 3 rats that died apparently of casein poisoning. The total dose of casein given to the latter 3 rats was 140, 340 and 830 g/kg given over 4, 8 and 15 days, respectively. If calculation of the LD_{50} can be applied under these circumstances, casein would have an LD_{50} well over 1000 g/kg.

Casein salts. Of the 10 rats given sodium caseinate, 2 died of gastric rupture during the first 24 hours and 3 died on the fourth and fifth days with no gastric rupture and no evidence of regurgitation asphyxia. The latter 3 animals had received 75 g/kg per day of sodium caseinate (containing approximately 1 g/kg per day of sodium) or a total of 300 to 375 g/kg over the interval to death. The indicated "LD_{50}" would be of the order of 400 to 500 g/kg. Death was preceded by marked loss of body weight, marked anorexia, marked diuresis, marked proteinuria, alkalinuria, diarrhea, listlessness and a premortal hypothermia. The local inflammatory reaction in the gut was confined mostly to the cecum. There occurred hepatic, renal, cerebral, cardiac, pulmonary, testicular, adrenal, thymic and splenic capillary-venous congestion and fatty degeneration of the renal tubules. Animals that survived had very marked diuresis and an augmented water intake.

Results in animals given casein sodium were similar to those obtained from sodium caseinate. Of the 10 rats given casein calcium, 8 died of stomach rupture during the first and second days and the reaction of the 2 survivors was similar to that seen in rats which survived administration of sodium caseinate.

Casein hydrolysate. The $LD_{50} \pm SE$ of enzymatic casein hydrolysate was found to be 26.0 ± 1.6 g/kg, the maximal LD_0 was 23.5 and the minimal LD_{100} was 28.6 g/kg. The mean $\pm$ SD interval to death was 3.6 ± 1.4 hours excluding one delayed death at 24 hours and a second at 27 days. The interval to death was shorter the higher the dose of the casein hydrolysate.

Clinical signs of toxicity during the first hour were listlessness, cyanosis, and diarrheic bowel movements which appeared

to consist mostly of casein hydrolysate. Hemoconcentration developed rapidly as shown in figure 1 and was greater the higher the dose of the casein hydrolysate as shown in figure 2. Death was due to respiratory failure in a cyanotic coma. At autopsy, most organs were found to have lost weight, as shown in table 1, due to loss of water, as shown in table 2. On gross observation, an intense congestion of the brain, hemorrhagic inflammation of the gut and a dark-colored liver were observed. Microscopic examination confirmed the gross pathology and disclosed vascular congestion in many other organs as indicated in table 3 and, in the delayed death, degenerative changes in the kidneys and lungs. Blood clots, noted in table 3, were due either to antemortem clotting or to accelerated postmortem clotting or to both, since they were not seen in controls given no casein enzymatic hydrolysate.

Survivors at 24 hours had lost body weight and exhibited anorexia, hyperdipsia, mild fever, diuresis, aciduria and proteinuria but appeared grossly normal, as indicated by results summarized in table 4. The data in table 4 are expressed as percentage of change from controls given 100 ml/kg of distilled water which in itself produced a moderate diuresis, alkalinuria, glycosuria and proteinuria. By the third day, clinical parameters were returning toward normal but not all organ weights and water

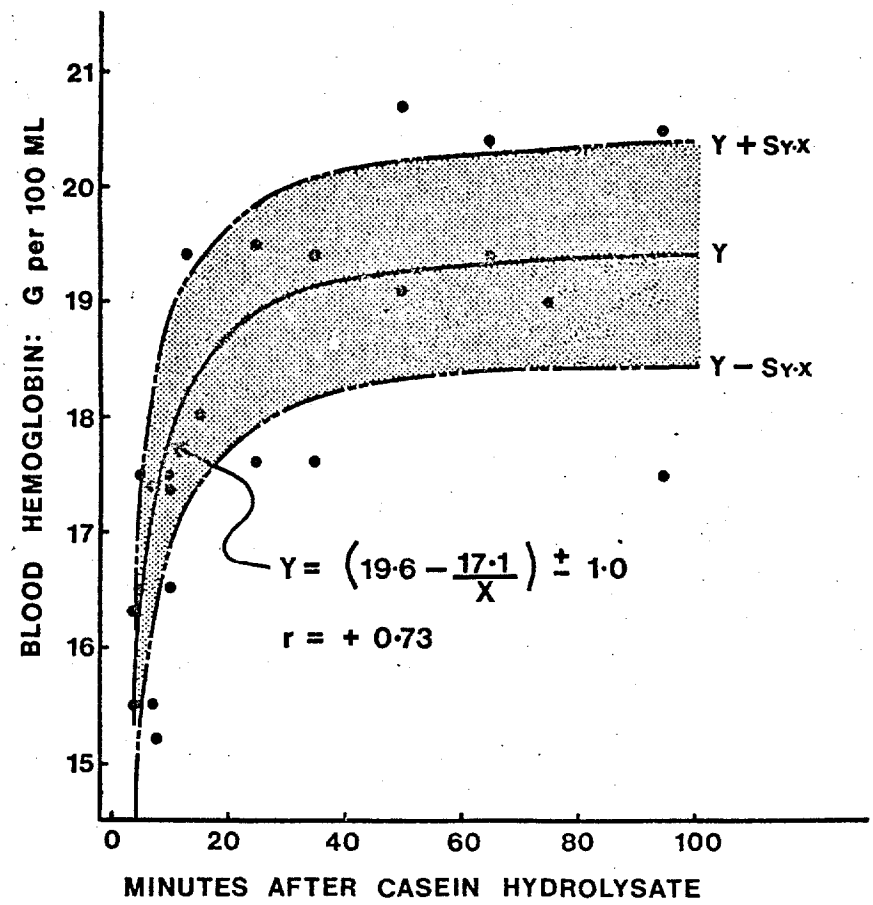

Fig. 1 The regression, on time in minutes, of values for blood hemoglobin following oral administration of casein enzymatic hydrolysate in a dose of 26 g/kg body weight.

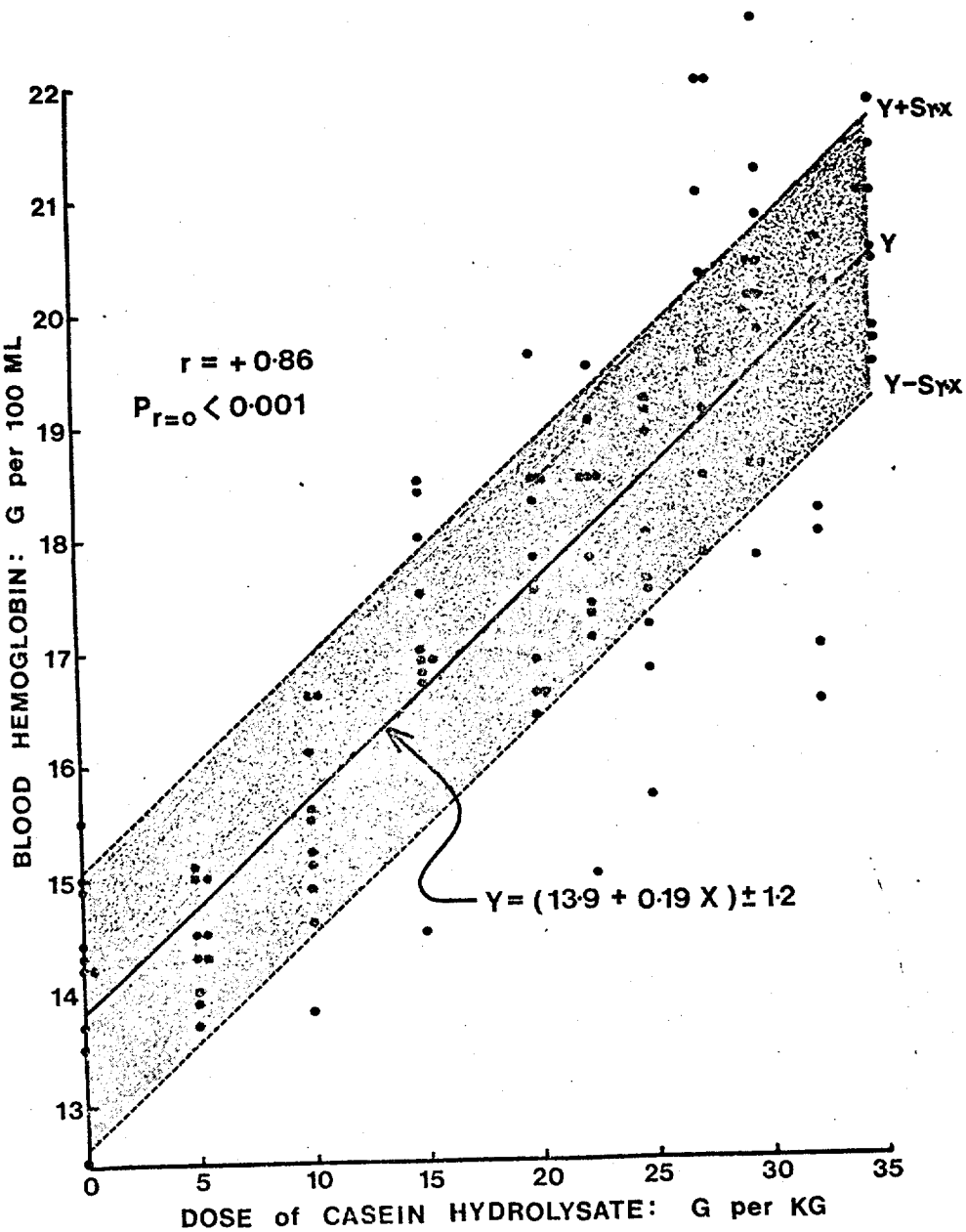

Fig. 2 The regression, on dose of casein enzymatic hydrolysate of values for blood hemoglobin measured at 30 minutes later.

content had reached normal values at 2 weeks and even at one month as indicated by data summarized in tables 1 and 2. All clinical parameters were normal at 2 weeks and one month.

DISCUSSION

The results from casein administration confirm conclusions reached by Bischoff (11) in his review of 1932 and by Hegsted (12) in 1964 that man and animals can

TABLE 1

Changes in the fresh weight of body organs at autopsy in albino rats given doses of casein enzymatic hydrolysate in the range of the oral LD_{50}[1]

Organ	At death (N = 17 + 19 controls)	2-week survivors (N = 15 + 14 controls)	1-month survivors (N = 18 + 16 controls)
Adrenal glands	− 4.3	− 3.8	−12.5 **
Brain	− 3.2 *	− 0.3	+ 0.1
Gastrointestinal tract:			
Cardiac stomach	−24.1 **	−17.7 *	+ 2.0
Pyloric stomach	−21.2 **	− 8.8	− 0.7
Small bowel	− 5.2	− 9.2	+ 9.5 **
Cecum	−19.7 **	+ 4.9	− 0.1
Colon	−18.9 **	−10.8 *	+ 3.6
Heart	− 2.4	+ 2.9	− 3.4
Kidneys	− 5.2 *	− 5.9 *	+ 4.0
Liver	− 6.6	− 5.0	+ 8.4 *
Lungs	+13.6	− 7.6 *	+ 1.5
Muscle (ventral abd. wall)	−30.8 **	− 3.6	−17.5 **
Salivary glands (submax.)	− 2.3	+ 1.5	− 0.6
Skin	−11.2 **	− 0.5	− 2.9
Spleen	−28.4 **	− 8.5	− 7.8
Testes	−17.1 **	− 2.3	− 3.0
Thymus gland	−17.4 *	−11.4 *	− 7.9
Residual carcass	−13.7 **	− 3.7 *	− 0.2
Total body wt	− 2.4	− 3.2 *	− 0.7

[1] The organs were weighed in grams and the results are expressed as mean percent change from controls, specifically as $((\bar{X}_d - \bar{X}_c) \div \bar{X}_c) \times 100$ where $\bar{X}_d$ is the mean in the drug (casein) treated rats and $\bar{X}_c$ in the respective controls.

* A mean difference significantly different from zero at $P = 0.05$ to 0.02.

** A mean difference significantly different from zero at $P = 0.01$ or less.

TABLE 2

Changes in the water content of body organs at autopsy on albino rats given doses of casein enzymatic hydrolysate in the range of the oral LD_{50}[1]

Organ	At death (N = 17 + 19 controls)	2-week survivors (N = 15 + 14 controls)	1-month survivors (N = 18 + 16 controls)
Adrenal glands	−24.6 **	+8.3 *	+7.6
Brain	−15.2 **	−0.3	+0.2
Gastrointestinal tract:			
Cardiac stomach	−41.0 **	−5.3	−0.2
Pyloric stomach	−41.9 **	−2.6	+3.2
Small bowel	−30.3 **	−0.6	+0.8
Cecum	−24.6 **	+0.9	+2.5
Colon	−33.2 **	+1.0	+3.9 *
Heart	−17.3 **	−0.6	−0.2
Kidneys	−17.8 **	−0.7	−0.4
Liver	−17.0 **	+0.5	−6.0 *
Lungs	−16.0 **	−2.2	+1.2
Muscle (ventral abd. wall)	−24.0 **	+0.9	−1.0
Salivary glands (submax.)	−16.2 **	+0.6	+2.5
Skin	−23.6 **	−2.2	−2.7
Spleen	−11.3 **	−0.7	+0.7
Testes	−17.6 **	+1.6 *	+0.6
Thymus gland	−19.5 **	−2.2	+2.3
Residual carcass	−21.3 **	−4.8 *	+3.0

[1] Water content was measured as grams water/100 g dry weight of tissue and the results are expressed as mean percent change from controls, specifically as $((\bar{X}_d - \bar{X}_c) \div \bar{X}_c) \times 100$ where $\bar{X}_d$ is the mean in the drug (casein) treated rats and $\bar{X}_c$ in the respective controls.

* A mean difference significantly different from zero at $P = 0.05$ to 0.02.

** A mean difference significantly different from zero at $P = 0.01$.

TABLE 3

Histopathologic observations in albino rats at death due to oral administration of a lethal dose of casein enzymatic hydrolysate

Organ	Histopathology
Adrenal glands	Sinusoidal erythrocytes packed and distorted; clotting; minute areas of early necrosis
Brain	Marked capillary-venous congestion and hemorrhages in the meninges and brain
Gastrointestinal tract:	
Cardiac stomach	Capillary-venous congestion of the submucosa with areas of lysis of the stratified squamous epithelium
Pyloric stomach	Capillary-venous congestion of the lamina propria and submucosa
Small bowel	Capillary-venous congestion of the lamina propria and submucosa and shrunken villi
Cecum	Capillary-venous congestion and hemorrhage of the lamina propria and submucosa and lysis of glands
Colon	Capillary-venous congestion of the lamina propria and submucosa
Heart	Coronary capillaries and veins congested and occasionally blood clots present
Kidneys	Vascular congestion especially in the loop region and tubular fatty degeneration in late deaths
Liver	Sinusoids packed with distorted erythrocytes and areas of venous clotting
Lungs	Venous clots in early deaths and areas of edema and hemorrhage in late deaths
Muscle	Fibers shrunken but otherwise normal in appearance
Salivary glands (submax.)	Normal appearance
Skin	Ischemic
Spleen	Red pulp shrunken, packed erythrocytes, venous clots
Testes	Tubules shrunken, extravascular clots, some tubular lysis
Thymus gland	Venous clots and some loss of thymocytes

tolerate large amounts of casein in their diets. Hegsted (12) notes that a high protein diet increases the need for water. When young rats in this laboratory (13) were fed a diet of 80% casein for 14 days, there occurred a marked diuresis, some generalized body organ dehydration and an increase in the weight of kidneys and liver but the appearance and growth of the animals were normal.

In the present study, an attempt was made to find a lethal dose of casein given by intragastric cannula to albino rats. Aqueous suspensions coagulated unless they were relatively dilute. The dilute suspensions coagulated and remained in the stomach and repeated administration produced gastric rupture or regurgitation asphyxia in 62 out of 70 animals. Of the 8 survivors, three died apparently from casein intoxication and calculations suggested that the "LD_{50}" of casein would be greater than 1000 g/kg administered over 15 days. Administration of such amounts required the simultaneous administration of distilled water in amounts up to 450 ml/kg per day. The separate administration of this daily volume of water produced clinical signs of toxicity similar to those seen in rats given casein except that there was no aciduria nor any deaths.[14] The widespread vascular congestion of body organs seen in rats dying apparently of casein intoxication was not seen in rats which died

[14] These results were obtained by S. J. Liu of this laboratory in current studies on the effects of daily administration of large volumes of distilled water to albino rats.

TABLE 4

Clinical measurements on survivors of death due to oral administration of casein enzymatic hydrolysate [1]

Measurement	Days after casein		
	1	2	3
		% change	
Body wt, g	− 3.3 ** DD	− 4.1 ** DD	− 1.8 *
Food intake, g/kg/24 hr	− 44.5 **	− 4.9	+ 0.2
Water intake, ml/kg/24 hr	+ 80.8 ** DD	+ 21.2 **	+ 3.6 *
Colonic temperature, °C	+ 0.7 ** DD	+ 0.4	+ 0.1
Urinary volume, ml/kg/24 hr	+ 82.3 ** DD	+ 35.8	+16.8
Urinary pH, 24-hr sample	− 4.4 **	− 0.2	−10.1
Urinary glucose output, mg/kg/24 hr	−100.0 **	+109.0	+36.1
Urinary protein output, mg/kg/24 hr	+494.0 ** DD [2]	− 6.0	−53.2 *
Listlessness, cyanosis, diarrhea, clinical units	0.0	0.0	0.0

[1] The results are expressed as mean percentage change from controls specifically as $((\bar{X}_d - \bar{X}_c) \div \bar{X}_c) \times 100$ where $\bar{X}_d$ is the mean in the drug (casein) treated survivor and X_c in the controls. Dose-dependence of the mean percentage change is indicatd by "DD."

[2] Urine during the first 24 hours was contaminated with diarrheal casein hydrolysate which may have contributed to the markedly increased output of urinary protein.

* $\bar{X}_d - \bar{X}_c$ significantly different from zero at $P = 0.05$ to 0.02.

** $\bar{X}_d - \bar{X}_c$ significantly different from zero at $P = 0.01$ or less.

of acute water intoxication (14). Death in rats given casein was due to a combination of the toxic effects of water and casein and the LD_{50} of casein is undoubtedly much higher than 1000 g/kg administered over 2 weeks.

The LD_{50} of the soluble sodium and calcium salts of casein was estimated to be some 400 to 500 g/kg given orally to rats over 5 days. The signs of intoxication included some which have been reported in water (14) and in sodium chloride (15) intoxications, mainly in the latter. If large amounts of this preparation were fed in substitution for casein it could produce toxic effects due only in part (if at all) to its casein component.

When casein is hydrolyzed into its component amino acids and polypeptides, it becomes water-soluble and osmotically active. When doses of the order of 25 g/kg were given orally to albino rats in concentrated aqueous solution, they produced a violent gastroenteritis, a withdrawal of water from tissues and blood, widespread capillary-venous congestion, coma and death within a few hours. The syndrome is similar to that found in acute poisoning from sucrose (16) and from concentrated solutions of raw egg white (9). It is obvious that when this preparation is substituted for casein, it should be given in amounts well below the toxic level.

LITERATURE CITED

1. Boyd, E. M., D. A. Mulrooney, C. A. Pitman and M. Abel 1965 Benzylpenicillin toxicity in animals on a synthetic high sucrose diet. Can. J. Physiol. Pharmacol., 43: 47.
2. British Pharmaceutical Codex 1963 The Pharmaceutical Press, London, p. 558.
3. Vademecum International V-I Canada, ed. 14 1967 J. Morgan Jones Publications, Montreal, pp. 232, 234, 236.
4. Ebbs, J. H. 1966 The nutrition and feeding of infants. In: Nutrition, Comprehensive Treatise, vol. 3, ed., G. H. Beaton and E. W. McHenry. Academic Press, New York, p. 1.
5. Boyd, E. M., and L. M. Knight 1963 Postmortem shifts in the weight and water levels of body organs. Toxicol. Appl. Pharmacol., 5: 119.
6. Croxton, F. E. 1959 Elementary statistics with applications in medicine and the biological sciences. Dover Publications, New York.
7. Boyd, E. M. 1965 Toxicological Studies. In: Clinical Testing of New Drugs, ed., A. D. Herrick and M. Cattell. Revere Publishing Company, New York, p. 13.
8. Davies, W. L. 1936 The Chemistry of Milk. Chapman and Hall, London, p. 119.
9. Boyd, E. M., J. M. Peters and C. J. Krijnen 1966 The acute oral toxicity of reconstituted spray-dried egg white. Ind. Med. Surg., 35: 782.
10. Spector, W. S., ed. 1956 In: Handbook of Toxicology, vol. 1. Acute toxicities of solids, liquids and gases to laboratory animals. W. B. Saunders Company, Philadelphia, p. 22.
11. Bischoff, F. 1932 The influence of diet on renal and blood vessel changes. J. Nutr., 5: 431.
12. Hegsted, D. M. 1964 Proteins. In: Nutrition, a Comprehensive Treatise, vol. 1, ed.,

G. H. Beaton and E. W. McHenry. Academic Press, New York, p. 115.

13. Peters, J. M. 1967 A separation of the direct toxic effects of dietary raw egg white powder from its action in producing biotin deficiency. Brit. J. Nutrition, *21:* 801.
14. Boyd, E. M., and I. Godi 1967 The acute oral toxicity of distilled water in albino rats. Ind. Med. Surg., 36: 609.
15. Boyd, E. M., M. M. Abel and L. M. Knight 1966 The chronic oral toxicity of sodium chloride at the range of the $LD_{50\ (0.1\ L)}$. Can. J. Physiol. Pharmacol., *44:* 157.
16. Boyd, E. M., I. Godi and M. Abel 1965 Acute oral toxicity of sucrose. Toxicol. Appl. Pharmacol., *7:* 609.

Acute Effect of Oral and Subcutaneous Administration of Monosodium Glutamate on the Arcuate Nucleus of the Hypothalamus in Mice and Rats

RECENT reports by Olney that monosodium glutamate (MSG) can cause acute neuronal necrosis in the developing brain of mice[1-3], rats[1] and monkeys[4], have been the subject of intensive debate[5-11]. Some people[9,11] deny that a single subcutaneous dose of monosodium glutamate can produce any brain damage in infant rats. Although Arees and Mayer[10] confirm the existence of a necrotic lesion in both mouse and rat brain they restrict the pathology to "microglial" cells. None of these investigators attempted actually to replicate Olney's methods but used entirely different methods of preservation and staining.

Because any reports of this nature demand independent confirmation, a blind study was undertaken to determine both the presence or absence of and the consistency of an MSG effect on the developing hypothalamus of mice using the exact methods of administration of MSG, fixation and staining outlined by Olney[2] (Table 1). Further studies were completed in a similar experimental situation on Wistar rats using Olney's techniques as well as those of Adamo and Ratner[9] (Table 1).

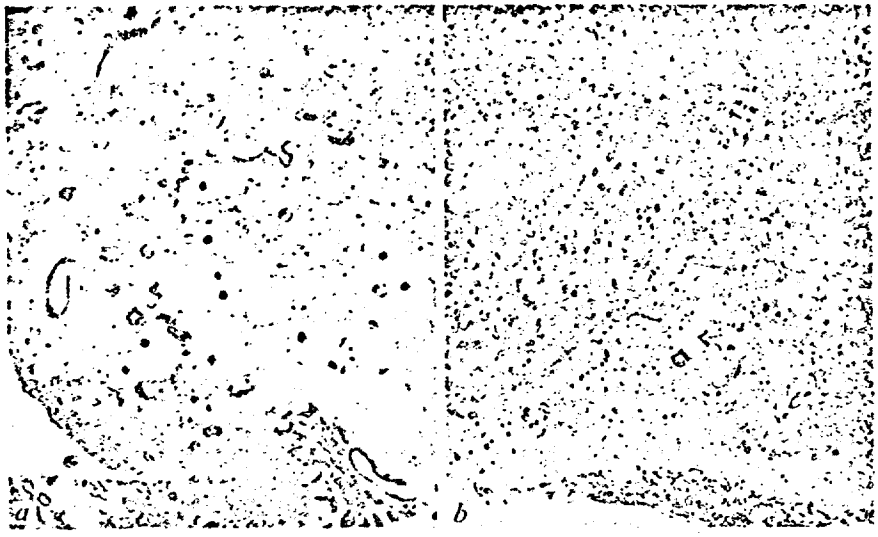

Fig. 1 *a*, Section through the hypothalamus of 10 day old Swiss albino mouse 5 h after oral administration of 1 mg/g of MSG, illustrating a distinct lesion in the region of the arcuate nuclei (AR). The neuronal elements are necrotic with a bloated cytoplasm and pyknotic nuclei (~ ×650). *b*, Section through the hypothalamus of 4 day old Wistar rat 5 h after oral administration of 4 mg/g of MSG, demonstrating a massive lesion involving the arcuate (AR) and ventromedial (VM) nuclei (~ ×450).

Monosodium glutamate was administered either orally or by subcutaneous injection. Sections for light microscopy were read independently by two of us who were unaware of the treatment schedule. Sections for electron microscopy were collected on slot grids and stained with uranyl acetate and lead citrate.

Table 1 Treatment Schedule and Fixation

Animal	Method of administration	Treatment MSG	Treatment NACl/saline	Perfusion method
Mouse	Oral	9 (1 mg/g)	9	Olney
Rat	Oral	5 (4 mg/g)	4	Olney
Rat	Oral	4 (4 mg/g)	4	Adamo and Ratner
Rat	Subcutaneous	6 (4 mg/g)	4	Adamo and Ratner
Rat	Subcutaneous	2 (4 mg/g) 2 (2 mg/g)	2	Olney

Light microscopic examination of the brains of infant mice treated orally with monosodium glutamate at a dose of 1 mg/g revealed that all the animals developed lesions in the arcuate area of the hypothalamus and median eminence (Fig. 1*a*), with complete correlation between independent examiners. No evidence of cellular pathology was noted in the controls. Light microscopic examination of the brains of infant rats treated by either route of administration with either 2 mg/g or 4 mg/g of monosodium glutamate similarly demonstrated arcuate lesions in all treated animals (Fig. 1*b*) with an absence of cellular pathology in control animals. Lesions were much more extensive in rats than mice, probably reflecting either the higher dosage used or possibly the younger age of the rats.

The infant rat brains perfused with formalin were extremely fragile. Tissue preservation was not satisfactory for photography, but the affected areas could not be identified and were in the periventricular arcuate area. The lesion could be seen better when haematoxylin and eosin were used instead of cresyl violet.

Examination of both rat and mouse material with the electron microscope revealed necrosis of the neuronal components of the arcuate nucleus. Perikaryon swelling, loss of cytoplasmic density and organelles and nuclear pyknosis are evident. The neuronal nature of these cells, at least in the mouse, is demonstrated by the presence of synaptic contacts both on cell bodies and dendrites (Fig. 2). The presynaptic components, that is, vesicles and membrane density, remain intact, while there is dissolution of the postsynaptic structure in the involved cells.

A more recent report by Olney[3] of studies using both light and electron microscopy, outlines the development of monosodium glutamate-induced lesions from acute neuronal necrosis through biological degradation and phagocytosis to an apparently normal residual cytology except for a markedly decreased population of neurones in the arcuate area. Thus, the photomicrographs of Adamo and Ratner[9], who examined only adult brains by electron microscopy and found no evidence

Fig. 2 Electron micrograph of degenerating neurones illustrating a dissolution of cytoplasmic components and alteration of the nuclear chromatin pattern. All the cytoplasmic structures have degenerated beyond recognition (×12,000). The inset on the lower right is a higher magnification of the area within the box. Apparently normal axon terminal with presynaptic vesicles and increased membrane density (arrow) in synaptic contact with the soma of a degenerating cell. A remnant of postsynaptic structure is evident (×50,000).

of cellular pathology at the ultrastructural level, are entirely consistent with Olney's[1].

The question remains why neither Adamo and Ratner[9] nor Oser *et al.*[11] found any MSG effect in their light microscopic studies of infant brains of animals. One can only speculate that the method of fixation and staining used by Adamo and Ratner obscured the existence of the lesion. On the other hand, Oser *et al.*[11] used a minimal effective dose and did not examine the rats and mice until 24 h after insult. Olney[3] has demonstrated that by 24 h after insult, all signs of oedema have disappeared and that necrotic cells are already being phagocytized. Oser *et al.*[11] reported finding occasional areas of small pyknotic neurones, large cytoplasmic vacuoles and scattered inflammatory cells. This is entirely compatible with a lesion late in evolution which would be expected if the insult was minimal.

The failure of Adamo and Ratner to find evidence of endocrine dysfunction is not surprising in face of their dose schedule. Olney[1] states that mice treated with a single dose of MSG are obese compared with control litter mates, but he does not allude to any reproductive dysfunction in this group. Reproductive dysfunction has been reported only in the group of animals treated with consecutive doses of MSG during infancy[12,13].

The interpretation by Arees and Mayer[10] that the lesion produced by MSG is limited to "microglia" but totally spares hypothalamic neurones is puzzling. Most cells normally present in the arcuate nucleus are small neurones[14]. Olney[3] has demonstrated, and we have confirmed, that most of the cells of the arcuate nucleus manifest extreme degenerative changes 5 h after MSG treatment even at the light microscopic level. The demonstration of synaptic involvement by Olney[3] and in this article, as well as the previously documented nature of the effect of MSG in the retinae[15-17], clearly points to a lesion involving neurones. These synapses were documented both on the soma and dendrites of damaged cells. Although there is considerable confusion surrounding the concept of "microglia", it is reasonably clear that axon terminals do not synapse on either the processes or the cell bodies of "microglia".

The purpose of this article is not to enter the debate on the safety of monosodium glutamate but merely to confirm or deny previous results in a scientifically valid manner. Using the exact experimental protocol described by Olney and Ho[2], and blind analysis of experimental and control specimens, we have confirmed their claim that 100% of infant mice treated orally with 1 mg/g of MSG develop hypothalamic lesions but that animals subjected to an equivalent oral dose of sodium chloride do not. The similar effect of MSG on the infant rat brain has been demonstrated by both the oral and subcutaneous route of administration. Finally, we believe that the exact duplication of experimental protocols, including age of animals, route of administration, doses and method of fixation, and careful interpretation of obtained results, in the light of carefully read previous reports, is necessary before valid comparisons can be made.

This work was supported in part by grants from the National Eye Institute. Animals were supplied by National Laboratory Animals, Missouri, and MSG was supplied by Sigma Chemical Company.

R. M. BURDE
B. SCHAINKER
J. KAYES

Department of Ophthalmology
and Oscar Johnson Institute,
Washington University School of Medicine,
Saint Louis,
Missouri 63110

Received March 5; revised May 11, 1971.

[1] Olney, J. W., *Science*, 164, 719 (1969).
[2] Olney, J. W., and Ho, O.-L., *Nature*, 227, 609 (1970).
[3] Olney, J. W., *J. Neuropathol. Exp. Neurol.*, 30, 75 (1971).
[4] Olney, J. W., and Sharpe, L. G., *Science*, 166, 386 (1969).
[5] Lowe, C. U., *Science*, 167, 1016 (1970).
[6] Zavon, M. R., *Science*, 167, 1017 (1970).
[7] Olney, J. W., and Sharpe, L. G., *Science*, 167, 1017 (1970).
[8] *Subcommittee on Safety and Suitability of MSG and other Substances in Baby Foods* (National Academy of Sciences—National Research Council, 1970).
[9] Adamo, N. J., and Ratner, A., *Science*, 169, 673 (1970).
[10] Arees, E. A., and Mayer, J., *Science*, 170, 549 (1970).
[11] Oser, B. L., Carson, S., Vogen, E. E., and Cox, G. E., *Nature*, 229, 411 (1971).
[12] Knittle, J. J., and Ginsberg-Follner, F., *Amer. Pediat. Soc. Bull.* (program abstract, April 29, 1970).
[13] Redding, R. W., and Schally, A. V., *Fed. Proc.*, 29 (1970).
[14] Christ, J. F., in *The Hypothalamus* (edit. by Haymaker, W., Anderson, E., and Nanta, W.), 36 (Thomas, Springfield, Illinois, 1969).
[15] Lucas, D. R., and Newhouse, J. P., *Amer. Med. Assoc. Arch. Ophthal.*, 58, 193 (1957).
[16] Cohen, A. I., *Amer. J. Anat.*, 120, 319 (1967).
[17] Olney, J. W., *J. Neuropathol. Exp. Neurol.*, 28, 455 (1969).

1155

Research Notes

MONOSODIUM GLUTAMATE IN CHICKS[1]

L. B. Carew, Jr. and D. C. Foss
Department of Animal Sciences, University of Vermont, Burlington, Vermont 05401

(Received for publication April 1, 1971)

Recently there has been much interest on the biological consequences of monosodium glutamate (MSG), particularly after parenteral administration. Olney (1969) reported that subcutaneous injections of MSG into neonatal mice produced an obesity that apparently did not depend on marked changes in food intake. These results suggest increased efficiency in the use of dietary energy for tissue synthesis. Since such effects might be economically important if they occur in domestic species, we performed the following experiments with broiler chicks.

PROCEDURE

Four experiments were conducted. In experiment 1, the subcutaneous toxicity of a single dose of MSG was studied in day-old chicks. The role of the sodium fraction in this toxicity was also considered. In experiment 2, graded doses of MSG were injected subcutaneously daily from 1 to 11 days of age. The chickens were observed for 112 days for differences in weight gain, feed intake, or outward appearance. The effects of feeding graded levels of MSG for 10 or 28 days on subsequent body weight and feed intake were studied in experiments 3 and 4.

All experiments were initiated with day-old broiler chicks obtained from a commercial hatchery. Standard battery management practices were used. A commercial starter ration was fed *ad libitum* throughout all experiments.

Except where noted otherwise, the following solutions were employed and were injected subcutaneously in the superior region of the neck: experiment 1, 0.4 g. MSG per ml. of water and 13.82% aqueous NaCl; experiment 2, 0.1 g. MSG per ml. of water.

RESULTS AND DISCUSSION

Results of the subcutaneous toxicity of a single dose of MSG are presented in Table 1. The LD_{50} (lethal dose, median) under these conditions was between 3 and 4 mg. MSG per g. of body weight and a dose of 5 mg. MSG per g. caused complete mortality. Doses of either 1 or 2 mg. of MSG per g. did not appear to cause an increased mortality, but only the lower of these levels did not significantly reduce body weight. Therefore, 1 mg. MSG per g. of body weight injected subcutaneously was chosen as the maximum tolerable dose for use in experiment 2. The toxic effect of MSG

Table 1.—*Tolerance of chicks for a single subcutaneous dose of monosodium glutamate (MSG) (Experiment 1)*

Injection treatment (per g. body weight)	Mortality[2,3] (0–7 days)	Average body weight gain[3] (0–7 days)
	No. chicks	g.
1. Control (no injection)	0	85
2. 0.9% NaCl[1]	0	88
3. 1 mg. MSG	1 (6.3)	84
4. 2 mg. MSG	1 (6.3)	70**
5. 3 mg. MSG	5 (31.3)	67**
6. 4 mg. MSG	13 (81.3)	40**
7. 5 mg. MSG	16 (100)	—
8. NaCl equimolar to trt. 3	0	84
9. NaCl equimolar to trt. 4	2 (12.5)	84
10. NaCl equimolar to trt. 5	0	80
11. NaCl equimolar to trt. 6	0	78*
12. NaCl equimolar to trt. 7	3 (18.7)	76

[1] Injections equal in volume to treatment 7.
[2] Sixteen day old chicks started per treatment.
[3] Figure in parentheses shows percent mortality.
[4] Asterisks indicate significant differences from treatment 2: * = P ≤ .05, ** = P ≤ .01; Student's "t" test.

[1] Vermont Agricultural Experiment Station Journal Article 250.

Poult. Sci
50: 1501-1502
(Sept. 1971)

TABLE 2.—*Effect of subcutaneous injection of monosodium glutamate (MSG) on body weight and feed intake of chickens (Experiment 2)*

Treatment[1,2]	Average body weight gain[4]			Average feed intake[4]		
	10 days	8 weeks	16 weeks	10 days	8 weeks	16 weeks
	g.	g.	g.	kg.	kg.	kg.
1. Control (no injection)	128	1,928	3,788	0.17	4.89	12.68
2. Control 0.9% NaCl[3]	120	1,915	3,738	0.16	4.99	12.53
3. 0.125 mg. MSG per g. body weight	126	1,958	3,817	0.17	4.91	12.82
4. 0.25 mg. MSG per g. body weight	120	1,944	3,792	0.16	4.78	12.82
5. 0.5 mg. MSG per g. body weight	116	1,867	3,660	0.16	4.77	12.09
6. 1.0 mg. MSG per g. body weight	124	1,878	3,918	0.17	4.85	12.54

[1] Duplicate groups of 10 male broiler chicks were started per treatment.
[2] Mortalities (in parenthesis) in the course of this study were the following: treatment 1 (1); treatment 2 (3); treatment 3 (1); treatment 4 (0); treatment 5 (1); treatment 6 (3).
[3] Injections equal in volume to treatment 6.
[4] Differences between all treatments at each age were not statistically significant ($P < .05$), by Duncan's multiple range test.

could not be equated with the sodium fraction supplied as NaCl. Even the highest equimolar dose of NaCl resulted in only a small increase in mortality and a slight depression in weight gain.

In experiment 2, repeated subcutaneous dosages of MSG were studied (Table 2). The chicks were weighed and injected daily for a 10-day period, which corresponds with the time interval used in mice (Olney 1969). Although the chickens that received the highest dose of MSG were slightly heavier by 16 weeks of age, the differences were not statistically significant ($P < .05$). Furthermore, the intermediate dose of 0.5 mg. MSG per g. body weight resulted in the lowest weight gain, indicating that little biological significance could be attached to the small variations. Average feed intakes did not change significantly ($P < .05$) with the various MSG treatments.

Examination of all chickens at monthly intervals revealed no differences in outward appearance or fleshing which might be indicative of an accumulation of tissue fat or obesity. We, therefore, concluded that a daily injection of as much as 1 mg. MSG per g. of body weight for 10 days caused no apparent change in the development of broilers. This shows that chicks respond differently to subcutaneous MSG injections compared to the mouse.

In conjunction with the above studies, we also determined the influence of oral administration of MSG on broiler performance. Graded dietary levels of MSG between 0.5% and 10.0% (experiment 3) or 0.5% and 2.5% (experiment 4) were fed at the expense of entire ration during the first 10 or 28 days of age, respectively. No significant effects on weight gain and feed intake nor increased mortality were observed for up to sixteen weeks of observation.

SUMMARY

The subcutaneous LD_{50} of monosodium glutamate was between 3 and 4 mg. per g. body weight in day-old broiler chicks. A subcutaneous dose of 1 mg. MSG per g. body weight was the maximum level tolerated with low mortality and no effect on body weight. The sodium moiety of MSG was not responsible for its toxicity. Nontoxic levels of MSG apparently did not influence growth rate or feed intake by either subcutaneous or oral routes.

REFERENCE

Olney, J. W., 1969. Brain lesions, obesity, and other disturbances in mice treated with monosodium glutamate. Science, 164: 719–729.

50076

1486

FOOD CHEMICALS CODEX

SECOND EDITION

Prepared by the
Committee on Specifications,
Food Chemicals Codex,
of the
Committee on Food Protection
National Research Council

National Academy of Sciences
Washington, D. C.
1972

Lead. A *Sample Solution* prepared as directed for organic compounds meets the requirements of the *Lead Limit Test*, page 929, using 10 mcg. of lead ion (Pb) in the control.

Reducing substances. Weigh accurately 10.0 grams into a 400-ml. beaker, dissolve the sample in 40 ml. of water, add phenolphthalein T.S., and neutralize with sodium hydroxide solution (1 in 2). Dilute to 50.0 ml. with water, and add 50 ml. of alkaline cupric tartrate T.S. Heat the mixture on an asbestos gauze over a Bunsen burner, regulating the flame so that boiling begins in 4 minutes, and continue the boiling for exactly 2 minutes. Filter through a Gooch crucible, wash the filter with 3 or more small portions of water, and place the crucible in an upright position in the original beaker. Add 5 ml. of water and 3 ml. of nitric acid to the crucible, mix with a stirring rod to ensure complete solution of the cuprous oxide, and wash the solution into a beaker with several ml. of water. To the beaker add sufficient bromine T.S. (5 to 10 ml.) until the color becomes yellow, and dilute with water to about 75 ml. Add a few glass beads, boil over a Bunsen burner until the bromine is completely removed, and cool. Slowly add ammonium hydroxide until a deep blue color appears, then adjust the pH to approximately 4 with glacial acetic acid, and dilute to about 100 ml. with water. Add 4 grams of potassium iodide, and titrate with 0.1 *N* sodium thiosulfate, adding starch T.S. just before the end-point is reached. Not more than 16.1 ml. is required.

Packaging and storage. Store in well-closed containers.

Functional use in foods. Acid; leavening agent; sequestrant.

L-GLUTAMIC ACID

Glutamic acid; L-2-Aminopentanedioic Acid

$HOOCCH_2CH_2CH(NH_2)COOH$

$C_5H_9NO_4$ Mol. wt. 147.13

DESCRIPTION

A white, practically odorless, free-flowing, crystalline powder. It is slightly soluble in water, forming acidic solutions. The pH of a saturated solution is about 3.2.

IDENTIFICATION

A. Dissolve about 150 mg. in a mixture of 4 ml. of water and 1 ml. of sodium hydroxide T.S., add 1 ml. of ninhydrin T.S. and 100 mg. of sodium acetate, and heat in a boiling water bath for 10 minutes. An intense, violet-blue color is formed.

B. The glutamic acid dissolves completely on stirring when either 5.6 ml. of 1 *N* hydrochloric acid or 6.8 ml. of 1 *N* sodium hydroxide is added to a suspension of 1 gram of the sample in 9 ml. of water.

SPECIFICATIONS

Assay. Not less than 99.0 percent of $C_5H_9NO_4$.

Specific rotation. $[\alpha]^{25°}_{546.1\ m\mu}$: Between +37.7° and +38.5°; $[\alpha]^{20°}_{D}$: between +31.5° and +32.2°.

Limits of Impurities

Arsenic (as As). Not more than 3 parts per million (0.0003 percent).

Chloride. Not more than 0.2 percent.

Heavy metals (as Pb). Not more than 20 parts per million (0.002 percent).

Lead. Not more than 10 parts per million (0.001 percent).

Loss on drying. Not more than 0.1 percent.

TESTS

Assay. Dissolve about 500 mg., accurately weighed, in 250 ml. of water, add bromothymol blue T.S., and titrate with 0.1 *N* sodium hydroxide to a blue end-point. Each ml. of 0.1 *N* sodium hydroxide is equivalent to 14.71 mg. of $C_5H_9NO_4$.

Specific rotation, page 939. $[\alpha]^{25°}_{546.1\ m\mu}$: Determine in a solution containing 11.8 grams in sufficient 1.5 *N* hydrochloric acid to make 100 ml.; $[\alpha]^{20°}_{D}$: determine in a solution containing 10 grams in sufficient 2 *N* hydrochloric acid to make 100 ml.

Arsenic. A *Sample Solution* prepared as directed for organic compounds meets the requirements of the *Arsenic Test*, page 865.

Chloride, page 879. Any turbidity produced by a 10-mg. sample does not exceed that shown in a control containing 20 mcg. of chloride ion (Cl).

Heavy metals. Prepare and test a 1-gram sample as directed in *Method II* under the *Heavy Metals Test*, page 920, using 20 mcg. of lead ion (Pb) in the control (*Solution A*).

Lead. A *Sample Solution* prepared as directed for organic compounds meets the requirements of the *Lead Limit Test*, page 929, using 10 mcg. of lead ion (Pb) in the control.

Loss on drying, page 931. Dry at 85° for 3 hours.

Packaging and storage. Store in well-closed containers.

Functional use in foods. Salt substitute; nutrient; dietary supplement.

GLUTAMIC ACID HYDROCHLORIDE

2-Aminopentanedioic Acid Hydrochloride

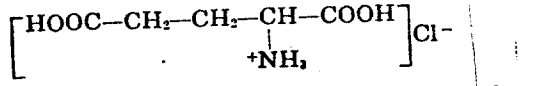

$C_5H_9NO_4.HCl$ Mol. wt. 183.59

DESCRIPTION

A white, crystalline powder. One gram dissolves in about 3 ml. of water. It is almost insoluble in alcohol and in ether. Its solutions are acid to litmus.

IDENTIFICATION

A. To 1 ml. of a 1 in 3 solution add 1 ml. of barium hydroxide solution (1 in 50), filter, and add 10 ml. of alcohol. A white, crystalline precipitate of barium glutamate forms on standing.

B. To 1 ml. of a 1 in 30 solution add 1 ml. of ninhydrin T.S. and 100 mg. of sodium acetate, and boil for 10 minutes. An intense violet-blue color is produced.

SPECIFICATIONS

Assay. Not less than 99.0 percent and not more than the equivalent of 101.0 percent of $C_5H_9NO_4.HCl$ after drying.

Specific rotation, $[\alpha]^{25°}_{546.1\ m\mu}$: Between +30.2° and +30.9°; $[\alpha]^{20°}_{D}$: between +25.2° and +25.8°.

Limits of Impurities

Arsenic (as As). Not more than 3 parts per million (0.0003 percent).

Heavy metals (as Pb). Not more than 20 parts per million (0.002 percent).

Lead. Not more than 10 parts per million (0.001 percent).

Loss on drying. Not more than 0.5 percent.

Readily carbonizable substances. Passes test.

Residue on ignition. Not more than 0.25 percent.

TESTS

Assay. Dissolve about 300 mg., previously dried at 80° for 4 hours and accurately weighed, in 50 ml. of water, add bromothymol blue T.S., and titrate with 0.1 *N* sodium hydroxide. Each ml. of 0.1 *N* sodium hydroxide is equivalent to 9.180 mg. of $C_5H_9NO_4.HCl$.

Specific rotation, page 939. $[\alpha]^{25°}_{546.1\ m\mu}$: Determine in a solution containing 14.7 grams in sufficient 0.7 *N* hydrochloric acid to make 100 ml.; $[\alpha]^{20°}_{D}$: determine in a solution containing 10 grams in sufficient 2 *N* hydrochloric acid to make 100 ml.

Arsenic. A *Sample Solution* prepared as directed for organic compounds meets the requirements of the *Arsenic Test*, page 865.

Heavy metals. Prepare and test a 1-gram sample as directed in *Method II* under the *Heavy Metals Test*, page 920, using 20 mcg. of lead ion (Pb) in the control (*Solution A*).

Lead. A *Sample Solution* prepared as directed for organic compounds meets the requirements of the *Lead Limit Test*, page 929, using 10 mcg. of lead ion (Pb) in the control.

Loss on drying, page 931. Dry at 80° for 4 hours.

Readily carbonizable substances. Dissolve 500 mg. of the sample in 5 ml. of sulfuric acid T.S. The solution is colorless.

Residue on ignition. Ignite 1 gram as directed in the general method, page 945.

Packaging and storage. Store in well-closed, light-resistant containers.

Functional use in foods. Salt substitute; flavoring agent.

GLYCERIN

Glycerol

$CH_2OH.CHOH.CH_2OH$

$C_3H_8O_3$ Mol. wt. 92.10

DESCRIPTION

A clear, colorless, syrupy liquid, having a sweet taste. It has not more than a slight characteristic odor, which is neither harsh nor disagreeable. It is hygroscopic and its solutions are neutral. Glycerin is miscible with water and with alcohol. It is insoluble in chloroform, in ether, and in fixed and volatile oils.

IDENTIFICATION

Heat a few drops of glycerin in a test tube with about 500 mg. of potassium bisulfate. The characteristic, pungent vapors of acrolein are evolved.

SPECIFICATIONS

Assay. Not less than 95.0 percent of $C_3H_8O_3$.

Specific gravity. Not less than 1.249.

Limits of Impurities

Acrolein, glucose, and ammonium compounds. Passes test.

Arsenic (as As). Not more than 3 parts per million (0.0003 percent).

Butanetriols. Not more than 0.2 percent.

MONOSODIUM L-GLUTAMATE

Monosodium Glutamate; Sodium Glutamate; MSG

$C_5H_8NNaO_4.H_2O$ Mol. wt. 187.13

DESCRIPTION

White, practically odorless, free-flowing crystals or crystalline powder. It is freely soluble in water, and is sparingly soluble in alcohol. It may have either a slightly sweet or a slightly salty taste.

IDENTIFICATION

A. To 1 ml. of a 1 in 30 solution add 1 ml. of triketohydrindene hydrate T.S. and 100 mg. of sodium acetate, and heat in a boiling water bath for 10 minutes. An intense violet-blue color is formed.

B. To 10 ml. of a 1 in 10 solution add 5.6 ml. of 1 *N* hydrochloric acid. A white crystalline precipitate of glutamic acid forms on standing. When 6 ml. of 1 *N* hydrochloric acid is added to the turbid solution, the glutamic acid dissolves on stirring.

C. A 1 in 10 solution gives positive tests for *Sodium*, page 928.

SPECIFICATIONS

Assay. Not less than 99.0 percent of $C_5H_8NNaO_4.H_2O$.

Clarity and color of solution. Passes test.

Specific rotation. $[\alpha]^{25°}_{546.1\ m\mu}$: Between +29.7° and +30.2°; $[\alpha]^{20°}_{D}$: between +24.8° and +25.3°.

pH of a 1 in 20 solution. Between 6.7 and 7.2.

Limits of Impurities

Arsenic (as As). Not more than 3 parts per million (0.0003 percent).

Chloride. Not more than 0.2 percent.

Heavy metals (as Pb). Not more than 20 parts per million (0.002 percent).

Lead. Not more than 10 parts per million (0.001 percent).

Loss on drying. Not more than 0.3 percent.

TESTS

Assay. Dissolve about 250 mg., accurately weighed, in 100 ml. of glacial acetic acid. A few drops of water may be added prior to the addition of the acetic acid to effect faster dissolution of the sample. Titrate with 0.1 *N* perchloric acid in glacial acetic acid, determining the end-point potentiometrically. Each ml. of 0.1 *N* perchloric acid is equivalent to 9.356 mg. of $C_5H_8NNaO_4.H_2O$.

Clarity and color of solution. A solution of 1 gram of the sample in 10 ml. of water is colorless and has no more turbidity (see page 959) than a standard mixture prepared as follows: Dilute 0.2 ml. of

Standard chloride solution (see page 879) to 20 ml. with water, add 1 ml. of dilute nitric acid (1 in 3), 0.2 ml. of a 1 in 50 solution of dextrin, and 1 ml. of a 1 in 50 solution of silver nitrate, mix, and allow to stand for 15 minutes.

Specific rotation, page 939. $[\alpha]^{25°}_{546.1\ m\mu}$: Determine in a solution containing 15 grams in sufficient 2.3 *N* hydrochloric acid to make 100 ml.; $[\alpha]^{20°}_{D}$: determine in a solution containing 10 grams in sufficient 2 *N* hydrochloric acid to make 100 ml.

pH of a 1 in 20 solution. Determine by the *Potentiometric Method,* page 941.

Arsenic. A *Sample Solution* prepared as directed for organic compounds meets the requirements of the *Arsenic Test,* page 865.

Chloride, page 879. Any turbidity produced by a 10-mg. sample does not exceed that shown in a control containing 20 mcg. of chloride ion (Cl).

Heavy metals. Prepare and test a 1-gram sample as directed in *Method II* under the *Heavy Metals Test,* page 920, using 20 mcg. of lead ion (Pb) in the control (*Solution A*).

Lead. A *Sample Solution* prepared as directed for organic compounds meets the requirements of the *Lead Limit Test,* page 929, using 10 mcg. of lead ion (Pb) in the control.

Loss on drying, page 931. Dry at 60° in a vacuum for 2 hours.

Packaging and storage. Store in tight containers.

Functional use in foods. Flavor enhancer.

MYRISTIC ACID

Tetradecanoic Acid

$CH_3(CH_2)_{12}COOH$

$C_{14}H_{28}O_2$ Mol. wt. 228.38

DESCRIPTION

A solid organic acid obtained from coconut oil and other fats. It occurs as a hard, white or faintly yellowish, somewhat glossy and crystalline solid, or as a white or yellowish white powder. Myristic acid is practically insoluble in water, but is soluble in alcohol, in chloroform, and in ether.

SPECIFICATIONS

Acid value. Between 242 and 249.

Saponification value. Between 242 and 251.

Titer (Solidification Point). Between 48° and 55.5°.

Free glycerin. Determine as directed in the general method, page 904.

Heavy metals. Prepare and test a 2-gram sample as directed in *Method II* under the *Heavy Metals Test*, page 920, using 20 mcg. of lead ion (Pb) in the control (*Solution A*).

Residue on ignition. Ignite 5 grams as directed in the general method, page 945.

Packaging and storage. Store in well-closed containers.

Functional use in foods. Emulsifier; stabilizer.

MONOAMMONIUM L-GLUTAMATE

Monoammonium Glutamate; Ammonium Glutamate

$C_5H_{12}N_2O_4 . H_2O$ Mol. wt. 182.18

DESCRIPTION

A white, practically odorless, free-flowing, crystalline powder. It is freely soluble in water but is practically insoluble in common organic solvents.

IDENTIFICATION

A. To 1 ml. of a 1 in 30 solution add 1 ml. of triketohydrindene hydrate T.S. and 100 mg. of sodium acetate, and heat in a boiling water bath for 10 minutes. An intense violet-blue color is formed.

B. To 10 ml. of a 1 in 10 solution add 5.6 ml. of 1 *N* hydrochloric acid. A white crystalline precipitate of glutamic acid forms on standing. When 6 ml. of 1 *N* hydrochloric acid is added to the turbid solution, the glutamic acid dissolves on stirring.

C. A 1 in 10 solution gives positive tests for *Ammonium*, page 926.

SPECIFICATIONS

Assay. Not less than 99.0 percent of $C_5H_{12}N_2O_4 . H_2O$.

Specific rotation, $[\alpha]^{25°}_{546.1\ m\mu}$. Between +30.1° and +31.6°.

pH of a 1 in 20 solution. Between 6.0 and 7.0.

Limits of Impurities

Arsenic (as As). Not more than 3 parts per million (0.0003 percent).

Heavy metals (as Pb). Not more than 20 parts per million (0.002 percent).

Lead. Not more than 10 parts per million (0.001 percent).

Loss on drying. Not more than 0.5 percent.

Residue on ignition. Not more than 0.1 percent.

TESTS

Assay. Dissolve about 250 mg., accurately weighed, in 100 ml. of glacial acetic acid. A few drops of water may be added prior to the addition of the acetic acid to effect faster dissolution of the sample. Titrate with 0.1 *N* perchloric acid in glacial acetic acid, determining the end-point potentiometrically. Each ml. of 0.1 *N* perchloric acid is equivalent to 9.109 mg. of $C_5H_{12}N_2O_4 . H_2O$.

Specific rotation. Determine in a solution containing 14.6 grams in sufficient 2.3 *N* hydrochloric acid to make 100 ml.

pH of a 1 in 20 solution. Determine by the *Potentiometric Method*, page 941.

Arsenic. A *Sample Solution* prepared as directed for organic compounds meets the requirements of the *Arsenic Test*, page 865.

Heavy metals. Prepare and test a 1-gram sample as directed in *Method II* under the *Heavy Metals Test*, page 920, using 20 mcg. of lead ion (Pb) in the control (*Solution A*).

Lead. A *Sample Solution* prepared as directed for organic compounds meets the requirements of the *Lead Limit Test*, page 929, using 10 mcg. of lead ion (Pb) in the control.

Loss on drying, page 931. Dry at 50° for 4 hours.

Residue on ignition, page 945. Ignite 1 gram as directed in the general method.

Packaging and storage. Store in tight containers.

Functional use in foods. Flavor enhancer; salt substitute.

MONOGLYCERIDE CITRATE

DESCRIPTION

A mixture of glyceryl monooleate and its citric acid monoester, manufactured by the reaction of glyceryl monooleate with citric acid under controlled conditions. It occurs as a soft, white to ivory colored, waxy solid having a lard-like consistency and a bland odor and taste. It is soluble in most common fat solvents and in alcohol, but is insoluble in water.

SPECIFICATIONS

Acid value. Between 70 and 100.

Total citric acid. Between 14.0 percent and 17.0 percent.

Saponification value. Between 260 and 265.

Limits of Impurities

Arsenic (as As): Not more than 3 parts per million (0.0003 percent).

acid in the sample taken by the formula $0.1C \times A_U/A_S$, in which C is as defined under *Standard Solution*, A_U is the absorbance of the final solution from the *Sample Solution*, and A_S is the absorbance of the final solution from the *Standard Solution*.

Saponification value. Determine as directed in the general method, page 914.

Arsenic. A *Sample Solution* prepared as directed for organic compounds meets the requirements of the *Arsenic Test*, page 865.

Heavy metals. Prepare and test a 2-gram sample as directed in *Method II* under the *Heavy Metals Test*, page 920, using 20 mcg. of lead ion (Pb) in the control *Solution A*).

Residue on ignition. Ignite 1 gram as directed in the general method, page 945.

Water. Determine by the *Karl Fischer Titrimetric Method*, page 977.

Packaging and storage. Store in well-closed containers.

Functional use in foods. Synergist and solubilizer for antioxidants.

MONOPOTASSIUM L-GLUTAMATE

Monopotassium Glutamate; Potassium Glutamate; MPG

$C_5H_8KNO_4.H_2O$ Mol. wt. 203.24

DESCRIPTION

A white, practically odorless, free-flowing, crystalline powder. It is hygroscopic, is freely soluble in water, and is slightly soluble in alcohol.

IDENTIFICATION

A. To 1 ml. of a 1 in 30 solution add 1 ml. of triketohydrindene hydrate T.S. and 100 mg. of sodium acetate, and heat in a boiling water bath for 10 minutes. An intense, violet-blue color is formed.

B. To 10 ml. of a 1 in 10 solution add 5.6 ml. of 1 *N* hydrochloric acid. A white, crystalline precipitate of glutamic acid forms on standing. When 6 ml. of 1 *N* hydrochloric acid is added to the turbid solution, the glutamic acid dissolves on stirring.

C. A 1 in 10 solution gives positive tests for *Potassium*, page 928.

SPECIFICATIONS

Assay. Not less than 99.0 percent of $C_5H_8KNO_4.H_2O$.

Specific rotation. $[\alpha]^{25°}_{546.1\ m\mu}$: Between +27.7° and +28.3°; $[\alpha]^{20°}_{D}$: between +22.5° and +24.0°.

pH of a 1 in 50 solution. Between 6.7 and 7.3.

Limits of Impurities

Arsenic (as As). Not more than 3 parts per million (0.0003 percent).

Chloride. Not more than 0.1 percent.

Heavy metals (as Pb). Not more than 20 parts per million (0.002 percent).

Lead. Not more than 10 parts per million (0.001 percent).

Loss on drying. Not more than 0.1 percent.

TESTS

Assay. Dissolve about 250 mg., accurately weighed, in 100 ml. of glacial acetic acid. A few drops of water may be added prior to the addition of the acetic acid to effect faster dissolution of the sample. Titrate with 0.1 *N* perchloric acid in glacial acetic acid, determining the end-point potentiometrically. Each ml. of 0.1 *N* perchloric acid is equivalent to 10.16 mg. of $C_5H_5KNO_4.H_2O$.

Specific rotation, page 939. $[\alpha]^{25°}_{546.1\ m\mu}$: Determine in a solution containing 16.3 grams in sufficient 2.3 *N* hydrochloric acid to make 100 ml.; $[\alpha]^{20°}_{D}$: determine in a solution containing 10 grams in sufficient 2 *N* hydrochloric acid to make 100 ml.

pH of a 1 in 50 solution. Determine by the *Potentiometric Method*, page 941.

Arsenic. A *Sample Solution* prepared as directed for organic compounds meets the requirements of the *Arsenic Test*, page 865.

Chloride, page 879. Any turbidity produced by a 20-mg. sample does not exceed that shown in a control containing 20 mcg. of chloride ion (Cl).

Heavy metals. Prepare and test a 1-gram sample as directed in *Method II* under the *Heavy Metals Test*, page 920, using 20 mcg. of lead ion (Pb) in the control (*Solution A*).

Lead. A *Sample Solution* prepared as directed for organic compounds meets the requirements of the *Lead Limit Test*, page 929, using 10 mcg. of lead ion (Pb) in the control.

Loss on drying, page 931. Dry at 60° in a vacuum for 2 hours.

Packaging and storage. Store in tight containers.

Functional use in foods. Flavor enhancer; salt substitute.

2235

Repression of glutaminase I in the rat retina by administration of sodium-L-glutamate

Jerome K. Freedman and Albert M. Potts

Newborn albino rats show the same loss of inner retinal layers and of b-wave on treatment with sodium L-glutamate as do mice. Values for four enzymes metabolizing glutamate or glutamine have been determined on normal and glutamate-treated rats. The retinas of normal rats contain almost twice as much glutaminase I per unit weight as those of glutamate-treated animals. There is no measurable "glutaminase II" activity in rat retina. There is no difference between retinas of normal and treated animals in content of glutamosynthetase and glutamotransferase. These findings are consonant with our hypothesis that glutamate action on the retina of the newborn rat is by repression of synthesis of an enzyme whose reaction product is glutamate itself. They do not eliminate the possibility that direct competitive inhibition by glutamate may play a role.

In an earlier report[1] one of us (A. M. P.) confirmed the finding of Lucas and Newhouse[2] that large doses of glutamate given to newborn mice resulted in failure to form or destruction of the ganglion cell layer and inner nuclear layer of the retina. Our report further described that such animals in which retinas consisted chiefly of receptor cells plus a narrow remnant of the inner layer showed a characteristically altered electroretinogram. The a-wave in these animals was intact and the b-wave was consistently abolished. We were impressed by the significant toxic effect of a normal body constituent and speculated in our previous publication that feedback repression of enzyme formation might be able to explain the phenomenon.

The present report represents further investigation of this hypothesis and describes the activity of a number of glutamate-metabolizing enzymes in treated and in untreated animals.

From the Section of Ophthalmology, Department of Surgery, The University of Chicago.

Supported in part by United States Public Health Service Grants B-2522 and B-2523.

Methods

In order to have more retinal material for chemical study, a brief survey of larger experimental animals was performed with regard to maturity of the retina at birth and its susceptibility to the glutamate effect. It was found that, with an identical dose per unit weight, newborn rats showed the glutamate effect both in the histologic picture and in electrophysiologic behavior. All the data to be reported here were obtained with albino rats (Sprague-Dawley strain) which were treated from the second through the twelfth day of life with glutamate according to the dose schedule previously published. Experiments were performed between the third and fifth weeks of life, and, in each case, experimental retinas were compared with those of control animals of identical age.

Animals were sacrificed by cervical dislocation, eyes were enucleated, and the retina was quickly removed and weighed. Retinas were placed in ice cold distilled water and 5 per cent homogenates were made with the Elvejehm-Potter homogenizer.

Four enzyme activities were determined: glutaminase I, glutaminase II, glutamosynthetase, and glutamotransferase.

Glutaminase I. Glutaminase I, a phosphate-dependent enzyme with pH optimum between 7.2

INVEST. OPHTHALMOL 1: 118-121 (1962)

and 7.6, was determined by measuring the amount of ammonia liberated from a specific quantity of glutamine, as described by Richterich-van Baerle, Goldstein, and Dearborn.[4] The reaction was run in 30 c.c. vials incubated in a shaker at 37° C. At the end of the reaction the ammonia formed was liberated by K_2CO_3 and allowed to diffuse to a drop of 10N sulfuric acid on an axial rod during rotation at room temperature. The collected ammonia was determined colorimetrically, as described by Seligson and Seligson,[5] and modified by Richterich-van Baerle and co-workers.

Glutaminase II. This enzyme system which requires a keto acid for optimal activity and which is most active at pH 8.6 to pH 8.5 was assayed as described by Goldstein, Richterich-van Baerle, and Dearborn.[4] The ammonia formed was determined exactly as described above for glutaminase I.

Glutamosynthetase. Formation of glutamine from glutamic acid is the function of this enzyme which requires ATP and Mg^{++}. It can utilize primary amines as well as ammonia and synthesize N-γ-substituted glutamines. Thus, in the presence of hydroxylamine, glutamohydroxamic acid is formed and the color, developed by this product in the presence of ferric ions, was utilized for its determination, according to Rudnick and Waelsch.[6]

Glutamotransferase. This enzyme catalyzes the transfer of the glutamyl radical from glutamine or glutamine peptides to other amine receptors. Here, too, hydroxylamine can be used, and the color of the resultant glutamohydroxamic acid can be utilized for determination, as described by Rudnick, Mela, and Waelsch.[7]

It should be noted that, because of the weights of the retinas obtained, each homogenate was made with the pooled retinas of 5 to 8 animals.

Results

Glutaminase I. Enzyme activity in liver, brain, and retina is shown in Table I. The relatively high level in brain tissue compared to the two other tissues is worth noting. Krebs'[8] figures for higher activity in retina than brain tissue were obtained at pH 8.5. The difference between liver in treated and untreated animals is of questionable significance because of scatter of results in the two animals in each group. No such scatter applies to the decrease of activity in the glutamate-treated retina as compared to the control. There is nearly twice as much activity in the control retinas, and this is a consistent finding in six groups of animals sacrificed at varying periods after completion of treatment.

Table I. Glutaminase I activity in rat tissues (as μM ammonia liberated 100 mg. wet tissue 30 min. incubation)

	Retina	*Brain*	*Liver*
Untreated	20.5	76.9	10.3
Treated	12.5	79.1	14.3

Table II. Glutamosynthetase and glutamotransferase activity of rat retinal homogenates (as μM of glutamohydroxamic acid produced 100 mg. wet tissue 30 min. incubation)

	Glutamosynthetase	*Glutamotransferase*
Untreated	7.1	12.0
Treated	7.0	12.0

Comparison of absolute values for our tissues with those obtained by others is of some interest. Although we noted modest variation in the values found in liver, all values for the three tissues were within the same order of magnitude and for any given tissue results were highly consistent. This contrasts markedly with glutaminase I values reported by others. Five different reports on enzyme activity of normal rat kidney, when converted to our units, vary from 0.83 μM to 150 μM per 100 mg. wet weight per 30 minutes.[9-12]

Glutaminase II. We found no glutaminase activity in the retinas studied that specifically required pyruvate. Since it has been shown that glutaminase II activity represents the action of at least two enzymes, i.e., a transaminase followed by a deaminase,[9] only one of the two might be missing. Work in progress shows a very active transaminase in the retina, so the likelihood is that the specific deaminase is lacking.

Glutamosynthetase. Results of this determination (Table II) were consistent and showed no differences between experimental and control retinas.

Glutamotransferase. Here again there

was amply measurable transferase activity but no difference between glutamate-treated and control animals (Table II). Thus, the only clear-cut effect on the enzymes studied was the marked decrease of glutaminase I in the glutamate-treated animals.

Discussion

We suggested in our previous publication that the mechanism by means of which the effect of glutamate on the retina can be explained is that of repression of enzyme synthesis. Gorini and Maas[12] have amply documented the fact that repression of enzyme formation by the products of the specific reaction can occur. Within the last few years specific instances have been found among glutamate and glutamine enzymes in vertebrate tissues. De Mars[13] reported on repression of glutamyltransferase formation in cultures of human cells by glutamine; and, while our own work was in progress, Goldstein[15] reported that sodium glutamate would suppress the increase of glutaminase I in the rat called forth by ammonium chloride.

It should be emphasized that our assumption about the effect of glutamate involves one further postulate, namely, that repression of the specific enzyme in question results in cell death or failure of cell development. The retinas with which we are working lack these cells which, according to our supposition, normally contain glutaminase I and possess only cells (that is, chiefly receptor cells) in which this enzyme does not play a major role. It is not easy to demonstrate that, in fact, the inner layers of the retina do contain relatively larger amounts of glutaminase, but experiments on this subject are now in progress. Determination of glutaminase activity in retinas where receptor cells have degenerated after iodoacetate treatment, and histochemical studies of glutaminase in retinas at various stages of development are being undertaken with this end in view.

Even if such a demonstration proves feasible, it does not eliminate the possibility that direct competitive inhibition of glutamic acid for glutaminase, as described by Krebs,[5] is responsible for our observations. It is not likely that concentrations capable of competitive inhibition are maintained for a significant period of time by a single daily dose of glutamate. However, one cannot rule out the possibility that a brief daily insult caused by direct inhibition of glutaminase is adequate to explain our findings. It is hoped that histochemical studies of glutaminase in developing retinas at increasing time intervals after the administration of glutamate will throw light on the matter. These results will be correlated when necessary with retinal content of radioactively labeled glutamate.

The question has been raised in the past on just how much injected glutamate reaches the retina after each dose. We note the work of Himwich, Petersen, and Allen,[16] who described ready access of glutamate to the brain at birth and establishment of a barrier to this compound by the tenth day. This finding makes us confident that glutamate reaches the eye of our newborn animals in high concentration. However, we shall again make direct measurements on the eye with labeled compound to confirm or deny the fact.

Until the studies projected above are complete, we can only state that the present results on glutaminase I are not incompatible with our original postulate that repression of enzyme formation is the means by which sodium glutamate exerts its retinotoxic effect.

REFERENCES

1. Potts, A. M., Modrell, R. W., and Kingsbury, C.: Permanent fractionation of the electroretinogram by sodium glutamate. Am. J. Ophth. 50: 900, 1960.
2. Lucas, D. R., and Newhouse, J. P.: The toxic effect of sodium l-glutamate on the inner layers of the retina. A. M. A. Arch. Ophth. 58: 193, 1957.
3. Richterich-van Baerle, R., Goldstein, L., and Dearborn, E. H.: Kidney glutaminases. I. Glutaminase I in the guinea pig kidney. Enzymologia 18: 190, 1957.
4. Seligson, D., and Seligson, H.: A micro-

diffusion method for the determination of nitrogen liberated as ammonia. J. Lab. & Clin. Med. 38: 324, 1951.

5. Goldstein, L., Richterich-van Baerle, R., and Dearborn, E. H.: Kidney glutaminases. II. The glutamine-α-keto acid transamination-diamidation system of the guinea pig. Enzymologia 18: 261, 1957.
6. Rudnick, D., and Waelsch, H.: Development of glutamotransferase and glutamine synthetase in the nervous system of the chick. J. Exper. Zool. 129: 309, 1955.
7. Rudnick, D., Mela, P., and Waelsch, H.: Enzymes of glutamine metabolism in the developing chick embryo. J. Exper. Zool. 126: 297, 1954.
8. Krebs, H. A.: Metabolism of amino acids. IV. The synthesis of glutamine from glutamic acid and ammonia, and the enzymic hydrolysis of glutamine in animal tissues. Biochem. J. 29: 1951, 1935.
9. Rector, F., Seldin, D. W., and Copenhaver, J. H.: Mechanism of ammonia excretion during ammonium chloride acidosis. J. Clin. Invest. 34: 20, 1955.
10. Goldstein, L., Richterich-van Baerle, R. W., and Dearborn, E. H.: Glutaminase I in guinea pig kidney. Proc. Soc. Exper. Biol. & Med. 93: 284, 1956.
11. Goldstein, L., and Copenhaver, J. H., jr.: Relation of glutaminase I activity to glutamic acid. Am. J. Physiol. 198: 227, 1960.
12. Weiss, M. B., and Longley, J. B.: Renal glutaminase I distribution and ammonia excretion in the rat. Am. J. Physiol. 198: 223, 1960.
13. Gorini, L., and Maas, W. K.: Feedback control of the formation of biosynthetic enzymes. *in* McElroy, William D., and Glass, Bentley, editors: The chemical basis of development. Baltimore, 1958. The Johns Hopkins University Press, pp. 469-478.
14. De Mars, R.: Inhibition by glutamine, of glutamyl transferase formation in cultures of human cells. Biochim. et biophys. acta 27: 435, 1958.
15. Goldstein, L.: Suppression of renal glutaminase I activity by sodium glutamate. Arch. Biochem. 82: 482, 1959.
16. Hemwich, W. A., Peterson, J. C., and Allen, M. L.: Hematoencephalic exchange as a function of age. Neurology 7: 705, 1957.

(2236)

Repression of glutaminase I in the rat retina by administration of sodium-L-glutamate II

Jerome K. Freedman and Albert M. Potts*

Further studies of the retinal glutamate effect have shown that not only is glutaminase I decreased in glutamate-treated rat retinas, but glutamic-aspartic transaminase is significantly increased. Direct competitive inhibition of glutaminase I by glutamate can be demonstrated. However, studies with labeled glutamate show that under the conditions of our experiments, retinal concentrations of glutamate reach, at most, the 10 per cent inhibitory level, and that for only a short time. This increases the likelihood that the observed effects are due to repression and induction of enzyme synthesis.

Unique and reproducible retinal damage has been shown to follow systemic administration of monosodium glutamate to newborn mice[1, 2] and rats.[3] This damage is twofold, including disappearance of the primitive ganglion cell layer along with failure of maturation of the bipolar cell layer. The tissue damage has been shown to be correlated with a loss of the b wave of the electroretinogram[2] and with severe depression of retinal glutaminase I. Because glutamate is the product of the deamidating action of glutaminase I on glutamine, it seemed likely that glutamate acted through the mechanism of feedback inhibition. What was not clear was whether glutamate acted by simply inhibiting the activity of the retinal enzyme or whether it repressed the formation of the enzyme in the affected newborn retinas. Subsequent to our earlier report,[3] we have carried out studies designed to cast further light on the specific mechanism of action of glutamate in the sensitive retinas. Further assays of retinal enzyme activity have been performed. Studies were made to analyze the pattern and quantity of tissue uptake of monosodium glutamate after treatment of newborn rats of various ages. Experiments have been conducted to elucidate the type of inhibition of glutaminase I, comparing the tissue concentration of the compound in the retina with the concentration required to directly inhibit the enzyme.

From the Section of Ophthalmology, Department of Surgery, The University of Chicago, Chicago, Ill.

This work was carried out under the auspices of the United States Public Health Service through Neurology Training Research Projects Nos. 11 and 13, and Public Health Service Special Fellowships BT-953 and BT-953(C1). Laboratory and equipment facilities were provided by United States Public Health Service Grants Nos. NB-02522 and NB-02523.

*This work has been accepted as partial fulfillment of the requirements for the S.M. Degree, Department of Surgery, The University of Chicago. Present address, 100 York St., New Haven 11, Conn.

Methods

Enzyme assays. The methods of assay of glutaminase I, the glutaminase II system, glutam-

Invest. Ophthalmol.
2(3): 252-8 (1963)

yltransferase, and glutamine synthetase have been described previously.[3] Glutamic oxalacetic transaminase was assayed indirectly by following the disappearance of reduced diphosphopyridine nucleotide (DPNH) photometrically in the presence of enzyme, substrate, and an excess of malic dehydrogenase.[4, 5, 6] The excess of malic dehydrogenase causes the conversion of oxalacetate to malate to be rapid enough so that the transaminase concentration is the rate-limiting factor. Materials prepared by the Worthington Biochemical Company, Freehold, New Jersey, were employed in our assay. The units of enzyme activity are expressed as the average decrease in optical density × 1,000 per minute per milligram fresh tissue. Thoroughly mixed 500-fold dilutions of 5 per cent retinal homogenate, prepared with icy-cold distilled water, were centrifuged in a refrigerated centrifuge. One half milliliter aliquots of the clear supernatant solution were used in each assay sample. The change in density at 340 mμ was followed at 30 second intervals on the Beckmann spectrophotometer through the 5 minute period following addition of the retinal enzyme.

Measurement of tissue uptake of monosodium glutamate. To measure the uptake of glutamate in several tissues, 2-C^{14}-dl-monosodium glutamate was used. The injected solution contained 50 μg of the labeled material with 0.5 Gm. of unlabeled glutamate per milliliter distilled water. Each animal was given the 5 day dosage of glutamate[2] of 3.2 mg. per gram body weight by intraperitoneal injection. The uptake of the glutamate was studied in the retinas, brains, and plasma of 5-, 10-, 12-, and 20-day-old animals. The rats were sacrificed by exsanguination via intracardiac puncture, with withdrawal of the blood into previously heparinized syringes. Measurements of tissue levels were performed at 1.5, 3, 6, 12, and 24 hours after a single intraperitoneal injection of the calculated amount of glutamate. The heparinized blood was centrifuged and the supernatant plasma was collected with a micropipette. Each counting vial contained 0.02 ml. of the supernatant. To each vial was added, in order, 0.5 ml. of hydroxide of Hyamine 10-X,* 4.0 ml. of redistilled methyl Cellosolve† solvent, and 3 to 4 drops of 10 per cent hydrogen peroxide. The peroxide was found to prevent spontaneous color production and the consequent quenching of the measured counts for 2 to 4 days. After thorough mixing of the previously added materials, 12.0 ml. of toluene scintillant‡ was added to each vial. Retinas and brain were dissolved in the Hyamine with gentle heating to a final concentration of 2.0 mg. fresh tissue per milliliter solution. The retinal preparation samples each contained both retinas of one animal. When 0.5 ml. aliquots of retina and brain were added to the vials, each vial contained 1.0 mg. fresh tissue. The remaining ingredients were added in the same quantities and order as described above for the plasma samples.

Counting was performed in an automatic Packard Tricarb scintillation counter. Duplicate and, wherever possible, triplicate samples were counted. The concentrations of glutamate in the three tissues were calculated by comparison with standard dilutions of the originally injected solution.

Analysis of retinal glutaminase I inhibition by monosodium glutamate. It was desired to analyze the type and amount of direct inhibition of retinal glutaminase I in order to evaluate what role such inhibition might play in the total retinal glutamate effect. Standard techniques for graphic analysis of such assays may be found in texts on enzyme chemistry, such as that by Dixon and Webb.[7] We employed the method of Lineweaver and Burke. This involves determination of the initial velocity of the glutaminase I catalyzed retinal reaction in the presence of varying substrate concentrations with 2 concentrations of inhibitor. A graph of the reciprocals of the initial velocities versus the reciprocals of the substrate concentrations for each of the 2 inhibitor concentrations gave 2 straight lines. If the 2 lines cross the ordinate at the same point, the maximum velocity of the reaction has not been altered by varying the concentration of the inhibitor. This is competitive inhibition. If, however, the 2 lines cross each other at the abscissa to the left of the ordinate, a change in maximum velocity with change in inhibitor concentration is denoted. This, in turn, indicates a change in the characteristics of the enzyme and is, therefore, a noncompetitive inhibition. If the 2 lines cross between the ordinate and the abscissa to its left, a mixture of competitive and noncompetitive inhibition has occurred.

Results

Enzyme assays. At the time of our first report we had measured the specific activities of four retinal enzymes: glutaminase I, the glutaminase II system, glutamine synthetase, and glutamyltransferase. Further studies have improved the accuracy of our glutaminase I data (Table I) and we now estimate that the specific activity of this retinal enzyme is decreased 48 per cent in treated animals as compared to that

*Packard Instrument Company.
†Carbon and Carbide Chemicals Company.
‡"Liquifluor," Pilot Chemical Company.

in controls. The absolute values of the activity of the enzyme in brain and liver have also been altered by our more recent work, but the original conclusion that glutamate treatment does not alter the specific activity of the enzyme in these latter tissues is unchanged. We originally[8] stated that no glutaminase II system activity was present in the retina, but we now report that such activity is present (Table II), but less than half that due to glutaminase I and unaltered by treatment of the animals. No change has been found in the previously reported values for glutamyltransferase and glutamine synthetase (Table II). Glutamic oxalacetic transaminase has been found to show a 40 per cent increase in specific activity in the retinas of treated rats as compared to those of the control animals (Table II).

Glutamate uptake in rat retina, brain, and plasma. In Fig. 1 it is seen that in 5-day-old rats the plasma glutamate level

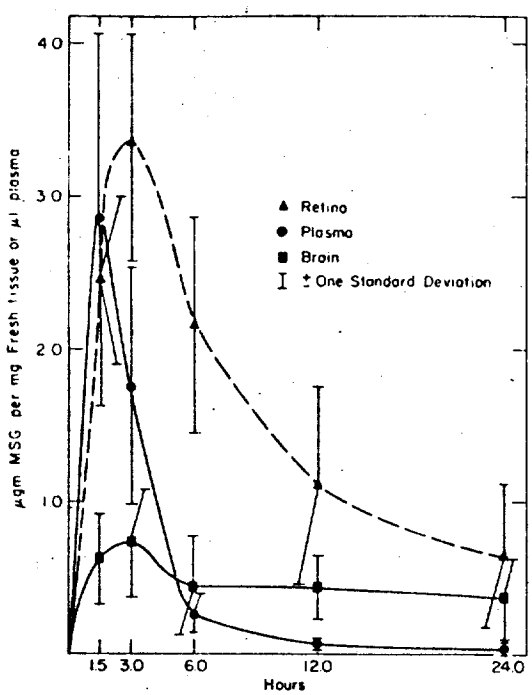

Fig. 1. Tissue levels of monosodium glutamate in 5-day-old rats. (Single dose of 3.2 mg. per gram rat.)

Table I. Glutaminase I activity in rat tissues as micromoles ammonia liberated/100 mg. wet tissue/30 min. incubation

	Retina	*Brain*	*Liver*
Untreated	19.49	81.76	13.52
Treated	10.19	78.10	18.02

Table II. The activity of rat retinal enzymes other than glutaminase I

	Untreated	*Treated*
Glutaminase II system (μM NH_3 100 mg. fresh tissue/30 min. at 37° C.)	8.04	7.66
Glutamine synthetase (μM GHA* 100 mg. fresh tissue 30 min. at 37° C.)	7.1	7.0
Glutamyltransferase (μM GHA* 100 mg. fresh tissue/30 min. at 37° C.)	12.0	12.0
Glutamic-oxalacetic transaminase (Units‡)	54,600	78,200

*GHA = glutamic hydroxamic acid.
‡Units = average decrease in optical density × 1,000/minute/milligram fresh tissue.

reaches its peak 1.5 hours after injection, while the retina and brain peak at 3 hours. It would seem that the retina and brain are not passively following the changes in plasma glutamate levels. The dissociation between retinal and plasma isotope levels increases through the 6 hour measurement. The retinal glutamate level always exceeds the brain and plasma levels.

The 10-day-old rats (Fig. 2) show important differences from the 5-day-old animals. The brain level reaches its peak at 1.5 hours with the plasma level, while the retinal peak remains independent, still peaking at 3 hours. This change in the brain pattern suggests that the brain has begun to follow the plasma changes passively and might indicate the incipient formation of the blood-brain barrier. There is a greater relative difference between

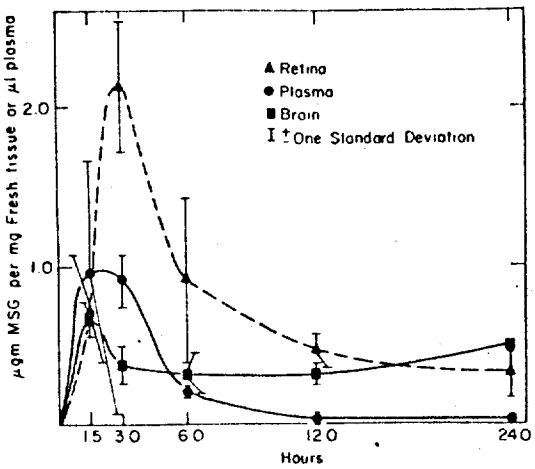

Fig. 2. Tissue levels of monosodium glutamate in 10-day-old rats. (Single dose of 3.2 mg. per gram rat.)

the retina and the other 2 tissues at the 3 hour point than in the 5-day-old animals.

The 12-day-old rats (Fig. 3) show marked decrease in the absolute values of labeled material in all 3 tissues at every point in the time course compared to that of the younger animals. Moreover, the retina now peaks with the plasma and brain at 1.5 hours and for the first time the plasma peak level is higher than that in the retina.

The 20-day-old animals (Fig. 4) demonstrate essentially the same picture as the 12-day-old rats.

In vitro inhibition of retinal glutaminase I by glutamate. A master regression line, plotting the reciprocal of the initial velocity on the ordinate and the reciprocal of the substrate concentration on the abscissa, was constructed from the data for 3 successive experiments for each of 2 inhibitor concentrations (Fig. 5). When the inhibitor concentration I_1 was 0.005 M, the regression line equation was $1/v_1 = 0.142\ 1/s + 1.2553$. The equation for the second inhibitor concentration ($I_2 = 0.0025$ M) was $1/v_2 = 0.0108\ 1/s + 1.2936$. The closeness of the values of the 2 equations for 1/v when $1/s \rightarrow 0$ suggests that we have the competitive inhibition of retinal glutaminase I by glutamate with respect to the substrate, glutamine.

Our statistical consultants suggested that analysis of each day's results separately might be preferable to the combined analysis. This was done. Individual regression lines were constructed for each day's work:

Day 1. $1/v_1 = 0.008\ 1/s + 1.7531$
Day 2. $1/v_1 = 0.0203\ 1/s + 0.7119$
Day 3. $1/v_1 = 0.0137\ 1/s + 1.2497$
Day 1. $1/v_2 = 0.0078\ 1/s + 1.7050$
Day 2. $1/v_2 = 0.0152\ 1/s + 0.9254$
Day 3. $1/v_2 = 0.0097\ 1/s + 1.2085$

The first analysis done was to determine if on each day $1/v_1$ [$1/s = 0$] − $1/v_2$ [$1/s = 0$] was 0 or not.[7] The calculated 95 per cent confidence intervals were: day 1 (−0.2683, + 0.4645), day 2 (−0.8679, + 1.2889), and day 3 (−1.8958, + 1.9422). Thus, it was suggested that for each day's experiment, the data were compatible with the hypothesis that the 2 lines met at the ordinate. An alternate analysis involved the construction of a difference line for the 2 inhibitor concentrations on each day. The value of the difference line when $1/s = 0$ was analyzed to learn whether it was 0 or not.[8] The 95 per cent confidence limits for the value of the difference lines when $1/s = 0$ were for day 1 (−0.478, + 0.593), for day 2 (−2.416, + 1.938), and for day 3 (−1.010, + 1.088). This indicated that the difference lines' values when $1/s = 0$ were in reality 0 and confirmed the 2 other

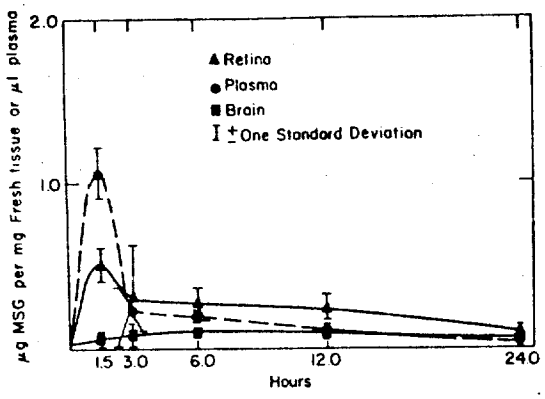

Fig. 3. Tissue levels of monosodium glutamate in 12-day-old rats. (Single dose of 3.2 mg. per gram rat.)

analyses. This work led us to conclude that the data are compatible with the hypothesis that the maximum velocity of retinal glutaminase I is not altered by variation of the concentration of glutamate, and that glutamate acts competitively with glutamine for the enzyme.

In experiments done without added glutamate, but with varying substrate concentrations, we have found that the maximum velocity of retinal glutaminase I is 0.74 μg of ammonia nitrogen per milligram fresh retina per minute. This compares favorably with the maximum velocities estimated

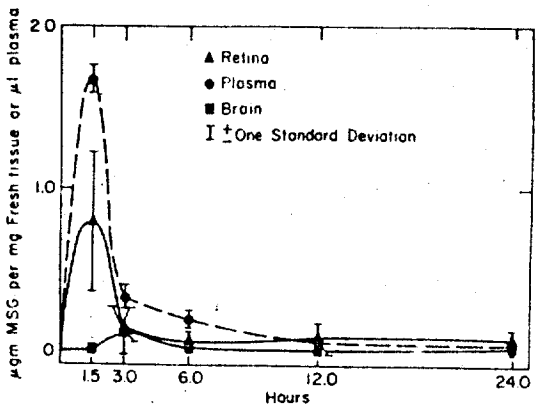

Fig. 4. Tissue levels of monosodium glutamate in 20-day-old rats. (Single dose of 3.2 mg. per gram rat.)

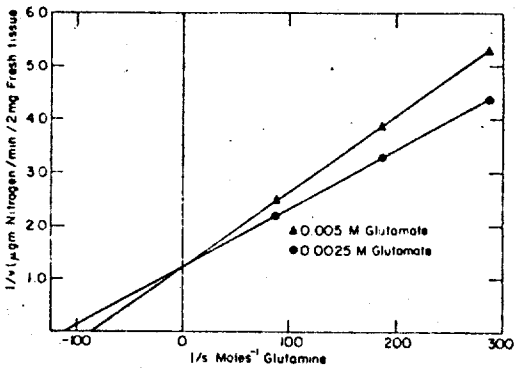

Fig. 5. A master regression line, constructed from data for 3 successive experiments for each of 2 inhibitor concentrations, which plots the reciprocal of the initial velocity on the ordinate and the reciprocal of the substrate concentration on the abscissa.

from the master regression lines of 0.80 for I_1 and 0.77 for I_2.

We have also studied the effect of glutamate on retinal glutaminase I in the presence of excess substrate. We have found that 50 per cent inhibition of enzyme activity occurs with a 0.035M concentration of glutamate (5.93 μg per milligram retina) and 10 per cent inhibition with a glutamate concentration of 0.016M (2.71 μg per milligram retina).

From our studies during the standard course of glutamate treatment, it is seen that we reach, at best, the tissue level of glutamate which gives 10 per cent inhibition of retinal glutaminase I. This low level is attained only in the 5-day-old animals of those ages measured and only for the 3½ hour period between 1.5 and 5 hours after injection. In the older animals we never reach even the 10 per cent inhibition level of retinal glutamate.

Discussion

The immediate consequence of glutamate treatment of newborn rats is a large increase in the retinal concentration of glutamate. Terner and associates[10] incubated fresh cattle retinas with glutamate and found that the retinal concentration of sodium glutamate rose from 1.085 μg per milligram fresh retina before incubation to 4.317 μg per milligram fresh retina after incubation. Our peak value of 3.36 μg of the same salt per milligram fresh retina in the 5-day-old rats compares well with the postincubation values. Extrapolating from Terner's direct measurements, we estimate that in our 5-day-old rats, the concentration of glutamate is increased about threefold by the intraperitoneal injection of glutamate, and that this level persists for about 3 hours.

One cannot be completely sure that the isotope label we measure is present exclusively as glutamate. In the Terner experiments quoted above, it was found that the concentration of glutamine rose from 0.15 μg per milligram fresh retina to 0.75 μg per milligram fresh retina after incubation

with glutamate. Thus, both glutamate and glutamine would appear to increase about threefold in concentration in cattle retinas incubated with glutamate. Thus, we assume that the label we measure in the retina and brain represents both glutamate and glutamine, with the latter accounting for at least half the label present. Since Lucas and Newhouse[1] were unable to produce the retinal effect in newborn mice by administering glutamine, we feel that the effective concentration of glutamate in our studies was even lower in affected retinas than the radioactivity figures suggest.

Of the five retinal enzymes studied (Tables I and II), only glutaminase I has been found to be depressed in specific activity in the treated animals. Both glutamine synthetase and glutamic oxalacetic transaminase require glutamate as a substrate, but only the latter enzyme is altered in specific activity in the retinas of treated animals (Table II). It is increased in activity. It is clear that the only compound in common between the two affected retinal enzymes is glutamate, the product of glutaminase I, and the substrate of glutamic oxalacetic transaminase. We have found that calculating the retinal uptake of glutamate as though all the label were glutamate, which is highly unlikely, we reach a tissue level of glutamate giving no more than 10 per cent inhibition of retinal glutaminase I. Moreover, this low level is present only for a few hours daily during the early days of treatment. It seems reasonable to suggest, therefore, that glutamate does not act by product inhibition of enzyme activity, which we measure as competitive inhibition. It seems more likely that product repression of enzyme formation is the mechanism of action of glutamate on retinal glutaminase I in newborn rats. Glutamate likely acts on glutamic oxalacetic transaminase by substrate induction of enzyme synthesis. Such repression and induction of enzyme synthesis has been well documented in biologic systems.[11]

We can draw no final conclusions on how the changes in enzyme synthesis cause cell death in the affected retinas. It is remotely possible that despite the changes in enzyme content reported here, some further enzyme system is also changed and is directly responsible for the histologic damage. Several enzymes are known to act in nucleic acid metabolism by utilizing the amide nitrogen of glutamine in the formation of the nucleic acid ring.[12-15] One might conceive that glutamate might affect these enzymes as it does glutaminase I since their products are also glutamate and ammonia. Cell death would be the consequence of impaired nucleic acid formation.

A possible explanation in the frame of reference of the enzymes already studied is the following: A decrease in the tissue content of glutaminase I without a corresponding decrease in glutamine synthetase will result in a net synthesis of glutamine. If one adds (as we found) an increase in glutamic-aspartic transaminase, this means that ketoglutaric acid may be drained from the tricarboxylic acid cycle to make glutamine. Even though oxalacetic acid is a product of such a reaction, the energy-producing steps ketoglutaric → oxalacetic would be lost. A somewhat analogous situation was hypothesized by Recknagel and Potter,[16] who suggested that the effect of added ammonia on liver homogenate was to exhaust α-ketoglutarate by glutamine formation. A test of this hypothesis will be to see whether glutamate plus oxalacetate will or will not cause retinal damage.

It would also be of possible value to analyze the in vitro effect of glutamate on the residual glutaminase I in the affected retinas of the young, treated animals. One wonders whether this residual enzyme has the same characteristics as the retinal glutaminase I we studied in the adult retinal in vitro experiments, or whether it resembles "renal glutaminase," unaffected by glutamate. Experiments in these areas are projected.

REFERENCES

1. Lucas, D. R., and Newhouse, J. P.: The toxic effect of sodium-L-glutamate on the inner layers of the retina, A. M. A. Arch. Ophth. **58**: 193, 1957.
2. Potts, A. M., Modrell, R. W., and Kingsbury, C.: Permanent fractionation of the electroretinogram by sodium glutamate, Am. J. Ophth. **50**: 900, 1960.
3. Freedman, J. K., and Potts, A. M.: Repression of glutaminase I in the rat retina by administration of sodium-L-glutamate, INVEST. OPHTH. **1**: 118, 1962.
4. LaDue, J. S., Wroblewski, F., and Karmen, A.: Serum glutamic oxaloacetic transaminase activity in human acute transmural myocardial infarction, Science **120**: 497, 1954.
5. Karmen, A., Wroblewski, F., and LaDue, J. S.: Transaminase activity in human blood, J. Clin. Invest. **34**: 126, 1955.
6. Wroblewski, F., and LaDue, J. S.: Serum glutamic oxalacetic transaminase activity as an index of liver cell injury: A preliminary report, Ann. Int. Med. **43**: 345, 1955.
7. Dixon, M., and Webb, E. C.: Enzymes, New York, 1955, Academic Press.
8. Brownlee, K. A.: Statistical theory and methodology in science and engineering, New York, 1960, John Wiley & Son, Inc. chap. 11.
9. Brownlee, K. A.: Statistical theory and methodology in science and engineering, New York, 1960, John Wiley & Son, Inc. chap. 11.
10. Terner, C., Eggleston, L. V., and Krebs, H. A.: Role of glutamic acid in transport of potassium in brain and retina, Biochem. J. **47**: 139, 1950.
11. Gorini, L., and Maas, W. K.: *In* McElroy, W. D., and Glass, B., editors: The chemical basis of heredity, Baltimore, 1958, Johns Hopkins University Press, p. 469.
12. Sonne, J. C., Lin, I., and Buchanan, J. M.: The role of N^{15}-glycine, glutamine, aspartate, and glutamate in hypoxanthine synthesis, J. Am. Chem. Soc. **75**: 1,516, 1953.
13. Buchanan, J. M., Flaks, J. G., Hartman, S. C., Lukens, L. N., and Warren, L.: *In* the Ciba Foundation Symposium on the Biology and Chemistry of the Purines, Boston, 1957, Little, Brown & Co., p. 233.
14. Hurlbert, R. B., and Kammen, H. O.: Formation of cytidine nucleotides from uridine nucleotides by soluble mammalian enzymes: Requirements for glutamine and guanosine nucleotides, J. Biol. Chem. **235**: 443, 1960.
15. Salzman, N. P., Eagle, R., and Sebring, E. D.: The utilization of glutamine, glutamic acid, and ammonia for the biosynthesis of nucleic acid bases in mammalian cell cultures, J. Biol. Chem. **230**: 1,001, 1958.
16. Chargaff, E., and Davidson, J. N.: The nucleic acids, vol. 3, New York, 1960, Academic Press, Inc., p. 307.
17. Chargaff, E., and Davidson, J. N.: The nucleic acids, vol. 3, New York, 1960, Academic Press, Inc., p. 308.
18. Lieberman, I.: Enzymatic amination of uridine triphosphate to cytidine triphosphate, J. Biol. Chem. **222**: 765, 1956.
19. Recknagel, R. O., and Potter, V. R.: Mechanism of ketogenic effect of ammonium chloride, J. Biol. Chem. **191**: 263, 1951.

STUDIES ON THE MODE OF ACTION OF GLUTAMATE IN INDUCING HYPOCHOLESTEROLEMIA IN MAN. J. D. Garlich* G. Bazzano* and Robert E. Olson. Grad. Sch. Pub. Health, Univ. of Pittsburgh & St. Louis Univ. Sch. Med., St. Louis, Mo.

If L-amino acids are fed in formulas to human subjects in lieu of protein in the proportions and amounts found in mixed diets (16.0 g N), no significant change in serum cholesterol occurs. If at this intake of N, the mixture is altered to supply the eight essential amino acids plus glutamate as the only source of non-essential nitrogen, a marked fall in serum cholesterol (30-60 mg%) occurs (Olson, et al., J. Clin. Invest. 43, 1233, 1964). Equimolar amounts of dietary glycine and ammonium acetate in place of glutamate were not hypocholesterolemic. Plasma amino acids were determined by the method of Moore and Stein (J. B. C., 211, 893, 1954) using a Beckman amino acid analyzer. In subjects fasting overnight, there were no striking changes in amino acid content of the plasma on different regimens which markedly altered serum cholesterol content. Alanine, but not glutamate, was elevated in the plasma of subjects receiving 137 g. of glutamate daily. (Supported by N. I. H. grant AM 09732)

Academy Food Committees: New Criticism of Industry Ties

The National Academy of Sciences (NAS), whose scientific advisory panels have been criticized on more than one occasion lately for a seeming alliance with industry, took another sharp rap on the knuckles last week from a new critic, Senator Charles H. Percy (R–Ill.). In Senate hearings, Percy said the academy had been "insensitive" to conflicts of interest among the scientists it picked to advise the government on such controversial subjects as the safety of food additives. And he suggested that the NAS would do well to follow the example of the American Bar Association, whose code of ethics forbids judges from hearing cases involving parties to whom they have financial or personal ties.

Percy's criticism came during 3 days of hearings on food additive legislation, which were held last week by the Select Committee on Nutrition and Human Needs. His remarks were prompted by disclosures that two of seven scientists appointed by the NAS in 1970 to investigate possible hazards of monosodium glutamate (MSG) had received research funds from major users and manufacturers of the widely used "flavor enhancer." In addition, witnesses told the committee that two other members of the MSG panel were employed at the time by major chemical companies. And on top of this, a fifth member of the NAS panel showed up at the same Senate hearing to testify in behalf of the Grocery Manufacturers of America, a lobbying organization that opposes stricter regulation of food additives.

The MSG study panel's financial ties to the food industry emerged from testimony by John W. Olney, an associate professor of psychiatry and a neurophysiologist at the Washington University Medical School in St. Louis. In 1969, Olney's own published research on MSG reported that massive subcutaneous doses of the additive had caused visible brain lesions in infant mice, rats, and one newborn monkey.

Partly as a result of Olney's work, the Food and Drug Administration in 1970 asked the NAS to organize a special study panel to determine whether MSG ought to be banned from baby food. The seven-man panel, headed by Lloyd J. Filer, Jr., a professor of pediatrics at the University of Iowa Medical School, began its work early in 1970 and handed in its 42-page final report that July. The panel concluded that animal studies and observations of human MSG eaters "confirmed the high degree of safety" of the additive. The panel did recommend that MSG be removed from baby food —a decision already made voluntarily by manufacturers—on the ground that, while MSG posed only an "extremely small risk," it also conferred no benefits. But the panel advised the FDA not to restrict supermarket sales of packaged MSG.

Last week, Olney charged that the panel's report smacked of an "industry-arranged whitewash" by a group of scientists with almost no experience in neuropathology. Olney said a reading of the report, and his experience with the panel, suggested that it had based its conclusions largely on what seemed to be negative evidence hastily produced by small laboratories dependent for their livelihood on—and therefore sympathetic to—the food and drug industries.

"Those who were unable to confirm the findings [of neurological damage in infant animals] turned out to be almost exclusively from a certain element of the scientific community . . . who maintain close ties to the food and drug industries," Olney said. "Some members of the team specialize in generating made-to-order evidence, while others are asked by FDA through the NAS to evaluate the evidence."

In his prepared testimony, Olney refrained from mentioning names. But, under questioning by the Senate committee, he let it drop that during the summer of 1970, Filer, the chairman of the MSG committee, had taken part in research on MSG supported partly by Gerber Products, Inc., a leading baby food manufacturer, and partly by the International Mineral and Chemical Corporation, which, at the time, pro-

duced most of the nation's monosodium glutamate.

In addition, Olney said, George M. Owen, a researcher in pediatric nutrition at Children's Hospital in Columbus, Ohio, had also been supported by Gerber not long before his appointment to the MSG panel. Two other members were employed by the toxicological units of major chemical companies, although their work had no obvious connection with MSG; one was John A. Zapp, Jr., of DuPont in Wilmington, Delaware, and the other was Virgil B. Robinson, a veterinary researcher with Dow Chemical Company in Zionsville, Indiana. Robinson is currently a member of the academy's Committee on Food Protection, which is a principal target of critics who allege industry bias on the part of the NAS.

A fifth panel member with a prior and conceivably vested interest in monosodium glutamate was Lloyd W. Hazelton, the founder of a research and testing laboratory in Falls Church, Virginia, that, on occasion, has performed animal studies of MSG under contract to International Mineral and Chemical.

Filer, who is currently chairman of the academy's Food and Nutrition Board, could not be reached for comment. It was subsequently learned, however, that he and three co-workers had obtained grants and equipment worth about $5000 from Gerber and International Mineral for feeding studies of MSG as early as April or May of 1970—3 months after Filer's appointment as chairman of the MSG panel, but more than 2 months before the panel released its report. During that summer, some new data from this study was hurriedly relayed to the NAS panel before the FDA received its report. The following June, Filer and his three co-workers published a paper describing their work and reporting that they could find no evidence that massive oral doses of MSG had caused brain lesions in the infant monkeys at their disposal. They suggested that earlier reports to the contrary, Olney's among them, may have been based on improperly prepared tissue specimens.

Interestingly enough, however, at least one of Filer's co-authors now thinks these conclusions may have been in error—that they somehow missed seeing microscopic brain lesions in their monkeys after all. One co-author, who asked not to be identified, also conceded in a telephone interview that the use of industry money under

the circumstances "looked like hell." Filer's colleague, however, was nevertheless quick to insist that Filer was a man of great integrity who had "never, *never* asked us to color or manipulate data."

As for Olney, the scientist said, "He's a very reputable researcher, although he's getting a bit paranoid about all this. Still, he's right in saying that a lot of people doing nutritional research have a vested interest in the food and drug industries."

George Owen, for his part, readily admits that he received research funds not only from Gerber but from Wyeth Laboratories (also a manufacturer of baby food). He says the grants preceded his appointment to the MSG panel by about a year, but that the work they supported had nothing to do with this particular additive. He too expressed dismay that anyone could think that "Jack Filer was in someone's pocket." He said that while he had been associated with Filer at the University of Iowa, companies like Gerber, Wyeth, and Mead Johnson & Co. had been generous in their support of pediatric research, but the money had always been given and accepted on the understanding that data would be reported factually.

At first, Olney's allegations met with something approaching disbelief by the Senate committee, partly because not all the details of the academy panel's financial connections were immediately available. Senator Percy, for one, observed skeptically that Olney seemed to imply "collusion" between industry and a scientific body that was "beyond reproach."

That was on Tuesday, 19 September. On Wednesday, the committee grew more reproachful as other witnesses tended to corroborate what Olney had said, if only in a general way.

First came Samuel S. Epstein, a professor of environmental health at Case Western Reserve University and an outspoken advocate of stronger controls on food additives, drugs, and pesticides. Epstein contended that "close identification of the NAS-NRC Food Protection Committee with industrial interests makes it singularly inappropriate as a major source of 'independent' advice" to the Food and Drug Administration. He told the hearing that "anyone can buy the data to support his case" and that the academy committee—of which the MSG panel was an ad hoc offshoot—was supported "strongly by the food, chemical, and packaging industries."

15 Lindsey Johnston

(Indeed, during 1970–71, academy records show that these industries paid $68,000 of the food protection committee's general administrative expenses.)

Another witness, Charles Edwards, the commissioner of the FDA, said the academy generally had done well by his agency in picking advisory panels. Nevertheless, Edwards said he thought the academy had, in the past, "not shown enough awareness of the problem" of conflicting interests.

The last straw, it seemed, was the appearance of Lloyd Hazelton, an alumnus of the MSG panel and now, or at least last week, a spokesman for the food industry lobby.

"Here is the same person acting as judge and jury," Percy commented. "Regardless of his objectivity and competence, it appears that there is a conflict of interest here. Aren't there enough scientists in the United States so we can select a panel that would be above reproach?"

The senator went on to say that he had the highest regard for members of the NAS, but that he thought the academy had been "insensitive to the fact that we have refused to seat a Supreme Court justice whose integrity no one could question, but who had experienced a conflict of interest." Percy suggested that this insensitivity might be a fit subject for hearings next year by the Government Operations subcommittee on research, of which he is a member.

The academy made no formal response to this criticism, but a spokesman noted that during the past year the academy had taken steps to avoid the appearance of conflicting interests among prospective panel members. Chief among these steps is a requirement that candidates for panels file a statement declaring potential conflicts. These "bias statements" are then used, the spokesman said, as a guide in achieving a balance of viewpoints among members of a given panel. In no case, however, are they used to disqualify a scientist from an advisory committee.

In spite of the academy's new precautions, the FDA has decided to go elsewhere for advice concerning the safety of some 600 food additives on the government's GRAS (or generally regarded as safe) list. Charles Edwards told the Senate committee that to carry out this large and highly sensitive review the FDA had turned instead to the Federation of American Societies for Experimental Biology (FASEB).

Edwards said the FDA had decided to pass over the academy in favor of FASEB partly because of industry representation on NAS panels. He was quick to add that the academy was being kept in reserve as an appeals body for judgments rendered by FASEB, but if the move was not a slap at the academy it certainly marked an important break with tradition.

Officials of FASEB, for their part, regard the job with eagerness tempered with more than a little trepidation. George Irving and C. Jelieff Carr, the two staff members who share responsibility for the project, agreed in an interview last week that reviewing the safety of food additives was a "new and unusual endeavor" both for the federation and the FDA, and one that could take several years.

Their plans call for a panel of nine scientists, Irving among them, to review the available literature on each additive as compiled in a series of monographs currently being prepared for the FDA under separate contracts. Research sponsored by the FDA will fill some of the gaps in the literature, and the NAS will compile data on dietary intakes of food additives, to help FASEB and the FDA assign priorities to individual chemicals.

How is the federation handling the problem of conflicting interests among its nine panelists? Like the academy, Carr said, they will require detailed statements of each member's connections with the food and chemical industries, if any. But unlike the academy, a panelist will be barred from sitting in judgment of a particular food additive if, for instance, companies using or manufacturing the additive have supported his research.—ROBERT GILLETTE

2654

The Hematologic Effects of Monosodium Glutamate in the Rat

STEPHEN R. GREENBERG, PH.D. Department of Pathology, The Chicago Medical School/University of Health Sciences, Chicago, Illinois 60612.

Rats of the Sprague-Dawley strain were fed diets containing large concentrations of monosodium glutamate for extended time periods. The consequences of the regimen were explored in the vascular and reticuloendothelial systems.

A marked increase of basket cells in the peripheral blood was noted after the experimental diet was instituted. After several weeks, large, abnormal lymphoid cells, similar to those characterized in the literature as "neoplastic cells," were observed. A third change associated with this diet was the presence of neutrophils which exhibited an abnormal nuclear pattern resembling the macropolycyte that Cooke described in some cases of granuloyctic leukemia.

Notwithstanding these alterations, it is thought that the principal effect of monosodium glutamate upon the vascular system is not one of leukemogenesis, but rather one of endothelial injury with the transformation of endothelial cells into phagocytes which are unduly fragile and degenerate into basket cells.

Laboratory Investigation
v 26, No. 4, 1972

International Academy Pathology
61st Annual meeting
Cincinnati, Ohio
March 15, 1972

Experimental Studies on the Effect of Sodium Iodate and Sodium l-glutamate on ERG and Histological Structure of Retina in Adult Rabbits

By Tsuneo Hamatsu

I. Introduction

II. Experimental Materials and Experimental Method

(A) Experimental Animal and the Method of Administration of Drugs

(B) The Method of ERG Measurment

(C) The Method of Histological and Histochemical Examination

III. Results

(A) ERG and Histological Findings on Administration of Sodium Iodate

1) The Group of 30.0mg/kg Administration

2) The Group of 10.0mg/kg Administration

3) The Group of 5.0mg/kg Administration

4) The Group of 2.5mg/kg Administration

5) The Group of 1.0mg/kg Administration

6) Summary

(B) ERG and Histological Findings on Administration of Sodium l-glutamate

1) The Group of 2.0 g/kg Administration

2) The Group of 1.0 g/kg Administration

3) The Group of 0.5 g/kg Administration

4) The Group of 0.25g/kg Administration

Nippon Ganka Gakkai Zasshi
68(1) 162-36
(1964)

5) The Group of 1.0 g/kg Administration
6) Summary
IV. Consideration
V. Conclusion
Literature

I. Introduction

To elucidate the cause of retinal degeneration, experimental investigations have been carried out very actively by using various drugs. However, the present condition is far from the solution of the problem. The trial to destruct the retinal layers selectively under some conditions has been pursued by many investigators, because it is considered to be the fundamental to elucidate the cause of retinal degeneration and explain the origin of ERG generation. Lucas and Newhouse[1], Hasegawa[2], and Potts et al[3] reported that non-oral administration of sodium l-glutamate(afterwards described as G) destroyed the brain parts of the retina of infant mice selectively, however they did not mention why it did not occur to adult mice.

This investigation was undertaken to investigate the question is whether the retinal degeneration is not caused in the adult rabbits when G was administered, and to find the condition to produce the degeneration if it is caused in the adult rabbits. ERG was measured when various doses of sodium iodate(afterwards described as I) was administered, which is known as poison of retinal degeneration. The minimum doses to change the amplitudes of a and b waves was determined. And

then it was examined whether any change appeared in ERG, when G was administered to a grown albino rabbit after the pretreatment of administration of the minimum dose of I.

Moreover, the interesting findings were obtained from the comparison of ERG and histological result of the retina, and reported in this paper.

II. Experimental Material and Experimental Method

[illegible] grown albino rabbits, about 2.0kg body weight,

(A) Experimental Animal and the Method of Administration of Drugs

Healthy grown albino rabbits, about 2.0kg body weight, were used as experimental animals. They had been reared over one week under certain condition, and their ERG and eyegrounds had been proved to be normal before they were used for experiment. They were classified into three classes according to the drugs and the method of administration.

That is, the groups of the rabbits, into the ear veins of which I was administered, belong to the first class. 30.0 mg/kg of 2.0% I aq. solution was injected once to 3 rabbits. 10.0mg/kg was injected to 4 rabbits once a day for 6 days. 5.0 mg/kg(to 3 rabbits), 2.5mg/kg(to 5 rabbits), and 1.0mg/kg (to 4 rabbits) were administered once a day for 16 days. That is, 19 rabbits of 5 groups in total belong to the first class.

The groups of the rabbits, in the abdominal cairty of which 25.0% G-aq. solution was injected, belong to the second class. 2.0g/kg(to 5 rabbits), 1.0g/kg(to 5 rabbits), 0.5g/kg

(to 3 rabbits), 0.25g/kg(to 5 rabbits), and 0.1g/kg(to 3 rabbits) were administered once a day for consecutive 16 days. That is, 21 rabbits of 5 groups in total belong to the second group.

The goups of the rabbits, to which 2.0 I aq. solution and 25.0% G aq. solution were injected intraveneously or in the abdominal cavity, respectively, belong to the third goup. 2.5mg/kg I and 0.25g/kg G(to 4 rabbits), and 1.0mg/kg I and 0.1g/kg G(to 4 rabbits) were administered once a day for consecutive 16 days. That is, 8 rabbits of 2 groups belong to the third group.

(B) The Method of ERG Measurement

1.0g/kg of 25.0 Urethan aq. solution was injected in the abdominal cavity as a general anesthetic to rabbits. Atopolin was used sufficiently and the rabbit was completely adapted to the dark for 30 minutes in the shielded dark room. And then ERG was measured.

The improved contact lenses of Riggs type for rabbits were used as an induction electrode, silver needle inserted under the skin of the outer eye angle part on the side of induction. As a neutral electrode, and ground electrode was inserted under the skin of the central part of the ear.

ERG was recorded by the amplifiers (APB-20 and AVS-1) manufactured by Japan Optical K.K, and by oscilloscopograph of Brown tube (VC-6). Time constant was 0.3 second, amplifica-

cation of 100μV was 5mm, and scanning speed was about 40cm/sec. Light was irradiated at the 30cm distance from the eyes by 1800 Lumen/sec stroboflash.

Under these conditions, ERG of 10 normal rabbits were measured for 7 days to examine the fluctuation range caused by the difference of rabbits, time and date. Amplitude of a-wave fluctuated between 50 and 140μV, amplitude of b-wave between 190 to 480μV, and fluctuation caused by the difference of date was within 30%. During the process of adaption to the dark, amplitude of b-wave irradiated by 20 Lux light was stabilized in 30 minutes after adaption to the dark.

Amplitude of a-wave was measured from the ground line and that of b-wave was measured from the deepest part of a-wave. Variation in amplitude of a- and b-waves was represented by the following equation.

$$\frac{\text{Amplitude after administration}}{\text{Amplitude before administration}} \times 100 - 100 = X\%$$

(C) Histological and Histochemical Examination Method

After the experiment, the rabbits were killed by the air plugging and eyeballs were picked out. One eyeball was fixed by Carnoy fixing solution and another was fixed by ether-alcohol(1/1) mixture solution, 8μ paraffin films of rear polar and equatorial parts were prepared. The one which treated with prefixing solution was stained with Hematoxylin-Eosin and examined by PAS reaction. The one which treated with postfix-

ing solution was examined by alkaline phosphatase reaction(the improved Gomori method--afterwards described as ALP ase reaction)

III. Results

(A) ERG and Histological Findings on Administration of Sodium Iodate

1) The Group of 30.0mg/kg Administration

(See Table 1 and Fig.1 and 2 and 16A)

At a dose level of 30.0mg per kg body weight,

At a dose level of 30.0 mg/kg body weight, amplitudes of a- and b-wave of ERG encreased temporally in 4 hours after the injection, and they began to decrease from the next day. However, the tolerence for I considerably depends on each rabbit. That is, one rabbit was dead in 2 days after the injection, amplitude of a- and b-wave in ESR of another one completely dissappeared in 7 days, and that of the other decreased substantially but still existed. In general, the amplitude of a- and b-wave sharply decreased on the first day after the drug administration, and then gradually decreased parallel by the 7th day.

As for histological findings, the pigment epithelial cell slightly swelled and degenerated, the pigment granules increased and became coarse, the visual cell disordered in arrangement and collapsed, the nuclei of the external and fell, the nuclei of the internal molecular layer swelled, condensed or fell, the nuclei of Müller's radial fibers partly increased,

the external and internal prexiform layer and the nerve fiber layer became loose, the ganglion cell disordered in arrangement, swelled or degenerated, the internal limiting membrane partially thickened, and Müller's radial fiber thickened.

As for PAS reaction, it was strongly positive in the pigment epitherial layer. The collapse of tissue was too heavy to observe in the visual cell, the external limiting membrane and the external molecular layer. The irregularly moderately positive parts was sometimes found in the collapsed external molecular layer. In general, a strong lesion of tissue was observed in the whole retina, and the degeneration was especially intense in the pigment epitherial layer, the visual cell layer and the external molecular layer.

(2) The Group of 10.0mg/kg Administration

(See Table 1,2,3 and Fig. 1,3,16B)

I was administered at a dose level of 10.0 mg/kg for 6 consecutive days, and it amounted to 108 to 138 mg in total. The amplitude of a-wave in ERG gradually decreased and on the 6th day, it decreased 50% in average compared with that before the injection. The amplitude of b-wave changed irregularly till the third day and then it decreased 40% on the 6th day. That is, the apparent decreasing rate of a-wave is higher than that of b-wave.

Histologically, the pigment epitherial cells swelled and degenerated, the pigment granules increased and became coarse, the visual cells disordered in arrangement and collapsed, the nuclei of the external molecular layer condensed and fell, the

the external prexiform layers became loose, the nuclie of the internal molecular layer swelled, the ganglion cell weakly swelled and the Müller's radial fiber thickened.

As for PAS reaction, it was strongly positive in the pigment epitherial layer and weakly positive in the inner and outer segments of the visual cell, And the reactions are intenser than normal in both parts. As for ALPase reaction, it was generally weaker than mormal in the whole retina, especially remarkably in the pigment epitherial layer. In sum, although the changes of this group are less than the group of 30.0 mg/kg, still considerably remarkable changes were observed in the outer layers of retina, especially in the pigment epitherial layer, as shown in Table 1,2 and 3.

(3) The Group of 5.0 mg/kg Administration

(See Table 1,2,3 and Fig. 1,4 and 16C)

I was administered at a dose level of 5.0 mg/kg for consecutive 16 days. And it amounted to 144 to 184 mg in total. The amplitudes of a- and b-wave of ESR slightly increased and changed parallel.

As for histological findings, the retina thinned a little as a whole, the pigment epitherial cell somewhat swelled and degenerated, the pigment granules increased and became coarse, the visual cell disordered in arrangement, degenerated and collapsed, the nuclei of the external molecular layer condensed, the nuclei of the internal molecular layer swelled, the internal and external prexiform layer and the nerve fiber

layer slightly loosened and the ganglion cell swelled to some extent. The degeneration of the outer and inner segments and the pigment epitherial layer was less than previous two groups.

As for PAS reaction, it was strongly positive in the pigment epithelial layer, weakly or moderately positive and intenser than normal in the inner and outer segments of the visual cell.

As for ALPase reaction, it is apparently weaker in the outer layers from the external prexiform than normal in the internal molecular layer, the nerve fiber layer and the internal limiting layer, and intenser than normal in the ganglion cell layer. From these findings it is known that the degeneration of this group is mostly produced in the outer layers of the retina.

(4) The Group of 2.5 mg/kg Administration

(See Table 1,2,3 and Fig. 1,5,and 17A)

I was administered at a dose level of 2.5 mg/kg a day for consecutive 16 days and it amounted to 72 to 92 mg in total. The amplitude of ESR complicatedly, that is, the amplitude of b-wave increased on the 5th day, decreased on the 10th or 13th day, and then increased again. However, the amplitude of a-wave inclined to increase on the 13th day in the opposite way to b-wave, and finally increased.

Histologically, the pigment granules of the pigment epitherial cell very slightly increased and became coarse, the outer segment of the visual cells disordered in arrangement, the nuclei of the external molecular layer condensed, the internal

prexiform layer loosened, and the ganglion cell swelled and degenerated. But these changes were all slight and the almost normal histological structure was observed.

As for PAS reaction, it is weakly positive partly in the outer and inner segments of the visual cess, but the pegment epitherial layer is almost normal. As for ALPase reaction, it was a little weak to the degree as the group of 5.0 mg/kg administration in the outer segment of the visual cell, but in the other layers the reaction was positive in almost the same degree as normal, (although it was weak in the external molecular layer and internal prexiform layer. In short, the histol gical change of this group is very slight.

(5) The Group of 1.o mg/kg Administration

(See Table 1,2,3 and Fig. 1 and 6)

I was administered at a dose level of 1.o mg/kg a day for consecutive 16 days, and it amounted to 28.8 to 36.8 mg. The amplitude of a both a- and b-wave temporally inclined to increase between the 5th and 13th day, but it is almost the same as before administration. Histologically, the tissue was almost normal, except the little swelling of the pigment granules of the pigment epitherial cell and a little disorder of the visual cell in arrangement. As for PAS and ALPase reactions, they were almost normal all over layer.

(6) Summary

From the above mentioned experimental results, the follow-

ing findings were obtained. The lesion of the retinal tissue caused by administration of I was generally intense in the pigment epitherial layer, the visual cell layer and the external molecular. It was intense especially in the visual cell layer. The location of the damaged retina and the degree of the lesion depended on the dose level of I. The cretical dose level of I which caused the retinal lesion was about 2.5 mg/kg. These findings were affirmed not only from Hematoxylin-Eosin double stain but also from the reactions of PAS and ALPase . In ERG, when the outer layers from the internal molecular layer of the retina were damaged, the amplitudes of a- and b- waves decreased parallel. It did not occur that the only amplitude of a- wave selectively decreased in the early period. It is interesting that at a dose level of 1.0 mg/kg, in whcih any change was not observed histologically and histochemically, the amplitude of a- and b-wave in ERG temporally inclined to increase but returned to the value of that before the treatment.

(B) ERG and Histological Findings on Administration of Sodium l-glutamate

1) The Group of 2.0 g/kg Administration

(See Table 1,2,3 and Fig. 7,8, and 17B)

When G was administered at a dose level of 2.0 g/kg a day for consecutive 16 days, 57.6 g to 73.6g in total, the amplitudes of both a- and b-wave of ERG gradually decreased parallel after the 10th day. The average decreasing ratio of a-wave on the 16th day after the administration was 51%, and that of

b-wave was 46%.

Histologically, the pigment epithelial cell ~~shrinked~~ shrank, the pigment granules became coarse, the visual cells disordered in arrangement and collapsed, the nuclei of the external molecular layer condensed, the external plexiform layer loosened, the nuclie of the internal molecular layer swelled, and ganglion cells slightly swelled. These findings are similar to that on administration of I at a dose level of 5.0 mg/kg, although the changes in the pigment epithelial layer, the visual cell layer and the external molecular layer were more in I groups than in G groups, and the changes in the internal molecular layer and ganglion cell were more in G groups. As for PAS reaction, it was strongly positive in the pigment epithelial layer, and slightly positive partly in the inner and outer segments of the visual cell. As for ALPase reaction, it was normal in the inner segment of the visual cell the external limiting membrane and the external plexiform layer, and in the other layers it was positive in almost the same degree as the group of 5.0 mg/kg I administration group. In general, in the outer layers from the external molecular layer, it was weakly positive, but it is interesting that ALPase reaction was a little intenser than normal in the ganglion cell layer.

2) The Group of 1.0g/kg Administration

(See Table 1,2,3 and Fig.7,9 and 17C)

When G was administered at a dose level of 1.0g/kg a day for consecutive 16 days, 28.8 to 36.8 g in total, as shown in Fig.7 and 9, the amplitudes of a- and b-wave of ERG changed

more compecatedly compared to the group of 2.0 g/kg administration, but they decreased parallel on the 16th day. The average decreasing ratio of a-wave was 35%, and that of b-wave was 32% at the final time. Histologically, the pigment nuclei in the pigment epithelial cell increased and became coarse, the outer segment of the visual cell disordered in arrangement and slightly collapsed, the nuclei of the external molecular layer slightly condensed, the nuclei of the internal molecular layer slightly swelled, the ganglion cell slightly swelled, disordered in arrangement, degenerated and fell, and the internal limiting membrane and the Müller's radial fiber thickened. But these changes were less than those of 2.0 g/kg administration group. As for PAS reaction, it was moderately positive in the pigment epithelial layer, slightly positive in the outer segment of the visual cell, and very slightly positive in the inner segment. In short, PAS reaction was a little intenser than normal in them. As for ALPase reaction, it was less intense than normal in the pigment epithelial layer, the external molecular layer and the external prexiform layer. That is, the result was almost the same as that of 5.0 mg/kg I administration or 2.0 g/kg G administration group. However, it is remarkable that the reaction was more intense than normal in the ganglion cell layer. In short of these findings, the lesion was less than that of 2.0 g/kg administration group, the main parts damaged were the pigment epithelial layer and the outer segment of the visual cell, and slight changes were also observed in the internal and external molecular layers and the ganglion cell layer. The amplitude of a- and b-waves in ERG evidently decreased, and it means that considerable

functional lesion was caused.

3) The Group of 0.5g/kg Administration

(See Table 1,2,3 and Fig. 7,10 and 16D)

G was administered at a dose level of 0.5g/kg a day for consecutive 16 days and it amounted to 14.4 to 18.4g in total. The amplitudes of a- and b-wave of ERG temporally inclined to increase between the 5th and the 13th day, but later they gradually decreased parallel. The average decreasing ratio of a-wave was 35% and that of b-wave was 28% at that point.

Histologically, the pigment granules in the pigment epithelial cell slightly became coarse, the visual cell disordered in arrangement and slightly collapsed, the nuclei of the external molecular layer condensed, the ganglion cell regressively degenerated, the nerve fiber layer loosened, and internal limiting membrane and the Müller's radial fibers thickened. That is, the histological structure was almost the same as that of 1.0g/kg administration group, except the following findings, such as no increase of the pigment granules, no swelling of the nuclei of the internal molecular layer, no looseness of the external prexiform layer, and no swelling and no falling of the ganglion cell.

As for PAS reaction, it was moderately or strongly positive in the pigment epitherial layer, and weakly positive partly in the inner and outer segment epitherial layer, the outer segment of the visual cell and the external molecular layer, but in other layers it was almost the same as normal case. Therefore, the lesion of tissue of this group was intense from

the external molecular layer to outer layer, and the amplitudes of a- and b-wave of ERG finally decreased.

4) The Group of 0.25g/kg Administration

(See Table 1,2,3 and Fig. 7, 11 and 17D)

G was administered at a dose level of 0.25g/kg a day for consecutive 16 days, and it amounted to 7.2 to 9.2g in total. The amplitudes of a- and b-wave of ERG gradually increased for 16 days, although it went temporally a little up and down, and finally they reached at higher points than before administration.

Histologically the outer segment of the visual cell disordered in arrangement, the nuclei of the external molecular layer condensed, and the ganglion cell swelled. The degree of these changes were very weak, and it was almost the same as normal.

As for PAS reaction, it was almost the same as normal. As for ALPase, it was slightly less intense than normal in the pigment epitherial layer, the visual ce-ll layer and the external molecular layer, and in other layers it was the same as normal.

From these findings, the retinal lesion of this group was not remarkable histologically, however it is assumed from the results of ALPase reaction that the enzyme function was a little disturbed.

5) The Group of 0.1g/kg Administration

(See Table 1,2,3 and Fig. 7, 12, 16E)

G was administered at a dose level of 0.1g/kg a day for consecutive 16 days, and it amounted to 2.88 to 3.68g in total. The amplitudes of both a- and b-wave slightly inclined to increase, and the variation of b-wave looks greater than that of a-wave. Histologically, it was almost normal except condensation of the nuclei of the external molecular layer.

As for PAS reaction, it was also almost normal all over layers. As for ALPase reaction, it was slightly less positive in the pigment epithelial layer, but in other layers it was almost the same as normal.

The fact that the amplitudes of a- and b-wave of ERG were larger than before administration as described above does not correspond to the histological change. The reason might be that the cell was temporally stimulated at a little dose and excited, but it is not certain whether it is true or not.

6) Summary

When G was administered at a dose level of 2.0g/kg, the regressive degeneration was found in the pigment epithelial layer, the inner and outer segment of the visual cell, the internal and external molecular layer, and the ganglion cell. The degree of the degeneration was similar to that of 5.0mg/kg I administration group. However, the degree of degeneration from the external plexiform to inner layer, was intenser in G administration groups.

In the experimental results of ERG, the amplitude, of a- and b-wave of G administration groups evidently decreased, and so the difference of both substances to cause lesion was very

remarkable. When G was administered at a dose level of 1.0g/kg or 0.5g/kg, the histological changes were less than at a dose level of 2.0g/kg, although the locations of lesion were similar, and the amplitudes of a- and b- wave finally decreased than before administration. At a dose level of 0.25g/Kg and 0.1g/kg, although any histological change caused by administration of G was not observed, the eminent variation of the amplitudes of a- and b-wave occured. It is remarkable that the final amplitudes were bigger than those before administration and that the variations of a- and b-wave went parallel.

C) ERG and Histological Findings on Combined Administration of Sodium Iodate and Sodium L-glutamate

1) The Group of 2.5mg/kg I and 0.25g/kg G Administration (See Table 1,2,3 and Fig. 13, 14, 16F)

2.5mg/kg I and 0.25g/kg G were simultaneously administered a day for consecutive 16 days, and I amounted to 72.o to 92.0 mg and G amounted to 7.2 to 9.2g in total.

In ERG the amplitudes of a- and b-wave inclined to decrease from the beginning, and in general they decreased parallel. The average decreasing ratio on the 16th day of a-wave was 75%, and tht of b-wave was 59%. The both amplitudes of a- and b-wave decreased evidently.

As for histological changes, the ratina slightly thinned, the pigment granules in the pigment epitherial cell became coarse, the visual cess disordered in arrangement and degenerated and collapsed, the nuclei of the external molecular layer condensed and fell, the nuclei of the internal molecular layer

swelled, the internal molecular layer and the internal prexiform layer and the nerve fiber layer loosened, the ganglion cell swelled, and the internal limiting membrane and the Müller's radial fiber thickened.

As for PAS reaction, it was evidently more positive in the pigment epithelial layer and in the inner and outer segments of the visual cell, compared to the case of single administration of I and G. On the other hand, as for ALPase reaction, it was normal in the internal molecular layer, the internal prexiform layer and the internal limiting membrane, it was weakly positive from the external prexiform layer to outer layers in the same degree as that of 5.0 mg/kg I administration group and it was positive in the ganglion cell layer and the nerve fiber layer in the same degree as that of 1.0 g/kg G administration group.

As mentioned above, on the simultaneous administration of a certain amount of I and G which was less than the minimum dose to produce the degeneration, the evident histological change was produced and the amplitudes of a- and b-wave of ERG ware effected. This considered to be the additive effects of toxicity of both substances.

2) The Group of 1.0 mg/kg I and 0.1g/kg G Administration (See Table 1,2,3 and Fig. 13, 15)

1.0 mg/kg I and 0.1g/kg G were administered a day for consecutive 16 days, 28.8 to 3.68g G in total. The amplitudes of a- and b-wave of ERG temporally increased between the 5th and the 13th day, and on the 16th day the amplitude of b-wave was

almost the same as that before administration, and that of a-wave was a little larger than that before administration.

Histologically the visual cell slightly disordered in arrangement, the nuclei of the external molecular layer a little condensed, the ganglion cell slightly swelled, and in other parts the histological structure was very close to normal. And PAS and ALPase reactions were almost normally positive.

3) Summary

When the minimum doses to produce the degeneration on the retina, that is 2.5mg/kg of I and 0.25g/kg of G, were simultaneously administered, the evident retinal degeneration was produced. The histological changes were strong in the pigment epithelial layer, the visual cell layer and the external molecular layer. Thet were weak in the internal molecular layer, the internal plexiform layer and the ganglion cell layer. In ERG, the amplitudes of a- and b-wave evidently decreased to half, different from the case of simple administration of each reagent. On the other hand, when 1.0 mg/kg of I and 0.1g/kg of G, which were less than half of minimum dose to produce degeneration, was simultaneously administered, no change was observed from the view of histology and ERG.

IV Discussion

Recently the administration of sod. l-glutamate or l-glutamic acid at a large dose level has been actively applied in the field of mental and nervous diseases. Zimmermann et

al[6] (1949) and Milliken et al[7] (1951) administered orally, and Sapirstein(1943), Elman(1946), Mayer-Gross et al[8] (1949) and Weil-Malherbe et al(1949) injected intraveneously at a large dose level, and they did not find any lesion. On the other hand, Schober(1954) injected it into ear veins of rabbits, and found that the hepatic and suprarenal lesions were produced.

In 1957, Lucas and Newhouse[1] found that special changes were caused in infant mice. That is, although only slight lesions were produced in the retinal external molecular layer and the visual cell layer,, strong degeneration was generated in the ganglion cell and deformatiom was caused in the internal molecular layer. However, they reported that these changes which were found in the infant mice were not produced in the adult mice, that only partial collapse of cells in the ganglion cell layers and the internal molecular layer was observed within one hour after the administration of the fatal dose of G, and that even these changes became unclear in 5 or 10 days after a hypodermic injection.

Potts et al.[3] took notice of the findings of Lucas and Newhouse[1], and they investigated ERG of the retina which was composed of only visual cells degenerated by G. They reported that when G was administered in the abdominal cavity of the infant mice for 7 consecutive 8 days, the degenerated histological structure was produced as reported by Lucas and Newhouse, that these retinal degeneration could not be produced in adult mice, and that ERG of these degenerated retinas has only a-wave and no b-wave at all.

231

Although there has been no definite explanation about the origin of each electric potential of ERG, a number of investigators[10 to 17] ascribed the origin of a-wave to the visual cell layer or the external layer of the retina. The findings of Potts et al.[3] support this explanation and it is one of the motives of the present experiment. For the author had two questions why G produced retinal degeneration only in infant mice and not so much in adult mice and why G selectively damaged the retina.

As the mechanism of development of toxicity by G, Lucas and Newhouse[1] proposed three hypotheses, that is, the disturbance of metabolism caused by change of potassium concentration because l-glutamic acid can keep high concentration of potassium in the retina, the disturbance of metabolism of carbohydrate, and direct stimulus of the suprarenal.

Potts et al[3] denied these three hypotheses of Lucas and Newhouse, and asserted[4)5)] that G did not directly disturb the activity of enzyme but restrained the formation of enzyme, since glutaminase I and glutamic aspartic transaminase in the rat to which G was administered, amoun five enzymes which relate to the metabolism of glutamate. Hasegawa[2] considered the literatures. He assumed that at first the cell of the retinal cerebral part was damaged and ceased to function properly, and that then regressive degeneration produced, since it is possible that the administration of large dose of G increases potassium ion concentration in the retina, brings TCA cycle out of order, and disturbs the synthesis of ATP high energy. Anyway, there is no generally admitted explanation about toxicity of G

so far.

The result of the present experiment proposes the definite counterevidence against the results 1) to 3) reported so far that single administration of G could not produce degeneration in the retina of the adult rabbit. It is believed to be new finding that when G was administered at a dose of 2.0 g/kg in the abdominal cavity, the retinal degeneration as shown in Fig. 7,8 and in Table 1,2,and 3 was produced and specific decrease of wave amplitude of ERG was detected.

This retinal degeneration was produced not only in the rear polar part but also in the equatorial part of the eyeball, or in total layers of the eyeball though in a slight degree. Histologically, the findings were very similar to those on administration of I at a dose level of 5.0 mg/kg. However the degeneration in the pigment epithelial layer, the visual cell layer and the external molecular layer was greater in I administration groups. It is remarkable that ALPase reaction of G groups was rather more intense than normal in the ganglion cell layer. In ERG when G was administered at a dose level of 2.0 g/kg, the amplitudes of a- and b-wave decreased and on the 16 th day they reached to half of that before administration. On the other hand, when I was adminstered at a dose level of 5.0 mg/kg, the amplitudes of a- and b-wave increased to a little higher value than that before administration on the final day. Therefore, when the doses of G and I, which produced the retinal degeneration almost in the same degree, were administered different results were shown in ERG and histological findings were also different although in slight degree. These facts may

suggest that G and I damaged the different part of the retina.

In the present experiment G was administered at several decreasing doses, and it was found that 0.25g/kg was the minimum dose to produce the generation in the retina, histologically and in ERG. When the minimum dose of G was administered, the amplitudes of both a- and b-waves inclined to increase compared to those before administration, and it may mean that the histologically undetectable changes occurrad in the retina. This new finding that the minimum dose of G to produce the degeneration of the retina is about 0.25g/kg should support the announcement that the oral administration of 20 to 30 g was harmless to the human of 70kg body weight.

On the other hand , I is considered to disturb breathing and catabolism of glucose to restrain the activity of other enzymes, [23) to 27)] and to produce the degeneration of the retina, and it is a characteristic of I that degeneration is slowly produced. [18) 19) 22)] Therefore, it is reasonable to speculate that when a little dose of I is administered to the adult rabbits during long period as pretreatment, the ratinal degeneration may be produced by administration of G in the adult rabbit. From this point of view, at first the minimum dose of I to produce the degenertion was determined, by the administration of several doses of I in the ear veins of adult rabbits, and by the examination of the histological changes and ESR of the retina.

The histological and histochemical findings on administration of 30.0 mg/kg I were almost the same as the results of other investigators. [15) 16) 18) to 32)] The change was observed

in all layers of the retina, especially intensely in the outer layers of the retina. In ERG, as shown in Fig 1 and 2, the amplitudes of a- and b-waves changed parallel, and the process was similar to the result of Sugita et al.[34] However, when it was examined in detail, the decreasing ratio of a-wave was larger than that of b-wave, as reported by Noell[15)16)] and Kubota.[33]

When the dose of I was decreased, the changes inclined to concentrate the outer layers of the retina. PAS reaction also indicates localization of changes. This result supports the opinions of other investigator.[15)16)18) to29)31)32)] that I selectively disturbs the pigment epitherial layer or visual cell layer, by the present new trial of decreasing dose experiment.

When 1.0 mg/kg of I was administered for consecutive 16 days, histological changes could not be detected, and when 2.5mg/kg was administered, toxicity of I was observed histologically. It suggests that the minimum dose to produce the degeneration of the retina is about 2.5mg/kg.

When the minimum doses of I and G to produce the degeneration of the retina, that is, 2.5mg/kg of I and 0.25g/kg of G was administered simultaneously, the degeneration was developed in the internal molecular layer, the external molecular layer, the visual cell layer and the pigment epitherial layer. But no degeneration was produced, when each reagent was simply administered at these dose. This degeneration was confirmed by PAS reaction in the external layers and by the decreasing

amplitudes of a- and b-waves in ERG, But these changes were not observed, when 1.0 mg/kg of I and 0.1g/kg of G, less than the minimum doses, was administered.

Before the consideration of the cause of these phenomena, the several hypotheses about the mechanism of the retinal degeneration by I or G should be introduced. Hypotheses about G were already mentioned, and so the hypotheses about G are introduced here. So far the toxicity of I to degenerate the retina has been ascribed to the following, that is, the disturbance of breasing and catabolism of glucose in the retina, 15)16)18) to22) the disturbance of the mechanism of oxidation and reduction because I is a strong oxidizing reagent, 20)21) 22)28) the destruction of cell by adrenochrome because I restrains the activity of monoamine oxidase and disturbs the catecholamine metabolism, and the occurrence of the retinal lesion because I restrains the sulphydryl enzyme activity. However, any one hypothesis is not enough to fully clarify the cause of the toxicity, as indicated by Mizuno. 24)-27)36)

By putting all these hypotheses together, the following mechanism can be speculated, as follows; I effects to the several enzymes in the outer layers of the retina, in so-called "Blood Retinal Barrier", disturbs the metabolism system complicatedly, and generates various uncertain toxic intermediate metabolism products which destroy the cells.

As mentioned above, it has been reported so far that I mainly damage the outer layers of the retina, and that G mainly damages the inner layers.

However, the reason why the localized degeneration was

was produced only in the outer layers of the retina, when the minimum doses of I and G were simultaneously administered in the present experiment, cannot be elucidated simply by the present experimental results. From the consideration of the above mentioned hypotheses proposed so far about the mechanism of the reaction of I and G, it is not concluded as the simple additive effect.

However, the fact that some changes of the amplitudes of a- and b-waves were observed in ERG on administration of I or G at a minimum dose level, probably means that the functional change was already produced in the outer layers of the retina at a minimum dose, although it could not be detected histologically. Originally, large dose of I produces the degeneration in the outer layers of the retina[9)-12)15)16)18)-32)] originally, so the blood retinal barrier[24)82)] which is said to be located in that region ought to be damaged, too, Therefore, it is speculated that G should also transferred into the outer layers of the retina through flowing blood, and so the toxicity of I and G might function additively to the outer layer of the retina. However, these speculations should be proved by accomplishment of the further systematic experiment.

V Conclusion

Various doses of sodium iodate and sodium l-glutamate were single or together administered on grown albino rabbits nonorally. Studies from the view of histology, histochemistry, and ERG, were performed and the following results were obtained.

1) When 30.0 mg/kg sodium iodate was administered, regressive degeneration was preduced on total layers of the retina. The degeneration was especially remarkable from outer granular layer to outer layers. On ERG, the amplitudes of a- and b-wave evidently decreased at the same time. The degree of decrease of a-wave was more than that of b-wave.

The minimum dose of I to produce the degeneration was about 2.5 mg/kg, and that of G was 0.25g/kg. When administered dose was less than each of them, degeneration was not produced. When the miminum dose was administered, the amplitudes of a- and b-wave enlarged in general.

2) When 2.0g/kg of sodium l-glutamate was singly administered for 16 days, retinal degeneration was produced. The degeneration spread on total layer, especially on the outer layer the degree was relatively intense. At this time, the amplitudes of a- and b-waves simultaneously decreased ~~smaller~~ to less than a half of before.

3) When sodium iodate and sodium l-glutamate were combined in the minimum doses, relatively intense degeneration was produced on outer layer of the retina. And the amplitudes of a- and b-waves in ERG decreased parallel.

At the end the author appreciates deeply my professor, Dr.Imaizumi for his kind instruction and his looking over this manuscript, Dr. Mita of department of Physiology and Dr. Katsura of department of pathology for their kind instruction and discussion. I also say thanks to Dr. Takahashi of ophthalmology laboratory for his continual help.

Symposium

M. Matsuyama:

1. I think there are considerable individual variations in the developement of the degeneration of the retina on I administration.

2. Please tell me about the period of the degeneration development in the retinal tissue, especially inner layer, glia tissue, and about the necessary amount of the drug to produce it.

3. I have observed abnormality of a blood vessel like microaneunysma in experimental degeneration of the retina. I think the change of a blood vessel should not be neglected.

K. Mizuno:

1. I think there is a change in the internal granular layer on G administration. How do you think?

2. How about ATPase reaction of Glia cell?

3. How about comparison of electron microscopical findings with ERG change?

T. Oya:

Sodium salts of GA(glutamic acid) and BOGA(β-hydroxy glutamic acid) were neutralized. 50 mg/kg and 200 mg/kg of both of them were injected into auricular veins of the adult albino rabbits, and the changes were observed for about 40 minutes. In BOGA in 10 minutes, the amplitudes of a- and b-waves increased about 50%, and in GA they increased and decreased about 10%.

1. Did you neutralize Na salt of GA on administration?
2. In my experiment the amplitude of a- and b-wave increased and decreased. Also in the present report, the increase in the amplitudes of a- and b-waves on administration at a small dose were observed. How do you think about it?

Y. Kubota:

Also in our laboratory, the experiment of the retinal degeneration and ERG on administration of $NaIO_3$ are continued. Although both a- and b-wave decrease at the same time in some examples, generally a-wave decrease earlier than b-wave. (The detail will be published by Takase) How do you think about the reason that the amplitudes of a- and b-waves increase in initial stage in your experiment?

Y. Hamatsu: (Answer)

To Matsuyama

1. I found the considerable individual variations in ~~be~~ the tolerence of the rabbits on administration of large dose of I.
2. The change of the inner layers were observed on the 16th day of daily administration of 5mg/kg I. I want to examine about Glial cell in future.
3. In the present experiment I did not observe the change of a blood vessel, but I will observe it in future.

To Mizuno

1. The degeneration in the internal granular layer was produced on G administration. But the degeneration in outer layers than the external granular layer looked intense.

To T. Oya

1. G was not neutralized on administration.

2. When the amplitudes of a- and b-waves increased on administration of G at a small dose, the histological change was not observed, however, some change occurred in enzyme level.

R. Takahashi: (Answer)

To Mizuno

It is not clear in the present experiment whether the variation of the amplitudes of a- and b-waves on administration of a small dose of I or G is caused by histological and morphological change which cannot be detected with an optical microscopy or the disturbance of enzyme system. The variation of enzyme system may be also considered.

To Kubota

The amplitude of both a- and b-waves decreases on administration of $NaIO_3$ (at large dose). The decreasing ratio of the amplitude of a-wave is larger. The cause of amplitude increase is inferred as mentioned before.

Literature

2) B. Hasegawa, Annual Report of Ind. Inst. of Yamaguchi Med. Coll.,

20) T. Nakamara, Nippon Ganka Gakkai Zasshi,

21) T. Sakai,

22) S. Ohta,

23) K. Mizuno,

24)

25)

26) T. Sakurai,

27) T. Oya

29) S. Tsubota,

30) S. Sonoda,

31) K. Shioya,

32) B. Hasegawa,

33) Y. Kubota,

34) Y. Sugita & T. Tanabe,

36) K. Mizuno, T. Sakurai & K. Nagata,

昭和39年10月10日 245～(1725)

91. グルタミン酸ソーダ及びヨード酸ソーダ投与家兎における ERG 並に網膜組織像 (図17, 表3)

浜 津 恒 男 (岩手医科大学眼科教室 主任 今泉亀撰教授)

Experimental Studies on the Effect of Sodium Iodate and Sodium 1-glutamate on ERG and Histological Structure of Retina in Adult Rabbits

Tsuneo HAMATSU

Department of Ophthalmology, Iwate Medical College. Morioka-shi

On grown albino rabbit, various doses of Sodium 1-glutamate (S-G) were injected in the abdominal cavity. Besides, intravenous injection of Sodium iodate (S-I) was performed singly or combined with above mentioned injection. Studies from the view of ERG, histology and histochemistry were performed and followings were obtained.

1) When 30.0mg/kg S-I was administered, regressive degeneration was produced on total layers of the retina. Especially, the degeneration was remarkable from outer granular layer to outer layer. On ERG, the amplitudes of a and b waves decreased remarkably at the same time. On a-wave, the degree of decrease was more remarkable than that of b-wave.

The minimum dose to porduce the degeneration was about 2.5mg/kg. When administered dose was less than it, degeneration was not produced.

2) When 2.0g/kg S-G was singly administered for 16 days, retinal degeneration was produced on grown rabbit. The degeneration spread on total layers, especially on the outer layer, the degree was relatively intense. At this time, the amplitudes of a and b waves simultaneously decreased smaller than a half of before.

The minimum dose to produce the degeneration was 0.25g/kg. The dose showed similar value to the one which was used on the human without any disturbance. When the dose was administered, the amplitudes of a and b waves enlarged in general.

3) When S-I and S-G were combined in the minimum doses, intense degeneration was produced on outer layer of the retina. And the amplitudes of a and b waves definitely decreased at the same time.

目 次

I 緒 言
II 実験材料並に実験方法
A) 実験材料並に薬剤投与方法
B) ERG測定法
C) 組織学的及び組織化学的検査法
III 実験成績
A) Sod. Iodate 投与による ERG と組織学的所見
1) 30.0mg/kg 投与群
2) 10.0mg/kg 投与群
3) 5.0mg/kg 投与群
4) 2.5mg/kg 投与群
5) 1.0mg/kg 投与群
6) 小 括
B) Sod. 1-glutamate 投与による ERG と組織学的所見
1) 2.0g/kg 投与群
2) 1.0g/kg 投与群
3) 0.5g/kg 投与群
4) 0.25g/kg 投与群

5）0.1 g/kg 投与群

6）小　括

C）Sod. Iodate 及び Sod. 1-glutamate

1）Sod. Iodatd 2.5mg/kg 及び Sod. 1-glutamate 0.25 g/kg 投与群

2）Sod. Iodate 1.0mg/kg 及び Sod. 1-glutamate 0.1 g/kg 投与群

3）小　括

Ⅳ　総括並に考按

Ⅴ　結　論

参考文献

Ⅰ 緒　言

網膜色素変性の成因を解明するため，種々の薬物による実験的網膜変性の研究が数多くなされているが，未だ解決には程遠い現状にある．何等かの条件を設け，網膜各層を選択的に破壊せんとする試みは，網膜色素変性の成因解明とERG発生理論の究明への基礎になる重要な問題を含むので，多くの学者の研究対象とされて来た．Lucas and Newhous[1]，長谷川[2]，Potts 等[3]はSodium 1-glutamate（以下Gとする）の非経口投与により幼弱マウスの網膜視層部を選択的に破壊し得ることを報告した．然し氏等は何故に成熟動物で斯かる現象が発生しないかには触れていない．

成熟家兎にGを投与して果して網膜変性が惹起しないものであろうか，若し起き得るとすればその条件は何であろうか等の問題を探求する目的で本実験を企てた．而して，網膜変性剤として知られている Sodium iodate（以下Iとする）の各種量投与時のERG測定を行い，ERGのa,b波振巾に変化の現れない限界量を決定して，前処置としてその限界量を投与した成熟家兎に，更にGを投与してERGに変化が出現するかどうかを調査した．

同時にERG所見と網膜の組織学的観察の結果を比較検討して興味ある知見を得たので報告する．

Ⅱ 実験材料並に実験方法

A）実験動物並に薬剤投与方法

実験動物には体重 2.0kg 前後の成熟白色雄家兎を用い，一定の条件下で1週間以上飼育したもので，ERG及び眼底が共に正常であることを確認してから実験に供した．実験動物を投与薬物の種類とその投与方法とによつて下記の3種類に分けた．

即ち，第1種類のI投与群は 2.0% I水溶液の30.0mg/kg（3羽）を1回のもの，或は10.0mg/kg（4羽）を毎日1回6日間のもの，或は 5.0mg/kg（3羽）及至 2.5mg/kg（5羽）乃至 1.0mg/kg（4羽）を夫々毎日1回ずつ16日間耳静脈に注入した，即ち5群19例である．

第2種類のG投与群としては，25.0%G水溶液の 2.0 g/kg（5羽），1.0 g/kg（5羽），0.5 g/kg（3羽），0.25 g/kg（5羽）及び 0.1 g/kg（3羽）を夫々1日1回16日間連日腹腔内に投与した，即ち5群21例である．

第3種類のI及びG併用群は，前記の 2.0% I水溶液と25.0%G水溶液のI 2.5mg/kgとG0.25 g/kg（4羽）及びI 1.0mg/kgとG 0.1 g/kg（4羽）を総て16日間夫々1日1回連日静脈内及び腹腔内に投与した，即ち2群8例である．

B）ERG 測定法

家兎に全身麻酔薬として25.0% Urethan 水溶液 1.0 g/kgを腹腔内に注射し，アトロピンで充分散瞳し，シールドされた絶対暗室で30分間暗順応した後にERGの測定を行つた．

誘導電極には Riggs 型の家兎用改良コンタクトレンズを用い，中性電極として銀針を誘導[illegible]眼角部の皮下に刺入，接地電極は耳中央部の皮下に刺入した．

ERG記録には日本光電KK製直流増巾器（APB-20）及び標準増巾器（AVS-1）を使い，ブラウン管オッシロ（VC-6）で記録した．時定数は 0.3秒，増巾度は 10 μV を 5 mm，掃引速度は40cm/sec 程度とし，光刺激は光量1800Lumen/sec の Stroboflash を用い眼前30cmから照射した．

以上の条件下で，正常家兎10羽の個体差，時間的並に日差的動揺の範囲を7日間調査したERGは，a 波振巾の変動範囲は50～ 140μV，b 波振巾のそれは 190～ 45[illegible] μV，日差が30%以内で，暗順応過程では20Lux の弱[illegible]光のb 波振巾が暗順応後約30分で安定した．

a波は基線から，b波はa 波の最深部から振巾を夫々測した．a,b 波の振巾変動は次の如く表現した．

$$\frac{\text{投与後振巾}}{\text{投与前振巾}} \times 100 - 100 = X\%$$

C）組織学的及び組織化学的検査法

実験終了後空気栓塞で屠殺して眼球を摘出し，[illegible]側眼球をCarnoy氏固定液，他[illegible]眼球をBouin-alcohol混液に投入して固定した．それぞれ視神経部及び[illegible]の8μ パラフィン切片を作製し，前固定液によるものは Hematoxylin-Eosin 重染色並にPAS反応を行い，[illegible]固定液によるものは Alkaline phosphatase (Gomori

氏法改良法—以下 ALPase とする）反応を行つた.

III 実験成績

A) Sod·Iodate 投与による ERG と組織学的所見

1) 30.0mg/kg投与群（第1表, 第1,2,16のA図参照）

30.0mg/kg 1回投与群では，ERGのa波とb波の振巾は，注射4時間後1時上昇するが，翌日からa波，b波共に平行して減小してくる．然しIに対する家兎の抵抗性にかなりの個体差があつて，注射2日目で死亡したものから，第7日目にa, b 波共全く消失したもの，大巾に振巾は減少するが未だa, b 波が残つていたもの等がある．何れにしても薬剤投与後1日目に a, b 波共急激に，次で，第7日目迄に徐々に平行して減小する．

組織学的所見としては，色素上皮細胞の軽度腫大と空胞変性，色素顆粒の増加と粗大化，視細胞の配列の乱れと消失，外顆粒層核の濃縮，破砕，脱落，内顆粒層核の腫大，濃縮或は脱落，時に Müller 氏支柱線維の核増生，内外網状層と神経線維層の浮腫化，神経節細胞の配列の乱れ，腫大或は変性脱落，内境界膜の部分的肥厚，Müller 氏支柱線維の結合織性肥厚等が見られた．

PAS反応では，色素上皮層で陽性，視細胞，外境界膜及び外顆粒層では組織間隙が著しくて観察出来ない，時に崩壊した外顆粒層内に不規則に中等度陽性部位が認められた．要するに網膜全層に亘り強い組織障害がみられるが，色素上皮層，視細胞層及び外顆粒層の変性が特に顕著である．

2) 10.0mg/kg投与群（第1,2,3表第1,3,16のB図参照）

本群ではIを10.0mg/kgずつ 6日間連続投与し，総量108～138mgに及んだ．a 波振巾は経過と共に次第に減少，6日目には注射以前の値より平均50%減小し，b 波振巾は，3日目迄は不規則に変動したが，6日目には平均40%と減小した．即ち見掛上a 波の減小率が大である．

組織学的には，色素上皮細胞の腫大，空胞変性，色素顆粒の増加並に粗大化，視細胞の配列の乱れ，消失，外顆粒層核の濃縮及び脱落，外網状層の浮腫化，内顆粒層核の腫大，神経節細胞の軽度腫大，Müller 氏支柱線維の肥厚等がある．

Fig. 1 Effect of intravenous Sod. Iodate on ERG in the adult rabbit.

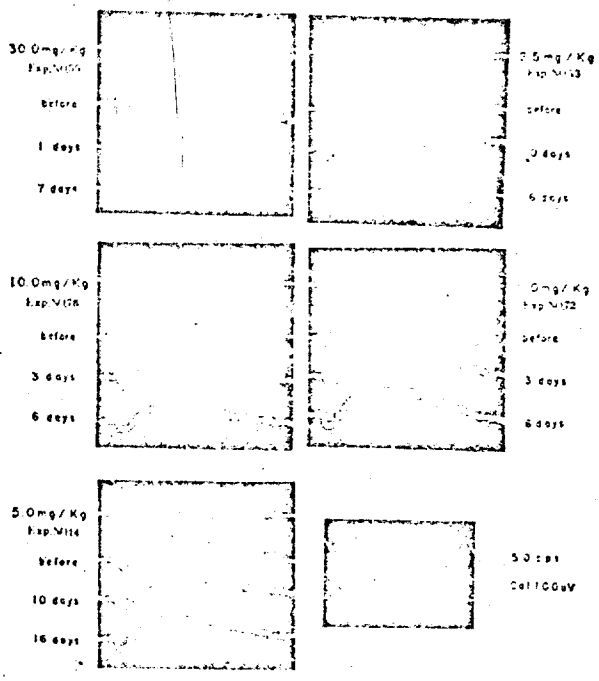

Fig. 2 Sod. Iodate administration (i,v) at a dose level of 30.0 mg per Kg body weight. Percent variation in amplitude of a and b-waves

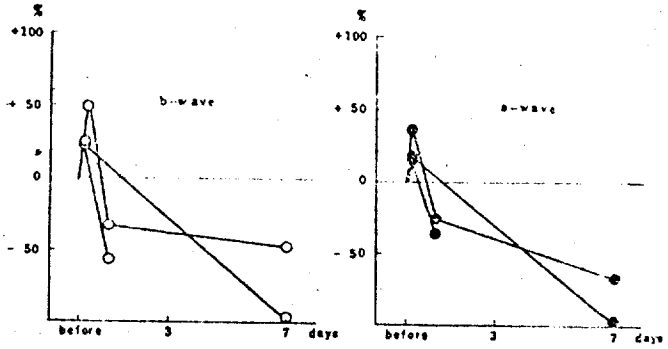

Table 1 Histological findings of experimental retinal degeneration in the adult rabbit

Group (Agents administrated)			Sod l-glutamate					Sod Iodate					Sod l-g / Sod iod	
Dose level per kg body weight			2.0 g	1.0 g	0.5 g	0.25 g	0.1 g	100 mg	50 mg	25 mg	10 mg		2.5 g / 25 mg	1.0 g / 10 mg
Duration of administration (days)			16	16	16	16	16	1	6	16	16	16	16	16
Thinning of retina			−	−	−	−	−	±	±	±	±−+	−	±	−
Pigment epithelial layer	Cell bodies	Swelling	−	−	−	−	−	+	+	+	−	−	−	−
		Degeneration	+	−	−	−	−	+	+	+	−	−	−	−
	Pigment granules	Increasing	−	+	−	−	−	++	+	+	±−+	−	−	−
		Disappearance	+	+	±	−	−	±	±	±	±−+	±	+	+
Visual cell layer	Outer segment	Swelling	+	+	+	±−+	−	++	++	++	±	±	++−+	±
		Degeneration	−	±	+	±−+	−	++	++	++	−	−	±−+	−
		Disappearance	+	±	±	−	−	++	+	+	−	−	−	−
	Inner segment	Swelling	−	−	+	−	−	++	++	++	±−+	±	++−+	±
		Degeneration	−	−	±	−	−	++	+	+	−	−	±−+	−
		Disappearance	+	−	±	−	−	++	+	+	−	−	±−+	−
Disorder of arrangement of fibers in the nerve layer			−	−	−	−	−	++	−	−	±−+	−	±−+	−
External molecular layer	Thickening		−	−	−	−	−	+	±	−	±−+	−	+	−
	Nuclei	Pyknosis	+	±	±	±	±	++	++	++	±	−	+	±
		Karyorrhexis	−	−	−	−	−	++	−	−	−	−	−	−
		Karyolysis	−	−	−	−	−	++	+	−	−	−	+	−
External preniform layer	Leukocytes		+	±	−	−	−	+	+	±	−	−	−	−
			−	−	−	−	−	−	−	−	−	−	±−+	−
Internal molecular layer	Nuclei	Swelling	+	+	−	−	−	++	+	+	−	−	±	−
		Pyknosis	−	−	−	−	−	−	−	−	−	−	−	−
		Karyorrhexis	−	−	−	−	−	(+)	−	−	−	−	−	−
	Phagocytes	Leukocytes	−	−	±	−	−	−	−	−	−	−	−	−
Internal preniform layer	Leukocytes		−	−	−	−	−	−	−	±	±−+	−	±	−
Ganglion cells	Cytoplasm	Swelling	+	−	±	−	−	±	−	−	−	−	−	−
		Nuclei	+	+	−	±−+	−	++	±	±	±	−	±	−
		Degeneration	+	±	(±)	−	−	+	±	−	±−+	−	±−+	−
		Fragmentation	±	±	−	−	−	+	−	−	−	−	−	−
Nerve fiber layer	Leukocytes		−	±	+	−	−	+	±	±	−	−	±	−
Internal limiting membrane	Thickening		−	−	+	−	−	(+)	−	+	−	−	+	−
	Leukocytes		−	−	−	−	−	−	−	−	−	−	−	−
Müllers radial fibers	Thickening		−	−	+	−	−	+	+	−	−	−	±	−

( ) Partial changes

PAS反応は色素上皮層が強陽性，視細胞内外節が中等度陽性であつて，何れも正常に比し反応は増強している．

ALPase 反応の陽性度は網膜全層に亘つて一般に正常より減弱し，特に色素上皮層で顕著である．

以上を総合すれば第1,2,3表にも明らかなように，変化は30.0mg/kg群より軽いとは言え，網膜外層，特に色素上皮層に尚相当強いことが認められる．

3) 5.0mg/kg投与群（第1,2,3表，第1,4,16のc図参照）

本群はIを5.0mg/kgずつ16日間連続投与し，総量1[illegible]～184mgにおよんだ．ERGは，第4図に見る如くa,[illegible]波共に軽度増大し，大体平行して経過する．

組織学的所見では，網膜全層が若干菲薄であり，色素上皮細胞の軽度腫大，空胞変性，色素顆粒の増加並に大化，視細胞の配列の乱れ，空胞変性及び崩壊，外顆層の核濃縮，内顆粒層核の腫大，内外網状層及び神経線維層の軽度膨粗化，神経節細胞の軽度腫大等がみられたが，之等の視細胞内外節及び色素上皮層の変性は前[illegible]よりは軽度である．

PAS反応は，色素上皮層に強陽性，視細胞内外[illegible]

Table 2 Periodic acid-Schiff reaction af experimental retinal degeneration in the adult rabbit.

Group (Agents administrated)		Normal	Sod-l-glutamate					Sod-Iodate					Sod l-g / Sod iod	
Dose level per Kg body weight			2.0 g	1.0 g	0.5 g	0.25 g	0.1 g	100 mg	50 mg	25 mg	10 mg		2.5 g / 25 mg	1.0 g / 10 mg
Duration of administration (days)			16	16	16	16	16	6	16	16	16	16	16	16
Pigment epithelial layer		++	+++	++−+	++−+	++	++	+++	+++	++	++	+++	++
Visual cell layer	Outer segment	−	(±)	±	(+)	−	−	+	++−+	(±)	−	++−+	−
	Inner segment	−	(+)	±	(+)	−	−	+	++−+	(±)	−	+	−
External limiting membrane		+	+	+	+	+	+	+	+	+	+	+	+
External molecular layer		±	±	±	±	±	±	±	±	±	±	±	±
External preniform layer		−	−	−	−	−	−	±	−	−	−	−	−
Internal molecular layer		−	−	−	−	−	−	−	−	−	−	−	−
Internal preniform layer		−	−	−	−	−	−	±	−	−	−	−	−
Ganglion cell layer		−	−	−	−	−	−	−	−	−	−	−	−
Nerve fiber layer		−	−	±	−	−	−	±	−	−	−	−	−
Internal limiting membrane		−	−	−	(±)	−	−	++−+	−	−	−	(+)	−
Müllers radial fibers		−	−	−	−	−	−	−	−	−	−	−	−

( ) Partial changes
++−+ Strong positive
++ Moderate positive
+ Weak positive
± Very weak positive
− Negative

Fig. 3 Sod. Iodate administration (i,v) at a dose level 10.0mg per Kg body weight. Percent variation in amplitude of a and b-waves

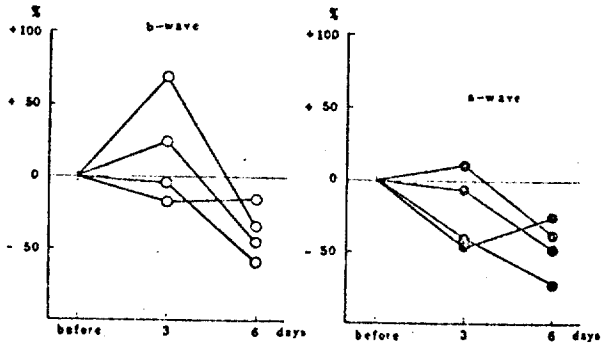

Table 3 Alkaline Phosphatase reaction of experimental retinal degeneration in the adult rabbit.

Group(Agents administrated)		Normal	Sod-l-glutamate					Sod-Iodate				Sod-g / Sod-od	
Dose level per Kg body weight			2.0 g	1.0 g	0.5 g	0.25 g	0.1 g	10.0 mg	5.0 mg	2.5 mg	1.0 mg	0.25 g / 2.5 mg	0.1 g / 1.0 mg
Duration of administration(days)			16	16	16	16	16	6	16	16	16	16	16
Pigment epithelial layer		++	●—+	●—+	++	●—●	●—+	+	●—+	++	++	●—+	●—●
Visual cell layer	Outer segment	+	±	+	±	±	+	±	±	±	±	±	+
	Inner segment	+	+	+	+	+—±	+	±	±	+	+	±	+
External limiting membrane		●—+	+	+	+	●—+	++	±	±	●—+	++	+—±	+
External molecular layer		++	+	+	+	●—+	++	+	+	●—+	+	+	+
External proziform layer		+	+	±	+	+	+	±—	±	+	+	+—±	+
Internal molecular layer		±	±	±	±	±	±	±	±	±	±	±—	±
Internal proziform layer		+—±	±	+—±	+	+—±	+	+—	±	+	±	+—±	±
Ganglion cell layer		±	+	+—±	±	±	±	±	+	±	±	+—±	±
Nerve fiber layer		±	±	±	±	±	±	±—	±	±	±	+—±	±
Internal limiting membrane		±	±	±	±	±	±	±—	±	±	±	±	±

●—● Strong positive
++ Moderate positive
+ Weak positive
± Very weak positive
— Negative

軽度乃至中等度陽性で，正常よりも増強し，ALPase 反応は，外網状層から外側の諸層で明らかに減弱し，内顆粒層，神経線維層及び内境界膜では正常と同程度で，神経節細胞では正常より少しく増強している．

以上の所見からして本群では尚外層の変性が主であることが判る．

4)　2.5mg/kg投与群（第1,2,3表，第1,5,17のA図参照）

本群では，16日間連続 2.5mg/kgずつ投与し，総量72～[illegible]に達した．ERGは複雑な変動を示し，一般にbは5日目で上昇し，10日目乃至13日目で下降し，後再び上昇する．しかるにa波は13日目にb波と逆に上昇傾向となり，最終的には上昇位を辿つた．

組織学的には，色素上皮細胞の色素顆粒は極く軽度に増加及び粗大化し，視細胞外節の配列の乱れ，外顆粒層核の濃縮，内網状層の鬆粗化，神経節細胞の腫大或は核融解等が認められるが，これらの変化は何れも軽度であつて正常に近い組織像である．

PAS反応は，視細胞内外節で部分的に弱陽性であるが，色素上皮層は殆んど正常，ALPase 反応も，視細胞外節で 5.0mg/kg 投与群と略同程度に減弱し，その他の諸層でも外顆粒層或は内網状層において時に多少減弱を示すものもあるが，既して正常と余り異ならない程度の陽性度である．即ち本群の組織的変化は非常に軽微のものと言い得る．

5)　1.0mg/kg 投与群（第1,2,3表，第1，6図参照）

この群にはIを1日 1.0mg/kgずつ連続16日間，総量28.8～36.8mg投与した．ERGの a, b 波は共に5乃至13日の間に1時上昇の傾向を示したが，16日目には投与前と略同じ振巾となつた．

組織的変化としては，色素上皮細胞内色素顆粒の若干の粗大化，視細胞配列の僅かな乱れが確認された外は，殆んど正常である．

PAS及び ALPase 反応は全層に亘り略正常に近い陽性度である．

6)　小括

以上の実験成果からして，Iによる網膜組織の障害は一般的に色素上皮層，視細胞層及び外顆粒層，特に視細胞層に強いこと，Iの投与量の多寡によつて障害される網膜部位と障害程度を異にすること，網膜障害を惹起するIの限界量は 2.5mg/kg近傍にあること等が判明した．

Fig. 4 Sod. Iodate administration (i,v) at a dose level of 5.0mg per Kg body weight Percent variation in amplitude of a and b-waves

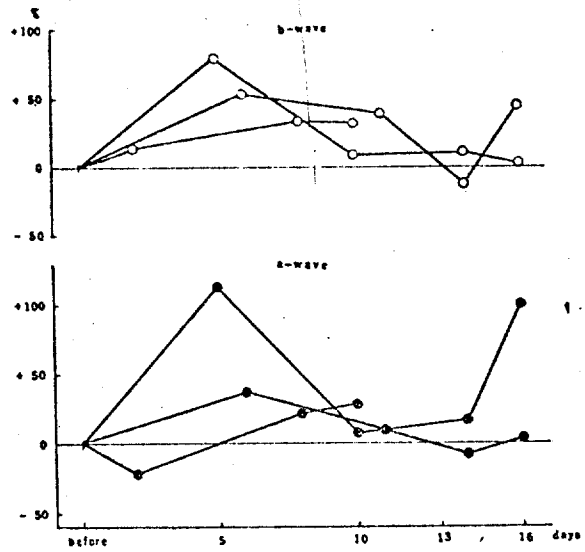

Fig. 5 Sod. Iodate administration (i,v) at a dose level of 2.5mg per Kg body weight Percent variation in amplitude of a and b-waves

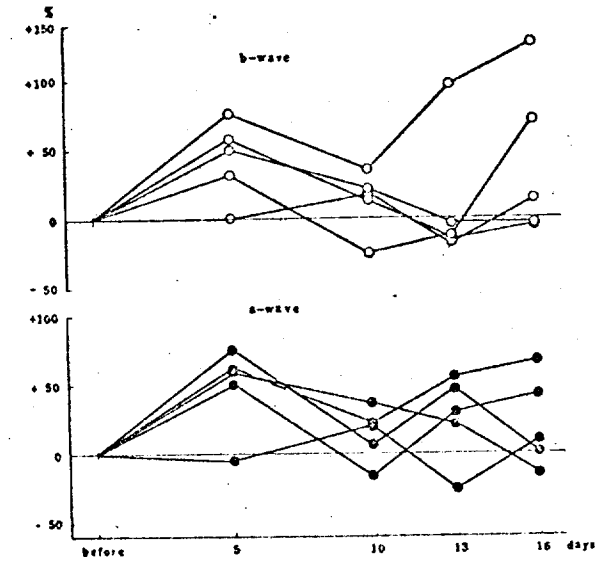

これ等のことは Hemstoxylin・Eosin 染色のみならずPAS反応及び ALPase 反応の結果からも一致して肯定される.

ERG学的に見れば，網膜の内顆粒層から外層が障害された時に a, b 波の振巾が平行的に減少した. a 波振巾のみが選択的に早期から減少する傾向はない. 而して組織学的，組織化学的に著変の認められない 1.0mg/kg 投与群のERG経過において，a, b 波振巾が1時上昇傾向を示すが，最終的には処置前の値に戻つていることは興味深い.

Fig. 6 Sod. Iodate administration (i,v) at a dose level of 1.0 mg per Kg body weight Percent variation in amplitude of a and b-waves

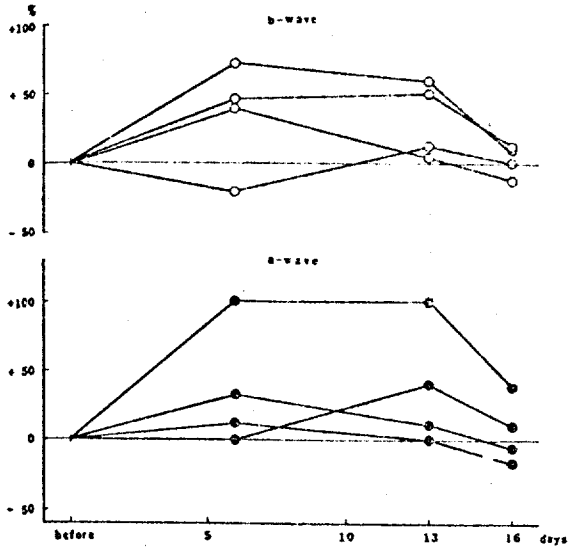

Fig. 7 Effect of intraperitoneal Sod. 1-glutamate on ERG in adult rabbit

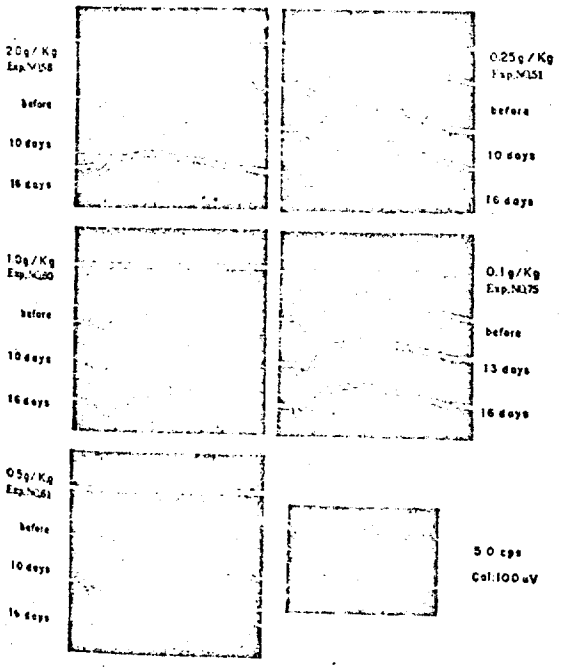

B) Sod. 1-glutamate 投与による ERG と組織学的所見

1) 2.0g/kg投与群（第1,2,3表，第7,8,17のB図参照）

Gを 2.0g/kgずつ連続16日間総量 57.6～73.6g投与した際のERGの a, b 波振巾は，共に平行して10日目以降次第に減小した．投与後16日目のa波減小率は平均51%，b 波減小率は平均46%である．

組織学的には，色素上皮細胞の萎縮及び色素顆粒の粗大化，視細胞の配列の乱れ及び崩壊，外顆粒層の核濃縮，外網状層の鬆粗化，内顆粒層の核腫大，神経節細胞の軽度腫大等である．これらの病的所見は，I 5.0mg/kgを注射した群の組織所見に類似しているが，色素上皮層，視細胞層及び外顆粒層における変化はI群に若干強く，内顆粒層及び神経節細胞の変化は本群に若干強い．

PAS反応は，色素上皮層で強陽性，視細胞内，外節では部分的に軽度陽性である．ALPase 反応は，視細胞内節，外境界膜及び外網状層で殆んど正常，その他の諸層では，I 5.0mg/kg 投与群と略同程度の陽性度を示し，概して外顆粒層から外層に陽性度が弱いが，注目すべきは，節細胞層の ALPase 反応が正常より稍強いことである．

2) 1.0g/kg投与群（第1,2,3,表，第7,9,17 のc図参照）

1日 1.0g/kg，16日間，総量28.8～36.8g 投与群では，第7及び9図に示したように，ERGの a, b 波の

Fig. 8. Sod. 1-glutamate administration (i,p) at a dose level of 2.0g per Kg body weight Percent variation in amplitude of a and b-waves

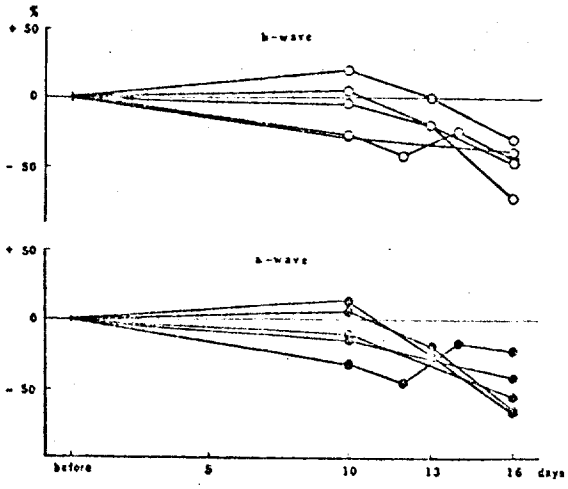

Fig. 9 Sod. 1-glutamate administration (i,p) at a dose level of 1.0 g per Kg body weight Percent variatioh in amplitude of a and b-waves

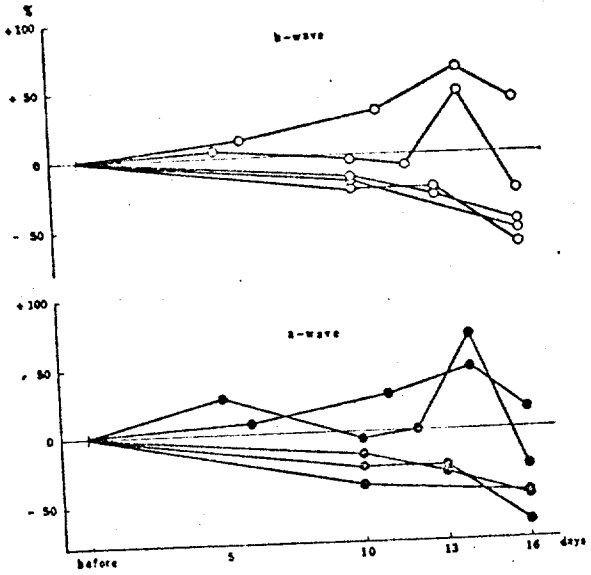

Fig. 10 Sod. 1-glutamate administration (i,p) at a dose level of 0.5g per Kg body weight Percent variation in amplitude of a and b-waves

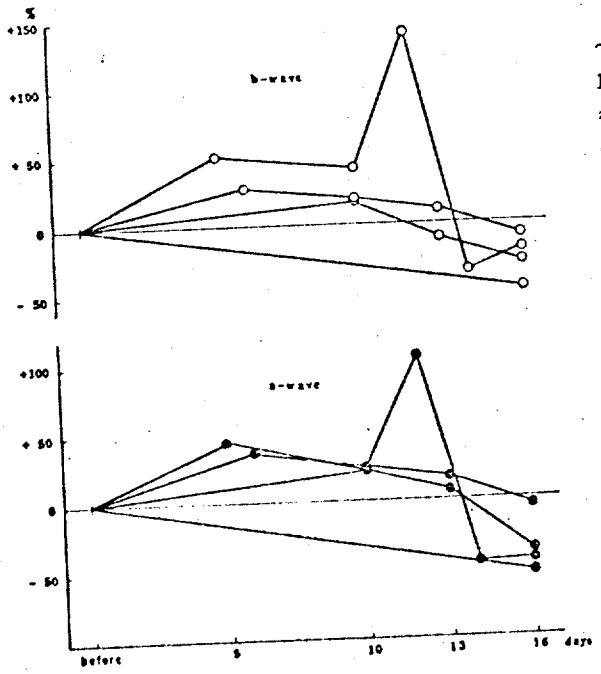

振巾は，2.0 g/kg 投与群に比較して経過中の変動が稍多いが，投与後16日目には共に平行して減少し，最終時点のa波の減小率は平均35%，b波減小率は32%である．

組織学的には，色素上皮細胞内色素顆粒の増加及び肥大化，視細胞外節の配列の乱れ及び軽度の崩壊，外顆粒層核の軽度濃縮，内顆粒層核の腫大，それぞれ軽度の神経節細胞の腫大，配列の乱れ及び変性脱落，内境界膜及び Müller 氏支柱線維の肥厚等が認められた．然しこれ等の諸変化の程度は 2.0 g/kg 投与群よりも弱い．

PAS反応は，色素上皮層で中等度陽性，視細胞外節では軽度，内節では微弱陽性で，正常に比して僅かの増強がみられた．

ALPase 反応は，色素上皮層，外顆粒層及び外網状層で何れも減弱し，多少の差異はあるが，I 5.0mg/kg 或はG 2.0 g/kg 投与群と略同程度である．然し節細胞では正常より増強している点が注目される．

以上の所見を要約すれば，障害の程度は 2.0 g/kg 投与群より全体として弱く，主な障害部位は色素上皮層及び視細胞外節で，極めて軽度の変化は内，外顆粒層及び節細胞層に見られる．この程度の障害によるERGの a, b 波振巾は明らかに低下しており，相当数の機能障害が惹起されたことを意味している．

3) 0.5 g/kg投与群 (第1,2,3表，第7,10,16図参照)

本群ではG 0.5 g/kg を16日間連続投与し，総量14.4～18.4 gになつた．ERGの a, b 波振巾は5日目より13日目迄に1時的に増大する傾向にあつたが，その後平行して次第に減小した．この時のa波の減小率は平均[illegible]%で，b波の減小率は平均28%である．

組織学的には，色素上皮細胞内色素顆粒の軽度肥大化，視細胞の配列の乱れと軽度崩壊，外顆粒層核の[illegible]，神経節細胞の散在性の退行性変性，神経線維層の[illegible]化，内境界膜及びMüller氏支柱線維層の結合織性肥厚[illegible] 1.0 g/kg投与群と略同様の組織像がみられたが，1.0 g/kg群と異なる所見は，色素顆粒の増加，内顆粒層[illegible]の腫大，外網状層の粗鬆化，神経節細胞の腫大或は[illegible]等がないことである．

PAS反応は，色素上皮層で中等度陽性，[illegible]胞の内外節では部分的に弱陽性で，ALPase 反応は色素上皮層，視細胞外節及び外顆粒層は正常より[illegible]度が低下している以外には，諸層では略正常の[illegible]である．従つて，本群の組織障害は外顆粒層から外層に[illegible]く，ERGの a, b 波振巾は最終的には低下した．

4) 0.25 g/kg 投与群（第1,2,3表，第7,11，17のD図参照）

本群はG0.25 g/kg ずつ連続16日間，総量 7.2～ 9.2 g投与した群であつて，ERGの a, b 波振巾は16日間の過程で，一時的に多少の増減はあるが，漸次増大し，最終日には総て投与前の振巾よりも高い値を示した．

組織学的所見は，視細胞外節における配列の乱れ，外顆粒層核の濃縮，時に神経節細胞の腫大等が認められたが，その変化の程度は何れも非常に軽度で略正常に近い．

PAS反応は網膜全層に亘り殆んど正常の陽性度で，ALPase反応は，色素上皮層，視細胞層及び外顆粒層で僅かに弱い程度で，その他の諸層は正常範囲内にある．

以上のことから，本群の網膜障害は形態学的には殆んど判然としないが，ALPase 反応の結果から見た酵素機能は幾分障害されている如く推察される．

5) 0.1 g/kg投与群（第1,2,3表，第7,12,16のE図参照）

本群はGを 0.1 g/kgずつ16日間連続投与し，総量2.88～3.68 gにおよんだ．ERGでは，a, b 波振巾が共に軽度上昇する傾向にあつて，b波振巾の変動がa波のそれよりも大きい様に見受けられる．

組織学的には，僅かに外顆粒層核の濃縮が認められる以外には略正常である．

PAS反応も各層を通じて正常の陽性度を示し，ALPase 反応も，色素上皮層で僅かに低いがその他の層では殆んど正常に近い陽性度を呈している．

叙上の如く本群のERGが a, b 波振巾共に薬剤投与前の値より上昇する傾向を示すことは，組織学的変化とは一致しない現象であるが，微量の投与量で細胞が一時的に刺激状態におかれ，興奮性が亢まつたためかは不明である．

6) 小括

G 2.0 g/kg 投与群の場合には，色素上皮層，視細胞内外節，内外顆粒層，神経節細胞等に退行性変性が認められ，その変性程度はIの 5.0 g/kg 投与群のそれに類似している．然し外網状層から内層の各層に及ぶ変性程度は，I投与の場合よりもG投与群に強い．ERGの実験成績からしても，G投与群では，a, b 波振巾が共に著減し，両物質の間の障害差は顕著である．1.0 g/kg 及び 0.5 g/kg のG投与の際の組織学的変化は 2.0 g/kg投与群に比較して軽度ではあるが障害部位は類似し，ERGの a, b 波振巾も最終的には投与前よりも低下して

Fig. 11 Sod. l-glutamate administration (i,p) at a dose level of 0.25 g per Kg body weight Percent variation in amplitude of a and b-eaves

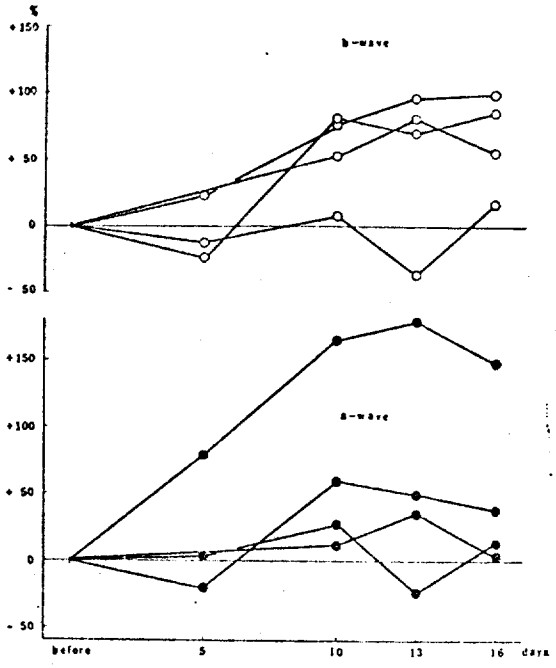

Fig. 12 Sod. l-glutamate administration (i,p) at a dose level of 0.1 g per Kg body weight Percent variaton in amplitude of a and b-waves

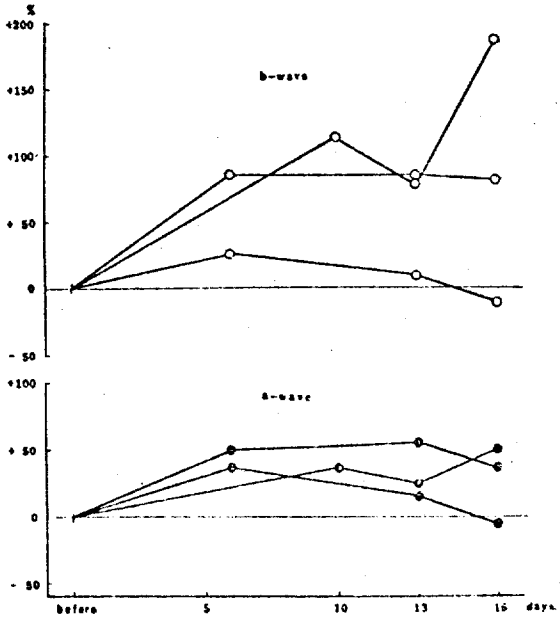

ている．しかし0.25 g/kg及び0.1 g/kg投与群ではG投与による組織学的変化は殆んど認められないにも拘らず，a, b 波振巾変動が著明に出現し，振巾は寧ろG投与前よりも高く留る傾向にあり，而もa, b 波振巾変動が既ね平行していることは注目すべきことである．

C) Soc. Iodate 及び Sd. l-glutamate 同時投与による ERG と組織学的所見

1) Sod. Iodate 2.5mg/kg及び Sod. l-glutamate0.25 g/kg投与群（第1,2,3表，第13, 14, 16のF図参照）

本群はIの 2.5mg/kg及びGの0.25 g/kg を同時に連続16日間投与し，総量Iは72.0～92.0mg，Gは 7.2～ 9.2 gにおよんだ．

ERGを見ると，a, b 波の振巾は初めから漸減傾向にあり，全体的に平行して減小している．16日目のa波の減小率は平均75%，b 波の減小率は平均59%で共に著明な振巾の減小を来している．

組織学的変化としては，網膜全層の軽度菲薄化，色素上皮細胞内色素顆粒の粗大化，視細胞の配列の乱れ，時に空胞変性及び崩壊，外顆粒層核の微縮と脱落，内顆粒

Fig. 13 Simultaneous effect of intravenous Sod. Iodate and intraperitoneal Sod. l-glutamate on ERG in the adult rabbit.

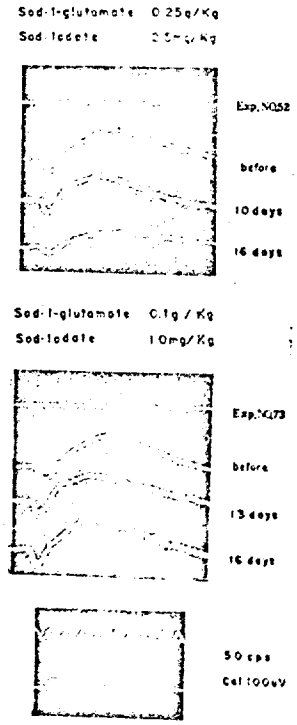

Fig. 14 Sod. l-glutamate with Sod. Iodate administration at a dose level of Sod. l-gl. (0.25 g) Sod. Iod. (2.5 mg) per Kg body weight Percent variation in amplitude of a and b-waves

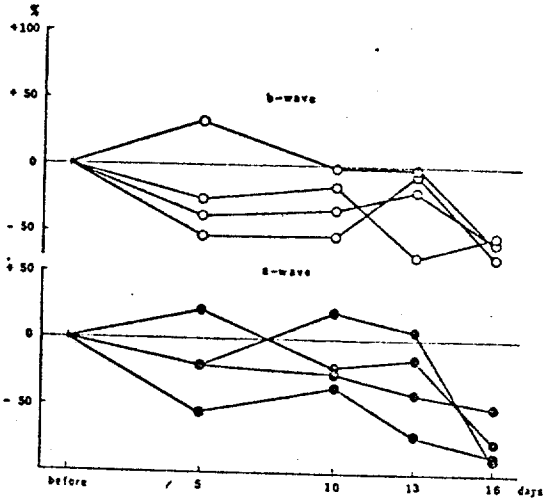

Fig. 15 Sod. l-glutamate with Sod. Iodate administration at a dose level of Sod. l-gl. (0.1 g) Sod. Iod. (1.0 mg) per Kg body weight Percent variation in amplitude of a and b-waves

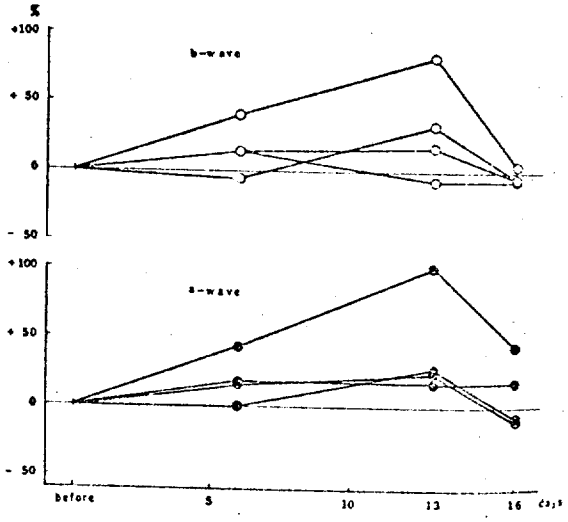

層核の腫大，内顆粒層，内網状層及び神経節細胞層の変化，神経節細胞の腫大，内境界膜及び Müller 氏支持繊維の肥厚等である．

PAS反応では，色素上皮層及び視細胞内外節に，I及びGの同量単独投与の場合に比較して，陽性度が特に著明に増強している．他方 ALPase 反応も内顆粒層，

Fig. 16 Histological findings of experimental retinal degeneration in the adult rabbit.



Fig 17. Histological findings of experimental retinal degeneration in the adult rabbit.



内網状層及び内境界膜では正常範囲内にあるが，外網状層から外側の諸層では，I 5.0mg/kg 単独投与群と同程度に低く，節細胞層及び神経線維層ではGの 1.0g/kg 単独投与群と同程度の陽性度である．

斯くの如く単独投与では組織並にERGに明瞭な変化を来さないようなI及びGの一定量を，同時投与することによつて明らかに組織学的変化を招来し，ERGのa, b波振巾にも顕著な影響を与えることに成功した．これは恐らく両物質に於ける毒性の相加作用によるものと思う．

2) Sod. Iodate 1.0mg/kg及び Sod. l-glutamate 0.1 g/kg（第1,2,3表，第13，15図参照）

この群にはI 1.0mg/kg及びG 0.1g/kg を毎日，連続16日間，総量I 28.8～36.8mg，G 2.88～3.68g投与した．ERGの a, b 波振巾は5日乃至13日の間に一時的に多少の上昇変動を示し，16日目にはb波振巾が投与前と略同値になり，a 波振巾の平均値が軽度上昇に留つた．

組織学的所見は，視細胞の配列の乱れ，外顆粒層核の濃縮，神経節細胞の腫大等が僅か乍ら認められ，その他は総て正常に近い組織像である．尚PAS反応及びALPase 反応は殆んど正常の陽性度である．

3) 小括

I及びGの単独投与によつては網膜に組織変化が生じない限界量，即ちIの 2.5mg/kg及びGの0.25g/kg を同時に投与することによつて明らかな網膜変性を発現することが出来た．この場合の組織学的変化は，色素上皮層，視細胞層及び外顆粒層に強く，内顆粒層，内網状層及び節細胞層の変性は弱い．ERGにおいても，各剤の単独投与の際とは異り，a, b波振巾は明瞭に半減していることが証明された．然し上述の限界量の半分量以下である 1.0mg/kgのI及び 0.1g/kgのGの併用投与では，組織学的にも或はERG学的にも変化は認められない．

IV　総括並に考按

近年 Sod. l-glutamate 或は L-glutamic acid の大量投与が臨床的に精神神経科領域において旺に応用されつつあり，Zimmermann 等[illegible]（1949），Milliken 等[illegible]（1951）は経口的に投与し，Sapirstein（1943），Elman（1946），Mayer-Gross 等[illegible]（1949），Weil-Malherbe（1949）等は大量静脈注射を行つて何等の障害もないと言つているが，他方 Schober（1951）は家兎の耳静脈内連続注射により，肝障害或は副腎障害を確認している．

1957年，Lucas and Newhouse[1] はGを投与した幼弱マウス網膜に特異な変化を惹起することに気付いた．即ち，Gの網膜の外顆粒層及び視細胞層には僅かな障害を与えるに過ぎないが，神経節細胞に高度変性と内顆粒層に形成不全とを招来するのを確認した．然し幼弱マウスに見られるこれ等の定型的変化は成熟マウスでは発現せず，Gの致死量投与後1時間以内に僅かに節細胞層及び内顆粒層の諸細胞の部分的壊死が見られるのみで，皮下注射の5乃至10日にはこの変化さえも不明瞭になつたと報じている．

Potts 等[3]は，Lucas and Newhouse[1] の業績に注目し，Gによつて変性した視細胞のみからなる網膜のERG学的研究を行い，幼弱マウスの腹腔内にGを連日7日間以上投与した場合，Lucas and Newhouseの報告した変性組織像が矛盾なく出現すること，成熟マウスではこれ等の網膜変性を発生させることが不可能なこと，斯かる変性網膜から得られるERGは a 波のみから成り，b 波を完全に欠除すること等の知見を発表した．

従来，ERG各要素電圧の起源については，確定した説がないが，a 波については，視細胞層，少くとも網膜外層にその起源を求める研究者[10～12]が多く，potts 等[3]の成績はこの説に有力な示唆を与えるものであつて，今回本実験を企てた大きな動機の1つとなつた．

即ちGによる実験的網膜変性に関して，何故に幼弱動物に比して成熟動物にはGの毒性作用が少いか，如何にしてGは網膜を選択的に障害するかと言う2つの疑問点が生じたからである．

Gの毒性発現の機構として Lucas and Newhouse[1] は，L-glutamic acid は網膜内に高い Kalium 濃度維持力を持つことから，Kalium 濃度の変化による代謝障害の存在，含水炭素代謝の障害及び副腎の直接的な刺激の3つの仮説を提唱した．

Potts 等[3]は Lucas and Newhouse の3つの仮説を否定し，Gを投与したラットで[4,5]，glutamate 代謝に関する5つの酵素の中，glutaminase I 及び glutamic aspartic transaminase の用者が増加することから，Gは酵素活性を直接阻害するのでなく，酵素の形成[illegible]するものであろうと説き，長谷川[illegible]は文献的に考察し，Gの大量投与が，網膜内 Kalium ion の増加，[illegible]制，TCA cycle の変調，ATP高 energy 合成[illegible]等の諸代謝異常を起す可能性の存在から，障害を受けない網膜脳層部の細胞機能の変調より退行性変性に進展するものであろうと述べているが，何れにしてもGの毒性

に対する統一見解は未だ見られない.

然るに本実験の成績は，Gの単独投与によつては成熟動物の網膜に変性を起し得ないとされていたこれまでの多くの研究結果[1~9]に対する決定的反証であつて，2.0 g/kgの割合にGを成熟家兎の腹腔内に投与することによつて，第7，8図及び第1，2，3表に明らかな如き網膜変性を生ぜしめ，ERGに特異性のある低下を検出したことはまさしく新知見であると信じる.

この網膜変性は，眼球後極部のみならず赤道部にも発現し，軽度ではあるが全層に亘り，その所見はI 5.0mg/kg投与時の変化に類似しているが，色素上皮層，視細胞層及び外顆粒層の組織像はI群に変性が強く，G投与で注目すべきは，ALPase反応が錐細胞層で正常より亢陽性度が高いことである．然しERG学的には，G 2.0 g/kg投与でa，b波は共にその振巾を減小し，16日目には投与前の略々に半減するのに反し，I 5.0mg/kg投与時a，b波は，最終日にむしろ投与前の振巾より幾分高くなる傾向にある．斯くの如く，組織学的に同程度の網膜変性を惹起するG及びIの投与量によつてERGに反映する相違は，上述の組織学的所見の僅微な相違と関連して，GとIの網膜侵襲点が異ることを暗示している.

本実験においてはGの投与量を系統的に減量して行けば，0.25 g/kgの量が組織学的にもERG学的にも網膜変性毒としての限界量であることが判明した．この際のERGは，a，b波共に投与前に比して振巾が増大する傾向にあつたが，この事実は組織学的に証明出来ない変化が網膜に起りつつあることを物語つているものと思う．Gの網膜変性毒としての限界量が0.25 g/kg近傍にあるとする本新知見は，臨床的に20乃至30 gの経口投与が例えば70kgの人体に無害であると言う発表を支持する根拠となるべき数字であろう.

他方Iは，呼吸並に解糖作用を阻害し[15)16)18)~22)]，他の酵素の活動を抑制して[23~27)]，網膜変性を生ずるものと想像され，しかも変性は緩慢に出現[15)19)22)]することが特徴とされている．従つて前処置として少量のIを長期に投与した成熟家兎にはG投与によつても網膜変性を発現し得るのではないかと考察するのは決して不当ではない．斯かる着眼点から出発して，本実験で最初に取りかかつたことは，Iの種々量を成熟家兎の耳静脈内に投与した場合のERG学的変化と組織学的変化を調べ，Iの毒性の限界量を知ることであつた.

30.0mg/kgのIを投与した際の組織学的及び組織化学的所見は，多数のI研究者[15)16)18~22)]の結果と大同小異で，網膜全層に変性が認められ，特に網膜外層の変性所見が強い．この時のERGは，第1及び2図に明らかな如く，a波とb波は平行してその振巾を減じ，その変化過程は杉田[34)]等の実験成績に略類似している．然し良く考察すれば，Noell[15)16)]及び窪田[33)]の意見の如くa波とb波の振巾の減小率はa波の方が大きい.

Iの投与量を減量して行けば，網膜の変性所見は次第に軽減して来るが，反面，変性が網膜外層の部位に集中する傾向が窺われ，一方PAS反応も良く変化の局在性を指示している．この成果は，Iが選択的に色素上皮層或は視細胞層を障害すると述べた諸研究者の見解[15)16)18)~20)31)32)]を，本実験の如き新しい試みである減量実験方法からも肯定し得ることを意味する.

更に本実験では，I 1.0mg/kg16日間連日投与によつては明らかな組織学的変化を検出することが出来ず，2.5 mg/kgの投与量によつて始めて組織学的にIの毒性作用を確認したことは，Iの網膜変性惹起限界量が2.5mg/kg近傍にあることを示唆している.

本実験で判明したI及びGの網膜変性毒としての限界量，即ちIの2.5mg/kg及びGの0.25 g/kgを同時投与した場合には各剤の単独投与では組織学的変化を来さない内顆粒層，外顆粒層，視細胞層及び色素上皮層に変性の発現を確認した．この変化は，更にPAS反応の外層における増強と，ERGのa，b波振巾の減小によつて裏づけされる．但しこの限界量を少し下廻つた1.0mg/kgのIと0.1 g/kgのGとを同時投与した際には，これ等の変化は認められない.

さて以上の現象の由来を考える前に，現在迄に報告されているI及びGの網膜変性発現の機序に関する諸説を挙げなければならないが，Gに就いては既に前述したので，茲にはIについて論ずる．従来Iの網膜変性毒に関しては，網膜の呼吸及び解糖を阻害すること[15)16)18~22)]，Iは強力な酸化剤[20)21)]であつて，酸化還元機構が障害されること，IはMonoamine oxidaseの活性を抑制して網膜にCatecholamine代謝異常を来し，adrenochromeが細胞を破壊すること[27~30)]，IはSulphydryl enzyme activityを抑制することが網膜障害を起す可能性があること[35)]等の諸説が唱えられている．然し何れの説にしても単独で充分に総てを説明することが不可能であることは，水野[24~27)36)]等が指摘した通りである.

以上の諸説を綜合するとIは，網膜外層の所謂Blood Retinal Barrierに存在する種々の酵素系に作用して，

複雑に代謝系統を阻害し，不特定の種々な有害な中間代謝産物を発生せしめ，そのものが細胞を死滅に追い込むものであろうと言うことは略推定出来る．

前述の如く従来Iは主として網膜外層を侵し，Gは幼弱動物の網膜内層を主に侵すと言われているのに，本実験においては，明確な網膜組織変性を生ぜしめないI及びGの限界量を同時投与した場合に，何故に網膜外層にのみ限局した変性が起きたかは，以上の成績のみからしては容易に解明出来ない問題であるが，叙上のI並にGの作用機序に関するこれ迄の仮説から考按すれば単純なる相加作用とは片付けられない．

然しERG学的に見て，I及びGの限界量投与時にa, b波振巾に変動を認めたことは，限界量投与によつても組織学的には証明出来ない程度の機能的変化が既に網膜外層に発現していると見做して良い．元来Iの大量は重点的に網膜外層に変性を[9~12)15)16)18~22)]起すのであるから，当然この部に存在すると言われる Blood Retinal Barrier[24)25)] も障害される筈であるから，Gも脈絡膜の流血中より多量に網膜外層へ移行すると推定され，その結果，I及びGの毒性が網膜外層に相加的に作用したものと考えられる．然しこれ等の点については更に系統的な実験を遂行することによつて解明されねばならない．

V 結　論

白色成熟家兎に，Sodium Iodate 及び Sodium l-glutamate の種々量を非経口的に，単独或は両者併用して投与し，組織学的，組織化学的並にERG学的検索を行い，次の結果を得た．

1) 30.0mg/kgの Sodium Iodate を投与すれば，網膜全層に退行性変性が起り，その変性は特に外顆粒層から外層に著明である．その際のERGは，a, b波振巾共に平行して顕著に減小し，a波の減小がb波のそれよりも大きい．

変性毒としての Sodium Iodate の限界量は 2.5mg/kg, Sodium l-glutamate の限界量は0.25 g/kgで，共にこの投与量以下では変性が起らない．この限界量投与時のERGは，a, b波が共に投与前に比して増大する傾向にある．

2) 2.0 g/kgの Sodium l-glutamate を単独で16日間投与すれば，網膜に変性が惹起され，その変性は網膜全層に亘るが，概して外層に強く現われる．この時のERGでは，a, b波振巾が平行して約50%以下に減小した．

3) 限界量の Sodium Iodate と Sodium-l-glutamate とを併用すれば，網膜外層に比較的強い変性が起り，その際のERGでは，a, b波の振巾が平行して減小する．

稿を終るにあたり御懇篤なる御指導，御校閲を賜つた恩師今泉教授，御指導，御教示を賜つた生理学第一講座三田教授並に病理学第二講座桂教授に深甚の謝意を表します．また絶えざる御援助を蔵いた眼科教室高橋講師に衷心より御礼申上げます．

Fig. 16 Histological findings of experimental retinal degeneration in the adult rabbit.

A) 7 days after intravenous injection of 30.0 mg/kg of Sod. Iodate. (H.E. stain., Exp. No. 4)

B) 6 days after intravenous injections of 10.0 mg/(Kg, day) of Sod. Iodate.(H.E. stain., Exp. No. 70)

C) 16 days after intravenous injections of 5.0 mg/(Kg, day) of Sod. Iodate.(PAS stain., Exp. No. 14)

D) 16 days after intraperitoneal injections of 0.5 g/(Kg, day) of Sod. l-glutamate. (PAS stain., Exp. No. 13)

E) 16 days after intraperitoneal injections of 0.1 g/(Kg, day) of Sod. l-glutamate. (H.E. stain., Exp. No. 31)

F) 16 days aftea intravenous injections of 2.5 mg/(Kg, day) of Sod. Iodate and so intraperitoneal injections of 0.25 g/(Kg, day) of Sod. l-glutamate. (H.E. stain., Exp. No. 40)

Fig. 17 Histological findings of experimental retinal degeneration in the adult rabbit.

A) 16 days agter intravenous injections of 2.5 mg/(Kg, day) of Sod. Iodate.(PAS Stain., Exp. No. 34)

B) 16 days after intraperitoneal injections of 2.0 g/(Kg, day) of Sod. l-glutamate. (PAS stain., Exp. No. 11)

C) 16 days after intraperitoneal injections of 1.0 g/(Kg, day) of Sod. l-glutamate. (PAS stain., Exp. No. 12)

D) 16 days after intraperitoneal injections of 0.25 g/(Kg, day) of Sod. l-glutamate. (PAS stain., Exp. No. 33)

文　献

1) Lucas, D.R. & Newhouse, J.P.: Arch. Ophth., 58 : 193, 1957.
2) 長谷川文吾：山口医大産研年報，7 : 106, 1958.
3) Potts, A.M., Modrell, R.W. & Kingsbury,

複雑に代謝系統を阻害し，不特定の種々な有害な中間代謝産物を発生せしめ，そのものが網膜を死滅に追い込むものであろうと言うことは略推定出来る．

前述の如く従来Iは主として網膜外層を侵し，Gは幼弱動物の網膜内層を主に侵すと言われているのに，本実験においては，明確な網膜組織変性を生ぜしめないI及びGの限界量を同時投与した場合に，何故に網膜外層にのみ限られた変性が起きたかは，以上の成績のみからしては容易に解明出来ない問題であるが，叙上のI並にGの作用機序に関するこれ迄の仮説から考按すれば単純なる相加作用とは片付けられない．

然しERG学的に見て，I及びGの限界量投与時にa, b波振巾に変動を認めたことは，限界量投与によつても組織学的には証明出来ない程度の機能的変化が既に網膜外層に発現していると見做して良い．元来Iの大量は重点的に網膜外層に変性を[9~12][15][16][18~22]起すのであるから，当然この部に存在すると言われる Blood Retinal Barrier[20][22] も障害される筈であるから，Gも脈絡膜の流血中より多量に網膜外層へ移行すると推定され，その結果，I及びGの毒性が網膜外層に相加的に作用したものと考えられる．然しこれ等の点については更に系統的な実験を遂行することによつて解明されねばならない．

V 結　論

白色成熟家兎に，Sodium Iodate 及び Sodium l-glutamate の種々量を非経口的に，単独或は両者併用して投与し，組織学的，組織化学的並にERG学的検索を行い，次の結果を得た．

1) 30.0mg/kgの Sodium Iodate を投与すれば，網膜全層に退行性変性が起り，その変性は特に外顆粒層から外層に著明である．その際のERGは，a, b波振巾共に平行して顕著に減小し，a波の減小がb波のそれよりも大きい．

変性毒としての Sodium Iodate の限界量は 2.5mg/kg, Sodium l-glutamate の限界量は0.25 g/kgで，共にこの投与量以下では変性が起らない．この限界量投与時のERGは，a, b波が共に投与前に比して増大する傾向にある．

2) 2.0 g/kgの Sodium l-glutamate を単独で16日間投与すれば，網膜に変性が惹起され，その変性は網膜全層に亘るが，殊して外層に強く現われる．この時のERGでは，a, b波振巾が平行して約50%以下に減小した．

3) 限界量の Sodium Iodate と Sodium-l-glutamate とを併用すれば，網膜外層に比較的強い変性が起り，その際のERGでは，a, b波の振巾が平行して減小する．

稿を終るにあたり御懇篤なる御指導，御校閲を賜つた恩師今泉教授，御指導，御教示を賜つた生理学第一講座三田教授並に病理学第二講座住教授に深甚の謝意を表します．また絶えざる御援助を賜いた眼科教室高橋講師に衷心より御礼申上げます．

Fig. 16 Histological findings of experimental retinal degeneration in the adult rabbit.

A) 7 days after intravenous injection of 30.0 mg/kg of Sod. Iodate. (H.E. stain., Exp. No. 4)

B) 6 days after intravenous injections of 10.0 mg/(Kg, day) of Sod. Iodate.(H.E. stain., Exp. No. 70)

C) 16 days after intravenous injections of 5.0 mg/(Kg, day) of Sod. Iodate.(PAS stain., Exp. No. 14)

D) 16 days after intraperitoneal injections of 0.5 g/(Kg, day) of Sod. l-glutamate. (PAS stain., Exp. No. 13)

E) 16 days after intraperitoneal injections of 0.1 g/(Kg, day) of Sod. l-glutamate. (H.E. stain., Exp. No. 31)

F) 16 days aftea intravenous injections of 2.5 mg/(Kg, day) of Sod. Iodate and so intraperitoneal injections of 0.25 g/(Kg, day) of Sod. l-glutamate. (H.E. stain., Exp. No. 40)

Fig. 17 Histological findings of experimental retinal degeneration in the adult rabbit.

A) 16 days agter intravenous injections of 2.5 mg/(Kg, day) of Sod. Iodate.(PAS Stain., Exp. No. 34)

B) 16 days after intraperitoneal injections of 2.0 g/(Kg, day) of Sod. l-glutamate. (PAS stain., Exp. No. 11)

C) 16 days after intraperitoneal injections of 1.0 g/(Kg, day) of Sod. l-glutamate. (PAS stain., Exp. No. 12)

D) 16 days after intraperitoneal injections of 0.25 g/(Kg, day) of Sod. l-glutamate. (PAS stain., Exp. No. 33)

文　献

1) Lucas, D.R. & Newhouse, J.P.: Arch. Ophth., 58 : 193, 1957.
2) 長谷川文吾：山口医大産研年報, 7 : 106, 1958.
3) Potts, A.M., Modrell, R.W. & Kingsbury,

C.: Am. J. Ophth., 50 : No. 5, Part II, 900, 1960.
4) Freedman, J.K. & Potts, A.M.: Inverst, Ophth., 1 : 118, 1962.
5) Freedman, J.K. & Potts, A.M.: Inverst. Ophth., 2 : 252, 1963.
6) Zimmerman, F.T., Burgemeister, B.B. & Putnam, T.J.: Arch. Neurol. & Psychiat., 61 : 275, 1949.
7) Milliken, J.R. & Standen, J.L.: J. Neurol. Neurosurg & Psychiat., 14 : 47, 1951.
8) Mayer-Gross, W. & Walken, J.W.: Biochem. J., 44 : 92, 1949.
9) Noell, W.K.: J. Appl. Physiol., 3 : 489, 1951.
10) Noell, W.K.: Am. J. Ophth., 38 : 126, 1952.
11) Noell, W.K.: Am. J. Ophth., 38 : 78 (July. pt. II), 1954.
12) Noell, W.K.: Am. J. Ophth., 43 : 470, 1957.
13) Brown, K.T. & Wiesel, T.N.: Am. J. Ophth. 46 : 91, 1958.
14) Brown, K.T. & Wiesel, T.N.: J. Physiol., 149 : 537, 1957.
15) Noell, W.K.: Arch. Ophth., 60 : 702, 1958.
16) Noell, W.K.: Am. J. Ophth., 48 : 317, (No. 3, pt. II), 1959.
17) Dowling, J.E.: Am. J. Ophth., 50 : (No. 5, pt. II), 875, 1960.
18) Noell, W.K.: Am. J. Ophth., 36 : 103, 1953.
19) Noell, W.K.: Am. J. Ophth., 40 : 60, 1955.
20) 中村敏喜：日眼，61 : 911，1957.
21) 酒井利武：日眼，61 : 1319，1957.
22) 太田昭吉：日眼，61 : 1332，1957.
23) 水野勝義：日眼，63 : 406，1959.
24) 水野勝義：日眼，63 : 2293，1959.
25) 水野勝義：日眼，64 : 2186，1960.
26) 桜井大成：日眼，64 : 2195，1960.
27) 大矢徳治：日眼，66 : 1493，1962.
28) Sorsby, A.: Brit. J. Ophth., 25 : 58, 1941.
29) 坪田芋子：日眼，61 : 1350，1957.
30) 園田　繁：日眼，63 : 2249，1957.
31) 塩谷健次郎：日眼，64 : 612，1960.
32) 長谷川文吾：日眼，65 : 1421，1961.
33) 窪田靖夫：日眼，66 : 1369，1962.
34) 杉田雄一郎，田辺竹彦：日眼，65 : 1526，1961.
35) Sorsby, A. & Harding, R.: Vision Res., 2 : 139, 1962.
36) 水野勝義，桜井大成，永田耕一：日眼，65 : 1596，1961.

討　論

松山　道郎　1) ヨード酸曹達負荷による網膜色素変性症発現には相当の個体差があるように思う．

2) 網膜組織特に内層，グリア組織の病変発現の時期，及びそれに要する薬剤の量的関係をお尋ねします．

3) 私は実験的網膜色素変性症でmicroaneunysma様の血管異常を観察している．本症に於ける血管病変は無視出来ないと思う．

水野　勝義　1. Glutamate 投与の組織標本をみると内顆粒層の変化がある様に思うが如何．

2. Glia 細胞の ATPase 染色を見たらどうか

3. 電顕的所見とERGの変化を比較したら如何．

大矢　徳治　白色成熟家兎にGA (glutamie acid) とBOGA (β-hydroxy glutamic acid) の Na 塩を中和を行い，夫々50mg/kg，200mg/kg の2種を耳静脈内へ投与し約40分間の経過観察をし，BOGAでは10分までの間に約50%の a, b 波振巾増加を認めたがGAでは10%内外の増加減少を示した．

① GAの投与に際し Na 塩ですので，中和をされて用いられましたか

② 私の実験では a, b 波振巾はGA投与で，増加と減少の2相性を示しました．又演者の只今の御報告でも低量投与で a, b 波振巾増大が認められていますが，その点いかなる御見解を有してみえますか．

窪田　靖夫　わが教室に於ても先年の私の $NaIO_3$ による網膜変性とERGの実験を続けておるが，a, b波が同時に減弱する例もあるが，消失は先ず a波が早く，b波が残存する事を確認した（詳細は教室の諸氏により原著として発表される予定である）

尚少量投与の場合 a, b 波が初期に増大すると云われるがその理由は如何でしょうか．

浜津　恒男　（答）松山氏に

1) 大量のヨード酸ソーダ負荷の場合，家兎の抵抗性に相当の個体差が認められた．

2) ヨード酸ソーダ5mg/kg，16日間連続投与より多量投与群について内層の変化が認められた．

グリヤ細胞については今後検索したい．

3) 今回は血管については観察していないが，観察して行きたい．

水野勝義氏に　1) Sod. l-glutamate 投与により内顆粒層の変性が起つて居る．然し外顆粒層から外層の変性が著しい様に見られた．

2) Glia 細胞については今後検索して行きたい．

3) 電顕的研究も今後行たいと思う．

大矢徳治氏に　1) Sod. l-glutamate 投与に際し中和はしなかつた．

2) Sod. l-glutamate 投与の少量投与で a, b 波振巾が増大したが，これは光学顕微鏡による組織変化は認められなかつたが，酵素学的に何等かの変化が起きているためによると思う．

高橋利兵衛（答）　水野氏に：少量のI或はG投与の場合の a, b 波振巾の変動は，光学顕微鏡で証明されない組織学的形態学的変化によるものか，或は酵素系の障害によるかは今回の成績からは不明である．酵素系の変動をも考えたい．

笹田氏に：$NaIO_3$（多量の）によつては ab 波共に平行して下降するが，a 波の振巾減少率は大きい．増大に対する見解は上記の通り推定している．

2804

Virchows Arch. Abt. B Zellpath. 4, 357—367 (1970)

Scanning Electron Microscopic Studies on the Long Term Effects of Sodium Glutamate on the Rat Retina

H. A. Hansson

Department of Histology and the Neuropathological Laboratory, Department of Pathology I, University of Göteborg, Göteborg, Sweden

Received August 12, 1969

Rasterelektronenmikroskopische Untersuchungen über die Langzeiteffekte von Natrium-Glutamat auf die Netzhaut der Ratte

Zusammenfassung. Elektronenmikroskopische Untersuchungen der Netzhautveränderungen bei Babyratten, hervorgerufen durch eine zweiwöchige Gabe einer sublethalen Dosis Natriumglutamat. Die Untersuchungen wurden ausgeführt in der Zeit nach 2—6 Monaten.

Die Nervenzellen in den Netzhäuten waren alle zerstört mit nur ganz seltenen Ausnahmen. Die Epithelzellen und die Photoreceptorzellen hatten normales Aussehen, obgleich es schien, daß einigen der letzteren die synaptischen Körperchen fehlten. Einige übrige Nervenzellen waren klein und entsprachen wahrscheinlich den amakrinen und bipolaren Nervenzellen. Die neuroglialen Zellen sind in ein oder zwei Reihen zwischen den Photoreceptorzellen und der inneren Grenzmembran geordnet. Der neurogliale Verlauf bildete oft schneckenförmige Strukturen. Kleine, meist untereinander verbundene cystoide extracelluläre Zwischenräume waren häufig.

Die Ergebnisse werden im Verhältnis zu anderen Typen von Reaktionen erörtert, welche die Zerstörung von Zellen in der Netzhaut hervorrufen. Die elektronenmikroskopische Untersuchung bringt wichtige Ergänzungen zu allen anderen zahlenmäßig bestimmten strukturalen Änderungen in der experimentellen Neuropathologie.

Summary. Suckling rats were treated with sublethal doses of sodium glutamate for two weeks. The retinae were examined after two to six months by scanning and transmission electron microscopy.

Almost all nerve cells in the retinae were destroyed. The epithelial cells and the photoreceptor cells retained their normal appearanced, although several of the latter seemed to lack their synaptic bodies. The few remaining nerve cells were small and probably corresponded to the amacrine and bipolar nerve cells. The neuroglial cells were arranged in one or two rows between the photoreceptor cells and the inner limiting membrane. The neuroglial processes often formed helical structures. Small extracellular cystoid spaces, mostly interconnected, were frequent.

The results are discussed in relation to other types of reactions to selective destruction of cells in the retina. The transmission- and scanning-electron-microscopy complement each other in evaluating structural alterations in experimental neuro-pathology.

The selective destruction of nerve cells by sodium glutamate in suckling rats and mice was first demonstrated by Lucas and Newhouse (1957). The retina consists, after the degeneration is completed, of epithelial cells, photoreceptor cells, neuroglial cells and a varying number of cells forming the residuing ganglion cell and inner nuclear layer (Lucas and Newhouse, 1957; Potts, 1965; Cohen, 1967). The rat retina is more severely damaged than that of mice. The glutamate-treated

retina forms a suitable model system to study reactive changes and the reorganization of a highly specialized nervous tissue, occurring after an apparently selective nerve cell damage (Olney, 1969).

The aim of this study was to investigate surface structures in the rat retina several months after the administration of sodium glutamate by scanning electron microscopy. Another aim was to examine reactive changes occurring in the neuroglial cells and in blood vessels.

Material and Methods

Treatment of the Animals. Albino Sprague-Dawley rats of both sexes were used. Ratlings were injected intraperitoneally from the second day after birth with sodium glutamate in increasing amounts as described by Lucas and Newhouse (1957) for 14 days. About half of the treated rats survived. The controls were injected with the same amount of saline. The rats were fed on commercial pellets supplemented with a vitamin mixture (SAX-bolagen, Malmö, Sweden). The iris constrictions on light stimulation were observed in a stereomicroscope on both light and dark-adapted glutamate-treated rats.

Preparation of Specimen. Most of the retinae were fixed by perfusion with or immersion in a 0.1 M cacodylate buffer of pH 7.4 containing 1 or 2.5% purified glutaraldehyde, 2% freshly prepared formalin and 25 mg calcium chloride per 100 ml (Karnovsky, 1965) or 1% osmium tetroxide in the same buffer. Retinal tissue pieces, unfixed or fixed, were frozen in propane chilled by liquid nitrogen and freeze-dried at about −70° C (Hetosico 70, Heto, Birkerod, Denmark). The specimens were thereafter coated with a 100 to 200 Å thick layer of carbon followed by another of gold or copper of the same thickness in a vacuum evaporator. The specimens were examined in a "Stereoscan" scanning electron microscope (Cambridge Instrument Co. Ltd., Cambridge, England) at a maximal accelerating voltage of 20 kV.

Fixed retinal tissue pieces were dehydrated in ethanol, embedded in Epon 812 or Araldite, sectioned in a LKB Ultrotome III, and examined in a Siemens Elmiskop 1 A transmission electron microscope.

Results

General Observations. The rats treated with sodium glutamate were shorter and fatter than their control litter mates. The mean weight of the former was 167 g, while that of the controls was 410 g at the age of 4 months. The glutamate-treated rats had smaller eyes and lighter lenses too. There was no obvious difference in the behaviour of the different animals.

All the rats treated with glutamate showed iris contractions on light stimulation and a significant strong or moderate consensual response, irrespectively of the extent of the structural changes in their retinae.

Scanning Electron Microscopy of the Retina. The retinae from sodium glutamate-treated rats had lost almost all of the nerve cells in the inner nuclear layer and in the ganglion cell layer. Therefore, the retina was only of about half of its usual thickness and dominated by the segments and the cell bodies of the photoreceptors.

The polyhedronal epithelial cells appeared normal, i.e. their vitreal surfaces were crowded by a large number of long, slender microvilli, forming a delicate network. The outer and inner segments, the connecting pieces and the bodies of the photoreceptor cells were of normal sizes and appearances. The neuroglial cells formed one or two tires of nuclei between the rod cells and the inner limiting membrane. The shape of the nucleus of the neuroglial cells varied but they were usually ovoid. Their cytoplasm appeared reticulated. There were many cystoid extracellular spaces ranging in size from 0.2 to 20 μ among the neuroglial cell

Fig. 1. Survey picture of the posterior pole of the retina of a 4 months old glutamate-treated rat. Unfixed, freeze-dried. × 1,100
Abbreviations: OS Outer segments of photoreceptor cells; IS inner segments of photoreceptor cells; ONL outer nuclear layer; ILM inner limiting membrane; S extracellular retinal space; VB vitreous body; *nc* nerve cells; SY synaptic end bulb

2804

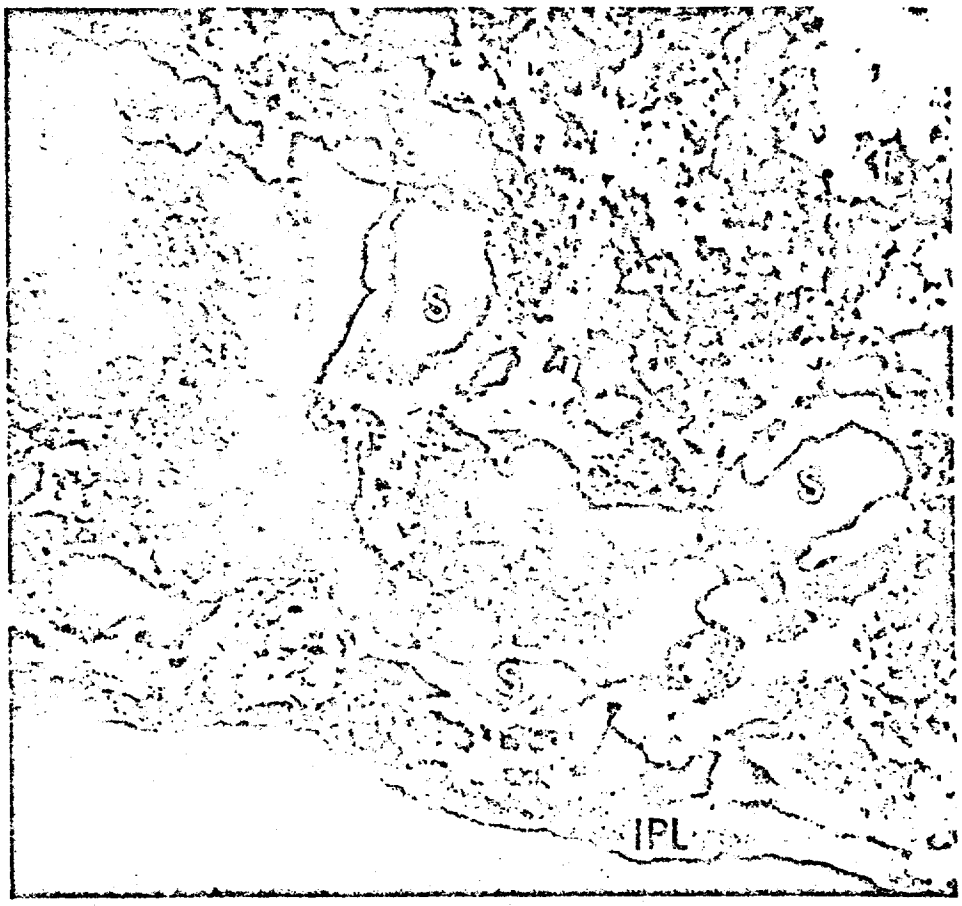

Fig. 2. The large, well-delimited extracellular spaces are easy to observe. Note the trabecles and the distinct regularly shaped apertures indicating connections between the different extracellular retinal spaces. Magnification of the central part of Fig. 1. ×7,100

between the photoreceptor cells and the inner limiting membrane. Cell processes curved in several of these spaces, which sometimes appeared interconnected.

Only a few nerve cells remained in most of the glutamate-treated rat retinae. Usually every millimeter of the retinal tissue pieces contained only one or a few nerve cells. Large nerve cells corresponding to the ganglion cells in the control retinae lacked completely. Most of the nuclei were oval with several irregular indentations and surrounded by scanty cytoplasm of reticular appearance. Others had only a thin rim of cytoplasm around the oval nucleus. The nerve cells were possible to identify by comparing their structural characteristics in the scanning electron microscope with those evident in thin sections. In a few litters of rats treated in an identical way, the retinae showed several persisting nerve cells in two distinct layers, i.e. a ganglion cell layer and an inner nuclear layer. Other rats showed intermediate types of structural arrangement of persisting nerve cells.

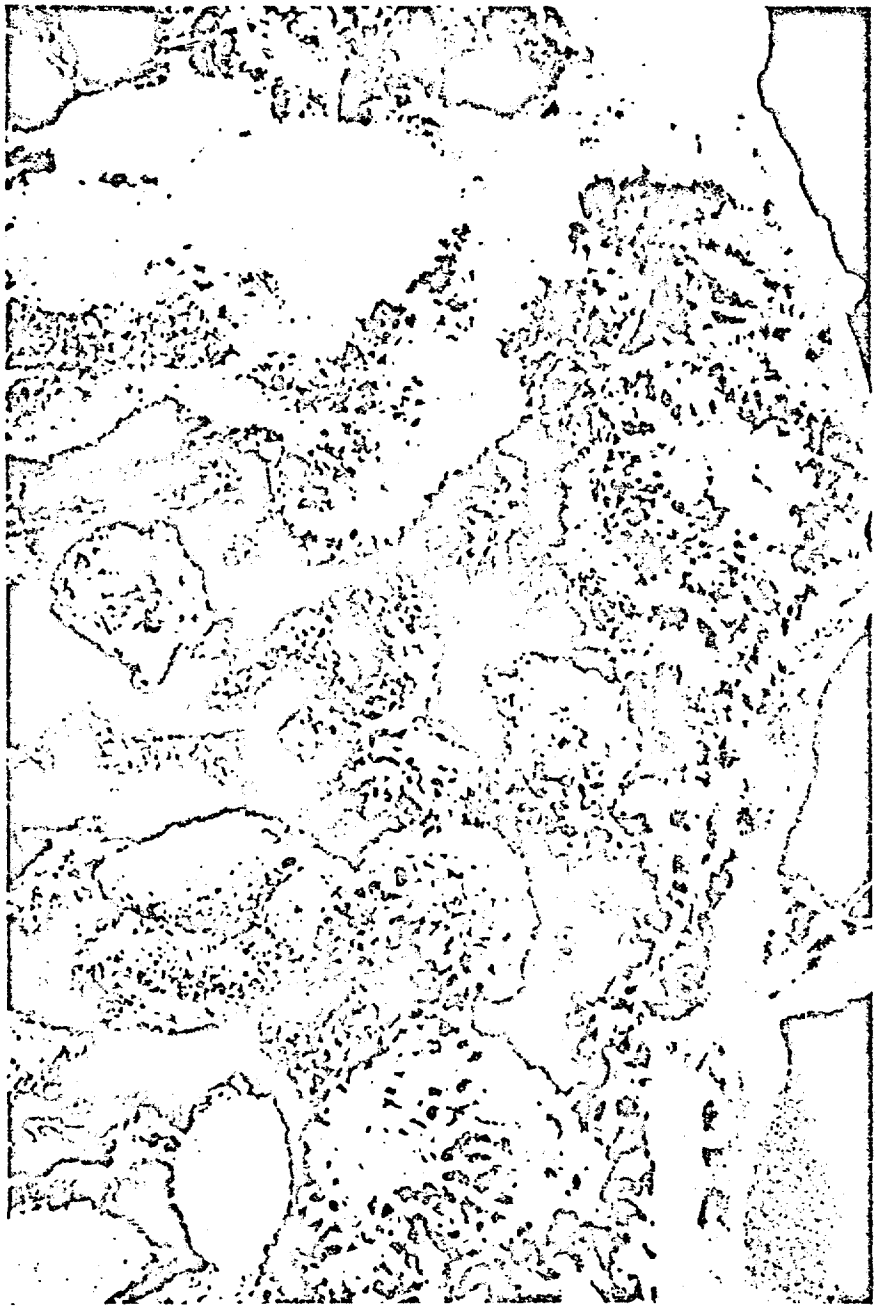

Fig. 3

Figs. 3 and 4. The sizes of the extracellular spaces varies considerably as can be seen in these figures. Specimen fixed for 10 minutes in glutaraldehyde-formaldehyde and then freeze-dried. × 4,200 and × 10,000 resp.

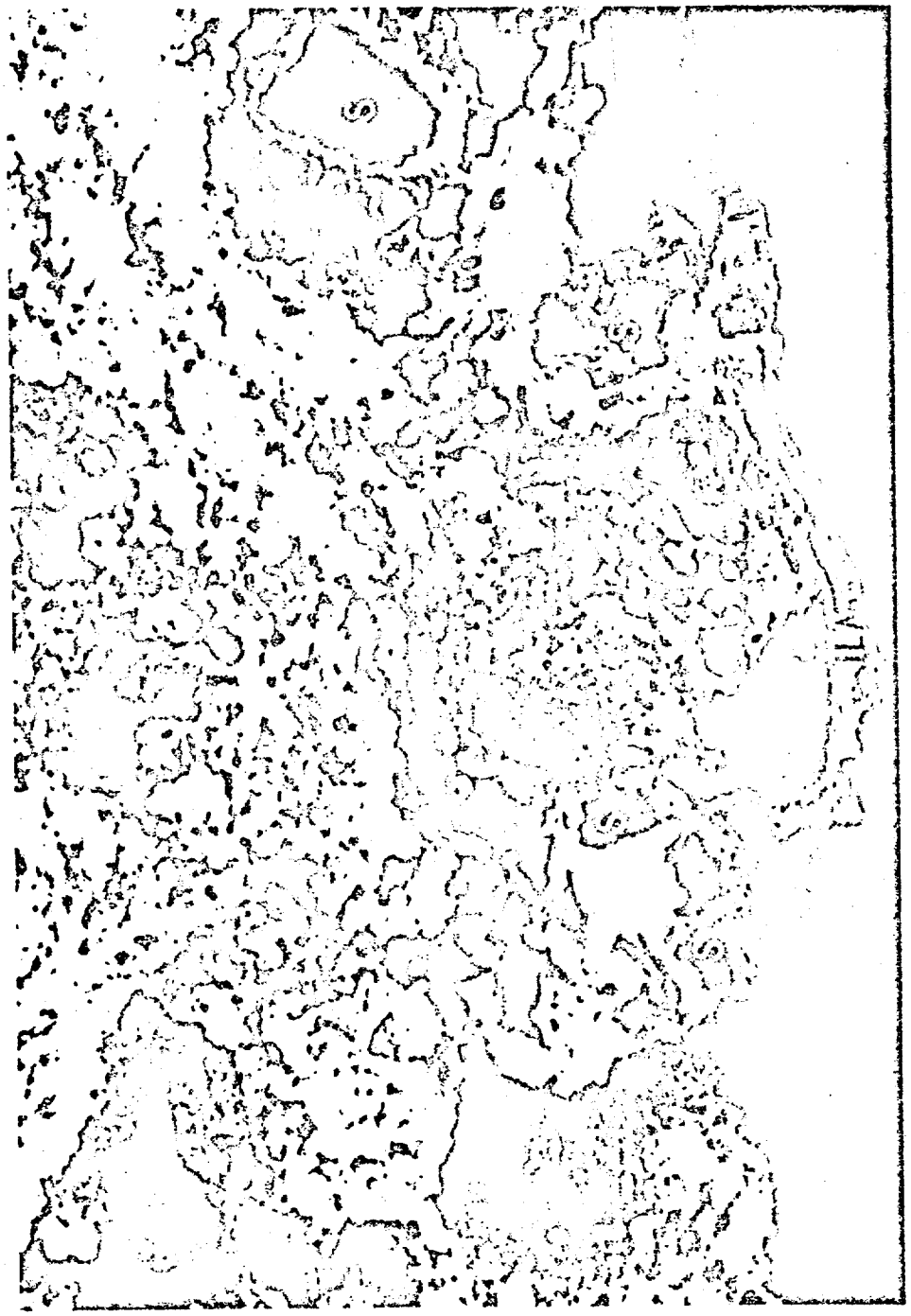

Fig. 1

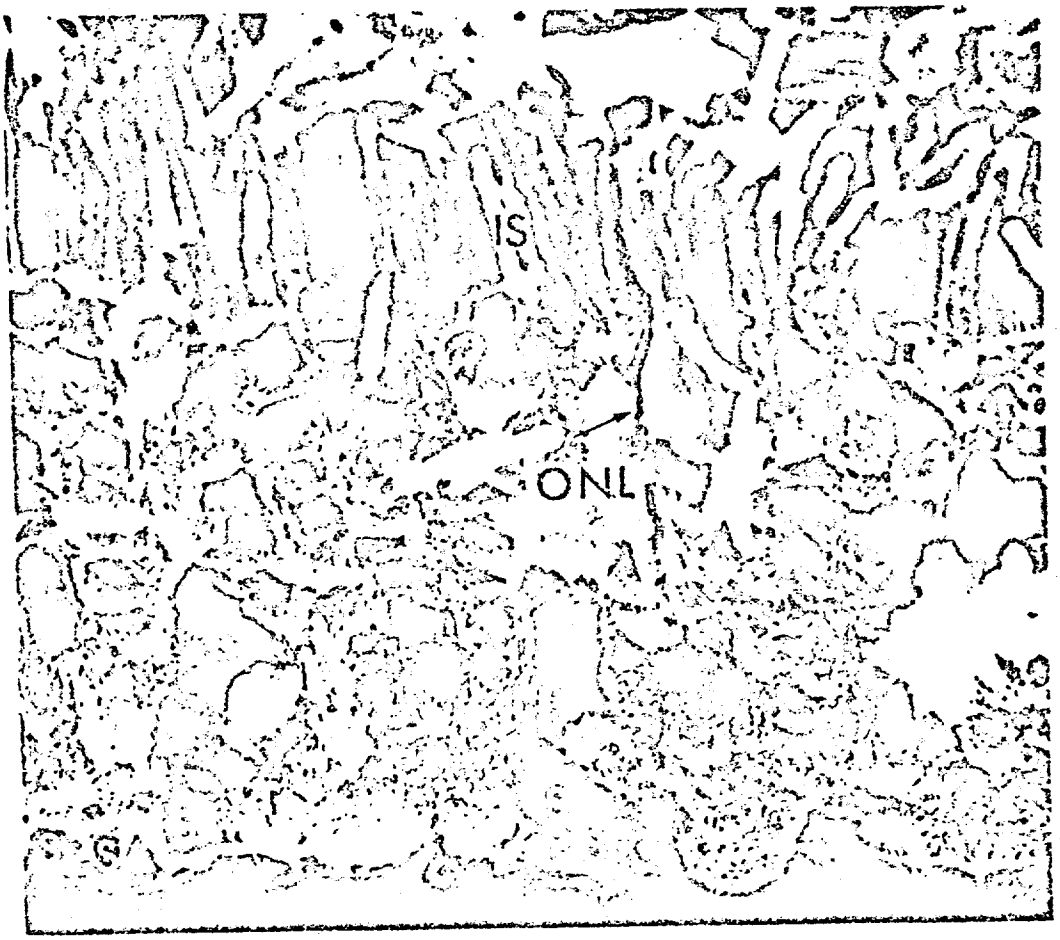

Fig. 5. Survey picture of the residuing retina from a 6 month old glutamate-treated rat. Note the many extracellular spaces close to the inner limiting membrane. Fixed for 2 minutes in glutaraldehyde-formaldehyde and then freeze-dried. ×4.300

Synaptic bodies of the same type as those observed in the outer plexiform layer in the controls appeared in varying numbers. The severely affected retinae almost lacking nerve cells showed the smallest number. The diameter of the pearshaped synaptic bodies was about 2 μ, i.e. the same as in the untreated controls.

The blood vessels were rare in the glutamate-treated retinae as compared to the control retinae. They were only observed among the neuroglial cells often close to the inner limiting membrane. The capillaries were few but appeared to correspond to the number of larger blood vessels.

The inner limiting membrane did not show any alterations in surface structure. There was no fibrous strands or related structures indicating inflammatory reactions in the vitreous body.

Fig. 6. The extracellular spaces along the inner limiting membrane are less frequent and smaller in some retinae from glutamate treated rats as shown in this picture. Litter mate to the rat in Fig. 5, treated parallelly. × 2,250

Discussion

The retinal nerve cells in rats are more sensitive to glutamate treatment than those in the mice. In the former case only a few of the nerve cells persisted as compared to thousands in the latter (Lucas and Newhouse, 1957; Potts, 1965; Cohen, 1967; Olney 1969). It may reflect differences in maturity and species susceptability between suckling mice and rats. In both cases glutamate treatment caused a retarded development of the animals.

Fig. 7. Inner half of the retina from litter mate to the rats in Fig. 5 and 6 and treated parallelly. Note the residuing nerve cells with synaptic end bulbs and the surface of the vitreous body. Treated as in Fig. 5. × 1,550

The persisting large nerve cells correspond to the amacrine cells and the small to the bipolar nerve cells while the ganglion cells apparently lacked. There seems to be a similar relation between the number of different types of nerve cells in the glutamate-treated mice (Cohen, 1967).

The almost complete degeneration of retinal nerve cells in the glutamate-treated ratlings means a considerable loss of cells including their processes and synaptic connections. Consequently, there follows a thorough reorganization involving the inner half of the retina, also reflected in the poor vascularization of the latter. The structural changes are further demonstrated by the reduction in the number of synaptosomes. However, the scattered nerve cells in the posterior pole of the eye are stated to have only a few synaptic connections (Polyak, 1941, 1957; Rohen, 1965). This discrepancy between the number of nerve cells and that

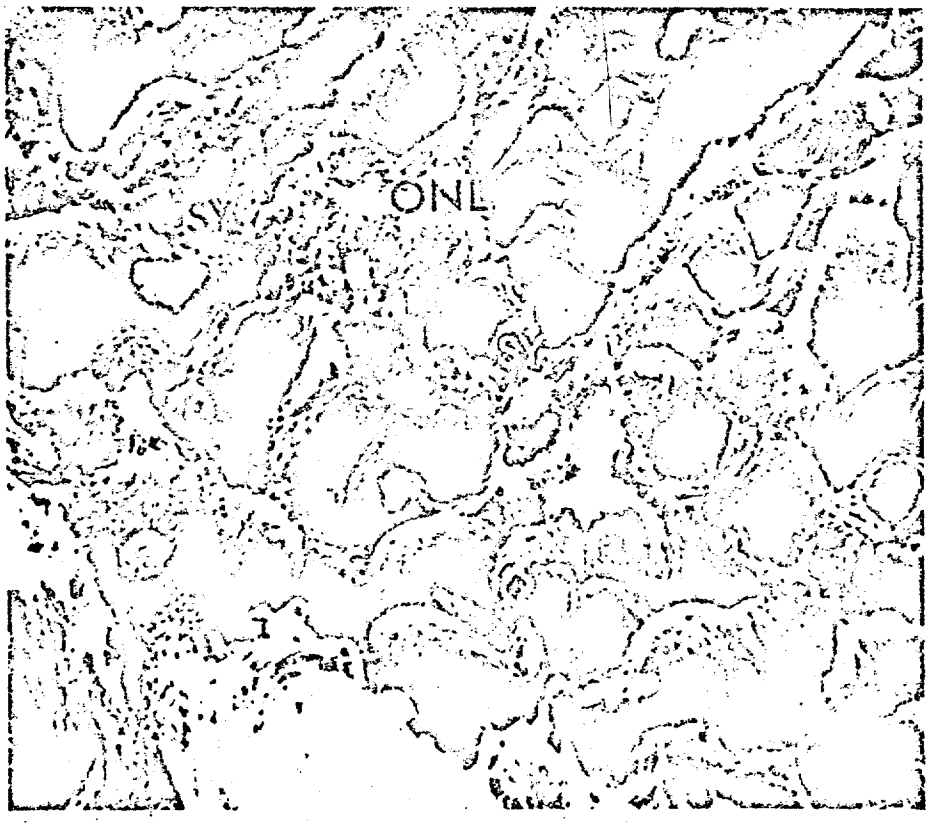

Fig. 8. The synaptic bulbs are clearly visible between the neuroglial cells and the nerve cells and the photoreceptor cells and most of them are arranged in a row between these cells. The inner limiting membrane is seen in the lower left corner. Specimen as in Fig. 7. × 3,000

of synaptosomes either indicate that the number of synaptic connections is increased or that there are centrifugal processes such as those in the pigeon retina (for discussion see Dowling and Cowan, 1966). In any case it seems unlikely that the photoreceptor cells are dependant on nervous contacts for maintaining their structure.

A direct pupillary response was noticed in all treated rats, although their retinae showed almost no nerve cell and their optic nerves only a few myelinated fibers (Hansson, to be published). This iris response has previously been observed by Cohen (1967). The pupillary reaction pattern is difficult to explain.

The cystoid spaces occurring in the glutamate-treated retina have not been described before (Lucas and Newhouse, 1957; Potts, 1965; Cohen, 1967; Olney, 1969). They were always extracellular. It seems likely that they correspond to those observed in experimentally detached mammallian retinae (Kroll and Machemer, 1969) and in vitamin A-deficient rat retinae (Hansson, 1970). The retina is damaged in all these three conditions but the epithelial cells remain intact. A main function of the latter cells is to control the retinal fluid and salt balance (for discussion see Hansson, 1969). The experimental damage of the retina change

the conditions for normal function of the epithelial cells. This conclusion is further supported by the observation that there are no cystoid spaces in the light damaged rat retina lacking epithelial cells (Hansson, 1969) and in the reattached retina in monkeys (Kroll and Machemer, 1969). An alternative explanation is that the cystoid extracellular spaces represent the room previously occupied by nerve cells. However, the latter explanation seems less likely as the cystoid spaces disappear if the detached retina is reattached (Kroll and Machemer, 1969) or if the vitamin A-deficient rats are adequately susbstituted (Hansson, 1970).

The information obtained from sections observed in the transmission electron microscope and that from the tissue pieces in the scanning electron microscope agree and supplement each other. The first method affords a high resolution of a limited number of cells while the other gives a three-dimensional picture of the surface of a large number of cells. An important advantage in using these two methods together is that it is easier to exclude or confirm if a morphological feature is an artifact.

Acknowledgements. Supported by grants from the University of Göteborg and the Swedish Medical Research Council (B70–12X–2543–02). I would like to thank the Swedish Silicate Research Institute, Göteborg, for using their scanning electron microscope and Miss M. Persson for exellent technical assistance.

References

Cohen, A. I.: An electron microscopic study of the modification by monosodium glutamate of the retinas of normal and rodless mice. Amer. J. Anat. 120, 319–355 (1967).

Dowling, J. E., Cowan, W. M.: An electron microscope study of normal and degenerating centrifugal fiber terminals in the pigeon retina. Z. Zellforsch. 74, 14–28 (1966).

Hansson, H. A.: To be published. 1969.

— Scanning electron microscopy of the retina in vitamin A-deficient rats. Virchows Arch. Abt. B 4, 368–379 (1970).

Karnovsky, M. J.: A formaldehyde-glutaraldehyde fixative of high osmolarity for use in electron microscopy. J. Cell Biol. 27, 137 A (1965).

Kroll, A. J., Machemer, R.: Experimental retinal detachment in the owl monkey. V. Electron microscopy of the reattached retina. Amer. J. Ophthal. 67, 117–130 (1969).

Lucas, D. R., Newhouse, J. P.: The toxic effect of sodium L-glutamate on the inner layers of the retina. Arch. Ophthal. 58, 193–201 (1957).

Olney, J. W.: Glutamate-induced retinal degeneration in neonatal mice. Electron microscopy of the acutely evolving lesion. J. Neuropath. exp. Neurol. 18, 455–474 (1969).

Polyak, S. L.: The retina. Chicago: Chicago University Press 1941.

— The vertebrate visual system. Chicago: Chicago University Press 1957.

Potts, A. M., in: Biochemistry of the retina, p. 155, ed. by Graymore, C. N. London: Academic Press 1965.

Rohen, J. W., in: Handbuch der mikroskopischen Anatomie des Menschen, ed. by Bargmann, W., vol. 3/4. Berlin-Göttingen-Heidelberg-New York: Springer 1964.

Docent Hans Arne Hansson
Department of Histology
University of Göteborg, Fack
S-400 33 Göteborg 33, Sweden

2805
2805

Virchows Arch. Abt. B Zellpath. 6, 1–41 (1970)
© by Springer-Verlag 1970

Ultrastructural Studies on the Long Term Effects of Sodium Glutamate on the Rat Retina

H.-A. Hansson

Department of Histology and the Neuropathological Laboratory, Department of Pathology I, University of Göteborg, Göteborg, Sweden

Received March 26, 1970

Summary. Suckling rats were treated with sublethal doses of monosodium-L-glutamate for from one day up to two weeks. The retinae and the optic nerves and tracts were examined after two to ten months by transmission electron microscopy.

The nerve cells in the ganglion cell layer and in the inner nuclear layer were destroyed with few exceptions. The occasionally remaining neurons were small and immature. The rest of the cells in the inner part of the glutamate-damaged retinae consisted of Müllerian neuroglial cells, astrocytes and occasionally observed oligodendrocytes. Scattered glial cells of an intermediate type, perhaps representing microglial cells or reactive neuroglial cells, were also observed. There were many extracellular spaces of varying size and shape among the glial cells. The neuroglial processes formed helical structures. There was a reduction in the number of synaptic bodies and a relative increase in the somatic type of rod cell synapses. The photoreceptor cells and the epithelial cells appeared otherwise unchanged.

The number of myelinated axons was reduced to about one per cent of the normal in the optic nerve and tract. Desmosomes were frequent between astrocytic processes.

The results are discussed in relation to those obtained in previous studies on retinal damage induced by glutamate.

Zusammenfassung. Babyratten wurden mit einer sublethalen Dosis monosodium-L-glutamat (1 Tag bis zu 2 Wochen) behandelt. Die Netzhäute und Sehnerven samt Umgebung wurden nach 2–10 Monaten elektronenmikroskopisch untersucht.

Die Nervenzellen in der Ganglienzellschicht und der inneren Körnerschicht waren mit einigen Ausnahmen zerstört. Die zufällig übriggebliebenen Neuronen waren klein und unreif. Die Zellreste im inneren Abschnitt der glutamatgeschädigten Netzhäute bestehen aus den Müllerschen neuroglialen Zellen, Astrocyten und zufällig beobachteten Oligodendrocyten. Auch zerstreute gliale Zellen eines dazwischenliegenden Typs, die vielleicht mikrogliale Zellen oder aktive neurogliale Zellen darstellen, wurden beobachtet. Zwischen den glialen Zellen fanden sich viele extracellulare Räume von wechselnder Größe und Form. Die neuroglialen Fortsätze bildeten schneckenartige Strukturen. Die Anzahl der synaptischen Körperchen war reduziert, der somatische Typ der Stabzellensynapsen hatte zugenommen. Die Photoreceptor- und Epithelzellen erschienen unverändert.

Die Anzahl der myelinisierten Axone in Sehnerven und Umgebung war auf ungefähr 1% der Norm reduziert. Desmosomen zwischen den astrocytischen Prozessen waren häufig zu sehen.

Die Ergebnisse werden mit denen vorangegangener Studien von glutamatbedingten Netzhautzerstörungen verglichen.

The damaging effect of monosodium-L-glutamate on the retina in suckling mice has been the subject for several studies since the first report by Lucas and Newhouse (1957). These studies have all confirmed that the nerve cells in the

ganglion cell layer and in the inner nuclear layer are more or less selectively damaged (Potts, 1965; Cohen, 1967; van Herreveld and Khattab, 1968; Olney, 1969). The rat retina seems to be more severely damaged than the mouse retina as only very few, scattered, small nerve cells remained after treatment with glutamate (Hansson, 1970a). Furthermore, the rat retina residuing after the glutamate treatment had a complicated network of interconnected spaces along its inner surface and was often virtually completely devoid of blood vessels when observed in the scanning electron microscope (Hansson, 1970a).

The aim of this study is to describe the ultrastructure of the rat retina several months after the treatment with monosodium-L-glutamate and to correlate the results with those obtained in previous studies and by scanning electron microscopy (Hansson, 1970a).

Materials and Methods

Treatment of the Animals. 31 litters of albino Sprague-Dawley rats of both sexes have been used. Ratlings were injected intraperitoneally from the second day after birth with sodium glutamate (pro analysi, Merck AG, Darmstadt, W-Germany; Sigma, St. Louis, USA) in increasing amounts as described by Lucas and Newhouse (1957) for one day or up to 14 days. The controls were injected intraperitoneally with the same amount of water, which was used to dissolve the glutamate. The iris constrictions on light stimulation were observed in a stereomicroscope on both light- and dark-adapted rats prior to the fixation procedure.

Preparation of Specimen. 76 animals (78 eyes) were used for ultrastructural studies at least 3 months after the beginning of the treatment with glutamate. They were fixed either by perfusion via the heart or by immersion in 0.1 M cacodylate buffer of pH 7.4 containing 1 or 2.5% purified glutaraldehyd, 2% freshly prepared formaldehyde and 25 mg calcium-chloride per 100 ml and or in 1 or 2% osmium tetroxide in the same buffer. The specimens were dehydrated in a graded serie of ethanol, embedded in Epon 812 or Araldite, and sectioned in an LKB Ultrotome III ultramicrotome sometimes after trimming in an LKB Pyramitome. The thin sections were stained with uranyl and lead and examined in a Siemens Elmiskop 1A transmission electron microscope.

Fixed or fresh thin slices of retina were observed by phase contrast microscopy or with aid of a Nomarski optical equipment (C. Zeiss, Oberkochen, Germany).

Results

Several of the retinae used in this study were also examined by scanning electron microscopy (Hansson, 1970a). Therefore, the main attention in this study will be paid to observations not possible to do in the scanning electron microscope.

In all 80 rats were treated with glutamate for about two weeks from the second day after their birth. Such a treatment resulted in severe damage with loss of the nerve cells both in the retina and in the central nervous system. However, the same effects were possible to obtain by a single injection of sodium glutamate. Care had to be taken during the injection to avoid reflux and thereby reduction of the amount deposed intraperitoneally. One third or one half of the treated rats got localized or generalized seizures and only 48 survived.

The thickness of the retina residuing after the glutamate-treatment was usually about the half of that in the control litter mates (Fig. 1). The main part of it consisted of the epithelial cells and the photoreceptor cells, while its inner or vitreal part was formed by a few rows of cells and spaces of varying size and shape.

The nerve cells forming the ganglion cell layer and the inner nuclear layer in the control retinae were all absent in the most severely damaged retinae (Figs. 2–7).

Fig. 1. Light microscopy of retina from a rat treated for 2 weeks with glutamate and fixed after 3 months. The photoreceptor cells (*r*) with their segments and the epithelial cells (*e*) form the major part of the residuing retina. Note the few cells and the spaces along the inner limiting membrane. ×590. Abbreviations: *e* epithelial cell; *s* intercellular space; *v* blood vessel; *sb* synaptic body; *r* photoreceptor cell; *m* Müller neuroglial cell; *mg* microglial cell; *cb* vitreous body; *o* oligodendrocyte

In other retinae scattered nerve cells remained. In a few of the 78 retinae examined there was variable number of surviving nerve cells and also retinae not possible to distinguish from the controls in spite of similar treatment. There was no certain difference in the distribution of the surviving nerve cells between the central and the peripheral parts of the retina. The nerve cells residuing were small and showed a less prominent rough endoplasmic reticulum with ribosomes than usual Ganglion cells were only observed in a few less afflicted animals.

Neuroglial cells dominated the inner part of the retina. Most of them fulfilled the criterions for the Müller cells but astrocytes and cells reminding of oligodendrocytes as defined by Peters, Palay and Webster (1970) were also observed (Figs. 2—6). Scattered cells with moderate density of their cytoplasm, mitochondria and several dense bodies, often containing lamellar profiles, were noticed among the neuroglial cells (Fig. 2). Their sparse, chiefly granular endoplasmic reticulum looked like tortuous long tubuli of slightly irregular diameter with only few interconnections distributed throughout the cells body. Tubular and filamentous structures seemed to lack.

Membranous processes from Müller neuroglial cells were arranged in several parallel layers often encircling cells (Figs. 2—4). They did sometimes form coils



Fig. 2. Survey picture of a glutamate-damaged retina. The cytoplasm of the Müller neuroglial cells (*m*) extends from border against the vitreous body (*vb*) to the photoreceptor cells (*r*). Note the synaptic bodies (*sb*), the extracellular spaces (*s*) and the glial cell (*mg*) to the right. Treated as in Fig. 1. 4,930

or helical structures reminding of myelin with cytoplasm retained between their plasma membranes around a central neuroglial process (Figs. 2—4). No axon or other neuronal structures have ever been observed inside these helical structures.

The innermost part of the glutamate-damaged retinae consisted to a considerable extent of many interconnected extracellular spaces of varying size and shape (Figs. 2—6). Their borders were formed by several neuroglial-cell processes, here and there arranged in layers or as helical structures. Vesicles and membranous profiles were often observed in spaces (Figs. 2—6).

Several types of synaptic bodies could be identified. The rod cell terminals, the spherules (Figs. 2, 4—6), were usually of normal appearance with regard to their ultrastructure as compared to those in the control retinae, although their number appeared to be reduced. A striking large number of the rod synaptic

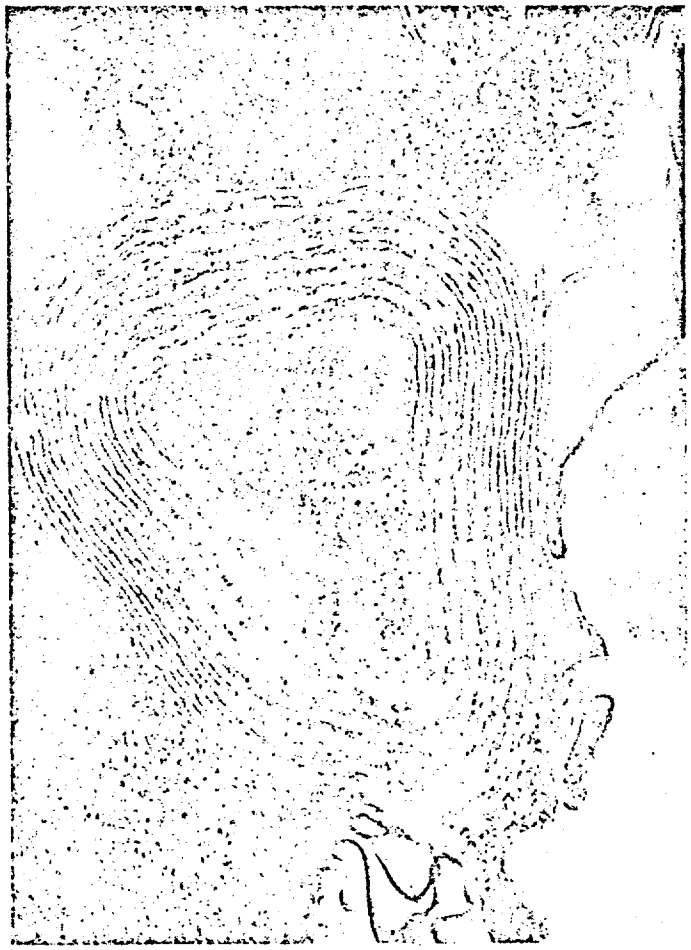

Fig. 3. Magnification of a coil with its central glial cytoplasm and its membranous processes (arrow). Note the microtubuli, filaments and glycogen granules in the cytoplasm in the lower left corner. 28,000

terminals were somatic in the glutamate-damaged retinae (Figs. 5, 6). Some of the synaptic bodies were electron denser and contained an increased number of vesicles of varying diameters as compared to those in the control retina (Figs. 5, 6). The processes, which invaginated the rod terminals, generally looked like those in the control retinae. Only a few incomplete synaptic bodies of the photoreceptor cells, i.e. lacking processes or other characteristic structures, have so far been observed (Fig. 6). Pedicles and triad arrangements could be seen but were rare (Fig. 6). None of the terminals were in synaptic connection with the perikarya of surviving nerve cell in agreement with the structural arrangement in the normal rat retina (Hansson, 1970b, c).

A striking observation was the low number of blood vessels in the severely damaged retinae. In 12 of the retinae no capillaries, arteries or veins could be observed at all in spite of careful light and electron microscopic studies. The few

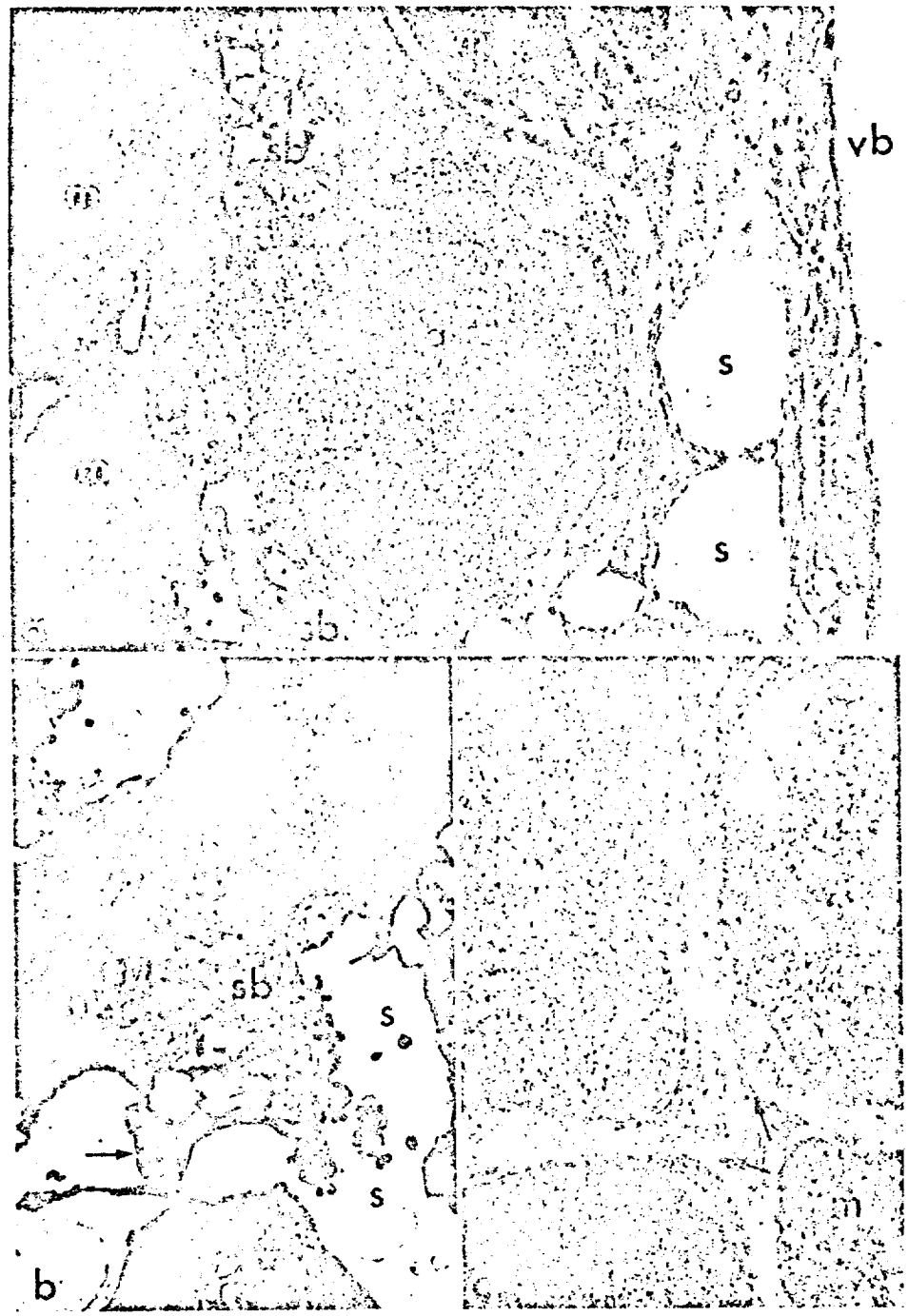

Fig. 4. a The cell in the centre is interpreted as an amacrine cell (*a*) with an irregularly shaped nucleus. A synaptic body (*sb*) is seen to the left. Treated by a single injection of glutamate and fixed after 3 months. × 8,550. b Several helical structures are seen (arrow) as well as large spaces. Note the synaptic bodies (*sb*). Treated as in Fig. 4 a. × 6,350. c The origin of processes (arrow) in a helical structure from a Müller neuroglial cell can be seen. × 13,300

Fig. 5. a An oligodendrocyte occupies the centre of the field surrounded by Müller neuroglial cells. Note the increased density in the oligodendrocyte as compared to other neuroglial cells. Treated with glutamate for 2 weeks and fixed after 6 months. 16,000. b A large number of rod cell synaptic bodies some of which with a large mitochondrium are seen among glial processes and extracellular spaces. Note the two somatic rod cell synapses in the upper part of the figure. Same retina as in Fig. 4a. 8,000



Fig. 6. a A somatic rod cell synapse which appears incomplete is seen in the centre. It is invaded by a process from a spherulae from above (arrow). Specimen as in Fig. 1. × 12,500. b A synaptic body, probably a pedicle to a cone cell, is seen with its three synaptic ribbons. Such structures were quite rare. Treated as in Fig. 4a. × 21,00. c The variations in size of the vesicles in the synaptic bodies is readily seen in these four synaptic bodies. Treated with glutamate for 2 weeks and fixed after 9 months. × 28,000. d An apparently incomplete rod cell spherulae is seen in a space with its vesicles, an oblique cut synaptic ribbon and a few neuroglial processes. Treated as in Fig. 4a. × 12,000

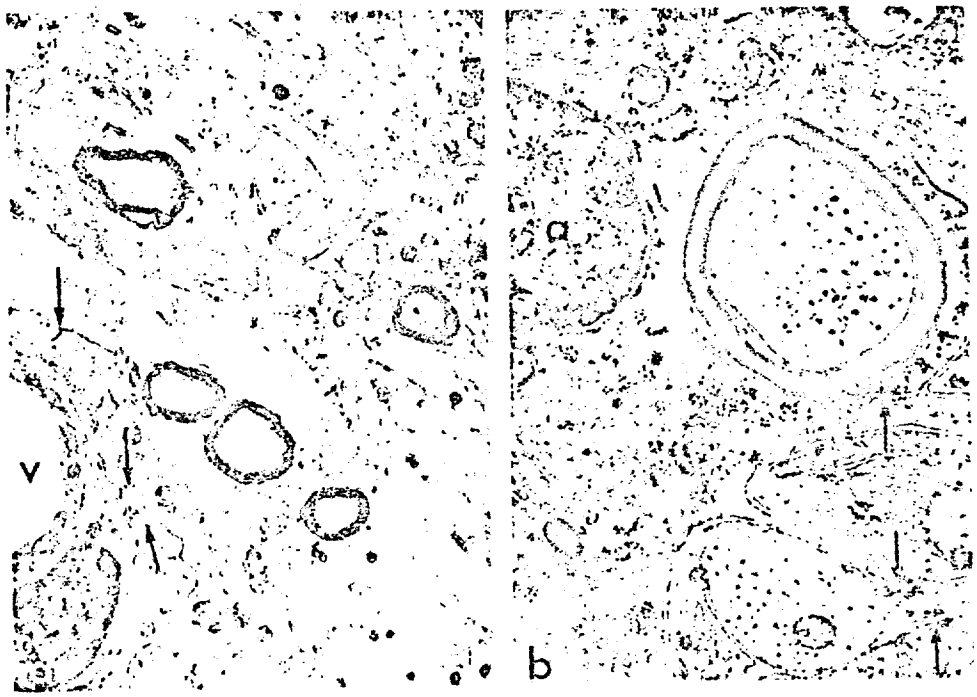

Fig. 7. a The hemi-desmosome-like structures (arrow) are common in the glial processes along the blood vessels as are desmosomes between astrocyte processes. Only a few of the numerous myelinated axons observed in the controls residue. Specimen as in Fig. 1. × 9,000. b A myelinated and an unmyelinated nerve cell process are seen separated by an astrocyte (a). Note the desmosomes (arrow) close to the nerve processes. Specimen as in Fig. 4a. × 24,600

residuing blood vessels in the other glutamate-damaged retinae showed a normal ultrastructure with regard to the thickness and appearance of both the cells and the basement membrane. No residues of obliterated or otherwise changed blood vessels have been observed.

The soma of the photoreceptor cells and their segments all showed the same ultrastructural features in both the glutamate-treated and in the control retinae. The same was true for the epithelial cells. There was no obvious reduction in the number and distribution of these cells. However, no quantitative estimations have been made.

Ultrastructure of the Optic Nerve of Glutamate Damaged Retinae. The optic nerve and tract looked like thin almost transparent or gray threads and were therefore easily overlooked during the examination and dissection of the animals. The number of myelinated nerve processes was reduced to about 200 to 700 in those animals that apparently lacked retinal nerve cells (Fig. 7). The latter figure corresponds to about one per cent of the number of myelinated fibers in the controls. There was no significant difference between the number of fibers in the optic nerve and in the optic tract. The unmyelinated nerve processes in the optic nerve was in contrast to the myelinated ones without demonstrable changes.

The neuroglial cells formed the main part of the optic nerve and tract. The astrocytes were the most numerous cell type. Their irregularly shaped nucleus

was lucid and the chromatin of uniform distribution. Its cytoplasm contained numerous filaments but only few organelles. Microtubular structures could not be demonstrated. Desmosomes were common along the many astrocyte processes (Fig. 7). Scattered dense oligodendrocytes could be observed, mostly in connection with myelinated nerve cell processes. A third glial cell type was also present as in the control optic nerves. They showed the same ultrastructural characteristics as the special type of glial cell observed in the glutamate-damaged retinae.

Discussion

The high sensitivity of the rat retinal nerve cells as compared to those in the mouse retina to glutamate-treatment has previously been described (Hansson, 1970a). That is reflected by the observation that almost all the retinal nerve cells degenerated. There does not seem to be any corresponding damage to the other cell types in the rat retina. Most of the animals were treated as described by Lucas and Newhouse (1957). However, the same extend of retinal damage was possible to produce with a single injection of monosodium-L-glutamate. Van Herreveld and Khattab (1968) recently demonstrated in an ultrastructural study that the immersion of free-dissected retinal tissue pieces in a glutamate-containing solution induced a pronounced swelling of the nerve cells. It seems likely that nerve cells in the retina as well as other parts of the central nervous system are primarily damaged and not secondarily due to vascular changes. The paucity of blood vessels do probably reflect secondary changes. That conclusion is further supported by the fact that vascular alterations have not been observed in glutamate-damaged mice retinae (Lucas and Newhouse, 1957; Potts, 1965; Cohen, 1967; Olney, 1969).

Few if any nerve cells residued after the glutamate treatment. Those observed had several ultrastructural features common with embryonic or immature nerve cells. The number of nerve cells was mostly less than the number of myelinated nerve cell processes in the optic nerve and the ganglion cells formed only a fraction of the total number of neuronal cells. It may reflect that islands of nerve cells were overlooked or that centrifugal myelinated nerve fibers do exist as previously discussed (Hansson, 1970a). A different pattern was observed in the retinae of glutamate-treated mice, where the number of persisting ganglion cells exceeded the number of myelinated optic nerve fibers (Cohen, 1967).

The third type of glial cells corresponded to the cell described by Vaughn (1967, 1969) and Vaughn and Peters (1968). Similar cells have been observed surrounding regenerating nerve cells in other parts of the central nervous system (Blinzinger and Kreutzberg, 1968; Hamberger, Hansson and Sjöstrand, 1970) and nerve cells undergoing neurofibrillary changes due to treatment with mitotic inhibitors (Hansson and Sjöstrand, 1970). They have much in common with the microglial cells described by light microscopy as recently discussed by Peters, Palay and Webster (1970) and do occur in large numbers in damaged nervous tissue.

The extracellular spaces in the glutamate-damaged rat retinae have not been observed in the mice retinae. They formed a complicated network of interconnected cystoid spaces of varying size and shape in the inner part of the residuing retina (Hansson, 1970a). They may either reflect holes after the many lost nerve cells and their processes or disturbances in the retinal fluid and salt balance controlled by the apparently intact epithelial cells.

A high frequency of somatic synapses in the rod cells was observed in all retinae with few persisting nerve cells after the glutamate treatment as well as a general reduction in the number of synaptic bodies. That indicate that the residuing retina and its cells are rebuilt and thereby adapted to the new structural conditions. It seems likely on the basis of the present material that the majority of the invaginating processes are coming from neighbour photoreceptor cells.

A large number of desmosomes was observed in the optic nerves of glutamate-treated rats (Fig. 7b). Such structures are observed scattered in a normal optic nervee of adult rats. However, hemi-desmosome-like structures are frequent (Fig. 7a), especially at the vascular end-feet of astrocytes as discussed by Peters, Palay and Webster (1970). It seems likely that the astrocytic desmosomes either are new-formed structures occuring during the reparative phase after the glutamate-induced retinal damage or a concentration of the preexisting hemi-desmosomes. Serial sectioning of the optic nerves seems to indicate that they form continuous structures between astrocytic processes for long distances. Their significance under these special conditions is difficult to state for certain.

Acknowledgements. Supported by grants from the University of Göteborg, "Riksföreningen mot Cancer" (265-B69-01X) and the Swedish Medical Research Council (B70-12X-2543-02, B71-12X-2543-03).

References

Blinzinger, K., Kreutzberg, G.: Displacement of synaptic terminals from regenerating motor-neurons by microglial cells. Z. Zellforsch. **85**, 145–157 (1968).

Cohen, A. I.: An electron microscopic study of the modification by monosodium glutamate of the retinas of normal and rodless mice. Amer. J. Anat. **120**, 319–355 (1967).

Hamberger, A., Hansson, H.-A., Sjöstrand, J.: Surface structure of isolated neurons: changes during nerve regeneration. J. Cell Biol., in press (1970).

Hansson, H.-A.: Scanning electron microscopic studies on the long term effects of sodium glutamate on the rat retina. Virchows Arch. Abt. B Zellpath. **4**, 357–367 (1970a).

— Scanning electron microscopy of the rat retina. Z. Zellforsch., **107**, 23–44 (1970b).

— Scanning electron microscopic studies on the synaptic bodies in the rat retina. Z. Zellforsch., **107**, 45–52 (1970c).

— Sjöstrand, J.: To be published (1970).

Herreveld, A. van, Khattab, F. I.: Electron microscopy of the mouse retina prepared by freeze-substitution. Anat. Rec. **161**, 125–140 (1968).

Lucas, D. R., Newhouse, J. P.: The toxic effect of sodium L-glutamate on the inner layers of the retina. Arch. Ophthal. **58**, 193–201 (1957).

Olney, J. W.: Glutamate-induced retinal degeneration in neonatal mice. Electron microscopy of the acutely evolving lesion. J. Neuropath. exp. Neurol. **18**, 455–474 (1969).

Peters, A., Palay, S. L., Webster, H. de F.: The fine structure of the nervous system. New York: Hoeber Med. Div. 1970.

Potts, A. M.: Selective action of chemical agents on individual retinal layers. In: Biochemistry of the retina, p. 155, ed. by Graymore, C. N. London: Academic Press 1965.

Vaughn, J. E.: Undifferentiated neuroglial cells in adult rat optic nerve. J. Cell Biol. **35**, 136A–137A (1967).

— An electron microscopic analysis of gliogenesis in rat optic nerves. Z. Zellforsch. **94**, 293–324 (1969).

— Peters, A.: A third neuroglial cell type. An electron microscope study. J. comp. Neurol. **133**, 269–288 (1968).

Docent Hans-Arne Hansson
Department of Histology
University of Göteborg, Fack
S-400 33 Göteborg 33, Sweden

3001

Ingested Sodium Glutamate and Plasma Levels of Glutamic Acid

WILLIAMINA A. HIMWICH AND INEZ M. PETERSEN, with the technical assistance of JUANITA P. GRAVES. *From the Thudichum Psychiatric Research Laboratory, Galesburg State Research Hospital, Galesburg, Illinois*

THIS investigation on plasma levels of glutamic acid was carried out in conjunction with a long term study of the effects of sodium glutamate on behavior in elderly individuals.[1] It was felt that three questions needed elucidation before definitive studies on the mechanism of action of glutamic acid could be made. *1)* The normal individual variation of basal plasma level of glutamic acid, *2)* the long term effect of feeding large amounts of sodium glutamate on the basal plasma level, and *3)* the immediate effects of the ingestion of sodium glutamate upon the blood level of glutamic acid and other constituents.

METHOD AND SUBJECTS

Determination of Glutamic Acid. The method of Prescott and Waelsch (1) as modified by Bessman *et al.* (2) was used. The following additional modifications were made; *a)* helium was used as the mixing gas rather than air to decrease the possibility of oxidation by contaminants; *b)* ninhydrin was added from a standard solution in absolute alcohol; *c)* samples were filtered rather than centrifuged to remove the excess ninhydrin; *d)* solutions of glutamic acid were used to construct the standard curve rather than solutions of B-formylproprionic acid. Under these conditions a recovery of 91-95% of glutamic acid added to plasma in concentrations between 12 and 50 gamma was consistently obtained. Chromatograms revealed that the eluate from the alumina columns showed a single spot which corresponded in position to that for glutamic acid. Successive samples drawn from pooled plasma were analyzed to determine the reproducibility of the method. In four experiments, two using quadruplicate samples and two, using duplicate samples the maximum difference between samples was 0.3 mg %. On this basis plasma samples that differed from each other by more than 0.4 mg % were considered to be significantly different.

Glutamines were determined by converting glutamine in the filtrate and washings from the adsorption funnels to glutamic acid by hydrolysis for 1 hour at 100° in 2 N HCl as suggested by Bessman *et al.* (2). The glutamic acid then was measured as described above. Only basal levels of glutamine are reported since Prescott and Waelsch (3) suggest that acid hydrolysis of glutamine may be less effective when blood sugar values are high.

Subjects. *H, W, S* and *F*, were staff members serving as normal controls for the glutamic acid study on elderly patients. In age they ranged from 28 to 35 years; *W* was the only female. The subjects for tolerance studies were male patients over 55 years of age, without disabling pathology and engaged in restricted physical activity.

Administration of Glutamic Acid. Glutamic acid was administered approximately half neutralized with sodium that is, as sodium glutamate, in 125 ml of tomato juice. For the long term study the glutamate was ingested three times a day for 12 weeks; the first week a dose equivalent to 15 gr glutamic acid was given, the second week 30 gr a day, and the next 10 weeks the full dose of 45 gr a day.

The placebo consisted of tomato juice containing sodium chloride, sodium bicarbonate and citric acid and was fed for a period of 12 weeks.

Tolerance Curves. Blood was drawn in the basal state for the control value. After the ingestion of the tomato juice-glutamate mixture, bloods were routinely collected at 30, 60, 120 and 180 minutes. Glutamic acid and glutamine were determined on the plasma and glucose, pyruvic and α-ketoglutaric acids on whole blood. The methods of Nelson (4) and of Friedemann and Haugen (5) were used for blood sugar and for the keto acids, respectively.

RESULTS

Basal levels of glutamic acid in plasma show considerable variation (table 1). Since plasma levels 30 minutes after the placebo showed no difference from the basal levels, these values for *W* and *H* have been included in the table and are marked with an asterisk. The values for subjects *H* and *W* down to the dotted line in the table represent samples drawn at weekly intervals, the others were collected at varying times over a period of more than a year.

In approximately 30 patients receiving sodium glutamate for 12 weeks (maximum level sodium glutamate equivalent to 45 gr day glutamic acid) there was no significant change in the basal level of either glutamic acid or glutamine (table 2). In the 19 cases the two

Received for publication March 8, 1954.

[1] The entire study will be reported elsewhere.

J. Supp. Nutr. 54 (2) 195-199

TABLE 1. REPEATED DETERMINATIONS OF BASAL PLASMA LEVELS OF GLUTAMIC ACID (GA) AND GLUTAMINE (GI) IN FOUR NORMAL SUBJECTS

Subject H		*Subject W*		*Subject F*		*Subject S*	
GA mg %	GI mg %	GA mg %	GI mg %	GA mg %	GI mg %	GA mg %	GI mg %
1.3		2.5	8.2	2.5		1.4	
1.6		4.5		3.7		1.2	9.4
1.3*		1.0*		2.0	19.4	3.5	17.6
1.6*		3.5*		2.5	17.1	1.0	20.6
1.3*		2.4*		2.5	16.5	1.6	19.4
1.3*		2.5*		1.5	18.2	1.6	14.1
1.8	20.0	2.0*		1.2	15.3	1.1	20.6
1.9*		2.5	12.9				
1.9*		2.5*					
1.5*		3.0*					
2.1*		2.5*					
1.1	14.1	1.2*					
		2.4*					
1.7	21.2	1.0*					
1.2	15.0	2.3*					
1.7	18.2	2.1	10.6				
1.0	19.4						
		2.4					
		4.8	21.8				
		2.5	9.4				
		1.4	9.4				
		2.6	18.8				
		2.4	11.2				
		2.9					

Dotted line marks end of weekly determinations.
* Values for blood drawn 30 min. after placebo.

alues were considered the same within the reproducibility of the method (checked within 1 mg %). For the other patients the change in evel could not be correlated with the glutamic acid intake.

In the basal state there did not seem to be a consistent relation between the glutamate and glutamine levels in the blood, although the average value for glutamine for the patients (table 2) was 7.7 times that for glutamic acid. Glutamine levels also showed a greater variation than glutamate levels.

Weekly determinations of plasma glutamate two subjects receiving glutamate determined 30 minutes after the daily morning dose of sodium glutamate containing 5 gr glutamic acid did not present a uniform picture. Low levels were obtained for both individuals when they were ill, but the other changes did not reveal any consistent trend.

Sixteen tolerance curves with a dose of sodium glutamate equivalent to 15 gr glutamic acid have been completed. Although the curves tend to be characteristic of the individual, four patterns predominate (fig. 1). At the end of 3 hours the majority of subjects showed a return of blood glutamate to normal levels. Ten grams tolerance curves (2 subjects) tend to follow the pattern of the 15 gr tolerance curve for an individual, while for the 5 gr curve the two subjects studied both showed a peak in the blood level at 30 minutes. In one individual recovery from hepatitis changed the tolerance curve pattern for 15 gr from a plateau, *type A* to a 60-minute high, *type C* curve. One tolerance curve with a dose of 15 gr of commercial monosodium glutamate showed the same type of curve as with half-neutralized glutamic acid prepared in the laboratory.

TABLE 2. BASAL LEVELS OF PLASMA GLUTAMIC ACID AND GLUTAMINE IN SUBJECTS WHILE ON PLACEBO AND ON GLUTAMIC ACID

Supplement	No. of Patients	Glutamic Acid mg %	No. of Patients	Glutamine mg %
Placebo	28	1.8±0.6	30	13.3±1.8
Glutamic acid	28	1.8±0.5	28	14.2±2.4

In the 15 gr tolerance tests blood sugar rose 10 mg % or more in 9 out of 16 cases. In three others the rise was 9 mg %. Glutamine tended to fall during the time glutamic acid was high in the blood and to approach the control level as glutamate returned to a normal level. Typical values for each curve were 1.2, 29.2, 20.8 and 1.6 mg % and 15.9, 11.2, 5.9 and 14.7 mg % for glutamic acid and glutamine, respectively, at 0, 60, 120 and 270 minutes. Changes in pyruvic and α-ketoglutaric acid were not consistent; although in some subjects there was a fall in pyruvate and increase in α-ketoglutaric, these changes were of small magnitude.

DISCUSSION

Although each of the four subjects studied over a period of several months (in the case of *W* and *H*, more than a year) tended to have a characteristic plasma level of glutamate, all four upon occasion showed wide swings in the value. These swings could not be explained upon the basis of any observed physiologic or pathologic change in the subjects. The presence of fatigue, emotional strain, infections and

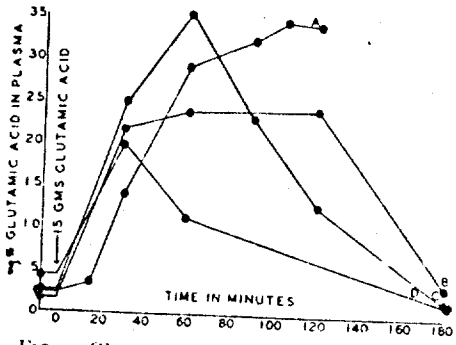

FIG. 1. Glutamic acid tolerance curves.

dietary changes all showed poor correlations with alterations of plasma glutamate. Undoubtedly the variations in plasma level are related to physiologic conditions but we do not yet have the necessary data for correlating them. In the case of the patients who were tested following a period of placebo and again following a period on sodium glutamate no correlation could be made between plasma levels of glutamate and chronic diseases such as are common in elderly individuals, e.g. hypertension, arthritis, cardiac disorders, etc. The high levels consistently shown by subjects *W* and *F* could not be related to any pathological changes such as White *et al.* (6) have reported in conjunction with high plasma levels. Our data suggest that a single plasma determination may not indicate an individual's usual level of glutamic acid.

In general the average plasma levels in this study are higher than those reported by Waelsch (7) and by Beaton *et al.* (8) but not as high as those reported by other investigators using methods other than chemical. The glutamine levels were higher also than those reported by Waelsch (7) and other investigators (table 3). Although in our experience glutamine values did not correlate well with glutamate levels, the average glutamine (table 2) was 7.7 times that of glutamic acid as compared to Waelsch's ratio of 7.5:1 (7).

The return of plasma levels to normal in most instances within 3 hours after the ingestion of a single dose of 15 gm and the failure of continued ingestion of sodium glutamate to raise basal levels suggest that the reported effects of glutamic acid on behavior (16) are not due to a continuing high level of blood glutamate. Even with three daily doses of 15 gr each the blood level would not be elevated for more than 9 hours of the day. With smaller doses the elevation would be of even shorter duration.

TABLE 3. PLASMA LEVELS OF GLUTAMIC ACID AND GLUTAMINE IN NORMAL SUBJECTS

No. of Observ.	Range mg %	Mean & St. D. mg %	Ref.
Glutamic acid			
20*	1.22–3.10	2.20	9
26*	0.7–2.0	1.2 ± 0.33	8
51†	0.5–1.8	1.0 ± 0.37	8
20*	1.22–3.08	2.29	10
17*	0.0–1.5	0.80 ± 0.39	11
	0.0–1.4		12
	1.3–5.9	3.41	13
36		1.1 ± 0.5	7
Glutamine			
14	4.0–10.6	7.51 ± 1.03	11
	2.7–7.8	5.78	13
	6.1–1.3		12
20*	6.19–9.83	7.68	10
20*	6.18–9.83	7.68	9
36		8.3 ± 1.5	7
	6.0–10.0		14
		5.85	15

* = male; † = female.

Our tolerance curves exhibit considerable variation as do the four curves obtained by Bessman *et al.* (2) with doses of 1 gr. 10 kg of body weight of unneutralized glutamic acid. Their tolerance curves showed increases over the basal value of 0.4, 0.6, 3.8 and 8.7 mg % at 60 minutes for the four subjects. For our subjects the relation of body weight to dosage seemed to have little bearing, since the two heaviest individuals whose tolerance to sodium glutamate was studied, showed completely dissimilar curves. One who weighed 99 kg had a very high peak at 60 minutes, (*C*, fig. 1), the other who weighed 83 kg had a very low peak at 30 minutes (*D* fig. 1). This is not unexpected since tolerance curves reflect the additive effects of gastro-intestinal absorption and tissue removal of the substance from the blood. Active tissue weight excluding fat might be related to tolerance to a given dose. We have no data on this point. The change in tolerance curve pattern after hepatitis suggests that the liver may play a major role in removing glutamate from the blood. The *type A* curve was obtained only in the subject with hepatitis and in elderly patients who may have had de

creased gastro-intestinal absorption or hepatic function or both. It had been our hope that we might obtain tolerance curves of the order of consistency of glucose tolerance curves. As is shown in figure 1 this was not the case, and the response especially to a large dose of sodium glutamate tends to be more individual than is the case with the response to glucose.

The rise in blood sugar due to the ingestion of glutamate suggests an adrenergic action such as has been emphasized by Weil-Malherbe (17). The tendency for glutamines to fall as glutamate rises has been noted by Bessman *et al.* (2) and by Christiensen *et al.* (18). In most instances the glutamine had returned to normal levels when the glutamic acid had fallen to the basal level. In cases where the glutamate was still high at 3 hours, the glutamine level continued to be low.

A consistent change in blood keto acids probably can not be shown at the dosage level used. Klingmüller and Vogelgesang (19) injecting intravenously doses of 0.3 gr kg of sodium glutamate in rabbits have found a definite fall in pyruvate values and a rise in α-ketoglutaric acid.

SUMMARY AND CONCLUSIONS

Fifty-three basal and post-placebo plasma levels of glutamic acid determined at intervals in four subjects showed a wide variation for each individual. The continued ingestion of sodium glutamate daily (equivalent to 45 gr glutamic acid) in approximately 30 subjects had no effect on the basal plasma level of glutamic acid or of glutamine. In 16 cases the response to a single dose of sodium glutamate, as judged by plasma levels, varied with the individual and with the dose.

ADDENDUM

Sackler, in a paper which appeared since this was accepted for publication, also reported fluctuations in basal values. (SACKLER, R. R. *Clin. Exper. Psychopath.* 15: 19, 1954.)

REFERENCES

1. PRESCOTT, B. A. AND H. WAELSCH. *J. Biol. Chem.* 164: 331, 1946.
2. BESSMAN, S. P., J. MAGNES, P. SCHWERIN AND H. WAELSCH. *J. Biol. Chem.* 175: 817, 1948.
3. PRESCOTT, B. A. AND H. WAELSCH. *J. Biol. Chem.* 167: 885, 1947.
4. NELSON, N. *J. Biol. Chem.* 153: 375, 1944.
5. FRIEDEMANN, T. E. AND G. E. HAUGEN. *J. Biol. Chem.* 147: 415, 1943.
6. WHITE, J. M., J. R. BEATON AND E. W. MCHENRY. *J. Lab. & Clin. Med.* 40: 703, 1952.
7. WAELSCH, H. *Advances in Protein Chem.* 6: 299, 1951.
8. BEATON, J. R., M. J. CAVAN, R. E. LAW, W. J. MCGANITY, E. W. MCHENRY AND G. L. WATT. *Am. J. Obst. & Gynec.* 62: 150, 1951.
9. MUNKVAD, I. *Acta psychiat. et neurol.* 25: 209, 1950.
10. ASTRUP, P. AND I. MUNKVAD. *Scandinav. J. Clin. & Lab. Invest.* 2: 133, 1950.
11. HARPER, H. A., M. E. HUTCHIN AND J. R. KIMMEL. *Proc. Soc. Exper. Biol. & Med.* 80: 768, 1952.
12. HARPER, H. A. *Arch. Biochem.* 15: 433, 1947.
13. KREBS, H. A., L. V. EGGLESTON AND R. HEMS. *Biochem. J.* 44: 159, 1949.
14. ARCHIBALD, R. M. *J. Biol. Chem.* 154: 643, 1944.
15. HAMILTON, P. B. *J. Biol. Chem.* 158: 375, 1945.
16. ALBERT, K., P. HOCH AND H. WAELSCH. *J. Nerv. & Ment. Dis.* 104: 263, 1946.
17. WEIL-MALHERBE, H. *Physiol. Rev.* 30: 549, 1950.
18. CHRISTENSEN, H. N., J. A. STREICHER AND R. L. ELBINGER. *J. Biol. Chem.* 172: 515, 1948.
19. KLINGMÜLLER, V. AND K. H. VOGELGESANG. Personal communication.

3440 3440

40021

This report contains the collective views of an international group of experts and does not necessarily represent the decisions or the stated policy of the World Health Organization or of the Food and Agriculture Organization of the United Nations.

WORLD HEALTH ORGANIZATION
TECHNICAL REPORT SERIES
No. 488

FAO NUTRITION MEETINGS REPORT SERIES
No. 50

EVALUATION OF FOOD ADDITIVES

SOME ENZYMES, MODIFIED STARCHES, AND CERTAIN OTHER SUBSTANCES: TOXICOLOGICAL EVALUATIONS AND SPECIFICATIONS AND A REVIEW OF THE TECHNOLOGICAL EFFICACY OF SOME ANTIOXIDANTS

Fifteenth Report
of the Joint FAO/WHO Expert Committee
on Food Additives

Rome, 16–24 June 1971

Published by
FAO and WHO

WORLD HEALTH ORGANIZATION
GENEVA
1972

3.1 Chemical preservatives

These should not be used in baby food except in special circumstances as specified in paragraph 2.2.1. Raw materials treated with nitrites or nitrates should be avoided.

3.2 Food colours

In keeping with the principles laid down in section 2, these should not be used for the express purpose of colouring.

3.3 Emulsifiers, stabilizers, and thickeners

These are necessary for a variety of baby foods. Experience from some countries suggests that starch is suitable for thickening and stabilizing purposes for infant formulas.[1] Lecithin, monoglycerides and diglycerides appear to be suitable for emulsification purposes. Gelatin and sodium and calcium caseinates, which are also used, are not regarded as additives.

3.4 Flavouring agents and flavour enhancers

These are not necessary in infant formulas. However, babies over 12 weeks of age may be capable of distinguishing flavours. All baby foods should be prepared in such a way that their natural flavour is retained, if desired. In certain processes, however, such as sterilization or deaeration, it is not always possible to retain the original flavour. In such cases, the restoration of desirable natural flavours may be justified. For the manufacture of some composite foods, including food ingredients from novel sources, the addition of natural flavours from edible products may also be justified. On the other hand, there appears to be no technological justification for flavour enhancers. Although salt may be regarded as a flavouring agent, sodium and chloride are necessary nutrients in infant formulas. If sodium chloride is added to other classes of baby foods for taste purposes, it should be limited to 0.25% by weight of the product to be consumed (see also section 5.5).

3.5 Antioxidants

Some antioxidants are needed for a variety of baby foods. Experience shows that, under favourable climatic conditions, a normally acceptable

---

[1] See the fourteenth report of the Joint FAO/WHO Expert Committee on Food Additives, *FAO Nutrition Meetings Report Series*, 1971, No. 48; *Wld Hlth Org. techn. Rep. Ser.*, 1971, No. 462.

shelf-life can be maintained for some foods solely by the use of such naturally occurring antioxidants as tocopherols and ascorbic acid, or their appropriate esters. Packaging under nitrogen or carbon dioxide may be required in certain cases.

3.6 Buffers and pH regulators

A variety of suitable chemical compounds are available.

4. TOXICOLOGICAL CONSIDERATIONS

4.1 Vulnerability of very young infants

Although breast feeding is recognized to be the commonest form in which the newborn infant receives its food supply in the early weeks of life, comparatively few babies are still breast fed at 6 weeks of age in the more highly developed countries. Many infants have by then experienced contact with infant formulas as substitutes for milk, and some may receive their entire food supply in that form from the day of birth. Furthermore, cereal-based infant foods and other classes of infant foods, such as strained foods and supplementary infant foods, may have been introduced at various ages and provide an appreciable proportion of the caloric intake for infants between 3 and 6 months. Thereafter, the child is increasingly fed from the family meals, while cereal consumption tends to wane and canned strained foods and " junior " convenience foods often become more important constituents of the diet.

Very young infants are especially vulnerable to foreign chemicals because the mechanisms that provide protection against these substances are absent or not fully developed. Although the evidence for this derives mainly from studies with drugs rather than with food additives, it is likely that such very young infants are less efficient than older children in metabolizing some food additives and may therefore accumulate them to excessive levels. If this occurs at a time when sensitivity to toxic effects is critical because of the delicately balanced growth and differentiation processes, there may be deleterious consequences that may not appear until much later in the child's development. Very young infants may also differ from older children in relation to physiological barriers protecting sensitive tissues, such as the blood-brain barrier or the protective barriers for retinal or lens tissue.

The known differences between the very young infant and the older child include the following : low gastric acid secretion, different biochemical capabilities of the gastrointestinal tract, inability to digest and absorb certain

substances, deficiency in methaemaglobin reductase systems, diminished renal excretory processes at both glomerular and tubular sites.

4.2 Toxicological testing

After reviewing the guidance given in the various FAO/WHO publications for the toxicological testing of intentional and unintentional food additives, it was considered that modification of some of the recommended procedures was necessary. Before a food additive is regarded as safe for use in food intended for infants up to 12 weeks of age, the toxicological studies should be extended to include animals in the corresponding period of life. There is, however, a lack of precise information relating to this developmental period in both animals and the human infant. It is difficult to recommend precise toxicological testing procedures until more basic research has been undertaken. There are also difficulties in selecting the appropriate species. In these circumstances short-term studies should be conducted in several species and should include the oral administration of the additive under test, at suitable dose levels, to newly born animals up to and including the end of the weaning period. This type of exposure is necessary in order to discover whether the existing species variation seriously affects the handling of the food additive by the test animals and to compensate partly for the serious lack of knowledge in this area both in animals and men.

When lifespan studies and multigeneration studies are carried out, they should be extended to include the oral administration of the food additive at suitable dose levels to a proportion of animals from the day of birth throughout the pre-weaning period. These animals should then be observed for the required period as laid down for the usual lifespan and multigeneration tests. Multigeneration tests should be carried out for at least 3 generations. If there are any indications of heritable mutagenic effects these tests should be followed by specific studies. Some members of the filial generations should be exposed to the additive for their lifespan. The enhanced sensitivity of the newborn of several species to certain carcinogenic agents is particularly relevant in this regard. It is also necessary to place greater emphasis in future on observations of the behavioural developments of animals used for toxicological testing, particularly in long-term studies. Because of uncertainties still existing in this field, the accumulation of experimental information is of paramount importance for the evaluation of the results in terms of human health hazard.

The Meeting emphasized the importance of the recommendations made by the WHO Scientific Group on Procedures for Investigating Intentional and Unintentional Food Additives with regard to the desirability of supplementing animal studies on additives by investigations in man. It considered that this applies specially to additives to be used in infant foods.

5. SPECIFIC FOOD ADDITIVES

Certain food additives in respect of which specific queries had been raised are considered below. These considerations do not imply that any greater significance should be accorded to these additives than to others not specially considered.

5.1 Modified starches

Certain modified starches were stated in the thirteenth report of the Joint FAO/WHO Expert Committee on Food Additives [1] to be equivalent to normal products of digestion. These included starches treated by physical means, acid-treated starches, enzyme-treated starches, and alkali-treated starches. The Meeting considered that there could be no objection to their being used as additives in foods for infants beyond 12 weeks of age.

5.2 Lactic acid

This food additive was re-evaluated at the thirteenth meeting of the Joint FAO/WHO Expert Committee [1] and the previous restriction on the use of the D-enantiomorph in the diet of very young infants was upheld. The evidence for this decision appears in the appropriate monograph.[2] No additional evidence has come forward to indicate a need to change the opinion expressed in the ninth report of the Joint FAO/WHO Expert Committee that only L-lactic acid be used in the preparation of infant foods.[3]

5.3 Nitrates and nitrites

There are wide variations in the occurrence of nitrates and nitrites in vegetables and certain prepared meat products. These substances are of special importance because of the extreme sensitivity of the human infant to the induction of methaemoglobinaemia. Because the mechanism of methaemoglobin reduction is poorly developed and because of the increased liability of fetal erythrocytes to methaemoglobin formation, during the first 2–3 months of life there is a greater risk of adverse reactions from absorbed nitrite. This nitrite is derived essentially from bacterial

---

[1] *FAO Nutrition Meetings Report Series*, 1970, No. 46; *Wld Hlth Org. techn. Rep. Ser.*, 1970, No. 445.

[2] *FAO Nutrition Meetings Report Series*, No. 40 A, B, C; WHO/Food Add/67.29.

[3] *FAO Nutrition Meetings Report Series*, 1966, No. 40; *Wld Hlth Org. techn. Rep. Ser.*, 1966, No. 339.

activity in the gastrointestinal tract, a process that occurs particularly readily in the very young infant because of the inadequacy of acid production in the stomach. It is therefore recommended that every effort should be made to reduce to a minimum the total nitrate and nitrite intake of infants. It is also necessary to consider the possibility of nitrosamine formation *in vivo* following simultaneous ingestion of nitrite and amine-containing foods. Almost all the nitrosamines hitherto examined in animal tests have been shown to possess a carcinogenic potential. In view of the particular sensitivity of the young infant to these toxic agents this is a further reason for restricting nitrate and nitrite intake to a minimum. It has also been shown that the presence of nitrate in water used in the processing of canned food may lead to excessive concentrations of tin with possible consequent deleterious effects.

5.4 Phosphates and calcium

The level of phosphates in the diet must be considered in relation to the calcium intake. There is a wide latitude for dietary variations in calcium content without significant toxicological effects and the calcium contributed from food additives is unlikely to make a substantial impact on total intake. The Meeting agreed that the calcium-phosphorus ratio in a baby food should not be less than 1 : 1.2. This provision should be made to apply at least to infant formulas and cereal-based baby foods.

The toxicological aspects of phosphates as food additives were reviewed in the seventh report of the Joint FAO/WHO Exper. Committee.[1] The contribution to the phosphate load from the carry-over of phosphates used as additives in certain ingredients of infant formulas should be allowed for when calculating the general adjustment of the calcium-phosphorus ratio in infant foods.

5.5 Sodium compounds

The investigation of various infant foods and infant formulas has revealed a considerable variation in the total amounts of sodium, depending largely on the combination of the foods. There is some evidence, both from animal experiments and from epidemiological studies in man, of a correlation between sodium intake and the appearance of hypertension. Restriction in the sodium content by limiting the amount of salt to be added to infant food is therefore recommended (see section 3).

---

[1] *FAO Nutrition Meetings Report Series*, 1964, No. 35; *Wld Hlth Org. techn. Rep. Ser.*, 1964, No. 281.

6. RECOMMENDATIONS

(1) Fundamental research should be carried out on methods of toxicological testing of substances intended for use as additives in infant foods, special attention being given to the problem of differences in pre-weaning development between the test animals and man, thus permitting more reliable predictions of toxicity to the human infant.

(2) WHO should promote toxicological studies of those additives, the use of which is essential in baby foods.

(3) As new pertinent information becomes available, the safety of additives in all foods taken by infants should be reassessed.

(4) A more thorough investigation should be made of the standards and criteria used for assessing the technological justification for the use of additives used in baby food.

(5) In evaluating the safety of food additives, the possibility should be borne in mind that certain classes of foods containing additives may be consumed by infants as well as by adults.

Human susceptibility to oral monosodium L-glutamate[1, 2]

R. A. Kenney,[3] Ph.D., and C. S. Tidball,[3] M.D., Ph.D.

It is generally accepted that certain individuals may experience idiosyncratic symptoms associated with the eating of specific food items. Not infrequently such symptoms may go unnoticed until attention is directed toward them. There have been numerous reports of symptoms following the eating of Chinese dishes (1–7) and certain of the more frequently occurring symptoms have been referred to as the Chinese Restaurant Syndrome. The first report (1) described the symptoms as "numbness at the back of the neck, gradually radiating to both arms and the back, general weakness and palpitation." The correspondence that followed the initial report expanded the spectrum of symptoms considerably to include a numbness of the jaw (2), lacrimation, periorbital fasciculation and syncope (3), temporal headache (4), or a vice-like pounding in the head (5). To this already extensive list was added sweating about the face and armpits (6). The most complete of the anecdotal reports was that of Gordon (7) who described the experience of seven persons who ate Chinese food. Seventeen minutes after beginning to eat the Chinese dishes there developed a sudden tightening of the face associated with numbness. There was weakness of the mouth and a sensation of dizziness, associated with flushing and sweating. A "band-like" headache occurred with orbital pain. Some experienced a facial anesthesia and a sinus tachycardia up to 100 beats/min. One diner had such intense heavy aching in his biceps and triceps as to be convinced that he was having an acute myocardial attack. Another experienced paresthesia and weakness of the upper extremities intense enough to suggest paralysis.

Ho Man-Kwok (1) in the first report had included monosodium L-glutamate (MSG) among the ingredients of Chinese cookery which might be implicated in the causations of symptoms. Schaumburg and Byck (8) also reported that at high levels of ingestion, MSG was capable of producing a triad of symptoms that would simulate the syndrome. These same workers showed that the symptoms could be produced by monopotassium L-glutamate, L-glutamic acid or monosodium DL-glutamate. No symptoms followed the administration of monosodium D-glutamate, monosodium L-aspartate, sodium chloride or glycine in quantities comparable with the effective dose of MSG. Morselli and Garattini (9) found no significant ($P > 0.05$) differences in any of a number of objective parameters (arterial blood pressure, heart rate, and respiratory frequency) nor were there differences ($P > 0.05$) in the reported character or frequency of sensations or symptoms, following the ingestion of broth containing MSG or normal broth. These authors (9) concluded that "many of the subjective symptoms considered to be part of the Chinese Restaurant Syndrome may also be present during a normal digestive process." Rosenblum, Bradley and Coulston (10) also recently reported a series of single and double-blind studies on human volunteers, involving MSG in control solutions of chicken stock, with or without salt. No significant ($P > 0.05$) difference was found between those taking MSG or the appropriate salt solution, in respect to incidence of symptoms, blood chemistry, or blood pressure, and heart rate.

A preliminary study in this laboratory, using subjects who believed that they had on some occasion experienced a Chinese Restaurant Syndrome, failed to reveal any

[1] With the technical assistance of Carol McKenna and Bruce Bon.

[2] Supported by a grant from *Nutrition Today*.

[3] Department of Physiology, George Washington University Medical Center, 1339 H Street, N.W., Washington, D.C. 20005.

The American Journal of Clinical Nutrition 25: FEBRUARY 1972, pp. 140–146. Printed in U.S.A.

change in the objective parameters that were monitored following the ingestion of 5 g MSG. Symptoms were reported but there was no change in blood pressure, heart rate, ECG, respiratory depth, or frequency. Skin temperature measured in areas giving a sensation of warmth or burning likewise showed no change while the subjects experienced the symptom.

In a second pilot series, 35 volunteers were studied. They received doses of MSG ranging from 1 to 20 g dissolved in water. The initial dose level received by a subject was 5 g in most cases and subsequent doses were selected on the basis of the response to the initial dose.

A total of 82 doses of MSG was administered to the 35 subjects and of these, 62 doses produced symptoms. This study confirmed the observation of Schaumburg et al. (11) on the extreme variation in susceptibility of individuals to MSG and further revealed an absence of correlation of dose with either latency of onset or duration of response. Tests on individuals on repeated occasions also revealed a lack of correlation between dose and symptoms. This study lacked placebo control and this fact taken in conjunction with the knowledge that the subject had regarding sensations previously reported (derived from the statement of informed consent, which the subject signed) called into question the whole validity of experiments of this type in assessing human susceptibility to MSG.

We now report a placebo-controlled study conducted on 77 normal volunteers. This study is divided into two phases: phase 1 was a screening test of the 77 subjects to detect positive reactors at the dosage level of 5 g MSG; and phase 2 was a study in depth of those members of this group who reacted at this level.

Phase 1 studies

The subjects were acquainted with the objectives of the study and had given their informed consent. The consent form specified that they might be given MSG and outlined the types of symptoms, which had been reported from elsewhere. The age, sex, and racial distribution of the subject population is shown in Table 1.

TABLE 1
Distribution of subjects by age, sex, and race

	20–24 years	25–29 years	30–40 years	> 40 years
Caucasian				
Male	21	3	7	6
Female	15	4	7	5
Negro				
Male	1	2	3	1
Female	1		1	

The subjects reported to the laboratory on each of three mornings after having been instructed that if breakfast were eaten before reporting, it should be the same meal on each of the 3 days and should be taken not later than 2 hr before the test. For the purposes of analysis, the subjects were grouped by the type of breakfast eaten. This classification was as follows: group 1, no breakfast at all; group 2, a "breakfast" of purely liquids, milk, tea, coffee, juice, or instant breakfast; group 3, a breakfast largely of carbohydrate (cereal, toast, or muffin with butter and jelly, et cetera); group 4, a breakfast containing first-class protein, i.e., eggs, ham, sausage, et cetera.

On each of the 3 days, the subjects received 150 ml tomato juice. On 1 day the juice contained 5 g MSG and on the other 2 days the juice had been adjusted to an equivalent taste by the addition of 0.8 g NaCl. Thirty to forty minutes after the subject drank the juice, a blood sample was taken from an antecubital vein and analyzed for glutamate content by the method of Bernt and Bergmeyer (12). Two hours after drinking the juice, the subjects were asked the following eleven questions in a standard form:

1) Did you find the juice you drank this morning palatable?
2) How would you describe the flavor of the juice?
3) Was the dominant taste sweet, salty, bitter, sour, or other? Specify.
4) When you had finished drinking the juice were you left with any after taste? Describe.
5) Did you experience any other sensation in your mouth?

TABLE 2
Analysis of symptom occurrence

Description of sensation	Location	MSG day	Placebo day
Warmth/burning	Face	1	2
	Head	2	0
	Neck	0	1
	Shoulders	0	1
	Arms	0	0
	Chest	0	0
	Elsewhere	1	0
Stiffness, tightness	Face	1	0
	Neck	1	3
	Arms	0	0
Weakness	Arms	0	1
	Legs	0	1
Pressure	Eyes	2	0
	Face	2	0
	Head	4	2
	Chest	4	0
Tingling	Mouth	1	0
	Jaws	1	0
	Tongue	1	2
	Teeth	2	1
	Head	2	0
	Shoulders	1	0
	Arms	1	0
Heartburn gastric discomfort		4	1
Lightheadedness		5	0
Headache		4	2
Total symptoms		40	17

TABLE 3
Reactions to MSG by sex

	Total	Male	Female
Number of subjects	77	44	33
Number of reactors	25	11	14
Percentage of reactors	32	25	42

6) Since drinking your juice have you experienced any other sensations?
7) How soon did these sensations begin?
8) How long did they last?
9) Are you still experiencing any of these sensations?
10) Do you think the juice you drank this morning contained MSG?
11) How does the juice you drank this morning compare with your previous test sample(s)?

If the answer to question 6 was positive, the subject was asked to describe these sensations. If the answer to question 9 was positive, the subject was contacted later to determine the duration of the symptoms.

Results

A total of 77 subjects was studied. Twenty-five persons reported one or more symptoms on the day juice containing MSG was drunk. Eleven subjects reported one or more symptoms on one of the days when the juice placebo was taken. No symptoms were reported by anyone on both placebo days; one subject reported reactions on one placebo day as well as the day MSG was taken. No report in this series was of the classical CRS triad. Of our Negro subjects, no one reported a reaction on either the MSG day or a placebo day.

The symptoms reported are analyzed in Table 2, whereas the reactions to MSG are recorded by sex in Table 3. The difference between frequency of occurrence of symptoms in male and female subjects is significant ($P < 0.01$).

In Table 4, reactions to the MSG are recorded grouped by type of breakfast taken by the subjects. There is no significant difference in frequency of occurrence of symptoms in subjects following different breakfast regimes. In Tables 5–7, the glutamate concentrations of the venous blood samples are recorded. Values are expressed as micrograms MSG per milliliter of blood. The differences in plasma level following MSG compared with the placebo ingestion is, in all cases, significant ($P < 0.01$). There is no significant difference between the post-MSG level of reactors and of the whole group. The racial difference between blood levels is not significant on placebo days nor following MSG ingestion. These results indicate that eating, or not eating, and the type of food eaten 2 hr prior to the MSG or placebo ingestion, does not influence the blood level nor does it significantly modify the extent of the rise in blood glutamate level following MSG ingestion.

TABLE 4
Reactions to MSG grouped by types of breakfast

	Group 1	Group 2	Group 3	Group 4
Number of subjects	12	20	29	16
Number of reactors	3 (25%)	7 (35%)	10 (34.5%)	5 (31%)
Number of non-reactors	9	13	19	11

In Table 8 the percentage changes in blood glutamate concentration seen in the total group are compared with the group reporting symptoms. The largest change seen, from a placebo day level of 21 to 53 μg/ml occurred in a non-reactor; the smallest rise from a placebo day level of 12 to 13 μg/ml occurred in a reactor.

In Phase 1 of the study, we appeared then to have identified 25 subjects out of our population of 77 who developed symptoms after a 5-g dose of MSG. An additional 11 subjects had reported symptoms on days when a lightly salted tomato juice placebo was taken. Neither "resting" level of blood glutamate nor the level achieved after MSG ingestion served to predict reaction or non-reaction in a subject.

Phase 2

Twenty-two of the twenty-five subjects who reported symptoms on the day on which they received tomato juice containing MSG

TABLE 5

	Mean	SD	SE
All subjects (77)			
Placebo day 1	16.6	3.99	0.46
Placebo day 2	17.05	5.03	0.60
MSG day	23.67	7.23	0.85
Male subjects (44)			
Placebo day 1	16.8	4.88	0.74
Placebo day 2	16.8	5.55	0.89
MSG day	22.7	8.13	1.24
Female subjects (33)			
Placebo day 1	16.4	2.39	0.42
Placebo day 2	17.2	4.45	0.79
MSG day	24.09	5.71	1.04
Negroes (9)			
Placebo day 1	16.4	3.27	0.67
Placebo day 2	18.3	5.82	1.16
MSG day	25.4	7.55	1.57

TABLE 6
Blood levels of glutamate analyzed by race

	Total group (77)	Negro (9)	Caucasian (68)
Placebo day			
Mean	16.8	21.8	16.3
SD	4.52	6.15	3.94
SE	0.37	1.49	0.34
MSG day			
Mean	24.2	27.0	23.8
SD	7.23	9.91	7.76
SE	0.84	3.30	0.94

TABLE 7
Results analyzed by type of breakfast and reaction or no reaction to MSG

Type of breakfast		Reactors (25)		Non-reactors (52)	
		Placebo	MSG	Placebo	MSG
1	Mean	15.1	26.5	20.0	30.9
	SD	2.92	11.59	5.40	8.56
	SE	1.31	6.69	1.27	2.85
2	Mean	16.5	24.0	16.0	20.0
	SD	5.49	4.49	4.45	5.34
	SE	1.47	1.70	0.91	1.48
3	Mean	16.7	24.5	15.7	22.1
	SD	3.55	8.41	3.16	6.05
	SE	0.80	2.66	0.51	1.39
4	Mean	20.6	26.2	15.7	25.7
	SD	5.66	8.39	4.36	11.10
	SE	1.79	3.75	0.93	3.35

formed the test group for the second phase of the investigation. The experimental pattern adopted was a double-blind administration of the test material. On each of 3 days, the subjects were given 150 ml solution to drink. These solutions were designated A, B, or C and were given in order decided at random. The subjects in this phase were given ques-

TABLE 8

	>50% rise in blood level on MSG day	<50% rise in blood level on MSG day
Total no. of subjects, 77	27	50
Percentage	35%	65%
Subjects who reacted to MSG, 25	10	15
Percentage	40%	60%

TABLE 9

Series	No of subjects	No. of doses administered	No. of positive responses	Percentage positive responses
Juice placebo (JP 1)	21	63	13	20.6
Water placebo (WP)	21	63	7	11.1
5 g MSG + 0.2 g NaCl in water (WM 5)	17	51	41	80.4
1 g MSG in tomato juice (JM 1)	15	44	3	6.8
2 g MSG in tomato juice (JM 2)	13	39	8	20.5
3 g MSG in tomato juice (JM 3)	13	39	22	56.4
4 g MSG in tomato juice (JM 4)	14	42	31	75.6
Juice placebo (JP 2)	13	39	7	17.9

TABLE 10

	No. of subjects	No. of symptoms reported	No. of symptoms/subject
1. JP 1	21	20	0.95
2. WP	21	10	0.48
3. WM 5	17	87	5.12
4. JM 1	15	6	0.4
5. JM 2	13	15	1.15
6. JM 3	13	42	3.23
7. JM 4	14	66	4.71
8. JP 2	13	11	0.85

tionnaires in precisely the form described for phase 1 and these they completed and returned to the laboratory 2 hr after drinking the juice. If there were any ambiguities these were then checked personally. No blood samples were taken.

Eight series of experiments were undertaken in this phase. The solutions administered in any one series, although designated as A, B, or C were always identical; the composition of the eight test solutions is as follows:

1) Series JP 1, 150 ml tomato juice containing 0.8 g NaCl served cold.
2) Series WP, 150 ml water containing 0.7 g NaCl served at room temperature.
3) Series WM 5, 150 ml water containing 5 g MSG plus 0.2 g NaCl served at room temperature.
4) Series JM 1, 150 ml tomato juice containing 1 g MSG served cold.
5) Series JM 2, 150 ml tomato juice containing 2 g MSG served cold.
6) Series JM 3, 150 ml tomato juice containing 3 g MSG served cold.
7) Series JM 4, 150 ml tomato juice containing 4 g MSG served cold.
8) Series JP 2, 150 ml tomato juice containing 0.8 g NaCl served cold.

The number of subjects varied between the series in this phase but a minimal core of 13 subjects took part in all tests.

In Table 9 are recorded frequencies of occurrence of symptoms (positive responses) in the eight series.

The number of symptoms reported in each series and an average value for symptoms per subject are recorded in Tables 10 and 11.

If the symptoms reported are analyzed as in Table 1 and totals calculated for characters of sensation, the profiles emerge for the series in which MSG was given as shown in Table 12.

An examination of the latency of onset of symptoms (Table 13) and the duration of symptom experience failed to reveal any significant dose dependency of these parameters, although duration of symptom experience showed a trend of this nature.

TABLE 11

Series	Total no. of subjects	No. of subjects giving positive response			
		on 3 days	on 2 days	on 1 day	on 0 day
JM 1	15	0	0	3	12
JM 2	13	0	1	7	5
JM 3	13	5	1	5	2
JM 4	14	7	4	3	0

These results would suggest that three basic forms of symptom appearance may be recognized:

1) The heartburn–gastric discomfort report that has little or no dose dependency; weakness in limbs falls into this class and possibly also lightheadedness.
2) The stiffness–tightness type of report that has a high degree of dose dependency and may appear at the low levels.
3) The pressure type of report (which may in rare cases go to the level of pain or distress) that does not appear to occur at low levels but above a threshold level becomes dose dependent. This applies also to warmth and burning. A tingling sensation may also belong in this class with the occasional appearance at low levels being nonspecific. Headache, too, has elements of threshold behavior and nonspecificity.

TABLE 12

	Series				
	JM 1 (15)	JM 2 (13)	JM 3 (13)	JM 4 (14)	WMJS (17)
Reports of warmth or burning	1	1	12	19	22
Reports of stiffness or tightness	1	3	10	13	17
Reports of weakness in limbs	0	3	3	2	2
Reports of pressure	0	0	6	12	19
Reports of tingling	2	2	2	10	13
Heartburn/gastric discomfort	0	2	3	3	0
Headache	1	1	4	5	8
Lightheadedness	1	3	2	2	6

These are total values not corrected for differences in the number of subjects tested. Number of subjects tested is recorded in parentheses alongside the series designation.

TABLE 13
Latency of onset and symptom duration

Dose of MSG	Latency of symptom onset in min	Duration of symptom experience in min
1 g	21 ± 7	(22 ± 6)[a]
2 g	17 ± 6	28 ± 18
3 g	18 ± 7	30 ± 20
4 g	22 ± 7	33 ± 24

Values are expressed as mean ± SD.
[a] Eliminated from this value are two observations, one of "fatigue" and one of "headache," which were unusually prolonged.

Discussion

The experiments reported here generally support earlier observations in terms of susceptibility to MSG of an unselected population and in terms of the sensations that may be experienced. Thirty-two percent of the persons tested responded at the 5-g level when challenged by a single placebo-controlled exposure. This value is slightly lower than those reported in the series without placebo control. We can confirm the findings of Morselli and Garattini (9) and of Rosenblum et al. (10) that symptoms may also be experienced following the ingestion of placebo materials, although the frequency with which this occurred is lower in the present series. There was an approximately 20% unreliability rate in our group of subjects who were classified by the screening procedure as reactors. In two series of exposures to three placebo trials, 21 and 18% positive responses were recorded; exposure of reactors to doses of MSG equal to that to which they initially responded produced an 80% positive response.

The symptoms experienced by our subjects match those previously reported but the combination of symptoms of the kind described by Schaumburg was rare in the dosage range used. Our subjects showed a dose-response relationship, particularly marked in the case of stiffness and tightness symptoms and somewhat less obvious in the case of pressure, warmth, and tingling sensations which exhibited a clear threshold for their appearance at the 2- to 3-g level.

However, in examining these data one must bear in mind that the subjects over the course of these trials appeared to develop a "set" in the form of their responses. This may be due to a genuine, individually specific nature of response or it may be an "attention" phenomenon. The subjects with repeated testing became extremely analytical of their reactions, as is evidenced by the greater number of symptoms reported in phase 2 exposures compared with phase 1. The symptoms are largely peripheral and it is tempting to locate the effect at peripheral

nerve endings. The fact that the sensation is variously described as pressure, warmth, burning, tingling (or in one subject, itching) suggests that the nerve endings involved might be the subcutaneous free-nerve endings of primitive chemical sense. An incidental observation supporting this notion is that if the skin is mildly abraded, the site of the abrasion becomes the site for the first appearance of sensation during the development of the response. Chemoceptor stimulation has already been suggested as a possible cause of the sub-sternal discomfort (11). Subjects experiencing headache not infrequently compare the pain with that of migraine with similar prodromata. The lack of correlation of blood glutamate level with the appearance of symptoms suggests that MSG per se is not the effective agent. Whereas a very extensive list of possible secondary agents could be generated including gamma-aminobutyric acid, serotonin and histamine, transient hypernatremia or hypokalemia or alteration in acid–base status have not been completely excluded. Reports of objective responses to MSG ingestion are few, although palpitation has been reported several times. In only two series has an actual change of heart rate been recorded.

The significance of these observations is difficult to assess as one becomes involved with the important nutritional phenomena of taste and palatability. It would appear that quantities of the order of 1 g/average serving are to be found in many foods and a typical daily intake of glutamic acid derived from dietary protein may be as high as 40 g. It seems likely that monosodium L-glutamate taken as the salt is not physiologically equivalent to glutamic acid ingested in protein. In our series, the subjects responded favorably in terms of taste and palatability of the tomato juice containing 1 g MSG in 150 ml and less favorably when larger quantities were given. It is also of interest that at this dose level there was a lower response rate than with a lightly salted placebo juice. On the basis of our observations, quantities less than 2 g/serving would have no more chance of producing symptoms than seasoned juice containing no added MSG. The evidence to date leaves no doubt that MSG is capable of producing symptoms but when used in appropriate culinary quantities only a very small minority of persons will be affected. The exhibition of quantities that might properly be regarded as bizarre in the culinary setting increases the possibility of symptom occurrence, in our experience to 30% of a test population at the 5-g level.

References

1. Man-Kwok, R. Ho. Chinese Restaurant Syndrome. *New Engl. J. Med.* 278: 796, 1968.
2. Kandall, S. R. Chinese-Restaurant Syndrome. *New Engl. J. Med.* 278: 1123, 1968.
3. Schaumburg, H. H. Chinese Restaurant Syndrome. *New Engl. J. Med.* 278: 1122, 1968.
4. Beron, E. L. Chinese Restaurant Syndrome. *New Engl. J. Med.* 278: 1123, 1968.
5. Menken, M. Chinese Restaurant Syndrome. *New Engl. J. Med.* 278: 1123, 1968.
6. McGaghren, T. J. Chinese Restaurant Syndrome. *New Engl. J. Med.* 278: 1123, 1968.
7. Gordon, M. E. Chinese Restaurant Syndrome. *New Engl. J. Med.* 278: 1123, 1968.
8. Schaumburg, H. H., and R. Byck. Sin cib-syn: accent on glutamate. *New Engl. J. Med.* 279: 105, 1968.
9. Morselli, P. C., and S. Garattini. Monosodium glutamate and the Chinese Restaurant Syndrome. *Nature* 227: 611, 1970.
10. Rosenblum, I., J. D. Bradley and F. Coulston. Single and double blind studies with oral monosodium glutamate in man. *Toxicol. Appl. Pharmacol.* 18: 367, 1971.
11. Schaumburg, H. H., R. Byck, R. Gerstl and J. H. Mashman. Monosodium glutamate: its pharmacology and role in the Chinese Restaurant Syndrome. *Science* 163: 826, 1969.
12. Bernt, E., and H-U. Bergmeyer. L-glutamate. Determination with glutamic dehydrogenase. In: *Methods of Enzymatic Analysis*, edited by H-U. Bergmeyer. New York: Academic, 1965, p. 384–389.

3829

Hoppe-Seylers Zeitschr.Physiol. Chem.,
300(1/3):97-106, 1955.

Studies on the Metabolism of L(+)-Glutamic Acid.

1. General Effects and Changes in Blood Chemistry, Particularly the Ketoacid Content of the Plasma after the Administration of L(+)-Glutamic Acid In Vivo

by

V. Klingmüller and K.H. Vogelsang

From: Physiological and Chemical Institute of the University of Hamburg (Director: Prof. K. Kühnau, M.D.)

Received: Jan. 13, 1955.

Little is known concerning glutamic acid administered per os or parenterally. It is known that it is a glucoplastic amino acid, is transferred by transamination into the citric acid cycle and is excreted in the urine in paired form. However, the important question raised by the studies of Christensen, Streicher and Elbinger (1), namely how excess glutamic acid influences the quantitative behavior and the metabolism of other amino acids in the living organism, still remains unanswered. Since this question is of great physiological importance, in view of the constancy of normal quantitative ratios of amino acids, we have carried out investigations on the fate of parenterally administered glutamic acid and on the changes in the level of other metabolites that originate from protein metabolism occurring after the injection of glutamic acid. In preliminary experiments the tolerance of

300(1/3)
97-106
(1955)

of injected glutamic acid was tested in the rat.

Methods

Glutamic acid solutions: the poorly soluble L(+)-glutamic acid was suspended in water, brought into solution with sodium hydroxide or ammonium hydroxide at pH 7.0 and diluted so that the content, calculated for glutamic acid, was 10 or 20%; in this manner essentially monosodium glutamate or monoammonium glutamate was present.

pH measurement: The blood was withdrawn by cardiac puncture and directly determined in the glass electrode.

Micobiological determination of glutamic acid: blood from the ear vein was immediately centrifuged; 1-3 ml serium was deproteinated according to Hier and Bergeim (2), diluted with 1.4 ml water per ml, mixed with 0.35 ml 0.6-n H_2SO_4 and 0.25 ml 10% sodium tungstate solution. For microbiological determination with Lactobacillus arabinosus 17-5, the clear filtrate was brought to pH 6.8 with sodium hydroxide. The determinations took place according to Snell (3a).

Enzymatic determination of pyruvic acid and α-ketoglutaric acid: 3-6 ml serum was deproteinated with the same volume of 6% perchloric acid; in the case of small ketoglutaric acid quantities, as for instance in the fasting plasma, extraction took place with peroxide-free ether; in the case of larger quantities, for instance after the administration of glutamic acid, no extraction was necessary, since the

disturbing substances had not increased correspondingly. The ether extract was mixed with water and the ether evaporated. The resulting aqueous solution was brought to pH 6.8 with 2-n KOH, like the non-extracted, protein-free filtrates, and the decrease in extinction after the addition of ammonium acetate n/20-triethanolamine buffer (pH 7.4), DPNH and enzymes (crystallized lactic acid dehydrogenase and crystalline glutamic acid dehydrogenase) was measured at 366 mμ.

Determination of free ammonium in the blood: 1.0 ml fresh blood drawn from the ear vein was pipetted into Conway diffusion dishes together with 1.0 ml saturated potassium carbonate solution and 2.0 ml 0.01-n H_2SO_4; after 120 min diffusion time the ammonium was determined in 1.5 ml of the fluid from the inner ring by photometry with Nessler's reagent.

Behavior of rats after injection of sodium glutamate, ammonium glutamate and ammonium chloride. Shifts in blood pH.

Intravenous injections of L(+)-glutamic acid may lead to nausea and vomiting in humans and dogs. Rats, and particularly mice were found to be less sensitive. The toxic dose was given as 100-129 mg/kg body weight. Pfeiffer (3b) administered more than 2 g/kg glutamic acid both orally and parenterally to guinea pigs and mice without observing any toxic phenomena, described as trembling or partial paralysis.

Continuing these experiments we administered neutralized glutamic acid intraperitoneally in rising concentrations to rats weighing 100-150 g. When using glutamic acid neutralized

with sodium hydroxide it was found that upon injection of at least 2.1 g/kg (corresponding to 14.5 mMol/kg) there was a pronounced acceleration of respiration after a period of latency, and increasing motor weakness. 19-55 min after the injection there was restlessness, often elicited by outside stimuli. The animals either began to tremble or made sudden violent jumps. A few clonic twitches finally gave way to seizures 23-72 min after the injection. Suddenly the entire voluntary musculature contracted in a strong tetanus, the legs being stretched to their fullest extent. If prolonged, these seizures led to death. In most cases, however, they broke up into attacks of clonic convulsions. Each seizure was followed by a phase of exhaustion, which frequently only lasted a few minutes. Thereafter there were repeated attacks of tetanic stretching, sometimes lasting for an hour, either arising spontaneously or elicited by sensory stimuli.

When more than 3.6 g/kg (corresponding to 25 mMol/kg) sodium glutamate was administered, more than 50% of the rats died within 100 min with seizures; occasionally death only occurred 12 hours later (Table 1). Intraperitoneal injection of glutamic acid neutralized with ammonium hydroxide led to increased restlessness and seizures after 2-4 min, in fact 0.09 g/kg (corresponding to 6.5 mMol/kg) was sufficient to elicit a picture of poisoning. Aside from the seizures, this was characterized by typical Kussmaul respiration, which often began before the seizure and was followed by loss of consciousness. These symptoms suggest acidotic metabolism.

With a quantity of ammonium glutamate only slightly higher than the seizure-eliciting dose, namely 1.0 g/kg, corresponding to 7.0 mMol/kg, more than 50% animals died in seizure or in an acidotic coma (Table 1).

Since this picture of poisoning after intraperitoneal administration of glutamic acid salts largely resembles the picture following ammonia poisoning, ammonium chloride was administered to rats for purposes of comparison. After intraperitoneal administration of at least 7 mMol/kg ammonium chloride, deeper respiration set in 5-10 minutes later, with violent stretch seizures. With 8 mMol/kg more than 50% of the animals died, usually during the first seizure (Table 1). While after the administration of sodium glutamate the seizure was most striking from the clinical standpoint, after the administration of ammonium glutamate the most striking symptoms are those indicating acidosis. Ammonium glutamate is somewhat more toxic than ammonium chloride both with regard to the elicitation of seizures and with regard to lethality.

The clinically manifested disturbances suggesting acidosis (Kussmaul respiration and coma) after injection of ammonium glutamate find a correlation in the behavior of the pH in the blood. 15 min after intraperitoneal injection of sodium glutamate there were normal values, but after injection of ammonium glutamate and after the injection of ammonium chloride the reaction shifted towards the acid side, to a degree distinctly dependent on the administered dose (Table 2).

To determine whether these high lethal glutamic acid

dosages affect the carbohydrate metabolism, particularly with regard to possible hypoglycemic involvement in seizure states, we investigated (3c) the blood sugar in the heart blood sub finem after intraperitoneal injection of 50 mMol/kg sodium glutamate in a 20% solution in 10 Sprague-Dawley rats. Seizures occurred between 40 and 80 min after the injection. The blood sugar values on the average were 90 mg% with a range of variation of 72 to 120 mg%.

Glutamic Acid Level in the Blood

For the study of the changes in the blood level of free glutamic acid after parenteral injection, healthy rabbits weighing 3-3.5 kg, kept fasting for at least 15 hours before the beginning of experimentation, received 300 mg/kg (2.0 mMol/kg) sodium glutamate intravenously, and 30 min previously and at certain time intervals after the injection blood was drawn from the other ear for microbiological determinations. The glutamic acid concentration rose after the injection from a blood level of 1.35 mg% (0.092 mMol per l) to 270 mg%, (18.4 mMol per l); after 30 min more than 50% of the quantity administered had disappeared from the serum and 3 hours thereafter the initial value was approximately reached once more (Fig. 1).

Studies on the Fate of Amino Nitrogen and the Carbon skeleton of Injected Glutamic Acid

In further experiments the influence of L(+)-glutamic acid on the citric acid cycle was studied by determining

the α-ketoglutaric acid content of the blood parallel with the glutamic acid determinations. Healthy rabbits weighing 3-3.5 kg received 300 mg/kg (2.0 mMol/kg) sodium glutamate intravenously. Immediately after the i.v. injection the keto-glutaric acid content increased considerably. The maximum was already reached within 5-6 min and was 10-13 times the initial value (Fig. 2). With intraperitoneal administration of 500 mg/kg sodium glutamate the value rose to 20 times the initial value. Like the glutamic acid concentration, keto-glutaric acid in the serum gradually decreased and after 120-180 min reached the initial value. The normal values for the rabbit were found to be 0.195-0.325 mg% α-ketoglutaric acid in the serum. The greatest rise after intravenous ad-ministration of 300 mg% sodium glutamate was 3.18 mg%, the smallest 1.90 mg%. After parenteral administration of 500 mg/kg sodium glutamate the highest value was 4.75 mg%, the lowest 4.30 mg%. The rise in the α-ketoglutaric acid concentration in the serum thus shows a distinct dependence upon the quantity of glutamic acid administered.

It could be assumed that the ketoglutaric acid originated from the glutamic acid administered. But in that case the fate of the amino group remained to be clarified. The most probable assumption was transamination to other keto acids. We therefore studied the behavior of pyruvic acid in the serum, and found that an increase in α-ketoglutaric acid was always

accompanied by a decrease in the pyruvic acid in the serum (Fig. 2).

We found the initial values of pyruvic acid in the rabbit serum to be 1.80-3.10, mg% corresponding to 0.2-0.35 mMol/l. After glutamic acid injections the values dropped down to 0.260 mg% or 0.03 μMol/l. In most cases the lowest pyruvic acid value was measured at the same time-point after the injection as the highest α-ketoglutaric acid aconcentration, but sometimes 5-15 min thereafter there was a further fall in the pyruvic acid in the serum. 60-90 min after the fall in α-ketoglutaric acid to the initial value, the pyruvic acid value also reached the initial value once more, although in some experiments the original level was still not reached after 4 hours.

If we calculate the molar ratio of the increase in α-ketoglutaric acid concentration in the serum to the decrease in pyruvic acid, it will be seen that the decrease in pyruvic acid corresponds to 88-96% of the increase in the α-ketoglutaric acid concentration.

This rapid and practically quantitative correlation would seem to justify the question of to what extent the blood itself gives rise to the shift in the normal ketoacid equilibrium after the injection of glutamic acid.

In the next experiments rabbit blood freshly drawn from the ear vein was defibrinated by shaking with glass beads

and 20 ml of this blood was shaken after addition of 50 mg sodium glutamate at 37° in the water bath in the presence of air. Before placing in the incubator samples were taken after 10, 20, and 30 min to determine α-ketoglutaric acid and pyruvic acid. Here again there was a distinct rise in ketoglutaric acid (Fig. 3), which only reached its maximum after 60 min and was accompanied by a corresponding decrease in pyruvic acid. The molar conversions in this in vitro experiment, with 93-96%, were almost quantitative; they behave in the same manner as the changes in glutamic acid, but do not quite correspond to the amount of added glutamic acid (Table 3). Apparently the blood itself is capable of transamination to quite a considerable degree.

It is entirely compatible with these experiments that the amino group of glutamic acid does not appear in the blood as free ammonium ion. After intravenous injection of 1.0 g sodium glutamate into a rabbit weighing 3500 g all NH_3 values of the serum remained within the range of the fasting value; none of the NH_3 values fell outside our limits of 0.12-0.36 mg%. At the time of maximum glutamic acid or ketoglutaric acid content or minimum pyruvic acid content the NH_3 content still did not increase. But if an equimolar quantity of ammonium chloride to the glutamic acid quantity is injected intravenously (100 mg/kg), even with a 13 mg% free ammonium content of the blood there is no decrease in the pyruvic acid concentration in the serum (Fig. 4). This tends to suggest transamination rather

than secondary amination of pyruvic acid following oxidative desamination of glutamic acid.

Discussion

Injected glutamic acid is relatively rapidly decomposed in the body. After a rapid increase of the blood level, as a rule its content decreases back to normal values after 120 min. This fact demonstrated microbiologically in the rabbit was confirmed by Himwich (5) by colorimetric detection of glutamic acid in humans. The capacity of an organism to utilize glutamic acid in the metabolism depends not only upon the immediate functional state, but, for instance, also upon the speed of the injection, as has been stressed by Schober (6). This also explains in part the fact that various authors have reported very diverse values for different animals with regard to tolerance.

According to Tigerman, MacVicar (7), after simultaneous oral administration of ammonium and glutamic acid, an increase of glutamine is observed in the tissues; glutamase rapidly synthesizes the well-tolerated glutamine (8) from the two compounds administered simultaneously. However, this mode of utilization does not apply to glutamic acid administered parenterally. Glutamic acid does not improve the picture of poisoning by ammonium chloride and conversely, ammonium that of glutamic acid; indeed ammonium glutamate is more toxic than sodium glutamate.

Ammonium chloride and ammonium glutamate lead to acidosis with very similar phenomena. This ammonium chloride acidosis according to Winterstein and Gökhan (9) is attributable to tissue alkalosis. For instance the the cerebrospinal fluid becomes alkaline, the NH_3 molecule presumably being the form of transport of basic valences from the blood to the cerebrospinal fluid. In view of the slight detoxifying effect of glutamase, the involvement of glutamine in the binding and transport of ammonium is not certain. Possibly here again it is the uncharged glutamine which migrates into the cerebrospinal fluid (10) and together with the binding and detoxification of ammonium is responsible for its transport across the membranes. Perhaps the phenomenon of poisoning after the administration of glutamate is based on a similar mechanism.

It has been established in prolonged analytical experiments and again confirmed by experiments with glutamic acid tagged with isotopes that in the final analysis amino nitrogen becomes urea, and acids and glucose can be formed from the carbon skeleton of the tricarboxylic acid cycle. Our investigations have shown the primary fate of glutamic acid. Free ammonium does not appear in the blood, but α-ketoglutaric acid is immediately formed with simultaneous reduction of pyruvic acid. Probably there is transamination which takes place predominantly in the liver (11). It could be demonstrated, however, that whole blood also plays an important role in carrying out transamination reactions.

Figures

1. L(+)-Glutamic acid in the serum after intravenous injection of 2.0 mMol/kg neutralized glutamic acid; rabbit.

2. Pyruvic acid content of the serum (broken line) and α-ketoglutaric acid (solid line); ↓ i.v. injection of 2.0 mMol/kg neutralized glutamic acid; rabbit (3500 g).

3. Shifts in α-ketoglutaric acid and pyruvic acid in in vitro experiments with rabbit blood; aerobic, 37°. Blood without additives: α-ketoglutaric acid in μMol/100 ml (broken line); pyruvic acid in μMol/100 ml (-..-..-); blood (20 ml) after addition of 50 mg sodium glutamate: α-ketoglutaric acid μMol/100 ml (solid line); pyruvic acid in μMol/ml (-.-.).

4. Shifts in ammonium (solid line) and pyruvic acid (broken line) in the blood of rabbits. ↓ intravenous injection of 1.8 mMol/kg ammonium chloride.

Tables

1. Glutamic acid tolerance in rats. Key: 1. Seizure-eliciting dose. 2. 50% lethality. 3. Sodium glutamate. 4. Ammonium glutamate. 5. Ammonium chloride.

2. pH of the blood 15 min after intraperitoneal injections in rats. Measurement with glass electrode. Key: 1. Ammonium chloride. 2. Ammonium glutamate. 3. Sodium glutamate.

3. α-Ketoglutaric acid and pyruvic acid in the defibrinated rabbit blood after shaking in water bath at 37°. 1. Blood without additive. Key: 1. Ketoglutaric acid. 2. Pyruvic acid. 3. Increase in ketoglutaric acid. 4. Decrease in pyruvic acid. 5. Yield. 6. Initial value. 7. II. After addition of 50 mg sodium

glutamate to 20 ml blood.

Summary

Please see English summary on p. 106.

Acknowledgements

We thank Drs. T. Bücher and G. Pfleiderer for their gift of crystalline lactic acid dehydrogenase, Prof. K. Wallenfels for crystalline glutamic acid dehydrogenase and Dr. F. Bramstedt for Lactobacillus arabinosus 17-5 for the glutamic acid determinations and for furnishing details of their method.

We thank Chemiewerk Homburg AG for their gift of sterile solutions of glutamtic acid salts.

Bibliography

See references in footnotes.

3c. J. Gayer, unpublished experiments.

5. W.A. Himwich, personal communication

Untersuchungen über den Stoffwechsel der L(+)-Glutaminsäure

I. Mitt.: Allgemeinwirkungen und Veränderungen des Blutchemismus, insbesondere des Gehalts an Ketosäuren im Plasma nach Verabreichung von L(+)-Glutaminsäure in vivo

Von

V. Klingmüller und **K. H. Vogelgesang**

Aus dem Physiologisch-Chemischen Institut der Universität Hamburg
(Direktor: Prof. J. Kühnau)

(Der Schriftleitung zugegangen am 13. Januar 1955)

Über das Verhalten von per os oder parenteral zugeführter Glutaminsäure ist nur wenig bekannt. Man weiß zwar, daß sie zu den glucoplastischen Aminosäuren gehört, durch Transaminierung in den Citronensäurecyclus eingeschleust und in gepaarter Form im Harn ausgeschieden wird; doch ist die wichtige, durch die Untersuchungen von Christensen, Streicher und Elbinger[1] aufgeworfene Frage, wie überschüssig zugeführte Glutaminsäure das quantitative Verhalten und den Umsatz der anderen Aminosäuren im lebenden Organismus beeinflußt, noch unbeantwortet. Da diese Frage angesichts der Konstanz der normalen Mengenrelation der Aminosäuren von großer physiologischer Bedeutung ist, haben wir Untersuchungen über das Schicksal parenteral verabreichter Glutaminsäure und über die nach Glutaminsäureinjektion auftretenden Verschiebungen im Haushalt anderer dem Eiweißumsatz entstammender Metaboliten angestellt. In Vorversuchen wurde die Verträglichkeit injizierter Glutaminsäure an der Ratte geprüft.

Methoden

Glutaminsäurelösungen: Die schlecht lösliche L(+)-Glutaminsäure wurde in Wasser suspendiert, mit Natronlauge oder Ammoniumhydroxyd bei p_H 7,0 in Lösung gebracht und so verdünnt, daß der Gehalt, auf Glutaminsäure berechnet, 10 oder 20% beträgt; dann liegt im wesentlichen Mononatriumglutaminat oder Monoammoniumglutaminat vor.

p_H-Messung: das Blut wurde durch Herzpunktion entnommen und direkt in der Glaselektrode bestimmt.

Mikrobiologische Bestimmung der Glutaminsäure: Blut aus der Ohrvene wird sofort zentrifugiert; 1—3 *ml* Serum wurde nach Hier und Bergeim[2] enteiweißt, indem es pro *ml* mit 1,4 *ml* Wasser verdünnt, mit 0,35 *ml* 0,6-*n*. H_2SO_4 und 0,25 *ml* 10-proz. Natriumwolframatlösung versetzt wurde. Zur mikrobiologischen Bestimmung mit *Lactobacillus arabinosus 17—5* wurde das klare Filtrat mit

[1] H. N. Christensen, J. A. Streicher u. R. L. Elbinger, J. biol. Chemistry **172**, 515 [1948].

[2] W. Hier u. O. Bergeim, J. biol. Chemistry **161**, 717 [1945].

Natronlauge auf p_H 6.8 gebracht. Die Bestimmung wurde nach den Angaben von Snell[3a] durchgeführt.

Enzymat. Bestimmung der Brenztraubensäure und α-Ketoglutarsäure: 3—6 ml Serum wurden mit gl. Vol. 6-proz. Perchlorsäure enteiweißt, bei kleinen Ketoglutarsäuremengen, wie z. B. im Nüchternplasma, wurde mit peroxydfreiem Äther extrahiert; bei größeren Mengen, z. B. nach Glutaminsäureverabreichung, war keine Extraktion nötig, weil die störenden Substanzen stark entsprechend angestiegen waren. Der Ätherextrakt wurde mit Wasser versetzt und der Äther abgedampft. Die entstandene wäßrige Lösung wurde ebenso wie die nicht extrahierten, eiweißfreien Serumfiltrate mit 2-n. KOH auf p_H 6.8 gebracht und bei 366 mμ die Abnahme der Extinktion nach Zugabe von Ammoniumsulfat, n 20-Triäthanolaminpuffer (p_H 7.4), DPNH und Fermenten (kristallisierter Brenztraubensäuredehydrogenase und kristallisierter Glutaminsäuredehydrogenase) gemessen.

Bestimmung des freien Ammoniums im Blut: 1.0 ml frisch aus der Ohrvene entnommenes Blut wird in Diffusionsschalen von Conway zusammen mit 1.0 ml gesätt. Kaliumcarbonatlösung und 2.0 ml 0.01-n. H_2SO_4 einpipettiert; nach 120 Min. Diffusionszeit wird das Ammonium in 1.5 ml der Flüssigkeit des äußeren Rings mit Nesslers Reagens photometrisch bestimmt.

Verhalten von Ratten nach der Injektion von Natriumglutaminat, Ammoniumglutaminat und Ammoniumchlorid; Verschiebungen des Blut-p_H

Intravenöse Injektionen von L(+)-Glutaminsäure können bei Menschen und Hunden zu Übelkeit und Erbrechen führen. Ratten und besonders Mäuse gelten als weniger empfindlich. Die toxische Dosis wird mit 100—129 mg/kg Körpergewicht angegeben. Pfeiffer[3b] konnte mehr als 2 g/kg Glutaminsäure sowohl oral wie parenteral an Meerschweinchen und Mäuse verabreichen, ohne daß irgendwelche toxischen Erscheinungen, die als Zittern oder partielle Paralysen beschrieben werden, zu beobachten waren.

In Weiterführung dieser Untersuchungen haben wir an Ratten von 100—150 g Körpergewicht neutralisierte Glutaminsäure intraperitoneal in steigenden Konzentrationen verabreicht. Bei Verwendung von mit Natronlauge neutralisierter Glutaminsäure zeigte sich, wenn mindestens 2.1 g/kg, entspr. 14.5 mMol/kg, injiziert worden waren, nach einer Latenzzeit eine starke Beschleunigung der Atmung und zunehmende motorische Schwäche. 19—55 Min. nach der Injektion kam es zu einer oft durch äußere Reize ausgelösten Unruhe. Die Tiere begannen entweder zu zittern oder sie machten plötzlich heftige Sprünge. Einige klonische Zuckungen leiteten schließlich 23—72 Min. nach der Injektion das Krampfstadium ein. In heftigem Tetanus zog sich plötzlich die gesamte willkürliche Muskulatur zusammen, wobei die Beine maximal gestreckt wurden. Bei längerer Dauer führte dieser Krampf zum Tode. Meist aber löste er sich unter stoßweisen klonischen Konvulsionen. Jedem Krampf folgte eine Erschöpfungsphase, die häufig nur wenige Minuten währte. Danach kam es, spontan oder durch sensible Reize ausgelöst, zu wiederholten Anfällen von tetanischen Streckungen, die oft eine Stunde lang anhielten.

[3a] E. E. Snell, Advances Protein Chem. 2, 85 [1945]; [3b] C. C. Pfeiffer in Flavor and Acceptability of Monosodium glutamate: Proc. of the Symposium, 4. März 1948: The Quartermaster and Container Institute for the Armed Forces and Associates, Chicago 9, Ill.

Bei einer Verabfolgung von mehr als 3.6 g/kg, entspr. 25 mMol/kg, Natriumglutaminat starben mehr als 50% der Ratten innerhalb von 100 Min. im Krampf; vereinzelt trat der Tod erst nach 12 Stdn. ein (Tab. 1). Intraperitoneale Injektion von mit Ammoniumhydroxyd neutralisierter Glutaminsäure führte bereits nach 2—4 Min. zu gesteigerter Unruhe und Krämpfen, und zwar genügen 0.09 g/kg, entspr. 6.5 mMol/kg, um das Vergiftungsbild hervorzurufen. Dieses ist neben Krämpfen durch eine typische Kussmaulsche Atmung charakterisiert, die häufig schon vor den Krampfanfällen einsetzt und von Bewußtlosigkeit gefolgt ist. Diese Symptome deuten auf eine acidotische Stoffwechsellage hin. Bei einer nur wenig über der krampferregenden Dosis liegenden Menge von Ammoniumglutaminat, nämlich 1.0 g/kg, entspr. 7.0 mMol/kg, starben bereits über 50% Tiere im Krampf oder acidotischem Koma (Tab. 1).

Tab. 1. Verträglichkeit der Glutaminsäure bei Ratten.

	1 Krämpfe erregende Dosis	2 50% Letalität
3 Natriumglutaminat	14.5 mMol/kg	25 mMol/kg
4 Ammoniumglutaminat	6.5 mMol/kg	7 mMol/kg
5 Ammoniumchlorid	7.0 mMol/kg	8 mMol/kg

Da dieses Vergiftungsbild nach intraperitonealer Verabreichung von Salzen der Glutaminsäure weitgehend dem einer Ammoniakvergiftung ähnelt, wurde zum Vergleich Ammoniumchlorid an Ratten verabreicht. Nach intraperitonealer Injektion von mindestens 7 mMol/kg Ammoniumchlorid kam es dabei nach 5—10 Min. zu einer Vertiefung der Atmung und heftigen Streckkrämpfen. Bereits bei 8 mMol/kg starben mehr als 40% der Tiere meist im ersten Krampfanfall (Tab. 1). Während nach Natriumglutaminat-Injektion der Krampf klinisch am augenfälligsten in Erscheinung tritt, treten nach Verabreichung von Ammoniumglutaminat besonders die auf eine Acidose hinweisenden Symptome hervor. Ammoniumglutaminat ist in bezug auf die Auslösung von Krämpfen und in bezug auf die Letalität um ein weniges toxischer als Ammoniumchlorid.

Die klinisch in Erscheinung tretenden, auf Acidose verdächtigen Symptomen (Kussmaulsche Atmung und Koma) nach Ammoniumglutaminat-Injektion finden ihr Korrelat im Verhalten des pH im Blut. 15 Min. nach intraperitonealer Injektion von Natriumglutaminat fanden sich normale Werte; aber nach Injektion von Ammoniumglutaminat verschob sich ebenso wie nach der von Ammoniumchlorid die Reaktion in starkem Ausmaß nach der sauren Seite, das eine deutliche Abhängigkeit von der verabreichten Dosis zeigt (Tab. 2).

Zur Klärung der Frage, ob sich diese hohen letalen Glutaminsäure-Dosierungen auf den Kohlenhydratstoffwechsel auswirken, besonders im Hinblick auf eventuelle hypoglykämische Beteiligungen bei den Krampf-

Tab. 2. p_H des Blutes 15 Min. nach intraperitonealen Injektionen bei Ratten; Messung mit der Glaselektrode.

1 Ammoniumchlorid		2 Ammoniumglutaminat		3 Natriumglutaminat	
mMol/kg	p_H	mMol/kg	p_H	mMol/kg	p_H
4,7	7,36	5,5	7,04	12,1	7,29
4,9	7,10	6,4	7,10	21,6	7,48
8,0	7,06	10,9	6,54 (Agone)	27,9	7,30
8,4	6,92 (Agone)	11,6	6,58 (Agone)		
9,2	6,66 (Agone)				

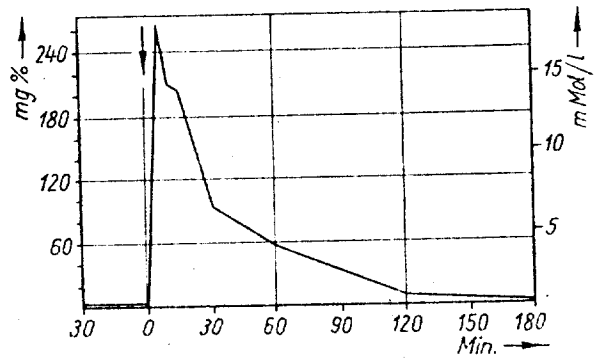

Abb. 1. L(+)-Glutaminsäure im Serum nach intravenöser Injektion von 2,0 mMol/kg neutralisierter Glutaminsäure; Kaninchen.

zuständen, untersuchten wir[3c] bei 10 Ratten (Sprague-Dawley) den Blutzucker aus dem Herzblut sub finem nach intraperitonealer Injektion von 50 mMol/kg Na-Glutaminat als 20-proz. Lösung. Die Krämpfe traten zwischen 40 und 80 Min. post injectionem auf. Die Blutzuckerwerte lagen im Mittel bei 90 mg % mit einer Variationsbreite von 72 bis 120 mg %.

Der Blutspiegel der Glutaminsäure

Für die Untersuchungen der Blutspiegelveränderungen der freien Glutaminsäure nach parenteraler Injektion wurden gesunden Kaninchen von 3—3,5 kg Körpergewicht, die mindestens für 15 Stdn. vor Versuchsbeginn nüchtern gehalten worden waren, 300 mg/kg (2,0 mMol/kg) Natriumglutaminat intravenös injiziert und 30 Min. vorher und in bestimmten Zeitabständen nach der Injektion aus dem anderen Ohr Blut zur mikrobiologischen Bestimmung entnommen. Die Glutaminsäurekonzentration stieg nach der Injektion von einem Blutspiegel von 1,35 mg %, entspr. 0,092 mMol pro l, auf 270 mg %, entspr. 18,4 mMol pro l; nach 30 Min. waren über 50 % der zugeführten Menge aus dem Serum wieder verschwunden und 3 Stdn. danach war der Ausgangswert annähernd wieder erreicht (Abb. 1).

[3c] J. Gayer, unveröffentlichte Versuche.

Untersuchungen über den Verbleib des Aminostickstoffs und des Kohlenstoffgerüsts injizierter Glutaminsäure

In weiteren Versuchen wurde der Einfluß der L(+)-Glutaminsäure auf den Citronensäurecyclus untersucht, indem parallel zu den Glutaminsäurebestimmungen der Gehalt des Serums an α-Ketoglutarsäure bestimmt wurde. Gesunden Kaninchen von 3–3,5 kg Körpergewicht wurden 300 mg/kg, entspr. 2,0 mMol/kg, Natriumglutaminat intravenös verabreicht. Sofort nach intravenöser Injektion stieg der Gehalt an Keto-

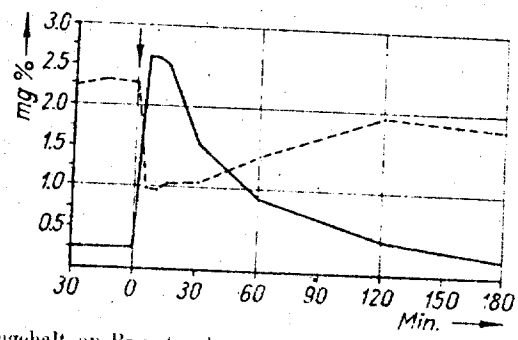

Abb. 2. Serumgehalt an Brenztraubensäure (- - - -) und α-Ketoglutarsäure (——): i. v. Injektion von 2,0 mMol/kg neutralisierter Glutaminsäure; Kaninchen (3500 g).

glutarsäure erheblich an, das Maximum war bereits nach 5–6 Min. erreicht und betrug das 10–13fache des Ausgangswertes (Abb. 2). Bei intraperitonealer Verabreichung von 500 mg/kg Natriumglutaminat stieg er bis zur 20fachen Menge des Ausgangswertes. Genau so wie die Glutaminsäurekonzentration nahm die der Ketoglutarsäure im Serum allmählich ab und erreichte nach 120–180 Min. wieder den Ausgangswert. Als Normalwerte fanden wir bei Kaninchen 0,195–0,325 mg% α-Ketoglutarsäure im Serum. Der höchste Anstieg nach intravenöser Verabreichung von 300 mg/kg Natriumglutaminat betrug 3,18 mg%, der geringste 1,90 mg%. Nach parenteraler Gabe von 500 mg/kg Natriumglutaminat war 4,75 mg% der höchste, 4,30 mg% der niedrigste Wert. Der Anstieg der α-Ketoglutarsäure-Konzentration im Serum zeigt eine deutliche Abhängigkeit von der Menge der zugeführten Glutaminsäure.

Es war anzunehmen, daß die Ketoglutarsäure aus der zugeführten Glutaminsäure stammt. Dann mußte aber das Schicksal der Aminogruppe geklärt werden. Am wahrscheinlichsten war es, eine Transamination auf andere Ketosäuren anzunehmen. Darum wurde das Verhalten der Brenztraubensäure im Serum untersucht. Tatsächlich war eine Zunahme der α-Ketoglutarsäure jedesmal von einer Abnahme der Brenztraubensäure im Serum begleitet (Abb. 2).

Als Ausgangswerte für Brenztraubensäure im Kaninchenserum fanden wir 1,80—3,10 mg%, entspr. 0,2—0,35 μMol/l. Nach Glutaminsäureinjektionen erniedrigten sich die Werte bis auf 0,260 mg%, entspr. 0,03 μMol/l. Zumeist wurde der niedrigste Brenztraubensäurewert zum gleichen Zeitpunkt nach der Injektion gemessen wie die höchste α-Ketoglutarsäure-Konzentration, manchmal aber kam es 5—15 Min. danach noch zu einem weiteren Absinken der Brenztraubensäure im Serum. 60—90 Min. nach dem Abfall der α-Ketoglutarsäure auf den Aus-

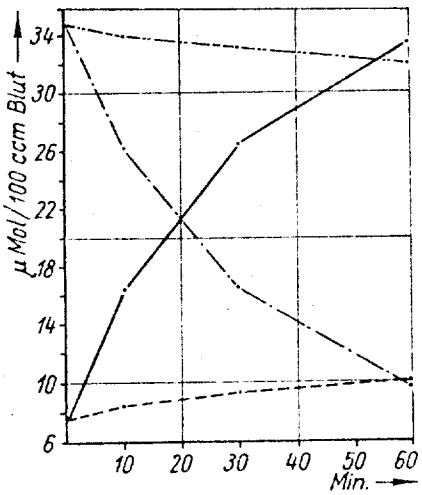

Abb. 3. Verschiebungen von α-Ketoglutarsäure und Brenztraubensäure bei Versuchen in vitro mit Kaninchenblut; aerob, 37°. Blut ohne Zusatz: α-Ketoglutarsäure in μMol/100 ml (- - - -); Brenztraubensäure in μMol/100 ml (— · · —); Blut (20 ml) nach Zusatz von 50 mg Natriumglutaminat: α-Ketoglutarsäure μMol/100 ml ( ); Brenztraubensäure in μMol/100 ml (— · — ·).

gangswert erreichte auch die Brenztraubensäure wieder die Ausgangslage im Serum, bei manchen Versuchen war die alte Höhe aber auch nach 4 Stdn. noch nicht erreicht.

Berechnet man das molare Verhältnis der Zunahme der α-Ketoglutarsäure-Konzentration im Serum zu der Abnahme der Brenztraubensäure, so sieht man, daß die Abnahme der Brenztraubensäure 88—96% der Zunahme der α-Ketoglutarsäure-Konzentration entspricht.

Diese schnelle und beinahe quantitative Beziehung läßt die Frage berechtigt erscheinen, inwieweit das Blut selbst die Verschiebung des normalen Ketosäuregleichgewichts nach Glutaminsäureinjektion bewirkt.

In den folgenden Versuchen wurde frisch aus der Ohrvene entnommenes Kaninchenblut durch Schütteln mit Glasperlen defibriniert und 20 ml davon ohne Zusätze als Kontrolle und 20 ml nach Zugabe von 50 mg Natriumglutaminat im Wasserbad in Gegenwart von Luft bei 37° geschüttelt. Vor dem Einsetzen in den Thermostaten, nach 10, 20 und 30 Min. wurden Proben zur Bestimmung von α-Ketoglutarsäure und Brenztraubensäure entnommen. Auch hier zeigt sich ein deutlicher

Anstieg der Ketoglutarsäure (Abb. 3), der erst nach 60 Min. sein Maximum erreicht und von einer entsprechenden Abnahme an Brenztraubensäure begleitet ist. Die molaren Umwandlungen sind bei diesem in vitro-Versuch mit 93—96% fast quantitativ; sie bewegen sich gleichsinnig wie die Glutaminsäureveränderungen, entsprechen aber nicht ganz der Höhe der zugesetzten Glutaminsäure (Tab. 3). Offenbar ist das Blut selber in einem nicht unbeträchtlichen Umfange zur Transaminierung befähigt.

Tab. 3. α-Ketoglutarsäure und Brenztraubensäure im defibrinierten Kaninchenblut nach Schütteln im Wasserbad bei 37°.

I. Blut ohne Zusatz

	L-Ketoglutarsäure		Brenztraubensäure		Zunahme Ketoglutarsäure	Abnahme Brenztraubensäure	Ausbeute in
	mg%	μMol	mg%	μMol	μMol	μMol	%
Ausgangswert:	1,10	7,5	3,06	34,8			
n. 10 Min.	1,23	8,4	2,99	34,0	+ 0,9	− 0,8	89
n. 30 Min.	1,36	9,3	2,93	33,3	+ 1,8	− 1,5	88,5
n. 60 Min.	1,48	10,1	2,84	32,3	+ 2,6	2,5	96

II. Nach Zusatz von 50 mg Natriumglutaminat zu 20 ml Blut

	Ketoglutarsäure		Brenztraubensäure		Zunahme Ketoglutarsäure	Abnahme Brenztraubensäure	Ausbeute in
	mg%	μMol	mg%	μMol	μMol	μMol	%
Ausgangswert:	1,10	7,5	3,06	34,8			
n. 10 Min.	2,41	16,5	2,23	26,4	+ 9,0	− 8,4	93,5
n. 30 Min.	3,89	26,5	1,46	16,6	+ 19,0	− 18,2	95,5
n. 60 Min.	4,93	33,7	0,86	9,7	+ 26,2	− 25,1	96

Zu diesen Versuchen paßt es durchaus, daß die Aminogruppe der Glutaminsäure nicht als freies Ammoniumion im Blut erscheint. Nach intravenöser Injektion von 1,0 g Natriumglutaminat bei einem 3500 g schweren Kaninchen blieben alle NH_3-Werte des Serums im Bereich ihres jeweiligen Nüchternwertes; kein NH_3-Wert fiel außerhalb unserer Grenzen von 0,12—0,36 mg%. Auch in dem Zeitpunkt des maximalen Glutaminsäure- oder Ketoglutarsäure-Gehaltes oder des Brenztraubensäure-Minimums stieg der NH_3-Gehalt nicht an. Gibt man dagegen eine der Glutaminsäure äquimolare Menge Ammoniumchlorid intravenös (100 mg/kg), so kommt es selbst bei einem Gehalt des Blutes an 13 mg% freien Ammoniaks nicht zu einer Abnahme der Brenz-

traubensäurekonzentration im Serum (Abb. 4). Dies spricht mehr für eine Transaminierung als für eine sekundäre Aminierung der Brenztraubensäure im Anschluß an eine oxydative Desaminierung der Glutaminsäure.

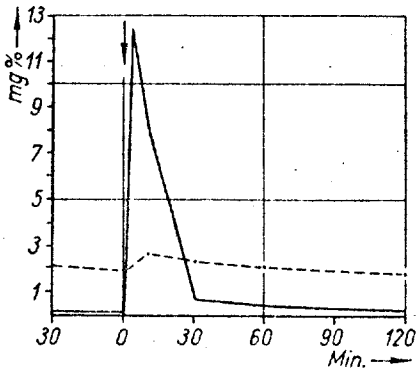

Abb. 4. Verschiebungen von Ammoniak (—) u. Brenztraubensäure (- - - -) im Blut von Kaninchen; ↓ intravenöse Injektion von 1,8 mMol/kg Ammoniumchlorid.

Besprechung der Ergebnisse[4]

Injizierte Glutaminsäure wird verhältnismäßig schnell im Körper abgebaut; nach schnellem Anstieg des Blutspiegels sinkt ihr Gehalt in der Regel nach 120 Min. auf normale Werte ab. Diese mikrobiologisch am Kaninchen gefundene Tatsache konnte von Himwich[5] mit einem kolorimetrischen Nachweis der Glutaminsäure am Menschen bestätigt werden. Die Fähigkeit eines Organismus, Glutaminsäure im Stoffwechsel zu verwerten, hängt nicht nur von dem augenblicklichen Funktionszustand, sondern z. B. auch von der Geschwindigkeit der Injektion ab, wie Schober[6] betont hat. Damit läßt sich z. Tl. auch erklären, daß für die Verträglichkeit von verschiedenen Autoren und auch bei verschiedenen Tieren sehr verschiedene Werte angegeben werden können.

Nach Tigerman, MacVicar[7] wird nach gleichzeitiger oraler Gabe von Ammonium und Glutaminsäure ein Anstieg von Glutamin in den Geweben gefunden: Glutaminase synthetisiert aus den beiden gleichzeitig gegebenen Verbindungen schnell das gut verträgliche Glutamin[8]. Aber dieser Verwertungsmodus gilt nicht für parenteral gegebene Glutaminsäure; Glutaminsäure verbessert nicht das Vergiftungsbild von

[4] H. Waelsch, Naturwissenschaften 40, 404 [1953]; H. Weil-Malherbe, ebenda 40, 541 [1953]; 41, 124 [1954]; V. Klingmüller, Biochemie, Physiologie und Klinik der Glutaminsäure, Editio Cantor KG, Aulendorf i. Württ., 1955, im Druck.

[5] W. A. Himwich, persönl. Mitteilung.

[6] R. Schober, Arzneimittel-Forsch. 4, 380 [1954].

[7] H. Tigerman u. R. MacVicar, J. biol. Chemistry 189, 793 [1951].

[8] P. Schwerin, S. P. Bessman u. H. Waelsch, J. biol. Chemistry 184, 37 [1950].

Ammoniumchlorid und umgekehrt Ammonium nicht das der Glutaminsäure: Ammoniumglutaminat ist sogar giftiger als Natriumglutaminat.

Ammoniumchlorid und Ammoniumglutaminat führen unter sehr ähnlichen Erscheinungen zu starker Acidose. Diese Ammoniumchlorid-Acidose ist nach Winterstein und Gökhan[9] auf Gewebsalkalose zurückzuführen: z. B. wird der Liquor alkalisch, wobei als Transportform basischer Valenzen vom Blut in den Liquor das NH_3-Molekül angenommen wird. Bei der geringen Wirkung der Glutaminase auf die Entgiftung ist eine Beteiligung des Glutamins an Bindung und Transport des Ammoniaks nicht gesichert. Möglicherweise ist es auch hier das ungeladene Glutamin, das in den Liquor einwandert[10] und zusammen mit der Bindung und Entgiftung des Ammoniaks auch für seinen Transport durch die Membranen verantwortlich ist. Vielleicht liegt den Vergiftungserscheinungen nach Glutaminat-Gaben ein ähnlicher Mechanismus zugrunde.

In langfristigen Bilanzversuchen ist festgestellt, und in Versuchen mit isotop markierter Glutaminsäure ist neu gesichert, daß aus dem Aminostickstoff letzten Endes Harnstoff wird und aus dem Kohlenstoffgerüst des Tricarbonsäurecyclus Säuren und Glucose gebildet werden können. In unseren Untersuchungen konnte gezeigt werden, welches primäre Schicksal die Glutaminsäure hat. Freies Ammoniak tritt im Blut nicht auf, dagegen bildet sich sofort α-Ketoglutarsäure unter gleichzeitiger Verringerung der Brenztraubensäure. Wahrscheinlich handelt es sich um Transaminierungen, die überwiegend in der Leber stattfinden[11]; aber es konnte hier gezeigt werden, daß auch dem Gesamtblut eine wichtige Rolle bei der Durchführung von Transaminierungsreaktionen zukommt.

Den Herren Prof. Dr. T. Bücher und Dr. G. Pfleiderer danken wir für die Überlassung der krist. Milchsäure-Dehydrogenase, Prof. Dr. K. Wallenfels für krist. Glutaminsäure-Dehydrogenase und Doz. Dr. F. Bramstedt für *Lactobacillus arabinosus 17 – 5* zu den Glutaminsäurebestimmungen und für Überlassung ihrer methodischen Vorschriften.

Dem Chemiewerk Homburg AG. danken wir für die Überlassung von sterilen Lösungen von Glutaminsäuresalzen.

Zusammenfassung

1. Intravenös zugeführte Glutaminsäure verschwindet schnell aus dem strömenden Blut.

2. Bei hoher Dosierung und schneller Injektion kann die Fähigkeit des Stoffwechsels, Glutaminsäure umzusetzen, überschritten werden und es kommt zu Unverträglichkeitserscheinungen.

3. Ammoniumglutaminat und Ammoniumchlorid sind wegen ihres freien $NH_4^{\oplus}$-Ions etwa doppelt so toxisch wie Natriumglutaminat.

[9] H. Winterstein u. N. Gökhan, Arch. int. Pharmacodynam. Thérap. **93**, 212 [1953].

[10] H. A. Krebs, Biochem. J. **43**, 51 [1948]; J. R. Stern, L. V. Eggleston, R. Hems u. H. A. Krebs, ebenda **44**, 410 [1949].

[11] E. V. Flock, M. A. Block, F. C. Mann, J. H. Grindlay u. J. L. Bollman, J. biol. Chemistry **198**, 427 [1952]; **200**, 529 [1953].

4. Der Gehalt an freiem Ammonium im Blut ist nach parenteraler Injektion von Glutaminaten nicht erhöht.

5. Etwa gleichzeitig mit den Veränderungen des Blutspiegels der Glutaminsäure steigt der von α-Ketoglutarsäure, während der von Brenztraubensäure abfällt.

Summary

1. Glutamic acid administered intravenously disappears rapidly from the blood stream.

2. In the case of larger amounts and more rapid injection the ability of the metabolism to transform glutamic acid can be exceeded so that symptoms of intolerance appear.

3. On account of their free ammonium ions ammonium glutamate and ammonium chloride are approximately twice as toxic as sodium glutamate.

4. The free ammonium content in the blood is not increased after parenteral injection of glutaminate.

5. The α-ketoglutaric acid level in the blood increases more or less simultaneously with the changes in the glutamic acid level while that of pyruvic acid falls.

3859

CELLULAR AND METABOLIC ALTERATIONS IN OBESE RATS TREATED WITH MONOSODIUM GLUTAMATE DURING THE NEONATAL PERIOD. Jerome L. Knittle and Fredda Ginsberg-Fellner. The Mount Sinai School of Medicine, Department of Pediatrics, N.Y.C. (Intr. by Richard L. Day).

Olney demonstrated that monosodium glutamate (MSG) administered to newborn mice produces stunted skeletal development and marked obesity in the adult animal. Little is known however about the cellular or metabolic basis of this form of obesity or if a similar effect can be achieved in other species. In the present report MSG was administered subcutaneously to newborn male Sprague Dawley rats daily for the first ten days of life. Untreated littermates served as controls. At 18 weeks of age the weight and cellularity of epidydimal fat pads was determined. The effect of epinephrine and insulin on in vitro glycerol release was also examined. The epidydimal fat pads from treated animals were significantly heavier than control animals-3.4 gm vs. 1.8 gm. This increase in weight was due to a marked increase in cell size-1.7 ug/cell vs. control 0.3 ug/cell. The larger cells of the treated animals also displayed diminished responsiveness to the lipolytic effect of epinephrine and an increased responsiveness to the antilipolytic effect of insulin. More striking, however, is the fact that adipose cell number was significantly decreased in the treated group-1.8×10^6 cells vs. 3.8×10^6 cells per pad in controls. These findings indicate that the obese state produced by MSG administration is due to an increase in adipose cell lipid content which is maintained in part by altered lipolytic responsiveness to epinephrine and insulin. It is further postulated that treatment with MSG results in a permanent decrease in adult adipose cell number. Thus MSG may prove a useful tool in future studies of cell division during early growth.

Fed. Am. Reds. Soc. Bull. (Presented April 29, 1970) p. 6

4042

Kraybill, H.F

June 30, 1971

BF-5

Glutamate Release and "Spreading Depression"

To V. O. Wodicka, Ph.D.
Director, Bureau of Foods (BF-1)

1. In a followup to a recent reference to some MSG research at California Institute of Technology, the writer received a detailed letter and some reprints from Dr. A. Van Harreveld, Division of Biology, at CIT. Dr. Van Harreveld's work is concerned with the phenomenon of "spreading depression" which is observed in the cerebral cortex and other regions of the brain, particularly in lower vertebrates such as rabbits, rats, and mice.

2. According to Dr. Van Harreveld this phenomenon essentially consists of the arrest of cell cortical functions which spreads slowly in a concentric fashion from a stimulated area. Spreading depression is characterized by severe depolarization of the nerves and a marked increase of electrical resistance of the tissue. The uptake of extracellular ions by cells and fibers of the tissue probably explains the increase in electrical resistance. The current used for the resistance measurement is mainly carried by these extracellular ions since the intracellular ions are prevented by a high resistance cell membrane from participating in the current transport. Thus a transport of extracellular ions into the intracellular compartment thus makes them (extracellular ions) unavailable for transport of current, which in turn explains the resistance increase.

3. For example, the transport of extracellular ions such as Na^+ in NaCl into the intracellular compartment could be explained by an increased Na permeability of the plasma membrane of the cellular elements involved. In like manner, glutamate as Na glutamate injected into the vicinity of nerve cells causes their depolarization due to an increase in the sodium permeability of the plasma membrane. Of interest is the fact that glutamate is present in a surprisingly high concentration in the brain (10 mM/Kg), according to Van Harreveld, and a release of glutamate which is presumably present in the intracellular compartment passes into the extracellular spaces and probably gives rise to the spreading depression. Van Harreveld found that glutamate topically applied to cerebral cortex causes a spreading depression.

4. It has been noted that isolated chicken retina which exhibits spreading depression can release glutamate and is perhaps stimulated by a stimuli which causes this phenomenon in the cerebral cortex.

5. With the foregoing information on passage of ions into and out of the various compartments (extracellular and intracellular) it has been found that in the adult animal the blood-brain barrier (BBB) prevents the accumulation of glutamate administered orally or i.v. in high enough concentrations in the brain to produce the effects described above. However, in the young, that is day old chicks or rodents, the BBB is not fully developed and thus i.v. administration of glutamate causes flattening of the electroencephelogram and thereby an increase of the tissue resistance which is observed during spreading depression. Dr. Van Harreveld noted that after growth of the animal (5 day old chick) the BBB is established and i.v. glutamate administration has no effect.

6. For further commentaries on the blood-brain barrier and its role in glutamate administration the following direct quote from Van Harreveld is relevant.

> "It is possible to circumvent the blood-brain barrier in the adult by injecting glutamate iontophoretically into the central nervous tissue. Recently a series of experiments of this kind have been concluded. Glutamate applied in this way causes a spot of grossly swollen tissue elements which appear as a light spot in sections stained with histological dyes. The swelling of these cellular elements can be explained by the uptake of NaCl from the intracellular space (due to the effect of glutamate on the plasma membrane) which for osmotic reasons has to be accompanied by water. The presence of swollen tissue elements in the glutamate spot was expected. Unexpected was the observation of severely shrunken dark neuronal cell bodies in the glutamate spot. These cells seem to be irreparably damaged. They are later phagocytized and disappear. A glutamate spot observed 2 weeks after the application of the amino acid appears therefore as a scar devoid of nerve cells. These experiments seem to complement the observations of Lucas and Newhouse on the retina and of Olney and his coworkers in the brain that glutamate applied to young animals (before the development of the blood-brain barrier) can result in damage of the nervous tissue."

3 - V. O. Wodicka, Ph.D.

Van Harreveld thus concludes insofar as this phenomenon is concerned, i.e. the spreading depression; that the adult is prevented by the blood-brain barrier from having an effect of glutamate on the brain. He goes on to state that he does not know when exactly the barrier develops in man. He believes that the FDA decision to limit and ban glutamate from baby food (original reference to NAS/NRC report) seems a good preventive measure.

Elsewhere, of course, work has been made on the probable effect of metabolic overloading of MSG on metabolic pathways, but this is a different type of investigation which relates to possible biochemical lesions.

I have reprints of Van Harreveld's work for those interested.

H. F. Kraybill, Ph.D.
Assistant Director for
Scientific Coordination

cc: BF-2 Dr. Kolbye
BF-120 Dr. Johnson
BF-124 Dr. Prosky
BF-335 Mr. Spiher

HFKraybill:mhg:6/30/71

(4197)

CHINESE-RESTAURANT SYNDROME

To the Editor. For several years since I have been in this country, I have experienced a strange syndrome whenever I have eaten out in a Chinese restaurant, especially one that served Northern Chinese food. The syndrome, which usually begins 15 to 20 minutes after I have eaten the first dish, lasts for about two hours, without any hangover effect. The most prominent symptoms are numbness at the back of the neck, gradually radiating to both arms and the back, general weakness and palpitation. The symptoms simulate those that I have had from hypersensitivity to acetylsalicylic acid, but are milder. I had not heard of the syndrome until I received complaints of the same symptoms from Chinese friends of mine, both medical and nonmedical people, but all well educated.

The cause is obscure. After some discussion my colleagues and I at first speculated that it might be caused by some ingredient in the soy sauce, to which quite a few people are allergic. However, we use the same type of soy sauce in our home cooking, which does not result in the symptoms described above. Some have suggested that these symptoms may be caused by cooking wine, which is used generously in most Chinese restaurants, because the syndrome resembles to some extent the effects of alcohol. Others have suggested that it may be caused by the monosodium glutamate seasoning used to a great extent for seasoning in Chinese restaurants.

Another alternative is that the high sodium content of the Chinese food may produce temporary hypernatremia, which may consequently cause intracellular hypokalemia, resulting in numbness of the muscles, generalized weakness and palpitation. The Chinese food causes thirst, which would also be due to the high sodium content. The syndrome may therefore be due merely to the large quantity of salt in the food, and the high dissociation constant of the organic salt, monosodium glutamate, may make the symptoms more acute.

Because we lack personnel for doing research in this area, I wonder if my friends in the medical field might be interested in seeking more information about this rather peculiar syndrome.

I shall of course be more than happy to co-operate.

ROBERT HO MAN KWOK, M.D.
Senior Research Investigator
National Biomedical Research Foundation
Silver Spring, Maryland

4246

AMINO ACID AND PROTEIN METABOLISM OF THE BRAIN—IV

THE METABOLISM OF GLUTAMIC ACID

A. LAJTHA, S. BERL and H. WAELSCH
Department of Biochemistry, College of Physicians and Surgeons, Columbia University, and the New York State Psychiatric Institute, New York, N.Y.

(*Received* 30 *June* 1958)

INTRODUCTION

THE evidence for a significant role of glutamic acid in the metabolism of nervous tissue rests almost exclusively on results obtained with isolated tissue preparations and on the fact of the high concentration of glutamic acid in this tissue (for reviews see WAELSCH, 1952, 1957; STRECKER, 1957). Although changes of glutamic acid concentration in insulin hypoglycemia (DAWSON, 1950; HIMWICH and SULLIVAN, 1956) and the results of perfusion experiments (BOULANGER *et al.*, 1950) are highly suggestive of a rapid glutamic acid metabolism, the rate of the conversion of the dicarboxylic acid has not been studied. Only very recently data on the rate of decarboxylation of glutamic acid to γ-aminobutyric acid* *in vivo* have become available (ROBERTS *et al.*, 1958). In order to contribute to the understanding of the *in vivo* metabolism of glutamic acid in the brain, the penetration of ^{14}C-labelled glutamic acid into this organ as well as its conversion to glutamine, Gaba, and GSH in brain, liver, kidney and muscle was studied.

Previous work in this laboratory showed no significant increase of the concentration of glutamic acid in the brains of animals in short time experiments when the concentration of the amino acid in the blood of rats or mice was raised from thirty to fifty times. The glutamic acid concentration of liver and muscle was moderately increased while a large increase was found in the kidneys. On the other hand, when glutamine was administered, the amide concentration increased in all organs, an increase which was accompanied by an elevation of glutamic acid concentration in liver, kidney and blood. It appears, therefore, that glutamine penetrates into the organs, and especially into brain, at a higher rate than glutamic acid, and that glutamine is deamidated rapidly to glutamic acid (SCHWERIN, BESSMAN and WAELSCH, 1950). The possibility cannot be dismissed that the failure to observe a net increase of glutamic acid in brain after the administration of the amino acid is the result of rapid metabolism and removal of any additional amounts, although it should be remembered that both in liver and in kidney increases in glutamic acid could be demonstrated after the administration of either the acid or its amide.

Recently, in further studies of the amino acid and protein metabolism of the brain, it was found that after systemic administration of minute amounts of the ^{14}C

* The following abbreviations are used in this paper: glutathione, GSH; γ-aminobutyric acid, Gaba; trichloroacetic acid, TCA.

J. Neurochem.
3(4): 322-332
(1959)

labelled amino acids, lysine (LAJTHA, FURST, GERSTEIN and WAELSCH, 1957) and leucine (LAJTHA, 1959) exchanged rapidly between the circulating blood and brain or liver. In spite of this rapid exchange, no net increase in the concentration of these compounds in the brain could be found, unless very large quantities of the amino acids were administered over long time periods (LAJTHA, 1958). In view of these results it appeared probable that a rapid exchange of glutamic acid between blood and brain may take place without a detectable net uptake by the organ. In the course of this investigation, the uptake of ^{14}C-labelled glutamic acid and of glutamine by brain and other organs from the circulating blood, as well as the rate of further metabolism of the dicarboxylic acid and its amide, was studied.

For the separation of glutamic acid, glutamine, Gaba and GSH, certain features of the recently developed method for the micro determination of these compounds were utilized (BERL and WAELSCH, 1958).

EXPERIMENTAL

Material. Glutamic acid ^{14}C uniformly labelled (11·3 mc/m-mole) was obtained from Nuclear Chicago Corp. and glutamine ^{14}C uniformly labelled (0·93 mc/m-mole) from Merck & Co. of Canada. Amberlite XE 59 was furnished by Rohm & Haas Co. (courtesy of Mr. R. PERCIVAL) and Dowex 50 × 4 -- 400 mesh by the Dow Co.

Animal experiments and preparations of organ extracts. The animals used were adult (about 100 day old) C_3H mice and adult Sprague-Dawley rats. Glutamic acid and glutamine were injected via the tail vein (for amounts see legends of Tables 2 and 4). The animals were killed by decapitation at the end of the experimental time period; brain and liver were excised, blotted free of blood on filter paper, and frozen in dry ice. The blood was collected in heparinized centrifuge tubes and centifuged for 3 min at 18,000 × g, and the plasma was frozen in dry ice. Four mice or two rats respectively were pooled for each experimental point. The frozen tissues were homogenized in 5% trichloroacetic acid (TCA) and centrifuged. This procedure was repeated two more times and the extracts combined.

Principle of the separation method. The tissue extracts were first chromatographed on Amberlite XE 59 columns. This resin retained the TCA and permitted the separation of glutamine and Gaba in one fraction and of glutamic acid (free from aspartic acid and GSH) in another fraction. The glutamine and Gaba were then separated on Dowex 50 and finally both the glutamic acid and the glutamine (the latter after hydrolysis to glutamic acid) were further purified on alumina columns. In those experiments in which GSH was also determined, the glutamic acid and GSH were chromatographed on alumina columns. The methods of separation and preparation of the Dowex and alumina columns were essentially those described by BERL and WAELSCH (1958).

Separation of the amino acids. Amberlite XE 59 was converted to the acetate form by stirring the resin for 2 hr with 10 vols 4N-acetic acid, filtering on a Buchner funnel, and washing with 10 vols 2N-acetic acid. This procedure of stirring and filtering was repeated three times with 2N-acetic acid, twice with water, and then three times with 5 vols 0·2 M-ammonium acetate buffer pH 5. The resin was stored in the pH 5 buffer, and, before use, was again washed on a Buchner funnel with the pH 5 ammonium acetate buffer. The resin must be washed just before use, since otherwise it colours the eluate. Finally it was poured into glass columns of 11 mm i.d. with an end tapered down to 2 mm i.d. and closed with a plug of glass wool. For 20 ml TCA extract, a 180 mm long resin column was used. The extract was put through the column and the column was washed with subsequent portions of 0·5 mole acetic acid. TCA was retained on the Amberlite column. Glutamine and Gaba came through in the first 53 ml of eluate (20 ml original extract + 33 ml acetic acid wash), while glutamic acid was eluted in the following 68-108 ml fraction.

The 53 ml eluates from the Amberlite columns were concentrated to 10 ml by lyophilization, the pH was adjusted to 2, and glutamine and Gaba were separated out on Dowex 50 × 4 — 400 mesh, as described by BERL and WAELSCH (1958); 5-ml fractions were placed on the columns and the eluates combined for determination and counting.

The Gaba fraction showed one spot on paper (phenol, water). After the determination of the

specific activity it was twice recrystallized from aqueous ethanol after addition of unlabelled Gaba with no change in specific activity. Glutamine was hydrolysed to glutamic acid with 2N-HCl at 100° for 2 hr. The HCl was then removed *in vacuo*. Both the hydrolysed glutamine and glutamic acid were further purified by adsorption and elution on alumina columns. Aliquots (5 ml) of the neutralized glutamic acid solutions were passed through 4 × 0·5 cm columns. The columns were washed twice with 2 ml of H_2O and the glutamic acid was eluted from the columns with 5 ml of 0·1 N-NH_4OH. Aliquots of the NH_4OH eluates were used for counting and for the determination of glutamic acid.

Determination of specific activity. For the determination of glutamic acid, glutamine, Gaba and GSH the method of BERL and WAELSCH (1958) was used. For the determination of radioactivity the solutions were plated on stainless steel planchets (1·25 in. diameter) and counted in a Nuclear Chicago C 110 B gas flow counter. Correction was made for self-absorption.

Efficiency of the methods of separating the various compounds. The degree of separation may be seen from the results of one representative experiment where ^{14}C glutamic acid is added to a TCA filtrate of brain corresponding to 1 g of tissue per 20 ml of 5% TCA (Table 1).

TABLE 1.—DISTRIBUTION OF COUNTS AFTER ADDITION OF ^{14}C GLUTAMIC ACID TO TCA EXTRACT OF BRAIN TISSUE

Step	Sample	Total counts	Glutamic acid (%)
1	Original solution*	101,000	100
2	Eluted from Amberlite, glutamine fraction	1940	2
3	Eluted from Amberlite, intermediate fraction	98	0·1
4	Eluted from Amberlite, glutamic acid fraction	91,400	91
5	Eluted from Amberlite, post glutamic acid fraction	7540	7·5
6	Sample 2 hydrolysed and purified on alumina	580	0·6
7	Sample 2 twice purified†	27	0·03
8	Gaba fraction purified on Dowex	18	0·02

* 101,000 counts ^{14}C glutamic acid were added to 20 ml of TCA extract of 1 g brain tissue.

† To the glutamine fraction as eluted from the Amberlite column ^{14}C glutamic acid was added and passed through alumina to remove the last traces of glutamic acid. The glutamine was subsequently hydrolysed and purified by alumina adsorption as described in the text.

Routinely, separations were carried through steps 1 to 6 and 8. Step 7 was used when a very high degree of separation was desired. It is apparent that when necessary the various fractions may be further purified by repetition of some of the steps described above. For the purpose of our study the separation of the different compounds was sufficient and the error introduced by impurities from other fractions was always below 2 per cent.

RESULTS

The concentrations of glutamic acid and related compounds in rat and mouse tissues found in the present study are in agreement with the values found in previous studies (SCHWERIN *et al.*, 1950; WAELSCH, 1951, 1957; BERL and WAELSCH, 1958).

The distribution of radioactivity in rat organs after the administration of uniformly labelled ^{14}C glutamic acid is shown in Table 2. Five minutes after administration, plasma glutamic acid has the highest specific activity but the glutamic acid in the organs is also significantly labelled. 'Total' radioactivity (Table 3) is much higher in the organs than in the plasma, a result which shows that most of the plasma glutamic acid had exchanged with glutamic acid of the tissue and of the liver particularly, which contains the higher 'total' amount of radioactivity. The brain glutamic acid is also significantly radioactive. In all organs, the specific activity of the glutamic acid

TABLE 2.—DISTRIBUTION OF RADIOACTIVITY IN RAT ORGANS 5 MIN AFTER ADMINISTRATION OF ^{14}C GLUTAMIC ACID

	Experiment 1			Experiment 2		
Organs	Glutamic acid	Glutamine	GSH	Glutamic acid	Glutamine	GSH
Plasma				3200	670	
Brain	32	27	18	43	17	16
Liver	800	530	110	1800	460	130
Kidney				860	470	560
Muscle				400	46	45

Two rats in each experiment received i.v. (tail vein) 0·1 ml of a solution containing 5 μc/ml uniformly labelled ^{14}C glutamic acid. Each animal received 11 γ glutamic acid comprising 7 per cent of the glutamic acid circulating in its plasma. All values are corrected for counts introduced by blood remaining in the excised organ (LAJTHA *et al.*, 1957). Values expressed as counts/minute per μmole.

TABLE 3.—TOTAL RADIOACTIVITY IN WHOLE RAT ORGANS*

	Experiment 1			Experiment 2		
	Glutamic acid	Glutamine	GSH	Glutamic acid	Glutamine	GSH
Plasma†				6400	4700	
Brain	640	220	81	860	140	72
Liver	15,000	20,000	6900	40,000	17,000	8200
Kidney				14,000	1600	4000
Muscle†				30,000	12,000	4700

* Derived from Table 2; expressed as counts/min in the whole organ.
† Estimated total weight.

fraction is higher than that of glutamine, an indication that the bulk of glutamic acid entered the organs as the acid. Because the amount of glutamic acid administered was small, we are dealing most probably with exchange but not with a net uptake.

Table 4 summarizes the results of similar experiments on mice. Uniformly labelled ^{14}C glutamic acid was injected and after the experimental period the animal was sacrificed and the concentration and radioactivity of the compounds determined. The results confirm in their essential aspects those obtained in the experiments with rats. In short term experiments (2–10 min) plasma glutamic acid has usually the highest specific activity although liver glutamic acid sometimes exceeds it. Glutamic acid of other organs is also significantly labelled, a finding which demonstrates a relatively rapid exchange of plasma glutamic acid with that of tissues. In brain and liver, the specific activities of glutamic acid and glutamine are close, glutamine occasionally having a higher specific activity. In Gaba of brain and in GSH of liver and brain a significant number of counts are found. Again, quantitatively, it can be seen that most of the radioactivity disappeared from the plasma and is widely distributed

throughout the organism as glutamic acid and its metabolic products. It should be noted that in many of the short time experiments the specific activity of blood plasma glutamine exceeded that of brain or liver glutamic acid or glutamine.

It is apparent that the animal rapidly converts glutamic acid to glutamine with a

TABLE 4.—SPECIFIC ACTIVITY OF COMPOUNDS AFTER INJECTION OF ^{14}C GLUTAMIC ACID

Duration of experiment (min)	Organ	Specific activity of compounds (counts/min per μmole)			
		Glutamic acid	Glutamine	γ-Amino-butyric acid	Glutathione
2	Plasma	45,000	5200		
	Brain	85	57	31	25
	Liver	2800	2100		150
2	Plasma	12,000	1900		
	Brain	15	13	3·4	8·3
	Liver	1100	510		38
	Red Blood Cells	1900	220		65
	Kidney	704	390		340
3	Plasma	8300	4500		
	Brain	620	160	20	
	Liver	12,000	20,000		
5	Plasma	6000	1900		
	Brain	90	36	33	
	Liver	1200	850		
5	Plasma	22,000	4100		
	Brain	95	78	34	51
	Liver	2400	2000		200
10	Plasma	8000	3000		
	Brain	920	230	60	
	Liver	9200	21,000		

Four adult mice were pooled for each point. They were injected with ^{14}C glutamic acid intravenously. 0·5 μc and 7 γ glutamic acid was injected in each animal corresponding to about 30 per cent of the plasma glutamic acid content and 4 per cent of blood volume. All values were corrected for counts introduced by blood remaining in the excised organ.

resultant rapid rise in specific activity of plasma glutamine. It was thought that the situation may be clarified if the specific activity of glutamine could be diluted by the injection of unlabelled glutamine along with the radioactive glutamic acid, and vice versa.

The results of such experiments are presented in Table 5. For the first two experiments ^{14}C glutamic acid was injected into mice together with ^{12}C glutamine. In experiment 1, relatively large amounts of ^{12}C glutamine (approximately twenty times

TABLE 5.—SPECIFIC ACTIVITIES OF GLUTAMIC ACID AND GLUTAMINE AFTER THEIR INJECTION INTO MICE

Exp.*	Compound injected	Duration of experiment (min)	Organ	Specific activity of compounds (counts/min per μmole)	
				Glutamic acid	Glutamine
1	^{14}C glutamic acid ^{12}C glutamine added	5	Plasma	20,000	12,000
			Brain	170	220
			Liver	3200	3500
2	^{14}C glutamic acid ^{12}C glutamine added	3	Plasma	130,000	700
			Brain	77	40
			Liver	1600	2000
3	^{14}C glutamine	5	Plasma	2500	5000
			Brain	69	200
			Liver	1800	3700
4	^{14}C glutamine ^{12}C glutamic acid added	5	Plasma	8300	11,000
			Brain	97	380
			Liver	3000	5900

* Four animals were used in each experiment. The following, contained in 0·2 ml, was injected into each animal.
(1) 2 mg ^{12}C glutamine + 7·5 γ ^{14}C glutamic acid, 400,000 counts/min. Injected within 2 sec.
(2) 4 mg ^{12}C glutamine + 7·5 γ ^{14}C glutamic acid, 400,000 counts/min. Injected slowly over a period of 3 min.
(3) 70 γ ^{14}C glutamine, 270,000 counts/min. Injected within 2 sec.
(4) 1 mg ^{12}C glutamic acid + 70 γ ^{14}C glutamine, 270,000 counts/min. Injected within 2 sec.

that normally present in the blood) had no effect on the specific activities of these two compounds in the liver and plasma. In experiment 2, with even larger amounts of ^{12}C glutamine (approximately forty times that normally present in the blood) dilution of the specific activity of the plasma glutamine was achieved when it was administered throughout the experimental period.

In the third experiment ^{14}C glutamine alone, and in the fourth experiment, ^{14}C glutamine together with ^{12}C glutamic acid was administered. In these experiments the glutamine was of higher specific activity than the glutamic acid in the plasma and liver, and this was also true for the brain.

These experiments again indicate the tremendous ability of the liver and the brain to quickly interconvert glutamic acid and its amide. When the specific activity of the plasma glutamic acid was considerably higher than the specific activity of the plasma glutamine, this was reflected in their relative specific activities in the brain. When the specific activities of the plasma glutamic acid and glutamine approached equality this also became true for the brain. This again supports the probability that plasma glutamic acid exchanges with brain glutamic acid. Glutamic acid and glutamine may have different rates of entry into the central nervous system but this is difficult to evaluate because five to ten times as much glutamine as glutamic acid

passes through the brain in the plasma in a given period of time. Therefore, any elevation of the brain glutamic acid specific activity over that of the brain glutamine specific activity becomes that much more significant.

Table 6 contains the results of experiments of longer duration. After several hours the specific activities of the compounds decreased in the organs.

TABLE 6.—DISTRIBUTION OF RADIOACTIVITY *in vivo* AFTER LONGER EXPERIMENTAL PERIODS

Duration of experiment (hr)*	Organ	Specific activities (counts/min per μmole)		
		Glutamic acid	Glutamine	γ-Aminobutyric acid
2	Plasma	1600	400	
	Brain	61	47	36
	Liver	92	100	
5	Plasma	2000	890	
	Brain	12	21	10
	Liver	34	92	
19	Plasma	2000	1300	
	Brain	20	4	(2)
	Liver	22	80	

* Each time point is the average of two experiments. For experimental conditions see legends for Table 4.

Table 7 contains the results of *in vitro* experiments. As shown, brain tissue is capable of producing glutamine and Gaba from glutamic acid. Liver also is capable of amide formation, but in these unfortified homogenates the speed of glutamic acid metabolism is much slower than in the *in vivo* experiments.

TABLE 7.—CHANGES IN SPECIFIC ACTIVITIES *in vitro*

Organ	Time of experiment (min)	Specific activity in the fractions (counts/μmole)		
		Glutamic acid	Glutamine	γ-Aminobutyric acid
Brain	0	13,000	0	0
	15	11,000	400	800
Liver	0	18,000	0	
	15	12,000	100	

Whole homogenate in 0·9% saline was incubated at 37° for 15 min. Brain was a 1 : 4 homogenate. Liver was a 1 : 2 homogenate.

DISCUSSION

The pivotal position of glutamic acid and its keto acid in amino acid and carbohydrate metabolism suggests their rapid metabolism, a fact which is indicated by many *in vitro* studies. The manifold metabolic functions of glutamic acid and the synthesis and oxidation of ketoglutaric acid through the citric acid cycle present obvious difficulties when an accurate rate of utilization and a preference for certain metabolic pathways are to be ascertained. When labelled with ^{14}C the marker will be rapidly diluted and distributed along the various metabolic pathways. The data presented in this report give an indication of the rapidity with which the system glutamic acid-glutamine operates *in vivo* in liver, kidney and brain, and of the rate at which glutamic acid is converted into Gaba in the central nervous system.

It should be noted that in some short time experiments the specific activity of the plasma glutamine exceeded not only that of the liver and kidney glutamine but also that of liver and kidney glutamic acid. Such a finding could be explained by an admixture of glutamic acid of high specific activity with the glutamine. Owing to the five to ten times higher concentration of glutamine than glutamic acid in plasma, the admixture of glutamic acid with the glutamine would have to be considerable even with a high specific activity of the former. Direct tests of the ability of the method to separate glutamic acid and glutamine indicate that the mutual impurities are not above the 1 per cent level (Table 1). Therefore, it has to be concluded that the source of the plasma glutamine is an organ other than those analysed—brain, liver, kidney—or that the highly labelled glutamic acid is converted into glutamine, e.g. without the acid or amide being mixed within the organ with the respective compounds. Part of glutamine would then be returned undiluted to the plasma and part would mix with the organ glutamine over a longer period. Glutamine of higher specific activity than the organ glutamic acid or glutamine may result from its synthesis from the administered glutamic acid in the wall of the blood vessels or in a particular cell species of brain and liver, with a direct return to the circulating blood without dilution with the glutamic acid and glutamine of the respective organ. It is undoubtedly too early to speculate as to the place of glutamine synthesis but is should be remembered that glutamine synthetase occurs mainly in the microsomal preparations of the liver and brain (Waelsch, 1958*a*; Sachs and Neidle, 1956). It could be visualized that the endoplasmic reticulum is the compartment in which glutamine is synthesized without being mixed with the amide occurring in other compartments of the cell, part of the newly synthesized glutamine being returned to the plasma without extensive dilution. On the basis of this reasoning, metabolic products of substances metabolized by the endoplasmic reticulum of an organ may reappear in the blood with a specific activity higher than found with the compound isolated from the whole organ. The assumption that glutamine is synthesized in a compartment and in a short time interval does not mix with the organ glutamine finds support in the observation that administration of unlabelled glutamine in addition to the ^{14}C-labelled glutamic acid did not dilute the specific activity of the plasma glutamine (Table 5, experiment 1). It appears therefore that the administered glutamine did not mix with the amide formed from the administered glutamic acid. It is not possible to decide at the present time whether these results indicate different pathways of removal and compartments of metabolism of glutamine and glutamic acid in the same tissue or metabolism of different organs. Only short time experiments of a length which does not permit mixing of all the pools

in an organ can give a true picture of the complexity of the system as well as of the compartmentalization of pools of metabolites.

Irrespective of all such considerations, the conversion of glutamic acid into glutamine is undoubtedly extremely rapid. In some of the experiments, within 2 minutes the specific activity of the liver glutamine approached that of the liver glutamic acid. In others, the liver glutamine had actually a higher specific activity than the liver glutamic acid, a fact which indicates that non-labelled glutamic acid was synthesized rapidly while the glutamine was not diluted to such an extent. It can be seen that whenever ^{14}C-glutamic acid was administered, the specific activity of the tissue glutamic acid was higher than that of glutamine and vice versa. This finding indicates that glutamic acid as well as glutamine is largely taken up as such from the circulating blood. This finding is in agreement with the observation that also from the gut glutamic acid and glutamine are taken up into the portal vein without extensive interconversion (BESSMAN, MAGNES, SCHWERIN and WAELSCH, 1948).

As far as the brain is concerned, the experiments demonstrate that glutamic acid from the blood exchanges rapidly with that from the brain although no net uptake of glutamic acid by the brain can be demonstrated after excessive elevation of the blood glutamic acid. This finding is in keeping with the observation made previously with lysine (LAJTHA, 1958) and leucine (LAJTHA, 1959). Both amino acids exchanged rapidly with the pool of free amino acids of the brain without a noticeable net uptake when the blood concentration was elevated and the experimental period was not longer than 30 minutes. Because of the high metabolic activity of glutamic acid the failure to detect a net uptake by the brain may be due to the rapid metabolic removal of the dicarboxylic acid, but as pointed out above, it appears more likely that the blood-brain barrier does not permit a net uptake of the dicarboxylic acid although permitting a rapid exchange.

The specific activity of the brain glutamine was lower than that of the brain glutamic acid, a fact which suggests that the amide is derived from the acid in the organ itself, particularly in view of the potent glutamine synthetase occurring in brain (LAJTHA, MELA and WAELSCH, 1953). Experiments, to be reported in detail later, with intracerebrally injected glutamic acid have shown that brain rapidly converts this acid to glutamine. The lack of dilution of brain glutamine specific activity by intravenously administered ^{12}C glutamine when the ^{14}C was injected in the glutamic acid form suggests synthesis of ^{14}C glutamine from ^{14}C glutamic acid in the brain under our experimental conditions. However, since glutamine can enter the brain from the circulating blood, part of the brain glutamine may have its origin in plasma glutamine.

A calculation of the flux of glutamic acid from the plasma into the organs and particularly into the brain is made difficult not only by the fact that we are measuring on the decreasing activity time curve, where small difference in time expresses itself in large variation in the plasma concentration, but also by the fact that the true specific activity of the brain glutamic acid is difficult to ascertain because of its high metabolic activity. Such a calculation, which cannot be anything else than highly approximate (Table 8), gives values of a flux of 0·15–4·0 γ amino acid/g of brain per minute. These values are in the range of those found for leucine and lysine and suggest that the exchange rate for the tested amino acids irrespective of whether they are acidic (glutamic acid) or basic (lysine) is of the same order of magnitude.

While there may be some doubt as to the origin of brain glutamine it is very likely

that the brain Gaba is derived from brain glutamic acid by decarboxylation. As can be seen from the respective specific activities, the rate of this conversion is quite rapid and suggests not only fast formation but also removal of Gaba. This finding is in full agreement with the data presented recently by ROBERTS *et al.* and does not suggest a metabolic inertness of Gaba, as may be surmised from its relative stability when incubated with brain cortex slices (ELLIOTT, 1958). It can also be seen from experiments reported in this paper that the conversion of ^{14}C glutamic acid into glutamine or Gaba is considerably slower in organ homogenates than *in vivo*.

TABLE 8.—TURNOVER OF FREE AMINO ACIDS IN BRAIN

		Flux	Half-life (min)	γ Substance/g fresh tissue	
				Plasma	Brain
Lysine	young	1·1–1·5	21–29	49	51
	adult	0·7–5·2	5–43	50	38
Leucine	adult	0·1–3·0	3–67	17	9·6
Glutamic acid	adult	0·15–4·0	200–5000	15	1600

Flux = γ amino acid/g fresh tissue per min exchanged.

Experiments of long duration support the evidence for the rapid metabolism of glutamic acid and its metabolic derivatives. Because of the speed of glutamic acid entry into the organs and its further metabolism, no definite conclusions can be drawn from these long term experiments, but the further breakdown of the acid and Gaba is shown. Plasma specific activities remain surprisingly high and indicate the possibility of a return of labelled compound from the organs to the blood and/or their binding to plasma proteins.

The data show the high metabolic activity of GSH, since considerable counts were found in GSH. Although this finding is in agreement with previous observations as to the high rate of GSH metabolism (WAELSCH and RITTENBERG, 1941) any definite statement as to this rate cannot be made without a knowledge of the distribution of counts in the amino acids. Although at the time of the original observation the turnover of the tripeptide seemed very rapid, it does not measure up to the rapidity of glutamic acid and glutamine conversion reported here and is probably in the range of the turnover of rapidly metabolized protein fractions of the various organs (cf. LAJTHA *et al.*, 1957*b*, WAELSCH, 1958*b*).

SUMMARY

The metabolism of ^{14}C-labelled glutamic acid was studied in intact rats and mice. It appears that the bulk of the administered amino acid enters brain, liver, kidney and muscle as such and not with prior conversion to the amide. The entry of the ^{14}C glutamic acid into the various organs was very rapid and within minutes the glutamic acid, glutamine, GSH fraction of the brain, liver and kidney, and the γ-aminobutyric

acid fraction of brain were significantly labelled. Within 2 minutes after the administration of ^{14}C glutamic acid the specific activity of the organ glutamine approached that of the dicarboxylic acid, a fact which indicates the rapidity of intraconversion of the glutamic acid–glutamine system.

In experiments of longer duration the specific activities of glutamic acid, glutamine, GSH, and γ-aminobutyric acid decreased as would be expected from their rapid metabolism. In a number of short time experiments the specific activity of plasma glutamine was higher than that of liver glutamic acid and glutamine. This finding is interpreted as suggesting that the amide is synthesized in a compartment of the organ (endoplasmic reticulum?) from labelled glutamic acid not diluted extensively by organ glutamic acid.

The flux of glutamic acid from the circulating blood into brain and liver is estimated. A method is presented for the efficient separation in isotope experiments of glutamic acid and its metabolic derivatives.

Acknowledgements—This work was supported by grants from the National Institute of Neurological Diseases and Blindness (Grants B-226 and B-557) of the National Institutes of Health, Public Health Service, Scottish Rites Supreme Council and by a contract between the Office of Naval Research and the Psychiatric Institute and by the Ford Foundation.

The excellent technical help of Mrs. P. MELA and Mr. E. TOTH is gratefully acknowledged.

REFERENCES

BERL S. and WAELSCH H. (1958) *J. Neurochem.* In press.
BESSMAN S. P., MAGNES J., SCHWERIN P. and WAELSCH H. (1948) *J. biol. Chem.* **175**, 817.
BOULANGER P., GRIFFIL R. A. and OSTEUX R. (1950) *J. Physiol. Path. gen.* **42**, 554.
DAWSON R. M. C. (1950) *Biochem. J.* **47**, 386.
ELLIOTT K. A. C. (1958) *Fed. Proc.* **17**, 216.
HIMWICH W. A. and SULLIVAN W. T. (1956) *J. nerv. ment. Dis.* **124**, 21.
LAJTHA A., MELA P. and WAELSCH H. (1953) *J. biol. Chem.* **205**, 553.
LAJTHA A., FURST S. and WAELSCH H. (1957) *Experientia* **13**, 168.
LAJTHA A., FURST S., GERSTEIN A. and WAELSCH H. (1957) *J. Neurochem.* **1**, 289.
LAJTHA A. (1958) *J. Neurochem.* **2**, 209.
LAJTHA A. (1959) *J. Neurochem.* **3**.
ROBERTS E., ROTHSTEIN M. and BAXTER C. F. (1958) *Proc. Soc. exp. Biol. N.Y.* **97**, 796.
SACHS H. and NEIDLE A. (1956) *Fed. Proc.* **15**, 344.
SCHWERIN P., BESSMAN S. P. and WAELSCH H. (1950) *J. biol. Chem.* **184**, 37.
STRECKER H. J. (1957) *Metabolism of the Nervous System* (Edited by RICHTER D.) p. 459. Pergamon Press, New York.
WAELSCH H. and RITTENBERG D. (1941) *J. biol. Chem.* **139**, 761.
WAELSCH H. (1951) *Advanc. Protein Chem.* **6**, 299.
WAELSCH H. (1952) *Advanc. Enzymol.* **13**, 237.
WAELSCH H. (1957) *Metabolism of the Nervous System* (Edited by RICHTER D.) p. 431. Pergamon Press, New York.
WAELSCH H. (1958*a*) Unpublished.
WAELSCH H. (1958*b*) *J. nerv. ment. Dis.* **126**, 33.

4255

RUMPLESSNESS OF CHICKEN EMBRYOS PRODUCED BY THE INJECTION OF INSULIN AND OTHER CHEMICALS

WALTER LANDAUER

Storrs Agricultural Experiment Station, University of Connecticut, Storrs, Connecticut

Incidental to other investigations it was observed that the injection of solutions of certain chemicals into unincubated chicken eggs led to the appearance of increased numbers of rumpless embryos and chicks. It was decided to make a systematic study of this problem, and the following is a first report on our work.

MATERIAL AND METHODS

The experiments were done chiefly with eggs from White Leghorn matings, but in one instance eggs from matings of Creeper fowl were used for a series of tests (insulin). Eggs were collected for periods of 1 week. During this time they were kept in an air-conditioned storage room. Eggs from the same mothers were distributed as evenly as possible into experimental and control groups. Prior to injecting the eggs they were allowed to stand in upright position for about 24 hours. After cleaning with alcohol a hole was drilled into the shell with a dental drill. This was done near the level of the short axis of the eggs. A tuberculin syringe was used for the injections, together with a no. 37, ¾-inch hypodermic needle. The amount of fluid injected was always 0.05 cc. The hole in the shell was sealed with Scotch tape. Treated and control eggs were incubated in the same forced-draft incubator.

The particular length of hypodermic needle used was chosen in order to be certain that the solutions would be injected into the yolk of the eggs. Was this actually accomplished and did the injected material not escape through the needle hole in the yolk membrane? Information in this respect was obtained by injecting eggs with 0.05 cc. of India ink, letting the eggs stand for 24 hours, hard-boiling them, and then opening them by a cut through their long axis. It was found that in each instance the major part of the ink was within the yolk, although traces were found along the path of the needle.

J. Exptl. Zool.
98: 65-77
(1945)

All embryos which had died between 14 and 18 days and between 18 and 22 days of incubation were examined for morphological abnormalities, as were the hatched chicks.

Standard errors are used throughout this report.

RESULTS

To start with, it was important to know if the damage done by insertion of the hypodermic needle or the injection of saline, which was in many instances used as solvent or diluent, has any effect on embryonic development. The results of such tests are given in table 1. Damage to the eggs, chiefly to the yolk membrane, is reflected in a greatly reduced percentage of hatched chicks. It is evident, however, that neither

TABLE 1

TREATMENT	NUMBER OF FERTILE EGGS	FERTILE EGGS HATCHED %	NUMBER OF EMBRYOS SURVIVING 17TH DAY	RUMPLESS %
Untreated control	253	76.7 ± 2.7	229	2.62 ± 1.05
Hypodermic needle inserted, but no injection	406	65.3 ± 2.4	337	4.45 ± 1.13
0.05 cc. saline injected	401	50.1 ± 2.5	241	2.70 ± 1.05

the insertion of a syringe needle nor the injection of saline into the egg yolk had any significant effect on the frequency with which rumplessness occurred. The same is true with regard to other developmental abnormalities.

Insulin

The insulin preparation used in our experiments was Iletin (Insulin, Lilly) in a concentration of 40 units per cubic centimeter. The amount injected was always 0.05 cc., i.e., 2 units. Table 2 shows the results of experiments with Leghorn eggs. Embryo mortality was greater than after the injection of saline, indicating a certain degree of toxicity of the insulin. The frequency of rumplessness among embryos which survived the seventeenth day of incubation was 41.6% as compared with 1.5% for the untreated controls, an increase of 2770%. The difference between treated and control lots was 40.1 ± 3.9%. Morphological abnormalities, other than rumplessness, were also more common in the insulin-treated material, but this difference was not statistically significant.

There are traces of zinc in Iletin, approximately 0.2 parts per million. Control experiments in which a much larger amount of zinc ions was injected (3.4γ $ZnCl_2$ per egg) did not result in a significant rise in the frequency of rumplessness.

The insulin preparation which we used contains 0.25% phenol and 1.6% glycerine and has a pH of between 2.5 and 3.5. In a search for possible sources of error a new series of experiments was undertaken in which, in addition to untreated controls, a third group of eggs was

TABLE 2

Results after injecting two units of insulin (Iletin) into Leghorn eggs.

DATE	TREATMENT	NUMBER OF FERTILE EGGS	FERTILE EGGS HATCHED %	NUMBER OF EMBRYOS SURVIVING 17TH DAY	RUMPLESS %	ABNORMALITIES OTHER THAN RUMPLESSNESS %
2/22/44	Iletin	93	20.4	39	46.2	10.3
	Control	112	75.0	104	0	0
3/7/44	Iletin	115	41.7	69	39.1	2.9
	Control	126	78.6	117	0.9	0.8
3/14/44	Iletin	118	40.7	65	41.5	1.5
	Control	132	71.2	111	3.6	1.8
Total	Iletin	326	35.3	173	41.6 ± 3.8	4.0 ± 1.5
	Control	370	74.9	332	1.5 ± 0.7	0.9 ± 0.5

injected with a solution which contained 0.25% phenol and 1.6% glycerine, and which was, with HCl, adjusted to a pH of 3. These experiments were done with eggs from matings of Creeper fowl. The results are given in table 3. It is evident that neither the phenol-glycerine admixtures, nor the hydrogen ion concentration were responsible for the high frequency of rumplessness which had been obtained in the earlier experiments. In fact, there is no significant difference between the phenol-glycerine group and the untreated controls. Insulin, on the other hand, again produced a high incidence of rumplessness. The difference in frequency of rumplessness among the insulin-injected group and the phenol-glycerine lot was 15.4 ± 2.2%, and that between the insulin group and the untreated controls amounted to 16.1 ± 2.2%.

It is evident, however, that fewer cases of rumplessness occurred after injecting Creeper eggs than had been obtained in the earlier experiments with Leghorn eggs. The difference in average frequency of rumplessness in these two groups amounted to 24.5 ± 4.3% and is highly significant. It will be noted that the experiments with Creeper

eggs were performed later in the year than those with Leghorn eggs. Are we dealing with a seasonal difference in response? In order to test this question some Leghorn eggs were injected with Iletin on May 9, 1944. In this experiment sixty-three embryos survived the seventeenth day of development and 28.6% of these were rumpless. If this result is compared with the experiments performed with Creeper eggs on April 25 and May 2, it is found that the Leghorn eggs again produced the greater number of rumpless embryos. The difference amounts to 16.7 ± 6.2% and is significant. Further tests with Leghorn eggs were

TABLE 3

Results after injecting two units of insulin (Iletin) into Creeper eggs.

DATE	TREATMENT	NUMBER OF FERTILE EGGS	FERTILE EGGS HATCHED %	NUMBER OF SURVIVORS OF 17TH DAY	RUMPLESS %
4/4/44	Iletin	96	37.5	54	24.1
	Phenol-glycerine	94	35.1	61	0
	Untreated	95	56.8	70	0
4/11/44	Iletin	98	31.6	55	23.6
	Phenol-glycerine	93	51.6	66	3.0
	Untreated	97	43.3	64	0
4/18/44	Iletin	94	50.0	65	18.5
	Phenol-glycerine	93	50.5	67	3.0
	Untreated	98	46.9	70	1.5
4/25/44	Iletin	132	42.4	84	11.9
	Phenol-glycerine	125	42.4	84	1.2
	Untreated	150	50.7	98	1.0
5/2/44	Iletin	137	28.5	76	11.8
	Phenol-glycerine	136	41.2	80	1.3
	Untreated	140	50.7	92	2.2
Total	Iletin	557	37.5 ± 2.1	334	17.1 ± 2.1
	Phenol-glycerine	541	43.8 ± 2.1	358	1.7 ± 0.7
	Untreated	580	49.8 ± 2.1	394	1.0 ± 0.5

conducted between June 20 and July 11. In these experiments a total of 455 embryos and chicks survived the seventeenth day of incubation and there were 112 or 24.6 ± 2.0% cases of rumplessness. This was again a significant excess over the response shown by Creeper eggs during the latter part of the season or even, in fact, throughout the whole experimental period. Hence it may be concluded that, as far as the production of rumplessness is concerned, the eggs of the particular Leghorn and Creeper stocks which were used in our work differed in degree of response to insulin. This conclusion is supported by observa-

tions on embryonic mortality. In comparing the two stocks in this respect, allowance must be made for the homozygous lethal effect of the Creeper factor, which reduces hatches by about 25%. If this is taken into account, it can be seen that injection of insulin into Creeper eggs reduces hatching to a much lesser degree than does the same treatment of Leghorn eggs; in other words, the insulin has a less toxic effect on eggs of the Creeper stock than on those of the Leghorn stock. It cannot be determined with certainty from our material whether the less drastic effect of insulin on Creeper eggs is due to the Creeper factor itself or to residual heredity. Among the fifty-seven rumpless embryos and chicks of this material thirty-two were Creeper and twenty-five normal, with an expectation of two Creepers to one normal. There is a deficiency of Creepers, as would be expected if the Creeper factor provided protection against the interference with normal rump formation, but the data are not good enough to establish this point.

The conclusion that the eggs of our Creeper stock tend to react less extremely to insulin is supported further by the more common occurrence of intermediate rumpless cases in this material. Among ninety rumpless embryos and chicks from the Leghorn experiments all but five (5.6%) were completely rumpless. Among fifty-seven rumpless embryos and chicks from the Creeper stock, on the other hand, ten or 17.5% showed stages intermediate between complete rumplessness and normal conformation.

The differences in response to insulin, obtained with Leghorn and Creeper eggs, are not entirely accounted for, however, by genetic dissimilaritiy of the stocks. Another interesting feature of our observations is the gradual decline in the percentage of rumpless embryos produced in successive experiments. In the Leghorn eggs 46.2% rumpless embryos and chicks were found in the test of February 22, but only 28.6% in that of May 9 and an average of 24.6% in four tests made between June 20 and July 11. In the Creeper eggs the percentage of rumpless embryos fell from an initial high of 24.1% (April 4) to 11.8% (May 2). Chemical changes in the insulin can be ruled out as a possible cause since the supply of Iletin was replenished twice in the course of the experiments. It is most likely that the observed changes in response represent a seasonal gradient due to gradually increasing environmental temperatures and consequent changes in the developmental stages of the eggs at the time the injections were made. This problem will be the subject of further studies.

The frequency of morphological abnormalities other than rumplessness was 3.0 ± 0.9% in the insulin-injected Creeper eggs, 1.1 ± 0.6% in

the phenol-glycerine controls, and 0.5% 0.4% in the untreated controls. As in the Leghorn material, there is a suggestion that the incidence of all abnormalities is increased by the influence of insulin, but the differences are not significant.

The records of the insulin-injected Leghorn eggs have been analysed with regard to homogeneity of response among the mothers which produced the eggs. The data were arranged in an R × 2 table. A χ^2 of 685.8 was found, with 104 degrees of freedom. Since the 1% point is about 6334 and the 5% point is 253, the data definitely suggest heterogeneity i.e., the mother's genetic constitution appears to influence the chances whether or not her eggs will respond to insulin injection with the production of rumplessness.

TABLE 4

Results of the injection of cystine. Experiments with Leghorn eggs.

TREATMENT	NUMBER OF FERTILE EGGS	FERTILE EGGS HATCHED %	NUMBER OF SURVIVORS OF 17TH DAY	RUMPLESS %
0.2 mg. cystine per cc.	181	55.8	111	6.4 ± 2.1
46.4 mg. cystine per cc.	194	57.7	158	6.3 ± 1.9
Total	375	56.8	229	6.3 ± 1.4

In earlier experiments it had been found that the injection of cysteine hydrochloride led to a considerable rise in the frequency with which rumplessness occurred. The eggs were injected with 0.05 cc. of a solution of 100 mg. per cubic centimeter of cysteine hydrochloride in saline. Among 111 embryos which survived the seventeenth day 12.6 ± 3.2% were rumpless. The difference from the untreated control eggs was 10.1 ± 3.3%. This result raised the question whether the effect of insulin is possibly due to its cystine content. Experiments were made to test this. Leghorn eggs were used. Cystine was dissolved in saline by addition of just enough HCl to obtain solution. In a first series the concentration of cystine was 0.2 mg. per cubic centimeter. By injection of 0.05 cc. of this solution into each egg, the amount of cystine was equivalent to that of two units of insulin, the quantity which was used in our experiments. In a second series the concentration of cystine was 232 times that of the first series (46.4 mg. per cc.). The data of these experiments are shown in table 4. The results were nearly identical in the two tests, in spite of the great difference in cystine concentration. The pH of both solutions was about 2. As compared with untreated controls, cystine injection produced a significant increase in the

occurrence of rumplessness. As compared with the insulin experiments, the results demonstrate that cystine alone is not responsible for the effect of insulin.

Experiments were made with one other amino acid, viz., glutamic acid hydrochloride. Both l- and dl-glutamic acid hydrochloride were used. We injected 0.05 cc. of a solution of 547 mg. per cubic centimeter of l- or dl-glutamic acid hydrochloride dissolved in saline. The results of these tests are assembled in table 5. The increase in frequency of rumplessness, as compared with the untreated controls, was 3.1 ± 1.0% for the l-glutamic acid hydrochloride and 6.8 ± 1.3% for the dl-glutamic acid hydrochloride. Both forms of glutamic acid hydrochloride produce

TABLE 5

Results of the injection of l- or dl-glutamic acid hydrochloride. Experiments with Leghorn eggs.

TREATMENT	NUMBER OF FERTILE EGGS	FERTILE EGGS HATCHED %	NUMBER OF SURVIVORS OF 17TH DAY	RUMPLESS %
l-glutamic acid hydrochloride	776	48.2	545	4.6 ± 0.9
dl-glutamic acid hydrochloride	772	48.6	556	8.3 ± 1.2
Untreated	822	68.7	726	1.5 ± 0.5

a significant rise in the frequency of rumplessness. The data also suggest the possibility that dl-glutamic acid hydrochloride is more effective than l-glutamic acid hydrochloride, the difference amounting to 3.68 ± 1.47%. On the other hand, there is certainly no suggestion in these data that the glutamic acid of insulin plays an important role in the insulin effect on rump development. No significant increase in incidence of morphological abnormalities other than rumplessness was produced by either of the glutamic acid hydrochlorides.

Tests with other substances

A series of experiments was run with l-, dl- and d-malic acid. The l- and dl-malic acids were commercial C.P. products. The d-malic acid was prepared for our experiments by Prof. A. W. Ingersoll. We injected 0.05 cc. of solutions containing 20 mg. per cubic centimeter of the three types, respectively, of malic acid. The results are shown in table 6. As judged by embryonic mortality, none of the three preparations had a pronounced, if any, toxic effect. Injection of d-malic acid had no significant influence on the occurrence of rumplessness. In the

group which was injected with dl-malic acid the frequency of rumplessness among embryos and chicks was 2.6 ± 1.1% greater than in the untreated controls. This suggests a significant increase. Such a rise in the production of rumplessness definitely followed the injection of l-malic acid, the difference from the control material being 3.0 ± 1.1%. If the results with dl- and l-malic acid are combined, it is found that there is an increase in rumpless frequency of 2.8 ± 0.9%. Abnormalities other than rumplessness occurred with the following frequencies: 0.2% in the controls, 1.5% each in the l- and d-malic acid groups, and

TABLE 6

Results of the injection of l-, dl-, and d-malic acid. Experiments with Leghorn eggs.

TREATMENT	NUMBER OF FERTILE EGGS	FERTILE EGGS HATCHED %	NUMBER OF SURVIVORS OF 17TH DAY	RUMPLESS %
l-malic	523	58.7	413	4.3 ± 1.0
dl-malic	513	57.3	401	3.9 ± 1.0
d-malic	519	59.0	401	2.0 ± 0.7
Untreated	526	69.4	457	1.3 ± 0.5

TABLE 7

Results of the injection of thioglycollic acid, hydrochloric acid and saline. The thioglycollic acid and saline were 0.2 molar with a pH of 7; the hydrochloric acid had a pH of about 1. Leghorn eggs.

TREATMENT	NUMBER OF FERTILE EGGS	FERTILE EGGS HATCHED %	NUMBER OF SURVIVORS OF 17TH DAY	RUMPLESS %
Thioglycollic acid	648	41.4	374	6.7 ± 1.3
Hydrochloric acid	1141	60.0	708	3.5 ± 0.6
Sodium chloride	864	46.5	537	2.2 ± 0.6
Untreated	1072	73.5	930	1.9 ± 0.5

2.2% in the series injected with dl-malic acid. The differences are suggestive of some effect in all groups, but are not significant.

In another series of experiments we compared the effects of thioglycollic acid, hydrochloric acid and a sodium chloride solution. The thioglycollic acid and sodium chloride solutions were 0.2 molar and had a pH of 7. The hydrochloric acid was adjusted to the same pH (about 1) as the solutions of glutamic acid hydrochloride which were discussed above. The molarity of the hydrochloric acid was the same as that of the least concentrated cysteine hydrochloride solution used in our experiments (20 mg. cysteine hydrochloride per cc.). The amount injected of each solution was 0.05 cc. per egg. The results are shown in table 7.

As compared with the untreated controls, thioglycollic acid accounted for a significant rise in the frequency of rumplessness, the difference between the two groups amounting to 4.8 ± 1.3%. The treatment with hydrochloric acid and sodium chloride, on the other hand, had no effect in this respect. It should be noted, however, that hydrochloric acid, if injected in concentrated form (0.05 cc.), probably does produce a significant rise in production of rumpless embryos. In such a test 3.8 ± 1.1% rumpless embryos were found as against 0.8 ± 0.5% among the untreated controls, the difference between the two groups amounting to 3.0 ± 1.2%. No significant increase in the frequency of malformations other than rumplessness was observed in any of these tests.

DISCUSSION

The outstanding result of our experiments is the high percentage of rumplessness produced by the injection of insulin. This appears to be the first recorded instance of a morphogenetic effect of insulin.

The morphological appearance of the distal end of the spine in insulin-induced rumplessness does, in most cases, resemble the sporadically occurring cases. Those rumpless embryos, in the insulin experiments, which died shortly before hatching time or which at the end of the incubation period were found alive within the shell were nearly all completely rumpless. In many of these embryos some of the synsacro-caudal vertebrae were missing in addition to the free tail vertebrae. In certain of the most extreme cases the posterior end of the body was edematous. Among the rumpless chicks which hatched, on the other hand, there were some which had a partial tail skeleton. In this respect the material differs from that of sporadic rumplessness since in the latter no intermediate forms have ever been observed.

In earlier experiments it was shown that rumplessness can be produced by mechanical shaking of eggs (Landauer and Baumann, '43). As in these shaking experiments, it was found after insulin treatment that the genetic constitution of the mother plays a role in the extent of response obtained under experimental conditions. It does not seem likely that the genetic factors which protect embryos from becoming rumpless on account of shaking of the eggs or because of the injection of insulin are the same ones.

In the case of shaking the evidence suggested that the results are brought about by injury to the blastoderm. It was shown that these mechanical forces not only raise the incidence of rumplessness, but also, and to a similar extent, that of all other commonly occurring malformations. This is not so in the case of insulin treatment. It is true

that the experiments suggest a slight (though not statistically significant) increase in the frequency of all types of abnormalities. This may be due to mechanical disturbances produced by injection per se. At any rate, it is obvious that insulin has a selective effect on rump development. It seems reasonable to assume that the selective response of the caudal part of the vertebral column is in some way related to developmental peculiarities of this region. Such perculiarities do actually exist. Degeneration of presumptive tail tissue plays a role in normal development of the tail and it is also the principal feature in the origin of dominant rumplessness (Zwilling, '42). In later stages cartilage differentiation in the tail lags behind that of other parts of the skeleton (Blinov, '38). These developmental features are probably in some way related to the effect which insulin has on formation of the tail.

How this effect is brought about cannot at present be determined with certainty, but it may be well to discuss some aspects of the problem. The physiological properties of insulin suggest the possibility that an interference with the embryo's carbohydrate metabolism may occur after its injection. But even if this assumption is correct, it remains entirely unknown why development of the tail should be affected selectively. Corda ('32) found that the injection of insulin into pregnant rabbits was followed by the abortion of undersized fetuses and the birth of small young. The results were ascribed to interference with the carbohydrate exchange between mother and fetuses, but the author envisioned also the possibility of a more direct action of insulin on the fetus. There were no teratological effects. Gregg and Pomerat ('42), working with developing Rana pipiens embryos, found that insulin was inhibiting and toxic above a concentration of 0.02%, but no effect of any kind was observed at lower concentrations. These results do not shed any light on our observations.

The fact that two of the amino acids which contribute most to the composition of insulin (cystine and glutamic acid), if injected by themselves, do not produce a rise in the occurrence of rumplessness comparable to that obtained with insulin, does not exclude the possibility that the rumpless effect may be due to still other amino acids or the combined action of more than one of them. This must be settled by further experiments.

It is of interest to point out that some of our most significant results were obtained after the injection of substances containing sulphur (insulin, cysteine, cystine, thioglycollic acid). The possible role of sulphur in the production of rumplessness requires further investigation. Our data show, however, that other substances, e.g., d-glutamic

acid hydrochloride, may lead to similar results. Ancel and Lallemand ('42) reported that treatment of early chicken embryos with certain chemicals resulted in rumplessness, but gave no further details.

Our observations do not support the conclusion that acidification per se is instrumental in diverting development in the direction of rumplessness.

It is known that differences in toxicity exist between the optical isomeres of certain substances (Cushny, '26; Gause, '41). If the production of rumplessness were a consequence of toxic action, then our observations on glutamic and malic acid could be taken as another instance of this kind. The isomeres which do not occur naturally are, in general, the ones which are more toxic. In the case of glutamic acid hydrochloride no differences in embryonic mortality existed after the injection of the l- and dl- forms, but the dl-glutamic acid hydrochloride produced nearly twice as many cases of rumplessness as did the l-glutamic acid hydrochloride. As judged by embryonic mortality there was also no difference in the effect produced by the isomeres of malic acid, but here it was the naturally occurring form (l-malic) which was most effective in bringing about the development of rumplessness. It is clear, therefore, that our results cannot be accounted for by differences in toxicity, but must be due to specific reactions of the embryo to particular isomeres.

Inhibitory and toxic effects of certain amino acids (tyrosine, phenylaline, cysteine) on embryonic development of a beetle (Eruchus quadrimaculatus Fabricius) were reported by Brauer ('42). This author also found selective susceptibility of certain embryonic regions and it must be such a selective response which accounts for the origin of rumplessness in our experiments.

Our observations demonstrate that rumplessness can be produced by a variety of chemical substances. In earlier work it was shown that rumplessness can also be induced by mechanical forces. The possible relation of these phenocopies to the developmental aspects of hereditary rumplessness cannot be discussed until a study of the embryonic development of experimentally-produced rumplessness has been made. In a general way, however, conclusions at which Grüneberg ('43, p. 243) arrived in a discussion of x-ray induced phenocopies in mice may apply also to hereditary rumplessness. He says: "One cannot help getting the impression that these structural changes, at any rate, are rather unspecific results of gene action. Some more fundamental change in development seems to upset those developmental processes, which at a given time happen to be in a critical and hence susceptible stage." With

regard to details of developmental events we do not know at present if any experimentally-produced phenocopy is truly analogous to its hereditary counterpart. Yet, even if this were not true for the present material, it would still remain a fact of considerable interest that, as in the case of the mutations for rumplessness and their modifiers, insulin can bring about either complete rumplessness or varied modifications intermediate between this condition and a normal tail.

SUMMARY

Experiments in which various chemical substances were injected into the yolk of eggs prior to incubation, had the following results.

After the injection of two units of zinc-free Iletin (Insulin, Lilly) into eggs of White Leghorn fowl 41.6 ± 3.8% of all embryos surviving the seventeenth day were rumpless. Among the controls there were only 1.5 ± 0.7% of rumpless embryos and chicks.

Similar experiments with eggs of Creeper fowl resulted in 17.1 ± 2.1% rumpless embryos with 1.0 ± 0.5% rumplessness among the controls.

The results are highly significant in both stocks. The difference between the stocks is due in part to variations in response on account of genetic dissimilarity and in part to seasonal influences. Significant heterogeneity in response of the eggs to insulin treatment was found among the hens involved in the experiment with Leghorn fowl.

Significant increases in the frequency with which rumplessness occurred were obtained also after the injection of cysteine hydrochloride, cystine, dl-glutamic acid hydrochloride, thioglycollic acid and l-malic acid. The effect of l-glutamic acid hydrochloride was much less pronounced than that of the dl- form; d-malic acid had no effect. Concentrated hydrochloric acid probably produced some increase in rumpless frequency, but this was not true for more dilute hydrochloric acid (pH 1). Injection of saline or mere insertion of a hypodermic needle gave no results.

None of the experiments led to a significant rise in abnormalities other than rumplessness; not, at any rate, among the late embryonic stages which we examined.

ACKNOWLEDGMENTS

The author is under great obligation to Prof. A. W. Ingersoll, Vanderbilt University, Nashville, Tennessee for preparing the d-malic acid used in our experiments and to Dr. F. B. Peck and the Lilly Research Laboratories, Eli Lilly and Company, Indianapolis, Indiana for pro-

viding the Iletin (Insulin, Lilly) as well as for information concerning this product.

The author is especially grateful to Dr. Heinrich Waelsch, New York State Psychiatric Institute and Hospital, New York City for advice and help in many ways.

The author is much obliged to Dr. E. M. Bailey, Department of Analytical Chemistry, Connecticut Agricultural Experiment Station, New Haven for a zinc determination in a sample of Iletin (Insulin, Lilly).

LITERATURE CITED

ANGEL, P. ET S. LALLEMAND 1942 Sur une malformation du bec et des membres obtenue chez l'embryon de poulet à l'aide de sulfamides. Comptes Rendus des Séances de la Société de Biologie, vol. 136, pp. 255–256.

BELINOV, V. A. 1938 Zur Frage nach der Zeit der Anlagenbildung und dem Differenzierungstempo des Knorpelgewebes in verschiedenen Organen des Vogelembryos. (Russian with German summary.) Biologicheskij Zhurnal, vol. 7, pp. 311–324.

BRAUER, A. 1942 Modification of development in Bruchid (Coleoptera) embryos by treatment with amino acids. Transactions, Kentucky Academy of Science, vol. 10, pp. 24–28.

CORDA, G. M. 1932 Ricerche sperimentali sulla influenza della iperglicemia e della ipoglicemia materna sul decorsa della gravidanza e sullo sviluppo dei feti. Annali di Ostetricia e Ginecologia, vol. 54, pp. 143–170.

CUSHNY, A. R. 1926 Biological Relations of Optically Isomeric Substances. Baltimore (Williams and Wilkins).

DUSE, G. F. 1941 Analysis of various biological processes by the study of the differential action of optical isomeres. Biodynamica, vol. 3, pp. 217–246.

EFFIG, J. R., AND C. M. POMERAT 1942 The glycogen content of the embryo of Rana pipiens during development. Growth, vol. 6, pp. 231–234.

GRÜNEBERG, H. 1943 The Genetics of the Mouse. Cambridge (University Press).

HANDAUER, W., AND L. BAUMANN 1943 Rumplessness of chicken embryos produced by mechanical shaking of eggs prior to incubation. J. Exp. Zool., vol. 93, pp. 51–74. 51–74.

ZWILLING, E. 1942 The development of dominant rumplessness in chick embryos. Genetics, vol. 27, pp. 641–656.

(4364)

SERUM GLUTAMIC ACID LEVELS AND THE OCCURRENCE OF NAUSEA AND VOMITING AFTER THE INTRAVENOUS ADMINISTRATION OF AMINO ACID MIXTURES

STANLEY LEVEY, PH.D., JOHN E. HARROUN, M.D.,* AND CHARLEY J. SMYTH, M.D.
DETROIT, MICH.

ONE of the difficulties in the intravenous use of protein digests is the occurrence of anorexia, nausea, and vomiting following rapid infusion. Mixtures of amino acid, on the other hand, have been given at rapid rates with few ill effects. Earlier work with both dogs[1, 2, 3, 4] and man[5] has indicated that the dicarboxylic amino acids, glutamic and aspartic acids, are the major factors in protein hydrolysates responsible for these undesirable reactions. In order to obtain more direct evidence concerning this relationship, the free glutamic acid† content was determined in the serum of subjects receiving the various amino acid preparations before and at the end of the infusion. The free glutamic acid content in the various preparations was also determined. A series of subjects received solutions of partially neutralized glutamic acid in saline, and estimates of the serum free glutamic acid content were made during this infusion. The observations which form the basis for this report indicate a direct correlation between the glutamic acid content of the various preparations and the incidence of nausea and vomiting. In addition, data concerning the quantitative relation of serum free glutamic acid and the occurrence of nausea and vomiting are presented.

METHODS

Three groups of patients were selected for study: Group A (forty-seven subjects) received five different amino acid preparations intravenously (three protein hydrolysates, two amino acid mixtures), all of known glutamic acid content; Group B (thirty-one subjects) received solutions containing glutamic acid which had been partially neutralized; Group C (eleven subjects) received an amino acid mixture fortified with glutamic acid sufficient to bring the content of this dicarboxylic acid up to that present in the acid hydrolysate of casein used in this study. All of the subjects in this study were men chosen at random from the wards of a general medical service. With very few exceptions each subject received only a single infusion.

The amino acid preparations that Group A received are designated by numbers I, II, III, V, and VI.‡ Preparation I was an enzymatic digest of casein; Preparation II was an

From the Departments of Physiological Chemistry and Medicine, Wayne University College of Medicine, Detroit, Mich., and the Wayne County General Hospital, Eloise, Mich.

This study was supported in part by grants-in-aid from Merck and Company, Inc., Rahway, N. J., Mead Johnson & Co., Evansville, Ind., and The Upjohn Company, Kalamazoo, Mich.

Received for publication, June 3, 1949.

*Present address: The Watson Clinic, Brookings, S. D.

†In this presentation the term "free glutamic acid" when used to express the content of the material in serum refers to the microbiologically available glutamic acid, and probably includes some of the glutamine.

‡The numbers of the amino acid preparations, except for number VI, are the same as used in a previous publication[6] from this laboratory.

J. Lab Clin. Med. 34 (9)

acid digest of casein fortified with tryptophane, and Preparation III was a mixture of synthetic amino acids consisting of the ten "essential" amino acids plus glycine. Preparation V, a mixture of amino acids, was formed by the recombination and fortification of fractions of a casein digest. Preparation VI was an enzymatic digest of beef blood proteins.* The volume of the unit dose for Preparations II, III, and V was 500 c.c., for Preparation I, 400 c.c., and for VI, 1,000 cubic centimeters.

In studying the blood free glutamic acid content during the infusion of the various amino acid preparations the following procedure was used. A sample of venous blood was obtained and allowed to clot in a centrifuge tube; the unit dose of amino acid solution was then infused through the same needle. The rate of infusion was intentionally varied from patient to patient, but for any one subject the rate was maintained constant either until the patient became nauseated or vomited or until the infusion was ended. At the appearance of the above-mentioned symptoms or at the end of the infusion a blood sample was withdrawn from the opposite arm.

The solutions given to the subjects in Group B were prepared in two concentrations, the lower containing 5.05 Gm. of glutamic acid plus 2.8 Gm. of $NaHCO_3$ per 400 ml. of physiologic saline, and the higher containing twice this amount of glutamic acid and bicarbonate. In order to obtain information regarding the effect of the method of sterilization of these products on the incidence of toxic symptoms, some subjects of Group B received solutions sterilized by autoclaving at 15 pounds pressure for fifteen minutes. Other subjects were given solutions identical in all other respects except that they were sterilized by filtration through a Seitz filter.

In the series of studies in which solutions of partially neutralized glutamic acid (Group B) were infused at increasing rates, the procedure was essentially the same as outlined for Group A, except that the rate of infusion was increased every ten to fifteen minutes. A sample of blood was withdrawn for determination of the free glutamic acid content just before each increase in rate. This procedure was continued either until the patient became nauseated or vomited or until the infusion was completd.

The subjects in Group C received intravenously Preparation Vb to which was added 5.05 Gm. of glutamic acid per 400 ml. of solution. The procedure for administering this solution was the same as for the other amino acid preparations (Group A).

To reduce the psychologic factors which might influence emesis, the intravenous injections of the amino acids or glutamic acid were given as part of the routine therapy. Since other patients in the ward were getting intravenous therapy it was not considered an unusual procedure. No leading questions were asked during the injections.

For the evaluation of the free glutamic acid content of the various preparations used and of the serum of the patients, the microbiologic method of Dunn[7] was employed, using *Lactobacillus arabinosus*. Protein-free filtrates were prepared according to the method of Hier,[8] modified to a slight extent by immersing the tubes containing the filtrates of serum in boiling water for a few moments to remove the last traces of protein. Using this procedure, there was no precipitation of protein during the autoclaving of the media containing the test sample. The free glutamic acid content of the various amino acid preparations was determined directly on the product. They were not subjected to a preliminary hydrolysis before analysis.

RESULTS

Studies Involving Amino Acid Preparations.—In Table I is presented the free glutamic acid content of the various preparations used. The arrangement of the preparations is in decreasing order of glutamic acid content per unit dose of amino acid solution. Since, clinically, the amino acids are usually injected in the amounts contained in the units in which they are supplied, it was desirable to determine the free glutamic acid content in such units; Preparation

*Preparation VI was a 5 per cent protein hydrolysate in distilled water supplied in 1,000 c.c. units through the courtesy of the Baxter Laboratories, Glenview, Ill.

II is an exception in that the solution supplied must be diluted before administration. Previous experience in this hospital[9] showed that the solution used was a satisfactory one if administered at a slow rate. All preparations did not have an equal nitrogen content. A number of different lots of each preparation were used to obtain the values listed in Table I. Two lots of Preparation V are listed; the first (Va) consisted of a batch which possessed the highest glutamic acid content of any of this type of mixture. In the second (Vb) a lower glutamic acid content was found and represents an amount closer to the average obtained for this preparation.

TABLE I. GLUTAMIC ACID CONTENT OF AMINO ACID PREPARATIONS

PREPARATION	AMINO ACID CONTENT (GM. PER CENT)	CONCENTRATION OF AMINO ACID SOLUTION INFUSED (GM. PER CENT)	VOLUME INFUSED (ML.)	GLUTAMIC ACID CONTENT OF INFUSED SOLUTION (GM.)
Preparation II	15	7.5	400	5.05
Preparation I	10	10	500	4.09
Preparation VI	5	5	1,000	2.65
Preparation V				
a	10	10	500	1.16
b	10	10	500	0.25
Preparation III	8	8	500	0.0

A summary of the information obtained by infusing Preparation II is listed in Table II. This preparation contained the highest glutamic acid content (5.05 Gm. per 400 c.c.) of those studied. It can be observed that high serum free glutamic acid levels were reached. Nausea and vomiting was the usual reaction if the glutamic acid content of the blood exceeded 15.9 mg. per 100 milliliters. The fact that marked variations in individual tolerance occurs is evident in that one subject did not become nauseated even though he had a serum free glutamic acid level of 42.6 mg. per 100 milliliters.

TABLE II. THE RELATIONSHIP BETWEEN BLOOD GLUTAMIC ACID LEVEL AND THE PRODUCTION OF NAUSEA AND VOMITING
(PREPARATION II, 5.05 GM. GLUTAMIC ACID PER 400 C.C. OF 7.5% SOLUTION)

AMINO ACID PREPARATION	SERUM FREE GLUTAMIC ACID		RATE OF INFUSION (C.C./MIN.)	REACTION
	BEFORE INFUSION (MG. PER CENT)	AFTER INFUSION (MG. PER CENT)		
Preparation II				
	4.1	10.6	3.1	0
	5.0	14.1	2.9	0
	3.9	15.9	4.5	0
	3.6	33.0	6.2	Nausea
	3.5	39.0	9.1	Nausea
	3.5	39.0	14.0	Vomited
	4.9	42.6	4.5	0
	4.0	43.0	10.2	Nausea
	2.8	43.2	5.7	Vomited
	--	85.0	3.7	Vomited

In Table III are summarized the results obtained by infusing Preparation I (4.09 Gm. glutamic acid per 500 c.c.). All subjects who had blood free glutamic acid levels above 16 mg. per cent became ill. One subject vomited at a lower level (10.9 mg. per 100 ml.). In general, serum free glutamic acid values were not as high after the administration of this preparation as with the previous one.

TABLE III. THE RELATIONSHIP BETWEEN BLOOD GLUTAMIC ACID LEVEL AND THE PRODUCTION OF NAUSEA AND VOMITING

(PREPARATION I, 4.09 GM. GLUTAMIC ACID PER 500 C.C.)

AMINO ACID PREPARATION	SERUM FREE GLUTAMIC ACID		RATE OF INFUSION (C.C./MIN.)	REACTION
	BEFORE INFUSION (MG. PER CENT)	AFTER INFUSION (MG. PER CENT)		
Preparation I	3.7	4.8	7.1	0
	4.0	7.3	6.1	0
	7.4	8.2	5.3	0
	4.2	8.8	6.2	0
	6.2	10.7	8.1	0
	4.1	10.8	10.2	0
	4.8	10.9	10.7	Vomited
	--	13.8	7.7	0
	6.6	16.2	8.6	Vomited
	3.9	22.5	5.5	Vomited
	8.3	23.2	6.5	Vomited
	4.4	23.9	9.4	Vomited
	8.0	28.7	5.5	Vomited

Preparation VI (Table IV), an enzymatic digest of bovine blood proteins, had a lower free glutamic acid content (2.65 Gm. per 1,000 c.c.) than the previous two preparations and this preparation could be administered at more rapid rates without increasing the toxic symptoms. One subject became nauseated at the rather low serum free glutamic acid level of 9.7 mg. per 100 ml., and one subject did not become ill in spite of the high blood level of 22.6 mg. per 100 milliliters.

TABLE IV. THE RELATIONSHIP BETWEEN BLOOD GLUTAMIC ACID LEVEL AND THE PRODUCTION OF NAUSEA AND VOMITING

(PREPARATION VI, 2.65 GM. GLUTAMIC ACID PER 1,000 C.C.)

AMINO ACID PREPARATION	SERUM FREE GLUTAMIC ACID		RATE OF INFUSION (C.C./MIN.)	REACTION
	BEFORE INFUSION (MG. PER CENT)	AFTER INFUSION (MG. PER CENT)		
Preparation VI	2.1	4.5	14.7	0
	2.0	6.7	20.2	0
	2.8	6.7	12.5	0
	1.7	7.8	20.0	0
	2.3	9.7	31.2	Nausea
	4.5	9.8	13.3	0
	4.4	10.3	14.5	0
	6.2	13.9	18.2	Vomited
	4.9	16.9	33.3	Vomited
	3.6	22.6	25.6	0

Table V summarizes the data obtained using the preparations containing none or small amounts (1.10 to 0.25 Gm.) of glutamic acid. The serum free glutamic acid values obtained following the infusion of 500 ml. of an amino acid mixture containing no glutamic acid is of particular interest. In spite of the exceedingly rapid rate of administration (50 and 62 ml. per minute), the two subjects showed no toxic symptoms and no appreciable increase in the serum free glutamic acid content. With Preparations Va and Vb attempts were made to produce elevated blood levels by increasing the rate of infusion. It was possible to increase the rate of injection of Preparation Va to such an extent (62.5

ml. per minute) that nausea occurred. At the same time the blood free glutamic acid level rose to 12 to 15 mg. per 100 milliliters. With Preparation Vb, in only one case of the twelve studied was toxicity noted, but there were no rates of administration which were comparable with the faster infusions given with Preparation Va.

TABLE V. THE RELATIONSHIP BETWEEN BLOOD GLUTAMIC ACID LEVEL AND THE PRODUCTION OF NAUSEA AND VOMITING

(PREPARATION VA, 1.10 GM. GLUTAMIC ACID; PREPARATION VB, 0.25 GM., AND PREPARATION III, 0.0 GM.)

AMINO ACID PREPARATION	SERUM FREE GLUTAMIC ACID		RATE OF INFUSION (C.C./MIN.)	REACTION
	BEFORE INFUSION (MG. PER CENT)	AFTER INFUSION (MG. PER CENT)		
Preparation Va				
	2.2	4.9	12.5	0
	2.7	7.0	14.3	0
	4.7	7.2	20.0	0
	6.2	7.5	13.5	0
	5.0	8.3	15.6	0
	4.1	9.1	16.4	0
	4.0	9.3	35.6	0
	5.5	12.3	62.5	Slight nausea
	--	14.7	62.5	Slight nausea
	4.9	15.7	71.4	Nausea
Preparation Vb				
	4.0	3.0	8.3	0
	3.1	3.7	9.1	0
	3.8	3.8	16.6	0
	--	4.8	12.5	0
	3.5	4.9	6.3	0
	5.2	5.8	9.6	0
	4.9	6.3	8.8	0
	1.9	6.3	7.1	0
	4.8	6.6	7.1	0
	3.9	7.4	21.7	Vomited
	3.9	7.9	23.8	0
	5.4	9.1	6.0	0
Preparation III				
	5.0	5.9	50.0	0
	5.4	6.3	62.5	0

The data presented in Tables I to V are summarized in Fig. 1. There is good correlation between the serum free glutamic levels and the per cent of subjects who either became nauseated or vomited. Without regard to the preparation used, when the blood free glutamic acid concentration reached 12 to 15 mg. per 100 ml. about one-half of the subjects became nauseated or vomited. Above these levels the incidence of ill effects was correspondingly greater.

The subjects of Group C received infusions consisting of Preparation Vb plus 5.05 Gm. of glutamic acid per 400 ml. of solution (Table VI). The glutamic acid content of the fortified preparation was thus made equal to an acid digest of casein (Preparation II). In this series there was a decidedly greater frequency of toxic symptoms as compared with this same mixture before glutamic acid was added (Table V). With Preparation Vb alone, the incidence of toxic symptoms was 8.3 per cent; with the addition of glutamic acid the incidence rose to 55 per cent. All of the subjects who experienced ill effects had serum free

glutamic acid levels equal to or above the 12 to 15 mg. per 100 ml. range. It is noteworthy that three of the subjects who had high serum glutamic acid values did not exhibit any gastrointestinal symptoms (Table VI).

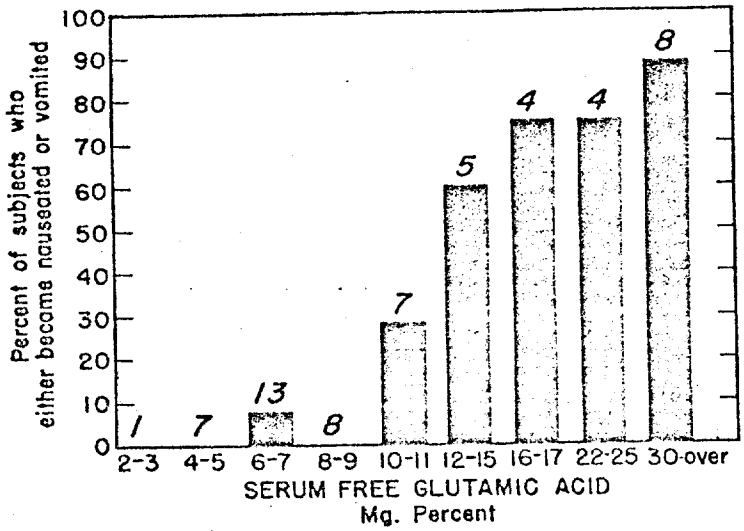

Fig. 1.

TABLE VI. THE EFFECT OF ADDING GLUTAMIC ACID TO PREPARATION VB ON THE OCCURRENCE OF NAUSEA AND VOMITING

(5.05 GM. OF GLUTAMIC ACID ADDED TO 400 C.C. OF PREPARATION VB AND STERILIZED BY AUTOCLAVING)

SERUM FREE GLUTAMIC ACID		RATE OF INFUSION (C.C./MIN.)	REACTION
BEFORE INFUSION (MG. PER CENT)	AFTER INFUSION (MG. PER CENT)		
2.0	9.0	5.8	0
4.5	9.4	9.3	0
--	11.8	8.0	Nausea
3.4	11.9	8.0	Nausea
3.0	18.0	12.0	Nausea
4.3	19.8	9.3	0
5.9	22.0	10.6	0
5.8	27.6	10.6	0
5.2	29.0	10.6	Nausea
4.8	30.0	9.3	Nausea
7.5	35.0	8.6	Nausea

Studies Involving Only Glutamic Acid Solutions.—In the next series of studies an attempt was made to determine whether there was a free glutamic acid level of the serum at which the occurrence of nausea and vomiting could be expected (Table VII, upper half). The first eight subjects received infusions of solutions containing 5.05 Gm. of partially neutralized glutamic acid per 400 ml. of solution; the next nine subjects received infusions of a solution containing 10.1 Gm. of glutamic acid per 400 milliliters. The level of serum glutamic acid reached was dependent on the concentration of the solution infused and the rate of injection. With the lower concentration none of the eight subjects who received the amino acid exhibited ill effects. Only two of these subjects had

serum free glutamic acid levels exceeding 12 mg. per 100 milliliters. Nine subjects received the stronger solution, five of whom became nauseated or vomited. It should be noted that with the stronger solution higher serum free glutamic acid levels were quickly obtained. Forty-five per cent of the subjects who had levels of glutamic acid above 12 mg. per 100 ml. became nauseated or vomited.

TABLE VII. THE RELATIONSHIP BETWEEN SERUM FREE GLUTAMIC ACID LEVELS AND THE OCCURRENCE OF NAUSEA AND VOMITING AFTER GIVING GLUTAMIC SOLUTION INTRAVENOUSLY

AMINO ACID PREPARATION	SERUM FREE GLUTAMIC ACID		RATE OF INFUSION (C.C./MIN.)	REACTION
	BEFORE INFUSION (MG. PER CENT)	AFTER INFUSION (MG. PER CENT)		
Sterilized by Autoclaving				
Glutamic acid 5.05 Gm./400 c.c.	6.8	5.5	5.3	0
	3.3	6.4	11.0	0
	5.7	7.1	4.0	0
	5.3	8.0	4.6	0
	8.4	8.8	5.3	0
	5.4	11.5	10.0	0
	7.5	16.6	8.0	0
	3.5	35.0	40.0	0
Glutamic acid 10.1 Gm./400 c.c.	4.3	20.0	9.3	Vomited
	3.1	22.7	8.0	Vomited
	5.7	25.5	9.3	Vomited
	2.7	29.3	10.0	0
	4.0	31.0	12.0	0
	2.0	37.2	10.0	Vomited
	2.1	39.9	15.0	0
	5.9	41.8	10.0	0
	4.1	53.0	9.3	Vomited
Sterilized by Filtering				
Glutamic acid 5.05 Gm./400 c.c.	3.9	12.0	8.0	0
	3.6	15.1	10.6	0
	3.5	18.0	8.0	0
	3.3	22.6	8.0	Nausea and vomiting
	5.0	26.4	10.6	0
	4.1	27.3	8.0	Nausea
Glutamic acid 10.1 Gm./400 c.c.	4.4	8.5	6.6	Vomited
	3.3	14.9	8.0	Nausea and vomiting
	2.7	19.3	6.6	Vomited
	2.6	22.4	6.6	Vomited
	4.8	24.0	8.0	Vomited
	6.7	29.7	6.6	Vomited
	2.7	30.9	10.0	Nausea
	2.9	60.0	10.0	Vomited

Since many of the commercial protein digests are sterilized by filtration rather than autoclaving and since heat promotes the conversion of glutamic acid to pyrrolidone carboxylic acid, it was decided to repeat these studies using only glutamic acid solutions which had been sterilized by filtration, employing both the lower and higher doses (Table VII, lower half). When the lower dose was administered, two of the six subjects tested became nauseated or vomited; with the higher doses all of the eight subjects tested became ill. One subject vomited but had a blood glutamic acid level of only 7.5 mg. per 100 milliliters.

DISCUSSION

Until the present investigation the quantitative relationship of glutamic acid to the production of anorexia, nausea, and vomiting following the intravenous administration of casein hydrolysates was based on indirect evidence. Previous studies in this hospital indicated that no significant ill effects attended the giving of amino acid preparations orally; however, a depression of appetite, nausea, or vomiting frequently occurred with or immediately after infusions of casein digests.[10] These ill effects could be reduced to a large extent by reducing the rate of infusion. It was next observed that mixtures of the ten essential amino acids could be given intravenously at very rapid rates without producing ill effects.[6, 9, 11] Both Eckhardt and Davidson[12] and Weinstein[13] have administered intravenously to patients amino acid preparations containing reduced amounts of glutamic and aspartic acids and they have reported few toxic symptoms even with rapid rates of infusion. In the case of the dog[1, 2, 3, 4] (and later confirmed in man[5]), it was noted that the addition of either glutamic or aspartic acids to parenterally administered amino acid mixtures reduced the tolerance of these mixtures. Additional evidence indicated that there was a marked correlation between the content of these two dicarboxylic amino acids in amino acid preparations and the tendency of the solutions to provoke nausea and emesis in man. On the other hand, Elman[14] has reported the intravenous injections of an unneutralized glutamic acid solution (1,000 ml. of solution contained 30 Gm.) into three patients without the occurrence of any ill effects. No reference was made by this investigator to the rate of infusion, or to the glutamic acid level which resulted. His interpretation, apparently based upon that study, that intravenously injected glutamic acid is not related to the production of nausea and vomiting, is at variance with our experience.

Hoffman and co-workers[15] reported that if the blood amino acid nitrogen following the administration of an acid hydrolysate of casein exceeds 10 mg. per cent, nausea and vomiting may occur. This finding has been confirmed previously in this laboratory[6] for the same preparation; however, using preparations which were either free of or very low in glutamic acid it was possible to obtain markedly elevated blood amino acid nitrogen values without ill effects. At that time it was suggested that the blood glutamic acid probably was more closely related to the nausea and vomiting than the amino acid nitrogen content. Kade[16] has suggested that following the intravenous administration of preparations rich in glutamic acid the blood level of glutamic acid rises faster than the amino acid nitrogen content of the same blood. Friedberg and Greenberg[17] have reported that glutamic acid is slowly cleared from the blood of rats after intravenous administration.

In this study the determination of the free glutamic acid content of serum was accomplished by using a microbiologic procedure employing *Lactobacillus arabinosus* as the test organism. This method has been shown to give reliable values when protein hydrolysates were investigated.[7] Recently it was stated by Prescott and Waelsch[18] that the microbiologic method for glutamic acid is not applicable in the presence of glutamine. By their chemical method it was found

that free glutamic acid of serum or plasma varied from 0.6 to 1.7 mg. per 100 ml., and the "apparent glutamine" content ranged from 8 to 12 mg. per 100 milliliters. Harper,[19] using a modified type of microbiologic method, more recently found glutamic acid and glutamine values in plasma similar to those given by the chemical method. The major portion of the preinfusion values for serum free glutamic acid reported in the present study would tend to show that a portion of the serum glutamine is being included in the value, because they are above the 0.6 to 1.7 mg. range. Since they are almost all below the 8 to 12 mg. range, not all the glutamine is being determined as free glutamic acid.

There appears to be some quantitative difference in the tolerance of glutamic acid when administered alone and when mixed with other amino acids. When 5.05 Gm. of glutamic acid were given intravenously as a solution containing only this amino acid, 14 per cent* (two of the fourteen studied) of the subjects either became nauseated or vomited. When a similar amount of glutamic acid was given intravenously in a mixture of amino acids (Preparation II), 60 per cent* (six of the ten tested) of the subjects showed ill effects. On the other hand, when the concentration of glutamic acid was increased to 10.1 Gm. and only this partially neutralized amino acid was given intravenously, 76 per cent (thirteen of the seventeen patients) of the subjects became nauseated or vomited. Thus, the incidence of nausea and vomiting following the intravenous administration of glutamic acid incorporated in an amino acid mixture is greater than that when an equivalent amount of partially neutralized glutamic acid is given alone. Both aspartic acid[2] and phenylalanine[20] have been reported to increase the toxicity of intravenously administered amino acid. dl-Methionine also has been listed as an amino acid which is poorly tolerated when given intravenously to the dog.[21] The amino acid preparations which are low in glutamic acid are also generally low in aspartic acid. Phenylalanine and methionine are probably not offenders in this manner, at least not without the dicarboxylic amino acids being present. Preparations III and V contained these acids and were well tolerated even at rapid rates. The possibility of other amino acids increasing the effect of glutamic acid in the production of nausea and vomiting following its intravenous administration should be further investigated.

In attempting to evaluate the data concerning the relative toxicity of the autoclaved as compared with the filtered solutions of glutamic acid, it was noted that 71 per cent* (ten of the fourteen cases) of the subjects that received the latter preparation became nauseated or vomited, while only 30 per cent* (five of the seventeen subjects) became ill after receiving the autoclaved material. Thus, the filtered material would appear to be slightly more toxic than the autoclaved. Olcott[22] reported that if glutamic acid were autoclaved at a temperature of 125° C. and in an acid media, pH 3.3 for four hours, 92 per cent of the amino acid would be converted to pyrrolidone carboxylic acid. The possibility of this occurring during the relatively short period of autoclaving used in the present

*Since the difference is greater than two times the standard error of the mean, these differences are considered significant.

study might be an explanation for the apparent difference in emetic effect. The likelihood of the pyrrolidone carboxylic acid assaying like glutamic acid (e.g., supporting the growth of the *Lactobacillus arabinosus*) while having an emetic action different from glutamic acid was investigated; in this case a high serum glutamic acid level might be attained without nausea and vomiting. Lyman found that this microorganism cannot utilize pyrrolidone carboxylic acid.[23] In the present study* it was found that pyrrolidone carboxylic acid neither stimulated nor inhibited the bacterial growth in that assay of glutamic acid when present in one-third to four times the concentration of glutamic acid. If much glutamic acid were converted to pyrrolidone carboxylic acid during the short period of autoclaving, then the concentration of free glutamic acid in the autoclaved material should decrease, since the pyrrolidone carboxylic acid does not support growth of the microorganism. This did not occur. Hence, it seems unlikely that pyrrolidone carboxylic acid could account for the apparent difference in toxicity of the filtered and autoclaved glutamic acid solutions.

SUMMARY AND CONCLUSIONS

The free glutamic acid content of five different types of amino acid preparations was estimated using microbiologic methods. They are, in decreasing order of glutamic acid content: an acid hydrolysate of casein fortified with tryptophane, an enzymatic hydrolysate of casein, an enzymatic digest of beef blood proteins, a mixture of amino acids produced by the recombination and fortification of fractions of a casein digest, and a mixture of the ten "essential" amino acids plus glycine. The occurrence of nausea and vomiting following the administration of the various preparations in a series of fifty-seven human subjects was found to parallel the free glutamic acid content of the mixture given.

Until the present investigation, only indirect evidence was obtained concerning the quantitative relationship of glutamic acid and the production of nausea and vomiting following its intravenous administration. A direct relationship between the free glutamic acid of the serum and the occurrence of toxic effects following the administration of amino acid preparations was found in this investigation. When the serum free glutamic acid level reached 12 to 15 mg. per 100 ml., nausea and vomiting occurred in more than half of the subjects.

Solutions containing only partially neutralized glutamic acid were administered intravenously to thirty-one individuals and estimates of the free glutamic acid content of the serum were made. A lower percentage of these patients became ill at elevated glutamic acid levels than in the group that received glutamic acid containing amino acid mixtures. This is interpreted as showing that the toxicity of glutamic acid may be potentiated by other amino acids.

A study of the effect of autoclaving and of sterilization by filtration upon the toxicity of glutamic acid solutions indicated that the filtered material was slightly more toxic. This difference could not be attributed to the presence of pyrrolidone carboxylic acid.

*These data are not included in the present report.

REFERENCES

1. Madden, S. C., Woods, R. R., Shull, F. W., Remington, J. H., and Whipple, G. H.: Tolerance to Amino Acid Mixtures and Casein Digests Given Intravenously; Glutamic Acid Responsible for the Reactions, J. Exper. Med. 81: 439, 1945.
2. Unna, K., and Howe, E. E.: Toxic Effects of Glutamic and Aspartic Acid, Federation Proc. 4: 138, 1945.
3. Sokalchuk, A., Ellis, B. A., Wester, M. R., Weston, K., Greisheimer, E. M., and Oppenheimer, M. J.: Comparative Effects of Protein Hydrolysates and Amino Acid Mixtures on Intestinal Motility and Blood Sugar Levels After Rapid Intravenous Injections, Gastroenterology 10: 831, 1948.
4. Lasichak, A. G., and Levey, S.: Glutamic Acid and Vomiting in Dogs: Its Administration Into the Portal System and Extremity Veins, Proc. Soc. Exper. Biol. & Med. 70: 74, 1949.
5. Smyth, C. J., Levey, S., and Lasichak, A. G.: The Relationship of Glutamic and Aspartic Acids to the Production of Nausea and Vomiting in Man, Am. J. M. Sc. 214: 281, 1948.
6. Smyth, C. J., Lasichak, A. G., and Levey, S.: The Effect of the Rate of Administration of Amino Acid Preparations and the Blood Amino Acid Nitrogen Level On the Production of Nausea and Vomiting, J. Lab. & Clin. Med. 32: 889, 1947.
7. Dunn, M. X., Camien, M. N., Rockland, L. B., Shankman, S., and Goldberg, S. C.: Investigations of Amino Acids, Peptides, and Proteins, XVII. The Determination of Glutamic Acid in Protein Hydrolysates by A Microbiological Method, J. Biol. Chem. 155: 591, 1944.
8. Hier, S. W., and Bergeim, O.: The Microbiological Determination of Free Leucine, Isoleucine, Valine, and Threonine in Dog Plasma, J. Biol. Chem. 161: 717, 1946.
9. Smyth, C. J., Levey, S., and Lasichak, A. G.: The Effects of the Rate of Administration of Amino Acid Preparations on Urinary Wastage of Amino Acid Nitrogen in Man, J. Clin. Investigation 27: 412, 1948.
10. Smyth, C. J., Lasichak, A. G., and Levey, S.: The Effect of Orally and Intravenously Administered Amino Acid Mixtures on Voluntary Food Consumption in Normal Man, J. Clin. Investigation 26: 439, 1947.
11. Werner, S. C.: The Use of Mixtures of Pure Amino Acids in Surgical Nutrition, Ann. Surg. 126: 169, 1947.
12. Eckhardt, R. D., and Davidson, C. S.: Urinary Excretion of Amino Acids Following the Rapid Injection of a Solution of Amino Acids in Man, J. Clin. Investigation 27: 727, 1948.
13. Weinstein, J. J.: Intravenous, Subcutaneous and Rapid Intramuscular Infusions of Protein Hydrolysates, Surg., Gynec. & Obst. 87: 93, 1948.
14. Elman, R.: The Intravenous Use of Protein and Protein Hydrolysates, Ann. New York Acad. Sc. 47: 345, 1946.
15. Hoffman, W. S., Kozoll, D. D., and Osgood, B.: Blood Chemical Changes Following Intravenous Administration of a Casein Hydrolysate to Human Subjects, Proc. Soc. Exper. Biol. & Med. 51: 137, 1946.
16. Kade, C. F.: Personal communication.
17. Friedberg, F., and Greenberg, D. M.: Partition of Intravenously Administered Amino Acids in Blood and Tissues, J. Biol. Chem. 168: 411, 1947.
18. Prescott, B. A., and Waelsch, H.: Free and Combined Glutamic Acid in Human Blood Plasma and Serum, J. Biol. Chem. 167: 855, 1947.
19. Harper, H. A.: The Microbiological Determination of Glutamine in Human Plasma, Arch. Biochem. 15: 433, 1947.
20. Madden, S. C., Bassett, S. H., Remington, J. H., Martin, F. J. C., Woods, R. R., and Shull, F. W.: Amino Acids in Therapy of Disease; Parenteral and Oral Administrations Compared, Surg., Gynec. & Obst. 82: 131, 1946.
21. Howe, E. E., Unna, K., Richards, G., and Seeler, A. O.: Comparative Tolerance to Mixtures of Natural and Racemic Amino Acids on Intravenous Infusion in the Dog, J. Biol. Chem. 162: 395, 1946.
22. Olcott, H. S.: A Method for the Determination of Glutamic Acid in Proteins, J. Biol. Chem. 153: 71, 1944.
23. Lyman, C. M., Kuiken, K. A., Blotter, L., and Hale, F.: The Microbiological Determination of Amino Acids. II. Glutamic Acid, J. Biol. Chem. 157: 395, 1945.

(4487)

The Toxic Effect of Sodium L-Glutamate on the Inner Layers of the Retina

D. R. LUCAS, M.D., and J. P. NEWHOUSE, B.Sc., London, England

L-Glutamic acid and its sodium salt have been widely used in the oral treatment of petit mal and mental deficiency (e. g., Zimmerman, Burgemeister, and Putnam, 1949; Milliken and Standen, 1951). Single doses of 20-30 gm. have also been administered intravenously without permanent ill-effects (Sapirstein, 1943; Elman, 1946; Mayer-Gross and Walker, 1949; Weil-Malherbe, 1949).

During an investigation of the influence of various substances of biochemical importance upon the progress in the mouse of an hereditary retinal dystrophy it was observed that the parenteral administration of sodium L-glutamate damaged the inner layers of the retina, which are not themselves involved in the genetic lesion. Since this lesion could also be produced in normal mice, a limited study was made of its histological development and the conditions necessary for its appearance in mouselings and adults of the Strong A2 (Glaxo) strain. Among substances related chemically or physiologically to glutamate, which were also tested, only sodium L-aspartate had a similar effect.

Methods and Materials

Animals.—All work was performed on an inbred colony of Strong A2 (Glaxo) mice, fed throughout on rat cake Diet 41 (Bruce and Parkes, 1949). Adult mice used weighed 15-36 gm.; suckling mice, from litters of five to eight animals, when destroyed for histological purposes at 17 days, weighed 5-7 gm.

Substances Administered.—These consisted of (1) L-glutamic acid; (2) L-glutamic acid, sodium salt monohydrate; (3) α-ketoglutaric acid, sodium salt; (4) L-aspartic acid, sodium salt; (5) L-glutamine; (6) ammonium carbonate; (7) epinephrine hydrochloride solution, 0.1% (w/v); (8) adenosinetriphosphate, sodium salt (ATP); (9) methanol; (10) quinine dihydrochloride, solution 20% (w/v); (11) 2,4-dinitrophenol, sodium salt.

The materials were made up in 0.85% saline or Krebs-Ringer solution and brought to pH 7.4 with phosphate buffer. Concentrations were adjusted to give injection volumes of 0.01-0.20 ml. in the mouselings and 0.5-1.2 ml. in the adults. Administration was subcutaneous unless otherwise specified.

Treatment.—To produce a severe retinal lesion by a single injection, a dosage of glutamate a little less than lethal was needed. This method proved suitable in the adult, but a course of injections at a lower level in the suckling mouse gave the same result with fewer casualties. A similar system of dosage was used in testing the other compounds upon adult and young mice. The latter were particularly liable to overdosage during their first 10 days of life and hence usually received during this period a smaller dosage (milligrams per gram of body weight) than that administered between 11 and 17 days.

Administration During Growth (Table 1).—(1) Glutamate: *(a)* To test the possibility that sodium glutamate might reach the fetus or suckling in effective quantity

Received for publication Feb. 1, 1957.

Wernher Group for Research in Ophthalmological Genetics (Medical Research Council), Royal College of Surgeons of England.

A.M.A. Arch. Ophth. 58(2) ~~1957~~ Aug. 1957 p. 193-201

TABLE 1.—*Dosage of Substances Given Daily to Mouselings Aged Two to Sixteen Days*

	Substances, Mg./Gm. Body Weight				
	Sodium L-Glutamate	Sodium L-Aspartate	L-Glutamine *	Epinephrine	Ammonium Carbonate
Age, days, & weight, † gm.					
2 (1.80)	2.20	0.50	1.10	0.004	0.20
6 (3.28)	3.70	0.90	2.30	0.006	0.20
10 (4.36)	4.60	0.90	3.20	0.012	0.20
13 (5.43)	4.80	1.00	3.20	0.014	0.20
16 (5.50)	5.40	1.30	3.00	0.014	0.20
Total dose,‡ mg.	240	45	125	0.40	8.3
Animals					
No. used	70	11	7	19	11
Survivors for hist. study, No.	39	5	7	10	5
Age when killed, days	2-40	17	17	17	17

* Dose given in two equal portions, six hours apart.
† Mean value based on five litters comprising 27 mouselings.
‡ Typical total dose given between 2 and 16 days.

from the mother adult females received this substance parenterally, in doses of 40 mg. per day, throughout gestation, lactation, or both; the 40 mouselings which were born received no special treatment but were examined at birth or 17 days later.

(*b*) For study of the lesion at various stages of development, some 70 mouselings were treated daily with sodium glutamate, according to the dosage schedule shown (Table 1); the 39 survivors were examined at ages of between 2 and 40 days. All were treated from 2 to 17 days, except 5 which were treated from 2 to 11 days and 4 which were treated from 11 to 17 days; these 9 were all examined at 17 days. The dosage schedule in Table 1 corresponds to a daily increment of 1.5-2.0 mg. sodium glutamate. Typical doses (in milligrams) given at various ages (days, in parentheses) were as follows: 2 (4); 12 (6); 20 (10); 26 (13); 30 (16).

(*2*) Other Substances: Particulars of dosage used of sodium aspartate, glutamine, epinephrine, and ammonium carbonate are given in Table 1.

Administration in Adult Life.—Details of the animals treated with glutamate and other substances are given in Table 2.

Histological Processing.—All the eyes were fixed intact in acid Zenker's fluid. After they were embedded in paraffin wax sections were cut at 5μ to 6μ. Routine staining was with Erhlich's hematoxylin and eosin Y method; a few sections were also

TABLE 2.—*Dosage of Substances Administered to Adult Mice*

Substance	Route *	Dosage,† Mg./Gm. Body Wt.	Mice, No.	Survivors Examined Histologically Mice, No.	Time After Last Dose, Days
Sodium L-glutamate	SC	4.0	3	3	
		6.0	9	7	1 hr.-21 days
		8.0	12	7	
		10.0	3	1	
		3.0 - 4.0 ‡	8	8	28
		1.0 - 1.5 §	6	6	1-10
Adenosinetriphosphate, sodium salt	IP	0.5**	6	1	10
Sodium α-ketoglutarate	SC	2.0	5	5	11
Ammonium carbonate	IP	5.2 - 6.8	5	3	10
Dinitrophenol, sodium salt	IP	0.31	3¶	3	10
Methanol	SC	0.0165	1	4	11
Quinine dihydrochloride	SC	8.0 - 10.0	15	5	3-11
		0.35	8	6	3-11

* SC, subcutaneous; IP, intraperitoneal.
† Animals received single doses unless otherwise stated.
‡ Four received 12 doses and four received 24 doses on successive days.
§ These animals were mothers of litters mentioned in Table 1 and received 30-420 doses.
** Three doses were given, one hour before, one hour after, and simultaneously with a single injection (SC) of sodium L-glutamate 8.0 mg./gm.
¶ These mice simultaneously received a single injection (SC) of sodium L-glutamate 4.0 mg./gm.
‡ Dosage based on Hunt (1904).

tained with Mallory's phosphotungstic acid and hematoxylin method.

Results

Suckling Mice.—(1) Effect of Sodium L-Glutamate: At birth the newborn mouse retina consists of a layer of ovoid nuclei some 65μ thick separated from two to three rows of ganglion-cell precursors by the inner fiber layer, which is some 12μ thick. By about six days after birth the ganglion cells have formed a single even row of cells. As seen in section, ganglion cells appear to vary considerably in size: in the adult, their nuclei range from 4μ to 8μ in diameter. From birth the cytoplasm of the ganglion cells is strongly basophilic.

While the ganglion-cell layer is differentiating, the inner nuclear layer becomes separated from the outer nuclear layer and the inner fiber layer increases rapidly in thickness until, by 17 days after birth, it is 30μ thick. Mitotic figures are not seen in the differentiating inner nuclear layer. The inner nuclear layer can be distinguished from the outer layer from about six days after birth in the area centralis, and the two layers are completely separated at about eight days.

Treatment of the mother alone with glutamate, either orally or parenterally, during gestation and lactation had no demonstrable effect on the retina at birth or subsequently, but treatment of the suckling mice themselves regularly resulted in severe retinal damage. Mice aged 2 to 4 days which were examined a few hours after injection on those days, showed pycnotic nuclei along the inner border of the future inner nuclear layer. Numbers of ganglion-cell nuclei were pycnotic or showed rather pale staining of the nuclear chromatin network, and there was concomitant cytoplasmic shrinkage and loss of normal basophilic staining. In the 4-day-old mice these changes were conspicuous (Fig. 2). By six to eight days after birth, the number of ganglion cells was substantially reduced and the inner nuclear layer was only half of its normal thickness at this age. The inner fiber layer, instead of growing, disappeared altogether by 8 to 10 days after birth. The remaining inner layer and ganglion cells gradually diminished, until by 17 days after birth only occasional cells remained. The outer nuclear layer was little affected, and differentiation of the visual cells proceeded almost normally, although the final number of rows of nuclei appeared slightly reduced. The only abnormality noted was the occasional eruption of groups of visual-cell nuclei through the outer limiting membrane to form mushroom-like protuberances among the rods themselves. This disturbance was first noted 10 days after birth and was sometimes severe enough to produce an appearance of arcading (Fig. 6), but the pigmented epithelium was never involved as in arcading due to chorioretinitis.

The optic nerve appeared much thinner in hematoxylin-and-eosin-stained sections in the treated animals than in the controls.

The mice treated up to 11 days after birth showed a similar picture, but a few more inner-layer and ganglion cells were preserved. The four survivors treated from 11 to 16 days after birth showed a still less severe picture. The inner layer was half its normal thickness, and numbers of recognizable ganglion cells were present. The outer nuclear layer was unaffected in both these groups treated over short periods.

Both litters and mothers withstood the routine treatment fairly well, though showing nervousness and tremor soon after injection. Larger doses (8-10 mg/gm.) often produced convulsions followed by a state of prostration, a finding similar to that of Goodman, Swinyard, and Toman (1946), who observed that a dosage of 8 mg/gm. given intraperitoneally to cats caused hyperpnea, seizures, and death.

(2) Effect of Other Substances Tested: Sodium L-aspartate. Three of the five animals receiving aspartate showed minimal lesions at the periphery of the retina. These lesions appeared to be identical in nature with the glutamate-induced lesion, although

Plate I

Fig. 1.—Normal mouse retina four days after birth; × 290. All sections were stained with hematoxylin and eosin.

Fig. 2.—Retina of 4-day-old mouse after injections of 4 and 8 mg. of sodium glutamate on the second and fourth days, showing pycnotic nuclei in inner border and among ganglion cells; × 290.

Fig. 3.—Normal mouse retina eight days after birth; × 290.

Fig. 4.—Retina of 8-day-old mouse after daily injections of sodium glutamate, showing severe damage to the inner layers; × 290.

Fig. 5.—Normal mouse retina 17 days after birth; × 290.

Fig. 6.—Retina of 17-day-old mouse after daily injections of sodium glutamate, showing survival of only the outer nuclear layer with irregular protrusions of visual cells through the outer limiting membrane; × 290.

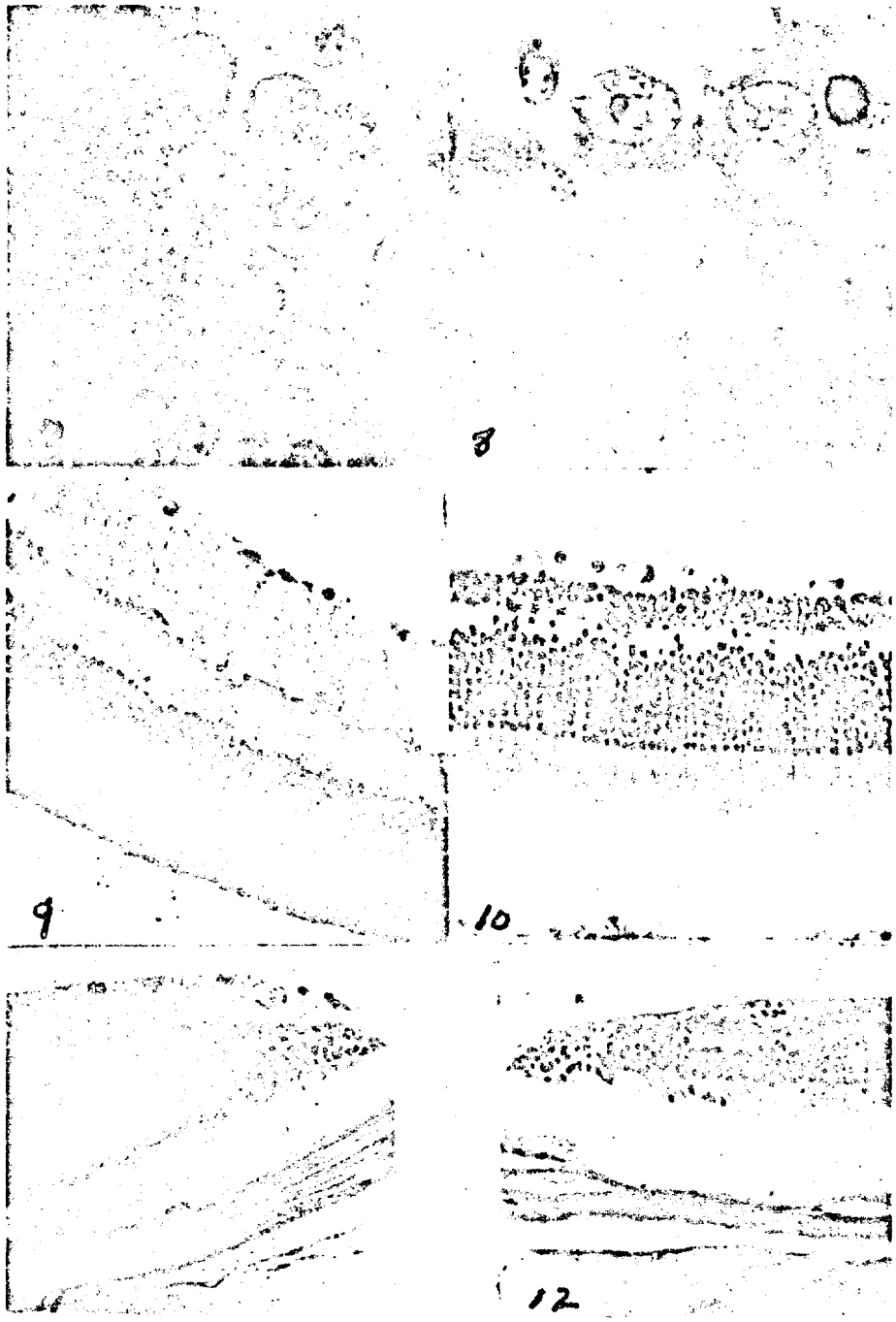

Plate II

Fig. 7.—Group of normal adult retinal ganglion cells; × 1000.

Fig. 8.—Group of adult retinal ganglion cells one hour after injection of 8 mg/gm. of sodium glutamate; two show chromatolysis and one has a pycnotic nucleus; × 1000.

Fig. 9.—Adult retina one day after injection of 8 mg/gm. of sodium glutamate, showing pycnotic nuclei in the ganglion-cell layer and inner nuclear layer and vacuolation of the inner fiber layer; × 290.

Fig. 10.—Adult retina 12 days after injection of 8 mg/gm. of sodium glutamate, showing severe destruction of the inner fiber layer and ganglion cells; × 290.

Fig. 11.—Ora serrata of normal adult; × 290.

Fig. 12.—Ora serrata 15 days after single injection of 6.0 mg./gm. of sodium glutamate (area centralis of this mouse was unaffected); × 290.

much more limited in extent. The remaining two animals showed no definite retinal abnormality.

Glutamine and epinephrine. None of the animals receiving these substances showed any demonstrable retinal abnormality.

Ammonium carbonate. This material was poorly tolerated; the animals tended to lose weight under treatment and to die before 17 days. None of the survivors showed any retinal abnormality.

Adult Mice.—(1) Effects of Sodium L-Glutamate: As in the suckling mice, the effect of sodium glutamate on the retina was manifested histologically as partial necrosis of the ganglion cells and inner-nuclear-layer cells. The periphery of the retina was regularly affected, but the central area sometimes escaped damage. The cells of the internal surface of the inner nuclear layer were more susceptible than those of the external surface. Even in the severely affected animals, complete destruction of the inner nuclear layer, as seen in the sucklings, did not occur.

Pathological changes were seen in the mouse killed 30 minutes after receiving 8 mg/gm.; in one, killed after 60 minutes, and in another, which died after 55 minutes, there were well-marked changes. The early changes seen were nuclear pycnosis both of the inner-layer and ganglion cells; the latter also showed loss of cytoplasmic staining. The inner fiber layer lost its characteristic reticulated appearance and became vacuolated. The outer fiber layer showed similar, but less well-marked, changes. Little change occurred during the next few days, but between 5 and 10 days after injection most of the necrotic tissue disappeared; there was no evidence of phagocytic removal such as occurs in the rabbit retina after destruction of the outer nuclear layer by iodoacetic acid (Karli, 1954).

The optic nerve was not systematically studied, but in several severely affected animals examined 12 to 15 days after receiving 8 mg/gm. of sodium glutamate, the fiber bundles in the papilla were found to be narrowed and the number of glial cells was increased.

The lesions produced by repeated doses do not require separate description, since they did not differ from the appearance found two to three weeks after a single injection.

The mouse surviving simultaneous treatment with sodium glutamate and ATP showed a severe retinal lesion identical with that seen after glutamate alone. Control animals receiving ATP alone were unaffected.

The histological changes varied rather widely at any given dosage level. The survivors of single doses of different magnitude have been classified into three grades of severity in Table 3. In the least severely affected, the lesion was so slight as to be only just recognizable at the ora serrata. In the severely affected, the damage involved the area centralis. The remaining grade was of intermediate severity.

The effects of the repeated doses cannot be compared accurately, since the dosage was not adjusted to body weight during the period of treatment. However, the weights of the animals when killed were recorded; so an approximate calculation is possible. Only one of the four animals receiving 12 doses of 100 mg. showed a lesion of moderate severity, but all the animals receiving 24 doses of 100 mg. (3.0 to 4.0 mg/gm.) were affected to a mild degree.

None of the mice which received a dose of 40 mg. (1.0 to 1.5 mg/gm.) daily over long periods was affected.

TABLE 3.—*Results of Single Doses of Sodium L-Glutamate in Adult Mice*

Dosage, Mg./Gm.	Animals, No.			
	Not Affected	Severity of Lesion*		
		+	++	+++
4	1	2	0	0
6	2	3	1	1
8	0	0	3	5

* +, The slightest detectable lesion; ++, lesion confined to the periphery; +++, lesion involving area centralis.

The mice treated with sodium glutamate and ammonium carbonate showed no retinal abnormality.

(2) Other Substances: The survivors in Table 2, after treatment with sodium α-ketoglutarate, quinine, or methanol, showed no histological abnormality.

Comment

The toxic action of sodium L-glutamate upon the retina does not appear to have been previously reported. The effect develops rapidly: Typical changes appear in the ganglion cells and inner nuclear layer of the mouse retina within 30 minutes after injection. Sublethal dosage is required to produce a lesion of consistent severity. The developing tissue (age 2 to 10 days) seems more sensitive than that of the older mouse.

Other agents reputed to produce comparable retinal lesions in various mammals proved ineffective when given in maximal dosage to the adult mouse. Methanol is reputed to damage the ganglion cells and optic nerves of mice (Weese, 1928; Harada, 1937), but the validity of these findings has recently been questioned by Hilger and Potts (1955) on technical grounds. While quinine appears to cause a similar lesion in the cat, dog, and rabbit (Holden, 1898; Birch-Hirschfeld, 1900; Druault, 1902), the present negative findings agree with those reported by Druault in the mouse.

The inner layers of the retina in structure resemble cerebral tissue, in which the functions of glutamate have been studied intensively. Though both tissues readily absorp glutamate from a glucose-saline medium (Stern, Eggleston, Hems, and Krebs, 1949), the content of this constituent is closely regulated in the brain of the intact animal. Schwerin, Bessman, and Waelsch (1950) and other investigators have shown that a dosage of sodium L-glutamate (1-2 mg/gm. body weight) capable of producing blood glutamate levels many times greater than those of brain or retina has little effect on the cerebral content in rats or mice. The chemical and pathological reactions of the retina in animals so treated have not been reported.

Possible Modes of Toxic Action.—Three possibilities arise:

1. Indirect Effect: That this substance acts indirectly via adrenal stimulation (cf., Weil-Malherbe, 1949) seems unlikely, since epinephrine and substances that excite its secretion, such as glycine and *p*-aminobenzoic acid, were not injurious to the mouse retina. Large doses of the immediate metabolites of glutamate were equally ineffective, apart from aspartate, which is readily converted into glutamate by transamination in the isolated tissue (Terner, Eggleston, and Krebs, 1950). Such findings, though not conclusive, suggest that the lesion arises from the properties of glutamate itself.

2. Interference with Ionic Exchange: The in vitro studies of Terner et al. (1950) indicate that L-glutamic acid is unique among amino acids in its ability to maintain the high retinal concentration of potassium. Both ions are absorbed in approximately equivalent quantities, and the process is dependent on glucose breakdown. A massive dosage (6-8 mg/gm.) of sodium glutamate could be expected to cause some simultaneous increase in the retinal uptake of both these ions. Their association in excessive amounts within the tissue could then conceivably interfere with the outstanding level of potassium turnover that accompanies functional activity in retina. Each substance is known to promote acetylcholine synthesis in both brain and retinal preparations, but excessive potassium has the reverse effect and can, in some circumstances, inhibit ganglionic discharge.

3. Interference with Carbohydrate Metabolism: On addition to brain slices, sodium glutamate (0.01 M) causes a depression in anaerobic glycolysis which becomes maximal by one hour, after which further uptake of glutamate ceases (Weil-Malherbe, 1938; Stern et al., 1949). This effect is abolished by adding adenosinetriphosphate. In retina

exposed to the same condition, the glycolytic inhibition is far smaller (0%-6%) but the concentration of glutamate (0.01 M) used in these earlier studies was not great, being perhaps a 10th of that feasible in the plasma of the injected animal. Current investigations indicate that anaerobic glycolysis in the excised retinae of mice killed one hour after glutamate injection is about a third lower than that of a control group, whereas respiration with pyruvate as substrate is unaffected.

An unusual property of glutamate, which it shares with potassium salts and 2,4-dinitrophenol, is its ability to maintain a high rate of respiration in brain and retina. The accompanying breakdown of carbohydrate does not, however, serve a useful purpose by providing energy for the synthesis of high-energy-phosphate-bond compounds necessary for functional activity. Indeed, all three substances when added to brain slices actually reduce the content of such products (McIlwain, 1951; 1952). Not only glycolysis and acetylcholine formation but also other important enzymatic processes, such as potassium transport and the glutaminase and glutamotransferase reactions, are dependent upon supplies of adenosinetriphosphate. That certain inner layers show an unusual degree of lactic dehydrogenase (Lowry, 1955) and cholinesterase activity (Francis, 1953) is indicative of the special functions occurring in this region. The reactions named would almost certainly be affected by a deficiency of high-energy phosphate compounds if glutamate is as effective against their synthesis in retina as it is in brain. Against this hypothesis are the facts that parenteral dinitrophenol did not produce a glutamate-type lesion in the mouse and that administration of ATP with glutamate did not prevent its usual occurrence. Whether these substances are able to penetrate to the inner layers of retina is unknown.

Summary

Subcutaneous administration of sodium L-glutamate (4-8 mg/gm. body weight) damaged the retina of albino mice. Necrotic changes affected the ganglion cells, inner fiber layer, and some of the bipolar cells within a few hours of injection; the visual-cell layer was not affected. In very young animals, damage to the inner layers was more extensive and groups of rod cells protruded through the outer limiting membrane.

Sodium L-aspartate (1.27 mg/gm. body weight) produced a similar but less severe lesion when given subcutaneously to very young animals.

L-Glutamine, sodium α-ketoglutarate, 2,4 dinitrophenol, epinephrine, or ammonium salts in large dosage had no similar effect in adult mice. Claims that quinine and methanol damage the inner retinal layers in adult mice could not be confirmed.

Various biochemical systems known to be influenced by glutamate, e. g., glycolysis and potassium transport, are discussed in relation to the mechanism of the effect.

Prof. P. C. Kolier and Prof. H. McIlwain gave advice in the present work, and Mrs. Doris B. Hatton, Mrs. Toby Necci, and Miss Diana Tremain gave technical assistance.

Lincoln's Inn Fields (W. C. 2).

BIBLIOGRAPHY

Birch-Hirschfeld, A.: Beitrag zur Kenntniss der Netzhautganglionzellen unter physiologischen und pathologischen Verhältnissen, von Graefes Arch. Ophth. 50:166-246, 1900.

Bruce, H. M., and Parkes, A. S.: Feeding and Breeding of Laboratory Animals: IX. A Complete Cubed Diet for Mice and Rats, J. Hyg. 47:202-208, 1949.

Druault, A.: Recherches sur l'amaurose quinique, Arch. opht. 22:19-32, 1902.

Ehman, R.: The Intravenous Use of Protein and Protein Hydrolysates, Ann. New York Acad. Sc. 47:345-357, 1946.

Francis, C. M.: Cholinesterase in the Retina, J. Physiol. 120:435-439, 1953.

Gilger, A. P., and Potts, A. M.: Studies on the Visual Toxicity of Methanol: V. The Role of Acidosis in Experimental Methanol Poisoning, Am. J. Ophth. 39:63-86 (Feb., Pt. 2) 1955.

Goodman, L. S.; Swinyard, E. A., and Toman, J. E. P.: Effects of L (+) Glutamic Acid and Other Agents on Experimental Seizures, Arch. Neurol. & Psychiat. 56:20-29, 1946.

Harada, M.: Pharmakologische und histologische

Untersuchungen über die Amblyopie, hervorgerufen durch Farnkrautpräparate, Jap. J. M. Sc., IV, Pharmacol. 10:85-89, 1937.

Holden, W. A.: The Pathology of Experimental Quinine Amblyopia, Arch. Ophth. 27:583-592, 1898.

Hunt, R.: Über die Toxicität einiger Chinin-Derivate, Arch. internat. pharmacodyn. 12:497-505, 1904.

Karli, P.: Contribution expérimentale à l'étude de la pathogénie des rétinoses pigmentaires, Ophthalmologica 128:137-162, 1954.

Lowry, O. H., in Biochemistry of the Developing Nervous System, edited by H. Waelsch, New York, Academic Press, Inc., 1955, p. 350.

McIlwain, H.: Glutamic Acid and Glucose as Substrates for a Mammalian Brain, J. Ment. Sc. 97:674-680, 1951.

Phosphates of Brain During in Vitro Metabolism: Effects of Oxygen, Glucose, Glutamate, Glutamine, and Calcium and Potassium Salts, Biochem. J. 52:289-295, 1952.

Mayer-Gross, W., and Walker, J. W.: The Effect of L-Glutamic Acid and Other Amino-Acids in Hypoglycaemia, Biochem. J. 44:92-97, 1949.

Milliken, J. R., and Standen, J. L.: An Investigation into the Effects of Glutamic Acid on Human Intelligence, J. Neurol. Neurosurg. & Psychiat. 14:47-54, 1951.

Sapirstein, M. R.: Effect of Glutamic Acid on the Central Action of the Ammonium Ion, Proc. Soc. Exper. Biol. & Med. 52:334-335, 1943.

Schwerin, P.; Bessman, S. P., and Waelsch, H.: The Uptake of Glutamic Acid and Glutamine by Brain and Other Tissues of the Rat and Mouse, J. Biol. Chem. 184:37-44, 1950.

Stern, J. R.; Eggleston, L. V.; Hems, R., and Krebs, H. A.: Accumulation of Glutamic Acid in Isolated Brain Tissue, Biochem. J. 44:410-418, 1949.

Terner, C.; Eggleston, L. V., and Krebs, H. A.: The Role of Glutamic Acid in the Transport of Potassium in Brain and Retina, Biochem. J. 47:139-149, 1950.

Weese, H.: Vergleichende Untersuchungenen über die Wirksamkeit und Giftigkeit der Dämpfe niederer aliphatischer Alkohole, Arch. Exper. Path. u. Pharmakol. 135:118-130, 1928.

Weil-Malherbe, H.: Observations on Tissue Glycolysis, Biochem. J. 32:2257-2275, 1938.

The Action of Glutamic Acid in Hypoglycaemic Coma, J. Ment. Sc. 95:930-944, 1949.

Zimmerman, F. T.; Burgemeister, B. B., and Putnam, T. J.: Effect of Glutamic Acid on the Intelligence of Patients with Mongolism, Arch. Neurol. & Psychiat. 61:275-287, 1949.

MATSUYAN, S: STUDIES ON EXPERIMENTAL OBESITY IN MICE TREATED WITH MSG
Jap. J. Vet. Sci., 32: 206, 1970.
(Translated from the Japanese by , Ci han Ho, MD)

2 mg/g body wt. of MSG (from 1 to 5 treatments) and 4 mg/g (only 1 treatment) were administered subcutaneously to infant ICR mice and obesity was observed. However doses of 0.5 mg/g given every other day for 5 treatments did not produce obesity. The obese mice showed the same growth pattern as controls until they reached approximately 8 weeks of age, then the growth curves separated with experimental animals gaining at a much more rapid rate. Some experimental animals continued gaining weight even after 50 weeks of age. In our experiments the heaviest experimental animal was 94 g. Obese female mice continued to have estrous cycles and male mice produced sperm with high motility. Autopsy revealed massive amounts of abdominal fat. Livers were slightly heavier than normal and showed fatty degeneration histologically. Changes in other organs (which organs being referred to is not indicated) were not striking. Testes had normal sperm and interstitial formation. The ovaries had follicles and lutuem bodies. In that these animals developed obesity from only one treatment with MSG in infancy, we were dubious whether brain damage could have occurred to explain the obesity. However, we studied the effects of MSG treatment on brain tissue at various doses and various time periods and found that necrosis of neurons was present about the 3rd ventricle of the hypothalamus two hours after treatment with 2 mg/g of MSG and also with 4 mg/g. We have also treated a few rats with MSG but not enough animals were treated to make reliable observations. Obesity in rats has not been observed, thus far, but in female rats treated with MSG we found that puberty was very much delayed.

97. 実験的肥満症の研究

Matsuyama, S.
松山 茂 大木与志雄 横木勇造
(家衛試)

ICR系マウスを用い，体重1gあたり2mg（1～5回）および4mg（1回）のグルタミン酸ナトリウム（MSG）を皮下注射することにより，確実に肥満症を発生し得たが，0.5mgずつ隔日5回連続投与しても肥満症とはならなかった．この肥満症マウスは初期においては対照群と同等の発育を示したが，8週令を過ぎた頃より生長曲線は分離し，以後50週令を過ぎてもなお体重が増えつづけている例も観察された．本実験においては最高94gを記録した．これら肥満マウスの殆の性周期は存在しており，雄は活力の高い精子を生産していた．剖検所見は体腔におびただしく貯留する脂肪を除くと内臓一般臓器においては肝臓以外に著変を認めるものは少なかった．肝臓は正常値よりやや重く，その組織像は脂肪肝の所見を呈した．精巣はすべて正常であり，その精子形成過程および精巣等には特に異常を認めなかった．また卵巣には卵胞，黄体ともに認めた．上述のように，本肥満症は新生マウスに過剰のMSGをただ一回投与することにより発現するので，脳の病変が十分に疑われる．そこで各投与量および経時的に脳組織所見を検討した結果，MSG 2mg/g 投与後2時間で視床下部第三脳室周囲に核濃縮の傾向を認めた．4mg/g 投与でも同様変化を認めた．なお少数例ながらラットを用い同様実験を試みたが肥満症は発現しなかった．但し雌における思周期開始がかなり遅れるものしあった．

発言 高橋迪雄（東大） 1) 肥満症を始めに報告したOLNEYによれば，採食量は対照と変らないのに肥満症状を現すといっていますが，先生の実験ではいかがだったでしょうか．

2) 質問者らはラットを用い，胎盤経由，乳汁経由の移行も考慮にいれて母ラットを及びその産仔の採食開始後に連続して日量1gのMSGを経口投与しましたが，肥満症，性周期の乱れは見られませんでしたが，皮下投与と経口投与の差をどのようにお考えでしょうか．

答：1) 必らずしもオルニーの報告通りではなく，多少採食量も多いようです．

2) MSGの場合皮下投与，経口投与の差は殆んどないと考えてよいと思います．私どももラットにおいて肥満症を製作することはできませんでした．またマウスでも性周期の著変は認めておりません．

5033 (7)
60025
4989

PHARMACEUTICA ACTA HELVETIAE

Originalarbeiten / Mémoires originaux

Department of Pharmacy, Panjab University, Chandigarh, India

Preparation and evaluation of certain protein hydrolysates

By *H.C. Mital* and *R.B. Mathur*

(Received September 12, 1968)

Introduction

Protein hydrolysates are gradually finding importance in well-being of persons under various physiological necessities and pathological conditions. These hydrolysates contain proteins in less complex but more digestible form and may be obtained from inexpensive protein rich materials such as oil seed cakes, by enzymic, acidic or alkaline hydrolysis. Out of these, enzymic hydrolysis is easy to process and is considered to be more effective[1] than acidic and alkaline hydrolysis. This is due to the fact that the hydrolysates obtained with the latter contain free amino acids whereas hydrolysates prepared by enzymic hydrolysis include many peptides which help in the synthesis of tissues in the body at a faster rate than the free amino acids.

Proteins have been evaluated[2] for their utilization in the body. Of the many methods[3] that have been proposed for the investigation of proteins, the study of time relation of protein metabolism helps in the assessment of the catabolism of the proteins and their constituent amino acids. The first step in the catabolism of most amino acids is deamination[4] i.e. loss of α-amino group which may be due to oxidation or transamination. This observation has been confirmed by *Ratner* and his coworkers[5]

[1] *Elman R.*, Advances in protein chemistry, Academic Press, New York, Vol. III, 1947, p. 269.
[2] *Allison J.B.*, Advances in protein chemistry, Academic Press, New York, Vol. V, 1949, p. 155.
[3] *Hawk P.B.*, Practical physiological chemistry, McGraw-Hill Book Co., New York, 14th Ed., 1965, p. 858, 1377.
[4] *Meister A.*, Biochemistry and physiology of nutrition, Academic Press, New York, Vol. 1, 1953, p. 102.
[5] *Ratner S.*, *Rittenberg D.*, *Keston A.S.* and *Shoenheimer R.*, J. biol. Chem. *134*, 665 (1940).

by feeding labelled amino acids to rats. Although the metabolic pathway is not the same in all the amino acids yet the utilization of nitrogen of the α-amino group in the formation of urea, uric acid or allantoin[4] which are ultimately excreted in the urine, is an indication of the rate of catabolism of amino acids in the body. Since proteins are hydrolysed to the component amino acids in the alimentary system, the usefulness of a protein would depend upon the absorption of its amino acids.

In the present study, the protein hydrolysates prepared from soybean and groundnut cakes have been evaluated by physicochemical and biological[3] methods. The latter have been selected because of their simplicity to assess the period which elapses between the ingestion of protein and the excretion in the urine of a quantity of nitrogen equivalent to that contained in the protein hydrolysate. Besides this, the protein hydrolysates were evaluated for their utilization in protein deficiency by noting the rate of growth in rats and calculating the protein efficiency.

Experimental

Preparation of protein hydrolysates. These were prepared from soybean and groundnut cakes obtained after the extraction of oil. The cakes were powdered and defatted completely with petroleum ether (40°–60°) in a soxhlet extractor. The traces of the solvent from the exhausted cake were removed at 50° in a forced air circulation oven. The defatted cake was stirred with ten times its quantity of water and the pH of the suspension was adjusted to 9,3–9,5 by the addition of 40 per cent sodium hydoxide solution. After one hour, the suspension was filtered through a basket centrifuge provided with a canvas lining. The clear filtrate was acidified with 6N hydrochloric acid to pH=4,5 to 4,6, thereby precipitating the proteins. After keeping it in a refrigerator overnight, the precipitate was collected and weighed on the dry mass basis yielding about 80 per cent of the proteins present in the cake.

The wet protein precipitate was suspended in 20 times its weight of distilled water and the pH adjusted to 5,8 with 40 per cent sodium hydroxide solution. The proteins were hydrolysed with papain (2,5 per cent w/w of precipitate) at 60° with constant stirring. After 6 h the pH of the suspension was adjusted to 7,2. It was filtered through the basket centrifuge and further clarified by passage through a layer of cellulose. For the biological evaluation, the protein hydrolysates were concentrated under vacuum by using climbing film evaporator and distillation under reduced pressure. This afforded dry protein hydrolysate containing 80 per cent of proteins.

Physicochemical evaluation. The physical and chemical characteristics of the cakes and the protein hydrolysates have been recorded in tables 1 and 2.

Table 1

Composition of the cakes

	Soybean [%]	Groundnut [%]
Protein (Nx 6.25)	38,99	45,91
Moisture	6,84	6,24
Carbohydrate	25,63	24,78
Ash	4,28	5,96
Ether extractives	19,42	7,34
Fibre	4,81	9,8

Table 2

Composition of the liquid protein hydrolysates

	Soybean [g/1000 ml]	Groundnut [g/1000 ml]
Total nitrogen	6,53	6,84
Amino nitrogen	1,41	1,50
Amide nitrogen	0,11	0,70
Phosphotungstic acid precipitate nitrogen	4,26	4,00
Tryptophan	0,09	0,006
Tyrosine	0,65	0,63
Carbohydrate	5,22	4,00
Ash	1,86	1,40
Total solids	50,30	51,18

Protein, moisture, carbohydrate, ash and ether extractives were determined by the usual methods while the percentage of fibre and amino nitrogen were obtained by the A.O.A.C. method[6]. The amide nitrogen was calculated by *Damodarn*[7] method, phosphotungstic acid precipitate nitrogen by *Van Slyke* method[8] and tryptophane and tyrosine by *Folin* and *Ciocalteu* procedure[9].

Chromatographic analysis. The amino acid contents of protein hydrolysates were determined by circular paper chromatography by applying 0,01 ml of the hydrolysate and the known amino acid solution on the WHATMAN No. 1 filter paper. After drying the spots, the papers were developed with phenol-water-*iso*propanol-ammonia[10] (70:25:5:0,1). The developed papers were dried in the air.

Different spots of amino acids were made visible by dipping the paper in the ninhydrin solution[11], drying in the air and then heating it in an oven at 100° for 10 min. The Rf value of each amino acid was calculated and compared with that of the known amino acids. The identified amino acids were further confirmed by repeating the experiment and using other spray reagents such as isatin[12] and alloxan[11] solutions which were found particularly useful for the differenciation of amino acids having the same Rf values. The mean Rf value (table 3) for each component was obtained by calculating the average of at least six different determinations. The concentration of amino acids in the hydrolysate was assessed by judging the intensity of coloured spots in the developed chromatograms.

Biological evaluation

a. Time relation of protein metabolism. It was determined by following the procedure of *Hawk*[3]. In these studies, white albino rats weighing between 180–200 g were used. A basal diet and the protein diet containing 30 per cent each of the two dry protein hydrolysates and protinex (a proprietary nutritive preparation containing protein, marketed by PFIZER Ltd.) respectively, were provided to these rats. Samples of urine were collected at specific intervals during 24 h and analysed separately for total nitrogen. These results are given in fig. 1.

6 *Horwitz W.*, Official methods of analysis of the Association of Official Agricultural Chemists, Washington, 9th Ed., 1960, p. 288, 301.
7 *Damodarn M.*, Biochem. J. *25*, 2123 (1931).
8 *Van Slyke D.D.*, J. biol. Chem. *10*, 15 (1911).
9 *Folin O.* and *Ciocalteu V.*, J. biol. Chem. *74*, 385 (1927).
10 *Oreskes I.* and *Saifer A.*, Anal. Chem. *27*, 854 (1955).
11 *Saifer A.* and *Oreskes I.*, Anal. Chem. *28*, 501 (1956).
12 *Patridge S.M.*, Biochem. J. *42*, 238 (1947).

Figure 1
Time relation of protein metabolism

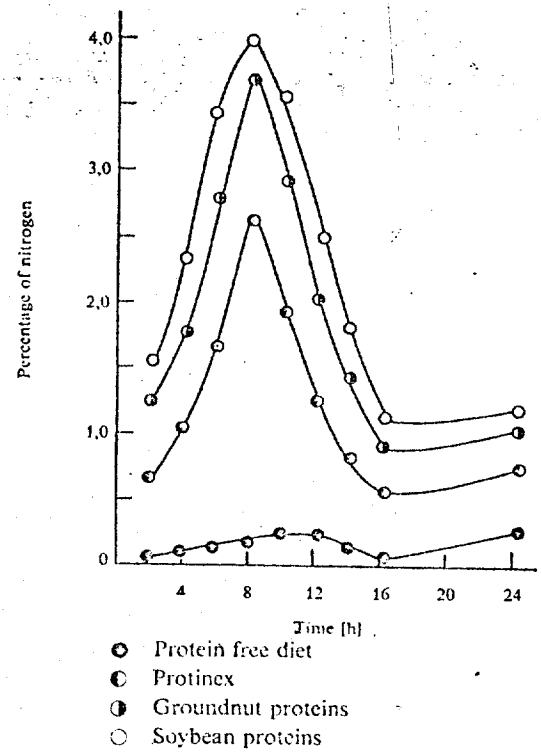

b) Growth promotion. The basal diet as well as protein diets were administered to different groups of rats for a period of two weeks. Animals were weighed on alternate days. For the sake of brevity, the increase in weight recorded after two weeks is given in table 4. The gain in weight, the protein efficiency[13] and the net protein value[14] were obtained to assess the growth promoting values of all the protein preparations.

Results and Discussion

The experimental data has revealed that the proteins could be extracted from the oil seed cakes by peptization with an alkaline solution, upto about 80 per cent. Papain has been found to be a promising hydrolysing agent for proteins as is evidenced by the presense of solubilized proteins in the hydrolysates (table 2). This is further supported by the circular paper chromatography (table 3) that the hydrolysates contain fairly large proportion of various amino acids which are essential for protein metabolism.

Fig. 1, regarding the protein metabolism in the experimental animals, indicates that there is excretion of small urinary nitrogen even when protein free diet is ad-

[13] *Osborne T.B., Mendel L.B.* and *Ferry E.L.*, J. biol. Chem. *37*, 223 (1919).
[14] *Mitchell H.H.* and *Carman G.G.*, J. biol. Chem. *60*, 613 (1924).

Table 3

Amino acid identified in the cake hydrolysates using phenol-water-iso-propanol-ammonia

Rf found	Rf reported	Probable amino acids	Proportion of amino acids in	
			Soybean	Groundnut
0,17	0,18	cystine	+ +	+ +
0,23	0,24	aspartic acid	–	+ + +
0,37	0,35	glutamic acid	+ + + +	+ + +
0,52	0,50	glycine	–	+ + +
0,57	0,55	threonine	+ + +	+ +
0,65	0,64	alanine, tyrosine	+ + +	+ + +
0,73	0,74	tryptophane	+ +	+ +
0,81	0,80	histidine, valine and methionine	+ + +	+ +
0,84	0,86	leucine, lycine, phenylalanine and arginine	+ + + +	+ + +
0,90	0,92	proline	+ + +	+

– absent; + low; + + fair; + + + good; + + + + high.

ministered to rats. This is, of course, derived from the tissue proteins. On the other hand, the metabolism of the tissue proteins is increased manyfold with the protein diets containing protein hydrolysates resulting in the excretion of higher percentage of nitrogenous products in the urine than with the protein free diet.

It is obvious that the metabolism of the protein diet could take place only if proteins and its components are absorbed rapidly trough the gastrointestinal tract. The higher percentage of urinary nitrogen in the experimental diet containing the soybean proteins seems to suggest that the soybean protein hydrolysate is absorbed more rapidly than the groundnut proteins or protinex. The higher percentage of nitrogen obtained in the last sample of urine in each case may be due to the multiplication of bacteria as the experiment was conducted at room temperature.

Table 4 reveals that the increase in weight is maximum with soybean proteins which also possesses the highest protein efficiency and the net protein value. It may, therefore, be concluded that the soybean proteins are superior to those of groundnut and protinex in growth promoting values.

Table 4

Growth promoting values of protein diet on rats

Protein sample	Gain in weight [%]	Average protein efficiency	Net protein value
Soybean	40	2,08	19,1
Groundnut	35	1,82	15,4
Protinex	25	1,30	9,4

Summary

The protein hydrolysates have been prepared from soybean and groundnut cake proteins by enzymic hydrolysis using papain which has proved to be a promising hydrolysing agent. The breakdown products of the cake proteins have been revealed by the physicochemical and chromatographic analysis of the protein hydrolysates. The biological evaluation of these hydrolysates has shown that they are readily absorbed by the gastro-intestinal tract, the maximum absorption being in the case of soybean protein hydrolysate. The latter has been found to possess superior growth promoting values as compared to other protein preparations.

Address of the authors: Dr. H.C. Mital, Faculty of Pharmacy, University of Science and Technology, *Kumasi*, Ghana;
Mr. R.B. Mathur, Lepetit Ranbaxy Ltd., *Okhla, New Delhi*, India.

Beitrag zur

1. Einleitung

Zahlreich si
allgemeinen[1-10]
Gruppen[11-58] be

* Gekürzte Fassu
Charakterisierun
[1] *Ismailov N. A.* u
[2] *Stahl E.*, Dünns
1967.
[3] *Stahl E.*, Pharm
[4] *Stahl E.*, Pharm.
[5] *Stahl E.*, Chem.
[6] *Stahl E.*, Fette,
[7] *Stahl E.*, Parfüm
[8] *Stahl E.*, Pharm.
[9] *Stahl E.*, Arch.
[10] *Stahl E.*, Angew
[11] *Haznagy A.*, Sz
[12] *Haznagy A.*, Sz
[13] *Hörhammer L.*
[14] *Hörhammer L.*
[15] *Hörhammer L.*
[16] *Hörhammer L.*

Fortsetzung der Fußnot

5130

5130

BRAIN LESIONS IN THE MOUSE FETUS CAUSED BY MATERNAL ADMINISTRATION OF MONOSODIUM GLUTAMATE (PRELIMINARY REPORT)

Ujihiro MURAKAMI and Minoru INOUYE

Reprinted from Congenital Anomalies, Volume 11,

No. 4, December, 1971.

Cong. Anom. (先天異常)
11 (4) : 171—177, 1971

BRAIN LESIONS IN THE MOUSE FETUS CAUSED BY MATERNAL ADMINISTRATION OF MONOSODIUM GLUTAMATE (PRELIMINARY REPORT)

Ujihiro MURAKAMI and Minoru INOUYE*

As suggested by a paper of Lucas *et al.* (1957) which argued that parenterally given monosodium glutamate (MSG) caused lesions in the inner retina layer of the neonatal mouse, Olney (1969[6]) indicated findings on lesions in the hypothalamus of the neonatal mouse, injecting with 0.5 to 4 mg/g of MSG while they were 2 to 9 days old. Futher, Olney showed that the body weight of these offspring fed until 9 months after birth, gained approximately double that of those in controls, and females had involvements in fertility. He thought these phenomena due to damage in the hypothalamus and that such lesions might lead to a disturbance in the endocline system. However, Lowe (1970[3]), Zavon (1970[9]). Adamo *et al.* (1970[1]) and Oster *et al.* (1971[8]) opposed Olney's findings.

Olney (1969[6]) was also sceptical that there would be possible influence upon fetal brain development when much MSG was administered pregant women. Since experimental studies to resolve his doubts seem not to have appeared as yet. these writers examined the effects of MSG given *in utero* parenterally to pregnant mice.

MATERIALS AND METHODS

Animals emloyed were CF#1-JCL mice supplied by Nippon CLEA Co. LTD., Tokyo. Procedures of feeding, breeding etc. were similar to experiments conducted in Murakami Laboratory of this Institute. Estrous females of at least 90 days or more were caged with slightly older males in pairs for one night and next morning those with vaginal plug considered to be in day zero of pregnancy.

1. Experiment on the neonate: Thirteen neonates were subjected to a single subcutaneous administration of 1 mg/g of MSG from day 2 to 4. MSG solution was prepared after Lucas *et al.* (1957[1]). The brains were removed at 1, 3, 6 and 24 hours after the injection. These were embedded in paraplast being fixed with Bodian II solution, sectioned at 7 microns and stained with hematoxylin and eosine or gallocyanine. Preparations of frontal sectioned and stained with the above dyes were examined under a light microscope. Corresponding untreated and saline controls also were prepared. The above experiments were done as a pilot examination.

2. Experiment on the fetus: Twenty-six mice were administered with 5 mg/g MSG subcutaneously once on day 17 or 18 of pregnancy. In the latter group, 2 mothers were allow-

* Research Institute of Environmental Medicine, Nagoya University

PRESEN ADDRESS: Institute for Developmental Research, Aichi Prefectural Colony, Kamiya-cho, Kasugai, Aichi 480-03/Japan

ed to give birth. Offspring from 1 mother were examined 1 week afterward, and those from another mother examined 3 weeks after birth respectively. Remaining fetuses were surgically removed at 3, 6 and 24 hours after treatment. The number of mothers in each group was not ample yet.

Brains taken from the fetus were fixed with Bouin's solution. After being embedded with paraplast, frontal sections of 7 microns were stained with hematoxylin and eosin or gallocyanine. These also were examined under a light microscope. Separately, controls were also prepared for each group.

EXPERIMENTAL RESULTS

1. Experiment on the neonate: All were examined. Among them, 10 cases presented the following changes in the brain. The common finding was necrosis of the neural elements in some localized parts of the brain. In the part involved, there were cells of which cytoplasm presented the appearance of being edematic, with blister or vacuole. In other cases, the cell was involved with swelling, having pyknotic nucleus. In the most apparent cases, pyknosis was evident and the stroma looked to be loosening (Figs. 1 & 2). These findings were evident 3 or 6 hours after treatment. The most obvious parts of the brain in which the above findings were selectively detected were the hippocampus and hypothalamus. In detail, in the roof of the 3rd ventricle, such necrotic foci were found symmetrically in the median part of the hippocampus and the bilateral medial habenular nuclei. On the floor of the hypothalamus, from the part anterior to the infundibulum to the region through the infundibulum, a little posterior to the former part, symmetric lesions were localized at the arcuate nucleus (Figs. 1 & 2). Further, in the ependyma fronting the lower part of the 3rd ventricle connected to the infundibular recessus, there were lesions and cellular disarrangement.

In those examined one hour after the administration, nuclei were still intact, while the cytoplasm and the stroma looked to be loosening. This may have shown an intial involvement.

The above experiment was conducted to confirm those described by Olney.

2. Experiment on the fetus: a. Results in the fetus treated on day 17; among 24 individuals picked up at random from 8 litters, 7 cases presented brain lesions. Acute lesions found 3 hours after the treatment were similar to those seen in the newborn described in findings in Experiment 1. Pyknotic nuclei were evident in the part involved. But edema, blister formations and swelling of the cytoplasm were not apparent compared with those in the newborn. Loosening of the stroma was no more prominent than in the former case (Figs. 3 & 4). There was a symmetric defect of the ependyma at the inferior region of the 3rd ventricle (Figs. 3 & 4).

In major cases, the cellular involvement was detected in bilateral ventromedial nuclei while the arcuate nucleus was not apprently involved as well as the ventromedial nucleus (Figs. 3 & 4). But there were cases with necrotic figures in the arcuate nucleus as well as with cases similar to those examined 3 hours after administration.

Fig. 1 Cross-sectio
tion 6 hours after
the stroma localiz
lesion in the lowe

Fig. 2 The part s
changes of the c



Fig. 3 Cross-se
showing lesion
The change is
nuclei are free
metrically is r

Fig. 4 The left
(400 X).

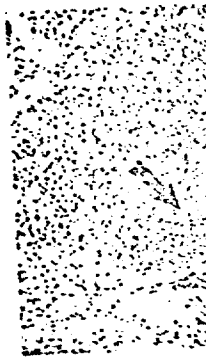

Fig. 5 Cross
showing les
The change

Fig. 6 The

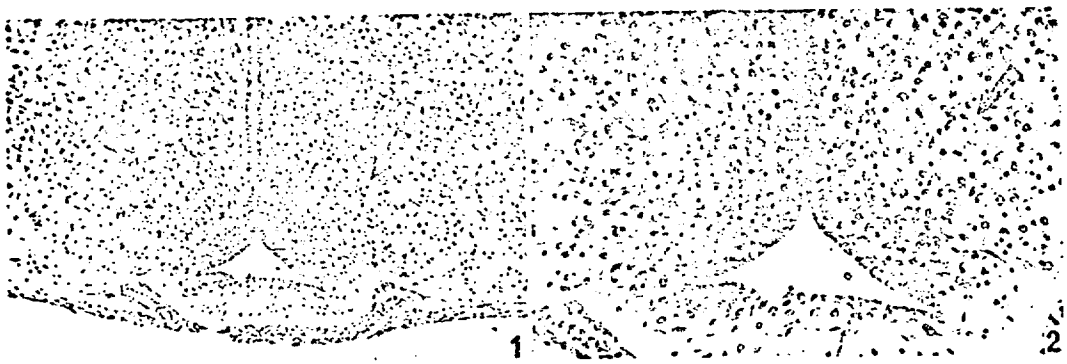

Fig. 1 Cross-section of the hypothalamus of 4-day-old CF#1 mouse showing lesion formation 6 hours after a subcutaneous injection of 1 mg/g MSG. Pyknosis and loosening of the stroma localize in the arcuate nucleus (↘ ↙). The ependyma presents asymmetric lesion in the lower part of the 3rd ventricle (200 X).

Fig. 2 The part shown in Fig. 1 under greater magnification. Besides pyknotic nuclei, changes of the cytoplasm and stroma are evident (400 X).



Fig. 3 Cross-section of the hypothalamus of a CF#1 mouse fetus on day 17 of pregnacy showing lesion formation 3 hours after maternal subcutaneous injection 5 mg/g MSG. The change is clearly detceted as limited to the ventromedial nuclei: and the arcuate nuclei are free (↘ ↙). The ependymal lining of a lower part of the 3rd ventricle symmetrically is missing (200 X).

Fig. 4 The left side of the part involved shown in Fig. 3 under greater magnification (↘) (400 X).



Fig. 5 Cross-section of the hyothalamus of a CF#1 mouse fetus on day 18 of pregnancy showing lesion formation 6 hours after a maternal subcutaneous injection of 5 mg/g MSG. The change localized in the arcuate nucles. Ependymal lining is free (↘ ↙) (200 X).

Fig. 6 The part involved shown in Fig. 5 under greater magnification (↘ ↙) (400 X).

Fig. 7 Cross-section of the hypothalamus of a CF#1 mouse on day 18 of pregnancy showing lesion formation of 5 mg/kg MSG. The change distributs in the ventromedial nucleus than in the arcuate nucleus. The ependymal lining is free (↘ ↗) (200 X).

Fig. 8 The part involved shown in Fig. 7 under greater magnification (↗) (400 X).

In those examined 24 hours after administration, among 9 cases, none of them presented necrosis of the neural element in the ventromedial nucleus. Generally, the above stated cellular necrosis was not always found in every case. Therefore, it would be difficult to define whether in cases without any lesions among those examined 24 hours after administration, the part involved had recovered, or whether the case originally had no lesion in the corresponding part of the brain.

Results in the fetus treated on day 18; 27 individuals were picked up at random from 9 litters and 16 cases showed brain lesions. In the 18 day case, the size of the nucleus of the cell comprizing the thalamus was much larger than in those examined on day 17, and the shape was more elliptic or polymorphic. The amount of cytoplasm looked to be smaller.

In the day 18 cases, the location of the lesion in the hypothalmamus was different from case to case. Some cases had lesions limited to the arcuate nucleus (Figs. 5 & 6). There was cellular necrosis both in the arcuate and ventromedial nuclei (Figs. 7 & 8). However, the lesion was generally apparent in the arcuate nucleus. Acute lesion was detected 3 hours after the treatment similarly to those treated on day 17.

Among 4 cases examined 24 hours after administration, no cases were involved.

Observations on newborn raised by 2 mothers allowed to give birth were not fruitful. Only 2 progeny survived for examination in each group. The remainder disappeared through cannibalism or simple death. These had no brain lesions.

In mother animals, similar findings seen in the hypothalamic region were also detected 3 hours after the treatment.

DISCUSSION

Because the purpose of this experiment was to observe influence of MSG upon the fetus of mothers to which it was administered, discussion on Experiment 1 was excluded.

In both cases treated on day 17 and 18, all fetuss were not examined. But as far as examined, incidence of fetuses with brain lesion seemed to be more prominent with those administered on day 18 rather than in those treated on day 17. whether this might be due

to the maturity of the neural element involved or not was difficult to define. Generally, in those treated on day 17, the lesion looked to be prominent in the ventromedial nucleus. In those treated on day 18, there were cases in which both the arcuate and ventromedial nuclei were involved.

It was not yet clear whether there were definite differences between those treated on day 17 and 18 as to the location of the lesion. Among cases administered on day 18, there were transitional cases compared with those treated on day 17. This may be caused by the difference in progression of development in each fetus. Not all cases administered on day 17 or 18 presented the lesion.

Marshall *et al.* (1955[3]) and Becher *et al.* (1965[2]) could produce lesions in the hypothalamus of the mouse with goldthioglucose (GTG). Ependymal involvement also arose after the treatment of GTG (Marshall *et al.* (1955[3]) & Becher *et al.* (1965[2]).

Since in this series of experiments there were no cases which had been bred for a long time after teament as well as in those of Olney, (1969[6]), it could not be said whether or not functional disturbances might arise. Parenteral administration of much MSG upon pregnant mice resulted in lesions similar with both the young and adults in their morphological appearance or the location involved. However, in many cases, such changes seemed to have the possibillity of recovery 24 hours after administration.

The similar effect of monosodium L-aspartate (MLA) when given to neonatal mice was also reported by Olney. (1970[7]). The present authors examined the fetotoxic effects of MLA in the pregnant mouse on day 18 too. Pyknosis in the lower part of the hypothalamus was detected in those observed 3 or 6 hours after administration.

Twenty-four hours after the treatment, no evidences of the lesion were detected. whether or not susceptibility of the corresponding brain tissue depended on the degree of maturity, and the question of the recovery process having taken place or the possibility that no lesions had originally arisen was still obscure. Further experiments will be required.

SUMMARY

One mg/g monosodium glutamate (MSG) was given subcutaneouasly to neonate CF#1 mice on day 2 or 4 after birth according to Olney's procedure. They were examined in sections under a light microscope 3 or 6 hours after the treatment, and results similar to those shown by him were confirmed. Then, the same strain of the mouse was treated with 5 mg/g MSG on day 17 or 18 of pregnancy subcutaneously. Fetal brains were similarly examined 3, 6 and 24 hours after the treatment. Similar necrosis of the neural element was detected in groups administered. Frequency of the involvement seemed to be higher in group treated on day 18. Cellular necrosis was seen both in the ventromedial and arcuate nuclei. In those examined on day 17, lesions were more predominant in the ventromedial nucleus than in the arcuate nucleus. These lesions in the ependyma fronting the 3rd ventricle especially in the ventral part of it. In those observed 24 hours after the injection, no cases showed the lesion in the medial ventromedial nucleus in those

treatedon day 17 or 18. Whether the recovery process had taken place or no lesions had originally arisen was difficult to venture. Further, relationship between susceptibility of the brain tissue involved and the maturity of the cell also required further studies.

Monosodium L-aspartate (MLA) caused similar lesions in the fetal brain. Generally, lesions caused by MSG or MLA present findings similar to those shown in adult mice by goldthioglucose (GTG).

The authors of the present paper wish to express their appreciation to Misao Mio, B. Sc. for her aids.

This work was supported by a Scientific Research Grant, No. 92058, of the Ministry of Education, Japan.

(Received on March 20, 1971)

REFERENCES

1) Adamo, N. J. and Ratner, A. Monosodium glutamate: Lack of effects on brain and reproductive function in rats. Science, 169 : 673-674, 1970.

2) Brecher, G., Laqueur, G. L., Cronkite, E. P., Edelman, P. M. and Schwartz, I. L. The brain lesion of goldthioglucose obesity. J. exptl. Med., 121 : 395-401. 1965.

3) Lowe, C. U. Monosodium glutamate: Specific brain lesion questioned. Science, 167 : 1019, 1970.

4) Lucas, D. R. and Newhouse, J. P. The toxic effect of sodium L-glutamate on the inner layer of the retina. A. M. A. Arch. Ophthalmol., 58 : 193-201, 1957.

5) Marshall, N. B., Barrnett, R. J. and Mayer, J. Hypothalamic lesions in goldthioglucose injected mice. Proc. Soc. exptl. Biol. Med., 90 : 240-244, 1955.

6) Olney J. W. Brain lesions, obecity, and other disturbances in mice treated with monosodium glutamate. Science, 164 : 719-721, 1969.

7) Olney, J. W. Brain damage in infant mice following oral intake of glutamate, aspartate or cystaine. Nature, 227 : 609-610, 1970.

8) Oser, B. L., Carson, S., Vogin, E. E. and Cox. G. E. Oral and subcutaneous administration of monosodium glutamate to infant rodents and dogs. Nature, 229 : 411-413, 1971.

9) Zavon, M. R. Monosodium glutamate: Specific brain lesion questioned. Science, 167 : 1017, 1970.

5143
(5143)

BBA 26664

THE TOXICITY OF MONOSODIUM GLUTAMATE IN YOUNG RATS

ISA K. MUSHAHWAR AND ROGER E. KOEPPE
Department of Biochemistry, Agricultural Experiment Station, Oklahoma State University, Stillwater, Okla. 74074 (U.S.A.)

(Received May 11th, 1971)

SUMMARY

Intraperitoneal or intragastric injection of monosodium L-glutamate (4 g/g) to infant rats invariably caused an increase in brain glutamine, never in brain glutamate. The toxicity (convulsions) observed after these doses was not unique to L-glutamate; monosodium L-aspartate or D-glutamate gave similar symptoms. Equimolar doses of glycine did not cause convulsions but did elevate brain glutamine. These results suggest that the toxicity (convulsions) of monosodium L-glutamate is not due to ammonia but to the amino acid anions.

During the past two decades L-glutamic acid has run the gamut from being proposed as therapeutically useful[1,2] to claims that large (1–4 mg/g) doses of monosodium L-glutamate caused degenerative lesions of the hypothalamus in mice, rats, and monkeys[3,4]. The latter reports have led to considerable controversy concerning the safety of monosodium glutamate as a food additive[2,5–12]. The findings of OLNEY[13] and the earlier claims that brains of young rats are permeable to plasma glutamate suggested to us that the toxicity reported by Olney could be due to high plasma glutamate concentrations causing an increase of brain glutamate. If this were the case, one would have an explanation for the toxicity reported by Olney and might have reason to believe that this toxicity was rather specific for L-glutamate.

In view of these facts we have given young rats (parents were obtained from the Holtzman Company) various doses of monosodium glutamate (1–4 mg/g) by intraperitoneal or intragastric injection. We have found that since the concentration of brain glutamate increases after birth one may observe substantial differences from litter to litter since the physiological age may not coincide with the chronological age. Therefore, litter mates of the treated animals were always used as untreated controls. After specified (see Table I) time periods brains were removed, rapidly blotted with filter paper, frozen in liquid N_2, and assayed for the various amino acids as previously described[14]. In some cases glutamate was assayed enzymatically, using glutamate decarboxylase (ref. 15, 16) and measuring the CO_2 released in a Gilson differential respirometer. In a few instances the amino acids were measured on a Technicon amino acid analyzer essentially according to the method of STEIN AND MOORE[17]. Suitable standards were

Biochim. Biophys. Acta
244 318-321
(Aug. 19, 1971)

assayed by all three methods; excellent agreement was invariably observed. Serum was assayed in a manner similar to that used for brain.

Most of our results are presented in Table I, data from animals given smaller doses are not presented. As expected, generally the lower doses were less toxic and resulted in lower serum glutamate concentrations.

TABLE I

THE CONCENTRATION OF GLUTAMATE AND GLUTAMINE IN BRAINS OF YOUNG RATS TREATED WITH MONOSODIUM GLUTAMATE (4 mg/g)

Number of animals per treatment is in parentheses.

Age (days)	*Treatment*	*Time* (min)*	*Glutamate (mM)*	*Glutamine (mM)*
6–7	Control		5.13 ± 0.10 (10)	3.85 ± 0.11 (9)
	Intraperitoneal	30	6.34 ± 0.23 (8)	6.68 ± 0.23 (7)*
			5.67 ± 0.28 (8)**	
	Intragastric	30	5.61 ± 0.18 (4)	
			5.43 ± 0.20 (4)**	
	Intragastric	60–90	5.17 ± 0.25 (12)	5.50 ± 0.28 (7)*
			4.86 ± 0.23 (12)**	
14–15	Control		7.37 ± 0.43 (14)	4.63 ± 0.18 (6)
	Intraperitoneal	60	7.50 ± 0.60 (5)***	4.82 ± 0.12 (5)*
			6.03 ± 0.07 (5)**,***	

* Between treatment and decapitation.

** Corrected by subtracting serum glutamate × 0.02 from brain glutamate, based on the assumption that the blood volume (in brain) is 3% (refs. 18, 19) and a determined whole blood serum glutamate concentration of 0.7. Therefore, serum glutamate × brain glutamate × 0.02 = "corrected" value × 0.02.

*** Because of extensive hemorrhaging, brains were washed with water and blotted prior to freezing. Hence, the low values are probably due to the action of glutamate decarboxylase during the interval between decapitation and freezing[22].

* Significantly different from "control" value ($P < 0.01$).

It was necessary to correct the brain glutamate values of treated animals for the small volume of blood trapped in the brain. The corrections which appear in Table I are based on the assumption that the blood volume in brain is 3% (refs. 18, 19). No correction was necessary for brain glutamine since serum glutamine concentrations only increased from 0.4 mM to a maximum of 1.2 mM. Treatment with monosodium glutamate resulted in serum glutamate concentrations of 30–70 mM when given intraperitoneally and 8–14 mM when given intragastrically.

We obtained no evidence to support the idea that in young rats high serum glutamate concentrations affect those of brain. SCHWERIN *et al.*[20], many years ago, and WOLLAN *et al.*[5], recently, reached similar conclusions for adult rats. There is only one claim [13], poorly documented, that high doses of monosodium glutamate to mature old rats result in elevated brain glutamate.

It will be noted in Table I that the concentration of brain glutamate in young rats is much lower than that in the adults. These data *plus* other values we have obtained from older and younger rats (not presented) indicate that at birth rat brain glutamate is about 4 mM and increases over a period of 20 days to the adult value of approximately 10 mM.

Although large doses of monosodium glutamate did not raise brain glutamate concentrations they invariably resulted in increases in glutamine of brain (Table I).

This finding strongly suggests that a portion of the toxicity of monosodium glutamate is indirect and is due to ammonia[21]. It will be noted that brain glutamine was elevated whether the dose of monosodium glutamate was administered intraperitoneally or intragastricly. However, the intraperitoneal dose resulted in a much greater toxicity, indicating that ammonia is not the only cause. When the 4 mg/g dose was given intragastricly, convulsions were seldom observed and then only after 90 min. A similar dose given intraperitoneally always caused convulsions with 2 mg/g. They were not observed after smaller intragastric doses. Controls given equimolar doses of NaCl never had convulsions but appeared listless and lethargic. Clearly, the toxicity of monosodium glutamate differs from that of NaCl[6].

The 14–15 day old rats often showed severe hemorrhaging on the brain surface after the administration of monosodium glutamate (4 mg/g). These animals had serum glutamate concentrations of about 70 mM, strongly suggesting osmotic problems. The concentration of glutamate would account for almost 50% of the anionic content of normal blood plasma.

To gain insight concerning the nature of monosodium glutamate toxicity we gave young rats large doses of monosodium L-aspartate or glycine (Table II). Ima-

TABLE II

CONCENTRATION OF GLUTAMINE AND ASPARTATE OR GLYCINE IN BRAINS OF 14-DAY-OLD RATS TREATED INTRAPERITONEALLY WITH MONOSODIUM L-ASPARTATE (3.5 mg/g) OR GLYCINE (2 mg/g), 30 min BEFORE DECAPITATION

Treatment	*Glutamine*	*Aspartate (mM)*	*Glycine*
Control	4.03 ± 0.18 (6)	1.70 ± 0.25 (7)	1.01 ± 0.05 (25)
Monosodium L-aspartate	5.40 ± 0.69 (4)*	2.48 ± 0.14 (5) 1.08 ± 0.15 (5)***	
Glycine	5.18 ± 0.22 (4)**		3.62 ± 0.45 (4) 3.13 ± 0.45 (4)**,***

* Significantly different from "control" value ($P < 0.05$).
** Significantly different from "control" value ($P < 0.01$).
*** "Corrected" for blood in brain. See Table I.

were approximately equimolar with monosodium glutamate, 4 mg/g. All the amino acids (glutamate, aspartate, glycine) significantly increased brain glutamine; only glycine increased its own concentration in brain (Tables I and II); only monosodium glutamate and aspartate caused convulsions. These results suggest that the toxicity (convulsions) of monosodium glutamate is not due to ammonia but rather to the amino acid anions. SNEISINGER AND SCOTT[23] have reached a similar conclusion from different experiments with chicks. The fact that D-glutamate (4 mg/g), which is not deaminated by the rat, caused convulsions similar to those observed with L-aspartate and L-glutamate, lends support to this idea. Therefore, we conclude that necrotic toxicity of monosodium glutamate reported by OLNEY AND SHARPE[4], since disputed by ADAMO AND RATNER[11], and confirmed by ARETS AND MAYER[22], is probably not unique to L-glutamate. OLNEY AND SHARPE[6] have reached a similar conclusion. However, the interesting "Chinese Restaurant Syndrome" observed in humans given much smaller doses of monosodium glutamate may be specific for L-glutamic acid[5].

ACKNOWLEDGEMENTS

This work is supported in part by a research grant from the National Institute of Neurological Diseases and Stroke (9 R01 NB 08115). We thank Betty Felber for competent technical assistance.

REFERENCES

1 *Nutr. Rev.*, 3 (1945) 135.
2 *Nutr. Rev.*, 28 (1970) 124.
3 J. W. OLNEY, *Science*, 164 (1969) 719.
4 J. W. OLNEY AND L. G. SHARPE, *Science*, 166 (1969) 386.
5 *Nutr. Rev.*, 28 (1970) 158.
6 C. U. LOWE, M. R. ZAVON, J. W. OLNEY AND L. G. SHARPE, *Science*, 167 (1970) 1016, 1017.
7 W. LEPKOWSKI, *Sci. Res.*, Sept. 29 (1969) 15.
8 *Chem. Eng. News*, March 9 (1970) 33.
9 *Chem. Eng. News*, April 20 (1970) 12.
10 T. W. REDDING AND A. V. SCHALLY, *Federation Proc.*, 12 (1970) 378.
11 N. J. ADAMO AND A. RATNER, *Science*, 169 (1970) 673.
12 *Chem. Eng. News*, August 17 (1970) 9, 13.
13 W. A. HIMWICH, J. C. PETERSEN AND M. L. ALLEN, *Neurology*, 7 (1957) 795.
14 R. M. O'NEAL AND R. E. KOEPPE, *J. Neurochem.*, 13 (1966) 835.
15 H. U. BERGMEYER, *Methods of Enzymatic Analysis*, Academic Press, New York, 1963, p. 374.
16 W. W. UMBREIT, R. H. BURRIS AND J. F. STAUFFER, *Manometric Techniques*, Burgess Publishing Co., Minneapolis, 1964, Chapters 6 and 7.
17 W. H. STEIN AND S. J. MOORE, *J. Biol. Chem.*, 211 (1954) 915.
18 N. B. EVERETT, B. SIMMONS AND E. P. LASHER, *Circulation Res.*, 4 (1956) 419.
19 H. L. ROSOMOFF, *J. Appl. Physiol.*, 16 (1961) 305.
20 P. SCHWERIN, S. P. BESSMAN AND H. WAELSCH, *J. Biol. Chem.*, 184 (1950) 37.
21 R. M. O'NEAL, C. H. CHEN, C. S. REYNOLDS, S. K. MEGHAL AND R. E. KOEPPE, *Biochem. J.*, 109 (1968) 669.
22 F. N. MINARD AND I. K. MUSHAHWAR, *Life Sciences*, 5 (1966) 1409.
23 F. A. AREES AND J. MAYER, *Science*, 170 (1970) 549.
24 D. C. SNETSINGER AND H. M. SCOTT, *Poultry Sci.*, 40 (1961) 1075.

5226

NATIONAL ACADEMY OF SCIENCES - NATIONAL RESEARCH COUNCIL

Subcommittee on Safety and Suitability of MSG and Other Substances in Baby Foods, National Academy of Sciences, National Research Council.

Safety and Suitability of Monosodium Glutamate for Use in Baby Foods

Report available from the Food and Drug Administration

GLUTAMATE-INDUCED RETINAL DEGENERATION IN NEONATAL MICE. ELECTRON MICROSCOPY OF THE ACUTELY EVOLVING LESION* †

JOHN W. OLNEY, M.D.

(St. Louis, Missouri)

In 1957, Lucas and Newhouse (1) demonstrated a degenerative lesion in mouse retina following the parenteral administration of monosodium L-glutamate (MSG). Treating the adult mouse produced only a partial lesion and was associated with a high mortality rate, but treating neonatal mice resulted in an extensive and predictable pattern of retinal degeneration with negligible mortality. By light microscopy the lesion was described as involving large numbers of several cell types in the inner retina while sparing cells of the outer retina, particularly the receptors.

Lucas and Newhouse (1) obtained essentially negative results from testing other compounds, either for their ability to produce a similar lesion or to protect the retina against the MSG effect. Vulnerability of neonatal rat retina to the MSG lesion was reported by Freedman and Potts (2) who found altered levels of several enzymes associated with glutamic acid metabolism in retinas studied 2 weeks following MSG treatment. Radioactive uptake studies by the same authors (3) indicated that glutamate uptake by the rat retina was high on the 5th postnatal day but had begun to decline by the 10th day. To obtain a maximal degree of retinal modification for purposes of electrophysiological studies, Potts and colleagues (4) treated neonatal mice with MSG daily for 17 consecutive days. In retinas thus treated only an "a" wave could be recorded in the electroretinogram 3 months following treatment. Cohen (5), who studied mouse retina with the electron microscope, 2 months and 1 year following MSG treatment, obtained the same pattern and extent of retinal modification with only 10 treatments given daily from the 1st to 10th postnatal days. Cohen found in retinas 2 months post treatment that, even though the ratio of receptors to inner neurons was markedly enhanced, residual synaptic relations and certain other aspects of cytoarchitectonics were indistinguishable from normal.

It is estimated that free glutamic acid exists in the central nervous system (CNS) at approximately 10 micromoles/gm (6), a concentration considerably higher than that of any other amino acid found in the CNS. That the sodium salt of this common CNS metabolite, following parenteral administration, induces a striking degenerative response on the part of retinal neurons poses intriguing toxicological questions and, in addition, provides an experimental model of acute neuronal necrosis in the developing CNS that can readily be

* From the Departments of Psychiatry and Ophthalmology, Washington University School of Medicine, St. Louis, Missouri 63110.

† This investigation was supported in part by grants from the United States Public Health Service (NB-04816, MH-7081, MH-5804, MH-38891).

J. Neuropathol. Exp
26(3) p. 455-474 Neur
1967

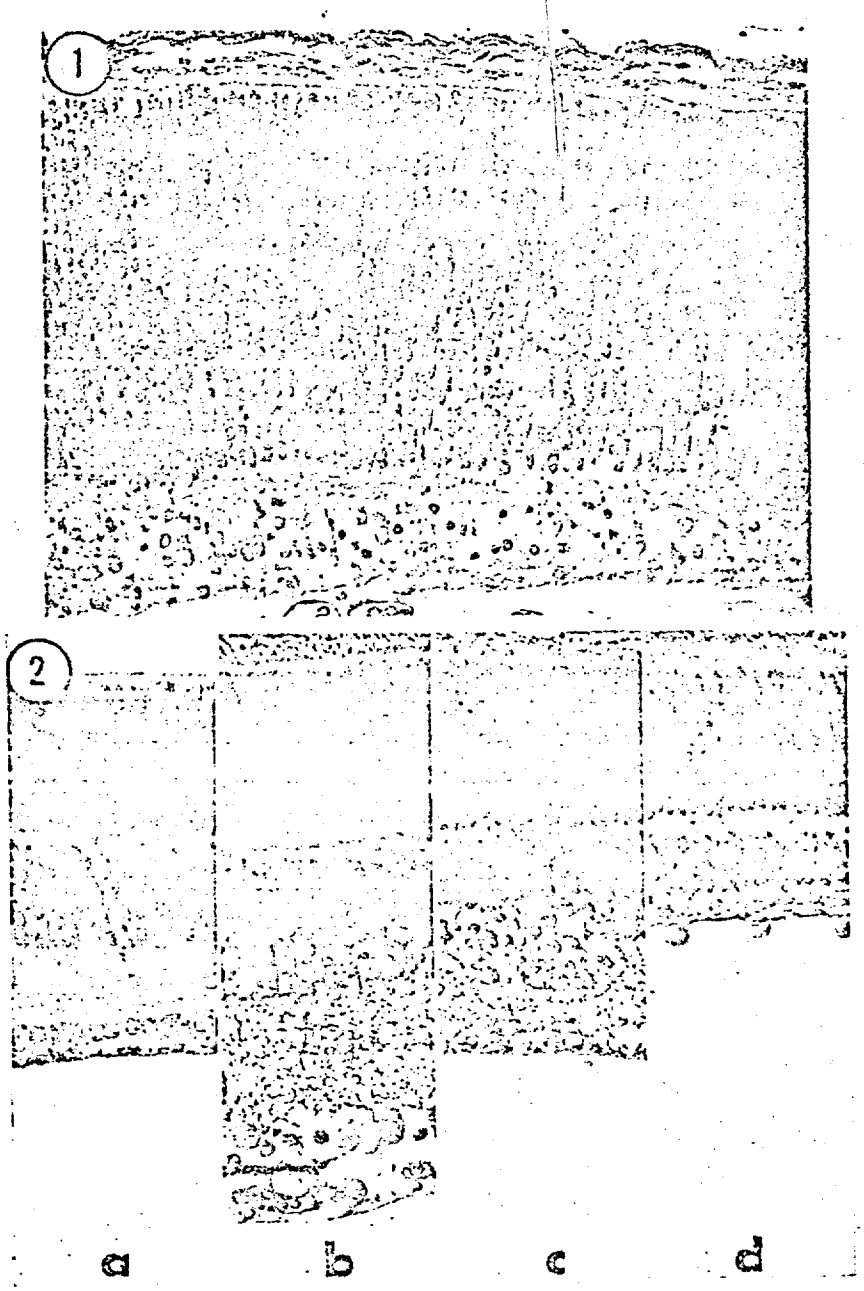

FIG. 1. Light micrograph of 2-day-old mouse retina, 3 hours post treatment, showing pattern and extent of lesion produced by a single subcutaneous injection of MSG, 4 mg/gm. Compare with Figure 2b. Many ganglion cells appear necrotic, but very few cells in the outer mantle are affected. The moth-eaten appearance of the inner plexiform zone is due to dilatation of ganglion cell dendrites. Richardson stain: × 250.

FIG. 2. Series of light micrographs, all from the same litter of mice. Each animal, except the untreated control, received a single subcutaneous injection of MSG, 4 mg/gm, early on the 10th postnatal day. a. Untreated control. Retina is histologically normal with no swelling of plexiform layers or of any cell bodies. b. Litter mate 3 hours post treatment. Marked

reproduced for study. It has not been determined whether there is a particular developmental stage in which the retina is maximally sensitive to MSG treatment nor is it known whether regions of the CNS other than the inner retina are vulnerable. The acutely evolving retinal lesion has not been examined with the electron microscope for ultrastructural clues regarding mechanisms of action. To provide data pertinent to these and related issues a morphological study, employing both light and electron microscopy, has been initiated in which the acute effects of MSG on the entire central nervous system of the neonatal mouse are under investigation. The present report pertains to the acute response of the neonatal mouse retina to parenterally administered MSG. The normal development of neonatal mouse retina was studied with the electron microscope as a preliminary to the present investigation and is reported elsewhere (7).

MATERIALS AND METHODS

In the course of the larger investigation of the effects of MSG on the entire central nervous system, over 200 mice received treatment with MSG according to a variety of treatment schedules. Retinas from approximately half of these animals have been examined to date. Some data presented in the text are based on the larger group of experimental animals, but all illustrations except Figure 1 were specifically taken from 3 litters of Swiss albino mice treated between the 9th and 10th postnatal days with a single subcutaneous injection of MSG at a dose level of 4 mg/gm of body weight. MSG was prepared in sterile distilled water and administered in a volume of approximately 0.2 cc *per* animal. The batch of MSG used was obtained from Nutritional Biochemical Corporation and contained no impurities which could be detected by thin layer chromatography in our laboratories. It was also established that freshly prepared MSG (by titration of NaOH with glutamic acid just prior to treatment) resulted in the same retinal pathology as when commercially prepared MSG was used. Experimental animals were sacrificed at serial post-injection intervals from 30 minutes to 48 hours and their retinas compared with those of litter mate controls receiving no treatment. All retinas were fixed *in situ* by immersion of the whole eye in 2 per cent osmium tetroxide buffered with 0.1M pyrophosphate. Specimens were dehydrated in graded ethanols, hemisected in absolute ethanol and embedded from toluene in Araldite. Sections approximately 1.5 microns in thickness were cut on a Porter Blum MT-2 microtome and stained by the Richardson method (8) for light microscopy. For fine structural analysis, ultrathin sections were mounted on formvar films over discs with a 1 mm x 2 mm hole, stained with both lead and uranium salts and examined in a Elmiskop 1A electron microscope.

---

tumescence of inner retina with widened, fenestrated inner plexiform layer and hydropic cytoplasm of ganglion cells and neurons in inner tiers of inner nuclear layer. Muller foot processes vitreal to ganglion cell layer are edematous. Swelling of processes invaginated into receptor bases is suggested by rarefaction of inner regions of the outer plexiform zone. The dark cell phenomenon is evident and in this particular scene affects predominantly ganglion cells. Small increase in thickness of outer nuclear layer is probably due to slight obliqueness of section. c. Litter mate 12 hours post treatment. Generalized tumescence of inner retina is reduced but individual neurons show advanced stages of necrosis, and inner plexiform layer appears degenerate with numerous vacuous compartments. d. Litter mate 48 hours post treatment. The general tissue density has returned to pretreatment appearance, but the inner retina is markedly modified. Ganglion cells are rare, the inner plexiform layer is very thin and the inner nuclear layer is reduced from 6 to 7 tiers of nuclei to 3 to 4 tiers. Some of the nuclei in the inner retina belong to macrophages. A further thinning of the inner nuclear layer to approximately 2 to 3 tiers will occur as macrophages leave and as the retinal circumference expands to mature proportions. Note the several "vitreocytes" lying against the vitreal surface of the retina. Richardson stain: × 290.

RESULTS

In experiments designed to determine whether the sensitivity of the retina to MSG-treatment remains constant throughout the developmental period it was found that a high dose (4 mg/gm) given as a single subcutaneous injection in the early neonatal period (days 1 to 3) tended to produce only a mild lesion essentially limited to one cell type, the ganglion cell (fig. 1). With increasing age, up to approximately the 10th postnatal day, an increasingly severe lesion, involving not only ganglion cells but many cells of the inner nuclear layer, could routinely be induced by a single injection at the same 4 mg/gm dose level (fig. 2b). Although considerable individual and litter variability of response was noted, in general a greater degree of retinal modification resulted from treating the 9- to 10-day-old animal than from treating a younger animal. When daily treatments from the 1st to 10th postnatal days were given, the resulting lesion was usually slightly more severe, but in several retinas was less severe, than was routinely induced by a single injection between the 9th and 10th days. It appeared, therefore, that developmental age and individual or litter variability were more critical determinants of lesion severity than was the number of separate injections given. The MSG effect may also be a dose related phenomenon, but experiments in the present study were not designed to study the dose systematically in relation to other variables. In order to achieve the maximal effect from a single injection, timing was quite critical in that retinal conditions changed abruptly between the 10th and 11th postnatal days. After the 10th to 11th days it was difficult, even with lethal doses of MSG, to produce a significant lesion in the retina. Such lesions as were produced by treatment subsequent to the 10th day showed a spotty distribution usually limited to the region of the ora serrata and to a few cells immediately surrounding the nerve head.

From its onset to resolution the MSG retinal lesion followed a rapid time course as is illustrated light micrographically in the Figures 2a–d. Mild changes were discernible within 30 minutes of a single subcutaneous injection and within 90 minutes an acute progressive swelling phase was well underway which resulted in 40 to 60 per cent increase in thickness of retinas examined in the 3 to 7 hour post treatment interval (fig. 2b). By 12 hours tumescence had subsided (fig. 2c), but necrotic debris remained distributed throughout the inner retina during the 12 to 24 hour period. By 48 hours degenerative elements were almost entirely eliminated and an overall reduction of retinal thickness to approximately 65 per cent of normal was evident (fig. 2d). Thus, an acute degenerative lesion induced in the 10-day-old retina by MSG, involving the death and biological degradation of a vast number of neurons, transpired almost completely in the short time span of 48 hours. Repair and reorganization phenomena, detectable only by electron microscopic examination, continued for several additional days.

In general, the early retinal response to MSG could be characterized as a massive edema formation restricted to the inner components of the retina. By electron microscopy the edema was entirely intracellular, although

in the 12 to 24 hour interval large extracellular spaces appeared, especially in regions of the inner retina adjacent to the vitreal surface (fig. 13).

The light microscopic impression that MSG treatment had no primary effect on photoreceptor cells was confirmed by electron microscopy. The majority of cells in the outer 2 or 3 tiers of the inner nuclear layer also underwent very little acute change. The tips of many processes invaginated into receptor bases, however, began swelling within 30 to 60 minutes of treatment (fig. 3). Most of these acutely swollen processes presumably originated from cells destined to undergo necrosis in the inner tiers of the inner nuclear layer. The majority of these processes rapidly degenerated beyond recognition, leaving many receptor bases devoid of invaginations when examined at 7 hours of treatment.

In cells of the inner nuclear layer which survived treatment, a specific intracytoplasmic organelle, the multivesicular body, became prominent in the post treatment period. This response to MSG treatment was particularly noticeable in that such organelles appeared in the tips of bipolar and/or horizontal cell processes which remained invaginated into receptor bases and were often so large as to fill the entire invagination (fig. 4). Although, in normal developing retina an occasional multivesicular body was encountered in the parakaryal cytoplasm of inner nuclear cells and in larger processes of the outer plexiform layer, they were not normally found in the tips of processes invaginated into receptor bases. The frequent appearance of such figures in invaginated processes of surviving cells suggests a role for these organelles in reversible injury and repair phenomena.

The cell bodies of affected bipolar, amacrine and ganglion cells began to swell within the first 2 hours and some showed frank necrosis in the 3 to 5 hour interval. Although it was difficult in most cases to trace the cellular origins of specific processes in the inner plexiform layer, certain processes having morphological characteristics consistent with those ascribed by Dowling (9) to the ganglion cell dendrite were markedly hydropic within an hour of treatment, whereas others, with morphology characteristic of the bipolar axon, tended to show fewer degenerative changes until a later period, approximately 5 to 7 hours following treatment (fig. 5). A preliminary examination of the ganglion cell axon at fiber tract, nerve head and optic nerve levels revealed a gradually developing reaction of delayed onset in contrast to the rapidly developing changes observed in many ganglion cell dendritic and somal constituents.

Several patterns of degenerative change were observed on the part of inner retinal neurons. In addition to generalized hydropic changes in both the cytoplasm and nucleoplasm, mitochondrial transformations were consistently observed within 30 to 90 minutes of treatment (figs. 6, 7). Bloating initially occurred in many mitochondria, although this sometimes affected only a portion of the mitochondrion. In the swollen portion the matrix appeared obliterated while in other areas of the same mitochondrion a dense matrix sometimes was evident. In a few cells, especially of the ganglion cell layer,

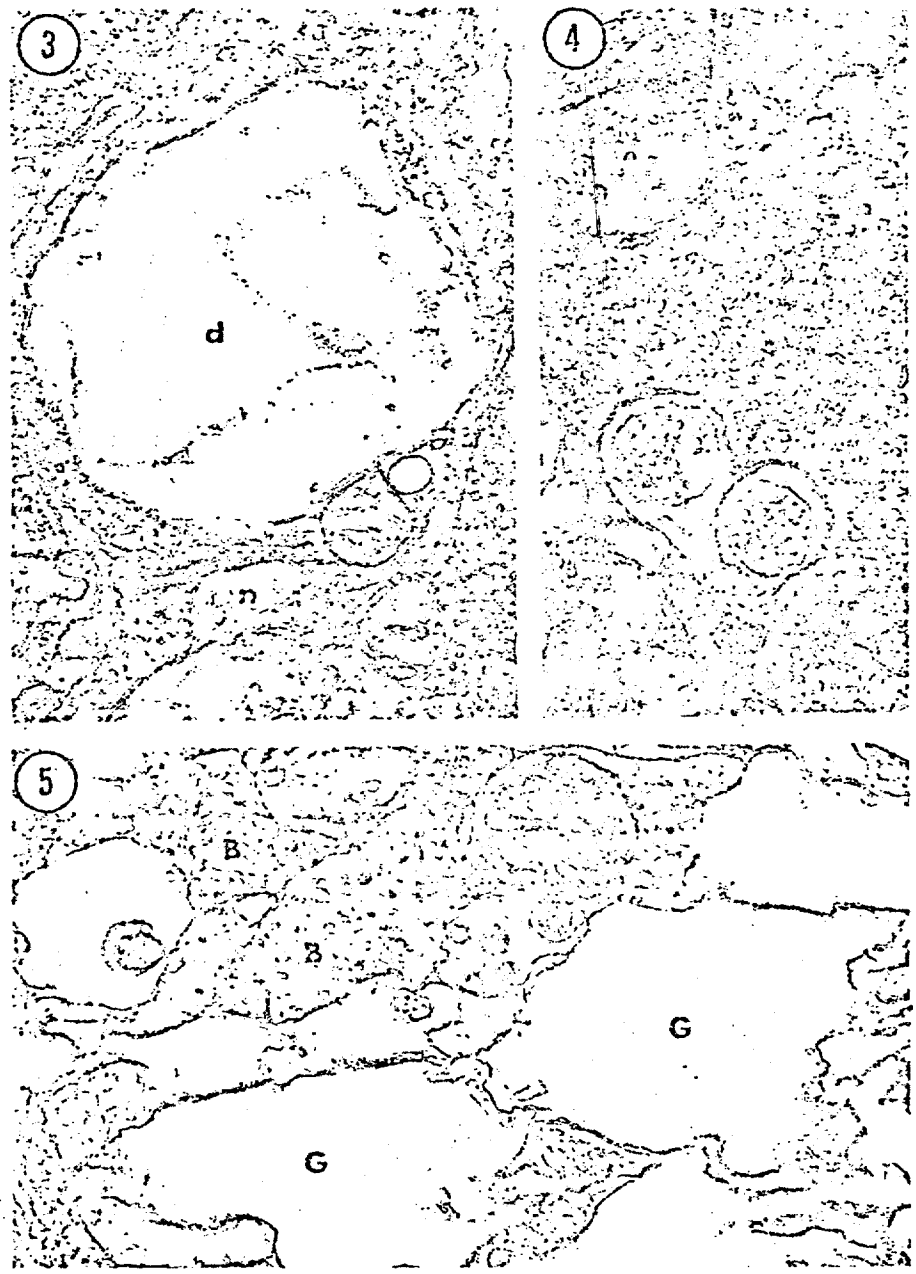

FIG. 3. Outer plexiform zone 2 hours post treatment showing dilated process invaginated into receptor base. A normal or relatively unaffected process invaginates the receptor base at lower center (n) for comparison with dilated invagination (a). Although compressed and distorted by the dilated invagination, the receptor terminal appears otherwise unaffected; × 28,000.

FIG. 4. Photoreceptor terminal, 24 hours post treatment, showing pair of large multivesicular bodies in invaginated tips of inner neuron processes; × 42,000.

FIG. 5. Inner plexiform layer, 3 hours post treatment, with large vacuous processes of presumptive ganglion cell origin (G) in the same field with a pair of bipolar axon terminals (B) identifiable by their vesicle content and small synaptic lamellae. Heterogeneity in size of synaptic vesicles in the bipolar terminal suggests mild early changes in contrast to more extreme changes in ganglion cell dendrites which are hydropic and devoid of content. The markedly dilated process in Figure 3 is probably a bipolar dendrite which reflects a greater degree of injury at 2 hours than is seen in the bipolar axons in Figure 5 at 3 hours; × 28,000.



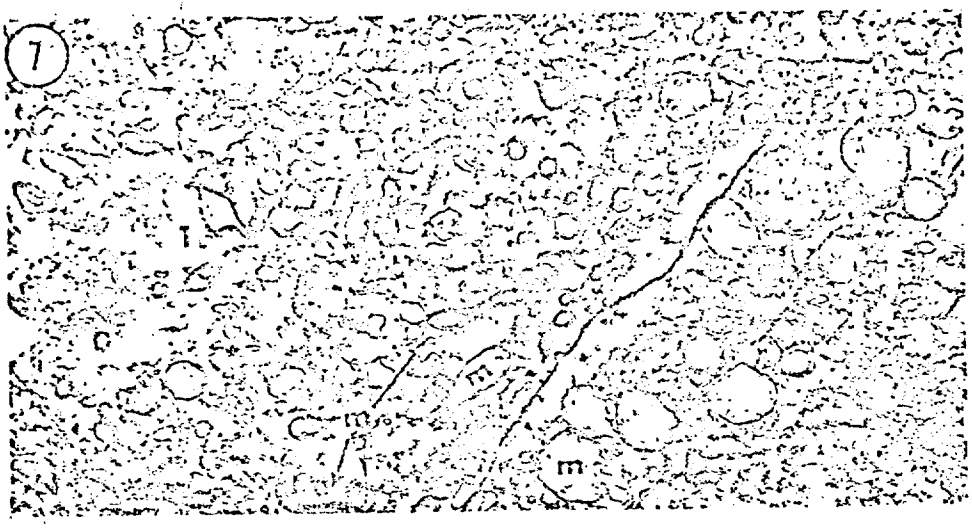

FIG. 6. Ganglion cell from 10-day-old untreated control animal which was a litter mate of animals from which micrographs 7 to 19 were taken. Typical appearance of mitochondrial (M) and other cytoplasmic constituents is illustrated. Note the density of nucleoplasm (n) and cytoplasm. Normal inner plexiform processes are also shown at right, top and bottom; × 14,000.

FIG. 7. Portions of two ganglion cells (1 and 2), 1½ hour post treatment. Magnification is same as in Fig. 6 for direct comparisons. Both cytoplasm and nucleoplasm (N) are of lowered density due to intracellular edema. In the 1st ganglion cell mitochondria (m) are pleomorphic with a few showing bloating but others appearing slim with smudged thickened membranes. Mitochondria in 2nd ganglion cell are markedly bloated; × 14,000.

other mitochondrial alterations could be detected early. In such cells mitochondria were often thinner than normal with internal contents compacted into thick septa surrounding vacuous compartments (fig. 7). A rounding up of mitochondria as is described below in connection with a more advanced stage of cellular degeneration was not seen in this early period.

Following the initial 2 to 3 hour period involving mild changes in many cells, divergent patterns of change became apparent. The most dramatic pattern noted was one suggesting an acute lytic process. In neurons thus affected, the cytoplasm appeared empty except for dispersed particulate debris and several remnants of formed elements such as a degenerate mitochondrion or a few profiles of rounded up endoplasmic reticulum (fig. 8). Nuclear pyknosis accompanied this type of cellular change with the nucleus becoming shrunken and dark. This pattern of cellular necrosis was not limited to a particular cell type. Although it must have represented an advanced state of degeneration, it was seen with greatest frequency in the 3 to 7 hour post treatment interval.

In a second, less acute pattern of cytopathology, which also was not limited to any particular cell type, mitochondria remained quite numerous but became uniformly spherical with a moderately dense matrix (figs. 9, 10). The granular endoplasmic reticulum gradually underwent severe fragmentation which resulted in a dispersion of ribosomes throughout the cytoplasm and was accompanied by a tendency for remnants of reticular membranes to round up into membrane bound vacuoles. In the process of formation some vacuoles appeared to incorporate small portions of cytoplasm (figs. 11, 12). Granulated vesicles (dense bodies) of variable size, resembling those which have been referred to alternatively as lipofuscin bodies (10) or as lysosomal "storage granules" (11) were observed, occasionally, in these cells but there was no suggestion of interaction between such granules and other cytoplasmic constituents. Nuclei underwent a gradual dissociation into 3 components: 1. A fine granular matrix, 2. dense particles or aggregates of particles embedded in this matrix and 3. moderately dense granular clumps (fig. 9). This type of degenerative change was not clearly manifest in any cells until approximately the 5th to 7th hours after treatment. In the 24 to 48-hour interval, macrophages were found containing phagocytized necrotic cells which could be identified by nuclear configuration as having undergone this gradual pattern of cellular necrosis (fig. 18). To facilitate description, this pattern of necrosis and the preceding one have been described as separate and distinct patterns of degeneration. In fact, some overlap between the two patterns occurred and an occasional degenerating cell appeared to have features of both patterns.

While the majority of amacrine and ganglion cells underwent a degenerative process terminating in cellular necrosis and were phagocytized or otherwise degraded and removed from the retina, a few cells of each type not only survived treatment, but showed almost no signs of being affected by the degenerative process. Every retina examined subsequent to the 5th post treatment hour contained a few such cells which, aside from mild mito-

FIG. 8. Retinal neuron from inner nuclear layer 3 hours post treatment showing rapid degenerative process. The cytoplasm is empty in many areas except for particulate debris and a few remnants of formed elements which, in this particular cell, appear to be grouped around the nucleus. Although cytoplasmic structures have undergone a marked degree of autolysis, the plasma membrane appears intact. The nucleus is darker and smaller than normal representing a moderate degree of nuclear pyknosis; × 14,000.

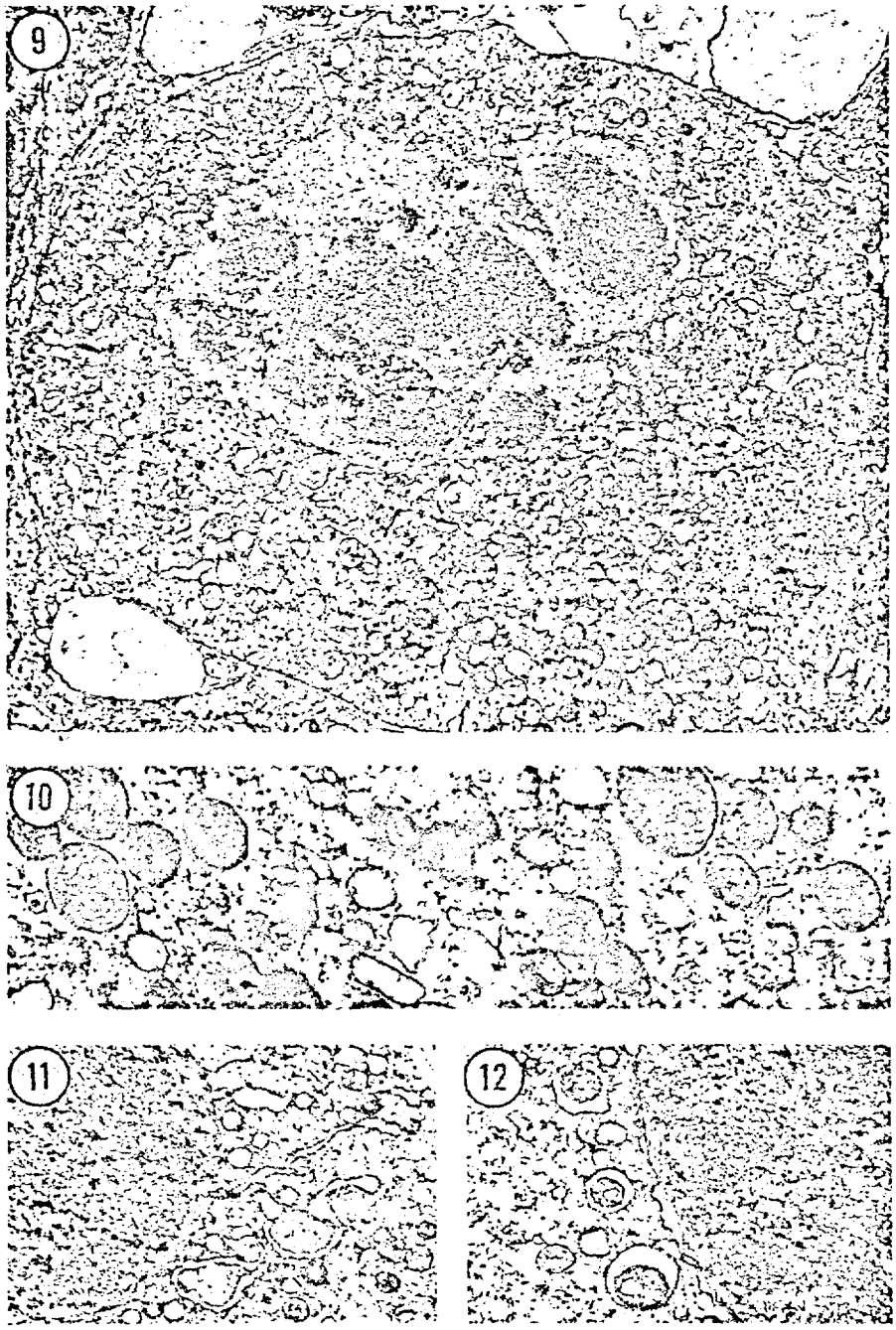

FIG. 9. Ganglion cell, 7 hour post treatment, undergoing gradual degenerative changes. Mitochondria are uniformly spherical and have relatively dense matrices. Endoplasmic reticulum is fragmented with some cisternae transformed into small vacuoles. Ribosomal granules are dispersed throughout the cytoplasm and the nucleus consists of 3 morphologically distinct components: a fine granular matrix; dense particles in clusters or strands; and dense granular clumps; × 12,000.

chondrial bloating, appeared normal in striking contrast to the surrounding field of necrotic debris.

In experimental retinas a dark cell phenomenon became evident 3 hours following treatment (fig. 2b) but was not seen in earlier post treatment intervals nor in any control retinas. No particular pattern of degeneration was a characteristic accompaniment of the dark cell appearance. Approximately ¼ of the cells in the inner retina were affected by this phenomenon which appeared to be a selective cellular dehydration process. In that the process occurred only in treated retinas and only in the region of the evolving lesion it was presumably induced either directly or indirectly by the administered load of MSG. Why it affected some cells but not others and by what specific mechanism it developed is not clear.

Changes interpreted as reactive rather than degenerative were noted in several non-neuronal cell types. In the vitreally oriented Muller process an increased amount of agranular endoplasmic reticulum was apparent within a few hours of treatment but the extent of increase was difficult to assess due to a variable degree of swelling affecting Muller processes in the early post treatment period. After the 12th hour, as swelling subsided, it was evident that most Muller processes did contain an increased amount of agranular endoplasmic reticulum (fig. 14) and, in addition, a marked tendency for the profiles of endoplasmic reticulum to appear in whorls or in circular concentric configurations became evident in this period (figs. 13, 15). A reduced glycogen content was suggested as an early response in Muller processes although this also was difficult to evaluate due to swelling and to the fact that the concentration of glycogen granules varies considerably in normal retinas from one process to another and from one animal to another. In the late post treatment period an excess accumulation gradually developed so that by 48 hours most Muller processes contained decidedly more glycogen than normal. Phagocytosis or "endocytosis" (12) was observed on the part of the Muller process as early as 3 hours and as late as 48 hours post treatment. Although an attempt to engulf entire cell bodies was not observed, slim pseudopodia extending from the main stalk of the Muller process were frequently seen enveloping less sizeable degenerating structures in the inner plexiform zone. Vacuoles of diverse size, apparently representing fragments of disintegrating neuronal processes, were routinely encountered at various post treatment intervals, incorporated within the

---

FIG. 10. Mitochondria 7 hours post treatment, from cell undergoing gradual degeneration as in Fig. 9. All mitochondria are essentially spherical. Although some appear more degenerate than others, none is being engulfed or acted upon in any recognizable way by other constituents of the cytoplasm. Particles in the cytoplasm are presumably dispersed RNA granules; × 31,000.

FIGS. 11 and 12. Two ganglion cells, 7 hours post treatment, each undergoing a pattern of degeneration similar to cell in Fig. 9. Fig. 11 illustrates vacuole formation by granular endoplasmic reticulum. Cisternae of the granular reticulum are curling upon themselves to form vacuoles which appear to be trapping portions of cytoplasm in the immediate environment. In Fig. 12, vacuoles appear to have already formed with small portions of the cytoplasm possibly enclosed within the vacuole. Whether a limiting membrane completely surrounds these apparent inclusions could only be established by careful serial sectioning which was not undertaken in the present study; × 15,000.

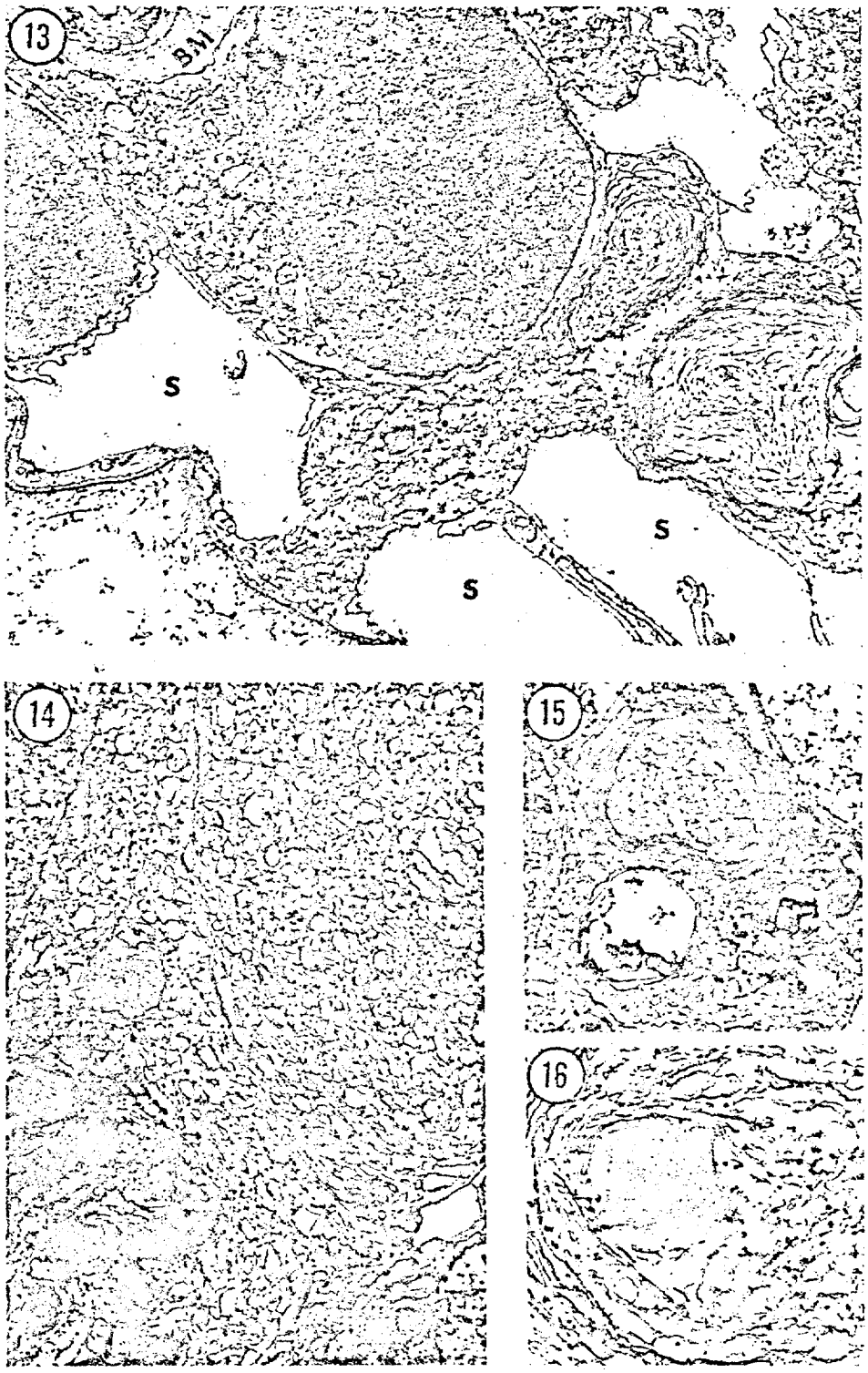

Figs. 13–16.

main body of cytoplasm of the Muller process (fig. 15). Numerous sizeable fat droplets accumulated in Muller processes of treated retinas (fig. 14) whereas in normal development the Muller process contains only occasional fat droplets. Whorls of agranular endoplasmic reticulum sometimes were closely associated with fat droplets (fig. 16) but often they were not, nor was there any clearly recognizable relation between these lamellar configurations and ingestion vacuoles (fig. 15).

In the post treatment period, many macrophages similar in appearance to the type normally present at various levels of the developing retina (7) gradually became engorged with degeneration products. In the pre-engorged state, macrophages typically contained abundant granulated vesicles (dense bodies) which, except for size variation, were of homogeneous appearance. Engorged macrophages lacked such vesicles but contained instead an assortment of pleomorphic inclusions ranging in content from recognizable formed elements of other cells to an admixture of myeloid figures, dense particles and amorphous debris (fig. 17). With the exception of fat droplets, which increased in size and number within macrophages in later post treatment periods, most inclusions were membrane bound. Some macrophages appeared to incorporate within their cytoplasm entire corpses of necrotic retinal neurons. Polymorphonuclear leukocytes which appeared in degenerating regions within 12 hours of treatment also performed a phagocytic function but on a smaller scale. In fact, several examples were noted in which polymorphonuclear leukocytes appeared to be engulfed along with degenerating neurons by retinal macrophages (fig. 18). As was observed by Weidman (13) in developing rat retina, spontaneous neuronal necrosis occurs to a limited extent as a natural concomitant of retinal development. Such necrotic neurons are routinely removed from developing mouse retina by macrophages similar in appearance to those evacuating debris from treated retina (14). Theories concerning the origin of retinal macrophages, phagocytosis and the degradation and disposal of necrotic debris were well reviewed recently (15). The present study sheds no additional light on the controversial aspects of these issues.

FIG. 13. Scene near vitreal surface, 18 hours post treatment. Large extracellular spaces (S) are present near vitreal surface. Muller process contains whorls of agranular endoplasmic reticulum. Central region of whorl also consists of endoplasmic reticulum which appears vesiculated. The paravascular cell lying in contact with the vascular basement membrane (BM) may be a glial cell. It is commonly seen in the fiber tract region of the developing retina but unlike the pericyte, is not surrounded by basement membrane; × 12,000.

FIG. 14. Muller processes illustrating hypertrophy of endoplasmic reticulum 24 hours post treatment. An accumulation of fat droplets is present at lower left. Glycogen granules are relatively abundant but are rendered inconspicuous by the dense background of hypertrophied reticulum; × 15,000.

FIG. 15. Muller process 12 hours post treatment showing whorl of agranular reticulum adjacent to several vacuoles of heterogeneous appearance. Except for a small fat droplet the whorl contains nothing but vesiculated agranular reticulum and it bears no particular relation to any of the nearby vacuoles; × 10,000.

FIG. 16. Muller process 24 hours post treatment showing layers of agranular reticulum in semicircular configuration appearing to drape around a fat droplet. In that the entire cytoplasm of the Muller process was filled with agranular reticulum, the apparent close association between reticular membranes and the fat droplet may only represent crowding; × 36,000.

FIG. 17. Macrophage in inner plexiform zone, 24 hours post treatment. This macrophage appears quite engorged with ingested materials, some of which are formed elements of degenerating neurons and some of which are broken down beyond recognition. Membrane bound granular vesicles (dense bodies) are a less conspicuous component in the makeup of this cell and fat droplets are more common than in pre-engorged macrophages; × 12,600.

A paravascular cell, similar in appearance to the retinal macrophage, but which in normal development is seen as a "vitreocyte" in close association with vitreal blood vessels, underwent a marked increase in numbers in the 24 to 48 hour interval following treatment. These cells appeared to follow a path of migration from vitreal blood vessels to the vitreal surface of the retina where, by 48 hours, they could be found in large numbers lying against the basement membrane separating the vitreal chamber from the retina (fig. 2d). Since such cells were never seen actually to enter the retina, their specific role in relation to the retinal lesion remains obscure. A hematogenous origin of the vitreocyte is suggested by the fact they increased in number in the post treatment period but were never seen to undergo mitosis.

In the normal development of mouse retina blood vessels migrate from the level of the fiber tract to the inner plexiform level by the 4th postnatal day and are present in the outer plexiform layer by the 8th postnatal day (7). In the present investigation it was observed that these normal vascular developments did not proceed according to schedule while the animal was under treatment with MSG. In animals treated with daily doses of MSG from the 1st to 10th postnatal days, vascularization of the retina was completely inhibited in that blood vessels could not be found beyond the fiber tract level on the 10th day. In retinas from animals similarly treated but examined

FIG. 18. A complex constellation of degenerate and non-degenerate constituents of an indeterminate number of cells. Two nuclei or nuclear lobes (n) which appear mildly condensed are interpreted as belonging to a polymorphonuclear leukocyte. Each nuclear component is surrounded by a clear cytoplasm containing numerous individual particles, presumably glycogen granules, and occasional dense granular vesicles plus accumulations of degenerate elements partially engulfed by the main cytoplasmic mass. The boundaries of the polymorphonuclear plasma membrane are demarcated by single arrows. At upper left is the corpse of a degenerate neuron. Its nucleus (N) is dissociated into 3 components as was illustrated in Fig. 9 as a pattern of gradual neuronal degeneration. Cytoplasmic fingers from the PMN leukocyte embrace but do not surround this neuronal corpse. Surrounding the entire complex is a slim continuous margin of cytoplasm (between single and double arrows), relatively rich in RNA granules, which is interpreted as the cytoplasm of a retinal macrophage in the process of incorporating one whole retinal neuron plus one whole PMN leukocyte plus portions of other retinal neurons which the leukocyte was attempting to phagocytize; × 12,000.

on the 20th day, vascularization was complete to the level of the outer plexiform layer. When a single MSG treatment was given on the 10th postnatal day, a retrogression in vascular development ensued. This appeared to be a delayed response primarily affecting vessels most recently developed,

i.e., those at the outer plexiform level. The walls of outer plexiform blood vessels appeared normal 12 hours following treatment, but a subsequent narrowing of vascular lumen was a common finding and a few vessels appeared completely closed at 24 hours. This occurred by a process of rounding up of the endothelial cell until its cell body fully compromised the vascular lumen. No specific signs of a degenerative process affecting the endothelial cell were detected but vessels were completely absent from the outer plexiform zone at 48 hours of treatment (12-day-old retina). Macrophages, normally seen at this retinal level in close association with the vasculature, remained abundant as wandering histiocytes. In the early post treatment period when neurons were undergoing acute necrotic changes, no signs of vascular disturbance were observed other than a possible dilatation of small vessels which appeared filled with red cells.

DISCUSSION

The finding that increasing numbers of cells and additional cell types became vulnerable to MSG treatment with advancing developmental age suggests that some degree of maturity may be a prerequisite of susceptibility to the MSG effect. Lucas and Newhouse (1) reported an absence of retinal degeneration in offspring of female mice treated throughout gestation with 1 Mg/Gm/day of MSG. Although this might be taken as evidence that the administered lead of MSG was effectively shielded from the fetal circulation by placental barriers, it might also be an indication that neurons in the mouse retina were simply not sufficiently mature prior to birth to be susceptible to the MSG effect. Evidence has been presented (16) that the primate placenta, by active transport mechanisms, maintains a glutamic acid concentration in the fetal circulation which is consistently in excess of that in the maternal circulation. In that the primate retina reaches a higher state of maturity *in utero* than does the mouse, this would be an ideal species to test the hypothesis that increased glutamate intake by the mother during gestation might produce retinal damage in the developing embryo.

The fact that MSG treatment of neonatal mice produces a highly predictable and rapidly developing pattern of retinal degeneration does not necessarily imply a direct cytopathic effect of glutamate on retinal neurons. Several lines of evidence, however, suggest that a relatively direct mechanism may be involved. That neurons are particularly sensitive to glutamate is suggested by iontophoretic studies (17) in which accelerated spike activity can be routinely induced by administration of MSG in the extracellular surroundings of cerebral or spinal neurons. According to Krnjevic and Phillis (18), this excitation effect occurs only when MSG is administered in the region of dendritic and somal constituents but is not obtained from regions concentrated in axons. A selective sensitivity of neuronal cell bodies and dendrites to MSG, as suggested by their data, is consistent with findings in the present study of early swelling and degenerative changes in these components of retinal neurons. *In vitro* studies on both retina (19) and brain

slices (20) have shown that glutamic acid uptake supports a high respiratory rate but leads to a net reduction in high energy stores. Early mitochondrial changes noted in the present study may have been a reflection of this phenomenon *in vivo* in that mitochondrial membranes are considered to be closely associated with enzyme systems promoting cellular respiration and oxidative phosphorylation. The marked intracellular edema which occurred very early may have represented fluid imbibition secondary to uptake of glutamic acid and potassium by the cell as is believed to be the phenomenon occurring under *in vitro* conditions (19). On the other hand, acute swelling is a relatively nonspecific change associated with many types of toxic or other injurious influences on cells and, therefore can be interpreted only with caution as a direct reflection of MSG uptake by the cell. Loss of glycogen by the Muller cell would be consistent with *in vitro* data that glutamate uptake by the retina is associated with glucose utilization (19). Hypertrophy of the agranular reticulum in liver cells of the hamster following the administration of drugs such as phenobarbital has been interpreted as an adaptive response enabling the liver to more efficiently eliminate these drugs (21). A similar interpretation might be placed on the observed hypertrophy and whorl formation of agranular reticulum in the retinal Muller process following administration of MSG. Such changes may also have been in response to degenerative products from dying cells; however, no consistent relation to ingestion vacuoles or other morphologic entities in the Muller process were noted.

For parenterally administered MSG to have a direct effect on retinal neurons, it must first gain entry to the retina. Cunha-Vaz *et al.* (22) place the blood retina barrier at the level of the capillary endothelium and have presented evidence that barriers are intact against trypan blue and carbon particles in the neonatal as well as adult retina of rat, cat and rabbit. Of course, barrier phenomena pertaining to trypan blue and carbon particles may well be irrelevant to the question of barrier permeability to MSG, especially in that glutamate is a naturally occurring substance in the blood stream and CNS. The demonstration by Freedman and Potts (2) of high uptake of isotopically labelled glutamate by the rat retina on the 5th postnatal day indicates, insofar as the early neonatal period is concerned, that glutamate can enter the retina from the blood stream. Decline of glutamate uptake by rat retina on the 10th postnatal day (2) may reflect maturational changes in blood retina barriers to MSG. This in turn, would explain the reduced vulnerability of mouse retina to MSG treatment after the 10th postnatal day, assuming vulnerability to be dependent on glutamate entering the retina. To further investigate the possibility of a direct cytopathic effect of MSG on retinal neurons, blood retina barriers could be circumvented and other variables brought under more precise control by use of *in vitro* retina preparations which could be followed for histological changes to supplement findings of a biochemical nature already available.

An alternative mechanism by which the entire retinal lesion might be

explained, and which would not require the passage of MSG across blood retinal barriers, would be through an impairment of blood supply to the inner retina. It was observed that vascularization of the neonatal retina underwent retrogressive changes following MSG treatment. A similar retrogressive effect on the developing retinal vasculature was demonstrated by Ashton (23) in neonatal mice exposed to increased oxygen tension. Although increased oxygen tension interfered drastically with the process of vascularization in the inner retina, acute neuronal necrosis did not ensue. Thus, an interference by MSG in retinal vascular development would probably not explain the acute degenerative changes noted in retinal neurons.

In some respects the acute retinal pathology associated with MSG treatment resembles the findings in retinal ischemia recently described by Shakib *et al.* (15). These authors induced focal ischemia experimentally by microembolization of arterioles in the inner retina of the pig. The lesion induced by this technique was of rapid onset, and affected the same neuronal cell types as does MSG treatment. Certain mitochondrial changes noted in ischemic neurons were the same as those found in the present study and swelling of many neural components accompanied by shrinkage or cytoplasmic condensation in others was featured in both cases. A relatively early clearing of the area by macrophages was noted in both studies. In several respects, however, the findings in these acutely evolving lesions differ. In the ischemic pig retina it was emphasized that degenerative changes in ganglion cell axons occurred very early (within the first hour), whereas, axonal involvement in the glutamate induced lesion was a relatively delayed phenomenon. No particular response was described for the Muller cell of infarcted pig retina but hypertrophy of the endoplasmic reticulum with whorl formation was a conspicuous change induced in Muller cells by MSG treatment. In the pig retina early narrowing of capillary lumina with absence of red cells was noted in regions undergoing neuronal necrosis. In MSG-treated mice neither capillary narrowing nor a reduced red cell content was detected in early periods when retinal edema and neuronal necrosis were strikingly evident. In a later period (24 to 48 hours post treatment) capillary closure was observed but only in the outer plexiform layer. In that species and age variables could account for some of the differences noted, the similarities between the acute histopathology induced by MSG treatment and the process of ischemic necrosis are perhaps all the more noteworthy. It would be helpful to determine with special dye injection and related techniques such as have been used successfully to study circulation dynamics of the retina (24), whether early vessel changes or altered blood flow to the inner retina accompany the administration of MSG. If further studies fail to support ischemia, some type of lesion affecting vascular function on a molecular level might be considered. A lesion paralysing some vital aspect of metabolic exchange between the vascular compartment and retinal neurons could account for acute neuronal necrosis with only minimal or delayed changes reflected in the endothelium.

SUMMARY

A pattern of degeneration affecting certain cells of the inner retina was induced in 9 to 10-day-old mice by a single subcutaneous injection of MSG. Retinas were studied by electron microscopy at serial post treatment intervals to provide a description of the acutely evolving lesion. Swelling of dendrites and cell bodies with mitochondrial transformations occurred as early changes in all neurons affected. Several patterns of degeneration leading to neuronal necrosis were described, but none was specific to a given type of neuron. The Muller process showed reactive reversible changes consisting of swelling, hypertrophied agranular reticulum, and alterations in glycogen content. Phagocytosis was observed on the part of several cell types including the Muller process, and nearly all products of degeneration were removed from the retina within 48 hours of treatment. An apparent primary effect of MSG on retinal vascular development was noted, the significance of which remains to be clarified. Incidental observations concerning the developmental period of greatest retinal vulnerability to the MSG effect were reported. Possible correlations between observed patterns of response to MSG and mechanisms of pathogenesis were discussed.

Acknowledgment: I wish to thank Dr. A. I. Cohen for valuable advice in connection with the present investigation and for the generosity with which he has made electron microscopy facilities available to me.

REFERENCES

1. Lucas, D. R., and Newhouse, J. P.: The Toxic Effect of Sodium L-Glutamate on the Inner Layers of the Retina. AMA Arch. Ophth., 58: 193, 1957.
2. Freedman, J. K., and Potts, A. M.: Repression of Glutaminase I In Rat Retina by Administration of Sodium L-Glutamate. Invest. Ophthal., 1: 118, 1962.
3. ——, and ——: Repression of Glutaminase I in Rat Retina by Administration of Sodium L-Glutamate. Invest. Ophthal., 2: 252, 1963.
4. Potts, A. M., Modrell, K. W., and Kingsbury, C.: Permanent Fractionation of the ERG by Sodium Glutamate. Am. J. Ophth., 50: 900, 1960.
5. Cohen, A. I.: An Electron Microscopic Study of the Modification by Monosodium Glutamate of the Retinas of Normal and "Rodless" Mice. Am. J. Anat., 120: 319, 1967.
6. McIlwain, Henry: *In* Biochemistry and the Central Nervous System, 3rd Edition, p. 148, Boston, Little, Brown, and Company, 1966.
7. Olney, J. W.: An Electron Microscopic Study of Synapse Formation and Other Aspects of Developing Mouse Retina. Invest. Ophthal., 7: 250, 1968.
8. Richardson, K. C., Jarett, L., and Finke, E. H.: Embedding in Epoxy Resins for Ultrathin Sectioning in Electron Microscopy. Stain Technol., 35: 325, 1960.
9. Dowling, J. E., and Boycott, B. B.: Organization of the Primate Retina: Electron Microscopy. Proc. Roy. Soc. B., 166: 80, 1966.
10. Gonatas, N. K., Terry, R. D., Winkler, R., Korey, S. R., Gomez, C. J., and Steine, A.: A Case of Juvenile Lipidosis: The Significance of Electron Microscopic and Biochemical Observations of a Cerebral Biopsy. J. Neuropath. & Exper. Neurol., 22: 557, 1963.
11. De Duve, Christian: The Lysosome. Scientific Am., 208: 64, 1963.
12. ——, and Wittiaux, R.: Functions of Lysosomes. Ann. Rev. Physiol., 28: 435, 1966.

13. Weidman, T. A., and Kuwabara, T.: Postnatal Development of the Rat Retina. Arch. Ophthal., 79: 470, 1968.
14. Olney, J. W.: Unpublished Data.
15. Shakib, M., and Ashton, N.: Ultrastructural Changes in Focal Retinal Ischemia. Brit. J. Ophthal., 50: 325, 1966.
16. Kerr, G. R., and Waisman, H. A.: *In* Transplacental Ratios of Serum free Amino Acids during Pregnancy in the Rhesus Monkey, in Amino Acid Metabolism and Genetic Variation. Ed. Nyhan, W. L., p. 429, Pub. N.Y., McGraw Hill, 1967.
17. Curtis, D. R., Perrin, D. D., and Watkins, J. C.: The Chemical Excitation of Spinal Neurones by Certain Acidic Amino Acids. J. Physiol., 150: 656, 1960.
18. Krnjevic, K., and Phyllis, J. W.: Iontophoretic Studies of Neurones in the Mammalian Cerebral Cortex. J. Physiol., 165: 274, 1963.
19. Terner, C., Eggleston, L. V., and Krebs, H. A.: The Role of Glutamic Acid in the Transport of Potassium in Brain and Retina. Biochem. J., 47: 139, 1950.
20. Woodman, R. J., and McIlwain, H.: Glutamic Acid, Other Amino Acids and Related Compounds as Substrates for Cerebral Tissues: Their Effects on Tissue Phosphate. Biochem. J., 81: 83, 1961.
21. Jones, A. L., and Fawcett, D. W.: Hypertrophy of the Agranular Endoplasmic Reticulum in Hamster Liver Induced by Phenobarbital (With a Review on the Functions of this Organelle in Liver). J. Histochem. Cytochem., 14: 215, 1966.
22. Cunha-Vaz, J. G., Shakib, M., and Ashton, N.: Studies on the Permeability of the Blood-Retinal Barrier. Brit. J. Ophthal., 50: 441, 1966.
23. Ashton, N.: Some Aspects of the Comparative Pathology of Oxygen Toxicity in the Retina, Brit. J. Ophthal., 52: 505, 1968.
24. Dollery, C. T., Henkind, P., Paterson, J. W., Ramalho, P. S., and Hill, D. W.: Ophthalmoscopic and Circulatory Changes in Focal Retinal Ischemia. Brit. J. Ophthal., 50: 285, 1966.

Reprinted from JOURNAL OF NEUROPATHOLOGY AND EXPERIMENTAL NEUROLOGY
Vol. XXX, No. 1, January, 1971
Printed in U.S.A.

GLUTAMATE-INDUCED NEURONAL NECROSIS IN THE INFANT MOUSE HYPOTHALAMUS

AN ELECTRON MICROSCOPIC STUDY* †

JOHN W. OLNEY, M.D.
(*St. Louis, Missouri*)

Acute necrosis of select neuronal populations of the retina (1–4) and hypothalamus (5–7) following either parenteral (1–6) or oral (7) administration of monosodium L-glutamate (MSG) to infant animals has been reported in several species. It has further been demonstrated that mice (5, 9) or rats (8–10), treated with MSG in infancy, manifest obesity and multiple endocrine disturbances as adults. In recent experiments with infant mice aimed at clarifying the specificity of the glutamate effect, aspartate and cysteine (7, 11), and related congeners such as cysteic and homocysteic acids (12), also gave rise to neuronal necrosis in both the inner retina and the arcuate region of the hypothalamus. A wide variety of other compounds, including sodium chloride, sodium glutamate, and a series of neutral and basic amino acids failed, at high doses, to produce such changes. Unneutralized glutamic acid was as effective as monosodium glutamate. That glutamate, aspartate and cysteine, but not basic or neutral amino acids, are capable of inducing striking degenerative changes in the developing central nervous system is of particular interest in view of evidence from other lines of research revealing that these compounds comprise a select group of amino acids having neuroexcitatory properties (13).

The primary purpose of the present report is to provide a more complete morphological description of glutamate-induced hypothalamic damage than has appeared in previous brief reports on the subject (5, 6). Preliminary electron microscopic observations (12) indicate that degenerative changes in the infant mouse hypothalamus following treatment with either cysteine or aspartate are indistinguishable from those associated with glutamate treatment. It is suggested, therefore, that the description given in this report be tentatively considered prototypic of a certain kind of regionally specific neuropathology which can be readily induced in the infant hypothalamus, not only by glutamate treatment, but by treatment with select other compounds as well.

MATERIALS AND METHODS

Between three and four hundred infant animals, primarily mice, have been treated in this laboratory over the past year with MSG and related test compounds, at various doses, by several routes of administration and at several stages of development. These animals were all sacrificed by perfusion fixation, and the brains processed as described below for alternative examination by either light or electron microscopy. For purposes of the present report,

* From the Department of Psychiatry, Washington University School of Medicine, St. Louis, Missouri 63110.

† Supported in part by grants from The United States Public Health Service (MH-38894, NS-09156, MH-07081).

varied materials were selected from this larger study. The description of the acutely evolving lesion is based primarily on a study of 3 litters (27 healthy infants) of Webster Swiss albino mice, 21 of which were treated subcutaneously on the 10th post natal day with a single 18 mmole/kg dose of MSG in 10 per cent aqueous solution and sacrificed at intervals from 15 minutes to 8 days following treatment. Six of the 27 infants, 2 from each litter, served as controls. Three were given 18 mmole/kg doses of sodium chloride and sacrificed 6, 12 or 24 hours following treatment and 3 were sacrificed on the 10th post natal day without treatment. The appearance of the hypothalamus 9 months following multiple treatments in infancy is illustrated by micrographs from adult mice that received daily MSG injections for the first 10 days of neonatal life according to a graduated subcutaneous dose schedule beginning with 2 gm/kg on the first post natal day and terminating with 4 gm/kg on the tenth day. Electron micrographs are also included from a study (reported with light micrographic illustrations elsewhere) (7) of infant mice that received single oral feedings of MSG on the 10th post natal day. The MSG used for all treatments was obtained from either Sigma Chemical Company or Nutritional Biochemicals Corporation. Thin layer chromatography performed in our laboratories revealed no impurities in either source of MSG. The method of sacrificing animals and preparing their brains for histopathological examination was the same for all animals. Chloral hydrate in 3.5 per cent aqueous solution was given intraperitoneally (approximately 1 mg/kg), and perfusion fixation of the central nervous system *via* the left ventricle and ascending aorta was begun within 30 to 45 seconds of entering the chest. An improvised clamp for securing the perfusion cannula within the ascending aorta markedly facilitated the perfusion procedure, particularly with infant animals. The perfusate consisted of 1 per cent paraformaldehyde and 1.5 per cent glutaraldehyde in 0.1 M cacodylate buffer. After 12 minutes of perfusion at room temperature the brains were removed from the cranium with care to avoid physical trauma to the median eminence region and transverse slabs ¾ mm thick were sliced serially from the preoptic region to the interpeduncular zone. These slabs were transferred directly to 1 per cent osmium tetroxide for additional fixation overnight then dehydrated in graded ethanols (30, 50, 70, 95, 100 per cent), further processed in toluene, and embedded flat in araldite. Serial sections at desired levels of the hypothalamus were cut 1 micron thick and stained by the Richardson method (14) for light microscopy. Adjacent ultrathin sections were obtained from areas of interest in any given block for examination with the electron microscope. All sections were cut on an MT-2 Porter Blum microtome with wide knives broken from ⅜ inch plate glass. Ultra thin sections of pale gold interference colors were mounted directly on formvar films suspended over 1 x 2 mm grid openings, stained with lead and uranium salts and viewed with a Philips 300 electron microscope. The use of slot grids with 1 x 2 mm openings permitted electron microscopic viewing of the entire ventral hypothalamus in cross section without interference from grid mesh bars.

RESULTS

The arcuate nucleus of the rodent hypothalamus, referred to as infundibular nucleus in some species (15), consists of small sized neurons grouped on either side of the midline directly over the floor of the third ventricle (fig. 1). The rostrocaudal limits of the arcuate nucleus are approximately coterminous with those of the median eminence over which its neurons form a continuous arch-like configuration. Serial light microscopic sections through the hypothalamus of 10-day-old mice sacrificed 6 hours after receiving 18 mmole/kg of MSG revealed a very clearly demarcated lesion involving the entire arcuate nucleus but not extending into other adjacent hypothalamic regions (fig. 2). It was determined that the general quality of fixation of these brains was satisfactory by examining regions lying outside the lesioned area and finding the ultrastruc-

ture uniformly well preserved. The brains of control animals, whether untreated or treated with sodium chloride, also appeared well preserved throughout hypothalamic regions and contained no changes even remotely suggesting a pathological process (figs. 1, 5a, 10).

The onset and evolution of the hypothalamic lesion induced by a single dose of MSG followed the same rapid time course as was described in a prior report on the degeneration of the inner retina following glutamate treatment (4). An initial stage of acute intracellular edema, detectable by light microscopy within the first hour, reached peak severity at approximately 6 to 8 hours following MSG by either the subcutaneous (fig. 2) or oral (fig. 5b) route of administration. By this time many neurons of the arcuate nucleus already appeared necrotic with pronounced parakaryal swelling, loss of cytoplasmic density, and nuclear pyknosis. In the 12 to 24 hour interval all signs of edema subsided, but evidence of a degenerative process lingered in the form of numerous dense bodies of variable size and shape (figs. 3 and 5c). These dense structures, identified with the electron microscope as necrotic cells being phagocytized, were transformed in the 24 to 48 hour interval into tiny dark specks barely detectable with the light microscope. Disappearance of these breakdown products in the ensuing 2 days left the arcuate region on the 4th post treatment day essentially unremarkable in appearance except for a substantially reduced population of neurons (fig. 4).

The earliest changes detected by electron microscopy following MSG treatment were in glial and ependymal cells (figs. 6 to 8). The processes and cell bodies of these non-neuronal cells exhibited swelling as early as 15 minutes following treatment, whereas neuronal involvement was not clearly evident until approximately 30 minutes following treatment. Unlike the response of neurons, however, changes in glial and ependymal constituents were reversible and did not progress beyond an acute edema stage. Intracellular organelles did not undergo degenerative changes nor did glial or ependymal nuclei exhibit chromatin clumping or become pyknotic. Acute changes were not detected in vascular pericytes or endothelial cells despite the fact that astrocytic processes in close contact with these cells were often edematous in the early post-treatment period (fig. 8). Neither stasis of red blood cells in the vascular lumen nor extravasation of blood cells or plasma into the affected area were observed, and blood vessels of all sizes in the arcuate region remained patent to perfusion fixation throughout the post-treatment period.

Extreme swelling of dendritic processes was a conspicuous early response of neurons to MSG treatment. Although fully developed synapses are not abundant in the 10-day-old mouse hypothalamus, those present in the arcuate region of treated animals exhibited changes in the post-synaptic (dendritic) component as early as 30 minutes after treatment. The presynaptic (axonal) component remained unaffected in this early post-treatment period (fig. 9).

Mitochondrial transformations also occurred early in degenerating arcuate neurons and were very similar to those described previously (4) in ganglion cells of the retina following MSG treatment (figs. 10–12). A transient condensa-

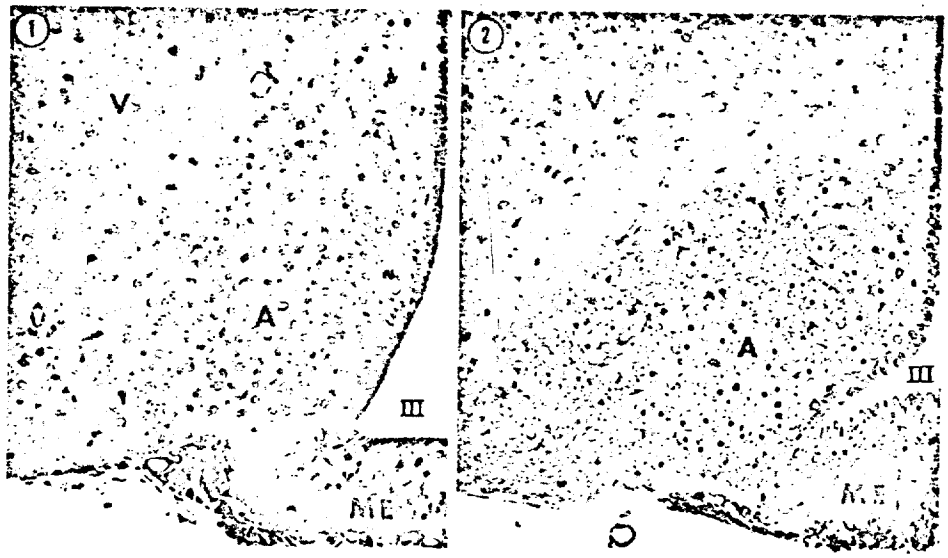

FIG. 1. Section through hypothalamus of untreated 10-day-old mouse illustrating the normal appearance of the arcuate nucleus (A) and the topographical relationship of its neurons to those of the ventromedial nucleus (V) and to the median eminence (ME) and third ventricle (III). The neurons of the arcuate nucleus are slightly smaller than those of the ventromedial nucleus; × 200.

FIG. 2. Hypothalamus of 10-day-old mouse, 6 hours following an 18 mmole/kg subcutaneous dose of MSG. Note the swollen cytoplasm and pyknotic nuclei of neurons throughout the arcuate region (A), the sharp demarcation of the lesion at the margin of the cell poor zone separating the arcuate (A) from the ventromedial nucleus (V) and the altered contour of the wall and floor of the third ventricle due to swelling in the regions of the arcuate nucleus and median eminence; × 200.



FIG. 3. Hypothalamus of 11-day-old mouse, 24 hours following an 18 mmole/kg subcutaneous dose of MSG. The arcuate region (A) is no longer edematous but is diffusely studded with dark staining dense bodies which in electron micrographs are recognized as degenerate cells undergoing phagocytosis. See also figs. 5c, 16 and 17; × 220.

FIG. 4. Hypothalamus of 14-day-old mouse, 4 days following an 18 mmole/kg subcutaneous dose of MSG. Degeneration products have disappeared from the arcuate region leaving it hypocellular (compare with fig. 1) and the majority of cells present are non-neuronal. The loss of nerve cell mass is accompanied by widening of the third ventricle (III); × 220.



FIG. 5. A composite of low power electron micrographs comparing the unremarkable appearance of the arcuate nucleus following NaCl (fig. 5a) with its altered appearance at several post treatment intervals following MSG (figs. 5b, c, d); all × 900. a. Ten-day-old mouse, 6 hours following an 18 mmole/kg subcutaneous dose of NaCl. The majority of cells present are typical arcuate neurons as they appear in the immature hypothalamus. b. Ten-day-old mouse. 6 hours following a 6 mmole/kg oral dose of MSG given by feeding tube. Degenerate neurons fill the field; see fig. 15 for detail. c. Eleven-day-old mouse. 24 hours following an 18 mmole/kg subcutaneous dose of MSG. Dense bodies are scattered throughout the field. The majority of nuclei present are non-neuronal. They appear larger than glial nuclei usually are which suggests they are in a stage of reactive hypertrophy; see fig. 16 for detail. d. Eighteen-day-old mouse. 8 days following an 18 mmole/kg subcutaneous dose of MSG. A few glial cells and other neuropil elements of unremarkable appearance fill the field. Glial nuclei are not hypertrophied; see fig. 18 for detail.

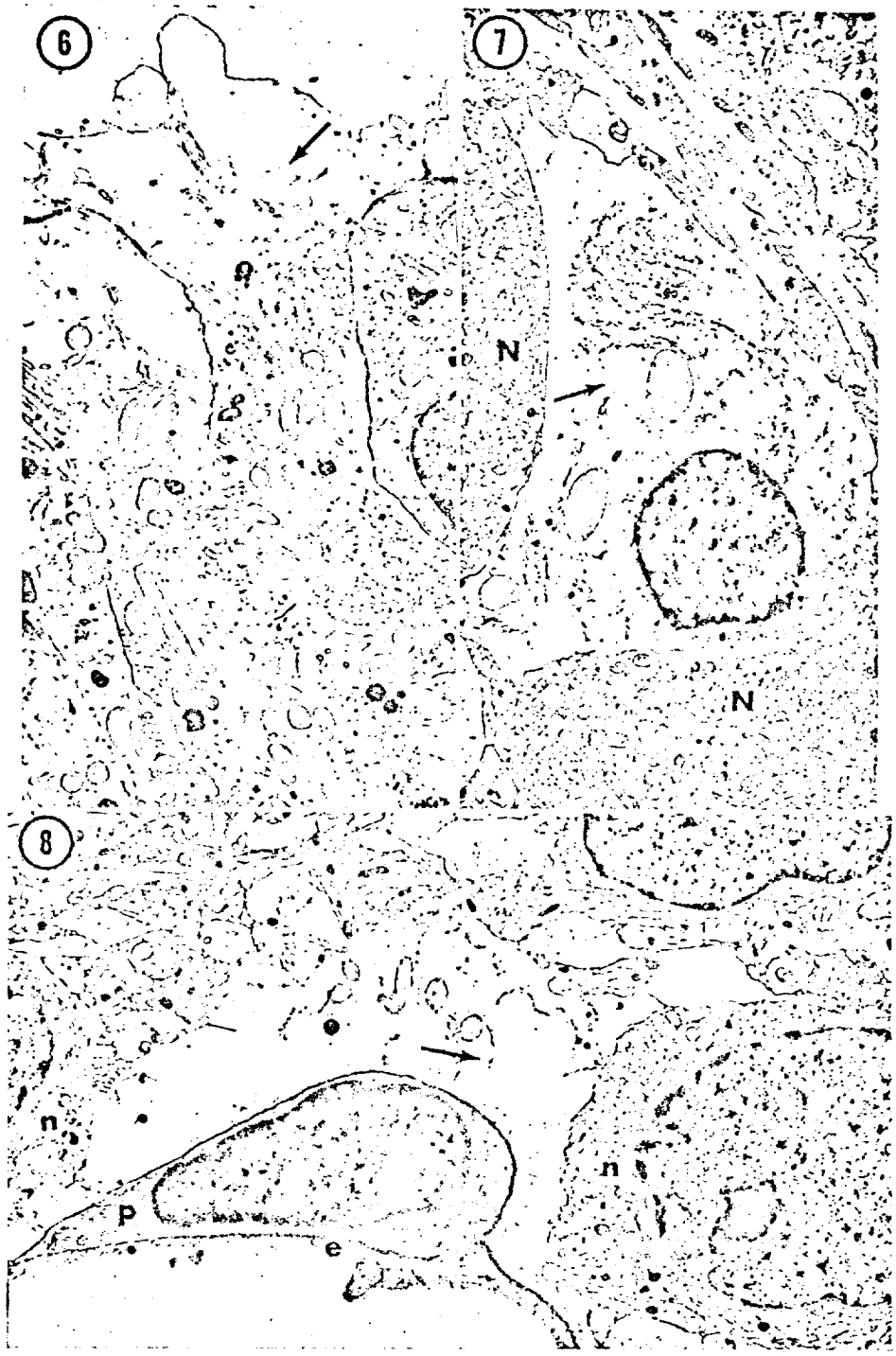

FIGS. 6, 7 and 8. Scenes from the arcuate region 15 minutes following an 18 mmole/kg subcutaneous dose of MSG. Figure 6 illustrates early swelling of ependymal cells lining the 3rd ventricle. Only the apical tips are swollen in this case but the entire ependymal cells will become edematous as the lesion develops. Several vacuoles of uncertain origin (arrow) are present; × 7,500. Figure 7 demonstrates a swollen glial cell, presumable an oligodendrocyte, in satellite position to neurons (N) which have not begun to show degenerate changes as yet. This type of glial cell usually has relatively dense cytoplasm. Note the same type of vacuole as was seen in Fig. 6 (arrow); × 7,500. Figure 8 shows a paravascular scene with an edematous structure presumed to be an astrocytic foot process abutting on the basement membrane investing a blood vessel and its pericyte (p). Neither the endothelial cytoplasm (e), the pericyte (p) nor adjacent neurons (n) exhibit edematous changes. The same type of vacuole seen in figs. 6a and b is present (arrow) in the swollen process; × 7,000.

tion phase, in which mitochondria appeared as thin elongate skeletal profiles with thickened membrane systems and little or no internal content (fig. 11), was evident in many arcuate neurons as early as 30 minutes following treatment. By one hour, however, only a rare cell contained organelles of this appearance, the majority of mitochondria having undergone marked swelling (fig. 12). During the swelling phase mitochondria became uniformly spherical, a configuration they tended to retain in subsequent stages of cellular degeneration.

The endoplasmic reticulum of arcuate neurons in the normal 10-day-old mouse is poorly developed and often consists of only a few scattered cisternal profiles (fig. 10). These began to dilate in MSG treated animals at approximately the same time or soon after the earliest changes in mitochondria were noted (figs. 11, 12). Disaggregation of polysomes and dispersal of ribosomes occurred as a concomitant of cell degeneration, although vacuolated remnants of the rough endoplasmic reticulum characteristically retained some ribosome-like particles in association with their limiting membranes even after most ribosomes had disappeared from the somal cytoplasm (fig. 15).

Progressive development of massive edema of the somal cytoplasm of rapidly degenerating neurons was accompanied first by peripheral clumping of nuclear chromatin (figs. 13, 14), then by central consolidation of the entire mass of clumped chromatin to form a solid core of dense material completely dissociated from the nuclear membrane (figs. 15, 16). Many neurons of the arcuate nucleus reached this advanced stage of nuclear pyknosis as early as 6 to 8 hours following treatment.

The evacuation of degeneration products from the arcuate region was a rapid and relatively inconspicuous process. In the 12- to 24-hour interval some degenerate elements were already being enveloped by cytoplasmic processes of non-neuronal cells, the origins of which were not determined (fig. 16). Some phagocytic cells incorporated considerable quantities of debris, including whole cell corpses (fig. 16), but none attained the massive vacuolated appearance of a typical Gitter cell. In the 24- to 36-hour interval they typically contained large aggregates of dense amorphous debris (fig. 17), but these large aggregates were processed so efficiently that by 48 hours the majority of phagocytes in the region contained only small inclusions, primarily myelin figures and fat droplets. By the 4th post treatment day there were very few cells in the arcuate region containing even these small inclusions and the region, in general, appeared well debrided of degenerated elements. A careful electron microscopic examination of the cell bodies present and of all neuropil areas in complete cross sections of the arcuate region 8 days following treatment revealed only that neurons were very sparse and that the neuropil appeared very similar to the neuropil usually found in the cell poor zone between arcuate and ventromedial nuclei (fig. 5d). The predominating cell type in the arcuate region after the deletion of neurons was the fibrous astrocyte (fig. 18), but neither the cell bodies nor fibrous processes of this cell type were sufficiently abundant in the arcuate region to warrant classifying the tissue reaction as one of gliosis or

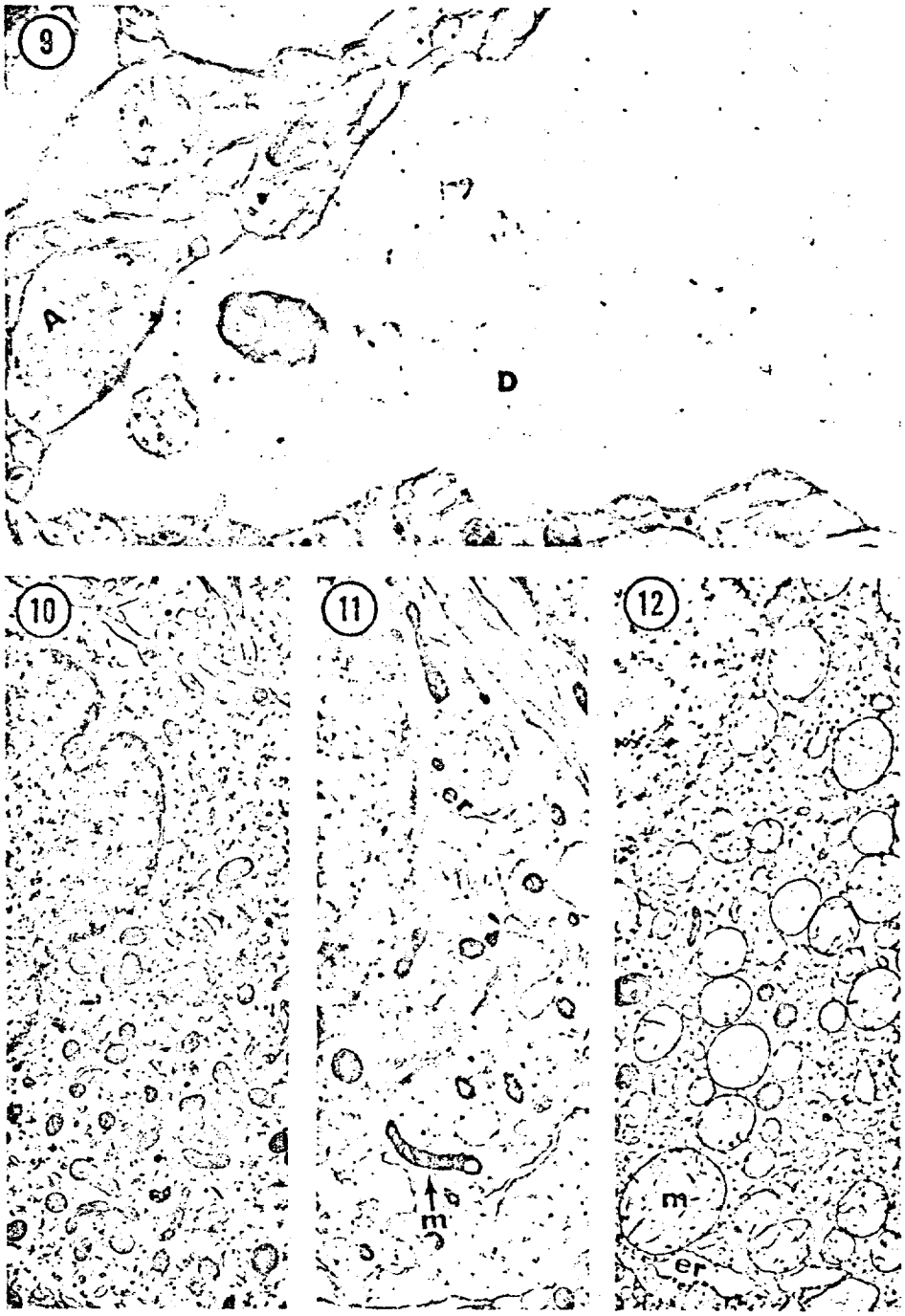

FIGS. 9 TO 12

fibrosis. Ependymal cells did not participate in any obvious way in phagocytic removal of degeneration products and neither glial nor ependymal processes exhibited the whorls of hypertrophied smooth endoplasmic reticulum seen in retinal Muller cell processes following MSG treatment.

The brains of a separate series of 9-month-old mice treated in infancy with consecutive daily doses of MSG for the first 10 days of life were also examined to provide observations on the appearance of the glutamate-damaged brain many months following treatment. These animals, heavily treated with MSG in infancy, had small adenohypophyses, were obese, and manifested a variety of neuroendocrine abnormalities reported in detail elsewhere (5, 9). On gross examination the region of the median eminence of treated animals was less prominent than the same region in like-sexed litter-mate controls. This difference was pronounced enough that an examiner without knowledge as to which animals received MSG treatment could pick out the treated animals 100 per cent of the time with the aid of a dissection microscope. An almost total absence of arcuate neurons was observed in serial light microscopic sections through the arcuate region (figs. 19, 20), but electron microscopic sections through the same region failed to reveal any abnormal tissue components. In keeping with the findings at 8 days following a single large dose of MSG, the hypothalamus 9 months after a series of treatments in infancy was unremarkable in neuropathological findings except for the almost total absence of arcuate neurons and minor adjustments in the configuration of the region due to this loss of tissue mass.

DISCUSSION

These data illustrate the subtle but acute and irreversible nature of glutamate-induced damage to the infant hypothalamus. Glial and ependymal cells were only involved transiently and reversibly, but neurons of the arcuate nucleus were selectively destroyed. Several days or many months following treatment there was little more than a decreased population of arcuate neurons to attest to the fact that brain damage had taken place. Yet in species studied for late occurring manifestations marked disturbances in neuroendocrine function

FIG. 9. The appearance of a synapse in the arcuate region 30 minutes following an 18 mmole/kg subcutaneous dose of MSG. The presynaptic axonal component (A) appears normal but the post synaptic dendritic process (D) is massively dilated and contains scattered particles and strands of degenerate material. The swollen dendrite also contains a multivesicle body and a dense vacuolated structure which may be a large mitochondrion exhibiting the kind of early transformation illustrated in fig. 11; × 36,000.

FIG. 10. A portion of the nucleus and parikaryon of an arcuate neuron 6 hours following the administration of an 18 mmole/kg dose of NaCl to a 10-day-old mouse. The nuclear and cytoplasmic structures are well preserved and there are no changes suggestive of a degenerative process; × 12,500.

FIG. 11. An arcuate neuron 30 minutes following an 18 mmole/kg subcutaneous dose of MSG revealing an early form of mitochondrial transformation. All of the mitochondria in this neuron have a condensed appearance as described in the text and the cisternae of rough endoplasmic reticulum (er) appear dilated; × 12,500.

FIG. 12. An arcuate neuron 1 hour following an 18 mmole/kg subcutaneous dose of MSG illustrating swelling of mitochondria (m). The cytoplasmic matrix appears quite dense. This is due, at least in part, to the fine particulate debris distributed diffusely throughout the cytoplasm, even within mitochondria, which is a characteristic feature of this stage of degeneration; × 12,500.

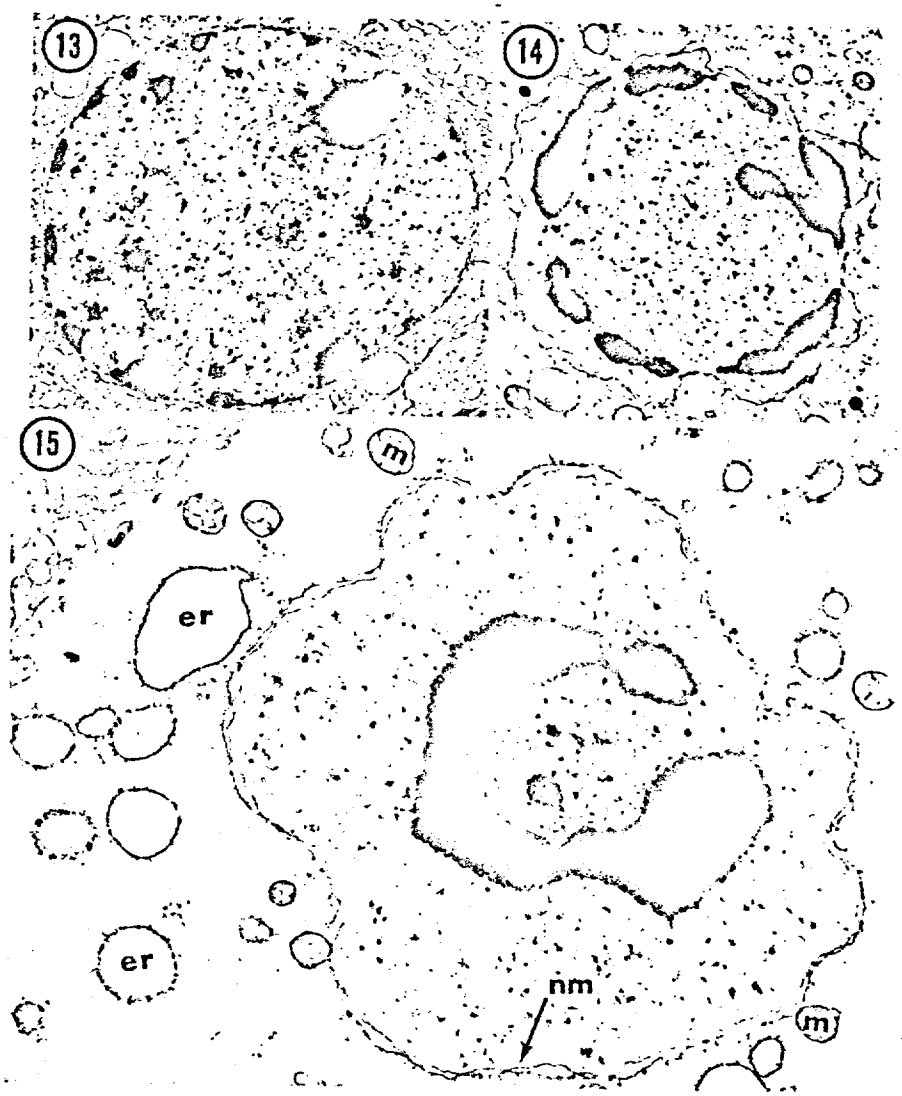

FIG. 13. The nucleus of an arcuate neuron 2 hours following an 18 mmole/kg subcutaneous dose of MSG. An early stage of chromatin clumping is evident and chromatin clumps are tending to organize peripherally about the nuclear membrane; × 8,000.

FIG. 14. The nucleus of an arcuate neuron 4 hours following an 18 mmole/kg subcutaneous dose of MSG. Peripheral clumping of chromatin is complete and the chromatin masses appear to be dissociating from the nuclear membrane; × 8,000.

FIG. 15. The nucleus and a portion of the cytoplasm of an arcuate neuron 6 hours following a 6 mmole/kg oral dose of MSG (detail of fig. 5b). The mass of nuclear chromatin is consolidating at the center of the nucleus and no longer maintains any contact with the nuclear membrane (nm). Vacuolated remnants of the endoplasmic reticulum (er) contain within their boundaries a fine particulate material and have associated with their limiting membranes complexes of slightly larger sized particles. Degenerate mitochondria (m) which can still be identified by remnants of cristae contained within them do not have particles adherent to their external surfaces; × 14,500.

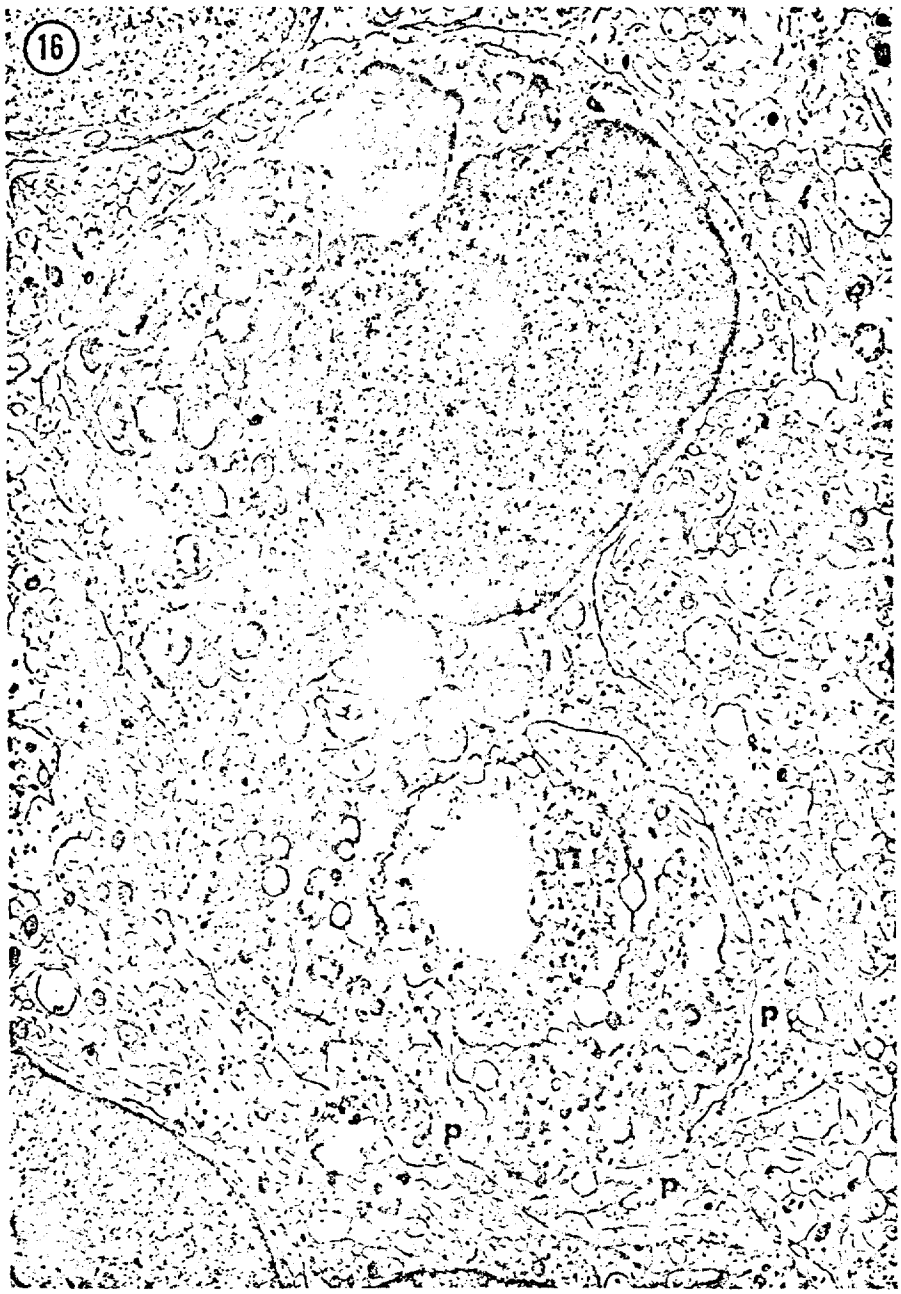

FIG. 16. A phagocyte in the arcuate region 24 hours following an 18 mmole/kg subcutaneous dose of MSG (detail of fig. 5c). In the lower portion of the figure a whole cell corpse appears to be enveloped by the cytoplasmic processes of the phagocyte (p). The nucleus (n) of the phagocytized cell displays an advanced stage of pyknosis but the cytoplasm (cp) and organelles which appear to be associated with this nucleus, although degenerate, are relatively intact. In the mid and upper portions of the figure it is evident that other degenerate structures have also been incorporated by this phagocytic cell; × 12,000.

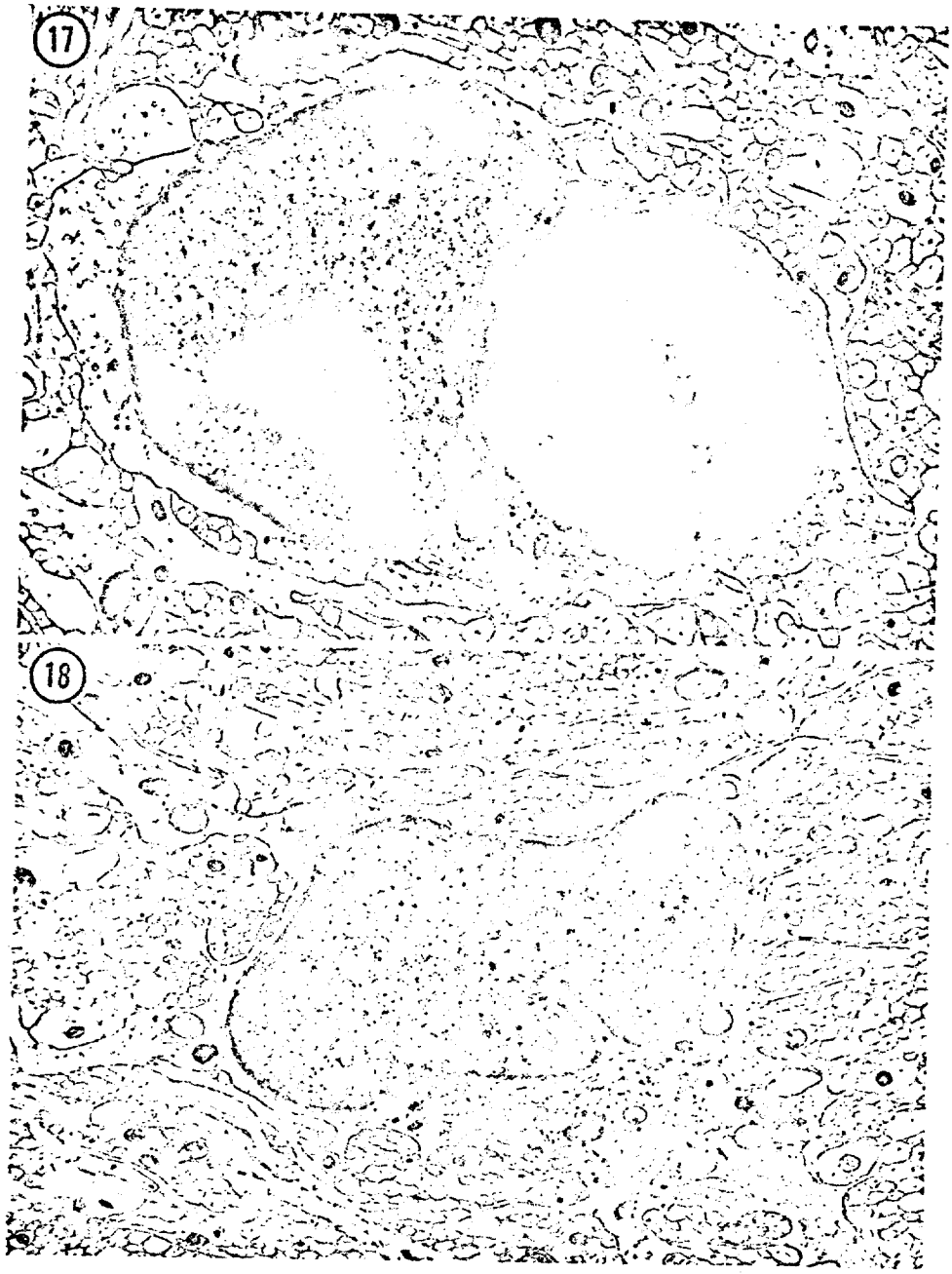

FIG. 17. A phagocyte in the arcuate region 30 hours following an 18 mmole/kg subcutaneous dose of MSG. The large dense mass within the cytoplasm of this cell can only be described as amorphous debris but by inference it represents the remains of one or more necrotic neurons. Many cells of this appearance containing similar dense masses were present in the arcuate region in the 24 to 36 hour post treatment interval; × 13,000.

FIG. 18. A cell from the arcuate region 8 days following an 18 mmole/kg subcutaneous dose of MSG (detail of fig. 5d). The majority of the limited number of cells remaining in the arcuate region 8 days following treatment with MSG were of this appearance and, therefore, might reasonably be considered fibrous astrocytes; × 12,000.



FIG. 19. The hypothalamus of a normal 9-month-old male Swiss albino mouse illustrating a well developed arcuate nucleus between the ventromedial nucleus (V) and the median eminence (ME). It was found by serially sectioning this brain and those of other normal adult mice that a rich collection of arcuate neurons was present continuously throughout all levels of the hypothalamus containing median eminence. An arcuate region without neurons, as is shown in fig. 20, is therefore, distinctly abnormal; × 220.

FIG. 20. The hypothalamus of a 9-month-old male Swiss albino mouse which received daily subcutaneous injections of MSG for the first 10 days of life. The arcuate region is much narrower than in fig. 19 and contains no neurons. The ventromedial nucleus (V) is displaced downward and the ventricle is widened. Electron microscopic examination of the arcuate region of this animal's brain revealed that the neuropil was comprised primarily of dendritic processes of ventromedial neurons and large numbers of axon terminals and axon tracts coursing through the area; × 220.

have been observed (5, 8–10). A reasonable explanation for at least some of these disturbances lies in the fact that neurons of the arcuate nucleus give rise to all or nearly all of the axons comprising the tubero-infundibular tract (15), a fiber system believed to carry releasing factors from the hypothalamus to the portal vasculature of the median eminence. Thus, treatment of infant animals with glutamate possibly destroys, in its inception, a final common pathway through which regulatory influences on the adenohypophysis are mediated.

In a prior report the possibility of glutamate exerting its effect on neurons secondarily through the mechanism of ischemic necrosis was entertained (4). The present study offers little support for this hypothesis. Perfusion of india ink, as has been used to facilitate interpretation of vascular involvement in the pathogenesis of gold thioglucose-induced hypothalamic damage (16), was not employed but the observation that blood vessels were patent to perfusion fixation throughout the time of lesion formation suggests the probability that they would also have been patent to india ink, the latter approach simply providing a more vivid illustration of patency.

The apparent selectivity of the glutamate effect for neurons of the arcuate nucleus raises a question whether susceptibility is dependent on some metabolic specialization peculiar to these cells. It is well established, however, that neurons of the inner retina are also selectively destroyed by MSG and, at doses higher than those used in the present experiment, it is possible to induce an identical form of acute neuropathological changes in several extrahypothalamic regions of the infant brain (5, 12). It has also been observed that a massive dose of glutamate given to the infant mouse on the first day of life induces a hypothalamic lesion that spreads beyond the arcuate region to indiscriminately destroy any neurons lying within a wide arc about the mediobasilar portion of the brain (12). Observations based on manipulation of variables such as age and dose, therefore, tend to weaken the interpretation that arcuate neurons are particularly susceptible to the glutamate effect by virtue of some metabolic peculiarity not shared with other neurons of the central nervous system. The alternative hypothesis, that regional variations in blood brain barrier permeability to MSG may account for the regional pattern of lesion distribution is perhaps more tenable. However, the ability of glutamate to pass across blood brain barriers has been studied only from the standpoint of whole brain uptake of parenterally administered glutamate (17). Studies designed more specifically to determine whether glutamate passes from the blood compartment into certain regions of the central nervous system more readily than into other regions will be needed to clarify mechanisms underlying the regional distribution of glutamate-induced neuronal necrosis.

Based on the observation that glial and ependymal cells were the first to respond to MSG treatment it is tempting to interpret the subsequent more devastating effect on arcuate neurons as a phenomenon secondary to a gliotoxic reaction. That is, with even a transient interference in glial function, the highly sensitive neuron, which may be dependent on minute to minute glial metabolic support, might expire even though glial cells subsequently recover. Recent experiments from this laboratory, which will be reported in full detail elsewhere (18), suggest that this is not a tenable explanation. A compound which is identical to MSG in chemical structure, except that it has one additional carbon atom (sodium DL-alpha aminoadipate), induces pronounced lesions in the infant central nervous system with regional specificity identical to that associated with MSG treatment. Both the inner retina and arcuate nucleus of the hypothalamus are selectively involved. Cytological specificity is very different, however, in that only glial and ependymal cells in the hypothalamus and Muller cells of the retina are affected. In fact, the acute reaction of glial and ependymal cells to alpha aminoadipate is more severe than that associated with MSG treatment, but arcuate neurons do not appear by either light or electron microscopy to be affected at all. It seems unlikely that the transient mild effect of MSG on glial cells *per se* would result in neuronal necrosis if the more severe effect of alpha aminoadipate on glial cells does not.

Since glutamic acid is a common metabolite of the central nervous system it

is reasonable to examine its several known metabolic pathways for a clue to the mechanism of glutamate-induced neurotoxicity. For example, Freedman and Potts (19, 20) have postulated an induced repression of glutaminase enzyme synthesis in an attempt to explain glutamate-induced degeneration of the rat retina. Based on ongoing studies in this laboratory it becomes increasingly evident, however, that glutamate is but one among several compounds which can produce an identical pattern of neuronal necrosis in the infant retina and hypothalamus. Focusing on glutamic acid metabolism alone may, therefore, be less fruitful than considering what these several compounds have in common. Thus far, the compounds found effective in producing the glutamate-type lesion include not only glutamate, aspartate and cysteine but an extensive assortment of congeners of each of these compounds. The N-methylated DL derivatives of glutamate and aspartate are markedly more potent inducers of neuronal necrosis in the infant central nervous system than are DL-glutamate or DL-aspartate and DL-homocysteic acid is much more potent than DL-cysteine (12). From the work of Curtis and others (13, 21) it appears that these compounds do have a very special feature in common. Each has been shown by iontophoretic application in the central nervous system to have neuroexcitatory properties. Furthermore, it has been demonstrated that DL-homocysteic acid and the N-methylated DL derivates of glutamate and aspartate stand out as more potent neuroexcitants than others in this select group. The observation that among amino acids there are a select few which have in common a molecular specificity for producing either excitation of neurons or destroying them, depending on conditions of the experiment, suggests that similar mechanisms may underly both phenomena.

SUMMARY

A lesion which can be induced in the arcuate nucleus of the infant mouse hypothalamus by either oral or subcutaneous administration of monosodium glutamate (MSG) was studied with both the light and electron microscope at several post treatment intervals. Although glial and ependymal constituents in the arcuate region exhibited edema in the early post treatment period, this was a reversible reaction unlike the necrotizing effect on neurons. The necrosis and biological degradation of arcuate neurons occurred very rapidly and with minimal tissue reaction so that few traces, other than a reduced population of neurons, were found in brains examined more than 2 to 4 days following treatment. The specificity of glutamate-induced hypothalamic damage, its selectivity for the arcuate region and other considerations regarding pathogenesis were discussed in the light of relevant experimental evidence currently available. It was emphasized that an identical pattern of neuronal necrosis can be induced in the infant hypothalamus by certain other amino acids which, like glutamate, have neuroexcitatory properties. The significance of this observation for elucidating the mechanism underlying glutamate-induced hypothalamic damage remains to be clarified.

REFERENCES

1. Lucas, D. R., and Newhouse, J. P.: The Toxic Effect of Sodium L-Glutamate on the Inner Layers of the Retina. AMA Arch. Ophth., 58: 193, 1957.
2. Potts, A. M., Modrell, K. W., and Kingsbury, C.: Permanent Fractionation of the ERG by Sodium Glutamate. Am. J. Ophth., 50: 900, 1960.
3. Cohen, A. I.: An Electron Microscopic Study of the Modification by Monosodium Glutamate of the Retinas of Normal and "Rodless" Mice. Am. J. Anat., 120: 319, 1967.
4. Olney, J. W.: Glutamate-Induced Retinal Degeneration in Neonatal Mice. Electron Microscopy of the Acutely Evolving Lesion. J. Neuropath. & Exper. Neurol., 28: 455, 1969.
5. ——: Brain Lesions, Obesity and Other Disturbances in Mice Treated with Monosodium Glutamate. Science, 164: 719, 1969.
6. ——, and Sharpe, L. G.: Brain Lesions in an Infant Rhesus Monkey Treated with Monosodium Glutamate. Science, 166: 386, 1969.
7. ——, and Ho, Oi-lan: Brain Damage in Infant Mice Following Oral Intake of Glutamate, Aspartate or Cysteine. Nature, 227: 609, 1970.
8. Redding, T. W., and Shalley, A. V.: The Effects of MSG on the Endocrine Axis in Rats. Fed. Proc., 29: 755, 1970.
9. Massie, B., Kipnis, D., and Olney, J. W.: Endocrine Disturbances in Rats and Mice Treated with Glutamate in Infancy. Submitted for Publication.
10. Knittle, J. L., and Ginsberg-Feller, F.: Cellular and Metabolic Alterations in Obese Rats Treated with Monosodium Glutamate during the Neonatal Period. Bulletin Am. Peds. Soc. Gen. Meeting, Program Abstracts, pg. 6, Apr. 1970.
11. Olney, J. W., and Sharpe, L. G.: Monosodium Glutamate: Specific Brain Lesion Questioned. Science, 167: 1017, 1970.
12. ——. Unpublished Data.
13. Curtis, D. R., and Crawford, J. M.: Central Synaptic Transmission-Microelectrophoretic Studies. Am. Rev. of Pharm., 9: 209, 1969.
14. Richardson, K. C., Jarett, L., and Finke, E. H.: Embedding in Epoxy Resins for Ultrathin Sectioning in Electron Microscopy. Stain Technol., 35: 325, 1960.
15. Christ, J. F.: Derivation of Hypothalamus with Atlas, *in* "The Hypothalamus", Ed. Haymaker, W., Anderson, E., and Nauta, W. J. H. p. 36 and 238, 1969. Charles Thomas, Springfield, Ill.
16. Arees, E. A., Veltman, B. I., and Mayer, J.: Hypothalamic Blood Flow Following Goldthioglucose-Induced Lesions. Exper. Neurol., 25: 410, 1969.
17. Lajtha, A., Berl, S., and Waelsch, H.: Amino Acid and Protein Metabolism of the Brain. J. Neurochem., 3: 322, 1959.
18. Olney, J. W.: Manuscript in Preparation.
19. Freedman, J. K., and Potts, A. M.: Repression of Glutaminase I in Rat Retina by Administration of Sodium L-Glutamate. Invest. Ophthal., 1: 118, 1962.
20. ——, and ——: Repression of Glutaminase I in Rat Retina by Administration of Sodium L-Glutamate. Invest. Ophthal., 2: 252, 1963.
21. Curtis, D. R., and Watkins, J. C.: The Pharmacology of Amino Acids Related to Gamma-Aminobutyric Acid. Pharm. Rev., 17: 347, 1965.

Monosodium Glutamate Effects

Adamo and Ratner (*1*) reported failure to detect brain damage in infant rats injected subcutaneously with monosodium glutamate (MSG). While noting that this was contrary to my findings in several species, including the rat, they proposed species variation to explain the discrepancy. Others have found both the rat (*2*) and mouse (*2, 3*) susceptible to MSG-induced brain damage.

In infant retina (*4*) and hypothalamus (*5*), susceptible nerve cells undergo rapid necrosis and are phagocytized, degraded, and evacuated from affected areas within 24 to 48 hours after MSG treatment. Thereafter, except for a reduced population of neurons, the affected areas appear normal when examined by either the light or electron microscope (*5, 6*). Thus, Adamo and Ratner's observation that normal neural components can be found in the adult brain of an animal treated with MSG in infancy does not constitute a valid basis for claiming that MSG lacks effect on infant brain. Adamo and Ratner omitted illustrating infant brain (*1*).

Although Adamo and Ratner considered their experiment "very similar" to mine, they departed from mine by confining their electron microscopic examination to adult brain and preparing infant brain according to a regimen for light microscopy which differs in every feature of tissue processing from the methods I employ (*5, 7, 8*). If I interpret them correctly, they also used an exceedingly hypertonic solution of MSG (40 percent?) rather than the 10 percent concentration I use with rodents (*5, 8, 9*). It is more reasonable to attribute Adamo and Ratner's negative findings to methodological problems than to species variation.

I also question Adamo and Ratner's conclusion that MSG has no effect on reproductive function in the rat. Others (*10, 11*) have systematically examined larger numbers of adult rats after multiple MSG treatments in infancy and have consistently found that average weights of the ovaries and adenohypophyses are about one-half those of control animals. Pituitary concentrations of trophic hormones, including luteinizing hormone, were also depressed (*10*). Since Adamo and Ratner studied very few animals, exposed each to only one injection of MSG, and did not measure the weights or hormone concentrations of adenohypophyses or attempt to compare the reproductive capacities of experimental and control animals, but did find the ovaries of experimental animals significantly smaller than controls, their conclusion that MSG lacks effect on reproductive function is probably a misinterpretation based on insufficient data.

JOHN W. OLNEY
Department of Psychiatry, Washington University School of Medicine, St. Louis, Missouri 63110

References

1. N. J. Adamo and A. Ratner, *Science* **169**, 673 (1970).
2. E. A. Arees and J. Mayer, *ibid.* **170**, 549 (1970); R. Burde, B. Shainker, J. Kayes, personal communication and manuscript in preparation.
3. F. Coulston, in Report of NAS, NRC, Food Protection Subcommittee on Monosodium Glutamate, July 1970.
4. J. W. Olney, *J. Neuropathol. Exp. Neurol.* **28**, 455 (1969).
5. J. W. Olney, *ibid.* **30**, 75 (1971).
6. A. J. Cohen *Amer. J. Anat.* **120**, 319 (1967).
7. J. W. Olney and L. G. Sharpe, *Science* **166**, 386 (1969).
8. J. W. Olney and O. L. Ho, *Nature* **227**, 609 (1970).
9. J. W. Olney, *Science* **165**, 1028 (1969).
10. R. W. Redding and A. V. Shally, *Fed. Proc.* **29** (1970).
11. B. Massie, D. Kipnis, J. Olney, manuscript in preparation.

22 September 1970; revised 7 January 1971

Our study (*1*) was the first report to suggest the possibility that a single subcutaneous injection of MSG may not produce neuronal necrosis in the arcuate nucleus of infant rats. This is contrary to the findings shown by Olney (*2*) in a 5-day-old Swiss albino mouse and by Olney and Sharpe (*3*) in an infant monkey. Olney reported (*2*) that brain lesions were found also in albino rats after MSG treatment in the neonatal period, but neither pictures nor descriptions of these lesions in rats were given. Light microscopic observation of tissue from treated infant rat brains (*1*) revealed different morphologic features from those shown in the light micrographs by Olney (*2*) and Olney and Sharpe (*3*). At the time of our publication (*1*) their reports (*2, 3*) presented the only published data concerned with the effect of a single subcutaneous injection of MSG on the hypothalamus.

We did not observe any acute changes in the arcuate nucleus by light microscopic examination. Although the tissue was examined carefully, it is possible that we failed to notice very subtle differences between treated and untreated rats; electron microscopy of the brains of infant rats after injection would have revealed this effect with certainty if it were present. Nevertheless, it is difficult to envision that effects such as reported by Olney (*2*) and Olney and Sharpe (*3*) would have escaped our attention, even with light microscopy. Such extensive damage in the infant brain, if present after a single injection, should have been indicated by morphologic differences between brains of adult controls and adult experimental rats treated in infancy.

In presenting our data (*1*) we neither implied nor negated the possibility that repeated doses of MSG might produce results different from ours. The abstract (*4*) referred to by Olney in his technical comment (this issue) reveals that, in rats repeated injections of MSG in increasing doses over a 10-day period results in marked inhibition of endocrine function. A comparison of the findings in this study (*4*) to the lack of effect noted by us in animals which received a single injection of MSG is not appropriate.

Since much of the discussion in Olney's comment alludes to unpublished data (*5*) unknown to us or to the scientific community in general, one must await the published reports and evaluate them accordingly.

NORMA JEAN ADAMO
Department of Anatomy, Louisiana State University Medical Center New Orleans 70112

ALBERT RATNER
Department of Physiology, University of New Mexico, Albuquerque 87106

References

1. N. J. Adamo and A. Ratner, *Science* **169**, 673 (1970).
2. J. W. Olney, *ibid.* **164**, 719 (1969).
3. ——— and L. G. Sharpe, *ibid.* **166**, 386 (1969).
4. R. W. Redding and A. V. Shally, *Fed. Proc.* **29** (1970).
5. R. Burde, B. Shainker, J. Kayes, in preparation; J. W. Olney, *J. Neuropathol. Exp. Neurol.*, in press; B. Massie, D. Kipnis, J. Olney, in preparation.

8 February 1971

Science
172: 294
Apr 16 1971

GLUTAMATE-INDUCED BRAIN DAMAGE IN INFANT PRIMATES*

JOHN W. OLNEY, M.D.,† LAWRENCE G. SHARPE, PH.D.,
AND RALPH D. FEIGIN, M.D.‡

(*St. Louis, Mo.*)

ABSTRACT

The brains of 9 infant rhesus monkeys were examined for acute cytopathology following treatment with monosodium L-glutamate (MSG) (6 infants) or NaCl (3 infants). Hypothalamic lesions identical to those described elsewhere in MSG-treated rodents were identified by light microscopy and verified with the electron microscope in each infant monkey given MSG. No cellular pathology was detected in the hypothalami of NaCl-treated controls. Infants given relatively low oral doses of MSG (1 and 2 g/kg) sustained small focal lesions confined primarily to the rostro-ventral aspect of the infundibular nucleus. Those treated with high subcutaneous doses developed lesions which spread throughout and sometimes beyond the infundibular nucleus. At all doses tested (1–4 g/kg) and by either route of administration, rapid necrosis of neurons (within 5 hours) was a striking feature of the MSG-induced reaction pattern. Blood glutamate curves from time of treatment to time of sacrifice (5 hours) suggest that the threshold for lesion formation in 1-week-old rhesus monkeys may be in the range of 20 mg%. Differences in research approach which might account for the failure of others to locate the lesions we describe are discussed as are some of the toxicological implications of our findings.

INTRODUCTION

Data from a number of laboratories (1–16) indicate that both mice and rats are susceptible to retinal and hypothalamic damage from either oral or subcutaneous administration of monosodium glutamate (MSG). The obesity and endocrine abnormalities which develop in adult mice or rats treated with MSG in infancy (6, 17–20) provide additional evidence for susceptibility of rodents to the hypothalamic lesion. Whether primates are also susceptible has been the focus of recent concern, largely because of the widespread use of MSG as a food additive but also because of the practice in pediatric medicine of administering intravenous feedings (protein hydrolysates) containing free glutamic acid to human infants. In an earlier report (21) we described an MSG-induced lesion in the hypothalamus of an infant rhesus monkey. MSG-type lesions have also

From the Departments of Psychiatry and Pediatrics, Washington University School of Medicine, St. Louis, Missouri 63110.

* Supported in part by grants from the United States Public Health Service (NS-09156 and MH 13002).

† Recipient of USPH Research Career Development Award MH 38894 from National Institutes of Mental Health.

‡ Recipient of USPH Research Career Development Award K4AI-46206 from National Institutes of Allergy and Infectious Diseases.

been detected in the hypothalami of MSG-treated rabbits (22) and chicks (23, 24). This suggests that primates, and possibly vertebrates in general, are susceptible to the neurotoxic mechanism of the glutamate effect.

Reynolds et al. have pursued an alternative hypothesis, that susceptibility to MSG-induced brain damage may be limited to sub-primates (25). These authors treated a series of infant monkeys with MSG (15) and found a "spectrum of degenerative changes" in hypothalamic neurons but attributed the changes to inadequate fixation rather than an MSG effect. Abraham et al., in a report dealing primarily with lysosomal changes in the arcuate nucleus of MSG-treated mice (10) also mentioned that they failed to detect hypothalamic cytopathology in 4 MSG-treated infant rhesus monkeys.

A subcommittee of nutritional experts appointed by the Food Protection Committee of the National Academy of Sciences (NAS) recently declared MSG to be a safe food additive requiring no regulation (26). They acknowledged susceptibility of infant rodents to brain damage from orally administered MSG (1 g/kg) but reasoned that the primate infant would probably not be vulnerable to such damage since it is believed to have a more mature central nervous system and more highly developed blood brain barriers at birth.

In this report we present data on a series of infant rhesus monkeys which support neither the thesis of Reynolds et al. nor the position of the NAS subcommittee.

MATERIALS AND METHODS

A total of nine rhesus infant monkeys (*Macaca mulatta*), six treated with MSG and three with NaCl, were studied. In order to obtain maximal information from the limited number of infants available we varied dose, routes of administration and age at time of treatment as indicated in table 1. Doses of NaCl used in control infants F, G and H were calculated on a mMole/kg basis to represent the molar equivalents of the MSG doses administerd to infants C, D and E. Oral treatments were prepared by adding enough NaCl or MSG to a 50/50 mixture of water and skim milk to provide the desired dose in a volume of 20 cc/kg body weight. These mixtures were all introduced directly into the stomach by nasogastric tube. Subcutaneous treatments were given in multiple injection sites as a 25% aqueous solution of MSG or 10% NaCl. Sernylan anesthesia was employed with all infants and all except infant A were sacrificed 5 hours after treatment by perfusion with a mixture of 1.5% glutaraldehyde and 1% paraformaldehyde in 0.1 M cacodylate buffer. Infant A, which was the subject of a previous brief report (21), was sacrificed 3 hours following treatment by perfusion with 3% glutaraldehyde in 0.1 M cacodylate and 0.02% $CaCl_2$. Tissue processing and examination methods were identical to those described elsewhere (7, 8) for performing a comprehensive histopathological evaluation by combined light and electron microscopy on the infant mouse hypothalamus. The larger size of the primate hypothalamus posed no problem except that a larger number of serial specimens from each hypothalamus had to be processed and examined.

Drops of blood were obtained on special filter paper squares just prior to treatment and at 30 minute intervals thereafter from each subject except infant A. These were analyzed by the method of Efron (27) as modified by Feigin et al. (28) for semiquantitatively determining amino acid concentrations from tiny samples (6 microliters) of whole blood. Blood glutamate curves were determined by one of us (R.F.) who was uninformed as to treatment schedules or neuropathological findings for the subjects being evaluated.

All infants used in this study were supplied from the primate colonies of Woodard Re-

search Corporation (29) and with the following exceptions all appeared to be well nourished full term rhesus infants in good health. Infant A appeared entirely healthy but was judged to be a premature infant because he was born several weeks earlier than was expected and had a very low birth weight (table 1). Infants I and H were born on the same day and appeared healthy at birth but infant I was rejected by her mother. An attempt to have the mother of infant H accept and nourish both infants was only transiently successful. When the infants were removed from the mother on the 4th postnatal day both appeared dehydrated, infant I to a greater extent than infant H. Rather than attempt, over a period of days, to restore these infants to maximal health with fluid and electrolyte therapy and bottle feedings, we decided to introduce both infants immediately into the experimental situation.

RESULTS

A detailed description of the arcuate nucleus of the infant mouse hypothalamus and the cytopathological reaction typically observed in this nucleus following MSG treatment was previously given (8). The comparable hypothalamic nucleus in primate brain is referred to alternatively as either the infundibular or arcuate-periventricular nucleus. The former term, being less cumbersome, will be used throughout this report. A major portion of the infundibular nucleus in either rodents or primates consists of cell masses positioned on either side of the midline immediately dorsolateral to the floor of the 3rd ventricle. This description, however, does not account for the significant number of neurons in either species which occupy a more ventral or subventricular position. Such neurons are found within the median eminence of rodent brain (30). Midline subventricular portions of the primate infundibular stalk, which roughly correspond to the median eminence region of rodent brain, also contain clusters of neurons and these continue caudally to form dense subventricular cell masses in the post-infundibular region (31). Infundibular neurons lying in subventricular locations, especially those within the infundibular stalk are of particular interest as we have found them, in either rodents or primates, to be the most vulnerable neurons in the brain to the damaging effects of MSG.

Infant A, a premature infant treated with MSG on the 1st postnatal day, developed a lesion which was quite conspicuous even as early as 3 hours following treatment. A view of the lesion in this infant's brain demonstrating its bilateral involvement of the entire infundibular nucleus was previously illustrated (21) as was evidence of massive dendritic swelling and cellular degeneration including coarse clumping of nuclear chromatin. In figures 1 and 2 we present additional views to illustrate the lesion at both rostral and caudal levels of the infundibular nucleus accompanied by illustrations from control brains at corresponding levels. The lesion rostrally affected not only the neuron clusters located ventrally in subventricular extensions of the infundibular nucleus (not shown) but spread dorsolaterally to include essentially all portions of the nucleus (fig. 1d). The dense collection of neurons populating the subventricular zone immediately caudal to the infundibular stalk, the subventricular nucleus of Sheehan and Kovacs (31), was severely affected (fig. 2b). Changes detected in the infundibular nucleus of infant A were identical in cytopathological detail to those described elsewhere in infant mice (8). No such changes were present at either rostral or caudal levels in control brains (figs. 1a–c and 2a).

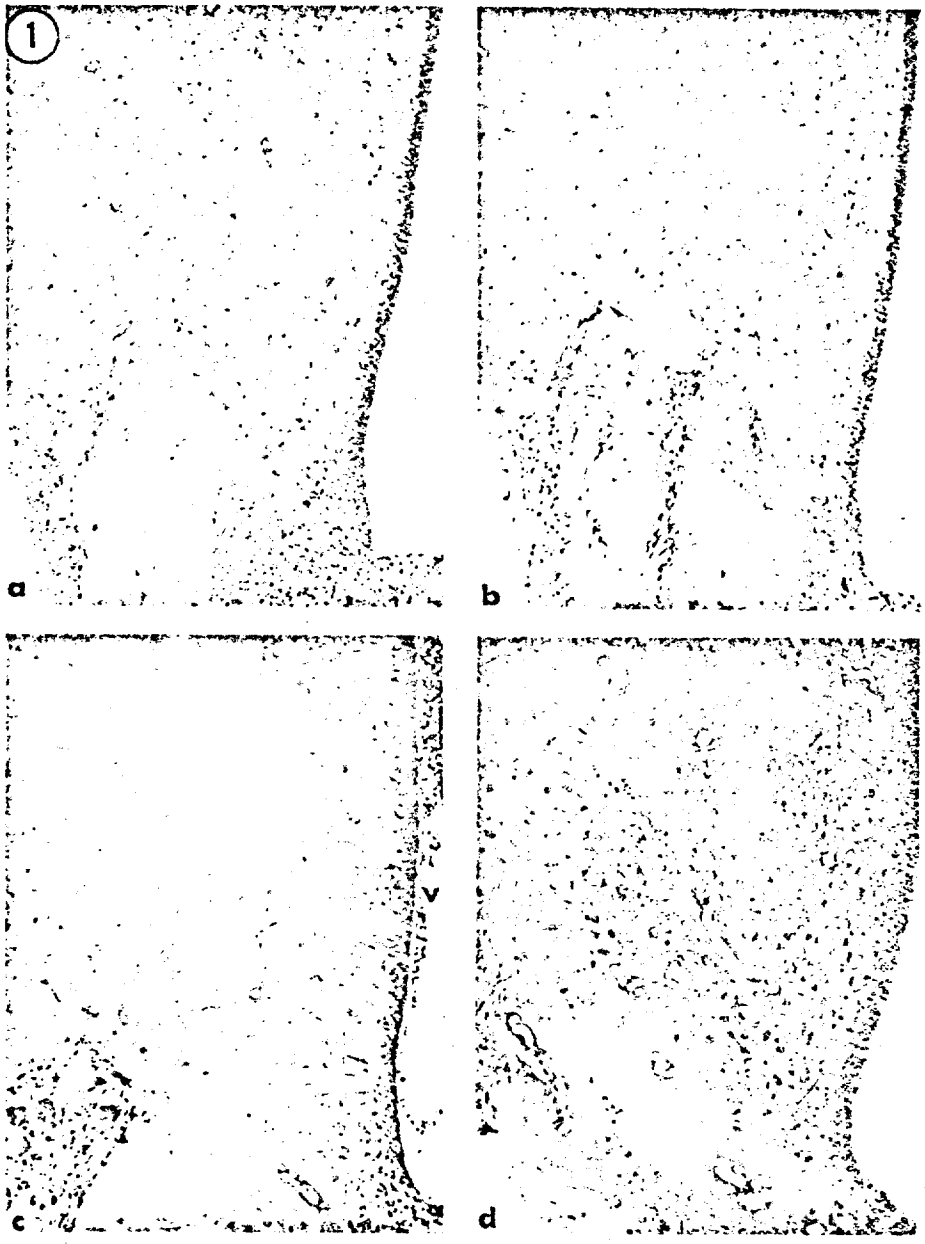

FIG. 1. Comparison of rostral infundibular nucleus of 3 NaCl controls (a–c) and an MSG-treated infant (d). a–c. Infants F, G and H respectively. The hypothalami of these infants appear normal except that red blood cells are accumulating in the 3rd ventricle (V) of infant H (fig. 1c), which received a high subcutaneous dose of NaCl. d. Infant A, treated subcutaneously with MSG, 2.7 g/kg and sacrificed 3 hours after treatment. The largest open spaces are dilated blood vessels but others are massively dilated processes and cell bodies which give the entire infundibular region a rarefied fenestrated appearance. By electron microscopy many dilated structures were identified as neuronal by virtue of their synaptic involvement. Some neurons are condensed and dark which is also a characteristic feature of an MSG-induced lesion. Relatively few cells have progressed to an advanced stage of nuclear pyknosis because of the early sacrifice of this infant (figs. 1a–d, all × 85).



FIG. 2. A more caudal view of the infundibular nucleus of an NaCl control (a) and an MSG-treated infant (b). The nucleus at this level becomes a unilateral midline collection of densely packed neurons confined largely to the floor of the 3rd ventricle. a. Infant H, treated with a high subcutaneous dose of NaCl. There are numerous normal appearing neurons present and the only suggestion of a pathological process is that reflected by the red blood cells in the 3rd ventricle (arrow) (× 260). b. Infant A, treated subcutaneously with 2.7 g/kg MSG. There are no red blood cells in the 3rd ventricle but essentially the entire population of neurons in this portion of the infundibular nucleus are acutely degenerating. The ependymal lining is normal and blood vessels are well dilated indicating adequate perfusion of the area by fixative (× 260).

TABLE 1

	Age (Days)	Sex	Wt (g)	Dose		Compound	Route	Acute Symptoms	Blood Glutamate (mg%) (at ½ hour intervals)										
				g/kg	mM/kg				0	0.5	1	1.5	2	2.5	3	3.5	4	4.5	5
A	0.5	M	260	2.7	16	MSG	SC	—	Not Studied										
B	7	F	507	2.7	16	MSG	SC	vomiting	12.5	70	70	70	70	60	60	60	55	50	30
C	7	M	430	1.0	6	MSG	Oral	—	7.5	12	12	20	12	12	12	12	10	7.5	7.5
D	7	F	330	2.0	12	MSG	Oral	—	7.5	10	7.5	7.5	20	12.5	7.5	7.5	7.5	7.5	7.5
E	7	M	507	4.0	24	MSG	Oral	vomiting	3	5	30	30	30	12.5	12.5	20	12.5	12.5	10
F	8	M	473	0.3	6	NaCl	Oral	—	7.5	10	7.5	7.5	7.5	3.0	5	5	5	5	5
G	7	M	440	0.6	12	NaCl	Oral	—	12.5	7.5	7.5	7.5	5	5	5	5	5	5	5
H	4	M	406	1.2	24	NaCl	SC	cyanosis	12	12	10	12	12	20	25	25	20	20	12
I	4	F	352	4.0	24	MSG	SC	cyanosis vomiting convulsions	20	50	80	100	100	100	100	100	90	80	80

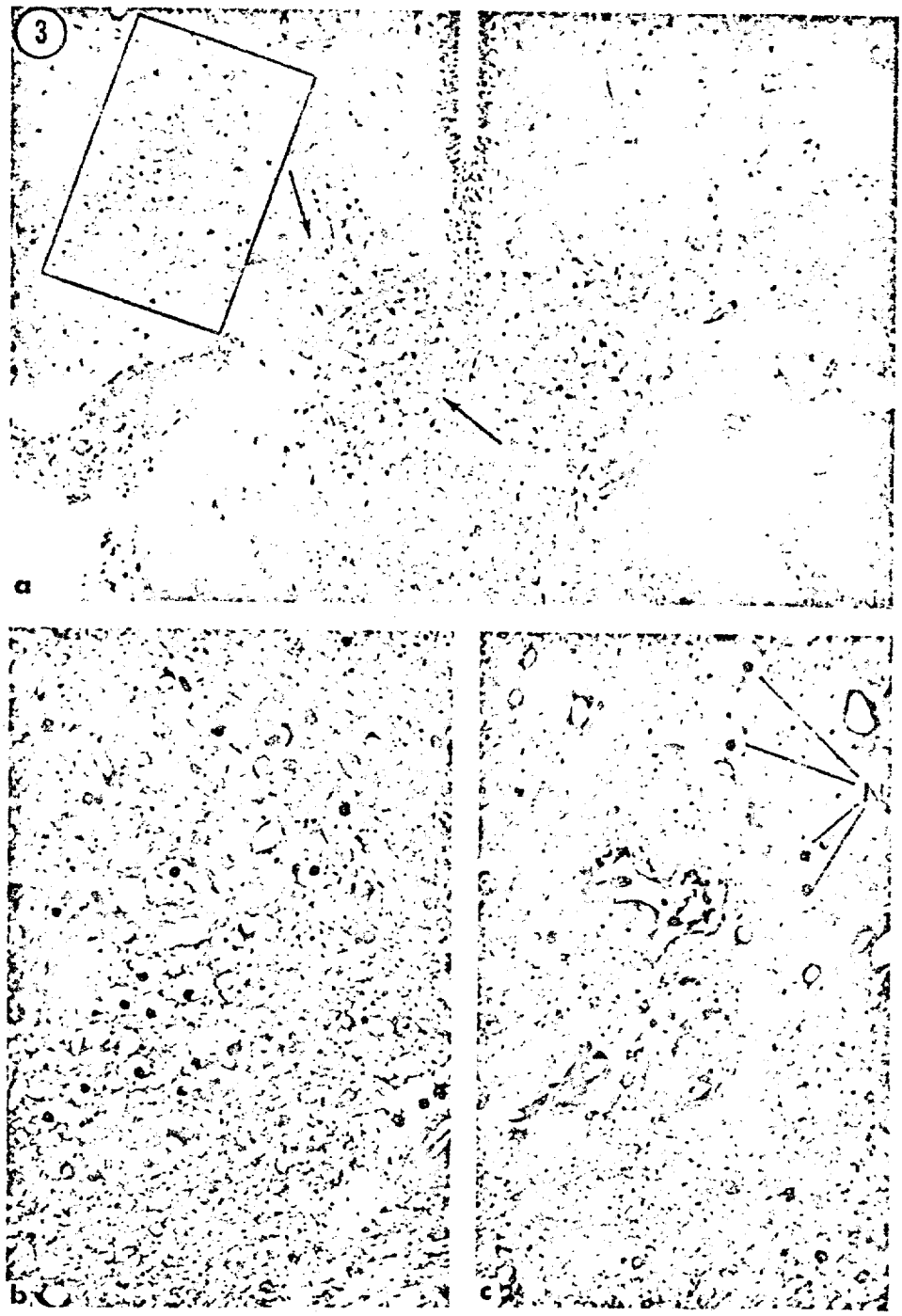

FIG. 3.

Infant B received the same subcutaneous dose of MSG given infant A (2.7 g/kg) but was a more mature infant at time of treatment (table 1). Infant B sustained a lesion identical in pattern of distribution to the lesion in infant A but it was slightly smaller in terms of the percentage of the infundibular nucleus involved (fig. 3a). Affected neurons in the brain of infant B had reached a more advanced stage of degeneration than those in the brain of infant A, a difference readily explained by the fact that infant A was sacrificed at 3 hours and infant B at 5 hours following treatment. We encountered no difficulties in perfusion fixation of the brains of either infant A or B, nor would inadequate fixation explain the distinctly necrotic appearance of neurons in a portion of the infundibular nucleus where other nearby tissue components were well preserved (fig. 3b).

Infants C, D and E were full term infants treated orally at 1 week of age with MSG at 6, 12 and 24 mM/kg (1, 2 and 4 g/kg) respectively. Infant E vomited soon after treatment (see below) so that the actual dose retained was probably much lower than 4 g/kg. In each of these brains we found small groups of acutely necrotic neurons located almost exclusively in rostral subventricular portions of the infundibular nucleus (figs. 4a–d). An exception was noted in the brain of infant D which also had mild involvement of dorsolateral portions of the infundibular nucleus (fig. 3c). The number of neurons undergoing acute degeneration in such lesion sites totalled only about 50 in the hypothalamus of infant C and from 80 to 90 each in infants D and E. Individual lesion sites, in cross section, therefore, were quite inconspicious, there being as few as 2 or 3 and rarely more than 10 necrotic cells lying in the plane of any given 1 micron section (figs. 4b–d). These tiny lesions are comparable to those which predictably occur in infant mice treated orally with low doses of MSG (fig. 17a).

A representative small lesion from the rostral subventricular region of infant D is illustrated in a series of electron micrographs (figs. 5–10) to demonstrate several features of the MSG reaction which distinguish it from fixation artefact. Degenerating cells with swollen somata and pyknotic nuclei can be recognized

FIG. 3. The infundibular nucleus of MSG-treated infant B illustrating a bilaterally symmetrical edema reaction which involves mixed glial and neuronal components about the tuberoinfundibular junction (between arrows) and a necrotizing reaction involving only neurons in more dorsolateral portions of the nucleus (boxed area). The reaction pattern depicted here is identical to that shown in the hypothalamus of infant A (figs. 1d and 2b) but degenerative changes are in a later stage of evolution (5 hours instead of 3) and this section was selected from a portion of the infundibular nucleus lying midway between the rostral (fig. 1d) and caudal (fig. 2b) views illustrated from the brain of infant A. See figure 3b for detail of degenerating neurons in boxed region (× 135). b. Detail from boxed region of figure 3a. A collection of necrotic neurons with swollen cell bodies and pyknotic nuclei. With the electron microscope we identified these cells and the dilated processes scattered throughout the lower half of the figure as neuronal by virtue of their synaptic involvement. Numerous normal appearing neurons are present in the upper half of the field (× 260). c. A view from the brain of infant D, treated orally with MSG, depicting the same reaction pattern in the same region of the hypothalamus as was shown for infant B (figs. 3a and b). There are fewer reactive elements but the pattern is similar with dilated dendritic processes in the lower portions of the field and necrotic neurons (N) dispersed among numerous normal neurons in the upper field (× 240).

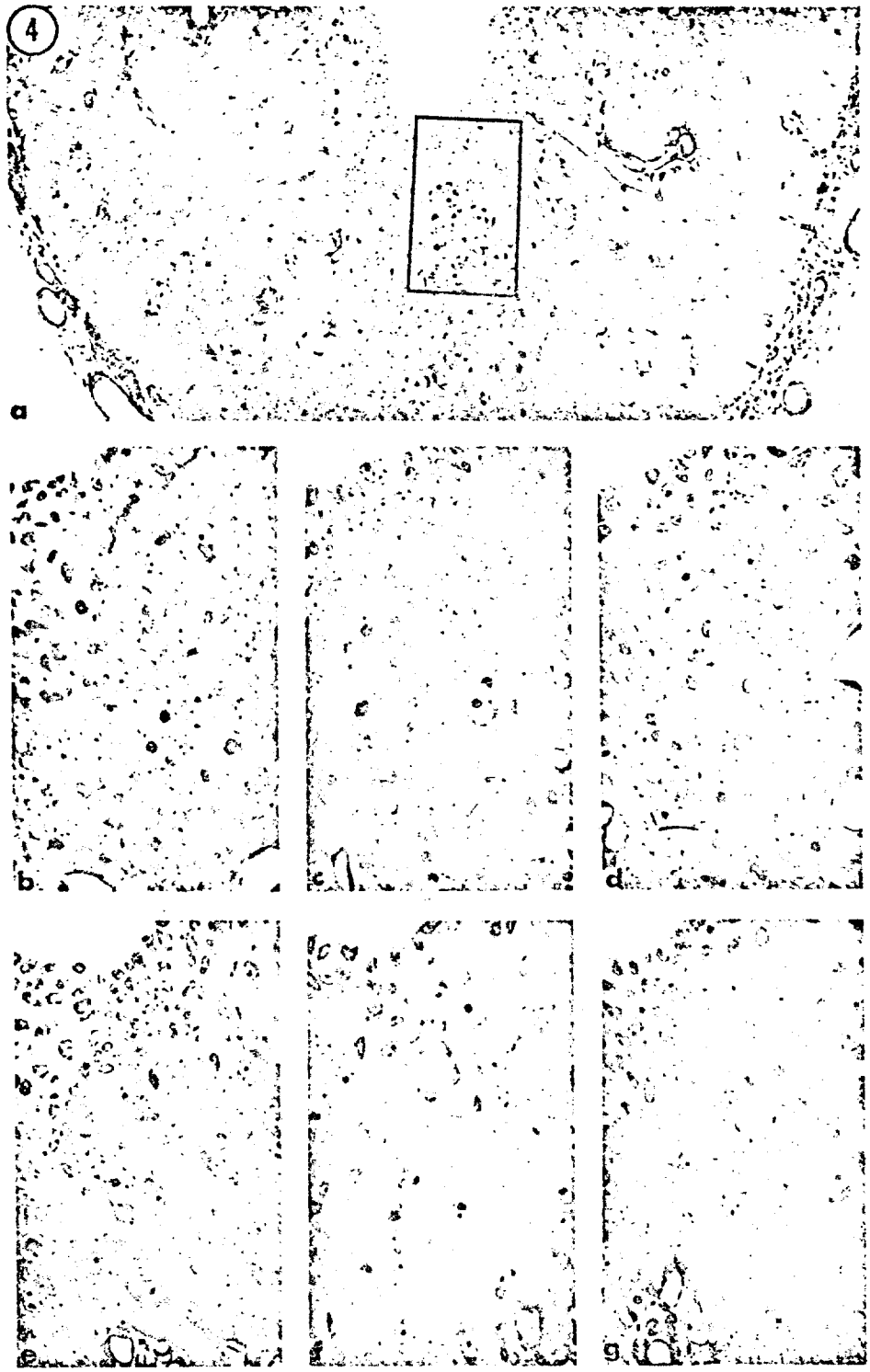

FIG. 4.

in the survey view (fig. 5) at low magnification. A typical infundibular neuron lying at the margin of the lesion and not involved in the pathological process is shown at higher magnification to illustrate the quality of fixation in this region of this particular brain (fig. 6). A cell lying within the lesion site exhibiting the variety of gross degenerative changes typically seen in the neuronal reaction to MSG (fig. 7) and a phagocyte ingesting degenerate cell fragments nearby (fig. 8) are also shown. In the lumen of a blood vessel located near the lesion site is a white blood cell apparently migrating from the vascular compartment into brain tissue, possibly in response to the MSG-induced inflammatory process (fig. 9). One degenerating cell is shown at higher magnification (fig. 10a) to be a neuron by virtue of the synaptic contacts terminating on its cell surface (fig. 10b). Figure 11 depicts an electron microscopic scene from a comparable region in control brain G in which tissue preservation appears adequate and there is no disturbance in the pattern of nuclear chromatin or in the appearance of mitochondria, synaptic morphology or other cellular components.

A series of electron micrographs from a small lesion in the brain of infant C (figs. 12–14) illustrates that the changes in this infant's brain following a 1 g/kg oral dose of MSG are identical in cytopathological detail to those described in the hypothalamus of infant mice treated with the same oral dose of MSG (8). Degeneration of intracellular organelle systems, gross clumping of nuclear chromatin and a phagocyte incorporating an entire cell corpse are depicted at low magnification in figure 12. One cell undergoing degeneration is identified as a neuron by an axosomatic synapse in contact with its cell surface (fig. 13). The typical vacuolization of endoplasmic reticulum, rounding up of mitochondria and central consolidation of clumped chromatin (nuclear pyknosis) are easily recognized in figure 14. (See figs. 5b and 15 in Ref. 8 from mouse brain for comparison). A survey electron micrograph (fig. 15a) and detail view (fig. 15b) from a corresponding region of control brain F reveal that adequate preservation of tissue was achieved and there are no signs of a cytopathological reaction.

Infants F, G and H received 6, 12 and 24 mM/kg doses of NaCl respectively either orally (F and G) or subcutaneously (H). Serial light microscopic sec-

FIG. 4. A series of photographs from the rostral subventricular portion of the infundibular nucleus of 3 experimental infants treated orally with MSG (a–d) and 3 NaCl treated controls (e–g). a. A small lesion (boxed region includes upper half of lesion) from rostral subventricular region of brain of MSG-treated infant D. This zone corresponds roughly with the median eminence of rodent brain. The micrographs below (figs. 4b–g) depict this same zone in 6 infant brains. See figure 4c for detail of boxed region (× 110). b. Infant C, treated orally with MSG, 1 g/kg. A small lesion identical in location and appearance to the lesion site shown in figure 4a and c from infant D. For detailed electron micrographic analysis of the necrotic cellular elements in this lesion see figures 12–14. c. Infant D, treated orally with MSG, 2 g/kg. This is a detail view from boxed region in figure 4a. Necrotic neurons, with swollen cell bodies and pyknotic nuclei are evident. For electron micrographic analysis of this lesion site, see figures 5–10. d. Infant E, treated orally with MSG 4 g/kg (but vomited an unknown portion of this dose). A lesion site similar in location and appearance to those shown in infant C (fig. 4b) and D (figs. 4a and c). e–g. NaCl-treated control infants F, G and H respectively. The rostral subventricular scenes shown here which correspond to regions in brains of infants C, D and E where lesions occurred are normal in appearance. For electron micrographic illustrations of normal neural components from these areas, see figures 11 and 15. (Figs. 4b–g, all × 250.)

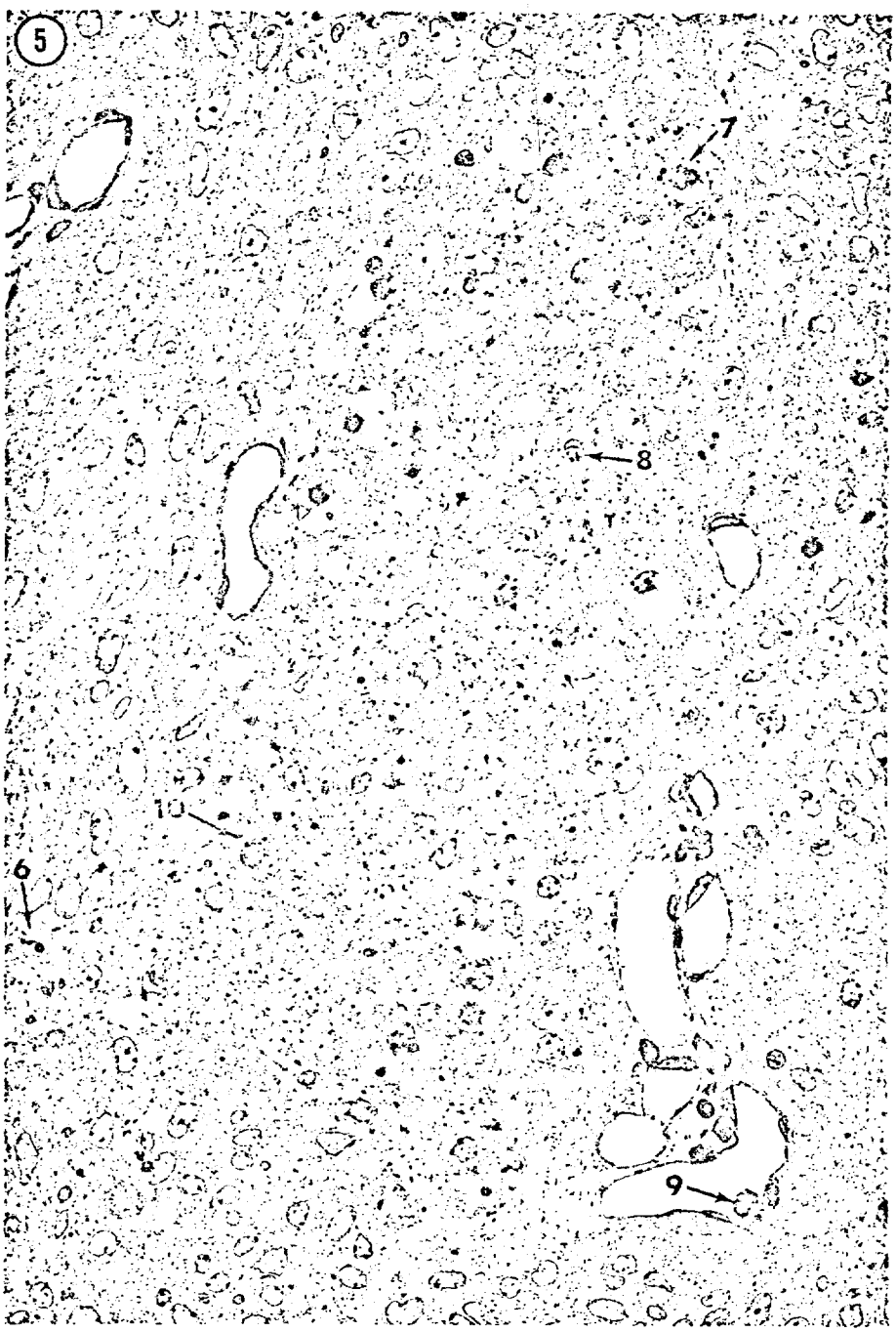

FIG. 5. Survey electron micrograph from rostral subventricular area of infant D's brain illustrating a small MSG-induced lesion site. Some affected neurons exhibit perikaryal swelling and pyknotic nuclear changes. Others are uniformly dark and condensed in both nuclear and cytoplasmic compartments. The lesion area is oval-shaped and is bordered on all sides by normal well preserved tissue. Blood vessels are dilated suggesting adequate perfusion of the area with fixative. Numerals 6–10 with arrows designate cells which are presented at higher magnification in figures 6–10 respectively (× 850).

tions from the optic chiasm to the pre-mammillary region of each brain were examined carefully with particular attention directed toward locating cellular profiles resembling those of the necrotic neurons detected in MSG treated infants. No such cytopathology was identified in any of the 3 control brains (figs. 1a–c, 2a, 4e–g). Electron micrographic maps were prepared across regions of these control brains corresponding to areas where small focal lesions occurred in the brains of infants C, D and E. In each control brain there was satisfactory preservation of ultrastructure and no evidence of a cellular degeneration process (figs. 11, 15a and b). Dilatation of glial processes in the region of the tuberoinfundibular sulcus was detected routinely in both MSG and NaCl-treated brains. These changes were easily distinguished from the neurodegenerative effects of MSG because the processes involved bore no synaptic contacts and swelling was the only change detected. Mitochondria in these processes were normal as were mitochondria and other cytoplasmic constituents within cell bodies and there was no clumping of nuclear chromatin or nuclear pyknosis as occurs in the neuronal reaction to MSG.

While acute symptoms associated with MSG treatment of infant primates are uncommon, two acute reactions, vomiting and convulsions, do occur and appear to be both dose and age related. Vomiting of adult dogs has been described (32, 33) following intravenous (0.2 g/kg) or oral (0.5–1 g/kg) administration of MSG. In adult humans vomiting ensues when serum glutamate levels exceed approximately 15 mg% (34). We have observed vomiting to be a reaction of adult rhesus monkeys to MSG in subcutaneous doses of 1 g/kg (22). We were, therefore, surprised that the first rhesus infant we treated (infant A) tolerated a subcutaneous dose of 2.7 g/kg without vomiting and infants C and D tolerated oral doses of 1 and 2 g/kg without vomiting. Infant E, however, when given an oral dose of 4 g/kg vomited twice, once at 15 minutes and a second time at about 50 minutes after treatment. We did not attempt to replace the amount of MSG vomited and do not know what portion of the 4 g/kg dose was actually absorbed into the infant's system. Infants B and I which received doses of 2.7 and 4 g/kg respectively vomited but this did not affect control of dosage since the route of administration was subcutaneous. we suspect the mechanism responsible for MSG-induced vomiting is relatively insensitive in the immature primate which would explain why infant A, a premature infant did not vomit following a 2.7 g/kg dose whereas other infants in this series receiving this much or more MSG and adult rhesus monkeys receiving lower subcutaneous doses vomited.

Goodman et al. (35) observed in 1946 that an 8 g/kg dose of MSG induced lethal convulsions in the adult cat. More recently Bhagavan et al. (36) have described convulsions in adult rats following intraperitoneal doses of 20 mM/kg (3.4 g/kg). In adult mice we have noted that subcutaneous doses sufficient to induce hypothalamic lesions (5–7 g/kg) often result in lethal convulsions. Two-week-old mice usually convulse to death from subcutaneous doses between 5 and 6 g/kg but these doses in 1-day-old infant mice are lethal without producing convulsions (22).

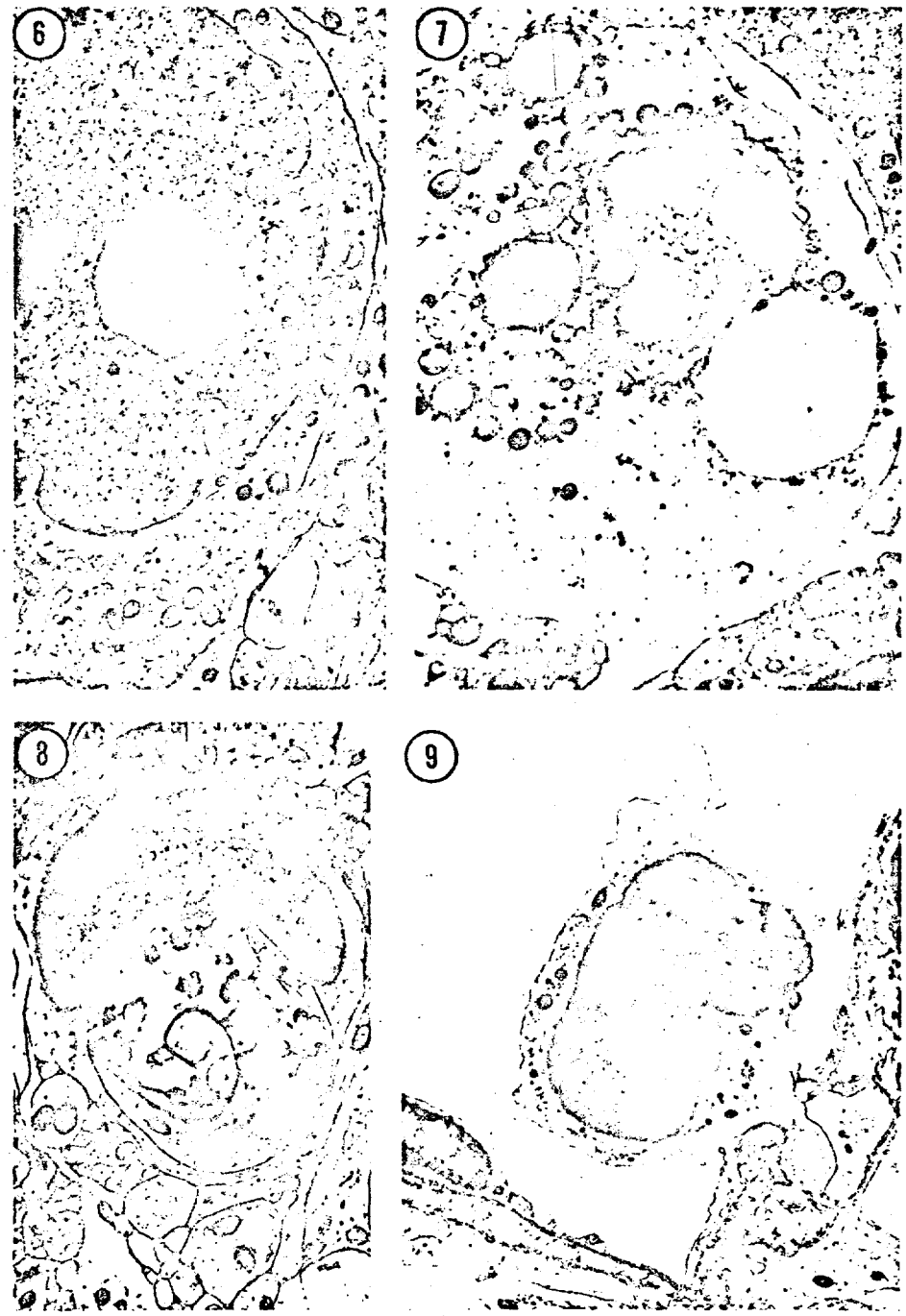

FIGS. 6–9.

In our series of infant primates only infant I which received a 4 g/kg subcutaneous dose of MSG convulsed. This infant became acutely ill following treatment. His cry became weak, lethargy developed and a cyanotic complexion as well as periodic myoclonic seizures were noted. Infant H which received an equimolar dose of NaCl also became lethargic and cyanotic but did not convulse or appear as ill as infant I. In the brains of each infant there were petechial perivascular hemorrhages, primarily localized to white matter regions. This was accompanied in both infants by extravasation of red blood cells into sub-arachnoid spaces and the ventricular cavities. It was of interest that in neither infant was there more than a rare sign of hemorrhage in hypothalamic regions. The hypothalamus of infant H was essentially normal in appearance (figs. 1c, 2a, 4g, 16a) except that blood vessels were partially collapsed, perivascular spaces were widened and vascular lumina were occasionally plugged with clumped blood components. These changes, which were also present in the brain of infant I and are consistent with an antemortem thrombotic diathesis, could relate to the hemorrhaging noted throughout many extrahypothalamic regions of both brains. Hemodynamic disturbances associated with intracranial hemorrhaging together with drastic reduction in cerebrospinal fluid pressure has been noted in infants of several species, including humans, where a clinical condition of severe hypernatremic dehydration was present (37). The high sodium content of the MSG or NaCl given infants I and H respectively and their dehydrated status from the beginning of the experiment, therefore, probably account for these pathological changes.

Of greater significance in the present context, the hypothalamus of infant I was affected by a conspicuous edema reaction, not present in the hypothalamus of infant H, which tended to involve glial and ependymal elements as well as neurons and had spread laterally to include regions lying beyond the boundaries of the infundibular nucleus (fig. 16b). This pattern of spreading edema, which we also observed in the hypothalamus of infant A (fig. 1, Ref. 21) and to a

FIG. 6. Detail from figure 5. An infundibular neuron lying just beyond the border of the lesion site. A large nucleolus with an associated mass of heterochromatin are the only significant consolidations of nuclear material. The inner and outer membranes of the nuclear envelope are continuously in close apposition. The invaginated nuclear contour is a normal characteristic of this type of neuron. Mitochondria and other cytoplasmic constituents are well preserved and of normal appearance (× 10,000).

FIG. 7. Detail from figure 5. A neuron from the lesion site which has reached a relatively advanced stage of degeneration. There is no recognizable endoplasmic reticulum, although vacuoles which probably originated from reticular cisternae are prominent. Mitochondria are spherical and many cytoplasmic regions are empty except for particulate debris. The coarse clumping of nuclear chromatin, which represents a stage in the development of nuclear pyknosis (8) is evident and saclike spaces are forming between the inner and outer nuclear membranes (× 14,000).

FIG. 8. Detail from figure 5. A phagocytic cell with processes encompassing a fragment of degenerate tissue. Although this scene is from within the lesion site, many surrounding neuropil elements appear normal as is typically the case in a small MSG-induced lesion (× 10,500).

FIG. 9. Detail from figure 5. White blood cell in the lumen of a blood vessel beside the lesion site. This cell was not washed out of the vascular lumen when the perfusate was introduced because its foot process was inserted through the endothelial wall. The cell appears to be migrating from the blood compartment into brain, possibly as an inflammatory response to the MSG-induced lesion (× 11,500).

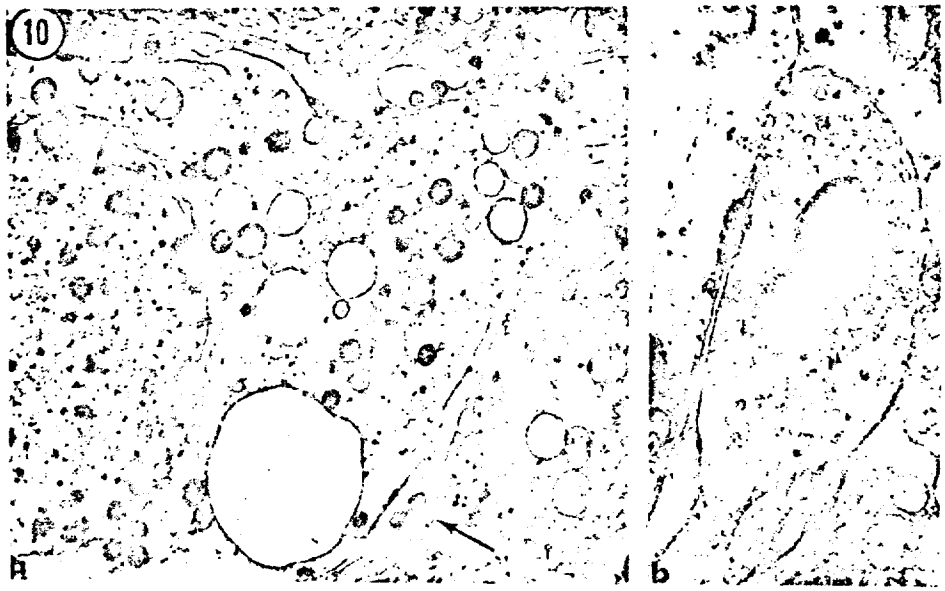

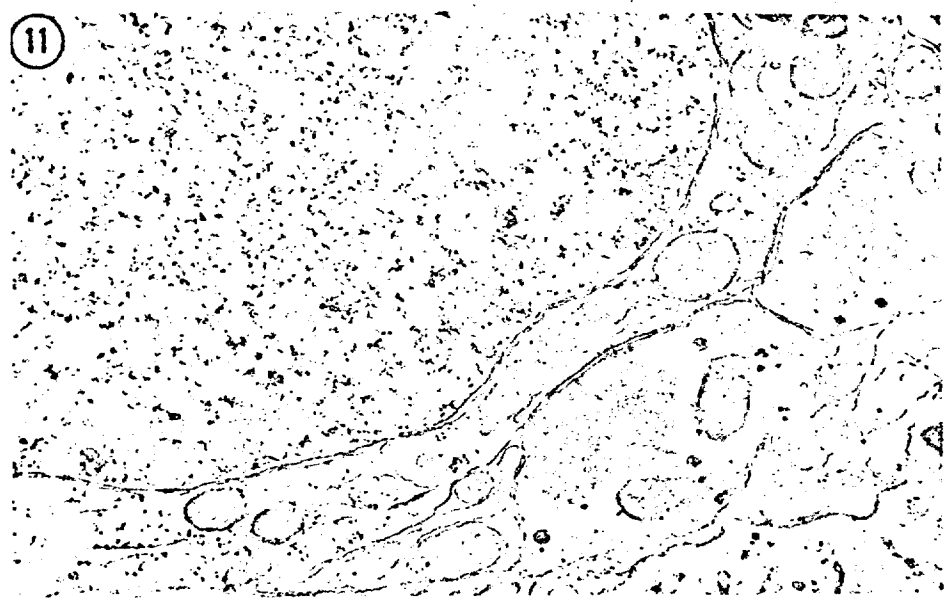

FIG. 10. Detail from figure 5. A cell manifesting relatively early degenerative changes of the kind typically seen in an MSG-induced lesion. This cell is identified as a neuron by the several axo-somatic synapses impinging upon its surface. One synapse (arrow) is shown at higher magnification in figure 10b (× 10,500). b. Detail from figure 10a. An axon terminal in synaptic contact with the somal surface of a degenerating neuron. Increased densification and smudging of the post-synaptic membrane, as is apparent here, represents one stage in the deafferentation of a neuron affected by MSG. The next stage (9) involves displacement of the axon terminal so that it is no longer aligned with the post-synaptic density (× 48,000).

FIG. 11. A nerve cell from the rostro-subventricular region (shown by light micrography in fig. 4f) of NaCl control infant G. The distribution of chromatin in the nucleus appears normal as do mitochondria, the endoplasmic reticulum and all features of the two axosomatic synapses terminating on the surface of this neuron (× 32,000).

lesser extent in infant B, occurs routinely in infant mice given high doses (4–6 g/kg) of MSG either subcutaneously or orally (MSG-treated mice do not vomit). Figures 17a and b provide examples of typical reaction patterns seen in the infant mouse hypothalamus following low (fig. 17a) compared to high (fig. 17b) doses of MSG. Our findings for infants C, D and E compared with those for A, B and I indicate that comparable changes in reaction pattern also occur in the infant primate treated from low to high extremes over the same dose range.

Blood glutamate values over the 5 hour post-treatment period for all infants except infant A are given in table 1. The highest and most sustained elevations of blood glutamate occurred in infants treated subcutaneously with high doses (infants B and I) which correlates well with the severity of pathology in these infants' brains (figs. 3 and 16b). Presumably, had we measured blood glutamate in infant A, a similarly high sustained elevation would have been recorded. None of the 3 infants treated orally (infants C, D and E) developed more than a moderate elevation which is consistent with the low doses administered to infants C and D and with the vomiting observed in infant E following a higher dose. The one glutamate curve which was inconsistent with expectation was that for infant H which started from a relatively high base line value of 12 mg% and rose to 25 mg% 2½ hours after a large subcutaneous dose of NaCl. The other two control infants treated orally with lower doses of NaCl in dilute skim milk had no increase in blood glutamate concentrations. The high base line value for infant I (20 mg%) probably reflects a hemoconcentration phenomenon in that this infant had poor skin turgor and appeared dehydrated at the beginning of the experiment.

DISCUSSION

In contrast to Reynolds et al. (15) and Abraham et al. (10) who reported no differences between brains of control and MSG-treated primate infants, we found evidence for a neuron-necrotizing process in the hypothalamus of each of 6 infant rhesus monkeys treated with MSG and in none of 3 NaCl-treated controls. A comparison of these studies with ours reveals no important differences in age and sex of treated infants or in dose and routes of administration of MSG. The discrepancy in findings, however, may relate to certain other features of research design and methodology which do distinguish the present study from the prior two (15, 10).

Reynolds, et al. included 6 MSG-treated rhesus infants but no rhesus controls in their study. Two of their rhesus infants, each treated with low oral doses of MSG, were examined by electron microscopy. However, since only a spot sampling technique was employed, the possible occurrence of small lesions in these brains was not actually ruled out. The other 4 rhesus infants were examined only by light microscopy after preparation of brains by a method (formalin, paraffin, cresyl violet) which others have found unsatisfactory for evaluating even large MSG-induced lesions in infant rodent brain (14). The uniformly negative data obtained by these authors, even in infants given doses of MSG as

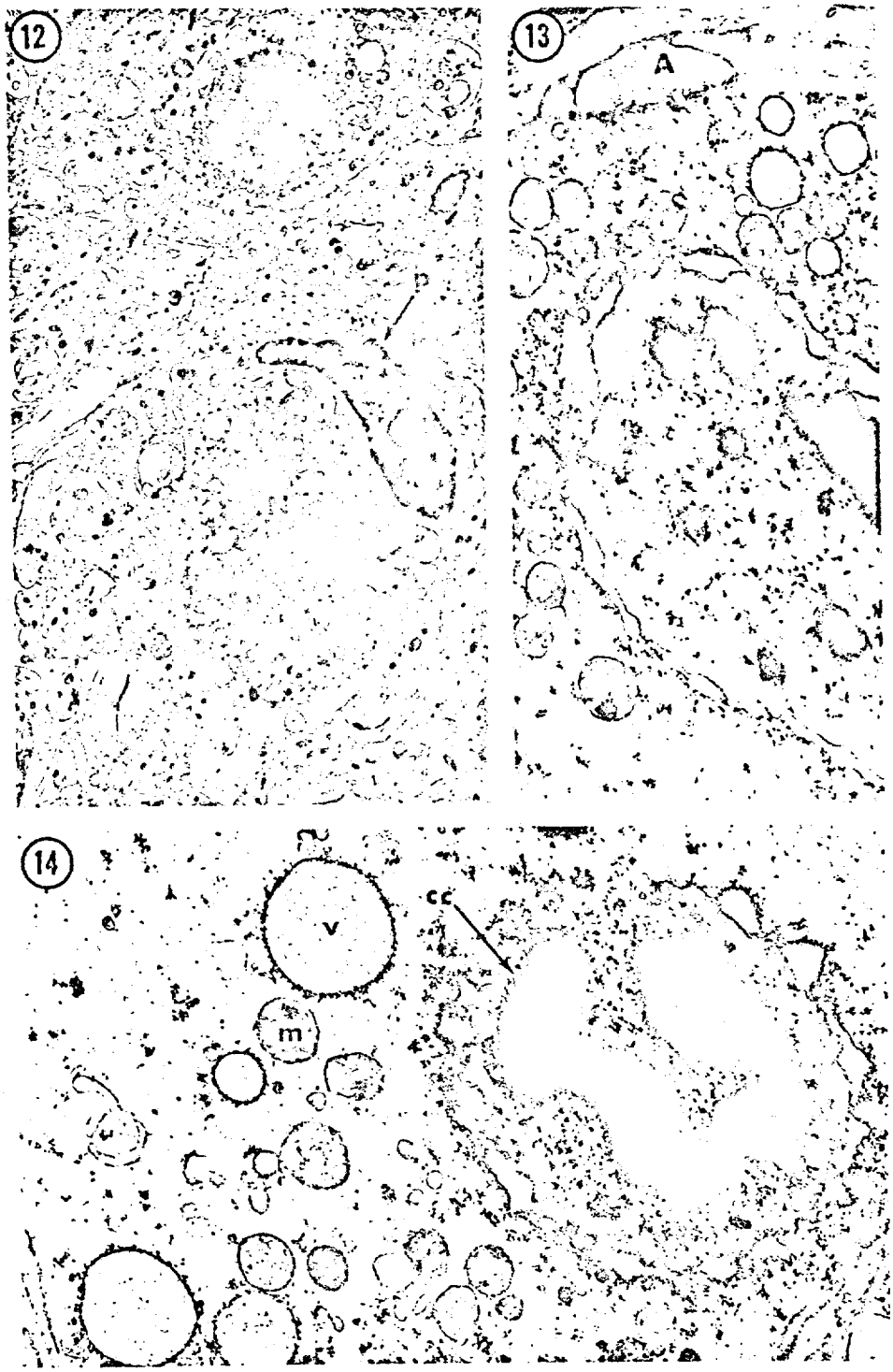

FIGS. 12–14.

high as 4 g/kg, may also relate to the emetic properties of MSG. In discussing their data at a recent meeting (25), W. A. Reynolds mentioned that some of their infants vomited an unknown portion of the administered dose.

Abraham et al. (10) supported their negative findings with a single light micrograph (H and E stain) from a rhesus infant sacrificed 24 hours following oral intake of an emetic dose (4 g/kg) of MSG. Since their description of methods for studying primate infants was confined almost entirely to the few remarks accompanying this illustration, it is difficult to evaluate the technical adequacy of their approach. However, because of the remarkable efficiency with which degenerate elements are removed from the scene of an MSG-induced lesion (minimal lesions are cleared from mouse brain within 12 to 18 hours), it is essential to examine the brain earlier than 24 hours. This is particularly true if, due to vomiting, the infant retained very little MSG and, therefore, sustained only a minimal lesion. But Abraham et al. also reported (10) arcuate lesions in only 60% of infant mice treated subcutaneously with 4 g/kg doses of MSG. In our experience subcutaneously administered MSG predictably destroys neurons in 100% of infant mice treated at any dose exceeding 0.5 g/kg. The 4 g/kg dose administered by Abraham et al., in fact, destroys not only the arcuate nucleus but kills neurons in the medial habenular nucleus, the subfornical organ, midline portions of the cingulate cortex, the anterior hippocampus (dentate gyrus) and the superior colliculus (6). This distribution of lesions following high doses of MSG and the predictability that an arcuate lesion will occur even at low doses have both been confirmed in other laboratories (11, 13, 14, 16, 25). The high yield of negative findings by Abraham et al. in either mice or monkeys despite high doses of MSG reportedly given, therefore, suggests some repeating defect(s) in their treatment approach or in their timing or technique of tissue collection, preparation and examination.

It is puzzling that blood glutamate concentrations rose to 25 mg% in infant H after a subcutaneous dose of NaCl and no hypothalamic cytopathology developed, whereas, hypothalamic lesions did develop in MSG-treated infants C and D whose blood glutamate concentrations rose only to 20 mg%. Since no exogenous glutamate was administered to infant H, any real increase in blood glutamate content must have occurred either by generation of glutamate by

FIG. 12, 13 and 14. All are from a rostro-subventricular lesion site (shown by light micrography in fig. 4b) in the brain of infant C, treated orally with MSG, 1 g/kg. 12. Two degenerating neurons (top and center) are shown, one (N) which is being encircled by the processes of a phagocytic cell (P). In the surrounding neuropile some elements appear normal and well preserved, others are exhibiting such acute degenerative changes as are characteristically seen in MSG-induced lesion sites (× 3,900). 13. A degenerating cell which is clearly a neuron because of the axon terminal (A) in synaptic contact with its surface. This degenerating cell appears identical to neurons undergoing degeneration in the brains of MSG-treated mice. The densities present in mitochondria of this cell appeared in degenerating cells of each MSG-treated monkey in our series. We did not describe such mitochondrial densities in mouse (8) because they were encountered only infrequently in that species (× 18,000). 14. Compare the appearance of this degenerating neuron from the lesion in infant C's brain with that of a degenerating neuron we previously illustrated (fig. 15, Ref. 8) in the brain of a mouse treated orally with MSG. The vacuolated endoplasmic reticulum (v), spherical mitochondria (m) and clumped chromatin (cc) which is consolidating centrally to produce the typical appearance of a pyknotic nucleus are features these degenerating cells from 2 different species clearly have in common (× 23,000).



FIG. 15. a. Survey electron microscopic view from the rostro-subventricular region of NaCl control infant F's brain. There are no degenerate cellular components present. In several portions of the field there are discontinuities in tissue density because this section was cut tangential to one large vascular complex and transversely across another so that much of the field contains perivascular spaces and adventitial elements. Numerous neurons (N) are also present in small clusters in this subventricular location. One neuron (boxed region) from a small cluster is shown at higher magnification in figure 15b (× 1,000). b. Neuron from boxed region of figure 15a. Cytoplasmic and nuclear components of this cell and the surrounding neuropile all appear normal. We interpret a miscellaneous vacuole (arrow) in an otherwise well preserved and normal appearing cell as an insignificant finding in either control or experimental tissue (× 13,500).

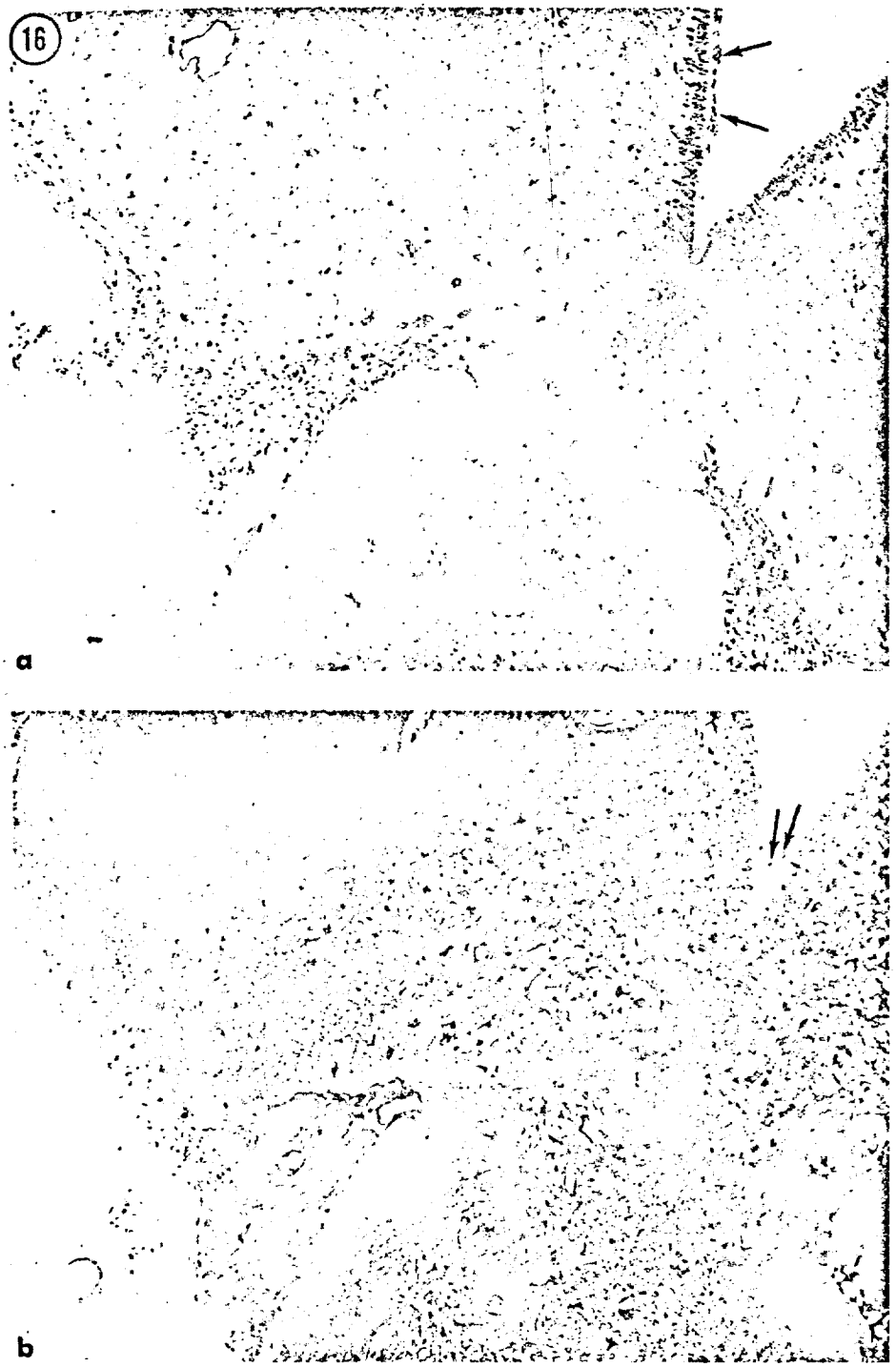

FIG. 16. Photographs from the same brain region of two rhesus infants, one treated with a high subcutaneous dose of NaCl (a), the other with an equimolar (4 g/kg) subcutaneous dose of MSG (b). a. Infant H. Red blood cells in the ventricular cavity (arrows) is the only obvious abnormality. Many blood vessels appear poorly dilated, an effect possibly related to hemodynamic disturbances associated with hypernatremic dehydration (× 110). b. Infant I. A massive edema and necrotizing reaction affecting mixed glial and neuronal components has spread throughout the infundibular nucleus and stalk region and laterally beyond the boundaries of the infundibular nucleus. A few red blood cells (arrows) are present in the ventricular cavity revealing that intracranial bleeding also occurred in this brain (× 130).

FIG. 17. Comparison of a minimal and maximal MSG effect in the hypothalamus of the infant mouse. a. The hypothalamus of a 10 day old infant mouse given MSG, 0.5 g/kg orally by feeding tube. The necrotizing reaction is confined to a few neurons in the floor and at the angles of the 3rd ventricle (median eminence). The infundibular (arcuate) nucleus proper is hardly involved (× 300). b. A massive spreading lesion induced by administering a large dose (4 g/kg) of MSG to a 1 day old infant mouse. The reaction is not confined to the median eminence or even to the infundibular (arcuate) nucleus, but has spread dorsolaterally to include the entire mediobasilar portion of this neonatal brain (× 75).

blood elements or by a shift of glutamate from other tissue compartments into blood. The brain contains a higher natural glutamate concentration than other tissues of the body (38). An efflux of glutamate from brain to blood may have been at least partially responsible for the elevation of blood glutamate. In contrast, it has been found in infant mice that an exogenous load of MSG (2 g/kg) results in a massive but selective transfer of glutamate from blood into a particular region of brain, the infundibular (arcuate) nucleus (39). Presumably unless tissue concentrations of glutamate in the infundibular nucleus rise above some threshold level, a lesion will not develop. We would postulate that the glutamate content of the infundibular nucleus of infant H did not exceed such a threshold level despite the increased blood concentration of glutamate. Since infant H was judged to be dehydrated at the onset of the experiment, it is possible that at least some of the rise in blood glutamate following an injection of hypertonic NaCl reflected, not an increased amount of total blood glutamate, but rather a hemoconcentration phenomenon. This, in turn, may have promoted an efflux of glutamate from brain into blood since various ions are known to be shifted from intracellular compartments into blood under conditions of hypernatremic dehydration (37). The role of biological variation must also be consid-

ered. Assuming a blood glutamate concentration of 20 mg% to be the threshold value for occurence of brain lesions in the average healthy primate infant, an occasional individual might, nevertheless, be resistant to damage from blood glutamate levels in this range.

Our data do not support the view that only subprimates are susceptible to MSG-induced neurotoxicity. The lesions in our primate infants A, B and I following relatively high subcutaneous doses of MSG were so similar to those consistently observed in mice treated with high doses of MSG that it seems unrealistic to deny primate susceptibility to the MSG effect. Since lesions we detected in infants treated orally with lower doses were also similar in localization and identical in cytopathological detail to those we routinely find in infant mice treated orally with low doses of MSG, a causal link between low oral doses of MSG and necrosis of neurons in the infant primate hypothalamus also seems likely. However, since the lesions in these infants were quite small, careful consideration should be given to possible explanations other than MSG toxicity.

Because of the very nature of the changes involved in these lesions (neuronal necrosis) we believe the fixation artefact thesis of Reynolds et al. can reasonably be discarded. In particular, it is difficult to explain clumping of nuclear chromatin and nuclear pyknosis in terms of fixation vagaries. It would be more plausible to consider such tiny necrotic lesions as manifestations of the necrobiosis process (spontaneous death of neurons during natural development). However, necrobiosis is not a process selectively affecting clusters of neurons in the infundibular nucleus but tends rather to affect neurons individually in scattered distribution throughout the developing central nervous system. Further, in our experience the perikaryon of a neuron undergoing necrobiosis is not swollen and vacuous, rather the entire cellular profile is uniformly dark and condensed. Five hours following MSG treatment some cells in the lesion site appear dark and condensed but within the same lesion there are always others with acutely swollen cell bodies and pyknotic nuclei. Also, we have noted that while necrobiotic cellular profiles are frequently encountered in the fetal central nervous system, they are exceedingly rare in the 1-week-old infant primate brain. And finally, it is inconsistent with the necrobiosis interpretation that neither we nor others (10, 15) could find acutely swollen infundibular neurons with pyknotic nuclei in brains of infant monkeys not treated with MSG.

Although it has been established that rodents receiving MSG in infancy have endocrine abnormalities and obesity as adults (6, 17–20) the late occurring sequelae of MSG-intake by infant primates has not been studied. Sheehan and Kovacs (31), reporting on human adults found that neurons in a subventricular portion of the infundibular nucleus, which they termed the subventricular nucleus, were hypertrophied in women who were post-menopausal, parapartum or who suffered from post-partum hypopituitarism. In the latter condition a decreased number of neurons in the subventricular nucleus was also described. This suggests an involvement of these particular neurons in neuroendocrine regulatory function. Probably, since the subventricular nucleus of Sheehan and Kovacs was badly damaged as were more dorsolateral portions of the infundib-

ular nucleus in infants A, B and I, these infants would have manifested endocrine abnormalities in adulthood. It would be of value, but may require very sensitive tests, to determine whether infants having sustained only minimal lesions localized about the subventricular zone would have an increased liability to develop endocrine disturbances as adults.

According to an NAS Subcommittee (26), "in considering the safety of added MSG in baby foods, one must remember that the levels added are small—not higher than 0.6 g% . . .". This means that one small jar of baby food (130 g) would provide about 0.78 g of MSG or 0.13 g/kg of body weight for a human infant weighing 6 kg. Based on our findings that an oral dose of 1 g/kg in the primate or 0.5 g/kg in the mouse (7) is sufficient to destroy hypothalamic neurons, this leaves a 4- to 8-fold margin of safety for a human infant eating one jar, a 2- to 4-fold margin if two jars are eaten and so forth. This is substantially less than the 100-fold margin generally recommended to accommodate contingencies such as species or individual differences in susceptibility to the mechanism of a toxic compound. Although age at time of exposure is undoubtedly an important variable, there is no reliable way to determine how a human infant compares in sensitivity to the MSG effect with any particular animal species at any particular developmental age.

In support of their assumption that human infants are invulnerable to MSG-induced brain damage, the NAS Subcommittee (26) pointed to absence of behavioral manifestations in human infants given intravenous infusions of protein hydrolysates providing 0.3 g/kg/day of free glutamic acid. Our demonstration that MSG destroys hypothalamic neurons in monkeys as well as mice (7) at intake doses lower than those required to produce acute behavioral manifestations points to a serious flaw in this line of reasoning. The subcutaneous injection of protein hydrolysate (0.2 cc) produces, in 10 day old infant mice, a hypothalamic lesion unaccompanied by behavior disturbances (22). It may be important that there are at least three neurotoxic amino acids present in a protein hydrolysate (glutamate, aspartate and cysteine) and these are capable of acting in concert, by an additive mechanism, to destroy hypothalamic neurons (7, 22). It is relevant to the food safety issue that commercially available preparations such as bouillon cubes and broths (40), which might be used in the home to prepare infant meals, contain unspecified amounts of added MSG, plus added cysteine and hydrolysed protein (more free glutamate, aspartate and cysteine).

Although the focus of attention in the MSG controversy has been on the potential risk of exposure to exogenous sources of MSG, the significance of our findings can better be appreciated within a broader context. Elsewhere we have shown in infant mice that several acidic amino acids which occur naturally in brain (glutamic, aspartic, cysteic, and cysteine sulfinic acids) cause the MSG type of hypothalamic lesion (9). One non-acidic amino acid (L-cysteine), at relatively low doses (0.8–1.2 g/kg), induces a more disseminated neurodegenerative reaction throughout other brain regions, possibly by conversion intracerebrally to its acidic analogues (41). Although the effect of the acidic compounds may not transmit across the placenta (at least of the rodent) the

neurotoxicity of cysteine does (24). If any of these natural metabolites were to accumulate, even transiently in local regions of the developing brain, nerve cells would be deleted, residual traces of tissue damage would be minimal or absent but functional deficits, perhaps of the "minimal brain dysfunction" variety might develop. The natural occurrence in brain of these amino acids, the additive neurotoxic mechanism they share and the fact that at least one of them transmits its effects across the placenta to produce a disseminated neurodegenerative syndrome must all be taken into consideration in evaluating the potential significance of our demonstration that susceptibility to the MSG type of neurotoxic mechanism is not limited to subprimates.

Acknowledgments: The assistance of Dr. Richard M. Torack, Department of Neuropathology, Washington University School of Medicine, St. Louis, Missouri, in interpreting both our control and experimental material is gratefully acknowledged.

REFERENCES

1. Lucas, D. R., and Newhouse, J. P.: The toxic effect of sodium L-glutamate on the inner layers of the retina. AMA Arch. Ophth., 58: 193, 1957.
2. Potts, A. M., Modrell, K. W., and Kingsbury, C.: Permanent fractionation of the ERG by sodium glutamate. Am. J. Ophth., 50: 900, 1960.
3. Freedman, J. K., and Potts, A. M.: Repression of glutaminase I in rat retina by administration of sodium L-glutamate. Invest. Ophthal., 2: 252, 1963.
4. Cohen, A. I.: An electron microscopic study of the modification by monosodium glutamate of the retinas of normal and "rodless" mice. Am. J. Anat., 120: 319, 1967.
5. Olney, J. W.: Glutamate-induced retinal degeneration in neonatal mice. Electron microscopy of the acutely evolving lesion. J. Neuropath. Exp. Neurol., 28: 455, 1969.
6. ——: Brain lesions, obesity and other disturbances in mice treated with monosodium glutamate. Science, 164: 719, 1969.
7. ——, and Ho, O. L.: Brain damage in infant mice following oral intake of glutamate, aspartate or cysteine. Nature, 227: 609, 1970.
8. ——: Glutamate-induced neuronal necrosis in the infant mouse hypothalamus: an electron microscopic study. J. Neuropath. Exp. Neurol., 30: 75, 1971.
9. ——, Ho, O. L., and Rhee, V.: Cytotoxic effects of acidic and sulphur containing amino acids on the infant mouse central nervous system. Exp. Brain Res., 14: 61, 1971.
10. Abraham, R., Doughtery, W., Goldberg, L., and Coulston, F.: The response of the hypothalamus to high doses of monosodium glutamate in mice and monkeys. Cytochemistry and ultrastructural study of lysosomal changes. Exp. Molec. Path., 15: 43, 1971.
11. Arees, E., and Mayer, J.: Monosodium glutamate-induced brain lesions. Electron microscopic examination. Science, 170: 549, 1970.
12. ——, Sandrew, B., and Mayer, J.: MSG-induced brain lesions in infant mice following subcutaneous injection. Fed. Proc., 30: 521, 1971.
13. ——, and Mayer, J.: Monosodium glutamate-induced brain lesions in mice. Paper presented at 47th Annual Meeting of Am. Assoc. Neuropath. in Puerto Rico, June, 1971.
14. Burde, R. M., Schainker, B., and Kayes, J.: Monosodium glutamate: acute effect of oral and subcutaneous administration on the arcuate nucleus of the hypothalamus in mice and rats. Nature, 233: 58, 1971.
15. Reynolds, W. A., Lemky-Johnston, N., Filer, L. J., Jr., and Pitkin, R. M.: Monosodium glutamate: absence of hypothalamic lesions after ingestion by newborn primates. Science, 172: 1342, 1971.
16. Everly, J. L.: Light microscopic examination of MSG-induced lesions in brain of fetal and neonatal rats. Anat. Rec., 169: 312, 1971.

17. Redding, T. W., Shalley, A. V.: The effects of MSG on the endocrine axis in rats. Fed. Proc., 29: 755, (1970).
18. ——, ——, Aromura, A., and Wakabolashi, I.: Effects of monosodium glutamate on some endocrine functions. Neuroendocrin., 8: 245, 1971.
19. Knittle, J. L., and Ginsberg-Feller, F.: Cellular and metabolic alterations in obese rats treated with monosodium glutamate during the neonatal period. Bulletin Am. Peds. Soc. Gen. Meeting, Program Abstracts, p. 6, 1970.
20. Matsuyan, S.: Studies on experimental obesity in mice treated with MSG. Jap. J. Vet. Science, 32: 206, 1970.
21. Olney, J. W., and Sharpe, L. G.: Brain lesions in an infant rhesus monkey treated with monosodium glutamate. Science, 166: 386, 1969.
22. ——. Unpublished data.
23. Snapir, N., Robinson, B., and Perek, M.: Brain damage in male domestic fowl treated with monosodium glutamate. Poultry Science, 50: 5, 1971.
24. Olney, J. W., Rhee, V., Ho, O. L., and Schainker, B.: In preparation.
25. Reynolds, W. A., Lemky-Johnston, N., Filer, L. J., Jr., and Pitkin, R. M.: Monosodium glutamate: absence of hypothalamic lesions after ingestion by newborn primates. Paper presented and discussed at 47th Annual Meeting, Amer. Assoc. Neuropath., Puerto Rico, June, 1971.
26. Report of Subcommittee on Safety and Suitability of MSG and other substances in baby foods. National Academy of Sciences, National Research Council. Aug. 7, 1970.
27. Erfon, M. L., Young, D., Moser, H. W., and MacCready, R. A.: A simple chromatographic screening test for the detection of disorders of amino acid metabolism. New Eng. J. Med., 270: 1378, 1964.
28. Feigin, R. D., Klainer, A. S., and Beisel, W. R.: Factors affecting circadian periodicity of blood amino acids in man. Metabolism, 17: 764, 1968.
29. Banerjee, B. N., and Woodard, G.: A comparison of outdoor and indoor housing of Rhesus monkeys (*Macaca mulatta*). Lab. Anim. Care, 20: 80, 1970.
30. Craigie's Neuroanatomy of the Rat, Revised by Zeman, W., and Innes, J. R., p. 120, Acad. Press, N.Y., Lon., 1963.
31. Sheehan, H. L., and Kovacs, K.: The subventricular nucleus of the human hypothalamus. Brain, 89: 589, 1966.
32. Madden, S. D., Woods, R. R., Skull, F. W., Remington, J. H., and Whipple, G. H.: Tolerance to amino acid mixtures and casein digests given intravenously. J. Exp. Med., 81: 439, 1945.
33. Unna, K., and Howe, E. E.: Toxic effects of glutamic and aspartic acid. Fed. Proc., 4: 138, 1945.
34. Levey, S., Harroun, J. E., and Smyth, C. J.: Serum glutamic acid levels and the occurrence of nausea and vomiting after intravenous administration of amino acid mixtures. J. Lab. Clin. Med., 34: 1238, 1949.
35. Goodman, L. S., Swinyard, E. A., and Tomans, J. E. P.: Effects of L-glutamic acid and other agents on experimental seizures. Arch. Neurol. Psych., 56: 20, 1946.
36. Bhagavan, H. N., Coursin, D. B., and Stewart, C. N.: Monosodium glutamate induced convulsive disorders in rats. Nature, 232: 275, 1971.
37. Finberg, L.: Hypernatremic dehydration. Advance Pediat., 16: 325, 1969.
38. Tollan, H. H.: A survey of amino acids and related compounds in nervous tissue. *In* Amino Acid Pools (Ed. by J. T. Holden) p. 471, Elsevier Publ. Co., Amsterdam, 1962.
39. Perez, V. J., and Olney, J. W.: J. Neurochem., in press, 1972.
40. Chicken or Beef Bouillon Cubes, made and packed by Wyler Foods, Borden, Inc., Chicago, Ill. See label on 2 oz. bottle.
41 Olney, J. W.: Neurotoxic effects of acidic and sulphur-containing amino acids on the developing central nervous system. Presented at the 47th Annual Meeting of Amer. Assoc. Neuropath., Puerto Rico, June, 1971.