MONOGRAPH

ON

VITAMIN A

B32

#78 vol.V

Monograph on **Vitamin** A-Volume 5 #78 1/31/75

B 32

MONOGRAPH

ON

VITAMIN A

Volume 5

TR-72-1552-65

Submitted Under:
Contract No. FDA 74-104

January 31, 1975

INFORMATICS INC.
6000 Executive Boulevard
Rockville, Maryland 20852

Sadhu-'47
Bib. No. 7938

Am. J. Physiol. 149:400-403. 1947.

Reproduced by permission
of the copyright owner

EXCESS VITAMIN A INGESTION, THYROID SIZE AND ENERGY METABOLISM

DULAL PADA SADHU[1] AND SAMUEL BRODY

From the Department of Dairy Husbandry, University of Missouri, Columbia

Received for publication January 25, 1947

A curious effect of heavy vitamin A administration is that it depresses basal metabolism (1). The mechanism thereof is not known but it seems to be associated with the endocrine system. This paper presents quantitative data on the effect of heavy vitamin A administration, alone and in combination with thyroxine or thiouracil, on some metabolic and anatomic responses of white rats, together with attempts to interpret the interrelations.

METHODS. Metabolic and anatomic observations were made on the following groups of white rats: controls; fed percomorph oil containing about 30,000 I.U. vitamin A per day; injected 1 mgm. thyroxine per kgm. body weight at the beginning of each weekly experiment; injected thyroxine and fed percomorph oil in the above dosages; fed thiouracil (feed contained 0.1 per cent thiouracil); thiouracil plus vitamin A; dinitrophenol 2.5 mgm. per kgm. body weight; dinitrophenol plus vitamin A; partly and completely oxidized vitamin A.

RESULTS. The effect of vitamin A, of thyroxine, and of combinations of the two on basal metabolism are graphed in figure 1 and the effects on thyroid size are listed in table 1.

Figure 1 shows that vitamin A in large doses depresses the rate of oxygen consumption of normally-fed rats by about 10 per cent; and it depresses the metabolism of the thyroxine-injected rats by about 20 per cent. These results have been confirmed by repeating the experiments several times.

Feeding potassium iodide lowered slightly the metabolism in the normal but not in the thyroxine-treated rats.

Table 1 shows that the rats that received the excess vitamin A supplement had smaller thyroids than those that did not get the vitamin A supplement. The males were affected somewhat less by the vitamin A than the females or the castrated males. The sex difference, however, was not great.

"Completely oxidized" vitamin A (air bubbled through the hot oil for 6 hrs.) had no effect; but "partly oxidized" vitamin A (air bubbled 1 to 2 hrs.) exerted the thyroid-reducing effect.

DISCUSSION. Table 1 and figure 1 demonstrate in a quantitative manner that excess vitamin A depresses the metabolic rate and reduces the thyroid size of normal, thiouracil-treated and thyroxine-treated rats. What are the mechanisms of these effects?

Belasco and Murlin (2) suggested that since vitamin A has a double bond, it may become iodinated and relieve certain hyperthyroid conditions, such as increased metabolic rate, as do some other iodine compounds. This suggestion

[1] India Government Scholar.

was tested by feeding potassium iodide to the thyroxine-treated rats. The potassium iodide depressed slightly the metabolic rate of the controls but not those treated with thyroxine.

We should like to suggest that when vitamin A is fed in excess, its double bond takes up the iodine from the thyroxine, thus rendering the thyroxine ineffective and thereby reducing the metabolic rate. The iodinated vitamin A so formed may, however, depress the secretion of the anterior pituitary thyrotrophic hormone as thyroxine does, and thus diminish thyroid size. This seems to explain quite simply how excess vitamin A reduces thyroid size (table 1) by depressing

TABLE 1

The influence of vitamin A, thyroxine, thiouracil, and dinitrophenol on thyroid weight

SUBJECT	NO. OF RATS	AVERAGE BODY WEIGHT	THYROID WEIGHT MGM. PER 100 GRAMS BODY WT.			DECREASE IN THYROID WEIGHT	STATIST. SIGNIF.
			Aver.	Stand. dev.	Range		
		gram				%	
Control, female	10	148.5	10.05	1.329	7.34–11.98		
Vitamin A, female	10	147.3	6.57	1.030	4.87– 8.61	35	38*
Thiouracil, female	10	138.7	34.23	4.654	28.27–40.49		
Thiouracil plus vitamin A, female	10	170.4	27.48	4.125	23.11–37.19	20	11*
Control, male	8	208.5	8.18	0.248	7.21– 9.31		
Vitamin A, male	8	228.0	5.72	0.102	5.33– 6.27	30	61*
Dinitrophenol, male	8	179.1	5.22	0.171	4.45– 6.20		
Dinitrophenol plus vitamin A, male	6	183.3	4.81	0.122	4.38– 5.62	7	2(N.S.)
Control, castrated	10	158.4	7.42	0.079	6.90– 7.80		
Vitamin A, castrated	7	206.6	4.86	0.117	4.43– 5.50	36	256*

* There is less than one chance in one hundred trials that the differences between thyroid weights could have arisen by chance. The tests for significance were made by means of Snedecor's Tables (see Snedecor, G. W., *Statistical methods*, p. 174, 1937).
N.S. = not significant.

the production of thyrotrophic hormone; and how it depresses the metabolic rate (fig. 1) by inactivating the thyroxine.

Other simple explanations may be suggested which, however, may be criticised. For instance, the recent dramatic developments in the field of anti-vitamins, illustrated by the effectiveness of the sulfonamides and related substances in displacing essential vitamins, suggests that excess vitamin A may act analogously as an anti-thyroid. Vitamin A in excess may displace thyroxine from metabolically essential systems and thus reduce the metabolic rate. The thyroxine thus set free will depress the production of thyrotrophic hormone and therefore reduce thyroid size. The objection to this theory is that excess vitamin

A also decreases the thyroid size of thiouracil-fed rats (table 1), that is, when the thyroxine stores were presumably exhausted. This objection does not hold in the preceding theory in which it is assumed that the iodinated vitamin A, not the thyroxine, depresses the secretion of thyrotrophic hormone and therefore reduces the thyroid size. We are attempting to determine the effects of iodinated vitamin A on thyrotrophic hormone secretion, that is, on thyroid size.

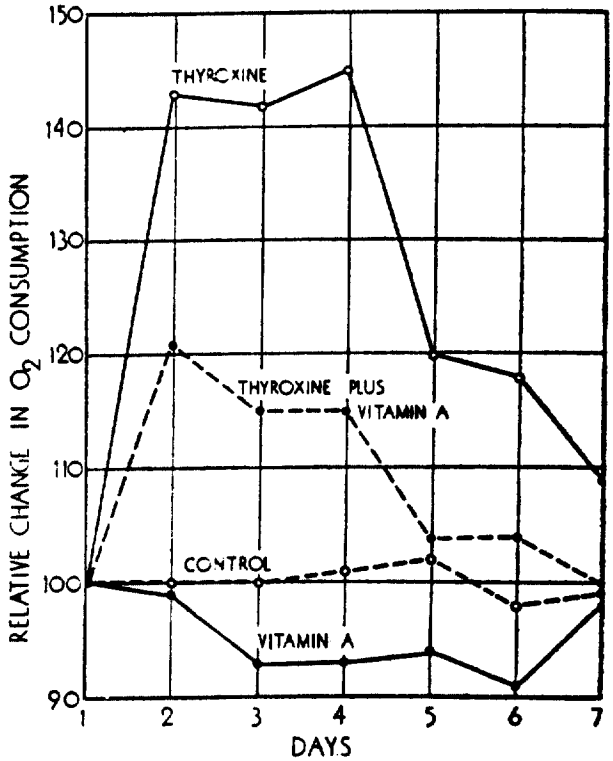

Fig. 1. Influence of vitamin A, thyroxine and thyroxine plus vitamin A administration on oxygen consumption. The thyroxine was injected once, at the beginning of the experiment, at the rate of 1 mgm. per kgm. body weight. The vitamin A was fed daily, in the form of percomorph oil, at the rate of 30,000 I.U. per rat per day.

Other, more far-fetched, explanations come to mind. For instance, since vitamin A has an unsaturated linkage, it may act as a redox perhaps as a part of an electron-transfer system and compete with some oxidative enzyme. The vitamin A may thus depress tissue oxidation indirectly and reduce the metabolic rate, just as if the thyroid function were depressed. This hypothesis was tested, rather crudely, by partly oxidizing the vitamin A as previously explained, when it continued to depress the thyroid size; but if the vitamin A was completely oxidized, the thyroid-depressing effect was lost.

Having established the fact that vitamin A depresses the metabolism-stimulating effect of thyroxine one wonders whether vitamin A might not similarly

depress the metabolism-stimulating effect of dinitrophenol. This idea was subjected to experimental test but could not be demonstrated perhaps because, unlike thyroxine, dinitrophenol acts very rapidly. Moreover (3), dinitrophenol is toxic, it blocks normal glycogen synthesis and upsets the normal course of the metabolic sequence.

SUMMARY

1. Heavy vitamin A medication, while allowing normal growth of the rats, depressed their basal metabolism and reduced the weight of their thyroids. The excess vitamin A also depressed the thyroid size of thiouracil-treated rats.

2. Heavy vitamin A medication tends to neutralize the increased metabolic effect of thyroxine injection.

3. While potassium iodide decreased somewhat the metabolic rate of control rats, it did not decrease the metabolism of the thyroxine-treated rats.

4. Partly oxidized—but not fully oxidized—vitamin A reduced the thyroid size.

5. Several theories are suggested for the observed effects of excess vitamin A ingestion in depressing the metabolic rate and thyroid size; the simplest is that the thyroxine iodine is taken up by the double bond of the vitamin A. This reaction removes the metabolism-stimulating effects of thyroxine and the resulting iodinated vitamin A, like thyroxine, depresses pituitary thyrotrophic hormone secretion, thereby reducing the thyroid size.

REFERENCES

(1) Drill, V. A. Physiol. Rev. **23**: 335, 1943.
Brody, S. Bioenergetics and growth, pp. 177–8. New York, 1945.
(2) Belasco, I. J. and J. R. Murlin. J. Nutrition **20**: 577, 1940.
(3) Clifton, C. E. Enzymologia **4**: 246, 1937. J. Bact. **37**: 523, 1923.
(4) Doudoroff, M. Enzymologia **9**: 59, 1940.

J. Exptl. Zool. 151(3):279-285. 1962.

The Effect of Excess Vitamin A on the Oxygen Consumption of Young Female Rats

MYRA M. SAMPSON, ESTHER CARPENTER[1] AND ROLAND WIGHT
Department of Zoology,[2] Smith College, Northampton, Massachusetts

The purpose of the following experiments was to determine the effect of different levels of excess vitamin A in the diet on the activity of the thyroid gland as indicated by determinations of oxygen consumption in relation to body weight.

METHODS

Twenty-seven female rats of the Sprague-Dawley strain were used in sets of three litter-mates each. Different sets were run at different times. Initial ages of the sets ranged from 41 to 48 days. The weight range was from 116 to 157 gm. In individual sets the weight variation was from 1 to 20 gm.

All animals were supplied with a purified basal diet with tri-weekly additions of adequate vitamin supplements (table 1). The amount of vitamin A included was between 3 and 6 I.U. daily per gram of body weight. After a week on this diet, the experimental rat of a set was given additional vitamin A orally in the form of palmitate, six times a week, by means of a calibrated pipette. Initial doses of 25,000 I.U. per day per rat were continued for 38 and 42 days in sets L and N when the experiments were terminated. This dosage provided between 100 and 200 I.U. per gram of body weight. Progressive increase in dosage reached 300 to 400 I.U. per gram of body weight in sets K and J; 400 to 500 in sets H, C, E and M; and a maximum of 500 to 525 I.U. in set F. Only in set F did the final dosage per rat exceed 80,000 I.U. daily.

TABLE 1
Diet for all rats

Casein, "Labco"	22 parts
Corn starch, Staley	51 parts
"Crisco"	9 parts
Lard, Swift's silver leaf	6 parts
Salt mixture, Hubbell, et al.	4 parts
B vitamins, Brewer's yeast	8 parts
Tri-weekly additional vitamins:	
Vitamin A	1,599 I.U., Distillation Products
Vitamin D	750 I.U., Winthrop, Stearns
Vitamin E	0.12 I.U., Abbott Co.
Vitamin C	50 mg ascorbic acid, Lederle

Each experimental animal had two litter-mate controls, one allowed food ad libitum and the other allowed only as much food as was consumed on the previous day by the rat receiving excess vitamin A. Such double controls were suggested by Rodahl ('50) as a check on the possibility that some of the symptoms reported as due to vitamin A toxicity might be caused by inanition. Daily records were kept of food intake, body weight, and symptoms of vitamin A toxicity. The length of the experimental period was determined by the condition of the hypervitaminotic-A rat and varied from 16 days in set H to 42 days in set N (see table 2).

During the experimental period, each set of rats was subjected to 4 to 13 tests of oxygen consumption (table 3) in a modification of the closed respiratory metabolism apparatus described by Grad ('52). Food was removed from the cages at least five hours before the tests were run. The temperature of the water around the chamber was maintained at 28 ± 1°C, the critical temperature for the albino rat according to Benedict and MacLeod ('28). Bright lights were employed to induce the rat to remain quiet during the two 15-minute runs. The lower of the two measurements was used to calculate the oxygen consumption per hour. This was then converted to milliliters of oxygen per hour per 100 gm of body weight so that all results would be comparable. Sherwood

[1] Supported in part by grants from the American Cancer Society, CP-71a and b, and by USPHS grant A-5261.
[2] Contribution No. 241.

TABLE 2

Initial and final oxygen consumption and weights[1]

Set	Days of exp.	O_2 ml/hr/100 gm		Difference in O_2 consumption	Weight in grams		Difference in weight
		Intake paired	Excess vit. A		Intake paired	Excess vit. A	
L	38	149	163	+14	123	130	+ 7
		121	118	− 3	188	181	− 7
N	42	103	99	− 4	143	149	+ 6
		128	119	− 9	224	228	+ 4
K	36	211	195	−16	125	135	+10
		105	122	+17	223	215	− 8
J	33	161	158	− 3	149	157	+ 8
		113	121	+ 8	219	208	−11
H	16	163	167	+ 4	147	148	+ 1
		141	141	0	170	188	+18
C	19	139	129	−10	171	157	−14
		112	120	+ 8	185	160	−25
E	22	158	134	−24	131	131	0
		117	150	+33	171	157	−14
M	29	176	157	−19	125	132	+ 7
		134	158	+24	184	169	−15
F	30	124	108	−16	148	147	− 1
		104	151	+47	199	180	−19

[1] Sets are arranged in order of increasing terminal doses of vitamin A per gram of body weight: L and N, 100–200; K and J, 300–400; H, C, E and M, 400–500; and F, 500–525 I.U.

TABLE 3

Oxygen consumption and level of vitamin A

I.U. vitamin A		Number of tests	Comparison with intake paired controls	
Per day per rat	Per gram body weight		Higher	Lower
25,000	100–200	21	7	14
		9	3	6
		6	2	4
50,000	249–260	13	8	5
	300–360	10	4	6
75,000	349–360	3	2	1
	400–500	15	12	3
100,000	500–525	2	2	0

(36) considered weight more reliable than surface area. Since there seems to be no generally accepted formula for calculating the basal metabolism of the rat, the data were taken no further.

The day before the termination of an experiment, each rat in a set was injected subcutaneously with a solution containing 5 microcuries of radioactive iodine. At autopsy the thyroids were removed for autoradiographic and histological study and the skeletons preserved for later examination.

The vitmain A concentrate and palmitate were kindly supplied by Distillation Products Industries.

OBSERVATIONS

Since no significant differences were noted between the controls allowed unlimited food and those which were pair-fed all comparisons were made between

the latter and the experimental rats receiving excess vitamin A, unless otherwise stated.

a. Food intake

The average daily food intake of the controls allowed unlimited food was approximately 12 gm. Rats receiving 100–200 I.U. of vitamin A per gram of body weight (sets L and N) ate about 11 gm daily. Towards the end of the experiment some of the rats receiving 400 to 525 I.U. (sets J, C and M) ate as little as 5 gm daily.

b. Efficiency of food utilization

There was a decrease in efficiency of food utilization with increasing age in normal rats as observed by Mayer and Krehl ('48). This tendency was accelerated in the vitamin A rats and was the first symptom of vitamin A toxicity, even preceding reduction in food intake. In sets L and N this became apparent when the dosage reached 100–200 I.U. per gram of body weight following smaller doses given over a period of 24 to 30 days. In sets K and J it occurred after 6 doses of 200–300 I.U. per gram which had been preceded by 6 to 12 doses of 100–200 I.U. while in set H the decrease was apparent after two additional doses of 400–500 I.U. of vitamin A per gram of body weight.

c. Visible symptoms of toxicity

Rats receiving 100–200 and 200–300 I.U. of vitamin A palmitate per gram of body weight developed mild symptoms of vitamin A toxicity including alopecia, inflammation of the eyelids and margins of the nose and mouth. With subsequent doses of 349–525 I.U. per gram of body weight, more severe symptoms appeared including greater inflammation around the eyes (fig. 1a); roughness of hair (fig. 1b) and greater hair loss; bleeding at external orifices; a yellow discharge from the vagina; loss of balance; deformity of the spinal column and fractures of the bones of the appendages. Postmortem examination revealed extensive hemorrhages. Skeletal preparations showed thinning of many bones and osteoporosis.

d. Oxygen consumption

The normal decrease in oxygen consumption with increasing age and weight noted by Sherwood ('36) occurred in all controls but those of set N in which the oxygen consumption increased throughout the experimental period.

Compared with their food intake-controlled litter mates the rats receiving dosages between 100–200 I.U. of vitamin A per gram of body weight showed a lower oxygen consumption in two-thirds of the 36 tests run. However, when the dosage reached 300–525 I.U. the oxygen consumption of the hypervitaminotic A rats was greater than that of the pair-fed controls in two-thirds of the 30 tests run (see table 3). The greater oxygen consumption with higher levels of vitamin A was most evident in sets E, M and F in which the percentage increase was 17, 16 and 18. Towards the end of an experiment when the weight of the experimental rat had fallen below that of the intake paired control (see table 2), the percentage difference in oxygen consumption was increased by approximately another 10%.

DISCUSSION

The toxic effects of feeding excessive amounts of rich sources of vitamin A to rats, reported by Takahashi et al. ('25) have been repeatedly confirmed by many later investigators to whom the crystalline form of the vitamin has been available (Wolbach and Bessey, '42; Moore and Wang, '43 and '45; Sampson, Carpenter and Wight, '56).

As early as 1934 Sherwood, Toth and Carr noted changes in the histological structure of the thyroid, in rats receiving excess vitamin A, which are usually considered indicative of increased metabolic activity: loss of colloid; reduction in size of follicles; irregularity in outline of follicles and increased height of follicular epithelium. These changes have been confirmed by Sherwood and Luckner, '35; Uotila, '38; Wegelin, '39; and Carpenter and Sampson, '56.

In spite of the histological picture, investigators studying the oxygen consumption or basal metabolism of the rat receiving excess vitamin A have reported apparently contradictory results. No effect was

found by Sherwood et al. ('34); Belasco and Murlin ('40); and Sheets and Struck ('42). A lowering of oxygen consumption was reported by Chevallier and Baert ('34); Rappai and Rosenfeld ('35); and Sadhu and Brody ('47). The level of vitamin A given daily seems to have been not more than 50 I.U. per gram of body weight in the experiments of Chevallier and Baert ('34); Abelin ('35); Logaras and Drummond ('38) and Belasco and Murlin ('40). However, Sadhu and Brody ('47) and Sheets and Struck ('42) gave as much as 200 I.U. per gram of body weight. The latter investigators gave daily doses for 50 days and made oxygen consumption determinations weekly. They were unable to reach a firm conclusion on the effect of excess vitamin A on oxygen consumption in either the otherwise normal or the hyperthyroid rat.

In hyperthyroid rats administration of vitamin A has been reported to lower the high oxygen consumption to some extent by Abelin ('35); Rappai and Rosenfeld ('35); Logaras and Drummond ('38); Belasco and Murlin ('40); and Sadhu and Brody ('47). Both Greaves and Schmidt ('36) and Sure and Buchanan ('37) have suggested that thyroxin may induce a vitamin A deficiency. Reduction in the degree of hyperthyroidism in hyperthyroid rats by administration of increased amounts of vitamin A may be explained on this theory as an alleviation of a vitamin A deficiency (Belasco and Murlin, '40). According to Baumann and Moore ('39), however, if both vitamin A and thyroxin are given at the same time in sufficiently large amounts to be toxic but not immediately fatal, additive rather than antagonistic effects may be obtained. Such large doses were not given in the previously cited experiments.

In our own experiments when the amount of vitamin A did not exceed 200 I.U. per gram of body weight, two-thirds of the tests (24 out of 36) indicated that the experimental rats had a lower oxygen consumption than their pair-fed controls. When the dosage was increased to levels between 300 and 525 I.U. per gram of body weight, the trend was reversed and the hypervitaminotic-A rats showed a higher oxygen consumption than their litter-mate controls in 20 out of 30 tests (see table 3). Our terminal doses of vitamin A were considerably higher than most of those previously reported in the literature and all of our comparisons have been made between litter-mate females. From our results it appears that the increased oxygen consumption observed in the majority of the rats receiving very high dosages of vitamin A per gram of body weight may indicate a hyperactive condition of the thyroid gland during the later stages of severe hypervitaminosis-A.

SUMMARY AND CONCLUSIONS

Nine sets, each consisting of three young female litter-mates of the Sprague-Dawley albino rat strain, were used in these experiments. Two rats in each set served as controls, one of them having its food intake limited to that of the experimental rat. The latter in each set was given increasing amounts of vitamin A orally, in some cases up to a level of approximately 500 I. U. per gm of body weight. Tests of oxygen consumption were made at intervals and recorded as milliliters of oxygen used per hour per 100 gm of body weight. Since no marked differences were observed in the two types of controls comparisons were made between the experimental rats and their food intake-paired controls.

Hypervitaminotic-A rats receiving not more than 200 I. U. per gram of body weight consumed less oxygen than their litter-mate controls in two-thirds of the tests run. Those receiving from 300 to 525 I. U. per gm of body weight consumed more oxygen than their litter mate controls in two-thirds of the tests run. This reversal became more pronounced when the weight of the experimental rat fell below that of its litter-mate control eating the same amount of food.

The increased oxygen consumption of the female rat on very high levels of vitamin A in relation to body weight lends support to the histological evidence of increased thyroid activity. The extent of the effect appears to be dependent on the number of doses and the level of the vitamin reached in relation to the body weight and would thus account for what have appeared to be conflicting observations in the past.



1a

1b

PLATE 1

EXPLANATION OF PLATE

1 Two views of the experimental rat of set M, age 77 days, after four weeks on increasing amounts of vitamin A as follows: 20,000 I. U. the first week (6 times a week); 53,000 I. U. the second week, and 79,000 I. U. during the third and fourth weeks. The experiment was begun when the rats of this set were 48 days old. During the last week the weight of the experimental rat fell from 170 gm to 137 gm. During the same period the intake paired control went from 184 gm to 168 gm.

Note the eyes, the rough coat and the humped back of the experimental rat. One foreleg was fractured and internal hemorrhages were extensive. None were found in the control.

LITERATURE CITED

Abelin, I. 1935 Ueber den antagonismus A-vitamin; thyroxin. Zeit. Vitaminforsch., 4: 120–128.

Baumann, C. A., and T. Moore 1939 Thyroxine and hypervitaminosis-A. Biochem. J., 33: 1639–1644.

Belasco, I. J., and J. R. Murlin 1940 The effect of vitamins A and C on experimental hyperthyroidism. J. Nutrition, 20: 577–588.

Benedict, F. G., and G. MacLeod 1928 Heat production of the albino rat. II. Influence of environmental temperature, age and sex; comparison with the basal metabolism of man. J. Nutrition, 1: 367–398.

Carpenter, E., and M. M. Sampson 1956 The effect of excess vitamin A in the diet on the thyroid gland of young female albino rats. Anat. Rec., 124, 391 (abstract).

Chevallier, A., and H. Baert 1934 De l'influence de la vitamine A sur le metabolisme du rat et du cobaye. Compt. Rend. Soc. Biol., 116: 1037–1039.

Grad, B. 1952 A simple method for the measurement of the oxygen consumption and heart rate of rats. Endocrinology 50: 94–99.

Greaves, J. D., and C. L. A. Schmidt 1936 Studies on the vitamin A requirement of the rat. Am. J. Physiol., 116: 456–467.

Logaras, G., and J. C. Drummond 1938 Vitamin A and the thyroid. Biochem. J., 32: 964–968.

Mayer, J., and W. A. Krehl 1948 Influence of vitamin A deficiency on the gross efficiency of growth of rats. Yale J. Biol. and Med., 20: 403–405.

Moore, T., and Y. L. Wang 1943 The toxicity of pure vitamin A. Biochem. J., 37: viii-lx.

——— 1945 Hypervitaminosis A and bone formation. Ibid., 39: 222–228.

Rappai, S., and P. Rosenfeld 1935 Gaswechselversuche bei mit thyroxin und vitamin A behandelten Tieren. Pflüger's Archiv ges. Physiol., 236: 464–470.

Rodahl, K. 1950 Hypervitaminosis A in the rat. J. Nutrition, 41: 399–421.

Sadhu, D. P., and S. Brody 1947 Excess vitamin A ingestion, thyroid size and energy metabolism. Am. J. Physiol., 149: 400–403.

Sampson, M. M., E. Carpenter and R. Wight 1956 Effects of excess vitamin A palmitate in paired feeding experiments on albino rats. Fed. Proc., 15: 571 (abstract).

Sheets, R. F., and H. C. Struck 1942 Vitamin A and the thyroid. Science, 96: 408–409.

Sherwood, T. C. 1936 The relation of season, sex and weight to the basal metabolism of the albino rat. J. Nutrition, 12: 223–236.

Sherwood, T. C., and W. G. Luckner 1935 Further studies on the effect of cod liver oil on the thyroid gland. Ibid., 9: 123–129.

Sherwood, T. C., L. A. Toth and K. Carr 1934 Effects of cod-liver oil on basal metabolism and on the thyroid gland. Endocrinology, 18: 254–255.

Sure, B., and K. S. Buchanan 1937 Influence of hyperthyroidism on vitamin A reserves of the albino rat. J. Nutrition, 13: 521–524.

Takahashi, K., Z. Nakamiya, M. Kawakimi and T. Kitasato 1925 On the physical and chemical properties of biosterin (a name given to fat soluble-A) and on its physiological properties. Sci. Papers, Inst. Phys. Chem. Res., Tokyo, 3: 81–145.

Uotila, U. 1938 Ueber die Schilddrüsen Veränderungen bei A, B, C, D Avitaminosen. Virchow's Arch., 301: 535–546.

Wegelin, C. 1939 On the antagonism between thyroxine and vitamin A. Western J. Surg. Obstet. Gyn., 47: 147–154.

Wolbach, S. B., and O. H. Bessey 1942 Tissue changes in vitamin deficiencies. Physiol. Rev., 22: 233–289.

Selvaraj-'70
Bib. No. 8279

ESTIMATION OF SERUM VITAMIN A BY A MICROFLUOROMETRIC PROCEDURE

R. JAMES SELVARAJ AND T. PARAMASIVAM SUSHEELA
Nutrition Research Laboratories, Indian Council of Medical Research, Jamai-Osmania, Hyderabad-7 (India)
(Received September 10, 1969)

SUMMARY

A simple spectrofluorometric method for the assay of vitamin A in 50 μl samples of serum is described. Assays of serum samples were performed at microlitre level by the fluorometric technique and by the standard spectrophotometric technique at millilitre level and the results are compared. The fluorometric assay offers a twenty-fold increase in sensitivity with little sacrifice of analytical accuracy or reliability when compared to an established spectrophotometric procedure.

Determinations of vitamin A concentrations in biological materials have been carried out in the past both by ultraviolet absorption and fluorescent procedures[1-3]. The fluorescent properties of vitamin A have been extensively exploited by the earlier workers for the identification and quantitation of vitamin A in histochemical sections of tissues[4]. However, in spite of the inherent greater sensitivity, fluorescent methods have not enjoyed wide use for routine quantitative assay of the vitamin. This paper reports the results of investigations on the development of a simple, sensitive and reliable microfluorometric procedure for the assay of vitamin A in serum.

PRINCIPLE

Protein-bound vitamin A is released and vitamin A esters hydrolysed from serum by hot alcoholic potassium hydroxide. The vitamin A alcohol formed is extracted with xylene. The xylene layer is separated and excited at 350 mμ and the fluorescence measured at 490 mμ. Non-specific fluorescence, if any, is measured at the same wavelengths following ultraviolet destruction of vitamin A in the xylene extract and subtracted from the total fluorescence, to yield the net fluorescence due to vitamin A. The vitamin A content of the sample is obtained by comparing the net fluorescence with that produced by standard vitamin A.

MATERIALS AND METHODS

Water, double distilled, from all-glass apparatus was used to prepare all solutions. All chemicals used were of analytical quality, and were commercially obtained. All solvents were of reagent grade, further purified by distilling from an all-glass apparatus, with a long fractionating column. The first 10% and the last 25% of the distillate were rejected. Alcohol was further purified by refluxing over potassium hydroxide pellets for 8 h, prior to fractional distillation. Vitamin A palmitate was obtained from Roche Products Ltd., Bombay.

Fluorescence measurements were carried out in a Farrand spectrofluorometer attached to a Varian recorder. Micro-cuvettes (Corning glass) of 3 mm internal diameter and 0.3 ml capacity, matched for fluorescent characteristics at the specified wave lengths were used along with the micro-cuvette adapter. Band width, at half of peak transmission, using 2-mm wide slits was stated by the manufacturer to be 20 mμ. No primary filter was used. A secondary filter, transmitting above 480 mμ was used.

Absorption measurements were done with a Beckmann DU-2 spectrophotometer. Ultraviolet irradiation of the samples was carried out in the micro-cuvettes, with an Osram HBO mercury vapour lamp, equipped with a small fan to cool the samples. Calibrated, Lang–Levy constriction pipettes[5] were used for transferring microlitre quantities of reagents and samples. All mixings were done in a Beckmann micro-vortex mixer. All manipulations were carried out in partially darkened area avoiding especially direct sunlight and fluorescent lights.

Procedure

Blood was collected by finger prick in small glass centrifuge tubes or in plastic micro-test tubes of 0.5 ml capacity (Beckmann, Fullerton, California) and allowed to clot. It was then centrifuged and 50 μl of serum was transferred into 2-ml glass centrifuge tubes. Fifty μl of 1 N alcoholic potassium hydroxide, prepared the same day by dilution of 19 N potassium hydroxide in water with 95% ethanol, was added to the serum aliquot and mixed in the vortex mixer. The tubes were then kept in a hot water-bath, maintained at 60° for 20 min to extract and hydrolyse vitamin A esters to alcohol. The tubes were cooled and the vitamin A alcohol was extracted with 0.3 ml of xylene, by vigorously mixing the two phases in the micro-vortex mixer for 20 sec. The upper xylene layer was separated by centrifugation and transferred to the microcuvettes. Fluorescence was measured in the Farrand fluorometer at 490 mμ with excitation at 350 mμ (uncorrected). The cuvettes were then covered with glass beads (5 mm diameter) to avoid evaporation, and irradiated for 10 min in an irradiation chamber, similar to the one described by Bessey[1]. Fluorescence readings were again taken following irradiation and the net fluorescence destroyed by ultraviolet irradiation was calculated.

A series of standards of vitamin A palmitate, containing 0.01–0.05 μg in 50 μl, was treated in a similar manner to the serum sample. Simultaneously, the absorbance of an alcoholic solution of the standard containing approximately 3 μg/ml of vitamin A palmitate was measured in a Beckmann DU spectrophotometer at 328 mμ. The exact vitamin A content of the standard was calculated from the absorbance by using the conversion factor $E^{1\%}_{1cm} = 940$ (ref. 6). A standard curve was constructed

relating the fluorescence of these standards with the concentration and was used for estimating the vitamin A content of the unknown sample.

RESULTS AND DISCUSSION

Hydrolysis of vitamin A esters were carried out essentially by the method of Bessey *et al.*[1]. Recently, Hansen and Warwick[7] have described a fluorometric micromethod for serum vitamin A determination, where vitamin A was extracted from unhydrolysed serum samples by cyclohexane. However, in our hands, added vitamin A palmitate to different samples of serum gave erratic recoveries (70–105%), if the hydrolysis step was omitted. This is possibly due to either incomplete extraction of the vitamin A esters in absence of hydrolysis[1,8] or due to the different fluorescence characteristics of vitamin A alcohol and its esters[2,9].

Of the various solvents examined for extracting and measuring the fluorescence of vitamin A, xylene was found to be most suitable. Kahan[10], investigating the effects of different solvents on the yield of fluorescence, concluded that cyclohexane is superior to heptane, ethyl ether, toluene, ethanol, isopropanol or chloroform. In our hands, xylene shows 16.9 ± 2.2% (8 experiments) higher fluorescence yield, when compared to cyclohexane. Further, the significantly lower volatility of xylene when compared to cyclohexane is a decided advantage, especially to prevent concentration changes due to evaporation during irradiation destruction of the vitamin. Xylene extracts vitamin A quantitatively (as shown by recovery experiments—Table I and ref. 1) and has been used successfully in quantitative extraction of the vitamin from tissue sections[6] for fluorescence studies.

The relationship between the amount of vitamin A and fluorescence intensity is shown in Fig. 1. From the graph, it can be seen that 0.005 μg of vitamin A alcohol in 0.3 ml solvent will give reliable fluorescence. In comparison, for a sample containing 0.1 μg in 0.3 ml cyclohexane the absorbance obtained in the Beckmann spectrophotometer in a 1-cm light path microcuvette is only 0.058 ($E^{1\%}_{1cm}$ 1737), which is very close to the lower limit of the instrument's useful range. Thus, the fluorometric assay is approximately 20 times more sensitive than the spectrophotometric assay. No marked deviation from the standard curve was noticed over a period of six months. However, it is still felt necessary to run standards with each assay to compensate for

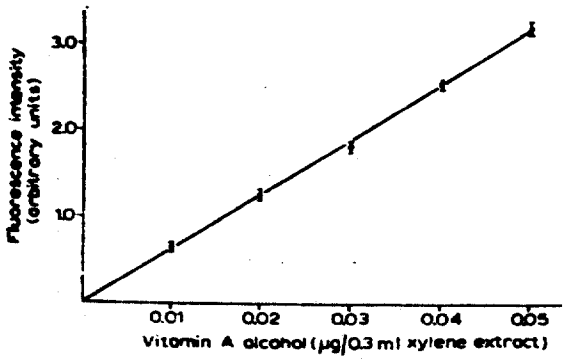

Fig. 1. Relative fluorescence intensities of vitamin A alcohol as a function of concentration. Results are means ± standard deviations of 9 experiments.

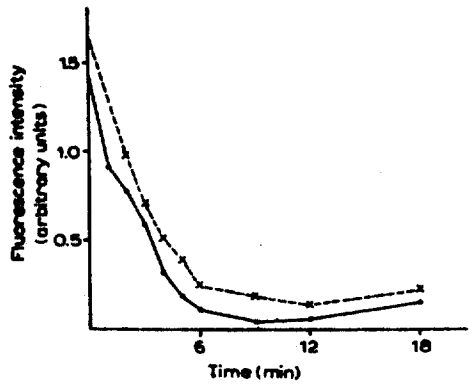

Fig. 2. Ultraviolet destruction of standard and serum vitamin A. Irradiation was carried out with an Osram HBIO mercury vapour lamp, in an irradiation chamber similar to the one described by Bessey *et al.*[1]. ---- Vitamin A extracted from 50 μl of serum. —— Standard vitamin A.

instrument variations, solvent and chemical decompositions. Further, the unstable nature of vitamin A necessitates that the concentration of the stock standard should be checked periodically by ultraviolet absorption spectrophotometry.

Bessey *et al.*[1] presented adequate evidence for the selective destruction of vitamin A alcohol in xylene–kerosene extracts of serum samples, by ultraviolet irradiation using spectrophotometric assay. Fig. 2 shows the kinetics of the destruction of vitamin A by ultra-violet irradiation of standard vitamin A and xylene extracts of hydrolysed serum. The similarities of the two curves indicate the specific nature of the destruction of fluorescence in the serum extract. Further evidence of specificity of the method was obtained by a study of the excitation and fluorescent spectra following ultraviolet irradiation. Fig. 3 presents the data obtained with serum sample and standard vitamin A. The similarities of the spectra indicate that most of the fluorescent substance extracted by this procedure is vitamin A. Residual, non-

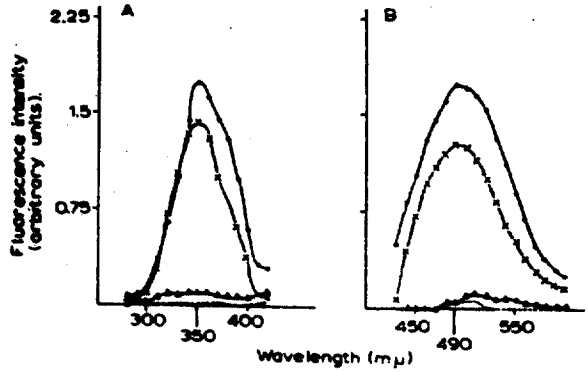

Fig. 3. Excitation and fluorescence spectra of serum and standard vitamin A before and after destruction by ultraviolet irradiation. ●-●-● Vitamin A from 50 μl of serum before ultraviolet irradiation. -▲-▲-▲- Vitamin A from 50 μl of serum after ultraviolet irradiation. ×-×-× Standard Vitamin A before ultraviolet irradiation. ---- Standard vitamin A after ultraviolet irradiation. A, Excitation spectra (fluorescence wave length fixed at 490 mμ). B, Fluorescence spectra (excitation wave length fixed at 350 mμ).

TABLE I

RECOVERIES OF VITAMIN A ADDED TO SERUM

Vitamin A in serum µg/50 µl	*Vitamin A added (µg)*	*Total vitamin A found (µg)*	*% Recovery*
0.0321	0.01	0.04142	93.2
0.0316	0.01	0.04199	103.9
0.0346	0.01	0.04492	103.2
			100.1 ± 3.46*
0.0321	0.02	0.05150	97.0
0.0316	0.02	0.05224	103.2
0.0346	0.02	0.05592	106.2
			102.1 ± 2.71*
0.0321	0.03	0.06096	96.2
0.0316	0.03	0.06175	100.5
0.0346	0.03	0.06235	92.5
			96.4 ± 2.31*
0.0321	0.04	0.07002	94.8
0.0316	0.04	0.06976	95.4
0.0346	0.04	0.07536	101.9
			97.4 ± 2.27*

* Mean and Standard Deviation.

specific fluorescence, resistant to ultraviolet destruction is also very small in serum extracts.

The reliability of the method was evaluated by recovery of added vitamin A palmitate to serum. Duplicate serum samples analysed on the same day for this experiment varied by less than 5%. However, when analysed on separate days the deviations were as much as 10%. Table I presents the data obtained on the percentage recovery of added vitamin A to serum. The recoveries were virtually quantitative, varying between 96.4–102.1%, and were within the analytical precision of the method.

The spectrofluorometric assay of vitamin A was also compared with the standard spectrophotometric estimation[1] to find the correlation between the two methods. For the spectrophotometric assay 1.5 ml of serum was hydrolysed with an equal volume of 1 N alcoholic potassium hydroxide and the vitamin A alcohol formed was extracted with 3 ml of cyclohexane. The absorbance of the extract was measured at

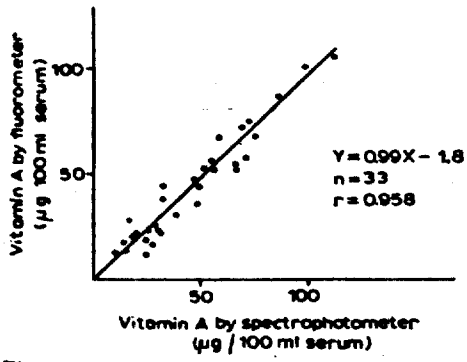

Fig. 4. Scatter diagram showing the relationship between spectrophotometric and fluorometric methods for vitamin A estimation. Vitamin A was estimated in the fluorometer by the present method and in the spectrophotometer by the method of Bessey *et al.*[1].

326 mμ before and after ultraviolet irradiation. From the net absorbance, vitamin A content was calculated using extinction coefficient $E_{1\%}^{1cm} = 1737$ (ref. 11). The vitamin content was also estimated from a 50-μl aliquot of the serum by the spectrofluorometric method as described above. Fig. 4 shows the results obtained as a scatter diagram. The high degree of correlation between the two methods demonstrates the reliability of the spectrofluorometric method for the estimation of vitamin A in serum samples.

The microfluorometric procedure described here is being successfully used in our laboratory for field studies for evaluating vitamin A nutritional status in children (ref. 12).

ACKNOWLEDGMENT

We wish to thank Dr. B. S. Narasinga Rao for his valuable criticism and help in developing this method.

REFERENCES

1 O. A. Bessey, O. H. Lowry, M. J. Brock and J. A. Lopez, *J. Biol. Chem.*, 166 (1946) 177.
2 A. Fujita and M. Aoyama, *J. Biochem. (Japan)*, 38 (1951) 271.
3 J. Kahan, *Scand. J. Clin. Lab. Invest.*, 18 (1966) 679.
4 H. Popper, *Phys. Rev.*, 24 (1944) 205.
5 M. Levy, *Compt. Rend. Trav. Lab. Carlsberg, Ser. Chim.*, 21 (1936) 101.
6 J. G. Baxter and C. D. Robeson, *J. Am. Chem. Soc.*, 64 (1942) 2407.
7 L. G. Hansen and W. J. Warwick, *Am. J. Clin. Pathol.*, 50 (1968) 525.
8 P. K. Nakane and D. Glick, *J. Histochem. Cytochem.*, 13 (1965) 640.
9 H. Sobotka, S. Kann and W. Winternitz, *J. Biol. Chem.*, 152 (1944) 635.
10 J. Kahan, *Acta Chem. Scand.*, 21 (1967) 2515.
11 J. Boldingh, H. R. Cama, F. D. Collins, R. A. Morton, N. T. Gridgeman, O. Isler, M. Kofler, R. J. Taylor, A. S. Welland and T. Bradbury, *Nature*, 168 (1951) 598.
12 T. P. Susheela, *Ind. J. Med. Res.*, 57 (1969).

Seyle-'57
Bib. No. 8281

Endocrin. (1957) 16, 231–235

PREVENTION OF VITAMIN A OVERDOSAGE BY SOMATOTROPHIC HORMONE

By H. SELYE

From the Institut de Médecine et de Chirurgie expérimentales, Université de Montréal, Montreal, Canada

(*Received* 3 *July* 1957)

SUMMARY

Experiments on albino rats indicate that the intense osteoclastic bone absorption that is characteristically produced by vitamin A overdosage can be prevented by suitable treatment with somatotrophic hormone (STH). Although luteotrophic hormone (LTH) shares several of the actions characteristic of STH, it cannot substitute for the latter hormone in counteracting the effect of vitamin A intoxication.

Earlier observations have shown that hormones often play a decisive role in the development of pathological lesions that are primarily due to non-hormonal agents. In many instances, an excess or deficiency of a hormone does not produce disease but only regulates (conditions) disease susceptibility. The importance of this type of endocrine participation was first clearly demonstrated in the case of inflammatory, traumatizing and anaphylactoid reactions. The immediate causes of these morbid states are non-hormonal agents—an infectious micro-organism or a chemical irritant (e.g. croton oil, formalin, dextran, egg-white)—but whether or not such potential pathogens will actually produce disease depends largely upon endocrine conditions and, in the examples just mentioned, particularly upon the balance between pro- and anti-inflammatory hormones [Selye, 1950, 1951; Selye & Heuser, 1955–6; Selye & Horava, 1952, 1953].

It was possible to show more recently that hormones may also play a decisive conditioning role in determining susceptibility to a non-inflammatory skeletal disease. Osteolathyrism is characterized by degenerative and proliferative changes in ossification cartilages as well as by the development of excessive periosteal bone and exostoma-like osteophytes at the site of tendon insertions. This disorder can be produced by the ingestion of the seeds of *Lathyrus odoratus* or by treatment with certain aminonitriles, but whether or not a given dose of lathyrogenic compound will, in fact, produce bone lesions depends upon the balance between certain hormones in the treated organism. Thus somatotrophic hormone (STH) and luteotrophic hormone (LTH) greatly sensitize the skeleton to otherwise subthreshold doses of lathyrogens, while gluco-corticoids and thyroxine can completely prevent the development of bone changes in animals treated with otherwise highly effective doses of lathyrogenic compounds [Selye, 1957*a*].

Since lathyrism is characterized by excessive bone proliferation, it seemed of interest to establish whether an experimental disease in which bone absorption is the outstanding feature could also be thus influenced by hormones. It is a well-established

fact that overdosage with vitamin A can produce extraordinarily intense bone absorption [see Fell, 1953; Nieman & Klein Obbink, 1954; Lowe & Morton], often accompanied by spontaneous fractures, multiple haemorrhages and intense loss of weight. It is the purpose of this communication to report upon experiments to show that these morbid changes can be inhibited by STH. Since LTH shares some of the characteristic metabolic effects of STH [Selye, 1957*a*, *b*], its possible influence upon hypervitaminosis A was also investigated but, unlike the latter hormone, it proved to be quite inert in this respect.

MATERIALS AND METHODS

Sixty female Sprague-Dawley rats with an average initial body weight of [illegible] (range 94–112 g) were subdivided into six equal groups and treated as outlined in Table 1.

Table 1. *Prevention by STH of vitamin A overdosage*

Group	Treatment	Final body weight (g)*	Bone absorption	Spontaneous fractures	Haemorrhages
I	None	138 ± 5·1	0	0	0
II	STH	214 ± 2·9	0	0	0
III	Vitamin A	97 ± 9·7	+ + +	+ + +	+ +
IV	STH + vitamin A	157 ± 8·6	0	0	Minimal
V	LTH	168 ± 5·2	0	0	0
VI	LTH + vitamin A	105 ± 4·9	+ + +	+ + +	+ +

* Initial weight range: 94–112 g.

Vitamin A was administered as its palmitate at a dose of 20,000 i.u./day during the first 7 days and of 30,000 i.u./day from then on until the termination of the experiment. The daily dose was always given in 0·4 ml. of sesame oil, by stomach tube.

Both STH and LTH were administered in daily doses of 4 mg (2 mg in 0·2 ml. of water, subcutaneously, twice daily) throughout the experiment. We employed highly purified preparations of STH and LTH which have recently been made available for investigative purposes through the Endocrinology Study Section of the United States National Institute of Health, Bethesda, Maryland.

As reported by the distributors, the characteristics of the STH preparation (bovine growth hormone, 'Somar', Armour) are the following:

Primary potency: 106·2 ± 15·9 % of Armour Standard. Relative potency (in terms of USP Reference Standard) not yet established.

Limits of contamination:

- Adrenocorticotrophic hormone (ACTH): no activity detectable at doses of 0·25 and 4 mg/100 g body weight. Estimate: < 0·06 mu. (USP)/mg.
- Thyrotrophic hormone (TSH): approximately 0·008 mu. (USP)/mg.
- Follicle stimulating hormone (FSH): total doses of 3, 5 and 8 mg, injected over a 3-day period, fail to augment the increase in ovarian weight induced by 20 i.u. human chorionic gonadotrophin (HCG), simultaneously administered to immature female rats.
- Luteinizing hormone (LH): total doses of 7·5, 10 and 15 mg, injected over a 4-day period, fail to increase the weight of seminal vesicles, ventral prostate or testes of immature male rats.
- Luteotrophic hormone (LTH): < 0·1 i.u./mg.
- Vasopressin: < 0·01 u. (USP)/mg.
- Oxytocin: < 0·008 u. (USP)/mg.

The characteristics of the LTH preparation (ovine prolactin, 'Panlitar', Armour) are:

Primary potency: 20 i.u./mg.
Estimates of contamination:
ACTH: <0·001 and >0·0005 i.u./mg.
TSH: <0·0004 u. (USP)/mg.
FSH: total doses of 1, 3, 5 and 8 mg, injected over a 3-day period, fail to potentiate the increase of ovarian weight brought about by 20 i.u. HCG, simultaneously administered to immature female rats.
LH: a total dose of 10 mg, injected over 3 days, produced no increase in the weight of the ventral prostate, and a small, barely significant increase in the weight of the seminal vesicles of immature male rats.
STH: <1 % and >0·1 %, of the activity of a highly purified bovine growth hormone standard (ratio of potencies estimated: 725/1).
Vasopressin: not more than 0·05 u./mg.
Oxytocin: not more than 0·05 u./mg.

All animals were killed after 20 days of treatment. Immediately after autopsy, the lower extremity of the right femur was fixed and simultaneously decalcified in formol solution for subsequent histological study of paraffin-embedded sections stained with haematoxylin and eosin. Then the rest of the skeleton was carefully inspected in each case, special attention being given to the femur (as an example of a typical tubular bone) as well as to the scapula and mandible which are particularly predisposed to bone absorption during hypervitaminosis A. The intensity of bone absorption (judged by the macroscopic and microscopic appearance of the bones), the frequency of spontaneous fractures and the intensity of subcutaneous and internal haemorrhages were expressed in arbitrary scales, with scores ranging from 0 to + + +. The means of all these scores, as well as the mean final body weights in the six groups, are summarized in Table 1.

RESULTS

The gain in body weight was approximately normal in the untreated controls (group I) and in the rats treated with LTH only (group V). STH produced the expected increase in somatic growth (group II), while vitamin A alone (group III) or in combination with LTH (group VI) completely suppressed the normal growth at the dose levels given. On the other hand, in the group which had received vitamin A in combination with STH (group IV), the growth-inhibitory effect of hypervitaminosis was totally prevented by growth hormone.

The intense bone absorption and the development of multiple fractures under the influence of hypervitaminosis A were likewise prevented by STH, but not by LTH. The rats treated with vitamin A alone showed intense remodelling of the femur with absorption of shaft tissue especially near the distal end of the bone, while the condyles themselves were not appreciably affected. In the mandible, the condyloid and coronoid processes, as well as the angle of the jaw, had become extremely atrophic, and the bone was perforated by many holes. Similar surface erosions were visible in the scapulae. On the other hand, the corresponding bones of the rats treated with vitamin A and STH were essentially similar to those of untreated, normal controls (Plate, figs. 1–3).

Histological observations revealed that the subperiosteal proliferation of [illegible] clasts (that is characteristic of hypervitaminosis A) was particularly pronou[illegible] all our rats treated with vitamin A alone or in combination with LTH. On th[illegible] hand, this change was absent—or at least greatly diminished—in those [illegible] which, in addition to vitamin A, were also treated with STH.

It is difficult to assess the intensity of the haemorrhages that are charact[illegible] vitamin A intoxication. In some rats bleeding is massive but localized, [illegible] others almost no haemorrhages can be seen despite manifest anaemia which [illegible] case is presumably due to multiple, minute haemorrhages throughout th[illegible] Furthermore, in the presence of spontaneous fractures, it is impossible to app[illegible] whether haemorrhage around a broken bone is merely the result of the fractu[illegible] or whether it is accentuated owing to the generalized haemorrhagic ten[illegible] hypervitaminotic animals. Nevertheless, it was obvious at autopsy that the [illegible] receiving vitamin A alone or in combination with LTH were uniformly anaem[illegible] usually showed multiple haemorrhages in the subcutaneous tissue, the peri[illegible] the thymus and around bone fracture sites, while the rats treated with vitamin [illegible] STH were not anaemic, and only two of them showed minute traces of haem[illegible] in the subcutaneous tissue.

DISCUSSION

It is evident from our findings that STH can counteract both the inhibition of [illegible] growth and the bone absorption that are characteristic of intense hypervitamin[illegible] Hence, in the syndrome of vitamin A intoxication, we have yet another inst[illegible] a morbid condition in which a change in the hormonal milieu can abolish susceptib[illegible] to a non-hormonal (vitamin A) pathogen.

It is interesting that the haemorrhagic manifestations of hypervitaminosis A [illegible] also diminished by STH, although they were not as effectively prevented as were [illegible] inhibition of anabolism and the skeletal manifestations of the syndrome.

It is also noteworthy that the same STH, which is so effective in suppressing [illegible] skeletal manifestations of hypervitaminosis A, exerts an opposite, sensitizing [illegible] upon the development of another nutritional bone disease, namely, osteolath[illegible] [Selye, 1957*a*].

The investigations were performed with the aid of a grant from the Gustav[illegible] Louise Pfeiffer Research Foundation and of a grant from the Department of H[illegible] of the Province of Quebec. The author is particularly indebted to the Endocri[illegible] Study Section of the National Institute of Health, Bethesda, Maryland, [illegible] supplying generous amounts of STH and LTH, as well as to Hoffmann-La Roche [illegible] for contributing the vitamin A palmitate used in these investigations.

REFERENCES

Fell, H. B. [1953]. In *Connective tissues*. p. 142. New York: Josiah Macy Jr. Foundation.
Lowe, J. S. & Morton, R. A. [1956]. *Vitam. & Horm.* 14, 97.
Nieman, C. & Klein Obbink, H. J. [1954]. *Vitam. & Horm.* 12, 69.
Selye, H. [1950]. *Stress*. Montreal: Acta Inc.
Selye, H. [1951]. *First annual report on stress*. Montreal: Acta Inc.
Selye, H. [1957*a*]. *Rev. canad. Biol.* 16, 1.

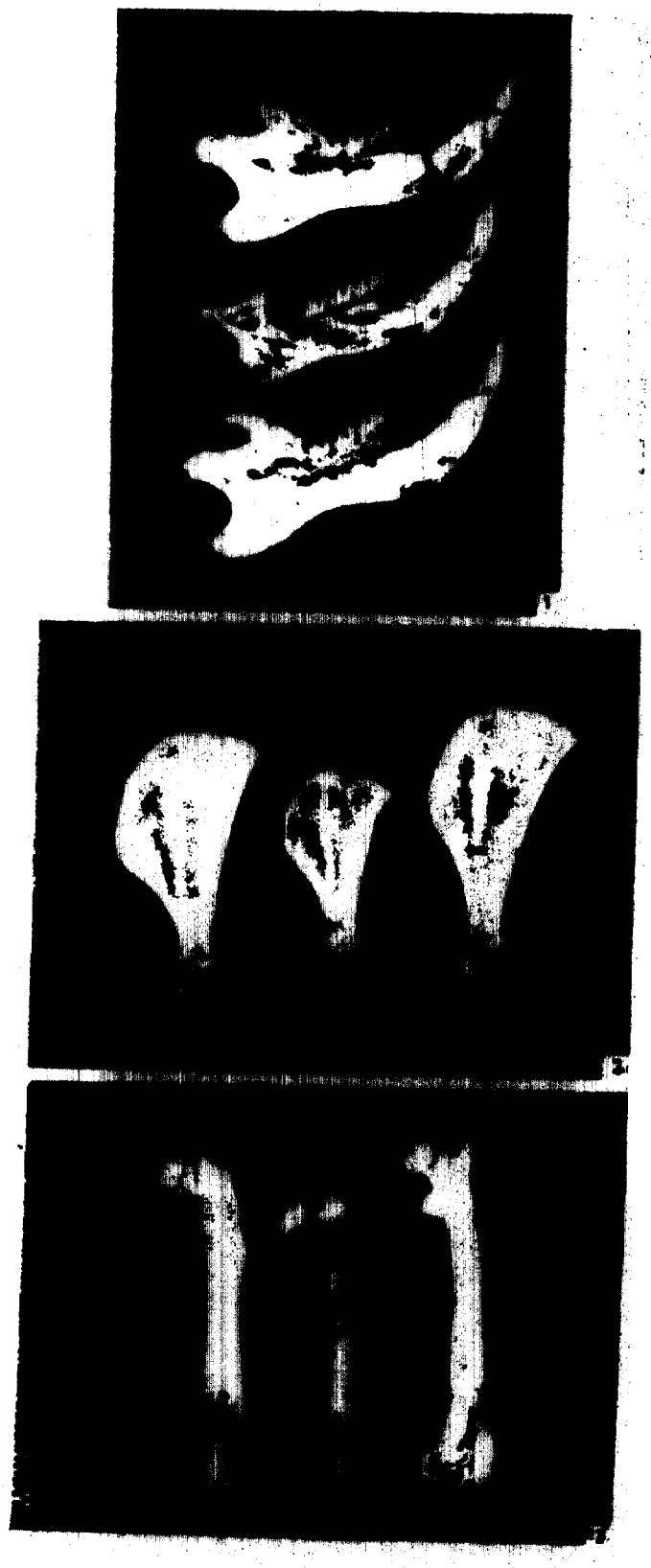

(Facing p. 236)

Selye, H. [1957*b*]. *J. Urol.* (in Press).
Selye, H. & Heuser, G. [1954]. *Fourth annual report on stress.* Montreal: Acta Inc.
Selye, H. & Heuser, G. [1955–6]. *Fifth annual report on stress.* Montreal: Acta Inc.
Selye, H. & Horava, A. [1952]. *Second annual report on stress.* Montreal: Acta Inc.
Selye, H. & Horava, A. [1953]. *Third annual report on stress.* Montreal: Acta Inc.

DESCRIPTION OF PLATE

Fig. 1. Mandible of normal (top), vitamin A-treated (middle) and vitamin A + STH-treated rat. Note that hypervitaminosis A resulted in several perforations within the flat part of the mandible and in absorption of the coronoid and condyloid processes with disappearance of the angle of the jaw. All these changes have been completely prevented by STH.

Fig. 2. Scapula of normal (left), vitamin A-treated (middle) and vitamin A + STH-treated rat. Again, the resorption of bone normally produced by vitamin A has been prevented by STH.

Fig. 3. Femur of a normal (left), a vitamin A-treated (middle) and vitamin A + STH-treated rat. The antagonism between STH and vitamin A is clearly visible.

Sewell-'67
Bib. No. 8315

Reproduced by permission
of the copyright owner

Internat. Z. Vitaminforsch. 37:301-306. 1967.

Vitamin A acetate (tritium labeled
determination of vitamin in
organs
determination of radioactivity
dynamic state of vitamin stores
half-time of vitamin A

Mobilization of Liver Vitamin A in Rats[1,2]

H. B. Sewell[3], G. E. Mitchell, Jr., C. O. Little
and B. W. Hayes

Department of Animal Science
University of Kentucky, Lexington, Kentucky

Abstract: Twenty female rats, averaging 100 g, received oral doses of 50 µg vitamin A acetate labeled with 4.1 µc of tritium. Feces and urine were collected for 5 days. Groups of 4 each were sacrified 5, 15, 25, 35 and 45 days after treatment. Liver, kidney and blood samples were collected. Vitamin A determinations were made on kidney and liver samples and all samples analyzed for radioactivity. Eight percent of the administered activity was recovered from rats sacrified after 5 days. Activity was recovered from urine (3.3 %) and ether extracts of feces (1.1 %), liver (3.6 %), kidneys (0.01 %) and blood (0.01 %). Liver stores of vitamin A were maintained at steady levels (383 to 448 µg). After 15 days, radioactivity in the livers declined at an exponential rate with an estimated half-time of 57 days. Detection of radioactivity in all samples of blood also supported the conclusion that vitamin A stores are in a dynamic state in rats in which total vitamin A storage is not changing.

Liver reserves of vitamin A are widely used to evaluate the vitamin A status of animals and their ability to compensate for a dietary inadequacy of the vitamin. An improved understanding of the processes involved in the deposition and removal of vitamin A from the liver and other storage sites would increase the usefulness of such evaluations. Many workers have studied changes in vitamin A stores during periods of vitamin A depletion or following vitamin A therapy (Moore, 1957). Little attention has been given to the stability of vitamin A stores in animals in which total vitamin A storage is not changing. The experiment reported here was designed to test the hypothesis that vitamin A stores conform to the classical theories of Schoenheimer (1942) concerning the dynamic state of body constituents.

---

[1] The investigation reported in this paper (No. 65-5-83) is in connection with a project of the Kentucky Agricultural Experiment Station and is published with the approval of the Director.

[2] This investigation was supported in part by Public Health Service Research Grant AM 08355-01, from the National Institute of Arthritis and Metabolic Diseases.

[3] Present address: University of Missouri, Columbia, Missouri.

Experimental Procedure

Twenty female Wistar strain rats, averaging 100 g, were randomly divided into 5 groups of 4 each. Prior to and throughout the experiment they were fed a commercial laboratory diet[4] containing adequate vitamin A *ad libitum*. At the start of the experiment each rat received 50 μg of vitamin A acetate labeled with tritium on carbons 15 and 16[5] suspended in ½ ml of 20% aqueous Tween "80" by the procedure of Bieri (1951) and mixed with 5 g of moistened diet. Feces and urine were collected for 5 days after treatment. Groups were sacrificed by terminal ether anesthesia 5, 15, 25, 35 and 45 days after dosing. Blood was collected from the posterior vena cava before circulation stopped. The liver and kidneys were then removed. Serum was obtained by centrifugation 12 hr after blood was collected. Samples were stored at −20° C until analyzed.

Serum was extracted by the method of Kimble (1939). Liver, kidney and fecal samples were saponified and extracted as described by Gallup and Hoefer (1946). Vitamin A in the extracts was determined with trifluoroacetic acid as described by Dugan et al. (1964). Radioactivity determinations were made with a liquid scintillation counter[6]. Duplicate 1-ml aliquots of petroleum ether extracts were combined with 15-ml portions of a scintillator solution containing 4 g 2, 5 diphenyloxazole (PPO) and 50 mg 1, 4-di 2- (5-phenyloxazolyl)-benzene (POPOP) per liter of toluene. Larger volumes of low activity extracts were evaporated to dryness and redissolved in 1 ml of petroleum ether. Urine was assayed for radioactivity by the method of Langham et al. (1956). Background determinations were made with reagent blanks, and counting efficiencies were determined by adding tritiated toluene to the samples and recounting.

Separations of vitamin A alcohol and vitamin A ester were conducted by the procedures of Thompson et al. (1949) after extracting liver and kidney samples with ethyl ether as described by Ames et al. (1954).

Results and Discussion

Sacrifice of the first group was delayed for 5 days after dosing to allow for passage of the material through the gastrointestinal tract and some stabilization of the labeled vitamin A in the storage sites. Table 1 summarizes the recovery of activity in extracts of the tissues and excreta. Only 8% of the administered radioactivity was recovered. This was found mainly in the liver, urine and feces; but activity was also detected in the blood and kidneys. Deposition of 3.63% of the dose in the liver was much less than previously reported by other workers (Lemley et al., 1947; Davies and Moore, 1948) after oral administration of vitamin A to depleted rats by somewhat different procedures. Nevertheless, the level of storage established was adequate for the study of possible turnover. The small amounts of activity found in the kidneys and feces agree with previous reports that female rats have low kidney stores (Moore and Sharman, 1950) and that little vitamin A is excreted in the feces (Baumann et al., 1934). The recovery of

---

[4] Ralson Purina, St. Louis, Missouri.
[5] Prepared and donated by Hoffmann-La Roche, Inc., Nutley, N. J.
[6] Baird Atomic Model 745.

Table 1. Total H^3-Activity recovered in extracts of rat tissues and excreta

Sample	Rats sacrificed at 5 days		All rats	
	Activity [a]	% dose [b]	Activity [c]	% of dose [b]
	10^3DPM		10^3DPM	
Liver	330.8 ± 7.25	3.63		
Kidney	0.9 ± 0.13	.0099		
Blood	0.6 ± 0.10	.0068		
Feces	97.0 ± 17.4	1.07	77 ± 6.5	0.84
Urine	300.0 ± 59.6	3.30	286 ± 34.0	3.14
Total	729.3	8.01		

[a] Means ± standard error. 4 animals
[b] Administered dose 4.1 μc
[c] Means ± standard error. 20 animals

radioactivity in the urine was somewhat less than the 7 to 12 % reported by Garbers and Gillman (1960) after administering larger doses of C^{14}-labeled vitamin A. It was not ether extractable and was presumably no longer associated with vitamin A (Wolf et al., 1957). Much of the unrecovered activity might be expected to have passed into the feces as water-soluble breakdown products of vitamin A (Willmer and Laughland, 1957). Either vitamin A or labeled degradation products may have been present in tissues which were not studied.

Table 2. Total Vitamin A and radioactivity of ether extract of liver and kidneys of rats sacrificed at ten-day intervals after treatment [a]

Days after dosing [b]	Vitamin A	Activity
	μg	10^3DPM
	Liver	
5	383 ± 9.4 [c]	331 ± 7.3
15	443 ± 44	331 ± 34
25	432 ± 91	305 ± 29
35	433 ± 60	253 ± 31
45	439 ± 22	238 ± 14
	Kidneys	
5	1.8 ± 0.4	0.9 ± 0.13
15	2.0 ± 0.2	1.07 ± 0.10
25	2.1 ± 0.3	2.63 ± 0.90
35	2.3 ± 0.4	2.30 ± 0.47
45	2.2 ± 0.4	1.93 ± 0.36

[a] 4.1 μc per rat from tritium-labeled vitamin A
[b] Four rats per group
[c] Standard error of mean

The vitamin A and tritium activities of the liver and kidneys of each group at the time of sacrifice are given in table 2. After some apparent increase between 5 and 15 days, the total vitamin A stores in the liver appeared to remain steady for the remainder of the experiment. There was no change in tritium activity in the livers of groups sacrificed at 5 and 15 days. Each succeeding group had less tritium activity in the liver. The apparent stability in the labeled vitamin A content of the livers between 5 and 15 days might be attributed to possible variation in initial storage or translocation of labeled vitamin A from other storage sites during this period. There was a significant ($P<.01$) linear regression of the log of tritium activity with time between 15 and 45 days (figure 1).

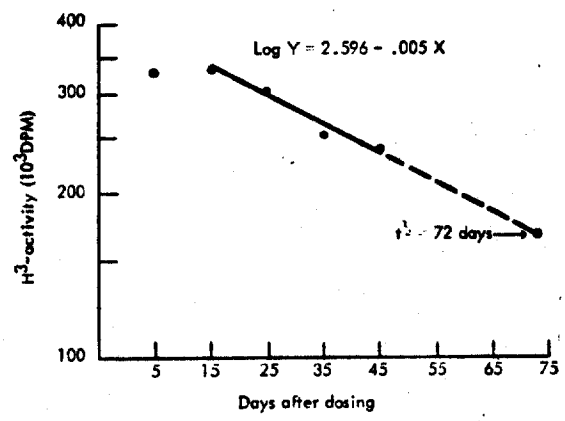

Figure 1. Total H^3-Activity of livers plotted on a logarithmic scale against time

Although the last group was sacrificed earlier than would have been desirable for estimation of turnover rates, extrapolation of this line to 72 days gives an estimated half-time of 57 days (72-15 = 57) or a turnover time of 82 days (Zilversmit, 1960) when day 15 is taken as the starting point. This provides strong evidence fort the dynamic state of vitamin A stores but suggests a longer turnover time than has been observed for many other body constituents. Levels of total vitamin A and radioactivity in the kidneys were too low for them to be considered a significant factor in vitamin A storage or a source of vitamin A which might be translocated to the liver.

The levels of radioactivity in the blood were also low (table 3). However, the detection of radioactivity in every blood sample tested gives strong support to the evidence obtained from the liver data that vitamin A stores are in a dynamic state.

Table 3. Radioactivity in blood at time of sacrifice

Days after dosing	Serum [a] volume	Activity	Total activity
	ml	10^3DPM/ml	10^3DPM
5	3.35	0.176	0.59 ± 0.10 [c]
15 [b]	3.42	1.41	4.81 ± 2.90
25	3.48	2.57	8.96 ± 2.60
35 [b]	3.65	4.36	15.92 ± 8.57
45	3.75	0.744	2.79 ± 0.92

[a] Estimated volume per rat assuming 6.7 ml of blood per 100 g: 50 % serum
[b] 3 samples, others have 4
[c] Standard error of mean

When the ether extract of livers was separated into vitamin A ester and vitamin A alcohol fractions, 63.2 % of the tritium activity and 62.2 % of the total vitamin A were found in the ester fraction. The close correspondence between these values provides evidence that the tritium activity was associated with the vitamin A molecule. The portion of the vitamin A in the ester fraction was somewhat lower than has been reported previously (High and Wilson, 1956). The procedure used gave complete separation of standards. However, ether extracts from livers of rats from another experiment yielded 92 % of the vitamin A in the ester fraction. This suggests possible hydrolysis during the handling of samples. Krause and Powell (1953) have reported that liver readily hydrolyzes vitamin A acetate but not vitamin A palmitate. Presumably, most of the vitamin A ester in the liver would be palmitate but this was not verified.

These data demonstrate turnover of vitamin A stores beyond that inherent in their accumulation or depletion. Under the conditions of this experiment the half-time of vitamin A in the liver was estimated to be 57 days.

LITERATURE

1. *Ames, S. R., H. A. Risley* and *P. L. Harris:* Anal. Chem. *26*, 1378 (1954). — 2. *Baumann, C. A., B. M. Riising* and *H. Steenbock:* J. Biol. Chem. *107*, 705 (1934). — 3. *Bieri, J. G.:* J. Nutrition *44*, 327 (1951). — 4. *Cartland, G. F.* and *F. C. Koch:* Am. J. Physiol. *85*, 540 (1928). — 5. *Davies, A. W.* and *T. Moore:* Biochem. J. *42*, LXIII (1948). — 6. *Dugan, R. E., N. A. Frigerio* and *J. M. Siebert:* Anal. Chem. *36*, 114 (1964). — 7. *Garbers, C. F.* and *J. Gillman:* Biochem. J. *75*, 124 (1960). — 8. *Gallup, W. D.* and *J. A. Hoefer:* Ind. Eng. Chem. Anal. Ed. *18*, 288 (1946). — 9. *High, E. G.* and *S. S. Wilson:* Arch. Biochem. Biophys. *62*, 163 (1956). — 10. *Kimble, M. S.:* J. Lab. Clin. Med. *25*, 1055 (1939). — 11. *Krause, R. F.* and *L. T. Powell:* Arch. Biochem. Biophys. *44*, 57 (1953). — 12. *Langham, W. H., W. J. Eversole, F. N. Hayes* and *T. T. Trujillo:* J. Lab. Clin. Med. *47*, 819 (1956). — 13. *Lemley, J. J., R. A. Brown, O. D. Bird* and *A. D. Emmett:* J. Nutrition *33*, 53 (1947). — 14. *Moore, T.:* Vitamin A. Elsevier Publ. Comp., New York (1957). —

15. *Moore, T.* and *I. M. Sharman:* Biochem. J. *47*, XLIII (1950) — 16. *Schoenheimer, R.:* The Dynamic State of Body Constituents. Harvard Univ. Press (1942). — 17. *Thompson, S. Y., J. Ganguly* and *S. K. Kon:* Brit. J. Nutrition *3*, 50 (1949). — 18. *Wolf, G., S. G. Kahn* and *B. C. Johnson:* J. Am. Chem. Soc. *79*, 1208 (1957). — 19. *Willmer, J. S.* and *D. H. Laughland:* Can. J. Biochem. and Physiol. *35*, 819 (1957). — 20. *Zilversmit, D. B.:* Am. J. Med. *29*, 832 (1960).

Prof. George E. Mitchell, Jr., Dept. Animal Sciences, College of Agriculture and Home Economics, University of Kentucky, Lexington, Kentucky 40506 (U. S. A.)

Sherman-'61
Bib. No. 8357

Jour. Invest. Dermatol. 37:469-480. 1961.

Reproduced by permission of the copyright owner

THE EFFECT OF VITAMIN A ON EPITHELIAL MITOSIS *IN VITRO* AND *IN VIVO**

BURTON S. SHERMAN, PH.D.[1]

One of the major functions of vitamin A in biological systems is the maintenance of normal epithelial structure. Vitamin A is necessary for maintenance of the structure of the skin and the corneal epithelium as well as the epithelium of the upper respiratory tract and genito-urinary tract (1). The vitamin A-deficient animal is characterized by an almost immediate reduction in rate of growth and a progressive keratinizing metaplasia of most epithelia. However, the role of vitamin A in maintaining the normal structure of epithelia is unknown.

The experimental approach to vitamin A-deficiency began with the early studies of Mori (2) and Goldschmidt (3), who described the cornification of the conjunctiva in the rat and similar changes in the lining of the pharynx, trachea and ducts of the salivary glands. Wolbach and Howe (1, 4, 5) later extended the study and emphasized the wide distribution of these effects on lining epithelia of the body, both in the rat and guinea pig. Hyperkeratosis of the skin as a result of vitamin A deficiency has been observed in man and experimentally produced in animals (6–13).

The keratinizing metaplasia and hyperkeratosis of epithelia found in experimental vitamin A deficiency may be related to changes in epithelial mitotic activity and the rate of cellular replacement in these tissues. It has been reported that the mitotic activity of epithelia in vitamin A-deficient animals was increased (1). However, Friedenwald *et al.* (14) and Alov (15) stated that the mitotic activity of "A"-deficient animals was not significantly different from that of normal animals. The administration of vitamin A has produced an increase in mitotic index (15, 16). However, other experiments showed that the vitamin caused no significant change in mitotic activity (5, 17).

The reasons for the diversity of results found by other workers may be related to three factors; (a) the nutritional state of the animals; *i.e.*, normal or vitamin A-deficient, (b) the type of epithelia examined for mitotic activity and (c) the concentration of vitamin A employed in the study. In the experiments reported herein these factors have been taken into consideration.

It is the purpose of these studies to examine the problem of keratinizing metaplasia and hyperkeratosis found in vitamin A-deficient animals by determining the effect of vitamin A and/or a deficiency of the vitamin on epithelial mitotic index and cellular replacement using both *in vitro* and *in vivo* technics.

MATERIALS AND METHODS

A. Production of Vitamin A-Deficient Rats

The animals used in these studies were young male Wistar albino rats. A total of 309 rats were used for all the experiments described herein. The litters of animals were combined and then assigned either to an experimental or one of the control groups.

At weaning (21–22 days of age), those animals to be rendered vitamin A-deficient were placed on a Vitamin A Test Diet (U.S.P. XIV) and given water *ad libitum*. The animals were weighed daily throughout the experiment. Animals on the Vitamin A Test Diet were considered depleted when their body weight remained stationary for seven days and/or severe xerophthalmia developed. In addition, these animals exhibited matted and lustreless hair, diarrhea, "hunchback" posture and extreme irritability.

Normal animals were raised on a stock diet consisting of Big Red Dog Pellets.

The last group of animals were placed at weaning on a Vitamin A Test Diet (U.S.P. XIV) and in addition were supplemented daily with an oral dose of 30 μg. of vitamin A acetate throughout the course of the experiment. These animals will

* From the Department of Anatomy, State University of New York, Downstate Medical Center, Brooklyn, New York.

This investigation was supported in part by Research Grant RG-4456 (C4) from the National Institutes of Health, United States Public Health Service.

Received for publication January 25, 1961.

[1] Taken in part from the dissertation submitted to the Department of Anatomy, Graduate Educational Program, State University of New York, Downstate Medical Center in partial fulfillment of the degree of Doctor of Philosophy, March 1960.

subsequently be referred to as "A" Test Diet + "A" animals.

During the experimental period, the animals were placed in individual cages.

B. *Method to Demonstrate the Effect of Vitamin A on Epithelial Mitosis in Vitro*

The procedure of Bullough and Johnson (18) and Bullough (19, 20) was used in studying the effect of vitamin A on the mitotic index of epidermis and corneal and tracheal epithelia *in vitro*. The animals employed in the study consisted of 21 young male albino rats. Male animals were selected because Bullough (19) has shown that estrogenic hormones have a residual effect on the tissues and play a considerable role in *in vitro* mitosis, while androgenic hormones as a factor are negligible. Seven animals were placed on the vitamin A-deficient diet, seven were raised on the stock diet, and the remaining seven animals were placed on the "A"-deficient diet supplemented orally with a daily dose of 30 μg. of vitamin A. All animals were sacrificed when physical signs of deficiency were apparent in the first group. Specimens of epidermis, cornea and trachea were taken from each animal and cut into small pieces (approximately 2 x 4 mm. in size). Specimens of tissue of the same type were placed in glass-stoppered flasks containing 4 ml. of a phosphate-buffered saline solution at pH 7.4 (18, 19). Each flask contained seven specimens of tissue, one from each animal in the group.

Isotonic glucose was added to the buffer solution to give the optimum concentration of 0.02 M. In addition, sodium glutamate in final concentration of 0.02 M was added. The gas phase was oxygen (99.5% O_2-0.5% CO_2).

Aqueous suspensions of vitamin A acetate in 16% Tween 20 (a water dispersant) were prepared in concentrations of 10, 100, 1,000 and 10,000 μg. of vitamin A per ml. respectively. Tissues were incubated in the buffered solutions containing various concentrations of vitamin A. Other specimens of tissues were incubated in buffered solutions containing the aqueous dispersant. Tissues used for controls were incubated in flasks with only the saline-phosphate buffer.

The flasks containing the tissues were placed in a shaking incubator at 38°C. and gently rocked for one hour. At this time, 0.016 mg. of colchicine dissolved in 0.01 ml. of physiological saline was introduced into each flask. The incubation was continued for four hours. The specimens were then fixed in Bouin's solution, sectioned in paraffin at 8 μ and stained with Delafield's hematoxylin and eosin. Estimates of mitotic indexes were made by direct counts of 1,000 consecutive basal cells in the tissues at a magnification of 450 ×.

Five separate counts were made for each specimen of tissue and seven specimens of tissue were used at each concentration of vitamin A or control. Thus, 35 individual enumerations of mitotic index were performed to arrive at a mean mitotic index for each type of epithelia at each concentration level.

C. *Method to Demonstrate the Effect of Vitamin A on Epithelial Mitosis in Vivo*

In the following series of experiments, 28 weanling male albino rats were used. The animals were divided into three groups and placed on either the vitamin A-deficient diet or stock diet or vitamin A-deficient diet supplemented with daily oral doses of 30 μg. of vitamin A.

1. *Period of vitamin A depletion.* Two rats from each group were sacrificed at weaning and at weekly intervals thereafter for seven weeks. The animals were injected subcutaneously with colchicine (0.1 mg./100 gm. of body weight) and sacrificed four hours later by exsanguination while under light ether anesthesia. Blood serum was analyzed for vitamin A content by the method of Sobel and Snow (21). The livers and kidneys of the animals were also taken for chemical vitamin A analyses using a modification of the method of Bessey *et al.* (22) as described by Sobel *et al.* (23).

At sacrifice, samples of skin, cornea and trachea were taken and placed in Bouin's fluid. These tissues were used for histological analysis and estimation of mitotic index.

2. *Topical application of vitamin A.* Aqueous suspensions of vitamin A acetate in 16% Tween 20 were prepared in concentrations of 10, 100, 1,000 and 10,000 μg. of vitamin A per 0.2 ml. Three days before treatment, the hair from the scapular region of the animals was clipped with an electric clipper. Each animal was then placed in a separate cage for topical treatment with the appropriate vitamin A suspension or of the aqueous dispersion medium. In addition, one group of animals received no topical treatment.

Rats from the vitamin A-deficient, stock and "A" Test Diet + "A" groups were sacrificed before treatment (0 hour) and 4, 8, 24 and 48 hours after a single topical application of 0.2 ml. of the appropriate preparation to the scapular region. Four hour mitotic counts were performed on specimens of cornea and tracheal epithelia and epidermis from the treated scapular region and an untreated lumbar area at each time interval of the 48 hour testing period. The subcutaneous injection of colchicine (0.1 mg./100 gm. of body

weight) was used to arrest mitotic figures. In addition, blood was taken from each animal at sacrifice for serum vitamin A analysis. It should be noted that two male rats were used at each concentration level and time interval.

3. *Oral administration of vitamin A.* Concentrations of either 100 or 10,000 μg. of vitamin A acetate per 0.1 ml. in an aqueous suspension containing 16% Tween 20 were administered to the vitamin A-deficient, normal and "A" Test Diet + "A" rats using a tuberculin syringe fitted with a feeding needle with a rounded end. The preparation was expelled through the syringe and needle into the esophagus of the animal. Four hour mitotic counts and serum vitamin A analyses were performed for each animal as described in the preceding section.

OBSERVATIONS

A. *Physical Signs of Vitamin A Deficiency*

The first grossly visible signs of vitamin A deficiency appeared in those animals on the vitamin A Test Diet approximately 42 days after weaning. At this time, the animals exhibited a slight bloody exudate and crusting of the margins of the palpebral fissures. Their coats of hair became less smooth and less glossy. In addition, their body weights were considerably less than that of the normal rats and the "A"-deficient diet + "A" rats (see weight gain in Tables IV, V and VI). During the following week, the condition grew progressively worse. Thus, at 49 days after weaning, these animals

TABLE I

The effect of vitamin A on the mitotic index of corneal epithelium in vitro

Concentration of Vitamin A	Mean Number of Mitotic Figures per 1000 Basal Cells		
	Normal cornea	"A"-deficient cornea	"A" test diet + "A" cornea
μg./total volume			
0	30.7 ± 0.7†	8.2 ± 0.4	32.6 ± 0.9
0 + Vehicle	30.6 ± 0.6	7.1 ± 0.4	30.4 ± 1.7
10	49.9 ± 0.9*	59.5 ± 0.8*	51.6 ± 0.8*
100	63.9 ± 0.8*	74.4 ± 0.8*	65.1 ± 1.6*
1000	16.1 ± 0.6*	5.0 ± 0.3*	13.2 ± 0.7*
10,000	6.1 ± 0.6*	5.3 ± 0.4*	7.5 ± 0.7*

* Indicates that this Mean is statistically significant at the < 0.5 confidence level when compared to the Mean of the group containing no vitamin A. The data were analyzed by the method of Fisher (25).

† All figures are expressed as Mean ± Standard Error.

TABLE II

The effect of vitamin A on the mitotic index of epidermis in vitro

Concentration of Vitamin A	Mean Number of Mitotic Figures per 1000 Basal Cells		
	Normal epidermis	"A"-deficient epidermis	"A" test diet + "A" epidermis
μg. total volume			
0	7.2 ± 0.3†	1.5 ± 0.1	7.8 ± 0.4
0 + Vehicle	7.3 ± 0.4	1.5 ± 0.2	8.0 ± 1.0
10	12.6 ± 0.4*	15.6 ± 0.5*	13.1 ± 1.1*
100	18.3 ± 0.4*	22.8 ± 0.5*	20.3 ± 0.9*
1000	3.2 ± 0.3*	1.7 ± 0.2	2.6 ± 0.2*
10,000	1.1 ± 0.2*	1.1 ± 0.1	1.0 ± 0*

* Indicates that this Mean is statistically significant at the < 0.5 confidence level when compared to the Mean of the group containing no vitamin A. The data were analyzed by the method of Fisher (25).

† All figures are expressed as Mean ± Standard Error.

TABLE III

The effect of vitamin A on the mitotic index of tracheal epithelium in vitro

Concentration of Vitamin A	Mean Number of Mitotic Figures per 1000 Basal Cells		
	Normal trachea	"A"-deficient trachea	"A" test diet + "A" trachea
μg./total volume			
0	3.3 ± 0.4†	1.0 ± 0.1	3.6 ± 0.4
0 + Vehicle	2.8 ± 0.3	1.0 ± 0.2	3.9 ± 0.5
10	7.9 ± 0.4*	10.8 ± 0.4*	8.9 ± 0.8*
100	12.6 ± 0.4*	16.7 ± 0.7*	13.9 ± 1.4*
1000	2.5 ± 0.4*	0.9 ± 0.1*	1.6 ± 0.2*
10,000	1.0 ± 0.1*	1.0 ± 0.1*	1.0 ± 0*

* Indicates that this Mean is statistically significant at the < 0.5 confidence level when compared to the mean of the group containing no vitamin A. The data were analyzed by the method of Fisher (25)

† All figures are expressed as Mean ± Standard Error.

TABLE IV

Mitotic index of epithelia during depletion of vitamin A in male albino rats

Days Depleted	Mean Weight Gain	Mean Number of Mitotic Figures per 1000 Basal Cells			Liver + Kidney Vitamin A	Serum Vitamin A
		Cornea	Epidermis	Trachea		
	gm.				*μg./total*	*μg./100 ml*
0	—	36.4 ± 6.5†	9.9 ± 1.0	5.4 ± 1.0	36.4 ± 1.6	35.2 ± 3.9
7	15	33.4 ± 6.1	8.3 ± 1.1	4.2 ± 0.5	29.4 ± 2.3*	33.8 ± 2.6
14	27	30.7 ± 8.3	8.1 ± 1.6	5.0 ± 0.2	29.6 ± 0.5*	36.1 ± 3.9
21	39	32.8 ± 1.5	7.9 ± 0.8	3.9 ± 1.1	13.6 ± 0.8*	30.2 ± 2.9
28	44	31.7 ± 2.5	8.0 ± 0.8	4.7 ± 0.5	7.1 ± 0.3*	34.0 ± 4.0
35	54	34.2 ± 2.9	7.7 ± 0.9	4.1 ± 0.7	4.7 ± 0.2*	31.5 ± 2.0
42	61	16.1 ± 1.5*	3.2 ± 0.5*	2.0 ± 0.3*	2.1 ± 0.1*	10.1 ± 2.3*
49	63	7.6 ± 1.4*	1.4 ± 0.3*	0.9 ± 0.7*	0.5 ± 0*	1.1 ± 0*

* Indicates that this Mean is statistically significant at the < 0.5 confidence level when compared to the Mean at the "0 Days Depleted" level. The data were analyzed by the method of Fisher (25)

† All figures are expressed as Mean ± Standard Error.

demonstrated well developed signs of acute vitamin A deficiency, characterized by severe xerophthalmia, matted and lustreless hair, diarrhea, "hunchback" posture and extreme irritability. At this time analyses of blood, liver and kidney revealed the presence of minimal amounts of vitamin A (Table IV).

B. The Effect of Vitamin A on Epithelial Mitosis in Vitro

In the control group of tissues which received no vitamin A in the incubating flasks (see zero concentration of vitamin A in Tables I to III), the mitotic index of epidermis, corneal and tracheal epithelia of vitamin A-deficient animals is significantly less than that of epithelia from normal or "A" Test Diet + "A" animals. The mitotic index of the epithelia is not significantly altered due to the presence of the aqueous dispersion vehicle (Tables I to III). The addition of 10 μg. of vitamin A to the *in vitro* system causes an increase in the mitotic index of all epithelia as compared to the zero concentration controls. An even greater increase in epithelial mitotic index is observed when 100 μg. of the vitamin is added to the system (Tables I to III).

In most instances, the presence of high concentrations of vitamin A (1,000 or 10,000 μg.) significantly lowers the mitotic index of the epithelia as compared to the zero concentration controls. In several instances, however, the high concentrations of vitamin A do not

statistically significant lowered values for mitotic index. This is mainly true for epidermis and tracheal epithelium taken from vitamin A-deficient animals. However, the number of mitotic figures present in the control samples of these epithelia are extremely low at the outset and toxic doses of the vitamin can probably do little to cause further depression of the mitotic index.

It is interesting to note that the results obtained from the tissues of those animals on the "A"-deficient diet supplemented with daily oral doses of 30 μg. of vitamin A are essentially the same as the results obtained from rats on the normal diet.

C. The Effect of Vitamin A on Epithelial Mitosis in Vivo

1. ***Topical application.*** It may be seen from Table IV that the mitotic index of epidermis, corneal and tracheal epithelia remains fairly constant in animals on the vitamin A-deficient diet from the time of weaning (0 days depleted) to the fifth week of the depletion period. During this period, these animals gain less weight than the stock-fed animals and there is a progressive loss of vitamin A from their liver and kidney hstorage depots. However, there is *no* significant change in the concentration of vitamin A in the blood serum up to this point. When the stores of vitamin A are no longer capable of maintaining the level of vitamin A in the blood (42 days depleted), and the serum "A" drops precipitously, there is a concomitant fall in mitotic index in all the epithelia investigated. At approximately the same time, keratinizing metaplasia of these tissues is becoming evident.

The mitotic index of the epithelia of stock-fed rats and "A" Test Diet + "A" rats remains constant during this seven week period of time (Tables V and VI). There are no changes in the serum vitamin A levels and the stores of vitamin A in the liver and kidney show a significant increase during this period.

The stages of hair growth were noted in all the animals in these studies; however mitotic counts were confined to the cells of the surface epithelium and no attempt was made to estimate the mitotic activity of the hair follicles. In these studies, it appears that a deficiency of vitamin A tends to retard the hair growth cycle in the albino rat. During the depletion period, the animals on the "A"-deficient diet pass through the second of their hair growth cycles but fail to enter into the third cycle of growth. Thus after seven weeks on the Vitamin A Test Diet (10 weeks of age), the dorsal scapular hairs of these animals remain in Telogen while the follicles of the animals on the stock diet or the "A" Test Diet + "A" have progressed into the third cycle of growth and are found in the anagen IV–VI stages of development.

Once vitamin A deficiency has been achieved, there is very little fluctuation in either the epithelial mitotic index or level of serum vitamin A of the untreated "A"-deficient animals during

TABLE V

Mitotic index of epithelia of normal male albino rats at various times after weaning

Days After Weaning	Mean Weight Gain	Mean Number of Mitotic Figures per 1000 Basal Cells			Liver + Kidney Vitamin A	Serum Vitamin A
		Cornea	Epidermis	Trachea		
	gm.				*μg./total*	*μg./100 ml.*
0	—	35.2 ± 2.5†	10.8 ± 1.2	5.0 ± 0.7	30.4 ± 0.8	31.5 ± 4.1
7	20	31.2 ± 2.7	8.4 ± 0.6	4.0 ± 0.3	49.5 ± 0.7*	38.2 ± 5.5
14	46	30.7 ± 2.3	8.3 ± 0.7	4.6 ± 0.6	91.5 ± 1.0*	30.4 ± 0.4
21	69	32.5 ± 2.0	8.0 ± 0.7	4.2 ± 0.5	130 ± 3.4*	32.4 ± 5.0
28	88	29.7 ± 1.1	8.4 ± 0.8	4.0 ± 0.4	178 ± 10.0*	36.2 ± 6.6
35	119	32.7 ± 2.4	7.7 ± 1.1	4.9 ± 0.6	218 ± 7.0*	29.5 ± 2.0
42	141	31.9 ± 2.3	8.1 ± 0.8	3.7 ± 0.7	257 ± 12.6*	32.8 ± 5.3
49	160	33.8 ± 3.0	8.3 ± 1.2	4.6 ± 1.0	309 ± 15.0*	34.7 ± 1.6

* Indicates that this Mean is statistically significant at the < 0.5 confidence level when compared to the Mean at the "0 Days After Weaning" level. The data were analyzed by the method of Fisher (25).

† All figures are expressed as Mean ± Standard Error.

TABLE VI

Mitotic index of epithelia of "A" test diet + "A" male albino rats at various times after weaning

Days After Weaning	Mean Weight Gain	Mean Number of Mitotic Figures per 1000 Basal Cells			Liver + Kidney Vitamin A	Serum Vitamin A
		Cornea	Epidermis	Trachea		
	gm.				*μg./total*	*μg. 100 ml.*
0	—	31.7 ± 2.7†	8.9 ± 1.1	5.3 ± 0.6	34.6 ± 1.5	34.6 ± 2.6
7	18	29.5 ± 2.0	8.1 ± 0.7	4.6 ± 0.6	56.3 ± 2.6*	31.6 ± 1.6
14	40	31.7 ± 1.6	7.6 ± 0.8	4.7 ± 1.1	100 ± 3.1*	30.6 ± 0.9
21	64	29.8 ± 0.7	7.9 ± 1.6	4.0 ± 0.3	128 ± 6.8*	33.4 ± 2.7
28	86	33.5 ± 3.1	8.1 ± 1.6	4.2 ± 0.5	190 ± 14.0*	36.1 ± 3.4
35	122	30.2 ± 1.6	8.0 ± 0.6	4.9 ± 0.5	240 ± 11.0*	30.4 ± 1.6
42	146	31.7 ± 2.4	7.6 ± 0.9	4.6 ± 0.5	290 ± 20.0*	34.4 ± 1.8
49	156	32.1 ± 3.6	7.9 ± 0.8	5.0 ± 0.6	360 ± 22.4*	36.4 ± 2.6

* Indicates that this Mean is statistically significant at the < 0.5 confidence level when compared to the Mean at the "0 Days After Weaning" level. The data were analyzed by the method of Fisher (25).

† All figures are expressed as Mean ± Standard Error.

the subsequent 48 hour testing period (Nil animals in Table VII). In contrast to the low values found in the "A"-deficient animals, the mitotic indexes and vitamin A levels of the untreated normal rats and untreated "A" Test Diet + "A" rats are much higher (Nil animals in Tables VIII and IX). Although there is a tendency for variation during the day in epithelial mitotic index in the normal rat, especially at the 4 and 8 hour time intervals, it is not borne out by statistical analyses.

The topical application of the aqueous dispersant does not seem to cause any significant alteration in the mitotic index of the cornea, trachea or at the site of application and untreated site of the epidermis at any time interval in either the "A"-deficient animals or the normal or the "A" Test Diet + "A" animals (Tables VII to IX). In addition, the presence of the aqueous dispersant does not significantly alter the level of vitamin A in the blood of these animals.

When 10 μg. of vitamin A are topically applied to vitamin A-deficient rats, there is a significant increase in the mitotic index of the epidermis at the site of application four hours after treatment (Table VII). Eight hours after treatment, a significant elevation in mitotic index is still present at the site of application of the vitamin. However, the mitotic index returns to its original low level 24 hours after treatment and remains there at the 48 hour time interval. There is no significant change in the mitotic index of the untreated site of epidermis or the epithelia of cornea or trachea. In addition, there is no observable elevation of serum vitamin A when this small amount of vitamin A is employed. Approximately the same situation occurs when 10 μg. of vitamin A is topically applied to normal or "A" Test Diet + "A" animals. In these instances, however, the rise in mitotic index at the site of application is found four hours after treatment and at no other time thereafter (Tables VIII and IX).

Thus it is seen that the topical application of a low concentration of vitamin A is capable of producing an immediate local increase in mitotic index independent of the level of the vitamin in the blood. Furthermore, this effect is not prolonged over an extended period of time.

The topical application of 100 μg. of vitamin A to vitamin A-deficient rats results in an increase in mitotic index of both the treated and untreated areas of epidermis four hours after treatment (Table VII). This elevation of mitotic index is still present eight hours after treatment and is extended to the epithelia of the cornea and trachea. Associated with this increase is an elevated serum vitamin A. However, 24 hours following treatment, mitotic indexes and serum vitamin A concentrations have returned to original levels. Table VIII and IX illustrate the topical application of 100 μg. of "A" to normal and "A" Test Diet + "A" rats. In these in

TABLE VII

Mitotic index of epithelia in vitamin A-deficient male albino rats following topical and oral treatment

Type of Treatment	Hours After Treatment	Mean Number Mitotic of Figures per 1000 Basal Cells				Serum Vitamin A
		Epidermis		Cornea	Trachea	
		Site of application	Untreated site			
						μg./100 ml.
Nil	0		1.5 ± 0.3†	8.6 ± 2.0	0.4 ± 0.2	0.5 ± 0.3
	4		2.1 ± 0.5	8.0 ± 1.3	1.1 ± 0.3	0.7 ± 0
	8		1.0 ± 0.2	7.6 ± 1.5	0.6 ± 0.2	0
	24		0.9 ± 0.7	8.1 ± 1.3	0.5 ± 0.2	1.8 ± 0.4
	48		2.6 ± 0.7	7.0 ± 1.1	1.0 ± 0.3	0.6 ± 0.1
Topical Aqueous Dispersant	0	0.9 ± 0.3	1.1 ± 0.5	7.9 ± 1.5	1.2 ± 0.2	2.7 ± 0.8
	4	1.7 ± 0.4	1.3 ± 0.4	8.6 ± 1.4	0.6 ± 0.2	0.4 ± 0
	8	1.0 ± 0.3	0.7 ± 0.2	8.1 ± 0.7	1.1 ± 0.4	1.7 ± 0.2
	24	1.3 ± 0.4	2.0 ± 0.4	7.7 ± 1.4	1.0 ± 0.2	0.9 ± 0.1
	48	2.1 ± 0.7	1.4 ± 0.6	8.7 ± 1.7	0.7 ± 0.4	0
Topical 10 μg Vitamin A	0	1.9 ± 0.4	1.1 ± 0.2	8.6 ± 1.6	1.3 ± 0.3	1.8 ± 0.2
	4	10.9 ± 1.1*	1.7 ± 0.6	7.7 ± 1.5	1.6 ± 0.5	2.6 ± 0.1
	8	8.6 ± 0.9*	0.8 ± 0.3	8.8 ± 1.4	0.9 ± 0.2	1.1 ± 0
	24	0.9 ± 0.2	2.1 ± 0.6	9.4 ± 1.2	2.0 ± 0.5	2.3 ± 0.3
	48	1.7 ± 0.3	1.6 ± 0.6	8.0 ± 0.8	1.2 ± 0.4	1.0 ± 0.3
Topical 100 μg Vitamin A	0	1.8 ± 0.3	1.3 ± 0.4	8.9 ± 1.2	1.3 ± 0.5	2.0 ± 1.1
	4	17.5 ± 1.4*	2.7 ± 0.2*	11.5 ± 1.1	1.7 ± 0.9	10.3 ± 0.5*
	8	20.1 ± 1.2*	3.0 ± 0.5*	12.9 ± 1.1*	3.2 ± 0.5*	13.2 ± 0.6*
	24	1.5 ± 0.3	0.7 ± 0.3	7.8 ± 0.9	1.9 ± 0.2	2.9 ± 0.4
	48	1.6 ± 0.5	0.9 ± 0.2	9.0 ± 2.1	0.9 ± 0.2	2.1 ± 0.1
Topical 1000 μg Vitamin A	0	2.0 ± 0.2	1.6 ± 0.2	9.6 ± 1.1	0.8 ± 0.3	1.2 ± 0.2
	4	1.1 ± 0.3	8.7 ± 0.8*	29.5 ± 2.4*	4.6 ± 0.5*	31.7 ± 2.5*
	8	2.3 ± 0.6	9.4 ± 0.9*	32.7 ± 2.3*	5.3 ± 0.4*	42.7 ± 2.6*
	24	1.7 ± 0.4	7.9 ± 1.3*	33.8 ± 3.9*	4.9 ± 0.9*	27.5 ± 3.8*
	48	8.0 ± 0.6*	8.6 ± 1.0*	26.4 ± 1.3*	5.1 ± 0.5*	29.6 ± 0.6*
Topical 10,000 μg Vitamin A	0	1.5 ± 0.4	2.2 ± 0.4	8.9 ± 0.9	0.7 ± 0.3	2.1 ± 0.5
	4	0.2 ± 0.2*	0.9 ± 0.7*	5.1 ± 1.6*	1.0 ± 0.2	267 ± 21.3*
	8	1.0 ± 0.2	2.9 ± 0.9	8.3 ± 1.6	1.3 ± 0.5	175 ± 5.0*
	24	4.9 ± 0.9*	9.0 ± 0.5*	35.4 ± 2.1*	5.0 ± 0.5*	59.6 ± 9.6*
	48	8.3 ± 1.1*	8.7 ± 1.3*	31.9 ± 2.6*	5.4 ± 0.7*	33.5 ± 2.1*
Oral 100 μg Vitamin A	0		2.1 ± 0.6	9.2 ± 1.8	0.6 ± 0.2	0.9 ± 0.3
	4		8.7 ± 1.0*	33.6 ± 2.0*	4.6 ± 0.9*	29.8 ± 0.2*
	8		8.3 ± 0.9*	30.2 ± 3.4*	5.0 ± 0.2*	43.7 ± 5.4*
	24		7.6 ± 0.8*	29.3 ± 3.1*	4.7 ± 0.8*	31.6 ± 2.6*
	48		7.9 ± 0.5*	34.2 ± 2.5*	5.1 ± 0.9*	33.4 ± 3.3*
Oral 10,000 μg Vitamin A	0		1.1 ± 0.4	8.7 ± 1.2	1.1 ± 0.3	1.5 ± 0.5
	4		1.0 ± 0.2	4.3 ± 1.3*	0.3 ± 0.2*	495 ± 15.0*
	8		1.6 ± 0.4	5.2 ± 0.9*	1.3 ± 0.3*	620 ± 30.0*
	24		4.9 ± 0.9*	17.6 ± 2.3*	2.1 ± 0.5	215 ± 10.0*
	48		7.1 ± 0.9*	34.4 ± 3.8*	3.9 ± 0.7*	73.4 ± 4.0*

* Indicates that this Mean is statistically significant at the <.05 confidence level when compared to the Mean at the "0 hour" in its respective Type of Treatment category. The data were analyzed by the method of Fisher (25).

† All figures are expressed as Mean ± Standard Error.

TABLE VIII

Mitotic index of epithelia in normal male albino rats following topical and oral treatment

Type of Treatment	Hours After Treatment	Mean Number of Mitotic Figures per 1000 Basal Cells				Serum Vitamin A
		Epidermis		Cornea	Trachea	
		Site of application	Untreated site			
						μg./100 ml.
Nil	0		7.2 ± 0.8†	29.2 ± 1.0	4.8 ± 0.9	29.4 ± 4.3
	4		9.3 ± 1.2	32.2 ± 2.2	5.3 ± 0.9	33.8 ± 3.6
	8		8.0 ± 0.8	28.7 ± 2.3	4.9 ± 0.8	31.5 ± 0
	24		7.6 ± 0.9	29.5 ± 2.9	5.1 ± 0.8	30.4 ± 2.6
	48		7.9 ± 0.8	32.3 ± 2.8	4.6 ± 0.9	32.7 ± 6.7
Topical Aqueous Dispersant	0	8.0 ± 0.5	8.3 ± 1.1	31.5 ± 2.9	4.0 ± 0.3	28.7 ± 1.3
	4	8.7 ± 0.9	9.0 ± 0.6	34.7 ± 1.8	4.5 ± 0.4	30.1 ± 0.3
	8	7.7 ± 0.5	8.8 ± 1.1	30.3 ± 2.6	5.1 ± 1.0	27.8 ± 0.2
	24	7.9 ± 0.5	8.6 ± 1.0	29.5 ± 0.8	4.9 ± 0.6	32.6 ± 2.3
	48	8.4 ± 0.8	8.0 ± 0.9	27.9 ± 1.5	4.9 ± 0.9	30.0 ± 0
Topical 10 μg Vitamin A	0	7.0 ± 0.7	7.4 ± 0.8	31.7 ± 2.8	4.7 ± 0.7	33.7 ± 3.4
	4	10.6 ± 1.0*	8.6 ± 1.3	34.2 ± 2.5	4.4 ± 0.7	26.5 ± 0
	8	8.3 ± 0.5	7.9 ± 0.6	29.4 ± 1.5	3.9 ± 0.7	30.2 ± 0.6
	24	7.4 ± 0.8	8.6 ± 0.9	28.6 ± 0.9	5.1 ± 0.6	32.1 ± 0
	48	7.8 ± 1.0	8.0 ± 0.9	31.4 ± 2.5	4.0 ± 0.8	28.3 ± 1.7
Topical 100 μg Vitamin A	0	7.9 ± 1.0	8.3 ± 1.3	34.3 ± 2.2	5.1 ± 0.9	36.5 ± 1.3
	4	14.7 ± 1.5*	8.9 ± 0.2	35.7 ± 1.9	5.4 ± 0.8	41.3 ± 0
	8	12.6 ± 1.6*	8.4 ± 1.1	31.4 ± 1.0	4.6 ± 0.8	37.2 ± 3.0
	24	8.3 ± 1.2	7.6 ± 1.1	30.6 ± 1.4	4.6 ± 0.5	30.4 ± 0
	48	7.1 ± 0.9	7.4 ± 0.7	32.5 ± 1.8	5.2 ± 0.7	29.6 ± 5.0
Topical 1000 μg Vitamin A	0	8.3 ± 0.6	7.9 ± 0.8	33.2 ± 1.7	4.6 ± 0.7	34.2 ± 1.0
	4	1.5 ± 0.4*	8.3 ± 0.8	37.5 ± 2.8	5.0 ± 0.9	47.1 ± 5.1*
	8	2.3 ± 0.8*	9.0 ± 0.8	41.5 ± 2.3*	4.6 ± 0.7	53.6 ± 2.0*
	24	4.1 ± 0.5*	7.4 ± 0.8	32.2 ± 2.7	4.0 ± 0.3	36.1 ± 0
	48	7.6 ± 0.6	7.8 ± 1.2	34.1 ± 1.2	5.3 ± 0.7	29.3 ± 2.6
Topical 10,000 μg Vitamin A	0	7.4 ± 0.6	7.9 ± 1.1	33.7 ± 1.7	5.3 ± 0.8	28.1 ± 0.6
	4	1.3 ± 0.4*	5.1 ± 0.8*	20.0 ± 1.9*	2.9 ± 0.7*	195 ± 5.0*
	8	1.0 ± 0.3*	6.8 ± 0.2	22.3 ± 2.0*	3.9 ± 0.8	167 ± 18.0*
	24	6.9 ± 0.8	8.4 ± 0.9	35.8 ± 2.2	4.1 ± 0.6	39.5 ± 1.5
	48	8.0 ± 0.6	8.3 ± 1.0	32.1 ± 2.0	4.7 ± 1.1	34.2 ± 4.0
Oral 100 μg Vitamin A	0		7.4 ± 1.3	35.3 ± 2.2	4.5 ± 0.6	34.2 ± 2.5
	4		11.3 ± 1.2*	42.6 ± 2.7*	7.6 ± 0.5*	54.7 ± 2.3*
	8		12.6 ± 1.0*	38.3 ± 2.1	8.0 ± 0.8*	51.3 ± 0.2*
	24		8.0 ± 1.0	30.4 ± 2.0	4.1 ± 0.6	30.2 ± 3.5
	48		7.3 ± 0.5	30.5 ± 1.4	4.5 ± 0.4	34.5 ± 4.5
Oral 10,000 μg Vitamin A	0		8.8 ± 1.4	29.3 ± 2.3	4.1 ± 0.9	27.5 ± 0
	4		4.3 ± 0.4*	12.6 ± 1.2*	2.3 ± 0.6*	378 ± 19.0*
	8		4.6 ± 1.1*	10.3 ± 1.0*	2.6 ± 0.5	505 ± 20.0*
	24		7.9 ± 0.7	24.5 ± 1.6	4.8 ± 0.9	140 ± 10.0*
	48		8.0 ± 0.9	34.2 ± 1.6	4.2 ± 0.6	42.5 ± 2.0*

* Indicates that this Mean is statistically significant at the <.05 confidence level when compared to the Mean at the "0 hour" in its respective Type of Treatment category. The data were analyzed by the method of Fisher (25).

† All figures are expressed as Mean < Standard Error.

TABLE IX

Mitotic index of epithelia in "A" test diet + "A" male albino rats following topical and oral treatment

Type of Treatment	Hours After Treatment	Mean Number of Mitotic Figures per 1000 Basal Cells				Serum Vitamin A
		Epidermis		Cornea	Trachea	
		Site of application	Untreated site			
						μg./100 ml.
Nil	0		7.0 ± 0.4†	30.4 ± 2.1	4.6 ± 0.3	30.4 ± 2.6
	4		8.4 ± 1.0	32.7 ± 1.6	4.9 ± 0.6	34.2 ± 2.1
	8		7.6 ± 0.8	30.1 ± 0.7	4.7 ± 0.8	30.6 ± 1.7
	24		7.4 ± 1.0	29.7 ± 1.8	4.3 ± 0.6	31.2 ± 4.1
	48		7.8 ± 0.9	29.4 ± 1.2	4.6 ± 1.0	29.6 ± 4.4
Topical Aqueous Dispersant	0	7.4 ± 0.6	8.0 ± 1.0	30.4 ± 1.0	5.0 ± 0.2	27.8 ± 1.7
	4	7.9 ± 1.0	8.4 ± 1.2	33.6 ± 2.2	5.1 ± 1.1	32.8 ± 1.9
	8	7.0 ± 0.6	7.8 ± 0.6	29.7 ± 1.6	4.7 ± 0.7	30.2 ± 0.6
	24	7.3 ± 0.9	7.9 ± 0.4	30.6 ± 0.6	4.8 ± 0.6	31.4 ± 2.3
	48	8.0 ± 0.7	7.6 ± 0.6	31.2 ± 1.0	4.9 ± 0.8	29.2 ± 0.2
Topical 10 μg Vitamin A	0	7.6 ± 1.1	7.5 ± 1.1	29.1 ± 1.0	4.7 ± 0.6	31.5 ± 0.6
	4	11.5 ± 0.6*	8.1 ± 0.7	29.9 ± 0.6	4.8 ± 0.7	32.8 ± 1.7
	8	8.1 ± 0.6	8.0 ± 0.6	30.2 ± 0.8	4.9 ± 0.5	27.8 ± 3.0
	24	7.7 ± 0.2	7.5 ± 0.8	31.4 ± 1.6	4.0 ± 0.5	29.5 ± 0.7
	48	7.8 ± 1.2	7.7 ± 0.7	30.2 ± 2.2	4.6 ± 0.9	31.7 ± 2.9
Topical 100 μg Vitamin A	0	7.6 ± 0.6	8.1 ± 0.7	28.4 ± 2.6	4.8 ± 0.9	30.4 ± 2.7
	4	12.7 ± 1.2*	8.6 ± 1.4	32.8 ± 1.7	5.3 ± 0.3	34.2 ± 0.6
	8	11.1 ± 0.6*	8.0 ± 0.2	30.1 ± 1.6	4.7 ± 0.5	34.1 ± 0.3
	24	7.5 ± 0.6	7.8 ± 0.6	31.4 ± 2.1	4.4 ± 0.4	30.3 ± 1.6
	48	7.6 ± 1.1	7.6 ± 0.6	29.6 ± 2.0	4.8 ± 0.4	32.1 ± 3.0
Topical 1000 μg Vitamin A	0	7.5 ± 0.4	8.0 ± 0.8	30.4 ± 2.1	5.1 ± 0.6	30.6 ± 0.6
	4	2.0 ± 0.2*	8.1 ± 1.2	39.7 ± 3.6*	5.0 ± 1.1	51.7 ± 3.6*
	8	2.6 ± 0.3*	7.7 ± 0.6	44.1 ± 1.6*	4.8 ± 0.7	56.5 ± 4.1*
	24	4.9 ± 0.6*	7.2 ± 0.4	30.6 ± 0.9	5.1 ± 0.9	31.6 ± 0.7
	48	7.3 ± 1.0	7.6 ± 0.9	28.7 ± 1.9	4.7 ± 1.0	32.7 ± 1.6
Topical 10,000 μg Vitamin A	0	7.3 ± 1.0	7.7 ± 1.1	31.6 ± 3.8	5.1 ± 0.6	31.5 ± 2.6
	4	1.0 ± 0.2*	4.8 ± 1.0*	19.6 ± 1.9*	2.7 ± 0.2*	210 ± 17.0*
	8	1.9 ± 0.4*	7.9 ± 0.6	23.4 ± 0.6*	3.1 ± 0.7*	170 ± 4.8*
	24	7.0 ± 1.6	8.0 ± 1.6	34.2 ± 2.7	4.9 ± 1.0	34.1 ± 1.6
	48	7.6 ± 0.6	7.6 ± 0.6	32.8 ± 2.8	4.8 ± 1.0	29.6 ± 1.9
Oral 100 μg Vitamin A	0		7.7 ± 0.6	33.6 ± 1.9	4.7 ± 0.6	28.4 ± 2.7
	4		12.6 ± 2.7*	45.8 ± 2.7*	8.3 ± 1.1*	60.2 ± 3.8*
	8		13.0 ± 1.9*	32.1 ± 3.8	4.9 ± 0.6	58.1 ± 1.6*
	24		7.7 ± 0.6	30.6 ± 0.6	4.6 ± 0.7	29.6 ± 0.7
	48		7.6 ± 1.0	33.6 ± 0.6	5.0 ± 0.3	30.7 ± 1.0
Oral 10,000 μg Vitamin A	0		7.5 ± 0	30.6 ± 0.8	4.4 ± 0.6	32.7 ± 1.0
	4		4.0 ± 0.2*	8.6 ± 1.1*	2.0 ± 0.3*	405 ± 21.0*
	8		3.6 ± 0.6*	11.1 ± 0.9*	2.0 ± 0.4*	460 ± 16.0*
	24		7.7 ± 1.3	27.8 ± 3.8	4.6 ± 1.0	165 ± 8.5*
	48		7.6 ± 0.9	28.6 ± 2.6	4.9 ± 0.7	61.5 ± 4.4*

* Indicates that this Mean is statistically significant at the < 0.5 confidence level when compared to the Mean at the "0 hour" in its respective Type of Treatment category. The data were analyzed by the method of Fisher (25).

† All figures are expressed as Mean ± Standard Error.

stances, increase in mitotic activity is confined to the local area of application and is unaccompanied by an increase in blood "A".

When 1,000 μg. of vitamin A are topically applied to "A"-deficient animals, there is an elevation in the mitotic index of cornea, trachea and epidermis of the untreated site four hours after treatment (Table VII). This is probably a result of a blood "A" level which has been raised to what is considered the normal range (30–40 μg/100 ml). This effect is maintained over the entire 48 hour period of the experiment. At the site of application, there is no increase in mitotic activity during the first 24 hours, but there is a significant elevation 48 hours after the application of "A". This failure of high concentrations of vitamin A to stimulate mitotic activity at the site of application may be explained by observing Tables VIII and IX which illustrate the topical application of 1,000 μg. of vitamin A to normal and "A" Test Diet + "A" rats. Here one can see that such a high dose of vitamin A actually depresses the mitotic index at the site of application for at least 24 hours after treatment. This inhibitory phenomenon of large amounts of vitamin A is a local one since there is no generalized systemic inhibitory effect.

The topical application of an extremely high dose of vitamin A (10,000 μg.) to vitamin A-deficient rats results in a significant depression in mitotic index at the site of application, the untreated epidermis and in the corneal epithelium four hours following treatment (Table VII). This is associated with an extremely high blood level of vitamin A. When the elevated blood level decreases at 8 hours, the mitotic indexes of the epithelia return to initial values. On the other hand, at 24 and 48 hours after treatment, the mitotic indexes of the tissues are rising. Significant increases in mitotic index of all epithelia are observable, while serum "A" levels have descended to more normal levels. Tables VIII and IX demonstrate that this high dose of vitamin A has a similar effect on the epithelial tissues of the normal and "A" Test Diet + "A" animals. With a return of the elevated blood levels of "A" to normal, 24 hours after treatment, epithelial mitotic activity returns to original levels.

2. *Oral administration.* The oral administration of 100 μg. of vitamin A to "A"-deficient rats results in an elevation of serum vitamin A to normal levels and a generalized increase in epithelial mitotic index four hours after treatment. This systemic effect of vitamin A is maintained throughout the entire 48 hour experimental period (Table VII). This same treatment given to normal animals and "A" Test Diet + "A" animals produces an increase in mitotic activity of the tissues only as long as the serum "A" is elevated to above normal levels (Tables VIII and IX).

The oral administration of 10,000 μg. of vitamin A to "A"-deficient animals produces either a depression in epithelial mitosis or no change in mitotic index (Table VII). When the blood levels of "A" begin to descend to more normal levels, instead of obtaining an inhibitory effect, a reversal occurs and the mitotic index of epithelia is significantly stimulated. The effect of this oral toxic dose of vitamin A on epithelial mitosis of normal animals is shown in Table VIII and for the "A" Test Diet + "A" animals in Table IX. Here too, one can see a systemic inhibition of mitotic activity, when the levels of vitamin A in the blood are raised to extraordinarily high values.

DISCUSSION

Animals on the vitamin A-deficient diet appear to be relatively normal until the sixth week of the depletion period. At this time, there is an acute drop in blood vitamin A, a marked depression in epithelial mitotic index and evidence of keratinizing metaplasia. Until this time, the only grossly observable changes in these animals are a retarded rate of growth and a gradual loss of vitamin A from the storage depots. This sequence of events in the process of vitamin A deficiency may be explained on the basis of the amount of vitamin A stored and the level of circulating "A". The weanling rat has relatively small amounts of vitamin A in his liver and kidneys. Since the animal is deprived of the vitamin in his diet he must rely entirely on his stores of "A" to supply his physiological requirements. Initially these stores are adequate to maintain the blood level of "A", which in turn is sufficient to meet the demands of epithelia. However, the stores of "A" are insufficient to satisfy the requirements of general body weight gain. As long as the liver and kidney levels of "A" are able to maintain a normal level of circulating "A", little change is demonstrable. However, when the stores

of "A" fall below some critical level, blood vitamin A can no longer be sustained. It is at this point that the effects of vitamin A deficiency on epithelia become apparent. In other words, the functional and morphological integrity of epithelia depends upon an adequate supply of vitamin A. The vitamin is normally supplied by the circulatory system, but in certain instances epithelia can directly utilize the vitamin when topically applied.

The present studies on mitosis in vitamin A-deficient rats demonstrate that there is a significant fall in mitotic index of epithelia concomitant with a decrease in serum vitamin A. This is not in agreement with the results of Wolbach and Howe (1) who found an increase in mitotic activity with "A"-deficiency, and Friedenwald *et al.* (14) who claimed that the number of mitoses per 1,000 basal cells in the corneal epithelium of vitamin A-deficient rats was not significantly different from that of rats on a normal diet. The discrepancies between the present study and the previous ones cannot be fully explained at the present time, but may be related in some manner to the fact that the authors of the previous studies used older rats which were chronically "A"-deficient while the animals in the present study were younger and suffered from an acute vitamin A deficiency. In addition, Wolbach and Howe (1) did not use colchicine to arrest mitoses and did not perform a statistical evaulation of their observations.

The results of the present experiments show that the administration of physiological amounts of vitamin A causes a significant increase in the mitotic index of epithelia, while high toxic doses of the vitamin significantly diminish mitotic activity in "A"-deficient, normal and "A" Test Diet + "A" rats. This is in agreement with the results of Lawrence and Bern (16) and Alov (15) who found that vitamin A greatly stimulated cell division and increased the mitotic activity of epithelia. Greenberg *et al.* (24) also take the view that vitamin A is an important factor in the regulation of the mitotic activity of epidermis.

It is interesting to note that the results on mitotic index obtained from normal rats and those obtained from the "A" Test Diet + "A" rats are similar. Thus, when considering the effect of vitamin A on epithelial mitosis, we can consider these two groups of animals essentially the same

It appears that vitamin A can affect the mitotic index of epithelia by either of two methods. First, there is a direct local effect on mitotic index of epidermis. Secondly, there is a general response of epithelia which is related to an increase in the level of vitamin A in the blood. In both instances, it seems that the effect of vitamin A on epithelial mitotic index is maintained only for that period of time in which the vitamin is supplied to the tissues in adequate amounts. When the amount of vitamin A delivered to the epithelia drops below some critical level, the mitogenic effect of vitamin A in that area is lost.

The effect of vitamin A on *in vitro* epithelial mitosis reveals similar results to that found in the intact animal. Moderate doses of the vitamin enhance the mitotic index of epithelia of "A"-deficient, normal and "A" Test Diet + "A" animals, while toxic doses of the vitamin depress mitotic activity. In both instances, it appears that in considering mitotic indexes, the vitamin A-deficient epithelia are more responsive to the action of vitamin A than are epithelia taken from normal and "A" Test Diet + "A" animals.

SUMMARY AND CONCLUSIONS

The effects of vitamin A (including deficiency effects) on the mitotic index of epidermis, corneal and tracheal epithelia are observed in the male albino rat.

A considerable reduction in mitotic index is found in the epithelia of vitamin A-deficient male albino rats. This decrease in mitotic index and the appearance of keratinizing metaplasia appear late in the depletion period and are associated with an abrupt decline of serum vitamin A. It is suggested that the functional and morphological integrity of epithelial tissues depends upon an adequate supply of vitamin A, which is normally supplied by the circulatory system.

Topical application and oral administration of vitamin A in physiological amounts causes an increase in epithelial mitotic index, both *in vivo* and *in vitro*. Extremely high toxic concentrations of the vitamin, however, can significantly depress the mitotic index of the epithelia investigated. Vitamin A can have a direct local effect on mitotic index as well as a systemic effect; the latter related to adequate amounts of vitamin A in the circulation.

It is concluded that vitamin A is a factor in the

regulation of the mitotic activity of epithelial cells.

ACKNOWLEDGMENT

I should like to express my appreciation to Dr. Jerome P. Parnell, Department of Anatomy, State University of New York, Downstate Medical Center for his association in developing the concepts and hypotheses presented in this article.

REFERENCES

1. Wolbach, S. B. and Howe, P. R.: Tissue changes following deprivation of fat-soluble A vitamin. J. Exp. Med., **42**: 753–778, 1925.
2. Mori, M.: Ueber den sogenanten Hikam (Xerosis conjunctivae infantum) eventuell keratomalocie. Jahrb. f. Kinderheilk., **59**: 175–195, 1904.
3. Goldschmidt, M.: Experimenteller Beitrag zur Aetiologie der Keratomalacie. Arch. f. Ophth., **90**: 354–366, 1915.
4. Wolbach, S. B. and Howe, P. R.: Vitamin A deficiency in the guinea pig. Arch. Path. Lab. Med., **5**: 239–253, 1928.
5. Wolbach, S. B. and Howe, P. R.: Epithelial repair in recovery from vitamin A deficiency. J. Exp. Med., **57**: 511–526, 1933.
6. Frazier, C. N. and Hu, E. K.: Cutaneous lesions associated with deficiency of vitamin A in man. A.M.A. Arch. Intern. Med., **48**: 507–514, 1931.
7. Harris, L. J., Innes, J. R. M. and Griffith, A.S.: On the pathogenesis of avitaminosis A: vitamin A as the anti-keratinizing factor. Lancet, **223**: 714–617, 1932.
8. Carleton, A. and Steven, D.: Keratosis follicularis: a study of four cases. Arch. Dermat. u. Syph., **48**: 143–150, 1943.
9. Leitner, Z. A. and Moore, T.: Vitamin A and skin disease. Lancet, **251**: 262–265, 1946.
10. Frazier, C. N. and Marmelszadt, W. L.: Vitamin A deficiency and the skin in retrospect: a historical search into nosological antecedents. Bull. Hist. Med., **22**: 766–795, 1948.
11. Dublin, W. B. and Hazen, B. M.: Relation of keratosis seborrheica and keratosis senilis to vitamin A deficiency. A.M.A. Arch Derm., **57**: 178–183, 1948.
12. Moult, F. H.: Histopathology of rat skin in avitaminosis A. A.M.A. Arch. Derm., **47**: 768–777, 1943.
13. Lowe, J. S., Morton, R. A. and Harrison, R. G.: Aspects of vitamin A deficiency in rats. Nature, **172**: 716–719, 1953.
14. Friedenwald, J. S., Buschke, W. and Morris, M. E.: Mitotic activity and wound healing in the corneal epithelium of vitamin A-deficient rats. J. Nutr., **29**: 299–308, 1945.
15. Alov, I. A.: Cell division and vitamin A Byull. Eksptl. Biol. i Med., **43**: 76–80, 1957.
16. Lawrence, D. J. and Bern, H. A.: On the specificity of the response of mouse epidermis to vitamin A. J. Invest. Derm., **31**: 313–325, 1958.
17. Jewell, H. A., Taube, H., Nicholls, M. E. and Lehmann, R. A.: Action of vitamin A on the skin following intracutaneous injection. Proc. Soc. Exp. Biol. Med., **96**: 162–165, 1957.
18. Bullough, W. S. and Johnson, M.: A simple technique for maintaining mammalian epidermal mitosis *in vitro*. Exp. Cell. Res., **2**: 445–453, 1951.
19. Bullough, W. S.: A study of the hormonal relations of epidermal activity *in vitro*. I Technique. Exp. Cell. Res., **7**: 176–185, 1954.
20. Bullough, W. S.: A study of the hormonal relations of epidermal activity *in vitro*. II Insulin and pituitary growth hormone. Exp. Cell Res., **7**: 186–196, 1954.
21. Sobel, A. E. and Snow, S. D.: The estimation of serum vitamin A with activated glycerol dichlorohydrin. J. Biol. Chem., **171**: 617–632, 1947.
22. Bessey, O. A., Lowry, O. H., Brock, M. J. and Lopez, J. A.: The determination of vitamin A and carotene in small quantities of blood serum. J. Biol. Chem., **166**: 177–188, 1946.
23. Sobel, A. E., Parnell, J. P., Sherman, B. and Bradley, D. K.: Percutaneous absorption of vitamin A. J. Invest. Derm., **30**: 315–331, 1958.
24. Greenberg, R., Cornbleet, T. and Domovsky, R.: Conversion of carotene to vitamin A by sebaceous glands. A.M.A. Arch. Derm., **76**: 17–23, 1957.
25. Fisher, R. A.: Statistical methods for research workers, pp. 126–128. Edinburgh, Oliver and Boyd Ltd., 1936.

Singh-'68
Bib. No. 8504

Life Sci. 7(5)(Pt. 1):239-247. 1968.

EARLY EFFECTS OF FEEDING EXCESS VITAMIN A: HEPATIC GLYCOGEN, BLOOD LACTIC ACID, PLASMA NEFA AND GLUCOSE TOLERANCE IN RATS.

Malathy Singh, Vishwa Nath Singh and T.A. Venkitasubramanian

Department of Biochemistry, Vallabhbhai Patel Chest Institute, University of Delhi, Delhi-7.

(Received 16 September 1967: in final form 27 November 1967)

THERE are contradictory reports in literature regarding the effect of hypervitaminosis A on the glycogen level in the liver. Ray and Sadhu[1] reported a decrease in the liver glycogen, and diminished glucose utilization and glycogen synthesis by the diaphragm muscle in rats fed 30,000 IU of vitamin A daily for ten days. On the other hand, in a later study Kumar et al.[2] observed considerable increase in the liver glycogen of rats which had been intramuscularly injected with large doses of vitamin A for 14 days. Since in the above two studies animals were arbitrarily subjected to vitamin A toxicity for 10 and 14 days, findings are likely to have been influenced by the secondary changes which might have set in during this long period. Furthermore, Kumar et al.[2] did not pair-feed the animals and since in hypervitaminosis A food intake is considerably lowered, effect of partial starvation in their study cannot be ruled out. Thus, in the present study early effects of feeding excess vitamin A on glycogen level of the liver, glucose tolerance and blood lactic acid content in rats have been investigated. Present findings offer a possible explanation for the disagreement between the findings of the previous workers and also throw some light on the mechanism of the derangement of hepatic glycogen metabolism in rats fed excess vitamin A.

Of late study of plasma non-esterified fatty acids (NEFA) has

attracted considerable attention. A close relationship between carbohydrate metabolism and plasma NEFA is now well recognized. In a recent report, on the basis of their own findings and data available in the literature Randle and coworkers have postulated that abnormalities of glucose phosphorylation, glycogen metabolism, glycolysis and pyruvate oxidation in muscle of diabetic or starved animals or animals treated with growth hormone and corticosteroids are secondary to the release of more fatty acids or ketone bodies for oxidation.[3] Thus, in the present study plasma NEFA levels in rats fed excess vitamin A and in appropriate controls have been estimated and an attempt to correlate plasma NEFA, glucose tolerance and blood lactic acid level has been made.

Materials and Methods

Young, male albino rats weighing 70-90 g were divided into two groups, 'Control' and 'Experimental'. Each experimental animal was orally fed 30,000 IU of vitamin A alcohol (Prepalin, Glaxo) in ethyl oleate per day for a period specified in the pertinent tables of results. Each control animal received appropriate amount of ethyl oleate in lieu of Prepalin. Animals were pair-fed and were fasted for 18-20 hours before sacrificing unless otherwise specified. For lactic acid estimation blood was collected by decapitating the animals which had been anaesthetized by a subcutaneous injection of 1.2% nembutal sodium (pentobarbital sodium) in 0.85% NaCl at a dose level of 5 mg per 100 g body weight. Animals used for other estimations were stunned by a blow on the head and quickly exsanguinated by decapitation.

Almost immediately after killing the animal, right lobe of the liver was quickly excised and used for the isolation of glycogen.[4] After reprecipitating once, glycogen was estimated by phenol-

sulphuric acid method.[5]

Blood sugar and lactic acid were estimated by the method of Somogyi[6] and Barker and Summerson[7] respectively. Non-esterified fatty acids were measured in freshly separated plasma.[8]

Results and Discussion

As evident from Table 1, there was considerable increase in fasting hepatic glycogen level of rats as a result of feeding excess vitamin A for as short a period as 2 days. However, there was no significant difference in the glycogen levels of fed control and fed vitaminotic rats (Table 2). It may be inferred from these findings that ability of liver to degrade glycogen during 18-20 hour-fasting is impaired in rats fed excess vitamin A. Thus, it is suggested that increase in the fasting glycogen level of the liver of rats as a result of ingestion of large doses of vitamin A, may be due to diminished breakdown of the polysaccharide. This

TABLE 1

EFFECT OF FEEDING 30,000 IU OF VITAMIN A FOR 2, 4 AND 8 DAYS ON THE HEPATIC GLYCOGEN LEVEL IN RATS.

Each value given in the table is the Mean ± S.E. of the results of four experiments; one rat being used for each experiment. Control and vitamin A-fed rats are referred to as 'C' and 'V' respectively.

Animals	Duration of feeding (days)	Glycogen content of the liver	
		mg/100 mg tissue	mg/100 g body weight
C	2	0.42 ± 0.02	12.5 ± 1.7
V	2	2.98 ± 0.23	132.0 ± 20.0
C	4	0.53 ± 0.03	16.0 ± 2.0
V	4	3.82 ± 0.42	167.0 ± 45.9
C	8	0.60 ± 0.03	20.9 ± 3.8
V	8	3.87 ± 0.10	150.0 ± 21.0

also explains why Kumar *et al.*[2] who have used fasted rats, observed an increase whereas Ray and Sadhu[1] who have used fed animals, noted slight decrease in the glycogen content of the liver in the rats fed excess vitamin A.

TABLE 2

EFFECT OF FASTING ON THE HEPATIC GLYCOGEN LEVEL OF CONTROL AND VITAMIN A - FED RATS.

Whereas fed animals had access to food all the time, food was withdrawn from fasted animals 18-20 hours before they were sacrificed. Each value given in the table is Mean ± S.E. of the results of six experiments; one rat being used for each experiment. Control and vitamin A-fed rats are referred to as 'C' and 'V' respectively.

Animals	Period of fasting	Glycogen content of the liver	
		mg/100 mg tissue	mg/100 g body weight
C	Nil	7.10 ± 0.28	280 ± 9.7
V	Nil	7.30 ± 0.80	296 ± 8.9
C	18-20 hr	0.42 ± 0.02	12.5 ± 1.7
V	18-20 hr	2.98 ± 0.23	132 ± 20.0

Results given in Table 3 show that feeding 30,000 IU of vitamin A for two days brought about significant elevation in the glucose and lactic acid levels of blood. Findings of oral glucose tolerance test of control and vitaminotic rats are given in Fig.1. In control animals, highest glucose concentration was obtained 45 minutes after feeding glucose to 18-20 hour-fasted rats at the level of 200 mg per 100 g body weight and at the end of 3 hours blood glucose was slightly lower than the fasting level. In vitamin A-fed rats too the peak reached 45 minutes after glucose feeding but blood glucose levels at fasting and at all the intervals after glucose feeding were considerably higher than the corresponding levels in control animals. Furthermore, in the vitamin A-fed rats.

TABLE 3

LEVELS OF PLASMA NEFA AND BLOOD GLUCOSE AND LACTIC ACID IN CONTROL AND VITAMIN A-FED RATS.

Values given in the table are Mean ± S.E. Figures given in parantheses indicate the number of rats used for the estimation. Data have been statistically evaluated and P ≤ 0.05 has been considered significant.

Estimation	Control	Vitamin A-fed	P Values
NEFA (μeq./litre plasma)	712 ± 33 (6)	1331 ± 30 (6)	< 0.001
Lactic acid (mg/100 ml blood)	8.0 ± 0.52 (8)	11.6 ± 0.80 (8)	< 0.01
Glucose (mg/100 ml blood)	49.0 ± 3.6 (16)	62.0 ± 4.8 (16)	< 0.05

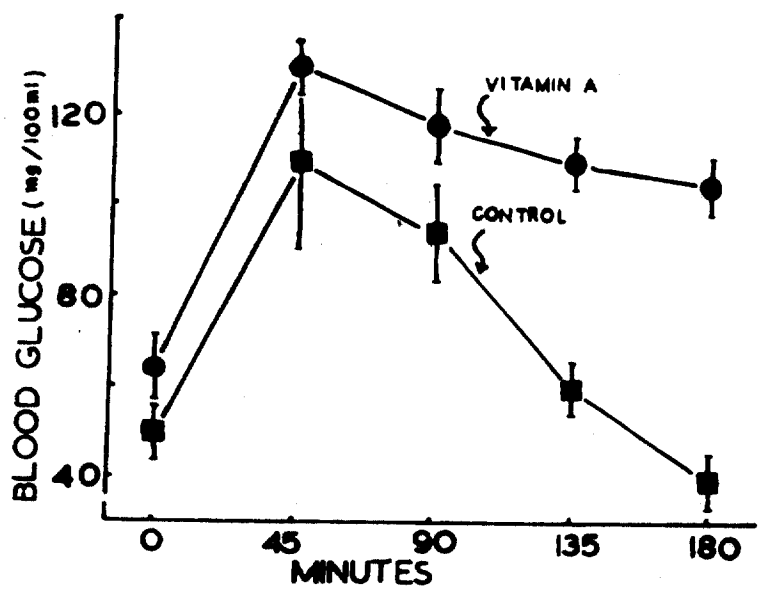

FIG. 1

Effect of feeding excess vitamin A on the glucose tolerance in rats. For determining fasting blood glucose level, blood samples were collected at the end of 18-20 hour-fasting. Thereafter additional blood samples were collected at 45, 90, 135 and 180 minutes after orally feeding 50% glucose solution at the level of 2 g per Kg body weight. Each value given in the figure is Mean ± S.E. of the results obtained from six animals.

unlike in the control animals, glucose level even at the end of 3 hours after glucose feeding was more than 150 per cent of the fasting level. Thus, it is obvious that feeding excess vitamin A to rats causes considerable lowering in the glucose tolerance.

Estimation of NEFA levels of the plasma in control and vitamin A-fed rats revealed that ingestion of excess vitamin A resulted in marked elevation (more than 80 per cent) in the NEFA concentration (Table 3). It is now well recognized that lipid is mobilized from the fat depots in the form of non-esterified fatty acids which are bound to albumin and transported to the site of utilization.[9-12] The mobilization of NEFA from adipose tissue is subject to multiple controls which act by influencing rate of lipolysis and/or esterification of fatty acids. The mobilization of NEFA can thus be achieved either by acceleration of lypolysis as it happens under the influence of adipokinetic agents[13] or due to diminished availability of glucose or insulin.[3,12] Many hormonal and nutritional abnormalities of carbohydrate metabolism such as diabetes, starvation, carbohydrate deprivation and impaired glucose tolerance, are known to be associated with the high plasma level of NEFA.[3] Glucose and insulin alter profoundly NEFA level of plasma by influencing the rate of re-esterification.[12] Thus, impaired glucose utilization as indicated by lowered glucose tolerance observed in the present study, may be responsible for the increase in plasma NEFA level in rats fed excess vitamin A. However, opposite may also be true, i.e. release of NEFA itself may be responsible for impaired glucose utilization.[3]

The oxidation of pyruvate by perfused heart and isolated diaphragm muscle of rats has been reported to be impaired by the addition of fatty acids and ketone bodies to the perfusion or

incubation medium.[14,15] Also, recent studies of Weil et al.[16] have shown that increased utilization of NEFA influences the metabolic fate of glucose resulting in higher concentrations of tissue and subsequently blood pyruvate and lactate. Since removal of NEFA from plasma by myocardium,[17-20] skeletal muscle,[21,22] liver[23] and kidney[20-24] has been shown to be a direct function of the concentration of NEFA in the blood, the observed increase in the blood lactic acid levels in rats fed excess vitamin A, may be due to the decreased oxidation of pyruvate as a result of increased plasma NEFA.

The accumulation of lipid in the liver under many experimental conditions has frequently been associated with the fat mobilization from adipose tissue. Increase in serum NEFA induced by constant intravenous infusion of norepinephrine has been reported to cause marked increase in glyceride content of liver but slight change in phospholipid.[25] Findings of certain perfusion studies also lend support to the view that elevation of serum fatty acid concentration per se is an adequate basis for development of fatty liver.[12,26-28] Thus increased level of plasma NEFA observed in the present study, becomes of interest in view of reports in the literature showing accumulation of lipid in rat liver as a result of hypervitaminosis A.[1,29]

Summary

Oral administration of 30,000 IU of vitamin A daily for even two days resulted in more than 600 per cent increase in the fasting hepatic glycogen level in rats. A study of the effect of 18-20 hour-fasting on the liver glycogen content of normal and vitamin A-fed rats revealed that whereas fasting brought about more than 90 per cent reduction in the glycogen level of normal rats, there was less than 60 per cent decrease in that of vitamin A-fed rats under

similar conditions. This is considered indicative of an impairment of the ability of the liver to degrade glycogen during fasting in vitamin A-fed rats.

Furthermore, an elevation of plasma NEFA and blood lactic acid and glucose levels and lowering of glucose tolerance were noticed in rats fed excess vitamin A.

Acknowledgment - The authors are grateful to Mr. S.C. Sharma for technical assistance.

References

1. A. RAY and D.P. SADHU, Nature 184, 1323 (1959).
2. M. KUMAR, U.K. MISRA and T.A. VENKITASUBRAMANIAN, Naturewissenschaften 52, 39 (1965).
3. P.J. RANDLE, P.B. GARLAND, C.N. HALES and E.A. NEWSHOLME, Lancet 1, 785 (1963).
4. C.A. GOOD, H. KRAMER and M. SOMOGYI, J. Biol. Chem. 100, 485 (1933).
5. R. MONTGOMERY, Arch. Biochem. Biophys. 67, 378 (1958).
6. M. SOMOGYI, J. Biol. Chem. 195, 19 (1952).
7. S.B. BARKER and W.H. SUMMERSON, J. Biol. Chem. 138, 535 (1941).
8. V.P. DOLE and H. MEINERTZ, J. Biol. Chem. 235, 2595 (1960).
9. D.S. FREDRICKSON and R.S. GORDON, Jr., Physiol. Rev. 38, 585 (1958).
10. R.S. GORDON, Jr., and A. CHERKES, J. Clin. Invest. 35, 206 (1956).
11. V.P. DOLE, J. Clin. Invest. 35, 150 (1956).
12. D. STEINBERG, in J.K. GRANT (Ed.), "The Control of Lipid Metabolism", Academic Press, London, 1963, p. 111.
13. D. RUDMAN, J. Lipid Res. 4, 119 (1963).
14. J.R. EVANS, H. OPIE and A.S. RENOLD, Am. J. Physiol. 205, 971 (1963).
15. P.B. GARLAND, E.A. NEWSHOLME and P.J. RANDLE, Nature 195, 381 (1962).

16. R. WEIL, P. HO and N.ALTSZULER, Am. J. Physiol. 208, 887 (1965).

17. F.B. BALLARD, W.H. DANFORTH, S.NAEGLE and R.J. BING, J. Clin. Invest. 39, 717 (1960).

18. A. CARLSTEN, B. HALLGREN, R. JAGENBURG, A. SVANBORG and L. WERKO, Scand. J. Clin. Lab. Invest. 13, 418 (1961).

19. J.C. SCOTT, L.J. FINKELSTEIN and J.J. SPITZER, Am. J. Physiol. 203, 482 (1962).

20. M. GOLD and J.J. SPITZER, Am. J. Physiol. 206, 153 (1964).

21. P. EATON and D. STEINBERG, J. Lipid Res. 2, 376 (1961).

22. J.J. SPITZER and M. GOLD, Am. J. Physiol. 206, 159 (1964).

23. W.T. McELROY, Jr., W.L. SIEFERT and J.J. SPITZER, Proc. Soc. Exptl. Biol. Med. 104, 20 (1960).

24. F.J. HOHENLEITNER and J.J. SPITZER, Am. J. Physiol. 200, 1095 (1961).

25. E.B. FEIGELSON, W.W. PFAFF, A. KARMEN and D. STEINBERG, J. Clin. Invest. 40, 2171 (1961).

26. P.J. NESTEL and D. STEINBERG, J. Lipid Res. 4, 461 (1963).

27. L.I. GIDEZ, P.S. ROHEIN and H.A. EDER, Fed. Proc. 21, 289 (1962).

28. M.B. FINE and R.H. WILLIAMS, Am. J. Physiol. 199, 403 (1960).

29. U.K. MISRA, Biochem. J. 95, 30 P (1965).

J. Lipid Res. 10:395-401. 1969.

Singh-'69
Bib. No. 8508

Reproduced by per...
of the copyright owner

Early effects of feeding excess vitamin A: mechanism of fatty liver production in rats

VISHWA NATH SINGH, MALATHY SINGH, and T. A. VENKITASUBRAMANIAN

Department of Biochemistry, Vallabhbhai Patel Chest Institute,
University of Delhi, Delhi-7, India

ABSTRACT Oral administration of vitamin A (30,000 IU daily for 2 days) to young rats caused a marked increase in hepatic glycogen, cholesterol, and glycerides, while hepatic phospholipid content remained almost unaltered.

In an examination of the pathogenesis of the lipid accumulation, it was found that more glucose-^{14}C was incorporated into liver lipids in vitamin A-fed rats, whereas incorporation of glucose-^{14}C and DL-glycine-^{14}C into liver protein remained unaltered. The increase in glucose-^{14}C incorporation was confined to the glyceride-glycerol portion of the lipids; incorporation into liver fatty acids was inhibited. Plasma free fatty acid concentrations were elevated.

It is postulated that in the vitamin A-fed rats, increased accumulation of lipids in the liver is caused by a stimulation of fatty acid mobilization from adipose tissue and enhanced formation of glycerophosphate through glycolysis, with consequent increase in the glyceride synthesis in the liver.

The weight of the adrenals was increased, whereas cholesterol concentration in the gland was decreased, after administration of vitamin A to rats. This indicates adrenocortical stimulation. Interestingly enough, vitamin A feeding did not affect either the level of liver lipids or of plasma FFA in adrenalectomized rats.

SUPPLEMENTARY KEY WORDS lipid mobilization · glyceride-glycerol synthesis · adrenal weight · cholesterol · ascorbic acid · adrenalectomy

It is now well recognized that ingestion of large doses of vitamin A causes toxic manifestations (1–5). Earlier reports from this laboratory have shown considerable elevation in the lipid content of rat liver as a result of intramuscular administration of 100,000 IU of vitamin A daily for total periods of 10–14 days (6, 7). However, these studies were confined to changes in the levels of various lipid components of the liver, and the mechanism of vitamin A-mediated accumulation of lipids in the liver has not as yet been explained. The present investigation was, therefore, undertaken to study the early effects of feeding excess vitamin A (30,000 IU daily for 2 days) on the lipids of the liver, on the plasma free fatty acids (FFA), and on the lipogenic capacity of the liver of young (60–90 g of body weight) rats. In this study glucose-U-^{14}C has been chosen as a precursor for the study of lipogenesis, because it is the only physiological precursor that is of quantitative significance in lipogenesis. Furthermore, in view of the known effects of adrenal hormones on the mobilization of lipids from adipose tissue (8–10), we were prompted also to study the effects of vitamin A on adrenal cortical function and on liver lipids and plasma FFA of adrenalectomized rats.

Abbreviation: FFA, free fatty acids.

MATERIALS AND METHODS

Male albino rats weighing 60–90 g were divided into two groups, "vitaminotic" and "control." Each animal in the vitaminotic group was fed 30,000 IU of retinol in 0.4 ml of ethyl oleate (Prepalin, Glaxo Ltd., Bombay, India) once daily for 2 days, whereas animals of the control group received appropriate volumes of ethyl oleate. The rats were killed about 24 hr after administration of the second dose. The animals, which had been fasted overnight (18–20 hr), were stunned by a blow on the head and quickly exsanguinated after decapitation. The liver was excised and dropped immediately into chilled (0–4°C) physiological saline solution. The tissue was quickly used for various analyses.

Estimation of Plasma FFA

FFA was determined in freshly obtained plasma by the method of Dole and Meinertz (11).

Estimation of Liver Glycogen

Immediately after the animals had been killed, the right lobe of the liver was quickly excised, cleaned of extraneous materials, and dropped into 30% aqueous KOH. Glycogen was isolated (12), purified by reprecipitating twice with alcohol, and estimated by the phenol–sulfuric acid method (13).

Estimation of Liver Lipids

A portion of the liver (about 1 g) was dropped into 20 volumes of chloroform–methanol 2:1 and finely ground with the help of a glass pestle and mortar. Lipid was then extracted and purified (14). Aliquots of the lipid solution in chloroform were used for the estimation of total lipids (gravimetrically), phospholipid [phosphorus (15, 16) × 25] and cholesterol (17). Glyceride was estimated either by difference (total lipid minus phospholipid and cholesterol) or by determination of glyceride-glycerol (18). In the former case, we corrected for the contribution of vitamin A on the assumption that all the vitamin in the liver (determined as described below) was in the form of retinyl palmitate. Before the measurement of glyceride-glycerol, phospholipids were removed from the neutral lipids as follows. An aliquot of the lipid solution (about 4 mg of lipid) in chloroform was mixed and shaken with 0.3 g of silicic acid (100–200 mesh) (19). The silicic acid was removed by centrifugation at about 2000 *g* for 10 min and washed with 4 × 3 ml of chloroform, each time with centrifugation. The combined solutions were evaporated to dryness and the residue (neutral lipids) was redissolved in a known volume of chloroform for glyceride-glycerol estimation (18), with tripalmitin as a standard.

Aliquots of the lipid solution in chloroform were used for the estimation of vitamin A by the antimony trichloride procedure of Carr and Price as described by Embree, Ames, Lehman, and Harris (20).

Protein Determination

2 volumes of 10% trichloroacetic acid were added to a suitable amount of 10% liver homogenate in 0.25 M sucrose and the insoluble residue was washed with ethanol–ether (3:1) mixture and then with ether. The dry powder thus obtained was dissolved in 0.1 N NaOH and protein content was estimated by the biuret method (21).

Estimation of Deoxyribonucleic Acid

Deoxyribonucleic acid (DNA) was isolated from liver by the method of Schmidt and Thannhauser as described by Munro and Fleck (22). DNA content was determined by measuring deoxyribose.

Incorporation of Glucose-U^{14}C Into Liver Lipids

To rats which had been fasted for 18–20 hr, 30 μc (200 mg) of glucose-U-^{14}C was fed per 100 g of body weight. 3 hr later they were killed. Total lipids were isolated from about 2 g of the liver (14). An aliquot of the lipid solution in chloroform was plated on stainless steel planchets and radioactivity was determined in a gas-flow counter with an efficiency of about 40%. The remaining solution was evaporated to dryness under nitrogen and the lipids were saponified (23). Nonsaponifiable materials and fatty acids were extracted into petroleum ether (boiling range 40–60°C) from the alkaline alcoholic digest (24). The aqueous layer was regarded as the glyceride-glycerol fraction. The validity of this procedure for measuring glyceride-glycerol-^{14}C has been tested and confirmed (25). Suitable aliquots of these fractions were plated on stainless steel planchets for radioactivity determination.

Incorporation of ^{14}C-Labeled Precursors into Liver Proteins

Rats fasted overnight (18–20 hr) were fed either 30 μc (200 mg) of glucose-U-^{14}C/100 g of body weight or intraperitoneally injected with 15 μc (specific activity 3.2 mc/mmole) of DL-glycine-2-^{14}C/100 g of body weight. 3 hr later, animals were killed and the liver was excised and homogenized in chilled (0–4°C) 0.25 M sucrose solution. 2 volumes of 10% trichloroacetic acid was added to an aliquot of the liver homogenate. The trichloroacetic acid-insoluble material was collected by centrifugation and freed from acid-soluble compounds, nucleic acids, and lipids (26). The dry protein was dissolved in a suitable volume of concentrated (85%) formic acid. An aliquot of this solution was plated for radioactivity determination.

Determination of Adrenal Cholesterol and Ascorbic Acid

The adrenal glands were excised, cleaned of adhering fat, and finely ground in chloroform–methanol 2:1. The chloroform–methanol extract was evaporated to dryness and lipids were extracted with chloroform. An aliquot of the chloroform solution was taken for cholesterol determination (17).

The adrenals were finely ground in cold (0–4°C) 5% trichloroacetic acid and ascorbic acid was estimated by the method of Roe and Keuther (27).

Studies on Adrenalectomized Rats

Rats weighing 70–85 g were bilaterally adrenalectomized and were maintained on 0.9% saline solution instead of drinking water throughout the experimental period. 5 days after adrenalectomy, rats were divided into two groups, "control" and "vitaminotic." Each vitaminotic rat was fed 30,000 IU of vitamin A in ethyl oleate once daily for 2 days, whereas control animals were admin-

istered appropriate amounts of the ethyl oleate for the same period. Liver lipids and plasma FFA were then determined as described above.

RESULTS

It is evident from the data presented in Table 1 that administration of excess vitamin A for only 2 days increased liver weight and hepatic glycogen, vitamin A, and lipid contents, but led to no change in the protein level. The decrease in hepatic DNA level was not statistically significant. In subsequent studies we investigated the effect of feeding excess vitamin A on the concentration of the various major components of liver lipids. The findings are given in Table 2. Results have been expressed as mg/g of liver and also as mg/mg of hepatic DNA. The latter parameter has been used to assess lipid content per cell. Hepatic cholesterol and glycerides per mg of DNA increased by 90 and 100%, respectively, as a result of feeding vitamin A. The phospholipid content remained essentially unaltered.

Plasma FFA were estimated as an indicator of the effect of vitamin A on the lipid mobilization from the adipose tissue. Table 3 shows that vitamin A administration caused more than an 85% elevation in the concentration of plasma FFA. 3 hr after feeding 2 g of glucose/kg of body weight, plasma FFA concentration in the control animals was reduced by about 25%, whereas that of the vitaminotic rats did not change.

To assess the lipogenic capacity of the liver, we studied the in vivo incorporation of glucose-U-^{14}C into lipids (Table 4). Vitamin A feeding increased the ^{14}C-incorporation into total lipids, the increase being about 40% when the results were expressed as cpm/mg of DNA. The lipids were saponified, and nonsaponifiable compounds, fatty acids, and glyceride-glycerol were separated. The ^{14}C count of each fraction showed that the observed increase in the incorporation of glucose-^{14}C into lipids was confined to the glyceride-glycerol moiety of the lipid. The increase in ^{14}C-incorporation into the glyceride-glycerol was more than 50%, expressed as cpm/mg of DNA. In contrast, incorporation of glucose-^{14}C into fatty acids of the lipids was significantly lowered. ^{14}C-incorporation into the nonsaponifiable lipid fraction was unaffected.

To see the effect of feeding vitamin A on the ability of the liver to synthesize protein, we investigated the incorporation in vivo of glucose-U-^{14}C and glycine-2-^{14}C into liver protein. As can be seen from Table 5, incorporation of both glycine-^{14}C and glucose-^{14}C into liver protein was unaffected by vitamin A feeding.

The adrenal weight and adrenal cholesterol and ascorbic acid contents were determined in vitamin A-fed rats, in an effort to learn the effect of vitamin A on adrenocortical function. The administration of the vita-

TABLE 1 EFFECT OF FEEDING EXCESS VITAMIN A ON WEIGHT AND MAJOR CHEMICAL CONSTITUENTS OF RAT LIVER

	Control	Vitaminotic	P
Liver wt (g)	2.79 ± 0.08 (38)	3.25 ± 0.16 (38)	<0.001
Liver/100 g of body wt (g)	3.36 ± 0.12 (38)	4.10 ± 0.19 (38)	<0.005
Protein (g/100 g of liver)	21.0 ± 0.31 (10)	20.5 ± 0.48 (10)	
Total lipid (mg/g of tissue)	38.9 ± 1.78 (6)	50.7 ± 3.46 (6)	<0.02
Glycogen (g/100 g of liver)	0.22 ± 0.02 (18)	2.90 ± 0.23 (18)	<0.001
DNA (mg/g of liver)	2.64 ± 0.15 (6)	2.36 ± 0.13 (6)	
Vitamin A (μg/g of liver)	22.80 ± 3.10 (6)	1163 ± 96 (6)	<0.001

Each value given in the Table is mean ± SEM. The number of animals is given in the parentheses.

TABLE 2 EFFECT OF FEEDING EXCESS VITAMIN A ON LIPIDS OF RAT LIVER

Lipid Fraction	per g of Liver		per mg of DNA	
	Control	Vitaminotic	Control	Vitaminotic
Total lipid (mg)	38.9 ± 1.78	50.7 ± 3.46 $P < 0.02$	14.8 ± 0.67	21.8 ± 1.48 $P < 0.005$
Phospholipid (mg)	23.7 ± 1.50	23.2 ± 1.24	9.00 ± 0.57	10.0 ± 0.52
Cholesterol (mg)	2.20 ± 0.12	3.90 ± 0.22 $P < 0.001$	0.83 ± 0.05	1.67 ± 0.08 $P < 0.001$
Glycerides* (mg)	12.8 ± 1.09	21.4 ± 2.82 $P < 0.02$	4.82 ± 0.40	9.15 ± 1.08 $P < 0.005$
Glyceride-glycerol (μmoles)	14.4 ± 0.85	23.4 ± 1.28 $P < 0.005$	5.53 ± 0.39	9.91 ± 0.62 $P < 0.001$

Each value is mean ± SEM from six separate experiments (six animals).

* Obtained by subtracting phospholipid plus cholesterol from the total lipids. In the case of vitamin A-fed rats, correction was made for the presence of vitamin A, on the assumption that all the vitamin A present in the liver existed as retinyl palmitate.

TABLE 3 Levels of Plasma FFA in Control and Vitamin A-Fed Rats

Nutritional State	Plasma FFA		P
	Control	Vitaminotic	
	μeq/liter		
Fasted	712 ± 33.0	1330 ± 30.0	<0.001
Glucose-fed*	527 ± 22.2	1300 ± 69.4	<0.001

* Animals were fed glucose (2 g/kg of body wt) 3 hr before they were killed.

Each value given in the Table is mean ± SEM from six separate experiments (six animals).

min resulted in considerable increase in the weight and marked decrease in the cholesterol content of the adrenal glands (Table 6). The decrease in ascorbic acid content was not statistically significant.

The effects of vitamin A on the liver lipids and plasma FFA of adrenalectomized rats were investigated. As evident from Table 7, in the absence of intact adrenals, vitamin A did not affect either the level of the liver lipids or that of plasma FFA.

DISCUSSION

The results show that feeding excess vitamin A (30,000 IU daily) for even as short a period as 2 days causes increased accumulation of lipids in rat liver (Table 1). The increase was only in the glyceride and cholesterol fractions of the lipid the phospholipid content remaining unaltered (Table 2). The knowledge gained from the studies of fatty livers caused by the administration of ethionine, CCl_4, puromycin, and ethanol (28–31) has led to the concept that the development of fatty liver is due to one (or a combination of more than one) of the following factors: increased hepatic lipogenesis, enhanced mobilization of FFA from the adipose tissue, decreased oxidation of fatty acids in the liver, or impairment of the hepatic triglyceride secretory mechanism.

In the present study, vitamin A administration caused marked lowering of the glucose-^{14}C incorporation into the liver fatty acids (Table 4). Enhanced hepatic synthesis of fatty acids as a factor causing accumulation of hepatic glycerides in vitamin A-fed rats can therefore be ruled out.

Plasma FFA levels were estimated and used as a measure of lipid mobilization from the adipose tissue. There was a more than 85% increase in plasma FFA level as a result of feeding excess amounts of vitamin A (Table 3). Increased mobilization of fatty acids from the adipose tissue may thus be considered a potentially major factor responsible for the excessive lipid accumulation in the vitamin A-fed rats.

It is now well recognized that triglycerides are synthesized in the liver from fatty acids and glycerol 3-phos-

TABLE 4 Incorporation of Glucose-U-^{14}C Into Lipid Fractions of the Liver of Control and Vitamin A-Fed Rats

Lipid Fraction	cpm/g of Liver		cpm/mg of DNA	
	Control	Vitaminotic	Control	Vitaminotic
Total lipid	11,500 ± 964	14,600 ± 1,870 $P < 0.2$	4,300 ± 231	6,110 ± 570 $P < 0.025$
Fatty acids	1,390 ± 271	702 ± 78 $P < 0.05$	515 ± 60	311 ± 25 $P < 0.01$
Cholesterol	660 ± 194	618 ± 35	240 ± 70	258 ± 16
Glyceride-glycerol	9,600 ± 512	13,300 ± 660 $P < 0.005$	3,610 ± 285	5,510 ± 277 $P < 0.001$

Mean ± SEM is given for data from six separate experiments (six animals).

TABLE 5 Effect of Feeding Excess Vitamin A on In Vivo Incorporation of ^{14}C-Labeled Precursors Into Rat Liver Protein

Mode of Expression of Results	DL-Glycine-2-^{14}C		D-Glucose-U-^{14}C	
	Control	Vitaminotic	Control	Vitaminotic
cpm/mg of Protein	306 ± 21.0	328 ± 6.1	75.0 ± 5.1	71 0 ± 4.6
cpm/g of Liver	53,700 ± 1270	50,100 ± 1200	17,200 ± 721	17,500 ± 473
cpm/100 g of body wt*	166,000 ± 3800	17,600 ± 3600	63,200 ± 1970	69,200 ± 2870
cpm/mg of DNA	20,600 ± 402	20,900 ± 348	6,870 ± 348	7,600 ± 373

Mean ± SEM is given for six separate experiments (six animals).

* $\frac{\text{cpm/g of liver} \times \text{total weight of the liver (g)} \times 100}{\text{body wt (g)}}$

TABLE 6 EFFECT OF FEEDING EXCESS VITAMIN A ON WEIGHT AND CHOLESTEROL AND ASCORBIC ACID LEVELS OF ADRENALS

Measurement	Control	Vitaminotic	P
Total weight (mg)	24.20 ± 0.54 (8)	31.50 ± 0.58 (8)	<0.001
Cholesterol (μg/mg)	17.01 ± 1.66 (8)	8.48 ± 0.72 (8)	<0.001
Ascorbic acid (μg/mg)	3.72 ± 0.55 (4)	2.43 ± 0.37 (4)	<0.1

Each value is mean ± SEM. Number of animals is given in parentheses.

TABLE 7 EFFECT OF FEEDING EXCESS VITAMIN A ON LIVER LIPIDS AND PLASMA FFA OF ADRENALECTOMIZED RATS

Lipid Fraction	Control	Vitaminotic
Total lipid (mg/g of liver)	42.3 ± 2.55	43.5 ± 2.00
Cholesterol (mg/g of liver)	3.72 ± 0.03	3.60 ± 0.14
Phospholipid (mg/g of liver)	21.5 ± 0.89	20.0 ± 0.25
Vitamin A (μg/g of liver)	21.0 ± 1.31	1150 ± 114
Glycerides* (mg/g of liver)	17.1 ± 1.51	17.90 ± 1.70
Free fatty acids (μeq/liter of plasma)	492 ± 43	400 ± 15

Each value is mean ± SEM from five animals.

* Obtained by subtracting cholesterol plus phospholipid from the total lipids. In the case of vitamin A-fed rats a correction for the presence of vitamin A was made, assuming that all the vitamin A present in the liver was in the form of retinyl palmitate.

phate (32). Furthermore, there is ample evidence to show that the rate of triglyceride synthesis in the liver is directly proportional to the concentrations of both the substrates (8, 33–36). As mentioned earlier, the increase in the plasma FFA level was perhaps sufficient to supply fatty acids for enhanced hepatic triglyceride formation in the vitamin A-fed rats. However, for the esterification of fatty acids to bring about increased glyceride synthesis, generation of glycerol phosphate must be simultaneously stimulated. Glycerol phosphate can be formed in liver by two pathways: (*a*) by the action of glycerol phosphate dehydrogenase (EC 1.1.99.5) on the dihydroxyacetone-phosphate formed during the glycolytic breakdown of sugar or during the gluconeogenic process (37), and (*b*) by the phosphorylation of glycerol by the glycerokinase reaction (38). However, of the two pathways, only the first is considered to be of quantitative importance (37). We therefore determined the incorporation of glucose-^{14}C into the glyceride-glycerol in order to assess the production of glycerol phosphate via the glycolytic pathway. It was considerably enhanced (Table 4) in vitamin A-fed rats. Thus, increased synthesis of glycerides as a result of (*a*) enhanced mobilization of fatty acids from adipose tissue and (*b*) increased glycerol phosphate formation via the glycolytic pathway in the liver seems to be a major, if not the only, factor responsible for the fatty liver.

From the present data the effect of vitamin A administration on fatty acid oxidation in the liver cannot be ascertained. However, unlike the fatty liver caused by administration of ethionine, puromycin, or CCl_4 (28, 29), the lipid accumulation in the liver of vitamin A-fed rats cannot possibly be ascribed to diminished lipoprotein formation and (or) secretion into the blood for the following reasons: (*a*) The liver is the major, if not the only, site of synthesis of plasma triglycerides, and the triglycerides formed in the liver are released into the blood in the form of very low density lipoproteins (29, 39). Thus, a diminution of lipoprotein synthesis and (or) secretion would be expected to result in lowering the blood lipids, especially the plasma triglyceride content, as has been reported to occur after the administration of ethionine, CCl_4, puromycin, phosphorus, or orotic acid (28, 29). In contrast, the vitamin A-fed rats show a considerable increase in plasma total lipids and plasma triglycerides (40). (*b*) Since the protein moiety of the very low density lipoproteins is synthesized mainly in the liver (28, 39), a block in the synthesis and (or) secretion of lipoproteins is ordinarily accompanied by a diminished synthesis of protein in the liver (28, 29), except in the case of orotic acid feeding which is known to interfere with the synthesis and (or) secretion of very low density lipoproteins without affecting hepatic protein synthesis (41–46). The data presented in this report show that administration of vitamin A did not affect protein synthesis in the liver. Thus, findings showing elevation in the level of plasma triglyceride (40) and unaltered hepatic protein synthesis provide strong evidence that synthesis and (or) secretion of lipoproteins is probably not impaired in vitamin A-fed rats.

The present findings have brought to light another noteworthy phenomenon, namely, inhibition of fatty acid synthesis from glucose in vitamin A-fed rats (Table 4). It must be pointed out here that, since the acetyl CoA pool was not measured in the present study, the extent to which a possible alteration in the acetyl CoA pool could have influenced the incorporation of ^{14}C from glucose-^{14}C into fatty acids cannot be evaluated. However, in view of the fact that incorporation of glucose-^{14}C into cholesterol and protein was not inhibited by vitamin A feeding, it seems unlikely that the entire decrease of about 40% in the glucose-^{14}C incorporation into fatty acids could have been caused only by a change in the acetyl CoA pool. Furthermore, since incorporation of glucose-^{14}C into cholesterol was not influenced by vitamin A feeding, a block in fatty acid synthesis should be

localized at some step or steps subsequent to acetyl CoA formation (either acetyl CoA carboxylase reaction or subsequent condensation of acetyl CoA and malonyl CoA). However, since acetyl CoA carboxylase reaction has been reported to be a rate-limiting step in the fatty acid biosynthesis (47), a block at this step is conceivable.

Since it has been reported that fatty acids and fatty acyl CoA inhibit the biosynthesis of fatty acids (47), the vitamin A-mediated inhibition of hepatic fatty acid synthesis from glucose-^{14}C could, perhaps, be attributed to increased availability of fatty acids as a result of the enhanced mobilization of lipids from adipose tissue indicated by elevated plasma FFA. Nevertheless, other possibilities such as decreased availability of NADPH cannot be ruled out.

The adrenal weight and its cholesterol and ascorbic acid contents have generally been used as a measure of adrenocortical function. The stimulation of adrenocortical function is ordinarily accompanied by an increase in the weight and lowering of cholesterol and ascorbic acid contents of the gland (48). Thus, the present results (Table 6) can be considered to suggest that vitamin A stimulates the adrenocortical function. It is interesting to note that vitamin A administration to the adrenalectomized rats did not alter either the levels of liver lipids or those of plasma FFA. These findings indicate that intact adrenals are needed for the manifestation of the vitamin A-mediated alterations in the levels of plasma FFA and liver lipids. However, from the present findings it is not clear whether adrenal plays a permissive or a direct role. Also, since complete adrenals (both medulla and cortex) were removed during the adrenalectomy, it is not possible to define the exact role of adrenal medulla and cortex in the vitamin A-mediated changes in the lipid metabolism. It seems pertinent to recall here that adrenalectomy has been reported to abolish or lower the susceptibility to alcohol (30) and ethionine (29) with regard to the development of fatty livers. Furthermore, Wool and Goldstein (49) and Wool, Goldstein, Ranney, and Levine (50) presented evidence to show that both adrenal medulla and cortex were involved in the development of ethionine-mediated fatty liver and suggested that the major role of epinephrine was to mobilize FFA from the adipose tissue and that cortisone perhaps plays a permissive role. The above findings have subsequently been confirmed by Hutterer (51).

This investigation was supported by a grant from the Indian Council of Medical Research, New Delhi, India. Dr. S. L. Katyal's help in performing adrenalectomy and the technical assistance of Mr. S. C. Sharma are gratefully acknowledged. The authors wish to thank Professor A. S. Paintal, the Director, for providing facilities and constant encouragement.

Manuscript received 15 October 1968; accepted 3 March 1969.

References

1. Nieman, C., and H. J. K. Obbink. 1954. *Vitamins Hormones.* **12:** 69.
2. Moore, T. 1957. Vitamin A. Elsevier Publishing Company, Amsterdam. 340.
3. Moore, T. 1964. *Exp. Eye Res.* **3:** 305.
4. Wolf, G., and B. C. Johnson. 1960. *Vitamins Hormones.* **18:** 439.
5. Singh, M., V. N. Singh, and T. A. Venkitasubramanian. 1968. *Life Sci.* **7:** 239.
6. Misra, U. K. 1966. *Nature.* **209:** 910.
7. Misra, U. K. 1968. *Can. J. Biochem.* **46:** 697.
8. Steinberg, D. 1963. *In* The Control of Lipid Metabolism. J. K. Grant, editor. Academic Press, Inc., London. 111.
9. Rudman, D. 1963. *J. Lipid Res.* **4:** 119.
10. Winegard, A. I. 1962. *Vitamins Hormones.* **20:** 141.
11. Dole, V. P., and H. Meinertz. 1960. *J. Biol. Chem.* **235:** 2595.
12. Good, C. A., H. Kramer, and M. Somogyi. 1933. *J. Biol. Chem.* **100:** 485.
13. Montgomery, R. 1958. *Arch. Biochem. Biophys.* **67:** 378.
14. Folch, J., M. Lees, and G. H. Sloane Stanley. 1957. *J. Biol. Chem.* **226:** 497.
15. Bartlett, G. R. 1959. *J. Biol. Chem.* **234:** 466.
16. Marinetti, G. V. 1962. *J. Lipid Res.* **3:** 1.
17. Hanel, H. K., and H. Dam. 1955. *Acta Chem. Scand.* **9:** 677.
18. van Handel, E., and D. B. Zilversmit. 1957. *J. Lab. Clin. Med.* **50:** 152.
19. Carlson, L. A. 1963. *J. Atheroscler. Res.* **3:** 334.
20. Embree, N. D., S. R. Ames, R. W. Lehman, and P. L. Harris. 1957. *Methods Biochem. Anal.* **4:** 43.
21. Gornall, A. G., C. J. Bardawill, and M. M. David. 1949. *J. Biol. Chem.* **177:** 751.
22. Munro, H. N., and A. Fleck. 1966. *Methods Biochem. Anal.* **14:** 113.
23. Fain, J. N., R. O. Scow, and S. S. Chernick. 1963. *J. Biol. Chem.* **238:** 54.
24. Entenman, C. 1957. *In* Methods in Enzymology. S. P. Colowick and N. O. Kaplan, editors. Academic Press, Inc., New York. **3:** 299.
25. Sandler, R., and N. Freinkel. 1966. *Metabolism.* **15:** 1020.
26. Singh, V. N., E. Raghupathy, and I. L. Chaikoff. 1965. *Biochim. Biophys. Acta.* **103:** 623.
27. Roe, J. H., and C. A. Kuether. 1943. *J. Biol. Chem.* **147:** 399.
28. Lombardi, B. 1966. *Lab. Invest.* **15:** 1.
29. Farber, E. 1967. *Advan. Lipid Res.* **5:** 119.
30. Isselbacher, K. J., and N. J. Greenberger. 1964. *N. Eng. J. Med.* **270:** 402.
31. Lieber, C. S. 1967. *Annu. Rev. Med.* **18:** 35.
32. Kennedy, E. P. 1961. *Fed. Proc.* **20:** 934.
33. Tzur, R., E. Tal, and B. Shapiro. 1964. *Biochim. Biophys. Acta.* **84:** 18.
34. Nikkila, E. A., and K. Ojala. 1964. *Life Sci.* **3:** 1021.
35. Nikkila, E. A., and K. Ojala. 1965. *Life Sci.* **4:** 937.
36. Rose, H., M. Vaughan, and D. Steinberg. 1964. *Amer. J. Physiol.* **206:** 345.
37. Stein, Y., and B. Shapiro. 1957. *Biochim. Biophys. Acta.* **24:** 197.
38. Bublitz, C., and E. P. Kennedy. 1954. *J. Biol. Chem.* **211:** 951.
39. Fredrickson, D. S., R. I. Levy, and R. S. Lees. 1967. *N. Engl. J. Med.* **276:** 32.
40. Misra, U. K. 1968. *Agr. Biol. Chem.* **32:** 707.
41. Hankin, L. 1963. *J. Nutr.* **79:** 519.
42. Sidransky, H., E. Verney, and B. Lombardi. 1963. *J. Nutr.* **81:** 348.
43. Rubin, R. J., and R. G. Pendleton. 1964. *Fed. Proc.* **23:** 126.
44. Roheim, P. S., S. Switzer, A. Girard, and H. A. Eder. 1966. *Lab. Invest.* **15:** 21.
45. Windmueller, H. G. 1964. *J. Biol. Chem.* **239:** 530.
46. Deamer, D. W., F. A. Kruger, and D. G. Cornwell. 1965. *Biochim. Biophys. Acta.* **97:** 147.
47. Vagelos, P. R. 1964. *Annu. Rev. Biochem.* **33:** 139.
48. Sayers, G. 1950. *Physiol. Rev.* **30:** 241.
49. Wool, I. G., and M. S. Goldstein. 1953. *Amer. J. Physiol.* **175:** 303.
50. Wool, I. G., M. S. Goldstein, E. R. Rammey, and R. Levine. 1954. *Amer. J. Physiol.* **178:** 427.
51. Hutterer, F. 1963. *Exp. Mol. Pathol.* **2:** 541.

Sobel, A. E.
Bib. No. 8596

J. Invest. Derm. 32:569-576. 1959.

THE INFLUENCE OF CONCENTRATION ON THE PERCUTANEOUS AND ORAL ABSORPTION OF VITAMIN A*

ALBERT E. SOBEL, Ph.D., BURTON S. SHERMAN, M.S., DOROTHY K. BRADLEY, M.S. AND JEROME P. PARNELL, Ph.D.†

In recent years, large oral doses of vitamin A have been employed therapeutically for skin disorders related to a local deficiency of the vitamin (1-7). Despite the curative effects of these oral doses, concern has developed over the possibility of vitamin A toxicity with prolonged treatment. A recent report of a case of vitamin A poisoning in an adult brings to light the acute dangers involved in prolonged oral therapy with high potency vitamin A (8). This patient's condition had remained undiagnosed for a period of 8½ years, during which time she was hospitalized 10 times.

Our investigations on the ability of the skin to absorb and transport topically applied vitamin A, and the restorative effects of such applications on "A"-deficient skin were undertaken to determine a possible solution to the problem of "A"-toxicity and to provide a direct route for the clinical treatment of "A"-deficient skin. It has been our contention that a local "A"-deficiency in a tissue of animal receiving adequate dietary "A" and showing adequate intestinal absorption of the vitamin, is fundamentally a problem of transportation. This is related not only to the circulation within the lymph and blood but also to vitamin transfer across membranes of storage depots and utilization areas. If these membranes become resistant to transportation of the vitamin, a barrier develops resulting in a differential in concentration of the vitamin on either side of the membrane. A further increase in the differential by the artificial elevation of blood levels probably does little to restore the normal function of the membranes. It is possible that the barrier becomes progressively enhanced, resulting in an intensified local deficiency syndrome (9). Therefore, these studies were designed to bypass any barriers to "A" transportation that may have developed as the deficiency was being produced, and to deal directly with the restoration of the "A"-depleted skin by means of topical applications of vitamin A.

Pioneer studies related to skin restoration and/or increase in body weight of "A"-depleted animals encouraged our investigations of the dermal transportation of vitamin A (10-13). Sabella *et al.* (14) reported a study on ovariectomized adult rats in which the application of 120 γ of vitamin A per day to the shaved dorsum skin resulted, within 10 days, in a local increase in the thickness of the epidermis, notably in the extent of the stratum granulosum, decreased keratin formation, and possibly an increased rate of keratohyalin formation. These observations, coupled with Montagna's observation of fluoresence in the sebum of normal skin tissue (15), indicated that the "A"-deficiency of the skin described by Wolbach and Bessey (16), Moult (17), Harris (18), and Frazier *et al.* (19, 20), would respond to topical vitamin A therapy. Further stimulus to the study was obtained from the fragmentary work of Eddy and Howell (21), describing some increase in body weight in rats exposed to dermal application of 6 U.S.P. units of "A" for 2 to 6 minutes daily.

Prior to the time of the completion of our initial studies, substantial chemical evidence of the ability of the skin to absorb and transfer vitamin A had not been reported in the literature. However, dermal absorption of vitamin D and its use in the prevention and cure of ricketts has been described (22-24). Vitamin A fortified ointments and salves have been described as beneficial in the promotion of wound healing and the restoration of local skin deficiencies (25-31). However, these latter studies report clinical manifestations without quantitative chemical proof. An excellent review of percutaneous absorption in its broader aspects has been compiled

* Presented in part before: (1) The Section on Dermatology and Syphilology at the 104th Annual Meeting of the American Medical Association, Atlantic City, June 6-10, 1955, and (2) the Fourth International Congress of Nutrition, Paris, July 26-August 1, 1957.

Supported by the Desitin Chemical Company, Providence, R. I.

† From the Department of Biochemistry, Jewish Hospital of Brooklyn, N. Y. and Department of Anatomy, State University of New York, Downstate Medical Center, Brooklyn, N. Y.

Received for publication August 9, 1958.

and discussed by Rothman in his book on the physiology and biochemistry of the skin (32).

The present study was devised to investigate the influence of concentration of vitamin A on the percutaneous absorption of the vitamin in normal and "A"-deficient albino rats.

EXPERIMENTAL

Albino rats of an inbred Wistar strain, born of healthy females, were used in these studies. Litters containing 8 to 10 healthy animals were selected and weaned at 20 to 22 days of age. Animals to be depleted of vitamin A were fed an "A"-deficient diet (U.S.P. XIV[1]) *ad libitum* until the body weight remained stationary for 7 days and/or xerophthalmia developed. Littermates to serve as controls were raised on the stock diet of Bills (33). At the time of depletion one or two "A"-depleted animals and their stock-fed littermates were sacrificed to serve as controls. The animals were separated into groups and placed on oral or topical therapy for 28 days. The groups were as follows:

1) Normal stock-fed—oral vitamin A
2) "A"-deficient—oral vitamin A
3) Normal stock-fed—topical vitamin A
4) "A"-deficient—topical vitamin A

These animals receiving oral therapy (Groups 1 and 2) were given daily oral supplements (by stomach tube) of concentrations of vitamin A acetate[2] ranging from 0 to 10,000 γ, contained in corn oil.

Animals in groups 3 and 4 received the topical application of vitamin A to the skin of the scapular region. This was accomplished by shaving a 3 cm.^{2} area of skin in the scapular region on the day before depletion. After depletion, 0.3 ml of corn oil containing the vitamin A was placed on the shaved skin area, which was then covered with an absorbent cotton pad and a white cardboard shield. The "pack" was secured in place with gauze bandage and adhesive tape in a "figure 8" pattern. Vitamin A was applied daily to the skin surface under the "pack" and spread on the skin by exerting gentle pressure on the "pack". The animals were each housed in separate cages and precautions were taken to prevent ingestion of the vitamin preparation. The "packs" were replaced at weekly intervals and the animals weighed daily during both the depletion and repletion periods.

At the end of the 28 day experimental period, each animal was anesthetized with ether, and the ventral skin of the neck was slit longitudinally to expose the left jugular vein. The animal was suspended over a funnel resting in a 5 ml test tube, the vein punctured, and allowed to bleed into the vessel. As all respiratory and cardiac reflexes remained intact, it was possible to collect 2 to 5 ml of blood. The serum was separated and the vitamin A content determined on a saponified aliquot by the activated glycerol dichlorohydrin method of Sobel and Snow (34) using 6 cm. light path cuvettes. Liver and kidney tissue were analyzed for their vitamin A content using a modification of the method of Bessey *et al.* (35). The liver and kidney were removed and all extraneous fat and connective tissue cleaned from the organs. They were then weighed, chopped finely and placed in 1 N KOH (5.0 ml per gram of tissue) in a 125 ml flask. The mixture was brought to a boil (78°C) on a water bath and allowed to simmer until the tissue was dissolved. The solution was made up to 50 or 100 ml. volume in volumetric flasks with distilled water. Appropriate aliquots were taken into all-glass extraction tubes and the vitamin A was extracted into 10 ml. of 1:1 xylene-kerosene. When necessary, dilution of the extractant was made to ensure a concentration of 0.5 to 3.0 γ/ml. of vitamin A. The final dilutions were read in the Beckman D.U. Spectrophotometer at 328 mμ. A correction was made for interfering substances that may also give an absorption at 328 mμ, by destroying the vitamin A with ultraviolet irradiation for one hour. A post-irradiation reading at the same wavelength served as a blank for each individual sample. The total vitamin A content of the liver and kidney tissues were calculated by reference to a standard curve taking into account the dilution and aliquot of the samples.

RESULTS

The chemical data are reported in Tables I–V. Growth and storage curves are illustrated in Figures 1–5.

When various concentrations of vitamin A in corn oil are administered to vitamin A-deficient animals, either topically or orally, the animals show an increase in body weight, disappearance of the physical signs of "A"-deficiency and an increase in the storage of the vitamin in the liver and kidney.

In all the groups, whether given vitamin A topically or orally, there appears to be a direct relationship between the dosage of vitamin A administered and the absolute amount of the vitamin stored. As the concentration of the vitamin administered increases, larger amounts of vitamin A are found stored by the animals. When the logarithms of the daily dose of vitamin A are

[1] Obtained from General Biochemicals, Inc., Chagrin Falls, Ohio.

[2] Kindly supplied by Hoffman-LaRoche, Inc., Nutley, N. J.

TABLE I

Oral administration of vitamin A in corn oil to stock fed albino rats

Dosage	Number of animals	Age at sacrifice	Gain in body wt.*	Liver and kidney stores of Vitamin A			Serum Vitamin A
				γ/total†	γ/gm.	% administered dose	
γ/day		*days*	*gms.*				*γ%*
nil	2	82	98	132‡ ±10.1	12.3 ±1.1	—	33 ±2.6
1	2	82	95	18.0 ±.9	3.1 ±.4	64 ±4.0	29 ±1.0
10	3	82	104	172 ±18.5	21.5 ±2.0	61 ±4.6	36 ±1.5
100	3	82	98	1703 ±141	136 ±10.7	61 ±3.1	35 ±1.3
1000	4	82	94	10768 ±938	843 ±61.3	38 ±1.7	59 ±1.4
10000	4	82	46	63150 ±4056	5463 ±501	23 ±1.1	125 ±3.8

* Gain in body weight from time of "A"-depletion of littermates.

† Net amount stored, i.e., amount of vitamin A stored due to oral treatment (calculated by subtracting 132 γ stored by the nil animals from the total amount found in the livers and kidneys).

‡ Mean ± standard error.

plotted against the logarithms of the vitamin storage, straight line relationships are found (Fig. 5). However, examination of the relative amount of vitamin A stored in respect to the total dosage reveals a different relationship.

In "A"-deficient animals given vitamin A orally, there appears to be an inverse relation between the total daily dosage and the percentage of the administered dose stored by the liver and kidney (Table II). Animals receiving one γ of vitamin A per day store 53% of the total dose. This relationship continues in a descending fashion until it is seen that those animals given 10,000 γ of vitamin A daily store only 7 to 12 per cent of the administered dose. In those "A"-deficient animals receiving 10,000 γ of "A" orally per day, toxic conditions developed in two animals after 7 days and in another two after 17 days of treatment. These animals were sacrificed when paralysis of the hind limbs prevented them from obtaining nourishment. The high blood serum level, loss of body weight, and vast stores of vitamin A indicated that hypervitaminosis A was present. One animal survived the 28 day period of treatment. That the animals used in these experiments were truly "A"-deficient is evidenced by the fact that those animals sacrificed when the physical signs of "A"-deficiency were maximal (53 days of age) also demonstrate minimal storage and circulation of the vitamin.

It may be seen from Fig. 2 that an oral dose of 20 to 30 γ of vitamin A per day is optimal for maintaining a normal rate of growth, since at this concentration level the rate of growth parallels that of control animals (untreated stock-fed

TABLE II

Oral administration of vitamin A in corn oil to vitamin A-deficient albino rats

Dosage	Number of animals	Age at sacrifice	Gain in body wt.*	Liver and kidney stores of Vitamin A			Serum Vitamin A
				γ/total	γ/gm.	% of administered dose	
γ/day		*days*	*gms.*				*γ%*
0	2	53	—	2.3† ±.2	.1 ±.02	—	2.4 ±.2
1	5	80	42	14.9 ±1.7	2.3 ±.3	53 ±3.8	34 ±2.0
10	3	80	46	113 ±9.3	15.2 ±2.0	40 ±2.6	39 ±3.2
20	3	81	86	200 ±19.8	18.4 ±2.6	36 ±1.8	45 ±3.7
30	5	77	86	306 ±23.7	20.1 ±4.3	36 ±2.2	36 ±2.6
100	3	80	46	873 ±70.2	158 ±10.2	31 ±1.7	49 ±4.4
500	3	82	54	4057 ±327	733 ±52.6	29 ±2.7	28 ±1.7
1000	3	80	25	7483 ±521	1268 ±101	27 ±1.9	69 ±5.9
10000	1‡	84	39	42250 ±0	4582 ±0	15 ±0	37 ±0
	2§	68	12	20408 ±1602	3914 ±252	12 ±.9	90 ±9.7
	3‖	59	−9	5050 ±301	1195 ±97.4	7.2 ±1.1	500 ±41.5

* Gain in body weight from time of depletion of vitamin A.

† Mean ± standard error.

‡ Sacrificed after 28 days of treatment.

§ Sacrificed after 17 days of treatment due to toxic symptoms of hypervitaminosis A.

‖ Sacrificed after 7 days of treatment due to toxic symptoms of hypervitaminosis A.

TABLE III

Topical administration of vitamin A in corn oil to stock fed albino rats

Dosage	Number of animals	Age at sacrifice	Gain in body wt.*	Liver and kidney stores of Vitamin A			Serum Vitamin A
				γ/total†	γ/gm.	% of administered dose	
γ/day		days	gms.				γ%
nil	2	84	43	111‡ ±9.7	13.5 ±2.8	—	24 ±3.7
10	5	80	48	70 ±6.8	10.1 ±1.7	25 ±1.8	34 ±2.9
100	4	83	51	600 ±41.7	81 ±7.7	21 ±2.7	28 ±1.8
1000	5	79	29	2239 ±219	351 ±36.7	8 ±.9	47 ±4.0
10000	5	81	25	11218 ±957	1697 ±106	4 ±.8	36 ±3.6

* Gain in body weight from time of "A"-depletion of littermates.

† Net amount stored, i.e., amount of vitamin A stored due to topical treatment (calculated by subtracting 111 γ stored by the nil animals from the total amount found in the livers and kidneys).

‡ Mean ± standard error.

rats). One γ per day is insufficient to maintain a normal growth rate, while concentrations of 100 to 10,000 γ per day depress the rate of weight-gain to varying degrees.

TABLE IV

Topical administration of vitamin A in corn oil to vitamin A-deficient albino rats

Dosage	Number of animals	Age at sacrifice	Gain in body wt.*	Liver and kidney stores of Vitamin A			Serum Vitamin A
				γ/total†	γ/gm.	% of administered dose	
γ/day		days	gms.				γ%
10	8	83	40	23.1 +4.6	2.6 +.6	8.3 +.7	29 +2.7
30	10	74	46	60.3 ±5.8	10.5 ±1.7	7.0 ±.8	36 ±3.0
100	9	86	43	122 ±13.8	16.0 ±2.1	4.3 ±.1	30 ±3.4
1000	8	82	53	1850 ±150	258 ±19.6	6.6 ±.2	47 ±4.0
10000	8	84	30	9140 ±803	1326 ±111	3.3 ±.1	66 ±7.4

* Gain in body weight from time of depletion of vitamin A.

† Mean ± standard error.

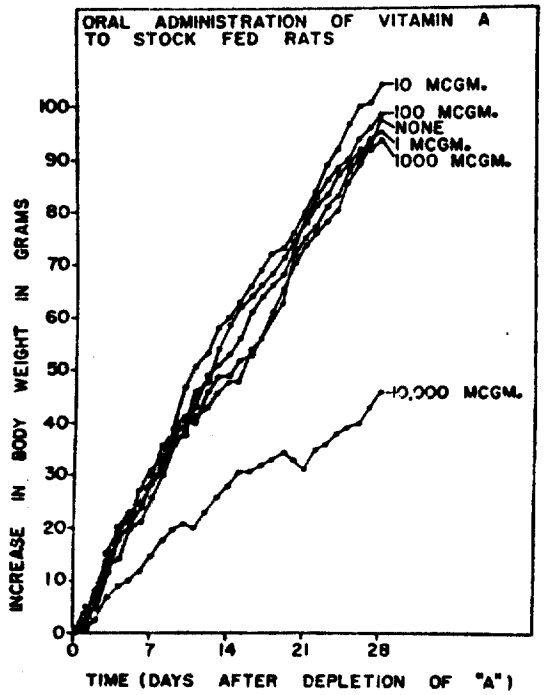

FIG. 1. Growth Curves Following Oral Administration of Vitamin A to Stock Fed Rats. Refer to Table I.

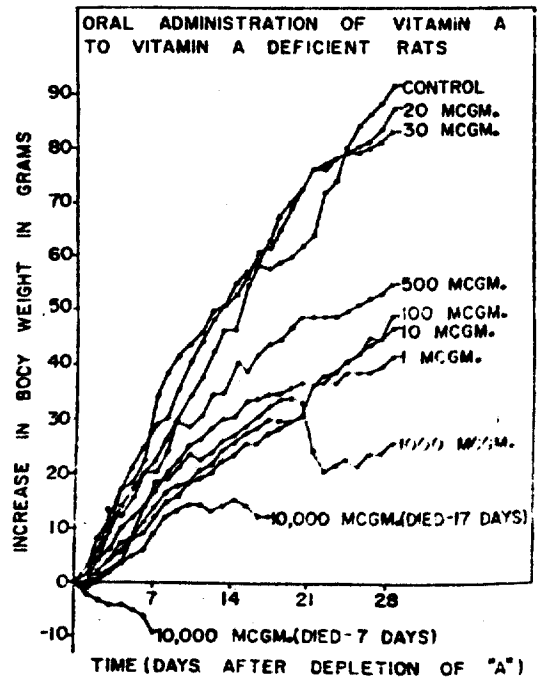

FIG. 2. Growth Curves Following Oral Administration of Vitamin A To Vitamin A Deficient Rats. Refer to Table II.

Normal stock-fed animals given oral vitamin A supplements exhibit this same inverse relationship between per cent of the vitamin stored and total dosage administered. The values range from 64% of the vitamin stored for animals receiving one γ per day to 23% for animals given 10,000 γ of the vitamin orally per day (Table I). Fig. 1 reveals that the rate of growth of these stock-fed animals is not as drastically effected by high oral doses of vitamin A as it is in the case of "A"-deficient rats. In this instance, concentrations up to 1,000 γ of "A" per day do not appreciably affect the gain in body weight of experimental animals as compared to the stock-fed rat receiving no treatment. However, when a toxic dose of 10,000 γ per day is administered, the rate of growth declines markedly, although not as drastically as in the A-deficient animals. Thus it appears that stock-fed animals can resist the loss of body weight caused by high doses of "A" to a greater degree than can "A"-deficient animals.

Topical administration of vitamin A to "A"-deficient animals results in storage of the vitamin by the rats (Table IV). In this instance however, the inverse relationship between per cent of administered dose stored and total dosage is not as marked as in the preceding groups of animals, since the values range from 8.3 to 3.3%. The growth curve illustrated in Fig. 4 indicates that maximal growth occurs when 1,000 γ of "A" are topically applied per day; 10 γ to 100 γ are not as effective, while 10,000 γ per day is toxic. None of the dose levels utilized are sufficient to promote growth paralleling that of a normal animal.

When vitamin A is topically applied to normal stock-fed animals, the inverse relationship between total dosage and amount of vitamin stored is again observed (Table III). The rate of growth is not remarkably different from that of an untreated stock-fed animal at most of the dose levels employed. However, here again one may

TABLE V

Comparison of mean values for total liver and kidney vitamin A stores

Groups Compared	Dosage (γ/day)				
	1	10	100	1000	10000
Oral "A"					
Stock-fed animals	18.0*	172	1703	17068	63150
	±.9	±18.5	±141	±938	±4056
"A"-deficient animals	14.9	113	873	7483	42250
	±1.7	±9.3	±70.2	±521	—
"P"†	>.2	.01	<.01	.01	<.01
Topical "A"					
Stock-fed animals	—	70	600	2239	11218
		±6.8	±4.7	±219	±957
"A"-deficient animals	—	23.1	122	1850	9150
		±4.6	±13.8	±150	±803
"P"†		<.01	<.01	.02	.05
Stock-fed animals					
Oral "A"	—	172	1703	10768	63150
		±18.5	±141	±938	±4056
Topical "A"	—	70	600	2239	11218
		±6.8	±4.7	±219	±957
"P"†		<.01	<.01	<.01	<.01
"A"-deficient animals					
Oral "A"	—	113	873	7483	42250
		±9.3	±70.2	±521	±0
Topical "A"	—	23.1	122	1850	9150
		±4.6	±13.8	±150	±803
"P"†		<.01	<.01	<.01	<.01

* Mean ± standard error (for liver and kidney stores of vitamin A in γ/total).

† The results are evaluated by the statistical method of Fisher (37). When P is less than .05, the difference between the means is regarded as statistically significant.

see a depression in body weight gain when toxic levels of vitamin A are administered (Fig. 3).

If we compare the mean values for total stores of vitamin A (Table V), it is seen that stock-fed animals store significantly more vitamin A than do "A"-deficient animals, when the vitamin is *orally* administered. This is true for all dosage levels except when a minimal amount (1 γ) is given per day. Furthermore, the stock-fed rat stores from 1.2 to 5 times as much of the vitamin when "A" is *topically* applied. *Oral* administration of vitamin A is 2.5 to 7 times more effective than *topical* application in promoting liver and kidney storage of the vitamin when a comparison is made at equivalent dosage levels.

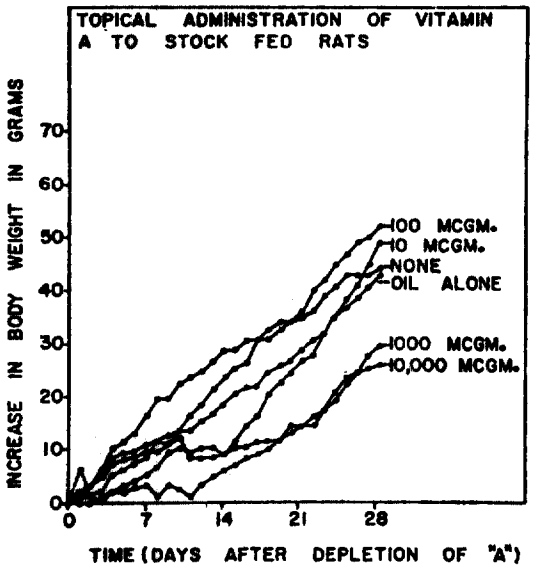

FIG. 3. Growth Curves Following Topical Application of Vitamin A to Stock Fed Rats. Refer to Table III.

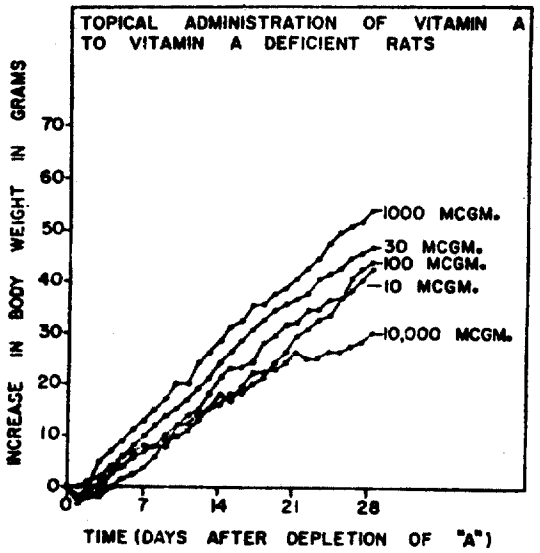

FIG. 4. Growth Curves Following Topical Administration of Vitamin A to Vitamin A Deficient Rats. Refer to Table IV.

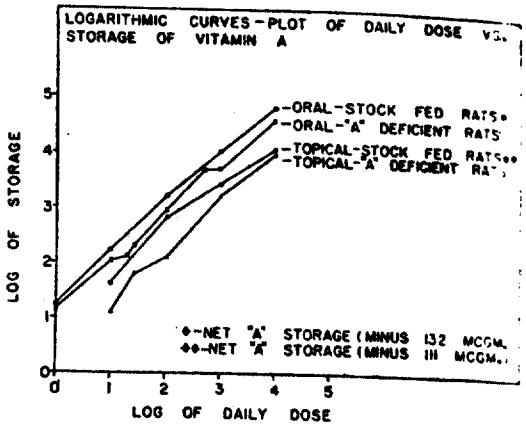

FIG. 5. Logarithmic Curves of Liver Storage of Vitamin A Following Topical and Oral Administration in the Stock Fed and "A"-Deficient Rats

Serum vitamin A levels appear to be within normal limits in all the groups, except in those animals receiving 10,000 γ of vitamin A per day. When a toxic dose of 10,000 γ per day is administered either topically or orally, the serum vitamin A level increases to varying degrees.

DISCUSSION

Previous investigations by this laboratory have demonstrated that the percutaneous absorption of vitamin A is possible in the albino rat (10–13). The present studies on the quantitative transfer of the vitamin across the skin indicate that the absolute amount absorbed, either through the normal or "A"-deficient skin, appears to increase with the concentration of the application. Vitamin A deficient skin absorbs the vitamin less efficiently than does normal skin. It appears that optimum growth and probably optimum storage for health in the albino rat occurs when about 20 to 30 micrograms of the vitamin is ingested daily. As the daily intake increases, the absolute amount of the liver and kidney stores increase, but at the same time the ratio of total amount of vitamin administered to liver and kidney stores decreases, and the rate of optimum growth decreases. With high oral intake, toxicity

develops as there appears to be no regulatory mechanism, either in the intestinal mucosa or storage depots, to prevent the continued absorption and storage of vitamin A.

Almquist, in a review (36), discussed the principle known as the "law of diminishing returns" and its relation to vitamin nutrition. This principle accounts for the failure of the stock-fed normal animals given increasing amounts of vitamin A orally to gain in body weight since the optimal amount of vitamin A is already obtained from the diet. When toxic doses are given we see a decline in weight response. Almquist's data shows that the optimal dosage for maximal weight gain is about 20 to 30 γ per day. It is also demonstrated that, in accordance with the diminishing returns principle, the liver storage bears the same relationship to blood vitamin A content as does the oral intake. Both sources appear to function in the same way in the maintenance of the blood vitamin A level. This, in part, explains why liver storage is fairly directly related to oral intake.

SUMMARY AND CONCLUSIONS

1. Vitamin A acetate in corn oil applied topically to the shaved skin of "A"-depleted or normal albino rats is absorbed and transferred to the liver and kidney tissue for storage.

2. The amount of the vitamin stored in the liver and kidney tissues varies with the concentration of the vitamin applied.

3. Normal skin appears to behave differently from "A"-depleted skin as evidenced by the larger stores accumulated in the liver and kidney tissues in normal animals.

4. Oral intake exceeding 500 γ per day slows the rate of growth, and toxic hypervitaminosis A develops rapidly when 10,000 γ of vitamin A per day is fed.

5. Topical application of high concentrations of vitamin A in corn oil tend to slow the rate of growth of the albino rat.

6. Vitamin A, topically applied in physiological amounts, is effective in relieving the symptoms of "A"-deficiency in the rat.

REFERENCES

1. Dublin, W. B. and Hazen, B. M.: Relation of keratosis seborrheica and keratosis senilis to vitamin A deficiency. Arch. Dermat. & Syph., **57**: 178, 1948.
2. Leiter, A. and Moore, T.: Vitamin A and skin disease. Lancet, **2**: 262, 1946.
3. Davidson, A. M. and Sobel, A. E.: Aqueous vitamin A in acne vulgaris. J. Invest. Dermat., **12**: 221, 1949.
4. Griesemer, R. D., Frazier, C. N. and Blank, I. H.: Nutritional influences on the physiology of the skin: Observations on the metabolism of vitamin A. Medicine, **32**: 293, 1953.
5. Straumfjord, J. V.: Vitamin A; its effect on acne. Northwest Med., **42**: 219, 1943.
6. Crawford, G. H.: Treatment of acne. Modern Medicine Annual, Minneapolis, p. 316, 1951.
7. Lahiri, K. D. and Scandrett, F. J.: Vitamin A in acne vulgaris. J. Ind. Med. Assoc., **23**: 247, 1954.
8. Gerber, A., Raab, A. P. and Sobel, A. E.: Vitamin A poisoning in adults. Am. J. Med., **16**: 729, 1954.
9. Sobel, A. E.: The problem of the absorption and transportation of fat-soluble vitamins. Vitamins and Hormones, **10**: 47–67, Academic Press Inc., New York City, 1952.
10. Sobel, A. E. and Rosenberg, A.: Transfer of topically applied vitamin A through the skin. Abstracts, Division of Biological Chemistry, American Chemical Society, 124th Meeting, p. 62c, Chicago, Ill., September 11–15, 1953.
11. Sobel, A. E., Rosenberg, A., Bradley, D. K. and Parnell, J.: Transfer of topically applied vitamin A through skin. Voeding, **16**: 773, 1955.
12. Parnell, J. P., Sobel, A. E. and Bradley, D. K.: The absorption of topically applied vitamin A in "A"- deficient rats and the effect upon the skin at the site of application. Anat. Rec., **121**: 349, 1955.
13. Sobel, A. E., Parnell, J. P., Sherman, B. S. and Bradley, D. K.: Percutaneous absorption of vitamin A. J. Invest. Dermat. **30**: 315, 1958.
14. Sabella, J. D., Bern, H. A. and Kahn, P. F.: Effect of locally applied vitamin A and estrogen on rat epidermis. Proc. Soc. Exper. Biol. & Med., **76**: 499, 1951.
15. Montagna, W.: Penetration and local effect of vitamin A on the skin of the guinea pig. Proc. Soc. Exper. Biol. & Med., **86**: 668, 1954.
16. Wolbach, S. B. and Bessey, O. A.: Tissue changes in vitamin deficiencies. Physiol. Rev., **22**: 233, 1942.
17. Moult, F. H.: Histopathology of rat skin in avitaminosis A. Arch. Dermat. & Syph., **47**: 768, 1943.
18. Harris, L. J., Irmes, J. R. M. and Griffith, A. S.: Pathogenesis of avitaminosis A as antikeratinizing factor. Lancet, **223**: 614, 1932.
19. Frazier, C. N. and Hu, C. K.: Cutaneous lesions associated with deficiency of vitamin A in man. Arch. Int. Med., **48**: 507, 1931.
20. Frazier, C. N., Hu, C. K. and Chu, F. T.: Variations in the cutaneous manifestations of vitamin A deficiency from infancy to puberty. Arch. Dermat. & Syph., **48**: 1, 1943.
21. Eddy, W. H. and Howell, J. L.: Topical application of vitamin A; Efficiency judged by growth stimulation. New York State J. Med., **39**: 406, 1939.
22. Amrhein, J. J.: Absorption of vitamin D from

the skin. J. Amer. Pharm. Assoc., **23**: 182, 1934.

23. HUME, E. M., LUCAS, N. S. AND SMITH, H. H.: On the absorption of vitamin D from the skin. Biochem. J., **21**: 362, 1935.
24. ASTROWE, P. S. AND MORGEN, R. H.: Dermal absorption of vitamin D. Am. J. Dis. Child., **49**: 912, 1935.
25. BALACHOVSKI, A.: Sur la possibilitie d'insuffisance locale en vitamine. Presse med., **42**: 1404, 1934.
26. BALACHOVSKI, A. AND RATCHEVSKI, F.: Recherches sur quelques propietes nouvelle du ca rotene. Existe-t-il une insuffisance locale en vitamine. Bull Soc. chim. biol., **16**: 220, 1934.
27. DRIGALSKI, W. V.: Local vitamin action in cod liver oil treatments. Ztschr. f. Vitaminforsch., **3**: 260, 1934.
28. BRANDALEONE, H. AND PAPPER, E.: The effect of local and oral administration of cod liver oil on the rate of wound healing in vitamin A-deficient and normal rats. Ann. Surg., **114**: 791, 1941.
29. BEHRMAN, H. T., COMBES, F. C., BROBOFF, A. AND LEVITICUS, H.: Dermatological therapy with cod liver oil ointment. Indust. Med., **18**: 512, 1949.
30. SIEMERS, C. F. AND SLEIZER, P. E.: Vitamin A in cosmetic creams and lotions. Drug and Cosmetic Industry, (a review), Jan., 1954.
31. McLAUGHLIN, R. R. M.: Skin vitamin, vitamins A and D topical applications. Med. Times, New York, **67**: 303, 1939.
32. ROTHMAN, S.: Physiology and Biochemistry of the Skin. Chicago, Ill., Univ. of Chicago Press, 1954.
33. BILLS, C. E., HONEYWELL, E. M., WERECK, A. M. AND NUSSMEIER, M.: A critique of the line test for vitamin D. J. Biol. Chem., **90**: 619, 1931.
34. SOBEL, A. E. AND SNOW, S. D.: The estimation of serum vitamin A with activated glycerol dichlorohydrin. J. Biol. Chem., **171**: 617, 1947.
35. BESSEY, O. A., LOWRY, O. H., BROCK, M. J. AND LOPEZ, J. A.: The determination of vitamin A and carotene in small quantities of blood serum. J. Biol. Chem., **166**: 177, 1946.
36. ALMQUIST, H. J.: Evaluation of fat-soluble vitamins. Federation Proc., **14**: 650, 1955.
37. FISHER, R. A.: Statistical methods for research workers, pp. 128, and Table IV. London, Oliver and Boyd, Ltd., 1936.

Sorensen-'54
Bib. No. 8617

Am. J. Vet. Res. 15:258-260. 1954.

Cerebrospinal Fluid Pressure of Normal and Vitamin A Deficient Swine as Determined by a Lumbar Puncture Method

D. K. SORENSEN, D.V.M., M.S.; T. KOWALCZYK, V.S., D.V.M., M.S.; J. F. HENTGES, JR., Ph.D.

Madison, Wisconsin

DURING a series of experiments to determine the minimum carotene requirements of swine, it was necessary to develop a method of measuring the cerebrospinal fluid pressures of young pigs. Sykes and Moore [4] and Eveleth *et al.*[1] found in cattle and sheep, respectively, that avitaminosis A caused an increase in cerebrospinal fluid pressure.

This report describes the lumbar puncture method used for cerebrospinal fluid pressure measurement in swine and gives the values obtained by this method with normal and vitamin A deficient swine. An Ayer spinal fluid manometer was found to be satisfactory for recording the pressure and for withdrawal of fluid for analysis. This apparatus consists of two-glass manometer tubes graduated in millimeters, a special three-way stopcock, and a 20-gauge 3¼-in. rustless spinal needle with stylet. As the apparatus can be sterilized by chemical disinfectants, it is adaptable for field use.

It is necessary for the pig to be anesthetized while the reading is taken because movement by the pig can result in an increased pressure reading. An intraperitoneal injection of 5 per cent chloral hydrate at the rate of 2 ml. per pound of body weight proved to be a satisfactory anesthetic. The anesthetized animal is laid in lateral recumbency with the spinal column as nearly horizontal as possible. An extensive area in the lumbosacral region is shaved, washed with ether, and painted with tincture of iodine.

The puncture is usually made between the last lumbar vertebra and the sacrum. The needle may be inserted between any of the lumbar vertebrae, however. Insertion of the needle into the lumbosacral space is recommended because blood may occasionally be mixed with the cerebrospinal fluid, in which case a rapid puncture may be made higher up and fluid obtained which is free from blood. The lumbosacral space is located by drawing an imaginary line across the anterior border of the wings of the ilii and palpating approximately 2 to 3 in. posterior to this line and exactly on the median line. Location of this space is facilitated if an assistant is available to bend the back by moving the hind legs of the pig while the operator is palpating the area.

The puncture is made in the median line with the needle directed ventrally and anteriorly. The total depth of the puncture will vary with the age and degree of fatness of the animal. A slight "give" will be felt when the needle passes through the dura and arachnoid layers into the subarachnoid space. If the needle is inserted too deeply, the point will come against the body of the vertebra; in such instances, the needle must be withdrawn slowly. The stylet should be withdrawn when it is believed that the needle has entered the subarachnoid space. The first drops of fluid should appear after a few seconds. If no fluid appears, or if flow is too slow, a rotation of the needle or its slight withdrawal usually allows the fluid to flow freely. When the fluid is observed in the needle, the stopcock apparatus, with the graduated glass tube in a vertical position, is attached to the needle. The fluid will rise in the tube until it comes to rest, at which point the height of the fluid in millimeters is recorded. A small fluctuation in the level of the fluid to the extent of 4 to 6 mm. will result from expiration and inspiration of air in normal respiration. An absence of these pulsations may indicate lodging of tissue on the point of the needle.

When the initial pressure reading has been recorded, the assistant should apply moderate pressure to both sides of the neck to compress the jugular veins. The fluid should rise rapidly in the tube and subside slowly when the pressure on the

TABLE 1—Cerebrospinal Fluid Pressures of Apparently Normal Pigs

Pig (No.)	Age (weeks)	Cerebrospinal fluid pressures (mm.)
2	9	128
6	9	102
15	9	140
21	9	86
27	9	122
5	10	100
26	10	108
3	10	90
13	10	100
1A	20	80
2A	20	112
3A	20	80
4A	20	145
5A	20	138
Average pressure		109.5 mm.

From the Department of Veterinary Science (NS 133) (Sorensen and Kowalczyk) and the Department of Animal Husbandry (Hentges), University of Wisconsin, Madison. Published with the approval of the director of the Wisconsin Agricultural Experiment Station. Dr. Hentges is now assistant professor at the University of Florida, Gainesville, in the Department of Animal Husbandry and Nutrition.

neck is released. Failure of the fluid to rise rapidly may indicate either an obstruction in the needle or a subarachnoid block, resulting in an abnormal pressure reading.

Many different disturbances can cause fluctuations of the pressure. The action of the muscles, coughing, pressure of the hand on the abdomen, differences in position, mental excitement, and fear are a few of these influences. For these reasons, it is imperative that the pig be anesthetized.

The operation is rarely fatal if the anesthetic is properly administered and the spinal pressure is not lowered by removal of an excessive quantity of fluid or by drainage of fluid through the puncture canal.

The values obtained by this method on normal growing pigs varying in weight from 50 to 100 lb. are shown in table 1.

The average cerebrospinal fluid pressure for all the determinations was 109.5 mm., with a range of values from 80 to 145 mm.

Figure 1 shows the average cerebrospinal fluid pressures of growing pigs at three stages of an experiment in which all pigs, after being depleted of their vitamin A reserves, were allotted into four groups of 4 pigs each for supplementation with oral doses of crystalline carotene in cottonseed oil as follows: Lot 1 served as a control group and received no carotene supplement; lots 2, 3, and 4 received respectively 10, 25, and 40 μg. carotene per kilogram of body weight daily during the supplementation period. Two pigs in the control lot died during the experiment and the remaining 2 pigs exhibited severe deficiency symptoms and cerebrospinal fluid pressures of 212 and 220 mm. It is of interest that the cerebrospinal fluid pressures of pigs in lots 3 and 4 decreased during the supplementation period, but it did not return to the initial reading even though the animals were receiving adequate provitamin A to restore the vitamin A in their blood plasma to normal levels and to permit some storage of vitamin A in the liver. From these observations, it appears that cerebrospinal fluid pressures are of value for detecting the onset of a vitamin A deficiency but of less value for determining the state of vitamin A nutrition of animals which had previously been deficient in this vitamin.

Summary

A method is described for determining the cerebrospinal fluid pressure of pigs by lumbar puncture.

The average cerebrospinal fluid pressure

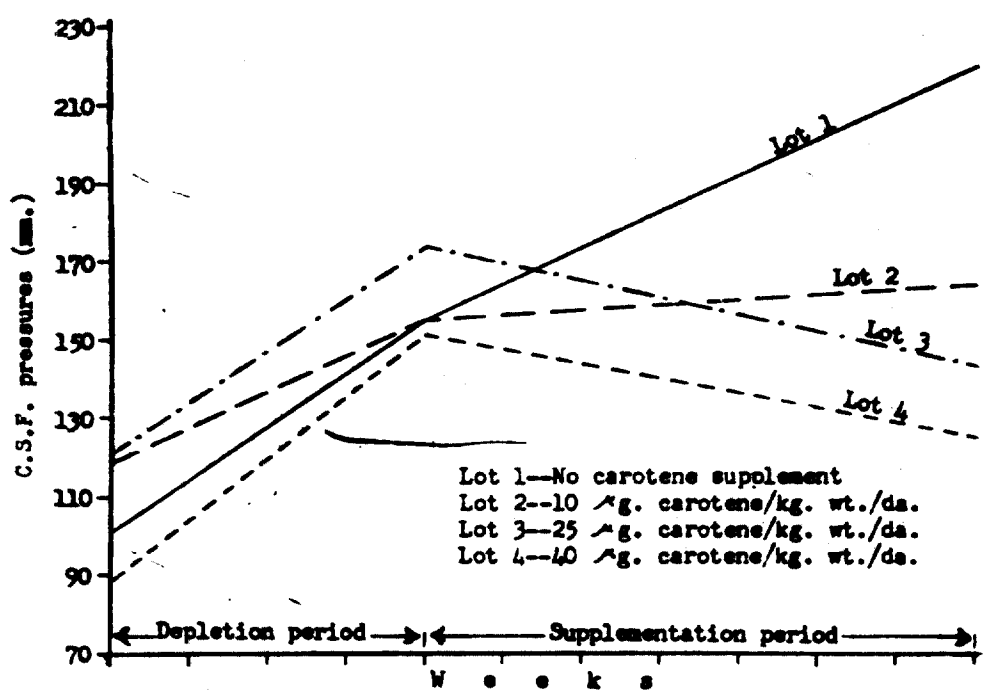

Fig. 1—Average cerebrospinal fluid pressures of pigs during vitamin A depletion and subsequent carotene supplementation.

of 14 apparently normal pigs was 109.5 mm. The values ranged from 80 mm. to 145 mm.

An increase in cerebrospinal fluid pressure up to 220 mm. was observed in pigs which were deficient in vitamin A. This method may be used to detect the onset of a vitamin A deficiency.

References

[1] Eveleth, D. F., Bolin, D. W., and Goldsby, A. I.: Experimental Avitaminosis A in Sheep. Am. J. Vet. Res., *10*, (1949): 250.

[2] Greenfield, J. G., and Carmicheal, E. H.: Cerebrospinal Fluid in Clinical Diagnosis. Macmillan and Co., Ltd., London, 1925.

[3] Pappenheim, Martin: Lumbar Puncture. John Bale, Sons and Danielson, Ltd., London, 1925.

[4] Sykes, J. F., and Moore, L. A.: The Normal Cerebrospinal Fluid Pressure and a Method for Its Determination in Cattle. Am. J. Vet. Res., *3*, (1942): 364.

Sorsby-'66
Bib. No. 8623

Nature 210(5040):1011-1015. 1966.

EFFECT OF VITAMIN A DEFICIENCY ON THE RETINA OF THE EXPERIMENTAL RABBIT

By PROF. ARNOLD SORSBY and DR. H. W. READING

Wernher Research Unit on Ophthalmological Genetics (Medical Research Council), Royal College of Surgeons of England, London

AND

J. BUNYAN

Walton Oaks Experimental Station, Tadworth, Surrey

TANSLEY[1,2] reported that severe vitamin A deficiency in the rat and in the dog produced characteristic histological damage in the rod and pigment layers of the retina. Confirmatory findings for the rat came from Johnson[3] and for the horse from Anderson and Hart[4]. No such damage was, however, observed by Mann, Pirie, Tansley and Wood[5] in a series of fifty vitamin A-deficient rabbits, although three animals showed localized changes which were interpreted as evidence of spontaneously occurring hereditary retinal degeneration such as is frequently seen in inbred rat colonies—a reading supported by the fact that two of three affected rabbits were littermates and that the same lesion was seen in another littermate which served as one of the ten controls in this experiment.

Johnson[6] and Wald[7] suggested that the structural retinal derangement described in the vitamin A-deficient rat might be responsible for the lasting or permanent effect of nightblindness which persists after the deficiency has been relieved. More recently Dowling and Wald[8,9], and in a series of communications summarized and listed in Dowling[10], have reported that, while vitamin A acid can replace vitamin A in maintaining rats in good health, such replacement is inadequate for the retina (as was originally suggested as a possibility by Moore[11]): they observed extensive degenerative changes in the rods and the pigment epithelium in vitamin A-deficient rats kept generally fit on supplements of vitamin A acid. The changes in the retina recall those seen in retinitis pigmentosa in man and in spontaneously occurring hereditary retinal degeneration in the rat. These findings are therefore of particular interest in that they may help to elucidate not only the role of vitamin A in the metabolism of the retina, but also the mechanism of retinitis pigmentosa in man—probably the commonest of the hereditary blinding affections.

These are fundamental issues. The present investigation of the significance of vitamin A aldehyde in the metabolism of the retina in the intact animal was undertaken in the rabbit partly because spontaneous retinal degeneration has not been definitely recorded in this animal and mainly because in the rabbit it is possible to watch any developing lesion by means of an ophthalmoscope.

Dutch rabbits were used throughout. Two separate experiments were carried out:

(1) In the first experiment of six young litter mates, two were used as controls—one being kept on a vitamin A-deficient diet without any supplement and the other on the deficient diet supplemented by vitamin A palmitate. The remaining four were kept on the same diet deficient in vitamin A but supplemented by vitamin A acid. Three of the four animals so treated were kept for 30 months and one for 22·5 months under the conditions to be described; the first of the two controls was destroyed at 12·5 months, and the second accidentally at 14·5 months.

(2) The second experiment began 5·5 months later; six baby rabbits from three litters were used. All the six animals, the weights of which ranged from 560 g to 640 g, were kept on a vitamin A-deficient diet until they ceased to gain weight, when their diet was supplemented by vitamin A acid. One was destroyed at 14·5 months and a second at 18·5 months, both for histological studies. The remaining four were kept for 24 months.

In both series, all animals were submitted to ocular examination, including ophthalmoscopy, at intervals, generally of 2 months. Electroretinography was carried out in six animals 4 months before they were destroyed for histological examination: three of the first batch at 26 months and three of the second batch at 20 months, with a repeat examination of one animal in each series at 30 months and 24 months, respectively.

Dietetic procedures

(a) *The vitamin A-deficient diet.* The composition of the vitamin A-deficient diet used is given in Table 1.

Table 1

Groundnut meal	17·5 g
Sugar-beet pulp	10 g
Oatmeal	27 g
Fine wheatfeed	13 g
Molasses	3 g
Linseed oil meal	23 g
Common salt	0·5 g
Dried brewer's yeast	4 g
Salt mixture†	2 g
D-α-tocopheryl acetate*	40 mg/rabbit/week
Vitamin D_2*	1,000 I.U./rabbit/week

* In oil by mouth until 13 months when these vitamins were incorporated in the diet (vitamin D in protected form).

† The salt mixture supplied consisted of (g/kg diet): sodium chloride, 1·1; $CaH_4(PO_4)_2 \cdot 2H_2O$, 8·7; ferric citrate, 0·8; sodium dihydrogen phosphate, 2·3; $MgSO_4 \cdot 7H_2O$, 1·7; potassium chloride, 5·4; potassium iodide, 0·02; sodium fluoride, 0·0009; $MnSO_4 \cdot 4H_2O$, 0·0044.

This diet is similar to that used by Lamming, Woollam and Millen[12]. Chemical analysis showed it to contain less than 0·07 I.U. true vitamin A/g, together with β-carotene equivalent to 0·08 I.U. provitamin A/g and a xanthophyll fraction estimated as 1·1 μg/g. From the seventeenth month of the first experiment (12·5 months of the second experiment) each batch of basal diet was tested for absence of vitamin A before being used.

(b) *Supplements used.* When vitamin A acid was given the dose was 15 mg/kg of diet. Vitamin A palmitate (for control rabbit *B*) was given in a dose of 2·5 mg/kg of the vitamin A-deficient diet. After 7 months, vitamin A palmitate was omitted from the diet and given to the rabbit by mouth, at the rate of 40 mg/week for 2 months followed by 0·8 mg/week until the end of the observations at 14·5 months.

(c) *Nutritional history*

The first series: The six litter mates—whose mother was put on a vitamin A-deficient diet 12 days after their birth—were kept on a vitamin A-deficient diet from the age of 12-25 days, and on this diet with the acid supplement for the next 10 days. Thereafter, rabbits Nos. 1-4 were continued on this supplemented diet, while control rabbit *B* had vitamin A palmitate as the supplement instead of vitamin A acid, and control rabbit *A* had the vitamin A-deficient diet without any supplement.

All the rabbits grew well except control rabbit *A* which showed a decline in weight and necessitated giving it

vitamin A acid supplement at the age of 4·5 months. It finally developed a flaccid paralysis 8 months later and was destroyed.

The second series: The six rabbits were all maintained on a vitamin A-deficient diet for a preliminary depletion period of up to 5·5 months of age before giving them the vitamin A acid supplement. They had all reached a weight plateau at this time and they showed weight gain on receiving the supplement.

Change of diet after the onset of the retinal lesion. Five and a half months before the end of the experiment in both series, when the retinal lesion was fully established, rabbits Nos. 1, 4, 7, 8 and 9 were given modified diets to determine whether the lesion could be reversed. Rabbit No. 1 was given a normal diet (diet *S.G.*1 (Rank)) and the remaining rabbits (Nos. 4, 7, 8 and 9) were given the vitamin A-deficient diet and an oral dose of 6 mg vitamin A palmitate/rabbit/week. These modifications were continued until the end of the experiment (at 30 months in the first series and at 24 months in the second).

Accidental administration of vitamin A palmitate. On one occasion, at 13 months and 7·5 months in the two series respectively, all survivors receiving vitamin A acid supplement were accidentally given 0·6 mg vitamin A (instead of an intended dose of vitamin D). These animals were later put back on a vitamin A-deficient diet without any supplement for 5 weeks and then returned to their diet containing vitamin A acid supplement.

(d) Estimation of vitamin A and vitamin A aldehyde. At the end of the experiment estimation of the concentration of vitamin A and vitamin A aldehyde was carried out for several tissues. The procedures used were:

Vitamin A. This was estimated in liver and brain by the method of Ames, Risley and Harris[13]. Very concentrated extracts of tissues believed to be deficient in vitamin A were prepared and tested, giving a lower limit of sensitivity of about 2–3 I.U./g tissue (that is, about 1 μg/g).

Vitamin A aldehyde. This was measured by the thiobarbituric acid method of Futterman and Saslaw[14]. The eyes were preserved at −10° overnight, allowed to thaw, and then dark-adapted. Each eye was dissected under a dim red light, and the cornea, lens and vitreous were removed. The remainder of the eye was extracted with alcohol in an M.S.E. top-drive steel-bladed homogenizer, using the 10-ml.-sized goblet. The amounts of retinone in a single rabbit retina proved too small to be detected by this procedure. (At the time these estimations were carried out, it was not realized that storage of the eyes *post mortem* destroyed the vitamin A aldehyde content and the capacity for its regeneration. Subsequent estimations have shown that it is necessary to carry out the estimations as soon as possible after enucleation.)

RESULTS

The salient ocular findings and the conditions under which they were observed have been set out in Table 2. Rabbit *A*, kept on a vitamin A-deficient diet without any supplement, was in a poor state by 4·5 months and had to be put on vitamin A acid supplement for the rest of the experiment. It had developed typical xerosis of the conjunctiva and cornea at 7·5 months and at 9·5 months it showed white dots at the fundus similar to the lesions observed at the same time in rabbits Nos. 2 and 4 which were thriving on the same deficient diet supplemented by vitamin A acid from the beginning. The same fundus lesion was observed 6 weeks later in the two remaining treated animals of the first experiment (Nos. 1 and 3), but at no time during the 14·5 months' observation was a fundus lesion seen in control rabbit *B*, which received the vitamin A-deficient diet supplemented by vitamin A palmitate. The five rabbits on a vitamin A-deficient diet supplemented by vitamin A acid therefore all showed a fundus lesion at about 10 months.

It will also be seen from Table 2 that all six rabbits in the second experiment—all kept on a vitamin A-deficient diet supplemented by vitamin A acid—developed fundus lesions, first clearly seen at 13·5 months.

The fundus lesions were not the only ocular changes. As can be seen from Table 2, xerosis of the cornea was present in one of the four treated animals in the first series (in addition to the expected corneal lesions seen in the control animal *A*) and in four of the six animals in the second series. It is possible that this complication (which interfered with opthalmoscopic examination) was partly

Table 2. (i) OBSERVATIONS ON SIX LITTER MATES BORN ON OCTOBER 19, 1961

No. of animal	Diet	Period of observation (months)	Xerosis of cornea at (months)	Fundus lesion first observed at (months)	Severity of lesion towards the end of the second year	Modification of diet for the last 5·5 months (after lesion fully established)	Effect on lesion
A	Vitamin A deficient	12·5	7·5	9·5	(General condition very poor at 4·5 months; given vitamin A acid from then on; destroyed at 12·5 months because of flaccid paralysis)		
B	Vitamin A deficient + vitamin A palmitate	14·5	—	—			
1	Vitamin A deficient + vitamin A acid	30	—	11	+ +	Normal diet	No regression
2	Vitamin A deficient + vitamin A acid	22	+ 7·5	9·5	+ +		
3	Vitamin A deficient + vitamin A acid	30	—	11	+ + +	None	
4	Vitamin A deficient + vitamin A acid	30	—	9·5	+ + +	Intensive vitamin A palmitate	No regression

(ii) OBSERVATIONS ON ANOTHER SIX LITTER MATES BORN ON APRIL 4, 1962

No. of animal	Diet	Period of observation (months)	Xerosis of cornea at (months)	Fundus lesion first observed at (months)	Severity of lesion towards the end of the second year	Modification of diet for the last 5·5 months (after lesion fully established)	Effect on lesion
5	Vitamin A deficient + vitamin A acid	18·5	—	13·5	+ + +		
6	Vitamin A deficient + vitamin A acid	24	± 5	13·5	+ + +	None	
7	Vitamin A deficient + vitamin A acid	24	± 5	13·5	+	Intensive vitamin A palmitate	No regression
8	Vitamin A deficient + vitamin A acid	24	+ 5	13·5	+ +	Intensive vitamin A palmitate	No regression
9	Vitamin A deficient + vitamin A acid	24	—	13·5	+ +	Intensive vitamin A palmitate	No regression
10	Vitamin A deficient + vitamin A acid	13·5	+ 5	13·5	+ + when destroyed at 13·5 months		

In this experiment the vitamin A acid supplement was only given after 5·5 months when the animals ceased to gain weight on the vitamin A-deficient diet.

responsible for the delay in establishing the presence of fundus lesions in the second series.

The Fundus Lesion

(i) *Ophthalmoscopic appearances.* The fundus lesion in all these animals was highly characteristic. The first changes were inconclusive and consisted of an indefinite breaking up of the reddish background, suggestive of a geographical map. Within some 6–8 weeks these changes had become more defined by the appearance of white dots in the lower half of the fundus, beginning at about 1 disk distance below the disk, and extending downwards. These white dots first appeared at the periphery, the central area below the disk becoming affected last. That the lesion was definitely pathological, and not a physiological variant of the rather wide range of the normal appearances of the rabbit fundus, was not beyond question until about 9 months from the beginning of the observations.

Once the white dots appeared in the fundus they progressed steadily and sometimes rapidly, so that the indicated in Table 2, two of the four treated animals in severity of the lesions varied in the different animals. As the first series were regarded as severe (Nos. 3 and 4), the remaining two being moderately affected. Likewise, only two of the second series (Nos. 5 and 6) were severe; the rest, except for No. 7 which showed a mild lesion, were moderately affected. The range of ophthalmoscopic appearances is shown by Figs. 1*a*, *b* and *c*.

The fundus lesion proved irreversible. Three of the rabbits in the first series had survived at 24 months, and four of the second series at 18 months. Four of these seven animals were given intensive vitamin A therapy (6 mg vitamin A palmitate/week) and one was kept on a normal rabbit diet; none of these five animals showed any regression of their lesion during the 6 months of observation.

(ii) *Electroretinography.* Rabbits Nos. 1, 3 and 4 had electroretinographic examination at 26 months, and rabbit No. 1 a repeated test at 30 months. Rabbits Nos. 6, 8 and 9 had such an examination at 20 months with a repeat test for rabbit No. 6 at 24 months. These tests showed a consistent pattern. In all animals the *b* wave was most affected, being small or absent; the amplitude was not influenced by dark adaptation. Lesser and indefinite anomalies were seen in the *c* wave. The photoptic components of the electroretinogram were normal. In contrast to the normal rabbit, which shows a predominantly rod type of electroretinogram, these rabbits showed a cone type of tracing.

(iii) *Histological appearances.* All animals were destroyed by the injection of air into the vein of the ear except control rabbit *B* and rabbit No. 5, both of which died from an overdose of anaesthesia, the first while having an abscess of the upper jaw treated, and the second while undergoing an electroretinographic test. In all animals the eyes were excised immediately after death and those destined for histological study were fixed in acid Zenker solution. Paraffin sections were stained with haemalum and eosin. Both eyes were used for histology in rabbits Nos. 2, 5 and 10 and in the control rabbits; in the animals destroyed at the end of the experiment (Nos. 1, 3, 4, 6, 7, 8 and 9) one eye was kept for biochemical tests. Of the eleven animals kept on a vitamin A-deficient diet supplemented by vitamin A acid (ten from the beginning and one after 4·5 months) sections for histological study were obtained in only nine.

Pathological changes were recognized in all the sections. They were most prominent in the area centralis, but extended into the mid-peripheral area as well. Debris appeared between the outer rod segments and the pigmented epithelium. It consisted partly of foamy, lightly eosinophilic material coating the pigmented epithelium and of local aggregations of circular masses staining much more deeply with eosin (Fig. 2*a*). In addition, a few large macrophage-like cells were observed (Fig. 2*b*). Occasionally, these contained pigment granules or small masses of material resembling the eosinophilic debris. The pigmented epithelium itself in the area centralis had a ragged appearance and there was patchy loss of pigment. In places the macrophage-like cells were seen adhering to normal-looking pigmented epithelial cells. Elsewhere the latter appeared in process of rounding up as though they were transforming into macrophage-like cells (Fig. 2*c*).

Changes in the retina proper were slight. Local thinning of the outer nuclear layer was seen, often in association with aggregates of debris. The visual cells which remained appeared largely intact, though some of the deeply staining eosinophilic debris may have been derived from degenerated rod outer segments.

Biochemical Control

The following observations were made as to the vitamin A concentration in the liver: (1) Control rabbit *A* on a vitamin A-deficient diet, destroyed at 12·5 months. The liver contained no vitamin A. (2) Control rabbit *B*, on the same diet supplemented by vitamin A palmitate, accidentally killed at 14·5 months. The liver showed 70 mg of vitamin A. (3) Treated rabbits on vitamin A-deficient diet and vitamin A acid supplement. No. 10 destroyed at 14·5 months, No. 6 destroyed at 24 months, and No. 3 destroyed at 30 months. The liver contained no vitamin A. (4) Treated rabbits on vitamin A-deficient diet supplemented by vitamin A acid, and given a normal diet (No. 1) or vitamin A palmitate supplement subsequent to the development of the retinal lesion (rabbits Nos. 4, 7, 8 and 9). Vitamin A was present in the liver in the



a *b* *c*

Fig. 1. Fundus appearances in rabbits maintained on vitamin A-deficient diet supplemented by vitamin A acid. *a*, A severe lesion in rabbit No. 6, maintained on the vitamin A-deficient diet for 24 months. *b* and *c*, A moderate lesion in rabbit No. 9 and a mild lesion in rabbit No. 7, respectively; both animals had intensive vitamin A supplement during the last 5·5 months of the 2-year period of observation without effect on their lesions



Fig. 2. Histological appearances. *a*, Retina. Ventral mid-periphery showing an aggregation of deeply staining eosinophilic debris. There is also a local thinning of the outer nuclear layer. (Haemalum and eosin × 600). *b*, Pigmented epithelium. Ventral mid-periphery showing macrophage-like cells adhering to it (the retina has become detached during preparation). (Haemalum and eosin × 600). *c*, Pigmented epithelium. Ventral mid-periphery showing one macrophage-like cell and a pigmented epithelial cell rounding up. The coating of foamy debris can also be seen. (Haemalum and eosin × 600)

following quantities: 5 mg, 25 mg, 27 mg, 32 mg and 41 mg, respectively.

In addition, the brains of rabbits Nos. 3, 4, 6, 7, 8 and 9 were examined for vitamin A with negative results. The retinae of these animals were tested for vitamin A aldehyde also with negative result by the method used.

DISCUSSION

(1) *Vitamin A aldehyde in the visual purple cycle.* In the mammal, visual pigment consists of a molecular compound between retinene (vitamin A aldehyde) and the protein opsin. Vitamin A alcohol, the precursor of retinene, is oxidized in the eye to its aldehyde (retinene) under the action of an enzyme, alcohol dehydrogenase—the same enzyme system being responsible for the reduction of retinene to vitamin A following the bleaching action of light. A further degree of biological specificity is found in the visual cycle in that a particular geometrical configuration of retinene is obligatory for the synthesis of visual pigment. Vitamin A and retinene exist in a variety of *cis trans* isomeric forms, and, in the visual pigment, retinene is in the 11-*cis* configuration. Isomerization of vitamin A and/or retinene occurs in the eye under the action of a specific enzyme, retinene isomerase[15]. The primary action of light on the visual pigment is to convert the 11-*cis* retinene into its all-*trans* isomer, and then to break apart the molecular bond between retinene and the protein opsin. A cyclic series of reactions involving synthesis and bleaching of visual pigment is therefore continuously occurring in the retina under the influence of light stimulation and dark adaptation.

In this mechanism vitamin A acid has no place. It is itself the oxidation product of retinene and so far, within the body, no system has been demonstrated which is capable of reversing the process.

(2) *The histological findings in the present investigation.* The following observations are relevant: (i) It is highly probable that the white dots seen with the ophthalmoscope are aggregates of eosinophilic debris. (ii) The macrophage-like cells might be modified pigmented epithelial cells. They also resemble the 'interstitial cells' described in normal mouse retina[15a]. (iii) The aggregates of eosinophilic debris recall the bundles of extracellular lamellae described by Dowling and Sidman[16] in rats with inherited retinal dystrophy. (iv) The pathological changes differ from those seen in known retinopathies induced by various chemical agents. (v) These changes also differ from those described by Dowling and Wald[17] in vitamin A deficiency in the rat in which changes appear first in the rod outer segment, there is fairly rapid diminution in the number of visual cells, and the pigmented epithelium remains normal.

(3) *The fundus lesion observed in the present investigation as the counterpart of retinitis albi punctatus.* The outstanding feature of the observations in the present investigation on vitamin A aldehyde deficiency in the rabbit is the lack of any substantial effect on the rods. The striking fundus lesion seen ophthalmoscopically has a surprisingly slight histological basis: only the pigment epithelium shows any substantial changes, and even these are relatively mild. The electroretinographic tracings are consistent with disturbed dark adaptation and, though they do not exclude damage to the rod system, they do not support such an assumption either.

The lesion in the rabbit is in fact reminiscent of the features seen in vitamin A deficiency in man and in retinitis albi punctatus. In both these affections, night-blindness is an outstanding feature, and in both white dots on the fundus are the characteristic ophthalmoscopic appearances.

The white dots which can be seen using the ophthalmoscope in vitamin A deficiency are not a feature widely known. It is not seen by ophthalmologists practising in affluent countries, but in the Far East, with its massive nutritional problems, it seems to be well recognized since it was first described by Uyemura in 1928 (ref. 18) (Fig. 3). (The literature is reviewed by McLaren[18].) It is likely that in man the associated—and possibly earlier—corneal

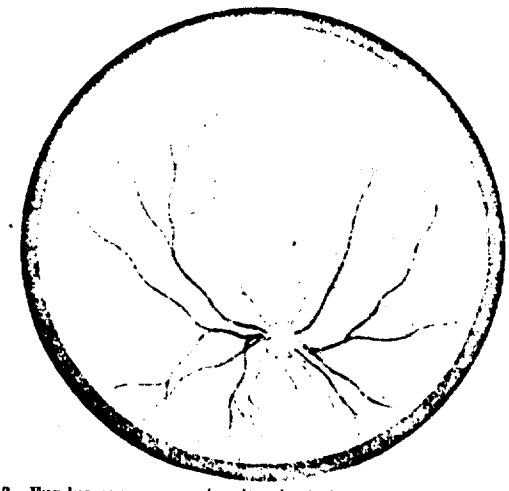

Fig. 3. Fundus appearances in vitamin A deficiency. (After Uyemura (ref. 18))

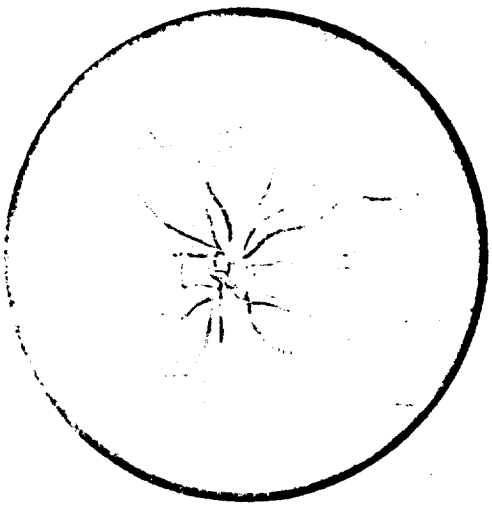

Fig. 4. Fundus albi punctatus. (After François (ref. 21))

xerosis makes the recognition of this fundus lesion difficult in many cases, and it is perhaps significant that, in such of the rabbits as developed corneal xerosis in the present experiment, the corneal lesion preceded a recognizable fundus lesion.

Retinitis albi punctatus has the same ophthalmoscopically visible white dots (Fig. 4) and nightblindness. It is a well-established, though rare, genetic affection, described by Lauber in 1910 (ref. 20), and shows a recessive mode of inheritance. Its clinical importance lies in the fact that, unlike retinitis pigmentosa, it is a stationary affection. It is apparently congenital; it does not lead to pigmentary disturbances, shrinking fields of vision and ultimately total or sub-total blindness. Its mild course excludes any possible involvement of the rods, and the nightblindness and the white dots are presumably the result of an anomaly in the pigment layer—as they appear to be in the rabbit. Though histological evidence is lacking in retinitis albi punctatus, and inconclusive in vitamin A deficiency in man, it is not unreasonable to assume that the experimental lesion in the rabbit is a closely allied disturbance—possibly their counterpart.

These findings in the rabbit fully substantiate those of Wald and Dowling in the rat as to the adequacy of vitamin A acid for the body as a whole, and the dependence of the pigment epithelium (and the visual pigment) on vitamin A aldehyde. They differ, however, in limiting the dependence to this tissue and this cycle: the integrity of the rods is apparently not dependent on vitamin A aldehyde. In the rabbit, in any event, the deprivation of vitamin A aldehyde does not give a picture similar to retinitis pigmentosa, but a considerably less serious disturbance, and it is possible that the pigment epithelium is the major and perhaps the exclusive site of conversion of vitamin A into the specific chromophore for the visual pigment.

Further investigations on both the rat and the rabbit are needed to assess this discrepancy in the findings and its bearing on the fundamental problem whether vitamin A deficiency is an aspect of retinitis pigmentosa with its affection of the rods.

We thank the directors of Vitamins, Ltd., for providing facilities for the animal experiments at their Walton Oaks Experimental Station, and Messrs. Roche Products, Ltd., and their medical adviser, Dr. A. L. Morrison, for generous supplies of vitamin A acid. Dr. Hisako Ikeda of the Institute of Ophthalmology and Mr. A. I. Friedmann of the Royal College of Surgeons and the Royal Eye Hospital carried out and interpreted the electroretinographic tests, while Dr. David Lucas of the Radiobiological Research Unit, Harwell, was responsible for part of the histological study of the retinae. We also thank Miss E. G. Nairne, Miss R. J. Castle and Mr. R. Harding for technical help.

[1] Tansley, K., *Proc. Roy. Soc.* B., **114**, 79 (1933).
[2] Tansley, K., *Biochem. J.*, **30**, 839 (1936).
[3] Johnson, M. L., *J. Exp. Zool.*, **81**, 67 (1939).
[4] Anderson, A. C., and Hart, G. H., *Amer. J. Vet. Res.*, **4**, 307 (1946).
[5] Mann, I., Pirie, A., Tansley, K., and Wood, C., *Amer. J. Ophthal.*, **29**, 812 (1946).
[6] Johnson, M. L., *Amer. Med. Assoc. Arch. Ophthal.*, **29**, 793 (1943).
[7] Wald, G., *Amer. J. Ophthal.*, **40**, 18 (1955).
[8] Dowling, J. E., and Wald, G., *Proc. U.S. Nat. Acad. Sci.*, **44**, 648 (1958).
[9] Dowling, J. E., and Wald, G., *Proc. U.S. Nat. Acad. Sci.*, **46**, 581 (1960).
[10] Dowling, J. E., *Exp. Eye Res.*, **3**, 348 (1964).
[11] Moore, T., *Symp. on Nutrition*, edit. by Herriott, R. M. (Johns Hopkins Press, Baltimore, 1953).
[12] Lamming, G. E., Woollam, D. H. M., and Millen, J. W., *Brit. J. Nutrit.*, **8**, 303 (1954).
[13] Ames, S. R., Risley, H. A., and Harris, P. L., *Anal. Chem.*, **26**, 1378 (1954).
[14] Futterman, S., and Saslaw, L. D., *J. Biol. Chem.*, **236**, 1652 (1961).
[15] Wald, G., *Exp. Cell Research*, Suppl. 5, 389 (1958).
[16] Sidman, R. L., *Ann. N.Y. Acad. Sci.*, **74**, 182 (1958).
[17] Dowling, J. E., and Sidman, R. L., *J. Cell. Biol.*, **14**, 73 (1962).
[18] Dowling, J. E., and Wald, G., *Vitamins and Hormones*, **18**, 515 (1960).
[19] Uyemura, M., *Klin. Monatsbl. Augenheilk.*, **81**, 471 (1928).
[20] McLaren, D. S., *Malnutrition and the Eye*, 162 (Academic Press, New York and London, 1963).
[21] Lauber, H., *Klin. Mbl. Augenheilk.*, **48** (1), 133 (1910).
[22] François, J., *Amer. Med. Assoc. Arch. Ophthal.*, **59**, 98 (1958).

Stainer-'60
Bib. No. 8674

Reproduced by permission
of the copyright owner

Canadian Journal of
Biochemistry and Physiology

Issued by THE NATIONAL RESEARCH COUNCIL OF CANADA

VOLUME 38 NOVEMBER 1960 NUMBER 11

ISOMERIZATION OF 11-*cis* VITAMIN A IN VIVO[1]

D. W. STAINER,[2] T. K. MURRAY, AND J. A. CAMPBELL

Abstract

Single oral doses of all-*trans* and 11-*cis* vitamin A acetate were given to young, vitamin A deficient rats and the proportion of *cis* isomer in the intestinal tract and liver measured. Some conversion of 11-*cis* to all-*trans* occurred in the stomach and intestine, and a mixture of the two isomers was absorbed and stored in the liver. The high proportion of *cis* isomer found in the liver stores 5 hours after a dose of 11-*cis* vitamin A disappeared completely in 23 days. Oral doses of both all-*trans* and 11-*cis* vitamin A produced greater liver stores than the same doses given subcutaneously. The relative biological potency of the 11-*cis* isomer was the same by either route, which indicated that the low potency of this isomer was not due only to poor absorption from the intestine.

Although the 11-*cis* isomer of vitamin A plays an essential role in scotopic vision it has, in common with other *cis* isomers, a low biological potency when measured by growth or liver storage methods (1). It is not normally found in any mammalian tissue other than the pigment epithelium of the retina (2). Dowling and Wald presented evidence (3) that injected 11-*cis* vitamin A was transformed to the all-*trans* form before entering the rhodopsin cycle and Plack (4) found that the 11-*cis* isomer was absorbed after oral administration but quickly disappeared from the liver, apparently by conversion to the all-*trans* form. Earlier work in this laboratory (5) with neovitamin A (13-*cis*) showed that isomerization took place in the intestinal tract as well as in the liver. It is the purpose of this paper to describe the behavior of 11-*cis* vitamin A in the intestinal tract and liver and attempt to relate the results to the low biological potency of this isomer.

Procedure and Results

Isomer Content of the Gastrointestinal Tract and Liver following Oral Doses of All-trans or 11-cis Vitamin A

Young, male, vitamin A deficient rats of an inbred Wistar strain were divided into two groups of 10 animals and were dosed orally with all-*trans* or 11-*cis** vitamin A acetate. In the first experiment, one group received 2820 units of 11-*cis* vitamin A, the other 2370 units of all-*trans* vitamin A, determined by the antimony trichloride reaction. In experiment 2, the doses con-

[1]Manuscript received June 24, 1960.
Contribution from Food and Drug Laboratories, Department of National Health and Welfare, Ottawa.
[2]N.R.C. Postdoctorate Fellow 1959.
*Donated by Dr. W. Oroshnik, Ortho Research Foundation, Raritan, N.J.

tained 2800 and 2200 units respectively. In all cases, the total dose was contained in 0.1 ml of corn oil and was administered with a tuberculin syringe and blunted needle. The animals were killed by decapitation 5 hours after dosing and the gastrointestinal tract and liver removed and analyzed for total vitamin A and *cis* isomer content by the techniques previously described (5). Table I shows the results obtained. After a dose of 11-*cis* vitamin A, the

TABLE I

Vitamin A and *cis* isomer content of the gastrointestinal tract and liver 5 hours after an oral dose of 11-*cis* or all-*trans* vitamin A

		11-*cis* vitamin A*		All-*trans* vitamin A*	
Tissue	Experiment	% of dose	% *cis* isomer	% of dose	% *cis* isomer
Stomach	1	5	62	2	33
	2	8	67	9	39
Intestinal contents	1	4	43	3	24
	2	2	53	3	23
Intestine	1	2	43	2	12
	2	1	42	2	12
Liver	1	5	24	19	3
	2	4	36	14	6
Caecum	1	4	58	1	58
	2	2	66	3	50

*The dose of 11-*cis* was 2820 units in experiment 1 and 2800 in experiment 2.
All-*trans* dose was 2370 units in experiment 1 and 2200 in experiment 2.
Both determined by $SbCl_3$ reaction.

vitamin in the stomach comprised some 60% *cis* isomer, that in the intestinal tract 43–53%, and that in the intestine 43%. The vitamin found in the liver 5 hours after an oral dose contained only 24–36% *cis* isomer. When all-*trans* vitamin A was given orally the *cis* isomer content of the stomach, intestinal contents, intestine, and liver was 33–39%, 23–24%, 12%, and 3–6% respectively. The vitamin in the caeca of both groups of animals contained more than 50% *cis* isomer. The all-*trans* dose produced three to four times greater liver stores than did the 11-*cis* but there was no difference in the total vitamin A found in the digestive tract.

Vitamin A Depletion following a Dose of 11-cis or All-trans Vitamin A

Vitamin A deficient rats, similar to those used in the previous study, were dosed subcutaneously with 1590 units of all-*trans* vitamin A acetate or 1505 units of 11-*cis* vitamin A acetate, both dispersed in water with the aid of Tween 80. After periods of 2, 9, 23, and 37 days, eight animals from each group were killed by decapitation and the livers analyzed for total vitamin A and *cis* isomer content. Results are shown in Table II. Total vitamin A content of the liver increased up to 9 days and then declined steadily. When 11-*cis* vitamin A was administered, liver vitamin A contained 20% *cis* isomer after 2 days, 6.4% after 9 days, and was undetectable thereafter. The liver stores of rats given all-*trans* vitamin A did not at any time contain appreciable amounts of *cis* isomer.

TABLE II

Vitamin A depletion following a subcutaneous dose of 11-*cis* or all-*trans* vitamin A

		Days after dosing							
		2		9		23		37	
Tissue	Dose	Vit. A units*	% *cis* isomer	Vit. A units	% *cis* isomer	Vit. A units	% *cis* isomer	Vit. A units	% *cis* isomer
Liver	1590 units* all-*trans*	655	1.7	770	0.6	452	1.5	297	N.D.
Liver	1505 units 11-*cis*	227	20.0	237	6.4	63	N.D.	37	N.D.

*Determined by $SbCl_3$ reaction.
N.D. Not detectable.

Liver Storage of Vitamin A after Oral and Subcutaneous Doses of All-trans and 11-cis Vitamin A

Young male rats were divided into four groups of 10 and were given a single dose, orally or subcutaneously, of all-*trans* or 11-*cis* vitamin A acetate. The vitamin was dispersed in water with the aid of Tween 80 and the potency of the doses was determined by the antimony trichloride method. Two similar experiments were completed; in one the animals were killed 2 days after dosing, in the other 8 days after dosing when the stores from the injected dose had been found to be near their peak. The total vitamin A and *cis* isomer content of the livers is shown in Table III.

TABLE III

Liver storage of vitamin A after oral and subcutaneous doses of all-*trans* and 11-*cis* vitamin A

Dose	Days after dose	Liver stores (% of dose)	% *cis* isomer
Experiment 1			
1590 units all-*trans* orally	2	50.5	0.7
1590 units all-*trans* subcutaneously	2	41.2	1.7
1505 units 11-*cis* orally	2	18.7	9.4
1505 units 11-*cis* subcutaneously	2	15.1	20.0
Experiment 2			
1900 units all-*trans* orally	8	61.4	1.8
1900 units all-*trans* subcutaneously	8	57.4	1.3
1957 units 11-*cis* orally	8	24.2	14.0
1957 units 11-*cis* subcutaneously	8	20.4	16.5

In experiment 1, oral dosing produced significantly greater liver stores than did the subcutaneous route for both isomers. In the second experiment the differences, though similar to those in experiment 1, were not significant. Subcutaneous injection of the 11-*cis* isomer appeared to result in a higher proportion of the *cis* isomer in the liver stores than did oral dosing. By either route of administration the liver stores produced by the 11-*cis* vitamin A dose amounted to 36–39% of those produced by the all-*trans* dose.

Discussion

When 11-*cis* vitamin A was given orally to rats there was considerable conversion to the all-*trans* form in the stomach and intestine. Nevertheless, the

cis isomer was absorbed and, 5 hours after dosing, some 30% of the vitamin stored in the liver was in this form. The total amount of vitamin A stored was one-quarter to one-third that stored from a dose of all-*trans* vitamin A, but the amount remaining in the intestinal tract was the same for both isomers. There was, therefore, no evidence that the smaller liver stores were the result of poorer or slower absorption of the 11-*cis* isomer. These results are similar to those reported earlier (5) for neovitamin A, except that a larger proportion of the latter isomer was converted to all-*trans* in the intestinal tract and more was stored in the liver.

The ability of the liver to convert *cis* isomers of vitamin A to all-*trans* has been demonstrated here with the 11-*cis* isomer as it was earlier with neovitamin A (5). When 11-*cis* vitamin A was injected subcutaneously, the *cis* isomer content of the vitamin stored in the liver was 20% 2 days after dosing, 6% after 9 days, and 0 after 23 days. The greatest decrease in *cis* isomer content occurred during the first 9 days when the total liver stores of the vitamin were on the increase. There seems little doubt that the decrease in *cis* isomer content represents conversion to all-*trans* and not preferential removal of the *cis* isomer from the liver. Plack (4), who measured the *cis* isomer content of liver for 7 days after dosing, reached the same conclusion.

Oral administration of either all-*trans* or 11-*cis* vitamin A resulted in larger liver stores than did subcutaneous injection but the storage of the 11-*cis* dose, relative to that of all-*trans*, was similar for both routes of administration. It should be noted that storage of the 11-*cis* isomer was greater (36–39% that of all-*trans*) than its reported potency would have suggested.

It can be concluded from these experiments that the low potency of the 11-*cis* isomer was not due to the inability of the intestine to absorb the *cis* isomer. Considerable all-*trans* was formed in the stomach, but a mixture of the two isomers was absorbed. Nor could it be shown that more of an 11-*cis* dose reached the caecum, i.e. was not absorbed. Furthermore, the 11-*cis* vitamin A had the same biological potency whether administered subcutaneously or orally. It has therefore been shown that a factor other than intestinal absorption is responsible for the low biological potency of the 11-*cis* isomer of vitamin A.

References

1. S. R. Ames, W. J. Swanson, and P. L. Harris. J. Am. Chem. Soc. **77**, 4134 (1955).
2. G. Wald and S. P. Burg. J. Gen. Physiol. **40**, 609 (1957).
3. J. F. Dowling and G. Wald. Proc. Natl. Acad. Sci. U.S. **44**, 648 (1958).
4. P. A. Plack. Brit. J. Nutrition, **13**, 111 (1959).
5. T. K. Murray, D. W. Stainer, and J. A. Campbell. Can. J. Biochem. and Physiol. **37**, 1469 (1959).

Sternberg-'37
Bib. No. 8736

Arch. Dermatol. Syphilol. 35:247-250. 1937.

INFLUENCE OF AVITAMINOSIS A ON EXPERIMENTALLY PRODUCED CUTANEOUS INFECTIONS IN RATS

THOMAS H. STERNBERG, M.D.
AND
DONALD M. PILLSBURY, M.D.
PHILADELPHIA

The question of an increased susceptibility of the skin to infection in avitaminosis A has been the subject of much discussion. Frazier and Hu [1] noted that pyogenic dermatosis occurred frequently as a late phenomenon in patients suffering from this deficiency. McCoy [2] in studying vitamin A deficiency in young albino rats found that animals with this disorder exhibited a definitely lowered resistance to Trichinella spiralis administered orally. Furthermore, in the rats with vitamin A deficiency any immunity to a second inoculation failed to develop, whereas controls were rendered completely immune by one inoculation. Workman,[3] Green and Mellanby,[4] Boynton and Bradford [5] and others have also noted that in rats with vitamin A deficiency there was a general lack of resistance to experimental infections in various body structures other than the skin. MacKay [6] in a large clinical study attempted to determine the effect of prophylactic treatment with vitamin A. One group of infants and children studied was partially deficient in vitamin A while the other group received a diet to which an

This research was aided by a grant from the Faculty Research Committee of the University of Pennsylvania.

From the Department of Physiological Chemistry, D. Wright Wilson, Ph.D., Director, and the Department of Dermatology and Syphilology, John H. Stokes, M.D., Director, University of Pennsylvania School of Medicine.

1. Frazier, C. N., and Hu, C.: Cutaneous Lesions Associated with a Deficiency in Vitamin A in Man, Arch. Int. Med. **48**:507 (Sept.) 1931.

2. McCoy, O. R.: Effect of Vitamin A Deficiency of Rats on Resistance to Infection with Trichinella Spiralis, Am. J. Hyg. **20**:169 (July) 1934.

3. Workman, C. H.: Immunologic Significance of Vitamins: Influence of the Lack of Vitamins on Resistance of Rat, Rabbit and Pigeon to Bacterial Infection. J. Infect. Dis. **32**:255, 1923.

4. Green, H. N., and Mellanby, E.: Vitamin A as an Anti-Infective Agent, Brit. M. J. **2**:691, 1928.

5. Boynton, L. C., and Bradford, W. L.: Effect of Vitamins A and D on Resistance to Infection. J. Nutrition **4**:323, 1931.

6. MacKay, H. M. M.: Vitamin A Deficiency in Children: Vitamin A Requirement of Babies; Skin Lesions and Vitamin A Deficiency, Arch. Dis. Childhood **9**:133 (June) 1934.

adequate amount of this substance was added. The results of this study indicated a definite increase in resistance of the skin to minor infections in the group given vitamin A. The incidence of minor cutaneous irritations such as napkin erythema and of cutaneous infections such as intertrigo, boils and whitlow was 27 per cent in this group as compared to 52 per cent in the group with vitamin A deficiency. MacKay concluded that a slight vitamin A deficiency diminishes the resistance of the skin to infection.

Loewenthal,[7] on the other hand, was impressed by the infrequent occurrence of pyogenic cutaneous infections in patients with vitamin A deficiency, particularly in those who bathed often. Sweet and K'ang[8] in a series of 203 cases of avitaminosis A in Chinese patients found infection of the skin to be rare. Impetigo and cutaneous ulcers were seen in less than 5 per cent of the cases, an incidence considered by the authors to be low in view of the economic state and the poor hygienic environment of the patients. Furthermore, Sweet and K'ang expressed the belief that excess vitamin A in the diet exercises no protective action against infection of the skin. Wright and his co-workers[9] and Hess[10] have submitted evidence tending to refute the conception that a deficiency of vitamin A in the diet predisposes to acute infections of the respiratory tract.

A papular dermatosis attributed to vitamin A deficiency by Loewenthal, Frazier and Hu, Sweet and K'ang and others has not been discussed, as it does not seem to bear any relation to infection per se.

A complete summary of the literature on this subject has not been attempted, but, as has been pointed out by Clausen,[11] purely experimental evidence concerning the relation of avitaminosis A to cutaneous infection is lacking.

MATERIALS AND METHODS

Animals.—Because of the ease with which vitamin A deficiency may be produced in these animals, young albino rats from a laboratory stock were selected. It is well known that the skin of rats is resistant to infection, but it was believed that any marked difference in susceptibility encountered would be significant. The mothers of these rats were fed the Steenbock[12] stock diet to which 2 per cent yeast was added.

7. Loewenthal, L. J. A.: A New Cutaneous Manifestation in the Syndrome of Vitamin A Deficiency, Arch. Dermat. & Syph. **28**:700 (Nov.) 1933.

8. Sweet, L. K., and K'ang, H. J.: Clinical and Anatomic Study of Avitaminosis A Among the Chinese. Am. J. Dis. Child. **50**:699 (Sept.) 1935.

9. Wright, H. P.; Frost, J. B.; Puchel, F., and Lawrence, M. R.: Vitamin A and the Common Cold, Canad. M. A. J. **25**:65, 1931.

10. Hess, A. F.: Diet, Nutrition and Infection, New England J. Med. **207**: 637, 1932.

11. Clausen, S. W.: Influence of Nutrition upon Resistance to Infection, Physiol. Rev. **14**:309 (July) 1934.

12. Steenbock, H.: Satisfactory Ration for Stock Rats, Science **58**:449, 1923.

Diet.—The basal vitamin A-deficient diet consisted of the following ingredients:

Casein (alcohol extracted)	18 per cent
Agar	2 per cent
Salt 40[13]	4 per cent
Yeast	6 per cent
Dextrinized starch	70 per cent
Viosterol, 3 drops per kilogram of diet.[14]	

The control animals were given 0.2 cc. of cod liver oil three times a week in addition to the aforementioned diet. The rats on the diet lacking vitamin A continued to gain weight for from four to six weeks, at which time a peak was reached. Loss of weight and xerophthalmia then appeared.

Technic.—The same strains of staphylococci and streptococci were used throughout the experiment. These organisms when injected intradermally in dogs and in rabbits caused ulcerative necrotic infections. All the rats were infected by the following technic: After the abdomen was shaved 0.5 cc. of a twenty-four hour broth culture of both the streptococci and the staphylococci was injected intracutaneously. The abdomen was then scratched in two places, and a drop of each culture was rubbed into the excoriated area. The severity and duration of the resulting infections were then observed.

RESULTS

The results are given in the table.

Observations on Vitamin A-Deficient and on Normal Rats

Group A* Vitamin A-Deficient Rats		Group B Normal Rats	
Rat	Severity of Infection*	Rat	Severity of Infection*
1	Moderate	3	Moderate
2	Minimal	4	Minimal
5	Moderate	10	Minimal
6	None	11	Minimal
7	None	12	None
8	Minimal	13	Minimal
9	Minimal	14	Minimal
15	Minimal	18	Minimal
16	Minimal	19	Minimal
17	Minimal	20	Moderate

* "Minimal" designates a 0.5 to 1 cm. inflammatory reaction with a pustular crust and superficial ulceration or an inflammatory nodule 0.5 cm. in diameter. "Moderate" designates deeper ulcerative lesions or inflammatory nodules 1 cm. or more in diameter.

Group A was composed of rats which showed definite signs of vitamin A deficiency (loss of weight and xerophthalmia) at the time of inoculation. Of the ten rats in this group, eight showed definite evidence of infection of the skin in the form of superficial pustular crusting and ulceration or, in the case of animals inoculated intra-

13. The composition of salt 40 is explained in the following articles: Steenbock, H., and Nelson, E. M.: Fat Soluble Vitamine: Light in Its Relation to Ophthalmia and Growth. J. Biol. Chem. **56**:355. 1923. Steenbock, H., and Gross, E. G.: Fat-Soluble Vitamine, ibid. **40**:501. 1919.

14. The viosterol used contained 1,000,000 U. S. P. XI units of vitamin per gram. It was furnished by Mead Johnson & Co.

dermally, pea-sized inflammatory nodules, which occasionally broke down and discharged pus. Nine of the ten rats in the control group (group B) showed signs of infection similar to those seen in animals of group A. The grade of infection for animals in both groups as a whole was minimal. It is noted that of the five more severe infections three occurred in rats in group B and two in rats in group A. The duration of infection was from five to ten days, depending on the severity of the reaction. Several of the rats in group A showed rapidly healing infections at the sites of inoculation while dying of vitamin A deficiency. The animals were equally resistant to both the streptococci and the staphylococci used. No reaction resulted from scratch or intracutaneous inoculation of sterile broth.

Thus a critical comparison of the response of the rats in these two groups to experimental inoculation of the skin with pathogenic organisms failed to reveal any differences worthy of note.

CONCLUSION

Avitaminosis A in rats has no apparent effect on the resistance of the skin to experimentally produced infection with streptococci and staphylococci.

Dr. J. H. Jones supplied the rats used in these experiments.

Strebel-'69
Bib. No. 8782

Reproduced by permission
of the copyright owner

Arch. Pathol. 87(3):290-297. 1969.

Cardiovascular Calcification in Rats With Hypervitaminosis A

Ralph F. Strebel, PhD; Rene J. Girerd, MD; and Bernard M. Wagner, MD, New York

Intraperitoneally administered aqueous vitamin A (50,000 US Pharmacopeia units/rat/day during 16 consecutive days) induces the following symptomatology in virgin female rats weighing 200 gm: (1) medial arterial calcification; (2) myocardial muscle necrosis and calcification; (3) kidney calcification and degeneration; (4) elevated plasma calcium, phosphorus, and urea nitrogen; (5) depressed plasma alkaline phosphatase; (6) bone rarefaction; (7) body weight loss; and (8) alopecia. Orally administered vitamin A (dosage as above) induces comparable bone rarefaction, body weight loss, and plasma alkaline phosphatase depression. However, no renal-cardiovascular pathology was induced when vitamin A was taken orally. Prior parathyroidectomy or thyroparathyroidectomy failed to prevent vitamin A (intraperitoneal)-induced cardiovascular calcification. The results indicate that the route of vitamin A administration is crucial for causing cardiovascular calcification, which is similar morphologically to human Mönckebergs arteriosclerosis and to cardiovascular calcinosis induced by excessive vitamin D or dihydrotachysterol.

ACCORDING to Moore,[1] animals manifest hypervitaminosis A only under experimental conditions. However, man has sustained injury from excessive vitamin A in the following several ways: Arctic explorers have eaten excessive amounts of polar bear liver which is extremely rich in vitamin A; young infants have been given more vitamin A than they could tolerate; and adult patients with skin diseases such as ichthyosis and Darier's disease have been treated by prolonged and heavy dosing in attempts to ameliorate the skin lesions.[1] Under conditions of hypervitaminosis A, new bone is readily deposited and, at the same time, bone resorption proceeds at a rapid rate. Although there is an increase in bone mineral turnover associated with vitamin A overdosage, there is little evidence that this fat soluble vitamin is capable of inducing soft tissue calcinosis. In fact, Clark and Bassett[2] state that soft tissue calcification is never found under conditions of hypervitaminosis A. On the other hand, Thomas et al,[3] reporting on an autopsy series of ten rabbits, found metastatic calcification in the kidneys of two rabbits

Accepted for publication Sept 3, 1968.

From the Department of Pathology, New York Medical College, New York. Doctor Girerd is now with the Department of Pathology, Morristown Memorial Hospital, Morristown, NJ. Doctor Wagner is now with the Department of Pathology, College of Physicians and Surgeons, Columbia University, New York.

Read in part before the 51st annual meeting of the Federation of American Societies for Experimental Biology, Chicago, April 16-21, 1967.

Reprint requests to Department of Pathology, New York Medical College, Fifth Avenue and 106th Street, New York 10029 (Dr. Strebel).

after hypervitaminosis A was induced intraperitoneally. Cardiovascular damage was not reported by the latter investigators.

Unique in the present communication is the finding that the route of vitamin A administration is of primary pathogenic importance for the production of cardiovascular calcification in virgin female rats. As will be seen in the following experimental series, the intraperitoneal administration of excessive vitamin A induces severe myocardial and medial arterial calcinosis. To our knowledge these pathological changes have not been previously produced under conditions of hypervitaminosis A.

Materials and Methods

Virgin female rats (Holtzman), with an average initial body weight of 228 gm (range, 220 to 235 gm), were used in this experimental series. As seen in Table 1 and 2, vitamin A was administered intraperitoneally to the intact rats of group 2, the animals in group 3 that underwent thyroparathyroidectomy (Thyr-X + Ptr-X), and the rats in group 4 that underwent parathyroidectomy (Ptr-X). The animals from group 7 received vitamin A orally. Aquasol A Parenteral, a water-miscible vitamin A in the form of its palmitate ester, was delivered to the rats (either orally or intraperitoneally) at the dose of 50,000 US Pharmacopeia (USP) units (1 ml)/rat/day during 16 consecutive days. Control groups consisted of normal untreated rats (group 1), Ptr-X rats (group 5), and Thyr-X + Ptr-X rats (group 6). Thyr-X + Ptr-X was accomplished surgically by the bilateral excision of the entire thyroid-parathyroid complex. Ptr-X was done by means of thermocautery. Both types intervention were made one week prior to the onset of vitamin A administration. On the day following the last day of vitamin A treatment, all surviving rats were killed with chloroform. At death, blood was taken for the determination of the following parameters: plasma calcium (Ca),[4] plasma phosphorus (PO_4),[5] plasma alkaline phosphatase (AlPH),[6] and plasma blood urea nitrogen (BUN).[7] For the latter chemical determinations, jugular blood was obtained in heparinized syringes under light ether anesthesia at the time of death. The Student t-test was used to make intergroup comparisons in regard to the level of significance of the various blood parameters (Table 2). From all animals that were killed and all mortality cases, the scapulae were evaluated grossly and the hearts, aortas, and kidneys were obtained for histological examination. At necropsy, the latter soft tissues were fixed in an alcohol-formaldehyde solution for 48 hours, dehydrated in two changes of dioxane for 48 hours, embedded in paraffin, and subsequently stained with the phloxine-von Kóssa technique for the demonstration of calcium and other structural changes. The percentage of rats manifesting various pathological changes and the relative severity of pathological involvement were used to evaluate the gross and histological material (Table 1).

Throughout the course of the experiment, the animals were maintained on commercial laboratory chow (Purina) and tap water and were housed in groups of five in suspended steel cages.

Results

Table 1 indicates that a substantial percentage of animals receiving vitamin A intraperitoneally (groups 2, 3, and 4) sustained moderate mortality, renal-cardiovascular damage, bone rarefaction, and body weight loss. Although rats receiving vitamin A orally (group 7) were generally comparable to the animals receiving vitamin A intraperitoneally (groups 2, 3, and 4) in terms of mortality, bone rarefaction, and body weight loss, the animals of group 7 remained free of renal-cardiovascular pathology under conditions of excessive oral administration of vitamin A. It is of interest that removal of the parathyroids either alone or in combination with thyroidectomy does not afford protection against lesions induced by the injection of vitamin A. The latter observation was evidenced by the fact that coronary artery calcification, myocardial necrosis, and aortic calcification were aggravated in group 3 (vitamin A given intraperitoneally + Thyr-X + Ptr-X), while coronary artery calcification was aggravated in group 4 (vitamin A given intraperitoneally + Ptr-X). Renal damage, both calcific and degenerative, was prominent in all animals given vitamin A intraperitoneally (groups 2, 3, and 4). In this experimental series any renal damage induced by the injection of vitamin A could not have caused cardiovascular le-

sions by secondary parathyroid stimulation because the parathyroids were absent in groups 3 and 4.

More specifically, in assessing the renal-cardiovascular lesions of the animals given vitamin A intraperitoneally (groups 2, 3, and 4), it was clear that any differences in the nature of the lesions between the latter groups was one of quantity and not of quality. The coronary artery and aortic calcification was of the medial type (Mönckeberg's) with concretions of calcium deposited along the elastic fibers of the media. Figure 1 illustrates a severely calcified coronary artery from an animal in group 2 (vitamin A given intraperitoneally alone). Severe aortic calcinosis from an animal in group 4 (vitamin A given intraperitoneally + Ptr-X) is shown in Fig 2. In the latter figure, heavy concretions of calcium follow the elastic lamellae and actually distort the contour of the arterial wall. Animals in groups 2, 3, and 4 had frequent coronary artery calcification, but not necessarily in association with myocardial calcification or myocardial necrosis or both. Myocardial calcification from an animal in group 3 (vitamin A given intraperitoneally + Thyr-X Ptr-X) can be seen in Fig 3. Note that some muscle fibers appear completely obliterated by calcific concretions, while in others the calcium deposition is less severe and sometimes assumes a stippled appearance. Necrotic muscle fibers in the myocardium often manifested dystrophic calcification, but frequently they appeared as large confluent pure necrotic areas without any evidence of calcium involvement. Typical kidney damage from an animal in group 4 (vitamin A given intraperitoneally + Ptr-X) is illustrated in Fig 4. Aside from renal tubular calcification and intratubular calcific casts, certain areas of the tubular epithelium showed a loss of cytoplasm and nuclei. The damage described was focal in nature and did not appear to possess any selectivity for any one of the groups receiving vitamin A intraperitoneally. Although renal-cardiovascular damage is associated with vitamin A given intraperitoneally but not with vitamin A given orally, it is interesting that bone rarefaction is of comparable incidence and severity in animals receiving vitamin A by either route. The bleached scapulae in Fig 5 represent a comparison between a normal untreated control animal (group 1), an animal given vitamin A intraperitoneally (group 2), and an animal given vitamin A orally (group 7). It is clear from the latter illustration that vitamin A administered orally or intraperitoneally will induce bone rarefaction as indicated by the confluent eroded areas on the surface of the scapulae. Rats receiving vitamin A by both routes of administration manifested varying degrees of alopecia, tenderness in the soft tissues above the joints, and spontaneous fractures of the long bones. Aside from the low incidence and severity of cardiac necrosis encountered in control group 5 (Ptr-X) and control group 6 (Thyr-X – Ptr-X), these animals did not manifest any additional pathology.

Table 1.—Percentage of M

Group No.	Experimental Condition †	Mortality Rate
1	Untreated (control)	0/10
2	Vitamin A i.p.	3/29
3	Vitamin A i.p.+Thyr-X+Ptr-X	5/25
4	Vitamin A i.p+Ptr-X	4/27
5	Ptr-X (control)	0/10
6	Thyr-X–Ptr-X (control)	0/10
7	Vitamin A p.o.	6/23

As indicated in Table 2, the animals given vitamin A intraperitoneally (groups 2, 3, and 4) were significantly different statistically from normal untreated animals (group 1) in regard to plasma Ca, PO_4, Al-PH, and BUN values. However, the animals given vitamin A intraperitoneally (groups 2, 3, and 4) were not statistically significant (not shown in Table 2) from each other in respect to

[illegible] Pathological Changes Under Conditions of Vitamin A Intoxication

	% of Histopathological Changes *					Gross Changes	
				Kidney			
Coronary Artery Calcium	Myocardial Calcium	Myocardial Necrosis	Aortic Calcium	Calcium	Degen	Bone Rarefaction (Scapula)	Body Weight % Change From Initial to Final
0	0	0	0	0	0	0	+15
62 (M)	34 (L)	31 (L)	41 (M)	97 (L)	100 (M)	100 (S)	−32
80 (S)	60 (M S)	68 (M)	68 (S)	96 (L)	100 (M)	100 (S)	−30
88 (S)	29 (L)	33 (L)	44 (M)	80 (L)	100 (M)	100 (S)	−32
0	0	10	0	0	0	0	+11
0	0	20 (L)	0	0	0	0	0
0	0	0	0	0	0	100 (S)	−27

* S indicates severe; M, moderate; L, light.
† I.P. indicates intraperitoneal administration; p.o., oral. Dosage was 50,000 USP units/rat/day during 16 consecutive days. They were killed the following day; data are from both living and dead rats.

Table 2.—Effect of Hypervitaminosis A on Various Blood Parameters *

Group No.	Experimental Condition †	No. of Animals	Calcium (Ca) (mg/100 ml)	Inorganic Phosphorous (PO_4) (mg/100 ml)	Alkaline Phosphatase (AL-PH) (mg/100 ml)	Blood Urea Nitrogen (BUN) (mg/100 ml)
1	Untreated (control)	10	9.9	6.1	73.9	24.6
2	Vitamin A i.p.	26	13.0 (a)	8.4 (a)	33.8 (a)	72.0 (a)
3	Vitamin A i.p. + Thyr-X + Ptr-X	20	12.7 (a)	7.6 (a)	28.3 (a)	77.7 (a)
4	Vitamin A i.p. + Ptr-X	23	12.7 (a)	7.7 (b)	37.3 (a)	69.3 (a)
5	Ptr-X (control)	10	7.1 (a)	9.8 (a)	72.6 (ns)	26.0 (ns)
6	Thyr-X + Ptr-X (control)	10	6.4 (a)	8.9 (a)	82.9 (ns)	26.7 (ns)
7	Vitamin A p.o.	17	10.0 (ns)	6.4 (ns)	44.2 (a)	35.0 (ns)

* Levels of significance for comparison with untreated control animals (group 1) only: ns indicates not significant. a, $P<0.001$; b, $P<0.01$.
† I.P. indicates intraperitoneal administration; p.o., oral. Dosage was 50,000 USP units/rat/day during 16 consecutive days. They were killed the following day; data are from both living and dead rats.

these blood values. It is clear from the data that vitamin A given intraperitoneally causes marked hypercalcemia in the presence or in the absence of the parathyroid glands. Parathyroidectomy, in the case of groups 3 and 4, apparently failed to induce the expected hypocalcemic reaction, because of the overwhelming hypercalcemic effect of intraperitoneally administered vitamin A. Although the hyperphosphatemia in the animals given vitamin A was not extraordinarily high, it does reflect the tendency for vitamin A to induce high Ca and PO_4 values concurrently when given by this method. This is in contrast to dihydrotachysterol (a vitamin D derivative) which induces marked hypercalcemia associated with relatively normal PO_4 values.

Referring again to Table 2, note that the animals receiving vitamin A orally (group 7) were not statistically different from normal control animals (group 1) for any of the blood parameters except for the A1-PH value which, like those of the animals receiving vitamin A intraperitoneally (groups 2, 3, and 4), was significantly depressed. One reason for the A1-PH depression may be that all animals given vitamin A both ways were cachectic. Although not included in Table 2, the statistical comparison of blood values between animals given vitamin A orally (group 7) and animals given vitamin A intraperitoneally (groups 2, 3, and 4) is as follows: The Ca and BUN values of animals given vitamin A orally were significantly lower ($P<0.001$) than those of the animals in all groups given vitamin A intraperitoneally. Likewise, the PO_4

Fig 1.—Coronary artery calcification from an animal in group 2 (vitamin A given intraperitoneally only). Note the severe calcification (black) in the medial aspect of the vessel wall. Area between vessel and surrounding myocardium is edematous (phloxine-von Kóssa's stain, × 240).

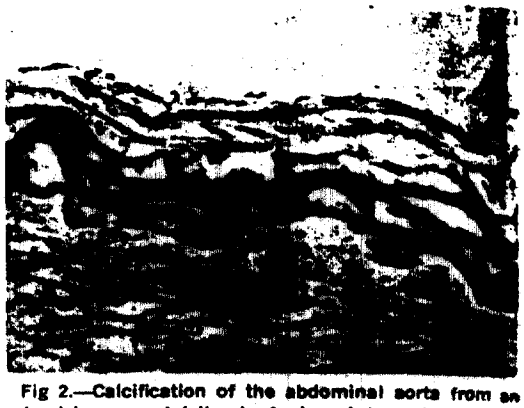

Fig 2.—Calcification of the abdominal aorta from an animal in group 4 (vitamin A given intraperitoneally + Ptr-X). Heavy confluent concretions of calcium (black) appear to follow the elastic lamellae within the medial aspect of vessel wall (phloxine-von Kóssa's stain, × 135).

Fig 3.—Myocardial calcification from a rat in group 3 (vitamin A given intraperitoneally + Thyr-X + Ptr-X). Note apparent complete obliteration of certain myofibers by calcific deposits (black), while other muscle bundles (top right) have a stippled appearance due to less severe calcification (phloxine-von Kóssa's stain, × 240).

Fig 4.—Kidney from an animal in group 4 (vitamin A given intraperitoneally + Ptr-X) illustrating calcification within tubular epithelium, intratubular calcific casts, and disappearance of tubular cytoplasm nuclei (phloxine-von Kóssa's stain, × 720).



Fig 5.—Comparison of scapulae: Top, from a normal animal (group 1); bottom left, from an animal given vitamin A intraperitoneally (group 2); and bottom right, from an animal given vitamin A orally (group 7). Note that both animals that received vitamin A had severe bone rarefaction as indicated by the large confluent areas of eroded bone on the surface of each scapula (fresh perioxide bleached sections, × 4).

values of the animals receiving vitamin A orally were significantly lower than those receiving vitamin A intraperitoneally. (Between group 7 and groups 2 and 3, the level of significance was $P < 0.001$, and between group 7 and group 4 the level of significance was $P < 0.01$). Although the A1-PH values of the animals given vitamin A orally were significantly higher ($0.001 < P < 0.01$) than those animals in group 3 given vitamin A intraperitoneally, they were not significantly different from those animals in groups 2 and 4 given vitamin A by the same method.

The surgical control animals of group 5 (Ptr-X) and group 6 (Thyr-X + Ptr-X) were not significantly different from un-

treated control animals (group 1) in respect to Al-PH and BUN values. However, as might be expected, both surgical control groups manifested significantly lower Ca values and significantly higher PO_4 values when compared to the untreated control animals of group 1. The hypocalcemia and hyperphosphatemia observed in groups 5 and 6 were not unexpected since comparable electrolyte shifts are known to occur after parathyroidectomy.

Comment

The route of administration can be a crucial factor in the ultimate expression of pathological changes due to drug toxicity. Although Thomas et al[3] mentioned that injected vitamin A has been reported to be less effective than vitamin A by mouth, it is intriguing that our experimental animals manifested comparable bone damage by both routes and yet sustained renal-cardiovascular damage only by the intraperitoneal route. It is possible that during its passage through the intestinal wall and through the liver, vitamin A may lose its renal-cardiotoxic effect. On the other hand, the intraperitoneal administration of vitamin A may allow a more direct action on some of the target organs (heart, aorta, and kidney) before ultimately passing through the intestine and liver.

Fell and Mellanby[8] investigated the effect of excessive vitamin A on organ cultures of embryonic chick limb bones and fetal mouse limb bones. Under conditions of hypervitaminosis A, the cartilage matrix of the chick explants showed drastic changes such as shrinkage of intercellular partitions, softening and loss of basophilia, and metachromasia. The mouse limb bone explants showed pronounced osteolysis in the presence of excessive vitamin A. These vitamin A effects could be explained, as suggested by Fell et al,[9] by an alteration of the permeability of intracellular particles such as lysosomes and mitochondria. The concept that vitamin A has a direct action on membrane permeability gained further strength when Dingle and Lucy[10] demonstrated that rat liver lysosomes treated with vitamin A released a proteolytic enzyme with an acid pH optimum. Additional work on in vitro liver preparations was done by Dingle[11] who, by ultracentrifugation, isolated the mitochondrial fraction of rat liver and then subjected it to excess vitamin A. The latter author reported that a proteolytic enzyme was released by the mitochondria. Although the exact mechanism of altered mitochondrial membrane permeability is not known, the dependence of the vitamin A effect upon temperature and pH suggest an enzymatic mechanism. Swelling of mitochondria, due to vitamin A has been reported by Lucy et al.[12] The notion that vitamin A alters membrane permeability was further substantiated when Dingle and Lucy[13] showed that vitamin A not only effects lysosomal membrane permeability but also influences the membrane stability of other entirely different structures such as the erythrocyte. It is tempting to speculate that the site of action of vitamin A overdosage may be at the lipoprotein membrane of cells and their intracellular organelles (lysosomes). Should this assumption be correct, then vitamin A could be regarded as capable of releasing a variety of hydrolases (a cathepsin, a ribonuclease, a deoxyribonuclease, a phosphatase, a glucuronidase, and a sulfatase) which, according to de-Duve,[14] are present in lysosomes. Dingle[11] supports the view that some, or all, of the above mentioned bound hydrolases may be released by vitamin A overdosage, and that the above mentioned complex of enzymes may be responsible for many of the changes seen in tissues treated with excessive vitamin A.

In the present experimental series, the renal-cardiovascular pathology associated with vitamin A given intraperitoneally may constitute a direct in vivo effect of the vitamin on such target organs as the heart, vessels, and kidney. Since a certain amount of vitamin A given by intraperi-

toneal injection directly bathes the target organs before passing through the liver, it is conceivable that the vitamin could alter cell, organelle, and lysosomal membrane permeability and thus trigger the uncontrolled release of damaging hydrolytic enzymes. The vitamin A preparation administered in the present experiments was in the form of an ester (palmitate). When given by mouth, vitamin A ester is known to be hydrolyzed to the alcohol form in the lumen of the intestine, reesterified with palmitic acid in the intestinal mucosa, transported to the liver by lymphatics and blood circulation as an ester, and ultimately stored as such in the liver. Prior to mobilization from the liver, vitamin A ester is again hydrolyzed to the alcohol form of vitamin A and passes in the latter form via the blood stream to the tissues. Thus, by oral administration, it can be assumed that vitamin A ester (palmitate) ultimately reaches target organs in the alcohol form. On the other hand, the administration of vitamin A ester by intraperitoneal injection permits a certain amount of the vitamin to reach target organs in the original ester form because of no initial passage through the intestine and liver. Our results demonstrate that the oral administration of vitamin A ester (reaches targets in alcohol form) causes bone damage without associated renal-cardiovascular pathology, while the intraperitoneal injection of vitamin A ester (some reaches targets in ester form) causes both bone and renal-cardiovascular damage. In view of these results, it is possible that both the alcohol and the ester form of vitamin A are toxic to bone, but that the ester form of vitamin A is pathogenic to the renal-cardiovascular system. The latter notion has not yet been verified experimentally.

The emphasis on the possible importance of the form of vitamin A as a factor in the etiology of the observed pathological changes should not detract from the possibility that the damaged kidneys may play a dominant role in vitamin A (given intraperitoneally)-induced cardiovascular pathology. Although our results do not indicate how the kidneys may be involved, they show that any renal-induced cardiovascular damage does not depend on parathyroid participation.

In further considering the differences in the pathological effects of vitamin A given orally and intraperitoneally, dietary factors may be of importance since it is known, for instance, that vitamin A absorption from the intestine is impaired by a low dietary intake of protein.[15] Obviously, our vitamin A (given both by intraperitoneal injection and by mouth) treated animals who did not ingest an adequate amount of food as reflected by the percentage loss of body weight shown in Table 1. Among the animals receiving vitamin A orally, the decreased food (consequently protein) intake may have caused some impairment of the absorption of vitamin A from the intestine so that the animals treated orally may have received relatively less vitamin A than the animals treated by intraperitoneal injection.

Vitamin A given intraperitoneally induces a symptomatology that is in some respects similar to that induced by vitamin D or dihydrotachysterol (a vitamin D derivative). The latter agents are effective sensitizers for the production of Selye's[16] calciphylaxis. It would be of interest to determine if vitamin A given by intraperitoneal injection can be effective as a systemic calciphylactic sensitizer. If vitamin A, as perhaps other widely different agents, can be found to be an effective calciphylactic sensitizer, it would further broaden the significance of this unique biological phenomenon.

Excessive intake of vitamins from the prenatal period to old age is common in well advanced societies. In this connection, Taussig[17] emphasizes the danger of vitamin D overdosage during early life as regards the later development of cardiovascular pathology. Since vitamin D and vitamin A given by intraperitoneal injec-

tion have several cardiotoxic effects in common, it may be appropriate to investigate if overdosage of vitamin A in early life could, like vitamin D, have long term cardiovascular effects.

This study was supported by Public Health Service research grants HD 02261-02 and HE 12140-01 from the National Institutes of Health.

The Aquasol A Parenteral was supplied by USV Pharmaceutical Corp., New York.

Mr. Joseph Conetta, Mrs. Elizabeth Fulop, and Mrs. Meletta Strebel gave technical assistance.

References

1. Moore, T.: Vitamin A Deficiency and Excess, Symposium of the Nutrition Society on Vitamin A, *Proc Nutr Soc* 24:127-155 (March) 1965.

2. Clark, L, and Bassett, C.A.L.: The Amelioration of Hypervitaminosis D in Rats With Vitamin A, *J Exp Med* 115:147-155 (Jan) 1962.

3. Thomas, L., et al: Comparison of the Effects of Papain and Vitamin A on Cartilage: I. The Effects of Rabbits, *J Exp Med* 111:705-718 (May) 1960.

4. Kepner, B.L., and Hercules, D.M.: Fluorimetric Determination of Calcium in Blood Serum, *Anal Chem* 35:1238-1240, 1963.

5. Fiske, C.H., and Subbarow, Y.: The Colorimetric Determination of Phosphorous, *J Biol Chem* 66:375-400 (Dec) 1925.

6. Bodansky, A.: Phosphatase Studies: II. Determination of Serum Phosphatase; Factors Influencing the Accuracy of the Determination, *J Biol Chem* 101:93-104 (June) 1933.

7. Ceriotti, G., and Spandrio, L.: A Spectrophotometric Method for Determination of Urea, *Clin Chim Acta* 8:295-299 (March) 1963.

8. Fell, H.B., and Mellanby, E.: The Effect of Hypervitaminosis A on Embryonic Limb-Bones Cultivated In Vitro, *J Physiol* 116:320-349, (March) 1952.

9. Fell, H.B.; Lucy, J.A.; and Dingle, J.T.: Studies on the Mode of Action of Vitamin A: I. The Metabolism, Composition and Degradation of Chick-Limb Cartilage In Vitro, abstracted, *Biochem J* 78: 11 (Jan) 1961.

10. Dingle, J.T., and Lucy, J.A.: Studies on the Mode of Action of Vitamin A: II. The Release of a Bound Protease by the Action of Vitamin A, abstracted, *Biochem J* 78:11 (Jan) 1961.

11. Dingle, J.T.: Studies on the Mode of Action of Vitamin A: III. Release of a Bound Protease by the Action of Vitamin A, *Biochem J* 79:509-512 (June) 1961.

12. Lucy, J.A.; Luscombe, M.; and Dingle, J.T.: Studies on the Mode of Action of Excess Vitamin A: VIII. Mitochondrial Swelling, *Biochem J* 88:419-425 (Dec) 1963.

13. Dingle, J.T., and Lucy, J.A.: Studies on the Mode of Action of Excess Vitamin A: V. The Effect of Vitamin A on the Stability of the Erythrocyte Membrane, *Biochem J* 84:611-621 (Sept) 1962.

14. deDuve, C.: *Subcellular Particles*, New York: Ronald Press, Co., 1959, p 128.

15. Plack, P.A.: Occurrence, Absorption, and Distribution of Vitamin A, Symposium of the Nutrition Society on Vitamin A, March 12, 1965, *Proc Nutr Soc* 24:146-153 (March) 1965.

16. Selye, H.: *Calciphylaxis*, Chicago: University of Chicago Press, 1962.

17. Taussig, H.B.: Possible Injury to the Cardiovascular System from Vitamin D, *Ann Intern Med* 65:1195-1200 (Dec) 1966.

Studer-'49
Bib. No. 8793

Schweiz. Med. Wochenschr. 79(17):382-384. 1949.

From the Medical Research Division of Hoffman-La Roche & Co.A.G. Basle

On changes in the skin of the rat after large oral doses of Vitamin A

by A. Studer and J.R. Frey

Reproduced by permission
of the copyright owner

Introduction

Vitamin A has been used for a long time in the form of cod liver oil for the treatment of hemeralopia, xerophthalmia, keratomalacia, and certain skin disorders (phrynoderma). These specific vitamin A deficiencies heal in a short time with relatively small amounts of vitamin A which are contained in cod liver oil. The amounts of vitamin A necessary for the normal development vary between 5000 and 10 000 I.U. daily.

When concentrates could be produced from natural vitamin A it was possible to administer much higher doses. Vitamin A can be used in disorders where it is not necessary to cure a deficiency, but where a certain pharmacodynamic effect is to be achieved. Thus doses of 100,000 to 400,000 I.U. were given daily during several weeks in Basedow disease, hypertonia and certain skin disorders, such as Darier disease, pityrisasis rubra pilaris and ichtyosis.

The treatment of these skin diseases with vitamin A has been done heretofore strictly on an empirical basis, since a relation between vitamin A and the skin - apart from the conditions in a deficiency - could not be established. Though vitamin A deficiency can be excluded for the ethiology of above mentioned skin diseases, good results are partly achieved with high doses of vitamin A. It can therefore be assumed that vitamin A has an effect on the normal skin, though it can not yet be objectively determined.

The object of the present study is to demonstrate such an effect of vitamin A. We were led to systematic investigations by changes in the skin of the rat which we noticed in investigations of the effect of high doses of vitamin A on experimental leukopenias. (1). The investigations were facilitated by the fact that exact and high dosages with pure preparations were

possible, thanks to the synthesis of vitamin A by Isler and coworkers (2).

Test arrangement 36 white rats of both sexes, weighing 60 - 70 g, received daily per os 40,000 I.U. of a 34% concentrate of synthetic vitamin A acetate containing 1,000,000 units per cc. One of two animals were sacrificed in intervals of 1-4 days in order to examine histoligically the skin of the back and of the belly. After fixing the skin material in Bouin solution, the paraffin sections were stained with hemalum eosin. For comparison we used the skin of 15 normal rats and of 7 rats with A-avitaminosis, which had received a vitamin A deficiency diet for 8 weeks. (casein Wanter 18%, manjoca starch 54%, coconut fat 13%, salt mixture 5%, dry yeast 10%).

Macroscopic findings During the first 3 days the animals remained unchanged. On the 4th day we noticed reddening and swelling of the mouth edges, changes which soon extended to the skin of the lower jaw, neck, chest and axillas, At these points there was also a slight diffuse fall-out of hair, so that the reddened skin underneath could be seen. On the 7th day reddening and swelling increased, and the fallout of hair was complete in these areas. On the 9th day these changes reached their maximum. The animals showed at the mouth reddening, swelling and sharply defined bald centers. On the neck, chest and axillas in addition slight exsudation and crusts. Though vitamin A administration was continued, the inflammatory changes disappeared on the 12th day. Scaling appeared in the bald centers and somewhat later the hair began to grow again, first as a fine fuzz. Toward the end of the 3rd week most animals were normal again, and only a few still showed bald, scaly areas.

On the rest of the fur we noticed only minor changes during the entire test. The hair became shaggy agglutinzed on the belly and inguinal folds, and could be pulled out easier. The general condition of the animals was unchanged during the entire test. The animals were lively even during the most severe skin changes. From the 8th to the 12th day the weight curve was

somewhat flatter.

Histological findings

Notes regarding the normal skin of the rat - According to our observations, the layer thickness of the epidermis varies considerably, also the degree of hornification. Since the stratum corneum frequently splintered off with the technique used by us, we obtained from a detailed description and a photographis reproduction in order to avoid wrong conclusions. Stratum germinativum, stratum spinosum and stratum granulosum are so sharply separated from each other that the subdivision customary in the human skin is doubtful in the rat skin. But in order to be able to describe changes of the epidermis topographically, we maintained the above mentioned terms. A stratum lucidum is not visible. The most important difference with regard to the human skin is the complete absence of epithelial cones extending into the corium. Corium and epidermis show a plane contact surface (see fig. 1).

Tab. 1 Schematic representation of the epidermis thickness of the rat under different test conditions

Skin changes after treatment with vitamin A - We will not discuss the changes on the skin of the back and belly, as they appeared chronologically in the course of the test. The changes of the skin at the mouth and neck will be discussed in a later report since they are caused by contact.

Findings after:

1 x 40,000 I.U. - No finding deviating from the norm.

2 x 40,000 I.U. The epidermis shows individual circumscribed thickenings, of which fig.2 represents an example. These are formed by loosening of the entire cell structure and by a great increase of the individual cells of the stratum spinosum. We find blistery swelling of the cell body with vacuolizations which far exceed any shrinkage and deformation of the nuclei caused by fixing. The nuclear layer is stained more intensively than normal and is

visible as a dark band on the base of the epidermis. A stratum granulosum is not visible.

1 x 40,000T.I. The epidermis is thickened in its entire extension and has undergoneenormous changes which vary from animal to animal and also on the same section. The separation of the individual layers, which is difficult on the normal animals, is here easily possible. The highly eosinophile stratum corneum is not thickened to the same extent as the rest of the epidermis and can always be delimited from the clearly visible stratum granulosum. The size of the granules varies from fine granules (fig.3) to the dark large round clods. The stratum spinosum is also involved to a large extent in the widening of the epidermis. It is loosened and shows individual irregularly placed enormous, partly lixiviated nuclei. These nuclei have frequently conspicuously large nucleoli. They frequently bear on the nuclear membrane, which is particularly sharply contoured, because of the lack of chromatin in these enormous nuclei. (fig.3). Between these enormous nuclei we find low-structured zones where it cannot always be differentiated whether they consist of nuclear fragments or of protoplasm components. The nuclear layer can also be clearly defined because of its intensive staining. (fig.3) The round to oval nuclei are likewise increased, compared to the norm, the occasional stratification of the cells indicates proliferation (Nitose studies by means of colchicin (Dustin reaction) are not yet completed.) The widening of the epidermis extends also to the lining of the hair follicles whose epithelium becomes multi-layered. In the corium we find occasionally histocytic elements to a greater extent.

7 x 40,000 T.I. Slight additional widening of the epidermis. Otherwise identical results

11 x 40,000 T.I. The low-structured zone of the stratum spinosum has disappeared. The even further increased cells of the stratum germinativum can

sometimes be observed up to the stratum granulosum, which is here less pronounced.

12 - 15 x 40,000 I.U. The epidermis has become more compact. Its width begins to decrease again in some animals. In one animal, however, the epidermis of the belly skin reached enormous dimensions (fig.4), which is the more important as the belly skin is generally somewhat thinner than the back skin. The hornification varies, but it is mostly not very intensive. The cells of the stratum germinativum are impressive by their size; their cubic form is in contrast to the flat basal cells of the normal skin. Again we find large nucleiol in the large cells.

18 - 19 x 40,000 I.U. The thickness of the epidermis has generally decreased and has approached to a large extent the normal state. Qualitatively we find still irregularity in the cell structure. The basal nuclei are again flat and less numerous.

22 x 40,000 I.U. Similar finding, only slight widening of the epidermis, compared to the norm.

Notes regarding the skin of the A-avitaminotic rat We will not discuss here the known changes in the skin in vitamin A deficiency. We only want to mention here the highly atrophic epithelium, which frequently consists only of a single layer of elongated flat cells (fig.6).

Measurement of the thickness of the epidermis on the histological section

Method - In order not to confine ourselves to subjective estimates regarding the thickness of the epidermis, we made measurements with the ocular micrometer on the histological section. The stratum corneum was not included in these measurements because of the above described error possibilities. In order to obtain comparable results, we measured only the back skin and indicated the measured value in μ. They comprise thus the total thickness of stratum germinativum, stratum spinosum and stratum granulosum. Each section was measured at 4-6 points and the average was plotted as a column in a coordinate

system (see table 1).

Result - In the 14 control animals there are substantial individual differences in the thickness of the epidermis. The central column row in the table shows that the epidermis begins to thicken in the course of the treatment with vitamin A, starting from the 2nd to 3rd day, attains a maximum toward the 11th to 13th day and decreases again clearly toward the 15th day. But this great enlargement does not remain despite continued treatment with high doses of vitamin A. The measurement in the 7 A-avitaminotic animals (8 weeks on vitamin A deficiency diet) shows the finding of atrophy and indicates that the epidermis of each of these animals is substantially thinner than in the normal animals.

Other organs - Changes in the liver, spleen, kidney and skeleton system, about the pathogenesis of which we have reported elsewhere (3) are outside the framework of these considerations insofar as they were only observed occasionally and toward the end of the test. At the time of the appearance of the skin changes, the organs were not damaged, only the recitucolendothelial tissue in the liver and spleen was more pronounced. The effect of vitamin A does not extend to all epithelia; thus the urinary bladder, trachea and salivary gland show no abnormal findings.

Fig. 1 Skin, back, Magn. 1200 x Untreated rat- Cells of the stratum germination are layered flat. Individual layers can not be seen throughout.

Fig. 2 Skin rat , Magn. 1200 x Condition after 3 x 40,000 I.U. vitamin E Widening of the epidermis. Loosening of the stratum spinosum. Vacuolization and increase of the cells. Stratum germinativum greatly stained.

Fig. 3 Skin back Magn. 1200 x. Condition after 4 x 40,000 I.U. vitamin A Clear separation of the individual layers. The originally flat cells of the stratum germinativum become cubic and partly multi-layered (proliferation).

Cells of the stratum spinosum show enormous nuclei. Stratum granulosum wide with fine granulation.

Fig. 4 Skin, belly, Magn. 1200x. Condition after 15 x 40,000 I.U. vitamin A Greatest widening of the epidermis. Cells of the stratum germinativum very large. Nucleioli likewise increased. Granules of the stratum granulosum consist of large clods. Increase of the histiocytic elements in the corium.

Fig. 5 Skin, back. Magn. 1200x. Condition after 19 x 40,000 I.U. vitamin A Epidermis narrower again. Basal cells elongated and rather numerous. Above brighter cells with granulation.

Fig. 6 Skin back. Magn. 1200x. After 8 weeks of vitamin A déficiency diet. Epidermis narrowed until it is one-layered.

Discussion of the findings

As the present investigations on the rat had shown, there are generalized changes in the epidermis after oral administration of high doses of vitamin A which are histologically, qualitatively and quantitatively quite considerable, as microphotographs show. Macroscopically substantial changes (reddening, swelling, fallout of hair) appear at the mouth and on the neck down to the axillas. These changes are completely absent however, as control tests have shown, if vitamin A is injected intramuscularly. Incomplete tests on the local application of high doses of vitamin A on the skin confirm the view that the above described changes at the mouth and neck are not reactions with a predilected area characteristic of the administration of oral vitamin A, but the consequence of a contact effect of vitamin A. It is impossible to present minute quantities of the preparation from getting into the proximity of the mouth, from where they are carried further by cleaning movements of the animal.

If we look against the course of the test we are surprised at the rapid appearance of the skin changes after 3 to 4 doses of vitamin A already. The changes increase slowly up to the 116h to 13th day, to disappear again despite continued treatment. The findings observed at the end of the test after 22 days differed only insignificantly from the normal. We are thus dealing here with a sort of "habituation" which was never observed before with excess doses of vitamin A. In view of the high doses of vitamin A used, the reason does not lie in the relative reduction of the dose caused by the increase in body weight.

The skin changes by contact with vitamin A, about which we will report later, disappear in a similar manner as after oral administration. The habituation can thus not be accounted for by an increase of the resorption of the gastro-intestinal tract, we are rather dealing here with an adaptation of the epidermis cells to changed conditions. It is significant that habituation occurs in all cellular reactions.

The widening of the epidermis in the treated animal to 1½ to 3 times the normal combination with the quantitative changes proves that there is a relation between vitamin A and epidermis which was hitherto observed only on animals with vitamin A deficiency.

The skin changes appearance with total doses of vitamin A which are not yet harmful to the organism, particularly since they set in at a time (3rd to 4th day of treatment) when there is only a slight increase of Kupffer's cells of the liver in the rest of the organism.

We see the significance of the findings for the therapy in that they prove a morphologically determinable effect of vitamin A on the skin in the animal experiment. They thus help perhaps to explain the clinical successes achieved in the treatment of these skin diseases which are based exclusively on empirical findings. We are probably dealing here with a pharmacodynamic effect of vitamin A rather than with the elimination of a state of deficiency.

Summary - The effect of high doses of vitamin A on the skin of the white rat after daily oral administration of 40,000 I.U. was investigated histologically. The entire epidermis thickness, starting on the 2nd to 4th day, and attains its maximum toward the 11th to 13th day, to approach the norm again despite continued treatment with vitamin A. The thickness of the epidermis was measured with the ocular micrometer on the histological section. In the pretreated animals we find - in contrast to the controls - a widening of the epidermis by 1½ to 3 times, in the animals with vitamin A - deficiency a narrowing by half. The widening involves all layers of the epidermis and is caused by an increase and proliferation of the cells. The considerable cytological changes are described.

[illegible] wurde [illegible] insofern aus dem Rahmen dieser Befunde tungen heraus, als sie nur vereinzelt und gegen das Ende des Versuches festgestellt wurden. Im Zeitpunkt des Auftretens der Hautveränderungen liegen keine Organschädigungen vor; es wird lediglich stärkeres Hervortreten des reticuloendothelialen Gewebes in Leber und Milz beobachtet. Insbesondere erstreckt sich die Wirkung Vitamin A nicht schlechthin auf alle Epithelien; so zeigen [illegible]nblase, Trachea und Speicheldrüse keinen von der Norm abweichenden Befund.

Besprechung der Befunde

Wie die vorliegenden Untersuchungen an der Ratte ergeben haben, kommt es bei oraler Verabreichung von Vitamin A in hohen Dosen zu generalisierten Veränderungen der Epidermis, die histologisch, wie die Mikrophotographien erkennen lassen, qualitativ und quantitativ erheblich sind. Makroskopisch treten wesentliche Veränderungen (Rötung, Schwellung, Haarausfall) an der Schnauze und am Hals bis zu den Achselhöhlen in Erscheinung. Diese Veränderungen fehlen aber, wie Kontrollversuche ergeben haben, bei intramuskulärer Verabreichung von Vitamin A völlig. Noch nicht abgeschlossene Versuche über lokale Applikation hoher Dosen von Vitamin A auf die Haut bestätigen die Auffassung, daß die beschriebenen Veränderungen an Schnauze und Hals nicht für orale Verabreichung charakteristische Reaktionen mit einer Prädilektionsstelle, sondern Folgen einer Kontaktwirkung von Vitamin A sind. Es läßt sich nicht vermeiden, daß kleinste Mengen des Präparates in die Umgebung des Maules gelangen und durch Reinigungsbewegungen des Tieres weitergetragen werden.

Ueberblicken wir nochmals den Verlauf des Versuches, so erstaunt das rasche Auftreten der Hautveränderungen schon nach 3–4maliger Verabreichung von Vitamin A. Die Veränderungen nehmen bis zum 11.–13. Tag langsam zu, um dann trotz Weiterbehandlung sich wieder zurückzubilden. Die bei Versuchsabschluß, nach 22 Tagen erhobenen Befunde unterscheiden sich nur unwesentlich von der Norm. Wir haben es also mit einer Art „Gewöhnung" zu tun, die bisher bei Ueberdosierungsversuchen mit Vitamin A nie beobachtet wurde. Der Grund liegt angesichts der verwendeten hohen Dosen von Vitamin A nicht in der durch die Zunahme des Körpergewichts bedingten relativen Verminderung der Dosis.

Die Hautveränderungen durch Kontakt mit Vitamin A, über die später berichtet werden soll, klingen in ähnlicher Weise ab wie nach oraler Verabreichung. Damit kommt als Erklärung für die Gewöhnung nicht eine Abnahme der Resorption von Magen-Darm-Kanal in Frage, sondern es liegt eine Anpassung der Epidermiszellen an veränderte Verhältnisse vor. Hierbei ist als bedeutsam hervorzuheben, daß es auch bei zellulären Reaktionen zu einer Gewöhnung kommt.

Die Verbreiterung der Epidermis beim behandelten Tier auf das 1½ bis fast 3fache der Norm beweist im Verein mit den qualitativen Veränderungen, daß zwischen Vitamin A und Epidermis eine Beziehung besteht, die bisher nur am A-Mangeltier bekannt war (4, 5).

Die Hautveränderungen traten bei Gesamtdosen von Vitamin A auf, die den Organismus noch nicht schädigen, zumal sie in einem Zeitpunkt (3.–4. Behandlungstag) einsetzen, zu welchem sich im übrigen Organismus erst eine geringgradige Vergrößerung der Kupfferschen Sternzellen der Leber einstellt.

Wir erblicken die Bedeutung der erhobenen Befunde für die Therapie darin, daß sie eine morphologisch faßbare Wirkung von Vitamin A auf die Haut im Tierexperiment beweisen. Sie tragen damit vielleicht zur Erklärung der ausschließlich auf empirischer Grundlage basierenden klinischen Erfolge in der Behandlung [illegible]ser Hautkrankheiten bei. Es dürfte sich hier eher um eine pharmakodynamische Wirkung von Vitamin A als um die Behebung eines Mangelzustandes handeln.

Zusammenfassung. Die Wirkung hoher Dosen Vitamin A auf die Haut der weißen Ratte nach täglicher oraler Verabreichung von 40000 I.E. eines Konzentrates von synthetischem Vitamin-A-Acetat wurde histologisch untersucht. Es entsteht eine am 2.–4. Tag einsetzende Verdickung der gesamten Epidermis, die ihr Maximum gegen den 11.–13. Tag erreicht, um dann trotz Weiterbehandlung [illegible] Schnitt gemessen. Bei den vorbehandelten Tieren findet sich – im Vergleich zu den Kontrollen – eine Verbreiterung um das 1½ bis 3fache, bei den Vitamin-A-Mangeltieren eine Verschmälerung um die Hälfte. Die Verbreiterung erfaßt sämtliche Schichten der Epidermis und kommt durch Vergrößerung und Vermehrung der Zellen zustande. Die erheblichen cytologischen Veränderungen werden beschrieben.

1. *Studer, A.*: Experientia 4, 11, 445 (1948). – 2. *Isler, O., Huber, W., Ronco, A.*, und *Kofler, M.*: Helv. Chim. Acta 30, 1911 (1947). – 3. *Studer, A.*: 128. Jahresversammlung schweiz. naturforsch. Gesellschaft, 4.–5. September 1948, in St. Gallen. – 4. *Moult, F. A.*: Arch. Derm. (Am.) 47, 768 (1943). – 5. *Sullivan, M.*, und *Evans, V.*: J. Nutrit. 25, 319 (1943).

normal aussehen. Der Allgemeinzustand der Tiere blieb während des ganzen Versuchs unverändert. Die Tiere waren auch während der schwersten Hautveränderungen munter. Vom 8.–12. Tag wurde die Gewichtskurve etwas flacher.

Histologische Befunde

Bemerkungen zur normalen Haut der Ratte. Nach unseren Beobachtungen wechselt die Schichtdicke der Epidermis ziemlich stark, ebenso der Grad der Verhornung. Da das Stratum corneum bei der angewandten Technik oft abspliitterte, verzichteten wir, um Fehlschlüsse zu vermeiden, auf seine genaue Beschreibung und photographische Wiedergabe. Stratum germinativum, Stratum spinosum und Stratum granulosum sind so unscharf voneinander getrennt, daß die Berechtigung der bei der menschlichen Haut üblichen Unterteilung an der Rattenhaut angezweifelt werden kann. Um jedoch Veränderungen der Epidermis topographisch beschreiben zu können, haben wir an den genannten Begriffen festgehalten. Ein Stratum lucidum ist nicht sichtbar. Der wohl wesentlichste Unterschied zur menschlichen Haut besteht im vollständigen Fehlen epithelialer Zapfen in das Corium; Corium und Epidermis zeigen eine ebene Berührungsfläche (siehe Abb. 1).

Hautveränderungen nach Behandlung mit Vitamin A. Im folgenden wird auf die Veränderungen der Rücken- und Bauchhaut eingegangen, wie sie chronologisch im Verlaufe des Versuches entstanden sind. Die Veränderungen der Haut der Schnauze und des Halses werden, da sie durch Kontaktwirkung entstehen, in einer späteren Arbeit behandelt werden.

Befunde nach:

1mal 40000 I.E.: Kein von der Norm abweichender Befund.

3mal 40000 I.E.: Die Epidermis zeigt einzelne umschriebene Verdickungen, von denen Abb. 2 ein Beispiel wiedergibt. Diese entstehen durch Auflockerung des ganzen Zellgefüges und durch starke Vergrößerung einzelner Zellen des Stratum spinosum. Es handelt sich um blasige Auftreibungen des Zelleibes mit Vacuolenbildungen, die eine durch Fixierung bedingte evtl. Schrumpfung und Formveränderung der Kerne weit übertreffen. Die Keimschicht färbt sich intensiver als normal und ist als dunkles Band an der Basis der Epidermis erkennbar. Ein Stratum granulosum ist nicht sichtbar.

4mal 40000 I.E.: Die Epidermis ist in ihrer ganzen Ausdehnung verdickt und hat gewaltige Umänderungen erfahren, die sowohl von Tier zu Tier als auch am gleichen Schnittpräparat mannigfaltig wechseln. Die an der normalen Haut schwierige Abgrenzung der einzelnen Schichten gelingt hier leicht. Das stark eosinophile Stratum corneum ist nicht in gleichem Maße verdickt wie die übrige Epidermis und stets gegen das deutlich in Erscheinung tretende Stratum granulosum abgrenzbar. Die Größe der Granula wechselt von feinen Körnchen (Abb. 3) bis zu sehr dunkel gefärbten großen, runden Schollen. An der hochgradigen Verbreiterung der Epidermis ist das Stratum spinosum ebenfalls beteiligt. Es ist aufgelockert und zeigt einzelne, unregelmäßig gelagerte, riesige, z. T. ausgelaugte Kerne. Solche Kerne haben oft auffallend große Nucleoli. Diese liegen häufig der Kernmembran an, die infolge der Chromatinarmut des Kernes besonders scharf konturiert ist (Abb. 3). Zwischen diesen riesigen Kernen finden sich strukturarme Zonen, bei denen nicht immer differenziert werden kann, ob sie aus Kerntrümmern oder Protoplasmabestandteilen bestehen. Stets ist die Keimschicht infolge ihrer starken Färbung deutlich abgrenzbar (Abb. 3) Die rundlichen bis ovalen Kerne sind gegenüber der Norm ebenfalls vergrößert, die gelegentliche Mehrschichtigkeit der Zellen weist auf Proliferation hin[8]). Die Verbreiterung der Epidermis erstreckt sich auch auf die Auskleidung der Haarfollikel, deren Epithel mehrschichtig wird. Im Corium sind da und dort histiocytäre Elemente vermehrt anzutreffen.

7mal 40000 I.E.: Geringe weitere Verbreiterung der Epidermis. Sonst gleiche Befunde.

11mal 40000 I.E.: Die strukturarme Zone des Stratum spinosum ist verschwunden. Die noch mehr vergrößerten Zellen des Stratum nukosum verfolgen, das hier weniger eindrucksvoll ausgebildet ist.

12–15mal 40000 I.E.: Die Epidermis ist kompakter geworden. Ihre Breite beginnt bei einzelnen Tieren bereits wieder etwas abzunehmen. Bei einem Tier allerdings erreicht die Epidermis der Bauchhaut enorme Ausmaße (Abb. 4), was um so mehr ins Gewicht fällt, als die Bauchhaut im allgemeinen etwas dünner als die des Rückens ist. Die Verhornung wechselt, ist aber meist noch besonders intensiv. Die Zellen des Stratum germinativum imponieren durch ihre Größe; ihre kubische Form steht im Gegensatz zu den flachen basalen Zellen der normalen Haut. Wieder sind in den mächtigen Zellen des Stratum spinosum große Nucleoli erkennbar.

18–19mal 40000 I.E.: Die Dicke der Epidermis hat allgemein abgenommen und sich weitgehend dem Normalbefund genähert. Qualitativ ist vielfach noch eine Unregelmäßigkeit im Zellaufbau festzustellen. Die basalen Kerne sind wieder flach gelagert und weniger zahlreich (Abb. 5).

22mal 40000 I.E.: Aehnlicher Befund, nur noch geringe Verbreiterung der Epidermis im Vergleich zur Norm.

Bemerkungen zur Haut der Vitamin-A-Mangelratte. Auf die bekannten Veränderungen der Haut bei Vitamin-A-Mangel soll hier nicht eingegangen werden. Es sei nur auf das stark atrophische Epithel, das vielfach bloß aus einer einzigen Zellage langgestreckter, flacher Zellen besteht, hingewiesen (Abb. 6).

Messung der Dicke der Epidermis am histologischen Schnitt

Methode. Um es bezüglich der Schichtdicke der Epidermis nicht bei subjektiven Schätzungsangaben bewenden zu lassen, wurden am histologischen Schnitt Messungen mit dem Okularmikrometer vorgenommen. In diese Messungen wurde wegen der bereits besprochenen Fehlermöglichkeiten das Stratum corneum nicht mit einbezogen. Um vergleichbare Resultate zu erhalten, haben wir ausschließlich die Rückenhaut gemessen und die ermittelten Werte in μ angegeben. Sie umfassen also die Gesamtdicke von Stratum germinativum, spinosum und granulosum. Jeder Schnitt wurde an 4–6 Stellen gemessen und der Durchschnitt als Säule in einem Koordinatensystem aufgetragen (siehe Tab. 1.)

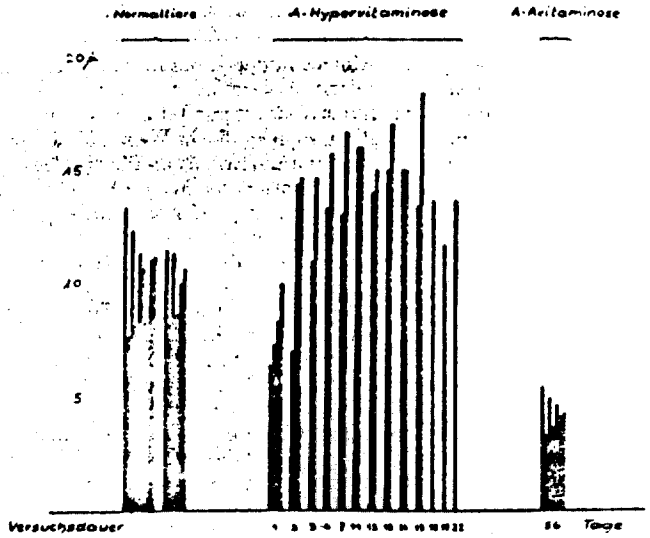

Tab. 1. Schematische Darstellung der Epidermisdicke der Ratte unter verschiedenen Versuchsbedingungen.

Ergebnis. Bei den 14 Kontrolltieren bestehen in der Dicke der Epidermis wesentliche individuelle Unterschiede. Die mittlere Säulenreihe der Tabelle läßt erkennen, daß die Epidermis im Verlauf der Behandlung mit Vitamin A vom 2.–3. Tag an dicker wird, gegen den 11.–13. Tag hin ein Maximum erreicht und gegen den 15. Tag hin wieder deutlich abfällt. Die starke Verbreiterung bleibt also trotz Weiterbehandlung mit hohen Dosen Vitamin A nicht bestehen. Die Messung bei den 7 A-avitaminotischen Tieren (8 Wochen auf Vitamin A-Mangelkost) gibt den Befund der Atrophie wieder und zeigt, daß die Epidermis jedes dieser Tiere wesentlich dünner ist als beim Normaltier.

Andere Organe. Veränderungen von Leber, Milz, Niere und Skelettsystem, über deren Pathogenese von uns (3) an anderer Stelle

[8]) Nitosestudien mittels Colchicin (Dustin-Reaktion) sind noch nicht abgeschlossen.



Abb. 1. Haut. Rücken. Vergr. 1200fach. Unbehandelte Ratte. – Zellen des Stratum germinativum sind flach gelagert. Einzelne Schichten sind nicht durchwegs erkennbar.



Abb. 2. Haut, Rücken. Vergr. 1200fach. Status nach 3mal 40000 I. E. Vitamin A. – Verbreiterung der Epidermis. Auflockerung des Stratum spinosum. Vakuolisierung und Vergrößerung der Zellen. Stratum germinativum stark angefärbt.

Abb. 3. Haut, Rücken. Vergr. 1200fach. Status nach 4mal 40000 I. E. Vitamin A. – Deutliche Abgrenzung der einzelnen Schichten. Die vorher flach gelagerten Zellen des Stratum germinativum werden kubisch und z. T. mehrschichtig (Proliferation). Zellen des Stratum spinosum zeigen riesige Kerne. Stratum granulosum breit mit feiner Granula.



Abb. 4. Haut, Bauch. Vergr. 1200fach. Status nach 15mal 40000 I. E. Vitamin A. – Stärkste Verbreiterung der Epidermis. Zellen des Stratum germinativum sehr groß. Nucleoli ebenfalls vergrößert. Granula des Stratum granulosum bestehen aus groben Schollen. Vermehrung der histiocytären Elemente im Corium.

Abb. 5. Haut, Rücken. Vergr. 1200fach. Status nach 19mal 40000 I. E. Vitamin A. – Epidermis wieder schmäler. Basale Zellen langgestreckt und weniger zahlreich. Darüber aufgehellte Zone mit Granula.



Abb. 6. Haut, Rücken. Vergr. 1200fach. Nach 8 Wochen auf Vitamin-A-Mangelkost. – Verschmälerung der Epidermis bis zur Einschichtigkeit.

Acta Anat. 71:403-422. 1968.

Studer-Marxer-'68
Bib. No. 8797

HISTOLOGICAL AND HISTOCHEMICAL STUDIES ON THE INFLUENCE OF VITAMIN A DEFICIENCY AND OVERDOSAGE ON THE ENDOMETRIUM OF SEXUALLY MATURE RATS

Introduction

In the literature on changes in sexually mature rats due to vitamin A deficiency or overdosage, no differences worth mentioning have been described in the area of the female genital tract as compared to that of control animals.

But, according to the findings of Geiger on the ovaries of sexually mature rats under the influence of hypovitaminosis and hypervitaminosis, differences were present in the sequence of the cyclic changes as well as in the intensity of histochemical reactions.

We therefore decided to study the endometrium of rats during vitamin A deficiency and overdosage by histological and histochemical methods.

Material and Technique

For our tests we had at our disposal 78 female rats from the same test series that Geiger had used. (Table 1) Only such animals were used that had once previously born a litter. The control animals and the animals with hypervitaminosis received normal food (Z lol +Z 102 by Hoffmann-LaRoche) and lettuce. The hypervitaminosis was attained by administering to the animals on three consecutive days so much vitamin A acetate in peanut oil per os that liver storage values between 40-50,000 I.U. were registered, corresponding to a definite hypervitaminosis. Thereupon they were mated. Vitamin A avitaminosis was achieved by using the diet described by Milicic. At the appearance of definitive deficiency symptoms, the animals were mated.

When, after the mating, sperm could be detected in the vaginal smears, the animals were killed by either narcosis between 10 and 110 hours after ovulation (See table 1).

Immediately after death, we fixed a caudal piece of the left uterus horn of each animal in Carnoy solution. Then we embedded it in the usual fashion

over methyl benzoate in paraffin. We prepared a continuous series of 800 - 1000 cuts of 7 μ thickness from each block. We stained these cuts alternatingly by the following methods: Azane, silver impregnation according to Gomory for the representation of argyrophilic fibers, PAS reaction, methyl-green-pyronine, and glycogen reaction according to Bauer.

A caudal piece of the right uterus horn of each animal was frozen in dry ice and cryostate cuts of 10 μ thickness prepared. On these we performed the following histochemical reactions:

1. Alkaline phosphatase: alpha-naphthyl phosphate, echtrotsalz TR, 0.1 m veronal buffer pH 9.2, 10% magnesium sulfate.

   30 minutes incubation time at room temperature (20-25°C)

2. Acid phosphatase: alpha-naphthyl phosphate, echtrotsalz ITR, 0.1 m acetate buffer pH 6.5

   Incubation of the cuts 60 minutes at room temperature (20-25°C)

   The sections for both phosphatase reactions were prefixed for 20 minutes in formol-dextran.

3. DPNH-diaphorase: MTT, 0.5 m cobalt chloride, 0.2 m trisbuffer pH 8.0 polyvinyl pyrrolidone (PVP), reduced diphosphopyridinium nucleotide (DPNH), and amytal

   60 minutes incubation at 37°C. Afterfixation of the sections for 20 minutes in formol-dextran.

The specimens were photographed immediately after performing the reaction. The following stain tests were performed on the cryostat sections: Hemalaun-benzopurpurin and methylgreen-pyonin after fixation of the sections or 20 minutes in 96% alcohol. Fat stain with Sudan black B after 20 minutes fixation in 4% formol solution: the nuclei were counterstained with kernecht red.

I. Histological Findings

1. Uterus Lumen

In cross section, the uterus cavity lies excentrically, usually it is mesometrically displaced. Its lumen is narrow and it has differently shaped folds and diverticula. These flatten somewhat at 20 hours after ovulation. At the age of 80 to 90 hours there are distinctive strong local dilations of the uterus cavity of the control animals which extend over approximately 1.5 to 2 mm. In these places, the surface smoothness, and changes in the epithelium become visible. These local dilations of the lumen are still present 105/110 hours after ovulation.

The uterus lumina of hypervitaminotic animals showed such dilations only 110 hours after the follicle break. Among deficiency animals, such dilations could only be detected in a single specimen (105 hours after ovulation).

2. Lumen Epithelium

Control Animals

The uterus lumen is lined with a single layer cylinder epithelium. Its height decreases between 10 and 40 hours and remains constant during later stages. The nuclei are basally positioned. Degenerated nuclei and mitotic stages are found towards the lumen. Mitotic activity has reached its peak at the age of 30/40 hours and then decreases again. The cytoplasm of the epithelium cells shows an even intensive basophilia with the methylgreen-pyronin stain.

The epithelium is infiltrated by leucocytes. Their number decreases with increasing age. Only sporadic leucocytes are present 80 hours after the follicle break, none after 110 hours. Conspicuous are the giant nucleus-size vacuoles which appear about 15 hours after ovulation in the apical epithelial zone and which have disappeared again after 30 hours. (Fig. 1). At later stages (80-110 hours after ovulation) an edging of small vacuoles is

visible basally in some places.

The uterus areas with conspicuously widened lumen are lined with a single-layer plate epithelium.

The basal membrane is smooth up to 50 hours after ovulation. Later, the epithelium is intermeshed with the subepithelian connective tissue.

Animals with Vitamin A Overdosage

The difference with the control animals is only slight. Most of the time,the uterus epithelium of hypervitaminotic animals is slightly higher than that of the controls. This is most obvious 10-20 hours after the follicle rupture; however, in later stages the difference diminishes again. Mitotic activity is more intensive than in the controls. 80 hours after the follicle rupture, there are still a few mitoses in the epithelium, while none are present any more in the control animals.

Leucocyte infiltration is lower for the whole group. Aftter only 80 hours, no leucocytes can be detected in the epithelium. The apical vacuoles in the epithelium cell which appear in the controls at 10-15 hours after ovulation are more numerous and larger in the hypervitaminotic animals. After 20 hours they are still clearly visible (See fig. 1), but at 30 hours after follicle rupture, they have disappeared as they have in the control animals. The small basal vacuoles appear much earlier (30-40 hours after ovulation). The intermeshing of epithelium and subepithelian connective tissue takes place already at 40 hours after ovulation.

Animals with Vitamin A Deficiency

The lumen epithelium is of variable height, the cells are lower than in the controls. The number of mitoses is considerably lower than in the hypervitaminotic, most of the time also smaller than in the control animals. There are still sporadic mitoses present in the uterus epithelium 80 hours after ovulation. Leucocyte infiltration is considerably stronger, and frequently

leucocytes are also found in the uterus lumen.

In deficiency animals too, large vacuoles can be recognized around 15 hours apically in the epithelium cells, but they are smaller and less numerous than in the control and hypervitaminotic animals (See fig. 1). In one case (R 780) these vacuoles still exist 30 hours after the follicle rupture. The small basal vacuoles appear after 60 hours.

3. Connective tissue

In all three groups, the connective tissue of the endometrium shows two layers which blend into each other:

1. A subepithelian stratum rich in nuclei and

2. a peripheral stratum with fewer cells and more copious fibrous material. The thickness of the subepithelian layer increases between 10 and 60 hours after ovulation and then remains constant. It is narrower mesometrically than antimesometrically. Throughout the whole test series, the subepithelial connective tissue cells are more strongly basophilic than the cells of the peripheral endometrium. Initially, the subepithelian cells are small, oblong, and narrow, Around 55/60 hours, large cells appear with large roundish nuclei which contain 1-2 nucleoli. These large elements increase in number and displace the smaller connective tissue cells. The number of free cells varies.

4. Blood Vessel Supply

The arrangement of the capillaries in the endometrium is essentially identical in all three groups. They are somewhat more numerous and of wider lumen subepithelially than towards the myometrium (Fig. 2).

The endometrium of the animals with an overdose of vitamin A shows severe hyperemia. The capillaries are more numerous and wider than in the controls.

There is no such obvious difference for the deficiency animals as for the hypervitaminotic animals. The subepithelian blood vessel supply corres-

ponds to that of the controls. The vessels are somewhat more sparse in the peripheral endometrium. Only around sites of inflammation are they numerous and strongly dilated.

5. Glands

Control Animals

The glandular ducts lie predominantly in the antimesometrical section. The change in lumen of the group from 10 to 110 hours after ovulation is striking: At 10 hours, the glands have a wide lumen lined with a single layer cubic epithelium. (Fig. 4). Already at 30 hours their lumen becomes narrower and their epithelium higher. From 65 hours on, the glandular lumina can hardly be recognized any longer. The epithelium has become single-layer, low-cylindrical (Fig.5). Its height increases yet a little up to 90 hours. Mitoses in the epithelium appear during the narrowing of the gland lumina. They are most frequently found at 30/40 hours after the follicle rupture.

With methylgreen-pyronin, the gland epithelia stain a weaker red than the lumen epithelia. Between 10 and 55 hours, an even read stain of the cytoplasm of the gland cells can be observed, and from 65 hours on, a distinct basophilia (Fig.4 and 5).

Only in very early stages (10/15 hours after ovulation) can leucocytes be found in the glandular lumen as well as in the epithelium and the surrounding connective tissue.

Animals with Vitamin A Overdosage

The same processes as in the controls can be observed in hypervitaminotic animals. The glands have a slightly wider lumen. Only around 80 hours after the follicle rupture are the glandular lumina hardly recognizable.(Fig. 6). The epithelium is correspondingly single-layer cubic or cylindrical. The highest mitotic activity occurs around 30/40 hours after ovulation. At 60 hours, the mitoses are visible only in cross sections with wide lumina. Except at 10

hours, no leucocytes are present in the epithelium, and they are less numerous than in the control animals.

Animals with Vitamin A Deficiency

Frequently, fewer gland canals are encountered in the section than in the control and hypervitaminotic animals. Their lumina are of varying width, often more strongly dilated than in hypervitaminotic animals. The epithelium is of irregular height. Only few mitoses are present. Leucocytes, however, are much more numerous. In nearly all cases there are sites of inflammation of varying size. In part, this involves only cell infiltration of the glands, in part, the glandular ducts are strongly dilated, and cell necroses and cell debris are found in the surrounding connective tissue. The capillaries surrounding the sites of inflammation are strongly dilated (Fig. 7 and 8).

6. PAS Reaction

In the PAS reaction, the basal membrane stains a weak red. A weak red edge is visible in the apical area of the gland and lumen epithelia.

This reaction is somewhat stronger in hypervitaminotic animals, while no differences can be observed between control and dificiency animals.

II Histochemical Findings

1. Alkaline Phosphatase

Control Animals

The alkaline phosphatase activity is mainly restricted to the apical cell third of the lumen and gland epithelium. It shows in the form of a reddish-brown granular edge. In the cytoplasm of the lumen epithelium, the granula are very sparse and diffuse. The nuclei are negative. The reaction of the gland epithelium is weaker the granular edge narrower than in the lumen epithelium. Since granula can be discerned at the cell boundary of the gland cells. The capillaries of the endometrium react very strongly positive (Fig. 9b).

From 10-110 hours after ovulation, the lumen epithelium shows a definitive

decrease of alkaline phosphatase activity. Up to 85 hours, a continuous apical granular edge can be detected everywhere, while later on the reaction is only visible in spots, and may even be negative. The granula diffused in the cytoplasm of the epithelium cells disappear already at 60 hours after the follicle rupture. The activity of the gland epithelia does not decrease at the same speed as that in the lumen epithelium. The gland epithelium cells remain weakly positive until 110 hours after ovulation.

Animals with Vitamin A Overdosage

The sections show a similar result and the same granula distribution as the sections from the control animals. But the activity in the lumen as well as in the gland epithelium cells is noticeably reduced. The reaction of the capillaries, however, remains equally strongly positive (See fig. 9a and 9b) as in the control animals.

Animals with Vitamin A Deficiency

The reaction with equal incubation time is more strongly positive than with the control animals. Here too, the granula distribution remains the same. Especially obvious is the increase in activity in the lumen epithelium, somewhat less so in the gland epithelium. After 60/65 hours after the follicle rupture, many granula can still be recognized in the cytoplasm of the lumen epithelium. The reaction of the capillaries remains very strongly positive (See Fig. 9a, 9b and 9c).

2. Acid Phosphatase

Control Animals

The test for acid phosphatase is much weaker than that for alkaline phosphatase.

The acid phosphatase activity is negative up to 35 hours after ovulation, then becomes positive and increases slowly in intensity with increasing number of hours. It shows in the lumen epithelium as a weak, narrow, apical granular

edge. The reaction is strinctly limited to the apical epithelium area. The reaction of the gland epithelia is still weaker than that of the lumen epithelium. Here too, the granula are found predominantly in the apical position. The capillaries are weakly positive.

Animals with Vitamin A Overdosage

The sections from the hypervitaminotic animals react more strongly positive than those of the controls. The intercellular distribution of the granula, however, remains the same as in the latter.

An increase in the activity in the lumen epithelium can already be observed from 20 hours on. 60 hours after ovulation, a definitive decrease of the reaction can be observed which is then again followed by an increase in activity. At 105/110 hours, the reaction is again somewhat diminished. The reaction in the gland epithelium is always weaker than in the lumen epithelium. It is also strongest in the apical area.

Animals with Vitamin A Deficiency

The reaction is less strongly positive than in the controls. Up to 55 hours after the follicle rupture, we find mostly a negative in spots a rather weakly positive reaction in the lumen and gland epithelium. From 60-90 hours, the activity in the lumen epithelium increases somewhat, but then decreases again at 105-110 hours. The reaction in the gland epithelium between 60 and 90 hours is equally strong as in the lumen epithelium and then also decreases at 105/110 hours after ovulation.

3. DPNH-Diaphroase

Animals with Vitamin A Overdosage

The granula remain in the same arrangement from 10 to 110 hours after the follicle rupture. In the lumen epithelium cells, they are distributed through the whole cytoplasm and form basally an increasingly positive edge (Fig. 10a). In the gland epithelium cells, they are evenly distributed

throughout the whole cell, but their activity is lower than in the lumen epithelium. 80/85 hours after ovulation, the enzyme activity increases noticeably, with the reaction in the gland epithelium much more intensive than in the lumen epithelium.

Animals with Vitamin A Deficiency

The distribution of the granula remains the same as in the hypervitaminotic animals, the difference is only one of intensity.

Up to 55 hours after ovulation, the activity in all parts is weaker than with the hypervitaminotic animals. At 60/65 hours, however, the sections react moch more strongly positive. The granula appear in the whole cytoplasm of the lumen epithelium cells, a basal edge shows only indistinctly. Between 80 and 110 hours after the follicle rupture, the intensity of the reaction diminishes again, it is again weaker than in the animals with vitamin A overdosage (See fig. 10a and 10b).

Analysis of the Findings and Discussion

The most conspicuous findings on the control animals is the widening of the uterus lumen at 80-90 hours after ovulation, the lowering of the lumen epithelium from 10 to 60 hours, the leucocyte infiltration between 10 and 80 hours, and the large mitotic activity 30/40 hours after the follicle rupture. The glands have initially a very wide lumen, develop a narrow lumen 60 hours after ovulation, with a simultaneous increase in the height of their epithelium. Cell elements with large nuclei appear in the connective tissue and displace the long, narrow fibrocyte cells. Our results agree substantially with the findings of different other research scientists.

The alkaline phosphatase content in the apical area of the lumen epithelium and the disappearance of the activity up to 110 hours after ovulation have also been described, in agreement with our findings, by Pritchard, as well as Wislicki and Dempsey. Pritchard also determined that the activity disappears

from the gland epithelium only about 20 hours later than from the lumen apithelium.

The tests for acid phosphatase indicated a very slight increase of the reaction intensity in the lumen epithelium of the control animals from 40 hours on. A similar observation in the literature is not known to us.

There are no major differences between the animals with vitamin A overdosage and the controls. The course of the normal processes in the endometrium between ovulation and implantation appears to be delayed by 10-20 hours. The widening of the uterus lumen is only observed at 110 hours after the follicle rupture, which might possibly cause delayed implantation. The epithelium is somewhat higher and the mitotic frequency larger. Mitoses can still be found in the epithelium at 80 hours after ovulation. Also, the cross sections of the glands narrowed 10 - 20 hours later than those of the control animals. Noteworthy is the hyperemia of the endometrium. Studer and Winkelmann have found in cases of hypervitaminosis A also a general hyperemia of kidney and spleen. however, not of the endometrium.

The test for alkaline phosphatase in the hypervitaminotic animals is weaker than in the controls. This contradicts the increase of activity, described in the literature, in the brush edge of the principal body of the kidney and the epithelium of the small intestine, in spleen, bone marrow, the interlobular structures of the liver, and in the serum in the cases of vitamin A overdosage. Acid phosphatase gives a very weak reaction in vitamin A hypervitaminosis. The DPNH-diaphorase reaction is considerably more intensive than in deficiency animals.

The most obvious findings in the endometrium of animals with vitamin A deficiency are: The absence of the dilations of the uterus lumen, a lower epithelium, fewer mitoses, and a strong infiltration by leucocytes in lumen epithelium and connective tissue. We could not detect in our specimens any

appearances of thickening of the epithelium and subepithelial sites of degenerating cells as described by Wolback and Howe and Cramer. Noteworthy are the many sites of inflammation issuing from the glandular ducts in the endometrium. Similar observations have been described by Tyson and Smith on the tongue, the salivary glands, and the pancreas of rats. These research scientists found in those organs a dilation of the glandular ducts as well as a metaplasis of the epithelium, accompanied by inflammations of their exit tubes. Follis observed sites of infection in gravid rats at the transition places between maternal and infantile tissue, and also degenerating cells. These observations on animals with a short term vitamin A-free diet leave the question unanswered if the frequently mentioned thickening of the epithelium might not be a tissue reaction to these manifestations of inflammation.

The rise in alkaline phosphatase activity in animals on a vitamin A free diet is also apparent in the endometrium. The same observation was made by Baur on liver, intestine, kidney bone marrow, serum, and by Milicic on the kidney. The reaction for acid phosphatase is weaker than in the controls, and the DPNH-diaphorase reaction is mostly less intense.

Our results can be seen as a confirmation of the opinion that the fat soluble vitamins act mainly on the cell membranes and their permeability. The question may therefore be asked if these membrane properties of vitamin A may not have a delaying influence on the cyclic processes in the endometrium and on the implantation.

An interrelation may also be caused by the influence of vitamin A on the steroid hormone producing cells in the ovary. Supporting this theory is the fact that the activity of the unspecific esterases in the endometrium of the guinea pig decreases when the animals have previously been treated with estrogen-gestagen combinations. This finding resembles the decrease of the alkaline phosphatase reaction which we observed in animals with vitamin A overdosage.

Further research is planned to clarify these interrelations.

SUMMARY

A description is given of the histological and histochemical changes occurring in the endometrium of female rats suffering from an overdose or deficiency of vitamin A during the first 110 hours of pregnancy.

In the animals with hypervitaminosis, a delay in the endometrical processes of 10-20 hours as compared with the control animals was observed. Tissular hyperemia was also evident. The reaction for alkaline phosphatase in the endometrium was weaker, unlike the histochemical reactions in the other organs and the serum, while there was an increase in acid phosphates activity compared with the vitamin deficient animals.

In the vitamin A deficient animals, the strong leucocyte infiltration and the large number of sites of inflammation were particularly noticeable, while no thickening of the epithelium was observed. Alkaline phosphatase reaction was noticeably more intense than in the control animals, while the reaction for acid phosphatase and DPNH-diaphorase was very weak.

Figure 1 a-c

rat uterus, cross section 15 hours after ovulation, 7 μ Azane, magnification 360x. - a) Hypervitaminosis A R 730, sedion 13/2/3.- b) control . R 608, section 7/5/4. - c) Hypovitaminosis A. R 757, section 3/5/1. PAS reaction. Observe that the vacuoles in the apical area of the lumen epithelium are larger in the hypervitaminotic animals than in the controls 15 hours after ovulation. Only sporadic small vacuoles are visible in the animals with vitamin A deficiency.

Figure 2

Rat uterus, cross section, R 603. control, 65 hours after ovulation, 7 μ, PAS reaction, section 3/5/5 magnification 90x. Survey photograph for distribution of vessels in connective tissue of the endometrium in a

control animal. No capillaries with unusually wide lumen visible in section.

Figure 3

Rat uterus, cross section. R 733a. hypervitaminosis A 15 hours after ovulation, 7 μ. PAS reaction, section 3/5/2. Magnification 110 x

Observe the numerous, strongly dilated vessels in the connective tissue of the endometrium of hypervitaminotic animals.

Figure 4

Rat uterus, cross section, R 611, control, 11 hours after ovulation 7 μ methylgreen-pyronin, section 4/8/2 magnification 160x.

The glandular lumina are dilated, the epithelium is single-layer cubic. The cytoplasm of the glandular epithelium is evenly stained.

Figure 5

Rat uterus, cross section, R 603, control, 65 hours after ovulation, 7 μ methylgreen-pyronin, section 4/4/4, magnification 160 x.

The glandular ducts have collapsed, the epithelium has become single-layer cylindrical. It is obvious that the glandular epithelium cells are more strongly stained basically than apically.

Figure 6

Rat uterus, cross section, R 756, hypervitaminosis A, 65hours after ovulation, 7 μ, methylgreen-pyronin, section 10/5/3 magnification 160 x.

In hypervitaminotic animals the gland lumina are still very visible 65 hours after ovulation. In the gland cross sections with wide lumen, the epithelium is single-layer cubic, in those with narrow lumen, cylindrical.

Figure 7

Rat uterus, cross section, R 764, hypovitaminosis A, 65 hours after ovulation, 7 μ, section 16/7/1, methylgreen-pyronin magnification 270x.

Dilated gland cross section with flattened epithelium. The lumen is tightly packed with leucocytes.

Figure 8

Rat uterus, cross section, R 733, hypovitaminosis A, 90 hours after ovulation, 7 μ, PAS reaction, section 9/7/5, magnification 160 x.

Site of inflammation in deficiency animal. Gland epithelium not everywhere recognizable. Strong leucocyte infiltration into the connective tissue surrounding the site of inflammation.

Figure 9 a-c

Rat uterus, cross section, 10 hours after ovulation, alkaline phosphatase, 10 μ, magnification 150x a) R 738, hypervitaminotic animal.- b) R 607, control animal c) R 767 Vitamin A deficiency animal. Observe the difference of intensity, especially in the lumen epithelium.

Figures 10 a and b

Rat uterus, cross section 105 hours after ovulation. DPNH-diaphroase reaction, 10 μ, magnification 150x a) R 748, hypervitaminotic animal b) R 760, hypovitaminotic animal.

The more strongly positive reaction with equal distribution of granula is clearly recognizable in figure 10a.

Table I

number of hours after ovulation	number of animals per group		
	controls	A overdosage	A deficiency
10 - 11 h	2	3	2
15 h	2	3	2
20	1	1	1
32 - 35	3	3	3
40	2	2	2
57		1	1
60		4	2
63 - 65	3	3	2
80 - 81	1	3	2
85		1	3
90		1	1
104-106	4	4	2
108-111	2	4	1
Number of animals per test series	20	33	25

(Translated by Carl Demrick Associates,Inc/CG/t)

Studer-Marxer-'68
Bib. No. 8797

Acta anat. 71: 403–422 (1968)

Abteilung Anatomie der Rheinisch-Westfälischen Technischen Hochschule
Aachen, Deutschland
Vorstand: Prof. Dr. K. S. Ludwig
und
Anatomisches Institut der Universität Basel, Schweiz
Vorsteher: Prof. Dr. Dr. G. Wolf-Heidegger

Histologische und histochemische Untersuchungen über den Einfluß von Vitamin-A-Mangel und -Überdosierung auf das Endometrium geschlechtsreifer Ratten[1]

URSULA STUDER-MARXER

Einleitung

In der Literatur über die bei Vitamin-A-Mangel und -Überdosierung auftretenden Veränderungen bei geschlechtsreifen Ratten werden im Bereich des weiblichen Genitaltraktes keine nennenswerten Unterschiede zu denjenigen von Kontrolltieren beschrieben (PARKES and DRUMMOND [1925], MASON [1935], ZBINDEN und STUDER [1958]).

Nach den Befunden von GEIGER [1968] am Ovar von geschlechtsreifen Ratten unter dem Einfluß von Vitamin-A-Mangel und -Überdosierung zeigen sich aber Unterschiede sowohl im Ablauf der zyklischen Veränderungen als auch in der Intensität von histochemischen Reaktionen.

Daher haben wir uns die Aufgabe gestellt, das Endometrium von Ratten bei Vitamin-A-Mangel und -Überdosierung histologisch und histochemisch zu untersuchen.

Material und Technik

Für unsere Versuche standen uns aus der gleichen Versuchsserie, wie sie auch GEIGER [1968] benützt hat, 78 geschlechtsreife weibliche Ratten zur Verfügung (Tab. I). Es wurden nur Tiere verwendet, die schon einmal Junge geworfen hatten. Die Kontrolltiere und die Tiere mit Vitamin-A-Überdosierung erhielten normales Standardfutter (Z 101 + Z 102 der Firma F. Hoffmann-La Roche) und Salat. Die Vitamin-A-Überdosierung wurde erreicht, indem man den Tieren an 3 aufeinanderfolgenden Tagen soviel Vitamin-A-acetat in 0,5 ml Arachisöl *per os* verabreichte, daß Leberspeicherwerte zwischen 40–50 000 I. E. Vitamin A festgestellt werden konnten, was einer ausgesprochenen Hypervitaminose entspricht; darauf paarte man sie. Zum

[1] Mit Unterstützung durch eine Forschungsbeihilfe der Firma F. Hoffmann-La Roche & Co. AG, Basel, der wir ebenfalls für die Überlassung der Tiere sowie deren Wartung und Pflege unseren besten Dank aussprechen möchten.

Erreichen der Vitamin-A-Avitaminose wurde die gleiche Diät benützt, wie sie MILIČIĆ [1962] beschrieben hat. Bei Anzeichen von deutlichen Mangelerscheinungen paarte man die Tiere.

Wenn nach der Paarung in den Vaginalausstrichen Spermien nachzuweisen waren, wurden die Tiere zwischen 10 und 110 Stunden nach der Ovulation in Äthernarkose getötet (vgl. Tabelle I).

Sofort danach fixierten wir von jedem Tier ein kaudales Stück des linken Uterushornes in Carnoy-Lösung. Dann betteten wir diese in der üblichen Weise über Methylbenzoat in Paraffin ein. Von jedem Block stellten wir eine lückenlose Serie von 800–1000 Schnitten von 7μ Dicke her. Die Schnitte färbten wir alternierend nach folgenden Methoden: Azan, Silberimprägnation nach Gömöri zur Darstellung der argyrophilen Fasern, PAS-Reaktion, Methylgrün-Pyronin und Glykogen-Reaktion nach Bauer.

Ein kaudales Stück des rechten Uterushornes von jedem Tier froren wir mit Kohlensäureschnee ein und stellten davon Kryostatschnitte von 10μ Dicke her. An diesen führten wir folgende histochemische Reaktionen durch:

1. Alkalische Phosphatase: α-Naphthylphosphat, Echtrotsalz TR, 0,1 m Veronalpuffer pH 9,2, 10 % Magnesiumsulfat.

Inkubation während 30 min bei Zimmertemperatur (20–25° C).

2. Saure Phosphatase: α-Naphthylphosphat, Echtrotsalz ITR, 0,1 m Acetatpuffer pH 6,5.

Inkubation der Schnitte während 60 min bei Zimmertemperatur (20–25°C).

Die Schnitte für beide Phosphatase-Reaktionen wurden 20 min in Formol-Dextran vorfixiert.

3. DPNH-Diaphorase: MTT, 0,5 m Cobaltchlorid, 0,2 m Trispuffer pH 8,0, Polyvinylpyrrolidon (PVP), reduziertes Diphosphopyridinnucleotid (DPNH) und Amytal.

Tabelle I

Anzahl Stunden nach der Ovulation	Anzahl Tiere pro Gruppe		
	Kontrollen	A-Überdosierung	A-Mangel
10– 11 h	2	3	2
15 h	2	3	2
20 h	1	1	1
32– 35 h	3	3	3
40 h	2	2	2
57 h		1	1
60 h		4	2
63– 65 h	3	3	2
80– 81 h	1	3	2
85 h		1	3
90 h		1	1
104–106 h	4	4	2
108–111 h	2	4	1
Anzahl Tiere pro Versuchsserie	20	33	25

Inkubation während 60 min bei 37°C. Nachfixation der Schnitte 20 min in Formol-Dextran.

Nach der Durchführung der Reaktionen wurden die Präparate sofort photographiert.

Außerdem führten wir an Kryostatschnitten folgende Färbungen aus: Hämalaun-Benzopurpurin und Methylgrün-Pyronin nach der Fixierung der Schnitte während 20 min in 96% Alkohol. Die Fettfärbung mit Sudanschwarz B nach 20-minütiger Fixation der Präparate in 4%iger Formollösung; die Kerne wurden mit Kernechtrot gegengefärbt.

I. Histologische Befunde

1. Uteruslumen

Im Querschnitt liegt die Uterushöhle exzentrisch, meist ist sie nach mesometral verschoben. Sie ist englumig und zeigt verschieden ausgebildete Falten und Seitentaschen. Diese flachen 20 Stunden nach der Ovulation etwas ab. Im Alter von 80–90 Stunden fallen bei den Kontrolltieren starke lokale Ausweitungen der Uterushöhle auf, welche sich über ungefähr 1,5–2 mm erstrecken. An diesen Stellen wird die Oberfläche glatt, und es zeigen sich Epithelveränderungen. 105/110 Stunden nach der Ovulation sind die lokalen Ausweitungen des Lumens immer noch vorhanden.

Die Uteruslumina von hypervitaminotischen Tieren zeigen solche Ausweitungen erst 110 Stunden nach dem Follikelsprung. Bei Mangeltieren konnten diese Ausweitungen nur bei einem einzigen Tier (105 Stunden nach der Ovulation) festgestellt werden.

2. Lumenepithel

Kontrolltiere

Das Uteruslumen ist von einem 1-schichtigen Zylinderepithel ausgekleidet. Seine Höhe nimmt zwischen 10 und 40 Stunden ab und bleibt in späteren Stadien konstant. Die Zellkerne stehen basal. Lumenwärts finden sich degenerierte Zellkerne und Mitosestadien. Die Mitoseaktivität hat im Alter von 30/40 Stunden ihren Höhepunkt erreicht und fällt dann wieder ab. Das Cytoplasma der Epithelzellen zeigt bei der Methylgrün-Pyroninfärbung eine gleichmäßige, intensive Basophilie.

Das Epithel ist von Leukozyten infiltriert. Ihre Zahl nimmt mit zunehmendem Alter ab. 80 Stunden nach dem Follikelsprung sind

nur noch vereinzelte, nach 110 Stunden keine Leukozyten mehr vorhanden. Auffallend sind die riesigen, kerngroßen Vakuolen, die um 15 Stunden nach der Ovulation im apikalen Epithelbereich auftreten und die nach 30 Stunden wieder verschwunden sind (Abb. 1). Bei älteren Stadien (80–110 Stunden nach der Ovulation) ist basal stellenweise ein Saum von kleinen Vakuolen zu erkennen.

Die Uterusstellen, deren Lumen auffällig erweitert ist, sind mit einem 1-schichtigen Plattenepithel ausgekleidet.

Die Basalmembran ist bis zu 50 Stunden nach der Ovulation glatt. Später ist das Epithel mit dem subepithelialen Bindegewebe verzahnt.

Tiere mit Vitamin-A-Überdosierung

Die Veränderungen gegenüber den Kontrolltieren sind nur gering. Meist ist das Uterusepithel von hypervitaminotischen Tieren etwas



Abb. 1a–c. Rattenuterus quer, 15 Stunden nach Ovulation, 7μ, Azan, Vergrößerung: 360×. – a) Hypervitaminose A. R 730, Schnitt 13/2/3. – b) Kontrolle. R 698, Schnitt 7/5/4. – c) Hypovitaminose A. R 757, Schnitt 3/5/1, PAS-Reaktion. Man beachte, daß die Vakuolen im apikalen Bereich des Lumenepithels bei den hypervitaminotischen Tieren 15 Stunden nach Ovulation größer sind als bei den Kontrolltieren. Bei den Tieren mit Vitamin-A-Mangel sind nur vereinzelte kleine Vakuolen zu sehen.

höher als das der Kontrollen. Am ausgesprochensten ist dies 10–20 Stunden nach dem Follikelsprung; in späteren Stadien wird der Unterschied jedoch wieder kleiner. Die Mitoseaktivität ist intensiver als bei den Kontrollen. 80 Stunden nach dem Follikelsprung finden sich immer noch wenige Mitosen im Epithel, während bei den Kontrolltieren schon keine mehr vorhanden sind.

Die Leukozyteninfiltration ist bei der ganzen Gruppe geringer. Schon bei 80 Stunden lassen sich keine Leukozyten im Epithel mehr nachweisen. Die apikalen Vakuolen in den Epithelzellen, die bei den Kontrollen um 10–15 Stunden nach der Ovulation auftreten, sind bei den hypervitaminotischen Tieren zahlreicher und größer. Nach 20 Stunden sind sie noch deutlich zu sehen (vgl. Abb. 1), während sie 30 Stunden nach dem Follikelsprung, wie bei den Kontrolltieren, verschwunden sind. Die kleinen basalen Vakuolen erscheinen viel früher (30–40 Stunden nach der Ovulation). Die Verzahnung des Epithels mit dem subepithelialen Bindegewebe findet sich schon 40 Stunden nach der Ovulation.

Tiere mit Vitamin-A-Mangel

Das Lumenepithel ist unterschiedlich hoch, die Zellen sind niedriger als bei den Kontrollen. Die Zahl der Mitosen ist wesentlich geringer als bei den hypervitaminotischen, meist auch kleiner als bei den Kontrolltieren. 80 Stunden nach der Ovulation sind immer noch vereinzelte Mitosen im Uterusepithel vorhanden. Die Leukozyteninfiltration ist bedeutend stärker, und oft finden sich auch Leukozyten im Uteruslumen.

Auch bei den Mangeltieren lassen sich um 15 Stunden große Vakuolen apikal in den Epithelzellen erkennen, doch sind sie kleiner und weniger zahlreich als bei den Kontroll- und hypervitaminotischen Tieren (vgl. Abb. 1). In einem Fall (R 780) sind diese Vakuolen 30 Stunden nach dem Follikelsprung noch vorhanden. Die kleinen basalen Vakuolen treten nach 60 Stunden auf.

3. Bindegewebe

Bei allen drei Gruppen läßt das Bindegewebe des Endometriums zwei ineinander übergehende Schichten erkennen:

1. Eine subepitheliale kernreiche Schicht und
2. eine periphere Schicht mit weniger Zellen und reichlicherem Fasermaterial. Die Dicke der subepithelialen Schicht nimmt zwi-

schen 10 und 60 Stunden nach der Ovulation zu und bleibt dann konstant. Sie ist mesometral schmaler ausgebildet als antimesometral. Durch die ganze Versuchsreihe sind die subepithelialen Bindegewebszellen stärker basophil als die Zellen des peripheren Endometrium. Anfangs sind die subepithelialen Zellen klein, länglich und schmal. Um 55/60 Stunden treten große Zellen mit großen, rundlichen Kernen auf, die 1–2 Nukleolen enthalten. Diese großen Elemente nehmen an Zahl zu und verdrängen die kleinen Bindegewebszellen. Es sind unterschiedlich viele freie Zellen vorhanden.

4. Gefäßversorgung

Bei allen drei Gruppen ist die Anordnung der Kapillaren im Endometrium prinzipiell gleich. Subepithelial sind sie etwas zahlreicher und weitlumiger als gegen das Myometrium hin (Abb. 2).

Das Endometrium der Tiere mit Vitamin-A-Überdosierung zeigt eine starke Hyperämie. Die Kapillaren sind zahlreicher und weiter als bei den Kontrollen (Abb. 3).

Bei den Mangeltieren ist kein so auffallender Unterschied zu sehen wie bei den hypervitaminotischen Tieren. Die subepitheliale Gefäßversorgung entspricht derjenigen der Kontrollen. Im peripheren Endometrium sind die Gefäße etwas spärlicher. Nur im Bereich von Entzündungsherden sind sie zahlreich und stark dilatiert.

5. Drüsen

Kontrolltiere

Die Drüsenschläuche liegen vorwiegend im antimesometralen Schnitteil. Auffallend ist die Lumenänderung bei der Gruppe von 10–110 Stunden nach der Ovulation: bei 10 Stunden sind die Drüsen weitlumig und mit einem 1-schichtigen kubischen Epithel ausgekleidet (Abb. 4). Schon bei 30 Stunden wird ihr Lumen enger und ihr Epithel höher. Von 65 Stunden an sind die Drüsenlumina kaum mehr zu erkennen. Das Epithel ist 1-schichtig, niedrig-zylindrisch geworden (Abb. 5). Seine Höhe nimmt bis zu 90 Stunden noch ein wenig zu. Mit dem Engerwerden der Drüsenlumina treten Mitosen im Epithel auf. Am häufigsten finden sie sich bei 30/40 Stunden nach dem Follikelsprung.

Die Drüsenepithelien färben sich bei der Methylgrün-Pyroninfärbung schwächer rot an als die Lumenepithelien. Zwischen 10 und 55 Stunden ist eine gleichmäßige Rotfärbung des Cytoplasma der

Abb. 2. Rattenuterus quer, R 603, Kontrolle, 65 Stunden nach Ovulation, 7μ, PAS-Reaktion, Schnitt 3/5/5, Vergrößerung: 90×.
Übersichtsaufnahme der Gefäßverteilung im Bindegewebe des Endometrium bei einem Kontrolltier. Im Schnitt sind keine Kapillaren mit auffallend weitem Lumen zu erkennen.

Abb. 3. Rattenuterus quer, R 733a, Hypervitaminose A, 15 Stunden nach Ovulation, 7μ, PAS-Reaktion, Schnitt 3/5/2, Vergrößerung: 110×.
Man beachte im Bindegewebe des Endometrium von hypervitaminotischen Tieren die zahlreichen, stark dilatierten Gefäße.

Drüsenzellen, und von 65 Stunden an basal eine ausgeprägtere Basophilie zu erkennen (Abb. 4 und 5).

Nur bei sehr frühen Stadien (10/15 Stunden nach der Ovulation) sind Leukozyten sowohl im Drüsenlumen als auch im Epithel sowie im umgebenden Bindegewebe zu finden.



4

5

Tiere mit Vitamin-A-Überdosierung

Bei den hypervitaminotischen Tieren sind die gleichen Vorgänge wie bei den Kontrollen zu beobachten. Die Drüsen sind etwas weitlumiger. Erst um 80 Stunden nach dem Follikelsprung sind die Drüsenlumina kaum mehr zu erkennen (Abb. 6). Das Epithel ist entsprechend 1-schichtig kubisch oder zylindrisch. Die höchste Mitoseaktivität findet sich um 30/40 Stunden nach der Ovulation. Bei

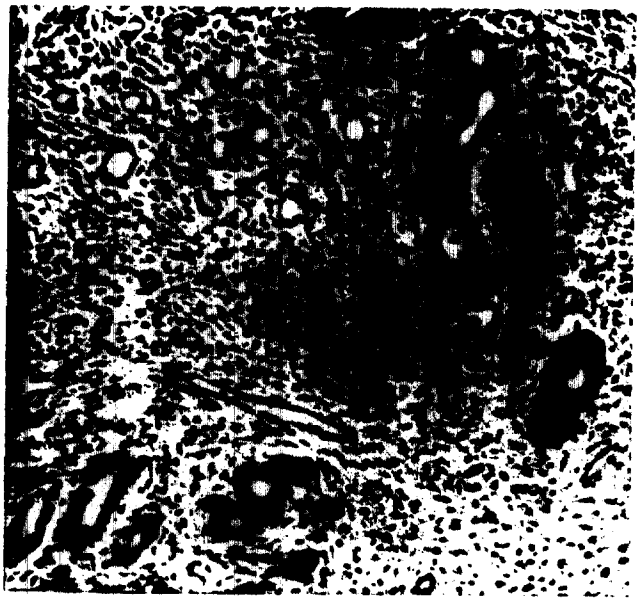

Abb. 6. Rattenuterus quer, R 754, Hypervitaminose A, 65 Stunden nach Ovulation, 7μ, Methylgrün-Pyronin, Schnitt 10/5/3, Vergrößerung: 160×.
Bei Tieren mit Vitamin-A-Überdosierung sind die Drüsenlumina 65 Stunden nach Ovulation noch gut zu erkennen. In den weitlumigen Drüsenquerschnitten ist das Epithel 1-schichtig kubisch, in denjenigen mit engerem Lumen 1-schichtig zylindrisch.

Abb. 4. Rattenuterus quer, R 611, Kontrolle, 11 Stunden nach Ovulation, 7μ, Methylgrün-Pyronin, Schnitt 4/8/2, Vergrößerung: 160×.
Die Drüsenlumina sind dilatiert, ihr Epithel ist 1-schichtig kubisch. Das Cytoplasma des Drüsenepithels ist gleichmäßig angefärbt.

Abb. 5. Rattenuterus quer, R 603, Kontrolle, 65 Stunden nach Ovulation, 7μ, Methylgrün-Pyronin, Schnitt 4/4/4, Vergrößerung: 160×.
Die Drüsenschläuche sind kollabiert, das Epithel ist 1-schichtig zylindrisch geworden. Man sieht, daß die Drüsenepithelzellen basal kräftiger angefärbt sind als apikal.

7

8

Abb. 7. Rattenuterus quer, R 764, Hypovitaminose A, 65 Stunden nach Ovulation 7μ, Schnitt 16/7/1, Methylgrün-Pyronin, Vergrößerung: 270 ×.
Dilatierter Drüsenquerschnitt mit abgeplattetem Epithel. Das Lumen ist prall mit Leukozyten gefüllt.

Abb. 8. Rattenuterus quer, R 733, Hypovitaminose A, 90 Stunden nach Ovulation 7μ, PAS-Reaktion, Schnitt 9/7/5, Vergrößerung: 160 ×.
Entzündungsherd bei Vitamin-A-Mangeltier. Das Drüsenepithel ist nicht mehr überall erkennbar. Starke Leukozyteninfiltration in das den Entzündungsherd umgebende Bindegewebe.

60 Stunden sind die Mitosen nur noch in den weitlumigen Querschnitten zu sehen. Außer bei 10 Stunden sind keine Leukozyten im Epithel vorhanden, sie sind auch weniger zahlreich als bei den Kontrolltieren.

Tiere mit Vitamin-A-Mangel

Oft sind weniger Drüsenschläuche im Schnitt getroffen als bei den Kontroll- und hypervitaminotischen Tieren. Ihre Lumina sind unterschiedlich weit, oft stärker dilatiert als bei den hypervitaminotischen Tieren. Das Epithel ist unregelmäßig hoch. Es sind nur wenig Mitosen vorhanden. Dagegen sind die Leukozyten viel zahlreicher. In fast allen Fällen treten Entzündungsherde von verschiedener Größe auf. Zum Teil handelt es sich nur um zellige Infiltrationen der Drüsen, zum Teil sind die Drüsenschläuche sehr stark dilatiert, und im Epithel und im umgebenden Bindegewebe finden sich Zellnekrosen und Zelltrümmer. Die Kapillaren in der Umgebung der Entzündungsherde sind stark dilatiert (Abb. 7 und 8).

6. PAS-Reaktion

Bei der PAS-Reaktion färbt sich die Basalmembran schwach rot an. Im apikalen Bereich der Drüsen- und Lumenepithelien ist ein schwacher roter Saum zu erkennen.

Die Reaktion fällt bei den hypervitaminotischen Tieren etwas kräftiger aus, während zwischen den Kontroll- und den Mangeltieren keine Unterschiede auffallen.

II. Histochemische Befunde

1. Alkalische Phosphatase

Kontrolltiere

Die alkalische Phosphatase-Aktivität ist vorwiegend auf das apikale Zelldrittel des Lumen- und Drüsenepithels beschränkt. Sie zeigt sich in Form eines rot-braunen Granulasaumes. Im Cytoplasma des Lumenepithels sind die Granula sehr spärlich und diffus verteilt. Die Zellkerne sind negativ. Die Reaktion des Drüsenepithels ist schwächer, der Granulasaum schmaler als im Lumenepithel. An den Zellgrenzen der Drüsenzellen sind einzelne Granula erkennbar. Die Kapillaren des Endometrium reagieren sehr stark positiv (Abb. 9b).

Von 10–110 Stunden nach der Ovulation zeigt das Lumenepithel eine deutliche Abnahme der alkalischen Phosphatase-Aktivität. Bis zu 85 Stunden ist überall ein kontinuierlicher apikaler Granulasaum nachzuweisen, während später die Reaktion nur noch stellenweise sichtbar, zum Teil sogar negativ ist. Die diffus verteilten Granula im Cytoplasma der Epithelzellen verschwinden schon um 60 Stunden nach dem Follikelsprung. Die Aktivität der Drüsenepithelien nimmt nicht im gleichen Maße ab wie diejenige im Lumenepithel. Die Drüsenepithelzellen bleiben bis 110 Stunden nach der Ovulation schwach positiv.

Tiere mit Vitamin-A-Überdosierung

Die Schnitte zeigen ein ähnliches Resultat und die gleiche Granulaverteilung wie die Schnitte der Kontrolltiere. Nur ist die Aktivität sowohl in den Lumen- als auch in den Drüsenepithelzellen deutlich herabgesetzt. Die Reaktion der Kapillaren jedoch bleibt gleich stark positiv (vgl. Abb. 9a und 9b) wie bei den Kontrolltieren.

Tiere mit Vitamin-A-Mangel

Die Reaktion ist bei gleicher Inkubationszeit stärker positiv als bei den Kontrollen. Auch hier bleibt die Granulaverteilung dieselbe. Besonders deutlich ist die Aktivitätssteigerung im Lumenepithel, etwas weniger auffallend in den Drüsenepithelien. Noch 60/65 Stunden nach dem Follikelsprung sind viele Granula im Cytoplasma des Lumenepithels erkennbar. Die Reaktion der Kapillaren bleibt sehr stark positiv (vgl. Abb. 9a, 9b und 9c).

2. Saure Phosphatase

Kontrolltiere

Die Reaktion auf saure Phosphatase fällt viel schwächer aus als diejenige auf alkalische Phosphatase.

Die saure Phosphatase-Aktivität ist bis zu 35 Stunden nach der Ovulation negativ, wird dann positiv und nimmt mit steigender Stundenzahl langsam an Intensität zu. Sie fällt im Lumenepithel als

---

Abb. 9a–c. Rattenuterus quer, 10 Stunden nach Ovulation, alkalische Phosphatase 10μ, Vergrößerung: 150×. – a) R 738, Tier mit Vitamin-A-Überdosierung. b) R 607, Kontrolltier. – c) R 767, Tier mit Vitamin-A-Mangel.
Man beachte die Intensitätsunterschiede vor allem im Lumenepithel.

a
b
c

schwacher, schmaler, apikaler Granulasaum auf. Die Reaktion ist ausschließlich auf den apikalen Epithelbereich beschränkt. In den Drüsenepithelien ist die Reaktion noch geringer als im Lumenepithel. Die Granula sind ebenfalls vorwiegend apikal zu finden. Die Kapillaren sind schwach positiv.

Tiere mit Vitamin-A-Überdosierung

Die Schnitte von hypervitaminotischen Tieren reagieren stärker positiv als diejenigen der Kontrollen. Die intrazelluläre Granulaverteilung bleibt jedoch gleich wie bei den letzteren.

Im Lumenepithel ist schon von 20 Stunden an eine Aktivitätszunahme zu beobachten. 60 Stunden nach der Ovulation läßt sich ein deutlicher Abfall der Reaktion erkennen, dem dann wieder eine Aktivitätssteigerung folgt. Bei 105/110 Stunden ist die Reaktion wieder etwas vermindert. Im Drüsenepithel ist die Reaktion immer schwächer als im Lumenepithel. Sie ist ebenfalls apikal am stärksten ausgeprägt.

Tiere mit Vitamin-A-Mangel

Die Reaktion fällt weniger stark positiv aus als bei den Kontrollen. Bis zu 55 Stunden nach dem Follikelsprung finden wir meistens eine negative, stellenweise eine ausgesprochen schwach positive Reaktion im Lumen- und im Drüsenepithel. Von 60–90 Stunden nimmt die Aktivität im Lumenepithel etwas zu, fällt dann aber bei 105/110 Stunden wieder ab. Die Reaktion im Drüsenepithel ist zwischen 60 und 90 Stunden gleich stark ausgeprägt wie im Lumenepithel und nimmt dann ebenfalls bei 105/110 Stunden nach der Ovulation wieder ab.

3. DPNH-Diaphorase

Tiere mit Vitamin-A-Überdosierung

Die Granula bleiben von 10–110 Stunden nach dem Follikelsprung gleich angeordnet. In den Lumenepithelzellen sind sie im ganzen Cytoplasma verteilt und bilden basal einen verstärkt positiven Saum (Abb. 10a). In den Drüsenepithelzellen sind sie gleichmäßig über die ganze Zelle verteilt, doch ist die Aktivität geringer als im Lumenepithel. 80/85 Stunden nach der Ovulation steigert sich die Enzymaktivität merklich, wobei sogar die Reaktion im Drüsenepithel viel intensiver ist als im Lumenepithel.

Tiere mit Vitamin-A-Mangel

Die Granulaverteilung bleibt dieselbe wie bei den hypervitaminotischen Tieren; es handelt sich nur um Intensitätsunterschiede.

Bis zu 55 Stunden nach der Ovulation ist die Aktivität in allen Teilen schwächer als bei den hypervitaminotischen Tieren. Bei 60/65

Abb. 10a und b. Rattenuterus quer, 105 Stunden nach Ovulation, DPNH-Diaphorase-Reaktion, 10 μ, Vergrößerung: 150 ×. – a) R 748, Tier mit Vitamin-A-Überdosierung. – b) R 760, Tier mit Vitamin-A-Mangel.
Die stärker positive Reaktion bei gleicher Granulaverteilung ist in Abb. 10a deutlich erkennbar.

Stunden jedoch reagieren die Schnitte viel heftiger positiv. In den Lumenepithelzellen treten die Granula im ganzen Cytoplasma auf, ein basaler Saum ist nur noch undeutlich nachzuweisen. Zwischen 80 und 110 Stunden nach dem Follikelsprung fällt die Reaktionsintensität wieder ab, sie ist wieder schwächer als bei den Tieren mit Vitamin-A-Überdosierung (vgl. Abb. 10a und 10b).

Besprechung der Befunde und Diskussion

Die auffälligsten Befunde an den Kontrolltieren sind die Ausweitung des Uteruslumens um 80–90 Stunden nach der Ovulation, das Niedrigerwerden des Lumenepithels von 10–60 Stunden, die Leukozyteninfiltration zwischen 10 und 80 Stunden und die große Mitoseaktivität 30/40 Stunden nach dem Follikelsprung. Die Drüsen sind zunächst sehr weitlumig, werden 60 Stunden nach der Ovulation englumig, wobei gleichzeitig ihr Epithel höher wird. Großkernige Zellelemente treten im Bindegewebe auf und verdrängen die langen, schmalen Fibrozytenzellen. Unsere Ergebnisse stimmen mit den Befunden verschiedener Forscher weitgehend überein (BURCKHARD [1901], ALLEN [1931]).

Der Gehalt an alkalischer Phosphatase im apikalen Bereich des Lumenepithels und das Verschwinden der Aktivität bis zu 110 Stunden nach der Ovulation werden übereinstimmend mit unseren Befunden auch von PRITCHARD [1947] sowie WISLOCKI und DEMPSEY [1947] beschrieben. PRITCHARD [1947] stellt ebenfalls fest, daß die Aktivität in den Drüsenepithelien erst etwa 20 Stunden später verschwindet als im Lumenepithel.

Die Reaktionen auf saure Phosphatase zeigen bei den Kontrolltieren eine ganz geringe Zunahme der Reaktionsintensität im Lumenepithel von 40 Stunden an. Eine ähnliche Beobachtung ist uns aus der Literatur nicht bekannt.

Zwischen den Tieren mit Vitamin-A-Überdosierung und den Kontrollen finden sich keine großen Unterschiede. Der Ablauf der normalen Vorgänge im Endometrium zwischen Ovulation und Implantation scheint um 10–20 Stunden verzögert zu sein. Die Ausweitung des Uteruslumens wird erst bei 110 Stunden nach dem Follikelsprung beobachtet, was vielleicht ein Grund für eine verzögerte Implantation sein könnte. Das Epithel ist etwas höher und die Mitosehäufigkeit ist größer. Mitosen sind noch bei 80 Stunden nach der Ovulation im Epithel zu finden. Ebenfalls 10–20 Stunden später als bei den Kontrolltieren werden die Drüsenquerschnitte englumig. Auffallend

ist die Hyperämie des Endometriums. STUDER und WINKELMANN [1954] haben bei Hypervitaminose A an Niere und Milz ebenfalls eine allgemeine Hyperämie festgestellt, nicht dagegen im Endometrium.

Bei den hypervitaminotischen Tieren ist die Reaktion auf alkalische Phosphatase schwächer als bei den Kontrollen. Dies steht im Gegensatz zu der in der Literatur beschriebenen Aktivitätssteigerung im Bürstensaum der Hauptstücke der Niere und des Dünndarmepithels, in Milz, Knochenmark, den interlobulären Gebilden der Leber und im Serum bei Vitamin-A-Überdosierung (vgl. BAUR [1948/49], RAHALKAR *et al.* [1956], LUDWIG [1962], MILIČIĆ [1962]). Die saure Phosphatase zeigt eine sehr schwache Reaktion bei Vitamin-A-Hypervitaminose. Die DPNH-Diaphorase-Reaktion fällt wesentlich intensiver aus als bei den Mangeltieren.

Die auffälligsten Befunde im Endometrium von Tieren mit Vitamin-A-Mangel sind: Das Fehlen der Ausweitungen des Uteruslumens, ein niedrigeres Epithel, weniger Mitosen und eine starke Leukozyteninfiltration im Lumenepithel und Bindegewebe. Verhornungserscheinungen im Epithel und subepitheliale Herde degenerierender Zellen, wie sie von WOLBACH und HOWE [1925] und CRAMER [1942] beschrieben wurden, konnten wir in unseren Präparaten nicht nachweisen. Auffallend sind die vielen von den Drüsengängen im Endometrium ausgehenden Entzündungsherde. Ähnliche Beobachtungen sind von TYSON und SMITH [1929] an der Zunge, den Speicheldrüsen und am Pankreas von Ratten beschrieben worden. Diese Forscher fanden in den erwähnten Organen eine Dilatation der Drüsenschläuche sowie eine Metaplasie des Epithels, begleitet von Entzündungen der Ausführungsgänge. FOLLIS [1948] beobachtete Infektionsherde bei graviden Ratten an den Übergangsstellen von mütterlichem und kindlichem Gewebe, sowie degenerierende Zellen. Diese Beobachtungen an kurzfristig Vitamin-A-frei ernährten Tieren lassen die Frage offen, ob das oft beschriebene verhornende Epithel (WOLBACH und HOWE [1925], TYSON und SMITH [1929]) eine Reaktion des Gewebes auf diese Entzündungserscheinungen bildet.

Der Anstieg der alkalischen Phosphatase-Aktivität bei Vitamin-A-frei ernährten Tieren ist auch im Endometrium zu sehen. Die gleiche Feststellung wurde von BAUR [1948/49] in Leber, Darm, Niere, Knochenmark, Serum und von MILIČIĆ [1962] in der Niere gemacht. Die Reaktion auf saure Phosphatase ist schwächer als bei den Kontrollen, und die DPNH-Diaphorase-Reaktion ist meist weniger intensiv ausgeprägt.

Unsere Ergebnisse können als Bestätigung der Auffassung angesehen werden, daß die fettlöslichen Vitamine vor allem auf die Zellmembranen und ihre Permeabilität wirken (WISS [1964]). Man kann sich daher fragen, ob nicht diese Membraneigenschaften von Vitamin A einen verzögernden Einfluß auf die zyklischen Vorgänge im Endometrium und die Implantation haben.

Ein Zusammenhang könnte auch durch die Einwirkung des Vitamin A auf die Steroidhormon-produzierenden Zellen im Ovar gegeben sein. Dafür spricht die Tatsache, daß die Aktivität der unspezifischen Esterasen im Endometrium von Meerschweinchen abnimmt, wenn die Tiere zuvor mit Oestrogen-Gestagen-Kombinationspräparaten behandelt wurden (KÜHNEL *et al.* [1968]). Dieser Befund erinnert an die von uns beobachtete Abnahme der alkalischen Phosphatase-Reaktion bei Tieren mit Vitamin-A-Überdosierung. Durch weitere Untersuchungen soll versucht werden, diese Zusammenhänge zu klären.

Zusammenfassung

Die histologischen und histochemischen Veränderungen des Endometriums werden bei Vitamin-A-Mangel und -Überdosierung bei weiblichen Ratten während der ersten 110 Stunden der Trächtigkeit beschrieben.

Bei den Tieren mit Vitamin-A-Überdosierung wurde eine Verzögerung der Vorgänge im Endometrium von 10–20 Stunden gegenüber den Kontrolltieren festgestellt. Außerdem ist eine Hyperämie des Gewebes aufgefallen. Die Reaktion auf alkalische Phosphatase ist im Endometrium herabgesetzt im Gegensatz zu den histochemischen Beobachtungen in anderen Organen und im Serum. Dagegen sind die saure Phosphatase-Aktivität, verglichen mit den Kontrolltieren und die DPNH-Diaphorase-Aktivität, verglichen mit den avitaminotischen Tieren, gesteigert.

Bei den Vitamin-A-Mangeltieren sind vor allem eine starke Leukozyteninfiltration und die vielen Entzündungsherde aufgefallen, während eine Verhornung des Epithels nicht beobachtet wurde. Die alkalische Phosphatase-Reaktion ist bedeutend intensiver als bei den Kontrolltieren, dagegen sind die Reaktionen auf saure Phosphatase und DPNH-Diaphorase sehr schwach.

Summary

A description is given of the histological and histochemical changes occurring in the endometrium of female rats suffering from an overdose or deficiency of vitamin A during the first 110 hours of pregnancy.

In the animals with hypervitaminosis, a delay in the endometrial processes of 10–20 hours as compared with the control animals was observed. Tissular hyperemia was also evident. The reaction to alkaline phosphatase in the endometrium was decreased, unlike the histochemical reactions in the other organs and in the serum, while there was an increase in acid phosphatase activity compared with the control animals and in DPNH diaphorase activity compared with the vitamin deficient animals.

In the vitamin A deficient animals, the strong leukocyte infiltration and the large number of sites of inflammation were particularly noticeable, while no thickening of the epithelium was observed. Alkaline phosphatase reaction was noticeably more intense than in the control animals, while the reaction to acid phosphatase and DPNH diaphorase was very weak.

Résumé

On a étudié les modifications histologiques et histochimiques de l'endomètre de rattes en avitaminose A et en hypervitaminose A, au cours des premières 110 heures de la gestation.

Chez les animaux en hypervitaminose les modifications de la muqueuse utérine sont retardées de 10–20 heures par rapport aux témoins normaux. On a constaté en plus une hyperémie des tissus. L'activité de la phosphatase alcaline est diminuée contrairement aux observations histochimiques faites au niveau d'autres organes et dans le sérum. Par contre, l'activité de la phosphatase acide est augmentée par comparaison aux témoins, et l'activité de la DPNH-diaphorase est augmentée par comparaison à celle des animaux en avitaminose.

Les animaux en avitaminose A présentent surtout une forte infiltration leucocytaire et de nombreux foyers inflammatoires dans l'endomètre: on n'a pas observé de kératinisation de l'épithélium. L'activité de la phosphatase alcaline est nettement plus forte que chez les témoins normaux; celle de la phosphatase acide et de la DPNH-diaphorase est par contre très faible.

Literatur

ALLEN, W. M.: Cyclical alterations in the endometrium of the rat during normal cycle, pseudopregnancy and pregnancy. Production of deciduomata during pregnancy. Anat. Rec. *48:* 65–103 (1931).

BAUR, H.: Tierische Phosphatasen. Physiologie, Pathologie und klinische Bedeutung. Z. Vitamin-, Hormon-, Fermentforsch. *2:* 507–595 (1948/49).

BURCKHARD, G.: Die Implantation des Eies der Maus in die Uterusschleimhaut und die Umbildung derselben zur Decidua. Arch. mikr. Anat. *57:* 528–569 (1901).

CRAMER, H.: Wachstumssteuerung gefährdeter Epithelialgebiete. Dtsch. med. Wschr. *68:* 809–814 (1942).

FOLLIS, H. R., JR.: The pathology of nutritional disease (Blackwell, Oxford 1948).

GEIGER, CH.: Der Einfluß von Vitamin-A-Mangel und -Überdosierung auf das Ovar geschlechtsreifer Ratten. Arch. Gynäk. *206:* 411–430 (1968).

KÜHNEL, W.; PETRY, G. und AMAR, H.: Der Einfluß von sogenannten Ovulationshemmern auf die Esterase-Aktivität im Endometrium. Experientia *24:* 715–716 (1968).

LUDWIG, K. S.: Vitamin-A-Mangel und -Überdosierung und ihre Beziehungen zum Gehalt an alkalischer Phosphatase der interlobulären Gebilde in der Rattenleber. Acta anat. *50:* 163–169 (1962).

MASON, K. E.: Foetal death, prolonged gestation and difficult parturition in the rat as a result of vitamin-A-deficiency. Amer. J. Anat. *57:* 303–349 (1935).

MILIČIĆ, M.: Der Einfluß von Vitamin-A-Mangel und -Überdosierung auf Niere, Dünndarm und Leber unter besonderer Berücksichtigung der alkalischen Phosphatase. Acta anat. *50:* 312–325 (1962).

PARKES, A. S. and DRUMMOND, J. C.: The effect of fat-soluble vitamin-A-deficiency on reproduction in the rat. Brit. J. exp. Biol. *3:* 251–273 (1925).

PRITCHARD, J. J.: The distribution of alkaline phosphatase in the pregnant uterus of the rat. J. Anat., Lond. *81:* 352–364 (1947).

RAHALKAR, A. D.; NERUKAR, M. K. and SAHASRABUDHE, M. B.: Influence of the hypervitaminose A on the alkaline phosphatase levels in various organs of the young rat. Indian J. med. Sci. *10:* 716–719 (1956).

STUDER, A. und WINKELMANN, W.: Zur Frage der A-Hypervitaminose. Mod. Probl. Pädiat. *1:* 293–305 (1954).

TYSON, M. D. and SMITH, A. H.: Tissue changes associated with vitamin-A-deficiency in the rat. Amer. J. Path. *5:* 57–71 (1929).

WISLOCKI, G. B. and DEMPSEY, E. W.: Histochemical relations of the endometrium in pregnancy. Amer. J. Anat. *77:* 365–403 (1945).

WISS, O.: Über die Wirkungsweise der Vitamine auf molekularer Ebene. Vortrag Naturforschende Ges., Basel 1964.

WOLBACH, S. B. and HOWE, P. R.: Tissue changes following deprivation of fat-soluble vitamin A. J. exp. Med. *42:* 753–777 (1925).

ZBINDEN, G. und STUDER, A.: Tierexperimentelle Untersuchungen über die chronische Verträglichkeit von β-Carotin, Lycopin, 7,7′-Dihydro-β-carotin und Bixin. Z. Lebensmittel-Unters. Forsch. *108:* 113–134 (1958).

Eingegangen 25. März 1968

Adresse der Autorin: Ursula Studer-Marxer, Anatomisches Institut der TH Aachen (Bundesrepublik Deutschland); z. Z. Pestalozzistraße 20, *CH-4056 Basel* (Schweiz)

Sutton-'65
Bib. No. 8854

Bull. N.Y. Acad. Med. 41(3):326-329. 1965.

*Histochemical Changes in the Choroid Plexus in Hypervitaminosis A**

CARL H. SUTTON

Lucy and Henry Moses Research Laboratories of the Laboratory Division
Montefiore Hospital, New York, N. Y.

Experimental evidence in the past has confirmed the participation of the choroid plexus as a whole in the elaboration of cerebrospinal fluid, but has failed to define the specific role of the choroidal epithelial cells. These cells have been shown to be capable of the uptake at their ventricular surfaces of certain dyes,[1] proteins,[2] and inorganic colloids[3] in experimental animals and *in vitro*, but conclusive evidence for macromolecular transport through the cytoplasm of these cells in a vascular-to-ventricular direction has remained lacking. It was felt that such transport could be most effectively studied *in vivo* by observing the behavior of those subcellular organelles shown to be associated with the process of pinocytosis[4] in normal choroidal epithelial cells and in those engaged in increased cerebrospinal fluid production, as in overproduction hydrocephalus.

One mechanism for the experimental production of this type of hydrocephalus was suggested by a number of reports in the literature concerning apparent cerebospinal fluid pressure elevation resulting from acute or chronic hypervitaminosis A. An acute syndrome of transient hydrocephalus has been described in infants within 12 to 24 hours following ingestion of excessive vitamin A, and has been produced experimentally in puppies.[5] The resulting syndrome was ascribed to an increase in cerebrospinal fluid production. Cases of pseudotumor cerebri with associated visual disturbances have also been reported in adolescents[6] and adults[7] as a result of prolonged daily intake of vitamin A. In at least one patient subtemporal decompression was required.[8]

Accordingly, large single or daily doses of vitamin A were administered to groups of weanling and adult Wistar rats as a convenient method for producing an acute hydrocephalus, and their choroid plexuses were compared histologically with those of untreated animals. For the detection of any structural alterations, reproducible histochemical methods were used to demonstrate the individual subcellular organelles by virtue of their specific enzymatic activities. These methods have previously been successfully applied to the morphological study of normal and pathological conditions of the nervous system and its cellular components.[9-11] The marker enzymes demonstrated in the choroid plexus in our investigation included acid phosphatase for lysosomes, thiamine pyrophosphatase for the Golgi apparatus and blood vessels, DPN-diaphorase for mitochondria, adenosine triphosphatase for plasma membranes and blood vessels, and alkaline phosphatase for blood vessels and stroma.

The most striking changes in the choroidal epithelial cells were seen in rats given a single massive dose of vitamin A and sacrificed 18 to 24 hours later. These cells displayed an increase in the number and size of their lysosomes, which were located in maximal concentration at the ventricular poles of these cells in contrast with the normal random distribution. The Golgi apparatus in most of these cells displayed apparent shortening and rounding of its lamellae. These changes were not seen in hypervitaminotic adult animals, although the cytomembranes of their choroidal epithelial cells did contain adenosine triphosphatase activity in both the treated and control groups; similar activity was lacking in weanling rats. Hydrocortisone, which has been reported to provide lysosomal protection against the toxic effects of vitamin A,[12] had no effect on either the normal or ex-

*This investigation was supported in part by a Public Health Service Fellowship number 5 F3 CA-13,380-02 from the National Cancer Institute of the National Institutes of Health, Bethesda, Md.

perimentally produced enzyme patterns in weanling rat choroid plexus.

In an effort to differentiate between increased cellular activity and toxic injury to these organelles as the basis for the reproducible morphological changes resulting from excessive vitamin A, an enzymatic protein, horseradish peroxidase, was administered intravenously, and its uptake and transport by the choroidal epithelial cells observed. The peroxidase was localized in granular bodies, which migrated progressively through the cytoplasm of each cell from its vascular pole to the ventricular surface. The rate of peroxidase uptake and intracellular transport in acutely hypervitaminotic weanling rats was more rapid than in untreated ones. In the chronically treated group, one half of the weanling animals exhibited a lesser increase in the rate and amount of peroxidase uptake, although no morphological changes in the organelles themselves could be demonstrated with routine histochemical methods.

In these studies the utilization of an exogenous protein to trace cellular uptake and transport provided information concerning the functional status of these processes and thereby permitted a correlation of structural and functional alterations within the choroidal epithelial cells resulting from hypervitaminosis A. The increase in number and size of lysosomes was accompanied by an accelerated uptake and transport of the tracer protein. The ventricular polarization of lysosomes in these cells was associated with a progressive transport of the tracer substance in a vascular-to-ventricular direction within granular bodies, resembling lysosomes in size and configuration, which have been termed "phagosomes" by Straus.[13] Both sets of observations suggest the presence of an increased cellular activity of the choroidal epithelium in hypervitaminosis A rather than the existence of disruptive lysosomal changes, such as those reported in the liver[14] and in leukocytes[15] from the direct action of vitamin A. These results appear to confirm the feasibility of utilizing the rate of uptake and transport of horseradish peroxidase as one parameter for evaluating the effects of drugs or pathological states on choroidal epithelial function. These observations further suggest that the lysosomes probably participate in the formation of the cerebrospinal fluid, particularly its macromolecular fractions, and that morphological changes in these organelles can accompany a drug-induced alteration in its production.

The mechanism by which hypervitaminosis A produces these morphological alterations and the increased activity within the choroidal epithelial cells remains undetermined. A previous investigation indicated that vitamin A itself does not reach the cerebrospinal fluid, despite frequent extreme elevations of the blood level,[5] so that there is no reason to postulate the uptake or transport of this substance by the choroidal cells. The inclusion of peroxidase within discrete cytoplasmic bodies after ingestion appears to indicate its cellular uptake by the process of pinocytosis, in which the lysosomes and Golgi aparatus have been shown to be involved.[4] Although the choroidal epithelium is not normally required to transport horseradish peroxidase, it has been shown that proteins and similar macromolecules enter cells through pinocytosis.[16] Indeed, proteins are among the most efficient inducers of this process,[17] rendering them especially desirable as pinocytosis-tracing substances. It seems conceivable, therefore, that the structural and functional lysosomal alterations in the choroidal epithelium of hypervitaminotic weanling animals might perhaps result from a secondary induction and acceleration of pinocytosis by macromolecules released into the blood stream by the toxic action of excessive vitamin A elsewhere in the body. Lysosomal enzymes, liberated by disruption of the lysosomal membranes by vitamin A, would constitute a possible source of such macromolecules. A direct action of the vitamin A on the choroidal epithelium cannot be ruled out as the cause, however, without further biochemical and ultrastructural study of the choroid plexus.

While this interpretation is highly speculative, it can be concluded from these studies that the choroidal epithelium is capable of a vascular-to-ventricular protein transport in weanling rats, and that this appears to be accelerated by hypervitaminosis A, with associated morphological alterations in the lysosomes and Golgi apparatus of these cells.

REFERENCES

1. Lumsden, C. E. Observations on the choroid plexus maintained as an organ in tissue culture. In *The Cerebrospinal Fluid:* Production, Circulation and Absorption (Ciba Foundation Symposium.) Wolstenholme, G. E. W. and O'Connor, C. M. eds. Boston, Little, Brown, and Company, 1958, pp. 97-123.
2. Smith, D. E., Streicher, E., Milkovic, K. and Klatzo, I. Observations on the transport of proteins by the isolated choroid plexus, *Acta Neuropath. 3*:372-386, 1964.
3. Tennyson, V. M. and Pappas, G. D. Electron microscopic studies of the developing telencephalic choroid plexus in normal and hydrocephalic rabbits. In *Disorders of the Developing Nervous System.* Fields, W. S., and Desmond, M. M., eds. Springfield, Ill., Charles C. Thomas, 1961, pp. 267-325.
4. Novikoff, A. B. Lysosomes and related particles. In *The Cell: Biochemistry, Physiology, Morphology.* Brachet, J. and Mirsky, A. E., eds. New York, Academic Press, 1961, vol. 2, pp. 423-488.
5. Marie, J. and Sée, G. Acute hypervitaminosis A of the infant; its clinical manifestation with benign acute hydrocephalus and pronounced bulge of the fontanel: a clinical and biological study, *Amer. J. Dis. Child. 87*:731-736, 1954.
6. Morrice, G. Jr., Havener, W. H., and Kapetansky, F. Vitamin A intoxication as a cause of pseudotumor cerebri, *J. A. M. A. 173*:1802-1805, 1960.
7. Oliver, T. K., Jr. Chronic vitamin A intoxication: report of a case in an older child and review of the literature, *A. M. A. J. Dis. Child. 95*:57-68, 1958.
8. Gerber, A., Raab, A. P., and Sobel, A. E. Vitamin A poisoning in adults, *Amer. J. Med. 16*:729-745, 1954.
9. Becker, N. H. and Sutton, C. H. Pathologic features of the choroid plexus. I. Cytochemical effects of hypervitaminosis A, *Amer. J. Path. 43*:1017-1030, 1963.
10. Becker, N. H., Goldfischer, S., Shin, W. Y., and Novikoff, A. B. Localization of enzyme activities in the rat brain, *J. Biophys. Biochem. Cytol. 8*:649-663, 1960.
11. Becker, N. H., Novikoff, A. B., and Goldfischer, S. A cytochemical study of the neuronal Golgi apparatus: Experimental diphtheritic encephalitis in rats, *Arch. Neurol. 5*:497-503, 1961.
12. Thomas, L. Papain, vitamin A, lysosomes and endotoxin: an essay on useful irrelevancies in the study of tissue damage, *Arch. Intern. Med. 110*:782-786, 1962.
13. Straus, W. Rapid cytochemical identification of phagosomes in various tissues of the rat and their differentiation from mitochondria by the peroxidase method, *J. Biophys. & Biochem.*
14. Dingle, J. T. Studies on the mode of action of excess of vitamin A. 3. Release of a bound protease by the action of vitamin A, *Biochem. J. 79*:509-512, 1961.
15. Janoff, A. and McCluskey, R. T. Effect of excess vitamin A on acid phosphatase content of guinea pig peritoneal leukocytes, *Proc. Soc. Exp. Biol. Med. 110*:586-589, 1962.
16. Holter, H. Pinocytosis. In *Enzymes and Drug Action* (Ciba Foundation Symposium). Mongar, J. L., and deReuck, A. V. S., eds. Boston, Little, Brown and Company, 1962, pp. 30-59.
17. Chapman-Andresen, C., and Prescott, D. M. Studies on pinocytosis in the amoebae *Chaos chaos* and *Amoeba proteus. Compt. rend. Lab. Carlsberg. Ser. Chim. 30*:57-78, 1956.

DISCUSSION

H. M. ZIMMERMAN: For years the debate raged in this country on the part of many investigators as to the function of the choroid plexus, and this debate ended only when the chief combatants disappeared from the scene a number of years ago. The group represented by the Baltimore anatomists felt that the choroid plexuses were the main source of secretion of cerebrospinal fluid. The process which Dr. Sutton described so convincingly for you this evening was challenged by a group led by George Hassin that was more vociferous, if less accurate. This group thought that the choroid plexus was the absorptive site of the cerebrospinal fluid, and it had the idea that ventricular fluid was secreted in the arachnoid villi, that it went down over the surfaces of the brain through the foramen of Luschka to the fourth ventricle, and was absorbed by the choroid plexus. Most neuropathologists and neurosurgeons in this country did not hold, in the main, with the idea expressed by Hassin and his group. It has been common practice in neurosurgery, in cases of young children who have communicating hydrocephalus, to extirpate the choroid plexuses and thereby stop the developing hydrocephalus; in some instances this actually has worked. This was indirect evidence that the choroid plexus actually secretes fluid and that the arachnoid villi probably are fundamental in absorbing this fluid.

Now, for the first time, we have an anatomical illustration supported by means which can not be held in question, showing conclusively that the epithelium of the choroid plexus has some function in the secretion of ventricular fluid. I think that Dr. Sutton has given us an exceedingly nice demonstration which resolves the problem that has plagued most neuropathologists and neurosurgeons for a long time. The work which Dr. Sutton did was actually done in collaboration with my associate, Dr. Norwin Becker, and perhaps he would like to comment.

NORWIN BECKER: Ever since the studies of Dandy, there seemed to be no question, physiologically, that the choroid plexus was producing fluid. However, as soon as this work was taken out of the hands of the physiologists and put in the hands of the anatomists, nobody has been able to show a cellular vascular-ventricular transport, although it has been tried with such substances as dyes and thorotrast. I think that Dr. Sutton has opened this question again but, as usual, has left us with many unanswered questions which we are continuing to study in our laboratory:

1) Why is this effect predominantly limited to young animals? We can't explain this as yet, except to note that this is consistent with what happens in humans. It may be related to the fact that the adult choroid plexus has fewer lysosomes. This may reflect less pinocytotic activity. In addition, the adult choroid plexus has an ATPase activity among its membranes which the young rat does not, and this may also play a role in the pinocytotic activity.

2) The other important question that we are trying to answer is: Just what is the basis for this vitamin A effect? As most of you know, the latest concept is that vitamin A is capable of compromising the integrity of lysosomes with release of acid hydrolases. Is this what is going on here? It seems to me that if this were true in this case, then you would have seen a progressive lysosomal lysis over a period of days when in reality what we are demonstrating is an acute, not a chronic effect. Moreover, this effect of vitamin A on lysosomes is supposed to be ameliorated by steroids. We have tried steroids, without effect.

I think we must now pass out of the light histochemical level and go on to fine structural histochemical studies, which Dr. Sutton, Dr. Cancilla, and I are proceeding to do.

Takekoshi-
Bib. No. 8956

J. Embryol. Exp. Morph. 12(2):263-271. 1964.

The mechanism of vitamin A induced teratogenesis

by SHOICHI TAKEKOSHI[1]

From the Department of Oto-rhino-laryngology, School of Medicine, Gunma University

WITH TWO PLATES

It is generally recognized that some congenital malformations may be caused by an abnormal environment surrounding the mother in pregnancy. Many experiments have been reported concerning the teratogenesis due to various hypovitaminoses, but there are relatively few reports on teratogenesis resulting from the administration of a large quantity of vitamin. Among the latter, the best known are malformations caused by hypervitaminoses A and D.

In spite of many experiments on the effect of hypervitaminosis A carried out by Cohlan (1953, 1954, 1961), Giroud & Martinet (1955, 1956, 1957, 1959, 1960), Millen & Woollam (1957*a*, 1957*b*, 1958*a*, 1958*b*, 1958*c*, 1961), Kalter & Warkany (1961), Härtel & Härtel (1960), and also by many Japanese workers (Inaba, 1958; Nakamura, 1958; Araki, 1958; Yukioka, 1958; Tsuruhara, 1959; Kuzukawa, 1960), the mechanism of such a teratogenesis still remains obscure. Cohlan (1954) and Giroud (1957) considered a direct action of vitamin A on the foetus, because vitamin A content in the liver of the foetus was markedly increased when the former was given in excessive dose to the mother in pregnancy. Takekoshi (1961*a*, 1961*b*) observed that cortisone, trypan blue, urethane and chondroitin sulfate enhanced the teratogenic activity of vitamin A, and that the adrenal weight of animals given a large dose of vitamin A was increased, while the lipid droplets of the adrenal cortex became minute in size and increased in number. From these facts, he concluded that excessive production of adrenal cortical hormone in these cases might not be negligible as compared to the direct action of vitamin A on the foetus.

It may be easily assumed that the intimate reciprocal actions between various hormones and vitamins are necessary for the normal development of foetuses. Therefore, in the present study, special attention was paid to thyroid function in animals which were given a large amount of vitamin A, and the relationship

[1] *Author's address:* Department of Oto-rhino-laryngology, School of Medicine, Gunma University, Maebashi, Japan.

between blood concentration of thyroid hormone and teratogenesis due to vitamin A was investigated.

MATERIAL AND METHODS

Experiments on teratogenesis

Female mice of ddN strain weighing about 25 g. were used. The day on which a copulation plug was observed was taken as day 0 of pregnancy. The mice were divided into four groups, and the following treatments were performed daily for 4 days from the 10th to the 13th day of pregnancy.

Group 1, intramuscular injection of 0·2 ml. (30 mg.) of Tween 80 (the vitamin A solvent); group 2, intramuscular injection of 10,000 I.U. of vitamin A; group 3, intraperitoneal injection of 8 mg. of methylthiouracil (MTU); and group 4, intramuscular injection of 10,000 I.U. of vitamin A plus intraperitoneal injection of 8 mg. of MTU.

On the 17th day of pregnancy, animals of all these groups were sacrificed under ether anesthesia, the foetuses were taken out and examined macroscopically for the existence of malformations. Skeletons of the foetuses were studied by the method of Dawson (1926). (The vitamin A was a product of Eisai Co., Tokyo, and the MTU was a product of Chugai Pharmaceutical Co., Tokyo.)

Effects of vitamin A on thyroid function and on adrenal and testicular weights

It is well known that some changes in thyroid function may be elicited by pregnancy and by estrogen administration. Because the thyroid of the mouse is too small to be examined for its detailed function and it is impossible to obtain enough blood from one mouse in order to enable determination of protein bound iodine (PBI), male rats of Wistar strain were used. They were maintained on low-iodine food for 10 days prior to sacrifice in order to elevate I^{131} uptake.

Twenty-seven rats were divided into four groups, and subjected to the following treatments daily for 4 days: Group 1, intramuscular injection of 150 mg. (1 ml.) of Tween 80; group 2, intramuscular injection of 50,000 I.U. (1 ml.) of vitamin A; group 3, intraperitoneal injection of 20 mg. of MTU; and group 4, intramuscular injection of 50,000 I.U. of vitamin A plus intraperitoneal injection of 20 mg. of MTU.

The animals of all groups were given intraperitoneal injection of 1 μc. of I^{131}, 24 hr. before being sacrificed. At the time of sacrifice, thyroid, adrenal and testis were taken out, weighed by a torsion balance, and the weight of each organ per 100 g. body weight was computed. The 24-hr. I^{131} uptake by thyroid was determined with a well-type scintillation counter. For the determination of serum PBI, blood was taken from the jugular vein at the time of sacrifice.

RESULTS

Teratogenic effects of vitamin A

As shown in Table 1, no malformation was induced in the Tween 80 group. From the group which was given 10,000 I.U. of vitamin A, 34 per cent. of the foetuses showed cleft palate, and 71·2 per cent. had some kind of macroscopically observable malformation. On the other hand, no malformations were observed in the group given MTU alone, whereas in the group given both MTU and vitamin A, the number of abnormal animals was increased. Cleft palate and digital malformations were observed in all the foetuses of this group.

The palate of the foetus often showed a complete cleft palate, and the nasal septa were widened due to the abnormal hyperplasia of the cartilage (Plate 1, Fig. A).

TABLE 1

Combinative teratogenic effect of vitamin A and methylthiouracil on mice embryos

Group	Treatment	Number of dams	Number of living embryos	Number of young with cleft palate (%)	Number of young with finger malformation (%)	Number of young with toe malformation (%)	Number of young with any kind of malformation (%)
1	Tween 80 30 mg.	12	104	0	0	0	0
2	Vitamin A 10,000 I.U.	11	94	32 (34·0%)	14 (14·1%)	65 (69·1%)	67 (71·2%)
3	MTU 8 mg.	10	80	0	0	0	0
4	Vitamin A 10,000 I.U. and MTU 8 mg.	12	60	60 (100%)	55 (90·2%)	60 (100%)	60 (100%)

Various types of limb defects, namely oligodactylia or syndactylia in both the fore- and hind-legs are observed (Plate 1, Figs. B, C, D, E, F, G, H, I). Furthermore staining of the skeleton revealed that the limb defects were caused by the reduction, or in the worst cases the complete absence, of long bones such as the humerus, radius, ulna, femur, tibia or fibula (Plate 2, Figs. L, M). The appearance of such deformed foetuses may closely resemble the phocomelia (Plate 2, Figs. J, K) attributed to thalidomide taken during pregnancy.

Effects of vitamin A on thyroid weight, thyroidal I^{131} uptake, serum PBI, adrenal and testicular weights

As shown in Table 2, the thyroid weight evidently increased in vitamin A given animals, and at the same time thyroidal I^{131} uptake was elevated. Serum

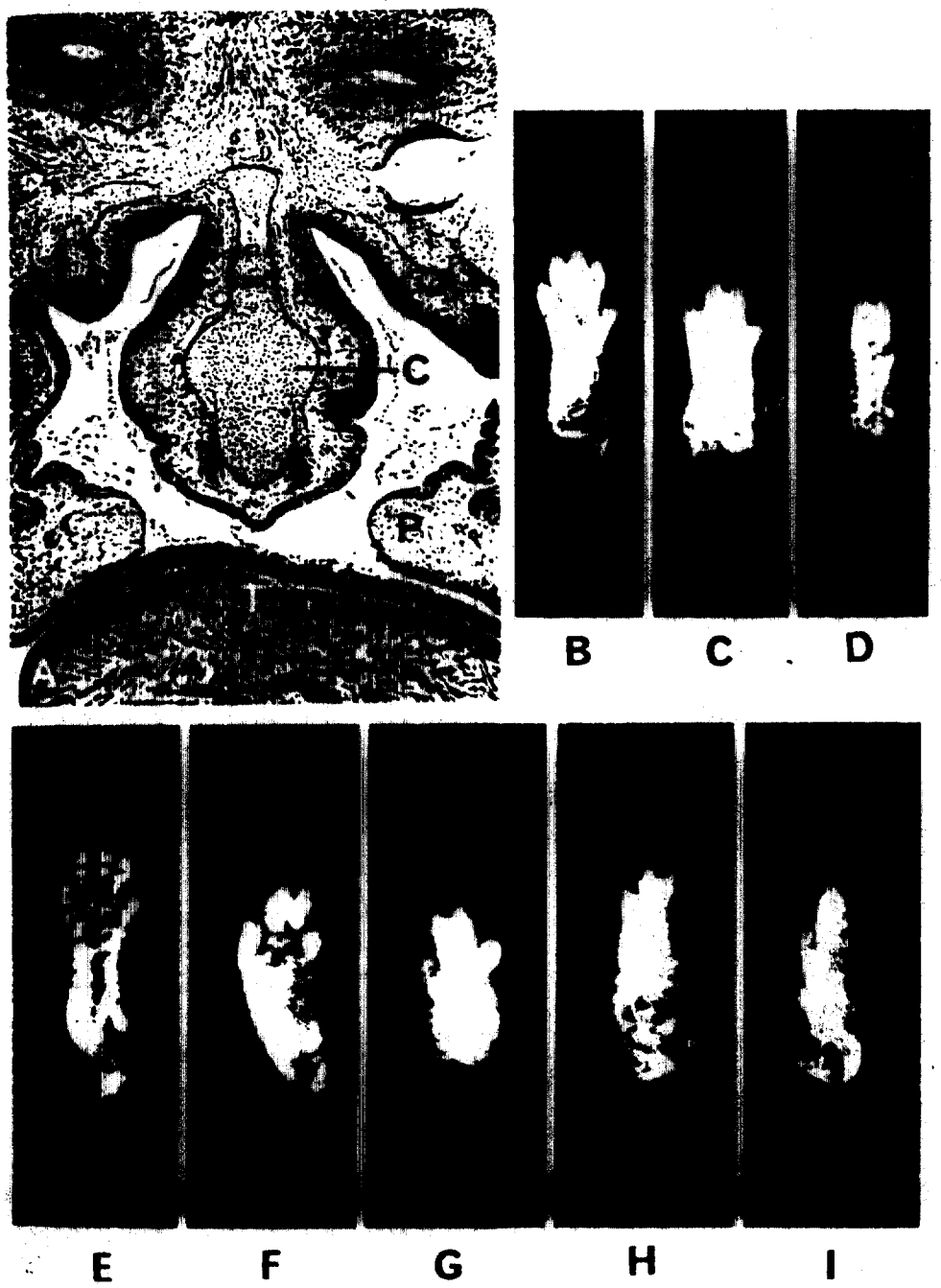

PLATE 1

FIG. A. A frontal section through the face of a mouse foetus with the cleft palate induced by excess vitamin A. Hyperplasia of the cartilage of the nasal septum. C: Abnormal hyperplasia of the septal cartilage; N: Nasal septum; P: Palate; T: Tongue. × 36.

FIG. B. The foreleg of normal mouse foetus. × 5.

FIGS. C, D. Various types of finger defect found in the group given both MTU and vitamin A. × 5.

FIG. E. The hind leg of normal mouse foetus. × 5.

FIGS. F, G, H, I. Various types of toe defect found in the group given both MTU and vitamin A. × 5.

S. TAKEKOSHI

(Facing page 264)

PLATE 2

FIG. J. A 17-day normal mouse foetus. ×2·5.

FIG. K. A 17-day abnormal mouse foetus found in the group given both MTU and vitamin A. Note the peculiar shape of limbs. ×2·7.

FIG. L. Skeleton of a 17-day normal mouse foetus. ×3.

FIG. M. Skeleton of a 17-day abnormal mouse foetus. Reduction in long-bone formation. ×3.

PBI was determined on the animals given an excess of vitamin A, and was found remarkably decreased. With group 4, which received combined administration of vitamin A and MTU, more remarkable goitres were produced than in group 3, which was given MTU alone.

TABLE 2

Effect of vitamin A on thyroid weight, thyroid I^{131} uptake, serum PBI, adrenal and testicular weight

Group	Treatment	Body weight (g.)	Number of animals	Thyroid weight (mg.)	Thyroidal I^{131} uptake	Serum PBI (γ/dl.)	Adrenal weight (mg.)	Testis weight (g.)
1	Tween 80 150 mg.	107±3	7	13·1±0·8	38·4±3·9	3·7±0·3	25·5±0·9	1·49±0·11
2	Vitamin A 50,000 I.U.	90±3	7	17·1±1·6	50·2±3·0	2·4±0·3	29·6±3·2	1·42±0·10
3	MTU 20 mg.	110±4	7	20·1±0·9	6·9±1·2	2·7±0·2	23·7±1·8	1·24±0·11
4	Vitamin A 50,000 I.U. and MTU 20 mg.	95±5	6	25·8±2·2	11·8±2·0	2·1±0·2	44·7±3·9	1·41±0·16

Results expressed as mean ± standard error of mean.

Administration of vitamin A did not elicit any change in testicular weight, but apparently increased adrenal weight. A similar result was earlier obtained with mice (Takekoshi, 1961*a*). Further, it is important to note that more increase in adrenal weight was obtained by combined administration of vitamin A and MTU than by administration of vitamin A alone.

DISCUSSION

According to an article by Drill (1943), McCarrisson discovered as early as 1923 that cod-liver oil retarded metamorphosis of tadpoles, and in 1936 Rokhlina observed that carotene had the same effect on axolotls, and in 1933 and 1935 Eufinger and Gottleib found that when vitamin A was administered to tadpoles, it depressed the metamorphosis-accelerating action of thyroxin. On the other hand there are reports that the administration of vitamin A decreased the size of the thyroid gland, that it lowered oxygen consumption (Logaras & Drummond, 1938; Sadhu, 1948; Sadhu & Brosy, 1947), and that it diminished serum PBI (Donowski *et al.*, 1955). Sometimes vitamin A was clinically used for treatment of hyperthyroidism (Dietrich, 1936). All these reports indicate that a large dose of vitamin A can elicit some changes in thyroidal function.

It was found in our experiments that the blood concentration of thyroid hormone was significantly reduced in vitamin A treated animals, while thyroid

weight and thyroidal uptake of I^{131} were significantly increased. It can therefore be considered that the blood concentration of thyroid hormone which was lowered by MTU would have further been lowered by the addition of vitamin A, consequently producing more significant goitre in group 4. The result was just as anticipated from the viewpoint of the feedback theory (Hoskins, 1949). But why was the blood concentration of thyroid hormone lowered by the administration of vitamin A? This point has already been discussed in detail by Shichijo & Shimoda (1962), and it was shown that vitamin A accelerates de-iodination of thyroxin and the concentration of circulating thyroid hormone may be decreased as a result.

On the other hand there are some reports that hypothyroidism of the mother may cause the congenital malformation of her child (Hodge *et al.*, 1952; Eliphinstone, 1953), and that congenital malformations occur frequently in such areas where endemic goitre is prevalent (Pasma, 1948). Langman *et al.* (1955) succeeded in producing malformations of the eye, cleft palate and harelip in the young by performing partial thyroidectomy or by giving MTU to the mother animal to induce hypothyroidism.

From these facts it is concluded that a fall in the blood concentration of thyroid hormone may have a close connection with teratogenesis due to vitamin A. If this is right, the administration of vitamin A in combination with anti-thyroidal substance must produce more malformations. Already Millen & Woollam (1958*a*) reported that when rats were orally given both vitamin A (from the 9th to 13th day of pregnancy) and MTU (from the 1st to the 9th day of pregnancy), teratogenesis was significantly greater than when vitamin A alone was given. Also, in the present experiment in which mice received injections of vitamin A and MTU from the 10th to 14th day of gestation, the results were exactly the same as those of Millen & Woollam, namely that the teratogenic action of vitamin A was enhanced by the simultaneous administration of MTU. The result can be explained by assuming that combined administration of vitamin A and MTU reduces the blood concentration of thyroid hormone more than the administration of MTU alone.

It has already been reported that trypan blue and vitamin A might also act synergistically in teratogenesis (Takekoshi, 1961*b*) (Table 3). Since Yamada (1960*a*, 1960*b*) observed that the administration of trypan blue decreased thyroid weight, thyroidal uptake of I^{131} and blood concentration of PBI, and Shimoda *et al.* (1962) assumed that trypan blue might probably exert inhibitory action on TSH secretion from the hypophysis, a similar explanation may be applied to the teratogenic activity of the combination of trypan blue and vitamin A. The combined administration of these two, both of which reduce PBI, may enhance the rate of producing malformations.

From the facts described above, it is evident that the mechanism of teratogenic action of vitamin A may involve the thyroid gland as well as the adrenal gland, on which the author reported previously (Takekoshi, 1961*a*). Teratogenic

TABLE 3

Combinative teratogenic effect of vitamin A and trypan blue on mice embryos

Treatment	*Number of dams*	*Number of living embryos*	*Number of young with cleft palate* (%)	*Number of young with tail malformation* (%)	*Number of young with any kind of malformation* (%)
1% trypan blue 0·2 c.c.	10	59	1 (1·6%)	0	1 (1·6%)
Vitamin A 5,000 I.U.	11	97	0	1 (1·0%)	8 (8·3%)
1% trypan blue 0·2 c.c. and vitamin A 5,000 I.U.	15	58	6 (10·3%)	5 (8·6%)	12 (20·7%)

1 per cent. trypan blue solution was injected subcutaneously on the 7th day of pregnancy. Vitamin A was injected intramuscularly for 4 days from the 10th to 13th day of pregnancy.

action of vitamin A, however, can by no means be explained by dysfunction of these endocrine glands only, for if malformation were simply the result of the fall of blood concentration of thyroid hormone, the administration of MTU alone would produce frequent malformations. But under the condition of the present experiments—with regard to the time and duration of MTU administration—no teratogenesis could be induced with MTU alone. It may, of course, be considered that the total dose of MTU in the present experiments was insufficient to lower the blood concentration of thyroid hormone, but at the same time one cannot deny the possibility that some unknown factor may be involved in the mechanism of teratogenesis besides endocrine dysfunction.

For these reasons it is impossible to draw any definite conclusion as to the mechanism of teratogenic action of vitamin A at the present time. But at least the present experiments have shown that there is a close relation between teratogenesis and fall of the blood concentration of the thyroid hormone.

SUMMARY

Investigations were carried out with ddN strain mice on the teratogenic effects of large doses of vitamin A. At the same time the relationship between the teratogenesis and thyroid function was examined with Wistar rats in order to elucidate the mechanism of the teratogenesis. The following results were obtained.

1. Administration of 10,000 I.U. of vitamin A alone to pregnant mice produced malformations in 71·2 per cent. of their living foetuses. Administration of 8 mg. of MTU alone could not produce any malformations, whereas combined administration of 10,000 I.U. of vitamin A and 8 mg. of MTU produced malformations in 100 per cent. of the foetuses.

2. Administration of 50,000 I.U. of vitamin A elicited a remarkable increase

in thyroid weight and in thyroidal uptake of I^{131}, and a remarkable fall in blood concentration of thyroid hormone.

3. Combined administration of 20 mg. of MTU and 50,000 I.U. of vitamin A produced more remarkable goitre than did the administration of 20 mg. of MTU alone. For this reason it is considered that the blood concentration of thyroid hormone, which is lowered by the administration of MTU, might have dropped still more by the addition of vitamin A.

4. In vitamin A treated animals, there were no changes in testis weight, but evident increase in adrenal weight. This tendency was still more significant when MTU was also given.

5. From these data it was suggested that besides the adrenal gland, the thyroid gland has a close connection with teratogenesis due to vitamin A. A fall in blood concentration of thyroid hormone was especially emphasized as one of the important factors.

RÉSUMÉ

Le mécanisme de la tératogénie induite par la vitamine A

Les recherches ont été effectuées sur la souche de Souris ddN pour éprouver les effets tératogéniques de hautes doses de vitamine A. En même temps, on a étudié la relation entre la tératogénèse et la fonction thyroidïenne sur des rats Wistar, afin d'élucider les mécanismes tératogéniques.

1. L'administration de 10.000 U.I. de vitamine A seule à des souris gestantes a provoqué des malformations chez 71,2% des foetus vivants. L'administration de 8 mg. de MTU seul ne provoque aucune malformation, tandis que l'administration combinée de 10.000 U.I. de vitamine A et ed 8 mg. de MTU provoque des malformations chez 100% des foetus.

2. L'administration de 50.000 U.I. de vitamine A provoque une importante augmentation du poids de la thyroïde, de l'assimilation thyroïdienne de I^{131}, et une chute importante de la concentration de l'hormone thyroïdienne dans le sang.

3. L'administration combinée de 20 mg. de MTU et de 50.000 U.I. de vitamine A pour effet de provoquer des goïtres plus importants que l'administration de MTU seul. On peut donc admettre que la concentration de l'hormone thyroïdienne dans le sang, qui est diminuée par l'administration de MTU, peut s'abaisser plus encore par l'addition de vitamine A.

4. Chez les animaux traités par la vitamine A, il n'y a aucun changement de poids des testicules, mais une augmentation manifeste du poids des surrénales. Cette tendance est encore plus significative, quand on donne en plus du MTU.

5. Ces données suggèrent qu'à côté de la surrénale, la thyroïde est en liaison étroite avec les malformations provoquées par la vitamine A. Une chute de la concentration d'hormone thyroïdienne dans le sang peut être considérée comme un facteur important dans le mécanisme tératogénique.

ACKNOWLEDGEMENT

The author expresses his deep thanks to Dr Ishii, chairman of the Department of Oto-rhino-laryngology and Dr Shimoda of the Department of Internal Medicine (Director: Prof. K. Shichijo), Gunma University, who gave him continuous aid concerning studies on the thyroid gland.

REFERENCES

ARAKI, E. (1958). Morphogenesis of cranial malformation due to excessive vitamin A. *J. Osaka City Med. C.* **7**, 445–52 (Japanese).

COHLAN, S. Q. (1953). Excessive intake of vitamin A as a cause of congenital anomalies in the rat. *Science*, **117**, 535–6.

COHLAN, S. Q. (1954). Congenital anomalies in the rat produced by excessive intake of vitamin A during pregnancy. *Pediatrics*, **13**, 556–67.

COHLAN, S. Q. & STONE, S. M. (1961). Observations on the effect of experimental endocrine procedures on the teratogenic action of hypervitaminosis A in the rat. *Biol. Neonat., Basel*, **3**, 330–42.

DAWSON, A. B. (1926). A note on the staining of the skeleton of cleared specimens with alizarin red S. *Stain Technol.* **1**, 123–4.

DIETRICH, H. E. (1936). Vitaminbehandlung der Schilddrüsen-überfunktion mit Vogan. *Münch. med. Wschr.* **83**, 313–14.

DONOWSKI, T. S., WIRTH, P., BLACK, M. H., BARTON, E. & BASTIANI, R. M. (1955). Effect of vitamin A supplements on serum PBI level, and disposal of exogenous thyroxine. *J. clin. Endocrin.* **15**, 1262–9.

DRILL, V. A. (1943). Interrelation between thyroid function and vitamin metabolism. *Physiol. Rev.* **23**, 355–79.

ELPHINSTONE, N. (1953). Thiouracil in pregnancy. *Lancet*, **i**, 1281–3.

GIROUD, A. et MARTINET, M. (1955). Hypervitaminosis 'A' et anomalies chez le faetus de rat. *Int. Z. Vitaminforsch.* **26**, 10–18.

GIROUD, A. et MARTINET, M. (1956). Tératogénèse par hautes doses de vitamin A enfonction des states du dévelopment. *Arch. Anat. micr.* **45**, 77–98.

GIROUD, A., GOUELLE, H. et MARTINET, M. (1957). Données quantitatives sur le taux de la vitamin A chez le rat lors d'expériences de tératogénèse par hypervitaminose A. *Bull. Soc. Chem. biol., Paris*, **39**, 331–6.

GIROUD, A. et MARTINET, M. (1959). Extension à plusieurs éspeces de mammifères des malformations embryonnaires par hypervitaminose A. *C. R. Soc. Biol., Paris*, **153**, 201–2.

GIROUD, A. et MARTINET, M. (1960). Teratogenic action of hypervitaminosis A in the mouse as a function of the embryonic stage. *C. R. Soc. Biol., Paris*, **154**, 1353–5.

HÄRTEL, A. & HÄRTEL, G. (1960). Experimental study of teratogenic effect of emotional stress in rats. *Science*, **132**, 1483–4.

HODGE, R. E., HAMILTON, H. E. & KEETEL, W. C. (1952). Pregnancy myxedema. *Arch. intern. Med.* **90**, 863–8.

HOSKINS, R. C. (1949). The thyroid-pituitary apparatus as a servo (Feed-Back) mechanism. *J. clin. Endocrin.* **9**, 1429–31.

INABA, T. (1958). Experimentally reproduced congenital malformations of rats by excessive vitamin A diet. *J. Osaka City Med. C.* **7**, 558–66 (Japanese).

KALTER, H. & WARKANY, J. (1961). Experimental production of congenital malformation in strains of inbred mice by maternal treatment with hypervitaminosis A. *Amer. J. Path.* **38**, 1–21.

KUZUKAWA, S. (1960). Embryological studies on the inner ear malformation of rats due to excessive vitamin A. *J. Osaka City Med. C.* **9**, 1469–81 (Japanese).

LANGMAN, J. & FAASSEN, F. (1955). Congenital defects in the rat embryo. *Amer. J. Ophthal.* **40**, 65–76.

LOGARAS, G. & DRUMMOND, J. C. (1938). Vitamin A and the thyroid. *Biochem. J.* **32**, 964–8.

MILLEN, J. W. & WOOLLAM, D. H. M. (1957*a*). Influence of cortisone on teratogenic effects of hypervitaminosis A. *Brit. med. J.* **5038**, 196–7.

MILLEN, J. W. & WOOLAM, D. H. M. (1957*b*). Effect of cortisone on the incidence of cleft-palate induced by experimental hypervitaminosis A. *Brit. med. J.* **5038**, 197–8.

MILLEN, J. W. & WOOLLAM, D. H. M. (1958*a*). Influence of 4-methyl-2-thiouracil on the teratogenic activity of hypervitaminosis A. *Nature, Lond.* **181**, 992–3.

MILLEN, J. W. & WOOLLAM, D. H. M. (1958*b*). Insulin-cortisone relationship in experimental teratogenesis, *Nature, Lond.* **181**, 418.

MILLEN, J. W. & WOOLLAM, D. H. M. (1958*c*). Effect of vitamin B complex on the teratogenic activity of hypervitaminosis A. *Nature, Lond.* **182**, 940.

MILLEN, J. W. & WOOLLAM, D. H. M. (1961). Influence of uterine position on the response of the mouse embryo to the teratogenic effects of hypervitaminosis A. *Nature, Lond.* **190**, 184–5.

NAKAMURA, S. (1958). Experimental studies on auditory organs, especially inner ear of rat fetuses born to mother animals fed with excessive vitamin A. *J. Osaka City Med. C.* **7**, 486–94 (Japanese).

PASMA, T. (1948). Der Zusammenhang zwischen Kropf und angeborenen Missbildungen. *Ned. Tijdschr. Geneesk.* **92**, 3630. Cited by Langman *et al.* (1955).

SADHU, D. P. & BROSY, S. (1947). Excess vitamin A ingestion, thyroid size and energy metabolism. *Amer. J. Physiol.* **149**, 400–3.

SADHU, D. P. (1948). Vitamin A, iodide and thyrotrophic hormone content of the anterior pituitary. *Amer. J. Physiol.* **152**, 263–6.

SHICHIJO, K. & SHIMODA, S. (1962). Effect of fatsoluble vitamin on thyroid function. *Folia endocrin. jap.* **37**, an extra, 100 (Japanese).

SHIMODA, S., TOMIZAWA, T., YAMADA, T. & SHICHIJO, K. (1962). Further studies on the inhibitory effect of diazo dye on the thyroid function in the rat. *Endocrinology*, **71**, 414–21.

TAKEKOSHI, S. (1961*a*). On teratogenicity of overdose of vitamin A. *Kitakanto Med. J.* **12**, 104–18 (Japanese).

TAKEKOSHI, S. (1961*b*). Teratogenesis due to hypervitaminosis A in combination with other teratogenic factor (cortisone, trypan blue, noise stimulation, urethan and chondroitin sulfate). *Jap. J. Otol.* **64**, 1489–97 (Japanese).

TSURUHARA, T. (1959). An embryological study on the abnormalities of the urinary tract system of rat due to excessive vitamin A. *J. Osaka City Med. C.* **8**, 1379–86 (Japanese).

YAMADA, T. (1960*a*). The effect of trypan blue on thyroid function in the rat. *Endocrinology*, **67**, 204–11.

YAMADA, T. (1960*b*). Mechanism of action of trypan blue in suppressing thyroid function. *Endocrinology*, **67**, 212–21.

YUKIOKA, K. (1958). Morphogenesis of experimental cleft palate due to excessive vitamin A. *J. Osaka City Med. C.* **7**, 725–34 (Japanese).

(*Manuscript received 21st November 1963*)

Targan-'69
Bib. No. 8995

Clin. Chem. 15(6):479-486. 1969.

Fractionation and Quantification of β-Carotene and Vitamin A Derivatives in Human Serum

Stephan R. Targan, Samuel Merrill, and Arthur D. Schwabe*

Concentrations of β-carotene, retinyl esters, retinol, retinal, and retinoic acid were determined quantitatively in human serum. Extraction of the compounds was accomplished with a petroleum ether-ethanol system and fractionation by thin-layer chromatography. Each fraction's absorbance was measured by ultraviolet spectrophotometry and expressed as micrograms per 100 ml. By this method, 85% or more of individual premeasured standards and more than 69% of premeasured combined standards could be recovered. The levels of β-carotene and Vitamin A derivatives recovered from the serums of 10 males and 10 females compared favorably with those obtained with other methods. The procedure outlined is rapid, simple, and reproducible.

A NUMBER OF VITAMIN A METABOLITES and β-carotene have been extracted from animal tissue, lymph, and plasma by a variety of methods (*1–5*). Separation of these fractions usually has been carried out by column chromatography and quantification by ultraviolet and visible spectrophotometry. The purity of each of the separated compounds subsequently has been determined by thin-layer chromatography. β-Carotene, Vitamin A esters (retinyl esters), Vitamin A aldehyde (retinal), Vitamin A alcohol (retinol), and an incompletely characterized, "more polar" fraction, which may contain Vitamin A acid (retinoic acid), have been identified, separated, and measured by these methods.

Since these methods are difficult and cumbersome, they have been applied almost exclusively to research problems. Recently, direct separation of a number of Vitamin A derivatives in serum has been accomplished by thin-layer chromatography (*6*). The method reported

From the Department of Medicine, University of California School of Medicine, Los Angeles, Calif 90024.

Supported by Grant AM-09082-03GM from the National Institute of Arthritis and Metabolic Diseases, US Public Health Service, and in part by General Research Support Grant 05354, University of California School of Medicine, Los Angeles.

Received for publication Aug 27, 1968; accepted for publication Oct 11, 1968.

*Supported by the Norman Jolliffe Medical Student Fellowship Award.

here represents a simplified, rapid approach, which may have clinical application and which has the added advantage of measuring retinoic acid directly.

Reagents and Materials

The β-carotene (100%), retinoic acid, retinol, and retinal in the all-trans forms were obtained from Eastman Kodak and all-trans retinyl acetate from General Biochemicals. The following other reagents were used: benzene and n-hexane (J. T. Baker), petroleum ether with a boiling point of 30–60°, ethyl ether (reagent grade ACS), ethyl alcohol 95% (Matheson), silica gel G with UV indicator (Brinkman Instruments). Weighed quantities of the five standards—ie, β-carotene and the four Vitamin A derivatives—were dissolved in spectro-grade chloroform (Merck) just prior to chromatography each day.

Experimental Procedures

Preparation and Processing of Measured Standard Samples

Weighed quantities of each of the five standards were dissolved in chloroform. Carefully measured aliquots of each were then spotted *separately* on specially prepared silica gel plates and developed as outlined in the third section below. After development, the spots were visualized by UV light, scraped off the plate separately, and measured spectrophotometrically as described in the fourth section below.

The above procedure was repeated, but this time aliquots of the five standards were spotted *together* at the origin. These mixed standards were separated and measured as detailed below.

An internal standard was prepared by adding 20-μg quantities of retinal dissolved in 50 μl of ethanol to 3 ml of human serum. This prepared standard and a control sample of serum were then carried through the extraction, fractionation, and quantification procedures described below.

Extraction of Carotene and Vitamin A Derivatives from Human Serum

First 20 ml of venous blood were drawn from each of 10 male and 10 female normal subjects in the fasting state. The blood was allowed to clot at room temperature for 20 min and the serum separated by centrifuging for 20 min at 2700 rpm.

In order to obtain a nonsaponified sample, the carotenoid pigments were extracted by a modification of the procedure of Blankenhorn (7). Then 3 ml of 95% ethanol were pipetted into each of two 15-ml stoppered centrifuge tubes, and 1.5 ml of serum was added dropwise through the ethanol into each tube. Finally, 3.0 ml of petroleum ether

was added to each of the tubes, which were then stoppered tightly. The tubes were shaken vigorously by hand for 10 min in order to liberate the carotene and Vitamin A derivatives from the carrier proteins (8), and then centrifuged for 10 min at 1500 rpm. The petroleum ether (upper phase) of the two tubes, containing the pigmented compounds, was carefully pipetted off and pooled into a single stoppered tube. The aqueous ethanol (lower phase), containing phospho- and neutral lipids and the precipitated protein, was discarded. The pooled extract was taken to dryness under a stream of nitrogen and dissolved in 0.5 ml of n-hexane just prior to chromatography.

Fractionation by Thin-Layer Chromatography

First, 20 × 20 × 0.5 cm glass chromatography plates were washed with Haemo-sol detergent, rinsed thoroughly with distilled water, and dried with acetone. The plates were coated to a thickness of 0.5 mm with a mixture of silica gel G and distilled water, 1:2 (w/v). The coated plates were then activated in a drying oven for 1 hr at 85°. The chromatographic procedures were performed in a dark room illuminated only with a red light. A line was drawn on the plate 13 cm from the origin, and all silica gel above this line was scraped off with a razor blade. Then 40 μl of each of the five standards were spotted with a Hamilton microsyringe on the left quarter of the plate. The entire 0.5 ml of the n-hexane extract of serum was spotted horizontally across the remaining three-fourths of the plate. The plates were placed immediately into developing tanks containing a solvent system of benzene and ethyl ether, 90:10 (v/v), and developed to 13 cm in a nitrogen atmosphere for periods of 25–30 min.

Quantitative Measurement of Fractions

Immediately after the plates were removed from the developing tank, the standard spots were visualized by UV light. The respective R_f values for the various standard fractions are listed in Table 1. The corresponding areas of each serum sample were zoned by drawing lines across the plate above and below each standard spot. Beginning with the uppermost zone containing both the β-carotene and retinyl esters and continuing with areas of decreasing R_f, each zone was scraped off the plate with a razor blade and placed into a test tube containing 4 ml of chloroform. In addition, a blank was taken from the area between the retinol and retinal and was processed similarly. This entire step took 4–5 min to complete.

The contents of the tubes were mixed and allowed to stand for 5–10 min under nitrogen, in order to separate the fractions from the silica

Table 1. QUANTITATIVE RECOVERY OF INDIVIDUAL STANDARDS

	R_f values	Maximum wavelength (nm)	Quantity (μg) Used	Quantity (μg) Recovered*	Recovery (%)	Recovery (%) Mean*	Recovery (%) SD
β-Carotene	0.90–1.00	466	20	19.4	97.0	97.4	±3.5
			40	37.0	92.5		
			60	60.0	100.0		
			80	80.0	100.0		
Retinyl esters	0.90–1.00	331	20	20.0	100.0	97.8	±3.2
			30	28.0	93.3		
			40	40.0	100.0		
			50	49.0	98.0		
Retinal	0.69	385	10	8.1	81.0	90.0	±7.8
			20	18.3	91.5		
			40	40.0	100.0		
			60	54.9	90.8		
Retinol	0.33	331	30	23.4	78.0	85.0	±5.2
			50	44.0	88.0		
			75	67.0	89.0		
			80	70.0	87.5		
Retinoic acid	0.08	361	15	13.0	86.7	85.5	±8.7
			20	16.0	80.0		
			30	23.3	77.7		
			40	39.0	97.5		

* Mean of 4 samples from stock solutions.

gel. The separation of the eluates from the silica gel was then completed by filtering the mixture through Whatman No. 1 filter paper (9.0 cm), which was saturated with chloroform. Under the present experimental conditions β-carotene and the retinyl esters are not separable chromatographically and were eluted as one fraction. The quantities of β-carotene and retinyl esters were estimated by measuring the absorptions at their respective maxima.

The 4.0-ml eluate of each fraction then was measured immediately by reading its absorbance in a Beckman Model B spectrophotometer at the appropriate wavelength. The following fractions were read at their maximum wavelengths in chloroform of their appropriate spectrums: β-carotene at 466 nm, retinal at 385 nm, retinoic acid at 361 nm. The retinol and retinyl esters were read at their maximum wavelengths (331 nm) and at one wavelength on each side of the maximum (343 and 319 nm) according to the procedure of Freed (*9*). Each fraction's total absorbance was converted to micrograms per milliliter by using conversion factors obtained from appropriate standard curves. The results

were converted to micrograms per 100 ml according to the following formula:

$$\mu g/ml \times 4.0 \times 33.3 = \mu g/100 \text{ ml serum}$$

Results

The absolute and mean amounts of four different, premeasured samples of the five standard fractions recovered by this method are shown in Table 1. Recovery was 85% or greater for all of the five fractions.

When aliquots of all five standard solutions were combined in a single spot at the origin of the silica gel plate on three separate occasions, the average amounts of each substance recovered after fractionation were somewhat lower, ranging from 69.7% for retinoic acid to 79.1% for retinal. When retinal was used subsequently as an internal standard in serum, the difference of the mean recovery value from that obtained by the previous procedure was not statistically significant (Table 2).

The results of fractionation of blood samples from the 20 subjects are listed in Tables 3 and 4. In males, β-carotene, retinyl ester, retinol,

Table 2. Separation and Quantitative Recovery of Combined Standards

	Quantity (μg)		*Recovery (%)*	*Recovery (%)*	
	Used	*Recovered*		*Mean*	*SD*
β-Carotene	25	19.4	77.6	76.6	± 1.6
	25	19.4	77.6		
	25	18.7	74.8		
Retinyl esters	25	16.3	65.2	77.6	±15.9
	25	23.9	95.6		
	25	18.0	72.0		
Retinal	20	16.4	81.5	79.1	± 2.1
	20	15.5	77.5		
	20	15.7	78.5		
Retinal*	20	16.4	82.0	81.3	± 3.6
	20	16.9	84.5		
	20	15.5	77.4		
Retinol	15	11.0	73.3	76.8	± 7.3
	15	12.8	85.3		
	15	10.8	72.0		
Retinoic acid	25	16.0	64.0	69.7	± 6.7
	25	19.3	77.2		
	25	17.0	68.0		

* Internal standard in serum.

and retinal tended to be higher than in females, but the difference was statistically significant only in the case of retinol. No retinoic acid was detectable in any subject in the fasting state. However, small quantities of retinoic acid were found in 2 additional fasting subjects on a weight-reduction diet (2.0 and 6.3 μg/100 ml) and in 1 out of 4 nonfasting subjects (10.4 μg/100 ml).

Discussion

Any technic for the quantitative fractionation of the carotenes and Vitamin A derivatives must take into consideration the minute serum concentrations and the rapid oxidation of these compounds. These considerations were met largely by the use of an extraction method,

Table 3. Separation and Quantification of β-Carotene and Vitamin A from the Serum of 10 Female Control Subjects

Subject	Age (yr)	β-Carotene (μg/100 ml)	Retinyl esters (μg/100 ml)	Retinol (μg/100 ml)	Retinal (μg/100 ml)	Retinoic acid (μg/100 ml)
1 P.M.	24	34.0	7.3	17.6	0	0
2 M.J.	24	22.6	5.2	15.5	0	0
3 N.C.	28	22.6	10.3	17.6	2.3	0
4 S.R.	20	8.0	7.3	19.8	0	0
5 M.S.	28	96.2	0	14.7	0	0
6 M.W.	25	55.5	0	22.7	4.5	0
7 R.G.	21	29.4	15.4	12.5	2.3	0
8 A.S.	34	18.1	5.2	15.4	7.0	0
9 S.B.	36	28.6	5.9	15.3	6.8	0
10 B.B.	29	33.9	10.3	15.4	0	0
Mean	26.9	34.9	6.7	16.6	2.3	0
SD (±)		24.9	4.7	2.9	2.9	0

Table 4. Separation and Quantification of β-Carotene and Vitamin A Derivates from the Serum of 10 Male Control Subjects

Subject	Age (yr)	β-Carotene (μg/100 ml)	Retinyl esters (μg/100 ml)	Retinol (μg/100 ml)	Retinal (μg/100 ml)	Retinoic acid (μg/100 ml)
1 A.S.	43	27.2	12.5	22.6	2.3	0
2 S.T.	22	51.0	12.5	22.6	3.5	0
3 J.C.	16	35.1	10.3	17.6	5.3	0
4 S.M.	28	31.7	10.2	12.5	5.7	0
5 L.W.	27	28.3	8.1	13.2	7.9	0
6 R.C.	29	144.9	0	79.1	20.4	0
7 E.S.	36	30.0	12.4	10.3	5.7	0
8 F.S.	40	22.6	8.1	7.3	5.7	0
9 T.K.	23	62.3	10.3	30.0	9.1	0
10 B.W.	47	45.3	8.8	20.5	5.7	0
Mean		48.7	9.3	23.6	7.1	0
SD (±)		19.1	3.6	12.6	5.0	0

which does not involve saponification: by the rapid and complete separation of the fractions by thin-layer chromatography; and by a rapid elution procedure. In order to determine that retinol was completely extracted from the serum, the method outlined was compared with a more commonly used extraction method employing chloroform and methanol (*2, 4*). There were no significant differences between the results obtained by the two methods. After the plates are developed, it is vital to elute the zone fractions within 4–5 min—ie, before any appreciable evaporation of the benzene-ether solvent system has taken place. Once the filtration has been completed, however, the eluates may be kept up to 1 hr without significant decomposition or change in the concentration of the fractions. Thus, oxidation can be minimized by performing all steps rapidly in a dark room under constant nitrogen saturation. When these precautions are taken, it is felt that the efficiency of silica gel G as an absorbent is comparable to alumina gel or silica gel buffered to pH 8 with phosphate buffer. Significant variation in the loss of compounds recovered from the serums were not observed on the many occasions when samples were run in duplicate.

All determinations were made in blood samples obtained from subjects in the fasting state, since rises in β-carotene, retinyl esters, and retinoic acid have been observed shortly after their oral administration or the ingestion of certain foods (*1, 10–12*). In the measurement of retinol and the retinyl esters, the method proposed by Freed (*9*) was used instead of the more commonly employed Carr-Price reaction. Although the Carr-Price reaction may be slightly more sensitive, it is difficult to control and is subject to interference by compounds other than retinol and retinyl esters (*2, 13, 14*). In order to determine whether the accuracy of the quantitative analysis was impaired by using very small quantities of serum, 3- and 10-ml samples of the same serum were extracted, applied to the plate, and carried through the procedure. The results obtained were comparable with the 5% range, which suggests that the method was accurate for even small quantities of serum.

The quantities of the various fractions recovered are consistent with those reported by other investigators (*10–12, 15*). The main advantages of the method outlined seem to be simplicity, speed, sensitivity, and the ability to quantify not only retinol and retinyl esters, but also retinal and retinoic acid.

References

1. Fujita, A., and Kimura, K., An improved micromethod for fractional determination of vitamin A alcohol and ester and the changes in both types of vitamin A in blood plasma, milk and liver after loading with both types of vitamin and β-carotene. *J. Vitaminol. (Kyoto)* 6, 6 (1960).

2. Olson, J. A., The conversion of radioactive β-carotene into vitamin A by the rat intestine in vivo. *J. Biochem.* **236**, 349 (1960).
3. Kubler, W., and Lorenz, H., Determination of vitamin A ester, free vitamin A and carotenoids in healthy adults. *Intern. Z. Vitaminforsch.* **33**, 411 (1963).
4. Huang, H. S., and Goodman, D. W. S., Vitamin A and carotenoids: I. Intestinal absorption and metabolism of C^{14}-labeled vitamin A alcohol and β-carotene in the rat. *J. Biol. Chem.* **240**, 2839 (1965).
5. Kuznetsova, L., and Kavalyova, V. N., Thin layer chromatography and quantitative determination of vitamin A alcohol and its esters. *Ukr. Biokhim. Z.* **36**, 302 (1966).
6. Kahan, J., Thin layer chromatography of vitamin A metabolites in human serum and liver tissue. *J. Chromatog.* **30**, 506 (1967).
7. Blankenhorn, D. H., Carotenoids in man. II. Fractions obtained from atherosclerotic and normal aortas, serum and depot fat by separation on alumina. *J. Biol. Chem.* **227**, 963 (1957).
8. Garbers, C. F., Gillman, J., and Peisach, M., The transport of vitamin A in rat serum with special reference to the occurrence of unidentified metabolites of vitamin A in the rat. *Biochem. J.* **75**, 124 (1960).
9. Freed, M., *Methods of Vitamin Assay* (ed. 3). Interscience, New York, 1966, p. 63.
10. Week, E. F., and Sevigne, F. J., Vitamin A utilization studies. *J. Nutr.* **40**, 563 (1950).
11. Ganguly, J., Absorption, transport and storage of vitamin A. *Vitamine Hormone* **18**, 387 (1960).
12. Jurkowitz, L., Determination of vitamin A acid in human plasma after oral administration. *Arch. Biochem. Biophys.* **98**, 337 (1962).
13. Owen, E. C., Some aspects on metabolism of vitamin A and carotene. *World Rev. Nutr. Dietet.* **5**, 132 (1965)
14. Mahadevan, S., Ayyoub, N. I., and Roels, O. A., Hydrolysis of retinol palmitate by rat liver. *J. Biol. Chem.* **241**, 57 (1966).
15. Hoch, H., and Hoch, R., The state of vitamin A in human serum. *Brit. J. Exptl. Pathol.* **27**, 316 (1946).

Thomas, et al-'60
Bib. No. 9077

Reproduced by permission
of the copyright owner

J. Exp. Med. 111:705-718. 1960.

COMPARISON OF THE EFFECTS OF PAPAIN AND VITAMIN A ON CARTILAGE

I. The Effects in Rabbits*

By LEWIS THOMAS, M.D., ROBERT T. McCLUSKEY, M.D., JACOBUS L. POTTER,‡ M.R.C.P.E., and GERALD WEISSMANN,§ M.D.

(From the Departments of Medicine and Pathology, New York University–Bellevue Medical Center, Third (N. Y. U.) Medical Division, Bellevue Hospital, New York and Strangeways Research Laboratory, Cambridge, England)

Plates 53 to 57

(Received for publication, January 16, 1960)

It was previously shown that an intravenous injection of papain in young rabbits results in prompt depletion of the basophilic component of matrix in all cartilaginous tissues, accompanied by a loss of the structural integrity of cartilage manifested by collapse of the rabbits' ears (1). This effect is demonstrable with crystalline papain protease, and appears to be due to a direct enzymatic action on chondromucoprotein which results in the release of chondroitin sulfate from cartilage (2, 3). In the gross, the ears recover their rigidity within 3 to 5 days, but the normal histologic appearance of cartilage may not be completely restored until 3 weeks (4). Administration of cortisone prevents reconstitution of cartilage matrix (1), presumably by directly interfering with the capacity of cartilage cells to resynthesize the components of cartilage (4).

Fell and Mellanby (5), in a study of the effects of excess vitamin A on organ cultures of embryonic mouse and chicken bones, found that the basophilia disappeared from cartilage matrix within a few days after introducing the vitamin. The end product was a small, deformed structure in which the cartilage cells were packed closely together, although evidently viable and healthy, with little or no basophilic matrix between the cells. They reported that chondroitin sulfate had largely disappeared from the cartilage of rudiments grown in the presence of excess vitamin A (6).

Because of the histological resemblances between the cartilage of rabbits treated with papain, and that of embryonic bone cultures exposed to vitamin A, a study was undertaken to see whether the effects of vitamin A, *in vivo*, would parallel those of papain.

* This work was aided by grants from the United States Public Health Service (H-2022 and A-1395) and from the Armed Forces Epidemiological Board (DA-49-007-MD-590).

‡ Supported by a Fellowship from the John Polachek Foundation for Medical Research.

§ Fellow of the Arthritis and Rheumatism Foundation, 1958–59.

It has been learned that the administration of vitamin A in large doses to young rabbits usually brings about partial collapse of the rabbits' ears within a few days, attended by loss of basophilia and of the chondroitin sulfate of cartilage matrix. Although the depletion of matrix is less extensive than that previously reported to occur after papain, it has been found that a small dose of papain, sufficient only to cause slight drooping of the ears, produces changes which are remarkably similar to those caused by vitamin A. The present paper is concerned with a description of these events. In a separate communication, it will be shown that the addition of papain protease to embryonic bone cultures brings about changes in cartilage matrix which resemble those previously encountered with vitamin A (7).

Materials and Methods

Rabbits.—Young, hybrid, male, albino rabbits, obtained from several breeding sources, were maintained on commercial pellets and water. The animals weighed approximately 1 kilogram.

Vitamin A.—Solutions of vitamin A palmitate in corn oil were obtained from Merck and Company, Rahway, New Jersey, and from Nutritional Biochemicals Corporation, Cleveland. The vitamin A was administered by intraperitoneal injection or by gastric intubation in amounts described below.

Histology.—The animals were killed by injection of nembutal and the tissues were fixed in 10 per cent buffered formalin. Sections were prepared from ear, trachea, and the distal end of the femur; from several of the animals sections of heart, lung, cornea, skin, aorta, liver, spleen, and kidney were taken as well. Bones were decalcified in dilute formic acid. Sections were stained as routine with hematoxylin and eosin and in some instances with toluidine blue by the method of Kramer and Windrum (8) and with Alcian blue according to the method of Wagner and Shapiro (9). Some sections were stained by the periodic acid–Schiff method.

Sulfated Mucopolysaccharides.—A turbidimetric procedure was used to estimate the concentrations of chondroitin sulfate-like material in the serum of the animals. This was a modification of the method of Vouras and Schubert (10) as previously described (11). From blood obtained by cardiac puncture, a 0.4 ml. sample of serum was dialyzed at 4°C. for 48 hours against 6 liters of distilled water. The contents of the bags were emptied into 10 × 75 mm. tubes and the volume adjusted to 2.2. ml. by the addition of distilled water. The tubes were centrifuged for 20 minutes at 2000 R.P.M. The supernatant was transferred to matched Coleman, Jr., spectrophotometer cuvettes and the apparent absorbance at 615 mμ determined, using distilled water as a blank. Five minutes after the addition of 0.2 ml. of a 0.5 per cent w/v solution of hexamminecobaltic chloride in distilled water, the apparent absorbance was again determined and the result of the test was recorded as the difference between the 2 readings. The solution of hexamminecobaltic chloride was freshly prepared from material twice recrystallized as described previously (10).

Carrier-free sulfur-35 was obtained as sodium sulfate in water. The dosage used was calculated on the basis of data provided by the supplier. In each of the rabbits given sulfur 35, 0.5 mc. was administered intraperitoneally. Serum obtained by cardiac puncture from these animals was subjected to the following procedures: (*a*) 0.1 ml. samples were plated in planchettes of 2.5 cm. diameter and dried by heating at 90°C. for at least 48 hours; (*b*) 0.4 ml. samples were dialyzed and diluted as described above, and 0.1 ml. samples of the dilute serum were obtained before the addition of the cobalt reagent and were plated and dried in planchettes; (*c*) after measurement of the turbidity produced by addition of the hexamminecobaltic

hloride, the cuvettes were centrifuged at 2000 R.P.M. for 20 minutes and 0.1 ml. samples of the supernatant were dried as before. No satisfactory method was devised for directly measuring the sulfur-35 activity in the precipitates produced by the addition of hexamminecobaltic chloride.

Samples were counted in duplicate in a gas flow counter with a micromil end window (Nuclear, Chicago). In one experiment, rabbits were kept in metabolic cages and urine was collected under phenol. Sulfur-35 activity was measured on 0.1 ml. samples of the urine excreted in 24 hours.

Autoradiographs were prepared from paraffin-embedded sections cut at 5 μ using Kodak contrast process ortho film for gross autoradiographs according to the method of Dziewiatkowski (12), and with stripping film AR 10 (Kodak, Ltd.) for microautoradiographs by the method of Pelc (13).

Chondromucoprotein was prepared by the method of Malawista and Schubert (14), from acetone-dried pooled ear cartilage plates obtained from rabbits given sulfur-35. The crude chondromucoprotein was not reprecipitated. Hexosamine was determined by a modification of the method of Elson and Morgan described in reference 15, using glucosamine hydrochloride as the standard. Nitrogen was determined by the Kjeldahl method. The mucoprotein was dissolved in 0.1 M phosphate buffer (pH 7.01) to a concentration of 1 mg. per ml., and 0.1 ml. of this solution was counted for sulfur-35 activity as above.

Crude papain (Nutritional Biochemicals Corp.) was dissolved in 0.05 M phosphate buffer (pH 7) by grinding with mortar and pestle. The insoluble material was removed by filtration through paper. The protein concentration of the solution was determined by the biuret method.

EXPERIMENTAL

Gross Changes Following Vitamin A.—In preliminary experiments, vitamin A was fed to 10 rabbits by stomach tube, in a single dose of 400,000 international units dissolved in 2 ml. of corn oil. Within 2 days the ears of 6 of these animals had become partially collapsed, with curling of the distal third, as illustrated in Fig. 1. Histological studies revealed depletion of the basophilic component of the matrix in articular, epiphyseal, and tracheal cartilage. It was then found that similar changes occurred when vitamin A was injected intraperitoneally, and because of its greater convenience in experiments involving large numbers of rabbits this route of administration was used in all subsequent work. Higher doses were generally employed, in view of reports that vitamin A is less effective when injected than when given by gastric intubation.

Forty-six rabbits were given daily injections of 1 million units of vitamin A and killed for histological study at intervals ranging from 24 hours to 7 days. Of these, 31 (67 per cent) showed curling of the tips of their ears at some stage during the period of observation. This change (Fig. 1), was characterized by loss of the rigidity and erectness of the distal 1 to 2 cm. of the ears. It never involved the more proximal portions of the ear, in contrast to the complete collapse which usually follows an injection of 5 mg. of crude papain in rabbits of this size. In the majority of animals affected, curling occurred within 72 hours. In some it appeared as early as 24 hours, in others as late as 6 days. Recovery of the erect state of the ears occurred in 5 of the animals after 72

hours, while vitamin A was still being administered. Weights were recorded regularly throughout the experiment, and most animals either failed to gain weight or lost weight. The rabbits given vitamin A for 5 days or longer usually developed loss of hair, especially in the region of the mouth and paws.

Control animals consisted of 11 rabbits kept under the same conditions and given daily intraperitoneal injections of corn oil without vitamin A, and 11 litter mates which received no treatment. None of these animals showed the abnormalities of cartilage observed in the treated group.

Histologic Changes.—Histologic sections were prepared from tissues in 30 rabbits injected with vitamin A. Three animals were killed 24 hours after one injection; these showed no changes in cartilage. In most of the rabbits killed 2 or more days after the first injection, there were characteristic alterations in cartilage, affecting especially articular and epiphyseal cartilage. Examination of ear cartilage was unsatisfactory because of the variability of staining properties in normal rabbits and only equivocal depletion of ear cartilage was seen in vitamin A-treated rabbits. Sections from the distal end of the femur showed reduction or disappearance of basophilic, metachromatic, and Alcian blue staining of the articular cartilage and of the epiphyseal plates associated with thinning of these structures (Figs. 2 to 7). The cartilage cells appeared to be intact but were smaller than normal and showed little or no basophilia or metachromasia. In sections stained by the periodic acid–Schiff method, the cells showed reduction in the amount of PAS-positive material. The cartilaginous cores of the metaphyseal bony trabeculae and of the trabeculae adjacent to the articular cartilage stained normally with hematoxylin, toluidine blue, and Alcian blue. The frequency and severity of the changes in cartilage increased with the number of days of treatment. It should be noted, however, that in 8 of 23 rabbits killed after 5 days of injections, there were no changes in cartilage.

The earliest alterations seen in the epiphyseal plates were present in 2 of the 4 animals killed 2 days after the first injection and consisted of loss of basophilic staining and slight thinning of the plates (Fig. 5). In animals killed after 5 days, there were usually more severe changes in the epiphyseal plates. In some animals, vascularization of the zone of proliferating cartilage extended in from the metaphysis (Fig. 6). In others, the epiphyseal plate was reduced to a thin layer of completely eosinophilic, non-metachromatic tissue with little or no arrangement of cartilage cells into columns (Fig. 7). This was associated with increased numbers of metaphyseal bony trabeculae immediately adjacent to the epiphyseal plate (Fig. 7).

In all the rabbits that showed changes in the epiphyseal plates, there was also depletion and slight thinning of articular cartilage (Figs. 2 and 3).

Changes were present in the tracheal cartilage in 8 of the 23 rabbits that were killed 2 or more days after the first injection, and consisted of loss of basophilic staining of certain areas of cartilage matrix. Where the cartilage plate was thin, its entire thickness was sometimes involved, but usually the depletion was seen only in the peripheral portions of cartilage with the central area remaining normally basophilic (Figs. 8 and 9). Sections of the tracheal cartilage from control rabbits occasionally showed absence of basophilic staining toward the periphery, but in 8 of the vitamin A-injected animals the lack of basophilia was far more extensive than that seen in any of the control animals.

Sections of heart, lung, liver, spleen, kidney, aorta, skin, and cornea were prepared from 10 experimental animals. The only abnormalities found were slight fatty change in the liver of 3 animals and metastatic calcification in the kidney of 2 animals.

Measurement of Cobalt-Precipitable Material in the Serum of Vitamin A-Treated Rabbits.—The histologic changes in cartilage described above indicated

that chondroitin sulfate was lost from cartilage. In order to see if this was associated with release of chondroitin sulfate into the blood, determinations of cobalt-precipitable material in serum were made, by the method described above, in 22 rabbits injected daily with 1 million units of vitamin A, in 11 rabbits injected daily with corn oil, and in 11 untreated controls.

The upper limit of normal, based on measurements in 50 rabbits kept under similar conditions and bled repeatedly, was found by this method to be 0.065 absorbance units.

This level was not exceeded at any time in the 11 untreated, control animals tested in these experiments, nor in 11 rabbits given daily intraperitoneal injections of corn oil.

TABLE I

Incidence of Increased Cobalt Turbidity in Serum of Rabbits Given Daily Injections of Vitamin A, 1 Million Units

No. of days after 1st injection of vitamin A	No. of rabbits tested	Increased cobalt turbidity*		Controls‡
		No.	Percentage	
0	19	0	0	0/17
1	15	3	20	0/13
2	22	8	36	0/18
3	18	9	50	0/12
4	7	6	86	0/7
6	17	10	59	0/13

* Absorbance increment greater than 0.065. = upper limit of normal in normal rabbits

‡ Daily injections of corn oil, 11 rabbits. No treatment, 11 rabbits.

In the rabbits injected daily with vitamin A, however, there was a progressive increase in the incidence of abnormally elevated serum cobalt turbidity. Between the 3rd and the 6th day after the first injection of vitamin A, 25 of 33 samples showed increased serum cobalt turbidity (Table I). While additional data are necessary to establish the precise quantitative significance of these values in terms of chondroitin sulfate, on the basis of *in vitro* experiments in which known amounts of chondroitin sulfate were added to a variety of sera (11), it is estimated that on the average there was a 10-fold increase and in some cases a 50-fold increase in the serum level of chondroitin sulfate at 48 and 72 hours. When beef nasal septum chondroitin sulfate was added to normal rabbit serum at a concentration of 1 mg./ml. and carried through the above turbidimetric procedure, the absorbance at 615 mμ was 0.150 units.

The Effect of Vitamin A Administration on Incorporated Sulfur-35.—It has been established that when sulfur-35 is administered to animals as inorganic sulfate, a large percentage of the injected activity is excreted within a few days.

The retained sulfur-35 is incorporated mainly in sulfated mucopolysaccharides (16, 17), such as the chondroitin sulfate of cartilage (16). In order to study the effect of vitamin A administration on incorporated sulfur-35, the following experiment was performed:

10 rabbits were each given 0.5 millicurie of carrier-free sulfur-35 as $Na_2S^{35}O_4$ intraperitoneally. Five days later, daily injections of 1 million units of vitamin A were initiated in 7 of these animals and continued for 5 days. The remaining 3 rabbits were given a similar course of injections of corn oil. Serum levels of sulfur-35 were measured immediately before treatment and daily thereafter for 7 days, at which time the rabbits were sacrificed, and histologic sections and autoradiographs prepared. Activity was determined in whole serum, dialyzed serum and in the supernatants following removal of the material precipitated by hexamminecobaltic chloride.

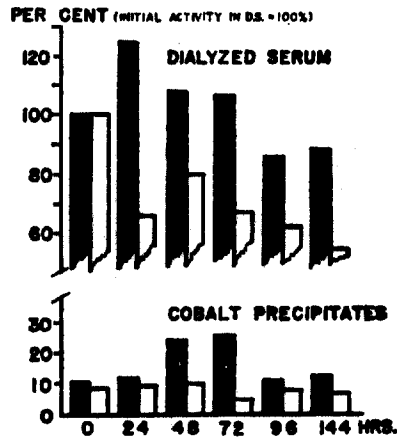

TEXT-FIG. 1. Sulfur-35 activity in dialyzed serum and cobalt precipitates. Mean Values for vitamin A-treated rabbits (black) and controls injected with corn oil (open). Daily injections of vitamin A and corn oil were initiated at 0 hours, and were continued for 5 days.

Sulfur-35 activity in material precipitated by hexamminecobaltic chloride was calculated from the amount of activity lost from dialyzed serum following removal of the precipitates. All values are expressed as percentages of the activity in dialyzed serum (D.S.) at 0 hours.

From the sulfur-35 activity in blood and urine prior to administration of vitamin A or corn oil, it was apparent that the amount of the isotope retained by different animals varied considerably. For this reason the data have been expressed as percentages of the activity in dialyzed serum at the start of the treatment. The averages calculated from these percentages are therefore not weighted in favor of animals which retained larger amounts of sulfur-35. In all samples of serum from both treated and control groups, little or no reduction of sulfur-35 activity occurred during dialysis, the maximum loss being 20 per cent, and this only from initial samples. The euglobulin precipitated by dialysis with distilled water had negligible sulfur-35 activity.

Twenty-four hours after the first injection of vitamin A, the sulfur-35 activity of dialyzed serum increased in 6 of the 7 rabbits, to an average for the whole group of 125 per cent of the initial activity (Text-fig. 1). Some increase was still apparent in the 48 and 72 hour samples of dialyzed serum from the vitamin A–treated rabbits.

In contrast, there was no similar increase at any stage in serum from the control animals, and in addition the ultimate level of activity in this group was considerably below that of the vitamin A–treated rabbits.

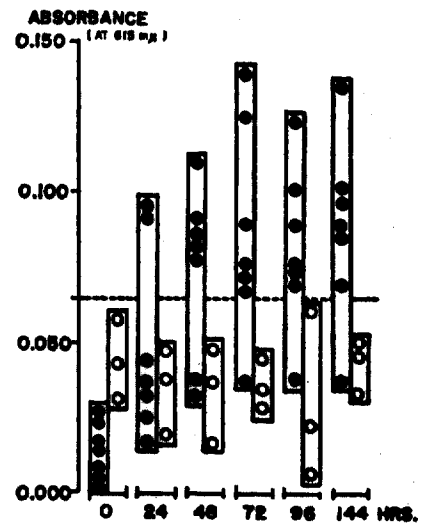

TEXT-FIG. 2. Hexamminecobaltic chloride turbidity of rabbit serum following administration of vitamin A. Turbidity was measured before and after vitamin A 1 million units daily in 7 rabbits (black circles) and corn oil 1 ml. daily in 3 rabbits (open circles).

Increased amounts of cobalt-precipitable material were present in the serum of 6 of the 7 vitamin A–treated rabbits at 72, 96, and 144 hours after the start of treatment. Of these 6, 5 also showed significant elevation at 48 hours and 2 at 24 hours. No significant increase was observed at any stage in serum from the control group (Text-fig. 2).

Initially, the sulfur-35 activity removed by precipitation with hexamminecobaltic chloride was about 10 per cent of the total in dialyzed serum in the control and experimental groups. At 48 and 72 hours this increased to about 25 per cent in the vitamin A–treated animals, but did not change in the controls (Text-fig. 1).

Urine was collected from the 3 control rabbits and 2 of the experimental animals. Sulfur-35 activity was measured in 0.1 ml. aliquots from each 24 hour collection, and the total output calculated. Shortly following administration of

the isotope, a large amount of radioactivity was present in the urine of all 5 rabbits. This rapidly declined in the next 6 days, the last 2 of which were in the experimental period. Thereafter, the 2 vitamin A–treated rabbits excreted nearly twice as much sulfur-35 as the 3 controls (Text-fig. 3).

The Isolation of Chondromucoprotein from Rabbits with Incorporated Sulfur-35.—Following sacrifice of these animals, the cartilage plates of the ears were stripped of skin and underlying tissues, diced, and dried in acetone. The chondromucoprotein obtained was weighed and analyzed for hexosamine and nitrogen. Sulfur-35 activity was measured in samples. The results are presented in Table II. While the amount of extracted chondromucoprotein per gram of

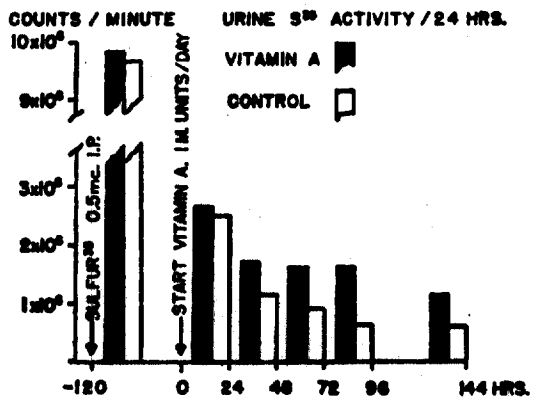

TEXT-FIG. 3. Urinary output of sulfur-35 in experimental and control groups. Means of total sulfur-35 activity in 24 hour collections of urine from vitamin A–treated rabbits (black columns) and controls (open columns). Initial value is the average daily output between administration of sulfur-35 and first injection of vitamin A or corn oil.

dry cartilage was essentially the same in both control and experimental animals, the cartilage from the control group yielded slightly more hexosamine and less nitrogen than that from vitamin A–treated rabbits. The sulfur-35 activity of chondromucoprotein from the control animals was nearly twice that of vitamin A–treated rabbits.

Histologic and Autoradiographic Findings.—Of the 7 rabbits treated with vitamin A in this experiment, 6 showed moderate or severe depletion of matrix with loss of basophilic, metachromatic, and Alcian blue–positive material in epiphyseal plates and in articular cartilage in sections taken from the lower end of the femur. There was moderate or severe thinning of the epiphyseal plates in all of the affected animals.

Gross autoradiographs showed that in these 6 animals there was only a faint image corresponding to the epiphyseal plate and over articular cartilage, in contrast to the 3 control rabbits which showed an intense image over these

structures (Figs. 10 to 17). The 7th animal in the vitamin A group showed a normal distribution of sulfur-35 in these areas and normal staining properties of cartilage. In the 6 vitamin A–treated animals with changes in cartilage, there was a zone of increased density in the metaphysis and a dense image just beneath the articular cartilage. These findings were studied by microautoradiographs which are illustrated in Figs. 12, 13, 16, and 17. There was marked reduction in the number of sulfur-35 granules over the articular cartilage and over the epiphyseal plates. The image overlying the cartilaginous cores of the metaphyseal trabeculae showed the same intensity as in controls (Fig. 18); this together with the increased number of metaphyseal trabeculae in the vitamin A–treated group accounted for the zone of increased density seen in this region in the gross autoradiographs. There was also a normal amount of sulfur-35 in the cores of newly formed bone immediately beneath the articular

TABLE II

Comparison of Crude Chondromucoprotein Obtained from Control and Vitamin A—Treated Rabbits, 1 Million Units Daily

	Control	Vitamin A
Yield of chondromucoprotein*	65.00 mg.	77.50 mg.
Yield of residue*	871.00 mg.	866.00 mg.
Hexosamine, *per cent*	10.0	8.6
Nitrogen, *per cent*	6.5	8.1
Nitrogen/hexosamine ratio	8.3	12.0
Counts per minute S^{35}*	23,500.	13,700.

* Per gram of dry cartilage.

cartilage and this was responsible for the image seen in this area in the gross autoradiographs.

The Production by Small Doses of Papain of Changes in Cartilage Resembling Those Seen Following Vitamin A.—The changes seen in cartilage following vitamin A treatment differed from those usually observed in young rabbits after the injection of 5 mg. of crude papain, in that with papain there is complete collapse of the rabbits' ears and complete disappearance of basophilic staining in all cartilaginous tissue throughout the body. An investigation was undertaken to see whether smaller doses of papain would produce changes in cartilage more nearly resembling those brought about by vitamin A.

Accordingly, 18 rabbits averaging 1000 gm. were treated as follows: 5 received a single intravenous injection of 0.5 mg. of crude papain and were killed 2 days later; 5 rabbits were given 3 daily injections of 0.25 mg. of crude papain and killed 1 day after the last injection; 5 rabbits were given 5 daily injections of 0.12 mg. of crude papain and killed 1 day after the last injection. Three rabbits were used as controls. Histologic sections were prepared from ear, trachea, and distal end of the femur and stained with hematoxylin and eosin, toluidine blue, and Alcian blue.

The alterations in cartilage in the 3 groups of papain-treated rabbits were remarkably similar to those seen after vitamin A administration. There was almost complete loss of basophilic, metachromatic, and Alcian blue–positive material in articular cartilage in every experimental animal (Fig. 19). The epiphyseal plates were narrowed and showed diminution or absence of the usual staining properties of cartilage in all of the papain-injected rabbits (Fig. 20). In some rabbits, vascularization extended from the metaphysis into the zone of proliferating cartilage. These changes in epiphyseal plates were indistinguishable from those seen in vitamin A-treated rabbits showing moderate thinning of epiphyseal plates. The cartilaginous cores of the bony trabeculae adjacent to epiphyseal plates and articular cartilage stained normally in the papain-injected animals, as in the rabbits given vitamin A. Sections of trachea from the rabbits injected with papain showed only slight and irregular depletion of cartilage matrix in 6 animals, which was similar to that seen in vitamin A–injected rabbits. Sections of ear showed only equivocal loss of basophilic staining.

DISCUSSION

On the basis of the experiments reported here it is evident that depletion of cartilage matrix can be produced in intact animals by the administration of large amounts of vitamin A. This effect has not previously been described in intact animals, but the changes in cartilage are similar to those observed in organ cultures in the presence of excess vitamin A.

There are several independent lines of evidence showing that chondroitin sulfate is lost from the cartilage of rabbits given large amounts of vitamin A. These include the diminution or disappearance of basophilic, metachromatic, and Alcian blue—positive material from cartilage, especially in certain areas (articular and epiphyseal cartilage); the loss of previously incorporated sulfur-35 from these sites, as shown by autoradiography; and the appearance in the blood of cobalt-precipitable material presumed to be chondroitin sulfate. In addition, the finding of increased amounts of non-dialyzable sulfur-35 activity in the serum, the relative increase in the amount of sulfur-35 in the urine, the reduction in the sulfur-35 activity, and the increased nitrogen/hexosamine ratio of extracted crude chondromucoprotein support this interpretation.

Evidence indicating that the cobalt turbidity technique is a relatively specific method for measuring serum chondroitin sulfate levels above 250 μg./ml. has been presented elsewhere (11).

In the present investigation it was found that after the administration of vitamin A, a marked increase in non-dialyzable sulfur-35 activity preceded the appearance in serum of elevated levels of cobalt-precipitable sulfur-35 activity. Maximum sulfur-35 activity was present in the cobalt-precipitable material in serum obtained 72 hours after the first injection of vitamin A.

Samples of sera obtained after 72 hours continued to have increased amounts of cobalt-precipitable material, but the sulfur-35 activity of these precipitates fell progressively to insignificant levels at 144 hours.

These findings are open to several interpretations. The initial increase in sulfur-35 activity in dialyzed serum may be due to the liberation from cartilage of components of chondroitin sulfate that are not capable of forming a complex with hexaminecobaltic chloride. Alternatively, non-precipitable material containing sulfur-35 may be liberated from other tissues at this stage. The cobalt-precipitable sulfur-35 activity seen at 48 and 72 hours most probably represents chondroitin sulfate liberated from cartilage. A similar increase of cobalt-precipitable material containing sulfur-35 activity has been observed in association with depletion of cartilage matrix produced by papain (11). The low sulfur-35 activity of cobalt precipitates at 96 and 144 hours could be due to the liberation from cartilage of the most recently synthesized chondroitin sulfate, which would contain relatively little sulfur-35.

Although most of the rabbits given 5 daily injections of 1 million units of vitamin A showed striking changes in cartilage, some of the rabbits receiving such treatment showed no changes in cartilage in any location.

Acute hypervitaminosis A in the rabbit affects cartilage of joint surfaces and epiphyseal plates more regularly and severely than in ear and trachea. It is noteworthy that repeated injections of minute amounts of papain produce depletion of cartilage matrix in the same areas. With larger doses of papain, depletion of matrix occurs in all cartilaginous tissue throughout the body.

The changes occurring in the epiphyseal plates following vitamin A treatment are more complicated than those involving cartilage in other locations. Two processes appear to be involved in the production of marked narrowing of the epiphyseal plate: one, the depletion of cartilage matrix; and two, the concurrent vascularization and ossification of the zone of proliferating cartilage. As a result, the epiphyseal plate is reduced to a thin zone of non-basophilic cartilage abutting directly on metaphyseal bony trabeculae. The ossification of part of the epiphyseal plate, together with absence of continued growth of this structure, accounts for the increased number of bony trabeculae seen in the metaphysis. The reason for the vascularization and ossification of the zone of proliferating cartilage is not clear. It might be the result of accelerated ossification secondary to changes in the cartilage matrix or simply the result of the continuation of the normal rate of ossification in the face of diminished or absent growth of the epiphyseal plate.

It is interesting to compare the results of the present study with previous observations on hypervitaminosis A in experimental animals. Most of the earlier studies have been made in the rat, in which the most conspicuous changes reported are spontaneous hemorrhages and bony abnormalities characterized by resorption of bone and pathological fractures (18-20). Thinning and ossi-

fication of the epiphyseal plates have been observed in rats given large doses of vitamin A, but apparently no description of depletion of cartilage matrix in this or other locations has been recorded. Hypervitaminosis A in the rabbit has been less extensively studied, but in the few reports concerning this species, there is no description of changes in cartilage matrix (21).

The experiments reported here provide no direct information about the fundamental mechanism whereby vitamin A effects depletion of cartilage matrix, but the results suggest two general possibilities. The depletion might be caused by the inhibition of synthesis in the presence of normal degradation; or by increased breakdown, either by acceleration along normal pathways or by an entirely abnormal means of destruction. The data indicate that increased breakdown is the more likely mechanism. The appearance of increased amounts of material presumed to be chondroitin sulfate in the blood, demonstrated by the cobalt method and sulfur-35, supports this interpretation. Moreover, the depletion of previously incorporated sulfur-35 from articular and epiphyseal cartilage, as demonstrated by autoradiography, is also indicative of increased breakdown. It has been shown in earlier work that cortisone, which inhibits synthesis of chondroitin sulfate, produces histological changes in cartilage (4); these changes are substantially different from those which follow vitamin A treatment. No experiments have been performed to investigate the possibility of a change in the rate of synthesis of cartilage matrix accompanying the breakdown seen after vitamin A administration. There is no evidence to show whether the increased breakdown is due to acceleration of normal processes or to an entirely different mechanism.

The fact that the histological alterations in cartilage produced by vitamin A were remarkably similar to those produced by small doses of papain suggests the possibility that an endogenous proteolytic enzyme is activated by vitamin A under these experimental conditions. While these effects on cartilage were produced by the administration of massive doses of the vitamin and may, therefore, be unrelated to the normal role of vitamin A, the possibility remains that these changes are the result of an exaggeration of normal processes. It is possible that the changes in cartilage are mediated by mechanisms involved in the normal metabolism of vitamin A.

SUMMARY

The administration of large amounts of vitamin A to rabbits has been shown to result in depletion of cartilage matrix. The normal basophilic, metachromatic, and Alcian blue staining properties of the matrix are lost, especially in articular and epiphyseal cartilage. The cartilage cells remain intact, but are reduced in size.

These changes sometimes appeared as early as 48 hours after the initiation of daily injection of 1 million units of vitamin A, and were usually well estab-

lished by 5 days. Some rabbits failed to show changes in cartilage, even after 5 daily injections.

Increased amounts of material presumed to be chondroitin sulfate were present in the sera of vitamin A–treated rabbits, usually by 72 hours after the first injection. This was demonstrated by a turbidimetric procedure using hexamminecobaltic chloride.

In rabbits given sulfur-35 ($Na_2S^{35}O_4$) 5 days before the initiation of vitamin A treatment, it was shown that sulfur-35 was lost from articular and epiphyseal cartilage. This was associated with an increase in the non-dialyzable sulfur-35 in both serum and in the cobalt-precipitable material. These rabbits also excreted more sulfur-35 than rabbits not given vitamin A. There was a reduction in sulfur-35 activity in chondromucoprotein extracted from the ear cartilage of vitamin A–treated rabbits.

The changes are interpreted as indicating that the administration of large amounts of vitamin A to rabbits results in removal of chondroitin sulfate from cartilage matrix.

The administration of small amounts of crude papain causes histologic changes in cartilage that are remarkably similar to those seen in vitamin A–treated rabbits.

The possibility is suggested that the changes in cartilage produced by administration of vitamin A to rabbits may be the result of activation of a proteolytic enzyme or enzymes, with properties similar to those of papain.

BIBLIOGRAPHY

1. Thomas, L., Reversible collapse of rabbit ears after intravenous papain, and prevention of recovery by cortisone, *J. Exp. Med.*, 1956, **104**, 245.
2. McCluskey, R. T., and Thomas, L., The removal of cartilage matrix, *in vivo*, by papain. Identification of crystalline papain protease as the cause of the phenomenon, *J. Exp. Med.*, 1958, **108**, 371.
3. Bryant, J. H., Leder, I. G., and Stetten, D., Jr., The release of chondroitin sulfate from rabbit cartilage following the intravenous injection of crude papain, *Arch. Biochem. and Biophysics*, 1958, **76**, 122.
4. McCluskey, R. T., and Thomas, L., The removal of cartilage matrix, *in vivo*, by papain. Prevention of recovery by cortisone, hydrocortisone and prednisilone by a direct action on cartilage, *Am. J. Path.*, 1959, **35**, 819.
5. Fell, H. B., and Mellanby, E., The effect of hypervitaminosis A on embryonic bones grown in tissue culture, *J. Physiol.*, 1956, **127**, 427.
6. Fell, H. B., Mellanby, E., and Pelc, S. R., Influence of excess vitamin A on the sulphate metabolism of bone rudiments grown *in vitro*, *J. Physiol.*, 1956, **134**, 179.
7. Fell, H. B., and Thomas, L., Comparison of the effects of papain and vitamin A on cartilage. II. The effects on organ cultures of embryonic skeletal tissue, *J. Exp. Med.*, 1960, **111**, 719.

8. Kramer, H., and Windrum, M., The metachromatic staining reaction, *J. Histochem. and Cytochem.*, 1955, **3**, 227.
9. Wagner, B. M., and Shapiro, S. H., Application of Alcian blue as a histochemical method, *Lab. Inv.*, 1957, **6**, 472.
10. Vouras, M., and Schubert, M., The outer sphere association of chondroitin sulfate with polyvalent complex cations, *J. Am. Chem. Soc.*, 1957, **79**, 792.
11. Weissmann, G., Potter, J. L., McCluskey, R. T., and Schubert, M., Turbidity produced by hexamminecobaltic chloride in the serum of rabbits injected intravenously with papain, *Proc. Soc. Exp. Biol. and Med.*, 1959, **102**, 584.
12. Dziewiatkowski, D. D., Radioautographic visualization of sulfur-35 disposition in the articular cartilage and bone of suckling rats following injection of labelled sodium sulfate, *J. Exp. Med.*, 1951, **93**, 451.
13. Pearse, A. G. E., Histochemistry, Theoretical, and Applied, Boston, Little, Brown and Company, 1953, 488.
14. Malawista, I., and Schubert, M., Chondromucoprotein; new extraction method and alkaline degradation, *J. Biol. Chem.*, 1958, **230**, 535.
15. Einbinder, J., and Schubert, M., Separation of chondroitin sulfate from cartilage, *J. Biol. Chem.*, 1950, **185**, 725.
16. Dziewiatkowski, D. D., Effect of thyroxine and thiouracil on S^{35} deposition in articular cartilage, *J. Biol. Chem.*, 1951, **189**, 187.
17. Schiller, S., and Dorfman, A., The metabolism of mucopolysaccharides in animals. The effect of cortisone and hydrocortisone on rat skin, *Endocrinology*, 1957, **60**, 376.
18. Strauss, K., Beobachtungen bei Hypervitaminose A. *Beitr. path. Anat u. allg Path.*, 1934–35, **94**, 345.
19. Wolbach, B. S., Vitamin A deficiency and excess in relation to skeletal growth, *J. Bone and Joint Surg.*, 1947, **29**, 171.
20. Irving, J. T., The effects of avitaminosis and hypervitaminosis A upon the incisor teeth and incisor alveolar bone of rats, *J. Physiol.*, 1949, **108**, 92.
21. Rodahl, K., Hypervitaminosis A, Oslo, Norsk Polarinstitutt Skrifter 95, 1950.

EXPLANATION OF PLATES

PLATE 53

FIG. 1. Rabbit given 2 daily injections of 1 million units of vitamin A. This shows the maximal extent of ear collapse seen in the rabbits injected with vitamin A. × ¾.

FIG. 2. Section of articular cartilage of distal end of femur from control rabbit. There is intense metachromatic staining of the cartilage. Toluidine blue stain. × 100.

FIG. 3. Section of articular cartilage from vitamin A—injected rabbit. There is absence of metachromatic staining of articular cartilage, but there is normal staining of the cartilaginous cores of the underlying bony trabeculae. Toluidine blue stain. × 100.



(Thomas *et al.*: Effects of papain and vitamin A on cartilage. I)

Am. J. Pathol. 42:271-283. 1963.

Thomas-'63
Bib. No. 9079

Reproduced by permission
of the copyright owner

PREVENTION BY CORTISONE OF THE CHANGES IN CARTILAGE INDUCED BY AN EXCESS OF VITAMIN A IN RABBITS

LEWIS THOMAS, M.D.; ROBERT T. MCCLUSKEY, M.D.;
JOHN LI, M.D., AND GERALD WEISSMANN, M.D.*

From the Departments of Medicine and Pathology of the New York University School of Medicine, New York, N.Y.

The administration of large doses of vitamin A to rabbits was previously reported to cause collapse of the ears and loss of chondroitin sulfate from cartilage.[1] The effects were strikingly similar to those demonstrated by Fell and Mellanby[2] when excess vitamin A was added to the culture of embryonic bone explants. In view of the similarities between this property of vitamin A and the action of intravenous papain in the rabbit,[3] and of papain added to embryonic bone cultures,[4] it was suggested that vitamin A might act by causing the release of proteolytic enzymes from cartilage cells or their organelles into the matrix of cartilage. Subsequently, Lucy, Dingle and Fell[5] found that embryonic bone explants contained a protease which was activated by acidification; loss of chrondroitin sulfate from cartilage was demonstrated *in vitro* under conditions in which this enzyme was activated. These investigators then showed that vitamin A caused release of a similar protease, presumed to be a cathepsin, from embryonic cartilage. Postulating that the source of the enzyme might be the lysosomes of cartilage cells, Dingle investigated the action of vitamin A on the lysosomes of rat liver.[6] It was found that vitamin A caused the release of acid protease from suspensions containing the bulk of hepatic lysosomes.

Fell and Thomas found that hydrocortisone inhibited the action of vitamin A on the cartilage of embryonic bone explants.[7] It was then shown that the lysosome-rich fraction taken from the livers of rats pretreated with hydrocortisone released less acid protease than controls upon ultraviolet irradiation.[8] De Duve, Wattiaux and Wibo had previously demonstrated that hydrocortisone diminished the release of acid phosphatase, another lysosomal enzyme, from rat liver granules *in vitro*.[9] On the basis of these observations it was suggested that hydrocortisone had the property of stabilizing lysosomes against several forms of injury, including excess vitamin A. However, two reports contradictory to this

Supported by Grants (A 5316, RG 6367 (C2) and A 1395) from the National Institutes of Health, and a contract from the Surgeon General's Office (DA 49 007 MD 590).
Accepted for publication, October 5, 1962.
* Senior Investigator, Arthritis and Rheumatism Foundation.

hypothesis exist, both involving *in vivo* systems. Selye[10] reported that the bone damage produced by hypervitaminosis A in young rats was aggravated by cortisone, and Weissman described synergistic damage in toad tadpoles by simultaneous treatment with hydrocortisone and vitamin A.[11]

The present report concerns the effect of cortisone on hypervitaminosis A in the rabbit. It will be shown that cortisone exerts a definite protective action against an excess of vitamin A palmitate and vitamin A acid in this animal.

Material and Methods

Young albino rabbits of either sex, weighing between 800 and 1,200 gm., were used.

Vitamin A palmitate in a solution of cottonseed oil was obtained from Nutritional Biochemicals Corporation, Cleveland, Ohio. Vitamin A acid was obtained in crystalline form through the courtesy of Hoffman-LaRoche, Nutley, New Jersey. It was suspended in corn oil (100 mg. per ml.) before administration. The vitamin A preparations were administered by gastric intubation.

Cortisone acetate in aqueous suspension (25 mg. per ml.), from Merck and Company, West Point, Pennsylvania, or Philadelphia Ampoule Laboratories, was administered intramuscularly. Hydrocortisone sodium succinate (Solu-Cortef ®, Upjohn Company, Kalamazoo, Michigan) was diluted with saline to a final concentration of 1.5 mg. per ml. before intra-articular injection.

The rabbits were killed by an injection of Nembutal ®. Tissues were fixed in 10 per cent buffered formalin. Bones were decalcified in dilute formic acid. Sections were prepared from the lower end of the femur, trachea and ear and were stained with hematoxylin and eosin and with toluidine blue according to the method of Kramer and Windrum.[12]

Acute hypervitaminosis A in the rabbit affects the cartilage of joint surfaces and epiphyseal plates more regularly and severely than that of the ear or trachea.[1] For this reason estimation of the degree of depletion of cartilage matrix was estimated in sections of the distal end of the femur and graded as follows: —, normal metachromatic and basophilic staining of articular and epiphyseal cartilage; ±, equivocal reduction in metachromatic and basophilic staining; +, mild reduction in metachromatic and basophilic staining with little or no thinning of articular cartilage or epiphyseal plates; ++, moderate loss of metachromatic and basophilic staining with slight thinning of articular cartilage and mild to moderate thinning of epiphyseal plates; +++, virtually complete absence of metachromatic and basophilic staining with moderate thinning of articular cartilage and marked thinning of epiphyseal plates.

Experimental Results

Prevention by Cortisone of Cartilage Depletion Following Vitamin A Palmitate

Two experiments were performed in which rabbits given vitamin A palmitate were treated with cortisone. In the first experiment 4 groups of rabbits were used as follows: In group I, 9 rabbits were given 500,000 I.U. vitamin A palmitate every day for 6 days. In group II, 9 rabbits were given vitamin A as in group I. On the day preceding and throughout the period of vitamin A administration, each rabbit also received a sin-

gle daily injection of 12.5 mg. of cortisone. In group III, 9 rabbits received cortisone as in group II. In group IV, 9 control rabbits received no treatment. All the rabbits were killed on the day following the last treatment.

The results of this experiment are summarized in Table I. The rab-

TABLE I

PREVENTION BY CORTISONE OF CARTILAGE MATRIX DEPLETION IN RABBITS TREATED WITH VITAMIN A PALMITATE

Exper. no.	Treatment	No. of rabbits	No. with ear collapse	No. of rabbits with cartilage matrix depletion				
				o	±	+	++	+++ *
1	Vitamin A †	8	4				1	7
	Vitamin A plus cortisone ‡	9	0	2	5	2		
	Cortisone	9	0	9				
	Controls	9	0	9				
2	Vitamin A §	8	4				3	5
	Vitamin A plus cortisone ¶	8	2	3	2	2	1	

* See text for manner of grading.
† Vitamin A palmitate, 0.5 million units daily for 5 days.
‡ Cortisone, 12.5 mg. daily for 6 days.
§ Vitamin A palmitate, 1 million units daily for 3 days.
¶ Cortisone, 25 mg. then 12.5 mg. daily for 3 days.

bits given vitamin A only (group I) showed changes similar to those previously reported.[1] Grossly, in 4 of the 9 rabbits there was collapse of the distal part of the ear. Loss of hair was obvious in all. One rabbit died on the fifth day. Histologically, all the rabbits were found to have moderate or severe depletion of the matrix in articular and epiphyseal cartilage (Figs. 1 and 3). Sections of trachea showed mild focal depletion of cartilage matrix in 5 rabbits. Examination of ear cartilage showed mild reduction of staining in 2 instances.

In the rabbits treated with cortisone during the period of vitamin A administration (group II), the findings were quite different from those just described. None of the rabbits developed ear collapse or showed loss of hair. Two rabbits exhibited mild depletion of articular and epiphyseal cartilage matrix; in 5 rabbits there was only equivocal depletion and in 2 rabbits no alterations were found (Figs. 2 and 4). In sections of ear and trachea no loss of cartilage matrix was evident.

In the rabbits treated with cortisone only (group III) no reduction of metachromatic or basophilic staining of cartilage matrix was encountered. However, as in earlier studies.[12] slight thinning of epiphyseal plates and reduction in the number of newly formed metaphyseal bony trabeculae was observed. This was also observed in rabbits in group II.

In the untreated rabbits (group IV) no abnormalities of cartilage were found.

In the second experiment, using vitamin A palmitate and cortisone, 2 groups of rabbits were employed. Group I consisted of 8 rabbits given 1 million units of vitamin A daily for 3 days. Group II consisted of 8 rabbits given vitamin A as in group I and in addition 25 mg. of cortisone on the day preceding vitamin A treatment and then 12.5 mg. of cortisone daily for 3 days. All rabbits were killed on the day following the last day of treatment.

Cortisone treatment partially prevented the changes due to vitamin A (Table I). Four of the rabbits given only vitamin A developed collapse of the distal portion of the ears. Two rabbits treated with cortisone and vitamin A showed slight curling at the tips of the ears. All of the rabbits given only vitamin A showed severe loss of hair, whereas among the rabbits given cortisone as well, only 3 showed hair loss. Of the rabbits treated with vitamin A, 5 exhibited severe depletion (3+) of articular and epiphyseal cartilage and 3 showed moderate depletion (2+). In the rabbits treated with both cortisone and vitamin A, 3 were found to have normal cartilage, 2 showed equivocal depletion, 2 showed mild depletion (+) and only 1 showed moderate depletion (2+).

Depletion of Cartilage Matrix by Vitamin A Acid and Prevention by Cortisone

Four groups of rabbits were used in these experiments: In group I, 9 rabbits received 250 mg. of vitamin A acid in corn oil (2.5 ml.) daily for 5 days. In group II, 9 rabbits received vitamin A acid as in group I and 50 mg. of cortisone a day for 5 days. In group III, 9 rabbits were given 50 mg. of cortisone daily for 5 days and 2.5 ml. of corn oil daily. In group IV, 9 control rabbits received 2.5 ml. of corn oil by intubation daily for 5 days. All rabbits were killed 4 hours after the last treatment (Table II). Within 24 to 48 hours, 4 animals in group I showed curling

TABLE II

PREVENTION BY CORTISONE OF CARTILAGE MATRIX DEPLETION IN RABBITS TREATED WITH VITAMIN A ACID

Treatment	No. of rabbits	No. with ear collapse	No. of rabbits with cartilage matrix depletion				
			0	±	+	++	+++
Vitamin A *	9	8			3	3	3
Vitamin A and cortisone †	6	0	2	2	2		
Cortisone	9	0	9				
Controls	9	0	9				

* Vitamin A acid, 250 mg. daily for 5 days.

† Cortisone, 50 mg. daily for 5 days.

of the distal third of the ears. By 72 hours 8 of the 9 exhibited this change. In contrast, only 1 animal in group II had curling of the ears; this developed at 72 hours. All of the animals in group I showed a remarkable loss of hair, which began to be quite noticeable at 48 hours. No significant hair loss was apparent in group II. None of the animals in group III or IV had ear collapse or hair loss. In all of the rabbits in group I there was moderate or severe depletion of articular and epiphyseal cartilage matrix (Fig. 5), whereas among animals in group II only 2 rabbits showed definite depletion, which was of mild degree (Fig. 6).

The Local Prevention by Hydrocortisone of Depletion of Cartilage Matrix Induced by Vitamin A

In order to see if the prevention by cortisone of cartilage depletion due to vitamin A was the result of a direct action of the steroid on cartilage, the following experiment was performed.

Ten rabbits were given 750,000 units of vitamin A palmitate by gastric intubation daily for 3 days. During the same period each rabbit received injections of hydrocortisone, 0.15 mg. in 0.1 ml., in the right knee joint and 0.1 ml. of saline into the left knee twice daily. All rabbits were killed one day after the last treatment (Table III). In 3 of the rabbits

TABLE III

EFFECT OF LOCAL HYDROCORTISONE ON ARTICULAR CARTILAGE DEPLETION IN VITAMIN A-TREATED RABBITS *

Knee joint injected with:	Degree of depletion			
	0	±	+	++
Hydrocortisone †	0	7	3	0
Saline	0	4	3	3

* Vitamin A, 0.75 million units P.O. for 3 days.
† Hydrocortisone, 0.15 mg. intra-articularly B.I.D. for 3 days.

the degree of matrix depletion in the articular cartilage was less in the hydrocortisone-injected joint than in the joint injected with saline (Figs. 7 and 8). In 4 rabbits only equivocal depletion was found in both sides, and in 3 rabbits equal, mild depletion of cartilage matrix was present in both joints.

DISCUSSION

The present observation has shown that the depletion of cartilage matrix produced *in vivo* in rabbits by an excess of vitamin A palmitate or acid could be largely prevented by the concurrent administration of cortisone. The degree of protection appeared to be related to the dose of vitamin A employed. At essentially the same dosage of cortisone there was less protection when 1 million units of vitamin A palmitate were

given daily than when 500,000 units were given. The protective action of adrenal corticoids seemed to be the result of a direct effect on cartilage; in rabbits given an excess of vitamin A palmitate, the injection of hydrocortisone into one knee joint partially prevented the depletion of that articular cartilage matrix as compared with the contralateral joint. Aside from the protection against the changes in cartilage, cortisone largely prevented the striking loss of hair seen in rabbits treated with excess vitamin A. The mechanism leading to hair loss is not known.

Vitamin A acid has not previously been shown to cause depletion of cartilage matrix *in vivo*, although such an effect on embryonic limb bone rudiments *in vitro* has been reported by Fell, Dingle and Webb.[14] Thompson and Pitt,[15] in a preliminary report, have shown that vitamin A acid in excess caused lesions in the bones of rats comparable to those produced by other forms of the vitamin.

The present observations provide further support for the hypothesis that the lysosomes of cartilage are rendered more resistant to the effects of hypervitaminosis A by adrenal corticoids. Evidence for the protection of liver lysosomes against the action of an excess of vitamin A *in vivo* and *in vitro* will be presented in a separate paper.[16] Cortisone and its analogues appear to decrease the release of lysosomal hydrolases from liver granules caused by a variety of agents such as bacterial endotoxin,[17] ultraviolet irradiation[8] and exposure to acid pH.[9] DOCA is ineffective in such circumstances.[17]

It is of interest to note that Wolf[18] reported that vitamin A appears to be necessary for the biosynthesis of sulfated mucopolysaccharides in intestine; this synthetic activity seems to reside in a granular fraction whose sedimentation properties are similar to the particles studied by Dingle.[6] It is not clear whether this reflects another action of vitamin A on lysosomes or whether the vitamin in this situation is acting on different cellular elements.

The present findings are in contrast to those reported by Selye[10] and by Weissmann.[11] Selye reported that the simultaneous administration of cortisol and vitamin A to rats resulted in intense bone absorption not observed with vitamin A alone. These experiments differed considerably from ours in that a different species was employed, a different end point looked for (bone resorption instead of cartilage depletion), and the course of treatment was more prolonged. In experiments with larvae of *Xenopus laevis*, hydrocortisone led to acceleration of connective tissue damage and gastrointestinal changes induced by vitamin A alcohol. In recent experiments, however, it was found that the simultaneous administration of hydrocortisone protected larvae against the similar effects produced by vitamin A acid.[19]

If it is assumed that the mechanism of action of excess vitamin A in the experiments of Weissmann[11] and of Selye[10] was the same as in the rabbit, how can these discordant results be explained? It was previously proposed that the acceleration of connective tissue changes observed in larvae by hydrocortisone was due to the release of vitamin A from hepatic stores.[11] The release of stored vitamin A under the influence of cortisone and corticotropin has been demonstrated in the rat by McGillivray[20] and in human subjects by Wang and associates.[21] Since vitamin A acid is not stored to any extent in the liver, the protection by hydrocortisone against vitamin A acid but not against vitamin A alcohol (which is stored in an esterified form in the liver) is consistent with this suggestion. The release of hepatic stores of vitamin A does not appear to be relevant to the experiments reported in this paper, since it was shown by McGillivray[20] that blood levels of vitamin A alcohol (the active form) did not rise significantly until the seventh day after steroid therapy. In our rabbit experiments, cortisone was given for only 6 days. In the experiments of Selye[10] and of Weissmann,[11] on the other hand, prolonged steroid therapy was used and may have resulted in significant elevation of blood levels of vitamin A.

Another, and perhaps more probable, explanation can be offered for the additive effects of hydrocortisone and vitamin A *in vivo*. It has been shown previously that cortisone or hydrocortisone prevent the reconstitution of cartilage matrix following depletion by papain, apparently by a direct inhibitory effect on the synthesis of constituents of the matrix.[3,13] If the circumstances of the experiment are such that the lytic effect of vitamin A is not completely prevented by cortisone, and if cortisone and vitamin A are administered over a relatively long period, there might occur both depletion and suppression of reconstitution of cartilage matrix.

In any case, the observations reported here show that cortisone has the capacity of blocking the effects of excess vitamin A *in vivo* under appropriate circumstances. It is of interest that the combined effects of cortisone and vitamin A in the rabbit are matched by those observed in an *in vitro* system[8] and in tissue culture.[7] In view of the demonstration by de Duve and co-workers[9] that the stability of lysosomes *in vitro* can be drastically altered by a variety of agents with differing physicochemical properties, it is useful to have the additional information provided by an *in vivo* system, as in the present study, as an aid in evaluation of the biologic significance of substances affecting lysosomes. It is possible that the protective effect of cortisone against excess vitamin A, apparently due to increased stability of lysosomes, reflects a fundamental biologic action of this hormone.

Summary

Acute hypervitaminosis A was induced in young rabbits by the oral administration of vitamin A palmitate or vitamin A acid. Gross effects included loss of hair and collapse of the distal third of the rabbits' ears. Histologically, depletion of cartilage matrix was seen, especially of articular and epiphyseal cartilage. These alterations were largely prevented by the simultaneous administration of cortisone. A local protective effect of adrenal corticoids was demonstrated by the intra-articular injection of hydrocortisone in rabbits with hypervitaminosis. The protective effect of the adrenal corticosteroids may be due to an increased stability of lysosomes.

References

1. Thomas, L.; McCluskey, R. T.; Potter, J. L., and Weissmann, G. Comparison of the effects of papain and vitamin A on cartilage. I. The effects in rabbits. *J. Exper. Med.*, 1960, 111, 705–718.
2. Fell, H. B., and Mellanby, E. The effect of hypervitaminosis A on embryonic limb-bones cultivated *in vitro*. *J. Physiol.*, 1952, 116, 320–349.
3. Thomas, L. Reversible collapse of rabbit ears after intravenous papain, and prevention of recovery by cortisone. *J. Exper. Med.*, 1956, 104, 245–252.
4. Fell, H. B., and Thomas, L. Comparison of the effects of papain and vitamin A on cartilage. II. The effects on organ cultures of embryonic skeletal tissue. *J. Exper. Med.*, 1960, 111, 719–744.
5. Lucy, J. A.; Dingle, J. T., and Fell, H. B. Studies on the mode of action of excess of vitamin A. 2. A possible role of intracellular proteases in the degradation of cartilage matrix. *Biochem. J.*, 1961, 79, 500–508.
6. Dingle, J. T. Studies on the mode of action of excess of vitamin A. 3. Release of a bound protease by the action of vitamin A. *Biochem. J.*, 1961, 79, 509–512.
7. Fell, H. B., and Thomas, L. The influence of hydrocortisone on the action of excess vitamin A on limb bone rudiments in culture. *J. Exper. Med.*, 1961, 114, 343–362.
8. Weissmann, G., and Dingle, J. Release of lysosomal protease by ultraviolet irradiation and inhibition by hydrocortisone. *Exper. Cell Res.*, 1961, 25, 207–210.
9. De Duve, C.; Wattiaux, R., and Wibo, M. Effects of fat-soluble compounds on lysosomes *in vitro*. (Abstract) *Biochem. Pharmacol.*, 1961, 8, 30.
10. Selye, H. Sensitization of the skeleton to vitamin-A overdosage by cortisol. *Arthritis & Rheumatism*, 1958, 1, 87–90.
11. Weissmann, G. Changes in connective tissue and intestine caused by vitamin A in amphibia, and their acceleration by hydrocortisone. *J. Exper. Med.*, 1961, 114, 581–592.
12. Kramer, H., and Windrum, G. M. Metachromatic staining reaction. *J. Histochem.*, 1955, 3, 227–237.
13. McCluskey, R. T., and Thomas, L. The removal of cartilage matrix *in vivo* by papain. Prevention of recovery with cortisone, hydrocortisone and prednisolone by a direct action on cartilage. *Am. J. Path.*, 1959, 35, 819–833.

14. FELL, H. B.; DINGLE, J. T., and WEBB, M. Studies on the mode of action of excess of vitamin A. 4. The specificity of the effect on embryonic chick-limb cartilage in culture and on isolated rat-liver lysosomes. *Biochem. J.*, 1962, 83, 63–69.

15. THOMPSON, J. N., and PITT. G. A. J. Vitamin A acid and hypervitaminosis A. (Letter to the editor) *Nature, London*, 1960, 188, 672–673.

16. WEISSMANN, G., and THOMAS, L. Studies on lysosomes. II. The effect of cortisone on the release of acid hydrolases from a large granule fraction of rabbit liver induced by an excess of vitamin A. (In preparation)

17. WEISSMANN, G., and THOMAS, L. Studies on lysosomes. 1. The effects of endotoxin, endotoxin tolerance, and cortisone on the release of acid hydrolases from a granular fraction of rabbit liver. *J. Exper. Med.*, 1962, 116, 433–450.

18. WOLF, G. Some thoughts on the metabolic role of vitamin A. *Nutrition Rev.*, 1962, 20, 161–163.

19. WEISSMANN, G., BELL, E., and THOMAS, L. Prevention by hydrocortisone of changes in connective tissue induced by an excess of vitamin A acid in amphibia. *Am. J. Path.*, 1963, 42. (To be published)

20. MCGILLIVRAY, W. A. Some factors influencing the release of vitamin A from the liver. *Brit. J. Nutrition*, 1961, 15, 305–312.

21. WANG, P.; GLASS, H. L.; GOLDENBERG, L.; STEARNS, G.; KELLY, H. G., and JACKSON, R. L. Serum vitamin A and carotene levels in children with rheumatic fever. *Am. J. Dis. Child.*, 1954, 87, 659–672.

[*Illustrations follow*]

Legends for Figures

All sections were stained with toluidine blue.

Fig. 1. Rabbit treated with vitamin A, 500,000 units daily for 6 days. The articular cartilage is thin and shows complete loss of metachromatic staining. The bony trabeculae stain normally. × 150.

Fig. 2. Rabbit treated with vitamin A, 500,000 units daily for 6 days, and with cortisone, 12.5 mg. daily. The articular cartilage is of normal thickness and shows normal metachromatic staining. × 150.

Fig. 3. Rabbit shown in Figure 1. The epiphyseal plate is markedly narrowed and devoid of metachromatic staining. × 150.

Fig. 4. Rabbit shown in Figure 2. The epiphyseal plate is slightly thin but shows normal metachromatic staining. × 150.

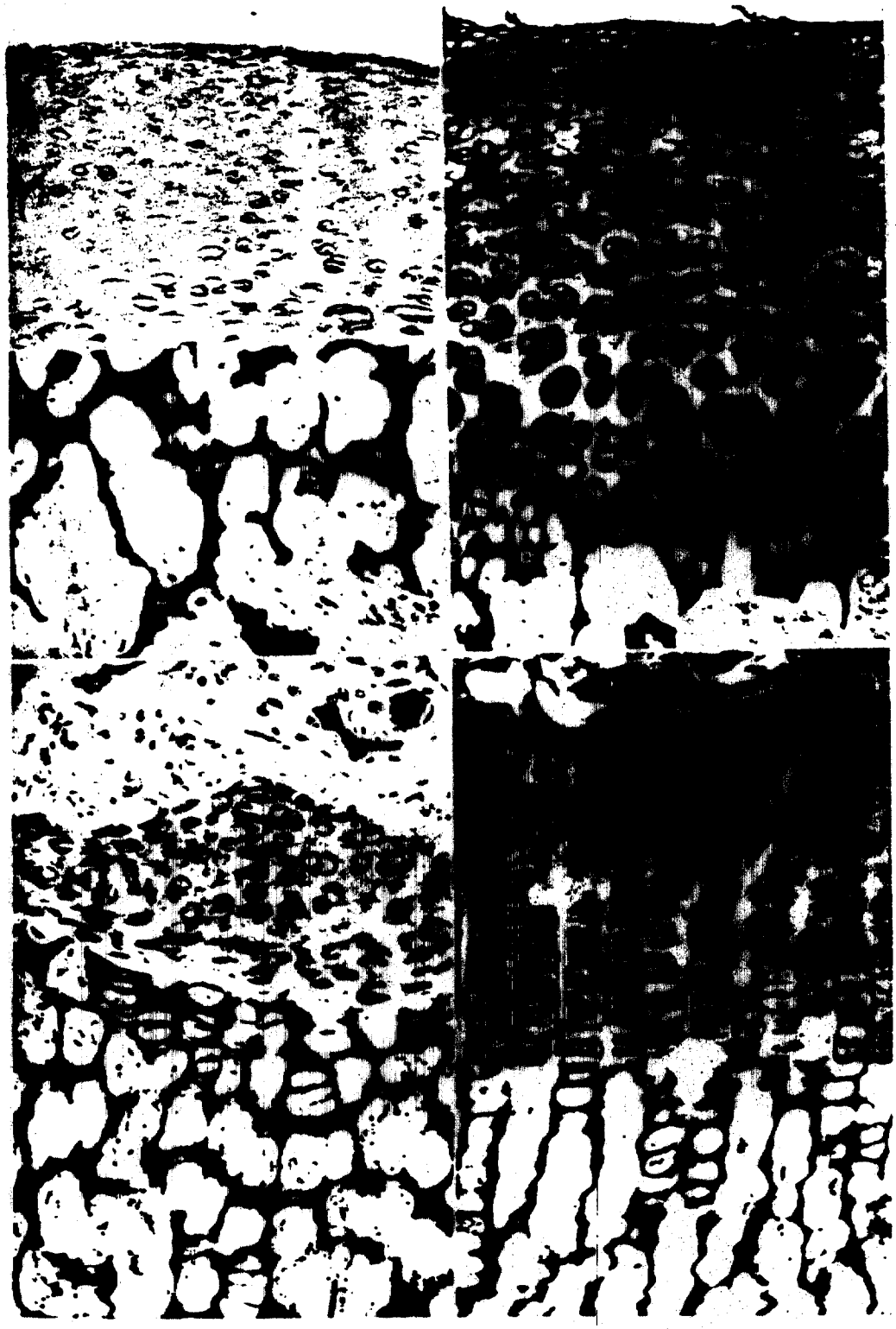
1
2
3
4

FIG. 5. Rabbit given vitamin A acid, 250 mg. daily for 5 days. The articular cartilage is thin and shows no metachromatic staining. × 150.

FIG. 6. Rabbit given vitamin A acid. 250 mg. daily for 5 days, and concurrently treated with cortisone, 50 mg. daily. The cartilage shows normal staining. × 150.

FIG. 7. The articular cartilage of the left knee (saline-injected joint) from a rabbit given vitamin A palmitate by stomach tube, 750,000 units daily for 3 days. Moderate depletion of cartilage matrix is manifest. × 150.

FIG. 8. The articular cartilage of the right knee (hydrocortisone-injected joint) from the rabbit shown in Figure 7. The articular cartilage exhibits only slight depletion. × 150.

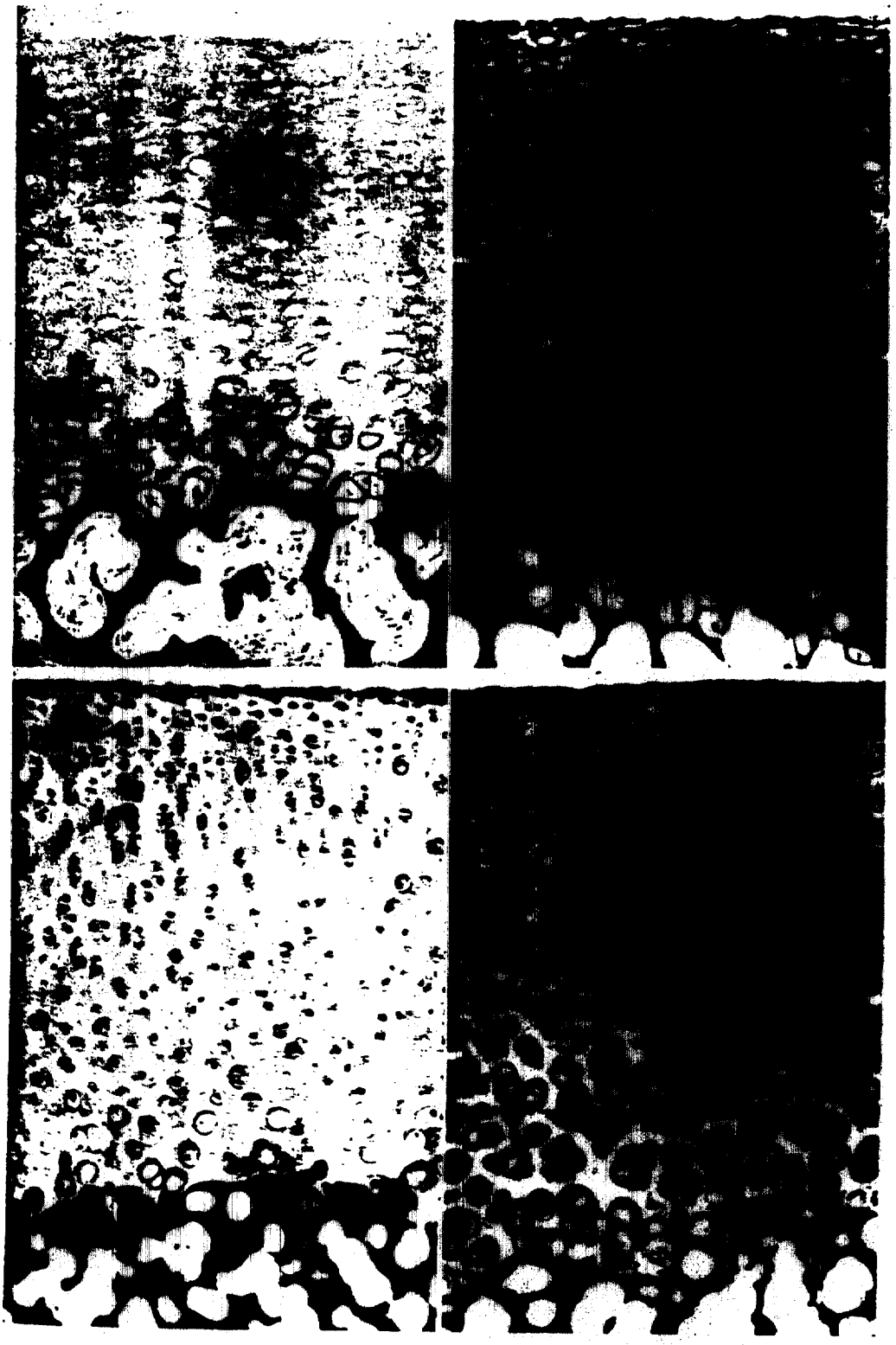

5 6

7 8

Thompson-'63
Bib. No. 9096

BC 2353

The conversion of retinyl methyl ether (vitamin A methyl ether) to retinol (vitamin A alcohol) *in vivo*

Many compounds chemically related to retinol* (vitamin A alcohol) have been investigated for biological activity and most appear to fall into one of two classes. Either (a) they have little or no vitamin A activity, or (b) they are converted *in vivo* to retinol and work by serving as a precursor of the true vitamin. Apart from the A_2 (3-dehydroretinol) series of compounds, the only proved exception to this generalization is retinoic acid (vitamin A acid) which, despite not being converted to retinol[2],

* In accordance with the definitive rules for the nomenclature of vitamins approved by the Commission on the Nomenclature of Biological Chemistry of the International Union of Pure and Applied Chemistry[1], vitamin A_1, vitamin A_1 methyl ether and vitamin A_1 acid will be referred to as retinol, retinyl methyl ether and retinoic acid respectively.

Biochim. Biophys. Acta, 78 (1963) 753–755

supports life, growth and health in animals on a diet otherwise deficient in vitamin A[3,4]. It does not, however, replace retinol in vision[4], or in its specific function in reproduction in rats[5-7].

Retinyl methyl ether (vitamin A methyl ether) has been reported to be approximately as effective as retinol in promoting growth[8,9], and it also has some activity albeit less pronounced, in inducing hypervitaminosis A[10]. To test the activity of retinyl methyl ether in maintaining reproduction in female rats, we gave a daily oral dose of 20 μg during pregnancy to two rats on a diet[7] containing retinoic acid but no retinol. Both animals gave birth to litters. Feeding retinyl methyl ether prevented the resorption of foetuses which occurred in two control animals maintained on retinoic acid alone, as has been demonstrated previously[6,7]. Retinyl methyl ether, in contrast with retinoic acid, fulfilled therefore the specific role of vitamin A in reproduction in female rats[6,7].

ISLER[11], commenting on his preliminary experiments with retinyl methyl ether said "unsere Versuche machen es wahrscheinlich, dass der Methyläther im Körper umgeformt wird, und dass nach seiner Verfütterung in der Leber Vitamin-A-Ester gespeichert wird", *i.e.* it would fall into class (b) above. On the other hand, some workers, *e.g.* OROSHNIK *et al.*[12], appear to have assumed that the ether is not a precursor of the alcohol but, in common with retinoic acid, itself possesses activity. To the best of our knowledge, no published experimental evidence permits a choice to be made between these two views.

Three weanling male rats were therefore put on a diet[7] deficient in retinol, but containing 10 μg methyl retinoate (vitamin A acid methyl ester)/g food. When 150 days old, by which time their liver stores of retinyl (vitamin A) esters would long since have been exhausted[13], they were each given daily oral doses of 800 μg crystalline retinyl methyl ether, dissolved in arachis oil, over a period of 29 days. The rats were then killed and their combined livers saponified. The unsaponifiable residue, which showed an absorption maximum at 325 mμ in ethanol and fluoresced in ultraviolet light, was dissolved in petrol and chromatographed on a column of neutral alumina (Hopkin & Williams, partially deactivated by the addition of 4 % water), which was developed with various percentages (2 %, 5 %, 10 % 25 %, v/v) of ether in petrol. All the material showing an absorption peak (in ethanol) near 326 mμ was found in the ether–petrol (25:75) fraction, which fluoresced strongly in ultraviolet light; on addition of dry hydrogen chloride[14,15], the 326-mμ maximum was replaced by three more intense peaks at 350 mμ, 369 mμ and 390 mμ. These spectroscopic and fluorescent properties are common to retinol and retinyl methyl ether[8], but with pure substances on a similar alumina column, retinol only was eluted with 25 % ether in petrol, retinyl methyl ether was removed by 2 % ether in petrol.

The 326-mμ absorbing material in the livers of the rats fed retinyl methyl ether was therefore not the ether, but appeared to be the alcohol. This was confirmed by chromatographing a portion of the ether–petrol (25:75) fraction on a thin layer of silicic acid (Kieselgel G, Merck, für Dünnschichtchromatographie nach Stahl), using petrol–methylheptenone (11:2)[16]. The material fluorescing brightly in ultraviolet light behaved in this system mainly as all-*trans*-retinol (R_F 0.3), and partly as an isomer (R_F 0.38) probably 13-*cis*-retinol. In contrast, pure retinyl methyl ether put on the same plate ran closely behind the solvent front.

To confirm that the retinol had not been formed from the ether during the analy-

tical procedures, retinyl methyl ether was added to the liver of a vitamin A-deficient rat, which was saponified and chromatographed in the same way. The retinyl methyl ether was all eluted from the alumina column with ether–petrol (2:98); no retinol was detected in any chromatographic fraction.

From 230 μmoles retinyl methyl ether fed to the three rats, 50 μmoles were recovered in the livers as the alcohol (measured by ultraviolet absorption[17]), *i.e.* 22 % of the total given. Since at this high dosage level, liver storage of retinol (in ester form) is not very efficient[18], the rats must have converted a large proportion of the retinyl methyl ether to retinol. Despite the very big amounts given, no unchanged retinyl methyl ether was found in the livers.

The ultraviolet-absorbing material found by OROSHNIK *et al.*[12] in the livers of rats after being fed a crude preparation of retinyl methyl ether was presumably not the ether as the authors thought, but the alcohol formed from it and no doubt the same can be said of "α-vitamin A methyl ether" (3,7-dimethyl-9-(2,6,6-trimethyl cyclohex-2-enyl)-nona-2,4,6,8-tetraenyl methyl ether) investigated later[19].

Our results therefore confirm ISLER's[11] view that retinyl methyl ether is active as a result of its ready conversion to retinol.

This work was supported by a grant from the Agricultural Research Council to Professor R. A. MORTON, F.R.S., whom we thank for his advice. We are also grateful to Dr. O. ISLER of Hoffmann-La Roche & Co., Basel, for giving us the retinyl methyl ether and retinoic acid, and to Miss C. HAUGHTON for technical assistance.

Department of Biochemistry, University of Liverpool, Liverpool (Great Britain)

J. N. THOMPSON
G. A. J. PITT

[1] International Union of Pure and Applied Chemistry: Commission on the Nomenclature of Biological Chemistry, *J. Am. Chem. Soc.*, 82 (1960) 5581.
[2] J. F. ARENS AND D. A. VAN DORP, *Nature*, 158 (1946) 622.
[3] J. F. ARENS AND D. A. VAN DORP, *Nature*, 157 (1946) 190.
[4] J. E. DOWLING AND G. WALD, *Proc. Natl. Acad. Sci. U.S.*, 46 (1960) 587.
[5] J. McC. HOWELL, J. N. THOMPSON AND G. A. J. PITT, *J. Reprod. Fertility*, 5 (1963) 159.
[6] J. N. THOMPSON, J. McC. HOWELL AND G. A. J. PITT, *Biochem. J.*, 80 (1961) 16P.
[7] J. N. THOMPSON, J. McC. HOWELL AND G. A. J. PITT, *Proc. Roy. Soc. London Ser. B*, in the press.
[8] A. R. HANZE, T. W. CONGER, E. C. WISE AND D. I. WEISBLAT, *J. Am. Chem. Soc.*, 70 (1948) 1253.
[9] O. ISLER, A. RONCO, W. GUEX, N. C. HINDLEY, W. HUBER, K. DIALER AND M. KOFLER, *Helv. Chim. Acta*, 32 (1949) 489.
[10] S. B. WOLBACH AND C. L. MADDOCK, *Proc. Soc. Exptl. Biol. Med.*, 77 (1951) 825.
[11] O. ISLER, *Chimia*, 4 (1950) 103.
[12] W. OROSHNIK, G. KARMAS AND A. D. MEBANE, *J. Am. Chem. Soc.*, 74 (1952) 295.
[13] J. N. THOMPSON, G. A. J. PITT AND R. A. MORTON, *Biochim. Biophys. Acta*, 45 (1960) 396.
[14] J. R. EDISBURY, A. E. GILLAM, I. M. HEILBRON AND R. A. MORTON, *Biochem. J.*, 26 (1932) 1164
[15] E. M. SHANTZ, J. D. CAWLEY AND N. D. EMBREE, *J. Am. Chem. Soc.*, 65 (1943) 901.
[16] C. VON PLANTA, U. SCHWIETER, L. CHOPARD-DIT-JEAN, R. RÜEGG, M. KOFLER AND O. ISLER, *Helv. Chim. Acta*, 45 (1962) 548.
[17] H. R. CAMA, F. D. COLLINS AND R. A. MORTON, *Biochem. J.*, 50 (1951) 48.
[18] T. MOORE, I. M. SHARMAN AND R. J. WARD, *Biochem. J.*, 49 (1951) xxxix.
[19] W. OROSHNIK, *J. Am. Chem. Soc.*, 76 (1954) 5499.

Received July 29th, 1963

Thompson-64
Bib. No. 9098

Proc. Roy. Soc. Ser. B. Biol. Sci. 159(976):510-535. 1964.

Vitamin A and reproduction in rats

By J. N. Thompson, J. McC. Howell and G. A. J. Pitt
Departments of Biochemistry and Veterinary Pathology, University of Liverpool

(*Communicated by R. A. Morton, F.R.S.—Received* 13 *May* 1963)

Retinoic acid (vitamin A acid), the carboxylic acid corresponding to the primary alcohol retinol (vitamin A), has previously been thought to fulfil all the functions of vitamin A except in vision, since rats fed a diet deficient in retinol but supplemented with retinoic acid grow well, outwardly appearing healthy, yet become blind.

This paper reports that female rats on such a diet had normal oestrous cycles and became pregnant when mated, but always resorbed the foetuses and no litters were born. The first abnormalities detected were necrosis and slight polymorph infiltration around the periphery of the placental disk about the sixteenth day of pregnancy. Supplementation with retinol as late as the tenth day resulted in the birth of a healthy litter. Retinoic acid therefore maintained the early but not the later stages of gestation.

When very small amounts of retinol were given during pregnancy, dead or weak young were born; on higher supplements of the vitamin, litters were weaned successfully. By this means young rats were produced with negligible stores of retinol.

Male rats fed retinoic acid but not retinol had small and often oedematous testes. The germinal epithelium sloughed off and in some tubules the lumen was obliterated, but in others the lumen remained, and in these some spermatocytes and spermatogonia were held tenaciously. The seminal vesicles were smaller than in controls given retinol. In rats born with negligible stores of retinol—see above—and maintained on retinoic acid, the testes remained infantile; spermatids were never formed.

Feeding retinol restored spermatogenesis in degenerate testes and promoted the normal development of testes that had remained infantile; it also ensured the growth of the seminal vesicles.

Retinoic acid did not therefore serve in reproduction, although it replaced the true vitamin in maintaining life, growth and general health. Besides the latter so-called systemic function, vitamin A must have a discrete and specific role in reproduction, viz. that performed by retinol but not by retinoic acid. From among the many previously reported features of disordered reproduction in vitamin A-deficient animals, it was possible to distinguish which had arisen from a failure of this specifically 'reproductive' role and which from a 'systemic' deficiency.

The inactivity of retinoic acid in reproduction demonstrates that in rats vitamin A has not two, as previously thought, but three dissociable modes of action: (1) systemic; (2) in vision; and (3) in reproduction.

Introduction

Vitamin A has two dissociable functions: a dichotomy most clearly shown by Dowling & Wald (1960) using retinoic acid (vitamin A acid, $C_{19}H_{27}COOH$), the carboxylic acid corresponding to the primary alcohol, retinol (vitamin A, $C_{19}H_{27}CH_2OH$).* Rats were fed a diet deficient in retinol but containing retinoic acid: although they grew well, outwardly appearing healthy and normal, they

* In accordance with the rules for the nomenclature of vitamins approved by the Commission on the Nomenclature of Biological Chemistry of the International Union of Pure and Applied Chemistry (1960), vitamin A (alcohol), vitamin A esters and vitamin A acid will be called retinol, retinyl esters and retinoic acid respectively. We shall also refer to vitamin A aldehyde (retinene, $C_{19}H_{27}CHO$) as retinaldehyde since many workers prefer to use the term retinal as an adjective. As the recommended nomenclature has not yet become universal, we shall sometimes employ the older terms, particularly in a nutritional context.

became blind. They were unable to reduce retinoic acid to retinaldehyde, which is required as the chromophoric group of the visual pigments and is formed by enzymic dehydrogenation of retinol in animals on normal diets. This experiment of Dowling & Wald (1960) separated the function of vitamin A in vision from that in maintaining life, growth and the general health of animals—its so-called systemic action.

Much of the mechanism of the visual function of vitamin A is understood (Wald & Hubbard 1960). In contrast, extensive work on vitamin A-deficient animals has failed to produce a generally acceptable explanation of the systemic activity of the vitamin. The deficiency signs have been well recorded (Moore 1957) but they are numerous and too diffuse to fix the biochemical mode of action of the vitamin. They include defects in epithelial tissues, the nervous system, bone formation, reproduction and endocrine functions, with many other pathological changes which undoubtedly include secondary manifestations of more fundamental defects.

Retinoic acid prevents and cures many of these features of avitaminosis A. Most obviously, it keeps animals alive and growing (Arens & van Dorp 1946*a*; Dowling & Wald 1960); more specifically, it maintains normal epithelial tissues (Dowling & Wald 1960; Wodsak 1959) and the synthesis of mucopolysaccharides (Wolf & Varandani 1960; Wolf, Bergan & Sundaresan 1963); it increases the conversion of cholesterol to corticosterone in adrenal homogenates (Van Dyke, Wolf & Johnson 1960); it supports the regular pattern of isoprenoid metabolism in rats (Thompson, Pitt & Morton 1960; Weber, Gloor & Wiss 1960) and it maintains normal cerebrospinal fluid pressure (Nelson, Dehority, Teague, Grifo & Sanger 1962). Furthermore, many tissue changes induced by large amounts of retinol both *in vivo* and *in vitro* can be produced by retinoic acid, usually more effectively (Thompson & Pitt 1960; Harris 1960; Boguth, Horn, Soliman & Weiser 1960; Matschiner & Doisy 1962; Wood 1962; Fell, Dingle & Webb 1962; Weitzel, Wahl & Buddecke 1962). There seemed at the time, and subsequently, ample justification for the comment by Dowling & Wald (1960) 'it appears from these experiments that the only function vitamin A may perform directly in the rat is to supply the prosthetic group of its visual pigments. All other functions—growth, general tissue maintenance—are served equally well by vitamin A acid.'

No investigations, however, had been made of the ability of retinoic acid to maintain reproduction. Vitamin A deficiency results in degeneration of the seminiferous epithelium in male rats (Evans 1932; Mason 1933, 1939); female rats mate successfully with normal males but their foetuses are either resorbed or born dead after a prolonged gestation period (Sure 1928; Mason 1935, 1939).

We report here that rats maintained on retinoic acid show similar defects in reproduction; in this respect retinoic acid does not replace retinol. (Brief preliminary communications have been presented to the Biochemical Society; Thompson, Howell & Pitt 1961*a*, *b*.)

Experimental

Animals

Hooded rats were used, from the closed colony kept in the Biochemistry Department of the University of Liverpool. Those described as normal stock animals were reared on standard food cubes (diet 4, British Extracting Co., Bromborough, Cheshire). The first day of pregnancy was taken as that on which spermatozoa were found in the vaginal smears at the routine morning examination. All young were weaned between 3 and 4 weeks of age.

Experimental diets

Diet I, deficient in vitamin A, consisted of sucrose (65 %), casein (Genatosan, vitamin-free) (18 %), dried yeast B.P.C. (8 %), ground-nut oil (5 %), minerals (based on the mixture of Hubbell, Mendel & Wakeman 1937) (4 %) and choline chloride (0·1 %). Animals on diet I were given twice-weekly supplements of 3 mg synthetic α-tocopheryl acetate. Diet II consisted of diet I, with the following added to each kilogramme: thiamine hydrochloride (5 mg), pyridoxine hydrochloride (5 mg), riboflavin (10 mg), *p*-aminobenzoic acid (10 mg), nicotinic acid (20 mg), calcium pantothenate (50 mg), inositol (400 mg), folic acid (1 mg), biotin (38 μg), *dl*-α-tocopheryl acetate (150 mg), ergocalciferol (10 μg) and either menadione (5 mg) or vitamin K_1 (2 mg); in some experiments cyanocobalamin (50 μg) was also included.

Retinoic acid (crystalline, all-*trans*) was a gift of Hoffmann-La Roche and Co., Basel; the methyl ester was prepared from it by the method of Robeson (1952).

Details are given in the text of the administration of retinoic acid to animals on diet I. Methyl retinoate (vitamin A acid methyl ester) was incorporated into diet II by being dissolved with the fat-soluble vitamins in the ground-nut oil. This solution was mixed with the sucrose and the water-soluble vitamins; casein and yeast were added, followed by the minerals. The resulting powder was stored at −15 °C for periods of up to a week, and in these conditions appeared to maintain its vitamin A potency. The diet was moistened with water (15 ml./100 g powder) when given to the animals.

Supplements of retinyl acetate (vitamin A acetate) were given in ground-nut oil either by mixing into the daily ration or, more usually, by pipette directly into the mouth; the latter procedure was always used for small amounts of the vitamin.

Tissues

The wet weights of the testes and seminal vesicles are recorded; care was taken to minimize loss of fluid from the seminal vesicles but it could not always be prevented completely.

The histological procedures for examining the tissues of the reproductive tract and the retina are described elsewhere (Howell, Thompson & Pitt 1963*a*, *b*). The pituitary glands were removed as soon as possible after death and fixed in formol-sublimate (1:9); they were embedded in paraffin wax, sections were cut at 5 μm, stained by haematoxylin and eosin and by the periodic acid–Schiff procedure as described by Purves & Griesbach (1951).

Results

(a) *Female rats*

The inability of vitamin A acid to maintain pregnancy

Thirty-three weanling female rats were put on diet I, which was deficient in vitamin A. After 3 weeks their growth slowed, and some of the animals showed the red encrusted eyelids characteristic of early vitamin A deficiency.

They were then divided into three groups of eleven. Group 1 received twice-weekly supplements of 350 μg retinoic acid (as the sodium salt, added to the food). Group 2 had the same supplements of retinoic acid, but given as the methyl ester, which Redfearn (1960) found to have a more prolonged effect than the free acid. Group 3 were given twice-weekly supplements of 350 international units vitamin A in the form of a few drops of high-potency fish liver oil (350 units = 105 μg retinol).

The deficiency signs disappeared, all groups grew well, and after 10 weeks the animals were mated with normal stock males, which were interchanged between groups to ensure that all the females had equal opportunities for successful mating.

All rats in group 3 (viz. those given retinol) had normal litters, and eight of the eleven were weaned normally. Two of the other litters died soon after birth. The mother of the third had to be killed as a result of an injury received in an unrelated accident; the litter, which was then 16 days old, healthy and developing normally, was killed at the same time. In all, eighty-eight young were born to the eleven animals in group 3; fifty-nine were weaned, and nine healthy pups had to be killed when 16 days old.

In contrast, no young were born of any of the twenty-two rats in groups 1 and 2 maintained on retinoic acid. Most of these animals showed an initial increase of weight after mating—in one case, 35 g—followed by a decline (as in figure 1). During the period of weight loss, bleeding from the vagina was visible externally in seven of the rats, and could have occurred unnoticed in the others. Although the animals often appeared unwell and ate poorly during the stages of vaginal bleeding and weight decline, they soon recovered completely. These signs indicated that the rats had become pregnant, but had resorbed their foetuses, as observed by Sure (1928) and Mason (1935) in rats severely deficient in vitamin A.

In this experiment, retinoic acid, in twice-weekly doses of 350 μg per rat, did not replace vitamin A in maintaining gestation, but the possibility was considered that other dose levels (either higher—or perhaps lower) might have been effective.

It seemed unlikely that these doses had been too small. Estimates of the potency of retinoic acid vary with the criterion chosen and the mode of administration: in normal physiological responses they range from 100 % of the activity of retinol (van Dorp & Arens 1946*b*) down to 8 % (van Dorp & Arens 1946*a*). Even at the lowest value, which is much below most estimates, the dose would have been equivalent to 25 i.u. vitamin A daily, and greatly in excess of the minimal amounts of the vitamin required to maintain pregnancy (Tansley 1936; Newton 1938; Browman 1939). On the other hand, Arens & van Dorp (1946*b*),

Sharman (1949), Harris (1953) and many other workers have found that retinoic acid is metabolized very speedily in the body. If the acid does not penetrate quickly into and across the placenta, its rapid catabolism might lower its potency in maintaining pregnancy below what it has been previously judged to be, using other criteria.

The experiment was therefore repeated in a modified form to allow for the possibly transient existence of retinoic acid. The rats of groups 1 and 2 were kept on the basic diet supplemented with the same amounts of sodium retinoate and methyl retinoate respectively for a rest period of 2 weeks to allow complete recovery from the interrupted pregnancy. The method of giving the acid was then changed. Instead of twice-weekly supplements, a more uniform supply was ensured by mixing retinoic acid into the daily ration at a level of 8 μg/g food; the sodium salt was given to group 1, the methyl ester to group 2. This régime would therefore provide a continuous dose of the acid amounting to 80 to 120 μg/day. The twenty-two animals were then mated with normal stock males.

During the period of mating, the bucks were given the same diet as the females, and after a few days many of the males died as a result of internal and external haemorrhages. Despite this complication, all the female rats became pregnant. Their weights increased, by up to 40 g, and then fell as before. They showed vaginal bleeding, so profuse that six of them died. On examining the uteri of the dead animals, many sites were found containing foetuses, some well developed, others in various stages of resorption. No litter was born to any of the twenty-two females.

The excessive vaginal bleeding and the deaths in both sexes were found to be caused by avitaminosis K. Diet I has been used successfully for many years, despite its low vitamin K content, presumably because rats satisfy their needs by coprophagy. Large amounts of dietary vitamin A can, however, precipitate vitamin K deficiency in animals on a marginal intake (Light, Alscher & Frey 1944) and, as was reported subsequently by Matschiner & Doisy (1962), retinoic acid appears to be even more potent in this respect than retinol. In other experiments (not reported here in detail) designed to elucidate the cause of the multiple deaths, adult male rats given diet I containing methyl retinoate (10 μg/g food, mixed daily) suffered severely from haemorrhages and frequently died within a week; the addition of menadione (5 μg/g food) completely protected them.

It was unlikely that the resorption of the foetuses resulted from a shortage of vitamin K, as female rats are usually very resistant to K deficiency even when pregnant (Metta & Johnson 1960), but this possibility was eliminated in a further experiment using the sixteen surviving females. They were allowed 15 weeks to recover, on diet I supplemented with retinoic acid, and then divided into two groups of eight (redesignated groups 4 and 5). Both groups were given diet I supplemented with menadione (5 μg/g diet) and, to reinforce the continuous dosing, even larger amounts of methyl retinoate—100 μg/g diet, mixed daily. Group 5 was also given 5 μg retinyl acetate/g food—the acetate is a more convenient form to feed to animals and, since it is readily hydrolysed to the alcohol, is equivalent to giving retinol.

When mated with normal males (which were fully protected by the menadione from the very high level of retinoic acid in the diet), seven of the eight females given retinol (group 5) delivered litters after a normal period of gestation. The animals in group 4, maintained on retinoic acid alone, showed an initial gain followed by a fall; this was accompanied by vaginal bleeding which, although externally visible in most cases, was much less copious than previously and no fatal haemorrhages occurred. No litters were born to group 4.

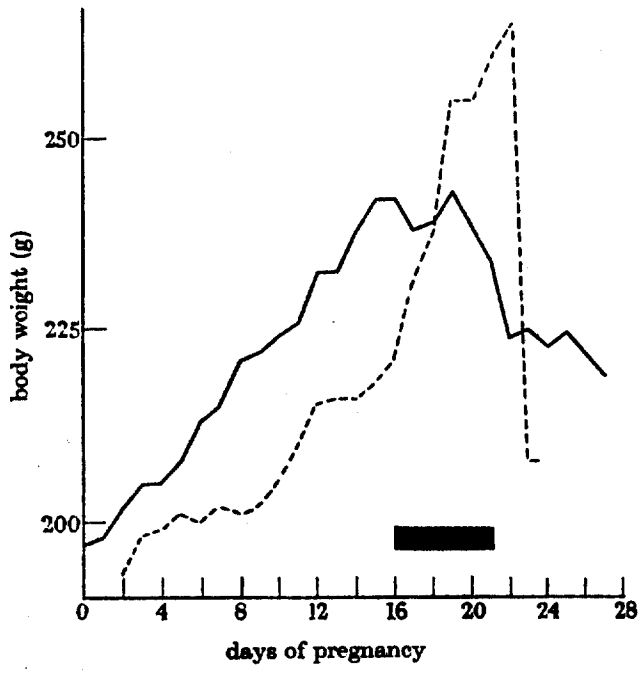

FIGURE 1. Weight changes in pregnant rats: (1) —, maintained on diet II and retinoic acid; (2) ----, on same diet plus daily doses of 1 μg retinyl acetate during pregnancy. Vaginal bleeding ▬ seen in rat (1) between the 16th and 21st days.

This experiment demonstrated that resorption still occurred on a diet supplemented with vitamin K and with higher amounts of retinoic acid than were used in the earlier trials. Females that had previously resorbed two litters on the retinoic acid diet had been brought through pregnancy by giving retinol.

A number of similar experiments were performed—many in connexion with work described later in this paper—using the improved diet II containing extra fat-soluble and water-soluble vitamins (to guarantee that no other dietary essential was in short supply) and supplemented with levels of methyl retinoate ranging from 10 μg to 100 μg/g food. All animals had normal oestrous cycles as judged by vaginal smears (Mason & Ellison 1935*a*), which showed no indication of vitamin A deficiency. When placed with normal stock males, they readily mated and became pregnant but the foetuses were always resorbed (see figure 1) unless retinol was given; if the vitamin was provided in sufficient amount (see below), healthy litters were born.

Retinoic acid, even at levels as high as 100 μg/g food, i.e. over 1 mg rat^{-1} day^{-1}, did not maintain pregnancy. Although the results of these experiments cannot be ascribed to inadequate doses of retinoic acid, pregnancy can be interrupted not only by insufficient vitamin A, but also by excessive amounts, some of the consequences being similar to those observed in our rats (Moore & Wang 1945). Hypervitaminosis A cannot be the cause of the reproductive failure in the female rats given retinoic acid since they (e.g. group 5) were protected by extra retinol. To confirm this a further eleven normal stock females were kept throughout pregnancy on standard food cubes containing a plentiful supply of retinol and given up to 1 mg methyl retinoate/day. They cast normal litters of which only one failed to survive to weaning. The failure of retinoic acid to maintain pregnancy cannot be ascribed to any toxic activity.

TABLE 1. EFFECTS OF SMALL QUANTITIES OF RETINOL ON PREGNANT FEMALE RATS MAINTAINED ON RETINOIC ACID

daily dose of retinyl acetate (μg)	number of pregnancies	outcome: complete resorption	outcome: litter stillborn or died	outcome: some young weaned
0·1	2	2	—	—
0·5	7	0	7	—
various doses between 0·5 and 1·0	26	1	18	7
1·0	43	0	22	21
2·0	49	0	24	25

Supplementation with vitamin A during pregnancy

The animals in group 5 were brought through pregnancy by far larger doses of retinol than are needed to maintain gestation in orthodox vitamin A deficiency (Tansley 1936; Newton 1938; Browman 1939). Very small amounts of retinol when given to other rats on diet II were found to have a striking effect in preventing foetal resorption. Considerable variation was found, however, in the amounts of the vitamin required to produce viable litters; the young were frequently stillborn or died within a few days. No attempt was made to determine a mean effective dose, but our experiences are summarized in table 1.

Daily doses during pregnancy of 0·1 μg retinyl acetate were ineffective; 0·5 μg retinyl acetate/day prevented resorption but the litters were either stillborn or died soon after birth. Increasing the daily dose above 5·0 μg enabled some to survive and be weaned successfully, but, even with 2 μg retinyl acetate/day, mortality was severe. Many of the weaned litters were normal in number, but there was an unusually high proportion containing only a few young (3 or less), the remainder of the litter having died soon after birth. These survivors gained weight and developed as well as normal animals of our stock colony. The death of the remainder of the litter in the first day or so of life could not, therefore, have been due to failure of lactation in the mother, but must be ascribed to an inherent weakness of these young.

No comparable investigations were made with higher doses of the vitamin; the amounts were deliberately kept low to produce young which had received only minimal quantities of retinol, for use in work described later in this paper.

Foetal resorption, stillbirths and weak young have been observed by many earlier workers with vitamin A-deficient rats (Sure 1928; Mason 1935; Tansley 1936; Newton 1938). Our results show clearly that complete deficiency of retinol results in resorption of the foetuses, while a lesser degree of deficiency allows young to be born, but not to survive.

The dosing with retinol was stopped on the last day of pregnancy. Yet of the pregnant animals given 1 μg/day—a quantity so small that very little could have been stored—nearly half were able to maintain lactation and bring their young successfully to weaning. Many of the litters were of normal size, grew well and appeared healthy, with none of the outward signs of deficiency (e.g. xerophthalmia) seen by Mason (1935) in young born of mothers on very low levels of vitamin A. The litters in our experiments were probably maintained by retinoic acid secreted into the milk.

Mason (1935) reported that giving vitamin A to deficient rats on or before the ninth day of pregnancy (using our convention for numbering the days) ensured the delivery of normal litters. Even if the supplementation was delayed until the thirteenth day, pregnancy was still completed in most cases, although mortality was high among the young. We have made only a few experiments in which we started to add retinol part way through pregnancy but, whenever it was given by the twelfth day, a litter was born, although in a number of cases the young were not viable. Our results when beginning supplementation on various days of pregnancy can be summarized as follows: seventh day—1 litter weaned; eighth day—4 litters weaned, 3 died; ninth day—1 weaned, 1 died; tenth day—1 weaned; twelfth day—1 litter died.

Our results support the conclusion of Mason (1935) that the heavy call on vitamin A is for the later stages of pregnancy and show that retinol is not required for the earlier events in gestation, which can be maintained by retinoic acid.

Lesions seen at foetal sites

In a preliminary experiment, a number of female rats maintained on retinoic acid were mated with normal stock males and killed at various stages of pregnancy for histological investigation. The foetal sites appeared normal up to the thirteenth day of pregnancy.

Nineteen other female rats reared from weaning on diet II plus retinoic acid were mated when 100 to 112 days old with normal stock males. The females were kept on diet II containing 10 μg methyl retinoate/g.

Ten were given 500 μg retinyl acetate at mating and 250 μg on both the seventh and the fourteenth days of pregnancy. Two were allowed to complete gestation and had litters of six and eight. The other eight rats given retinol were killed for histological examination, two on each of the fifteenth, sixteenth, seventeenth and eighteenth days of pregnancy. One of the rats killed on the fifteenth day, and another on the seventeenth day, were found not to be pregnant.

The remaining nine of the nineteen rats were maintained on retinoic acid. One was allowed to survive; its weight rose, then declined and bleeding was seen from the vagina; no young were born. The other eight rats on retinoic acid alone were killed during pregnancy for examination: one on the fourteenth day, one on the fifteenth, and two on each of the sixteenth, seventeenth and eighteenth days—all were pregnant.

Implantation in the eight rats maintained on retinoic acid (an average of 8·9 placental sites each) was neither abnormal nor inferior to that in the six animals given retinol (average: 7·3 placental sites).

Of the rats given retinoic acid alone, the one examined on the fourteenth day of pregnancy had ten foetal sites and nine seemed to be normal; the exception was smaller than the others and contained a necrotic placental disk, with an almost completely resorbed foetus. In the fifteenth-day animal, again only one of the ten sites had a detectable abnormality: here, too, there was marked necrosis of the placental disk and advanced foetal resorption. In the two sixteenth-day rats, ten of the fifteen sites were normal; in the five others, histological investigation revealed an area of necrosis at the edge of the placental disk. In the two seventeenth-day rats, this lesion was more extensive and severe. Of the eighteen sites, fifteen showed varying degrees of abnormality. At one extreme, there was only histologically detectable necrosis at one edge of a section of the disk, with the foetus apparently normal. In other sites, the damage was so extensive as to be obvious macroscopically; much of the tissue of the placental disk was necrotic, this lesion being accompanied by advanced dissolution of the foetus. Sites undergoing resorption were often adjacent to normal ones; affected sites were distributed randomly. The eighteenth-day rats showed essentially similar changes; by this time all of eighteen sites were involved, but, to judge from the variations in severity, the onset had been random, a feature characteristic of avitaminosis A as contrasted with avitaminosis E (Mason 1935).

The rats given retinol were also examined in a similar way. The results can be briefly summarized as: fifteenth day—no abnormalities; sixteenth—six sites normal, two sites with histologically detectable areas of necrosis at one edge of the placental disk; seventeenth day—no abnormalities; eighteenth day—fifteen sites normal, one with a very small histologically detectable area of necrosis at the edge of the placental disk.

The first abnormality we detected in the foetal sites of animals relying on retinoic acid was necrosis with slight polymorph infiltration around the periphery of the placental disk. This was similar to a lesion observed by Mason (1935) in some of his pregnant rats suffering from orthodox vitamin A deficiency. The first detectable damage in our animals was in the placenta rather than in the foetus, a characteristic of A-deficiency as opposed to vitamin E-deficiency where the ill-effects are first observed in the foetus (Mason 1935). Since very small areas of necrosis at the placental margin were occasionally seen in our rats given retinol, it may be that they occur at times in normal pregnancy, but their severity and consistent occurrence in rats on retinoic acid predicate their significance in the initiation of foetal resorption.

Contrary to the experience of Mason (1935) with rats deficient of all forms of vitamin A, we observed no widespread lesion before the sixteenth day of pregnancy, no retardation of the growth of the maternal decidua and no infection at the placental sites.

It is hoped to publish elsewhere fuller details of our histological investigations (Howell *et al.* 1963*b*).

TABLE 2. BODY AND TESTIS WEIGHTS OF RATS ON VARIOUS DIETS

pair	régime	body weights (g)	testis weights (mg)	
8	A-deficient	86	394	408
		106	370	360
9	retinoic acid	193	604	681
		217	857	924
10	retinoic acid + retinol	182	1270	1303
		231	1108	1150

(*b*) *Male rats*

Degeneration of testes

Six male rats, aged 28 days, were divided into three pairs (8, 9 and 10). Pair 8 were given diet II, deficient in vitamin A; pair 9, the same diet containing 10 μg methyl retinoate/g; and pair 10, the diet with the same amount of methyl retinoate plus retinyl acetate (3·3 μg/g food).

Pairs 9 and 10 grew well and appeared healthy; the deficient animals in pair 8 reached a growth plateau at 50 days of age, and within a week showed the characteristic eye signs of vitamin A deficiency. One rat from each of the other pairs was killed when 73 days old, the second at 75 days.

Gross examination of the testes revealed marked differences between the pairs (see table 2). The very low testis weights in the completely deficient pair (8) are due in part to the poor growth and eventual loss of weight by the animals, but the testes clearly weighed less in those rats fed retinoic acid (pair 9) than in those receiving retinol, even though there was little disparity in the body weights.

The differences between the pairs were even more prominent on histological examination. The testes of the rats given retinol were completely normal: all the tubules had a healthy germinal epithelium showing complete spermatogenesis; the epididymal ducts were full of spermatozoa.

In the deficient animals of pair 8, the germinal epithelium had undergone the anticipated changes: the seminiferous tubules were lined by Sertoli cells, spermatogonia and a few spermatocytes; all the spermatids had sloughed off. The epididymal ducts contained only desquamated cells and eosinophilic debris. This picture is typical of the testicular lesion in A-deficient rats as described by Mason (1933).

The testes of the rats fed retinoic acid alone (pair 9) resembled those of the deficient animals. One rat showed very little difference from the deficient pair;

in some of the tubules of the other rat, the lesion had not progressed quite so far but the testes were clearly undergoing the same degenerative changes. The ductus epididymis of these rats contained many desquamated cells associated with a few spermatozoa.

In this experiment the feeding of retinoic acid failed to prevent the deterioration of the germinal epithelium which occurs in vitamin A deficiency, even though the animals grew normally and had healthy epithelial tissues elsewhere in the body. Although the amounts of retinoic acid given were many times greater than the minimum required for optimal growth, it is possible that even more might be required to maintain the germinal epithelium. As discussed earlier in connexión with the females, the rapid catabolism of retinoic acid could perhaps interfere with the penetration of acid to the target tissue in adequate amounts.

To see if larger doses would be effective, four litter-mate rats, nos. 11, 12, 13 and 14, were reared from weaning on diet II containing 10 μg methyl retinoate/g. From 9 to 17 weeks of age, each was given a daily oral dose of 1 mg methyl retinoate dissolved in 0·1 ml. ground-nut oil. During this period of 8 weeks, animals 13 and 14 were also given weekly doses of 140 μg retinyl acetate.

At the beginning of the heavy dosing period, the rats weighed between 171 and 183 g and throughout the experiment appeared in excellent condition. They grew at similar rates and after 8 weeks weighed between 233 and 260 g. At this stage (17 weeks of age), they were killed. The only obvious macroscopic difference between the two pairs of rats was in the appearance of the testes. Those from the rats given retinol were normal in size and appearance (weights: rat 13, 1·03 g, 1·04 g; rat 14, 1·36 g, 1·32 g); those from the animals given only retinoic acid were small, discoloured and slightly oedematous (weights: rat 11, 0·51 g, 0·42 g; rat 12, 0·49 g, 0·50 g).

Histologically, the testes of the animal given retinol were normal, the tubules showing complete spermatogenesis, with the epididymal ducts full of spermatozoa. In contrast, the epididymides of the rats given only retinoic acid contained eosinophilic debris, desquamated cells and sperm heads. No spermatozoa were found, apart from a few in the tail of the epididymis of rat 12. The seminiferous tubules in both animals were lined only by Sertoli cells, spermatogonia and a few spermatocytes; no spermatids or sperm were seen.

Despite the use of such large quantities, retinoic acid failed to maintain spermatogenesis and thus did not replace retinol. Two more rats on diet II were fed from 28 days of age still higher amounts of methyl retinoate (increasing in stages from 10 to 500 μg/g food). They showed the characteristic signs of hypervitaminosis A—bone fractures and bleeding from eyes and nose—so severely that to avoid unnecessary suffering they had to be killed when 67 days old and, to judge from our previous experiences (Thompson & Pitt 1960), with only a few days to live. On histological examination, the testes showed the early signs of vitamin A deficiency as described above. Thus these animals given very large doses of retinoic acid showed in different tissues at the same time typical signs of both hypervitaminosis A and avitaminosis A.

Although high doses of retinyl palmitate have been found to harm the testes of

rats (Maddock, Cohen & Wolbach 1953), the testicular damage in rats maintained on retinoic acid cannot be ascribed to hypervitaminosis A since it differs in histological detail from that described by Maddock *et al.* (1953) and—even more convincingly—in pair 10 and rats 13 and 14 it was prevented by extra amounts of retinol. It must therefore be due to a deficiency of retinol.

Reversibility of lesion

A characteristic feature of vitamin A deficiency in the testis is that the effects can be reversed by feeding the vitamin; this is in contrast with the lesion produced by vitamin E-deficiency, which is completely irreversible at any stage (Mason 1933).

The ability of retinol to repair the lesions found in our animals was therefore tested by using 14 rats (nos. 15 to 28) reared from weaning on diet II containing 10 μg methyl retinoate/g. They were divided into pairs at various ages between 10 and 18 weeks; the right testis was removed from both animals and weighed; the testis and epididymis were examined histologically. One of each pair was left on the same retinoic acid diet while the other was given an additional weekly supplement of 200 μg retinyl acetate. After a further period of 10 to 14 weeks, both animals of a pair were killed, the remaining testis being removed and weighed (in some cases the seminal vesicles were also weighed); the testes and epididymides were examined histologically.

Table 3 gives details of the age of the rats when the testes were removed, the weights of the testes and seminal vesicles, and an indication of the histological appearance of the testes.

The development of the lesion can be followed from the histological changes in the right testicle: the longer the animals were maintained on retinoic acid alone, the more severe the damage. In the rats that were 10 weeks old, the seminiferous tubules appeared normal but the epididymal duct contained an abnormal number of sloughed cells. In rats that were 18 weeks old, many of the seminiferous tubules were filled with Sertoli cells, others still contained spermatogonia and a few spermatocytes. In the animals maintained on retinoic acid alone throughout the experiment, i.e. up to 21 to 30 weeks of age (nos. 15, 17, 20, 23, 25 and 27), the degeneration continued in the left testicle until almost all the tubules were filled with Sertoli cells, only an occasional tubule containing a few spermatogonia and spermatocytes. All such testes were oedematous, some of them exceedingly so.

The wet weights of the testes in general declined with increasing time on the retinoic acid diet, but in two animals (23 and 25) they rose as a result of the oedema. The wet weight of the testis is thus a less reliable guide to the degree of degeneration than is the histology.

In contrast with the progressive deterioration seen in the left testes of the rats maintained on retinoic acid throughout the experiment, the damage was repaired in the rats fed retinol (16, 18, 21, 22, 24, 26 and 28). The extent of regeneration varied with the condition of the testis when retinol feeding began. If the vitamin was given at a very early stage in the development of the lesion (rats 16 and 18), the germinal epithelium was completely restored to normal; if fed slightly later (rat 21), normal spermatogenesis reappeared in almost all the tubules. With

increasing degeneration, reversal became more difficult (rats 24 and 26), and if the damage had been severe, the number of fully repaired tubules was small.

The time of onset of testicular degeneration hinges on when the animal exhausts its stores of retinol and this depends largely on the reserves of the vitamin acquired before weaning. Individual animals and litters differ in this respect and in

TABLE 3. REPAIR BY RETINOL OF TESTICULAR LESION IN RATS MAINTAINED ON RETINOIC ACID

rat	age (weeks) when testicles removed: right	age (weeks) when testicles removed: left	retinol supplementation*	weights of testicles (mg): right	weights of testicles (mg): left	histological condition of testicles: right	histological condition of testicles: left	combined weight of seminal vesicles (mg)
15	10	21	–	1098	753	*D*	*DDDD*	not weighed
16	10	21	+	897	1280	*D*	*N*	not weighed
17	10	23	–	1116	868	*D*	*DDDD*	not weighed
18	10	23	+	1318	1746	*D*	*N*	not weighed
19	11†	—	—	1034	—	*D*	—	—
20	11	25	–	1119	575	*D*	*DDD*	282
21	11	25	+	710	1047	*DD*	*RRRR*	434
22	11	25	+	944	485	*DD*	*RR*	441
23	14	28	–	621	783‡	*DDD*	*DDD*	402
24	14	28	+	542	657	*DDD*	*RRR*	792
25	18	28	–	694	1328‡	*DDDD*	*DDDD*	171
26	18	28	+	501	696	*DDDD*	*RR*	689
27	18	30	–	494	491	*DDD*	*DDD*	116
28	18	30	+	443	908	*DDDD*	*R*	1428

* + Denotes supplemented with retinol after removal of right testicle; – maintained on retinoic acid throughout the experiment.

† Died under anaesthetic.

‡ testicles very oedematous.

Key to abbreviations used to describe histology of testes.

Degeneration. *D*: histological appearance of tubules normal, but sloughed cells seen in epididymis. *DD*: histological signs of degeneration, but varying in severity between tubules —some still showing complete spermatogenesis. *DDD*: severe degeneration; most tubules containing only spermatogonia, Sertoli cells and a few spermatocytes. *DDDD*: very severe degeneration; many tubules filled with Sertoli cells, others have a lumen but contain only Sertoli cells, spermatogonia and occasional spermatocytes.

Regeneration. *R*: slight signs of regeneration; spermatids present in some tubules. *RR*: very incomplete regeneration; only a few tubules restored to normal. *RRR*: regeneration obvious with about half the tubules showing complete spermatogenesis. *RRRR*: almost complete regeneration; majority of tubules showing complete spermatogenesis. *N*: completely normal.

other experiments, not reported here in detail, we have noted variations in the time scale of testicular degeneration, but the same sequence of changes is always found.

The retinas from all rats were examined histologically at the end of the experiment and showed no atrophy of the visual cell layer, as observed by Dowling & Wald (1960) in animals maintained for long periods on retinoic acid. Although there was a striking contrast in the condition of the testes between the animals fed retinol and those given only retinoic acid, the retinas in both groups appeared

normal. Judged by histological criteria, the effect of a lack of retinol is seen in the testis long before any damage is recognized in the eye.

The rapid sloughing of the germinal epithelium, the retention of spermatogonia after long periods without retinol, the repair by feeding retinol, and the detailed histology (which is published in full elsewhere—Howell *et al.* 1963*a*): all are features described by Mason (1933) as characteristic of vitamin A deficiency. In males, as in females, retinoic acid fails to support reproduction: it does not maintain spermatogenesis in the absence of retinol.

Seminal vesicles

In table 3 are recorded the weights of the seminal vesicles of some of the rats (20 to 28); in general those from animals maintained on retinoic acid alone were smaller than those from paired animals fed retinol. Male rats suffering from orthodox vitamin A deficiency show atrophy of the accessory sex organs, but this has been considered a non-specific consequence of systemic deficiency (Mason 1933, 1939). This explanation cannot be true for our rats fed retinoic acid.

A further experiment was therefore made to check this point, as the results detailed in table 3 might have been complicated by the unilateral orchidectomy.

Eleven male rats (nos. 29 to 39) were reared from weaning on diet II containing 10 μg methyl retinoate/g. When 11 weeks old, they were divided into one group of five animals (29 to 33) and two groups of three (34 to 36 and 37 to 39). Rats 29 to 33 were then given diet II (i.e. containing neither retinol nor retinoic acid) and weekly doses of 1 μg retinyl acetate. These trace amounts of retinol, together with the small amounts of methyl retinoate presumed to be stored in the body (Redfearn 1960), were sufficient to maintain life, but not growth, and most of these animals suffering from chronic mild deficiency slowly lost weight. The vitamin A dosing was discontinued at 20 weeks of age and the deficiency signs grew worse. By 24 weeks of age, the rats were emaciated and showed typical signs of prolonged A-deficiency, e.g. xerophthalmia and absence of pigment from the teeth. Rats 34 to 36 were kept on diet II containing 10 μg methyl retinoate/g; rats 37 to 39 had diet II with the same amount of methyl retinoate and extra weekly supplements of 200 μg retinyl acetate.

All the animals were killed at 24 weeks of age; their testes and seminal vesicles were weighed, and the testes examined histologically. Details of the organ weights are given in table 4, which shows that the animals fed retinoic acid alone grew as well as those given retinol and that the deficient group lagged. As regards weights and histology, the testes of the retinol-supplemented rats were completely normal except for no. 38, but this had reached the final stages of regeneration (*RRRR* of table 3). The testes of the group given only retinoic acid (34 to 36) showed severe degeneration (*DDD*); the completely deficient animals (29 to 33) were rather worse (*DDDD*).

The differences between the various groups in the weight of the seminal vesicles ran parallel to the findings in the testes. In agreement with the results of previous workers (Wolbach & Howe 1925; Mason 1933, 1939; Van Os 1936; Mayer & Truant 1949), the seminal vesicles were smaller in vitamin A-deficient animals

than in retinol-fed controls but they also remained small in the animals fed retinoic acid. These figures (table 4) confirm the impression given earlier (table 3) that, as regards the weights of seminal vesicles, retinoic acid-maintained rats resemble more the completely deficient animals than those given retinol. Previous explanations of the small size of the seminal vesicles in rats suffering from complete vitamin A deficiency have relied on failure of the systemic action of the vitamin (Wolbach & Howe 1925; Mason 1933, 1939). Our results confirmed that this could be a contributing factor: seminal vesicles in the completely deficient group (29 to 33) showed squamous metaplasia and some contained pus. No such lesions, however, were seen in the seminal vesicles of the rats given retinoic acid (34 to 36) —indeed the epithelium appeared to be quite healthy. The small size of their accessory sex organs cannot be ascribed to systemic deficiency.

TABLE 4. WEIGHTS OF BODY, TESTES AND SEMINAL VESICLES IN RATS MAINTAINED ON RETINOL, RETINOIC ACID AND VITAMIN A-DEFICIENT DIETS

rat	diet	body weight (g)	weights of testes (mg)		weights of seminal vesicles (mg)	
29	vitamin A-deficient	238	1156	1133	270	254
30		132	400	368	107	132
31		164	725	739	125	169
32		186	800	451	200	195
33		172	400	437	261	246
34	retinoic acid	282	751	747	217	186
35		320	805	781	110	123
36		325	549	761	135	123
37	retinol	285	1416	1288	490	747
38		287	1123	1254	337	412
39		311	1343	1366	395	408

Mason (1933, 1939), Van Os (1936), Mayer & Truant (1949) and Mayer & Goddard (1951) have produced evidence that androgen production is decreased in vitamin A-deficient animals, probably as a result of lowered pituitary activity. We have not made detailed studies of the interstitial tissue in the testes of retinoic acid-fed rats, but no abnormalities were detected in sections stained with haematoxylin and eosin. The pituitaries of retinoic acid-fed male rats appeared to differ from those of retinol-fed animals only in having large numbers of 'signet-ring' cells, the so-called 'castration' cells found in the absence of a functioning seminiferous epithelium (Mottram & Cramer 1923; Nelson 1937).

Whatever the explanation may be, retinol appears to be necessary for the proper development of the seminal vesicles and retinoic acid does not suffice.

Sexual maturation

Once a rat has lost its reserves of retinol, retinoic acid does not maintain the seminiferous epithelium. In the experiments so far described in this paper, weanlings were put on a diet deficient in retinol but their stores of the vitamin delayed the onset of deficiency signs for about 4 to 6 weeks, depending on the amount they

had accumulated before weaning. Although the feeding of retinoic acid does not spare the rat's liver stock of retinyl esters (Dowling & Wald 1960), no testicular degeneration will occur until all the reserves of retinol have disappeared, and before this happens, the animals will have undergone considerable sexual development.

The role of retinol in the maturation of the testes can therefore be studied only by obtaining animals whose stores are exhausted at a very early age. A method of producing such rats arose in the experiments already described where females maintained on retinoic acid were given small amounts of retinol during pregnancy to enable them to deliver and rear young.

Female rats, fed from weaning diet II containing 10 μg methyl retinoate/g, were mated with normal stock males and given 1 or 2 μg retinyl acetate daily during pregnancy. This supplement was stopped when the litter was born. That the young had exceedingly small stores of retinol was confirmed in the case of a litter of 10 born of a female given 2 μg retinyl acetate per day during pregnancy. Immediately after parturition, the mother was put on to diet II, completely deficient in retinol and retinoic acid. The litter did well at first, possibly because the mother was able to secrete into her milk some methyl retinoate while her tissue stocks (Redfearn 1960) were being run down, but the young rats ceased to thrive and by 21 days of age they were all showing the eye lesions characteristic of vitamin A deficiency. Seven of them died 2 days later. The three survivors were given retinoic acid; they recovered and grew well.

This experiment confirmed that such young animals were born with minimal stocks of retinol and would normally be free from it at weaning. The routine procedure adopted to obtain such young differed from this experiment in that the mothers were usually fed, during lactation, diet II supplemented with 10 μg methyl retinoate/g, which would provide an adequate supply for secretion into the milk and also directly to the young when they began to eat small amounts of solid food towards the end of the third week of life.

This normal and obviously desirable practice of supplying adequate amounts of retinoic acid to litters did not however prevent their exhausting any stores of retinol well before sexual maturity. Three male rats (40, 41 and 42) were taken on weaning (22 days old) from a 'low retinol' litter obtained by the routine procedure. Two (40 and 41) were given diet II, completely deficient of any form of vitamin A; their growth fell behind that of their litter-mate (42) given the same diet containing 10 μg methyl retinoate/g and at 32 days of age they stopped gaining weight. Both rats developed eye symptoms of vitamin A deficiency which rapidly intensified. When 40 days old they were killed. They were then on the point of death, and showed clear signs of avitaminosis A, e.g. xerophthalmia, depigmentation of teeth and with stratified squamous epithelium in the urethra with early keratinization. Their weights were 61 and 65 g; their litter-mate maintained on retinoic acid weighed 105 g. Since the supplies of methyl retinoate obtained before separation from their mother would have maintained the weanling animals for a short time, the appearance of vitamin A-deficiency signs after only 10 days confirmed that the retinol stocks of these animals were negligibly small.

The testes of the deficient rats (40 and 41) and of the litter-mate (42) given retinoic

acid were compared with those of a normal rat, also aged 40 days, reared on standard food cubes, and weighing the same (105 g) as the animal fed retinoic acid. In all seminiferous tubules of this normal rat, spermatogenesis was active and spermatids were present. In the deficient rats (40 and 41), the tubules had not developed a lumen but were lined with Sertoli cells, spermatogonia and a few spermatocytes. The tubules looked very similar in the rat fed retinoic acid (42), which, in contrast with the deficient rats, had grown normally and appeared healthy. Thus retinoic acid did not appear to permit the normal development of the testes.

A larger experiment was made using 24 male rats produced with very low reserves of retinol by the routine method described. They were divided at weaning into 12 pairs of litter-mates (pairs 43 to 54). One of each pair (suffixed AC in table 5) remained on diet II containing 10 μg methyl retinoate/g; the other (suffixed AL) was given the same diet and an extra weekly supplement of 200 μg retinyl acetate. The retinol supplementation was started at weaning or within the following three weeks.

To test the effects of high dietary levels of retinoic acid, 2 pairs (53 and 54) were given, in addition to the normal supplements appropriate to each pair, a daily oral dose of 500 μg methyl retinoate. They developed signs of mild hypervitaminosis A—a rough coat, bleeding at the eyelids, and subnormal growth.

The animals were killed at various times between 56 and 128 days of age. The testes and seminal vesicles were weighed (see table 5) and the testes, epididymides, seminal vesicles and prostate examined histologically.

The addition of retinol to the basic diet allowed normal development of the testes in most rats, as judged by weight and histological examination. The only exceptions were animals 46 AL, 48 AL, and 50 AL (see table 5). 46 AL had an undescended testis; this is a congenital defect that appears occasionally in our stock colony. 50 AL had one small testicle which had differentiated only up to the spermatocyte stage; the large testicle of the same animal was normal save for a few tubules containing multinucleate giant cells (which were also found in the small testicle). The giant cells were also seen in a few tubules in both testes of 48 AL. Otherwise the testes of 48 AL appeared normal histologically, although they were markedly smaller than in other animals killed at about the same age. These were the exceptions; in general, the testes in animals fed retinol, even when together with very large extra doses of retinoic acid, were normal and showed complete spermatogenesis.

In contrast, the testes always remained infantile in size and structure in rats maintained on retinoic acid alone at both the regular and the hypervitaminotic levels of dosing. A lumen was formed in the seminiferous tubules of these rats and in animals killed when 56 days old numerous spermatocytes were present, but spermatids were never formed. As the length of time on the diet increased, the testes showed severe degenerative changes. The partly developed germinal epithelium was sloughed and many of the tubules were filled with Sertoli cells.

Full details of these histological investigations on the testes of rats maintained on vitamin A acid are published elsewhere (Howell *et al.* 1963*a*).

The absence of retinol appears to check the development of the testes before the spermatid stage. By using these animals with very low reserves of retinol, we have been able to show the testicular lesions of vitamin A deficiency at a far earlier stage than has hitherto been possible. Just as retinol was able to restore spermatogenesis in older rats (table 3) so it could here induce testicular development even when given as late as 42 days of age, by which time the retarding effect of its absence would have been severe (cf. rat 42).

TABLE 5. DEVELOPMENT OF RATS BORN WITH LOW RESERVES OF RETINOL

rat	age when retinol given (days)	age when killed (days)	body weight (g)	weights of testes (mg)		weights of seminal vesicles (combined) (mg)
43AL	25	56	118	716	647	70
43AC	—	56	87	191	208	18
44AL	28	62	134	508	462	48
44AC	—	62	137	378	382	40
45AL	42	68	211	749	760	not weighed
45AC	—	68	182	410	411	
46AL	25	82	189	642*	1359	320
46AC	—	82	167	330	345	148
47AL	25	105	219	1713	1512	750
47AC	—	105	183	482	538	446
48AL	42	123	303	818	766	464
48AC	—	123	253	374	353	406
49AL	42	123	243	1364	1364	414
49AC	—	123	164	470	501	33
50AL	42	126	281	2081	1283*	882
50AC	—	126	253	297	295	38
51AL	28	128	290	1643	1626	921
51AC	—	128	217	433	479	480
52AL	28	128	273	1279	1224	917
52AC	—	128	221	335	367	477
53AL†	25	84	129	1187	1149	248
53AC†	—	84	157	248	248	16
54AL†	25	84	198	1327	1331	353
54AC†	—	84	206	407	430	108

* Testis undescended or abnormal (see text).
† Given extra 500 μg methyl retinoate daily.

The testes of rats maintained on retinoic acid, although immature in size and structure, descended in the normal manner. When adult, such animals copulated with females. Nevertheless, their accessory sex organs did not develop in the regular way. It had previously been seen (tables 3 and 4) that retinoic acid did not support the growth of seminal vesicles as well as did retinol. Table 5, too, shows that the animals fed retinoic acid had smaller seminal vesicles than their litter-mates given retinol, but the differences were very variable, being very great for some (e.g. pairs 49, 50 and 53) and at the other extreme (pair 48) so small as to be of doubtful significance.

Another notable difference between the paired litter-mates was in the texture of the fur. Those fed retinol had the normal rather coarse fur of our stock colony male rats; in those on retinoic acid alone, the fur was softer and finer, intermediate

between the normal male and female textures. Male animals in other experiments maintained for many months on retinoic acid invariably had fur resembling the soft, fine, female type, regardless of whether they had retinol reserves at weaning or not. Such rats could readily be distinguished from controls fed retinol, merely by outward appearance and feel.

Growth of animals born with low reserves of vitamin A

Table 5 shows another, unexpected, feature of these rats born with low reserves of retinol; those subsequently fed retinoic acid did not grow as well as their litter-mates given retinol. No such difference has been noticed in animals born from normal stock females and weaned in the usual way on to a diet containing retinoic acid. Animals obtained by this hitherto customary procedure have retinol reserves sufficient for several weeks, and from then onwards retinoic acid at levels of 5 to 50 μg/day can support growth as well as retinol (Dowling & Wald 1960; Dowling 1961; see also table 4). The AC animals shown in table 5 had 100 to 200 μg retinoic acid per day yet lagged in growth behind their AL litter-mates given retinol.

This finding needs further investigation. The differences in growth rates could perhaps be due to a small extent to the partial castration of these male rats (see, for example, Lawless 1936; Rubinstein, Abarbanel & Kurland 1939) but female rats born with trace amounts of retinol also tended, though very much less definitely than the males shown in table 5, to have smaller body weights when maintained on retinoic acid than when given retinol. The females otherwise developed well and had normal oestrous cycles. When mated with stock colony bucks and given retinol during pregnancy, they delivered litters. As would be expected from work described earlier in this paper, retinoic acid permits normal development of the ovaries, of oogenesis and of the oestrous cycle, although it does not support maturation of the testes or spermatogenesis.

Discussion

The role of vitamin A in reproduction has commonly been considered part of its systemic function—the maintenance of life, growth and the general health of tissues. More specifically, the disorders of reproduction in vitamin A deficiency have been associated with the characteristic failure of many epithelia (see, for example, Wolbach & Howe (1925), Mason (1933, 1935, 1939), Kudrjashov (1935) and Moore (1957)).

The experiments reported here show that in the rat vitamin A has a role in reproduction different from the maintenance of normal epithelia and its general systemic function. Its derivative retinoic acid (vitamin A acid) prevents epithelial keratinization and supports life, growth and health, but at all dosage levels fails completely to allow reproduction. In the rat vitamin A therefore has three distinguishable functions: in vision, where it works as retinaldehyde in a *cis-trans* isomerization cycle (Wald & Hubbard 1960); its 'systemic' role, concerned with the maintenance of life, growth and health, which can be discharged by both retinol and retinoic acid; and, thirdly, in reproduction, where retinol is effective, but retinoic acid is not.

These divergent properties of the acid and alcohol open a new approach to a specific function of vitamin A in reproduction in the rat which we designate as that served by retinol but not by retinoic acid. Hitherto it has been impossible to dissociate the 'reproductive' function of vitamin A from its systemic activity. Since vitamin A is required for the life and growth of the rat, any defect in this systemic action will inevitably impinge on reproduction. Thus our control animals suffering from complete vitamin A deficiency (e.g. group 9 and nos. 29 to 33) showed rather more severe lesions in the reproductive tract than did corresponding animals fed retinoic acid. Previous studies on the function of vitamin A in reproduction have been made of necessity on animals suffering from various consequences of vitamin A deficiency, notably inanition and infection, which have often bedevilled the main investigation. In contrast, rats brought up on retinoic acid grow well, and are quite healthy, save for their defects in vision and reproduction.

Not only are they free from the non-specific effects of vitamin A-deficiency on reproductive processes but they are also completely deficient of retinol. In earlier work on reproduction using so-called vitamin A-deficient animals, removal of all retinol from their tissues would not have been feasible, being incompatible with life. Rats given no retinol and maintained on retinoic acid, because they show a complete, and at the same time uncomplicated, deficiency of retinol, are a very useful and novel preparation for studying the special function of vitamin A in reproduction.

In some circumstances their visual defects might be a drawback, as light stimulation is known to influence reproductive organs. Lack of vision might have had some effect on the seminal vesicles of our animals (Fiske 1941), as discussed below; it might also have relevance to the poor growth of rats born with very low stocks of retinol, but reproduction in animals with normal vitamin reserves at weaning was unlikely to have been greatly affected by their progressive failure of vision, since Dowling & Wald (1960) found that such rats did not go completely blind until they had been on the retinoic acid diet for several months. Our histological investigations of the eyes, while not so comprehensive as those of Dowling & Wald (1960), indicated that severe degenerative changes occurred in the testis long before any damage was seen in the retinas, which in our animals appeared normal up to at least 7 months of age. Similarly, most of the female rats mentioned in this paper had mated and had resorbed their foetuses before they were 5 months old. We therefore do not think that the inability of retinoic acid to work in vision will invalidate any of our conclusions.

Our results reported here, on rats deficient in retinol and maintained on retinoic acid, confirm, clarify and extend earlier findings on disorders of reproduction in vitamin A-deficient rats. In the males, our findings agree in general with those of previous workers, viz.—small or oedematous testes, failure of spermatogenesis, and degenerative changes visible on histological examination of the seminiferous epithelium (Wolbach & Howe 1925; Evans 1932; Mason 1933, 1939). Thus our results corroborate more directly the accuracy of earlier descriptions of testicular damage and prove that it is truly due to lack of vitamin A rather than to inanition, general debility or a similar consequential effect. On the other hand, our evidence demolishes a favoured explanation of the testicular damage. It has been argued

(Wolbach & Howe 1925; Mason 1933) from the proved need for vitamin A in the normal functioning of many epithelia that the seminiferous epithelium is merely one of the most sensitive to a deficiency of the vitamin. The failure of the seminiferous epithelium must be due to some fundamentally different cause, as all the remaining epithelia are normal in our male rats maintained on retinoic acid.

Our results on the seminal vesicles are not so uniformly decisive as those on the testes—other workers appear to have had similar experiences with completely deficient animals (Moore 1957; Mayer & Truant 1949; Mayer & Goddard 1951)—but they clearly bear out earlier reports that the seminal vesicles are smaller in vitamin A-deficient rats than in controls (Wolbach & Howe 1925; Mason 1933, 1939; Van Os 1936; Mayer & Truant 1949).

From the female-like fine appearance of their fur, and the small size of their seminal vesicles, it appears that androgen secretion is subnormal in male rats maintained on retinoic acid. We have not yet investigated if this is an effect operating through the pituitary, as suggested by Mason (1933, 1939), Van Os (1936) and Mayer & Goddard (1951) for rats suffering from orthodox vitamin A deficiency.

Lack of vision might have affected our rats born with very low stocks of retinol (table 5) (Fiske 1941), but animals with normal reserves at weaning (tables 3 and 4) are unlikely to have been markedly handicapped in this way, as they would have retained their sight through most of the experimental period. We therefore do not think that the inability of retinoic acid to serve in vision is a major cause of the small size of the seminal vesicles.

The problem needs further study, but our present findings reveal the inadequacy of two hypotheses advanced in the past to explain the atrophied accessory sex organs in vitamin A-deficient rats. The small seminal vesicles in our rats are not due to the effect of vitamin A-deficiency on epithelia (Wolbach & Howe 1925), nor can they be ascribed to an indirect influence of deficiency on body weight or general nutritional state, probably via inanition, as suggested by Mason (1933, 1939). These hypotheses are probably valid in part for rats suffering from orthodox vitamin A-deficiency, but our results show that the atrophy of the accessory sex organs in such animals cannot be dismissed entirely as a non-specific consequence of the systemic failure of vitamin A.

Earlier workers were not as unanimous in their findings on vitamin A-deficient females as they were on males, but they agreed on some points. Cornification of the vaginal epithelium, an early deficiency sign (Evans & Bishop 1922; Evans 1928), impeded the use of the vaginal smear method in demonstrating the operation of the oestrous cycle in A-deficient rats, but it was accepted that the cycle failed only at a very late stage in the development of the deficiency syndrome (Mason & Ellison 1935*a*, *b*). Most female rats would mate even when so short of vitamin A as to be incapable of bearing young (Evans 1928; Mason 1935) and the changes associated with the oestrous cycle have been seen in the uterus when masked in the vagina (Kudrjashov 1935). Since, in our rats fed retinoic acid, the operation of a normal cycle can be demonstrated unmistakably and directly by vaginal smears, vitamin A in its specifically reproductive function cannot be concerned with the operation of the oestrous cycle. We have therefore confirmed the

conclusion of Mason & Ellison (1935*b*) that the irregular cycles observed in severe orthodox vitamin A deficiency arise from breakdown of the systemic activity of the vitamin, and such sequelae as inanition and general debility are also presumably responsible for the failure of severely deficient females to mate (Cannon 1940; Warkany & Schraffenberger 1946).

Wolbach & Howe (1925), Evans (1928), Mitzkewitsch (1934) and Mason (1935) found the rat ovary to be unaffected by vitamin A deficiency; ovulation and formation of corpora lutea were normal. Our findings agree with theirs. Opinions, however, have differed on whether vitamin A deficiency has any effect on conception and implantation. Some workers assert that it does (Evans 1928; Newton 1938; Cannon 1940); on the other hand, Mason (1935) in his very careful study of gestation in A-deficient females discounts this, and lays far greater stress on foetal resorption or death, prolongation of pregnancy, difficult labour and the birth of dead or weakly young, features which have been observed by many other workers (see Mason 1939). We have verified Mason's opinion that vitamin A in its specifically reproductive role is not required for ovulation, conception and implantation. That other workers (Evans 1928; Newton 1938) have found these earlier stages of gestation to be affected is possibly the result of systemic vitamin A deficiency e.g. arising from epithelial changes in the female genital tract (Evans 1928; Kudrjashov 1935).

Our results agree with Mason's opinion that vitamin A need need not be given during the first week to ensure the successful completion of pregnancy. As discussed above, our rats maintained on retinoic acid were much more deficient of retinol than were Mason's animals. We have therefore shown, even more conclusively than did Mason (1939), that retinol is not required for the early stages of pregnancy.

We have also demonstrated that lesser degrees of vitamin A deficiency, insufficient to induce foetal resorption, lead to the birth of dead or non-surviving young. Which of these phenomena were observed by earlier workers presumably depended on the level of vitamin A deficiency they were able to induce and maintain in their experimental animals. We have found that in the absence of retinol the foetuses are always resorbed. Delivery of young, alive or dead, has never occurred in our animals unless retinol has been given, and the birth of young to vitamin A-depleted females reported by earlier workers (see Mason 1939) attests to incomplete deficiency in such rats.

Of the young born in our experiments of mothers given small amounts of retinol during pregnancy many failed to survive, apparently owing to their inherent weakness consequent upon an inadequate supply of the vitamin to the mother during pregnancy. Mason (1935), too, observed this in A-deficient rats, but also found inferior mammary function to be a contributing factor to the high death-rate among the young. Although we cannot be certain that lactation was normal in our animals, all our observations are consistent with their having an adequate supply of milk and in this we differ from Mason (1935). The failure of his animals to lactate adequately was presumably due to secondary effects of systemic deficiency of vitamin A.

There have been many reports (reviewed by Moore 1957) that young born from

mothers given only minimal amounts of vitamin A have an unusually high incidence of congenital malformations. We have not enough data to discuss this question, as we made no detailed examinations of the non-viable young born in our experiments but, apart from oedema and cyanosis, we noted no frequent occurrence of obvious external abnormalities such as those affecting the eyes or the central nervous system (cf. Warkany 1954; Kalter & Warkany 1959; Rokkones 1956).

We agree with Mason (1935, 1939) that the main 'reproductive' role of vitamin A in females is to maintain the placenta, prevent foetal resorption, and ensure the birth of viable young. There are, however, discrepancies between our histological observations and those made by Mason (1935) in his detailed study of pregnancy in A-deficient rats. Mason found damage from the eighth day of pregnancy onwards: we found no substantial changes earlier than the sixteenth day, even though our rats would have been much more deficient of vitamin A alcohol than his. Unlike Mason, we saw no retardation of the growth of the maternal decidua as early as the eighth day. Above all, we detected no infection at the placental sites, a feature given much prominence by Mason. The first sign of reproductive failure we noticed in our female rats was the appearance of necrosis around the edge of the placental disk on about the sixteenth day of pregnancy, presaging inevitable foetal death and resorption—a lesion recorded by Mason in some of his rats.

Mason (1935, 1939) concluded that the lesions he observed arose because vitamin A is required for many epithelia and so in its absence alterations occurred in the epithelial lining of the uterus, which led to infection. This seems a plausible explanation of some of his findings, e.g. the lesions early in pregnancy, the retarded development of the maternal decidua, and infection at the placental sites, but it cannot account for our findings, for our rats, unlike his, did not suffer from general epithelial damage, inanition or (perhaps most important) infection. Mason's conclusion is therefore inadequate as a complete explanation of the reproductive role of vitamin A in females.

Work with our rats fed retinoic acid instead of retinol has thus enabled us to reinvestigate the many previously reported features of disordered reproduction in vitamin A-deficient animals, and to distinguish which were due to systemic deficiency of the vitamin and which to a lack of a specifically 'reproductive' function of the vitamin. All the major features of avitaminosis A affecting male reproductive organs arise from a failure of this 'reproductive' role: the stopping of spermatogenesis, the degeneration of the seminiferous epithelium, the small or oedematous testes and, probably, the small seminal vesicles. In females, failure of the 'reproductive' function results in lesions in the placenta and foetal resorption or, if less severe, the birth of dead or weakly young. Other features sometimes seen in orthodox vitamin A-deficiency are associated with a decline in the 'systemic' function: cornification of the vaginal epithelium, failure to mate, irregularities of the oestrous cycle, failure of conception or implantation, inadequate lactation and, in particular, uterine infection, which was presumably responsible for the complications in subsequent pregnancies on inadequate vitamin A as observed by Mason (1935) and Browman (1939).

In general, we have confirmed the descriptions given by earlier workers of many of the reproductive disorders in vitamin A-deficient rats, but we have also demonstrated the inadequacy of the previously accepted explanations of the damage seen in the placenta, the germinal epithelium of the testes and the seminal vesicles. In their place, we can suggest only that in rats vitamin A has a specific role in reproduction fundamentally different from its other actions, and we cannot as yet characterize it more closely. The major faults in the reproductive processes of rats deficient in retinol are the failure of spermatogenesis and the development of placental lesions followed by foetal resorption. There is no obvious connexion between these defects. In gross outline, although not in detail, they are not dissimilar to those found in other kinds of nutritional reproductive failure, but what has been studied in our experiments is beyond question a specific effect of vitamin A deficiency: the diet contains all other known factors and maintains reproduction well when retinol is added.

The female-like appearance of the fur and the small seminal vesicles denote a hormonal deficiency in the males. Previous work on vitamin A-deficient animals has indicated that while pituitary insufficiency might account for these secondary features, there is no evidence that it is responsible for the changes in the seminiferous epithelium (Mason 1933, 1939; Van Os 1936; Mayer & Goddard 1951). Also the complex hormonal apparatus required for the cyclical oestrous changes was operating normally in the females. Although much more detailed work is needed on our animals fed retinoic acid, our findings do not so far permit us to explain the salient features of the reproductive failure in terms of an obvious or simple endocrine deficiency.

Since we do not know how retinol works in reproduction, we cannot suggest why retinoic acid is ineffective. The possibility was considered that it had failed to penetrate to the sites of action. Although difficult to disprove formally, our results show that this surmise is highly unlikely to be true, since even very big doses of retinoic acid were completely ineffective. It can therefore be said only that retinoic acid, for some as yet unknown reason, lacks the correct structural requirements to replace vitamin A in reproduction in the rat, just as it fails to serve in vision.

The problem is complicated in that retinoic acid is not just a synthetic substance; it can be formed by tissues from retinol (Futterman 1962; Mahadevan, Murthy & Ganguly 1962). Indeed, Dowling & Wald (1960) suggested that retinol served merely as a precursor of two active forms: retinaldehyde in the visual pigment; and retinoic acid—or a metabolite (Wolf *et al.* 1963)—functioning systemically. The hypothesis was represented in outline by Dowling & Wald (1960) as follows:

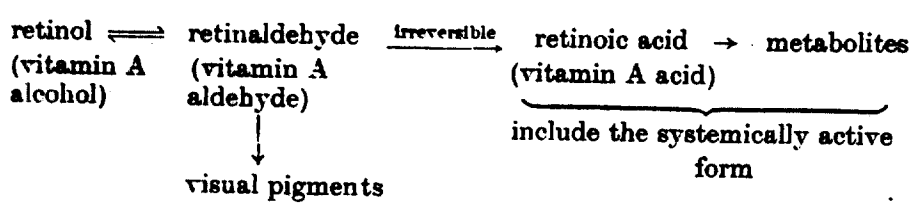

It explains admirably why retinoic acid carries out the systemic function of the vitamin, yet is ineffective in vision, for there is conclusive evidence (see Dowling & Wald 1960) that the acid cannot be reduced to the aldehyde. If this scheme is true, in the rat vitamin A must work in reproduction as the alcohol, aldehyde or some derivative on the retinaldehyde side of the 'metabolic watershed' (Moore 1953) between the aldehyde and the acid.

There is not enough evidence to justify even a guess about the exact form involved in reproduction. The superficially pertinent discovery of retinaldehyde in the eggs of various oviparous vertebrates (see Plack & Kon 1961) in fact seems irrelevant to the present problem, as in our rats the fertilized ova develop apparently normally to give well-formed foetal tissues before any fault is detectable.

Much has been published on the structural requirements for a molecule to show vitamin A activity (see, for example, Milas 1954; Moore 1957), but almost all such work has concentrated on the systemic function—in particular, the promotion of growth. There remains the relatively neglected field of the structural requirements for the other roles of the vitamin in vision and reproduction, and rats maintained on retinoic acid are an excellent preparation for such work.

We thank the Agricultural Research Council for financial support, Hoffmann-La Roche and Co., Basel, for gifts of retinoic acid and Messrs J. Bibby and Sons for ground-nut oil. We are grateful to Miss M. W. Royston, A.I.M.L.T., and Miss C. Houghton for technical assistance and to Professor R. A. Morton, F.R.S., and Professor D. L. Hughes for helpful advice.

References

Arens, J. F. & van Dorp, D. A. 1946*a* *Nature, Lond.* **157**, 190.
Arens, J. F. & van Dorp, D. A. 1946*b* *Nature, Lond.* **158**, 622.
Boguth, W., Horn, V., Soliman, M. K. & Weiser, H. 1960 *Int. Z. Vitaminforsch.* **31**, 6.
Browman, L. G. 1939 *Amer. J. Physiol.* **125**, 335.
Cannon, M. D. 1940 *Proc. Soc. Exp. Biol., N.Y.*, **44**, 129.
Dowling, J. E. 1961 *Amer. J. Clin. Nutr.* **9**, no. 4, pt. II, p. 23.
Dowling, J. E. & Wald, G. 1960 *Proc. Nat. Acad. Sci., Wash.*, **46**, 587.
Evans, H. M. 1928 *J. Biol. Chem.* **77**, 651.
Evans, H. M. 1932 *Amer. J. Physiol.* **99**, 477.
Evans, H. M. & Bishop, K. S. 1922 *Anat. Rec.* **23**, 17.
Fell, H. B., Dingle, J. T. & Webb, M. 1962 *Biochem. J.* **83**, 63.
Fiske, V. M. 1941 *Endocrinology*, **29**, 187.
Futterman, S. 1962 *J. Biol. Chem.* **237**, 677.
Harris, P. L. 1953 In *Symposium on nutrition*, p. 70. (Ed. Herriott, R. M.). Baltimore: Johns Hopkins Press.
Harris, P. L. 1960 *Vitam. & Horm.* **18**, 341.
Howell, J. McC., Thompson, J. N. & Pitt, G. A. J. 1963*a* *J. Reprod. Fertil.* **5**, 159.
Howell, J. McC., Thompson, J. N. & Pitt, G. A. J. 1963*b* *J. Reprod. Fertil.* (In press.)
Hubbell, R., Mendel, L. B. & Wakeman, A. J. 1937 *J. Nutr.* **14**, 273.
International Union of Pure and Applied Chemistry: Commission on the Nomenclature of Biological Chemistry. 1960 *J. Amer. Chem. Soc.* **82**, 5581.
Kalter, H. & Warkany, J. 1959 *Physiol. Rev.* **39**, 69.
Kudrjashov, B. A. 1935 *Arch. exp. Path. Pharmak.* **178**, 295.
Lawless, J. J. 1936 *Anat. Rec.* **66**, 455.
Light, R. F., Alscher, R. P. & Frey, C. N. 1944 *Science*, **100**, 225.

Maddock, C. L., Cohen, J. & Wolbach, S. B. 1953 *Arch. Path.* **56**, 333.
Mahadevan, S., Murthy, S. K. & Ganguly, J. 1962 *Biochem. J.* **85**, 326.
Mason, K. E. 1933 *Amer. J. Anat.* **52**, 153.
Mason, K. E. 1935 *Amer. J. Anat.* **57**, 303.
Mason, K. E. 1939 In *Sex and internal secretions*, 2nd ed. p. 1149. (Ed. Allen, E.). Baltimore: Williams and Wilkins.
Mason, K. E. & Ellison, E. T. 1935*a* *J. Nutr.* **9**, 735.
Mason, K. E. & Ellison, E. T. 1935*b* *J. Nutr.* **10**, 1.
Matschiner, J. T. & Doisy, E. A. 1962 *Proc. Soc. Exp. Biol., N.Y.*, **109**, 139.
Mayer, J. & Goddard, J. W. 1951 *Proc. Soc. Exp. Biol., N.Y.*, **76**, 149.
Mayer, J. & Truant, A. P. 1949 *Proc. Soc. Exp. Biol., N.Y.*, **72**, 436.
Metta, V. C. & Johnson, B. C. 1960 *J. Nutr.* **72**, 455.
Milas, N. A. 1954 In *The vitamins*, vol. 1, p. 4. (Eds. Sebrell, W. M. and Harris, R. S.). New York: Academic Press.
Mitzkewitsch, M. S. 1934 *Arch. exp. Path. Pharmak.* **174**, 339.
Moore, T. 1953 In *Symposium on nutrition*, p. 28. (Ed. Herriott, R. M.). Baltimore: Johns Hopkins Press.
Moore, T. 1957 *Vitamin A*. Amsterdam: Elsevier.
Moore, T. & Wang, Y. L. 1945 *Biochem. J.* **39**, 222.
Mottram, J. C. & Cramer, W. 1923 *Quart. J. Exp. Physiol.* **13**, 209.
Nelson, E. C., Dehority, B. A., Teague, H. S., Grifo, A. P. & Sanger, V. L. 1962 *Fed. Proc.* **21**, 474.
Nelson, W. O. 1937 *Cold Spr. Harb. Symp. Quant. Biol.* **5**, 123.
Newton, W. H. 1938 *J. Physiol.* **92**, 32.
Plack, P. A. & Kon, S. K. 1961 *Biochem. J.* **81**, 561.
Purves, H. D. & Griesbach, W. E. 1951 *Endocrinology*, **49**, 244.
Redfearn, E. R. 1960 *Arch. Biochem. Biophys.* **91**, 226.
Robeson, C. D. 1952 U.S. Patent 2,583,594.
Rokkones, T. 1956 *Int. Z. Vitaminforsch.* **26**, 1.
Rubinstein, H. S., Abarbanel, A. R. & Kurland, A. A. 1939 *Endocrinology*, **25**, 397.
Sharman, I. M. 1949 *Brit. J. Nutr.* **3**, viii.
Sure, B. 1928 *J. Agric. Res.* **37**, 87.
Tansley, K. 1936 *Biochem. J.* **30**, 839.
Thompson, J. N., Howell, J. McC. & Pitt, G. A. J. 1961*a* *Biochem. J.* **80**, 16P.
Thompson, J. N., Howell, J. McC. & Pitt, G. A. J. 1961*b* *Biochem. J.* **80**, 25P.
Thompson, J. N. & Pitt, G. A. J. 1960 *Nature, Lond.* **188**, 672.
Thompson, J. N., Pitt, G. A. J. & Morton, R. A. 1960 *Biochim. biophys. Acta*, **45**, 396.
Van Dorp, D. A. & Arens, J. F. 1946*a* *Rec. Trav. chim. Pays-Bas*, **65**, 338.
Van Dorp, D. A. & Arens, J. F. 1946*b* *Nature, Lond.* **158**, 60.
Van Dyke, R. A., Wolf, G. & Johnson, B. C. 1960 *Biochem. Biophys. Res. Commun.* **3**, 123.
Van Os, P. M. 1936 *Acta brev. neerl. Physiol.* **6**, 151.
Wald, G. & Hubbard, R. 1960 In *The enzymes*, 2nd ed. vol 3, p. 369. (Eds. Boyer, P. D., Lardy, H. & Myrbäck, K.). New York: Academic Press.
Warkany, J. 1954 *J. Cell. Comp. Physiol.* **43** (suppl.), p. 207.
Warkany, J. & Schraffenberger, E. 1946 *Arch. Ophthal. N.Y.* **35**, 150.
Weber, F., Gloor, U. & Wiss, O. 1960 *Helv. physiol. Acta*, **18**, C 97.
Weitzel, G., Wahl, P. & Buddecke, E. 1962 *Hoppe-Seyl. Z.* **327**, 109.
Wodsak, W. 1959 *Fette Seifen Anstrichmittel*, **61**, 672.
Wolbach, S. B. & Howe, P. R. 1925 *J. Exp. Med.* **42**, 753.
Wolf, G., Bergan, J. G. & Sundaresan, P. R. 1963 *Biochim. biophys. Acta*, **69**, 524.
Wolf, G. & Varandani, P. T. 1960 *Biochim. biophys. Acta*, **43**, 501.
Wood, J. D. 1962 *Canad. J. Biochem. Physiol.* **40**, 529.

Thompson-'69
Bib. No. 9102

The biological activity of retinoic acid in the domestic fowl and the effects of vitamin A deficiency on the chick embryo

By J. N. THOMPSON,* J. McC. HOWELL, G. A. J. PITT
and CATHERINE I. McLAUGHLIN

Departments of Biochemistry and Veterinary Pathology, University of Liverpool

(*Received* 17 *July* 1968—*Accepted* 21 *February* 1969)

1. Male and female chickens were reared from hatching on vitamin A-free diets, either unsupplemented or containing retinoic acid (vitamin A acid), methyl retinoate or retinyl acetate (vitamin A acetate). The birds given retinyl acetate grew well and had a normal appearance, but those given the unsupplemented diet died before 4 weeks of age after developing typical signs of avitaminosis A. The birds given retinoic acid or methyl retinoate did not show overt signs of vitamin A deficiency or other abnormalities except for a progressive failure of vision. Minimal histological changes were found in their retinas, and their vision was rapidly restored after feeding with retinyl acetate.

2. The cocks maintained with retinoic acid or methyl retinoate had normal testes and the hens laid eggs at a normal rate, but although their eggs could be obtained fertile the development of the embryo became abnormal after 2 days incubation and it always died. The development of the embryos could be stimulated and sometimes restored to normal by injection of various forms of vitamin A into the eggs before incubation, or by previous administration of retinyl acetate to the hens.

3. It is concluded that feeding retinoic acid as the sole source of vitamin A enables the hen to produce eggs that lack vitamin A but are otherwise normal, thus permitting the demonstration of a hitherto undescribed requirement of the early chick embryo for vitamin A.

4. The toxicity of vitamin A derivatives to chick embryos was investigated; injected retinoic acid was found to be extremely toxic.

In experiments with rats, retinoic acid (vitamin A acid) has been shown to replace the corresponding alcohol, retinol (vitamin A), in the prevention of most of the diverse abnormalities which make up the vitamin A deficiency syndrome. The acid maintains growth and general health in rats (Arens & van Dorp, 1946; Dowling & Wald, 1960), but even when administered in large amounts it will not maintain reproduction (Thompson, Howell & Pitt, 1964) nor will it serve as a precursor of retinal (vitamin A aldehyde), the prosthetic group of the visual pigments, and thus will not maintain vision (Dowling & Wald, 1960). Female rats maintained with retinoic acid mate with normal males, but invariably resorb their foetuses (Howell, Thompson & Pitt, 1964), and male rats maintained with retinoic acid have degenerate testes and are sterile (Howell, Thompson & Pitt, 1963). These abnormalities indicate the nature and significance of the involvement of vitamin A in reproduction in the normally nourished animal. The defects can be prevented by small quantities of retinol and they occur, with other systemic abnormalities, in rats made completely deficient in all forms of vitamin A (Mason, 1939). Similar defects of reproduction have been observed in guinea-pigs maintained with retinoic acid (Howell, Thompson & Pitt, 1967).

It is not possible to associate the inactivity of retinoic acid in reproduction with any known aspect of vitamin A metabolism or biochemistry. A major obstacle is the meagre

* Present address: Department of Poultry Science, Cornell University, Ithaca, New York, 14850.

and largely conjectural nature of present knowledge of the mode of action of vitamin A at the molecular level, other than in vision. Retinoic acid is, nevertheless, of value in the investigation of reproductive abnormalities resulting from the absence of vitamin A, because it permits these defects to be produced in animals unaffected by other systemic consequences of avitaminosis, such as impaired growth, reduced appetite, epithelial abnormalities, infection and early mortality.

Retinoic acid had earlier been used by Dowling & Wald (1960) to study in rats the visual role of vitamin A. Rats maintained on a vitamin A-free diet supplemented with retinoic acid become depleted of visual pigment (rhodopsin) and have elevated electroretinogram thresholds. The disappearance of the prosthetic group of the visual pigment is followed by the loss of the protein portion, opsin, and degeneration of receptor cells, which can be seen in histological sections of the retina.

Following upon our investigations with rats (Thompson *et al.* 1964) and guinea-pigs (Howell *et al.* 1967), experiments were undertaken to test the effect of replacing the vitamin A in the diet of fowl with retinoic acid. The domestic fowl was chosen firstly because of obvious major differences from laboratory rodents in the reproductive system, and secondly because, in contrast with rats and guinea-pigs, the fowl has a retina in which the cones outnumber the rods (Walls, 1942). It was hoped that extension of the tests with retinoic acid to the fowl would reveal information on the role of vitamin A in reproduction in birds, and also demonstrate in the living bird that cone vision involves retinal as a chromophore.

The results obtained on completion of the first experiment with retinoic acid in the fowl were considered to be sufficiently important to justify further investigations; eventually, over a period of 4 years, three experiments were completed in which chicks of both sexes were reared to maturity on semi-synthetic diets free from vitamin A and provitamins A but with supplements of retinoic acid. The results of these experiments, some of which have been briefly described previously (Thompson, Howell, Pitt & Houghton, 1965), are summarized in this paper.

EXPERIMENTAL AND RESULTS

Birds, diets and management

Day-old chicks were reared to maturity on semi-synthetic diets free from carotenoids and preformed vitamin A, but supplemented with either methyl retinoate or free retinoic acid. Some control groups of birds were given the unsupplemented basal diet, or the basal diets supplemented with retinyl acetate. The supplements of retinoic acid, methyl retinoate and retinyl acetate were dissolved in arachis oil and were mixed in the diets at a level of 3 μg/g diet, except where specifically stated.

The chicks used in Expt 1 were White Leghorn × Buff Rock; those in Expts 2 and 3 were Thornber 404 strain. Different types of basal diets were used to allow for the nutritional requirements of the birds at each stage of development (see Table 1). The first type (brooder diets, B) was given to the chicks until they were 6 weeks old and the second type (rearer diets, R) was given from then onwards. When at the point of lay, the hens were given the third type of diet (laying diets, L).

Diets B1, B2, R1, R2, L1 and L2 were orthodox purified diets in which gelatin and extracted casein were used as sources of protein, and from previous experiments with rats the constituents were known to be free from trace quantities of retinol and its precursors. Diets R3 and L3 were based on extracted soya-bean meal, which was found by chemical analysis and biological assay to contain negligible quantities of provitamins A.

Table 1. *Percentage composition of the basal vitamin A-free diets*

	Brooder diet		Rearer diet			Laying diet		
	B1	B2	R1	R2	R3	L1	L2	L3
Extracted soya-bean meal	—	—	—	—	40	—	—	40
Vitamin-free casein	20	20	15	15	—	15	15	—
Gelatin	15	15	—	10	10	10	10	—
Arginine hydrochloride	0·6	0·6	0·5	0·5	—	0·5	0·5	—
Methionine	0·6	0·6	0·5	0·5	0·5	0·5	0·5	0·5
Glycine	1	1	—	—	—	—	—	—
Arachis oil	9	9	4	4	4	4	2	2
Vitamin supplement in oil*	1	1	1	1	1	1	1	1
Vitamin supplement in glucose†	1	1	1	1	1	1	1	1
Choline chloride in glucose‡	1	1	1	1	—	1	1	—
Dried brewer's yeast	—	—	—	—	—	5	5	5
Cellulose	3	3	3	3	—	3	20	—
Mineral mixture§	6	—	6	—	—	—	—	—
Mineral mixture‖	—	6	—	6	6	6	6	6
$CaCO_3$	—	—	—	—	—	2·0	4·5	4·5
$CaHPO_4$	—	—	—	—	—	—	0·5	0·5
Glucose	41·8	41·8	58	58	47·5	51·0	33·0	39·5

* A solution in arachis oil containing 2 μg cholecalciferol and 2 mg DL-α-tocopheryl acetate per g.

† A mixture triturated in glucose containing per g: cyanocobalamin 3 μg, biotin 30 μg, menaphthone 100 μg, folic acid 400 μg, pyridoxol hydrochloride 800 μg, *p*-aminobenzoic acid 800 μg, riboflavine 1·0 mg, calcium pantothenate 2·0 mg, thiamine hydrochloride 2·5 mg, nicotinic acid 10 mg and inositol 10 mg.

‡ A mixture of 800 mg glucose and 200 mg choline chloride.

§ Salt mixture of Briggs, Spivey, Keresztesy & Silverman (1952).

‖ Salts N of Fox & Briggs (1960) with the following additions to each 60 kg: $Na_2MoO_4.2H_2O$ 5 g, Na_2SeO_3 200 mg, NaF 500 mg, $CoCl_2.6H_2O$ 2 g, H_3BO_3 10 g, $K_2Al_2(SO_4)_4.24\,H_2O$ 50 g, $Na_2SiO_3.9H_2O$ 50 g.

Chicks were reared to 6 weeks of age in electrically heated brooders and were then transferred to battery fattening cages. From 18 weeks of age the hens were housed individually in battery laying cages and the cocks were kept in threes, pairs, or individually in specially built pens.

The poultry houses were illuminated entirely by artificial light. Throughout Expt 1 18 h light was provided daily. In Expts 2 and 3 an orthodox lighting programme for rearing laying pullets was arranged: during the first 10 weeks the daily period of light was reduced gradually from 22 h to 8 h, and it was kept constant at this level until the birds were 22 weeks old, when the daily period was increased by an average of 30 min weekly until 18 h light was provided each day.

Hens were inseminated artificially (Cooper, 1963) with 0·2 ml semen. The inseminations were made twice weekly at a time of day which was not more than 4 h before the lights were extinguished.

Incubation experiments

Eggs were collected daily and were usually set in a Curfew electric observation incubator (Curfew Appliances Ltd, Ottershaw, Surrey) on the day of laying.

In many experiments, substances were injected into eggs either dissolved in arachis oil or suspended in saline. Saline suspensions were prepared by diluting, into 100 volumes of saline, solutions of the test substance in ethanol containing Tween 80. The saline had been freshly boiled and cooled to eliminate micro-organisms and also to remove dissolved oxygen which otherwise would have a deleterious effect on vitamin A derivatives. Eggs for injection were cleaned with a swab moistened with ethanol, and then a hole was made in the shell with a dental drill. The test solution (0·1 ml) was injected into the albumen away from the embryo, using a hypodermic syringe, the hole being afterwards sealed with a domestic adhesive (Bostik 1; Bostik Ltd, Leicester). Most of the injections were made before setting, but in some experiments injections were made after varying periods of incubation, and in these instances holes were drilled and sealed before setting in the usual fashion, and the injections were subsequently made through the adhesive plug, which was then resealed.

Embryological studies

Eggs were routinely candled after 5 days incubation and those not showing normal development were opened for examination; those remaining were usually allowed to continue incubation until the expected time of hatching. In most of the experiments the early embryos were examined by the naked eye, or with the aid of a binocular dissection microscope. Black ink was injected beneath the embryo to provide a contrasting background. When it was necessary to preserve whole embryos for repeated and more detailed examinations, the embryos and membranes were first fixed on the yolk surface with formol nitric, and then, after removal to a dish of water, with Heidenhain's Susa. After staining with alum cochineal, dehydration in alcohols and clearing in dibutyl phthalate, the specimens were mounted in methyl methacrylate polymer for examination with a low-power microscope.

Retinal histology

In order to obtain sections of the retina, birds were killed by chloroform inhalation and the eyes immediately removed and fixed in Zenker's fluid. The eyes were later bisected, the lens was removed and each half embedded in low-viscosity nitrocellulose. Sections were cut at 12 μm and stained by haematoxylin and eosin. Selected sections were also stained by cresyl violet and by phosphotungstic acid haematoxylin.

Vitamin A derivatives

Retinoic acid, β-carotene, β-apo-8′-carotenoic acid and ethyl-β-apo-8′-carotenoate were provided by F. Hoffmann-La Roche & Co., Basel. Methyl retinoate was prepared from retinoic acid by the method of Robeson (1952) and methyl-5,6-epoxyretinoate was made by the procedure of Morgan & Thompson (1966). All these, and other vitamin A compounds used, were crystalline.

Expts 1–3: procedure and results

Details of the diets and of the dietary supplements used are shown in Table 2. The results of all three experiments will be considered together.

The chicks given the unsupplemented basal diets (groups 1 A and 2 A) became ataxic and died when between 3 and 4 weeks old. Other signs of vitamin A deficiency included areas of squamous metaplasia in the nasal epithelium and urate deposits in the kidneys and ureters.

Table 2. *Chicks used in experiments and their dietary regimes*

Expt no.	Strain	Group	No. of birds	Sex	Basal diets*	Supplement†
1	White Leghorn × Buff Rock	1A	9	♂	B1	None
			13	♀	B1	None
		1B	14	♂	B1, R1	Methyl retinoate
			15	♀	B1, R1, L1	Methyl retinoate
		1C	13	♂	B1, R1	Retinyl acetate
			13	♀	B1, R1, L1	Retinyl acetate
		1D	13	♂	Commercial	None
			13	♀	Commercial	None
2	Thornber '404'	2A	75	♂	B2	None
		2B	75	♀	B2, R2, L2	Retinoic acid
			27	♂	B2, R2	Retinoic acid
3	Thornber '404'	3B	64	♀	B2, R3, L3	Retinoic acid

* See Table 1.
† 3 μg per g diet.

Table 3. *Mean body-weights (g) of chicks (Expt 1) at various ages*

Sex	Group	Dietary regime	Age: 1 day	4 weeks	8 weeks	16 weeks
♂	1B	Methyl retinoate	42	416	1119	2059
	1C	Retinyl acetate	41	412	1160	2327
	1D	Commercial	41	321	997	2204
♀	1B	Methyl retinoate	40	370	905	1653
	1C	Retinyl acetate	40	396	980	1789
	1D	Commercial	41	290	826	1619

The chicks given methyl retinoate (group 1 B), retinoic acid (groups 2 B and 3 B) and retinyl acetate (group 1 C) grew rapidly to maturity and did not show any overt signs of vitamin A deficiency. The rapid growth of these birds is indicated by the mean body-weights recorded in Expt 1 (see Table 3).

Examination of birds given either retinoic acid or methyl retinoate, which were killed at various times during all three experiments, confirmed the normal condition of their internal organs, and the absence of the characteristic epithelial metaplasia of vitamin A deficiency. Spectroscopic examination of the liver non-saponifiable lipid revealed no trace of retinol, indicating that in the fowl, as in the rat, the acid is not reduced to the alcohol or (since the alcohol and aldehyde are readily interconvertible) to the aldehyde.

Effects on vision

Hens and cocks maintained with retinoic acid (groups 2 B and 3 B) or methyl retinoate (group 1 B) were regularly examined for signs of impaired vision. The first indication of a visual defect was an abnormally wide dilatation of the pupils when the birds were placed in dimmer light. By the time the birds were 80 days old the abnormal dilatation of the pupils was detectable even in normal lighting conditions, and by 120 days the behaviour of the birds indicated that they had poor vision even in bright light. After 200 days on the diet the birds seemed to be blind; some behavioural and pupillary response could, however, be elicited with very bright lights—even after 2 years on the experiments.

Blindness had little indirect effect on general health and it did not seriously impair the ability of the birds to find food and water. The affected hens continued to lay at a normal rate (see below) and the cocks possessed all the vigour and aggressiveness of the normally sighted controls given retinyl acetate.

Histological examinations were made of the retinas of cocks in Expt 1 between 102 and 1122 days of age. No abnormalities were seen in any of the retinas of birds fed with commercial diet (group 1 D) or retinyl acetate (group 1 C) (Pl. 1 *a*). In birds maintained on methyl retinoate (group 1 B), retinas appeared normal at 102 days of age (two birds) but in two birds killed on days 131 and 133 there was some irregularity of the structures in the rod-cone layer; this was not seen in a bird killed at 148 days, but was present in another killed after 155 days. A loss of density and an alteration in the structures of the rod-cone layer were seen in all birds maintained on retinoic acid that were killed after 194, 222, 370 and 446 days (Pl. 1 *b*). No changes were seen in the outer limiting membrane or in the cellular layers of the retina. The changes in the rod-cone layer were more obvious at the periphery of the retina than near the optic nerve; they progressed slowly and were still limited in a bird that had been fed on the diet for 1122 days (Pl. 1 *c*).

Vision in these birds maintained with retinoic acid was found to be restored after feeding with retinyl acetate. Two hens (from group 1 B) which had been on the diet supplemented with methyl retinoate for over a year were each given by mouth 1 mg retinyl acetate dissolved in oil. Two days after the treatment normal pupillary responses returned and within a week the vision of the birds seemed to be normal. Curative effects were also observed in another two birds given 1 mg 3-dehydroretinol (vitamin A_2). In similar experiments thirty hens from group 2 B that had been on the diet supplemented with retinoic acid for 12 months were given supplements of retinyl acetate. The restoration of vision, as judged by pupillary responses to light, was variable and continued over several weeks, but no evidence was found of an irreversible change.

Reproduction in the male

Male birds in Expt 1 were killed at various times between 102 and 446 days of age. Normal spermatogenesis was seen in all, whether given a commercial diet (group 1 D—six birds examined), retinyl acetate (1 C—eight birds) or methyl retinoate (1 B—ten birds) (see Pl. 2 *a*). We saw no evidence of a gross abnormality similar to that invariably

found in rats and guinea-pigs maintained on retinoic acid (Howell *et al.* 1963, 1967). Normal quantities of semen containing highly motile spermatozoa were obtained from the cocks fed with methyl retinoate in Expt 1 (group 1 B) or retinoic acid in Expt 2 (group 2 B). The fertilizing power of the pooled semen from the cocks fed methyl retinoate (group 1 B) was proved by inseminating four hens reared on a commercial ration (0·1 ml semen to each hen once weekly). The first 100 eggs laid subsequently by these hens were incubated and nintety-two proved to be fertile.

In an investigation of the effect of a complete deficiency of vitamin A on the testes of birds, fourteen cocks from group 2 B after 29 weeks on the experiment were separated into three subgroups and were given the basal diet. Birds in one subgroup (2 BX—four birds) were given supplements of retinoic acid, those in another subgroup (2 BY—four birds) were given supplements of retinyl acetate and those in the remaining subgroup (2 BZ—six birds) were left unsupplemented. The cocks in the unsupplemented subgroup (2 BZ) developed signs of vitamin A deficiency and one died; after 17 days all the remaining birds were killed and examined histologically. In five of the six deficient birds in subgroup 2 BZ the testes were smaller (mean weight 5·6 g) than those from subgroups 2 BX (17·0 g) and 2 BY (16·0 g). The testes of the sixth bird in 2 BZ were enlarged by inflammatory changes and deposited urates. Histological evidence of degeneration of the semeniferous epithelium was clearly present in five birds of subgroup 2 BZ: all tubules had lost spermatids and many were lying in the lumen of the tubules. In the sixth deficient bird spermatids in some tubules had been sloughed into the lumen, indicating that degenerative changes had recently commenced. No abnormalities were observed in the testes of birds in the groups given retinyl acetate or retinoic acid (Pl. 2*a*).

Reproduction in hens

Egg production was essentially normal in all surviving groups. All the birds on the purified rations laid eggs with colourless yolks because the diets did not contain significant quantities of xanthophyll pigments. There was a similar noticeable absence of pigment from the beaks and shanks. No evidence was found to suggest that egg production by the hens given retinoic acid or methyl retinoate was in any way inferior to that by the hens given retinyl acetate.

The birds on the casein–gelatin diets in Expts 1 and 2 consistently laid eggs which were smaller in size and in weight than those laid by control hens of the same age given a commercial ration. These differences were attributed to unidentified defects in the purified diets which were unrelated to the vitamin A status. In Expt 3, the hens in group 3 B given the soya-bean meal diet laid eggs of normal size and weight.

Fertility and embryonic development

After regular inseminations with semen from normal cocks, fertility was found to be high in the eggs from the hens given methyl retinoate (group 1 B) and retinoic acid (groups 2 B and 3 B). Eggs from the control group of hens given retinyl acetate (group 1 C) were obtained fertile and, although hatchability did not attain normal levels, most of these eggs developed beyond the 1st week of incubation.

Uninjected eggs from the hens given retinoic acid or methyl retinoate (groups 1 B, 2 B and 3 B), although fertile, never hatched nor did any develop normally for more than 2 days of incubation. In most of these eggs a characteristic abnormality of development of the embryo was observed and this is described below; the remaining exceptions, which represented a small proportion of the total, consisted of either infertile eggs or eggs in which the embryos died during the first day of incubation. Typically, the embryos examined during the first 48 h of incubation were found to be normal in appearance but slightly retarded in development when compared with controls. The rate of development during this period in normal eggs varies considerably, and it is therefore impossible, without comparing large numbers of eggs, to establish when the retardation in deficient eggs begins; however by 36 h the deficient eggs were consistently less mature than controls. The affected embryos eventually reached a stage of development similar to that attained by normal embryos after about 48 h (i.e. stage 13 of Hamburger & Hamilton, 1951). At this stage in normal eggs the circulatory system in the *area vasculosa* shows signs of a marked increase in activity and the uniform network of capillaries surrounding the embryo is rapidly transformed into well-defined arteries and veins. In the eggs from hens fed retinoic acid the development of the embryos invariably failed to continue beyond stage 13 and some died earlier. The expansion of the *area vasculosa* usually continued, but there was never an active circulation of any magnitude nor did major vessels form.

Examination of over a thousand unfixed and unstained embryos from eggs of hens maintained with retinoic acid or methyl retinoate after 5 days incubation consistently confirmed that development had been arrested at about the 48 h stage. To supplement these observations on the early changes, eggs were opened after varying periods of incubation and the embryos were examined, after fixing and staining, under a low-power microscope. The eggs for this experiment were obtained from the hens given the soya-bean meal diet and retinoic acid (group 3 B), as the soya-bean meal basal diet was considered to be nutritionally the most satisfactory and thus the diet least likely to introduce complications due to dietary deficiencies unrelated to the vitamin A status. Eggs for a control group of embryos were obtained from a few hens taken from the same group (3 B) and given supplements of 1 mg retinyl acetate per hen per day until the end of the experiment; the hatchability of such eggs was quite good—see, for example, subgroup 3 BN in Table 10.

Eggs were removed from the incubators after 36, 42, 54 and 66 h, and the embryos with membranes were fixed and stained for examination. The embryos from individual fertile eggs were classified in stages (see Table 4) according to the scheme of Hamburger & Hamilton (1951). The embryos from the control group of eggs appeared normal at all stages (see Table 4), confirming other experiments to be described below, which suggest that the abnormality of embryonic development in the eggs from the unsupplemented hens is due to a deficiency of vitamin A. No abnormality was apparent in the eggs from the untreated group after 36 and 42 h incubation, and the developmental stages attained by the embryos were not markedly different from normal. However, at 48 h, the embryos in the eggs from the unsupplemented hens were beginning to show signs of aberrant development: the over-all elongation of the trunk was

retarded, and somites were noticeably crowded, particularly in the anterior region where they appeared to be compressing the hind-brain. Embryos in all the eggs from this group of hens examined at 54 and 66 h were abnormal.

Although abnormalities were first detected in the 'deficient' group after 48 h incubation, some aspects of normal development had continued in eggs incubated for longer periods: the malformed embryo head sometimes rotated, the number of somites increased, and often clear indications of limb buds could eventually be discerned. The *area vasculosa* expanded and the heart (which regularly was found to be beating, albeit

Table 4. *Development of embryos in eggs from hens reared on vitamin A-deficient diet supplemented with retinoic acid (group 3B)*

(Embryos were classified in stages according to Hamburger & Hamilton (1951). Those marked with an asterisk showed evidence of abnormality. Normal progress of development is shown by the embryos in eggs from hens taken from group 3B and given retinyl acetate)

Diet of hen	Time of incubation (h)	No. of embryos at stage: 6	7	8	9	10	11	12	13	14	15	16
Basal	36	2	1	9	1	1	—	—	—	—	—	—
Basal + retinyl acetate	36	—	—	2	5	—	—	—	—	—	—	—
Basal	42	—	1	3	11	7	2	2	—	—	—	—
Basal + retinyl acetate	42	—	1	1	5	13	8	—	—	—	—	—
Basal	48	—	—	—	1	8	15*	8*	6*	—	—	—
Basal + retinyl acetate	48	—	—	—	1	—	4	11	4	—	—	—
Basal	54	—	—	—	—	—	—	5*	34*	—	—	—
Basal + retinyl acetate	54	—	—	—	—	—	—	3	7	1	—	—
Basal	66	—	—	—	—	—	—	—	(24 abnormal)			
Basal + retinyl acetate	66	—	—	—	—	—	—	—	—	—	—	16

slowly, on first opening the eggs) accumulated more blood. There was never, however, any evidence of large-sized blood vessels spanning the network of capillaries in the *area pellucida*, and the circulatory system in the embryo, if in existence, received blood from the extra-embryonic blood islands and the *sinus terminalis* only by what appeared to be a slow, passive drainage. After several days' incubation the grossly malformed embryos disintegrated. There remained a large expanding *area vasculosa*, and at its perimeter the *sinus terminalis*, which, in accumulating much of the blood from the blood islands, gave the eggs a characteristic 'blood ring' appearance when candled.

Effect of vitamin A derivatives on embryonic development

A possible explanation of the death of the embryos, in the eggs from the hens maintained with retinoic acid or methyl retinoate, was that retinoic acid and its ester were unable to meet an hitherto undescribed requirement of the early embryo for vitamin A. This effect could have been due either to inherent inability of the acid to function in some essential role in the embryo, or to the failure of the hen to deposit retinoic acid or its ester in the egg. To test these possibilities, vitamin A-active substances were injected into the eggs before incubation, and the effects on the subsequent development of the embryo were observed.

In some cases, solutions of the substances in oil (0·5 or 1 mg in 0·1 ml) were injected,

and thus it was demonstrated that retinol, retinal and retinyl acetate would maintain embryonic development in the eggs from hens maintained with methyl retinoate (group 1 B). The eggs were candled after 5 days incubation; those developing normally were returned to the incubators, and the remainder were opened and examined. The results (Table 5) indicated that many of the fertile injected eggs were stimulated to develop normally to 5 days and some even to hatching.

Table 5. *Effect of vitamin A derivatives on development of embryos in eggs from hens maintained with methyl retinoate (group 1 B)*

(The eggs were injected once before incubation with 500 μg or 250 μg of the derivatives dissolved in 0·1 ml arachis oil. After candling at 5 days the eggs not developing normally were examined and classified as (A) infertile or very early death of embryo; (B) dead embryo at about stage 13)

	No. of eggs				
		Abnormal at 5 days			
Substance injected	Total	A	B	Normal at 5 days	No. of chicks hatched
None	107	29	78	0	0
Arachis oil	55	18	37	0	0
Retinol	129	49	40	40	12
Retinal	6	0	1	5	2
Retinyl acetate	12	1	8	3	1

In more extensive tests with eggs from hens maintained with retinoic acid (group 2 B) the embryos were classified after 5 days incubation into five categories. Three of these included stages of development which might be attained in untreated eggs, i.e. the eggs were infertile (category I), the embryos had died at very early stages (II), or they had died after about 48 h incubation (III). The remaining categories included only embryos that had developed beyond the stages at which those in untreated eggs would have become abnormal. Thus these eggs either contained normal embryos (V) or embryos which had developed far enough to stimulate the formation of prominent major blood vessels in the *area vasculosa* (IV). From the numbers of eggs in each of these categories after a particular treatment, the percentage stimulation of fertile eggs was calculated from

$$\frac{\text{number of embryos classified IV+V}}{\text{number of embryos classified II+III+IV+V}} \times 100.$$

The results of some of these experiments, in which eggs were injected once before incubation with saline suspensions of various test substances, are summarized in Table 6. Besides those detailed in Table 2, other nutrients such as phylloquinone, folic acid, cyanocobalamin and biotin were also injected into these eggs, but these substances did not stimulate development of the embryo. In all, 2518 eggs were used with an overall fertility of 81%. Of 876 eggs that were either untreated or were injected with materials with no vitamin A activity, none showed signs of embryonic development beyond that observed previously in uninjected eggs from hens maintained with retinoic acid. Injections of free retinoic acid had only a slight stimulating effect (groups 4–7), whereas the activity of its methyl ester (groups 8–12) approached that

Table 6. *Effect of vitamin A derivatives on the development of embryos in eggs from hens maintained with retinoic acid (group 2B)*

(Eggs were injected with suspensions of the test substances in 0·1 ml saline and the embryos were examined and classified according to the stage of development after 5 days of incubation)

Group	Injection: Substance	Injection: Quantity (μg/egg)	No. of eggs	No. of embryos,* after 5 days, in category: I	II	III	IV	V	% fertile eggs stimulated (see p. 480)
1	Untreated	—	560	90	40	430	0	0	0
2	Saline	—	140	20	12	108	0	0	0
3	Lutein	100	63	17	5	41	0	0	0
4	Retinoic acid	0·2	49	3	7	38	1	0	2
5	Retinoic acid	0·5	68	26	12	29	0	1	2
6	Retinoic acid	1	103	30	42	29	2	0	3
7	Retinoic acid	2	78	18	23	36	1	0	2
8	Methyl retinoate	2	49	9	7	15	9	9	45
9	Methyl retinoate	4	18	9	3	3	1	2	33
10	Methyl retinoate	10	78	10	36	11	3	18	31
11	Methyl retinoate	50	102	17	37	15	9	24	39
12	Methyl retinoate	100	256	60	104	53	13	26	20
13	Retinol	0·1	29	4	3	20	0	2	8
14	Retinol	0·5	33	3	0	12	6	12	60
15	Retinol	2	164	29	11	24	14	86	74
16	Retinol	20	51	16	6	17	2	10	34
17	Retinal	2	33	5	4	12	3	9	43
18	Retinal	4	32	10	5	7	2	8	45
19	Retinal	50	34	7	8	4	8	7	56
20	Retinal	100	130	19	32	43	12	24	32
21	Retinyl acetate	20	50	14	4	23	3	6	25
22	Methyl 5,6-epoxyretinoate	2	128	34	9	54	19	12	33
23	Methyl 5,6-epoxyretinoate	20	36	13	5	6	2	10	52
24	β-carotene	100	121	9	20	78	7	7	13

* I, infertile; II, very early death of embryo; III, died at about 48 h; IV, major blood vessels developed; V, normal.

Table 7. *Effect of injecting retinol at varying times into eggs from hens maintained on retinoic acid (group 2B)*

Period of incubation before injection (h)	No. of eggs injected	% fertile eggs containing embryos developed beyond stage 13
0	164	74
7	37	56
18	71	48
29	61	46
36	29	35
41	26	19
44	32	4
51	25	
89	36	0

of retinol (groups 13–16). The latter two substances had their optimal effect when 2 μg were administered to each egg before incubation.

Retinal (groups 17–20), retinyl acetate (group 21), methyl 5,6-epoxyretinoate (groups 22–23) and β-carotene (group 24) also stimulated development.

Injections of retinol were effective even if incubation had proceeded for some time; results demonstrating this effect are shown in Table 7. Groups of eggs were injected with 2 μg retinol in saline after varying periods of pre-incubation and the eggs were examined after a total of 5 days incubation. The results indicate that although stimulation of development is possible during the first 2 days of incubation, it becomes less probable as the period of pre-incubation increases.

Toxic effect of retinoic acid on normal embryos

When injections of free retinoic acid were made into eggs to test if it was as effective as the true vitamin in maintaining embryonic development it was discovered that the substance was extremely toxic to the chick embryos. Thus single injections containing more than 1 μg retinoic acid had a deleterious effect on embryos, irrespective of

Table 8. *Toxicity to embryos of vitamin A derivatives injected in oil solution into normal eggs*

Injection			No. of embryos classified, after 5 days incubation, as:		
Substance	Quantity (μg/egg)	No. of eggs injected	Infertile or early death of embryo	Dead embryo	Normal
None	—	44	11	1	32
Oil	—	45	17	3	25
Retinoic acid	20–500	75	75	0	0
Retinoic acid	10	30	28	2	0
Retinoic acid	5	15	14	1	0
Retinoic acid	2·5	30	21	5	4
Retinoic acid	1·0	15	8	2	5
Retinoic acid	0·5	15	6	0	9
Retinoic acid	0·1	15	2	1	12
Retinol	1000	15	13	1	1
Retinol	500	15	2	0	13
Retinol	250	15	5	0	10
Methyl retinoate	2	15	3	1	11
Methyl retinoate	5	15	2	1	12
Methyl retinoate	25	15	4	2	9

whether the eggs were from hens fed normal diets or from hens fed purified diets containing retinoic acid. In Table 8 are summarized the results of testing the toxic effects of oil solutions of retinoic acid in normal eggs obtained from a commercial breeding flock. The eggs were injected immediately before incubation and were examined 5 days later. Amounts of acid between 1 μg and 5 μg resulted in dead embryos at 5 days which, with their membranes, appeared to be disintegrating. Larger quantities of the acid often caused almost complete dissolution of the blastoderm, leaving only a few caseous streaks on the yolk surface as evidence of development.

Retinol had a similar toxic effect, but it was necessary to administer more than 500 μg in oil solution to each egg to demonstrate this.

The methyl ester of retinoic acid in oil solution was injected in amounts up to 25 μg per egg with no toxic effects on the early development of the embryo.

Similar results were obtained when the vitamin A derivatives were administered in saline suspensions. Table 9 compares the toxicity of retinoic acid with that of methyl retinoate, β-apo-8′-carotenoic acid and ethyl β-apo-8′-carotenoate. The latter three substances did not have the toxic effects of free retinoic acid.

Table 9. *Toxicity to embryos of vitamin A derivatives injected in saline suspension into normal eggs*

Injection			No. of embryos classified, after 5 days incubation, as:		
Substance	Quantity (μg/egg)	No. of eggs injected	Infertile or early death of embryo	Dead embryo	Normal
Saline + Tween 80 alone	—	20	2	0	18
Retinoic acid	1	15	10	2	3
Retinoic acid	5	15	15	0	0
Methyl retinoate	4	10	1	0	9
Methyl retinoate	8	10	3	0	7
Methyl retinoate	16	10	1	4	5
Methyl retinoate	32	10	4	5	1
Methyl retinoate	64	10	4	2	4
β-apo-8′-carotenoic acid	2	10	0	0	10
β-apo-8′-carotenoic acid	10	10	1	0	9
β-apo-8′-carotenoic acid	100	10	0	0	10
Ethyl β-apo-8′-carotenoate	2	10	1	0	9
Ethyl β-apo-8′-carotenoate	10	10	3	0	7
Ethyl β-apo-8′-carotenoate	100	10	3	1	6

Embryonic development in eggs from hens given graded levels of retinyl acetate

Four subgroups (3BK, 3BL, 3BM, 3BN), each of five hens, were selected from group 3B reared on the soya-bean meal basal diet containing retinoic acid. Each of the hens was given daily a gelatin capsule containing 0 (subgroup 3BK), 10 μg (3BL), 50 μg (3BM) or 1 mg (3BN) retinyl acetate. Eggs produced were incubated until hatching or until the death of the embryo, and the stage of development reached by each embryo was recorded. The observations on embryonic development were started a week before the first dose of retinyl acetate was given to the hens and were continued for 6 weeks. The results are summarized in Table 10. The hens given 1 mg retinyl acetate (3BN) laid eggs of high hatchability during the first week of dosing. Eggs from the hens given 50 μg (3BM) reached, although more slowly, the same level of hatchability. A daily dose of 10 μg retinyl acetate to the hens of subgroup 3BL was insufficient to allow any eggs to hatch, but significantly stimulated the development of the embryo beyond the state at which development always stopped in the eggs from unsupplemented hens (subgroup 3BK).

Table 10. *Survival of embryos in eggs from hens (from group 3B) given supplements of retinyl acetate*

(Hens were dosed daily beginning at the end of week 1)

Subgroup of hens	Daily supplement of retinyl acetate (μg)	Week	No. of embryos dying at various stages of development (Hamburger & Hamilton, 1951): No visible development	<8	9–13	14–26	27–34	35–45	46	No. of eggs showing visible development	No. of chicks hatched
3BK	0	1	0	1	23	—	—	—	—	24	0
		2	—	1	29	—	—	—	—	30	0
		3	1	—	28	—	—	—	—	28	0
		4	2	—	26	—	—	—	—	26	0
		5	1	—	27	—	—	—	—	27	0
		6	4	—	25	—	—	—	—	25	0
3BL	10	1	9	1	20	—	—	—	—	21	0
		2	8	—	20	—	—	—	—	20	0
		3	8	—	9	7	—	—	—	16	0
		4	10	—	4	8	7	—	—	19	0
		5	7	—	3	9	5	1	—	18	0
		6	12	—	2	5	6	—	—	13	0
3BM	50	1	12	—	20	—	—	—	—	40	0
		2	2	—	12	—	4	2	4	22	2
		3	1	—	—	2	2	1	1	20	14
		4	1	1	3	—	—	—	—	17	13
		5	3	—	—	1	—	2	—	14	11
		6	12	—	—	1	—	1	—	13	10
3BN	1000	1	4	—	25	—	—	—	—	25	0
		2	1	—	2	1	3	—	—	20	14
		3	2	1	—	3	—	1	—	22	17
		4	3	—	2	3	—	—	2	22	15
		5	3	—	—	—	—	—	—	14	14
		6	9	—	—	—	—	—	2	11	9

DISCUSSION

Since the first demonstration of a vitamin A requirement in poultry (Emmett & Peacock, 1923) there have been many investigations of the effects of vitamin A deficiency on chicks and adult birds. When chicks are given from hatching a diet free from vitamin A and its precursors, the carotenoid provitamins, they develop ataxia (Wolbach & Hegsted, 1952; Howell & Thompson, 1965), kidney lesions and urate deposits in the viscera (Elvehjem & Neu, 1932; Hart, Steenbock, Lepkovsky & Halpin, 1924) and eventually they die. Histological studies have revealed epithelial abnormalities (Seifried, 1930; Jungherr, 1943; Howell & Thompson, 1967*a*) and an overgrowth of periosteal bone (Howell & Thompson, 1967*a*). Adult fowl made deficient in vitamin A also become ataxic and develop epithelial lesions (Almquist & Mecchi, 1939; Lowe, Morton, Cunningham & Vernon, 1957; Howell & Thompson, 1967*b*) and, as demonstrated recently (Howell & Thompson, 1967*b*), an abnormal overgrowth of periosteum.

An early consequence of vitamin A deficiency in adult birds is a rapid fall in egg production. The cessation of laying by deficient hens, which is dramatic evidence of a role of vitamin A in egg formation, has obscured the effects of deficiency on hatchability. There have, however, been many apparently successful demonstrations of effects of vitamin A deficiency and vitamin A supplementation on hatchability (Landauer, 1961). As critical reviews by Rubin & Bird (1942) and McClymont & Hart (1948) indicate, doubt exists as to the significance of many of these experiments. McClymont & Hart (1948) state: 'Apparently enough vitamin A for complete embryonic development and hatching, if it is required at all for these purposes, is stored in the eggs while there is a sufficient vitamin A reserve in the body of the hen to maintain any egg production at all.'

There have been comparatively few investigations of the effect of vitamin A deficiency on the testes in poultry. Several reports (Wagener & Harms, 1943; Schumacher, Scott, Hughes & Peterson, 1944; Bohren, Carrick & Andrews, 1945; Ferrand & Bohren, 1948) suggest that vitamin A deficiency does not affect the reproductive performance of cocks, whereas others claim there is degeneration or underdevelopment of the testes (Seifried & Köcher, 1943; Lowe *et al.* 1957).

Our investigations of the role of vitamin A in poultry nutrition differ from previous work in that we have used diets supplemented with retinoic acid. It was found that methyl retinoate and retinoic acid maintain growth and general health in the domestic fowl, and prevent overt signs of vitamin A deficiency, namely poor growth, ataxia, epithelial metaplasia, kidney lesions and arrest of egg production. These observations on poultry, which agree with those of Krishnamurthy, Bieri & Andrews (1963) and de Man, van Leeuven & Roborgh (1964), extend previous tests of the growth-promoting and vitamin A-like properties of retinoic acid in rats (Arens & van Dorp, 1946; Dowling & Wald, 1960; Thompson *et al.* 1964), guinea-pigs (Howell *et al.* 1967) and hamsters (unpublished observations).

Investigation of the vitamin A activity of retinoic acid in rats has revealed that although the acid has growth-promoting activity it is not converted in vivo into the true vitamin, retinol. This conclusion was supported by the failure to detect retinol in the

livers of animals fed substantial quantities of retinoic acid. Furthermore, the ready interconversion of retinol and the corresponding aldehyde, retinal (Glover, Goodwin & Morton, 1948) indicated that retinoic acid could not act as a precursor of the aldehyde, which has been identified as the prosthetic group of the visual pigments. The deduction that retinoic acid would not maintain vision (Arens & van Dorp, 1949; Moore, 1953) was confirmed in the rat by electroretinogram measurements (Dowling & Wald, 1960). It was also discovered that in the rats maintained with retinoic acid the failure of vision was accompanied by irreversible histological changes in the eye. In the rat the expected depletion of the visual pigment chromophore, retinal, was followed by an unexpected loss of the protein moiety, opsin, and eventually degeneration of the receptor cells and histological changes in the retina; the histological lesion at the onset of these changes consisted of a reduction in the number of rod outer segments, but as the degeneration continued there was loss of inner segments and eventually of visual cell nuclei. Dowling & Wald (1960) explained the breakdown of visual receptor structures in terms of a concept that the constituents were stabilized by each other and their over-all integrity thus depended on the presence of the retinal molecule. The disappearance of visual pigment is an inevitable consequence of an insufficiency of the chromophore, retinal, but our observations on poultry and other animals suggest that the reason for the subsequent loss of the protein moiety, opsin, in the rat, and the breakdown of the visual cells is less obvious. Histological abnormalities were not found in the retinas of guinea-pigs maintained for long periods on vitamin A-deficient diets containing retinoic acid (Howell *et al.* 1967), nor was marked histological degeneration found in the retinas of our birds in the present experiments. The anatomical changes in the rat retinas are thus more of an enigma than an indication of the general rule implied in the discussion by Dowling & Wald (1960).

Although our birds maintained with retinoic acid and methyl retinoate did not develop the severe histological changes in the retina which were typical in rats, we did find evidence of histological abnormality in poultry in that there was a loss of density in the receptor outer segment layers. This change was minimal, however, even in a bird which had been on the experiment for over 3 years. The most prominent change in the vision of our birds was gradual, but eventually major, functional impairment occurred as demonstrated by eye pupil dilatation in bright light and by behaviour. The almost complete lack of response to light which eventually characterized the birds maintained with retinoic acid, and the restoration of vision following the administration of retinol, demonstrated unequivocally a major role of vitamin A in vision in poultry. Our results thus provide direct support for the concept of a retinal-containing visual pigment (iodopsin) as the basis of cone vision in birds (Wald, Brown & Smith, 1954–5).

We noted that supplements of 3-dehydroretinol also restored vision in birds, although it was not established that this was due to replacement of the normal visual pigment by a new pigment containing 3-dehydroretinal (Wald, Brown & Smith, 1955).

The ability of retinoic acid to maintain spermatogenesis in cocks reared on retinol-free diets was indicated by the histological appearance of the testes of our birds and by the fertilizing power of their semen. The normal reproductive tissues in cocks

maintained with methyl retinoate or retinoic acid contrast with the degenerate seminiferous tubules in rats (Howell *et al.* 1963) and guinea-pigs (Howell *et al.* 1967) maintained on similar regimes, and it must be concluded that the fowl testis is unlike that of the other two species and probably of mammals in general, in that it does not have a requirement which cannot be met by retinoic acid (Thompson, Howell & Pitt, 1965). The difference could be due either to an ability of the cock to utilize retinoic acid in an aspect of spermatogenesis that in other animals requires retinol specifically, or to the absence in the fowl of this requirement for vitamin A in the germinal epithelium. In the absence of conclusive evidence to indicate the contrary, we prefer the hypothesis that the fowl differs from other animals in its ability to utilize various forms of vitamin A rather than that it does not employ the vitamin in spermatogenesis.

It was demonstrated in our experiments, as in those of previous workers (Seifried & Köcher, 1943; Lowe *et al.* 1957), that a complete deficiency of vitamin A has a harmful effect on the germinal epithelium in cocks. In animals deprived of all forms of vitamin A it is difficult to distinguish the direct effects of a lack of the vitamin from the non-specific changes which accompany inanition and general debility. The harmful effect of vitamin A deficiency on the testis in birds is therefore not conclusive evidence of a direct role of vitamin A in spermatogenesis.

In our hens reared on retinol-free diets containing methyl retinoate or retinoic acid, egg production and fertility were normal. It is well known that egg production requires an adequate provision of vitamin A (Moore, 1957) and the ability of hens to maintain normal rates of laying demonstrates that retinoic acid is able to replace retinol in this aspect of reproduction. There is no evidence that vitamin A deficiency directly affects the formation of fertilizable eggs in any species so far investigated, so the finding that our hens laid fertile eggs was expected.

When these eggs were incubated the embryos failed to develop beyond stage 13 of Hamburger & Hamilton (1951), and some failed to reach even this stage. This curious abnormality in embryonic development did not occur in eggs from the control birds given retinyl acetate or in eggs from birds given normal diets. That it was due to a lack of vitamin A was confirmed firstly be injecting retinol and other forms of vitamin A into the eggs before incubation, when in most instances there was stimulation of embryonic development, and secondly, by feeding retinyl acetate to the hens, which completely restored the hatchability of their eggs. During experiments in which substances were injected into eggs before incubation, it was discovered that retinoic acid was exceptional among vitamin A-active substances in its toxicity to embryos. As the appearance of the embryos killed with retinoic acid was unlike that of the embryos in the eggs of the hens maintained with retinoic acid, it is unlikely that the abnormalities in the latter were due to penetration of toxic quantities of retinoic acid into the eggs before laying. Such a mechanism would not be compatible with the beneficial effect of retinol, retinal and retinyl acetate when injected into the eggs, unless antagonistic effects, which we have been unable to demonstrate, are postulated. More direct evidence against this possibility was obtained in the experiments in which we showed (Table 6) that retinoic acid itself can restore development in these eggs when injected before incubation, especially when it is administered in the form of its methyl ester,

which in the early stages of incubation does not possess the toxic properties of the free acid.

Our experiments show that the early chick embryo requires vitamin A. There remains from these results, however, a doubt as to whether or not there exists a period during the first 2 days of incubation in which there is no requirement for vitamin A. It is possible that small amounts of retinoic acid, perhaps as an ester, or small amounts of some other vitamin A-active substance, penetrate to the egg during its formation and permit the early development of the embryo. Against this theory was the finding that a majority of the embryos ceased normal development at the same stage of development, although this may be merely an indication of the time of a marked increase in the requirement for the vitamin. If the early embryo can develop to approximately stage 13 (Hamburger & Hamilton, 1951) in the absence of vitamin A, this will limit the possible biochemical mechanisms involved in the mode of action of vitamin A. Also embryological and phylogenetic comparisons might suggest a specific stage in evolution at which the need for vitamin A appeared.

Another problem of general significance concerns the mechanism underlying the vitamin A requirement of the embryos beyond stage 13 and the relationship between the mode of action of the vitamin in these early embryos and its role in more mature birds. There is no obvious connexion between the general arrest of development of the early chick embryo and the epithelial and bone abnormalities in vitamin A-deficient chicks. The effect of deficiency on the embryo would appear to indicate a more fundamental role for the vitamin than is indicated by the manifestations of deficiency in the chick in specific tissues. In general, our observations on the effects of vitamin A deficiency on the chick embryo do not correlate well with any of the numerous theories and generalizations concerning the mode of action of vitamin A that have been suggested in the past, although the participation of vitamin A in the activation of sulphate (Varandani, Wolf & Johnson, 1960) might explain the defective circulation in embryos due to their inability to form cardiac jelly and blood vessels (Johnston & Comar, 1957).

The marked differences in effects observed after direct administration to the embryo of retinoic acid, retinoic acid esters and retinol reveal relationships between chemical structure and biological properties that have not hitherto been suspected. The effect of esterification of retinoic acid in reducing toxicity and thus increasing the stimulatory effect on embryo development is especially remarkable. Esterification of retinoic acid could also be necessary for the vitamin A-like effects of retinoic acid in chicks and in other animals; free retinoic acid might be highly toxic to many growing tissues.

Our demonstration that the early chick embryo requires vitamin A suggests that the vitamin A content of practical laying diets might in some circumstances affect hatchability. The need for vitamin A during egg production however makes it unlikely that conditions will arise, without the use of retinoic acid, in which the vitamin A content of the egg will be low enough to result in the invariable early death of the embryos as occurred in our experiments. Trace quantities of retinol that would be transferred to the last few eggs from hens fed vitamin A free diets would either result

an successful hatching or, more likely, death of embryos at late stages of incubation.

We wish to thank Professor D. L. Hughes and Professor R. A. Morton, FRS, for encouragement and advice, Mrs M. W. Harling, AIMLT, for technical assistance and Mr E. O'Neill for the photography. We also thank Hoffmann-La Roche and Co., Basel, for gifts of retinoic acid and β-apo-8'-carotenoic acid, and Dr B. Morgan for the preparation of methyl-5,6-epoxyretinoate. One of us (J.N.T) was a British Egg Marketing Board Fellow and the work was supported by a grant from the British Egg Marketing Board.

REFERENCES

Almquist, H. J. & Mecchi, E. (1939). *Poult. Sci.* 18, 129.
Arens, J. F. & van Dorp, D. A. (1946). *Nature, Lond.* 157, 190.
Arens, J. F. & van Dorp, D. A. (1949). *Produits pharm.* 4, 249.
Bohren, B. B., Carrick, C. W. & Andrews, F. N. (1945). *Rep. agric. Exp. Stn Purdue Univ.* no. 37.
Briggs, G. M., Spivey, M. R., Keresztesy, J. C. & Silverman, M. (1952). *Proc. Soc. exp. Biol. Med.* 81, 113.
Cooper, D. M. (1963). *Br. vet. J.* 119, 194.
de Man, T. J., van Leeuwen, P. H. & Roborgh, J. R. (1964). *Nature, Lond.* 201, 77.
Dowling, J. E. & Wald, G. (1960). *Proc. natn. Acad. Sci. U.S.A.* 46, 587.
Evenhjem, C. A. & Neu, V. F. (1932). *J. biol. Chem.* 97, 71.
Emmett, A. D. & Peacock, G. (1923). *J. biol. Chem.* 56, 679.
Fernand, R. H. & Bohren, B. B. (1948). *Poult. Sci.* 27, 759.
Fox, M. R. S. & Briggs, G. M. (1960). *J. Nutr.* 72, 243.
Glover, J., Goodwin, T. W. & Morton, R. A. (1948). *Biochem. J.* 43, 109.
Hamburger, V. & Hamilton, H. L. (1951). *J. Morph.* 88, 49.
Hart, E. B., Steenbock, H., Lepkovsky, S. & Halpin, J. G. (1924). *J. biol. Chem.* 60, 341.
Howell, J. McC. & Thompson, J. N. (1965). *Br. J. exp. Path.* 46, 18.
Howell, J. McC. & Thompson, J. N. (1967*a*). *Br. J. Nutr.* 21, 741.
Howell, J. McC. & Thompson, J. N. (1967*b*). *Br. J. exp. Path.* 48, 450.
Howell, J. McC., Thompson, J. N. & Pitt, G. A. J. (1963). *J. Reprod. Fertil.* 5, 159.
Howell, J. McC., Thompson, J. N. & Pitt, G. A. J. (1964). *J. Reprod. Fertil.* 7, 251.
Howell, J. McC., Thompson, J. N. & Pitt, G. A. J. (1967). *Br. J. Nutr.* 21, 37.
Johnston, P. M. & Comar, C. L. (1957). *J. biophys. biochem. Cytol.* 3, 231.
Jungherr, E. (1943). *Bull. Storrs agric. Exp. Stn* no. 250.
Krishnamurthy, S., Bieri, J. G. & Andrews, E. L. (1963). *J. Nutr.* 79, 503.
Landauer, W. (1961). *Monogr. Storrs agric. Exp. Stn* no. 1.
Lowe, J. S., Morton, R. A., Cunningham, N. F. & Vernon, J. (1957). *Biochem. J.* 67, 215.
McClymont, G. L. & Hart, L. (1948). *Aust. vet. J.* 24, 5.
Mason, K. E. (1939). In *Sex and Internal Secretions*, 2nd ed., p. 1149. [E. Allen, editor.] Baltimore: Williams and Wilkins.
Moore, T. (1953). In *Symposium on Nutrition*, p. 28. [R. M. Herriott, editor.] Baltimore: Johns Hopkins Press.
Moore, T. (1957). *Vitamin A*. Amsterdam: Elsevier.
Morgan, B. & Thompson, J. N. (1966). *Biochem. J.* 101, 835.
Robeson, C. D. (1952). *U.S. Patent* 2583594.
Rubin, M. & Bird, H. R. (1942). *Bull. Md agric. Exp. Stn* no. A12, p. 339.
Schumacher, A. E., Scott, H. M., Hughes, J. S. & Peterson, W. J. (1944). *Poult. Sci.* 23, 529.
Seifried, O. (1930). *J. exp. Med.* 52, 519.
Seifried, O. & Köcher, E. (1943). *Z. InfektKrank. parasit. Krankh. Hyg. Haustiere* 95, 32.
Thompson, J. N., Howell, J. McC. & Pitt, G. A. J. (1964). *Proc. R. Soc.* B 159, 510.
Thompson, J. N., Howell, J. McC. & Pitt, G. A. J. (1965). In *Biological Council Symposium on Agents Affecting Fertility*, p. 34. [C. R. Austin and J. S. Perry, editors.] London: Churchill.
Thompson, J. N., Howell, J. McC., Pitt, G. A. J. & Houghton, C. I. (1965). *Nature, Lond.* 205, 1006.
Varandani, P. T., Wolf, G. & Johnson, B. C. (1960). *Biochem. biophys. Res. Comm.* 3, 97.
Wagener, K. & Harms, F. (1943). *Z. InfektKrankh. parasit. Krankh. Hyg. Haustiere* 95, 303.
Wald, G., Brown, P. K. & Smith, P. H. (1953). *Science, N Y.* 118, 505.

Wald, G., Brown, P. K. & Smith, P. H. (1954–5). *J. gen. Physiol.* 38, 623.
Walls, G. L. (1942). *The Vertebrate Eye and its Adaptive Radiation*, p. 661. Bloomfield Hills, Michigan: Cranbrook Institute of Science.
Wolbach, S. B. & Hegsted, D. M. (1952). *Archs Path.* 54, 13.

EXPLANATION OF PLATES

PLATE 1

Sections of retina of domestic fowl, *a* and *b* stained with haematoxylin and eosin, *c* stained by phosphotungstic acid haematoxylin. *A*, ganglion cell layer; *B*, inner nuclear layer, *C*, outer nuclear layer; *D*, rod-cone layer; *E*, pigment epithelium. All birds were reared on a basal diet deficient in vitamin A, plus supplements as indicated.

(*a*) Bird given retinyl acetate for 222 days (group 1C). The retina is normal.

(*b*) Bird given methyl retinoate for 222 days (group 1B). The rod-cone layer is abnormal.

(*c*) Bird given methyl retinoate for 1122 days (group 1B). The rod-cone layer is abnormal but the changes are still only limited in extent.

PLATE 2

Sections of testes of domestic fowl, stained by haematoxylin and eosin.

(*a*) Bird killed 17 days after withdrawal of methyl retinoate supplement from diet. Many spermatids have been sloughed; few mature spermatids remain.

(*b*) Bird given basal diet deficient in vitamin A but supplemented with methyl retinoate. Normal seminiferous epithelium; mature spermatids line the lumen.



J. N. THOMPSON AND OTHERS

(*Facing p.* 490)

0·01 cm
(a)

0·01 cm
(b)

Thompson-'69
Bib. No. 9103

THE AMERICAN JOURNAL OF CLINICAL NUTRITION
Vol. 22, No. 8, August, 1969, pp. 1063-1069
Printed in U.S.A.

Vitamin A in Development of the Embryo[1,2]

J. N. THOMPSON

VITAMIN A deficiency in laboratory and farm animals is known to have a disastrous effect on the outcome of pregnancy. There are numerous reports of congenital malformations in young born to vitamin A-deficient mothers, and severely deficient animals resorb their fetuses (1–4).

It is often impossible to unravel the direct effects of avitaminosis on embryonic tissues from secondary effects resulting from deficiency in the parent. Some insight into the role of vitamin A in pregnant rats and guinea pigs was obtained in experiments with retinoic acid (5–8). The ability of retinoic acid to replace the true vitamin in the prevention of overt signs of deficiency is well documented (5–10); however, it does not function in vision (10) nor does it maintain reproduction in laboratory rodents (5). Female rats maintained on retinoic acid instead of retinol grow well and outwardly appear normal; when mated they conceive, but their fetuses invariably resorb. Although experiments with retinoic acid demonstrated a requirement for vitamin A (retinol) during pregnancy, they did not distinguish the needs of the embryo and fetus from those of the maternal tissues. In histological investigations of the fetal sites in rats fed retinoic acid, the first abnormality detected was in the placenta (7, 8). Soon after the appearance of this lesion, the fetal tissues degenerated. As fetal resorption could have been a consequence of the primary lesion in the placenta, clear-cut evidence of a role of vitamin A in fetal tissues was not obtained.

An early consequence of vitamin A deficiency in birds is a rapid drop in egg production (3). The failure of vitamin A-deficient hens to produce eggs has impeded investigation of the effects of avitaminosis on chick embryos (11).

Recently the artifice of using retinoic acid in place of the true vitamin in poultry diets led to the demonstration of a role of vitamin A in the early development of the chick embryo (12). These experiments, which were done at the University of Liverpool in collaboration with Dr. J. McC. Howell and Dr. G. A. J. Pitt, are briefly reviewed.

PRODUCTION OF VITAMIN A DEFICIENCY IN CHICK EMBRYO USING RETINOIC ACID

During an empirical investigation of the biological activity of retinoic acid in poultry, baby chicks were given diets in which the acid or its methyl ester (3 μg/g feed) were substituted for vitamin A (retinol) and its carotenoid precursors. Growth of the birds given retinoic acid was vigorous and equal to that of controls given a similar diet containing retinyl acetate. It is well known that retinoic acid does not maintain vision (10), and the birds given retinoic acid became blind as expected. There was no evidence to suggest that blindness had a deleterious effect on the general health. The hens produced eggs at a satisfactory rate, and fertility was high after artificial insemination.

[1] From the Department of Poultry Science, Cornell University, Ithaca, New York.

[2] Supported by a grant from the British Egg Marketing Board.

FIG. 1. Embryo after 48 hr incubation in egg from hen given retinoic acid. This embryo is similar to a 42-hr normal embryo.

FIG. 2. Embryo after 48 hr incubation in egg from hen given retinyl acetate. Note the beginnings of major blood vessels in the area vasculosa; these vessels did not appear in the eggs from hens given retinoic acid.

FIG. 3. Embryo after 72 hr incubation in egg from hen given retinyl acetate, showing extensive extraembryonic circulatory system.

FIG. 4. Embryo after 72 hr incubation in egg from hen given retinoic acid. The embryo is malformed. The area vasculosa has expanded but still lacks major blood vessels.

However, the eggs from the hens given retinoic acid or its ester (henceforth termed "retinoic acid eggs") invariably failed to hatch. Development was normal for 48 hr (Fig. 1) but from then onwards it was severely stunted. A major event at the 48-hr stage in normal eggs is the sudden appearance of conspicuous blood vessels in the area vasculosa (Figs. 2 and 3). These vessels did not appear in retinoic acid eggs. The area vasculosa continued to expand for several days, and the blood remained confined in islands, in the sinus terminalis and in the embryo. The embryo had a markedly abnormal appearance after 48 hr and eventually it disintegrated (Fig. 4).

A large number of fertile retinoic acid eggs were incubated and development was arrested in almost all of them at about the 48-hr stage; the only exceptions were a small number of eggs in which embryos died even earlier.

The abnormalities in embryonic development in the retinoic acid eggs were attributed to a deficiency of vitamin A in the embryo and its associated membranes. The deficiency was considered to be a consequence of the inability of the hen to transfer retinoic acid and its derivatives to the eggs. Support for this explanation was obtained by giving small amounts of retinyl acetate to some of the hens fed the retinoic acid-supplemented diet. Hens convert retinyl acetate to other retinyl esters, free retinol, and retinal; these substances are deposited in egg yolk (14) and are thus readily accessible to the embryo. Groups of five hens were given gelatin capsules containing 0, 10 μg, 50 μg, or 1 mg retinyl acetate daily for 5 weeks. Their eggs were incubated and the stage of development reached by each embryo was determined (Table 1). Development continued beyond the 48-hr stage at which it was usually arrested (stage 13 of Hamburger and Hamilton (15)) after feeding all three levels of retinyl acetate. With 10-μg doses the embryos died at various stages of incubation, but the use of 50-μg and 1-mg doses resulted in good hatchability.

INJECTION OF VITAMIN A AND RELATED SUBSTANCES INTO THE EGG

Although the most effective method of supplying chick embryos with vitamin A was through the hen, it was possible to demonstrate a response by adding the vitamin directly to the contents of the eggs. In these experiments, small holes were drilled in the shells of fresh retinoic acid eggs, and vitamin A derivatives, dissolved in oil or suspended in water, were injected with a syringe into the yolk or albumin. The holes were sealed and then the eggs were incubated.

After injection of 92 fertile eggs with

TABLE 1

Survival of embryos in eggs from hens given vitamin A-deficient diets containing retinoic acid and supplements of retinyl acetate

Retinyl acetate supplement μg/hen per day[a]	Numbers of dead embryos at stages of development[b]							Number of chicks hatched
	No visible development	8	9–13	14–26	27–34	35–45	46	
0	8	1	135	0	0	0	0	0
10	45	0	38	29	18	1	0	0
50	19	1	15	4	4	6	5	68
1,000	18	1	4	7	3	1	4	69

[a] Groups containing five hens were used for each treatment. Eggs were collected during the first 5 weeks of dosing. [b] The stages are those of Hamburger and Hamilton (15).

solutions of 0.25 or 0.5 mg retinol in 0.1 ml oil, embryos developed beyond 48 hr in 52 eggs, and 12 chicks were hatched. Similar results were obtained after injection of retinal and retinyl acetate dissolved in oil. Aqueous suspensions did not result in satisfactory hatchability, but they were very effective in prolonging development for a few days.

These experiments led to the invention of a bioassay with chick embryos in which aqueous suspensions of vitamins and other substances were injected into retinoic acid eggs. After 5 days' incubation the eggs were opened, infertile ones were discarded and stimulated embryos were counted (Table II). As untreated eggs never possessed conspicuous major blood vessels in the area vasculosa (an assertion supported by observations on more than a thousand eggs) the occurrence of these vessels in injected eggs was an easily recognizable sign of stimulated development.

The embryos were classified after 5 days of incubation into five categories. Three of these categories included stages of development that might be attained in untreated eggs, i.e., the eggs were infertile (*group I*), the embryos had died at very early stages (*group II*), or they had died at an incubation of about 48 hr (*group III*). The remaining categories included only embryos that had developed beyond the stages at which those in untreated eggs would have

TABLE II

Effect of vitamin A derivatives and other substances on embryonic development

Substance administered[a]	Quantity, μg/egg	Total number of eggs	Stage of development after 5 days					% Fertile eggs stimulated[b]
			I	II	III	IV	V	
Untreated		560	90	40	430	0	0	0
Saline		140	20	12	108	0	0	0
Lutein	100	63	17	5	41	0	0	0
Vitamin K_1	100	32	4	1	27	0	0	0
Folic acid	1,000	32	2	2	28	0	0	0
Vitamin B_{12}	100	27	3	8	16	0	0	0
Biotin	100	22	4	2	16	0	0	0
Retinoic acid	0.2	49	3	7	38	1	0	2
Retinoic acid	0.5	68	26	12	29	0	1	2
Retinoic acid	1	103	30	42	29	2	0	3
Retinoic acid	2	78	18	23	36	1	0	2
Methyl retinoate	2	49	9	7	15	9	9	45
Methyl retinoate	4	18	9	3	3	1	2	33
Methyl retinoate	10	78	10	36	11	3	18	31
Methyl retinoate	50	102	17	37	15	9	24	39
Methyl retinoate	100	256	60	104	53	13	26	20
Retinol	0.1	29	4	3	20	0	2	8
Retinol	0.5	33	3	0	12	6	12	60
Retinol	2	164	29	11	24	14	86	74
Retinol	20	51	16	6	17	2	10	34
Retinal	2	33	5	4	12	3	9	43
Retinal	4	32	10	5	7	2	8	45
Retinal	50	34	7	8	4	8	7	56
Retinal	100	130	19	32	43	12	24	32
Retinyl acetate	20	50	14	4	23	3	6	25
Methyl 5,6-epoxyretinoate	2	128	34	9	54	19	12	33
Methyl 5,6-epoxyretinoate	20	36	13	5	6	2	10	32
β-Carotene	100	121	9	20	78	7	7	12

[a] In 0.1 ml saline. [b] See text.

become abnormal. Thus these eggs either contained normal embryos (*group V*) or embryos that had developed far enough to stimulate the formation of prominent major blood vessels in the area vasculosa (*group IV*). From the numbers of eggs in each of these groups after a particular treatment, the "percentage stimulation of fertile eggs" was calculated from:

$$\frac{\text{number of eggs in } groups\ (IV + V)}{\text{number of eggs in } groups\ (II + III + IV + V)} \times 100$$

Microgram quantities of retinol, retinyl acetate, and retinal stimulated development: an optimum effect was obtained with 2 μg retinol, which represents 0.04 μg/g egg contents. Retinoic acid stimulated a few embryos and the methyl ester was remarkably active. Methyl 5,6-epoxyretinoate and β-carotene, both of which have vitamin A activity in animals, also stimulated development of the embryos.

TOXIC EFFECTS OF RETINOIC ACID ON NORMAL CHICK EMBRYOS

When retinoic acid was injected into retinoic acid eggs, the embryos often died at very early stages of incubation. Using normal fertile eggs, it was confirmed that retinoic acid in oily and saline suspensions was extremely toxic to all chick embryos, irrespective of their vitamin A status (Tables III and IV). Injection of more than 5 μg in saline, or more than 20 μg in oil, killed the embryos at a very early stage and usually there was no embryonic tissue visible after 5 days of incubation. Smaller quantities (1–10 μg in oil per egg) killed the embryos at later stages and often remnants of embryonic membranes remained on the yolk surface after 5 days of incubation. Comparable quantities of retinol did not have a detectable effect, but after injection of 1 mg retinol in oil per egg, some toxicity was demonstrated. β-Apo-8′-carotenoic acid and its ethyl ester did not possess the high toxicity of retinoic acid; even more remarkable was the relatively innocuous effect of methyl retinoate.

DISCUSSION

At first sight there are two plausible alternative explanations for the abnormalities of embryonic development in retinoic acid eggs: *a*) retinoic acid is present in toxic amounts in the eggs or *b*) the em-

TABLE III

Toxicity of vitamin A derivatives injected into normal eggs in oil solution

Substance administered	Quantity, μg/egg	Number eggs injected	Classification after 5 days' incubation		
			Infertile or early death of embryo	Dead embryo	Normal
Oil		45	17	3	25
Retinoic acid	0.1	15	2	1	12
Retinoic acid	0.5	15	6	0	9
Retinoic acid	1.0	15	8	2	5
Retinoic acid	2.5	30	21	5	4
Retinoic acid	5	15	14	1	0
Retinoic acid	10	30	28	2	0
Retinoic acid	20–500	75	75	0	0
Retinol	250	15	5	0	10
Retinol	500	15	2	0	13
Retinol	1,000	15	13	1	1
Methyl retinoate	2	15	3	1	11
Methyl retinoate	5	15	2	1	12
Methyl retinoate	25	15	4	2	9

TABLE IV

Toxicity of vitamin A derivatives when injected into normal eggs in saline suspension

Substance administered	Quantity, μg/egg	Number of eggs injected	Classification after 5 days' incubation		
			Infertile, or early death of embryo	Dead embryo	Normal
Saline		10	1	0	9
Retinoic acid	1	15	10	2	3
Retinoic acid	5	15	15	0	0
Methyl retinoate	4	10	1	0	9
Methyl retinoate	8	10	3	0	7
Methyl retinoate	16	10	1	4	5
Methyl retinoate	32	10	4	5	1
Methyl retinoate	64	10	4	2	4
β-Apo-8′-carotenoic acid	2	10	0	0	10
β-Apo-8′-carotenoic acid	10	10	1	0	9
β-Apo-8′-carotenoic acid	100	10	0	0	10
β-Apo-8′-carotenoic acid ethyl ester	2	10	1	0	9
β-Apo-8′-carotenoic acid ethyl ester	10	10	3	0	7
β-Apo-8′-carotenoic acid ethyl ester	100	10	3	1	6

bryos require vitamin A but fail to obtain it. The high toxicity of retinoic acid to normal chick embryos is evidence in favor of the first hypothesis, *a*. However, the beneficial effects of retinol and its derivatives on embryonic development make this hypothesis untenable unless an antagonism between retinoic acid and the other vitamin A-active substances is postulated. Even this supposition fails to account for the beneficial effects of injections of small amounts of retinoic acid; obviously, retinoic acid cannot antagonize itself.

Retinoic acid is rapidly metabolized in animals and it is not stored in tissues (9, 16). It is plausible, therefore, that the hen is unable to transfer retinoic acid to her eggs, and this is implied by hypothesis *b*. Thus, the evidence suggests that retinoic acid does not penetrate to the egg, and as a result, the embryo becomes vitamin A-deficient and dies.

It is essential to account for the normal development of the embryos in these allegedly vitamin A-free eggs during the first 48 hr of incubation. One explanation might be that there are small amounts of retinoic acid, perhaps as an ester, present in vitamin A acid eggs which can meet the needs of the embryo during this brief early period. However, it is unlikely that all eggs would contain identical quantities of this hypothetical vitamin A-active substance; it is, therefore, difficult to account for the observation that most of the embryos died after identical periods of incubation. Furthermore, similar experiments with Japanese quail, fed retinoic acid, revealed that their embryos died at exactly the same stage. There is, thus, circumstantial evidence to suggest that retinoic acid eggs do not contain vitamin A-active substances and that chick and quail embryos do not require vitamin A before the critical 48-hr stage of development.

Another problem of general significance concerns the mechanism underlying the vitamin A requirement of embryos at and beyond the 48-hr stage and the relationship between the mode of action of the vitamin in these early embryos and its role in hatched chicks. There is no obvious similarity between the general arrest of development of the early chick embryo and the

epithelial and bone abnormalities in vitamin A-deficient animals. The effect of deficiency on the embryo would appear to indicate a more fundamental role for the vitamin than is suggested by the manifestations of deficiency in the chick, which are limited to specific tissues. In general, observations on the effects of vitamin A deficiency on the chick embryo do not correlate well with any of the numerous theories and generalizations that have been suggested in the past concerning the mode of action of vitamin A.

In the experiments in which substances were injected into the deficient eggs, the biological properties of retinoic acid were shown to be different from those of methyl retinoate, retinyl acetate, and retinol. The effect of esterification on retinoic acid, in reducing its toxicity and improving its stimulatory effect on embryos, is especially remarkable. The toxicity of retinoic acid in the egg may be related to the hypervitaminosis A syndrome observed in rats (17, 18).

CONCLUSION

Investigations with eggs from hens fed retinoic acid in place of the true vitamin A have revealed a role of vitamin A in embryonic development and hitherto unsuspected relationships between chemical structure and biological activity. The vitamin A-deficiency syndrome in the chick embryo is suggested as a promising area for future histological and biochemical investigations concerning the mode of action of vitamin A.

Retinoic acid was a gift from Dr. O. Isler of Hoffmann-La Roche Inc., Basle, Switzerland, and methyl 5,6-epoxyretinoate was a gift of Dr. B. Morgan.

REFERENCES

1. Mason, K. E. Relation of the vitamin to the sex glands. In: *Sex and Internal Secretions* (2nd ed.), edited by E. Allen. Baltimore: Williams & Wilkins, 1939, p. 1149.
2. Warkany, J. Manifestation of prenatal nutritional deficiency. *Vitamins Hormones* 3: 73, 1945.
3. Moore, T. *Vitamin A*. Amsterdam: Elsevier, 1957.
4. Kalter, H., and J. Warkany. Experimental production of congenital malformation in mammals by metabolic procedure. *Physiol. Rev.* 39: 69, 1959.
5. Thompson, J. N., J. M. Howell and G. A. J. Pitt. Vitamin A and reproduction in rats. *Proc. Roy. Soc., London, Ser. B.* 159: 510, 1964.
6. Howell, J. M., J. N. Thompson and G. A. J. Pitt. Changes in the tissues of guinea-pigs fed on a diet free from vitamin A but containing methyl retinoate. *Brit. J. Nutr.* 21: 37, 1967.
7. Howell, J. M., J. N. Thompson and G. A. J. Pitt. Histology of the lesions produced in the reproductive tract of animals fed a diet deficient in vitamin A alcohol but containing vitamin A acid. II. The female rat. *J. Reprod. Fertility* 7: 251, 1964.
8. Calaustro, E. Q., and I. J. Lichton. Effects of retinoic acid and progesterone on reproductive performance in retinol-deficient female rats. *J. Nutr.* 95: 517, 1968.
9. Roels, O. A. Active compounds and vitamin A antagonists. In: *The Vitamins*, edited by W. H. Sebrell and R. S. Harris. New York: Academic, vol. 1, 1967, p. 153.
10. Dowling, J. E., and G. Wald. The biological function of vitamin A acid. *Proc. Natl. Acad. Sci., U. S.* 46: 587, 1960.
11. Rubin, M., and H. R. Bird. Relation of vitamin A to egg production and hatchability. *Maryland Expt. Station Bull.* A12: p. 339, 1942.
12. Thompson, J. N., J. M. Howell, G. A. J. Pitt and C. I. Houghton. Biological activity of retinoic acid ester in the domestic fowl: production of vitamin A deficiency in the early chick embryo. *Nature* 205: 1006, 1965.
14. Plack, P. A. The amounts of vitamin A aldehyde, esters and alcohol and of carotenoids in hen's eggs and in day-old chicks. *Brit. J. Nutr.* 17: 243, 1963.
15. Hamburger, V., and H. L. Hamilton. A series of normal stages in the development of the chick embryo. *J. Morphol.* 88: 49, 1951.
16. Krishnamurthy, S., J. G. Bieri and E. L. Andrews. Metabolism and biological activity of vitamin A acid in the chick. *J. Nutr.* 79: 503, 1963.
17. Thompson, J. N., and G. A. J. Pitt. Vitamin A acid and hypervitaminosis A. *Nature* 188: 672, 1960.
18. Kochhar, D. M. Teratogenic activity of retinoic acid. *Acta Pathol. Microbiol. Scand.* 70: 398, 1967.

J. Lab. Clin. Med. 33:67-74. 1948.

Van Bruggen-'48
Bib. No. 9346

HIGH VITAMIN A INTAKE AND BLOOD LEVELS OF CHOLESTEROL, PHOSPHOLIPIDS, CAROTENE, AND VITAMINS C, A, AND E

JOHN T. VAN BRUGGEN,* PH.D., AND JON V. STRAUMFJORD, M.D.
ASTORIA, ORE.

THE literature contains several reports relating vitamin A to the blood and tissue lipids. Josephs[1, 4] has reviewed most of the pertinent articles and from them and his own work concluded that the hypolipemia seen in a vitamin A-deficient animal is due to a specific pathologic effect of an actual internal deficiency of vitamin A. It was found that the abrupt administration of large amounts of this vitamin caused a marked rise in total serum lipids of both normal and vitamin A-deficient rats. Josephs[2, 3] suggested a simple fat solubility relationship between the vitamin and other lipids to account for this effect of vitamin A. Green,[5, 6] in studies on serum esterase and fat absorption, and Monaghan and Schmitt,[7] who investigated the effect of vitamin A upon unsaturated fatty acids, were inclined to relate vitamin A action to metabolic processes of essential cellular structures involving phospholipid complexes.

A number of workers have not been able to demonstrate the hypolipemia of vitamin A deficiency and the hyperlipemia of high vitamin A intake. Smith,[8] in fact, found an increase in blood fatty acids and cholesterol in deficient rats and Sure, Kik, and Church[9] found no change in blood fatty acids, cholesterol, and phospholipids in vitamin A-deficient albino rats. Ralli and Waterhouse[10] found an increase of blood cholesterol in deficient dogs.

If the hyperlipemia observed by Josephs in a child[4] and the hypercholesterolemia induced by vitamin A in the patients studied by Lasch[11] and Jusatz[12] are a normal response in man to large doses of the vitamin, then a study of this response may help to uncover the role of this vitamin in human biochemical processes. In addition, if this blood lipid response is a general phenomenon induced by ingestion of vitamin A, the extent of these changes needs to be determined because of the association of hyperlipemia and hypercholesterolemia with important pathologic processes.

That vitamin A may be interrelated with a number of other vitamins is clearly pointed out in the review of this subject by Moore.[13] In the present study an attempt has been made to investigate not only the relation of vitamin A intake to blood lipid levels but also to the blood levels of several of the other vitamins interrelated with vitamin A.

General Considerations.—We have had the opportunity of studying the effects of daily supplementation with 100,000 I.U. of vitamin A on a group of patients in the Western State Hospital.† Some of the effects of this supple-

From the Astoria Extension Research Laboratory (Department of Biochemistry, University of Oregon Medical School).

Received for publication, Oct. 9, 1947.

*Present address: Department of Biochemistry, University of Oregon Medical School, Portland, Ore.

†The patients and facilities of the hospital at Steilacoom, Wash., were kindly put at our disposal by Dr. W. N. Keller for a long-term study of the effects of vitamin A supplementation. Without the assistance of Dr. William B. Dublin and Dr. Bernice M. Hazen this work would not have been possible.

mentation on the skin of these patients will be reported by Dublin and Hazen.[14] The present paper is concerned with a comparative study of the blood vitamins A, E, and C, cholesterol, and phospholipid levels in a group of patients supplemented with 100,000 units of vitamin A daily and in an unsupplemented group of patients. We have been unable to find in the literature any reports of work in which supplementation with large doses of vitamin A was continued over a long period of time and in which blood assays for these vitamins and for lipids were performed on a sufficient number of individuals to warrant a statistical treatment of the results.

The number of patients in each group at the beginning of the study was thirty-six. The patients in these groups were in similar mental and physical condition as indicated by examination and distribution curves for age, height, and weight.

The supplemented group received at all times the same institutional diet as the control group but, in addition, one capsule* daily containing 100,000 I.U. of vitamin A. Determinations† of plasma carotene, vitamin A, vitamin E, free and total cholesterol, and phospholipid as well as whole blood vitamin C were done on five occasions—once before supplementation was started and after intervals of approximately eighteen, twenty-four, and thirty-six months of supplementation. Additional determinations were made at forty-two months, six months after supplementation was discontinued. The analyses of vitamins and lipids made at the beginning of the experiment as well as the lipid analyses at the eighteen-month period have been rejected because of unsatisfactory analytical methods.

Since the blood samples were taken from the patients at Steilacoom, Wash., and a period of four to six hours necessarily elapsed before analytical work could be started in the laboratory at Astoria, Ore., the preparation and storage of blood samples will be described briefly. Fifteen to twenty milliliter samples of blood were collected from each patient of a group of fifteen to twenty-five patients approximately sixteen to eighteen hours after the last meal and sixteen to twenty-four hours after the last dose of vitamin A. Coagulation was prevented by mixing with oxalate in 30 ml. centrifuge tubes dried as described by Van Bruggen.[15] Two milliliter samples of whole blood were immediately added to 6 ml. of 6 per cent trichloracetic acid containing norit. After thorough mixing, the samples were stored on ice for transport. The plasma from the remaining blood was separated and 1 ml. was added to 24 ml. of alcohol-ether (3:1) in a 50 ml. glass-stoppered cylinder. Immediately upon arrival at Astoria the trichloracetic acid samples were filtered and the filtrates refrigerated for twenty-four to forty-eight hours until the vitamin C analyses could be made. The alcohol-ether extracts were filtered upon arrival at Astoria and analysis for cholesterol and phospholipid was begun immediately. The remaining plasma was kept on ice until the analytical work for carotene and vitamins A and E had been completed. These analyses were usually finished within forty-eight hours.

Since only twenty to twenty-five blood samples could be assayed at one time, a complete assay of the two groups required three to four weeks at intervals of 0, 18, 24, 36,

*The vitamin A capsule, known as Oleum A, is prepared by Bioproducts, Oregon Ltd., Warrenton, Oregon. Analysis shows this product to contain the following constituents, all analyses being reported as per capsule:

Weight of contents, 0.430 Gm.; free cholesterol, 2.8 mg.; total cholesterol, 8.4 mg.; phosopholipid, 0.65 mg.; vitamin E, 0.67 mg.; vitamin A, 100,000 I.U. (equivalent to 33 mg. of pure vitamin A).

†We gratefully acknowledge the assistance of Distillation Products, Inc., Rochester, N. Y., in the establishment of carotene and vitamin A and E methods. We are especially grateful to Dr. Mary L. Quaife of that organization for her practical help on this problem.

and 42 months, so that the time periods listed in this paper are given as approximately eighteen, twenty-four, thirty-six and forty-two months. To insure comparable results, an equal number of patients in each group was sampled at each assay trip.

METHODS

Petroleum ether extracts of 4 ml. of plasma were prepared for the determination of carotene, vitamin A, and vitamin E. The plasma was well mixed with 4 ml. of alcohol and then extracted once with 12 ml. of purified low-boiling petroleum ether. Extraction was done in a 50 ml. glass-stoppered cylinder by shaking for ten minutes in a horizontal position in a mechanical shaker at a speed of 160 strokes per minute with an excursion of three inches per stroke. Refrigeration of the cylinders for one hour insured good separation of the layers. Four milliliters of the petroleum ether extract were used for carotene and vitamin A determinations and 4 ml. for vitamin E.* Carotene was measured at 440 mμ and after the solvent was evaporated at 60° C. under nitrogen the vitamin A† was estimated by the Carr-Price reaction (that is, the residue was taken up in 0.5 ml. of dry chloroform, 1 drop of acetic anhydride was added, and 3.5 ml. of Carr-Price reagent were added from an all-glass apparatus that insured rapid yet accurate delivery of an anhydrous reagent). Vitamin A values were corrected for the blue color contribution of the carotene present in the sample.

Vitamin E was determined on the 4 ml. aliquot of the petroleum ether extract by the method of Quaife and Harris,[16] modified only in that smaller volumes of extract and reagents were used. The interference of vitamin A and carotinoids was eliminated by catalytic hydrogenation as described by Quaife and Biehler.[17]

Standard curves‡ for vitamin A, carotene, and vitamin E were prepared and frequently checked during the progress of the assays.

Whole blood vitamin C was determined by our semimicro modification of the method of Roe and Kuether.[18] The final total color volume was 4 milliliters.

Free and total cholesterol were determined by the digitonin method of Sperry[19] with minor modifications. The use of alcoholic solutions of digitonin as suggested by Sobel and Mayer[20] and the washing of precipitates by solutions forcibly ejected from a syringe and needle made the use of individual stirring rods unnecessary.

The lipid phosphorus fraction was obtained by evaporation of the alcohol-ether filtrate, extraction with petroleum ether, and precipitation with acetone and magnesium chloride.[21] Final phosphate determinations were made with the reagent described by Gomori.[22] The factor of 26 was used for conversion to lipid phosphorus.

Many of the various analyses were conducted in duplicate with good agreement.

RESULTS

Since the data presented below represent the results of some 1,600 determinations, space does not permit the tabulation of individual determinations. Table I gives the values of the various assays ± their standard deviation. Significance of differences in the supplemented and unsupplemented groups is indicated by "t" values.

It is apparent that although the supplemented patients received daily an amount of vitamin A at least ten or twenty times that contained in the diet of

*All colorimetric determinations were done with a Model 11 Coleman spectrophotometer. It is possible to use 4 ml. volumes in the large cuvettes of this instrument without affecting the sensitivity if the cuvette is raised, by a suitable seat in the cuvette holder, and the opening of the holder is masked to exclude the rounded portion of the cuvette and the unfilled portion of the cuvette from the path of the incident light.

†To obtain reasonably stable Carr-Price end points with the Model 11 instrument, it is necessary to reduce the intensity of the incident light to a minimum value as recommended by Caldwell and Parrish.[27]

‡Pure tocopherol, crystalline carotene (90 per cent, 10 per cent), and a distilled vitamin A concentrate containing 201,500 I. U. per gram were kindly supplied by Distillation Products, Inc., Rochester, N. Y.

TABLE I. BLOOD LEVELS OF CAROTENE, VITAMINS A, E, AND C, CHOLESTEROL, AND PHOSPHOLIPID OF INSTITUTIONAL PATIENTS, ONE-HALF OF WHOM RECEIVED A CAPSULE CONTAINING 100,000 UNITS OF VITAMIN A A DAY

	18 MONTHS				24 MONTHS				36 MONTHS				42 MONTHS*			
	N	M	± σ	t	N	M	± σ	t	N	M	± σ	t	N	M	± σ	t
Vitamin A (I.U. %)																
Control	36	149	40.9	7.95	35	185	53.4	7.1	30	135	31.0	8.0	29	123	36.7	3.2
Supplemented	35	256	68.3		33	307	84.5		25	304	101		24	156	35.7	
Carotene (μg %)																
Control	36	216	66.5	0.86	35	213	60.8	0.43	30	193	57.4	0.95	29	213	65.5	0.43
Supplemented	36	203	60.3		33	207	53.7		25	208	64.2		24	206	67.5	
Vitamin E (mg. %)																
Control	35	1.04	0.25	2.5	35	0.98	0.24	3.4	30	1.01	0.17	4.7	29	0.99	0.19	0.2
Supplemented	36	1.20	0.26		33	1.20	0.28		25	1.27	0.22		24	1.09	0.23	
Vitamin C (mg. %)																
Control					31	0.87	0.36	0.13	27	0.99	0.36	0.07	24	0.64	0.35	0.09
Supplemented					32	0.86	0.31		25	0.99	0.35		21	0.59	0.31	
Free Cholesterol (mg. %)																
Control					34	53.4	16.9	2.0	30	53.0	10.9	3.5	29	50.8	12.3	1.1
Supplemented					33	60.8	15.7		25	63.8	11.6		24	54.6	14.3	
Total Cholesterol (mg. %)																
Control					34	207	44.7	2.2	30	202	39.5	3.9	29	208	42.5	1.2
Supplemented					33	236	42.6		25	247	43.7		24	223	47.6	
Ratio F/T																
Control					34	25.6	4.4	0.83	30	26.3	3.2	0.44	29	24.3	8.8	0.04
Supplemented					33	26.4	1.1		25	26.0	2.5		24	24.4	8.2	
Phospholipid (mg. %)																
Control					34	220	63.4	1.37	30	218	32.3	2.4	29	210	50.7	0.6
Supplemented					33	243	72.7		25	246	47.9		24	219	53.9	

N, Number of patients assayed.

M, Mean of N observations ± standard deviation which is equal to $\sqrt{\frac{\Sigma\ (y-M)^2}{n-1}}$.

t, Fisher's[22, 23] test of the significance of differences; in practice it is equal to $\frac{D\ \text{(difference of means)}}{E_D\ \text{(standard error of difference)}}$. For numbers of samples between 25 and 30 a factor of 2 is assumed to be significant ($P < 0.05$).

*At thirty-six months the vitamin A given to supplemented patients was discontinued.

the unsupplemented patients, the blood level of vitamin A in the supplemented group was less than three times that in the unsupplemented group. This difference, however, was maintained throughout a period of thirty-six months of supplementation. In the six-month period when supplementation was withdrawn, the blood level of vitamin A of the supplemented group fell to a value approximating that of the unsupplemented patients.

Plasma carotene and whole blood vitamin C seem to be entirely unaffected by the supplementation, and the minor fluctuations in these two substances, seen in both groups, no doubt reflect seasonal variations in the dietary. The assays at twenty-four and thirty-six months were done in the fall and those at eighteen and forty-two months in the spring.

The small but statistically significant increases in the vitamin E level of the blood of the supplemented patients have not been reported previously. That this increase was due to the supplementation is evidenced by the abrupt return to the control level when vitamin A was withdrawn.

The supplemented patients showed a significant increase in blood cholesterol and phospholipid. At twenty-four months and thirty-six months the supplemented group was 11 per cent and 22 per cent higher in total cholesterol and 10.5 per cent and 12.8 per cent higher in phospholipid than the control group. Since these increases in cholesterol occurred in both free and total cholesterol fractions, the F/T ratio remained normal. Although the increase in cholesterol was statistically significant at twenty-four months, the phospholipid values did not become significantly different until thirty-six months. The decrease in plasma levels of both cholesterol and phospholipid of the supplemented patients, after discontinuance of supplementation, suggests a specific effect of the supplement upon the level of these lipid constituents.

DISCUSSION

Glover, Goodwin, and Morton[25] have investigated the relation of plasma vitamin A levels to those of liver stores in rats and point out that the blood level of vitamin A is proportional to the amount of free or alcohol form present in the liver and not to the total liver stores of the vitamin.[26] They suggest that the free or alcohol form of the vitamin is the "functional" form and that to supply body tissues with greater amounts of vitamin A there must be an increase in blood vitamin A alcohol. These workers found that an increase in post-absorptive free vitamin A in the blood can be obtained only by massive dosing which, by virtue of the alcohol-ester equilibrium in the liver, increases the blood vitamin A alcohol content. This fact appears to be related to the prolonged period of treatment necessary in certain skin diseases which has been reported.[27, 28]

A "sparing" or "synergistic" action of vitamin E upon vitamin A and carotene has been reported by Hickman and co-workers[29] and Harris and associates[30] and this subject has been reviewed by Moore.[13] That vitamin A has a similar effect on vitamin E is suggested by our data. Both these substances have been shown to have a similar protective effect on unsaturated fatty acids.[31] It is possible that the increased blood level of vitamin E with vitamin A sup-

plementation may be related to an antioxidative effect of vitamin A upon the oxidative destruction of vitamin E or to decreased utilization or to both.

Under the conditions of our experiment, there appears to be a clearly significant increase in plasma cholesterol and phospholipid as a result of vitamin A supplementation. Whether these increases are a direct effect of vitamin A upon the oxidative, storage, or transport mechanisms of lipids is unknown. Chalier, Jeune, Simon, and Alacoque[32] and Wendt[33] suggested a relation of vitamin A to the thyroid gland. Recently Sadhu and Brody[34] reported that doses of 30,000 units of vitamin A a day to rats decreased thyroid size and basal metabolism. From this work they postulate a direct relationship between vitamin A, thyroid, and thyrotropic hormone. Such a relationship might account for a lowered tissue oxidation of metabolites and thus lead to an increase in blood levels of lipids. It must be kept in mind, however, that doses of this order of magnitude are close to the toxic level for rats and far exceed the nontoxic amounts used in our study.

Although the cholesterol and phospholipid levels of the supplemented patients were significantly higher than those of the unsupplemented patients, it should be pointed out that the mean values are within normal range. The relation, moreover, between the several lipids is normal. Peters and Van Slyke[35] have charted ratios for both normal and abnormal amounts of cholesterol and phospholipid. Their lipid phosphorus cholesterol ratio charted against F/T cholesterol ratios defines the limits of normal variations of these lipids. Our figures, both for supplemented and unsupplemented patients, fall within their normal area number 5. This indicates that the hyperlipemia induced by 100,000 units of vitamin A daily lies within normal limits.

The effect of supplementation for periods greater than thirty-six months cannot yet be stated with any accuracy. Preliminary treatment of data obtained from patients in the private practice of one of us (J. V. S.) who were taking 100,000 units of vitamin A daily for 5 to 10 years, indicates plasma vitamin A, vitamin E and lipid levels indistinguishable from those of patients supplemented for three years.

As far as we know, the 100,000 units of vitamin A in the capsule used in this work was the only significant added substance in the dietary intake of the patients. The cholesterol and phospholipid and oil content of the capsule was only a small increment of the daily intake of these substances and the vitamin E content was approximately 3 per cent of the estimated human daily requirement.[36]

SUMMARY

Thirty-six unsupplemented patients and thirty-six patients supplemented with 100,000 units of vitamin A daily for thirty-six months were studied. Blood assays at eighteen, twenty-four, and thirty-six months and a final assay at forty-two months, six months after supplementation was discontinued, are reported.

1. It was found that the mean plasma vitamin A level after thirty-six months of supplementation was 125 per cent higher than that of the unsupplemented patients. Six months after supplementation was discontinued, the mean levels, although still statistically higher than those of the controls, had fallen to half of their peak values.

2. No effect upon the carotene and vitamin C blood levels was observed.

3. After eighteen, twenty-four and thirty-six months the vitamin E levels of the supplemented patients were 15.4, 22.5, and 25.7 per cent, respectively, higher than control levels.

4. Both free and total plasma cholesterol levels of the supplemented patients were increased at twenty-four and thirty-six months to the extent of 13.8 and 20.8 per cent for free and 11.1 and 22.3 per cent for total cholesterol. F/T ratios, however, remained normal. Each of the increases seen in Vitamin E and cholesterol proved to be statistically significant.

5. Although the phospholipid levels of the supplemented patients were 10.4 and 18.5 per cent higher than those of the controls at twenty-four and thirty-six months, respectively, only the thirty-six month figure proved to be statistically significant.

6. Assays made six months after high vitamin A supplementation was discontinued showed that the previously indicated elevations of vitamin E, cholesterol, and phospholipid had returned to levels not statistically different from the controls.

REFERENCES

1. Josephs, H. W.: Studies in Vitamin A. Influence of Vitamin A on Serum Lipids of Normal and Deficient Rats, Bull. Johns Hopkins Hosp. 71: 265, 1942.
2. Josephs, H. W.: Lipid Response to Vitamin A Administration. A Possible Test for Vitamin A Deficiency, Bull. Johns Hopkins Hosp. 77: 402, 1945.
3. Josephs, H. W.: Studies in Vitamin A. Relation of Vitamin A and Carotene to Serum Lipids, Bull. Johns Hopkins Hosp. 65: 112, 1939.
4. Josephs, H. W.: Hypervitaminosis A and Carotenemia, Am. J. Dis. Child. 67: 33, 1944.
5. Green, H. N.: Fat Metabolism in Vitamin A Deficiency: The Blood Serum Esterase, Biochem. J. 28: 16, 1934.
6. Green, H. N.: Fat Metabolism in Vitamin A Deficiency: The Utilization of Fat and the Desaturation of Fat in the Liver, Biochem. J. 28: 25, 1934.
7. Monaghan, B. R., and Schmitt, F. O.: The Effects of Carotene and of Vitamin A on the Oxidation of Linoleic Acid, J. Biol. Chem. 96: 387, 1932.
8. Smith, M. E.: The Effect of Vitamin A Deficiency on the Concentration of the Blood Lipids of Albino Rats, J. Nutrition 8: 675, 1934.
9. Sure, B., Kik, M. C., and Church, A. E.: Effect of Vitamin A Deficiency on Concentration of Blood Lipids of Albino Rats, Proc. Soc. Exper. Biol. & Med. 30: 620, 1933.
10. Ralli, E. P., and Waterhouse, A.: Blood Cholesterol in Dogs on an A Deficient Diet, Proc. Soc. Exper. Biol. & Med. 30: 519, 1933.
11. Lasch, F.: Untersuchungen über die Beeinflussung des Serumcholesterins durch Vitamin A, Klin. Wchnschr. 13: 95, 1934.
12. Jusatz, H. J.: Die Bedeutung des A-Vitamins für die Entstehung und Bekampfung von Infectionen, Deutsch. Med. Wchnschr. 60: 573, 1934.
13. Moore, T.: Interrelation of Vitamins, Vitamins & Hormones 3: 1, 1943.
14. Dublin, W. B., and Hazen, B. M.: To be published.
15. Van Bruggen, J. T.: A Rapid Method for Drying Oxalate Solutions, J. Lab. & Clin. Med. 31: 717, 1946.
16. Quaife, M. L., and Harris, P. R.: The Chemical Estimation of Tocopherols in Blood Plasma, J. Biol. Chem. 156: 499, 1944.
17. Quaife, M. L., and Biehler, R.: A Simplified Hydrogenation Technique for the Determination of Blood Plasma Tocopherols, J. Biol. Chem. 159: 663, 1945.
18. Roe, J. H., and Kuether, C. A.: The Determination of Ascorbic Acid in Whole Blood and Urine Through the 2,4-Dinitrophenylhydrazine Derivative of Dehydroascorbic Acid, J. Biol. Chem. 147: 399, 1943.
19. Sperry, W. M.: The Schoenheimer-Sperry Method for the Determination of Cholesterol, New York, 1943. Personal communication.
20. Sobel, A. E., and Mayer, A. M.: Improvements in the Schoenheimer-Sperry Method for the Determination of Free Cholesterol, J. Biol. Chem. 157: 255, 1945.
21. Bloor, W. R.: The Oxidative Determination of Phospholipid (Lecithin and Cephalin) in Blood and Tissues, J. Biol. Chem. 82: 273, 1929.

22. Gomori, G.: A Modification of the Colorimetric Phosphorus Determination for Use With the Photoelectric Colorimeter, J. LAB. & CLIN. MED. 27: 955, 1942.
23. Fisher, R. A.: Statistical Methods for Research Workers, Edinburgh, 1934, Oliver & Boyd.
24. Patterson, D. D.: Statistical Technique in Agricultural Research, New York, 1939. McGraw-Hill Book Company, Inc.
25. Glover, J., Goodwin, T. W., and Morton, R. A.: Studies in Vitamin A. The Relationship Between Blood Vitamin A Levels and Liver Stores in Rats, Biochem. J. 41: 97, 1947.
26. Clausen, S. W.: The Absorption of Vitamin A and Its Storage in the Tissues, The Harvey Lectures, Lancaster, Pa., 1942-43, Science Press Printing Co., p. 199.
27. Straumfjord, J. V.: Lesions of Vitamin A Deficiency. Their Local Character and Chronicity, Northwest Med. 41: 229, 1942.
28. Straumfjord, J. V.: Vitamin A: Its Effect on Acne. A Study of One Hundred Patients, Northwest Med. 42: 219, 1943.
29. Hickman, K. C. D., Kaley, M. W., and Harris, P. L.: Covitamin Studies. I. The Sparing Action of Natural Tocopherol Concentrates on Vitamin A, J. Biol. Chem. 152: 303, 1944.
30. Harris, P. L., Kaley, M. W., and Hickman, K. C. D.: Covitamin Studies. II. The Sparing Action of Natural Tocopherol Concentrates on Carotene, J. Biol. Chem. 152: 313, 1944.
31. Hove, E. L., and Harris, P. L.: Covitamin Studies. V. The Interrelation of Alpha-Tocopherol and Essential Unsaturated Fat Acids, J. Nutrition 31: 699, 1946.
32. Chalier, J., Jeune, M., Simon, F., and Alacoque, P.: Sur les relations entre la vitamine A et le taux du cholestérol sanguin, Compt. rend. Soc. de biol. 129: 606, 1938.
33. Wendt, H.: Beitrage zur Kenntnis des Carotin- und Vitamin A-Stoffwechsels, Klin. Wchnschr. 14: 9, 1935.
34. Sadhu, D. P., and Brody, S.: Excess Vitamin A Ingestion, Thyroid Size and Energy Metabolism, Am. J. Physiol. 149: 400, 1947.
35. Peters, J. R., and Van Slyke, D. D.: Quantitative Clinical Chemistry, Interpretations, vol. 1, ed. 2, Baltimore, 1946, Williams and Wilkins Company, p. 473.
36. Embree, N.: Recent Advances in the Chemistry and Nutrition of the Fat-Soluble Vitamins, Oil & Soap 23: 305, 1946.
37. Caldwell, M. J., and Parrish, D. B.: The Effect of Light on the Stability of the Carr-Price Color in the Determination of Vitamin A, J. Biol. Chem. 158: 181, 1945.

Klin Monatsbl. Augenheilk 110:116

Vancea, P.
Bib. No. 9347

1. ***Vancea, P.:*** **Untersuchung über die Ausscheidung von NaCl in den Tränen bei der A-Hypovitaminose.**

Um den Mechanismus der Xerophthalmie bei A-Hypovitaminose zu ergründen, wurde bei 4 während 20 Tage A-Vitamin-frei ernährten Hunden die NaCl-Ausscheidung in den Tränen ermittelt. Es stellte sich eine Erhöhung der NaCl-Werte heraus, die als ein der Epithelschädigung vorangehender Konzentrationsprozess angenommen wird.

Investigation of the secretion of NACIin the tears in A-hypovitaminosis.

P. Vancea

In order to study the mechanism of kerophthalmic in A-hypovitaminosis, the NACI secretion in the tears of 4 dogs was ascertained during 20 days of vitamin A-free feeding. There was an increase in the NACI value, which was taken to be one of the epithelial damages of the preceeding concentration process.

Van Dyke-'60
Bib. No. 9354

Vol. 3, No. 1 BIOCHEMICAL AND BIOPHYSICAL RESEARCH COMMUNICATIONS July 1960

THE FUNCTION OF VITAMIN A IN ADRENAL STEROID PRODUCTION

R. A. Van Dyke, G. Wolf and B. Connor Johnson

Department of Animal Science
and Radiocarbon Laboratory
University of Illinois
Urbana, Illinois

Received July 5, 1960

Vitamin A deficiency has been found to cause a decrease in total steroid production by quartered rat adrenal glands (Van Dyke and Wolf, 1958), and using adrenal homogenates it has been found that vitamin A deficiency causes a decrease in the incorporation of cholesterol-4-C^{14} into corticosterone (Van Dyke, Johnson and Wolf, 1960). In this paper we would like to report the effect of the *in vitro* addition of vitamin A on the incorporation of radioactivity from cholesterol into corticosterone.

To minimize general morbidity effects, rats were used while still in the relatively early stages of deficiency. In Experiment 1 and 3 (Tables I and III) the rats showed no gross symptoms but had plateaued in weight, although no loss had been demonstrated. These rats had been consuming the vitamin A-deficient diet for 2 weeks (Wolf, Lane and Johnson, 1957). In Experiment 2 (Table II) the rats had been on the deficient diet for 5 weeks and were losing weight.

Table I
Conversion of Cholesterol to Corticosterone in Adrenal Tissue

Incubation Addition	C^{14} Activity in Corticosterone in Deficient Tissue	C^{14} Activity in Corticosterone in Normal Tissue
	dpm	dpm
Homogenate	2650	7548
Homogenate + glucose-6-phosphate*	3104	9196
Homogenate + glucose-6-phosphate* + glucose-6-phosphate dehydrogenase**	2412	8552

DPN and TPN, 0.5 mM; ATP, 1 mM. 0.65 μc cholesterol-4-C^{14} was added to each incubation. Incubated for 2 hours under 95% O_2, 5% CO_2 at 37° C. Total volume was 3 ml.

*Glucose-6-phosphate, 4 mM.

**Glucose-6-phosphate dehydrogenase, activity to produce 3 μmoles TPNH per minute.

Table II
Effect of *In Vitro* Addition of Vitamin A Acid on the Conversion of Cholesterol to Corticosterone

Incubation Addition	C^{14} Activity in Corticosterone in Deficient Tissue	C^{14} Activity in Corticosterone in Normal Tissue
	dpm	dpm
Homogenate	2862	14,086
Homogenate + vitamin A acid*	7641	13,975

Incubation conditions were the same as in Table I.

The adrenals were removed from the animals and homogenized in the medium of Eichhorn and Hechter (1957), an equal weight of deficient and normal adrenal tissue being used in all cases. In all incubations 3 ml of the whole homogenate, which contained 50 mg wet weight of adrenal tissue, were used. The incubations with cholesterol-4-C^{14} were carried out as given in the tables.

The incubations were stopped by the addition of acetone and the precipitate was removed. The acetone was than removed under nitrogen and the aqueous solution was extracted with benzene-chloroform (6:1) three times to remove the steroids. The benzene-chloroform mixture containing the steroids were separated by chromatography in the propylene-glycol-toluene system of Burton, Zafforoni and Keutmann (1951). Following chromatography the radioactive compounds were eluted and the eluates were counted in a Packard Tri-Carb liquid scintillation counter. The different steroids were identified by chromatography and comparison with standards as well as by preparation of their acetates and rechromatographing.

The data in Table I show a marked depressing effect of vitamin A deficiency on the incorporation of cholesterol-4-C^{14} into corticosterone. Added TPNH regenerating systems were tried and found to have essentially no effect on corticosterone synthesis.

The data in the second experiment show a definite increase in corticosterone production when vitamin A acid is added to the deficient adrenal homogenates *in vitro*. The experiment was repeated in order to examine the effect of *in vitro* addition of vitamin A alcohol as well as of the acid, and as can be seen in Table III, both vitamin A alcohol and vitamin A acid increased corticosterone production.

*1.3 μmoles of vitamin A acid added per incubation.

Table III
Effect of the *In Vitro* Addition of Vitamin A Acid on the Conversion of Cholesterol to Corticosterone

Incubation Addition	C^{14} Activity in Corticosterone in Deficient Tissue	C^{14} Activity in Corticosterone in Normal Tissue
	dpm	dpm
Whole homogenate	9630	13,706
Whole homogenate + vitamin A alcohol*	14,998	-**
Whole homogenate + vitamin A acid*	16,576	-**

DPN and TPN, 0.5 mM; ATP, 1 mM. 1 μc cholesterol-4-C^{14} was added to each incubation. Incubated for 1 hour under 95% O_2, 5% CO_2 at 37° C. Total volume was 3 ml.

It must be pointed out that the aberration in adrenal glucocorticoid biosynthesis occurs very early in the development of the deficiency and before the block in cholesterol biosynthesis shown by Gloor and Wiss (1959) can be demonstrated in an *in vitro* system (Wright, Wolf and Johnson, 1960). In the rats used in these experiments it was not possible to demonstrate a decrease in cholesterol biosynthesis by liver homogenates (Wright, Wolf and Johnson, 1960), but as noted in the tables, a marked decrease in the ability of the homogenates to synthesis corticosterone from cholesterol was shown.

The ability to restore, at least partially, the synthesis of corticosterone in an *in vitro* system by the addition of vitamin A alcohol and acid may indicate the possibility that some form of vitamin A may be functioning as a cofactor or coenzyme for one of the enzymes necessary for the transformation of cholesterol to corticosterone.

This investigation was supported in part by grants from the National Vitamin Foundation and the U. S. Atomic Energy Agency, Contract AT (11-1)-67, Project 2.

*Vitamin A alcohol and vitamin A acid added at levels of 1.3 μmoles per incubation.
**Not determined.

References

Burton, R. B., Zaffaroni, A., and Keutmann, E. H., J. Biol. Chem. 188, 763 (1951).

Eichhorn, J., and Hechter, O., Proc. Soc. Expt. Biol. Med. 95, 311 (1957).

Gloor, U., and Wiss, O., Arch. Biochem. Biophys. 83, 216 (1959).

Van Dyke, R. A., Johnson, B. Connor, and Wolf, G., Fed. Proc. 19, 412 (1960).

Van Dyke, R. A., and Wolf, G., Fed. Proc. 17, 327 (1958).

Wolf, G., Lane, M. D., and Johnson, B. Connor, J. Biol. Chem. 225, 995 (1957).

Wright, G. J., Wolf, G., and Johnson, B. Connor, Unpublished Data (1960).

THE INFLUENCE OF HYPERVITAMINOSIS A ON BONE GROWTH

THOMAS E. VAN METRE, JR.[1]

From the Department of Pathology, Harvard Medical School, Boston, Mass.

Received for publication July 16, 1947

The objective of this experiment was to determine the effect of hypervitaminosis A on the longitudinal growth of the long bone of the rat. Collazo showed that large amounts of vitamin A will produce fractures in the long bones of growing rats (1) (2) (3). This work has been duplicated by others. The literature on the subject has been adequately reviewed by Wolbach and Bessey (4) and by T. Moore and Wong (5). Wolbach (6) has recently shown that the effect of hypervitaminosis A on the growing bone is a composite of several factors: first, a speeding up of maturation, degeneration and death of cartilage cells in the epiphysis; second, correspondingly active replacement bone formation with early closure of epiphyses that normally close, and third, concurrent acceleration of remodelling of the shaft of the bone, normal in location and execution, but sufficiently abnormal in rate so that the rapid replacement of strong old bone with new weak bone produces a structure insufficiently strong, because of the normal lag in calcification, to resist fracture under the strains imposed by normal activity. Remodelling of the long bone has been interpreted as a function of stress and strain for two reasons—first, bone adapts itself in external form and internal trabeculation so that a maximum of strength is achieved with a high degree of economy of material; second, as Glucksman (8) (9) has well shown, bone in tissue culture grows in such a form that it most efficiently resists the strains applied to it. It therefore seemed desirable to Wolbach to correlate the accelerated remodelling of bone resulting from excessive vitamin A administration with the rate of longitudinal growth of bone, in order to ascertain whether remodelling is solely the result of mechanical factors. This experiment was therefore performed in his laboratory, under his direction, to ascertain whether or not an increased rate of longitudinal growth was present.

[1] Present address Johns Hopkins Hospital, Baltimore, Maryland.

MATERIALS AND METHODS

The experiment consisted essentially of measuring longitudinal growth of the left tibia, body weight, and food intake of a number of rats given varying excessive doses of vitamin A.

The rats were albino rats of the Wistar strain, obtained from the Harvard Biological Laboratories. They were 21 day old "weanlings" at the onset of the experiment.

The vitamin A used was winterized, vitamin A concentrate, containing 500,000 international units per gram, distilled from fish liver and vegetable oils by Distillation Products, Inc. This compound contains vitamin A 14.3%, unidentified sterols less than 10%, tocopherols less than 1% in solution in distilled fat. The vitamin D content is well under 100 units per gram. (10) This preparation was administered orally, the given amount being placed on the back of the animal's tongue. The dosage of vitamin A, the number of animals treated, and the duration of the experiment is indicated in the graph summarizing the results. It was previously determined (4) (6) that crystalline vitamin A (obtained from the Distillation Products, Inc., Rochester, New York) produced all of the bone changes concerned in this experiment.

Bone growth was measured by taking weekly roentgenograms of the left tibia. To eliminate the necessity of using anesthesia, a special frame was designed for holding the animals motionless (Fig. 1). It was not difficult to secure the animals by tightening the tapes with the peg-winches and proper application of the spring clips. The distance on the roentgenograms between the midpoints of the proximal and distal ends of the bone was measured with calipers and considered to represent the length of the bone. With the x-ray tube set at a target-film distance of 90 cm. to insure perpendicular rays, minor variations in the position of the leg inherent in this technique did not introduce an error of more than 0.1 mm. Measurements with considerable comparative value, therefore, could be obtained.

Weight gain was followed by weighing the animals daily. Food intake was measured each day. Purina dog chow checkers were used as food. An amount somewhat above the daily expected intake was weighed out and put into the cages. At the end of twenty-four hours

Johns. Hopk. Hosp. Bull. 81:305. 1947.

Van Metre-'47
Bib. No. 9372

the intake was calculated after weighing the residue. The animals were housed in separate cages with wire mesh floors which allowed a certain loss of food, introducing an error into these measurements; however, being relatively constant throughout, this loss did not



FIG. 1. APPARATUS FOR HOLDING ANIMALS WHILE ROENTGEONGRAMS ARE BEING TAKEN

particularly distort the comparative value of the figures obtained. The animals were allowed free access to water.

Alterations in the gross morphology of the left tibia were followed by roentgenograms and observation of the bone at autopsy. Changes in histology were followed by study of microscopic sections.

RESULTS

Weanling rats receiving 250, 275, 625, or 1250 international units of vitamin A per gram of body weight per day developed changes in the left tibia similar to those described by Wolbach (6).

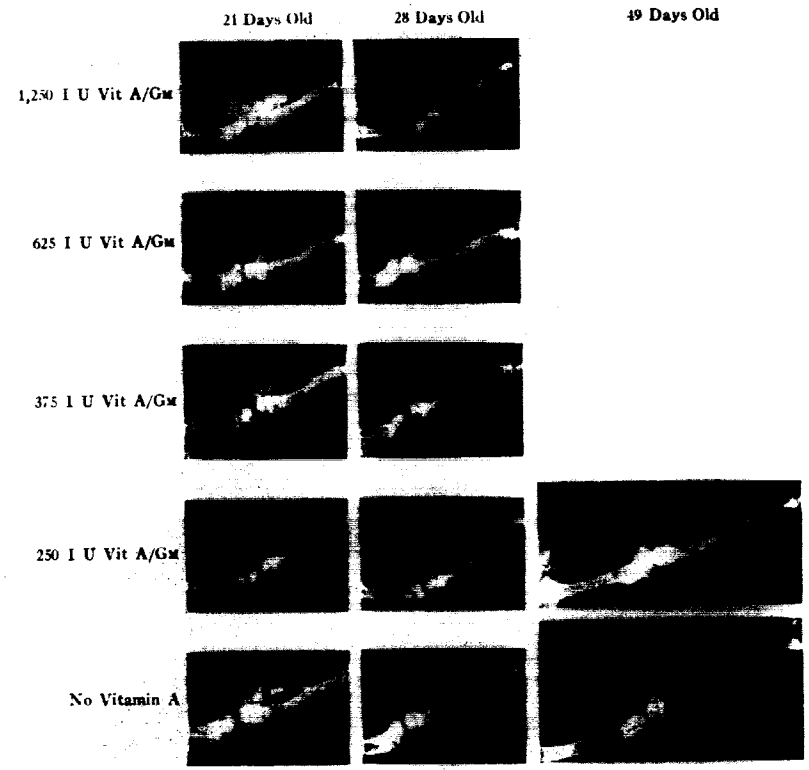

FIG. 2. The influence of hypervitaminosis A on the gross morphology of the left tibia of the growing rat as revealed by roentgenograms. The indicated amount of vitamin A was given every day beginning just after the "21 days old" X-ray was taken.

The gross changes are shown in the reproductions of the roentgenograms in Figure 2. The bones are seen to be more slender than normal controls. The cortex of the metaphysis is less opaque to the roentgen ray. The epiphyseal cartilage is decreased in width. Within the range of dosage used, the greater the amount of vitamin A given,

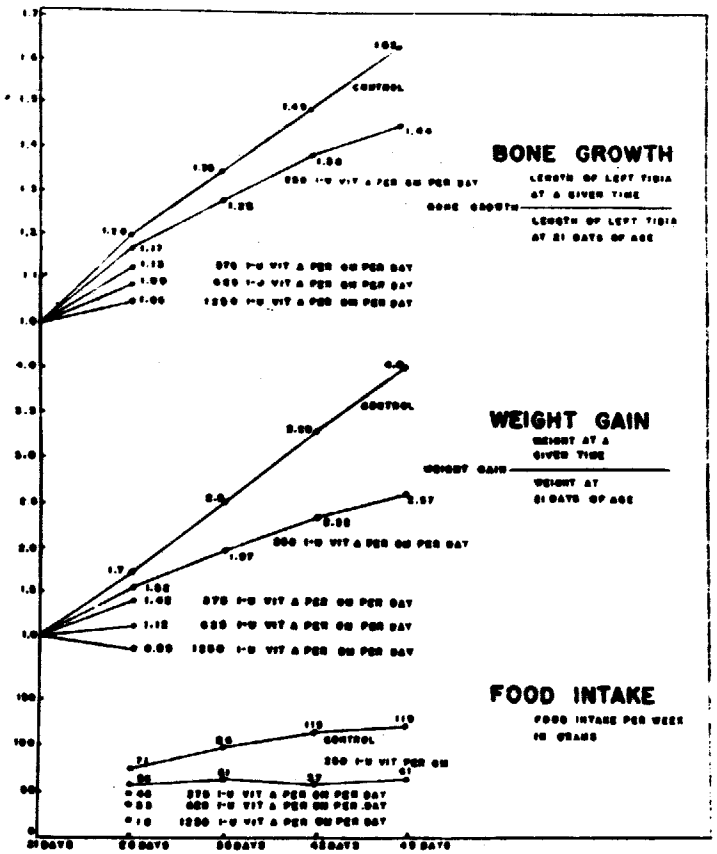

FIG. 3. THE INFLUENCE OF HYPERVITAMINOSIS A ON BONE GROWTH, WEIGHT GAIN AND FOOD INTAKE

Number of Animals

Control: No Vit. A supplement: 16 rats for 1st week 8 thereafter
250 1-U Vit. A per gm. per day: 12 rats for 1st week 8 thereafter
375 1-U Vit. A per gm. per day: 10 rats
625 1-U Vit. A per gm. per day: 16 rats
1250 1-U Vit. A per gm. per day: 16 rats

the more pronounced the effect. These roentgenograms were taken too early to demonstrate fracture. Fracture was always observed, however, across the region of decreased density between the 7th and 14th day of treatment when 625 or 1250 international units of vitamin

A per gram of body weight per day were given, but only after the fourth week of treatment when 250 international units of vitamin A were given.

The microscopic changes were entirely similar to those described by Wolbach (6). Indeed, some of his observations were made on sections taken from these very animals. *The magnitude of change again was directly proportional to the amount of vitamin A administered.*

Coincidental to these gross and microscopic changes, and likewise increasing in degree in direct proportion to the amount of vitamin A given, was retardation of longitudinal growth of the left tibia, weight gain, and food intake as shown in Figure 3.

DISCUSSION

These animals were given a fish oil concentrate containing vitamin A. Under the experimental condition outlined, this distillate produced morphologic changes in the long bones of rats identical with those described by Wolbach (6); morphologic changes which he has produced using crystalline vitamin A as well as a similar distillate; morphologic changes which are therefore almost surely specific manifestations of hypervitaminosis A. It is felt in agreement with Wolbach and for the reasons which he advances that these morphologic changes may be interpreted as due to the acceleration of normal processes; to wit, the acceleration of maturation, degeneration, and death of epiphyseal cartilage cells, replacement bone formation, and the acceleration of normal remodelling of the bone. These morphologic changes may be produced by all of the dosages of vitamin A administered, but are the more pronounced the larger the dose of vitamin A given. Coincidental with these morphologic changes and again proportional to the amount of vitamin A given is a retardation of longitudinal bone growth. Therefore, in hypervitaminosis A, those bones that elongate most slowly because of larger doses, remodel most quickly. Accelerated longitudinal growth is therefore not the factor that makes these bones remodel more rapidly than normal bones. It seems likely, therefore, as Wolbach has already suggested (6), that some factor other than stress and strain must be important in the rapid remodelling seen in hypervitaminosis A.

These experiments establish the fact that in hypervitaminosis A longitudinal growth of long bones is retarded. They do not explain

why this phenomenon occurs. The reduction in food intake, which so closely parallels the reduction of bone growth and similarly is proportional to the amount of vitamin A given, may be one factor responsible. The proportional diminution in weight gain suggests that this retardation of growth may apply to tissues other than bone. The mechanism of growth retardation and the extent of its influence in hypervitaminosis A warrant further investigation.

CONCLUSIONS

Under the experimental conditions outlined, it has been demonstrated that:

(1) Hypervitaminosis A produced accelerated remodelling of the tibia of the growing "weanling" rat. This acceleration was proportional to the amount of vitamin A given.

(2) Hypervitaminosis A in the same animals produced retardation of longitudinal growth of the tibia. This retardation was proportional to the amount of vitamin A given.

It is, therefore, possible to have accelerated remodelling of bone that is secondary to no readily appreciable increase in the stress and strain operating in and on that bone.

BIBLIOGRAPHY

1. Collazo, J. A., Rubino, P., and Vorela, B.: Knochenbildung und Wachstumastor Ungen Bei Ratten Nach Grossen Dosen Destrahlten Ergosterins. Deutsch. Med. Wchnschr., **55:** 1794, 1929.
2. Collazo, J. S., and Rodriquez, J. S.: Hypervitaminose A. Klin. Wchnschr., **12:** 732–768, 1933.
3. Collazo, J. S., and Rodriquez, J. S.: Hypervitaminosis A. Exoftalmos y Fracturas Espontaneas. Ann. de Med. Int. (Madrid), **2:** 647, 1933.
4. Wolbach, S. B., and Bessey, O. A.: Tissue Changes in Vitamin Deficiencies. Physiol. Rev., **22:** 233, 1942.
5. Moore, T., and Wang, Y. L.: Hypervitaminosis A. Biochem. J., **39:** 222, 1945.
6. Wolbach, S. B.: 22nd Ludvig Hektoen Lecture. Proc. Inst. Med. of Chicago, **162:** March 22, 1946. J. Bone and Joint Surg., **29:** 171, 1947.
7. Koch, J. C.: The Laws of Bone Architecture. Am. J. Anat., **21:** 177, 1917.
8. Glucksman, A.: Studies on Bone Mechanics in Vitro. Influence of Pressure on Orientation of Structure. Anat. Rec., **72:** 1, 1938.
9. Glucksman, A.: Studies on Bone Mechanics in Vitro. II. Role of Tension and Pressure in Chondrogenesis. Anat. Rec., **73:** 1, 1939.
10. Private Communication from Distillation Products, Inc., Rochester, N. Y.

Varma-'63
Bib. No. 9384

PN 1307

Conversion of *retro*-vitamin A to vitamin A in the vitamin A-deficient rat

SHANTZ[1] reported in 1950 that crystalline anhydrovitamin A (λ_{max} 351, 371 and 392 mμ and $E^{1\%}_{1\,cm}$ 2540, 3680 and 3200, respectively, at these wavelengths), when fed to vitamin A-deficient rats, was converted to "rehydrovitamin A" (λ_{max} 351 and 368 mμ with an inflexion at about 330 mμ) which could be isolated from the non-saponifiable fraction of the rat-liver oil. The name "rehydrovitamin A" was proposed for this compound based on the hypothesis that it was formed *in vivo* by the addition of water to the terminal double bond of the anhydrovitamin A molecule. The term "*retro*-vitamin A" is preferred to "rehydrovitamin A" because of its structural relationship to vitamin A, and will therefore, be used in this paper. The structural relationship of anhydrovitamin A, *retro*-vitamin A and vitamin A are shown below.

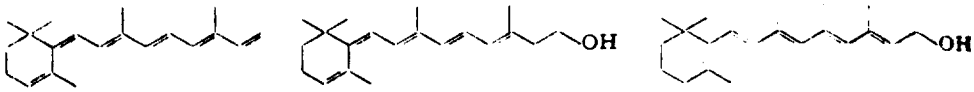

Anhydrovitamin A (λ_{max} 351, 371 and 392 mμ)[1] — *Retro*-vitamin A (λ_{max} 332, 348 and 366 mμ)* — Vitamin A (λ_{max} 324)*

SHANTZ[1] found that the reaction product of *retro*-vitamin A and $SbCl_3$ had an absorption maximum at 612 mμ, and assumed that it had about the same molar extinction coefficient as that of vitamin A alcohol. On the basis of the blue color, the potency of a preparation of *retro*-vitamin A ($E^{1\%}_{1\,cm}$ 2.3 at 351 mμ) was determined by the rat-growth assay as about 1/15 that of vitamin A alcohol and about 20 times that of anhydrovitamin A. *Retro*-vitamin A was also prepared by BEUTEL *et al.*[2] from crystalline all-*trans* vitamin A acetate by treating the latter with aqueous HBr.

Recently we observed a compound with ultraviolet absorption maxima at 332, 348 and 366 mμ in several deteriorated samples of liquid multivitamin preparations. In addition, these samples contained vitamin A, anhydrovitamin A and oxidized form(s) of vitamin A. Chromatography of the non-saponifiable fractions of these liquid multivitamin samples on 4% water-weakened alumina columns indicated that the compound with λ_{max} 332, 348 and 366 mμ moved close to vitamin A and a quantitative separation of the two compounds was not possible. The two compounds (in the alcohol form) could, however, be well-separated by thin-layer chromatography on alumina using 1% (v/v) methanol in cyclohexane with R_F values of 0.32 ± 0.03 and 0.18 ± 0.02 for the compound with λ_{max} 332, 348 and 366 mμ and vitamin A, respectively. The ultraviolet absorption maxima, chromatographic behaviour, $SbCl_3$ reaction product (λ_{max} at about 575 mμ) and the partition coefficient (50:50 between petroleum ether and 83% ethanol in water for the alcohol form) of this compound indicated that it was *retro*-vitamin A, identical to the alcohol form of the *retro*-vitamin A prepared by BEUTEL *et al.*[2]. Since SHANTZ[1] reported an absorption maximum at 612 mμ for the $SbCl_3$ reaction product of *retro*-vitamin A, it was of interest to study the biological behaviour of the *retro*-vitamin A prepared in the laboratory according to BEUTEL *et al.*[2].

Retro-vitamin A was prepared essentially as described by BEUTEL *et al.*[2]. The purity of the preparation was checked by thin-layer chromatography on alumina

* These absorption maxima measured in petroleum ether were obtained by the present authors.

The R_F values of *retro*-vitamin A acetate and vitamin A acetate were 0.36 ± 0.03 and 0.19 ± 0.03, respectively, when the developing solvent was 10 % (v/v) benzene in cyclohexane. The ultraviolet absorption spectrum of *retro*-vitamin A acetate (λ_{max} 332, 348 and 366 mμ) is shown in Fig. 1. In the Carr-Price color test, the reaction product of *retro*-vitamin A alcohol and $SbCl_3$ had an absorbancy maximum at 575 mμ, the $E^{1\%}_{1\,cm}$ at this wavelength being approx. 3910.

Ten vitamin A-deficient male rats were dosed orally for three consecutive days with 4.074 mg of *retro*-vitamin A acetate in 0.1 ml corn oil. The animals were sacrificed 48 h after the last dose, the livers removed and saponified individually and the non-saponifiable material extracted into diethyl ether. An aliquot of each of the non-saponifiable fractions was taken up in petroleum ether and chromatographed on 4 % water-weakened alumina. The "vitamin A fraction" from the column was subjected to thin-layer chromatography on alumina with the solvent system, 1 % (v/v) methanol in cyclohexane. In every case, both vitamin A and *retro*-vitamin A were detected.

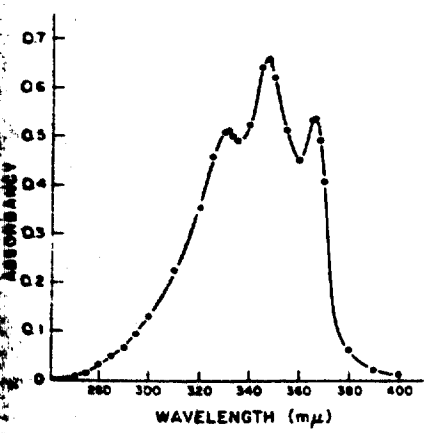

Fig. 1. Ultraviolet absorption spectrum of *retro*-vitamin A acetate in petroleum ether measured on a Beckman DU spectrophotometer ($E^{1\%}_{1\,cm}$ at 332, 348 and 366 mμ equal to 1430, 1840 and 1470, respectively).

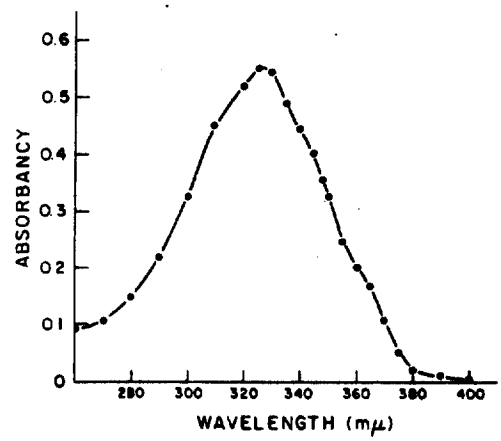

Fig. 2. Ultraviolet absorption spectrum of the "vitamin A fraction" obtained after column chromatography on alumina of the non-saponifiable fraction of the liver of a rat fed *retro*-vitamin A acetate.

The ultraviolet spectrum of the "vitamin A fraction" obtained on column chromatography of one of the non-saponifiable fractions is shown in Fig. 2. Vitamin A and *retro*-vitamin A in the "vitamin A fractions" were determined as follows: known mixtures of pure vitamin A and pure *retro*-vitamin A were prepared and the ratios of A_{324}/A_{348} were plotted against the composition. By means of this curve, it was estimated that the mean value for the ratio of vitamin A to *retro*-vitamin A in the "vitamin A fractions" from the column was about 80:20. In such a mixture, the corrected absorbancy at 324 mμ, used for the calculation of vitamin A (ref. 3), was about 20 % more than the actual absorbancy at this wavelength due to vitamin A. This approximation was used in the calculation of the amount of vitamin A in the "vitamin A fraction". From this value, the amount of *retro*-vitamin A was calculated. It was then estimated that the mean liver storage values for vitamin A and *retro*-vitamin A were 900 μg and 227 μg representing approx. 7.4 % and 1.85 %, respectively, of the total of *retro*-vitamin A.

This experiment clearly indicates that, contrary to the conjecture made by SHANTZ[1], *retro*-vitamin A can be converted to vitamin A in the vitamin A-deficient rat. Experiments are now in progress to isolate *retro*-vitamin A from rats fed anhydro-vitamin A and ascertain whether or not this compound is the same as the one chemically formed from vitamin A in the aqueous HBr reaction[2]. Since *retro*-vitamin A is often encountered in liquid multivitamin preparations, its biological potency is also under investigation.

Vitamins and Nutrition Section, Food and Drug Laboratories, Department of National Health and Welfare, Ottawa (Canada)

T. N. R. VARMA*
T. K. MURRAY

[1] E. M. SHANTZ, *J. Biol. Chem.*, 182 (1950) 515.
[2] R. H. BEUTEL, D. F. HINKLEY AND P. I. POLLAK, *J. Am. Chem. Soc.*, 77 (1955) 5166.
[3] H. R. CAMA, F. D. COLLINS AND R. A. MORTON, *Biochem. J.*, 50 (1951) 48.

Received August 8th, 1963

* National Research Council of Canada Post-doctoral Fellow.

Varma-'65
Bib. No. 9387

BBA 25274

THE UTILIZATION OF ANHYDROVITAMIN A BY THE VITAMIN A-DEFICIENT RAT

T. N. R. VARMA*, P. ERDODY AND T. K. MURRAY

Vitamins and Nutrition Section, Food and Drug Directorate, Department of National Health and Welfare, Tunney's Pasture, Ottawa (Canada)

(Received October 8th, 1964)

SUMMARY

Anhydrovitamin A was fed to vitamin A-deficient rats and its metabolites isolated from the livers. These consisted of two monohydroxy and one dihydroxy derivatives and their esters. None was identical with retro-vitamin A prepared chemically from vitamin A. Neither anhydrovitamin A nor its derivatives gave rise to any detectable amount of vitamin A in the liver; nor was anhydrovitamin A present as such in the liver. Similar results were obtained after subcutaneous injection of a water dispersion of anhydrovitamin A. Two compounds similar to those isolated from the liver also were found in the kidneys. The results suggested that (a) anhydrovitamin A whether fed orally or injected subcutaneously was not absorbed and stored to any measurable extent by the rat, (b) hydroxylation mechanisms were involved in the utilization of anhydrovitamin A and (c) the growth-promoting activity of anhydrovitamin A was due to one or more of its derivatives formed *in vivo*.

INTRODUCTION

Anhydrovitamin A, the hydrocarbon formed by the dehydration of vitamin A alcohol, has been detected in fish oils[1] and its occurrence in synthetic multivitamin preparations recently was demonstrated[2]. Its biological potency was estimated to be 0.4% that of vitamin A in the rat growth assay[2]. The ultraviolet absorption spectrum of anhydrovitamin A exhibited three maxima at 351, 371 and 392 mμ (ref. 3)

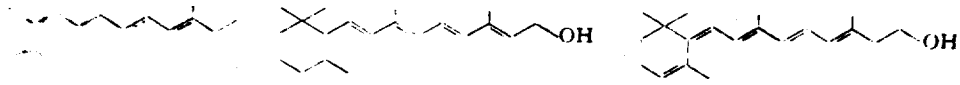

Anhydrovitamin A Vitamin A alcohol Retro-vitamin A alcohol

in contrast to the broad peak of vitamin A near 325 mμ. The two compounds, however, showed the same λ_{max} (620 mμ) in the $SbCl_3$ color test with similar $E^{1\%}_{1cm}$ values at this wavelength[3]. When fed to vitamin A-deficient rats, anhydrovitamin A gave rise to "rehydrovitamin A" in the liver[4]. This substance has ultraviolet max. at 351 and

* National Research Council of Canada Post-doctoral Fellow 1962–'64.

369 mμ with an inflection at 331 mμ, and showed a peak at 612 mμ in the $SbCl_3$ color test[4]. On the basis of its spectroscopic properties, the chromatographic behavior and distribution ratio, "rehydrovitamin A" was assigned the structure of retro-vitamin A (ref. 4), a compound which was later prepared by BEUTEL *et al.*[5] by treating vitamin A with aqueous hydrobromic acid. It was, however, noticed that in the $SbCl_3$ color test retro-vitamin A showed an λ_{max} at 575 mμ (ref. 6) in contrast to the λ_{max} at 612 mμ of "rehydrovitamin A". Retro-vitamin A also was shown to have a biological potency of 11 % that of vitamin A in the liver storage assay and 12 % that of vitamin A in the vaginal smear assay[2]. In the growth assay the biological potency of "rehydrovitamin A" was estimated to be 8 % that of vitamin A. The marked difference shown in the $SbCl_3$ color test by "rehydrovitamin A" and retro-vitamin A prompted further characterization of "rehydrovitamin A". This report is concerned with the separation and partial characterization of the metabolites of anhydrovitamin A from the livers and kidneys of rats, and their disappearance during a 30-day period following the last dose of anhydrovitamin A.

METHODS

Preparation of anhydrovitamin A

Anhydrovitamin A was prepared from crystalline all-*trans*-vitamin A alcohol by treatment with anhydrous methanolic hydrogen chloride[3] and purified by repeated chromatography on 6 % (v/w) water-weakened alumina. The final preparation showed λ_{max} at 350, 368 and 390 mμ with $E^{1\%}_{1\,cm}$ values of 2340, 3130 and 2600, respectively, at these wavelengths and appeared as a single spot (R_F value = 0.95) when subjected to thin-layer chromatography[7].

Grouping and dosing of rats

Eighty vitamin A-deficient male Wistar rats, of the Food and Drug Colony, were divided into six groups. The animals were approx. 7 weeks old at the beginning of the experiment. Group I contained 30 animals and groups II to VI contained 10 animals each. Anhydrovitamin A was dissolved in corn oil or dispersed in water by means of Tween 80 to give a concentration of 2.22 mg in 0.1 ml. The animals in groups I to V were dosed orally on six successive days with 0.1 ml of the oil solution and killed by decapitation at the end of 2, 9, 16, 23 and 30 days, respectively, after the last dose. Similarly, the animals in group VI were injected subcutaneously with the water-dispersion, and killed 2 days after the last dose. The livers and kidneys were excised and stored frozen until analyzed.

Extraction, saponification and chromatography of the lipids

Liver lipids were extracted by two methods. In one, the liver was ground with anhydrous sodium sulfate and extracted with peroxide-free diethyl ether according to AMES *et al.*[8]. In the other, the liver was saponified with 25 ml of 12 % (w/v) ethanolic potassium hydroxide under gentle reflux, extracted with diethyl ether and washed free of alkali. Diethyl ether extracts obtained by either method were evaporated to dryness under reduced pressure and the residue dissolved in petroleum ether (40–60°). Initially four livers from group I and two livers from each of groups II and III were

saponified and analyzed individually to determine the number of different derivatives (in the alcohol form) of anhydrovitamin A. In order to study ester fractions the remaining livers were analyzed without saponification. Anhydrovitamin A-derivatives in the liver extracts were separated by column chromatography on 6 % (v/w) water-weakened alumina (Woelm, neutral activity grade I). The bands were located on the column visually and by means of ultraviolet light and were eluted individually by the step-wise addition of solvent systems consisting of 0 to 40 % (v/v) diethyl ether in petroleum ether. Any band not eluted in this manner was eluted with diethyl ether followed by methanol after the alumina was extruded from the column.

Kidneys of the same group of animals were pooled and the lipids extracted without saponification and analyzed.

Characterization of anhydrovitamin A-derivatives isolated from the liver

The ultraviolet absorption spectra (260–400 mμ) of fractions obtained by column chromatography were determined in a Beckman DU spectrophotometer. The spectrum of the $SbCl_3$ reaction product was recorded in a Beckman DK2 spectrophotometer within 20 sec after the addition of the Carr–Price reagent.

Partition between petroleum ether and 83 % ethanol–water was carried out as follows: The anhydrovitamin A-derivative whose partition coefficient was to be determined was dissolved in petroleum ether saturated with the ethanol–water mixture and the absorbancy, A_1, measured at the λ_{max}. 10 ml of this solution were transferred to a measuring cylinder and mixed with an equal volume of ethanol–water saturated with petroleum ether, by slowly inverting the stoppered cylinder twenty times. An aliquot was withdrawn from the petroleum ether layer and the absorbancy, A_2, measured again at the λ_{max}. The distribution ratio was expressed as $100\ A_2/A_1$: $100 - 100\ A_2/A_1$.

Ester fractions were saponified, and the partition coefficient and chromatographic behaviour of the non-saponifiable matter compared with those obtained before saponification.

Thin-layer chromatography was carried out as described previously[7].

The allylic or non-allylic nature of the hydroxyl groups was determined by treating the material with anhydrous methanolic hydrogen chloride, which reacts with allylic hydroxyl groups to form methyl ethers[9]. The great difference in polarity brought about by this change in the functional group afforded a means of ascertaining ether formation.

Quantitative estimation of the metabolites of anhydrovitamin A

Three metabolites of anhydrovitamin A, designated components 4, 5a and 6 (Table I) were isolated from liver in the alcohol form. These were estimated on the basis of the absorbancy values shown below:

Component 4 (6 conjugated double bonds; 1 hydroxyl group): The assumption was made that this hydroxylated form of anhydrovitamin A had the same E_{max} as anhydrovitamin A and therefore an $E^{1\%}_{1\,cm}$ value of 3000 at 390 mμ. This value was approximately equivalent to a value of 3200 for crystalline anhydrovitamin A at 392 mμ (ref. 3).

Component 5a (5 conjugated double bonds; 1 hydroxyl group): This compound

TABLE I

PROPERTIES OF ANHYDROVITAMIN A-DERIVATIVES ISOLATED FROM RAT LIVERS

Component	Eluting solvent: % (v/v) diethyl ether in petroleum ether	Fluorescence	Distribution ratio*	λ_{max} (mμ)		Possible No. of				
				Ultraviolet	$SbCl_3$ color test	Ester groups			Hydroxyl groups	
						Double bonds	Allylic	Non-allylic	Allylic	Non-allylic
1	0–2	orange	98:2	350, 368, 390	612	6	0	1	0	0
2	2–5	greenish yellow	95:5	332, 348, 366	618	5	1	0	0	0
3	5–8	greenish yellow	95:5	332, 348, 366	618	5	1	1	0	0
4	12–15	orange	52:48	350, 368, 390	612	6	0	0	0	1
5a	15–20	greenish yellow	50:50	332, 348, 366	618	5	0	0	1	0
5b	15–20	greenish yellow	50:50	332, 348, 366	618	5	1	0	0	1
5c	15–20	greenish yellow	50:50	332, 348, 366	618	5	0	1	1	0
6	40	greenish yellow	22:78	332, 348, 366	618	5	0	0	1	1

* Between petroleum ether and 83% ethanol–water mixture.

TABLE II

ANHYDROVITAMIN A-DERIVATIVES ISOLATED FROM THE LIVERS AND KIDNEYS OF RATS AT VARIOUS TIME INTERVALS

Mode of administration	Days after last dose	No. of rats	μg/liver of component						μg/pair of kidneys of component					
			1	2	3	4	5a 5b 5c	6	1	2	3	4	5a 5b 5c	6
Subcutaneous	2	10	8.92	0.78	4.97	4.02	4.09							
Oral	2	26	19.60	8.38	61.75	4.66	4.22	9.85	0.66	—	0.18	—	—	—
	9	8	9.72	5.26	49.90	5.76	2.96	5.30	1.64	—	—	—	—	—
	16	8	1.05	0.57	14.16	—	—	7.55	1.25	—	0.04	—	—	—
	23	10	0.13	0.07	4.85	—	—	—	1.20	—	—	—	—	—
	30	10	—	—	—	—	—	—	0.53	—	0.04	—	—	—

was assumed to have the same E_{max} as retro-vitamin A alcohol and hence an $E^{1\%}_{1\,cm}$ value of 2100 at 366 mμ (ref. 2).

Component 6 (5 conjugated double bonds; 2 hydroxyl groups): This was assumed to have the same E_{max} as component 5a and hence an $E^{1\%}_{1\,cm}$ value of 1990 at 366 mμ.

Other components in Table I were shown to be the ester derivatives of the above components and were, therefore, expressed in terms of the corresponding alcohols. Components 5a, 5b and 5c occurred only in small amounts and were estimated quantitatively as a mixture using an $E^{1\%}_{1\,cm}$ value of 2100 at 366 mμ.

Feeding of components 1 and 3

The liver stores of two rats, each dosed with 175 μg of component 1 in 0.4 ml corn oil and three rats, each dosed with 400 μg of component 3 in 0.3 ml corn oil were examined as described above.

RESULTS AND DISCUSSION

Chemical studies

The properties of anhydrovitamin A-derivatives obtained from the livers without saponification and separated by column chromatography are shown in Table I. The liver contained at least seven components related to anhydrovitamin A. This is in contrast to the single fraction designated "rehydrovitamin A" reported by SHANTZ[4]. Possibly the chromatographic method employed by SHANTZ did not separate these various components. The components could be classified broadly into three groups: (1) containing no hydroxyl groups (components 1, 2 and 3); (2) containing one hydroxyl group (components 4, 5a and the mixture of 5b and 5c) and (3) containing two hydroxyl groups (component 6). Each of components 1 and 2 had one ester group as judged by the distribution ratio before (98:2 and 95:5, respectively) and after (52:48 and 50:50, respectively) saponification. Based on the same criterion, component 3 was assigned two ester groups (Table I). The non-saponifiable fractions of components 1, 2 and 3 were identical with components 4, 5a and 6, respectively, as judged by R_F values and mixed chromatography on thin-layer chromatograms of alumina, distribution ratios, ultraviolet absorption maxima, λ maxima of the $SbCl_3$ reaction products and the number and positions of the hydroxyl groups. The number of conjugated double bonds was judged by the ultraviolet absorption maxima. Comparison with anhydrovitamin A and retro-vitamin A indicated that components 1 and 4 had six conjugated double bond systems and the remaining components had five conjugated double bond systems. The allylic or the non-allylic position of the ester group was determined after saponification and treatment of the alcohol with anhydrous methanolic hydrogen chloride. Although chromatography of the whole liver lipids did not separate component 5a from the mixture of 5b and 5c, saponification and thin-layer chromatography of the mixture resulted in the separation of two components, one of which was identical with component 5a and the other identical with component 6. This indicated that component 5a had only one hydroxyl group and no ester groups, but components 5b and 5c had one hydroxyl group and one ester group in each. The existence of two different components 5b and 5c was not

proven, but was assumed possible because either of the hydroxyl groups in component 6 could be esterified.

It is interesting to note that none of the compounds formed biologically from anhydrovitamin A gave λ_{max} near 575 mμ in the $SbCl_3$ color test. This suggested that although these compounds possessed the retro-structure, as evident from their ultraviolet absorption maxima, they were different from the retro-vitamin A prepared according to BEUTEL *et al.*[5]. Vitamin A, possessing an allylic hydroxyl group at carbon 15 (nomenclature according to the Karrer system usual in carotenoid chemistry) was easily converted to anhydrovitamin A and vitamin A methyl ether by treatment with anhydrous methanolic hydrogen chloride; under identical conditions, retro-vitamin A remained unchanged indicating the hydroxyl group at carbon 15 was non-allylic. In the $SbCl_3$ color test, the regenerated product from vitamin A alcohol and ester was identical with anhydrovitamin A, whereas, that obtained from retro-vitamin A alcohol and ester was identical with the starting material. Since all anhydro-vitamin A-derivatives obtained in the present work showed λ_{max} in the region 612–618 mμ in the $SbCl_3$ color test, it is presumed that those which possessed six conjugated double bonds (ultraviolet λ_{max} 350, 368 and 390 mμ) had their ester or hydroxyl groups in non-allylic positions (at carbon 2 or one of the *gem*-dimethyl carbons) or in positions from where they could not easily be eliminated without altering the double bond system (at the methyl carbons attached to carbons 5, 9 or 13). Those which possessed five conjugated double bonds (ultraviolet λ_{max} 332, 348 and 366 mμ) had at least one ester or hydroxyl group in the allylic position which would be eliminated in the presence of the strongly acidic $SbCl_3$ reagent. This would suggest that the location of the ester groups in components 2 and 3, the hydroxyl group in component 5a, the ester or hydroxyl group in components 5b and 5c, and one of the hydroxyl groups in component 6 was at carbon 14. If the addition of water to the terminal double bond of anhydrovitamin A took place through an ionic mechanism preceding esterification, as would be normal in biological systems, then the hydroxyl group would be attached at the carbon atom having the lesser number of hydrogen atoms, *i.e.*, at carbon 14.

Biological studies

Quantitative changes in the liver stores of anhydrovitamin A derivatives during one month following the last dose are shown in Table II. Of the ingested anhydro-vitamin A, only 0.8 % was recovered as its derivatives after two days, 83 % in the ester form and 17 % as the alcohol. Assuming a normal storage for vitamin A of 60 % of the dose and full vitamin A activity of the derivatives stored, this would indicate a biological activity of about 1.3 % that of vitamin A. This is of the same order as that reported by SHANTZ[3] but since the metabolism of the anhydrovitamin A derivatives is unknown, the calculation of potency by liver storage is probably not justified.

After thirty days none of the anhydrovitamin A derivatives could be detected in the liver. This is equivalent to the disappearance of about 3.3 μg per day, a rate not unlike that found for vitamin A. During the same period the blood lipids gave a blue color with $SbCl_3$, the intensity of which decreased steadily with time. The compounds responsible for this blue color were, however, not identified.

Only the two major components (1 and 3) were detected in the kidney. These

were present in only small amount but persisted until the end of the experiments. The increase in component 1 at nine days was similar to the increase found in kidney stores of vitamin A during depletion[10].

Subcutaneous injection of anhydrovitamin A resulted in only 26% as much liver storage of derivatives as did oral administration. Reduction in storage was confined to components 1, 3 and 6 with the latter two being the most seriously affected.

No trace of unaltered anhydrovitamin A was detected in the liver extracts which indicated that either the rat was unable to absorb and store anhydrovitamin A or converted it rapidly in the liver to other compounds.

Vitamin A was not found in the livers of the rats fed anhydrovitamin A at any time during the experiment. This suggests that the derivatives of anhydrovitamin A possessed biological activity *per se* or were converted to vitamin A as required. This latter process, if it occurs at all, must be very slow because no vitamin A accumulates and even large doses of anhydrovitamin A do not maintain a normal vaginal smear[2]. When components 1 and 3 were re-fed to vitamin A-deficient rats, they gave rise to no vitamin A in the liver. SHANTZ[4] reported that the growth-promoting activity of anhydrovitamin A was due to "rehydrovitamin A" which was not converted to vitamin A. The present study confirmed SHANTZ' results and in addition showed that "rehydrovitamin A" was a mixture of several compounds. In contrast to these results it was found[2,6] that chemically prepared retro-vitamin A was converted to vitamin A and had a biological potency of 11% that of vitamin A (ref. 2). Further work is necessary to explain these biological phenomena.

ACKNOWLEDGEMENT

The authors wish to acknowledge the technical assistance of Mr. C. DESLOGES.

REFERENCES

1 H. J. DRUEL, Jr., *Lipids*, Vol. 1, Interscience, New York, 1951, p. 736.
2 T. N. R. VARMA, P. ERDODY AND T. K. MURRAY, *J. Pharm. Pharmacol.*, submitted for publication.
3 E. M. SHANTZ, J. D. CAWLEY AND N. D. EMBREE, *J. Am. Chem. Soc.*, 65 (1943) 901.
4 E. M. SHANTZ, *J. Biol. Chem.*, 182 (1950) 515.
5 R. H. BEUTEL, D. F. HINKLEY AND P. I. POLLEK, *J. Am. Chem. Soc.*, 77 (1955) 5166.
6 T. N. R. VARMA AND T. K. MURRAY, *Biochim. Biophys. Acta*, 78 (1963) 556.
7 T. N. R. VARMA, T. PANALAKS AND T. K. MURRAY, *Anal. Chem.*, 36 (1964) 1864.
8 S. R. AMES, H. A. RISLEY AND P. L. HARRIS, *Anal. Chem.*, 26 (1954) 1378.
9 F. J. PETRACEK AND L. ZECHMEISTER, *J. Am. Chem. Soc.*, 78 (1956) 1427.
10 T. K. MURRAY, J. L. BEARE AND J. A. CAMPBELL, *Can. J. Biochem. Physiol.*, 38 (1960) 663.

Vass-'62
Bib. No. 9394

Int. Conf. Gerontol., Budapest 851-855. 1962.

INFLUENCE OF POLYVITAMIN PREPARATIONS ON HYPOVITAMINOSIS IN OLD AGE

by

M. VASS and L. ÁCS

Benczur-Street Geriatric Hospital, Budapest

Hypovitaminosis is very common in old age. It derives from various causes, such as malnutrition or malabsorption of nutritive materials including mineral salts, in consequence of mucosal atrophy of the alimentary tract. The frequency of skeletal abnormalities and of difficulties of locomotion in elderly patients have directed our attention to problems of the calcium and phosphorus metabolism. Bürger in his monograph, "Altern und Krankheit" refers to the investigations of Greisheimer, Johnson and Ryan, who tested the serum calcium level in more than 300 healthy persons belonging to different age groups and found at 78 years of age an average value of 9.7 mg% in women and 10 mg% in men, but never below 9 mg%. The values found by Schill in 220 persons between 66 and 92 years of age range from 9.6 to 11 mg%.

The serum levels of calcium and anorganic phosphates have been studied in 86 elderly patients of our hospital. We adopted the Fekete–Popper–Szmuk complexometric method, the accuracy of which had been checked against the flame-photometric method without any notable difference. Inorganic phosphate values determined by the method of Fiske and Subbarow were found normal, i.e. between 3 and 4.5 mg%, whereas in 64.7% of our 86 patients between the age of 58 and 95 years, the Ca values were below 9 mg%. The percentual distribution of the serum Ca values are presented in Table I.

TABLE I

Serum Ca		
below 9 mg%	between 9 and 10 mg%	over 10 mg%
64.7%	26.7%	8.6%

In contradistinction to the statements of the above-mentioned authors our tests showed that the Ca values diminish below the physiological level in old age. We ascribe this discordance to the fact that 85% of our patients were in a more or less advanced stage of arteriosclerosis, moreover they had been inactive, mostly bedridden for periods between 0.5 and 1.5 years. Impaired absorption owing to gastric hypo- and anacidity and to mucosal atrophy of the alimentary tract, conditions known to be very common in old age, may also cause calcium deficiency.

We studied the influence of polyvitamin preparations on senile hypocalcaemia. To this end we applied, beside the Hungarian *Gerovit* and *Polyvitaplex 8* preparations, *Gresuton (Bayer)*. The composition of these preparations is shown in Table II.

TABLE II

Components	per one capsule of *Gerovit*	per one tablet of *Polyvitaplex 8*	per one capsule of *Gresuton*
Vitamin A	250 IU	3000 IU	2500 IU
Vitamin D	250 IU	1000 IU	—
Vitamin E	1.0 mg	—	1.5 mg
Vitamin K	2.5 mg	—	—
Vitamin B_1	0.75 mg	5.0 mg	—
Vitamin B_2	1.0 mg	0.5 mg	—
Vitamin B_6	0.25 mg	0.5 mg	—
Vitamin B_{12}	0.5 gamma	1.0 gamma	
Nicotinacid amid	15.0 mg	10.0 mg	—
Bayer's yeast extract	—	—	33.0 mg
Vitamin C	50.0 mg	50.0 mg	—
Methylandrostenediol	0.5 mg	—	—
Choline iodide	0.1 gr	—	—
Padutin	—	—	5.0 U
Reserpine	—	—	0.033 mg
Theophylline	—	—	15.0 mg

The difference between the three preparations is that one capsule of *Gerovit* contains 250 IU of vitamins A and D, one tablet of *Polyvitaplex 8* contains 3000 IU of vitamin A, and 1000 IU of vitamin D and one capsule of *Gresuton* contains 2500 IU of vitamin A, but does not contain the vitamins D and C. Each tablet of *Gerovit* contains 0.5 mg of methylandrostenediol with proteinanabolic effect, 0.1 g of choline iodide with lipotropic effect, while *Gresuton* contains small amounts of padutin, reserpine and theophylline – for the reduction of blood pressure.

TABLE III

Preparation	No. of cases	Serum Ca					
		below 9 mg%		between 9 and 10 mg%		over 10 mg%	
		Control %	Treated %	Control %	Treated %	Control %	Treated %
Gerovit	30	53.3	13.4	36.7	70.0	10.0	16.6
Polyvitaplex 8 . .	5	40.0	—	40.0	80.0	20.0	20.0
Gresuton	5	80.0	—	20.0	80.0	—	20.0

TABLE IV

Name	Age	Diagnosis	Se Ca before treatment (mg%)	Se. Ca (mg%) Daily 9000 IU of vitamin A	
				After 1 week	After 2 weeks
L.K.	59	Previous bilateral amputation of the toes, because of congelation	9.4	9.2	10.0
L.J.	82	Hypertension of moderate degree with arteriosclerosis	9.8	9.0	9.8
P.E.	76	No abnormality	8.2	8.6	9.8
W.J.	83	No abnormality	7.8	10.0	10.0
R.R.	69	Previous femoral fracture on the right side	8.6	9.4	9.8
R.A.	75	Previous femoral fracture on the left side	7.8	8.8	9.8
T.J.	75	Previous cerebral thrombosis	8.0	9.2	10.0

Our investigations were performed on 40 patients between 58 and 98 years of age, the average age ranging, in 77.5%, between 60 and 80 years. Treatment was continued for a period of 3–4 weeks, the patients were

given two capsules of *Gerovit*, or *Gresuton* twice a day and one tablet of *Polyvitaplex 8* three times a day. The results of our observations are represented in Table III.

Table III shows that all three drugs are able to raise the serum Ca level, but while elevation over 10 mg% was obtained with *Gerovit* in 86% of the cases *Gresuton* and *Polyvitaplex 8* brought about the same effect in 100%. Vitamin D is known to raise the blood calcium level, but though *Gresuton* does not contain any vitamin D, it was fund to raise the calcium level in 100% of the cases. The patients had been given, in the daily 4 capsules of *Gerovit*, 1000 IU of vitamin D and 1000 IU of vitamin A, in the 3 tablets of *Polyvitaplex 8*, 3000 of IU vitamin D and 9000 IU of vitamin A, while with the 4 capsules of *Gresuton* 10,000 IU of vitamin A were given without any vitamin D. This observation raised the question whether vitamin A alone had any influence on the Ca level. In order to decide this, we selected 8 patients with marked hypocalcaemia and administered to them vitamin A in daily doses of 3000 IU for a month, the intention having been to give them, in addition to the amount of vitamin A contained in the food, an extra 3000 units, that is, the daily requirement of a healthy adult. However, in none of the cases did normalization of the Ca level occur.

On the basis of our observations with polyvitamin preparates we modified our experiments, by administering, to 7 patients, 9000 IU of vitamin A for a period of two weeks. The result of our findings are given in Table IV.

Two of the seven patients were normocalcaemic, five were hypocalcaemic; after one week's treatment the calcium level of the hypocalcaemic patients rose and after another week's treatment it became perfectly normal, while in the normocalcaemic patients it remained practically unchanged during these two weeks. These results show that Vitamin A, given in doses of 9000 IU is capable to restore the normal calcium blood level in case of hypocalcaemia. This is presumably due to the stimulating effect of such massive doses of vitamin A on the biologic functions of the intestinal mucosa, including absorption of calcium.

Summary

1. In aged, inactive, bedridden patients, hypocalcaemia is very common.

2. Polyvitamin preparations are able to restore the normal blood calcium level in case of hypocalcaemia.

3. Vitamin A is capable of restoring the blood calcium level even when given alone, provided it is administered in doses three times as high as the daily vitamin A requirement of a healthy adult.

4. Normalization of the serum calcium level by polyvitamin preparations requires adequate doses of vitamin A.

5. The inference is drawn from the present findings that vitamin A deficiency plays a large part in the development of hypovitaminosis in old, bedridden, inactive persons.

Vasudevan-'69
Bib. No. 9397

Indian Vet. J. 46(8):658-663. 1969.

CLINICAL SYNDROMES IN EXPERIMENTAL VITAMIN A DEFICIENT CALVES

By

B. Vasudevan and Brahm Dutt

Division of Pathology,
Indian Veterinary Research Institute,
Izatnagar, U.P.

Vitamin A deficiency has been observed in farm animals at pasture during severe droughts, or stall-fed upon diets low in carotene. Clinical symptoms of fat sickness in cattle, persumably due to deficiency of vitamin A, were described as early as 1896 by Connell and Carson. The condition was characterised by inflammation of the eye and loss of eye sight.

Vitamin A deficiency symptoms have also been produced experimentally and studied in cattle by various workers. Guilbert *et al* 1934) reported signs of avitaminosis A in steers, as night blindness,

mucous discharge from nose, lachrymation, facial paralysis and muscular incoordination. Madsen and Earle (1947) reported the development of anasarca and convulsion in prolonged vitamin A deficiency in beef cattle. Moore and Sykes (1940) reported malformation of bones and raised C.S. fluid pressure in vitamin A deficient calves.

Gastro-intestinal disturbance of diarrhoea were noted by Keene *et al* 1942 in vitamin A deficiency calves. Respiratory tract has been reported to be frequently affected with pneumonia in vitamin A deficiency (Sutton *et al* 1940).

As no systematic study, to find the effect of vitamin A deficiency in cattle has been carried out in India, a series of investigations were initiated towards this end. The present paper reports the clinical syndromes recorded is experimental vitamin A deficient calves.

Materials and Methods

Eight calves, 4 males and 4 females of about 3½–4½ months of age and two heifer calves of about one year of age, were kept on a low carotene diet but otherwise adequate in regard to other essential nutrients. Six calves of the same age group (4 of 3½–4½ months age and 2 of one year age) were kept on a carotene adequate diet for comparative study.

The ration of the experimental animals consisted of (1) wheat straw well exposed to sunlight and containing negligible quantities of carotene, as a roughage and fed *ad libitum*, (2) concentrate mixture made up of equal parts of crushed linseed cake, barley and wheat bran fed in quantity according to Morrison's feeding standard so as to meet the D.C.P. and T.D.N. requirements. Carotene was present only in traces. The calves were fed mineral mixture ("supermineral" Boots Pure Drug Co., India) at the rate of 1% of the concentrate mixture daily. The requirement of vitamin D for the animals was met by exposing them to sunlight for four hours in the morning and on the rainy days by supplementations with 500 i.u.s. of vitamin D. (E. Merck Co.) in oil for each animal. Vitamin E was supplemented at the rate of 15 mg. α tocopherol (E. Merck Co.) to each animal daily.

The control group (carotene adequate group) was given in addition to the above, concentrate mixture, greens about 1½ to 2½ lb. for each animal every day and the rest of their roughage requirement was met by wheat straw.

Vitamin A levels in blood plasma of all the calves were estimated according to the method of Yudkin (1941). The clinical symptoms exhibited by the calves were recorded.

Results

Ocular system: The earliest symptom observed in the vitamin A deficient calves, was night blindness after about 3 to 4½ months of experimental feeding and their blood vitamin A levels were found to have fallen to about 10 to 12 μg./100 ml. from their initial values of 24 to 50 μg./100 ml.

Xerophthalmia associated with infection was observed in 5 experimental calves of the younger age group. Initially, the eyes were severely inflamed. Eyelids were swollen and there was profuse lachrymation. White milky spots and varying degree of opacity had developed on the cornea. As the infection subsided, the corneal and conjunctival mucous membrane became xerotic, terminating in softened, necrotic and ulcerated cornea (Fig.). Xerophthalmia was not noted in the rest of the non-infected vitamin A deficient calves.

Neither ocular abnormalities nor infection were contracted by any of the control calves at any time during the experimental observations, though they were housed in the same stall and were even allowed to mix with the infected vitamin A deficient calves.

One vitamin A deficient calf of the older age group, after 16 months of experimental feeding, began to lose its sight gradually and became totally blind after some time. At autopsy, blindness was found to have resulted from marked constriction of the optic nerve in the bony cavity of the optic canal and optic foramen and as it emerged from the optic foramen.

Nervous symptoms: All calves on vitamin A deficient diet, manifested convulsions and incoordination of gait, when the blood vitamin A level had fallen further to about 8 μg. and less/100 ml., convulsions were more severe and frequent as blood vitamin A level was further lowered to 6 μg./100 ml.

Digestive disorders: All the calves on vitamin A deficient diet excepting one calf, suffered from intermittent diarrhoea, when their blood vitamin A levels were lowered to about 10 μg. and less/100 ml. Appetite was normal in the earlier stages of the deficiency. It was, however, reduced in the extreme deficient status, when the blood vitamin A levels of the calves were below 5 μg./100 ml.

Respiratory disorders: Three calves of the younger age group, after five and a half months on vitamin A deficient diet, showed

pneumonic symptoms. They were treated symptomatically and the animals recovered after a week.

At no time during the experimental feeding, the control calves manifested respiratory disorders.

Urinary system: Four calves of the younger age group, showed symptoms pertaining to involvement of the urinary tract and indicative of the presence of stones and infection of the tract. They showed symptoms of nephritis and passed urine in droplets containing blood and mucous a few days before death.

Skin: The hairs of the vitamin A deficient calves were rough and standing and their coat became lustreless in the late stages of the deficiency.

Growth: Growth rate was normal during the first sixteen weeks of experimental feeding but later on as the deficiency progressed, there was a decline in the live weight gain, when the blood vitamin A levels fell below 10 to 12 μg./100 ml.

Discussion

Low blood plasma vitamin A levels have been reported to produce characteristic evidence of deficiency. Level of 7 to 8 μg. of vitaminA/100 ml. is considered to be on the border line in foreign breeds of cattle. Level of 10 μg./100 ml is regarded as essential for growth. When the levels were below 7 to 8 μg./100 ml., the animals manifested vitamin A deficiency symptoms (Boyer *et al*, 1942). As the levels fell to 4 μg./100 ml and less, typical and consistent metaplasia (Eaton *et al.*, 1951) and cystic pituitary glands (Hodgson *et al.*, 1946) are said to occur.

In the present study, it was observed that when the blood plasma vitamin A levels fell below 10 to 12 μg./100 ml., the calves began to show earliest symptoms of deficiency such as night blindness and diarrhoea. The growth rate was affected in many of them. Convulsions appeared when the blood vitamin A levels fell to 8 μg. and less/100 ml. when the blood vitamin A levels fell to 5 μg. and less/100 ml. plasma, the animals became emaciated in condition, corresponding to extreme deficient status.

It was observed that avitaminosis A in calves, particularly in young ones, lowers their resistance to infection and predisposes them to respiratory, gastro-intestinal and urinary tract ailments.

Xerophthalmia has been reported to occur in rats, man and cattle in vitamin A deficiency. In the present experiment, xeroph-

thalmia was observed only in those vitamin A deficiency calves which had secondary infection of the eye. Opacity necrosis and ulceration of the cornea were observed in such cases. This finding is in accord with the hypothesis of Yudkin and Lambert (1923) that the associated eye lesion of xerophthalmia was due to bacterial infection rather than to a primary effect of the deficiency.

Permanent blindness in vitamin A deficiency calves, resulting from degeneration of the optic nerves has been reported long ago (Moore 1939). In the present experiment, one calf of the older age group had developed permanent blindness after a period of sixteen months of feeding on vitamin A deficient diet. Blindness, resulting from degenerative changes in the optic nerve, terminates in a permanent and irrepairable loss of the eye sight.

Summary

Clinical syndromes observed in experimental vitamin A deficient calves are reported.

Night blindness and diarrhoea were the earliest symptoms noted, when the blood plasma vitamin A levels fell below 10–12 μg./100 ml. Convulsions appeared, when the blood vitamin A levels were reduced to 8 μg. and less/100 ml. ; when further lowered to 5 μg. and less/100 ml., the animals were found to be in very poor condition corresponding to extreme deficient status.

It was observed that avitaminosis A in calves, particularly in young ones, lowers their resistance to infection and predisposes them to respiratory, gastro-intestinal and urinary tract ailments.

Xerophthalmia was observed only in those vitamin A deficient calves which had secondary infection of the eyes.

Permanent blindness due to constriction of the optic nerve was observed in one calf after a period of 16 months of feeding on the vitamin A deficient diet.

Acknowledgment

The authors express their grateful thanks to Dr. V. Mahadevan, Head of the Division of Animal Nutrition, Indian Veterinary Research Institute for providing necessary facilities and for the keen interest taken in carrying out this investigation.

REFERENCES

Boyer, P. D., Phillips, P. H., Lundquist N. S., Jensen, C. W. and Rupel, I. W. (1942) ... *J. Dairy Sci.*, 25 : 433.

Connel, J. H. and Carson, J. W. (1896) ... Texas, Agr. Exp. sta. Bull. No. 41.

Eaton, A. D., Helboldt, C. F., Jungherr, E. L. and Carpenter, C. A. (1951) ... *J. Dairy Sci.*, **34**: 386.

Guilbert, H. R. and Hart, C. H. (1934) ... *J. Nutr.* **8**: 25.

Hodgson, R. E., Hall, S. R., Sweetman, W. J., Wiseman, N.G. and Converse, H. (1946) ... *J. Dairy.* Sci., **29**: 669.

Keener, H. A., Bechdel, S. I., Guerrant, N. B. and Therp, W. T. S. (1942) ... *Ibid.* **25**: 571.

Madsen, L. L. an Karle, I. P. (1947) ... *J. Nutr.*, **34**: 603.

Moore, L. A. (1939) ... *Ibid.* **17**: 443.

——— and Sykes, J. F. (1940). *Am. J. Physiol.*, **130**: 684.

Sutton, T. S., Krause, W. E. and Hansard, L. S. (1940) ... *J. Dairy. Sci.*, **23**: 574.

Yudkin, S. (1941) ... *Biochem. J.*, **35**: 551.

Yudkin, A. M. and Lambert, R. A. (1923) ... *J. exp. Med.*, **38**: 17.

CONCERNING THE TOXICITY OF VITAMIN A

EDWARD B. VEDDER AND CHARLES ROSENBERG
Department of Experimental Medicine, George Washington University Medical School

(Received for publication December 17, 1937)

Several investigators have described a pathological condition which they called hypervitaminosis A. Von Drigalski and Laubman ('33) fed six rats 1 cc. of an oil concentrate of vitamin A. These rats died in from 5 to 14 days, and post mortem examination showed glomerular nephritis with calcification to which the death of the animals was attributed. Pathologic changes on a smaller scale were noted in the spleen, liver and testicles. Collazo and Rodriguez ('33) also fed several 50-gm. rats a vitamin A concentrate, Vogan, prepared by E. Merck of Darmstad, Germany. The rats were fed 0.5 cc. daily, or a dosage of 20,000 units of vitamin A. The outstanding features of the disease produced in about 10 days were failure to grow, inflammatory changes in the eyes with exophthalmos and changes in the bones resulting in spontaneous fractures. Bumskov and Seeman ('33) obtained similar results in eleven rats from the administration of Vogan, and somewhat similar observations have been published by Harris and Moore ('29) and others.

The results obtained were attributed to vitamin A by these authors chiefly because the administration of similar amounts of sesame oil and other vegetable oils containing no vitamin A are harmless, and because several observers had found that vitamin A was destroyed by ultra-violet irradiation and that the toxicity of the oil was also lost. Thus von Drigalski and Laubman ('33) submitted the toxic Vogan to ultra-violet

irradiation, and finding that this destroyed the toxic power of this concentrate, concluded that this proved that the toxic effect was produced by vitamin A. This conclusion does not necessarily follow because the toxic effect may have been due to some other constituent in the oil also destroyed by ultra-violet radiation. Peacock ('26) showed that irradiated cod liver oil lost its normal fluorescence in addition to the loss of vitamin A and that these two phenomena were different and independent. Irradiation of such an oil also produced vitamin D which is supposed to have an antagonistic action to vitamin A. For these reasons, the above experiments, performed moreover on very small series of rats, hardly prove that the toxicity of a complicated fish liver oil concentrate is caused by its vitamin A content. It is also known that the feeding of carotene, the pro-vitamin A, is entirely harmless, a fact that we have confirmed by feeding several young rats 40,000 international units both alone and in solution in vegetable oil for 100 days without ill effect.

Since Vogan is unobtainable in this country, we obtained a vitamin A concentrate from the British drug houses, having a Carr-Price blue value of not less than 50,000. Lathbury ('34) has shown that there is a constant ratio between the results of the biological, chemical and physical methods of testing purified vitamin A concentrates. Half a cubic centimeter of this concentrate was administered to 50-gm. rats daily, but this preparation was so objectionable that rats so treated refused any food and died of starvation in 4 days.

In the following experiments we have used 140 rats, of which 127 form the basis of this report, the remainder being various controls. These experiments were all performed with oil from the liver of the jewfish (Stereolepis gigas), which is the richest source of vitamin A known at present, being many times more potent than concentrates from ordinary oils. All of the oil so used was furnished us through the courtesy of Dr. Charles E. Bills, director of the Research Laboratory of Mead Johnson and Company.

J. Nutr. 16(1):57-68. 1938.

Vedder et al-'38
Bib. No. 9407

Technic. Healthy male rats of the Wistar strain and of 50 gm. weight were used in all experiments, except that females were introduced at times to determine breeding capacity. The diet fed was Purina dog chow, which is a complete diet for rats. Stock rats so fed grew and bred normally. This diet was used for its convenience in weighing in order to determine the amount eaten daily. The oils used were administered daily by means of a pipette, and dosage was kept at 0.5 cc., changes in concentration being effected by proper dilution with oil of sesame, shown in controls to be inert. The vitamin A potency of the oil was determined by vitameter readings, and it had been planned to dose all rats with multiples of 25,000 international units. Unfortunately, it was found later that owing to some unknown constituent in the jewfish liver oil, the vitameter readings were about one-third higher than the results of the biological test. In experiments performed later, 100,000 units by biological test were used.

The experiments were all continued for 100 days unless death occurred earlier. It was assumed that if rats continued to grow normally for 100 days, the oil administered was non-toxic. A post mortem examination was made on all rats that died as a result of the treatment, and later all the surviving rats were killed not only for post mortem examination, but to determine the vitamin A content of their livers.

The number of units stored in the liver was determined by the blue reaction with antimony trichloride. The antimony trichloride is used in a 30% chloroform solution (weight in volume). The liver to be tested was dissolved in a 10% solution of potassium hydroxide; this solution was extracted in a separatory funnel with ether; the ether evaporated, and the residue redissolved in chloroform. To 0.2 cc. of this chloroform solution, which was usually made up to 500 cc., 2 cc. of the antimony trichloride was added, and the resultant blue color matched against the standard glasses of a Lovibond tintometer, in accordance with the method described in "The Vitamins: Symposium on the present Status of the Knowledge of Vitamins." J. Am. Med. Assn., April 23 to August 6, 1932.

We were unable to confirm the pathological findings of von Drigalski and Laubman ('33). At post mortem, all the organs except the bones appeared normal grossly. Microscopic sections showed that the stomach and intestines, the testes,

adrenals, thyroid and parathyroid were normal. There were often mild congestion of the lungs, marked congestion and some cloudy swelling and, at times, fatty infiltration of the liver, moderate congestion and cloudy swelling of the tubules of the kidney, the glomeruli appearing normal, and a spleen slightly congested. In some cases there appeared to be some swelling of the heart muscle fibers, and a loss of staining of their nuclei. While these findings were by no means invariable, they were frequent enough to indicate that death was probably caused by an insufficiency of the cardiac muscle with accompanying congestion of the abdominal viscera.

The symptoms agreed very well with those described by Collazo and Rodriguez ('33) except that they were only manifested by some of our rats. They included a diminished growth curve, hemorrhages from the eyes often with exophthalmos, hemorrhages from the nose, rales in the chest, and the bone lesions. The bone lesion is rarefaction with a pronounced tendency to spontaneous fracture. If the animal lived, the fractures healed in spite of the continuance of the large dosage of vitamin A.

In the following tables presenting the results of our experiments, both vitameter readings and the results of the biological test are given. Since three separate lots of jewfish liver oil were used, there are three series of experiments tabulated.

Series 1. This lot of oil contained 550,000 international units of vitamin A per cubic centimeter (vitameter) and 4500 units of vitamin D.

Results. Series 1

RATS	DOSAGE I.U.A.[1]	AVERAGE FINAL WEIGHT	REMARKS
1– 4	25,000	259.	Normal except some decrease in weight
5– 8	50,000	241	One rat died in 40 days. All had fractures
9–20	100,000	45	No rat lived 100 days. Fractures and hemorrhages.

[1] By biological test these amounts were 16,000, 33,000 and 66,000 international units, respectively.

Series 2. This lot of oil contained 663,000 international units of vitamin A per cubic centimeter (vitameter), and 4500 units of vitamin D.

Results. Series 2

RATS	DOSAGE I.U.A.[1]	AVERAGE FINAL WEIGHT	REMARKS
1– 4	25,000	250	Normal
5– 8	50,000	194	Fractures in two rats. All lived 100 days
9–16	100,000	127	Two rats lived 100 days. Six had fractures

[1] By biological test these amounts were 16,000, 33,000 and 66,000 international units, respectively.

Series 3. This lot of oil contained 600,000 international units of vitamin A per cubic centimeter (vitameter) and 5000 units of vitamin D.

Results. Series 3

RATS	DOSAGE I.U.A.[1]	AVERAGE FINAL WEIGHT	UNITS VITAMIN A PER GRAM LIVER	REMARKS
1– 4	50,000	319	1766	Normal. All rats lived 100 days
5–12	100,000	123	1704	Three rats lived 100 days. Two rats had fractures

[1] By biological test these amounts were 33,000 and 66,000 international units, respectively.

Series 4. One liter of jewfish oil having 530,000 international units of vitamin A per gram was submitted to molecular distillation by Dr. K. Hickman of the research laboratories of the Eastman Kodak Company. Six lots of oil were used as follows:

1. The original oil as a control containing 530,000 I.U. vitamin A per gram
2. Distilled fraction 1 containing 515,000 I.U. vitamin A per gram
3. Distilled fraction 2 containing 865,000 I.U. vitamin A per gram
4. Distilled fraction 3 containing 805,000 I.U. vitamin A per gram
5. Distilled fraction 4 containing 248,000 I.U. vitamin A per gram
6. The residue from distillation containing 53,000 I.U. vitamin A per gram

In the first five cases, the oil was so diluted with sesame oil that each 0.5 cc., the daily dosage, contained 100,000 international units of vitamin A. In the case of the residue, 2 cc. of undiluted oil were administered daily.

Results. Series 4

RATS	DOSAGE I.U.A. 100,000	AVERAGE FINAL WEIGHT	UNITS VITAMIN A PER GRAM LIVER	REMARKS
1– 4	Original oil	87	818	Only one lived 100 days. Fractures
5– 8	Fraction 1	135	4722	Three rats lived 100 days. No fractures
9–12	Fraction 2	97	3250	One rat lived 100 days. No fractures
13–16	Fraction 3	89	3250	One rat lived 100 days. Three had fractures
17–20	Fraction 4	38		Average life was 12 days. Hemorrhages
21–24	Residue	272	2199	All lived 100 days. Normal

Fraction 1 and the residue were less toxic than the other fractions. To be sure that this was the fact, each was repeated on a new lot of four rats, with precisely the same result. One female was introduced in the four receiving the residue, and nine young were born on the fifty-second day of the experiment. All nine lived.

Since jewfish oil was undoubtedly toxic in amounts equivalent to 100,000 international units of vitamin A, we next endeavored to ascertain whether this toxic effect was due to vitamin imbalance. For this purpose we used lot three of the jewfish oil, which was non-toxic in doses of 50,000 international units, and decidedly toxic in doses of 100,000 units (vitameter reading). Other vitamins were administered in addition. Vitamin D was administered from appropriate dilutions of a solution of irradiated ergosterol containing 1,000,000 units per cubic centimeter. Vitamin B_1 was used in two forms: an adsorbate received through the courtesy of the Eli Lilly Company, and crystalline vitamin synthesized and furnished us through the kindness of Merck and Company.

Vitamin C was also the synthetic product, furnished by Merck and Company. The results in the following table should be compared with the results in series 3 in which the same lot of jewfish oil was used alone.

Results from addition of other vitamins

RATS	DOSAGE	AVERAGE FINAL WEIGHT	UNITS VITAMIN A PER GRAM IN LIVER	REMARKS
1– 4	50,000A + 50,000D	44		Average life 27 days. No fractures
5– 8	50,000 + 25,000D	209	2731	Three lived 100 days. One rat had fractures
9–12	100,000A + 100,000D	39		Average life 10 days. No fractures
13–20	100,000A + 50,000D	190	2093	Five lived 100 days. No fractures
21–24	100,000A + 500 B_1	54		None lived 100 days. Average life 44 days. All had fractures
25–36	100,000A + 50,000D + 500 B_1	84	2750	Three lived 100 days. Two had fractures
37–48	100,000A[1] + 5 mg. ascorbic acid	241	2560	All lived 100 days. All normal and one raised ten young

[1] One hundred thousand international units vitamin A per cubic centimeter by biological test.

DISCUSSION

The term toxicity means poisonous. Many food materials such as sodium chloride or iodine can become deleterious in large quantities, but they are not called poisons. Neither should fish oils be called poisons because they are injurious when fed in enormous quantities. But some term is necessary to refer to this deleterious action in these experiments, and we have used toxicity, with the understanding that in the usual doses the various ingredients of such oils may be necessary in the diet.

The question as to the toxicity of large doses of vitamin A cannot be regarded as completely settled by these experiments, and the complete answer must await the isolation of

vitamin A in pure form. Nevertheless, several facts appear to indicate that the toxicity of jewfish liver oil is due to some constituent of the oil other than vitamin A. In the same dosage of vitamin A, the toxicity varies for each lot of oil. According to the European observers, Vogan is highly toxic, killing rats in about 2 weeks in doses containing 20,000 units of vitamin A. No sample of jewfish liver oil was toxic in less than 33,000 international units daily and the toxicity of lot 3 of the jewfish liver oil only commenced at 66,000 international units daily. Further, our 50-gm. rats receiving 33,000 units lived 100 days as a rule. It would seem that if vitamin A is the toxic factor, the toxicity of different samples of fish liver oil should be proportional to their vitamin A content. This is certainly not the case.

Still more significant is the fact that when lot 4 of the jewfish liver oil was submitted to molecular distillation, the toxic substance was separated from vitamin A. In the dosage of 100,000 international units of vitamin A daily, fraction four killed all rats in from 9 to 26 days, while three out of four rats receiving the same dosage of vitamin A from fraction one, lived 100 days. Finally, the four rats receiving 100,000 units of vitamin A from the residue from the distillation not only lived 100 days, but grew normally and were capable of bearing and rearing young. This result cannot be due to vitamin D which was only present in the original oil in doses of 5000 units. If it had all been distilled in one fraction, a most improbable supposition, it would have been quite insufficient to balance 100,000 units of vitamin A. We have shown that about 50,000 units of D are required for this purpose. We may conclude from this experiment, which was repeated with the same result, that if vitamin A is toxic, it must be given in higher dosage than 100,000 international units daily to 50-gm. rats, and that at least the greater part of the toxicity of the various fish liver oils must be due to some other factor than vitamin A. Since there is an increase of one-third in the vitameter reading over the result of the biological test as applied to jewfish liver oil, this discrepancy

is due to some unknown constituent in this particular oil. It is possible that this unknown constituent is the toxic fraction.

The greater part of vitamin A administered in these large doses must be either excreted or broken down in the body. In the course of 100 days at a dosage of 100,000 units daily, 10,000,000 units have been given. The maximum amount found in any liver per gram was 5000 units, which, with a 7-gm. liver was sufficient vitamin A to last this rat many years. The largest total amount found in the liver of any rat was rat no. 3 of series 3, with 2794 units per gram, which with 17 gm. of liver equalled 47,550 units. While lesser amounts are stored in other organs, only about 1 day's dosage, or one-hundredth part of the 10,000,000 units administered, can be accounted for. This fact is more obvious in our experiments than in those of other observers, because we have used much larger dosage, and kept our rats for much longer periods. No vitamin A is excreted in the urine, and of several rats tested, only from 500 to 600 units were excreted daily in the feces. Since the rat eliminates so little vitamin A, it seems certain that most of the vitamin A administered is destroyed in the body, and this constitutes another argument against the toxicity of this vitamin.

The neutralization of the toxic effect of fish liver oil by the administration of other vitamins has been suggested by numerous observers. Bell, Gregory and Drummond ('33) and others believe that the disturbance in the growth of rats that occurs when the diet contains a considerable percentage of fish liver oil may be compensated by an increased amount of the vitamin B complex. So far as our experiments with jewfish liver oil are concerned, the administration of 500 international units of B_1 daily appeared to be not only of no value, but to be positively injurious. McHenry ('36) has shown that the addition of vitamin B_1 to rats on a basal diet practically doubles the percentage of fat in the liver. Whether used alone, or in combination with vitamin D, and whether used as an adsorbate or as crystalline vitamin, the results were poorer than control series without B_1. Of the rats receiving vitamin

A at 66,000 units, with vitamin D and vitamin B_1, only three out of twelve lived 100 days; but on the same dosage of A and D without B_1, five out of eight lived 100 days.

Thoenes ('35) and others have asserted that vitamin A and vitamin D are physiologically antagonistic; that is, that vitamin D is antagonistic to vitamin A concentrates. Our experiments afford some confirmation of this view, or at least that administration of considerable amounts of vitamin D relieves the toxic effects caused by jewfish liver oil. When the unitage of vitamin D exceeded that of vitamin A, the combination was far more toxic than the same amount of vitamin A alone. But vitamin D was of distinct benefit when its dosage was somewhat less than that of the vitamin A of jewfish oil. Thus when jewfish liver oil was given so as to administer 66,000 international units of vitamin A and 50,000 units of vitamin D, five out of eight rats lived 100 days; whereas, with the same lot of jewfish liver oil alone, administered in the same dosage, only two out of eight lived 100 days. Perhaps a still better proportion between the vitamin A containing fish liver oil and vitamin D dosage is possible, since we only tried two proportions.

The most striking result of these experiments, and one that so far as we are aware has never been suggested, is the pre-eminent protective action of pure crystalline ascorbic acid or vitamin C. Five milligrams of this vitamin given daily is apparently sufficient to protect all rats receiving such doses of jewfish oil as those containing 100,000 international units of vitamin A. Eleven out of twelve rats receiving such dosage of jewfish liver oil not only lived 100 days, but many of them grew normally. The only rat of this series that died earlier had a severe intercurrent infection which probably excludes it from consideration. No other dosage of vitamin C was used, and it is possible that smaller doses would suffice, since ½ mg. daily should be approximately the amount required by an animal the size of a rat. On the other hand, larger doses may give a better result, as indicated by the fact that several of these rats developed fractures.

Since the rat is known to be capable of synthesizing vitamin C and is not susceptible to scurvy, it is difficult to explain this action of vitamin C. A possible explanation is that vitamin C destroys the toxic factor and that all the vitamin C synthesized by the rat is used up in this process, leaving it susceptible to scurvy. Scurvy of the rat has never been described, but the symptoms produced by fish liver oils are not unlike scurvy; they include failure to grow, hemorrhages, particularly from the eyes and nose but to some extent from other mucous membranes, and abnormal rarefaction and fragility of the bones.

In a few rats, the urine was collected and titrated with 2,6-dichlorophenol indophenol. After administration of jewfish liver oil equivalent to 100,000 units of vitamin A for about 3 weeks, the excretion of vitamin C decreased to the vanishing point, but reappeared in the urine in considerable amounts after the daily administration of 5 mg. of crystalline ascorbic acid. While this is suggestive, since the physiological action of vitamin C is quite unknown, the correct explanation of its remedial action for jewfish liver oil must await further experimentation.

CONCLUSIONS

If vitamin A is ever toxic, it is in doses in excess of 100,000 international units daily for 50-gm. rats.

The greater part of the vitamin A administered in such large dosage is destroyed in the body of the rat.

In addition to vitamin A, fish liver oils contain a toxic principle, at present not identified. The toxicity of various samples of these oils and their concentrates varies greatly for rats.

Vitamin B_1 was of no value in counteracting the toxicity of jewfish liver oil for rats.

Vitamin D in proper dosage at least partially counteracts this toxicity of jewfish liver oil as administered to rats.

Ascorbic acid (crystalline vitamin C) in doses of 5 mg. daily almost completely counteracted the toxicity of jewfish liver oil administered to rats.

LITERATURE CITED

BELL, M. E., ELIZABETH GREGORY AND J. C. DRUMMOND 1933 Alleged toxic action of cod liver oil and concentrates of vitamin A. Ztschr. f. Vitaminforsh., Bd. 2, S. 161–182.

BUMSKOV, C., AND GEORG SEEMAN 1933 Über eine Wirkung des Vitamin A auf den Mineralaushalt. Ztschr. f. die ges. Exper. Med., Bd. 89, S. 771.

COLLAZO, J. A., AND J. S. RODRIGUEZ 1933 Hypervitaminosis A. Klinische Wochenschrift, Bd. 12, S. 1732, 1768.

HARRIS, L. J., AND THOMAS MOORE 1929 Hypervitaminosis and vitamin balance. Biochem. J., vol. 23, p. 1114. Also vol. 22, p. 1461.

LATHBURY, K. C. 1934 Vitamin A determination: relation between the biological, chemical and physical methods of test. Biochem. J., vol. 28, p. 2254.

MCHENRY, E. W. 1936 Vitamin B_1 and fatty livers. Proc. Physiological Society, J. Physiol., vol. 86, p. 27P.

PEACOCK, P. R. 1926 The action of light on cod liver oil. The Lancet, vol. 2, p. 328.

THOENES, F. 1935 Über die Korrelation von Vitamin A und D. Deutsche Med. Wochenschrift, Bd. 61, S. 2079.

VON DRIGALSKI, W., AND W. LAUBMAN 1933 Injury from vitamin A. Klin. Wchnschr., Bd. 12, S. 308, 1171.

Vestr. Dermatol. Venerol. 42(1):35-38. 1968.

Effect of Various of Doses of Vitamin A on the Epidermis of Rats

I. N. Vedrova and I. M. Sapelkina

There has been extablished a definite effect of vitamin A on the functional state of the epithelium; its mechanism, however, has not been sufficiently studied. Generally, an examination is made of the effect of vitamin A on the epithelium under conditions of its insufficiency and excess.

In the dissertional study of T. I. Suchkova, an analysis has been made of the effect of A-avitaminosis on the course of purulent inflammation and on skin regeneration in rats. The author has observed that in avitaminized animals, staphylococcus infections run a serious course as a result of a markedly reduced resistivity on the part of the organism. At the area of introduction, as a rule, there develops a phlegmonous inflammation, and the regenerative process in A-avitaminized rats are markedly slowed down. The effect of vitamin A is not limited by the reduction in the reactivity of the organism. Its insufficiency, in addition to this, leads to persistent changes in the skin. Welbach, Bessey and Moore have observed that keratinization is intensified under conditions of vitamin A insufficiency.

E. Ya. Gertsenberg, V. L. Arkhangel'skii and T. A. Fafius-Gordon consider pathognomenic for A avitaminesis metaplastic processes of the epithelium and serious affections of the germinal apparatus.

The data connected with Sobel, Parnell and Sherman, Bradley are interesting; they have established that vitamin A, upon applying it locally, restores the epithelium in animals with an insufficiency of this vitamin.

The investigations of Parnell and Sherman have shown that the skin of animals with an insufficiency of vitamin A is subject to definite changes. There is a discontinuance in the growth of hair, the epidermis thins out, there is a diminution in the fatty interlayer, and the processes of cornification (keratinization) are accelerated. With a local application of

vitamin A, in this case, the epidermis becomes thicker, and germinal, the granular layers increase in size, the hair follicle starts to grow, and the fat glands grow larger. The structure of the skin is regenerated. Domagh and Debenek have described, for the first time, changes in the epithelial tissues which are brought about by an excess of vitamin A. The authors have shown that after feeding the animals with large doses of this vitamin, the horny layer thins out and there is an increase in all the other layers of the epithelium in the rat's rumen (paunch). Similar changes in the case of monkeys are described by Ziskin, Rosensteein and Drucker.

Studer and Frey have shown in rats, that following the administration of large doses of vitamin A, the epidermis thickened with a simultaneous vacuolation of the cells in the Malpighian layer. Data relative to the horny layer are absent in view of the fact that, as a result of employing histological techniques, there developed frequent fissures and losses of this layer. The same authors have reported that epidermal thickening and hyperplasia, brought about by vitamin A, considerably diminished following the injection of cortisone.

Weiss, James tested the brief action of vitamin A on the skin of a chick in vitro. The transformed epithelium, subsequently, did not fully keratinize. Szabo has shown that cell cultures of human skin and those of rats grow better in the presence of vitamin A.

An attempt to explain the mechanism involved in the action of vitamin A on the epithelial cells was made by N. N. Drozdova and S. D. Balakhovskii, and also, by Morston. In the opinion of the indicated authors, an intensified keratinization in the case of A-avitaminosis leads to the removal of the inhibition. The authors assume that vitamin A or its derivatives control keratinization, suppressing the catalytic activity of copper.

The present paper is devoted to a description of the effect of various doses of vitamin A, and also, of its deficiency, on the structural elements of

epithelial tissue. In order to clarify the effect of the indicated vitamin on the keratinization processes, we took biopsies of the skin in 57 rats. All the rats were divided into 4 groups. The rats of 3 groups received vitamin A in doses of 20, 40 and 80 micrograms to an animal. The rats of the 4th group, in the course of 3 months, were on an A-avitaminized diet (casein, a salt mixture, baker's yeast, starch, straw pulp, and hydrogenized sunflower oil); as a reult of this, they developed avitaminesis. In the rats of the 4th group, material was gathered following the appearance of clear symptoms of avitaminosis (xerophthalmia, loss of hair, losses in weight, and epizooty (murrain)).

The rats were put to death after 2 - 3 months following the beginning of the experiment. For purposes of investigation, there were taken small pieces of skin from the back of the animals, and also, the parenchymatous organs, the trachea, and the urinary bladder. The material was treated to the usual manner adopted in histological practice; the preparations were stained with hematoxylin-eosin and with sudan (dye).

Two groups of rats, with 12 animals in each (receiving 20 and 40 micrograms of vitamin A, each), relative to the weight, size and behavior, did not differ from the rats being kept on the customary diet.

In the histological examination of the skin in the animals of this group, all the layers of the epidermis were clearly manifested. The cells of the epidermis were arranged in 3 - 5 rows. The nuclei of the basal and spiniform (prickle) layers were succulent, round, there was a clear view of the chromatin structure, and mitoses were constantly encountered.

Over the entire extent, there is a pronounced granular layer consisting of 1 - 2 rows of cells. The nuclei of the cells are flattened, hyperchromic, and around them was found a delicate graininess (the grains of keratohyalin). The horny layer was thin in the sections that came in contact with the granular

layer and crumbly on the surface. Scaling of the horny layer was noted. In the lumen of the hair sheath hairs were always evident. In the ostium, the epidermis fit closely around the hair. The cells of the fat glands were found to be in different stages of sebaceous secretion production.

In the parenchymatous organs, and also, in the epithelium of the urinary bladder and of the trachea, there were no changes (with the exception of 2 animals, in which pneumonia was disclosed upon autopsy and during histological examination.

Interesting changes were disclosed in a group of rats (16 animals) that had received 80 micrograms of vitamin A. An excess amount of it led to an increase in the thickness of the epidermis as a result, for the main part, of granular and nitid(ous) layers. There was also observed a proliferation of cells in the basal layer of the epidermis. Simultaneously with this, there was a change in the character of cornification; this was manifested in the considerable increase in the granular layer; its cells were large, with a well marked nucleus and brightly stained fine and large grains of keratohyalin around it. In addition to this, the nuclei of the cells and the keratohyalin graininess were maintained in the nitid layer (which is well marked here) and even in the horny one. The horny layer is thick, with a stratification, and it scaled readily. Vitamin A in a dose of 80 micrograms brought about a change in the hair follicle (sometimes there were encountered empty hair follicles). In the ostium of the follicle there was an accumulation of granular-layer cells that hung over it.

On the surface of the external hair sheath there appeared a nitid homogeneous layer. The fat glands were large, with the greater part of the cells in a state of disintegration, overfilled with a sebaceous secretion. In the parenchymatous organs, apart from a weakly pronounced fatty dystrophy in the liver cells, it was not possible to disclose any changes.

In the 4th group (17 animals), in the A-avitaminized rats, there was observed a thinning out of the sprounting layer of the epidermis, and also, a marked dystrophy on its part. The nuclei in the cells of the sprounting layer were of varying dimensions, had an irregular shape, and were angular; in some cells, they were constricted by a vacuole and acquired the shape of a crescent -- a hydropic dystrophy of the cells in the epidermis. The granular layer is clearly marked, but it was not manifested over the entire extent. Accumulations of cells in the granular layer, with a large amount of keratohyalin were encountered in the vicinity of the hair follicles. Over the granular layer was situated a rather crumbly layer that was stained with a gray-violet color. The horny layer was thick, and in it were held cell nuclei and grains of keratohyalin. The surface part of the horny layer was crumbly. The hair follicles, as a rule, were empty, their ostia were covered over with stratifications that consisted of cells from the horny and granular layers.

In the histological examination of the organs in animals belonging to this group, there were disclosed changes in the mucous membranes of the trachea and of the urinary bladder. Their epithelium, in the process of metaplasia, acquired the traits of tessellated (stratified) squamous epithelium with cornification. There was also disclosed an atrophy of the heart muscle and of the liver; there were noted 11 cases of pneumonia. The histological picture confirmed the presence of A-avitaminosis in this group of animals.

As has been shown by our investigations, the effect of vitamin A on the epithelium in the skin of animals is indubitable, and it is manifested particularly clearly in the administration of large doses of vitamin A, and also. in the event of its absence.

Apparently, the normal state of the epidermis in rats is assured by a daily dose of vitamin A amounting to no less than 20 and no more than 40 micrograms. Doses that go beyond the indicated limit, bring about distinct

histological changes in the epithelium of the skin.

BIBLIOGRAPHY

Balakhovskaya, S. D., Drezdova, N. N., Biokhimia (Biochemistry), 1957, no. 2, p. 330.

Gertsenberg, E. Ya., Arkhangel'skii, V. L., Fafius-Gordon, I.A., Sov. klin. (Soviet Clinic), 1933, vol. 19, Nos. 5-8, p.638.

Drozdova, N. N., Balakhovskii, S. D., Theses of Proceedings of the 4th All-Union Conference on Vitamins, M(oscow), 1957, p. 19.

Suchkova, T. I., Effect of A-avitaminosis on the Course of Purulent Inflammation and on the Regeneration of Skin Wounds, Candidates' Dissertations, M(oscow), 1952.

Domagh, G., Dobenek, P., Arch. path. Anat., 1933, Bd 290, S. 385.

Morston, H. R., Physiol. Rev., 1952, v. 32, p. 66.

Moore, T., Vitamin A, Amsterdam, 1957.

Sobel, A. E., Parnell, J. P., Sherman, B. S., et al, J. Invest. Derm., 1958, v. 30, p. 315.

Studer, A., Frey, J. R., Schweiz. med. Wschr., 1949, Bd 79,S. 382.

Weiss, P., James, K., Exp. Cell Res, 1955, Suppl. 3, p. 381.

Wolbach, S., Bessey, O. A., Physiol. Rev., 1942, v. 22, p.233.

Ziskin, D. E., Resenstein, N., Drucker, L., Am. J. Orthodent. (Oral Surg. Sect.), 1943, v. 29, p. 163.

Vedrova-'68
Bib. No. 9411

Vestr. Dermatol. Venerol. 42(1):35-38. 1968.

ВЛИЯНИЕ РАЗЛИЧНЫХ ДОЗ ВИТАМИНА А НА ЭПИДЕРМИС КРЫС

И. Н. Ведрова и И. М. Сапелкина

Установлено определенное влияние витамина А на функциональное состояние эпителия, однако механизм его изучен недостаточно. Обычно рассматривают влияние витамина А на эпителий в условиях его недостаточности и избытка.

В диссертационной работе Т. И. Сучковой анализируется влияние авитаминоза А на течение гнойного воспаления и на регенерацию кожи крыс. Автор отмечает, что у авитаминозных животных стафилококковые инфекции протекают тяжело в результате резко сниженной сопротивляемости организма. На месте введения, как правило, возникает флегмонозное воспаление; регенеративные процессы у А-авитаминозных крыс резко замедлены. Влияние витамина А не ограничивается снижением реактивности организма. Недостаточность его, кроме того, приводит к стойким изменениям в коже. Wolbach, Bessey и Moore отмечают, что кератинизация усиливается в условиях недостаточности витамина А.

Е. Я. Герценберг, В. Л. Архангельский и И. А. Фафиус-Гордон считают патогномоничным для авитаминоза А метапластические процессы эпителия и тяжелые поражения герминативного аппарата.

Интересны данные Sobel, Parnell и Sherman, Bradley, установивших, что витамин А при местном его применении восстанавливает эпителизацию у животных с недостатком этого витамина.

Исследования Parnell и Sherman показали, что кожа животных с недостаточностью витамина А подвергается определенным изменениям. Прекращается рост волос, истончается эпидермис, уменьшается жировая прослойка и ускоряются процессы ороговения. При местном применении витамина А в этом случае эпидермис становится толще, зародышевый и зернистые слои увеличиваются в размере, начинает расти волосяной фолликул и увеличиваются сальные железы. Структура кожи восстанавливается. Domagh и Dobenek впервые описали изменения эпителиальных тканей, к которым приводит избыток витамина А. Авторы показали, что после вскармливания животных большими дозами этого витамина истончается роговой слой и увеличиваются все другие слои эпителия преджелудка крысы. Подобные изменения у обезьян описаны Ziskin, Rosenstein и Drucker.

Studer и Frey показали на крысах, что после введения больших доз витамина А эпидермис утолщался с одновременной вакуолизацией клеток мальпигиева слоя. Данные о роговом слое отсутствуют, так как в результате применения гистологической техники возникали частые расщепления и потеря этого слоя. Эти же авторы сообщили, что эпидермальное утолщение и гиперплазия, вызванные витамином А, значительно уменьшались после инъекции кортизона.

Weiss, James испытывали непродолжительное действие витамина А на кожу цыпленка in vitro. Преобразовавшийся эпителий в дальнейшем полностью не кератинизировался. Szabó указал, что клеточные культуры кожи человека и крысы растут лучше в присутствии витамина А.

Попытку объяснить механизм действия витамина А на эпителиальные клетки сделали Н. Н. Дроздова и С. Д. Балаховский, а также Morston. По мнению указанных авторов, усиленная кератинизация при А-авитаминозе приводит к снятию торможения. Авторы предполагают, что витамин А или его производные контролируют кератинизацию, подавляя каталитическую активность меди.

Настоящая работа посвящена описанию влияния различных доз витамина А, а также его дефицита на структурные элементы эпителиальной ткани. Для выяснения влияния указанного витамина на процессы кератинизации мы взяли биопсии кожи у 57 крыс. Всех крыс разделили на 4 группы. Крысы 3 групп получали витамин А в дозах 20, 40 и 80 мкг на животное. Крысы 4-й группы в течение 3 месяцев находились на А-авитаминозной диете (казеин, солевая смесь, пекарские дрожжи, крахмал, соломас, гидрогенизированное подсолнечное масло), в результате чего у них развился авитаминоз. У крыс 4-й группы материал брали после появления явных признаков авитаминоза (ксерофтальмия, выпадение волос, потеря в весе, падеж).

Крыс забивали через 2—3 месяца после начала опыта. Для исследования брали кусочки кожи со спины животных, а также паренхиматозные органы, трахею и мочевой пузырь. Материал обрабатывали общим методом, принятым в гистологической практике; препараты окрашивали гематоксилин-эозином и суданом.

Две группы крыс по 12 животных в каждой (получавшие по 20 и 40 мкг витамина А) по весу, размеру и поведению не отличались от крыс, содержащихся на обычном рационе.

При гистологическом исследовании кожи животных этой группы все слои эпидермиса четко выявлялись. Клетки эпидермиса располагались в 3—5 рядов. Ядра базального и шиповидного слоев сочные, круглые, четко видна структура хроматина, постоянно встречались митозы.

На всем протяжении выражен зернистый слой, состоявший из 1—2 рядов клеток. Ядра клеток уплощенные, гиперхромные, вокруг них располагалась нежная зернистость (зерна кератогиалина). Роговой слой тонкий в участках соприкосновения с зернистым слоем и рыхлый на поверхности. Отмечалось слущивание рогового слоя. В просвете волосяного влагалища всегда был виден волос. В устье эпидермис хорошо облегает волос. Клетки сальных желез находились в различной стадии продукции секрета.

В паренхиматозных органах, а также в эпителии мочевого пузыря и трахеи изменений не было (кроме 3 животных, у которых на вскрытии и при гистологическом исследовании обнаружена пневмония).

Интересные изменения выявлены в группе крыс (16 животных), получивших 80 мкг витамина А. Избыточное его количество приводило к увеличению толщины эпидермиса главным образом за счет зернистого и блестящего слоев. Отмечалась также пролиферация клеток базального слоя эпидермиса. Одновременно с этим изменялся характер ороговения, что выражалось в значительном увеличении зернистого слоя, клетки его крупные, с хорошо выраженным ядром и ярко окрашенными мелкими и крупными зернами кератогиалина вокруг него. Кроме того, ядра клеток и кератогиалиновая зернистость сохранялись в блестящем слое (который здесь хорошо выражен) и даже в роговом. Роговой слой мощный со слоистостью, легко слущивался. Витамин А в дозе 80 мкг приводил к изменению волосяного фолликула (иногда встречались пустые волосяные фолликулы). У устья фолликула скапливались клетки зернистого слоя и нависали над ним.

На поверхности наружного волосяного влагалища появлялся блестящий гомогенный слой. Сальные железы крупные, бо́льшая часть клеток в состоянии распада, переполнена секретом. В паренхиматозных органах, кроме слабо выраженной жировой дистрофии клеток печени, изменений выявить не удалось.

В 4-й группе (17 животных) у А-авитаминозных крыс отмечались истончение росткового слоя эпидермиса, а также выраженная дистрофия его. Ядра клеток росткового слоя различных размеров, неправильной формы, угловатые, в некоторых клетках поджаты вакуолью и приобретали форму полумесяца — гидропическая дистрофия клеток эпидермиса. Зернистый слой отчетливо выражен, но выявлялся не на всем протяжении. Скопления клеток зернистого слоя с большим количеством кератогиалина встречались вблизи волосяных фолликулов. Над зернистым слоем располагался довольно рыхлый слой, окрашивавшийся в серо-фиолетовый цвет. Роговой слой толстый, в нем сохранялись ядра клеток и зерна кератогиалина. Поверхностная часть рогового слоя рыхлая. Волосяные фолликулы, как правило, пустые, устья их прикрывали наслоения, состоявшие из клеток рогового и зернистого слоев.

При гистологическом исследовании органов животных этой группы выявлены изменения слизистых оболочек трахеи и мочевого пузыря. Эпителий их в процессе метаплазии приобрел черты многослойного плоского эпителия с ороговением. Выявлена также атрофия мышцы сердца и печени, отмечено 11 случаев пневмоний. Гистологическая картина подтвердила наличие А-авитаминоза у этой группы животных.

Как показали наши исследования, влияние витамина А на эпителий кожи животных несомненно и особенно четко выявляется при введении больших доз витамина А, а также при отсутствии его.

По-видимому, нормальное состояние эпидермиса крыс обеспечивает ежедневная доза витамина А не ниже 20 и не выше 40 мкг. Дозы, выходящие за указанный предел, вызывают явные гистологические изменения эпителия кожи.

ЛИТЕРАТУРА

Балаховский С. Д., Дроздова Н. Н. Биохимия, 1957, в. 2, с. 330. — Герценберг Е. Я., Архангельский В. Л., Фафкус-Гордон И. А. Сов. клин., [illegible], т. 19, № 5—6, с. [illegible]. — Дроздова Н. Н., Балаховский С. Д. Тезисы докл. 4-го Всесоюзн. совещания по витаминам. М., 1957, с. 19. — Сучкова Т. И. Влияние [illegible] А на течение гнойного воспаления и на регенерацию ран кожи. Дисс. канд. М., [illegible]. — Domagh G., Dobenek P., Arch. path. Anat., 1933, Bd 290, S. 385. — Morston H. R., Physiol. Rev., 1952, v. 32, p. 66. — Moore T., Vitamini A. Amsterdam, 1957. — Sobel A. E., Parnell J. P., Sherman B. S. et al. J. Invest. Derm., 1958, v. 30, p. 318. — Studer A., Frey J. R., Schweiz. med. Wschr., 1949, Bd 79, S. 382. — Weiss P., James K., Exp. Cell Res., 1955, Suppl. 3, p. 381. — Wolbach S., Bessey O. A., Physiol. Rev., 1942, v. 22, p. 233. — Ziskin D. E., Rosenstein S. N., Drucker L., Am. J. Orthodont. (Oral. Surg. Sect.), 1943, v. 29, p. 163.

Pathol. Biologie 9(23-24):2285-2294. 1961.

Veil-'61
Bib. No. 9418

Vitamin A

French publication, Pathologie-Biologie, December 1961, pages 2285-94

The mechanism of action of vitamin A on basal metabolism

by Catherine Veil, E. Triantaphyllidis and H. Pharmand (*, 2235)

Vitamin A has long been used in the treatment of hyperthyroidism. The reader will find a complete bibliography in the excellent work which de Visscher has devoted to this question (9). Among the experimental works let us cite only those of V. Euler (1932) who demonstrated the antagonism between the action of vitamin A and of thyroidin on the growth of the rat(11).

The direct effect of vitamin A on basal metabolism was demonstrated by de Visscher on the rabbit: in the course of A hypervitaminosis the basal metabolism diminishes by more than 16% (9).

A rise in the metabolism has been described in the animal deficient in vitamin A. But the deficiency is accompanied by various troubles, including fever, which can falsify the interpretation of the results (2, 4).

From the very start, the researchers in this domain endeavored to demonstrate the role that the thyroid could play in the mechanism of action of vitamin A. The experimenters used histological techniques. The results obtained are contradictory.

Elmer et coll. (1935) find no modification in the histoligical aspect of the gland under the influence of vitamin A (10). Jotila (1938) observes a diffuse hyperplasia in the course of A hypervitaminosis, with signs of decelerated secretion (25). Schulze and Hundhausen (1939) find normal images with a slight tendancy to hyperfunctioning (18). Muscas (1941) with large doses of vitamin A, observes a rise in the height of the epithelian cells of the vesicles, matching a reduction in volume of the colloid; these are images of stimulation (15). Carpenter and Sampson also observe signs of stimulation with very large doses of vitamin A (3).

While Sadhu and Brody (1947) describe a thyroid of low weight and poor in colloid (17).

It is regrettable that in these projects, which were conducted with all desired rigor, insofar as histological techniques are concerned, the thyroid aspect alone was examined, and the metabolic effect of vitamin A was not studied simultaneously. As a result:

1) When no histological modification is observed, we could blame the very small doses of vitamin A administrated; with doses on this order, (100 units per day) there is no metabolic effect either (see below in the experimental chapter).

2) The hypofunctioning of the thyroid observed by certain experimenters, who did not take the precaution of injecting the control animals with the excipient lipid of the vitamin, could be attributed to the iodine contained in this lipid.

3) Finally, the images of stimulation are obtained with massive doses of vitamin. The animals grow thin rapidly, and are thus in a physiological state very different from that provoked by the fall in metabolism.

Another mechanism envisaged involves an acceleration of the peripheral metabolism of thyroxin. Danowski et coll. in their attempts to verify this hypothesis, observed no difference in the speed with which thyroxinemia falls after injection of massive doses of thyroxin (8). We will see in the chapter on Discussion, that the experimental conditions selected by these authors do not lend themselves to the demonstration of a possible difference.

The desensitization of the tissues to the metabolic effect of adrenalin, observed in the rabbit with adequate doses of vitamin A (9), cannot account for all of the metabolic effects of the vitamin, because we observe it in the experimental conditions in which the latter has no effect on the basal metabolism.

The marked thyroxin is manufactured by Abbott Laboratories (Oak Ridge); it is marked in 3'5'; the specific activities are 35 microcuries per microgram.

Fig.1, page 2286 - Metabolic fall as a function of the dose of vitamin A. Ordinate: % Basal metabolism; Abscissa: Units per day of vitamin A for 2 weeks. A - Controls; B - Hypervitaminize subjects.

Fig. 2 Metabolic fall as a function of the hypervitaminosis period (20,000 units per day). Ordinate: % Basal metabolism abscissa: Weeks. A. - Controls; B - Hypervitaminized subjects.

Fig. 3 Page 2287 - Effect of hypervitaminosis on basal metabolism of the thyroidectomized rat and the non-operated control. Ordinate: % Basal metabolism; Abscissa: Weeks. A - Units per day B - Normal diet, non-operated; C - Hypervitamin subjects, non-operated; D - Normal diet, thyroidectomized; E - Hypervitaminized subjects, thyroidectomized.

RESULTS

I - Choice of vitamin A doses, and of hypervitaminosis period

a) Doses - We utilized doses of 5,000; 20,000 and 30,000 IU. The metabolic fall obtained in two weeks is 8.6 ± 3.2% with 5,0000 IU, 12.1 ± 2.5% with 20,000, and 11.4 ± 4 % with 30,000 IU (fig.1).

During this same period, the basal metabolism of the controls varies by 4% around the mean.

A dose of 2,000 IU is therefore sufficient for obtention of a maximum effect on the basal metabolism. The dose of 30,000 IU is toxic to the animals: when administered for more than 4 weeks it entrains a high mortaility.

b) Duration - With 20,000 IU per day, the fall in metabolism is 12% at the end of the second week, and does not diminish further if we prolong the administration of the vitamin (fig.2).

The animals used for the various experiments described below all received a daily dose of 20,000 IU of vitamin A for 4 weeks or more.

II - Action of vitamin A on the metabolism of the thyroidless animal

Three weeks after thyroidectomy, the basal metabolism of the rats had dropped 32 ± 2.5%. This same level is retained for the entire duration of the experiment (9 weeks after the operation).

The hypervitaminosis provoked by doses of 5,000 IU per day for two weeks (*2287) 20,000 IU per day the next two weeks, and 30,000 IU next, does not modify the basalmetabolism.

The metabolism, 3 weeks after the thyroidectomy, and before the hypervitamin diet, has dropped 31.7 ± 2.7%; it changes to -32.7 ± 2.7% in the course of the following two weeks, then, 15 days afterwards, to -30.2 ± 2.1% and it remains at -31 ± 2.6% to the 9th week.

The figures for basal metabolism of the thyroidless and non-hypervitaminized animal are given in fig. 3. In this same figure we have shown the measurements for the metabolism of the non-operated, hypervitaminized animal, and that of the control subjected to normal diet.

Fig.4 page 2288 - Thyroid radioactivity in the hypervitaminized rat and its control after injection of a tracer dose of radioactive iodine.

Ordinate: a) Percentage of iodine fixed by the thyroid. b) Percentage of iodine fixed per 100 g of body weight. Abscissas: Days

A a) Control. Max 55 %, 10-24 hours. 8th day, 15%

B a) Hypervitaminized subjects Max. 55%, 10-24 hours, 8th day 14%

A b) Controls. Max. 18.4% 10 hours 8th day 5.3%

B b) Hypervitaminized subjects. Max. 17.4% 10-24 hours. 8th day 5%

We draw the reader's attention to the almost perfect coincidence of the two curves relative to the metabilisms of the thyroidless animals, whether hypervitaminized or not.

But the spread is substantial between the figures for basal metabolism of the non-operated hypervitamin animal and those obtained from the control subjected to normal diet.

This enables us to conclude that the action of vitamin A on the combustion is indeed linked to the thyroid function.

III - The thyroid function of the hypervitaminized animal

a) Weight of the thyroid

No appreciable change in the thyroid weight was observed, under the influence of an excess of vitamin A. With a diet rich in iodine, the average weight of the thyroid, reduced to 100 grams of body weight, is 5.55 mg in hypervitamin subjects, and 6 mg in the controls; with a diet poor in iodine, it is 8.1 mg for the two groups of animals.

b) Histology of the gland

The percentage of epithelium (E %), the ratio of the diameter of the vesicles to the number of cells (d/v), are very similar in the hypervitamine subject and the control.

c) Fixation of radioactive iodine

This was measured in the course of 5 series of experiments on animals subjected to a diet poor in iodine (63 animals in all), and on a series of animals subjected to a rich diet (12 animals).

The results are shown in table I and in fig. 4, A and B. Each figure in the table represents the average of three animals.

The percentage of iodine fixed by the thyroid reaches a maximum of 55% between the 10th and 24th hour in the two groups of animals (fig.4A). The decrease which follows is characterized by a period of 2.5 - 3 days for the two groups. On the 8th day the thyroids of the two groups of animals still contain 14 and 15% of the dose injected.

We have represented, as a function of the time, the percentages of fixed iodine, reduced to 100 grams of body weight; the curve obtained in the case of the hypervitaminized animals is no different, practically speaking, from the one drawn in the case of the controls (fig. 4,B). The slight differences

observed in the table, between the hypervitaminized subjects and the controls, when the percentages are reduced to one milligram of thyroid tissue, reveal differences in thyroid weights which have no statistical significance.

d) The chemical transformations of fixed radioactive iodine

Chromatographic analysis, the results of which are collected in table II and fig. 5 shows that the distribution of iodine between the various iodized amino acids is identical in the controls and in the hypervitaminized subjects. With the diet rich in iodine, the percentages of hormone are too small for us to compare the results of the two groups. With the poor diet, the percentages of hormone, the ratios T3/T4, the reactivity of the precursers (T3/T4/MIT/DIT) (6), show no appreciable difference between the hypervitamin subject and the control.

Fig.5, page 2290 Percentage of iodothyronins on the total radioactivity of the thyroids of hypervitamin and control rats. Ordinate: % Iodothyronin; Abscissa: Days Hypervitaminized subjects: + Controls.

Fig. 6 Biological period of marked T4 (plasmatic radioactivity). Ordinate: Nc/mn/cc; Abscissa: Hours after injection A - T i/2 = 11 hours; B - Hypervitaminized subjects: C - T ½, 15 hours; + Controls.

e) Autohistoradiography

Autohistoradiography has confirmed, as we could have predicted, the observations of the histological study and the study of the metabolism of iodine: the autohistoradiographs of the hypervitaminized subjects and of the controls are entirely superposable.

III - Study of a mechanism of action of vitamin A by modification of the peripheral metabolism of the thyroid

Sixteen animals were utilized for these measurements. After intraperitoneal injection of marked thyroxin, we measured the radioactivity of the serum, the liver, the (missing word), the muscle, the spleen and the brain. The

Table I - Thyroid fixation of radioactive iodine in the course of hypervitaminosis

a. Duration of hypervitaminosis (weeks)
b. Time after injection I 131
c. Hupervitaminosis % fixed
d. total per thyroid
e. Per 100 g of body weight
f. Per mg of thyroid tissue
g. Controls % fixed
h. Total per thyroid
i. Per 100 g of body weight
j. Per mg of thyroid tissue

		c			g		
a	b	d	e	f	h	i	j
					Causse Diet		
6	10 h	65 ± 18	19.3	1.96	55.5 ± 8.2	20.8	2.63
10	10 "	44.5 ± 4.7	12.9	1.6	53.6 ± 7.9	15.4	1.76
6	24 "	53.5 ± 6.3	16.4	1.81	54.8 ± 9.5	20.5	2.32
8	24 "	66 ± 7.5	20.0	1.49	54.5 ± 15	18.8	1.47
10	24 "	39 ± 6.6	14.9		43.8 ± 5.8	14.7	
6	48 "	54 ± 8.6	15.8	1.79	52 ± 5.7	19.0	2.34
10	48 "	37 ± 0.44	11.3	1.48	54.3 ± 2.2	14.5	2.06
6	4 j	32.8 ± 3.4	9.45	1.46	29.7 ± 1.5	12.0	1.84
6	6 j	15.8 ± 0.3	4.78	0.7	15.7 ± 7	5.55	0.65
6	8 j	14.7 ± 0.27	5.12	0.75	15.9 ± 7	5.8	0.63
					Soro-Labo Diet		
7	10 h	7.1 ± 4.1	2.46	0.41	9 ± 2.6	3.07	0.48
7	48 h	12.4 ± 2.8	3.5	0.69	9.6 ± 2.2	3.0	0.53

Table II - Chemical distribution of radioactive iodine fixed by the thyroid of the hypervitaminized rat (Chromatographic analysis)

Diet	Time after injection	Hypervitaminized rat % iodo-thyronin	T3/T4	T3/T4/MIT/DIT	Control % iodo-thyronin	T3/T4	T3/T4/MIT/DIT
Causse	10 h	10.5			15		
	10 h	10	0.8	0.57	8.5	0.52	0.35
	24 h	16.4	0.65	0.46	9.3	0.5	0.41
	48 h	26			13.7		
	48 h	14.6	0.58	0.46	15	0.6	0.5
	96 h	16.4	0.36	0.4	13.6	0.5	0.5
Average		15.6	0.6	0.47	12.5	0.53	0.44
Soro-Labo							
	10 h	1.1			1.8		
	48 h	4.3			3.2		

urines and feces were collected for all the animals, from the moment of injection until the sacrifice.

These results, taken as a whole are very coherent, and indicate an acceleration of the metabolism of thyroxin in the animal in a state of A hypervitaminosis.

a) The plasmatic radioactivity falls more radidly in the hypervitaminized subjects than in the controls, as shown by fig. 6 and table III. The biological period, averaging 15 hours in the control, is 11 hours in the hypervitaminized subject.

b) Urinary and fecal elimination is accelerated in the hypervitaminized subject (table III and fig. 7 and 8).

The differences in urinary and fecal radioactivity, which are already sharp when reduced to the gram of feces, become still more so when they are

expressed in the corresponding number of milliliters of serum:

1 milliliter of urine corresponds to 13.2 ml of serum in the hypervitaminized subject, and to 5 ml in the controls.

1 gram of feces to 76 ml of serum in the first, and 36.4 ml in the second.

The urinary radioactivity is due essentially to the iodide from the dehalation of thyroxin.

A substantial fraction of this iodide is fixed by the thyroids of the rats, and the radioactivity is found again in the serum in the form of thyroxin. This explains why differences in plasmatic radioactivity between hypervitaminized subjects and controls tend to blur beyond the 3rd day (fig.6).

c) The radioactivity of the organs is a function of the rates of penetration of thyroxin on the one hand, and on its peripheral metabolism on the other. We have expressed it in table IV in the form of a ratio:

$$\frac{\text{radioactivity of one gram of organ}}{\text{radioactivity of one ml of serum}}$$

This ratio is sharply increased for the liver and the kidney, where it is 50% higher than that of the control, with a Student test of 4.4 for the liver and 3.7 for the kidney, with a probability threshold of 0.01 for the two organs.

There is no difference for the muscle, the spleen and the brain.

The rise in these ratios in the liver and kidney signifies that the penetration of thyroxin is accelerated more than the catabolism of the hormone in these organs.

In the discussion of our results, we will examine the disturbances in the concentration of stable thyroxin represented by the modifications of these ratios established with the aid of marked thyroxin.

Fig.7 page 2291 - Evolution of urinary radioactivity after injection of marked thyroxin Ordinate: Nc/mn/cc; Abscissa: Days + Hypervitaminized subjects; o Controls.

Fig.8 - Evolution of fecal radioactivity after injection of marked thyroxin Ordinate: Nc/mn/g; Abscissa: Days + Hypervitaminized subjects; o Controls.

THE REACTIVITY OF THYROXIN TO THYREOSTIMULIN IN THE COURSE OF A HYPERVITAMINOSIS

The plasma thyroxin content drops when the catabolism of thyroxin is accelerated without any modification in the quantity of hormone secreted. Normally, such a drop is followed by hypersecretion of thyreostimulin (5) and, finally, by hyperthyroid activity.

Now, in our experience, the thyroid of the hypervitaminized subject is not stimulated any more than that of the controls, in spite of the drop in the amount of circulating thyroxin. This is a new and interesting fact that we will return to in the discussion of our results. But before this we will describe experiments tending to discover whether this absence of stimulations is due to a reduction in the reactivity of the thyroid to thyreostimulin.

To do this we injected thyreostimulin into hypervitaminized animals and their controls, and examined the degree of stimulation of their thyroid, with the aid of the tests used at present for this purpose, and in particular with the aid of chromatographic analysis (6, 7, 24).

The animals are subjected to a diet poor in iodine. The thyreostimulin comes from the Armour Laboratories (* 2292), we inject 2.5 USP of TSH per day for 3.5 days (7). We inject marked iodine 24 hours before sacrificing the animal.

The results are shown in table V.

Chromatographic analysis indicates an equal degree of stimulation for hypervitaminized animals and the controls: the percentage of iodothyronin goes from 15.4 in the non-injected animals to 25.2 in the hypervitaminized, injected ones, and to 22.3 in the non-hypervitaminized, injected ones. The

ratio T3/T4 MIT/DIT goes from 0.245 in the controls to 0.44 in the two groups of injected animals.

We can deduce from these measurements that, in the course of A hypervitaminosis, the reactivity of the thyroid to hypophysary stimulin is not modified.

DISCUSSION

The first authors who concerned themselves with the action of vitamin A on basal metabolism, attempted to explain it by a reduction in thyroid activity.

The results of the old experiments were contradictory, but the existence of iodine 131 made it possible to return to this study under more satisfactory conditions. But, in view of the fact that the thyroid intervenes for only one third of the calorific production at the level of basal metabolism, it was prudent to first make sure that vitamin A does not act by means of a mechanism completely independent of the thyroid. Now, the metabolism, which has been reduced 30% by thyroidectomy, is in no way modified when the animal is subjected to massive doses of vitamin A, while the same doses provoke a substantial drop in the metabolism of the non-operated control.

We thus hold the proof of a metabolic effect of vitamin A, depending exclusively on a thyroid relay.

The experiments of Money et coll.(1952) (13) did not demonstrate any reduction in the percentage of iodine fixed by the thyroid in the course of hypervitaminosis. We repeated these experiments, because the doses of vitamins used by these authors, 100 IU per day, appeared to us to be too small. Now, even 5,000 IU per day are still far from provoking the maximum drop in metabolism (fig. 1).

We provoked hypervitaminosis by administering to the animals, 20,000 IU per day for more than 4 weeks. In spite of a very definite action on the basal metabolism, which is reduced by 12%, the thyroid function does not seem to be modified: neither the percentage of fixed radioactive iodine nor the biological

Table III Plasmatic, urinary and fecal radioactivity after injection of marked thyroxin (Number of strokes per gram)

Hypervitaminized subjects

	Hours after injection						
	2	5	10	24	48	72	96
Serum	5,000	3,100	4,000	1,885	430	422	495
Urines	9,800	26,000	27,000	35,330	38,000	40,500	41,500
Feces		20,000	60,000	216,000	261,000	351,000	380,000

Controls

	Hours after injection						
Serum	7,300	7,550	3,000	3,060	380	385	[illegible]
Urines	3,300	10,000	11,000	18,000	23,000	28,000	29,000
Feces		10,000	22,000	148,000	215,000	252,000	321,000

Table IV Radioactivity of the organs after injection of marked thyroxin, expressed in the form of the ratio: g. organ/ml serum

	Liver	Kidney	Muscle
Hypervitamin. subject	1.35 ± 0.21	1.29 ± 0.29	0.212 ± 0.0[illegible]
Controls	0.87 ± 0.09	0.85 ± 0.12	0.181 ± 0.056

	Spleen	Brain	Urine	Feces
Hypervitamin. subject	0.088 ± 0.019	0.142 ± 0.07	13.2	[illegible]
Controls	0.080 ± 0.025	0.130 ± 0.076	5	72

Table V Chemical distribution of fixed radioactive iodine, after injection of hypophysary thyreostimulin in the hypervitaminized animal and the control

	No.	Weight Animal (g)	Weight Thyroid (mg)	% fixation of I 131 24 hrs after injection	% Iodo-thyronin	T3/T4	T3/T4/MIT/DIT
a.	1	203	22.5	42	25.6	0.44	0.37
	2	323	44	54	25	0.6	0.45
	3	315	42	50	25	0.64	0.51
Average	-	310	36.15	48.7	25.2	0.56	0.44
b	1	327	27	37.5	25	0.6	0.5
	2	324	31	55	20	0.34	0.3
	3	301	25	46.5	22	0.71	0.52
Average	-	317	27.65	46.3	22.3	0.55	0.44
c	1	300	32	65	17	0.35	0.3
	2	277	19	33.7	14.3	0.27	0.2
	3	282	22	35	15	0.38	0.24
Average	-	286	24.3	44.5	15.4	0.33	0.245

cycle (rate of secretion), nor the chemical distribution of the iodine substances formed, are modified by hypervitaminosis.

Although statistical calculation does not lead to a conclusion as to significant differences, it does authorize us to affirm that in any event, these differences would be too small to explain the drop in the basal metabolism of the animals. This results from the following calculation:

The basal metabolism is dropped 30% by thyroidectomy, and 12% by hypervitaminosis, or 4/10ths of the thyroid fraction. If, then, the metabolic drop observed were due to reduction of the thyroid function, the tissuary and plasmatic thyroxin content would have been reduced by 40%. As for the thyroid secretion, it would have been reduced, not by 40% but by more than 60%. Thyroxinemia being proportional to the square root of the quantity of hormone

secreted (19). There is no need at all for statistical control in order to affirm that the quantity of hormone secreted by the thyroid of our hypervitaminized animals is much above that provided by calculation.

As a matter of fact, it is the acceleration of the peripheral metabolism of thyroxin demonstrated by our measurements, which makes it possible to explain the drop in basal metabolism in the course of hypervitaminosis.

Danowski et coll. (1955) have already issued the hypothesis of an accelerated catabolism of the thyroid hormone in the hypervitaminized subject. This hypothesis seemed to be weakened by experiments in the course of which the rate of decrease of plasmatic iodemia was measured, after injection of 2 mg of thyroxin in the rat. Now, experimental work carried out since then has shown that the metabolism of thyroxin is greatly accelerated after injection of rather massive doses (19, 21, 23). This acceleration was able to mask the much less intense one provoked by hypervitaminosis.

In our experiments, in which thyroxin is injected in a tracer dose, its half-life in the organism is reduced by 30% if we measure on the curve of plasmatic radioactivity, by 50% if we deduce it from the urinary or fecal elimination. These values are quite close to the reduction of 40% of the tissuary thyroxin content which the drop in basal metabolism made it possible to predict.

Nevertheless, the reduction in thyroxin content does not seem to be the same for all organs. The radioactivity of the muscle, the spleen and the brain is reduced in the same proportions as that of the serum (ratio: gram of tissue/milliliter of unchanged serum) but not at all that of the liver and kidney; the ratio: gram of organ ml of serum is raised for these organs by 40 to 50%, in other words, their concentration of stable thyroxin would be on the same order as that of the liver or the kidney of the control animal, in spite of the reduction in thyroxinemia.

This observation is a surprise, inasmuch as the liver and kidney are among the organs most active metabolically.

The discovery of protein-thyroxin-porteuse (TBP) made for an understanding of the relations between the rate of dehalation and the plasmatic concentration of thyroxin. The fraction of free thyroxin - not bonded to T.B.P. - increases proportionally to the thyroxin content, when the T.B.P. content remains unaltered. Free thyroxin diffuses rapidly from the serum toward the organs and dehalation is accelerated (16).

We could therefore envisage, in order to explain the acceleration of dehalation in the hypervitaminized subject, in spite of the reduction of thyroxinemia, a drop in the T.B.P. content. As a matter of fact, the diffusion of the serum hormone toward the organs is still more accelerated than the dehalation, as appears from the increase of the ratio:

$$\frac{\text{gram of organ}}{\text{milliliter of serum}}$$

It is regrettable that the weak radioactivity of the injected doses did not enable us to measure the radioactivity of the hypophysis. As a matter of fact the hypophysis of the hypervitaminized animal does not seem to react to the reduction in thyroxinemia by a hypersecretion of thyreostimulin, as a hypophysis of the normal animal would do (5). This could explain why, in our experiments, there is no sign of thyroid hyperstimulation consecutive to the drop in thyroxinemia, in spite of unchanged reactivity to exogenic thyreostimulin.

The study of the mechanism of action of vitamin A on basal metabolism therefore led us to confirm the correctness of the therapeutic utilization of vitamin A in the course of hyperthyroidism. It also enabled us to attack certain problems of thyroid physiology at a new angle. (*2293)

Resume

A hypervitaminosis reduces basal metabolism by a mechanism involving thyroid secretion. Proof of this is that the vitamin has no effect on the metabolism of the thyroidless animal.

The mechanism does not involve the thyroid gland itself, as shown by the conjugated study of the histology of the gland and the thyroid metabolism of radioactive iodine.

Experiments utilizing marked thyroxin show that the reduction in basal metabolism is due to acceleration of the catabolism of the thyroid hormone. The relations between the level of basal metabolism and the thyroid hormone content of the various organs, as well as the thyreo-hypophysic relations are considered in the discussion of the results.

Footnotes

(* 2285) Laboratory of general physiology, Faculty of Science, Paris; and Histology Laboratory (Fr. J. Verne), Faculty of Medicin, Paris.

(*2287) We increased the doses gradually, owing to the fragility of the thyroidless animal.

(*2292) The thyreostimulin was given us through the kindness of Dr. Joseph D. Fischer, Biochemistry Research Department of Armour Company, and we are most grateful to him.

(* 2293) The radioactive substances were purchased with the aid of the Commissariat a l(Energie Atomique. We are very grateful to Professor J. Coursaget, Chief of the Biology Department.

(Translated by Carl Demrick Associates,Inc/GCT/t)

LE MÉCANISME D'ACTION DE LA VITAMINE A SUR LE MÉTABOLISME DE BASE

par Catherine VEIL, E. TRIANTAPHYLLIDIS
et H. FARMANE (*)

Il y a longtemps que la vitamine A a été utilisée dans le traitement de l'hyperthyroïdie. Le lecteur trouvera une bibliographie complète dans l'excellent ouvrage que M. de Visscher a consacré à cette question (5). Parmi les travaux expérimentaux citons seulement ceux de V. Euler (1932), qui a mis en évidence l'antagonisme entre l'action de la vitamine A et celle de la thyroïdine sur la croissance du rat (11).

L'effet direct de la vitamine A sur le métabolisme de base a été démontré par de Visscher chez le lapin : au cours de l'hypervitaminose A le métabolisme de base diminue de plus de 20 pour 100 (9).

On a décrit une augmentation du métabolisme chez l'animal carencé en vitamine A. Mais la carence s'accompagne de troubles divers y compris de fièvre, qui peuvent fausser l'interprétation des résultats (2, 4).

Dès le début, les recherches dans ce domaine se sont efforcées de mettre en évidence le rôle que la thyroïde pouvait jouer dans le mécanisme d'action de la vitamine A. Les expérimentateurs utilisent les techniques histologiques. Les résultats obtenus sont contradictoires.

Elmer et ses collaborateurs (1935) ne trouvent aucune modification de l'aspect histologique de la glande sous l'influence de la vitamine A (10). Uotila (1938) observe une hyperplasie diffuse au cours de l'hypervitaminose A avec des signes de sécrétion ralentie (25). Schulze et Hundhausen (1939) trouvent des images normales avec une légère tendance à l'hypofonctionnement (18). Muscas (1941) avec de fortes doses de vitamine A, observe une augmentation de la hauteur des cellules épithéliales des vésicules allant de pair avec une diminution de volume de la colloïde ; ce sont des images de stimulation (15). Carpenter et Sampson observent également des signes de stimulation avec de très fortes doses de vitamine A (3). Tandis que Sadhu et Brody (1947) décrivent une thyroïde de faible poids et pauvre en colloïde (17).

Il est regrettable que dans ces travaux, qui ont été conduits avec toute la rigueur désirable, pour ce qui est des techniques histologiques, l'aspect thyroïdien seul ait été examiné, et que l'effet métabolique de la vitamine A n'ait pas été recherché simultanément. Il en résulte que :

1) Lorsque aucune modification histologique n'est observée, on pourrait incriminer les très faibles doses de vitamine A administrée ; avec des doses de cet ordre (100 unités par jour) il n'y a pas non plus d'effet métabolique (voir plus loin le chapitre expérimental).

2) L'hypofonctionnement de la thyroïde observé par certains expérimentateurs, qui n'avaient pas pris la précaution d'injecter aux animaux témoins le lipide excipient de la vitamine, pourrait être imputé à l'iode contenu dans ce lipide.

3) Enfin, les images de stimulation sont obtenues avec des doses massives de vitamine. Les animaux maigrissent rapidement et sont ainsi dans un état physiologique très différent de celui que provoque l'abaissement du métabolisme.

Un autre mécanisme envisagé fait intervenir une accélération du métabolisme périphérique de la thyroxine. Danowski et coll. en cherchant à vérifier cette hypothèse, n'ont pas observé de différences dans la vitesse avec laquelle la thyroxinémie s'abaisse après injection de doses massives de thyroxine (8). Nous verrons au chapitre Discussion, que les conditions expérimentales choisies par ces auteurs se prêtent mal à la mise en évidence d'une différence éventuelle.

La désensibilisation des tissus à l'effet métabolique de l'adrénaline, observée chez le lapin avec des doses adéquates de vitamine A (9), ne peut rendre compte de la totalité des effets métaboliques de la vitamine, puisqu'on l'observe dans des conditions expérimentales où celle-ci est sans effet sur le métabolisme de base.

Enfin, il ne semble pas que l'éventualité d'un abaissement du métabolisme sans rapport avec la thyroïde ait été envisagée. Cette glande n'intervenant que pour un tiers environ dans la production calorifique de base, il n'est pas certain, *a priori*, qu'elle soit impliquée dans les modifications métaboliques provoquées par l'hypervitaminose. C'est pourquoi nous avons commencé

(*) *Laboratoire de physiologie générale de la Faculté des Sciences de Paris et Laboratoire d'Histologie du Pr J. Verne de la Faculté de Médecine de Paris.*

Path.-Biol., 1961, Vol. 9, N° 23-24, 2285-2294.

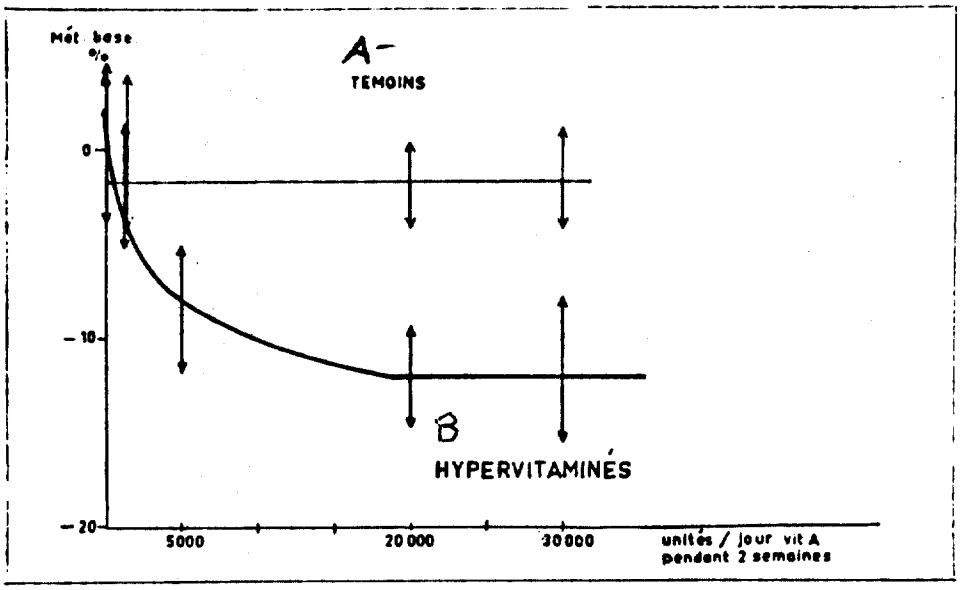

FIG. 1. — Abaissement métabolique en fonction de la dose de vitamine A.

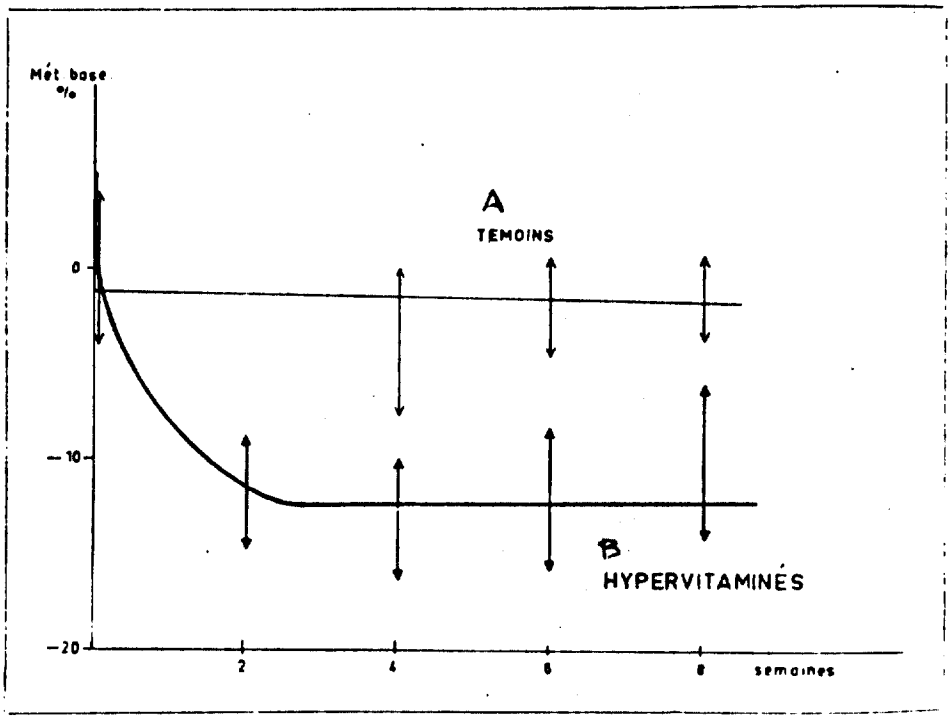

FIG. 2. — Abaissement métabolique en fonction de la durée de l'hypervitaminose (20 000 u./jour).

par une étude de l'effet de la vitamine A sur l'animal éthyroïdé.

Nous avons recherché auparavant, sur des témoins non éthyroïdés, d'une part les doses de vitamine qui, sans être toxiques, suffisent à modifier le niveau du métabolisme, d'autre part le temps pendant lequel ces doses doivent être administrées à l'animal.

TECHNIQUES

Les animaux sont des rats adultes mâles de souche Wistar, provenance « Commentry ». Ils sont maintenus à température constante, à 20°-23°.

Les régimes utilisés sont : 1°) régime synthétique équilibré (12) riche en iode ; 2°) biscuits Sorolabo riches en iode (3-4 mg d'iode par kg) ; 3°) biscuits Causse pauvres en iode (0,2-0,3 mg par kg) (22).

La vitamine A est de provenance Byla (Amunine gouttes). Elle est administrée par voie orale au moyen d'une canule. Les témoins reçoivent l'huile d'arachide qui sert d'excipient à la vitamine.

Le métabolisme basal est mesuré à l'aide de l'appareil de Bargeton (1).

La thyroïdectomie est totale et comprend l'exérèse de l'isthme (7).

L'iode radioactif est injecté sous forme d'INa. La radioactivité thyroïdienne est mesurée, après sacrifice de l'animal, à l'aide d'un compteur à scintillation à cristal creux.

L'analyse chromatographique de l'extrait thyroïdien est faite sur papier Whatmann n° 1, après hydrolyse trypsique de la glande. Les solvants utilisés sont : le butanol acétique 10 pour cent, butanol-dioxanne NH_4OH 2N, et l'alcool amylique tertiaire NH_4OH 2N, en une ou deux dimensions.

La thyroxine marquée est fabriquée par les laboratoires Abbott (Oak Ridge) ; elle est marquée en 3 5' ; les activités spécifiques sont de 35 microcuries/microgramme.

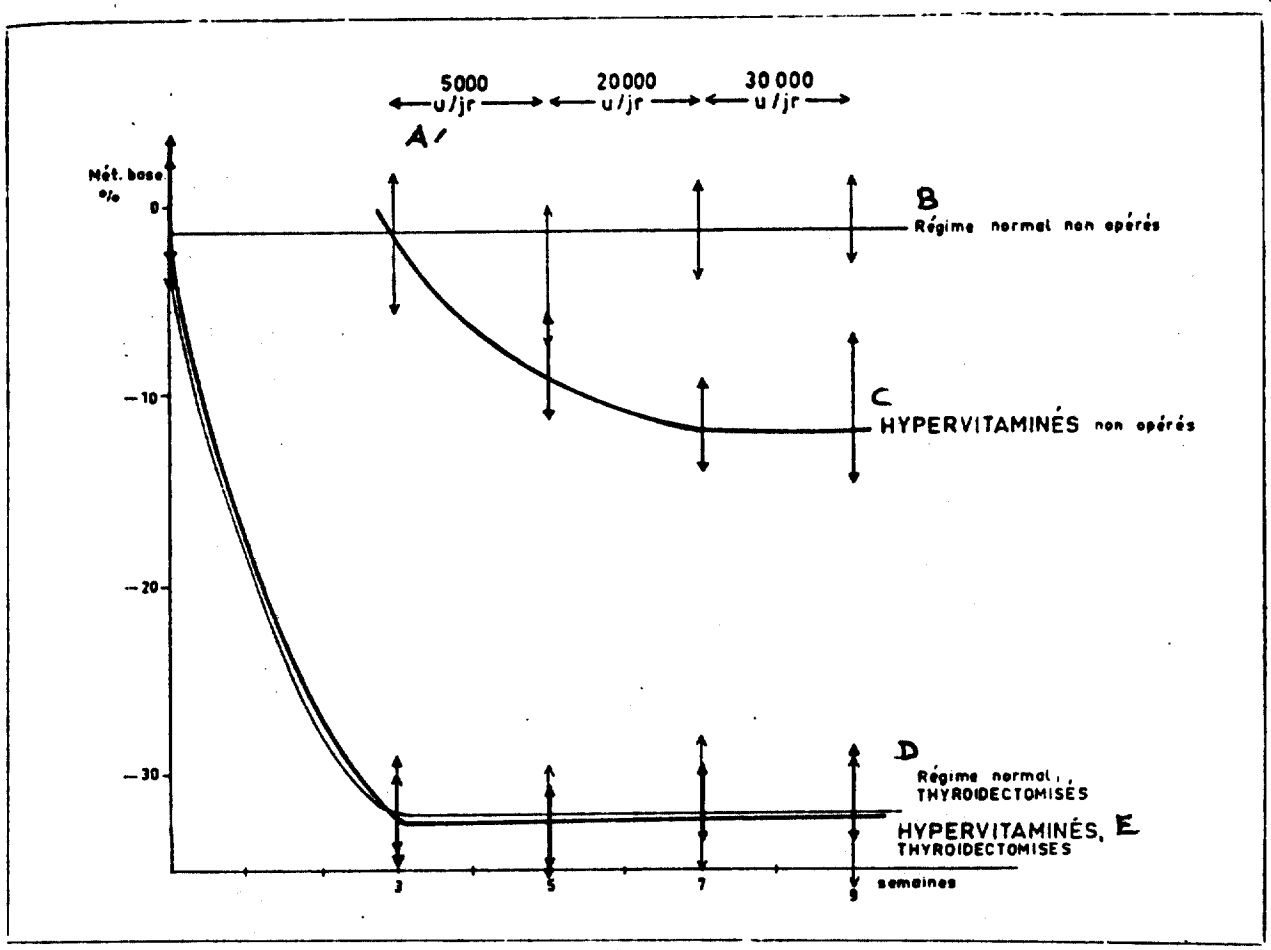

FIG. 3. — Effet de l'hypervitaminose sur le métabolisme de base chez le rat thyroïdectomisé et son témoin non opéré.

RÉSULTATS

I. — CHOIX DES DOSES DE LA VITAMINE A ET DE LA DURÉE DE L'HYPERVITAMINOSE.

a) *Doses.* — Nous avons utilisé des doses de 5.000, 20.000 et 30.000 U.I. L'abaissement métabolique obtenu en deux semaines est de 8,6 pour cent ± 3,2 avec 5.000 U.I., 12,1 pour cent ± 2,5 avec 20.000 et 11,4 pour cent ± 4 avec 30.000 U.I. (fig. 1).

Pendant cette même période le métabolisme de base des témoins varie de 4 pour cent autour de la moyenne.

Une dose de 20.000 U.I. est donc suffisante pour obtenir un effet maximum sur le métabolisme de base. La dose de 30.000 U.I. est toxique pour les animaux : administrée pendant plus de 4 semaines, elle entraîne une forte mortalité.

b) *Durée.* — Avec 20.000 U.I. par jour, l'abaissement métabolique est de 12 pour cent à la fin de la deuxième semaine et ne diminue pas davantage si on prolonge l'administration de la vitamine (fig. 2).

Les animaux utilisés pour les diverses expériences décrites plus loin recevaient tous une dose quotidienne de 20.000 U.I. de vitamine A depuis 4 semaines ou plus.

II. — ACTION DE LA VITAMINE A SUR LE MÉTABOLISME DE L'ANIMAL ÉTHYROÏDÉ.

Trois semaines après la thyroïdectomie, le métabolisme de base des rats est abaissé de 32 pour cent ± 2,5. Il conserve cette même valeur pendant toute la durée de l'expérience (9 semaines après l'opération).

L'hypervitaminose provoquée par des doses de 5.000 U.I. par jour pendant deux semaines (*), 20.000 U.I. par jour les deux semaines suivantes et 30.000 U.I. par la suite ne modifie pas le métabolisme de base.

Le métabolisme, 3 semaines après la thyroïdectomie et avant le régime hypervitaminé, est abaissé de 31,7 pour cent ± 2,7 ; il passe à — 32,7 pour cent ± 2,7 au cours des deux semaines suivantes, puis, 15 jours après, à — 30,2 pour cent ± 2,1 et il est à — 31 pour cent ± 2,6 à la 9e semaine.

Les valeurs du métabolisme de base de l'animal éthyroïdé, hypervitaminé et non hypervitaminé, sont portées sur la figure 3. Sur cette même figure nous avons porté les mesures du métabolisme de l'animal non opéré hypervitaminé et celui du témoin soumis au régime normal.

(*) Nous avons augmenté les doses progressivement à cause de la fragilité de l'animal éthyroïdé.

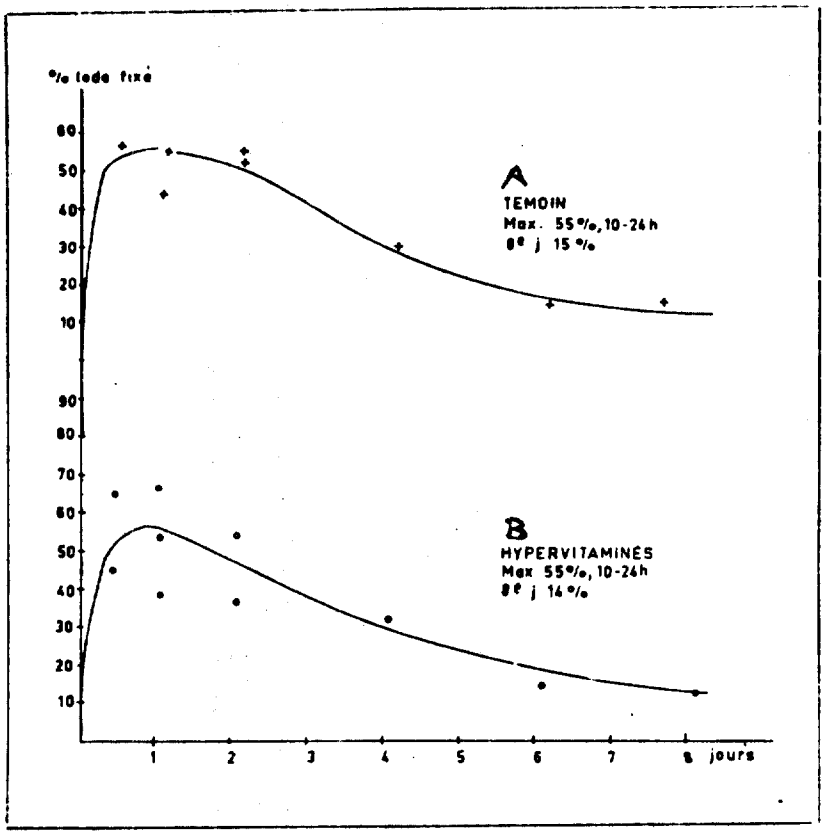

FIG. 4. — Radioactivité thyroïdienne chez le rat hypervitaminé et son témoin après injection d'une dose traceuse d'iode radioactif.

a) Pourcentage d'iode fixé par la thyroïde.

b) Pourcentage d'iode fixé pour 100 g de poids corporel.

4 a

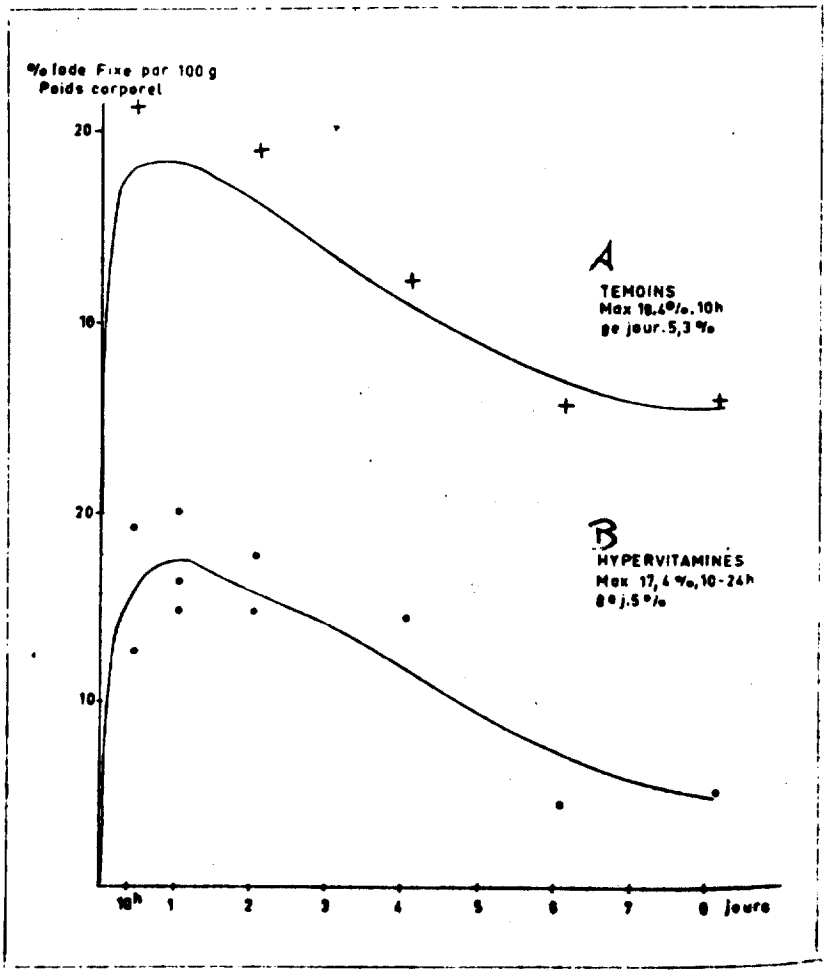

4 b

TABLEAU I. — **Fixation thyroïdienne de l'iode radio-actif au cours de l'hypervitaminose**

Durée hypervitaminose (semaines)	Temps après injection I^{131}	Hypervitaminés % fixé — Total par thyroïde	Hypervitaminés % fixé — Pour 100 g. de poids corporel	Hypervitaminés % fixé — Par mg de tissu thyroïdien	Témoins % fixé — Total par thyroïde	Témoins % fixé — Pour 100 g. de poids corporel	Témoins % fixé — Par mg. de tissu thyroïdien
				Régime Causse			
6	10 h.	65 ± 18	19,3	1,96	55,5 ± 8,2	20,8	2,63
10	10 h.	44,5 ± 4,7	12,9	1,6	53,6 ± 7,9	15,4	1,76
6	24 h.	53,5 ± 6,3	16,4	1,81	54,8 ± 9,5	20,5	2,32
8	24 h.	66 ± 7,5	20,0	1,49	54,5 ± 15	18,8	1,47
10	24 h.	39 ± 6,6	14,9		43,8 ± 5,8	14,7	
6	48 h.	54 ± 8,6	15,8	1,79	52 ± 5,7	19,0	2,34
10	48 h.	37 ± 0,44	11,3	1,48	54,3 ± 2,2	14,5	2,06
6	4e j.	32,8 ± 3,4	9,45	1,46	29,7 ± 1,5	12,0	1,84
6	6e j.	15,8 ± 0,3	4,78	0,7	15,7 ± 7	5,55	0,65
6	8e j.	14,7 ± 0,27	5,12	0,75	15,9 ± 7	5,8	0,63
				Régime Soro-Labo			
7	10 h.	7,1 ± 4,1	2,48	0,41	9 ± 2,6	3,07	0,48
7	48 h.	12,4 ± 2,8	3,5	0,69	9,8 ± 2,2	3,0	0,53

Nous attirons l'attention sur la coïncidence quasi parfaite des deux courbes relatives au métabolisme des animaux éthyroïdés, hypervitaminés ou non.

Par contre, l'écart est important entre les valeurs du métabolisme de base chez l'animal non opéré hypervitaminé et celles obtenues chez le témoin soumis au régime normal.

Cela nous permet de conclure que l'action de la vitamine A sur les combustions est bien liée à la fonction thyroïdienne.

III. — Le fonctionnement thyroïdien de l'animal hypervitaminé.

a) Poids de la thyroïde.

Aucune modification appréciable du poids thyroïdien n'a été observée sous l'influence d'un excès de vitamine A. Avec un régime riche en iode, le poids moyen de la thyroïde, rapporté à 100 grammes de poids corporel, est de 5,55 mg chez les hypervitaminés et de 6 mg chez les témoins ; avec un régime pauvre en iode, il est de 8,1 mg pour les deux groupes d'animaux.

b) Histologie de la glande.

Le pourcentage d'épithélium (E %), le rapport du diamètre des vésicules au nombre des cellules (d/v), sont très voisins chez l'hypervitaminé et chez le témoin.

c) La fixation de l'iode radioactif.

Elle a été mesurée au cours de 5 séries d'expériences sur des animaux soumis à un régime pauvre en iode (63 animaux au total), et sur une série d'animaux soumis à un régime riche (12 animaux).

Les résultats sont portés sur le tableau I et sur la figure 4, A et B. Chaque valeur du tableau représente la moyenne de trois animaux.

Le pourcentage d'iode fixé par la thyroïde atteint un maximum de 55 pour cent entre la 10e et la 24e heure dans les deux groupes d'animaux (fig. 4, A). La décroissance qui suit est caractérisée par une période de 2,5-3 jours pour les deux groupes. Au 8e jour, les thyroïdes des deux groupes d'animaux contiennent encore 14 et 15 pour cent de la dose injectée.

Nous avons représenté, en fonction du temps, les pourcentages d'iode fixé, rapportés à 100 grammes de poids corporel : la courbe obtenue dans le cas des animaux hypervitaminés ne diffère pratiquement pas de celle tracée dans le cas des témoins (fig. 4, B). Les légères différences observées sur le tableau entre les hypervitaminés et les témoins, lorsque les pourcentages sont rapportés au milligramme de tissu thyroïdien, relèvent de différences du poids thyroïdien, non significatives statistiquement.

d) Les transformations chimiques de l'iode radioactif fixé.

L'analyse chromatographique, dont les résultats sont consignés sur le tableau II et la figure 5, montre que

TABLEAU II. — **Distribution chimique de l'iode radio-actif fixé par la thyroïde du rat hypervitaminé (Analyse chromatographique)**

Régime	Temps après injection	Hypervitaminés — % iodothyronine	Hypervitaminés — T_3/T_4	Hypervitaminés — $T_4/T_3/MIT/DIT$	Témoins — % iodothyronine	Témoins — T_3/T_4	Témoins — $T_4/T_3/MIT/DIT$
Causse	10 h.	10,5			15		
	10 h.	10	0,8	0,57	8,5	0,52	0,35
	24 h.	16,4	0,65	0,46	9,3	0,5	0,41
	48 h.	26			13,7		
	48 h.	14,6	0,58	0,46	15	0,6	0,5
	96 h.	16,4	0,36	0,4	13,6	0,5	0,5
Moyenne		15,6	0,6	0,47	12,5	0,53	0,44
Soro-Labo	10 h	1,1			1,8		
	48 h.	4,3			3,2		

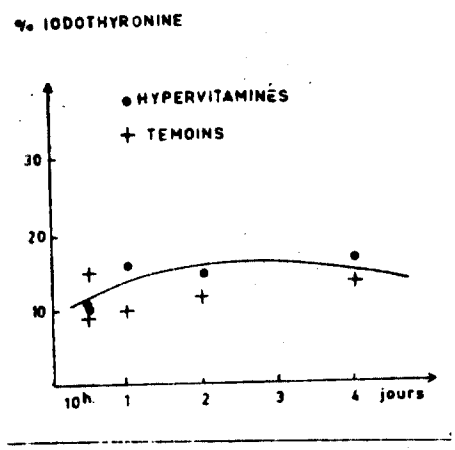

FIG. 5 — Pourcentage des iodothyronines sur la radioactivité totale des thyroïdes de rats hypervitaminés et témoins.

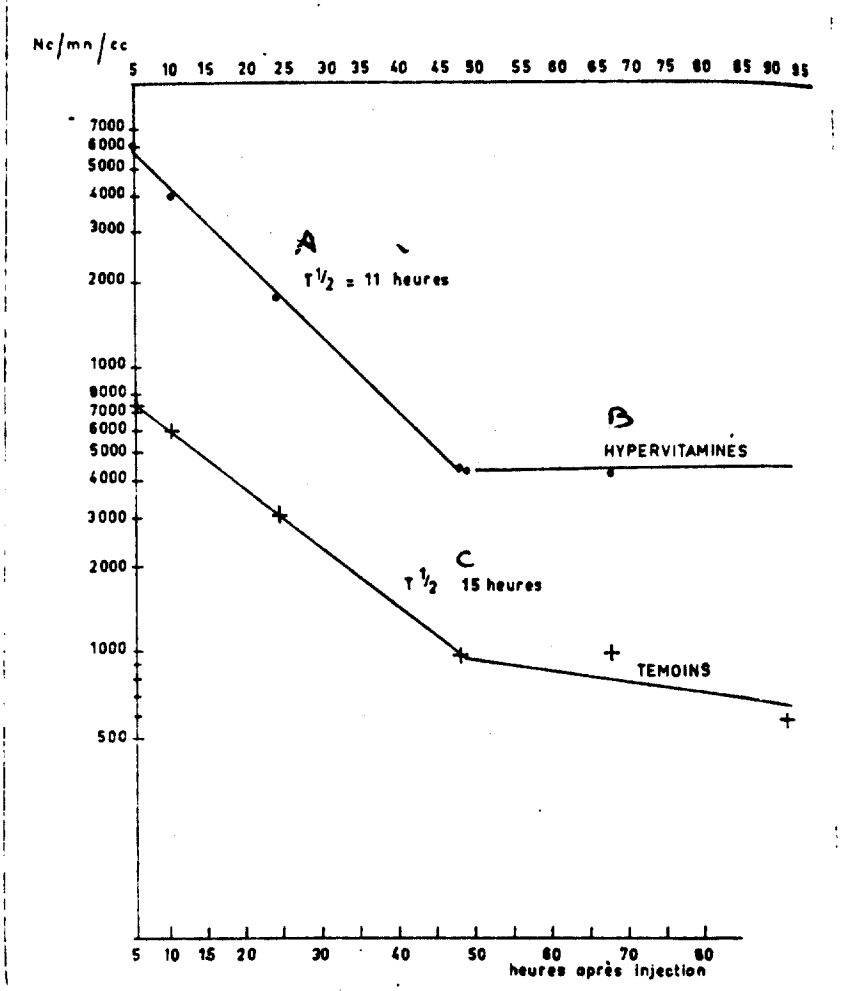

FIG. 6. — Période biologique de la T4 marquée (radio-activité plasmatique).

la distribution de l'iode entre les divers acides aminés iodés est identique chez les témoins et les hypervitaminés. Au régime riche en iode, les pourcentages d'hormone sont trop faibles pour qu'on puisse comparer les résultats des deux groupes. Au régime pauvre, les pourcentages d'hormone, les rapports T3/T4, la réactivité des précurseurs (T_3/T_4/MIT/DIT) (6), ne présentent pas de différence appréciable entre l'hypervitaminé et le témoin.

e) L'autohistoradiographie.

L'autohistoradiographie a confirmé, ainsi qu'on pouvait le prévoir, les constatations de l'étude histologique et de l'étude du métabolisme de l'iode : les autohistoradiogrammes des hypervitaminés et des témoins sont tout à fait superposables.

IV. — RECHERCHE D'UN MÉCANISME D'ACTION DE LA VITAMINE A PAR MODIFICATION DU MÉTABOLISME PÉRIPHÉRIQUE DE LA THYROXINE.

Seize animaux ont été utilisés pour ces mesures. Après injection intrapéritonéale de thyroxine marquée nous avons mesuré la radioactivité du sérum, du foie, du rein, du muscle, de la rate, du cerveau. Les urines et les fèces ont été recueillies pour tous les animaux depuis le moment de l'injection jusqu'à celui du sacrifice.

L'ensemble de ces résultats est très cohérent et indique une accélération du métabolisme de la thyroxine chez l'animal en état d'hypervitaminose A.

a) *La radioactivité plasmatique* baisse plus rapidement chez les hypervitaminés que chez les témoins, ainsi qu'il ressort de la figure 6 et du tableau III. La période biologique, de 15 heures en moyenne chez le témoin, est de 11 heures chez l'hypervitaminé.

b) *L'élimination urinaire et fécale* est accélérée chez l'hypervitaminé (tableau III et figure 7 et 8).

Les différences de radioactivité urinaire et fécale, déjà nettes lorsqu'elles sont rapportées au gramme de fèces ou d'urine, le deviennent plus encore dès qu'elles sont exprimées en nombre de millilitres de sérum correspondants :

1 millilitre d'urine correspond à 13,2 ml de sérum chez les hypervitaminés et à 5 ml chez les témoins.

1 gramme de fèces à 76 ml de sérum chez les premiers et 36,4 ml chez les seconds.

La radioactivité urinaire est due essentiellement à

TABLEAU III. — Radioactivité plasmatique, urinaire et fécale après injection de thyroxine marquée (Nombre de coups par gramme).

	Hypervitaminés							Témoins						
	Heures après injection							Heures après injection						
	2	5	10	24	48	72	96	2	5	10	24	48	72	96
Sérum	5.000	6.100	4.080	1.885	430	422	495	5.300	7.550	6.000	3.060	980	985	562
Urines	9.800	26.000	27.000	35.330	38.000	40.500	41.500	6.800	10.000	11.000	18.000	23.000	28.000	29.000
Fèces		20.000	60.000	216.000	261.000	351.000	380.000		10.000	32.000	148.000	215.000	252.000	261.000

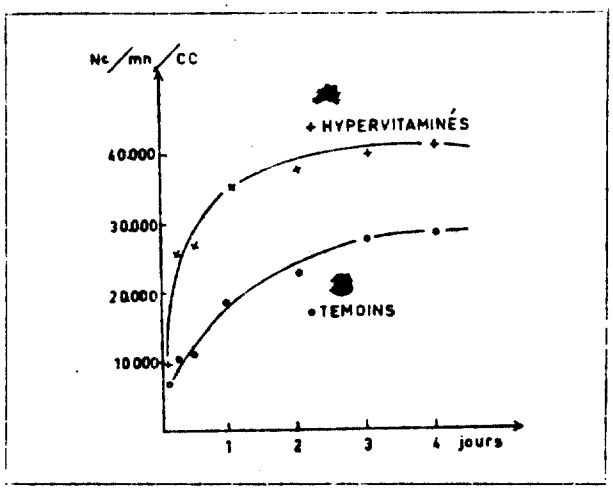

FIG. 7. — Evolution de la radio-activité urinaire après injection de thyroxine marquée.

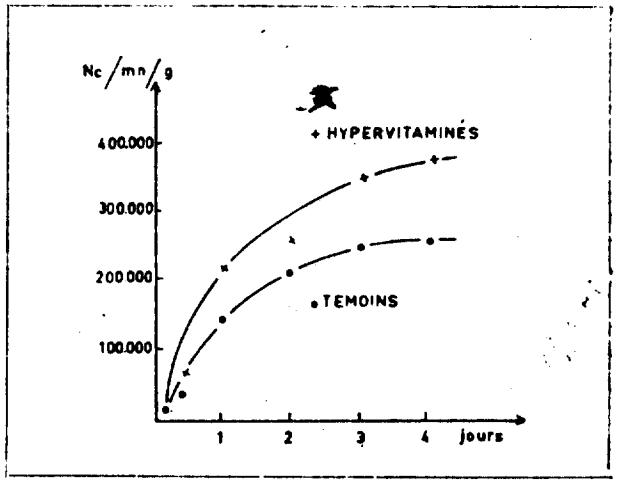

FIG. 8. — Evolution de la radio-activité fécale après injection de thyroxine marquée.

l'iodure provenant de la déshalogénation de la thyroxine.

Une fraction importante de cet iodure est fixée par la thyroïde des rats et la radioactivité se retrouve dans le sérum sous forme de thyroxine. Cela explique que les différences de la radioactivité plasmatique entre les hypervitaminés et les témoins tendent à s'estomper au-delà du 3e jour (fig. 6).

c) *La radioactivité des organes* est fonction des vitesses de pénétration de la thyroxine d'une part, de son métabolisme périphérique d'autre part. Nous l'avons exprimé au tableau IV, sous forme de rapport :

$$\frac{\text{radioactivité d'un gramme d'organe}}{\text{radioactivité d'un ml de sérum}}$$

Ce rapport est nettement augmenté pour le foie et le rein, où il est de 50 pour cent supérieur à celui du témoin, avec un test de Student de 4,4 pour le foie et 3,7 pour le rein et un seuil de probabilité de 0,01 pour les deux organes.

Il n'y a pas de différence pour le muscle, la rate et le cerveau.

L'augmentation de ces rapports dans le foie et le rein signifie que la pénétration de la thyroxine est accélérée plus que n'est le catabolisme de l'hormone dans ces organes.

Nous examinerons dans la discussion de nos résultats les perturbations de la concentration en thyroxine stable que représentent les modifications de ces rapports établis à l'aide de la thyroxine marquée.

LA RÉACTIVITÉ DE LA THYROIDE A LA THYRÉOSTIMULINE AU COURS DE L'HYPERVITAMINOSE A.

Le taux de la thyroxine plasmatique baisse lorsque le catabolisme de la thyroxine est accélérée sans modification de la quantité d'hormone sécrétée. Normalement, un tel abaissement est suivi d'hypersécrétion de thyréo-

TABLEAU IV. — Radioactivité des organes après injection de thyroxine marquée, exprimée sous forme de rapport : g. organe/ml sérum.

	Foie	Rein	Muscle	Rate	Cerveau	Urine	Fèces
Hypervitaminés ..	1,25 ± 0,21	1,29 ± 0,29	0,216 ± 0,024	0,068 ± 0,019	0,143 ± 0,07	13,2	36,4
Témoins	0,87 ± 0,09	0,85 ± 0,12	0,181 ± 0,056	0,086 ± 0,025	0,130 ± 0,076	5	76

TABLEAU V. — Distribution chimique de l'iode radio-actif fixé après injection de thyréostimuline hypophysaire, chez l'hypervitaminé et le témoin.

	N°	Poids animal (g)	Poids thyroïde (mg)	P. 100 de fixation I[131] 24 h. après l'injection	P. 100 d'iodothyronine	T_3/T_4	T_3/T_4/MIT/DIT
a Hypervitaminés + Thyréostimuline	1	293	22,5	42	25,6	0,44	0,37
	2	323	44	54	25	0,6	0,45
	3	315	42	50	25	0,64	0,51
Moyenne	–	310	36,15	48,7	25,2	0,56	0,44
b Témoins + Thyréostimuline	1	327	27	37,5	25	0,6	0,5
	2	324	31	55	20	0,34	0,3
	3	301	25	46,5	22	0,71	0,52
Moyenne	–	317	27,65	46,3	22,3	0,55	0,44
c Témoins + Sérum physiologique	1	300	32	65	17	0,35	0,3
	2	277	19	33,7	14,3	0,27	0,2
	3	282	22	35	15	0,38	0,24
Moyenne	–	286	24,3	44,5	15,4	0,33	0,245

stimuline (5) et, en définitive, d'une hyperactivité thyroïdienne.

Or, dans nos expériences, la thyroïde des hypervitaminés n'est pas stimulée plus que celle des témoins, malgré l'abaissement du taux de la thyroxine circulante. C'est là un fait nouveau et intéressant, que nous reprendrons dans la discussion de nos résultats. Mais auparavant, nous allons décrire des expériences tendant à rechercher si cette absence de stimulation est due à une diminution de la réactivité de la thyroïde à la thyréostimuline.

Nous avons, pour cela, injecté de la thyréostimuline aux animaux hypervitaminés et à leurs témoins et examiné le degré de stimulation de leur thyroïde, à l'aide des tests actuellement utilisés dans ce but et en particulier à l'aide de l'analyse chromatographique (6, 7, 24).

Les animaux sont soumis à un régime pauvre en iode. La thyréostimuline provient des Laboratoires Armour (*), nous injectons 2,5 U.S.P. de TSH par jour pendant 3 jours et demi (7). Nous injectons l'iode marqué 24 h. avant le sacrifice de l'animal.

Les résultats figurent dans le tableau V.

L'analyse chromatographique indique un degré égal de stimulation pour les animaux hypervitaminés et pour les témoins : le pourcentage d'iodothyronine passe de 15,4 chez les non injectés à 25,2 chez les hypervitaminés injectés, et à 22,3 chez les non hypervitaminés injectés. Le rapport T_3/T_4 MIT DIT passe de 0,245 chez les témoins à 0,44 pour les deux groupes d'animaux injectés.

Nous pouvons déduire de ces mesures qu'au cours de l'hypervitaminose A, la réactivité de la thyroïde à la thyréostimuline hypophysaire n'est pas modifiée.

DISCUSSION

Les premiers auteurs qui se sont intéressés à l'action de la vitamine A sur le métabolisme de base ont tenté de l'expliquer par une diminution de l'activté thyroïdienne.

Les résultats des expériences anciennes étaient contradictoires, mais l'existence de l'iode 131 permettait de reprendre cette étude dans des conditions plus satisfaisantes. Mais, étant donné que la thyroïde n'intervient que pour le tiers de la production calorifique au niveau du métabolisme de base, il était prudent de s'assurer d'abord que la vitamine A n'agit pas au moyen d'un mécanisme complètement indépendant de la thyroïde. Or, le métabolisme, abaissé de 30 pour cent par la thyroïdectomie, n'est nullement modifié lorsque l'animal est soumis à des doses massives de vitamine A, alors que les mêmes doses provoquent un abaissement important du métabolisme chez le témoin non opéré.

Nous tenons ainsi la preuve d'un effet métabolique de la vitamine A dépendant exclusivement d'un relais thyroïdien.

Les expériences de Money et coll. (1952) (13) n'avaient pas montré de diminution du pourcentage d'iode fixé par la thyroïde au cours de l'hypervitaminose. Nous avons répété ces mesures car les doses de vitamines utilisées par ces auteurs, soit 100 U.I. par jour, nous ont paru, dès l'abord, trop faibles. Or, même 5.000 U.I. par jour sont encore loin de provoquer l'abaissement maximum du métabolisme (fig. 1).

Nous avons provoqué l'hypervitaminose en administrant aux animaux 20.000 U.I. par jour pendant plus de 4 semaines. Malgré une action très nette sur le métabolisme de base qui est diminué de 12 %, le fonctionnement de la thyroïde ne semble pas modifié : ni le pourcentage d'iode radioactif fixé, ni la période biologique (vitesse de sécrétion), ni la distribution chimique des substances iodées formées ne sont modifiés par l'hypervitaminose.

Si le calcul statistique ne permet pas de conclure à des différences significatives, il nous autorise, par contre d'affirmer qu'en tout état de cause, ces différences seraient trop faibles pour expliquer la diminution du mé-

(*) La thyréostimuline nous a été fournie gracieusement par le Dr Joseph D. Fischer, du Biochemistry Research Department de la Société Armour ; nous l'en remercions très vivement.

tabolisme de base des animaux. Cela ressort du calcul suivant :

Le métabolisme de base est abaissé de 30 % par la thyroïdectomie et de 12 % par l'hypervitaminose, soit des 4 dixièmes de la fraction thyroïdienne. Si donc l'abaissement métabolique constaté était dû à la réduction du fonctionnement thyroïdien, le taux tissulaire et plasmatique de la thyroxine aurait été abaissé de 40 %. Quant à la sécrétion thyroïdienne, elle aurait été réduite, non pas de 40 % mais de plus de 60 %, la thyroxinémie étant proportionnelle à la racine carrée de la quantité d'hormone sécrétée (19). Point n'est besoin de contrôle statistique pour pouvoir affirmer que la quantité d'hormone sécrétée par la thyroïde de nos animaux hypervitaminés est très supérieure à celle prévue par ce calcul.

En fait c'est l'accélération du métabolisme périphérique de la thyroxine mise en évidence par nos mesures, qui permet d'expliquer l'abaissement du métabolisme de base au cours de l'hypervitaminose.

Danowski et coll. (1955) avaient déjà émis l'hypothèse d'un catabolisme accéléré de l'hormone thyroïdienne chez l'hypervitaminé. Cette hypothèse semblait infirmée par des expériences au cours desquelles la vitesse de décroissance de l'iodémie plasmatique était mesurée, après injection de 2 mg de thyroxine, chez le rat. Or, des travaux expérimentaux réalisés depuis ont montré que le métabolisme de la thyroxine est très accéléré après injection de doses aussi massives (19, 21, 23). Cette accélération a pu masquer celle, beaucoup moins intense, provoquée par l'hypervitaminose.

Dans nos expériences, où la thyroxine est injectée à dose traceuse, sa demi-vie dans l'organisme est diminuée de 30 % si on la mesure sur la courbe de radioactivité plasmatique, de 50 % si on la déduit de l'élimination urinaire ou fécale. Ces valeurs sont bien proches de la réduction de 40 % du taux de la thyroxine tissulaire que laissait prévoir l'abaissement du métabolisme de base.

Néanmoins, la diminution du taux de la thyroxine ne semble pas être la même pour tous les organes. La radioactivité du muscle, de la rate, du cerveau, est abaissée dans les mêmes proportions que celle du sérum (rapport gramme de tissu millilitre de sérum inchangé) mais non point celle du foie et du rein ; le rapport gramme organe/ml de sérum est augmenté pour ces organes de 40 à 50 %, autrement dit leur concentration en thyroxine stable serait de même ordre que celle du foie ou du rein de l'animal témoin, *malgré la diminution de la thyroxinémie*.

Cette constatation est surprenante dans la mesure où le foie et le rein sont parmi les organes les plus actifs métaboliquement.

La découverte de la protéine thyroxine-porteuse (TBP) a permis de comprendre les relations entre la vitesse de déshalogénation et la concentration plasmatique de la thyroxine. La fraction de thyroxine libre — non liée au T.B.P. — augmente proportionnellement au taux de la thyroxine, lorsque le taux du T.B.P. reste inchangé. La thyroxine libre diffuse rapidement du sérum vers les organes et la déshalogénation est accélérée (16).

On pourrait donc envisager, pour expliquer l'accélération de la déshalogénation chez l'hypervitaminé malgré la diminution de la thyroxinémie, une diminution du taux du T.B.P. En effet, la diffusion de l'hormone du sérum vers les organes est encore plus accélérée que la déshalogénation ainsi qu'il ressort de l'augmentation du rapport :

$$\frac{\text{gramme d'organe}}{\text{millilitre de sérum}}$$

Il est regrettable que la radioactivité faible des doses injectées ne nous ait pas permis de mesurer la radioactivité de l'hypophyse En effet l'hypophyse de l'animal hypervitaminé ne semble pas réagir à la diminution de la thyroxinémie par une hypersécrétion de thyréostimuline, ainsi que l'aurait fait l'hypophyse de l'animal normal (5). Cela pourrait expliquer qu'il n'y ait, dans nos expériences, aucun signe d'hyperstimulation thyroïdienne consécutive à la diminution de la thyroxinémie, et cela malgré une réactivité inchangée à la thyréostimuline exogène

L'étude du mécanisme d'action de la vitamine A sur le métabolisme de base nous a donc conduits à confirmer le bien-fondé de l'utilisation thérapeutique de la vitamine A au cours de l'hyperthyroïdie. Elle nous a permis, par ailleurs, d'aborder certains problèmes de la physiologie thyroïdienne sous un angle nouveau (*).

(*) Les substances radio-actives ont été achetées avec l'aide du Commissariat à l'Energie atomique. Nous en remercions très vivement le Professeur J. Coursaget, Chef du Département de Biologie.

RÉSUMÉ

L'hypervitaminose A abaisse le métabolisme de base par un mécanisme qui fait intervenir la sécrétion thyroïdienne. La preuve en est que la vitamine est sans effet sur le métabolisme de l'animal éthyroïdé.

Ce mécanisme ne fait pas intervenir la glande thyroïde elle-même ainsi que le montre l'étude conjuguée de l'histologie de la glande et du métabolisme thyroïdien de l'iode radioactif.

Les expériences utilisant la thyroxine marquée montrent que l'abaissement du métabolisme de base est dû à l'accélération du catabolisme de l'hormone thyroïdienne. Les relations entre le niveau du métabolisme de base et la teneur en hormone thyroïdienne des différents organes ainsi que les relations thyréo-hypophysaires sont envisagées lors de la discussion des résultats.

SUMMARY

A hypervitaminosis lowers the basal metabolism by a mechanism in which thyroid secretion is instrumental. This is verified by the fact that the vitamin has no effect on a thyroid-deprived animal.

This mechanism does not call on the thyroid gland itself, as shown by the joint study of the gland's histology and of the thyroid metabolism of radio-active iodine.

Experiments using labelled thyroxin show that the decrease of the basal metabolism is due to the acceleration of the catabolism of the thyroid hormone.

The relations between the level of the basal metabolism and the thyroid hormone contents of the various organs, as well as the thyreo-hypophysic relations are considered with the discussion of results.

RESUMEN

La hipervitaminosis A rebaja el metabolismo basal por un mecanismo que hace intervenir la secreción tiroídica. La prueba de ello es que la vitamina queda sin efecto sobre el metabolismo del animal etiroideado.

Este mecanismo no hace intervenir la misma tiroides, según lo demuestra el estudio conjugado de la histología de la glándula y del metabolismo tiroídico del yodo radioactivo.

Los experimentos que emplean la tiroxina marcada muestran que el abajamiento del metabolismo basal se debe a la aceleración del catabolismo de la hormona tiroídea.

Las relaciones entre el nivel del metabolismo basal y el tenor en hormona tiroídica de los diferentes órganos así como las relaciones tireohipofisarias se consideran cuando la discusión de los resultados.

ZUSAMMENFASSUNG

Die A-Hypervitaminose erniedrigt den Grundumsatz durch einen Mechanismus, der in den Sekretionsvorgang der Schilddrüse eingreift. Diese Deutung ist sehr wahrscheinlich, da Vitamin A den Stoffwechsel eines thyreoidektomierten Tieres nicht beeinflusst.

Die Schilddrüse selbst wird durch die A-Hypervitaminose nicht beeinträchtigt, wie die kombinierte Untersuchung der Histologie und des Stoffwechsels der Schilddrüse mit Radiojod zeigt.

Experimente mit markiertem Thyroxin zeigen, dass die Grundumsatzerniedrigung auf einem beschleunigten Abbau des Schilddrüsenhormons beruht.

Die Beziehungen zwischen der Höhe des Grundumsatzes und dem Gehalt der verschiedenen Organe an Schilddrüsenhormonen werden ebenso wie die thyreo-hypophysären Beziehungen bei der Diskussion der Ergebnisse erwähnt.

BIBLIOGRAPHIE

1. BARGETON D., KRUMM-HELLER C. — *J. Physiol.*, 1949, *41*, 119-124.
2. BLAIZOT J., BENAC R. — *C. R. Soc. Biol.*, 1955, *149*, 810-813.
3. CARPENTIER E. et SAPSON M. M. — *Anat. Rec.*, 1956, *124*, 391.
4. CHEVALIER A. et BAERT H. — *C. R. Soc. Biol.*, 1934, *116*, 1037-1039.
5. COURRIER R. — *Rev. Fr. Endocrinol.*, 1928, *1*, 10.
6. CUKIER R. et TRIANTAPHYLLIDIS E. — *C. R. Acad. Sc.*, 1959, *248*, 1222.
7. CUKIER R. — *Thèse* (Sciences), 1960, Paris.
8. DANOWSKI T. S., WIRTH P., BLACK M. H., BARTON E., BASTIANI R. M. — *J. Clin. Endocrinol.*, 1955, *15*, 1262.
9. DE VISSCHER M. — La réculation hormonale du métabolisme et la vitamine A, 1946, Masson et Cie éd., Paris.
10. FEMER A., GITPOSZ B. et SCHERS M. — *C. R. Soc. Biol.*, 1935, *120*, 560.
11. EULER H. von. — *Ergebn. der Physiol.*, 1932, *34*, 360.
12. FARMAND H. — *Thèse* (Sciences), 1960, Paris.
13. MONEY W. L., FAGER J., LUCAS V., RANSON R. W. — *Endocrinology*, 1952, *51*, 87.
14. MOURIQUAND G., ROLLET J., CHAIX, PETEY. — *Soc. Méd. H. de Lyon*, juin 1931.
15. MUSCAS J. — *Ormoni*, 1941, *3*, 147.
16. ROBBINS J., RALL J. E., PETERMANN M. L. — *J. Clin. investig.*, 1957, *36*, 1333.
17. SADHU D. P., BRODY S. — *Am. J. Physiol.*, 1947, *149*, 400.
18. SCHULZE E. et HUNDHAUSEN G. — D'après de VISSCHER : La régulation hormonale du métabolisme et la vitamine A., 1946, Masson et Cie éd., Paris.
19. TRIANTAPHYLLIDIS E., AMBROSINO G., TUBIANA M. et CUKIER R. — *Ann. Endocrinol.*, 1955, *16*, 733.
20. TRIANTAPHYLLIDIS E., AMBROSINO G., TUBIANA M. et CUKIER R. — *J. Physiol.*, 1956, *48*, 726.
21. TRIANTAPHYLLIDIS E. — *Ann. Rech. Méd.*, 1957, *4*, 1159.
22. TRIANTAPHYLLIDIS E. — *Thèse* (Sciences), 1957, Paris, Imprimerie Nationale.
23. TRIANTAPHYLLIDIS E. — *Arch. Sc. Physiol.*, 1958, *XII*, 3, 247.
24. TRIANTAPHYLLIDIS E. et CUKIER. — *Ann. Endocr.* (Paris), 1959, *20*, 564.
25. UOTILA U. — *Virchow's Arch.*, 1938, *301*, 535.

Riv. Ital. Stomat. 20: 717-732, 1965.

Vichi-'65
Bib. No. 9446

DENTAL CLINIC OF THE UNIVERSITY OF FLORENCE

PROFESSOR F. VICHI, DIRECTOR

HYPERVITAMINOSIS A AND THE CONGENITAL MALFORMATIONS IN RAT FETUSES

by

F. VICHI P. PIERLEONI P.L. MASI I. TOLLARO

On the subject of chemical factors a role of primary importance must be attributed to the vitamins, whose essential function in regulating and activating the organic processes are well known.

In experimental teratogenesis the attention of the authors was drawn particularly and for a long time on the vitamin deficiencies which have frequently been the cause of congenital anomalies. However, the excess of vitamins has recently been introduced into the experiment.

Hansborough (1947), administering an excess of nicotinic acid to chicken embryos, obtained nervous and vascular malformations in the chick. Subsequently Neuweiler (1950), administering high doses of vitamins C and of group B vitamins to guinea pigs, observed a decrease in fertility and death of the fetus. These results were later confirmed by Mouriquand and Edel (1954).

The most indicative investigations revolve around the use of high doses of vitamin A which in all experiments constantly proved capable of determining many malformations.

Moore and Wang (1943) have pointed out that an excess of vitamin A (50,000 units) caused fetal resorptions in the rat, as well as a decrease in the number of the litters and a reduction in size.

Cohlan (1953-154), administering 35,000 units per day of vitamin A to Wistar rats via oral route from the second to the sixteenth day of gestation, noticed a decrease in the overall number of fetuses and in the number of live-

born fetuses, furthermore observing many congenital malformations. Of these the most frequent and typical involved the cranium and the encephalon; there were also sporadic cases of ocular defects and anomalies of the oral region such as cleft lips, cleft palates and macroglossia.

In a series of experiments involving the rat, Giroud and Martinet (1954, 1955, 1956) made discoveries of substantial interest on the teratogenic role of hypervitaminosis A. With respect to the dosage the authors report that the administration "per os" of 35,000 units continued from the fourth to the fifteenth day of gestation determines death and reabsorption of all the fetuses; the administration of 20,000 units from the second or fourth day to the twelfth or fifteenth day on the other hand determines, aside from a certain percentage of death and of fetal resorptions, a considerable number of anomalies involving the nervous system (anencephaly, 6%), the eye (anophthalmia and microphthalmia, 25%), and the oral cavity (cleft palate, 28%).

The administration of greater doses, 60,000 units, limited to only three consecutive days (in periods included between the fifth and the twentieth day), causes different results according to the period of pregnancy:

Fifth -sixth -seventh day - 43% resorptions
20% fetal death
80% normal fetuses
small percentage of anencephaly and anophthalmia

Eighth-Ninth-Tenth day - Anencephaly, anophthalmia or microphthalmia, forked spine

Tenth-Eleventh-Twelfth day - Cleft palate, manibular cleft and forked tongue, malformations of the ear.

Eleventh-Twelfth-Thirteenth Day-
Cleft palate, undeveloped eyelid, micromelia, syndactylism.

Fourteenth, Fifteenth, Sixteenth Day -

Cleft Palate only.

Eighteenth, Nineteenth, Twentieth Day -

Cataracts only.

On the subject of this research it is interesting to note that the greatest incidence of anomalies involving the oral cavity occurred with administrations from the tenth to the sixteenth day and that from the fourteenth to to sixteenth day the hypervitaminosis produces always and only cleft palate.

Subsequently Woollam and Millen (1957) administered "per os" to rats 60,000 units per day of vitamin A from the eighth to the thirteenth day, obtaining 7.8% of cranial and encephalic anomalies and 29.7% of cleft palates. The same authors, administering vitamin A at the above doses and for the same days and injecting cortisone subcutaneously at dose of 20 milligrams from the ninth to the twelfth day, obtained 100% of cleft palates. The subcutaneous administration of vitamin A alone, from the eighth to the twelfth day, as well as the administration of cortisone alone from the ninth to the twelfth day, produced no result; on the other hand the use of the same doses of Vitamin A and of cortisone combined during the same period and also administered subcutaneously produced 1.4% of cleft palates.

Deuschle, Geiger and Warkany (1959) administered per os individual doses of Vitamin A (from 75,000 to 150,000 units) respectively on the ninth, tenth and eleventh day, obtaining in the progeny of the treated rats interesting results such as exophthalmos, welding of the maxillo-mandibular, presence of ectopic cartilage in the maxillary arc, cleft palate, absence of some molar germs, presence of a polyp type formation under the palatine process.

Vichi, Masi, Orlando and Di Gangi (1962) introduced vitamin A in the rat via intramuscular route obtaining, with 80,000 units from the eighth to the tenth day, micrognathia with microgenia, defective welding of the chin and partial furrowing of the tongue; with 60,000 units from the eleventh to the

thirteenth day, macroglossia, micrognathia with microgenia. The same 60,000 units administered via gastric route from the tenth to the twelfth day determined micrognathia with microgenia.

The administration of vitamin A in high doses was experimented by Giroud and Martinet (1959) also in animal species other than the rat and particularly the guinea pig, the rabbit and the mouse for the purpose of assaying in such animals the possibility of the teratogenic effects so widely demonstrated in the rat.

In the guinea pig the administration per os of vitamin A in doses of 50,000 units for three consecutive days, determined, in addition to a considerable number of abortions, also the appearance of medium fissures of the mandibule with forked tongue, this being observed in a single case. In our opinion the fact that the authors did not specify the phase of pregnancy during which the administration of vitamin A was first made, nor the number of animals treated, is an evidence of the fact that the teratogenic effect appeared in a single case, making it difficult to evaluate the significance of the results reported.

In the rabbit, with doses varying between 125,000 and 150,000 units administered per os for three, and respectively for five consecutive days, beginning with the fifth day of pregnancy,the same authors obtained abortions with the same frequency as that observed in the guinea pig. On the other hand the results due to disturbed development were more numerous than in the guinea pig, and therefore remarkable as true and real malformations. In one litter, in fact, all the fetuses appeared affected by the same anomalies: syndactylism, facial malformation represented by transversal contractions of the face with hypoplasia of the mandibules and a bird like profile, and also ocular alterations represented by hemorrhages of the crystallin, detached retinas, retro-retinal hemorrhages and fibrosis of the citreum.

In a series of experiments performed on the mouse at various doses and

during different phases of gestation Giroud and Martinet (1959, 1960 and 1962) brought out numerous data rich in interest. With 100 units for three consecutive days (8th to tenth) the authors obtained abortions in 9.9% of the cases and death and intrauterine resorptions in 7.5%. With 250 units (8th to tenth day), in addition to a greater percentage of abortions and of resorptions, anencephal (19%) and malformations of the face (18%) were encountered. With 500 units (8th to tenth day) abortions and resorptions in modest percentage, anencephaly (10%) and various unspecified malformations in 36% of the cases. Finally, the administration in much greater doses, equal to 3,000 units, if done from the eighth to the tenth day, determined cases of anencephaly not associated with ocular anomalies in 28% of the cases; in addition, and more rarely, cardiac anomalies characterized especially by interventricular communication. The same dose administered by the eleventh to the thirteenth day caused mostly fissures in the rear portion of the palate, whose frequency reached 90%.

This difference found in the teratogenic effect in function of the embryonic state was abundantly documented by the same authors who, by varying the time of administration, obtained different malformations of varying intensity. With individual early administrations (sixth, seventh, eighth, ninth day) anencephaly was obtained in various percentages, with a maximum incidence of 21.6% on the seventh day. The later treatments (ninth, tenth, eleventh and thirteenth day) determined cleft palates in percentages up to 68 and 70%, respectively on the eleventh and on the twelfth day.

Always with the mouse, Kalter and Warkany (1961), with the use of 10,000 units of vitamin A in a single dose on the eighth or ninth day, encountered cleft palates in 70.8% of the cases, microstomia, welding of the maxillo-mandibular, microgenia, mandibular separation, ankyloglossia, absence of the chewing muscles, absence of salivary glands, ectopic sub-maxillary glands and dental anomalies consisting of fused, super-numerary and ectopic teeth.

Administration on the tenth day determined microgenia and cleft palates, but in smaller percentage (36.5%).

PERSONAL CONTRIBUTION

For our experiments we used three lots, respectively of ten, ten and five animals each, of rats of the same race (rattus norvegicus), Wistar strain, of the same age, varying in weight between 210 and 253 grams, with an average value of 220 grams, belonging to families which, having been studied for various generations, never presented spontaneous malformations. The female rats, kept under a normal laboratory diet, were mated with the male and the beginning of pregnancy was determined and calculated from the time of penetration of the spermatozoa into the vaginal tract.

Vitamin A in an oil solution in the form of palmitate, at a concentration of 500,000 units per cc, was administered via oral route by means of a probe at a dosage of 50,000 units per day. In the first lot the administration was done on the tenth, eleventh and twelfth day of pregnancy; in the second lot on the eleventh, twelfth and thirteenth day. The third lot was used as control. The animals were sacrificed on the twenty-first day, and before delivery the fetuses were removed from the uterus. The results of the malformations encountered are summarized as follows:

First lot, ten rats - 50,000 units vitamin A per day, per os, on the tenth, eleventh and twelfth day:

No. 1 - litter of nine embryos -	2 anencephaly
	1 bifid spine with meningomyolocele
	3 cleft palates
	2 cleft palates and slight meningocele

No. 2 - litter of seven embryos-

1 anencephaly and bifid spine with meningomiolocele

1 anencephaly

1 cleft palate

2 slight meningocele

1 resorption

No. 3 - litter of 3 embryos

2 anencephaly

2 slight meningocele

3 resorptions

No. 4 - litter of 10 embryos -

1 anencephaly

3 slight meningocele

2 cleft palates

No. 5 - litter of 7 embryos -

1 anencephaly with cleft palate

3 cleft palates

2 resorptions

No. 6 - litter of 8 embryos -

1 anencephaly and bifid spine with meningomyolocele

2 anencephaly

No. 7 - litter of 9 embryos

1 anencephaly

1 cleft palate

No.'s 8, 9 and 10 -

Resorptions and intrauterine death of the fetuses.

Second lot, ten rats - 50,000 units vitamin A per day, per os on the eleventh, twelfth, thirteenth day.

No. 1 - litter of six embryos -	3 cleft palates
	2 resorptions
No. 2 - litter of eight embryos	7 cleft palates
No. 3 - litter of eleven embryos	4 cleft palates
No. 4 - litter of nine embryos	4 cleft palates
	3 slight meningocele
No. 5 - litter of eight embryos	5 cleft palates
	1 resorption
No. 6 - litter of seven embryos	3 cleft palates
No. 7 - litter of seven embryos	3 cleft palates
	1 slight meningocele
	1 resorption
No. 8 - litter of 10 embryos	4 cleft palates
No. 9 - 10	Resorption and intrauterine death of the fetuses.

Third lot - five female rats - controls.

Altogether 53 fetuses were obtained; all of them were morphologically normal.

COMMENTS

The cleft palate condition, observed in the first lot in the percentage of 21.4 and in the second lot in the percentage of 54.5 involves exclusively the posterior palate, while the anterior palate appears constantly unchanged. Of these, only a few are limited to the posterior portion of the posterior palate, while most cases involve the entire posterior palate (Fig. 1), beginning from behind the papilla palatina at the point where the naso-palatine canal opens (Figs. 2 & 3).

The total fissures extend more or less in the width (Fig. 1 & 4) according to the degree of arrested development of the palatine processes. In the wider

fissures in some points the processes seem altogether absent.

The characteristics described above are idential in all the animals, whether from the first or from the second lot.

The cranial-encephalic malformations which we encountered in the first lot with an incidence of 19.6% are to be considered, more than as true and actual anencephalies, as exencephaly determined by the absence of the cranial vault and tegument (Fig. 5). In certain cases belonging to the first or to the second lot, we found slight meningocele, consisting in a slight extroflexion of the dura, made possible by a defect of the cranial vault.

In three cases, amounting to 5.3%, all belonging to the first lot, we observed an anomaly of the rachis which could be classified as bifid spine. This appears in the lumbar region and is characterized by a wide opening of the vertebrae and of the spinal medulla, the edges of which continue into the epidermis (Fig. 6).

CONCLUSIVE CONSIDERATIONS

Analysis of the data contained in the literature on this subject and evaluation of the results obtained from the above personal experimental investigations enable us to formulate certain considerations.

1. First of all, it clearly appears that the teratogenic effect possessed by vitamin A is demonstrable in all the species of animals used and that is in the rat, in the mouse, in the rabbit and in the guinea pig. However this effect does not manifest itself with equal intensity in all the animals used in the experiments, conceivably because of the different sensitivity of the species to the substance administered.

2. Furthermore, the intensity and the frequency of the results seem to depend, in addition to the sensitivity of the animal species, also on the dose and the method of administration. In support of this there is the observation that, while excessive doses determine especially death or fetal resorption, doses varying between 20,000 and 60,000 units in the rat, between

25,000 and 150,000 units in the rabbit and doses of 3,000 units in the mouse appear the most apt to cause numerous and multiple anomalies. In this last animal, however, Giroud and Martinet demonstrated that considerably smaller doses, of 250 and 500 units, are already able to determine, in addition to abortions and resorptions, which can be observed even at doses of only 100 units, also various malformations such as a substantial percentage of cranial-encephalic and facial malformations. The evaluation by the same authors of these doses referred to body weight (500 units - 12,500 units per kilo; 250 units - 6,500 units per kilo; 100 units - 2500 units per kilo) appear interesting for comparison with doses used in clinical therapy which, represented from 1,000 to 3,000 units per kilo and per day, come very close to the doses used in the experiment. It seems therefore justified to assume that, like many other well documented chemical substances, also vitamin A is teratogenic at relatively small doses, fairly similar to those used therapeutically in man.

It is also known that vitamin A, in contrast with water soluble vitamins which are easily eliminated, accumulates in the organism and remains there for a long time, before being eliminated, in amounts sufficient to be able to determine teratogenic effects even after the treatment has ceased.

It has been demonstrated furthermore that the passage of vitamin A from the mother to the fetus is possible in various animal species (Dann, Zunin and Testa, Henry and wo-workers) and in man (Wendt, Neuweiler). Giroud, Gounelle and Martinet, confirming the passage of vitamin A from the mother to the fetus, have shown that the concentration of the vitamin in the fetal organism depends on that of the mother's organism - as is demonstrated by the fact that the vitamin A content in the fetuses of treated mothers appears more or less double that of the controls - and that the action of vitamin A on the product of conception is independent of an excessive concentration in the mother's tissues and acts directly on the embryo.

3. It is also important to note that the effect of hypervitaminosis A depends also on the method of administration. In fact, in the experiments of Woollam and Millen, vitamin A injected under the skin in rats at the dose of 60,000 units did not cause any malformation whereas the same dose, administered during the same days (from the eighth to the thirteenth) but via oral route, causes frequent malformations (cleft palate). It is the opinion of the authors that the low degree of absorption following administration via subcutaneous route prevents the vitamin from reaching the fetus at a concentration sufficient to determine a teratogenic effect. In our previous experiments, however, we did not note significant differences in the quantity and quality of anomalies obtained with vitamin A administered either via intramuscular or via oral routes. It should be kept in mind, however, that the experimental conditions in the different lots were not identical insofar as the doses and the times of administration were concerned.

4. Of particular interest are the congenital anomalies of the oral tract found constantly in the four species of animals treated with hypervitaminosis A. Of these anomalies the most frequent is without doubt the cleft palate, observed in the rat (Cohlan, Giroud and Martinet, Woollam and Millen, Deuschle, Geiger and Warkany, Vichi and colleagues) and in the mouse (Giroud and Martinet, Kalter and Warkany). Only exceptionally was cleft palate due to hypervitaminosis A observed in association, in the rat, with cleft lips (Cohlan) in contrast with what happens with other substances (cortisone, aminopterin) with which a high incidence of hare lip is seldom encountered along with the presence of cleft palate. Anomalies of the tongue, generally represented by macroglossia, bifid tongue and ankyloglossia, were evidenced in the rat (Cohlan, Giroud and Martinet), (Vichy and Colleagues), in the guinea pig (Giroud and Martinet) and in the mouse (Kalter and Warkany).

We have described various anomalies involving the maxillary bones, some of which concern the upper maxillary, which appeared transversally contracted

in the rabbit (Giroud and Martinet) or hypoplasic in the rat (Vichi and Coll.); other anomalies involve the mandible, which is poorly joined in the rat (Vichi and Coll.) as well as in the guinea pig (Giroud and Martinet), hypoplacic in the rat (Vichi and Coll.) and in the mouse (Kalter and Warkany), and sometimes altogether missing in the ascending branches. We have also observed anomalies associated with both jaws, particularly maxillo-mandibular joining in the rat (Deuschle, Geiger and Warkany) and in the mouse (Kaleter and Warkany); maxillo-mandibular disgenesis in the rabbit (Giroud and Martinet); micronesia with microgenia in the rat (Vichi and Coll.). In addition to this we observed the presence of heterotopic cartilage in the jaws, in the rat (Deuschle, Geiger and Warkany) as well as in the mouse (Kalter and Warkany).

5. Not to be underestimated are the malformations found in organs and tissues topographically adjacent and functionally bound to the oral tract, such as those described by Kalter and Warkany in the mouse and consisting of aplasia of the chewing muscle and of the major salivary glands and respective ducts, as well as ectopia of the sub-maxillary gland; all the more since such anomalies are more often associated with an unusual malformation, microstomia, which ranged from a moderate reduction of the oral tract opening to an apparent complete absence of this opening.

6. Substantial, but not constant like that of the oral malformations, was the incidence of ocular anomalies found only in the rat and most often represented by anophthalmia, microphthalmia, absence of eyelids and cataracts (Cohlan, Giroud and Martinet).

By far less frequent are the anomalies of the ear - arrested development of the mid-ear, otucephaly, absence of the external ear and presence of auricular appendices - described in the rat and in the rabbit by Giroud and Martinet.

7. Hypervitaminosis A produces with remarkable frequency in the rat, in the rabbit and in the mouse, cranial-encephalic malformations, essentially

represented by anencephalia. However we wish to point out two other alterations, better defined as exencephaly rather than true and actual anencephaly; these are the various malformations we observed. On the other hand, it is known that anencephaly obtained in the rat, which are frequently associated with anophthalmia and microphthalmia, can be differentiated from those found in the mouse, in which there is a constant absence of the ocular anomalies and where, therefore, there is a type of malformation considered by Giroud and Martinet as similar to that known in human pathology.

The analysis and discussion of the malformations induced in experimental animals by hypervitaminosis A cannot be considered complete without considering, after the question concerning dosage and method of administration, also the problem of the time of treatment. It is known, in fact, that the type, the seat and the intensity of the individual anomalies are in close relation with the stage of embryonic development on which the teratogenic agent exerts its action. In the rat, which is the animal most often used in experiments of teratogenesis with hypervitaminosis A, the cleft palate is first observed, associated with mandibular separation and malformations of the ear, following treatment from the tenth to the twelfth day; it is later encountered, and associated with aplasia of the eyelids and malformation of the members, with treatment from the eleventh to the thirteenth day; finally it is found alone, but with a substantially lower frequency, from the fourteenth to the sixteenth day.

In the mouse the greatest percentage of cleft palates, together with other anomalies of the oral tract, are observed following treatments performed on the ninth to the twelfth day, while administration on the tenth day determines a minimal incidence of palatine fissures. This behavior can be explained by assuming with Giroud and Martinet that vitamin A acts in a first phase on the rudiments of the palatine processes, later interfering with the specific growth of these processes.

We also wish to stress that, in the rat, early administration from the fifth to the seventh day already determines the appearance of anencephaly, whose major incidence is found, however, from the eighth to the tenth day. In the mouse the greatest percentage of anencephaly is found with treatment on the seventh and eighth days, while on the sixth and ninth day, the incidence is minimal. The few incidences of anencephaly encountered following later treatments (eleventh day) could be ascribed to a failure of the encephalic tube to close.

With respect to bifid spine it should be noted that this appears in the rat following treatment from the eighth to the tenth day; much more rarely from the eleventh to the thirteenth day. It appears therefore as a defect which takes place later than anencephaly. This confirms what has already been demonstrated by Hicks (1954) with the use of radiation.

From the above it can be seen that also concerning anomalies caused by hypervitaminosis A one may assume a narrow dependence of the stage of development of the embryo on which the teratogenic action is exerted. The importance of the "sensitive stage", now recognized in addition to the chemical substances, also for the physical and infective agents used in teratogenesis, does not however diminish the function assigned to the specificity of the substance employed.

Concluding these considerations, we would like to point out that our own personal investigations confirm:

1. The teratogenic role of hypervitaminosis A; 2. The particularly frequency of the anomalies of the oral tract, among which the most important is cleft palate, as compared with anomalies of the other organs and apparatus.

Finally we would like to stress that the importance of the results obtained in teratogenesis with hypervitaminosis A derives also from the observation that this substance is widely used in therapy and that the anomalies it

produces in various species of experimental animals - in some cases, such as in the mouse, also at relatively modest doses - present singular analogies with those found in human pathology.

Fig. No. 1. The first figure at top right shows the normal palate of the control rat; the second, always at the top from the right, represents the partial fissure of the posterior palate; the other figures illustrate total fissures of the posterior palate, in different widths.

Fig. No. 2. Median longitudinal section of the head of a full term fetus removed from the untreated mother. Normal morphology of the palate with naso-palatine canal at the limit between the anterior and the posterior palate.

Fig. No. 3. Median longitudinal section of the head of a full term fetus removed from a treated mother, which demonstrates a total separation of the posterior palate.

Fig. No. 4. Total fissures of the posterior palate, of different widths; note that the palatine processes are incomplete and in some points completely missing. Fig. No. 5. Example of exencephaly.

Fig. No. 6. Cleft rachis and meningomyelocele of the lumbar region.

Vichi-'65
Bib. No. 9446

Riv. Ital. Stomat 20: 717-732, 1965.

CLINICA ODONTOIATRICA DELL'UNIVERSITÀ DEGLI STUDI DI FIRENZE
Direttore Inc.: Prof. F. Vichi

IPERVITAMINOSI A E MALFORMAZIONI CONGENITE IN FETI DI RATTO

F. VICHI P. PIERLEONI P.L. MASI I. TOLLARO

Nel capitolo dei fattori chimici un ruolo di primaria importanza deve essere attribuito alle vitamine di cui è ben nota la funzione essenziale come regolatrici e attivatrici dei processi organici.

Nella teratogenesi sperimentale l'attenzione degli AA. è stata posta soprattutto, e per parecchio tempo, sulle deficienze vitaminiche che sono apparse causa frequente di anomalie congenite. Tuttavia abbastanza di recente è stato introdotto nell'esperimento l'eccesso di vitamine.

Hansborough [22] (1947), somministrando acido nicotinico in eccesso in embrioni di pollo, ottenne nel pulcino malformazioni nervose e vascolari. Successivamente Neuweiler [29] (1950), somministrando a cavie alte dosi di vitamina C e di vitamine del gruppo B, osservò una diminuzione della fertilità e morte del feto. Tali risultati furono in seguito confermati da Mouriquand e Edel [28] (1954).

Le indagini più dimostrative vertono sull'impiego di alte dosi di vitamina A che in tutti gli esperimenti si è costantemente dimostrata capace di determinare numerose malformazioni.

Moore e Wang [27] (1943) avevano segnalato che un eccesso di vitamina A (50.000 U) provoca nel ratto riassorbimenti fetali, diminuzione del numero delle portate e riduzione della taglia.

Cohlan [1 2] (1953-1954) somministrando a ratti Wistar 35.000 U pro die di vitamina A per via gastrica dal 2° al 16° giorno di gestazione, notò una diminuzione del numero globale dei feti e di quello dei nati vivi, osservando inoltre numerose malformazioni congenite. Di queste le più frequenti e tipiche erano a carico del cranio e dell'encefalo, pur risultando sporadicamente presenti difetti oculari ed anomalie dell'ambito orale quali labioschisi, palatoschisi e macroglossia.

In una serie di esperienze effettuate nel ratto Giroud e Martinet [8 9 10 11 12 13] (1954, 1955, 1956) hanno apportato acquisizioni di notevole interesse sul ruolo teratogeno dell'ipervitaminosi A. Per quanto riguarda il dosaggio gli AA. riferiscono che la somministrazione per os di 35.000 U protratta dal 4° al 15° giorno di gestazione determina morte e riassorbimento di tutti i feti; la somministrazione di 20.000 U dal 2°-4° al 12°-15° giorno

determina invece, accanto ad una certa percentuale di morti e di riassorbimenti fetali, un numero notevole di anomalie a carico del sistema nervoso (anencefalie, 6%), dell'occhio (anoftalmie e microftalmie, 25%), del cavo orale (palatoschisi, 28%).

La somministrazione di dosi maggiori, 60.000 U, limitata a soli tre giorni consecutivi (in periodi compresi fra il 5° e il 20° giorno), provocava risultati diversi a seconda del periodo di gravidanza:

5° - 6° - 7° giorno	- 43% di riassorbimenti - 20% di morti fetali - 80% di feti normali - Piccola percentuale di anencefalie e anoftalmie
8° - 9° - 10° giorno	- Anencefalie, anoftalmie o microftalmie, spina bifida.
10° - 11° - 12° giorno	- Palatoschisi, schisi mandibolare e lingua bifida, malformazioni dell'orecchio.
11° - 12° - 13° giorno	- Palatoschisi, aplasia palpebrale, micromelia, sindattilia.
14° - 15° - 16° giorno	- Soltanto palatoschisi.
18° - 19° - 20° giorno	- Soltanto cateratte.

A proposito di tali ricerche è interessante notare come la maggiore incidenza di anomalie a carico dell'ambito orale si sia verificata con somministrazioni dal 10° al 16° giorno e come dal 14° al 16° giorno la ipervitaminosi provochi sempre e soltanto palatoschisi.

Successivamente Woollam e Millen [23 33] (1957) hanno somministrato per os a ratti 60.000 U pro die di vitamina A dall'8° al 13° giorno ottenendo il 7,8% di anomalie craniche ed encefaliche e il 29,7% di palatoschisi. Gli stessi AA., somministrando vitamina A alle dosi suddette e per gli stessi giorni e iniettando sottocute cortisone alla dose di 20 mg. dal 9° al 12° giorno, hanno ottenuto il 100% di palatoschisi. La somministrazione di sola vitamina A per via sottocutanea, dall'8° al 12° giorno, così come la somministrazione di solo cortisone dal 9° al 12° giorno, non ha fornito alcun risultato; invece l'impiego delle stesse dosi di vitamina A e di cortisone associate nello stesso periodo e per la stessa via sottocutanea hanno fornito l'1,4% di palatoschisi.

Deuschle, Geiger e Warkany [4] (1959) hanno somministrato per os singole dosi di vitamina A (da 75.000 a 150.000 U) rispettivamente al 9°, 10° e 11° giorno, ottenendo nella prole dei ratti trattati interessanti risultati quali esoftalmo, saldatura maxillo-mandibolare, presenza di cartilagine ectopica nell'arco mascellare, palatoschisi, assenza di alcuni germi di molari,

presenza di una formazione canalizzata a tipo polipo sotto il processo palatino.

Vichi, Masi, Orlando e Di Gangi [31] (1962) hanno introdotto la vitamina A nel ratto per via intramuscolare ottenendo con 80.000 U dall'8° al 10° giorno, micrognazia con microgenia, difetti di saldatura della sinfisi mentoniera e solcatura parziale della lingua; con 60.000 U dall'11° al 13° giorno macroglossia, micrognazia con microgenia. Le stesse 60.000 U somministrate per via gastrica dal 10° al 12° giorno hanno determinato micrognazia con microgenia.

La somministrazione di vitamina A in alte dosi è stata sperimentata da Giroud e Martinet [15 16] (1959) anche in specie animali diverse dal ratto e precisamente nella cavia, nel coniglio e nel topo allo scopo di saggiare in tali animali la possibilità di effetti teratogenetici largamente dimostrata nel ratto.

Nella cavia la somministrazione per os di vitamina A in dosi di 50.000U per tre giorni consecutivi, ha determinato, accanto ad un numero notevole di aborti, anche la comparsa di fessure mediane della mandibola con lingua bifida, osservata peraltro in un solo caso. A nostro avviso il fatto che gli AA. non abbiano precisato l'epoca della gravidanza in cui ha avuto inizio la somministrazione di vitamina A, né il numero degli animali trattati, e la constatazione che l'effetto teratogeno si è reso evidente in un solo caso, rendono di difficile valutazione il significato dei risultati resi noti.

Nel coniglio, con dosi variabili fra 125.000 e 150.000 U somministrate per os per tre e, rispettivamente, per cinque giorni consecutivi a partire dal 5° di gravidanza, gli stessi AA. hanno ottenuto aborti con la medesima frequenza notata nella cavia. Più numerosi invece che nella cavia i risultati dovuti a turba di sviluppo e pertanto considerabili come vere e proprie malformazioni. In una portata, infatti, tutti i feti apparivano colpiti dalle stesse anomalie: sindattilia, disgenesia facciale rappresentata da contrazione trasversale della faccia con ipoplasia della mandibola e profilo d'uccello ed inoltre alterazioni oculari rappresentate da emorragie del cristallino, scollamento della retina, emorragie retroretiniche e fibrosi del vitreo.

In una serie di esperimenti effettuati sul topo in dosi diverse e in differenti periodi di gestazione Giroud e Martinet [15 17 18 19 20] (1959, 1960 e 1962) hanno messo in evidenza numerosi dati ricchi di notevole interesse. Con 100 U per tre giorni consecutivi (8° - 10°) gli AA. hanno ottenuto aborti nel 9,9% dei casi e morti e riassorbimenti intrauterini nel 7,5%. Con 250 U (8° - 10°), oltre ad una più alta percentuale di aborti e di riassorbimenti sono state riscontrate anencefalie (19%) e malformazioni della faccia (18%). Con 500 U (8° - 10°) aborti e riassorbimenti in modesta percentuale, anencefalie nel 10% e malformazioni diverse, non meglio precisate, nel 36% dei casi. La somministrazione infine di dosi molto più ele-

vate, pari a 3.000 U, se effettuata dall'8° al 10° giorno, ha determinato nel 28% dei casi anencefalia non associata ad anomalie oculari; inoltre, più raramente, anomalie cardiache caratterizzate soprattutto da comunicazione interventricolare. La stessa dose somministrata dall'11° al 13° giorno ha provocato prevalentemente fessure del palato posteriore la cui frequenza ha raggiunto il 90%.

Tale differenza riscontrata negli effetti teratogeni in funzione dello stadio embrionario è stata abbondantemente documentata dagli stessi AA. i quali, variando l'epoca di somministrazione, hanno ottenuto malformazioni diverse e di diversa intensità. Con somministrazioni singole precoci (6°, 7°, 8°, 9° giorno) sono state ottenute anencefalie in varia percentuale, con un massimo di incidenza del 21,6% al 7° giorno. I trattamenti più tardivi (9°, 10°, 11° e 13° giorno) hanno determinato palatoschisi in percentuali fino al 68 e 70%, rispettivamente all'11° e al 12° giorno.

Sempre nel topo Kalter e Warkany [25] (1961), con l'impiego di 10.000 U di vitamina A in unica dose all'8° o al 9° giorno, hanno riscontrato palatoschisi nel 70,8%, microstomia, saldatura maxillo-mandibolare, microgenia, schisi mandibolare, anchiloglossia, assenza del massetere, assenza di ghiandole salivari, ghiandole sottomascellari ectopiche ed anomalie dentali consistenti in denti fusi, soprannumerari ed ectopici. La somministrazione al 10° giorno ha determinato microgenia ed ancora palatoschisi, ma in minor percentuale (36,5%).

CONTRIBUTO PERSONALE

Per le nostre esperienze abbiamo utilizzato tre lotti, rispettivamente di dieci, dieci e cinque animali ciascuno, di ratti omogenei per razza (Rattus norvegicus), ceppo (Wistar) ed età, di peso oscillante fra 210 e 253 gr., con valore medio di gr. 220, appartenenti a famiglie che, seguite per diverse generazioni, non hanno mai presentato malformazioni spontanee. Le ratte, mantenute a normale regime di allevamento, sono state accoppiate col maschio e l'inizio della gravidanza è stato accertato e calcolato dal riscontro di spermatozoi nello striscio vaginale.

La vitamina A in soluzione oleosa sotto forma di palmitato, alla concentrazione di 500.000 U per cc., è stata somministrata per via orale mediante sondino alla dose di 50.000 U pro die. Nel primo lotto la somministrazione è stata effettuata al 10°, 11° e 12° giorno di gestazione; nel secondo lotto all'11°, 12° e 13° giorno. Il terzo lotto è stato utilizzato come controllo. Agli animali, sacrificati al 21° giorno, prima del parto, è stato effettuato il prelievo dei feti dai corni uterini.

I risultati delle malformazioni riscontrate vengono così sintetizzati:

1° *lotto*: N. 10 ratte - 50.000 U Vit A pro die, per os, 10°, 11°, 12° g.

N° 1 - Portata di 9 embrioni - 2 anencefalie
1 spina bifida con meningomielocele
3 palatoschisi
2 palatoschisi e meningoceli leggeri

N° 2 - Portata di 7 embrioni - 1 anencefalia e spina bifida con meningomielocele
1 anencefalia
1 palatoschisi
2 meningoceli leggeri
1 riassorbimento

N° 3 - Portata di 6 embrioni - 2 anencefalie
2 meningoceli leggeri
3 riassorbimenti

N° 4 - Portata di 10 embrioni - 1 anencefalia
3 meningoceli leggeri
2 palatoschisi

N° 5 - Portata di 7 embrioni - 1 anencefalia con palatoschisi
3 palatoschisi
2 riassorbimenti

N° 6 - Portata di 8 embrioni - 1 anencefalia e spina bifida con meningomielocele
2 anencefalie

N° 7 - Portata di 9 embrioni - 1 anencefalia
1 palatoschisi

N° 8-9-10 - Riassorbimenti e morte intrauterina dei feti.

2° *lotto*: N. 10 ratte - 50.000 U Vit A pro die, per os 11°, 12°, 13° g.

N° 1 - Portata di 6 embrioni - 3 palatoschisi
2 riassorbimenti

N° 2 - Portata di 8 embrioni - 7 palatoschisi

N° 3 - Portata di 11 embrioni - 4 palatoschisi

N° 4 - Portata di 9 embrioni - 4 palatoschisi
3 meningoceli leggeri

N° 5 - Portata di 8 embrioni - 5 palatoschisi
1 riassorbimento

N° 6 - Portata di 7 embrioni - 3 palatoschisi

N° 7 - Portata di 7 embrioni - 3 palatoschisi
1 meningocele leggero
1 riassorbimento

N° 8 - Portata di 10 embrioni - 4 palatoschisi

N° 9-10 - Riassorbimenti e morte intrauterina dei feti.

3° *lotto* - N. 5 ratte - Controlli.

Si sono avuti complessivamente 53 feti, tutti morfologicamente normali.

COMMENTO

Le palatoschisi, osservate nel primo lotto nella percentuale del 21,4 e nel secondo lotto del 54,5 interessano esclusivamente il palato posteriore, mentre il palato anteriore appare costantemente rispettato. Di esse soltanto poche sono limitate alla porzione posteriore del palato posteriore, mentre la maggior parte interessa tutto il palato posteriore (Fig. 1), iniziando al di dietro della papilla palatina nel punto in cui si aprono i canali naso-palatini (Figg. 2 e 3).

Le fessure totali sono più o meno estese in larghezza (Figg. 1 e 4) a seconda del grado di arresto di sviluppo dei processi palatini. Nelle fessure più larghe in alcuni punti i processi sembrano del tutto assenti.

Le caratteristiche sopra descritte sono identiche in tutti gli animali, sia provenienti dal primo che dal secondo lotto.

Le malformazioni cranio-encefaliche da noi riscontrate nel primo lotto con una incidenza del 19,6% sono da considerarsi, più che delle vere e proprie anencefalie, come dell'exencefalie determinate da mancanza della volta cranica e dei tegumenti (Fig. 5). In alcuni casi appartenenti sia al primo che al secondo lotto è stato riscontrato meningocele leggero, consistente

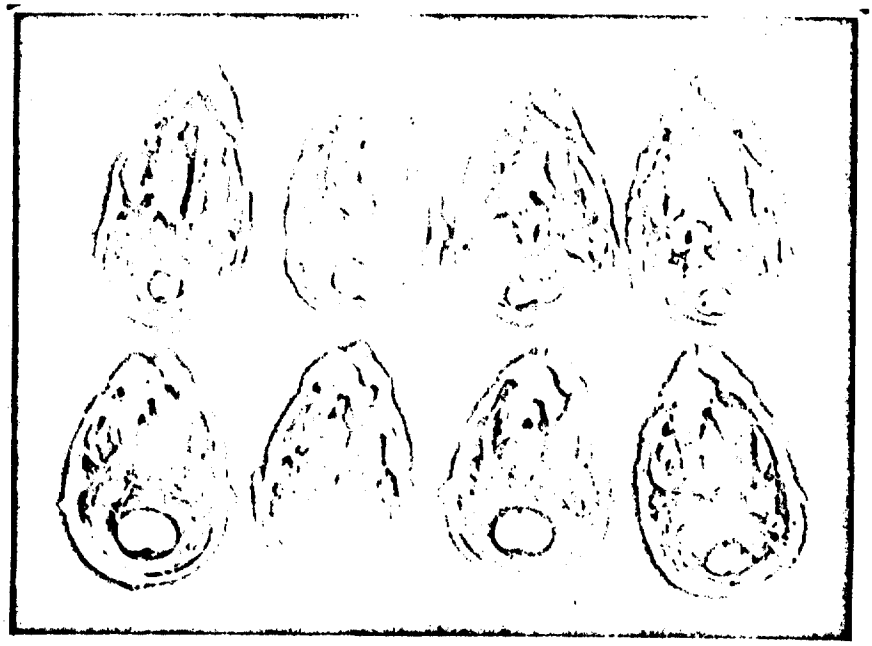

Fig. 1 - La prima figura in alto a destra mostra il palato normale di ratto controllo; la seconda, sempre in alto da destra, rappresenta una fessura parziale del palato posteriore; le rimanenti illustrano fessure totali del palato posteriore di differente larghezza.

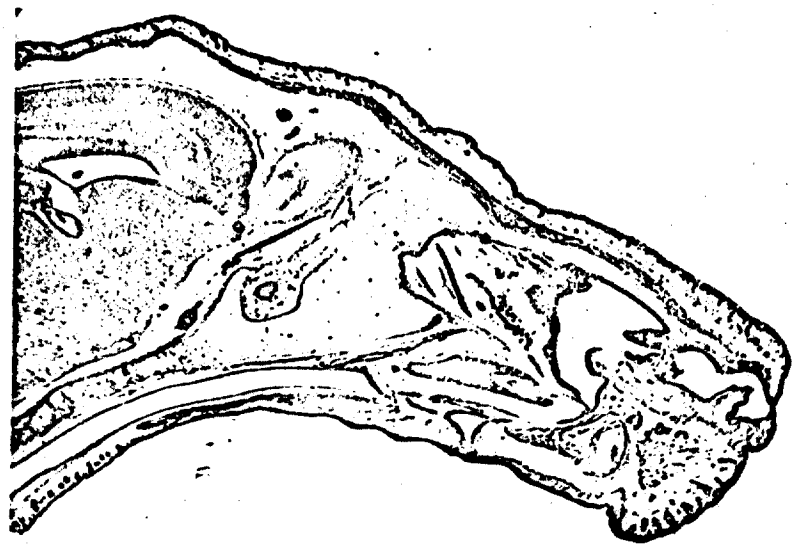

Fig. 2 - Sezione sagittale mediana di testa di feto a termine prelevato da madre non trattata. Morfologia normale del palato con canale naso-palatino al limite fra palato anteriore e palato posteriore.

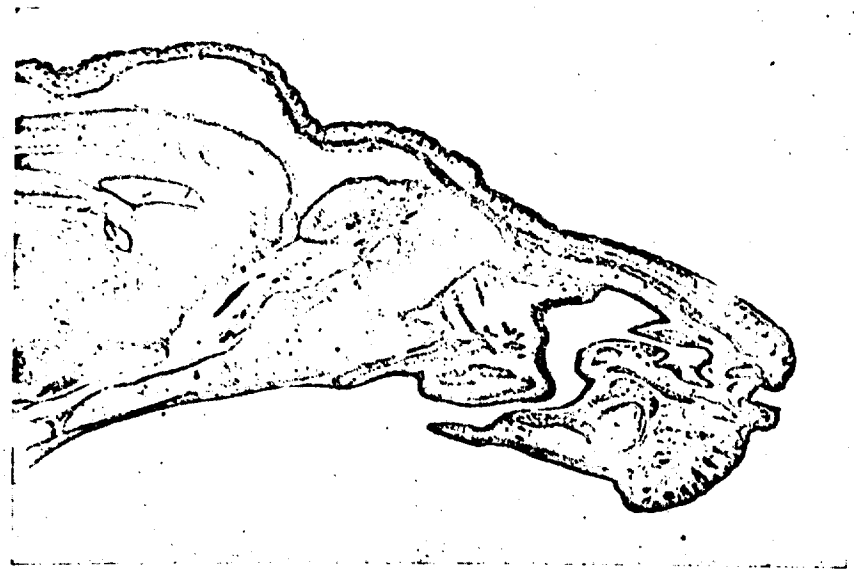

Fig. 3 - Sezione sagittale mediana di testa di feto a termine prelevato da madre trattata che dimostra una schisi totale del palato posteriore.



Fig. 4 - Fessure totali del palato posteriore di diversa larghezza: si noti come i processi palatini siano incompleti e in alcuni punti del tutto mancanti.

Fig. 5 - Exencefalie.

in una lieve estroflessione della dura, resa possibile dal difetto della volta cranica.

In tre casi, pari al 5,3%, tutti appartenenti al primo lotto, è stata osservata una anomalia del rachide classificabile come spina bifida. La rachischisi si presenta nella regione lombare ed è caratterizzata da una ampia apertura delle vertebre e del midollo spinale, i cui bordi si continuano con l'epidermide (Fig. 6).

CONSIDERAZIONI CONCLUSIVE

L'analisi dei dati contenuti nella letteratura sull'argomento e la valutazione dei risultati conseguiti con le personali indagini sperimentali sopra riferite ci consentono di formulare alcune considerazioni.

1) Innanzitutto risulta chiaro che l'effetto teratogeno posseduto dalla vitamina A è dimostrabile in tutte le specie animali utilizzate e cioè nel ratto, nel topo, nel coniglio e nella cavia. Tale effetto non si manifesta però



Fig. 6 - Rachischisi e meningomielocele nella regione lombare.

con uguale intensità in tutti gli animali impiegati nella sperimentazione, verosimilmente a causa della differente sensibilità di specie alla sostanza somministrata.

2) L'intensità e la frequenza dei risultati sembrano peraltro dipendere, oltre che dalla sensibilità della specie animale, anche dal dosaggio e dalla via di somministrazione. A sostegno di ciò sta la constatazione che, mentre dosi eccessive determinano prevalentemente morti o riassorbimenti fetali, dosi variabili fra 20.000 e 60.000 U nel ratto, fra 25.000 e 150.000 nel coniglio e dosi di 3.000 U nel topo appaiono le più idonee a provocare numerose e molteplici anomalie. In quest'ultimo animale, però, Giroud e Martinet [20] hanno dimostrato come dosi assai più leggere, di 250 e 500 U, siano già capaci di determinare, oltre ad aborti e riassorbimenti, osservabili d'al-

tronde anche con dosi di sole 100 U, malformazioni diverse di cui in non piccola percentuale quelle cranio-encefaliche e facciali. La valutazione, ad opera degli stessi AA., di queste dosi rapportate a kg di peso (500 U - 12.500 U per Kg; 250 U - 6.500 U per Kg; 100 U - 2.500 U per Kg) appare interessante per la comparazione delle dosi utilizzate in terapia clinica che, rappresentate da 1000-3000 U pro kilo e pro die, si avvicinano molto a quelle dell'esperimento. Sembra pertanto giustificato ammettere che, come altre ben documentate sostanze chimiche, anche la vitamina A sia teratogena a dosi relativamente leggere e assai vicine a quelle di impiego terapeutico nell'uomo.

È noto d'altronde come la vitamina A, a differenza delle vitamine idrosolubili che possono essere facilmente eliminate, si accumuli nell'organismo e vi si mantenga per parecchio tempo, prima della sua eliminazione, con tassi tali da poter determinare effetti teratogeni anche dopo la cessazione del trattamento.

È stato dimostrato inoltre come sia possibile il passaggio di vitamina A dalla madre al feto in diverse specie animali (Dann [3], Zunin e Testa [31], Henry e Coll. [23]) e nell'uomo (Wendt [32], Neuweiler [30]). Giroud, Gounelle e Martinet [7], confermando il passaggio della vitamina A dalla madre al feto, hanno messo in evidenza che la concentrazione della vitamina nell'organismo fetale dipende da quella dell'organismo materno — come verrebbe dimostrato dal fatto che il tenore in vitamina A nei feti di madri trattate appare pressappoco raddoppiato rispetto ai controlli — e che l'azione della vitamina A sul prodotto del concepimento è indipendente da una concentrazione eccessiva nei tessuti materni e si esplica direttamente sull'embrione.

3) Importante è pure notare come l'effetto della ipervitaminosi A dipenda anche dalla via di somministrazione. Infatti negli esperimenti di Woollam e Millen [26 33] la vitamina A iniettata sottocute nei ratti alla dose di 60.000 U non ha provocato alcuna malformazione laddove invece la stessa dose, somministrata negli stessi giorni (dall8° al 13°) ma per via orale, ha provocato frequenti malformazioni (palatoschisi). L'opinione degli AA. è che il basso grado di assorbimento consecutivo alla somministrazione per via sottocutanea impedisca alla vitamina di raggiungere il feto ad una concentrazione sufficiente a determinare un effetto teratogeno. In nostri precedenti esperimenti tuttavia non sono state notate significative differenze nella quantità e nella qualità delle anomalie ottenute con vitamina A somministrata sia per via intramuscolare che per via orale. È doveroso tener presente però che non esistevano identiche condizioni di esperimento nei diversi lotti, per quanto riguarda le dosi e le epoche di somministrazione.

4) Un interesse del tutto particolare rivestono le anomalie congenite del cavo orale riscontrate costantemente nelle quattro specie animali trattate con ipervitaminosi A. Di tali anomalie è senza dubbio più frequente la palatoschisi, osservata nel ratto (Cohlan [1 2], Giroud e Martinet [8 9 10 11 13], Woollam e Millen [26 33], Deuschle, Geiger e Warkany [4], Vichi e Coll [31]) e nel topo (Giroud e Martinet [15 18 20], Kalter e Warkany [25]). Solo eccezionalmente la palatoschisi da ipervitaminosi A è stata osservata associata, nel ratto, a labioschisi (Cohlan [1]), all'opposto di quanto succede con altre sostanze (cortisone, aminopterina) nelle quali all'alta incidenza del labbro leporino fa riscontro raramente la presenza di palatoschisi. Anomalie della lingua, generalmente rappresentate da macroglossia, lingua bifida e anchiloglossia, sono state evidenziate nel ratto (Cohlan [1], Giroud e Martinet [12], Vichi e Coll. [31]), nella cavia (Giroud e Martinet [15]) e nel topo (Kalter e Warkany [25]).

Varie sono le anomalie descritte a carico delle ossa mascellari, di cui alcune riguardano il mascellare superiore che è apparso contratto trasversalmente nel coniglio (Giroud e Martinet [15 16]) o ipoplasico nel ratto (Vichi e Coll. [31]); altre la mandibola, che è risultata priva di saldatura alla sinfisi sia nel ratto (Vichi e Coll. [31]) che nella cavia (Giroud e Martinet [15]), ipoplasica nel ratto (Vichi e Coll. [31]) e nel topo (Kalter e Warkany [25]), talvolta mancante delle branche ascendenti. Sono state osservate anche anomalie associate di ambedue i mascellari e precisamente saldatura maxillo-mandibolare nel ratto (Deuschle, Geiger e Warkany [4]) e nel topo (Kalter e Warkany [25]); disgenesia maxillo-mandibolare nel coniglio (Giroud e Martinet [15 16]); micrognazia con microgenia nel ratto (Vichi e Coll. [31]). Oltre a ciò è stata segnalata presenza di cartilagine eterotopica nei mascellari, tanto nel ratto (Deuschle, Geiger e Warkany [4]) che nel topo (Kalter e Warkany [25]).

5) Né da sottovalutare ci sembrano le malformazioni riscontrate in organi e tessuti topograficamente contigui e funzionalmente legati al cavo orale quali quelle descritte da Kalter e Warkany [25] nel topo e consistenti in aplasia del muscolo massetere e delle ghiandole salivari maggiori e rispettivi dotti, nonché in ectopia delle ghiandole sottomascellari; tanto più che tali anomalie risultavano per lo più associate ad una insolita malformazione, la microstomia, che andava da una modesta riduzione di apertura del cavo orale ad una apparente assenza dell'apertura stessa.

6) Notevole, ma non costante come quella delle malformazioni orali, l'incidenza di anomalie oculari riscontrate solo nel ratto e per lo più rappresentate da anoftalmie, microftalmie, assenza delle palpebre e cateratte (Cohlan [1], Giroud e Martinet [11 12 13]).

Di gran lunga meno frequenti appaiono le anomalie dell'orecchio — arresto di sviluppo dell'orecchio medio, otocefalia, mancanza dell'orecchio esterno e presenza di appendici auricolari — descritte nel ratto e nel coniglio da Giroud e Martinet [13].

7) L'ipervitaminosi A produce con notevole frequenza nel ratto, nel coniglio e nel topo, malformazioni cranio-encefaliche, essenzialmente rappresentate da anencefalia. Desideriamo tuttavia far rilevare che figurano delle alterazioni meglio definibili come exencefalie piuttosto che vere e proprie anencefalie; e tali sono appunto le malformazioni da noi osservate. È noto d'altronde come le anencefalie ottenibili nel ratto, che frequentemente si associano con anoftalmie e microftalmie, si differenziano da quelle riscontrabili nel topo, dove mancano costantemente le anomalie oculari e dove, pertanto, si realizza un tipo di malformazione ritenuto da Giroud e Martinet [17] sovrapponibile a quello conosciuto in patologia umana.

L'analisi e la discussione delle malformazioni indotte negli animali da esperimento dall'ipervitaminosi A non possono ritenersi esaurite senza che venga affrontato, dopo l'argomento concernente la posologia e la via di somministrazione, il problema dell'epoca del trattamento. È noto infatti, come il tipo, la sede e l'intensità delle singole anomalie siano in stretta relazione con lo stadio di sviluppo embrionale in cui l'agente teratogeno esplica la sua azione. Nel ratto, che è l'animale più frequentemente impiegato negli esperimenti di teratogenesi con ipervitaminosi A, la palatoschisi comincia ad osservarsi, associata a schisi mandibolare ed a malformazioni dell'orecchio, in seguito a trattamenti dal 10° al 12° giorno; si riscontra poi, ed associata ad aplasia delle palpebre ed a malformazioni delle membra, con trattamento dall'11° al 13° giorno; si manifesta infine da sola, ma con frequenza notevolmente più bassa, dal 14° al 16° giorno.

Nel topo la maggiore percentuale di palatoschisi, insieme ad altre anomalie del cavo orale, si osserva a seguito di trattamenti effettuati al 9° e al 12° giorno, mentre la somministrazione al 10° giorno determina una incidenza minima di fessure palatine. Tale comportamento può essere spiegato ammettendo con Giroud e Martinet [13] che la vitamina A agisca in un primo tempo sugli abbozzi dei processi palatini, interferendo successivamente sulla crescita specifica dei processi stessi.

Desideriamo anche sottolineare come nel ratto la somministrazione precoce dal 5° al 7° giorno già determini la comparsa di anencefalie, la cui maggiore incidenza si riscontra però dall'8° al 10° giorno. Nel topo la maggiore percentuale di anencefalie si osserva con trattamento al 7° giorno e all'8°, mentre al 6° e al 9° l'incidenza è minima. Le poche anencefalie riscontrabili a seguito di trattamenti più tardivi (11° giorno) sarebbero imputabili a mancata chiusura del tubo encefalico.

Per quello che riguarda la spina bifida è da notare come essa compaia nel ratto in seguito a trattamento dall'8° al 10° giorno; molto più raramente dall'11° al 13°. Essa si presenta quindi come un difetto a comparsa più tardiva rispetto all'anencefalia. Il che conferma quanto già era stato dimostrato da Hicks [24] (1954) con l'impiego di radiazioni.

Da quanto sopra risulta come anche per le anomalie provocate con ipervitaminosi A possa essere ammessa una stretta dipendenza dallo stadio di sviluppo dell'embrione a carico del quale si è esplicata l'azione teratogena. L'importanza dello « stadio sensibile », ormai riconosciuta oltre che per le sostanze chimiche anche per gli agenti fisici ed infettivi impiegati in teratogenesi, non diminuisce però la funzione che viene assegnata alla specificità della sostanza impiegata.

A conclusione delle considerazioni fin qui esposte teniamo a mettere in rilievo come la nostra attuale personale indagine confermi: 1) il ruolo teratogeno dell'ipervitaminosi A; 2) la particolare frequenza delle anomalie del cavo orale, fra cui primeggia la palatoschisi, rispetto a quelle di altri organi ed apparati.

Desideriamo infine sottolineare come l'importanza dei risultati ottenibili in teratogenesi con l'ipervitaminosi A derivi anche dalla constatazione che tale sostanza trova larga applicazione in terapia e che le anomalie con essa conseguibili nelle diverse specie di animali da esperimento — in alcune delle quali, come nel topo, anche a dosi relativamente modeste — presentano singolari analogie con quelle riscontrabili in patologia umana.

BIBLIOGRAFIA

1 COHLAN S.Q., Science, 117, 535, 1953.
2 COHLAN S.Q., Pediatrics, 13, 556, 1954.
3 DANN W.J., Bioch. J., 26, 1072, 1932.
4 DEUSCHLE F.M., GEIGER J.F., WARKANY J., J. Dent. Res., 38, 149, 1959.
5 FILIPPI B., Min. Otorinolar., 7, 151, 1957.
6 GIROUD A., GOURNELLE H., MARTINET M., C.R. Soc. Biol., 150, 2064, 1956.
7 GIROUD A., GOUNELLE H., MARTINET M., Bull. Soc. Chim. Biol., 39, 331, 1957.
8 GIROUD A., MARTINET M., C.R. Soc. Biol., 148, 1742, 1954.
9 GIROUD A., MARTINET M., Arch. Franç. Ped., 12, 3, 1955.
10 GIROUD A., MARTINET M., Rev. Int. Vitamin., 26, 10, 1955.
11 Giroud A., Martinet M., Arch. Anat. Micr. Morph. Exper., 45, 77, 1956.
12 Giroud A., Martinet M., Et Néo-Nat., 5, 55, 1956.
13 Giroud A., Martinet M., Rev. Stom., 57, 454, 1956.
14 Giroud A., Martinet M., C.R.A. Biol., 151, 872, 1957.
15 GIROUD A., Martinet M., Arch. Franç. Ped., 16, 971, 1959.
16 GIROUD A., MARTINET M., Bull. Soc. Ophtalm., n. 3, 1959.
17 GIROUD A., MARTINET M., Acta Anat., 43, 358, 1960.
18 GIROUD A., MARTINET M., C.R.Soc. Biol., 154, 1353, 1960.
19 GIROUD A., MARTINET M., Rev. Neurol., 103, 356, 1960.
20 GIROUD A., MARTINET M., C.R. Soc. Biol., 156, 449, 1962.
21 GRUNEBERG H., *The genetics of the mouse*. The Hague, 1952.
22 HANSBOROUGH L.A., Growth, 11, 177, 1947.
23 HENRY e Coll., Brit. J. Nutr., 3, 301, 1949.
24 HICKS S.P., Am. J. Roent., 69, 272, 1954.
25 KALTER H., WARKANY J., Am. J. Path., 38, 1, 1961.
26 MILLEN J.W., WOOLLAM D.H., Brit. Med. J., 5038, 196, 1957.
27 MOORE L.A., WANG Y.L., Bioch. J., 8, 37, 1943.
28 MOURIQUAND G., EDEL V., C.R. Soc. Biol., 148, 1422, 1954.
29 NEUWEILER W., Ztschr. Vitaminforsch., 22, 392, 1950.
30 NEUWEILER W., Int. Z. Vitaminforschr., 26, 87, 1955.
30 NEUWEILER W., Int. Z. Vitaminforschr., 26, 87, 1955.
31 VICHI F., MASI P.L., ORLANDO S., DI GANGI F., Min. Stom., 11, 275, 1962.
32 WENDT H., KLIN. WSCHR., 15, 222, 1936.
33 WOOLLAM D.M., MILLEN J.W., Brit. M. J., 5038, 197, 1957.
34 ZUNIN C., TESTA F., Atti Soc. It. Path., 3, 637, 1953.

Warkany-'44
Bib. No. 9653

Proc. Soc. Exptl. Biol. and Med. 57(1):49-52. 1944.

14695 P

Congenital Malformations of the Eyes Induced in Rats by Maternal Vitamin A Deficiency.*

JOSEF WARKANY AND ELIZABETH SCHRAFFENBERGER.
From the Children's Hospital Research Foundation, Cincinnati, Ohio.

It has been repeatedly suggested that congenital blindness in animals may be caused by a maternal nutritional deficiency. Blindness in cattle associated with a constriction of the optic nerve of probable nutritional origin was reported by Moore *et al.*[1] who also reviewed the literature concerning this subject. Hale [2] reported the occurrence of anophthalmos and microphthalmos in pigs whose mothers had been fed a diet deficient in vitamin A. No corresponding findings have been reported in rats. Mason[3] who studied reproduction of vitamin A deficient rats described foetal death, prolonged gestation and difficult parturition but not congenital malformations of the offspring. Cannon[4] also reported failure to produce congenital anomalies in the young of rats whose mothers were depleted of vitamin A.

We have recently observed congenital defects of the eyes in the offspring of rats raised on a diet containing very small amounts of carotene and bred on a diet entirely free of carotene and vitamin A. The preparatory diet (Diet U) fed for approximately 3 months after weaning had the following percentage composition: Ground whole wheat, 74; crude casein (Borden), 15; brewer's yeast (Mead Johnson), 10; sodium chloride C.P., 1. This diet was supplemented by 60 I.U. of vitamin D (Drisdol, Winthrop) and 25 μg of carotene (SMACO) in cottonseed oil every tenth day. This small amount of carotene made possible slow growth and maturation but no storage

* This work was aided in part by a grant from the Nutrition Foundation, Inc., New York, N.Y.

[1] Moore, L. A., Huffman, C. F., and Duncan, C. W., *J. Nutr.*, 1935, **9**, 533.

[2] Hale, F., *J. Hered.*, 1933, **24**, 105.

[3] Mason, K. E., *Am. J. Anat.*, 1935, **57**, 303.

[4] Cannon, M. D., PROC. SOC. EXP. BIOL. AND MED., 1940, **44**, 129.

FIG. 1.
Showing abnormal "open eye" in newborn rat.

of the vitamin. If the growth curves of the rats became flat during this preparatory period, which happened about 3 or 4 times, each rat was given 5 g of horse muscle.

The purified diet (Diet W) which was completely free of vitamin A had the following percentage composition: Sucrose, 68; vitamin test casein, 18; vegetable oil, 10; salt mixture,[3] 4. One hundred grams of this diet were supplemented by 0.8 mg thiamine hydrochloride, 0.8 mg pyridoxine hydrochloride, 0.8 mg riboflavin, 1 mg calcium pantothenate, 10 mg niacinamide, and 100 mg choline chloride. This diet was supplemented every tenth day by vitamin D (1 drop of a 1:4 dilution with olive oil of Drisdol), vitamin E (1 drop of a solution of 5 g alpha-tocopherol in 100 ml of olive oil), and vitamin K (1 drop of a solution of 1 mg of 2-methylnaphthoquinone in 5 ml of olive oil).

[3] Hubbell, R. B., Mendel, L. B., and Wakeman, A. J., *J. Nutr.*, 1937, **14**, 273.

Twenty female rats of the Sprague-Dawley strain were raised on diet U until they reached a weight of 150-160 g and regular oestrus cycles were established. Then they were placed on the purified diet W and bred to males of the same strain. These males had been fed an adequate diet. Twelve of the females bred as was confirmed by the finding of sperm in the vaginal smears. Within a week the females fed diet W showed marked signs of nutritional deficiency and only three mothers carried their litters to or near term, while nine females resorbed their embryos. The three litters obtained by caesarean sections consisted of 19 dead young, all of which had abnormal eyes.

In 14 of these young the abnormality could be recognized by external examination. Instead of the closed eyes seen in normal newborn rats "open eyes" of a reddish color were seen (Fig. 1). These eyes as well as the closed eyes of 5 of the young were abnormal on histological examination.

Fig. 2A
Section of the eye of a normal 19-day rat fetus. (× 70.)

Fig. 2B
Section of an abnormal "open eye." (× 70.)

Fig. 2A represents the eye of a normal 19-day rat fetus and Fig. 2B an "open eye." In the normal eye the lids, the conjunctival sac, the cornea, the anterior chamber and the iris appear as well defined separate structures and spaces. In the abnormal eye there is no

clear differentiation of the lids and the cornea; the anterior chamber is present in a rudimentary form only. In the normal eye the vitreous can be seen between the lens and the retina, while the same space in the abnormal eye is filled with connective tissue. The retina of the abnormal eye is folded and disorganized. In the closed abnormal eyes the lids are fused with the cornea and the anterior chamber appears as a linear space between the thick membrane thus formed and the lens. In several specimens a cleft can be seen in the inferior part of the retina and a strand of connective tissue which penetrates this cleft, spreads out in the space between the lens and the retina. This cleft represents a coloboma of the retina.

As controls 62 females of the same strain were fed diet W supplemented with vitamin A. They had 410 young, none of which showed abnormal "open eyes."

Arch. Ophthalmol. 35(2):150-169. 1946.

Warkany-'46
Bib. No. 9654

CONGENITAL MALFORMATIONS INDUCED IN RATS BY MATERNAL VITAMIN A DEFICIENCY

I. Defects of the Eye

JOSEF WARKANY, M.D.
AND
ELIZABETH SCHRAFFENBERGER, A.B.
CINCINNATI

ALTHOUGH congenital blindness of the offspring of poorly nourished animals has often been described, the early reports were specific neither in the analysis of the nutritional deficiency nor in the description of the ocular defects. Most of the observations were made on cattle, and Moore, Huffman and Duncan [1] have reviewed the literature pertaining to this field. Two types of congenital blindness can be distinguished: "the true vitamin A type," which is obviously a severe form of xerophthalmia,[2] and another type which is associated with constriction of the optic foramen.[3] The latter, characterized by a dilated pupil and absence of inflammation of the external structures of the eye, is due to atrophy of the optic nerve caused by its passage through the optic foramen, apparently because of bony pressure.[1] It was difficult to attribute this congenital ocular defect to maternal vitamin A deficiency until Wolbach and Bessey [4] demonstrated that the neural lesions of vitamin A deficiency are caused by a disproportionate growth of the central nervous system in relation to the surrounding bone. Constric-

This work was aided in part by a grant from the Nutrition Foundation, Inc., New York.

From the Children's Hospital Research Foundation, Department of Pediatrics, University of Cincinnati College of Medicine.

1. Moore, L. A.: Huffman, C. F., and Duncan, C. W.: J. Nutrition **9**:533, 1935.

2. (*a*) Mason, K. E.: Am. J. Anat. **57**:303, 1935. (*b*) Hart, G. H., and Guilbert, H. R.: Bulletin 560, California Agricultural Experiment Station, 1933, p. 3. (*c*) Jones, I. R.; Eckles, C. H., and Palmer, L. S.: J. Dairy Sc. **9**:119, 1926. (*d*) Mead, S. W., and Regan, W. M.: ibid. **14**:283,1931.

3. Crocker, W. J.: Cornell Vet. **9**:171, 1919. Reed, O. E.; Huffman, C. F., and Addington, L. H.: J. Dairy Sc. **11**:488, 1928. Halverson, J. O., and Sherwood, F. W.: Technical Bulletin 39, North Carolina Agricultural Experiment Station, 1930, p. 5. Converse, H. T., and Meigs, E. B.: Proc. Am. Soc. Animal Production **24**:141, 1932. Datta, S. C. A.: Indian J. Vet. Sc. **3**:254, 1933. Moore, L. A.: J. Nutrition **17**:443, 1939; J. Dairy Sc. **22**:803, 1939.

4. Wolbach, S. B., and Bessey, O. A.: Vitamin A Deficiency and the Nervous System, Arch. Path. **32**:689 (Nov.) 1941.

tion of the optic foramen can now be considered a "true" manifestation of vitamin A deficiency. Davis and Madsen [5] made quantitative studies of carotene intake of cattle and of plasma levels of carotene and vitamin A during pregnancy in heifers who gave birth to weak and blind calves. They found that heifers receiving 30 and 45 micrograms of carotene remained apparently normal but gave birth to defective calves.

The manifestations of prenatal vitamin A deficiency in pigs described by Hale [6] were of an entirely different character. This investigator fed gilts of known stocks a diet deficient in vitamin A and possibly in other nutritional factors. Owing to anophthalmos or microphthalmos, the offspring were blind. They also showed other malformations, such as accessory ears, cleft palate and harelip, subcutaneous cysts and misplaced kidneys. Hale proved the nutritional origin of these malformations by preventing them when the experimental diet was supplemented with cod liver oil or green fodder. He also proved that genetic factors could be ruled out as the cause of the malformations, since matings of abnormal sons to their mothers or of abnormal brothers to their abnormal sisters resulted in normal offspring if the females were fed an adequate diet during pregnancy.

Reproduction on diets deficient in vitamin A has been thoroughly studied in the rat,[7] particularly by Mason,[2a] who described fetal death, prolonged gestation and difficult parturition but not congenital malformations of the offspring. Cannon [8] attempted to induce malformations in the offspring of female rats which were depleted in vitamin A. He observed sterility, premature resorption of the fetuses, stillbirths and prolonged gestation. However, no congenital malformations were induced.

In 1944 we [9] reported the appearance of congenital malformations in the offspring of female rats that were depleted of vitamin A. The depletion of the mothers was achieved by placing female rats of the Sprague-Dawley strain for approximately three months after weaning on a preparatory diet (diet U) which had the following percentage

5. Davis, R. E., and Madsen, L. L.: J. Nutrition **21**:135, 1941.

6. Hale, F.: J. Hered. **24**:105, 1933; Am. J. Ophth. **18**:1087, 1935; Texas State J. Med. **33**:228, 1937.

7. Evans, H. M., and Bishop, K. S.: Anat. Rec. **23**:17, 1922. Evans, H. M.: J. Biol. Chem. **77**:65, 1928. Sherman, H. C., and MacLeod, F. L.: J. Am. Chem. Soc. **47**:1658, 1925. Tansley, K.: Biochem. J. **30**:839, 1936. Newton, W. H.: J. Physiol. **92**:32, 1938.

8. Cannon, M. D.: Proc. Soc. Exper. Biol. & Med. **44**:129, 1940.

9. Warkany, J., and Schraffenberger, E.: Proc. Soc. Exper. Biol. & Med. **57**:49, 1944.

composition: ground whole wheat, 74; crude casein (Casein Company of America), 15; brewers' yeast (Mead Johnson and Company), 10; sodium chloride C. P., 1. This diet was supplemented with 60 U. S. P. units of vitamin D (Drisdol, Winthrop Chemical Company) and 4 micrograms of carotene (S. M. A. Corporation) in cottonseed oil every tenth day. The small amount of carotene was added to allow growth and maturation to proceed, without storage of vitamin A. During this preparatory period about 10 Gm. of frozen ground horse muscle without bones was given weekly to each rat to promote growth.

When the female rats reached a weight of 150 to 160 Gm. and regular estrus cycles were established, they were placed on the purified diet (diet W) and bred immediately to males of the same strain which had been reared on an adequate diet.

The purified diet (diet W), which was completely free of vitamin A, had the following percentage composition: sucrose, 68; vitamin test casein, 18; vegetable oil, 10, and salt mixture 4[10]; 100 Gm. of this diet was supplemented with 0.8 mg. of thiamine hydrochloride, 0.8 mg. of pyridoxine hydrochloride, 0.8 mg. of riboflavin, 1 mg. of calcium pantothenate, 10 mg. of nicotinamide and 100 mg. of choline chloride. Every tenth day preparations of vitamin D (1 drop of a 1:4 dilution of Drisdol in olive oil), vitamin E (1 drop of a solution of 5 Gm. of alphatocopherol in 100 cc. of olive oil) and a vitamin K analogue (1 drop of a solution of 1 mg. of menadione in 5 cc. of olive oil) were also given.

A daily vaginal smear was made from each mature female in order to confirm breeding by the finding of sperm and to watch for signs of beginning resorption. Loss of weight and profuse vaginal bleeding were considered to mean interruption of pregnancy. The profuse bleeding of resorption must be distinguished from the normal blood sign, which appears between the tenth and the fifteenth day and which consists of a small amount of blood in the vaginal smear. In case of interruption of pregnancy the animals were opened and the fetuses removed and examined. When the young were carried to term, the mothers were opened on the twenty-second day of gestation. No attempt was made to keep alive the young thus removed.

One hundred and forty females were raised and bred in this manner, and in 96 of them sperm were found. Neither fetuses nor young were obtained from 60 females which died before the fourteenth day of gestation or resorbed their embryos completely. Litters of 29 females whose pregnancy was interrupted after the thirteenth day were examined. One litter was removed on the thirteenth day (8 fetuses), 2 on the fourteenth day (16 fetuses), 7 on the fifteenth day (54 fetuses), 11 on

10. Hubbell, R. B.; Mendel, L. B., and Wakeman, A. J.: J. Nutrition 14:273, 1937.

the sixteenth day (68 fetuses), 5 on the seventeenth day (14 fetuses), 1 on the eighteenth day (7 fetuses), 1 on the nineteenth day (9 fetuses) and 1 on the twentieth day (2 fetuses). Seven mothers carried their young to term. Thirty-nine mature young were obtained from them. Twenty-one of these were born alive, and 18 were stillborn.

Fig. 1.—Abnormal "open eye" in a newborn rat

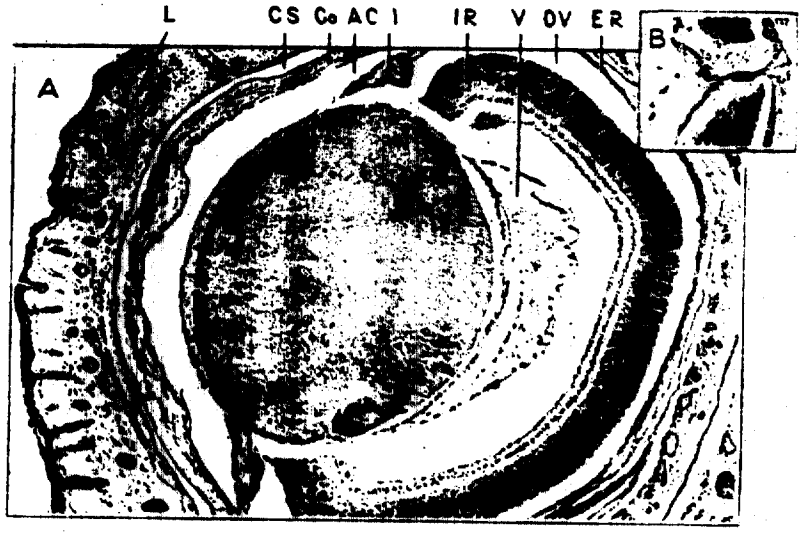

Fig. 2.—*A*, section of the eye of a normal newborn rat (approximately × 33). In this figure, and in figure 4, *L* indicates lower lid; *CS*, conjunctival space; *Co*, cornea; *AC*, anterior chamber; *I*, iris; *IR*, internal leaf of retina; *V*, vitreous; *OV*, space of optic vesicle; *ER*, external leaf of retina.

B, region of the optic nerve of the same eye (approximately × 33).

Twenty-five of the young born at term showed an external abnormality of the eye. In place of the closed eye of the normal newborn

rat "open eyes" (fig. 1) were seen. This open eye, which showed sometimes a red discoloration between the rudimentary lids, was present bilaterally in 22 young and unilaterally in 3 young. Serial sections were made of the heads of 16 of these young. Some of them had open eyes, and in others the eyes appeared externally normal. However, all the eyes sectioned proved abnormal on histologic examination. The degree of abnormality varied, but a fibrous retrolenticular membrane containing the vascular network of the hyaloid artery was seen in all the eyes examined.

The long axis of the eye of the newborn rat deviates from the sagittal plane, since its anterior end points anterolaterally. In spite of this deviation, in the following description the region of the anterior pole of the eyeball will be called "anterior" and that of the posterior pole "posterior," although "anterolateral" and "posteromedial" would be more correct. The sections were made in the frontal plane, proceeding in a ventrodorsal direction from the nostrils to the pharynx.

Three representative sections of an abnormal eye will be described in the following paragraphs.

Figure 3 illustrates a ventral section through the right eye of an abnormal newborn rat, which showed externally a definite red discoloration in the region of the eyes. Superficial comparison with figure 2*A*, a ventral section through the eye of a normal newborn rat, discloses a number of defects in the abnormal eye. In the anterior portion is found almost complete obliteration of the lower conjunctival sac and of the intraocular chambers. No traces of the upper conjunctival sac can be seen. Behind the point of junction of the upper and lower lids, the sclera and the external leaf of the retina are recognizable. The space between the lower conjunctival sac and the lens is occupied by a dense tissue, which apparently represents the mesoderm, which in the normal eye contributes to the formation of the cornea and of the iris. The lens appears essentially normal. The margin of the optic cup extends forward well past the equator above and barely reaches the equator below, so that the lower parts of the lens are in direct contact with mesodermal tissue. This defect in the lower portion of the cup represents the anterior portion of the persisting fetal fissure. The vitreous is not developed. The internal leaf of the retina is approximately of normal thickness but of completely abnormal structure. This will be described in detail later. The external leaf of the retina consists of a single layer of epithelial cells. The space between the two layers, the lumen of the optic vesicle, is filled with blood. The upper margin of the optic cup, which is placed in front of the equator of the lens, is formed by the junction of the outer and the inner leaf of the retina. The internal leaf decreases abruptly in height near the margin. The

angle between the external and the internal leaf is wide open, and its sides represent the rudiments of an iris.

In figure 4, which is a section approximately through the center of the eye, the lids appear to be closed, and a line of fusion is visible. This line of fusion traverses the lids in an oblique direction, and its cells are directly connected with those that fill out the conjunctival sac. The conjunctival space is not developed, since the palpebral and the

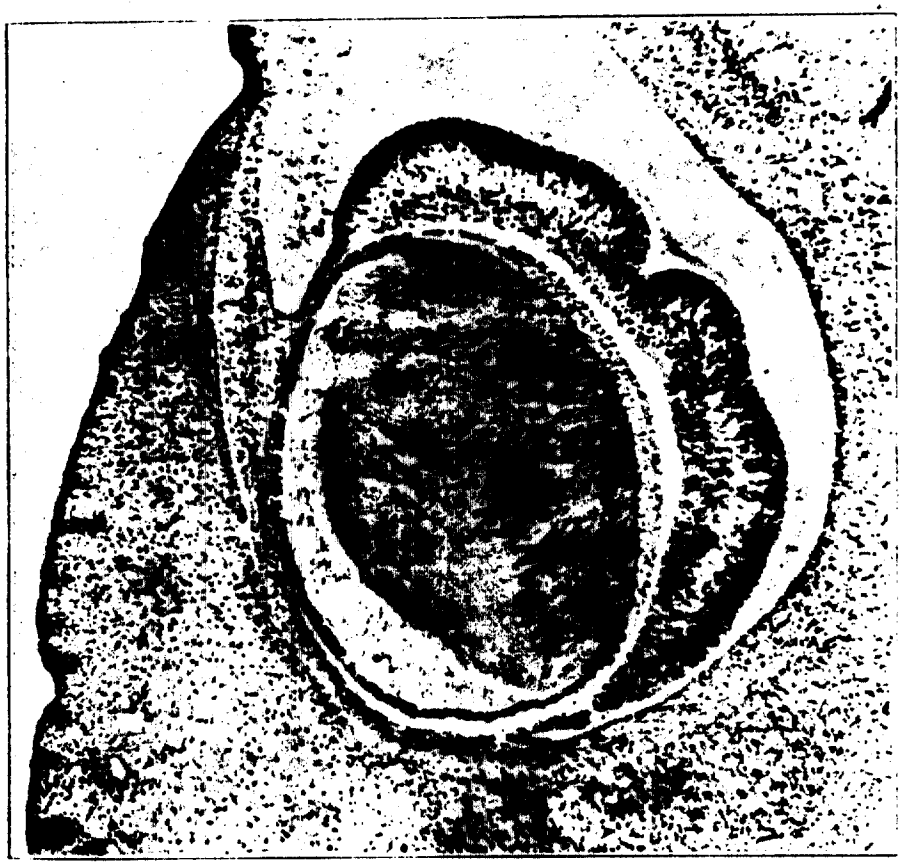

Fig. 3.—Section of the eye of an abnormal newborn rat, showing the lack of differentiation in the anterior parts of the eye (approximately × 80). The lower part of the optic cup does not enclose the lens.

bulbar conjunctival epithelium are in close contact. The bulbar epithelium adheres firmly to a mass of mesodermal tissue, which corresponds to the cornea and probably also to the stroma of the iris. This mesodermal tissue can be divided into a loosely woven anterior part and a dense posterior part. The dense portion is covered posteriorly by a complete row of epithelial cells, which is a direct continuation of

the external leaf of the retina. Thus, the anterior chamber, the iris, the ciliary body and the posterior chamber cannot be recognized as individual structures. Behind the epithelial cells of the external leaf a linear space is seen, which represents a part of the cavity of the optic vesicle. This space enlarges toward the upper part of the eye, where it becomes dome shaped. It forms only a narrow cleft in the lower

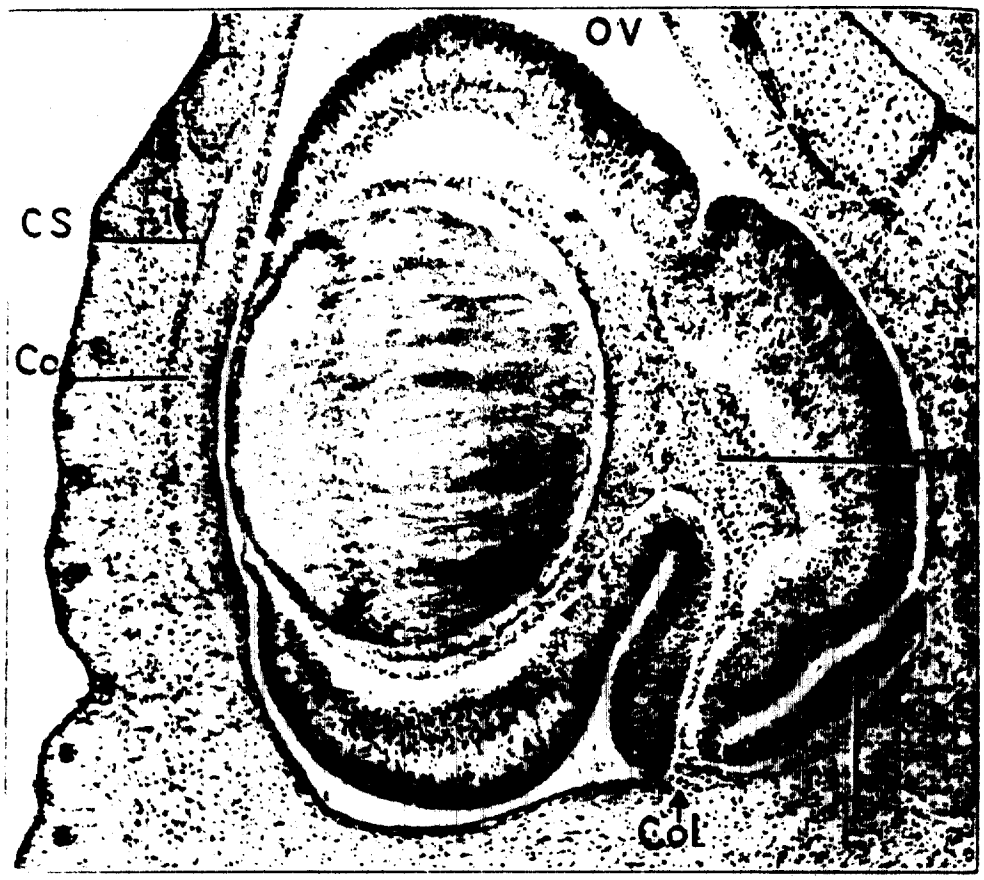

Fig. 4.—Section of the eye of an abnormal newborn rat, showing coloboma (Col), eversion of the retina (*E*) and fibrous retrolenticular membrane (*RM*) connected with extraocular mesoderm (approximately × 80).

and posterior portion of the eye. The internal leaf of the retina is of approximately normal thickness with the exception of the most anterior part, which forms a single layer in front of the lens. This layer corresponds to the pigment layer of the normal iris (pars iridica retinae). The lower and posterior part of the internal leaf of the retina is split by a strand of connective tissue which connects extraocular meso-

derm and the retrolenticular connective tissue replacing the vitreous humor. This fibrous tissue, which occupies the space of the vitreous, consists of a dense network of cells in which a number of capillaries can be discerned. The connective tissue cells immediately behind the lens have small, dark and oblong nuclei, the long axes of which run parallel with the posterior surface of the lens. The network of cells between the capillaries is somewhat looser, and larger, round nuclei which are poor in chromatin are interspersed with dark, small nuclei. There is no sharp borderline toward the layer of nerve fibers of the retina. The fibrous retrolenticular tissue decreases in thickness toward the equator of the lens, where it ends. The apparent split of the retina by mesodermal tissue represents an oblique section through the fetal fissure somewhat behind the equator of the eye. The internal leaf of the retina forms several folds and is distinctly everted behind the point where the retrolenticular and the extraocular mesoderm join. Thus, there is a duplication of the internal leaf of the retina, and the "innermost" layers of the everted portion are turned outward and face the choroidea. Posteriorly the everted retina ends abruptly; it diminishes in height at the point of junction with the external leaf of the retina, which consists of a single layer of cells. In the areas not folded the internal leaf of the retina is of normal thickness; it has differentiated into two ill defined layers of cells, separated by a loose network of fibrils. The denser outer layer consists of twelve to fifteen rows of cells with round, light nuclei. Within the loose cellular layer, a layer of nerve fibers can be seen.

Figure 5 represents a dorsal section through the right eye of another abnormal newborn rat near the optic nerve. The internal leaf of the retina is folded in many places and everted below and anterior to the retinal cleft. The center of the cleft is traversed by a thick strand of connective tissue which links extraocular mesoderm with the retrolenticular fibrous membrane. This strand is pierced in its entire length by a long and thin blood vessel, which is lined by a single layer of endothelial cells. In the retinal gap nerve fibers are seen on both sides of the mesodermal strand. In more dorsal sections this strand becomes thinner and more enclosed in nerve fibers.

The sections described illustrate some of the more obvious anomalies seen in the eyes of the young of mothers fed a diet deficient in vitamin A. In spite of variations in the individual eyes, certain features common to the majority of them can be discussed. The abnormalities of the lids vary greatly. Externally they may appear closed, although the line of fusion is abnormal. Their conjunctival surface is frequently closely attached to the corneal epithelium, since the conjunctival space does not develop. In "open eyes" the lids are not fused, and an

abnormal, fibrotic and often blood-tinged tissue is found in place of the cornea within the palpebral fissure. In case of absence of the anterior chamber a thick mesodermal membrane is seen between the lids, on one side, and the external leaf of the retina or the lens, on the other side. This membrane consists of the two layers of different texture. The anterior layer appears to correspond to the substantia propria of the cornea, and the denser posterior layer, to the stroma of the iris. The iris is present in a rudimentary form only. Its stroma

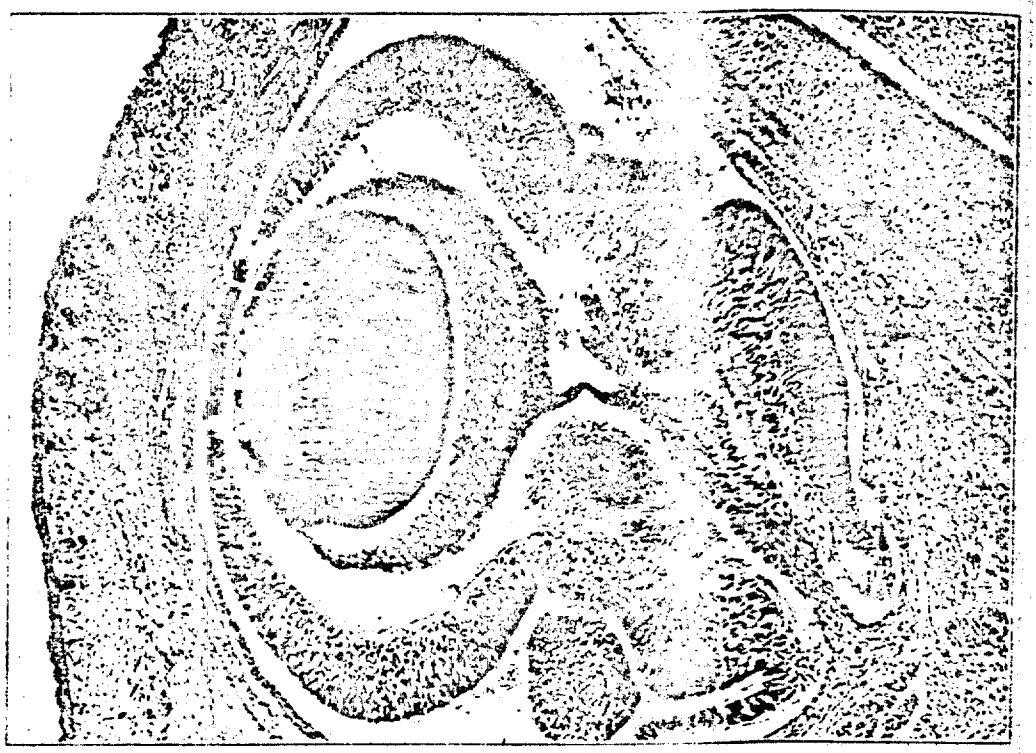

Fig. 5.—Section of the eye of an abnormal newborn rat near the optic nerve, showing coloboma, eversion of the retina and a fibrous band which links the retrolenticular membrane with extraocular mesoderm (approximately × 66).

is in the central ("pupillary") area closely connected with the anterior pole of the lens. In its peripheral parts it is covered posteriorly by the external leaf of the retina. The most anterior part of the internal leaf of the retina, which consists of a single layer of cells (fig. 3) and which corresponds to the pigment layer of the mature iris, is separated throughout from the external leaf by the lumen of the optic vesicle. Thus many features of the fetal rudiments of the iris are maintained in these abnormal eyes of young born at term.

Extensive changes are found in the lower parts of the optic cup. These areas, which are phylogenetically and ontogenetically the youngest parts of the eye, are particularly susceptible to modification and mutation.[11] The first section described (fig. 3) shows the optic cup open anteriorly in its lower part. While the cup encloses completely the upper half of the lens, the failure of the fetal fissure to fuse in this region makes it appear as though the lower half is not encased in the ectodermal parts of the eye but rests directly on mesoderm. The second

Fig. 6.—Section through posterior portion of an abnormal eye. *L* indicates the lens; *RM*, the retroienticular membrane; *Ro*, rosette; *HA*, branch of hyaloid artery (approximately × 70).

section (fig. 4) illustrates a gap in the lower part of the optic cup and eversion of the retina posterior to it. The gap is traversed by a strand of mesodermal tissue. The third section (fig. 5) shows also a retinal cleft with retinal eversion near the optic nerve. Within the fibers of the optic nerve a thick band of mesodermal tissue is seen, which

11. Mann, I. C.: Developmental Abnormalities of the Eye. Cambridge, England, Cambridge University Press, 1937.

encloses remnants of the hyaloid artery. This mesoderm spreads out behind the lens and occupies the space taken by the corpus vitreum in the normal eye. The mesodermal band, as well as the mesodermal retrolenticular membrane (figs. 4 and 5) seen in these sections, is definitely overgrown, as compared with the retrolenticular tissue in

Fig. 7.—Sections of (*A*) retina of normal newborn rat; (*B*) retina of abnormal newborn rat enclosing space of the optic vesicle; (*C*) brain tissue of abnormal newborn rat, enclosing parts of lateral ventricle (approximately × 160).

normal fetuses. The changes in the lower parts of the optic cup—persistent fetal fissure, eversion of the retina and penetration of the cup by mesodermal tissue—are characteristic of the typical coloboma. In some abnormal eyes the posterior portions of the internal retinal leaf form many folds (figs. 5 and 6). These folds when cut transversely appear in the sections as "rosettes," in which the retinal cells are radially

arranged around a well defined inner circle. The space within this circle corresponds to the cavity of the fold, which is a part of the lumen of the optic vesicle. The histologic structure of the internal leaf of the retina shows little resemblance to that of the retina of a normal newborn rat. This is well borne out by a comparison of *A* and *B* of figure 7; in fact, the abnormal retina (fig. 7*B*) resembles brain tissue (fig. 7*C*) rather than normal retinal tissue. Hemorrhages are frequently seen in the abnormal eyes. They can be found in the orbits, in the cavity of the optic vesicle, in the retina and near the palpebral fissure.

In our opinion, the sections just discussed are representative of the congenital malformations of the eye found in the young of vitamin A-depleted rats. However, there were variations in the eyes of the 16 abnormal young that were examined histologically. As mentioned, the serial sections of all 32 eyes showed a fibrous retrolenticular membrane. In both eyes of 1 animal this membrane was apparently the only abnormality present. This rat was the only member of the litter that was carried to term. If there had been other fetuses in this litter, they were resorbed in the early stages of development. In 10 eyes the retrolenticular membrane was continuous with a thick strand of connective tissue which was embedded in the optic nerve and was carried along with it into the eye, but there were no signs of coloboma. In 13 eyes there were similar retrolenticular tissue and a retinal gap and eversion near the optic nerve, that is, coloboma of the disk. In 1 eye such a coloboma combined with a peripheral or anterior coloboma, but the two fissures were not continuous. Four eyes had complete colobomas, which were continuous from the region of the disk to the anterior part of the eye. In 30 eyes the structure of the retina was abnormal (fig. 7). In 28 eyes the iris and the ciliary body were rudimentary or abnormal, and in 28 eyes the anterior and posterior chambers were not formed. The mesoderm, which corresponds to the stroma of the cornea and of the iris, was partly or completely fused anteriorly with the conjunctival epithelium in 18 eyes and was fused posteriorly with the epithelium of the external retinal leaf in 30 eyes. The conjunctival sac was partly or completely occluded in 18 eyes. Seventeen of the 32 eyes sectioned were "open" and 15 closed. As a rule the character and degree of abnormalities were similar in litter mates. However, there were exceptions to this rule, and variations in the eyes of litter mates, as well as in the eyes of one and the same animal, were seen.

Most of the young with abnormalities of the eyes also had malformations of other soft tissues and of the skeleton. The changes observed in the other organs will be described in another communication. Although removed at term, the average weight of the young was only 3.4 Gm.

The following control experiments were undertaken. Eighty-six mothers of the Sprague-Dawley strain fed an adequate stock diet had

1,183 young which on careful inspection did not show "open eyes" at birth. Serial sections were made of the eyes of 20 of these young. None of the abnormalities just described were found in the 40 eyes examined. Sixty-four females of the same strain were raised on an adequate diet and bred on the purified diet W supplemented with 60 U. S. P. units of vitamin A daily. They had 423 young, none of which had open eyes at birth. Ten females were raised on the preparatory diet U and bred on the purified diet W supplemented with 60 U. S. P. units of vitamin A daily. They had 103 young, none of which were born with open eyes. The eyes of 18 of these young were

Fig. 8.—*A*, normal rat fetus approximately 16 days old; *B*, abnormal rat fetus approximately 16½ days old. The eye is not seen externally.

sectioned serially, and all 36 eyes were examined and found normal. Twelve females were raised on diet U and bred on diet W without giving birth to young. After they had lost about 40 Gm. of weight and had begun to show pronounced signs of vitamin A deficiency, they were given large amounts of vitamin A until they recovered and sexual cycles were restored. Then they were bred again and 54 young were obtained. None of these had open eyes. The eyes of 4 of these young were serially sectioned, and all 8 were found normal. Thus the abnormalities of the eyes described were found only in the young of mothers raised on diet U and bred on diet W. Female rats fed an adequate diet or diet W supplemented with vitamin A during pregnancy had young with normal eyes.[12]

(Footnote on next page.)

EMBRYOLOGIC STUDIES

One hundred and fifty-four fetuses were removed between the fifteenth and the twentieth day of gestation from mothers reared on diet U and bred on diet W. The majority of these females were killed because they showed signs of beginning resorption. Many 15, 16 and 17 day old fetuses of this origin could be recognized externally as abnormal. The eyes of normal fetuses 15 to 17 days old have open palpebral fissures, since the lids do not develop and fuse before the eighteenth day of prenatal life. In most of the abnormal fetuses 15 to 17 days old the palpebral fissures could not be seen, and the eyes appeared absent or deeply embedded and removed from the surface (fig. 8 *B*).

Figure 9 illustrates the development of the normal eye from the fifteenth to the eighteenth day of prenatal life (*A*, *B*, *C* and *D*), as compared with the development of the abnormal eye (*E*, *F*, *G* and *H*). On the fifteenth day the normal eye (fig. 9 *A*) has an open palpebral fissure and is enclosed in a semicircular elevation which protrudes from between the rudimentary eyelids. The cornea lies on the surface of the body. It is a thin membrane, which consists of surface epithelium and one layer of mesodermal cells. The iris and ciliary body are not yet developed. The fetal fissure has closed. Between the lens and the retina a loose network of cells is seen, which consists of capillaries of the hyaloid system. The optic nerve is slightly closer to the lower than to the upper margin of the optic cup. Above the optic nerve the external leaf of the retina is somewhat thickened but well demarcated from the internal leaf. In the abnormal eye of a fetus of the same age (fig. 9 *E*) the lens is separated from the surface epithelium by mesodermal tissue which is much thicker than the normal cornea. The lens and the optic cup therefore appear far removed from the surface of the body. The cup is wide open near the optic nerve, since the retina is everted below the nerve. Through the opening enter, in addition to the optic nerve, the hyaloid artery and a band of mesodermal connective tissue which links extraocular mesoderm with the dense fibrous retrolenticular tissue. The everted parts of the retina decrease gradually in height. The coloboma illustrated in figure 9 *E* can be traced through anterior sections, which show that in this eye the fetal fissure is open its entire length.

In the section of the eye of a normal 16 day old embryo (fig. 9 *B*) it can be seen that the cornea has increased in thickness. The mesodermal tissue consists of several layers of cells and is posteriorly limited by an endothelium. A pupillary membrane divides the space

12. "Open eyes" were found in 3 of 2,000 young born of female rats of the Sprague-Dawley strain that had been bred on a diet deficient in riboflavin (Warkany, J., and Nelson, R. C.: Anat. Rec. **79**:83, 1941. Warkany, J., and Schraffenberger, E.: J. Nutrition **27**:477, 1944). These eyes were serially sectioned and showed no retrolenticular membrane and no coloboma. The iris and the retina were normal.

posterior to the cornea into two compartments. The optic nerve divides the cup into two equal parts. The lumen of the hyaloid artery can be seen in the center of the nerve stem. The layer of nerve fibers is developing in the internal leaf of the retina, and formation of the vitreous

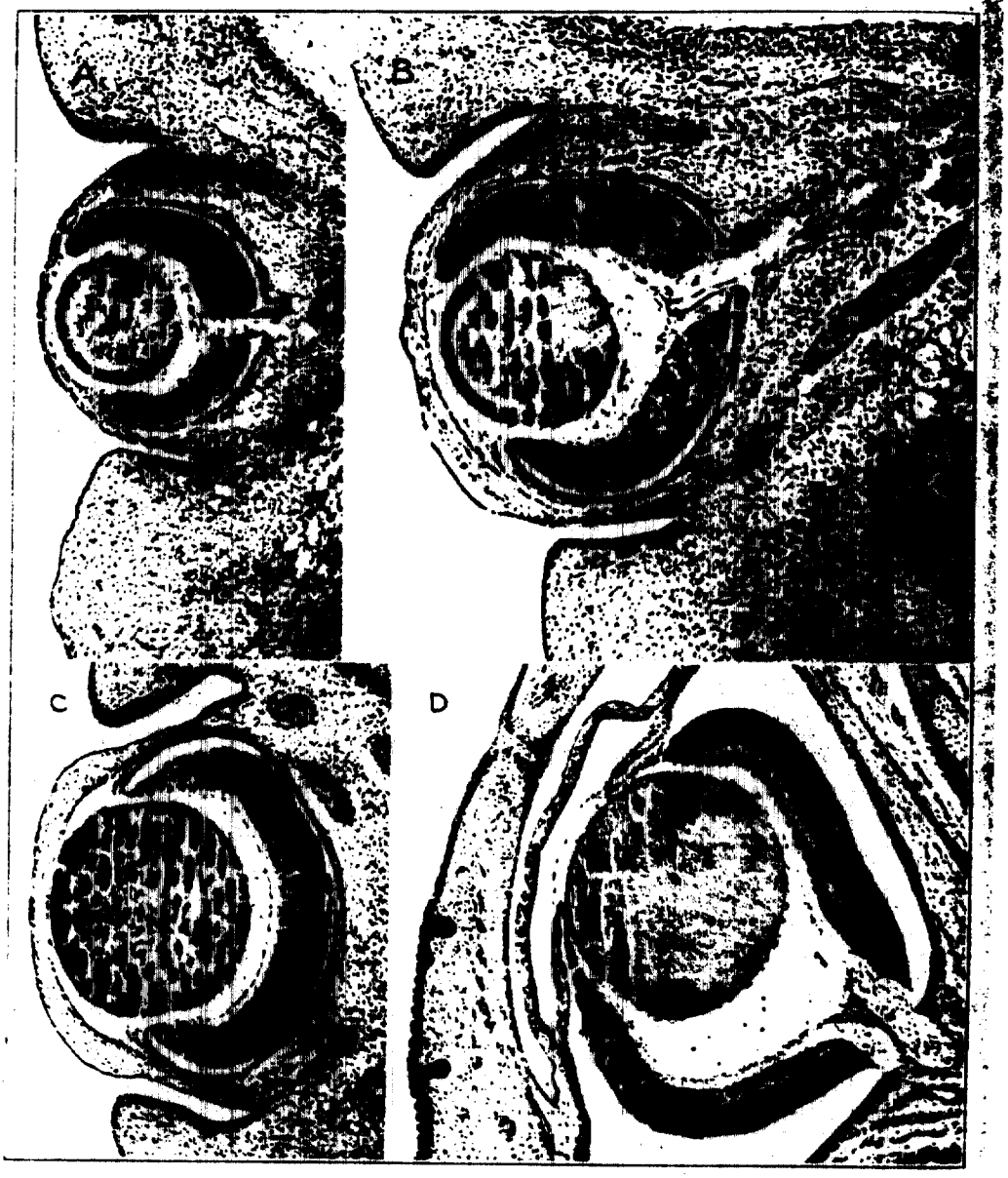

Fig. 9 *A-D*.—Sections of (*A*) eye of normal rat fetus approximately 15 days old; (*B*) eye of normal rat fetus approximately 16 days old; (*C*) eye of normal rat fetus approximately 17 days old; and (*D*) eye of normal rat fetus approximately 18 days old. (*A* and *B* approximately × 80; *C* and *D* approximately × 62.)

in the retrolenticular space has taken place. Few capillaries of the hyaloid system can be seen in this space. The abnormal eye (fig. 9 *F*) is separated from the surface by a thick layer of mesodermal tissue, which

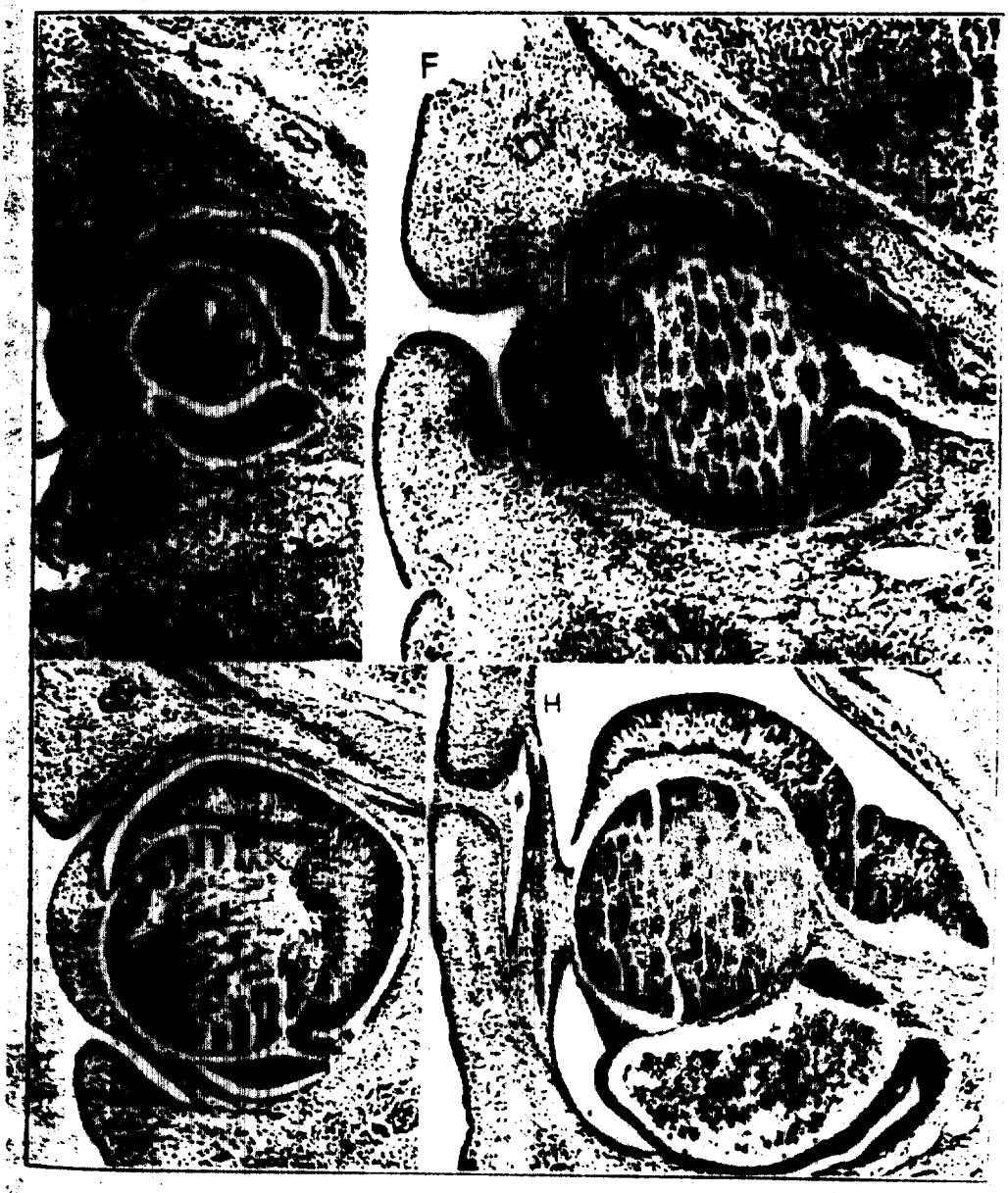

Fig. 9 *E-H.*—Sections of (*E*) eye of abnormal rat fetus approximately 15 days old; (*F*) eye of abnormal rat fetus approximately 16 days old; (*G*) eye of abnormal rat fetus approximately 17 days old; and (*H*) eye of abnormal rat fetus approximately 18 days old. (*E* and *F* approximately × 80; *G* and *H* approximately × 62).

is covered by surface epithelium. In front of the region of the eye two folds of skin are formed, which almost meet. The mesodermal tissue in front of the eye is in close contact with the anterior epithelium of the lens, so that the space usually present in the normal eye anterior to the lens appears entirely occluded. The optic nerve divides the optic cup into two unequal halves. The upper half is much longer and reaches farther forward than the lower half. Such proportions are seen in earlier embryonic stages of normal eyes but not in the normal 16 day old fetus. At this age they indicate an arrest of development.

Figure 9 *C* represents the eye of a normal 17 day old fetus; the section reproduced is ventral to the entrance of the optic nerve. The lids are still open. The chamber is well developed, but the iris is still absent. The vitreous is clearly seen. The internal leaf of the retina shows no formation of layers, but it is lined toward the vitreous by a stratum of nerve fibers. Figure 9 *G* illustrates the appearance of the eye of an abnormal 17 day old fetus. The anterior parts of this eye are normal; the lids are open; the cornea is of normal thickness, and a narrow chamber is seen. In contrast to the normal eye, there is a loose arrangement of the cells of the internal retinal leaf. The vitreous is absent, and its place is taken by a thin layer of connective tissue cells; this layer of retrolenticular fibrous tissue is much better developed in dorsal sections of the same eye. A cleft of the retina with eversion of the internal retinal leaf is seen in the lower part of the optic cup. This cleft represents a coloboma, which in this case extends throughout the length of the eye.

The eye of the normal 18 day old fetus (fig. 9 *D*) is covered by eyelids which are completely fused. A wide conjunctival space has formed; the cornea and the anterior chamber are well developed, and a primitive iris can be recognized. It consists of two layers, the distal one being a continuation of the external retinal leaf, which is covered toward the anterior chamber by cells of mesodermal origin. The posterior layer of the iris is the most anterior part of the internal retinal leaf. Between the two leaves the space of the optic vesicle can still be recognized. Between the margins of the cup the pupillary membrane is seen. The space of the vitreous has increased in size. In the internal leaf of the retina three layers can be distinguished: a dense outer nuclear layer, an inner nuclear layer of lesser density and the layer of nerve fibers. The blood vessel embedded in the optic nerve divides into numerous capillaries as soon as it reaches the vitreous.

The eye (fig. 9 *H*) of an abnormal 18 day old fetus is covered by lids which are completely fused. The conjunctival space exists in rudimentary form only. A thick layer of mesodermal tissue takes the place

of the cornea and of the anterior chamber. The margin of the optic cup represents the rudiments of the ectodermal parts of the iris. There is no vitreous, but a retrolenticular fibrous membrane is seen in its place. This membrane is linked with extraocular mesoderm by a band of connective tissue. There is a coloboma of the retina. The layers of the upper parts of the internal leaf of the retina are not well defined, and the structure of its lower parts has been destroyed by a hemorrhage. Blood cells can be seen below the lens and below the fibrous retrolenticular tissue.

The abnormal eyes of fetuses 19 to 21 days old resemble the eyes of mature abnormal young so much that it seems unnecessary to describe them here.

COMMENT

The experiments described in this report were planned as a study of the effects of extreme maternal vitamin A deficiency on the fetus. To this end the female rats of the parent generation were raised on a preparatory diet (diet U) which contained enough carotene to make possible growth and maturation but prohibited storage of vitamin A. At maturity the rats were placed on a purified diet (diet W) which was completely free of carotene and vitamin A. While on this diet the females were bred to normal males of the same strain. The mothers showed signs of vitamin A deficiency within one or two weeks, and their young presented, among other malformations, the ocular defects described. This method appears to induce a borderline deficiency in the mothers which in some instances permits termination of pregnancy at term, although the development of the young suffers. In other instances the females do not breed, or they resorb their young.

As controls, females of the same strain were raised and bred on an adequate diet. No congenital defects of the type described in this communication were found in the offspring. They were also absent in the offspring of females raised on the preparatory diet U and bred on diet W when the latter was supplemented with vitamin A. This permits the conclusion that vitamin A in the maternal diet prevents the defects in the young.

These congenital abnormalities of the eyes consist partly of structures arrested in early ontogenetic stages and partly of formations that do not correspond to normal embryonic conditions. The coloboma and eversion of the retina, its penetration by mesodermal tissue, the low insertion of the optic stalk in the cup, the absence of the chambers and the lack of fusion of the constituents of the iris can be explained by arrest of development. However, the overgrowth of connective tissue between the hyaloid vessels in the place of the vitreous and the peculiar structure of the retina have no equivalents in early fetal stages.

Some of the ocular malformations induced by maternal vitamin A deficiency resemble those seen in the defective eyes which are hereditary in certain strains of rabbits. These eyes, which have been thoroughly studied by von Hippel,[13] von Szily,[14] Koyanagi [15] and others, show coloboma, eversion of the retina and often microphthalmos and orbital cysts. However, the mesodermal tissue which enters the fetal fissure remains fine and delicate and is not always present. In the abnormal eyes described in this communication the corresponding mesodermal tissue is firm and closely knitted; it could be demonstrated in all abnormal eyes which were histologically examined. Orbital cysts and microphthalmos were not observed. These differences are of considerable theoretic interest, since the theories of causation of colobomas have been decidedly influenced by the changes observed in the eyes of rabbits of colobomatous stock.

The fact that a malformation such as coloboma, which has been observed as a hereditary defect, can also be induced by maternal dietary deficiency is in agreement with the conception [16] that a specific malformation can be the result of a genic mutation in 1 case and of an environmental modification in another. The coloboma induced by maternal nutritional deficiency represents a "phenocopy" [17] of the colobomas which are genetically determined.

In the description of the abnormal eyes we have emphasized certain anatomic features and have disregarded others which require further investigation. There is also need for additional experimental work which will aid in the explanation of the mechanism by which the defects are brought about. It is planned to ascertain the critical period in which the abnormalities are determined by supplementing the deficient diet with vitamin A on the various days of gestation, and experiments are in progress on the fate of some of the abnormal structures in postnatal life.

SUMMARY

When female rats were raised and bred on a dietary regimen which led to extreme vitamin A deficiency during pregnancy, congenitally deformed offspring were obtained. These newborn rats had various

13. von Hippel, E.: Arch. f. Ophth. **55**:507, 1903.

14. von Szily, A.: Ztschr. f. d. ges. Anat. (Abt. 1) **84**:1, 1924.

15. Koyanagi, Y.: Arch. f. Ophth. **104**:1, 1931.

16. Landauer, W.: Arch. f. Entwecklngsmechn. d. Organ. **110**:195, 1927. Dunn, L. C., in Harvey Lectures, 1939-1940, Lancaster, Pa., Science Press, 1940, pp. 135-165. Warkany, J.; Nelson, R. C., and Schraffenberger, E.: Congenital Malformation Induced in Rats by Maternal Nutritional Deficiency: IV. Cleft Palate, Am. J. Dis. Child. **65**:882 (June) 1943.

17. Goldschmidt, R. B.: Physiological Genetics, New York, McGraw-Hill Book Company, 1938.

defects of the skeleton and of some of the soft tissues. Histologic sections of the eyes were studied, and a fibrous retrolenticular membrane was found in place of the vitreous in every specimen. In addition, there were frequently colobomas, eversion and abnormal structure of the retina, rudimentary development of the iris and of the ocular chambers, defects of the cornea and of the conjunctival sac and lack of fusion of the lids. In case of the last defect the abnormal eyes could be recognized by external inspection. When the maternal diet was supplemented with vitamin A during pregnancy, the eyes of the young were normal.

J. Anim. Sci. 27(6):1657-1662. 1968.

Webb-'68
Bib. No. 9676

POLYURIA IN VITAMIN A-DEFICIENT SHEEP[1]

K. E. WEBB, JR., G. E. MITCHELL, JR., C. O. LITTLE AND G. H. SCHMITT[2]
University of Kentucky, Lexington

ALTHOUGH nephritis in rats was associated with vitamin A deficiency as early as 1925 (Jackson), most attempts to relate vitamin A deficiency to renal function in ruminants involved either autopsy findings (Hart and Guilbert, 1937; Sutton *et al.*, 1940; Langham *et al.*, 1941; Eveleth *et al.*, 1949) or studies of urinary calculi (Schmidt, 1941; Beeson *et al.*, 1943; Lindley *et al.*, 1953; Swingle and Marsh, 1956) until Woelfel *et al.* (1965) reported marked changes in volume and osmolality of urine excreted by vitamin A-deficient heifers. The experiments reported here continued this area of investigation in sheep with the following specific objectives: (1) to quantitate the polyuria in vitamin A-deficient wethers; (2) to study relationships between polydipsia and the polyuria; (3) to study the influence of vitamin A deficiency on the ability of the kidneys to concentrate urine during feed and water deprivation; and (4) to study alterations in plasma and urine composition which may be related to polyuria.

Procedures

General Procedures. Four mature wethers with chronic vitamin A deficiency and four controls were used in these experiments. Classic signs of vitamin A deficiency including night blindness and convulsions were present. Only traces of vitamin A were found in biopsy samples of livers of the deficient wethers (Tucker *et al.*, 1967). Levels of vitamin A detected in plasma of the wethers during each experiment are presented in table 1. Vitamin A was extracted by the method of Kimble (1939) and the color developed by the trifluoroacetic acid method described by Dugan (1964).

The carotene-deficient diets fed during these experiments (table 2) were composed of ground corn cobs, ground milo, soybean meal and glucose with minerals added.

Each wether was fed 454 gm. twice daily. A level of 1,000 I.U. of vitamin A palmitate per head was fed daily to the control wethers during all experiments.

Stanchion-type metabolism crates were used in all experiments to facilitate urine collection every 12 hr. In the third and fourth experiments it was collected under toluene. Specific gravity and pH were determined on aliquot samples immediately and samples were then frozen for later analysis of other constituents. Heparinized blood samples were taken by jugular puncture and the plasma was removed after centrifugation and frozen for later analysis.

Sodium and potassium concentrations of plasma and urine were determined by flame photometry (Seligson, 1958). Plasma and urine chloride, inorganic phosphate and urea were determined by the procedures of Zall *et al.* (1956), Fiske and Subbarow (1925) and Skeggs (1957), respectively. Calcium was determined by atomic absorption spectrophotometry. Creatinine in plasma and urine samples was determined by the Folin and Wu procedure taken from Hawk, Oser and Summerson (1954). The procedures for chloride, inorganic phosphate, urea and creatinine were modified for application to automated analytical equipment. The pH, specific gravity and osmolality of urine and osmolality of plasma were determined by standard procedures.

Analysis of variance procedures described by Snedecor (1959) were used to evaluate the data.

Experiment 1. Experiment 1 was composed of two 7-day trials, each being one-half of a switch-back metabolism study with two levels of protein (diets 1 and 2, table 2). *Ad libitum* water intake of each animal was recorded.

Experiment 2. Each animal was offered only 750 ml. of water after each feeding (1,500 ml. per day). Diet 2 (table 2) was fed. Urine was collected daily throughout the 7-day experiment.

Experiment 3. Each animal was fed 454 gm. of diet 3 (table 2) twice daily and had water available *ad lib.* during this 4-day experiment. The urine collection period was 24 hr., with the urine being transferred periodically from the collection flask to an airtight container. Volume, specific gravity and pH were deter-

[1] The investigation reported in this paper (No. 67-5-112) is in connection with a project of the Kentucky Agricultural Experiment Station and is published with the approval of the Director.

[2] Department of Pharmacology, College of Medicine, University of Kentucky, Lexington.

TABLE 1. CONCENTRATIONS OF VITAMIN A IN PLASMA OF WETHERS[a]

Animals	Experiment 1	Experiment 2	Experiment 3–4
Vitamin A-deficient 1	9.0	12.6	13.2
Vitamin A-deficient 2	13.8	15.8	14.6
Vitamin A-deficient 3	10.6	11.8	15.0
Vitamin A-deficient 4	15.0	16.2	19.0
Mean	12.1[b]	14.1[b]	15.45[b]
Standard error	1.39	1.12	1.24
Control 1	40.6	47.8	57.0
Control 2	33.0	26.8	42.6
Control 3	22.0	27.0	47.0
Control 4	26.0	35.6	44.6
Mean	30.4	34.3	47.8
Standard error	4.09	4.94	3.20

[a] Expressed as μg per 100 ml. of plasma.
[b] Significantly different from controls, P<.01.

mined at the time of collection. Samples were frozen and later analyzed for sodium, potassium, inorganic phosphate, calcium, creatinine, urea and osmolality.

Experiment 4. Feed and water were withheld from all wethers in replicated trials for a 72-hr. period. Urine was collected every 12 hr., and plasma samples were obtained at 0 time and at 72 hr. Samples were analyzed as described for experiment 3 with pH and specific gravity omitted on plasma samples.

Results

Experiment 1. The average daily excretions on both protein levels in trial 1 were significantly (P<.01) greater for the vitamin A-deficient wethers than for the controls (table 3). Although urine volumes were lower in trial 2, the average for the vitamin A-deficient sheep was again significantly (P<.05) greater. Vitamin A-deficient wethers consumed an average of 738 ml. more water daily.

Experiment 2. With the exception of one

TABLE 2. RATION COMPOSITIONS (%)

Composition	Diet 1	Diet 2	Diet 3
Ingredient			
Ground corn cobs	55	55	58.9
Ground milo	24	18	11.8
Soybean meal	.	11	19.7
Glucose	16	11	7.8
Minerals	5[a]	5[a]	1.8[b]
Crude protein analysis	3.2	6.87	11.79

[a] Composed of NaCl, 0.87%; K_2HPO_4, 1.12%; KCl, 0.75%; $CaHPO_4 \cdot 2H_2O$, 1.30%; $MgSO_4$, 0.3495%; $CaSO_4 \cdot 2H_2O$, 1.47%; $CaCO_3$, 0.105%; $FeSO_4$, 0.0275%; KI, 0.002%; $ZnSO_4$, 0.001%; $CuSO_4 \cdot 5H_2O$, 0.0011%; $CoSO_4 \cdot H_2O$, 0.0006%; CaF_2, 0.005%; $MnSO_4 \cdot H_2O$, 0.005%.
[b] Composed of salt, 50.22%; dicalcium phosphate, 25.02%; ground limestone, 19.52%; sulfur, 4.20%.

TABLE 3. AVERAGE DAILY URINE VOLUMES (ML.) OF WETHERS WITH WATER *AD LIBITUM* (EXPERIMENT 1) OR RESTRICTED (EXPERIMENT 2)

Animals	Experiment 1 Trial 1	Experiment 1 Trial 2	Experiment 2
Vitamin A-deficient 1	1998	2116[c]	1218
Vitamin A-deficient 2	1845[c]	1294	1052
Vitamin A-deficient 3	2131	2262[c]	1008
Vitamin A-deficient 4	1603[c]	1436	1141
Mean	1894[b]	1738[a]	1105[b]
Standard error	113.3	211.3	46.8
Control 1	609	691[c]	480
Control 2	1047[c]	863	758
Control 3	884	1297[c]	530
Control 4	1337[c]	695	558
Mean	969	886	581
Standard error	152.3	142.6	61.0

[a] Significantly different from controls, P<.05.
[b] Significantly different from controls, P<.01.
[c] Highest protein ration.

control, each animal consumed 1,500 ml. of water per day for the 7-day period. The animal designated control 1 consumed only 891 ml. on the first day. Daily urine excretion (table 3) remained significantly (P<.01) higher in the vitamin A-deficient group.

Experiment 3. As shown in table 4, the difference in urine volume continued to be significant (P<.01). Specific gravity (P<.01), osmolality (P<.01) and pH (P<.05) of urine were lowered by vitamin A deficiency. Inorganic phosphate excretion was markedly increased (P<.05) and calcium excretion markedly decreased (P<.01) by deficiency. Observed differences in the excretion of urea, creatinine, sodium and potassium were not significant.

Experiment 4. Urine volume decreased significantly from the first 24 hr. to the end of the experiment for both vitamin A-deficient (P<.01) and control wethers (P<.05). More urine was excreted daily by the deficient group than by the control group throughout the experiment (table 5). Specific gravity measurements indicated that a much less concentrated urine was being formed by the vitamin A-deficient wethers. Further evidence of the production of dilute urine is afforded by the significantly lower osmolality of urine from the deficient wethers. The pH measurements on the fresh urine indicated that the vitamin A-deficient wethers produced a more acidic urine. Significant increases in pH were observed in both groups from the first to the final collections at 72 hours.

TABLE 4. DAILY EXCRETION OF URINARY COMPONENTS OF WETHERS FED DIET 3 WITH WATER *AD LIBITUM* (EXPERIMENT 3)

Item	Vitamin A-deficient		Controls	
	Mean	Standard error	Mean	Standard error
Volume, ml./day	970[b]	43.8	582	53.4
Specific gravity	1.032[b]	0.0018	1.047	0.0024
Osmolality, mOsm. kg. H_2O	775[b]	28.6	1278	105.9
pH	5.22[a]	0.028	5.61	0.130
Sodium, gm./day	2.290	0.105	2.012	0.179
Potassium, gm. day	6.380	0.563	5.557	0.323
Inorganic Phosphate, mg., day	559.41[a]	188.41	16.26	8.02
Calcium mg./day	38.90[b]	4.38	195.05	42.30
Urea gm./day	6.74	0.44	6.06	0.58
Creatinine, gm./day	1.106	0.08	1.266	0.05

[a] Significantly different from controls, $P<.05$.
[b] Significantly different from controls, $P<.01$.

Urine output of sodium decreased significantly in both vitamin A-deficient ($P<.01$) and control wethers ($P<.01$) from the beginning to the end of the experiment. The vitamin A-deficient animals were excreting significantly less ($P<.01$) sodium on the first day, but the difference was not significant after removing feed and water for 72 hours. Control wethers were excreting significantly ($P<.01$) more chloride in the urine on the first day but not on the third day. The amount excreted by the control wethers was approximately 1 gm. per day greater than that excreted by deficient wethers. The decline in excretion from the first to the third day was significant ($P<.01$) for both groups. Potassium excretion decreased significantly ($P<.01$) during the experiment but was not significantly affected by treatment. There was a marked elevation ($P<.05$) in the excretion of inorganic phosphate by the vitamin A-deficient wethers. Deficient wethers excreted less calcium ($P<.05$) than the controls on the first day and the decline in excretion from the first to the third day was significant for both groups ($P<.01$). Observed differences in urinary excretion of urea and creatinine were not significant.

Plasma osmolality remained essentially unchanged for the vitamin A-deficient group but increased in the control animals (table 6). Initial plasma sodium levels were similar, but control wethers had significantly ($P<.05$) higher plasma sodium on the third day. The plasma chloride levels of vitamin A-deficient wethers declined significantly ($P<.01$) from 0 to 72 hours. Differences in plasma potassium levels between deficient and control sheep were not significant. Vitamin A-deficient wethers had plasma inorganic phosphate levels higher than control wethers throughout the experiment, but the differences were not significant. Plasma calcium concentrations were not affected by treatment or time. Vitamin A-deficient sheep had more urea in their plasma both at 0 time ($P<.05$) and at 72 hr. ($P<.01$). Significant ($P<.05$) increases in concentration of plasma urea were observed after 72 hr. in both groups. Concentrations of plasma creatinine were higher for the vitamin A-deficient wethers throughout the trial and were significantly ($P<.05$) higher at the end. Again an increase in plasma concentration from 0 to 72 hr. was observed in both the deficient ($P<.05$) and the control ($P<.01$) wethers.

Discussion

The first three experiments of this study demonstrated a polyuria in wethers which was associated with a deficiency of vitamin A. In all three experiments the control wethers excreted slightly more than 50% as much urine as the wethers deficient in vitamin A. Furthermore, in experiment 2 where each animal consumed the same volume of water daily, the polyuria was still present, showing that the polyuria was not due to polydipsia. A similar polyuria has been reported in hypovitaminosis A heifers (Woelfel *et al.*, 1965). Cystic pituitaries associated with vitamin A deficiency have been reported (Madsen *et al.*, 1942), suggesting that the release of the antidiuretic hormone, vasopressin, may be affected. Polyuria would result in a hemoconcentration such as that observed in vitamin A-deficient rats by McLaren *et al.* (1965).

Johnson and Wolf (1960) reported that several steps in the synthesis of adrenal steroids appeared to be inhibited and that there was an accumulation of some corti-

TABLE 5. DAILY EXCRETION OF URINARY COMPONENTS OF WETHERS WITH FEED AND WATER WITHHELD FOR THREE DAYS (EXPERIMENT 4)

Item	Hours off feed and water	Vitamin A-deficient: Mean	Vitamin A-deficient: Standard error	Controls: Mean	Controls: Standard error
Volume, ml./day	24	694[a]	56.3	531[c]	74.0
	48	440	15.7	292	18.1
	72	356	25.7	266	53.4
Specific gravity	24	1.036[a]	.0021	1.048	.0042
	48	1.035	.0013	1.049	.0027
	72	1.035[b]	.0019	1.049	.0024
Osmolality, mOsm./kg. H_2O	24	974[a, c]	74.2	1402	153.3
	48	1023	47.6	1571	111.2
	72	1164[b]	68.6	1644	101.7
pH	24	5.51[a, d]	.138	6.44[d]	.369
	48	6.11	.209	7.49	.366
	72	6.99[a]	.345	7.73	.318
Sodium, gm./day	24	.950[b, d]	.185	1.751[d]	.192
	72	.328	.068	.422	.080
Potassium, gm./day	24	4.364[d]	.283	4.014[d]	.275
	72	1.256	.126	1.566	.367
Chloride, gm./day	24	2.655[b, d]	.223	3.664[d]	.262
	72	.858	.079	.973	.235
Inorganic phosphate, mg./day	24	407.76[a, c]	95.49	70.15	64.94
	72	112.05	35.95	31.46	23.79
Calcium mg./day	24	24.92[a, d]	4.96	111.63[d]	33.33
	72	2.42	.40	7.80	2.83
Urea gm./day	24	8.366	.777	7.430	.602
	72	6.859	.583	6.785	.560
Creatinine gm./day	24	1.105	.054	1.154	.062
	72	1.019	.071	1.150	.240

[a] Significantly different from controls, $P < .05$.
[b] Significantly different from controls, $P < .01$.
[c] Significantly different from 72 hours, $P < .05$.
[d] Significantly different from 72 hours, $P < .01$.

costeroids in the adrenals of vitamin A-deficient rats. If the levels of these hormones were elevated in vitamin A-deficient sheep, altered physiological responses might be expected. Malami et al. (1963) postulated that vitamin A deficiency leads to reduced synthesis of steroid hormones which are known to regulate water balance. Dingman and Despointes (1962) suggested that glucocorticoids enhance water diuresis by inhibiting the hypothalamic control of vasopressin release. However, Green et al. (1966) have shown that in the absence of vasopressin glucocorticoids are necessary to produce a water diuresis.

Experiments 1 and 2 were conducted with diets containing a high level of minerals. This may have accentuated the polyuria present in the vitamin A-deficient animals. In the second experiment, in which water intake of all animals was equalized and the same diet fed, deficient wethers still excreted nearly twice as much urine. Reducing mineral content of the ration to approximately required levels (N.R.C., 1964) resulted in a narrowing of

the differences in urine volumes, while salt retention by both groups was essentially equal (experiment 3). In experiment 4, with fasting animals consuming no minerals, the deficient wethers produced more urine than the controls; but the difference was not significant. Sodium and chloride excretion by the deficient wethers was lower on the first day, but there was little difference by the third day.

Results of these studies indicate that there is a polyuria associated with the vitamin A-deficient state in wethers. Multiple changes in the composition of plasma and urine accompany this polyuria. Many explanations may be offered for each individual observation; however, collectively they suggest an altered adrenal metabolism resulting in the secretion of elevated levels of glucocorticoids. This would in part explain the hyposthenuria observed in the vitamin A-deficient sheep. Experiments designed to investigate qualitatively and quantitatively the influence of vitamin A status on these hormones would be useful in answering the questions arising from these studies.

Summary

A series of experiments was designed to quantitate the polyuria observed in vitamin A-deficient wethers and to investigate renal function parameters which might be affected. In two trials designed to quantitate changes in urine volume, control wethers excreted only one-half as much urine as vitamin A-deficient wethers.

Since control wethers receiving equal amounts of water excreted only 53% as much urine as did deficient wethers (experiment 2), it was concluded that polydipsia was not a primary causative factor in the observed polyuria.

When less minerals and more protein were fed (experiment 3), total volumes decreased one-half for both groups, but the controls still excreted less urine than deficient wethers. Lower osmolality and specific gravity accompanied the increase in urine volume. A marked elevation in inorganic phosphate excretion and a decline in calcium excretion were also observed.

When feed and water were withheld (experiment 4), both groups were capable of concentrating urine. Decreased sodium and chloride excretion by the deficient wethers suggested that they were retaining more salt. An alteration in nitrogen metabolism was suggested by increased plasma urea. Increased inorganic phosphate excretion and decreased

TABLE 6. PLASMA ANALYSES OF WETHERS WITH FEED AND WATER WITHHELD FOR THREE DAYS (EXPERIMENT 4)

Item	Hours off feed and water	Vitamin A-deficient		Controls	
		Mean	Standard error	Mean	Standard error
Osmolality, mOsm/kg. H_2O	0	311	5.6	[illegible]	4.2
	72	310	1.8	[illegible]	3.9
Sodium, meq./l.	0	150	2.2	[illegible]	1.5
	72	152[a]	1.3	[illegible]	2.1
Potassium, meq./l.	0	5.74	.177	[illegible]	.223
	72	5.95	.251	[illegible]	.369
Chloride, mg./100 ml.	0	434.84[a]	5.61	[illegible]	[illegible]
	72	417.96[a]	4.57	[illegible]	[illegible]
Inorganic phosphate, mg./100 ml.	0	6.68	.321	[illegible]	[illegible]
	72	7.97	.724	[illegible]	.577
Calcium, mg./100 ml.	0	10.20[a,c]	.295	[illegible]	[illegible]
	72	10.54	.526	[illegible]	[illegible]
Urea, mg./100 ml.	0	19.20[a,c]	2.02	[illegible]	1.12
	72	25.96	1.24	[illegible]	.92
Creatinine, mg./100 ml.	0	1.10[a]	.061	1.01[a]	.044
	72	1.23	.063	1.21	.058

[a] Significantly different from controls, $P<.05$.
[b] Significantly different from controls, $P<.01$.
[c] Significantly different from 72 hours, $P<.05$.
[d] Significantly different from 72 hours, $P<.01$.

calcium excretion by the deficient wethers suggested possible alterations in bone metabolism.

It was concluded that a deficiency of vitamin A in wethers results in polyuria accompanied by changes in the composition of both the plasma and urine.

Literature Cited

Beeson, W. M., J. W. Pence and G. C. Holm. 1943. Urinary calculi in sheep. Am. J. Vet. Res. 4:120.

Dingman, J. E. and R. H. Despointes. 1960. Adrenal steroid inhibition of vasopressin release from the neurohypophysis of normal subjects and patients with Addison's disease. J. Clin. Invest. 39:1851.

Dugan, R. E., N. A. Frigui and J. M. Seibert. 1964. Colorimetric determination of vitamin A and its derivatives. Anal. Chem. 36:114.

Eveleth, D. F., D. W. Bolin and A. I. Goldsby. 1949. Experimental avitaminosis A in sheep. Am. J. Vet. Res. 10:[illegible]

Fiske, C. H. and Y. Subbarow. 1925. The colorimetric determination of phosphorus. J. Biol. Chem. 66:375.

Green, H. H., A. R. Harrington and H. Valtin. 1966. Impaired water diuresis in rats with hereditary hypothalamic diabetes insipidus (DI) after adrenalectomy. International Congress of Nephrology Sept. 1966, p. 202 (Abstr.).

Hart, G. H. and H. R. Guilbert. 1937. Symptomology of vitamin A deficiency in domestic animals. J.A.V.M.A. 91:193.

Hawk, P. B., B. L. Oser and W. H. Summerson. 1954. Practical Physiological Chemistry. (13th ed.). McGraw-Hill Book Company, Inc., New York.

Jackson, C. M. 1925. Spontaneous nephritis and compensatory renal hypertrophy in albino rats deficient in vitamin A. Proc. Soc. Exp. Biol. and Med. 22:410.

Johnson, B. C. and G. Wolf. 1960. The function of vitamin A in carbohydrate metabolism: its role in adrenocorticoid production. Vit. and Horm. 18:457.

Kimble, M. S. 1939. The photoelectric determination of vitamin A and carotene in human plasma. J. Lab. Clin. Med. 24:1055.

Langham, R. F., L. B. Sholl and E. T. Hallman. 1941. The pathology of the bovine kidney in vitamin A deficiency. Am. J. Vet. Res. 2:319.

Lindley, C. E., E. D. Taysom, W. E. Ham and B. H. Schneider. 1953. Urinary calculi in sheep. J. Animal Sci. 12:704.

Madsen, L. L., S. R. Hall and H. T. Converse. 1942. Cystic pituitary in young cattle with vitamin A deficiency. J. Nutr. 24:15.

Malathi, P., P. S. Sastry and J. Ganguly. 1961. Amino acid patterns in vitamin A-deficient rats. Nature 189:660.

McLaren, D. S., M. Tchalian and Z. A. Ajans. 1965. Biochemical and hematologic changes in the vitamin A-deficient rat. Am. J. Clin. Nutr. 17:131.

National Research Council. 1964. Nutrient requirements for sheep. N.R.C. publ. 1193. Washington, D.C.

Schmidt, H. 1941. Vitamin A deficiencies in ruminants. Am. J. Vet. Res. 2:373.

Seligson, D. 1958. Standard Methods of Clinical Chemistry. Vol. 2. Academic Press, Inc., New York.

Skeggs, L. T. 1957. An automated method for colorimetric analysis. Am. J. Clin. Path. 28:311.

Snedecor, G. W. 1956. Statistical Methods (5th ed.). The Iowa State College Press, Ames, Iowa.

Sutton, T. S., W. E. Krause and L. S. Hansard. 1940. The effect of vitamin A deficiency on the young male bovine. J. Dairy Sci. 23:574.

Swingle, K. F. and H. Marsh. 1956. Vitamin A deficiency and urolithiasis in range cattle. Am. J. Vet. Res. 17:415.

Tucker, R. E., G. E. Mitchell, Jr. and C. O. Little. 1967. Yellow pigments excreted by vitamin A-depleted sheep. J. Nutr. 93:518.

Woeliel, C. G., R. C. Hall, Jr., M. C. Calhoun, J. E. Rosseau, Jr. and H. D. Eaton. 1965. Volume and osmolality of urine of hypovitaminotic A Holstein heifers. J. Dairy Sci. 48:1346.

Zall, D. M., D. Fisher and M. Q. Garner. 1956. Photometric determination of chloride in water. Anal. Chem. 28:1665.

Weissmann-'63
Bib. No. 9706

Proc. Soc. exp. Biol, N. Y. 112:284. 1963

Acute Hypervitaminosis A in Guinea Pigs. I. Effects on Acid Hydrolases.* (28017)

GERALD WEISSMANN,† JONATHAN W. UHR AND LEWIS THOMAS
Department of Medicine, New York University School of Medicine, New York City

Experiments by Dingle(1) indicate that the addition *in vitro* of an excess of Vit. A alcohol to lysosome-rich fractions of rabbit liver releases acid hydrolases. Since phagocytic cells contain abundant lysosomes (2), a similar release of lysosomal enzymes occurring *in vivo* might have profound effects on immunological mechanisms.

Accordingly, the effects of acute hypervitaminosis A in guinea pigs, were studied with attention to: 1. distribution of lysosomal hydrolases in subcellular fractions of guinea pig liver. 2. stability of granular fractions *in vitro* to incubation and U-V irradiation and 3. serum levels of one of these enzymes (beta-glucuronidase).

The effect of this treatment upon delayed-type hypersensitivity is reported in the following paper (28018).

Materials and methods. Vitamin A acid was generously provided by the Hoffmann-La Roche Co., Nutley, N. J. The yellow crystals were suspended in corn oil (80 mg/ml) and the animals fed one or 2 ml by mouth, as indicated below. In most experiments, animals were given 80 mg on 2 successive days and killed 24 hours after the last dose. Control animals were given the same volume of corn oil. Since Vit. A acid is not stored in the liver, these experiments should not be complicated by *in vitro* effects of the stored vitamin.

Fractionation of guinea pig liver. Animals were killed by a blow on the head and livers were removed and promptly minced in chilled 0.25M sucrose until the washing fluid was free of gross blood. All subsequent procedures were performed at 4°C. The wet tissue was weighed, and a 1:10 w/v homogenate in sucrose was made in a glass homogenizer with a motor-driven Teflon pestle at 900 r.p.m. (Tri-R Stir-R, Tri R Co., Jamaica, N. Y.). Nuclei, debris and unbroken cells were separated by centrifugation at 800 *g* for 10 minutes in a Servall "Superspeed" centrifuge. The pellet was resuspended as a 1:10 w/v suspension which was called the "nuclear" fraction. The supernatant solution was centrifuged at 15,000 *g* for 20 minutes; the pellet was resuspended in sucrose 1:10 w/v, washed a second time at 15,000 *g*, and resuspended in a glass homogenizer by hand. As a 1:10 suspension this fraction was used for studying distribution of enzymes; as a 1:5 suspension this fraction, called the "large granule" fraction was used in experiments detailed below. The supernatant of the first, 15,000 *g* centrifugation was spun at 100,000 *g* for 2 hours in a Spinco model "L" preparative ultracentrifuge. The pellet was resuspended 1:10 in sucrose and the resultant suspension termed the "small granule" fraction; the "supernatant" was directly assayed. All fractions were mechanically disrupted in a Waring blendor (micro attachment) for 3 minutes before enzyme activities were determined.

Incubation and irradiation. These procedures have been described(3). Briefly: Aliquots of the twice-washed large granule fraction were placed in 600 ml beakers, and fixed in a water bath at 37°C. To test the relative stability of lysosomes, granular fractions were subjected to 2 types of incubation: with and without irradiation(4). Fractions to be irradiated were placed 32 cm beneath a Hanovia 100 watt high-pressure mercury arc lamp, whose rated output of energy below 3130 A is 250 microwatts/cm^2 as measured at 50 cm in free air. Duplicate samples were incubated in the same water bath, but shielded from radiation by means of aluminum foil. Another portion of each large granule fraction was homogenized in a Waring blendor for 5 minutes and then incu-

* Aided by grants from the U.S.P.H.S. and Commission on Immunization, Armed Forces Epidemiological Board.

† Senior Investigator, Arthritis & Rheumatism Foundation.

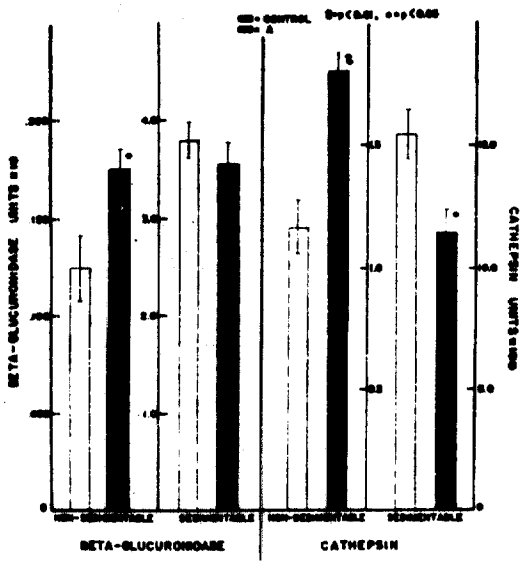

FIG. 1. Homogenates of control (open bars) and vitamin A acid-treated guinea pig liver (closed bars) have been made in 0.25M sucrose. Activities of cathepsins and beta-glucuronidase were measured in the fraction nonsedimentable at 15,000 × *g*, and in the fraction sedimentable at 15,000 × *g* (after disintegration of the granules in a Waring blendor).

bated to liberate the "total" activity of enzymes. Following incubation, these suspensions were again centrifuged at 15,000 *g* and the supernatants were analyzed for enzyme activity. "Unsedimentable" activity was determined by directly assaying that portion of the original homogenate which was not sedimentable at 15,000 *g*.

Cathepsin was determined by the method of Anson, using acid hemoglobin as substrate, as previously described(5).

Beta-glucuronidase of tissue extracts was measured by the method of Fishman *et al.* (6) using phenolphthalein glucuronide as the substrate. Serum beta-glucuronidase was determined as 0.2 ml samples of serum (obtained by retro-orbital bleeding) which were incubated with buffer and substrate for 18 hours.

Acid phosphatase was measured by the method of Huggins and Talalay(7) using phenolphthalein diphosphate (Sigma) as the substrate.

Protein was determined by the method of Lowry *et al.*(8) using crystalline egg white lysozyme as a standard.

Tabulation of results. All experiments with the large granule fraction were done simultaneously with control samples: "t" tests for differences between paired samples were used to test significance. Enzyme activity was expresed as units (μg of substrate hydrolyzed/μg protein/hr) or as % of total activity of the sample.

Results. Effect of acute hypervitaminosis A on distribution of acid hydrolases in liver. Sedimentation properties of acid protease(s) or cathepsin, and of beta-glucuronidase changed after 2 doses of Vit. A acid (80 mg) (Fig. 1). A decrease in activity of each enzyme contained within the large granule fraction (sedimenting between 800-15,000 × *g*) was accompanied by an increase in activity remaining in the supernatant (15,000 × *g*). The latter effect was more noticeable with beta-glucuronidase. To determine whether "unsedimentable" enzyme activity was entirely free in cell sap, or still remained bound to organelles or their breakdown products, a fractionation procedure described above was employed, and 4 fractions: nuclear, large granule, small granule and supernatant, were prepared. As seen in Table I, activities of 3 acid hydrolases were decreased in the large granule fraction prepared from vitamin A-treated animals, with comparable increases in the activity recovered in the supernatants and the small granule fractions (Table I). Enzymes recovered in this latter fraction could represent enzymes still attached to fragmented lysosomes, or non-specifically bound to microsomes, or enzymes associated with smaller lysosomes newly formed in the endoplasmic reticulum.

Lysosomal enzymes released from the large granules of liver might enter into the circulation. Serum beta-glucuronidase determinations summarized in Fig. 2 show that levels of this enzyme were significantly elevated in the serum of Vit. A-treated animals. The source of elevated serum beta glucuronidase is not necessarily the liver, therefore, an increased synthesis of enzyme at other sites could also result in these levels, as could a decrease in the removal of beta-glucuronidase from the circulation.

Release of acid hydrolases from the large

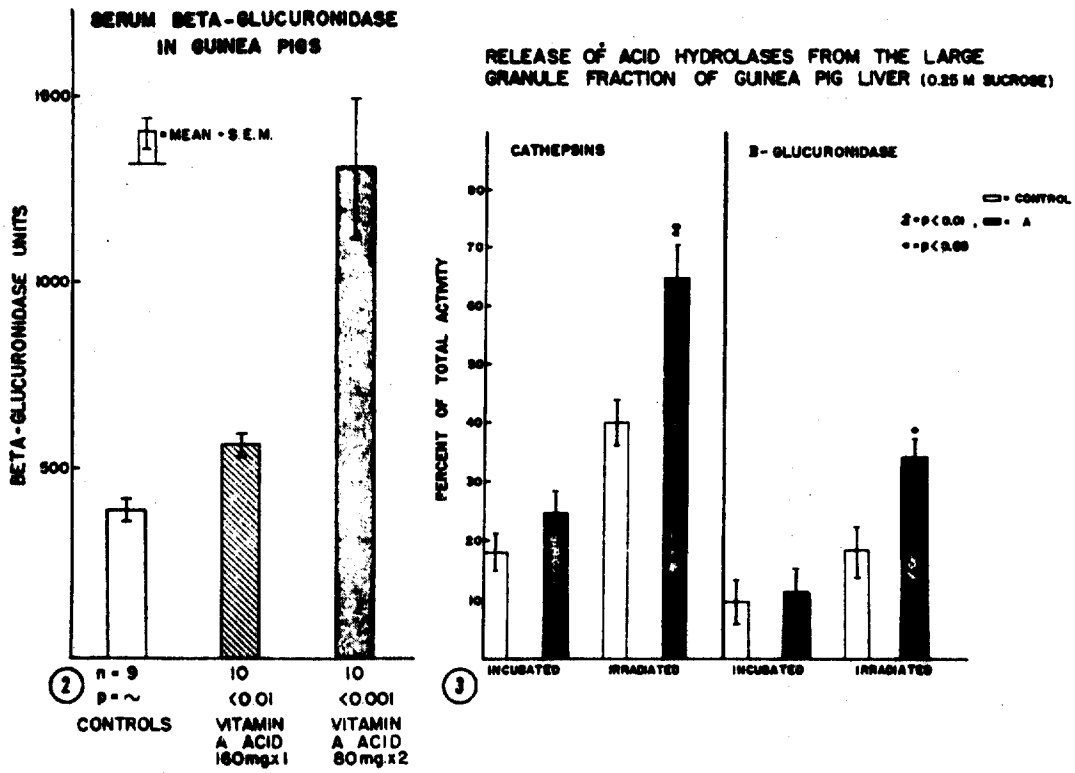

FIG. 2. Serum beta-glucuronidase in guinea pigs.

FIG. 3. Release of acid hydrolases from large granule fraction of guinea pig liver (0.25M sucrose). Large granule fractions sedimenting between 800 and 15,000 × *g* were isolated from normal (open bars) and vitamin A acid-treated guinea pig liver (closed bars). They were incubated with or without mercury arc irradiation for 40′ (see text). Following this treatment, suspensions were again centrifuged at 15,000 × *g* and the enzyme activity (expressed as % of total activity of the fraction) determined in the supernatant.

granule fraction of guinea pig liver. When the large granule fractions of guinea pig liver were incubated, particularly in the presence of mercury-arc irradiation, lysosomal hydrolases were more readily released from fractions which had been prepared from the livers of Vit. A-treated animals (Fig. 3). In view of similar findings in the rabbit and rat after endotoxin or traumatic shock(3,9) this finding could indicate an increased "fragility" of hepatic lysosomes. In accord with previous studies in rabbits of lysosomal damage induced by several different agents,(10,3,9) the release of acid protease(s) exceeds that of beta-glucuronidase from lysosome-rich fractions. This observation may indicate selective release of particular enzymes.

Discussion. These experiments suggest that Vit. A can cause release of lysosomal en-

TABLE I. Distribution of Acid Hydrolases in Subcellular Fractions of Guinea Pig Liver (0.25M Sucrose).

Animals	Fraction	Acid phosphatase	Beta glucuronidase	Cathepsin
Controls	Nuclear	16.1*	18.0*	27.5*
	Large granule	49.5	66.8	46.0
	Small "	19.8	9.9	22.0
	Supernatant	14.6	5.3	.5
	Total activity recovered (in units)	6.95†	2.76†	26.7‡
Vit A	Nuclear	18.7*	14.6*	28.8*
	Large granule	37.8	58.2	32.4
	Small "	22.0	16.9	18.3
	Supernatant	21.5	10.3	20.5
	Total activity recovered (in units)	5.53†	2.85†	29.5‡

* % of recovered activity.

† μg phenolphthalein liberated/10.0 μg protein/hr.

‡ μg acid-soluble tyrosine liberated/100 μg protein/hr.

zymes *in vivo*. A large dose of Vit. A acid in the guinea pig not only caused a change in subcellular distribution of lysosomal enzymes, but also rendered the granules more "fragile" to *in vitro* incubation and irradiation. It is, therefore, suggested that along with other effects(11), Vit. A acts upon the surface of lysosomes to cause release of acid hydrolases. The demonstration of increased serum levels of beta-glucuronidase after administration of Vit. A acid indicates that the enzymes not only leave granules within the cell, but also enter the circulation. The consequences of this regimen of Vit. A on immune responses in these animals are discussed in the following paper.

Summary. Acute hypervitaminosis A was induced in guinea pigs by oral administration of Vit. A. This treatment caused much of the activity of acid phosphatase, beta-glucuronidase and cathepsin to become unsedimentable at 15,000 *g* in homogenates prepared in 0.25M sucrose. Lysosome-rich fractions of hypervitaminotic livers released beta-glucuronidase and cathepsin more readily into the incubation medium *in vitro* than did control fractions. These events were accompanied by increases of serum beta-glucuronidase, and are compatible with a direct effect of excess Vit. A on lysosomes.

1. Dingle, J. T., *Biochem. J.*, 1961, v79, 509.

2. Novikoff, A., in *The Cell* (J. Brachet, A. E. Mirsky, eds.) New York, Academic Press, 1961, v2, 364.

3. Weissmann, G., Thomas, L., *J. Exp. Med.*, 1962, v116, 443.

4. Weissmann, G., Dingle, J. T., *Exp. Cell Res.*, 1961, v25, 207.

5. Anson, M. L., *J. Gen. Physiol.*, 1936, v20, 565.

6. Fishman, W. H., Springer, B., Brunetti, R., *J. Biol. Chem.*, 1948, v173, 449.

7. Huggins, C., Talalay, P., *ibid.*, 1945, v153, 339.

8. Lowry, O. H., Rosebrough, N. J., Farr, A. L., Randall, R. J., *ibid.*, 1951, v193, 265.

9. Janoff, A., Weissmann, G., Zweifach, B. W., Thomas, L., *J. Exp. Med.*, 1962, v116, 451.

10. Weissmann, G., Thomas, L., *J. Clin. Invest.*, in press.

11. Wolf, G., *Nutrition Rev.*, 1962, v20, 161.

Received November 13, 1962. P.S.E.B.M., 1963. v112.

Weissman & Thomas-'63
Bib. No. 9707

J. Clin Invest. 42(5):661-69. 1963.

Journal of Clinical Investigation
Vol. 42, No. 5, 1963

STUDIES ON LYSOSOMES. II. THE EFFECT OF CORTISONE ON THE RELEASE OF ACID HYDROLASES FROM A LARGE GRANULE FRACTION OF RABBIT LIVER INDUCED BY AN EXCESS OF VITAMIN A *

By GERALD WEISSMANN † AND LEWIS THOMAS

(*From the Department of Medicine, New York University School of Medicine, New York, N. Y.*)

(Submitted for publication October 24, 1962; accepted January 17, 1963)

Recent studies on the dissolution of cartilage matrix by vitamin A *in vivo* and *in vitro* have indicated that the vitamin acts, at least in part, by releasing endogenous acid proteases from cartilage cells (1–5). Dingle (6) found that vitamin A alcohol *in vitro* liberated acid protease(s) from a particulate fraction of rat liver homogenized in 0.25 M sucrose. This fraction of tissue homogenates contained the bulk of acid hydrolases intimately bound to lysosomes, cytoplasmic organelles described by de Duve (7).

Observations from this laboratory, based on earlier experiments by Dingle, suggested that the induction of hypervitaminosis A *in vivo* caused a similar release of acid protease from lysosomes (8, 9); the action of such enzymes was held responsible for the degradation of protein-polysaccharide complexes in connective tissue. Morphologic expressions of this phenomenon could be seen in rabbit ear and articular cartilage (8) and in the connective tissue (9) of amphibian tails, tentacles, and chondrocranium. These studies, and others carried out at the Strangeways Research Laboratory in Cambridge, England, have also indicated that cortisone and hydrocortisone antagonized the effects of excess vitamin A (10), perhaps by stabilizing the lysosomes of tissues against the vitamin and other injurious agents. Hydrocortisone retarded the release of acid hydrolases from a large granule fraction prepared from rat and rabbit liver after traumatic shock (11) or the injection of bacterial endotoxins (12), and diminished the release effected by mercury arc irradiation (13). It appeared possible, therefore, that adrenal steroids might partially protect isolated lysosomes against an excess of vitamin A *in vivo* and *in vitro*.

Evidence presented in this paper suggests that an excess of vitamin A, when fed to young rabbits, caused the augmented release of acid hydrolases from a large granule fraction of liver homogenates *in vitro;* an appreciable increase in the nonsedimentable activity of these enzymes *in vivo* was also observed. Depletion of cartilage matrix in hypervitaminotic animals was associated with an increased liberation of acid hydrolases from cartilage. Both effects were diminished in animals given cortisone together with the vitamin. Hydrocortisone added to rabbit liver homogenates partially antagonized the effects of an excess of vitamin A administered during life.

MATERIALS AND METHODS

Animals. Young hybrid, male, albino rabbits were obtained from commercial sources and fed a stock laboratory diet. They weighed between 800 and 1,000 g.

Vitamin A. The yellow crystals of Vitamin A acid [1] were suspended in corn oil, 50 mg per ml, before feeding animals by stomach tube. Vitamin A alcohol [2] was dissolved in anhydrous ethanol before use. The vitamin A palmitate [2] was dissolved in cottonseed oil, 10^6 international units per ml, and was also administered by stomach tube.

Cortisone acetate. Cortisone acetate in aqueous suspension [3] was given intramuscularly, 50 mg per kg, for 3 days. On day 4, 50 mg of *hydrocortisone hemisuccinate* (Solu-Cortef) [4] was given intravenously 30 minutes before death of animals by air embolus. For *in vitro* experiments, hydrocortisone was added to the whole homogenates 30 minutes before further fractionation.

Incubation and irradiation. These procedures are described in detail elsewhere (12). Briefly, a large granule

* Supported by grants A 5316 and RG 6367 (C2) from the National Institutes of Health, Bethesda, Md., and contract DA 49 007 MD 590 from the Surgeon General's Office, Dept. of the Army, Washington, D. C.

† Senior Investigator, Arthritis and Rheumatism Foundation.

[1] Hoffman-LaRoche Co., Nutley, N. J.
[2] Nutritional Biochemicals, Inc., Cleveland, Ohio.
[3] Philadelphia Ampoule Laboratories, Philadelphia, Pa.
[4] The Upjohn Company, Kalamazoo, Mich.

TABLE I

*Fractionation scheme for preparation of rabbit liver granules**

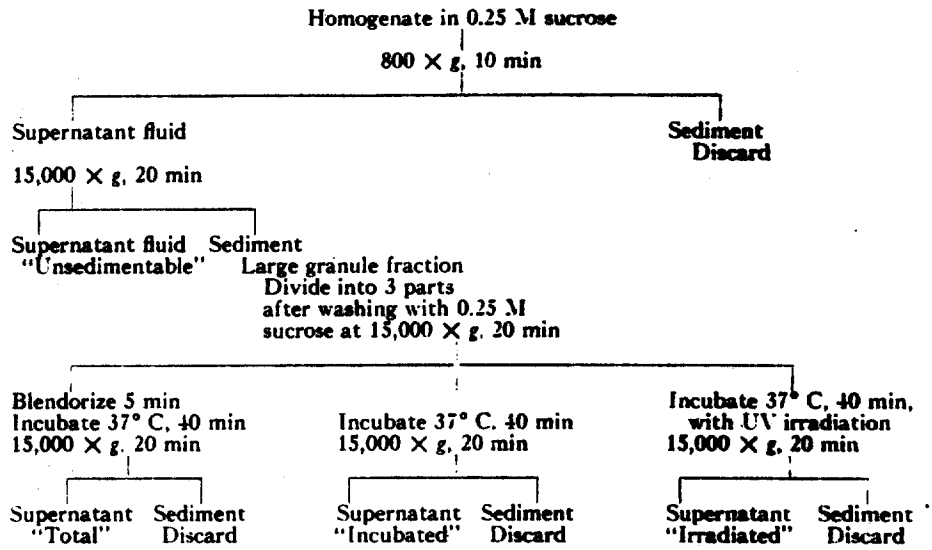

* See text for details of this scheme and reference 12.

fraction of rabbit liver homogenized in 0.25 M sucrose was isolated between 800 × *g* for 10 minutes and 15,000 × *g* for 20 minutes in a Servall superspeed centrifuge. Samples of the large granule fraction were either incubated at 37° C for various times, or the fragility of lysosomes was tested by incubating them in the presence of mercury-arc irradiation, a procedure leading to the formation of lipid peroxides (14) and release of lysosomal enzymes (13). After incubation and irradiation, fractions were again centrifuged at 15,000 × *g* for 20 minutes, and the enzyme activities of the supernatant fluids determined. These samples are termed "incubated" and "irradiated." "Total" activity represented activity released into the 15,000 × *g* supernatant fluid of the large granule fraction after it had been mechanically disintegrated in a Waring Blendor for 5 minutes. "Unsedimentable" activity represented enzyme activity in the original homogenate which was unsedimentable after an initial 15,000 × *g*, 20-minute centrifugation. Our use of this term differs slightly from that of de Duve (7). These steps are summarized in Table I.

Enzyme assay. Cathepsin was assayed by the method of Anson (15), beta-glucuronidase by the method of Fishman, Springer, and Brunetti (16), and acid phosphatase by the method of Huggins and Talalay (17) with phenolphthalein diphosphate as the substrate. Protein was determined by the method of Lowry, Rosebrough, Farr, and Randall with crystalline egg-white lysozyme as a standard (18). Details of these procedures have been described before (8).

Tabulation of results. Paired samples were used in most experiments, and the appropriate *t* test performed. Results are expressed as percentage of total enzyme activity of the large granule fraction, or in absolute units, micrograms substrate hydrolyzed per 100 μg protein per hour. It must be emphasized that changes in protein concentration could therefore alter these values, independent of any changes in enzyme activity. In cases where the effects of several agents were to be compared, all data have been transposed to percentages of control values.

Viscosity studies. Samples of a purified chondromucoprotein from bovine nasal septum (PP-L) in powdered form were generously provided by Dr. Maxwell Schubert. The preparation and properties of this material are described elsewhere (19). Solutions, 0.5% wt/vol, in 0.1 M acetate buffer at pH 4.5 were freshly prepared daily. Viscosities were determined in Ostwald viscosimeters having a water flow time of 30 to 40 seconds at 37° C. PP-L solutions, 2.5 ml, were placed together with 0.5-ml samples of the 15,000 × *g* supernatant fluids of the irradiated large granule fractions prepared from the livers of normal and vitamin A-treated rabbits. Sucrose, 0.5 ml, was added to control samples; in some experiments, cysteine hydrochloride, 10 mmoles, or iodoacetamide, 10 mmoles, was also added to each viscosimeter.

Incubation of cartilage slices. Immediately after sacrifice, ears were removed from rabbits in a cold room at 4° C. Skin and perichondrial tissues containing soft tissue and blood vessels were dissected free, and the thin, avascular cartilagenous plates were sliced into squares (0.5 cm × 0.5 cm). Slices obtained from both ears of each animal were incubated at 37° C for 18 hours in 40 ml of acetate buffer, pH 4.5, 0.1 M. The supernatant medium was decanted, filtered through Whatman no. 1 filter paper, and the slices washed three times in acetone

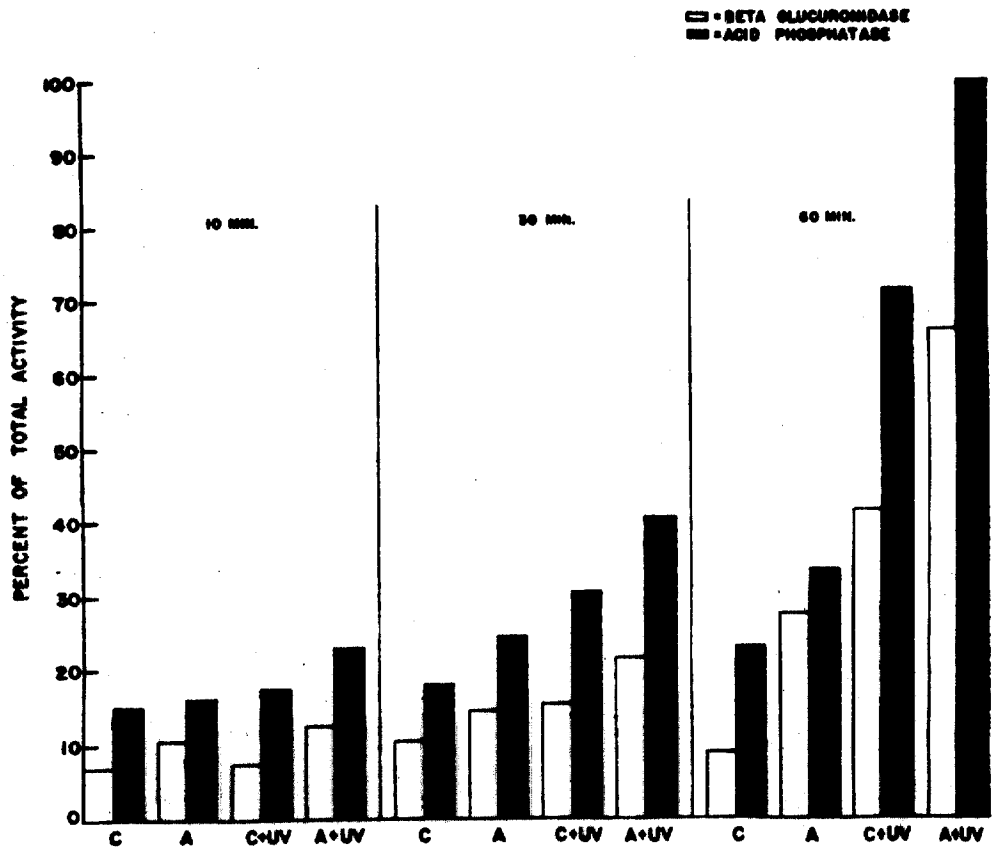

FIG. 1. VITAMIN A ALCOHOL *in vitro*. Vitamin A induced release of beta-glucuronidase and acid phosphatase from the large granule fraction of rabbit liver homogenized in 0.25 M sucrose. The fractions sedimenting between 800 and 15,000 × *g* were incubated and irradiated *in vitro* at 37° C for times shown. They were then centrifuged for 20 minutes at 15,000 × *g* and the enzyme activity of the supernatant fluid determined. C = control liver fraction incubated at 37° C; C + UV = control liver fraction, incubated and irradiated by a mercury arc lamp at 37° C; A = liver fractions incubated with vitamin A alcohol, 3.5×10^{-4} M at 37° C; and A + UV = liver fraction incubated with vitamin A alcohol 3.5×10^{-4} at 37° C, and irradiated.

and dried *in vacuo* over $CaCl_2$ to a constant weight. Enzyme activities were determined in samples of the buffer medium, and expressed as micrograms substrate hydrolyzed per milligram dry weight of the cartilage slices.

RESULTS

The effects of vitamin A alcohol in vitro on release of acid hydrolases from a large granule fraction of rabbit liver. Dingle (6) had found that 3.5×10^{-4} M vitamin A alcohol would release bound protease from the large granule fraction of rat liver. This amount of the vitamin was added in ethanol to the large granule fraction of rabbit liver; an equal volume of ethanol (0.25 ml per 50 ml) was added to control suspensions. Fractions, 20 ml, were incubated and irradiated for periods indicated in Figure 1, when 5-ml portions were withdrawn. It may be seen that the vitamin *in vitro* caused gradual release of acid phosphatase and beta-glucuronidase, more being released from those fractions which were exposed to the mercury beam. A period of 40 minutes' incubation was chosen for subsequent experiments. Data in Table II show that three acid hydrolases are released in roughly parallel fashion. Enzyme activities of unsedimentable and total fractions did not differ significantly from controls, since the vitamin was added *in vitro*. The results suggest that all three enzymes were released as a result of the addition of vitamin A, and that the vitamin

TABLE II

Activity of acid hydrolases in rabbit liver

Animals	Treatment of animals	Treatment of granules	Fraction*	Cathepsins: Enzyme activity	Cathepsins: SD	Beta-glucuronidase: Enzyme activity	Beta-glucuronidase: SD	Acid phosphatase: Enzyme activity	Acid phosphatase: SD
no. 21	None (control)	None (control)	Incubated	11.7†	± 3.3	9.2†	± 2.3	16.1†	± 7.3
			Irradiated	27.0†	± 5.9	22.0†	± 3.9	32.9†	± 6.7
			Total	21.0‡	± 3.8	6.1§	± 1.4	1.60§	± 0.14
			Unsedimentable	1.7‡	± 0.2	0.025§	± 0.004	0.75§	± 0.12
				Percentage of control values‖		Percentage of control values‖		Percentage of control values‖	
6	None	Vitamin A alcohol, 3.5×10^{-4} M	Incubated	154.0¶	± 20.	151.0¶	± 19.3	179.0**	± 19.2
			Irradiated	200.2**	± 18.	165.0¶	± 21.9	141.5¶	± 17.6
			Total	112.8	± 20.1	100.3	± 14.3	107.8	± 16.1
			Unsedimentable	100.4	± 13.0	109.1	± 12.9	94.0	± 14.5
9	Vitamin A acid, 50 mg/kg × 4	None	Incubated	138.0¶	± 17.4	93.9	± 19.8	154.0¶	± 18.9
			Irradiated	152.2¶	± 20.2	100.8	± 23.2	119.0	± 20.2
			Total	95.2	± 24.3	69.0¶	± 12.6	110.2	± 17.3
			Unsedimentable	147.0**	± 12.4	130.0**	± 8.7	140.4**	± 12.1
4	Vitamin A acid, 50 mg/kg × 4, and cortisone	None	Incubated	53.0¶	± 21.7	75.4	± 26.2		
			Irradiated	49.0¶	± 20.7	79.6	± 22.2		
			Total	90.1	± 21.4	35.5**	± 18.3		
			Unsedimentable	15.5**	± 16.4	26.0**	± 12.7		
4	Cortisone, 50 mg/kg × 4	None	Incubated	87.2	± 20.2	67.0	± 19.2		
			Irradiated	83.0	± 23.2	83.6	± 30.0		
			Total	82.8	± 18.2	79.3	± 28.1		
			Unsedimentable	17.5**	± 12.3	54.0¶	± 17.4		
4	Vitamin A acid, 50 mg/kg × 4	Hydrocortisone, 10^{-6} M	Incubated	39.5¶	± 20.6	70.8	± 26.2		
			Irradiated	69.6¶	± 19.8	82.5	± 28.3		
			Total	110.5	± 24.3	77.1	± 16.4		
			Unsedimentable	134.1¶	± 12.6	138.0¶	± 15.2		
4	None	Hydrocortisone 10^{-6} M	Incubated	77.8	± 24.	72.4	± 20.3		
			Irradiated	77.2	± 19.	71.8	± 28.4		
			Total	106.8	± 17.3	101.2	± 21.3		
			Unsedimentable	101.3	± 10.8	96.4	± 12.8		
4	Vitamin A palmitate, $10^{4} \times 4$	None	Incubated	81.2	± 19.4	93.2	± 21.2		
			Irradiated	106.7	± 32.1	90.7	± 19.8		
			Total	94.3	± 24.3	84.9	± 23.2		
			Unsedimentable	123.6	± 14.8	99.7	± 18.9		

* See Table I for preparation of these fractions.
† Activity found in the supernatant fluid of incubated or irradiated granules after centrifugation at 15,000 *g* for 20 minutes expressed as percentage of the value similarly obtained for the Blendor-treated preparation (total).
‡ Cathepsin unit: μg acid-soluble tyrosine per 100 μg protein per hour.
§ Beta-glucuronidase or acid phosphatase unit: μg phenolphthalein liberated per 100 μg protein per hour.
‖ Control values arbitrarily assigned, 100%.
¶ $p < 0.05$.
** $p < 0.01$ vs. controls.

augmented the release effected by mercury arc irradiation. This is compatible with an effect upon the stability of lysosomes.

The effect of vitamin A acid in vivo on release of acid hydrolases from a large granule fraction of rabbit liver. To determine whether the *in vivo* effect of vitamin A in excess would be similar to the *in vitro* action, vitamin A acid was chosen. This form of the vitamin is not stored in the liver to any appreciable degree (20), and therefore the amount still present in subsequent *in vitro* studies would be negligible. An earlier study (8) has indicated that significant cartilage lesions may be effected by 250 mg of vitamin A acid a day given orally. To determine whether a lesser amount, not associated with epilation, weight loss, or other toxicity, would affect liver lysosomes, vitamin A acid was given for four successive days

at a dose of 50 mg per kg in corn oil, while controls received corn oil alone. The last dose was given one hour before sacrifice. In Figure 2 the results of this treatment upon the subsequent release of acid protease *in vitro* may be seen. In each case, the vitamin A-treated fractions released more enzyme than did controls. This effect was magnified in fractions exposed to the mercury beam. In subsequent experiments, an incubation period of 40 minutes was used, and the vitamin was given at a dose of 50 mg per kg. In Table I the results of this treatment on release of acid hydrolases may be seen. A 30 to 40% increase in the unsedimentable activity of all three enzymes was found. This is compatible with a release of these enzymes from granules into the cytoplasm *in vivo*, before homogenization. A comparable decrease in the total, or sedimentable, activity was constant only in the case of beta-glucuronidase. A compensatory increase in synthesis of acid protease and acid phosphatase may have followed hypervitaminosis A. Such a finding has been reported by Dingle and Fell (21) for bone rudiments exposed to vitamin A *in vitro*. *In vitro* incubation and irradiation showed that this treatment schedule resulted in more active release of acid protease and acid phosphatase than of beta-glucuronidase from the particles *in vitro*. A preferential release of the protease has been noted previously in fractions prepared from animals injected with bacterial endotoxin (12).

The effect of cortisone and hydrocortisone upon the release of acid hydrolases from a large granule fraction of rabbit liver. When cortisone was administered intramuscularly in doses of 50 mg per kg together with the vitamin, release of enzymes into the unsedimentable fraction was significantly inhibited (Table II). Whereas no appreciable change in the total content of acid protease remaining sedimentable was noted, beta-glucuroni-

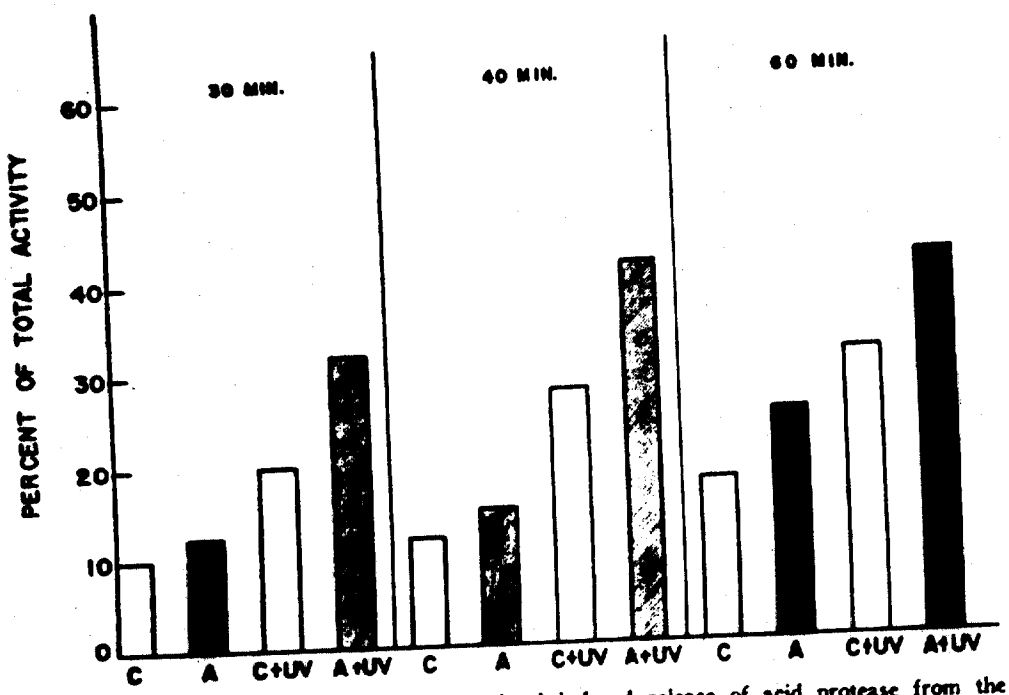

FIG. 2. VITAMIN A ACID *in vivo*. Vitamin A induced release of acid protease from the large granule fraction of rabbit liver homogenized in 0.25 M sucrose. The fractions sedimenting between 800 to 15,000 × *g* were incubated and irradiated *in vitro* at 37° C for times shown. They were then centrifuged for 20 minutes at 15,000 × *g* and the enzyme activity of the supernatant fluid determined. C = control liver fraction incubated at 37° C; C + UV = control liver fraction incubated and irradiated with a mercury arc lamp at 37° C; A = liver fraction prepared from a rabbit given 50 mg vitamin A acid for 4 days, incubated at 37° C; and A + UV = liver fraction prepared from a rabbit given 50 mg vitamin A acid for 4 days, incubated at 37° C.

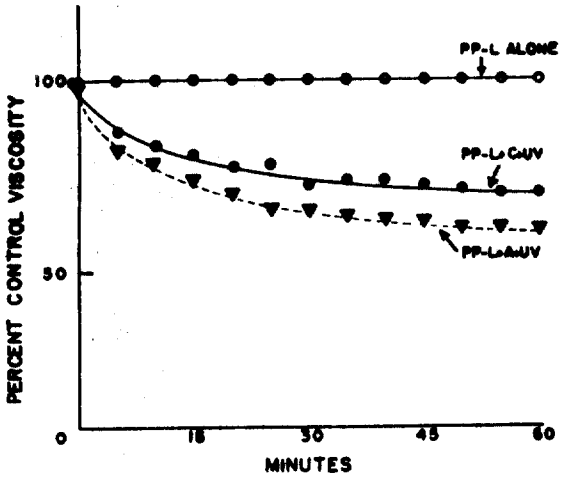

FIG. 3. VISCOSITIES OF A CHONDROMUCOPROTEIN FRACTION FROM COW NASAL SEPTUM (PP-L) IN 0.1 M ACETATE BUFFER, pH 4.5, 37° C. PP-L alone = 2.5 ml 0.5% PP-L plus 0.5 ml sucrose: PP-L + C + UV = 2.5 ml 0.5% PP-L plus 0.5 ml of C + UV fraction (see Figure 2); and PP-L + A + UV = 2.5 ml 0.5% PP-L plus 0.5 ml of A + UV fraction (see Figure 2).

dase was depressed even more than in animals given vitamin A alone. An additive effect of vitamin A and steroid may be seen in the data for animals given cortisone alone. Beta-glucuronidase is decreased significantly in these total fractions. *In vitro* release of acid protease from the large granule fraction prepared from animals given vitamin A and steroid together was significantly lower than from control fractions. Comparison of these data with those obtained from animals given cortisone alone (Table II) suggests that the stabilizing effect of adrenal corticoids is relatively independent of the presence of the vitamin.

When animals were made hypervitaminotic and hydrocortisone, 10^{-3} M, was added *in vitro*, release of hydrolases was retarded, both in incubated and irradiated fractions (Table II). This suggested that steroids given after the initial insult to the particles could still serve to stabilize the system(s) responsible for their integrity. This amount of hydrocortisone itself, in the absence of excess vitamin A, caused a 25 to 30% decrease of enzymes released from all fractions. This decrease was as marked for beta-glucuronidase as for acid protease.

The effect of vitamin A palmitate on release of acid hydrolases. Vitamin A palmitate given by stomach tube in doses of 10^6 international units per day causes collapse of the ears of rabbits (4, 8). Yet this form of the vitamin, which is eventually stored as an ester in the liver, is unable to release acid protease from rat liver particles *in vitro* and is similarly inactive to causing damage to embryonic cartilage in organ culture (22). When the palmitate was administered to rabbits, the expected cartilage changes followed (8), but as may be seen in Table II, no effects on hepatic lysosomes could be demonstrated. A modest increase of unsedimentable activity was noted, but no other changes were seen. This would imply that the esterified vitamin is not active upon lysosomes of the tissues in which it is chiefly stored.

The effect of enzyme(s) from the large granules of rabbit liver on a chondromucoprotein. To study whether the protease(s) released from the large granule fraction of rabbit liver could be held responsible for degradation of connective tissue following hypervitaminosis A, viscosities of PP-L were determined in the presence of *1*) sucrose alone, *2*) the supernatant fluid of a large granule fraction prepared from a normal rabbit and subsequently exposed to a mercury beam, and *3*) the supernatant fluid of a similar fraction from a rabbit given 50 mg per kg of vitamin A acid for four days. The results of such an experiment are shown in Figure 3. There was insufficient proteolytic activity in nonirradiated fractions to change the viscosity of PP-L. When similar incubations were carried out in the presence of 10 mmoles cysteine, no increase in the viscosity-reducing effects of the fractions could be detected, and 10 mmoles iodoacetamide did not cause any change in the opposite direction. Changes in viscosity of

TABLE III

Release of acid hydrolases from rabbit ear cartilage in vitro *

Animals	Acid phosphatase†	Beta-glucuronidase†	Acid protease‡
Control	1.00	2.66	6.36
Vitamin A§	1.15	3.90	11.60
Vitamin A + cortisone§	1.10	2.86	7.34
Cortisone§	1.02	1.53	2.94

* Cartilage slices were incubated in 0.1 M acetate buffer, pH 4.5, for 18 hours at 37°C, the medium was filtered, and enzyme activity determined.

† Micrograms phenolphthalein hydrolased per milligram cartilage per 18 hours.

‡ Micrograms acid-soluble tyrosine released per milligram cartilage per 18 hours.

§ See text for treatment schedule.

similar substrates brought about by papain (23, 24), trypsin (25), or plasmin (26) are generally regarded to result from the action of protease upon a protein-polysaccharide complex, with the formation of a protein-poor chondroitin sulfate of lesser molecular weight and lesser relative viscosity. Failure of sulfhydryl compounds to alter the curves would suggest absence of sulfhydryl-dependent proteases in the irradiated supernatant fluids.

The effect of hypervitaminosis A on release of hydrolases from cartilage slices in vitro. Cartilage slices from normal rabbits, from rabbits given vitamin A acid, 50 mg per kg, from rabbits given cortisone, 50 mg per kg, and from rabbits given both the vitamin and the steroid were incubated as described above. Results are listed in Table III. All three hydrolases were released to a greater degree from the cartilage of animals given only the vitamin than from the other three groups. This would suggest that vitamin A acted not only upon hepatic lysosomes, but also upon those of cartilage cells. It is of course impossible to determine whether increased synthesis also played a role in such a system.

DISCUSSION

The data presented above support the hypothesis that vitamin A *in vivo* as well as *in vitro* (6) causes release of acid hydrolases from lysosomes. This has been shown not only for particles isolated from the liver of rabbits, but also for cartilage slices. Adrenal glucocorticoids inhibited the release of lysosomal enzymes, both *in vitro* and *in vivo*. These findings also agree with the hypothesis that one action of cortisol and its analogues is the stabilization of lysosomes against the effects of vitamin A in excess.

The limitations inherent in this isolation procedure of hepatic granules with the presence of numerous mitochondria have been discussed at length elsewhere (8). Changes in protein concentration caused by various treatments would of course alter the interpretation of results; similar objections could be raised against use of dry weight, wet weight, or DNA measurements as a reference in treated animals.

During these experiments, and in experiments dealing with the effects of endotoxin, shock, and mercury arc irradiation (11–13), it has become increasingly apparent that the particles within the large granule fraction may be quite heterogeneous. At low *in vivo* doses of vitamin A, *in vitro* studies indicate a fragility of the particles mainly with respect to acid protease, and very little with respect to beta-glucuronidase. Similarly, both hypervitaminosis A and cortisone pretreatment can reduce the total activity of beta-glucuronidase of the granules, without changing the activity of acid protease or acid phosphatase. Most *in vitro* experiments in which agents are added to the fractions after isolation indicate a parallel release of all lysosomal enzymes (27). This was the effect of vitamin A *in vitro*, and the actions of other *in vitro* agents on lysosomes such as mechanical disintegration (27), freezing and thawing (28), exposure to detergents (27, 28), and mercury-arc irradiation have been similar. The discrepancy between *in vivo* and *in vitro* effects suggests that lysosomes *in vivo* may respond selectively to various stimuli by release or storage of particular enzymes.

Although hypervitaminosis A may have more general membrane effects than upon the lysosomes alone (29), it would appear that damage to cartilage matrix and connective tissue (30) may be attributed to release of acid protease from lysosomes. Lysosomal protease has been studied in acute experiments at pH 4.5 (6). In longer experiments, however, Dingle has found such enzymes to be active on matrix at near-neutral pH (31). Since acid proteases are active upon chondromucoprotein *in vitro* and are released in increased amounts from cartilage removed from hypervitaminotic animals, the above hypothesis would seem warranted. Further evidence is afforded by the histologic similarities between the effects of vitamin A excess and the exogenous protease, papain *in vivo* (4) and *in vitro* (5). This plant protease can degrade chondromucoprotein (24), and upon intravenous injection, papain causes a loss of metachromasia from cartilage (32). These actions can be simulated by enzyme(s) released from lysosomes by hypervitaminosis A.

A protective effect of adrenal glucocorticoids on isolated granules of rat and rabbit liver has been previously demonstrated against damage caused by ultraviolet irradiation (13), injections of bac-

terial endotoxins (12), and simple incubation at acid pH (33). Indeed, several fat-soluble agents, such as vitamin D_2, act *in vitro* to labilize the granules; others, such as cholesterol, act to stabilize them (33). Thus, a coincidence between the *in vitro* and *in vivo* actions of vitamin A as a labilizer and cortisol as a stabilizer can conceivably be fortuitous. However, on morphologic grounds, too, protection of lysosomes by glucocorticoids has been shown against hypervitaminosis A *in vivo* (8, 9) and *in vitro* (10), and against ultraviolet irradiation *in vivo* (34) and *in vitro* (35). Desoxycorticosterone acetate was not effective in such systems. It seems reasonable, therefore, to assume that cortisone acts, at least in part, by stabilizing lysosomes in a variety of situations. Since recent experiments by Janoff and Kaley (36) have indicated that lysosomal enzymes are a potent inflammatory stimulus in the skin of small laboratory animals, the anti-inflammatory action of cortisol and its analogues may also be partially due to a stabilization of lysosomes.

SUMMARY

Vitamin A acid was fed to young rabbits and the activities of three lysosomal hydrolases determined in liver homogenates prepared in 0.25 M sucrose. An excess of the vitamin *in vivo* caused an increase in the activities of acid protease, beta-glucuronidase, and acid phosphatase unsedimentable at 15,000 × *g*. *In vitro* incubation and ultraviolet irradiation caused a greater release of acid protease and acid phosphatase from granular fractions prepared (between 800 and 15,000 × *g*) from hypervitaminotic animals than from control fractions. The simultaneous administration of cortisone largely prevented the change of sedimentability and retarded release of hydrolases from granules. Hydrocortisone *in vitro* also stabilized the granules against the effects of pretreatment with vitamin A. Cartilage slices prepared from the ears of hypervitaminotic rabbits released significantly more acid hydrolases into the surrounding medium; extracts of their liver granules caused a reduction in the viscosity of chondromucoprotein. These results are compatible with the hypothesis that excess vitamin A releases acid hydrolases from liver and cartilage lysosomes *in vivo* and *in vitro*, and that cortisone antagonizes this action.

ADDENDUM

Experiments initiated before the ones described in this paper and confirming an action of excess vitamin A on lysosomes *in vivo* have recently been reported (37).

ACKNOWLEDGMENT

We thank Mr. Ernest Bell and Miss Beverly Becher for their valuable technical assistance. We also thank Dr. Honor B. Fell and Mr. John Dingle for many stimulating suggestions and advice.

REFERENCES

1. Fell, H. B., and L. Thomas. Comparison of the effects of papain and vitamin A on cartilage. II. The effects on organ cultures of embryonic skeletal tissue. J. exp. Med. 1960, 111, 719.
2. Dingle, J. T., J. A. Lucy, and H. B. Fell. Studies on the mode of action of excess of vitamin A. I. Effect of excess of vitamin A on the metabolism and composition of embryonic chick-limb cartilage grown in organ culture. Biochem. J. 1961, 79, 497.
3. Lucy, J. A., J. T. Dingle, and H. B. Fell. Studies on the mode of action of excess of vitamin A. II. A possible role of intracellular proteases in the degradation of cartilage matrix. Biochem. J. 1961, 79, 500.
4. Thomas, L., R. T. McCluskey, J. L. Potter, and G. Weissmann. Comparison of the effects of papain and vitamin A on cartilage. I. The effects in rabbits. J. exp. Med. 1960, 111, 705.
5. Weissmann, G. Alterations in connective tissue and intestine produced by hypervitaminosis A in *Xenopus laevis*. Nature (Lond.) 1961, 192, 235.
6. Dingle, J. T. Studies on the mode of action of excess of vitamin A. III. Release of a bound protease by the action of vitamin A. Biochem. J. 1961, 79, 509.
7. De Duve, C. Lysosomes: a new group of cytoplasmic particles *in* Subcellular Particles, T. Hayashi, Ed. New York, Ronald. 1959, p. 128.
8. Thomas, L., R. T. McCluskey, J. Li, and G. Weissmann. Prevention by cortisone of the changes in cartilage induced by an excess of vitamin A in the rabbit. Amer. J. Path. 1963, 42, 271.
9. Weissmann, G., E. Bell, and L. Thomas. Prevention by hydrocortisone of changes in connective tissue induced by an excess of vitamin A acid in amphibia. Amer. J. Path. In press.
10. Fell, H. B., and L. Thomas. The influence of hydrocortisone on the action of excess vitamin A on limb bone rudiments in culture. J. exp. Med. 1961, 114, 343.
11. Janoff, A., G. Weissmann, B. Zweifach, and L. Thomas. Studies on the pathogenesis of irreversible shock. IV. Studies on lysosomes in normal and tolerant animals subjected to lethal trauma and endotoxemia. J. exp. Med. 1962, 116, 451.

12. Weissmann, G., and L. Thomas. Studies on lysosomes. I. The effects of endotoxin, endotoxin tolerance, and cortisone on the release of acid hydrolases from a granular fraction of rabbit liver. J. exp. Med. 1962, 116, 433.

13. Weissmann, G., and J. Dingle. Release of lysosomal protease by ultraviolet irradiation and inhibition by hydrocortisone. Exp. Cell Res. 1961, 25, 207.

14. Barber, A. A., and A. Ottolenghi. Effect of EDTA on lipide peroxide formation and succinoxidase inactivation by ultraviolet light. Proc. Soc. exp. Biol. (N. Y.) 1957, 96, 471.

15. Anson, M. L. The estimation of cathepsin with hemoglobin and the partial purification of cathepsin. J. gen. Physiol. 1936, 20, 565.

16. Fishman, W. H., B. Springer, and R. Brunetti. Application of an improved glucuronidase assay method to the study of human blood β-glucuronidase. J. biol. Chem. 1948, 173, 449.

17. Huggins, C., and P. Talalay. Sodium phenolphthalein phosphate as a substrate for phosphatase tests. J. biol. Chem. 1945, 159, 399.

18. Lowry, O. H., N. J. Rosebrough, A. L. Farr, and R. J. Randall. Protein measurement with the Folin phenol reagent. J. biol. Chem. 1951, 193, 265.

19. Gerber, B. R., E. C. Franklin, and M. Schubert. Ultracentrifugal fractionation of bovine nasal chondromucoprotein. J. biol. Chem. 1960, 235, 2870.

20. Dowling, J. E., and G. Wald. The role of vitamin A acid. Vitamins and Hormones 1960, 18, 515.

21. Dingle, J. T., and H. B. Fell. Unpublished observations.

22. Fell, H. B., J. T. Dingle, and M. Webb. Studies on the mode of action of excess of vitamin A. IV. The specificity of the effect on embryonic chick-limb cartilage in culture and on isolated rat-liver lysosomes. Biochem. J. 1962, 83, 63.

23. Muir, H. The effect of papain on the viscosity of chondroitin sulfate. Biochem. J. 1956, 62, 26 P.

24. Weissmann, G., J. L. Potter, R. T. McCluskey, and L. Thomas. The effects of papain on cartilage and chondromucoprotein. Biochem. J. 1961, 78, 32 P.

25. Shatton, J., and M. Schubert. Isolation of a mucoprotein from cartilage. J. biol. Chem. 1954, 211, 565.

26. Lack, C. H. Chondrolysis. Ann. phys. Med. 1961, 6, 93.

27. De Duve, C., B. C. Pressman, R. Gianetto, R. Wattiaux, and F. Appelmans. Tissue fractionation studies. 6. Intracellular distribution patterns of enzymes in rat-liver tissue. Biochem. J. 1955, 60, 604.

28. Cohn, Z. A., and J. G. Hirsch. The isolation and properties of the specific cytoplasmic granules of rabbit polymorphonuclear leukocytes. J. exp. Med. 1960, 112, 983.

29. Lucy, J. A., and J. T. Dingle. The effect of vitamin A on the stability of the erythrocyte membrane. Biochem. J. 1962, 82, 31 P.

30. Weissmann, G. Changes in connective tissue and intine caused by vitamin A in amphibia, and their acceleration by hydrocortisone. J. exp. Med. 1961, 114, 581.

31. Dingle, J. T. Unpublished observations.

32. Thomas, L. Reversible collapse of rabbit ears after intravenous papain, and prevention of recovery by cortisone. J. exp. Med. 1956, 104, 245.

33. De Duve, C., R. Wattiaux, and M. Wibo. Effects of fat-soluble compounds on lysosomes *in vitro*. Biochem. Pharmacol. 1961, 9, 97.

34. Järvinen, K. A. J. Effect of cortisone on reaction of skin to ultra-violet light. Brit. Med. J. 1951, 11, 1377.

35. Weissmann, G., and H. B. Fell. The effect of hydrocortisone on the response of fetal rat skin in culture to ultraviolet irradiation. J. exp. Med. 1962, 116, 365.

36. Janoff, A., and G. Kaley. To be published.

37. Dingle, J. T., I. M. Sharman, and T. Moore. The influence of vitamin A status on the proteolytic activity of lysosomes from the livers and kidneys of rats. Proc. Nutr. Soc. 1963, 10, 22.

Weslaw-'38
Bib. No. 9741

Klin. Wochshr. 17(22):777-781. 1938.

Klinische Wochenschrift, May 28, 1938

SYMPTOMATOLOGY AND COURSE OF A-HYPERVITAMINOSIS IN RATS AS A CONSEQUENCE OF ENTERAL, SUBCUTANEOUS AND PERCUTANEOUS ADMINISTRATION OF VITAMIN A CONCENTRATES

Part I

Oral and Subcutaneous Administration of Vitamin A

by

W. Weslaw and B. Wronski, A. Wroblewski and B. Wroblewski

From the Institute of General and Experimental Pathology of the University of Poznan
(Director: Prof. I. Hoffman, M.D.)

I. Introduction. Recently, the question of hypervitaminosis has attained great practical and theoretical significance, since, thanks to progress in biochemistry, the production and appearance on the market of certain vitamins in completely pure (vitamins D and B_1), highly concentrated (vitamin A) and even synthetic form (vitamins B_2 and C) was made possible. More detailed knowledge concerning the conditions of hypervitaminosis, of which thus far hypervitaminosis D (Askew, Bourdillon, Bruce et al., Hesse and others) and A are recognized, offers not only an insight into the mechanism of action of the vitamins, but can above all contribute to the elucidation of the correlation between separate vitamins.

The closely-related, reciprocal action of the vitamins, which can be either synergistic or antagonistic depending upon the quantitative ratio, is already known. The excess of a certain vitamin can -- while inhibiting the effect of the antagonistic vitamin -- manifest itself as a corresponding hypo-- or avitaminosis, and inversely, avitaminoses can sometimes resemble hypervitaminoses. Correlation phenomena in the case of A and D, A and C and B and D can serve as examples (Thoenes, Gross-Selbeck, Bomskov and

Seemann, Wendt and Schroder, Harris and Moore, Chevallier, Cornil and Combe and others).

Our present knowledge concerning A-hypervitaminosis, regarded from the above standpoint, still contains many unexplained points. Even the symptomatology of this hypervitaminosis, despite numerous studies since 1933, has not yet been established without contradictions (see Drigalski, Moll, Domagk and Laquer, Peters, Collazo and Sanches-Rodriguez, Bomskov and Seemann, Chevallier, Cornil and Chabre, Kanter, Strauss, Davis and Moore, Levis and Reti, Ypsilanti, Przezdziecka). While several researchers observed only general cachexy, a rough coat and phenomena of inflammation on the eyelids of rats (see Drigalski, Moll, Domagk and Laquer, Peters), others determined the appearance of hairless spots on the snout and the surrounding parts of the skin. Collazo and Sanches-Rodriguez, Bomskov and Seemann, as well as Strauss, have observed the appearance of spontaneous bone fractures in the case of A-hypervitaminosis. In general, the researchers are not in agreement concerning the description and interpretation of the clinical picture and the anatomopatholofical changes in this hypervitaminosis.

It is the goal of our work to fill in the gaps in the research of hypervitaminosis A, by using a greater number of animals (110) and administering the Vitamin A preparations both orally and parenterally.

II. Experimental conditions. The experiments claimed a period of time from September 1936 to May 1937 and from October to December 1937. We used white rats, only a few gray ones, raised by us, and receiving a mixture of barley and wheat as feed. They were given water to drink. The animals were kept under muted light and at a temperature of 19-20° C. Under these conditions, the animals experienced completely normal development of growth and reproductive faculty.

We used the following vitamin A concentrates, well-purified and standardized according to different methods (biologically, colorimetrically and spectrophotometrically): Vogan "Merck" (1 ccm = 120,000 i.E.) and Cresavit

"Speiss" (Warsaw). The latter, which like Vogan is produced from the liver-oil of variou types of fish and is prepared with sesame oil, was administered to the animals in commercial form (1 ccm = 25,000 i.E.), but predominantly in a concentrated form specially prepared for our purposes (50,000 to 100,000 i.E. in 1 ccm).*

A. Oral administration. For oral administration, by means of a pipette, we used 45 animals, of which 30 received Cresavit and 15 Vogan. We also had 10 control animals. These received sesame oil in amounts that corresponded volumetrically to the administered doses of the vitamin concentrates.

Table I shows the experimental material, the doses administered, the duration of the experiment etc.

III. The clinical picture. a) Cresavit animals. The clinical phenomena among the cresavit animals are very similar, whereby the total picture of these phenomena is most characteristic after administration of moderately toxic doses, presupposing that the duration of the experiment was sufficiently long. From among the Cresavit animals, the second and third groups (see table I) correspond to these experimental conditions, and for this reason we will discuss in detail the symptomatology of hypervitaminosis A in the case of the animals of this group, where it was nearly always identical.

In spite of numerous characteristic phenomena, the general condition of the animals, even at the end of the experiment, was still relatively good. These phenomena can be divided into 3 groups: phenomena of the skin and eyes, those in the bone system and those in the sexual organs.

The changes in the skin usually are localized in those spots which, during the administration, came into contact with the vitamin A concentrate, thus chiefly in the snout. On the seventh to the tenth day, the pelt,

* These preparations were kindly provided for us in large amounts by the above-mentioned firms, for which we express our heartfelt thanks.

Table I

Group	No., Sex and Weight of animals	Dose per day in thousand i.E.	Duration of exp. days	Total dose in thousand i.E.	Result
		Cresavit orally (30 animals)			
1	5 animals 1♂ and 4♀ 42-45 g	50	7-10	350 to 500	All animals perishedbetween the 7th and 10th days after administration.
2	5 animals ♀ 50-56 g	25 x 11 12 x 59	70	983	On the last day of administration the animals, in a slightly dulled condition, were killed.
3	5 animals ♀ 61-64 g	20	52-55	1,040 to 1,100	As above.
4	3 animals ♀ 85-90 g	50 x 22 25 x 10	32	1,350	General condition of the animals as above. Further observation for 8 days.
5	4 animals ♂ 127-156 g	50	60	3,000	On the last day of administration the animals, in a slightly dulled condition, were killed.
6	3 animals ♀ 75-79 g	25 x 11 10 x 15	26	425	Good general condition of the animals at the end of the experiment. Further observation for 14 days.
7	5 animals 2♂, 3♀ 56-65 g	6.25 x 9 12.5 x 21	30	318.75	Condition of animals as above. Further observation for 10 days.
		Vogan orally (15 animals)			
1	5 animals ♂ 116-124 g	120	44	5,280	On the last day of administration or 2-3 days later, the animals, in a state of considerable weakness and emaciation, were killed.
2	5 animals ♀ 75-85 g	60 w/o admin. 120	60 16 24/100	6,480	As above.
3	5 animals 3♂, 2♀ 53-59 g	60	25	1,500	General condition of the animals quite good. Killed on last day of administration.

Table I (cont'd)

Group	No., sex and weight of animals	Dose per day in thousand i.E.	Duration of exp. days	Total dose in thousand i.E.	Result
		Controls; Sesame oil orally (10 animals)			
1	5 animals 3 ♂, 2 ♀ 45-55 g	1.0 ccm	35	--	General condition of animals during the entire time of the experiment completely healthy.
2	3 animals ♀ 85-90 g	1,0 ccm	35	--	As above.
3	2 animals ♀ 120 and 123 g	1.0 ccm	40	--	As above.

which had grown yellow from the residue of the concentrate, became coarse and rough, and the hairs fell out at the touch. In the case of several animals we determined reddening, swelling and sticking of the eyelids, often only on one side, and caused by the animals itself, due to rubbing of the vitamin concentrate residue in the area of the eyes, upon cleaning of the snout. The inflammation of the eyelids lasts only a few days, but can repeat itself. On the 12th to the 15th day, the upper epidermis layers began to loosen, along with the hair, from the lower layers. As they are hanging on just very slightly, they give the impression of a wig. Upon slight touch, the separated epidermis with hair falls off in pieces. Bald spots appear, covered with smooth, initially somewhat red but soon normal, pink-colored skin. The hair loss, which is initially localized in the snout, can spread over the chest and the anterior areas of the front paws (fig. 1).

Fig. 1. Skin changes in the case of hypervitaminosis A (rat). Cresavit administration orally. Extensive baldness. On the right side of the snout we see a piece of scaling and separated epidermis layer with hair.

In the case of 6 animals, their was hair loss on the eyelids as well, which led to so-called "spectacle formation". It should be noted that the eyelashes and the whiskers were never affected by the hair loss process. The changes in the skin were characterized by the fact that their intensity varied from greater to lesser. Despite continued administration of the vitamin A concentrate, the hair grew anew on the bald spots, the pelt regained its normal appearance on these spots, while the hair loss spread to other areas, e.g. the chest. On the 40th to the 42nd day, the hair loss began anew on the freshly-covered spots, and on around the 50th day, the

hair began to grow back in again. After cessation of vitamin administration, the pelt returned to normal in a short time.

Changes in the bone system. Difficulties in locomotion were noted in all 5 animals of the second group and 3 animals of the third group from the 11th to the 18th day. The animals kept one or the other paw contracted and clearly were very careful with it when moving. The x-rays revealed fresh bone fractures (fig. 2), always located at the proximal end or in the middle of the tibia and humerus, and at the distal end of the radius. The femur was never broken.

Fig. 2. Bone fractures in the case of hypervitaminosis A (rat). Oral Vogan administration.

In the case of 4 animals, the bone fractures were combined with hemorrhage, due to which, in the place of the tumor, a swelling appeared on the member in question. On about the 30th day, the fractures healed, but because of displacement of the bone-splinters and the callus, the extremities were left shortened and deformed. At the same time or even earlier (on about the 25th day), further fractures in the other extremities appeared, up until the end of the experiment. From these observations we conclude that the changes in the bone system, in a manner similar to the phenomena involving the skin, occur in characteristic phases. The sequence of bone fractures of rat 27, of group 2, serves as an example (table 2).

Table 2

Day of exp.	left radius and ulna	right humerus	left humerus	right tibia and ulna	left tibia and ulna
11	--	--	--	fracture	fracture
23	fracture	--	--	--	--
27	--	--	--	--	--
30	healing	--	fracture	--	healing
39	--	fracture	--	healing	--
44	--	--	improvement	--	--

The phenomena that occurred in the sex organs in the case of hypervitaminosis A, which, as it seems, have so far never been described, deserve particular attention. They appear most clearly in the males. In the case of all the animals of group 3, a swelling of the testicles in the scrotum was noted on around the 44th day. We were not able to push the testicles into the abdominal cavity, which can be done with ease in the case of most normal animals, even though we exerted quite a bit of pressure on them. In the case of 2 animals, besides the swelling of the testicles, there was a considerable thickening and lengthening of the member, the initially hard consistency of which became more flaccid with time. This type of erection lasted for 10-11 days, until the animals were killed (fig. 3). The strongly



Fig. 3. Priapism in the case of hypervitaminosis A (rat). Oral Cressavit administration.

protruding and swollen bright-red penis, which was moist and shiny at first, became dry after a few days and took on a bluish coloring. During the killing of the animals, by means of Bulbi section, the semen, containing

numerous living sperm, was ejected. The phenomenon described above, which occurred with particular intensity in the case of subcutaneous administration of the vitamin A preparation, will be called "priapism", and we will for the time being not concern ourselves with a more exact interpretation of this occurrence.

The symptomatology of hypervitaminosis A in the case of the animals of the 4th and 5th group corresponds exactly to the phenomena described above, which were only slightly less marked.

The general well-being of the animals of the 6th and especially of the 7th group was completely fine, and any symptoms very slight.

In the first group (highly toxic doses), the clinical picture was likewise not very characteristic, because the animals died between the 8th and 10th days of administration.

b) Vogan animals. The clinical picture of hypervitaminosis A in the case of the Vogan animals is also most characteristic in the case of use of moderately toxic doses (animals of group 1). Since the phenomena of hypervitaminosis A appeared later in these animals, with the exception of bone fractures, but otherwise entirely resembled the symptoms of cresavit administration, we will not discuss them more closely.

It should only be stressed that in the case of 3 animals of the second group (♀), permanent swelling and reddening of the external genital organs could be noted after about 80 days.

c) Controls. In the case of all the controls, which received 10 ccm sesame oil per day, and the general condition of which was always good, we observed no pathological changes.

The graphs shown here represent the weight variations of the experimental and control animals (fig. 4).

Note: The animals were weighed every second day. The dotted line shows the period before administration, the solid line the administration period. The arrow shows the beginning of the administration, or the transition to a different dose. The number next to the arrow indicates the dose of

vitamin A in thousands of i.E, per day. The daily amounts of sesame oil are indicated in cubic centimeters.

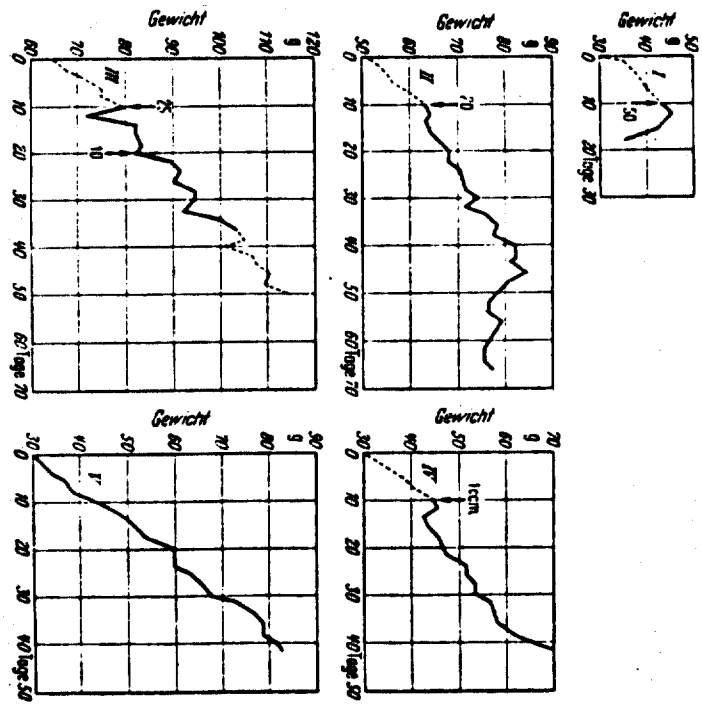

Fig. 4. Weight curves of rats with hypervitaminosis A. Oral administration of the vitamin A concentrate Cresavit. Curves 1-3: Cresavit animals of groups 1, 3 and 6. Curve 4: sesame oil (first group). Curve 5: normal, untreated animal (see table 1).

B. Subcutaneous Administration

Since, as is known, numerous substances exert a greater or lesser effect after parenteral administration than after oral administration, we also used the method of subcutaneous (and percutaneous) administration of vitamin A, all the more because the bibliographic references concerning this are quite meager.

As far as is known to us, toxic doses of vitamin A were used subcutaneously only by Ypsilanti (in mice), but the picture of hypervitaminosis A obtained by this researcher stirs some reservations, since the controls revealed anatomo- and histopathological changes of a severity equal to that of the experimental animals. The amounts of vitamin A administered subcutaneously by Giedosz (in rabbits) were too small to call forth symptoms

of hypervitaminosis A.

In our experiments, we continued to use, as heretofore, chiefly white rats, of which 11 received "Speiss" Cresavit and 11 "Merck" Vogan. The controls received sesame oil in corresponding quantities. Since the vitamin A preparations are absorbed with difficulty as oleus solutions, and we thus administered them to the animals at intervals of several days, the daily dose can be indicated only approximately.

The following table shows the experimental material, the doses administered, etc.

Table 3

Group	No., sex and weight of animals	Dose per day in thousand i.E.	Duration of exp. in days	Total dose in thousand i.E.	Result
		Cresavit subcutaneously (11 animals)			
1	4 animals ♂ 79-85 g	100 x 2	12(8)	650	One animal died on the 8th day, the rest on the 12th day of administration.
2	4 animals 2 ♂, 2 ♀ 82-89 g	250 x 1 100 x 4 50 x 11	40	1,200	2 animals died on the last day of the experiment, the other two were killed at the same time, in a condition of considerable weakness and apathy.
3	3 animals ♂ gray 64-68 g	100 x 1 75 x 6	7	550	Administration was interrupted on the 7th day, with the condition one of considerable weakness. Further observation for 40 days.
		Vogan subcutaneously (11 animals)			
1	4 animals ♂ 110-115 g	60 x 27	27	1,620	The animals were killed on the last day of the administration.
2	3 animals ♂ 83-86 g	60 x 29 240 x 1 300 x 2	85	2,580	The administration was interrupted due to animals' state of considerable weakness. Further observation fo-

Table 3 (cont'd.)

Group	No., sex and weight of animals	Dose per day in thousand i.E.	Duration of exp. in days	Total dose in thousand i.E.	Result
					73 to 75 days
3	4 animals ♀ 51-58 g	30 x 43	43	1,290	On the last day, very slight weakness occurred. Further observation for 10 days.
		Controls: sesame oil subcutaneously			
1	2 animals ♂ 60 and 65 g	1.0 ccm	35	--	Animals' condition perfectly healthy during the entire experimental period.
2	2 animals ♀ 75 and 80 g	2.0 ccm	35	--	As above.

The clinical picture. a) Cresavit animals. The toal picture of hypervitaminosis A is most typical in the case of the animals of group 2, for which the length of the experiment was longest (40 days). Interruptions in administration varied from 1 to 4 days and totalled 24 days. This procedure made possible almost complete absorption of the injected preparation, and only after 30 days, in the case of 3 animals, did concretions consisting of thickened, unabsorbed residue of the preparation, in the form of cherry-sized tumors, filled with a gruely kind of mass, appear under the skin.

The symptoms of hypervitaminosis A after subcutaneous administration are nearly identical to those that appear after oral administration, and manifest themselves in the form of alterations in the skin, the bones, and the sexual organs. However, there are some differences in intensity and the temporal appearance of these symptoms.

In the case of the animals of the above-mentioned group, the skin

changes appeared after about 8 days, in the form of slight hair loss, and later as sharply-defined bald spots in the area of the shoulder blades, thus at a considerable distance from the point of injection. At the end of the experiment, the pelt, with the exception of those spots (regio glutea), at which concretions of unabsorbed residue of the preparation had collected under the skin, had returned to its nearly normal appearance. These regions of the skin became bald on about the 30th day, and did not alter in appearance to the end of the experiment (see fig. 5). In the case of 2 animals, the eyelids also became bald (so-called "spectacle formation", see fig. 6).



Fig. 5. Characteristic skin changes in a rat after subcutaneous administration of the vitamin A concentrate Cresavit. On the anterior portion of the skin of the back, sharply-defined spots partially covered with fresh hair-growth appear. In the sacral region, on the other hand, at the spot of the unabsorbed preparation residue, we see more extensive hair loss.

Bone fractures were observed in 2 animals on the 37th and 39th day. In both males of this group, priapism appeared on the 30th day of the administration, and lasted until the end of the experiment.

Fig. 6. So-called "spectacle formation" in hypervitaminosis A in the case of subcutaneous administration of this vitamin to a rat (Cresavit animal).

In the case of the animals of the third group, which consisted of 3 gray male rats, the skin changes were marked by extraordinary intensity, and were as follows in the case of one of the animals.

On the 7th day, the pelt on the entire body became coarse and fell off in the are of the crown and back of the head. On the 9th day, this part of the head skin was completely bald. The hair-loss process spread rapidly to the entire body, and on the 21st day of observation, the animal was nearly entirely bald. The appearance of the bald skin was completely normal.(fig. 7).



Fig. 7. Nearly complete hair loss of a rat after subcutaneous administration of the vitamin A concentrate Cresavit.

From the above description we see that the intensity of the skin changes was at its highest long after cessation of the experiment, since the administration of the vitamin A preparation did not last any longer than 7 days. The accumulation of unabsorbed residue of the vitamin preparation under the skin which we determined could be viewed as a cause for this. On the 22nd day of observation, soft downy hair was found over the entire skin, and on the 39th day, the pelt was completely normal. See also the weight curves of these animals (fig. 8, curve 3).

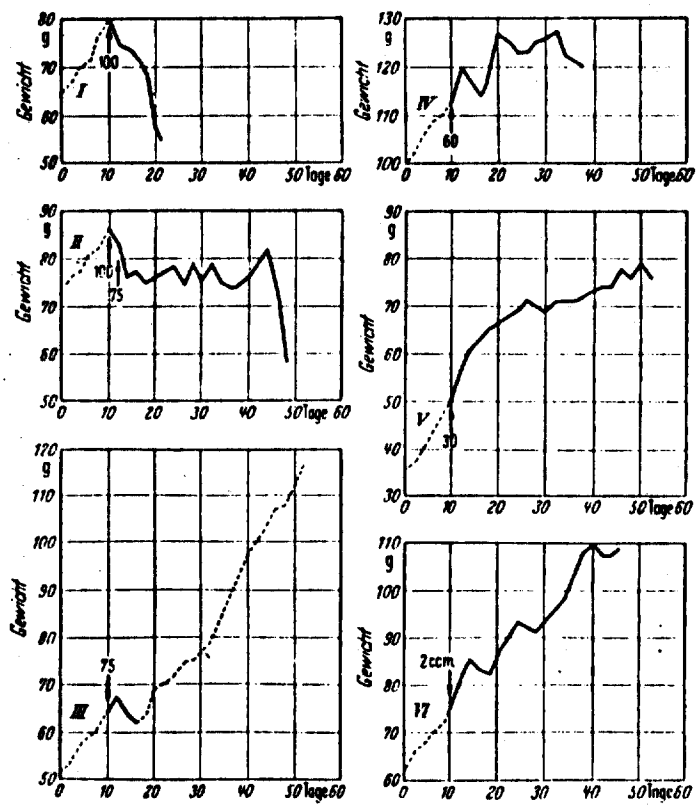

Fig. 8. Weight curves of rats with hypervitaminosis A. Subcutaneous administration of concentrates of this vitamin: Cresavit and Vogan. Curves 1-3: Cresavit animals of the first, second and third groups. Curves 4 and 5: Vogan animals of groups 1 and 3. Curve 6: controls (sesame oil subcutaneously) from the second group (see table 3 and the note to fig. 4).

In the case of the other animals of this group, we observed similar, but somewhat less extensive skin changes.

As concerns the rapid death (8th to 12th day) of the Cresavit animals of group 1, the clinical picture was not very characteristic.

b). Vogan animals. We obtained the most characteristic symptoms after subcutaneous administration of Vogan among the animals of group 2 (see table 3). We were able to keep these animals alive for a long time, in spite of a large total dose of the preparation, thanks to numerous interruptions in the administration (2-14 days). The animals were observed for 73-75 days. Under these circumstances, we obtained a complete picture of hypervitaminosis A, identical to that described above for the Cresavit

animals.

It should be mentioned that the typical priapism that appeared in the case of two animals lasted until the end of the observation period, i.e. 130 days. The animals with the priapism reveal a normal sex drive after being placed in a cage with female rats, and one female became pregnant and bore healthy offspring (5 young).

The controls (4) received sesame oil subcutaneously for 35 days straight: 1 or 2 ccm per day (see table 3). This oil was absorbed well. The general condition of the animals was entirely normal.

The appended curves show the weight variations of the experimental and control animals (fig. 8).

The anatomopathological changes, discussion of the results, and relevant literature will be found at the end of the second part.

Weslaw-'38
Bib. No. 9741

Klin. Wochshr. 17(22):777-781. 1938.

SYMPTOMATOLOGIE UND VERLAUF DER A-HYPERVITAMINOSE BEI RATTEN INFOLGE ENTERALER, SUBCUTANER UND PERCUTANER DARREICHUNG VON VITAMIN A-KONZENTRATEN*.

I. Mitteilung.

Perorale und subcutane Verabreichung des Vitamin A.

Von

Dozent W. WESLAW und cand. med. B. WROŃSKI,
A. WRÓBLEWSKI und B. WRÓBLEWSKI.

Aus dem Institut der Allgemeinen und Experimentellen Pathologie der Universität Poznań (Vorstand: Prof. Dr. med. I. HOFFMAN).

1. Einleitung. Die Frage der Hypervitaminose gewann zur Zeit große praktische sowie auch theoretische Bedeutung, da dank der Fortschritte der Biochemie die Herstellung und das Erscheinen im Handel gewisser Vitamine in vollkommen reiner (Vitamin D und B_1) oder auch stark konzentrierter (Vitamin A) und sogar synthetischer Form (Vitamin B_2 und C) zustande kam. Nähere Erkenntnis der Hypervitaminosezustände, von denen bisher die Hypervitaminosen D (ASKEW, BOURDILLON, BRUCE u. Mitarb., HESSE u. a.) und A bekannt sind, gibt nicht nur einen Einblick auf die Wirkungsweise der Vitamine, sondern kann vor allem zur Aufklärung der Wechselbeziehungen zwischen einzelnen Vitaminen beitragen.

Das enge, gegenseitige Einwirken der Vitamine, das je nach dem quantitativen Verhältnis synergistisch oder auch antagonistisch sein kann, ist bereits bekannt. Der Überschuß eines gewissen Vitamins kann sich — indem er die Wirkung des antagonistischen Vitamins hemmt — als entsprechende Hypo- oder Avitaminose offenbaren, und umgekehrt, Avitaminosen können bisweilen Hypervitaminosen ähneln. Als Beispiel können Korrelationserscheinungen bei A und D, A und C sowie B und D dienen (THOENES, GROSS-SELBECK, BOMSKOV und SEEMANN, WENDT und SCHRÖDER, HARRIS und MOORE, CHEVALLIER, CORNIL und COMBE u. a.).

Unser gegenwärtiges Wissen über die A-Hypervitaminose vom obigen Standpunkt betrachtet, weist noch zahlreiche unaufgeklärte Punkte auf. Selbst die Symptomatologie dieser Hypervitaminose ist bisher, trotz zahlreicher Forschungen seit dem Jahre 1933, nicht übereinstimmend festgestellt (v. DRIGALSKI, MOLL, DOMAGK und LAQUER, PETERS, COLLAZO und SANCHES-RODRIGUEZ, BOMSKOV und SEEMANN, CHEVALLIER, CORNIL und CHABRE, KANTER, STRAUSS, DAVIS und MOORE, LEVIS und RETI, YESILANTI, PRZEŹDZIECKA). Während einige Forscher nur allgemeine Kachexie, struppiges Fell und Ent-

* Diese Arbeit wurde auf dem 15. Kongreß der Polnischen Ärzte und Naturforscher in Lwów (1.–7. VII. 1937) vorgetragen.

zündungserscheinungen an den Augenlidern bei Ratten beobachteten (v. DRIGALSKI, MOLL, DOMAGK und LAQUEUR, PETERS), stellten die andern das Auftreten von haarlosen Flecken an der Schnauze und den benachbarten Partien der Haut fest. COLLAZO und SANCHES-RODRIGUEZ, BOMSKOV und SEEMANN wie auch STRAUSS haben das Auftreten von spontanen Knochenfrakturen bei A-Hypervitaminose beobachtet. Im allgemeinen sind die Forscher bei der Beschreibung und der Interpretation des klinischen Gesamtbildes als auch der anatomopathologischen Änderungen in dieser Hypervitaminose nicht einig.

Das Ziel unserer Arbeit ist, die Lücken bei Erforschung der A-Hypervitaminose auszufüllen, indem wir eine größere Anzahl Tiere (110) benutzten und die Vitamin A-Präparate sowohl peroral als auch parenteral verabreichten.

II. Versuchsbedingungen. Die Untersuchungen beanspruchten einen Zeitraum vom September 1936 bis Mai 1937 und vom Oktober bis Dezember 1937. Wir benutzten weiße Ratten, nur ausnahmsweise schwarzweiße, eigener Zucht, die als Nahrung eine Mischung von Gerste und Weizen bekamen. Zum Trinken diente Wasser. Die Tiere wurden bei gedämpftem Licht und einer Temperatur von 19—20° gehalten. Unter diesen Umständen fand eine vollständig normale Entwicklung des Wachstums und der Fortpflanzungsfähigkeit der Tiere statt.

Wir verwandten folgende, gut gereinigte und mit verschiedenen Methoden (biologisch, colorimetrisch und spektrophotometrisch) standardisierte Vitamin A-Konzentrate: Vogan „Merck" (1 ccm = 120000 i. E.) und Cresavit „Spieß" (Warschau). Letzterer, der ähnlich wie Vogan vom Lebertran gewisser Fischarten erzeugt wird und auf Sesamöl präpariert ist, wurde den Tieren in Handelsform (1 ccm = 25000 i. E.), überwiegend jedoch in einer extra zu unserem Zwecke vorbereiteten, konzentrierten Form (50000 bzw. 100000 i. E. in 1 ccm) gereicht*.

A. Perorale Darreichung. Für perorale Darreichung, mittels Pipette, benutzten wir 45 Tiere, von denen 30 Cresavit und 15 Vogan bekamen und außerdem 10 Kontrolltiere. Die letzteren erhielten Sesamöl in Mengen, die den dargereichten Dosen der Vitaminkonzentrate volumetrisch entsprachen.

Die Zusammenstellung des Versuchsmaterials, der verabreichten Dosen, der Versuchsdauer usw. gibt Tabelle 1.

III. Das klinische Bild. a) Cresavittiere. Die klinischen Erscheinungen bei den Cresavittieren ähneln sich sehr, wobei das Gesamtbild dieser Erscheinungen am meisten charakteristisch nach Verabreichung von mittelmäßig toxischen Dosen hervortritt, vorausgesetzt, daß die Versuchsdauer genügend lang war. Diesen Versuchsbedingungen entsprechen unter Cresavittieren die 2. und 3. Gruppe (vgl. Tabelle 1), und deshalb werden wir die Symptomatologie der A-Hypervitaminose bei den Tieren dieser Gruppe, die fast identisch war, genau besprechen.

Das Allgemeinbefinden der Tiere, auch am Ende des Versuchs, war trotz zahlreicher charakteristischer Erscheinungen noch verhältnismäßig gut. Diese Erscheinungen können in 3 Gruppen geteilt werden: die Erscheinungen an der Haut und den Augen, im Knochensystem und in den Geschlechtsorganen.

Die Veränderungen der Haut lokalisieren sich gewöhnlich an diesen Stellen, die, während der Einführung, mit dem Vitamin A-Konzentrat in Berührung kamen, also hauptsächlich an der Schnauze. Am 7. bis 10. Tage wurde das von den Überresten des Konzentrats gelb gewordene Fell struppig, und die Haare fielen beim Berühren leicht aus. Bei einigen Tieren stellten wir, oft nur einseitig, Rötung, Schwellung und Zusammenkleben der Augenlider fest, was vom Tier selbst durch Einreiben in die Augengegend von Resten des Vitaminkonzentrats, beim Reinigen der Schnauze, hervorgerufen wurde. Die Entzündung der Augenlider hält nur einige Tage an, kann sich jedoch wiederholen. Am 12. bis 15. Tage fangen die oberen Epidermisschichten an, sich mitsamt den Haaren immer mehr von den unteren Schichten abzulösen. Indem sie nur noch lose anliegen, machen sie den Eindruck einer Perücke. Bei leichter Berührung fällt das abgesonderte Epidermis mit Haaren stückweise ab. Es entstehen kahle Stellen, die mit glatter, anfangs etwas gerötteter, bald aber normal, leicht rosa

* Diese Präparate wurden uns von den obenerwähnten Firmen in größerer Menge freundlichst zur Verfügung gestellt, wofür wir unseren besten Dank aussprechen.

Tabelle 1.

Gruppe	Zahl, Geschlecht und Gewicht der Tiere	Dosis pro die in Tausenden i. E.	Versuchsdauer in Tagen	Gesamte Dosis in Tausenden i. E.	Ergebnis
		Cresavit per os (30 Tiere).			
1	5 Tiere 1 ♂ u. 4 ♀ 42—45 g	50	7—10	350 bis 500	Alle Tiere gingen am 7 bis 10 Tage nach der Verabreichung an.
2	5 Tiere. ♀ 50—56 g	25×11 12×59	70	983	Die Tiere wurden in unbedeutendem Schwerfälligkeitszustand a. letzten Tage der Verabreichung getötet
3	5 Tiere ♂ 61—64 g	20	52—55	1040 bis 1100	Wie oben.
4	3 Tiere ♀ 85—90 g	50×22 25×10	32	1350	Allgemeiner Zustand der Tiere wie oben. Weitere Beobachtung 8 Tage.
5	4 Tiere ♂ 127—156 g	50	60	3000	Die Tiere wurden in unbedeutendem Schwerfälligkeitszustand a. letzten Tage der Verabreichung getötet.
6	3 Tiere ♀ 75—79 g	25×11 10×15	26	425	Am Ende des Experiments guter allgemeiner Zustand der Tiere. Weitere Beobachtung 14 Tage.
7	5 Tiere 2 ♂ u. 3 ♀ 56—65 g	6,25×9 12,5×21	30	318,75	Zustand der Tiere wie oben. Weitere Beobachtung 10 Tage.
		Vogan per os (15 Tiere).			
1	5 Tiere ♂ 116—124 g	120	44	5280	Die Tiere wurden in erheblichem Schwäche- und Abmagerungszustand am letzten Tage der Verabreichung oder 2—3 Tage später getötet.
2	5 Tiere ♀ 75—85 g	60 ohne Verabreichung 120	60 16 24 100	6480	Wie oben.
3	5 Tiere 3 ♂ u. 2 ♀ 53—59 g	60	25	1500	Allgemeiner Zustand der Tiere ziemlich gut. Sie wurden am letzten Tage der Verabreichung getötet.
		Kontrolltiere; Ol. Sesami per os (10 Tiere)			
1	5 Tiere 3 ♂ u. 2 ♀ 45—55 g	1,0 ccm	35	—	Allgemeiner Zustand der Tiere während der ganzen Untersuchungszeit vollkommen gesund.
2	3 Tiere ♀ 85—90 g	1,0 ccm	35	—	Wie oben.
3	2 Tiere ♀ 120 u. 123 g	1,0 ccm	40	—	Wie oben.

gefärbter Haut bedeckt sind. Der anfangs nur an der Schnauze lokalisierte Haarausfall kann sich bis über die Brust und die vorderen Flächen der Vorderpfoten ausbreiten (Abb. 1).

Bei 6 Tieren trat der Haarausfall auch an den Augenlidern auf, wodurch es zu der sog. „Brillenbildung" kam. Es sei bemerkt, daß die Wimpern und der Bart niemals in den Haarausfallprozeß mit hineingezogen waren. Die Veränderungen der Haut kennzeichneten sich dadurch, daß ihre Intensität abwechselnd heftiger und schwächer war. Trotz weiterer Verabfolgung des Vitamin A-Konzentrates wuchsen die Haare an den kahlen Stellen von neuem, das Fell gewann an diesen Stellen sein normales Aussehen wieder, während sich der Haarausfall an anderen Stellen, z. B. auf der Brust, weiter verbreitete. Am 40. bis 42. Tage begann der Haarausfall an den mit frischem Fell bedeckten Stellen von neuem, und ungefähr am 50. Tage begannen die Haare abermals nachzuwachsen.

Nach Unterbrechung der Verabfolgung des Vitamins wurde Fell in kurzer Zeit normal.

Änderungen im Knochensystem. Am 11. bis 18. Tage zeigten sich bei allen 5 Tieren der 2. Gruppe und bei 3 Tieren der 3. Gruppe Fortbewegungsschwierigkeiten. Die Tiere hielten eine oder die andere Pfote zusammengezogen und schonten sie deutlich beim Fortbewegen. Das Röntgenbild ergab frische, stets am proximalen Ende oder auch in der Mitte der Tibia und Humerus und am distalen Ende des Radius lokalisierte Knochenfrakturen (Abb. 2). Das Femur war niemals gebrochen.

Abb. 1. Hautänderungen bei A-Hypervitaminose (Ratte). Cresavitdarreichung per os. Stark verbreitete Kahlheit. An der rechten Seite der Schnauze sieht man ein Stück abgeschuppter und abgehobener Epidermisschicht mit Haaren.

Bei 4 Tieren waren die Knochenfrakturen mit einem Bluterguß verbunden, wodurch am betreffenden Glied, an Stelle der Fraktur, eine Anschwellung hervortrat. Ungefähr am 30. Tage erfolgte die Heilung der Frakturen, jedoch waren die Extremitäten infolge Verschiebung der Knochensplitter und Callus verkürzt und deformiert. Zu gleicher Zeit oder noch früher (ungefähr am 25. Tage) traten weitere Frakturen

Abb. 2. Knochenfrakturen bei A-Hypervitaminose (Ratte). Vogandarreichung per os.

an den anderen Extremitäten hervor usw., bis an das Ende des Versuches. Aus diesen Beobachtungen geht hervor, daß die Änderungen im Knochensystem ähnlich wie die Erscheinungen in der Haut, in charakteristischen Phasen auftreten. Als Beispiel kann die Reihenfolge der Knochenfrakturen bei der Ratte 27, der 2. Gruppe, dienen (Tabelle 2).

Tabelle 2.

Tag des Versuches	Radius et Ulna sin.	Humerus dext.	Humerus sin.	Tibia et Ulna dext.	Tibia et Ulna sin.
13.	—	-	-	Fraktur	Fraktur
23.	Fraktur	—	—	-	-
27.	—	—	—	—	-
30.	Heilung	—	Fraktur	—	Heilung
39.	—	Fraktur	—	Heilung	-
44.	—	—	Besserung	—	-

Besondere Aufmerksamkeit erwecken die Erscheinungen in den Geschlechtsorganen bei A-Hypervitaminose, die, wie es scheint, bisher nirgends geschildert worden sind. Am ausdrücklichsten treten sie bei den männlichen Tieren auf. Bei allen Tieren der 3. Gruppe machte sich ungefähr am 44. Tage eine Anschwellung der ständig im Hodensack sich befindenden Hoden bemerkbar. Es gelang nicht, die Hoden in die Bauchhöhle hineinzudrängen, was sich bei normalen Tieren mit Leichtigkeit ausführen läßt, obgleich auf sie ein ziemlich starker Druck ausgeübt wurde. Bei 2 Tieren trat außer der Anschwellung der Hoden eine erhebliche Verdickung und Verlängerung des Gliedes auf, dessen anfangs harte Konsistenz mit der Zeit schlaffer wurde. Diese Art von Erektion hielt 10—11 Tage an, bis die Tiere getötet wurden (Abb. 3). Die



Abb. 3. Priapismus bei A-Hypervitaminose (Ratte). Cresavitdarreichung per os.

stark vorgeschobene und geschwollene grellrote Eichel, die anfangs feucht war und glänzte, wurde nach einigen Tagen trocken und nahm eine bläuliche Färbung an. Während des Tötens der Tiere mittels Sectio Bulbi kam es zur Ausspritzung des Samens, welcher zahlreiche lebende Spermien enthielt. Das beschriebene Phänomen, welches besonders stark bei subcutaner Verabreichung der Vitamin A-Präparate hervortrat, werden wir kurz „Priapismus" nennen und uns vorläufig nicht mit einer genauen Beurteilung dieser Erscheinungen befassen.

Die Symptomatologie der A-Hypervitaminose bei den Tieren der 4. und 5. Gruppe entsprechen vollkommen den vor-

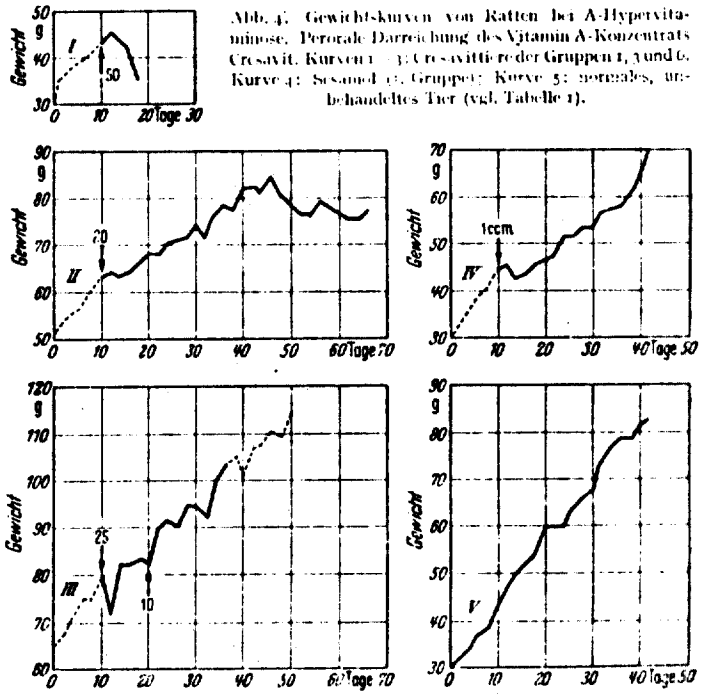

Abb. 4. Gewichtskurven von Ratten bei A-Hypervitaminose. Perorale Darreichung des Vitamin A-Konzentrats Cresavit. Kurven 1—3: Cresavittiere der Gruppen 1, 3 und 6. Kurve 4: Sesamöl 1. Gruppe; Kurve 5: normales, unbehandeltes Tier (vgl. Tabelle 1).

her beschriebenen Erscheinungen, die nur schwächer ausgeprägt waren.

Das Allgemeinbefinden der Tiere der 6. und besonders 7. Gruppe war vollkommen gut und die Erscheinungen sehr gering.

In der 1. Gruppe (stark toxische Dosen) war das klinische Bild ebenfalls wenig charakteristisch, weil die Tiere am 8. bis 10. Tage der Darreichung zugrunde gingen.

b) Vogantiere. Das klinische Gesamtbild der A-Hypervitaminose ist bei Vogantieren ebenfalls am meisten charakteristisch bei Anwendung von mittelmäßig toxischen Dosen (Tiere der 1. Gruppe). Da die Erscheinungen der A-Hyper-

vitaminose bei diesen Tieren nur etwas später, mit Ausnahme der Knochenfrakturen, hervortraten, im übrigen aber den Symptomen bei Cresavitdarreichung sehr ähnelten, werden wir uns nicht näher mit ihnen beschäftigen.

Es sei nur betont, daß bei 3 Tieren der 2. Gruppe (4) sich nach ungefähr 80 Tagen andauernde Schwellung und Rötung der äußeren Genitalorgane bemerkbar machten.

c) Kontrolltiere. Bei allen Kontrolltieren, die 1 ccm Sesamöl pro die erhielten und deren Allgemeinbefinden stets gut war, beobachteten wir keineswegs pathologische Änderungen.

Die beigefügten Kurven stellen die Gewichtsschwankungen der Versuchs- und Kontrolltiere dar (Abb. 4).

Anmerkung: Die Tiere wurden jeden 2. Tag gewogen. Die punktierte Linie gibt den von der Verabreichung freien Zeitabschnitt an, die volle Linie die Zeitdauer der Verabfolgung. Der Pfeil zeigt den Beginn der Darreichung oder auch den Übergang auf andere Dosis an. Die Zahl bei dem Pfeil bedeutet die Dosis des Vitamins A in Tausenden der i. E. pro die angegeben. Die Tagesmengen des Sesamöls sind in Kubikzentimeter angegeben.

B. Subcutane Darreichung.

Da zahlreiche Substanzen nach parenteraler Verabreichung bekanntlich eine stärkere oder auch abweichende Wirkung als nach peroraler Darreichung ausüben, haben wir auch die subcutane (und percutane) Einverleibung des Vitamins A angewandt, um so mehr, da die bibliographischen Angaben in dieser Hinsicht sehr spärlich sind.

Soweit uns bekannt ist, wurden toxische Dosen des Vitamins A subcutan nur von YPSILANTI angewandt (bei Mäusen), jedoch erweckt das durch die Forscherin erhaltene Gesamtbild der A-Hypervitaminose ernstlich Vorbehalt, da die Kontrolltiere ähnliche schwere anatomo- und histopathologische Änderungen wie die Versuchstiere aufweisen. Die von GIEDOSZ subcutan angewandten Mengen des Vitamin A (bei Kaninchen) waren zu gering, um hypervitaminotische Erscheinungen hervorzurufen.

Bei unseren Untersuchungen benutzten wir, wie bisher, hauptsächlich weiße Ratten, von denen 11 Cresavit „Spieß" und 11 Vogan „Merck" erhielten. Die Kontrolltiere bekamen Sesamöl in entsprechenden Mengen. Da die Vitamin A-Präparate als ölige Lösungen sich schwer resorbieren und wir dieselben den Tieren aus diesem Grunde öfters in Abständen von einigen Tagen einführten, kann die Tagesdosis nur annähernd angegeben werden.

Die Zusammenstellung des Versuchsmaterials, der verabreichten Dosen usw. gibt folgende Tabelle (Tabelle 3).

Das klinische Bild. a) Cresavittiere. Am meisten typisch ist das klinische Gesamtbild der A-Hypervitaminose bei den Tieren der 2. Gruppe, bei denen die Zeitdauer des Experiments am längsten war (40 Tage). Die Unterbrechungen in der Verabreichung schwankten zwischen 1—4 Tagen und betrugen insgesamt 24 Tage. Dieses Verfahren ermöglichte die fast vollkommene Resorption des injizierten Präparats, und erst nach 30 Tagen traten bei 3 Tieren unter der Haut aus verdickten, unresorbierten Überresten des Präparats bestehende Konkremente in Form von kirschgroßen, mit grützartiger Masse gefüllten Beulen hervor.

Die Symptome der A-Hypervitaminose bei subcutaner Darreichung sind mit denen, die nach peroraler Einführung auftreten, fast identisch und offenbaren sich in Form von Änderungen an Haut, Knochen und Geschlechtsorganen. Es treten jedoch gewisse Unterschiede in der Intensität und im zeitlichen Auftreten dieser Erscheinungen zutage.

Bei den Tieren der obenerwähnten Gruppe zeigten sich die Hautänderungen ungefähr nach 8 Tagen in Form von leicht auftretendem Haarausfall, später als scharf begrenzte kahle Flächen in der Schulterblättergegend, also in erheblicher Entfernung von der Verabreichungsstelle. Am Ende des Experiments hatte das Fell, mit Ausnahme von diesen Stellen (Regio glutea), an denen sich unter der Haut Konkremente von nichtresorbierten Resten des Präparats angesammelt hatten, fast normales Aussehen wiedererlangt. Diese Regionen der Haut wurden ungefähr am 30. Tage kahl und änderten bis zur Beendigung des Experimentes ihr Aussehen nicht (s. Abb. 5). Bei 2 Tieren wurden außerdem noch die Augenlider kahl (die sog. „Brillenbildung", vgl. Abb. 6).

Tabelle 3.

Gruppe	Zahl, Geschlecht und Gewicht der Tiere	Dosis pro die in Tausenden i. E.	Versuchsdauer in Tagen	Gesamte Dosis in Tausenden i. E.	Ergebnis
		Cresavit subcutan (11 Tiere).			
1	4 Tiere ♂ 70–85 g	100 × 2 70 × 6	12 (8)	650	Ein Tier ging am 8., alle anderen am 12. Tag der Verabreichung zugrunde.
2	4 Tiere 2 ♂ u. 2 ♀ 82–89 g	250 × 1 100 × 4 50 × 11	40	1200	2 Tiere gingen am letzten Tag des Experiments zugrunde, die beiden anderen wurden in derselben Zeit im erheblichen Schwerfälligkeits- und Apathiezustand getötet.
3	3 Tiere ♂ schwarz-weiße 64–68 g	100 × 1 75 × 6	7	550	Die Verabreichung wurde am 7. Tage bei erheblichem Schwerfälligkeitszustand d. Tiere unterbrochen. Weitere Beobachtung 40 Tage.
		Vogan subcutan (11 Tiere).			
1	4 Tiere ♂ 110–115 g	60 × 27	27	1620	Die Tiere wurden in extremis am letzten Tag der Verabreichung getötet.
2	3 Tiere ♂ 83–86 g	60 × 29 240 × 1 300 × 2	85	2580	Die Verabreichung wurde bei ziemlich erheblichem Schwerfälligkeitszustand d. Tiere unterbrochen. Weitere Beobachtung 73 bis 75 Tage.
3	4 Tiere ♀ 51–58 g	30 × 43	43	1290	Am letzten Tag trat sehr unbedeutende Schwerfälligkeit hervor. Weitere Beobachtung 10 Tage.
		Kontrolltiere: Ol. Sesami subcutan.			
1	2 Tiere ♂ 60 u. 65 g	1,0 ccm	35	—	Vollkommen guter Zustand der Tiere während der ganzen Versuchszeit.
2	2 Tiere ♀ 76 u. 80 g	2,0 ccm	35	—	Wie oben.

Knochenfrakturen sind bei 2 Tieren am 37. und 39. Tage beobachtet worden. Bei den beiden Männchen dieser Gruppe trat am 30. Tage der Verabreichung Priapismus hervor, der bis zur Beendigung des Experimentes anhielt.

Abb. 5. Charakteristische Hautänderungen bei einer Ratte nach subcutaner Darreichung des Vitamin A-Konzentrats Cresavit. An dem vorderen Teil der Rückenhaut treten scharf begrenzte, teilweise mit frischem Haarwuchs bedeckte Stellen hervor. In der Sacralgegend dagegen, an Stelle der nichtresorbierten Überreste des Präparates, bemerkt man mehr ausgedehnten Haarausfall.

Die Hautänderungen zeichneten sich bei den Tieren der aus 3 schwarzweißen männlichen Ratten bestehenden dritten Gruppe durch außergewöhnliche Intensität aus und gestalteten sich besonders ausdrücklich bei einem der Tiere wie folgt.

Am 7. Tage wurde das Fell am ganzen Körper struppig und fiel in der Scheitel- und Hinterhauptgegend aus. Am 9. Tag war dieser Teil der Kopfhaut schon vollständig kahl. Ferner verbreitete sich der Haarausfallprozeß rasch auf den ganzen Körper, und am 21. Tag der Beobachtung war das Tier fast vollständig kahl. Das Aussehen der kahlen Haut war vollkommen normal (Abb. 7).

Aus obiger Beschreibung geht hervor, daß die Intensität der Hautänderungen längst nach Unterbrechung des Experiments am höchsten war, da die Verabreichung des Vitamin A-Präparats nicht länger als 7 Tage dauerte. Als Ursache dieser Erscheinung könnte das von uns festgestellte Ansammeln unter der Haut von nicht vollkommen resorbierten Überresten des Vitaminpräparats angesehen werden. Am 22. Tage der Beobachtung zeigte sich auf der ganzen Haut zartes Flaumhaar, und am 39. Tag war das Fell wieder vollkommen normal. Vgl. auch Gewichtskurve dieses Tieres (Abb. 8, Kurve 3).



Abb. 6. Sog. „Brillenbildung" in der A-Hypervitaminose bei subcutaner Darreichung dieses Vitamins bei einer Ratte (Cresavittier).

Bei den anderen Tieren dieser Gruppe beobachteten wir ähnliche, jedoch etwas weniger ausgedehnte Hautänderungen.

Abb. 7. Fast vollkommener Haarausfall bei einer Ratte nach subcutaner Darreichung des Vitamin A-Konzentrats Cresavit.

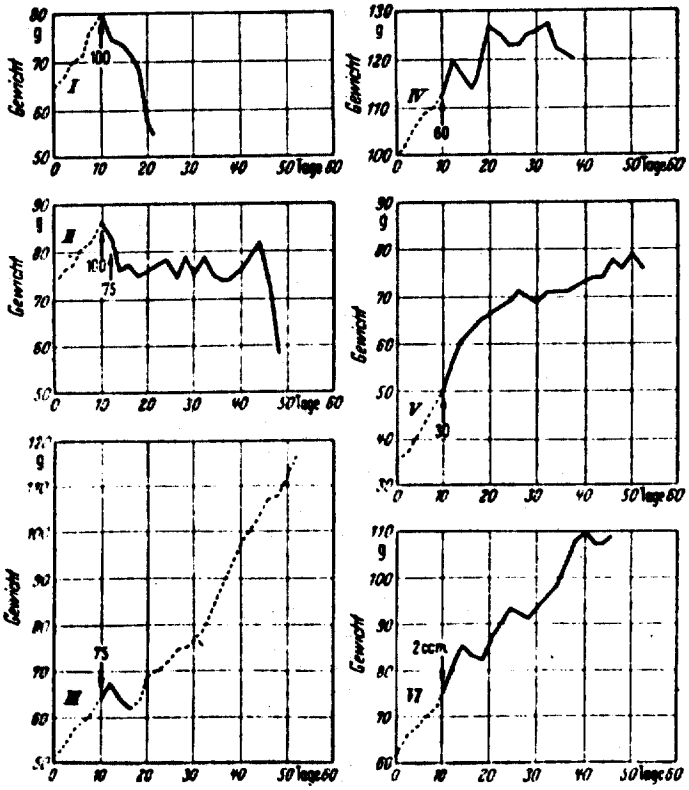

Abb. 8. Gewichtskurven von Ratten bei A-Hypervitaminose. Subcutane Darreichung der Konzentrate dieses Vitamins: Cresavit und Vogan. Kurven 1—3: Cresavittiere der 1., 2. und 3. Gruppe. Kurven 4 und 5: Voganiere der 1. und 3. Gruppe. Kurve 6: Kontrolltier, (Öl Sesam subcutan) aus der 2. Gruppe (vgl. Tabelle 3 und die Anm. zur Abb. 4).

Mit Rücksicht auf den schnell eintretenden Tod (am 8. bis 12. Tag) der Cresavittiere der 1. Gruppe war das klinische Gesamtbild wenig charakteristisch.

b) Voganiere. Die am meisten charakteristischen Erscheinungen haben wir nach subcutaner Einverleibung von Vogan bei den Tieren der 2. Gruppe (vgl. Tabelle 3) erhalten. Es gelang uns, diese Tiere trotz einer großen Gesamtdosis des Präparates, dank zahlreicher Unterbrechungen in der Darreichung (2—14 Tagen), lange Zeit am Leben zu erhalten. Die Tiere wurden 73—75 Tage hindurch weiterhin beobachtet. Unter diesen Umständen erhielten wir ein vollkommenes Gesamtbild der A-Hypervitaminose, das mit dem oben bei Cresavittieren dargestellten identisch war.

Es sei nur bemerkt, daß der bei 2 Tieren hervortretende typische Priapismus bis zur Beendigung der Beobachtung, d. h. 130 Tage hindurch, anhielt. Die erwähnten Tiere mit dem Priapismus weisen, nachdem man sie in einen Käfig mit weiblichen Tieren gesetzt hatte, normalen Geschlechtstrieb auf, wobei ein Weibchen befruchtet wurde und gesunde Nachkommenschaft (5 Junge) hatte.

Die Kontrolltiere (4) erhielten 35 Tage hindurch subcutan Sesamöl: 1 oder 2 ccm pro die (vgl. Tabelle 3). Dieses Öl wurde gut resorbiert. Das Allgemeinbefinden der Tiere war ganz normal.

Die beigefügten Kurven stellen die Gewichtsschwankungen der Versuchs- und Kontrolltiere dar (Abb. 8).

Die anatomopathologischen Änderungen, die Besprechung der Ergebnisse und betreffende Literatur werden wir am Ende der zweiten Mitteilung angeben.

Wilhelm-'54
Bib. No. 9789

REGENERATION OF THE TRACHEAL EPITHELIUM IN THE VITAMIN-A-DEFICIENT RAT

D. L. WILHELM

From the Department of Morbid Anatomy, University College Hospital Medical School, and the Lister Institute of Preventive Medicine, London

(PLATES LXXX AND LXXXI)

AFTER shallow curettage of the tracheal mucosa in normal rats, hæmorrhage and clotting take place over the curetted area. A thin layer of epithelium spreads inwards under the clot and a curetted area 2 mm. wide is covered in 36-48 hours, provided the elastic layer of the lamina propria is intact. The new epithelium becomes stratified and then differentiates into ciliated low columnar epithelium. The process is complete in 10-14 days after curettage (Wilhelm, 1953). This paper describes regeneration after similar curettage of the metaplastic squamous epithelium that constitutes the tracheal mucosa in rats suffering from vitamin-A deficiency.

MATERIAL AND METHODS

Production of vitamin-A deficiency in weanlings. Pregnant albino Wistar rats were fed on pellets of Parkes no. 41 diet. From about 3 days before littering until their young were weaned, they were fed on the same diet in meal form but without cod liver oil. Young rats were weaned when they weighed approximately 40 g. and fed on the following basal diet.

Casein (vitamin-free) . . .	20 parts
Cane sugar	60 ,,
Arachis oil	15 ,,
Dried yeast	10 ,,
Mineral mixture	5 ,,

The mineral mixture contained sodium chloride 50 g., calcium phosphate 400 g., iron citrate 35 g., potassium iodide 1 g., magnesium sulphate 80 g., mono-sodium acid phosphate 105 g., potassium chloride 250 g., sodium fluoride 0·44 g., manganese sulphate 0·2 g.

Supplements of vitamin D (1 drop of Radiostol, B.D.H.), vitamin E (1 drop of 5 per cent. tocopheryl acetate in arachis oil w/v) and vitamin K (1 drop of 0·25 per cent. 2-methyl 1 : 4 naphthoquinone in arachis oil, w/v) were given to each rat weekly. Since straw and hay are sources of vitamin A, the weaned rats were housed in cages with a wire mesh floor without bedding. A group of 4 rats was killed at weaning, and at weekly intervals for 7 weeks, to determine histologically when squamous metaplasia had occurred.

Tracheal curettage in vitamin-A-deficient rats. In 36 rats with advanced xerophthalmia, shallow tracheal curettage was performed as described by Wilhelm. Under ether anæsthesia the trachea was exposed, but not opened, by a midline thyroid-splitting incision. Using a small aural spoon curette, the mucosa on the anterior tracheal wall was curetted from the larynx to the thoracic inlet.

The incisions were closed and the rats were fed on the basal diet until killed at intervals from 1 hour to 8 days after operation. After longer intervals the rats died from vitamin-A deficiency.

The curetted length of each trachea was fixed in buffered 10 per cent. formalin, the trachea being kept extended to maintain the length it had in the living animal, and embedded in paraffin. Transverse sections 5 μ thick were cut from the lower end and stained with Ehrlich's acid hæmatoxylin and eosin and with Hart's modification of Weigert's elastic stain.

From camera lucida outline drawings in 20 rats, the average tracheal circumference at the mucosal base was 5·1 mm. (4·5-5·4 mm.) and the average width of the curetted areas was 2·25 mm. (1·8-2·45 mm.).

Results

Squamous metaplasia

At weaning, the tracheal epithelium is ciliated, cuboidal or low columnar, and has a basal germinal layer of spindle-shaped cells with their long axes parallel to the surface. It increases in height during the following 3-4 weeks (fig. 1).

After 3-4 weeks on the deficient diet, multiple small foci of squamous metaplasia appear in the mucosa. They are most common in the vicinity of the mid-dorsal aspect. In such foci the columnar cells have swollen and eosinophilic cytoplasm, their boundaries are blurred or lost and their nuclei are either swollen and pale or pyknotic. These changes are followed by necrosis.

At the same time stratified cells derived from the basal germinal layer proliferate under the degenerating ciliated columnar epithelium, which is displaced towards the lumen and finally shed. This new epithelium spreads laterally and undermines the adjacent healthy columnar epithelium, which in turn degenerates and is cast off (fig. 2). Some of the degenerating cells lose their cilia early, others retain them until the sloughing stage.

Squamous metaplasia is sometimes complete during the fifth week and usually by the end of the sixth. The epithelium is 3-5 cells deep, including a basal germinal layer of elongated cells with their long axes at right angles to the surface (fig. 3). Keratinisation is most prominent when dense neutrophil infiltration is present. This histological sequence is similar to that described in older vitamin-A-deficient rats by Wolbach and Howe (1925). Œstrin treatment of mice causes similar metaplasia of columnar epithelium of the reproductive organs (Burrows, 1935).

In most of the deficient rats infection of the air passages supervenes. As a result of infection a layer of pus covers the mucosa. The submucosa is always infiltrated by plasma cells and lymphocytes and in acute infection by moderate but variable numbers of neutrophils. Rats kept on the basal diet nearly all die in the sixth and seventh weeks, often with terminal diarrhœa.

Curettage was performed about 34-40 days after weaning, when the metaplasia was complete. At this stage the rats are wasted, with

REGENERATION OF TRACHEAL EPITHELIUM



FIG. 1.—Ciliated columnar epithelium of the tracheal mucosa of a normal adult rat. Hæmatoxylin and eosin. ×550.

FIG. 2.—Early squamous metaplasia of tracheal mucosa; from a young rat which was fed on vitamin-A-deficient diet for 28 days. H. and E. ×185.

FIG. 3.—Fully developed squamous metaplasia of tracheal mucosa; from a young rat which was fed on vitamin-A-deficient diet for 36 days. H. and E. ×385.

thin and ragged fur. There are bilateral and equally severe ocular lesions. The conjunctivæ are infected and hæmorrhagic, and some of the rats are blind.

Regeneration of squamous epithelium

Repair proceeds in 4 stages corresponding to those for normal tracheal epithelium.

Hæmorrhage and clotting. As infection usually accompanies metaplasia, the submucosal vessels are engorged and post-operative hæmorrhage, though not severe, is greater than in normal rats. Within one hour a fibrin clot with entangled blood cells and peripheral serous exudate covers the curetted surface ; it is shed when epithelialisation is complete. The infection present before curettage may be sufficient to mask post-operative inflammation.

Regeneration of epithelium over the curetted surface. Within 1-2 hours simple flat cells arise from the intact marginal epithelium and from the curetted necks of submucous glands and spread over the exposed elastic layer of the lamina propria (fig. 4). Most of the spreading cells arise from marginal squamous cells immediately under the superficial keratinised layer and glide over the deeper squamous and basal germinal cells, leaving the keratinised layer *in situ* (fig. 5). The advancing line of cells is very thin and undermines the fibrin clot or pus, keeping in contact with the elastic layer.

Metaplastic squamous epithelium covers the curetted areas at a rate similar to that for normal tracheal epithelium. Each margin advances approximately 200-250 μ in 8 hours, 400 μ in 12 hours and 750 μ (400-1000 μ) in 24 hours. When the elastic layer is intact, areas 1·75 mm. wide are epithelialised in 36 hours and areas 2·0-2·4 mm. wide in 48 hours (*i.e.* a mean advance of about 20-25 μ/hour).

When the elastic layer is damaged or breached the advancing margin of new epithelium may spread on the surface of blood clot or may form a relatively deep focus of squamous epithelium which slowly spreads on the submucous connective tissue, taking up to 96 hours to cover elastic breaches 0·5 mm. wide.

Between 12 and 36 hours after curettage, mitoses appear in most of the original epithelium except the first 10-15 cells adjacent to the curetted margins. Mitosis begins after the start of epithelialisation and ceases before its completion. In the new epithelium, mitoses are uncommon until 48 hours after curettage.

Stratification of the new epithelium. When epithelialisation is complete the new epithelium is 2-3 cells deep at its margins and 1-2 cells deep in the middle. Between 48 and 96 hours after curettage, the deepest cells divide to produce a simple stratified epithelium 4-6 cells deep. Mitosis in the new epithelium is much less pronounced than in the corresponding stage of regeneration of normal tracheal epithelium.

Differentiation of the new epithelium. The stages of stratification

and differentiation merge one into the other and are mainly distinguishable by the absence of mitotic activity during differentiation. Six days after curettage the new epithelium is keratinised and has a basal layer of germinal cells. After 8 days the mucosal surface is covered by as much shed keratin and cell debris as on the mucosa before curettage (fig. 6).

The new epithelium readily becomes squamous. For example, when breaches of the elastic layer delay regeneration, the new epithelium quickly becomes deep and squamous in type. Another example is provided by three clinically deficient rats in which no metaplasia had occurred. The original epithelium was columnar 6-8 days after curettage; nevertheless the regenerated epithelium was squamous and keratinised, ended abruptly at the curettage margins and had even begun to undermine the adjacent columnar epithelium as described in metaplasia.

Discussion

After shallow tracheal curettage in vitamin-A-deficient rats the pattern and rate of epithelial regeneration of the metaplastic squamous epithelium is similar to that of ciliated columnar epithelium in normal rats (Wilhelm). The new epithelial cells arise from squamous cells at the wound margins and from the curetted necks of submucous glands. Curetted areas 2 mm. wide are epithelialised in 48 hours.

Epithelialisation of shallow skin wounds 2 mm. wide in rats takes up to 5 days (Akaiwa, 1919). Possibly the character of the surface on which epithelium has to spread influences the rate of regeneration. A surface of collagen and intermingled elastic tissue or of granulation tissue of the dermis seems to be less suitable for rapid epithelialisation than the firm elastic layer of the tracheal lamina propria. Epidermal cells of the bug Rhodnius rapidly "epithelialise" glass surfaces. Lüscher (1947) inserted glass capillary tubes into the tibial stumps of Rhodnius and observed that, at a temperature of 25° C., the epidermal cells spread on the glass tubes at a rate of 30-40 μ/hour. This was a linear spread. The spread over the denuded trachea was measured along the 2 mm. width of areas over 20 mm. long, cut so that there could be no contribution by advancing epithelium from the ends and consequently may also be regarded as linear. It is interesting that here also the rate of spread (20-25 μ/hour) was of the same order.

After epithelialisation, the new epithelium in vitamin-A-deficient rats differentiates into squamous epithelium in 6-8 days, but takes 12-14 days to differentiate into ciliated epithelium in normal rats. This is not surprising, since ciliated epithelium with its goblet cells is much more highly specialised.

Vitamin A is important in the control of keratinisation and hence of squamous differentiation, and proliferating cells are especially vulnerable to vitamin-A deficiency (Fell and Mellanby, 1953). In

REGENERATION OF TRACHEAL EPITHELIUM

FIG. 4.—Tracheal mucosa showing the well-defined elastic layer of the lamina propria; from a rat 2 weeks after weaning. Modified Weigert's elastic stain and carmalum. ×300.

FIG. 5.—Six hours after shallow tracheal curettage in a vitamin-A-deficient rat. Simple flat cells from the marginal squamous epithelium are spreading over the curetted surface. H. and E. ×345.

FIG. 6.—Eight days after tracheal curettage in a vitamin-A-deficient rat. The regenerated epithelium is squamous and is covered by keratin and amorphous debris. H. and E. ×385.

squamous metaplasia, the squamous epithelium grows from the basal germinal cells of the tracheal mucosa. Also, when tracheal curettage is performed in vitamin-A-deficient rats before squamous metaplasia has occurred, the regenerated epithelium is squamous and undermines the adjacent columnar epithelium as in metaplasia.

In normal rats, moderate tracheal submucous infection delays columnar differentiation. In vitamin-A-deficient rats gross tracheal infection does not interfere with epithelialisation or subsequent squamous differentiation. Indeed squamous metaplasia is often best developed when infection is marked.

Cameron and Mehrotra (1953) observed a difference in the rate of repair of hepatic and testicular tissues subjected to injury by freezing, according to their position in the body; *i.e.* whether in the natural organ or implanted in various sites. It is interesting that in spite of gross nutritional differences, metaplastic squamous epithelium, being in the same cellular environment as in the normal animal, responds similarly to curettage.

Summary

The tracheal mucosa of weaned rats on a vitamin-A-deficient diet undergoes squamous metaplasia in 5-6 weeks.

After removal of the mucosa by shallow tracheal curettage, simple flat cells from the marginal epithelium and from curetted necks of submucous glands spread out over the elastic layer of the lamina propria.

The advancing sheet of cells undermines the clot over the injury at the rate of about 0·2-0·25 mm. in 8 hours, 0·4 mm. in 12 hours, 0·75 mm. in 24 hours, 0·9 mm. in 36 hours and 1·0-1·2 mm. in 48 hours.

Epithelialisation is unaffected by acute infection but is delayed when the elastic layer is damaged or removed by the curette.

The pattern and rate of epithelialisation is similar to that for normal tracheal epithelium.

Squamous differentiation of the new epithelium takes 6-8 days; it is not delayed by infection and occurs even when the original epithelium has not undergone squamous metaplasia.

I wish to thank Dr T. Moore, Dunn Nutrition Laboratory, Cambridge, who very kindly supplied instructions for the vitamin-A-deficient diet.

REFERENCES

Akaiwa, H. . . . . 1919. *J. Med. Res.*, xl, 311 and 371.
Burrows, H. . . . . 1935. This *Journal*, xli, 423.
Cameron, G. R., and Mehrotra, R. M. L. 1953. This *Journal*, lxv, 1.
Fell, Honor B., and Mellanby, E. 1953. *J. Physiol.*, cxix, 470.
Lüscher, M. . . . . 1947. *Nature*, clx, 873.
Wilhelm, D. L. . . . . 1953. This *Journal*, lxv, 543.
Wolbach, S. B., and Howe, P. R. 1925. *J. Exp. Med.*, xlii, 753.

Wilson-'47
Bib. N0. 9857

Proc. Soc. Exptl. Biol. Med. 64:419-422. 1947.

15814

Epithelial Keratinization as Evidence of Fetal Vitamin A Deficiency.*

JAMES G. WILSON AND JOSEF WARKANY.

From the Department of Anatomy, School of Medicine and Dentistry, University of Rochester and from the Children's Hospital Research Foundation, Department of Pediatrics, College of Medicine, University of Cincinnati.

The appearance of stratified keratinized epithelium in places where such epithelium is not ordinarily found is the cardinal sign of vitamin A deficiency. It has been stated that this histologic change, referred to as keratinizing metaplasia, occurs in all vertebrates regardless of age.[1] However, it has not been described in fetal or newborn animals whose mothers were in a state of vitamin A deficiency during pregnancy. This is noteworthy, since Hale,[2] using the pig, and Warkany and Schraffenberger,[3] using the rat, obtained fetuses that bore severe morphologic

* This work was aided in part by a grant from the Nutrition Foundation, Inc., N. Y.

[1] Wolbach, S. B., and Bessey, O. A., *Physiol. Rev.*, 1942, **22**, 233.

[2] Hale, F., *Am. J. Ophth.*, 1935, **18**, 1087.

[3] Warkany, J., and Schraffenberger, E., *Arch. Ophth.*, 1946, **35**, 150.

anomalies when the mothers were deprived of vitamin A during pregnancy.

The present communication is a report of the finding of keratinizing metaplasia in the genito-urinary tract of fetal rats taken from mothers that were deficient in vitamin A during pregnancy. It is based on a study of serial sections of 14 fetuses and newborns from as many different litters, the gestational age of which ranged from the 16th through the 22nd day. Maternal deficiency was induced and maintained by the same diets and experimental procedures as were used by Warkany and Schraffenberger.[3] Fetuses of comparable ages and newborn rats from mothers fed an adequate diet were sectioned and studied as controls in order to rule out the possibility of keratinization of genito-urinary epithelia by maternal estrogens during the latter part of pregnancy. The histology of the normal epithelia will not be described in this paper, and only those histologic features which represent distinct deviations from the normal will be described for the A-deficient animals. Nevertheless, it should be stated that keratinization normally does not occur in any part of the genito-urinary tract of fetal and newborn rats except in the most distal portion of the urethra, *i.e.*, the external orifice and a short segment contiguous with it.

Neither the control fetuses nor those subjected to maternal vitamin A deficiency exhibited keratinization in any part of the body prior to the 18th day of gestation. All fetuses older than 18 days whose mothers were fed the A-deficient diet, however, showed keratinizing metaplasia in at least some of the genito-urinary epithelia which constituted, or were derived from, the urogenital sinus. A precise localization of the affected epithelia in terms of definitive organs is not feasible in the present report, since the differentiation of the entire urogenital sinus was conspicuously retarded and this retardation, in turn, complicated by the occurrence of several frank malformations. Until a larger series of animals has been studied and plastic reconstructions prepared, no attempt will be made to analyze the malformations, and the location of areas of metaplasia will be described only in a general way.

The 18th day of gestation was the earliest time at which metaplastic keratinization appeared in the offspring of A-deficient mothers. A male fetus of this age was found to possess a small area of truly keratinized epithelium within the urethral plate and another area in the pelvic part of the urogenital sinus where, although no completely keratinized cells were seen, the cytoplasm of superficial cells was hyalinized and contained keratohyalin granules. These changes might be designated "prekeratinization." The findings seem particularly interesting in view of the fact that the epidermis and other ultimately cornified epithelia had not undergone keratinization in either this animal or control fetuses of the same age.

True keratinization, typified by cornification and desquamation of the surface-cells and by hyalinization and keratohyalin granulation in the superficial layers of cells, was consistently found in fetuses of a gestational age of 20 days. It was limited, however, to the distal two-thirds of the urogenital sinus, specifically to the segment lying between the point of juncture of the genital ducts with the sinus, cephalically, and the exterior of the body, caudally. Metaplasia occurred as a continuous strip along the dorsal wall of this segment but, curiously, had affected to a much less striking degree, or not at all, the lateral and ventral walls of this region of the sinus. The point at which keratinization was most pronounced, both in degree and in circumferential extent, was where the genital ducts joined the sinus. This was also the most cephalic part of the affected area. This fact speaks against the possibility that keratinizing changes spread into and along the sinus from the already keratinized epidermis on the exterior, and seems to indicate instead that an *in situ* transformation to a keratinized type of epithelium had occurred. No true cornification was seen in 20-day fetuses above the point of entry of the genital ducts, but prekeratinization changes, beginning hyalinization of the cytoplasm and the appearance of keratohyalin granules in the

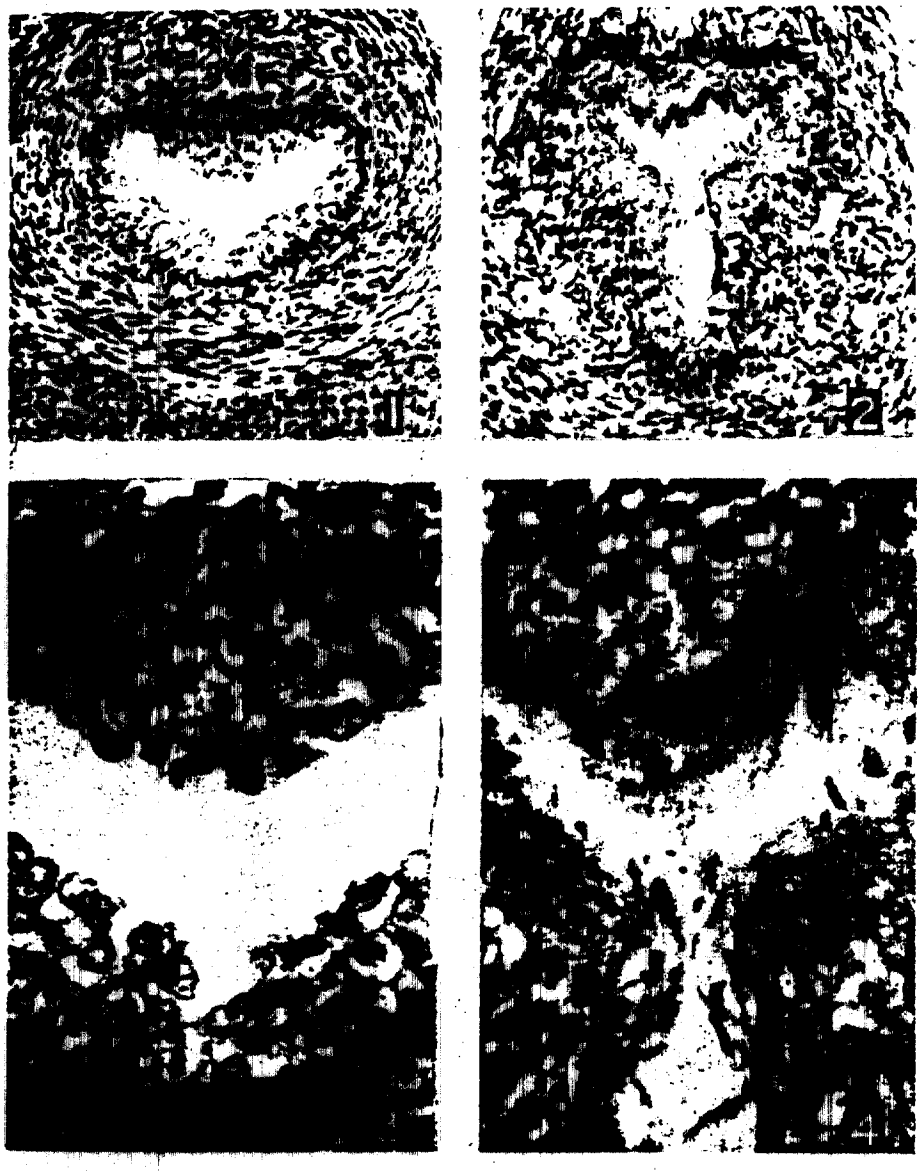

Fig. 1-4.

Fig. 1. Urethra at the level of the urethral sinus of a newborn rat, offspring of a mother fed an adequate diet. (×210)

Fig. 2. Urethra at the level of the urethral sinus of a newborn rat, offspring of a mother fed a vitamin A-deficient diet. (×210)

Fig. 3. Higher magnification of the urethra shown in Fig. 1. (×650)

Fig. 4. Higher magnification of the urethra shown in Fig. 2. (×650)

These photomicrographs are oriented with the "dorsal" wall toward the top of the page. As used here, the term "dorsal" refers to that wall of the urethra derived from the dorsal wall of the embryonic urogenital sinus, and does not accurately describe the relative position of this wall in the newborn rat.

surface-cells, were observed in the region of the upper sinus that roughly corresponded to the neck of the bladder.

Fetuses taken on the 21st and newborns taken on the 22nd day showed perhaps a more advanced degree of cornification (Fig. 1-4), with considerable desquamation at some points, but the extent of the affected area was

scarcely greater than at 20 days. Again, structures derived from the urogenital sinus distal to its juncture with the genital ducts were keratinized throughout their length; and metaplasia was always more pronounced on, and tended to be limited to, the dorsal aspect of these structures. In one newborn male an area of true metaplasia was observed in the vesico-urethral portion of the sinus at a point corresponding to the upper prostatic urethra. Otherwise, only prekeratinization changes were seen in this more cephalic portion of the sinus. Even in these newborns and more mature fetuses no histologic deviations from normal were seen in the epithelia in regions of the definitive bladder, ureters, kidneys, mesonephric ducts or Müllerian ducts.

Comment. These observations reveal that genito-urinary epithelia in fetal rats, like many other epithelia in older animals, require vitamin A for their morphologic integrity. It appears that this requirement is not manifested by keratinizing metaplasia until the fetal tissues have undergone a certain degree of differentiation. In the urogenital sinus this is attained by, or shortly before, the 18th day of gestation. The fact that keratinization did not affect other epithelia, which in older animals do respond to A-deficiency by undergoing metaplastic changes, does not prove that the unaffected epithelia were differentiated to a lesser degree than those of the urogenital sinus. Nevertheless, it is suggestive in this direction, and it undoubtedly reflects some unobserved morphologic or perhaps functional difference between those tissues that undergo metaplasia during the fetal period and those that react in this fashion to A-deficiency only at an older age.

The prevalence of congenital malformations in the genito-urinary tract of these fetuses is probably somehow related to the particular susceptibility of epithelia in this region to keratinizing metaplasia, although any attempt to evaluate such a relationship must await a more thorough study of the malformations.

Summary. Keratinizing metaplasia in epithelia of the genito-urinary tract was observed in fetal rats taken from mothers fed a vitamin A-deficient ration. Only structures derived from the fetal urogenital sinus were affected. The earliest metaplastic changes were seen in a fetus of 18 days gestational age; by the 20th day keratinization was seen in the dorsal wall of all organs distal to the termination of the genital ducts. Epithelia in other parts of the body were not affected by these changes.

Wilson-'48
Bib. No. 9859

Am. J. Anat. 83(3):357-407. 1948.

MALFORMATIONS IN THE GENITO-URINARY TRACT INDUCED BY MATERNAL VITAMIN A DEFICIENCY IN THE RAT[1]

JAMES G. WILSON[2] AND JOSEF WARKANY[3]

[2] *Department of Anatomy, University of Rochester School of Medicine and Dentistry, Rochester, New York and* [3] *Children's Hospital Research Foundation, Department of Pediatrics, University of Cincinnati College of Medicine, Cincinnati, Ohio*

TWENTY SIX FIGURES

That a lack of vitamin A in the maternal diet during gestation may result in defective offspring is a well-establish fact. From sows maintained prior to and during the first 30 days of pregnancy on a ration restricted in this vitamin, Hale ('35) obtained pigs that had severely malformed eyes, harelip, cleft palate, ectopic kidneys and accessory external ears. Warkany and Schraffenberger ('44, '46) produced a variety of developmental defects in the eyes of fetal and newborn rats by raising the mothers on a diet containing very small amounts of carotene and breeding them on a diet entirely free of carotene and vitamin A. The offspring of mother rats treated in this manner have been shown by Wilson and Warkany ('47a) to exhibit at least one of the classical signs of vitamin A deficiency, namely, keratinizing metaplasia in certain epithelia of the genito-urinary tract in fetuses older than the 18th day of gestation. Also, in a preliminary report (Wilson and Warkany, '47b) it was stated that the genito-urinary tract of such offspring bore many frank malformations. It is the purpose of the present communication to describe these malformations more fully, to analyze them in

[1] This study was aided by grants from the Nutrition Foundation, Inc., New York.

terms of incidence and their interrelationships to each other, and, wherever possible, to indicate the abnormality of embryonic processes responsible for the maldevelopment.

METHODS AND MATERIAL

Maternal vitamin A deficiency was induced by the procedure described by Warkany and Schraffenberger ('44, '46). Young female rats of the Sprague-Dawley and Albino Farm strains weighing 30 to 40 gm were placed on a preparatory diet (diet U) for the first two or three months after weaning. This preparatory diet had the following percentage composition: ground whole wheat, 74; crude casein (Borden), 15; brewers' yeast (Mead Johnson), 10; sodium chloride of C.P. grade, 1. Each rat received by oral dosing 60 U.S.P. units of vitamin D (Drisdol, Winthrop) every 10th day. This diet was supplemented by small quantities of carotene sufficient to permit growth and maturation but inadequate for appreciable storage (Warkany and Roth, '48). When the rats reached a weight of 150 to 160 gm and regular estrous cycles were established, they were transferred to a purified diet (diet W) completely free of carotene and vitamin A and were then permitted to mate with males of the same strain which had been reared on an adequate diet. The purified diet had the following percentage composition: sucrose, 68; vitamin test casein, 18; vegetable oil, 10; and salt mixture, 4 (Hubbell, Mendel and Wakeman, '37). One hundred grams of this diet was supplemented with 0.8 mg of thiamine hydrochloride, 0.8 mg of pyridoxine hydrochloride, 0.8 mg riboflavin, 1 mg of calcium pantothenate, 10 mg of nicotinamide and 100 mg of choline chloride. This diet was further supplemented by oral dosing every 10th day with vitamin D (1 drop of a 1:4 dilution of Drisdol with olive oil), and vitamin E (1 drop of a solution of 5 gm of alpha tocopherol in 100 ml of olive oil), and vitamin K (1 drop of a solution of 1 mg of 2-methylnaphthoquinone in 5 ml of olive oil). On this diet the female rats were bred and kept throughout pregnancy.

In order to determine the beginning of pregnancy and to follow its course, daily vaginal smears and weight records were made. Pregnancy was dated from the day on which sperm was found in the vaginal smear, this being designated as *day 1*. The authors do not wish to imply by this designation that the products of conception were "1 day old" when sperm were found but, rather, that they were "in the 1st day of gestation." Accordingly, when in the following sections of this paper a fetus is referred to as being, for example, 18 days of gestational age, such a statement should be interpreted as "in the 18th day of gestation." In following the course of pregnancy special attention was given to the recognition of beginning resorption. Impending resorption of the conceptuses was usually indicated by the presence of large amounts of blood in the vaginal smear and by a marked weight loss. This profuse bleeding that precedes termination of pregnancy can generally be distinguished from the normal blood sign, which appears between the 10th and 15th days, since in the latter only a small amount of blood is present in the vaginal smear. When early termination of pregnancy threatened, the animal was opened and the fetuses removed and fixed. As a rule the mothers who carried their young to the 22nd day of gestation were also opened and the young removed; however, some of the mothers were allowed to deliver their young spontaneously. Although many young were obtained by both methods, none with malformations lived for more than a few hours after delivery.

The fetuses used in this study were obtained in two series of experiments involving maternal vitamin A deficiency. While these experiments differed in certain details (Warkany and Roth, '48), the anomalies observed were of the same pattern. Of 400 females subjected ot the experimental conditions described above, 334 mated as evidenced by the presence of sperm in the vaginal smear; but no offspring were obtained from 184 of these, due to early resorption or other forms of gestational failure. Offspring were obtained from 150 females but only 37 of these mothers carried their young to

the 22nd day of gestation. In the remaining 113 pregnancies the fetuses were removed between the 13th and 21st days, on finding indications that pregnancy might be terminated spontaneously.

Examination of serial sections through the region of the eyes in at least one fetus thus obtained from each mother revealed that about 75% of the fetuses had ocular anomalies (Warkany and Schraffenberger, '46). For the present investigation 42 of the fetuses and newborns were serially sectioned through the abdominal and pelvic regions and prepared for histologic study. Forty of those selected were known to have varying degrees of ocular abnormality but the remaining two possessed normally developed eyes. Judged on the basis of ocular anomalies, the fetuses used in this study included a higher percentage of severely affected individuals than was proportional in the offspring from A-deficient mothers. Therefore, the percentile occurrence of genito-urinary anomalies to be described should not be taken to represent the exact proportion in which such defects occurred in all of the young obtained. Animals of both sexes and of all ages from the 17th through the 22nd days were included. Seventeen control fetuses, from mothers fed an adequate diet were similarly prepared for histologic study. The controls also included both sexes and covered the same range of age as the offspring of vitamin A deficient mothers. In order to better visualize certain of the abnormalities, wax-plate reconstructions were made of the genito-urinary tract, exclusive of kidneys and gonads, of 8 A-deficient and 6 control fetuses.

OBSERVATIONS

To appreciate fully many of the abnormalities to be described here, there is need for at least a general understanding of the normal development of the reproductive and urinary systems of the rat. Some aspects of the embryology of these systems have been described by Torrey ('43, '45 and '47), but his observations concern primarily the early organogenesis of the kidney and gonads. Also, Greene, Burril and Ivy

('39, '40) have described the structure of several reproductive and urinary organs at the time of birth, but have made only brief references to the prior development of these organs. Since none of the previous reports adequately discusses the developmental changes that are of particular interest in the present study, the following section on normal embryology is included as a necessary background for discussing the abnormalities to be described. It is not presented as a complete account of all phases of development in this region: it deals largely with those normal structures and processes which were rendered abnormal by maternal vitamin A deficiency. For the sake of brevity only developmental conditions existing on the alternate days, 17th, 19th and 21st days of gestation, are described in any detail.

Normal embryology of the genito-urinary tract

The 17th day is taken as the starting point for the description of both normal and abnormal fetuses since prior to this age many parts of the genito-urinary tract have not reached a sufficient degree of differentiation to permit unequivocal recognition of deviations from the normal condition. At this age the metanephric primordia are well established, gonadal differentiation has occurred, both sets of genital ducts are present and terminate in the urogenital sinus, and the urorectal septum has completely partitioned the cloca into urogenital sinus and rectum. Sexual dimorphism, however, is not yet evident in the genital ducts or in the urogenital sinus.

Kidneys. On the 17th day the kidneys lie in the lumbar region with their cephalic poles at vertebral level L 2 but with the caudal poles still lying in the lower abdominal region. The hili are directed ventro-medially and the two kidneys are separated by a distance slightly less than the width of the vertebral body. No characteristic glomeruli have appeared but the first generation of Bowman's capsules is in process of formation. The lumina of the renal pelves and calyces are not open. By the 19th day both the definitive position and orien-

tation have been attained: the upper pole is at the level of L 1 and the hili are directed medially. A few well-formed glomeruli are present and, judging from the mild dilation seen in the surrounding Bowman's capsules, some degree of renal function may have begun. Convoluted tubules and Henle's loops are recognizable but rudimentary; the latter extend only for a short distance toward the medullary region. The lumina of the calyces and pelves are now mildly dilated, a condition which is first apparent on the 18th day and one which, it is believed, marks the beginning of fluid transfer across the glomerulus. By the 21-st day the kidneys have undergone considerable further differentiation. Several generations of apparently mature nephrons are present and the extension of their loops of Henle into the medullary region has made a sharp distinction between this and the cortical region. At 22 days, full term, the kidneys are relatively more laterally situated; their hili now lie in the same sagittal plane as the tips of the transverse processes of the vertebra. A broad cortical zone contains many generations of mature glomeruli, but there remains a thin peripheral region in which nephrogenesis is in progress.

Gonads. The gonads become distinguishable as ovaries or testes on the 14th or 15th day, according to Torrey ('45). At the 17th day sexual distinction is readily made on the basis of histologic characteristics; but the testes and ovaries remain similarly located, at their site of origin in the mid-lumbar region, which at the present stage places them along the lateral aspect of the metanephric kidney. For the purposes of this report there is no need for a discussion of histogenesis of the gonads, and further remarks will be limited to a description of their changing position. The absolute position of the ovaries changes little in later development, although relative to the kidney they move caudally until at the 21-st day of gestation they are found just below the caudal pole of the kidneys, in the mid-lumbar region, where they will remain. Between the 17th and 19th days the testes descend from their original position to the upper part of the pelvic cavity where they lie

dorso-lateral to the bladder. On the 21st day they are seen to have moved further caudally to lie beside the bladder and almost on the pelvic floor in the inguinal region. At the time of birth the testes vary in position, but they are usually found in the inguinal fossa very near the internal inguinal ring.

Genital ducts. Both sets of genital ducts are present at 17 days and exhibit a similar degree of development and preservation in the two sexes, despite the fact that the gonads were sexually differentiated somewhat earlier. Since sexual dimorphism is not apparent, the following description of genital ducts will apply to both males and females. The mesonephric (Wolffian) ducts appear to begin at the level of the gonads where they receive a few persisting mesonephric tubules, the more cephalic extent of the ducts having undergone involution earlier. From this point they proceed uninterruptedly through the urogenital fold along the dorsal wall of the lower abdomen and pelvis to terminate in the urogenital sinus. The Müllerian ducts begin cephalically at an open, somewhat flared ostium located at a slightly higher level than the gonads or mesonephric ducts. From the ostium they diminish in size as they continue caudally along the lateral aspect of the mesonephric ducts, and in the lower abdominal region they pass ventrally to the mesonephric ducts to take a position medial to the latter. Beyond this they proceed to make contact separately with the dorsal wall of the urogenital sinus at a point medial to and slightly more cephalic than the point of entry of the mesonephric ducts (fig. 1a). The Müllerian ducts do not unite with each other in their more caudal portions to form a utero-vaginal canal until later. That the Müllerian ducts have just completed their caudalward growth toward the urogenital sinus, at the 17th day, is indicated by the fact that in some specimens the caudal tips of the ducts have united with the sinusal epithelium while in others the ducts approach closely or make contact with the sinus but do not effect complete union with it.

At the 19th day sexual dimorphism of the genital ducts is clearly seen: the mesonephric ducts have continued develop-

ment in males and have begun to regress in females, while the Müllerian ducts have begun to regress in males and have continued development in females. In males the mesonephric ducts, in the region of the testes, have become elaborated toward formation of the epididymides; but in their caudal portions they have remained as simple tubes, with no indication of the outgrowth of seminal vesicles. Small Müllerian-duct remnants persist in the male as inconspicuous epithelial strands (fig. 9), except in the lower pelvic region where they remain as relatively large, patent structures that unite to form a utero-vaginal canal (fig. 1b). The latter continues for a short distance and then bifurcates just before reaching the urogenital sinus, one branch passing laterally to enter the sinus on either side near the entry of mesonephric ducts. This more caudal and well-preserved portion of the Müllerian ducts remains permanently as the vagina masculina. In the female, mesonephric ducts have undergone conspicuous regression but they are still intact throughout their extent as small, atrophic tubes accompanying the much larger Müllerian ducts (fig. 13). Müllerian ducts in the females have grown considerably and have united with each other in the pelvic region to form the utero-vaginal canal (fig. 1c). This canal, as does its homologue in the male, bifurcates just before reaching the dorsal wall of the urogenital sinus; the resulting branches diverge and enter the lateral margins of the sinus near and medial to the entry of the vestigial mesonephric ducts. The vagina has not begun formation.

By the 21st day, in either sex, the homologous set of genital ducts has undergone further elaboration toward the definitive

ABBREVIATIONS

Ba., bulbourethral gland
G.T., genital tubercle
Mes., mesonephric (Wolffian) duct
Mul., Müllerian duct
Pel. S., pelvic portion of urogenital sinus
Phal. S., phallic portion of urogenital sinus
S.H., sinusal horn
U., ureter
Ug.M., urogenital membrane
U.P., urethal plate
U.V.C., utero-vaginal canal
Ves.S., vesical portion of urogenital sinus

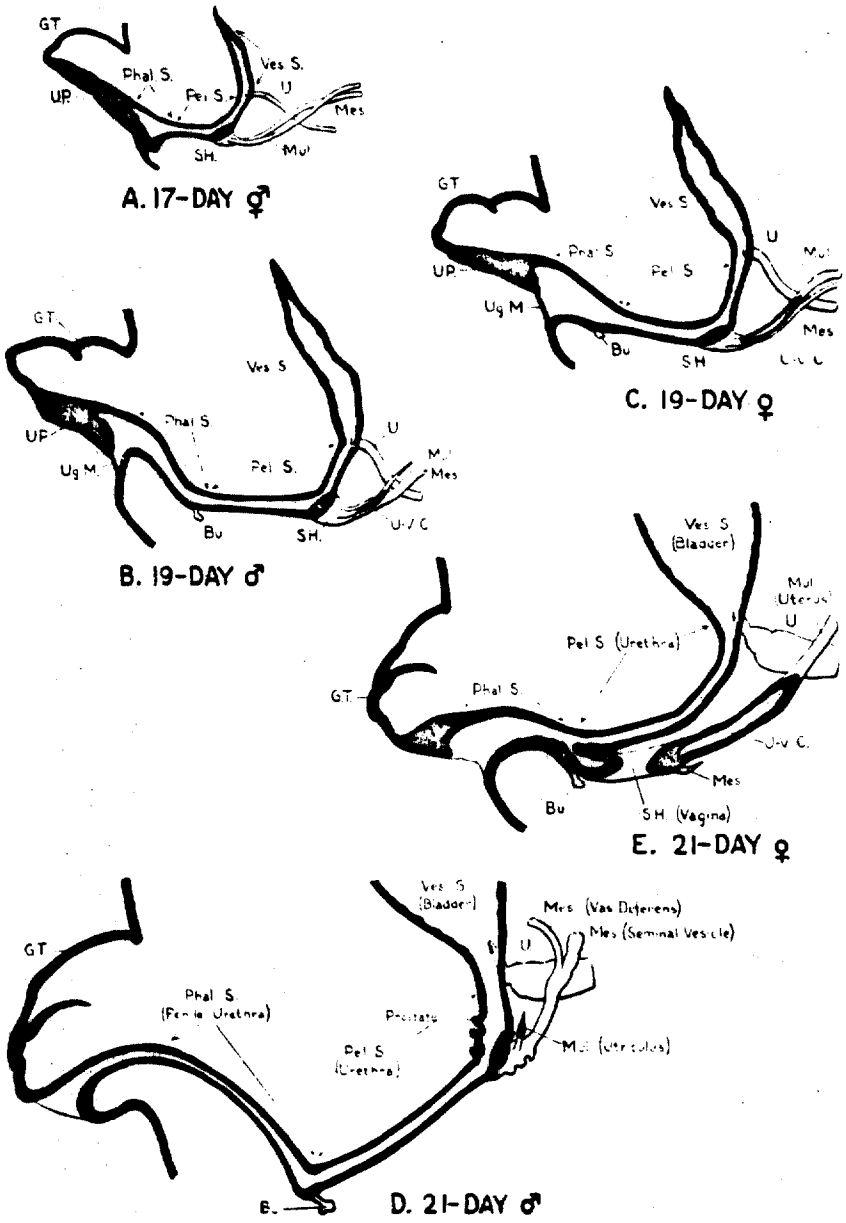

Fig. 1. Schematic sagittal sections to illustrate development and sexual differentiation in the urogenital sinus of normal rat fetuses of 17, 19 and 21 days gestational age. The right-hand margin of the page corresponds to the cranial and the bottom of the page to the caudal aspects. All drawings are at approximately the same scale.

form, while the heterologous set has disappeared except for small remnants at the extreme cephalic and caudal ends. Mesonephric ducts in the male have been transformed into epididymides and vasa deferentia, and in the pelvic region a bud from the wall of each duct has given rise to the seminal vesicles (fig. 1d). A caudal remnant of the Müllerian ducts, consisting of the lower part of the utero-vaginal canal and its two distal branches which join the urethra, constitute the vagina masculina in the male. In the female the most caudal portions of the mesonephric ducts persist as small pouches from the wall of the sinus horns and serve to mark the point of juncture between the cervico-vaginal canal, of Müllerian-duct origin, and the sinus horns of urogenital sinus origin (fig. 1e). Müllerian ducts of the female have undergone changes in the abdominal region toward differentiation of the fallopian tubes and uterine horns, and in the pelvic region toward formation of the cervix and the utero-vaginal canal. The latter structure, consisting of the confluent caudal ends of the Müllerian ducts, apparently forms the upper portion of the vagina. The extent to which the Müllerian ducts contribute to development of the vagina, however, is a matter of controversy for mammals generally, and one that has not been critically investigated in the rat. The present authors have made certain observations that are pertinent to this subject, but these can better be presented in conjunction with the embryology of the urogenital sinus.

At birth the organs derived from the genital ducts differ from those described for the 21st day primarily in the extent of further growth and histologic differentiation that has occurred. An exception to this is the vagina which is still incompletely formed at birth.

Accessory sexual glands. On the 19th day the bulbourethral (Cowper's) glands are present as simple pedunculated buds, one on either caudo-lateral aspect of the purogenital sinus in the region where the pelvic and phallic portions of the sinus are continuous (fig. 1b). The homologous glands in the female are less well-defined but are recognizable at a more distal

point on the sinus than in the male, due to the comparative shortness of the phallic segment of the sinus in females of this age (fig. 1c). Neither prostatic buds nor seminal vesicles have yet appeared.

On the 21st day the bulbourethral glands of the male are elongated tubular structures while in the female they remain as small buds attached to the caudal wall of the urogenital sinus where the newly formed vaginal canal joins the lower urethra (figs. 1d and e). Numerous prostatic buds are growing out from all sides of the male urethra in the region of the colliculus and some of these have elongated into simple tubular glands. Seminal vesicles have appeared on the lateral wall of the vasa deferentia (mesonephric ducts) and have already attained considerable length by growth in a cranial direction. Thus, by the 21-st day all major accessory sexual structures are present, and future development has only to do with the elaboration of these into their final form.

Ureters. The ureteric buds first appear on the mesonephric ducts, near their juncture with the urogenital sinus, during the 13th day; and during the 14th day they establish contact with the metanephric blastema. Between this and the 16th day the ureteric orifice moves distally along the mesonephric duct and onto the wall of the urogenital sinus. By the 17th day the ureteric openings have almost reached their final position, in the vesical portion of the urogenital sinus. Although the bladder is not sharply marked off from the remainder of the sinus at this time, the slightly enlarged cephalic portion of the sinus which extends into the peritoneal cavity may be designated as the bladder-region. It is into the base of this portion of the sinus that the ureters empty. Between the 19th and 21st days a dilatation appears in the caudal one-fourth of the ureters, the portion which traverses the pelvic floor. Coincident with this, the bladder becomes moderately dilated also; and it should be recalled that approximately one day earlier, on the 18th day, Bowman's capsules and the renal pelves began to show signs of the accumulation of fluid within their lumina. Since by the 21st day an

appreciable number of nephrons have reached an advanced stage of development, it is assumed that the expansion of the bladder and ureters is associated with some degree of renal function.

Urogenital sinus. At 17 days the urorectal septum has completed the partitioning of the primitive cloaca to form the rectum and the urogenital sinus. Although no sexual dimorphism is yet apparent and the sinus has undergone very little differentiation, as a matter of expedience in description it may be arbitrarily divided into three regions (fig. 1a). The more cranial one-fourth has expanded more than the remainder especially in a lateral direction, which together with the fact that the ureters terminate at its caudal limit, indicates this segment as the *vesical portion* or bladder. Caudal to this, the middle two-fourths of the sinus constitutes the *pelvic portion*, which extends almost to the surface of the body at a point near the base of the genital tubercle. It receives both sets of genital ducts which terminate about midway on its dorso-caudal wall. This segment will form the prostatic urethra, the colliculus seminalis and the membranous urethra in the male, and a major portion of the urethra and the vagina, to an uncertain extent, in the female. The most distal one-fourth of the sinus, the *phallic portion*, lies at the base of the genital tubercle into which its epithelial walls extend to become directly continuous with the urethral plate. This region of the sinus together with the urethral plate will later form the penile urethra of the male and the bulbourethral glands of both sexes.

Detailed description of all the developmental changes that occur, as the bipotential urogenital sinus is transformed into the lower genito-urinary tract of the male or the female, are not necessary for the present purpose; therefore, only certain pertinent points will be mentioned. The principal changes that are associated with sexual differentiation and subsequent development are diagrammatically represented in figure 1. A matter of special interest, however, is the manner of juncture of the genital ducts with the sinus. The mid-

region of the pelvic portion of the sinus is flattened cephalo-caudally and its lateral margins curve caudalward so that in cross section the walls of the sinus are crescent shaped in outline. These cando-lateral flanges are most pronounced where the genital ducts join the sinus and at this level are called *sinus horns*. The mesonephric ducts enter the tips of the sinus horns and the Müllerian ducts enter the medial aspect of the horns near their base.

As stated earlier, the Müllerian ducts join the dorso-caudal wall of the pelvic portion of the urogenital sinus by the 17th day. The two ducts are separate, that is, they have not yet united to form the utero-vaginal canal; and each joins the sinus on the medial aspect of the sinus horn of that side (fig. 1a). At its tip or cando-lateral extremity, each sinus horn receives a mesonephric duct as well. In fact, when a reconstruction of this region is viewed, the sinus horn appears to be nothing more than the flared termination of the mesonephric duct on the wall of the urogenital sinus. Histologically, however, the horns are unmistakably part of the sinus: their epithelial lining is identical with the transitional type in the remainder of the sinus and thus quite unlike the cuboidal epithelium found in either set of genital ducts. The sinus horns, therefore, are bilateral projections from the urogenital sinus that extend dorsalward to receive the mesonephric ducts at their tips and the Müllerian ducts on their medial walls.

In the 19-day female the sinus horns have grown in about the same proportion as the remainder of the sinus (fig. 1c). The Müllerian ducts have united to form a utero-vaginal canal, but the caudal extermity of the canal bifurcates and each branch, representing the terminal end of one of the originally separate ducts, proceeds to enter its respective sinus horn. Mesonephric ducts are vestigial but intact and enter the sinus horns lateral to the Müllerian ducts. The original point of juncture of Müllerian ducts with sinus horns is clearly marked, both by the differing character of the epithelia and by the termination of the mesonephric ducts.

The vagina is unmistakably present at the 21st day, although it is of rudimentary form and terminates caudally in the urethra (fig. 1e). The points at which the bifurcated ends of the fused Müllerian ducts (utero-vaginal canal) join the tips of the sinus horns are still recognizable by an abrupt transition in epithelial types as well as by the terminal remnants of the mesonephric ducts. Caudal to these points the sinus horns proceed separately for some distance, running parallel with the urethra; but just cranial to the level of the bulbourethral glands the sinus horns converge to unite as a solid epithelial mass which turns ventrally and gradually blends into the dorsal wall of the urethra. Thus, it appears that the tip of each sinus horn is anchored, relatively, near the point of original attachment of the genital ducts, while its attachment to the urogenital sinus or urethra moves distally along the sinus, with the result that the intervening segment of the horns is greatly lengthened. On the basis of careful study of the material at hand it is concluded that the structure just described represents part of the definitive vagina. At the 21st day, its more cranial and bilaterally duplicated portion is undoubtedly derived from the sinus horns; but the more caudal, united segment may represent either a fusion of the distal ends of the much elongated horns, or an epithelial mass that is being separated off, or "pulled" away from, the caudal wall of the lower urogenial sinus. In either case, it is apparent that a considerable portion of vagina, perhaps the distal two-thirds, is derived from the urogenital sinus and its derivative sinus horns. The remaining cephalic portion of the vagina must, then, be formed from the confluent caudal ends of the Müllerian ducts, the so-called utero-vaginal canal.

At birth the vagina is still not complete and, since the landmarks that persisted at the 21st day are no longer conspicuous, a more precise statement regarding the proportion of the definitive vagina derived from the urogenital sinus, on the one hand, and from the Müllerian ducts, on the other, must await a more extensive study of the problem than was necessary for the present paper.

Malformations in fetuses from A-deficient mothers

Within the genito-urinary tracts of the animals studied here there was great variety in the types of malformations as well as in the severity of any particular abnormality. There was, however, some degree of conformtiy among offspring from the same mother, at least to the extent that siblings of the same sex tended to show malformations in the same organs, although these were rarely identical and were not always of the same type. In general, either all individuals from a given pregnancy were malformed or none was.

Kidneys. The metanephroi were subject to two major types of abnormalities: (1) those of position, in reference to both cranio-caudal level as well as transverse distance between the two kidneys, and (2) those reflecting faulty or retarded development within the renal parenchyma. Concerning the transverse relationship or the distance between the kidneys, all intermediate conditions were observed from the normal para-vertebral position (figs. 2 and 3) to one in which complete fusion had resulted in a solitary median kidney. The entire group of 42 fetuses contained only 17 whose kidneys were properly spaced for their respective gestational ages. In 8 specimens the kidneys were closer together than normally (fig. 4), some being almost in contact across the midline. Direct contact or fusion at the caudal poles to produce horseshoe kidneys was noted in 13 cases. Within the group of so-called horseshoe kidneys were included those cases in which the renal capsules of the originally separate organs remained intact (fig. 6), those in which the capsules were deficient thus allowing direct contact of parenchymatous elements (fig. 5), and those in which the parenchyma were intermingled and the shape and orientation of the original organs altered to the extent that an amorphous mass resulted (fig. 7). Complete fusion of kidneys into a solitary median mass occurred in 4 instances (fig. 8). All types of fused kidneys were more prevalent in the younger fetuses, and the solitary variety was not observed in any fetus older than 18

days. Hence, this type of renal anomaly appears to be associated with, although not necessarily responsible for, early fetal death. The relatively advanced ages and developmental conditions of the fetuses available for study were such that no observations were made which might have a bearing on the frequently asserted explanation that fused kidneys result from undue medial deflection of the kidneys as they pass between the umbilical arteries on their ascent from the pelvis. No condition resembling the "crossed ectopia" of human teratology was seen.

Positional variations in cranio-caudal level were not precisely correlated with variations in transverse relationship; but, in general, all kidneys abnormal in the latter respect tended to be situated too far caudally. In every instance solitary kidneys were at a low lumbar or sacral level and a majority of the horseshoe kidneys were at lower than normal levels by as much as two or three vertebrae. The non-fused kidneys were less conspicuously ectopic; nevertheless, those that were abnormally close together or showed other defects (to be specified later) were often slightly more caudally situated than usual. Nothing in the nature of an obstruction was observed to account for the incomplete ascent of the kidneys; hence, this abnormality is regarded as retardation or arrest of an embryonic process, one normally initiated but not having gone to completion. Alterations in the orientation of the hilus were in most instances associated with abnormal transverse proximity; in the kidneys that were closer together than normally, the hili tended to be directed ventro-medially rather than medially (fig. 4). In both types of fused kidneys the pelves invariably emerged from the ventro-medial or ventral surfaces (figs. 5, 6, and 7). Improper orientation of hili in fused kidneys is accounted for by assuming that fusion occurred at the developmental stage when the hili were normally directed ventrally, thus making permanent the primitive orientation; but regarding the non-fused kidneys which were also sometimes improperly oriented, one can only sug-

gest the existence of some abnormal but obscure mechanical relationship.

Faulty or retarded development of the renal parenchyma was manifested in a majority of these kidneys by several histologic features. For the present study, however, it was considered advisable to omit the complex detail necessary to describe developmental defects in the individual nephron, and, instead, to present quantitative data based on a single easily recognizable feature. In order for such data to have real significance the feature selected must, to some degree, reflect the over-all developmental state of the kidney. The abnormality most nearly meeting these specifications was judged to be the failure of the renal pelvis and calyx to undergo normal dilatation beginning on the 18th day. The opening of these lumina is coincident with the appearance of the first few well-formed glomeruli and is thought to be associated with the initiation of some type of excretory function by the kidney. Regardless of the validity of this as an indicator of proper parenchymal development, the fact remains that the pelvis and calyx were not open in 25 of 30 fetuses that were 19 days or more of gestational age (figs. 4, 5, and 7). Of the remaining 5 the lumina were normally open in 4 and partially open in the fifth. All kidneys with open pelvis and calyx were also normally placed in the abdomen, whereas only about half of those with collapsed lumina were in the usual location, the remainder being too close together or fused. Thus, abnormality within the kidney was not always coincident with abnormality in the position of the organ as a whole.

Other defects of a less conspicuous but possibly more fundamental nature were present in these kidneys; for example, the process of nephron formation was retarded and may in addition have been aberrant. A more detailed study, including earlier stages, will be required to evaluate correctly such probabilities. In this connection, it is worth recording that no cystic or polycystic conditions were seen, a fact that also has a bearing on the earlier suggestion that renal function

was impaired, in the sense that cyst-formation presupposes excretory activity within the nephron.

Gonads. The sexual differentiation of the gonads and their subsequent histogenesis were not conspicuously affected by maternal vitamin A deficiency. Germinal elements were present and appeared to have undergone the usual proliferative activity. Regarding the position of the gonads with respect to vertebral levels, ovaries were always found within what was considered a normal range of location, which is not remarkable since during development the ovary of the rat is not involved in any considerable positional change. The ovaries varied in their relationship to the kidneys but this was due to positional abnormality of the kidneys. The testes, on the other hand, were frequently arrested at some point along the course of their descent, between their site of formation and their neonatal position in the inguinal region. Between the 19th and 21st days the testes normally arrive in the pelvis to lie beside the bladder near the inguinal fossa. In only two of 16 male fetuses of this age and older were both gonads within the pelvis; in the remainder the testes were retained at various levels in the abdominal cavity, and of these at least half were judged to have remained at the site of origin. No satisfactory explanation was found for failure of testicular descent. In a few instances in which testes were retained in the mid-lumbar region it was noted that the urogenital fold persisted as a broad connection between the gonad and the dorsal body wall, rather than having become attenuated as the delicate ligament usually seen in the older rat fetuses. The gubernaculum was poorly developed in several cases, that is, small in size or indistinctly differentiated from surrounding tissues, and occasionally it did not make connection with the mesorchium. None of these defects, however, was invariably associated with abnormal position of the testis. Irrespective of the cause, all testes retained in an abnormal position beyond the 19th day of gestation are regarded as potentially cryptorchid.

Genital ducts. Many varieties and degrees of abnormality affected the Müllerian and mesonephric ducts; but these usually conformed, to some extent, to a prevailing pattern. The common tendency, in both males and females, was toward a condition of pseudo-hermaphroditism, that is, a tendency for both sets of genital ducts to be retained in either sex. Normally at the 17th day Müllerian and mesonephric ducts are approximately equally developed in males and females alike (fig. 1a), but beyond this age the set of ducts that is heterologous to the gonads undergoes rapid regression (figs. 1b, 1c, 9 and 13).

Müllerian ducts in male fetuses from A-deficient mothers were usually preserved to a greater extent than normally and occasionally were as well preserved in females (figs. 10, 11 and 12). An exception to this generalization was found in the case of the 17-day fetuses, in which 5 of 6 animals, representing both sexes, had no Müllerian ducts and the sixth animal had only rudimentary ones. Absence of the female ducts at this age is due to retarded formation rather than to agenesis, since all fetuses of both sexes older than 17 days possessed some form of Müllerian-duct tissue. Accordingly, of 21 males older than 17 days, 6 had retained one or both Müllerian ducts in their entirety from the vicinity of the gonad to their termination in the urogenital sinus; and 15 had retained some form of these ducts, varying from well-preserved ducts that ended blindly at some point in the pelvis (fig. 12) or lower abdomen to those that were intermittent and conspicuously, although not normally, regressed. The extent to which female ducts were retained was not closely related to the age of the fetus; for example, there was no consistent difference in the extent of retention in 18-day and 22-day males. The *presence* of the ducts, therefore, cannot be entirely attributed to a delay of normal regression, since in some cases there appeared to have been a complete arrest of regression.

Müllerian ducts in female fetuses were also frequently abnormal; but no regression of previously formed ducts, as was observed in several males, was seen in the females. In

females, as in males, the caudalward growth of the ducts was often arrested short of juncture with the urogenital sinus. A group of 16 female fetuses ranging in age from 18 to 22 days contained only two possessing Müllerian ducts that were complete in extent as well as properly united in the pelvic region to form a utero-vaginal canal. Of the remaining 14 fetuses, in three both ducts were complete but did not unite to form a utero-vaginal canal, in three one duct was complete and the other ended blindly in the upper pelvis or lower abdomen, in 7 both ducts ended blindly short of their usual termination, and in one there was agenesis of one duct but the other was complete. Failure of Müllerian ducts to reach the urogenital sinus could not be correlated with age; therefore, it was assumed that permanent arrest of the growth process had occurred and that, had these females lived beyond birth, the genital tract would have been anomalous in all but two cases. The reason for failure of otherwise complete ducts to be united to form a utero-vaginal canal is not understood, but the consequence of this defect would undoubtedly have been duplication of the upper vagina and possibly also complete separation of the two cervical canals. Failure of either or both ducts to reach the urogenital sinus would have had the obvious consequence of incomplete or absent cervix and deficient uterine horns. The effect of these Müllerian-duct abnormalities upon development of the vagina cannot at present be fully evaluated. It was observed, however, that the sinus horns, from which the mid-vagina is normally formed, were always present regardless of the presence or absence of the usual juncture with the Müllerian ducts. On the other hand, it was also observed that the only animals in which unequivocal vaginal development occurred were the two females in which Müllerian ducts were not only complete but also united caudally as a utero-vaginal canal. The implication of these observations is that the sinus horns, although concerned to a large extent in normal vaginal development, are not able to proceed in the formation of a vagina in the absence of normal juncture with Müllerian ducts.

Mesonephric ducts were likewise often present in both sexes but in general, exhibited a greater degree of sexual dimorphism than Müllerian ducts; that is, they were invariably present and complete in extent in male fetuses, whereas in several female fetuses they were present as no more than the usual vestiges. Normally in females of 19 days mesonephric ducts have largely disappeared (fig. 13). In a group of 14 females of this age or older from A-deficient mothers, normal regression of the male ducts had occurred in 4, regression of all but the pelvic portions had occurred in 6, and partial regression in at least the abdominal region had occurred in the remaining 4 (fig. 14). At younger ages the mesonephric ducts of the females were usually complete. Considering all age groups, it was observed that abnormal retention of the male ducts tended to diminish as age increased; but this is not to contradict the fact that there was also a tendency for mesonephric ducts to be retained longer than normally in these females. It appears that the process of regression, in the case of male ducts in female fetuses, was retarded but not arrested.

Mesonephric ducts were present and complete in extent in all male fetuses (figs. 10, 11 and 12). Differentiation of these ducts toward the definitive male genital tract, however, was deficient to some extent in a major portion of the animals. Fifteen males older than 19 days displayed a broad range of developmental deficiencies, from a completely undifferentiated, primitive condition to one in which the epididymis, vas deferens and seminal vesicle were recognizable but generally less advanced than in normal males of the same age. In the more primitive type the epithelium lining the ducts appeared atrophic and, in the older fetuses, the muscle and other characteristic tissues comprising the walls had not appeared or were poorly formed. All of these abnormalities resulted from retardation of progressive developmental processes, or perhaps, in the case of the seminal vesicles, aplasia; but none represents aberrant forms of development. Associated with the more extreme cases of failure of the ducts

to undergo proper differentiation, another type of abnormality was frequently seen, namely, retention of the primitive emptying of ureters into mesonephric ducts (see section on *ureters*).

Accessory sexual glands. By the 20th day the major accessory sexual structures, bulbourethral glands, seminal vesicles, and prostate glands, had appeared in all control males. Fetuses of comparable ages and older from A-deficient mothers, however, usually showed poor or no development of these accessory structures. Of 15 such male fetuses, the bulbourethral glands, which were easily recognizable as early as the 19th day in controls, were only moderately developed for their age in three, were present as rudiments in two others, and were absent in the remaining 10. Seminal vesicles were more or less well developed in 5 fetuses of this age group, and were probably present in two others as small buds from the epithelium lining the mesonephric ducts, but in 8 instances they had not appeared. Prostatic buds were present in all male fetuses of 20 days or older, but they were conspicuously fewer in number and less well developed than normally in 6 of the 15 animals. As would be expected, absence of the seminal vesicles was associated with a primitive or undifferentiated condition of the mesonephric ducts. Likewise, absence or defective development of prostate and bulbourethral glands was found in animals in which the urogenital sinus as a whole was defective or retarded in development. Abnormalities in the accessory glands, then, appear to have been related to defective development of the structures from which they originate.

Ureters. Structurally the ureters were rarely malformed, but with great regularity they were found to terminate at abnormal sites in the lower genito-urinary tract. During the course of normal development the ureteric orifice progresses from its original site on the mesonephric duct to a position on the wall of the urogenital sinus, whence it is further transferred, by processes not entirely clear, in a cephalic direction to the vesico-urethral portion of the sinus. By the

17th day of gestation the ureters open at approximately their definitive site, at the base of the developing bladder (fig. 1a). Of the 42 animals included in the present study, only 5 had ureters that emptied into the bladder at or near the usual location (fig. 15). The ureters retained their primitive juncture with the mesonephric ducts in 15 instances (fig. 16), in all of which there was little or no evidence of progression from the original site of formation of the ureteric bud. In 14 fetuses the ureters entered the sinus horns directly (fig. 17); and in 4 fetuses the orifices were found at some point in the upper urogenital sinus, between the sinus horns and the base of the bladder (fig. 18). The ureters on the two sides emptied at different abnormal sites in three animals; for example, the right ureter emptied into the right mesonephric duct while the left ureter emptied into the left sinus horn. Complete failure of one ureter to join any part of the lower genito-urinary tract was noted in one fetus, but this defect must be attributed to secondary regression and not incomplete formation, since the kidney and upper ureter were present. Although abnormalities in ureteric termination were not closely related to any other single anomaly, some variety of this condition was generally found in animals in which either mesonephric ducts or urogenital sinus or both were retarded in development or were otherwise abnormal. The overt cause of these ectopic ureteric openings was failure of proper "migration" of the orifice from its primitive to its definitive site; but, since the factors concerned in this transfer are poorly understood for normal animals, nothing can be said regarding its failure in the offspring of vitamin A-deficient mothers.

Urogenital sinus. Several developmental defects affecting localized regions of the urogenital sinus have already been mentioned: ectopic ureteric openings, absence or poor development of prostatic and bulbourethral glands, and failure of vaginal development. Additional localized defects were observed in the lower or phallic portion of the sinus, particularly where this region of the sinus joined the urethral plate at the base of the genital tubercle. The urethral plate

appears prior to the 17th day of gestation as a solid epithelial ingrowth from the ectoderm on the caudal surface of the genital tubercle, extending in the mid-sagittal plane from the base to the tip of the tubercle (fig. 1a). Normally in 19-day males the proximal end of the urethral plate has become canalized in its deeper portion, thus extending the lumen of the phallic part of the sinus into the base of the urethral plate (fig. 1b), thereby establishing luminal continuity between these two primordia of the penile urethra. This lumen is separated from the exterior at one point by only a thin epithelial wall, the urogenital membrane; but in subsequent development the thinned area in the urethral wall is reinforced by an invasion of connective tissue, with the result that urethral epithelium is separated from the epidermis of the perineum by a considerable interval (fig. 1d). By what appears to be a similar encroachment of mesodermal tissue, the urethral plate is pinched off from its attachment along the caudal surface of the genital tubercle in all regions but the tip of the tubercle, where the urethral orifice appears. Correct formation of the penile urethra of the male is, therefore, dependent upon several complicated processes, the most critical of which appear to be (1) exclusion of the phallic segment of the urogenital sinus from the surface of the body by ingrowth of connective tissue and (2) obliteration of the superficial and uncanalized portion of the urethral plate by ingrowth from either side, also, of connective tissue.

In males from vitamin A-deficient mothers these processes leading to formation of the penile urethra were often incomplete or defective. Hypospadias was the result in 7 of 15 males that were older than 19 days (figs. 19 and 20). In all instances the abnormal urethral opening occurred at the base of the genital tubercle or penis, the approximate location of the thin urogenital membrane at earlier ages. Another abnormality always associated with hypospadias but noted also in three additional males, was persistence of the urethral plate in more or less complete form. It was still attached along the caudal surface of the penis; and it seems likely that had

the epithelial connection between the deeper, canalized portion and the surface remained beyond the time of birth, this might later have broken down to extend the hypospadias cleft along the entire caudal aspect of the penis.

Since, under ordinary conditions, both reinforcement of the urogenital membrane and separation of the urethral plate from the ectoderm apparently depend upon an ingrowth of surrounding mesodermal tissue, there is at least presumptive evidence that the abnormalities in this region were due as much to failure of proper mesodermal growth as to defective epithelial changes. Supporting this view were the observed facts that: (1) the urethral plate remained intact between the hypospadiac opening and the usual urethral orifice, except for the normal canalization of the deep portion, and (2) the hypospadiac opening was at the site of the former urogenital membrane and gave every appearance microscopically of having resulted from rupture of the attenuated, unsupported membrane and not from opening up of any part of the urethral plate.

The urethra of the female was also subject to abnormalities but of a different sort than those in the male. A major portion of the female urethra is derived from the pelvic part of the urogenital sinus; this part apparently undergoes considerable relative lengthening while the phallic part of the sinus undergoes a proportional shortening (fig. 1a, c and e). Only the extreme distal end of the definitive urethra represents the phallic segment of the sinus, and even this is, to some extent, of urethral plate origin. An arrest or retardation of the caudalward shift of the pelvic part of the sinus would have the consequence of preserving a relatively larger portion of the phallic segment. Reference to figure 1e will reveal that at one time the phallic part of the sinus had a lumen of considerable antero-posterior extent which was separated from the exterior by only the thin and elongated urogenital membrane. Retarded differentiation of the sinus together with rupture of the urogenital membrane would produce an external orifice in the form of an elongated slit, extending from

the base of the genital tubercle caudally for some distance along the perineum. Such a defect was actually observed in 6 of 14 female fetuses older than 19 days. Indeed, the entire lower genito-urinary tract in these females was of approximately the same relative proportion and disposition as is characteristic of the urogenital sinus of much younger, normal fetuses. Since there was neither vaginal development nor restriction of the external orifice, it is perhaps more suitable to refer to this region of the tract as urogenital sinus than as urethra. In less severely affected females there was a greater degree of restriction of the external opening; and in the two instances noted earlier in which vaginal development was in progress, the urethral orifices were of the usual size and at the usual site on the caudal surface of the genital tubercle.

The urogenital sinus as a whole was frequently retarded or arrested in its development, apart from the specific defects already mentioned. Pointed evidence of retardation was seen in the fact that formation of the sinus itself was sometimes delayed, that is, the urorectal septum had not completely partitioned the cloaca into urogenital sinus and rectal canal at the proper time. This separation of the caudal ends of digestive and genito-urinary tracts is normally completed by the 17th day, but 6 animals in a group of 12 that had reached 17 or 18 days of age still showed incomplete division of the cloaca. In older fetuses the over-all retardation of the sinus was difficult to characterize, for in degree it ranged from the retention of very primitive conditions to developmental conditions deviating but slightly from the normal. Only by means of wax-plate reconstructions was it possible to appreciate fully the developmental deficiency in a given fetus; and, since this was never precisely duplicated in other fetuses, it is of little value to attempt a discussion of any one set of conditions and not practicable to discuss all. Some idea of the diversity of proportion, size and extent of differentiation may be gained by reference to figure 21 (a to d) for the males and figure 22 (a to c) for the females.

Epithelial keratinization in the genito-urinary tract. In an earlier publication (Wilson and Warkany, '47) the occurrence of keratinizing metaplasia in certain epithelia lining the lower genito-urinary tract of fetuses from vitamin A-deficient mothers was reported. It was stated that the metaplasia: (1) affected only epithelia derived from the urogenital sinus, (2) appeared in a majority of fetuses older than the 18th day of gestation, and (3) affected most severely those epithelia derived from the dorso-caudal wall of the primitive sinus. The present more detailed study of a much larger group of animals does not require that the earlier conclusions be modified in any essential point, nor does it require extensive further description. A few additional details are perhaps worthy of mention, but the principal justification for re-introducing the subject is in order that epithelial metaplasia may be discussed in relation to the occurrence of other genito-urinary abnormalities.

As observed in the fetuses of A-deficient mothers, the histologic changes incident to the appearance of keratinizing metaplasia are briefly as follows. The first sign of deviation from the normal transitional type of epithelium (fig. 23) is thickening of the epithelial layer. As this continues the cytoplasm of the cells on and near the luminal surface becomes hyalinized, that is, of a more homogeneous and translucent character; and, while hyalinization spreads deeper into the epithelial layer, the most superficial cells become pyknotic and more intensely staining. Since metaplasia sometimes does not proceed beyond this point, the changes thus far mentioned may be considered as constituting the first stage of keratinizing metaplasia, which is here called *pre-keratinization* (fig. 24). If the process continues, the pyknotic cells disappear and in their place flattened cells containing keratohyalin granules appear. Soon thereafter the most superficial cells lose their granules and become cornified, squamous or truly keratinized cells which tend to adhere to the surface but are gradually lost by desquamation. These latter changes, i.e., keratohyalin granulation, cornification, and desquamation, are

characteristic of complete or *true keratinization*, which may affect only localized areas (fig. 25) or may involve the entire expanse of the epithelium (fig. 26).

Regarding the histogenesis of epithelia affected by metaplasia, it may be restated, as a general rule, that only epithelia derived from the urogenital sinus undergo abnormal keratinization; but this must be qualified to the following extent. One animal has been encountered in which a small area of the epithelium covering the soft palate showed keratohyalin granulation, cornification, and desquamation of the superficial cells — hence, this must be considered an exception. The esophagus and, to a variable extent, the stomach are normally lined by stratified squamous epithelium in older fetuses. Thickening of this epithelium with hyalinization and moderate desquamation of superficial cells was noted in several fetuses from A-deficient mothers; but keratohyalin granules and cornification were not seen and the cells were desquamated individually or in small groups rather than in plaques, as is typical of true keratinizing metaplasia.

No metaplasia has been observed prior to the 18th day of gestation. In fact, the only instance of true keratinization at the 18th day happens to be the one animal mentioned in the earlier report. Five additional animals of this age have now been studied. Of these, two show no deviations from the epithelial type normal to the urogenital sinus, and the remaining three show only pre-keratinizing changes. More significant than the precise age at which it occurs is the fact that keratinizing changes did occur in the genito-urinary tract at an earlier age than in the epidermis of these animals or of the controls. Keratinization in the epithelium of the skin is scarcely beginning on the 19th day and not until the 20th day is it complete. The epidermis of fetuses from vitamin A-deficient mothers was keratinized neither earlier nor otherwise differently than that of control fetuses.

In fetuses of 20 days and older, metaplasia had typically affected epithelia throughout much of the distal half of the urogenital sinus or organs derived therefrom. The cranial

limit of this more extensively affected area was the level at which the sinus horns join the sinus. Above this limit lay the vesico-urethral and upper half of the pelvic portions of the primitive urogenital sinus, portions which give rise to the bladder and upper part of the urethra. The epithelium of the bladder never underwent metaplastic change of any sort. In only two instances was true keratinization seen in the upper prostatic urethra, involving small areas just above the sinus horns. Pre-keratinizing changes were seen in this segment of urethra, but in somewhat less than half of the animals studied.

Within the more commonly affected region, that extending caudally from the sinus horns, true keratinization was observed in all but three of 29 animals that were 20 days of gestational age or older. All areas in this part of the sinus were not always metaplastic, and when they were they were not always equally affected. Epithelium in the sinus horns was most frequently keratinized; but metaplasia was also commonly seen in the regions of the colliculus, urethral sinus (bulbar portion of urethra) and penile urethra in males, and lower and mid-urethra in females. (It should be borne in mind that in a majority of these females the urethra was analogous to that of the males, since the phallic portion of the urogenital sinus had undergone little or none of the relative reduction of length that occurs in normal female fetuses.) Although complete keratinization rarely affected the epithelial lining of all localities caudal to the sinus horns, its presence in one area was usually associated with at least pre-keratinization in other localities. It was consistently noted here, and was emphasized in the earlier report, that metaplasia always appeared first in, and was often limited to, epithelia corresponding to what was the dorso-caudal wall of the primitive urogenital sinus (fig. 25). A satisfactory explanation for the peculiar susceptibility of this wall of the sinus has not been found.

No degree of metaplasia was seen in any other part of the genito-urinary tract than the regions of urogenital sinus, and derivatives, already specified. The genital ducts, although

terminating in the sinus horns which were almost universally keratinized, contained only cuboidal epithelium. The same was true of renal pelvis and calyx and of ureters, regardless of where the latter terminated. Accessory sexual glands were not affected, but these structures generally did not form when the region of sinus wall from which they ordinarily arose was metaplastic.

Within broad limits, a correlation of the occurrence of keratinizing metaplasia in the urogenital sinus with the presence of other abnormalities in the genito-urinary tract is possible. Of the many genito-urinary abnormalities described, epithelial metaplasia proved to be the most sensitive morphologic indicator of a critical level of maternal vitamin A deficiency. All fetuses older than 18 days gestational age, with the probable exception of one 22-day female, exhibited some degree of metaplastic change, either pre-keratinization or true keratinization, in the urogenital sinus and its derivatives. No other abnormality occurred with such regularity except the more-than-normal retention of Müllerian ducts in males; but this was limited to the males and is not applicable to the entire group. Atresia of the renal pelvis was observed in all but 5 instances, which is less inclusive than was metaplasia; but it is important to note that the group of 5 fetuses with normally dilated pelves included the one animal with no metaplasia, two others with only pre-keratinization, and two with minimal keratinization. Direct comparison with other defects outside the urogenital sinus itself is hardly feasible, since several of these were much less frequent than was metaplasia. A general correlation existed, nonetheless, in the sense that fetuses bearing multiple and or severe malformations elsewhere in the genito-urinary tract also exhibited extensive keratinization in the urogenital sinus, whereas those with few or milder forms of abnormalities elsewhere tended to be subject to less extensive metaplastic changes in the sinus.

A more precise correlation was found between epithelial metaplasia and the state of over-all differentiation within the urogenital sinus. In other connections, it has been pointed

out that: (1) the sinus horns and the phallic portion of the sinus were most frequently involved in metaplastic changes, and (2) these same regions of the sinus were most often the sites of localized defects, e.g., ectopic ureters, hypospadias. It remains only to call attention to the fact that the general retardation commonly observed in the urogenital sinus affected most strikingly the pelvic and phallic portions, which were the only portions in which epithelial metaplasia of any sort occurred.

DISCUSSION

The diversity of malformations observed in the genito-urinary tract of these fetuses requires that they be classified as nearly as possible into logical or related groups. It is proposed to discuss the malformations in terms of abnormality in the embryonic process by which they were produced, rather than in terms of the manner in which they affected particular organs; therefore, the type of process concerned will be used as the basis for classification. Embryonic processes may be abnormal in one or perhaps more of 4 days, which are designated as paraplasia, aplasia, hypoplasia, and hyperplasia. The last of these, hyperplasia, is characterized by over-growth or over-activity of an embryonic process; but, since no abnormalities of this sort were encountered in the present study, it will be given no further consideration.

Paraplasia is defined as a process that has become aberrant, or gone awry; and it results in conditions entirely foreign to normal embryology, that is, conditions not simulated during the course of normal development. Examples of this in the genito-urinary tract were limited to fused kidneys and possibly an occasional instance of stenosis in ureters and in an homologous set of genital ducts. Considering the whole range of all abnormalities, these were few in type and infrequent in occurrence. One additional paraplastic malformation following maternal vitamin A deficiency was described by Hale ('35) who found accessory external ears in newborn pigs. Also in this category, but induced by a different nutritional deficit, was the fusion of ribs in newborn rats from riboflavin-deficient

mothers, reported by Warkany and Schraffenberger ('43). These relatively few examples of paraplastic malformations, when compared with the great number of malformations of other types that have been induced by nutritional deficiency, make it apparent that inadequate diet of the mother does not often cause aberrant forms of development.

Aplasia is defined as complete failure of development of a structure or part which under ordinary circumstances is always formed. The normal embryonic process responsible for the development of a structure in question fails to be initiated, and frequently, although not always, the failure is associated with demonstrable abnormality in the primordia from which the structure arises. Aplasia was exemplified here by failure of the appearance of male accessory glands, particularly seminal vesicles and bulbourethral glands, and by lack of vaginal development. It will be recalled that all of these structures appear relatively late in gestation, a circumstance which raises the possibility that these are cases of tardy appearance or hypoplasia rather than aplasia. This possibility cannot be ruled out; but it is rendered unlikely by the fact that in all cases of developmental failure, the primordial structures were defective. For example, when seminal vesicles were absent, the mesonephric ducts showed an extreme lack of differentiation; and when the vagina was lacking, the Müllerian ducts were defective and the urogenital sinus was relatively undifferentiated. Then, there is ample reason to doubt that the structures classified as aplastic would ever have appeared.

Hypoplasia is defined as incomplete development; abnormalities of this sort result when an embryonic process proceeds at a slower-than-normal rate or when a process is arrested short of the usual completion. Normal embryonic processes include, in addition to numerous progressive types of development, certain processes that are primarily regressive in nature. Since to yield normal offspring, both progressive and regressive processes must proceed at a given rate, and since retardation or arrest of either type of process results in

maldevelopment, retardation of regressive as well as progressive changes may logically be considered as hypoplastic.

Hypoplasia characterized by retardation of progressive developmental processes was exemplified by: late partitioning of the cloaca, tardy appearance of Müllerian ducts, and slow differentiation of the urogenital sinus. Probable examples of this type were: primitive state of nephrogenesis, few and poorly developed prostatic buds, and some of the cases of intra-abdominal testes. These conditions were always less advanced in development than is typical for the age of the animal in which they were found; but when fetuses of successively older ages were compared, these conditions were observed to undergo some degree of progressive development, although at a rate slower-than-normal. Some of these processes were seen to reach a tardy completion, and others might have done so at some time after birth.

Hypoplasia characterized by an arrest of progressive development was seen in cases of: positional abnormalities of the kidneys (exclusive of fused kidneys), ectopic ureteric openings, incomplete caudalward growth of Müllerian ducts, poor differentiation of mesonephric ducts, hypospadias,[2] and failure of testicular descent in which the mesorchium remained thick or the gubernaculum was defective. Perhaps this group should also include instances in which the urogenital sinus persisted in an extremely primitive form. This is the most extensive single category, both in the number of separate types of malformations and in the number of individual cases. The basis for concluding that a particular malformation had resulted from an arrested process was lack of signs of further progress in development when successively older fetuses were compared.

[2] Strictly speaking, hypospadias in the rat is as much a paraplastic as a hypoplastic malformation. Urethral development in the male rat differs from that in many mammalian species in that the urogenital sinus does not open directly onto the surface of the body, hence no condition simulating hypospadias is present during normal development.

Hypoplasia in the special sense of retarded or arrested regressive processes, as defined above, was exemplified by: persistence of heterologous genital ducts in both sexes, and retention of the urethral plate. Regarding the question of which of these incomplete regressions was due to retardation and which to arrest, it was clearly indicated that the persistent mesonephric ducts in females were only retarded in regression, since they became less prominent in successively older female fetuses. In case of persistence of the urethral plate and of the Müllerian ducts in males, the question remains in doubt. The Müllerian ducts in some near-term male fetuses, however, were as well preserved as mesonephric ducts, which strongly suggests a lack of regression or an early arrest of the regressive process. This group of malformation includes only three specific types, but each type was moderately high in frequency of occurrence.

Considering the various types of hypoplastic malformations collectively, it is obvious that this category includes a great majority of all the abnormalities reported here. Recalling the method by which these abnormalities were induced, one is not surprised to find that nutritional inadequacy was responsible for morphological derangements that were predominantly the expression of retarded or arrested developmental processes. It has not been demonstrated that inanition or specific dietary deficiency of the gestating mother has any direct effect on embryonic processes; nevertheless, retardation of development from these causes during postnatal life is well known.

If it is considered that these malformations were of the nature of deficiency manifestations, it is still not possible to say whether the immediate cause was: (1) failure of placental function, (2) generalized metabolic imbalance in the fetus resulting from the same or some other metabolic imbalance in the mother consequent to her A-deficiency, or (3) vitamin A deficiency *per se* in the fetus. Regarding the first of these possibilities, it can be said that there were no gross indications of placental pathology, and that a large degree of

placental function was evidenced in the surviving fetuses by apparently normal development of several organ-systems. Placentas were not examined histologically in the present study. Mason ('35) found that the placentas from vitamin A-deficient mothers frequently contained areas in which there were variable degrees of infection, necrosis and hemorrhage associated with fetal death and resorption. Malformations, however, were not reported. No evidence bearing on the second of the above possibilities is available except that no general metabolic upset in the fetus seems likely since many aspects of fetal development appeared to have progressed normally. As to the 3rd, the existence of vitamin A deficiency in the fetus, comparable in at least one respect to that in the mother, was evidenced by keratinizing metaplasia.

Epithelial metaplasia as observed here is not regarded as a developmental defect, since it did not result from an aberrant or altered embryonic process. Keratinizing metaplasia is almost a universal sign of vitamin A deficiency in postnatal animals of a great many species (Wohlbach and Bessey, '42); and its occurrence in the fetuses under discussion is the justification for considering that these fetuses were experiencing *in utero* a state of vitamin A deficiency similar to that in the mothers. This deficient state within the fetus cannot be designated as the sole cause for the developmental malformations, however, because it does not preclude the possibility of growth defects resulting secondarily from metabolic imbalance or from faulty placental functions. Nevertheless, until there is positive evidence that the latter two factors are concerned, the malformations may be tentatively regarded as manifestations of vitamin A deficiency in the fetus. To do so would appear to introduce a new symptom into the familiar pattern of morphological changes associated with A-deficiency; but it should be recalled that by far the greater number of malformations were attributed to hypoplasia, defined as a slowing or cessation of growth processes, whether progressive or regressive. Alterations in the rate of

growth are commonly observed in postnatal animals suffering deficiency of vitamin A.

The sharp limitation in the extent of keratinizing metaplasia to the epithelia of the lower genito-urinary tract is not understood. Epithelia in the respiratory tract, the digestive tract and its associated glands, as well as throughout much of the genito-urinary tract are commonly affected by metaplasia in older A-deficient animals; although it has been noted by Mason and Ellison ('45) and others that the epithelium of the vagina is usually the first to be so affected. It is doubtful that the selective distribution of metaplasia in the fetus is related to the degree of maturity in differentiation, or even in the functional state, of the epithelia concerned, because organs of the lower genito-urinary tract are among the last in the entire body to reach an advanced stage of organogenesis and histogenesis. It is possible that the epithelia derived from the distal half of the embryonic urogenital sinus are peculiarly susceptible to keratinizing metaplasia, even at early stages in their differentiation and regardless of the nature of the agent responsible for the change. Indeed, Burns ('42), has demonstrated that the epithelium in the lower urogenital sinus of the fetal opossum readily undergoes keratinizing metaplasia under the influence of injected estrogenic hormones. Zuckerman ('41) after extensive experimentation and study of the literature has concluded that in postnatal animals estrogen-induced metaplasia occurs almost exclusively in epithelia derived from the embryonic urogenital sinus. The fact that tissues in the same region respond by keratinizing metaplasia to two entirely different types of inductive agent, estrogenic stimulation and vitamin A deficiency, indicates that these tissues are inherently more susceptible to this type of change than those in other regions of the body. That these tissues have a common embryonic origin has been demonstrated, but the particular structural or metabolic characteristics of these tissues that make them subject to keratinization have not been determined.

SUMMARY

The genito-urinary tracts were studied histologically in 42 fetal and newborn rats, from mothers maintained prior to and during pregnancy on vitamin A-deficient diets, and were compared with controls of comparable ages, from mothers fed the same diets supplemented with vitamin A.

A great variety of malformations was found throughout the genito-urinary tract in the offspring of A-deficient mothers. Certain of these were almost as common in occurrence as the ocular abnormalities (approximately 75%) previously reported.

Anomalies of paraplasia, that is, those resulting from aberrant embryonic processes, were exemplified by: fused kidneys and an occasional instance of stenosis in ureters and homologous genital ducts. These were relatively rare, both in type and individual incidence.

Aplasias, or anomalies characterized by failure of a structure or part to develop, were represented by instances of failure of the male accessory glands to appear, particularly the seminal vesicles and bulbourethral glands, and in the complete lack of vaginal development in most of the females. These were also few in type, but the incidence within each type was high.

Malformations of hypoplasia, those resulting from the arrest or retardation of an embryonic process, whether progressive or regressive in character, accounted for a large majority of all abnormalities observed. Retarded progressive development was exemplified by: late partitioning of the cloaca, tardy appearance of Müllerian ducts, and slow differentiation of the urogenital sinus. Examples of arrested progressive development were: positional abnormalities of the kidneys, ectopic ureteric openings, incomplete caudalward growth of Müllerian ducts, poor differentiation of mesonephric ducts, hypospadias and failure of testicular descent. Hypoplasia in the special sense of retarded or arrested regressive processes of development was seen in: persistence of heter-

ologous genital ducts in both sexes, and retention of the urethral plate.

No instance of hyperplastic malformations, those characterized by over-growth or over-activity of an embryonic process, was encountered.

All newborns and fetuses older than 18 days gestational age which bore malformations also exhibited keratinizing metaplasia in epithelia derived from the embryonic urogenital sinus. Epithelial metaplasia was found at no place in the body other than in the lower genito-urinary tract, where it appeared at an earlier age than did the normal keratinization of the epidermis. The occurrence of keratinizing metaplasia was the justification for concluding that these fetuses were experiencing *in utero*, a state of vitamin A deficiency similar to that in the mothers.

LITERATURE CITED

BURNS, R. K., JR. 1942 The origin and differentiation of the epithelium of the urinogenital sinus in the opossum, with a study of modifications induced by estrogens. Carnegie Contrib. to Embryol., *30:* 65–86.

GREENE, R. R., M. W. BURRILL AND A. C. IVY 1939 Experiental intersexuality: the effect of antenatal androgens on sexual development of female rats. Am. J. Anat., *65:* 415–469.

——— ——— 1940 Experimental intersexuality: the effects of estrogens on the antenatal sexual development of the rat. Am. J. Anat., *67:* 305–345.

HALE, F. 1935 The relation of vitamin A to anophthalmos in pigs. Am. J. Ophth., *18:* 1087–1092.

HUBBELL, R. B., L. B. MENDEL AND A. J. WAKEMAN 1937 New salt mixture for use in experimental diets. J. Nutrition, *14:* 273–285.

MASON, K. E. 1935 Fœtal death, prolonged gestation, and difficult parturition in the rat as a result of vitamin A-deficiency. Am. J. Anat., *57:* 303–349.

MASON, K. E., AND E. T. ELLISON 1935 Changes in the vaginal epithelium of the rat after vitamin A-deficiency. J. Nutrition, *9:* 735–755.

TORREY, T. W. 1943 The development of the urinogenital system of the albino rat. I. The kidney and its ducts. Am. J. Anat., *72:* 113–147.

——— ——— 1945 The development of the urinogenital system of the albino rat. II. The gonads. Am. J. Anat., *76:* 375–397.

——— ——— 1947 The development of the urinogenital system of the albino rat. III. The urinogenital union. Am. J. Anat., *81:* 139–178.

WARKANY, J., AND C. B. ROTH 1948 Congenital malformations induced in rats by maternal vitamin A deficiency. II. Effect of varying the preparatory diet upon the yield of abnormal young. J. Nutrition, *35:* 1–12.

WARKANY, J., AND E. SCHRAFFENBERGER 1943 Congenital malformations induced in rats by maternal nutritional deficiency. V. Effects of a purified diet lacking riboflavin. Proc. Soc. Exp. Biol. and Med., *53:* 92–94.

——— 1944 Congenital malformations of the eyes induced in rats by maternal A deficiency. Proc. Soc. Exp. Biol. and Med., *57:* 49–52.

——— 1946 Congenital malformations induced in rats by maternal vitamin A deficiency I. Defects of the eye. Arch. Ophthal., *35:* 150–169.

WILSON, J. G., AND J. WARKANY 1947a Epithelial keratinization as evidence of fetal vitamin A deficiency. Proc. Soc. Exp. Biol. and Med., *61:* 419–422.

——— 1947b Abnormalities of the genito-urinary tract induced by maternal A deficiency in fetal rats. Anat. Rec., (suppl.) *97:* 60.

WOLBACH, S. B., AND O. A. BESSEY 1942 Tissue changes in vitamin deficiencies. Physiol. Rev., *22:* 233–289.

ZUCKERMAN, S. 1940 The histogenesis of tissues sensitive to estrogen. Biol. Rev., *15:* 231–271.

PLATE 1

EXPLANATION OF FIGURES

2 Kidneys of a normal 19-day rat fetus, from a mother fed an adequate diet. The transverse distance between the kidneys is approximately the same as the width of the vertebral body. Note that the pelves and calyces are dilated and that the pelves emerge on the medial surface. × 20.

3 Kidneys of a normal 21-day fetus, from a mother fed an adequate diet. The transverse distance between the kidneys is greater than the width of the vertebral body. Note that pelvis, calyx and ureter are widely dilated. × 20.

4 Kidneys of a 20-day fetus from a mother fed a vitamin A-deficient diet. The transverse distance between the kidneys is considerably less than the width of the vertebral body. Note that the pelves and calyces are not dilated and that they are more ventrally directed than normally. × 20.

5 Typical horseshoe kidney, sectioned through region of fusion, in a 21-day fetus from an A-deficient mother. Note that the renal capsule does not separate the parenchyma of the two original kidneys. Ureters are not dilated and emerge on the ventro medial surface. × 20.

6 Horseshoe kidney, sectioned through region of contact, in a 20-day fetus, from an A-deficient mother. Note that the parenchyma of the two original kidneys are separated by the renal capsule which have fused but not disappeared. × 20.

7 Horseshoe kidney in a 20-day fetus, from an A-deficient mother. The highly amorphous character appears to have been associated with disorientation of the original right kidney-mass. The collapsed calyx seen in the photograph belongs to the original left kidney. × 20.

8 Solitary median kidney in an 18-day fetus from an A-deficient mother. The original two kidneys have fused into a single median mass which has remained at the level of the 6th Lumbar vertebra. × 20.

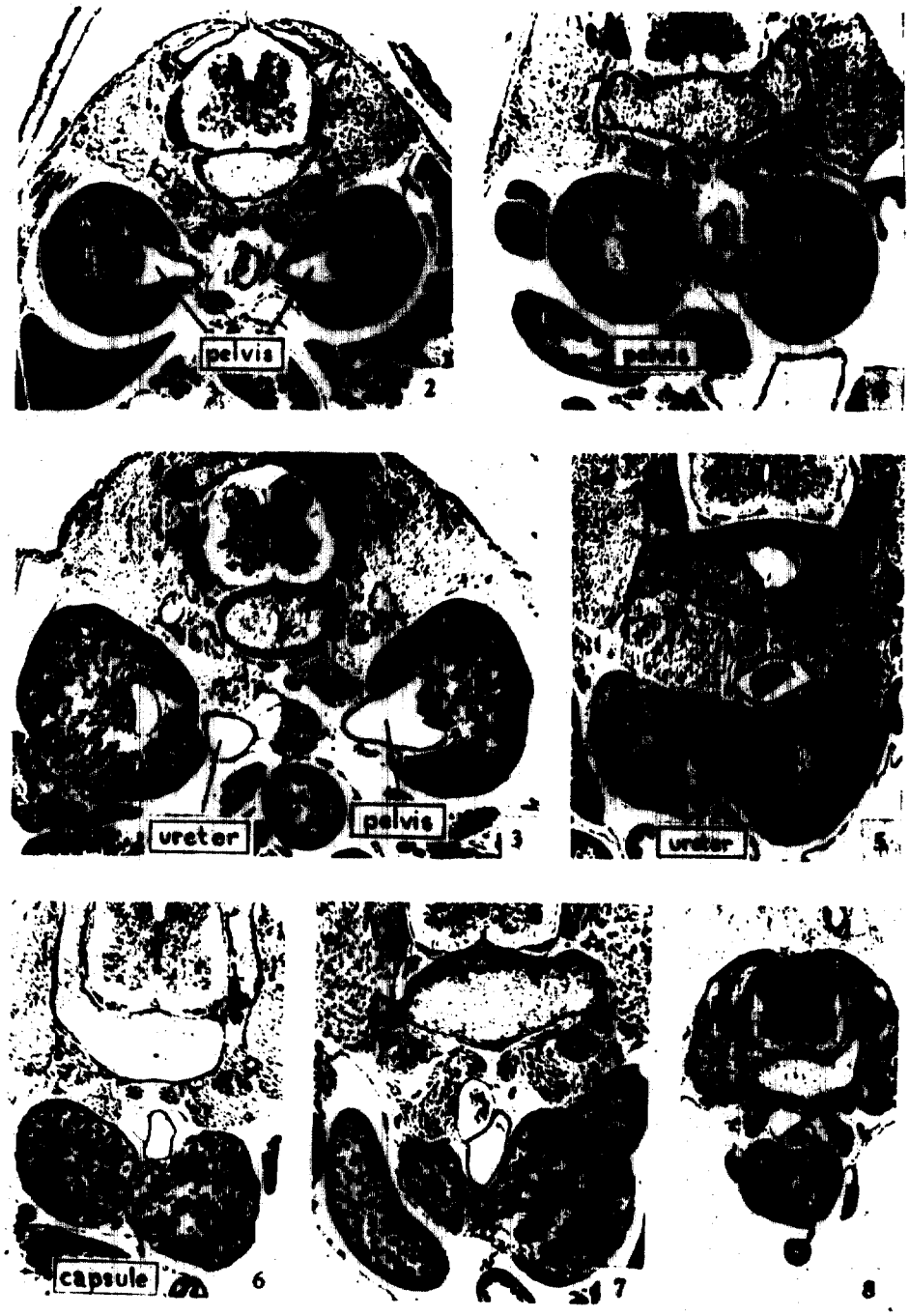
pelvis
2
pelvis
ureter
pelvis
3
ureter
5
capsule
6
7
8

PLATE 2

EXPLANATION OF FIGURES

9 Genital ducts in a 19-day normal male fetus from a mother fed an adequate diet. The section is through the pelvic cavity. Mesonephric ducts are prominent in the center of the urogenital fold, but Müllerian ducts have regressed to the extent that they are recognizable only as mesenchymal condensations along the medial margins of the urogenital folds. × 42.

10 Genital ducts in a 22-day male fetus from a mother fed a vitamin A-deficient diet. The section is through the abdominal cavity. Müllerian ducts are equally as well preserved as are mesonephric ducts. Both Müllerian ducts end blindly as they enter the pelvis. The mesonephric ducts are retarded in development for this age and are also ectopic. × 42.

11 Genital ducts in a 21-day male fetus, from an A-deficient mother. The section is through the lower pelvic cavity. The Müllerian ducts are well preserved at this and the more cephalic levels, but a few sections caudal to this level the right Müllerian ducts ends blindly, and only the left duct continues to join the sinus horn. The ureters join the mesonephric ducts just before the latter empty into the sinus horns, at a more caudal level. × 42.

12 Wax-plate reconstruction of lower genito-urinary tract of a 22-day male fetus from an A-deficient mother. The Müllerian ducts are well preserved as they enter the pelvis but they end blindly, without having united to form a cervico-vaginal canal, before they reach the sinus horns. Mesonephric ducts (vasa deferentia) continue to join the sinus horns, but just before terminating the are joined by the ureters. No seminal vesicles were formed.

13 Genital ducts in a 19-day normal female fetus from a mother fed an adequate diet. The section is through the pelvic cavity. Müllerian ducts are prominent in the urogenital folds but mesonephric ducts have regressed to scarcely recognizable strands coursing through the lateral portion of the folds. × 42.

14 Genital ducts in a 20-day female fetus from an A-deficient mother. The section is through the pelvic cavity. Both Müllerian and mesonephric ducts are present in this section and at more cephalic levels, but both sets of ducts are small and atrophic. The Müllerian ducts end blindly a few sections caudal to this, and only mesonephric ducts continue to join the sinus horns. × 42.

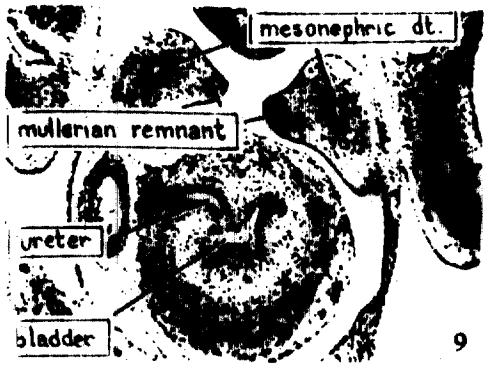

9



12

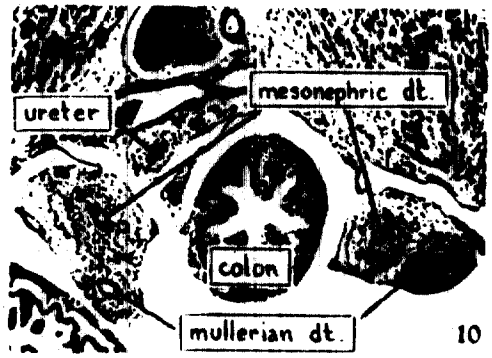

10

13

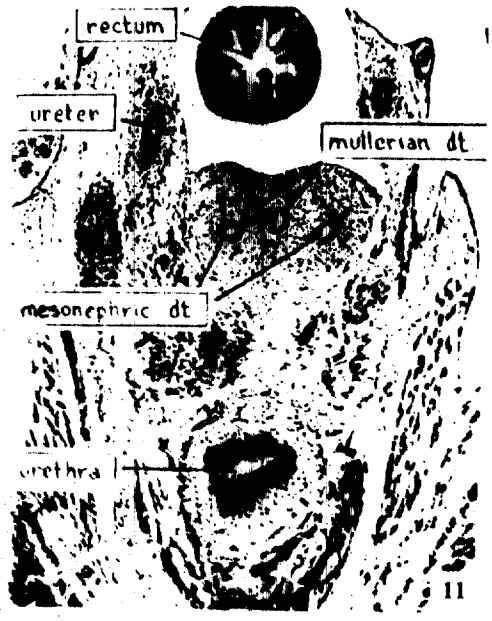

11

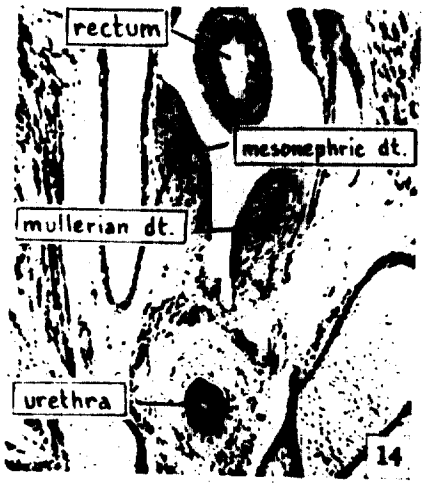

14

PLATE 3

EXPLANATION OF FIGURES

15 Ureters emptying into bladder in a normal 19-day male fetus, from a mother fed an adequate diet. Note that the bladder is covered by peritoneum on all but its ventral surface, which fact distinguishes the vesical region from the remainder of the urogenital sinus. A normally situated testis is seen in the upper right corner. × 42.

16 Ureters joining mesonephric ducts in a 22-day male fetus, from a mother fed a vitamin A-deficient diet. On the left side (reader's right) the ureter is just making contact with the mesonephric duct which has not yet reached its respective sinus horn. On the right side the same situation exists a few sections more caudally. No Müllerian ducts appear in this section, having ended blindly at a more cephalic level. × 42.

17 Ureters joining sinus horns in a 20-day female fetus, from an A-deficient mother. The ureter on the right side (reader's left) is entering the tip of the sinus horn but the mesonephric duct of that side has not yet reached the sinus horn. On the left side both ureter and mesonephric duct have already joined the sinus horn, in similar fashion. The Müllerian ducts are not present in the section, having ended blindly at a more cephalic level. × 42.

18 Ureters emptying into upper urethra in a 21-day female fetus, from an A-deficient mother. The left ureter (reader's right) is sectioned in two places; the more distal portion is seen entering the dorsal wall of the upper urethra. The right ureter does likewise a few sections caudally. Note that the peritoneum does not surround this region of the urinary tract, hence it is urethra and not bladder. The genital ducts (only Müllerian) appear normal at this level. × 42.

19 Penile urethra in a normal 21-day male fetus, from a mother fed an adequate diet. The urethra is sectioned in two places, proximally in the region of the mid-penis and distally as it enters the glans. At no point except at its external orifice does the urethra have any epithelial connection with the epidermis. × 42.

20 Hypospadias in a 21-day male fetus, from an A-deficient mother. This section is at a level that corresponds to the mid-penis. The hypospadiac cleft is seen opening on the surface at the base of the genital tubercle, but the cleft actually extends several sections caudally into the perineum and also cephalically along the ventral surface of the genital tubercle. Beyond the most cephalic extent of the cleft the urethra terminates in an approximately normal fashion at the tip of the genital tubercle. This segment of urethra, however, is connected [illegible] × 42.

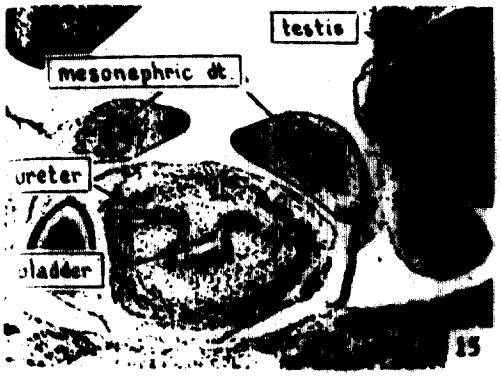
testis
mesonephric dt.
ureter
bladder
15

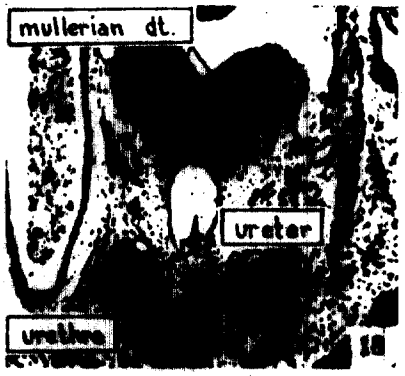
mullerian dt.
ureter
urethra
18

mesonephric dt.
ureter
sinusal horn
16

mesonephric dt.
ureter
sinusal horn
17

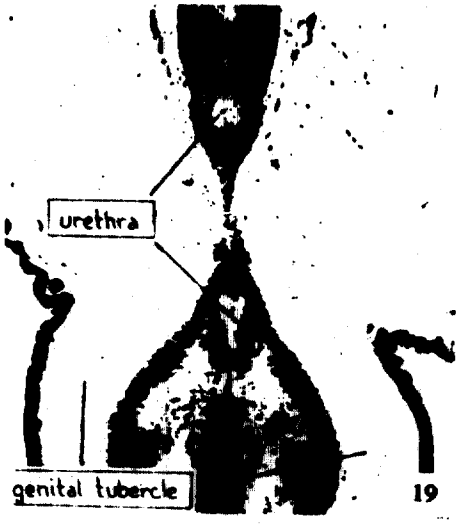
urethra
genital tubercle
19

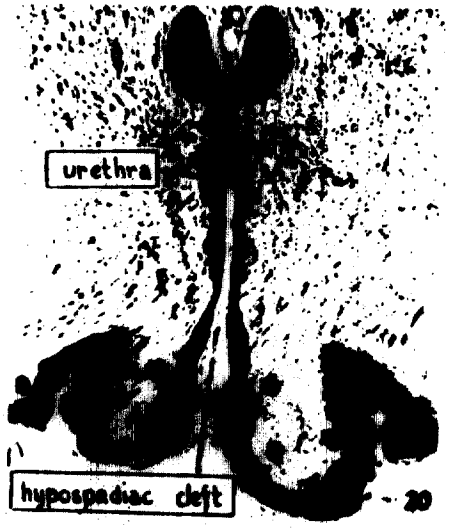
urethra
hypospadiac cleft
20

PLATE 4

EXPLANATION OF FIGURES

21 Wax plate reconstructions of the urogenital sinus and associated structures in near-term male fetuses. In most instances only the lower third of the bladder and the terminal portions of the genital ducts and ureters were reconstructed.

A. Normal 21-day fetus from a mother fed an adequate diet. The urethra is completely formed as an elongated tubular structure, and has given rise to the bulbourethral glands and numerous prostatic buds (neither labeled). All that remains of the Müllerian ducts is the small cone-shaped vagina masculina (utriculus masculinus). Mesonephric ducts have given rise to the seminal vesicles and proximally have been converted into vast deferentia. The ureters open into the base of the bladder and, like the bladder, are considerably distended.

B. A 22-day male fetus from an A-deficient mother. The urethra has retained many of the characteristics of the primitive urogenital sinus. No bulbourethral glands and only a few very small prostatic buds have formed. Müllerian ducts are well preserved but they end blindly shortly below the point of the label, never having reached the urogenital sinus. Mesonephric ducts are small and undifferentiated and have not given rise to seminal vesicles. Ureters open not into the bladder but into the urethra, just above the entry of mesonephric ducts. The bladder and ureters are collapsed. Note that the urethral plate has persisted.

C. A 21-day male fetus from an A-deficient mother. The following abnormalities are present: primitive urethra, no bulbourethral glands, few prostatic buds, urethral plate persists, sinus horns persist and receive mesonephric ducts, no seminal vesicles, Müllerian ducts persist but end blindly, hypospadias (not visible), and bladder not distended.

D. A 22-day male fetus from an A-deficient mother. The following abnormalities are present: primitive urethra, no bulbourethral glands, few prostatic buds, urethral plate persists, sinusal horns persist and receive both mesonephric ducts and ureters, no seminal vesicle, Müllerian ducts persist but end before reaching sinus horn, and bladder and ureters are not distended.

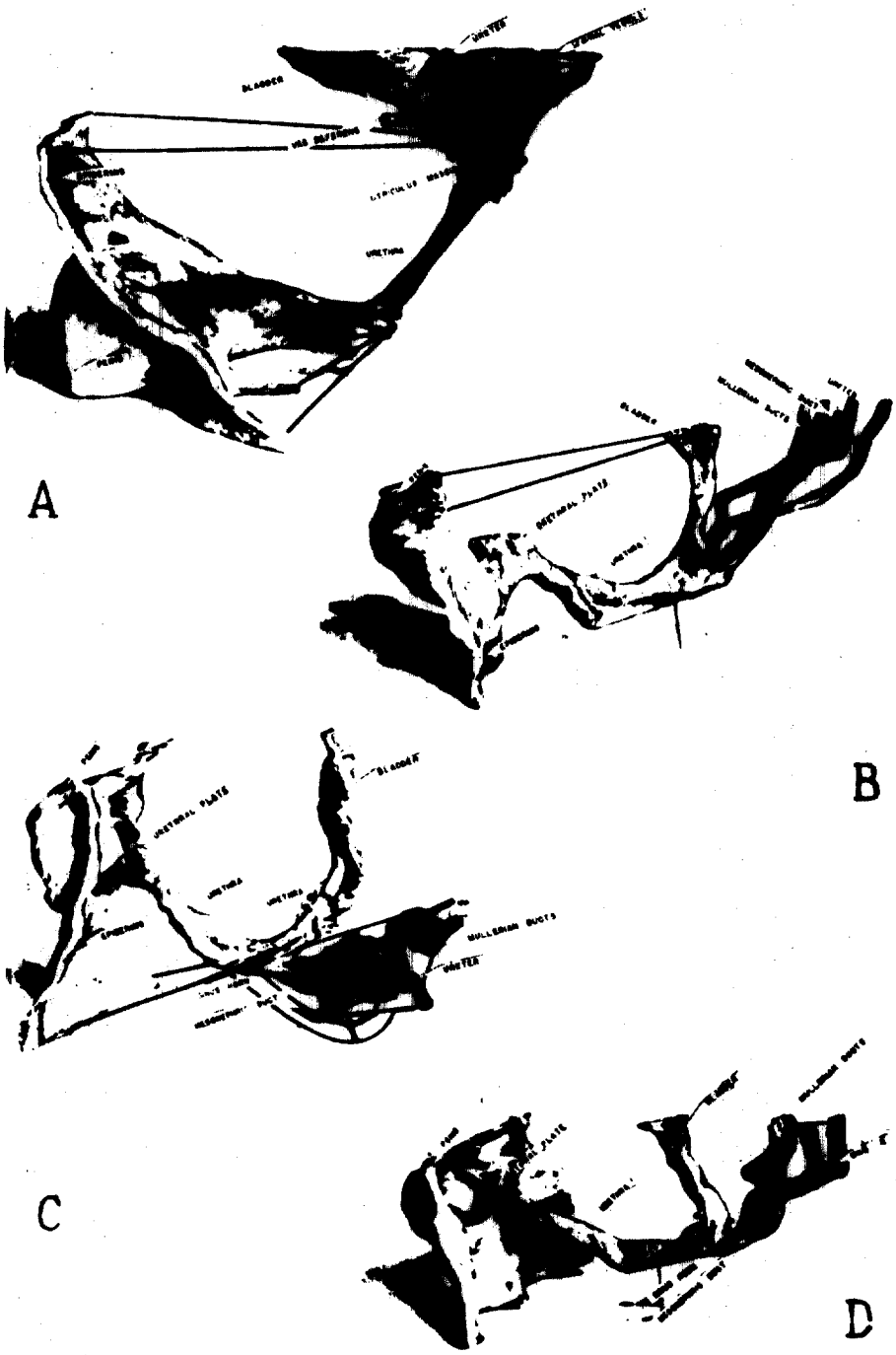
A
B
C
D

PLATE 5

EXPLANATION OF FIGURES

22 Wax-plate reconstructions of the urogenital sinus and associated structures in near-term female fetuses. Only the lower third of the bladder and the terminal portions of the genital ducts and ureters were reconstructed.

A. Normal 21-day female fetus from a mother fed an adequate diet. The upper urethra, derived from the pelvic part of the urogenital sinus, is complete; but the phallic part of the sinus, although relatively shortened, persists and receives the vagina and upper urethra. A major portion of the structure labeled *vagina* represents the sinus horn, which has elongated as its attachment to the sinus moved caudally. The point of juncture of the sinus horns and the Müllerian ducts is marked by the small mesonephric remnant (indicated by arrow). The bladder receives the ureters, and both of these structures are dilated.

B. A 22-day female fetus from an A-deficient mother. The following abnormalities are present: retarded differentiation of urogenital sinus, no vaginal development, sinus horns receive persistent mesonephric ducts, ureters join mesonephric ducts. Müllerian ducts do not reach sinus horns, and bladder and ureters are not dilated.

C. A 21-day female fetus from an A-deficient mother. The following abnormalities are present: retention of primitive urogenital sinus, no vaginal development, ureters and mesonephric ducts join sinus horns, Müllerian ducts do not reach sinus horns, and bladder and ureters are not dilated.


BLADDER
URETER
UTERUS
EPIDIDYMIS
URETHRA

A

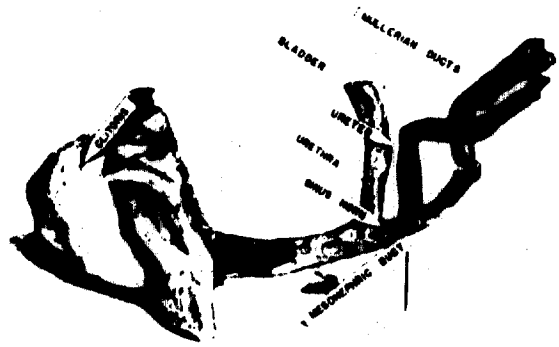
MULLERIAN DUCTS
BLADDER
URETHRA

B

BLADDER
MULLERIAN DUCTS
URETHRA

C

PLATE 6

EXPLANATION OF FIGURES

23 Normal "transitional" epithelium in the urethra of a 21-day normal male fetus, from a mother fed an adequate diet. Note that the cytoplasm is clear and the nuclei are densely stained throughout the epithelial layer. × 310.

24 Pre-keratinization in the urethral epithelium of a 21-day female fetus, from a mother fed a vitamin A-deficient diet. The entire epithelial layer has thickened and the cytoplasm of the more superficial cells has become cloudy or hyalinized. Nuclei in the most superficial cells are extremely pyknotic. × 310.

25 True keratinization on the dorsal wall of the urethra in a 21-day male fetus, from an A-deficient mother. True keratinization has occurred only on the central portion of the dorsal wall where, in addition to hyalinization of cytoplasm in the more superficial cells, a few keratohyalin granules are present in the most superficial cells and a plaque of dead, keratinized cells has accumulated on the surface. Epithelium on the lateral walls of the urethra have undergone only prekeratinization while on the ventral wall the epithelium has remained approximately normal. × 310.

26 True keratinization on all aspects of the urethral epithelium except the most ventral, in a 22-day male fetus, from an A-deficient mother. Typical cytoplasmic hyalinization, keratohyalin granulation, and desquamation of keratinized cells are conspicuous on the dorsal and both lateral walls. × 310.

23

24

25

26

Wilson-'49
Bib. No. 9860

Am. J. Anat. 85(1):113-155. 1949.

AORTIC-ARCH AND CARDIAC ANOMALIES IN THE OFFSPRING OF VITAMIN A DEFICIENT RATS[1]

JAMES G. WILSON
Department of Anatomy, School of Medicine and Dentistry, University of Rochester
and
JOSEF WARKANY
Department of Pediatrics, College of Medicine, University of Cincinnati

THIRTY-TWO FIGURES

Malformations following maternal vitamin A deficiency were first reported by Hale ('35), who observed microphthalmia, anophthalmia, cleft palate and lip, and ectopic kidneys in newborn pigs from mothers maintained on a vitamin A restricted ration during the first part of pregnancy. Using a much stricter regime of maternal deficiency on rats Warkany and Schraffenberger ('46) obtained fetuses and newborns about 75% of which bore one or more ocular defects, including retrolental fibroplasia, coloboma, eversion of retina and "open eyes." The discovery in the fetal rats of keratinizing metaplasia in epithelia of the lower genito-urinary tract was interpreted as indicating that they experienced a state of vitamin deficiency *in utero* similar, in at least one respect, to that in postnatal animals (Wilson and Warkany, '47). Various frank malformations were also found throughout the genito-urinary tract. These were described in terms of incidence and morphology, and were analyzed on the basis of the probable abnormality of developmental processes underlying the observed malformations (Wilson and Warkany, '48). Recently in a

[1] This study was aided by grants from the Nutrition Foundation, Inc., New York.

different laboratory[2] the original experiments of Warkany and Schraffenberger have been repeated using their prescribed diets but a different strain of rats. In all important respects the original work was confirmed; that is, the same malformations were produced in a similar incidence (Wilson and Barch, unpublished data).

The present report is one of a series in which it is proposed to present a general survey of all malformations resulting from maternal vitamin A deficiency in the rat. The data and descriptions herein pertain to anomalies in the heart and in the arteries derived from the embryonic aortic-arch system.

MATERIAL AND METHODS

The fetal and newborn rats used in this study were obtained from several experiments involving maternal vitamin A deficiency (Warkany and Roth, '48). Not all offspring from A deficient mothers are abnormal; approximately 25% possess no recognizable abnormality; but the remainder are abnormal to varying degrees, the most prevalent defects being ocular anomalies and epithelial keratinization in the genitourinary tract. The presence of some defect, usually ocular maldevelopment, was used as the basis for the selection of 64 fetuses and newborns for the present study. They represent both sexes and all ages from the 17th to the 22nd days of gestation, inclusive. Fetal age was determined by counting the day on the morning of which sperm were found in the vaginal smear of the mother as the first day of gestation.

It should be emphasized that pregnancy was not interrupted at will to obtain fetuses of a given age. The policy followed in most of the experiments was to allow pregnancy to go to full term on the 22nd day, unless there were prior indications that a spontaneous termination of pregnancy was imminent; but actually, less than 30% of the pregnancies proceeded to the 22nd day. All others were terminated by sacrificing the mother when it became apparent that some of the fetuses had

[2] At the University of Rochester—the original experiments were carried out at the Children's Hospital Research Foundation, University of Cincinnati.

undergone intrauterine death or were in process of being resorbed. This was recognized by the finding of excessive amounts of blood in the vaginal smear and a loss of weight in the mother. It was sometimes difficult to distinguish between the normal "placental sign," which appears between the 10th and 14th days of pregnancy, and the vaginal bleeding associated with beginning destruction of the conceptuses; but the more profuse and persistent bleeding in the latter instance was usually a reliable criterion. On this basis, pregnancy was interrupted prematurely in a majority of cases and all living and non-resorbed, dead fetuses were removed and preserved in 10% formol. The younger fetuses were more likely to be severely affected than were fetuses removed at term; since the former were removed under conditions probably resulting from greater duress of critical vitamin A deficiency.

The 64 fetuses thus selected were serially sectioned through the neck and thoracic regions and prepared for histologic study.[3] As controls a group of 16 fetuses ranging in age from 17 to 22 days of gestational age were removed from mothers fed an adequate diet and similarly prepared for histologic study. Also available and serving as "treated controls" were serial sections of 9 full-term or near-term fetuses that were entirely free of ocular or other abnormalities, despite the fact that they were taken from A deficient mothers. To confirm the accuracy with which the anomalies were interpreted from study of serial sections, wax-plate reconstructions of the heart and major arteries were prepared from 5 animals in which these viscera were malformed, and from two controls. The normal embryology of the aortic arches and heart was studied in a series of 23 carefully timed embryos removed from normal mothers on days 11 through 16 of pregnancy.

OBSERVATIONS

The cardiac and arterial anomalies to be described were those found in fetuses older than the 16th day of gestation.

[3] Imbedded in paraffin, sectioned at 10 μ and stained with hematoxylin and eosin.

The definitive pattern of the major arteries derived from the embryonic aortic-arch system is established by the 16th day; but not until the 17th day is organogenesis of the heart complete, in the sense that all of the septal structures that will be formed before birth have been completed. In limiting this study to fetuses of 17 days gestational age and older, therefore, the recognition and evaluation of anomalous and retarded development was greatly facilitated. Embryos of younger ages were studied and were found to show many cardiovascular anomalies, but they are not discussed in this report because in some instances the presumed deviations from normal could not be unequivocally excluded from the normal range of developmental conditions for that age.

The following section on normal embryology is included to serve as a basis for interpreting the malformations to be described later.

Normal embryology of the aortic arches and the heart

The development of the aortic-arch system of the rat, from the appearance of the first arch to the establishment of the definitive pattern, was described in some detail by Tandler ('02). The present authors after re-studying the same period of development have been able to confirm the principal points of Tandler's observations; but a recapitulation of some of the more important events is advisable, since the earlier author made no reference to the age of his embryos. The embryology of the heart of the rat, likewise, has been thoroughly studied by Burlingame and Long ('39); but in order to relate the events of development directly to age, a brief summary of cardiogenesis between the 11th and 17th days is presented here.

Eleventh day. The first pair of aortic arches is complete and each passes laterally and dorsally around the pharynx near its cephalic end to effect direct connection between the truncus arteriosus and the dorsal aortae of the respective side. An endothelial bud occasionally seen arising from the

truncus near the origin of the first arch is assumed to be the beginning of a second arch.

The heart is in the primitive single-tube stage of development, the earlier bilateral primordia having united medially to form a single tubular structure, except at the caudal end where the atria diverge to lie laterally to the anterior intestinal portal. Umbilical and vitelline veins may or may not have joined the atria.

Twelfth day. First, second and third pairs of aortic arches are present. The second pair is considerably larger than either of the others; the first is of moderate size but frequently consists of more than one channel in its ventral portion, and the third is small and often irregular in its course. No 4th arch is present, but its beginning is sometimes indicated by an endothelial bud from the truncus arteriosus caudal to the origin of the third arch.

The heart is still of tubular form, but is now sharply convoluted, exhibiting the two characteristics flexures at the cono-ventricular and the atrio-ventricular junctures. Dorsal to the atrial region the sinus venosus lies symmetrically across the midline and receives from either side the umbilical and vitelline veins, as well as the newly-formed anterior cardinal veins. No cellular proliferation into the myo-endocardial space (cardiac jelly) is apparent.

Thirteenth day. Third and 4th aortic arches are invariably present and of large caliber. Sixth arches are also recognizable, but are small in size and frequently irregular in course. A small channel extending caudally from each 6th arch toward the lung bud is probably the pulmonary artery. The first aortic arch has become plexiform as it passes through the mandibular arch, hence, is no longer a complete artery; but its ventral and dorsal ends are still easily recognizable. The second aortic arch, like the first, tends to be plexiform as it passes laterally around the pharynx, but the interruption is usually less extensive and occasionally a continuous vessel persists.

The heart is at a primitive 4-chambered stage, with the future chambers indicated by localized dilatations but with little or no septal formation in evidence. On the dorso-cephalic wall of the atrium the interatrial septum primum has appeared, but it has grown no more than one-third of the distance toward the atrio-ventricular canal. No atrio-ventricular endocardial cushions or trunco-conal (aorto-pulmonary) septal ridges are yet clearly indicated, although cellular proliferation into the myo-endocardial spaces has begun in these localities.

Fourteenth day. Third, 4th and 6th aortic arches are all well developed. The 4th right arch is slightly smaller than the left, which is the first indication of asymmetry in the aortic-arch system. Both first and second arches have broken down into plexuses in their ventral and lateral portions, but the dorsal stumps persist and retain their connection with the dorsal aortae. Secondary branches have arisen from these dorsal stumps. The dorsal aortae are relatively smaller in diameter between the third and 4th arches than they are in regions cephalic or caudal to this segment. Cephalic to the origin of the third arch the ventral aortae are difficult to follow and rapidly become plexiform.

The septal structures of the heart are in process of formation but none is complete. The trunco-conal septal ridges are clearly seen projecting into the lumen of the truncus and conus arteriosus, but they have not yet contacted each other, except occasionally in the region of the future semilunar valves. Between the two atria the septum primum has grown about three-fourths of the distance toward the atrio-ventricular endocardial cushions, and its dorso-cephalic portion has been perforated to form the interatrial foramen secundum. Well-formed endocardial cushions project into the atrio-ventricular canal but have not made contact. The muscular portion of the interventricular septum is conspicuous.

Fifteenth day. Third, 4th and 6th aortic arches are present; but the right 4th arch has diminished to about half the diameter of its counterpart on the left side; and the right

6th arch has been reduced to a very narrow isthmus or a non-patent strand between the right pulmonary artery and the right dorsal aorta. The dorsal stump of the first aortic arch is scarcely recognizable, but its secondary branches to the region of the face have enlarged considerably and appear to be supplied with blood largely through a new anastomotic branch from the dorsal stump of the second aortic arch. This anastomotic channel, the principal branch of the dorsal remnant of the second arch, passes through the region of the middle ear, particularly through the primordium of the stapes, hence its name, stapedial artery. No visible connection exists between the ventral and dorsal aortae in the region of the first or second branchial arches, indeed, the ventral aortae themselves become plexiform a short distance cephaled to the origin of the third aortic arch. Both dorsal aortae between the third and 4th aortic arches have completely regressed or have been reduced to non-patent cords. The right dorsal aorta persists caudal to the right subclavian (7th segmental) artery and the remnant of the right 6th arch, but it is only about one-third or one-fourth the diameter of the left dorsal aorta. A transitory 5th aortic arch may occasionally be represented by a blind diverticulum on the caudal aspect of the 4th arch, or possibly by a connection of near-capillary caliber between the 4th and 6th arches.

In the heart the septal structures are well formed and some are in process of final closure. The trunco-conal septal ridges have become apposed and fused throughout the truncus, and in some instances the fusion has extended beyond the region of the semilunar valves and into the conus. The interventricular septum is complete except in the region of the membranous portion where the interventricular foramen persists. Some of the primordia that will form the membranous portion of the septum may be identified. The atrio-ventricular endocardial cushions have just come together and are beginning to fuse, thereby dividing the atrio-ventricular canal into right and left parts. The interatrial septum primum has completed its caudalward growth and is in process of fusion

with the cushions of the atrio-ventricular canal. A large interatrial foramen secundum is seen in the dorso-cephalic portion of septum primum.

Sixteenth day. The embryonic pattern of paired aortic arches has now been largely transformed into an asymmetrical pattern that closely approximates the definitive arrangement of arteries in the head, neck and thorax. (Compare figs.

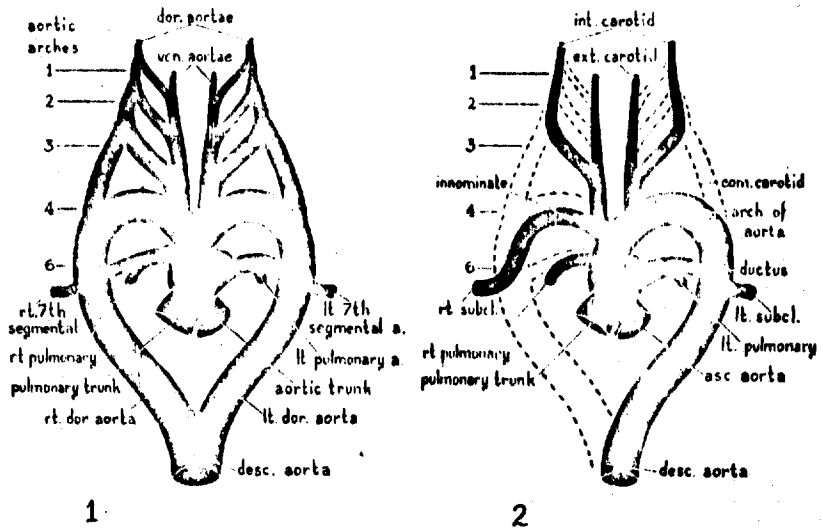

Fig. 1 Hypothetical embryonic pattern of aortic arches. At no time during mammalian development are all the arches present simultaneously, but they are represented here in cumulative arrangement in order to emphasize their positional relationships.

Fig. 2 Definitive pattern of arteries, L4 L6, derived from the embryonic aortic-arch system. The parts of the embryonic system that underwent complete or partial regression are indicated in broken lines.

1 and 2.) No part of the original first aortic arch is recognizable and the secondary branches which arose from its dorsal stump at an earlier age are now supplied through the stapedial artery from the dorsal stump of the second arch. The only identifiable remnant of the second arch is that which forms the first part of the stapedial artery. Both third arches have persisted in their complete form as direct connections between the ventral and dorsal aortae; but, since the dorsal

aortae between the third and 4th arches have disappeared, the third arches and the contiguous, cephalic portion of the dorsal aortae may now be designated internal carotid arteries. The ventral aortae cephalic to the origin of each third aortic arch are still small and tend to be plexiform, but their branches of distribution are such that they may be identified as the external carotid arteries. Between the third and 4th aortic arches the ventral aortae remain as the common carotid arteries, which are seen to bifurcate into internal and external carotids at a level slightly cephalic to the laryngeal primordia. Both 4th arches remain but with somewhat different connections. The right has no connection with the descending aorta since the right dorsal aorta between the descending aorta and the 7th segmental artery has disappeared. Thus, the right 4th arch, together with a short intervening segment of dorsal aorta, continues into the 7th segmental artery to form the right subclavian artery. The left 4th arch retains its connection with the left dorsal aorta which, in turn, persists as the first part of the descending aorta, hence the left 4th arch forms that portion of the definitive arch of the aorta between the left common carotid and left subclavian. Of the 6th arches, the left has been retained as the ductus arteriosus but the right has completely regressed except in its most proximal portion which is represented in the first part of the right pulmonary artery (fig. 14). The future ascending aorta is represented by the undivided portion of the ventral aorta (truncus arteriosus) as far as the origin of the innominate artery, and by the left ventral aorta (left branch of the truncus) as far as the origin of the common carotid. The future innominate artery is derived from the first part of the right ventral aorta (right branch of the truncus). With completion of the trunco-conal septum the pulmonary trunk is now separated from the aortic trunk.

In the heart the unfused tips of the trunco-conal septal ridges have extended caudally into the ventricular region to partially obstruct the interventricular foramen. Further

diminution of the foramen has resulted from the outgrowth of a mass of endocardial cushion tissue from the now fused cushions of the atrio-ventricular canal. These primordia of the membranous interventricular septum are well formed, but since no union has yet occurred, a small communication still exists between the ventricles (fig. 15).

Seventeenth day. Although the definitive pattern of major arteries leaving the heart was established during the 16th day, certain relationships to other structures are not attained until the 17th day. By this time the bifurcation of the common carotid artery has moved relatively caudally to lie beside the larynx, thus the remains of the third aortic arch, which is represented by the first part of the internal carotid artery, is located at the level of the cephalic end of the larynx. The arch of the aorta and the first part of the right subclavian artery, both representing the 4th embryonic arches, now lie within the thorax at a level between the first and third ribs. The ductus arteriosus, derived from the left 6th aortic arch, is at the level of the 4th rib.

The heart is completely partitioned in so far as prenatal development goes. Previously separate components of the membranous interventricular septum have fused to close the interventricular foramen (fig. 16). The interatrial septum remains open through the foramen secundum, as closure at the point does not normally occur until after birth.

Anomalies in arteries derived from the embryonic aortic arches

The arterial anomalies observed in the fetuses and newborns from vitamin A deficient mothers may best be described by relating them to the embryonic aortic-arch system (fig. 1). The normal pattern of major arteries in the neck and thorax (fig. 2) is derived from this embryonic system by retention of certain parts and regression of others. At some time during development all of the paired arches served to transmit blood from the heart to the dorsal and descending

aortae, but in newborn mammals only two of the arches normally remain to function in this capacity. These "functional arches" are the left 4th, represented in the arch of the aorta, and the left 6th, represented by the ductus arteriosus. In the present survey the absence of either of these or the presence of any other arch was considered an "aortic-arch anomaly"; and on this basis, that is, the number and arrangement of functional arches, the malformations herein described were classified. Other variations than those concerning the number of persisting functional arches were encountered, but these are presented as variants of the principal arch-pattern which they represent. In a few instances the normal pattern of functional arches, L4-L6 (left 4th and left 6th), was preserved but other abnormalities were found.

Left 4th and left 6th arches preserved but with associated abnormalities. In 4 fetuses the heart and descending aorta were connected in the usual manner, through persisting left 4th and 6th arches; but the right subclavian artery was abnormal in that it arose from the descending aorta (figs. 3, 17) rather than as a branch of the innominate artery. These distally arising subclavians always passed dorsal to the esophagus in their course toward the shoulder region. The underlying developmental defect was failure of the right 4th arch to appear or to persist, assuming it did appear, with the consequence that that portion of the subclavian derived from the 7th segmental artery (p. 121) lost or never had direct connection with the ventral aortic trunk. Thus deprived of blood through the usual channel, the 7th segmental became dependent upon the right 6th arch or upon the caudal segment of the right dorsal aorta. Neither of the latter structures ordinarily remains much beyond the 15th day of gestation, but in these 4 fetuses the caudal segment of the right dorsal aorta persisted and was utilized as the first part of the right subclavian. No other arterial anomalies were found in three of the animals; but the 4th had no left pulmonary artery, associated with agenesis of the left lung, although the ductus arteriosus was well formed and on the left side.

In one fetus the normal arch-pattern L4-L6 was preserved, but, in addition, the right 4th arch was functional in that it retained its connection with the descending aorta through a persisting right dorsal aorta, thus making the total arch-pattern L4-R4-L6 (figs. 4, 18). This constituted a typical "double arch" in which the trachea and esophagus were completely encircled by an arterial ring composed of the right

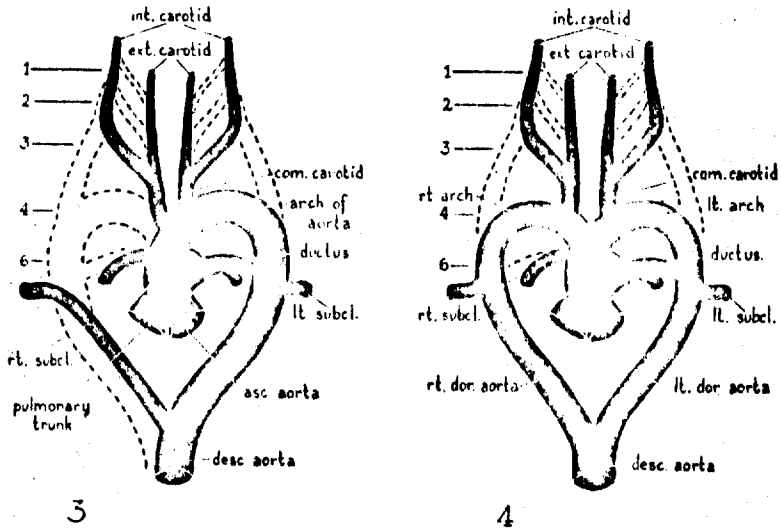

Fig. 3 Normal pattern of functional arches, L4-L6, but with the right subclavian artery arising distally from the descending aorta. In one animal with this anomaly the left pulmonary artery was absent.

Fig. 4 Double arch-left ductus, L4-R4-L6. This is a "vascular ring" anomaly in which the bilateral arches together with their respective dorsal aortae encircle the trachea and esophagus.

4th arch and dorsal aorta, and the left 4th and 6th arches and dorsal aorta. One limb of such a double arch, in this case the right, must pass dorsal to the esophagus to reach the descending aorta. No innominate artery was present, since the right subclavian artery, like the left, arose from its respective dorsal aorta. The only developmental fault was persistence of the right dorsal aorta between the 7th segmental artery and the descending aorta.

Retention of the right 4th arch, the right 6th arch and the right dorsal aorta, in addition to the usual L4-L6 was seen in one instance (fig. 5). The total arch-pattern was L4-R4-L6-R6 and may be designated "double arch-double ductus." Again, an arterial ring encircles the trachea and esophagus, but in this case the ring is more closely applied to these viscera since the presence of both 6th arches reduces its inside

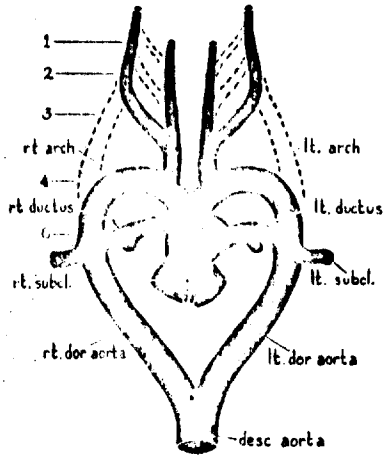

5

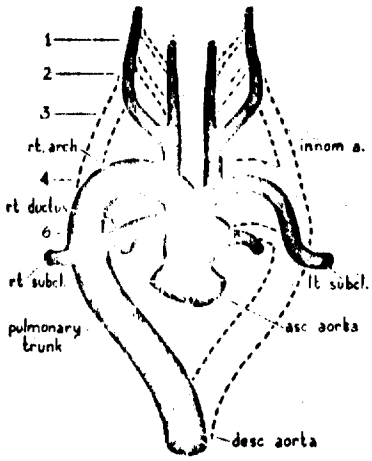

6

Fig. 5 Double arch-double ductus, L4-R4-L6-R6. In this pattern the functional arches are bilaterally symmetrical, a condition normally found only in early embryonic stages. A vascular ring closely encircles the trachea and esophagus.

Fig. 6 Right arch-right ductus, R4-R6. The major vessels, excepting the ascending aorta and the pulmonary trunk, are arranged as a mirror-image of the normal. The variants of this arch-pattern included: absence of left pulmonary artery, distally arising left subclavian artery, and presence of a carotid trunk.

circumference. Hence, the caudal portion of the right dorsal aorta and the distal portion of the right 6th arch failed to undergo involution by the 16th day of gestation. It is noteworthy that in this malformation the bilateral symmetry characteristic of early stages in the development of the aortic-arch system was retained; thus, whatever factors normally determine asymmetry in these arteries were not operative.

The subclavian arteries arose from their respective dorsal aortae.

Right 4th and right 6th arches as the basic pattern. The right 4th and right 6th arches, instead of the left 4th and left 6th, remained as the functional connections between the heart and descending aorta in 4 fetuses. This condition, "right-sided arch," was present in uncomplicated form in one animal, in which the arrangement of major arteries simulated a mirror-image of the normal pattern (figs. 6, 19). The developmental fault consisted of persistence of the right dorsal aorta, instead of the left, between the 7th segmental artery and the descending aorta, and persistence of the complete right instead of the left 6th arch. This explanation holds also for one of the variants on this arch-pattern in which the only deviation was absence of the left pulmonary artery, associated with agenesis of the left lung. In a second variant the left pulmonary artery was missing also, and, in addition, the left subclavian artery arose distally from the right-sided descending aorta and coursed dorsal to the esophagus to reach the left shoulder, and both common carotid arteries arose as a single carotid trunk from the right-sided 4th arch. The list of developmental faults for this fetus must be extended to include the probability that the left 4th arch failed to develop, since the left dorsal aorta was retained to supply the 7th segmental artery of that side. Also, the usual splitting of the ventral aorta into bilateral branches failed to progress as far caudally as the level of the 4th arches, since the carotids arose from a persisting common stem. The third variant resembled the second in that the two common carotid arteries arose from a single carotid trunk, but differed in that the left subclavian artery appeared to arise from the pulmonary trunk. Actually, the left subclavian in this instance was a direct continuation of a persistent left 6th arch (figs. 7, 20). A likely embryologic explanation for this situation is that the left 4th arch failed to develop, or never attained an appreciable size, and the caudal segment of the left dorsal aorta underwent early involution, thereby leaving

only the left 6th arch to supply the 7th segmental (subclavian) artery.

To the basic arch-pattern R4-R6 was added in one fetus a persisting left 6th arch and left dorsal aorta, thus completing an additional functional connection between the heart and descending aorta and making the arch-pattern R4-L6-R6 which might be designated "right arch-double ductus"

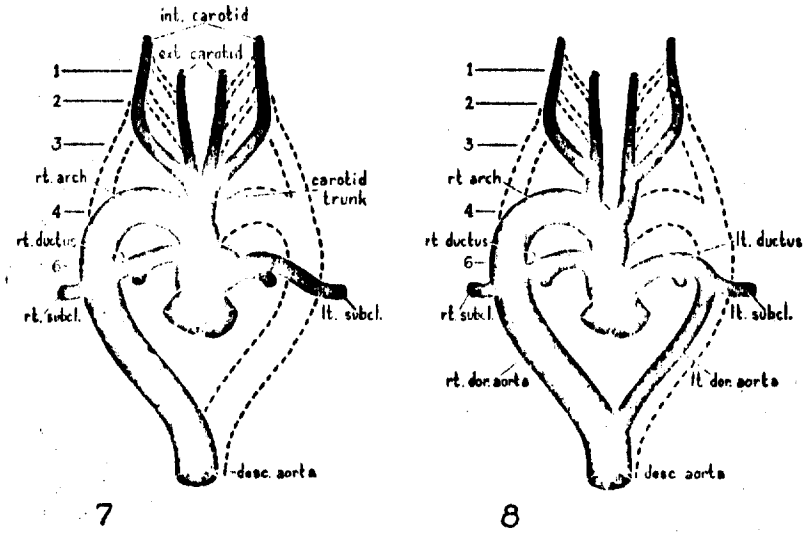

Fig. 7 Right arch-right ductus, R4-R6, with left subclavian artery arising from pulmonary trunk. The first part of the left subclavian was formed from the left 6th arch.

Fig. 8 Right arch-double ductus, R4-L6-R6. A vascular ring exists, since both 6th arches carry blood from the heart to the descending aorta; but only the left delivers blood from the right ventricle as usual, while the right 6th arch arises from the ascending aorta and carries blood from the left ventricle.

(fig. 8). A remarkable peculiarity was noted in this instance, namely, that although both 6th arches were well preserved, only the left arose from the pulmonary trunk; the right arose from the ascending (ventral) aorta. Each of the arches gave off a well-developed pulmonary artery, but that on the right side carried blood primarily from the left ventricle while that on the left delivered blood, as usual, from the right

ventricle. Developmentally this situation could arise only as a result of misalignment of the trunco-conal septum during the process of partitioning the trunco-conal region into pulmonary and aortic trunks. Ordinarily, the septum begins to form in the lateral walls of the truncus arteriosus between the points of origin of the 4th and 6th aortic arches, whence it proceeds caudally in a spiralled fashion, such that the 6th arches are separated from the remainder of the aortic arch system but are brought into communication with the right ventricle. In this instance the septum evidently excluded only the left 6th arch from the truncus (ventral aorta), leaving the right 6th arch with the remainder of the aortic-arch system. Also noteworthy was the fact that the left subclavian arose from the arterial arch formed by the left 6th aortic arch and the left dorsal aorta. There was no indication that a left 4th arch had ever formed.

Absence of functional 6th arch on both sides. The 6th arches failed to persist as a connection between the heart and the dorsal aortae on either side in 4 fetuses. In one of these, the left 4th arch connected the heart with the left dorsal aorta in the usual manner, but no ductus arteriosus was seen on either side (L4-no 6). Probably a left 6th arch was partially represented in the first part of the left pulmonary artery which was well formed, but a complete 6th arch on this side may never have developed. The right subclavian artery appeared to be a direct continuation of the main pulmonary trunk beyond the point at which the right pulmonary artery arose (fig. 9). Undoubtedly the first part of this right subclavian was formed from a persisting right 6th arch, which at one time must have terminated in the right dorsal aorta. When the dorsal aorta of this side was interrupted both cephalic and caudal to the segment into which the 6th arch emptied and from which the 7th segmental artery arose, these two structures became continuous as the subclavian. It is doubtful that a 4th arch developed on the right side, otherwise one would expect it to have been utilized in forming the first part of the subclavian, as is normally the case.

In two additional animals there was also no ductus arteriosus, but the right instead of the left 4th arch served as the sole connection between the heart and the descending aorta. One of these animals exhibited a "mirror-image" arrangement of the carotid, subclavian, and innominate arteries, but differed from the usual right-arch pattern in the absence of

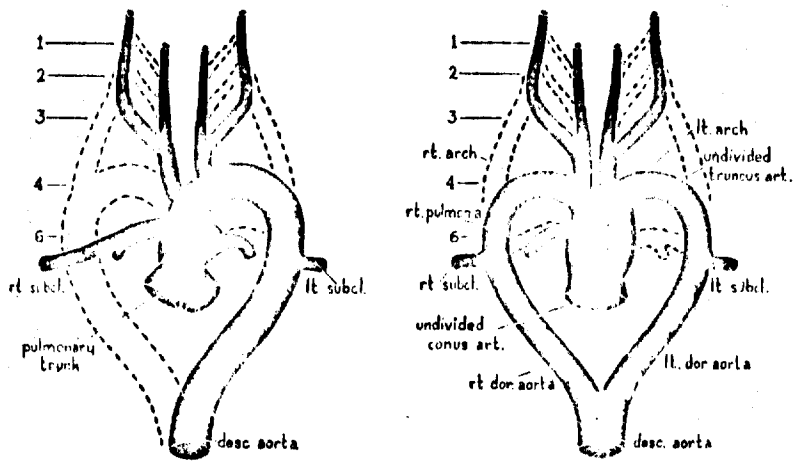

9 10

Fig. 9 Left arch-no ductus, L4-no 6. There is no functional 6th arch connecting the right ventricle with the aorta but the right 6th arch persists as the first part of the right subclavian, which artery thus receives blood only from the right ventricle. The mirror-image of this pattern, that is, right-sided arch, was also seen.

Fig. 10 Double arch-no ductus, L4-R4-no 6, with incompletely divided truncus and conus. A vascular ring exists but is atypical in that no ductus is present. The incomplete partitioning of the trunco-conal region constitutes a condition that was functionally similar to *truncus arteriosus communis persistens* but was structurally different in that some degree of separation of pulmonary and aortic trunks was evident.

both the right-sided ductus and the left pulmonary artery (fig. 21) — the left lung was supplied solely by the bronchial arteries. In a second case of absent ductus, in which the right 4th arch alone connected the heart with the descending aorta, the left subclavian artery arose distally from the descending aorta, again suggesting that the left 4th arch never de-

veloped. Also, the two pulmonary arteries arose from different sources: the left from the pulmonary trunk as usual, the right from the ascending aorta. The developmental fault underlying this condition must have been improper alignment of the trunco-conal septum with respect to the 6th arch primordia (see p. 128), but it must be borne in mind that in this instance there is no proof that complete 6th arches were ever present.

A 4th case of absent ductus was noted in a fetus in which both 4th arches as well as both dorsal aortae had persisted (fig. 10). This pattern (L4-R4-no 6) constitutes an encircling ring about the trachea and esophagus, but other anomalies in addition to the absence of a ductus exclude it from the classification of typical "double arch." The primitive ventral aorta or truncus arteriosus was incompletely partitioned into pulmonary and aortic trunks; that is, only the central portion of the pulmonary trunk was separate while its two ends were confluent with the aortic trunk, simulating the condition of *truncus arteriosus communis* (figs. 22, 23). A single pulmonary artery, the right, arose from the separate central portion of the pulmonary trunk. The developmental deficiencies in this instance consisted of failure of a complete 6th arch to persist, failure of the caudal segment of the right dorsal aorta to regress, and incomplete partitioning of the trunco-conal segment.

Absence of functional 4th arch on both sides. In three fetuses there was no indication that either 4th aortic arch had ever been present. One such fetus possessed a large ductus on the left side which served as the only connection between the heart and descending aorta (no 4-L6). The aortic trunk arose from the left ventricle as usual, but it made no connection with the descending aorta, was small in size, and terminated in the neck by giving rise to the two common carotid arteries (figs. 11, 24). In the absence of 4th arches, the right subclavian arose distally from the descending aorta and passed dorsal to the esophagus. A second fetus of this arch-pattern possessed a large ductus on the right side (no 4-R6)

which served as the only connection between the heart and descending aorta. The left subclavian artery arose distally from the right-sided descending aorta, consequently the arrangement of arteries in this instance is a mirror-image of that in the preceding case. Again, the aortic trunk gave rise to no systemic branches except the two common carotids.

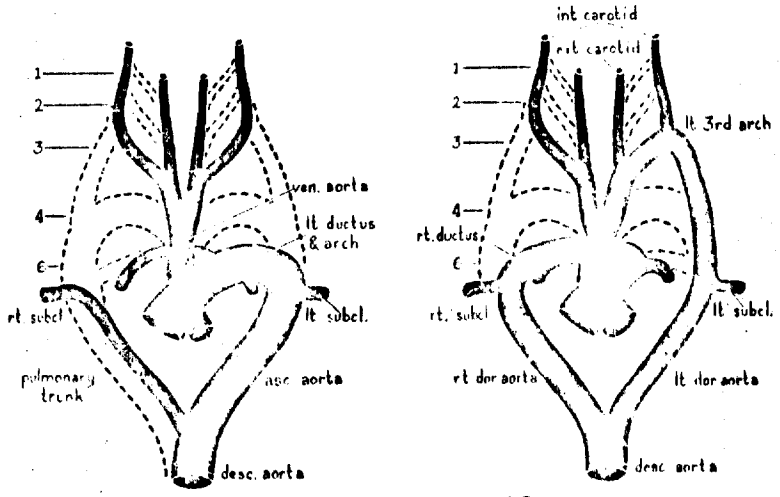

Fig. 11 Left ductus as arch, no 4-L6, with distally arising right subclavian. The ascending aorta had no connection with the descending aorta and terminated in the carotid arteries. All other parts of the systemic circulation, as well as the pulmonary circulation were served directly by the right ventricle through the pulmonary trunk and enlarged left 6th arch. A mirror-image of this pattern was also seen.

Fig. 12 Left third arch and right ductus, L3 no 4-R6. This constitutes a highly asymmetrical vascular ring in which the left half extends into the neck to the level of the larynx while the right half extends no higher than the third rib. No left common carotid is present since the formation of this artery as such depends upon regression of the dorsal aorta between the third arch and the next successive functional arch, if any.

The third variant of this general arch-pattern, like the one just described, consisted of a persisting right-sided 6th arch connecting the heart with the descending aorta; but an additional connection existed in the form of a persisting left third arch (fig. 12). This arrangement, L3-no 4-R6, con-

stitutes a double arch, since there is an aortic arch in either side between the heart and descending aorta; but the arterial ring thus formed is highly asymmetrical. The right component (fig. 25), made up of the right 6th arch and the caudal segment of right dorsal aorta, lay within the thorax caudal to the level of the second rib; whereas, the left component (fig. 26), consisting of the left third arch and a large part of the left dorsal aorta, extended into the neck as far cephalically as the larynx. The fact that the left-sided arch was located beside the larynx was used as a clue to its identity; the third embryonic aortic arch first appeared and ultimately remained in the vicinity of the larynx (p. 122). Another clue was absence of a common carotid on this side; the external and internal carotids arose separately from the crest of the arch. The third embryonic arch normally forms the first part of the internal carotid and serves to connect it with the ventral aorta after the dorsal aorta between the third and 4th arches regresses. Subclavian arteries arose from the dorsal aortae on the respective sides.

Absence of functional 4th and 6th arches on both sides. In 4 fetuses there was no indication that 4th arches had formed and, furthermore, no complete 6th arches persisted, although the presence of pulmonary arteries suggests that at least ventral stumps of 6th arches were formed. The only channels conveying blood from the heart to the descending aorta in those instances were one or both third arches which had retained their connection with the respective dorsal aorta. As mentioned above, persisting third embryonic arches were identified by: (1) their proximity to the larynx, and (2) the fact that internal and external carotid arteries arose separately from the crest of the arch. One of the fetuses in this category possessed only a left third arch connecting the heart and descending aorta (figs. 27, 28), but in three other fetuses both third arches persisted and were functional (fig. 13). In the former instance, L3-no 4-no 6, the right common carotid and subclavian arteries arose from an innominate artery which in turn arose from the much elongated aortic trunk

(ascending aorta). In all of the latter group, L3-R3-no 4-no 6, no common carotids were present, the external and internal carotids arose directly from the arch of that side, and the subclavians arose from their respective dorsal aortae. The pulmonary trunk was small in all of these fetuses and was especially so in one in which the left pulmonary artery was missing.

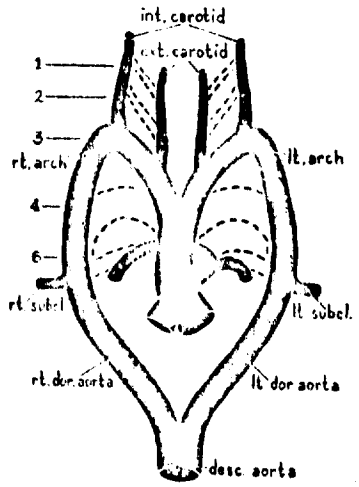

13

Fig. 13 Double third arch, L3-R3-no 4-no 6. There was no indication that any part of either 4th arch had ever formed. The same is true as regards complete 6th arches, although the presence of pulmonary arteries indicates that at least ventral stumps of 6th arches must have formed.

Anomalies of the heart

Interventricular septal defect. The interventricular septum was incomplete in 22 of the 64 fetuses and newborns from vitamin A deficient mothers. In a majority of instances the defect was localized within the usual limits of the membranous portion of the septum, and appeared to have resulted from deficient growth or improper union of the three masses of endocardial-cushion tissue that ordinarily form this part of the septum. In three animals the components of the membranous septum were of the correct size and appeared to be

in correct alignment but had not completely fused, leaving small slit-like communications between the right and left ventricles. It is possible that these might have fused belatedly and, in any event, the patency was so small that it probably would have been of no consequence functionally. In several cases deficient growth of primordia of the membranous septum was clearly evidenced in that these components were of insufficient size to occlude the foramen (fig. 29). The muscular part of the septum as well as other related structures were well formed, signifying that the foramen was not unduly large. Since these primordia are derived from the trunco-conal septal ridges and the cushions of the atrio-ventricular canal, one might expect to find associated defects in the region of the trunco-conal septum and the septum of the atrio-ventricular canal. In three instances, noted in the preceding section, the trunco-conal septum was severely malformed and in a few additional fetuses the most caudal portion of this septum was incomplete (fig. 30); nevertheless, by no means all of the interventricular septal defects were associated with trunco-conal septal defects. The atrio-ventricular-canal septum was complete in every fetus examined.

The interventricular foramen was sufficiently large in 5 fetuses to suggest that the muscular as well as the membranous part of the septum was deficient (fig. 31). The heart in one of these resembled the condition *cor triloculare biatrium* in that the ventricular region consisted of a single chamber with very little indication of even the muscular septum.

Myocardial defects. The myocardium, particularly that of the ventricular walls, was poorly developed in certain of the offspring of A deficient mothers. Hearts thus affected had thinner, less compact walls than hearts from control fetuses of the same age. The inner aspect of the wall was often trabeculated (fig. 31), imparting a spongy appearance characteristic of earlier stages of myocardial development. In part accounting for this apparent deficiency in the quantity of cardiac muscle was the fact that the individual fibers were

of smaller diameter, and often seemed to be fewer in number, than is typical of normal fetuses at the age of those in question. In the absence of any gross abnormalities in the disposition and arrangement of muscle, it was concluded that the myocardial defect was not as much a true malformation as a specific retardation of differentiation and growth of cardiac muscle.

Deficient myocardial development was not limited to those hearts in which the interventricular septum was defective, neither was it always associated with anomalies of the aortic-arch system. It was observed in several animals in which there were no other cardiovascular abnormalities, and it was not observed in a few animals which had other anomalies of the heart and vascular system. An exact enumeration of the incidence of this defect is not presented since the condition was not sharply characterized by any set of histologic criteria and varied in its manifestation from a barely perceptible to a pronounced degree. It is estimated that myocardial development was retarded to some extent in about one-half of all offspring otherwise affected by vitamin A deficiency.

Correlation of anomalies with each other and with the age of the fetus

In the fetuses studied the incidence of aortic-arch anomalies and of interventricular septal defect was the same (table 1); but the two types of malformations did not always occur in the same individual. Twenty-eight fetuses were affected by at least one malformation, but only 16 by both. Of these instances of simultaneous occurrence, interventricular septal defect was noted in every animal in which the aortic-arch pattern was characterized by absence of both 4th and/or both 6th arches, and in all patterns containing only one functional arch. Other arch patterns, namely, those in which at least one 4th and one 6th arch were functional, were associated with interventricular septal defect in only about half the cases. When the number of functional arches exceeded two, providing one 6th arch was included, the interventric-

ular septum was usually closed. Hence, the number of functional arches available for delivering blood from the heart to the aorta appears to have been a factor in determining whether or not the interventricular septum closed. In the case of absence or incompleteness of a 6th arch, failure of the interventricular septum to close presents a situation that may be amenable to explanation on a mechanical basis. Without a ductus arteriosus to deliver blood from the right ventricle to the aorta, the interventricular foramen must, to some extent, compensate for the deficiency of normal outlet

TABLE 1

Incidence of aortic arch anomalies and interventricular septal defect in fetuses removed at different ages from vitamin A deficient mothers

GESTATIONAL AGE	NUMBER OF FETUSES STUDIED	AORTIC ARCH ANOMALIES		INTERVENTRICULAR SEPTAL DEFECT		FETUSES WITH BOTH ANOMALIES	TOTAL AFFECTED FETUSES
		Number	%	Number	%		
days							
22	16	1	6	1	6	0	2
21	10	1	10	3	30	1	3
20	10	4	40	3	30	2	5
19	5	2	40	1	20	0	3
18	7	4	57	4	57	4	4
17	16	10	63	10	63	9	11
Total	64	22		22		16	28

by conveying blood directly into the left ventricle, if the fetus is to live and the usual proportions of the heart maintained. Such an added functional burden on the interventricular foramen may very well have interfered with its normal closure.

There was an apparent correlation between the age of the fetuses at the time pregnancy was interrupted and the incidence of these cardio-vascular anomalies: the earlier the fetuses were removed the more likely they were to show such anomalies (table 1). Although literally true, this statement must be interpreted in consideration of other factors. It should be recalled that the pregnancies were usually inter-

rupted, not at random, but after the detection of signs indicating that part of the conceptuses of that pregnancy had already undergone intrauterine death or resorption. The fact that a pregnancy was terminated artifically before full term on the 22nd day generally meant that the fetuses had been so severely affected by maternal A deficiency that chances of further survival of any of the fetuses were slight. Conversely, pregnancies that went to or near the 22nd day without indication of fetal death or resorption were usually those from which less severely affected fetuses, occasionally unaffected fetuses were obtained. Then, the data in table 1 indicate that aortic-arch and septal anomalies were more often associated with early fetal death than with survival of the fetus to full term. There is no proof that these defects were responsible for fetal death; indeed, it seems unlikely that many of them were, in view of the broad latitude of circulatory deviations known to be compatible with intrauterine life in human beings. A much more likely interpretation is that the cardiovascular anomalies were manifestations of the same underlying cause that produced other malformations which in themselves did contribute directly to early fetal death. One such contributory defect may have been retarded nephrogenesis and the consequent failure of fluid excretion by the kidneys, as already reported by Wilson and Warkany ('48).

Fetuses from the same mother rarely showed identical anomalies of the aortic arches and interventricular septum. Of the 8 groups of siblings (table 2) included in the series of animals studied, only one set (group 1) showed consistent developmental conditions in the heart and aortic arches—the cardiovascular system in all was normal although other structures were abnormal. All other groups of siblings showed various conditions in the different individuals. One set of three (group VII) included two fetuses with identical aortic-arch patterns, but the pattern in the third member was entirely different. Three of the groups of siblings (III, VI and VIII) contained both normal and abnormal individuals, with regard to aortic arches. Since there was no consistency in

cardiovascular malformations among fetuses from the same mother, it may be concluded that the factors contingent on maternal vitamin A deficiency and acting to alter developmental processes in this region were subject to variations of degree in littermate fetuses. A qualitative difference in the

TABLE 2

Variation among siblings of the aortic-arch pattern and the condition of the interventricular septum

GROUPS OF SIBLINGS STUDIED		AORTIC ARCH PATTERN	INTERVENTRICULAR FORAMEN
I	a,b,c,d	all normal[1]	all closed
II	a	normal	closed
	b	normal	open, very small
III	a	normal	closed
	b	R4 L6 R6	closed
IV	a	L3 no 4 no 6	open, moderate
	b	R4 no 6	open, moderate
V	a	R4 R6	open, small
	b	R6 no 4	open, moderate
	c	L3 no 4 R6	open, very small
VI	a	normal	closed
	b	L4 R4 L6 R6	closed
VII	a	L3 R3 no 4 no 6	open, large
	b	L3 R3 no 4 no 6	open, moderate
	c	Normal, but with distal rt. subclavian	open, large
VIII	a	R4 no 6	open, large
	b	R4 L6 R6	open, very small
	c	Normal, but with distal rt. subclavian	open, moderate
	d	normal	open, small

[1] As used in this table the term *normal* refers only to cardiovascular structures. All animals included in the table, as well as all animals from A deficient mothers described in this paper, possessed some abnormality.

factors affecting fetuses of the same pregnancy seems unlikely, and it will be pointed out subsequently that a slight difference in the time at which these factors became operative could logically account for the individual variations.

No particular pattern of anomalous arteries occurred with sufficient frequency to justify its being taken as typical of developmental alterations induced by maternal vitamin A

deficiency. The most frequently occurring pattern was that involving the distal origin of a right subclavian artery from an otherwise normal left descending aorta, but this condition was observed in uncomplicated form in only three instances. When specific variations of individual parts of the aortic arch system were listed and plotted against each other on a checkerboard graph, rarely were groups of specific variations found to occur in the same combination more than twice. Hence, under the influence of maternal A deficiency the differentiation of the aortic-arch system may be deranged; but, when it is, the form of the overall arch-pattern and especially the variations of parts within the pattern appear to be determined by chance. This generalization does not apply to the concurrence of open interventricular septum with certain abnormal arch-patterns; for, as mentioned earlier, the number of functional arches was found to be rather closely correlated with closure of the interventricular septum. Likewise, it may be found that chance alone does not determine the arch-patterns, when more information is available on the time at which A deficiency becomes manifest, relative to altered differentiation of the aortic-arch system.

DISCUSSION

The knowledge that maternal vitamin A deficiency can cause cardiovascular anomalies in the developing offspring is of considerable interest in itself; but it poses a question, the answer to which would be of even greater importance to those concerned with problems of nutrition, as well as to those studying the processes of development. By what means is a lack of this vitamin in the maternal diet able to alter the course of development in the fetal heart and arteries? The answer was not obtained in the present study, but certain inferences can be drawn that may prove useful in formulating an answer and that are, albeit, worthy of mention here.

The aortic-arch anomalies, despite their apparent complexity and variability, can all be resolved to a common developmental basis. When analyzed in terms of embryonic

history, it becomes apparent that each resulted from alterations in the processes determining normal differentiation in a circumscribed region of the embryonic aortic-arch system, beginning at a fairly definite time in development. The region in question is the caudal part of the aortic-arch system, more specifically, the 4th and 6th aortic arches and contiguous portions of the two dorsal aortae and the ventral aorta. Concerning the time in development, it should be recalled that the paired aortic arches appear in temporal succession between the 10th and 14th days, as well as in positional succession from the cephalic toward the caudal ends of the pharynx. For example, on the 11th day the first arches are well formed and caudal to them the second arches are beginning to appear; on the 12th day the first and second arches are well-formed and caudal to the second, the third arches are forming; on the 13th day the third and 4th arches are well formed, the first and second are regressing, and the 6th are just appearing caudal to the 4th. In none of the fetuses studied was there any indication that the first, second or third arches had differentiated abnormally. Therefore, the available evidence suggests that the factors governing differentiation of the aortic-arch system were not impaired during the period of formation of the first, second and third arches, that is, during the 10th, 11th and possibly the 12th days; but until embryos at these earlier ages are studied, the possibility remains that altered development at these ages results in early death. By the same reasoning, it may be concluded that the processes of differentiation were impaired between the 12th and 15th days in those fetuses with aortic-arch anomalies, since this is the period when the 4th and 6th arches are first formed and when these arches together with the caudal segments of dorsal and ventral aortae are transformed into the definitive arterial pattern.

To illustrate the foregoing, specific malformations can be analyzed. In the cases of distally arising right subclavian artery the normal arch pattern L4-L6 was preserved, but faulty differentiation was nonetheless evident in the fact that

the caudal part of right dorsal aorta instead of the right 4th arch was utilized to form the first part of the subclavian artery. The most likely explanation for this is that the right 4th arch either failed to develop or never attained its usual size or relationships, with the consequence that the caudal segment of right dorsal aorta did not regress but was retained as the source of supply for the 7th segmental artery. That the 4th arch was subject to aplasia or faulty development in many of these fetuses was further evidenced by the several cases in which there was no indication that either 4th arch had ever been present.

Additional evidence of localized interference with differentiation was seen in those instances in which no complete 6th arches were present, those in which a right instead of left 6th arch was retained, and those in which a 6th arch was utilized not as a functional arch, but to form the first part of the subclavian artery. Since this pair is the last to appear, there is some justification for assuming that, when the 6th arches are the ones principally affected, the factors interfering with development became operative relatively late. When both 4th and both 6th arches were absent in the same individual, the argument favoring the existence of influences suppressing development in the caudal region of the aortic-arch system is greatly strengthened. Such influences were not necessarily regionally specific but, rather more likely, were specific only in the time at which they became effective.

Thus far the idea of localized interference with developmental processes has been applied principally to anomalies characterized by the absence of one or more arches. May the same idea be applied to those anomalies in which more than the usual number of arches was retained? A fact not to be overlooked is that normal development includes many processes that are regressive in nature, that is, processes that involve the complete removal or a relative reduction in size of a structure previously formed. For the production of normal offspring these regressive processes, like the ones concerned with progressive developments, must begin at the ap-

propriate time and proceed at the proper rate. Failure of these regressions to occur, or to occur at the proper time and rate, constitutes one variety of maldevelopment. Thus, the persistence of aortic arches that ordinarily undergo involution or partial regression, likewise, reflects an interference with normal developmental processes. With a given arch, however, or any other structure subject to regression under ordinary circumstances, there is a temporal difference in influences affecting its progressive development and influences affecting its regressive development. Interference with the former results in either aplasia or hypoplasia; interference with the latter results in abnormal retention. Therefore, the abnormal retention of an aortic arch indicates that the adverse influence that altered normal development reached a critical level of effectiveness at a relatively later time than did a similar influence that caused aplasia of the same arch in another animal.

Several of the aortic-arch anomalies found in the rat fetuses were characterized by a reversal of normal asymmetry, that is, a tendency toward preservation of the right 4th and 6th arches as the basic pattern, instead of the usual L4–L6. Such transposition of the arterial pattern also reflects interference with development in this localized region, but it may come about as a consequence of either one of two possible developmental errors. On one hand, simple aplasia of the left-sided arches would necessitate a shift in the main load of arterial blood toward the right side, thereby averting the usual regression of the right dorsal aorta and 6th arch, if the animal is to survive. In only one instance, however, was this explanation applicable, since in all other cases of right-sided predominance there was proof that at least one of the left-sided arches (4th or 6th) had formed. Hence, another type of developmental error must be postulated. Although it is not understood why certain viscera and organ-systems become asymmetrical during normal development, these structures do acquire a specific sidedness with remarkable consistency. Nevertheless, it is possible that the same factors capable of

altering other developmental processes in this region might also be capable of interfering with whatever influences normally determine the direction of asymmetry. Instead of the interference resulting in too much or too little preservation of the embryonic aortic-arch system, it might be expressed in the form of right-sided rather than left-sided dominance. If only a single detrimental factor is assumed to be operating, it is still within the limits of possibility that this one factor could vary quantitatively to induce different manifestations of interference with development. It should be stated that, aside from the aortic-arch anomalies, no other example of reversal of asymmetry has been found in the viscera of fetuses from A deficient mothers.

Anomalies in the genito-urinary tract of offspring from vitamin A deficient mothers, reported earlier (Wilson and Warkany, '48), were classified on the basis of the apparent manner in which normal developmental processes had been altered in order to produce the observed abnormality. The 4 categories which seemed to cover all types of malformation were (1) *paraplasia*, resulting from aberrant processes, (2) *aplasia*, complete absence of a structure ordinarily present, (3) *hypoplasia*, resulting from arrested or slowed processes, and (4) *hyperplasia*, characterized by over-activity of a process, overgrowth. One means of correlating the present with the earlier observations is to attempt to apply the same system of classification to the anomalies in the cardiovascular system as was used for those in the genito-urinary system. Consistent with the earlier observations on malformations induced by maternal vitamin A deficiency, anomalies of hyperplasia or overgrowth in the cardiovascular system were not found. Also of interest is the fact that hyperplastic malformations were not induced by maternal deficiency of another vitamin, namely, riboflavin (Warkany, Nelson and Schraffenberger, '43).

Paraplasia, resulting from the deviation of a developmental process from its usual course, was apparently represented in at least some of the cases of reversed asymmetry. As already mentioned, one of these cases can be explained on the basis

of expedient retention of right-sided arches in the face of aplasia of the usual left-sided members. Others of this type, however, gave evidence of the left 4th or left 6th arches or both having developed and having been utilized to some degree in the definitive pattern. These were attributed to a reversal of whatever factors normally determine left-sided dominance, with the consequence that the right instead of the left arches became the functional ones. The developmental processes responsible for asymmetry may have been quantitatively normal but were, nonetheless, aberrant in that they were reversed in direction. Thus, reversed asymmetry in the aortic-arch pattern may be classified as a malformation of paraplasia. Unquestionably the result of paraplastic development were two instances in which the trunco-conal septum formed in such fashion as to exclude only one 6th arch from the remainder of the aortic arch system, leaving the other 6th arch as the only branch of the pulmonary trunk.

Aplasia, or failure of a structure to develop to recognizable form, was considered responsible for the lack of any vestige of one or either 4th arch, noted in several instances. The same may hold also for those cases in which there was no complete 6th arch, although the presence of pulmonary arteries was taken to mean that at least proximal stumps of 6th arches were present at the time pulmonary arteries were forming. Pulmonary arteries were themselves subject to unilateral agenesis in 6 fetuses. In every instance only the left artery was missing and in 5 there was associated agenesis of the left lung. One fetus had a properly developed left lung which was supplied solely through the bronchial arteries. In 4 cases the entire left 6th arch, as well as the left pulmonary artery, was absent; hence, at least in these animals agenesis of a 6th arch seems unequivocal. It was not determined whether agenesis of left pulmonary arteries was secondary to agenesis of left lungs, or the reverse.

Hypoplasia, resulting in slowed or arrested developmental processes, was clearly exemplified in deficient myocardial development and in failure of the interventricular septum to

close, particularly when the primordia of the membranous septum were present but of insufficient size. If hypoplasia be defined as retardation or arrest of a developmental process, then in a broad sense it may be extended to cover retardation of processes that are normally regressive in nature, as well as those that are primarily progressive. Hypoplasia, in the special sense of regressive embryonic processes that proceeded at a slower than normal rate or were actually arrested before any appreciable regression occurred, was responsible for certain aortic-arch anomalies. Examples were those instances in which the normal arch pattern L4-L6 was preserved but was supplemented by the retention of additional arches: "double 4th arch" and "double arch-double ductus." Regardless of whether the latter aortic-arch anomalies are included, malformations of hypoplasia were, nevertheless, more numerous than any other type.

An analysis of the genito-urinary anomalies in the offspring of A deficient mothers, (Wilson and Warkany, '48), revealed that in that region, also, a large majority of the malformations appeared to have been the result of hypoplasia. The mechanisms by which maternal deficiency of vitamin A induces malformations are not known, but at least in the case of anomalies of hypoplasia a certain parallelism exists between the effects of vitamin deficiency on prenatal and on postnatal developmental processes. A striking symptom of deficiency in older animals is retardation or arrest of growth. Equally striking was the manner in which developmental processes in the fetus were often retarded or arrested by maternal vitamin A deficiency. An exact degree of parallelism of effects before and after birth cannot be expected, however, if one considers that postnatal development consists almost entirely of growth, whereas prenatal development consists of a complex interrelation of proliferation, differentiation, involution and growth.

In the previous report (*loc. cit.*) the possible means by which the injurious effects of maternal vitamin A deficiency might be transmitted to the developing offspring were discussed. No new information on this subject was obtained

from the present study, but several new manifestations of these injurious effects were seen. Perhaps of greater significance than the various manifestations was the present observation that the deleterious action of maternal A deficiency was not evidenced by visible alterations in developmental processes until the 13th day of gestation. In other words, all of the cardiovascular abnormalities can be attributed to interference with normal development on or subsequent to the 12th or 13th day. In retrospect, it appears that a similar relationship also held for the genito-urinary and ocular anomalies reported earlier, although in the latter two regions the interference may have become critical at a later period in gestation. Then, at present there is no evidence that maternal vitamin A deficiency is able to alter embryonic development perceptibly during the first 12 days of gestation.

SUMMARY

Fetal and newborn rats from mothers fed vitamin A deficient diets prior to and during pregnancy exhibited some degree of malformation in 75% of the cases. Ocular and certain genito-urinary anomalies were the most frequent and were used as the basis on which 64 of the abnormal offspring, ranging from 17 to 22 days gestational age, were selected for a survey of conditions in the heart and in the arteries derived from the aortic-arch system.

Aortic-arch anomalies were observed in 22 of these offspring. The malformations were classified in terms of the number and position of arches functioning as a connection between the heart and the descending aorta. The simplest and one of the most common of the abnormalities was one in which the normal arch pattern, left 4th and left 6 arches, was preserved but in which the right subclavian artery arose distally from the descending aorta and coursed dorsal to the esophagus to reach the right shoulder. Other variations on the otherwise normal, basic pattern were those in which both 4th, both 6th, or both 4th and both 6th arches were retained.

Another group of anomalies exhibited reversed asymmetry, that is, the right instead of the left 4th and 6th arches comprised the basic pattern. Supernumerary arches and other minor variations were also noted in this group. Absence of both 4th arches, both 6th arches, or both 4th and both 6th arches characterized additional patterns, all of which had in common the feature that neither member of one or more pairs of arches had persisted. When both members of both 4th and both 6th pairs were missing, one or both third embryonic arches were retained as functional connections between the heart and descending aorta.

The heart was subject to two types of abnormality. The interventricular septum failed to close, leaving an interventricular foramen of variable size, in 22 of the offspring from A deficient mothers. This defect occurred simultaneously with aortic arch anomalies in 16 instances. A second cardiac abnormality consisted of general retardation of myocardial development, with the result that the wall of the heart had a highly trabeculated, spongy appearance. Some degree of the latter condition was noted in about half of the animals studied, but its occurrence was not closely correlated with that of either interventicular septal or aortic-arch anomalies.

All of the cardiovascular defects were more common in younger fetuses, indicating that they were associated with, but not necessarily responsible for, early fetal death. Sibling fetuses were rarely affected by the same malformation, which suggests that the different types of malformations were not specifically related to the state of A deficiency or its sequelae in the mother, since such maternal influences presumably would be common to all siblings.

The manner in which developmental processes must have been altered in order to produce the observed anomalies was analyzed. It was concluded that all of the malformations were the result of interference with normal processes occurring on or subsequent to the 12th day of gestation.

REFERENCES

BURLINGAME, P. L., AND J. A. LONG 1939 Development of the heart in the rat. Univ. Calif. Publ. in Zool., *43:* 249.

HALE, F. 1935 The relation of vitamin A to anophthalmos in pigs. Am. J. Ophth., *18:* 1087–1092.

TANDLER, J. 1902 Zur Entwicklungsgeschichte der Kopfarterien bei den Mammalia. Morphol. Jahrb., *30:* 275–373.

WARKANY, J., AND C. B. ROTH 1948 Congenital malformations induced in rats by maternal vitamin A deficiency. II. Effect of varying the preparatory diet upon the yield of abnormal young. J. Nutrition, *36:* 1–12.

WARKANY, J., R. C. NELSON, AND E. SCHRAFFENBERGER 1943 Congenital malformations induced in rats by maternal nutritional deficiency. III. The malformations of the extremities. J. Bone and Joint Surg., *5:* 261–270.

WARKANY, J., AND E. SCHRAFFENBERGER 1946 Congenital malformations induced in rats by maternal vitamin A deficiency. I. Defects of the eye. Arch. Ophth., *35:* 150–169.

WILSON, J. G., AND J. WARKANY 1947 Epithelial keratinization as evidence of fetal vitamin A deficiency. Proc. Soc. Exp. Biol. and Med., *64:* 419–422.

——— 1948 Malformations in the genito-urinary tract induced by maternal vitamin A deficiency in the rat. Am. J. Anat., *83:* 357–408.

PLATE 1

EXPLANATION OF FIGURES

All photomicrographs on this plate were made from sections 10 μ in thickness, stained with hematoxylin and eosin. Magnification $\times$ 35.

14 Definitive condition of arteries derived from the caudal end of the aortic-arch system, in a 16-day normal fetus, from a mother fed an adequate diet. The unequal differentiation of the 6th arches is evident in that the left has been retained in complete form while all of the right, except the proximal end represented in the right pulmonary artery, has disappeared.

15 Interventricular foramen in final stages of closure in a 16-day normal fetus, from a mother fed an adequate diet. This narrow fissure is all that remains of the original foramen which is being occluded by the rapidly growing primordia of the membranous septum.

16 Interventricular septum completed after union of the primordia of the membranous septum, in a 17-day normal fetus, from a mother fed an adequate diet.

17 Distally arising right subclavian artery passing dorsal to esophagus, in its course from the left-sided descending aorta to the right shoulder region, in a 19-day fetus from an A deficient mother.

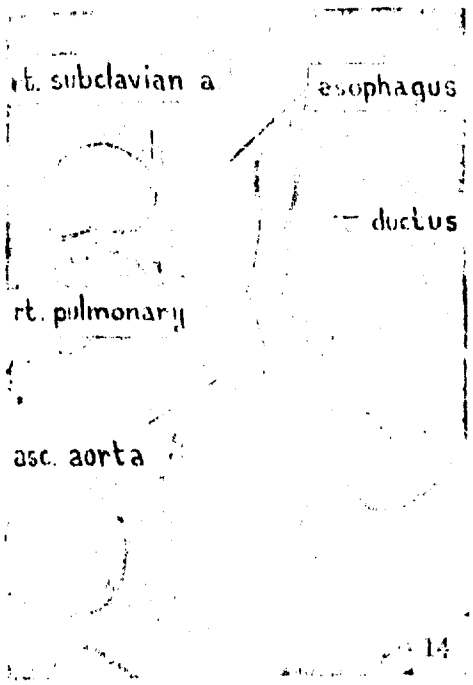
rt. subclavian a
esophagus
ductus
rt. pulmonary
asc. aorta

14

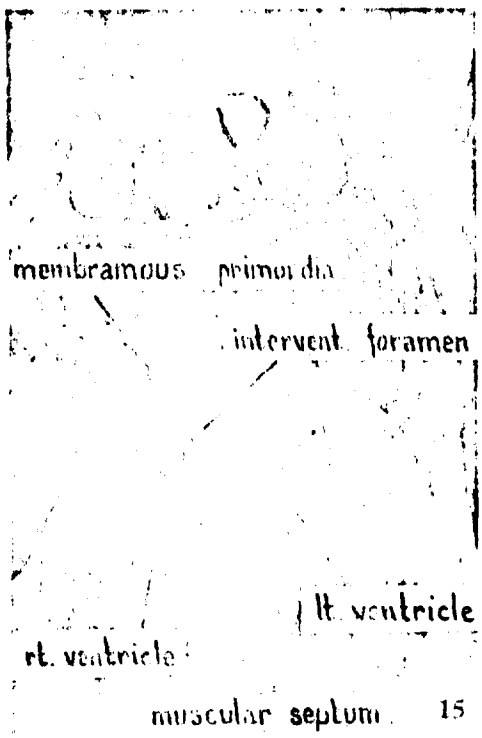
membranous primordia
intervent. foramen
lt. ventricle
rt. ventricle
muscular septum

15


membranous primordia
lt. ventricle
ventricle
muscular septum

16

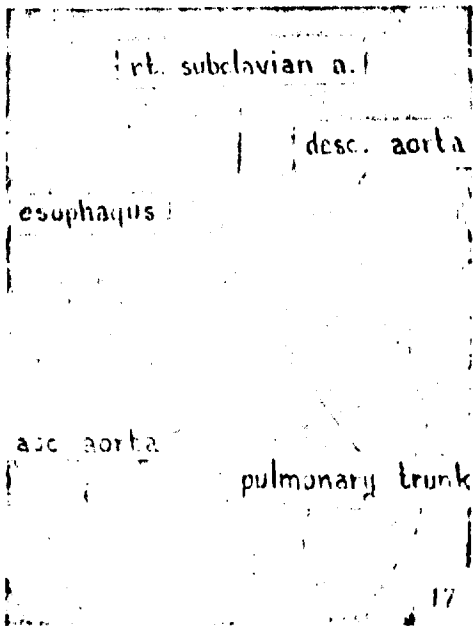
rt. subclavian a.
desc. aorta
esophagus
asc. aorta
pulmonary trunk

17

PLATE 2

EXPLANATION OF FIGURES

All photomicrographs on this plate were made from sections 10 μ in thickness, stained with hematoxylin and eosin. Magnification $\times$ 35.

18 Double arch-left ductus in a 20-day fetus from an A deficient mother. The bilateral arches of aorta are not shown but two dorsal aortae are here sectioned just below the arches. A normally situated ductus enters the left dorsal aorta.

19 Right arch-right ductus in a 17-day fetus from an A deficient mother. The right-sided ductus is seen entering the right-sided descending aorta. The major arteries of the thorax were arranged as a mirror-image of the normal pattern.

20 Right arch-right ductus with left subclavian from the pulmonary trunk, in a 17-day fetus from an A deficient mother. It was not possible to show in a single section the direct continuity between the left subclavian and the pulmonary trunk because of curvature in these vessels. Their proximity in this section is only suggestive of their actual continuity.

21 Right arch-no ductus, with agenesis of left pulmonary artery, in a 20-day fetus from an A deficient mother. The small pulmonary trunk is seen to terminate in the right pulmonary artery, since no ductus or left pulmonary artery is present. A right-sided arch of aorta was seen a few sections cephalic to this.

22 Double arch-no ductus, with incomplete partitioning of the trunco-conal segment of ventral aorta, in a 17-day fetus from an A deficient mother. This section is through the point at which the pulmonary and aortic trunks reunite to form a common trunk (see text fig. 10). The two dorsal aortae receive blood through the two 4th arches, a few sections cephalic to this.

23 Same animal as pictured in figure 22 but sectioned at a more caudal level to show the undivided condition of the conus.


rt. dor. aorta
lt. dor. aorta
esophagus
ductus
asc. aorta
16
esophagus
lt. subclavian a.
desc. aorta
rt. ductus
asc. aorta
19
desc. aorta
esophagus
lt. subclavian a.
esophagus
rt. pulmonary
asc. aorta
pulmonary trunk
21
pulmonary trunk
20
rt. dor. aorta
esophagus
esophagus
aortic valve
lt. dor. aorta
lt. dor. aorta
undivided conus
rt. pulmonary
undivided truncus
rt. ventricle

PLATE 3

EXPLANATION OF FIGURES

All photomicrographs on this plate were made from sections 10 μ in thickness, stained with hematoxylin and eosin. Magnification $\times$ 35.

24 No 4th arch, left ductus serving as arch, in a 17-day fetus from an A deficient mother. The large ductus seen here is the only connection between the heart and descending aorta. Note the small size of the ascending aorta which has no branches other than the carotids.

25 Left third, no 4th, and right 6th arches in an 18-day fetus from an A deficient mother. The right 6th arch is here seen passing into the right dorsal aorta; thus, it serves both as the source of the pulmonary arteries and as a right-sided arch.

26 Same animal as pictured in figure 25 showing the left third arch connecting the left ventral and dorsal aortae at the level of the larynx.

27 Left third, no 4th, and no 6th arches, in a 20-day fetus from an A deficient mother.

28 Same animal as pictured in figure 27, showing the small pulmonary trunk which terminates in the pulmonary arteries, without any connection with the descending aorta.

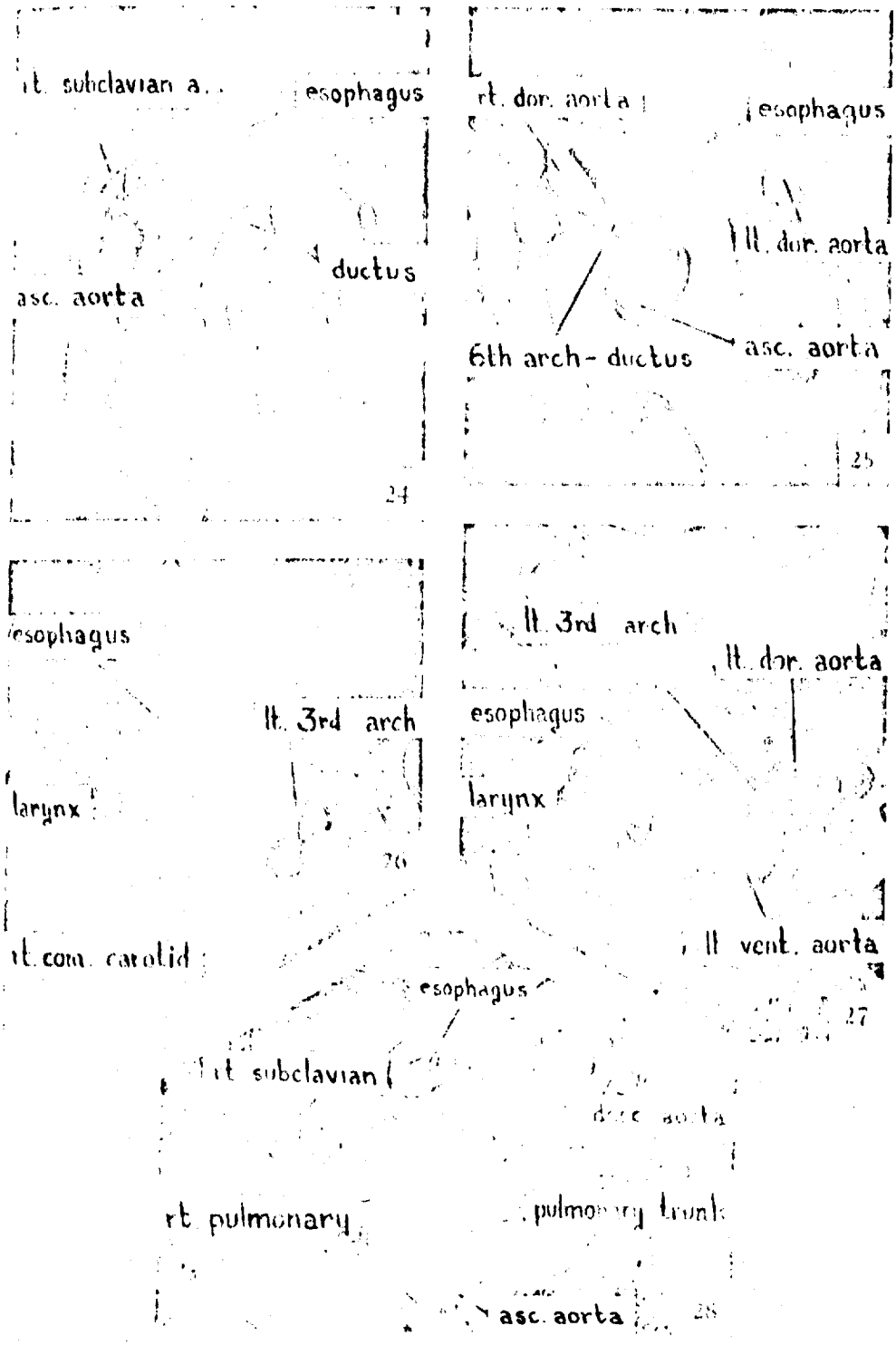
rt. subclavian a.
esophagus
ductus
asc. aorta
24
rt. dor. aorta
esophagus
lt. dor. aorta
6th arch - ductus
asc. aorta
25
esophagus
lt. 3rd arch
larynx
26
lt. 3rd arch
lt. dor. aorta
esophagus
larynx
lt. com. carotid
lt. vent. aorta
27
esophagus
rt. subclavian
rt. pulmonary
pulmonary trunk
asc. aorta
28

PLATE 4

EXPLANATION OF FIGURES

All photomicrographs on this plate were made from sections 10 μ in thickness, stained with hematoxylin and eosin. Magnification $\times$ 35.

29 Interventricular septal defect of moderate size occupying entire region of the membranous portion of the septum, in a 20-day fetus from an A deficient mother. Note that the muscular portion of the septum is well formed.

30 Incomplete truncoconal septum in a 20-day fetus from an A deficient mother. The communication between the region of the aortic valve and the pulmonary conus, seen here, in more caudal sections became wider and eventually continuous with a moderately large interventricular septal defect.

31 Large interventricular septal defect in an 18-day fetus from an A deficient mother. The foramen is of such large size as to suggest that the muscular portion of the septum, as well as the membranous component, was under developed.

32 Highly trabeculated heart muscle in an 18-day fetus from an A deficient mother. The ventricular wall has a spongy character resembling that seen in much younger normal hearts (compare with fig. 15), but much more highly trabeculated than a normally compact heart (see fig. 30).


intervent. foramen
lt. ventricle
rt. ventricle
muscular septum

29

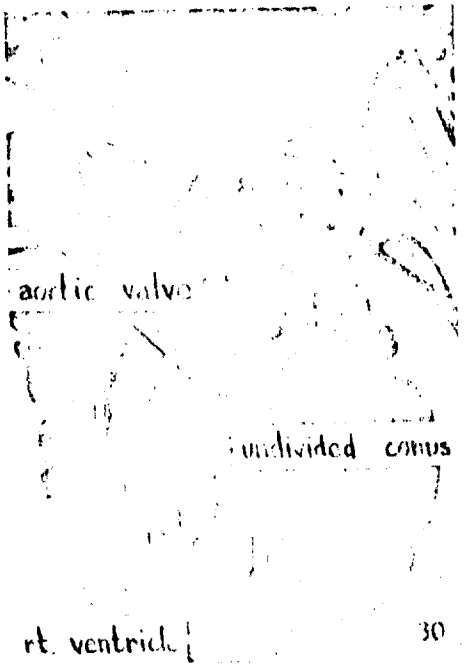
aortic valve
undivided conus
rt. ventricle

30


aortic valve
intervent. foramen
muscular septum
rt. ventricle

31

rt. ventricle
lt. ventricle

32

Wilson-'49
Bib. No. 9862

Proc. Soc. Exptl. Biol. Med. 72(3):687-693. 1949.

Fetal Death and Maldevelopment Resulting from Maternal Vitamin A Deficiency in the Rat.* (17543)

JAMES G. WILSON AND STEPHANIE BARCH (Introduced by Karl E. Mason)

From the Department of Anatomy, School of Medicine and Dentistry, University of Rochester, Rochester, N. Y.

The course of pregnancy may be severely altered by feeding female rats a diet restricted in vitamin A, the severity of the alteration being roughly proportional to the degree of vitamin deprivation. Death and resorption of the fetuses, prolongation of pregnancy, and delivery of stillborn young were reported by Mason(1) and Cannon(2) who employed deficient diets with little or no supplement of vitamin A or carotene. Warkany and Schraffenberger(3,4) using similar diets supplemented with small amounts of carotene also noted a high incidence of fetal resorption; but, by interrupting pregnancy at various times from the 13th day to term, they were able to obtain a number of living and recently dead fetuses and newborns suitable for histologic study. The eyes of these offspring were found to bear several developmental anomalies, notably: folding and eversion of the retina, persistence of the choroidal fissure, absence of the ciliary body, and postlenticular fibroplasia. Thus, deficiency of vitamin A in the diet of female rats prior to and during pregnancy not only reduces fecundity by

* Supported by a grant from the Nutrition Foundation, Inc., New York.

1. Mason, K. E., *Am. J. Anat.*, 1935, v57, 303.
2. Cannon, M. D., PROC. SOC. EXP. BIOL. AND MED., 1940, v44, 129.
3. Warkany, J., and Schraffenberger, E., PROC. SOC. EXP. BIOL. AND MED., 1944, v57, 49.
4. Warkany, J., and Schraffenberger, E., *Arch. Ophthal.*, 1946, v35, 150.

causing fetal death and resorption, but also causes developmental anomalies in many of the fetuses that escape intrauterine death.

The widespread interest aroused by the success of Warkany and his collaborators in producing congenital malformations by means of maternal vitamin A deficiency makes it desirable that the work be repeated in another laboratory. To date the only published account of attempts to repeat the experiment elsewhere was that of Jackson and Kinsey,(5) who did obtain a few newborn rats with ocular malformations; but the positive results of this investigation were of such limited nature as to cast doubt on the facility and regularity with which such defective young might be produced. One of us (J.G.W.) has been associated with Dr. Warkany in a morphologic and embryologic study of the malformed fetuses and newborns obtained from the experiments carried out in Cincinnati. Since certain material needed for further investigation of this subject (placentae and early embryonic stages prepared especially for histochemical study) was not readily available from Dr. Warkany's laboratory, it was decided to produce it in this laboratory. The present report relates the repetition of the original experiment and, in addition, presents some observations not previously recorded.

Experimental. Vitamin A deficiency was induced and maintained by the same diets and experimental procedures as were employed in Warkany's original experiments,(3,4) except for the quantity and method of administration of the carotene supplement, and a few other matters of incidental nature specified below. Rats of two strains were used, the Albino Farms and the Wistar; the latter had not been used previously for this type of experiment. Since no difference in reaction to the experimental procedures was detected in animals from the different sources, the matter of strain will receive no further mention. A total of 36 young females were raised from weaning on a semipurified, "preparatory" diet which contained very little vitamin A or carotene. To insure continued growth to maturity a 15 microgram dose of carotene in olive oil was administered orally each week. Presumably this dosage did not permit appreciable storage of vitamin A. When the animals had attained a body weight of about 160 g, each female was given an opportunity to breed with a male of the same strain fed an adequate diet. If mating occurred, as indicated by presence of sperm in the vaginal smear, the female was transferred to a more highly purified diet which was adequate in all known respects except for the lack of vitamin A. No further supplemental dosing with carotene was given. The day on the morning of which sperm were found in the vaginal smear was considered the first day of pregnancy. Eight control females were fed the same diets and subjected to the same procedures but were given weekly supplements of 150 μg of carotene, both prior to and during pregnancy.

From the experience of other investigators,(1,2,6) it was expected that a large percentage of the pregnant females on vitamin A deficient diets would resorb all of their conceptuses at some time before term. On the other hand, Warkany and Roth(6) found that approximately 25% of the conceptuses which survived until the latter part of pregnancy were developmentally normal. The margin between fetal destruction and normal development, therefore, appears to be very narrow. One of the aims of the present experiment was to attempt to establish criteria by which one might predict ultimate destruction of the conceptuses, thereby making it possible to obtain prior to death embryos which were destined to undergo resorption later. Mason(1) observed that the presence of cornified cells in the vaginal smear during pregnancy was frequently associated with subsequent fetal death and resorption. Warkany and Schraffenberger(4) considered excessive amounts of blood in the vaginal smear and a loss of weight by the mother as indications that resorption had already begun. It was hoped that by carefully watching for all of these signs (cornified cells in the vaginal smear, excessive blood in the smear, and loss of weight

5. Jackson, B., and Kinsey, V. E., *Am. J. Ophthal.*, 1946, v29, 1236.

6. Warkany, J., and Roth, C. B., *J. Nutrition*, 1948, v35, 1.

TABLE I.
Course and Termination of Pregnancy in Vitamin A Deficient and Control Rats.

Age of fetuses when removed or delivered, days	Days of pregnancy on which untoward signs were observed			Condition of young		
	Cornified cells in smear (25% or more)	Abnormal blood in smear	Wt loss by mother	No. dead or resorb.	No. living	Mal-formed
22	—	—	19	0	11	No
22	—	—	—	2	7	Yes
22	—	—	11	2	8	Yes
20	6–16, 18, 20	18, 20	14	all		
19	7–14, 17, 18	10, 11, 16, 19	—	3	6	Yes
19	—	19	14	4	8	Yes
19	19	15, 17, 18	15, 18, 19	all		
19	7–18	10, 11, 19	15, 16	all		
18	4–11, 13, 14, 17, 18	15, 17, 18	13	all		
17	—	15, 16, 17	12, 13, 15	7	5	Yes
16	13–16	15	12, 14	all		
16	8, 10, 11	11, 15	14, 15, 16	all		
15	8–15	15	—	all		
15	1–13	11	14, 15	all		
15	9–11, 13	15	11	all		
15	4, 9, 14	15	13, 15	5	5	Yes
Controls						
22	—	—	12	3	9	No
22	—	15, 16	—	0	3	No
22	13, 14	17–20	13	4	4	No
22	—	—	—	0	14	No
22	—	—	—	0	7	No
20	—	—	—	1	13	No
17	—	—	13	0	11	No

by the mother) the future course of pregnancy might be determined with some degree of accuracy.

Fetal death. Of the 36 females raised until maturity on the preparatory diet 34 mated as indicated by sperm in the vaginal smear, but only 30 were later verified to have become pregnant. The first 16 pregnancies, after being transferred to the more highly purified diet, were allowed to continue to term or until there was definite evidence of prior resorption of some of the fetuses. Thus, this group provided a check on the reliability of the proposed criteria to be used in predicting intra-uterine destruction of the fetuses. Only 3 of these 16 pregnancies were sufficiently uneventful that they were allowed to proceed to the 22nd day of gestation (Table I). Thirteen were interrupted earlier by killing the mother when it was judged unlikely that any of the conceptuses would survive until term. Such judgment was made after at least two, and usually all, of the following signs became positive: 1) 25% or more of cornified cells in the vaginal smear during pregnancy; 2) blood in the vaginal smear in excess of, or at times other than, that characteristic of the "placental sign", which appears normally as a trace between the 11th and 15th days; and 3) a loss of weight by the mother, particularly after the 10th day.

It is apparent from the data in Table I that these criteria were of value in indicating the fate of the fetuses. In the absence of cornified cells and abnormal quantities of blood in the vaginal smear, a majority of the fetuses may be expected to survive until the 22nd day, as was observed in 3 vitamin A deficient and a large percentage of the control mothers. Conversely, cornified cells, to the extent of 25% or more were observed at one time or another in 11 of 13 females whose pregnancy was later interrupted. All fetuses in 9 and several in the remaining 2 pregnancies were dead or already undergoing resorption. Two A deficient females, whose pregnancy was interrupted for other reasons, failed to show as much as 25% of cornified

FIG. 1. a. Varying degrees of edema in young rats removed on the 22nd day of gestation from a mother fed vitamin A deficient diets. b. A normal newborn rat from a mother fed vitamin A deficient diets but supplemented with 150 μg of carotene per week.

FIG. 2. Abnormal eye of a 22-day rat fetus, from a vitamin A deficient mother. The nervous layer of the retina is deeply folded, contains cysts, and is everted on to the pigmented layer in the region of the optic stalk and along the persistent choroid fissure. The vitreous chamber is reduced to a small cone-shaped volume which is filled with fibrous connective tissue and remnants of the hyaloid artery. Retinal coloboma was present but is not apparent in this section. × 25.

FIG. 3. Ectopic openings of ureters in a 19-day rat fetus from an A deficient mother. The left ureter is seen to terminate in the urethra, at some distance below its usual termination at the base of the bladder (normally attained by the 17th day). The right ureter emptied at an even lower level in the urethra. × 25.

FIG. 4. Horseshoe kidney in a 19-day rat fetus from an A deficient mother. × 25.

FIG. 5. Persisting interventricular foramen in the heart of a 19-day rat fetus from an A deficient mother. The foramen is normally closed by the 17th day of gestation. × 25.

FIG. 6. Right-sided aorta and right-sided ductus arteriosus in a 19-day rat fetus from an A deficient mother. The left subclavian artery is also anomalous in that it arises from the descending aorta and passes behind the esophagus to reach the left shoulder. × 25.

cells at any time during pregnancy; and both yielded some living young.

Blood in the vaginal smear, in excess of or at times other than that seen during the placental sign, was noted in all of the pregnancies which were later interrupted (Table I). This would seem to be in itself an excellent indicator of fetal destruction, were it not for the fact that a subjective estimate of the quantity of blood is necessary when it appears at the same time as the placental sign. A further limitation of this criterion was noted in that, prior to the 15th day, death and partial resorption of all fetuses often occurred before excessive blood was present in the vagina. On the other hand, when resorption of some conceptuses began during the last third of pregnancy, the quantity of abnormal blood was roughly proportional to the extent of fetal destruction. Two controls showed what was judged to be abnormal blood, and in both cases there was evidence that resorption of some fetuses had begun late in pregnancy.

Loss of weight in the mother was recorded for all but 2 of the pregnancies interrupted prematurely. Also, it was observed in 3 of the controls. The degree of loss was of more significance than the mere fact that a female failed to gain weight. Both the degree and rate of loss appeared to be determined by the number of fetuses undergoing resorption at any one time, as well as by the size of the fetuses at the time of their death.

Thus, of the 3 criteria used in following the course of pregnancy in vitamin A deficient females, no one was found to entirely reliable as an indicator of fetal destruction. However, when all 3 of these signs became positive during pregnancy, several if not all of the fetuses of that pregnancy were later found to have undergone intra-uterine destruction. Pregnancies interrupted after the appearance of only 2 of the criteria, despite the fact that they were not interrupted immediately, generally yielded some living young.

In an additional group of 14 vitamin A deficient females (not included in Table I) pregnancy was interrupted immediately when the second of any 2 of the signs described above became positive. Accordingly, all of these were killed between the 11th and 15th days. Of this group, 12 females yielded intact embryos, and all but one of these contained more intact than resorbed embryos. This procedure, therefore, proved successful as a means of recognizing impending destruction of the conceptuses, thereby providing embryos and placentae which, although doubtless affected by maternal vitamin A deficiency, had not yet begun disintegration. This material is being prepared for histologic and histo-chemical study of the early stages of abnormality in the embryos and of possible associated changes in the placentae.

Malformation of the surviving fetuses. Nineteen of the vitamin A deficient females mentioned in the preceding section yielded offspring suitable for histologic study, but only the fetuses of 15 days gestational age or older have yet been examined for malformations. Of the 7 "litters" comprising the latter group (Table I), all but one contained malformed fetuses. The one litter of normal offspring was from one of the 3 pregnancies which proceeded to term without appreciable indica-

tions of fetal destruction. No malformations or other abnormalities were found in the offspring of the control animals, which were fed the same diets and subjected to the same procedures as the A deficient mothers except that the controls were given 150 micrograms of carotene per week, both prior to and during pregnancy.

From the 6 abnormal litters older than the 14th day, at least 2 and in most cases all of the young have been serially sectioned and studied. Abnormality of the older fetuses was evident before sectioning by external appearance alone: the characteristic edema of head, neck and thorax was apparent to a variable degree in all (Fig. 1 a and b). Hemorrhage in the region of the eye and prenatal opening of the lids were occasionally noted.

Warkany and collaborators(7) have reported that ocular abnormality was the most prevalent type of developmental defect resulting from material vitamin A deficiency. This was substantiated by microscopic study of animals from the 6 abnormal litters listed in Table I. All such animals examined had ocular anomalies, the more common of which were: folding and eversion of the retina, presence of a mass of fibrous connective tissue in the much reduced vitreous chamber, persistence of the choroidal fissure (coloboma), and absence of the ciliary body (Fig. 2).

Genito-urinary organs also were frequently found to be the sites of malformation in earlier observations.(8) The same types of defects have again been encountered in a similar percentage of animals. Among the commoner abnormalities in both instances were hypoplasia of renal parenchyma, renal ectopia, ectopic ureteric openings (Fig. 3), incomplete development of Müllerian ducts, abnormal retention of heterologous genital ducts in both sexes, aplasia of vagina and faulty differentiation of the urogenital sinus. Less frequent abnormalities were horseshoe kidneys (Fig. 4), cryptorchidism, hypospadias, and atresia of genital ducts and ureters.

Cardiovascular anomalies were found in 44% of a selected group of fetuses and newborns from vitamin A deficient mothers in a previous study.(9) In the present, somewhat smaller group of animals an even higher incidence (more than 60%) of malformations of the heart and major arteries was observed. In general, the anomalies were of the same type, but a few varieties not previously seen were encountered. Failure of the interventricular septum to close was again the most common defect of the heart (Fig. 5). Variations in the aortic-arch pattern frequently observed in both instances were: distally-arising right subclavian artery, right-sided arch of aorta (Fig. 6), double arch of aorta, absence of left arch, absence or bilateral persistence of the ductus arteriosus, and absence of a pulmonary artery.

The occurrence of keratinizing metaplasia in epithelia of the lower genito-urinary tract of the offspring from A deficient mothers has been interpreted as indicating that such offspring had themselves experienced *in utero* a state of deficiency similar to that in the mother.(10) The same interpretation may be applied to the present group of animals, in which metaplastic keratinization was again observed in the genito-urinary tract of fetuses older than 18 days gestational age.

Summary. This report constitutes a confirmation of the original experiments of Warkany and co-workers in which congenital malformations were induced in fetal and newborn rats by maintaining the mothers on vitamin A deficient diets. In addition, a method has been standardized which permits prior recognition of imminent death and resorption of the conceptuses, thereby making it possible to collect many severely malformed fetuses that would otherwise be destroyed *in utero*. Three criteria that proved reliable in anticipating prenatal destruction of fetuses were: 1) the presence of more than 25% of cornified cells in the vaginal smear at any time during pregnancy: 2) the presence of blood in the vaginal smear in excess of or at times other than that

7. Warkany, J., Roth, C. B., and Wilson, J. G., *Pediatrics*, 1948, v1, 462.

8. Wilson, J. G., and Warkany, J., *Am. J. Anat.*, 1948, v83, 357.

9. Wilson, J. G., and Warkany, J., *Am. J. Anat.*, 1949, v85, 113.

10. Wilson, J. G., and Warkany, J., PROC. SOC. EXP. BIOL. AND MED., 1947, v64, 419.

comprising the usual placental sign; and 3) a loss of weight by the mother after the 10th day of pregnancy.

Malformations involving the eye, cardiovascular system, and genito-urinary tract were found in the fetuses or newborns from all but one of the pregnancies from which intact offspring were obtained after the 14th day of gestation.

Received October 26, 1949. P.S.E.B.M., 1949, v72.

Wilson-'50
Bib. No. 9863

Pediatrics 5(4):708-725. 1950.

CARDIAC AND AORTIC ARCH ANOMALIES IN THE OFFSPRING OF VITAMIN A DEFICIENT RATS CORRELATED WITH SIMILAR HUMAN ANOMALIES

By JAMES G. WILSON, M.D., AND JOSEF WARKANY, M.D.
Cincinnati

INTEREST in congenital malformations of the heart has increased in recent years. Roentgenologic, electrocardiographic and other clinical methods now make possible the diagnosis of many types of congenital cardiac malformations which previously could not be recognized during life. Progress in diagnostic and operative technic has led to excellent results in cardiac surgery and a better prognosis for many children with congenital heart disease. Simultaneously, there has arisen a renewed interest in the etiology and development of congenital malformations of the heart.

Regarding etiology, many students of this subject (Abbott,[1] Brown,[2] Thomson,[3] Schoenberg[4] and others) have concluded that genetic factors are not prominent in the causation of congenital cardiac anomalies, although in rare instances certain defects have been attributed to inheritance. Septal defects in a parent and child were observed by Debré,[5] Seitz and Baumann[6] (father and four children), Walker and Ellis[7] and Tucker and Kinney.[8] Patent ductus arteriosus was reported in a father and four of his children by Walker and Ellis[7] and in a man, two of his children and two grandchildren by Taussig.[9] Coarctation of the aorta in father and son was described by Walker.[10] Brown[2] states that dextrocardia in four generations of one family was described by Lancisi in 1701 and in three generations by Muir. It has been frequently reported that there is a high incidence of congenital heart disease in arachnodactyly[2,9] which is often inherited as a dominant trait. These examples suggest that occasionally congenital anomalies of the heart are inherited by a dominant mode of transmission.

When congenital anomalies of the heart are observed in more than one member of a family, they are more often seen in siblings than in successive generations.[1] This fact can be interpreted in two ways: either as a manifestation of recessive inheritance or as the result of unfavorable environmental (including maternal) conditions common to several pregnancies. That recessive inheritance may play a role in the causation of congenital heart disease in indicated by several observations. Roesler,[11] as well as Lamy and Schweisguth,[12] found a higher incidence of consanguinity among the parents of children with congenital heart disease than in the general population. Congenital heart disease sometimes occurs in syndromes which are considered genetic in origin and

From the Department of Anatomy, School of Medicine and Dentistry, University of Rochester, N.Y., and from the Children's Hospital Research Foundation, Department of Pediatrics, College of Medicine, University of Cincinnati, Cincinnati, Ohio.

Read before the 58th Annual Meeting of the American Pediatric Society in Quebec, Canada, May 26, 1948.

This work was aided in part by grants from the Nutrition Foundation, Inc., New York, N.Y.
(Received for publication July 15, 1949.)

inherited as recessive traits. Cockayne[13] has pointed out that there is, in addition to dextrocardia, a high incidence of congenital heart disease in individuals with complete transposition of the viscera, an anomaly which he considers to be inherited as a recessive trait. Similarly, anomalies of the heart are not rare in patients with gargoylism or with the Laurence-Moon-Biedl syndrome, which are both thought to be inherited as recessive traits. Thus it is likely that in certain instances congenital anomalies of the heart are genetically determined.

On the other hand, there is no doubt that the heart can be deformed by adverse environmental conditions in early fetal life. This has been demonstrated clearly by the finding of congenital cardiac defects, such as patent ductus arteriosus, patent foramen ovale and interventricular septal defect in children whose mothers had rubella in the first two months of pregnancy.[14,15] Other maternal factors are probably responsible for congenital anomalies of the heart which occur in mongoloid children. The nature of these factors is not yet known but they are present in older mothers more often than in younger ones.

It may be said, then, that genetic as well as environmental factors may determine abnormal development of the heart. However, in the majority of children with congenital heart disease, the determining etiologic factor remains obscure.

It is of interest that in rat experiments disturbance of the embryo brought about by maternal dietary deficiency may result in congenital malformations of the heart and the great vessels. Such experiments do not simulate human conditions and it is not suggested that dietary deficiency of the mother is an important cause of congenital cardiac malformations in man. However, it should be kept in mind that nutritional disturbance of the fetus may be induced by factors other than maternal dietary deficiency. Maternal disease, maternal metabolic imbalance, or anomalies of the embryonic membranes or placenta have been proposed as conditions which may interrupt the normal nutrition of the embryo and thus may conceivably result in anomalous development. In this sense, the experiments presented here could exemplify a mechanism by which malformations may be brought about through interference with the normal metabolism of the embryo.

The offspring of female rats fed vitamin A deficient diets prior to and during pregnancy are known to bear congenital malformations in several organ-systems.[16] Approximately 75% of such offspring had various developmental anomalies of the eyes.[17] Numerous malformations were found in the genito-urinary organs,[18] and some of these were almost as frequent in occurrence as the ocular defects. Anomalies of the heart and major thoracic arteries were noted less frequently, but these are of particular interest because they show remarkable similarity to many congenital cardiovascular conditions that occur in man. An embryologic and anatomic analysis of these defects in the heart and major arteries of the rat has recently been presented.[19] The purpose of the present report is to emphasize the similarities between the cardiovascular anomalies produced experimentally in the rat and some of those which occur "spontaneously" in man. Thereby, it is hoped that analogies drawn between the anomalies in the two species may contribute toward a better understanding of these conditions in human beings.

Methods

The method by which vitamin A deficiency was induced and maintained in female rats has been described in detail elsewhere,[11] and only a summary of the general experimental procedures need be presented here. After weaning, young female rats were placed on a diet that was nutritionally ade-

quate but contained only the minimal quantity of carotene that would permit continued growth. Presumably this allowed for little or no storage of vitamin A. This diet was continued until the animals reached a weight of 160 gm. at which time they were approximately 3 mo. of age and had attained sexual maturity. The females were then given a purified diet containing no carotene or vitamin A, and were given the opportunity to breed with males of the same strain that had been fed an adequate diet. Successful matings were indicated by the presence of sperm in the vaginal smear. The incidence and course of pregnancy was determined by taking daily weight and vaginal smear records. Of a group of 400 females subjected to this procedure, 334 mated, as evidenced by sperm in the vaginal smear; but no offspring were obtained from 184 of these due to early resorption or other forms of gestational failure. Offspring were obtained from 150 females, but only 37 of the mothers carried their young to term on the 22nd day. Fetuses were removed from 113 females between the 13th and 21st days, when it became apparent that pregnancy might be terminated spontaneously. Thus a total of 1,168 young was obtained.

As mentioned, about 75% of the offspring from vitamin A deficient mothers possessed some developmental defect of the eyes. No instance has yet been found of another anomaly existing in the absence of ocular malformation. Therefore, using ocular abnormality as a criterion, 64 fetuses and newborns known to be affected by maternal vitamin A deficiency were selected for study of the heart and major thoracic arteries. Only fetuses of 17 days' gestational age and older were included in this group since the definitive conditions of the cardiac septa and of the aortic arches are not normally attained until shortly before the 17th day. The animals thus selected from the young of vitamin A deficient mothers, together with 19 control fetuses and newborns of comparable age from mothers fed an adequate diet, were serially sectioned and prepared for microscopic study. Wax-plate reconstructions of the heart and major arteries were prepared from 5 animals in which these viscera were malformed, and from 2 of the controls, in order to verify the accuracy with which anomalies could be diagnosed from a study of serial sections. Many of the young sectioned were selected because of their abnormal appearance or because of conspicuous anomalies of the eyes. The percentage incidence of cardiovascular malformations in this selected group of fetuses is, therefore, probably higher than that in the total of offspring obtained from all pregnancies in this experiment.

Results

Septal Defects

Interventricular Septal Defect: Normally the interventricular septum is completely closed in the rat by the 17th day of gestation.[19] However, in 22 of 64 fetuses and newborns (34.4%) removed from vitamin A deficient mothers between the 17th and 22nd days of gestation, the septum was not closed and a foramen of variable size persisted between the right and left ventricles. In a majority of these the defect was localized in the base of the septum (Fig. 1). The defects in three fetuses were of such small size that it is doubtful they would have been of any functional significance in postnatal life. On the other hand, five fetuses possessed interventricular foramina of sufficiently large size to indicate that the muscular as well as the membranous septum was deficient. In three of these, the interventricular defect was associated with incomplete closure of the caudal end of the aortic-pulmonary septum. The heart in one of the latter resembled the condition Cor triloculare biatrium in that the ventricular region consisted of a single chamber, with only slight indication of even the muscular septum. In several instances the origin of the aorta appeared to be dextraposed and to override the septal defect, simulating the Eisenmenger complex of human cardiology. Since the position of the aorta may change in early postnatal life, and undergo a relative shift to the left, thus correcting the dextroposition, the final outcome might still have been a simple interventricular defect.

It is evident from the foregoing that the interventricular septal defects observed in rats

were morphologically similar to and covered about the same range of variation as the comparable defect in man. In both species this anomaly has been found more often in association with other cardiovascular defects than as an isolated anomaly. Only 6 of 22 cases in rats occurred in the absence of any other cardiovascular malformation. Abbott[20] cites 274 instances in man, of which only 50 were not complicated by other defects of the heart or major arteries.

The present authors know of no attempt to correlate the occurrence of interventricular defect with that of any particular aortic arch anomalies in man, although such a correlation has been possible to some extent in the animals used in this study. It was noted[19] that the

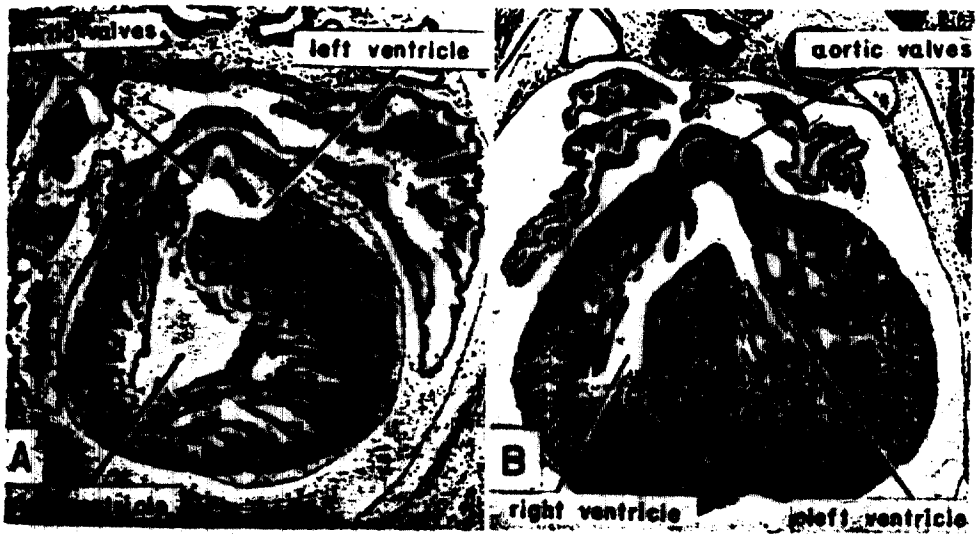

FIG. 1. Sections of hearts of abnormal young rats from vitamin A deficient mothers. A. Small interventricular defect. B. Larger interventricular defect.

septum always remained open when the arch of the aorta (fourth embryonic arch) was absent, or when a ductus arteriosus (sixth embryonic arch) failed to form or to remain patent during the latter part of fetal life. In either circumstance the ventricles of the heart could not have developed properly unless the interventricular septum had remained open to provide a shunt from one chamber to the other (except in the rare contingency of a persisting third embryonic arch). Conversely, the septum was rarely open when the persisting embryonic arches connecting the heart with the descending aorta exceeded the usual number. If similar correlations could be established for human cardiovascular anomalies, such information might prove useful in clinical or surgical considerations.

Aortico-Pulmonary Septal Defect: In addition to the three cases mentioned in which the caudal end of the aortico-pulmonary septum was incomplete, there was found in one specimen a more extensive defect of this septum. In this case, which is described on page 718 in detail, there was a partial truncus communis persistens. The ascending aorta and the pulmonary trunk were confluent in their proximal and distal portions, being separated only in a short middle segment. Partial truncus arteriosus communis was described as early as 1875 by von Rokitansky and by Clarke in 1885.[21] In an analysis of 1000 cases of congenital cardiac disease, Abbott[20] reported 10 cases of partial and 21 of complete truncus persistens.

Aortic Arch Anomalies

As employed here, the term "aortic arch anomaly" refers to any divergence from the normal pattern in the major arteries that are derived from the aortic arch system of the embryo. Aortic arch anomalies were found in 22 of the 64 fetuses and newborns from vitamin A deficient mothers. This rate of incidence happens to be the same as that noted for ventricular septal defect, but as already stated these two types of cardiovascular malformation did not always occur simultaneously. In 16 instances aortic arch anomalies were associated with open ventricular septum, but in six cases they occurred alone.

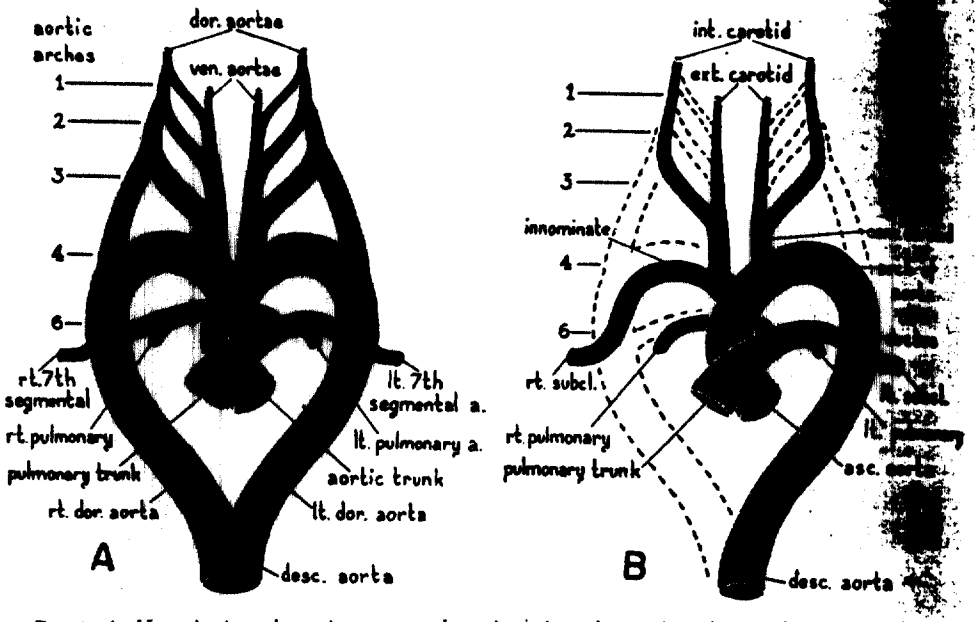

FIG. 2. A. Hypothetic embryonic pattern of aortic arches. At no time during development in mammals are all arches present simultaneously, but they are represented here in cumulative arrangement in order to emphasize their positional relationships. B. Definitive pattern of arteries derived from embryonic aortic arch system. Parts of embryonic system that underwent complete or partial regression are indicated in broken lines.

The aortic arch system of the embryo is transformed into the definitive pattern of major arteries of the chest and neck by processes involving retention of some embryonic parts and involution of others. These processes of differentiation are normally completed by the 16th day of gestation in the rat.[19]

A total of six pairs of aortic arches is said to comprise the aortic arch system of higher vertebrates; but in most mammals, including rat and man, the fifth pair remains rudimentary or unrecognizable. At no time are all of the arches present simultaneously for they appear in temporal succession and before the last pair appears the first two pairs have undergone regression. The third, fourth and sixth pairs are retained and utilized in the formation of the definitive pattern of major arteries. The manner in which this transformation occurs is schematically represented in figure 2.

Right Subclavian Artery Arising Distally and Passing Dorsal to Esophagus: This condition in man is variously designated as "retro-esophageal right subclavian artery," "right subclavian artery as last branch of aortic arch" and simply "anomalous right subclavian artery."

The anomaly in question consists of the right subclavian artery arising as the last major branch of the thoracic aorta, instead of from the innominate artery, and passing posterior to the esophagus on its course to the right shoulder region.

This variation was observed in uncomplicated form in four rat fetuses from vitamin A deficient mothers, and was the most commonly occurring anomaly of the several types encountered. All the published cases of the corresponding anomaly in man have not been collected and enumerated, but a minimal estimate would place the reported cases at several hundred (see Poynter[21]). Unquestionably this is the most frequently encountered congenital abnormality of thoracic arteries that may have clinical significance. Exactly as in the comparable

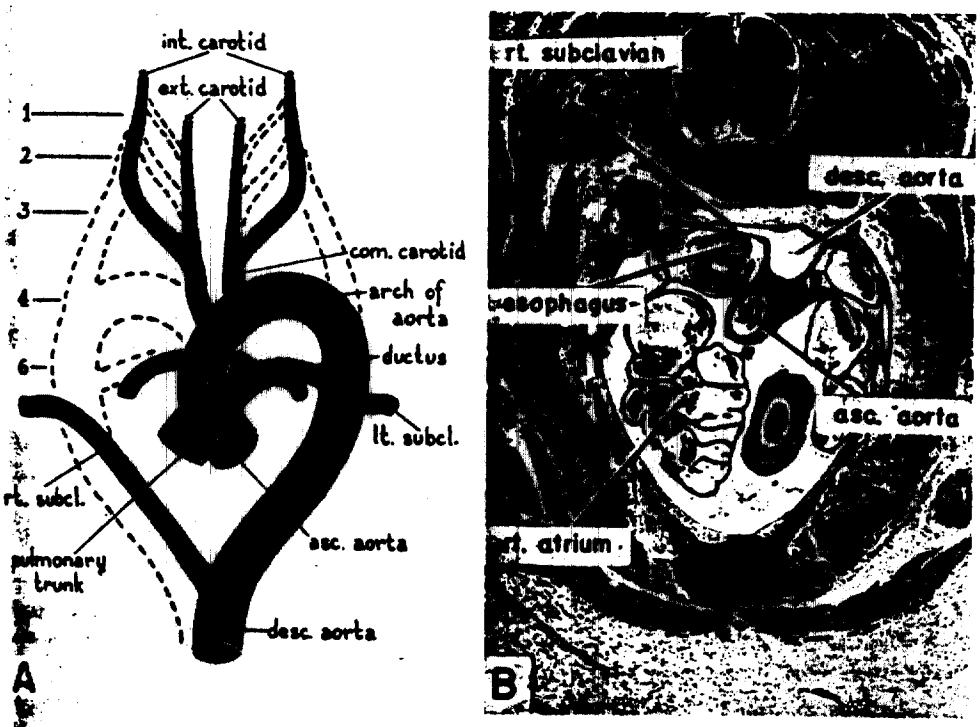

FIG. 3. A. Scheme of right subclavian artery that arises distally and passes dorsally behind esophagus. B. Photomicrograph of section through upper thoracic region of abnormal newborn rat showing distally arising right subclavian artery as it leaves descending aorta to cross midline behind esophagus.

malformations in man, the right subclavian artery of the rats arose as the last major branch of the thoracic aorta and crossed from the left to the right side of the midline by passing between the vertebral column and the esophagus (Fig. 3). The posterior aspect of the esophagus in the rat was not appreciably indented at the point at which it was traversed by the anomalous artery, but one would hardly expect a conspicuous degree of "notching" until the esophagus assumed full functional activity after birth. This anomaly of the right subclavian artery has been well known since the 18th century and was first explained developmentally by Wood in 1859.[21] It was described as a cause of dysphagia by Bayford in 1794,[22] but it is known now that pathologic manifestations of this anomaly are the exception rather than the rule. When crossing between the esophagus and the vertebral column, an anomalous right subclavian artery may press on the esophagus and reduce its

lumen, an impingement which can be demonstrated by roentgenographic examination of a barium-filled esophagus.[23] In case of dysphagia the abnormal subclavian artery can be divided and the esophageal pressure thereby relieved.[24] In a series of 610 cyanotic patients with a preoperative diagnosis of pulmonic stenosis, Blalock[25] observed a retroesophageal subclavian artery 26 times, and the anomalous vessel was used by him to complete an anastomosis between the pulmonary and systemic circulation.

Right-sided Arch of the Aorta: In five rat fetuses the right fourth instead of the left fourth embryonic arch was retained as the arch of the aorta (Fig. 4). The arterial pattern

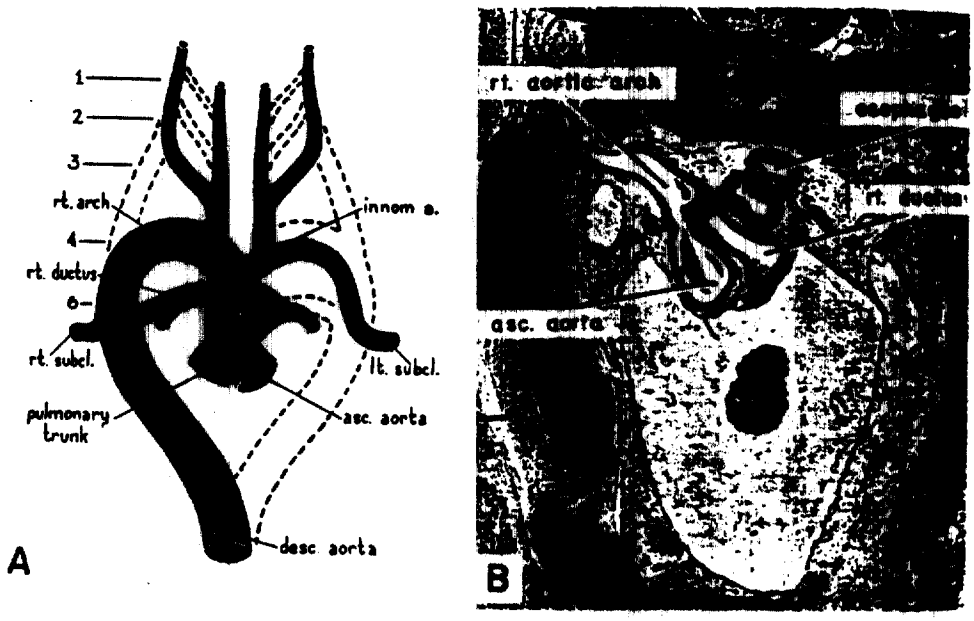

FIG. 4. A. Scheme of right aortic arch which is mirror-image of normal aortic arch pattern. Right-sided ductus arteriosus seen in this scheme and observed in several rats is only rarely seen in man. B. Photomicrograph showing right aortic arch and right ductus arteriosus.

in no two of these was quite alike, owing to variations in other arteries. Only one fetus had an arrangement of arteries that comprised a mirror image of the normal pattern: That is, the arch of the aorta, the ductus arteriosus, and the descending aorta were all on the right side of the midline; and the innominate artery arose as the first branch of the arch and passed to the left. This is not a common type of right-sided arch in man, but it has been recognized in some human cases in which the ligamentum arteriosum as well as the arch was on the right side.[26] A second variant of the right-arch pattern seen in one rat differed from the one just described in that it lacked a left pulmonary artery.

The right-arch-right-ductus pattern was varied further in one fetus which had a distal left subclavian artery arising as the last major branch of the right-sided aorta and coursing behind the esophagus to reach the left shoulder region. This situation represents a mirror-image of the distal right subclavian arising from the normal left-sided aorta. It is rare in man;[27] only about 10 cases have been recorded. This pattern in the rat fetus was modified by the absence of a left pulmonary artery and by the origin of both common carotid arteries from a single carotid trunk.

A fourth variant of the right-arch-right-ductus pattern was seen in one rat in which the

left subclavian arose, not from a left-sided innominate or directly from the right-sided thoracic aorta, but from the left pulmonary artery. This particular arrangement of arteries has never been described in man, but on theoretic grounds it could occur. The outstanding symptom of such a hypothetic case probably would be cyanosis limited to the left shoulder and upper extremity, since these regions would receive blood primarily from the right ventricle. No major vessel would course obliquely behind the esophagus; hence, notching or anterior displacement of the latter structure would not be expected.

The fifth type of right-arch-right-ductus anomaly, also found in only one rat, consisted

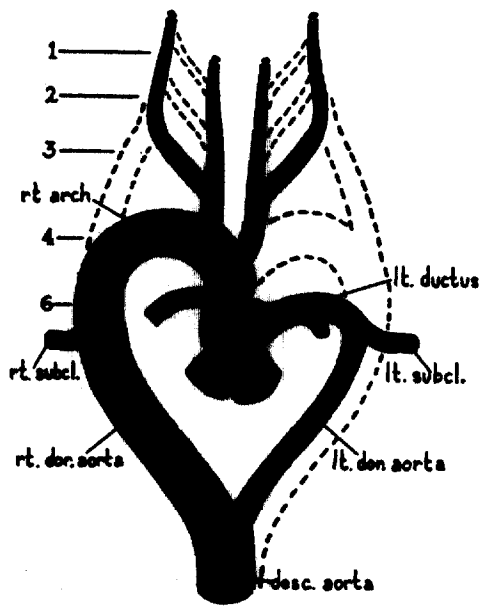

FIG. 5. Scheme of right aortic arch illustrating type which is relatively frequently found in man. Left ductus joins distal left subclavian which arises from left dorsal aortic root.

of a left as well as a right ductus arteriosus (sixth embryonic arch) with the former joining a distal left subclavian artery. This arrangement constituted a vascular ring which encircled the trachea and esophagus; with the right half of the ring formed by the right arch of the aorta, right ductus and right-sided descending aorta; and the left half by the left ductus and the remains of the embryonic left dorsal aorta. The left subclavian artery arose from the left half of the ring at the point where the left ductus joined the left aortic remnant. If after birth the left ductus had undergone the usual type of regression to form a ligamentum arteriosum, the arterial pattern would have closely resembled the right arch with distal left subclavian as described. This arrangement, right-arch-double-ductus, has not been recorded in man. It might easily have been overlooked, however, for if both the right and left ducti underwent regression after birth, the apparent resulting pattern would have been simply right arch with distal left subclavian. An additional ligamentum arteriosum on the right side could be missed in surgery or necropsy unless specifically sought, and in many of the reported cases the position was not stated. Of incidental interest in the present connection is the fact that in the rat fetus with right-arch-double-ductus, the right sixth arch (ductus and pulmonary artery) arose from the ascending aorta instead of from the pulmonary trunk. The most common type of right arch in man is one in which a single ductus

(ligamentum) arteriosus is present on the left side and attached to a distal left [illegible] artery. In such cases the subclavian artery is usually described as arising from [illegible] diverticulum" (see Gross and Ware,[24] Fig. 3) which is in reality the remain[illegible] dorsal aorta of the embryo.

Two varieties of right-sided arch of aorta described relatively frequently in [illegible] found in the present group of rat fetuses and newborns. In both of these ty[illegible] ligamentum arteriosum passes from the pulmonary trunk to the left side. In [illegible] alluded to above, the ligamentum appears to join a distal left subclavian which [illegible] a left aortic diverticulum (Fig. 5). In the other the ligamentum joins the left [illegible]

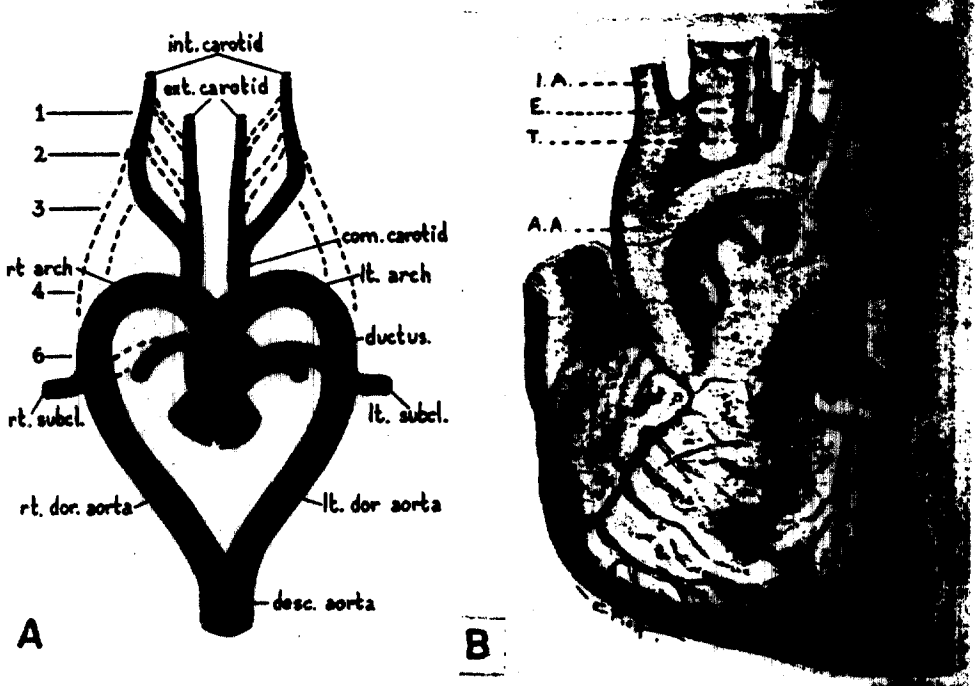

FIG. 6. A. Scheme of double aortic arch with left-sided ductus (ligamentum) arteriosus. [illegible] aortic arch in child with respiratory difficulties. Child was successfully operated on by D[illegible] R. E. Gross.[22] Ascending aorta bifurcates into 2 branches; one passes behind esophagus; other [illegible] in front of trachea. Two branches join to form descending aorta. Within vascular ring esophagus and trachea are compressed. AA-ascending aorta; E-esophagus; IA-innominate artery; J-junction of 2 aortic arches; LA-ligamentum arteriosum; LCCA-left common carotid artery; LSA-left subclavian artery; PA-pulmonary artery, and T-trachea. Ligamentum arteriosum was divided to allow pulmonary artery to be displaced forward. Anterior arch of aorta was divided to relieve compression of trachea. (Courtesy of Dr. R. E. Gross.)

ticulum which is connected with the descending aorta, while the left subclavian arises from a left-sided innominate artery. The latter group is characterized by a descending aorta which begins in the right side but then makes a sharp bend toward the left side and crosses the midline behind the esophagus to descend on the left side.[9, 24] In both instances the trachea and esophagus are, in effect, encircled by a vascular ring; but the left half of the ring is not patent since the ductus, or the ductus plus the remnant of the left dorsal aorta, underwent regression shortly after birth to form a fibrous cord known as the ligamentum arteriosum. The sharply oblique course of the descending aorta from right to left

which occurs in both of these types of right arch, is apparently due to relative contracture of the ligamentum after it becomes sclerosed. The presence of an encircling ring about the trachea and esophagus, which may possibly be tightened by a relative or actual contracture of the fibrosed part of the ring, could well account for the fact that the two types of right-sided arch under discussion are those most likely to produce clinical symptoms. Chronic stridor and, less often, dysphagia may be caused by a persistent right aortic arch.[28] The diagnosis can be made during life by roentgenographic examination.[29] Surgical treatment of this anomaly has been attempted in a child who had difficulty in breathing and feeding since birth.[24] Right aortic arch is often associated with tetralogy of Fallot[9] and it



Fig. 7. Wax reconstruction model of heart and major arteries in rat with double aortic arch. A. Anterior view. B. Posterior view.

occurred in 144 of 610 cyanotic patients upon whom Blalock[25] operated. In such patients the operation is facilitated by the fact that the left subclavian artery is usually a long vessel which can be approximated to the left pulmonary artery without great difficulty.

Double Arch of Aorta: When both embryonic fourth arches are retained as connections between the ascending and descending aortae, the condition known as double arch is the result. This arrangement was found in two rat fetuses; but these differed in that one had the usual left-sided ductus arteriosus (Fig. 6A), whereas in the other both embryonic sixth arches had been retained, presenting the unusual situation of a ductus on either side. In both cases the bilateral arches arose from the ascending aorta, passed on either side of the trachea and esophagus, and reunited to form the descending aorta; thus a vascular ring was formed about the trachea and esophagus. In the animal with left-sided ductus the arches of the aorta were not of equal size, the left arch was somewhat the larger (Fig. 7). Also in this fetus the descending aorta lay on the left side; consequently, the right arch passed not only to the right of but dorsal to the esophagus in order to reach the descending aorta. In the case of double-arch-double-ductus the descending aorta was near the midline,

and although it veered toward the left side as it descended through the thorax, the two arches of aorta united almost directly behind the esophagus. In both instances the esophagus was displaced anteriorly in the region where these large arteries lay behind it, but it was not sharply notched, and there were no signs of constriction of either trachea or esophagus by the vascular ring in these fetal rats.

Double arch is a relatively infrequent anomaly in man, having been reported only about 40 times (to the knowledge of the present writers). In many instances it causes no adverse symptoms in the persons affected. However, infants have been described who had stridorous breathing, chronic cough, susceptibility to bronchopneumonia, head retraction, dysphagia and malnutrition.[30] The anomaly can be recognized by roentgenographic examination[31] and it was recently shown by Gross[32] to be amenable to surgical repair in children with clinical manifestations. Association of double aortic arch with tetralogy of Fallot is rare.[25] Of the types discussed for the rat, only the double-arch-left-ductus pattern has been described in man. Generally the two arches do not lie symmetrically on either side of the trachea and esophagus; but instead the right passes to the left and anterior to these viscera, both members then uniting in a left-sided descending aorta (Fig. 6B). The left-sided descending aorta seems to be a constant feature, and one wonders if the presence of the ductus (ligamentum) on the left side has not been the determining factor in causing a shift toward the left of what was at one time in the embryo a symmetric arrangement of arteries. Rarely in man are the two arches of equal calibre: the right and posterior arch is larger than the left in the ratio of about 5:1. The smaller of the two is frequently of such reduced size that it is considered stenosed.[26]

Absence of a Ductus Arteriosus: In four fetuses no complete embryonic sixth arch persisted; consequently, no ductus arteriosus was found connecting the pulmonary with the systemic circulation. In the absence of such a connection through the ductus, the heart theoretically could not develop proportionately in its right and left ventricles unless there were a persisting interventricular communication within the heart. The hearts of all four of these rats had moderately large interventricular septal defects. One of these hearts had the usual type of left-sided arch of aorta and descending aorta, discounting the absence of the ductus; but the right subclavian artery was quite unusual in that it arose from the pulmonary trunk at the origin of the right pulmonary artery. A similar anomalous origin of a subclavian artery was noted on page 715. Two of the animals without a ductus had a right-sided arch of aorta. One of these exhibited a mirror-image of innominate, carotid and subclavian arteries; but it lacked not only a ductus but a left pulmonary artery as well. The second pattern of right-arch-no-ductus differed in that the left subclavian artery arose distally from the right-sided descending aorta, and the right pulmonary artery arose from the ascending aorta. In this case the right lung would receive in postnatal life oxygenated blood from the left ventricle. The remaining case of absent ductus possessed a double arch of aorta, with the two subclavian arteries arising from the respective arches. This arch pattern was further anomalous in that the ascending aorta and the pulmonary trunk were confluent at their origin, then separate for a short distance, only to reunite at the point of origin of the two arches of aorta. Such failure of complete partitioning of the embryonic truncus arteriosus to form separate pulmonary and aortic trunks is designated truncus arteriosus persistens. As applied to this rat fetus, the term must be qualified as "partial," since the pulmonary and aortic trunks were separate for a short distance (page 711). A single pulmonary artery, the right, arose from the separated segment of the pulmonary trunk; the left pulmonary artery was missing.

Absence of a functional ductus connecting the pulmonary and systemic circulation during fetal life is not compatible with normal development of the heart. Absence of a ligamentum arteriosum in postnatal life should be indicative of either (1) disproportionate development of the cardiac ventricles or (2) a congenital shunt between pulmonary and systemic circulation, e.g., an open interventricular septum. Therefore, when surgery is performed on the major arteries of the thorax, failure to find a ligamentum arteriosum connecting a pulmonary artery with the aorta may be of aid in evaluating conditions within the heart. If externally the ventricles appear properly proportioned, the possibility of an inter-

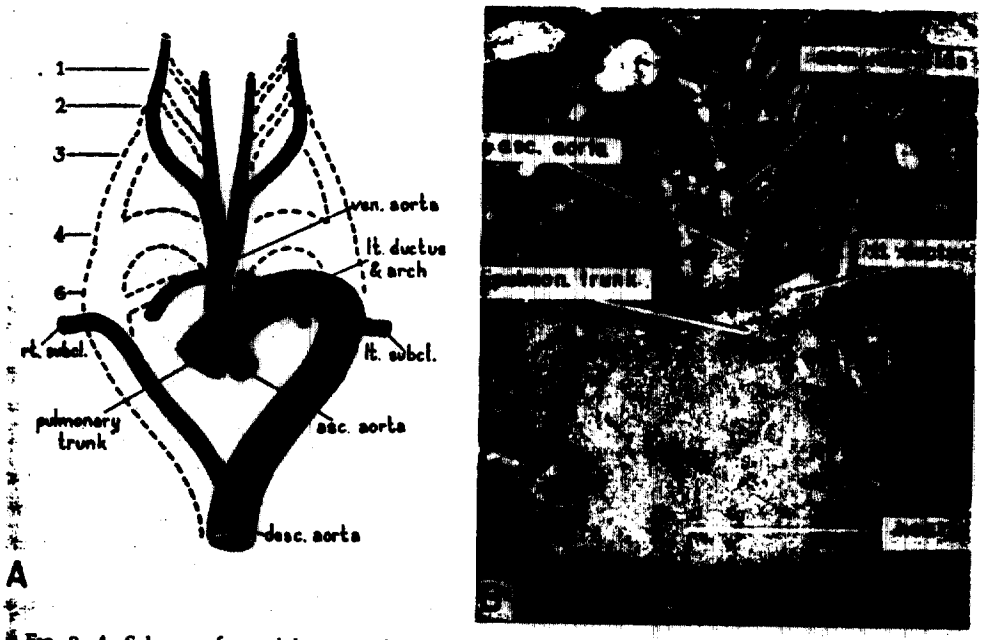

FIG. 8. A. Scheme of arterial pattern in one variety of absence of aortic arch (4th embryonic arch) seen in rats. Pulmonary trunk and enlarged ductus arteriosus serve as connection between heart and descending aorta. Small ascending aorta terminates by dividing into 2 common carotids; it does not communicate with descending aorta. B. Heart and large vessels of newborn child with respiratory difficulty and attacks of generalized cyanosis who died on 7th day of life. Small ascending aorta terminates in common carotid arteries and does not communicate with descending aorta. Pulmonary trunk is connected with descending aorta through ductus arteriosus. (Courtesy, Dr. Ralph Johansmann and Dr. P. S. Pierson.)

ventricular communication or an aortico-pulmonary fistula should be considered. In a large series of operations on patients with cyanotic congenital heart disease, Blalock[23] failed to find a ligamentum attached to the aorta in more than 100 instances. All these presumably had interventricular septal defects. The aortic arch pattern in these was that of right arch with the left subclavian from a left innominate, and the only ligamentum arteriosum ran from the left pulmonary to the left subclavian artery—a pattern not observed in rats. The mirror-image of this configuration, that is, left arch of aorta with a right-sided ligamentum joining an otherwise normal right subclavian artery, has been cited by Poynter[21] in four instances.

Absence of Arch of the Aorta: Failure of either embryonic fourth arch to persist as the main connection between the ascending and descending aortae is called absence of aortic

arch. In such cases either a sixth or a third embryonic arch, or both, must be retained to convey blood from the heart to the descending aorta. When an embryonic sixth arch alone serves as the arch of the aorta, the arterial pattern consists of an enlarged ductus arteriosus which arises from the pulmonary trunk and then continues directly into the descending aorta; and of an ascending aorta which is somewhat smaller than usual and terminated by giving rise to two common carotid, or two innominate arteries, or one of each. This general arrangement was found in two rat fetuses. In one the left ductus served as the arch and at the point where it continued into the descending aorta, the left subclavian artery arose; the right subclavian artery arose distally from the descending aorta at a lower level and passed behind the esophagus to reach the right shoulder. Consequently, the only branches from the ascending aorta were the two common carotids (Fig. 8). The other rat with this general pattern possessed a mirror-image arrangement of the one just described. Hypothetically, had these rats had no other cardiovascular defect and lived after birth, they should have been cyanotic in all parts of the body except the head and neck. Actually, both had moderately large interventricular septal defects. Indeed, the ventricles could not have developed in their normal proportion if the interventricular foramen had not remained open; for the relatively much greater demands upon the right ventricle would have resulted in its enlargement, with a corresponding degree of atrophy of the left ventricle.

Similar anomalies, characterized by lack of any connection between ascending and descending aortae, have been noted in human beings. In one of the types, reported at least three times, the pulmonary trunk through the left ductus served as the only source of blood to the descending aorta. The left subclavian artery, as in the experimental rats, received blood from the right ventricle, since it arose at the juncture of the enlarged ductus with the descending aorta (Fig. 8B). The right subclavian artery, however, was a branch of a right innominate artery; the latter and the left common carotid artery were the terminal branches of the ventral aorta. A second type known in man differs from that just described in that both subclavian arteries arise from respective innominate arteries, which are the last and only branches from the ascending aorta. Approximately 10 instances of this pattern have been recorded in man (see Sewart[33]). Regarding the course of blood and clinical manifestations, the latter type of anomaly has many features in common with the infantile type of coarctation of the aorta. The absence of a connecting strand between the descending aorta and the first part of the left subclavian distinguishes absent arch from coarctation of the arch. Furthermore, it indicates that in the case of absent arch of the aorta the left embryonic fourth arch lost its continuity with the descending aorta prior to birth, probably early in fetal life. On theoretic grounds one would expect a patient with absent arch of aorta to exhibit cyanosis of the trunk and lower extremities but not of the head.[9] Cyanosis of the upper extremity would be variable, for either or both subclavian arteries may arise from the descending or the ascending aorta. Actually, such partial cyanosis has not always been observed. Cyanosis of the entire body and complete lack of cyanosis have been noted in children with this anomaly.[34]

Persistence of an Embryonic Third Arch Between Ascending and Descending Aortae: When the ascending aorta passes high into the neck, gives off separate external and internal carotid branches, then turns caudally into the descending aorta, the arch of aorta represents a persisting third embryonic arch. If there is no ductus on that side, the inferior (recurrent) laryngeal nerve arises from the vagus in the neck and goes directly to the larynx by passing under the third arch. This unusual situation was recognized in five

rat fetuses from vitamin A deficient mothers. No indication of a fourth embryonic arch was found in any of these. One animal had such a third arch on the left side; but on the right side there was an additional arch between the heart and the descending aorta, in the form of an enlarged right-sided ductus arteriosus connecting the pulmonary trunk with the descending aorta (Fig. 9A and Fig. 10). Since there were bilateral arches, this pattern constituted a vascular ring about the trachea and esophagus. The ring, however, was highly asymmetric and not constricting: its left half extended into the neck to the level of the larynx, but its right half rose no higher than the level of the third rib. The subclavian

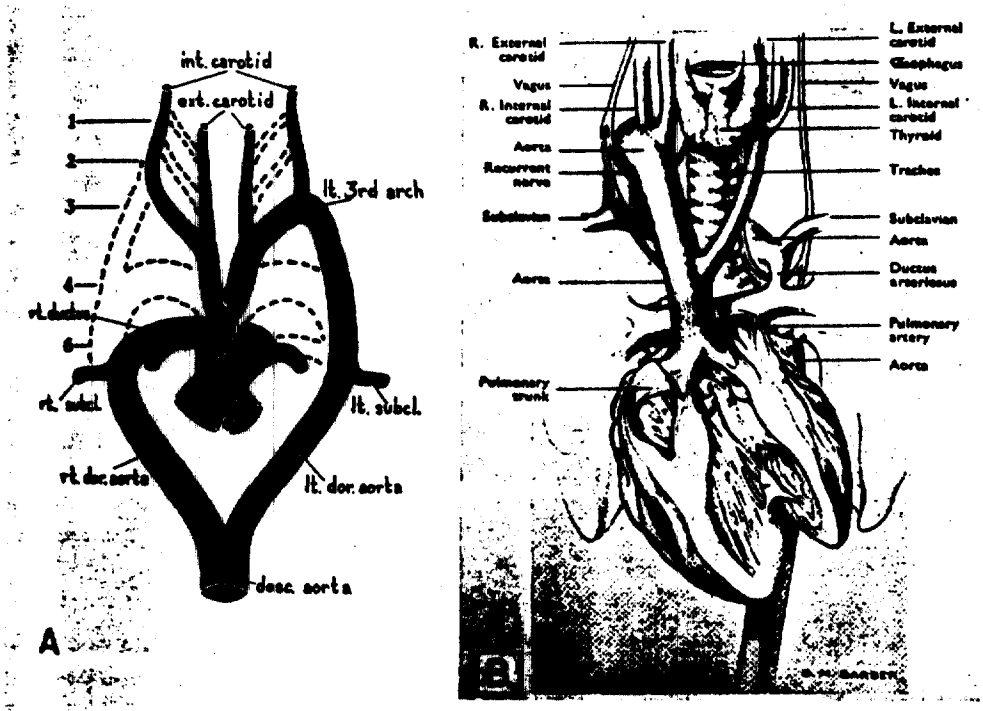

FIG. 9. A. Scheme of persistent left 3rd aortic arch which ascends into neck to level of larynx and gives off separate external and internal carotid arteries. No 4th arch persists on either side. Pulmonary trunk and enlarged right-sided ductus arteriosus constitute additional communication between heart and descending aorta. B. Drawing of postmortem specimen of heart and great vessels of child diagnosed during life as having aneurysm of common carotid artery. This arterial pattern represents mirror image of that shown in 9A; that is, right instead of left 3rd embryonic arch has been retained as arch of aorta. (Courtesy, Dr. T. E. D. Beavan and Dr. L. Fatti;[35] reproduced with the permission of the *British Journal of Surgery*.)

arteries arose from the respective arches (or dorsal aortae) and the right common carotid artery arose from the much elongated ascending aorta. There was no left common carotid.

At least one instance of a similar arch-pattern has been observed and reported in man. Beavan and Fatti[35] described a case which during life was diagnosed as aneurysm of the right common carotid artery, on the basis of a large pulsating mass on the side of the neck above the clavicle. At necropsy it was discovered that the pulsating mass was in reality the arch of the aorta connecting the ascending and descending aortae; and, since it was located in the neck and there gave rise to separate external and internal carotid branches, it was considered to be a persisting third embryonic arch. The arterial pattern in this case

was a mirror-image of that described in the rat above; the third arch was on the right side instead of the left. The left subclavian artery arose distally from the ascending aorta; but the left-sided ligamentum joined this subclavian artery, indicating that during fetal life the ductus served as an additional arch of the aorta, as was the case in the rat fetus. The left common carotid artery arose from the elongated ascending aorta (Fig. 9B). It is possible that other instances of third embryonic arch, represented by a pulsating mass on the side of the neck, have been mistaken for aneurysms or other vascular disease, particularly when no postmortem examination was performed.

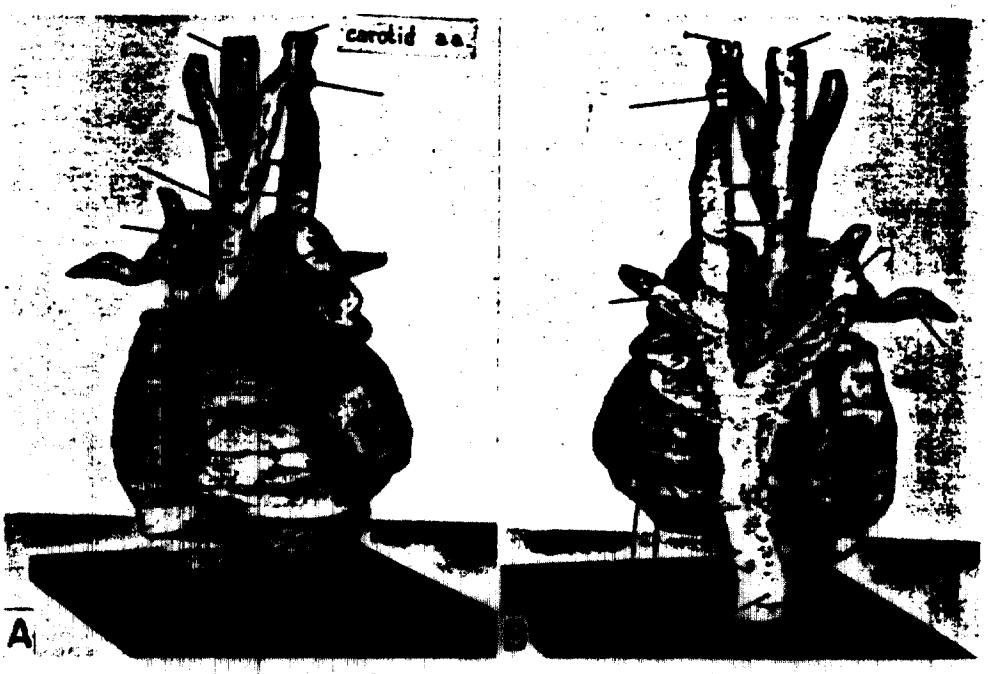

FIG. 10. Wax reconstruction model of heart and major arteries in rat with arterial pattern shown in Fig. 9A. A. Anterior view. B. Posterior view.

Four additional examples of persisting third embryonic arch were observed in the rat. In one the only connection between heart and descending aorta was a persisting left third arch that ascended to the level of the larynx; there was no ductus. The left subclavian artery arose from the left-sided descending aorta, and the right subclavian together with the right common carotid artery arose from an innominate artery which, in turn, came off the elongated ascending aorta. Left external and internal carotids originated separately from the crest of the left third arch. The three remaining instances of persisting third arch in the rat were identical and consisted of double third arches. No ductus and no common carotid were present on either side. Subclavian arteries arose from the dorsal aortae which formed the posterior limb of the respective bilateral arches. Pulmonary trunks were small in all, and this was especially so in one specimen in which the left pulmonary artery was missing.

Abnormalities of Pulmonary Arteries: Agenesis of the left pulmonary artery has been mentioned incidentally in six instances in the foregoing description of the various aortic arch anomalies. In five of these cases absence of the pulmonary artery was associated with agenesis of the left lung. It cannot be definitely stated that absence of the artery was secondary to agenesis of the lung, or the reverse, since no early stages of this condition

have been observed. However, one of the fetuses with missing left pulmonary artery had a well developed left lung, which was supplied through unusually large bronchial arteries. This case demonstrates that the lung and the pulmonary artery may be formed independently of each other. An additional fetus, not mentioned previously because it has no anomalies of the arches or heart, also had no left pulmonary artery and no left lung. It is mentioned here because it indicates that agenesis of the pulmonary artery is not necessarily associated with other cardiovascular anomalies.

Another abnormality of the pulmonary artery occurred in two animals in which the right pulmonary artery arose from the ascending aorta. In one of these a ductus continued beyond the pulmonary artery to join a right-sided descending aorta. Embryologically this type of malformation probably resulted from improper alignment of the aortic-pulmonary septum during the process of its formation,[19] so that the origin of the right sixth embryonic arch was included in the aortic rather than the pulmonary trunk. In connection with abnormalities of pulmonary arteries, it should be recalled that two instances of a subclavian artery arising jointly with a pulmonary artery from the pulmonary trunk have already been discussed (pp. 711 and 718).

Anomalies similar to those just described are known to occur in man. Anomalous pulmonary vessels have a possible significance in surgery even if they do not cause clinical symptoms. In recent years the increasing frequency with which the region of the hilus of the lung is approached surgically for pulmonary lobectomy and for repair of congenital defects, has made knowledge of such vessels important. Blalock[25] encountered agenesis of pulmonary arteries in nine cases operated for treatment of cyanotic congenital heart disease. Miller[26] described congenital absence of the right pulmonary artery in a newborn infant, but in the rats examined by us agenesis of pulmonary arteries was limited to the left side.

In regard to the aortic origin of a pulmonary artery, seen twice in our animals, it should be stated that Douglass[27] described four instances in which pulmonary arteries arose from the descending aorta. He also reviewed 23 additional cases of anomalous origin of pulmonary arteries from various sources, including subclavian and innominate arteries. No mention has been found of a pulmonary artery arising from the ascending aorta, but embryologic considerations and the fact that such an anomaly was noted in rats lends credence to the belief that its occurrence in man is a possibility.

Comment

None of the abnormalities described were seen in the controls which were sectioned and studied in the same manner as the experimental animals. Furthermore, such defects have not been described as occurring spontaneously or under other experimental conditions in the rat. Therefore, it seems justifiable to conclude that the cardiovascular anomalies of the young rats described here were induced by the experimental procedures to which their mothers were subjected. All the young with cardiovascular anomalies also had other malformations which were previously noted to be characteristic of a high percentage of the offspring of vitamin A deficient mothers.[16] The changes of the great vessels and of the heart occurred in association with anomalies of the eyes, of the genitourinary system and of the diaphragm with such regularity that they may be considered as part of the syndrome of malformations which results from these experimental conditions. However, cardiovascular defects were less frequently a component of the syndrome than were ocular and genitourinary defects; they were usually seen only in the more severely affected offspring.

These animal experiments provide an example of the influence of environmental

factors in altering development of the heart and great vessels. On the other hand, Sawin[illegible] demonstrated that genetic factors play a role in the determination of the aortic arch pattern in rabbits. These facts illustrate again that the embryonic development of an organ system may be similarly altered by either genetic or environmental factors.

Summary

Fetal and newborn rats from mothers fed vitamin A deficient diets prior to and during pregnancy exhibited some degree of malformation in 75% of the cases. Twenty-eight of 64 severely abnormal young studied after serial sectioning showed congenital cardiovascular malformations. These consisted of defects in the interventricular septum and in the aortico-pulmonary septum; and of various aortic arch anomalies, such as retroesophageal subclavian artery, right aortic arch, double aortic arch, absence and other variations of the ductus arteriosus and absence of a pulmonary artery. There were also several cases in which the fourth aortic arch was absent and the heart communicated with the descending aorta through the pulmonary trunk and an enlarged ductus arteriosus; in other instances the communication was affected through a persisting third arch which rose high into the neck.

Many of the cardiovascular anomalies observed in the rats closely simulated malformations observed in man; others have not been reported to occur in man but they are considered theoretic possibilities. If they are encountered in children, their interpretation may be facilitated by the description of these experimental results in the rat. It is emphasized that present clinical and experimental observations indicate that environmental as well as genetic factors may alter the development of the cardiovascular system.

References

1. Abbott, Maude E., Congenital heart disease, in Nelson Loose-Leaf Medicine, New York, Thomas Nelson & Sons, 1946, chap. 4, p. 207.
2. Brown, J. W., Congenital Heart Disease, London, John Bale, Sons & Curnow, Ltd., 1939.
3. Thomson, J., Congenital malformations of heart and large vessels, in Oxford Medicine, New York, Oxford University Press, 1947, vol. 2, p. 371, pt. 2, 376.
4. Schoenberg, H., Über Hemmunungsbildungen, Frankfurt. Ztschr. f. Path. 52:125, 1938.
5. Debré, R., Cordey, F., and Olivier, Une mère et son enfant atteints de maladie de Roger: Hérédité similaire d'une cardiopathie congénitale, Bull. et mém. Soc. méd. d. hôp. de Paris 47:1742, 1923.
6. Seitz, R., and Baumann, H., Familiäres Vorkommen von angeborenen Herzfehlern, Ztschr. f. Kreislaufforsch. 27:13, 1935.
7. Walker, G. C., and Ellis, L. B., cited by Taussig, H. B., Congenital Malformations of Heart, New York, Commonwealth Fund, 1947.
8. Tucker, A. W., and Kinney, T. D., Interventricular septal defect (Roger's disease) occurring in mother and her six-month fetus, Am. Heart J. 30:54, 1945.
9. Taussig, H. B., Congenital Malformations of Heart, New York, Commonwealth Fund, 1947.
10. Walker, W. G., Coarctation of aorta in father and son, New England J. Med. 211:1192, 1934.
11. Roesler, H., Beiträge zur Lehre von den angeborenen Herzfehlern, Untersuchungen an einem Fall von Pulmonalstenose der Aorta, Wien. Arch. f. inn. Med. 15:495, 1928.
12. Lamy, M., and Schweisguth, O., Etiologie des Malformations du Coeur, Ann. Pediat. 171:245, 1948.
13. Cockayne, E. A., Genetics of transposition of viscera, Quart. J. Med. 7:479, 1938.
14. Gregg, N. M., Congenital cataract following German measles in mother, Tr. Ophth. Soc. Australia (1941) 3:35, 1942.
15. Swan, C., Study of three infants dying from congenital defects following maternal rubella in early stages of pregnancy, J. Path. & Bact. 56:298, 1944.
16. Warkany, J., Roth, C. B., and Wilson, J. G., Multiple congenital malformations: Consideration of etiologic factors, PEDIATRICS 1:462, 1948.

17. Warkany, J., and Roth, C. B., Congenital malformations induced in rats by maternal vitamin A deficiency. II. Effect of varying preparatory diet upon yield of abnormal young, J. Nutrition 35:1, 1948.
18. Wilson, J. G., and Warkany, J., Malformations in genito-urinary tract induced by maternal vitamin A deficiency in rat, Am. J. Anat. 83:357, 1948.
19. Wilson, J. G., and Warkany, J., Aortic arch and cardiac anomalies in offspring of vitamin A deficient rats, Am. J. Anat. 85:113, 1949.
20. Abbott, Maude E., Atlas of Congenital Cardiac Disease, New York, American Heart Association, 1936.
21. Poynter, C. W. M., Arterial anomalies pertaining to aortic arches and branches arising from them, Lincoln, Nebraska Univ. Studies, 1916.
22. Bayford, D., Singular case of obstructed deglutition, Mem. M. Soc. London 2:275, 1794.
23. Copleman, B., Anomalous right subclavian artery, Am. J. Roentgenol. 54:270, 1945.
24. Gross, R. E., and Ware, P. F., Surgical significance of aortic arch anomalies, Surg., Gynec. & Obst. 83:435, 1946.
25. Blalock, A., Surgical procedures employed and anatomical variations encountered in treatment of congenital pulmonic stenosis, Surg., Gynec. & Obst. 87:385, 1948.
26. Edwards, J. E., Anomalies of derivations of aortic arch system, M. Clin. North America 32:925, 1948.
27. Hammer, G., Situs inversus arcus aortae (Hohe Rechtslage der Aorta), Fortschr. a. d. Geb. d. Röntgenstrahlen 36:517, 1926.
28. Faber, H. K., Hope, J. W., and Robinson, F. L., Chronic stridor in early life due to persistent right aortic arch, J. Pediat. 26:128, 1945.
29. Assmann, H., Die hohe Rechtslage der Aorta: Klinische Roentgendiagnostik der inneren Erkrankungen, Leipzig, F. C. W. Vogel, 1924.
30. Wolman, I. J., Syndrome of constricting double aortic arch in infancy, J. Pediat. 14:527, 1939.
31. Arkin, A., Double aortic arch with total persistence of right and isthmus stenosis of left arch: New clinical and x-ray picture, Am. Heart J. 11:444, 1936.
32. Gross, R. E., Surgical relief for tracheal obstruction from vascular ring, New England J. Med. 233:586, 1945.
33. Sewart, M., Congenital interruption of aortic arch, Arch. Dis. Child. 23:63, 1948.
34. Abbott, Maude E., Congenital cardiac disease, in Modern Medicine, edited by W. Osler and T. McCrae, Philadelphia, Lea & Febiger, 1927, chap. 4, p. 775.
35. Beavan, T. E. D., and Fatti, L., Ligature of aortic arch in neck, Brit. J. Surg. 34:414, 1947.
36. Miller, J. F., Congenital absence of right pulmonary artery in newborn infant, with resulting necrosis of lung and spontaneous pneumothorax, Am. J. Dis. Child. 53:1268, 1937.
37. Douglass, R., Anomalous pulmonary vessels, J. Thoracic Surg. 17:712, 1948.
38. Sawin, P. B., Genetic background of transformation of aortic arches in rabbit, Anat. Rec. 100: 708, 1948.

Wilson-'53
Bib. No. 9864

Am. J. Anat. 92(2):189-217. 1953.

AN ANALYSIS OF THE SYNDROME OF MALFORMATIONS INDUCED BY MATERNAL VITAMIN A DEFICIENCY. EFFECTS OF RESTORATION OF VITAMIN A AT VARIOUS TIMES DURING GESTATION [1]

JAMES G. WILSON, CAROLYN B. ROTH AND JOSEF WARKANY

Departments of Anatomy and Pediatrics
and The Children's Hospital Research Foundation
College of Medicine, University of Cincinnati, Cincinnati, Ohio

The broad array of congenital malformations observed in the offspring of vitamin A deficient female rats has been referred to as a "syndrome" (Warkany, Roth and Wilson, '48). Approximately 75% of such offspring exhibited developmental anomalies in one or more organs. The eye was the structure most frequently involved (Warkany and Schraffenberger, '46), and in the less severely affected animals it was sometimes the only site of malformation. Only slightly less frequent were malformations of the genito-urinary tract, affecting several different organs to varying degrees (Wilson and Warkany, '48). Next in order of incidence was diaphragmatic hernia, observed in about two-thirds of animals that were otherwise abnormal. Somewhat less prevalent were malformations of the heart and of the major arteries derived from the embryonic aortic-arch system (Wilson and Warkany, '49). The respiratory tract was occasionally affected, agenesis of one lung being noted in about 10% of the animals with some other abnormality. Anomalies in other regions were also observed, but were so infrequent as to be considered not regular components of the syndrome.

[1] This study was supported in part by grants from the Nutrition Foundation, Inc., New York.

These varied anomalies could hardly have developed simultaneously, in view of the temporal sequence in which the organs concerned are known to differentiate embryologically. The time at which the different defects appeared extends over the entire latter half of the gestation period of the rat embryo. The teratogenic influence of vitamin A deficiency must therefore have been present throughout this period. For example, the most frequent components of the syndrome were defects in the eye and genito-urinary tract, systems which differentiate at different times — the eye begins its organogenesis on the 11th day of gestation, while that in certain genito-urinary organs is not completed at term.

The question arises, can the different components of the syndrome be selectively eliminated by administering therapeutic doses of vitamin A to the deficient mothers at progressively earlier intervals during the period of organ formation. To answer this question the present experiment was undertaken.

METHOD

This study is based upon 261 late-fetal or newborn rats from mothers maintained prior to and during pregnancy on vitamin A deficient diets. The composition of the diets and other details pertaining to the production and maintenance of maternal deficiency have been published elsewhere (see Warkany and Schraffenberger, '46; Wilson and Warkany, '48); and it will be necessary here only to outline the basic procedure. Soon after weaning, young female rats of the Sprague-Dawley or the Albino Farms strains were placed on a preparatory diet containing only traces of vitamin A. Every 10th day 25 μg of carotene was given by oral supplement. This was sufficient to insure growth to maturity but insufficient to allow for appreciable storage of vitamin A. When the rats reached a weight of 150 to 160 gm and regular estrous cycles were established, they were transferred to a purified diet completely free of carotene or vitamin A and were then permitted to mate with males of the same strain which had been raised on an adequate diet. The purified diet was supplemented with all vita-

mins known to be necessary for proper nutrition in the rat except vitamin A. The females were maintained on the regimen throughout pregnancy, or until the experimental procedure called for a therapeutic dose of vitamin A as explained below.

In order to determine the beginning of pregnancy and to follow its course, daily vaginal smears and weight records were made. Pregnancy was dated from the day on which sperm was found in the vaginal smear, this being designated as *day 1* (actually this should be interpreted as "in the first day of gestation"). Of 439 females that were known to have been inseminated, only 261 carried their conceptus to the time at which they were usable in this experiment; the remaining 178 females either showed no detectable signs of pregnancy or became pregnant but later resorbed the embryos. Pregnancy in one group of females was allowed to proceed to term without supplemental dosing with vitamin A. As in previous experiments of this sort, many of the females showed signs of impending resorption (loss of weight and excessive blood in the vagina) during the latter half of pregnancy. These were eliminated and only pregnancies which went until the 20th, 21st or 22nd days without overt indication of embryonic death were included in the present study. A total of 45 litters was thus procured from females given no vitamin A during pregnancy.

Six groups of pregnant females that had been previously maintained on the vitamin A deficient diets were given a single large therapeutic dose of vitamin A at various times during pregnancy. The dose in each case consisted of 16,000 I.U. of a vitamin A preparation (Winthrop's "Afaxin") administered orally. It was given to 21 rats on the 10th day of gestation, 32 on the 11th day, 27 on the 12th day, 44 on the 13th day, 50 on the 14th day and 43 on the 15th day. These particular days were selected because they represent the period of most active organogenesis in the rat embryo. After the single dosage no further treatment was given and the pregnancies were allowed to continue until the 20th, 21st or 22nd day, when these females, like those receiving no therapy, were killed and the fetuses re-

moved. All living and recently dead fetuses that were still intact were fixed in 10% formol.

One fetus or newborn from each litter was prepared for histologic study by embedding in paraffin, sectioning serially, and staining with hematoxylin and eosin. Fetuses and newborns of comparable age from 16 mothers fed an adequate diet during pregnancy were likewise prepared for histologic study as normal controls.

OBSERVATIONS

The control fetuses and newborns in the present experiment, like numerous others studied by the authors in previous experiments, showed none of the congenital defects described below. Several groups of control mothers have been maintained on the same diets as the experimental mothers, except that adequate amounts of carotene or vitamin A were supplied the controls by oral dosing. The anomalies in the offspring of the experimental females, then, may be regarded as having resulted solely from maternal vitamin A deficiency. This is further borne out by the fact that vitamin A deficient diets of three different compositions have been found to produce the same pattern of malformations (unpublished data).

The incidence of anomalies in the offspring of females maintained in vitamin A deficiency throughout pregnancy was somewhat lower in the present experiment than in previous studies on such animals. This was because only fetuses of 20 and 21 days' gestational age and newborn rats were studied here, whereas in the earlier reports many younger fetuses were included. The limitation of age seemed necessary in the present instance in order to make a valid comparison of the effects of complete deficiency with the effects of vitamin A therapy at different times during pregnancy. Such comparison was possible only if all organs under consideration were completely developed, or nearly so, at the time the offspring were removed for study. By the 20th day organogenesis is complete in all systems except the lower genito-urinary tract and here the process is sufficiently advanced that abnormality can be rec-

ognized. Any protective action on specific organs or systems by vitamin A administered on, for example, the 15th day of gestation, would thus be apparent. Elimination of the less mature fetuses, however, removed many of the more severely affected ones, for it has been repeatedly shown that litters containing highly abnormal fetuses tend to undergo resorption between the 15th and 20th days of pregnancy (see Wilson and Barch, '49). Furthermore, the incidence of a particular abnormality presented here was calculated on the basis of all offspring, both normal and abnormal, while that in previous studies was based on the abnormal fetuses and newborns only.

Eye. The primordium of the eye is first recognizable on the 11th day (as gestation is reckoned in this experiment) at which time it consists of a shallow evagination from the forebrain area of the neural plate. During the succeeding two days the evagination is transformed into a vesicle which then invaginates to form the typical double-walled optic cup. Simultaneously, the lens vesicle forms from the overlying ectoderm, breaks away and comes to lie in the opening of the cup. By the 14th day the cup is deeply indented by the choroid fissure which transmits the hyaloid artery to the interior of the cup and to the lens. The fissure is already closed behind the artery on the 15th day, enclosing within the cup a sparse reticulum of mesenchyme and the branches of the hyaloid vessels. Not until the 18th day do the lids and ciliary body form and the retina show an appreciable degree of differentiation.

The characteristic pattern of ocular defects in the offspring of females deprived of vitamin A throughout pregnancy includes: post-lenticular fibroplasia, incomplete closure of the choroidal fissure (coloboma), eversion and abnormal folding of the nervous layer of the retina, and less frequent defects involving the lids and lens (Warkany and Schraffenberger, '46). All of these typical defects were prevented by giving vitamin A to the mother on the 10th, 11th or 12th days of pregnancy, and only two animals were affected after dosing on the 13th day (table 1). A supplement on the 14th or 15th day afforded somewhat less protection, although either held the percentage

of total abnormality below what would have been expected had no therapy been given. Treatment on the latter two days reduced the incidence of post-lenticular fibroplasia relatively more than the other types of defect, indicating that in many instances the abnormal quantities of connective tissue characterizing this defect were not laid down, at least not irreversibly so, until after the 15th day. Abnormalities of the retina, however, appear to have been irreversibly established by the 15th

TABLE 1

Ocular anomalies in the offspring of vitamin-A deficient females

	PERCENTAGE [1] OF OFFSPRING AFFECTED						
	After treatment of mothers with vitamin A on specific days of pregnancy						Without therapy
	10th	*11th*	*12th*	*13th*	*14th*	*15th*	
Typical ocular defects	0	0	0	4	17	28	49
Types							
Postlental membrane	0	0	0	2	17	24	49
Eversion of retina	0	0	0	2	11	15	27
Coloboma	0	0	0	2	8	20	18
Others [2]	10	4	0	0	17	9	11

[1] Based on 21 animals from mothers treated on the 10th day, 32 on the 11th, 27 on the 12th, 44 on the 13th, 50 on the 14th, and 43 on the 15th; and on 45 animals from mothers receiving no treatment.

[2] These include several infrequent abnormalities which are not part of the typical vitamin A deficiency syndrome such as open lids, no lids, small lenses, displaced lenses, cataracts, cysts of the retina and in addition, two defects not previously observed (see text).

day; and those arising from improper closure of the choroidal fissure (coloboma) were neither prevented nor reduced in number after the 13th day.

Two animals from mothers treated on the 10th day exhibited ocular anomalies not previously seen in vitamin A deficient fetuses and newborns (table 1). One was anophthalmic, that is, lacking optic cup, stalk and lens; the other had extreme microphthalmia associated with complete degeneration of the optic stalk. Such abnormalities probably occur only in cases of extreme deficiency, cases in which early resorption is inevi-

table unless restorative therapy is also given early. In the present instance dosing the mothers on the 10th day appears to have salvaged two litters that would otherwise soon have undergone resorption. It should be pointed out, however, that microphthalmia and anophthalmia do occur "spontaneously" in certain strains of rats (Browman and Ramsey, '43), although such defects have not been observed in control animals in this or previous experiments by the present authors.

Conclusions to be drawn from the above observations are: (1) that dosing with vitamin A prior to the 13th day prevents all of the ocular abnormalities ordinarily seen in the offspring of vitamin A deficient females, and (2) that dosing on the 14th or 15th day does not prevent the typical pattern of ocular defects although it does reduce the percentage. It becomes obvious that the capacity of vitamin A to prevent abnormality is limited by the degree to which organogenesis has been completed at the time the vitamin becomes available to the embryo. Such therapy cannot correct an already established defect but can protect the embryo against abnormality if administered before aberrant development begins.

Aortic arches. During the 11th and 12th days of normal development the first, second and third pairs of aortic arches are established as definite channels connecting the arterial stem of the heart with the paired dorsal aortae. Fourth and 6th pairs (no 5th arch is ordinarily seen in the rat) appear on the 13th day, at which time the first and second pairs have already begun regression. Not until the 15th day, however, do the third, 4th and 6th, the three pairs which figure prominently in the definitive pattern, begin to assume some of their future relationships including the characteristic asymmetry toward the left side. An additional day is required to complete the transformation of the embryonic system of arches into a pattern that approximates the definitive major arteries of the thorax and neck.

In the absence of vitamin A supplement, aortic-arch anomalies occurred in 9% of offspring (table 2). There was no consistent pattern of abnormalities, but as was observed by Wilson

and Warkany ('49), a variety of types, including distally arising right subclavian artery, double arch of aorta, right-sided arch and ductus, truncus arteriosus communis and absence of ductus arteriosus, were observed with some regularity. Several other variations from the normal pattern were seen in both the previous and the present studies, but these are too diverse and infrequent to be listed separately.

TABLE 2

Aortic-arch anomalies in the offspring of vitamin-A deficient females

	PERCENTAGE [1] OF OFFSPRING AFFECTED						
	After treatment of mothers with vitamin A on specific days of pregnancy						Without therapy
	10th	*11th*	*12th*	*13th*	*14th*	*15th*	
All aortic-arch defects	0	0	15	14	17	17	9
Types							
Double arch of aorta	0	0	4	2	6	2	2
Distally arising right subclavian	0	0	4	6	6	11	2
Truncus arteriosus communis	0	0	0	6	2	4	2
No ductus arteriosus	0	0	0	4	6	4	4
Right-sided arch and ductus	0	0	0	4	2	0	0
Infrequent [2]	0	0	8	6	6	7	0

[1] See text or table 1 for numbers of animals.

[2] Several other patterns of abnormality were encountered, but they are not listed separately because of their infrequent occurrence.

Administration of vitamin A prior to the 12th day prevented all aortic-arch anomalies (table 2). Evidently the pattern of the system, whether normal or otherwise, is not predetermined on the 11th day; and the restoration of normal metabolic processes by administering vitamin A at this time or earlier permits unaltered action of the factors responsible for establishing the normal pattern. Then, as far as non-genetic influences are concerned, the 12th day appears to be critical in the determination of the aortic-arch system. When vitamin A supplements were given on days 12 to 15, the incidence of aortic arch anomalies showed little change irrespective of the date of

therapy; but in all 4 groups it was higher than in the untreated group (table 2). This is in contrast to the ocular anomalies in which the incidence was decreased by vitamin A therapy during gestation. The apparently paradoxical increase in aortic-arch anomalies following treatment can be resolved by assuming that the therapeutic dosage enabled certain of the more severely affected embryos to survive beyond the time at which they would ordinarily have died and undergone resorption. Early death of many animals with aortic-arch abnormalities has been demonstrated in another investigation (Wilson and Warkany, '49, table 1). Many fetuses otherwise destined to die were undoubtedly salvaged by the vitamin supplement to the mother, although the therapy came too late to correct the abnormal pattern of aortic arches, which, in many cases, must have been already determined by the 12th day. In view of the known cephalo-caudal sequence in which the various components of the aortic-arch system differentiate embryologically, it might be expected that therapy on the earlier days would tend to spare the more caudal parts of the system from abnormality. This was true to the limited extent that animals from mothers dosed on the 12th day did not show abnormalities of the ascending aorta or 6th arch complex (pulmonary conus and arteries), that is, parts situated in the more caudal portion of the system. Therapy on the 13th day and subsequently, however, did not appear to spare any particular part.

Heart. The earliest cardiac primordia become recognizable on the 10th day of normal development, and by the 11th day the heart is a sigmoid tube interposed between the major embryonic arteries and veins. On the 13th day a primitive 4-chambered configuration is attained, but the various septal structures that will eventually complete the partitioning of the chambers first become apparent on the 14th day. Complete separation of the two ventricles occurs between the 16th and 17th days as a result of final obliteration of the interventricular foramen; and at about the same time the common arterial stem is completely partitioned to separate the aortic and pulmonary

trunks. The interatrial septum does not normally close until after birth.

Offspring from mothers deprived of vitamin A throughout pregnancy exhibited relatively few cardiac anomalies (table 3) and these consisted mainly of two types, interventricular septal defect and trunco-conal (aortico-pulmonary) septal defect. The same types were observed in a somewhat higher percentage of incidence in animals from mothers dosed on days 13, 14 and 15 of pregnancy. Again, the higher incidence in treated animals is attributed to the probability that many animals with

TABLE 3

Cardiac anomalies in the offspring of vitamin-A deficient females

	PERCENTAGE [1] OF OFFSPRING AFFECTED						
	After treatment of mothers with vitamin A on specific days of pregnancy						Without therapy
	10th	*11th*	*12th*	*13th*	*14th*	*15th*	
All cardiac defects	5	6	8	18	25	13	4
Types							
Interventricular septal defect	5	6	4	14	21	11	4
Trunco-conal septal defect	0	0	0	6	11	7	4
Infrequent [2]	0	3	8	2	0	0	0

[1] See text or table 1 for numbers of animals.
[2] See text for types.

cardiac defects, like many with aortic-arch anomalies, were among the more seriously affected and would not have survived until the 20th day had therapy not been given. It is particularly noteworthy that cardiac anomalies were not prevented even when the mothers were dosed as early as the 10th day. The apparent explanation is that the early processes of cardiogenesis had begun before the vitamin became available; hence to prevent all cardiac anomalies vitamin A must be administered prior to the 10th day. This is in accord with the facts that the heart is one of the first major organs to begin development, its organogenesis and internal differentiation

precede that in any other organ, and it is the first to assume its functional role.

Although cardiac anomalies occurred after vitamin A was given to the mother on days 10, 11 and 12 (table 3), it should be pointed out that some types observed after later dosing were not seen. Defects involving the aortico-pulmonary septum did not occur following treatment on the earlier days; and interventricular septal defects, although present, were less frequent than after later therapy. This observation may throw some light on the relationship between the two defects. They occur conjointly with sufficient frequency, both in experimental studies of this sort and in human teratology, to suggest a causal interrelationship. The present observation does not rule out such a relationship, but it does indicate that the two defects are determined at different times in development.

Two additional types of cardiac malformation, neither of which has been previously observed in the offspring of vitamin A deficient mothers, were found in animals after treatment on the 11th, 12th and 13th days of pregnancy. One of these, noted in two instances, consisted of failure of the atrio-ventricular cushions to unite. As a result the atrio-ventricular canal remained undivided, a condition designated as *valvulus communis* in reference to the persistent common atrio-ventricular valve. The other type involved the pulmonary conus which was stenotic in one animal and atretic in another, both at the level of the pulmonary valve. These conditions evidently occur only in cases of extreme vitamin A deficiency and consequently are not seen except, as in the present instance, when early intrauterine death is averted by replacement therapy.

Lungs. The first indication of the respiratory tract, the laryngo-tracheal groove, appears on the 12th day of gestation. This structure becomes elongated and bifurcates at its growing tip, thus giving rise to the trachea and two lung buds on the 13th day. The normal asymmetry of the lung primordia is established on the 14th day with the appearance of 4 secondary bronchi on the right side and only one on the left. Rapid arborization during the succeeding two days results in formation

of the remaining air-conducting segments of the respiratory tree.

In the offspring of females in vitamin A deficiency throughout pregnancy, malformations of the respiratory tract were uncommon and limited to two types, agenesis and rudimentary lung. The incidence was 10% in a selected group of abnormal animals (Warkany, Roth and Wilson, '48), and only 4% in the present group consisting of all offspring from females maintained on deficient diets (table 4). Excepting one instance in which both lungs were absent, pulmonary agenesis has been observed to affect only the left lung, both here and in other experiments. Likewise, rudimentary lung has been almost in-

TABLE 4

Anomalies of the lung in the offspring of vitamin-A deficient females

	PERCENTAGE [1] OF OFFSPRING AFFECTED						
	After treatment of mothers with vitamin A on specific days of pregnancy						Without therapy
	10th	*11th*	*12th*	*13th*	*14th*	*15th*	
All lung defects	0	0	4	8	6	7	4
Types							
Agenesis of lung	0	0	4	2	2	4	2
Rudimentary lung	0	0	0	6	4	2	4

[1] See text or table 1 for numbers of animals.

variably found in the left side. The latter condition consisted of a small irregular mass of pulmonary-like tissue surrounding the tip of a short primary bronchus, the entire structure usually being embedded in the mediastinum. The right lung was rudimentary only when the left was either rudimentary or absent. Of possible significance in this connection is the fact that the left lung in normal animals is morphologically subordinate to the right, being smaller and having three less lobes.

When vitamin A supplement was provided the mother on the 10th or 11th day of pregnancy, no pulmonary abnormalities were found in the offspring. Therapy delayed until the 12th day or later, however, failed to prevent abnormalities; pulmonary agenesis and rudimentary lungs occurred in about the

same frequency as in the offspring of non-treated females (table 4).

Diaphragm. The formation of the diaphragm is a complex process which begins with the appearance of the septum transversum on the ventral aspect of the foregut on the 11th day of gestation. Although a major contributor to the substance of the diaphragm, the septum transversum does not completely partition the coelomic cavity of the thorax from that of the abdomen. Bilateral communications, the pleuro-peritoneal canals, persist for several days after the septum is in place; final closure of these canals depends upon growth and rearrangement of several neighboring viscera and large veins, together with the marshaling of additional formative tissue from the dorsal body wall. The numerous interrelationships involved cannot be discussed here, although it should be emphasized that the growth of the liver into the caudal aspect of the septum transversum is a predominant factor in transforming the latter into the thin expanse of pre-muscle mesenchyme which later forms the major portion of the diaphragm. The diaphragm is complete, in the sense of completely partitioning the thorax and abdomen, on the 16th day.

Andersen ('41, '49) has described a strain of rats in which diaphragmatic hernia occurred as an hereditary defect in 2.7% of the animals. In a very significant experiment it was demonstrated that the incidence of hernia in the young of this strain could be increased to 19% by maintaining the breeding stock on a vitamin A deficient diet. No other malformations were reported. In the strains of rats used by the present authors in several experiments, however, no instance of diaphragmatic hernia has been found in any of several hundred offspring from control mothers fed adequate diets.

The maternal deficiency of vitamin A induced in the present experiment and maintained throughout pregnancy resulted in a high incidence of diaphragmatic hernia in the offspring (table 5). Typically in these rats the defect was in the right dorsal portion of the diaphragm and sufficiently large to permit protrusion of a mass of liver into the right pleural cavity.

Occasionally the left side as well as the right was affected, but only very rarely (in previous experiments) was the left side alone defective. The herniated mass was sometimes of such size as to cause noticeable displacement of the thoracic viscera.

The incidence of diaphragmatic hernia was reduced from 31% to 24% by the administration of a single dose of vitamin A on the 15th day of gestation (table 5). Dosing at progressively earlier ages caused a further reduction in the incidence, and, if given as early as the 11th day, the therapy prevented all abnormality. Neither the reduction nor the prevention of

TABLE 5

Diaphragmatic hernia in the offspring of vitamin-A deficient females

	PERCENTAGE [1] OF OFFSPRING AFFECTED						
	After treatment of mothers with vitamin A on specific days of pregnancy						Without therapy
	10th	*11th*	*12th*	*13th*	*14th*	*15th*	
All diaphragmatic defects	0	0	8	16	23	24	31
Types							
Left side only	0	0	8	14	4	11	0
Right side only	0	0	0	2	11	7	24
Both sides	0	0	0	0	8	7	7

[1] See text or table 1 for numbers of animals.

this defect by therapy can be closely correlated with known events in the development of the diaphragm. In the offspring of dosed animals there was a curious change in the location of the defect. As mentioned above, animals given no supplement had diaphragmatic hernia predominantly on the right side. Those which developed hernia after being given supplemental dosing, however, were affected more often on the left side. The reason for this shift in the sidedness of the defect is entirely obscure.

Kidneys. The metanephroi are first indicated as buds on the caudal aspect of the mesonephric ducts on the 13th day of gestation; and by the 14th day the growing tips of the buds have become bulbous and are surrounded by a dense blastemal

cap. The two blastemal masses lie quite close together between the two umbilical arteries. On the 15th day the kidneys are no longer so closely crowded, having ascended to a level just above the umbilical arteries, although the caudal poles of the kidneys are still in fairly close proximity. Continued ascent and further growth bring the kidney to the mid-lumbar region by the 16th day. The final position at the level of the upper lumbar segments is attained on the 17th day, but not until the 18th day do the first glomeruli appear, accompanied by the first signs of fluid excretion. Although nephron formation is not complete until after birth, some degree of renal function during the last 4 days of gestation is evidenced by the accumulation of fluid in the urinary tract.

In the absence of vitamin A during development the kidneys are subject to two major types of abnormalities, those of position and those reflecting faulty or retarded development in the renal parenchyma (see Wilson and Warkany, '48). As regards positional abnormality in the present experiment, the kidneys were occasionally situated at a more caudal level than normally. The more common positional variation, however, concerned the transverse relationship or the distance between the two kidneys. In 6 instances they were closer together than normally and in three additional animals the caudal poles were actually fused to form typical horseshoe kidneys (table 6). Faulty or retarded development of the renal parenchyma was manifested in 36% of the present group by failure of the renal pelvis and calyx to become normally dilated after the 18th day of gestation. Lack of such dilation together with histologic signs of immaturity was taken as an indication of retarded or defective development of the parenchyma.

The administration of a single dose of vitamin A on days 13, 14 or 15 of gestation reduced the incidence of most developmental anomalies of the kidneys, and all were prevented by treatment on the 10th, 11th or 12th days (table 6). The different types of anomalies were not affected alike by the therapy. Abnormality of the parenchyma, reflected in failure of the pelvis and calyx to dilate, was a common defect when no treat-

ment was given, but was relatively rare after vitamin A dosing. Conversely, horseshoe kidneys were as often found in animals dosed on days 14 and 15 as in animals given no therapy. These observations can be correlated with the developmental schedule of the kidney. Since the parenchyma does not show an advanced degree of histogenesis (completion of the first nephrons) until the 18th day, it is not surprising that vitamin A administered prior to this sharply reduced the extent of abnormality. On the other hand, fusion of the kidneys most likely occurred on the 14th day when the two organs were

TABLE 6

Renal anomalies in the offspring of vitamin-A deficient females

	PERCENTAGE[1] OF OFFSPRING AFFECTED						
	After treatment of mothers with vitamin A on specific days of pregnancy						Without therapy
	10th	*11th*	*12th*	*13th*	*14th*	*15th*	
All developmental renal defects	0	0	0	2	13	20	38
Types							
Pelvis not dilated	0	0	0	2	8	7	36
Kidneys too close together	0	0	0	0	4	2	13
Kidneys fused (horseshoe)	0	0	0	0	4	11	7
Ectopia	0	0	0	0	0	0	4
Hydronephrosis	10	6	0	4	11	13	0

[1] See text or table 1 for numbers of animals.

thrown into very close proximity as they rose from the pelvis and passed between the two umbilical arteries. Dosing with vitamin A on the 14th or 15th day could hardly be expected to alter whatever factors were responsible for bringing the kidneys into direct contact so that they were able to fuse. The fact that no renal anomalies were found after dosing on days 10, 11 or 12 indicates that all aspects of renal development which are susceptible to vitamin A deficiency are determined subsequent to the 12th day of gestation.

A renal abnormality never observed in the offspring of females maintained in vitamin A deficiency throughout preg-

nancy was seen fairly frequently in the offspring of the dosed females. The kidneys were hydronephrotic, that is, conspicuously distended by accumulated fluid in the pelvis and calyx. In some instances it was the only renal abnormality (table 6), although it was occasionally found in conjunction with other defects. Hydronephrosis and the condition in which the pelvis failed to dilate, however, being diametrically opposite manifestations, were never observed in the same animal. Hydronephrotic kidneys were developmentally normal as far as could be determined by histologic study and were functionally competent as evidenced by the fluid accumulated within the pelvis and calyx. In the case of undilated pelvis, the kidneys were developmentally abnormal in that nephron-formation was conspicuously retarded and secretory activity did not occur prior to birth. Since hydronephrosis cannot be considered strictly a developmental defect of the kidney, it must be ascribed to some other cause, possibly to obstruction in the lower urinary tract. Such obstruction could have been anatomical or functional in nature; but as will be indicated below, anatomical obstructions of the urinary tract were rarely found.

Ureters. The ureteric buds first appear on the mesonephric ducts near the point of juncture with the urogenital sinus, during the 13th day of gestation. Between this and the 16th day the terminal orifice of the ureter moves distally along the mesonephric duct and onto the wall of the urogenital sinus. By the 17th day the ureteric openings have almost reached their final position in the vesical portion of the urogenital sinus. Although the bladder is not sharply marked off from the remainder of the sinus at this time, there is no doubt but that the terminal ends of the ureters have now migrated into the future bladder-region.

In the offspring of vitamin A deficient mothers the ureters were frequently abnormal, 36% in the present group (table 7) and approximately 90% in an earlier group of selected animals (Wilson and Warkany, '48). The principal abnormality in both instances consisted of ectopia, that is, termination of the ureters at some site other than the normal location in the base

of the bladder. The abnormal termination was always at some point along the course of normal migration of the ureteric orifice, that is, from the place at which it first appeared in the mesonephric duct to the upper segment of the urogenital sinus (urethra). Less frequently the ureters were hypoplastic, the usual tissue layers within the walls being poorly developed and the epithelium thin and atrophic in appearance. Only occasionally were the ureters occluded or interrupted.

All developmental anomalies of the ureter were prevented by dosing the mother with vitamin A on days 10, 11 and 12 of

TABLE 7

Ureteric anomalies in the offspring of vitamin-A deficient females

	PERCENTAGE [1] OF OFFSPRING AFFECTED						
	After treatment of mothers with vitamin A on specific days of pregnancy						Without therapy
	10th	*11th*	*12th*	*13th*	*14th*	*15th*	
All developmental ureteric defects	0	0	0	2	11	24	36
Types							
Ectopic termination	0	0	0	0	6	24	36
Hypoplastic	0	0	0	0	0	4	22
Occluded or interrupted	0	0	0	2	8	4	7
Hydroureter	10	6	4	4	8	7	0

[1] See text or table 1 for numbers of animals.

pregnancy (table 7) and treatment on day 13 prevented all but one instance of occluded ureter. Dosing on days 14 and 15 afforded less protection but, nevertheless, reduced the rate of malformation below what would have been expected without therapy. The hypoplastic condition seen when no supplement was given did not occur in any animal whose mother was treated prior to the 15th day and occurred in only two instances after treatment on the 15th day, indicating that the factors responsible for proper histogenesis of the ureteric wall became operative at this time. Although ectopia of ureters was observed in animals treated both on the 14th and 15th day, the anomaly was different in the two groups. The abnormal

ureteric terminations after 14th day treatment were limited to the upper urethra while those after 15th day treatment, like those after no treatment, were found all along the course of migration of the normal ureter. These circumstances suggest that when vitamin A becomes available as early as the 14th day the ureter usually reached its normal site of termination, or when occasionally failing this, only fell slightly short of the mark. Treatment delayed until the 15th day, well after the ureter normally begins its migration, is too late to restore the normal schedule of migration and the arrested ureters remain at or near the site of origin in the mesonephric ducts.

Retention of abnormal quantities of fluid in the ureter resulting in hydroureter, was almost as common as, and usually associated with, the similar condition in the kidney. Hydroureter also was never seen in the offspring of non-treated animals, but in those of dosed animals it occurred both alone and in combination with other ureteral defects (table 7). The distention was only occasionally associated with anatomical occlusion or interruption of the ureters. Ureters were distended in many instances in which the lumina below appeared to be patent; and even in the few instances in which the lumen was actually interrupted, the segment of ureter above the interruption was not always distended. The latter situation occurred in animals in which kidney development was retarded to the extent that no fluid was excreted. Furthermore, anatomical obstruction in the lower urinary tract (bladder and urethra) also was too infrequent to account for more than a few instances of hydronephrosis and hydroureter. Therefore, it appears that in most cases the fluid retention was due either to a "functional" obstruction, possibly hypertonicity of the urinary sphincters, or to over-excretion of fluid. Such explanations have been proposed for human infants born with distended urinary tract when no anatomical obstruction could be demonstrated.

Genital ducts. Both mesonephric and Müllerian ducts are present and exhibit similar degrees of development and preservation in 17-day embryos of either sex, although their

earlier origin and subsequent development differ markedly. The mesonephric ducts first appear in association with the pronephros on the 12th day and grow caudally to reach the cloaca on the 13th day. The Müllerian ducts first appear on the 15th day as bud-like invaginations of coelomic epithelium into the lateral aspect of the urogenital fold, where they grow caudally beside the mesonephric ducts to reach the urogenital sinus on the 17th day. In the pelvic region the two Müllerian ducts lie side by side and on the 19th day their caudal segments unite to form the cervico-vaginal canal. Also on the 19th day sexual dimorphism of the genital ducts becomes apparent: the mesonephric ducts have continued development in males and have begun to regress in females, while the Müllerian ducts have begun to regress in males and have continued development in females. On the 20th day the seminal vesicle appears as a bud near the caudal end of each mesonephric duct. The process of sexual differentiation continues through the 21st day, the homologous set of ducts undergoing further elaboration toward the definitive form, the heterologous set disappearing except for small remnants at the cephalic and caudal ends.

In the absence of vitamin A throughout gestation, the genital ducts became abnormal frequently and in a variety of respects (Wilson and Warkany, '48). For the present study only the commoner varieties of abnormality were recorded, including: absence or incomplete development of the homologous set of ducts, persistence of both sets (hermaphroditic tendency), failure of Müllerian ducts to unite caudally in females, and absence of seminal vesicles in males. No one type was predominant, but collectively the genital-duct anomalies were observed more often than defects in any other part of the body except the eyes (table 8).

All abnormalities of the genital ducts were prevented by dosing the mothers with vitamin A on the 10th and 11th days and dosing on the 12th day prevented all except absence of one Müllerian duct in one female. Agenesis and incomplete development of Müllerian ducts were encountered in all other

dosage groups (13th through 15th days), which is surprising since these structures do not normally begin development until the 15th day and are not completed until the 17th day. The persistence of both sets of ducts, noted in several instances after vitamin A therapy, was also surprising. The time lapse between the administration of the supplement and the usual time at which one set of ducts begins regression (19th day) seems sufficient to have permitted restoration of whatever factors normally control sexual dimorphism. Indeed, little correlation existed between the time at which the administration of

TABLE 8

Genital duct anomalies in the offspring of vitamin-A deficient females

	PERCENTAGE [1] OF OFFSPRING AFFECTED						
	After treatment of mothers with vitamin A on specific days of pregnancy						Without therapy
	10th	*11th*	*12th*	*13th*	*14th*	*15th*	
All genital duct defects	0	0	8	10	10	13	42
Types							
Homologous set absent or incomplete	0	0	8	4	8	7	16
Both sets present	0	0	0	6	6	7	16
Seminal vesicles absent or rudimentary	0	0	0	0	2	7	11
Müllerian ducts not united caudally	0	0	0	0	2	0	11

[1] See text or table 1 for numbers of animals.

vitamin A prevented any of the defects of the genital ducts and the time at which the structure involved was morphologically differentiated.

Lower genito-urinary tract. Development of the lower genito-urinary tract in both sexes is closely associated with differentiation of the urogenital sinus. The sinus itself is not separated from the cloaca until the 17th day of gestation, and the various organs derived from it appear during the subsequent several days. Even at term certain of these organs are incompletely formed: the prostate and bulbourethral glands

remain rudimentary and the vagina is scarcely more than indicated.

Twenty per cent of the offspring from mothers deficient throughout pregnancy bore defects attributable to improper differentiation of the urogenital sinus. This number does not include 5 females with absent or incomplete vagina and 5 males with absent or rudimentary seminal vesicles, both of which types of defect were included with anomalies of the genital ducts. As was noted in an earlier study (Wilson and Warkany, '48), incomplete development of the prostate gland and hypospadias were among the commonest specific defects.

The administration of vitamin A to the pregnant mother at any time from the 10th through the 15th day prevented the development of almost all anomalies of the genital organs. Only two exceptions were found: one animal with hypospadias from a mother dosed on the 13th day and one animal with occlusion of the urethra from a mother dosed on the 15th day. The virtual elimination of malformations of the genitalia by therapy administered prior to the 16th day is in accord with the fact that these organs do not begin development until somewhat later.

Gonads. Cryptorchidism was previously noted (Wilson and Warkany, '48) in approximately half of the abnormal male offspring from mothers deprived of vitamin A throughout pregnancy. In the present experiment 54% of males from such mothers likewise showed some degree of interference with the descent of the testes. Dosage with vitamin A on the 10th, 11th or 12th days of pregnancy prevented cryptorchidism. Dosage on the 13th, 14th and 15th days was followed by an incidence of cryptorchidism of 5%, 8% and 16%, respectively. Thus, although the testis does not normally begin descent until the 17th or 18th day of pregnancy, it appears that some factor concerned in its descent is occasionally susceptible to vitamin A lack as early as the 13th day. The ovary has never been found in an abnormal location in an animal from a vitamin A deficient mother, either in this or in a previous experiment;

and routine histologic study, likewise, has revealed no abnormality of histogenesis within the ovary.

Other anomalies. Additional abnormalities not typically seen in the offspring of females deficient throughout pregnancy were observed infrequently and were not associated with any particular dosage group. Cleft lip and palate were found in three animals, from mothers given vitamin A on either the 15th, 12th or 10th day of pregnancy. Single instances of encephalocele, spina bifida, umbilical hernia, agenesis of ovary and brachyesophagus (with thoracic stomach) occurred randomly throughout the various groups. Certain of these anomalies, cleft lip and palate, umbilical hernia and brachyesophagus, have been observed on rare occasion in previous studies of vitamin A deficiency, but they have not been considered as regular components of the A deficiency syndrome. Encephalocele, spina bifida and agenesis of the ovary have not been encountered in previous studies of this sort. None of these defects has been observed in the offspring of rats fed adequate diets; therefore they should perhaps be regarded as occasional manifestations of the maternal vitamin A deficiency.

DISCUSSION

Three conclusions may be drawn from the foregoing observations. The first and most obvious is that the administration of a single dose of vitamin A to deficient female rats at progressively earlier times in pregnancy progressively reduces the percentage of malformed offspring. Secondly, the syndrome of malformations that typically results from deficiency throughout pregnancy is modified by vitamin A therapy on particular days of pregnancy, both as to the types of defect as well as to the relative percentage incidence of the various defects. Thirdly, and perhaps most significantly, the teratogenic influence of vitamin A deficiency is exerted primarily on the process of organogenesis, rather than on presumptive but undifferentiated tissues, as is the case with certain other teratogenic agents such as radiations.

The extent of reduction in the total number of malformed offspring as vitamin A was given at progressively earlier days of pregnancy is summarized in table 9. When no therapy was given during pregnancy, more than half of the offspring bore some congenital defect. The incidence was reduced somewhat by treatment as late as the 14th or 15th day of pregnancy and was appreciably reduced by earlier treatment. However, the

TABLE 9

Summary of developmental anomalies in various organs and systems

	PERCENTAGE [1] OF OFFSPRING AFFECTED						
	After treatment of mothers with vitamin A on specific days of pregnancy						Without therapy
	10th	*11th*	*12th*	*13th*	*14th*	*15th*	
Offspring with typical defects	5	6	19	25	42	33	53
Organs affected							
Eyes	0	0	0	4	17	28	49
Aortic arch	0	0	15	14	17	17	9
Heart	5	6	8	18	25	13	4
Lungs	0	0	4	8	6	7	4
Diaphragm	0	0	8	16	23	24	31
Kidneys	0	0	0	2	13	20	38
Ureters	0	0	0	2	11	24	36
Genital ducts	0	0	8	10	10	13	42
Lower genito-urinary tract	0	0	0	2	0	2	20

[1] See text or table 1 for numbers of animals.

fact that dosing the mothers as early as the 10th or 11th days did not prevent all abnormalities of the eye (see table 1) and heart is deserving of comment. The ocular defects observed after treatment on these days were extreme and unusual types not previously seen following maternal vitamin A deficiency. The cardiac defects, on the other hand (tables 3, 9), represented types that had been seen previously; but it should be recalled that of all susceptible organs only the heart begins development as early as the 10th day. It seems likely, therefore, that cardiac anomalies also could have been prevented, had therapy been given on the 9th day.

The syndrome of anomalies typical of the young from mothers deficient throughout pregnancy was modified in several respects by dosing the mothers with vitamin A, the most striking change being in the relative percentage incidence of some of the defects (table 9). For example, when vitamin A deficiency was not interrupted by dosing, the organ most commonly defective was the eye, while anomalies of the cardiovascular system were among the rarest seen (table 9, last column). The situation was reversed by dosing the mothers on the 12th or 13th days of pregnancy: cardiovascular defects were among the commonest and ocular anomalies were among the rarest. Malformations of the lower genito-urinary tract were virtually eliminated by therapy at any time before the 16th day. Anomalies of the kidneys and ureters, although frequent when no treatment was given, were seen rarely or not at all when the mothers were treated on day 13 or earlier. Indeed, the syndrome as observed after treatment on either the 12th or 13th day would hardly be recognized as having the same etiology as that seen when no vitamin A was given.

Although many factors may have been involved in producing these changes in the syndrome, certainly an important one was the temporal correlation between therapy and the particular developmental processes that were in progress. A precise concurrence between these events was not always evident, owing in part to the inevitable lag between the dosing of the mother and the arrival within the embryo of effective amounts of the vitamin. Nevertheless, the administration of the vitamin prior to the beginning of critical processes in organ formation usually prevented aberration of these processes, whereas administration of the vitamin after the processes were well advanced did not protect against maldevelopment. Hence, certain cardiac anomalies were never prevented because therapy was not given before the earliest stages of cardiogenesis. Horseshoe kidneys were prevented by therapy prior to the 14th day, the time at which the kidneys are normally closest together and presumably most likely to fuse. Coloboma was as common after vitamin dosing on the 14th and 15th days as

after complete deficiency but was extremely rare following dosage earlier than the 14th day — probably relating to the fact that the choroid fissure does not normally begin closure until late in the 14th day. In the case of diaphragmatic and genital duct anomalies the prevention of malformations by therapy did not show a definite time relationship to any major event in development; but for the majority of organ systems this relationship was sufficiently close to indicate that the protective action of the vitamin depended upon its availability during critical events in development. Since such events within a single organ system may be scattered over several days, and for the embryo as a whole are distributed over the last 12 days of gestation, it is not surprising that the composition of the syndrome varied when therapy was given on different days of pregnancy.

Another factor contributing to the modification of the syndrome was the appearance of new and atypical varieties of malformations in the offspring of the mothers dosed during pregnancy. Some of these malformations were so rare as to be of little consequence, but hydronephrosis and hydroureter were sufficiently frequent (tables 6, 7) to account for an appreciable change in the syndrome. Another interesting change brought about by dosing the mothers was the prevalence of left- instead of right-sided diaphragmatic hernia in the young (table 5).

As regards mechanisms of abnormal development, the most significant conclusion to be drawn from these results concerns the time at which the malformations of the vitamin A deficiency syndrome were determined. In general it was shown that malformations could be prevented when vitamin A was available during the period of organ formation. In some instances this correlation was close (eye, heart and kidneys); in others (ureters, aortic arches, testicular position) it was only moderately so. Only in the case of the genital ducts was there any indication that deficiency of vitamin A might have affected a presumptive tissue, that is, one which had been induced or predetermined but which had not yet begun the processes involved

in organogenesis. Aside from this exception, therapy at any time prior to the beginning of organogenesis prevented maldevelopment. Thus, vitamin A deficiency exerted its teratogenic influence essentially on the actively differentiating organs and not upon undifferentiated primordia.

Data bearing on the time of action of other teratogenic agents are by no means abundant, but the agents for which information is available appear to act differently than vitamin A deficiency. Stockard ('21) demonstrated that lowering the temperature or the oxygen supply in the environment of developing sea minnows was most effective in causing maldevelopment when the embryos were in the blastopore stage, that is, when the induction of organs was occurring, but somewhat in advance of organ formation. Experiments involving the x-irradiation of rat embryos afford additional examples. Warkany and Schraffenberger ('47) described numerous skeletal anomalies in newborns irradiated several days before the first appearance of embryonic skeletal elements. Wilson, Jordan and Brent ('52) produced malformations of the eye, brain, face, spinal cord, aortic arches, heart and kidneys by irradiating embryos on the 9th day of gestation when the primordia of these structures were not yet recognizable. It has long been known that some malformations are genetically determined. Hence, congenital malformations may originate at at least three different periods in development: (1) before fertilization, as a result of germ-cell mutations; (2) prior to the period of organogenesis, by environmental influences (for example, radiations); (3) during the period of organogenesis, as a consequence of maternal vitamin A deficiency and possibly other factors (Ingalls et al., '50; Fraser and Fainstat, '51).

SUMMARY

Female rats were maintained on vitamin A deficient diets prior to and during early pregnancy. One group was allowed to continue throughout pregnancy in the deficient state while 6 other groups were given single large doses of vitamin A on the 10th, 11th, 12th, 13th, 14th or 15th day.

The offspring of females deficient throughout pregnancy frequently exhibited congenital defects of the eyes, diaphragm, kidneys, ureters, and genital ducts, and somewhat less frequently of the aortic arches, heart, lungs and lower genitourinary tract. These defects occurred with sufficient regularity to be considered as comprising a syndrome.

The administration of vitamin A to the deficient mothers at progressively earlier times during pregnancy resulted in a progressive reduction in offspring affected by malformation. Associated with this was an alteration in the composition of the typical A-deficiency syndrome. To a limited extent the types of defects, and to a considerable extent the relative percentage incidence of the various types, underwent change. An analysis of these observations led to the conclusion that the malformations resulting from maternal vitamin A deficiency were determined during the period of active organ formation, rather than at an earlier period as has been established for other teratogenic agents.

LITERATURE CITED

ANDERSEN, D. H. 1941 Incidence of congenital diaphragmatic hernia in the young of rats bred on a diet deficient in vitamin A. Am. J. Dis. Child., *62:* 888–889 (abstract).

——— 1949 Effects of diet during pregnancy upon the incidence of congenital hereditary diaphragmatic hernia in the rat. Am. J. Path., *25:* 163–185.

BROWMAN, L. G., AND F. RAMSEY 1943 Embryology of microphthalmos in Rattus norvegicus. Arch. Ophth., *30:* 338–351.

FRASER, F. C., AND T. D. FAINSTAT 1951 Production of congenital defects in the offspring of pregnant mice treated with cortisone. Pediatrics, *8:* 527–533.

INGALLS, T. H., F. CURLEY, JR. AND R. A. PRINDLE 1950 Anoxia as a cause of fetal death and congenital defect in the mouse. Am. J. Dis. Child., *80:* 34–45.

STOCKARD, C. R. 1921 Developmental rate and structural expression: an experimental study of twins, 'double monsters,' and single deformities, and the interaction among embryonic organs during their origin and development. Am. J. Anat., *28:* 115–277.

WARKANY, J., C. B. ROTH AND J. G. WILSON 1948 Multiple congenital malformations: a consideration of etiologic factors. Pediatrics, *1:* 462–471.

WARANY, J., AND E. SCHRAFFENBERGER 1946 Congenital malformations induced in rats by maternal vitamin A deficiency. I. Defects of the eye. Arch. Ophth., *35:* 150–169.

——— 1947 Congenital malformations induced in rats by Roentgen rays. Skeletal changes in the offspring following a single irradiation of the mother. Am. J. Roentgenol., *57:* 455–463.

WILSON, J. G., AND S. BARCH 1949 Fetal death and maldevelopment resulting from maternal vitamin A deficiency in the rat. Proc. Soc. Exp. Biol. and Med., *72:* 687–693.

WILSON, J. G., H. C. JORDAN AND R. L. BRENT 1953 Effects of irradiation on embryonic development. II. X-rays on the ninth day of gestation in the rat. Am. J. Anat., *92:* January.

WILSON, J. G., AND J. WARKANY 1948 Malformations in the genito-urinary tract induced by maternal vitamin A deficiency in the rat. Am. J. Anat., *83:* 357–407.

——— 1949 Aortic-arch and cardiac anomalies in the offspring of vitamin A deficient rats. Am. J. Anat., *85:* 113–155.

Wolbach-'41
Bib. No. 9950

ARCHIVES OF PATHOLOGY

VOLUME 32 NOVEMBER 1941 NUMBER 5

COPYRIGHT, 1941, BY THE AMERICAN MEDICAL ASSOCIATION

VITAMIN A DEFICIENCY AND THE NERVOUS SYSTEM

S. B. WOLBACH, M.D.
AND
OTTO A. BESSEY, PH.D.
BOSTON

The relation of vitamin A deficiency to lesions of the nervous system has long been an issue in a state of confusion. The solution has been found in the discovery that the deficiency when instituted at a sufficiently early age causes a disproportion between the central nervous system and its osseous envelopment. The effect is virtually that of an overgrowth of the central nervous system with consequent mechanical injuries to the brain, spinal cord and nerve roots as a result of pressure.

The substance of this paper comes chiefly from experiments on white rats. Confirmatory experiments have been made by us on guinea pigs and dogs. A review of the literature indicates that vitamin A deficiency in the young of several mammals and in fowls results in damage to the central nervous system and suggests that in all vertebrates the common consequence is that of disproportionate growth. The prediction is warranted that acute uncomplicated vitamin A deficiency in the human infant would produce similar results.

REVIEW OF PERTINENT LITERATURE

Hart, Miller and McCollum in 1916[1] probably were the first to describe and demonstrate nerve lesions due to vitamin A deficiency, in experiments on young swine kept on wheat meal rations. Malnutrition, ataxia and paralysis were obtained and were shown to be prevented by the addition of alfalfa meal. At that time the lesions were ascribed to toxicity of the high wheat diets. Vitamin A in the alfalfa was regarded as the protective factor.

Mellanby[2] reported severe nervous symptoms and nerve lesions in puppies maintained on cereal rations as being due to toxic substances, for which he suggested the name "toxamins." He ascribed a protective function to the fat-

From the Departments of Pathology and Biological Chemistry, Harvard Medical School.

1. Hart, E. B.; Miller, W. S., and McCollum, E. V.: J. Biol. Chem. 25:239, 1916.

2. Mellanby, E.: J. Physiol. 61:xxiv, 1926.

soluble vitamins. Later[3] he added proof that the lack of vitamin A was a causative factor in the production of the nerve lesions and that the same effects could be produced in young rabbits. He retained the belief that toxic products were also involved.

The distribution of lesions described by Mellanby in the rabbit included all the afferent nerves of the head: the optic nerves, sensory fibers of the fifth, and the auditory and vestibular fibers of the eighth nerve. In the body, also, the afferent nerves were affected, demonstrable in the dorsal roots. The anterior root fibers remained normal except when nutritional deficiency had been very prolonged. No lesions were found in the vagus nerves. In the spinal cord the ascending fibers were most involved: the dorsal and ventral spinocerebellar, the dorsal and ventral spinoreticulothalamic, and the tracts of the dorsal columns. Of descending tracts, he named the rubrospinal, the dorsal longitudinal bundle and the vestibulospinal. The pyramidal tracts generally escaped lesions.

Finally, from the study of deafness produced in puppies fed "on diets of natural foodstuffs but deficient in vitamin A and rich in cereals," Mellanby[4] reported compression of the eighth nerve by bony overgrowth of periosteal origin. He suggested that degenerative changes of other cranial nerves—the optic and the trigeminal—were due to bony overgrowth around foramens. No explanation was offered for the occurrence of nerve lesions elsewhere.

Mellanby's[4a] last publication, on the subject of nerve lesions and vitamin A deficiency in young dogs, reached us after this paper was in press. He describes overgrowth of bone in several locations—of the cranial bones, particularly those forming the posterior fossa, the vertebrae and the femurs. He regards this overgrowth as related (presumably through pressure effects) to degenerative changes in the brain and in the cranial and peripheral nerves. He states that "a function of vitamin A is to influence the structure of growing bone, probably by limiting the number and degree of activity of osteoblasts and osteoclasts. In its absence from the growing dog, osteoblastic and osteoclastic activity is increased, thus resulting in proliferation of cancellous bone at the expense of compact bone and causing many bones to lose their normally fine molding and outline and to become thickened and enlarged." He extends this idea to the epithelial changes in vitamin A deficiency by stating that the "fundamental change is overgrowth of epithelial cells of all kinds, keratinization and metaplasia being secondary to this overgrowth."

Hughes, Aubel and Lienhardt[5] reported paralysis and nerve lesions in weanling swine fed on white corn and tankage diets. Vitamin A, supplied by cod liver oil and other sources, prevented the disorder. They also reported severe nerve degeneration in chicks given vitamin A-deficient diets when a day old, and mentioned stiffness and incoordination in 3 mature cows fed a vitamin A-deficient diet. They also stated that impairment of the nervous system developed in some rats on similarly deficient diets.

Aberle, Zimmerman and Brill[6] reported paralysis and central and peripheral nerve lesions in rats nurtured on a diet low in vitamin A. The rats were given

3. Mellanby, E.: (*a*) Brain 54:247, 1931; (*b*) Edinburgh M. J. 40:197, 1933; (*c*) J. Path. & Bact. 38:391, 1934; (*d*) Brain 58:141, 1935.

4. Mellanby, E.: J. Physiol. 94:380, 1938.

4a. Mellanby, E.: J. Physiol. 99:467, 1941.

5. Hughes, J. S.; Aubel, C. E., and Lienhardt, H. F.: The Importance of Vitamin A and Vitamin C in the Ration of Swine, Technical Bulletin 23, Kansas State College of Agriculture, Agricultural Experimental Station, 1928. Hughes, J. S.; Lienhardt, H. F., and Aubel, C. E.: J. Nutrition 2:183, 1929.

6. Aberle, S. B. D.; Zimmerman, H. M., and Brill, L.: Anat. Rec. 48 (supp.): 7, 1931.

the diet at about 22 days of age. The first signs of paralysis appeared between the fifty-sixth and seventieth day of age. These rats were the basis of a careful pathologic study by Zimmerman.[7] Myelin sheath degeneration of the brachial plexuses, sciatic nerves and less frequently of the vagus nerves was found, but not of the optic nerves. In the spinal cord, myelin sheath degeneration of the sensory tracts on the periphery of the cord and in the posterior columns and occasionally in the cross and direct pyramidal tracts was found. The posterior nerve roots and less frequently the anterior nerve roots showed myelin sheath degeneration and "evidence was adduced to indicate that the changes in the sensory tracts of the spinal cord followed those in the posterior nerve roots."

Subsequent studies by Aberle[8] and Zimmerman and Cowgill[9] showed that the paralysis, while preventable by carotene or cod liver oil, could not be cured, although treatment restored a normal rate of growth.

Elvehjem and Neu[10] suggested that the staggering gait and general incoordination observed in vitamin A-deficient chicks might be due to nerve lesions. Six weeks old as well as day old chicks responded equally well.

Setterfield and Sutton[11] described ataxia and paralysis in vitamin A-deficient rats and used polarized light for the study of myelin sheath degeneration. Changes in the nerves could be demonstrated three to six days before symptoms appeared and could be arrested by giving adequate doses of vitamin A.

Irving and Richards[12] reported the constant production of nervous signs and nerve lesions in vitamin A-deficient rats. The rats were given the deficient diet at weaning. Lesions developed earlier in the rats which had access only to A-deficient food before they were weaned. The authors disproved that there was a possible toxic effect of cereals. Many of the rats showed marked nerve lesions while still gaining in weight. Female rats showed nerve lesions later than did males.

The first lesions (demyelination) occurred in the medulla in the funiculus praedorsalis at the level of the decussation of the pyramids. From this site the lesions extended higher in the medulla and down into the cervical cord. The funiculus praedorsalis, according to Irving and Richards, corresponds to the tectospinal tract in man and is a motor tract. Later, lesions of the spinocerebellar tract and the posterior columns (especially Burdach's column) developed.

Moore, Huffman and Duncan[13] reported blindness and paralysis in vitamin A-deficient calves, including calves born of vitamin A-deficient cows and calves fed on vitamin A-deficient rations. The blindness was due to bone overgrowth in the optic foramen causing stenosis and degeneration of the optic nerve by pressure.

Moore[14] extended and confirmed these observations and showed that the disorders could be prevented by adding crystalline carotene in cottonseed oil to the diet. Then Moore and Sykes[15] reported elevation of cerebrospinal fluid

7. Zimmerman, H. M.: J. Exper. Med. **57**:215, 1933.
8. Aberle, S. B. D.: J. Nutrition **7**:445, 1934.
9. Zimmerman, H. M., and Cowgill, G. R.: J. Nutrition **11**:411, 1936.
10. Elvehjem, C. A., and Neu, V. F.: J. Physiol. **97**:71, 1932.
11. Setterfield, H. E., and Sutton, T. S.: J. Nutrition **9**:645, 1935.
12. Irving, J. T., and Richards, M. B.: J. Physiol. **89**:2 P, 1937; **94**:807, 1938.
13. Moore, L. A.; Huffman, C. F., and Duncan, C. W.: J. Nutrition **9**:533, 1935.
14. Moore, L. A.: J. Nutrition **17**:443, 1939.
15. Moore, L. A., and Sykes, J. F.: Am. J. Physiol. **130**:684, 1940.

pressure in vitamin A-deficient calves and the development of papilledema. They suggested that the bone changes reported by Mellanby, affecting the eighth nerve, were related "in some manner to those reported in calves where a constriction of the optic nerve develops." They did not relate the bone changes to the elevation of cerebrospinal fluid pressure.

Phillips and Bohstedt,[16] by using diets similar to those employed by Moore and co-workers, produced in rabbits ataxia and paralysis and other signs of vitamin A deficiency but not stenosis of the optic foramen.

The best account of nerve lesions in vitamin A deficiency in fowls is that of Seifried.[17] Chicks 15 to 18 days old were largely used and gave very constant results; nervous manifestations appeared in about four months. Fowls 4 and 6 months old responded less regularly. Of 14 fowls given the deficient diet at 6 months of age, 5 exhibited evidence of nerve disorders. Ataxia, incoordination and convulsions were the manifestations. The lesions reported by Seifried were degeneration of ganglion cells in the anterior horns of the spinal cord and of the motor cortex, the nucleus dentatus and nuclei of the medulla, and of the Purkinje cells of the cerebellum. Demyelination was found in the spinal cord (tracts not stated) and in the brachial, sciatic and optic nerves.

THE PRESENT INVESTIGATION

The importance of early age and more specifically of an early period of growth as the essential factor in the production of nerve lesions in vitamin A deficiency came to be realized late in our studies, although clearly indicated in the data of the papers just reviewed. Likewise, an analysis of papers reporting failure to produce nerve lesions in rats,[18] dogs [19] and monkeys [20] reveals that the animals used had passed their early period of rapid growth.

Our studies, which have extended over a period of four years, were undertaken to answer the following questions:

1. What is the relation of vitamin A deficiency to nerve lesions in view of the conflicting observations recorded?

2. Are the epithelial changes of vitamin A deficiency secondary to nerve lesions, as suggested by Mellanby?[3c]

In the light of the solution of our problems it does not seem warranted to present in detail our initial fairly elaborate experiments in which rats and guinea pigs of considerable size were used. Normal and undernourished controls were observed in each experiment. Paralysis was not obtained. The epithelial changes of vitamin A deficiency were constant, and studies of nerves failed to show myelin sheath degenera-

16. Phillips, P. H., and Bohstedt, G.: J. Nutrition **15**:309, 1938.

17. Seifried, O.: Arch. f. wissensch. u. prakt. Tierh. **65**:140, 1932.

18. Wolbach, S. B., and Howe, P. R.: J. Exper. Med. **42**:753, 1925. Duncan, D.: Arch. Neurol. & Psychiat. **25**:327, 1931.

19. Suzman, M. M.; Muller, G. L., and Ungley, C. C.: Am. J. Physiol. **101**: 529, 1932. Eveleth, D. F., and Biester, H. E.: Am. J. Path. **13**:257, 1937.

20. Grinker, R. R., and Kandel, E.: Arch. Neurol. & Psychiat. **30**:1287, 1933.

tion in the spinal cord or in the brachial, sciatic and trigeminal nerves. (The modified Marchi technic of Swank and Davenport [21] was employed among other methods and was applied by Dr. Swank, who was associated with us during the first period of this work.)

The answer to the second question was emphatic and decisive. The epithelial changes characteristic of vitamin A deficiency were invariably produced in a large number of animals without demonstrable nerve changes.[22]

Observations which were the outcome of testing several strains of white rats from different laboratories with a few positive results led to the use of weanling rats and finally to the discovery that paralysis and nerve lesions invariably occur if the deficiency is established before the eighth week of life.

DIET AND PROCEDURES

Our stock colony is reared on Purina dog chow. The vitamin A-free diet is as follows:

	Per Cent
Casein	18
Osborn and Mendel salt mixture	3
Brewers' yeast	10
Peanut oil	8
Corn starch	60.9
Viosterol	0.1

In order to secure the early establishment of the deficiency, the mother and her young were given the diet fourteen days after birth. Large litters (8 to 12) were selected as often as possible because they show the development of neurologic signs earlier, presumably because each rat receives less vitamin A from the mother's milk. The young rats were weaned at 21 days of age and maintained on the vitamin A-deficient diet.

COURSE AND SYMPTOMS

About 500 rats were used in this study. The rats on the deficient diets continued to grow at a normal rate into the sixth week of age. Stationary weight or a loss of weight was usual in the ninth week. Signs of nerve lesions usually appeared between 6 and 9 weeks of age and developed rapidly.

In general, the paralysis appears at about the time the rate of weight gain begins to fall below the normal, which is about one week before a decrease in weight begins. In many rats paralysis developed while weight was still increasing

21. Swank, R. L., and Davenport, H. A.: Stain Technol. **9**:11, 1934.

22. Not only were no degenerative changes in the myelin found but the diffuse blackening of occasional fibers mentioned by Swank (J. Exper. Med. **71**:683, 1940) as a feature of prolonged malnutrition in rats was absent. In later experiments in rats examined by Dr. Swank, the same degree of blackening of myelin sheaths was found in rats with prolonged vitamin A deficiency but no neurologic disturbances as in their starvation controls. The significance of the "starvation effect" in myelin requires further study and confirmation of the premises.

at a normal rate and as much as two weeks before the deficiency could be detected by a decrease in weight or other gross signs. Rats in which marked loss of weight occurred early as a result of inanition, before nervous signs appeared, died with all the usual epithelial lesions of vitamin A deficiency but without the significant lesions of nerve degeneration.

The first sign is incoordination of the hindlegs, evidenced by an unsteady and uneven gait and by occasional overabduction or overadduction of one or both legs. One or both hindlegs may be affected, but the two legs may vary in incapacity of function. The disorder may not progress beyond ataxia and incoordination, especially if the onset was beyond the eighth week and the rat over 100 Gm. in weight. On the other hand, with early onset of signs, the disorder progresses to complete paralysis or inability to use the hindlegs.

Paralysis usually is present before the eighth week of life. If it appears after this age, it is less frequent and less severe. It has occurred in a significant number of rats up to the twelfth week but very rarely beyond this age (fig. 1). Rats which grow to weigh over 125 Gm., regardless of age, rarely show paralysis, although all the other signs of vitamin A deficiency develop.

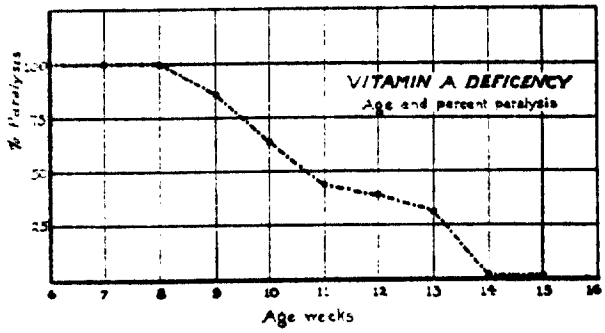

Fig. 1.—The chart presents graphically the frequency of occurrence of paralysis in 300 rats in relation to the age at which the deficiency was established as indicated by loss of weight. For example, the graph indicates that if the deficiency was established by the end of the eighth week, 100 per cent of the animals became paralyzed, whereas if it was established at the age of 10½ weeks, paralysis developed in only 50 per cent of the rats.

One very important fact, to be discussed more fully later, is that the onset of signs and the development of the nerve lesions are rapid and are established before the rats cease to gain weight. The onset of nervous signs can be prevented if the administration of vitamin A in some form is begun seven to ten days before they are expected to appear. Administration of vitamin A begun at 42 days of age always prevents paralysis and often does if begun as late as 47 days of age. Paralysis is usually apparent by the fifty-fourth day of age.

Animals whose deficiency is cured by the administration of vitamin A in some form after the development of paralysis remain permanently crippled, although they are restored to health in all other respects.

Administration of alpha tocopherol (vitamin E) does not prevent the development of the nerve lesions.

PATHOLOGIC OBSERVATIONS

The fact that the consistent production of nerve disorders in rats in consequence of vitamin A deficiency required the establishment of the deficiency at an early period of growth made the mere demonstration of myelin sheath degeneration in the peripheral and central nervous systems unsatisfactory unless there was correlation with some aspect of physiology or growth.

Routinely, myelin sheath degeneration was found in the sciatic and brachial nerves, spinal cord, medulla and posterior cerebellar peduncles. The trigeminal nerve very rarely showed a few degenerated fibers. Studies of the spinal cords, medullas and midbrains from 13 paralyzed rats confirmed, in general, the distribution of lesions as given by Mellanby [3d] for the rabbit, and Zimmerman [7] and Irving and Richards [12] for the rat.

Two factors came to light which were against the probability of finding a correlation either with the physiology of the nervous system or with its postnatal development. These were, for the first, the too great irregularity in distribution and in degree of involvement of the tracts in the spinal cord as shown by myelin sheath degeneration and, for the second, the lack of relation of the tracts most constantly involved to the order of postnatal myelination in the spinal cord of the rat as described by Watson [23] and Buckley.[24]

Differences in degree and in distribution of myelin degeneration in the spinal cord were marked when the preparations from different rats were compared. In individual rats there were often marked differences in the two sides of the spinal cord; occasionally tracts which showed many degenerated fibers on one side would be practically free from lesions on the opposite side.

In regard to postnatal development, the regions most regularly and most conspicuously degenerated in the vitamin A–deficient rats were those roughly described by Zimmerman [7] as the sensory tracts on the periphery of the spinal cord, and these [25] are among the very first to become myelinated. The posterior columns, which frequently contain many degenerated fibers, also are among the earliest to undergo myelination. As there are no myelinated fibers in the nervous system of the rat at birth [25] and myelination is still incomplete at 42 days of age, our observations seemed incompatible with the idea that vitamin A–deficiency directly affects maintenance or formation of myelin. If vitamin A were necessary for formation or maintenance of myelin, fibers

23. Watson, J. B.: Animal Education: An Experimental Study on the Psychial Development of the White Rat Correlated with the Growth of Its Nervous System, Chicago, University of Chicago Press, 1903.

24. Buckley, A. C.: J. Comp. Neurol. **66**:449, 1937.

25. Watson.[23] Buckley.[24]

undergoing myelination during the age period of the experiments should have exhibited the severest consequences of the deficiency.

Gross anatomic studies restricted to dried preparations of skeletons were unproductive. No significant differences were found in the exteriors of skeletons of paralyzed rats as compared with several types of controls. Serial sections of the lumbar and upper sacral vertebrae with spinal cord and nerves and adjacent soft tissues in situ were made of a few severely paralyzed rats, cut in the horizontal (frontal) plane and in cross section. These sections showed great distortions of the spinal ganglions and nerve roots and deep pits occupied by coiled nerve roots in the bodies of the lower lumbar and upper sacral vertebrae (fig. 2). Further progress in elucidation of the alterations was made by gross dissection of the central nervous system in situ.

The following description is based on the dissection of 25 vitamin A–deficient rats which had shown all stages of paralysis from the earliest signs to maximum severity.[26]

The appearance of the exposed nervous system of a markedly paralyzed rat is that of overcrowding—of a central nervous system too large for its bony encasement—with most striking evidences in the skull and in lumbar and sacral vertebrae.

The prominent features in the skull are a herniation of the cerebellum into the foramen magnum and multiple herniations of the cerebrum and cerebellum into the venous sinuses of the dura. In the spinal canal the prominent features are herniations of nerve roots into the intervertebral foramens and into the bodies of vertebrae and a low position of the conus medullaris.

The Brain.—The following description is a composite one, based on numerous examinations of rats which exhibited marked paralysis of seven to twenty-one days' duration and were killed at ages of from 56 to 77 days. Only the most apparent changes are described.

During exposure of the brain, thinning of the parietal and interparietal bones may be evident, and there may be loosening of the intervening sutures. The brain is flattened. The posterior border of the cerebellum presents as a deeply injected transverse band because of

26. The rats were prepared for dissection by evisceration and skinning, and fixation in solution of formaldehyde U. S. P. (1:10 D) after having been stretched on a board so as to keep the head and spine in as nearly straight a line as possible. After fixation the rats were decalcified in 5 per cent nitric acid, unless careful histologic studies were contemplated. Dissections were made under a low power, wide field binocular dissecting microscope and consisted of exposure of the brain, medulla and spinal cord by removal of bone from the dorsal side. Rarely, an approach was made from the ventral side in order to study the relations of the contents of pits in the vertebrae to the spinal ganglions. Dissections of undecalcified rats were not difficult, though they required more time.

molding of the posterior lobe into the foramen magnum (fig. 4 A). Herniations of the cerebellum and cerebrum are usually conspicuous in the transverse sinuses and in the lacunas which receive the superior

Fig. 2.—*A*, photomicrograph at 9 diameters; a vitamin A–deficient rat 65 days old, which had shown paralysis for nine days. The horizontal section shows, from right to left, the third and the fourth and a part of the fifth lumbar vertebra, to illustrate pitting of vertebrae.

B, photomicrograph at 15.5 diameters; a vitamin A–deficient rat 65 days old, which had shown paralysis for eight days. The horizontal section shows, from right to left, a part of the third and the whole of the fourth lumbar vertebra, to illustrate pitting of vertebrae.

cerebellar veins. The common sites of origin of the hernias are: for the posterior poles of the cerebral hemisphere, (1) the junction of superior petrosal and transverse sinuses and (2) the points where superficial veins of the cerebrum enter the transverse sinuses; for the cerebellum, (1) the junction of the superior cerebellar veins and the lacunas of the transverse sinuses into which they empty, (2) the angles at the junctions of the aforementioned lacunas and the transverse sinuses and (3) the junctions of the inferior cerebellar veins and the transverse

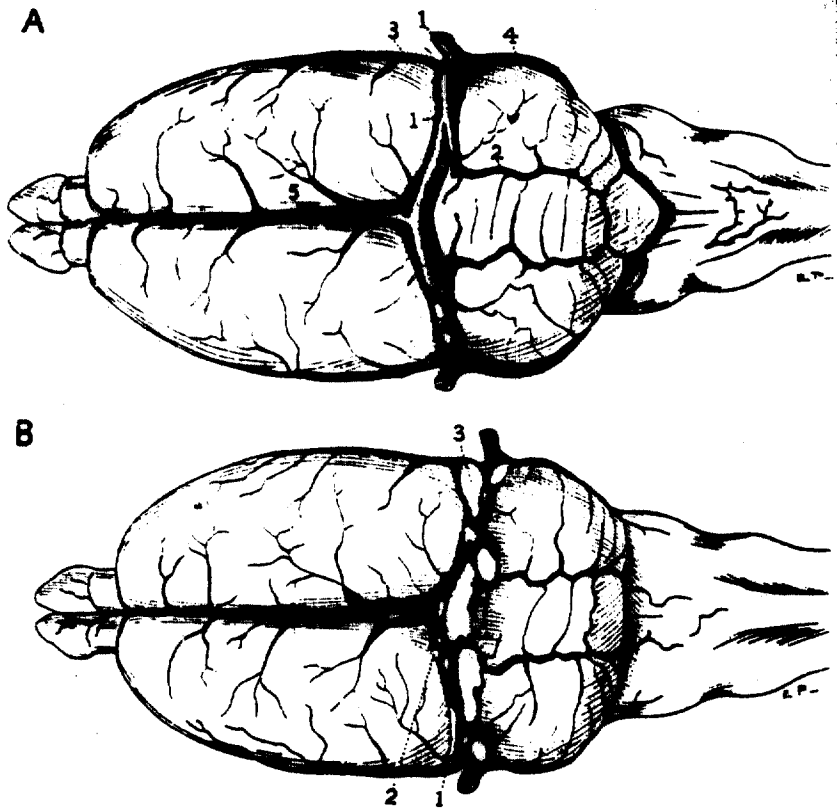

Fig. 3.—*A*, normal brain showing dural sinuses and cerebellar veins: *1*, transverse sinus; *2*, superior cerebellar vein; *3*, superior petrosal sinus; *4*, inferior cerebellar vein; *5*, superior sagittal sinus.

Note the lacunas of the transverse sinuses where the superior cerebellar veins enter. We have not found mention of this detail. The region seems to be an important one for the drainage of cerebrospinal liquid because of the abundance of arachnoidal villi.

B, composite drawing of herniations into the dural sinuses. *1*, *2* and *3* are herniations of the posterior poles of the cerebrum. *1* and *3* have entered at the junctions of the superior petrosal and transverse sinuses. The other herniations are of the cerebellum. Compare with the drawing of the vessels of the normal brain for points of entrance. Compare also with figure 4*A*.

sinuses. In some instances there was a herniation of the cerebellum into the torcular, presumably at the entrance of the straight sinus (figs. 3 and 4 A).

Fig. 4.—*A*, photograph at 5 diameters; brain of a vitamin A-deficient rat 9 weeks old, which had shown slight paralysis for sixteen days. Note the herniations (*H*) of cerebrum and cerebellum into the transverse sinuses and torcular and the flattening of the posterior lobe of the cerebellum where it was forced into the foramen magnum (bracket at *C*). Compare with figure 3 *B*.

B, photomicrograph at 16.7 diameters; a vitamin A-deficient rat 8 weeks old, which had shown paralysis for seven days. The sagittal plane section shows, from left to right, the fifth and sixth lumbar vertebrae.

In all of the aforementioned sites, structures corresponding to the arachnoidal villi of man have been found in normal rats by means of serial sections, made through these regions, of decalcified heads of normal rats. Arachnoidal villi, substantially identical with those of man, are present in relation to the venous sinuses and to the larger super-

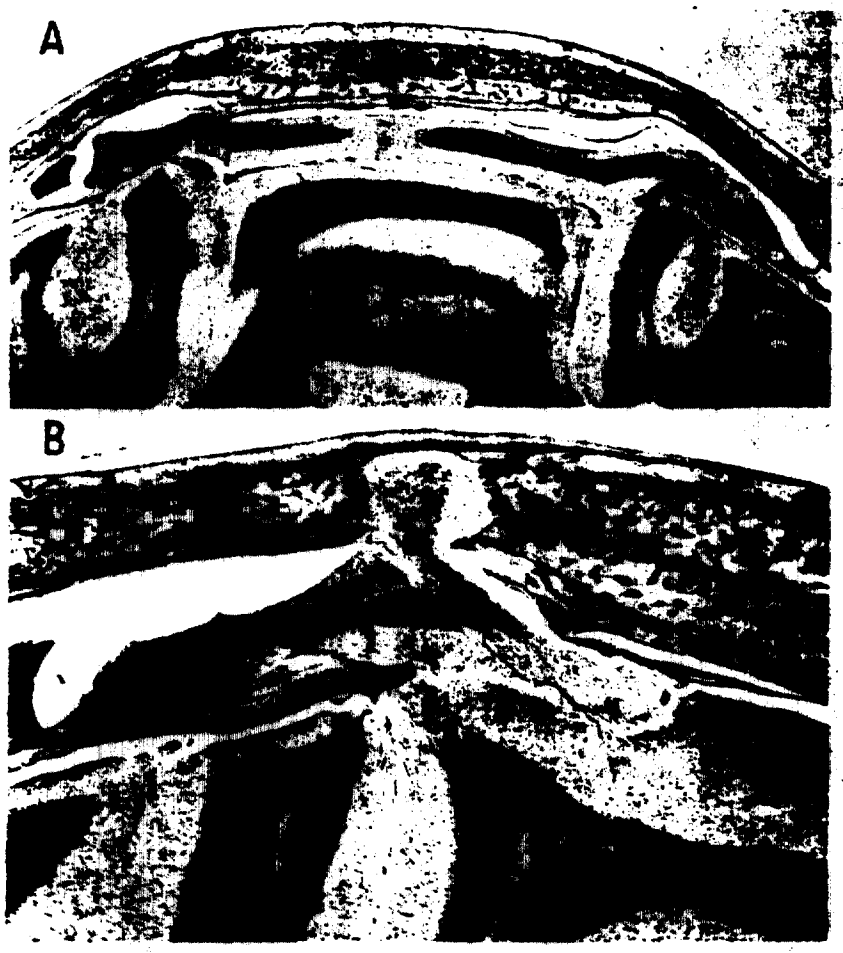

Fig. 5.—*A*, photomicrograph at 14.3 diameters: a vitamin A-deficient rat 10 weeks old which had shown paralysis for six days. The frontal plane section through skull and cerebellum shows a herniation on each side into the lacuna where the cerebellar vein enters the transverse sinus.

B, photomicrograph at 35 diameters from the same rat as *A* but at a different level, showing a pit in interparietal bone occupied by herniated cerebellar tissue. The increased thickness of the inner table is due to the proximity to the sutures with the parietal bones, but the new bone formation is somewhat greater than in normal rats.

ficial cerebral and cerebellar veins. At the junctions of the superior and inferior cerebellar veins with the transverse sinuses and at the junctions of superior petrosal and transverse sinuses, and at the confluence of the sinuses, there are projecting extensions of the arachnoid membrane structurally composed like human arachnoidal villi, usually sessile, less commonly pedunculated, and having the same relation to the blood stream.

The largest of these arachnoidal villi range in size—i. e., diameter at base—from 0.1 to 0.6 mm. They are most prominent in the angles of junctures of the superior cerebellar lacunas and transverse sinuses. The mechanism of herniation into arachnoidal villi in these rats is probably the same as that for the multiple herniations of the cerebrum and cerebellum into arachnoidal villi in man in consequence of increased intracranial pressure.[27]

The herniations may reach considerable size and may extend for a distance of 2 to 3.5 mm. into the transverse sinuses (figs. 5 *A* and 6 *A*). In a rat studied by serial sections made through brain and skull there were found (fig. 5 *B*) extensions of herniated cerebellar substance into the interparietal bone with pit formations extending to the outer table, presumably taking origin at points of entrance of emissary veins.

The few herniations of the cerebellum which have been studied histologically were capped by arachnoidal tissue (fig. 6 *B*) indicative of their sites of entrance and similar to findings in human herniations of similar genesis.[27]

Other distortions of the brain were found. Among the most conspicuous were: (1) incarceration and compression of the paraflocculi, the result of new bone formation in their fossae; (2) anteroposterior flattening and dorsal extrusion of the posterior colliculus; (3) dilatation of the cerebral ventricles (not constant), and (4) flattening and tortuosities of the optic nerves.

The new bone formation in the fossae housing the paraflocculi is of periosteal origin and is restricted to those parts of the fossae which are in direct relation to the bony labyrinths of the ears (figs. 7 *B* and 8). It is similar in structure to the periosteal bone formation described by Mellanby[4] in the internal auditory meatus of vitamin A–deficient puppies (fig. 7 *A*) and by Moore and associates[28] in the optic foramens of vitamin A–deficient calves.

The Spinal Cord and Nerve Roots.—There is no empty space in the spinal canal of the paralyzed vitamin A–deficient rat.[29] The dura is-

27. Wolbach, S. B.: J. M. Research **19**:153, 1908.

28. Moore and associates.[13] Moore.[14]

29. Cerebrospinal fluid relations have not been investigated. Appearances in celloidin-embedded spinal columns (fig. 2) suggest that cerebrospinal fluid may be entrapped in herniations into intervertebral foramens. However, great allowance must be made for shrinkage in decalcified and celloidin-embedded nerve tissues.

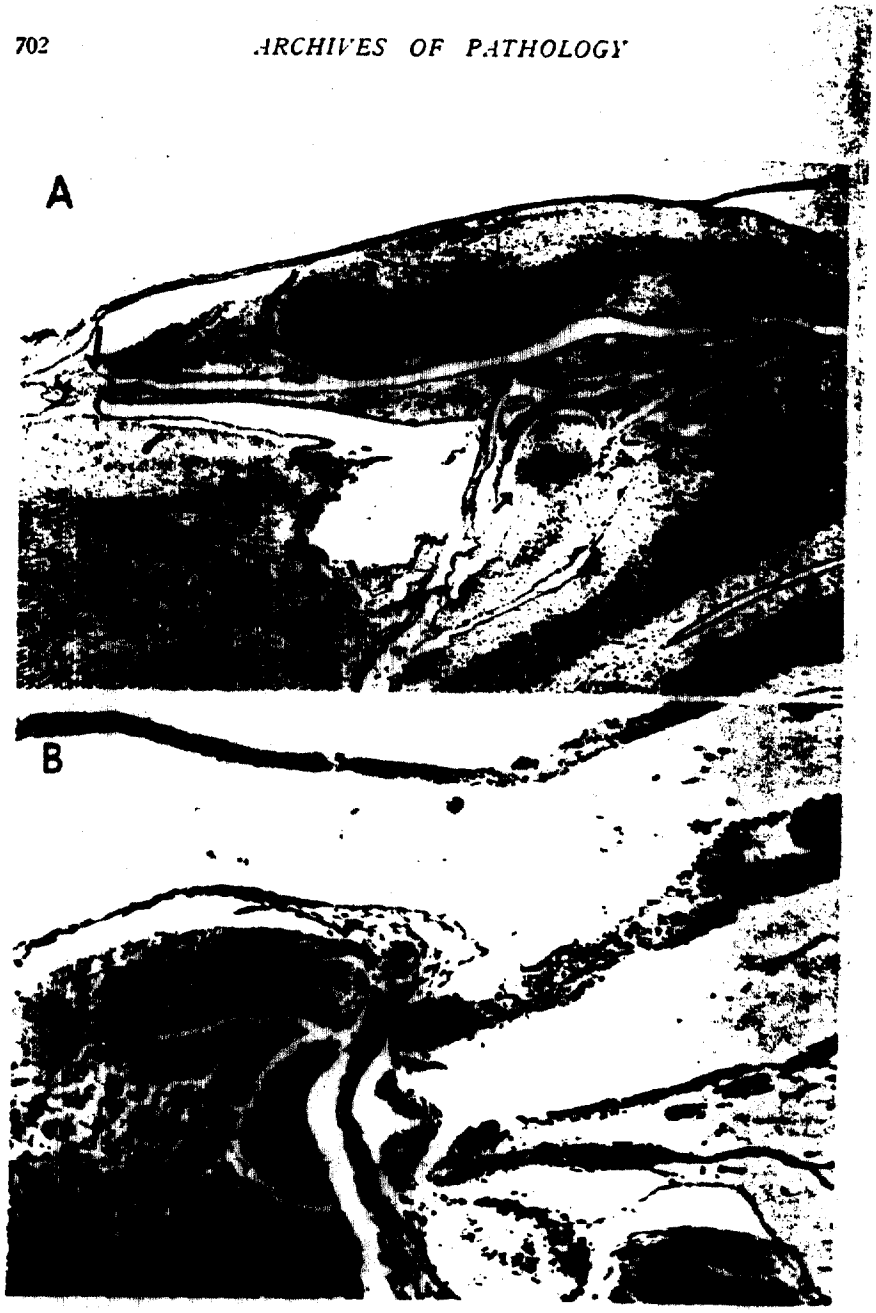

Fig. 6.—*A*, photomicrograph at 35 diameters; a vitamin A-deficient rat 60 days old, which had shown severe paralysis for eight days. This is a Nonidez-Cajal silver preparation to show one large and several small herniations of the cerebellum.

B, photomicrograph at 116 diameters; a vitamin A-deficient rat 60 days old, which had shown severe paralysis for eight days; hematoxylin and eosin. Note the herniation of the cerebellum into the transverse sinus. Note the arachnoidal villus cap.

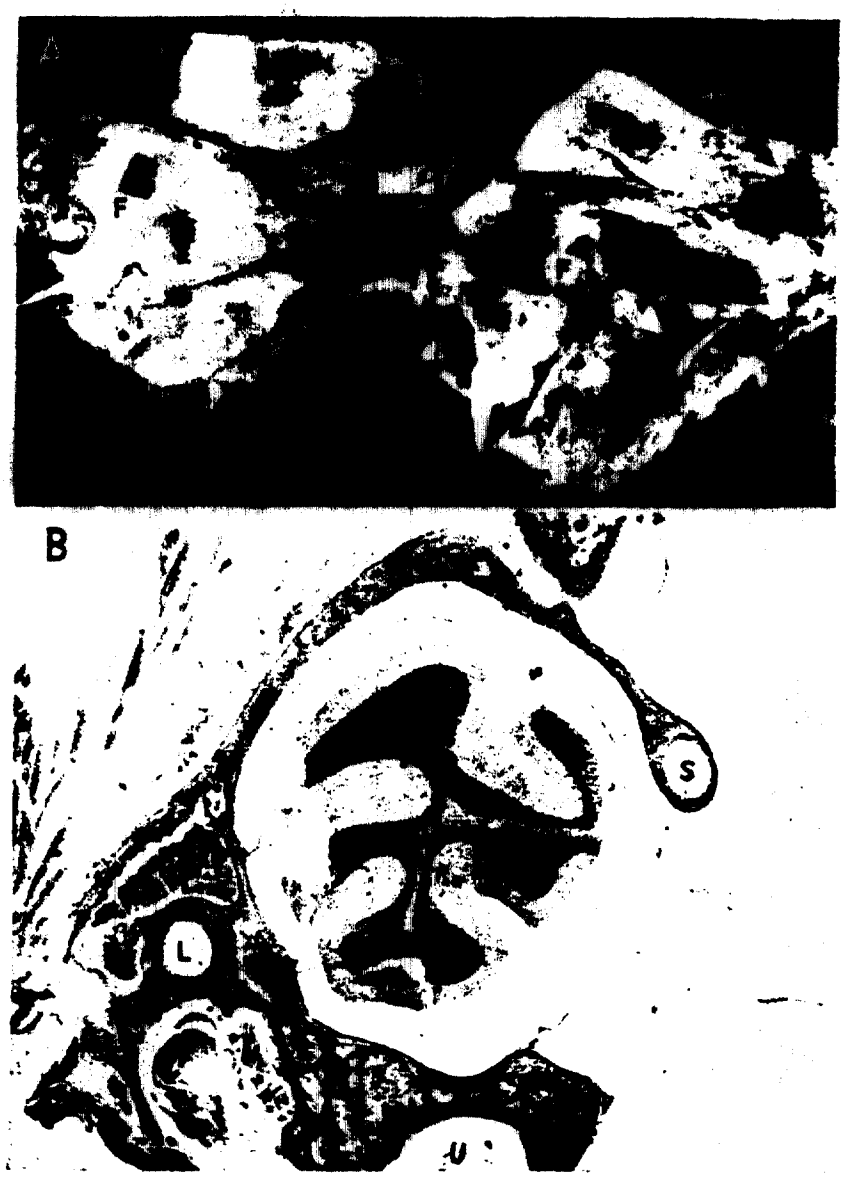

Fig. 7.—*A*, photographs at 1.6 diameters of the left petrous bones of litter mate puppies. That on the left is from the normal control. That on the right is from the puppy deficient in vitamin A. *F*, indicates the fossa for the paraflocculus; *E*, the internal auditory meatus. Note the general overgrowth of bone and the effect on *F* and *E*.

B, photomicrograph at 25 diameters; a normal control rat 54 days old; section through fossa of the right paraflocculus. *S* indicates the superior canal; *L*, the lateral canal, and *U*, the utricle.

Fig. 8.—*A*, photomicrograph at 26.3 diameters; a vitamin A-deficient rat 61 days old, which had shown paralysis for ten days; section through the fossa of the right paraflocculus.

B, photomicrograph at 26.3 diameters; a vitamin A-deficient rat 68 days old, which had shown paralysis for fifteen days; section through the fossa of the right paraflocculus.

tightly applied to the spinal cord and cauda equina. The posterior root ganglions of the lumbar and sacral regions are apparently enlarged, but after the dura has been opened, this apparent increase in size of the ganglions is seen to be due to extrusion of one to five or six flexed nerve roots (dorsal and ventral) into the intervertebral foramens (fig. 9). The ganglions are displaced laterally and are indented or invaginated by the herniated nerve roots (figs. 10, 11 and 12). The dura is outpocketed into the ganglions and tightly adherent thereto. Nerve roots from one side may cross the median line and be herniated into foramens of the opposite side. Rarely, and only in instances of long-continued severe paralysis, the lumbar cord is molded (herniated) in one or two places into intervertebral foramens or into pits containing nerve root herniations in the bodies of vertebrae (fig. 12).

The most striking manifestation of the disparity in size of the spinal canal and that of its contents is the bilaterally symmetric pitting of the bodies of the lower lumbar and upper sacral vertebrae (fig. 2). These pits contain herniations of the nerve roots which lie on the ventral and lateral sides of the spinal cord and usually contain also the flexed or coiled ends of anterior nerve roots before they take exit in their respective foramens. These pits reach a large size, as may be seen in figures 4 *B* and 13 *B*. The locations of the pits are, in our opinion, determined by the presence of large veins on the ventral side of the spinal canal which receive tributaries from the bodies of the vertebrae and which communicate through the intervertebral foramens with veins outside the spinal column. Serial cross sections of normal and vitamin A-deficient rats indicate that it is the yielding of these compressible veins which first determines the sites of flexures of nerve roots when the spinal canal becomes too small to accommodate the relative overgrowth of the nervous system. The intervertebral foramens also are obviously regions of yielding to pressure. The pits in the vertebrae may be larger on one side than on the other. Each occupies an almost central portion of the vertebral body, a trifle caudad in some instances. In cases of pitting at a very early stage and in instances in which paralysis has been prevented by administration of carotene or vitamin A at 42 days of age, sections show clearly that the resorption of bone is in relation to the veins mentioned.

Study of sections of pitted vertebrae show osteoclasis of trabecular bone intersected by the pits. The coiled nerves are surrounded by connective tissue derived presumably from the dura and certainly from periosteum. There is always a fairly continuous zone of osteoblasts surrounding the pit contents, and always there are traces of osteoid, indicative of the fact that formation of bone is not wholly inhibited by the deficiency during the period of pit formation. Exposure of the

Fig. 9.—*A*, photograph at 7.4 diameters; a vitamin A-deficient rat 9 weeks old, which had shown slight paralysis for seven days. The dissection shows dislodged herniation of nerve roots at the level of the sixth lumbar ganglions and below a partial dissection at the level of the first sacral ganglions.

B, photographs at 7.6 diameters; a vitamin A-deficient rat 11 weeks old, which had shown slight paralysis for fourteen days. The dissection shows a few nerve roots dislodged at the level of the sixth lumbar ganglions.

herniations in the bodies of vertebrae from the ventral side by removal of bone is readily accomplished because of the investure by connective tissue structures. Removal of the latter reveals the coiled nerve roots. Figures 10 *C* and 13 *A* show better than words the coiling and distortion of the nerve roots and the size and relation of the pits.

A remarkable feature of this pitting of vertebrae of significance in the consideration of the growth factors concerned in this study is the rapidity of their formation. Many experiments, each with litter mate controls, have proved that the nervous manifestations and all accompaniment of anatomic changes, excepting in some instances the first discernible effects, are prevented by the administration of carotene or vitamin A at 42 days of age. Deep pits, however, have been found at 56 days of age with considerable regularity, as well as in all rats which showed paralysis before this time. These pits attain about maximum size after eight to twelve days of paralysis, representing ages of from 60 to 70 days.

Microscopic study of vertebrae of paralyzed rats which have been treated with vitamin A shows complete walling-off of the pits with newly formed bone and also bone formation between nerve roots within the pits, conforming with the usual sequences and distribution of reparative bone production.

It does not seem worth while to describe in minute detail all the appearances and variations in distribution of the nerve root herniations. The degree of herniation must obviously depend on the degree of disproportionate growth. Degrees of asymmetry are probably due to chance and dependent on earlier initiation of herniation on one or the other side. An outstanding feature is that a single dorsal nerve root may herniate into several of the intervertebral foramens it passes between its origin and its foramen of exit (figs. 10 and 11). Dorsal roots of the second and third sacral ganglions have been found with four herniations above their foramens of exit. Likewise, ventral nerve roots may herniate into several pitted vertebrae and also into one or more intervertebral foramens as chance flexions determine. Anatomic relations determine the relative position of nerve roots in a given herniation (fig. 10 *B*); the outermost roots in a given herniation have the highest attachment to the spinal cord. In a preliminary report [30] we mentioned small excrescences seen in the course of nerve roots and suggested that they might be comparable to amputation neuroma. These excrescences are found in relation to sites of herniation of other nerve roots; they are also found presenting anterior and posterior to spinal ganglions and taking origin both from ventral and from dorsal nerve roots. It is perhaps permissible to refer to them as herniations of the excrescence type because

30. Wolbach, S. B., and Bessey, O. A.: Science **91**:599, 1940.

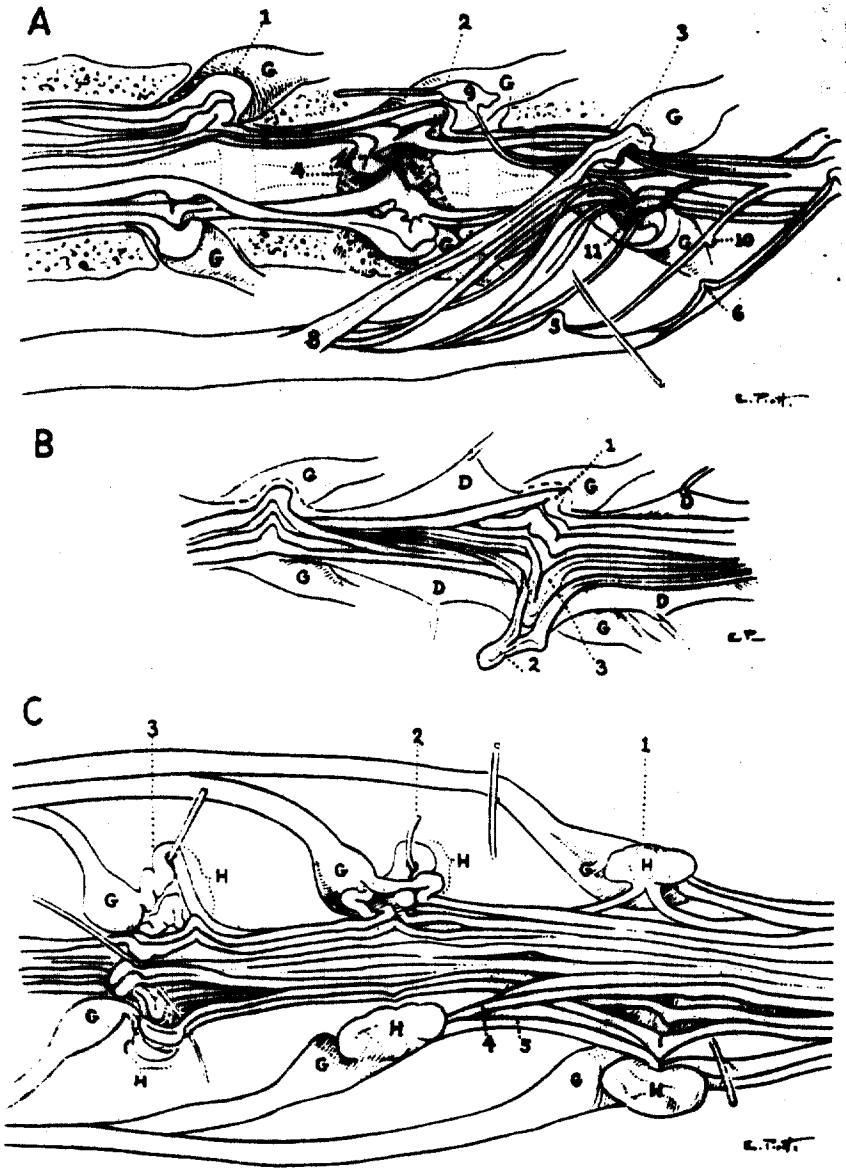

Figure 10

(See legend on opposite page)

they are produced by the buckling of degenerated nerve fibers in the direction of least resistance; more deeply situated nerve fibers in the trunks do swerve toward the excrescence, but there is no flexion of the nerve root as a whole.

Some degree of the disproportionate growth can be found in all nerve roots. In the upper dorsal and cervical roots no herniations have

---

EXPLANATION OF FIGURE 10

A, vitamin A–deficient rat 10 weeks old, which had shown severe paralysis for nine days; dorsal dissection exposing third, fourth, and fifth lumbar ganglions, indicated by *1*, *2* and *3* respectively.

4 indicates where the body of the fourth lumbar vertebra has been dissected away, exposing coiled nerve roots which have pitted the bone.

5, herniation of the spinal cord, which was extruded into the right fourth lumbar ganglion.

6, herniation of nerve roots removed from the fifth lumbar ganglion.

7, ventral root of the fourth lumbar ganglion lying in a pit in the body of the fourth lumbar vertebra.

8, dorsal roots to the sixth lumbar and first sacral ganglions from their origin to herniation into the fifth lumbar ganglion.

9, herniation of a coiled and swollen unidentified nerve root removed from the invaginated fourth lumbar ganglion.

10, small excrescence on the ventral nerve root removed from a fifth lumbar ganglion.

11, a deep pit in the fifth lumbar vertebra with entering and emerging nerve roots.

G, ganglions.

B, vitamin A–deficient rat 11 weeks old, which had shown severe paralysis for twenty-one days; dorsal dissection exposing fifth and sixth lumbar ganglions with herniated nerve roots.

1, ventral root of the first sacral ganglion herniated into the sixth lumbar, left side.

2, dorsal and ventral roots of the third sacral ganglion, right, removed from herniation into the sixth lumbar ganglion, right.

3, dorsal and ventral roots to the second right sacral ganglion dislodged from herniation into the right sixth lumbar ganglion.

G, ganglions.

D, dura. Its line of attachment to the ganglion is represented by dotted lines.

C, vitamin A–deficient rat 10 weeks old, which had shown severe paralysis for nine days; ventral dissection. The bone was dissected away from the herniations occupying pits in the bodies of the fourth, fifth, and sixth lumbar vertebrae, indicated respectively by *1*, *2* and *3*. *H* indicates herniation; *G*, ganglion. The herniations in relation to the fourth lumbar ganglions are covered by membranes. Partial dissections have been made elsewhere to give an idea of the complexity of the coils and the irregular thickening of the herniated nerve trunks. *4* and *5* indicate dorsal and ventral roots of the left fifth lumbar ganglion entering the hernial sac.

Fig. 11.—A photograph at 7.3 diameters of the preparation from which figure 11.1 was drawn: a vitamin A-deficient rat 10 weeks old, which had shown severe paralysis for nine days. The numerals *3*, *4*, *5* and *6* are placed over the third, fourth, fifth and sixth lumbar ganglions respectively. At *7* the bone of the fourth lumbar vertebra has been removed and shows the ventral root of the fourth lumbar ganglion within a pit. At *5* are many nerve roots entering and leaving pits in the fifth lumbar vertebra.

D indicates dura.

Fig. 12.—A photograph at 7.3 diameters: a vitamin A-deficient rat 10 weeks old, which had shown severe paralysis for fourteen days. The photograph shows molding and herniations of the spinal cord: one on the left, at *A*, into a pit in the fourth lumbar vertebra, and one on the right, at *B*, into the intervertebral foramen.

Fig. 13.—A, photograph at 6.5 diameters of the preparation from which figure 10 C was drawn; a vitamin A-deficient rat 10 weeks old, which had shown severe paralysis for nine days; ventral dissection at the levels of the fourth, fifth and sixth lumbar ganglions.

H indicates herniations; *G*, ganglions.

B, photomicrograph at 16.2 diameters; a vitamin A-deficient rat 9 weeks old, which had shown paralysis for eight to ten days; cross section of a lumbar vertebra showing pits occupied by nerve roots. The shrinkage due to embedding in celloidin gives the impression of much free space within the spinal canal. The cerebrospinal fluid relations have not been worked out in these vitamin A-deficient rats.

been found, but in rats exhibiting the most marked effects very definite bowing has been present. The degree of relative overgrowth of nerve roots increases from cervical to sacral regions and is maximal in lower dorsal and upper sacral roots.[31]

The length of the spinal cord from the posterior end of the fourth ventricle (calamus scriptorius) to the tip of the conus medullaris was measured in each dissected rat and the position of the tip of the conus medullaris recorded. Although in rats with vitamin A deficiency the compression of structures makes the determination of the exact position of the tip of the conus medullaris difficult and often uncertain, the difference between the normal position of this structure and that in the paralyzed rat is so great that errors of 1 or 2 mm. in locating it lose significance.

In normal rats and in rats severely stunted at an early age by being fed inadequate amounts of a complete ration and by riboflavin deficiency, the position of the tip of the conus medullaris throughout the age period of our experiments is approximately opposite the anterior (cephalad) end of the fifth lumbar vertebra. The variation is not much over 1 mm. in either direction. In the paralyzed rats with brain and nerve root herniations, the tip of the conus medullaris at 8 weeks of age is approximately opposite the anterior end of the sixth lumbar vertebra, and at 9 weeks of age or older it may be as low as the posterior (caudad) border of the sixth lumbar vertebra.

Observations of a small series of normally growing rats between 40 and 60 days of age give 5 mm. as the increase in length of the spinal cord each week. The average length of lumbar vertebrae at 56 to 63 days (taken from roentgen films) is very close to 5 mm.

The relative overgrowth of the spinal cord in vitamin A deficiency at 8 to 9 weeks of age is therefore approximately the length of one lumbar vertebra, a relative increase representing growth of at least one week.

The origins of the dorsal nerve roots of the lower lumbar and sacral ganglions are lower than the corresponding normal roots by distances of one fourth to three quarters of the length of a lumbar vertebra. Therefore, portions of a given nerve root totaling a length of 6 to 8 mm. may be involved in its numerous herniations.

Histologic Features of the Herniations.—The herniations of the cerebrum and cerebellum into the sinuses consist of cortical and medullary substance exhibiting various degrees of degeneration, necrosis and con-

31. Normally the growth of the spinal cord is proportionally less than that of the spinal column, so that the sacral end of the spinal canal moves away from the cord. The spinal nerve roots, therefore, elongate most markedly at the caudal end, and progressively less toward the head.

current cellular responses on the part of phagocytic cells and neuroglia. However, surprisingly well preserved cerebellar cortex and many apparently viable Purkinje cells are present in herniations of large size. Extensive loss of nerve fibers is apparent in preparations made by the use of Nonidez'[32] modification of Cajal's technic. No evidence of regeneration of axons could be found. The herniations into the venous sinuses are covered by pia-arachnoid and by endothelium derived from the blood vessel. The extremities of the herniations are capped with loose-textured arachnoidal tissue (fig. 6*B*) derived from the arachnoidal villi of the rat we have described.

A description of the nerve root herniations would include all the classic features of wallerian degeneration and many of the phenomena of axon regeneration. Serial sections of lumbar and sacral spinal ganglions and the accompanying herniated nerve roots from three rats, 55 to 60 days old and paralyzed seven to thirteen days, have been studied by ordinary technics for nerve cells and by Nonidez' silver impregnation technic.

Degenerations of myelin sheaths of nerve trunk fibers are conspicuous even with ordinary stains. With eosin–methylene blue and cresyl violet stains, surprisingly little damage could be found in spinal ganglions in view of the marked gross distortion in lumbar and sacral levels; only occasional ganglion cells show degenerative changes; rarely a cell at the periphery of a ganglion, where subjected to greatest pressure, is completely degenerated.

Nerve roots where sharply flexed in hernations are swollen and vacuolated. Nerve fibers are vacuolated and filled with myelin globules of all sizes and shapes, and phagocytic cells are numerous. On the concave side of acutely flexed trunks there are great numbers of cells, presumably of sheath of Schwann origin, many in mitosis (fig. 14). In general, the classic details of degeneration and early reparative reactions following traumatic injury to nerve trunks are present.

In the sections of the silver-impregnated preparations, particularly in the proximal (central) arms of herniated loops of anterior nerve roots, all the details described by Cajal[33] in his classic studies of degeneration and regeneration of nerves following crushing injuries are present. Nerve fibers undergoing regeneration can be traced into areas filled with products and sequelae of myelin degeneration. Fibers with collateral and terminal branching are abundant, and at greater distances proximal or central from the regions of greatest myelin degeneration great numbers of nerve fibers show varicosities and lateral polypoid

32. Nonidez, J. F.: Am. J. Anat. **65**:361, 1939.

33. Ramón y Cajal, S.: Degeneration and Regeneration of the Nervous System, translated and edited by R. M. May, New York, Oxford University Press, 1928.

Fig. 14.—*A*, photomicrograph at 52.6 diameters; a vitamin A-deficient rat 56 days old, which had shown paralysis for six days; fifth lumbar ganglion; cresyl violet stain. The preparation shows the relation of the dura (*D*) to the hernia. Note the massing of nuclei of Schwann cell origin where the emerging arm of the herniated nerve root is flexed, indicated by the arrow. Note vacuoles among the nerve fibers.

B, photomicrograph at 52.6 diameters; fourth lumbar ganglion, same rat, same technic, as of *A*. A herniation of the excrescence type is shown. Note the increase of Schwann cell nuclei and the marked vacuolation among the degenerated nerve fibers.

Figure 15

(See legend on opposite page)

sprouts, often reticulated. Huge or giant encapsulated clubs or spheres are very common, often reticulated, frequently degenerated or disintegrated. Fine terminal twigs are fairly numerous; rarely, they are found in bouquet form. Similar evidences of regeneration are seen in herniations of the excrescence type (fig. 15).

In the spinal ganglions similar, though less marked and apparently more recent, evidences of regeneration are present in the efferent (central) fibers near their points of exit. Few fibers in the ganglion itself show appearances of regeneration. Most of the fibers appear to be normal, as is true of the majority of fibers in the afferent nerve trunk. The motor nerve fibers outside the spinal canal at some levels are almost completely degenerated.

These few observations are recorded not because they are other than the expected consequences of injury to nerves produced by constriction but because they are proof that the axons in vitamin A deficiency have undiminished powers of regeneration. The appearances of many of our preparations approximate closely those of Cajal's for similar periods following injury if we rate the vitamin A deficiency lesion as beginning shortly before clinical signs appear.

COMMENT

Now that the genesis of the nerve lesions in vitamin A deficiency is clear, it is not profitable to discuss the diverse findings of various authors in regard to the neurons and tracts involved. The distribution of lesions is the consequence of pressure effects in the skull and spinal canal, and hence probably no type of neuron is exempt. We are certain that motor and sensory nerves and nerves of the special senses are

---

EXPLANATION OF FIGURE 15

A and *B*, photomicrographs at 610.5 diameters; a vitamin A-deficient rat 66 days old, which had shown severe paralysis for six days; Nonidez-Cajal silver technic. This is a dorsal root from an undetermined level which was herniated into the second sacral ganglion. Both photomicrographs are from the same field but at different levels. They show various types of sprouts and new fiber formation indicative of regenerative processes.

C, photomicrograph at 610.5 diameters from the same rat as *A* and *B*; Nonidez-Cajal silver technic; herniation of the excrescence type from an anterior nerve root into the fourth lumbar ganglion. Note the many lateral sprouts, often reticulated, and the terminal reticulated spheres.

D, photomicrograph at 610.5 diameters; Nonidez-Cajal silver technic; a vitamin A-deficient rat 55 days old, which had shown severe paralysis for thirteen days; herniation of the excrescence type of a dorsal nerve root of undetermined source into the fourth lumbar ganglion. Note the large spheres, some reticulated, others degenerated, also fibers with lateral sprouts of various types.

involved. The account of the distribution of lesions in the rat given by Irving and Richards [12] is most in accord of any in relation to genesis.

The nature of the lesions described in the foregoing pages and other facts gained from a number of experiments of a control type, described in later paragraphs, have forced us to the paradoxic conviction that the genesis of the nerve lesions of vitamin A deficiency requires an essentially normal rate of growth of a normal nervous system and that mechanical injury, the result of a disproportion between the central nervous system and its bony enclosure, is the explanation.

That the nervous system in vitamin A deficiency continues to grow at approximately the normal rate is concluded from the following considerations: 1. The spinal cord grows 5 to 7 mm. too long relative to the spinal canal during the two weeks' period (42 to 56 days of age) in which the lesions develop. This represents slightly more than one week's normal growth for rats of this age. 2. If it is assumed that growth of bone is completely suspended during this two week period, the minimum growth rate of the spinal cord represented by the 5 to 7 mm. excess length in relation to the spinal canal would be about 60 per cent of the normal. If it is assumed that the growth of bone continues during this period at a normal rate, the 5 to 7 mm. excess length in relation to the spinal canal would represent a maximum growth rate of about 60 per cent greater than normal for the spinal cord. 3. Since histologic studies of the epiphyses of vertebrae and of other bones show severe retardation but nevertheless not complete suspension of endochondral bone growth in these vitamin A–deficient rats at 56 days of age, it is probable that the growth rate of the spinal cord is close to the mean of the aforementioned percentages.

Therefore, in the absence of any evidence obtainable by histologic and cytologic studies that this deficiency leads to accelerated nerve growth, we believe that the nervous system continues to grow at approximately the normal rate during this critical period. This is in distinct contrast to the relations preserved between the central nervous system and the skeletal system in rats whose growth has been stunted by other means.

Rats whose growth has been stunted because the rations of a complete diet were inadequate or because of other deficiencies (riboflavin and pyridoxine [vitamin B_6]) do not have nerve lesions and when dissected are found to have normal relations in size between the nervous system and the bony investment of this system. Rats severely stunted because their rations were inadequate and because they were deficient in riboflavin have invariably shown a spinal cord terminating at the upper level of the fifth lumbar vertebra or slightly above. Dissections of vitamin A–deficient rats which had shown paralysis of any degree

invariably revealed herniations of nerve roots, and if the paralysis had been marked or prolonged, herniations of the brain as well.

Histologically, the nervous systems of the paralyzed rats have always been normal, except for lesions accounted for by direct pressure. Attempts at regeneration by the axons involved in the mechanical injuries take place promptly and proceed for a time as in normal animals.

Age is important only as an index of the degree of development of the animal. We have kept rats at a low weight (50 Gm.) by means of inadequate rations of a complete diet until 14 weeks of age and then caused paralysis to develop by supplying large amounts of a diet deficient in vitamin A. Such rats started on the deficient diet acquired nerve lesions in the same period of time as did weanlings.

Rats on inadequate amounts of a diet deficient in vitamin A will not show paralysis if the general growth rate is sufficiently retarded. The inanition of continued vitamin A deficiency is manifested by cessation of growth and loss of weight at about 63 to 70 days of age. This is probably the explanation of the fact that the deformities of the nervous system reach their maximum in about ten weeks, for thereafter growth of the nervous system becomes retarded through inanition.

If at 42 days of age the vitamin A–deficient rats are placed on a diet containing carotene and the caloric intake is reduced so that their weight graphs parallel those of litter mate controls retained on the vitamin A–deficient diet, signs of nerve lesions do not appear. Many experiments of this sort were done. The rats were usually put to death at 63 days of age. Those retained on the vitamin A–deficient diet invariably became paralyzed and when dissected showed the characteristic relative overgrowth of the nervous system. The litter mates which received vitamin A with restriction of the quantity of food did not show signs of nerve lesions and on dissection the relations of nervous system to bone were within normal limits.

The retardation of bone growth in vitamin A deficiency has long been known.[34] Briefly, the cessation of bone growth is strikingly evident in the endochondral bone formation. To the present time it has not been shown that the character of the effect of vitamin A deficiency on bone growth is different from that due to general inanition. Considerable study by one of us (S. B. W.[35]) has not revealed in vitamin A deficiency any specific effect in the sequence or in the morphologic characteristics of the cells concerned in endochondral bone formation. Our present studies bring to light an unexpected promptness of effect on bone growth, which suggests that specific factors are involved, inasmuch as

34. Hess, A. F., and Pappenheimer, A. M.: J. Biol. Chem. 47:395, 1921. Wolbach and Howe.[13]

35. Unpublished observations.

retardation of bone growth occurs before other consequences of general inanition are apparent.

The bones from the litter mate rats used for the study of the effects of carotene with restricted diet at 42 days of age have been utilized for microscopic studies after the rats were killed at 63 days of age. Owing presumably to the restriction of growth caused by reduction in the amounts of food, the effects of the administration of carotene at 42 days of age were not so pronounced as was expected. However, with rare exceptions, endochondral bone formation studied at the epiphyses of the lumbar vertebrae and at the lower end of the femur and the upper end of the tibia was somewhat more active in the rats that received carotene at 42 days of age and probably was the important factor in preventing the crowding of the central nervous system.

Since, however, the increased activity was not sufficient to produce a significant increase in the length of the spinal column by the end of the experiment as compared with the litter mate controls retained on the vitamin A–deficient diet, we could regard the prevention of paralysis in the rats of these experiments as possibly the result in part of the retardation of growth of the central nervous system consequent on the reduction in the quantity of food. We must remain indefinite on this point because we failed to make roentgenographic records of growth at intervals during the experiments.

Another indication of a possible specific effect of vitamin A on bone growth is the bony overgrowth in certain regions in the cranial cavity. Mellanby was the first to describe the periosteal deposit of bone in relation to the capsules of the labyrinths of young dogs and elsewhere in the skull. We have confirmed Mellanby's observation and have found similar bony overgrowth in the guinea pigs chiefly if not wholly limited to bone in relation to the bony capsule of the labyrinth, as is the case with rats. We have been unable thus far to find similar bone changes in other parts of the skeleton in rats. We have found in our vitamin A–deficient paralyzed rats, in the inner table of the skull, immediately adjacent to sutures (fig. 5), bone formation in excess of that found in normal rats of the same age but conforming in general to the normal pattern.

Naturally, we have given careful study to the cortical bone which forms the spinal canal. In the vitamin A–deficient rats this layer is usually a trifle thinner than it is in normal and undernourished control rats. There is no suggestion of new bone formation like that in the skull adjacent to the periotic bony capsule. However, the evidences of growth sequences on the ventral side of the canal which reveal the mechanism by which the caliber of the canal enlarges are nearly or completely absent. It is probable that a retardation of the rate of increase of the caliber of the canal contributes to the crowding effect on the cord.

The work of Moore and associates[36] indicates that in calves there may be a different distribution of productive bone change.

For the present the bone proliferation of periosteal origin in the skull presents an enigmatic contrast to the other responses of bone in vitamin A deficiency with but a single suggestive premise: the fact that the bony capsule of the labyrinth attains adult size before birth.

The deduction we are forced to make is that in vitamin A deficiency in the young growing animal during the age periods of our experiments the central nervous system grows at a rate approximately normal for the species while bone growth is promptly retarded. Because of the weight increase of the vitamin A–deficient rats preceding and accompanying the early period of paralysis, it is possible that there occurs a disproportionate growth of all soft tissues in relation to the skeleton. Critical studies to evaluate this possibility have not been made. We find no evidence that an adequate amount of vitamin A or a deficiency of vitamin A affects the nervous system.

The only fact in regard to the epithelial responses in vitamin A deficiency pertinent to this study is that the characteristic change of keratinizing metaplasia in many locations is present by the time signs of paralysis appear, and may be pronounced at 56 days of age.

The keratinizing metaplasia of epitheliums is invariably produced in vitamin A–deficient rats regardless of age or degree of growth.

SUMMARY

The epithelial changes due to vitamin A deficiency are wholly unrelated to the presence or the absence of lesions of the nervous system.

The nervous lesions of vitamin A deficiency are wholly of mechanical origin, the genesis of which is a disproportionate growth of the central nervous system in relation to the bone which surrounds it.

Two conspicuous consequences of the disproportionate growth are noted: 1. There is overcrowding of the cranial cavity, resulting in distortion of the brain, dislocation toward the foramen magnum with herniation of the cerebellum therein, and multiple herniations of the cerebrum and cerebellum into the venous sinuses of the dura at sites of arachnoidal drainage structures. 2. There is overcrowding of the spinal canal with distortion of the spinal cord and herniations of nerve roots into intervertebral foramens and into bodies of vertebrae.

Rats whose growth is stunted because their rations of a complete diet have been inadequate or because of certain vitamin deficiencies (riboflavin and pyridoxine [vitamin B_6]) show a normal relation between the central nervous system and its bony investment.

36. Moore,[34] Moore and Sykes.[35]

In vitamin A deficiency in young animals the normal growth rate of the central nervous system is maintained until the effects of general inanition as shown by a decided retardation of gain in weight of the animal as a whole become apparent. Also, the regenerative power of the axons and presumably their physiologic potentialities are not impaired.

The early retardation of growth of bone is suggestive of a specific effect which, because of histologic observations, is probably chiefly operative in cartilage of the epiphyses. The vis a tergo of osteogenesis per se is not lost and possibly not impaired before the period of general inanition is reached, as suggested by the findings in pitted vertebrae and in regions adjacent to the periotic bony capsule.

Some observations on the arachnoidal villi of the rat are included.

Wolbach-'47
Bib. No. 9954

J. Bone & Joint Surgery 29:171. 1947.

VITAMIN-A DEFICIENCY AND EXCESS IN RELATION TO SKELETAL GROWTH * †

BY S. BURT WOLBACH, M.D., BOSTON, MASSACHUSETTS

Bone is a peculiarly favorable tissue for the study of growth, because growth is not simply increase in size; it involves alterations of form. Bone, we know, undergoes continuous remodelling, rapidly during growth, slowly thereafter; and, because of this and similar responses common in pathological conditions, it is to be regarded as an exceedingly labile tissue. Fortunately, remodelling activities of bone leave a trail which can be read, a trail blazed by etched haversian systems, interrupted lamellae, and denser calcium deposits in the so-called cement lines which separate old from newly formed bone. The agents that cause resorption of bone are probably multiple, one of which will be considered in particular in this study. The information obtained from study of bone pathology and from a few connective-tissue behaviors, observable during cyclic physiological processes, leads to the conviction that all our collagenous structures are as labile as bone, subject to constant processes of resorption and new formation. Failure of such adjustments may be regarded as one consequence of age; such failure, indeed, may be the result of irreversible collagenous compounds, slowly accumulated and not amenable to the processes involved in maintenance.

All vitamin deficiencies that culminate in severe malnutrition (and most of them do) arrest growth of bone. Malnutrition caused by inadequate amounts of a perfect diet also arrests bone growth. In every instance where bone growth has ceased because of general inanition, a sturdy bone with normal contours is the result.

There are three vitamin deficiencies that affect bone growth directly. These are A, C, and D. The operations of A and D in bone growth specifically involve epiphyseal-cartilage-cell activities. In vitamin-C deficiency in growing animals, bone suffers in common with all collagenous structures.

It seems self-evident that lack of a vitamin causes suppression of the biochemical systems in which the vitamin is operative.

Vitamin A is unique, because it is the only vitamin which, as will be shown, when given in quantities greatly in excess of normal requirements, actually accelerates some normal growth sequences.

I have proof that the degree of acceleration of growth sequences bears quantitative relationships to the amount of vitamin A administered, and can be pushed to dramatic and disastrous consequences upon bones. In considering the effects of excessive introduction of vitamin A, we may speculate either in terms of increased reaction velocities or of increase in numbers of biochemical systems.

Vitamin A in deficiency and excess in relation to skeletal growth is my subject. I shall outline some of the premises which have led me to the conclusion that Vitamin A is specifically involved in mammalian skeletal growth. Both a deficiency and an excess of vitamin A affect profoundly the growth of bone. The deficiency suppresses, the excess accelerates epiphyseal-cartilage-cell sequences. I shall outline the consequences of such changes in epiphyseal-cartilage sequences upon the remodelling of bone which is an essential feature of bone growth. I shall present evidence which indicates that remodelling sequences attending growth of bone are induced by a factor elaborated in the maturation of epiphyseal-cartilage cells.

* Twenty-Second Ludvig Hektoen Lecture of the Frank Billings Foundation delivered before the Institute of Medicine of Chicago, March 22, 1946.

† Reprinted by permission from the *Proceedings of The Institute of Medicine of Chicago*, Vol. 16, No. 4, April 15, 1946.

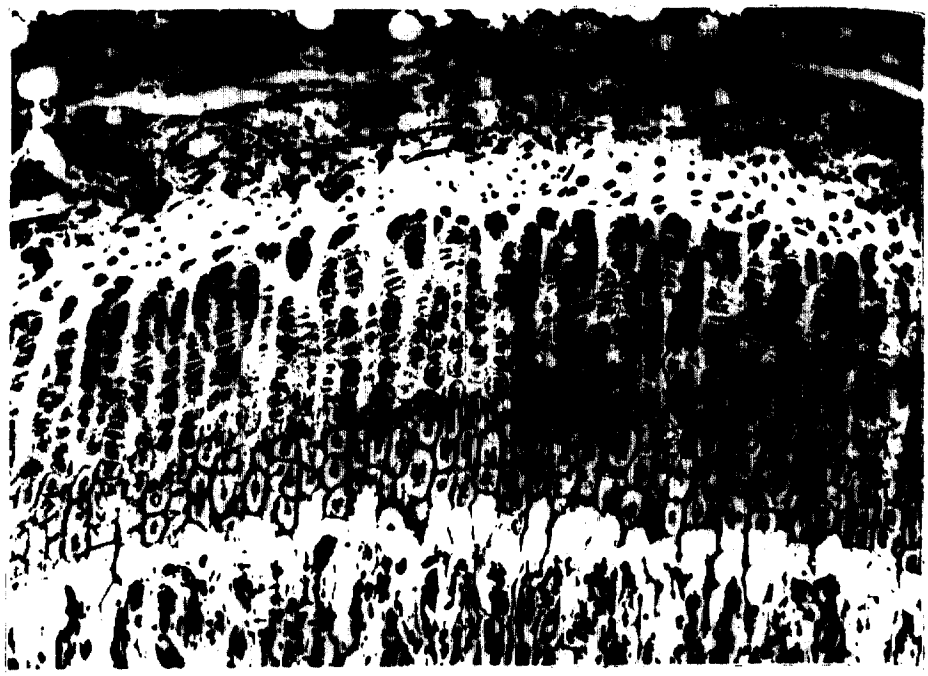

FIG. 1

Proximal epiphyseal cartilage of tibia of guinea pig, illustrating cytomorphosis of cartilage cells and growth of capillaries into spaces left by death of cells.

The substance of this lecture should be presented against a background, provided by an outline of normal bone growth and the effects thereon of vitamins C and D deficiencies.

Increase in size of most bones during growth of the skeleton—all those which are first laid down as hyaline cartilage in the embryo, including all of the long bones, the vertebrae, and bones of the base of the skull—is by endochondral bone formation, for which purpose, until growth is completed, cartilage persists at epidiaphyseal junctions. Growth of a long bone, for example, is accomplished by continuous proliferation of cartilage cells, arranged in columns on the epiphyseal side, and concurrent degeneration of mature cartilage cells on the diaphyseal side. The spaces which result from the degeneration and disappearance of the cartilage cells at the diaphyseal ends of the columns are penetrated by capillaries, accompanied by osteoblasts which are responsible for the deposition of bone matrix upon the exposed cartilage matrix. Multiplication, increase in size, maturation, and death of cartilage cells (cytomorphosis)[10] are, therefore, necessary sequences in normal skeletal growth[13] (Fig. 1).

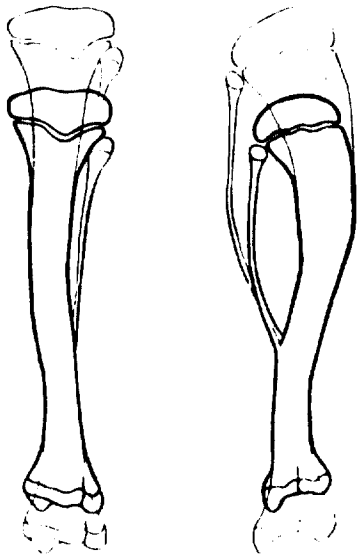

FIG. 2

Tibia and fibula of rat. Diagram to illustrate remodelling during growth, viewed from anterior aspect and in profile.

However, growth of bone is not a one-way process; preservation of conformation demands continuous remodelling, involving resorption of bone where reduction of size is necessary and new deposition of bone from endosteal and periosteal sources to preserve continuity of structure (Fig. 2). The deposition of bone by cells

endosteum and periosteum we refer to appositional bone formation. Some contours, especially those where ments, fasciae, tendons, muscles, and are attached, are built up by appo- ional bone formation. The growth of few bones which developed directly connective tissue—membraneous bone nation—including the bones of the rium, sides of the skull and most of rial bones, is by appositional bone with at the sutures and from peri- eum and endosteum. Such bones also dergo remodelling during growth, but have good reasons for the conviction that the pattern is set by the growth of those bones of the skull which are of car- tilaginous origin. In general, endochon- dral bone formation sets the pace and the pattern of skeletal growth. In the microscopic study of bone, one can usually get a clear picture of what is happening and, indeed, of what has happened, because the remodelling process leaves distinctive features. Regions of resorption are usually indicated by the presence of osteoclasts and breaks in continuity of lamellae. Regions of appositional bone formation can be identified easily by the presence of rows of osteoblasts and non-calcified matrix or osteoid. Where remodelling has occurred, boundaries between resorbed bone and bone subsequently deposited are indicated by cement lines, as well as by discontinuities of lamellae (Fig. 3).

Fig. 3

Cross section of fibula of normal rat to illustrate the pattern of remodelling in consequence of changes in its relation to the tibia, as indicated in Fig. 2. The arrows indicate the outward and posterior swing of this bone.

VITAMIN-C DEFICIENCY

We know of no untoward effect resulting from administration of excessive amounts of vitamin C. Man, monkeys, and the guinea pig are the only animals now known which are unable to synthesize vitamin C. The lesions resulting from vitamin-C deficiency in the young of these animals are the consequence of the failure of formation of intercellular materials. Bone formation, endochondral and appositional, is prevented because of the failure of matrix formation, specifically a failure in the synthesis of the protein or group of closely related proteins,—collagen. All evidence indicates that the physiology of calcification is not involved[15,16].

This failure of bone-matrix formation explains perfectly the gross pathology of vitamin-C deficiency or scurvy in infants. Cartilage sequences in endochondral bone formation continue, but cells accompanying the ingrowing blood vessel can deposit no matrix and hence discontinuity of epiphysis and diaphysis—infraction—takes place. Periosteal cells concerned in appositional bone growth through failure of matrix deposition permit the fibrous periosteum to pull away from bone. Not only is there failure to form collagenous matrices, but there is good reason for believing that resorption of matrices of bone and connective tissue takes place. Remodelling of non-calcified supporting tissues leaves no trail.

The administration of vitamin C to totally deficient guinea pigs is followed by prompt deposition of collagen and formation of the matrices of connective tissue, bone, and teeth. Careful studies by Boyle, Bessey, and Howe have shown that the amount of dentin matrix (predentine) formed is quantitatively related to the amount of vitamin C administered. The relation of vitamin C to growth and maintenance of bone resides solely in its effect upon the formation and maintenance of the organic matrix.

VITAMIN-D DEFICIENCY

Normal growth of bone in the human is dependent upon the action of vitamin D in maintaining efficient concentrations of calcium and phosphorus ions in the blood plasma. In the rat, normal bone growth in the absence of vitamin D continues, unless the diet is such as to produce in the blood a "relative deficiency of calcium or phosphorus or an absolute deficiency of either or both" [13].

It is not necessary to present the pathology of rickets in detail, because this would lead into controversial fields, some of which would not exist if more attention had been given to early recovery sequences in cure of experimental rickets. Experimental rickets in rats reproduces accurately the spontaneous disease in human infants and other animals. As in all deficiencies, an understanding is to be sought in terms of retardation or suppression of normal processes, in this instance growth sequences in epiphyseal cartilage and of calcification of bone and cartilage. The reason why the pathology of human rickets is apparently so complicated is that the deficiency in any individual studied may have been intermittent or of varying degrees from slight retardation to almost complete suppression. Endochondral growth of bone is dependent upon proliferation, differentiation, and degeneration, ending in death and disappearance of cartilage cells [17]. In rickets the cartilage cells fail to complete this sequence; they reach their maximum size, produce adequate amounts of matrix, but do not degenerate. For this reason, as proliferation continues, the epiphyseal cartilage accumulates. In the absence of spaces created by the disappearance of cartilage cells, there is no ingrowth of capillaries. Concurrently with the arrestment of cartilage-cell sequences, the matrix adjacent to the persistent cells fails to calcify. Absolute rickets in the sense of the complete cessation of the above sequences is of doubtful occurrence in humans and difficult of experimental achievement. The arrestment takes place irregularly across the diaphyseal face of the cartilage plate. Wherever cartilage cells degenerate, vascular ingrowth takes place, in normal direction or laterally as opportunity offers; but the bone matrix (osteoid) deposited about the capillaries does not calcify.

FIG. 4

Proximal epiphysis of tibia of rat. Showing repair of experimental rickets after seventy-two hours, and illustrating resumption of cytomorphosis.

Deposition of bone matrix (osteoid) continues to take place around capillaries of the

diaphysis adjacent to the cartilage. The accumulated osteoid and cartilage may become molded or distorted by the pressure of weight-bearing, in cartilage frequently resulting in keratification. In long-continued rickets there is disappearance of trabeculae of the diaphysis and resorption of cortical bone (osteoporosis), in response to more vital needs of the body for calcium.

The first cytological evidence of repair in the rat following vitamin-D therapy is the resumption of cytomorphosis (Fig. 4) visible in twenty-four hours through the presence of cleared or degenerated cells on the diaphyseal border of the cartilage, and accompanied by extensive penetration of capillaries within forty-eight hours, and concurrent calcification of adjacent matrix. The complicated patterns of capillary tufts in the epiphyses of rickets, which have occasioned much discussion and speculation by various authors [11], are satisfactorily explained by the occurrence of irregularly distributed groups of cartilage cells which have completed their sequences, a result of varying degrees of intermittency of the deficiency across the face of the epiphyseal plate. Thus, opportunities for ingrowth of capillaries in lateral and even diaphyseal directions can exist. Such capillary patterns may be seen in the early repair stages of advanced experimental rickets.

Calcification of cartilage matrix and of osteoid first takes place adjacent to capillaries which have entered the spaces left by the degenerated cartilage cells, wherever this has occurred. Subsequently the calcification of accumulated osteoid progresses toward the diaphysis. Excess osteoid, which has accumulated as a result of the deficiency, is removed only after calcification by osteoclasis. Apparently there is no mechanism for the removal of non-calcified bone and cartilage matrices.

Thus in rickets, two separate processes are involved,—one the failure of epiphyseal



FIG. 5

Proximal epiphysis of tibia of normal litter mate, control puppy to the vitamin-A deficient puppy, the source of Fig. 6.

FIG. 6

Proximal epiphysis of tibia of vitamin-A deficient puppy of the same litter as source of Fig. 5.

cartilage cells to complete the sequences of proliferation, maturation, and degeneration, the other the failure of matrices to calcify.

A comment made some years ago in regard to experimental rickets and which applies also to osteomalacia is perhaps worth repeating: "The degree or severity of rickets may be estimated and recorded on the basis of the prominence of anatomical changes demonstrable by roentgenograms or histological study. Obviously two factors enter into the production of the pathological picture, the duration of the deficiency and the degree of the deficiency as measured by calcium and phosphorus blood concentrations and ratios. Either factor can be made the variable and thus the time factor can be calibrated against the chemical factor — in so far as increased width of epiphyseal cartilage and accumulation of osteoid are concerned" [17].

HYPERVITAMINOSIS D

The administration of excessive amounts of vitamin D (activated ergosterol) produces untoward effects in bone and soft tissues, resulting from a great increase in serum calcium [1]. The physiological role of vitamin D is still generally regarded as one operative in the process of absorption of calcium from the intestines. The fact that, if the alimentary source of calcium is not adequate, calcium is obtained through resorption of bone [6,12] suggests that a more important role is to be found in the establishment of equilibrium conditions in the blood plasma. The stoichiometry of blood calcium seems to have quantitative relations with the amount of vitamin D introduced. The maintenance of high calcium levels in rats through its use results in short bones with non-calcified trabeculae of unusual thickness and number at the epiphyseal ends and resorption of cortical bone with non-

calcified matrix deposition of periosteal and endosteal origin. These changes have led one group of authors [5,6] to regard the effect as rachitic in type, in spite of the fact that epiphyseal-cartilage-cell sequences are not suppressed. The persistence of essentially normal cartilage-cell sequences under conditions which cause resorption of bone and prevent calcification of newly deposited bone matrix suggests either that the cartilage cells participate in alterations of equilibrium conditions affecting calcium, or that they do not require calcium but do require vitamin D for the sequence of growth, maturation, and degeneration. A single massive dose of activated ergosterol [4] causes a great rise of serum calcium, followed by deposition of calcium salts in many soft tissues concurrently with the fall in serum calcium.

VITAMIN-A DEFICIENCY

In vitamin-A deficiency, all epiphyseal-cartilage sequences cease (Figs. 5, 6 and 7). Cells cease to divide, and cells which have reached almost mature size undergo no further change. Only those cells which have progressed to the vesicular stage continue to change and finally disappear, permitting vascular penetration. The cartilage trabeculae calcified before the deficiency was established are resorbed by osteoclastic action. The matrix of the now atrophic epiphyseal cartilage becomes densely calcified for a depth of a few cells on the diaphyseal border, and eventually a thin bony plate is formed across the face of the epiphyseal disc. The resulting appearance is similar to that produced by inanition from inadequate amounts of a perfect diet, or by inanition resulting from other vitamin deficiencies not specifically related to bone growth, such as riboflavin and pyridoxine. However, in inanition from these various causes, the growth of all tissues is correspondingly retarded; whereas, in vitamin-A deficiency, endochondral bone growth ceases before the growth rate of the animal as a whole is seriously affected (Figs. 8 and 9). It is this disproportionate growth of the skeleton and soft tissues which is responsible for early disastrous consequences in the young of rats, dogs, guinea pigs, and chicks, because the cranial cavity and the spinal canal become too small for the central nervous

FIG. 7

Distal epiphysis of femur of rat, to illustrate the return of normal cartilage sequences and bone growth following therapy of severe vitamin-A deficiency. Note the plate of bone on the diaphyseal side.

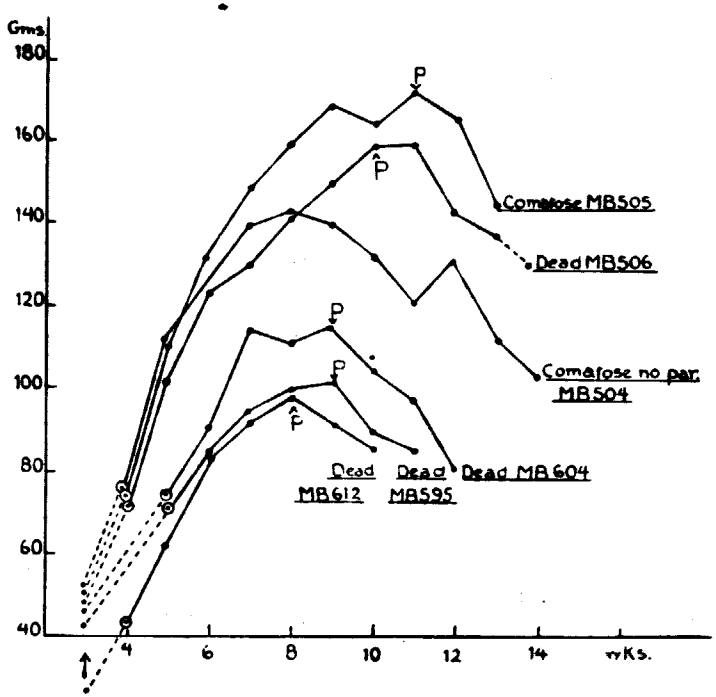

FIG. 8

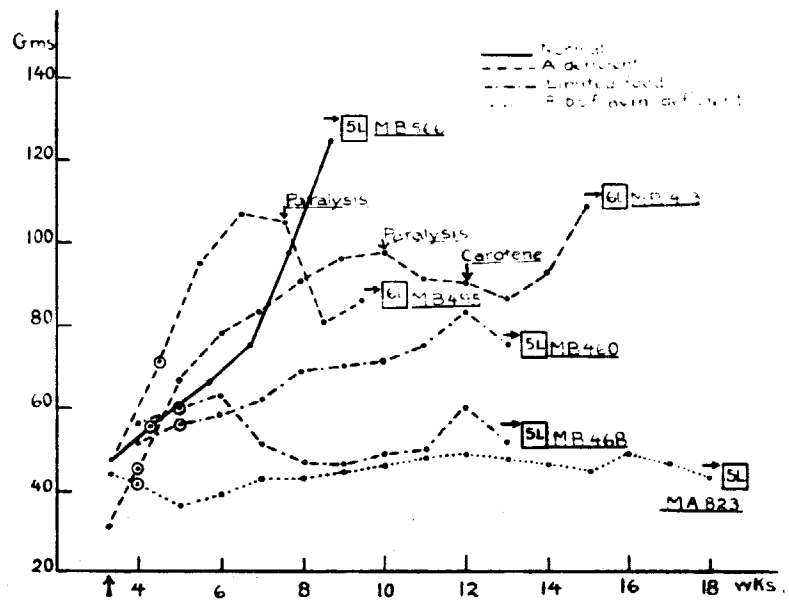

FIG. 9

Fig. 8: Weight curves of weanling rats on vitamin-A-deficient diet. To illustrate onset of paralysis, indicated by *P*, in relation to weight gain.

Fig. 9: Weight curves of two vitamin-A-deficient rats with onset of paralysis indicated. Two weight curves of rats with inanition produced by inadequate amounts of a complete diet, one weight curve of a greatly stunted rat on a riboflavin-deficient diet, and one curve of a normal rat. The rectangles at ends of the curves represent lumbar vertebrae. The arrows indicate levels of the conus terminalis. Notice that the conus of the vitamin-A-deficient rats is situated more than the length of one lumbar vertebra caudad to the normal and inanition controls (See Fig. 10). All six rats were three weeks old when placed on the experimental diets.

system which continues to grow at approximately normal rate until general inanition supervenes. The result of the disproportionate growth of bone and central nervous system is overcrowding of spinal canal and cranial cavity and paralysis, resulting from mechanical pressure upon brain, spinal cord, and nerve roots. The consequences are exhibited by multiple herniations of the cerebrum and cerebellum into arachnoidal villi, dislocation of the brain as a whole toward the foramen magnum, and buckling and herniation of nerve roots (rat and guinea pig) into intervertebral foramina and into the bodies of vertebrae. The latter is the result of atrophy of bone, caused by the pressure of buckled nerve-root trunks (Figs. 10 and 11).

Species differences in anatomy and growth patterns naturally affect the details resulting from the disproportionate growth. While identical in rat and guinea pig, there are as yet incompletely solved differences in the dog to which reference will be made later. In the chick, there are no herniations of nerve roots, because the spinal cord, unlike in most mammals, fills the entire spinal canal, and the roots leave the spinal cord through foramina at the levels of their origins in the spinal cord. However, overcrowding of the central nervous system is strikingly shown by distortion of the brain with voluminous herniations into arachnoidal villi and marked distortion of the spinal cord, shown by the cross ribbing in the lumbosacral region, which is produced by the bulging of the spinal cord into the ribbed spinal canal of this region.

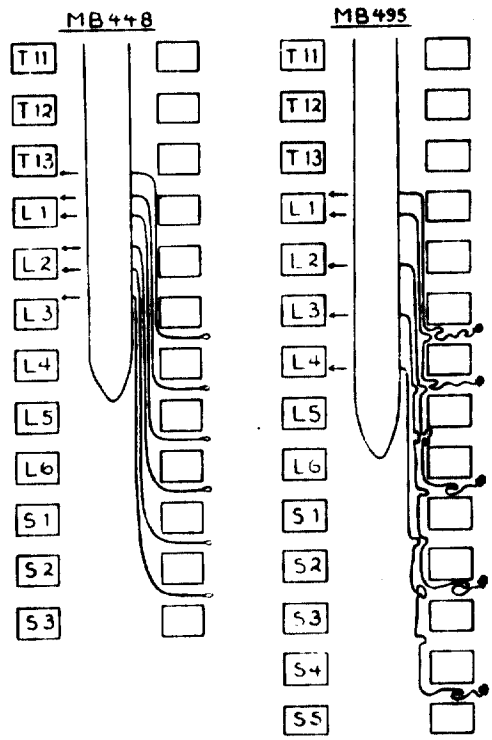

FIG. 10

Diagrams. *MB 448* illustrates the position of the conus terminalis in normal rats. The arrows indicate levels of origin from the spinal cord of a few nerve roots in relation to their foramina of exit.

MB 495 illustrates the position of the conus terminalis in a vitamin-A-deficient rat. (See Fig. 9 for weight curve.) Also, a few nerve roots are shown for sites of herniations and for levels of origins in relation to foramina of exit. This diagram is a partial record of the dissection of rat MB495. Notice several nerve roots with multiple herniations and the low position of the conus terminalis which has resulted from the continued growth of the central nervous system after growth of the skeleton was retarded.

Cessation of endochondral growth is not the whole story of the effect of vitamin-A deficiency upon young bones; remodelling ceases and appositional bone formation continues at different rates in locations which vary with the species, but which are in conformity with each normal growth pattern.

The long bones of vitamin-A-deficient animals are shorter and thicker than those of normal animals. The shortness of the long bones is the result of failure of endochondral bone growth. The increased thickness is produced by continued appositional bone growth and, near the ends of bones, by retardation of remodelling sequences in the final period of growth before complete deficiency is established. Mellanby has paid particular attention to apparently excessive periosteal bone formation in relation to the bony labyrinth of the ear, other bones of the skull, and cervical vertebrae. Wolbach and Bessey in their 1941 paper confirmed Mellanby's findings in regard to the changes in the petrous bones of dogs, and recorded similar findings in A-deficient rats and guinea pigs. In none of Mellanby's publications [7,8,9] is mention made of epiphyseal cartilages and endochondral (replacement) bone growth.

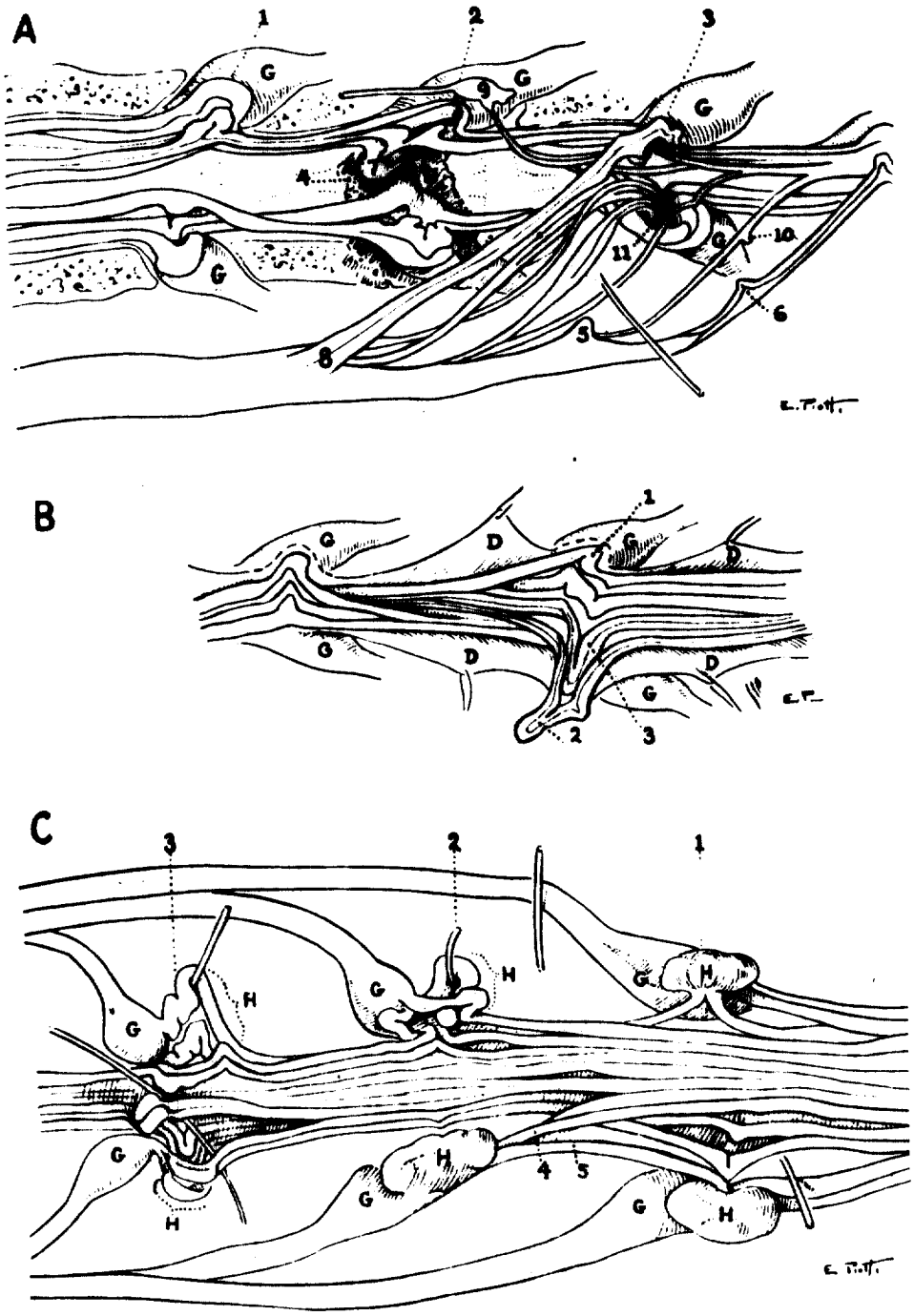

FIG. 11

A. Vitamin-A-deficient rat, ten weeks old, which had shown severe paralysis for nine days; dorsal d section, exposing third, fourth, and fifth lumbar ganglia, indicated by *1*, *2*, and *3*, respectively.
4: Indicates where the body of the fourth lumbar vertebra has been dissected away, exposing col nerve roots which have pitted the bone.
5: Herniation of the spinal cord, which was extruded into the right fourth lumbar ganglion.
6: Herniation of nerve roots removed from the fifth lumbar ganglion.
7: Ventral root of the fourth lumbar ganglion, lying in a pit in the body of the fourth lum vertebra.

FIG. 11 (*continued*)

8: Dorsal roots to the sixth lumbar and first sacral ganglia from their origin to herniation into the fifth lumbar ganglion.
9: Herniation of a coiled and swollen unidentified nerve root, removed from the invaginated fourth lumbar ganglion.
10: Small excrescence on the ventral nerve root removed from a fifth lumbar ganglion.
11: A deep pit in the fifth lumbar vertebra with entering and emerging nerve roots.
G: Ganglia.

B. Vitamin-A-deficient rat, eleven weeks old, which had shown severe paralysis for twenty-one days; dorsal dissection, exposing fifth and sixth lumbar ganglia with herniated nerve roots.
1: Ventral root of the first sacral ganglion, herniated into the sixth lumbar, left side.
2: Dorsal and ventral roots of the third sacral ganglion, right, removed from herniation into the sixth lumbar ganglion, right.
3: Dorsal and ventral roots to the second right sacral ganglion, dislodged from herniation into the right sixth lumbar ganglion.
G: Ganglia.
D: Dura. Its line of attachment to the ganglion is represented by dotted lines.

C. Vitamin-A-deficient rat, ten weeks old, which had shown severe paralysis for nine days; ventral dissection. The bone was dissected away from the herniation occupying pits in the bodies of the fourth, fifth, and sixth lumbar vertebrae, indicated respectively by *1*, *2*, and *3*. *H* indicates herniation; *G*, ganglia. The herniations in relation to the fourth lumbar ganglia are covered by membranes. Partial dissections have been made elsewhere to give an idea of the complexity of the coils and the irregular thickening of the herniated nerve trunks. *4* and *5* indicate dorsal and ventral roots of the left fifth lumbar ganglion entering the hernial sac.

(Reproduced by permission from *Archives of Pathology*, **32**: 708, 1941.)

My own studies had convinced me, several years ago, that, after endochondral bone formation had ceased in vitamin-A-deficient animals, appositional bone formation continued, and in certain locations apparently became excessive. Restudy of bones from vitamin-A-deficient animals, in the light of information obtained from the study of growth patterns of normal bones and of bones of animals which had been given greatly excessive amounts of vitamin A, has made clear the fact that appositional bone formation in the A-deficient animals continues, until inanition supervenes, *in strict conformity to normal growth patterns, both as to situation and rate*.

Some contours of long bones are formed by active appositional (periosteal) bone formation; examples in the rat are the third trochanter of the femur, the crest of the tibia, and the interosseous crests of tibia and fibula. In such regions the rate of appositional bone formation is much greater than elsewhere. Serial sections of the petrous bones of normal rats and dogs have shown that activity of appositional bone formation varies greatly in different regions,—for example, it is much greater on the internal (medial) side of the recess for the paraflocculus than on the external (lateral) side. In the latter situation in the rat, resorption of bone is active. Other locations of relatively greater activity in relation to the internal auditory meatus and cochlea have been identified, sufficient to warrant the statement that the apparently excessive appositional bone formation in the vitamin-A-deficient animal also is correlatable with the pattern and rate of formation of the normal of the two species. The normal pattern of this region in the rat is somewhat different from that of the dog; likewise the untoward consequences of the deficiency in the two species.

Both in rat and dog, the replacement of cancellous bone by compact bone, which occurs in normal growth and remodelling sequences, ceases. This feature of the deficiency is particularly well exhibited in the bones of the dogs' calvarium and vertebrae.

In the chick (age of experimentation from day of hatching to three or four weeks), I have been unable to find any continuation of appositional bone growth other than a slight degree of generalized appositional bone growth of all bones. The general picture is that of greatly reduced bone growth, resulting in cessation of endochondral bone growth, great diminution of trabecular bone and of cortical bone, and great retardation of compact bone formation.

In no situation have I found evidence of untoward pressure effect upon the nervous system, resulting solely from local, apparently excessive, appositional bone growth.

Before further consideration of the thesis that all *appositional* bone growth in vitamin-A deficiency is the result of the carrying out of a normal growth pattern, an account

FIG. 12

Fractured femur near distal epiphysis of a rat which received 1250 international units per gram of weight of pure vitamin A for seven days following weaning at twenty-one days of age.

FIG. 13

Fracture of upper end of femur of a guinea pig which received 600 international units per gram of weight for twenty-four days. Initial and final weights, 100 and 109 grams. Ascorbic acid was given (60 milligrams, daily) for the last eleven days of the experiment. Note closure of the epiphyses and site of fracture in a region of active remodelling in normal growth.

of the consequences of excessive vitamin-A administration upon growth of young animals—rats, guinea pigs, and dogs—is necessary.

HYPERVITAMINOSIS A

Fractures of the long bones of rats following the administration of excessive amounts of fish-oil concentrates, presumably the result of the vitamin-A content, were reported by Collazo and associates in 1929 [19]. A brief review of the subject has been written by Wolbach and Bessey [10], who also reported that fractures of the bones of weanling rats could be produced in from six to eleven days by the excessive daily administration of pure vitamin A. No complete explanation of this disastrous effect upon growing bones was given, but we did write: "An hypothesis we hold at the present time is that the early consequence of excessive vitamin-A administration is the acceleration of some processes of bone growth, notably: (a) periosteal proliferation, (b) epiphyseal-cartilage sequences preliminary to endochondral bone formation, and (c) remodelling of bone attended by osteoclasis".

Continuation of the study of hypervitaminosis-A effects upon bone growth has been made possible through the assistance of Dr. O. A. Bessey of the Public Health Research Institute of New York, Dr. P. R. Howe of the Forsyth Dental Infirmary, Dr. D. M. Hegsted of the Harvard School of Public Health, Mr. Thomas Van Metre, medical student, and Dr. Charlotte Maddock, Research Fellow in Pathology.

The following résumé of observations and conclusions is based upon the study of many rats and guinea pigs. Many chicks, a few mice, and two puppies were also studied. Because the growth pattern of young chicks is quite different from that of the mammals studied, and because too few mice and dogs were used, this account is based upon the experiments with rats and guinea pigs. *However, in all species, the results of excessive*

FIG. 14

From distal end of femur of guinea pig, illustrating early closure of the epiphysis. From nine days of age, this guinea pig received approximately 600 international units of vitamin A per gram, plus 120 milligrams of ascorbic acid for eighteen days, at which time it was killed. The large amounts of ascorbic acid did not influence the effect of the excessive vitamin A administered.

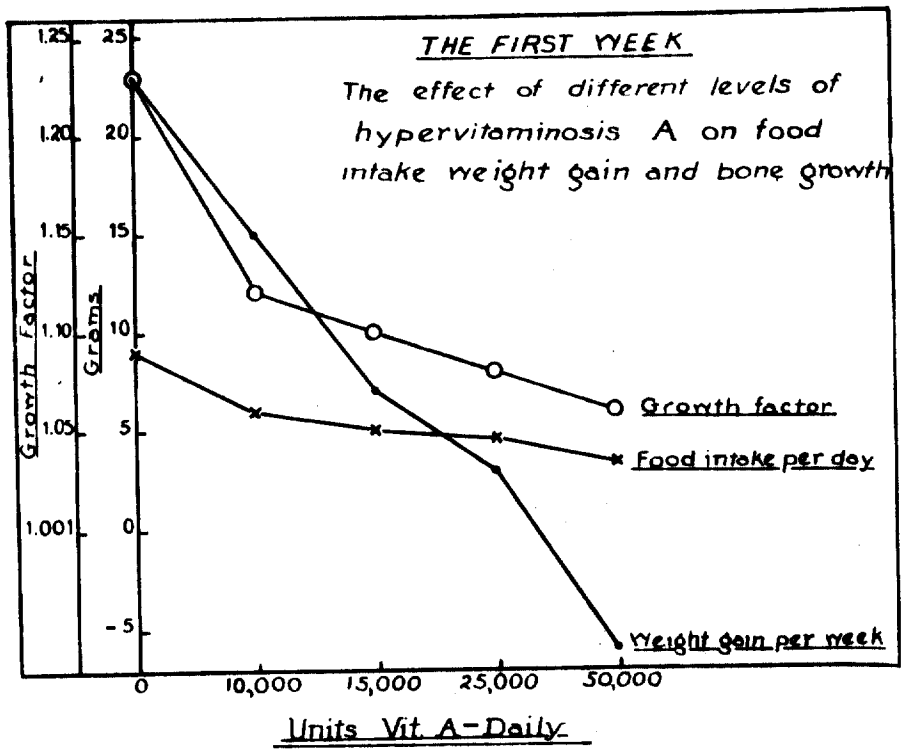

FIG. 15

Curves to show the relation of dosage of vitamin A to growth of a long bone (tibia), food consumption, and weight. All observations were upon weanling rats, twenty-one days of age; approximate weight at this age is forty grams. All measurements of bone were made from x-ray films, made daily. The values of growth given represent the percentage linear growth during one week. These curves are of little value except for documentation of the statement in the text, that rate of remodelling induced by vitamin A is independent of linear growth of bone.

vitamin-A administration are the same when correlated with the normal growth pattern of the bones, and can be precisely expressed in terms of accelerated sequences normal to the species and, in general, are the same as those of rats and guinea pigs.

In rats and guinea pigs there is great acceleration of all processes of bone growth which can be followed microscopically,—specifically, epiphyseal-cartilage sequences and the resorption of bone and appositional bone formation necessary in the remodelling of bone in skeletal growth.

In both species, fractures of long bones are produced in six to ten days, somewhat earlier and more frequently in rats than in guinea pigs (Figs. 12 and 13). The explanation of this difference may reside in the fact that in guinea pigs the epiphyses close, whereas in the rat many epiphyseal cartilages persist throughout life. In both species there is greatly accelerated maturation and degeneration of the epiphyseal-cartilage cells with concurrently rapid replacement by bone. In guinea pigs given excessive amounts of vitamin A (1000 to 1250 international units per gram of weight) from the age of ten days, the distal epiphysis of the femur and the proximal epiphysis of the tibia can be made to close in from ten to fifteen days—or at twenty to twenty-five days of age (Fig. 14). These epiphyses normally close after thirty and sixty weeks of age respectively [20]. In the rat, the adult marrow zone of quiescent epiphyseal cartilage may be attained in the same time period.

It was not difficult to prove, by means of serial sections of long bones (femur and tibia and fibula), that the accelerated remodelling processes were responsible for the product

of fractures; nor was it difficult to prove that the accelerated sequences, though disastrous in their consequences, were in complete conformity to normal growth patterns in character and localization. My first assumption was that the rate of remodelling was a function of linear growth. This logical rationalization had to be abandoned in light of the fact that in guinea pigs the remodelling sequences leading to fractures were in progress concurrently with the rapid consumption and ossification of the epiphyseal cartilages. Comparisons of the growth rates of the long bones of normal rats and litter mates receiving excessive amounts of vitamin A, by means of x-ray films were undertaken. The results showed clearly that in the first week, which covers the period in which fractures usually occur when large amounts of vitamin A are given, linear growth rate of bone is retarded, together with a decrease of food consumption and growth of the rat as a whole. The larger the amounts of vitamin A administered, *the greater is the retardation of growth and the greater is the rate and frequency of fracture* (Figs. 15, 16-A, 16-B, 16-C, and 16-D). The microscopic sequences tally perfectly with the gross changes. There is no evidence of increased rate of multiplication of cartilage cells; in fact, in both rats and guinea pigs, mitoses are fewer than in normal controls. Common to both guinea-pig and rat epiphyseal-cartilage sequences is the accelerated rate of growth, maturation, and death (cytomorphosis). The conclusion is warranted that an agent contributed by the dying or death of this specialized tissue—which maintains, until maturity of vertebrates, sequences essential to growth most commonly exhibited in the embryo and foetus—is responsible for the remodelling process of bone growth. Therefore, we may discard the simpler explanation that bone remodelling during growth is a response to shifting mechanics of the skeleton and musculature, and take recourse to the subtler processes revealed by experimental embryology and connoted by the term *induction*. In the present instance, epiphyseal cartilage is the *organizer* or *inductor*; the bone that undergoes resorption with concurrent appositional growth in conformity to a pattern is the *competent* tissue.

Fig. 16-A Fig. 16-B



Fig. 16-C Fig. 16-D

Four roentgenograms illustrating the effects of large *versus* relatively small doses of vitamin A upon the tibiae of rats.

Fig. 16-A: Normal 28-day-old rat.

Fig. 16-B: From 28-day-old rat which received 1250 international units per gram of weight for seven days prior to sacrifice.

Fig. 16-C: Tibia of a rat which received 250 international units per gram of weight from twenty-one days to sixty-nine days of age.

Fig. 16-D: Same rat with treatment continued to eighty-fifth day of age. The length of the tibia is within normal limits. The striking features are the thinness of the shaft and the contours near the epiphyses.

No attempt is made here to give a full account of the microscopic details of the effect



Fig. 17

Cross section of upper third of tibia of rat. This rat received 1250 international units daily from the twenty-first to the twenty-eighth day of age. Low-power photomicrograph, showing resorption of the cortex on the exterior, and newly formed partially calcified bone deposited internally. (See Figs. 18 and 19.)

already outlined. An intelligible brief description is possible, because no novel processes are involved and because the precise meaning of terms employed in descriptions of normal bone growth are applicable.

The Epiphyseal Cartilage

In guinea pigs and rats, the early change in the epiphyseal cartilage is the rapid maturation of the cartilage cells, so that the presence of vesicular cells extends far toward the epiphyseal side. Matrix production does not keep pace; and, in consequence, there is compression of the maturing cells on the diaphyseal side of the cartilage plate. There is deep and rapid penetration by capillaries, and often the capillaries in one column send off shoots laterally into cells of adjacent columns, giving rise to tuftlike patterns, similar to those seen in the initial periods of repair of experimental rickets. In guinea pigs, the acceleration of maturation results in complete consumption of the cartilage in ten to fifteen days, and, as osteoid production keeps pace with the vascular penetration, ossification of the epiphyseal cartilage (Fig. 14). *The rate of change varies with the dosage of vitamin A.* Calcification of cartilage matrix apparently progresses with corresponding rapidity, and superfluous trabeculae on the diaphyseal side are consumed by osteoclasis. The indifferent or undifferentiated cartilage which lies on the epiphyseal side of the growth cartilage becomes in part calcified and disposed of by osteoclasis and in part removed by capillary penetration into dead cells and ossification.

In the rat, the same speeding up of cytomorphosis takes place, possibly sustained for a brief period by multiplication of cells in the proliferative layer. I have not been able to find any evidence of an increased rate of multiplication; in fact mitoses seem fewer in number than in the normal. In the course of a few days, cell division ceases and, the cells continuing to mature and degenerate and to be replaced by bone, causes the epiphyseal cartilage to become greatly reduced in width (Fig. 12). Always, however, in the period covered by our experiments, there persist groups of crescentic discoid cells of the prolifer-

tive layer and, on the diaphyseal side, globular cartilage cells arrested early in the process of maturation. Comparison of this late or final stage of the epiphyseal cartilage in hypervitaminosis A with the epiphyseal cartilage of arrested bone growth of the rat (a) in old age and (b) in inanition resulting from (1) inadequate amounts of a normal diet, (2) riboflavin deficiency, and (3) pyridoxine deficiency, discloses that the final result of the accelerated cartilage sequences in the rat conforms to the normal in amount and character of the epiphyseal plate that remains after cessation of growth. Concurrently with the acceleration of the epiphyseal cartilage sequences, there is a great acceleration of remodelling sequences, involving absorption of bone and appositional bone formation. The effects are easily visible after two days of administration of 1250 international units per gram weight, always restricted, however, to the regions where remodelling normally takes place. In general, in the long bones, the important remodelling process is concerned with the reduction of cross-sectional diameters and, therefore, the resorption of cortical bone is from without (periosteal surface) and the new formation is from within (endosteal). Resorption is by osteoclasis, the histological details of which are precisely those of osteoclasis in normal growth. The number of osteoclasts present is far in excess of that in normal remodelling of bone. The number of osteoclasts increases with the rate of resorption, determined by the dosage of vitamin A. New-bone formation in its histological details also corresponds precisely with normal appositional bone growth. Where remodelling is symmetrical—for example, at the upper end of the tibia—the result is essentially the production of two concentric layers,—an inner of newly formed bone, and an outer of the eroded remains of previously formed cortical bone (Fig. 17). In about the mid-portion of the femur, the pattern is an eccentric one, because the remodelling, which is necessary on the outer aspect of the shaft in relation to its linear curvature and to the prominent third trochanter, is not neces-

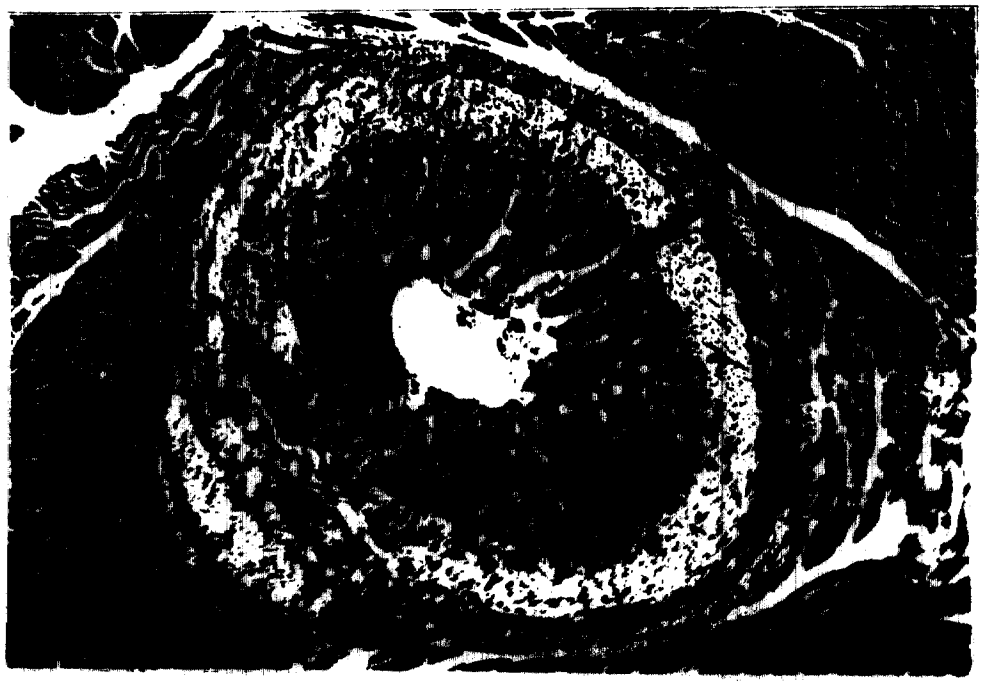

Fig. 18

Cross section of the humerus [illegible] mid-portion [illegible] in about one third of [illegible] The cortex not [illegible] ing is from a region which in [illegible] growth remains [illegible] If a femur of a rat is [illegible] on its long axis, there will come to view, on the postero-internal surface, a straight outline of about the middle third of the shaft.

FIG. 19

A high-power detail of Fig. 18, showing resorption of exterior of cortex and newly deposited bone internally.

sary on the inner aspect of the shaft, which is not linearly curved for a length of six to eight millimeters of its mid-portion (Figs. 18 and 19).

Fractures of long bones are easily accounted for by the extensive loss of previously formed cortical bone before the newly deposited bone has acquired firmness sufficient to meet mechanical requirements. They occur at sites where remodelling in normal growth is most active. The microscopic appearances of the newly formed bone indicate that its lack of firmness is the result of two failures,—one of the matrix to mature, analogous to the collagen changes in cicatrix formation in general and exhibited in part by shrinkage, and the other to incomplete calcification, exaggeratively expressive of the lag in calcification seen in normal appositional bone formation and exhibited by the line of non-calcified matrix or osteoid, where normal growth is in progress.

The fibula of the rat, as it grows, not only becomes more widely separated from the tibia, but swings to a more posterior position. In hypervitaminosis A, the remodelling may be so rapid that at the upper end this bone may, in the guinea pig as well, lose all its pre-existing structure. The pattern of remodelling conforms precisely with the shifting relations of tibia and fibula which, by virtue of cement lines, can be equally well demonstrated in the normal fibula.

Another as yet incompletely studied result of hypervitaminosis A in the rat, dog or guinea pig is the accelerated formation of compact bone which, as is the case with the chick, is most easily demonstrated in the bones of the skull, including those of the [illegible] varium.

In the normally rapidly growing incisor teeth of rats and guinea pigs, the seq[illegible] of enamel and dentine formation are unaffected; perhaps they are somewhat accele[illegible] As growth of teeth is a one-way process,—that is, no remodelling occurs—the effe[illegible] the hypervitaminosis A are histologically inapparent.

In the chick, our studies are incomplete in regard to the effects of hypervitaminosis A

ar experiments have included only the period from hatching to the thirty-second day. e problem in chicks has been complicated, because at hatching the replacement of car- age in the shafts of long bones is far from completed. At present, an acceleration of en- chondral bone formation and earlier establishment of the epiphyseal cartilage plates are e main results established. Acceleration of remodelling sequences can be seen, but has en inadequately studied because of lack of knowledge of the normal. The formation of mpact bone in the vertebrae and bones of the skull is greatly accelerated.

The question of whether or not the action of vitamin A upon bones is a direct one pon the cartilage concerned with growth or operative through any of the ductless glands as led to the study of these organs—the pituitary gland, thyroid, parathyroids, and drenals—both from A-deficient animals and from those exhibiting maximum effects from cessive vitamin-A administration.

In the excess-vitamin-A animals, I have found no changes demonstrable by ordinary chniques in pituitary gland, thyroid, and parathyroids. The adrenals do undergo changes, moderate degree in the rat, outstanding in the guinea pigs. These changes include in- ease in size, loss of lipoid in the cortex, and a marked increase in mitosis of the cells of the ona fasciculata. In the guinea pig, the zona glomerulosa becomes atrophied. Also in the uinea pig, mitosis often remains incomplete, the chromosomes become fragmented and isperse. These effects are those known to result from inanition produced by underfeed- ng[3,14]. The difference in degree of the responses in rat and guinea pig noted in hypervita- minosis A also applies to the adrenals of the underfed of these two species.

In vitamin-A-deficient animals, the thyroid undergoes atrophy. The pituitary gland and parathyroids seem to be unaffected. The adrenals of guinea pigs long maintained in the deficiency show the same changes, though in much less degree, as those from animals with excess vitamin A.

In the rat, guinea pig, and chick the massive dosage of vitamin A we have employed is incompatible with life. A prompt effect is decreased food intake, followed by loss of weight, and lesions of the skin, notably of the eyelids, in the neighborhood of the nostrils and finally of other parts of the body. The skin lesions histologically are not unlike those of some vitamin deficiencies, notably of the heat-stabile vitamin-B group. Histological study re- veals no lesions which can be held accountable for death. Certain changes in liver cells, rarely resulting in necrosis of individual cells, can be regarded as indicating that this organ is damaged directly, or equally well may be interpreted as the result of excessive vita- min-A storage. Metabolism studies on a broad front are plainly indicated for a search of heightened metabolisms. Calcium and phosphorus metabolism studies by methods usually employed have revealed no departure from the normal in rats, guinea pigs, and dogs. The phosphatase may be slightly increased, but, in view of the histology of the bone, is prob- ably of no significance in elucidation of accelerated bone-growth sequences.

In young puppies receiving 300 international units per gram of weight, the cholesterol and phospholipid blood levels remain normal until late in the experiments, when severe consequences are manifest, at which time there is a significant drop both in cholesterol and phospholipids.

In guinea pigs the terminal values of cholesterol and phospholipids are increased to more than double the normal.

Thus far, in rats and guinea pigs we have obtained no appreciable amelioration of the "toxic" effects of vitamin A or arrestment of accelerated growth sequences by the ad- ministration of greatly excessive amounts of vitamin C and the vitamins of the B-complex group.

SUMMARY AND CONCLUSIONS

Vitamin A is essential for the activities of epiphyseal-cartilage cells, without which they cannot carry out the sequence of growth, maturation, and degeneration essential in

the mechanism of endochondral or replacement bone growth. Vitamin-A deficiency suppresses epiphyseal-cartilage-cell sequences and hence endochondral bone growth. Remodelling sequences, involving concurrent resorption of bone with bone deposition and replacement of cancellous bone by compact bone, cease to operate. Appositional growth of bone of periosteal origin continues, until inanition supervenes, *at a rate in conformity to the normal growth pattern in each site. Skeletal growth as a whole ceases.*

Excessive vitamin-A administration accelerates in general those growth sequences of bone retarded by the deficiency. It causes rapid consumption of epiphyseal cartilage and, in appropriate species, greatly premature closure of epiphyses; also, excessive rapidity of remodelling processes unrelated to linear growth of bones, but *definitely related to rate of epiphyseal-cartilage-cell cytomorphosis.* Both the rates of remodelling processes and of cartilage-cell sequences are quantitatively related to the amounts of vitamin A administered. Substitution of compact bone for cancellous bone in conformity to normal growth patterns is greatly accelerated. The fractures and sites of occurrence are fully explained by acceleration of remodelling. Bone which does not require remodelling for maintenance of the normal growth pattern is not responsive to the excess vitamin introduced.

Application of the facts presented will explain easily and completely the results of vitamin-A deficiency upon any of the simpler bony structures of the skeleton. In the case of the skull, the problem is a complicated one, because of the intimate relations of the individual bones to one another in the absence of joints, and because of the many epiphyses or sites of endochondral bone growth and directions of such growth in the bones comprising the base of the skull. However, here too the changes in bones at the base of the skull, in-

FIG. 20

FIG. 21

FIG. 20. Dissection of the cranial base of a normal litter mate control puppy for comparison with Fig. 21, made from a vitamin-A-deficient puppy. Both of these dogs were thoroughly injected with formaldehyde immediately after sacrifice, so that the cranial nervous system was thoroughly hardened *in situ*.

FIG. 21. Vitamin-A-deficient litter mate of puppy of Fig. 20. Notice the tortuosity of the optic nerves in the orbits; also compression deformities of cerebrum and cerebellum. The tortuosity of the optic tracts is evidence of failure of dimensional increase of the bony orbit in a region which excludes deformation by pressure of bone.

cluding the petrous bone, are precisely correlatable with normal growth patterns. The remodelling of the calvarium presents an interesting problem, because the increase of cranial capacity is the result of area increase of the enclosing bones. Growth at the base in bones of cartilaginous origin ceases. The bones of the calvarium of membranous origin normally increase their areas by appositional bone growth at the sutures. Change in radii of curvature also takes place as the cranial capacity increases. In the normal, these two features of growth—area increase of individual bones and changes in curvature—result in a pattern of growth of the membranous bones, in which there is resorption of bone on the exterior of the skull and deposition of bone on the interior surface. This remodelling of flat bones of the skull is suppressed in vitamin-A deficiency, as well as the remodelling of bones of cartilaginous origin, and results in thicker bones, cancellous in structure. One illustration of the fact that the growth of the skull as a whole is suppressed is the fact that in rats and dogs the extracranial lengths of the optic nerves are tortuous, because they become longer than the size of the orbits require (Figs. 20 and 21).

We may conclude that the pattern of bone growth is determined by epiphyseal-cartilage activities for which vitamin A is as essential, apparently without the intermediation of other organs, as it is in vision. We may deduce that in the maturation of the cartilage cells there is produced an inductor factor which is responsible for the maintenance of remodelling of bone during the growth period. Because the accelerated remodelling processes caused by excess of vitamin A adhere precisely to the normal growth pattern, bone which disappears during growth may be referred to as competent bone.

Recent crude experiments in which finely comminuted epiphyseal cartilage from calves has been injected into young rats have yielded results which indicate the correctness of the deduction that epiphyseal cartilage is the source of a factor or factors governing the remodelling of bone during growth.

The effects we have obtained do not duplicate in several ways those produced by excessive vitamin-A administration; nevertheless, they are quite distinctive and unlike those of any other agent affecting bone growth. Briefly, they are the continuation of normal epiphyseal-cartilage sequences, premature resorption of the trabeculae of the primary spongiosa, and, therefore, failure of incorporation of trabecular bone into cortical bone near the epiphyses, and great resorption of cortical bone at sites of remodelling. Osteoclasts are much less numerous than in excessive vitamin-A experiments, and appositional bone formation is not accelerated. Such bones have fractured in the course of handling the rats.

While the cartilage-injection experiments have yielded results of the general nature of acceleration of remodelling, important features of the normal processes are lacking, conceivably because labile factors have been lost in the preparation and preservation of the cartilage prior to injection.

REFERENCES

1. Bills, C. E.: Physiology of Sterols, Including Vitamin D. Physiol. Rev., **15**: 1–97, 1935.
2. Blumenthal, H. T., and Loeb, L.: Two Antagonistic Effects of Underfeeding on Adrenal Cortex of Guinea Pig. Am. J. Pathol., **18**: 615–631, 1942.
3. Boyle, P. E.; Bessey, O. A.; and Howe, P. R.: Rate of Dentin Formation in Incisor Teeth of Guinea Pigs on Normal and on Ascorbic Acid-Deficient Diets. Arch. Pathol., **30**: 90–107, 1940.
4. Ham, A. W.: Mechanism of Calcification in Heart and Aorta in Hypervitaminosis D. Arch. Pathol., **14**: 613–628, 1932.
5. Ham, A. W., and Lewis, M. D.: Hypervitaminosis D Rickets: Action of Vitamin D. British J. Exper. Pathol., **15**: 228–234, 1934.
6. Harris, L. J., and Innes, J. R. M.: Mode of Action of Vitamin D; Studies on Hypervitaminosis D; Influence of Calcium-Phosphate Intake. Biochem. J., **25**: 367–390, 1931.
7. Mellanby, E.: The Experimental Production of Deafness in Young Animals by Diet. J. Physiol., **94**: 380–398, 1938.
8. Mellanby, E.: Skeletal Changes Affecting Nervous System Produced in Young Dogs by Diets Deficient in Vitamin A. J. Physiol., **99**: 467–486, 1941.

9. Mellanby, E.: Croonian Lecture; Nutrition in Relation to Bone Growth and Nervous System. Proc. Roy. Soc., London, s.B., **132**: 28-46, 1944.
10. Minot, C. S.: The Problem of Age, Growth and Death. Popular Science Monthly, **70**: 481-486; **71**: 97-120, 193-216, 1907.
11. Park, E. A.: Observations on Pathology of Rickets with Particular Reference to Changes at Cartilage-Shaft Junctions of Growing Bones; Harvey Lecture. Bull. New York Acad. Med., **15**: 495-543, 1939.
12. Shelling, D. H., and Asher, D. E.: Calcium and Phosphorus Studies; Reaction of Calcium and Phosphorus of Diet to Toxicity of Viosterol. Bull. Johns Hopkins Hosp., **50**: 318-343, 1932.
13. Shohl, A. T., and Wolbach, S. B.: Rickets in Rats; Effect of Low Calcium-High Phosphorus Diets at Various Levels and Ratios upon Production of Rickets and Tetany. J. Nutrition, **11**: 275-291, 1936.
14. Whitehead, R.: Fat of Adrenal Cortex in Fasting Guinea-Pigs and Rabbits. J. Pathol. and Bacteriol., **54**: 169-176, 1942.
15. Wolbach, S. B., and Howe, P. R.: Intercellular Substances in Experimental Scorbutus. Arch. Pathol and Lab. Med., **1**: 1-24, 1926.
16. Wolbach, S. B.: Controlled Formation of Collagen and Reticulum. A Study of the Source of Intercellular Substance in Recovery from Experimental Scorbutus. Am. J. Pathol., **9**, Supplement: 689-700, 1933.
17. Wolbach, S. B.: Vitamin Deficiency Experimentation as a Research Method in Biology. Science **86**: 569-576, 1937.
18. Wolbach, S. B., and Bessey, O. A.: Vitamin A Deficiency and Nervous System. Arch. Pathol., **32**: 689-722, 1941.
19. Wolbach, S. B., and Bessey, O. A.: Tissue Changes in Vitamin Deficiencies. Physiol. Rev., **22**: 233-289, 1942.
20. Zuck, T. T.: Age Order of Epiphyseal Union in Guinea Pig. Anat. Record, **70**: 389-399, 1938.

Because the chick bones studied were those of controls in experiments upon chicks kept upon abnormal dietary regimens from two to three days after hatching to 23 days of age, our studies were made at ages of 19 to 23 days, according to the duration of the experiments.

The regions selected for the study of growth sequences in normal and experimental chicks were the distal end of the femur, proximal end of the tibiotarsus, lumbar and sacral vertebrae, and the base of the skull.

THE DIET OF CONTROL CHICKS

The composition of the diet fed the control chicks was as follows:

Sucrose	51.0 gm.
Vitamin-free casein	18.0 gm.
Corn oil	5.0 gm.
Gelatin	10.0 gm.
Salts IV*	5.0 gm.
$CaHPO_4$	1.0 gm.
Brewer's yeast	10.0 gm.
Choline chloride	0.3 gm.
Thiamine hydrochloride	400.0 μ
Riboflavin	800.0 μ
Pyridoxine hydrochloride	400.0 μ
Nicotinic acid	3,000.0 μ
Calcium pantothenate	1,500.0 μ
Viosterol	2,000.0 I. U.

In addition, 100 μ of 2-methyl-1,4-naphthoquinone (Menadione U. S. P.), 100 μ of alpha-tocopherol in corn oil, and 1 drop of haliver oil (approximately 5,000 I. U. in vitamin A) were fed twice a week to each chick by medicine dropper.

* Hegsted, D. M.; Mills, R. C.; Elvehjem, C. A., and Hart, E. B.: J. Biol. Chem. 138:459, 1941.

Normal Chicks Used for Histological Study

No.	Source of Vitamin A in Diet	Other Additions	Weight, Gm. 15 Days	16 Days	19 Days	Age Killed, Days	Final Weight, Gm.
414	Haliver oil	1.5% liver extract	...	110	140	22	164
430	Haliver oil	1.5% liver extract	...	115	148	22	182
431	Haliver oil	.....	...	121	...	18	148
460*	1% cod liver oil added	.....	...	110	130	32	213
457	1% cod liver oil added	.....	...	127	150	32	252
303	2% cod liver oil added	5% liver extract	97	...	...	32	246
357	2% cod liver oil added	5% liver extract	105	...	...	32	233
360	2% cod liver oil added	5% liver extract	119	...	...	32	255
362	2% cod liver oil added	5% liver extract	122	...	...	32	252
186	Kept on commercial chick ration	.....	113	...	...	26	218

* This chick had diarrhea, 14th to 17th days of age.

All chicks fed this diet were killed between the 18th and 22d day of age, inclusive. Other chicks were fed the diet with haliver oil omitted and 1% cod liver oil added, and some were kept on a commercial chick food.

The chicks killed on the 32d day of age were kept on slightly different rations in that haliver oil was omitted and additions of 2% cod liver oil and 5% liver extract were made.

ENDOCHONDRAL BONE GROWTH IN LONG BONES[4]

The growth of the long bones in all birds[2] presents differences from that in mammals.

In both birds and mammals the first bone formed is of periosteal origin. In the chick, as soon as shell of bone is formed in the midshaft region, the enclosed carti-

4 All descriptions are made from bones fixed in 10% formalin (4% formaldehyde solution), embedded in celloidin, and stained with hematoxylin and eosin.

lage, after the blood vessels have entered from the periosteum, is excavated without being replaced by trabecular bone, unlike that in the mammal. Growth at the ends is wholly cartilaginous. As the cartilage core is undergoing destruction, the only ossification in the shaft is at the periphery of the cartilage, where the latter becomes tunneled by blood vessels. At hatching, cones of cartilage are present at the ends of the bones. Concurrent erosion of the cartilage and tunneling by blood vessels result, on about the 14th day, in the establishment of the counterpart of the epiphyseal cartilage of mammals. No separate center of ossification forms at the epiphysis. During the growth period a zone of hyaline cartilage is present between the epiphyseal cartilage and the articular cartilage. At the age period 18 to 32 days, with which the present study is concerned, we can distinguish three zones, articular, hyaline, and epiphyseal or growth cartilage (Figs. 1 and 2).

Fig. 1.—Longitudinal section through the distal end of the femur of an 18-day-old normal chick (No. 431). At the upper right the articular cartilage is shown. Note the vascularization of the cartilaginous epiphysis and the absence of resorption where blood vessels pass through the proliferative zone of the epiphyseal cartilage. Reduced from 20.8 diameters.

The articular cartilage is a relatively thin stratum of flattened cells having an eosinophilic matrix. Adjacent to attachments of the joint capsule and the ligaments of the knee joint it merges into fibrocartilage. Deep to the surface of the joint it merges into the hyaline cartilage through a succession of cells of increasing size. Although the transition into cartilage with isogenous grouping of cells is rather abrupt, there is no definite line of demarcation between the articular cartilage and the zone of hyaline cartilage which may be regarded as a cartilaginous epiphysis.

The zone of hyaline cartilage is characterized by a basic-staining matrix and isogenous groups of cells with thin but definite "capsules." It is penetrated by blood vessels which extend into it from the epiphyseal cartilage and which branch and

anastomose with one another. It is clearly demarcated from the epiphyseal cartilage, chiefly because of the deeper staining of the cells and the matrix of the latter. When stained with thionin blue after formalin fixation, the matrix of the cartilaginous epiphysis is colored clear blue in sharp contrast to that of the epiphyseal cartilage, which is colored bluish purple. In adult chickens this cartilaginous epiphysis is

Fig. 2.—Higher power magnification of a part of Figure 1. Note the loss of the columnar arrangement of cartilage cells in the zones of growth and maturation, the loops of advancing blood vessels, and the lateral excavations of the tunnels. × 50.

absent. Presumably, the blood vessels and surrounding cells which we have described are, at a later period of growth, concerned in its removal. Adjacent to the epiphyseal cartilage the cells of the cartilaginous epiphysis become more and more flattened and in longitudinal sections of the long bones appear as narrow spindle-shaped cells, placed singly and in end-to-end pairs. In sections transverse to the

long axis of the bone these cells appear in various discoid forms, hemicircular, crescentic, and triangular.

The blood vessels of the cartilaginous epiphysis are surrounded by small, undifferentiated cells similar in appearance to cells surrounding the advancing tips of the blood vessels tunneling the epiphyseal cartilage. The blood vessels include small arteries, veins, and capillaries; the last, where exclusively present, may be tortuous and show anastomoses between adjacent loops. Whether the vessels entering from the shaft of the bone communicate with blood vessels from the perichondrium has not been positively determined; but, because in cross sections at the level where blood vessels from the epiphyseal cartilage enter the cartilaginous epiphysis no blood vessels with a media could be found, the arteries and the veins in the cartilaginous epiphysis must have origin elsewhere.

The zone of proliferating cells of the epiphyseal cartilage is very wide as compared with that of mammalian bones. The cells are extremely flattened, closely packed, crescentic, or wavy as seen in longitudinal sections. In general, the crescentic shape prevails, with the concavity toward the diaphysis. In sections transverse to the long axis of bones the cells appear discoid with irregular outlines. Mitotic figures are present throughout the considerable width of the proliferating zone, which presumably ends on the diaphyseal side, where the cells have become distinctly larger, with plump, ovoid nuclei, and surrounded by an increased amount of matrix. In the epiphyseal border of the zone of proliferation the cells are packed in columns narrowly separated from one another, but this arrangement is wholly lost where the cells have reached sufficient size to be globular in shape. There is presented to the blood vessels advancing from the diaphysis a zone of enlarged (hypertrophic) cells without arrangement in columns and equally embedded on all sides with matrix, in striking contrast to the columns of maturing and matured cells in the mammalian epiphyseal cartilage.

Vascular penetration of the epiphyseal cartilage in chicks (and in all birds and cold-blooded vertebrates [2]), while functionally similar, is quite different from that in mammals in pattern and in important details. The cytological sequences of the cartilage from the discoid cell of the zone of proliferation to the mature cell are essentially similar to those in the mammal except that (in the chick) degeneration is less complete preparatory to ossification sequences. Shrunken but viable appearing nuclei, surrounded by fragments of cytoplasm, persist until the capsule has been eroded through, both in advance of and lateral to the blood vessels tunneling the epiphyseal cartilage.

The pattern of vascular tunneling of the epiphyseal cartilage of the chick is very different from that of mammals. In the latter, the epiphyseal cartilage on the diaphyseal side is composed of cells in linear arrangement, each row or column one cell in thickness and surrounded by calcified matrix of considerable thickness, while the matrix between individual cells of the columns is very much thinner. Each column, following degeneration of the presenting cartilage cell, is penetrated by capillary loops accompanied by osteoblasts, resulting in tunnels whose cross-sectional dimensions are those of mature cartilage cells (Fig. 3). The walls of the tunnels consist of calcified acellular matrix upon which osteoblasts deposit bone. The tunnels persist as such only for a short distance toward the diaphysis, often not exceeding in length the width of the epiphyseal cartilage, but varying as the growth rate of the bone varies under experimental conditions. Bone is deposited on the calcified

cartilage of the tunnels, which are soon destroyed by partial or complete osteoclastic resorption, which may vary in rate and extent according to experimentally produced conditions. Left behind is the familiar structure of cancellous bone of the metaphyseal region. Cartilage matrix incorporated in the deposit of bone persists for a long time, particularly where, as a result of remodeling, trabeculae of endochondral bone growth become surrounded in the shaft by appositional bone of endosteal and

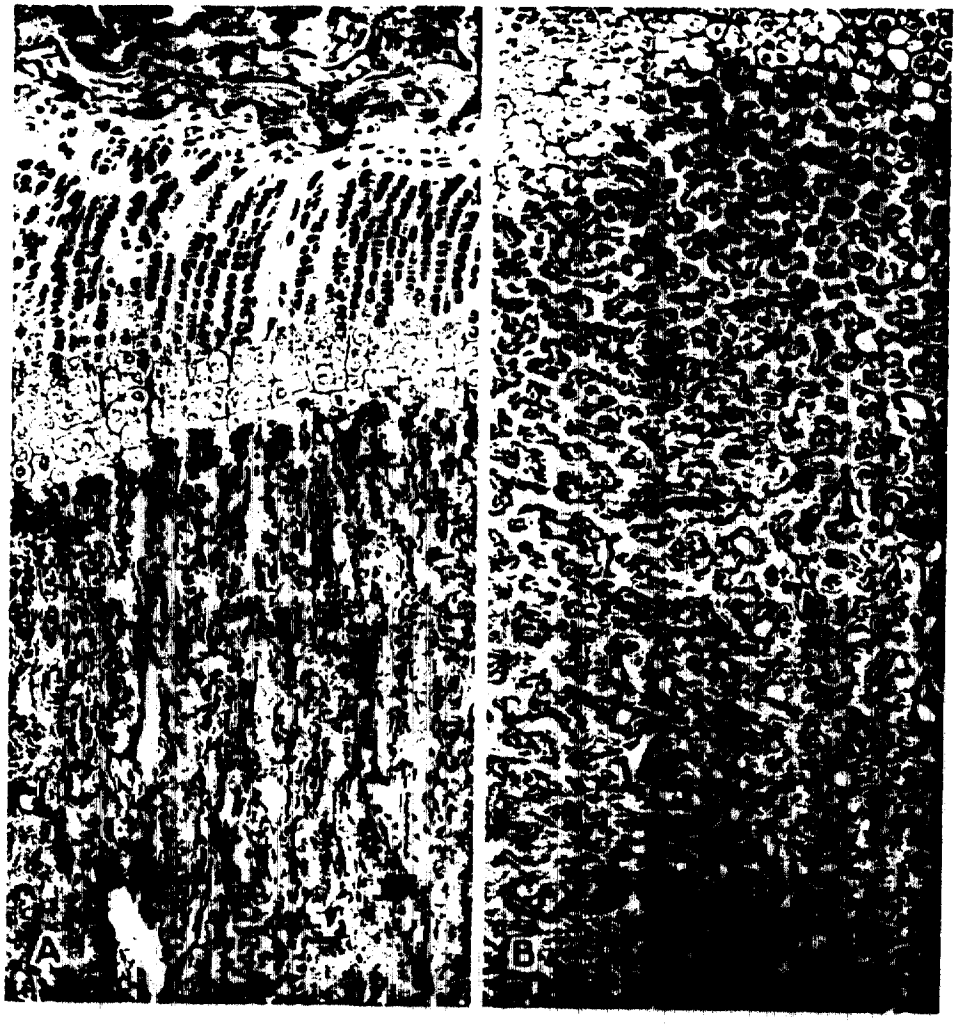

Fig. 3.—*A*, longitudinal section of the distal femoral epiphyseal cartilage of a young rat. × 120.

B, cross section of the distal femoral epiphyseal cartilage of a young rat. At the upper end, because of the convexity of the condylar surface, "cleared" cartilage cells are seen as well as the earliest penetration by blood vessels. × 120.

periosteal origin. It becomes less and less in amount as the bone grows. The mechanism of its final disappearance is unknown.

In the chick the tunneling of the mature cartilage is widely and fairly uniformly spaced (Figs. 1 and 4). Longitudinal sections and transverse sections at various levels through the epiphyseal cartilage of normal chicks 18 to 32 days of age show

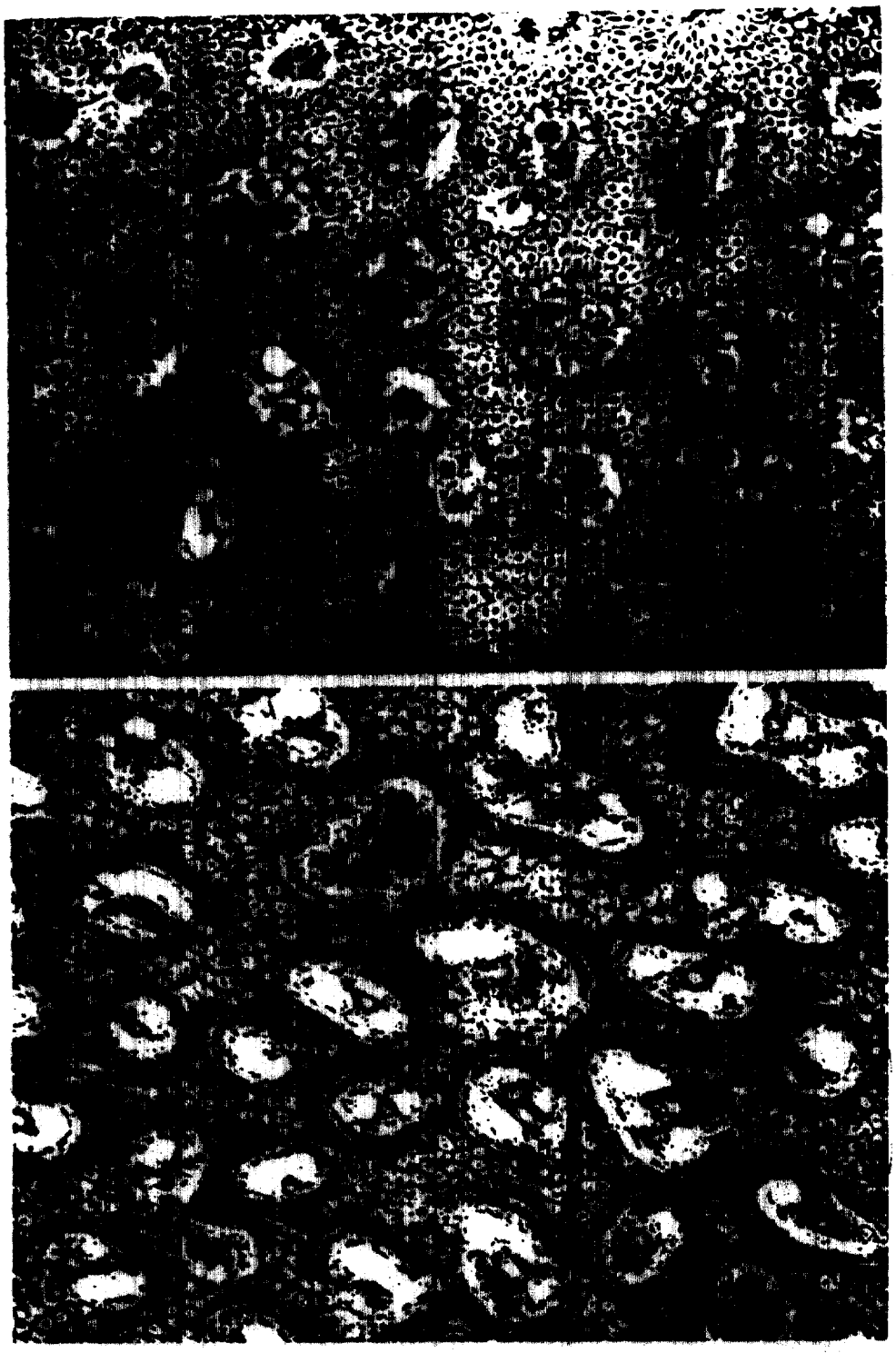

Fig. 4.—*A*, cross section of the epiphyseal cartilage of a 22-day-old normal chick (No. 414), to show early tunneling before osteoid deposition has occurred. Note the number of blood vessels in each tunnel and the disappearance of cartilage cell capsules on the sides adjacent to the tunnels. Note absence of chondroclasts and osteoblasts. × 120.

B, section from the same block from which *A* was obtained, to illustrate a later stage of tunneling. Note the early stages of the lateral resorption of the cartilage walls, the presence of osteoid deposits, and rows of osteoblasts and multinucleated giant cells. × 120.

only slight variations in individual chicks. At the levels of most advanced penetration of the epiphyseal cartilage the spacing of the tunnels during the 18- to 32-day period, measured between centers, varies from 0.27 to 0.35 mm. Vessels from the tunnels that have passed through the proliferative zone into the cartilaginous epiphysis are also fairly evenly distributed, and in the latter structure are 0.44 to 0.6 mm. apart from one another.

The fact that the spacing of the tunneling of the epiphyseal cartilage has notable uniformity and constancy implies the presence of a determining factor. No morphological indication of such in normal chicks can be seen in the zone of mature cartilage cells in advance of the invading blood vessels. The advancing blood vessels at levels where erosion of cartilage predominates over osteogenesis consist of thin-walled tubes without media. They give off branches which freely anastomose with one another. The extreme tip is a loop (Fig. 2). In transverse sections through the van of vessel penetration, two to seven or more vessels of capillary dimensions appear in cross section. Often the cross sections are elliptical and crescentic in shape, indicative of tortuosity and anastomoses (Fig. 4*A*).

Blood vessels with a smooth muscle media are present only at the level where bone deposition is abundant.

The blood vessels, even at the very tips, are surrounded by cells. Those at the tips of advancing blood vessels are closely packed together and often lie enclosed by the terminal capillary loop. They are two to three times the size of the red blood corpuscles, are oat-shaped, and presumably are undifferentiated cells. Diaphysealward the accompanying cells become more and more numerous. Multinucleated giant cells—chondroclasts—are abundant wherever cartilage is being resorbed. An occasional one may be at the tip of an invading vessel. Other cells, in order of frequency in progression diaphysealward, are elongated connective-tissue-like cells, osteoblasts, and marrow cells of all types.

The multinucleated giant cells—chondroclasts—are identical in appearance with the multinucleated giant cells—osteoclasts—present in the same bones in regions of bone resorption. They become more numerous in the cartilage tunnels in the direction toward the diaphysis, presumably in relation to increasing degrees of calcification of the cartilage matrix. While undoubtedly operative in the opening of cartilage cells and in removal of bone deposited on the tunnel walls, their numbers do not seem sufficient for regarding them as the whole or major agent in the first tunneling of the epiphyseal cartilage. Multinucleated giant cells may not be present or identifiable in foci where cartilage cell capsules have been opened. Instead there are groups of osteoblasts. The presence of these cells, surrounded by osteoid matrix, within the capsules, may explain the conviction of some authors that cartilage cells can transform to osteoblasts. Cartilage cells in the immediate proximity of advancing blood vessels are abruptly changed to dimly outlined structures, with and without nuclear remains and without capsules on the side bordering the blood vessels. The content of the cells appears to be replaced by a faintly staining homogeneous material suggestive of an origin from greatly swollen disappearing capsules or matrix (Fig. 4*A*).

Multinucleated giant cells are usually not present at the extreme tip of vascular advancement. Cells of all sorts may be few, and the process seems to be one of chondrolysis wherever blood-containing capillaries come into close proximity to

mature epiphyseal cartilage cells. The caliber of the tunnels increases by a similar process for a short distance but increase of caliber becomes restricted and modified as soon as osteoblasts become applied to exposed cartilage matrix. After bone matrix deposition has been established, the cartilage between adjacent tunnels becomes irregularly removed by osteoclasis, and communications are established. The caliber of these passages is at first approximately that of the tunnels they connect, but as growth progresses they increase in size concurrently with the resorption of the walls of the tunnels. The continuation of this process, seen in cross sections, results in a labyrinth of tortuous canals with cartilaginous walls of irregular thick-

Fig. 5.—Detail of a cross section of epiphyseal cartilage of an 18-day-old chick. This chick, for the last three days, was fed a reduced amount of food, but the slowed growth sequences are wholly normal in character. Note the shrunken nuclei of mature cartilage cells and the details mentioned for Figure 4*B*. × 300.

ness, in places undergoing removal by chondroclasis, in places becoming coated with bone (Figs. 4*B* and 5).

When seen in longitudinal sections the remains of the walls of the tunnels appear as columns of cartilage cells, sometimes enclosed by layers of bone on both sides, often covered by bone on one side and undergoing chondroclastic resorption on the other. Diaphysealward the "columns" become thinner and more and more broken up by chondroclasis and osteoclasis until they disappear in the diaphyseal marrow.

In contrast to analogous sequences of growth in mammals is the survival, in the chick, of apparently viable cartilage cells in slender "columns" upon which bone has been deposited and far distant from their origin in epiphyseal cartilage. Because in the remodeling attending linear growth of long bones bone of endochondral origin becomes incorporated into cortical bone, cartilage cells may be found here in regions where all other bone of endochondral origin has disappeared. This corresponds to the persistence of cartilage matrix in a similar location in growing mammalian bones. In the chick the final vestige of cartilage appears as a basic-staining irregular tracery of remnants of the cell capsules. The manner in which cartilage cells disappear and the source of the osteoblasts which replace them in regions where they are apparently completely enclosed by bone present a problem not yet satisfactorily solved.

ENDOCHONDRAL BONE GROWTH IN THE AXIAL SKELETON

In the age period covered by this study, endochondral ossification is active in the vertebrae. We have employed serial sectioning of a few vertebrae in cross sections of the seventh thoracic vertebra and in longitudinal sections, one series inclusive of thoracic 7 to lumbosacral 12; another series inclusive of thoracic 6 to lumbosacral 10. The seventh thoracic vertebra, the 14 lumbosacral vertebrae, and the first coccygeal vertebra form a unit structure, the synsacrum, in which the spinal canal is greatly enlarged (lumbosacral vertebrae 3 to 10) to accommodate the egg-shaped glycogen body, a structure peculiar to birds, intimately connected with the spinal cord and traversed by the central canal and separating the dorsal funiculi to form the so-called sinus rhomboidalis.[5]

There are no joints between the vertebrae forming the synsacrum,[6] but there is epiphyseal cartilage at both ends of each vertebra; the vertebrae are separated from one another by hyaline cartilage. In the vertebrae of the chick, as in the long bones, there are no epiphyseal centers of ossification.

In sections of vertebrae, seven regions of endochondral ossification were studied, including the dorsal spine, the two lateral processes, the two of the body providing for increase in cross sectional diameters, and the ones at the anterior and posterior ends providing for linear growth.

In the skull, in frontal plane sections, endochondral ossification was observed at the articulations of the sphenoid and temporal bones, the articulations of the temporal and occipital bones, and several regions in the temporal bone complex not precisely anatomically identified.

In every essential detail, endochondral bone growth in the vertebrae and in the skull, in the chick, is identical with that at the ends of long bones and presents the same contrasts to endochondral bone growth in the same locations in mammals as do the growth processes at the ends of the long bones.

In the growth of all bones studied, epiphyseal cartilages increase in width by appositional growth from the perichondrium. The shapes of bones are preserved

5 Watterson, R. L.: Development of the Glycogen Body of the Chick Spinal Cord. J. Morphol. 85:337, 1949.

6 Kaupp, B. F.: Anatomy of the Domestic Fowl, Philadelphia and London, W. B. Saunders Company, 1918. Chamberlain, F. W.: Atlas of Avian Anatomy, East Lansing, Mich., Michigan State College Agricultural Experiment Station, 1943

during growth as in mammals by continuous remodeling that involves resorption of bone and new bone formation from endosteal and periosteal sources.

COMMENT

Skeletal growth in the chick, as in mammals, includes three processes: (1) growth of epiphyseal cartilage and its replacement by bone, (2) appositional growth of bone and cartilage, and (3) remodeling involving both resorption and new formation of bone. One and (3) are interdependent to a marked degree.

A detailed understanding of the morphological sequences of all three is essential for the recording and appraisal of effects produced upon skeletal growth by deficient diets or by substances added in excess of physiological needs.

The only age differences in the period we have covered (18 to 32 days after hatching) are a moderate decrease of the length of the cartilage tunnels with age and a diminution of the width of the zone of growing cells (zone of increase in size of cells) of the epiphyseal cartilage. These differences are negligible for the purpose of comparisons of the normal and experimentally produced modifications of growth.

Bone growth, until completed, is in all details a continuation of fetal growth and follows a pattern involving responses of competent tissues to organizing agents. With this in mind we have noted, without discussion, the passage of blood vessels, quite regularly distributed, through the epiphyseal cartilage into the cartilaginous epiphysis, unaccompanied by effect upon the zones of growth and proliferation. These blood vessels are apparently not concerned in the sequences of endochondral bone growth during the age period studied, although they arise from vessels situated in the top of the tunnels.

SUMMARY

Endochondral bone growth in the chick proceeds by widely spaced tunneling of epiphyseal cartilage by blood vessels and accompanying cells from the diaphyseal side. The epiphyseal cartilage, in contrast to that of mammals, does not present a columnar arrangement of matured or degenerated cartilage cells to the advancing blood vessels. Degeneration or clearing of cartilage cells is not complete as in mammals, and no differences are apparent between cartilage cells in immediate proximity to advancing blood vessels and those situated lateral to the paths to be followed by penetrating blood vessels.

In the tunneling process of the epiphyseal cartilage at the tips of advancing blood vessels, the matrix (including capsules of cells) disappears and the cells, though in part surrounded by capsules, degenerate and disappear. The sequences are similar to those described by Fell[3] in the early ossification of the chick's skeleton, and attributed to chondrolysis, a characterization with which we are forced to agree.

Multinucleated giant cells may or may not be present at the advancing tips of the tunnels; they become numerous in older regions of the tunnels—presumably because of greater degrees of calcification of the cartilage matrix.

Ossification proceeds by the depositing of bone upon the walls of the tunnels. This is not a symmetrical process, because soon after formation lateral resorption of cartilage accompanied by chondroclasts takes place at apparently irregularly distributed areas in the length of the tunnels and establishes communications between adjacent tunnels. At this stage, multinucleated giant cells—chondroclasts—are almost invariably present and seem to be the chief agent in the removal of the

Wolbach-'52
Bib. No. 9959

Arch. Pathol. 54(1):13-29. 1952.

VITAMIN A DEFICIENCY IN THE CHICK

Skeletal Growth and the Central Nervous System

S. BURT WOLBACH, M.D.
AND
D. MARK HEGSTED, Ph.D.
BOSTON

IN MANY mammalian species (rat, mouse, guinea pig, dog, ferret, calf) vitamin A deficiency has a profound effect upon the growth of bones, productive of pressure upon the nervous system.[1] Wolbach and Bessey [1a] proved that in the rat and the guinea pig skeletal growth was severely retarded before growth of soft tissues, including the nervous system, was impaired, so that the compression of the contents of the cranium and the spinal canal was solely responsible for paralyses. Wolbach,[1c, d] categorically stated that the retardation of skeletal growth was primarily that of endochondral bone growth accompanied by failure of the remodeling sequences which are essential for normal growth patterns of bone. Less growth of bone, abnormal in pattern because of continuation of appositional bone deposition, and retardation or failure of compact bone formation were other important features stressed by Wolbach.[1c, d]

Mellanby [1e] attributed the pressure upon the nervous system in dogs to overgrowth of bone, explainable by a preponderance of osteoblastic over osteoclastic activity. In his book [1e] he gives his first and only attention to epiphyseal cartilage responses to vitamin A deficiency, cursorily and disparagingly.

The purposes of this report are to document statements made by one of us [1c, d] in regard to the effects of vitamin A deficiency upon the skeletal growth of the chick, and to record the important and constant results obtained in a relatively small series of chicks at a time when attention is being paid to the skeletal and nervous system responses to vitamin A deficiency in another avian species.[2]

This study was aided by research grants from The Nutrition Foundation, the Williams-Waterman Fund for the Combat of Dietary Disease, and Swift and Company, Chicago.

From the Division of Nutritional Research, Division of Laboratories and Research of The Children's Hospital; the Department of Nutrition, Harvard School of Public Health, and the Department of Biological Chemistry, Harvard Medical School, Boston.

1. (*a*) Wolbach, S. B., and Bessey, O. A.: Vitamin A: Deficiency and the Nervous System, Arch. Path. **32**:689, 1941; (*b*) Tissue Changes in Vitamin Deficiency, Physiol. Rev. **22**:233, 1942. (*c*) Wolbach, S. B.: Vitamin A Deficiency in Relation to Skeletal Growth, Proc. Inst. Med. Chicago **16**:116, 1946; (*d*) J. Bone & Joint Surg. **29**:171, 1947. (*e*) Mellanby, E.: A Story of Nutritional Research: The Effects of Some Dietary Factors on Bones and the Nervous System, Baltimore, Williams & Wilkins Company, 1950, Chap. 6 and 8; (*f*) Chap. 7.

2. (*a*) Fletcher, D. E., and Rigdon, R. H.: Neurologic Manifestations Associated with Vitamin A Deficiency in Young Ducks, Arch. Neurol. & Psychiat. **61**:199, 1949. (*b*) Neurologic Manifestations Associated with Vitamin A Deficieicy in Young Ducks, editorial, Nutrition Rev. **7**:188, 1949. (*c*) Rigdon, R. H.; Rude, J. C., and Bierie, J. G.: Effect of Hypervitaminosis A and Hypovitaminosis A on the Skeleton of a Duck, A. M. A. Arch. Path. **52**:299, 1951. (*d*) Rigdon, R. H.: Pathologic Lesions in the Nervous System of the Duck Fed a Ration Deficient in Vitamin A, ibid. **53**:239, 1952.

EXPERIMENTAL STUDY

The diet, minus sources of vitamin A, was that described in the preceding paper on "Endochondral Bone Growth in the Chick."[3] The chicks were given the diet as soon as received from the hatchery at 1 or 2 days of age. Only those used for histological bone studies are listed in the accompanying table. Some of these and a few not listed were also used for gross dissections, after decalcification, of the cranium and portions of the spinal column.

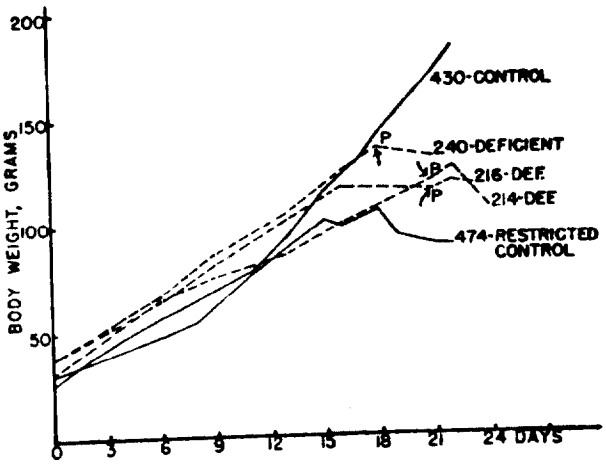

Fig. 1.—Weight graphs of three vitamin-A-deficient chicks, one normal control, and one fed a reduced amount of a normal diet. The arrows indicate the day on which paralyses were noted.

Data on Normal Chicks Used for Histological Study

	Paralyses		Maximum Weight		Death		
Chick	Day	Weight, Gm.	Day	Weight, Gm.	Day	Weight, Gm.	Comment
240	17	124	.	...	20	131	Died
229	19	146	20	148*	26	118	Killed
216	21	119	21	119	23	117	Died
214	21	120	22	126*	24	107	Died
236	23	131	24	136*	26	114	Killed
271	16	74	15	77	19	...	Died
473*	15	105	14	109	19	81	Force-fed last 4 days; killed
481*	15	114	15	114	21	81	Force-fed last 3 days; died
385*	15	112	21	139	21	139	Killed†
255	22	153	25	155*	27	147	Force-fed last 5 days; killed
207	24	162	25	163*	27	152	Force-fed last 3 days; killed

* These chicks received 5% instead of 10% yeast in the diet, and 1.5% liver extract was added.
† The gain in weight occurred during the last four days and was probably due to an error in feeding. The bones were typical of vitamin A deficiency.

All of the vitamin-A-deficient chicks were paralyzed before death, a few as early as the 15th day but usually not before the 20th day. In most instances weight gain was satisfactory until paralyses were noted and occasionally for one or two days following signs of paralyses. The weight graphs (Fig. 1) include those of three representative A-deficient chicks, and the days on which paralyses (*P*) were noted are indicated. The relation of onset of paralyses to gain in weight shows that in chicks, as well as in rats, and the soft tissues continue to grow at an approximately normal rate after severe retardation of skeletal growth has occurred.

3. Wolbach, S. B., and Hegsted, D. M.: Endochondral Bone Growth in the Chick, Arch. Path., this issue, p. 1.

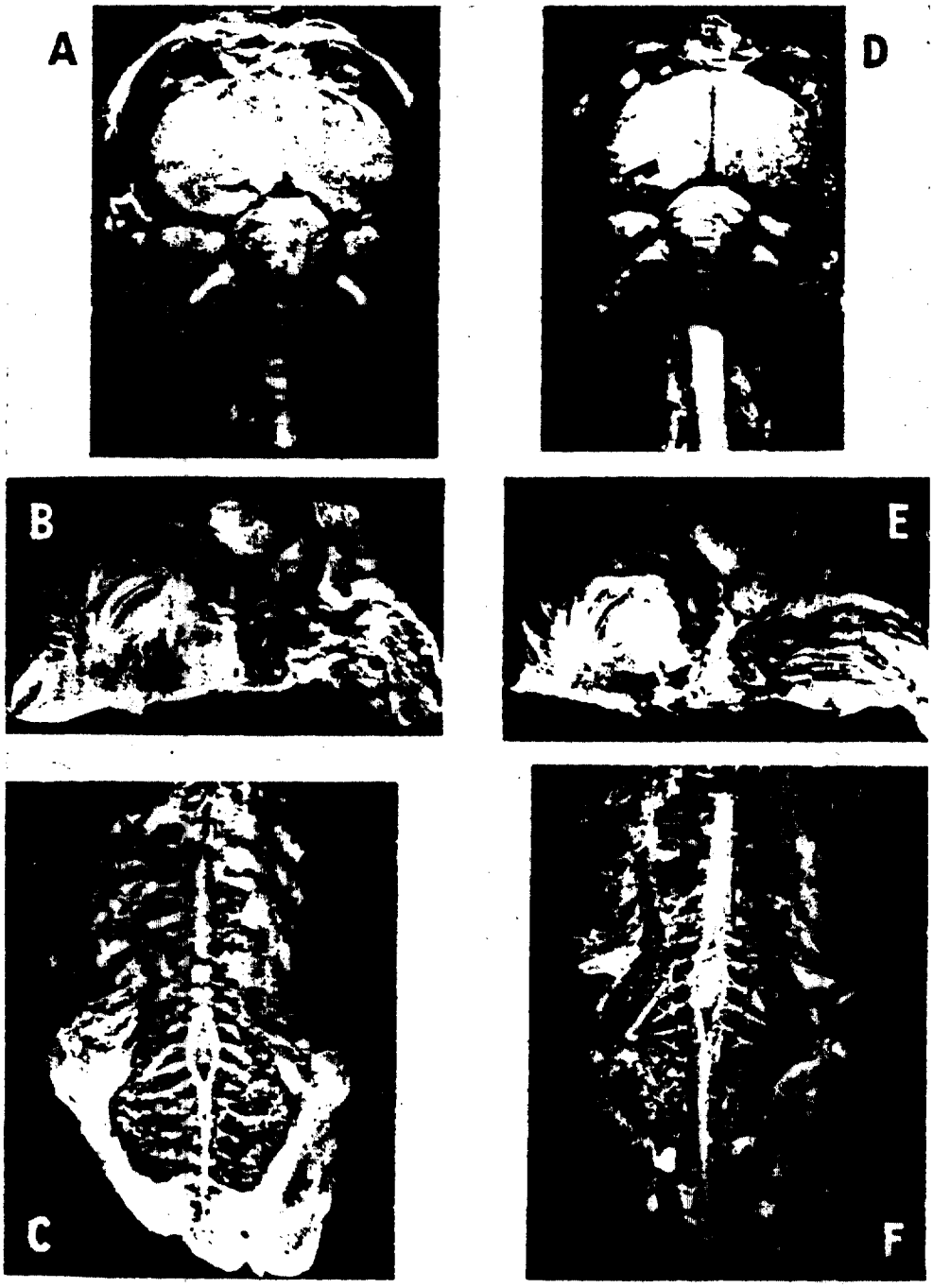

Fig. 2.—*A*, vitamin-A-deficient Chick 213. Note the shape of the cerebral hemispheres, the compression of the cerebellar folia, the distortion and elongation of the flocculi, and the molding of the medulla and the cervical spinal cord. See Figure 3*A* and *B* for brain herniating into the anterior confluence of vessels before the membranes were removed.

B, lateral view of the brain of Chick 214. Note the concave posterior surface of the cerebellum, the great prominence of the pontal flexure of the medulla, the molding of the medulla by the cerebellum, and the prominence of the tectum.

C, dissection of the lumbosacral spinal cord of vitamin-A-deficient Chick 214. The glycogen body has been removed. Note the transverse elevations of the spinal cord due to the molding of the cord into the roof of the synsacrum.

D and *E*, brain of a restricted-diet control chick. Compare this with the brain of the vitamin-A-deficient chick.

F, dissection of the lumbosacral spinal cord of a restricted-diet control chick. Compare the same regions in this and the vitamin-A-deficient chick. The glycogen body is in situ.

The restricted-diet control, Chick 474, is representative of four chicks whose food was reduced in amount on the 15th day of age. These four chicks were normal in all respects except for small size. Their central nervous systems were normally related to the spinal canals and cranial cavities, as seen on gross dissections (Fig. 2*D*, *E*, and *F*). The effect of the restricted diet upon endochondral bone growth will be described in our account of the microscopic studies which follows.

Histological studies were made of the soft tissues of only four chicks, Nos. 207, 255, and 473, listed in the table, and one other chick which was severely paralyzed when killed on the 27th day. All four of these chicks showed the normal epitheliums replaced by keratinizing epithelium in several locations, constantly in trachea and/or larynx, renal pelves and/or ureters, and esophageal glands. Other locations were conjunctiva, lingual glands, and bursa of Fabricius. In all instances, the replacement was focal, indicative of the early stages of the characteristic

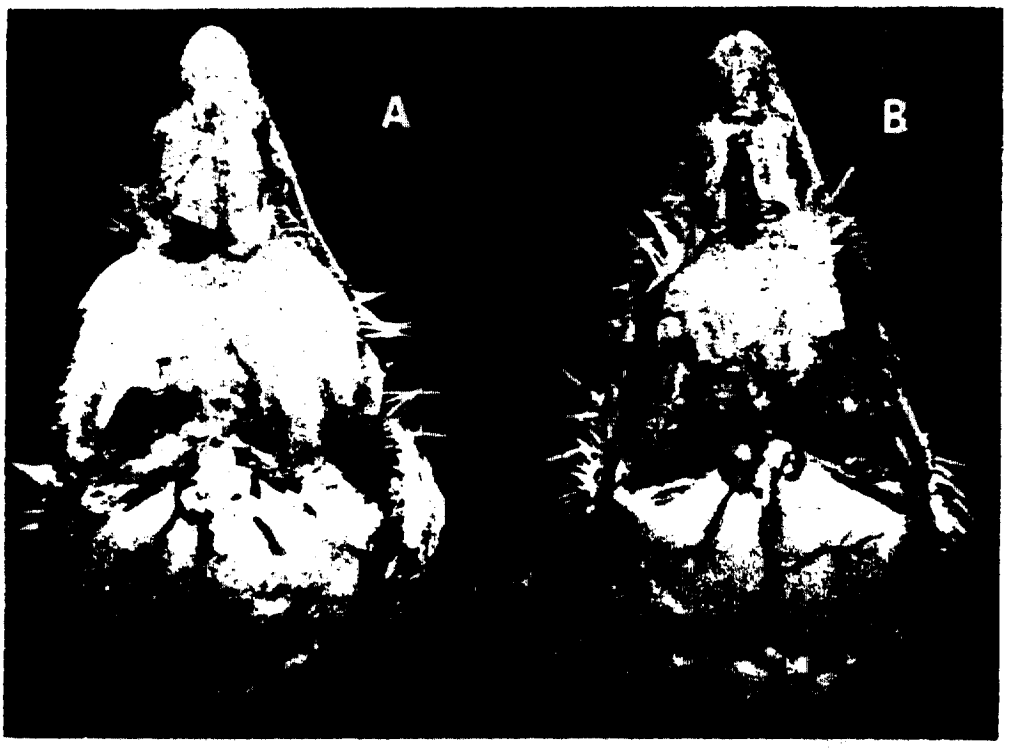

Fig. 3.—*A* is from Chick 214; *B*, from Chick 481. The photographs are enlarged to show how the brain herniates, via sites of arachnoidal villa, into the anterior confluence of vessels described in the text.

epithelial response to vitamin A deficiency. In the rat, also, the skeletal retardation can cause severe injury of the nervous system before the "keratinizing metaplasia" of epitheliums reaches an impressive degree.[14]

GROSS PATHOLOGY

No attempt was made to compare the bones, divested of soft tissues, of the vitamin-A-deficient chicks with normal or restricted-diet controls. In the dissections of the spine and the skull, after fixation in 10% formalin (4% formaldehyde solution), whether decalcified (5% aqueous nitric acid) or not, a very evident decrease of density was noted in the vertebrae and the cancellous bones of the skulls of the

Fig. 4.—*A*, frontal plane; section through olfactory bulbs (lobes) showing herniations therefrom completely filling the anterior confluence of vessels; × 22. Note also the texture of the frontal bones typical of vitamin A deficiency. Compare with Figure 13*A* and *B*.

B, frontal plane section; level of the fenestrae ovales and the columellae; × 174. Note the small herniation of the ventral surface of the cerebrum in the temporosphenoidal sinus.

vitamin-A-deficient chicks compared with those of the normal and the diet-restricted controls.

Evidences of greatly disproportionate growth of the central nervous system and the axial skeleton were found in the cranial cavity and the spinal canal. The venous sinuses of the head and the tributary veins were always found to be greatly engorged as compared with those of normal chicks and of restricted-diet controls. This engorgement revealed, as far as we could ascertain, a hitherto-undescribed expansion of the longitudinal sinus at its anterior end where it receives veins from the surface of the brain, the nose, and the orbits. This confluence of vessels lies over the tips of the cerebral hemispheres and the olfactory bulbs or lobes. Arachnoidal villi enter into it precisely as the arachnoidal villi of man and the rat [14] enter the veins and



Fig. 5.—Vitamin-A-deficient Chick 240; longitudinal section through distal end of femur; × 21.5. Note failure of tunneling. Compare with a similar section, Figure 8, from a restricted-diet control chick.

sinuses of the dura. In the A-deficient chicks this confluence was found always to contain herniations of the cerebrum and olfactory bulbs and in some instances was almost completely filled by the herniations (Figs. 3*A* and *B* and 4*A*). Caps of arachnoidal cells were found upon the smallest herniations. No systematic search was made for brain tissue herniating into other venous sinuses; incidental to the study of frontal plane sections of the cranium and its contents, minute herniations of the ventral surface of the cerebrum were found in the temporosphenoidal sinus (Fig. 4*B*).

Comparison of the contents of the cranial cavities (after fixation *in situ*) of vitamin A-deficient chicks, normal control chicks, and restricted-diet control chicks

revealed obvious compression effects in the vitamin-A-deficient chicks, in addition to the herniations seen in the anterior confluence of sinus and veins. Most conspicuous were the broadening of the hemispheres of the forebrain and the shortening of the longitudinal length of the brain as a whole. The angle formed by the pointed tips of the hemispheres was much wider and the olfactory bulbs were distorted and flattened (Fig. 2A). Viewed laterally (Fig. 2B) the optic lobes (tecta) were more prominent and, when separated from the hemispheres, showed molding by the

Fig. 6.—A higher-power view of a portion of the section shown in Figure 5; × 50. Note the deeper staining of the cartilage in the paths of advancing blood vessels and the great reduction of mature cells on the diaphyseal side. Compare with Figure 9, from a restricted-diet control chick, and with Figures 1 and 2 of the preceding paper,[3] showing corresponding sections made from a normal control chick.

posterior surfaces of the latter, indicated by a great increase in concavity of their anterior surfaces, which were bordered by sharp edges in contrast to the controls, where the anterior surfaces of the tecta were plane-like, with rounded borders. Alteration of the shape of the cerebellum viewed laterally was also very evident and included increase of its dorsoventral length, marked concavity of its posterior surface,

and molding into the medulla. Other evidences of compression of the cerebellum were slight extrusions into the fossae for the flocculi and elongation and flattening of the latter in the frontal plane. The fissures between the cerebellar folia were less evident than in the controls.

The medulla also (Fig. 2*A* and *B*), in all the A-deficient chicks, was compressed and molded into the foramen magnum. Its dorsal surface showed the imprint of the first cervical vertebra, and the upper cervical spinal cord also was similarly trans-

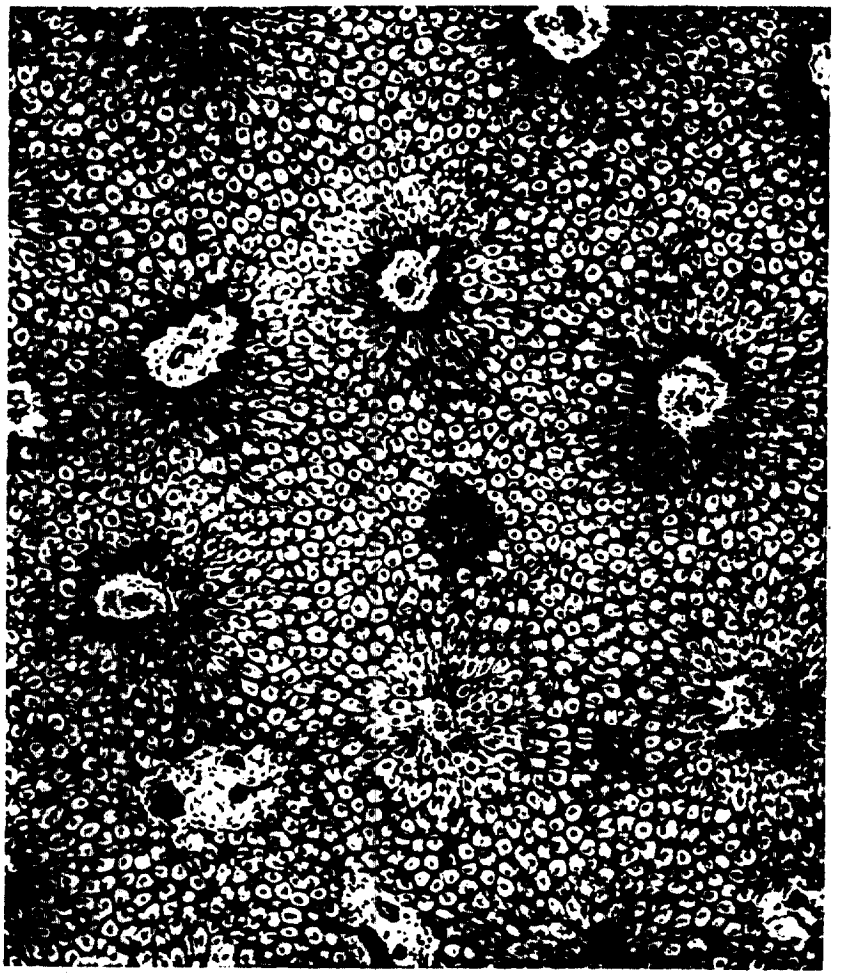

Fig. 7.—Cross section of the epiphyseal cartilage, distal end of femur, of vitamin-A-deficient Chick 385; × 120. Compare with the normal sections shown in Figure 4*A* and *B* of the preceding paper [8] and note wider spacing of the tunnels and decreased vascularity in the vitamin-A-deficient chick. The level of sectioning corresponds more nearly to that of *B* in Figure 4, from the normal.

versely molded by the yielding of the bone (shown in histological preparations) of the vertebrae to pressure. The ventral surface of the medulla showed small excrescences (herniations) at the origin of the vagus nerves. Viewed laterally, the A-deficient-chick medulla showed conspicuous enlargement of the pontal flexure (Fig. 2*B*).

Inspection of the ventral surface of the A-deficient brain showed equally prominent effects of compression and molding, such as the change in contour and dimensions of the forebrain, slight overriding of the medulla by the optic bulbs, and a displacement of the optic nerves and infundibulum in a ventral and caudad direction.

Evidences of compression of the spinal cord were found at all levels in the presence of some degree of transverse ribbing resulting from the yielding (resorption) of bone of vertebrae. In the lumbosacral spinal canal, where enlarged for housing of the glycogen body, a moderate degree of ribbing was present on the ventral surface of the spinal cord, permitted by the yielding (resorption) of bone of vertebral bodies, while a much more prominent ribbing both of spinal cord and glycogen body was present on the dorsal surface where these structures were molded

Fig. 8.—Longitudinal section of a restricted-diet control Chick, 474, whose weight graph is compared with those of vitamin-A-deficient chicks in Figure 1. Note the regularity of the tunnels, the clear demarcation of the epiphyseal cartilage zones, and the degree of ossification; × 22.5. Compare with Figure 5.

into the intervertebral transverse concavities normal to the roof of the synsacral enlargement of the spinal canal (Figs. 2*C* and 10*B*).

We could find no gross evidence of injury or distortion of the spinal nerve roots. It should be recalled that in the chick the spinal cord, unlike that of most mammals, extends the entire length of the spinal canal and that the nerve roots leave the spinal cord at right angles.[4]

4. Longitudinal serial sections were made of four lumbosacral spines of A-deficient chicks. Neither in these nor in transverse serial sections of lumbar vertebrae could we find evidence of mechanical pressure at foramens of exit. Degeneration of ganglion cells of root ganglions was found but could be explained as the result of central nervous system lesions caused by pressure.

MICROSCOPIC PATHOLOGY [5]

The Long Bones.—Comparison of normal and pathologic skeletal growth demands consideration of endochondral bone growth, appositional bone growth, compact bone formation, and remodeling sequences.

The most obvious effect of vitamin A deficiency upon bone growth in the chick [1a] (as in mammals), compared with the normal and restricted-diet controls, is upon

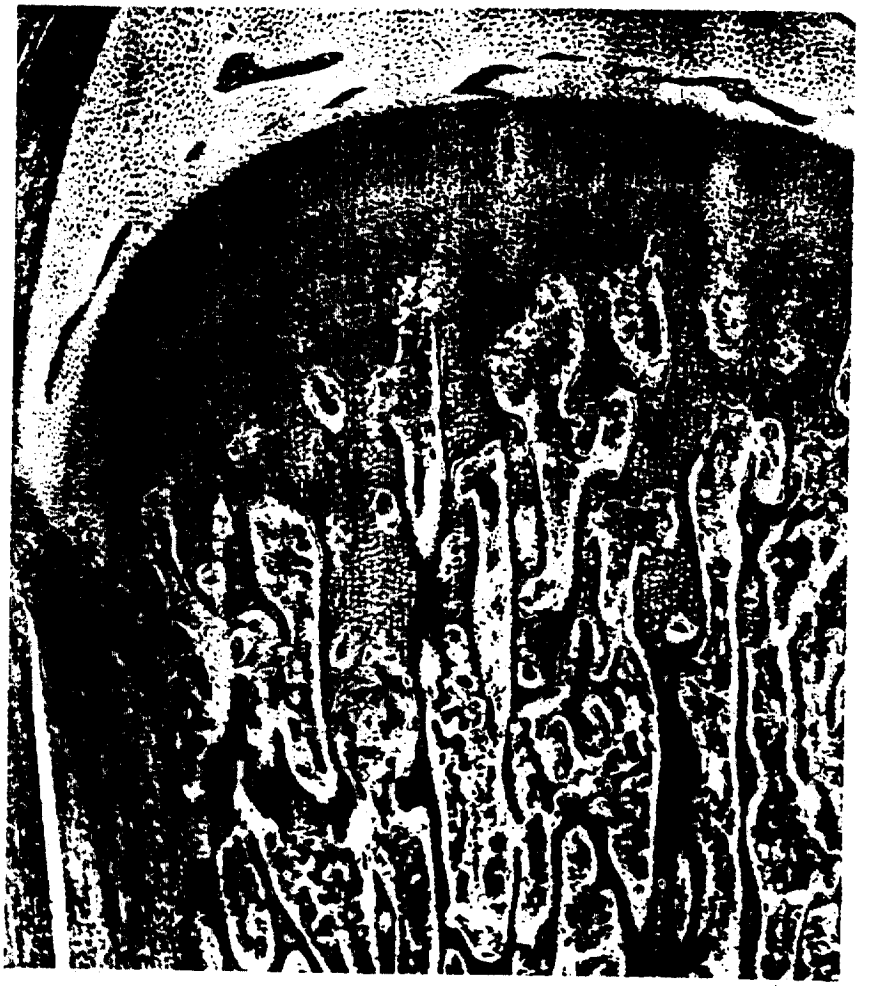

Fig. 9.—Higher-power view of a portion of the section shown in Figure 8; × 50. Compare with Figure 6. Note that in the restricted-diet control the degree of ossification is much greater than that shown in Figure 6, from the vitamin-A-deficient chick.

epiphyseal cartilage sequences and endochondral bone growth. The tunneling of the epiphyseal cartilage is irregular, often forked or branched, and less extensive (Fig. 5). The zone of proliferating cartilage cells is less clearly demarcated, and cells in mitosis are absent. The intercellular matrix gradually increases, and there

5. All histological descriptions were made from bones fixed in 10% formalin (4% formaldehyde solution), embedded in celloidin and stained with hematoxylin and eosin.

is formed a broad zone of moderately enlarged cells in noncalcified matrix. Cells of mature size surrounded by calcified matrix constitute a narrow and irregular zone in the diaphyseal side where tunneling is present (Fig. 6). A longitudinal streaking of the epiphyseal cartilage, not apparent in normal or restricted-diet controls, is present in the A-deficient chicks and is produced by alternate zones of

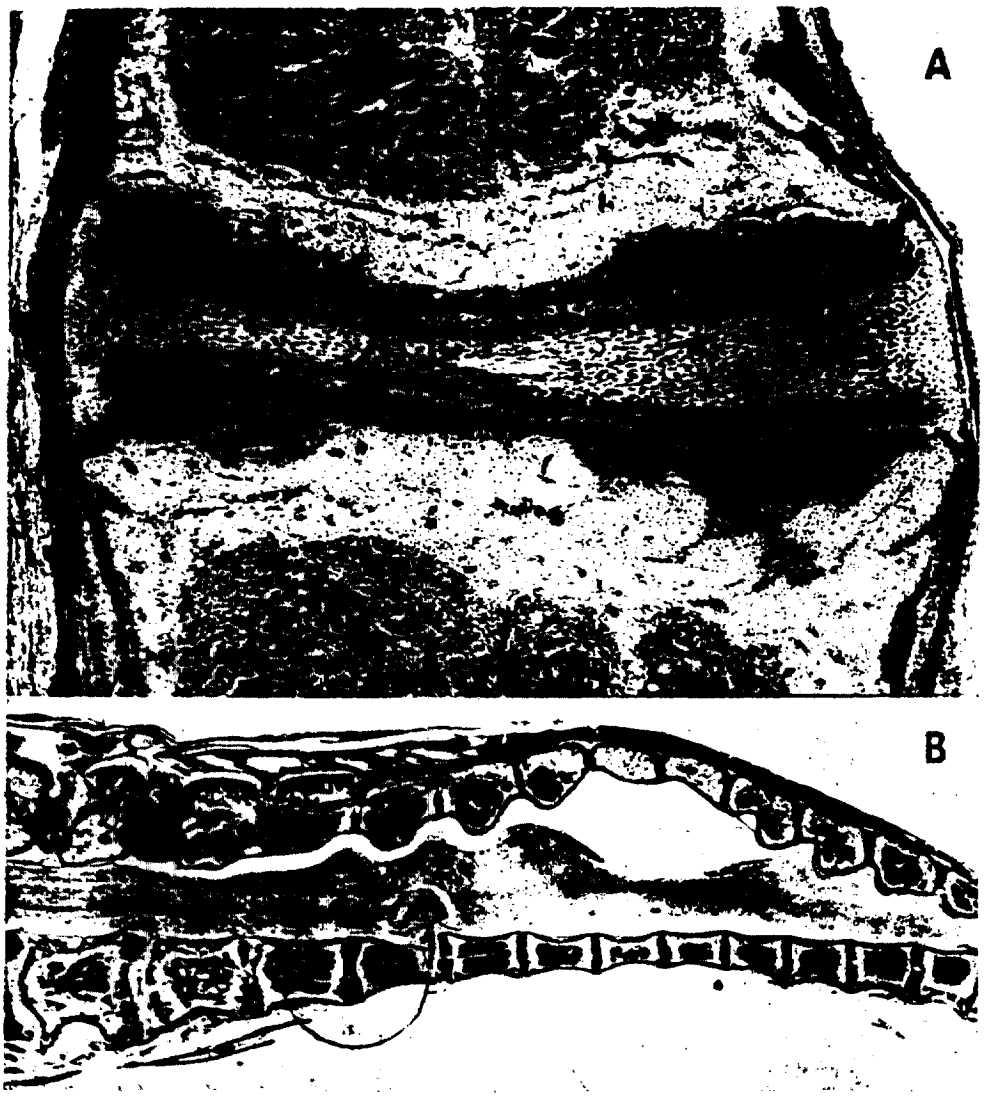

Fig. 10.—Sections from vitamin-A-deficient Chick 214: *A*, section of the cartilage between the first and second lumbosacral vertebrae; × 56.5. See ring in *B*. Note complete absence of endochondral bone growth activities, absence of trabecular bone, and thinness of cortical bone. Compare with Figure 11*A*.

B, longitudinal section of the synsacrum of vitamin-A-deficient Chick 214. Note the molding of the spinal cord and glycogen body described in the text. At the caudal end of the second lumbosacral vertebra the break with extrusion of nerve tissue is an artefact. Compare with Figure 11*B*.

maturing and nonmatured cells. Because these zones correspond in size with the dimensions of the tunnels in normal growth, it is our conviction that the retardation produced by the deficiency reveals evidence that the determining factor in the pattern of tunneling resides in the epiphyseal cartilage.

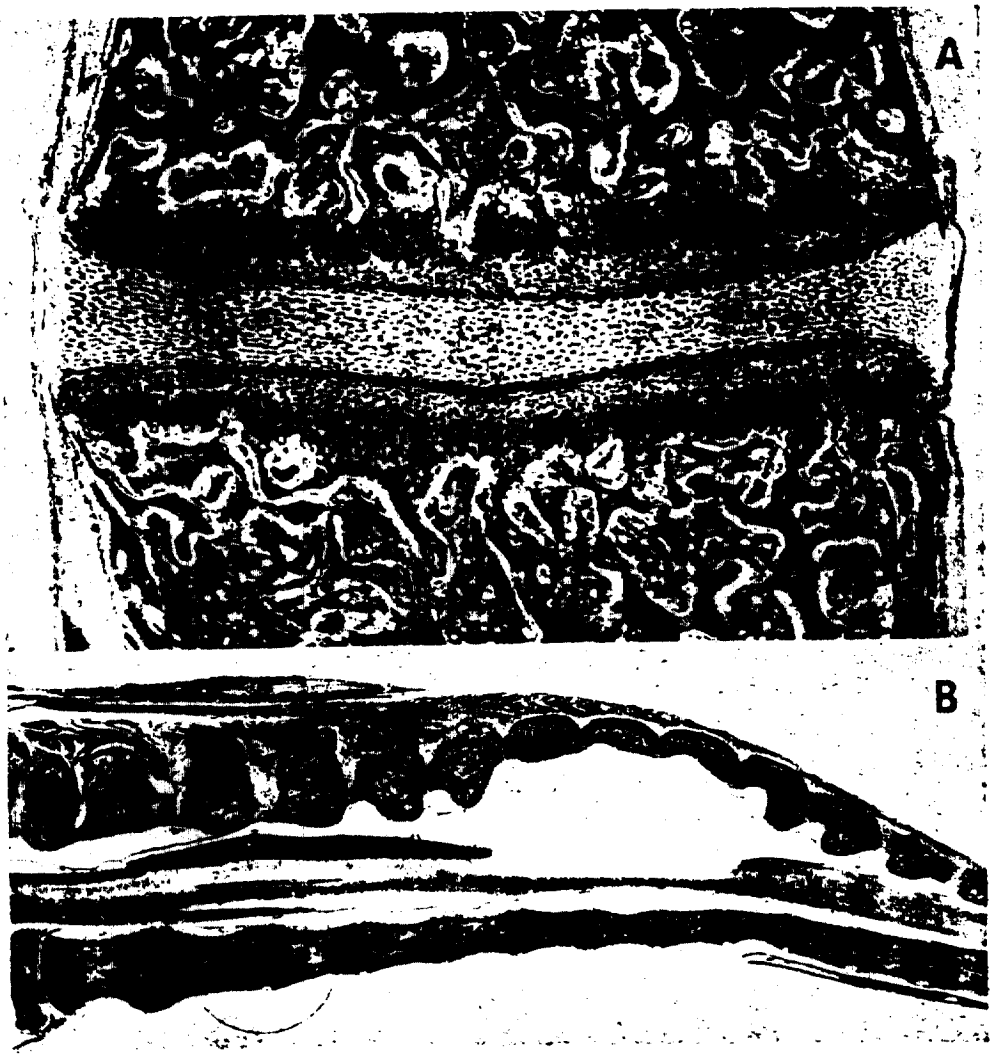

Fig. 11.—Sections from a normal control chick—Chick 431 of the preceding paper.[3] *A*, section of the cartilage between the first and second lumbosacral vertebrae; 56.5. See ring in *B*. Note the endochondral bone growth, abundant trabecular bone, and the cortical bone. Compare with Figure 10*A*.

B, longitudinal section of the synsacrum of Chick 431 (normal control); × 5. Compare with Figure 10*B*.

Detailed description of endochondral bone growth in the deficient chicks would be largely repetitious of that of normal chicks.[3] The changes are those of retarded multiplication, growth, and maturation of cartilage cells, delayed calcification of

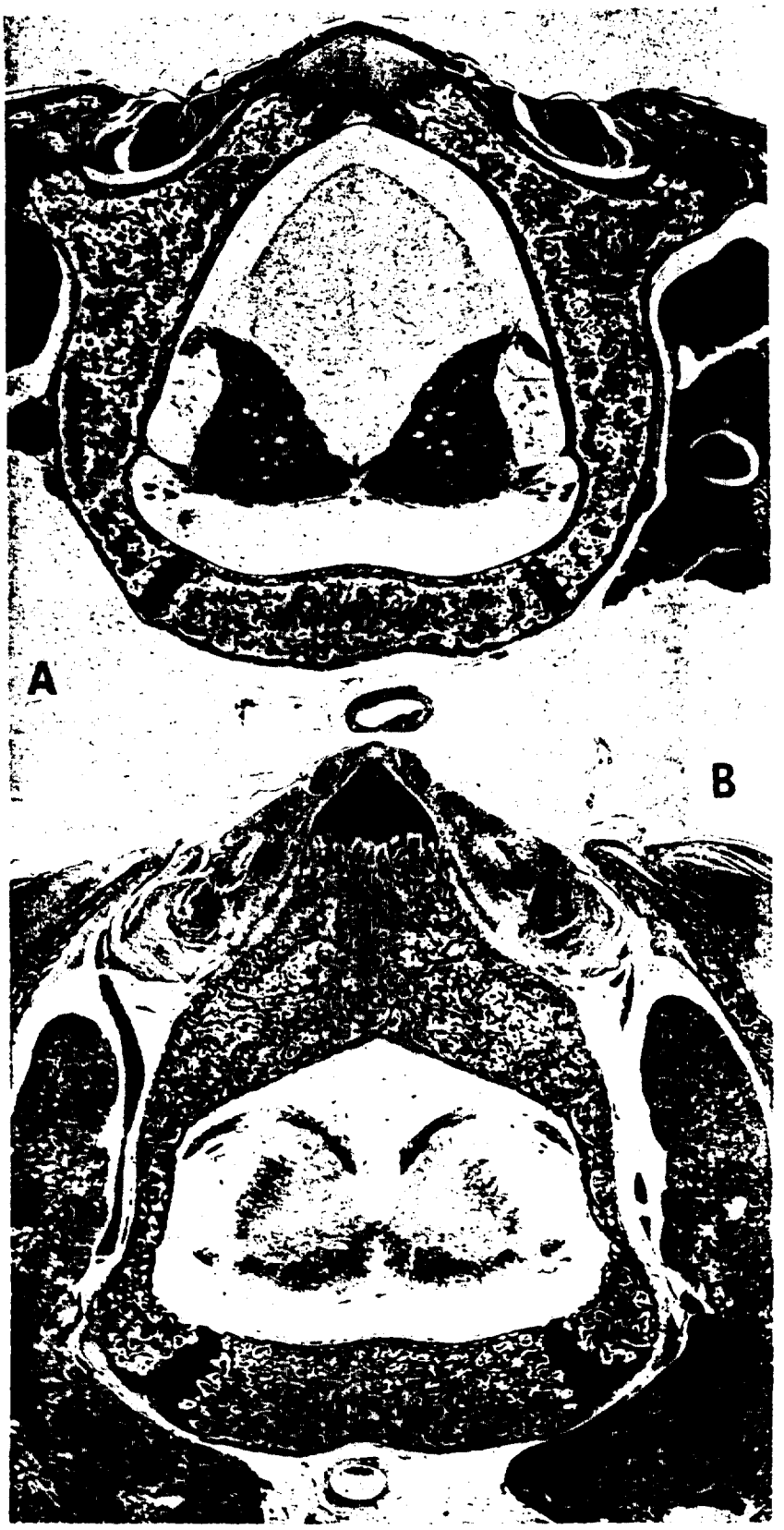

Fig. 12.—*A*, cross section of a lumbosacral vertebrae through the glycogen body of vitamin-A-deficient Chick 473; × 12.5. Note the texture of the bone.

B, cross section of seventh thoracic vertebra of a restricted-diet control chick; × 12.5. Compare *A* and *B*.

Fig. 13.—Frontal planes. Cross sections through the skull at the level of the olfactory bulbs (lobes) showing the anterior confluence of vessels. *A*, restricted-diet control, Chick 474[illegible] (See graph, Fig. 1.) Note the structure of the frontal bones and compare with the same [illegible] in vitamin-A-deficient chick, Figure 4*A*, and the normal, Figure 13*B*.

B, similar section from a normal chick, 430, of the preceding paper.[3] Compare with Figures 4 and 13*A*.

cartilage matrix, and less evidence of chondrolysis in advance of and lateral to entering blood vessels (Figs. 6 and 7). These retarded sequences account for the less extensive tunneling of the epiphyseal cartilage.

Appositional bone growth is retarded earlier than in mammals, even in the chicks which were force-fed or killed before inanition became dominant. In all the deficient chicks, osteoblasts, periosteal and endosteal, were fewer and individually smaller than in restricted-diet controls. Much less cancellous bone was present in the metaphyseal region, and the adjacent cortical bone was thinner and less dense than in either normal chicks or restricted-diet controls (Figs. 8 and 9). In all the A-deficient bones, remodeling sequences had ceased, as shown by the great scarcity of osteoclasts.

Vertebrae and Bones of the Skull.—Longitudinal and cross sections of vertebrae showed, in all regions of endochondral ossification, retardation or complete inactivity of growth. Retardation and suppression of bone formation per se was more striking than in the long bones, so that the bodies of the vertebrae were very deficient in cancellous bone, and the cortical bone was thin and wholly devoid of compact bone (Figs. 10, 11, and 12*A* and *B*).

In frontal plane sections of the skull the findings were similar in regard to all aspects of bone growth (Figs. 4*A* and 13*A* and *B*). Sections with the brain *in situ* showed microscopic herniations of the brain into venous sinuses (Fig. 4*A* and *B*) in addition to the grossly visible herniations into the confluence of veins and sinus on the dorsal surface of the anterior tips of cerebral hemispheres. Tufts of arachnoidal cells could occasionally be found at the apices of herniations proving without question that the herniations were related to the arachnoidal villi present in sections of the same regions made from normal and restricted-diet control chicks.

COMMENT

In the account we have given, of the effects of vitamin A deficiency upon the growing skeleton of the chick, we have purposely omitted many histological minutiae seen in normal and deficient chicks not relevant to the comparison of essentials of skeletal growth. The retardation of all sequences of bone growth and especially of endochondral bone growth when examined with consideration of weight graphs and onset of paralyses (Fig. 1) satisfactorily proves that in chicks as in mammals there occurs a disproportionate growth of the central nervous system and its bony investment. Gross and microscopic examinations have yielded objective evidence of compression of the brain and spinal cord as a result of the disproportionate growth. In the cranial cavity the most apparent effects—the brain herniating into venous sinuses, the cerebellum distorted, and the medulla dislocated caudad into the foramen magnum—are strikingly similar to the consequences of the overcrowding of the human cranial cavity which results from the growth of intracranial tumors.[6]

The effect of the restricted diet upon skeletal growth can best be described as a balanced retardation of all growth sequences. The bones are smaller, but bone formation and bone resorption in remodeling maintain normal relations to each

6. Wolbach, S. B.: Multiple Hernias of the Cerebrum and Cerebellum Due to Intracranial Pressure. J. M. Res. **19**:153, 1908.

other. Epiphyseal cartilage cell growth and maturation are slowed down, but the zones of proliferation, growth, and maturation are well demarcated from one another and preserve essentially normal relationships. Appositional bone growth continues, conforming to endochondral bone growth, as does compact bone formation. The results are that the contours of all bones are normal and that the bones are sturdy structures in which there are normal relationships in configuration and in volume of metaphysis, cancellous bone, and cortical bone to one another (Figs. 8, 9, 12*B* and 13*A*).

Our findings are totally in variance with those of Adamstone,[7] who found no gross lesions of the central nervous system and stated that "while the skeletal structures of A-deficient chicks grow more slowly than normal, their brains are also much smaller. . . ."

Fletcher and Rigdon,[20] Rigdon, Rude, and Bieri,[20] and Rigdon[20] in their studies of vitamin A deficiency in young ducks could find no evidence of effects caused by vitamin A deficiency upon skeletal growth adequate to explain the neurologic consequences. Fletcher and Rigdon[20] and Rigdon[20] did give some thought to skeletal growth and recorded the bizarre finding of cancellous bone with hematopoietic cells in the substance of the spinal cord in ducks maintained on a vitamin-A-deficient diet for 10 to 15 days. The photomicrographs submitted to document this phenomenon in both papers are more convincing of artefact than of osseous metaplasia in the central nervous system. They did consider mechanical compression of the spinal cord. Rigdon, Rude, and Bieri[20] failed in their studies "to demonstrate in the skeleton of the duck either pathologic or roentgenographic changes that might be attributed to vitamin A deficiency."

It is impossible for us to appraise these three papers upon vitamin-A-deficient ducks because of the great differences in method of study employed by their authors and by us. It seems to us incredible that there should be greater differences between two avian species than between one avian species and the several mammalian species we have studied.[8] As brought out by Lubosch,[9] the patterns of bone growth of all birds are similar and have greater resemblance to those of cold-blood vertebrates than to those of mammals.

SUMMARY AND CONCLUSIONS

The results of vitamin A deficiency upon skeletal growth in young chicks are, except for differences in the patterns of endochondral bone growth, similar to those in young mammals.

All sequences concerned in skeletal growth are retarded before growth as a whole (estimated by weight increase) is materially affected and before there is extensive replacement of glandular epitheliums by stratified keratinizing epithelium.

Linear growth of long bones and the vertebral column and the growth of the cranium become retarded and finally completely suppressed by failure of endochondral bone growth.

---

7. Adamstone, F. B.: Histologic Comparison of the Brains of Vitamin A Deficient and Vitamin E Deficient Chicks, Arch. Path. **43**:301, 1947.

8. Experiments upon ducklings fed vitamin-A-deficient diets have been begun by us and will be reported later.

9. Lubosch, W.: Die Bildung des Knochenmark beim Hühnchen und bei Säugetieren und das Wesen des endochondralen Ossifikation in historischen Betrachtung, Morphol. Jahrb. **53**:49, 1923-1924.

All epiphyseal cartilage cell sequences are retarded, namely, multiplication, growth, and maturation. Concurrently and in consequence there results retardation of tunneling and of ossification. In vertebrae and skull, complete suppression of endochondral growth may occur.

In contrast to mammalian bone growth, appositional bone formation ceases early, so that localized appositional bone growth concerned in the formation of some normal bony contours is not found disproportionate to endochondral bone growth.

The effect upon epiphyseal cartilage is distinctive and specific and is a primary result of vitamin A deficiency in the sense that it is not secondary to inanition.

The neurologic disturbances of vitamin A deficiency in the chick are the result wholly of compression of the central nervous system produced by retardation of growth of vertebrae and bones of the cranium.

The histological preparations were made by Mr. John J. Burke, departmental technician. The photomicrographs were made by Mr. John Carabitses, of the Department of Pathology, The Children's Hospital.

Wolbach & Hegsted-'52
Bib. No. 9960

Arch. Pathol. 54(1), 1952.

HYPERVITAMINOSIS A AND THE SKELETON OF GROWING CHICKS

S. BURT WOLBACH, M.D.
AND
D. MARK HEGSTED, Ph.D.
BOSTON

THE PURPOSE of this report is to record the effects of hypervitaminosis A upon the growth of the bones in young chicks.

The effects of the administration of excessive amounts of vitamin A upon the growth of bone have been described for several mammalian species: rat, mouse, guinea pig[1] and dog.[2] These effects[1a] are the acceleration of all processes of bone growth—epiphyseal cartilage sequences concerned in endochondral bone growth, remodeling sequences involving resorption of bone and appositional bone formation, osteogenesis per se, and compact bone formation. The rate and the degree of the acceleration were found to bear no relation to linear growth of long bones but were directly related to the amounts of vitamin A administered.[1a,b]

Although only a few chicks (four) were studied histologically and only a few bones from each—the bones of the knee joints (femur, fibula and tibiotarsus), the hock joints (tibiotarsus and tarsometatarsus), vertebrae, and the skull, including those of the calvarium, the sphenoid, occipital and temporal bones—the findings were so consistent and so decisive that further processing of additional chicks seemed unnecessary.

Recently Rigdon, Rude, and Bieri[3] failed to find any effect of hypervitaminosis A upon growth of bones in young ducks.

EXPERIMENTAL STUDY

The diet, plus 1% cod liver oil, given from the first or second day after hatching, was that described in our account of endochondral bone growth in the chick.[4]

This study was aided by research grants from The Nutrition Foundation, the Williams-Waterman Fund for the Combat of Dietary Disease, and Swift and Company, Chicago.

From the Division of Nutritional Research, Division of Laboratories and Research of The Children's Hospital; the Department of Nutrition, Harvard School of Public Health, and the Department of Biological Chemistry, Harvard Medical School, Boston.

1. (a) Wolbach, S. B.: Vitamin A Deficiency and Excess in Relation to Skeletal Growth, Proc. Inst. Med. Chicago **16**:1[illegible], 1946. (b) J. Bone & Joint Surg. **29**:171, 1947. (c) Van Metre, T. E., Jr.: The Influence of Hypervitaminosis A on Bone Growth, Bull. Johns Hopkins Hosp. **81**:[illegible], 1947. (d) Wolbach, S. B., and Maddock, C. L.: Hypervitaminosis A: An Adjunct to Present Methods of Vitamin A Identification, Proc. Soc. Exper. Biol. & Med. **77**:825, 1951.

2. Maddock, C. L.; Wolbach, S. B., and Maddock, S.: Hypervitaminosis A in the Dog, J. Nutrition **39**:117, 1949.

3. Rigdon, R. H., Rude, J. C., and Bieri, J. G.: Effect of Hypervitaminosis A and Hypovitaminosis A on the Skeleton of a Duck, A. M. A. Arch. Path. **52**:299, 1951.

4. Wolbach, S. B., and Hegsted, D. M.: Endochondral Bone Growth in the Chick, A. M. A. Arch. Path., this issue, p. 1.

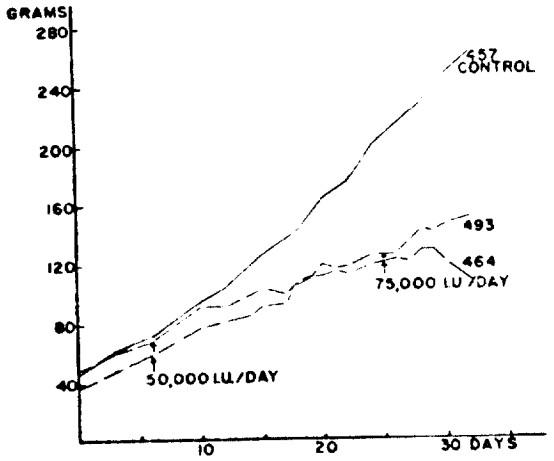

Fig. 1.—Graph to illustrate the growth of hypervitaminosis A chicks, No. 464 and No. 493, in comparison with a normal control chick, 457.

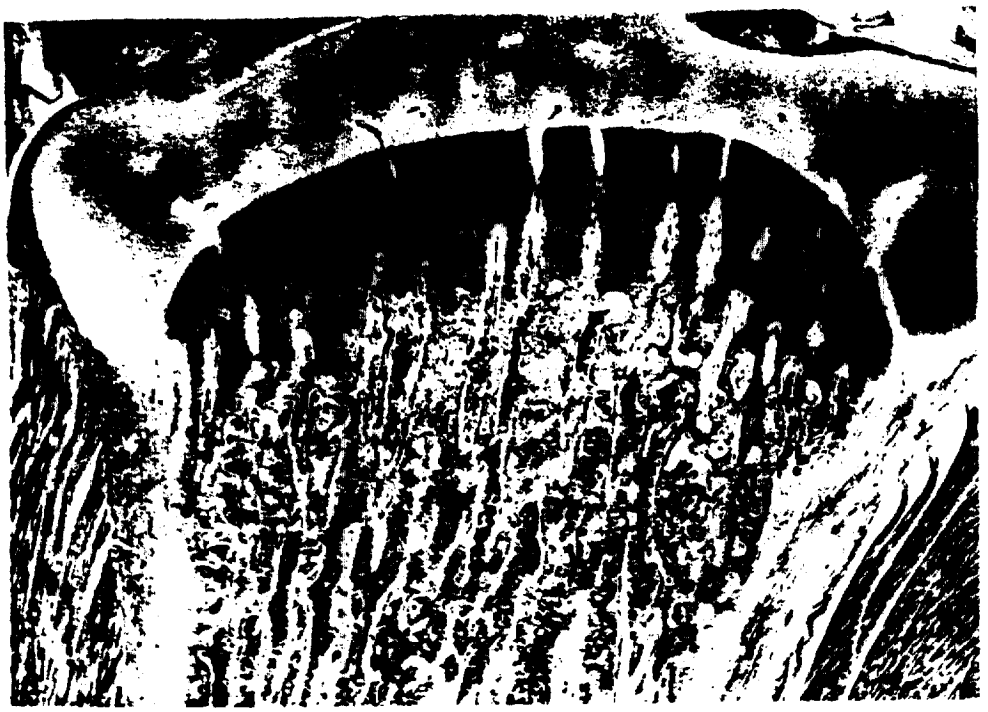

Fig. 2.—Distal end of femur of hypervitaminosis A chick 493, killed at 32 days of age. × 21.6. (See graph, Fig. 1.) Compare with the normal in Figure 1 of a preceding paper on endochondral bone growth in the chick.[1]

Beginning on the sixth or seventh day after hatching, when the weights of the chicks were 55 to 75 gm., 50,000 I. U. vitamin A were given daily by medicine dropper so that the dosages ranged from approximately 600 I. U./gm. to 900 I. U./gm. daily. After 20 days the dosage of two chicks, each weighing 125 gm., was increased to 75,000 I. U. daily (600 I. U./gm.). One chick (initial weight, 50 gm.) was killed in poor condition after 11 days on the 50,000 I. U. regimen.

Fig. 3.—Higher-power view of a portion of Figure 2; × 43.75. Compare with the corresponding photomicrograph of the normal, illustrated in Figure 2 of a preceding paper.[4] Note the diminution of the width of all layers of the epiphyseal cartilage, the more extensive tunneling, the greater consumption of the tunnel walls, and the extent and volume of ossification.

The clinical signs of the hypervitaminosis A were retardation of weight gain with final weight loss (Fig. 1). Swelling and crusting of the eyelids and inflammatory lesions of the nares, the mouth, and adjacent skin, and of the skin of the feet were other signs.

The gross postmortem findings were those of emaciation. No fractures were demonstrated. We neglected to investigate the deformed feet of two chicks, which could have been the result of fracture or of luxation of phalanges.

MICROSCOPIC PATHOLOGY[5]

The Long Bones.—Epiphyseal Cartilage: There is a narrowing of all zones of the epiphyseal cartilages. The zone of proliferation is less clearly defined than in the normal, because there is earlier diaphysealward increase in matrix than in normal control chicks. Mitotic figures are about as numerous as in normal controls, so that the narrowing of this zone is evidently the result of more rapid growth of

Fig. 4.—Higher-power detail of Figure 2 to illustrate the lateral excavation of the wall of a tunnel after deposition of bone; × 300. Note the multinucleated giant cells and the clearing of surrounding cartilage cells, apparently by chondrolysis. On the extreme left the ossified border of the adjacent tunnel is shown. This region is shown in Figure 2 just to the left of the midline. Compare with Figure 7 of the paper on enochondral bone growth in the chick.[4]

the cells. The zone of growth is narrowed because it rapidly merges into the zone of maturation. The tunneling of the cartilage, which is evenly placed, extends the full width of the zone of matured cells and thus approaches much closer to the distal

5. All descriptions were made from formalin-fixed bones, embedded in celloidin and stained with hematoxylin and eosin.

margin of the epiphyseal cartilage than in the normal. Lateral excavations of the tunnels are present throughout the zones of matured cells (Figs. 2, 3, and 4).

Cross sections of the epiphyseal cartilage made through the advancing ends of the tunnels show an increase in the size of the blood vessels, a great increase in the diameters of the tunnels, and the early establishment of communications between tunnels as compared with corresponding sections of normal control chicks. Other features seen in cross section at this level are somewhat wider zones of chondrolysis and widespread maturation of cartilage cells as shown by disappearance of cytoplasm, shrunken, deeply stained nuclei, and deeply stained capsules (Fig. 5*A* and *B*). Osteoid deposits on the walls of the tunnels at corresponding levels are much more abundant than in normal controls (Figs. 3 and 4). Multinucleated giant cells—chondroclasts and osteoclasts—engaged in their respective activities are much more numerous than in the normal controls. Complete consumption of the cartilage by the concurrent processes of resorption and osteogenesis, and the formation of cancellous bone, rapidly succeed the zone of maturation. The result is that cancellous bone and marrow cells are found much closer to the epiphyseal end than in normal specimens.[8]

The rapid appearance of marrow cells of all types in advancing ends of tunnels may be regarded as one of the accelerations of hypervitaminosis A.

Remodeling Sequences: That remodeling sequences are more active than in normal bones is evidenced by an increase of osteoclasts in relation to both trabecular bone and cortical bone adjacent to the epiphyseal ends.

Periosteal Bone Formation: The deep layer of the periosteum is less cellular than that of normal controls. More and denser cortical bone has been deposited than in the normal chicks at corresponding age periods, and the appearances suggest those of bone approaching completion of growth.

Cortical Bone: In chicks of the same early age, the cortical bone of the hypervitaminosis-A chick is exceedingly dense (Fig. 6*A* and *B*). In all regions we have studied, compact bone rapidly replaces cancellous bone. Haversian systems mature rapidly, and in the short period of our experiments the cortical bone acquired the density of adult avian bone.

The Axial Skeleton.—In vertebrae and the skull the outstanding feature is the density of the bone, which can be attributed to the compact bone replacing cancellous bone. This replacement we have found in the calvarium and in bones of the base of the skull, the bony capsule of the internal ear, the ossicle (columella), and the bodies and processes of the vertebrae (Fig. 7*A* and *B*).

Endochondral ossification in the bones of the base of the skull and in vertebrae is characterized by the same features described in our account of the epiphyseal cartilage of long bones, though less evident because of the slower rate of growth normal to skull and vertebrae.

---

8. The epiphyseal cartilage of undernourished chicks used for controls to vitamin A deficiency studies at low magnification appears a superficial resemblance to that of hypervitaminosis A chicks because of the narrowing of the epiphyseal cartilage as a whole. In the undernourished chicks the demarcation between proliferative and growth zones is sharply defined. The cells of the growth zone show little matrix, while the zone of matured cells is largely consumed by the sequences of osteogenesis. Mitotic figures could not be found in the zone of proliferation. (See Figs. 8 and 9 of the preceding paper, A. M. A. Arch. Path., this issue, p. 13.)

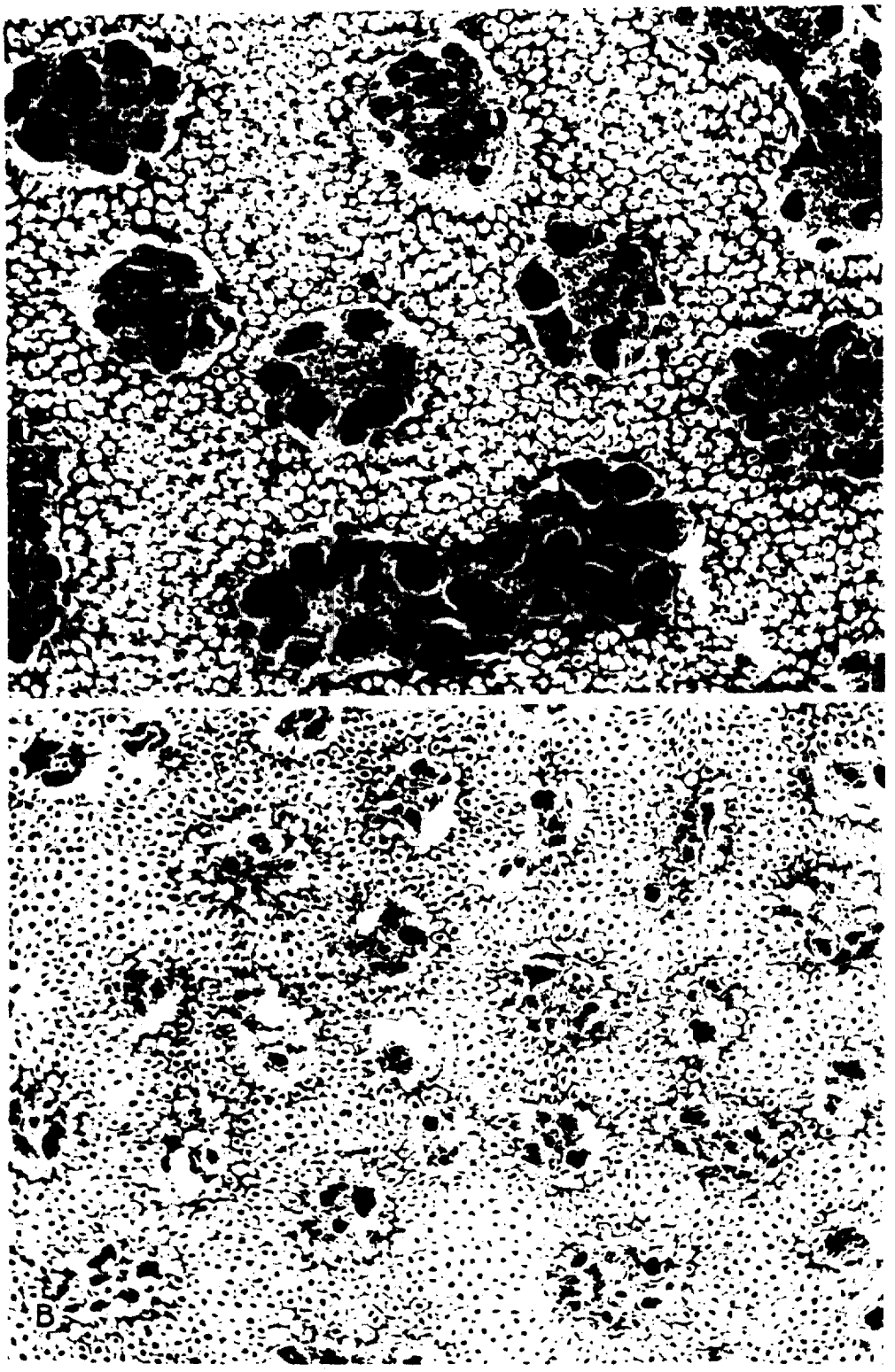

Fig. 5—*A*, cross section of advanced cartilage tunnels in hypervitaminosis *A*; distal femoral epiphysis of a 26-day old chick; × 120. Compare with the normal size in *B*.

B, corresponding level of tunneling in a normal chick 22 days old; distal femoral epiphysis of Chick 414; × 120.

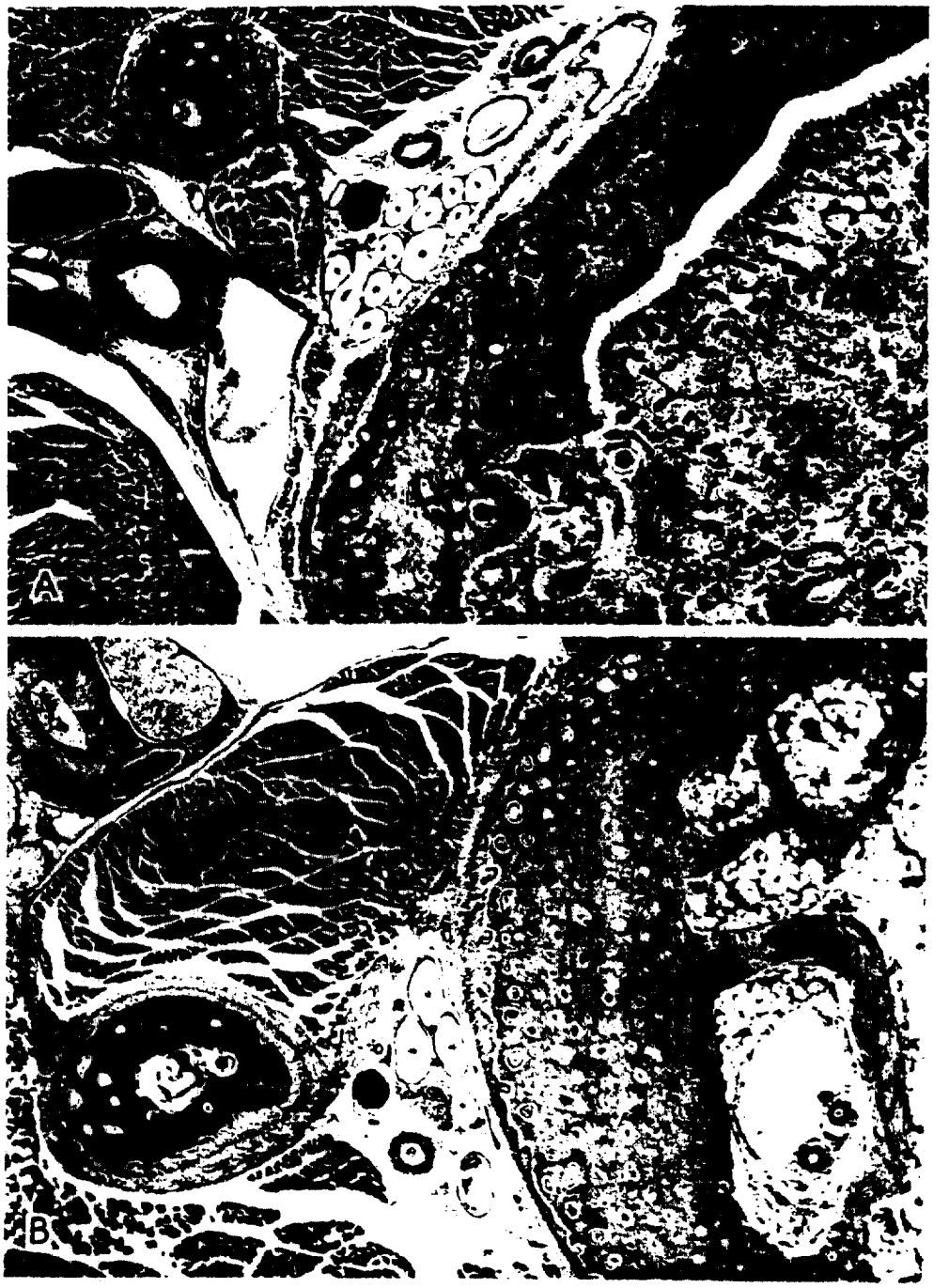

Fig. 6.—*A*, cross section of the tibiotarsus and fibula of hypervitaminosis-A Chick 464. (See graph, Fig. 1.) Note the density of the cortical bone. Compare with *B*, from a normal age-control chick which weighed 212.5 gm.

B, cross section of the tibiotarsus and fibula of a normal age-control chick made at a level corresponding to that of *A*. Note the texture of the cortical bone and the continued activity of periosteal bone formation.

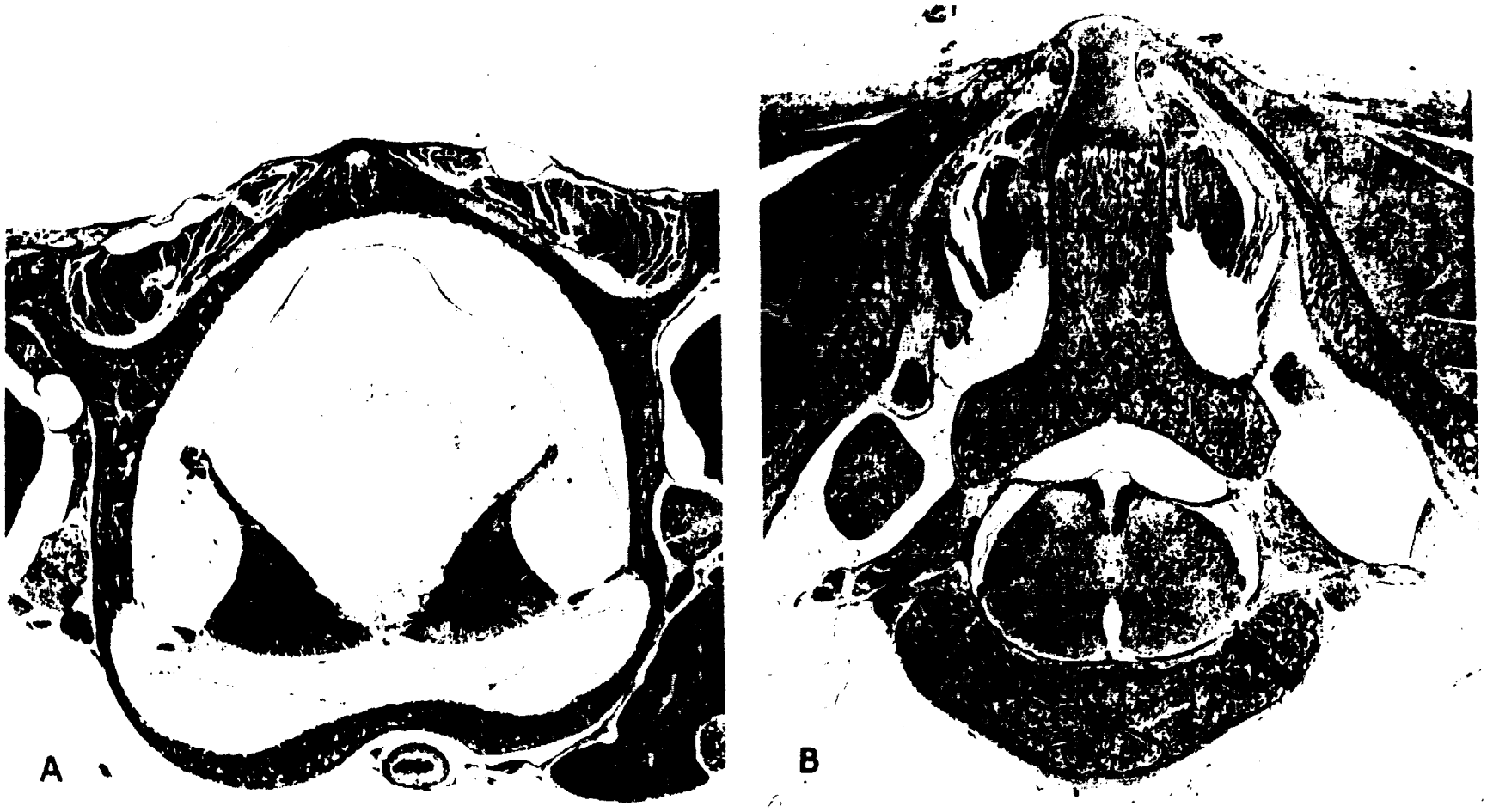

Fig. 7.—*A*, cross section of the spinal canal—synsacrum—through the sixth lumbosacral vertebra; × 12.5. (See Fig. 11*B* of the preceding paper, "Vitamin A Deficiency in the Chick" [A. M. A. Arch. Path., this issue, p. 13]). Note the density of the bone. Compare with *B*.

B, cross section of the seventh thoracic vertebra of normal Chick 430,[3] 22 days old; × 12.5. Note texture of the bone.

COMMENT

The effects of hypervitaminosis A on the skeletal growth of young chicks are like those produced in young mammals. In general, all those sequences retarded in vitamin A deficiency are accelerated, namely, epiphyseal cartilage sequences preliminary to bone replacement, endochondral bone growth, remodeling processes, and compact-bone formation. Acceleration of the last is outstandingly more prominent than in rats and guinea pigs.

The pattern of bone growth is not changed, but each feature of the composite is caused to proceed at a rate much more rapid than is normal. No other vitamin given in excess of physiologic needs has a similar effect upon the growth sequences of any structure.

Recently we have shown in rats [7] that the skeletal responses to hypervitaminosis A are not mediated through the anterior pituitary and probably not through the adrenal cortex.

Because the hypervitaminosis-A bone effects, like the patterned growth of fetal bone, are unrelated to concurrent functioning of the skeleton and because postnatal bone growth is plainly a continuation of fetal growth, we cannot avoid the inference that vitamin A has properties like those of inductor or evocator agents.

CONCLUSIONS

The skeletal responses to hypervitaminosis A in young chicks are precisely of the same nature as those in mammals, though differences in the pattern of endochondral bone growth must be considered.

As in mammals, hypervitaminosis A in growing chicks accelerates all histological sequences concerned in bone growth in conformity with the normal growth patterns.

Mr. John J. Burke, departmental technician, made the histological preparations. Mr. John Carabitses, of the Department of Pathology, The Children's Hospital, made the photomicrographs.

7. Wolbach, S. B., and Madbeck, C. L.: Vitamin-A Acceleration of Bone Growth Sequences in Hypophysectomized Rats, A. M. A. Arch. Path. **53**:273, 1952.

Wolbach-'52
Bib. No. 9961

Arch. Pathol. 54:548-563. 1952.

VITAMIN A DEFICIENCY IN THE DUCK

Skeletal Growth and the Central Nervous System

S. BURT WOLBACH, M.D.
AND
D. MARK HEGSTED, Ph.D.
BOSTON

THE NECESSITY of vitamin A for the growth of the skeleton of young ducks was questioned by Fletcher and Rigdon [1] and later categorically denied by Rigdon, Rude, and Bieri [2] and by Rigdon.[3] In each of these three papers a direct and primary effect of vitamin A deficiency upon the nervous system was asserted. The conclusions of these authors—that the duck responds differently to vitamin A deficiency than do the chick [4] and numerous species of mammals [5]—have twofold importance: 1. If they are verifiable, the domestic duck becomes a bird of great interest. 2. If they are not verifiable and not discredited, they create a source of confusion to nutritionists, anatomists, and pathologists.[6]

This study was undertaken for the purpose of ascertaining the effect of a vitamin-A-deficient diet upon endochondral bone growth of young ducks, with particular reference to the axial skeleton and possible results involving the central nervous system.

It is not our intention to describe in detail all the departures from the normal that we found in the vitamin-A-deficient ducks. We will describe our findings.

This study was aided by research grants from the Nutrition Foundation, the Williams-Waterman Fund for the Combat of Dietary Disease, and Swift and Company.

From the Division of Nutritional Research, Division of Laboratories and Research, the Children's Hospital; the Department of Nutrition, Harvard School of Public Health, and the Department of Biological Chemistry, Harvard Medical School.

1. Fletcher, D. E., and Rigdon, R. H.: Neurologic Manifestations Associated with Vitamin A Deficiency in Young Ducks: Clinical and Pathologic Study, Arch. Neurol. & Psychiat. **61**:199, 1949.

2. Rigdon, R. H.; Rude, J. C., and Bieri, J. G.: Effect of Hypervitaminosis A and Hypovitaminosis A on the Skeleton of a Duck, A. M. A. Arch. Path. **52**:299, 1951.

3. Rigdon, R. H.: Pathologic Lesions in the Nervous System of the Duck Fed a Ration Deficient in Vitamin A, A. M. A. Arch. Path. **53**:239, 1952.

4. Wolbach, S. B., and Hegsted, D. M.: Vitamin A Deficiency in the Chick: Skeletal Growth and the Central Nervous System, A. M. A. Arch. Path. **54**:13, 1952.

5. (a) Wolbach, S. B.: Pathologic Changes Resulting from Vitamin Deficiency, J. A. M. A. **108**:7, 1937. (b) Follis, R. H., Jr.: The Pathology of Nutritional Disease, Springfield, Ill., Charles C Thomas, Publisher, 1948. (c) Wolbach, S. B.: Vitamin A Deficiency and Excess in Relation to Skeletal Growth, Proc. Inst. Med. Chicago **16**:116, 1946; J. Bone & Joint Surg. **29**:171, 1947.

6. Neurologic Manifestations Associated with Vitamin A Deficiency in Young Ducks editorial, Nutrition Abst. & Rev. **7**:188, 1949. Wolbach, S. B.: Letter to the Editor, ib. **7**:319, 1949.

documented with photographs and photomicrographs, which prove that vitamin A deficiency in young ducks results in prompt retardation of endochondral bone

TABLE 1.—*Vitamin-A-Deficient Diet for Duck Experiment*

	Gm./Kg.		Per Kg.
Glucose	523	Thiamine hydrochloride	4 mg.
Casein	180	Riboflavin	8 mg.
Gelatin	80	Pyridoxine hydrochloride	4 mg.
Celluflour*	30	Calcium pantothenate	25 mg.
Corn oil	70	Nicotinic acid	40 mg.
Salts IV†	50	Folic acid	1 mg.
$CaPHO_4$	10	Biotin	200 mcg.
Brewer's yeast	50	Menadione	100 mcg.
Cystine	2	Alpha tocopherol	50 mg.
Choline chloride	5	Vitamin D_3	1,000 I. U.

* Chicago Dietetic Supply Co., Chicago.
† Hegsted, D. M.; Mills, R. C.; Elvehjem, C. A., and Hart, E. B.: J. Biol. Chem. 138:459, 1941.

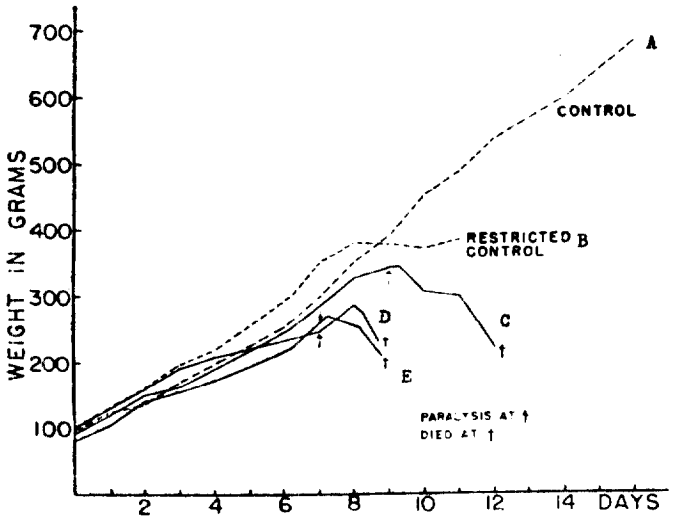

Fig. 1.—Weight graphs of three vitamin-A-deficient ducks, one normal control, and one duck fed a reduced amount of normal diet. The arrows indicate the day on which paralyses were noted and the cross the day of death. These ducks were selected because the photographs and photomicrographs were made from them. *A*, Normal Control Duck 4; *B*, Restricted-Diet Control Duck 2; *C*, Vitamin-A-Deficient Duck 5; *D*, Vitamin-A-Deficient Duck 4; *E*, Vitamin-A-Deficient Duck 2.

growth and therefore a disproportionate growth of the axial skeleton and central nervous system adequate to account wholly for all consequent neurologic manifestations.

EXPERIMENT

Six 3-day-old Pekin ducks were placed on a vitamin-A-deficient diet (Table 1). Five 3-day-old Pekin ducks were placed on the same diet plus an adequate amount of vitamin A acetate.

Pertinent data are shown in the tables. Important facts are that the vitamin-A-deficient ducks became paralyzed sooner than chicks[4] and that in three instances paralysis occurred before the duck had attained maximum weight (Fig. 1). Paralysis was noted first in the other three ducks on the day of maximum weight (Tables 2 and 3).

GROSS PATHOLOGY

All dissections were made after fixation in 10% formalin (formaldehyde 4%) solution of the eviscerated ducks and decalcification in 5% aqueous nitric acid. After decalcification and washing, the ducks were preserved in 10% formalin solution until dissected.

We found it advantageous to inspect the contents of the cranial cavity with dura intact. In the vitamin-A-deficient duck, the longitudinal sinus usually contained little blood, while the lateral sinuses and their tributaries were always engorged, including communicating veins in the parietal and occipital bones and veins of the cerebral hemispheres. In contrast to the chick, there is no anterior confluence of

TABLE 2.—*Vitamin-A-Deficient Ducks*

	Paralyses		Maximum Weight		Death	
No.	Day	Weight, Gm.	Day	Weight, Gm.	Day	Weight, Gm.
1	7	222	8	262	10	180
2	9	258	9	258	9	255
3	10	370	10	370	12	315
4	7	252	9	284	9	284
5	10	344	10	344	13	220
6	9	320	10	330	13	200

TABLE 3.—*Control Ducks, Weight in Grams*

	Food Limited After 5th Day		Food Unlimited		
Day	Duck 1	Duck 2	Duck 3	Duck 4	Duck 5
1	95	100	90	90	100
3	144	150	136	130	150
5	204	212	195	180	214
7	275	304	272	240	306
8	330	348	325	298	384
9	370	380	390	350	460
10	330	333	425	390	520
11	355	370	500	450	600
12	352	370	550	485	640
13	320	335	620	570	750

veins in the duck. In the latter, the veins from the orbits and nose enter separately into the longitudinal sinus and cross the tips of the cerebral hemispheres just posterior to the olfactory bulbs. In vitamin-A-deficient ducks, herniations of the brain could be seen projecting into the longitudinal sinus and into the veins from the orbit and nose (Fig. 2). If the dura was carefully reflected, the herniations remained unseparated from the brain (Fig. 3), a situation not always possible of achievement if the dura and bone are removed together.[7]

Other evidences of compression of the brain were like those found in vitamin-A-deficient chicks,[4] but most conspicuous in the vitamin-A-deficient ducks were dis-

7. In removal of the dura we found no extension between the cerebral lobes or between cerebellum and cerebrum and therefore no obvious falx cerebri or tentorium cerebelli. Both these structures, if they merit the names, are quite delicate and histologically, in sections made through skulls of normal and vitamin-A-deficient ducks, are continuous with the pia arachnoid.

tortion and lateral narrowing of the olfactory bulbs, grooving of the tips of the cerebral hemispheres where crossed by the veins from orbits and nose (Fig. 3), a considerable degree of lateral and posterior overriding of the tecta by the cerebral hemispheres, noticeable anterior molding of the cerebellum between the posterior lobes of the cerebrum, and marked flattening of the flocculi. On the ventral surfaces of the vitamin-A-deficient duck brains the findings were like those described for

Fig. 2.—Vitamin-A-Deficient Duck 3. Paralysis occurred on the 10th day of age, death occurred on the 12th day. The brain with dura intact; enlarged photograph. The arrows point to herniations of the brain which were verified histologically.

the vitamin-A-deficient chick.[4] Frontal-plane sections of three of the vitamin-A-deficient ducks showed in all some degree of herniation of the brain into the foramina of exit of the roots of the fifth nerve and of the eighth nerve.

Examination of the spinal cord in the synsacrum also showed compression effects precisely similar to those described for vitamin-A-deficient chicks (Fig. 4).

MICROSCOPIC PATHOLOGY

The Long Bones.—Endochondral bone growth was studied in the distal end of the femur and proximal end of the tibiotarsus as seen in longitudinal sections through the knee joints. Vitamin-A-Deficient Ducks 1, 2, 5, and 6 (Table 2) and Restricted-Diet Control Duck 2 and Normal Control Duck 4 (Table 3) were used. The controls were killed at 13 days of age.

Fig. 3.—Vitamin-A-Deficient Duck 1. Paralysis occurred on the seventh day and death on the ninth day. The brain with dura removed; enlarged photograph. Note the distortion of the olfactory bulbs, deep grooving of the tips of the cerebral hemispheres, and numerous herniations of the brain, which were carefully dislodged from the veins on stripping off of the dura. Note also the congestion of the veins of the pia. The arrows point to a few herniae cerebri.

We have found endochondral bone growth in normal young ducks to be precisely similar in all details to that in young chicks, which we have studied and recently described.[8]

8. Wolbach, S. B., and Hegsted, D. M.: Endochondral Bone Growth in the Chick, A. M. A. Arch. Path. 54:1, 1952.

In the vitamin-A-deficient young ducks, possibly because they were studied at an earlier age (9 to 13 days), the over-all appearance at the ends of the bones (distal part of the femur and proximal part of the tibiotarsus) was different from that of vitamin-A-deficient chicks,[5a] although resulting from the same retarded sequences of endochondral bone growth. The difference was visible upon splitting

Fig. 4.—*A*, Restricted-Diet Control Duck 2. Spinal cord exposed; glycogen body in situ; enlarged photograph. The arrow points to an artefact caused by a longitudinal cut of the dorsal column on the right caudad to the glycogen body. *B*, Vitamin-A-Deficient Duck 2. Paralysis and death occurred on the ninth day of age. Glycogen body in situ; enlarged photograph. Note the deep transverse grooving of the spinal cord, cephalad and caudad to the glycogen body, and compression of the latter by the dorsal columns of the spinal cord.

of the decalcified bones preparatory to embedding and consisted of an apparently much deeper metaphyseal zone as compared with the vitamin-A-deficient chick and the normal and restricted-diet duck controls (Figs. 5 and 6).

Fig. 5.—*A*, Vitamin-A-Deficient Duck 5. Paralysis occurred on the 10th day and death on the 13th day of age. Distal end of the femur; × 6.6. Note the absence of a clearly marked boundary between proliferative and growth zones and the long narrow tunnels for blood vessels without evidences of removal of cartilage walls. On the diaphyseal side widening of tunnels and lateral extensions indicate the narrow zone of retarded endochondral bone growth. *B*, Normal Control Duck 4; unrestricted as to food; killed at 13 days of age. Distal end of the femur; × 6.6. Note the sharp delineation of zones of proliferation and growth. Note also that endochondral bone growth has extended epiphyseal ward, a condition comparable to that of the normal 18-day-old chick illustrated by Figure 1 of a previous paper.[2]

Much of this zone of cartilage, while penetrated by longitudinally directed blood vessels, was not undergoing replacement by bone. The blood vessels for much of their length epiphysealward were not surrounded by fully matured cartilage cells and chondroclasts, and evidences of chondrolysis were absent. In this region these blood vessels, unaccompanied by sequences preparatory to replacement by bone,

Fig. 6.—Restricted-Diet Control Duck 2, killed at 13 days of age. Distal end of the femur; ×7.3. Note the sharp delineation of zones of epiphyseal cartilage and extension of endochondral growth sequences toward the epiphyseal end comparable to the effect of similar conditions in the chick illustrated by Figure 8 of a previous paper.[4]

were like those we have described in the chick [8] as passing through the proliferative zone of the epiphyseal cartilage to enter the cartilaginous epiphysis.

In none of the vitamin-A-deficient ducks studied histologically was there a clearly defined demarcation of zones of proliferation and growth in the distal femoral

Fig. 7.—*A*, Vitamin-A-Deficient Duck 4. Paralysis occurred on the seventh day and death on the ninth day. Longitudinal sagittal section of the body of a lumbar vertebra; × 37. Endochondral bone growth has ceased. Note the marked concavity of the dorsal side—the result of pressure exerted by the spinal cord. Compare with Figures 7*B* and 8. *B*, Restricted-Diet Control Duck 1, killed at 13 days of age. Longitudinal sagittal section of the body of a lumbar vertebra; × 37. Endochondral bone growth has not entirely ceased. Note the straight line of the cortical bone on the dorsal surface.

epiphyseal cartilage. In Vitamin-A-Deficient Ducks 1 and 6 the proximal tibiotarsal epiphyseal cartilage did show clearly demarcated zones of proliferation and growth. In all the vitamin-A-deficient ducks the proximal tibiotarsal epiphyseal cartilage showed greater activities in endochondral ossification than were found in the distal femoral epiphyseal cartilages, presumably the expression of the greater rate of growth of the tibiotarsus.

The distal femoral epiphyseal cartilages of the normal duck and the restricted-diet control duck showed clearly demarcated zones of proliferation and growth. In both types of controls the zone of growing cells was very narrow as compared with that of the vitamin-A-deficient duck, and lateral resorption of matured cartilage



Fig. 8.—Control Duck 4; unrestricted as to food; killed at 13 days of age. Longitudinal section of the body of a lumbar vertebra; × 33.8. Endochondral bone growth is normal. Compare with Figure 7.

cells and the establishment of communications between adjacent canals differed but slightly from corresponding processes in the normal and restricted-diet chick [9] (Figs. 5 *B* and 6).

The outstanding feature of the epiphyseal cartilage of the vitamin-A-deficient duck was the width of the zone of immature cartilage cells, with corresponding absence of bone growth sequences. The zone of matured cells with bone growth sequences in progress was relatively narrow, as was the case with the vitamin-A-deficient chicks. The cytology of the different zones in the duck resembled in all details that described for the chick.[4] The differences between the epiphyseal cartilages of the vitamin-A-deficient ducks and the normal and restricted-diet controls were wholly those resulting from retardation of the sequences necessary for growth of bone—proliferation, growth, and maturation of cartilage cells. The greater width

9. Wolbach and Hegsted.[4, 8]

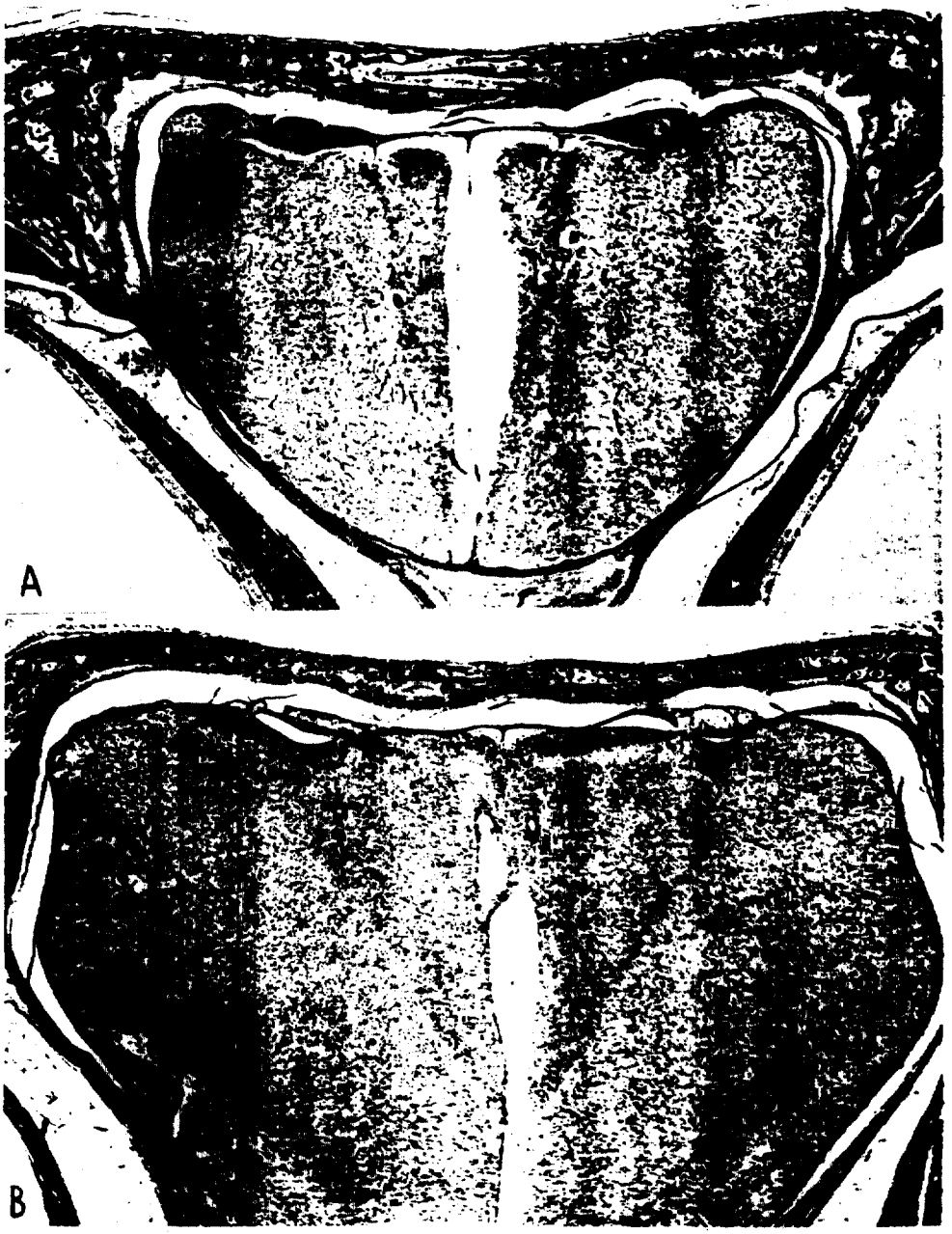

Fig. 9.—*A*, Vitamin-A-Deficient Duck 5. Paralysis occurred on the 10th day of age and death on the 13th day. Frontal-plane section through olfactory bulbs; × 16.6. A relatively large hernia can be seen on the left side and a smaller one on the right. Both project into veins (left from the orbit, right from the nose) filled with blood, which has photographed black. *B*, Vitamin-A-Deficient Duck 4. Paralysis occurred on the seventh day of age and death on the ninth day. Frontal-plane section through the tips of the cerebral hemispheres. Note the herniations on both sides into veins from the orbits.

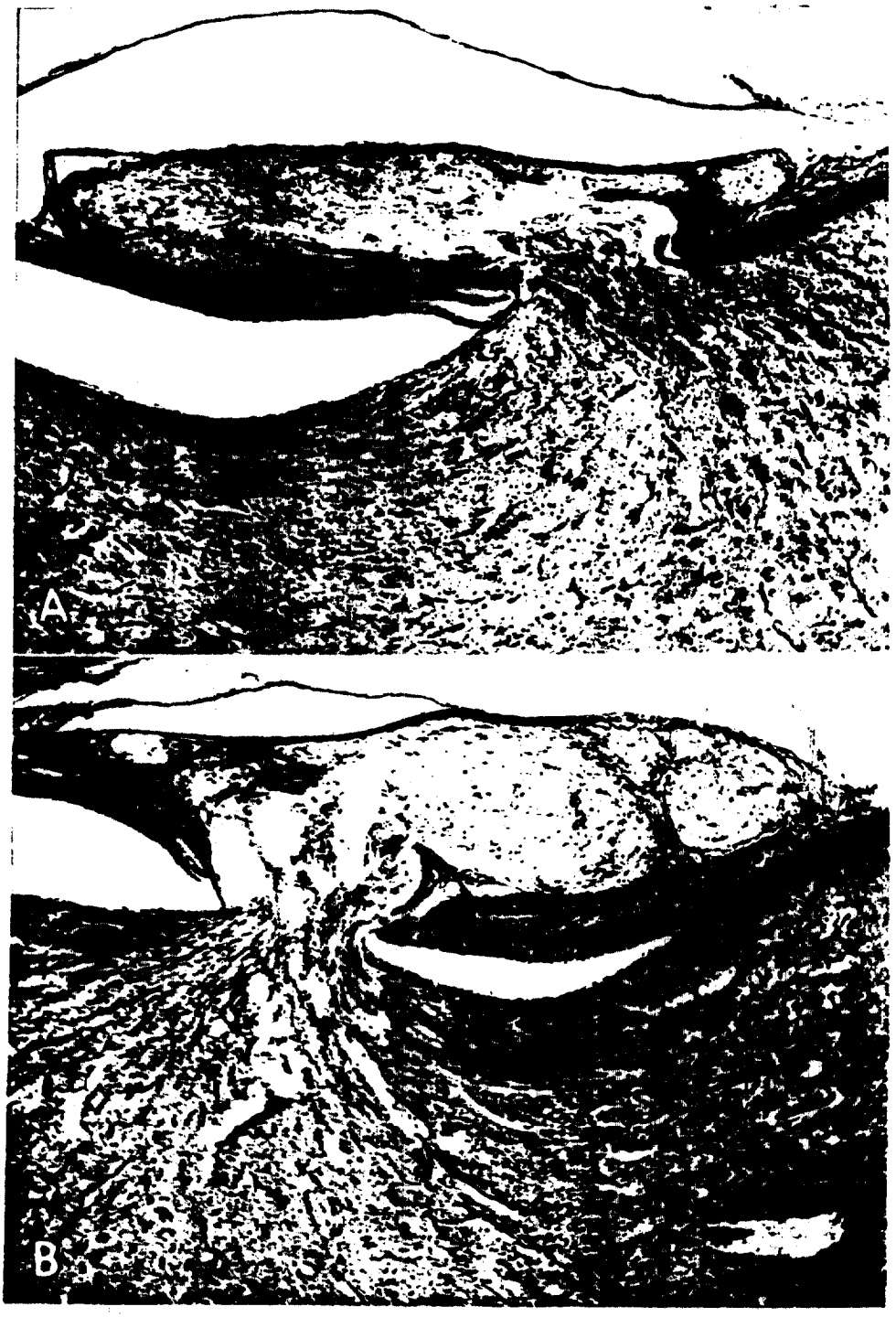

Fig. 10.—Higher-power photomicrographs, × 120, of Figure 9*B*.

Fig. 11.—Both these photomicrographs at 190 diameters are from Vitamin-A-Deficient Duck 5, from which Figure 9A was made. Both show herniae cerebri into the temperosphenoidal sinuses. From frontal-plane serial sections.

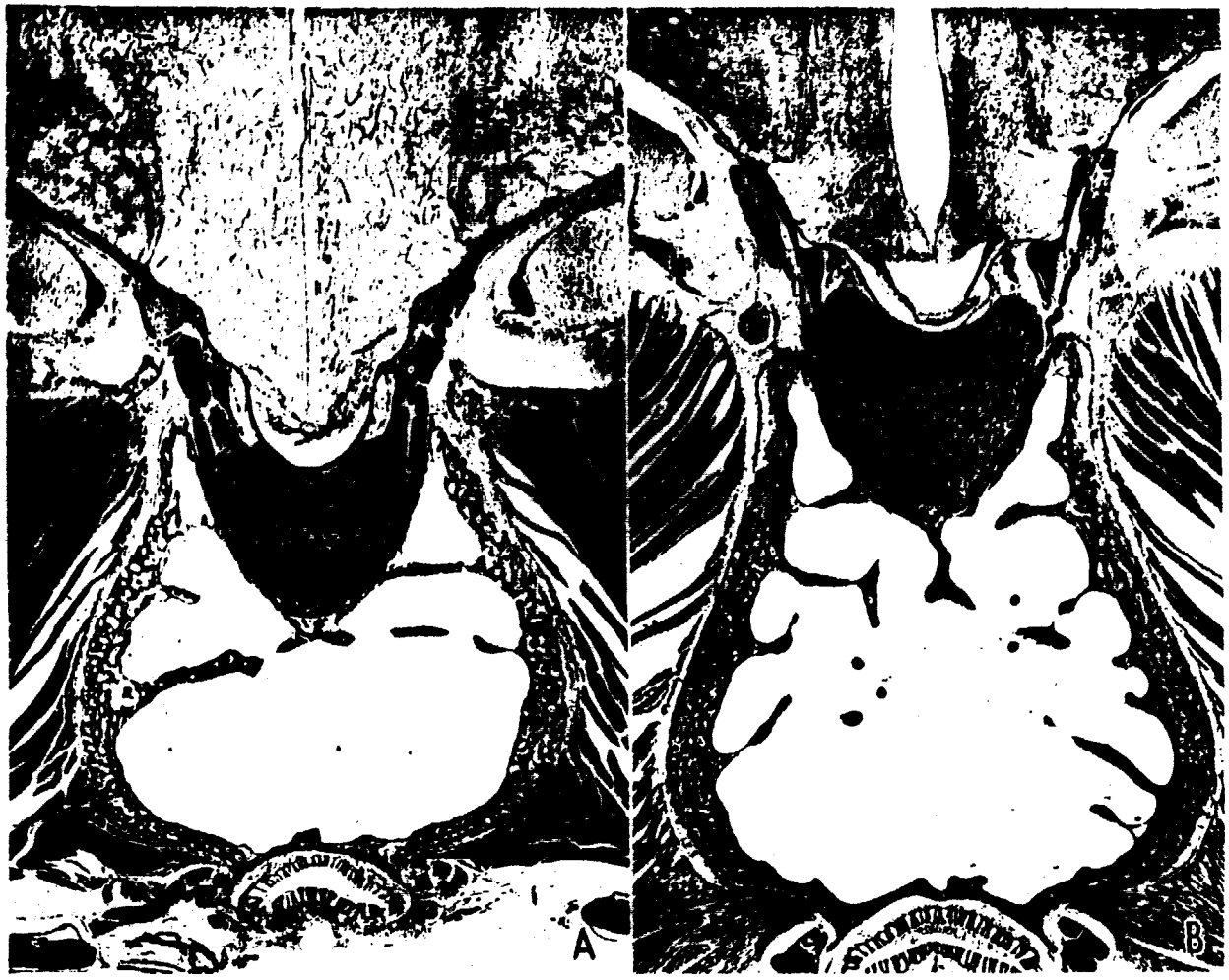

Fig. 12.—*A*, Vitamin-A-Deficient Duck 5. Frontal-plane section, × 16.6, showing compression of the third ventricle and of the infundibulum and downward dislocation into the sella turcica. Note the deep indentation of the anterior lobe of the hypophysis. Note the texture of the sphenoid bone and its pneumatization. *B*, Unrestricted-Diet Control Duck 4. Frontal-plane section, × 16, selected from serial sections for its level corresponding to that in *A*, also one of a set of serial sections. Note the normal third ventricle and infundibulum and the texture of the sphenoid bone.

of the cartilage at the distal end of the femur we believe to be delayed establishment of the epiphyseal cartilage in its completed form. The lack of clearly demarcated zones of proliferation and growth and in one instance (Vitamin-A-Deficient Duck 2) the presence of fetal cartilage in the midshaft of the femur supported this conviction. Another fact of importance is that the ages of the vitamin-A-deficient ducks at death averaged 11 days; those of vitamin-A-deficient chicks we studied,[4] 23 days.

Vertebrae and Bones of the Skull.—Changes in the cancellous bone and cortical bone of the base of the skull were less pronounced than those we described for the chick,[4] but were noticeable, as shown in Figures 7 and 8 for vertebrae and Figure 12 for the sphenoid bone in relation to the sella turcica. The pneumatization of the sphenoid bone apparently had not been affected by the deficiency.

Longitudinal sections of the vertebrae through the synsacrum—lower lumbar and sacral vertebrae—showed marked retardation to complete cessation of endochondral bone growth. The vertebrae of the deficient ducks were shorter than corresponding vertebrae of normal and restricted-diet control ducks, and the bodies of the vertebrae, in contrast to those of the controls, showed less cancellous bone and less dense cortical bone (Figs. 7 and 8).

Frontal-plane sections of the skulls fixed with the brain in situ showed in all regions of endochondral bone formation the same retardation of cartillage cell sequences and bone formation, notably at the junctions of the sphenoid and temporal bones.

The gross findings of herniations into the veins of the nose and orbit on the dorsal and lateral surfaces of the olfactory bulbs were confirmed (Figs. 9 and 10). Also, microscopic herniations into the temperosphenoid sinuses were found. Frequently, tufts of arachnoidal cells were found at the tips of the herniations (Fig. 11), indicating the relationship of arachnoidal villi to multiple herniations of the brain resulting from increased intracranial pressure, as shown for the rat,[10] chick,[4] and human.[11]

Other evidences of increased intracranial pressure were seen in the form of varying degrees of extrusion of the brain into the foramina of exit of the cranial nerves, notably of the roots of the fifth nerve and of the eight nerve. More striking was the compression of the third ventricle, the infundibulum, and stalk of the hypophysis accompanying the forcing of this structure into the sella turcica (Fig. 12).

COMMENT

Because the results of our study of the effects of vitamin A deficiency in young ducks in regard to skeletal growth and the central nervous system are so diametrically opposed to those of Rigdon and associates,[12] we prefer not to discuss or criticize the contents of their papers. Our conclusions entail categorical denials of their statements that the skeletal growth of the duck is not affected by vitamin A deficiency and that the central nervous system lesions necessarily have another origin than that of disproportionate growth of nervous system and bony envelopment.

10 Wolbach, S. B., and Bessey, O. A.: Vitamin A Deficiency and the Nervous System, Arch. Path. **32**:089, 1941.

11 Wolbach, S. B.: Multiple Hernias of the Cerebrum and Cerebellum Due to Intracranial Pressure, J. Med. Res. **19**:153, 1908.

12 Fletcher and Rigdon,[1] Rigdon, Rude, and Bieri,[2] Rigdon.[3]

Allowing for minor anatomical differences, the very rapid growth rate[13] and earlier age of death, the effects of vitamin A deficiency in young ducks upon growth of the axial skeleton and consequent lesions of the central nervous system are identical with those in the chick.[14]

For birds as well as for mammals, vitamin A is as essential for the epiphyseal cartilage cell sequences concerned in endochondral bone growth as it is for vision and for the maintenance of function of many epitheliums. In the duck and chick, as well as in the rat, disastrous results of retarded growth of the axial skeleton appear before growth as a whole is substantially affected.

SUMMARY AND CONCLUSIONS

Vitamin A deficiency in young ducks results in prompt retardation and suppression of epiphyseal cartilage cell sequences concerned in endochondral bone growth. This effect, in common with that in several mammalian species studied[4c] and in chicks, results in a disproportionate growth of the axial skeleton and central nervous system, which continue to grow. The result is compression of the growing central nervous system demonstrable by the occurrence of distortions of brain and spinal cord and multiple herniae cerebri into sinuses and veins of the dura and pia arachnoid at the sites of arachnoidal villi.

13. Hegsted, D. M., and Stare, F. J.: Nutritional Studies with the Duck: 1. Purified Rations for the Duck, J. Nutrition **20**:37, 1945.

14. Wolbach and Hegsted.[4] We have found that the administration of excessive amounts of vitamin A to young ducks produces the same acceleration of endochondral bone growth sequences—contrary to the conclusions of Rigdon and associates[2]—described by us for chicks (Wolbach, S. B., and Hegsted, D. M.: Hypervitaminosis A and the Skeleton of Growing Chicks, A. M. A. Arch. Path. **54**:30, 1952). A short paper on the subject is being prepared for publication.

Wolf-'58
Bib. No. 9968

J. Biol. Chem. 230(2):979-990. 1958.

THE FUNCTION OF VITAMIN A IN METABOLISM

II. VITAMIN A AND ADRENOCORTICAL HORMONES*

By GEORGE WOLF, SHREEPAD R. WAGLE, RUSSELL A. VAN DYKE, AND B. CONNOR JOHNSON

(From the Radiocarbon Laboratory and the Division of Animal Nutrition, University of Illinois, Urbana, Illinois)

PLATE 1

(Received for publication, July 1, 1957)

The data presented in the first paper of this series (1) clearly pointed to a block, caused by vitamin A deficiency, in a reaction between triose and glucose in glucose biosynthesis in the intact rat. In an attempt to test this hypothesis in a more readily definable system, rat liver homogenates from normal (pair-fed) and from severely deficient animals were compared in their ability to synthesize glucose. Fructose was chosen as a substrate, following the demonstration by Hers and Kusaka (2) and by Leuthardt *et al.* (3) that fructose, in liver, is readily converted to fructose 1-phosphate and hence to dihydroxyacetone phosphate and glyceraldehyde. Thus, fructose can serve as a source of triose and triose phosphate in liver, and glucose production from fructose should give an indication of a block in glucose formation from triose. However, no differences were observable in glucose formation in normal and vitamin A-deficient homogenates, nor was there any effect of the vitamin deficiency on oxidative phosphorylation.

After having demonstrated the absence of an enzymatic lesion as the cause of the impaired glucose production observable in the intact vitamin A-deficient rat, it was necessary to postulate an indirect action of the vitamin, possibly on the formation of a hormone controlling glyconeogenesis. The striking similarity between the effect of adrenalectomy, as reported by Long (4), and that of vitamin A deficiency (1) on liver glycogen formation was noted. Long found that the ability to produce glycogen was impaired in adrenalectomy to a much greater extent from precursors such as malate, lactate, and glycerol than from glucose or fructose. Glyconeogenesis could be restored by hydrocortisone administration. Similarly, Welt *et al.* (5) showed increased glyconeogenesis upon cortisone

* This investigation was supported by a grant from the National Vitamin Foundation, Inc., and by the United States Atomic Energy Commission contract No. AT(11-1)-67 with the University of Illinois. Presented in part at the Forty-first annual meeting of the Federation of American Societies for Experimental Biology at Chicago, April, 1957.

treatment in the intact rat. Ershoff (6) suggested the possibility of a deficiency in adrenocortical hormones caused by vitamin A deficiency, and Popper and Greenberg (7) showed that the adrenal cortex contained a high concentration of vitamin A, but only in the zona fasciculata, that layer which is surmised to be the source of the glucocorticoid hormones (8, 9). Lowe *et al.* (10) observed a depletion in phospholipide content in that layer in vitamin A-deficient animals, suggesting some disturbance in their glucocorticoid hormone secretion. Experiments were therefore undertaken to test the hypothesis that vitamin A is required for the normal production of these hormones.

EXPERIMENTAL

The animals used, and their diet, were identical with those described previously (1). For the studies *in vitro*, animal pairs (normal and deficient, the rats having been pair-fed from weaning) were used about 2 weeks after onset of deficiency symptoms, when death from the deficiency could be expected to occur within a few days. The method used to study conversion of fructose to glucose was adapted from that of Cori *et al.* (11). The rat pairs were starved for 24 hours prior to the experiment and then killed, their livers were perfused with ice-cold 0.9 per cent NaCl solution and excised, and each was separately homogenized with 3.3 volumes of 0.9 per cent KCl solution for 2 minutes in a loose fitting glass Potter-Elvehjem homogenizer, filtered through gauze, and dialyzed at 4°, in separate tanks, against 12 liters of 0.4 per cent KCl solution. The homogenate, with appropriate additions (Tables I and II), was incubated with shaking in an atmosphere of oxygen at 38° for 2 hours. The reaction was stopped, and protein and organic phosphates were precipitated by the addition of 1 ml. of saturated $Ba(OH)_2$ solution, followed by an equivalent amount of 5 per cent $ZnSO_4$ solution. The precipitate was removed by centrifugation, washed, and recentrifuged, and the supernatant solution and washings were combined and diluted with water to 6 ml. Aliquots of 0.05 ml. were withdrawn for simultaneous analysis for the remaining fructose and newly formed glucose by the anthrone method (12). A blank incubation (without substrate) was always included to correct for endogenous glucose, the amount of which was subtracted to give the glucose values shown in Tables I and II. For a radioactivity assay, an aliquot of 0.1 ml. was paper chromatographed on Whatman No. 1 filter paper by double descent (total length traversed, 90 cm.) in a butanol-pyridine-water (6:4:3) mixture. Two separate peaks of radioactivity were obtained, as revealed by the paper strip radioactivity scanner (Actigraph, Nuclear Instrument and Chemical Corporation, Chicago, Illinois), corresponding to glucose (R_F 0.40) and fructose (R_F 0.43). They were eluted and assayed for radioactivity in an internal gas flow counter (1).

The ratio of inorganic phosphate disappearance to oxygen consumption (P:O ratio) was determined with isolated liver mitochondria by the method of Copenhaver and Lardy (13), with livers of normal (pair-fed), depleted, and vitamin A-deficient rats. The depleted rats had been on the deficient diet for approximately 2 weeks and were used at a time when weight gain had ceased for 3 days. Oxygen consumption was measured by the conventional Warburg technique; inorganic phosphate was determined by the method of Fiske and Subbarow (14).

For the whole animal experiments, the usual pairs (normal and deficient, pair-fed from weaning) were used and starved for 24 hours before isotope injection. The rats were killed 4 hours after receiving the radioactive compounds. Liver glycogen was isolated and assayed for radioactivity as previously described (1). Adrenocorticotropic hormone (ACTH) (Armour and Company, Chicago, Illinois) was injected intraperitoneally for 9 days (0.04 mg. per day dissolved in saline) prior to the experiment, as indicated in Table VI. The authors are grateful to Mr. S. F. Marotta for aiding with the adrenalectomies.

For the time study of the development of vitamin A deficiency, rats were started on the normal or deficient diets after weaning. Animals were killed at the times indicated 4 hours after the usual isotope injections, liver glycogen was isolated and assayed for radioactivity, and the adrenals were removed, fixed in formal-calcium, and treated with dichromate-calcium. The cortex was sectioned in the frozen state and stained with acid hematein (15).

RESULTS AND DISCUSSION

Table I shows that good yields of glucose were obtainable from fructose with a homogenate system similar to that described by Cori *et al.* (11), except for the increased concentration of Mg^{++}. As shown, no significant differences in glucose formation could be detected between the normal and deficient homogenates. Similar results were obtained when radioactive fructose was used and radioactivity incorporation into glucose was measured, and when normal fructose was used and the formation of glucose measured colorimetrically. A greatly lowered amount of adenosine triphosphate (ATP) had little effect on glucose formation, although no glucose was produced in the absence of ATP. Some differences were noted in the absence of glutamic acid, though they cannot be considered large enough to account for the effect observable in the intact rat.

On working over a shorter part of the reaction sequence towards glucose formation, no differences could be detected in glucose production from fructose 1,6-diphosphate and from fructose 6-phosphate in normal and deficient rat liver homogenates (Table II). Since, as will be shown below, depression in glucose production in the intact vitamin A-deficient animal

is caused by insufficiency in cortisone or other glucocorticoid hormone, it is of interest to note that there is no inactivation of liver fructose-1,6-diphosphatase. Glucose is formed normally from fructose 1,6-diphosphate in the deficient homogenate (Table II). Mokrasch *et al.* (16) had shown that cortisone administration increased the amount of liver fructose-1,6-diphosphatase; it is clear from the present work that deficiency in cortisone does not decrease the amount of this enzyme.

TABLE I

Glucose Formation from Fructose in Liver Homogenates

1.5 ml. of liver homogenate were incubated with 0.6 ml. of buffer solution which, for the complete system, contained 55 μmoles of KH_2PO_4, 25 μmoles of $MgSO_4$, 27.8 μmoles (13.9 μmoles for Incubation 16) of fructose, 68 μmoles of glutamic acid; pH adjusted to 7.1. In addition, either 0.1 ml. (10 μmoles) or 0.01 ml. (1 μmole) of a solution of the sodium salt of adenosine triphosphate was added. For the radioactive experiments, radioactive fructose (650,000 c.p.m., specific activity 3.88×10^9 c.p.m. per μmole) was also added.

Incubation No.	ATP added	Glutamic acid added	Fructose recovered				Glucose formed				Glucose yield	
			Normal liver		Deficient liver		Normal Liver		Deficient liver			
			Weight	Radioactivity	Weight	Radioactivity	Weight	Radioactivity	Weight	Radioactivity	Normal liver	Deficient liver
	μmoles		μmoles	c.p.m. × 10^3	μmoles	c.p.m. × 10^3	μmoles	c.p.m. × 10^3	μmoles	c.p.m. × 10^3	per cent	per cent
10	10	+	22.0		20.3		9.4		8.5		33.8	30.6
8	10	+	22.6		25.2		6.3		5.7		22.6	20.5
10	10	+		432		444		218		176	33.6	27.2
15	1	+	22.2		16.7		5.4		5.6		19.5	20.1
16	1	+		483		433		167		216	25.7	33.3
14	10	−	22.0		23.0		3.5		1.4		12.6	5.1
15	10	−	21.4		18.1		8.9		3.6		32.0	12.9
16	10	−		396		438		254		212	39.1	32.6
14	1	−	22.6		22.7		0		0.8		0	2.9

The authors are indebted to Dr. C. S. Vestling and Dr. W. G. Robinson for the gift of radioactive fructose.

Table III demonstrates that oxidative phosphorylation in liver is not affected by vitamin A deficiency in either mildly or seriously affected animals. The values obtained for ratios of inorganic phosphate disappearance to oxygen consumption agree well with those reported by others for normal animals (13, 17). This observation is in line with that of Bouman and Slater (18), who were unable to detect any vitamin A in their, albeit non-phosphorylating, mitochondrial particles.

Summarizing the experiments *in vitro*, one can conclude that no enzyme system in glucose synthesis, between triose and glucose, is affected by vita-

min A deficiency and that there is no shortage of high energy phosphate or phosphorylating power. The slightly lowered glucose production in

TABLE II

Glucose Formation from Fructose Phosphates in Liver Homogenate

1.5 ml. of rat liver homogenate were incubated with 0.6 ml. of buffer solution as described in Table I, except for the absence of fructose, glutamic acid, and ATP. Instead, 0.1 ml. (10 μmoles) of a solution of either fructose 1,6-diphosphate or fructose 6-phosphate (both from the Nutritional Biochemicals Corporation, Cleveland, Ohio) was added.

Substrate used	Glucose formed			
	Normal liver		Deficient liver	
	Amount	Yield	Amount	Yield
	μmoles	*per cent*	*μmoles*	*per cent*
Fructose 1,6-diphosphate	8.34	83.4	8.34	83.4
" 6-phosphate	4.45	44.5	3.89	38.9

TABLE III

P:O Ratio Determination

The following components were pipetted into Warburg flasks: 0.1 ml. of 0.25 M KF (25 μmoles), 0.1 ml. of 0.6 M glutamate (60 μmoles) (pH 7.3), 0.1 ml. of 0.4 M KH_2PO_4 (40 μmoles) (pH 7.3), 0.1 ml. of 0.15 M $MgSO_4$ (15 μmoles), 0.1 ml. of 0.003 M cytochrome *c* (0.03 μmole), 0.1 ml. of 0.06 M ATP (6.0 μmoles), 0.5 ml. of mitochondrial suspension, 0.1 ml. of 0.01 M malonate (1 μmole) (pH 7.3), 0.95 ml. of isotonic KCl (142.5 μmoles). The following were pipetted into the side arms: 0.1 ml. of 0.5 M glucose (50 μmoles), 0.25 mc. of hexokinase (10 mg. per ml.). 0.2 ml. of 20 per cent KOH on filter paper was used to absorb CO_2. Samples were taken for phosphate analysis at zero time. Incubation was carried out for 15 minutes at 30°. Two separate determinations, from two rats, were done for each category.

	O_2 uptake		Phosphate consumption		Ratios, $\frac{P}{O}$	
	Δ O_2 readings	Δ O_2 mean	Δ P readings	Δ P mean	Separate	Mean
	μatoms	*μatoms*	*μmoles*	*μmoles*		
Normal	4.2, 4.4	4.3	13.10, 14.08	13.59	3.12, 3.20	3.16
Depleted	4.5, 4.8	4.65	13.55, 14.64	14.09	2.99, 3.05	3.02
Deficient	4.4, 4.65	4.52	12.58, 12.67	12.61	2.86, 2.94	2.90

the absence of glutamate in the deficient homogenate may be interpreted as indicating a slight drop in reducing power (reduced di- or triphosphopyridine nucleotide).

Searching for an indirect effect of vitamin A deficiency on glucose syn-

thesis, attention was focused on the glyconeogenesis-stimulating hormones of the adrenal cortex. In a test of the hypothesis that vitamin A may be affecting glucose synthesis through its prior influence on glucocorticoid hormones, the experiment illustrated in Table IV was undertaken. It shows that, as found previously (1), incorporation of radioactivity from acetate into glycogen is severely inhibited in the vitamin A-deficient rat. Cortisone treatment was now found to reverse this condition completely. That this is not an effect on glycogen deposition but on glucose production was shown, as before, by injection of glucose-C^{14}. In further confirmation of the hypothesis that vitamin A is required for the formation of a cortical hormone, a set of vitamin A-deficient rats was adrenalectomized to deter-

TABLE IV

Glycogen Formation and Cortisone Treatment

The rats were treated with cortisone acetate (Merck and Company, Rahway, New Jersey), (5 mg. per day) for 4 days, where indicated, then given 300 mg. of non-radioactive glucose, and, after 30 minutes, 7.5×10^6 c.p.m. of radioactive compound intraperitoneally.

Compound injected	Cortisone treatment	Weight of rat		Weight of liver glycogen		Specific activity of liver glycogen		Total activity of liver glycogen	
		Normal	Deficient	Normal	Deficient	Normal	Deficient	Normal	Deficient
		gm.	*gm.*	*mg.*	*mg.*	*c.p.m. per mg.*	*c.p.m. per mg.*	*c.p.m.*	*c.p.m.*
Acetate-1-C^{14}	−	143	116	252.0	67.5	118.2	40.2	28,800	2,540
"	+	146	110	267.0	83.5	79.0	292.0	21,100	24,400
Glucose-1-C^{14}	−	146	111	285.0	63.0	426.0	1610.0	121,200	101,200
"	+	137	99	237.0	77.5	527.4	1545.0	125,000	120,000

mine whether, in the absence of the adrenals, vitamin A would or would not retain its activity in glucose synthesis. As shown in Table V, the vitamin A-deficient, adrenalectomized rat, when given vitamin A, is still unable to incorporate radioactivity into glycogen, but, when given cortisone, even in the absence of vitamin A, can produce glycogen normally. Of course, without vitamin A and cortisone, no glycogen is formed, and, with both, glycogen formation is unimpaired. The rats were almost instantly reponsive in their appetite, weight gain, and appearance to vitamin A treatment, though much less so to cortisone treatment. These results would then be completely consistent with a function of vitamin A through the adrenal cortex.

It was necessary, at this point, to eliminate the possibility that vitamin A deficiency and cortisone treatment might influence glyconeogenesis by opposite, but independent, and separate mechanisms. This was achieved

by an experiment with ACTH instead of cortisone treatment. If vitamin A deficiency does indeed, as postulated, produce "chemical adrenalectomy,"

TABLE V

Glycogen Formation, Adrenalectomy, and Cortisone Treatment

The rats were all vitamin A-deficient. They were adrenalectomized 5 days prior to injection of 7.5 × 10^6 c.p.m. of acetate-1-C^{14}. Those receiving vitamin A were given it 5 days prior to injection in amounts as described (1). 300 mg. of non-radioactive glucose were injected 30 minutes before acetate-1-C^{14}.

Adrenals*	Cortisone treatment	Vitamin A treatment	Initial weight	Final weight	Weight difference	Weight of liver glycogen	Specific activity of liver glycogen	Total activity of liver glycogen
			gm.	*gm.*	*gm.*	*mg.*	*c.p.m. per mg.*	*c.p.m.*
−	−	+	55	61	+6	60.5	63.0	3,811
−	+	−	75	73	−2	72.5	306.0	22,140
−	−	−	77	61	−16	55.0	45.0	2,475
−	+	+	75	89	+14	206.0	102.0	21,012
+	−	−	84	80	−4	72.0	61.0	4,231

* + = present; − = absent.

TABLE VI

Glycogen Formation and ACTH Treatment

Vitamin A-deficient and normal rats were treated with ACTH for 9 days after adrenalectomy where indicated, then given 300 mg. of non-radioactive glucose and, after 30 minutes, 8.0 × 10^6 c.p.m. of acetate-1-C^{14}.

Rat No.	Adrenals*	ACTH treatment	Vitamin A status	Initial weight	Final weight	Weight difference	Weight of liver glycogen	Specific activity of liver glycogen	Total activity of liver glycogen
				gm.	*gm.*	*gm.*	*mg.*	*c.p.m. per mg.*	*c.p.m.*
1	−	+	+	182	205	+23	134.6	16.3	2,200
2	+	+	−	111	76	−35	36.9	24.9	920
3	+	+	Slightly deficient	156	145	−11	88.7	52.4	4,640
4	+	+	+	190	207	+17	249.5	60.6	15,120
5	+	+	+	193	217	+24	147.0	52.8	7,760
6	+	−	+	159	179	+20	155.6	60.2	9,360

* + = present; − = absent.

then ACTH, which is known normally to cause increased secretion of the glucocorticoid hormones, should fail to do so in vitamin A deficiency and, therefore, not restore glyconeogenesis to normal. If, on the other hand, vitamin A deficiency depresses glyconeogenesis by one mechanism and cortisone treatment raises it by another, then ACTH should increase glyconeo-

genesis even during the vitamin deficiency. The results shown in Table VI clearly demonstrate that vitamin A deficiency actually destroys glucocorticoid hormone production. Incorporation of labeled acetate into liver glycogen was lowered by vitamin A deficiency (Rat 2, Table VI), as much as by surgical adrenalectomy (Rat 1), in spite of simultaneous ACTH treatment in both cases. That this treatment raises incorporation of labeled acetate into glycogen, presumably by glucocorticoid hormone stimulation, is shown in Rats 4 and 5.

In another experiment (Table VII) adrenalectomized weanling rats were put on either cortisone treatment or vitamin A diet for 32 days. As can be seen, in the absence of the adrenal glands and without cortisone, but

TABLE VII

Glycogen Formation and Adrenalectomy in Weanling Rats

The rats were adrenalectomized where indicated at weaning. They were given vitamin A in the diet in amounts as described (1) or alternatively given cortisone intraperitoneally (5 mg. per day). After 32 days they received 10.0×10^6 c.p.m. of acetate-1-C^{14}, 30 minutes after receiving 300 mg. of non-radioactive glucose.

Adrenals*	Cortisone treatment	Vitamin A treatment	Initial weight	Final weight	Weight gain	Weight of liver glycogen	Specific activity of liver glycogen	Total activity of liver glycogen
			gm.	*gm.*	*gm.*	*mg.*	*c.p.m. per mg.*	*c.p.m.*
−	−	+	36	120	+84	187.0	96.4	18,020
−	+	−	38	94	+56	62.5	2040	127,500
+	−	+	40	122	+82	203.0	669	135,900

* + = present; − = absent.

with the administration of vitamin A, the rat grew normally and showed no symptoms of the deficiency, except *in the impairmen of glucose synthesis.* On the other hand, the animal receiving no vitamin A, but treated with cortisone, lost weight and came down with xerophthalmia and all the other symptoms of the deficiency, but *produced glucose normally.* It is possible to conclude therefore that vitamin A is required for glucocorticoid synthesis in a way which is independent of its function in the rest of the organism. However, it is more rational to conclude that vitamin A does not, in fact, function through its influence on cortical hormone synthesis at all, but rather that vitamin A deficiency leads to a degeneration of certain cells and tissues, including those of the adrenal cortex, and hence to a deficiency in glucocorticoid hormones. The histological data described below will bear out this hypothesis.

A time study was undertaken in which a set of weanling rats, fed a vitamin A-deficient diet and pair-fed with a set of normal control rats, were

injected with radioactive acetate at different stages of the deficiency and killed 4 hours after the isotope injection. As shown in Table VIII, no depression in glyconeogenesis appeared after feeding the deficient diet for 2 weeks (Pair 1). A loss in the ability to synthesize glucose to the extent of about 40 per cent was observed at a time when the weight gain curve had just begun to flatten (Pair 3, Table VIII). Almost complete loss of glyconeogenesis occurred only 2 days after weight loss had set in, before any other

TABLE VIII

Gross Symptoms and Glycogen Biosynthesis in Vitamin A Deficiency

Rats started at 45 gm. Pair-fed rats gained an average of 5 gm. per day. Before killing, the rats were injected with 6×10^6 c.p.m. of sodium acetate-C^{14}, 30 minutes after receiving 250 mg. of non-radioactive glucose. Rats killed 4 hours after isotope injection.

Pair No.	Condition of deficient rat	Final weight		Weight of liver glycogen		Specific activity of liver glycogen		Total activity of liver glycogen	
		Normal	Deficient	Normal	Deficient	Normal	Deficient	Normal	Deficient
		gm.	*gm.*	*mg.*	*mg.*	*c.p.m. per mg.*	*c.p.m. per mg.*	*c.p.m.*	*c.p.m.*
1	Normal weight gain, no symptoms	118	110	370.8	358.6	117	118	43,500	42,300
2	Normal weight gain, no symptoms	114	107	300.5	243.3	140	154	42,200	37,600
3	Little weight gain, no symptoms	120	101	158.6	130.9	71	54	11,300	7,060
4	Weight loss (2 days), no symptoms	108	98	135.7	61.3	89	33	12,090	203
5	Severe weight loss, xerophthalmia	126	99	137.8	80.8	83	29	11,480	236
6	Severe weight loss, severe symptoms	89	68	108.6	0	91	0	9,930	0

symptoms became apparent (Pair 4). Histologically, this sequence was paralleled by a decrease in phospholipide in the zona glomerulosa, leading ultimately to the situation described by Lowe *et al.* (10). Figs. 2, 3, and 4 show sections of the adrenal cortex stained for phospholipide (15) from the deficient animals of Pairs 1, 3, and 6 (Table VIII). It can be observed that, in the normal cortex (Fig. 1), there is no phospholipide-staining material in the zona glomerulosa. At a time (2 weeks) before vitamin A deficiency had set in *even before glyconeogenesis was depressed*, phospholipide appeared in the zona glomerulosa and began to disappear in the zona fasciculata (Fig. 2), revealing a disturbance or degeneration in those cells concerned with the production of glucocorticoid hormones (8, 9). This

process became more pronounced as the deficiency proceeded (Fig. 3) until, in severe deficiency, there was no phospholipide in the zona fasciculata, whereas the zona glomerulosa stained heavily for it (Fig. 4).

It is of importance to note that the stage in vitamin A deficiency at which depression of glyconeogenesis takes place is an early one, when weight gains begin to drop, a time known to coincide with the depletion of liver vitamin A stores (7). It has now been shown that a disorder in the cells of the adrenal cortex precedes this event. Lowe *et al.* (10) demonstrated histologically that young rats kept on a diet marginal in vitamin A, sufficient for growth but not for storage, already showed signs of this disturbance in the adrenal cortex. It can therefore be concluded that vitamin A deficiency leads to partial chemical adrenalectomy, a consequence of which is the disturbed glucocorticoid hormone formation or secretion, and therefore depression of glyconeogenesis.

It is a pleasure to acknowledge the helpful advice and stimulating discussions throughout the course of this work, for which the authors are indebted to Dr. J. Larner.

SUMMARY

The severe depression in glucose biosynthesis from triose observed in the intact vitamin A-deficient rat was not found in liver homogenates from deficient rats nor was oxidative phosphorylation affected.

Depression of glyconeogenesis in the intact vitamin A-deficient rat was reversed by cortisone treatment, and in vitamin A-deficient, adrenalectomized rats cortisone could, whereas vitamin A could not, restore glyconeogenesis to normal. Glyconeogenesis remained depressed in vitamin A deficiency, as much as after adrenalectomy, despite simultaneous administration of the adrenocorticotropic hormone.

When adrenalectomized weanling rats were put on a vitamin A diet or on cortisone treatment without vitamin A for a month, then those rats receiving vitamin A but no cortisone were normal in all respects except for impaired glyconeogenesis; the vitamin A-deficient rats receiving cortisone, on the other hand, showed all deficiency symptoms except for normal glyconeogenesis. A time study showed that glyconeogenesis is depressed at a very early stage in vitamin A deficiency, at a point where weight gains decrease. It was demonstrated histologically that there is a disturbance in those adrenal cortex cells producing glucocorticoid hormones, even before glyconeogenesis depression occurs. It was concluded that vitamin A deficiency leads first to a degeneration of those cells and only secondarily to a depression in glyconeogenesis, through impaired glucocorticoid hormone production.

BIBLIOGRAPHY

1. Wolf, G., Lane, M. D., and Johnson, B. C., *J. Biol. Chem.*, **225**, 995 (1957).
2. Hers, H. G., and Kusaka, T., *Biochim. et biophys. acta*, **11**, 427 (1953).
3. Leuthardt, F., Testa, E., and Wolf, H. P., *Helv. chim. acta*, **36**, 227 (1953).
4. Long, C. N. H., *Recent Progress Hormone Res.*, **11**, 397 (1955).
5. Welt, I. D., Stetten, D., Jr., Ingle, D. J., and Morley, E. H., *J. Biol. Chem.*, **197**, 57 (1952).
6. Ershoff, B., *Vitamins and Hormones*, **10**, 79 (1952).
7. Popper, H., and Greenberg, R., *Arch. Path.*, **32**, 11 (1941).
8. Deane, H. W., and Greep, R. O., *Am. J. Anat.*, **79**, 117 (1946).
9. Cain, A. J., and Harrison, R. G., *J. Anat.*, **84**, 196 (1950).
10. Lowe, J. S., Morton, R. A., and Harrison, R. G., *Nature*, **172**, 716 (1953).
11. Cori, G. T., Ochoa, S., Slein, M. W., and Cori, C. F., *Biochim. et biophys. acta*, **7**, 304 (1951).
12. Mokrasch, L. C., *J. Biol. Chem.*, **208**, 55 (1954).
13. Copenhaver, J. H., Jr., and Lardy, H. A., *J. Biol. Chem.*, **195**, 225 (1952).
14. Fiske, C. H., and Subbarow, Y., *J. Biol. Chem.*, **66**, 375 (1925).
15. Baker, J., *Quart. J. Micr. Sc.*, **87**, 441 (1946).
16. Mokrasch, L. C., Davidson, W. D., and McGilvery, R. W., *J. Biol. Chem.*, **222**, 179 (1956).
17. Maley, G. F., and Lardy, H. A., *J. Biol. Chem.*, **215**, 377 (1955).
18. Bouman, J., and Slater, E. C., *Nature*, **177**, 1181 (1956).

EXPLANATION OF PLATE 1

Sections of adrenal cortex of normal and vitamin A-deficient rats stained with acid hematein and enlarged 112 × to show the zona fasciculata (*f*) and the zona glomerulosa (*g*). Fig. 1, normal cortex. Fig. 2, cortex after 2 weeks of deficiency, no symptoms (Table VIII, deficient rat of Pair 1). Fig. 3, cortex after weight loss set in (Table VIII, deficient rat of Pair 3). Fig. 4, severe deficiency (Table VIII, deficient rat of Pair 6).



(Wolf, Wagle, Van Dyke, and Johnson, Function of vitamin A. II)

Wolf-'60
Bib. No. 9969

Biochimica et Biophysica Acta 43(3):501-512. 1960.

STUDIES ON THE FUNCTION OF VITAMIN A IN MUCOPOLYSACCHARIDE BIOSYNTHESIS

GEORGE WOLF AND PARTAB T. VARANDANI

The Radiocarbon Laboratory and The Division of Animal Nutrition, University of Illinois, Urbana, Ill. (U.S.A.)

(Received February 17th, 1960)

SUMMARY

An *in vitro* system of rat colon segments and of rat colon homogenates was elaborated, which incorporated [^{35}S]sulfate and [^{14}C]glucose into mucopolysaccharide.

Mucopolysaccharide was identified by paper chromatography and paper electrophoresis along with chondroitin sulfate carrier; by co-precipitation and dialysis with chondroitin sulfate; by hydrolysis and identification of labeled sulfate or labeled glucosamine.

The homogenate system required adenosine triphosphate, diphosphopyridine nucleotide, glucose and glutamine. The level of incorporation was lowered to about one-half in colon segments and homogenates from vitamin A-deficient rats. Vitamin A, vitamin A-aldehyde and vitamin A-acid (but no other fat-soluble vitamin tested) restored incorporation to normal. With graded levels of vitamin A added, a maximum of incorporation was reached at 10 μg/6 mg of protein in the homogenates. Using glucosamine or galactosamine instead of glucose and glutamine, or uridine diphosphate acetylglucosamine, uridine diphosphate glucuronic acid, uridine diphosphate glucose and acetylglucosamine, incorporation of labeled sulfate was still dependent on vitamin A. This fact shows that the vitamin may be required either in the polymerization reaction of the uridine derivatives, or the activation or transfer of sulfate. It was shown that the vitamin A-destroying enzyme lipoxidase can lower or abolish incorporation into mucopolysaccharide.

INTRODUCTION

The problem of the metabolic function of vitamin A, outside of the process of vision, remains as yet unsolved. Observations described in previous papers of this series[1,2] pointed to an involvement of vitamin A in the biosynthesis of the glucocorticoid hormones. An entirely different approach to the problem was prompted by the results obtained by FELL *et al.*[3,4] and by FRAPE *et al.*[5]. The former showed that excess vitamin A, when added to the medium of bone cells grown in tissue culture, inhibited

Abbreviations: MPS, mucopolysaccharides; CS, chondroitin sulfate; TCA, trichloroacetic acid; UDPGA, uridine diphosphate glucuronic acid; UDPAG, uridine diphosphate acetylglucosamine; UDPG, uridine diphosphate glucose; AG, acetylglucosamine; ATP, adenosine triphosphate; DPN, diphosphorpyridine nucleotide.

the synthesis of new cartilage and caused the transfer of sulfate groups bound in chondroitin sulfate to soluble sulfate containing compounds; and that excess vitamin A caused embryonic chick ectoderm to differentiate into mucus-secreting epithelium and inhibited keratinization. FRAPE and his group found that, *in vivo*, vitamin A deficiency caused an increased sulfate uptake into connective tissue mucopolysaccharide, whereas a decrease was obtained when the vitamin was fed. These observations led us to the hypothesis that vitamin A, acting like a hormone, regulates the formation of mucopolysaccharides; excess vitamin A leading to an increase in the mucus type, a deficiency to an increase in the connective-tissue type.

A search was made for a mucus-forming tissue which could serve to test this hypothesis *in vitro*. Rat colon was found to be the most suitable, following the techniques developed by PASTERNAK *et al.*[6] for guinea pig colon. Using this system, it was possible to demonstrate that vitamin A has a direct function in the biosynthesis of colon mucopolysaccharide.

METHODS

Preparation of rats

For the preparation of vitamin A-deficient and pair-fed control rats, the strain, diet and techniques described by WOLF *et al.*[1] were used. The animals were deemed "deficient" at a time after feeding the deficient diet when weight loss had just set in[4].

Incubation of colon segments

After the rats were killed by decapitation, the colons were removed and cleaned of feces with ice-cold 0.9% saline. They were everted with the aid of a glass rod and cut into segments of about 1 cm long. The segments, weighing about 200 mg per incubation, were incubated with [^{35}S]sulfate (as [^{35}S]sodium sulfate, carrier free, from Abbott Laboratories) and 2 ml of Krebs–Ringer phosphate buffer, pH 7.3, containing glucose, as described by PASTERNAK *et al.*[6], at 37° for 4 h in a Dubnoff shaker in an atmosphere of 95% oxygen and 5% carbon dioxide. The [^{35}S]MPS were precipitated from the decanted medium at the end of the incubation by the addition of alcohol-benzene, as described below.

Incubation of colon homogenates

All steps were carried out at 4°. The rats were killed, the colons were removed and cleaned as described, and homogenized with 3.5 volumes of calcium and magnesium-free Krebs–Ringer phosphate buffer (0.01 *M*, pH 7.3), containing nicotinamide (0.3 *M*), for 2 min in a motor-driven, loose-fitting glass Potter-Elvehjem homogenizer. Debris and nuclei were removed by centrifugation at 600 × *g* for 15 min. The resulting supernatant suspension was used for incubation, by mixing with the co-factors and [^{35}S]sulfate or [^{14}C]glucose, described in the Tables to a final volume of 1 ml. The incubation was carried out at 37° for 2.5 h in an atmosphere of oxygen–carbon dioxide (95:5) in a Dubnoff shaker. The [^{35}S]MPS were isolated by the double precipitation method described below.

Isolation of mucopolysaccharides

The MPS formed during the incubations were isolated by two methods:

Single precipitation: After incubation, 9 volumes of alcohol–benzene (1:1, v/v)[7] were added to the incubation mixture, which was then left overnight at 4°, when a precipitate appeared. The mixture was centrifuged and the supernatant solution discarded. The precipitate was washed 3 times with the alcohol–benzene mixture and dissolved in 0.5 ml distilled water. To this was added 0.5 ml of an 8% aqueous solution of TCA. The precipitated proteins were removed by centrifugation and the MPS in the supernatant solution was purified by descending paper chromatography. An aliquot of 0.2 ml of the solution was applied as a band to the baseline of a sheet of Whatman No. 1 filterpaper and developed in 1 *M* ammonium acetate–ethanol (2:5, v/v)[8]. MPS remained at the origin, whereas free sulfate moved with an R_F of 0.23. Similarly, during electrophoresis in barbital buffer at pH 8.8, MPS remained at the origin; in citrate buffer (0.05 *M*, pH 5.6), MPS moved 7 cm in 7 h (300 V).

Double precipitation: After precipitation and deproteinization as described above, the MPS were again precipitated from the remaining solution by addition of 9 volumes of the alcohol–benzene mixture, and left overnight at 4°. The precipitate was washed three times with alcohol–benzene and paper chromatographed as described.

Identification of mucopolysaccharides

The MPS were identified by paper chromatography and paper electrophoresis, as described above along with known samples of chondroitin sulfate, and agreement of the radioactive spots with the color spots given with the toluidine blue spray[9], was obtained.

Further, a sample of [^{14}C]MPS was hydrolyzed as described for CS by KORN[10] and the hexosamines isolated on a Dowex-50 column, along with carrier glucosamine, by the method of BOAS[11]. On paper chromatography, the spot of radioactive glucosamine coincided with the ninhydrin-color given by the carrier glucosamine.

A sample of the radioactive glucosamine was transformed into the osazone[12], along with carrier glucosamine, which was then recrystallized to constant specific activity.

A sample of [^{14}C]MPS (1.002 μC) isolated as described, was precipitated by cetylpyridinium bromide together with carrier CS (50 mg) (obtained from Nutritional Biochemical Corp.), as described by KORN[10], and the precipitate dialyzed, whereupon the radioactivity was retained in the non-dialyzable cetylpyridinium bromide complex of CS.

A further sample of [^{35}S]MPS, isolated as described, was hydrolyzed with 4 *N* hydrochloric acid at 100° for 2 h[8]. The hydrolysed solution was evaporated to dryness *in vacuo* over solid KOH and paper chromatographed in the ammonium acetate–ethanol system described above. All the radioactivity traveled with free sulfate (R_F 0.23) (R_F of methionine, 0.70; of cystine, 0.36)[5].

Vitamin A solution

Two mg of crystalline vitamin A were dissolved in 0.3 ml of absolute alcohol, followed by grinding of the solution with 1.7 ml of 0.2% crystalline bovine plasma albumin in 0.1 *M* phosphate buffer, pH 7.4, in a glass homogenizer for approx. 2 min. The suspension was then centrifuged for 5 min at 500 × *g*. The supernatant solution was used after spectrophotometric assay of its vitamin A content. Vitamin A aldehyde and acid were dissolved similarly.

Protein determination

The protein content of the homogenate was determined by turbidity measurement. Suitable aliquots of homogenate were diluted to 3 ml with distilled water and mixed. To each tube, 3 ml 10% TCA were added, mixed and read after 10 min at 420 mμ in a Coleman colorimeter. A standard curve was made with crystalline bovine plasma albumin.

Estimation of hexosamine

The MPS formed, isolated by paper chromatography, was eluted from the paper with water. The eluate was evaporated to dryness in a stream of nitrogen on the steambath. To the dry residues, 1 ml of 3 N HCl was added and the MPS was hydrolyzed by refluxing for 4 h. Hexosamine was determined by the ELSON AND MORGAN procedure as modified by NEUHAUS AND LETZRING[13].

Measurement of radioactivity

A radioactivity scanning apparatus ("Actigraph", Nuclear Chicago Corporation) was used to determine ^{35}S and ^{14}C-activity on paperstrips. The paper chromatograms were passed beneath the counting tube of the scanner and peaks corresponding to radioactive spots were obtained on the chart of an automatic recorder. The paper under the peak corresponding to MPS was cut out and weighed. The weight of the paper was proportional to, and converted into, counts/min with the help of a calibration curve prepared by chromatographing and counting known quantities of [^{35}S]sulfate.

RESULTS

Effect of vitamin A-deficiency on the incorporation of [^{35}S]-sulfate into MPS

By rat colon segments: It was necessary to determine, whether there are differences between the synthesis of MPS in vitamin A deficient compared to normal rats. For this purpose, the colon segments from deficient and normal rats were prepared and incubated with [^{35}S]sulfate in Krebs–Ringer phosphate buffer, pH 7.4, as described. The MPS synthesized and secreted into the medium were isolated by the single precipitation method, purified by paper chromatography and counted by the scanning apparatus, as also previously described. The results are presented in Table I.

The incorporation of [^{35}S]sulfate into MPS by deficient colon segments was found to be about one-half compared to that of normal colons. When a suspension con-

TABLE I

INCORPORATION OF $^{35}SO_4^{=}$ INTO MUCOPOLYSACCHARIDES BY COLON SEGMENTS

The values are averages of the number of incubations shown in parentheses. Activity added, 10×10^6 counts/min; incubation period 4 h. —, deficient rat; +, normal

Vitamin A status	Mucopolysaccharide counts/min
—	4247 (5)
+	1620 (3)

TABLE II

EFFECT OF ADDED VITAMIN A ON INCORPORATION OF $^{35}SO_4$ INTO MUCOPOLYSACCHARIDES BY COLON SEGMENTS

The values are averages of the number of incubations shown in parentheses. Incubation period 3.5 h, activity added $19 \cdot 10^6$ counts/min; +, normal rat; —, deficient rat.

Vitamin A status	*Vitamin A added*	*Mucopolysaccharide counts/min*
—	—	1279 (4)
—	10 μg (alcohol)	3515 (4)
—	10 μg (aldehyde)	3001 (4)
+	—	2685 (4)

TABLE III

INCORPORATION OF $^{35}SO_4^{=}$ INTO MUCOPOLYSACCHARIDES BY COLON HOMOGENATES

Each incubation contained $13.5 \cdot 10^6$ counts/min of activity and 16 mg of protein.

ATP 10 μmoles	*Mg^{++} 6 μmoles*	*Glutamine 1 μmole*	*DPN 3 μmoles*	*Glucose 10 μmoles*	*Mucopolysaccharide counts/min*
+	+	+	+	+	1,307
+	+	+	+	—	268
+	+	+	—	—	0
+	+	—	—	—	0
+	+	+	—	+	536
+	+	—	+	+	0
—	—	+	+	+	0
—	+	+	+	+	0

taining 10 μg of vitamin A was added to the incubation medium of the deficient colons, the incorporation was raised to the level of the normal (Table II). Both vitamin A and vitamin-A-aldehyde (retinene) were effective.

By rat colon homogenates: The conditions under which the incorporation of [^{35}S]-sulfate into MPS by rat-colon homogenates would take place, were first determined. The rat-colon homogenates, prepared as described, were mixed with the co-factors, as indicated in Table III, and incubated. The MPS were isolated by the double precipitation method, purified by paper chromatography and counted in the scanning apparatus as described. The incorporation was highest when the medium contained ATP, DPN, glucose and glutamine. When ATP or glutamine were omitted, no incorporation could be obtained, and on deletion of glucose or DPN, the incorporation was lowered. In all the experiments subsequently described, all the above co-factors were added to the incubation medium, and this will be referred to as "complete system".

Identification of MPS

Hexosamine contents, determined as described, of MPS before and after incubation were 3.8 μg and 17.4 μg per incubation, respectively, indicating net MPS-synthesis by rat-colon homogenates. Incubating [^{14}C]glucose, instead of [^{35}S]sulfate,

[^{14}C]mucopolysaccharide was isolated, presumably by formation of labeled hexosamine and glucuronic acid moieties of MPS.

As shown in Table IV, after hydrolysis of the [^{14}C]MPS obtained, the hexosamines, isolated by means of carrier glucosamine, retained constant radioactivity through recrystallizations of the osazone, as well as on paper chromatography. For further identification of the MPS, the toluidine spray of HAMERMAN[9] was used on the paper chromatograms and after paper electrophoresis, of the isolated MPS. A pink spot against a blue background, coinciding with the radioactive spot and with a CS spot, proved the presence of labeled MPS.

When [^{14}C]MPS, isolated in the usual manner, was mixed with carrier CS and precipitated with cetylpyridinium bromide, the complex thus formed retained radioactivity which, moreover, was not dialysable.

A sample of [^{35}S]MPS, when hydrolyzed under conditions leading to hydrolysis of the sulfate group only[8], yielded free radioactive sulfate. The same level of radioactivity incorporation was obtained whether incubation of the colon homogenate was carried out in presence or absence of chloromycetin.

Homogenates were then prepared from vitamin A-deficient and normal rat colons and incubated with the complete system. The results are summarized in Table V. The [^{35}S]sulfate incorporated into MPS by homogenates from deficient colons was once again about one-half that of normal colons. The addition of vitamin A-suspension to the deficient homogenates restored incorporation to normal. The suspending medium alone (serum albumin-ethanol) had no effect (Table V).

Specificity of vitamin A

To determine the specificity of vitamin A in reversing the decrease in the synthesis of MPS due to vitamin A-deficiency, suspensions of vitamins D, E and K_1 were added to the complete system of vitamin A-deficient colon homogenates. No fat-soluble vitamin except vitamin A could completely reverse the decrease in the synthesis of MPS. Vitamin E reversed partially. If vitamins E and A were added together, the increase in MPS synthesis went beyond that obtained with vitamin E alone. The results are shown in Table VI. Recently DOWLING AND WALD[14] have demonstrated that rats on a diet containing vitamin A-acid instead of vitamin A grew normally, although they developed night blindness. In our system also, vitamin A-acid, when added to the incubation medium of deficient homogenates, restored to normal the decrease in incorporation of [^{35}S]sulfate into MPS (Table VI).

Effect of addition of graded levels of vitamin A

It was of some interest to find out the effect of the addition of graded levels of vitamin A on restoring the decrease in the incorporation of [^{35}S]sulfate into MPS due to vitamin A-deficiency. The results in Table VII show that the maximum incorporation could be obtained when the amount of vitamin A added was 10–15 μg to mg of protein.

Experiments with hexosamines

The foregoing experiments have established that, under the conditions studied, the *in vitro* synthesis of MPS by rat colon is enhanced by vitamin A. The synthesis of MPS is complex and not all the steps are as yet known. The next object, therefore,

TABLE IV

INCORPORATION OF [^{14}C]GLUCOSE INTO HEXOSAMINES OF MPS SYNTHESIZED BY COLON HOMOGENATES

The complete system consisted of 10 μmoles ATP, 6 μmoles of $MgCl_2$, 1 μmole glutamine, 3 μmoles of DPN, 20 μmoles of Na_2SO_4 and 1,000,000 counts/min of [^{14}C]glucose

	Counts/min
Total [^{14}C]MPS isolated	15,200
Total [^{14}C]hexosamine obtained therefrom	9,232
Specific activity of hexosamine	*Counts/min/mmole*
After addition of carrier (54 μmoles)	5,000
After 2nd crystallization of osazone	6,800
After 3rd crystallization of osazone	6,750

TABLE V

INCORPORATION OF $^{35}SO_4^{=}$ INTO MUCOPOLYSACCHARIDES BY COLON HOMOGENATES

The values are averages of the number of incubations shown in parentheses. The complete system contained 10 μmoles of ATP, 6 μmoles of Mg^{++}, 1 μmole of glutamine, 3 μmoles of DPN and 10 μmoles of glucose — final volume 1 ml. Each incubation contained $10.6 \cdot 10^6$ counts/min of radioactive sulfate and 14 mg of protein. +, normal rat; —, deficient rat.

Vitamin A status	*Vitamin A added 10 μg*	*Mucopolysaccharide counts/min*
—	—	340 (3)
—	+	805 (2)
+	—	930 (4)
—	Serum-albumin-ethanol	268 (2)

TABLE VI

INCORPORATION OF $^{35}SO_4^{=}$ INTO MUCOPOLYSACCHARIDES BY COLON HOMOGENATES: SPECIFICITY OF VITAMIN A

The values are averages of the number of incubations, shown in parentheses. The complete system was that shown in Table V. Each incubation contained $9.78 \cdot 10^6$ counts/min of activity and 14 mg of protein.

Status of animal	*Addition (10 μg)*	*Mucopolysaccharide counts/min*
Normal	—	496 (2)
Deficient	—	453 (2)
Deficient	Vitamin A alcohol	341 (2)
Deficient	Vitamin A acid	805 (1)
Deficient	Vitamin D	232 (1)
Deficient	Vitamin E	668 (2)
Deficient	Vitamin E + vitamin A	752 (2)
Deficient	Vitamin K_1	435 (2)

TABLE VII

EFFECT OF ADDITION OF GRADED LEVELS OF VITAMIN A ON THE INCORPORATION OF $^{35}SO_4^{=}$ INTO MUCOPOLYSACCHARIDES

The values are averages of the number of incubations, shown in the parentheses. The complete system of Table V was used. Each incubation contained $10.6 \cdot 10^6$ counts/min of activity and 16 mg of protein.

Vitamin A status	*Vitamin A added µg*	*Mucopolysaccharide counts/min*
Deficient	—	265 (2)
Deficient	5	409 (2)
Deficient	10	574 (2)
Deficient	15	584 (2)
Deficient	20	505 (2)
Deficient	30	571 (2)
Normal	—	562 (2)

TABLE VIII

EFFECT OF ADDITION OF HEXOSAMINES ON THE INCORPORATION OF $^{35}SO_4^{=}$ INTO MUCOPOLYSACCHARIDES BY COLON HOMOGENATES

The values are averages of the number of incubations, shown in parentheses. The complete system was that shown in Table V. In Expts. 2 and 3 glucosamine and galactosamine were substituted for glucose and glutamine. Each incubation contained $9.7 \cdot 10^6$ counts/min and 14 mg of protein.

Vitamin A status	*Addition 11 µmoles*	*Mucopolysaccharide counts/min*
Deficient	—	250 (2)
Deficient	Glucosamine	215 (1)
Deficient	Galactosamine	233 (2)
Normal	—	562 (2)

was to localize the function of vitamin A in a specific step in the synthesis of MPS.

It was found that the vitamin is not involved in the formation of hexosamine, because glucosamine or galactosamine, when substituted for glucose and glutamine in the incubation medium of deficient homogenates, could not restore the decrease in incorporation (Table VIII).

Experiments with uridine diphosphate derivatives

Many workers have presented evidence that the UDP-derivatives are intermediates in the synthesis of MPS[15,16]. It was decided, therefore, to find out whether vitamin A is required in a step before or after the involvement of UDP-derivatives.

At first, a system, requiring UDP-derivatives and capable of incorporating [^{35}S]-sulfate into MPS by rat-colon homogenates had to be developed. Table IX shows that the maximum incorporation of [^{35}S]sulfate in MPS occurs, when the incubation medium contained UDPAG, UDPGA, UDPG, AG, glutamine and ATP. This system shows an absolute requirement for glutamine, UDPAG and UDPGA, and partial requirement for UDPG and AG.

The system, containing UDP-derivatives, when incubated with deficient colon

TABLE IX

INCORPORATION OF $^{35}SO_4^{=}$ INTO MUCOPOLYSACCHARIDES BY COLON HOMOGENATES CONTAINING UDP-DERIVATIVES

Each incubation contained $8.5 \cdot 10^6$ counts/min and 14 mg protein. The complete system was that described in Table V, with the UDP-derivatives substituted for glucose.

UDPGA 1 μmole	*UDPAG* 1 μmole	*UDPG* 1 μmole	*Glutamine* 1 μmole	*AG* 8 μmoles	*ATP* 1 μmole	*Mg* 10 μmoles	*Mucopolysaccharides* counts/min
+	—	+	+	+	+	+	895
+	—	+	+	+	+	+	770
—	—	+	+	+	+	+	0
+	—	+	+	+	+	+	0
+	+	—	+	+	+	+	286
+	+	+	—	+	+	+	0
+	+	+	+	—	+	+	376

TABLE X

EFFECT OF VITAMIN A ON THE INCORPORATION OF $^{35}SO_4^{=}$ INTO MUCOPOLYSACCHARIDES BY COLON HOMOGENATES CONTAINING UDP-DERIVATIVES

The values are averages of the number of incubations, shown in parentheses. The complete system consisted of 1 μmole of UDPGA, 1 μmole of UDPAG, 1 μmole of UDPG, 1 μmole of glutamine, 8 μmoles of AG, (all obtained from Sigma Chemical Corporation) 1 μmole of ATP and 10 μmoles of Mg^{++}. Each incubation contained $8.5 \cdot 10^6$ counts/min of activity and 14 mg of protein; + normal rat; —, deficient rat.

Vitamin A status	*Addition of vitamin A* 10 μg	*Mucopolysaccharides* counts/min
+	—	832 (2)
—	—	270
—	+	681

TABLE XI

EFFECT OF LIPOXIDASE ON $^{35}SO_4^{=}$ INCORPORATION INTO MUCOPOLYSACCHARIDES BY COLON HOMOGENATES

Complete system was that shown in Table V. Each incubation contained $10.6 \cdot 10^6$ counts/min of activity and 14 mg of protein. Crystalline soybean lipoxidase was obtained from Nutritional Biochemical Corporation.

Preincubation for 1 h with lipoxidase (3 mg/ml)	*Addition of vitamin A* 10 μg	*Mucopolysaccharide* counts/min
0.01 ml	—	305
0.01 ml	+	538
0.04 ml	—	268
0.04 ml	+	0
0.07 ml	—	0
0.07 ml	+	0
0.10 ml	—	0
0.10 ml	+	0

homogenates, showed once again the lower incorporation of [^{35}S]sulfate into MPS (Table X). This decrease in the incorporation could be restored by the addition of vitamin A. It can, therefore, be inferred that vitamin A functions at some step beyond the synthesis of the UDP-derivatives.

Preincubation with lipoxidase

In an attempt to achieve independence from the use of vitamin A-deficient animals, and to find a means of destroying vitamin A *in vitro*, the colon homogenates were pre-incubated for 1 h with lipoxidase, an enzyme known to destroy vitamin A. This pre-incubation, as shown in Table XI, lowered or abolished the incorporation of [^{35}S]sulfate into MPS. However, addition of vitamin A restored incorporation only at low concentrations of lipoxidase, presumably because the added vitamin was destroyed by the excess lipoxidase present in the incubation medium.

DISCUSSION

Vitamin A-deficiency has for long been known to result in abnormal epithelial cells, leading to keratinization. Epithelia of mucus secreting cells, as for instance the salivary gland duct cells, are the first to be affected. Upon administration of vitamin A, these cells return to normal, both in morphology and function. In the work presently described, it could be shown that vitamin A is required for the synthesis of MPS of the type secreted by colon. It represents the first instance, apart from the reactions of the visual cycle, in which added vitamin A functions in a biochemical reaction sequence in a cell-free, *in vitro* system.

The assay used for MPS synthesis in the present work was the uptake of labeled sulfate from the medium into the final product of a many-step synthesis. Hence, the requirement of vitamin A for any particular step can only be derived by inference. For a more direct analysis, a dissection of the reaction sequence into constituent enzymic steps, and the influence of the vitamin thereon, is under way in this laboratory and will be the subject of a subsequent publication. In the meantime, it is possible to infer, albeit tentatively, from the present results, that the vitamin is not required for the following known steps: in the conversion of glucose to hexosamines; in the acetylation of hexosamines; in the conversion of hexosamines and glucose into their UDP derivatives; in the oxidation of UDPG to UDPGA. These conclusions could be reached because, starting with any of the above intermediates in place of glucose and glutamine, sulfate incorporation into MPS was still dependent on vitamin A. By a process of elimination, then, one could conclude that vitamin A functions either in the polymerisation of the UDP derivatives, or the activation or transfer of sulfate to the polymer. Confirmation of either of these alternatives must await the isolation of the separate reaction steps involved.

The very low level of incorporation (between 0.0022 and 0.025 %) of the added labeled sulfate needs some comment, since it might call into question the identity of the MPS produced. The following considerations support the contention that labeled MPS was synthesized: (a) The isolation procedure is designed specifically for MPS; (b) coincidence of a specific color reaction and radioactivity on paper after paper chromatography and paper electrophoresis in two solvent systems, and coincidence

with the spot of carrier CS; (c) coincidence of ^{35}S and ^{14}C-radioactivity on paper chromatography and paper electrophoresis, after incubation with [^{35}S]sulfate and [^{14}C]glucose, respectively; (d) upon hydrolysis of the [^{14}C]MPS and isolation of the hexosamines with carrier glucosamine on a Dowex-50 column, the glucosamine carried radioactivity upon paper chromatography, as well as after conversion to, and recrystallization of, the osazone derivative; (e) the [^{14}C]MPS is precipitable, with carrier CS, by the specific MPS precipitation reagent, cetylpyridinium bromide. The precipitated complex retains radioactivity upon dialysis; (f) the [^{35}S]MPS can by hydrolyzed under conditions known to hydrolyze the sulfate group of MPS, producing free radioactive sulfate, identified by paper chromatography. Any sulfur-containing amino acids would have traveled at greatly different rates.

To exclude the possibility that the incorporation of labeled sulfate or glucose might be caused by bacterial infection of the homogenates, incubations were carried out in presence and absence of chloromycetin. No difference in incorporation was detectable.

The great differences in per cent incorporation of the added labeled sulfate from experiment to experiment requires some comment. The level of incorporation of labeled sulfate into colon MPS depends on the nutritional state of the animal. Although care was taken to use rats only at the point in the progress of their deficiency at which the weight-curve began to level off, the actual weights and nutritional states differed in each experiment. The animals for each separate experiment, on the other hand, were litter mates, and the deficient and normal were pair-fed, to ensure equality in weight, the only difference being due to the deficiency. Hence, each experiment is self-consistent, with its own normal controls, with which the results obtained from its own deficient animals should be compared.

That vitamin A is required in MPS synthesis could not be claimed unless evidence were obtained that the vitamin is present in colon mucosa. In fact, the unsaponifiable fraction of pig colon mucosa gave a positive Carr-Price reaction, indicating 3.7 μg of vitamin A/100 g of mucosa.

In view of the recent results of DOWLING AND WALD[14], it is of interest to note that vitamin A-acid as well as vitamin A and vitamin A-aldehyde are active in the present system, whereas other fat-soluble compounds are inactive. Using graded levels of vitamin A, a maximum response was obtained. Moreover, the vitamin A-destroying enzyme lipoxidase lowered or abolished MPS synthesis.

In order to achieve independence of the use of vitamin A-deficient animals, attempts were made to lower mucosal activity by isoctane extraction, by irradiation at 326 mμ, and by oxidation. In all three methods, sulfate incorporation by mucosal homogenate was lowered and could be raised to normal after addition of vitamin A. However, this was found to be non-specific, since vitamins E and K_1, and cholesterol achieved the same result.

In a different series of experiments carried out in this laboratory[17], it was found that corticosterone production by rat adrenal cortex *in vitro* was lowered in vitamin A-deficiency, and restored to normal by addition of TPNH (or TPNH generators such as glucose-6-phosphate or glycogen). In order to obtain a link between these, so far disconnected, functions of vitamin A, the above co-factors were added to deficient colon homogenate incubations, but failed to restore lowered MPS synthesis to normal.

ACKNOWLEDGEMENTS

The authors gratefully acknowledge the continued help and support of Dr. B. C. JOHNSON in this work. The investigation was supported by a grant from the National Vitamin Foundation and by the United States Atomic Energy Commission contract No. AT(11-1)-67 with the University of Illinois. One of us (P.T.V.) is a Fulbright Scholar from India.

REFERENCES

[1] G. WOLF, M. D LANE AND B. C. JOHNSON, *J. Biol. Chem.*, 225 (1957) 995.
[2] G. WOLF, S. R. WAGLE, R. A. VAN DYKE AND B. C. JOHNSON, *J. Biol. Chem.*, 230 (1958) 979.
[3] H. B. FELL, E. MELLANBY AND S. R. PELC, *J. Physiol.* (London), 134 (1956) 179.
[4] H. B. FELL AND E. MELLANBY, *J. Physiol.* (*London*), 119 (1953) 470.
[5] D. L. FRAPE, R. S. ALLEN, V. C. SPEER, W. V. HAYS AND D. V. CATRON, *J. Nutrition*, 68 (1959) 189.
[6] C. A. PASTERNAK, P. W. KENT AND R. E. DAVIES, *Biochem. J.*, 68 (1958) 212.
[7] Z. DISCHE, P. D. S. AGNESE AND J. YOULOS, *Federation Proc.*, 17 (1958) 212.
[8] C. A. PASTERNAK AND P. W. KENT, *Biochem. J.*, 68 (1958) 452.
[9] D. HAMERMAN, *Science*, 122 (1955) 924.
[10] E. KORN, *J. Biol. Chem.*, 234 (1959) 1325.
[11] N. F. BOAS, *J. Biol. Chem.*, 204 (1953) 553.
[12] R. G. SPIRO, *J. Biol. Chem.*, 234 (1959) 742.
[13] O. W. NEUHAUS AND M. LETZRING, *Anal. Chem.*, 29 (1957) 1230.
[14] J. E. DOWLING AND G. WALD, *Federation Proc.*, 18 (1959) 217.
[15] J. A. CIFONELLI AND A. DORFMAN, *J. Biol. Chem.*, 228 (1957) 547.
[16] A. MARKOVITZ, J. A. CIFONELLI AND A. DORFMAN, *Biochim. Biophys. Acta*, 28 (1958) 453.
[17] R. A. VAN DYKE, G. WOLF AND B. C. JOHNSON, *Am. Chem. Soc. Abstracts, 135th Meeting, Boston*, 1959, 9A.

W-16-160
Bib. No. 0972

VITAMIN A AND MUCOPOLYSACCHARIDE SYNTHESIZING ENZYMES

GEORGE WOLF, PARTAB T. VARANDANI AND B. CONNOR JOHNSON

Radiocarbon Laboratory and Department of Animal Science, University of Illinois, Urbana, Ill. (U.S.A.)

(Received May 14th, 1960)

SUMMARY

An enzyme fraction was obtained from pig colon mucosal homogenates, after removal of nuclei, mitochondria and microsomes, by precipitation at pH 5.2, which, upon incubation with labeled sulfate or labeled glucose, produced labeled mucopolysaccharide. This enzyme fraction ("pH 5 enzymes") required glucose, glutamine and diphosphorpyridine nucleotide, but no adenosine triphosphate for mucopolysaccharide synthesis, and was stimulated by uridine triphosphate. Its pH optimum was at 6.8. The [^{35}S]mucopolysaccharide produced by the pH 5 enzymes could be precipitated with carrier chondroitin sulfate by cetylpyridinium bromide. The [^{14}C]mucopolysaccharide obtained from [^{14}C]glucose yielded labeled hexosamine on hydrolysis. The pH 5 enzymes contain about 50% cent of the vitamin A of whole mucosa. Treatment with lipoxidase lowered incorporation, which could be restored by added vitamin A. The pH 5 enzymes from vitamin A deficient pigs showed lowered activity, again restorable by added vitamin A, specifically. Pig colon mucosa catalyzed the activation of sulfate to phosphoadenosine phosphosulfate, and pH 5 enzymes the transfer of sulfate to *p*-nitrophenol.

INTRODUCTION

In the previous paper of this series[1], it was shown that added vitamin A is able to restore to normal the greatly reduced ability of colon homogenates from vitamin A-deficient rats to incorporate labeled sulfate into mucopolysaccharides.

Since the amount of colon mucosa in the rat is exceedingly small and difficult to homogenize without admixture of colon wall, a more plentiful source of clean mucosa was sought. The present paper describes the properties of a pig colon mucosal protein fraction which can synthesize MPS, and the influence of vitamin A thereon.

Abbreviations: MPS, mucopolysaccharide; ATP, adenosine triphosphate; UTP, uridine triphosphate; DPN, diphosphopyridine nucleotide; PAPS, phosphoadenosine phosphosulfate.

METHODS

Preparation of sub-cellular fractions and "pH 5 enzymes" from pig colon mucosa

Excised colons of freshly killed pigs, washed by flushing through them cold tap water, were cut open and further washed with ice-cold distilled water and finally with ice-cold 0.9 % NaCl. The mucosae from the inside of the colons were scraped off and homogenized with 2.5 volumes of pH 7.6 homogenizing medium (composition given below) for 2 min, using a motor-driven Teflon homogenizer. The homogenates were then separated into various subcellular fractions by differential centrifugation. The debris, nuclei, and mitochondria were sedimented by centrifuging at 8,500 × g for 15 min in a cooled Servall-SS-1 centrifuge. The microsomes were sedimented by centrifuging the resultant supernatant at 105,000 × g for 1 h in a refrigerated Spinco preparative centrifuge.

An enzyme fraction was then precipitated from the microsomal supernatant by adjusting the pH from 7.6 to 5.2, by adding dropwise cold 1 *M* acetic acid with constant stirring. The precipitated enzymes (henceforth called "pH 5 enzymes") were collected by centrifugation in a Servall-SS-1 centrifuge at 20,000 × g for 30 min.

Homogenizing medium

The homogenizing medium used was similar to that of ZAMECNIK *et al.*[2]. Its composition was: $MgCl_2$, 0.01 *M*; K phosphate buffer, 0.02 *M*, pH 7.8; $KHCO_3$, 0.035 *M*; KCl, 0.025 *M*; sucrose, 0.25 *M*; and nicotinamide, 0.01 *M*, final pH 7.6. The $MgCl_2$ was added just before use to prevent the precipitation of magnesium phosphate.

Incubation of subcellular fractions and pH 5 enzymes with radiosulfate

The subcellular fractions and pH 5 enzymes were incubated with substrates, cofactors and radioactive sodium sulfate (carrier-free, obtained from Abbott Laboratories) as described in Tables I to IV at 37° for 2.5 h in oxygen–carbon dioxide (95:5) in a Dubnoff shaker. At the end of the incubation period an equal volume of 8 % trichloroacetic acid solution was added, and an aliquot of the supernatant solution,

TABLE I

INCORPORATION OF [^{35}S]SULFATE INTO MUCOPOLYSACCHARIDE BY SUBCELLULAR FRACTIONS AND pH 5 ENZYMES OF PIG COLON MUCOSA

The values are averages of the number of incubations, shown in parentheses. The complete system consisted of 10 μmoles ATP, 6 μmoles $MgCl_2$, 3 μmoles DPN, 1 μmole glutamine and 10 μmoles glucose. The radioactivity added per incubation, $9 \cdot 10^6$ counts/min made to final volume of 1 ml with phosphate buffer, pH 7.4.

Subcellular fraction	*Mucopolysaccharide count/min/mg protein*
Supernatant free from mitochondria and nuclei	1293 (4)
Supernatant free from mitochondria, nuclei and microsomes	1521 (4)
Supernatant free from mitochondria, nuclei, microsomes, and pH 5 enzymes	326 (1)
Microsomes	516 (4)
pH 5 enzymes	1728 (4)
pH 5 enzymes and microsomes	1770 (3)

after centrifugation, was subjected to paper chromatography, and the radioactivity in MPS was determined as previously described[1]. A protein determination on the incubation was carried out, also as described[1].

Incubation with [1-^{14}C]glucose

In place of radiosulfate, the pH 5 enzymes were incubated with [1-^{14}C]glucose (1 mC/mmole, obtained from Volk Radiochemical Co.) and 40 μmoles of nonradioactive sulfate along with other required cofactors as shown in Table V. The [^{14}C]MPS formed was separated by paper chromatography and eluted with water as described previously[1]. The eluates were combined and concentrated to dryness in a steam-bath under nitrogen. To the dry concentrate was added 1.5 ml of 3 *N* HCl and 10 mg glucosamine as carrier. The mixture was hydrolyzed by heating on a steam-bath for 10 h. The HCl was then removed by repeated evaporation in a steam-bath.

The dry residue was taken up in a small amount of water and applied to a Dowex-50 column[3]. The column was washed with 500 ml of distilled water and the hexosamine was eluted with 20 ml of 2 *N* HCl. The HCl was evaporated and the residue dissolved in 0.5 ml of water. An aliquot of 0.1 ml was applied to a Whatman No. 1 filter paper and chromatographed in butanol–pyridine–water (6:4:3), (descending). The radioactive spot was located by the scanning apparatus[1] and the non-radioactive glucosamine spotted with ninhydrin.

Estimation of vitamin A

Vitamin A was estimated by the Carr-Price reaction as described by JOHNSON[4]. 52 g of pig colon mucosa were saponified by refluxing with 0.5 *N* alcoholic KOH for 1 h. The resulting solution was extracted 4 times with 100-ml volumes of ether (peroxide free). The ether extract was washed with water until free from alkali. The ether solution was then dried over anhydrous Na_2SO_4 and concentrated to dryness *in vacuo* under nitrogen. It was taken up in 1 ml of chloroform and the O.D. read in the Evelyn colorimeter following the addition of 9 ml of antimony trichloride reagent. This was compared with a standard curve.

Preparation of vitamin A-deficient pigs

Two- to three-day-old pigs were fed *ad libitum* a vitamin A-free α-protein synthetic milk diet[5]. The pigs were killed for *in vitro* experiments one week after they began to lose weight.

Preparation of [^{35}S]phosphoadenosine phosphosulfate

[^{35}S]PAPS was prepared essentially by the method described by ROBBINS AND LIPMANN[6]. The incubation mixture containing 40 μmoles ATP, 20 μmoles $MgCl_2$, 10 μmoles cysteine, 150 μmoles imidazole hydrochloride and 35 μC carrier-free [^{35}S]-sulfate was adjusted to pH 7.0 and incubated with 30 mg of the protein from the supernatant fraction of pig colon mucosa at 37° for 1 h. The reaction was stopped by heating for 1 min to 95° and chilling in ice. [^{35}S]PAPS was isolated by subjecting the reaction mixture to paper electrophoresis in 0.05 *M* citrate buffer, pH 5.6, for 5 h at 300 V. Under this condition it migrated 17 cm. An u.v. absorbing band, representing PAPS, coincided with a radioactive band due to ^{35}S. The compound was eluted with glass-distilled water, the purity checked by u.v. absorption at 260 mμ, and the solution lyophilized.

Preparation of chondroitin

Chondroitin was prepared by chemical desulfation of chondroitin sulfate as described by KANTOR AND SCHUBERT[7].

Transfer of sulfate from [^{35}S]PAPS to p-nitrophenol

[^{35}S]PAPS (140,000 counts/min), along with 5 μmoles $MgCl_2$, 10 μmoles cysteine, 0.02 μmoles of *p*-nitrophenol, 100 μmoles imidazole hydrochloride, pH 7.0, and 3 to 6 mg protein from a pH 5 enzyme fraction of pig colon were incubated at 37° for 30 min under O_2–CO_2 (95:5). The reaction was stopped by heating to 95° for 1 min and chilling in ice. Radioactivity of *p*-[^{35}S]nitrophenol sulfate was assayed after isolating the compound by paper chromatography according to the method of KENT AND PASTERNAK[8], and colorimetrically by the method of HILZ AND LIPMANN[9].

RESULTS

Mucopolysaccharide synthesis by subcellular fractions

Experiments were carried out with pig colon mucosa homogenates to determine the subcellular fraction or fractions responsible for MPS synthesis. Table I shows that these enzymes are present in the supernatant solution of the homogenate, after removal of nuclei, mitochondria and microsomes, and that they are precipitable at pH 5.2. Table II shows the degree of purification achieved by isolating the pH 5 enzymes.

TABLE II

PURIFICATION OF THE ENZYMES SYNTHESIZING MUCOPOLYSACCHARIDE

The values are averages of the number of incubations, shown in parentheses. The complete system consisted of 10 μmoles of glucose, 1 μmole of glutamine, 3 μmoles of DPN and $^{35}SO_4^{=}$, $12 \cdot 10^6$ counts/min made to final volume of 1 ml in the phosphate buffer, pH 6.8.

Subcellular fraction	*Mucopolysaccharide counts/min/mg protein*	*Purification*
Supernatant free from nuclei and debris	500 (2)	1
pH 5 enzymes	1314 (2)	2.6

Cofactor requirements of pH 5 enzymes

In order to determine the cofactor requirements of pH 5 enzymes, they were incubated with the cofactors as indicated in Table III, and MPS was isolated as described. The system has a requirement for glutamine, glucose and DPN, but not for ATP. When UTP is added, the incorporation of [^{35}S]sulfate increases more than two-fold.

Effect of period of incubation

Having found that the complete system for the synthesis of MPS is located in the pH 5 enzymes, it was necessary to determine some of the properties of these enzymes so that further work on fractionation could be carried out.

The pH 5 enzymes were mixed with all the cofactors and incubated for different lenghts of time, and MPS was isolated by paper chromatography as described. The

TABLE III

REQUIREMENT OF COFACTORS BY pH 5 ENZYMES FOR INCORPORATION OF $^{35}SO_4^{=}$ INTO MUCOPOLYSACCHARIDE

The values are averages of the number of incubations, shown in the parentheses. Radioactivity added per incubation, $9 \cdot 10^6$ counts/min made to final volume of 1 ml with phosphate buffer, pH 7.4.

ATP 10 μmoles	*$MgCl_2$* 6 μmoles	*DPN* 3 μmoles	*Glutamine* 1 μmole	*Glucose* 10 μmoles	*UTP* 4 μmoles	*Mucopolysaccharide* counts/min/mg protein
+	+	+	+	+	—	2234 (2)
—	—	+	+	+	—	2349 (2)
+	+	—	+	+	—	1713 (2)
+	+	+	—	+	—	798 (2)
+	+	+	+	—	—	560 (2)
—	—	+	+	+	+	5723 (2)

TABLE IV

EFFECT OF PERIOD OF INCUBATION ON THE INCORPORATION OF $^{35}SO_4^{=}$ INTO MUCOPOLYSACCHARIDE BY pH 5 ENZYMES OF PIG COLON MUCOSA

The values are averages of the number of incubations, shown in parentheses. The complete system was that shown in Table I.

Period of incubation (min)	*Mucopolysaccharide counts/min/mg protein*
0	197 (1)
30	714 (2)
60	882 (2)
90	964 (2)
120	970 (2)

results (Table IV) show that the maximum incorporation of [^{35}S]sulfate into MPS is attained within a 1.5 h period.

Effect of pH

The pH 5 enzyme preparation was suspended in phosphate and phosphate–citrate buffers of different pH's and incubated with the complete system. The results are graphically represented in Fig. 1. The figure shows a broad peak, indicating that more than one enzyme present in the pH 5 enzyme is responsible for the synthesis of MPS.

Identification of MPS

As discussed in the previous paper[1], owing to the relatively low level of incorporation of [^{35}S]sulfate into MPS, it was essential to ascertain that the spot on the paper chromatogram assayed for MPS was truly that substance. The following methods were used. (a) Toluidine blue spray. Paper chromatograms of MPS were sprayed with the toluidine blue reagent specific for MPS[1]. Pink spots against a blue background appeared at the spots associated with radioactivity. (b) Incorporation of [^{14}C]-glucose into hexosamine of MPS. [1-^{14}C]glucose, together with unlabeled sodium sulfate, was incubated with the pH 5 enzymes, as shown in Table V. [^{14}C]MPS was isolated by the same method as for [^{35}S]MPS and was hydrolyzed as described. [^{14}C]hexosamines were isolated by ion exchange chromatography and paper chromatography as outlined

in the experimental section. The radioactive spot obtained corresponded exactly to the ninhydrin spot of the carrier glucosamine mixed with the radioactive hexosamines. Another aliquot of [^{14}C]hexosamines, with carrier glucosamine, was converted to the osazone[1], which retained constant specific radioactivity on recrystallization (Table V).

(c) Precipitation with carrier chondroitin sulfate. [^{35}S]MPS was prepared with pH 5 enzymes and assayed in the usual manner. The spot from the paper chromatogram (5184 counts/min) was then eluted and 25 mg carrier chondroitin sulfate (obtained from Nutritional Biochemicals Corporation) were added. The radioactive MPS, along with the carrier, were precipitated with cetylpyridinium bromide in 0.25 N sodium chloride solution, using the method of KORN[10], known to be specific for MPS. The

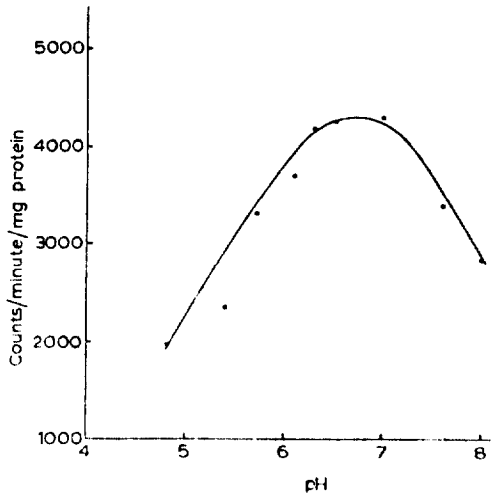

Fig. 1. Effect of pH on the incorporation of $^{35}SO_4^{=}$ in mucopolysaccharides by pig colon mucosal pH 5 enzymes.

TABLE V

INCORPORATION OF [1-^{14}C]GLUCOSE INTO HEXOSAMINE OF MUCOPOLYSACCHARIDE SYNTHESIZED BY pH 5 ENZYMES

The complete system consisted of 10 μmoles of glucose, 1 μmole of glutamine, 3 μmoles of DPN, 40 μmoles of sodium sulfate, $1 \cdot 10^6$ counts/min of [1-^{14}C]glucose, made up to 1 ml with phosphate buffer, pH 6.8.

	counts/min
^{14}C-mucopolysaccharides formed/mg of protein	1,575
Total ^{14}C-mucopolysaccharides eluted	15,750
Total ^{14}C-hexosamines isolated	4,320

	counts/min/mmole
Specific activity of hexosamines after addition of carrier glucosamine	30,150
After 3rd crystallization of osazone	16,470
After 4th crystallization of osazone	21,800

precipitated complex, adsorbed on Celite and dissociated in 4 N sodium chloride solution, showed an activity of 5400 counts/min. However, this activity could be dialyzed out within 4 h. Apparently the MPS synthesized are of comparatively low molecular weight.

The effect of vitamin A on the activity of pH 5 enzymes

After it was established that pH 5 enzymes can incorporate labeled sulfate into MPS, it was necessary to investigate the influence of vitamin A on this process. Therefore, pigs were made deficient in vitamin A and the pH 5 enzymes were extracted from their colon mucosa as described. Table VI shows that, as in rats, vitamin A

TABLE VI

EFFECT OF VITAMIN A DEFICIENCY ON THE INCORPORATION OF $^{35}SO_4^{=}$ INTO MUCOPOLYSACCHARIDE AND SPECIFICITY OF VITAMIN A IN pH 5 ENZYMES

The values are averages of the number of incubations, shown in the parentheses. The complete system consisted of 10 μmoles of glucose, 1 μmole of glutamine, 3 μmoles of DPN and $^{35}SO_4^{=}$ $12 \cdot 10^6$ counts/min, made up to 1 ml with phosphate buffer, pH 6.8.

Vitamin A status	*Add vitamin 10 μg*	*Mucopolysaccharide counts/min/mg protein*
+	—	2349 (2)
—	—	1407 (2)
—	Vitamin A	2556 (2)
—	Vitamin E	1564 (2)
—	Vitamin D	1530 (2)

TABLE VII

EFFECT OF PREINCUBATION WITH LIPOXIDASE ON THE INCORPORATION OF $^{35}SO_4^{=}$ INTO MUCOPOLYSACCHARIDE SYNTHESIZED BY pH 5 ENZYMES

The values are averages of the number of incubations, shown in the parentheses. The complete system consisted of 10 μmoles of glucose, 1 μmole of glutamine, 3 μmoles of DPN and $^{35}SO_4^{=}$ $12 \cdot 10^6$ counts/min, made up to 1 ml with phosphate buffer, pH 6.8.

Lipoxidase 0.3 mg/ml	*Add vitamin A 10 μg*	*Mucopolysaccharide counts/min/mg protein*
—	—	2706 (4)
0.1 ml	—	1213 (4)
0.1 ml	+	2188 (4)

deficiency lowers MPS synthesis and that this synthesis can be specifically restored to normal by the addition of vitamin A to the enzyme system. In order to avoid the costly and cumbersome procedure of having to rear vitamin A-deficient pigs, an effort was made to destroy the vitamin A in pH 5 enzyme of normal pig colons. Table VII shows that lipoxidase has such an action on the enzymes, reflected in the lowered MPS synthesis after treatment with the vitamin A-destroying enzyme. With the small amount of lipoxidase used in this experiment it was possible to restore MPS synthesis partially to normal by addition of the vitamin.

The transfer of sulfate from PAPS to *p*-nitrophenol, measured by radioactivity or spectrophotometrically, was not affected by pre-incubation of pH 5 enzymes with

lipoxidase. Two per cent of incubated *p*-nitrophenol was sulfated from PAPS under the conditions described. Neither chondroitin sulfate nor chondroitin could act as acceptors of sulfate, using [^{35}S]PAPS. The last-named compound was produced in good yield by pig colon mucosal homogenates.

DISCUSSION

In the previous paper of this series[1], it was shown that vitamin A functions in the incorporation of labeled sulfate into MPS in rat colon homogenates. In order to purify this system, an enzyme fraction which consistently incorporated both labeled sulfate and glucose (as hexosamine) into MPS was obtained from pig colon homogenate supernatant solution by precipitation at pH 5.2. This pH 5 enzyme precipitate represents a 2.6-fold purification over crude mucosal homogenate. Some of the properties of the enzyme fraction were explored: it requires glucose, glutamine and DPN, but it is noteworthy that no ATP requirement was found. It thus apears that it still contains the enzymes necessary to produce high-energy bonds from glucose. It is significant that added UTP increased the activity of the pH 5 enzymes to twice the normal value. That the pH activity curve would show no sharp peak might be expected in view of the number of enzymes which must be required for MPS synthesis.

The fact that the radioactivity was precipitable along with carrier chondroitin sulfate by cetyl pyridinium bromide, and that the labeled glucose was incorporated into the hexosamine moiety of the MPS would establish that MPS was synthesized by the pH 5 enzymes. The fact that only 27 % of the total radioactivity from isolated MPS was obtained as hexosamines (Table V) after incubation with labeled glucose may be due to the incorporation of the labeled glucose into other sugar derivatives contained in the MPS. Confirmation of this hypothesis must await work which is under way on the analysis of the various constituents of the MPS synthesized.

As previously reported[1], vitamin A is found to be present in pig colon mucosa (3.7 μg/100 g). Of this amount, 1.8 μg (48.6 %) were shown to be present in the pH 5 enzymes upon isolation of the enzymes, denaturation and extraction. On treatment with vitamin A-destroying lipoxidase, MPS synthesizing activity in pH 5 enzymes dropped and was restored by added vitamin A. The reactivation of the pH 5 enzymes of pig colons from vitamin A-deficient pigs was also possible specifically with added vitamin A.

These results show that pig colon mucosa, like rat colon mucosa, contains enzymes which synthesize MPS and which require vitamin A for their function. Previous work[1] showed that the action of the vitamin must be either in the polymerization step of the uridine-combined substrates to MPS, or in the activation or transfer of sulfate to the polymer. The present data show that colon homogenate can activate sulfate to phosphoadenosine-phosphosulfate, and transfer it efficienctly to an artificial acceptor. The sulfate transfer reaction was not affected by lipoxidase treatment, under conditions which led to inhibition of MPS synthesis. Preliminary observations by the present authors, on the other hand, showed that vitamin A deficiency severely lowered formation of PAPS, an inhibition which could be overcome by *in vitro* addition of vitamin A. These results, then, would indicate that vitamin A exerts its influence on MPS synthesis through its effect on, or participation in, the sulfate activation reactions.

ACKNOWLEDGEMENTS

This investigation was supported by a grant from the National Vitamin Foundation and by the U.S. Atomic Energy Commission contract No. AT(11-1)-67 with the University of Illinois.

REFERENCES

1 G. WOLF AND P. T. VARANDANI, *Biochim. Biophys. Acta*, 43 (1960) 501.
2 P. C. ZAMECNIK AND E. B. KELLER, *J. Biol. Chem.*, 209 (1954) 337.
3 N. F. BOAS, *J. Biol. Chem.*, 204 (1953) 553.
4 B. CONNOR JOHNSON, *Methods of Vitamin Determination*, Burgess Publishing Co., Minneapolis, 1948, p. 32.
5 A. J. SHEPPARD AND B. CONNOR JOHNSON, *J. Nutrition*, 61 (1957) 195.
6 P. W. ROBBINS AND F. LIPMANN, *J. Biol. Chem.*, 229 (1957) 837.
7 T. G. KANTOR AND M. SCHUBERT, *J. Am. Chem. Soc.*, 79 (1957) 152.
8 P. W. KENT AND C. A. PASTERNAK, *Biochem. J.*, 69 (1958) 453.
9 H. HILZ AND F. LIPMANN, *Proc. Natl. Acad. Sci. U.S.*, 41 (1955) 880.
10 E. D. KORN, *J. Biol. Chem.*, 234 (1959) 1325.

Wolke, Nielsen, & Rousseau
Bib. No. 9989

Am. J. Vet Pos. 29:1009-1024. 1968.

Bone Lesions of Hypervitaminosis A in the Pig

R. E. Wolke, D.V.M., M.S.; S. W. Nielsen, D.V.M.; Ph.D.; J. E. Rousseau, Jr., Ph.D.

SUMMARY

Thirty crossbred 7-week-old pigs were fed graded levels of vitamin A to determine the effects of hypervitaminosis A on growing bone. The levels of vitamin A fed were 39.7, 119.0, 6,614, and 19,842 μg./kg. of body weight per day for 5 weeks.

Osseous lesions were not observed grossly, radiographically, or histologically in the control pigs, and few lesions were observed in pigs which were mildly hypervitaminotic (given 6,614 μg.). Lesions in pigs fed the greatest level of vitamin A (19,842 μg.) were severe in both endochondral and intramembranous bone. Long bones were decreased in length and width, with greatest tissue loss in the epiphysis due to lysis of chondroid matrix. Spicules of spongiosa were fewer but larger, and numbers of osteoblasts were significantly decreased. Change in subperiosteal osteoclastic activity was not observed. Intramembranous bone was thinner and had few osteoblasts and normal numbers of osteoclasts.

It was proposed that excessive doses of vitamin A in the growing pig produced lesions in endochondral bone by destruction of epiphyseal cartilage and decreased production of matrix in the presence of normal remodeling processes. In intramembranous bones, the lesions were the result of inadequate production of matrix coupled with normal osteoclastic activity.

In growing animals, bone lesions caused by the excess of vitamin A were attributed to an acceleration of normal remodeling processes. Lesions included spontaneous fractures, cortical thinning, reduction in bone size, and osteoporosis.[7,40,42] Descriptions of histologic changes, however, were conflicting. Early destruction of epiphyseal cartilage, thinning of cortical bone, and decreased bone mass were observed, but the question of relative activity of osteoblasts versus osteoclasts was not resolved. The lesions were attributed to increased osteoblastic and osteoclastic activity.[33,41,42] Conversely, lesions also were attributed to decrease

Received for publication June 12, 1967.

From the Department of Animal Diseases, University of Connecticut, Storrs, Conn. 06268.

Scientific Contribution No. 257, Storrs Agricultural Experiment Station, University of Connecticut, Storrs.

This study was supported in part by funds from U.S. Public Health Service Grants 5 TIGM 985-05 and NB 02108-06.

in osteoblastic activity with no change in osteoclasia.[17,20,21]

Osseous lesions in children were studied principally by radiographic methods. Cortical thickening, periosteal swelling, secondary soft tissue swelling, hyperostosis, and localized arrest of growth were described.[24,36,39] Similar changes were not reported in experimental hypervitaminosis A of animals.

The present experiment was initiated to re-evaluate the effects of excess vitamin A on endochondral and intramembranous bone formation in the growing pig, an animal in which the toxicosis seems analogous to that in children.

Materials and Methods

Thirty Yorkshire-Hampshire crossbred pigs, 4 to 5 weeks of age, were placed in individual concrete-floor pens with wood shaving for bedding. Six pigs were allotted to 3 groups in a pilot study to test the toxicity of 3 arbitrary levels of vitamin A. Levels of vitamin A fed were 55 (pilot group 1), 8,800 (pilot group 2), and 26,400 (pilot group 3) μg./kg. of body weight per day. The remaining 24 pigs were all males and were placed in 6 replicates of 4 littermates each.

The basal ration was calculated to be adequate in all nutrients as suggested by the National Research Council, and its composition was described by Eaton *et al.*[12] Experimental design and nutritional regimen were similar to those described by Hurt *et al.*[19]

In the definitive experiment, the levels of vitamin A fed were 39.7 and 119.0 (control, group A), 6,614 (mildly hypervitaminotic, group B), and 19,842 (severely hypervitaminotic, group C) μg./kg. of body weight per day. Each pig within the replicate was placed at one of these levels and maintained on the diet for 5 weeks (Table 1).

The vitamin A supplement * was analyzed twice, and results of analyses indicated the content of 110.3 and 114.5 mg. of vitamin A (as retinol) per gram of supplement.

The pigs were weighed each week. Whole and citrated blood samples were obtained from the anterior vena cava and prepared on the day before the start of feeding respective pigs the designated levels of vitamin A supplementation and on the last day of the 5th week of feeding vitamin A.

Bone tissues for histologic examination were collected immediately after the pigs were euthanatized, fixed in 10% formalin, and decalcified with 18% solution of formic and hydrochloric acids by means of an ionic bone decalcifier.* The sections were then placed in saturated solution of lithium carbonate for 24 hours, rinsed, and replaced in formalin. Tissue blocks were embedded in paraffin and sectioned at 10 μ. All sections were stained with hematoxylin and eosin. Sections of costochondral cartilage were also stained with toluidine blue and Alcian blue.

Right and left radiuses, right 9th rib, and right frontal and squamous occipital bones of each pig were measured grossly and microscopically. Gross examination of the left radius included determinations of weight, length, shortest distance between epiphyseal margins, distance from the proximal epiphyseal ridge to the point of distal epiphyseal-metaphyseal juncture closest to the diaphysis, and diaphyseal shaft area. Measurements of the right radius were made of width of diaphysis at the narrowest point, angle of metaphyseal flare, and porosity changes. Degrees of porosity were estimated from photographs of macerated, dried, cancellous areas of the distal part of the radius.

The angle of metaphyseal flare (Fig. 1) was determined from tracings of radiographs, thus: Points A and A′ were placed at point of narrowest width of the diaphysis and were used as a base from which to draw 4 equi-distant arcs bisecting at points B and B′. Line C was drawn to connect points B and B′. Line P was drawn perpendicular to line C through the lateral-most aspect of the epihyseal line. Line Q was drawn perpendicular to line P and tangent to the epiphyseal line. Line R was drawn along the greatest slope of the distal lateral metaphysis, and the angle of flare was measured.

Dorsoventral thickness of frontal bone and cephalic-caudal thickness of squamous occipital bone were measured by filar micrometer.

Frontal bone sections were taken from the area immediately above the falx cerebri

* Dry vitamin A acetate beadlets, Type 325-40, Lot No. 013113, guaranteed potency of 325,000 U.S.P. units per gram, Hoffmann-LaRoche, Inc., Nutley, N.J.

* The Martin Sweets Company, Louisville, Ky.

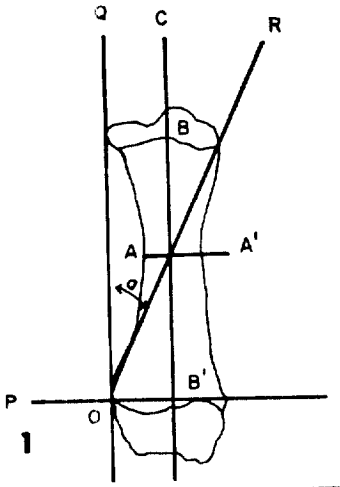

Fig. 1—Lines used for determination of the angle of distal metaphyseal flare (angle a) superimposed on right radius.

and included the frontal occipital synarthrosis. The area measured was the narrowest in a distance 1.0 mm. anterior to the synarthrosis.

Squamous occipital sections were taken at midline and extended from the foramen magnum to the parietal synarthrosis. The area measured was the narrowest point in a distance 1.0 mm. from the parietal synarthrosis.

Counts of osteoblasts were made from sections of proximal end of right radius. Six high-powered fields (x 500) within the primary spongiosa of the section were chosen, and all osteoblastic cells in the microscopic fields were counted.

Radiographic procedures were similar to those described by Grey *et al.*[17]

Fat-free ash content of the epiphysis (including 5.0 mm. of metaphysis immediately below epihyseal margins) and diaphysis were determined by procedures cited by Dehority *et al.*[9] The remaining bone was considered diaphysis. Determinations of organic matter were by difference of the fat-free, moisture-free left radius.

Vitamin A levels (in plasma) were determined by the Kimble procedure.[23] Alkaline and acid phosphatase activities (in serum) were determined by the method of Babson and Read[4] and Klein *et al.*[28]

Results

Feed Consumption and Weight Gains.—Feed consumption and body weight gain were depressed, and feed required per unit of live weight gain was increased in group C pigs; details are described by Hurt *et al.*[19]

Clinical Signs.—Clinical signs were seen only in pigs in group C. Anorexia, erythema of ventral aspects of the body, and abnormal stance, characterized by an arched back, were first observed during the 2nd week. The erythema lasted throughout the experiment but reached maximal severity by the 3rd week.

Lameness, pain, and stiffness of hindlegs was a common sign in all pigs fed the largest dose level. After the 3rd week, the pigs preferred a sitting or recumbent position and refused to walk.

During the 4th week, slight but constant hemorrhaging was observed around the ear tag. There was a thick, crusty mass of serum and debris in this area for the duration of the experiment.

Macroscopic Pathologic Changes

Group C pigs were stunted and debilitated and had reddened skin of the ventral abdominal area, moderate conjunctival injection, and a black, greasy discharge which stained the area below the medial canthus of both eyes.

The principal gross changes were in the bones of group C pigs; the bones were more readily cut and snapped readily when bent at the diaphysis.

Endochondral Bone.—Radius.—Radiuses from group C pigs were significantly decreased in weight, length, diaphyseal width, and area (Table 1). Since the mean distance between epiphyseal margins was 6.3 cm. for pigs of group A and 6.2 cm. for pigs of group C, the overall decrease in length was mainly attributable to loss of epiphyseal tissue.

Twenty-three of 24 left and right radiuses from group B and C pigs had subperiosteal exostoses, 1.0 cm. in diameter, on the proximal medial metaphysis near the insertion of the brachialis muscle.

The mean angles of metaphyseal flare (Fig. 1) were 121 and 127 degrees in radiuses of control pigs, 122 degrees in

TABLE 1—Effect of Hypervitaminosis A on Bones of Pigs

Group identification	No. of pigs	Level of vitamin A fed (µg./kg./day)	Left radius						Right radius			
			Weight (cm.)	Length (cm.)	Shaft area (sq. mm.)	Length between epiphyseal margins (cm.)	Length between proximal epiphyseal ridge and distal epiphyseal margin (cm.)	Diaphyseal width at narrowest point (cm.)	Angle of metaphyseal flare (degrees)	Thickness of frontal bone (mm.)	Width of squamous occipital bone (mm.)
A (controls)	6	39.7	26.8	9.0	61.0	6.3	7.2	1.5	121.0	5.0	2.8
	6	119.0	28.1	9.0	65.0	6.3	7.2	1.5	127.0	3.6	2.4
B (mildly hypervitaminotic	6	6,614.0	26.5	9.3	57.0	6.6	7.3	1.4	122.0	3.7	1.6
C (severely hypervitaminotic)	6	19,842.0	16.4	8.2	31.0	6.2	6.8	1.1	133.0	1.3	0
Standard deviation per pig			1.8	0.2	7.0	0.2	0.3	0.14	6.9	1.0	1.3

Results are averages of 6 pigs in each group fed different levels of vitamin A.

radiuses of group B pigs, and 133 degrees in radiuses of group C pigs.

Intramembranous Bone.—Skull.—Gross lesions of intramembranous bones consisted of a loss in porosity and thickness (Table 1).

Skulls of group A pigs were normal, but those of group B pigs were slightly smaller. Skulls of group C pigs had less bone mass, and the squamous occipital bone was, in all instances, so thin that it was possible to crush the cerebellum by external manual pressure (with fingers). As a result, 2 pigs had extensive subdural hemorrhage over the caudal portion of the cerebellum. The bony tissue, approximately 5.0 mm. lateral to the midline and just dorsal to the synarthrosis of the squamous and basilar portions of the occipital bones, was displaced caudally and ventrally, forming an S-shaped curve before continuing dorsally (Fig. 2).

Microscopic Pathologic Changes

Endochondral Bone.—Radius.—Epiphysis, spongiosa, and cortex from radiuses of the control pigs did not have any abnormalities (Fig. 4).

Fig. 2—Occipital bone from an area lateral to the midline at left (from control pig of group A). Squamous portion at right (from pig fed at dose level of 19,842 µg./kg. in group C) is displaced caudoventrally (arrow) but basilar portion is normal. Rule is in centimeters.

Fig. 3—Subperiosteal, highly vascular, coarsely woven exostosis of the proximal, medial radial metaphysis, (group C pig). H&E stain; x 25.

a) Epiphyseal Plate.—The main difference in radiuses from group B pigs was a decrease in thickness of the epiphyseal plate (Fig. 5). The average plate width was approximately three-quarters that of the group A (control) pigs; but in some areas, the total width of the plate was half that of the control pigs. The chondrocytes were normal in size and shape. In localized areas, there was a lack of transition between the zone of resting cartilage and the zone of degenerating chondrocytes. The areas were characterized by absence of longitudinally oriented columns of multiplying chondrocytes and replacement by packets of 2 to 6 chondrocytes. Thicker and fewer tongues of cartilage matrix protruded into the zone of provisional calcification. Invasion of the hypertrophied chondrocytes by vascular buds was normal.

In the zone of secondary ossification, there were fewer groups of chondrocytes and, subsequently, fewer groups of hypertrophied cartilage cells to be invaded by vascular buds. The tongues of calcified

Fig. 4 (left)—Group A pig. Normal dorsoventral thickness of epiphyseal plate. H&E stain; x 10.

Fig. 5 (center)—Group B pig (fed at the 6,614 μg./kg. dose level). The dorsoventral thickness of the epiphyseal plate is decreased. H&E stain; × 10.

Fig. 6 (right)—Group C pig. There is severe loss of epiphyseal plate matrix and decreased number of spongiosa spicules. H&E stain; x 10.

cartilage were, therefore, thicker and less numerous than in the controls.

In group C pigs, there was marked decrease in width of dorsoventral plate (Fig. 6). A thin band of cartilage was all that remained, and in some areas the plate was absent. Where no plate existed, it was substituted by bony trabeculae with centers composed of spicules of calcified cartilage. In the portions remaining, the width was not uniform, resembling lesions of group B pigs. The zone of multiplying and degenerating chondrocytes was most severely affected, the remaining plate being composed chiefly of resting cartilage. The morphologic features of the chondrocytes remained normal. The zone of multiplying chondrocytes was significantly smaller. The columns were much fewer and often disorganized. The tongues of matrix between the columns were subsequently thicker and fewer than those in group A or group B pigs. Similar lesions were observed in the zone of secondary ossification.

b) Spongiosa.—Primary spongiosa of group B pigs was composed of fewer spicules of bone with thickened cartilaginous centers. In the zones of primary and secondary ossification, the osteoid borders of the spicules were slightly thinner than those in the controls. These spicules were well lined with osteoblasts, but there were fewer of these cells than in group A pigs, and there were more resting or inactive forms of the cell. An increase in osteoclasts was not observed in either zone of spongiosa.

Spicules from the primary spongiosa of group C pigs were fewer, with thinner borders of bony tissue and osteoid surrounding calcified cartilage. Few osteoblasts lined the spicules, and those which did were flattened and inactive. The secondary spongiosa had relatively more spicules of mature bone than that of group B pigs.

c) Cortex.—The metaphyseal and diaphyseal cortex of radiuses from group B pigs were slightly thinner than those of the control pigs. The mature lamellar bone contained larger haversian canals which were lined by few osteoblasts. The cortices of radiuses from group A and B pigs had masses of coarsely woven bone occupying the areas of interstitial lamellae. A difference in osteoclasts was not observed.

Cortical bone from group C pigs in both metaphyseal and diaphyseal areas was morphologically similar to that of group B pigs, but the lesions were more severe. In 5 of 6 radiuses examined, an area of subperiosteal new bone proliferation was observed in the medial metaphyseal region. The area was similar to the proliferative region observed grossly near the insertion of the brachialis muscle. The lesion consisted of thickened osteogenic layer of the periosteum immediately above a zone of numerous neocapillaries (Fig. 3). The mass of new bone was of the coarsely woven type and contained many small irregular spaces within which there were blood vessels and fibrous tissue. These spaces were suggestive of primitive haversian canals. A difference in numbers of osteoclasts was not observed in the subperiosteal metaphyseal area of remodeling.

Rib.—The distal part of the 9th rib and adherent portion of costal cartilage were examined microscopically. The ribs of control pigs were normal (Fig. 7).

a) Costochondral Junction.—In group B pigs fed 6,614 μg. of vitamin A, the lesions were slight. Morphologic abnormality was not seen in the chondrocytes of the resting or growing zones of cartilage. Both the vascular channels passing through the matrix and their surrounding cartilage were normal. When compared with ribs of the controls, there was no difference in width of the area extending from the zone of hypertrophy to the zone of vascular invasion. There were fewer columns of multiplying and degenerating cartilage cells, and the tongues of cartilage matrix were correspondingly thicker and fewer than those in the control pigs. Invasion of chondrocytes by vascular buds and calcification of the matrix was normal. The

interspicular areas of the zone of provisional calcification were hemorrhagic.

Ribs from group C pigs had a marked lack of cartilage matrix. Along with this loss, there was a decided loss of basophilia in much of the remaining cartilage. The periphery of the cartilage was invaded by whirls of connective tissue and neocapillaries. In a few areas, there were masses of coarsely woven bone in the midst of connective tissue. The vascular channels passing through the matrix were greatly increased in diameter and were filled with fibrous connective tissue (Fig. 8). Often, this connective tissue was diffusely hemorrhagic. Around the circumference of the vascular channels, the matrix was strongly acidophilic. This same area of acidophilia had less metachromasia with toluidine blue stain as well as less affinity for Alcian blue stain. The zone extended into the surrounding cartilage for 100 to 200 μ, gradually becoming basophilic. The zone of cartilaginous growth was disorganized and characterized by diffuse, irregular scattering of chondrocytes. The tongues of cartilage matrix were thick, few, and quite irregular. Hemorrhages were common in the zone of provisional calcification.

b) Spongiosa.—Spicules of spongiosa bone from group B pigs were numerically equal to, or only slightly fewer than, the spicules in the controls, but osteoblastic activity was decreased.

There were fewer spicules of primary spongiosa in group C pigs than in the controls, and these were composed mainly of calcified cartilage with little osteoid on their borders. Relatively fewer spicules were seen in the secondary spongiosa, and many of these were composed of coarsely woven bone. There were few osteoblasts, and those seen were the resting or inactive form.

c) Cortex.—Differences were not seen in thickness of cortical bone in the pigs in group B. The osteogenic layer of the periosteum was thickened, and there was excessive fibrous tissue in the peripheral marrow spaces.

The cortex of group C pigs was composed of irregular masses of coarsely woven bone beneath a much thickened osteogenic layer of the periosteum. The marrow spaces within this bone were filled with immature fibrous tissue, hemorrhages, and 1 or more blood vessels. In some areas, these masses of immature bone were one-fourth of the total diameter of the rib. There was no difference in number of osteoclasts.

Intramembranous Bone.—Frontal.—All sections of bone from group A pigs were normal (Fig. 9). The average thickness was 5.0 mm. in pigs fed vitamin A at the dose level of 39.7 μg. and 3.6 mm. in pigs fed vitamin A at the 119.0-μg. dose level (Table 1).

The dorsoventral thickness of sections of bone from group B pigs was 3.7 mm. In many areas, especially subperiosteally, the bone was the compact type rather than the cancellous type. There were fewer spicules of cancellous bone, and diameters of the spicules were larger. The spicules were composed of more mature lamellar bone with finer fibers than those in control pigs. Due to the spicular maturity, fine basophilic cement lines were more evident. The lines were irregular, resulting in a mosaic pattern. The inner surface of the marrow cavities lacked the thin osteoid border seen in sections of bone from control pigs, and osteoblasts were fewer. Fewer osteoblasts and lack of osteoid tissue were also observed at the surface of the existing spicules. All layers of the periosteum on both dorsal and ventral surfaces were thinner, and the osteogenic layer was inactive. Number of osteoclasts in the area of remodeling seemed normal.

All frontal bones from group C pigs were severely decreased in the dorsoventral measurement (Table 1). Remaining bone was the compact type, and it was more finely fibered (Fig. 10). The osteoid seams lining spicules were narrow or absent and contained few osteoblasts which were the resting type. The periosteal layers were flattened. Numbers of osteoclasts in the zone of remodeling

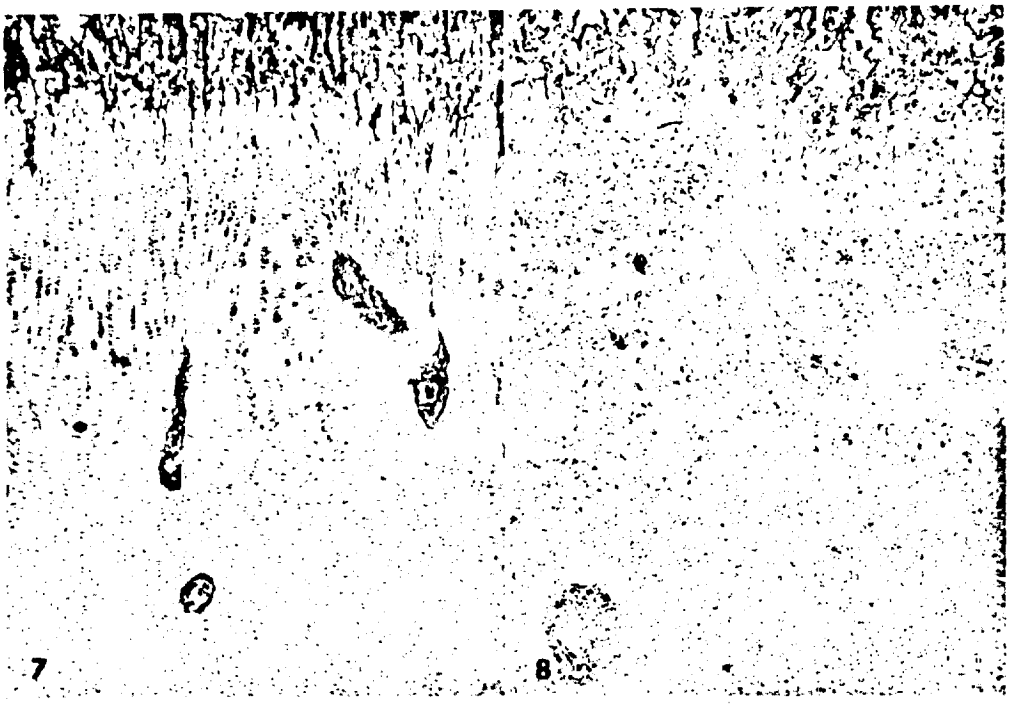



Fig. 7—Costochondral junction of 9th right rib (group A control pig). Basophilia of chondroid matrix surround normal vascular channels. H&E stain; x 25.

Fig. 8—Costochondral junction of 9th right rib (group C pig). The vascular channels are large, contain fibrous tissue, and are surrounded by a zone of acidophilia. H&E stain; x 25.

Fig. 9—Cancellous frontal bone with normal dorsoventral thickness (group A control pig). H&E stain; x 10.

Fig. 10—Frontal bone (group C pig) in which dorsoventral thickness is decreased, and the cancellous bone replaced by compacta. H&E stain; ×10.

Squamous occipital bones—cerebellar surface is at the left.

Fig. 11—Normal cephalic-caudal width and spicule development (group A pig). H&E stain; x 10.

Fig. 12—Decreased cephalic-caudal width and a more compact spicular structure (group B pig). H&E stain; x 10.

Fig. 13—Massive loss of bone with collagenous tissue replacement (group C pig). H&E stain; x 10.

were comparable with those of control pigs.

Squamous Occipital.—Squamous occipital bones of group A pigs were normal (Fig. 11). The mean cephalic-caudal width of the bone was 2.5 mm. (Table 1).

In group B pigs, the cephalic-caudal width of the squamous occipital bone was less than that of the bones of the control pigs (Table 1). The area between the cephalic and caudal cortical plates was thinner and occupied by thickened spicules which were often interdigitated with either cortex. These spicules remained cancellous but seemed more compact. The spicules were composed of both the coarsely woven and the lamellar types of bone and did not differ in this respect from those of the controls (Fig. 12). Osteoblastic activity and periosteal thickness were decreased.

Squamous occipital bones from group C pigs lacked bone, collagenous tissue occurring in its place for a variable distance ventrally toward the dorsal wall of the foramen magnum (Fig. 13). In most instances, fine, coarsely woven bone spicules were apparent a few millimeters above the dorsal wall. In areas where the cortices previously existed, collagen was mature and surrounded a thin center of immature fibroblasts and osteogenic layer of periosteum. There was no difference in the number of osteoclasts.

Osteoblastic Activity.—Six microscopic fields (x 500) of the primary spongiosa from matching areas of all radiuses were examined, and the osteoblasts were counted. The number of osteoblasts per field was inversely proportional to the level of vitamin A fed to the pigs. The mean number of osteoblasts in radiuses of control pigs was 161; in radiuses of group B pigs, 124; and in radiuses of group C pigs, 101 (with a standard deviation of 29).

Osteoblasts were of different shapes and sizes, with 2 readily differentiated forms. Active osteoid-producing cells lined spicules in a continuous row in the control pigs (Fig. 14). The osteoblasts were plump, ovoid to rectangular, and had a well-outlined basophilic cytoplasm. The long axis of the cell was oriented at right angles to the surface of the spicule on which it rested. The nucleus was eccentric and usually was at the periphery of the cell furthest from the surface of the spicule. These cells were "active" osteoblasts.[32]

Osteoblasts of group C pigs were flattened and spindle shaped, with large intercellular intervals (Fig. 15). The cells were strongly basophilic, with an ovoid, flattened, and centrally located nucleus; they were "inactive."[32]

Osteobast counts did not reflect the relative proportion of active to inactive cells observed; however, a great proportion of inactive forms were found in pigs fed the higher levels of vitamin A.

Porosity Determinations and Radiologic Features

Porosity changes in primary spongiosa of macerated, dried proximal radiuses were difficult to determine by gross examination in pigs from groups B and C. Trabeculae from group C pigs seemed as thick and numerous per unit area as those from group A pigs (Fig. 16, 17).

Radiographic changes of radiuses from group C pigs included cortical thinness, increased radiopacity of the epiphyseal line, medial metaphyseal subperiosteal exostosis, and greater angle of metaphyseal flare resulting in the "pagoda" effect (Fig. 18, 19).

Chemical Determinations

At the start of the experiment, mean levels of vitamin A (in plasma) were 21 μg./100 ml. Terminally, group A pigs had a mean level of 24 μg./100 ml.; group B pigs, 62 μg./100 ml.; and group C pigs, 190 μg./100 ml. (Table 2).

Alkaline phosphatase and acid phosphatase activity values were decreased in all pigs during the comparison period, but the magnitude of the decrease was not statistically significant according to levels of vitamin A fed (Table 2).

Ash determinations were made of epiphyseal and diaphyseal portions of the left radius. A difference of 4.6 Gm./100

Legends for Illustrations on Opposite Page

Fig. 14—Plump, basophilic "active" osteoblasts line spongiosa spicules from radius of group A pig. H&E stain; x 153.

Fig. 15—Spicules from radius of group C pig. Osteoblasts are absent. H&E stain; x 153.

Fig. 16—Primary spongiosa of macerated dried proximal right end of radius of group A pig has thick trabeculae and normal porosity. H&E stain; x 3.5.

Fig. 17—Primary spongiosa of macerated dried proximal right radius of group C pig. Trabeculae are as thick and numerous as those in the control pig, and an increase in porosity is not evident. H&E stain; x 3.5.

Fig. 18—Radiograph of right radius of group A pig, with normal dense cortices extending into metaphysis, radiolucent epiphyseal line, and angle of metaphyseal flare.

Fig. 19—Radiograph of right radius of group C pig. The cortices are decreased in thickness and do not extend into the metaphysis. The epiphyseal lines have lost much of their radiolucency, and the angle of metaphyseal flare has increased, resulting in the "pagoda" effect.



14



15

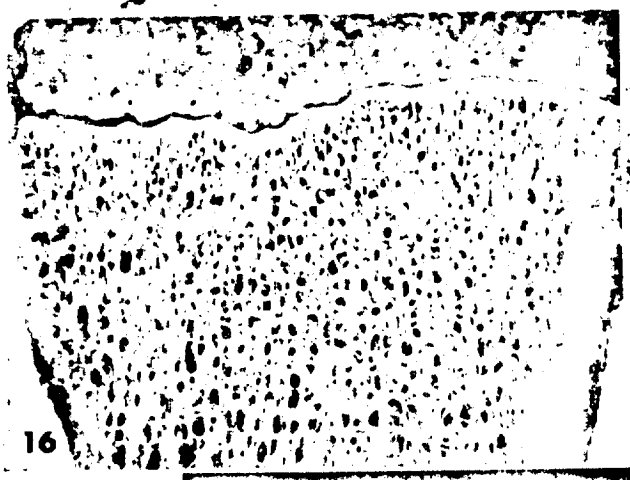

16

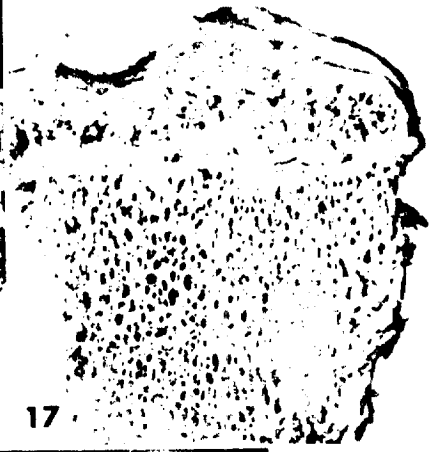

17



18



19

Table 2—Effect of Excessive Vitamin A Intakes on Concentration of Vitamin A in Plasma, Phosphatases in Serum, Bone Ash, and Organic Matter of Pigs

Group identification	No. of pigs	Level of vitamin A fed (μg./kg./day)	Vitamin A in plasma (μg./100 ml.)			Phosphatases in serum (Klein-Babson-Read unit *./100 ml.)						Ash † (Gm./100 Gm.)		Organic matter † (Gm./100 Gm.)	
				Terminal		Alkaline			Acid						
			Initial	Actual	Log	Initial	Terminal	Change **	Initial	Terminal	Change **	Epiphysis	Diaphysis	Epiphysis	Diaphysis
A (controls)	6	39.7	20	23	1.35	25	14	−11 (−7)	18	16	−2 (−2)	53.5	65.1	46.5	34.9
	6	119.0	23	25	1.39	22	12	−10 (−9)	15	14	−1 (−4)	54.2	64.4	45.8	35.6
B (mildly hypervitaminotic)	6	6,614.0	20	62	1.78	20	10	−10 (−11)	19	17	−2 (0)	55.1	65.0	44.9	35.0
C (severely hypervitaminotic)	6	19,842.0	22	190	2.24	17	12	−5 (−11)	19	17	−2 (0)	58.5	66.3	41.5	33.7
Standard deviation per pig			4		0.11	7	3	7 (4)	4	3	5 (3)	2.1	1.0	2.1	1.0

* Amount of enzyme that will liberate 1.0 mg. of phenolphthalein in 30 minutes at 37 C. ** Adjusted by covariance for initial values. † Statistic for left bone, fat-free, and moisture-free basis.

Results are averages of 6 pigs in each group fed different levels of vitamin A.

Gm. of ash of radial epiphysis existed between pigs of groups A and C. The difference in the concentration of diaphyseal ash was less, being 1.2 Gm./100 Gm. (Table 2).

Organic matter reflected the increased ash values only at the greater level of intake of the vitamin.

Discussion

Doses of excess vitamin A administered to growing pigs resulted in the following clinical signs: anorexia, cutaneous erythema and hemorrhage, and posterior lameness. Both tubular and flat bones were decreased in overall length and thickness, and at necropsy, the bones were more fragile, broke and could be cut readily. These changes were similar to those described in other animals by previous investigators.[8,17,33,37] Unlike other animals previously studied, the pig did not have any pathologic fractures, but did develop cortical exostoses similar to those described in man by Caffey[5] and in cattle by Swerczek.* The squamous occipital bone of the pig was especially vulnerable to the effects of excess vitamin A and was completely destroyed at the midline, resulting in stress deformities and subdural hemorrhage. The vulnerability of this bone to vitamin A toxicosis seems to be a species peculiarity which has not been described previously.

In the discussion of the effects of vitamin A toxicosis on growing bone, it is necessary to distinguish between the lesions in endochondral bone and those in intramembranous bone, due to the specific effect of the vitamin on cartilage. Results of both *in vitro* and *in vivo* experiments have indicated the ability of the vitamin to bring about lysis of cartilaginous matrix.[15,38]

Destruction of the epiphyseal plate was reported by several investigators.[6,25,42] A lysis of rabbit cartilage, which resembled the effect of papain administration.

* Swerczek, T. W.: The Pathology of Soft Tissues in Calves during Vitamin A Excess and Reversal. M.S. Thesis, University of Connecticut, Storrs, 1966.

was mentioned by Thomas *et al.*[38] In investigations with organ cultures, increased proteolytic activity due to the presence of vitamin A was observed.[11] Lysosomal fractions were isolated from cartilage limb rudiments and shown to release an acid protease in the presence of vitamin A.[14] This acid protease attacks the protein moiety of the mucoprotein complex and leads to loss of chondroitin sulfate and eventual destruction of the cartilage.[13] Upon histologic examination of the epiphyseal plate and costochondral cartilage of hypervitaminotic pigs, less cartilaginous matrix was observed. The peripheral costochondral cartilage was absent and was replaced by fibrous tissue, and the vascular channels passing through the matrix were much larger and filled with fibrous tissue. For a variable width surrounding such channels, the matrix lost its metachromasia and strong basophilic staining affinity and was acidophilic. Loss of basophilia in organ cultures of embryonic mouse and chicken bones[15] and loss of metachromasia in cartilage of rabbits treated with vitamin A have been reported.[38] The difference in staining affinity of the cartilage matrix of hypervitaminotic pigs indicates a loss of chondroitin sulfate. There is early cartilage destruction in perivascular areas, which most logically would be the first to come into contact with the vitamin.

Endochondral bone grows from a cartilaginous template and is dependent on epiphyseal cartilage for its rate and extent of growth. Under the effect of excess vitamin A, cartilage growth is retarded and the bone fails to lengthen normally.

Radiuses from pigs affected with vitamin A toxicosis were markedly shorter, primarily due to less epiphyseal cartilage, since the distance between epiphyseal margins was the same in the control and affected pigs. If the epiphysis is selectively destroyed, the overall effect is that of dwarfing with normal development of diaphysis.[34] However, in the hypervitaminotic pig, overall diaphyseal growth was affected, since in these animals, decreased shaft width and increased metaphyseal flare occurred.

The altered diaphyseal growth may be explained by considering the second error of metabolism involved in vitamin A intoxication, that of failure to produce new matrix. Growth was retarded; therefore, diaphyseal width did not increase and, as remodeling processes proceeded at a normal rate, the angle of metaphyseal flare became more acute. The decrease of osteoblasts at the larger dose levels of vitamin A substantiates this retardation of growth. Results of radioisotopic studies add further evidence for this hypothesis. Strontium-90 uptake and growth are greatly decreased when large doses of the vitamin are fed.[35]

Size and weight of bones from animals fed the greatest level of vitamin A were less. However, no significant changes in linear measurement or weight were observed in those pigs fed the mildly hypervitaminotic diet. The lesions of vitamin A toxicosis are a function of the amount of the vitamin fed.[28] The pig seemed able to tolerate doses of 6,614 μg./kg. of live weight per day over a period of 5 weeks with few clinical effects.

Radiographic lesions of hypervitaminotic endochondral bones were early closure of the epiphysis, thinner cortical bone, and metaphyseal exostosis (Fig. 18, 19). Mildly hypervitaminotic A bones had few radiographic lesions. Increased angle of metaphyseal flare (pagoda effect) was described in instances of vitamin A toxicosis in man[29] and calves[17] and was also observed in hypervitaminotic pigs. This phenomenon is due to the increase in the angle of metaphyseal-diaphyseal juncture, and its production may be explained in terms of retarded bone growth with normal remodeling (metaphyseal osteoclasia) processes.

Periosteal exostosis is a radiographic manifestation of chronic vitamin A intoxication in man.[5,24,29,43] The calf is the only other species in which this lesion has been reported.* In the hyper-

* Swerczek, T. W.: The Pathology of Soft Tissues in Calves during Vitamin A Excess and Reversal. M.S. Thesis, University of Connecticut, Storrs, 1966.

vitaminotic A pig, periosteal swellings were seen at the medial metaphysis of the radius and, in one instance, at the medial metaphysis of the femur. The area of the radius involved was near the point of insertion of the brachialis muscle. Since this area was consistently involved, the exostosis seemed to be caused by forces of pull exerted on the periosteum and cortex from the muscle insertion. A similar radiographic lesion of the femur was reported in severely undernourished growing pigs.[31]

Microscopically, changes in endochondral bone consisted of loss in dorsoventral width of epiphyseal plate, disorganization of the zones of maturing and degenerating chondrocytes, fewer but thicker spicules of spongiosa, and decrease in osteoblastic activity. The first 2 of these lesions were described by Wolbach,[42] and decreased osteoblastic activity was reported by Irving.[20,21] Due to the decrease in osteoblastic activity, less osteoid tissue lined the spicules of the primary spongiosa. This was also seen in the calf by Grey *et al.*[17] Unlike what had been reported, there was no apparent increase in subperiosteal osteoclastic activity.[33,42]

Intramembranous bone does not arise from a cartilaginous model, and the effect of excess vitamin A seems due to a decrease in osteoblastic activity accompanied by normal osteoclastic activity. These processes lead to a progessive decrease in bone mass that is most severe in areas initially having little bone volume.

Microscopically, lesions of intramembranous bone consisted of partial to complete loss of osseous tissue, with a tendency for the remaining bone to be of the compact type with irregular cement lines. This resembled the semicompact bone described in diaphyseal sections taken from growing pigs with severe malnutrition.[26,30] As in tubular bones, the number and activity of osteoblasts were found to be decreased without increase in osteoclastic activity. Differences in numbers of osteoblasts and thickness in the frontal and squamous occipital bones from group C pigs were significant at the 5% level of probability.

The effect of the toxicosis on intramembranous bone must be considered in relation to time of exposure to the vitamin. The lesions may be attributed to normal osteoclastic activity in the presence of retarded formation. As this progresses, the resulting bone becomes thinner but more compact, so that in the earlier stages of the toxicosis there is no loss of bone volume per unit of area. Later, however, the bone is destroyed. This change was evident in the squamous occipital bone which had initially little bone mass and was, therefore, most severely affected.

The term "osteoporosis" may be defined in relation to its pathogenesis as a failure of osteoblasts to produce matrix.[1-3] Results of microscopic observations of porcine hypervitaminotic A intramembranous and endochondral bone indicated this failure, since there were fewer osteoblasts and less osteoid production. Another definition of osteoporosis is a decrease in bone mass[2,27] or a decrease in absolute volume of tissue when the area encompassed by the periosteum is the same in the osteoporotic and normal bone.[16] It is, therefore, a decrease in absolute volume in 2 equal areas of bone; absolute volume being defined as ". . . the volume remaining after subtracting the volume of all holes present in the bone."[16] To indicate changes in absolute volume of endochondral bone, the spongiosa of macerated, dried, cancellous radiuses was photographed. Increased porosity was not evident when photographic enlargements of equal areas of the control and severe hypervitaminotic A bones were compared (Fig. 16, 17).

Changes in serum phosphatase activities were not statistically significant and did not reflect decreased osteoblastic activity nor possible lysosomal destruction. Increase in ash content of the epiphysis and diaphysis from radiuses in group C pigs is in accord with the work of previous investigators and resembles the ab-

normally high calcium:collagen ratio in bone of undernourished animals.[10,18]

The pathogenesis of bone lesions in porcine hypervitaminosis A depends on the type of bone involved. In endochondral bone, the changes may be attributed to destruction of epiphyseal cartilage in conjunction with decreased osteoblastic activity and normal subperiosteal osteoclastic activity. In intramembranous bone, the changes are due to decreased osteoblastic activity in the presence of normal remodeling.

References

1. Aegerter, E., and Kirkpatrick, J. A., Jr.: Orthopedic Diseases. W. B. Saunders Company, Philadelphia, Pa., 1963.

2. Albright, F.: Osteoporosis. Ann. Int. Med., 27, (1947): 861.

3. Albright, F., and Reifenstein, E. C.: The Parathyroid Glands and Metabolic Bone Diseases. Williams & Wilkins Company, Baltimore, Md., 1948.

4. Babson, A. L., and Read, P. A.: A New Assay for Prostatic Acid Phosphatase in Serum. J. Clin. Path., 32, (1959): 88–91.

5. Caffey, J.: Chronic Poisoning Due to Excess Vitamin A. Pediatrics, 5, (1950): 672-688.

6. Cappellin, M., and Crepax, P.: Azione della Vitamina A in Forti Dosi sul Sistema Osseo del Ratto Albino. Boll. Soc. ital. biol. Sper., 26, (1950): 1495–1497.

7. Collazo, J. A., and Rodriguez, J. S.: Hypervitaminose A. II. Exophthalmus und Spontanfrakturen. Klin. Wchnschr., 12, (1933): 1768–1771.

8. Davies, A. W., and Moore, T.: Vitamin A and Carotene. XI. The Distribution of Vitamin A in the Organs of Normal and Hypervitaminotic Rats. Biochem. J., 28, (1934): 288–295.

9. Dehority, B. A., Rousseau, J. E., Jr., Eaton, H. D., Myers, G. S., Jr., Grifo, A. P., Jr., Dicks, M. W., Hazzard, D. G., Helmboldt, C. F., Gosslee, D. G., Thomas, J. W., Sykes, J. F., and Moore, L. A.: Effects of Addition of Magnesium, Tocopherol, and Cod Liver Oil to a Whole Milk Diet on some Biochemical Constituents in Serum, Soft Tissue, and Bone of Calves. J. Dai. Sci., 44, (1961): 58–84.

10. Dickerson, J. W. T., and McCance, R. A.: Severe Under Nutrition in Growing and Adult Animals. III. The Composition of the Long Bones. Brit. J. Nutr., 15, (1961): 567–576.

11. Dingle, J. T., Lucy, J. A., and Fell, H. B.: Studies on the Mode of Action of Excess Vitamin A. I. Effect of Excess Vitamin A on the Metabolism and Composition of Embryonic Chick-Limb Cartilage Grown in Organ Culture. Biochem. J., 79, (1961): 497–500.

12. Eaton, H. D., Boucher, W. B., and Shah, P. C.: Vitamin A in Serum and Liver of Weanling Pigs Fed a Protein Deficient Diet and Fixed Intakes per Unit of Live Weight of Carotene in Oil. J. Nutr., 82, (1964): 343–352.

13. Fell, H. B.: The Role of Organ Cultures in the Study of Vitamins and Hormones. Vitamins & Hormones, 22, (1964): 81–127.

14. Fell, H. B., and Dingle, J. T.: Studies on the Mode of Action of Excess Vitamin A. VI. Lysosomal Protease and the Degradation of Cartilage Matrix. Biochem. J., 87, (1963): 403–408.

15. Fell, H. B., and Mellanby, E.: Effects of Hypervitaminosis A on Foetal Mouse Bones Cultivated *in Vitro*. Brit. Med. J., 2, (1950): 535-539.

16. Frost, H. M.: Bone Remodeling Dynamics. Charles C Thomas Publishers, Springfield, Ill. (1963): 7; 18.

17. Grey, R. M., Nielsen, S. W., Rousseau, J. E., Jr., Calhoun, M. C., and Eaton, H. D.: Pathology of Skull, Radius and Rib in Hypervitaminosis A of Young Calves. Path. Vet., 2, (1965): 446-467.

18. Hazzard, D. G., Woelfel, C. G., Calhoun, M. C., Rousseau, J. E., Jr., Eaton, H. D., Neilsen, S. W., Grey, R. M., and Lucas, J. J.: Chronic Hypervitaminosis in Holstein Male Calves. J. Dai. Sci., 47, (1964): 391–401.

19. Hurt, H. D., Hall, R. C., Jr., Calhoun, M. C., Rousseau, J. E., Jr., Eaton, H. D., Wolke, R. E., and Lucas, J. J.: Chronic Hypervitaminosis A in Weanling Pigs. University of Connecticut, Coll. of Agric. Exper. Sta., Bull. 400, 1967.

20. Irving, J. T.: The Effects of Avitaminosis and Hypervitaminosis A Upon the Incisor Teeth and Alveolar Bone of Rats. J. Physiol., 108, (1949): 92–101.

21. Irving, J. T.: A Comparison of the Influence of Hormones, Vitamins and Other Dietary Factors Upon the Formation of Bone, Dentine and Enamel. Vitamins & Hormones, 15, (1967): 291–323.

22. Kimble, M. S.: The Photocolorimetric Determination of Vitamin A and Carotene in Human Plasma. J. Lab. & Clin. Med., 24, (1939): 1055–1065.

23. Klein, B., Read, P. A., and Babson, A. L.: Rapid Method for the Quantitative Determination of Serum Alkaline Phosphatase. Clin. Invest., 6, (1960): 269.

24. Knudson, A. G., and Rothman, P. E.: Hypervitaminosis A. A.M.A. Am. J. Dis. Child., 85, (1953): 316–334.

25. Maddock, C. L., Wolbach, S. B., and Maddock, S.: Hypervitaminosis A in the Dog. J. Nutr., 39, (1949): 117–137.

26. McCance, R. A.: Severe Undernutrition in Growing and Adult Animals. I. Production and General Effects. Brit. J. Nutr., 14, (1960): 59–73.

27. McLean, F. C., and Urist, M. R.: Bone, 2nd ed. University of Chicago Press, Chicago (1961): 215–220.

28. Nieman, C., and Klein Obbink, H. J.: The Biochemistry and Pathology of Hypervitaminosis A. Vitamins & Hormones, 12, (1954): 69–99.

29. Pease, C. N.: Focal Retardation and Arrestment of Growth of Bones Due to Vitamin A Intoxication. J. Am. M. A., 182, (1962): 10

30. Pratt, C. W. M. and McCance, R. A.:

Severe Undernutrition in Growing and Adult Animals. II. Changes in the Long Bones of Growing Cockerels Held at Fixed Weights by Undernutrition. Brit. J. Nutr., 14, (1960): 75–84.

31. Pratt, C. W. M., and McCance, R. A.: Severe Undernutrition in Growing and Adult Animals. XIV. The Shafts of the Long Bones in Pigs. Brit. J. Nutr., 18, (1964): 4.

32. Pritchard, J. J.: The Osteoblast. In *The Biochemistry and Physiology of Bone*. Edited by G. H. Bourne. Academic Press, New York (1956): 181.

33. Rodahl, K.: Hypervitaminosis A. Norsk Polarinstitutt, Skrifter #95, Oslo, Norway, 1950.

34. Rubin, P.: Dynamic Classification of Bone Dysplasias. Year Book Medical Publishers, Inc., Chicago (1964): 38–57.

35. Schmidt, B., and Long, K.: Zur Beeinflussung des Stoffwechsels von Strontium 90 und Calcium bei der wachsenden Ratte durch fettlösliche Vitamine. 2. Teil: Der Einfluss von Vitamin A. Klin. Wchnschr., 43, (1965): 375–382.

36. Stowens, D.: Pediatric Pathology. Williams and Wilkins Company, Baltimore, Md., 1959.

37. Takhashi, K., and Nakamiya, J.: Physiological Significance of Biosterin (So-Called Vitamin A). Japan Med. World, 5, (1925): 2–9.

38. Thomas, L., McCluskey, R. T., Potter, S. L., and Weissmann, G.: Comparison of the Effects of Papain and Vitamin A on Cartilage. I. The Effect in Rabbits. J. Exptl. Med., 111, (1960): 705–718.

39. Toomey, J. A., and Morissette, R. A.: Hypervitaminosis A. A.M.A. Am. J. Dis. Child., 73, (1947): 473–480.

40. Vedder, E. B., and Rosenberg, C.: Concerning the Toxicity of Vitamin A. J. Nutr., 16, (1938): 57–68.

41. Wolbach, S. B., and Bessey, O. A.: Tissue Changes in Vitamin Deficiencies. Physiol. Rev., 22, (1942): 233–289.

42. Wolbach, S. B.: Vitamin A Deficiency and Excess in Relation to Bone Growth. J. Bone & Joint Surg., 29, (1947): 171–192.

43. Wyatt, T., Carabello, C. A., and Fletcher, M. E.: Hypervitaminosis A. J. Am. M. A., 144, (1950): 304–305.

Shika Gaku Ho (Dental Science Report, Vol. 67, No. 11 (1967), pp. 1329-1336.

The Effects of Several Medicines upon the Development of Abnormalcy, due to the Administration of an Excessive Amount of Vitamin A.

1. Effect of Cortisone

By Toshio Yamaguchi, Dental College of Tokyo, Faculty of Corrective Science
(Director: Professor Yoshishige Yamamoto) and Dental College of Tokyo, Pharmacological Faculty (Director: Professor Toshikichi Tamura).

(The manscript was received on September 11, 1967).

Introduction

There are a number of reports published on the factors responsible for the development of such abnormalcies as those of the skull, eyes, teeth and faces including cleft palate, abnormal jaw bones, limbs, etc.

H. Kalter and J. Warkany (12) wrote a comprehensive book on the effects of both the excess and deficiency of various medicines. Since Cohlan (1953) (2) published a report on the development of a large number of abnormalcies due to the excessive administration of vitamin A, which has been administered in comparatively large quantities in the past, there have been published the reports of Giroud and Matinet (1959) (8), (1962) (9), Millen and Woolam (1957) (16), Inaba (1958) (24), Baba et al. (1959) (1), Deuschle et al. (1959) (5), Kalter and Warkany (1959) (13), (1961) (14), Takekoshi (1961) (26), Murakami et al. (1965) (18), Esaki (1964) (22), Ihara et al. (1966) (23) and Kajiwara et al. (1965) (25).

In these reports, the amount of administrations, the time of administrations, the method of administrations, the kind of animals used and the systems were different, with a result that the experimental results were different. However, it was clarified that, if an excessive amount of vitamin A is ad-

ministered during pregnancy, abnormalities develop at high frequency according to a large number of researchers.

The fact that abnormalities are developed by the administrations of cortisone during pregnancy has been described in a large number of reports describing the experiments using mice and rats by such researchers as Courrier, and Colonge (1951) (3,4), Glaubach, Antopoli and Graff (1951) (10), Seifter, Christian and Ehrich (1951) (19). The development of cleft palate was easy in the case of mice and rabbits. It seems that the ordinary researchers are of the belief that, even though it is easy to develop cleft palate, etc. in rabbits and mice, it is impossible to develop such abnormalities in the case of rats.

By administering an excessive amount of vitamin A to rats with the application of cortisone, Millen and Woollam (16, 17) found that the number of abnormalities of brains and skull increased and reported that cleft palate is developed 100 per cent.

The present authors have examined the change in the development of abnormalities in the brain and skull, and the cleft palate and the general bone structure by the administrations of an excessive amount of vitamin A, added by the administration of cortisone, when the amounts and methods of such administration were held constant, by using rats of the Wistar system since 1950.

Experimental Method

Experimental Animals:

Healthy Wistar albino rats, whose hereditary factors were made comparatively equal, whose individual differences were comparatively small and which had been raised since 1950 at the Tamura Experimental Medical Research Laboratory were used. The number of mother rats which were used in the experiments was as follows: Seventeen rats in the control group, 15 rats in the group administered Vitamin A and 10 rats in the group administered vitamin

A plus cortisone.

Environment:

It is reported that the frequency of the development of abnormalities which are experimentally induced is affected by the seasonal change, noise and group living, etc. The authors raised the experimental animals in a quiet constant-temperature and constant-humidity room (at the temperature in the range between 20 and 25 degrees centigrade and humidity in the neighborhood of 60 per cent) in a metal net cage with a sufficiently large area for each animal.

Experimental Feed:

The mixed feed for the experimental rats consisted of 80 per cent of smashed wheat, 15 per cent of casein, four per cent of salts, and one per cent of comprehensive vitamins. Approximately 20 per cent of protein was contained in this feed. Thus, this feed could be termed an ideal feed from the standpoint of nutrition. Fifteen (15) grams of this feed was given to a grown-up rat per day. Therefore, 375 I. U. of vitamin A was contained in the feed for one rat.

It is mentioned in this connection that the experimental animals were allowed to drink water freely.

Determination of Pregnancy:

The estrus of female rats was determined by the use of a vaginal ointment. Then, from around six o'clock in the evening to the following morning, the female rat was caused to live with a healthy male rat 10 to 11 weeks old. By determining the existence of sperms inside the vagina of the female rat, a determination was made as to her pregnancy. Zero o'clock A. M. on this day was considered to be the start of her pregnancy, for the calculation of the period of pregnancy.

Conditions for the Administration of Medicines;

The kind, amount, method, timing and dosages of the medicines administered are shown in Table 1.

(Insert Table 1 on p. 1330. Experimental conditions.)

Period of Observations:

On the 21st day of pregnancy or, to be exact, in 20 days and 12 hours of pregnancy, the mother rat was killed and the various states of the mother and fetuses were examined.

In other words, the mother rat was immediately opened in the stomach and the fetuses were taken out. After a measurement of their body weight and body length, the outside shapes were examined both by naked eye and under a microscope. Regarding the uterus of the mother rat, furthermore, the number of resorptions, placenta remnants and macerated fetuses were counted in the case of fetal deaths.

Skeleton specimens were prepared for fetuses after the completion of an observation of external abnormalities for the purpose of examining the skeleton abnormalities. The method of their preparation, which was a modification of the Noback method and the Dawson method, was as follows:

The method for the preparation of skeleton specimens:

1. The abdominal part of a fetus was cut open and the intestines were removed.

2. The above was fixed with 95% ethanol for a period of two days.

3. The skin and muscles were removed as much as possible.

4. The same was immersed for a period of 1.5 to two days in a solution which was prepared by mixing 20 milligrams of alizarine red S in one liter of one per cent KOH.

5. It was placed in a 20% glycerine solution for one day.

6. It was placed in a 50% glycerine solution for one day.

7. It was stored in a 80% glycerine solution.

The presence or absence of skeletal abnormalities and the extent of such abnormalities were observed both by the naked eye and under a microscope by using the skeletal specimens which had been prepared in the manner described above.

(Insert Table 2 on p. 1331. Body weight of pregnant mother (gram).)

Experimental Result

1. Weight of Mother Rat (Table 2)

Almost no difference in the increase in the weight of the mother rat was observed in the group of rats which were administered vitamin A (which will hereafter be abbreviated as Group A) as compared with the control group. However, the result was not satisfactory in the group where the animals were administered vitamin A plus cortisone (which group will hereafter be abbreviated as Group AC).

2. Fetal Implantation Conditions (Table 3)

(Insert Table 3 on p. 1331. Implantation Conditions.)

The mean fetal death was zero per mother rat in the control group which was given the authors' feed. However, it was 2.2 in Group A and 2.4 in Group AC.

The average weight of the fetuses was 4.07 plus/minus 0.14 grams in the control group whose animals were given the authors' feed. However, the average weight of the fetuses for Group A was 3.79 plus/minus 0.35 grams and the average weight of the fetuses for Group AC was 3.38 plus/minus 0.33 grams. In Group AC, in particular, the result was marked.

The number of growth retardations where body weight was less than 3.00 grams was 0.2 on an average per mother rat in the Control Group and 0.1 in Group A, whereas the number clearly increased to 2.0 in Group AC.

In the case of the sex ratio and placenta weight, no difference was observed between the two.

3. Fetal Abnormalities (Table 4).

No fetal abnormalities whatsoever were observed in the authors' experiment on the mother rats which were given the authors' feed.

In group A, however, abnormalities appeared in 82.6 per cent and, in Group AC, there was an increase to 100 per cent. The result obtained is shown in Table 4. In Group AC, the development of megaloglossia and megalognathia was four times as great as in Group A. In Group AC, further, the appearance of megalognathia and open eyelid was approximately twice as large as in Group A. In the case of cleft palate, moreover, its development was 1.3 times. Also, microcephalia was observed in Group AC. In addition, atomatic abnormalcy, cleft tongue, and micromelia were observed in Group A, even though the frequencies of their development were small. These were not observed in Group AC.

(Insert Table 4 on p. 1332. The occurrence and types of abnormalities.)

As for the names of abnormalities whose frequencies were more than 20 per cent, auricular abnormality was 40.4 per cent, cleft palate was 61.5 per cent and megaloglossia was 20.2 per cent in Group A, whereas cleft palate was 82.2 per cent, megaloglossia was 80.0 per cent, megalognathia was 37.8 per cent, open eyelid was 28.9 per cent and auricular abnormality was 26.7 per cent in Group AC.

4. Degree of fetal ossification (Tables 5 and 6).

(Insert Table 5 on p. 1332. Ossification patterns, (I).)

(Insert Table 6 on p. 1333. Ossification patterns (II).)

a. Degree of the Ossification of occipital bone:

As shown in Table 5, no ossification of occipital bone took place in the author's control group. In Group A,however, 72.7 per cent was the number for the retardation of the ossification of occipital bone in Group A and 71.1 per cent represented the number of the retardation of the ossification

of occipital bone in Group AC, all of these percentages being marked as compared with the Control Group. However, there was no difference in frequency between the two groups.

b. Degree of the Ossification of sternebrae bone

The retardation of the ossification of sternebrae was 16.7 plus/minus 1.4 per cent in the authors' control group.

In Group A, the number of fetuses with the retardation of the ossification of sternebrae was 75.5 plus/minus 3.4 per cent. In Group AC, the number of fetuses with the retardation of ossification of sternebrae was 70.0 plus/minus 7.2 per cent, clearly showing increases over and above the control. The result of an examination of such cases with the retardation of ossification is shown in Table 6.

The retardation of the ossification of sternebrae can be classified into (1) sternal deficiency and (2) the incompleteness of sternal fusion.

In Groups A and AC, there are many cases where the number is only one. In addition, there was a tendency for Group A to have many cases involving the incompleteness of sternal fusion and for Group AC to have many cases involving sternal deficiency.

In terms of sternal deficiency, the largest number of cases involve the lack of the second sternum and the next largest number of cases involve the lack of the fifth sternum.

c. Degree of the ossification of metacarpal and metatarsal bones and coccyx.

The mean number of the ossification retardation of metacarpal bones, metatarsal bones and coccyx is 7.89 plus/minus 0.24, 8.00 plus/minus 0.00 and 4.95 plus/minus 0.46 respectively in the control group, whereas they are 6.30 plus/minus 0.84, 7.89 plus/minus 0.25 and 5.00 plus/minus 0.64 in Group A. In Group A, there was clearly observed the retardation of the ossification

of metacarpal bones. In Group AC, on the other hand, these numerical values are 5.89 plus/minus 0.13, 7.64 plus/minus 0.37 and 4.19 plus/minus 0.97, with the incompleteness of ossification being increased in metacarpal bones and clearly being observed both in metatarsal bones and coccyx.

d. Abnormal Bone Structures in Fetuses (including the Deformation and Deviation of Bones).

The abnormalities of bone structure in fetuses did not appear in the control group. In Groups A and AC, the formation of the 14th rib appeared frequently, with almost no difference being observed between these two groups.

In Group A, cases involving the shortness of fibula, the shortness of tibia, the shortness of femur, the shortness of radius, the shortness of ulna, the abnormalcy of brachium and brachygnathia were found. In Group AC, however, abnormalcy was limited to the shortness of femur, the shortness of radius and the shortness of fibula, with these abnormalities appearing at frequent interval.

Observations

The authors administered an excessive amount of vitamin A to Wister-type albino rats during the past 17 years and observed the development of abnormalities stemming from it.

In addition, the effect of cortisone upon the development of abnormalities which are induced by the administration of an excessive amount of vitamin A was observed.

The effect of cortisone upon the development of abnormalities in rats has already been reported by Jost (11), Millen and Woollam (17), Courrier and Colonge (3, 4), Seifter, Christian and Ehrich (19). However, Lohmeyer (15) stated that he knew nothing about the development of cleft palate. Indeed, no cleft palate was observed in the experiments which the authors carried out by using more than ten pregnancy cases.

Despite the fact that a large number of studies have been carried out on the development of abnormalities, no clearcut reason has been discovered both in the case of cortisone and vitamin A.

Regarding the development of cleft palate, Strean et al. proposed a theory which was centered around the stress at the start of pregnancy. He observed the relationship between this factor and the cortisone secretion and believed that an excessive secretion of cortisone, creates a metabolic hindrance. Murakami et al. (18) stated an assumption as to whether the excess vitamin A administration might have an inhibitive effect.

In addition, there are a chemical theory which states that it develops because of the inhibition of metabolism, with the contraction of distal blood vessels such as serotinin and the flow of the blood current in the uterus being inhibited and a physical theory which states that it develops because the lowering of the tongue is prevented and the fusion of the palate becomes impossible. However, there is no fixed theory at the present time.

Further, the development of malformations is believed by Fraser (6) to be greatly affected by the kind of animals whose sensitivity is high, by the hereditary type whose sensitivity is high, a proper amount of administration, a proper stage of development, a proper method of administration, a proper environment, a proper method of observation and the selection of a proper control group.

However, Millen and Woollam (16) published a report stating that there is an increase in the number of cases involving grain, skull malformations and cleft palate when cortisone is added, as has already been pointed out.

Since their study was limited to the facial areas, additional test items were added and the malformation of fetuses and the degree of ossification, etc. were also observed.

As described in the reports of Millen and Woollam, and Giroud and Martinez,

the amount of the administration of vitamin A (30,000 I.U./100 grams of the rat weight) was sufficient to induce various malformations in the rats. Therefore, the same amount was used and 50 times the ordinary dosage people take (two milligrams per kg.) was used.

As regards the method of administering vitamin A, it is mentioned that the administration was made through the mouth. This was based on the reports (7, 21) to the effect that malformations are not created by the abdominal and the subcutaceous administrations.

The period of administration was limited to four days starting on the 10th day of pregnancy when external malformations are most likely to take place, according to the reports of Esaki (22) and Kajiwara et al. (25).

Because of the difference in the rat system and other factors, it can be stated to be natural that the result obtained by the present authors is different from the result obtained by Millen and Woollam (16).

By an addition of cortisone to the excessive administration of vitamin A, however,the growth of fetuses became dissatisfactory, the number of external malformations increased and the number of cases involving the retardation of ossification also increased in some bones.

Since cortisone prohibits the multiplication of fibrous cells (cells for the formation of joint tissues), makes the formation of collagen tissues incomplete and further causes incomplete lime sedimentation, thereby developing the malformations of bones and the retardations of ossification, it is further believed to show an assisting effect toward the metabolic hindrance due to the excess administration of vitamin A.

Conclusions:

The effect of the administration of cortisone upon the development of malformations caused by the administration of an excessive amount of vitamin A to the Wistar-type albino rats which had been raised during the past 17 years

was examined. In addition to the results obtained by Millen and Woollam, the following new facts were found:

1. As for the increase in the body weight of mother rats, there was observed almost no difference in the group where the experimental animals were administered an excessive amount of vitamin A (Group A) as compared with the control group. When cortisone was added tothe excessive amount of vitamin A (Group AC), the result obtained was markedly dissatisfactory.

2. The mean number of fetal deaths increased in Group A and Group AC. The mean weight of the fetuses was less in Group A and still less in Group AC as compared with the control group.

In addition, the number of cases involving the retardation of growth with body weight being less than 3.00 grams was the same in Group A as in the control group. However, this number was found clearly greater in Group AC.

3. The malformation of fetuses was 82.6 per cent in Group A as compared with the rate of zero in the control group. It increased to 100 per cent in Group AC. In the case of . . . (Translator's Note: a few characters are unclear) . . . , the cleft palate which would not appear by the administration of cortisone appeared to a greater extent in the administration of vitamin A plus cortisone than in the case where vitamin A alone was administered.

4. Regarding the degree of the retardation of fetal ossification,the number of cases involving the retardation of ossification increased by the administration of an excessive amount of vitamin A and the addition of cortisone to the vitamin A.

No difference was shown in the case of occipital bones and sternebrae even when cortisone was added. However, a difference was clearly shown in the case of metacarpal bones, metatarsal bones and coccyx. The malformation of the bone structure also increased when cortisone was added.

At the end, the authors would like to offer their gratitude to Professor

9: 681-685, 1951.

8) Giroud, A. et. Martinez, M.: Teratogenesis by hypervitaminosis A in the rat, the mouse, the guinea pig and the rabbit, Arch. Franc. Pediat. 16: 1-5, 1959.

9) Giroud, A. et Martinez, M.: Teratogenic dose of vitamin A, Compt. rend. soc. biol. 156 : 449-450, 1962.

10) Glaubach, S., W. Antopol and S. Graff.: Excessive doses of cortisone in pregnant mice: Effect on development and survival of the fetus and newborn and on the maternal breast tissue, Bull. N. York Acad. M. 27: 398, 1951.

11) Jost, A.: The age factor in some prenatal endocrine events. Ciba Foundation Colloq. on Ageing. 2: 18-27, 1956.

12) Kalter, H. and Warkany, J.: Experimental Production of Congenital Malformation in Mammals by Metabolic Procedure, Physiol. Rev. 39 : 69-115, 1959.

13) Kalter, J. and Warkany, J.: Teratogenic action of hypervitaminosis A in strains of inbred mice. Anat. Rec. 133 : 396-397, 1959.

14) Kalter, H. and Warkany, J.: Experimental production of congenital malformations in strains of inbred mice by maternal treatment with hypervitaminosis A. Amer. Pathol. 38, 1-21, 1961.

15) Lohmyer, H.: Cortison, Schwangerschaft und Misbildungen des Neugeborenen. Geburtsch u. Fraueheik. 21 : 560-565, 1961.

16) Millen, J W. and D. H M. Woollam: Influence of cortisone on teratogenic effects of hypervitaminosis A. Brit. Med. Journal 2 : 196-197, 1957.

17) Millen, J. W. and D. H. M. Woollam.: Insuline-cortisone relationship in experimental teratogenesis. Nature 181: 418, 1958.

18) Murakami, U., Kameyama, Y. and Nogami, H.: Malformations of the mouse fetus caused by hypervitaminosis A of the mother during pregnancy. Arch. Envision, Health, 10 : 732-741, 1965.

19) Seifter, J., J. J. Christian and W. E. Ehrich: Effect of cortisone and other steroids on the hibernating gland of the pregnant white rat. Fed. Proc. 10 : 334. 1951 (abst.).

20) Strean, L. P. and L. A. Peer: Stress as an etiologic factor in the developing of cleft palate. Plastic and Reconstr. Snrg. 18 : 1-8, 1956.

21) Woollam, D. H. M. and J. W. Millen: Effect of cortisone on the incidence of cleft palate induced by experimental hypervitaminosis-A. Brit. M. Jl. 2: 197-198, 1957.

22) Ezaki, Koxaburo: Effect of the administration of an excessive amount of vitamin A to pregnant rats. (1) The number of fetal deaths and the rate of live fetuses and the body weight of live fetuses. (2) Malformation of the live fetuses I, (3) Malformation of the live fetuses II. Prenatal abnormalities 4: 27-34, 35-42, 43-51, 1964.

23) Ito, Toshio, Masahiro Mizutani, Shoji Tanaka and Tsuyosni Kajiwara: Effect of the administration of an excessive amount of vitamin A on a few experimental animal fetuses, prenatal abnormalities 6 : 91-108, 1966.

24) Toyoshige Inaba: An experimental study on the development of malformations due to the administration of Vitamin A, Osaka Municipal Medical College Journal 7 : 558-566, 1958.

25) Kajiwara, Tsuyoshi: Development of malformations in various experimental animals - Effect of the administration of an excessive amount of vitamin A - Prenatal abnormalities 5 : 177-183, 1965.

26) Takegoshi, Shoichi: On the Development of Malformations due to the Administration of an Excessive Amount of Vitamin A, North Kanto Med. 11 : 104-118, 1961.

Yamaguchi-'67
Bib. No. 10052

Shika Gaku Ho (Dental Science Report, Vol. 67, no. 11 (1967), pp. 1329-1336.

歯科学報 Vol. 67 No. 11 (1967)

Vitamin A 過剰投与による催奇作用におよぼす数種の薬剤の影響について
1. Cortisone の影響について

東京歯科大学 矯正学教室（主任 山本義茂教授）
東京歯科大学 薬理学教室（指導 田村俊吉教授）

山口敏雄（やまぐち としお）

（1967年9月11日受理）

緒言

頭蓋，眼，歯牙，顔面の奇形，ことに兎唇，口蓋裂，顎骨の異常，脊椎，四肢，指趾の異常などをおこす催奇性因子については数多くの報告がある。

H. Kalter および J. Warkany[12] は種々の薬剤の過剰，欠乏について綜説的の展望を書いているが，一般に栄養学的に比較的多量予防内服された vitamin A 過剰によってかなり高度の奇形が出現することを Cohlam (1953)[2] によって報告されてから Giroud および Martinet (1959)[8] (1962)[9]，Millen および Woollam (1957)[16]，稲葉 (1958)[24]，Baba ら (1959)[1]，Deuschle ら (1959)[5]，Kalter および Warkany (1959)[13] (1961)[14]，竹越 (1961)[26]，Murakami ら (1965)[18]，江崎 (1964)[22]，伊原ら (1966)[23]，梶原ら (1965)[25] の報告がある。

これらの実験は投与量，投与時期，投与方法，動物の種類，系統も異なり，実験結果はやや異なるけれど，ウサギ，マウス，ラットは妊娠中に vitamin A の過剰を投与すればある頻度で奇形が発生することは多くの研究業績からも明らかである。

Cortisone を妊娠中投与することにより種々の奇形が発生することは Courrier および Colonge (1951)[3, 4]，Glaubach，Antopol および Graff (1951)[10]，Seifter，Christian および Ehrich (1951)[19] がマウス，ラットについて実験成績を報告してからその報告は多い。しかし，マウス，ウサギでは口蓋裂の発生など容易であるが，ラットにはこのような催奇現象は起させることができないということを現在一般の研究者は考えているようである。

Millen および Woollam[16, 17] はラットに vitamin A を過剰投与し，cortisone を併用すると脳，頭蓋冠の奇形の発生は増加し，口蓋裂は100%発生することを報告した。

著者は，1950年から封鎖飼育し，比較的個体差の少ない健康な Wistar 系ラットが，投与量，投与方法を一定にした場合，vitamin A 過剰投与によって惹起される脳，頭蓋冠の奇形，口蓋裂の発生のほか，外形異常，骨格異常が，さらに cortisone を与えると次のように変化するか調べた。

本稿の要旨の一部は，第171回東京歯科大学学会（昭和42年2月）および第36回日本薬理学会関東部会（昭和42年6月）で発表した。

実 験 方 法

実験動物：

日本実験医学研究所で1950年から封鎖的に飼育し、遺伝因子を比較的等しくした、個体差の比較的少ない健康な Wistar 系 albino rat を用いた。実験に用いたはラットの数は、対照群17匹、vitamin A 投与群15匹、vitamin A＋cortisone 投与群10匹である。

飼育環境：

実験群に表れた奇形の発生の頻度は季節によって異なるときいわれ、暑さ、寒さ、湿度などを要因となるという。著者は、静かな環境の中で、室温、約摂 20～25 C、60%前後の室内で、なるべく清潔で実験動物らの福祉の充分にある条件の中で飼育した。

実験資料：

ラットを飼育した混合飼料の組成は澱粉を80%、casein 15%、塩類4%、綜合 vitamin 1%からなっており、これには蛋白質が20%内外含有されて居り、種々の vitamin を含む栄養学的に完全な飼料といえよう。この飼料を成熟ラットでは1日に15g与えるので本文、1匹1日当りの vitamin A は375 I.U. である。

なお、飼料は自由に摂取できるようにした。

妊娠確定：

雌ラットの膣塗抹により発情期を確かめ、夕方6時頃から翌朝まで前に述べた雄の生殖器10～11週の成熟雄ラットと共に1匹ずつ同居させ、雌ラットの膣内精子の存在の確認によって妊娠を判定し、その日の午前0時を妊娠第0日と定め、妊娠期間を起算した。

薬物投与の条件：

投与薬物の種類、量、方法、時期および回数は第1表の通りである。

観察時期：

妊娠第21日目、正確には妊娠20日と12時間でラットを殺し、その母ラットの種々の状態を観察した。

すなわち、母ラットを直ちに開腹し生存胎仔をとり出し、体重、体長を測定後、骨格及び内臓異常の有無を肉眼および実体顕微鏡下にて観察した。また、母ラットの子宮については、胎仔死亡の場合には吸収胚、黄体数を数えた。

外形異常の有無の観察を終えた仔ラットは、骨格異常を示すための骨格標本を作った。その作成法は Noback 法、Dawson 法を参考にした方法で次の通りである。

骨格標本作製法：

1. 仔ラットの腹部を切開し、臓器を除去する。
2. 95% ethanol で2日間固定する。
3. 皮膚、筋肉を可及的除去する。
4. 1% KOH 1l 中に 20mg の alizarine red S を混和した溶液に1.5～2日間入れる。
5. 20% glycerine 溶液に1日入れる。
6. 50% glycerine 溶液に1日入れる。
7. 80% glycerine 溶液中で保存する。

以上の操作を経て完成した骨格標本について、骨格異常の有無、その程度を肉眼または実体顕微鏡を用いて観察、記録した。

Table 1. Experimental condition

Group	Drug	Doses	Route	Stage
Control	Physiological saline	1 ml 100g 0.5ml 100g	Oral administration Subcutaneous administration	From 10th to 13th day of pregnancy
A	Vitamin A	30,000 I.U. 100g	Oral administration	From 10th to 13th day of pregnancy
AC	Vitamin A Cortisone	30,000 I.U. 100g 10mg 100g	Oral administration Subcutaneous administration	From 10th to 13th day of pregnancy

Table 2. Body weight of pregnant mother (g)

	Control	A	AC
The first day of pregnancy	209.4	203.9	208.2
The first day of administration	229.5	235.6	228.6
The last day of administration	239.9	231.5	204.8
Autopsy day	409.4	297.3	244.2
Gained body weight	91.6±28.6	93.4±25.5	36.0±39.5

Table 3. Implantation condition

		Control	A	AC
No. of implantation (Mean number per a mother)		10.8	11.9	11.4
No. of fetal deaths	No. of resorption	0	1.3	2.2
	No. of placenta remnants	0	0.7	0.2
	No. of macerated fetuses	0	0.2	0
No. of survived fetuses		10.8	9.7	9.0
Sex ratio female/male		5.5/5.3	4.7/5.0	4.4/4.6
Mean weight of survivors (g)		4.07±0.11	3.79±0.35	3.39±0.33
No. of fetuses with growth retardation		0.2	0.1	2.0
Placenta weight (g)		1.20	3.99	4.04

実験成績

1. 母ラット体重 (第2表)

母ラットの体重の増加は，対照群に比べて vitamin A 投与群（A群と略す）では殆んど差異は認められなかったが，vitamin A + cortisone 投与群（AC群と略す）では不良であった。

2. 胎仔着床状態 (第3表)

平均胎仔死亡数は，著者の飼料で飼養した対照群では母ラット1匹当り0であったが，A群では2.2匹，AC群では2.4匹であった。

胎仔平均体重は，著者の飼料で飼養した対照群では 4.07±0.14g であったが，A群 3.79±0.35g，AC群 3.39±0.33g といずれも軽く，特にAC群では著明であった。体重 3.00g 以下の発育遅延胎仔数は，対照群では母ラット1匹当り平均0.2匹に対して，A群では0.1匹であったが，AC群では2.0匹と明らかにその数は増加した。

但し，胎盤重量では両者間に相違は認められなかった。

3. 胎仔外形異常 (第4表)

胎仔外形異常は著者の飼料で飼養した母ラットから著者の実験した例数では全く認められなかった。

しかし，A群では82.6%に出現し，AC群ではさらに100%に増加した。その成績は第4表の通りである。AC群はA群に対して舌巨大，下顎裂は約4倍近く，上顎巨大，眼瞼開裂は約2倍近く，口蓋裂1.3倍とその出現は増加した。また，外脳症もAC群に認められた。小頭，口吻異常，上肢短小，舌裂とその出現率は僅かであったがA群に

Table 4. The occurrence and types of abnormalities

	Control	A	AC
Mean number of survived fetuses per a mother	10.8	9.7	9.0
Mean number of abnormal fetuses per a mother	0	8.2	9.0
Percentage of abnormal fetuses (%)	0	82.6	100.0
Microcephalia (%)	0	5.5	0
Exencephalia (%)	0	0	4.4
Auricular abnormality (%)	0	40.4	26.7
Open eyelid (%)	0	14.7	28.9
Stomatic abnormality (%)	0	1.8	0
Megaloglossia (%)	0	20.2	80.0
Megalognathia (%)	0	17.4	37.8
Cleft palate (%)	0	61.5	82.2
Low jaw cleft (%)	0	10.1	37.8
Cleft tongue (%)	0	1.8	0
Micromelia (%)	0	0.9	0

Table 5. Ossification patterns (I)

	Control	A	AC
No. of fetuses with retardation of ossification of occipital bone (%)	0	72.7±3.6	71.1±6.7
No. of fetuses with retardation of ossification of sternebrae (%)	16.7±1.4	75.5±3.4	70.0±7.2
Mean number of ossification of metacarpal bones per a fetus	7.89±0.24	6.30±0.84	5.89±0.13
Mean number of ossification of metatarsal bones per a fetus	8.00±0.00	7.87±0.25	7.64±0.37
Mean number of ossification of coccyx per a fetus	4.95±0.46	5.00±0.64	4.19±0.97

認められたが、AC群では却って認められなかった。

20%以上の外形異常の出現した病型は、A群では口蓋裂 61.5%，耳殻異常 40.4%，舌巨大 20.2%に対して，AC群では口蓋裂 82.2%，舌巨大 80.0%，下顎裂 37.8%，下顎巨大 37.8%，眼瞼開裂 28.9%，耳殻異常 26.7%であった。

4. 胎仔化骨進行度 （第5，6表）

a. 後頭骨化骨進行度

第5表のように，著者の対照群では全例とも後頭骨化骨不全は出現しなかったが，A群では中 72.7%，AC群では 71.1%と対照群に比

Table 6. Ossification patterns (%)

	Number	Control	A	AC
No. of sternal deficiency (%)	0	91.4	69.4	51.1
	1	7.5	25.2	42.2
	2	1.1	4.8	4.4
	3	0	0.6	2.3
	4	0	0	0
	5	0	0	0
	6	0	0	0
Lack of the 2nd sternum (%)		3.4	15.0	37.8
Lack of the 5th sternum (%)		5.2	19.0	11.1
No. of incompleteness of sternal fusion (%)	0	90.8	37.4	66.7
	1	8.1	27.2	28.9
	2	1.1	18.4	2.2
	3	0	12.2	0
	4	0	4.8	2.2
	5	0	0	0
	6	0	0	0

Table 7. Deformity or deviation of bone structure in fetus

		Control	A	AC
Formation of the 14th rib	left (%)	0	27.9	24.4
	right (%)	0	24.5	26.7
Brachygnathia (%)		0	3.4	0
Abnormality of brachium (%)		0	8.2	0
Shortness of ulna (%)		0	8.8	13.3
Shortness of radius (%)		0	7.5	0
Shortness of femur (%)		0	4.1	8.9
Shortness of tibia (%)		0	1.4	0
Shortness of fibula (%)		0	8.2	20.0

著しく出現した。しかし、両群の間に出現率の差異はなかった。

b．腕骨核化骨進行度

腕骨核化骨不全は，著者の対照群では16.7±1.4%に出現した。

A群では75.5±3.4%，AC群では70.0±7.2%と対照群に比して明らかに化骨不全は増加した。その化骨不全像を詳細に観察した成績は第6表に示す通りである

腕骨核化骨不全像は腕骨核欠如と完全不全の二つに分けられる

AおよびAC群ではそれぞれ1個のものが最も多く，A群では完全不全型が，AC群では欠如型が多く出現する傾向を示した

また，欠如型では第2腕骨核の欠如が最も多く，次いで第5腕骨核に現われた

c．中手骨，中足骨および尺椎の化骨進行度

中手骨，中足骨および尺椎の平均化骨核数は，対照群では7.89±0.24，8.00±0.00，1.95±0.16の数値を示したのに比べて，A群では6.30±0.84，7.87±0.25，5.00±0.61という数値を示した。A群では明らかに中手骨の化骨不全が示された。これに対して，AC群ではその数値は5.89±0.13，7.64±0.37，4.19±0.97であり，化骨不全は中手骨では増強し，中足骨および尺椎いずれも明らかに認められた

d．胎仔骨格異常（骨の変形および変位）

胎仔の骨格異常は対照群では現われなかった。A群，AC群に第14肋骨形成がかなりの頻度で出現したが，両群の間には差異は認められなかった。

A群では上顎骨短小，上腕骨形態異常，橈骨短小，尺骨短小，大腿骨短小，脛骨短小，腓骨短小などの症状が現われたが，AC群では橈骨，大腿骨，脛骨の3部位に限られ，高い頻度で明らかに出現した。

考　　按

著者はvitamin Aを過剰に17日間封鎖的に飼育したWistar系ラットに与え，その発生する奇形を観察した。

さらに，cortisoneがvitamin A過剰によって発生する催奇作用にどのような影響をおよぼすかを検討した。

Cortisoneのラットに対する催奇作用については Jost[11]，Millen および Woollam[12]，Courrier および Colonge[3, 4]，Seifter，Christian および Ehrich[19]が報告しているが Lohmeyer[15] はラットでは口蓋裂の発生は私の知る限りではないと述べている。著者も10数例の妊娠ラットで実験したが口蓋裂は出現しなかった

奇形の発生についてはもっぱら研究がおこなわれているのにかかわらず，cortisoneにしてもvitamin Aにしてもその原因は明かっていない

Strean ら[20]は，口蓋裂の発生は変形，胎仔の stress を提唱し，これと cortisone の影響を関連して考察し cortisone の酸素分泌の代謝障害をおこすとみた。Murakami ら[16]もAの催奇は原基に分化する前段階または分化中に間葉に対して抑制的に作用するのではないかと述べている。

また，serotonin のように末梢血管の収縮をおこし，子宮内の血流障害のため発生するという，代謝の抑制によって発生すると考えられる化学説と，舌の下降が妨げられ口蓋の癒着が不可能となり発生するという物理説がある。しかし，いずれであるか定説はない

また，奇形の発生は Fraser[9] によれば，感受性の高い動物種，感受性のある遺伝子型，適正な投与量，適正な投与法，適正な発生段階，適正な環境，適正な観察法および適正な対照の選択の中で影響をうけることが大であるといわれている。

しかるに，Millen および Woollam[12]は cortisone を加えるとすでに述べたように脳，頭蓋骨の奇形，口蓋裂の発生が増加することを発表した

著者は彼等の研究が顔面に限られているので検査項目を追加して，胎仔外形異常，化骨進行度を併せて観察した。

Vitamin Aの投与量（30,000 I.U./100gラット体重）はMillen および Woollam，Giroud および Martinet の報告のように，ラットでは明らかの奇形をおこすのに充分な量であったのでこの量を用い，cortisone はヒトの常用量（2mg/kg

に50倍を用いた。

Vitamin A の投与方法は経口投与としたが，これは腹腔内，皮下投与では奇形が発生しないという報告[7, 21]に基づいた。

また，投与時期も江崎[22]，梶原ら[25]の報告のように，いずれも外形異常などをおこしやすい妊娠10日目から6日間とした。

[illegible]の点，その他の理由からも，著者の成績が Millen および Woollam[16] の成績と異なるのは当然といえよう。

さらに，vitamin A の過剰にさらに cortisone を加えることは，胎仔の発育は不良となり，外形異常は増加し，骨格不全もある程度には増加するようにみえる。

Cortisone は妊娠第[illegible]週にその最高の成長成熟しての増殖をする時に，collagen 線維の形成を不全とし，ひいては骨化過程を不良とし骨の奇形や骨格不全をおこすとされる。vitamin A 過剰による代謝障害に対してさらに協力作用を現わすものと考える。

結　　辞

17年間目的に飼育した Wistar 系 albino rat で vitamin A 過剰投与で発生する奇形が cortisone でどのような影響があるか調べたところ，Millen および Woollam の成績の他に次のような新事実を発見した。

1. 母ラットの体重の増加は，対照群に比して vitamin A 過剰投与群（A群）では殆んど差異を認めなかったが，vitamin A の過剰に cortisone を添加すると（AC群）著しく不良であった。

2. 母胎仔死亡数は，A群，AC群で増加した。また，胎仔平均体重は対照群に比してA群にはやや，AC群ではさらに低かった。

[illegible]

[illegible]

[illegible]

[illegible]

れない口蓋裂が，vitamin A に cortisone を添加すれば，vitamin A 単独投与よりもさらに著しく現われた。

4. 胎仔化骨進行度は，vitamin A の過剰投与，またこれに cortisone の添加で化骨不全の出現は増加した。

後頭骨，脊椎骨では cortisone を添加しても差異は現われないが，中手骨，中足骨，尾椎では明らかに現われた。骨格異常も cortisone を添加すると増加する成績をみた。

[illegible]

[illegible]

文　　献

1) Baba, T. and Araki, E. : Morphogenesis of malformation due to excessive vitamin A(1). Osaka City. Med. J. 5 : 9～15, 1959.

2) Cohlan, S. Q. : Excessive intake of vitamin A as a cause of congenital anomalies in the rat. Science 117 : 535～536, 1953.

3) Courrier, R. and A. Colonge : Cortisone et gestation chez la lapine. Compt. rend. Acad. Sc. 232 : 1161～1166, 1951.

4) Courrier, R., A. Colonge and M. Baclesse. : Action de la cortisone administrée à la mère sur la surrenale du foetus de Rat. Compt. rend. Acad. Sc. 233 : 333～336, 1951.

5) Deuschle, F. M., Geiger, J. F. and Warkany, J. : Analysis of an anomalous oculodentofacial pattern in newborn rats produced by maternal hypervitaminosis A. J. Dent. Res. 38 : 149～155, 1959.

6) Fraser, F. C. : Experimental teratogenesis in relation to congenital malformations in man. Second Intern. Conf. Cong. Mal. Lippincott Philadelphia Montreal 1964.

7) [illegible]

8) Giroud, A. et Martinet, M. : Tératogénèse par hypervitaminose A chez le rat, la souris, le cobaye et le lapin. Arch. Franc. Pediat. 16 : 1~5, 1959.

9) Giroud, A. et Martinet, M. : Légèreté de la dose tératogène de la vitamine A. Compt. rend. soc. biol. 156 : 449~450, 1962.

10) Glaubach, S., W. Antopol and S. Graff : Excessive doses of cortisone in pregnant mice : Effect on development and survival of the fetus and newborn and on the maternal breast tissue. Bull. N. York. Acad. M. 27 : 398, 1951.

11) Jost, A. : The age factor in some prenatal endocrine events. Ciba Foundation Colloq. on Ageing 2 : 18~27, 1956.

12) Kalter, H. and Warkany, J. : Experimental Production of Congenital Malformations in Mammals by Metabolic Procedure. Physiol. Rev. 39 : 69~115, 1959.

13) Kalter, J. and Warkany, J. : Teratogenic action of hypervitaminosis A in strains of inbred mice. Anat. Rec. 133 : 396~397, 1959.

14) Kalter, H. and Warkany, J. : Experimental production of congenital malformations in strains of inbred mice by maternal treatment with hypervitaminosis A. Amer. J. Pathol. 38 : 1~21, 1961.

15) Lommyer, H. : Cortison, Schwangerschaft und Misbildungen des Neugeborenen. Geburtsh. u. Frauenheilk. 21 : 560~565, 1961.

16) Millen, J. W. and D. H. M. Woollam. : Influence of cortisone on teratogenic effects of hypervitaminosis A. Brit. Med. J. 2 : 196~197, 1957.

17) Millen, J. W. and D. H. M. Woollam. : Insuline-cortisone relationship in experimental teratogenesis. Nature 181 : 418, 1958.

18) Murakami, U., Kameyama, Y. and Nogami, H. : Malformations of the mouse fetus caused by hypervitaminosis A of the mother during pregnancy. Arch. Envision. Health. 10 : 732~741, 1965.

19) Seifter, J., J. J. Christian and W. E. Ehrich. : Effect of cortisone and other steroids on the hibernating gland of the pregnant white rat. Fed. Proc. 10 : 334, 1951 (abst.).

20) Streau, L. P. and I. A. Peer. : Stress as an etiologic factor in the development of cleft palate. Plastic & Reconstr. Surg. 18 : 1~8, 1956.

21) Woollam, D. H. M. and J. W. Millen. : Effect of cortisone on the incidence of cleft-palate induced by experimental hypervitaminosis-A. Brit. M. J. 2 : 197~198, 1957.

22) 山崎孝一郎：41.8～7ヵ月ヒト胎児 vitamin A 過剰投与が胎仔に及ぼす影響
(1) 外表奇形発現，脂肪生存率および脂肪仔中心について，
(2) 生存脂仔の外形異常 I
(3) 生存脂仔の外形異常 II
先天異常 4 : 27~34, 35~42, 43~51, 1964.

23) 伊藤敏夫・木谷十郎・田中右二・脇坂淵一郎：実験動物脂仔に対する過剰ビタミンAの影響，とくに母血胎盤関係について 先天異常 6 : 91~108, 1966.

24) 福島豊茂：Vitamine A 過剰投与による奇形発生の実験的研究 阪市大医誌 7 : 558~566, 1958.

25) 梅原 強：種々の実験動物における奇形発生と過剰 vitamin A の影響 ―― 先天異常 5 : 177~183, 1965.

26) 竹越有一：ビタミンA過剰投与による畸形発生について 北関東医学 11 : 104~118, 1961.







Fig. 1 A fetus showing cleft palate.

Fig. 2 A fetus showing low jaw cleft.

Fig. 3 A fetus showing exencephalia.

Fig. 4 A fetus showing auricular abnormality

Fig. 5 A fetus showing open eyelid and megaloglossia.

Fig. 6 Left side : a skeletal preparation of a normal fetus
Right side : a skeletal preparation of an abnormal fetus showing retardation of ossification of occipital bone

7-A



7-B



8-A

8-B

8-C

Fig. 7-A A skeletal preparation of a normal fetus.

Fig. 7-B A skeletal preparation of an abnormal fetus showing abnormality of brachium and shortness of ulna, radius, femur and fibula.

Fig. 8-A A skeletal preparation of a normal fetus.

Fig 8-B A skeletal preparation of an abnormal fetus showing incomplete formation of the 14 th ribs.

Fig 8-C A skeletal preparation of an abnormal fetus showing complete formation of the 14 th ribs.

9-A

9-B

10-A



10-B

Fig. 9-A A skeletal preparation of a normal fetus.

Fig 9-B A skeletal preparation of an abnormal fetus showing brachy-gnathia.

Fig. 10-A A skeletal preparation of a normal fetus.

Fig. 10-B A skeletal preparation of an abnormal fetus showing lack of the 2nd sternum and incomplete fusion of the 5th sternum.

Yoshikami-'68
Bib. No. 10083

Vision Res. Vol. 9, pp. 633–646. Pergamon Press 1969. Printed in Great Britain.

VISUAL PIGMENTS OF THE VITAMIN A-DEFICIENT RAT FOLLOWING VITAMIN A_2 ADMINISTRATION

SHUKO YOSHIKAMI, JEROME T. PEARLMAN and FREDERICK CRESCITELLI[1]

Department of Zoology and Jules Stein Eye Institute, University of California, Los Angeles

(*Received* 25 *November* 1968)

INTRODUCTION

THE VERTEBRATE visual pigments are chromoproteins in which a protein, opsin, is covalently bonded to a coloured prosthetic group which is the aldehyde of either vitamin A_1 (retinol) or vitamin A_2 (3-dehydroretinol). Accordingly, there are two distinct classes of visual pigments: one based on retinal; the second, based on 3-dehydroretinal (WALD, 1959). The vitamin A_1 photopigments have been found to occur in the visual cells of mammals, birds, reptiles, some amphibia, many teleosts, and elasmobranchs. The vitamin A_2 pigments are more restricted in their distribution, occurring in the retinas of teleosts and amphibia (particularly in the larval stage). Some vertebrate species have representatives of both these classes in the retina, and these may be present together at the same time or occur successively in time as part of a metamorphic life cycle. In addition, there are teleost fishes, containing a pair of visual pigments representing both classes, in which the proportion of the two pigments varies with the season, apparently in relation to the seasonal photic cycle. These examples, documented and reviewed by DARTNALL (1962), illustrate the fact that within certain vertebrate species both classes of visual pigments can serve the visual functions and that interconversion between these two classes, according to developmental or environmental pressures, is a normal process.

In some vertebrates, e.g. mammals, the rod visual pigment is relatively stable changing neither with season, age of the animal, type of diet, nor other factors. This pigment, rhodopsin, is a vitamin A_1 photopigment with its absorption maximum in the region of 500 nm. Vitamin A_2 pigments have not been found in mammals. Is the ability to convert between these two classes lost in mammals or is it still present, requiring only the proper stimulus to become evident? This was the question for this investigation, which was concerned with the outcome of depleting the vitamin A reserves of the laboratory rat, while maintaining normal body functions with retinoic acid, and then supplementing the diet with crystalline vitamin A_2. What is the visual pigment in such rats? Is a 3-dehydroretinal photopigment formed or is the vitamin A_2 somehow converted to yield the normal rhodopsin of the rat? This question was examined some time ago by SHANTZ *et al.* (1946), even before chemically pure vitamin A_2 was available. They concluded that rats depleted

[1] Aided by a grant from the Division of Research Grants and Fellowships, National Institutes of Health, U.S. Public Health Service; a portion of this work represents the studies of Shuko Yoshikami, in partial fulfilment of the Ph.D. degree in Zoology at the University of California, Los Angeles. During the progress of this work Shuko Yoshikami held a Pre-doctoral Research Fellowship from N.I.H. and Jerome T. Pearlman had a special Post-doctoral Research Fellowship (N.I.H.).

of vitamin A and given, as supplement, an extract of the tissues of wall-eyed pike, produced in the retina, not rhodopsin, but a photopigment with maximum absorption at about 520 nm. They took this to indicate the formation of porphyropsin which, according to their interpretation, replaced 80 per cent, or more, of the rhodopsin. According to these investigators, the rat retina is able to employ vitamin A_2 directly in making visual pigment, and not much, if any, conversion to the rhodopsin takes place. Later, SHANTZ and BRINKMAN (1950) reiterated the conclusion of nonconvertibility. The results of SHANTZ *et al.* (1946) have been cited in support of certain data obtained with the human visual system. MILLARD and MCCANN (1949), for example, reported that human subjects, instructed to employ a diet limited in vitamin A but supplemented with pike liver concentrate, developed a small, but significant increase in their sensitivity to red light under scotopic conditions, as if a porphyropsin had formed in the retina.

Unfortunately, there are several uncertainties about the experiment of SHANTZ *et al.* (1946). Their conclusion was based on the use of a difference spectrum. Such a spectrum can be analytically useful if properly obtained, but the authors presented no data to justify their use of this spectrum to deduce the true photopigment absorbance curve. Neither the spectra before, nor after bleaching were shown, so the influence on the final result of the products of bleaching, which are known to be coloured, cannot be evaluated. The photopigment homogeneity of the extract was not tested by partial bleaching. In addition, the chemical nature of the prosthetic group—whether retinal or 3-dehydroretinal—was not tested. SHANTZ *et al.* (1946) found vitamin A_1 in the retina after six weeks of supplementary feeding, but only a trace of vitamin A_2 was detected. They explained this by stating: "it appears that retinas pick up A_2 extremely slowly and tend to maintain normal levels of A_1." If this is the case, why was so little rhodopsin found in their extract? In addition, there is the statement of CAMA *et al.* (1952)—itself unsupported by data—that no replacement of rhodopsin by porphyropsin occurred in vitamin A deficient rats given 3-dehydroretinal.

For these reasons we decided to re-open this question and to investigate the nature of the photopigment in the retina of the vitamin A deficient rat whose diet was supplemented by including crystalline vitamin A_2.

METHODS

The procedure involved a depletion of the vitamin A reserves of weanling, male albino rats (Sprague-Dawley); then, after sufficient depletion, adding crystalline vitamin A_2 to the diet. The effects of this addition were monitored histologically and electroretinographically. At certain periods in this schedule, indicated in the results, animals were sacrificed and the eyes removed and hardened in 4 per cent potassium alum. The retinas were then dissected out, and extracts were prepared to obtain the photopigment (CRESCITELLI, 1958). Analysis of these extracts was made by the method of partial bleaching (DARTNALL, 1957).

The experiments were carried out in two separate series and involved different animals. The first series, during 1965–1966, employed a group of 40 rats fed *ad libitum* on a vitamin A-free diet (USP vitamin A test diet) and provided with sterilized distilled water for fluid. These 40 rats were segregated into 4 subgroups of 10 animals each. Starting on the 15th week of this regimen and continuing to the 18th week, the rats in each of these 4 subgroups were given different supplements to the basic diet as indicated in Table 1. This first series also included two additional groups of animals: one was a group of 5 normal rats maintained for 18 weeks on the normal laboratory diet of Purina rat chow, the other was a group of 48 rats also divided into 4 subgroups as shown in Table 1. These 48 rats were employed for histological examination of the retinas.

At the time supplementation to the basic diet began, all rats, except for the group of 5 normal animals, began to receive retinoic acid (Eastman Organic Chemicals) dissolved as the sodium salt in phosphate buffer at pH 10·5 (VAN DORP and ARENS, 1946). Crystalline all-*trans* vitamin A_1 (Nutritional Biochem.

TABLE 1. SCHEDULE OF RATS MADE VITAMIN A DEFICIENT FOR 15 WEEKS AND THEN SUPPLEMENTED FOR 3 WEEKS AS SHOWN

Subgroup	Number of rats	Supplements in μg per day		
		Vitamin A_1	Vitamin A_2	Retinoic acid
1	10			18*
2	10	9		9
3	10		30	9
4	10	9	30	9

Basic diet for all rats was USP vitamin A test diet.
* Crisco oil was given in amount equal to that used as an excipient for the vitamin A in each of the other subgroups.

Corp.) and crystalline all-*trans* vitamin A_2 (Hoffman-La Roche, Inc.)[2] were dissolved separately in soybean oil (Crisco) containing butylated hydroxytoluene, butylated hydroxyanisole and methylated silicone as antioxidants. These solutions were prepared fresh each week and were kept in containers in an atmosphere of nitrogen and in the refrigerator (15°C) until needed. The biological activity of vitamin A_2 was taken to be about 30 per cent that of vitamin A_1 (FARRAR *et al.*, 1952) which explains the higher levels of administration (Table 1) for vitamin A_2. All solutions were given by stomach tube.

The second series of experiments during 1967–1968 followed essentially the same procedure and schedule. These animals were monitored electroretinographically each week during development of the deficiency and during the recovery that followed the vitamin A administration. The apparatus and techniques for recording the ERG were standard for such work and were the same as previously described from this laboratory (CRESCITELLI and GARDNER, 1961). All rats were eventually sacrificed, after dark adaptation overnight, and their retinas employed for the visual pigment assay.

RESULTS

1. *General observations*

After being placed on a vitamin A deficient diet the rats grew normally for the first 12 weeks, gaining approximately 20 g per week per rat for the first 8 weeks and about 10 g per week per rat thereafter. After the 12th week the growth rate decreased almost to zero. First signs of xerophthalmia appeared in some of the rats at the 14th week and on the 15th week the supplements to the diet (Table 1) were started. Xerophthalmia disappeared, the normal growth rate was restored, and at the 18th week the animals were sacrificed for the visual pigment analyses. One animal which was continued on the vitamin A deficient diet without supplementation showed aggravated deficiency symptoms, including weight loss, xerophthalmia, rough coat, urinary tract bleeding, and liquid feces. It died during the 20th week.

2. *Retinal histology*

On the 2nd, 4th, 6th, 12th and 15th weeks two rats from each of the 4 subgroups (Table 1) from the group of 48 rats were sacrificed and the retinas prepared for histological inspection. For the first 12 weeks no obvious signs of retinal damage were observed. During the 15th week the retinas from subgroup 1, which was the subgroup given only retinoic acid as supplement, were obviously abnormal. The outer segments showed evidences of disarray and deterioration but the inner segments and neuronal layers were

[2] We are indebted to Hoffman-La Roche, Inc. for generous gifts of the crystalline vitamin A_2.

apparently unaffected (Fig. 1). In contrast, the retinas taken from animals receiving vitamin A_1 or vitamin A_2 appeared to have visual cells with normal outer segments (Fig. 1). The main point here is that 3-dehydroretinol was able to prevent destruction of the visual cell layer on a diet otherwise deficient in vitamin A.

3. *The electroretinographic threshold*

Rats on a vitamin A deficient diet receiving only retinoic acid as a supplement showed increased ERG thresholds (Fig. 2, A^-), but addition to the diet of either vitamin A_1 or vitamin A_2 was able to restore normal threshold. This is indicated in Fig. 2 in which the *b*-wave height (microvolts) is plotted as a function of light intensity (log I). Each of these curves is based on mean data from only 3–5 animals and much variability was present from animal to animal, but the trend which is displayed is typical and significant, i.e. vitamin A_2, like vitamin A_1, was able to repair the loss in sensitivity to light brought on by the deficiency.

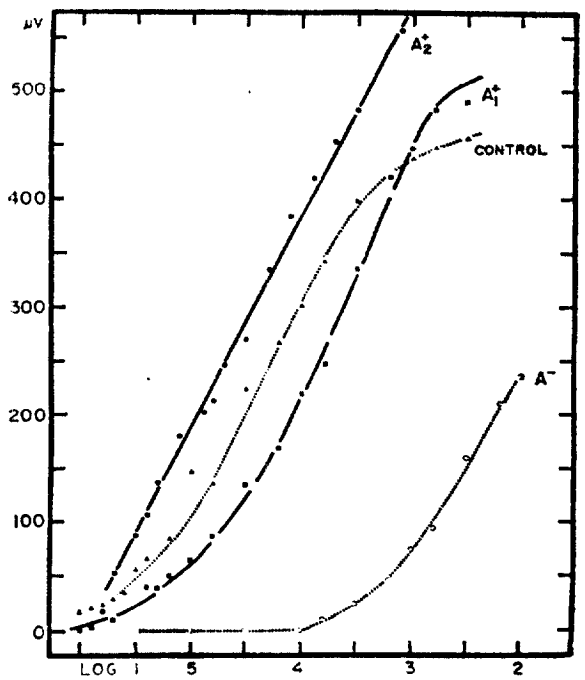

FIG. 2. Mean *b*-wave height (μV) as a function of log relative intensity (log I) for 4 control rats on a Purina rat chow; 5 rats depleted of vitamin A for 18–30 weeks (A^-); 3 rats supplemented with vitamin A_1 for 7–20 weeks (A_1^+); and 4 rats supplemented with vitamin A_2 for 7–20 weeks (A_2^+). All rats except the controls also received retinoic acid. Stimulus flash was white light at 100 msec. Rats were dark adapted overnight and given light urethane anaesthesia.

4. *The visual pigment content*

(a) *Rhodopsin of the normal rat.* Rats maintained on Purina rat chow yielded photosensitive retinal extracts, analysis of which revealed the presence of rhodopsin with properties similar to those reported for the rat by COLLINS and MORTON (1950) and BRIDGES (1959). The wavelength for maximal absorption was at 498 nm, and retinal—



FIG. 1. Retinal histology for three rats at the 15th week after the start of vitamin A deficiency and supplementation. These rats were from the group of 48 rats placed on the regimen of Table 1 from the day of weaning. A^- is the retina from a rat given only retinoic acid as supplement. A_1^+ is from a rat given retinoic acid and vitamin A_1. A_2^+ is from a rat receiving retinoic acid and vitamin A_2. Retinas were fixed in Kolmer's, dehydrated in ethanol–butanol mixtures, cut into 7–10 μ sections, stained with Harris haemotoxylin, and counterstained with eosin.

[facing page 636

identified from the spectrum of the oxime—was the constituent prosthetic group (Table 2). Even the yield of rhodopsin per retina (Table 2) agreed well with the figure of 0·021 given by COLLINS and MORTON (1950). These extracts, when tested by the method of partial bleaching (DARTNALL, 1957), showed that rhodopsin was the only photopigment present, a point already demonstrated by BRIDGES (1959) for the rat retina.

TABLE 2. RESULTS OF ANALYSES OF EXTRACTS FOR RATS OF FIRST SERIES

Group or subgroup	Aliquot	*Wavelength of maximum* Absorbance*	Difference loss†	Oxime	Pigment yield per retina‡
Normal	1	498			0·028
	2	498	498	368	0·019
Deficient					
1 Retinoic acid	1				0·0005
	2				0·0006
2 Vitamin A_1	1	498			0·010
	2	498			0·010
3 Vitamin A_2	1	504			0·005
	2	503	503	378	0·007
4 Both vitamins	1	498			0·009
	2	501	498	370	0·009

* These values have been corrected for impurities using method of CRESCITELLI and DARTNALL (1954).
† These figures are from analyses made in the presence of NH_2OH.
‡ This represents the density loss at maximum.
All wavelengths are accurate to ± 2 nm.

(b) *Rhodopsin of the deficient rat.* The vitamin A deficient rats showed very small quantities of photopigment released into the digitonin extracting medium. This amount—less than 0·001 per retina—was insufficient to carry out the usual identification procedures, but there is no reason to suspect this was anything but residual rhodopsin which would have completely disappeared if the deficiency had continued. It has been established (DOWLING and WALD, 1960) that retinoic acid, though it serves for growth and maintenance of general tissue functions, cannot be utilized by the eye for synthesizing visual pigment. In the presence of retinoic acid, the retina undergoes changes similar to those associated with unsupplemented vitamin A deficiency. This is what we also have found.

(c) *Rhodopsin of the vitamin A_1-supplemented rat.* The animals made deficient and then supplemented with both retinoic acid and vitamin A_1 yielded extracts containing normal rat rhodopsin (Table 2, Fig. 3). The wavelength for maximal absorption was at 498 nm, and in all respects the photopigment was similar to that of control rats, although the yield was lower (Table 2).

(d) *Visual pigments of the vitamin A_2-supplemented rat.* The results summarized above (a–c) are the expected ones and represent nothing new. They serve to indicate that the experiments were carried out properly and that no complications or difficulties were encountered. They are, in fact, controls on the results to be presented in this section.

The absorbance curve of an extract of retinas taken from vitamin A_2-supplemented animals is shown, along with comparable curves for extracts from retinas of normal rats and vitamin A_1-supplemented rats (Fig. 3). The wavelength for maximal absorption is not at 520 nm, the position given by SHANTZ *et al*, (1946) for their extract, but neither is it at 498 nm, the position for normal rat rhodopsin and for rhodopsin extracted from the

retinas of vitamin A_1-supplemented animals. It is, in fact, at about 503 nm. Just as significant is the higher absorbance at longer wavelengths shown by the curve for the vitamin A_2 animals (Fig. 3). What is the explanation for this aberrant absorbance curve for the animals receiving the 3-dehydroretinol? Is it the result of impurities absorbing at higher wavelengths; is it due to the presence of a single photopigment different from normal rat rhodopsin and characteristic of the vitamin A_2 administration; or is it the result of more than one photopigment? To obtain the answer we resorted to analysis by the method of partial bleaching (DARTNALL, 1957) which has served so well in testing the homogeneity of retinal extracts.

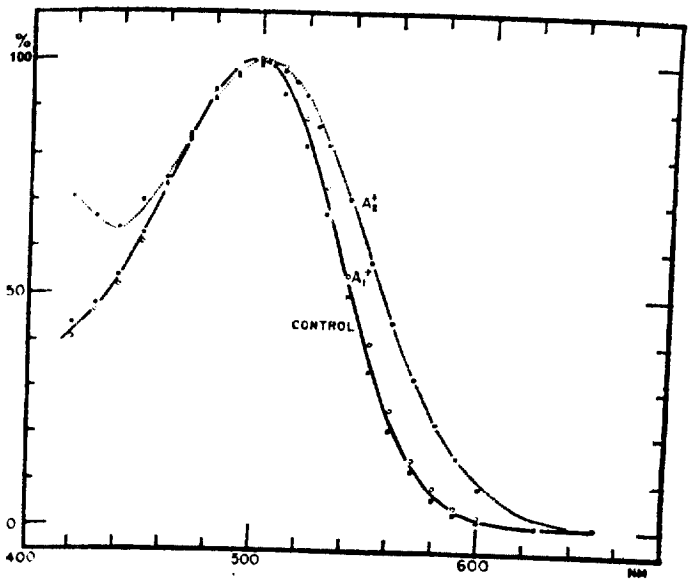

FIG. 3. Absorbance curves of retinal extracts from: 5 control rats fed on Purina rat chow (filled squares); 5 rats receiving vitamin A_1 (open circles); 5 rats receiving vitamin A_2 (filled circles). All rats except controls also received retinoic acid. Rats were sacrificed at 18th week of schedule of Table 1. All three curves scaled so that absorbance maxima were at 100 per cent value.

Before giving the results of the partial bleaching analysis, one important technical point about our procedure needs to be explained, a point which we elucidated by means of frog rhodopsin, which absorbs maximally at 502 nm. With our bleaching monochromator set at 650 nm, and with a 650 nm interference filter in the light output path, no measurable loss of frog rhodopsin occurred, even with exposures as long as 3 hr, and with the rhodopsin solutions denser than the rat retinal extracts. This means that any bleaching at this wavelength could be due only to the presence of a photopigment absorbing at longer wavelengths than 502 nm or to one with an unusually high photosensitivity.

An extract of the retinas of normal rats did not show any significant bleaching loss when exposed for 3 hr to this 650 nm illumination (Fig. 4). In contrast, the extract of retinas from vitamin A_2-supplemented animals, when similarly treated, suffered a density loss maximal at about 517 nm (Fig. 4). The density loss at maximum was about 0·014. A second illumination, this time at 600 nm, led to bleaching losses in both extracts (Fig. 4, Bleach 2), the maximal losses being at about 498 nm for the two extracts, i.e. the position

for normal rat rhodopsin. A third and terminal exposure to light, this time to 550 nm, resulted in major pigment bleaching for both extracts, the wavelength for maximal loss being again at 498 nm for both (Fig. 4, Bleach 3). The bleaching sequence of Fig. 4 suggests that the extract from normal rats contained only rhodopsin but that derived from vitamin A_2-supplemented rats consisted of a mixture of two photopigments: one absorbing maximally at 498 nm, and presumably rhodopsin; the second, a new pigment with maximal absorption at about 18–20 nm longer wavelength than rhodopsin. On a density basis this new pigment was present in the extract to the extent of about 10 per cent of the total photopigment content.

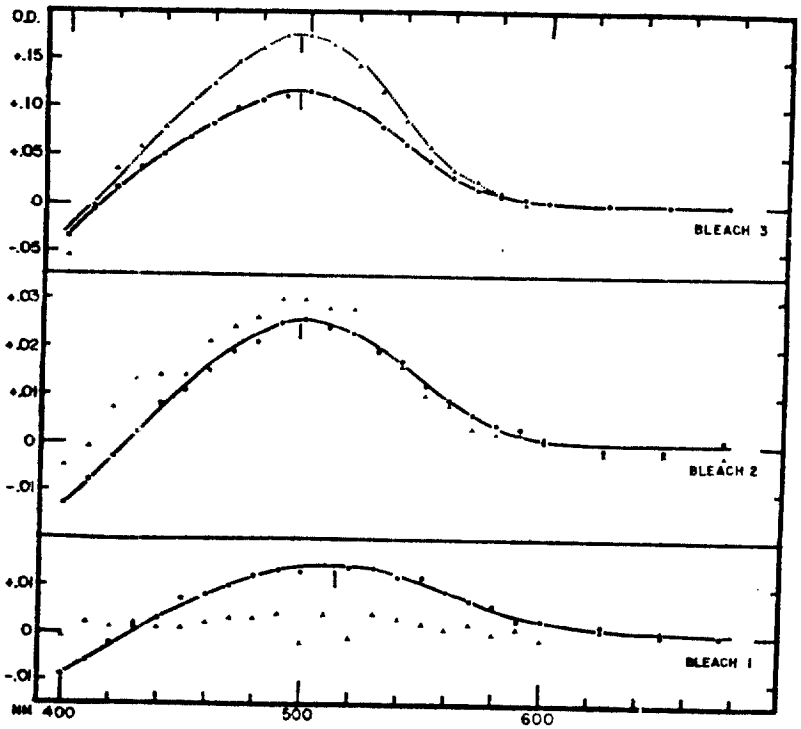

FIG. 4. Difference spectra for pigment loss after three successive bleachings for an extract of retinas from control rats (filled triangles and dotted line) and for an extract of retinas from rats receiving vitamin A_2 (filled circles and dashed line). Bleach 1: 3 hr exposure to light at 650 nm. Bleach 2: 1 hr exposure to light at 600 nm. Bleach 3: exhaustive bleaching—to completion—with light at 550 nm. All bleachings were carried out in presence of NH_2OH. This figure shows the optical density loss (−) or gain (−) as functions of wavelength (nm). The short vertical bars adjacent to each curve indicate wavelengths of maximal density loss.

What is the nature of the prosthetic group in these two pigments? To obtain the answer we performed the bleaching sequences of Fig. 4 with an extract of retinas from vitamin A_2-supplemented rats to which NH_2OH had been added before bleaching in order to identify the product of bleaching, i.e. to determine whether it was retinal oxime or 3-dehydroretinal oxime. As is shown by the product spectrum (Fig. 5), the 517-pigment was associated with an oxime whose spectrum, compared with that of the 498-pigment, was shifted to longer wavelengths. The results suggest that the 498-pigment is normal rhodopsin, containing retinal, but the 517-pigment is based on 3-dehydroretinal. The

difference in absorption maxima for these two pigments—18–20 nm— is correct for a system utilizing the same opsin but shifting from retinal to dehydroretinal. The pigment-loss difference spectra for these two photopigments, when properly normalized to permit comparison, conform to the nomogram-derived curves based on visual pigments. This point is made in Fig. 6 where the normalized data for the first bleach—to 650 nm—is compared with the curve constructed by use of the nomogram for 3-dehydroretinal pigments (MUNZ and SCHWANZARA, 1967), and the data for the third bleach—to 550 nm—is compared with the curve derived from the Dartnall nomogram (DARTNALL, 1953). In both cases, the fit of experimental data to nomograms is good enough to conclude that both photopigments are visual pigments, one being normal rhodopsin, the second, a new pigment induced by the conditions of the experiment.

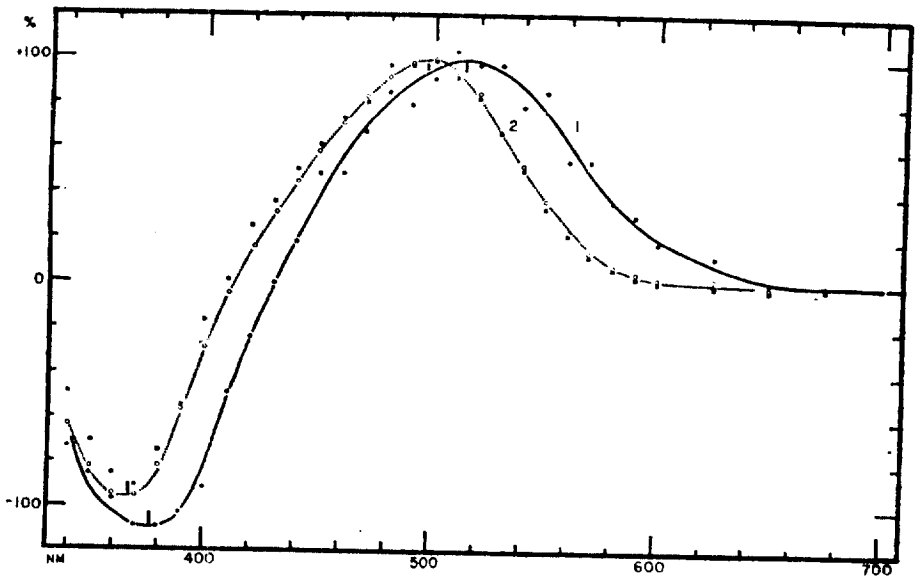

FIG. 5. Complete difference spectra showing density loss (+) and density gain (−) for extracts bleached in presence of NH_2OH. Curve 1 (filled circles): after a bleach for 3 hr to light at 650 nm of an extract of retinas from 11 rats receiving vitamin A_2. Curve 2 (open circles): after a bleach of the same extract to light at 550 nm. Curve 2 (filled squares): after a bleach to light at 550 nm of a retinal extract of normal rats. All data normalized so that maximal density losses were at 100 per cent. The short vertical bars indicate wavelengths of maximal density loss and gain.

DISCUSSION

The results of this study are summarized briefly: in laboratory rats depleted of vitamin A until the retinal histology, the electroretinographic threshold, and the visual pigment content are severely, but not irreversibly affected, the administration of vitamin A_2 repaired these deficiencies. The photopigments extracted from the retinas of such repaired animals consisted chiefly of normal rat rhodopsin along with a minor component consisting of a 3-dehydroretinal pigment absorbing maximally at about 517 nm. No evidence was obtained for the presence of a major component absorbing at 520 nm, as suggested by SHANTZ *et al.* (1946). Neither were we able to confirm the statement by CAMA *et al.* (1952) that no detectable replacement of rhodopsin by porphyropsin occurred in their rats.

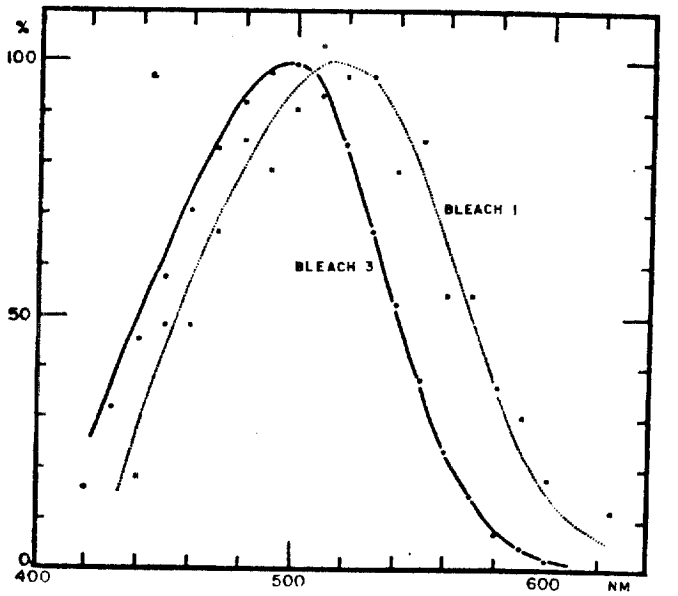

FIG. 6. Difference spectra for density loss in presence of NH_2OH. A retinal extract of rats receiving vitamin A_2 was bleached in three stages as in Fig. 4. Filled squares: data of bleach 1; dotted curve is nomogram curve for vitamin A_2 pigments for a pigment with maximal absorption at 517 nm. Filled circles: data of bleach 3; full curve is based on nomogram for a 498 nm vitamin A_1 pigment.

Three suggestions come to mind for an interpretation of these results. The first is that the repair to the visual cells is the result not of vitamin A_2, but of contaminating sources of vitamin A_1 inadvertently obtained by the animals. This suggestion is untenable for the reason that control animals treated identically to the experimental rats receiving vitamin A_2, except for the inclusion of 3-dehydroretinol in the diet, showed very small quantities of photopigment and no repair of the retinal histology and ERG threshold.

The second suggestion is that a source of vitamin A_1 exists in the rat body—perhaps in the retina—which is released by the admission of vitamin A_2. This is related to the idea of SHANTZ *et al.* (1946) that vitamin A_1 is tenaciously retained somewhere in the rat body. No analyses are available to test whether such hidden stores do in fact exist in the severely depleted rat. HEATON, LOWE and MORTON (1957) reported the absence of vitamin A in liver, skin, kidney, submaxillary gland, small intestine, stomach, bladder, vagina, and testis from vitamin A-deficient rats. No data for the retina were given, but LEWIS *et al.* (1942) showed that rats receiving no vitamin A for six weeks had none of this vitamin in the liver or blood plasma, but it was present in the retina, though the concentration was below normal. These investigators made no mention of a deficiency continued beyond the six week period. An insight into the effects of further deficiency is obtained from the work of DOWLING and WALD (1958). Rats on a deficient diet lost their liver vitamin A first, following which the blood retinol decreased. By about 4·5 weeks of deprivation the liver and blood content of vitamin A was reduced to zero. The rhodopsin then declined, reaching very low values by about the 8th week. After the 6th week, opsin itself began to disappear from the retina, a fact which suggests the presence of very little vitamin A available to the visual cells. Consequently, a hidden source of vitamin A_1 in the depleted

rat has not been revealed unless one makes the special assumption, for which there is no evidence, that only the admission of vitamin A_2 releases the hidden store of vitamin A_1 and makes this available to the visual cells. This assumption also makes it difficult to understand why SHANTZ *et al.* (1946) found vitamin A_1 in the retina but only a trace of vitamin A_2.

The third suggestion—and the one that appears to be the most reasonable in the light of present information—is that a conversion of 3-dehydroretinol to retinal somehow occurs, leading, of course, to the formation of rhodopsin. Several studies have been published indicating that interconversion between the two classes of visual pigments does occur in certain vertebrate species; the conversion of porphyropsin to rhodopsin in certain anurans during metamorphosis is an example (WALD, 1946; CRESCITELLI, 1958). Such conversion does not occur in all anurans, however, and interesting in this respect is the difference between the toad (*Bufo boreas*) and the tree frog (*Hyla regilla*). Tadpoles of both species were obtained from the same pond at the same time. They had developed, from the time of hatching, in the same photic environment and with the same available food supply. The two species were of comparable ages and sizes. Yet the tree frog tadpoles showed the presence of porphyropsin in the retinas, whereas the toad tadpoles had rhodopsin (CRESCITELLI, 1958). Adults of both species showed the presence of rhodopsin. This demonstrates that it is the innate metabolic characteristics, and not just diet and environment, that determine the nature of the visual pigment in a given species. WILT (1959a) also emphasized this point in the photopigment conversion of the bullfrog tadpole. He suggested that implantation of a pellet of thyroxin-cholesterol into the eye led to an increase in conversion of porphyropsin to rhodopsin, a finding that suggests that the mechanisms for conversion are located within or close to the retinal tissue (WILT, 1959b). In anurans in which this metamorphic conversion takes place, not only rhodopsin, but all the retinal photopigments are apparently involved. This is suggested by a study of *Rana pipiens* by LIEBMAN and ENTINE (1968), who showed that green rods, red rods, single cones and both members of the double cones participate in this metamorphic conversion.

Interconversion between these two classes of visual pigments can occur quite independently of any metamorphic transitions. An interesting example is the rudd, *Scardinius erythrophthalmus*, which was shown to have a pair of visual pigments representing both classes (DARTNALL, LANDER and MUNZ, 1961). It was discovered that the ratio of these two pigments changed with the season, apparently correlated with the seasonal photoperiod. BRIDGES (1964) confirmed the occurrence of seasonally-based conversions in two other species of fishes. Direct evidence of a vitamin A_1 to 3-dehydroretinal conversion was obtained (NAITO and WILT, 1962) by introducing tritium-labelled vitamin A_1 into a sunfish and recovering the label in the 3-dehydroretinal released from the visual pigment after bleaching. NAITO and WILT (1962) also reported that such a conversion could take place in the isolated eye and that it could be significantly lowered by the addition of triiodo thyronine. MUNZ and SWANSON (1965) reported that L-thyroxine added to the water in which rainbow trout were maintained resulted in an increase in ratio of the vitamin A_2 to vitamin A_1 visual pigments; thiourea was reported to produce the opposite effect.

All these published results offer evidence that mechanisms exist for the interconversion of visual pigments between the two classes, and that these mechanisms occur in the retina or in the tissues, e.g. the pigment epithelium, closely adjacent to the visual cells. We conclude that these mechanisms also exist in the rat eye but are not in evidence unless, under the condition of a large increase in the ratio A_2/A_1—as in the present experiment—

the mechanisms of conversion are driven into evidence. Leaving out for the time the isomerizing reaction, we may postulate the following possible sequences for the mechanism of conversion.

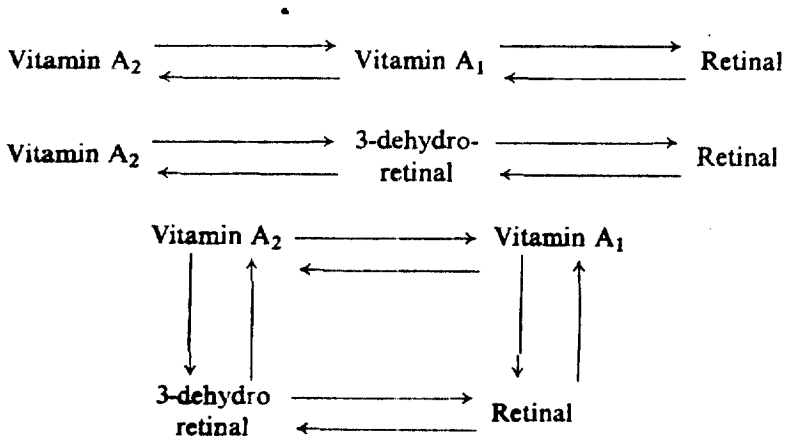

Sequence 1 is ruled out because it does not predict the formation of a 3-dehydroretinal photopigment which we have found as a minor, though significant, component. Neither does it explain the conversion of 3-dehydroretinal to vitamin A_1 in the rat which occurred in the experiments of CAMA *et al.* (1952). In addition, this sequence could not account for the conversion of vitamin A_1 to 3-dehydroretinal found by NAITO and WILT (1962) to occur in the sunfish. Sequence 2 is also ruled out by virtue of the finding of vitamin A_1 in the retinas of rats depleted of vitamin A and given vitamin A_2 in the form of an extract of pike tissues (SHANTZ *et al.*, 1946). Neither are the findings of CAMA *et al.* (1952) and of NAITO and WILT (1962) explained by sequence 2. This leaves sequence 3 which, for the moment, best explains all the data. In addition, sequence 3 best accounts for the various interconversions between the vitamin A_1 and vitamin A_2 photopigments which have been observed and mentioned previously in this discussion. This sequence makes it possible, by assuming the presence of controlling factors at various steps, to vary the relative rates of conversion and thus to obtain biological adaptability in the visual pigment content of a retina.

At present a variation of the opsin need not be invoked in these conversions since in the cases that we have discussed the opsin is probably unchanging. This is suggested by several reports in the literature. In those teleosts in which a conversion was induced by changes in the light, the total quantity of photopigment remained about the same though the ratio of the two pigments was altered (DARTNALL, LANDER and MUNZ, 1961; BRIDGES, 1965). WILT (1959a) obtained evidence that the opsin, released as a result of bleaching bullfrog tadpole porphyropsin, was able to combine with 11-*cis* retinal to form rhodopsin. Only the nature of the prosthetic group need be changed in bringing about these conversions. This is the expectation from the well known *in vitro* results of WALD (1953) who demonstrated that a given opsin was able to combine with either retinal or 3-dehydroretinal to form different photopigments. It is interesting that WALD (1953) obtained with cattle opsin and 3-dehydroretinal a photopigment, cattle "porphyropsin", with maximal absorption at 517 nm. This appears to be the test tube counterpart of the 517 nm pigment which we have detected as a minor component in extracts of retinas from rats receiving vitamin A_2.

In the present experiments when rats were given *both* vitamin A_1 and vitamin A_2 in physiologically equivalent amounts (subgroup 4, Table 1) the result was the formation only of rhodopsin. To a large extent, then, the visual pigment of the rat is independent of the qualitative content of dietary vitamin A. With vitamin A_1 alone, vitamin A_2 alone, or both vitamins in equivalent amounts, the end result was the formation of a rod pigment which was exclusively or predominantly rat rhodopsin. The outcome of this experiment in thyroidectomized rats is now being investigated.

REFERENCES

BRIDGES, C. D. B. (1959). Visual pigments of some common laboratory mammals. *Nature, Lond.* **184**, 1727–1728.

BRIDGES, C. D. B. (1964). Effect of season and environment on the retinal pigments of two fishes. *Nature, Lond.* **203**, 191–192.

BRIDGES, C. D. B. (1965). Absorption properties, interconversions, and environmental adaptation of pigments from fish photoreceptors. *Cold Spring Harb. Symp. quant. Biol.* **30**, 317–334.

CAMA, H. R., DALVI, P. D., MORTON, R. A. and SALAH, M. K. (1952). Studies in vitamin A. 21: Retinene$_2$ and vitamin A_2. *Biochem. J.* **52**, 542–547.

CRESCITELLI, F. and DARTNALL, H. J. A. (1954). A photosensitive pigment of the carp retina. *J. Physiol.* **125**, 607–627.

CRESCITELLI, F. (1958). The natural history of visual pigments. *Photobiology*, Proc. 19th Ann. Biol. Colloq., Oregon State College, 30–51.

CRESCITELLI, F. and GARDNER, E. (1961). Correspondences in the behavior of the electroretinogram and of the potentials evoked at the visual cortex. *J. gen. Physiol.* **44**, 911–928.

COLLINS, F. D. and MORTON, R. A. (1950). Studies on rhodopsin. 1. Methods of extraction and the absorption spectrum. *Biochem. J.* **47**, 3–10.

DARTNALL, H. J. A. (1953). The interpretation of spectral sensitivity curves. *Br. med. Bull.* **9**, 24–30.

DARTNALL, H. J. A. (1957). *The Visual Pigments*, Methuen, London.

DARTNALL, H. J. A., LANDER, M. R. and MUNZ, F. W. (1961). Periodic changes in the visual pigment of a fish. *Progress in Photobiology*, pp. 203–213, Elsevier, Amsterdam.

DARTNALL, H. J. A. (1962). The identity and distribution of visual pigments in the animal kingdom. In *The Eye* (edited by H. DAVSON), **2**, 367–426, Academic Press, London.

DOWLING, J. E. and WALD, G. (1958). Vitamin A deficiency and night blindness. *Proc. Natl Acad. Sci., U.S.* **44**, 648–661.

DOWLING, J. E. and WALD, G. (1960). The biological function of vitamin A acid. *Proc. Natl Acad. Sci., U.S.* **46**, 587–608.

FARRAR, K. R., HAMLET, J. C., HENBEST, H. B. and JONES, E. R. H. (1952). Studies in polyene series. Part XLIII—The structure and synthesis of vitamin A_2 and related compounds. *J. Chem. Soc.* Part 3, 2657–2668.

HEATON, F. W., LOWE, J. S. and MORTON, R. A. (1957). Aspects of vitamin A deficiency in the rat. *Biochem. J.* **67**, 208–215.

LIEBMAN, P. A. and ENTINE, G. (1968). Visual pigments of frog and tadpole (*Rana pipiens*). *Vision Res.* **8**, 761–775.

LEWIS, J. M., BODANSKY, O., FALK, K. G. and MCGUIRE, G. (1942). Vitamin A requirements in the rat. The relation of vitamin A intake to growth and to concentration of vitamin A in the blood plasma, liver and retina. *J. Nutrit.* **23**, 351–363.

MILLARD, E. B., JR. and MCCANN, W. S. (1949). Effect of vitamin A_2 on the red and blue threshold of fully dark adapted vision. *J. appl. Physiol.* **1**, 807–810.

MUNZ, F. W. and SWANSON, R. T. (1965). Thyroxine-induced changes in the proportions of visual pigments. *Am. Zool.* **5**, 683.

MUNZ, F. W. and SCHWANZARA, S. A. (1967). A nomogram for retinene$_2$-based visual pigments. *Vision Res.* **7**, 111–120.

NAITO, K. and WILT, F. H. (1962). The conversion of vitamin A_1 to retinene$_2$ in a fresh-water fish. *J. biol. Chem.* **237**, 3060–3064.

SHANTZ, E. M. and BRINKMAN, J. H. (1950). Biological activity of pure vitamin A_2. *J. biol. Chem.* **183**, 467–471.

SHANTZ, E. M., EMBREE, N. D., HODGE, H. C. and WILLS, J. H., JR. (1946). The replacement of vitamin A_1 by vitamin A_2 in the retina of the rat. *J. biol. Chem.* **163**, 455–464.

VAN DORP, D. A. and ARENS, J. F. (1946). Biological activity of vitamin A-acid. *Nature, Lond.* **158**, 60.

WALD, G. (1946). The chemical evolution of vision. *Harvey Lectures* Ser. **41**, 148–152.

WALD, G. (1953). Vision. *Fed. Proc.* 12, 606–611.
WALD, G. (1959). The photoreceptor process in vision. *Handb. Physiol.*, Section 1, Neurophysiol. 1, 671–692.
WILT, F. H. (1959a). The differentiation of visual pigments in metamorphosing larvae of *Rana catesbiana*. *Devel. Biol.* 1, 199–233.
WILT, F. H. (1959b). The organ specific action of thyroxin in visual pigment differentiation. *J. Embryol. exp. Morphol.* 7, 556–563.

Abstract—Male albino rats (Sprague-Dawley) were depleted of vitamin A and then given crystalline vitamin A_2 as supplement. During depletion the growth and general tissue functions were maintained in normal state by means of retinoic acid. The status of the retina during depletion and recovery was monitored by histological and electroretinographic examinations. It was found that vitamin A_2 restored the normal retinal histology and the normal ERG threshold. Examination of the photopigment content in the retinas of these rats revealed the presence of a major component, which was normal rat rhodopsin, and a minor component that absorbed maximally at 517 nm and contained 3-dehydroretinal as the prosthetic group. The experiment was controlled by using rats without vitamin A supplementation and rats supplemented with all-*trans* vitamin A_1. The former showed very small quantities of photopigment; the latter showed normal rat rhodopsin. It was concluded that a conversion of vitamin A_2 to retinal occurs in the rat, leading to the formation of normal rhodopsin, although a small amount of 3-dehydroretinal is also produced leading to the formation of the 517 pigment.

Résumé—On prive des rats albinos mâles (Sprague-Dawley) de vitamine A et on leur donne en remplacement de la vitamine A_2 cristallisée. Pendant la carence on maintenait en état normal la croissance et les fonctions générales des tissus au moyen d'acide rétinoïque. L'état de la rétine durant la carence et la récupération est surveillé par des examens histologiques et électrorétinographiques. On trouve que la vitamine A_2 restore l'histologie normale de la rétine et le seuil normal de l'ERG. L'examen du photopigment dans la rétine de ces rats révèle la présence d'une composante principale qui est la rhodopsine normale du rat, et une composante secondaire qui absorbe à son maximum à 517 nm et contient du 3-dehydrorétinal comme groupe prosthétique. On contrôle cette expérience avec des rats sans supplément de vitamine A et des rats recevant de la vitamine A_1 *trans*. Les premiers ne montrent que très peu de rhodopsine, les derniers sont normaux. On conclut que la conversion de vitamine A_2 en rétinal existe chez le rat et forme une rhodopsine normale, quoiqu'il se forme aussi une petite quantité de 3-dehydrorétinal qui conduit à la formation du pigment 517.

Zusammenfassung—Männlichen Albinoratten (Sprague-Dawley) wurde das Vitamin A entzogen und danach kristallisiertes Vitamin A_2 zugefüttert. Während der Entziehung wurden Gewuchs und die allgemeinen Gewebefunktionen mit Retinaloxydsäure im Normalzustand erhalten. Der Netzhautzustand wurde während der Entziehung und der Erholung mittels der Histologie und der Elektroretinographie überwacht. Es wurde gefunden, dass Vitamin A_2 die normale Netzhauthistologie und die normale ERG-Schwelle herstellt. Die Untersuchung des Photopigmentgehaltes der Netzhäute dieser Ratten offenbarte die Existenz zweir Teile, deren grösserer aus normalem Rattenrhodopsin bestand und deren kleinerer maximal bei 517 nm absorbierte und 3-Dehydroretinal in seiner prostetischen Gruppe enthielt. Der Versuch wurde kontrolliert, indem man Ratten ohne Vitamin-A-Zusatz und solche mit all-*trans* Vitamin-A_2-Zusatz benützte. Die ersteren enthielten sehr wenig Photopigment, die letzteren enthielten normales Rattenrhodopsin. Es wird geschlossen, dass es in der Ratte eine Umwandlung des Vitamins A_2 in das Retinal, welches zur Bildung des normalen Rhodopsins führt, gibt, obzwar eine kleine Menge von 3-Dehydroretinal, welches zur Erzeugung des 517-Pigmentes führt, auch gebildet wird.

Резюме — Самки белых крыс (Sprague-Dawley) были лишены витамина А и после определенного срока, когда у них в организме запасы витамина А были истощены, они получали в виде добавки кристаллический витамин A_2. В период, когда происходило истощение запасов вит. А, рост и общие функции тканей поддерживались в нормальном состоянии введением витамина-А-кислоты. Состояние сетчатки, во время истощения и восстановления, контролировалось гистологическими и электроретинографическими исследованиями. Было найдено, что витамин A_2 восстанавливает нормальную гистологическую картину сетчатки и

нормальный порог ЭРГ. Исследования содержания фотопигмента в сетчатках этих крыс обнаруживают присутствие основного компонента, который оказался нормальным крысиным родопсином, а также наличие второстепенного компонента с максимумом поглощения на 517 нм и который содержал 3-гидроретиналь в качестве простетической группы. Были проведены контрольные эксперименты на крысах, которые не получали вообще витамина А и крысах, которые получали полностью *-транс* витамин A_1. У первых оказалось очень малое количество фотопигмента, последние обнаруживали нормальный крысиный родопсин. Делается заключение о том, что превращение витамина A_2 в ретиналь, которое имеет место у крыс, ведет к образованию нормального родопсина, в то время как небольшое количество 3-дегидроретиналя, так же продуцируемое, приводит к образованию пигмента 517.

Reproduced by permission of the copyright owner Zachman-'64 Bib. No. 10119

Formation and Enterohepatic Circulation of Water-soluble Metabolites of Retinol (Vitamin A) in the Rat

BIOLOGICALLY active metabolites of retinoic acid are apparently formed in the stomach[1] and colon[2], and water-soluble metabolites of retinol or retinoic acid appear in the plasma, urine, and fæces of chickens and rats within 24 h after administration[3-6]. The organs involved in these transformations, the chemical nature of the products, and the route of excretion have not been defined in detail. This report concerns the conversion in rat liver of ^{14}C-retinol and ^{14}C-retinoic acid to water-soluble metabolites, which are afterwards excreted in the bile, are largely absorbed from the gut, and are re-excreted in the bile. Preliminary observations on the properties of these metabolites are presented.

Twenty-six μg of 6,7-^{14}C-retinol ($7{\cdot}6 \times 10^3$ c.p.m. per μg) or 10 μg of ^{14}C-retinoic acid ($19{\cdot}9 \times 10^3$ c.p.m. per μg) were rendered soluble with 'Tween-80' in 1·0 ml. of Krebs–Ringer bicarbonate buffer, *p*H 7·4, and were injected either into the portal vein or into a sac of the upper intestine of fasted male rats with cannulated bile ducts.

Appropriate aliquots (0·2–0·3 ml.) of the bile were diluted with methanol and either were chromatographed on an anion exchange resin or were extracted with hexane or acid ether. Aliquots of each fraction were plated, dried, and counted for a total of 10,000 counts in a window-less gas-flow Geiger–Müller counter.

Within 4 h after the intravenous injection of ^{14}C-retinoic acid, more than 40 per cent of the injected dose appeared in the bile as water-soluble metabolites (Fig. 1). At 24 h the liver contained < 1 per cent of the administered radioactivity. In the case of injected ^{14}C-retinol, 10–15 per cent of the original dose appeared in water-soluble metabolites within 4 h, and 15–20 per cent within 24 h (Fig. 1). At 24 h, 30 per cent of the injected retinol was present in liver as retinol ester and 1·5 per cent as free retinol. The same distribution of metabolites of retinol in the bile and liver was found with doses of 26–2,500 μg.

The isolated perfused liver technique[7] was used to demonstrate unequivocally that retinol was transformed in the liver into water-soluble metabolites of bile at a rate similar to that found *in vivo*. After 1 h of perfusion, 10 per cent of the radioactivity originally administered as ^{14}C-retinol was found in the bile as water-soluble metabolites which possessed the same chromatographic properties as those formed *in vivo*. Similarly, the liver contained 20–25 per cent of the original radioactivity as ^{14}C-retinol ester after 1 h of perfusion.

Radioactive metabolites also appeared in bile when ^{14}C-retinol or ^{14}C-retinoic acid was placed into duodenal sacs *in vivo* (Fig. 1). Under these conditions, the rate of appearance and ultimate amount of radioactivity recovered in the bile were the same whether retinol or retinoic acid was administered. When bile containing the carbon-14-labelled metabolites of ^{14}C-retinol was placed in an intestinal loop of another rat, 30 per cent of this radioactivity was again excreted in the bile within 24 h.

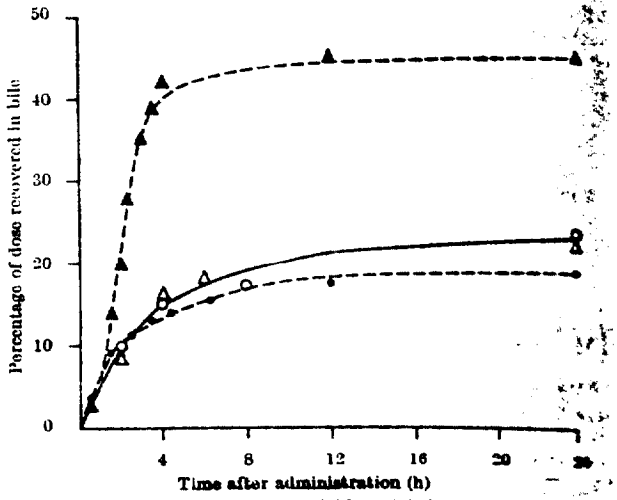

Fig. 1. Appearance in bile of water-soluble metabolites of intravenously administered (via the portal vein) retinol (●) and retinoic acid (▲) and of intraduodenally administered retinol (○) and retinoic acid (△)

The radioactivity in bile could be separated into several components by chromatography on 'Bio-Rad (*AG2–X8*)' anionic exchange resin in the acetate form (Table 1). The initial methanolic fraction comprised approximately 20 per cent of the bile radioactivity from animals given ^{14}C-retinol, but only about 10 per cent in animals receiving ^{14}C-retinoic acid or the ^{14}C-bile from an animal previously given ^{14}C-retinol. Free retinol, which would be eluted by methanol, could not be detected in this fraction, either before or after basic hydrolysis. In addition, the spectrum of the methanol fraction is not characteristic of retinol, but is shifted well below 300 mμ.

The fraction eluted by 1 per cent acetic acid was larger with administered retinoic acid than with retinol. Whether or not retinoic acid, which would be eluted in this fraction, is actually present here has not been determined.

Twenty to 30 per cent of the bile radioactivity was eluted by 10 per cent acetic acid, and 45–60 per cent by 100 per cent acetic acid. These fractions, which contain more polar and acidic products of retinol, have not been characterized as yet. Virtually no radioactivity of bile was retained on cationic exchange columns.

If ^{14}C-retinol were extensively metabolized in the liver into C_5 or C_2 moieties, radioactive sterols, bile salts, and other lipids should be present in rat bile[8]. This possibility is unlikely since the radioactivity in the bile was neither precipitated by digitonin nor localized in taurocholate on chromatography.

Apparently, retinol and retinoic acid are readily transformed by the liver to water-soluble metabolites, which are excreted in appreciable amounts in the bile. These

Table 1. CHROMATOGRAPHY OF ^{14}C-BILE METABOLITES ON ANIONIC EXCHANGE RESIN

Compound used	Mode of administration	Percentage of total radioactivity recovered: Methanol	1% acetic acid in methanol	10% acetic acid in methanol	100% acetic acid
^{14}C-Retinol	Intravenous*	21	7	23	[illegible]
	Perfusion	21	6	31	42
^{14}C-Retinoic acid	Intravenous*	10	12	21	57
^{14}C-Bile of intravenously administered ^{14}C-retinol	Intraduodenal*	11	16	24	[illegible]

* Average of 2–5 experiments.

metabolites may be absorbed by the intestine and re-secreted in the bile. Whether this enterohepatic circulation of retinol derivatives has functional significance in the control of retinol catabolism is being explored. The major portion of the metabolites formed are polar and acidic, and most likely are hydroxylated derivatives of retinoic acid. Characterization of these compounds is in progress.

We thank Prof. O. Wiss, of Hoffman-La Roche and Co., Basle, for providing the labelled retinol and retinoic acid, and Miss Marta B. Singer for her assistance. This work was supported by the U.S. National Institutes of Health (grant A-1278).

RICHARD D. ZACHMAN
JAMES ALLEN OLSON

Department of Biochemistry,
University of Florida,
Gainesville.

Rogers, W. E., Chang, Mei-Ling, and Johnson, B. C., *Fed. Proc.*, **22**, 433 (1963).
Sundaresan, P. R., and Wolf, G., *Fed. Proc.*, **22**, 293 (1963).
Krishnamurthy, S., and Bieri, J. G., *Fed. Proc.*, **21**, 475 (1962).
Krishnamurthy, S., Bieri, J. G., and Andrews, E. L., *J. Nutr.*, **79** (4), 503 (1963).
Wolf, G., Kahn, S. G., and Johnson, B. C., *J. Amer. Chem. Soc.*, **79**, 1208 (1957).
Barbers, C. F., Gillman, J., and Peisach, M., *Biochem. J.*, **75**, 124 (1960).
Zachman, R. D., and Olson, J. A., *J. Biol. Chem.*, **238**, 541 (1963).
Sidwick, M. J., and Glover, J., *Biochem. J.*, **66**, 36, P (1957).

Zachman-'66
Bib. No. 10121

Reproduced by permission
of the copyright owner

Formation and enterohepatic circulation of metabolites of retinol and retinoic acid in bile duct-cannulated rats*

R. D. ZACHMAN, P. E. DUNAGIN, JR., and J. A. OLSON
Department of Biochemistry, College of Medicine, University of Florida, Gainesville, Florida

ABSTRACT Four hours after intraportal injection of retinoic acid-^{14}C into bile duct-cannulated rats, less than 10% of the radioactivity was recovered in the liver, intestine, and kidneys. Within 6 hr, 40% of the radioactivity had appeared in bile. When suspensions of retinol-^{14}C or retinal were similarly injected, 25–35% of the dose was excreted in bile within 24 hr and equivalent amounts were deposited in the liver as retinol ester. The isolated perfused liver also produced these bile metabolites and is probably the major site of their formation in vivo. The intestine may metabolize retinoic acid, however, since some metabolites were found in the intestinal wall and lumen, even in bile duct-cannulated rats.

The bile metabolites of retinol-^{14}C and retinoic acid-^{14}C undergo extensive enterohepatic circulation. The bile radioactivity was not volatilized on boiling at acid pH, was not present in digitonin-precipitated sterols, and did not migrate with bile salts on reversed-phase paper chromatography. Anion-exchange chromatography resolved the metabolites of bile into three fractions containing nonionic compounds, acidic substances like retinoic acid, and more polar acidic derivatives.

KEY WORDS retinal-^{14}C · preparation · retinoic acid · retinol · retinal · metabolism · rat · metabolites · liver · intestine · bile · enterohepatic circulation · anion-exchange chromatography · excretion

Many aspects of the metabolism of retinol, retinal, and retinoic acid in mammals remain obscure. Dietary retinol and retinal are largely stored in the liver and other organs as retinol ester, whereas administered retinoic acid, which also promotes the growth of retinol-depleted animals, is found only in minute amounts in tissues (1–8), even when large doses are given. Retinoic acid may be formed from retinal by liver enzymes (9–12), however, and recently has been unambiguously identified as a natural product of retinal metabolism in vivo (13). Some metabolites of retinol and retinoic acid found in tissues and excreta have been partially purified (14), but most have not been well characterized (4, 6, 7, 15).

Recently, polar metabolites of retinol and retinoic acid have been found in large amounts in the bile from rat livers perfused with emulsions of these compounds (16). In the present investigation the uptake, metabolism, and disappearance of retinoic acid in various tissues was explored in detail, and the formation and excretion of bile metabolites of retinol and retinoic acid in vivo was described. The bile metabolites are reabsorbed by the intestine and reexcreted in the bile of bile duct-cannulated rats, thereby establishing an enterohepatic circulation of retinol derivatives. A preliminary report of some aspects of this work has appeared (17).

EXPERIMENTAL PROCEDURES

Retinol Substrates

Retinol-6,7-^{14}C and retinoic acid-6,7-^{14}C were supplied by Hoffmann-LaRoche, Inc., Basel, Switzerland. Labeled retinol was further purified by chromatography on deactivated alumina, and retinoic acid was purified either by ion-exchange chromatography or by silicic acid chromatography. Purified retinol-^{14}C was oxidized to retinal in good yield by treatment with activated MnO_2 (18) and the retinal was isolated by alumina chromatography. Nonradioactive crystalline retinol, retinal, and retinoic acid were obtained from Distillation

* Part of this paper has appeared as a synopsis in abstracts of the 6th International Congress of Biochemistry, New York, 1964, p. 592.

Products Industries, Rochester, N. Y., and were used without further purification.

Biological Techniques

Details of the techniques used in this study have been reported (16, 17). In brief, fasted male rats (Rolfsmeyer Farm, Madison, Wis.) weighing from 150 to 300 g were anesthetized and their bile ducts were cannulated. One milliliter of a suspension of the appropriate substrate in 5% Tween 80, Krebs-Ringer bicarbonate buffer, pH 7.4, was injected into the portal vein. Experiments were also carried out in which a suspension of retinol or retinoic acid in 5% Tween 80 (polyoxyethylene sorbitan monooleate) or 0.4% sodium glycocholate solution was injected into the upper duodenum. After the incision had been closed, the animal was placed in a restraining cage and the bile was collected at desired intervals. At predetermined times the animals were killed, various organs were homogenized in 20 volumes of $CHCl_3$–methanol 2:1, and the homogenates were filtered. In contrast to the method of Folch, Lees, and Sloane Stanley (19), the filtrates were not washed with aqueous $CaCl_2$, but were directly evaporated to dryness under reduced pressure, and the residue was taken up in a small volume of methanol.

Ion-Exchange Chromatography of Bile and Tissue Extracts

Methanolic solutions of bile and urine or methanolic extracts of organs were usually chromatographed on columns (1.9 cm i.d. × 6.5 cm) of Bio-Rad AG2-X8 (Bio-Rad Laboratories, Richmond, Calif.) anion-exchange resin (200–400 mesh) in the acetate form. Larger amounts of the extracts were chromatographed on preparative columns (5.0 cm i.d. × 7 cm) of the above resin or of Bio-Rad AG1-X4. The resin bed was equilibrated with methanol before use. Nonionic material was eluted with methanol, and further elution was carried out with increasing concentrations of acetic acid in methanol. The effluent was collected in 10 ml fractions by a Technicon drop-counting fraction collector (Technicon Chromatography Corp., Chauncey, N. Y.). All parts of the system in contact with acetic acid were constructed of Teflon, glass, or stainless steel. Each sample was monitored for absorbance at 350 mμ with a Coleman Universal Spectrophotometer and was further analyzed for radioactivity.

Measurement of Radioactivity

Samples dissolved in organic solvents were plated infinitely thin on aluminum planchets, and assayed in a windowless gas flow Geiger-Müller counter (Nuclear-Chicago Corporation, Des Plaines, Ill.). Alternatively, 0.1–10 ml aliquots of samples were placed in scintillation vials, diluted with either the dioxane–naphthalene scintillation fluid of Bray (20) or the toluene fluid recommended by the Packard Instrument Company [5 g of 2,5-diphenyloxazole and 0.3 g of 2,2-*p*-phenylenebis(5-phenyloxazole) per liter of toluene], and counted in a Tri-Carb liquid scintillation spectrometer (Packard Instrument Co., La Grange, Ill.). Bray's scintillation fluid was superior in most cases for counting methanol-soluble derivatives of retinol and retinoic acid. In order to correct for the quenching of acetic acid, an internal standard was added to each assay vial. Tubes containing yellowish solutions, which quenched considerably, were always checked with internal standards.

RESULTS

Rate of Appearance of Metabolites of Retinol, Retinal, and Retinoic Acid in Bile

Metabolites of retinol, retinal, and retinoic acid were rapidly excreted into the bile after intravenous injection of these compounds into the portal vein. With similar dosages (2–3.5 mg) of retinoic acid-^{14}C, retinal-^{14}C, and retinol-^{14}C, 10–15% of the radioactivity appeared in the bile within 2 hr (Fig. 1). Within 24 hr, 20–55% of the total injected radioactivity was recovered in bile, depending on the substrate administered. Five days after retinoic acid-^{14}C administration, 95% of the label was recovered in the bile. When lower, more physiological dosages (10–26 μg) of the retinol compounds were administered, the initial rate of appearance and total extent of bile metabolite formation and excretion

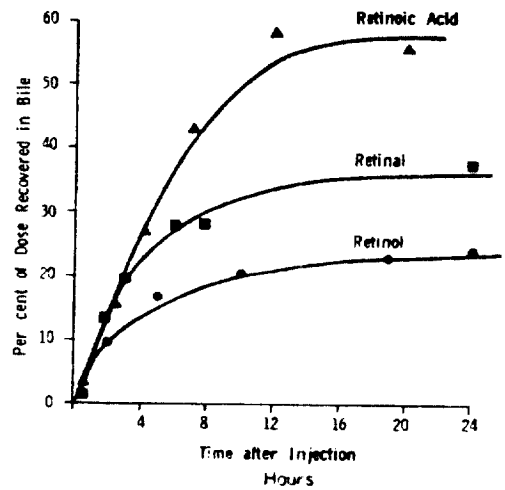

FIG. 1. The cumulative excretion rate of radioactivity into the bile after the intraportal administration of 2–3.5 mg of retinol-^{14}C, retinal-^{14}C, or retinoic acid-^{14}C. Plotted values represent averages of 2, 4, and 12 rats, respectively.

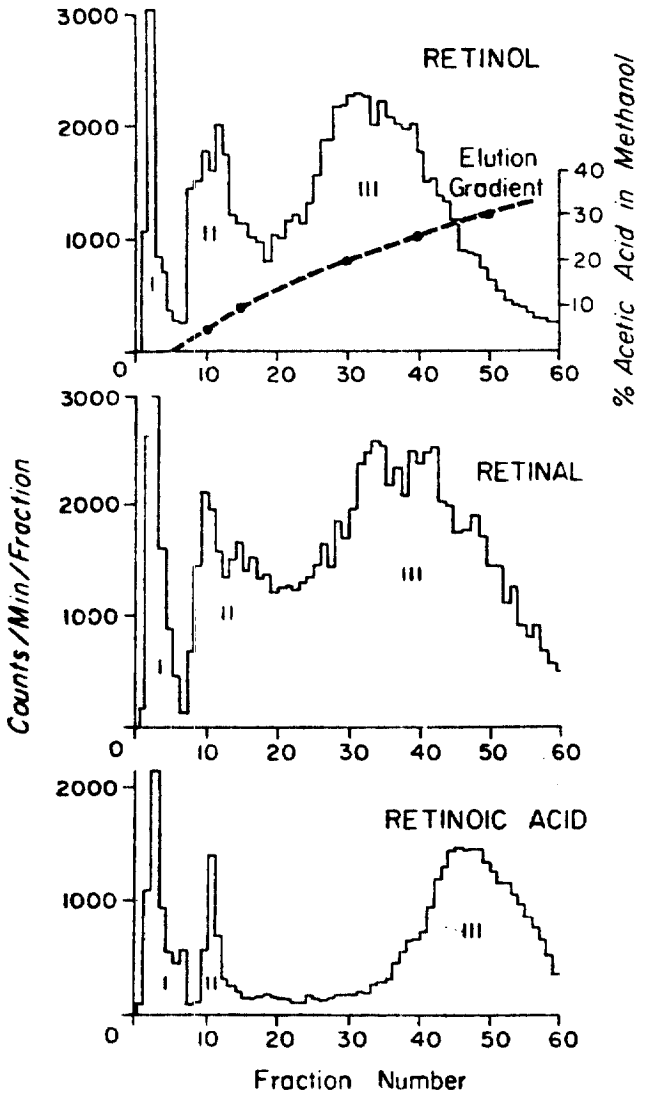

FIG. 2. Separation of bile by ion-exchange chromatography after administration of retinol-^{14}C, retinal-^{14}C, or retinoic acid-^{14}C. Bile was collected for a 6 hr period immediately following intraportal injection of each substrate, diluted with methanol, and chromatographed on an anion-exchange resin with an increasing gradient of acetic acid in methanol.

were similar to those found with larger doses: 40–50% of the radioactivity of the retinoic acid-^{14}C and 18–25% of retinol-^{14}C were excreted within 24 hr. Retinol-deficient rats excreted similar amounts of radioactivity in their bile after receiving labeled retinol or retinoic acid intravenously.

Radioactive metabolites also readily appeared in the bile when retinol-^{14}C or retinoic acid-^{14}C was placed in duodenal sacs or was administered by a stomach tube. In the former series, 26 μg of retinol-^{14}C or 10 μg of retinoic acid-^{14}C suspended with 50 μl of Tween 80 in 1 ml of Krebs-Ringer phosphate, pH 7.4, were injected into a duodenal loop made by loose ligatures at the pylorus and ligament of Treitz. On other occasions 1 ml of a Krebs-Ringer phosphate, 5% Tween 80 suspension of either 60 μg of retinol-^{14}C or 25 μg of retinoic acid-^{14}C were given via stomach tube. Under these conditions 10–15% of the administered radioactivity of either substrate appeared in the bile within 4 hr. Twenty-four hours after injection 20–25% of the label had appeared in the bile.

Properties of the Bile Metabolites

The radioactivity in the bile could be separated into three major radioactive fractions on anion-exchange columns (Fig. 2). Fraction I, eluted with methanol, contained 10–15% of the total radioactivity eluted from the column. Although free retinol, retinal, and retinol ester are quantitatively eluted in this fraction from control columns, their presence in Fraction I of bile could not be clearly demonstrated. Retinoic acid appears in Fraction II. After intraportal injection of labeled retinal or retinoic acid, approximately 30% of the radioactivity in Fraction II of bile was shown to be free retinoic acid by gas–liquid chromatography (13, 21). Fraction III, which was eluted with 30% acetic acid in methanol, contained 60–70% of the total radioactivity of bile. This fraction contains more polar and acidic products of retinol metabolism, including retinoyl β-glucuronide (22, 23).

The radioactivity in bile of rats injected with retinol-^{14}C was not volatilized by boiling under acidic conditions, was not precipitated by digitonin, and was not localized in taurocholate upon chromatography in a reversed-phase paper system (24). About 40% of the radioactivity could be extracted with diethyl ether after the bile was acidified. However, only 2–5% of the radioactivity was extracted by *n*-hexane from either acidic or basic bile solutions. The radioactivity in bile of rats administered either retinol-^{14}C or retinoic acid-^{14}C was dialyzable. Five hours after dialysis against 0.9% NaCl, 70–90% of the radioactivity was lost, and by 24 hr less than 10% remained within the dialysis tubing.

Rate of Disappearance of Metabolites of Retinol, Retinal, and Retinoic Acid from Tissues

After intraportal injection into intact animals, retinoic acid was rapidly eliminated from the liver, intestine, and kidney (Fig. 3). Four hours after the injection of retinoic acid-^{14}C, 6, 2.5, and 0.5% of the total dose was found in the liver, intestine, and kidneys, respectively. Thereafter, the radioactivity in these tissues steadily decreased, and by 40 hr only trace amounts were present.

Extracts of liver and intestine were chromatographed on anion-exchange resins (Table 1). After injection of retinol-^{14}C or retinal-^{14}C, 80–98% of the radioactivity

TABLE 1 DISTRIBUTION OF RADIOACTIVITY IN TISSUES AFTER THE ADMINISTRATION OF LABELED RETINOL, RETINAL, AND RETINOIC ACID TO BILE DUCT-CANNULATED RATS

The distribution of radioactivity in each chromatographic fraction is expressed as a percentage of the total ^{14}C eluted from the anion-exchange column. Recovery of radioactivity in all cases was ≥ 80%. For bile the percentage of the injected dose is the cumulative amount excreted in 24 hr. For liver and intestine, the percentage of the injected dose is the amount found in the tissue 24, 6, and 4.5 hr after the administration of retinol, retinal, and retinoic acid, respectively.

Compound Administered (2.5–4.0 mg)	Bile				Liver				Intestine			
	% of Injected Dose	% of Tissue Extract			% of Injected Dose	% of Tissue Extract			% of Injected, Dose	% of Tissue Extract		
		I*	II	III		I	II	III		I	II	III
Retinol-^{14}C	20	10	20	70	24	98	1	1	1.4	78	7	15
Retinal-^{14}C	40	10	19	71	22	97	2	1	0.7	81	10	9
Retinoic acid-^{14}C	55	16	14	70	6	4	79	17	2.3	4	50	46

* Fractions I, II, III as in Fig. 2. Fraction I identified as nonpolar metabolites; II, acidic metabolites resembling retinoic acid; III, more polar acidic metabolites.

of liver and intestinal extracts was in Fraction I, further identified on alumina chromatography as retinol ester, and only small amounts of radioactivity were present in acidic metabolites (Fractions II and III). After retinoic acid-^{14}C injection, Fraction II contained 80% of the radioactivity in liver extracts, and 50% of that in intestinal extracts. A small but significant amount of radioactivity (0.25–1.0%) was repeatedly found in the intestinal contents of bile duct-cannulated animals after the administration of any of the three radioactive retinol compounds. Urinary metabolites of bile duct-cannulated animals given retinol and retinal were largely ionic (Fractions II and III), but were not further characterized because of the small amounts present (0.1–0.2% of dose).

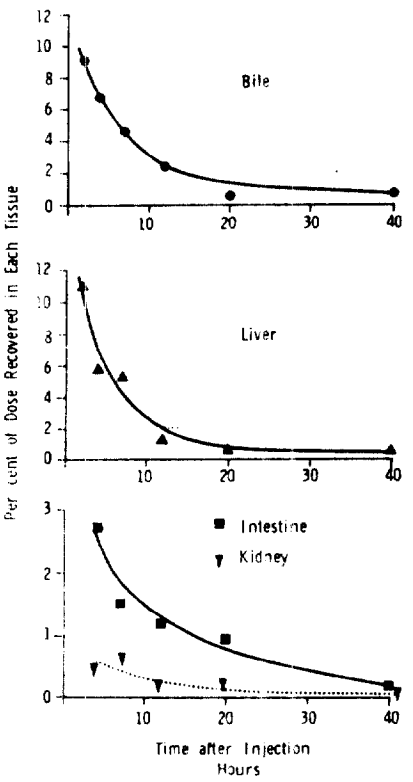

FIG. 3. Effect of time on the recovery of injected radioactive retinoic acid in bile and in various tissues. Two to 3.5 mg were administered to each of 12 rats and the tissues were analyzed for total radioactivity at the specified times.

Enterohepatic Circulation of Bile Metabolites of Retinol and Retinoic Acid

Several rats were given retinoic acid-^{14}C by stomach tube. Thereafter, one rat was cannulated every 12 hr for the following 3 days. Semilogarithmic plots of the amount of the bile radioactivity excreted by these rats in 24 hr against the time of cannulation gave an excretion rate of one-half that obtained from similarly plotting the amount of radioactivity excreted per hour during the 24 hr of cannulation when no recirculation of the bile occurred. This 2-fold rate difference was found with any 24 hr period, suggesting either that the rate of metabolite formation was increased when recirculation of the bile was prevented, or that some reabsorption of the metabolites normally occurred.

When whole bile containing the labeled metabolites of retinol-^{14}C was placed in an intestinal loop of another rat, 30% of this radioactivity was again excreted in the bile within 24 hr. Concomitantly, the radioactivity in the intestinal loop decreased (Fig. 4). Radioactive Fractions I, II, and III were isolated from the bile of animals injected with either radioactive retinol or retinoic acid. After evaporation of the chromatographic solvents, the radioactive residues were individually solubilized in 1 ml of Krebs-Ringer buffer with 0.4% sodium glycocholate, and were placed in duodenal loops of bile duct-cannulated rats. By 24 hr, each of the six recipient rats had excreted in their bile 25–40% of the intraduodenally administered radioactivity. This

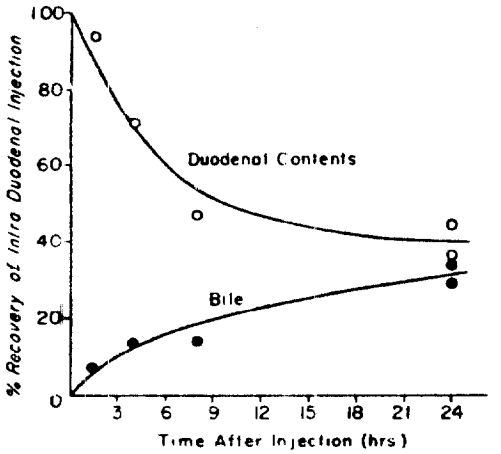

Fig. 4. Enterohepatic circulation of bile metabolites of retinol. Bile labeled with ^{14}C from a rat previously given an intraportal injection of retinol-^{14}C was placed in intestinal loops of bile duct-cannulated rats. Bile was collected from recipient rats for various periods of time and assayed for radioactivity. Contents of the intestinal sac were similarly assayed.

bile was rechromatographed on anion-exchange columns. As shown in Fig. 5, the radioactivity originally in Fraction III was absorbed and reexcreted in the bile as Fraction III, with only trace amounts appearing in Fractions I and II. In contrast, during enterohepatic circulation the radioactivity of Fractions I and II was converted largely into compounds chromatographing in Fraction III. No differences were noted in the metabolism of fractions derived initially from retinol or retinoic acid.

Excretion and Chromatography of Metabolites in the Bile and Perfusate of Isolated Perfused Livers

Isolated livers perfused with retinol-^{14}C or retinoic acid-^{14}C excrete about 10% of the total radioactivity into the bile within 1 hr (16). After perfusion with retinol, the distribution of bile radioactivity determined by ion-exchange chromatography was similar to that observed with whole animals (Fig. 2), except for a somewhat elevated Fraction I. With retinoic acid, chromatograms for the bile of perfused livers again were similar to those obtained from bile in vivo. The pattern of radioactivity in the perfusate, however, was strikingly different than for bile. After 1 hr of perfusion with either retinol-^{14}C or retinoic acid-^{14}C, the perfusate contained virtually no Fraction III. When retinol was the substrate, Fraction I contained most of the radioactivity, and when retinoate was used, Fraction II contained most of the radio-activity as expected.

DISCUSSION

The rapid disappearance of ingested retinoic acid from tissues, observed repeatedly in the past (1–6), was quantitatively analyzed in the present work. Four hours after an intraportal injection of retinoic acid, less than 10% of the injected radioactivity was in the liver, intestine, and kidneys. By 24 hr practically no retinoate remained in these organs. This loss of retinoic acid from tissues was accompanied by a rapid rise in the amount of metabolites of retinoic acid in bile. Forty per cent of the radioactivity of retinoic acid appeared in the bile of bile duct cannulated rats within 6 hr, and 95% of the injected dose was excreted via the bile within 5 days. On the other hand, when retinol-^{14}C or retinal was injected, 25–35% of the dose was deposited in the liver as retinol ester and a roughly equivalent amount was excreted in the bile in 24 hr. Thus, there is some correlation between the oxidation state of the injected compound and the amount of bile metabolite excreted in 24 hr. Goodman, Huang, and Shiratori (25) have recently reported recovering only 8–9% of the radioactivity in bile of rats intravenously injected with suspensions of chylomicrons containing radioactive retinol esters. This smaller amount of radioactivity excreted in the bile may be due to the utilization of the chylomicron form per se, but more probably is related to the fact that the retinol was injected in esterified form. Although the extent that retinol is metabolized by conversion to retinoic acid is unknown, the oxidation of retinal to retinoic acid may be important in determining the amount of bile metabolite produced from each substrate. It is well known that the oxidation of retinal is irreversible (11, 12), whereas esterification of retinol and its oxidation to retinal are not. Indeed, the equilibrium of the alcohol dehydrogenase system which oxidizes retinol to retinal strongly favors reduction (26). In addition, retinol-deficient animals will grow on daily supplements of retinoic acid, but quickly stop growing upon withdrawal of the supplement (27). In any event, biliary excretion is a major route by which metabolites of retinoic acid, retinal, and retinol leave the liver. Similar relative amounts of radioactivity appeared in bile after either physiological (10–26 μg) or high (2–3.5 mg) doses of retinol derivatives. The bile metabolites were readily produced after either intravenous, intraduodenal, or stomach tube administration of retinol and retinoic acid, and appeared in both deficient and normal rats. These facts support the thesis that the excretion of retinol metabolites in the bile is a normal and physiologically significant event, and not the expression of a detoxication phenomenon which is only activated by high intravenous doses of these potentially toxic compounds.

Since the isolated perfused rat liver produced bile metabolites (16) at an initial rate similar to that observed in vivo, the liver is probably the major site of their formation. The intestine, however, may also

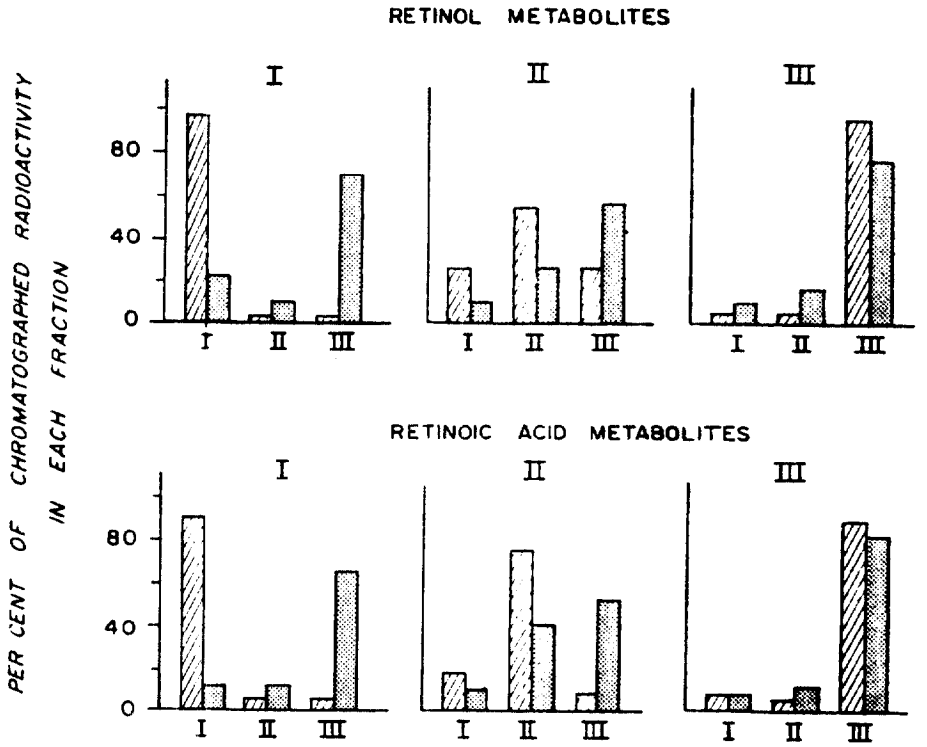

FIG. 5. Enterohepatic circulation of fractionated bile metabolites. Fractions I, II, and III were isolated from the bile of rats which had received intraportal injections of retinol-^{14}C or retinoic acid-^{14}C. Aqueous solutions of each fraction were placed in duodenal loops of bile duct-cannulated rats, and the resultant bile of each recipient rat was chromatographed on anion-exchange columns in the usual manner. The chromatograms of each of the individual fractions before (hatched columns) and after (dotted columns) reabsorption and reexcretion are shown. The initial Fraction II from retinol chromatographed poorly and contained appreciable amounts of Fractions I and III. The metabolism of that fraction is in accord, however, with other observed transformations.

metabolize retinoic acid. Metabolites similar to those in bile were noted in the intestinal wall and lumen, even in bile duct-cannulated rats. These probably were not transported to the intestine via the blood stream, since no significant amounts of metabolite were released into the perfusate in perfused liver experiments. In other laboratories biologically active products of retinoic acid have been isolated from the stomach (7), intestinal tract (8, 14), and liver (4), and water-soluble metabolites of retinol have been found in the plasma, urine, and feces of chickens and rats (6, 15, 28). With the exception of the compounds in the stomach, these metabolites might either arise in the liver and be excreted via the bile into the intestine, or be formed in part directly by the intestine. The metabolites of colon (6, 8) and feces (6, 15), however, may well arise from bile metabolites as a result of oxidation by intestinal bacteria.

The biliary metabolites of retinol compounds have been partially characterized. The bile radioactivity was not volatilized on boiling at acid pH, was not present in digitonin-precipitated sterols, and did not migrate with bile salts on reversed-phase paper chromatography. Apparently, the retinol-6,7-^{14}C compounds were not extensively catabolized to $^{14}CO_2$ or to small radioactive molecules, which then formed fatty acids, steroids, and bile acids (29). The radioactive bile metabolites, being readily dialyzable, are apparently not firmly bound to any large molecule or aggregate in bile. By anion-exchange chromatography the metabolites of bile were separated into three fractions, which contain nonionic compounds (I), acidic substances like retinoic acid (II), and more polar acidic derivatives (III). Whereas the rate of excretion of labeled metabolites in the bile increased with the oxidation state of the compound injected, the distribution of the radioactivity among the fractions was similar for all three retinol-^{14}C compounds (Fig. 2). Fraction I may consist of nonacidic esters of retinol and retinoic acid, and would include degraded nonacidic derivatives of the latter. Although the presence of retinol in bile has been reported (30), the 1% of the radioactivity of our bile metabolites which chromatographed with carrier retinol on alumina has not yet been identified as retinol. Fraction II, in addition to retinoic acid (13),

contains other labeled compounds which have not been characterized. Quantitatively, Fraction III is the most important fraction. Since Fractions I and II are converted into III, the latter contains the final polar and ionic metabolite common to all retinol compounds. The larger portion of this fraction, after retinoic acid-^{14}C administration, has been identified as retinoyl β-glucuronide (22, 23). Nearly half of the bile radioactivity obtained after injection of retinol ester-^{14}C was also hydrolyzed by β-glucuronidase (25). Most of the polar metabolites of tissues described elsewhere would also appear in Fraction III, including Wolf's compound 5 ester, one of the few purified metabolites of retinoic acid (14). The extensive characterization of the bile metabolites is the subject of another communication.

Enterohepatic circulation of biliary components, well-known for cholesterol, bile acids (31), and bile pigments (32), has now been shown to include metabolites of retinol. When whole bile containing labeled retinol metabolites or separate radioactive Fractions I, II, or III were placed in intestinal loops, about 30% of the radioactivity was reexcreted in the bile of the recipient rats within 24 hr. In the process, Fractions I and II were converted to Fraction III. Whether these conserved metabolites of retinol function as feedback inhibitors of their formation as in the cases of cholesterol and bile acids (31), have some function in intestinal physiology, are transport forms of retinoic acid, possess biological activity, or are merely excretion products are possibilities which merit further investigation.

We wish to thank Prof. O. Wiss, of Hoffmann-LaRoche, Ltd., Basel, Switzerland, for kindly providing the labeled retinol and retinoic acid, and Miss Marta B. Singer for her able technical assistance.

This research was supported in part by PHS Research Grant A-1278 from the National Institutes of Health, U. S. Public Health Service.

Manuscript received 9 June 1965; accepted 10 August 1965.

References

1. Sharman, I. M. *Brit. J. Nutr.* **3:** viii, 1949.
2. Yagishita, K., P. R. Sundaresan, and G. Wolf. *Federation Proc.* **23:** 294, 1964.
3. Redfearn, E. R. *Arch. Biochem. Biophys.* **91:** 226, 1960.
4. Zile, M., and H. F. DeLuca. *Federation Proc.* **23:** 294, 1964.
5. Jurkowitz, L. *Arch. Biochem. Biophys.* **98:** 337, 1962.
6. Krishnamurthy, S., J. G. Bieri, and E. L. Andrews. *J. Nutr.* **79:** 503, 1963.
7. Rogers, W. E., M. L. Chang, and B. C. Johnson. *Federation Proc.* **22:** 433, 1963.
8. Sundaresan, P. R., and G. Wolf. *Federation Proc.* **22:** 293, 1963.
9. Dmitrovskii, A. A. *Biokhimiya* **26:** 109, 1961.
10. Elder, T. D., and Y. J. Topper. *Biochim. Biophys. Acta* **64:** 430, 1962.
11. Futterman, S. *J. Biol. Chem.* **237:** 677, 1962.
12. Mahadevan, S., S. K. Murthy, and J. Ganguly. *Biochem. J.* **85:** 326, 1962.
13. Dunagin, P. E., Jr., R. D. Zachman, and J. A. Olson. *Biochim. Biophys. Acta* **90:** 432, 1964.
14. Yagishita, K., P. R. Sundaresan, and G. Wolf. *Nature* **203:** 410, 1964.
15. Wolf, G., S. G. Kahn, and B. C. Johnson. *J. Am. Chem. Soc.* **79:** 1208, 1957.
16. Zachman, R. D., and J. A. Olson. *J. Lipid Res.* **6:** 27, 1965.
17. Zachman, R. D., and J. A. Olson. *Nature* **201:** 1222, 1964.
18. Attenburrow, J., A. F. B. Cameron, J. H. Chapman, R. M. Evans, B. A. Hems, A. B. A. Jansen, and T. Walker. *J. Chem. Soc.* 1094, 1952.
19. Folch, J., M. Lees, and G. H. Sloane Stanley. *J. Biol. Chem.* **226:** 497, 1957.
20. Bray, G. A. *Anal. Biochem.* **1:** 279, 1960.
21. Dunagin, P. E., Jr. Ph.D. Dissertation, University of Florida, 1964.
22. Dunagin, P. E., Jr., E. Harris Meadows, Jr., R. D. Zachman, K. Nath, and J. A. Olson. *Federation Proc.* **24:** 527, 1965.
23. Dunagin, P. E., Jr., E. Harris Meadows, Jr., and J. A. Olson. *Science* **148:** 86, 1965.
24. Sjövall, J. *Arkiv Kemi* **8:** (27) 299, 1955.
25. Goodman, D. S., H. S. Huang, and T. Shiratori. *J. Lipid Res.* **6:** 390, 1965.
26. Bliss, A. F. *Arch. Biochem. Biophys.* **31:** 197, 1951.
27. Dowling, J. E., and G. Wald. *Proc. Natl. Acad. Sci. U. S.* **46:** 587, 1960.
28. Garbers, C. F., J. Gillman, and M. Peisach. *Biochem. J.* **75:** 124, 1960.
29. Fishwick, M. J., and J. Glover. *Biochem. J.* **66:** 36P, 1957.
30. Bohdal, M., and F. Hruba. *Acta Biol. Med. Ger.* **8:** 60, 1962.
31. Bergström, S. In *CIBA Foundation Symposium on Biosynthesis of Terpenes and Sterols.* Little, Brown and Co., Boston, 1959, p. 185.
32. Lester, R., and R. Schmid. *J. Clin. Invest.* **42:** 736, 1963.

cartilage. In older regions of the tunnels, bone, as well as cartilage, is removed and a greater complexity of cartilage columns, wholly or in part surrounded by bone, gives rise to an appearance of trabecular bone extending to the level of nearly completed ossification. The prevailing architecture, as seen in longitudinal sections, is that of parallel trabeculae in which apparently viable cartilage cells persist. In corresponding locations in mammalian bone growth, only remnants of calcified cartilage matrix are found. The manner of tunneling and the long duration of cartilage that is in process of concurrent ossification and resorption give rise to a metaphyseal region very much greater in extent than that found in mammalian bone growth.

The histological preparations were made by Mr. John J. Burke, department technician. The photomicrographs were made by Mr. John Carabitses, of the Department of Pathology, The Children's Hospital.