MONOGRAPH

ON

VITAMIN A

A32

#78 vol.IV

Monograph on Vitamin A-Volume 4 #78 1/31/75

A32

MONOGRAPH

ON

VITAMIN A

Volume 4

TR-72-1552-65

Submitted Under:
Contract No. FDA 74-104

January 31, 1975

INFORMATICS INC.
6000 Executive Boulevard
Rockville, Maryland 20852

Hale-'35
Bib. No. 3587

AMERICAN JOURNAL OF OPHTHALMOLOGY

VOLUME 18 DECEMBER, 1935 NUMBER 12

THE RELATION OF VITAMIN A TO ANOPHTHALMOS IN PIGS

FRED HALE, M.S.
COLLEGE STATION, TEXAS

Forty-two pigs (four litters) were born blind at the Texas Agricultural Experiment Station in the course of experiments relating to maternal vitamin-A deficiency. Other defects noted were cleft palate, cleft lip, accessory ears, and arrested ascension of the kidneys. Definite and complete genetic tests were made to determine whether or not an hereditary factor was responsible for the eye anomaly and close matings such as blind brother x blind sister, and normal mother x blind son, produced only normal pigs. These studies leave no reasonable doubt that maternal deficiency of vitamin A will result in a variety of defects in the offspring, including blindness and even a failure of complete development of eye tissue, together with those above-mentioned.

The normal mothers of these blind pigs were depleted to a very low state of vitamin A before breeding and were continued on the vitamin-A-free ration for the first 30 days of the gestation period (the time during which the eye develops in the pig embryo).

Vitamin-A deficiency is by no means uncommon in human diet and it may easily be that many of the eye weaknesses which we suffer today are due to maternal vitamin-A deficiency, just as Dr. H. M. Taylor has recently discovered that some of the deafness among Southern children is due to quinine taken by the mother during pregnancy. In any case, it is obvious that until we have evidence to the contrary, we should insist on an abundance of vitamin A in the diet of the expectant mother in the early stages of pregnancy when so many of the vital organs of the embryo are being formed. From the Division of Swine Husbandry, Texas Agricultural Experiment Station. Read before the Association for Research in Ophthalmology, Atlantic City, June 11, 1935.

Numerous publications have appeared relative to the effect of vitamin A on the health of the individual from birth to maturity, and also relative to the health of mature animals and human beings. Osborne and Mendel showed as early as 1913 that if vitamin A is withheld from the ration or diet, the subject will eventually contract a disease of the eye, variously known as ophthalmia, xerophthalmia, keratomalacia, conjunctivitis, or keratoconjunctivitis. It has been shown also that the nerves of animals degenerate when the ration is without vitamin A, but the literature is lacking concerning the relation of maternal vitamin-A deficiency to embryonic development.

In connection with an investigation on the effects of vitamin A on swine, at the Texas Agricultural Experiment Station, a gilt of the Duroc breed that had been fed a vitamin-A-free ration for a period of 160 days before breeding, and for the first 30 days after breeding, farrowed in 1932, a litter of eleven pigs, all of which were born without eyeballs, so far as could be determined by macroscopic examination.

Since anomalies of this nature had not previously been observed in this particular herd in the many years that it has been under observation, and since the ration fed to this gilt was deficient in vitamin A, the natural inference must be that the eye anomaly of the young pigs was in some way associated with maternal vitamin-A deficiency. Further experiments were immediately initiated to determine the relation between vitamin A and embryonic eye development.

Two gilts were placed on a vitamin-A-free ration in an attempt to duplicate this anomaly. At the same time, two other gilts were fed the vitamin-A-free ration, plus one percent of cod-liver oil. These two latter gilts were bred 154 days after they were started on test, and farrowed normal litters in March, 1933. One of the gilts fed on the vitamin-A-free ration failed to show the symptoms of estrus, while the other one was bred 160 days after she was

Fig. 1 (Hale). Showing pig without eyeballs, farrowed June 8, 1934, out of Dam No. 336. Note subcutaneous cysts on head and back.

Fig. 2 (Hale). Showing pig with double cleft lip, farrowed June 8, 1934, out of Dam No. 336. This pig was also born without eyeballs.

Fig. 3 (Hale). Showing pig with extra ear-like growths, farrowed May 11, 1935, out of Dam No. 49. This pig was also born without eyeballs.

Fig. 4 (Hale). Showing pig born with cleft palate, farrowed May 11, 1935, out of Dam No. 49. This pig was also born without eyeballs.

started on the vitamin-A-free ration, but failed to farrow at the end of the normal gestation period. A post-mortem examination by Schmidt indicated the litter had probably perished at an early stage, followed by complete resorption of the fetuses.

In 1933, two additional five-months-old gilts, weighing 102 and 116 pounds respectively, were placed on the vitamin-A-free ration. The gilts were self-fed in a dry lot, and had access to sunshine. On the 176th day after starting on feed, one of the gilts was so completely affected by the depletion of vitamin A that she was unable to get up. A two-ounce dose of cod-liver oil was administered, and she regained her strength so rapidly that she was able to walk within eight hours following the cod-liver-oil treatment. Both gilts were bred to a sire of the Duroc breed on the 190th day after starting on feed. It will be recalled that the litter with the eye defects farrowed in 1932 was sired by an Essex male, which is an altogether different breed. Symptoms of vitamin-A deficiency in the gilts at the time of breeding were evidenced by their wobbly gait, weaving, and crossing of the hind legs at the walk, drooping of the ears, and loss of weight. After the gilts were bred, they remained on the vitamin-A-free ration for the first 30 days of the gestation period, the time during which it is known that the eye develops in the pig embryo. After the first 30 days of the gestation period had passed, the gilts were given an abundance of vitamin A in the form of cod-liver oil, so as to furnish them every opportunity to complete a full gestation period.

On June 8, 1934, both gilts farrowed. The gilt that had gone through the entire 190 day period without vitamin A farrowed a litter of ten pigs. A macroscopic examination showed that all these pigs were born without eyeballs, an exact duplicate of the litter produced under similar conditions in 1932. The gilt that had received a single dose of cod-liver oil two weeks before conception, farrowed fourteen pigs. In this litter, macroscopic examination showed various combinations of eye defects; some with no eyes; some with one eye; some with one large and one small eye; but all were blind. Three pigs of this litter, all blind, were raised to maturity on a normal ration. In both litters, various other defects were also observed, such as accessory ears, subcutaneous cysts, hare lip, and misplaced kidneys.



Fig. 5 (Hale). Showing normal eye of pig (A), and a pair of defective eyes (B). The anomaly was from a pig farrowed June 8, 1934, out of Dam No. 187. Both the normal eye and the pair of blind eyes were removed from ten-months-old pigs.

Finally, on July 6, 1934, another five-months-old gilt weighing 106 pounds was placed on the vitamin-A-free ration, and fed under the same conditions as those previously described. She was bred 192 days after starting on test, to a Duroc male unrelated to any other sire used in these tests, and on May 11, 1935, she farrowed seven pigs, all without eyeballs, as determined macroscopically. Other defects observed in the pigs were: hare lip, cleft palate, accessory earlike growths at the base of the ear, malformed hind legs, and a failure of the kidneys to ascend from their embryonic position.

It might be assumed that the eye anomalies here described are due to heredity; that the genetic factors responsible for them are existent in our herd and have appeared only when certain matings were made. The evidence against hereditary transmission is almost overwhelming, and may be briefly set forth as follows: (1) No other blind pigs have been farrowed in our herd since this herd was established twenty

years ago. (2) The three sires and the four dams of the forty-two defective pigs had apparently normal vision. (3) The three sires have produced only normal pigs when bred to other sows. (4) were from gilts unrelated to the gilt that farrowed the eyeless pigs in 1932, and their sire was of a different breed. (6) The only eyeless pigs produced in our herd have been from sows that were

Table 1

DATA PERTAINING TO THE PRODUCTION OF BLIND PIGS FROM NORMAL SOWS FED RATIONS DEFICIENT IN VITAMIN A

Dam No.	Sire Breed-No.	Date Litter of Pigs Farrowed	No. of Pigs in Litter	No. of Pigs Born Blind	No. of Normal Pigs	Kind of Ration Fed Dam of Litter	Other Defects in Litter of Pigs
38	Essex-2	3-29-32	11	11	None	Vitamin-A deficient**	Misplaced kidneys in 2 pigs
38	Duroc-3	8-19-32	4	None	4	Vitamin-A deficient plus green pasture	None
114	Duroc-5	3-20-33	8	None	8	Vitamin-A deficient plus 1% cod-liver oil	None
20	Duroc-5	3-27-33	9	None	9	Vitamin-A deficient plus 1% cod-liver oil	None
336	Duroc-14	6-[illegible]-34	10	10	None	Vitamin-A deficient**	Subcutaneous cysts, cleft palates hare lip, misplaced kidneys, extra ear-like growths
187	Duroc-14	6-[illegible]-34	14	14	None	Vitamin-A deficient**	Misplaced kidneys
336	Duroc-45	12-17-34	10	None	10	Vitamin-A deficient plus green pasture	None
187	Duroc-45	12-20-34	11	None	11	Vitamin-A deficient plus green pasture	None
49	Duroc-1	5-11-35	7	7	None	Vitamin-A deficient**	Harelip, cleft palates, misplaced kidneys, extra ear-like growth
46	Blind boar son of sow 187	5-11-35	11	None	11	Vitamin-A deficient plus green pasture	None
187	Blind boar son of sow 187	5-19-35	8	None	8	Vitamin-A deficient plus green pasture	None
22*	Blind boar son of sow 187	5-26-35	7	None	7	Vitamin-A deficient plus green pasture	None

* Blind gilt out of sow 187.
** Dam started on cod-liver oil on 30th day of gestation period.

The 1932 eyeless condition was duplicated exactly in 1934 and again in 1935, but only in connection with vitamin-A-free rations. (5) The two litters of defective pigs farrowed in June, 1934, practically depleted of vitamin A at the time of conception. (7) Definite and complete genetic tests were made in order to determine whether or not we were working with an hereditary

anomaly already in the stock of pigs we were using. These tests included the mating of the blind male from one of the 1934 litters of blind pigs (a) to a normal, unrelated gilt, (b) mating the blind male back to his dam, (c) mating the blind male to his blind full sister and litter-mate. From these three matings, 26 normal pigs and no abnormal pigs were farrowed.

As a matter of fact, it will be obvious to any one familiar with the principles of heredity, that there are only two hereditary mechanisms by which normal parents could produce blind offspring. The first possibility assumes that both parents were heterozygous for recessive factors responsible for blindness, in which case one fourth of the offspring on the average would be expected to be blind, just as in humans two brown-eyed parents may have some blue-eyed children. This possibility is ruled out by the first litter of eleven blind pigs, even without additional evidence that has since accumulated. There is only one chance in about four million of all the offspring in a litter of this size being recessive, an event, for all practical purposes, not so much more common than an all-trump hand in bridge, or the birth of human quintuplets. The second possibility is that the two normal parents carried complementary factors which when combined in the offspring produced these various eye and other defects in the same way that the crossing of two white-flowered sweet peas sometimes produces purple flowers in the first generation. Such a situation could easily result in blindness in all of the offspring, but this hypothesis is ruled out because the blind pigs themselves have completely failed to transmit their blindness to their offspring, even in very close matings, such as brother and sister and mother and son (see table 1).

These studies leave no reasonable doubt that a maternal deficiency of vitamin A will result in a variety of defects in the offspring, including blindness and even a failure of complete development of eye tissues, cleft palates, hare lip, and the arrested ascension of the embryo kidney. The question at once arises as to the relation of these results to various eye defects and weaknesses in the human race. It may be argued that there is a vast gap between pigs and people, but from the biological and nutritional standpoint, the differences are not so great as might appear at first glance. Both are omnivorous mammals with a relatively long gestation period.

It must not be forgotten, of course, that the nutritional conditions which brought about our litters of blind pigs are extreme and exaggerated. It would be almost impossible for an expectant mother to be as nearly depleted of vitamin A as were the animals in our experiments. On the other hand, vitamin-A deficiency is by no means uncommon in human diet—especially where the variety of food is limited. Furthermore, the instance of the one gilt that received a single dose of cod-liver oil two weeks before conception, and subsequently gave birth to pigs with eyes, but with a variety of defects including blindness, points to the fact that there are various degrees in which a lack or deficiency of vitamin A can affect eye development. Just as Dr. H. M. Taylor has recently discovered that some of the deafness among Southern children is due to quinine taken by the mother during pregnancy, so it may easily be that many of the eye weaknesses which we suffer today, are due to maternal vitamin-A deficiency. Perhaps we have been forcing our spinach on the wrong victims; it ought to be administered to the mothers instead of the children. In any case, it is obvious that until we have evidence to the contrary, we should insist on an abundance of vitamin A in the diet of the expectant mother in the early stages of pregnancy when so many of the vital organs of the embryo are being formed.

Bibliography

Davidson, H. R. Reproductive disturbances caused by feeding protein-deficient and calcium-deficient rations to breeding pigs. Jour. of Agric. Sci. (England), 1930, v. 20, pp. 233-264, illustrated.

Friedericia and Holm. Relation of vitamin A to regeneration of visual purple in rat. Amer. Jour. Physiol., 1925, v. 73, p. 63.
Guyer, M. F. Further studies on inheritance of eye defects induced in rabbits. Jour. Exp. Zool., 1924, v. 38, pp. 449-474.
Hale, Fred. Pigs born without eyeballs. Jour. Hered., 1933, v. 24, pp. 105-106, illustrated.
———. Vitamin A and normal eye development. In Abt's The 1934 Year Book of Pediatrics, pp. 72-74, illustrated.
Hughes, E. H. Vitamin-A content of barley. Jour. Agric. Res., 1933, v. 47, pp. 387-49[illegible], illustrated.
———. Effects of vitamin-A-deficient diets of sows. Jour. Agric. Res., 1934, v. 49, pp. 943-953, illustrated.
Hughes, J. S., Aubel, C. E., and Lienhardt, H. F. The importance of vitamin A and vitamin C in the ration for swine, concerning especially their effect on growth and reproduction. Kansas Agricultural Experiment Station, Technical Bulletin 23, 43 pp., illustrated, 1928.
———. Nerve degeneration resulting from avitaminosis A. Jour. Nutrit., 1929, v. 2, pp. 183-186, illustrated.
Moore, L. A., Huffman, C. F., and Duncan, C. F. Blindness in cattle associated with a constriction of the optic nerve and probably of nutritional origin. Jour. Nutrit., 1935, v. 9, no. 5, pp. 533-551, illustrated.
Sherman, H. C., and MacLeod, F. L. The relation of vitamin A to growth, reproduction, and longevity. Jour. Amer. Chem. Soc., 1925, v. 47, pp. 1658-1662, illustrated.
Sure, B. Dietary requirements for fertility and lactation: Dietary sterility associated with vitamin-A deficiency. Jour. Agric. Res., 1928, v. 37, pp. 87-92, illustrated.
Yudkin, A. M. Congenital anophthalmos in a family of albino rats. Amer. Jour. Ophth., 1927, v. 10, no. 5, p. 341.

Discussion. DR. WALTER B. LANCASTER: I should like to ask if any investigation was made to see whether blindness in humans is connected with a deficiency in vitamin A.

MR. HALE: You mean in the literature. There is nothing in the literature that I could find that would indicate that any observations have been made and conclusions drawn to that effect, but, on the contrary, there is nothing to show it was not. I do not think the subject has been studied from the naternal vitamin-A-deficiency standpoint. Most of what I was able to find relates from the date of birth instead of previous to birth.

DR. A. M. YUDKIN: I should like to state that anophthalmos, microphthalmos, and macrophthalmos, unilateral and bilateral, were observed in our rat colony previous to 1927. These ocular malformations were not found in subsequent litters of the same combination of parents when subjected to a similar environment and fed the same type of diet. The rations were adequate in maintaining normal growth and good health.

A similar observation was made in another well-known rat colony in this country. It is not unusual to find ocular deformities in other laboratory animals, particularly in the rabbit.

If sterility is associated with a vitamin-A deficiency, would you expect to have specimens for examination? Even though the diet may be lacking in vitamin A, would you not find other types of ectodermal disturbance?

I should like to see further observation made in his and other agricultural stations on pigs before concluding that the ocular changes are directly due to vitamin-A deficiency.

MR. HALE: In the four gilts I showed you in the graph we had a complete setup, two gilts receiving vitamin-A-deficient rations, the other two receiving the same rations plus one percent of cod-liver oil. Only the gilts receiving the cod-liver oil that furnished the vitamin A had perfectly normal pigs. We have duplicated the condition we observed in 1932, three different times with unrelated animals and have taken these animals and have proved to the geneticist and to anyone familiar with heredity that the eye anomaly was not due to heredity.

We have taken these deficiency rations and added cod-liver oil and have never been able to get these defects on such rations. We have produced forty-two blind pigs with these vitamin-A-deficient rations. We have produced these defective pigs by using two points

of technique that are of paramount importance. First, the mother must be depleted to a very low state in vitamin A before breeding. Second, the vitamin-A-deficient ration must be continued after the animal is bred until the stage of embryonic eye development has passed, and there is nothing in the literature that I can find to show that such tests have been made other than what I have read here today according to our method of procedure.

DR. FREDERICK H. VERHOEFF: I should like to ask if it ever failed when you tried to do that?

MR. HALE: Yes, it has, but it is hard to tell when these animals are depleted to the state where vitamin A is practically depleted out of the body. You have to observe that yourself and be enough of an animal husbandman to know the symptoms exhibited by those pigs with vitamin-A deficiency. I doubt if anyone who is not familiar with pigs showing vitamin-A deficiency could ever succeed, except through trial and error for a good many periods.

We succeeded the very first effort we made, after we selected young gilts the same age and weight of the first gilt. When we failed, it was with mature animals. We thought the one-hundred-and-sixty-day period on which we kept the first gilt was of some significance, but found it is not of any significance. The important feature is to deplete the animal to a very low state in vitamin A. We kept mature animals on a deficient ration for one hundred and sixty days and failed, but never have failed when we withheld breeding until the animals showed depletion, by these vitamin-A symptoms, to a very low state.

DR. THOMAS B. HOLLOWAY: I should like to know whether sufficient time has elapsed to determine whether these blind pigs represented a true case of anophthalmos or simply instances of excessive microphthalmos. In one slide shown the optic nerves entered the orbits.

MR. HALE: It is not a true anophthalmos. Only by microscopic examination would you know there was no anophthalmos. We have not gone very far with microscopic work yet.

DR. C. W. RUTHERFORD: What effects of these experiments were noted on the orbits and the extraocular muscles?

MR. HALE: We have not made those observations yet. We have these animals, however, in formalin, and we intend to make very extensive studies along that line.

DR. EDWARD JACKSON: Would it not be a fair supplementary experiment to subject an entirely different species and different family of animals, rats, to a similar vitamin-A-deficiency diet and see what the effect would be on them? Would that be in the same line of experiment?

MR. HALE: These experiments are only four years old and are so new that they are just in their infancy. There are so many angles to the question that studies will have to proceed for several years before we can get at this problem from all angles.

But if we should use rats (we are using rats now) and fail, you might ask yourself the question—Will we say the lack of vitamin C does not cause scurvy because we cannot give scurvy to a rat?

DR. LANCASTER: Has it been tried in poultry?

MR. HALE: No, not in poultry.

Mikrochimica Acta [Wien] 1969, 53—58

From the West Regional Laboratories, Pakistan Council of Scientific and Industrial Research, Lahore, West Pakistan, and from the Panjab University Institute of Chemistry, Lahore, West Pakistan

Semiquantitative Determination of Fat-Soluble Vitamins by Circular Thin-Layer Chromatography

By

M. H. Hashmi, Farhat Rafique Chughtai, and M. I. D. Chughtai

(Received February 29, 1968)

In previous papers, a method has been described for the semiquantitative determination of iron, copper, cobalt, nickel and zinc from blood and tissue[1] and also for noble metals[2], anions[3], and aromatic and α,β-unsaturated aldehydes[4]. In the present paper, the same procedure has been extended for the semiquantitative determination of fat-soluble vitamins by making "circular spots" on chromatoplates with circular thin-layer chromatographic apparatus[5] and their comparison with sensitivity standard. The determinations have been carried on both alumina and silica layers with three different spray reagents. The accuracy of the method is ± 6%. The application of the procedure has been demonstrated by determination of these vitamins from multivitamin tablets.

Experimental

Reagents

All reagents were of analytical grade or comparable purity.

Aluminium oxide S (Hopkin & Williams) and silica gel (D–O, Camag, without binder) were used for preparing thin layers of uniform thickness[5] (0.25 mm) using the Camag applicator[5,6].

The following samples of vitamins were used for sensitivity standard and for semiquantitative determinations:

Vitamin A palmitate, vitamin D_2 (from British Drug House), Vitamin D_3, DL-α-tocopherol acetate, vitamin K_1 and vitamin K_3 (from E. Merck).

The test solution of vitamins was made in carbon tetrachloride or benzene. From a mixture or from multivitamin tablets, the fat-soluble

vitamins were separated from water-soluble vitamins and other substances by extraction with carbon tetrachloride or benzene[7].

For preparing "sensitivity standard" (limit of identification) individual solutions containing each vitamin were used separately while test solution contained all the vitamins determined with the present procedure.

The semiquantitative determination of the vitamins was carried out with the following three spray reagents[7]:

1. Sulfuric acid, concentrated, density 1.82;
2. Antimony pentachloride, saturated solution in CCl_4;
3. Perchloric acid, 70% (from E. Merck).

SA, AP and PA are the abbreviations used for sulfuric acid, antimony pentachloride and perchloric acid respectively in the Tables.

Table I. Sensitivity Standard of Fat Soluble Vitamins on Alumina Layers

Vitamin	Spray Reagent*	Alumina Layers		Silica Layers	
		Sensitivity Standard (μg)	R_f Value**	Sensitivity Standard (μg)	R_f Value**
A	(SA)	1.0	0.94	1.5	0.92
	(PA)	1.0		2.0	
	(AP)	3.0		3.5	
D_2	(SA)	0.3	0.46	0.6	0.38
	(PA)	0.3		0.6	
	(AP)	0.3		0.8	
D_3	(SA)	0.3	0.40	0.6	0.35
	(PA)	0.3		0.6	
	(AP)	0.4		0.9	
E (α-tocopherol)	(SA)	0.8	0.77	1.5	0.73
	(PA)	1.0		1.0	
	(AP)	3.0		1.5	
K_1	(SA)	0.8	0.85	1.5	0.84
	(PA)	0.7		1.0	
	(AP)	1.0		2.0	
K_3	(SA)	1.0	0.60	5.0	0.60
	(PA)	1.0		6.0	
	(AP)	2.0		4.0	

* Color of the "circular spots" with different spray reagents is the same as already reported[7].

** Mixture of cyclohexane and ether (4 : 1) was used as solvent except for the separation of vitamins D_2 and D_3 on alumina layers. Vitamins D_2 and D_3 were separated from a mixture in a separate chromatogram using a mixture of cyclohexane and methyl isopropyl ketone (9 : 1) and their R_f values with this solvent are recorded in the Table.

Hashimi-'69
Bib. No. 3712

Mixture of cyclohexane and ether (4 : 1) was used as a solvent except for the determination of vitamins D_2 and D_3 on alumina layers for which a mixture of cyclohexane and methyl isopropyl ketone (9 : 1) was used.

Procedure

The circular thin-layer chromatographic apparatus[5,6] was used for making circular spots for sensitivity standards and for semiquantitative assessment of vitamins on chromatoplates. The details of the technique[1,2] and apparatus[5,6] have been described in previous communications.

Results and Discussion

The sensitivity standard and corresponding R_f values of 6 fat-soluble vitamins on alumina and silica layers are given in Table I.

The "sensitivity standard" of a vitamin with particular spray reagent corresponds to the optimal concentration at a given R_f (i. e. "circular spot") where a solution furnishes a just visible reaction (i. e. the identification limit) and has been used as a standard of comparison for the respective vitamins.

Since the method is based on sensitivity and dilution[2], the original concentration of vitamin in the test solution does not matter because during analysis, the solution is to be diluted to an extent until a known volume spotted on the chromatoplate contains the same amount of the vitamin to be determined as shown on the "sensitivity standard". For each dilution of the same solution, a separate chromatogram is run. Since the volume of the original test solution, dilution made, and the sensitivity is known, the amount of the vitamins can be found by simple calculations.

The results for semiquantitative determination of these vitamins from a single drop of solution on alumina and silica layers using three different spray reagents are given in Tables II and III respectively which indicate the accuracy of the method to ± 6%. The determination of vitamins with different spray reagents provide a useful check on the accuracy of results[1,2].

Table II. Semiquantitative Determination of Fat-Soluble Vitamins on Alumina Layers

Vitamin	Spray reagent	Amount added µg/100 ml	Amount found µg/100 ml	Error, %
A	(SA)	800.0	833.0	4.12
	(PA)		750.0	6.25
	(AP)		763.0	4.63
				Mean... 5.00
D_2	(SA)	180.0	171.0	5.00
	(PA)		167.0	7.20
	(AP)		190.3	5.80
				Mean... 6.00
D_3	(SA)	200.0	189.0	5.20
	(PA)		208.3	4.15
	(AP)		212.0	6.00
				Mean... 5.12
E (α-tocopherol)	(SA)	440.0	422.0	4.09
	(PA)		465.0	5.70
	(AP)		461.5	4.89
				Mean... 4.89
K_1	(SA)	520.0	565.0	8.60
	(PA)		538.0	3.46
	(AP)		505.5	2.80
				Mean... 4.82
K_3	(SA)	300.0	313.0	4.33
	(PA)		311.0	3.70
	(AP)		280.0	6.60
				Mean... 4.88

Table III. Semiquantitative Determination of Fat-Soluble Vitamins on Silica-Gel Layers

Vitamin	Spray reagent	Amount added µg/100 ml	Amount found µg/100 ml	Error, %
A	(SA)	690.0	646.0	6.40
	(PA)		715.0	3.60
	(AP)		730.0	5.80
				Mean... 5.27
D_2	(SA)	540.0	518.0	4.07
	(PA)		555.0	2.80
	(AP)		571.0	5.70
				Mean... 4.19
D_3	(SA)	525.0	500.0	4.50
	(PA)		535.0	1.90
	(AP)		494.5	5.81
				Mean... 4.70
E (α-tocopherol)	(SA)	1000.0	940.0	6.00
	(PA)		925.0	4.80
	(AP)		1000.0	0.00
				Mean... 3.60
K_1	(SA)	310.0	295.0	4.90
	(PA)		312.0	0.70
	(AP)		333.0	7.40
				Mean... 4.35
K_3	(SA)	450.0	417.0	7.30
	(PA)		462.0	2.70
	(AP)		444.0	1.33
				Mean... 3.77

For separation and semiquantitative determination of fat-soluble vitamins, a mixture of cyclohexane and ether (4 : 1) was used as solvent. However, vitamins D_2 and D_3 on alumina layers cannot be determined with this solvent because of their very close R_f value e. g. 0.30 and 0.32 respectively[7]. Hence, vitamins D_2 and D_3 are determined semiquantitatively from a mixture in a separate chromatogram using a mixture of cyclohexane and methyl isopropyl ketone (9 : 1) as a solvent (*cf.* Table I).

The usefulness of the method has been illustrated by determining the fat-soluble vitamins from commercially available multi-vitamin tablets. The solution of multi-vitamin tablets is made in a mixture of water and chloroform (1 : 1), and fat-soluble vitamins are extracted with carbon tetrachloride or benzene and are determined as described above. The results are given in Table IV.

Table IV. Semiquantitative Determination of Fat-Soluble Vitamins from Multi-vitamin Tablets*

Sample	Vitamins present	Amount present mg/10 ml	Amount found mg/10 ml	Error, %
I	A	33.5	32.0	4.47
	D_3	18.0	17.0	5.55
II	E (α-tocopherol)	34.0	32.5	4.41
	D_2	16.0	17.0	6.25
III	K_1	32.0	33.3	4.15
	K_3	24.0	22.8	5.00

* Determinations were made on alumina layers using mixture of cyclohexane and ether (4 : 1) as solvent.

The method is simple, accurate and is specially suitable when quick results are required because chromatoplate takes 1 to 2 minutes for development with circular thin-layer chromatographic apparatus[5,6].

Summary

Semiquantitative Determination of Fat-Soluble Vitamins by Circular Thin-Layer Chromatography

A method for semiquantitative determination of fat-soluble vitamins such as vitamin A, D_2, D_3, E (α-tocopherol), K_1 and K_3 is described. It involves making "circular spots" or rings on chromatoplates using circular thin-layer chromatographic apparatus. The method is based on sensitivity and specificity of spot reactions and the comparison of the color intensity of a "circular spot" with that of sensitivity standard. The accuracy of the method is ± 6%. The usefulness of the procedure has been illustrated by determining the fat-soluble vitamins from multi-vitamin tablets.

Zusammenfassung

Ein Verfahren zur halbquantitativen Bestimmung fettlöslicher Vitamine (A, D_2, D_3, E, K_1 und K_3) wurde beschrieben. Es beruht auf der Herstellung kreisförmiger Flecken oder Ringe durch Dünnschicht-Ringchromatographie und auf der Empfindlichkeit und Spezifität von Tüpfelreaktionen. Die Farbintensität der Ringe wird mit der von Standardproben verglichen. Die Genauigkeit beträgt ± 6%. Die Methode wurde an der Bestimmung der fettlöslichen Vitamine in Multivitamintabletten überprüft.

References

[1] *M. H. Hashmi, F. R. Chughtai, N. A. Chughtai, A. Rashid,* and *M. A. Shahid,* Mikrochim. Acta [Wien] **1968**, 712.
[2] *M. H. Hashmi* and *A. S. Adil,* Mikrochim. Acta [Wien] **1968**, 947.
[3] *M. H. Hashmi* and *N. A. Chughtai,* Mikrochim. Acta [Wien] **1968**, 1040.
[4] *M. H. Hashmi* and *M. A. Shahid,* Mikrochim. Acta [Wien] **1968**, 1045.
[5] *M. H. Hashmi, M. A. Shahid,* and *A. A. Ayaz,* Talanta **12**, 713 (1965).
[6] *M. H. Hashmi, M. A. Shahid, A. A. Ayaz, F. R. Chughtai, N. Hassan,* and *A. S. Adil,* Analyt. Chemistry **38**, 1554 (1966).
[7] *M. H. Hashmi, F. R. Chughtai, A. S. Adil,* and *T. Qureshi,* Mikrochim. Acta [Wien] **1967**, 1111.

Hayes-'67
Bib. No. 3753

Reproduced by permission
of the copyright owner

J. Animal Sci. 26(4):855-857. 1967.

TURNOVER OF LIVER VITAMIN A IN STEERS [1, 2]

B. W. HAYES, G. E. MITCHELL, JR., C. O. LITTLE AND H. B. SEWELL [3]
University of Kentucky, Lexington

LIVER vitamin A stores are widely used to evaluate the vitamin A status of cattle and their ability to withstand short-term dietary deficiency without deleterious effects. An improved understanding of the processes involved in the deposition and removal of vitamin A from the liver would increase the usefulness of such evaluations. Several workers have studied changes in vitamin A stores during periods of vitamin A depletion or following vitamin A therapy (Moore, 1957); however, little attention has been given to the stability of vitamin A reserves when total vitamin A is not changing. Previous experiments with rats (Mitchell *et al.*, 1964) and sheep (Sewell *et al.*, 1966) suggest continuous turnover of such vitamin A reserves. The experiment reported here was designed to study the turnover of the vitamin A stores of steers fed adequate vitamin A.

Experimental

Each of six Hereford steers, averaging 170 kg., received jugular injections of 125 mg. vitamin A acetate,[4] labeled with 1.240 uc. of tritium which was suspended in 8 ml. of 20% aqueous "Tween 80" by the procedure of Bieri (1951). The tritium was attached to carbons on either side of the second double bond from the ester end of the vitamin A molecule. Each steer received 1.4 kg. of ground shelled corn containing 10,000 I.U. of vitamin A palmitate daily, plus alfalfa hay and minerals *ad libitum*.

Jugular blood was sampled from the vein not receiving the injection 5 and 30 min. and 1 and 6 hr. after injection of the labeled vitamin A acetate. Blood was also sampled at the end of the first and second days and at the time of each liver biopsy. Total feces and urine were collected and sampled daily for the first 9 days and for a 24-hr. period immediately prior to each liver biopsy. Liver samples were taken by the aspiration biopsy technique of Erwin *et al.* (1956) on the 9th day, and then at 3-week intervals. The first 9 days were allowed for the labeled vitamin A to become stabilized in the liver. Samples were stored at −20° C. until analyzed.

Serum was extracted by the method of Kimble (1939). Liver and fecal samples were saponified and extracted as described by Gallup and Hoefer (1946). Vitamin A in the extracts was determined with trifluoroacetic acid as described by Dugan *et al.* (1964). Radioactivity determinations were made with a Packard Model 4322 Tri-Carb scintillation counter. Counting error was 5% or less. Duplicate 1-ml. aliquots of petroleum ether extracts were combined with 15-ml. portions of a scintillator solution containing 4 gm. 2, 5 diphenyloxazole (PPO) and 50 mg. 1, 4-di 2-(5-phenyloxazolyl)-benzene (POPOP) per liter of toluene. When chromatographed on alumina (Thompson *et al.*, 1949), ether extracts of liver yielded from 90 to 99% recovery for both vitamin A and tritium activity, which suggests that most of the tritium activity was associated with the vitamin A molecule. Larger volumes of low activity extracts were evaporated to dryness and redissolved in 1 ml. of petroleum ether. Radioactivity of the water extractable portion of the feces and urine was also determined. Five-gram fecal samples were extracted with 10 ml. of deionized water for 15 min. on a mechanical shaker and centrifuged at 1,000 *g* for 15 minutes. One-milliliter aliquots of the fecal extract supernatant and 1-ml. samples of urine were assayed separately for radioactivity by the method of Langham *et al.* (1956).

Results and Discussion

Average tritium activities of daily eliminations of urine and feces are shown in table 1. Similar amounts of tritium activity were excreted in the urine and in water soluble products of the feces. Considerably less activity was recovered from the ether extractable portion of the feces. By 72 days after treatment, only trace amounts of tritium could be de-

[1] This investigation reported in this paper (No. 66 5-95) is in connection with a project of the Kentucky Agricultural Experiment Station and is published with the approval of the Director.

[2] This investigation was supported in part by Public Health Service Research Grant AM 08355-03, from the National Institute of Arthritis and Metabolic Diseases.

[3] Present address: Department of Animal Husbandry, University of Missouri, Columbia.

[4] Prepared and donated by Hoffman-La Roche, Inc., Nutley, N. J.

TABLE 1. TRITIUM ACTIVITY (10^5 DPM) RECOVERED FROM DAILY EXCRETA OF STEERS

Day	Urine	Feces	
		Ether extract	Water extract
1	1146	169	1175
4	78	19	149
9	50	6	74
30	22	1	15
51	12	1	11
72	7	..	..
93	6	..	..

tected in either the water or ether extracts of the feces. Zachman *et al.* (1966) reported that, within 6 hr. after chicks or guinea pigs received intraportal injections of C^{14}-labeled vitamin A or vitamin A acid, metabolites of these compounds were recovered from the bile via bile duct cannulas. Although bile was not included in the present study, much of the tritium activity detected in water extracts of the feces may have resulted from biliary secretion of vitamin A metabolites.

Vitamin A and tritium activities of serum are presented in table 2. Five minutes after injection, vitamin A in the serum was elevated, but at 30 min. it had decreased by about 40% to a concentration that remained relatively stable throughout the experiment. There was a similar decrease in tritium activity of the serum between 5 and 30 minutes. The rapid disappearance of intravenously injected vitamin A acetate from the blood is consistent with previous observations with sheep (Sewell *et al.*, 1966), calves (Kon *et al.*, 1955) and rats and rabbits (Kon *et al.*, 1955; and Pollard and Bieri, 1958). Disappearance of vitamin A from the blood could have resulted from its removal by the liver, its use by tissues or its destruction. Based on an estimated liver

TABLE 2. VITAMIN A AND TRITIUM ACTIVITY OF STEER SERUM

Time	Vitamin A (mcg. ml.)	H^3-Activity (10^5 DPM ml.)
5 min	1.06	259
30 min.	0.60	135
1 hr.	0.57	134
6 hr.	0.61	145
1 day	0.51	103
2 days	0.37	69
9 days	0.40	28
30 days	0.44	14
51 days	0.44	7
72 days	0.51	4
93 days	0.57	4

TABLE 3. VITAMIN A AND TRITIUM ACTIVITY RECOVERED FROM LIVERS OF STEERS

Day	Vitamin A (mcg./gm.)	H^3-activity (10^5 DPM/gm.)[a]
9	62.2	229±16
30	55.4	175±27
51	59.5	137±20
72	60.1	102±17
93	59.4	80±17

[a] Averages of 6 observations±standard errors.

size of 1.7 kg. Hadley, (1954), about 14% of the injected radioactivity was present in the liver after 9 days. With adequate vitamin A activity in the diet, the use of large quantities to meet tissue needs would not be expected. Pollard and Bieri (1958) reported that up to one-half of the vitamin A acetate injected into rats was destroyed within 5 minutes. In studying possible mechanisms for this destruction, they found that hemolyzed blood cells would destroy vitamin A *in vitro*.

Storage of tritium activity in the liver (table 3) was adequate for study of possible turnover. While the concentration of vitamin A in the liver was relatively constant, tritium activity decreased with time. This apparent continuous decrease in tritium activity of the liver and the detection of tritium in the blood throughout the trial provide strong evidence of continuous turnover of vitamin A stores.

Specific activity units (DPM/mcg. vitamin A) were calculated using the average values of vitamin A per gram of liver for individual steers, since statistical analysis showed that these values did not change with time. The significant ($P<.01$) linear regression of the log of specific activity with time is illustrated in figure 1. Zero day on the time scale repre-

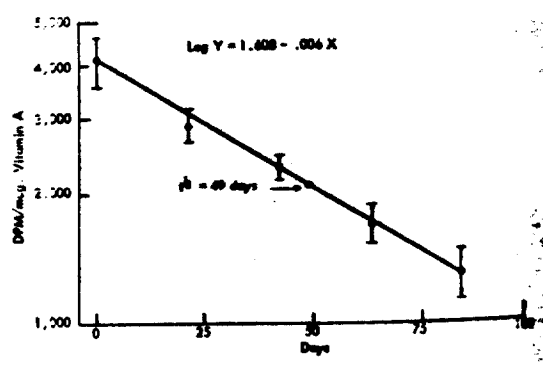

Figure 1. Specific activity of liver vitamin A stores plotted on a logarithmic scale against time. Each point represents an average of 6 observations, and vertical bars represent standard errors.

TABLE 4. TURNOVER OF H^3-LABELED VITAMIN A IN THE LIVER OF STEERS

Steer	Av. vit. A (mcg./gm.)	Initial H^3 activity (DPM/mcg. vit. A)	Regression equation	Half-time (days)	Turnover time (days)
1	76.0	3868	Log Y=1.587−.006X	50	72
2	77.6	3048	Log Y=1.449−.005X	61	88
3	42.9	5269	Log Y=1.707−.009X	33	48
4	59.1	3840	Log Y=1.594−.007X	43	62
5	47.4	5822	Log Y=1.639−.006X	50	72
6	52.9	4226	Log Y=1.626−.006X	51	73
			Mean±standard error	48±4	69±5

sents the 9th day after injection of the labeled vitaimn A acetate when the initial liver biopsy was taken. The regression equation for this relationship is log Y=1.608−.006 X, where Y is specific activity of vitamin A (DPM/mcg.) and X is days. The regression line gives an estimated half-time of 49 days or a turnover time of 71 days (Zilversmit, 1960). Using these same methods, half-time and turnover time for tritium labeled vitamin A in the liver were calculated for individual steers (table 4). Average half-time and turnover time with standard errors were 48±4 and 69±5, respectively. These values agree closely with those determined using average specific activity units (figure 1). Much of the variation observed can be attributed to steers 2 and 3. No obvious explanation for this variation is available; however, the physiological or environmental factors influencing such variation could be of considerable interest and may provide fruitful areas for further research. In a depletion study, Frey and Jensen (1947) reported that the level of vitamin A in the livers of steers was reduced by 47% in 40 days. Calculations from averages of values reported by Guilbert and Hart (1934) in another depletion study indicated that 58% of liver vitamin A reserves of steers was depleted in 93 days. Half-time for vitamin A in the liver was estimated to be 62 days for rats (Mitchell *et al.*, 1964) and 75 days for sheep (Sewell *et al.*, 1966).

Summary

Tritium-labeled vitamin A acetate was administered intravenously to calves fed adequate vitamin A and carotene. Declining specific activity of vitamin A in biopsy samples of liver and detection of radioactivity in the blood throughout the 93-day experiment indicated continuous turnover of liver vitamin A. Radioactivity was also detected in urine and feces. Average half-time of liver vitamin A was 48 days with a standard error of 4.

Literature Cited

Bieri, J. G. 1951. Stability of aqueous and oily vitamin A acetate and carotene solutions. J. Nutr. 44:327.

Dugan, R. E., N. A. Frigerio and J. M. Siebert. 1964. Colorimetric determination of vitamin A and its derivatives with trifluoroacetic acid. Anal. Chem. 36:114.

Erwin, E. S., I. A. Dyer, T. O. Meyer and K. W. Scott. 1956. Uses of aspiration biopsy technique. J. Animal Sci. 15:428.

Frey, P. R. and R. Jensen. 1947. Depletion of vitamin A reserves in the livers of cattle. Science 105:513.

Gallup, W. D. and J. A. Hoefer. 1946. Determination of vitamin A in liver. Ind. Eng. Chem. Anal. Ed. 18:288.

Guilbert, H. R. and G. H. Hart. 1934. Storage of vitamin A in cattle. J. Nutr. 8:25.

Hadley, F. B. 1954. Principles of Veterinary Science. W. B. Saunders Co., Philadelphia, Pa.

Kimble, M. S. 1939. The photoelectric determination of vitamin A and carotene in human plasma. J. Lab. Clin. Med. 24:1055.

Kon, S. K., W. A. McGuillivray and S. Y. Thompson. 1955. Metabolism of carotene and vitamin A given by mouth or vein in oily solution or aqueous dispersion to calves, rabbits and rats. Brit. J. Nutr. 9:244.

Langham, W. H., W. J. Eversole, F. N. Hayes and T. T. Trujillo. 1956. Assay of tritium activity in body fluids with use of a liquid scintillation system. J. Lab. Clin. Med. 47:819.

Mitchell, G. E., Jr., C. O. Little, H. B. Sewell and B. W. Hayes. 1964. Retention of radioactive vitamin A by rats. J. Animal Sci. 23:1[illegible] (Abstr.)

Moore, T. 1957. Vitamin A. Elsevier P[illegible] New York.

Pollard, C. J. and J. G. Bieri. 1958. The destruction of vitamin A by blood. Brit. J. Nutr. 12:359.

Sewell, H. B., G. E. Mitchell, Jr., C. O. Little and B. W. Hayes. 1966. Stability of vitamin A stores in sheep. J. Animal Sci. 25:262 (Abstr.)

Thompson, S. Y., J. Ganguly and S. K. Kon. 1949. The conversion of carotene to vitamin A in the intestine. Brit. J. Nutr. 3:50.

Zachman, R. D., M. B. Stinger and J. A. Olson. 1966. Biliary secretion of metabolites of retinal and of retinoic acid in the guinea pig and chick. J. Nutr. 88:137.

Zilversmit, D. B. 1960. The design and analysis of isotope experiments. Am. J. Med. 29:832.

Hayes-'70
Bib. No. 3762

LABORATORY INVESTIGATION

Vol. 22, No. 1, p. 81, 1970

The Fine Structure of Vitamin A Deficiency

I. Parotid Duct Metaplasia

K. C. HAYES, D.V.M., PH.D., H. L. MCCOMBS, M.D., AND T. P. FAHERTY

Department of Nutrition, Harvard School of Public Health, Boston, Massachusetts 02115

The fine structural differences in the parotid duct epithelium of calves receiving adequate or deficient supplements of vitamin A were compared. Control animals appeared to have two morphologic cell types, mucoid and fibrous. The mucoid cell was characterized by cisternal profiles of granular reticulum, extensive Golgi membranes, and dense aggregates of intracytoplasmic mucin. Fibrous cells did not actively synthesize mucus, but were characterized by cytoplasmic tonofibrils and a scarcity of granular endoplasmic reticulum and Golgi membranes. In the deficient epithelia, mucoid cells seldom developed, fibrous cells predominating without evidence of keratinization. These alterations suggest that vitamin A deficiency prevented the activation or differentiation of the mucus-producing cells.

Additional key words: Vitamin A, Epithelial differentiation, Metaplasia.

The squamous metaplasia and keratinization of epithelia induced by vitamin A deficiency in many animal species have been well documented,[18, 19, 31] and the metaplastic change of the parotid duct epithelium in calves has been a useful index in the diagnosis of vitamin A deficiency in this species.[27] Furthermore, the addition of vitamin A to cultures *in vitro* of embryonic epidermis can induce mucous metaplasia in normally keratinizing cells[9, 10, 12] although the area of epidermis[13] and type of epithelium[1] influence the nature and degree of this vitamin A-induced metaplasia. These relationships have resulted in the suggestion that this fat-soluble vitamin is associated with the histogenesis[31] or induction[30] of certain types of epithelial differentiation. From a general review of the many pathologic changes in the vitamin A-deficient animal,[14] it has been concluded that each of these changes may be related to failure in differentiation of specific cells. In order to characterize the morphologic alterations in fine structure of a mucus-secreting epithelium from a vitamin A-deficient animal, the parotid duct of calves was investigated.

MATERIALS AND METHODS

Six male Holstein calves, 1 day of age, were fed whole milk, limited calf starter, and chopped alfalfa hay *ad libitum*, according to a previously established regimen.[5] Starting at 35 days of age, each calf was fed a vitamin A depletion ration[5] to provide a weekly increase in live weight of 5 per cent and was assigned to either a deficient (8 μg. per kg. of body weight) or an adequate (108 μg. per kg. of body weight) daily supplement of vitamin A acetate. Weight gain and plasma vitamin A[20] were determined on a weekly basis. At the end of a 25-week comparison period, the calves were anesthetized with sodium pentobarbital. Then ventricular cerebrospinal fluid (CSF) pressure was measured with the calf in a sternal recumbent position,[3] and the head was perfused via the carotid arteries with 12 liters of a 3 per cent glutaraldehyde solution buffered at pH 7.3 by a 0.1 M sodium phosphate buffer. After perfusion, the parotid duct was excised and 1-mm. sections were taken at the point overlying the posterior angle of the mandible. These were immersed for 1 hour in fresh glutaraldehyde solution, rinsed in three changes of buffer, postfixed in 1 per cent osmium tetroxide, dehydrated in graded ethanols, and embedded in Dow epoxy resin (DER). Thick and thin sections were cut with glass and diamond knives on a Porter-Blum MT-1 ultramicrotome. Thick sections were stained with a 0.1 per cent toluidine blue solution, whereas thin sections were stained with methanolic uranyl acetate and lead citrate, and both were examined with a Philips EM-300 electron microscope at 60 kv. accleration voltage.

RESULTS

Growth of calves was comparable, irrespective of treatment even though the deficient supplement produced almost a 4-fold elevation in CSF pressure, inversely reflected by plasma vitamin A concentrations (Table 1).

The parotid duct epithelium from control calves was six to eight cells thick and consisted of a basal layer, a differentiating zone approximately two to four cells in thickness, and a zone of differentiated cells adjacent to the lumen. Approximately one-half of the differentiated cells were distended with dense globules, presumably mucus, which stained with toluidine blue and which

were occasionally seen partially extruded into the lumen of the duct. The intercellular space was conspicuous in the basal and differentiating layers and was bridged by cytoplasmic processes of adjoining cells. Near the luminal surface the intercellular space was obliterated (Fig. 1).

In electron micrographs of control epithelium the basal cells contained hemidesmosomes along the margin of an irregular basal lamina. The nuclei were round, with dispersed chromatin and one or two nucleoli. The cytoplasm was scanty and contained round, dense mitochondria, free ribonucleoprotein particles, short segments of granular reticulum, and a small Golgi apparatus that was not always present in the plane of section. Numerous tonofilaments coursed throughout the cytoplasm and were condensed into fibrils that terminated in desmosomes joining adjacent cells.

TABLE 1. MEAN TERMINAL VALUES[a] FOR BODY WEIGHT, PLASMA VITAMIN A CONCENTRATION, AND CEREBROSPINAL FLUID PRESSURE

Criterion	Vitamin A intake	
	μg./kg. body wt./day	
	8	1[illegible]8
Comparison period (wk.)	25	25
Body wt. (kg.)	201	207
Plasma vitamin A (μg./100 ml.)	12	34
CSF[b] pressure (mm. saline)	344	91

[a] Each mean represents three animals.
[b] CSF, Cerebrospinal fluid.

The differentiating zone contained two cell types. The first type (mucoid) had few glycogen granules or tonofilaments, but did have numerous tubular profiles of granular reticulum, Golgi membranes, and mitochondria with dispersed cristae and lightly osmiophilic matrices. More differentiated characteristics of this cell type included prominent cisternal profiles of granular reticulum, containing electron-dense material adjacent to the piled membranes and tubules of the Golgi apparatus. Amorphous, dense globules, presumably mucin, were located within the margins of the Golgi region (Fig. 2). In cells near the epithelial surface, these globules, which were membrane-bound, were so numerous that they packed and distended the cytoplasm in a pattern typical of the differentiated goblet cell (Fig. 3). Some of these cells were columnar and polar, stretching from the surface to three or four cell layers beneath it, the mucous globules within them bulging the apical surface, whereas the nuclei, dilated granular reticulum, Golgi membranes, and mitochondria were located predominantly in the basal portion of the cell (Fig. 4). Several cells had



FIG. 1. The control parotid duct epithelium (*A*) has an irregular surface, deeply stained mucous cells, and intraepithelial glands (*g*). *Arrows* point to mucus being extruded into lumen. Compare the vitamin A-deficient epithelium (*B*), which is thicker, has few mucous cells but many squamous cells near the lumen, and contains numerous monocytes (*arrows*) in the intercellular space. Toluidine blue: ×600.

Fig. 2. Control. A differentiating mucoid cell in the basal region with dilated granular reticulum (*gr*) and dense mucin droplets (*M*) aggregated within the ring of Golgi membranes (*Go*). Adjacent cells contain bands of tonofibrils and dense mitochondria. ×10,900.

ruptured plasma membranes, and mucus was spread over the luminal surface, which was coated by this fine, fuzzy secretion. In the mucoid cells near the surface mitochondria were few and glycogen granules were seen.

The second type of cell contained numerous tonofilaments and dense tonofibrils, whereas granular reticulum and Golgi membranes were scarce. Based upon these morphologic characteristics, these filament-containing cells were designated as fibrous. The mitochondria appeared smaller, the cristae were more closely packed, and the matrices more osmiophilic than those in the mucoid cell. In more differentiated fibrous cells the tonofibrils were dispersed and appeared as scattered filaments; resulting in a less dense cytoplasm. Glycogen granules were more numerous in this cell than in the mucoid type.

FIG. 3. Control. Mucous globules distend a goblet cell prior to extrusion into the lumen. Note the mucous "fuzz" on the surface, the small intercellular space, and the adjacent fibrous type cells. ×7200.



FIG. 4. Control. An elongated mucous cell extends alongside five fibrous cells containing tonofilaments and dense mitochondria. This polar cell has mucous droplets in the apical region (*right*) with nucleus and cell organelles in the basal area (*left*). ×5300.

and the nuclei in fibrous cells near the luminal surface were usually marked by two or three deep clefts. Within two or three cell layers of the surface these fibrous cells often contained clusters of small dense bodies in the cell periphery, especially along the apical margin, or as isolated bodies adjacent to Golgi membranes. They varied from amorphous granular bodies resembling small mucous droplets to less dense vesicular bodies, were approximately 0.1 to 0.2 μ in diameter, and were enclosed by a limiting membrane (Fig. 5).

The surface of the epithelium was sealed by tight junctions of the zonula occludens type,[8] and the cytoplasmic villous processes on the free surface were blunted and retracted in appearance. Within three cells of the surface, occasional intraepithelial lumina were seen, less than one cell diameter in width, but nonetheless sealed from the intercellular space by tight junctions (Fig. 6). Several of these lumina were lined by mucous cells extruding mucus into this space, shown by serial section to communicate with the lumen of the parotid duct. In effect, these lumina were considered a form of intraepithelial gland.

In vitamin A-deficient calves the epithelium was eight to 12 cell layers thick. The differentiating zone was wider than that of control epithelia (five to seven cells thick) and contained polyhedral or stellate cells with abundant, moderately dense cytoplasm. These cells were a monotonously uniform fibrous cell type, similar in most respects to those in control animals. The cytoplasm was packed with tonofibrils, and contained a number of mitochondria with closely packed cristae and dense matrices (Fig. 7). Near the surface, the cells were flattened into a squamous form. The small, dense bodies seen in the periphery of the fibrous cells in control animals were more prominent in these squamous cells, and clusters of the less dense, vesicular bodies were seen along the apical border, occasionally in communication with the intercellular space (Fig. 8). The intercellular space was wide up to the layer of flattened cells and was bridged by numerous cell junctions which combined to give a distinct, spinous cell appearance to the entire epithelium. Numerous mononuclear cells were found in the intercellular space at all levels of the epithelium (Fig. 1). This finding was frequently associated with the presence of plasma cells in the underlying connective tissue.

Mucoid cells with deeply staining mucous droplets were seldom seen, but when found were comparable in all respects to those in control epithelium. The hall-



FIG. 5. Control. Fibrous cells at the luminal surface contain amorphous granular bodies in the cell periphery which resemble small mucous droplets. Note the zonula occludens (*arrow*) and the tonofilaments dispersed throughout the cytoplasm. ×19,000.



FIG. 6. Control. An intraepithelial lumen is sealed by tight junctions (arrows). Mucus was often seen extruded into this space, which communicated with the lumen of the parotid duct. Adjacent fibrous cells have peripheral dense bodies (like those seen in Fig. 5) clustered along the luminal border. ×7600.

FIG. 7. Vitamin A-deficient epithelia. Fibrous type cells with bands of tonofibrils and round, dense mitochondria form a monotonous sheet of cells in the differentiating zone. A lymphocyte is located in the intercellular space. ×7300.



FIG. 8. Vitamin A-deficient epithelia. Surface cells are flattened into a squamous pattern and small vesicular bodies (*arrows*) are grouped along the apical border. Goblet cells are absent, and neither keratohyalin granules nor thickened plasma membranes are present. ×7500.

marks of keratinization—a thickened plasma membrane and keratohyalin granules—were not seen, nor were any of the intraepithelial glands described in control calves found in the tightly packed deficient epithelium.

DISCUSSION

The marked elevation in CSF pressure provided sufficient evidence of an induced vitamin A deficiency even though the deficient calves were comparable in weight and clinical appearance to their controls. The CSF pressure results from an increased resistance to CSF absorption,[4] and morphologic[15] and biochemical[6] descriptions related to this change appear elsewhere.

The squamous metaplasia seen in the parotid duct epithelium in deficient calves was similar to that described by previous investigators[26, 27] except that actual keratinization of the epithelium, not seen in the present experiment, has been reported by light microscopy in deficient calves.[26] The fact that neither keratohyalin granules nor a thickened plasma membrane were seen does

not mean that the parotid duct cannot keratinize but does indicate that for this degree of deficiency at this site in the duct, for this experimental period, and for a calf of this age, keratinization is not apt to occur.

Normal differentiation resulted in two morphologically distinguishable cell types, one (mucoid) active in mucous production and secretion, and the other (fibrous) active in the production of intracytoplasmic filaments and apparently functioning only as a structural component of the epithelium. The absence of the first cell type from deficient epithelia suggests that vitamin A may influence basal cells to differentiate into mucoid cells. That this influence is exerted upon the undifferentiated cell is suggested by the observation that epithelial repair, initiated by refeeding vitamin A, seems to proceed from the basal layer without modulation of the fibrous cell into the mucoid type.[32] More definitive studies of this reversal are in progress. This relationship of vitamin A to epithelium has led to the suggestion that the differentiating basal cell may utilize a common precursor—a nonfibrous, globular protein—either for the synthesis of protofibrils, adding cementing sulfhydryl groups of cysteine to form tonofibrils and keratin (keratinization), or for the addition of sulfated polysaccharides to the globular protein to form mucin (mucinization).[1] This ability to alternate between pathways of synthesis and different cell structure is reminiscent of the reduced number of osteoclasts and the predominance of osteoblasts produced by vitamin A deficiency in differentiating periosteal cells.[16, 17, 5] Together, these observations support the interpretation that the cell populations most affected by vitamin A deficiency are those which are subject to rapid turnover and which can differentiate in more than one direction.[14] Thus, differentiating epithelial and mesenchymal cells of growing animals, in general, and the highly differentiated, rapidly replaced mucous cells of the intestinal mucosa or parotid duct, specifically, would be most susceptible to deficiency, whereas the more slowly replaced epidermis (keratinization) of the adult is relatively refractile to deficiency. In theory, if one could stop growth and slow cellular turnover, vitamin A requirements might be eliminated or greatly reduced. This hypothesis gains support from the facts that certain aspects of cellular differentiation, such as casein production by mammary epithelial cells, seem to be dependent upon specific induction during cell division,[29] and that vitamin A-deficient germ-free rats seem to accommodate their deficient state by ceasing to grow, a process which can be reversed by the addition of vitamin A to the diet.[2]

The small, dense bodies in the cell periphery did not resemble keratohyalin granules; however, they were similar to descriptions of small mucous droplets in rumen epithelium[23] and frog epidermis.[28] The location of a few similar bodies near Golgi membranes in fibrous cells of control epithelium suggests that these peripheral bodies might be individual globules of dense mucus, whereas the more vesicular, less dense bodies were even more comparable, although smaller than, mucin droplets packed in the mucous cells. The marginal clustering and apparent communication of the vesicular bodies with the intercellular space were also comparable to the formation, localization, and activity of "membrane coating granules" during the process of keratinization by the epidermis.[24] However, the specific lamellar organization of the latter was not present in these granules.

The reduced prominence of Golgi complexes in deficient epithelial cells is of interest in light of the evidence that this organelle has been shown to sulfate polysaccharides,[22] the synthesis of which is depressed in intestinal mucosa of vitamin A-deficient rats.[7] Inasmuch as vitamin A is not required for the formation of mucopolysaccharides by fibroblasts grown in tissue culture,[3] it would appear that vitamin A does not affect mucopolysaccharide synthesis *per se* but is required by the relatively undifferentiated basal cell of the parotid duct or intestine if this cell is to attain the stage (protein synthesis, membrane formation) at which mucus synthesis can proceed.

The influx of monocytes and lymphocytes into the intercellular space of deficient epithelia and the numerous plasma cells in the subjacent connective tissues might represent a response to a failing barrier against infection normally provided by a surface coating of mucus. The protective nature of mucus has been reviewed,[11] and the increased susceptibility of the vitamin A-deficient animal to infection is a familiar entity to those who have worked with such animals.

Accepted for publication September 15, 1969.

This work was supported in part by a Public Health Service Postdoctoral Fellowship (1 F2, AM-39, 167-01) from the National Institute of Arthritis and Metabolic Diseases and by the Fund for Research and Teaching, Department of Nutrition, Harvard School of Public Health, Boston, Massachusetts 02115. Tissues were provided through the courtesy of Dr. H. D. Eaton (University of Connecticut), supported by a grant from the National Institutes of Health (NB-02018).

REFERENCES

1. Bern, H. A., and Lawrence, D. M. Influence of vitamin A on keratinization. In *Fundamentals of Keratinization*, edited by Butcher, E. O., and Sognnaes, R. F., p. 95. Washington, D. C. American Association for the Advancement of Science, 1962.
2. Bieri, J. G., McDaniel, E. G., and Rogers, W. E., Jr. Survival of germfree rats without vitamin A. *Science 163:* 574, 1968.
3. Calhoun, M. C., Hurt, H. D., Eaton, H. D., Rousseau, J. E., Jr., and Hall, R. C., Jr. Rates of formation and absorption of cerebrospinal fluid in Holstein male calves. University of Connecticut, *College of Agriculture Experiment Station, Bull. 401*, 1967.
4. Calhoun, M. C., Hurt, H. D., Eaton, H. D., Rousseau, J. E., Jr., and Hall, R. C., Jr. Osmotic flow during ventriculocisternal perfusion of vitamin A-deficient calves. *J. Dairy Sci. 51:* 1781, 1968.
5. Calhoun, M. C., Woelfel, C. G., Hall, R. C., Jr., Rousseau, J. E., Jr., Eaton, H. D., and Lucas, J. J. Growth of Holstein male calves fed an enzyme supplement, a combination of primary fungal and bacterial fermentation products, with limited milk replacer and starter and ad libitum hay, with observations on carotene utilization. University of Connecticut, *College of Agriculture Experiment Station, Progress Report 56*, 1964.
6. Cousins, R. J., Eaton, H. D., Rousseau, J. E., Jr., and Hall, R. C., Jr. Biochemical constituents of the dura mater in vitamin A deficiency. *J. Nutr. 97:* 409, 1969.
7. DeLuca, L., Little, E. P., and Wolf, G. Vitamin A and protein synthesis by rat intestinal mucosa. *J. Biol. Chem. 244:* 701, 1969.
8. Fawcett, D. W. *The Cell. Its Organelles and Inclusions*, p. 366. Philadelphia, W. B. Saunders Co., 1966.
9. Fell, H. B., and Mellanby, E. Metaplasia produced in cultures of

chick ectoderm by high vitamin A. *J. Physiol. (London) 119:* 470, 1953.

10. Fitton-Jackson, S., and Fell, H. B. Epidermal fine structure in embryonic chicken skin during atypical differentiation induced by vitamin A in culture. *Develop. Biol. 7:* 394, 1963.
11. Florey, H. Mucin and the protection of the body. *Proc. Roy. Soc. (Biol.) 143:* 556, 1955.
12. Hardy, M. H. Responses in embryonic mouse skin to excess vitamin A in organotypic cultures from the trunk, upper lip and lower jaw. *Exp. Cell Res. 46:* 367, 1967.
13. Hardy, M. H. Glandular metaplasia of hair follicles and other responses to vitamin A excess in cultures of rodent skin. *J. Embryol. Exp. Morph. 19:* 157, 1968.
14. Hayes, K. C. Vitamin A, differentiation, and reproduction. In *International Symposium on the Metabolic Function of Vitamin A*, edited by Wolf, G. *Amer. J. Clin. Nutr. 22:* 1081, 1969.
15. Hayes, K. C., and McCombs, H. L. Fine structure of the arachnoid granulations in vitamin A deficiency. *Fed. Proc. 28:* 489, 1969.
16. Hayes, K. C., Nielsen, S. W., and Eaton, H. D. Pathogenesis of the optic nerve lesion in vitamin A-deficient calves. *Arch. Ophthal. (Chicago) 80:* 777, 1968.
17. Irving, J. T. The effects of avitaminosis and hypervitaminosis A upon the incisor teeth and incisal alveolar bone of rats. *J. Physiol. (London) 108:* 92, 1949.
18. Jolly, M. Vitamin A deficiency. A review, I. *J. Oral Ther. 3:* 364, 1967.
19. Jolly, M. Vitamin A deficiency. A review, II. *J. Oral Ther. 3:* 439, 1967.
20. Kimble, M. S. The photocolorimetric determination of vitamin A and carotene in human plasma. *J. Lab. Clin. Med. 24:* 1055, 1939.
21. Kochhar, D. M., Dingle, J. T., and Lucy, J. A. The effects of vitamin A (retinol) on cell growth and incorporation of labelled glucosamine and proline by mouse fibroblasts in culture. *Exp. Cell Res. 52:* 591, 1968.
22. Lane, N., Caro, L., Otero-Vilardebó, L. R., and Godman, G. C. On the site of sulfation in colonic goblet cells. *J. Cell Biol. 21:* 339, 1964.
23. Lavker, R. M. Fine structure of mucus granules in rumen epithelium. *J. Cell Biol. 41:* 657, 1969.
24. Matoltsy, A. G., and Parakkal, P. F. Keratinization. In *Ultrastructure of Normal and Abnormal Skin*, edited by Zelickson, A. S. Philadelphia, Lea and Febiger, 1967.
25. Mellanby, E. *A Story of Nutritional Research*, p. 74. Baltimore, Williams and Wilkins Co., 1950.
26. Mills, J. H. L., Nielson, S. W., Rousseau, J. E., Jr., Woelfel, C. G., and Eaton, H. D. Experimental pathology of dairy calves ingesting one-third the daily requirement of carotene. *Acta Vet. Scand. 8:* 324, 1967.
27. Nielsen, S. W., Mills, J. H. L., Rousseau, J. E., Jr., and Woelfel, C. G. Parotid duct metaplasia in marginal bovine vitamin A deficiency. *Amer. J. Vet. Res. 27:* 223, 1966.
28. Parakkal, P. F., and Matoltsy, A. G. A study of the fine structure of the epidermis of *Rana pipiens*. *J. Cell Biol. 20:* 85, 1964.
29. Topper, Y. J. Multiple hormone interactions related to the growth and differentiation of mammary gland *in vitro*. *Trans. N. Y. Acad. Sci. 30:* 869, 1968.
30. Weiss, P., and James, R. Skin metaplasia *in vitro* induced by brief exposure to vitamin A. *Exp. Cell Res. (Suppl. 3)* 381, 1955.
31. Wolbach, S. B. Effects of vitamin A deficiency and hypervitaminosis A in animals. In *The Vitamins*, Vol. 1, p. 106. New York, Academic Press, Inc., 1954.
32. Wolbach, S. B., and Howe, P. R. Epithelial repair in recovery from vitamin A deficiency. *J. Exp. Med. 57:* 511, 1933.

Herbst-'44
Bib. No. 3832

Science 100:338-339. 1957.

Department of Pathology,
Duke University School of Medicine

TELANG LIVER AND VITAMIN A TOXICITY

During the past two years we have been making an investigation of the nutritional value of the telang

type of beef liver. Condemnations of livers for telangiectasis represent a tremendous waste of a valuable food since the condition occurs in nearly 3 per cent. of a total of nine million cattle marketed each year in the United States.[1]

The livers from affected animals show dark red or purplish sunken areas throughout the entire organ. Attempts to ascertain the cause of this liver condition by histopathological studies[2] have been quite unsuccessful and since the literature does not report any diagnosis of the condition in living animals, obviously treatment has not been prescribed.

The toxicity to weanling rats of a large number of different telang livers has been investigated. These studies revealed that about 20 per cent. of the diseased livers were toxic to rats when fed as the sole diet plus a daily supplement of twenty-five milligrams of calcium carbonate. The calcium carbonate was added to correct the undesirable Ca : P ratio (about 1:16) in the beef liver. Constant symptoms observed in young rats fed the toxic telang liver were growth failure and the development of multiple spontaneous fractures of the extremities. Usually bone fractures were observed in the animals after a week to ten days of liver feeding and fatalities occurred about a week after the onset of the symptoms.

The close similarity of these toxic effects of telang liver to those observed in rats fed high amounts of vitamin A[3] suggested that abnormally high stores of this vitamin might be present in some of the telangiectatic livers. Previous studies in this laboratory[4] on the comparative vitamin content of telang and normal livers had disclosed that vitamin A storage was in general greater in the former type of liver. Vitamin A was determined colorimetrically by the method of Davies[5] in a specific series of six telang livers, two of which had been toxic to young rats. The results of these analyses and the growth and toxicity data for rats fed the livers are shown in Table 1. These data revealed that the toxicity of a liver and its vitamin A content were closely correlated and that the amount of the vitamin ingested by rats receiving the calcium supplemented liver as their sole dietary was in excess of the reported toxic dosage of 15,000 I.U. per day.[3]

[1] H. R. Smith, *Proc. 23rd Ann. Meet. Amer. Soc. Animal Prod.*, 272–276, 1940.

[2] A. Carta, *Profilassi*, 11: 43–53, 1938; F. Schote, *Inaug. Diss.*, Friedrich-Wilhelms University of Berlin, 1936.

[3] A. W. Davies and T. Moore, *Biochem. Jour.*, 28: 288, 1934; C. A. Baumann and T. Moore, *Biochem. Jour.*, 33: 1639, 1939; K. Rodahl and T. Moore, *Biochem. Jour.*, 37: 166–168, 1943; H. W. Josephs, *Amer. Jour. Dis. Child.*, 67: 33, 1944.

[4] Unpublished data.

[5] A. W. Davies, *Biochem. Jour.*, 27: 1770, 1933.

TABLE 1

Vitamin A Content and Toxicity of Weanling Rats of Telang Livers

No. of telang liver	Vitamin A content	Intake of vitamin A per rat per day*	Time for symptoms to develop	Growth of rats
	I.U./100 gm	I.U.	days	gm/wk.
1	121,000	22,990	7	0
2	132,000	25,080	7	0
3	68,400	12,996	no symptoms	15
4	50,800	9,652	"	26
5	45,200	8,488	"	29
6	59,000	11,210	"	26

* Intake of vitamin A calculated from food consumption data.

Subsequent experiments in which crystalline vitamin A suspended in corn oil was fed to weanling rats as supplements to a complete stock ration, or to non-toxic liver, have demonstrated that the telang liver toxicity was a hypervitaminosis A. Identical symptoms of bone fragility and growth failure were observed in rats fed 20,000 I.U. of crystalline vitamin A as a supplement to the grain stock ration. If non-toxic liver supplying 10,000 I.U. of vitamin A per rat per day was fed, the symptoms of toxicity could be produced by a daily supplement of 10,000 I.U. of the crystalline vitamin.

Relative to use of telang livers in human and animal diets, there is little probability that the amount of liver usually eaten would furnish sufficient vitamin A to produce toxic symptoms. Certainly prolonged ingestion of large amounts of telang liver would be necessary to produce any irreversible changes such as noted in the rat experiments reported herewith.

Summary

(1) About 20 per cent. of fresh telang livers were toxic to weanling rats receiving the calcium supplemented livers as their sole dietary.

(2) The symptoms observed in rats were growth failure and multiple spontaneous fractures of the bones of the extremities.

(3) The toxicity of certain telang livers was due to their abnormally high stores of vitamin A. When these livers, supplemented only with calcium carbonate, were fed to weanling rats, the daily intake of vitamin A was in excess of the toxic dosage of 15,000 I.U. per day.

(4) Identical symptoms of toxicity were observed in weanling rats fed 20,000 I.U. of crystalline vitamin A per day in conjunction with a standard stock ration.

Edward J. Herbst
Paul L. Pavcek
C. A. Elvehjem

University of Wisconsin

Howell-'63
Bib. No. 4109

Reprod. Fertil. (1963) 5, 159-167

HISTOLOGY OF THE LESIONS PRODUCED IN THE REPRODUCTIVE TRACT OF ANIMALS FED A DIET DEFICIENT IN VITAMIN A ALCOHOL BUT CONTAINING VITAMIN A ACID. I. THE MALE RAT

J. McC. HOWELL, J. N. THOMPSON AND G. A. J. PITT

Departments of Veterinary Pathology and Biochemistry, University of Liverpool

(*Received* 20*th August* 1962)

Summary. Male rats maintained on a diet in which the vitamin A alcohol had been replaced by vitamin A acid developed lesions in the reproductive tract. The testicular changes were a sloughing of the cells of the germinal epithelium followed by an obliteration of the lumen of the tubule by Sertoli cells. Testicular regeneration was produced by the administration of vitamin A alcohol. The lesions are comparable to those of vitamin A deficiency as described by Mason (1933) but are uncomplicated by the secondary manifestations of vitamin A deficiency. The present paper also describes for the first time lesions in the testes of healthy growing prepubertal rats fed the vitamin A acid diet.

INTRODUCTION

Vitamin A acid, the carboxylic acid corresponding to the primary alcohol, vitamin A, was thought to replace vitamin A alcohol in all its known functions except that it could not provide vitamin A aldehyde for the prosthetic group of the visual pigments. Thus Dowling & Wald (1960) using a diet deficient in vitamin A alcohol, but supplemented with vitamin A acid, found that rats grew well and appeared normal, except that they were blind. It has been suggested that vitamin A acid is the form of the vitamin active systemically, i.e. concerned with growth and general tissue maintenance (Moore, 1953; Dowling & Wald, 1960). However, Thompson, Howell & Pitt (in preparation) have shown that rats maintained on a diet deficient in vitamin A alcohol, but containing vitamin A acid, showed normal mating behaviour but failed to reproduce. Lesions were present in the reproductive tract of male and female rats.

The purpose of this communication is to give a more detailed report of the histological changes in the male reproductive tract, and to discuss these changes in relation to those of orthodox vitamin A deficiency as described by Mason (1933).

MATERIALS AND METHODS

ANIMALS

The animals used in our experiments were hooded rats from the closed colony maintained in the Biochemistry Department of the University of Liverpool. They could be divided into two types according to their vitamin A reserves at weaning (*see* Table 1).

Type 1 rats were born of stock females which had been maintained on a diet containing a generous amount of vitamin A (Diet No. 4, British Extracting Co. Bromborough). The Type 1 rats were fed from weaning the basic diet (see below), i.e. a diet containing vitamin A acid but not vitamin A alcohol. They had stores of vitamin A alcohol in the liver which lasted from 4 to 5 weeks after weaning. The control rats were fed the basic diet with modifications as indicated in Table 1 and in the text.

TABLE 1

PARENTAGE AND DIETARY REGIME OF THE RATS USED IN THIS WORK

	Dam	*Diet*	*Vitamin A stores at weaning*
Type 1 rat	Stock rat	Basic diet from weaning	Present
Control to Type 1	Stock rat	Basic diet plus vitamin A alcohol given in oil by mouth as a weekly dose of 140 or 200 μg of vitamin A acetate OR the basal diet without vitamin A acid	Present
Type 2 rat	Type 1 rat given doses of 0·5 to 2·0 μg of vitamin A acetate in oil by mouth every day during pregnancy	Basic diet available from birth	Absent
Control to Type 2	Type 1 rat given doses of 0·5 to 2·0 μg of vitamin A acetate in oil by mouth every day during pregnancy	Basic diet plus vitamin A alcohol given in oil by mouth as a weekly dose of 140 or 200 μg of vitamin A acetate	Absent

Type 2 rats were born of Type 1 females which were maintained on the basal diet and given during pregnancy the minimal amount of vitamin A alcohol (given as the acetate) required for the successful delivery of living young (Thompson, Howell & Pitt, in preparation). The administration of vitamin A alcohol ceased as soon as the young were born. At weaning the Type 2 rats were continued on the basic diet. Any stores of vitamin A alcohol in the Type 2 rats were exhausted before these animals were weaned. Control rats, bred under this regimen, were fed the basic diet with modifications as indicated in Table 1 and in the text.

DIET

The basic diet (Thompson, Howell & Pitt, in preparation) consisted of: sucrose—65 %, casein—18 %, yeast—8 %, edible ground-nut oil—5 %, and minerals—4 %. Supplements were added containing adequate amounts of all known vitamins, with the exception of vitamin A alcohol. In the supplements vitamin A acid was substituted for vitamin A alcohol. The vitamin A acid was mixed into the food as the methyl ester, the dose being 10 μg/g of diet. A new supply of diet was mixed at least once a week and usually more frequently. Certain animals received higher levels of vitamin A acid given as 1 mg of vitamin A acid methyl ester by mouth every day in 0·1 ml of ground-nut oil or mixed with the diet at a level of up to 0·5 mg/g of diet. The basic diet contained 0·15 g *dl*-α-tocopheryl acetate per kg of diet.

EXPERIMENTAL TECHNIQUES

In our regeneration experiments, Type 1 rats were divided into pairs matched for body weight. Under ether anaesthesia the right testis of these rats was removed and fixed in Bouin's fluid. The animals were retained on the basic diet but one of the pair also received vitamin A alcohol as a dietary supplement, i.e. in addition to vitamin A acid. The vitamin A was given by mouth in oil as a weekly dose of 200 μg of vitamin A acetate.

All rats were killed by chloroform inhalation. Testes and seminal vesicles were removed and weighed prior to fixation. Material for histological examination was fixed in Bouin's fluid as soon as possible after death. The tissue was embedded in paraffin wax and sections were cut at 4 μ and stained with haematoxylin and eosin; selected sections were also stained by the periodic acid–Schiff technique. Where appropriate, sections were cut on the freezing microtome and stained with Sudan IV or by the PAS technique.

RESULTS

HISTOLOGY OF THE TESTIS AND EPIDIDYMIS

Type 1 rats

The rats were weaned on to the basic diet when they were 3 to 4 weeks old. At this time they had already accumulated a store of vitamin A alcohol. Such rats, given the basic diet from which the vitamin A acid was omitted, showed the classical symptoms of vitamin A deficiency (failure to maintain a gain in weight, xerophthalmia) after 4 to 5 weeks.

The first lesion in the male reproductive tract of the rats given the basic diet was seen after 5 weeks. This first lesion was an increase in the number of cells, probably spermatids, in the ductus epididymis (Pl. 1, Fig. 1). At 5 weeks the testes weighed less than those of an animal given this diet supplemented with vitamin A alcohol, but little difference could be seen in the histological structure.

As the length of time on the basic diet increased, the number of sloughed cells in the ductus epididymis became more numerous, being replaced by degenerate cells, which finally disappeared leaving only eosinophilic material.

The number of spermatozoa in the ductus epididymis decreased and they were absent from the ductus epididymis of rats killed when 20 weeks old. They were, however, seen to persist in the proximal part of the vas deferens and a few were found in this site in an animal killed when 11 months old.

The first lesion to be seen in the testis was a loss of spermatids. This was apparent after about 6 to 8 weeks on the basic diet. This lesion occurred at about the same time in animals completely deficient in vitamin A, i.e. animals fed the basic diet without the vitamin A acid. This early lesion was followed by a patchy loss of spermatocytes from the seminiferous tubules. At this time some tubules contained healthy spermatocytes together with a few cells having dark structureless nuclei and homogeneous darkly eosinophilic cytoplasm. These were thought to be degenerating spermatocytes. Although many spermatocytes had disappeared from the testes of rats examined after a period of 20 weeks on the diet, isolated spermatocytes persisted and were seen in the testes of one animal killed when 1 year old (Pl. 1, Fig. 2).

During the time that the spermatocytes were disappearing, vacuolation was seen in the cytoplasm of the Sertoli and spermatogonia cell layers (Pl. 1, Fig. 3). An examination of frozen sections revealed that these vacuoles contained neither sudanophilic nor PAS positive material. After the disappearance of the spermatocytes and spermatogonia, the lumen of the tubule became obliterated by a mass of Sertoli cells (Pl. 1, Fig. 4).

These lesions were patchily distributed throughout the degenerating testis. Thus in any one section of the testis the following changes could be seen: tubules completely filled with Sertoli cells, and tubules with a lumen, lined by Sertoli cells and spermatogonia. Many of the latter showed vacuolation and some contained spermatocytes (Pl. 1, Fig. 5).

Type 2 rats

These rats were given the basic diet as soon as they could eat. They were born with negligible stores of vitamin A which would not last until weaning. Thus they were deficient in vitamin A alcohol from the start of the experiment.

Type 2 rats fed on the basic diet never formed spermatids (Pl. 1, Fig. 6). A lumen was formed in the seminiferous tubule, only to be closed later by Sertoli cells. Healthy dividing spermatocytes and degenerating spermatocytes were seen in the same tubule (Pl. 2, Fig. 7) and in the early stages spermatocytes were numerous (Pl. 1, Fig. 6). They persisted in reduced numbers for a considerable period of time and some spermatocytes were still present in the tubules of a rat killed when 231 days old. Vacuolation was seen in the cytoplasm of Sertoli cells. Loss of spermatocytes and spermatogonia was followed by what would seem to be a proliferation of Sertoli cells to fill the seminiferous tubule. This was seen in animals only 61 days old (Pl. 2, Fig. 8) but filling of the tubule was still only to be seen in isolated tubules in the testes of rats aged [illegible] days. The majority of tubules were filled when the rats were 130 days old but even in a rat killed when 231 days old this lesion was not present in all the tubules (Pl. 2, Fig. 9). Varying stages in the development of the lesion could be seen in any one section of the testis.

The ductus epididymis of these rats at no time contained spermatozoa

2, Fig. 10). In a few rats one or two degenerating cells were observed but usual picture was of a ductus that was empty or which contained only inophilic material (Pl. 2, Fig. 11).

REGENERATION OF THE TUBULAR EPITHELIUM

ese experiments were performed on Type 1 rats. The right testis was re-oved after 2 to 4 months on the basic diet. This was done in order to observe generation from different stages in the development of the lesion. All stages the development of the lesion were seen, ranging from a testis with a normal tological structure but with an increase in the number of cells in the epi-dymis, to a testis having almost all its tubules filled with Sertoli cells.

The period allowed for regeneration varied from 49 days to 99 days. There s only slight evidence of regeneration in the left testis examined after 49 days, t definite evidence of regeneration was seen after longer periods on the basic t supplemented with vitamin A alcohol (Pl. 2, Fig. 12 and Pl. 3, Fig. 13). ections prepared from the testis removed at operation from one such animal, hown in Pl. 2, Fig. 12, contained no spermatids, but after 69 days regeneration permatids were present in about half the tubules of the remaining testis and here were some immature spermatozoa (Leblond & Clermont, 1952). Our esults indicated that regeneration could be produced in severely degenerate estes if spermatocytes or spermatogonia were present in the tubules.

In all cases the testes of the animals maintained on the basic diet alone howed a more severe degree of degeneration at the end of the experiment han did the testis that had previously been removed.

PREVENTION OF DEVELOPMENT OF THE LESION

Type 1 rats, whose diet was supplemented with vitamin A alcohol at or up to 3 weeks after weaning, did not show degeneration of the germinal epithelium. Normal testicular development was seen even in the Type 2 rats on such a egimen.

High dietary levels of vitamin A acid, even those sufficient to produce signs f hypervitaminosis A (Thompson & Pitt, 1960) in no way altered the develop-ment of the lesion. Animals on high levels of vitamin A acid who also received a supplement of vitamin A alcohol had normal testes.

MACROSCOPIC APPEARANCE OF THE TESTIS

In Type 1 rats the first macroscopic sign of testicular abnormality was a change n colour. There was a change from the normal white to a slightly pink appear-ance. This was followed by a reduction in size and weight; the degenerate estes had a greyish pink translucent appearance and they were markedly edematous. Even when the synthetic diet was supplemented with a high evel of vitamin A acid, the testes weighed less than those of similar rats whose iet was supplemented with vitamin A alcohol (Thompson, Howell & Pitt, n preparation).

The testes of the Type 2 rats were small and slightly pink but of a relatively irm consistency (Pl. 3, Fig. 14), and they were not markedly oedematous.

ACCESSORY SEXUAL ORGANS

The seminal vesicles of Type 1 and Type 2 rats fed on the basic diet smaller and weighed less than those of equivalent animals receiving the supplemented with vitamin A alcohol. In the regeneration experiment rats whose diet had been supplemented with vitamin A alcohol had seminal vesicles at the end of the experiment than those rats which had maintained on the basic diet alone (Thompson, Howell & Pitt, in preparation).

No marked histological changes were seen in either the prostatic acini or seminal vesicles. Foci of squamous metaplasia and keratinization were seen in any of the rats given the basic diet. Such lesions were frequently present in the prostate and seminal vesicles of rats fed this diet without vitamin acid.

DISCUSSION

Dowling & Wald (1960) concluded that ". . . the only function vitamin A may perform directly in the rat is to supply the prosthetic group of its visual pigments. All other functions—growth, general tissue maintenance—are served equally well by vitamin A acid". Our results have indicated that this statement must be modified (Thompson, Howell & Pitt, in preparation). Rats maintained on such a diet, the basic diet, show severe degenerative changes in the testes. These changes are similar to those described by Mason (1933) in rats deficient in vitamin A, although Mason's results can only be compared with those obtained in our Type 1 rats.

Mason observed the first changes in the reproductive organs at about the time xerophthalmia developed, and he illustrates this lesion in a rat that had been on the deficient diet for about 50 days. This lesion was essentially a sloughing of the cells of the germinal epithelium. The first cells to be sloughed were the spermatids. At this time many cells were seen in the ductus epididymis. He noted: "This sloughing process was often observed in sections of ductuli efferentes and ductus epididymis before any other pathological change could be noted in the tubules themselves". He further stated: "Often, small numbers of deeply staining pycnotic cells were observed throughout the epithelium of the seminiferous tubules". These were in all probability the cells that we consider to be degenerating spermatocytes. In the advanced stage of vitamin A deficiency few germ cells were left. Mason recorded a reduction in tubule size throughout the course of the development of the lesion, but did not mention vacuole formation although vacuole-like structures can be seen in Figs. 11 and 51 of his paper. Neither does Mason report that the lesion of vitamin A deficiency had a patchy distribution throughout the testes, but some evidence of a patchy distribution of the lesions can be seen in Figs. 8, 11, 26, 27 and 51 of his paper.

These are essentially the same lesions observed in our animals fed on a diet deficient in vitamin A alcohol but supplemented with vitamin A acid. They are the characteristic lesions of vitamin A deficiency as observed in the testes.

However, Mason did not report Sertoli cells filling the seminiferous tubules and this lesion was not seen in any of our control animals which were given

weaning a diet completely deficient in vitamin A, i.e. the basic diet without vitamin A acid. The proliferation of Sertoli cells was first seen in Type 1 rats fed from weaning the basic diet, when they were 11 weeks old, and the lesion was seen in one or two tubules only. However, Beaver (1961) working on vitamin A deficiency in germ-free rats does show Sertoli cells filling the seminiferous tubules (*see* Fig. 25 of his paper); three of the germ-free rats in his experiment lived for 109 days and the average survival time in eight animals allowed to die was 95 days. One would expect vitamin A deficient rats kept under normal laboratory conditions to die when about 9 weeks old.

It is thought that our results only differ from those of Mason in that our rats lived longer and did not suffer from inanition. Had Mason's deficient rats lived longer, presumably they too would have shown tubules full of Sertoli cells.

The results of our experiments in Type 1 and Type 2 rats indicate that the basic lesion of vitamin A deficiency in the testes is to be found at a stage in spermatocytogenesis before the meiotic division of the spermatocytes to form spermatids. Spermatids were never formed in our Type 2 rats. Degenerating spermatocytes were seen for a considerable period of time and during this time healthy and even dividing spermatocytes might be seen in the same tubule. Eventually all the spermatocytes and probably all the spermatogonia disappear leaving a tubule filled with Sertoli cells. The mechanism for these changes remains obscure.

In the Type 2 rats we have demonstrated for the first time, the importance of vitamin A in the development and maturation of the germinal epithelium of the testes.

Mason considered that one of the main differences between testicular damage due to vitamin A deficiency and that due to vitamin E deficiency was that regeneration could be produced in the former but not in the latter. Striking regeneration was produced in our rats by the administration of vitamin A alcohol.

Evidence has been cited by Mason (1939) that "variable degrees of gross atrophy and the occasional appearance of foci of epithelial keratinization, have been observed in the epididymis, vas deferens, seminal vesicle, prostate and preputial glands of the A deficient rat". He went on to say: "That (the atrophy) of the prostate and seminal vesicle appears to be more closely related to the body growth and nutritive state of the animal than to the degree of A deficiency." This cannot relate to our findings with vitamin A acid for in our experiments Type 1 rats had a body weight equal to that of the control rats on the same diet but supplemented with vitamin A alcohol, but the seminal vesicles of the former were smaller. It is interesting to note that in the regeneration experiment the rats receiving the vitamin A alcohol postoperatively had bigger seminal vesicles than the controls maintained on vitamin A acid (Thompson, Howell & Pitt, in preparation).

These results indicate that vitamin A alcohol has an effect on the seminal vesicles which is independent of its effect on the growth and nutritive state of the animal.

Fiske (1941) has shown that pituitary, seminal vesicle and testes weights of

rats kept in the dark were smaller than the weights of these organs in rats kept under normal laboratory conditions. However, there was little histological difference between the testes of these two groups.

In the Type 1 rats the testes were markedly degenerate and the seminal vesicles were reduced in size before one would have expected the rats to be blind (Dowling & Wald, 1960). Regeneration of the retina may have influenced the seminal vesicle weights of the rats receiving vitamin A alcohol in our regeneration experiment.

One would expect a much earlier development of the retinal lesion in the Type 2 rats. If this is so, blindness could be a contributory factor in the development of the lesions in the reproductive tract of these animals. This aspect of the problem is now being investigated.

ACKNOWLEDGMENTS

We wish to thank Professor D. L. Hughes and Professor R. A. Morton, F.R.S. for their encouragement and advice, Miss M. W. Royston, A.I.M.L.T. and Mr J. Camp for technical assistance, Mr G. Weston, F.I.M.L.T. for the photographs, and Dr O. Isler of F. Hoffmann-La Roche & Co, Basel for supplies of vitamin A acid. This work was supported in part by a grant from the Agricultural Research Council.

REFERENCES

BEAVER, D. L. (1961) Vitamin A deficiency in the germ-free rat. *Amer. J. Path.* **38**, 335.

DOWLING, J. E. & WALD, G. (1960) The biological function of vitamin A acid. *Proc. nat Acad. Sci. Wash.* **46**, 587.

FISKE, V. M. (1941) Effect of light on sexual maturation, oestrous cycles, and anterior pituitary of the rat. *Endocrinology*. **29**, 137.

LEBLOND, C. P. & CLEREMONT, Y. (1952) Spermiogenesis of rat, mouse, hamster and guinea-pig as revealed by the 'periodic acid–fuchsin sulfurous acid' technique. *Amer. J. Anat.* **90**, 167.

MASON, K. E. (1933) Differences in testes injury and repair after vitamin A deficiency, vitamin B deficiency and inanition. *Amer. J. Anat.* **52**, 153.

MASON, K. E. (1939) *Relation of the vitamins to the sex glands.* Sex and Internal Secretions, 2nd edn. Eds. E. Allen, C. H. Danforth and E. A. Doisy. Williams & Wilkins, Baltimore.

MOORE, T. (1953) *Vitamin A in the normal individual.* Symposium on Nutrition. Ed. R. M. Herriott. Johns Hopkins Press, Baltimore.

THOMPSON, J. N. & PITT, G. A. J. (1960) Vitamin A acid and hypervitaminosis A. *Nature, Lond.* **188**, 672.

EXPLANATION OF PLATES

PLATE 1

FIG. 1. Spermatozoa and sloughed cells in the ductus epididymis. Type 1 rat fed on the basic diet for 6 weeks, i.e. a diet containing vitamin A acid but not vitamin A alcohol. The histological structure of the testis was normal. Haematoxylin and eosin. ×189.

FIG. 2. Isolated spermatocytes present in the seminiferous tubule. One-year-old-Type 1 rat. Haematoxylin and eosin. ×375.

FIG. 3. Vacuolation in the cytoplasm of the cells lining the tubules. Type 1 rat fed the basic diet for 11 weeks. Haematoxylin and eosin. ×189.

FIG. 4. Tubules filled with Sertoli cells. Eosinophilic oedema fluid surrounds these tubules. Type 1 rat fed the basic diet for 15 weeks. Haematoxylin and eosin. ×189.

FIG. 5. Some tubules are filled with Sertoli cells, others have a lumen. Vacuolation and spermatocytes can be seen in the latter. Type 1 rat fed the basic diet for 15 weeks. Haematoxylin and eosin. ×52·5.

FIG. 6. Seminiferous tubule containing numerous spermatocytes but no spermatids. Fifty-six-day-old Type 2 rat. Periodic acid–Schiff reagent. ×375.

PLATE I

PLATE 2

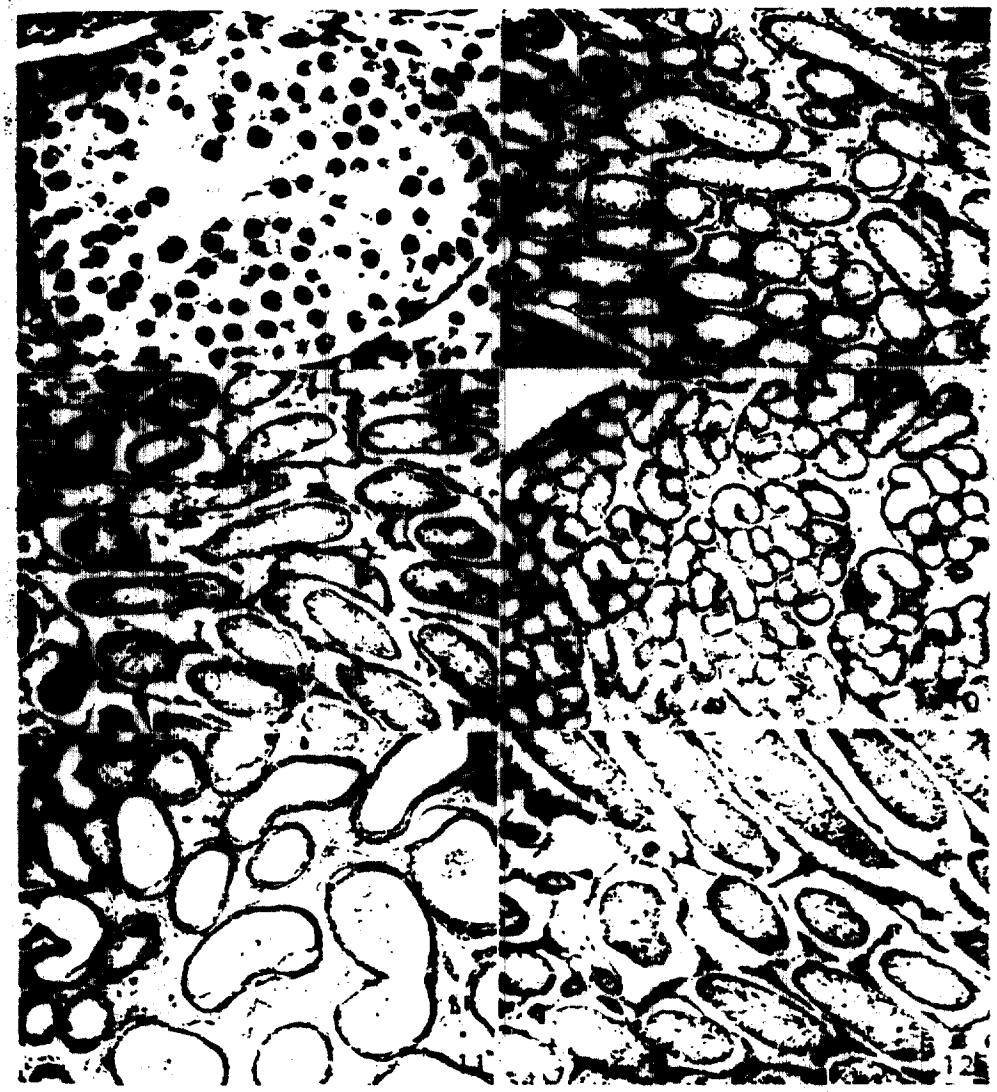

PLATE 3

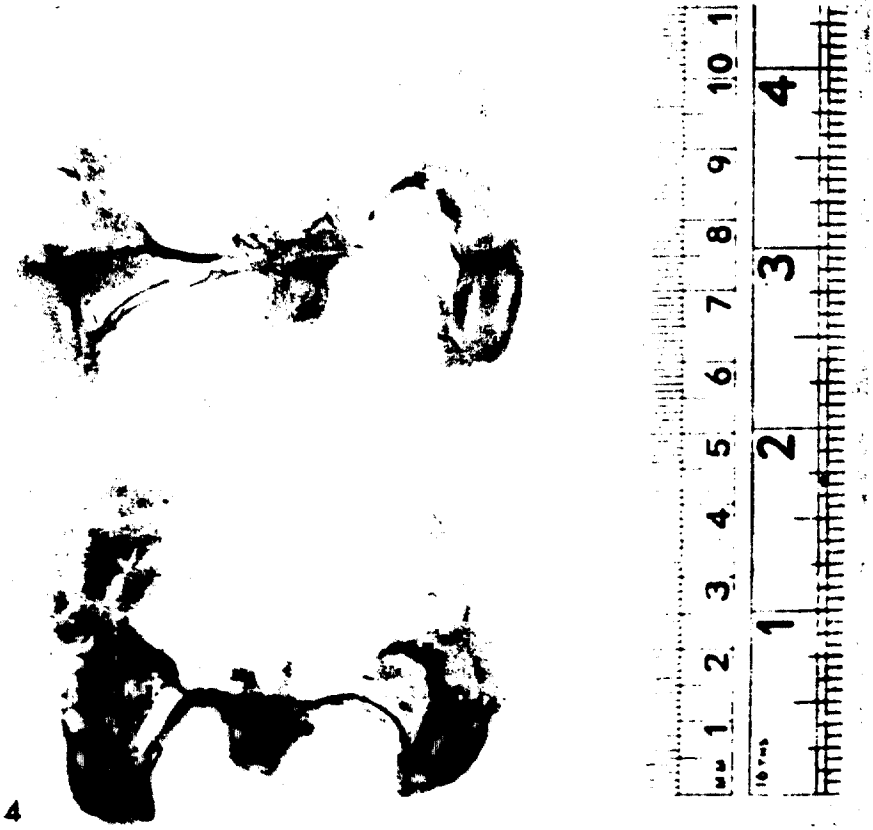

PLATE 2

FIG. 7. Tubule from the testis shown in Fig. 6. Healthy spermatocytes and degenerating cells are present. Periodic acid–Schiff reagent. ×500.

FIG. 8. The tubule in the centre of the field is filled with Sertoli cells. Sixty-one-day-old Type 2 rat. Haematoxylin and eosin. ×52·5.

FIG. 9. Testes. Some of the tubules still have a lumen. Two hundred and thirty-one-day-old Type 2 rat. Haematoxylin and eosin. ×52·5.

FIG. 10. The ductus epididymis is empty. Fifty-six-day-old Type 2 rat (*see* Fig. 6). Haematoxylin and eosin. ×52·5.

FIG. 11. The ductus epididymis is either empty or contains eosinophilic material. Two hundred and thirty-one-day-old Type 2 rat (*see* Fig. 9). Haematoxylin and eosin. ×52·5.

FIG. 12. Right testis showing severe degeneration. Tubule in the centre of the field contains spermatocytes. Eighteen-week-old Type 1 rat. This testis was removed surgically during a regeneration experiment. The animal had been fed on the basic diet. Haematoxylin and eosin. ×70.

PLATE 3

FIG. 13. Left testis removed 69 days after the surgical removal of the right testis which is shown in Fig. 12. Postoperatively the rat had been fed on the basic diet supplemented with a weekly dose of vitamin A alcohol, given in oil, by mouth as 200 μg of vitamin A acetate. Spermatids are present. Many of these are immature spermatozoa. Twenty-eight-weeks-old Type 1 rat. Haematoxylin and eosin. ×70.

FIG. 14. Testes and seminal vesicles of a 67-day-old Type 2 rat and of a 67-day-old control animal. The control animal was born on the same regimen as the Type 2 rat but from 40 days old it had been fed the basic diet supplemented with a weekly dose of vitamin A alcohol. The testes and seminal vesicles of this animal, shown at the top of the figure, are larger than those of the Type 2 rat.

Howell-'64
Bib. No. 4110

J. Reprod. Fertil. (1964) **7**, 251–258

HISTOLOGY OF THE LESIONS PRODUCED IN THE REPRODUCTIVE TRACT OF ANIMALS FED A DIET DEFICIENT IN VITAMIN A ALCOHOL BUT CONTAINING VITAMIN A ACID

II. THE FEMALE RAT

J. McC. HOWELL, J. N. THOMPSON AND G. A. J. PITT

Department of Veterinary Pathology and Department of Biochemistry, University of Liverpool

(*Received* 23*rd September* 1963)

Summary. It has previously been reported that female rats maintained on a diet in which vitamin A alcohol had been replaced by vitamin A acid, conceived when mated but always resorbed their foetuses. The histology of the lesions in the reproductive tract of such rats is described. The earliest detectable lesion was necrosis of cells in the placental labyrinth and junctional zone, which was seen at the 15th or 16th day of pregnancy, and was associated with an apparently healthy foetus. The foetal surface of the placenta quickly became necrotic and by this time the foetus was always undergoing resorption. The lesions are compared to those described by Mason (1935) in orthodox vitamin A deficiency. It is considered that the lesions seen in the placentae of rats fed a diet deficient in vitamin A alcohol but containing vitamin A acid represent the uncomplicated placental lesions of vitamin A deficiency.

INTRODUCTION

Vitamin A acid, the carboxylic acid corresponding to the primary alcohol, vitamin A, fulfils most but not all the functions of the vitamin. Rats fed a diet lacking vitamin A (alcohol) but containing instead vitamin A acid become blind (Dowling & Wald, 1960) and are infertile (Thompson, Howell & Pitt, 1964), but show none of the other signs usually associated with vitamin A deficiency. In such vitamin A acid-fed rats, it is therefore possible to observe clearly the effects of vitamin A deficiency on vision and reproduction in isolation from the other deficiency symptoms which would produce secondary complications and cause the early death of the animal.

The lesions in the testes of rats fed vitamin A acid instead of vitamin A alcohol have been described in detail (Howell, Thompson & Pitt, 1963). Female rats similarly maintained on vitamin A acid become pregnant but the foetuses are invariably resorbed. The purpose of this communication is to

report the histological changes in the reproductive tract of the pregnant female rat and to discuss these changes in relation to those of orthodox vitamin A deficiency as described by Mason (1935).

MATERIALS AND METHODS

ANIMALS AND DIETS

Hooded rats were used from the closed colony of the Biochemistry Department of the University of Liverpool. Those referred to as stock animals were maintained on standard food cubes (Diet No. 4, British Extracting Co, Bromborough). The other experimental animals were given a basic diet containing all the known vitamins except vitamin A for which vitamin A acid was substituted. This basic diet was made by incorporating 10 µg of vitamin A acid (as the methyl ester) into each g of diet No. II of Thompson *et al.* (1964). The

TABLE 1

PARENTAGE AND DIETARY REGIME OF THE RATS USED IN THIS WORK

Type	*Dam*	*Diet*	*Vitamin A stores at weaning*
1	Stock rat	Basic diet deficient in vitamin A alcohol but containing vitamin A acid given from weaning	Sufficient to maintain the animal for 4 to 5 weeks
2	Type 1 rat given daily doses of 1 to 2 µg of vitamin A acetate during pregnancy	Basic diet deficient in vitamin A alcohol but containing vitamin A acid available from birth	Absent

diet was stored at −15° C for periods of up to a week and in these conditions the vitamin A acid methyl ester appeared to be stable. Control animals received the basic diet containing vitamin A acid and were also given oral supplements of 140 or 200 µg of vitamin A acetate at mating and then every week throughout pregnancy. The experimental animals could be divided into two types (1 and 2) according to their vitamin A reserves at weaning (Howell *et al.*, 1963) (see Table 1).

Type 1 rats were bred from stock animals and fed the basic diet only from weaning, by which time they would have accumulated some weeks' reserve of vitamin A. This reserve would have been exhausted well before the animals became pregnant at 11 to 15 weeks of age, but Dowling & Wald (1960) showed that this period of deprivation of vitamin A would have caused only slight, if any, impairment of vision, and our histological findings have confirmed this. Type 2 rats were bred from Type 1 rats which had been given during pregnancy the minimal amount of vitamin A acetate required for the delivery of living young (Thompson *et al.*, 1964). The administration of vitamin A ceased as soon as the young were born, when the mother again received only the basic

diet, deficient in vitamin A alcohol but containing vitamin A acid. At weaning the Type 2 rats were continued on the basic diet. Any stores of vitamin A alcohol in the Type 2 rats were exhausted before these animals were weaned (Thompson *et al.*, 1964), and by 19 to 40 weeks of age, when they were used for the present work, histological examination revealed severe degenerative changes in the retina.

The day on which spermatozoa were found in the vagina was called the first day of pregnancy.

HISTOLOGICAL TECHNIQUES

All rats were killed by chloroform inhalation, and tissues were fixed in Bouin's fluid as soon after death as possible. The tissues were embedded in paraffin wax, sections were cut at 4 μ and stained with haematoxylin and eosin; selected sections were also stained by the periodic acid–Schiff technique.

RESULTS

Female rats fed from weaning the basic diet without vitamin A acid showed the typical deficiency sign of vaginal cornification: consequently oestrous cycles were difficult to detect (Evans & Bishop, 1922; Mason & Ellison, 1935). This was not so in the Type 1 female rats fed the basic diet containing vitamin A acid but not vitamin A alcohol. These rats appeared to have normal oestrous cycles and when placed with stock males they mated and became pregnant. There was an initial weight gain but the vaginal bleeding of the 'placental sign' was extended by a more copious discharge which often lasted until the 23rd day after mating, and during this period the early weight gain was rapidly reversed. These signs clearly indicated that the foetuses had died and were being resorbed, and indeed rats on such a dietary regimen never delivered young. However, if vitamin A alcohol was given to such rats during pregnancy, litters were born and reared. The details of these experiments have been given previously (Thompson *et al.*, 1964). Type 2 rats fed the basic diet containing vitamin A acid but not vitamin A alcohol also appeared to have normal oestrous cycles, and when mated with stock males they became pregnant, but again the foetuses were always resorbed. If vitamin A alcohol was given to these rats during pregnancy they produced living young, but the pups always died shortly after birth.

HISTOLOGICAL EXAMINATION

Tissues were examined from the following five groups of animals (*see* Table 2): Type 1 and Type 2 rats both with and without vitamin A supplements during pregnancy, and stock rats maintained on a diet containing a generous amount of vitamin A. The number of rats, the number of placentae and the day of pregnancy on which they were investigated are shown in Table 2. Six hundred and forty-nine placentae were examined. The histological findings for all groups of rats from the 14th to the 18th day of pregnancy are given in Table 3. The nomenclature used in this paper to describe the placenta is that used by Boggeman (1948a, b).

We did not see any evidence of retarded development of the placenta, foetus, infection of the uterus or localized areas of necrosis and leucocytic infiltration in the maternal decidua adjacent to the trophoblast. These are among the lesions described by Mason (1935) in vitamin A deficient pregnant rats.

The first departure from normal placental development was seen on the 16th day of pregnancy in our Type 1 rats, i.e. rats born from stock animals fed, from weaning, the basic diet deficient in vitamin A alcohol but containing vitamin A acid. The lesion was at the periphery of the placental disc.

TABLE 2

NUMBER OF PLACENTAE EXAMINED IN EACH OF THE FIVE GROUPS OF RATS FROM 11TH TO 20TH DAY OF PREGNANCY

Type of rat	*Diet given during pregnancy*	*No. rats (in parentheses) and placentae examined on the indicated days of pregnancy*								
		11	12	13	14	15	16	17	18	[illegible]
Type 1	Basic diet	(1) 2		(2) 12	(3) 25	(2) 18	(4) 33	(5) 47	(3) 26	[illegible]
Type 1	Basic diet and vitamin A alcohol					(1) 7	(2) 19	(3) 25	(2) 19	[illegible]
Type 2	Basic diet	(2) 14	(2) 16	(3) 23	(2) 15	(2) 16	(2) 16	(2) 17		[illegible]
Type 2	Basic diet and vitamin A alcohol	(2) 20	(2) 20	(2) 22	(2) 22	(2) 22	(2) 18	(2) 14		[illegible]
Stock	Standard food cubes		(1) 8	(1) 11	(2) 22	(3) 25	(4) 41	(2) 24	(2) 19	[illegible]

The basic diet was deficient in vitamin A alcohol but contained vitamin A acid.

consisted of necrotic cells, engorged sinuses and slight infiltration of polymorphonuclear leucocytes. The bulk of the lesion involved cells of the junctional zone but there was a definite spread into the tissues of the labyrinth (Pl. 1, Figs. 1 and 2). Necrosis of the cells of the labyrinth was present in placentae at the 17th and 18th days of pregnancy and appeared to spread across the surface of the labyrinth adjacent to the yolk sac (Pl. 1, Fig. 3). This was followed by a dissolution of the tissues of the placental disc. Sites in which necrosis was spreading across the foetal surface of the placenta always contained a resorbing foetus.

Apparently healthy foetuses were present in all sites showing the early lesion on the 16th day of pregnancy but by the 18th day of pregnancy resorbing foetuses were present in all placental sites.

Necrosis of cells at the periphery of the labyrinth and junctional zone was first seen on the 15th day of pregnancy in the Type 2 rats, i.e. rats born of Type 1 animals, given a supplement of vitamin A during pregnancy, the young subsequently being fed the basic diet, deficient in vitamin A alcohol but containing vitamin A acid. This lesion was identical with that seen in the Type 1

PLATE 1

FIG. 1. Type 1 rat, i.e. born from a stock animal and fed from weaning the basic diet deficient in vitamin A alcohol but containing vitamin A acid. Lesion in the placenta on the 16th day of pregnancy. Necrosis of cells at the periphery of the labyrinth at the junctional zone. Haematoxylin and eosin. × 35.

FIG. 2. A high magnification of labyrinth tissue from Fig. 1 at the junction of healthy and necrotic cells. Haematoxylin and eosin. × 243.

FIG. 3. Lesion in the placenta of a Type 1 rat on the 18th day of pregnancy. The tissues at the periphery of the placenta and over the yolk sac surface of the labyrinth are necrotic. Part of the resorbing foetus can be seen at the top of the figure. Haematoxylin and eosin. × 19.

FIG. 4. Placenta of a stock rat on the 16th day of pregnancy. A small area of necrosis in the junctional zone adjacent to the uterine lumen which is in the lower right-hand corner of the figure. Haematoxylin and eosin. × 70.

FIG. 5. Spontaneous resorption. Placenta of a stock rat on the 15th day of pregnancy. The uterine lumen is in the top left hand corner, maternal decidua is in the centre and the rest of the field is occupied by necrotic tissue. Haematoxylin and eosin. × 70.

FIG. 6. Placenta of a Type 1 rat given the basic diet and vitamin A alcohol during pregnancy and killed at the 18th day of pregnancy. The peripheral tissues of a normal placenta. Haematoxylin and eosin. × 34.

Verso p. 254

rats and again all the foetuses appeared to be healthy. However, on the 17th day of pregnancy in the Type 2 rats, all the foetuses were undergoing resorption and in fifteen of the seventeen sites necrosis was extending over the foetal surface of the labyrinth. This latter lesion was observed as early as the 15th

TABLE 3

PLACENTAL CHANGES IN ALL GROUPS OF RATS FROM 14TH TO 18TH DAY OF PREGNANCY

Day of pregnancy	*Type of rat and supplement, if any, given during pregnancy**	*No. placental sites*					*Total No. sites examined*
		Showing no changes (Pl. 1, Fig. 6)	*Necrotic cells at lateral lip of junctional zone and/or giant cell zone Pl. 1, Fig. 4)*	*Necrosis of lateral lip of junctional zone with spread to the labyrinth (Pl. 1, Figs. 1 and 2)*	*Necrosis extending over the surface of the placenta in the presence of a dead foetus (Pl. 1, Fig. 3)*	*Small necrotic placental site with little or no evidence of foetal tissue (Pl. 1, Fig. 5)*	
14th	Stock rat, stock diet	21				1	22
	Type 1 rat	21				4	25
	Type 2 rat	9				6	15
	Type 2 rat + vitamin A alcohol	20				2	22
15th	Stock rat, stock diet	20	1			4	25
	Type 1 rat	17				1	18
	Type 1 rat + vitamin A alcohol	7					7
	Type 2 rat	5	2	3	5	1	16
	Type 2 rat + vitamin A alcohol	14	1		1	6	22
16th	Stock rat, stock diet	17	20	3	1		41
	Type 1 rat	11	11	7	2	2	33
	Type 1 rat + vitamin A alcohol	11	7			1	19
	Type 2 rat	None		6	8	2	16
	Type 2 rat + vitamin A alcohol	8	9			1	18
17th	Stock rat, stock diet	17	6			1	24
	Type 1 rat	3	7	6	25	6	47
	Type 1 rat + vitamin A alcohol	14	8	1	1	1	25
	Type 2 rat	None		2	15		17
	Type 2 rat + vitamin A alcohol	6	7			1	14
18th	Stock rat, stock diet	13	2		1	3	19
	Type 1 rat	None		8	17	1	26
	Type 1 rat + vitamin A alcohol	16	3				19

* All Type 1 and Type 2 rats received the basic diet deficient in vitamin A alcohol but containing vitamin A acid.

day of pregnancy when it was present in five out of sixteen sites and again there was resorption of the associated foetus. The development of the placental lesion was earlier in the Type 2 animals and even by the 16th day all sites were abnormal.

In all our control rats, i.e. the stock rats and those of Types 1 and 2 that had the basic diet supplemented with vitamin A alcohol during pregnancy, only four placental sites were found which had a small area of necrosis involving cells of the labyrinth. Resorption of a foetus accompanied by extensive necrosis of the placental disc was found in each of the following rats: a Type 2 rat given the basic diet and vitamin A alcohol and killed on the 15th day of pregnancy, a Type 1 rat given the basic diet and vitamin A alcohol and killed on the 17th day of pregnancy, and one stock rat killed on the 18th day of pregnancy. This contrasts markedly with the rats that did not receive vitamin A alcohol during pregnancy (*see* Table 3).

In all five groups of rats from the 15th to the 18th day of pregnancy, several sites contained areas of necrosis, often restricted in extent, at the lateral lip of the placental disc in the giant cells or in the cells of the junctional zone (Pl. 1, Fig. 4). Occasionally both areas were involved. This lesion was present in most placentae on the 16th day of pregnancy but it was found in only five out of a possible sixty-four sites on the 18th day of pregnancy and it was not found in the eleven placentae of two stock rats killed on the 20th day of pregnancy.

In all five groups of rats and at all stages of pregnancy we observed small necrotic remnants of placental sites. In the majority of these sites all foetal elements were necrotic and disorganized, the only recognizable tissue being maternal decidua (Pl. 1, Fig. 5).

MAMMARY GLAND AND OVARY

The mammary gland was examined from the 14th day of pregnancy, and the ovaries from the 13th day, in all groups except for the Type 1 rats that were given vitamin A during pregnancy. In this latter group these structures were examined from the 15th day. No deviation from the normal was observed in any of the groups of rats.

DISCUSSION

Mason (1935) observed several changes in the placentae of vitamin A deficient rats. The three main lesions were: localized areas of necrosis, leucocyte infiltration and bacterial invasion in the maternal decidua adjacent to the trophoblast during early pregnancy; infection, haemorrhage and leucocyte infiltration at the periphery of the placenta or at the junction of the placenta and chorion during the latter part of pregnancy; and greatly retarded development in many of the foetal sites in which no necrosis or infection could be found.

In contrast, the earliest departure from normal placental development that was seen in our experiments was necrosis of cells at the periphery of the labyrinth and junctional zone. This was first observed at the 16th day in Type 1 rats and at the 15th day in Type 2 rats.

At about this time there are extensive changes in the placenta of the normal rat. By the 15th day the uterine lumen has excavated under the mesometrial attachment of the placenta and the placenta protrudes into the uterus like a button. On the 16th day the placenta reaches its greatest size and between this day and the 17th day Reichert's membrane ruptures, the diameter of the

placenta shortens and it becomes thicker from hilum to insertion (Bridgeman, 1948a). By the 18th day the periphery of the placental disc is rounded. From the 15th to the 18th day of pregnancy in all groups of rats in our experiments we saw foci of necrotic cells at the periphery of the junctional zone or in the giant cell zone at the periphery of the placenta (Pl. 1, Fig. 4). We consider this phenomenon to be associated with the changes that normally occur at this time and in particular with the rounding-off of the periphery of the placental disc. Necrosis of cells of the labyrinth adjacent to the junctional zone, which was the earliest detectable lesion in rats on the vitamin A acid diet, would thus seem to be an extension or an aberration of some normal mechanism.

A number of small necrotic placentae have been found in all groups of rats and at all stages of pregnancy. It is presumed that these represent spontaneous resorptions. Telford, Woodruff & Linford (1962) stated that 6 to 12% of all implantations in rats terminated in resorptions. One would expect it to be difficult to distinguish the terminal stages of the placental lesion following spontaneous foetal resorption and that produced by feeding our basic diet, and it may be that some of the lesions showing extensive necrosis of the labyrinth and death of the foetus at the 15th day in the Type 2 rats and at the 16th day in the Type 1 rats may be due to spontaneous resorption rather than to our experimental procedures.

The placental lesions found in our rats fed the basic diet deficient in vitamin A alcohol but containing vitamin A acid were at the site of the lesion observed by Mason (1935) during the later part of pregnancy—at the periphery of the placenta (Pl. 1, Figs. 1 and 3). The differences between these observations and those of Mason may be due to the uterine infection present in his rats. In this context the work of Payne (1957) on experimental bruceliosis in the pregnant rat is of great interest. He gave an intraperitoneal injection of a suspension of *Brucella abortus* organisms at the 12th or 13th day of pregnancy. Rats examined 2 to 3 days afterwards had large areas of necrosis in the junctional zone. He noted that: "The maternal placenta remains normal except where it adjoins the foetal tissues. Here small areas of necrosis can be seen in which polymorphs are migrating. Many organisms can be demonstrated in the areas of necrosis in this part ... " Four or 5 days after infection he saw polymorphs "in large numbers at the junction of the maternal and foetal tissues. They may remain localised in compact, pustule-like masses at this site ... " These are not unlike the lesions described by Mason (1935) during early pregnancy in the vitamin A deficient rat and indeed Mason wrote of the early lesion: "Furthermore, the cellular necrosis observed in these areas appeared to be the result of an infective process".

Rats fed a diet deficient in vitamin A alcohol but containing vitamin A acid (the basic diet) became blind, and on histological examination severe degenerative changes were found in the retina (Dowling & Wald, 1960). Apart from a failure of the reproductive processes, blindness was the only major difference between our rats given the basic vitamin A acid diet alone and those receiving the basic diet supplemented with vitamin A alcohol. It is considered most unlikely that blindness was an important contributing factor in foetal resorption particularly as our Type 2 animals still had most severe degenerative changes

in the retina after delivering a litter when given vitamin A alcohol throughout pregnancy, the period of pregnancy being too short to allow regeneration of the retina. In these animals the rod–cone layer was completely absent and the outer cellular layer was severely depleted of cells.

It is suggested that the changes occurring in the placenta of orthodox vitamin A deficient animals are a combination of an effect on the placenta as observed in our animals and other secondary effects of deficiency, the most significant of these in Mason's animals being uterine infection. It would be of the greatest interest to study the placental lesions produced by orthodox vitamin A deficiency in germ-free rats.

A lesion at the periphery of the placental disc has been associated with infertility in a number of conditions in the rat. It has been found in the Albany strain of rats (Burack, Wolfe & Wright, 1939), in rats given a fat-free diet (Maeder, 1937) and in experimental brucellosis of rats (Payne, 1957). It would seem that the placenta is able to react in only a limited number of ways and that different agents may produce a similar lesion.

ACKNOWLEDGMENTS

We wish to thank Professor D. L. Hughes and Professor R. A. Morton, F.R.S. for their encouragement and advice; Miss M. W. Royston, A.I.M.L.T., Miss C. Houghton and Miss P. M. McMahon for technical assistance; Mr G. Weston, F.I.M.L.T., for the photographs, and Dr O. Isler of F. Hoffmann-La Roche & Co, Basel for supplies of vitamin A acid. This work was supported by a grant from the Agricultural Research Council and the United States Public Health Service Grant, AM-05282-02.

REFERENCES

Bridgeman, J. (1948a) A morphological study of the development of the placenta of the rat. I. An outline of the development of the placenta of the white rat. *J. Morph.* **83**, 61.

Bridgeman, J. (1948b) A morphological study of the development of the placenta of the rat. II. An histological and cytological study of the development of the chorioallantoic placenta of the white rat. *J. Morph.* **83**, 195.

Burack, E., Wolfe, J. M. & Wright, A. W. (1939) Prolonged vaginal bleeding and foetal resorption in the Albany strain of rats. *Anat. Rec.* **75**, 1.

Dowling, J. E. & Wald, G. (1960) The biological function of vitamin A acid. *Proc. nat. Acad. Sci., Wash.* **46**, 587.

Evans, M. H. & Bishop, K. S. (1922) On an invariable and characteristic disturbance of reproductive function in animals reared on a diet poor in fat-soluble vitamine A. *Anat. Rec.* **23**, 17.

Howell, J. McC., Thompson, J. N. & Pitt, G. A. J. (1963) Histology of the lesions produced in the reproductive tract of animals fed a diet deficient in vitamin A alcohol but containing vitamin A acid. I. The male rat. *J. Reprod. Fertil.* **5**, 159.

Maeder, E. C. (1937) The effect of fat in simplified diets on the reproductive organs of the female albino rat during gestation. *Anat. Rec.* **70**, 73.

Mason, K. E. (1935) Foetal death, prolonged gestation and difficult parturition in the rat as a result of vitamin A-deficiency. *Amer. J. Anat.* **57**, 303.

Mason, K. E. & Ellison, E. T. (1935) Changes in the vaginal epithelium of the rat after vitamin A-deficiency. *J. Nutr.* **9**, 735.

Payne, J. M. (1957) Changes in the rat placenta and foetus following experimental infection with *Brucella abortus*. *J. Path. Bact.* **73**, 141.

Telford, I. R., Woodruff, C. S. & Linford, R. H. (1962) Foetal resorption in the rat as influenced by certain antioxidants. *Amer. J. Anat.* **110**, 29.

Thompson, J. N., Howell, J. McC. & Pitt, G. A. J. (1964) Vitamin A and reproduction in rats. *Proc. roy. Soc.* B. (In press).

Howell-'69
Bib. No. 4116

Br. J. exp. Path. (1969) **50**, 181.

THE DEVELOPMENT OF LESIONS IN VITAMIN A-DEFICIENT ADULT FOWL

J. McC. HOWELL*, G. A. J. PITT AND J. N. THOMPSON†

From the Department of Veterinary Pathology and the Department of Biochemistry, University of Liverpool*

Received for publication October 10, 1968

SUMMARY.—Twenty-five cocks aged 7 months and 43 hens aged 18 months had been fed from hatching diets free from retinol but supplemented with retinoic acid. The retinoic acid supplement was withdrawn from 20 cocks and 23 hens and the birds developed signs of vitamin A deficiency. The deficient birds together with control birds fed retinyl acetate were killed and examined at intervals throughout the 18 days of the experiment. Observations were made on clinical signs; changes in tissues, particularly nasal epithelium, nervous system and bone, and cerebrospinal fluid pressures were recorded. The behaviour of the deficient birds was abnormal by the 3rd day of the experiment, a degree of incoordination was seen after the 6th day, and by the 10th day the weight of the deficient birds was significantly lower than that of the controls. Changes in nasal epithelium and in the periosteum lining the cranial cavity and vertebral canal were seen by the 3rd day of the experiment and after 6 days new spicules of bone were being formed. Compression of central nervous system and nerve fibre degeneration were well established by the 10th day. Dramatic changes in the cerebrospinal fluid pressure were not seen. Only 2 deficient birds had values outside the normal range and these were both recorded at the end of the experiment. These results are discussed and we conclude that the CNS compression is related to the increased deposition of periosteal bone.

VITAMIN A deficient birds lose weight, become incoordinate and die. It has been shown that the central nervous system (CNS) is compressed and that there is an increase in the activity of osteoblasts (Howell and Thompson, 1965, 1967*a*). In adult fowl, new bone is laid down on the walls of the cranium and spinal canal (Howell and Thompson, 1967*b*). This increased subperiosteal bone deposition may be directly responsible for the lesions in the CNS. However, Woollam and Millen (1956) found an elevated cerebrospinal fluid (CSF) pressure in chicks fed a vitamin A deficient diet and this might produce or accentuate the ataxia.

This paper describes the sequence of changes that occur during the development of vitamin A deficiency in adult cocks and hens and includes the results of CSF pressure measurements. In order that the time of onset of deficiency would not be influenced by body stores of the vitamin obtained before the experiment began, birds were reared on a vitamin A deficient diet supplemented with retinoic acid (vitamin A acid). Retinoic acid replaces the true vitamin (retinol) in poultry in that it maintains growth and prevents nerve disorders (Thompson, Howell, Pitt and Houghton, 1965), but it is not stored in tissues, and thus signs of avitaminosis appear promptly when supplements of the acid are withdrawn (Howell and Thompson, 1967*b*).

† Present address: Department of Poultry Science, Cornell University, Ithaca, New York, 14850.

MATERIALS AND MEHTODS

Forty-three hens aged 18 months and 25 cockerels aged 7 months were of Thornber's 404 strain and had been fed from hatching diets free from retinol but supplemented with retinoic acid. They had been given diet B2 of Thompson, Howell, Pitt and McLaughlin (1969) until 6 weeks old, and then diet R3 of Thompson *et al.* (1969); at 18 weeks of age, the hens were changed to diet L3 of Thompson *et al.* (1969); retinoic acid, dissolved in arachis oil, was added to all at the level of 3 μg./g. diet. The birds were made deficient in vitamin A by withdrawing the retinoic acid from the diet.

The day on which the deficient diet was first fed was called day 0 and groups of hens and cocks were killed at intervals commencing on the 2nd and ending on the 17th day of the experiment (Table I). Three cocks and 5 hens were killed and examined as controls on the day before the deficient diet was fed. A further group of controls comprising 15 hens and 2 cocks was fed the synthetic diet supplemented with retinyl acetate (4 mg. per week *per os*). Groups of control hens were killed and examined on the 2nd, 4th, 6th, 10th and 18th days of the experiment (see Table II), and 2 control cocks were killed on the 19th day.

CSF pressure was measured at the atlanto-occipital space with the bird in lateral recumbency. Measurements were taken from all the living hens (Table II). The birds were anaesthetised with a halothane-oxygen (I.C.I. Fluothane) mixture flowing into a plastic bag loosely placed over the head. The skin over the occiput was cut away, together with part of the *biventer cervicus* and *rectus capitis posticus major* muscles in order that the needle could be placed with greater accuracy. The needle was connected by a column of heparinised saline through a Bell and Howell blood pressure transducer to a Devices pen recording apparatus.

The cocks were heparinised, killed by chloroform inhalation and perfused with 10 per cent formalin to which 1 per cent glacial acetic acid had been added. The hens were killed by halothane inhalation and their tissues fixed in neutral formalin. The head, spine and a femur were decalcified in formic-formaldehyde. A macroscopic examination of the viscera was made on all the birds and tissues were examined histologically from all deficient birds and control cocks but only from 2 of the hens in each of the control groups. The following material was taken for histological examination from cockerels and hens: a transverse section of the nose at the level of the commissures of the beak, a sagittal section of the cerebellum and medulla *in situ*, a transverse section of the cervical cord in the atlas, a sagittal section of the lumbosacral cord *in situ*, a transverse section of the mid shaft of the femur and a longitudinal section of the lower extremity of the femur; from hens only, a longitudinal section of the sciatic nerve; and from cockerels only, a transverse section of the frontal poles *in situ*. Tissues were embedded in paraffin wax; sections were cut at 5 μm. and stained by haematoxylin and eosin. Sections of sciatic nerve at 15 μm. were also stained by solochrome cyanin (Page, 1965). Frozen sections of lumbosacral spinal cord were stained by Sudan black in 50 per cent alcohol.

RESULTS

Clinical signs.—By the 3rd day the deficient birds spent most of the time in a huddled position and were disinclined to move about their cages. On the 6th day the third eyelid of most of the birds had moved to cover about half the surface of the eye and was not retracted. From the 6th day onwards they were disinclined to walk when placed upon the floor and had some difficulty in maintaining their balance. This was best seen when the birds were made to change direction quickly or made to perch on a horizontal pole that was slowly rotated. The birds were taken out of their cages and examined daily. During these examinations several of the cockerels and 1 hen had "fits". They fell over, sometimes backwards, beat their wings and moved their legs violently: the head and neck were waved from side to side and often food material escaped from the beak. After lying quietly for a few moments the birds stood again.

A difference in the mean weight of the deficient and control birds was seen by the third day of the experiment and by the 9th day in the hens and the 10th day in the cockerels the mean weight of the deficients was significantly lower than

TABLE I.—*Numbers of A-deficient Birds Showing Lesions*

Day of experiment	Sex of bird	No. of birds	Changes in nasal epithelium: Metaplasia to stratified squamous	Metaplasia to stratified squamous with keratinisation	No. of birds involved	Compression of the CNS: Changes in skull or vertebrae	Cerebrum	Spinal cord	No. of birds involved	Nerve fibre degeneration in spinal cord
2	Hen	5	0	0	0	0	0	1	1	0
3	Cock	4	4	0	4	3	3	1	4	1
4	Hen	3	3	0	3	3	1	3	3	0
6	Cock	4 } 9	2	2	9	4 } 9	3	3	9	2 } 2
	Hen	5	3	2		5	1	5		0
10	Cock	4 } 9	1	3	9	4 } 9	3	3	9	4 } 9
	Hen	5	—	5		5	5	4		5
13	Cock	4	—	4	4	1	4	3	4	4
16	Hen	2	—	2	2	2	2	2	2	2
17	Cock	4 } 7	—	4	7	4 } 7	4	2	7	4 } 6
	Hen	3	—	3		3	2	2		2

that of the controls ($P < 0{\cdot}05$). The difference became more marked as the experiment continued. At the start of the experiment 13 of the 23 hens that were to be fed the deficient diet were in lay. The subsequent record of eggs laid was as follows: day 1, 7 eggs; day 2, 8 eggs; day 3, 1 egg; day 4, 1 egg; day 5, 3 eggs; day 7, 1 egg; thereafter no eggs were produced.

Lesions in bone.—Changes were found in the periosteum of the bones lining the cranial cavity and vertebral canal (Table I). A patchily distributed increase in osteoblast size and number was seen by the 3rd day of the experiment and new spicules of bone were seen by the 6th day of the experiment (Fig. 1). After the 4th day changes in subperiosteal tissue were seen in all deficient birds. The osteoblastic changes and bone formation were first seen on the roof of the cranial cavity but changes in the vertebral canal were not long delayed. These changes were not seen in the control birds. In the skull and vertebral column of all birds endochondral plates were absent. The long bones of all birds were normal.

Lesions in the nervous system.—Details of the compression seen in the CNS of the deficient birds are given in Table I. Cerebral tissue was herniated into venous sinuses and the lumbosacral cord was compressed transversely (Howell and Thompson, 1967*b*). In the 17 control birds 1 small cerebral herniation and 5 slightly compressed lumbosacral cords were found.

Histological evidence of nerve fibre damage (Fig. 2) was found in the spinal cord of the ataxic birds (Table I). By the 10th day of the experiment ellipsoids and fragmenting nerve sheaths were found in the spinal cord of all the deficient birds. Changes were not seen in the sciatic nerves.

Cerebrospinal fluid pressure.—The CSF pressure was measured in the hens. Values were accepted only if the trace showed respiratory movements and gave a consistent value for at least 30 sec. The number of hens used and the values obtained are given in Table II. The mean value for the control birds was 95 mm. water with a range from 65–120. Two values for the CSF pressure of deficient birds were above this range and these were obtained on the last 2 days of the experiment.

DISCUSSION

The sequence of changes occurring during the development of vitamin A deficiency in adults differs from that seen in the chick (Howell and Thompson, 1967*a*). The chick loses weight, becomes markedly ataxic but shows no other outward signs of deficiency. The adult becomes lethargic and after the 6th day of deficiency the third eyelid is no longer retracted. Lethargy and the protruded third eyelid are the most striking external manifestations of vitamin A deficiency in adults whereas the ataxia and inability to stand are the most striking clinical changes in chicks.

Evidence of increased osteoblast activity was seen by the 3rd day and spicules of bone were seen by the 6th day of the experiment. The final lesions at these

---

EXPLANATION OF PLATES

FIG. 1.—Roof of vertebral canal after 6 days of the vitamin A deficient diet. The periosteum is thickened and many active osteoblasts are present. Small spicules of bone are growing into the subperiosteal tissue. H. and E. × 187.

FIG. 2.—Lumbosacral cord after 17 days of the vitamin A deficient diet. Many fragmented nerve fibres are present. Sudan black. × 500.

Howell, Pitt and Thompson

TABLE II.—*Cerebrospinal Fluid Pressure of Hens*

Day of measurement	Control			Deficient	
	Type of vitamin A supplement fed	No. of birds used	Acceptable readings	No. of birds used	Acceptable readings
Day before experiment started	Retinoic acid	5	65	—	—
			100	—	—
			95	—	—
2	Retinyl acetate	3	—	5	70
4	Retinyl acetate	4	100	3	80
			105		105
			110		—
6	Retinyl acetate	3	80	5	80
			80		80
			120		90
					100
10	Retinyl acetate	3	95	5	110
			110		—
16	—	—	—	1	130
17	—	—	—	3	105
					130
18	Retinyl acetate	2	—	—	—

Pressure in mm water to nearest 5 mm.

sites were similar to those previously reported in adult fowl (Howell and Thompson, 1967*b*). These changes were restricted to the walls of the cranial cavity and spinal canal of deficient birds. Long bones were not affected, which is in contrast to our previous findings (Howell and Thompson, 1967*b*), and the reason for this is not understood.

Compression of the CNS and nerve fibre degeneration were well established by the 10th day of the experiment (Table I). Of the 21 birds killed before the 10th day, 8 had cerebral and 13 had spinal cord compression, and nerve fibre degeneration was found in 3. In all adult birds there was less space between the spinal cord and the wall of the vertebral canal than was present in chicks and in 5 of the 17 control adults the spinal cord was slightly compressed although the rest of their CNS appeared to be normal. The reason for this is not known but it is possible that the slight compression of the spinal cord seen in some of the deficient birds killed early in the experiment may not have been related to vitamin A deficiency. Evidence of nerve fibre degeneration was based on fragmentation of myelin sheaths and the development of ellipsoids. The physical changes of myelin degeneration appear before the staining characteristics of the sheath change (Adams, 1965). Stains such as the Marchi technique were therefore not applicable to this experiment.

Dramatic changes in the cerebrospinal fluid pressure were not observed. In the deficient birds only 2 values were obtained outside the range of the controls and they were recorded on the last days of the experiment. This is in marked contrast to the findings of Woollam and Millen (1956) who found that the CSF pressure was elevated in birds fed a vitamin A deficient diet but in these birds signs of neurological disturbance were absent and bony abnormalities were not found at post-mortem examination. They found that the mean CSF pressure in

young adult birds was 100 mm. water; we found it to be 95 mm. water. It would appear that the removal of muscle and the small amount of bleeding that occurred did not appreciably affect the pressure. This has been confirmed in chicks and in 2 adult hens with naturally occurring vitamin A deficiency.

Our results confirm those of Wolbach and Hegsted (1952) and Howell and Thompson (1965, 1967*a*, *b*), who found evidence of compression of the CNS in vitamin A deficient birds. Our results suggest that the compression is due to an increased deposition of periosteal bone and is not dependent upon changes in endochondral growth (see Howell and Thompson, 1967*b*). We have not conclusively demonstrated that there is a change in CSF pressure, but if it is elevated it can only be so when the bone and CNS lesions are established.

J.N.T. was a British Egg Marketing Board Fellow and the work was supported by a grant from the British Egg Marketing Board. Retinoic acid was kindly given by F. Hoffmann-La Roche and Co., Basel, through Dr. O. Isler. We thank Dr. A Knifton and Mr. D. E. Jones of the Department of Pharmacology for assistance in measuring CSF pressure, and Mrs. M. W. Harling, Mrs. C. I. McLaughlin, Mrs. C. Savage, Mr. T. Howard and Mr. E. O'Neill for technical assistance.

REFERENCES

ADAMS, C. W. M.—(1965) "Neurohistochemistry". Amsterdam (Elsevier), p. 438.
HOWELL, J. McC. AND THOMPSON, J. N.—(1965) *Br. J. exp. Path.*, **46**, 18.—(1967*a*) *Br. J. Nutr.*, **21**, 741.—(1967*b*) *Br. J. exp. Path.*, **48**, 450.
PAGE, K. M.—(1965) *J. med. Lab. Technol.*, **22**, 224.
THOMPSON, J. N., HOWELL, J. McC., PITT, G. A. J. AND HOUGHTON, C. I.—(1965) *Nature, Lond.*, **205**, 1006.
THOMPSON, J. N., HOWELL, J. McC., PITT, G. A. J. AND McLAUGHLIN, C. I.—(1969) *Br. J. Nutr.* In press.
WOLBACH, S. B. AND HEGSTED, D. M.—(1952) *Archs. Path.*, **54**, 13.
WOOLLAM, D. H. M. AND MILLEN, J. W.—(1956) *Br. J. Nutr.*, **10**, 335.

J. Dairy Sci. 50:1941-1947. 1967.

Hurt-'67
Bib. No. 4163
Reproduced by perm
of the copyright own

Rates of Formation and Absorption of Cerebrospinal Fluid in Chronic Bovine Hypervitaminosis A [1]

H. D. HURT,[2] H. D. EATON, J. E. ROUSSEAU, JR., and R. C. HALL, JR.
Animal Nutrition, Animal Industries Department
Storrs (Conn.) Agricultural Experiment Station, Storrs

Abstract

Ventriculocisternal perfusion (VCP) of eight control and six chronic hypervitaminotic A Holstein male calves was conducted to estimate the rates of formation ($\dot{V}_f$) and bulk absorption (inulin clearance, C_{In}) that are associated with the lower cerebrospinal fluid (CSF) pressures observed in experimental hypervitaminosis A. The control and hypervitaminotic A calves received 108 and 10,800 μg of retinol (as vitamin A acetate)/kg live wt/day and were 147 and 146 ± 2 days of age, weighed 103 and 89 ± 10 kg with plasma vitamin A concentrations of 29.6 and 125.0 μg/100 ml, respectively. Initial intraventricular (IV) CSF pressures relative to the site of IV cannulation were −13 and −55 mm of synthetic CSF for the control and hypervitaminotic A groups, respectively. $\dot{V}_f$, in grams per minute, was unaffected by the imposed perfusion pressure and equalled 0.342 ± 0.059 for the control calves and 0.236 ± 0.059 for the hypervitaminotic A calves. Regression of C_{In} in g/min on imposed perfusion pressure (0 or +200 mm of synthetic CSF) relative to the initial IV pressure, X, for the control calves was: $C_{In} = 0.324 + 0.00159\ X \pm 0.095$ and for the hypervitaminotic A calves, $C_{In} = 0.322 + 0.00212\ X \pm 0.095$. The lower CSF pressure of the chronic hypervitaminotic A calf is apparently due in part to a reduced rate of formation of CSF and possibly to a decreased resistance to bulk absorption.

Received for publication June 28, 1967.

[1] Scientific contribution no. 287, Agricultural Experiment Station, University of Connecticut, Storrs. This study was supported in part by grant-in-aid funds provided by PHS research grant RO1 NB-02108-08, from the National Institute of Neurological Diseases and Blindness and by Agway, Inc., Syracuse, N. Y., Hoffmann-La Roche, Nutley, N. J., and Wirthmore Feeds, Inc., Waltham, Mass.

[2] Present address: Animal Science Department, Morrison Hall, Cornell University, Ithaca, N. Y. 14850.

The occurrence of elevated cerebrospinal fluid (CSF) pressure in the infant and adult human associated with excessive intakes of vitamin A has been reported (2, 16). It was suggested that the increased CSF pressure resulted from an alteration in the cellular integrity of the choroid plexus tissue, regarded to be the main site of CSF formation, thus causing an overproduction of CSF (3, 18). In recent studies, CSF pressure was lower in the young chronic hypervitaminotic A bovine (6, 8, 11), porcine, and canine (12) than that observed for control animals which had received an adequate level of vitamin A. Explanations that have been postulated for the observed decrease in CSF pressure are blockage between the sites of formation and sites of absorption, which has since been shown to be invalid (8); improper frontal bone growth, causing a thinning of the skull bones and thereby allowing a greater CSF space (9); an alteration in the secretory activity of the choroid plexuses, resulting in a decreased rate of CSF formation or an increase in the permeability of the membranes associated with the absorption of CSF. The present study was undertaken to ascertain the effects of chronic hypervitaminosis A on the rates of formation and bulk absorption of CSF by using the technique of ventriculocisternal perfusion essentially as described for the calf by Calhoun et al. (4, 5).

Experimental Procedure

Animals. Twenty one-day-old Holstein male calves were obtained from various Connecticut institutional herds from September to November, 1966. Upon arrival, each calf was given 100,000 USP units of vitamin A acetate orally and a 500-mg oblet of chlortetracycline (American Cyanamid's Aureomycin), with the latter continued for two additional days. The calves were housed and fed for the next 21 experimental week periods as previously described (4, 5). Exceptions were that each calf's ration was supplemented with vitamin A acetate at an amount equivalent to 108 μg of retinol/kg live weight/day, beginning the sixth and continuing through the ninth experimental week. In addition, beginning the first day of the tenth experimental week and continuing to the day

prior to ventriculocisternal perfusion (VCP), each calf's ration was supplemented with either a control intake of vitamin A acetate equivalent to 108 μg of retinol/kg live weight/day or a hypervitaminotic A intake of 10,800 μg of retinol/kg live weight/day. Also, beginning the tenth experimental week, feed intake was restricted to 60% of that used previously (4), to eliminate differences in feed consumption between the two groups of calves.

Ventriculocisternal perfusion (VCP). Following withdrawal of feed and water for 16 hr, each calf was anesthetized with pentobarbital sodium via the jugular vein, intubated with an endotracheal tube, and placed in a sternal recumbent position. The left lateral ventricle was cannulated and the intraventricular CSF pressure recorded at one-half-minute intervals for 10 min. Cisternal subarachnoid cannulation was followed by perfusion of the ventriculocisternal space with a synthetic CSF. After approximately 10 min of VCP, during which time it was ascertained that the perfusion system was performing satisfactorily, the outflow perfusate was collected for four 5-min intervals, followed by two additional 10-min intervals. Thereafter, perfusion continued with a synthetic CSF-containing inulin, 40 mg/100 ml, and creatinine 25 mg/100 ml, as tracers and effluent fluid collected for six 5-min intervals followed by six 10-min intervals. VCP for each calf was at either 0 or +200 mm of synthetic CSF relative to the calf's initially determined intraventricular CSF pressure.

While the above procedures have been described in detail (4, 5), exceptions were that a peristaltic action pump (Harvard Appratus no. 600-1200) was employed to deliver the perfusion fluid. The average inflow rate was 1.82 ± 0.16 g/min. After the loss of four calves during the VCP procedure, due to respiratory failure, it became apparent that artificial respiration was necessary. Therefore, a positive pressure respiratory pump (Harvard Apparatus Model 607-D) was used for all subsequent calves. A respiratory minute volume was calculated according to the tidal volume–live weight relationship of Guyton (10), and an assumed respiratory rate of 20. The actual tidal volume used was adjusted for the mean respiratory rate of the calf for the 60-min period following anesthetic induction. The ratio of inspiration to expiration for one respiratory cycle was 1.5 to 1.0. Twenty minutes prior to VCP with the synthetic CSF-containing tracers, the respiratory pump was connected to the endotracheal tube and left in place for the remainder of VCP. Approximately midway of all 10-min perfusate collections, the animal was hyperventilated by the use of an intermittent hyperinflation valve (Harvard Apparatus Model 615 modified) at a setting of 25 cm H_2O. Rumen cannulation to prevent increased intraruminal pressures was not necessary, since rumen fill was minimal, due to the restriction placed on feed intake.

Observations and analyses. Feed composition and consumption, growth, plasma vitamin A concentrations, and environmental conditions were determined as previously described (4, 5). The last day of the 10th through 21st experimental weeks all calves were observed for clinical signs characteristic of vitamin A toxicity.

Average daily minimum and maximum barn temperatures during this period, with their standard errors, were 13.7 ± 0.3 and 18.9 ± 0.2 C. Exposure to incandescent light, measured once every four weeks for each calf, averaged 66.7 ± 22.6 lux.

Osmolality of serum samples and inulin and creatinine concentrations of perfusion fluid samples were determined as described (4, 5); however, a standard inulin and creatinine blank value was not used for correcting outflow concentration of the tracers. Individual calf effluent perfusate samples were corrected for inulin and creatinine concentrations by a blank value determined from samples collected during the first two 5-min collection periods while perfusing with the tracer material following 40 min of perfusion with synthetic CSF containing no tracers. Due to the volume of the tubing, and the inflow rate delivered by the peristaltic pump, it was determined separately that the samples used for the blank correction did not contain tracers.

Immediately following the completion of VCP, the calf was sacrificed by exsanguination. Brain and total chorid plexuses tissue were removed, weighed, and dry matter subsequently determined (1).

The principles, assumptions, equations, and pertinent references employed to ascertain the rates of formation, and bulk absorption (inulin clearance), creatinine clearances, and volume of distribution of inulin by VCP were as previously cited (4, 5).

Statistical analysis of the data included estimation of the variability between the control and the hypervitaminotic A calves, and calves within each of these groups (error) by analysis of variance. When applicable, linear regressions of response on imposed VCP pressure were cal-

culated for the data of the control and hypervitaminotic A calves (17).

Results

Comparison period. The statistics of the comparison period, the 10th through the 21st experimental week, including the actual age, feed consumption, growth, and plasma vitamin A concentration of the 14 calves successfully perfused, are given in Table 1.

As previously mentioned, complete VCP data from four of the calves were not obtained, due to respiratory arrest. In addition, two calves receiving the toxic level of vitamin A succumbed prior to perfusion, due to congestive heart failure and an accumulation of body fluids in the pleural and abdominal cavities. This was believed to be related to their debilitated condition, apparently caused by the excessive intake of vitamin A.

TABLE 1

Comparison period data showing the vitamin A intake, age, feed consumption, growth, and plasma vitamin A levels of control and hypervitaminotic A calves successfully perfused

Criteria	Vitamin A status: Control calves	Vitamin A status: Hypervitaminotic A calves	SD per calf
Animals *(no.)*	8	6	.....
Duration of comparison period *(wk)*	12	12	.....
Vitamin A intake *(μg/kg live wt/day)*	108	10,800	.....
Actual age, start of comparison period *(days)*	64	65	2
Feed consumption *(kg/day)*			
Fed	1.61	1.68	0.09
Consumed	1.60	1.65	0.09
Growth			
Live weight, start of comparison period *(kg)*	68.5	75.3	8.6
Gain *(kg/day)*	0.42	0.16	0.07
Height at withers, start of comparison period *(cm)*	82.8	86.8	4.2
Gain *(cm/day)*	0.137	0.068	0.051
Plasma vitamin A *(μg/100 ml)*			
Start of comparison period	30.9	34.4	6.2
Comparison period average	30.1 (24.1-34.2)*	99.6 (68.7-122.7)	

* Range.

Ventriculocisternal perfusion. The actual age, live weight, plasma vitamin A concentration, the cannula depth required for intraventricular (IV) puncture, and the initial IV CSF pressure relative to the site of cannulation the day of VCP for the calves perfused at either their initial IV CSF pressure (0 mm) or at +200 mm synthetic CSF above their initial IV CSF pressure are presented in Table 2. The greater plasma vitamin A concentration, less live weight, and lower CSF pressure are characteristic of hypervitaminosis A (11).

Other data collected during VCP concerning anesthetic requirements, heart and respiratory rates, and changes in serum osmolalities during the VCP are presented in Table 3. The only notable differences were the lower heart rate and higher average serum osmolality of the animals receiving the greater intake of vitamin A.

Regressions of outflow volume minus inflow volume ($\dot{V}_o - \dot{V}_i$), inulin clearance (C_{in}), and the rate of CSF formation ($\dot{V}_f$), in grams per minute, Y, on the imposed perfusion pressure, in millimeters of synthetic CSF relative to the initially determined IV CSF pressure, X, with the respective SD's for the control and hypervitaminotic A calves, are presented in Figures 1 and 2, respectively. The points on the figures represent individual calf mean values of data collected from three 10-min samples obtained during 100 to 130 min of VCP and are representative of the steady state.

TABLE 2

Perfusion day data showing the age, live weight, plasma vitamin A, intraventricular cannula depth, and CSF pressure of control and hypervitaminotic A calves perfused at either 0 or +200 mm of synthetic CSF relative to their initial intraventricular CSF pressure

Criteria	Control calves		Hypervitaminotic A calves		SD per calf
	VCP pressure		VCP pressure		
	0	+200	0	+200	
Animals *(no.)*	4	4	3	3	.....
Actual age *(days)*	146	148	145	148	2
Live weight *(kg)*	100.7	105.7	83.0	94.3	10.0
Plasma vitamin A *(μg/100 ml)*	29.8 (26.6-33.0)[a]	29.4 (27.2-31.4)	127.1 (56.0-176.4)	122.8 (107.0-134.6)	.....
Intraventricular cannula depth *(mm)*	43	41	41	41	2
Intraventricular CSF pressure *(mm synthetic CSF)*					
Actual	−20	−6	−48	−62	.....
Log_{10}	1.894	1.952	1.694	1.241	0.393

[a] Range.

Neither $\dot{V}_e - \dot{V}_i$ nor C_{In} was different for the two sets of calves at their initially determined pressures (0 mm). However, the rate of decrease of $\dot{V}_e - \dot{V}_i$ with increasing VCP pressure was slightly greater for the hypervitaminotic A calves and the rate of increase of C_{In} with increasing VCP-imposed pressure was greater for the hypervitaminotic A group, but neither difference was statistically significant. The rate of CSF formation was independent of the imposed VCP pressure for both groups of calves, with the average rate being lower ($P < 0.01$) for the hypervitaminotic A calves.

Total creatinine clearance ($C_{Cr.t}$) and ventriculocisternal creatinine clearance ($C_{Cr.vc}$) in grams per minute, Y, in relation to the imposed VCP pressure in millimeters of synthetic CSF, X, for the control and hypervitaminotic A calves, are presented respectively, in Figures 3 and 4. Total creatinine clearance values were not different at the 0-mm pressure; however, there was a slight but not statistically significant greater positive slope for the hypervitaminotic A calves. The ventriculocisternal creatinine clearance values were found to be independent of the imposed VCP pressure for both the control and hypervitaminotic A calves. The average $C_{Cr.vc}$ value for the calves fed the excess vitamin A intake was greater ($P < 0.20$).

The ventriculocisternal volume of inulin distribution, as shown in Table 4, was slightly greater ($P < 0.20$) for the hypervitaminotic A calves, but was unaffected by an increase in VCP pressure. However, a slight increase ($P < 0.20$) was noted in the distribution vol-

TABLE 3

Perfusion data showing the amount of anesthetic required, time under anesthesia, heart and respiratory rates, respiratory pump tidal volume, and serum osmolality of control and hypervitaminotic A calves perfused at either 0 or +200 mm of synthetic CSF relative to their initial intraventricular CSF pressure

Criteria	Control calves		Hypervitaminotic A calves		SD per calf
	VCP pressure		VCP pressure		
	0	+200	0	+200	
Anesthetic required *(ml/kg live wt)*					
Induction	0.42	0.46	0.44	0.48	0.07
Maintenance	0.28	0.28	0.21	0.39	0.07
Time under anesthesia *(hr)*	2.75	2.86	2.86	2.95	0.08
Heart rate *(beats/min)*	162	140	123	114	17
Respiratory rate *(cycles/min)*	15	13	15	12	2
Respiratory pump tidal volume *(ml)*	993	1,199	827	1,005	203
Serum osmolality *(mOsm/kg H_2O)*					
Before VCP	282	286	293	295	5
After VCP	284	285	293	293	6

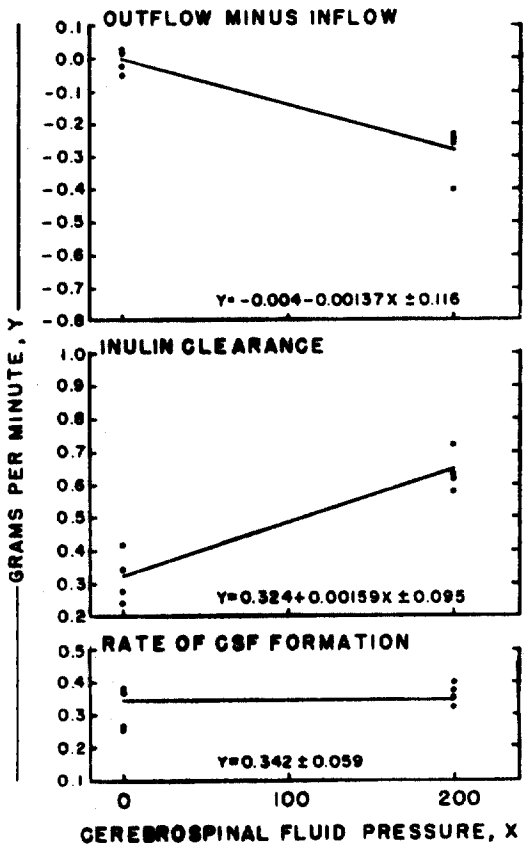

FIG. 1. Regression of outflow minus inflow, inulin clearance, and rate of CSF formation, all in grams per minute, Y, on imposed CSF pressure relative to the initially determined CSF pressure, X, for the control calves.

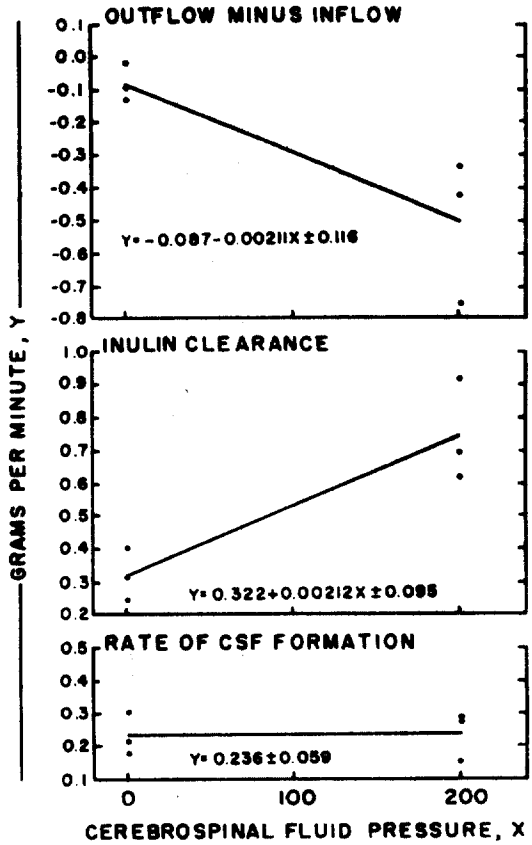

FIG. 2. Regression of outflow minus inflow, inulin clearance, and rate of CSF formation, all in grams per minute, Y, on imposed CSF pressure relative to the initially determined CSF pressure, X, for the chronic hypervitaminotic A calves.

ume of inulin, with an increase in VCP pressure for the control calves.

The actual brain and choroid plexus weights and dry matter of the controls and hypervitaminotic calves were not different (Table 4). When expressed on a per unit live weight basis, the brains of the hypervitaminotic A calves were heavier. The rate of CSF formation per unit wet weight of choroid plexus was also lower ($P < 0.01$) for the hypervitaminotic A calves.

Discussion

The lower CSF pressures of the chronic hypervitaminotic A calves appear to be due to a decreased rate of CSF formation by the choroid plexus tissue. Also contributing to the lower CSF pressures was a decreased resistance to bulk absorption, as evidenced by the slightly greater slopes for inulin and creatinine clearances on imposed VCP pressure for the hypervitaminotic A calves. In support of the possible increase in absorption of CSF are the findings of greater blood-brain membrane permeability to ^{42}K and ^{32}P of hypervitaminotic A young rats (13, 14). Because of the small number of calves perfused, and the greater animal-to-animal variation of the hypervitaminotic A calves, the $\dot{V}_f$ and C_{In} values obtained, particularly the latter, need to be confirmed by further study. It is also recognized that the greater serum osmolalities observed before and after VCP and lower heart rate during VCP of the hypervitaminotic A calves may have affected $\dot{V}_f$.

As previously mentioned (9), rarification of the frontal bones due to excessive intakes of vitamin A result in an increased space between the skull and the brain. The bones of the skull of the hypervitaminotic A calves in the present experiment exhibited essentially similar changes which possibly could have contributed to the lowered CSF pressure.

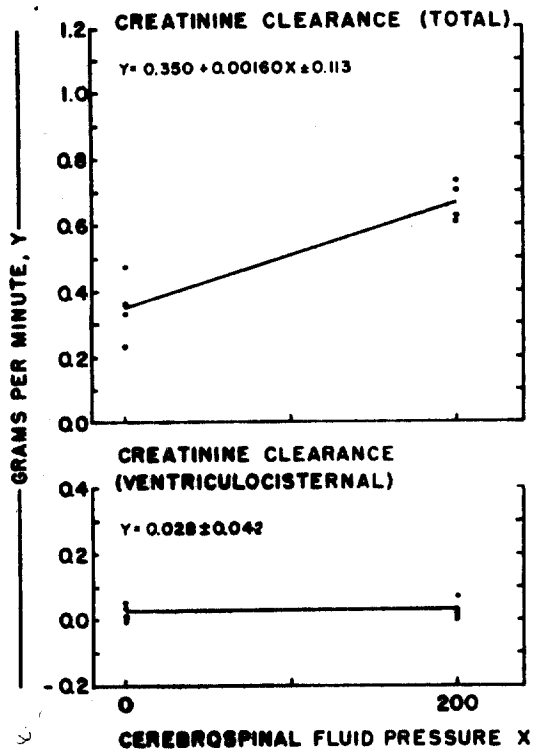

FIG. 3. Regression of total and ventriculocisternal creatinine clearance, in grams per minute, Y, on imposed CSF pressure relative to the initially determined CSF pressure, X, for the control calves.

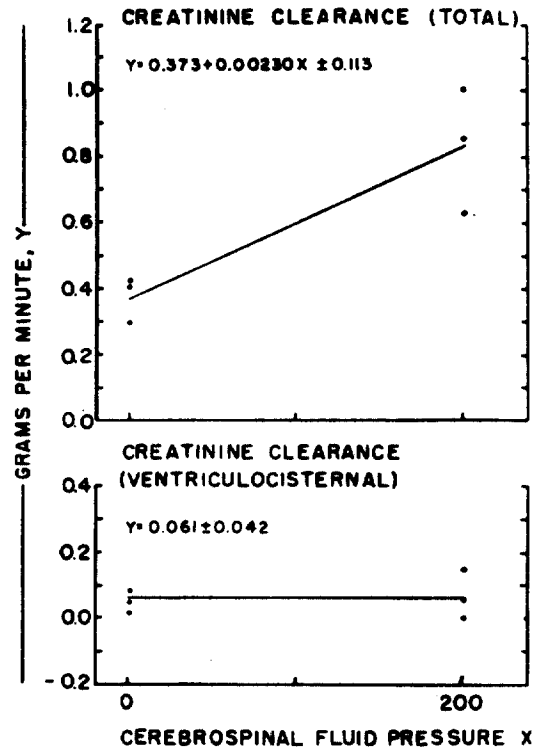

FIG. 4. Regression of total and ventriculocisternal creatinine clearance, in grams per minute, Y, on imposed CSF pressure relative to the initially determined CSF pressure, X, for the chronic hypervitaminotic A calves.

As determined by the volume of inulin distribution, the greater volume of CSF contained within the ventriculocisternal perfusion space of the hypervitaminotic A calves is in agreement with the previous report (9) of dilated ventricles in calves fed excessive intakes of vitamin A. While not of sufficient magnitude to be of statistical significance, the greater creatinine clearance within the VCP space of the hypervitaminotic A calves is interpreted as greater

TABLE 4

Summary of brain weight, choroid plexuses weight, rate of CSF formation, and volume of distribution of inulin of control and hypervitaminotic A calves perfused at either 0 or +200 mm of synthetic CSF relative to their initial intraventricular CSF pressure

Criteria	Control calves		Hypervitaminotic A calves		SD per calf
	VCP pressure		VCP pressure		
	0	+200	0	+200	
Brain					
Wet weight *(g)*	296	326	315	320	24
Per unit live weight *(g/kg)*	2.90	3.10	3.84	3.40	0.32
Dry matter *(g/100 g)*	19.9	20.3	21.0	20.6	0.4
Per unit live weight *(g/kg)*	0.58	0.63	0.81	0.70	0.08
Choroid plexuses					
Actual, wet weight *(g)*	0.891	0.976	1.065	0.940	0.149
Dry matter *(g/100 g)*	17.8	18.3	18.1	18.4	0.4
Rate of CSF formation *(g/min/g choroid plexuses)*	0.36	0.38	0.23	0.26	0.08
Volume of inulin distribution *(g of synthetic CSF)*	14.6	19.2	18.9	21.8	3.8

permeability of the ependyma of the ventricles (15).

Presumably the lower CSF pressure of the chronic hypervitaminotic A calf is due in part to an impairment in the secretory activity of the choroid plexus tissue and in addition to a slight increase in the permeability of the membranes associated with CSF absorption. The mechanisms of CSF absorption are apparently correlated with the vitamin A status of the calf. In a recent study (5), Calhoun et al. demonstrated that the elevated CSF pressure of vitamin A deficiency was due to an impairment of the sites responsible for CSF absorption. Thus, the present study on hypervitaminosis A and the previous one on hypovitaminosis A (5) provide direct evidence that in vitamin A deficiency there is decreased tissue permeability and that, in hypervitaminosis A, there is probably increased tissue permeability. These findings, therefore, lend support to one of the current postulated modes of action of vitamin A, that of maintenance of membrane stability (7).

Acknowledgments

The authors express their gratitude to B. A. Donohue and T. Watts, Sr., for their excellent care of the animals, and to M. R. Hogan, R. J. Cousins, and T. Dwyer for their assistance with the perfusion procedure and analysis of the data. We sincerely appreciate the editing of the manuscript by Dr. M. C. Calhoun of the University of Delaware, and the excellent secretarial assistance of Mrs. Mae Miller. The vitamin A supplement was a gift of Hoffmann-La Roche, Inc., Nutley, New Jersey, through the courtesy of Drs. J. C. Bauernfeind and R. H. Bunnell.

References

(1) Association of Official Agricultural Chemists. 1965. Official Methods of Analysis. 10th ed. Washington, D. C.

(2) Bass, M. H. 1957. The Relation of Vitamin A Intake to Cerebrospinal Fluid Pressure: A Review. J. Mt. Sinai Hosp., 24: 713.

(3) Becker, N. H., and Sutton, C. H. 1963. Pathologic Features of the Choroid Plexus. 1. Cytochemical Effects of Hypervitaminosis A. Am. J. Pathol., 43: 1017.

(4) Calhoun, M. C., Hurt, H. D., Eaton, H. D., Rousseau, J. E., Jr., and Hall, R. C., Jr. 1967. Rates of Formation and Absorption of Cerebrospinal Fluid in Holstein Male Calves. Univ. of Conn., Coll. of Agr. Exp. Sta., Bull. 401.

(5) Calhoun, M. C., Hurt, H. D., Eaton, H. D., Rousseau, J. E., Jr., and Hall, R. C. Jr. 1967. Rates of Formation and Absorption of Cerebrospinal Fluid in Bovine Hypovitaminosis A. J. Dairy Sci., 50: 1486.

(6) Calhoun, M. C., Rousseau, J. E., Jr., Hall, R. C., Jr., Eaton, H. D., Nielsen, S. W., and Lucas, J. J. 1965. Cisternal Cerebrospinal Fluid Pressure During Development of Chronic Bovine Hypervitaminosis A. J. Dairy Sci., 48: 729.

(7) Dingle, J. T., and Lucy, J. A. 1965. Vitamin A, Carotenoids, and Cell Function. Biol. Rev., 40: 422.

(8) Grey, R. M., Calhoun, M. C., Rousseau, J. E., Jr., Woelfel, C. G., Hall, R. C., Jr., Nielsen, S. W., Eaton, H. D., and Lucas, J. J. 1964. Cisternal and Intraventricular Cerebrospinal Fluid Pressures in Chronic Bovine Hypervitaminosis A. J. Dairy Sci., 47: 783.

(9) Grey, R. M., Nielsen, S. W., Rousseau, J. E., Jr., Calhoun, M. C., and Eaton, H. D. 1966. Pathology of Skull, Radius, and Rib in Hypervitaminosis A of Young Calves. Pathol. Vet., 2: 446.

(10) Guyton, A. C. 1947. Analysis of Respiratory Patterns in Laboratory Animals. Amer. J. Physiol., 150: 78.

(11) Hazzard, D. G., Woelfel, C. G., Calhoun, M. C., Rousseau, J. E., Jr., Eaton, H. D., Nielsen, S. W., Grey, R. M., and Lucas, J. J. 1964. Chronic Hypervitaminosis A in Holstein Male Calves. J. Dairy Sci., 47: 391.

(12) Hurt, H. D., Hall, R. C., Jr., Calhoun, M. C., Rousseau, J. E., Jr., Eaton, H. D., Wolke, R. E., and Lucas, J. J. 1966. Chronic Hypervitaminosis A in Weanling Pigs. Univ. of Conn., Coll. of Agr. Exp. Sta., Bull. 400.

(13) Mitashova, N. I. 1964. Impairment of Permeability of Hematoencephalic Barrier for ^{32}P in Rats with Hypervitaminosis A. Tr. Tsentr. Inst. Usoversh. Vrachei., 71: 221. (Chem. Abstr., 64: 5525f. 1966.)

(14) Mitashova, N. I., and Sokolov, A. B. 1964. The Permeability of the Hematoencephalic Barrier and Distribution of ^{42}K in Organs of Rats with Hypervitaminosis A. Tr. Tsentr. Inst. Usoversh. Vrachei., 71: 212. (Chem. Abstr., 64: 5525e, 1966.)

(15) Pappenheimer, J. R., Heisey, S. R., Jordan, E. F., and Downer J. deC. 1962. Perfusion of the Cerebral Ventricular System in Unanesthetized Goats. Amer. J. Physiol., 203: 763.

(16) Persson, B., Tunnell, R., and Ekengren, K. 1965. Chronic Vitamin A Intoxication During the First Half Year of Life. Acta Paediat. Scand., 54: 49.

(17) Steel, R. G. D., and Torrie, J. H. 1960. Principles and Procedures of Statistics. McGraw-Hill Publ. Co., New York, N. Y.

(18) Sutton, C. H. 1965. Histochemical Changes in the Choroid Plexus in Hypervitaminosis A. Bull. N. Y. Acad. Med., 41: 326.

Irving '48. Nature 162:377
Bib. No. 4213

Changes in the Incisor Teeth and Incisal Alveolar Bone of Rats in Hypervitaminosis A and Avitaminosis A

THE changes in bone in avitaminosis A have been reported by Mellanby[1], Wolbach and Bessey[2], and Wolbach[3], who consider that the vitamin is concerned with the control of bone modelling. Mellanby found excessive formation of bone in certain areas during avitaminosis and that the osteoblasts and osteoclasts could reverse their positions at the effective bony surfaces. Wolbach[3] considered that appositional bone formation continued in the normal site, but that concurrent resorption of bone ceased. Excessive doses of vitamin A have been found by many writers to cause spontaneous fractures of bones and internal hæmorrhages (see Moore and Wang[4] for a review of the literature). Wolbach[3] considered that bone remodelling was greatly accelerated and that a defective tissue was laid down.

The effects of vitamin A deficiency on the teeth are already well known[5]. A defective dentin is laid down by the odontoblasts, especially on the labial side. Pohto[5] and Wolbach[5] both reported that hypervitaminosis A has no effect upon the rat's incisor teeth.

Through the kindness of Dr. T. Moore and Mrs. S. E. Walker, of the Dunn Nutritional Laboratory, Cambridge, I obtained the heads of animals suffering from hypervitaminosis A. These were young rats and had been given 40,000 I.U. of vitamin A daily for 10–42 days. Their incisal alveolar bone and upper incisor teeth were examined microscopically. In the alveolus, the rate of bone formation was greatly reduced, many cementing lines were seen and active osteoblasts were much less prominent than usual. Osteoclasts appeared to be unaffected, so that the bone became abnormally thin and disappeared in places. In the teeth, only dentin formation was affected. This became decreased in appositional rate, the interfibrillar cementing substance was gradually reduced in amount, and the lingual odontoblasts had begun to atrophy.

The avitaminotic material studied was from rats previously investigated (Irving and Richards[6,6]). The animals had been on the vitamin-free diet used by us 28–53 days from weaning. The alveolar bones showed considerable over-production of new bone. This occurred in areas where apposition was usually seen and also in situations where resorption normally occurred. In the early stages of the deficiency, the osteoclasts endeavoured to overcome the latter abnormal apposition, while working alongside invading osteoblasts. Later they became displaced by osteoblasts and some osteoclasts were found on the opposite side of the bone. On faces where excessive apposition occurred in the usual site for apposition, osteoclasts were never found. The changes in the teeth in avitaminosis were the same as those reported by earlier workers.

It is concluded from these results that the primary action of vitamin A is upon the osteoblasts. Excessive dosage with vitamin A depresses the action of these cells, and, when the vitamin is lacking from the diet, these cells engage in disorderly overactivity. The reactions of the osteoclasts in avitaminosis are purely secondary, in an attempt to prevent excessive bone formation. In hypervitaminosis A these cells continue to act as usual. The odontoblasts, cells in the teeth comparable to the osteoblasts, react in a way similar to that of the bone-forming cells, producing less dentin in hypervitaminosis and excessive amounts in avitaminosis.

The expenses of this work were defrayed by grants from the South African Council for Scientific and Industrial Research and from the Staff Research Fund, University of Cape Town.

J. T. IRVING

Department of Physiology and Pharmacology,
Medical School,
University of Cape Town.

April 27.

[1] Mellanby, E., *J. Physiol.*, 94, 380 (1938); *J. Physiol.*, 105, 382 (1947); *Proc. Roy. Soc.*, B, 132, 28 (1944).

[2] Wolbach, S. B., and Bessey, O. A., *Arch. Path.*, 32, 689 (1941).

[3] Wolbach, S. B., *Proc. Inst. Med., Chicago*, 16, 115 (1946).

[4] Moore, T., and Wang, Y. L., *Biochem. J.*, 39, 222 (1945).

[5] Wolbach, S. B., and Howe, P. R., *Amer. J. Path.*, 9, 275 (1933). Pohto, M., "Mikroskopische Untersuchungen über die Schneidezähne der Ratten bei der A-Avitaminose, der Heilung derselben und der A-Hypervitaminose" (Helsinki, 1938). Irving, J. T., and Richards, M. B., *Nature*, 144, 905 (1939). Schour, I., Hoffman, M. M., and Smith, M. C., *Amer. J. Path.*, 17, 529 (1941).

[6] Irving, J. T., and Richards, M. B. (unpublished results).

Israels-'62
Bib. No. 4249

Thromb. Diath. Haem. 7:159-168. 1962.

The Coagulation Defect in Hypervitaminosis A in Rats*

From the Departments of Medicine and Pediatrics, University of Manitoba, Winnipeg, Manitoba, Canada

L. G. Israels, J. Foerster and A. Zipursky**

The etiological relationship of hypervitaminosis A to bleeding was firmly established by Vedder and Rosenberg (1), although the association of bleeding in rats on various diets containing an excess of cod liver oil had previously been noted by Harris and Moore (2) and by Hartwell (3). Light, Alscher and Frey (4), using the one-stage assay of Campbell et al (5) concluded that rats, fed vitamin A in excess, developed "hypoprothrombinemia" which could be prevented by the simultaneous administration of vitamin K (2-methyl-3 phytl-1 : 4 naphthoquinone). These findings were confirmed by Walker, Eylenburg and Moore (6) who were able to prevent the hypoprothrombinemia with 2-methyl-1 : 4 naphthoquinone. These findings were extended by Poole (7), who concluded that the effect of hypervitaminosis A on blood coagulation was that of a true prothrombin deficiency. Rizzo and Santangelo (8) from their studies on infants given vitamin A, found this to result in a decrease in factor V and factor VII, while Kammerell and Berger (9) in 15 patients given vitamin A to a dosage of 500 000 u daily, found no change in the recalcification time. In view of these conflicting findings, it was decided to re-examine this coagulation defect produced by hypervitaminosis A using the rat as the experimental animal.

Materials and Methods

1. The animals used in this study were 3 month old female hooded rats with an average weight of 210 g. The animals were kept in metal cages with wire mesh bottoms which effectively prevented the accumulation of feces. During the entire course of the experiment the animals had free access to a standard laboratory diet and water.

* This work was supported by a grant from the Manitoba Heart Foundation.

** With the technical assistance of Miss E. Friesen and Miss J. Skanderbeg.

2. Vitamin A acetate (one million units per gram) and vitamin K_1 (Nutritional Biochemicals Corporation, Cleveland, Ohio) were dispersed in corn oil and force fed to the animals by stomach tube. The duration of feeding in all groups was 28 days.

3. Four groups of animals were studied. The animals in each group were fed as follows:

Group A — 0.5 ml corn oil per day.

Group B — 70 000 units of vitamin A in 0.5 ml corn oil per day.

Group C — 70 000 units of vitamin A plus 15 to 30 µg of vitamin K_1 in 5 ml corn oil per day.

Group D — 70 000 units of vitamin A plus 60 to 120 µg of vitamin K_1 in 0.5 ml of corn oil per day.

The rats in all groups developed diarrhoea. This was the result of the corn oil feeding and was as marked in the Group A animals as in the other groups.

4. At the beginning and end of the experiment, the animals were lightly anesthetized with ether and bled by cardiac puncture. Plasma was obtained from blood taken into either 3.8% sodium citrate or 1.34% sodium oxalate in the ratio of 9 parts of blood to 1 part of anticoagulant. The cellular elements were removed by immediately centrifuging at 3000 rpm for 10 minutes. Serum was prepared from blood allowed to clot at 37° C. All plasma and serum samples were used immediately or stored at —20° C.

5. The thromboplastin generation test of Biggs and Douglas (10) was used with the following modifications:

a) The platelet suspension was replaced by cephalin prepared by the method of Bell and Alton (11).

b) Due to the rapid generation of thromboplastin in the rat system it was found necessary to test for thromboplastin generation at 15 seconds and 30 seconds following the addition of calcium to the generating mixture — in addition to testing at 1 minute intervals for 6 minutes.

c) Human plasma was used as substrate throughout.

6. Thromboplastin dilution curves were constructed according to the method of Biggs and Douglas (10).

7. The one-stage prothrombin time was determined by the method of Quick (12) using as thromboplastin an acetone extract of human brain (14).

8. The stypven time was carried out using Russell viper venom (Burroughs-Wellcome and Company) diluted 1 : 10 000 and suspended in cephalin (13).

9. The assay of prothrombin was by the one-stage method of Koller, Loeliger and Duckert (14).

10. Factor VII-complex was assayed by the one-stage method of Koller et al. (14) using beef plasma prepared by adsorption on wood charcoal in place of asbestos filtration (15). This method is sensitive to changes in factor VII and factor X (16).

11. Factor V activity was determined by the one-stage method of Wolf (17) using human plasma as substrate.

12. The 100% levels for all assays were taken as the mean pretreatment values of 10 normal rats.

13. Vitamin A determinations on rat sera were done by the method of Besse et al. (18).

Results

The results of long term feeding with corn oil are shown in Fig. 1. The cross hatched area represents the range of values obtained in five animals fed this suspending medium for 28 days (Group A). The findings in the other groups were then related to these control values.

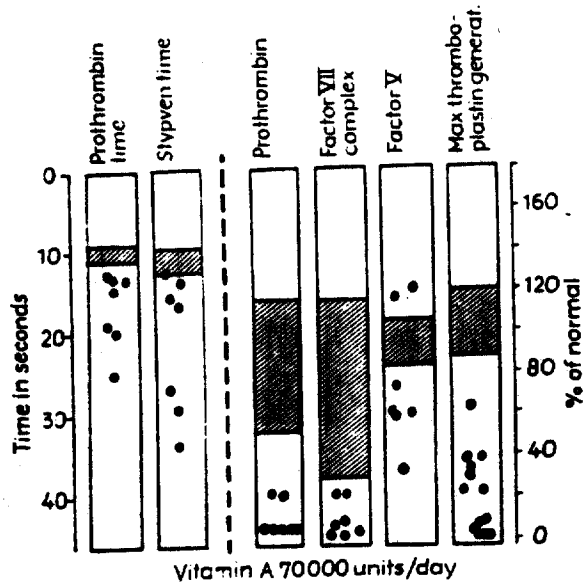

Fig. 1: The effect of feeding vitamin A — 70 000 u per day for 28 days. The cross hatched areas indicate the range of values in the control group of five rats fed the suspending medium (corn oil) for a similar period. Each dot represents one test animal (Group B)

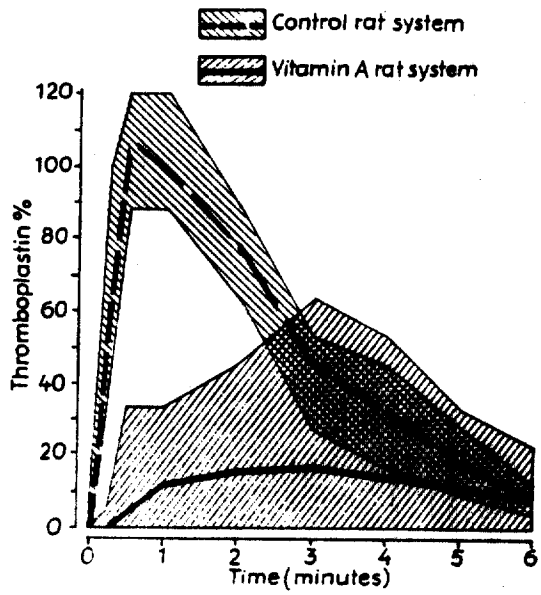

Fig. 2: Thromboplastin generation (mean and range) in five control rats (Group A) and 13 Vitamin A-fed rats (Group B)

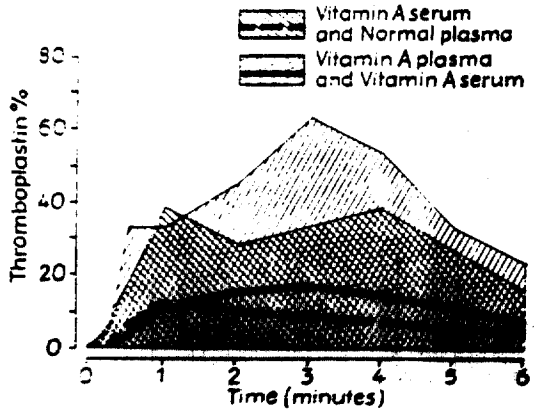

Fig. 3: Thromboplastin generation (means and ranges of 13 generating systems in each [illegible] using (1) serum from vitamin A-fed Group B rats and the $Al(OH)_3$ adsorbed plasma of normal rats and (2) $Al(OH)_3$ adsorbed plasma and serum of vitamin A-fed rats (Group B)

The effects of feeding vitamin A — 70 000 u/day (Group B) are shown in Fig. 1. It will be noted that following the 28 day feeding period, there was prolongation of the prothrombin time and the stypven time. This varied from

the upper limits of the controls to marked prolongation. The prothrombin and factor VII-complex activity were reduced in all animals. Factor V was reduced in five animals but was found to be higher than the control value in two rats. Thromboplastin generation was defective in all animals.

The defect in thromboplastin generation is shown in Fig. 2—4. It will be noted that thromboplastin generation proceeds more rapidly in the rat than in man, with maximum generation at 30 seconds to 60 seconds. The generation of thromboplastin in the rats fed vitamin A alone (Group B) compared with the normal control Group A, is shown in Fig. 2. Fig. 3 indicates that the defect in thromboplastin generation was present in the serum of the vitamin A fed group: the $Al(OH)_3$ adsorbed plasma of the vitamin A fed animals when combined with normal serum resulted in normal generation of thromboplastin (Fig. 4).

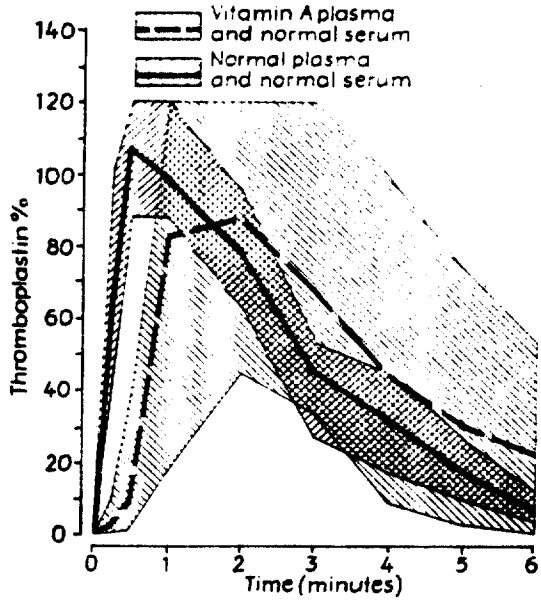

Fig. 4: Thromboplastin generation (mean and range) using the generating system of (1) five control rats, (2) the $Al(OH)_3$ adsorbed plasma of vitamin A-fed rats (Group B) plus the serum of normal rats (13 generating systems)

The addition of 15 μg to 30 μg of vitamin K_1 to the diet (Group C) produced no significant correction of the coagulation defects (Fig. 5). When the vitamin K_1 in the diet was increased to 60 μg to 120 μg per day (Group D) some correction of the coagulation defects was obtained (Fig. 6). The prothrombin time and stypven time were normal in this group at the end of the experimental period and

the prothrombin and factor VII-complex activity now approximated or exceeded the control values. The factor V activity again ranged from 45% to 150% and was not essentially different from those rats fed only vitamin A. Thromboplastin generation was normal in four animals but defective in six others — with three of the animals having less than 40% maximum generation.

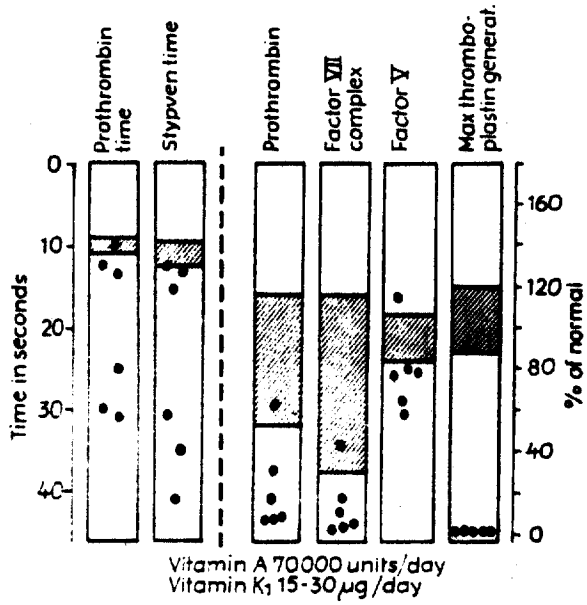

Fig. 5: The effect of feeding vitamin A — 70 000 u per day plus Vitamin K_1 15 to 30 µg day for 28 days. The cross hatched areas indicate the range of values in the control group of five rats fed the suspending medium (corn oil) for a similar period. Each dot represents one test animal (Group C)

The possibility of an inhibitor or anticoagulant as a cause of the defect found in thromboplastin generation in the vitamin A fed group was considered. Serum from four animals exhibiting this defect was incubated with normal rat serum in the ratio of 1 to 9 for 30 minutes at 37° C. This serum mixture was subsequently used in the thromboplastin generation test with $Al(OH)_3$ adsorbed normal rat plasma. In six thromboplastin generation tests done with this system the generation of thromboplastin was normal.

The mean serum vitamin A level in seven normal rats was 70.7 µg/100 ml (range 28 µg — 115 µg). The mean value in the six control rats (Group A) fed corn oil for 28 days was 51.5 µg (range 24 µg — 58 µg). At the end of the experimental period the Group B animals had mean values 473 µg (range 225 µg

to 933 μg) and the Group D rats a mean value of 487 μg (range 310 μg — 858 μg). Thus vitamin A feeding led to high serum levels of vitamin A which were not significantly different in those animals receiving only vitamin A and those receiving vitamin A plus vitamin K_1.

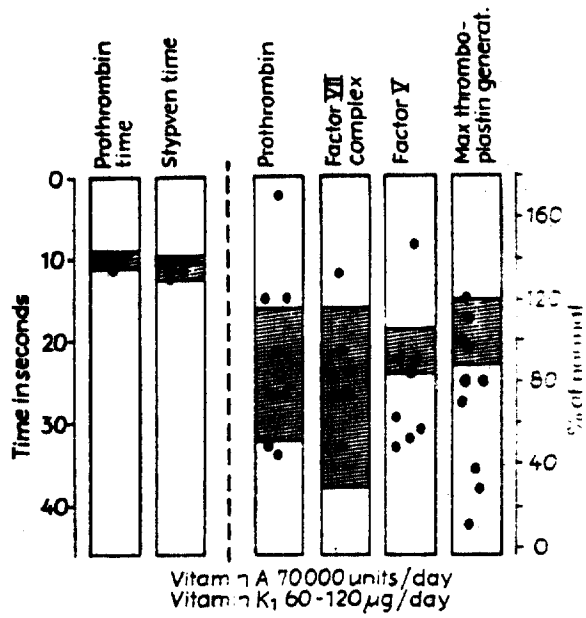

Fig. 6: The effect of feeding vitamin A — 70 000 u per day plus vitamin K_1 60 to 120 μg/day for 28 days. The cross hatched areas indicate the range of values in the control group of five rats fed the suspending medium (corn oil) for a similar period. Each dot represents one test animal (Group D)

Discussion

The initial work on the coagulation defect in hypervitaminosis A in rats by Light, Alscher and Frey (4) and by Walker, Eylenburg and Moore (6), utilized the one-stage prothrombin time method of Campbell et al. (5) which is now known to measure the entire "prothrombin complex" and is not specific for prothrombin. Poole extended these studies and, in addition to the one stage prothrombin time, was also able to show impairment of the calcium time and the thrombin generation test. No circulating anticoagulant was detected. The prolonged calcium time was corrected by normal plasma, not corrected by normal serum, and a two-stage prothrombin time indicated a true deficiency of prothrombin. This was interpreted as evidence of a pure prothrom-

bin deficiency (7). A study in infants by Risso and Santangelo using 30 000 units of vitamin A per kilo intramuscularly resulted in a prolonged recalcification time as well as a reduction in factor V and factor VII activity within 48 hours (8). This was interpreted as an antivitamin K effect of the vitamin A resulting in depression of all the factors of the "prothrombin complex".

In the present study all rats fed vitamin A in a dosage of 70 000 u/day over a 28 day period exhibited a prolongation of the one-stage prothrombin time. This was paralleled by a prolongation in the stypven time and a decrease in prothrombin and factor VII-complex. The factor V activity pattern was irregular with some decrease in five animals and increased levels in two. Thromboplastin generation was defective in all the animals, the defect residing in the serum. The changes in coagulation induced by vitamin A were not modified by the feeding of 15 µg to 30 µg of vitamin K_1. A vitamin K_1 intake of 60 µg to 120 µg per day resulted in normal prothrombin and stypven times and normal prothrombin and factor VII-complex activity. The factor V levels remained essentially the same as in the group that did not receive vitamin K_1. Thromboplastin generation, however, was completely corrected in only four of the 10 animals. The serum abnormality in thromboplastin generation in the presence of a normal prothrombin and stypven time, strongly suggests a defect analagous to a factor IX deficiency.

These findings would indicate that vitamin A intoxication in rats induces a hemorrhagic state due to a reduction of prothrombin, the factor VII-(X)-complex, an irregular reduction in factor V, and a marked reduction in factor IX activity. Vitamin K_1 in doses of 60 µg or more was able to correct the extrinsic system, but in over half the animals a defect in thromboplastin generation remained. This would indicate that the factor IX deficiency induced by vitamin A was not as readily corrected by vitamin K_1 as the defects in the other coagulation factors.

Summary

Rats fed vitamin A, 70 000 u daily for a period of 28 days developed a hemorrhagic state characterized by a prolonged prothrombin time and stypven time, a marked reduction in prothrombin and the factor VII-complex, and an inconstant decrease in factor V activity. A serum defect in thromboplastin generation was also noted. The defects in the extrinsic system were prevented by the simultaneous daily feeding of 60 µg to 120 µg of vitamin K_1 but this did not uniformly prevent the serum defect in thromboplastin generation which is thought to represent a depletion in factor IX.

Résumé

Les rats, auxquels on administre 70 000 U de vitamine A par jour pendant 28 jours, présentent un état hémorragique caractérisé par un temps de prothrombine et un temps de stypven prolongés, par une réduction marquée du taux de prothrombine et du complexe du facteur VII et par une diminution variable de l'activité du facteur V. Un défaut sérique de la formation de la thromboplastine a été observé. Les déficiences atteignant le système extrinsèque sont prévenues par administration simultanée quotidienne de 60 µg à 120 µg de vitamine K_1. Ce traitement ne prévient pas dans tous les cas le défaut de formation de la thromboplastine observé dans le sérum. Les auteurs pensent que ce phénomène est dû à une diminution du facteur IX.

Zusammenfassung

Ratten, die während 28 Tagen täglich mit 70 000 E Vitamin A gefüttert wurden, bekommen eine hämorrhagische Krankheit, die sich durch eine verlängerte Prothrombin- und Stypvenzeit, eine signifikante Verminderung von Prothrombin und Faktor-VII-Komplex, sowie eine allerdings nicht konstante Faktor-V-Aktivitätsabnahme manifestiert. Zudem wurde ein Serumdefekt bei der Thromboplastinbildung festgestellt. Die Defekte im „extrinsic System" können durch gleichzeitige Fütterung von 60 µg bis 120 µg von Vitamin K_1 vermieden werden, während dadurch der Serumdefekt in der Thromboplastinbildung nicht eindeutig vermieden werden kann, was man auf einen Mangel an Faktor IX zurückzuführen glaubt.

Acknowledgments

We are indebted to Burroughs-Wellcome and Company (Canada) Limited, for the Russell viper venom supplied as Stypven®.

References

(1) Vedder, E. B., C. Rosenberg: Concerning the toxicity of vitamin A. J. Nutr. 16: 57 (1938).

(2) Harris, L. J., T. Moore: Hypervitaminosis and vitamin balance. Biochem. J. 22: 1461 (1928).

(3) Hartwell, G. A.: Growth and reproduction on synthetic diets. Biochem. J. 21: 1076 (1927).

(4) Light, R. F., R. P. Alscher, C. N. Frey: Vitamin A toxicity and hypoprothrombinemia. Science 100: 225 (1944).

(5) Campbell, H. A., W. K. Smith, W. L. Roberts, K. P. Link: Studies on the hemorrhagic sweet clover disease. J. biol. Chem. 138: 1 (1941).

(6) Walker, S. E., E. Eylenburg, T. Moore: The action of vitamin K in hypervitaminosis A. Biochem. J. 41: 575 (1947).
(7) Poole, J. C. F.: The effects of hypervitaminosis A on blood coagulation in the rat. Quart. J. exp. Physiol. 43: 427 (1958).
(8) Rizzo, A., G. Santangelo: Vitamin A E complesso prothrombinico. Boll. Soc. ital. Biol. sper. 35: 43 (1958).
(9) Kommerell, B., H. D. Berger: Über die Veränderungen der Blutgerinnung nach Gaben der Vitamine A, E und B_6. Klin. Wschr. 38: 134 (1960).
(10) Biggs, R., A. S. Douglas: The thromboplastin generation test. J. clin. Path. 6: 23 (1953).
(11) Bell, W. N., H. G. Alton: A brain extract as a substitute for platelet suspensions in the thromboplastin generation test. Nature (Lond.) 174: 380 (1954).
(12) Quick, A. J.: The prothrombin in hemophilia and in obstructive jaundice. J. biol. Chem. 109: 523 (1935).
(13) Rapaport, S. I., K. Aas, P. A. Owren: The clotting action of Russell viper venom. Blood 9: 1185 (1954).
(14) Koller, F., A. Loeliger, F. Duckert: Le facteur VII. Rev. Hémat. 7: 156 (1952).
(15) Adamis, D., H. S. Sise, D. M. Kimball: The proconvertin test. A simplified method and its application to the study of anticoagulant processes. J. Lab. clin. Med. 47: 322 (1956).
(16) Denson, K. W.: The specific assay of Prower-Stuart factor and factor VII. Acta haemat. (Basel) 25: 105 (1961).
(17) Wolf, P.: A modification for routine use of Stefaninis' method of estimation of factor V activity in human oxalated plasma. J. clin. Path. 6: 34 (1953).
(18) Bessey, O. A., O. H. Lowry, M. J. Brock, J. A. Lopez: The determination of vitamin A and carotene in small quantities of blood serum. J. biol. Chem. 166: 177 (1946).

Jarrett & Spearman
Bib. No. 4305

Brit. J. Derm. 82:197-199. 1969.

Comment

VITAMIN A AND THE SKIN

In 1960, by international agreement, vitamin A alcohol was named Retinol, the acid became Retinoic acid, and the aldehyde, Retinaldehyde. Studies of vitamin A deficiency in man and animals have established that vitamin A is essential for the normal functioning of all epithelial tissues. In the deficient state, the mucous epithelia became keratinized, and hyperkeratotic changes occur in the skin around the hair follicles (Wolbach and Bessey, 1942). The toxic effects of abnormally large doses of parenteral vitamin A produce changes in the skin which include erythema, exfoliation, and in extreme cases a generalized exfoliative erythroderma (Sutton, 1956).

The production in 1949 of pure synthetic vitamin A acetate enabled quantitative experiments to be carried out on the histological and histochemical changes produced in human and animal skin by this vitamin. Very high cutaneous concentrations of vitamin A cannot be achieved by parenteral administration without evoking severe toxic systemic effects. Therefore, in order to attain high skin concentrations, the vitamin has to be applied locally. However, very little of the vitamin is absorbed from oily solutions: it has to be made artificially water-soluble by the use of Tweens (Sobel *et al.*, 1958; Lawrence and Bern, 1958; Jarrett and Spearman, 1964).

Our own work indicates that this water solubilization of the vitamin is of major consideration in achieving demonstrable effects on the skin, and it is certainly more important than the particular chemical form in which the vitamin is applied.

In early chick embryonic skin prior to the formation of a keratin layer, vitamin A induces epidermal mucous metaplasia, but this change does *not* occur in older embryos, in which the epidermal cells have already differentiated to form keratin (Fell, 1957). Nevertheless, the erroneous concept still persists and it is often repeated (*B.M.J.* leading article, 1969) that vitamin A has an anti-keratinization effect on adult epidermis. This has caused the greatest confusion in the interpretation of the effects of vitamin A on skin (Riley, 1969), the height of the chaos being reached by the conclusion that the thickening of the granular layer by vitamin A was evidence of an anti-keratinizing effect when it is all too obvious that a granular layer is required for the proper formation of a keratin layer in almost all regions of mammalian skin.

Even the greatest concentrations of vitamin A attained in fully keratinized adult human and animal skins have failed to prevent keratinization, and they certainly do not induce mucous metaplasia (Lawrence and Bern, 1958; New, 1963; Jarrett and Spearman, 1964). The respiratory mucous membrane is, however, different. Here a deficiency of vitamin A results in *abnormal* keratinization, and this undesirable cornification can be abolished by vitamin A therapy. Any mucous membrane which undergoes cyclical changes between a mucous secreting epithelium and a keratin producing epithelium may be affected by vitamin A in the direction of mucous production, and such a situation occurs in the case of the vaginal mucosa (Kahn, 1954). It is these exceptional instances that have reinforced the misconception of the anti-keratinizing action of vitamin A in general.

Action on the Skin

Vitamin A has a number of well established effects on adult skin. These include dilatation of the dermal blood vessels with a resultant erythema, and an increased epidermal mitotic division which causes a thickening of the epidermis which is directly related to the concentration of the applied vitamin (Jarrett and Spearman, 1964). Moderate concentrations cause the granular layer to become increased in depth, and it is of great interest that a granular layer can be induced to form where none previously existed, as for example in the tail-scale epidermis of the laboratory rat and mouse. However, high

concentrations cause parakeratosis due to increased epidermal mitosis. These two apparently paradoxical effects may be reconciled by examining the dynamics of each one of them separately.

One important action of vitamin A is its labilizing effect on lysosomal membranes (Dingle and Lucy, 1965; Jarrett and Spearman, 1964). In moderate concentrations the lysosomal envelopes in the upper part of the epidermis are broken down and their contained hydrolases liberated into the epidermal cells. The resulting lysis causes changes in the epidermal cells which in ordinary histological sections are recognized as being granular cells, and as more cells become affected, so the depth of the granular layer increases. However, with greater concentrations of vitamin A, lysosomes are labilized at lower levels of the epidermis and the liberation of small amounts of acid hydrolases in the cells of the basal layer and lower epidermis probably acts as a stimulus to increased cell division (Ryan and Cardin, 1967). This stimulus to mitosis is so great with increasing concentrations of vitamin A that the proliferation of the lower epidermis outweighs the effects of hydrolase release in the upper epidermis. The greatly increased rate of epidermal turnover precludes any effective action of the hydrolases as they have insufficient time to act before the cells become incorporated into the keratin layer. In these circumstances the epidermal cells fail to undergo hydrolysis and the cell, together with most of its contents including its nucleus, becomes involved in the production of the keratin which, because of the remnants of nuclei present, is recognized as parakeratotic by routine histological staining. The liberation of acid hydrolases with high concentrations of locally applied vitamin A was demonstrated by Reid and Jarrett (1967) both in normal human skin and in apparently unaffected normal skin from psoriatic patients.

This dual, and apparently paradoxical, effect of vitamin A on the epidermis would explain the peculiar association of a parakeratotic horny layer overlying a prominent granular layer following applications of vitamin A. These changes were first reported in human skin by Pucemelli and Bellone in 1948 and later by Reid and Jarrett (1967). They have also been described in the mouse by Bern *et al.* (1955) and Jarrett and Spearman (1964). Probably the dynamics of this situation is that initially the high concentration of vitamin A caused marked epidermal proliferation with the formation of a parakeratotic horny layer; as the effect waned in the lower epidermis, the relatively higher concentration in the upper epidermis caused an increased liberation of acid hydrolases in this region with a consequent production of a granular layer which became established under the parakeratotic layer produced by the initial high vitamin concentration.

Treatment of Skin Disorders

Skin diseases that have been treated experimentally with vitamin A are psoriasis (Jarrett and Spearman, 1959, 1964; Frost and Weinstein, 1969) and the various forms of ichthyosis (Flesch, 1952; Jarrett *et al.*, 1966). It will be readily appreciated that the induction of a granular layer by vitamin A would tend to improve psoriasis, but the increase in mitotic rate and the consequent thickening of the epidermis and the vasodilatory effect would make the condition worse. This is the same problem encountered by clinicians when they use other lysosomal liberating agents for the treatment of psoriasis, such as u.v. rays and dithranol. It is well recognized that these agents are dangerous if used to treat an acute spreading psoriasis, but often cause considerable improvement when used for the treatment of chronic plaques.

From our preliminary studies it appears that the state of the lysosomes is different in these 2 phases of psoriasis. In the acute state there seems to be a liberation of hydrolases throughout the epidermis, whereas the chronic plaques of psoriasis have relatively little hydrolase activity within the epidermis but a very high activity in the parakeratotic keratin. In neither instance would a granular layer be formed, because in the acute cases the enzymes are released below the transitional zone and in the chronic cases the delayed release occurs above the transitional zone. It will be seen that in chronic cases

labilization of hydrolases in the upper regions of the epidermis will tend to produce normal keratinization in a chronic psoriatic plaque. On the other hand, in the acute cases any agent which increases the release of hydrolase in the lower epidermis will make the condition worse.

In view of this problem, it was decided to combine vitamin A with triamcinolone cream. The addition of the fluorinated steroid suppresses the undesirable stimulation to mitotic division by the vitamin (Jarrett and Spearman, 1964) and therefore the mixture is useful for a greater range of psoriatic cases. Clearly, however, the most acute cases would not be benefited by even small amounts of vitamin A, and these are best treated by one of the fluorinated corticosteroids alone either locally, systemically, or by both. In contrast, chronic plaques can be treated by vitamin A alone in the same way as one would with dithranol. Thus, it will be seen that no one combination of vitamin and steroid is ideal for all cases of psoriasis, and the relative amounts should be titrated to the individual requirements of the patient. This makes this form of treatment rather laborious for the physician in the initial stages.

Ichthyosis, however, is an easier problem as, unlike in psoriasis, there is no hyperplasia of the epidermis in this condition and the vitamin A can in consequence be used alone, its concentration being determined by the severity of the disorder. For the most severe cases of X linked ichthyosis, 25,000 units per G. in Ung. emulsificans aquosum is used, and in the mildest cases a response can be obtained with as little as one-tenth of this amount.

Dermatology Department,
University College Hospital Medical School,
University Street, London, W.C.1.

A. JARRETT and R. I. C. SPEARMAN

REFERENCES

BERN, H. A., ELIAS, J. J., PICKETT, P. B., POWERS, T. R. and HARKNESS, M. N. (1955) Influence of Vitamin A on the Epidermis. *Am. J. Anat.*, **96**, 419.

DINGLE, J. T. and LUCY, J. A. (1965) Vitamin A, Carotenoids and Cell Function. *Biol. Rev.*, **40**, 442.

FELL, H. B. (1957) The Effects of Excess Vitamin A on Culture of Embryonic Skin Explanted at Different Stages of Differentiation. *Proc. R. Soc. Lond. B.*, **146**, 242.

FLESCH, P. (1952) Inhibition of Keratin Formation by Saturation Compounds. *J. invest. Derm.*, **19**, 353.

FROST, P. and WEINSTEIN, G. (1969) Topical Administration of Vitamin A Acid for Ichthyosiform Dermatoses and Psoriasis. *J. Am. med. Ass.*, **207**, 1863.

JARRETT, A. and SPEARMAN, R. I. C. (1959) The Value of Triamcinolone and Vitamin A in the Treatment of Psoriasis. *Br. J. Derm.*, **71**, 267.

JARRETT, A. and SPEARMAN, R. I. C. (1964) *Histochemistry of the Skin: Psoriasis.* London: English Universities Press.

JARRETT, A., SPEARMAN, R. I. C. and RILEY, P. A. (1966) *Dermatology. A Functional Introduction.* London: English Universities Press.

KAHN, R. H. (1954) Effect of Locally Applied Vitamin A and Oestrogen on Rat Vagina. *Am. J. Anat.*, **95**, 309.

LAWRENCE, D. L. and BERN, H. A. (1958) On the Specificity of the Response of Mouse Epidermis to Vitamin A. *J. invest. Derm.*, **31**, 313.

LEADING ARTICLE (1969) Vitamin A and the Skin. *Br. med. J.*, ii, 464.

NEW, D. A. T. (1963) Effect of Excess Vitamin A on Cultures of Skin and Buccal Epithelium of Embryonic Rat and Mouse. *Br. J. Derm.*, **75**, 320.

PUCCINELLI, V. A. and BELLONE, A. (1948) Relieve istologici sull'influenza della vitamin A per via topico in alcune dermatose parakeratosiche. *Giorn. ital. Derm.*, **89**, 840.

REID, J. and JARRETT, A. (1967) Enzymatic and Histological Effects of a Standard Stimulus. *Arch. Derm.*, **95**, 632.

RILEY, P. A. (1969) Vitamin A and the Skin. *Br. med. J.*, iii, 117.

RYAN, W. L. and CARDIN, C. (1967) Lysosomal Stimulation and Inhibition of the Growth of Cells in Tissue Culture. *Proc. Soc. exper. Biol. Med.*, **126**, 112.

SOBEL, A., PARNELL, J., BURTON, S., SHERMAN, M. and BRADLEY, D. (1958) Percutaneous Absorption of Vitamin A. *J. invest. Derm.*, **30**, 315.

SUTTON, R. L. (1956) *Diseases of the Skin.* 11th Edit. London: Kimpton, p. 731.

WOLBACH, S. B. and BESSEY, O. A. (1942) Tissue Changes in Vitamin Deficiencies. *Physiol. Rev.*, **22**, 233.

Jewell-'57
Bib. No. 4347

Reproduced by permission of the copyright owner

Proc. Soc. Exptl. Biol. Med. 96(1):162-165. 1957.

E. C. C., *Physiol. Rev.*, 1956, v36, 164.
15. Roberts, E., *J. Biol. Chem.*, 1948, v176, 213.
16. Fromageot, C., and Royer, A., *Enzymologia*, 1944, v11, 361.

Received July 22, 1957. P.S.E.B.M., 1957, v96.

Action of Vitamin A on the Skin Following Intracutaneous Injection. (23420)

HOWARD A. JEWELL, HARRY TAUBE, MAUDE E. NICHOLLS AND ROBERT A. LEHMAN

Research Laboratories, Campbell Pharmaceutical Co. and Department of Therapeutics, New York University College of Medicine

Recent clinical reports (Steinberg(1,2), Mullens(3)) indicate that the human wart papilloma and certain types of helomata may be dramatically resolved by injection of vit. A palmitate directly into the lesion. These findings are unexpected since attempts to treat these lesions with vit. A by systemic administration have given equivocal results(4). The experiments described below were therefore undertaken to study the effect of vit. A on normal epidermis when administered by the intracutaneous route.

Methods. A commercial vit. A palmitate solution (Keramin Injection) especially formulated for injection of skin lesions was used throughout. This solution has an activity of 50,000 U.S.P. units per cc in a vehicle consisting in 11% polysorbate 80, U.S.P., 0.25% citrate-phosphate buffer, pH 7, with 0.5% chlorobutanol, 0.4% dl-alpha tocopherol and 0.03% butylated hydroxyanisole as preservatives and antioxidants. A sterile solution containing all ingredients except vit. A was used for control injections.

New Zealand white male rabbits weighing 2-4 kg were used in all experiments. The dorsal thoracic and abdominal area of each rabbit was clipped closely, care being taken to avoid cutting the skin, and the entire surface was washed with 70% ethanol. A volume of 0.03 cc of the solution to be tested was injected intracutaneously by means of a 0.25 cc tuberculin syringe and a sharp, 27 gauge, ½ inch, regular point hypodermic needle. Injections were made only after the bevel of the needle was seen to be just below the surface. The needle was left in the skin for about ½ minute after injection to minimize leakage from the point of puncture. Pairs of injections were made on either side of the mid-dorsal line but never over a bony prominence. When vit. A was injected on the left side, vehicle was injected on the right side at the same level and vice versa. Sites of injection were marked with indelible pencil. The animals were sacrificed always in the late afternoon by concussion 1, 2, 4, 7, 14, 21 and 28 days after injection. In all cases, a strip of skin at the site of injection approximately 40 x 4 mm was excised for histology so as to contain a central injected region and uninjected skin on either side. These latter areas served as additional controls. Tissues were fixed in Bouin's fluid, sectioned through the long axis at 8 μ and stained with Mayer's acid alum hematoxylin and eosin. The thickness of the epithelial layer with the corneum excluded was estimated with an ocular micrometer at 450 X magnification. Measurements were made in the center of each section as well as at points approximately one-tenth of the length in from either edge (uninjected controls). Only areas between the hair follicles were used for evaluation. Mitotic figure counts were made in the regions where epithelial thickness was measured. Two hundred and fifty consecutive nuclei in the basal and spinous* layers were counted for the areas corresponding to vit. A injection, vehicle injection and normal uninjected controls.

* The term spinous layer used in this paper refers to the cells in the germinative layer other than the basal layer even though no "prickle cells" as such can be found in the skin.

Results. On gross examination of the living animals, a mild erythema is seen after vit. A injection which appears in 24 hours and lasts several days. Vehicle injections give rise to a less intense response of somewhat shorter duration.

FIG. 1. Section of rabbit skin 7 days after intracut. inj. of vehicle control showing essentially normal skin. H & E × 128.

FIG. 2. Higher magnification of Fig. 1. The epidermis is 1-2 cell layers thick and the corneum diffuse. H & E × 480.

FIG. 3. Section of rabbit skin 7 days after intracut. inj. of aqueous vit. A solution. Epidermis has thickened considerably. H & E × 128.

FIG. 4. Higher magnification of Fig. 3. Nuclei in the basal layer are larger than in controls. Cells in various stages of differentiation are present including several layers of granular cells. Corneum is dense, compact and closely adherent to epidermis. H & E × 480.

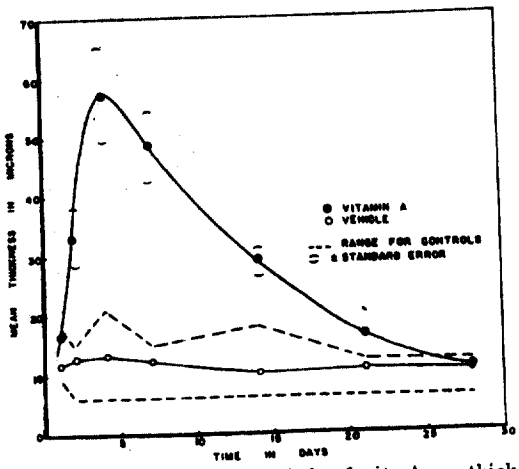

FIG. 5. Effect of a single inj. of vit. A on thickness of rabbit epidermis excluding corneum. Range only is given for the controls because of the relatively high measurement error in layers only a few cells thick.

Microscopic sections show minor changes in the dermis suggesting slight irritation. A dramatic change in the architecture of the epidermis occurs after vit. A but not after vehicle (Fig. 1 to 4). These changes may be summarized as follows: (a) *Epidermal thickness*: The epidermis (excluding corneum) increases about 5 fold in thickness within 4 days and gradually returns to its original dimensions about 2 weeks later (Fig. 5). Thickness of epidermis is unchanged by vehicle injections. (b) *Cyto-architecture*: Normal rabbit epidermis (or epidermis after injection of vehicle) is rarely more than 2 cells thick and consists in a basal layer over which more highly differentiated cells are distributed sporadically. The corneum is diffuse and basophilic. After vit. A injection the epithelium shows distinct layers of cells in various stages of maturation. Thus germinative, spinous and granular layers are clearly evident. The corneum is now thinner, denser and decidedly eosinophilic. No stratum lucidum can be seen in either control or treated tissues. It is of interest that the nuclei in the germinative layer after vit. A injection are larger and younger in appearance than in control epithelium. The increase in thickness of the epidermis is due to an increase in both size and number of cells. Formation of rete pegs has not been observed. (c) *Occurrence of mitosis*: In order to determine whether vit. A increases rate of cell division or slows down rate of maturation and death of cells, counts were made of the number of nuclei undergoing mitosis in the basal layer and spinous layer of tissues taken 2, 4 and 7 days after injection. As can be seen in the table, there is no striking difference between the number of nuclei undergoing mitosis in any group. However, minor differences in mitotic rate would hardly be detected because of the relatively small number of nuclei counted. (d) *Distribution of cell types*: It will be clear from the counts in the table that vit. A causes a change in the ratio of nuclei in the basal layer to the spinous layer from 9 to 1 to about 1 to 1.

Discussion. The effects of vit. A on the skin by topical application or systemic administration have been studied by others(5-8) and somewhat similar, but less dramatic and reproducible changes have been reported. It seems most likely that this is due to the comparatively low concentration which can reach the cells by these routes since still more profound changes in the epidermis have been reported by Fell and Mellanby(9) who found that very high concentrations of the vitamin, such as can be achieved only in tissue culture, will suppress keratinization altogether and change the epidermis to mucous secreting epithelium. After systemic administration (oral, intramuscular, intravenous, subcutaneous) storage of vitamin in the liver would operate

TABLE I. Occurrence of Mitosis in Rabbit Epidermis after Injection of Vit. A.

Time after inj., days	No. of slides counted	Mean % of various nuclei observed out of 250 cells counted: Basal layer, Normal nuclei	Basal layer, Mitotic nuclei	Spinous layer, Normal nuclei	Spinous layer, Mitotic nuclei
		Vitamin A			
2	8	62.5	.4	37.1	0
4	4	46.4	0	53.6	0
7	12	46.7	.2	53.0	0
		Vehicle			
2	8	89.1	.3	10.6	0
4	4	88.3	.1	11.6	0
7	12	89.2	.1	10.7	0
		Uninj. controls			
2	8	90.0	.3	9.7	0
4	4	88.8	0	11.2	0
7	12	88.0	.2	11.8	0

against attaining a high concentration in the skin. Topical application would also appear to be an unreliable approach to the epidermis especially in the case of human skin lesions since the conditions of interest present an unusually thick keratin barrier. Furthermore, the absence of sebaceous glands in plantar skin would almost preclude penetration of vit. A at this most common site of verrucae and other hyperkeratoses since the sebaceous glands form the normal pathway for absorption of the vitamin. Intraepidermal injection of vit. A is, of course, a practical impossibility, so that, intracutaneous injection would appear to be the only efficient method of introducing vit. A at the site of an epidermal lesion.

There seems to be only one possible interpretation for the results here reported. The presence of large (hence young appearing) nuclei in the basal and spinous cell layers of the epidermis coupled with a normal rate of mitosis, indicates that the physiologic sequence of maturation and death of these cells has been slowed. Therefore, cells of all types have accumulated and less keratin has been laid down. If these changes occur also in human skin it is reasonable to suppose that injection of vit. A at the site of an heloma would reverse the pathologic process since this lesion shows a central area of atrophy of the epidermis with an overlying plug of horny material. The mechanism of action in the case of verruca, a proliferative virus disease, is still obscure and future work will be directed toward its clarification.

Summary. It has been found that a single intracutaneous injection of vit. A in the rabbit causes an increase in thickness of the epidermis (excluding corneum) which is due to an increase in both number and size of the cells in the germinative and granular layers. The corneum becomes thinner and denser. The occurrence of large, young appearing nuclei in the absence of an increase in mitotic rate indicates that the maturation process is slowed.

1. Steinberg, M. D., *J. Nat. Assn. of Chiropodists*, 1954, v44, 17.

2. ———, *Surgery*, 1956, v39, 642.

3. Mullens, B. C., *J. Nat. Assn. of Chiropodists*, 1956, v46, 772.

4. Blank, H., and Rake, G., *Viral and Rickettsial Diseases*, 1955, Little Brown & Co., Boston, p174.

5. Montagna, W., PROC. SOC. EXP. BIOL. AND MED., 1954, v86, 668.

6. Studer, A., and Frey, J. R., *Schweiz med. Wchnschr.*, 1949, v79, 382.

7. Bern, H. A., Elias, J. J., Pickett, P. B., Powers, T. R., and Harkness, M. N., *Am. J. Anat.*, 1955, v96, 419.

8. Reiss, F., and Campbell, R. M., *Dermatologica*, 1954, v108, 121.

9. Fell, H. B., and Mellanby, E., *J. Physiol.*, 1953, v119, 470.

Received July 23, 1957. P.S.E.B.M., 1957, v96.

Johnson-'63
Bib. No. 4367

Arch. Dermatol. 88(5):607-612. 1963.

Relationship of Vitamin A and Oral Leukoplakia

R. JOHNSON, DDS; W. M. RINGSDORF, JR., DMD; AND E. CHERASKIN, MD, BIRMINGHAM, ALA

From a review of the literature it appears that local trauma is a factor in the genesis of oral hyperkeratoses.

The major concern of systemic influence has been focused upon vitamin A metabolism. Existing evidence indicates that a vitamin A deficiency can produce oral hyperkeratosis and that therapeutic amounts of vitamin A have an anti- or dekeratinizing effect on normal or hyperkeratotic oral mucosa.

An attempt was made in this investigation to study, under double-blind conditions (vitamin A versus placebo supplementation), the problem of leukoplakia in terms of its quantitative, qualitative, and histologic attributes.

Within the limits of this experiment, it appears that there is reduction in size, favorable qualitative change in the lesion, and histologic evidence of improvement in a substantial sample of leukoplakic cases subjected to vitamin A supplementation. No such changes were noted in the placebo group.

Within the limitations of this study, there is no clinical and biochemical (serum carotene) correlation.

The clinical and biochemical findings reported here are in accord with the limited studies reported by other investigators.

Review of the Literature

In the past, principal emphasis has been placed upon local irritation as a cause of oral leukoplakia. Recent evidence, however, indicates that vitamin A is playing a role in oral hyperkeratosis.

Vitamin A is necessary for the maintenance of epithelium.[1] This includes not only our external covering but the lining of all internal body cavities.[1,2] In the absence of vitamin A, cuboidal, columnar, and transitional epithelia tend to degenerate into a stratified, squamous, keratinized epithelium.[1-3] This seems to take place through a series of events, including a decrease in the mitotic activity of epithelial cells[2-4] with atrophy of the epithelium and a reparative mechanism resulting in keratinization.

The classical human skin lesions associated with avitaminosis A demonstrate hypoplasia and hyperkeratinization. When this occurs, the excessive keratin may cause plugging of the sebaceous glands and hair follicles, resulting in a roughened skin which is subject to chronic infection and eventual dermatosis.[5,6] Also, a contributing role played by the B complex vitamins in skin hyperkeratoses has been demonstrated in experimental animals.[7,8]

Significant changes in the oral mucous membranes of rats and dogs have been observed in a state of vitamin A deficiency. These have been described as hyperplasia of the gingiva with a thickening of the keratin layer.[9-11]

A reduction in the keratin of normal monkey gingiva has been achieved through the administration of 10,000 USP units of vitamin A daily for 30 days.[12] Similarly, in humans, the administration of a 150,000 unit buccal tablet of vitamin A daily for one month significantly reduced the number of keratin cells in normal epidermis in nine out

Department of Oral Medicine, University Medical Center.

This report is a condensation of a thesis submitted in partial fulfillment for the Master of Science in Dentistry (MS, Dentistry).

of ten volunteers.[13] The obvious anti-keratinizing effect of systemic and topical vitamin A in these and other [14-16] studies and the favorable response of vulvar leukoplakia [17] and senile keratoses [18] to this therapy suggested success in treating similar oral lesions.

A number of investigations into the effect of topical and topical-systemic vitamin A therapy on oral hyperkeratoses have been conducted.[19-23] Troches containing 150,000 USP units of synthetic vitamin A were employed in divided daily doses totaling 150,000 to 900,000 USP units. In only a few instances was there any laboratory evidence of a vitamin A deficiency. Though these dosages may approach a toxic level if continued,[24] no cases of hypervitaminosis A were reported as a result of one to nine months of therapy. Significant reversal of oral lesions, ranging in severity from epithelial hyperplasia to "leukoplakia," occurred, and no incidence of recurrence was given.

Thus, existing evidence indicates that a vitamin A deficiency can produce oral hyperkeratosis [9-11] and that excessive amounts of vitamin A can exert an anti- or dekeratinizing effect on normal or hyperkeratotic oral mucosa.[12-23] Since the vast majority of individuals with such oral lesions present very adequate blood levels of vitamin A, there seems to be no correlation between hypovitaminosis A and hyperkeratosis.[25] Several authors have suggested that a local tissue depletion may exist even in the presence of adequate blood levels of vitamin A.[19,22] This may explain the l correlation between blood levels of vit and carotene in the previously discus ports.[19-23] It is possible that local irri factors (chemical, mechanical, and th may create or intensify the depleti vitamin A in oral tissues, since their el tion has, in many instances, resulted disappearance of a hyperkeratotic l Thus, the degree of tissue saturation a needed diagnostic tool.[2]

Method of Investigation

The patients selected for this study pre variety of oral lesions all of which showed degree of keratosis. Patients were obtained the University of Alabama School of De University Hospital Tumor Clinic, and the mingham Veterans Administration Hospital nonwhite and white patients of both sexes pa pated in the study. Table 1 shows the fre of patient distribution in terms of age, sex race. Of the 40 subjects in the initial exami only 37 returned for follow-up study.

Clinical Examination.—It is admitted that no perfect technique for judging the clinical However, within the limits possible, the lesion graded by quantitative and qualitative measu

Lesion Size: The lesion was measured plastic rule calibrated in millimeters. The the flexibility of the rule permitted it to be ably adaptable within the oral cavity. The ured area was considered rectangular, and the was recorded in square millimeters. Since the lesions were not truly rectangular, the area is, in many instances, slightly greater th dimensions.

Quality of the Lesion: An attempt was m classify the lesion according to color, texture, height above the surrounding tissue. The cl scoring ranged from one to nine with the l score being assigned the lesion least pathologic

TABLE 1.—*Patient Distribution in Terms of Age, Sex, and Race*

Age Groups	Male		Female		Total
	White	Nonwhite	White	Nonwhite	
<40	1	—	1	0	2 (5.0 %)
40-49	4				4 (10.0 %)
50-59	4		4	2	10 (15.0 %)
60-69	6	1	6		13 (32.5 %)
70-79	1		5	4	10 (25.0 %)
>80			1		1 (2.5 %)
Total	16 (40.0 %)	1 (2.5 %)	17 (42.5 %)	6 (15.0 %)	40 (100.0 %)

TABLE 2.—*Clinical Evaluation of Leukoplakic Lesions*

1. Slightly white, smooth, nonelevated
2. Moderately white, smooth, nonelevated
3. Severly white, smooth, nonelevated
4. Slightly white, rough, elevated
5. Moderately white, rough, elevated
6. Severly white, rough, elevated
7. Slightly white, rough, ulcerated, fissured, elevated
8. Moderately white, rough, ulcerated, fissured, elevated
9. Severely white, rough, ulcerated, fissured, elevated

the highest score where evidence of disease was greatest (Table 2).

Histologic Exaluation.—An attempt was made to secure a biopsy in all cases. The biopsy reports were made by Dr. Leonard H. Robinson, Department of Oral Pathology, University of Alabama Medical Center, Birmingham, Ala. The biopsy findings were described in terms of the absence or presence of epithelial hyperplasia, hyperkeratosis, dyskeratosis, parakeratosis, acanthosis, inflammatory reaction and carcinoma in situ.

Biochemical Findings.—The subtle and most rapid changes in vitamin A metabolism are best reflected in the serum carotene concentration. In contrast, the serum vitamin A level changes more slowly.[8,29] Since the period of observation was relatively short (21 days), it was deemed advisable to measure serum carotene rather than serum vitamin A.

There is quite a wide range of values given by different authors for the physiologic serum carotene level. Normal limits are stated to be from 70μg to 300μg%.[8,27-29] The mean carotene level of 12 presumably healthy individuals (without oral leukoplakia) seen in the Oral Medicine Clinic was 160μg%. The mean score for 40 patients (without leukoplakia but being studied for malabsorption syndrome) at the University Hospital was 165μg%. The mean value for the 40 leukoplakic patients in this series was 174μg%. Table 3 outlines the serum carotene levels for the leukoplakia group of subjects.

Therapeutic Design.—For this study, subjects with keratotic lesions were selected from patients on recall lists with a history of known leukoplakia and from patients initially presenting themselves for treatment of a possible keratotic lesion. Some patients originally chosen and later found to have a malignant lesion were discounted.

At the initial appointment the size and quality of the lesion were determined according to the methods previously outlined. In addition, color photographs were taken, and a biopsy specimen was secured if possible. At the same time venous blood was drawn under nonfasting conditions to determine the serum carotene levels.[29]

The patients were subjected to one of two therapeutic regimens: (1) vitamin A (Aquasol, 50,000 IU per capsule), and (2) placebo (corn oil, volume per capsule same as Aquasol). At the initial visit the patients were instructed to take a total of eight capsules per day (400,000 IU), preferably two after each meal and two at bedtime. By the use of a table of random numbers, the patients were arranged into two groups. Technicians labeled the capsule boxes by number in order that neither the examiner nor the patient would know which preparation was being administered. The placebo and the vitamin A capsules were compounded to appear identical. The vitamin A group as well as the placebo group were both composed of 20 subjects. There were approximately 21 days between the initial and final appointments. At the second visit the patients were reexamined clinically, biopsies secured if possible, and the serum carotene levels once again determined. There was no knowledge of the previous scores when performing the second examination.

TABLE 3.—*Patient Distribution in Terms of Serum Carotene*

Initial Serum Carotene Level (μg%)	Number of Patients	Percentage of Patients
<100	5	12.5
100-199	20	50.0
200-299	13	32.5
300-399	2	5.0
Total	40	100.0

At the first visit 13 of the serum carotene determinations were performed twice by each of the two technicians. This was done to establish the experimental error. The reproducibility (intratechnician error) is made evident by a very significant ($P<0.005$) coefficient of correlation ($r=+0.998$) for each technician. For both technicians individually, there was no error in 65% of the cases. The mean error in micrograms per cent for technicians A and B was 2.3 and 2.7, respectively. There was no intertechnician (between technicians A and B) error in 46% of the cases, and the mean intertechnician error was 3.9μg%. The accuracy is heightened by a coefficient of correlation of +0.994 and a $P<0.005$. Thus, it appears that the experimental error is quite small at both the intra- and intertechnician levels.

Results

Two points deserve reiteration at this time. The leukoplakic lesions were all examined in terms of their size, quality, and histologic picture. Secondly, the only known variable was the introduction of vitamin A versus placebo supplementation. Accordingly, in

TABLE 4.—*Percentage Frequency Distribution Change in Size of Leukoplakic Lesion*

	Placebo Group		Vitamin A Group	
	Number of Subjects	Percentage of Subjects	Number of Subjects	Percentage of Subjects
Improvement	1	5	12	67
No change	16	84	6	33
Worsening	2	11	0	0
Total	19	100	18	100

this section an attempt will be made to answer three questions:

1. What is the effect of supplementation upon leukoplakic size?
2. What is the effect of supplementation upon the quality of the leukoplakic lesion?
3. What is the effect of supplementation upon the histopathologic picture?

Lesion Size.—Table 4 outlines the percentage frequency distribution change in size of the leukoplakic lesion in the subjects provided with placebo versus vitamin A supplementation. It will be noted that the overwhelming number in the placebo group (84%) remained unchanged with respect to the size of the lesion. In contrast, the greatest fraction (67%) of the vitamin A supplemented group improved.

Quality of the Leukoplakic Lesion.—Table 5 summarizes the percentage frequency distribution change in the quality of the leukoplakic lesion after vitamin A versus placebo supplementation. It will be noted that the majority of the patients (95%) provided with the placebo remained unchanged. In contrast, one-half of those given vitamin A demonstrated qualitative improvement.

TABLE 6.—*Percentage Frequency Distribution Change in the Histology of the Leukoplakic Lesion*

	Placebo Group		Vitamin A Group	
	Number of Subjects	Percentage of Subjects	Number of Subjects	Percentage of Subjects
Improvement	0	0	5	56
No change	10	100	4	44
Worsening	0	0	0	0
Total	10	100	9	100

TABLE 5.—*Percentage Frequency Distribution Change in Quality of the Leukoplakic Lesion*

	Placebo Group		Vitamin A Group	
	Number of Subjects	Percentage of Subjects	Number of Subjects	Percentage of Subjects
Improvement	1	5	9	50
No change	18	95	9	50
Worsening	0	0	0	0
Total	19	100	18	100

Histopathologic Results.—It is admittedly difficult to quantitate the histopathologic findings. However, admitting its crudity, the biopsy findings at the start and end of the study were classified in terms of the presence or absence of epithelial hyperplasia, hyperkeratosis, and dyskeratosis. It will be noted from Table 6 that no histopathologic change was noted in any of the individuals given placebo therapy. In contrast, 56% of the vitamin A subjects improved.

Combination Changes.—Table 7 summarizes the percentage frequency distribution of change on the basis of more than one parameter. Thus, only one subject (10%) given placebo capsules improved in two attributes. In contrast, 44% of the vitamin A group improved under these same circumstances. In all, six of the nine subjects studied showed improvement in two or all of the dimensions measured (size, quality, and histology of the lesion). On the other hand

TABLE 7.—*Percentage Frequency Distribution Change of Leukoplakic Lesion in Size, Quality, and Histopathologic Picture*

	Placebo Group		Vitamin A Group	
	Number of Subjects	Percentage of Subjects	Number of Subjects	Percentage of Subjects
Improvement in two parameters	1	10	4	44
Improvement in three parameters	0	0	2	22
Worsening in two parameters	0	0	0	0
Worsening in three parameters	2	20	0	0

only one in the placebo group improved, and two worsened.

Comment

On a percentage frequency distribution basis, the majority of the vitamin A supplemented group improved in one or more of the methods utilized to measure change. In contrast, the group given placebo medication remained essentially unchanged. Expressed in terms of percentage of improvement, the vitamin A supplemented group demonstrated a 21.4% reduction in lesion size, while the placebo group lesions increased in size by 2.4%. The qualitative improvement for the vitamin A and placebo groups, respectively, was 17.7% and 1.5%. Regression of the lesions, histopathologically, in the vitamin A treated group amounted to 55.5%; however, no evidence of histopathologic change was noted in the individuals receiving placebo supplementation. Not all the subjects given vitamin A improved, and, of those who did, all did not improve equally. It was, therefore, thought advisable to study the possible relationship between serum carotene levels and the clinical response.

In the six vitamin supplemented subjects whose leukoplakia decreased rapidly in size (from 533.3±331.2 to 273.3±275.1 sq mm), it is noteworthy that the serum carotene levels did not appreciably change ($P=0.500$).

A similar analysis of the six supplemented subjects with no change in size of the lesion also shows no significant change in the serum carotene level ($P>0.400$).

This lack of biochemical and clinical correlation has been noted by other investigators[23,30] who also observed that some individuals with clinical improvement continued to maintain low serum carotene levels.

Two points, therefore, should be emphasized. Firstly, there is no clinical-biochemical parallelism in this study. Secondly, the observations in this study support the limited conclusion of other investigators concerning the beneficial effects of vitamin A upon oral hyperkeratosis.

Limitations of the Study

It is appropriate to add a brief report regarding the shortcomings in this study.

Patient Problems.—In any clinical study with human subjects, there is the chance the patients may or may not follow instructions. In addition, environmental changes during the 21-day period may have played a role. For example, dietary vitamin A consumption may change or infection could influence vitamin A absorption or utilization.

Examiner Problems.—There are no completely satisfactory quantitative and qualitative methods for the evaluation of the oral lesion.

Laboratory Problems.—Inter- and intra-technician error in performing the laboratory tests has already been reported. It was significant that, while the laboratory errors proved small, the technicians did differ, and a particular technician did not always arrive at the same result with the same sample. In addition, the methods of measuring the samples may not be as accurate as they could be to show a true reflection of vitamin A status.

Project Problems.—In addition, there are a number of points in the experimental design which should be mentioned.

Sample Size: It should be recalled that 37 subjects were seen in this study on the two visits. This, indeed, is not a large clinical sample. When subgroups were analyzed, the samples were not large enough to be adequately studied by statistical techniques. For this reason, primary attention was focused on the frequency distribution change rather than the probability values.

Age, Sex, and Race: These factors, though recorded, were not considered in this investigation. This is an admitted shortcoming. However, to subdivide further, according to age, sex, and race, would have produced even smaller groups. These variables may well be most significant.

Time and Dose Factor: It should be recalled the interval between visits was 21 days. It is very possible that some of the group did not actually need vitamin A therapy. With

regard to those who required vitamin A therapy, there is no assurance that 21 days or the dosage given were enough.

Dr. Harvey S. Sadow and the Arlington-Funk Laboratories Division, United States Vitamin and Pharmaceutical Corporation, supplied the vitamin A (Aquasol 50,000 IU per capsule) and the indistinguishable placebo preparations (corn oil).

W. M. Ringsdorf, Jr., MD, Department of Oral Medicine, University of Alabama Medical Center, Birmingham 3, Ala.

REFERENCES

1. Nizel, A. E.: Nutrition in Clinical Dentistry, Philadelphia: W. B. Saunders Company, 1960, pp 154-162.

2. Follis, R. H., Jr.: Deficiency Disease, Springfield, Ill: Charles C Thomas, Publisher, 1958.

3. Sherman, B. S.: The Effect of Vitamin A on Epithelial Mitosis in Vitro and in Vivo, J Invest Derm 37:469, 1961.

4. Friedenwald, J. S.; Buschke, W. H.; and Morris, M. E.: Mitotic Activity and Wound Healing in the Corneal Epithelium of Vitamin A Deficient Rats, J Nutr 29:299, 1945.

5. Frazier, C. N., and Hu, C. K.: Cutaneous Lesions Associated With a Deficiency in Vitamin A in Man, Arch Intern Med 48:507, 1931.

6. Frazier, C. N.; Hu, C. K.; and Chu, F. T.: Variations in the Cutaneous Manifestations of Vitamin A Deficiency From Infancy to Puberty, Arch Derm Syph 48:1, 1943.

7. Sullivan, M., and Evans, V. J.: Nutritional Dermatoses in the Rat: XI. Vitamin A Deficiency Superimposed on Vitamin B Complex Deficiency, Arch Derm Syph 51:17, 1945.

8. Kreshover, S. J.: The Effect of Tobacco Smoke on Epithelial Tissues of Mice as Influenced by Vitamin B Deficiency and Gonadectomy, J Dent Res 31:487, 1952.

9. King, J. D.: Abnormalities in the Gingival and Subgingival Tissues Due to Diets Deficient in Vitamin A and Carotene, Brit Dent J 68:349, 1940.

10. Mellanby, M.: Diet and the Teeth: An Experimental Study, Medical Research Council, Special Report Series No. 153, 1930, London, H. M. Stationery Office.

11. Wolbach, S. B., and Howe, P. H.: Tissue Changes Following Deprivation of Fat-Soluble A Vitamin, J Exp Med 42:753, 1925.

12. Ziskin, D. E.; Rosenstein, S. N.; and Drucker, L.: Interrelation of Larger Parenteral Doses of Vitamin A and Estrogen and Their Effect on the Oral Mucosa, Amer J Orth Oral Surg 29:163, 1943.

13. Hunter, R., and Pinkus, H.: The Effect of Oral Vitamin A on the Number of Keratin Cells of Human Epidermis, J Invest Derm 37:459, 1961.

14. Flesch, P.: Studies on the Mode of Action of Vitamin A, J Invest Derm 21:421, 1953.

15. Flesch, P., and Hunt, M.: Local Depilatory Action of Some Unsaturated Compounds, AMA Arch Derm Syph 65:261, 1952.

16. Sabella, J. D.; Bern, H. A.; and Kalm, R. H.: Effects of Locally Applied Vitamin A and Estrogen on Rat Epidermis, Proc Soc Exp Biol Med 76:499, 1951.

17. Hyams, M. N., and Bloom, O. H.: Leukoplakia Vulvae: Its Etiology and Results of Treatment With Vitamin A, Amer J Obstet Gynec 53:214, 1947.

18. Savitt, L. E., and Obermayer, M. E.: Treatment of Acne Vulgaris and Senile Keratoses With Vitamin A: Results of a Clinical Experiment, J Invest Derm 14:283, 1950.

19. Zegarelli, E. V.; Kutscher, A. H.; and Silvers, H. F.: Keratotic Lesions of the Oral Mucous Membranes Treated With High Dosage Topical Systemic Vitamin A, New York Dent J 25:244, 1959.

20. Urbach, F.: The Clinical Use of Vi-Dom-A Buccal Tablets in the Treatment of Leukoplakia and Lichen Planus, Bull Ass Milit Derm 6:17, 1957.

21. Mulay, D. N., and Urbach, F.: Local Therapy of Oral Leukoplakia With Vitamin A, AMA Arch Derm Syph 78:637, 1958.

22. Monica, W. S.: Topical Vitamin A Therapy in Oral Keratosis, Med Times 89:1106, 1961.

23. Smith, J. F.: Clinical Evaluation of Massive Buccal Vitamin A Dosage in Oral Hyperkeratosis, Oral Surg Med Path 15:282, 1962.

24. Hillman, R.: Hypervitaminosis A: Experimental Induction in the Human Subject, Amer J Clin Nutr 4:603, 1956.

25. Youmans, J. B.: Vitamin A Nutrition and the Skin, Amer J Clin Nutr 8:789, 1960.

26. Davidson, S.; Meiklejohn, A. P.; and Passmore, R.: Human Nutrition and Dietetics, Baltimore: The Williams and Wilkins Company, 1958, pp 199-206.

27. Cheraskin, E.: Diagnostic Stomatology, New York: Blakiston Division, McGraw-Hill Book Company, Inc., 1961.

28. Natelson, S.: Microtechniques of Clinical Chemistry for the Routine Laboratory, ed 2, Springfield, Ill: Charles C Thomas, Publisher, 1961.

29. Ross, G., and Parker, J. G.: Serum Carotene Concentration in Normal Individuals and Its Clinical Interpretation, New York J Med 62:3584-3589, 1962.

30. Griesemer, C. N.; Frazier, C. N.; and Blank, I. H.: Nutritional Influences on Physiology of Skin; Metabolism of Vitamin A, Medicine 32:293-321, 1953.

Kahn-'54
Bib. No. 4486

Am. J. Anat. 95(2):309-335. 1954.

EFFECT OF LOCALLY APPLIED VITAMIN A AND ESTROGEN ON THE RAT VAGINA [1]

RAYMOND H. KAHN [2,3]

Department of Zoology and its Cancer Research Genetics Laboratory, University of California, Berkeley

TWENTY FIGURES

The rodent vaginal epithelium is of special interest as a target organ for studying the interaction of endocrine and dietary factors. One of the earliest and most reliable manifestations of a deficiency of vitamin A is the continued cornification of the vaginal epithelium in the rat. Similarly, the rodent vaginal epithelium undergoes marked keratinization and stratification under the influence of estrogenic stimulation.

Little is known regarding the basic factors underlying normal and abnormal vaginal cornification. Sherwood et al. ('36, '37) reported that oral administration of large doses of carotene suppressed the estrous vaginal smear picture in the normal rat. However, excessive doses of vitamin A administered orally (Burrill and Greene, '41) or subcutaneously (Brody and Goldman, '41) failed to affect either the normal estrous cycle or the response of the vaginal epithelium to estrogen administration. De Venanzi and Montenegro ('45) reported that either cod liver oil or β-carotene administered subcutaneously to the rat modified the vaginal smear so that epithelial cells predominated. Similarly, Thorborg ('48) noted

[1] From a thesis submitted to the Department of Zoology, University of California, Berkeley, in partial fulfillment of the requirement for the degree of Doctor of Philosophy.

[2] United States Public Health Service Research Fellow of the National Cancer Institute, January 1952 — August 1953.

[3] Present address: Department of Anatomy, University of Michigan School of Medicine, Ann Arbor, Michigan.

that cod liver oil and other vitamin A-containing materials when given subcutaneously to mice inhibited the cornified smear produced by estradiol benzoate. Kahn and Bern ('50) reported, as their initial findings, that large doses of crystalline vitamin A alcohol in sesame oil inhibited the vaginal keratinization induced by α-estradiol. As judged by vaginal smears, the estrogen-induced cornified cell smear changed to a nucleated cell smear upon simultaneous topical application of the vitamin. Masin ('50) found that oral fish liver oils lengthened the diestrus stage of the estrous cycle and reduced the number of cornified cells in the vagina. More recently Hohlweg ('51, '52) again demonstrated that oral vitamin A acetate inhibited the vaginal reaction resulting from estrogen administration to ovariectomized rats.

Consequently, vitamin A seems to play a prominent role in the response of this target organ to hormone action. The character of the inhibition of the vaginal response to estrogen by vitamin A (Kahn and Bern, '50) suggests an intimate relationship between the hormone and the vitamin. The data available in the literature do not warrant the conclusion that the interaction between vitamin A and estrogen is strictly a competitive one. Hence, a histological study of the influence of vitamin A in vaginal cornification was undertaken to elaborate on previous findings using vaginal smears. In addition, the present investigation deals with an attempt to determine the amount of vitamin A necessary to inhibit the vaginal cornification induced by known doses of estrogen. Finally, histochemical techniques were employed in an effort to obtain some information as to the metabolic role of vitamin A in normal epithelial maintenance.

MATERIALS AND METHODS

The vaginal epithelium of castrated rats was topically treated with varying amounts of sesame oil solutions of α-estradiol and/or crystalline vitamin A. Vaginal smears were used to ascertain the effects of such treatment, and a

semi-quantitative scoring technique was employed to measure the degree of vaginal response to the several treatments. Sections of the vaginae from all experimental groups were made, and comparative histological and histochemical findings described.

TABLE 1

Treatment of animal groups

TREATMENT	NUMBER OF ANIMALS	DAYS OF TREATMENT		DAILY DOSAGE (I.U.)		TOTAL DOSAGE (I.U.)	
		Estrogen	Vitamin A	Estrogen	Vitamin A	Estrogen	Vitamin A
Sesame oil	29	*	*	....	....	..	....
Estradiol	9	2	..	0.25	....	0.5	....
	9	2	..	0.15	....	0.3	....
	26	2	..	0.10	....	0.2	....
	10	2	..	0.05	....	0.1	....
	12	2	..	0.025	....	0.05	....
	6	6	..	0.10	....	0.6	....
Estradiol and vitamin A	9	6	4	0.10	1500	0.6	6000
	9	6	4	0.10	150	0.6	600
	26	6	4	0.10	15	0.6	60
	26	6	4	0.10	1.5	0.6	6.0
	28	6	4	0.10	0.15	0.6	0.6
	10	6	4	0.10	0.015	0.6	0.06
Vitamin A	5	..	4	...	150	..	600
	6	.	4	.	1.5	..	6.0

* Controls treated with sesame oil for two to 6 days.

A total of 105 bilaterally ovariectomized Long-Evans rats was used in this investigation. Some animals were used for more than one experiment; at least 4 weeks were allowed to elapse between experiments. All animals were of a highly inbred substrain and were sexually mature at the onset of the experiment, averaging 4 months of age at the time of ovariectomy. The animals were separated into 4 experimental groups (table 1), and all materials applied intravaginally were in oil solution, in volumes of 0.05 ml. They were instilled daily.

subsequent to obtaining vaginal smears, by means of a tuberculin syringe with a blunt 18-gauge needle. The following solutions were employed: (1) sesame oil as a control since it was used as solvent for both hormone and vitamin materials; (2) α-estradiol diluted with sesame oil to various concentrations; (3) crystalline vitamin A alcohol or crystalline vitamin A acetate diluted with sesame oil to various concentrations combined with a standard amount of α-estradiol; (4) crystalline vitamin A alcohol diluted with sesame oil to various concentrations.

Owing to the instability of vitamin A, the crystalline materials and the oil solutions were kept below 7°C.; after each use, the oxygen-containing atmosphere over the oil solutions was evacuated and replaced with nitrogen. In addition, the solutions were kept in complete darkness when not in use.

Desquamated cells from the vaginal epithelium were obtained daily during the period of investigation by a standard technique involving use of a cotton applicator, and the smears were stained with Wright's stain. The relative numbers of leucocytes, nucleated epithelial cells, nucleated vacuolated epithelial cells, precornified cells (containing nuclear remnants), and cornified cells were estimated and numerically rated according to the score method of Robson ('38).

On completion of the experiments, animals definitely demonstrating a given reaction were sacrificed by concussion, and the vaginae were removed. The vagina was cut open longitudinally and stretched out on a piece of stiff card so that the adventitia would adhere to the paper surface. This prevented folding of the tissue upon fixation. The tissue and card were sliced into a number of parallel longitudinal sections and fixed as promptly as possible. The following fixatives were used: chilled absolute acetone, Carnoy's fluid without chloroform, 1% trichloroacetic acid in 80% ethyl alcohol, and Bouin's fluid with 5% acetic acid. Paraffin-imbedded blocks were sectioned at 7 μ. Histological observations and measurements were made on tissues stained with hematoxylin and eosin and with Masson's trichrome stain.

A number of histochemical techniques were employed to demonstrate the following:

Alkaline phosphatase. After acetone fixation, tissues were treated by a modification of the Gomori-Takamatsu method (Barger, '47). Sections were incubated at 37°C. for 4 and 18 hours in approximately 0.01 M sodium glycerophosphate (52% alpha) buffered with barbital at pH 9.4. Control slides were processed identically except for poisoning of the substrate with approximately 0.01 M KCN. All slides were lightly stained with hematoxylin.

Polysaccharides. Carnoy-fixed tissues were stained according to the method of Hotchkiss ('48) using alcoholic periodic acid and subsequent coloration of the aldehydes with the Schiff reagent for 30 to 45 minutes (PAS method). Paired slides were processed identically, except for the addition of saliva to the deparaffinized slides for 30 minutes before the PAS treatment.

Protein-bound sulfhydryl (SH) groups. Tissues were fixed in 1% trichloroacetic acid in 80% ethyl alcohol or in Carnoy's. The tissues were incubated for one hour in a 0.05% solution of 2,2′ dihydroxy 6,6′ dinaphthyl disulfide (Barrnett and Seligman, '52) buffered at pH 8.5 with 0.1 M barbital. They were subsequently stained in a 0.1% solution of diazo blue B in 0.1 M Sørensen phosphate buffer (pH 7.4) for two minutes. Red coloration is indicative of sparse (monocoupled) SH groups while blue coloration represents concentrated (dicoupled) SH groups. Control slides oxidized in 0.0015 M iodine solution for 4 hours at pH 3.3 were virtually colorless.

RESULTS

In an attempt to determine the amount of vitamin A necessary to inhibit vaginal cornification, it was necessary to deal with minimally effective doses of estrogen. Intravaginal application permitted the use of minimal quantities of estrogen (Lyons and Templeton, '36) and, in addition, facilitated the administration of vitamin A and estrogen simultaneously. Local administration also precluded the need to relate dose

to body weight. The pertinent data on the sensitivity of the animals used are given in figure 1, and were obtained by the method used by Krichesky and Glass ('47). The data indicate that an approximately 75% positive response is obtained with a total local dose of 0.2 I.U. α-estradiol when divided into two equal doses and administered over two successive days. Only

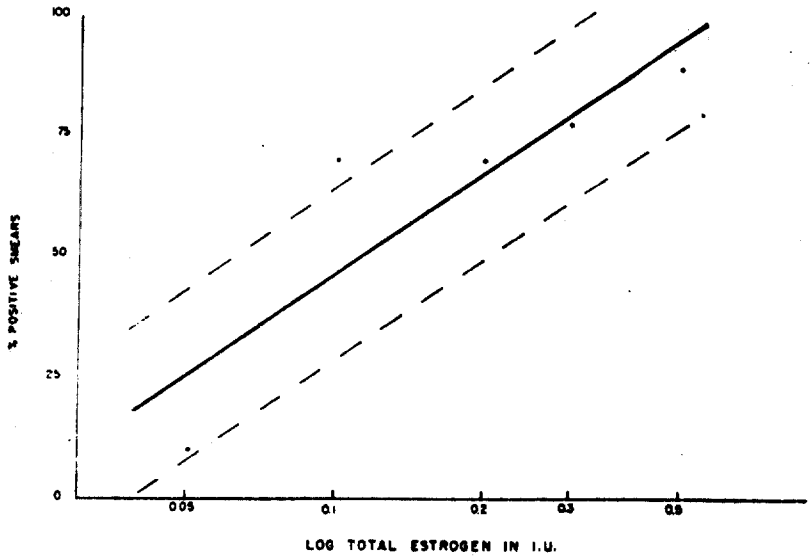

Fig. 1 Least square of the dose-response to intravaginal application of α-estradiol in ovariectomized rats. Smears recorded as positive if scored greater than "4" according to Robson ('38). Broken line indicates one standard error of the least square.

those animals which rate a "four" or more, according to Robson ('38), were considered as showing a positive reaction. After two days of treatment with α-estradiol, the smear recorded as positive consisted of at least 50% cornified cells, the remainder being precornified cells (with nuclear remnants) and polymorphonuclear leucocytes.

Upon intravaginal administration of varying amounts of an oil solution of vitamin A and α-estradiol (vitamin A + estrogen) for 4 days to those animals demonstrating a positive smear, the vitamin was found to inhibit quantitatively the

estrogen-induced cornification. As can be seen from figure 2, vitamin A follows a typical dose-response curve in its action. The effect, as measured by vaginal smears, is one of "degree of change" rather than a simple all-or-none relationship. Since every animal does not demonstrate the same degree of cornification subsequent to treatment with α-estradiol for two days, it is impossible to rate them according to the final reaction alone. However, if one considers the "degree of change" as being the difference between the score assigned

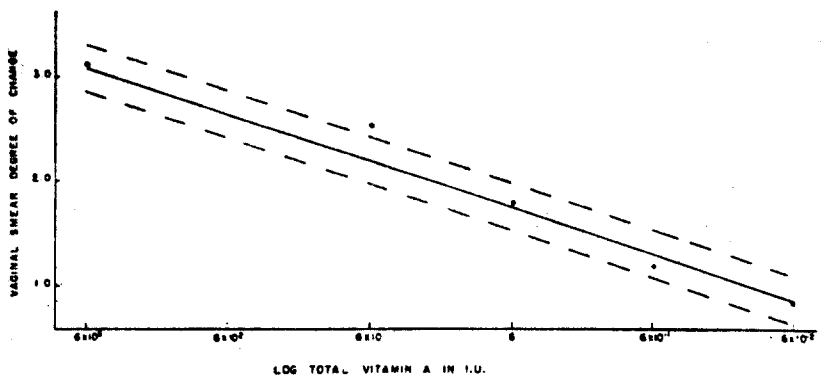

Fig. 2 Effects of local application of oil solutions of vitamin A to vaginal epithelium of estrogen-treated ovariectomized rats. "Degree of change" is the difference between the mean maximal estrogen response and the mean response after 4 days of vitamin A + estrogen. Broken line indicates one standard error of the least square.

any particular animal prior to treatment with vitamin A + estrogen, reflecting the maximal estrogen response, and the score assigned following vitamin A + estrogen treatment, then an index of the effect of vitamin A is obtained. A total dose of as little as 0.6 I.U. of vitamin A affects the estrogen-induced cornification, although minimally. The smallest amount of vitamin A applied (total dose of 0.06 I.U.) did not produce a demonstrable change in the estrogen-induced smear. Thus, vitamin A can be shown to inhibit quantitatively the cornification induced by local estrogen stimulation. The changes as seen in the vaginal smears have been described

previously (Kahn and Bern, '50). Briefly, the smears after two days of treatment with vitamin A and estrogen exhibit large quantities of precornified cells (cells with nuclear remnants) usually along with some nucleated epithelial cells. Subsequently, the smears consist almost entirely of nucleated epithelial cells, some of which show marked vacuolation. By the 4th day, all animals that react show nucleated epithelial cells and some polymorphonuclear leucocytes.

Histologically, the vaginal epithelium of the ovariectomized animal serves as a control for the effects induced by estrogen and the further response of the vaginal epithelium to vitamin A + estrogen. Because the vehicle used for treatment with both estrogen and vitamin A + estrogen was sesame oil, the control animals were treated with sesame oil for 2–6 days. The epithelium ranges from one to 6 cell layers in thickness, and the mean thickness was $30.9 \pm 1.4\,\mu$ (see fig. 3). The mucosa is similar to that of a resting epithelium with a few squamous cells at the surface, relatively few epithelial pegs, few mitotic figures, and no keratinization except at the vestibule.

Upon intravaginal application of 0.1 I.U. of α-estradiol daily for two successive days, the smear becomes cornified in about three-fourths of our animals, and the epithelium at the end of 6 days appears hyperplastic. Whereas the basal cells are cuboidal in character, the cells of the stratum spinosum, with their intercellular bridges, are navicular in shape and become progressively more squamous, the outermost layer being keratinized (fig. 4). Occasionally sections show the replacing epithelium immediately below nucleated epithelial cells (fig. 5). This would indicate the replacing epithelium to be differentiating by stratification, displacing the original epithelium. The mucosa displays large numbers of mitotic figures, many epithelial pegs and few polymorphonuclear leucocytes. The epithelium ranges in thickness from about 10 to 30 cell layers, with a mean thickness of $62.0 \pm 2.4\,\mu$, exclusive of the keratinized layers.

Subsequent to treatment with α-estradiol for two days and ensuing treatment for 4 days with vitamin A + estrogen in varying amounts, the epithelium is still hyperplastic and demonstrates a greater hypertrophy than in animals treated with sesame oil alone. This hypertrophy is a reflection of a general increase in cell size in the superficial layers. The surface cells are nucleated (fig. 6), and keratinization is no longer visible.

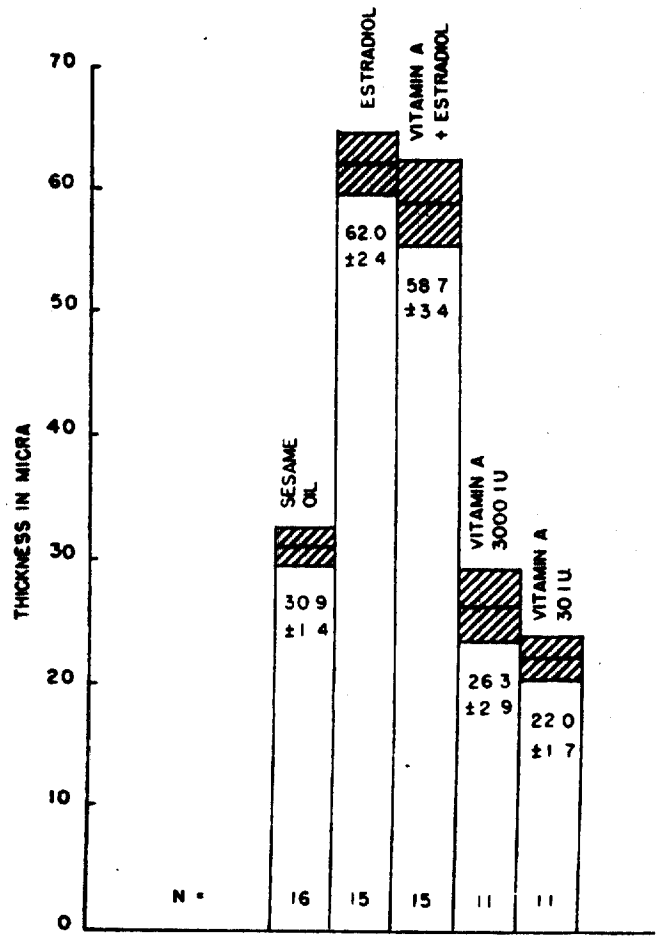

Fig. 3 Effects of local application of oil solutions to the vaginal epithelium. Line bisecting hatched area = mean thickness of epithelium exclusive of stratum corneum. Hatched area = standard error of mean.

However, occasionally one may see signs of the replacing epithelium subjacent to exfoliating keratin, the replacing epithelium consisting entirely of cuboidal cells (fig. 7). The epithelium is still quite thick, with a mean height of $58.7 \pm 3.4\,\mu$ which is not statistically different at the 1% level of confidence from that in the estrogen-treated animals.

Under the influence of vitamin A alone, either in high doses (total dose of 600 I.U.) or low doses (total dose of 6 I.U.), the vaginal epithelium is not markedly different from that of animals treated with sesame oil alone. The epithelium is similarly thin, two to 6 cell layers, with a mean thickness of $26.3 \pm 2.9\,\mu$ and $22.0 \pm 1.7\,\mu$, respectively for the high and low vitamin A doses, which are not statistically different either one from the other or from the sesame oil-treated controls. The mucosal surface is not keratinized (fig. 8), although the epithelium at the vestibule, as in all experimental groups, is cornified.

Histochemical changes in the vaginal epithelium

Alkaline phosphatase. In sections of sesame oil-treated control vaginae, the alkaline phosphatase activity grades from highly positive at the free surface to weak or completely negative in the basal cells. In addition, there is a gradient of activity from completely negative at the keratinized vestibule (fig. 9) to completely positive (except for the basal cells) at the cervical end of the vagina (figs. 10, 11). The increase in alkaline phosphatase from the vestibule to the cervix is concomitant with the decrease in keratohyalin granules in the vagina proper. With a 4-hour incubation period, alkaline phosphatase is present uniformly in the surface cells, but there is a "halo" around the nucleus in cells of the subjacent stratum spinosum, the cell boundaries showing the highest activity. The polymorphonuclear leucocytes in the lumen of the vagina show alkaline phosphatase activity, as do the capillaries of the stroma. Incubation for 18 hours in the glycerophosphate substrate results in a more generalized and uniform

coloration of the epithelium, but the picture remains essentially the same.

After treatment with estrogen, the epithelium again demonstrates the vestibule-cervix gradation mentioned above, as well as the basalis-superficialis gradation. The basal cells remain negative with both the 4- and 18-hour incubations. The stratum corneum demonstrates a negative or negligible reaction, while the cell boundaries of the stratum spinosum were intensely positive (fig. 12). Occasionally, one sees further evidence of the growth process of the replacing epithelium in that the basal cells are alkaline phosphatase-negative, the stratum spinosum positive, and the keratin negative, while the most superficial nucleated cells, in the process of exfoliation, display alkaline phosphatase activity. With 18-hour incubation, the reactions are similar except for a more uniform reaction in the epithelium, the basal cells remaining inactive.

Morphologically and histochemically, insofar as alkaline phosphatase is concerned, the estrogen + vitamin-treated vaginal epithelium resembles that from sesame oil-treated animals except for the hypertrophy and hyperplasia in the former (figs. 13, 14). The alkaline phosphatase reaction seems to be generally more intense throughout the stratum superficialis; the halo effect in the cells of the stratum spinosum is more obvious. The gradations mentioned above are also seen here.

Polysaccharides. Sections treated with the periodic acid-Schiff (PAS) method, including those sections treated with saliva, manifest a remarkable resemblance to those treated for the localization of alkaline phosphatase. In both the phosphatase-treated sections and the PAS-treated sections the vestibular epithelium is always negative regardless of experimental treatment, whereas the endothelium of the capillaries in the stroma is always positive for both reactions. In sesame oil-treated animals, as well as in the animals treated with estrogen + vitamin A, the cells of the stratum superficialis demonstrate homogeneous distribution of both the phosphatase and mucopolysaccharides (figs. 15, 17). The

estrogen-treated groups show a definite PAS coloration of the cell boundaries in the superficialis similar to the localization of alkaline phosphatase (fig. 16). In the stratum spinosum of all groups, the alkaline phosphatase is relatively more diffuse in its localization than are PAS-positive materials which are strictly limited to the cell boundary regions. In general, the transition from negative to positive from vestibule to cervix and from basalis to superficialis applies both to the distribution of these mucopolysaccharides and to the distribution of alkaline phosphatase.

Protein-bound SH. The method for demonstration of sites of protein-bound thiol groups reveals that the vaginal epithelium reacts positively and uniformly throughout the stratum basalis, stratum spinosum and stratum superficialis. Where keratinization is present, as in the estrogen-treated animals, the keratinizing cells and the keratin seem to be more reactive than cells of the deeper layers (fig. 19). The cell boundaries and the nuclear membrane are responsible for most of the reaction. The pictures seen in the sesame oil-treated and the estrogen-treated animals are much alike, except of course for the stratum corneum of the latter (fig. 18). In those animals treated with estrogen + vitamin A, the vaginal epithelium appears only moderately reactive (as judged by its pink color; such pink color indicates sparse, widely separated sulfhydryl groups according to Barrnett, '53) (fig. 20). Occasionally, the stratum superficialis of these estrogen + vitamin A animals shows an intense red color. In general, then, vitamin A seems to decrease the concentration of SH groups in the epithelium of estrogen-treated animals.

DISCUSSION

Intravaginal instillation of estrogen produces the typical keratinization and hyperplasia well described by Allen et al. ('39), while treatment with estrogen + vitamin A does not result in superficial keratinization. Nevertheless, as shown in figure 3, the vitamin does not inhibit the estrogen-induced hyperplasia. The hyperplasia, as has been previously indi-

cated, is a consequence of basal cell proliferation. The lack of superficial keratin under simultaneous treatment with estrogen and vitamin A can be explained as (1) a direct antagonism of the vitamin to the estrogen, (2) an interference with the process of fibrous protein production, or (3) a local chemical reduction of the fibrous protein as it is formed.

Insofar as a direct antagonism is concerned, preliminary experiments demonstrate that vitamin A does not lose its activity, insofar as the Carr-Price ('26) antimony chloride reaction is concerned, when physically mixed with estrogen for as long as two months. Furthermore, there is no apparent chemical similarity between this steroid and the fat-soluble vitamin to suggest competitive inhibition.

Since the early work of Fell and Danielli ('43) on the relation of alkaline phosphatase to wound healing in rats, a number of investigators have supported the view that this phosphomonoesterase is associated with fibrous protein synthesis. Such a relationship is supported by the studies of Bradfield ('46, '49, '51) on the synthesis of silk proteins; of Jeener ('47, '48), Kamell and Atkinson ('48), and Ring ('50) on hormonal stimulation of the vaginal mucosa of mice and rats; and of Atkinson and Elftman ('47) on changes in the mouse uterus. It seems that this proposed relationship cannot be generalized, since Marchant ('49) and Robertson et al. ('50) found no consistent correlation between the presence of alkaline phosphatase and collagen synthesis. In addition, Roche and Bern ('51) concluded that alkaline phosphatase activity did not accompany all instances of fibrous protein synthesis in the cases investigated by them. Bern and Levy ('52) also failed to demonstrate alkaline phosphatase activity in certain experimentally induced lesions involving keratin production.

In sesame oil-treated animals alkaline phosphatase occurs despite the castrate condition. Atkinson and Elftman ('46, '47), Pritchard ('49), and Harris and Cohen ('51) reported that there was a decrease in uterine alkaline phosphatase activity upon castration of the rodent. Similarly Kamell and

Atkinson ('48), Ring ('49, '50), and Sani and Hanau ('52) found that vaginal alkaline phosphatase activity was correlated with the presence of estrogen, and that the amount of enzyme demonstrated in the castrate condition was negligible. Inasmuch as the sesame oil-treated animals manifest some alkaline phosphatase activity, it is suggested that the decreased activity reported in the literature is a reflection of a general atrophy of the vaginal epithelium. When considered on the basis of cell number and cell sizes, the decreased enzyme activity of the castrate epithelium may reflect merely less cytoplasm. In animals treated with estrogen + vitamin A, the alkaline phosphatase activity resembles that of estrogen-treated animals despite the inhibition of keratinization. The enzyme activity may here again reflect degree of cellularity rather than increased activity owing to estrogen stimulation.

Investigation of the vaginal alkaline phosphatase activity shows a general gradation from absence of the enzyme at the vestibule to an intense reaction at the cervical end of the vaginal epithelium, regardless of the presence or absence of keratin. Generalizing, it is felt that this further supports the lack of a constant relationship between alkaline phosphatase and fibrous protein synthesis. In addition, Fell and Danielli ('43), Biesele and Biesele ('44), and Sabella et al. ('51), among others, noted a virtual lack of alkaline phosphatase in the normal epidermis with the exception of limited activity in the hair follicles and sebaceous glands.

A relation between alkaline phosphatase activity and the presence of glycogen has been previously indicated by Boettiger ('46) and Arzac and Blanchet ('48). More recently Moog and Wenger ('52) and Kroon ('52) have shown an association of alkaline phosphatase activity with a diastase-resistant polysaccharide, and the former suggested that this mucopolysaccharide was a part of the cytoskeleton to which phosphomonoesterase is bound. In my study a correspondence in localization of alkaline phosphatase and diastase-resistant PAS-positive materials (presumably mucopolysaccharides) was found with the exception of the basement membrane which

stains with Schiff's leucofuchsin after periodic acid oxidation and lacks alkaline phosphatase activity.

Zuckerman ('40, p. 255) states ". . . histochemically, there is at present no obvious criterion by which to differentiate between the stratified squamous oestrogenic response of the vagina, that of the vestibule, and that of the skin lying more peripherally to the vestibule." The gradation in alkaline phosphatase activity and associated PAS-positive polysaccharide in the vaginal and vestibular epithelium is a histochemical distinction. The vestibule, as mentioned above, exhibits an absence of alkaline phosphatase activity similar to the skin, despite its sensitivity to estrogens. This would suggest an ingrowth of estrogen-reactive ectoderm becoming continuous with the vagina proper.

As regards a chemical reduction of keratin as it is formed, Flesch ('52, '53) suggested that vitamin A, among other substances, has the ability to inhibit sulfhydryl (SH) activity due to the presence of $-C=C-$ bonds in the molecule which combine with the free SH groups of tissue protein. The depilatory action of certain unsaturated compounds including vitamin A is supposedly due to their combination with free SH groups and a consequent inability to form the disulfide linkage of keratin. Sections treated with Barrnett and Seligman's ('52) technique for the demonstration of protein-bound SH groups suggested a decrease in protein-bound sulfhydryl in vitamin A + estrogen-treated animals, whereas the vaginal epithelium of the estrogen-treated animals reacted strongly, especially the surface keratin. An abundance of SH groups in the stratum corneum is evident not only in my sections, but also in Barrnett's observations ('53) on the estrous rat vagina and those of Eisen et al. ('53) on the epidermis. Van Scott and Flesch ('54) have confirmed these histochemical findings by chemical studies. It is noteworthy in my study that protein-bound SH groups should be found in keratin and that the SH content is decreased where keratin formation is inhibited. These results might be used in support of Flesch's thesis ('52); however, other data do not support such a con-

tention. Flesch ('52) contends that the depressive action of vitamin A on keratin formation is a "drug action" rather than a vitamin effect, in that large doses of vitamin A are required over a long period of time in the treatment of certain cutaneous diseases. Observations on the rat vaginal epithelium, wherein occurs a quantitative inhibition of the estrogen-induced cornification by vitamin A, do not corroborate the so-called "drug action." The results of these studies show a significant change in the vaginal smear picture with doses of vitamin A as little as 0.6 I.U. (fig. 2). Insofar as the vaginal epithelium is concerned, these minimal doses, sufficient to inhibit keratinization, are not considered pharmacological. In any case, Sobel ('52) suggests that the reason high doses of vitamin A are required orally may be defective absorption and transportation.

The fundamental question in the process of vaginal cornification and, for that matter, in all keratinization, rests on the determination of how keratin is produced. There are several processes of epithelial differentiation which lead to this common endpoint of keratinization. Included are the normal keratinization that occurs in the epidermis, as well as the reversible and cyclic differentiation occurring in the epithelium of the rodent vagina; metaplastic changes in which tissues respond to traumatic stimulation, deficiency of vitamin A, or estrogen administration; neoplasia resulting in squamous cell carcinoma. Moritz ('43, p. 302) suggested that keratinization represents the ". . . höchste Differenzierungsstufe in des Epithels . . ." He further considers vitamin A to exert a general inhibitory and stabilizing action to prevent the differentiation of all epithelial tissues to the keratinized type. What is to be considered a "higher" or a "lower" state of differentiation is open to question.

My experiments suggest that vitamin A may well play a general role in the prevention of all keratin formation, apart from that accompanying the deficiency metaplasia which it also prevents. It is conceivable, on the basis of this and other investigations, that vitamin A is intricately involved in the anabolism of all epithelial cells and that keratinization may

represent a moribund response rather than a "highly differentiated state." Vitamin A, in terms of Moritz' notions ('43), becomes a differentiation-accelerator rather than an inhibitor of progressive differentiation, whereas vitamin A deficiency and other factors such as estrogen, trauma, etc., induce a dedifferentiating response. It is of great interest that recently Fell and Mellanby ('53) were able not only to suppress the expected keratinization of chick ectoderm cultivated *in vitro* with high doses of vitamin A but also to cause the ectoderm to differentiate into a ciliated, mucus-secreting epithelium.

SUMMARY AND CONCLUSIONS

1. An investigation has been made of the quantitative, histological, and histochemical aspects of the relationship between vitamin A and estrogen in keratin formation using the vaginal epithelium of the rat as a target organ.

2. As judged by vaginal smear assay, crystalline vitamin A inhibits estrogen-induced cornification of the vaginal epithelium when instilled intravaginally in oil solution. The relationship can be shown to follow a typical dose-response curve, wherein as low a total dose as 0.6 I.U. of vitamin A significantly inhibits the cornification resulting from a total dose of 0.6 I.U. of α-estradiol.

3. Histological sections of the vagina corroborate previous findings with vaginal smears, in that the animals treated with vitamin A + estrogen demonstrate a stratified cuboidal epithelium rather than the typical estrogen-induced cornification.

4. Study of the vaginal epithelium in various states using histochemical methods demonstrated:

(a) No evidence of a constant relationship between alkaline phosphatase activity and fibrous protein production as has been suggested previously;

(b) With the exception of the basement membrane, a correspondence in localization of alkaline phosphatase activity with mucopolysaccharides demonstrated by the periodic acid-Schiff method;

(c) A decrease in the concentration of protein-bound sulfhydryl groups with vitamin A treatment, as judged by the Barrnett-Seligman method.

5. The possible role of vitamin A and its relation to estrogen-induced keratinization is considered. Vitamin A is thought to be involved in protein anabolism and therefore to play a general role in inhibiting keratin formation.

ACKNOWLEDGMENTS

The author wishes to express his gratitude to Professors Howard A. Bern and Kenneth B. DeOme for their invaluable criticisms and advice throughout the course of this investigation. He is indebted also to Dr. G. K. Hawkins of Schering Corporation, Bloomfield, N. J., for generously supplying the α-estradiol and to Dr. P. L. Harris of Distillation Products Industries, Rochester, N. Y., for the vitamin A alcohol and acetate.

LITERATURE CITED

ALLEN, E., F. L. HISAW AND W. U. GARDNER 1939 The endocrine functions of the ovary. In Allen et al. (ed.): Sex and Internal Secretions. Williams and Wilkins. 2nd ed., 452–629.

ARZAC, J. P., AND E. BLANCHET 1948 Alkaline phosphatase and glycogen in human endometrium. J. Clin. Endocrinol., *8:* 315–324.

ATKINSON, W. B., AND H. ELFTMAN 1946 Effect of steroid sex hormones on distribution of alkaline phosphatase in uterus of mouse. Proc. Soc. Exp. Biol. and Med., *62:* 148–150.

——— 1947 Mobilization of alkaline phosphatase in the uterus of the mouse by estrogen. Endocrinology, *40:* 30–36.

BARGER, J. D. 1947 A simplification of the technic for demonstrating alkaline and acid phosphatase in tissues. Arch. Path., *43:* 620–623.

BARRNETT, R. J. 1953 The histochemical distribution of protein-bound sulfhydryl groups. J. Nat. Cancer Inst., *13:* 905–925.

BARRNETT, R. J., AND A. M. SELIGMAN 1952 Histochemical demonstration of protein-bound sulfhydryl groups. Science. *116:* 323–327.

BERN, H. A., AND R. S. LEVY 1952 The effects of castration, estrogen administration, and methylcholanthrene carcinogenesis on phosphatase activities in the genital tract of male rats, guinea pigs, and rabbits. Am. J. Anat., *90:* 131–165.

BIESELE, J. J., AND M. M. BIESELE 1944 Alkaline phosphatase in mouse skin under methylcholanthrene treatment. Cancer Res., *4:* 751–755.

BOETTIGER, E. G. 1946 Changes in the glycogen and water content of the rat uterus. J. Cell. and Comp. Physiol., *27:* 9–14.

BRADFIELD, J. R. G. 1946 Alkaline phosphatase in invertebrate sites of protein secretion. Nature, *157:* 876–877.

——— 1949 Phosphatase cytochemistry in relation to protein secretion. Exp. Cell Research, Suppl., *1:* 338–350.

——— 1951 Phosphatase and nucleic acids in silk glands; cytochemical aspects of fibrillar protein secretion. Quart. J. Micr. Sci., *92:* 87–114.

BRODY, H., AND S. GOLDMAN 1941 Relationship of vitamin A and estrogens. Endocrinology, *29:* 164.

BURRILL, M. W., AND R. R. GREENE 1941 Vitamin A and the vaginal response to sex hormones in the rat: I. Estrogens. Endocrinology, *28:* 765–766.

CARR, F. H., AND E. A. PRICE 1926 Colour reactions attributed to vitamin A. Biochem. J., *20:* 497–501.

DEVENANZI, F., AND J. MONTENEGRO 1945 Inhibicion estral y luteinizacion ovarica en la rata determinados por la administracion de vitamina A. Ann. d. Inst. Med. Exper. d. Caracas (Venezuela), *3:* 140–154.

EIBEN, A. Z., W. MONTAGNA AND H. B. CHASE 1953 Sulfhydryl groups in the skin of the mouse and guinea pig. J. Nat. Cancer Inst., *14:* 341–353.

FELL, H. B., AND J. F. DANIELLI 1943 The enzymes of healing wounds. I. The distribution of alkaline phosphomonoesterase in experimental wounds and burns in the rat. Brit. J. Exper. Path., *24:* 196–203.

FELL, H. B., AND E. MELLANBY 1953 Metaplasia produced in cultures of chick ectoderm by high vitamin A. J. Physiol., *119:* 470–488.

FLESCH, P. 1952 Inhibition of keratin formation with unsaturated compounds. J. Invest. Dermat., *19:* 353–363.

——— 1953 Studies on the mode of action of vitamin A. J. Invest. Dermat., *21:* 421–434.

HARRIS, R. S., AND S. L. COHEN 1951 The influence of ovarian hormones on the enzymatic activities of tissues. Endocrinology, *48:* 264–272.

HOHLWEG, W. 1951 Über die Hemmung der Oestrusreaktion durch Vitamin-A-Überdosierung. Klin. Wchnschr., *29:* 193–195.

——— 1952 Die Testierung von Vitamin A-Präparaten mit Hilfe der Antioestrusreaktion. Die Pharmazie, *5:* 280–284.

HOTCHKISS, R. D. 1948 A microchemical reaction resulting in the staining of polysaccharide structures in fixed tissue preparations. Arch. Biochem., *16:* 131–141.

JEENER, R. 1947 Cytochemical effects of oestradiol. Nature, *159:* 578.

——— 1948 Acides nucléiques et phosphatases au cours de phénomènes de croissance provoqués par l'oestradiol et la prolactine. Biochim. et Biophys. Acta, *2:* 439–453.

KAHN, R. H., AND H. A. BERN 1950 Antifolliculoid activity of vitamin A. Science, *111:* 516–517.

KAMELL, S. A., AND W. B. ATKINSON 1948 Effect of ovarian hormones on certain cytoplasmic reactions in the vaginal epithelium of the mouse. Proc. Soc. Exp. Biol. and Med., *68:* 537–540.

KRICHESKY, B., AND S. J. GLASS 1947 Estrogen activity of rabbit whole blood determined by the intravaginal pellet method. Endocrinology, *40:* 192–198.

KROON, D. B. 1952 Phosphatase and the formation of protein-carbohydrate complexes. Acta Anat., *15:* 317–328.

LYONS, W. R., AND H. J. TEMPLETON 1936 Intravaginal assay of urinary estrin. Proc. Soc. Exp. Biol. and Med., *33:* 587–589.

MARCHANT, J. 1949 Alkaline phosphatase activity in normal and degenerated peripheral nerves of the rabbit. J. Anat., *83:* 227–237.

MASIN, F. 1950 Effect of giving large amounts of concentrates from fish liver oil on the cytology of the vaginal smear in rat. Acta Cient. Veneozolana, *1:* 26–29.

MOOG, F., AND E. L. WENGER 1952 The occurrence of a neutral mucopolysaccharide at sites of high alkaline phosphatase activity. Am. J. Anat., *80:* 339–371.

MORITZ, W. 1943 Das Vitamin A als Differenzierungshemmer des gesamten Epithels. Ztschr. Anat. u. Entw., *112:* 271–303.

PRITCHARD, J. J. 1949 Alkaline phosphatase in the uterine epithelium of the rat. J. Anat., *83:* 10–24.

RING, J. R. 1949 Alkaline phosphatase activity of oral and vaginal epithelium of the rat during the estrous cycle. Anat. Rec., *103:* (suppl.): 82.

——— 1950 Changes in alkaline phosphatase activity of rat vaginal epithelium during the estrous cycle. Anat. Rec., *107:* 121–131.

ROBERTSON, W. VAN B., F. W. DUNIHUE AND A. B. NOVIKOFF 1950 The metabolism of connective tissue: absence of alkaline phosphatase in collagen fibers during formation. Brit. J. Exper. Path., *31:* 545–549.

ROBSON, J. M. 1938 Mechanism of oestrus inhibition in the mouse during pregnancy. Quart. J. Exper. Physiol., *28:* 195–203.

ROCHE, J., AND H. A. BERN 1951 Activité phosphatasique et synthèse des scléroprotéines. Comp. rend. Soc. Biol., *145:* 1836–1838.

SABELLA, J. D., H. A. BERN AND R. H. KAHN 1951 Effect of locally applied vitamin A and estrogen on rat epidermis. Proc. Soc. Exper. Biol. and Med., *76:* 499–503.

SANI, G., AND R. HANAU 1952 La fosfatasi alcalina nell'apparato genitale femminile del ratto in rapporto al ciclo sessuale ed alla somministrazione di ormoni. Arch. Ital. Anat. e Embriol., *57:* 211–224.

SHERWOOD, T. C., M. A. BREND AND E. A. ROPER 1936 Changes in the vaginal epithelium of the rat on an excessive vitamin A diet. J. Nutrition, *11:* 593–597.

SHERWOOD, T. C., O. R. DEPP, G. P. BIRGE AND H. P. DOTSON 1937 Further studies on the effect of excessive vitamin A on the estrous cycle of the rat. J. Nutrition, *14:* 481–486.

SOBEL, A. E. 1952 The problem of absorption and transportation of fat-soluble vitamins. Vitamins and Hormones, *10:* 47–67.

THORBORG, J. V. 1948 On the Influence of Oestrogenic Hormones on the Male Accessory Genital System. Copenhagen: Einar Munksgaard.

VAN SCOTT, E. J., AND P. FLESCH 1954 Sulfhydryl and disulfide in keratinization. Science, *119:* 70–71.

ZUCKERMAN, S. 1940 The histogenesis of tissues sensitive to oestrogens. Biol. Rev., *15:* 231–271.

PLATES

PLATE 1

EXPLANATION OF FIGURES

4 Vaginal epithelium from a castrate female rat after 6 days of intravaginal application of 0.6 I.U. of α-estradiol dissolved in sesame oil. Hematoxylin-eosin. × 500.

5 Vaginal epithelium of castrate treated with estrogen as above. Note the superficial nucleated epithelial cells being replaced by stratified squamous epithelium. Hematoxylin-eosin. × 300.

6 Vaginal epithelium from a castrate rat after 4 days of intravaginal application of α-estradiol combined with crystalline vitamin A dissolved in sesame oil. Note absence of keratin and the presence of nucleated epithelial cells at the surface. Hematoxylin-eosin. Cf. figure 4. × 500.

7 Vaginal epithelium from a castrate rat treated with both estrogen and vitamin A as in figure 6. Note the superficially keratinized stratified squamous epithelium being replaced by cuboidal nucleated epithelial cells. Cf. figure 5. Hematoxylin-eosin. × 300.

8 Vaginal epithelium from a castrate rat after 4 days of intravaginal application of vitamin A dissolved in sesame oil. Hematoxylin-eosin. × 100.





PLATE 2

EXPLANATION OF FIGURES

All photomicrographs in this plate are of paraffin sections of acetone-fixed tissues, 7 μ thick, with nuclear coloration largely due to hematoxylin and dense extranuclear coloration to alkaline phosphatase activity. Barger ('47) technic; incubation for 4 hours in sodium glycerophosphate.

9 Vestibule epithelium from a castrate rat treated with sesame oil. Note the complete lack of alkaline phosphatase activity. The superficial cells contain hematoxylin-staining keratohyalin granules. × 200.

10 Vaginal epithelium of castrate rat treated with sesame oil. Note the presence of alkaline phosphatase activity in all except the basal layers. × 200.

11 Vaginal and vestibule epithelium from a castrate rat treated with sesame oil. Note the gradation of alkaline phosphatase activity from negative at the vestibule (left) to positive cervically (right). × 200.

12 Vaginal epithelium from a castrate rat treated with estrogen as in figure 4. Note the dense extranuclear coloration in the cell and the apparent "halo effect" indicative of phosphatase activity. Basal cells are negative. Cf. figure 10. × 200.

13 Vaginal epithelium from a castrate rat treated with vitamin A and estrogen as in figure 6. Note that the cell boundaries demonstrate the greatest activity of alkaline phosphatase. × 300.

14 Vaginal epithelium from a castrate rat treated with vitamin A and estrogen as in figure 6. Note the presence of alkaline phosphatase activity superficially and its relative absence basally. Cf. figure 12. × 200.

9

10

11

12

13

14

PLATE 3

EXPLANATION OF FIGURES

15 Castrate vaginal epithelium treated with sesame oil. Note the presence of polysaccharides in the basement membrane, cell boundaries and superficially. Periodic acid-Schiff (PAS) technic. × 200.

16 Vaginal epithelium of castrate rat treated with estrogen as in figure 4. Note the similarity to sesame oil-treated animal above. The cell boundaries and the basement membrane are positive for polysaccharides. PAS. × 200.

17 Vaginal epithelium from a castrate rat treated with estrogen and vitamin A simultaneously as in figure 6. Note the presence of polysaccharides in basement membrane and in the cell boundaries, especially the superficial nucleated cells. PAS. × 200.

18 Vaginal epithelium from a castrate rat treated with sesame oil. Dense coloration is indicative of a blue color and therefore a concentration of protein-bound sulfhydryl groups. Barrnett-Seligman technic. × 200. Green filter (4600 Å–6250 Å with peak at 5300 Å).

19 Vaginal epithelium of a castrate rat treated with estrogen as in figure 4. Note the density of (blue) coloration of the keratin. Barrnett-Seligman technic. × 200. Green filter as in figure 18.

20 Vaginal epithelium of a castrate rat treated with estrogen and vitamin A simultaneously as in figure 6. Note the lack of density (reflecting a pink coloration) indicative of more dispersed protein-bound sulfhydryl groups. Barrnett-Seligman technic. × 200. Green filter as in figure 18.

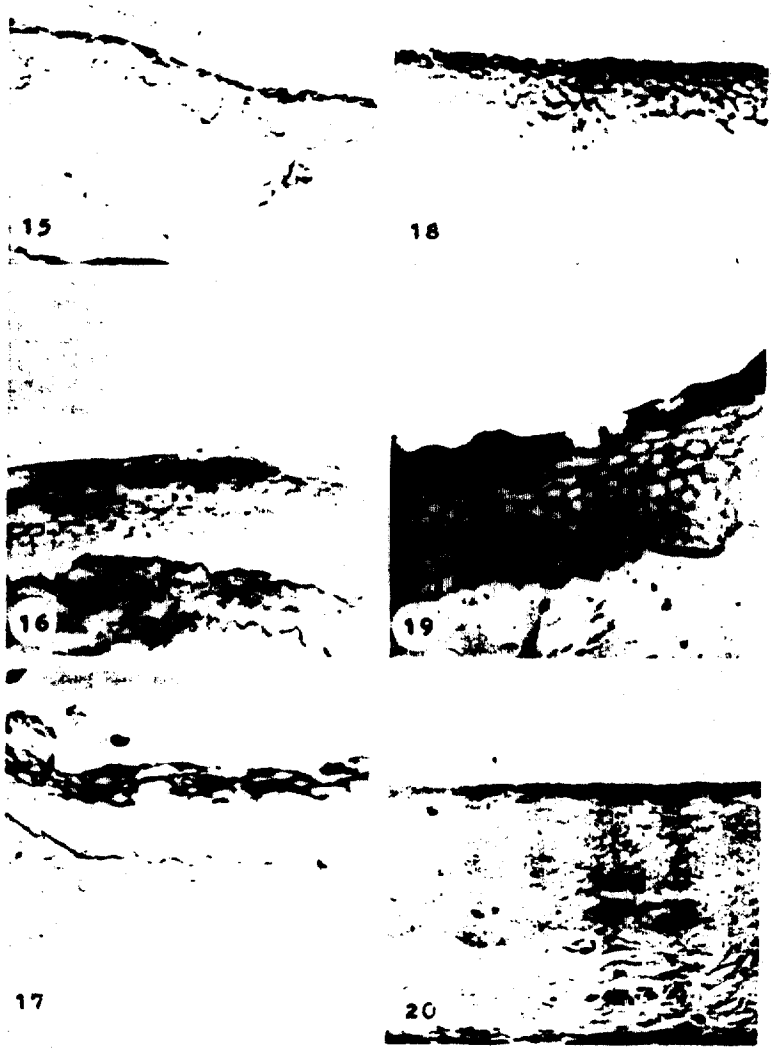
15
18
16
19
17
20

Kalter-'61
Bib. No. 4511

Am. J. Path. 38(1):1-21. 1961.

Reproduced by permission of the copyright owner

THE AMERICAN JOURNAL OF PATHOLOGY

VOLUME XXXVIII JANUARY, 1961 NUMBER 1

EXPERIMENTAL PRODUCTION OF CONGENITAL MALFORMATIONS IN STRAINS OF INBRED MICE BY MATERNAL TREATMENT WITH HYPERVITAMINOSIS A

HAROLD KALTER, PH.D., AND JOSEF WARKANY, M.D.

From the Children's Hospital Research Foundation and the Department of Pediatrics, College of Medicine, University of Cincinnati, Cincinnati, Ohio

A variety of methods is now available for producing congenital malformations in mammals by metabolic procedures.[1] Among these is a method employing relatively large doses of vitamin A, first devised by Cohlan,[2,3] who found with rats that it very successfully induced malformations such as exencephaly, hydrocephalus, spina bifida, cleft palate, cleft lip, brachygnathia, shortening of the maxilla, and gross eye defects. The efficacy of this technique was confirmed by Giroud and Martinet,[4] who in general found similar malformations but who were also able to demonstrate a differential effect on fetal development by starting treatment at several different periods of gestation.[5] Giroud and Martinet also paid special attention to Cohlan's observation[3] that the amniotic sacs of the abnormal embryos were swollen with excess, often blood-stained fluid. They found[6] that the amniotic sacs of fetuses with anencephaly contained more than 10 times the amount of fluid than was contained in sacs of fetuses without anencephaly. In addition, Giroud and Martinet used this means to produce exencephaly in order to investigate the morphogenesis of anencephaly,[7] and also made special studies of the malformations of the face[8] and of the urinary tract[9] induced by this method. Deuschle, Geiger and Warkany studied hypervitaminosis A-induced skeletal anomalies of the face leading to protrusion of the eye.[10]

This study was supported in part by grants from the National Institute of Arthritis and Metabolic Diseases (RG-7107) of the National Institutes of Health, United States Public Health Service, and the National Vitamin Foundation, Inc., New York, N.Y.
Accepted for publication, June 23, 1960.

That similar malformations can be induced in mice by this technique was shown by Giroud and Martinet,[11] using Swiss Webster mice. Since it has been found in other experiments [12,13] that teratogenic agents varied in their effects according to the genetic constitution of inbred mouse strains employed, it seemed of interest to examine the effects of hypervitaminosis A upon the young of such inbred strains. In the course of these experiments, it was found that the malformations produced were in some respects similar to those observed in rats. However, malformations also made their appearance that had never been observed in other teratologic experiments.[14-16] Since many of these malformations simulated congenital malformations known to occur in human beings, it seemed worth while to report briefly upon the production of such developmental defects in experimental animals.

Material and Methods

Female mice of the A/J, DBA/1J, and C3H/J inbred strains were placed with males of their own strains, one pair to a cage, and observed each morning thereafter for a copulation plug. The presence of a plug was taken to indicate that ½ day had passed since conception. The impregnated female was then placed in a cage by herself. At 7½, 8½, 9½, 10½, 11½, or 12½ days after conception the females were given a single dose of 10,000 I.U. of vitamin A by mouth, by means of a blunt-ended 19-gauge needle and tuberculin syringe. The vitamin, originally containing 300,000 I.U. of vitamin A palmitate per cc. in sesame oil, was diluted to 50.000 I.U. per cc. with sesame oil, and 0.2 cc. was administered. The mice received Purina Laboratory Chow and fresh tap water *ad libitum* throughout pregnancy. The females were killed at 17½ days after conception; that is, about 2 days before term. Resorption sites were counted, and the fetuses were removed. examined macroscopically, and then fixed in Bouin's solution for serial sectioning or in 95 per cent alcohol in preparation for staining of the skeleton by the Schulze-Dawson method.[17]

Results

To the time of writing, no strain differences in type or frequency of induced congenital malformations have been detected, and therefore the treated females and their offspring will be discussed without distinction as to strain.

A total of 92 females have so far been treated in the manner described. Treatment of 7 females at 7⅓ days after conception caused all but one of the 53 young conceived to be resorbed. The animals treated after this time had at sacrifice 375 live young and 213 resorption sites. Malformations produced in these offspring affected many organ systems and were usually not compatible with postnatal life.

A widespread and complex syndrome of malformations resulted from a single administration of vitamin A to 34 females at 8⅓ days after conception; these had 99 young and 139 resorption sites. Only a part of this syndrome was induced by treatment at 9⅓ days after conception.

Eighteen females were treated at this time, and they had 97 young and 42 resorption sites. The defects that these two groups of offspring had in common will be considered first, and for this purpose these groups will be combined. Both groups had defects of the head, face and mouth, but those treated at 9½ days after conception had more severe abnormalities of these parts than those treated earlier.

Of the 196 young in these two groups, 193 were abnormal in one way or another (98.5 per cent). The most frequent defect was cleft palate, which occurred in 109 of the 154 young (70.8 per cent) whose mouths were examined (Fig. 1). Inspection of many palates was made impossible by the presence of an unusual anomaly, microstomia, which occurred in 64 cases (32.6 per cent; Figs. 2 to 4). This abnormality was characterized by reduction in size of the oral aperture, ranging from a moderate decrease to apparent obliteration of the opening. The defect was associated with anomalies of the skin, face, mouth, teeth, the underlying soft tissues and the cartilaginous and osseous skeletons. Included in this array were massive maxillomandibular ankylosis; reduction in length of the mandible due to foreshortening and absent or defective rami; heterotopic cartilage; lateral ankyloglossia (Fig. 26); absent, fused, supernumerary (Fig. 27), and ectopic teeth; absent masseter muscle; absent parotid, sublingual, and submaxillary glands and ducts; ectopic submaxillary glands, etc. These malformations and defects were recently described in detail.[16]

Another frequent defect of the head was exophthalmos of various degrees (Figs. 3 and 8), often with absence of the eyelids (32.2 per cent). The basis for this anomaly was great reduction in the size of the orbit, probably due to defective development of the facial skeleton, especially of the zygomatic arch. The eye itself, however, was normal. In addition, abnormalities of the pinna occurred quite often (57.7 per cent) and included external ears that were absent or small, defective, and placed in a low position (Figs. 2 to 4). Atresia of the eustachian tubes was also found in sectioned tissues.

Of great interest was an anomaly found in sectioned offspring from mothers treated at either of the two periods in pregnancy. This was an accessory thymus and various degrees of undescended thymus. In the latter, the organs ranged in location from those in a slightly elevated position, just below the thyroid, to those high in the neck, where a parapharyngeal or para- and moderately intra-pharyngeal location was occupied (Fig. 28). In those with this extreme form, remnants of the embryonic pharyngeal clefts (*ductus pharyngobranchialis III*) persisted, producing passages from the pharynx into the thymic tissue. In such animals the area of the normal position of the thymus in the

superior mediastinum just cephalic to the parietal pericardium appeared empty, and consisted of a space of about the size to accommodate the normal thymus (Fig. 5). Figure 6 shows the location and size of the thymuses in a control. The accessory thymus(es) occupied various positions in the neck, but in several cases a nodule of accessory thymus tissue was located in one or both eustachian tubes about half way along their courses (Fig. 25). The histologic structure of the ectopic thymus was denser than in controls of the same age, but was nevertheless recognizable. In specimens with these abnormalities there were no obvious defects of the parathyroid or thyroid glands except absence of the isthmus of the thyroid in some cases.

The only malformations other than those listed above produced by single treatment at 8⅓ or 9½ days after conception were of the tail. The defects of the tail (Fig. 8) were bent or wavy tail (2 and 27.8 per cent), short or abnormal tail (18.2 and 22.7 per cent), and absent tail (12.1 and 3.1 per cent).

In addition to the defects mentioned, treatment at 8⅓ days after conception also produced many anomalies that did not appear or appeared only rarely following treatment at 9⅓ days. Many of these anomalies were internal and were seen only in sectioned tissue: viz., 10 animals selected from the apparently severely deformed young, which were serially sectioned at 20 μ and stained with hematoxylin and eosin. These were defects of the central nervous system, median cleft mandible (10.1 per cent; Fig. 9), fused ribs (Fig. 7), cardiovascular anomalies, urogenital defects, anal atresia (15.1 per cent; Fig. 8), and others.

Externally visible malformations of the central nervous system were exencephaly and spina bifida aperta at the lower lumbar or sacral levels (Figs. 10 to 13). In two instances these defects appeared together in the same animal (Fig. 14). In the hypervitaminosis A experiments with rats, exencephaly occurred quite frequently,[3,4] but in the present study with mice only 5 examples of this defect were encountered. In sections of exencephalic young it was found that the cerebral hemispheres enclosed the lateral ventricles; the diencephalon, however, was not closed as is usual, but protruded between and overlay the hemispheres so that parts normally forming the roof of the third ventricle were contiguous with the skin of the temporal area. This is a common feature of exencephaly, for which the pathogenesis and structure have been described.[7] Although spina bifida aperta did not occur very often either (10 cases), 3 instances of spina bifida occulta were found in sections of 5 young with no outwardly overt defect of the spine and in whom this malformation was not suspected. It is possible, therefore, that spina bifida occulta occurred with quite appreciable frequency in these

animals. The structure of the spina bifida aperta was not greatly different from that previously described,[18,19] but the spina bifida occulta presented some novel features (Figs. 15 and 16).

One other defect of the central nervous system seen in sectioned material can probably best be called "crowded brain." In this defect the brain appeared too large for the cranium, with decrease or obliteration of the basal, pericerebellar, and perimedullary cisternas and reduction in size or complete closure of the rostral region of the aqueduct. Despite the latter phenomenon, no sign of hydrocephalus was noted. It is likely, however, that had the young been left *in utero* longer, hydrocephalus would have developed.

Five of the 10 sectioned animals exhibited crowded brain and a closed or narrow Sylvian aqueduct; all of these had spina bifida (4 aperta, 1 occulta). On the other hand, another 3 animals had brains with normal surrounding spaces; of these, 2 had normal spinal cords and 1 had spina bifida occulta. In the latter specimen with normal brain and spina bifida occulta, however, the aqueduct was narrow. The final 2 of the sectioned specimens had exencephaly, 1 with spina bifida aperta and the other with spina bifida occulta.

Another defect found was a craniopharyngeal duct. This occurred in 6 of the sectioned specimens, but was not present in sections of 6 controls of the same age or in sections of 4 young from mothers treated at 9⅓ days after conception. This anomaly consisted of a narrow passage from the rear part of the nasopharynx through the center of the presphenoid and ending at the base or in the parenchyma of the pituitary.

Malformations of interest were also found in the heart and great vessels. These included narrow and angulated ductus arteriosus (Figs. 17 and 18), complete transposition of the great vessels, entrance of the aorta and pulmonary trunk into a large right ventricle, high interventricular septal defect alone or combined with "overriding" aorta (Figs. 19 and 20), and a probable coronary aneurysm occupying a large space between the ventricles and communicating at its base with the right ventricle. The latter defect occurred in the specimen showing complete transposition.

Severe and complex urogenital malformations were present in 9 of the 10 sectioned animals. All 9 (6 males, 2 females, and 1?) had rectovesical fistulas (Fig. 29) and anal atresia. Renal abnormalities included bilateral renal agenesis; crossed ectopic kidney, the left kidney being shifted toward or to the right and fused to the right kidney (Figs. 21 and 22); midline fused and "lump" kidney (Figs. 23 and 24); and hydronephrosis. In the animal with renal agenesis, the ureters and genital ducts were also absent. Other defects of the latter structures

were double ureter, single midline ureter, ureteric atresia and absent ureter; confluence of the ureter with the genital duct and of the genital ducts with each other; anastomosis of the genital ducts and of the ureters; hydroureter; crossing of a genital duct from one side to the other and entering the bladder on the side opposite from which it originated; and ectopic point of entrance of the ureter and genital duct into the bladder. Further, there occurred vesical diverticula and ectopic ovaries.

In all 10 sectioned specimens the umbilical artery was absent. Mice of the fetal age examined normally possess a single umbilical artery, passing usually to the right of the bladder. In the defective animals, apparently in compensation for the lack of the umbilical artery, the superior mesenteric artery was greatly enlarged, traversed the abdominal cavity and entered the umbilicus. To such a degree had the superior mesenteric artery undertaken a leading role that the celiac artery originated from it instead of, as normally, from the aorta. In fact, caudal to the emergence of the superior mesenteric artery from the aorta, the latter was greatly reduced in caliber, being transformed into a relatively small vessel. In this condition it passed dorsal to the fused kidneys where it was greatly compressed against the inferior vena cava. The latter also traveled dorsal to the kidneys until it bifurcated more anteriorly than normal into the iliac arteries. In one instance the reduced aorta split into iliac arteries just cephalic to the midline "lump" kidney, one iliac descending dorsal and the other ventral to the kidney. The fetal venous system was usually normal.

Treatment at 10⅓, 11⅓ or 12⅓ days after conception produced syndromes of congenital malformations that were greatly alike and almost completely different from those resulting from the earlier treatments. The disorders following later treatment, however, were most severe and frequent when vitamin A was administered at 11⅓ days after conception. Thirty-three females treated at these times had 179 young and 48 resorbed implantation sites at sacrifice. A total of 106 of the 179 young were malformed in one way or another (59.2 per cent). Cleft palate without cleft lip occurred in 62 of 170 young examined (36.5 per cent). This was usually accompanied by foreshortened mandible.

Most characteristic of the defects produced by treatment at these periods were two types of limb abnormalities. The first consisted of various grades of micromelia, in the most severe instances of which the forearms and forelegs were completely absent. In the second type the second digit on the hands or feet was either very short, bent toward and syndactylous with the pollex or hallux, or it was completely absent, producing oligodactyly.

In cleared specimens there were various skeletal anomalies: absent femur, tibia, and fibula; moderately to severely short, thick and bent humerus, radius, ulna, femur, tibia, fibula, and ilium; absent deltoid process; and absent or partially absent sacral tuberculum of the ilium. In addition, various scapular and costal defects and anomalies of the base of the skull were noted.

No other defects were noted in sections of 2 offspring from females treated at 11⅛ days after conception.

Discussion

It is clear that hypervitaminosis A is a potent teratogen in mice, as it is in rats. The external defects occurred often, and their frequencies were easily determined. But it is not possible to state the percentage of internal defects, since all the specimens were not dissected or sectioned. Among the malformations are some that have occurred in previous experimental teratologic studies and have been repeatedly described. Such a defect is exencephaly. The form of this anomaly as produced by the administration of a large dose of vitamin A is well known; its gross aspects, indicating defects in closure of the neural tube, are similar to those produced in rats and mice by other teratogens.[20] Hypervitaminosis A-induced spina bifida aperta conformed, in general, to that previously described, in having an open neural plate, fused median spinal ganglia, overgrowth of nervous tissue, vertebral defects, etc.[18,19] The association noted in past studies, clinical and experimental, between spina bifida and the Arnold-Chiari malformation was also observed in the present investigation. In the rat, however, where the Arnold-Chiari malformation is simulated to a great extent following maternal treatment with trypan blue,[18,19] one characteristic of the malformation, the crowding of the brain, appears to be restricted to the metencephalon and myelencephalon. In the vitamin A-treated mice, however, the crowding was also present much further rostrally, usually starting at the optic chiasm. As in rats, the mice showed no herniation of the cerebellum through the foramen magnum, a cardinal sign of the Arnold-Chiari malformation in human subjects.

In selected sectioned young, malformations of great interest were found that have not yet been described as being produced experimentally; some of these occasionally occur in man. These are supernumerary upper and lower incisors, ankyloglossia lateralis, cervical thymus, coronary aneurysm, crossed ectopic kidney, rectovesical fistula, and absent umbilical artery.

Cervical thymus in man has been described quite recently by Michelson and Sender.[21] They recorded radiologic evidence of absence of the

organ in the chest of a child from whose neck was removed a hyperplastic thymus. In the older literature, absence of the thymus from the chest was also recorded by Harington[22] and Clark[23] both of whom apparently failed, however, to search the neck for primordia. In this century, cervical thymus was also described by Gruber[24] and Gilmour[25]; the latter and Weller[26] recorded the occurrence of less extreme variations of thymic maldevelopment. It is of interest that in a case reported by Gruber[27] there was also underdevelopment of the mandible and tongue, resulting in micrognathia, microglossia, and microstomia, as in specimens in the present study.

The only occurrence that we have discovered in human subjects of a situation resembling the intra-eustachian tube thymus described in this paper was that mentioned by Hagens.[28] This was a newborn, in whom there was a unilateral defect of the auditory apparatus with a mass of thymus tissue in the cavum tympani on the affected side.

In human beings, fusion of the tip of the tongue to the floor of the mouth or to the vault of the palate has been noted a number of times,[29-34] and has been termed superior ankyloglossia. However, lateral ankyloglossia is apparently a very rare anomaly in man, since we have been able to discover a record of lateral margin fusion of the tongue to the gum in one instance only.[35]

The latest case of coronary aneurysm described in man[36] brings to approximately 68 the number recorded in the literature, the latest surveys being those of Crocker, Sobin and Thomas,[37] Currarino, Silverman and Landing[38] and Scott.[39] The coronary aneurysm produced in the present experiment communicated with the right ventricle, as it frequently does in human beings.[40] In this instance, however, it occurred in a heart with transposition of the great vessels, and the arteriovenous fistula that would ordinarily have resulted was thus avoided.

All 10 specimens sectioned showed urologic maldevelopment; in 9 of these, severe disturbances were present, and in the tenth the left kidney lay in a moderately mediad position. The renal anomalies consisted mainly of deviations in location and in fusions. The kidneys were not reduced in size, and in some instances may have been enlarged. The one exception was the animal with bilateral renal agenesis. The ectopies and fusions occurred with a range of variation similar in some degree to that noted in human malformations. In man, one form, crossed renal ectopia with fusion, was the subject of a comprehensive review by Wilmer 20 years ago,[41] and the literature on this has only recently been brought up to date.[42]

Absence of an umbilical artery in human beings has been the subject of recent articles by Little[43] and by Benirschke and Bourne.[44] Little

examined 1,200 and Benirschke and Bourne 1,500 consecutive placentas, and found 16 and 15, respectively, with one missing umbilical artery, an incidence of about 1 in 100. This is a much higher rate of occurrence than is generally believed. Among these 31 cases, 10 had associated malformations in the infant. It is of interest that one child[44] had renal agenesis and atresia ani. This was observed in some of the mice in the present study. In a previous investigation[45] of absent umbilical artery, 27 instances were associated with defective infants, many of whom had renal defects and imperforate anus. In the studies cited,[43,44] roughly one third of placentas with an absent umbilical artery were associated with malformed infants; the authors, therefore, drew attention to the possible diagnostic significance of this vascular anomaly to the obstetrician.

Many experiments in teratogenesis have been made using mice as subjects. A partial list of the agents and the means used to disturb embryonic and fetal development of mice, culled from a recent review,[1] includes: deficiency of riboflavin, folic acid, and niacin; fasting, insulin, cortisone, ACTH and other pituitary preparations; radioiodine, estrogen, trypan blue, hypoxia, nitrogen mustard, and nicotine. It has been made clear from these investigations that quite different malformations and syndromes can be produced by different teratogens, so that even if treatment is administered at roughly the same times during pregnancy, many of these agents induce more or less distinct effects on development. Some examples of these effects in mice are: skeletal anomalies of long bones, esophageal atresia, and hydrocephalus, especially of the fourth ventricle, induced by riboflavin deficiency[18]; exencephaly, eye defects, cleft lip, cleft palate, median facial cleft, fused ribs, digital abnormalities, and gastroschisis, caused by folic acid deficiency[46–48]; and cleft palate and defects of the appendicular and axial skeletons, produced by niacin deficiency.[49] Fasting caused exencephaly, cleft palate, and costal and vertebral malformations.[46,50] Cortisone, compound F, and ACTH caused cleft palate only.[51–54]

An aspect of experimental teratology that has been greatly neglected in published reports is the extent and form of variability in the effects of teratogens on prenatal development. It is a common experience, we are sure, for great differences in severity and frequency of congenital defects to be found from litter to litter as well as from offspring to offspring within a single litter.

Two examples of the variability encountered in mice in our laboratory follow: In summarizing experiments carried out over a 5-year period, using cortisone administration in pregnant mice of a certain genetic constitution, it was discovered that the offspring of females treated between November and April showed cleft palate in 56 per cent; in those

treated from May to October this lesion appeared in 36 per cent.[55] This was a quantitative variation, apparently associated with season. In the second example the variation was qualitative. This experience occurred soon after the experiment forming the basis of this paper was brought to a temporary halt in early March, 1959. It was noticed, when the study was resumed several weeks later, that the same dose of vitamin A administered in the same manner at 8⅓ days after conception to mice of the same inbred strains no longer produced certain malformations that had been observed during the winter months. Malformations of the pinna and cleft palate continued to appear frequently, and mild and moderate microstomia was common. However, none of the defects of the central nervous system, anus, and tail that could be detected upon external examination in the young of females treated during the winter months were found in the litters from females treated in late March and April. In other words, of the entire array of anomalies produced in the first series, only a portion could be evoked in the second. While the basis for most of this variability is unclear, it need not remain entirely obscure. Such a problem was investigated and partly resolved in a series of experiments using cortisone.[56,57]

In contradistinction to variability of environmental origin, some of the variation found in certain studies appears to be of genetic nature. To detect such variability, it is necessary to utilize genetically uniform stocks of animals which are genetically distinct from all examples of other stocks. This condition of homogeneity can be observed only by the use of long-inbred strains. At the present time the only inbred strains of animals easily obtainable are strains of mice; some 200 now exist.[58] Such inbred strains are valuable for several reasons. The basis for this value is the uniformity and temporal constancy of their hereditary constitutions. Most important is the fact that, environmental conditions being equal, genetically determined responses of an inbred strain to an experimental manipulation will usually be less variable than the responses of a heterogeneous population. Consequently, one can repeat experiments and compare results with greater confidence of validity with inbred strains than with noninbred animals. Finally, because different strains may react quite differently to the same experimental procedure,[12,13,39,60] it is possible by use of inbred strains to investigate the genetic bases for these responses.

As stated previously, some of the effects of hypervitaminosis A in the prenatal development of mice are similar to those described in rats, i.e., exencephaly, exophthalmia, cleft palate, spina bifida, etc.[3,4,10] On the other hand, many of the anomalies induced in mice have not yet been reported in rats after such treatment. These are ankyloglossia,

dental defects, craniopharyngeal duct, cervical thymus, cardiovascular defects, ectopic fused kidney, rectovesical fistula, anal atresia, etc. To what extent these discrepancies are due to species differences and to what extent they have other explanations remains to be determined.

Summary

Congenital malformations were induced in the offspring of pregnant mice of inbred strains by the administration of relatively large amounts of vitamin A during the early stages of embryonic development. Anomalies produced affected the skin, ears, eyes, face, mouth, teeth, tongue, palate, thymus, ribs, brain, spinal cord, heart, great vessels, fetal circulation, kidney, ureter, bladder, genital ducts, rectum, anus, tail, and limbs. Some of the defects produced, not previously recorded in experimental teratogenesis, were supernumerary upper and lower incisors, ankyloglossia lateralis, craniopharyngeal duct, cervical thymus, coronary aneurysm, crossed ectopic kidney, rectovesical fistula, and absent umbilical artery. The occurrence of several of these defects in man is discussed.

References

1. Kalter, H., and Warkany, J. Experimental production of congenital malformations in mammals by metabolic procedure. *Physiol. Rev.*, 1959, 39, 69–115.
2. Cohlan, S. Q. Excessive intake of vitamin A as a cause of congenital anomalies in the rat. *Science*, 1953, 117, 535–536.
3. Cohlan, S. Q. Congenital anomalies in the rat produced by excessive intake of vitamin A during pregnancy. *Pediatrics*, 1954, 13, 556–567.
4. Giroud, A., and Martinet, M. Malformations embryonnaires par hypervitaminose A. *Arch. franç. pédiat.*, 1955, 12, 292–300.
5. Giroud, A., and Martinet, M. Tératogénèse par hautes doses de vitamine A en fonction des stades du développement. *Arch. anat. micr.*, 1956, 45, 77–98.
6. Giroud, A., and Martinet, M. Production d'un excès de liquide amniotique dans l'anencéphalie. *Compt. rend. Soc. biol.*, 1955, 149, 452–453.
7. Giroud, A., and Martinet, M. Morphogénèse de l'anencéphalie. *Arch. anat. micr.*, 1957, 46, 247–264.
8. Giroud, A., and Martinet, M. Malformations de la face et hypervitaminose A. *Rev. stomatol.*, 1956, 57, 454–463.
9. Giroud, A.; Martinet, M., and Roux, C. Urétéro-hydronéphrose expérimentale chez l'embryon par hypervitaminose A. *Arch. franç. pédiat.* 1958, 15, 540–551.
10. Deuschle, F. M.; Geiger, J. F., and Warkany, J. Analysis of an anomalous oculodentofacial pattern in newborn rats produced by maternal hypervitaminosis A. *J. Dent. Res.*, 1959, 38, 149–155.
11. Giroud, A., and Martinet, M. Extension à plusieurs espèces de Mammifères des malformations embryonnaires par hypervitaminose A. *Compt. rend. Soc. biol.*, 1959, 153, 201–202.

12. KALTER, H. The inheritance of susceptibility to the teratogenic action of cortisone in mice. *Genetics*, 1954, 39, 185–196.

13. KALTER, H., and WARKANY, J. Congenital malformations in inbred strains of mice induced by riboflavin-deficient, galactoflavin-containing diets. *J. Exper. Zool.*, 1957, 136, 531–565.

14. KALTER, H., and WARKANY, J. Teratogenic action of hypervitaminosis A in strains of inbred mice. (Abstract) *Anat. Rec.*, 1959, 133, 396–397.

15. KALTER, H. Hypervitaminosis A-induced internal congenital malformations in strains of inbred mice. (Abstract) *Anat. Rec.*, 1959, 134, 589–590.

16. KALTER, H. The teratogenic effects of hypervitaminosis A upon the face and mouth of inbred mice. *Ann. New York Acad. Sc.*, 1960, 85, 42–55.

17. DAWSON, A. B. A note on the staining of the skeleton of cleared specimens with alizarin red S. *Stain Technol.*, 1926, 1, 123–124.

18. GUNBERG, D. L. Spina bifida and the Arnold-Chiari malformation in the progeny of trypan blue injected rats. *Anat. Rec.*, 1956, 126, 343–367.

19. WARKANY, J.; WILSON, J. G., and GEIGER, J. F. Myeloschisis and myelomeningocele produced experimentally in the rat. *J. Comp. Neurol.*, 1958, 109, 35–64.

20. WARKANY, J.; KALTER, H., and GEIGER, J. F. Experimental teratology. With special reference to congenital malformations of the central nervous system. *Pediat. Clin. North America*, 1957, Nov., 983–994.

21. MICHELSON, H., and SENDER, B. Cervical thymus; report of a case. *A.M.A. Arch. Surg.*, 1956, 72, 275–276.

22. HARINGTON, H. Absence of the thymus gland. (Letter to the editor.) *London M. Gaz.*, 1828–1829, 3, 314.

23. CLARK, A. A case of absence of the thymus gland in an infant. *Lancet*, 1896, 2, 1077.

24. GRUBER, G. B. Über Variationen der Thymusform und -lage. *Ztschr. ang. Anat.*, 1920, 6, 320–332.

25. GILMOUR, J. R. Some developmental abnormalities of the thymus and parathyroids. *J. Path. & Bact.*, 1941, 52, 213–218.

26. WELLER, G. L., JR. Development of the thyroid, parathyroid and thymus glands in man. *Contrib. Embryol. Carnegie Inst.*, 1933, 24, 95–138.

27. GRUBER, G. B. Die Entwicklungsstörungen der Thymusdrüse. In: Schwalbe, E. Die Morphologie der Missbildungen des Menschen und der Tiere. Gruber, G. B. (ed.) G. Fischer, Jena, 1932, Vol. 3, part 15, chapt. 10, pp. 710–757.

28. HAGENS, E. W. Malformation of the auditory apparatus in the new-born; associated with ectopic thymus. *Arch. Otolaryng.*, 1932, 15, 671–680.

29. ROUTIER. Ankyloglosse totale datant de 17 ans. *Bull. et Mém. Soc. de Chir. Paris*, 1889, 15, 707–708.

30. JOLY. Observation d'ankyloglosse. *Normandie méd.*, 1894, 9, 310–312.

31. KRAMER, W. Zur Entstehung der angeborenen Gaumenspalte. *Zentralbl. Chir.*, 1911, 38, 385–387.

32. PHILIP, J.-A. Ankyloglosse supérieur congénital. *Arch. méd. des enfants*, 1920, 23, 243–244.

33. ESAU, P. Seltene angeborene Missbildungen. *Arch. klin. Chir.*, 1921, 118, 817–820.

34. COSACK, G. Die angeborene Zungen-Munddach-Verwachsung als Leitmotiv eines Komplexes von multiplen Abartungen. (Zur Genese des Ankyloglossum superius.) *Ztschr. Kinderheilk.*, 1953, 72, 240–257.

35. FISCHER. Verwachsung des linken Zungenrandes mit dem Zahnfleisch. *Ztschr. f. Wundärzte u. Geburtsh, Winnenden*, 1883, **34**, 37–38.

36. GORE, I.; SMITH, J., and CLANCY, R. Congenital aneurysms of the coronary arteries, with report of a case. *Circulation*, 1959, **19**, 221–227.

37. CROCKER, D. W.; SOBIN, S., and THOMAS, W. C. Aneurysms of the coronary arteries. Report of three cases in infants and review of the literature. *Am. J. Path.*, 1957, **33**, 819–843.

38. CURRARINO, G.; SILVERMAN, F. N., and LANDING, B. H. Abnormal congenital fistulous communications of the coronary arteries. *Am. J. Roentgenol.*, 1959, **82**, 392–402.

39. SCOTT, D. H. Aneurysm of the coronary arteries. *Am. Heart J.*, 1948, **36**, 403–421.

40. GASUL, B. M.; ARCILLA, R. A.; FELL, E. H.; LYNFIELD, J.; BICOFF, J. P., and LUAN, L. L. Congenital coronary arteriovenous fistula. Clinical, phonocardiographic, angiocardiographic and hemodynamic studies in five patients. *Pediatrics*, 1960, **25**, Suppl., 531–560.

41. WILMER, H. A. Unilateral fused kidney. A report of five cases and a review of the literature. *J. Urol.*, 1938, **40**, 551–571.

42. WILLIAMS, D. I. Urology in Childhood. Springer, Berlin, 1958, 353 pp.

43. LITTLE, W. A. Aplasia of the umbilical artery. *Bull. Sloane Hosp. Women*, 1958, **4**, 127–131.

44. BENIRSCHKE, K., and BOURNE, G. L. The incidence and prognostic implication of congenital absence of one umbilical artery. *Am. J. Obst.*, 1960, **79**, 251–254.

45. BENIRSCHKE, K., and BROWN, W. H. A vascular anomaly of the umbilical cord. The absence of one umbilical artery in the umbilical cords of normal and abnormal fetuses. *Obst. & Gynec.*, 1955, **6**, 399–404.

46. RUNNER, M. N. Inheritance of susceptibility to congenital deformity—embryonic instability. *J. Nat. Cancer Inst.*, 1954–1955, **15**, 637–649.

47. TUCHMANN-DUPLESSIS, H., and MERCIER-PAROT, L. Sur l'action tératogène de l'acide x-méthylfolique chez la Souris. *Compt. rend. Acad. sc.*, 1957, **245**, 1963–1965.

48. TRASLER, D. G. Genetic and other factors influencing the pathogenesis of cleft palate in mice. Ph.D. thesis, McGill University, Montreal, 1958.

49. PINSKY, L., and FRASER, F. C. Production of skeletal malformations in the offspring of pregnant mice treated with 6-aminonicotinamide. *Biol. Neonat.*, 1959, **1**, 106–112.

50. KALTER, H. Preliminary studies on the metabolic factors involved in the production of cleft palate in mice. (Abstract) *Genetics*, 1954, **39**, 975.

51. FRASER, F. C., and FAINSTAT, T. D. Production of congenital defects in the offspring of pregnant mice treated with cortisone. *Pediatrics*, 1951, **8**, 527–533.

52. KALTER, H., and FRASER, F. C. Production of congenital defects in the offspring of pregnant mice treated with compound *F*. (Letter to the editor.) *Nature, London*, 1952, **169**, 665.

53. INGALLS, T. H., and CURLEY, F. J. The relation of hydrocortisone injections to cleft palate in mice. *New England J. Med.*, 1957, **256**, 1035–1039.

54. HEIBERG, K.; KALTER, H., and FRASER, F. C. Production of cleft palates in the offspring of mice treated with ACTH during pregnancy. *Biol. Neonat.*, 1959, **1**, 33–37.

55. KALTER, H. Seasonal variation in frequency of cortisone-induced cleft palate in mice. (Abstract) *Genetics*, 1959, **44**, 78–79.

56. KALTER, H. Modification of the teratogenic action of cortisone in mice by maternal age, maternal weight, and litter size. *Am. J. Physiol.*, 1956, 185, 65–68.

57. KALTER, H. Factors influencing the frequency of cortisone-induced cleft palate in mice. *J. Exper. Zool.*, 1957, 134, 449–467.

58. SNELL, G. D.; STAATS, J.; LYON, M. F.; DUNN, L. C.; GRÜNEBERG, H.; HERTWIG, P., and HESTON, W. E. Standardized nomenclature for inbred strains of mice: second listing. *Cancer Res.*, 1960, 20, part 1, 145–169.

59. INGALLS, T. H.; AVIS, F. R.; CURLEY, F. J., and TEMIN, H. M. Genetic determinants of hypoxia-induced congenital anomalies. *J. Hered.*, 1953, 44, 185–194.

60. SMITHBERG, M. Teratogenic effects of some hypoglycemic agents in mice. (Abstract) *Anat. Rec.*, 1960, 136, 280.

We are indebted to Hoffman-LaRoche, Inc., Nutley, N.J., for generous supplies of vitamin A.

LEGENDS FOR FIGURES

Except where indicated, photomicrographs were prepared from sections stained with hematoxylin and eosin.

FIG. 1. Ventral view of the head with the lower jaw removed, showing a cleft palate. × 5.

FIG. 2. Head of a young mouse with microstomia. Note the small oral aperture. × 6.

FIG. 3. Head of a mouse with "astomia." Note the apparent absence of an oral aperture and the exophthalmos. × 5.

FIG. 4. Offspring with microstomia and abnormal pinna. × 3.5.

FIG. 5. Section through the upper thorax, showing the space (arrow) where the thymus should be. Comparison with control in Figure 6 reveals displacement of the trachea relative to the position of the esophagus. × 11.

FIG. 6. Section through the upper thorax of a control mouse, showing the normal location and structure of the thymus (arrows). × 14.

FIG. 7. Ribs in an alizarin-stained specimen, showing extensive bilateral fusions. × 6.5.

FIG. 8. Young mouse with an absent tail and imperforate anus. There are also microstomia and exophthalmos. × 2.5.

FIG. 9. Median cleft mandible. × 6.

FIG. 10. Side view of a mouse, showing exophthalmos and exencephaly and the absence of the pinna and tail. × 2.5.

FIG. 11. Offspring with an open eye, exencephaly, gastroschisis, short lower trunk, and absent tail. Sections revealed bilateral renal agenesis and absence of ureters and genital ducts. × 3.

FIG. 12. View of the lower trunk, showing spina bifida aperta at the sacral level. × 6.

FIG. 13. Young mouse, showing exophthalmos, absent pinna, umbilical hernia, and spina bifida aperta at the lumbrosacral level. × 3.5.

FIG. 14. Rear view, showing exencephaly and spina bifida aperta at the lumbosacral level. × 3.

1, 2
3, 4
5
6, 7
8, 9
10, 11
12
13, 14

FIG. 15. Sagittal section of a spina bifida occulta. Also seen is the crossed ectopic fused kidney. × 9.

FIG. 16. Sagittal section of a slightly protruberant spina bifida occulta. This was not noted upon external examination. × 12.

FIG. 17. Section of the chest, showing the heart with a narrow, crooked ductus arteriosus (arrow). × 17.

FIG. 18. Control. Normal ductus arteriosus. × 16.

FIG. 19. Cross section of a heart with a high interventricular septal defect (arrow). R = right ventricle; L = left ventricle. Compare with control in Figure 20. × 21.

FIG. 20. Control heart. R = right ventricle; L = left ventricle. × 21.

FIG. 21. A crossed ectopic fused kidney with a left hydroureter. The inferior vena cava and aorta lie between the midline portion of the left kidney and the vertebra. × 17.

FIG. 22. Cross section of a fused ectopic kidney with 3 ureters (just ventral to the kidney); the dilated one becomes atretic caudally; another (closest to kidney) will enter the left Wolffian duct. The bladder is moderately dilated and at its left dorsolateral border the musculature is absent. Dorsal to the bladder are two structures. The one at the animal's right is an aberrant genital duct abnormally situated. At the left is the colon, the lumen of which is about to communicate with that of the bladder. (In animals with "rectovesical" fistula, the rectum is actually absent and it is the colon that is involved in the fistula.) × 14.

FIG. 23. Midline fused kidneys with bilateral hydroureter ending blindly caudally. × 13.

FIG. 24. Midline "lump" kidney (arrow) between defective vertebrae. Ventral to it is a normal ureter and a hydroureter. Ventral to the ureters is a greatly dilated, thin-walled bladder. At the dorsal surface there is a spina bifida aperta. × 13.

FIG. 25. Frontal section through the nasopharynx (N). Above the basisphenoid is the midbrain with the pituitary beneath the hypothalamus. Lateral to N are atretic eustachian tubes in which lie ectopic thymic tissue (arrows). × 25.

15, 16

17, 18

19

20, 21

22

23, 24

25

FIG. 26. Frontal section through the mouth, showing bilateral fusion of the tongue to the gingiva, with outpouchings of the oral cavity beneath and at the sides of the tongue. × 56.

FIG. 27. Frontal section through a microstomia, showing a supernumerary lower incisor on the left (arrow). × 56.

26

27

FIG. 28. Frontal section through the pharynx (P) with adjacent cervical thymuses (arrows). × 34.

FIG. 29. Sagittal section, showing dilated bladder, crossed ectopic fused kidney, and a rectovesical fistula (arrow). × 35.

28

29

Kalter-'64
Bib. No. 4512

Reproduced by permission
of the copyright owner

Exp. Eye Res. (1964) 3, 228-229

Teratogenically Induced Congenital Aphakia*

H. KALTER

Children's Hospital Research Foundation and Department of Pediatrics College of Medicine, University of Cincinnati, Ohio, U.S.A

(*Received 17 June 1964*)

Forty-five offspring of pregnant DBA mice treated with a single large dose of vitamin A were serially sectioned. Nearly all of the young had bilateral "typical" retinal coloboma with otherwise well-developed eyes. One of them, however, had more severe abnormalities, consisting of a microphthalmic left eye and an extensively malformed right one, in which all of the structures of the anterior segment were missing. It was postulated that the aphakia and accompanying ocular anomalies were the consequences of total retinal coloboma, i.e., an exaggeration of the defect that occurred commonly, and that secondary destruction of the lens was responsible for its absence.

1. Introduction

Experimental mammalian teratology is concerned with the prenatal induction of congenital malformations in laboratory animals. The methods that have been used to produce structural deviations in embryos are numerous, and the types of abnormalities produced are many and diverse (Kalter and Warkany, 1959). These defects often closely resemble their human counterparts.

Among the most effective teratogenic (i.e. malformation-producing) means is hypervitaminosis A. Single large doses of vitamin A given to pregnant mice during early embryogenesis cause morphological anomalies of the face, mouth, heart, spinal cord, genitourinary system, rectum, skeleton, etc. (Kalter and Warkany, 1961). Recently, one offspring with an unusual malformation of an eye was found.

2. Methods

The mother of this animal, a mouse of the DBA/IJ inbred strain, was given a single dose of 40,000 IU of vitamin A palmitate in sesame oil by oral intubation. The administration was made at about 8–1/3 days after fertilization, i.e. early during the organogenetic period of embryonic development, at a time before the appearance of any optic structures. The pregnant female was killed about 2 days before expected delivery and the offspring removed, fixed in Bouin's solution, and serially sectioned at 20 μ and stained with hematoxylin and eosin.

3. Results and Discussion

The female had only one full-grown offspring. As Plate 1 shows, the offspring's left eye was microphthalmic. Its most distinctive features, aside from smallness, were the thick cornea and the absence of the anterior chamber and of the optic nerve (see the control eye in Plate 2). Plate 3 shows a frontal section through the brain and

*This investigation was supported in part by a grant from the National Association for Retarded Children, New York, New York, and in part by a PHS research grant (RG–7107) from the National Institute of Arthritis and Metabolic Diseases, U.S. Public Health Service.

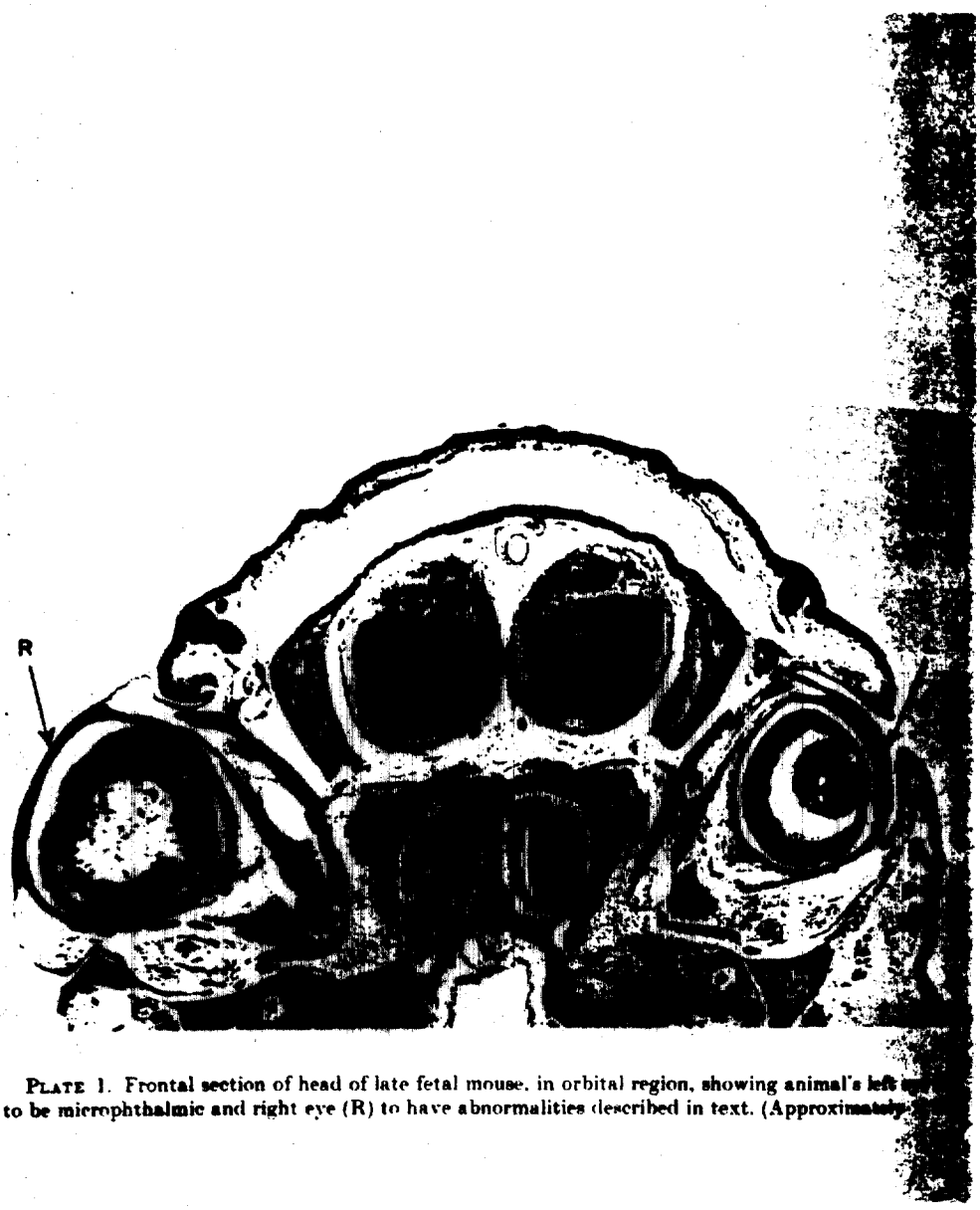

PLATE 1. Frontal section of head of late fetal mouse, in orbital region, showing animal's left eye to be microphthalmic and right eye (R) to have abnormalities described in text. (Approximately

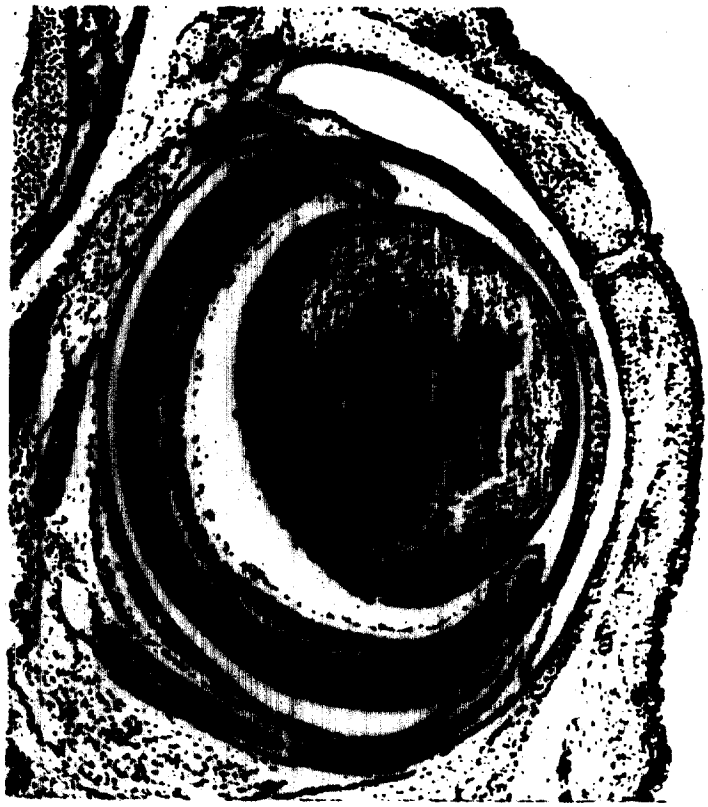

PLATE 2. Control eye, same fetal age as that of abnormal specimen. Note closed eyelid, normal for [illegible] of this age, and spatial relationships among well-developed, relatively large lens, well-contoured [illegible], and anterior chamber. (Approximately [illegible] 75)

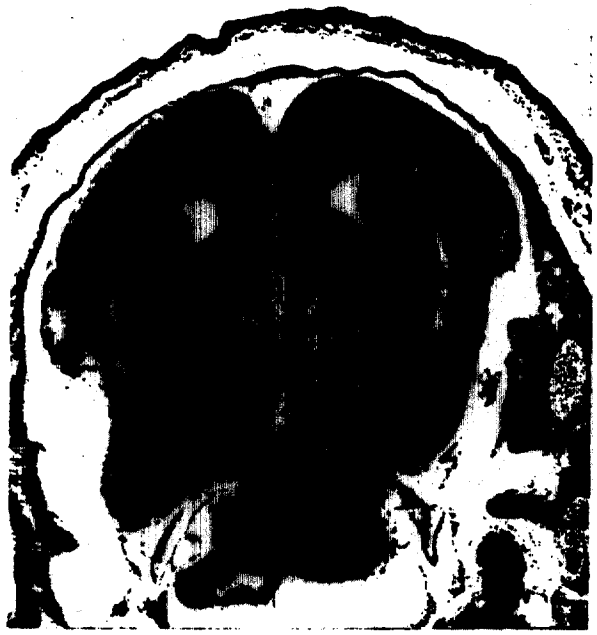

PLATE 3. Frontal section of abnormal head through optic chiasm, showing no optic fibers on left since microphthalmic eye had no optic nerve. (Approximately × 30)

Figure 4. Abnormal right eye, filled with thick retina and showing no lens, iris, pupil, cornea, anterior chamber, or ciliary body. This eye had an optic nerve. (Approximately × 70)

PLATE 5. Aphakic eye, showing extensive retinal coloboma. (Approximately × 73)

PLATE 6. Retinal coloboma of the type seen in almost all eyes of 45 serially sectioned offspring from pregnant mice given a large dose of vitamin A. In this defect, the lens has never been involved or even of less than normal size. (Approximately × 84)

PLATE 7. Loosely filled sac projecting outward from aphakic eye, possibly representing or containing remnants of extruded lens. (Approximately × 85)

the optic chiasm. No optic fibers are present on the left side. Microphthalmia and absence of the optic nerve have been encountered repeatedly in experimental mammalian teratogenesis (Kalter and Warkany, 1959).

The right eye, however, presented a type of malformation that it is believed has not been previously reported as induced in mammals. The eye was represented by a vesicular structure almost entirely composed of a thick retina and contained none of the structures of the anterior segment, i.e., lens, iris, cornea, anterior chamber, pupil and ciliary body (Plate 4). The retina showed an extensive coloboma (Plate 5). and into the cleft, filling the cavity, there ran a thick band of tissue that was continuous with the circumferential mesodermal layer (Plates 4 and 5).

In 45 serially sectioned offspring from a group of females given an excess of vitamin A this was the only specimen with microphthalmia or aphakia. However, the other eye defect that occurred in almost every animal was retinal coloboma alone (Plate 6), which was of the sort called "typical" by Mann (1957), following as it does the line of the normal fetal fissure. Hence it may be conjectured that in the present case there occurred an exaggeration of the retinal defect commonly found; that the extreme abnormalities noted were secondary consequences of this severe form of retinal maldevelopment and overgrowth; and that the aphakia was probably the result of extrusion of the lens, remnants of which may be present in the loosely filled cyst that projected outward from the eye (Plate 7).

This abnormality, occurring in an eye of approximately normal size, may thus be an instance of secondary destruction of the lens and a part of the picture of severe fetal retinal coloboma. As such, this lens defect is quite different in origin from the secondary aphakias cited by Mann (1957) and by Duke-Elder (1963) as occurring in human beings, since in those cases the defect appears to have been intrinsic to the lens.

REFERENCES

Duke-Elder, Sir Stewart (1963). *System of Ophthalmology*, Vol. 3, p. 690. Mosby, St. Louis.
Kalter, H. and Warkany, J. (1959). *Physiol. Rev.* 39, 69.
Kalter, H. and Warkany, J. (1961). *Amer. J. Path.* 38, 1.
Mann, I. (1957). *Developmental Abnormalities of the Eye*, 2nd Ed., pp. 74, 306. Lippincott, Philadelphia.

Khogali-'66
Bib. No. 4707

Reproduced by permission of the copyright owner

Quart. J. exp. Physiol. (1966) **51**, 120–129

BONE STRENGTH AND CALCIUM RETENTION OF RATS IN HYPERVITAMINOSIS-A.

By A. KHOGALI.* From The Department of Physiology, University of St. Andrews, at Queen's College, Dundee.

(*Received for publication 6th September* 1965)

Newly-weaned male albino rats were fed by gavage excessive doses of vitamin A for 4 weeks either alone or with one of the thyroid hormones: L-triiodothyronine and D-triiodothyronine. Some rats were given the thyroid hormones alone. It was found that:

1. The rats fed 6000 i.u. and 12,000 i.u. vitamin A per day gained weight normally and did not sustain spontaneous fractures.
2. A dose of 24,000 i.u. vitamin A per day retarded the growth of the rats and spontaneous fractures of the long bones (mainly tibiæ) occurred.
3. The bones of the animals suffering from hypervitaminosis-A were abnormally thin and their bending moment at breaking was significantly reduced. The breaking stress (quality) of the bones was also reduced but this can be explained by a change in texture of the bones and is not due to altered quality of the bony material. The stiffness (E) of the bones was not affected.
4. The percentage mineral content of the bones from hypervitaminotic rats was normal, but the total calcium retention of the animals was reduced.
5. L-triiodothyronine and D-triiodothyronine in doses of 5 μg. per day aggravated the skeletal changes in hypervitaminosis-A.
6. The thyroid hormones alone did not produce any significant changes in the physical properties of the femora of rats.

It is suggested that, in hypervitaminosis-A, the quantity and distribution of the bony material is disturbed but its quality is probably unaltered.

THE occurrence of spontaneous fractures in rats fed excessive amounts of vitamin A was first reported by Collazo and Rodriguez [1933 *a* and *b*] and since then has been confirmed by many workers [Bomskov and Seeman, 1933; Davies and Moore, 1934; Hoff and Jeddeloh, 1934; Moore and Wang, 1943, 1945; Rodahl, 1949, 1950]. The cause of such fractures, however, is still obscure. Several workers [Bomskov and Sievers, 1933; Moore and Wang, 1945; Rodahl, 1949] have found that the mineral content of bones from hypervitaminotic rats is normal. Recently Nerukar and Sahasrabudhe [1956] reported that rats fed with large doses of vitamin A develop a negative balance for calcium, phosphorus and nitrogen. They [Nerukar and Sahasrabudhe, 1956] detected no changes in the blood calcium and phosphorus levels and the ash composition of the bones was not altered.

Whether the *in vivo* effects of vitamin A on bones are due to a direct action or whether more complex metabolic disturbances are involved is not known. Baumann and Moore [1939] obtained no evidence for a specific antagonism between thyroxine and vitamin A.

The question posed here is: are the bone changes and spontaneous fractures seen in hypervitaminosis-A caused by a change in the quality or quantity of bone material?

Although many workers have reported on the X-ray appearances of the long bones and sites of fracture in hypervitaminosis-A, they did not measure

* Present address: Physiology Department, University of Khartoum.

bone dimensions or bone strength. To fulfil its function as a supporting structure, a bone must be strong enough to withstand the stresses and strains of an active life. It was thought appropriate, therefore, to assess in quantitative terms the strength and quality of bones in hypervitaminosis-A by the methods described by Bell *et al.* [1941]. The total calcium retention of the animals was also estimated with a view to correlating the physical and chemical observations. Furthermore, the influence of low doses of L- and D-triiodothyronine on the bony changes induced by excess vitamin A was studied.

Materials and Methods

The animals used were weanling male albino rats weighing 50–65 g. There were four to six groups in each experiment with six rats in each group. All rats were fed *ad libitum* on rat cake. Vitamin A acetate was diluted in arachis oil and given by gavage. The thyroid hormones were injected subcutaneously daily in aqueous solutions rendered slightly alkaline with sodium hydroxide. The animals were weighed every other day and the duration of each experiment was 4 weeks. Animals that showed clinical evidence of fracture during the experiment were anaesthetized with ether and X-rayed.

Bending Tests. – At the end of each experiment the animals were killed with ether and X-rayed. All femora were carefully dissected out, cleaned and allowed to dry at room temperature for several days. After that the bones were X-rayed, weighed and their physical properties measured by the methods described by Bell *et al.* [1941] which are based on the tests used by engineers to measure the strength of materials. The properties measured are bending moment at breaking, breaking stress, stiffness (Young's Modulus of elasticity, E) and strain at the elastic limit. The bending moment at breaking is a measure of the strength of the bone as a whole and it depends on the shape and dimensions of the central section of the shaft. Bending moment is expressed in pound-inches (lb. in.). The breaking stress is an evaluation of the quality of the bone substance and, since it is expressed in pounds per square inch (lb. sq. in.), it is independent of the size or shape of the bone. The stiffness (E) of a bone signifies its resistance to deflexion and is a measure of the elastic quality of the bone material. E is expressed in pounds per square inch. Strain is the change in length per unit length of the bone during the bending test. It is expressed here as a percentage.

Chemical Methods. – At the beginning of each experiment a representative group of two or three rats was killed with ether and the calcium content of the degutted animals was determined. The methods used for the preparation and ashing of the carcasses were described by Bell *et al.* [1941]. The calcium content of the ash was determined by the Clark-Collip modification of the standard method for serum calcium [King and Wootton, 1956].

At the end of each experiment, after the animals had been killed with ether, two or three rats from each group were weighed, degutted and weighed again. The femora and tibiæ were then dissected out and the calcium content of the carcasses determined. The femora were used for the bending tests described above and for histology. The tibiæ were carefully cleaned and dried in an oven at 105° C. for 3 days. After weighing, the dry tibiæ were ashed in an electric furnace at 600° C. and the percentage of ash in each tibia calculated. On the assumption that the percentage of ash in the tibiæ and femora from the same animal is the same, the calcium content of the femora removed for the bending tests or histology was calculated so that it was possible to estimate the calcium retention of the whole animal.

Histology. – Histological examination of the sites of fracture and mid-femoral sections were made. The bones were fixed in 10 per cent formol saline and decalcified in 4 per cent phloroglucin-nitric acid. After complete decalcification the bones were embedded in paraffin and sections 8 μ in thickness were stained with hæmatoxylin-eosin.

Results

Experiment I. The Effects of Graded Doses of Vitamin A on Rats. – There were four groups of six rats in this experiment. Group A (control) received no vitamin A supplement; group B each received 6000 i.u. vitamin A acetate daily; group C, 12,000 i.u.; and group D, 24,000 i.u.

Table I. Rate of Growth of the Different Groups in Experiment I

Treatment	Mean initial weight (g.)	Mean final weight (g.)	Mean weight gain/day (g.)
Six rats in each group:			
(A) Control – rat cake only	55	157	3·6
(B) 6000 i.u. vitamin A/day	54	167	4·0
(C) 12,000 i.u. vitamin A/day	53	157	3·7
(D) 24,000 i.u. vitamin A/day	54	89	1·3

The growth of the rats fed 24,000 i.u. vitamin A per day was markedly inhibited (Table I). The lower doses of the vitamin did not retard growth. It is interesting to note that the rats given 6000 i.u. vitamin A per day gained more weight than the controls.

Table II. Mean Femur Weight and Dimensions in Experiment I. (B, D, b, and t are in inches)

Treatment	Femur weight (g.)	B	D	b	t
Six rats in each group:					
(A) Control	0·323	0·119	0·096	0·082	0·018
(B) 6000 i.u. vitamin A/day	0·332	0·110	0·094	0·072	0·020
(C) 12,000 i.u. vitamin A/day	0·297	0·101	0·087	0·064	0·019
(D) 24,000 i.u. vitamin A/day	0·159	0·080	0·079	0·055	0·015

B = maximum external diameter.
D = minimum external diameter.
b = width of marrow cavity.
t = thickness of the wall.

The growth of the rats in group D which received 24,000 i.u. vitamin A daily (see Table I) was retarded and the animals showed signs of intoxication in the form of œdema of the eyelids, soreness of the eyes, exophthalmos and alopecia round the mouth. There was no difference in appearance between the rats in groups B, C and the controls (group A).

By the end of the 2nd week of the experiment, four out of the six rats

FIG. 1. Radiograph of rat from group D of experiment 1 to show characteristic fractures produced by large doses of vitamin A (actual size).

2A 2D

FIG. 2. Radiograph of control rat (group A of experiment 1) and rat from group D which had been given doses of vitamin A. The constriction deformity in the tibia of the latter occurs at the site of fracture shown in fig. 1. The two animals were X-rayed simultaneously on one film. The original photograph showed a very greatly decreased density of the bones in the treated rat. The contrast was reduced in making this positive to demonstrate the anatomical differences more satisfactorily (actual size).

[To face page 122

FIG. 3. Cross section of femur of rat from group D of experiment 1. The spongy nature of the endosteal bone contrasts with the normal concentric compact bone on the periphery. ×20.

receiving 24,000 i.u. vitamin A sustained fractures of one or both tibiæ. The upper one-third of the tibia was the common site of fracture (fig. 1). The shafts of the bones from the same group were abnormally thin and in some cases the fibulæ almost disappeared. Some tibiæ also showed a constriction deformity, similar to that described by Rodahl [1950], at the site where

TABLE III. PHYSICAL PROPERTIES OF THE BONES IN THE VARIOUS GROUPS IN EXPERIMENT I.

Treatment	Bending moment lb./in.	Breaking stress lb./sq. in. $\times 10^6$	Stiffness (E) lb./sq. in. $\times 10^6$	Strain percentage
(A) Control	3·02±0·51	33·55±4·26	1·45±0·24	2·07±0·32
(B) 6000 i.u. vitamin A/day	2·79±0·24	33·31±2·49	1·49±0·18	1·87±0·26
(C) 12,000 i.u. vitamin A/day	2·24±0·26	33·50±2·85	1·64±0·32	1·89±0·37
(D) 24,000 i.u. vitamin A/day	0·96±0·10	24·10±2·58	1·61±0·38	1·46±0·32

fractures commonly occurred (fig. 2). No fractures were seen in the animals fed the lower doses of vitamin A.

The dimensions of the femur as measured at mid-shaft (Table II) were reduced in the animals fed vitamin A, the reduction being greatest in the group receiving 24,000 i.u. per day, in which the maximum external diameter (B) was reduced to about two-thirds that of the controls. The minimum external diameter (D) was not affected to the same extent. On the whole the thickness of the wall (t) of the femur was not much different from normal.

TABLE IV. MEAN TIBIAL ASH AND CALCIUM RETENTION OF RATS IN EXPERIMENT I

Treatment	Percentage ash in dry tibia	Percentage Ca in ash	Ca content of degutted control (g.)	Total Ca retention (g.)	Percentage Ca in degutted animal
(A) Control	53·6	32·6	0·601	1·066	0·735
(B) 6000 i.u. vitamin A/day	55·0	32		1·096	0·741
(C) 12,000 i.u. vitamin A/day	57·7	34		0·968	0·689
(D) 24,000 i.u. vitamin A/day	53·7	33·2		0·378	0·504

but the width of the marrow cavity (b) was markedly diminished in the hypervitaminotic group. The average weight of a femur from the group that received 24,000 i.u. vitamin A per day was only about half that of the control group.

The physical properties of the bones from the various groups in this experiment are shown in Table III as means and standard deviations. The bending moment at breaking of the bones in groups C and D was significantly reduced ($P<0·01$ and 0·001 respectively). Group D also showed a significant fall in breaking stress (quality) of the bones ($P<0·001$). The stiffness of the bones (E), on the other hand, was not significantly altered in any of the groups ($P<0·6$, 0·1 and 0·5 for groups B, C and D respectively). Strain at the elastic limit was significantly reduced in group D only ($P<0·001$).

The ash content of tibiæ and the calcium content of the ash was almost the same in hypervitaminiotic and control animals. The calcium retention over the period of the experiment, however, was markedly reduced in the rats fed 24,000 i.u. vitamin A per day (Table IV).

Histological examination of the femur in the different groups showed that the endosteal bone in group D (24,000 i.u. vitamin A) was laid down in a spongy fashion instead of the usual compact form (fig. 3). Microscopic examination of the site of fracture showed little apart from osteoclastic activity and irregularity of the bone at and above the fracture site. There was no evidence of any specific pathological process.

Experiment II. The Effect of L-triiodothyronine and D-triiodothyronine on the Lesions Produced by Excess Vitamin A. – There were six groups of six

TABLE V. GROWTH OF RATS IN EXPERIMENT II

Treatment	Mean initial weight (g.)	Mean final weight (g.)	Mean weight gain/day (g.)
(A) Control	64	156	3·3
(B) 24,000 i.u. vitamin A/day	60	138	2·8
(C) 5 μg. L-TRI/day	65	162	3·5
(D) 5 μg. D-TRI/day	63	164	3·6
(E) 24,000 i.u. vitamin A + 5 μg. L-TRI/day	61	140	2·8
(F) 24,000 i.u. vitamin A + 5 μg. D-TRI/day	61	118	2·0

rats each in this experiment with one group acting as control (Table V). Vitamin A acetate was fed in a dose of 24,000 i.u. per day. The thyroid hormones L-triiodothyronine (L-TRI) and D-triiodothyronine (D-TRI) were given in doses of 5 μg. per day. This dose was chosen because Bell *et al.* [1962] found that it produced marked inhibition of the skeletal lesions induced in young rats by β-aminopropionitrile (BAPN).

The rats given vitamin A plus either form of triiodothyronine (groups E and F) showed signs of intoxication with vitamin A and looked more miserable than the animals fed vitamin A alone. The appearance of the rats in groups C and D did not differ from that of the controls.

Animals from groups B, E and F sustained spontaneous fractures similar to those seen in the first experiment. No fractures were seen in rats in the other groups. As in the first experiment the femora of the rats fed 24,000 i.u. vitamin A per day were smaller and lighter than normal. In the groups that received vitamin A plus either form of triiodothyronine the femora were lighter and their dimensions smaller than those of the rats given vitamin A alone (Table VI). Neither form of triiodothyronine given alone had any appreciable influence on the weights or external dimensions of the femora.

The values of the physical properties of the bones from the various groups in this experiment are shown in Table VII as means and standard deviations.

The bending moment at breaking of the bones was significantly lower than normal in groups B, E and F ($P<0·001$ for each group). The bones from the

same groups also showed reduced breaking stress ($P<0.02$, 0·05 and 0·05 for groups B, E and F respectively). Although the breaking stress of the bones from groups E and F was slightly higher than that in group B, the difference

TABLE VI. MEAN FEMUR WEIGHT AND DIMENSIONS IN EXPERIMENT II (B, D, b, and t are in inches)

Treatment	Femur weight (g.)	B	D	b	t
(A) Control	0·309	0·118	0·099	0·086	0·017
(B) 24,000 i.u. vitamin A/day	0·270	0·096	0·092	0·061	0·018
(C) 5 μg. L-triiodothyronine day	0·305	0·115	0·097	0·083	0·017
(D) 5 μg. D-triiodothyronine day	0·312	0·115	0·097	0·081	0·017
(E) 24,000 i.u. vitamin A + 5 μg. L-TRI/day	0·242	0·090	0·086	0·058	0·017
(F) 24,000 i.u. vitamin A + 5 μg. D-TRI/day	0·204	0·082	0·083	0·051	0·016

B = maximum external diameter.
D = minimum external diameter.
b = width of marrow cavity.
t = thickness of the wall.

was not statistically significant ($P<0.4$ and <0.2 respectively). The stiffness (E) of the bones was not significantly different from normal in any of the groups. The strain at the elastic limit was not much changed.

The calcium retention (Table VIII) of the rats fed vitamin A alone and of those given vitamin A plus the thyroid hormones was lower than that of the

TABLE VII. PHYSICAL PROPERTIES OF THE BONES IN THE VARIOUS GROUPS OF EXPERIMENT II.

Treatment	Bending moment lb./in.	Breaking stress lb./sq. in. $\times 10^3$	Stiffness (E) lb./sq. in. $\times 10^6$	Strain percentage
Six rats in each group:				
(A) Control	3·02 ± 0·21	33·66 ± 2·39	1·67 ± 0·32	1·74 ± 0·25
(B) 24,000 i.u. vitamin A day	1·63 ± 0·67	27·52 ± 5·52	1·59 ± 0·30	1·53 ± 0·35
(C) 5 μg. L-triiodothyronine day	2·73 ± 0·36	31·86 ± 2·52	1·55 ± 0·24	1·65 ± 0·28
(D) 5 μg. D-triiodothyronine day	2·84 ± 0·27	32·94 ± 2·47	1·49 ± 0·24	1·84 ± 0·27
(E) 24,000 i.u. vitamin A − 5 μg. L-TRI day	1·68 ± 0·50	29·38 ± 4·45	1·68 ± 0·22	1·40 ± 0·29
(F) 24,000 i.u. vitamin A − 5 μg. D-TRI day	1·48 ± 0·43	30·62 ± 3·39	1·95 ± 0·49	1·47 ± 0·36

control animals and that of the animals receiving the thyroid hormones only. The calcium retention of the animals given the vitamin together with the thyroid hormones was even lower than that of the rats fed vitamin A alone. It is interesting to note that the calcium retention of the animals given the triiodothyronines alone was slightly higher than that of the control animals. The ash content of tibiæ and the calcium content of the ash remained unchanged in all groups.

Microscopic examination of femoral sections from groups B, E and F showed sponginess of the endosteal bone similar to that observed in the first experiment. No abnormality was seen in the femoral sections from the other groups.

Discussion

In the first experiment a dose of 24,000 i.u. vitamin A per day proved to be toxic to young rats and produced in them spontaneous fractures, whereas smaller doses of the vitamin, namely 12,000 i.u. and 6000 i.u. per day, had no

Table VIII. Tibial Ash and Calcium Retention of Rats in Experiment II

Treatment	Percentage ash in dry tibia	Percentage Ca in ash	Ca content of degutted control (g.)	Total Ca retention (g.)	Percentage Ca in degutted animal
(A) Control	55·6	32·3	0·550	0·894	0·680
(B) 24,000 i.u. vitamin A day	53·3	31·0		0·613	0·593
(C) 5 μg. L-triiodothyronine/day	56·1	33·6		0·975	0·727
(D) 5 μg. D-triiodothyronine/day	54·8	33·2		1·101	0·772
(E) 24,000 i.u. vitamin A – 5 μg. L-TRI day	53·6	31·8		0·597	0·606
(F) 24,000 i.u. vitamin A – 5 μg. D-TRI day	55·4	32·2		0·535	0·529

such effect. On the contrary, animals that received 6000 i.u. of vitamin A per day gained more weight than the controls (Table I).

The common site of fractures in hypervitaminotic animals was the upper third of the tibia. In some rats the fibula and humerus also fractured, but none of the animals sustained a fracture of the femur. The bending moment at breaking (Table III), which depends on the size of the bones, was significantly reduced in the animals given 12,000 i.u. and 24,000 i.u. vitamin A per day ($P<0·01$ and $<0·001$ respectively). It is to be noted, however, that the fall in bending moment was more marked in the latter group. This is in line with the observed reduction in femoral dimensions which was greater in the animals fed 24,000 i.u. of the vitamin per day (Table II). In both experiments, the groups given the higher dose of the vitamin also showed a significant fall in breaking stress (quality) of the bones ($P<0·001$ in the first experiment and $<0·02$ in the second experiment). This fall in breaking stress was not associated with a change in the percentage mineral content of the bones. The percentage ash content of the tibiæ and the calcium content of the bone ash was almost the same in hypervitaminotic and normal animals. This is in agreement with the observations of other workers [Moore and Wang, 1945; Rodahl, 1950] who found no changes in the ash content of bones in hypervitaminosis-A. Furthermore, the stiffness (E) of the bones, which is also a measure of bone quality, was not significantly altered in any group in either experiment (Tables III and VII). The strain at the elastic

limit seemed to be reduced slightly with high dosage of vitamin A (Tables III and VII). It is tempting, but probably unwise, to speculate that this reduction is an indication of a disturbance in the collagen in hypervitaminosis-A.

The endosteal bone of the femora from animals fed 24,000 i.u. vitamin A per day was laid down in a spongy fashion instead of the usual concentric compact form. This change in texture of the bone is almost certainly responsible for the fall in breaking stress observed in this group and to which reference has been made earlier. Bell and Sharma [1960] have pointed out that the fall in breaking stress of bones from rats fed β-aminopropionitrile (BAPN) can be explained by the sponginess of the bones in that condition and is not necessarily due to any alteration in the quality of the bony material. The new bone laid down on the endosteal side of the shafts of hypervitaminotic animals explains the reduction in width of the marrow cavity of the bones from such animals (Tables II and VI).

Although the bones in hypervitaminosis-A contained the normal proportion of mineral, the total calcium retention of hypervitaminotic rats was markedly lower than normal. This low calcium retention might be due to one or more of the following factors:—

(*a*) reduced calcium intake by the animals due to poor appetite.
(*b*) reduction of calcium absorption from the intestine.
(*c*) mobilization and excretion of bone calcium.

It is unlikely, however, that the bone changes seen in hypervitaminosis-A are due simply to deprivation of calcium since Bell *et al.* [1941] showed that the external dimensions of femora were not altered by much reduced calcium intake when the supply of other nutrients was adequate. Excessive bone resorption from the periosteal surface of bones in hypervitaminosis-A has been noted by earlier workers [Wolbach, 1947; Rodahl, 1950]. The work of Barnicot [1950] and Fell and Mellanby [1950] on bone in tissue culture indicates that vitamin A is capable, in some way, of causing the differentiation and multiplication of osteoclasts and bone resorption. Presumably a similar mechanism is responsible for the skeletal changes in intact animals. Nerukar and Sahasrabudhe [1956] showed that the administration of large doses of vitamin A to rats produced in them a negative balance for calcium, phosphorus and nitrogen. It seems, therefore, that excess vitamin A drains the mineral stores of the bones without causing any gross changes in their percentage composition. The present experiments indicate that the quantity and distribution rather than the quality of the bone material is affected.

The cause of spontaneous fractures in hypervitaminosis-A is still obscure. The bones in this condition contain the normal proportion of mineral but they are lighter and thinner than normal. It is reasonable to speculate that in hypervitaminosis-A the bending moment needed to break the bones is reduced to such an extent that fractures are produced by forces occurring in the normal activity of the animal. However, Bell *et al.* [1947] in their experiments on rachitic rats obtained lower values of bending moment at breaking than those found in the present experiments and yet their animals

did not sustain spontaneous fractures. Moreover it is difficult to explain why the tibia of all bones should be the commonest site of fracture in hypervitaminosis-A. Presumably the constriction deformity (fig. 2) in the upper third weakens the bone locally and fracture is liable to occur there, but the cause of this deformity is still unexplained. Microscopic examination of the site of fracture shows no evidence of a specific pathological process.

Neither D- nor L-triiodothyronine in doses of 5 μg. per day offered any protection against the effects of vitamin A excess. The animals that received the hormones together with large doses of vitamin A sustained spontaneous fractures. In some cases the external bone dimensions were even smaller than those of the animals fed vitamin A alone. The breaking stress and stiffness (E) of the bones from the groups fed vitamin A plus the thyroid hormones were not significantly different from those of the animals given vitamin A only. The calcium retention of the animals treated with vitamin A plus triiodothyronine was lower than that of the animals given either substance alone. The percentage mineral composition of the bones, however, remained unchanged.

Bell and Cuthbertson [1943] found that the quality of the bones of young rats was not affected by the administration of thyroid gland (thyroideum siccum. B.P.). Furthermore, they did not observe any significant difference in the percentage of calcium in the femora of control and thyroid-treated animals. Munro *et al.* [1958] could find no abnormality in calcium metabolism when L-thyroxine was administered. In the present experiments neither form of triiodothyronine, in the doses used, had any effect on the physical properties or the mineral content of the bones of young rats. The animals treated with the thyroid hormones gained more weight and their calcium retention was higher than that of control animals. However, as might be expected from the different effects on metabolic rate, the L-TRI treated animals had a lower calcium retention than those injected with D-TRI. It can be surmised that small doses of triiodothyronine do not by themselves interfere with calcification or cause any deterioration in the quality of the bones of young rats. But, as already mentioned, animals treated with vitamin A together with triiodothyronine have a lower calcium retention than animals treated with either substance alone. It seems, therefore, that the thyroid hormones potentiate rather than antagonize the effects of hypervitaminosis-A.

Acknowledgments

I wish to thank Professor G. H. Bell for his valuable advice and interest in this work.

I am grateful to Miss C. M. Popplewell, of the Computing Machine Laboratory, the University, Manchester, who helped with the calculations.

The vitamin A used in these experiments was kindly supplied by Glaxo Laboratories, Limited. The thyroid hormones were given by Smith Kline & French Laboratories, Philadelphia. To these firms I extend my thanks.

The apparatus used was obtained from a grant from The Medical Research Council.

REFERENCES

BARNICOT, N. A. (1950). 'The local action of vitamin A on bone', *J. Anat.* (*Lond.*) **84**, 374–387.

BAUMANN, C. A. and MOORE, T. (1939). 'Thyroxine and hypervitaminosis-A', *Biochem. J.* **33**, 1639–1644.

BELL, G. H., CHAMBERS, J. W. and DAWSON, I. M. (1947). 'The mechanical and structural properties of bone in rats on a rachitogenic diet', *J. Physiol.* (*Lond.*) **106**, 286–300.

BELL, G. H., CHAMBERS, J. W. and WEIR, J. B. DEV. (1949). 'Elastic properties of normal and rachitic rat femora', *J. Physiol.* (*Lond.*) **108**, 19*P*.

BELL, G. H. and CUTHBERTSON, D. P. (1943). 'The effect of various hormones on the chemical and physical properties of bone', *J. Endocr.* **3**, 302–309.

BELL, G. H., CUTHBERTSON, D. P. and ORR J. (1941). 'Strength and size of bone in relation to calcium intake', *J. Physiol.* (*Lond.*) **100**, 299–317.

BELL, G. H., KHOGALI, A. and SHARMA, D. N. (1962). 'Quantitative studies on the suppression of skeletal lesions in rats produced by β-aminoproprionitrile', *Quart. J. exp. Physiol.* **47**, 244–251.

BELL, G. H. and SHARMA, D. N. (1960). 'Quantitative effects of β-aminopropionitrile on bone growth', *J. Physiol.* (*Lond.*) **154**, 46*P*.

BOMSKOV, C. and SEEMANN, G. (1933). 'Über eine Wirkung des Vitamin A auf den Mineralhaushalt', *Z. ges. exp. Med.* **89**, 771–779.

BOMSKOV, C. and SIEVERS, G. (1933). 'Über die Wirkung des A-vitamins auf die Zusammensetzung des Blutes', *Z. ges. exp. Med.* **89**, 780–785.

COLLAZO, J. A. and RODRIGUEZ, J. S. (1933 *a*). 'Hypervitaminose A. Die symptomatologie der durch Fütterung von reinem A-Vitamin an jungen Ratten hervorgerufenen Hypervitaminose A', *Klin. Wschr.* **12**, 1782–1734.

COLLAZO, J. A. and RODRIGUEZ, J. S. (1933 *b*). 'Hypervitaminose A. Exophthalmus und Spontanfrakturen', *Klin. Wschr.* **12**, 1768–1771.

DAVIES, A. W. and MOORE, J. (1934). 'Vitamin A and carotene. The distribution of vitamin A in the organs of the normal and hypervitaminotic rat', *Biochem. J.* **28**, 228–295.

FELL, H. B. and MELLANBY, E. (1950). 'Effects of hypervitaminosis A on fœtal mouse bones cultivated *in vitro*', *Brit. med. J. ii*, 535–539.

HOFF, F. and JEDDELOH, B. (1934). 'Experimentelle Untersuchungen mit Epithelkörperhormon und mit Vitamin A', *Z. ges. exp. Med.* **95**, 67–76.

KING, E. J. and WOOTTON, I. D. P. (1956). 'Microanalysis in Medical Biochemistry'. 3rd ed. pp. 100–103. London: Churchill.

MOORE, T. and WANG, Y. L. (1943). 'The toxicity of pure vitamin A', *Biochem. J.* 37, Proc. viii.

MOORE, T. and WANG Y. L. (1945). 'Hypervitaminosis A', *Biochem. J.* **39**, 222–228.

MUNRO, D. S., SATOSKAR, R. S. and WILSON, G. H. (1958). 'Bone calcium and sodium content in bones from rats treated with thyroxine and parathormone', *J. Physiol.* (*Lond.*) **142**, 447–452.

NERUKAR, M. K. and SAHASRABUDHE, M. B. (1956). 'Metabolism of calcium, phosphorus and nitrogen in hypervitaminosis A in young rats', *Biochem. J.* **63**, 344–349.

RODAHL, K. (1949). 'The toxic effect of polar-bear liver', *Norsk. Polarinst. Skr.* **92**, 1–90.

RODAHL, K. (1950). 'Hypervitaminosis A: a study of the effect of excess of vitamin A in experimental animals'. *Norsk. Polarinst. Skr.* **95**, 1–206.

WOLBACH, S. B. (1947). 'Vitamin A deficiency and excess in relation to skeletal growth', *J. Bone Jt Surg.* **28**, 171–192.

Kochhar-'65
Bib. No. 4817

Embryol. exp. Morph., Vol. 14, Part 3, pp. 223–238, December 1965
Printed in Great Britain

Morphological and autoradiographic studies of cleft palate induced in rat embryos by maternal hypervitaminosis A

by DEVENDRA M. KOCHHAR *and* E. MARSHALL JOHNSON[1]
From the Department of Anatomy, College of Medicine, University of Florida

WITH FOUR PLATES

INTRODUCTION

In the laboratory many teratogenic procedures have been found to produce cleft palate in conjunction with other congenital malformations (Kalter & Warkany, 1959), but only in embryos of cortisone treated mice has this malformation been reported to occur singly (Baxter & Fraser, 1950). However, a carefully controlled treatment with hypervitaminosis A can produce a high incidence of cleft palate which is only rarely accompanied by other malformations (Giroud & Martinet, 1956). These two teratogenic treatments have other similarities in that both similarly affect the ultimate chemical composition of tissues. That is, both *in vivo* and *in vitro*, cortisone depresses the ability of tissues to synthesize chondroitin sulfate (Layton, 1951*a*, 1951*b*; Schiller & Dorfman, 1957) and, in animals receiving excessive doses of vitamin A, chondroitin sulfate was removed from the matrix of epiphyseal and articular cartilages (Thomas *et al.*, 1960). In addition, incorporation of S^{35}-labelled inorganic sulfate into embryonic limbs cultivated *in vitro* was inhibited by the presence of vitamin A in the culture medium (Fell, Mellanby & Pelc, 1956).

It was suggested by Larsson (1960) that the occurrence of cleft palate in response to cortisone treatment might be due to interference in the synthesis of chondroitin sulfuric acid. It was demonstrated later by this author (Larsson, 1962) that in mouse embryos from cortisone treated mothers there was a reduced S^{35}-incorporation (presumably into sulfated-mucopolysaccharides) in the palatine shelves as well as in other regions of the embryo. Since the morphological sequence of cortisone induced cleft palate had been described previously (Walker & Fraser, 1957), the present experiment endeavored (1) to compare this sequence with early

[1] *Authors' address:* Department of Anatomy, College of Medicine, University of Florida, Gainesville, Florida, U.S.A.

morphogenesis of cleft palate induced by hypervitaminosis A and (2) to investigate further the effects of maternal hypervitaminosis A on S^{35}-incorporation into the rat embryo.

MATERIALS AND METHODS

Eighty proestrus black-hooded female rats ranging from 60–90 days of age and weighing 150–200 g. were placed overnight with males of the same strain. The presence of a sperm plug or of free spermatozoa in a smear of vaginal contents the next morning indicated that mating had occurred and this day was considered as day 0 of pregnancy. The pregnant animals were divided into two major groups and maintained by a stock diet and water *ad libitum*. Commencing on days 9 or 10 of gestation and continuing for 3 successive days, females received 60,000 international units (i.u.) per day of vitamin A acetate in one ml. cottonseed oil by oral intubation. Control animals were similarly given 1 ml. of pure cottonseed oil. Experimental and control groups were subdivided for specific experiments as indicated below.

For study of the genesis of cleft palate and its incidence at term, a series of treated and control animals were sacrificed at 10.00 A.M. either on day 15, 16, 17 or 20 of gestation corresponding to Witschi's standard stages 31, 33, 34 and 35 a p respectively. At autopsy, the fetuses were fixed in either: (1) Bouin's fluid for measurement and subsequent examination of 1–2 mm. thick freehand frontal sections or (2) alcohol-formalin for histological study. Sections were stained by the following procedures: (*a*) 0·1 per cent. toluidine blue in 30 per cent. ethyl alcohol for identification of acid mucopolysaccharides (Kramer & Windrum, 1955) as contrasted to hyaluronidase treated controls; (*b*) periodic acid-Schiff technique (PAS) for identification of glycogen (McManus, 1948) as contrasted to alpha amylase treated controls; (*c*) methyl green pyronin for detection of ribonucleoproteins (Bracket, 1942) as contrasted to ribonuclease treated controls (Pearse, 1960); (*d*) Feulgen stain for deoxyribonucleic acid (Feulgen & Rossenbeck, 1924 as referred to in Pearse, 1960); (*e*) iron hematoxylin.

For indication of mucopolysaccharides in normal and abnormal development of the secondary palate, pregnant females which had been treated as above with either excess vitamin A or with cottonseed oil were given a single intraperitoneal dose of carrier free S^{35}-sodium sulfate on either day 13, 14, (10 microcuries gm. body weight) or day 15 (5 microcuries gm. weight) of gestation. Two days after injection the females were sacrificed and the young were embedded and serially sectioned for autoradiography (Messier & Leblond, 1957) with Kodak NTB-3 liquid emulsion. In this manner adequate time was allowed for uptake of the sulfur and the age of the embryo at autopsy was 15, 16 or 17 days of age which corresponded with the age of the embryos described previously which were studied by standard and histochemical means. The radioactive sections were exposed to the emulsion for 12 days in a dry ice chest before the emulsion was developed and the sections stained with toluidine blue.

RESULTS

The teratogenic effects of hypervitaminosis A observed on term fetuses are summarized in Table 1. Among the embryos from treated mothers, 80 per cent. or more had cleft palate when the three-day treatment period was started on either day 9 or day 10 of pregnancy. Furthermore, the frequency of eye defects such as microphthalmia, anophthalmia, open eye, and exophthalmos was similar, but exencephaly occurred only if vitamin A treatment was instituted on the earlier day. Intra-uterine mortality was also much higher after earlier treatment. Only a slight decrease in mean fetal weight and crown rump length was observed in living fetuses from vitamin A treated mothers.

Normal morphogenesis of the secondary palate

Because palatal closure occurs in these rats on day 16 of gestation, examinations were made of fetuses of 15, 16 and 17 days gestational age. Data concerning the reproductive performance and external embryonic morphology at each of these ages is summarized in Table 2. The embryos as represented in this table had a pattern of palatal development which was characteristic for each of the three days selected for examination.

On day 15 the palatine shelves of control embryos were vertically oriented at either side of the tongue and on the basis of mesenchymal cells, preosteoblasts and intercellular ground substance, they could be divided into anterior, middle and posterior thirds. In the anterior one third of the shelf mesenchymal cells were dispersed uniformly within the metachromatic ground substance to form the core of the shelf and preosteoblasts with basophilic glycogen-containing cytoplasm were present. In the middle third of the palatine shelf the mesenchymal cells were closely packed, particularly along the medial border, and the ground substance was strongly metachromatic. This medial portion of the palatine shelf was delineated from the rest of the palatal tissue by an epithelial notch. Preosteoblastic tissue extended into both the medial and lateral portions. In the posterior third of the palatine shelves the epithelial notch became deeper and consequently separated the shelf from the more laterally placed maxillary areas and, as a result, in frontal sections the shelf appeared as a vertically oriented plate. The cell density was still greater than in the middle third and metachromatic ground substance was abundant. In this region, the preosteoblastic tissue was assembled at the dorsomedial edge of the palatine shelves which were covered by a low, simple columnar epithelium. This epithelium was continuous laterally with the two to three layered columnar epithelium covering the lateral surface of the shelf as well as the rest of the oral cavity.

On day 16 of gestation the palatine shelf was still divisible into these three regions (Plate 1, Figs. A–C). On this day evidence of movement by the palatine shelves from the vertical to the horizontal position was observed at the junction of the middle and posterior thirds where the osteogenic tissue executed a curve

TABLE 1

Teratogenic Action of Hypervitaminosis A Observed in Term Fetuses

Treatment and days of gestation treatment administered	*Number of litters*	*Number of implantation sites*	*% Resorbed*	*% Survivors malformed*			*Weights (g.)*
				Cleft palate	*Eye defects*	*Exen-cephaly*	
60,000 i.u. Vitamin A 9–11	13	114	54	80	58	15	3·09 ± 0·44
60,000 i.u. Vitamin A 10–12	11	112	22	83	48	0	3·20 ± 0·42
Cottonseed Oil 9–11	9	87	12	0	0	0	3·64 ± 0·45

TABLE 2

Comparison of Control and Hypervitaminotic A Embryos on Days 15, 16 and 17 of Pregnancy

Embryonic age	*Treatment*	*Number of litters*	*% Resorbed*	*Number of living embryos*	*Average weights (g.)*	*Average crown rump length (mm.)*	*Average head length (mm.)*
15th day	Control	4	10	37	0·263 ± 0·030	10·8	6·1
	Vitamin A	11	54	63	0·264 ± 0·029	10·2	5·5
16th day	Control	7	15	56	0·468 ± 0·046	13·5	7·3
	Vitamin A	16	62	86	0·467 ± 0·039	13·0	7·2
17th day	Control	3	7	27	0·933 ± 0·026	17·4	9·8
	Vitamin A	6	56	37	0·754 ± 0·062	16·8	8·7

into a medially directed extension of palatal mesenchymal tissue (Plate 1, Fig. D). This extension progressively enlarged while the vertical portion of the shelf was gradually withdrawn into the body of the shelf. This movement of the palatine shelves to the horizontal plane then appeared to extend both anteriorly and posteriorly and in this manner 35 per cent. of the control embryos on this day had shelves which had risen above tongue (Plate 1, Fig. E).

At day 17 the palate of control embryos was complete in that the shelves were horizontal and fused with each other and with the nasal septum. In the anterior portion of the palate a slight accumulation of preosteoblasts in the midline region was observed (palatal preosteoblastic area) but the rest of the palate at this level was composed of loosely arranged mesenchymal cells (Plate 1, Fig. F). At a slightly more posterior level the palate became highly arched (Plate 1, Fig. G) and the maxillary bone occupied a small triangular area in the lateral half of the palate. At this level the medial angle of maxilla was continuous with the palatal preosteoblastic area and the latter had split into right and left halves (Plate 1, Fig. G). The stage of osteogenesis in the mandible of these normal control animals was identical with that observed in the maxilla, and the dental primordia for the upper and lower molars were considerably advanced in their development and were deeply lodged within their respective alveoli.

Morphogenesis of cleft palate

Again from Table 2, it can be ascertained that no major difference in mean embryonic weight and crown rump length was observed between control and treated embryos on days 15 and 16. The first gross external manifestation of treatment was seen on day 17, when treated embryos weighed about 200 mg. less than controls. In marked contrast, however, affected palates in treated embryos could be recognized in frontal sections of the head on day 15. In comparison with control embryos, palatine shelves of 72 per cent. of the treated embryos were abnormal on day 15 (Text-fig. 1). They were either rounded instead of triangular, reduced in size, or in some instances, completely absent (compare Plate 2, Figs. H and I). A considerably lesser amount of mesenchymal tissue formed the posterior region of the palatine shelves of treated embryos even if they had a normal complement of palatal tissue anteriorly (Plate 2, Figs. J and K). The palatine shelves of treated embryos on day 16 also had a deformed outline (compare Plate 2, Figs. L_1 and L_2). Surprisingly, however, the movement of palatine shelves from the vertical to the horizontal position had occurred in 61 per cent. of the treated embryos on this day compared to only 35 per cent of the controls (Text-fig. 2). In spite of this, only a few of the treated embryos were able to complete successfully the shelf movement as illustrated by the fact that more than 40 per cent of the treated embryos had palatine shelves so severely malformed that a horizontal or vertical designation could not be assigned and were therefore designated as being in an intermediate position (Text-fig. 2).

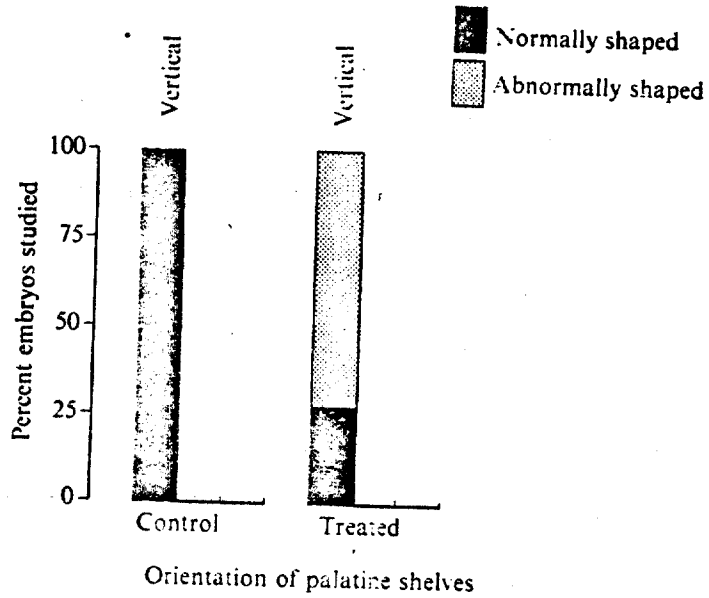

TEXT-FIG. 1. Comparison of the percentages of day 15 control and vitamin A treated embryos on the basis of shape and orientation of their palatine shelves.

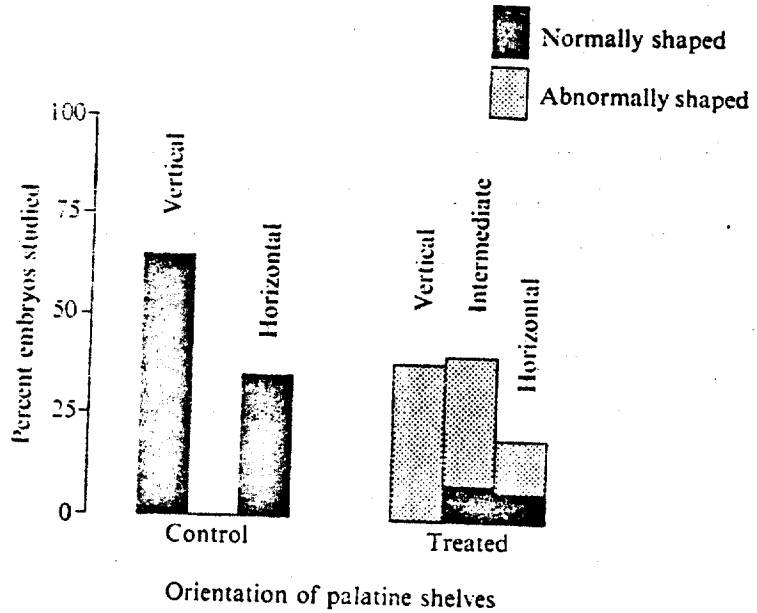

TEXT-FIG. 2. Comparison of the percentages of day 16 control and vitamin A treated embryos on the basis of shape and orientation of their palatine shelves.

The palatine shelves of all control and most treated embryos on day 17 (stage 34 of Witschi, 1956) were horizontal and superior to tongue (Text-fig. 3). The palatine shelves of treated embryos were, however, widely separated from each

other and deformed in outline in contrast to controls where the palate was complete by this time (Plate 3, Figs. M & N).

A marked difference between control and vitamin A treated embryos was the occurrence of chondrogenesis in and around maxillary areas of all treated embryos. In day 17 embryos from vitamin A treated mothers this heterotopic cartilage partially or wholly replaced the maxillary bone, and sometimes was continuous with mandibular bone thereby producing maxillo-mandibular ankylosis (Plate 3, Figs. M and N). Frequently associated with this heterotopic cartilage were pockets of mesenchymal tissue which were separated from the tissue of original palatine shelf by infoldings of oral epithelium (Plate 3, Fig. N). This process of heterotopic chondrogenesis within maxillary preosteoblastic tissue could also be detected in embryos on days 15 and 16 (Plate 2, Figs. I and L) because of the accumulation of a typically metachromatic cartilage matrix around the cells of the primordial area.

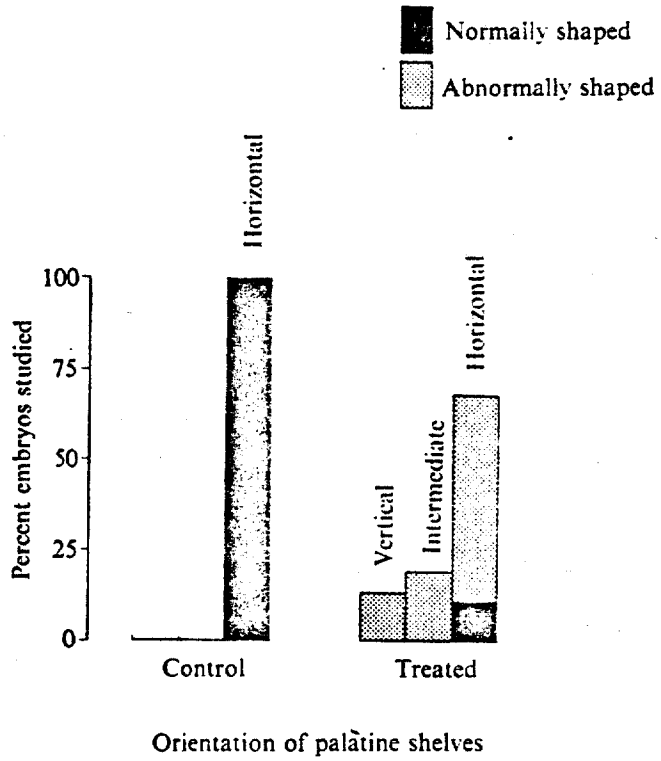

TEXT-FIG. 3. Comparison of the percentages of day 17 control and vitamin A treated embryos on the basis of shape and orientation of their palatine shelves.

Because of the above abnormality in the formation of maxillary bone, the further development of those dental laminae which did not lodge in bone was arrested (Plate 3, Fig. N) and in some instances the two limbs of the dental laminae diverged and thus separated the palatal tissue from maxilla (Plate 3, Fig. O).

Incorporation of S^{35} into tissues of normal and cleft palate rat embryos

Autoradiographs of sections from 15 day old normal control embryos showed incorporation of the label primarily into tissues derived from mesenchyme which coincided with regions of toluidine blue metachromasia. Palatine shelves and mesenchymal tissue in other regions of control embryos of this age showed slight radioactivity (Plate 3, Fig. P), while aggregations of cells in precartilaginous tissue of nasal septum and Meckel's cartilage showed moderate S^{35}-activity. A higher density of developed particles was observed in the cartilage of the limb bud, where considerable metachromatic matrix also was present.

Nasal and limb cartilages in the treated embryo showed S^{35}-incorporation comparable to that in controls, although mesenchymal tissue in the treated embryos, including that of palatine shelves, revealed a considerably increased incorporation above that seen in comparable areas of control embryos. (Compare Plate 3, Fig. Q with Fig. P). Although the maxillary preosteoblastic tissue in

---

EXPLANATION OF PLATES

PLATE 1

FIGS. A–E are frontal sections of the heads from day 16 control embryos. × 40.
FIGS. F & G are frontal sections of the head from a day 17 control embryo. × 40.
FIG. A. Section through anterior third of vertical palatine shelves (PS). Observe the osteogenic tissue (OST) within the shelves. Periodic acid-Schiff (PAS) stain.
FIG. B. Section through middle third of vertical palatine shelves. Dense accumulation of osteogenic tissue (OST) occurs in medial aspect of the shelves. PAS stain.
FIG. C. Section through posterior third of vertical palatine shelves. Aggregation of osteogenic tissue (OST) occurs on dorsalmost aspect of the shelves. PAS stain.
FIG. D. During shelf movement a bend occurs in the preosteoblastic tissue of the palatine shelves. (Compare with Fig. B). PAS stain.
FIG. E. Palatine shelves are completely horizontal but unfused. Toluidine blue stain.
FIG. F. Section through anterior region of palate showing normal closure. Toluidine blue stain.
FIG. G. Section through a level posterior to that of Fig. F. Maxilla (M) on each side associates with palatal osteogenic tissue. Toluidine blue stain.

PLATE 2

FIGS. H–K are frontal sections of the heads from day 15 embryos.
FIGS. L_1 & L_2 are frontal sections of the heads from day 16 embryos.
FIG. H. Control. Section at a level comparable to that of Fig. I. PAS stain. × 40.
FIG. I. Vitamin A treated. Palatine shelves (PS) small or completely absent. Maxilla contains heterotopic cartilage (HC). (Compare with Fig. H). PAS stain. × 40.
FIG. J. Control. Palatine shelf is composed of a large column of cells. Section at a level comparable to that of Fig. K. Iron hematoxylin. × 120.
FIG. K. Vitamin A treated. Palatine shelf contains lesser number of cells. (Compare with Fig. J). Iron hematoxylin. × 120.
FIG. L_1. Control. Observe the distribution of osteogenic tissue in maxilla and horizontal palatine shelves. Section at a level comparable to that of Fig. L_2. PAS stain. × 40.
FIG. L_2. Vitamin A treated. Heterotopic cartilage (HC) is present within osteogenic tissue of maxilla and palate. (Compare with Fig. L_1). Palatine shelves are deformed. PAS stain. × 40.

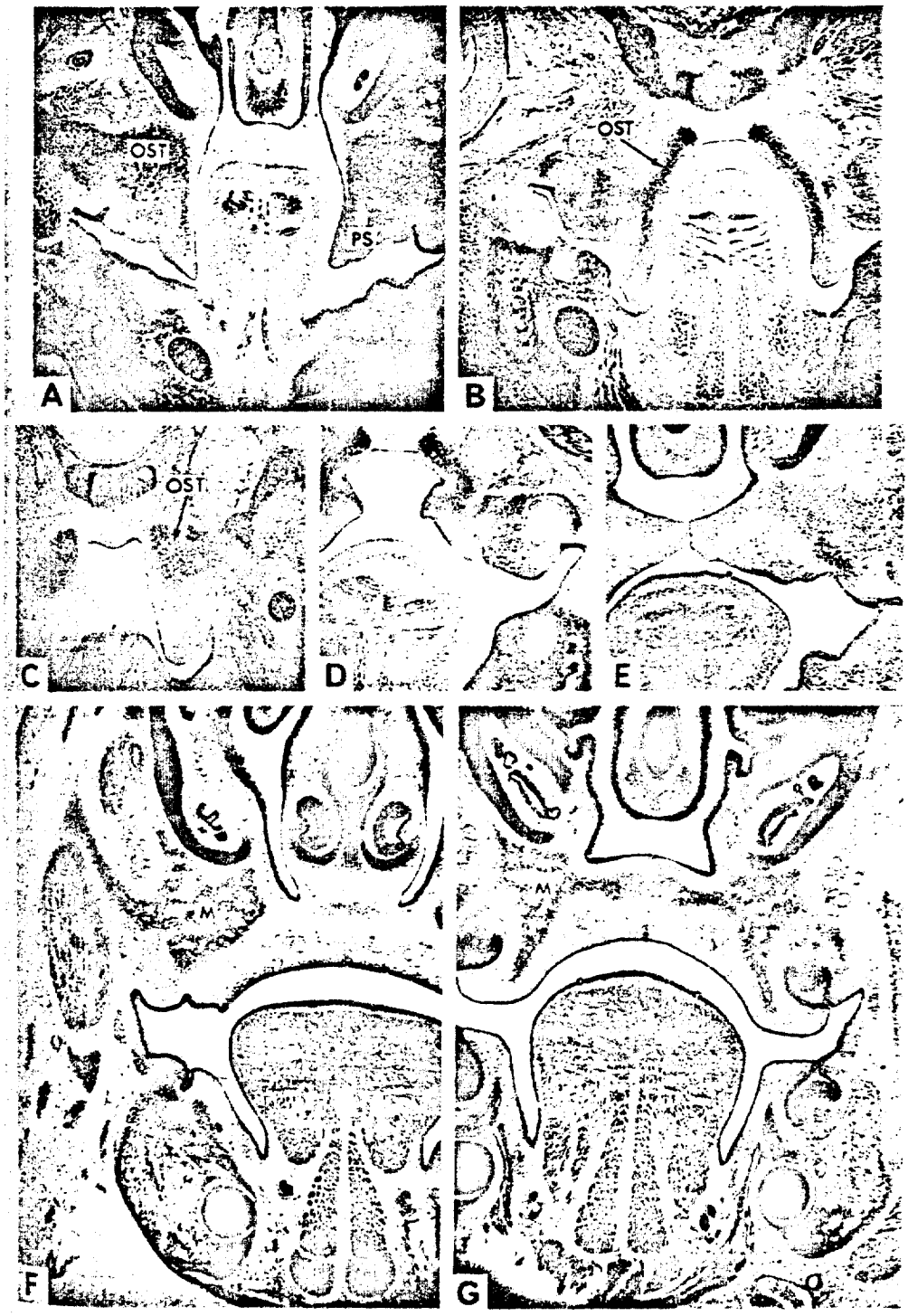

PLATE I

D. M. KOCHHAR and E. M. JOHNSON

(*Facing page 230*)

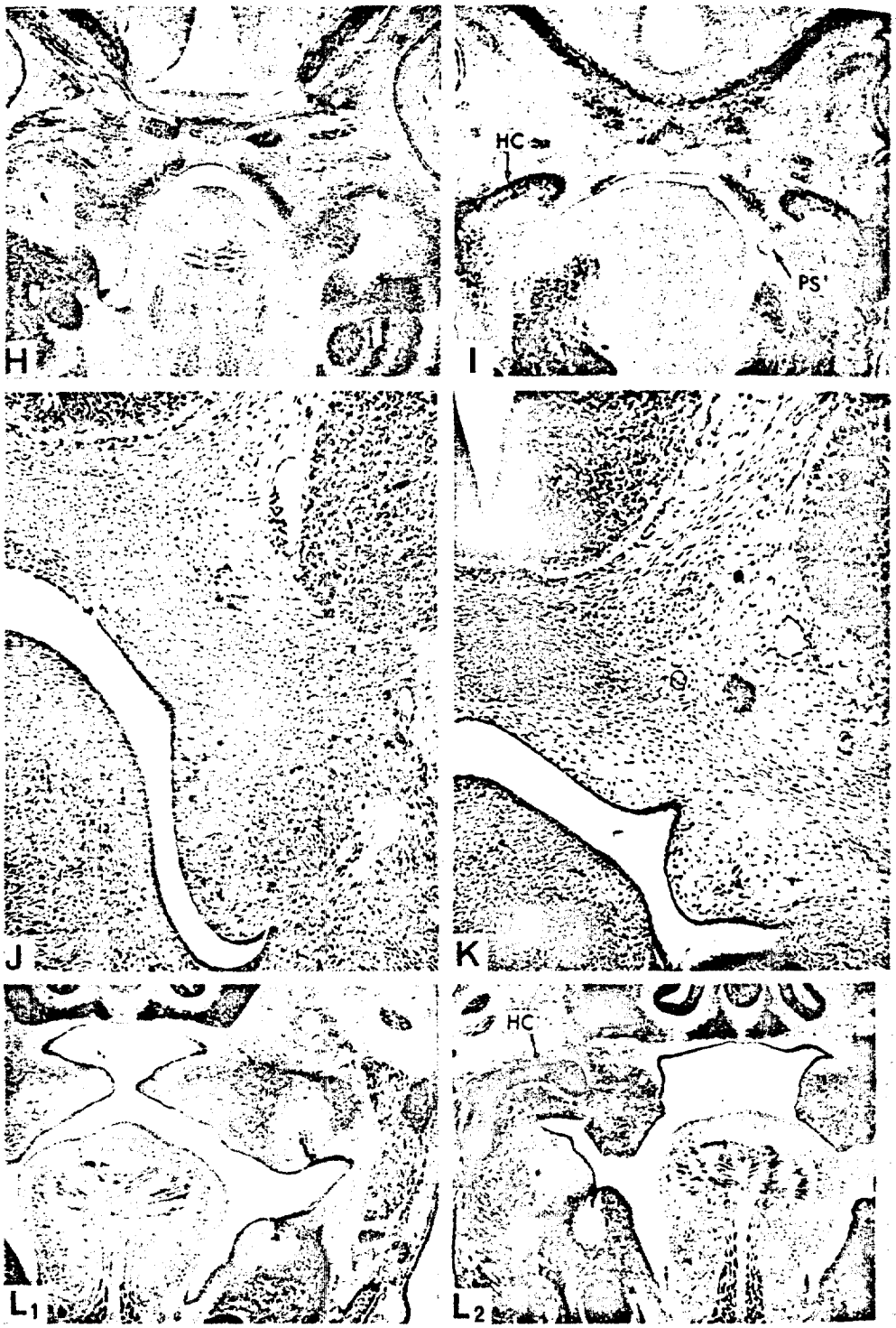

PLATE 2

D. M. KOCHHAR and E. M. JOHNSON

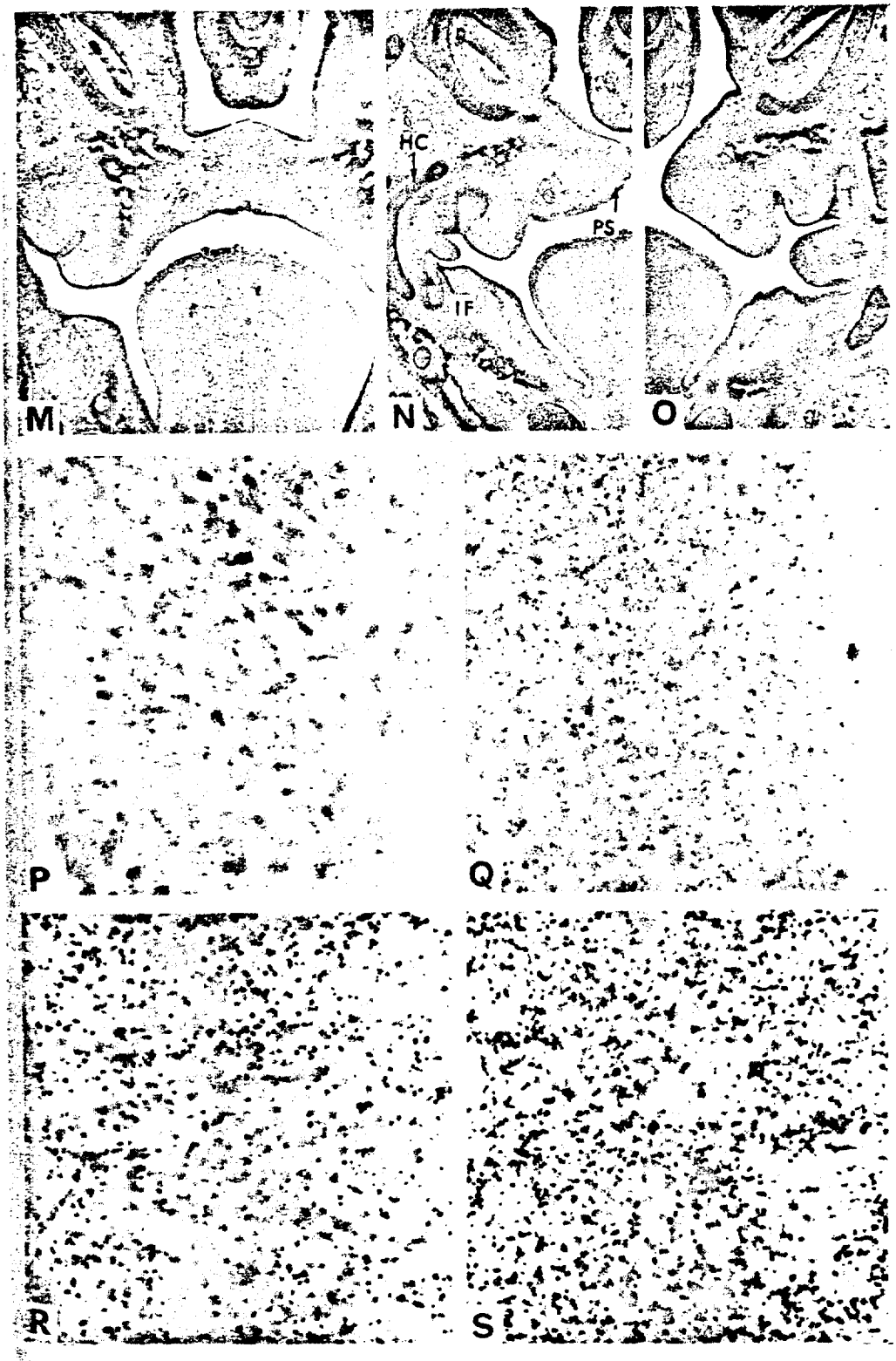

PLATE 3

D. M. KOCHHAR and E. M. JOHNSON

PLATE 4

D. M. KOCHHAR and E. M. JOHNSON

(Facing page 231)

treated embryos had S^{35} activity similar to controls, some regions within this tissue had marked radiotracer incorporation and also toluidine blue metachromasia which indicated the presence of heterotopic cartilage.

By day 16, incorporation of S^{35} had increased markedly in control embryos from what it was on the previous day. The most radioactive component was cartilage (Plate 3, Fig. R), but incorporation into the palatine shelves and mesenchymal tissue of other areas also was increased in embryos of this age. Of especial interest was the fact that the medial boundary of the shelf had a greater incorporation of tracer than the lateral portion.

Incorporation of S^{35} into the nasal (Plate 3, Fig. S) and limb cartilages of treated embryos was very much greater than that exhibited by controls (compare with Plate 3, Fig. R). Such increased S^{35}-incorporation was also observed in the mesenchymal tissue of the palatine shelves in treated embryos (Plate 4, compare Fig. T and U). The presence of heterotopic cartilage in the maxillae of treated embryos made these areas much more radioactive than the maxillary osteogenic areas of the control embryos.

Explanation of plates

Plate 3

Figs. M–O are frontal sections of the heads from day 17 embryos. PAS stain. × 40.
Figs. P & Q are autoradiographs of frontal sections of the palatine shelves from day 15 embryos. Toluidine blue stain. × 1800.
Figs. R & S are autoradiographs of frontal sections of nasal cartilage of day 16 embryos. Toluidine blue stain. × 2300.
Fig. M. Control. Completed palate at a level comparable to those of Fig. N and O.
Fig. N. Vitamin A treated. One-half of a section showing: incomplete palate with deformed palatine shelf (PS). Heterotopic cartilage (HC) and infoldings (IF) of oral epithelium are present. (Compare with Fig. M).
Fig. O. Vitamin A treated. One-half of a section showing: dental lamina is not lodged in defective maxilla; epithelium of the lamina has opened up into two separate limbs.
Fig. P. Control. Focus is on particles above the section.
Fig. Q. Vitamin A treated. Compare the labelling with Fig. P.
Fig. R. Control. Note the higher magnification of particles.
Fig. S. Vitamin A treated. Compare the labelling with Fig. R.

Plate 4

Figs. T & U are autoradiographs of frontal sections of palatine shelves of day 16 embryos. Toluidine blue stain. × 1800.
Figs. V & W are autoradiographs of frontal sections of palatine shelves of day 17 embryos. Toluidine blue stain. × 1800.
Figs. X & Y are autoradiographs of frontal sections of limb cartilages of day 17 embryos. Toluidine blue stain. × 1800.
Fig. T. Control.
Fig. U. Vitamin A treated. Compare the labelling with Fig. T.
Fig. V. Control.
Fig. W. Vitamin A treated. Compare the labelling with Fig. V.
Fig. X. Control.
Fig. Y. Vitamin A treated. Compare the labelling with Fig. X.

In contrast, comparison of autoradiographs from day 17 control and treated embryos showed that tissues in the palatine shelves and neighbouring areas of the control embryo had a greater S^{35}-incorporation (Plate 4, Fig. V) than palatine shelves of the incomplete palate in the treated embryo (Plate 4, Fig. W). Of interest however, was the finding that palatal mesenchymal tissue of treated embryos which had been entrapped by infoldings of oral epithelium had a greater incorporation than other regions of the palate. Radioactivity in the nasal and limb cartilages of control embryos was also greater than in the treated embryos (Plate 4, Figs. X and Y).

DISCUSSION

From the standpoint of morphogenesis, cleft palate can be considered to develop in several possible ways which have been summarized by Burston (1959), and Fraser (1955, 1960). Since the correct positioning of the left and right palatine shelves on the superior aspect of tongue is essential for the normal closure of the secondary palate, the classical concept insisted that the failure on the part of the tongue to descend from between the vertically disposed palatine shelves may lead to cleft palate. Some of the modern experimental studies also provide evidence for this concept, e.g., cleft palate was reported to occur in embryos (1) after forcible pressing of the head against the chest (Trasler *et al.*, 1956) and (2) in association with retarded growth of mandible (Asling *et al.*, 1960).

In contrast to previous studies, Walker & Fraser (1956, 1957) presented another concept on the genesis of cleft palate in mouse embryos from cortisone treated mothers. Observing an active wave-like motion in the palatine shelves which were preparing to change their position from vertical to horizontal plane, these authors conceived of some factor or force residing within the palatine shelves which was responsible for initiation of their movement. Cleft palate in the cortisone treated embryos was assumed to occur as a result of delay in initiation of the shelf movement. When the vertical palatine shelves ultimately did become horizontal, growth of the head had taken them so far apart that they were unable to meet and fuse. Support of this concept has been given by authors studying the teratogenic influence of such agents as hypervitaminosis A (Walker & Crain, 1960; Kamei, 1962), riboflavin deficiency (Walker & Crain, 1961) and X-irradiation (Callas & Walker, 1963).

The present study indicates that cleft palate in rat embryos in response to maternal hypervitaminosis A is not due to the failure of shelf movement. When the orientation of the palatine shelves was observed during early developmental stages it became evident that in a major percentage of the embryos from vitamin A treated mothers shelf movement was initiated on time and cleft palate developed in these embryos in spite of the fact that the barrier of the tongue had been crossed and the palatine shelves were horizontal.

In studies of the morphological and chemical basis for shelf movement, Walker & Fraser (1956), Walker (1960, 1961) and Larsson (1962) made histo-

logical and histochemical studies of the palatine shelves of mouse embryos, and found that prior to initiation of shelf movement the only components making up the palatine shelves were a core of loose mesenchymal tissue covered by an epithelium. The mesenchymal cells were embedded in a ground substance which was metachromatically stainable with toluidine blue, and it was suggested that the shelf movement was initiated by a factor which probably resided in the acid-mucopolysaccharides of this intercellular ground substance. Walker & Fraser (1956) described the occurrence of osteogenesis in maxillary areas proximal to the base of the shelves. However, in their material no projection of osteogenesis into the palatine shelves was evident. In the present study of rats, however, osteoblastic and dense mesenchymal tissue was continuous with similarly differentiated tissue of the maxilla and was one of the first components to extend medially into an outfolding which indicated the beginning of shelf movement from the vertical to the horizontal position.

Also in the current study several purely morphological factors were encountered in embryos from hypervitaminotic A rats which were suggestive of participation in the development of cleft palate. In the first place it was seen that cleft palate resulted when insufficient mesenchymal tissue outfolded from the maxillary process into palatine shelf, resulting in the latter either being very small or entirely absent. In most cases, however, the reduction in size of palatine shelves occurred only posteriorly while in anterior regions the size was comparable to that in normal embryos. In contrast cleft palate developed in some embryos in spite of the apparent presence of sufficient palatal tissue, both anteriorly and posteriorly, to bridge the gap across the roof of the oral cavity.

In all treated embryos the development of the maxillary bone primordium was defective at the preosteoblastic stage of organization. Some of the preosteoblastic cells apparently underwent heterotopic transformation into chondroblasts and thence into chondrocytes surrounded by a typically metachromatic matrix. In subsequent development this heterotopic cartilage progressively replaced the maxillary bone until in 17-day-old embryos the maxilla was represented by scattered bone trabeculae at the periphery of the heterotopic cartilage and also some of the palatal mesenchymal tissue became entrapped into abnormal infoldings of oral epithelium. This maxillary cartilage was instrumental in producing maxillomandibular ankylosis. Such heterotopic cartilage was also observed in this region by Deuschle *et al.* (1959) in newborn rats from hypervitaminotic A mothers.

Reduction in size of the maxillary bone due to the presence of maxillary cartilage appeared to participate in the production of cleft palate in at least two ways. Firstly, the development of dental laminae for the upper molars which did not encounter the maxillary bone became abortive; i.e., the two limbs of the lamina diverged and thus separated the palatal tissue from the maxilla. Secondly, owing to the absence of the maxillary bone from its normal position with respect to the palate, due to its replacement by cartilage, the likelihood exists that normal pres-

sure and stress of the developing bone to aid the progression of the horizontal palatine shelves towards the midline could be partially or completely absent in the treated embryo. Both these factors could perhaps explain the persistence of widely separated but horizontal palatine shelves.

Larsson (1962) related the production of cleft palate in embryos from cortisone treated mice to the inhibition of acid-mucopolysaccharide synthesis within the palatine shelves which, therefore, failed to develop enough force within themselves to enable them to move from the vertical to the horizontal position. This conclusion was based on autoradiographic studies which revealed that incorporation of S^{35} into palatine shelves and other areas of cleft palate embryos was depressed. Larsson suggested that other agents like hypervitaminosis A which also possibly reduced the amount of acid-mucopolysaccharides in tissues might be teratogenic due to their possession of this biochemical property. Histochemical methods in the present study, such as metachromatic staining with toluidine blue, revealed no difference between control and vitamin A treated embryos in the intensity of metachromasia either in the mesenchymal tissues of the palate or in the various cartilaginous structures. Fixation of S^{35} by tissues of embryos from hypervitaminotic A rats, however, needs special mention. In 15- and 16-day-old treated embryos, whose mothers were treated with vitamin A on 9, 10 and 11 days of gestation and were injected with S^{35}-sulfate 48 hrs. before autopsy, the mesenchymal tissue in the abnormally shaped palatine shelves and in other areas revealed a considerably higher S^{35}-incorporation than seen in comparable areas of control embryo. The same occurrence was true of nasal capsule cartilages, Meckel's cartilage and cartilage models in the limb. Heterotopic cartilage within maxilla also actively fixed S^{35}.

Investigation of fetal stages by Giroud, Gounelle & Martinet (1956, 1957) demonstrated a slight increase in vitamin A concentration in rat fetuses after treatment of their mothers by large doses of vitamin A. If such an increase in vitamin A concentration were present in embryonic tissues in the present study it might have caused increased incorporation of S^{35} into the embryo. Increased rate of S^{35}-uptake following vitamin A administration was also observed by Dziewiatkowski (1954) in the skeleton and skin of rats which were previously on a vitamin A deficient diet. He also demonstrated that incorporation of S^{35} as sulfate groups had occurred into sulfomucopolysaccharides. Wolf, Varandani & Johnson (1961) demonstrated that the addition of vitamin A to a homogenate of colon from vitamin A deficient rats resulted in normal levels of incorporation of S^{35}-radioactivity into mucopolysaccharides. The present report is the only known study which examines the *in vivo* effects of maternal vitamin A treatment on fixation of S^{35} by the embryo. Results obtained from studies of tissue culture however (Fell, Mellanby & Pelc, 1956) demonstrated that excess vitamin A caused dissolution of embryonic cartilage matrix as evidenced by removal of previously incorporated S^{35}. These results were substantiated by other studies on the effects of excess vitamin A on adult cartilage and bone, both *in vivo* and *in vitro* (Thomas *et al.*, 1960 and Fell & Thomas, 1960). In addition to dissolving the

cartilage matrix, hypervitaminosis A in intact animals also was reported to impair the ability of chondrocytes to synthesize chondroitin sulfate in tissue culture (McElligott, 1962).

Dissolution of cartilage matrix as observed by Thomas *et al.* (1960) appeared to result only when the animals were given very large amounts of vitamin A. Thomas *et al.* (1960) and McElligott (1962) administered 1 million i.u. of vitamin A daily to rabbits for 5 to 7 days and brought about dissolution of cartilage matrix. The dose level of vitamin A employed for teratogenesis in the present study was not sufficiently high to dissolve the matrix of either maternal cartilage (Kochhar, 1964) or the cartilage of 15- and 16-day fetuses. It was noticed, however, that in the epiphyseal cartilage of adult rats receiving teratogenic doses of vitamin A (60,000 i.u. per day for 3 days) the matrix showed no reduction of metachromatic staining by toluidine blue from that present in rats receiving only cottonseed oil.

Depletion in cartilage matrix of its metachromatically stainable component was, however, observed when the dosage of vitamin A was increased to 100,000 i.u. or 200,000 i.u. daily for three days. Dissolution of intercellular matrix may be responsible for the detection of decreased S^{35}-incorporation observed in the tissues of day seventeen treated embryos.

It is clear that the effects of hypervitaminosis A on acid-mucopolysaccharide content of maternal and embryonic organisms are very much different from those of cortisone, and since morphogenesis of cleft palate with these two agents is also dissimilar, it may be that two different pathways for the production of cleft palate are involved.

SUMMARY

1. Oral administration of 60.000 international units of vitamin A acetate to pregnant rats for 3 consecutive days beginning on either day 9 or 10 of pregnancy resulted in more than 80 per cent. of their embryos developing cleft palate.

2. The initiation of palatine shelf movement in normal control embryos was associated with an aggregation of preosteoblastic tissue on the medial aspect of the vertically oriented shelves at the junction of their anterior two-thirds and posterior one-third.

3. Delay in the movement of palatine shelves from the vertical to the horizontal position was not observed in a major percentage of the vitamin A treated embryos.

4. In many vitamin A treated embryos a considerably lesser amount of mesenchymal tissue was contributed by the maxillary processes to form the palatine shelves.

5. A process of heterotopic chondrogenesis was detected within the preosteoblastic tissues of maxillae and palatine shelves as early as day 15 and by day 17 had replaced a major portion of the maxillary bone.

6. On the basis of the methods employed, more S^{35} was fixed by the tissues of treated embryos than by those of normal controls prior to the time of palatal closure.

RÉSUMÉ

Recherches morphologiques et autoradiographiques sur la fissuration palatine induite chez des embryons de rat par hypervitaminose A maternalle.

1. Chez la ratte gestante, des doses de 60.000 U.I. d'acétate de Vitamine A, administrées par voie orale pendant trois jours, à partir du neuvième ou du dixième jour de la gestation, ont provoqué des fissures palatines chez plus de 80 per cent. des embryons.

2. Chez les embryons témoins le mouvement initial du processus palatin a été accompagné d'une accumulation de tissu préostéoblastique à la face médiane de la paroi latérale, au niveau de la jonction des deux tiers antérieurs et du tiers postérieur.

3. Aucun retard du mouvement des processus palatins n'a été observé chez la plupart des embryons soumis au traitement avec vitamine A.

4. Chez un grand nombre des embryons traités, la contribution en mésenchyme de la part du bourgeon maxillaire au processus palatin a été considérablement réduite.

5. Un phénomène de chondrogenèse hétérotipique dans le tissu préostéoblastique des maxillaires et des processus palatins a été décelé à partir du quinzième jour et cette chondrogenèse avait remplacé l'os maxillaire en grande partie lors du dix-septième jour.

6. D'après les méthodes employés, les tissus des embryons soumis au traitement ont incorporé plus de S^{35} que ceux des témoins normaux avant le moment ou intervient la soudure palatine.

ACKNOWLEDGEMENTS

The authors are grateful to Professors James G. Wilson and Donald C. Goodman for their constructive criticism of the manuscript. This investigation was supported by Public Health Service Training Grant 3T1 GM 579-0451 and by Research Grant HD 00109.

REFERENCES

ASLING, C. W., NELSON, M. M., DOUGHERTY, H. L., WRIGHT, H. V. & EVANS, H. M. (1960). The development of cleft palate resulting from maternal pteroylglutamic (folic) acid deficiency during the latter half of gestation in rats. *Surgery Gynec. Obstet.* **III**, 19–28.

BAXTER, H. & FRASER, F. C. (1950). Production of congenital defects in offspring of female mice treated with cortisone. *McGill Med. J.* **19**, 245–9.

BRACHET, J. (1942). La localisation des acides pentosenucléiques dans les tissus animaux et les œufs d'Amphibiens en voie de développement. *Arch. Biol., Paris et Liege*, **53**, 207–57.

BURSTON, W. R. (1959). The development of cleft lip and palate. *Ann. R. Coll. Surg.* **25**, 225–33.

CALLAS, G. & WALKER, B. E. (1963). Palate morphogenesis in mouse embryos after X-irradiation. *Anat. Rec.* **145**, 61–71.

DEUSCHLE, F. M., GEIGER, J. F. & WARKANY, J. (1959). Analysis of an anomalous oculodentofacial pattern in newborn rats produced by maternal hypervitaminosis A. *J.A.Res.* **38**, 149–55.

DZIEWIATKOWSKI, D. D. (1954). Vitamin A and endochondral ossification in the rat as indicated by the use of sulfur^{35} and phosphorus^{32}. *J. exp. Med.* **100**, 11–24.

FELL, H. B., MELLANBY, E. & PELC, S. R. (1956). Influence of excess vitamin A on the sulfate metabolism of bone rudiments grown *in vitro*. *J. Physiol., Lond.* **134**, 179–88.

FELL, H. B. & THOMAS, L. (1960). Comparison of the effects of papain and vitamin A on cartilage. II. The effects on organ cultures of embryonic skeletal tissue. *J. exp. Med.* **111**, 719–44.

FRASER, F. C. (1955). Thoughts on the etiology of clefts of the palate and lip. *Acta genet. Statist. med.* **5**, 358–69.

FRASER, F. C. (1960). Some experimental and clinical studies on the causes of congenital clefts of the palate and of the lip. *Archs. Pediat.* **77**, 151–6.

GIROUD, A., GOUNELLE, H. & MARTINET, M. (1956). Concentrationde la vitamine A chez la mere et le foetus au cours de la teratogenese par hypervitaminose A. *C. r. Séanc. Soc. Biol.* **150**, 2064–65.

GIROUD, A., GOUNELLE, H. & MARTINET, M. (1957). Données quantitatives sur le taux de la vitamine A chez le rat lors d'expériences de tératogénèse par hypervitaminose A. *Bull. Soc. Chim. biol.* **39**, 331–6.

GIROUD, A. & MARTINET, M. (1956). Teratogenese par hautes doses de vitamine A en fonction des stades du developpement. *Archs. Anat. Microsc.* **45**, 77–98.

KALTER, H. & WARKANY, J. (1959). Experimental production of congenital malformations in mammals by metabolic procedure. *Physiol. Rev.* **39**, 69–115.

KAMEI, T. (1962). Embryological and histochemical studies on the artificially induced cleft palate in mice. *Acta anat. nippon.* **37**, 140–58.

KOCHHAR, D. M. (1964). Effects of maternal hypervitaminosis A on cleft palate formation in rat embryos. Ph.D. thesis. Gainesville: University of Florida.

KRAMER, H. & WINDRUM, G. M. (1955). The metachromatic staining reaction. *J. Histochem. Cytochem.* **3**, 227–37.

LARSSON, K. S. (1960). Studies on the closure of the secondary palate. II. Occurrence of sulpho-mucopolysaccharides in the palatine processes of the normal mouse embryo. *Expl. Cell Res.* **21**, 498–503.

LARSSON, K. S. (1962*a*). Studies on the closure of the secondary palate. III. Autoradiographic and histochemical studies in the normal mouse embryo. *Acta morph. neerl.-scand.* **4**, 349–67.

LARSSON, K. S. (1962*b*). Studies on the closure of the secondary palate. IV. Autoradiographic and histochemical studies of mouse embryos from cortisone-treated mothers. *Acta morph. neerl.-scand.* **4**, 369–86.

LARSSON, K. S. (1962*c*). Closure of the secondary palate and its relation to sulpho-mucopolysaccharides. *Acta odont. scand.* **20**, 1–35.

LAYTON, L. L. (1951*a*). Cortisone inhibition of mucopolysaccharide synthesis in the intact rat. *Archs. Biochem.* **32**, 224–6.

LAYTON, L. L. (1951*b*). Effect of cortisone upon chondroitin sulfate synthesis by animal tissues. *Proc. Soc. exp. Biol. Med.* **76**, 596–8.

MCELLIGOTT, T. F. (1962). Decreased fixation of sulfate by chondrocytes in hypervitaminosis A. *J. Path. Bact.* **83**, 347–55.

MCMANUS, J. F. A. (1948). Histological and histochemical uses of periodic acid. *Stain Tech.* **23**, 99–108.

MESSIER, B. & LEBLOND, C. P. (1957). Preparation of coated radioautographs by dipping sections in fluid emulsion. *Proc. Soc. exp. Biol. Med.* **96**, 7–10.

PEARSE, A. G. E. (1960). *Histochemistry, theoretical and applied.* Boston: Little, Brown and Co.

SCHILLER, S. & DORFMAN, A. (1957). The metabolism of mucopolysaccharides in animals: the effect of cortisone and hydrocortisone on rat skin. *Endocrinology*, **60**, 376–81.

THOMAS, L., MCCLUSKEY, R. T., POTTER, J. L. & WEISSMANN, G. (1960). Comparison of the effects of papain and vitamin A on cartilage. I. The effects in rabbits. *J. exp. Med.* **111**, 705–18.

TRASLER, D. G., WALKER, B. E. & FRASER, F. C. (1956). Congenital malformations produced by ammiotic-sac puncture. *Science*, **124**, 439.

WALKER, B. E. (1960). A special component of embryonic mesenchyme. *Anat. Rec.* **136**, 298.

WALKER, B. E. (1961). The association of mucopolysaccharides with morphogenesis of the palate and other structures in mouse embryos. *J. Embryol. exp. Morph.* **9**, 22–31.

WALKER, B. E. & CRAIN, B. (1960). Effects of hypervitaminosis A on palate development in two strains of mice. *Am. J. Anat.* **107**, 49–58.

WALKER, B. E. & CRAIN, B. (1961). Abnormal palate morphogenesis in mouse embryos induced by riboflavin deficiency. *Proc. Soc. exp. Biol. Med.* **107**, 404–6.

WALKER, B. E. & FRASER, F. C. (1956). Closure of the secondary palate in three strains of mice. *J. Embryol. exp. Morph.* **4**, 176–89.

WALKER, B. E. & FRASER, F. C. (1957). The embryology of cortisone-induced cleft palate. *J. Embryol. exp. Morph.* **5**, 201–9.

WITSCHI, E. (1956). The standard stages of rat development (based on the Iowa collection) figures in: *Development of Vertebrates.* Philadelphia: W. B. Saunders Company.

WOLF, G., VARANDANI, P. T. & JOHNSON, B. C. (1961). Vitamin A and mucopolysaccharide synthesizing enzymes. *Biochim. biophys. Acta* **46**, 59–67.

(*Manuscript received 15th May 1965*)

Kochhar-'68
Bib. No. 4820

Teratology 1:299-310. 1968.

Reproduced by permission of the copyright owner

Studies of Vitamin A-induced Teratogenesis: Effects on Embryonic Mesenchyme and Epithelium, and on Incorporation of H^3-thymidine

D. M. KOCHHAR [1]
The Rockefeller University, New York, New York

ABSTRACT Some aspects of tissue differentiation were studied in 13-day rat embryos after vitamin A treatment of their mothers on days 10, 11, and 12 of gestation. Severely affected embryos showed extensive growth retardation. Inhibition of cell proliferation, assumed from a decreased rate of H^3-thymidine uptake, was found in the liver, loose mesenchyme of the cephalic region, posterior region of the palatine shelves, trigeminal nucleus, and in some areas of the skin. Other tissues investigated showed no inhibition.

Development of the face in these embryos was characterized by the appearance of defects in the mesoderm of the maxillary process and in the oral epithelium. It is suggested that palatal and dental abnormalities of vitamin A-treated embryos arise because of some initial changes in the epithelium, which subsequently lead to a disrupted epithelial-mesodermal relation in this region, so essential for normal development.

Some physicochemical properties of vitamin A, such as its high surface activity and its effect on membrane permeability, enable it to have widespread effects. Information about the importance of these phenomena in the developing embryo must await further elucidation of the mechanism of action of vitamin A in biological organisms in general.

The mode of action of excess vitamin A in the experimental production of congenital malformations is not yet understood. Maternal hypervitaminosis A in rats and mice has been shown to produce changes in the acid-mucopolysaccharide metabolism of embryonic tissues, reflected in higher uptake of S^{35}-labeled sulfate (Kochhar and Johnson, '65; Kochhar et al., '68); and morphological changes accompanying metabolic alterations have provided clues as to the mechanism of origin of some malformations, e.g., cleft palate (Kochhar and Johnson, '65). However, further studies are needed to elaborate these findings and to explain other malformations produced by vitamin A (see summary by Kaiser and Warkany, '59).

MATERIALS AND METHODS

The animals used in the present study were black-hooded rats of Long-Evans origin. Proestrus females weighing about 200 g were caged overnight with males. The onset of pregnancy was indicated by finding spermatozoa in vaginal smears the next morning. This day was designated day 0 of pregnancy. Pregnant females were caged singly and supplied with pelleted stock diet and water ad libitum.

Experimental females received by oral intubation 60,000 IU vitamin A acetate (Nutritional Biochemical Corporation, Cleveland, Ohio) dissolved in 1 ml cottonseed oil on the morning of days 10, 11, and 12 of pregnancy. Control animals were given 1 ml cottonseed oil at these times. The females were killed on the morning of day 13 and the embryos were removed from their membranes and fixed in either Bouin's fluid or alcohol-formalin (3 parts 95% ethanol + 1 part 40% formaldehyde). Serial histological sections were prepared both in frontal and sagittal planes and stained with hematoxylin and eosin or toluidine blue, or by the periodic-acid Schiff technique.

Three control and three vitamin A-treated rats were used in the investigation of the incorporation of thymidine-H^3 by embryonic tissues. Thymidine-H^3, specific activity 1.9 c/mmole, was purchased from Schwarz BioResearch, Inc., Orangeburg.

[1] Present address: Departments of Anatomy and Oral Biology, University of Iowa, College of Medicine and Dentistry, Iowa City, Iowa 52240

New York. On the morning of day 13 of pregnancy, i.e., 24 hours after the last dose of vitamin A, each female received by intracardiac injection 1 μc thymidine-H^3 per g body weight in sterile aqueous solution. The females were killed two hours later; the embryos were removed and fixed in alcohol-formalin and sectioned at 6 μ. The glass slides carrying the sections were coated with Kodak NTB-3 liquid emulsion and exposed in the dark for six weeks. Upon being developed, the sections were stained with the techniques mentioned above.

Serial sagittal section of three embryos from each female were studied for a measure of the number of cells labeled with thymidine. Photomicrographs of ten to twenty consecutive sections of a given tissue were taken (see Results). The number of cells showing a cluster of five or more reduced silver grains in the autoradiograph was recorded. Comparison of the number of labeled cells in tissues of control and treated embryos was made on the basis of the mean number of labeled cells per microscopic field at a constant magnification of 480 ×.

RESULTS

The embryos corresponded in their development to stages 26 and 27 of Witschi ('56). Control embryos ranged from 7.5–8 mm crown-rump length, and weighed 70–80 mg each when freshly removed from the mother. Vitamin A-treated embryos demonstrated various degrees of growth retardation, despite which there seemed to be very little difference between them and controls in the level of organogenesis (fig. 1). The treated embryos, however, usually showed abnormal dorsal curvature, protrusion of the mesencephalic region of the brain, fewer somites than are usually present at this stage, and cellular disorganization (fig. 1). The posterior region was often more severely stunted than the anterior one.

It is known that a large percentage of vitamin A-treated embryos develop cleft palate, the development of which was shown to be closely associated with the formation of an abnormal cartilage in the maxilla (Kochhar and Johnson, '65). A detailed comparison of control and treated day-13 embryos was made therefore to study various tissues taking part in the development of the palate.

Fig. 1. Sagittal sections of day-13 embryos. a, Control. b and c, vitamin A treated. Note the extensive growth retardation, abnormal dorsal curvature, exencephaly, and the defective development of the somites. 13.

Sections of the head region of control embryos showed that facial processes — frontonasal, mandibular, and maxillary — had already appeared, but that the mesenchyme in none of them showed any preosteoblastic condensations as yet (fig. 2). Precartilaginous condensations in other parts of the embryo, e.g., limb buds and vertebra, had also not yet begun. Treated embryos showed parallel development except for the appearance in the maxillary processes of most of them of a well-defined area comprising a compact cell mass (fig. 3). In some embryos this area was quite large but was always distinct from the surrounding mesenchyme (fig. 4). From its location this condensation of cells appeared to be the forerunner of the abnormal cartilage noticed in the maxilla of older fetuses (Kochhar and Johnson, '65).

This cellular condensation in the maxillary mesenchyme of treated embryos was usually accompanied by another modification. At a point where the maxillary and mandibular processes are continuous the epithelium covering them orally showed a few proliferative outpocketings extending into the maxillary mesenchyme. No epithelial proliferations of this type were seen in control embryos of the same age (figs. 5, 6).

Figures 7 and 8 compare sagittal sections of corresponding areas of palatal regions of a control and treated embryo. The mass of cells forming the palatal process of the treated embryo was much smaller than that of the control. In addition the blood vessel in this area was much enlarged in the treated embryo.

The fact that treated embryos were small pointed to the possibility that vitamin A may somehow interfere with the process of cell multiplication. This phenomenon would be expected to lead to abnormal morphogenesis in susceptible areas such as the palate. Incorporation of thymidine-H^3 in various tissues of these embryos was therefore examined (table 1). The rates of cell proliferation, inferred from the number of cells in the population picking up the label in preparation for division, differed among various tissues in the same embryo. The ratio of the number of labeled cells to the total number of cells present in a microscopic field was much greater in the liver and the wall of the gastrointestinal tract than in other regions studied (table 1).

Major differences between control and treated embryos in the number of labeled cells were found in the liver, loose mesenchyme in the head, and the posterior region of the palatine shelves, treated tissues always showing fewer labeled cells (table 1). But labeling of cells in other organs, such as stomach and rest of the palatine shelves, was identical in control and treated embryos (figs. 9, 10). Distribution of labeled cells in the dorsal skin of treated embryos was peculiar. Cells were crowded

TABLE 1

Cell proliferation in tissues of control and vitamin A-treated day-13 rat embryos

Tissue	Control		Vitamin treated		P[2]
	Total number labeled[1]	Labeled	Total number labeled[1]	Labeled	
		%		%	
Liver	126 ± 7	23.6	79 ± 9	15.0	<0.005
Stomach					
epithelium	18 ± 3	22.5	16 ± 4	20.0	NS[3]
mesoderm	59 ± 6	27.8	50 ± 9	23.5	NS
Trigeminal nucleus	46 ± 6	8.7	32 ± 6	6.5	<0.02
Skin					
on cranium	16 ± 4	5.2	14 ± 3	5.4	NS
on dorsal body	17 ± 2	14.5	17 ± 4	9.9	NS
Palatine shelf mesoderm					
anterior	52 ± 8	11.4	52 ± 16	11.4	NS
middle	57 ± 14	12.5	50 ± 7	13.5	NS
posterior	56 ± 7	12.3	32 ± 5	9.5	<0.005
Cephalic mesenchyme	42 ± 8	11.4	23 ± 3	7.7	<0.005

[1] Number of nuclei ± standard deviation.
[2] Probability of chance difference.
[3] Not significant.
Nuclei labeled per microscopic field after 2-hr exposure to thymidine-H^3.

together with much less intercellular space than in controls. Therefore, although the number of labeled cells per microscopic field was the same for control and treated embryos, in the latter the ratio of labeled cells to the total population of cells in the field was much reduced (table 1).

Many parts of the brain could not be compared because of the diffuse nature of the labeling. No difference, however, was found in control and treated embryos in the labeling pattern of the thinned myelencephalic roof, measured together with the overlying skin (table 1, figs. 11, 12). The trigeminal nucleus in treated embryos showed only a slight reduction in the number of labeled cells compared to the control level (table 1).

DISCUSSION

Congenital malformations usually associated with hypervitaminosis A are cranioschisis, sacral rhachischisis (spina bifida), anencephaly and exencephaly, microphthalmia and anophthalmia, cleft palate and dental anomalies, agenesis of limb bones, etc. (Cohlan, '54; Kalter and Warkany, '59, '61; Deuschle et al., '59; Marin-Padilla, '66; Kochhar, '67). Embryological considerations indicate that not all of these anomalies are primary, i.e., that many are the outcome of subsequent development superimposed on an initial defect.

Some of the initial defects observed in the embryos following maternal hypervitaminosis A are described in the present report. It was seen that in the development of the face certain tissues show faults in differentiation, while overall organogenesis progressed more or less normally. Mesodermal cells in the maxillary process showed a response that indicated they were precociously organizing themselves to produce cartilaginous elements. The same tissue in control embryos will later on give rise to maxillary bone without intermediation of cartilage.

The epithelial lining of the oral cavity also showed a significant change. At some places, usually near the sites where chondrogenic tissue was being induced in the mesoderm, the oral epithelium showed proliferations such as are usually associated with the development of glands. This change occurred in what is possibly the region where future dental lamina make their appearance. If we follow the fate of this epithelial structure in older embryos and fetuses it becomes apparent how it participates in the production of palatal and dental anomalies that are encountered later.

Figure 13 is a schematic representation of temporal development of the palatal area in cross-sectional profile beginning with stage-26 normal embryos (day 13). At first the palatal tissue is roughly triangular in outline (figs. 13A, B). By further growth the medial portion of the palatal shelf takes the form of a vertically oriented plate separated from the lateral portion by a notch (fig. 13C); the medial portion is concerned mainly with the problem of rising above the level of the tongue and progressing toward the midline to fuse with the opposite side (figs. 13D, E). Upper dental laminae make their appearance at the most lateral end of the palatal area.

According to the results of the present study epithelial proliferations in vitamin A-treated embryos, probably representing an exaggerated and premature appearance of dental laminae, make their appearance from the oral epithelium (fig. 13F). With further development this epithelium enlarges and, unlike the closely apposed limbs of the dental epithelium of normal embryos, its two limbs separate and come to line what looks like a recess in the otherwise smooth epithelium (fig. 13G). Comparing the corresponding areas in figures 13E and H, which represent development on days 16 and 17, it is apparent that the abnormal development of epithelium has disrupted the synchronized development and the spatially well-organized normal relation of the surrounding tissues, and has resulted in malformations in the palate and teeth. The teeth in treated embryos, particularly molars, were usually hypoplastic and occasionally absent.

The competence of normal epithelium and interdependence of epithelium and mesoderm for induction and formation of many organs during development have been previously emphasized (Zwilling, '56; Kallman and Grobstein, '65; Green, '67). In a study of the morphogenesis of viscera

in mice carrying the mutant gene dominant hemimelia (*Dh*), Green ('67) showed that the presence of a defective coelomic epithelium is closely associated with the origin of gastrointestinal abnormalities in the mutant embryos. Green ('67) suggested that the initial effect of the gene *Dh* is possibly on the structure of splanchnic mesoderm, which as a consequence fails to induce the endoderm to form a normal digestive tract. She also suggested a mechanism by which the abnormalities of the limb and axial skeleton caused by *Dh* may be related to those of the viscera.

The type of malformations encountered in the cranial structures of vitamin A-treated embryos can be envisaged as occurring because of the disrupted inductive relation between epithelium and mesoderm. In support of this possibility, previous studies have revealed that vitamin A participates directly in processes of cellular transformation in the epithelium. Vitamin A-deficient animals show squamous metaplasia and keratinization of their secretory epithelial membranes (Wolbach and Howe, '25). It was discovered by Fell and Mellanby ('53) that when embryonic chick skin is grown in medium containing excess of vitamin A the epidermis is transformed into a mucus-secreting, usually ciliated epithelium instead of a squamous and keratinized type commonly obtained in normal medium.

It cannot be said with certainty that the epithelial proliferations observed in the present study were reminiscent of mucous metaplasia, since only a limited number of embryonic stages were examined. Some secretory granules were, however, observed in these cells, but their histochemical nature was not investigated.

Concerning the cellular effects of vitamin A, it is still an open question whether they are mediated by the participation of the vitamin in cellular metabolism, which thereby channels the biosynthetic and morphological properties of cells, or the observed cellular changes are only reflections of the physical characteristics of the vitamin, or perhaps both. Some biological consequences of the physicochemical properties of vitamin A have been summarized by Dingle and Lucy ('65), who point out that because of its amphipathic molecular structure retinol is highly surface active. Its ability to penetrate rapidly into lipid monolayers, and hence into the plasma membrane of cells, is structure specific (Bangham et al., '64). This property would explain to some extent the action of retinol on isolated erythrocytes, i.e., the production within a short time of treatment of cells of bizarre appearance with greatly increased surface area, which are subsequently lysed (Glauert et al., '63). Dingle and Lucy ('65) concluded from these facts that the damaging action of hypervitaminosis A results when, following interaction between membrane phospholipids and retinol molecules, oxidation of the double bonds of retinol and co-oxidation of membrane lipids occur. Such a phenomenon would to some extent explain the rapid swelling of rat liver mitochondria (Lucy et al., '63) and release of acid protease from rat liver lysosomes (Dingle, '61; Fell and Dingle, '63) in response to excess vitamin A treatment. Increase in membrane permeability may also explain the results of a recent experiment in which mouse fibroblasts of the 3T6 line were cultured in a medium containing excess retinol (Kochhar et al., '68). When these cells were exposed to C^{14}-labeled glucosamine, although they synthesized two to four times the normal quantity of the labeled product, most of it was released into the medium and the cells retained no more than the usual control level. Increase in membrane permeability, rather than any stimulatory effect of vitamin A on the biosynthetic process, was proposed by the authors to explain this enhanced release of the synthesized product. They also suggested that, similar to the phenomenon observed by Fell and Dingle ('63) concerning the release and synthesis of a lysosomal acid protease by retinol-treated cartilaginous explants, the accelerated removal of the labeled product may be accompanied by a compensatory increase in its synthesis.

It should be kept in mind, however, that present knowledge of the systemic functions of vitamin A and of its physical properties fall far short of explaining its role in cellular functions. It now seems established beyond reasonable doubt that excess vitamin A, at levels comparable to those

existing in the plasma of patients with hypervitaminosis A, markedly inhibits cell multiplication in cell cultures (Kochhar et al., '68). Inhibition of cell proliferation, assumed from a decreased rate of thymidine uptake, was also demonstrated in some of the embryonic tissues examined in the present study. This inhibition was noticeable in the liver, loose mesenchyme of the cephalic region, posterior region of the palatine shelves, some areas of the skin, and to a smaller extent in the trigeminal nucleus. Other tissues investigated showed no inhibition. It is important to realize that when the incorporation of H^3-thymidine was investigated, 24 hours had elapsed since the end of vitamin A treatment. It is possible then that parts of the stunted embryos had by this time attained a rate of cell multiplication near normal or only slightly below normal, and that other areas still showing inhibition would have gradually attained a normal rate. The fact that the posterior region of the palatine shelves was among the tissues that continued to show lesser thymidine uptake coincides with previous observations (Kochhar and Johnson, '65) that in vitamin A-treated embryos, even in those few that were able to develop a fused secondary palate, it was the posterior region of palatine shelf that suffered greater reduction in size.

Interference with mitosis has been observed by Aydelotte ('63a, b) in vitamin A-treated epithelial tissues in vitro and by Langman and Welch ('67) in the neuroepithelial cells of cerebral cortex of mouse embryos after maternal hypervitaminosis A. Langman and Welch ('67) calculated that the total generation time of neuroepithelial cells is increased from a normal of 11 hours to approximately 16 hours.

To what extent mitotic inhibition and deviations in cell and tissue differentiation participate in the production of experimentally produced congenital malformations has not yet been established for most teratogens. Even for those teratogens that are known to be cytotoxic the possibility cannot be ruled out that modification in patterns of cell organization and tissue interaction, in addition to and as a consequence of mitotic inhibition, may lead to specific malformations. The present study has suggested that there is a relation between vitamin A-induced changes in epithelial-mesenchyme interaction and the origin of facial defects. Apart from hypoplastic palatine shelves resulting in cleft palate, the precise role of inhibition of cell multiplication is not clear with regard to the origin of other malformations induced by vitamin A.

ACKNOWLEDGMENTS

This work was carried out during the tenure of a Research Fellowship from the Helen Hay Whitney Foundation, New York. The author is indebted to Rosemarie Mahalingam for valuable assistance.

LITERATURE CITED

Aydelotte, M. B. 1963a The effects of vitamin A and citral on epithelial differentiation in vitro. 1. The chick tracheal epithelium. J. Embryol. Exp. Morph., *11*: 279–291.

——— 1963b The effects of vitamin A and citral in epithelial differentiation in vitro. 2. The chick esophageal and corneal epithelia and epidermis. J. Embryol. Exp. Morph., *11*: 621–635.

Bangham, A. D., J. T. Dingle and J. A. Lucy 1964 Studies on the mode of action of excess of vitamin A. 9. Penetration of lipid monolayers by compounds in the vitamin A series. Biochem. J., *90*: 133–140.

Cohlan, S. Q. 1954 Congenital anomalies in the rat produced by excessive intake of vitamin A during pregnancy. Pediatrics, *13*: 556–567.

Deuschle, F. M., J. F. Geiger and J. Warkany 1959 Analysis of an anomalous oculodentofacial pattern in newborn rats produced by hypervitaminosis A. J. Dent. Res., *38*: 149–155.

Dingle, J. T. 1961 Studies on the mode of action of excess of vitamin A. 3. Release of a bound protease by the action of vitamin A. Biochem. J., *79*: 509–512.

Dingle, J. T., and J. A. Lucy 1965 Vitamin A, carotenoids and cell function. Biol. Rev., *40*: 422–461.

Fell, H. B., and J. T. Dingle 1963 Studies on the mode of action of excess of vitamin A. 6. Lysosomal protease and the degradation of cartilage matrix. Biochem. J., *87*: 403–408.

Fell, H. B., and E. Mellanby 1953 Metaplasia produced in cultures of chick ectoderm by high vitamin A. J. Physiol., *119*: 470–488.

Glauert, A. M., M. R. Daniel, J. A. Lucy and J. T. Dingle 1963 Studies on the mode of action of excess of vitamin A. 7. Changes in the fine structure of erythrocytes during haemolysis by vitamin A. J. Cell Biol., *17*: 111–121.

Green, M. C. 1967 A defect of the splanchnic mesoderm caused by the mutant gene dominant hemimelia in the mouse. Dev. Biol., *15*: 62–89.

Kallman, F., and C. Grobstein 1965 Source of collagen at epitheliomesenchymal interfaces during inductive interaction. Dev. Biol., *11*: 169–183.

Kalter, H., and J. Warkany 1959 Experimental production of congenital malformations in mammals by metabolic procedures. Physiol. Rev., *39:* 69–115.

——— 1961 Experimental production of congenital malformations in strains of inbred mice by maternal treatment with hypervitaminosis A. Am. J. Path., *38:* 1–21.

Kochhar, D. M. 1967 Teratogenic activity of retinoic acid. Acta. Path. Microbiol. Scand., *70:* 396–404.

Kochhar, D. M., J. T. Dingle and J. A. Lucy 1968 The effects of vitamin A (retinol) on cell growth and incorporation of labeled glucosamine and proline by mouse fibroblasts in culture. Exp. Cell Res., in press.

Kochhar, D. M., and E. M. Johnson 1965 Morphological and autoradiographic studies of cleft palate induced in rat embryos by maternal hypervitaminosis A. J. Embryol. Exp. Morph., *14:* 223–238.

Kochhar, D. M., K. S. Larsson and H. Boström 1968 Embryonic uptake of S^{35}-sulfate: change in level following treatment with some teratogenic agents. Biol. Neonat., *12:* 41–53.

Langman, J., and G. W. Welch 1967 Excess vitamin A and development of the cerebral cortex. J. Comp. Neur., *131:* 15–26.

Lucy, J. A., M. Luscombe and J. T. Dingle 1963 Studies on the mode of action of excess of vitamin A. 8. Mitochondrial swelling. Biochem. J., *89:* 419–425.

Marin-Padilla, M. 1966 Mesodermal alterations induced by hypervitaminosis A. J. Embryol. Exp. Morph., *15:* 261–269.

Witschi, E. 1956 The Development of Vertebrates. Saunders. Philadelphia and London.

Wolbach, G. B., and P. R. Howe 1925 Tissue changes following deprivation of fat-soluble A vitamin. J. Exp. Med., *42:* 753–777.

Zwilling, E. 1956 Reciprocal dependence of ectoderm and mesoderm during chick embryo limb development. Am. Nat., *90:* 257–265

PLATE 1

EXPLANATION OF FIGURES

Frontal sections of head region of day-13 embryos

2 **Control. Preosteoblastic differentiation in the maxillary tissues has not yet begun.** × 60.

3 **Vitamin A treated. A mass of compact cells (HC) is being formed in the maxillary process.** × 60.

4 **Vitamin A treated. Note the large area occupied by the abnormal precartilaginous cells (HC).** × 90.

5 **Control.** × [illegible].

6 **Vitamin A treated. Note the development of proliferations (EP) from the oral epithelium.** × 90.

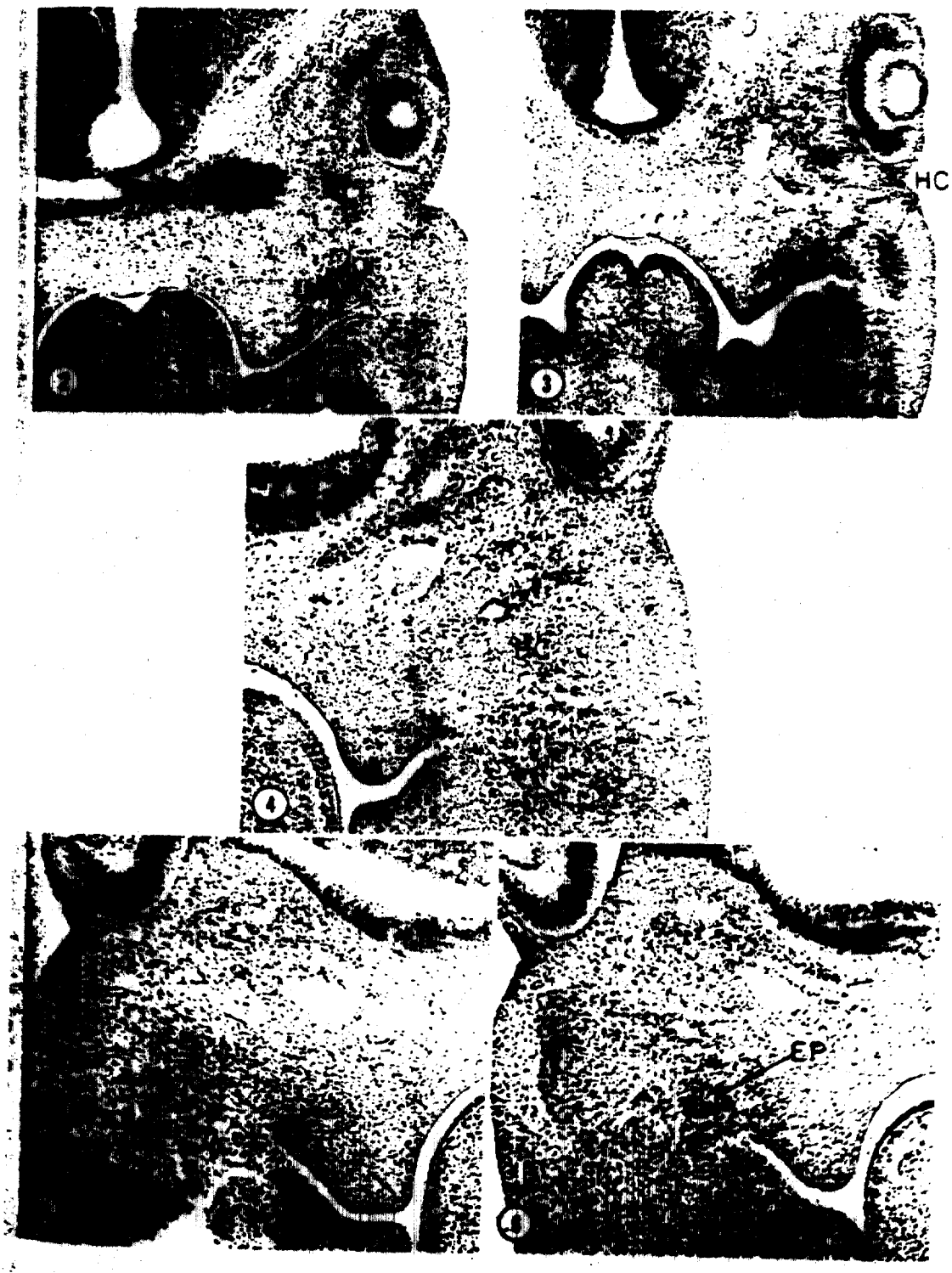
HC
EP

PLATE 2

EXPLANATION OF FIGURES

Sagittal sections of day-13 embryos

7 Control. Head region showing maxillary and mandibular processes and the tongue. × 60.

8 Vitamin A treated. Note the reduction in the number of cells composing the maxillary process and the dilatation of the blood vessel. × 60.

9–10 Autoradiographs of the anterior palatal area of the maxillary process in control (9) and vitamin A-treated (10) specimens. No difference was observed in the number of H^3-thymidine labeled cells. See table 1 for details. × 480.

11–12 Autoradiographs of the thinned roof of myelencephalon along with the overlying skin in control (11) and vitamin A-treated (12) animals. × 480.

7
8
11
10
12

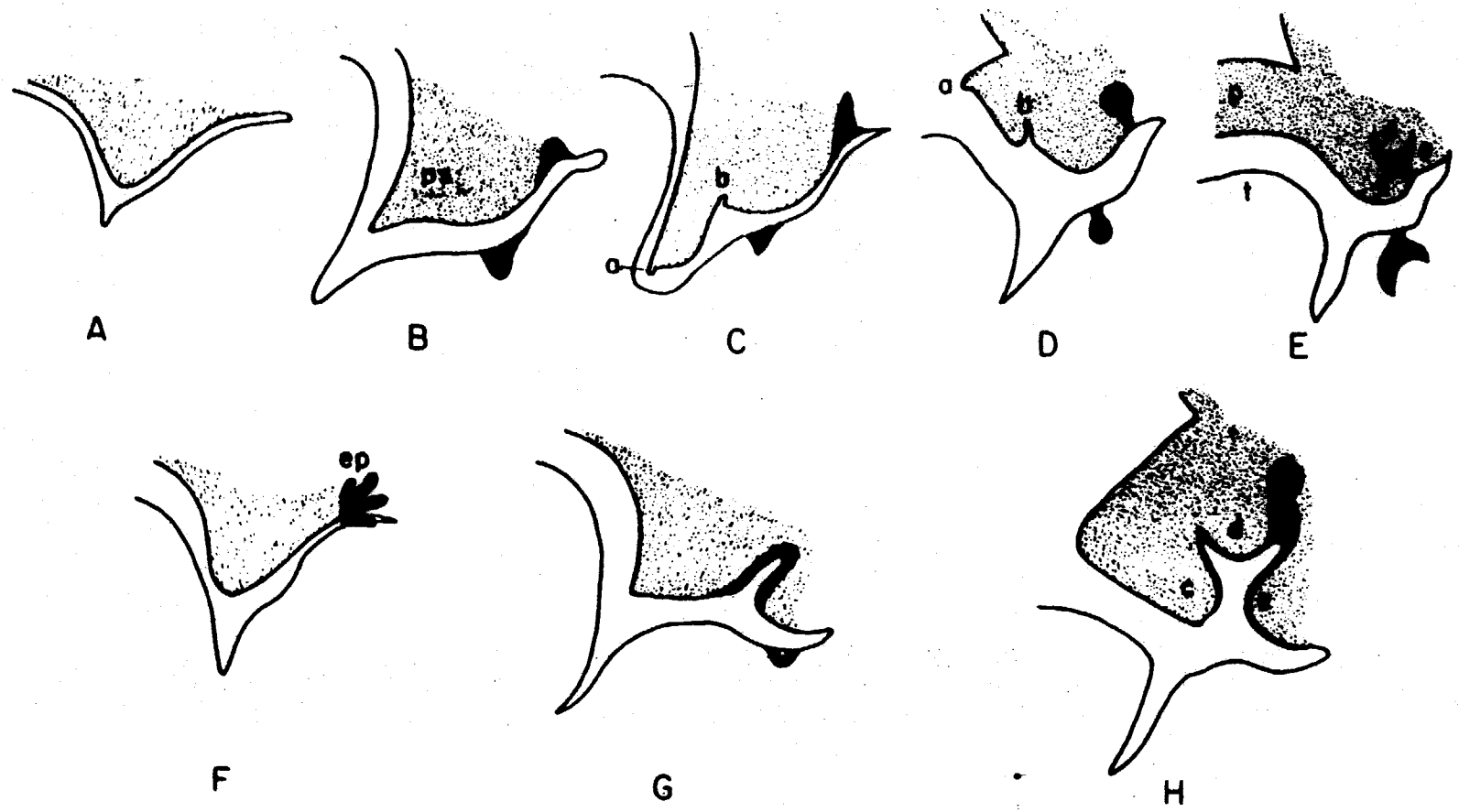

EXPLANATION OF FIGURE

13 Drawings representing the cross-sectional profile of the development of palatal area beginning with day-13 embryos. A–E. Control embryos. Development of the palatine shelf (ps), its horizontalization, and subsequent closure (p) are depicted. Palatal tissue only between points a and b is involved in its movement towards the superior surface of the tongue (t). F–H. Vitamin A treated embryos. Note the premature appearance of epithelial proliferations (ep) from oral epithelium at locations to be later occupied by dental lamina in control embryos. Further development of the abnormal 'dental' epithelium (G and H) has separated otherwise apposed areas c, d, and e from each other (compare E with H).

Koizumi-'69
Bib. No. 4850

BBA 26111

EFFECT OF EXCESS VITAMIN A ON ACID MUCOPOLYSACCHARIDES IN RAT LIVER

TAKEO KOIZUMI, NOBUTO NAKAMURA, NAMIO IWABORI, YOSHIKATSU FURUKAWA AND HIROSHI ABE

Department of Medicine, Osaka University Medical School, Osaka (Japan)

(Received October 9th, 1968)
(Revised manuscript received December 19th, 1968)

SUMMARY

Oral administration of excess vitamin A caused a marked decrease of acid mucopolysaccharides in rat liver. This decrease was pronounced in the non-sulfated fraction of acid mucopolysaccharides, but a reduction of chondroitin sulfates A and C was also noticed with prolonged administration. An increase of hepatic hyaluronidase activity in the whole homogenate and the release of the enzyme into the soluble fraction were found with the hypervitaminotic A treatment. The mechanism which causes quantitative and qualitative changes in hepatic acid mucopolysaccharides with hypervitaminosis A is discussed in relation to the changes in hepatic hyaluronidase activity.

INTRODUCTION

The administration of large amounts of vitamin A causes labilizing of lysosomes followed by a decrease of acid mucopolysaccharides in connective tissue matrix, both *in vivo* and *in vitro*[1-6]. Recent reports have indicated the presence of significant amounts of acid mucopolysaccharides in the liver[7] and of hydrolytic enzymes in liver lysosomes, catalyzing the degradation of acid mucopolysaccharides[8-11]. The effects of excess vitamin A had been studied for cartilage and skin but not for the liver. This study was designed to determine the effects of varying dosages and periods of administration of excess vitamin A on the quantitative and qualtative changes of acid mucopolysaccharides in the liver.

MATERIALS AND METHODS

Preparation of hypervitaminotic animals

Male albino rats (Sprague–Dawley strain, 200–250 g body weight) kept on an uncontrolled water and standard laboratory diet were used in the experiments.

In the massive administration group, daily doses of 20000 I.U. of vitamin A acetate per 100 g of body weight were given orally through a stomach tube, and the animals were sacrificed on the 5th and the 9th days. In the long-term administration

experiments, daily doses of 2000 I.U. of vitamin A palmitate per rat were administered orally for 4 weeks.

Extraction and separation of acid mucopolysaccharides

Extraction of acid mucopolysaccharides from liver tissue was performed as previously described[7]. Non-sulfated and sulfated fractions of acid mucopolysaccharides were obtained by the method of SCHILLER, SLOVER AND DORFMAN[12]. The uronic acid content of each fraction was measured by a modified carbazole reaction[13], using glucuronic acid as a standard. All determinations were done in duplicate.

Fractionation of acid mucopolysaccharides on a cellulose microcolumn

Samples for cellulose microcolumn chromatography were prepared as follows. Aliquots of the acid mucopolysaccharides solution prepared as described above were brought to a NaCl concentration of 2.1 M. Cetylpyridinium chloride in the solution was precipitated with 0.5 ml 1 M KCNS per 10 ml and excess heavy Celite[14], then centrifuged. The supernatant fluid was dialyzed against running tap water overnight, then at 4° for 48 h against distilled water which was changed every 24 h, to remove free KCNS and NaCl completely. 3 vol. of 5% potassium acetate in ethanol were added to the contents of the dialysis bag and left at 4° overnight. The precipitate was obtained by centrifugation, washed sequentially with ethanol, ethanol–ether (50:50, v/v), and ether, then dried *in vacuo*.

The fractionation of acid mucopolysaccharides on the cellulose microcolumn was performed as described by ŠVEJCAR AND ROBERTSON[15]. Commercial hyaluronic acid, chondroitin sulfates A, B, C and heparin were satisfactorily recovered in each fraction indicated. The non-sulfated fraction of acid mucopolysaccharides from biological materials as well as partially degraded hyaluronic acid, as mentioned by ŠVEJCAR AND ROBERTSON[15], were eluted into both Fractions 1 and 2.

In this study, therefore, these two fractions were combined and expressed as "Fraction 1–2". The amount of acid mucopolysaccharides in each fraction was expressed as uronic acid which was determined by a modified carbazole reaction[13].

Determination of hydroxyproline

20 mg of dry defatted liver was used. Hydrolysis and determination of hydroxyproline were performed as previously reported[7].

Assay of hepatic hyaluronidase activity

The liver homogenate and fractions of subcellular particles were prepared as described elsewhere[8]. Hyaluronidase activity was determined by a modified method of HUTTERER[9]. A 0.1% solution of hyaluronic acid from umbilical cord, dissolved in 0.05 M acetate buffer (pH 3.9), was used as a substrate. The incubation mixture consisted of 0.5 ml of substrate solution and 0.5 ml of the liver enzyme solution containing 1.0–3.0 mg of protein. After incubation for 6 h at 37°, 0.2 ml of 0.8 M potassium tetraborate solution (pH 9.1) was added to each tube, boiled for 3 min, then centrifuged. A 0.5 ml aliquot of the supernatant fluid was used for the determination of liberated *N*-acetylglucosamine endgroups by the method of REISSIG, STROMINGER AND LELOIR[16]. The enzyme activity was expressed as μmoles of *N*-acetylglucosamine/g of wet liver per 6 h for total activity, and nmoles of *N*-acetylglucosa-

mine/mg of protein per 6 h for specific activity. Protein was measured by the method of LOWRY *et al.*[17] using bovine serum albumin as a standard.

RESULTS

Daily administration of 20000 I.U. of vitamin A per 100 g body weight caused a decrease of hepatic acid mucopolysaccharides which was significant in the 8-day group compared with the control (Table I). A similar effect was seen with reduced dosage and long-term administration. No significant changes in hepatic hydroxyproline concentration were found in any of the groups.

TABLE I

ACID MUCOPOLYSACCHARIDES AND HYDROXYPROLINE CONTENT IN THE LIVERS OF RATS WITH HYPERVITAMINOSIS A

Massive dosage: daily doses of 20000 I.U. of vitamin A acetate per 100 g body wt. Reduced dosage: daily doses of 2000 I.U. of vitamin A palmitate per rat.

	Number of animals	*Acid mucopolysaccharides*		*Hydroxyproline (μg/mg of dry defatted liver)*
		*Total amount**	*Percentage*	
Control	4	159 ± 17	100	0.50 ± 0.09
Massive dosage				
4 days	4	135 ± 20	85	0.57 ± 0.06
8 days	4	87 ± 7**	55	0.56 ± 0.05
Reduced dosage				
4 weeks	5	106 ± 12**	67	0.55 ± 0.09

* μg of uronic acid per g of dry defatted liver.
** Statistically significant ($P < 0.01$).

TABLE II

NON-SULFATED AND SULFATED ACID MUCOPOLYSACCHARIDES IN THE LIVERS OF RATS WITH HYPERVITAMINOSIS A

Massive and reduced dosages: see Table I.

	Number of animals	*Non-sulfated fraction (1)*		*Sulfated fraction (2)*		*(1) : (2)*
		*Total amount**	*Percentage*	*Total amount**	*Percentage*	
Control	4	77 ± 12	100	82 ± 13	100	0.90
Massive dosage						
4 days	4	43 ± 10***	56	92 ± 14	112	0.47
8 days	4	31 ± 5***	40	56 ± 7***	68	0.55
Reduced dosage						
4 weeks	5	37 ± 4***	48	69 ± 9	84	0.54

* μg of uronic acid per g of dry defatted liver.
** Ratio of non-sulfated acid mucopolysaccharides to sulfated acid mucopolysaccharides.
*** Statistically significant ($P < 0.02$).

After 4 days' administration of the massive dosage, non-sulfated acid mucopolysaccharides in the liver fell to nearly half of the control value (Table II). The sulfated fraction, however, remained unchanged at this stage. The massive dose given for 8 days caused a more pronounced decrease in the non-sulfated fraction, and also a decrease of sulfated acid mucopolysaccharides. Thus, the ratio of non-sulfated fraction to sulfated fraction was lowered with excess vitamin A.

In the reduced-dosage administration group, a marked decrease of non-sulfated acid mucopolysaccharides was detected. Although the sulfated fraction appeared to be slightly decreased, the difference was not statistically significant.

TABLE III

CELLULOSE MICROCOLUMN FRACTIONATION OF ACID MUCOPOLYSACCHARIDES FROM THE LIVERS OF RATS WITH HYPERVITAMINOSIS A

Amounts of acid mucopolysaccharides were expressed as μg of uronic acid per g of dry defatted liver. Fractions 1+2, 4, 5 and 6 were identified, with the aid of bacterial chrondroitinase[19], as hyaluronic acid and or chondroitin, chondroitin sulfates A, C and B, respectively.

No. Fraction	Control	Hypervitaminotic*	
		4 days	8 days
1+2	65	33	31
3	32	36	19
4	15	11	5
5	16	22	6
6	23	24	20
7	8	9	6

* Daily doses of 20000 I.U. of vitamin A acetate per 100 g of body wt.

To study more precisely the nature of the hepatic acid mucopolysaccharides affected, acid mucopolysaccharides from each group were fractionated on a cellulose microcolumn (Table III). The non-sulfated fraction (Fraction 1+2) decreased markedly both in amount and percentage of the total amount with 4 days' administration,

TABLE IV

HYALURONIDASE ACTIVITY IN THE LIVERS OF RATS WITH HYPERVITAMINOSIS A

Total activities were expressed as μmoles of N-acetylglucosamine/g of wet liver per 6 h. Specific activities were expressed as nmoles of N-acetylglucosamine/mg of protein per 6 h.

	Number of animals	Total activity	Specific activity		
			Nucleus cell debris	Particle	Supernatant
Control	4	8.15 ± 1.10	39.3 ± 6.0	46.8 ± 4.7	11.0 ± 4.7
Hypervitaminotic* 4 days	4	13.43 ± 2.90	49.6 ± 14.0	91.9 ± 16.3	27.3 ± 7.4
» 8 days	4	9.51 ± 0.48	35.4 ± 1.8	101.7 ± 1.4	20.5 ± 3.8

* Daily doses of 20000 I.U. of vitamin A acetate per 100 g of body wt.

and slight changes were seen in the sulfated fraction (Fractions 3–7). The 8-day group showed a decrease of the non-sulfated fraction and Fractions 3, 4 and 5. The decrease of Fractions 4 and 5 was pronounced but Fractions 6 and 7 were scarcely affected by the hypervitaminosis A treatment. These sulfated acid mucopolysaccharide fractions were identified as chondroitin sulfates A, C, B, and heparin, respectively, by SVEJCAR AND ROBERTSON[15] and by the method of SAITO, YAMAGATA AND SUZUKI[16] using bacterial chondroitinase in our laboratory.

Total hepatic hyaluronidase activity was increased after 4 days' administration of excess vitamin A, the elevation of the enzyme activity being more marked in the supernatant fraction (Table IV). After 8 days' administration, the enzyme activity in the particle and supernatant fractions remained at a higher level, although the activity of the whole homogenate decreased to the control value.

DISCUSSION

The data presented indicates that hypervitaminosis A is more effective in decreasing the non-sulfated acid mucopolysaccharides than the sulfated ones. Data obtained from microcolumn fractionation showed that the decrease of chondroitin sulfates A and C was marked and that chondroitin sulfate B and heparin were not affected by the hypervitaminotic treatment.

The mechanism causing this specific change to the connective tissue matrix with excess vitamin A was considered to be an activation of lysosomal hydrolytic enzymes, mainly proteolytic enzymes, splitting the protein polysaccharide complex[1,18,20]. It seems unlikely, however, that the changes in acid mucopolysaccharides described above are due to the action of the activated lysosomal proteases alone. The presence of other enzymes concerned with the degradation of acid mucopolysaccharides are indicated, such as hyaluronidase, β-glucuronidase and *N*-acetyl-β-glucosaminidase[11,21,22]. Hepatic lysosomal hyaluronidase, particularly, is known to degrade non-sulfated acid mucopolysaccharides more easily and chondroitin sulfates A and C at a slower rate, but does not affect chondroitin sulfate B (refs. 9, 10). These properties of hepatic hyaluronidase seem to bear a close relationship to the qualitative changes of hepatic acid mucopolysaccharides we have found. With hypervitaminotic treatment, the enzyme activity was increased about 60% compared to that of control animals, and release of the enzyme to the soluble fraction was observed. Almost the same results had been obtained with hepatic *N*-acetyl-β-glucosaminidase activity[8].

These results seem to indicate that the hypervitaminosis A-induced changes in acid mucopolysaccharides in rat liver are not simply the result of activation of proteolytic enzymes which attack the protein–polysaccharide linkage as suggested by THOMAS *et al.*[1], but the result of activation of hydrolytic enzymes which split the polysaccharide chain directly, especially lysosomal hyaluronidase.

ACKNOWLEDGEMENT

The authors thank Miss Nobu Aoki, Miss Masako Tanino and Mr. Yoshiharu Matsubara for their excellent technical assistance.

REFERENCES

1 L. THOMAS, R. T. MCCLUSKEY, J. L. POTTER AND G. WEISSMANN, *J. Exptl. Med.*, 111 (1960) 705.
2 J. T. DINGLE, J. A. LUCY AND H. B. FELL, *Biochem. J.*, 79 (1961) 497.
3 B. MUKHERJI AND B. K. BACHHAWAT, *Indian J. Biochem.*, 3 (1966) 1.
4 T. F. MCELLIGOTT, *J. Pathol. Bacteriol.*, 83 (1962) 347.
5 A. C. CHUNG AND J. C. HOUCK, *Proc. Soc. Exptl. Biol. Med.*, 115 (1964) 631.
6 J. C. HOUCK AND Y. M. PATEL, *Am. J. Pathol.*, 45 (1964) 1045.
7 T. KOIZUMI, N. NAKAMURA AND H. ABE, *Biochim. Biophys. Acta*, 148 (1967) 749.
8 T. KOIZUMI, T. SUEMATSU, N. IWABORI AND H. ABE, *Biochim. Biophys. Acta*, 151 (1968) 628.
9 F. HUTTERER, *Biochim. Biophys. Acta*, 115 (1966) 312.
10 N. N. ARONSON AND E. A. DAVIDSON, *J. Biol. Chem.*, 242 (1967) 441.
11 D. PLATT AND R. HARTMANN, *Klin. Wochschr.*, 45 (1967) 998.
12 S. SCHILLER, G. A. SLOVER AND A. DORFMAN, *J. Biol. Chem.*, 236 (1961) 983.
13 T. BITTER AND H. M. MUIR, *Anal. Biochem.*, 4 (1962) 330.
14 E. D. KORN, *J. Biol. Chem.*, 234 (1959) 1325.
15 J. ŠVEJCAR AND W. B. ROBERTSON, *Anal. Biochem.*, 18 (1967) 333.
16 J. L. REISSIG, J. L. STROMINGER AND L. F. LELOIR, *J. Biol. Chem.*, 217 (1956) 959.
17 O. H. LOWRY, N. J. ROSEBROUGH, A. L. FARR AND R. J. RANDALL, *J. Biol. Chem.*, 193 (1951) 265.
18 H. SAITO, T. YAMAGATA AND S. SUZUKI, *J. Biol. Chem.*, 243 (1968) 1536.
19 J. A. LUCY, J. T. DINGLE AND H. B. FELL, *Biochem. J.*, 79 (1961) 500.
20 J. T. DINGLE, *Biochem. J.*, 79 (1961) 509.
21 A. J. BOLLET, W. M. BONNER AND J. L. NANCE, *J. Biol. Chem.*, 238 (1963) 3522.
22 J. CONCHIE, J. FINDLAY AND G. A. LEVVY, *Biochem. J.*, 71 (1959) 318.

Krause-'49
Bib. No. 4965

J. Nutr. 38(4):535-542. 1949.

A PARADOXICAL RELATIONSHIP BETWEEN SERUM LEVEL AND LIVER CONTENT OF VITAMIN A[1]

R. F. KRAUSE
Department of Biochemistry, College of Medicine, University of Vermont, Burlington

ONE FIGURE

(Received for publication March 9, 1949)

At the present time at least two views exist regarding the relationship between blood levels and the amount of vitamin A stored in the liver. Steigmann and Popper ('44) believe that if a sufficiently large number of cases is studied, some degree of parallelism may be observed between blood and liver levels. This has been attributed to the free vitamin A concentration in the liver (Glover, Goodwin and Morton, '47). Lewis, Bodansky, Falk and McGuire ('42), on the other hand, feel that blood levels of vitamin A are regulated by some means other than the amount stored in the liver. On reviewing the evidence in support of these two views it seemed probable that conditions such as age, sex, amount of supplementation and the degree of vitamin A depletion might determine which process regulates the relationship between vitamin A blood and liver levels.

The work of Lewis et al. ('42) was done on young male and female rats, three to 4 weeks old, that had been given supplements prior to depletion tests. It was therefore decided to examine this blood-liver relationship in older rats that had not received vitamin A supplements, and in similar rats under the influence of varying degrees of vitamin A depletion.

[1] This work was supported in part by grants from Merck and Co., Inc., Milbank Memorial Fund and National Vitamin Foundation, Inc.

METHODS AND PROCEDURES

Rats used were from a commercially supplied Wistar strain. The females weighed 125 to 150 gm and the males 175 to 225 gm at the beginning of the study.

Blood samples were taken by cardiac puncture and total livers removed from 51 female and 61 male rats; 27 males and 19 females were on normal diets [2] and the remainder were on a vitamin A-free diet [3] for periods ranging from 4 to 20 weeks.

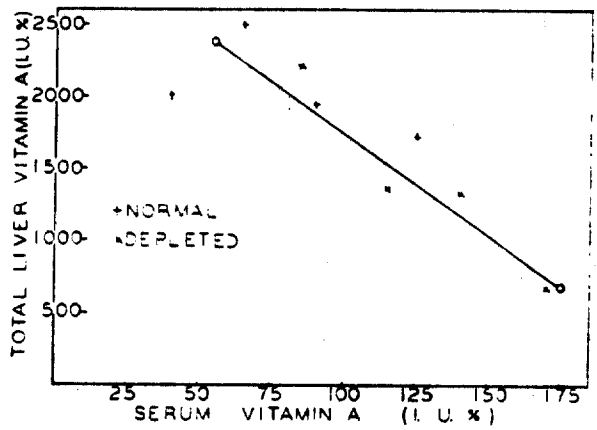

Fig. 1 The relationship between serum vitamin A and total liver content in normal and partially depleted female rats.

All animals were fasted 12 hours prior to taking the samples. Serum vitamin A was determined on duplicate samples by the method of Bessey et al. ('46). The livers were weighed, finely sectioned, thoroughly mixed and aliquots taken for the determination of vitamin A by the method of Oser et al. ('43).

RESULTS

A summary of the results is presented in figure 1 and tables 1 and 2. The points for the graph were determined by arranging the data into groups for which the interval for serum levels of vitamin A was 25 I.U./100 ml. The average serum

[2] Rats on a Purina Laboratory Chow diet.
[3] Rats on a vitamin A test diet, U.S.P. XII.

level in each group was plotted against the corresponding average value for the total vitamin A in the liver. In this figure the points were determined and plotted separately for normal and depleted females. The line of regression drawn between the points for normal and depleted female rats was determined by the method of least squares. A relation similar to the above for females was noted for normal male rats.

TABLE 1

Average weight, serum level and total liver content of vitamin A in normal and partially depleted rats

DIET	NO. OF RATS	WEIGHT		SERUM LEVEL			TOTAL LIVER LEVEL		
		Ave.	S.D.	Ave.	S.D.	Range	Ave.	S.D.	Range
Females		*gm*		*I.U. %*			*I.U.*		
Normal	27	140	± 15	70	± 37	(55–125)	2,226	± 705	(1,019–3,280)
Vit. A-free, 4 wks.	6	160	± 18	135	± 24	(110–175)	1,161	± 172	(850–1,360)
Vit. A-free, 8 wks.	6	180	± 12	115	± 26	(55–150)	1,368	± 681	(715–1,960)
Vit. A-free, 16 wks.	6	190	± 11	115	± 34	(80–165)	1,436	± 946	(141–3,020)
Vit. A-free, 20 wks.	6	190	± 10	140	± 26	(125–175)	1,073	± 511	(600–2,130)
Males									
Normal	19	290	± 24	125	± 49	(55–175)	3,021	± 1727	(1,517–6,230)
Vit. A-free, 4 wks.	10	250	± 25	135	± 46	(25–200)	362	± 156	(100–600)
Vit. A-free, 8 wks.	20	279	± 26	95	± 52	(20–165)	174	± 126	(39–499)
Vit. A-free, 12 wks.	12	304	± 23	65	± 45	(0–155)	61	± 26	(27–106)

The relationship between the serum vitamin A level and liver content of the partially depleted male rats is presented in table 2. These rats were divided into two groups on the basis of their liver content of vitamin A and not according to the time on the vitamin A-deficient diet. In group I were placed those rats whose livers contained only apparent vitamin A: the remaining depleted male rats, whose total liver vitamin A content ranged between 103 and 499 I.U., were placed in group 2.

TABLE 2

The serum level and liver content of two groups of partially depleted male rats

	NO. RATS	TOTAL LIVER CONTENT		SERUM LEVEL	
		Ave.	Range	Ave.	S.D.
		I.U.		*I.U.*	
Group I	19	63 [1]	36–95	75	43
Group II	23	277	103–499	120	44
Serum level difference (group II — group I)				45 [2]	

[1] This value should be labelled "apparent vitamin A," since the color developed by adding the Carr-Price reagent to the extracts from these livers did not produce a characteristic color for vitamin A. A similar observation has been described by Mattson et al. ('47).

[2] The standard error of the difference between the mean serum levels as determined by the formula $\sigma_D = \sqrt{\frac{\sigma_1^2}{N_1} + \frac{\sigma_2^2}{N_2}}$ (Arkin and Colton, '46) was found to be 14 I.U., thus indicating the statistical significance of the difference between the mean serum levels for groups I and II.

It is evident from an examination of these data that an inverse relationship exists between the blood and liver levels of vitamin A in normal male and female rats within the ranges tested. It may also be noted that this inverse relationship holds true in the case of the vitamin A-depleted female animals. The coefficient of correlation [4] for the line of regression as drawn in figure 1 was found to be —0.95, indicating that the relationship is significant.

In the male rats the depletion was more severe than in the females, as is indicated by the lower vitamin A content of the

[4] $r = \sqrt{1 - \frac{\sigma_{y'}^2}{\sigma_y^2}}$ (Arkin and Colton, '46).

liver (see tables 1 and 2). Here a direct relationship was found between the blood and liver levels; that is, as the liver content decreased the serum level also decreased.

From table 1 it will be noted that the average serum vitamin A levels were lower and the liver content higher in the normal female group of rats than in those subjected to the stress of depletion. In the males, however, the serum level and liver content were both lower in the depleted group than in the normal group.

It may be noted that there was a sharp decline in the average amount of vitamin A in the livers of rats after they were on a deficient diet for 4 weeks. The males were more severely affected than the females. Some female rats had as high as 3,000 I.U./total liver after being on a vitamin A-free diet for 20 weeks, whereas in the male group (12 rats), after a similar diet for 12 weeks, all except one had a liver content of vitamin A of less than 100 I.U. The inverse relationship between blood and liver levels held for the former but not for the latter case.

The degree of stress placed on these animals was not sufficient to produce any of the usually accepted physical signs of vitamin A deficiency. The male rats gained weight throughout the test period, whereas the females, after 12 weeks of depletion, did not show an increase in weight but remained constant up to 20 weeks.

DISCUSSION

The evidence presented in figure 1 supports the hypothesis that there is a regulatory mechanism controlling the blood vitamin A level of rats which, under the conditions of this experiment, operates to give an inverse relationship between the blood level and liver content of vitamin A. This regulatory process was found to function in both normal male and female rats and also in those females subjected to vitamin A depletion. It is obvious, however, that the range of this relationship is limited and that it would not apply under conditions of excessive supplementation or extreme depletion. This

latter limitation is shown by the group of male rats on the vitamin A-free diet, in which it will be noted that a low liver content is associated with a low serum level. This change in relationship may be attributed to a breakdown of the regulatory mechanism by the depleted state of the animal. It is of course possible that certain sexual factors may also affect this process.

Sex differences in the rate of loss of liver stores have been previously summarized by Brenner et al. ('42) as favoring the females. This view is further substantiated by the present findings; namely, that in general the male rats were more severely depleted of their vitamin A liver stores in a period of 4 weeks than were the females over a 20-week period.

If low liver content and serum levels of vitamin A are an indication of a deficiency state, it is difficult to account for the continued increase in weight of all male rats, especially in those whose serum levels were zero and whose livers contained less than 100 I.U. of apparent vitamin A. It seems to the author that either vitamin A is not as important a factor in the growth and development of older rats as it is for younger rats, or that a measure of the liver content and serum level is not adequate for determining a deficiency state.

This study confirms the rapid loss of the vitamin A liver depots in the first 4 weeks as noted by Popper and Brenner ('42) and Davies and Moore ('35). The evidence contained in histological studies by Popper and Brenner ('42) and the more recent work of Glover and Morton ('48) suggests that this early and great loss may involve a specific labile type of vitamin A, stored in the hepatic cells as a protein complex, which in turn is readily available for liberation into the blood stream. The more gradually depleted form may represent that vitamin A stored in the Kupffer cells.

It is impossible, with the evidence at hand, to present a satisfactory explanation for the two relationships found to exist between liver content and serum level of vitamin A. It is suggested on the basis of the inverse relationship that perhaps tissue demand is a more potent factor governing serum

blood levels than is liver depot content. Various factors such as age, sex, disease and amount of vitamin A stored undoubtedly affect this relationship.

In conclusion it may be stated that the evidence gained from this study plus the observations described by other workers (see above) support the view that it is difficult to assess the body's need or its reserve of vitamin A on the basis of blood level per se. In light of these findings it seems evident that additional investigation must be made in order to determine whether these factors affect the serum vitamin A level in man.

SUMMARY

An examination was made of the relationship between serum level and liver content of vitamin A in normal rats and those under the influence of varying degrees of vitamin A depletion. The following points were observed:

(1) An inverse relationship existed between blood and liver levels of vitamin A in normal male and female rats and those depleted female animals whose liver content ranged as low as 600 I.U./total liver.

(2) When the total liver content fell below 600 I.U. in the males there was a parallelism between blood and liver levels.

LITERATURE CITED

ARKIN, H., AND R. R. COLTON 1946 An Outline of Statistical Methods. Barnes and Noble, Inc., New York.

BESSEY, O. A., O. H. LOWRY, M. J. BROCK AND J. A. LOPEZ 1946 The determination of vitamin A and carotene in small quantities of blood serum. J. Biol. Chem., *166:* 177.

BRENNER, S., M. C. H. BROOKES AND L. J. ROBERTS 1942 The relation of liver stores to the occurrence of early signs of vitamin A deficiency in the white rat. J. Nutrition, *23:* 459.

DAVIES, A. W., AND T. MOORE 1935 Vitamin A and carotene: elimination of vitamin A from livers of rats previously given massive doses of vitamin A concentrates. Biochem. J., *29:* 147.

GLOVER, J., T. W. GOODWIN AND R. A. MORTON 1947 The relationship between blood vitamin A levels and liver stores in rats. Ibid., *41:* 97.

GLOVER, J., AND R. A. MORTON 1948 The administration, storage and metabolism of vitamin A. Ibid., *43* (XII, Proceedings of Biochemical Society).

LEWIS, J. M., O. BODANSKY, K. G. FALK AND G. MCGUIRE 1942 Vitamin A requirements in the rat. The relation of vitamin A intake to growth and to concentration of vitamin A in the blood plasma, liver and retina. J. Nutrition, *23:* 351.

MATTSON, F. H., J. W. MEHL AND H. J. DEUEL, JR. 1947 The site of conversion of carotene to vitamin A in the rat. Arch. Biochem., *15:* 65.

OSER, B. L., D. MELNICK AND M. PADER 1943 Estimation of vitamin A in food products. Ind. Eng. Chem., Anal. Ed., *15:* 724.

POPPER, H., AND S. BRENNER 1942 The fate of excess vitamin A stores during depletion. J. Nutrition, *23:* 431.

STEIGMANN, F., AND H. POPPER 1944 The influence of large doses of vitamin A upon the plasma vitamin A levels. Am. J. Med. Sci., *207:* 468.

Kryukova-66
Bib. No. 5045

Information Company of America 2204 Walnut Street, Philadelphia, Pa. 19103 215/569-9717

VARIATION OF BLOOD SERUM AND LIVER PROTEIN IN RATS GIVEN EXCESS DOSES OF VITAMIN A

(Ob izmenenii belkov syvorotki krovi i pecheni krys pri izbytochnom vvedenii vitamina A)

By

L. V. Kryukova

Of

Biochemistry Department, Altai Medical Institute

from

Vop. Pitan. 25 (6): 57-60 (1966)

Translation from Russian ANHD/mj

4791

VARIATION OF BLOOD SERUM AND LIVER PROTEIN IN RATS GIVEN EXCESS DOSES OF VITAMIN A

By

L. V. Kryukova

The literature contains data on the effect of vitamin A on protein metabolism. In the presence of a vitamin A deficit, the synthesis of albumins is suppressed, leading to hypoalbuminemia[1-5]. On the other hand, it has been found that the quantity of axerophthol in the organs depends on the level of protein in the food[6-8].

The problem of shifts in protein metabolism in cases of A-hypervitaminosis has been less well studied. The available information indicates a decrease in the protein content of the liver and blood plasma[3,9,10]. In this case, the ratio of protein fractions in the blood and cerebrospinal fluid changes[10].

The present study is in part an investigation of the influence of large doses of vitamin A on certain biochemical processes in the organism. Our task comprised a study of the protein spectrum of the blood serum and liver proteins in animals with A-hypervitaminosis.

The experiment was performed on 87 rats fed ordinary diets and receiving 2,000 IU of vitamin A every day; 66 rats served as controls. 30-35 days later, the animals were sacrificed. The total blood serum protein was determined by Lowry's method[11]. The fractional composition of the serum proteins was investigated by the method of electrophoresis on paper[12]. A veronal-acetate buffer (pH 8.6) was used. The potential gradient was 3 volts per 1 cm. The exposure was 18 hours at a current

force of 0.3 ma on 1 cm cross section of the paper strip. Upon completion of the electrophoresis, the dried-out strips were stained with bromophenol blue, then cut into fractions. Each protein fraction was elutriated with a 0.01 *N* solution of caustic soda. The eluates were photometered in a yellow light filter on the FEK M-1 photoelectrocolorimeter. The water-soluble and alkali-soluble proteins were separated from the liver tissue after L. I. Palladina and A. M. Gudina[13]. The quantity of protein in the fractions was determined after Lowry.

The total protein of the blood serum and the absolute protein fraction content of the rats who received the vitamin A were found to be lowered in comparison to those of the control animals (Table 1). The depression was most pronounced on the part of the albumins and β-globulins, while other fractions varied to a lesser degree. The impairment of the relative content of serum proteins in rats with hypervitaminosis was characterized by hypoalbuminemia and hyperalphaglobulinemia. A similar tendency of variation was detected also in the analysis of the liver protein composition (Table 2). The excessive administration of vitamin A evoked a decrease in both water-soluble and alkali-soluble proteins.

A large single dose of vitamin A, while having no effect on the general condition of the animal, is capable of causing impairment of protein metabolism in as little as 20 hours. Table 3 shows that the rats who received 113,000 IU of vitamin A per os 20 hours before the analysis had some reduction in the total serum protein content, a significant lowering of the absolute content of albumins and β-globulins. The α-globulin content decreased slightly, that of the γ-globulins noticeably increased in 2 rats. The relative content of the protein fractions was

Table 1. Effect of excess vitamin A on protein content in blood serum of rats

Animal Group	Vitamin Dose	Statistical Index	Total Serum Protein (in g%)	Protein fractions in g %				Protein fractions in rel. %			
				Albumins	Globulins α	Globulins β	Globulins γ	Albumins	Globulins α	Globulins β	Globulins γ
First (66)	Control	$M \pm m$	8,7±0,200	3,04±0,267	1,81±0,095	2,07±0,145	1,48±1,110	37,36±1,000	22,20±0,530	21,70±0,750	19,75±0,590
Second (87)	2,000 IU	$M \pm m$ P	7,0±0,300 <0,001	2,46±0,123 <0,01	1,43±0,058 <0,01	1,46±0,070 <0,001	1,11±0,092 <0,02	33,61±0,790 <0,01	24,79±0,520 <0,02	22,93±0,560 <0,2	18,71±0,70 0,5
Third (8)	20,000 IU	$M \pm m$ P	7,68±0,640 <0,2	2,03±0,200 <0,001	2,27±0,230 0,5	1,83±0,220 0,5	1,62±0,26 0,5	27,76±3,090 <0,01	28,70±1,63 <0,01	23,60±1,55 0,5	20,16±2,61 0,5

Remark: The number of animals is given in parentheses.

characterized by hypoalbuminemia and hypergammaglobulinemia in 2 of the animals. Thus, again, a reduction of the albumin fraction was dominating.

Table 2. Effect of excess vitamin A on the protein content in the liver of rats.

Animal Group	Number of animals	Protein fractions (in mg % wet weight)	
		Water-soluble	Alkali-soluble
Control	23	147,62±10,2	19,32±0,90
Experimental (administration of 2000 IU of vit. A)	10	112,25±11,0	14,94±1,25
P		<0,02	<0,01

The quantity of water-soluble liver proteins was significantly reduced in only 1 rat, while the quantity of alkali-soluble proteins decreased in all 3, which is possibly evidence of their great sensitivity to vitamin A.

Table 3. Effect of a single vitamin A load on the protein content of the blood serum and liver of rats

Number of Rats	Total Protein of Blood Serum (in g %)	Protein fractions of blood serum								Liver proteins (in mg %)	
		in g %				in rel. %					
		Albumins	Globulins α	Globulins β	Globulins γ	Albumins	Globulins α	Globulins β	Globulins γ	water soluble	alkali soluble
1	7,8	2,21	1,75	1,70	2,17	28,31	22,45	21,63	27,87	175,0	19,40
2	6,9	2,85	1,65	1,23	0,98	42,76	23,90	19,11	14,18	150,0	9,88
3	7,4	1,58	1,86	1,66	2,25	21,30	25,10	22,90	30,40	87,5	16,88

The shifts in the protein composition of the blood serum that were noted after a single administration of a shock dose of vitamin A become more noticeable in the case of 50-70 day exposure to 20,000 IU of the vitamin per 24-hour day (see Table 1). The total serum protein remains unchanged in comparison with its index in rats who received the vitamin dose of 2,000 IU. The ratios of the protein fractions changes abruptly. The decrease in the albumin content in comparison with the controls becomes even more pronounced, and the increase in the α and γ globulin content is unreliable. The same regular pattern is also manifested in the analysis of the relative content of the protein fractions. In this case, especially profound disturbances are noted on the part of the albumins.

The results obtained provide a basis for supposing the impairment of protein synthesis under the influence of excessive quantities of vitamin A. This is also pointed out in data in the literature testifying to the retarded incorporation of labeled methionine in the liver protein of animals with A-hypervitaminosis as well to a reduction in the DNA content[14].

The increase in the content of globulins that accompanied the hypoalbuminemia and which was especially manifested at the vitamin A dose of 20,000 IU day can be explained by the electrophoretic homogenization, a series of proofs of whose existence was presented by G. V. Troitskii and V. I. Okulov[15]. It is possible that vitamin A, while being transported by the albumins, alters their electrophoretic mobility, bringing it nearer to the mobility of the α-globulins.

УДК 616.391.01 : 577.[illegible]07 : [616.
153.96+616.[illegible]39.6]-074

ОБ ИЗМЕНЕНИИ БЕЛКОВ СЫВОРОТКИ КРОВИ И ПЕЧЕНИ КРЫС ПРИ ИЗБЫТОЧНОМ ВВЕДЕНИИ ВИТАМИНА А

Л. В. Крюкова

Кафедра биохимии (зав. — проф. И. И. Матусис) Алтайского медицинского института

В литературе есть данные о влиянии витамина А на обмен белков. При дефиците витамина А угнетается синтез альбуминов, что приводит к гипоальбуминемии [1—5]. С другой стороны, показано, что количество аксерофтола в органах зависит от уровня белка в пище [6—8].

Менее изучен вопрос о сдвигах в белковом обмене при гипервитаминозе А. Имеющиеся сведения указывают на уменьшение содержания белка в печени и плазме крови [3, 9, 10]. При этом меняется соотношение белковых фракций в крови и спинномозговой жидкости [10].

Таблица 1

Влияние избытка витамина А на содержание белков в сыворотке крови у крыс

Группа животных	Доза витамина	Статистический показатель	Общий белок сыворотки (в г%)	Белковые фракции							
				в г%				в отн. %			
				альбумины	глобулины			альбумины	глобулины		
					α	β	γ		α	β	γ
1-я (66)	Контроль	$M \pm m$	8,7±0,200	3,04±0,287	1,81±0,095	2,07±0,145	1,48±1,110	37,36±1,000	22,20±0,530	21,70±0,750	19,75±0,560
2-я (87)	2 000 ИЕ	$M \pm m$ P	7,0±0,300 <0,001	2,46±0,123 <0,01	1,43±0,058 <0,01	1,46±0,070 <0,001	1,11±0,092 <0,02	33,61±0,790 <0,01	24,79±0,520 <0,02	22,93±0,560 <0,2	18,71±0,70 0,5
3-я (8)	20 000 ИЕ	$M \pm m$ P	7,68±0,640 <0,2	2,03±0,200 <0,001	2,27±0,230 0,5	1,83±0,220 0,5	1,62±0,26 0,5	27,76±3,030 <0,01	29,70±1,63 <0,01	23,60±1,55 0,5	20,16±2,61 0,5

Примечание. В скобках — число животных.

Настоящая работа является частью исследования о влиянии больших доз витамина А на некоторые биохимические процессы в организме. В нашу задачу входило изучение белкового спектра сыворотки крови и белков печени у животных с гипервитаминозом А.

В опыт было взято 87 крыс, находившихся на обычном рационе вивария и получавших внутрь ежедневно 2000 ИЕ витамина А; 66 крыс служили контролем. Спустя 30—35 дней животных забивали. Общий белок сыворотки крови определяли по методу Лоури [11]. Фракционный состав сывороточных белков исследовали методом электрофореза на бумаге [12]. Использовали веронал-ацетатный буфер (pH 8,6). Градиент потенциала составлял 3 *в* на 1 *см*. Экспозиция 18 часов при силе тока 0,3 *ма* на 1 *см* поперечного разреза бумажной полосы. По окончании электрофореза высушенные полосы окрашивали бром-феноловым синим, затем разрезали по фракциям. Каждую белковую фракцию элюировали 0,01 н. раствором едкого натра. Элюаты фотометрировали при желтом светофильтре на фотоэлектроколориметре ФЭК М-1. Выделение водо- и щелочерастворимых белков из печеночной ткани производили по Л. И. Палладиной и А. М. Гудиной [13]. Количество белка во фракциях определяли по Лоури.

Общий белок сыворотки крови и абсолютное содержание белковых фракций у крыс, получавших витамин А, оказались пониженными по сравнению с животными контрольной группы (табл. 1). Понижение было наиболее выраженным со стороны альбуминов и β-глобулинов, в то время как другие фракции изменялись в меньшей степени. Нарушение относительного содержания сывороточных белков у крыс с гипервитаминозом характеризовалось гипоальбуминемией и гипералфаглобулинемией. Аналогичная направленность измене-

ей была обнаружена и при анализе белкового состава печени (табл. 2). Избыточное введение витамина А вызывало уменьшение как водо-, так и щелочерастворимых белков.

Однократная большая доза витамина А, не влияя на общее состояние животного, способна уже через 20 часов вызвать нарушения со стороны белкового обмена. Из табл. 3 видно, что у крыс, за 20 часов до анализа получивших рег 113 000 ИЕ витамина А, имелось некоторое уменьшение содержания общего белка сыворотки, значительное снижение абсолютного содержания альбуминов и β-глобулинов. Содержание α-глобулинов снизилось незначительно, γ-глобулинов заметно возросло у 2 крыс. Относительное содержание белковых фракций характеризовалось гипоальбуминемией и гипергаммаглобулинемией у 2 животных. Таким образом, доминирующим было опять-таки снижение альбуминовой фракции.

Таблица 2

Влияние избытка витамина А на содержание белков в печени крыс

Группа животных	Число животных	Белковые фракции (в мг/г сырого веса)	
		водорастворимые	щелочерастворимые
Контрольная . .	23	147,62±10,2	19,32±0,90
Опытная (введение 2000 ИЕ витамина А) . .	10	112,25±11,0	14,94±1,25
P		<0,02	<0,01

Количество водорастворимых белков печени значительно понизилось только у 1 крысы, в то время как количество щелочерастворимых

Таблица 3

Влияние однократной нагрузки витамином А на содержание белков в сыворотке крови и печени крыс

№ крысы	Общий белок сыворотки крови (в г%)	Белковые фракции сыворотки крови								Белки печени (в мг/г)	
		в г%				в отн. %					
		альбумины	глобулины			альбумины	глобулины			водорастворимые	щелочерастворимые
			α	β	γ		α	β	γ		
1	7,8	2,21	1,75	1,70	2,17	28,31	22,45	21,63	27,87	176,0	13,40
2	6,9	2,85	1,65	1,23	0,98	42,70	23,90	19,11	14,18	150,0	9,62
3	7,4	1,58	1,86	1,66	2,25	21,30	25,10	22,90	30,40	87,5	14,62

уменьшилось у всех 3, что, возможно, свидетельствует об их большой чувствительности к витамину А.

Сдвиги в белковом составе сыворотки крови, наметившиеся при однократном введении ударной дозы витамина А, делаются более заметными при 50—70-дневном воздействии 20 000 ИЕ витамина в сутки (см. табл. 1). Общий белок сыворотки остается без изменения по сравнению с показателем его у крыс, получивших дозу витамина 2000 ИЕ. Соотношения белковых фракций резко меняются. Уменьшение содержания альбуминов по сравнению с контролем делается еще более выраженным, возрастание содержания α- и γ-глобулинов недостоверно. Та же закономерность проявляется и при анализе относительного содержания белковых фракций. И в этом случае особенно глубокие нарушения отмечаются со стороны альбуминов.

Полученные результаты дают основание предположить нарушение белкового синтеза под влиянием избыточных количеств витамина А. На это указывают и литературные данные, свидетельствующие о замедлен-

ном включении меченого метионина в белки печени животных с гипервитаминозом А, а также об уменьшении содержания ДНК [14].

Повышение содержания глобулинов, сопровождавшее гипоальбуминемию и особенно проявившееся при дозе витамина А 20 000 ИЕ в сутки, можно объяснить электрофоретической гомогенизацией, ряд доказательств существования которой представили Г. В. Троицкий и В. И. Окулов [15]. Возможно, витамин А, транспортируясь альбуминами, меняет их электрофоретическую подвижность, приближая ее к подвижности α-глобулинов.

ЛИТЕРАТУРА

1. Гасанов А. С., Каплан Б. Г. В кн.: Рефераты секционных сообщений 5-го Международного биохимического конгресса. М., 1961, т. 1, с. 487.—2. Леуцкая З. К. Бюлл. экспер. биол., 1957, № 10, с. 57.—3. Squibb R. L., Poultry Sci., 1963, v. 42, p. 1332.—4. Vakil U. K., Roels O. A., Trout M., Brit. J. Nutr., 1963, v. 18, p. 217.—5. Harmon B. G., Miller E. R., Hoefer J. A. et al., J. Nutr., 1963, v. 79, p. 263.—6. Леутский К. М. В кн.: Рефераты секционных сообщений 5-го Международного биохимического конгресса. М., 1961, т. 1, с. 500.—7. Bohdal N., Hrubá F., Csl. Gastroent. Vyz., 1961, т. 15, с. 420.—8. Rechcigl M. Jr., Berger S., Loosli J. K. et al., J. Nutr., 1962, v. 76, p. 435.—9. Bhattacharya R. K., Esh G. C., Ann. Biochem., 1962, v. 22, p. 83.—10. Hazzard D. G., Woelfel C. G., Calhoun M. C. et al., J. Dairy Sci., 1964, v. 47, p. 391.—11. Тодоров И. Клинические лабораторные исследования в педиатрии. София, 1961.—12. Гурвич А. Е. В кн.: Современные методы в биохимии. М., 1964, с. 73, 110.—13. Палладина Л. И., Гудина А. М. Укр. біохім. ж., 1963, № 6, с. 841.—14. Леутский К. М. Витамин А. Черновцы, 1959. — 15. Троицкий Г. В., Окулов В. И. Труды Крымск. мед. ин-та. Симферополь, 1961, т. 31, с. 5.

Поступила 13/IV 1965 г.

Kumar-'65
Bib. No. 5077

Naturwiss. 52(2):39-40. 1965.

Effect of Hypervitaminosis A on the Liver Glycogen of Rats

After initial reports[1],[2]) of hypervitaminosis A in humans, a number of workers have described the clinical symptoms of toxicity due to an excessive vitamin A ingestion. In laboratory animals, most of the workers have studied the effects of excess vitamin A on the organ culture, particularly embryonic chick limb in relation to mucopolysaccharide synthesis. Symptoms of hyper-vitaminosis A have been reported in rats[3],[4]). WOLF et al.[5]) have suggested the involvement of vitamin A in the synthesis of mucopolysaccharides by the polymerisation of uridine derivatives which, as is known, are also required in the synthesis of glycogen. Therefore, it was planned to study the effect of hypervitaminosis A on the liver glycogen level. Male young rats were divided into two groups. Animals in both the groups were fed *ad lib.* a stock diet and water. In one group the animals were administered intramuscularly a total of 50,000 units of vitamin A per animal

Table. *Effect of hypervitaminosis A on rat liver glycogen in normal (norm.) and vitamin A treated (Vit. A) animals. 6 animals in each group. Mean + standard error*

Group	Weight		Glycogen	
	I	II	a	b
Norm.	70 ± 7.5	2.79 ± 0.12	0.65 ± 0.07	1.81 ± 0.17
Vit. A	87 ± 6.2	4.44 ± 0.22	40.39 ± 9.93	189.26 ± 55.79
p	> 0.05	< 0.001	< 0.05	< 0.01

I Body weight in g. — II Quotient 100× liver weight/body weight. — a Glycogen expressed as mg/g wet liver, b expressed as mg/100 g body weight.

(Prepalin 100,000 i. μ/ml Glaxo, India) in the first week and a total of 100,000 units in the next week when the experiment was terminated. The doses were given daily in equal amounts. Animals were starved for 18 hours and sacrificed, pieces of liver were immediately excised, blotted to remove adhering blood, weighed, dropped into 30% aq. KOH and digested in a boiling water bath. Glycogen was precipitated by the method of GOOD et al.[6]) and estimated[7]) colorimetrically.

Results have been expressed in the table. As the weight of liver per 100 g body weight significantly increased in the vitamin A treated animals ($p < 0.001$), glycogen values have been expressed in terms of 100 g body weight also. The results show that excessive administration of vitamin A for a period of two weeks brings about a significant increase in liver glycogen when expressed as mg/g wet tissue ($p < 0.05$) as well as mg/100 g body weight ($p < 0.01$).

Vitamin A has been reported to cause the release of a proteolytic enzyme[8]) which could obviously increase the total body amino acid pool and thereby enhance the process of gluconeogenesis. In the organ culture experiments an increased lactic acid concentration and lowered oxygen and glucose uptake have been reported[9]). If similar changes could be brought about in rats by the administration of vitamin A, it would obviously shift the equilibrium towards an increased glycogen formation, therefore, further attempts are being undertaken towards the elucidation of this pathway.

The authors are grateful to Dr. R. VISWANATHAN, Director of this Institute for his interest in this work. Messers. P. P. DUA and N. SRIVASTAVA rendered technical assistance.

Department of Biochemistry, Vallabhbhai Patel Chest Institute, University of Delhi, Delhi-6, India

MAHENDRA KUMAR, U. K. MISRA
and T. A. VENKITASUBRAMANIAN

Eingegangen am 5. August 1964

[1]) JOSEPH, H. W.: Am. J. Dis. Child. 67, 33 (1944). — [2]) RODAHL, K., and T. MOORE: Biochem. J. 37, 166 (1944). — [3]) WOLBACH, B. S.: J. Bone and Joint Surg. 29, 171 (1947). — [4]) IRVING, J. T.: J. Physiol. (London) 108, 92 (1949). — [5]) WOLF, G., and P. T. VARANDANI: Biochim. et Biophys. Acta 43, 501 (1960). — [6]) GOOD, C. A., H. KRAMER, and M. SOMOGYI: J. Biol. Chem. 100, 485 (1933). — [7]) MONTGOMERY, R.: Arch. Biochem. Biophys. 67, 378 (1957). — [8]) DINGLE, J. T., J. A. LUCY, and H. B. FELL: Biochem. J. 79, 497 (1961).

Lakshmanan-'69
Bib. No. 5127

Vitamin A status and the metabolism of cholesterol in the rat

By M. R. LAKSHMANAN, W. E. J. PHILLIPS and R. L. BRIEN

Research Laboratories, Food and Drug Directorate, Department of National Health and Welfare, Ottawa, Canada

(*Received* 26 *March* 1968—*Accepted* 23 *August* 1968)

1. The interrelationship between cholesterol and vitamin A metabolism has been studied in rats.

2. The effect of cholesterol feeding in increasing the liver storage of cholesterol was enhanced during vitamin A deficiency.

3. This effect was due to an increased rate of absorption of cholesterol and not due to a decreased turnover rate.

4. Feeding of high levels of vitamin A markedly depressed the cholesterol absorption; however, its turnover was unaffected.

The importance of blood lipids in general and cholesterol in particular in the pathogenesis of atherosclerosis has led to a search for dietary regimens to control hypercholesterolaemia. Dietary fish oils are effective in lowering serum cholesterol (Bronte-Stewart, Antonis, Eales & Brock, 1956; Anderson, Keys & Grande, 1957; Ahrens, Insull, Hirsch, Stoffel, Peterson, Farquhar, Miller & Thompson, 1959; DeGroot & Reed, 1959). In studies using chickens Wood (1960) demonstrated that vitamin A was the active hypocholesterolaemic factor in fish oils. Later, it was shown that vitamin A feeding prevented the rise in serum and liver cholesterol levels induced by dietary cholesterol in rats (Bring, Ricard & Zaehringer, 1965) and chickens (Wood & Topliff, 1961; Beeler, Rogler & Quackenbush, 1962; March & Biely, 1963). Sampson & Potter (1947) in a brief communication reported that vitamin A-deficient rats stored more cholesterol than controls when maintained on a diet containing cholesterol. On the other hand, Green, Horner, Lowe & Morton (1957) concluded that cholesterol feeding decreased liver vitamin A storage in male rats. All these studies suggest an inverse relationship between cholesterol and vitamin A but the exact mechanism by which this is manifested is not fully understood. The most likely processes through which vitamin A or cholesterol may control the metabolism of each other are (*a*) absorption across the intestine, (*b*) transport and storage in the liver, and (*c*) turnover rate. The present investigations were undertaken in an attempt to elucidate the complex interrelationships between cholesterol and vitamin A metabolism.

EXPERIMENTAL

Animals. Albino rats of the Wistar strain were weaned at 21 days of age and fed the appropriate experimental diets *ad lib.*

Analysis of tissues. Tissues from each group were bulked and saponified in Expts 1 and 2; in Expts 3 and 4 individual tissues were saponified (in the presence of ethanolic

pyrogallol). The non-saponifiable fraction was chromatographed on neutral alumina partially deactivated to Brockman grade 3, as described by Mervyn & Morton (1959). The vitamin A and sterol fraction was isolated as described previously (Phillips, 1967). Absorption spectra were determined over the range of 220 nm to 360 nm with a recording spectrophotometer.

Radioactive tracer and assay. [4-^{14}C]Cholesterol (specific activity 30·2 mc/mM) with a radiochemical purity greater than 99% was obtained from the Radiochemical Centre, Amersham. The material to be assayed for radioactivity was dissolved in toluene containing 0·5% (w/v) 2,5-diphenyloxazole and 0·03% (w/v) 1,4-bis[2-(5-phenyloxazolyl)]benzene and counted in a liquid scintillation spectrometer (Nuclear Chicago Inc.) using the channel ratio method to account for quenching.

Expt 1. Twenty male weanling rats were allocated randomly to one of four diets. The basal diet for all groups was free from cholesterol and fat and had the following composition: vitamin-free casein 25%, sucrose 55%, Alphacel 16%, USP 14 salt mix 4%, and a vitamin fortification mixture (Nutritional Biochemical Corp., Cleveland, Ohio) with vitamin A omitted. The vitamins added per kg diet were: thiamine hydrochloride 22 mg, riboflavine 22 mg, calcium pantothenate 71 mg, nicotinic acid 88 mg, pyridoxol hydrochloride 22 mg, menaphthone 40 mg, α-tocopherol 110 mg, folic acid 2·2 mg, biotin 0·4 mg, *p*-aminobenzoic acid 110 mg, inositol 110 mg, calciferol 0·06 mg, choline chloride 1·68 g. Two groups were fed on this diet supplemented with vitamin A (10000 i.u./kg in the form of stabilized vitamin A powder of potency 20000 i.u./g; Nutritional Biochemical Corp., Cleveland, Ohio) and the other two groups received the basal ration with no vitamin A supplement. Cholesterol in powder form at a level of 2% was incorporated into half of each of the above diets.

Treatments were replicated four times, a total of eighty rats being used. The experimental design is shown in Table 1. The results were subjected to analysis of variance and individual degrees of freedom were isolated for vitamin A, sterol, and the interaction.

Expt 2. Expt 2 was designed to study the effects on the liver non-saponifiables of dietary cholesterol when dissolved in oil. A vitamin A-free diet (Phillips, 1961) containing 5% cottonseed oil was used as the basal diet. Thirty-two animals, sixteen of each sex, were divided into eight groups of four rats. The experimental design is shown in Table 2. Each group of rats received either cholesterol (final concentration 2% in the whole diet) or vitamin A (10000 i.u./kg) or both.

Expt 3. Sixty-four male weanling rats were divided into two groups of thirty-two rats each and while one was maintained on the vitamin A-free basal diet the other was fed on this diet supplemented with vitamin A (10000 i.u./kg). Rats fed on the vitamin A-free diet ceased gaining weight after 4–5 weeks. At this stage of vitamin A-deficiency rats from both groups received, by stomach tube, a dose of 1 mg cholesterol having a radioactivity of 2 μc in 0·5 ml cottonseed oil. Eight animals from each group were killed 4, 6, 12 and 24 h after the tracer dose, as shown in Fig. 1. The small intestine, from the pyloric sphincter to the ileocaecal junction, and the liver were excised. Unabsorbed material in the intestinal lumen was removed by flushing with

50 ml of ice-cold physiological saline. The liver and intestine were analysed for radioactivity in the non-saponifiable fraction. The radioactivity in the non-saponifiable fraction as such was taken as a measure of the radioactivity in the sterol fraction since in the initial experiments it was found that after chromatography on deactivated alumina and precipitation with digitonin more than 95% of the radioactivity from the non-saponifiable fraction of these tissues remained in the digitonide precipitate.

Expt 4. Seventy-two male weanling rats were divided into three groups of twenty-four and maintained on diet 1 (vitamin A-free basal diet), diet 2 (diet 1 + 400 i.u. vitamin A/kg diet) or diet 3 (diet 1 + 40000 i.u. vitamin A/kg diet). When the rats on diet 1 reached the weight plateau stage of vitamin A deficiency, each rat from all the groups was dosed by stomach tube with 1 mg cholesterol in 0·5 ml cottonseed oil (radioactivity 1 μc). The rats to be killed 96 h after the tracer dose each received 2 μc cholesterol. Six animals from each group were killed 24, 48, 72 and 96 h after dosing and the livers and intestines were analysed for radioactivity in the non-saponifiable fraction as described in Expt 3.

RESULTS

Expt 1 was terminated after giving the experimental diet for 36 days. Animals not receiving a dietary supplement of vitamin A were at the plateau stage of the deficiency syndrome. Although vitamin A influenced growth ($P = 0{\cdot}01$), the feeding of 2% cholesterol did not modify growth or liver weight either in the presence or absence of vitamin A (Table 1). Feeding 2% cholesterol increased ($P = 0{\cdot}01$) the percentage of

Table 1. *Expt 1. Effect of dietary cholesterol and vitamin A in a fat-free diet on some liver non-saponifiable constituents of rats*

(Mean values with their standard errors for four replicate determinations)

Treatment		Final body-wt (g)	Liver wt (g)	Non-saponifiables (%)	Sterol in liver (mg/g)
Vitamin A	Cholesterol				
+	—	241 ± 1	11·17 ± 0·17	0·383 ± 0·008	2·48 ± 0·07
+	+	236 ± 3	10·95 ± 0·19	0·553 ± 0·024	3·78 ± 0·39
—	—	189 ± 6	7·88 ± 0·27	0·408 ± 0·013	2·65 ± 0·07
—	+	184 ± 4	7·85 ± 0·18	1·182 ± 0·204	8·90 ± 1·30

liver non-saponifiable constituents, the increase being greater in those animals not receiving dietary vitamin A than in those receiving vitamin A ($P = 0{\cdot}05$). A parallel effect was observed in the concentration of liver crude sterol. The effects of vitamin A, cholesterol feeding and the interaction between vitamin A and cholesterol feeding were all highly significant ($P = 0{\cdot}01$). The accumulation of liver sterol in animals receiving 2% dietary cholesterol was less in the presence of vitamin A than in its absence.

In Expt 2 it was necessary to kill the male animals after 45 days feeding and the females after 55 days, owing to the sex difference in reaching the avitaminotic state. The effects of dietary treatments on hepatic sterols are shown in Table 2. The relative concentrations of liver sterols resulting from the feeding of cholesterol dissolved in

the dietary oil was similar to that observed in Expt 1. The degree of absorption and consequent levels of liver sterol were much greater, however. The extremely high accumulation of liver sterols in the male vitamin A-deficient group receiving cholesterol (group 4) would appear to be a direct reflection of the degree of avitaminosis. This group exhibited the most severe weight loss of all groups on the deficient diet.

Table 2. *Expt 2. Effect of dietary cholesterol and vitamin A on some liver non-saponifiable constituents of rats*

Group	Treatment: Vitamin A	Treatment: Cholesterol	Sex	Mean maximum body-wt (g)	Mean final body-wt (g)	Mean liver wt (g)	Non-saponifiables (%)	Sterol in liver (mg/g)
1	+	−	♂	180	180	10·28	0·342	2·23
2	+	+	♂	211	211	14·34	1·356	11·49
3	−	−	♂	125	113	5·10	0·458	2·18
4	−	+	♂	137	114	7·11	5·530	40·39
5	+	−	♀	177	177	7·76	0·372	2·28
6	+	+	♀	174	174	8·35	0·897	7·58
7	−	−	♀	126	109	3·60	0·523	2·74
8	−	+	♀	143	131	5·96	1·842	11·65

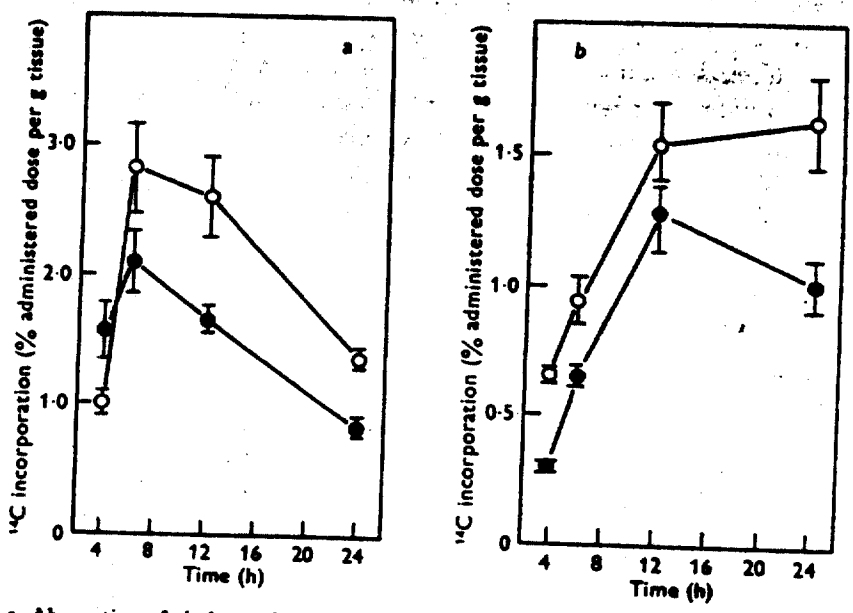

Fig. 1. Absorption of cholesterol in (*a*) intestine and (*b*) liver of normal (● — ●) and vitamin A-deficient (○ — ○) rats. Each value represents the mean of eight individual observations with its standard error.

The results of Expt 3 are presented in Fig. 1 which shows the percentage of the [4-^{14}C]cholesterol incorporated per g fresh weight of tissue as a function of time in the liver and intestine of both vitamin A-deficient and normal animals and thus gives a measure of the absorption of cholesterol. The radioactivity in the intestine reached the maximum between 4 and 12 h after dosing in both groups; however, the activity was higher in the vitamin A-deficient animals than in the normal ones. The average

weight of the small intestine in normal animals was 6·17 g and 4·89 g in vitamin A-deficient animals. The radioactivity in both groups then fell rapidly with a concomitant greater uptake by the vitamin A-deficient livers throughout the various time intervals. It was also noteworthy that, while the amount of radioactivity in vitamin A-deficient liver was not significantly different between 12 and 24 h, the normal liver showed a distinct downward trend.

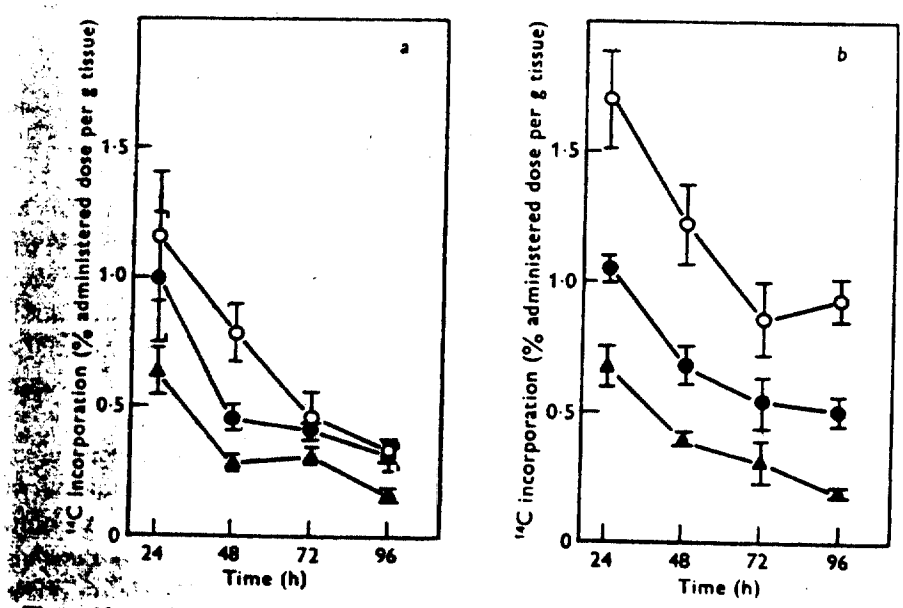

Fig. 2. Absorption and turnover of cholesterol in (*a*) liver and (*b*) intestine of normal (●—●) and vitamin A-deficient (○—○) rats and in rats given high levels of vitamin A (▲—▲). Each value represents the mean of six individual observations with its standard error.

Having observed that the absorption of cholesterol was markedly enhanced during vitamin A deficiency the next objective was to investigate whether the turnover rate of cholesterol was affected by vitamin A deficiency or high levels of dietary vitamin A. It was also pertinent to study simultaneously the absorption of cholesterol in rats given high levels of dietary vitamin A. The results of Expt 4 are presented in Fig. 2. The amount of radioactivity per g of liver at 24 h was taken as an index of absorption of [4-^{14}C]cholesterol and the activity at 48, 72 and 96 h as an estimation of the turnover rate. It was apparent that the radioactivity in the liver was increased by 62% at 24 h in the vitamin A-deficient group when compared with that from the group given diet 2 containing 400 i.u. vitamin A/kg. On the other hand, there was a 35% drop in the amount of radioactivity in the group receiving high levels of vitamin A. The fact that there were no significant differences in the rates at which radioactivity declined in the various groups indicated that vitamin A did not affect the turnover of liver sterols.

DISCUSSION

Cholesterol feeding is known to increase the hepatic storage of cholesterol in rats. The present studies clearly established that irrespective of the form in which choles-

terol is fed this effect is accentuated during vitamin A deficiency (Tables 1 and 2) and is more pronounced in males than in females. These findings fully support the earlier observations of Sampson & Potter (1947). Furthermore, studies on [4-^{14}C]cholesterol absorption and turnover have revealed that this effect of vitamin A deficiency is due to an increased rate of cholesterol absorption and not to its decreased turnover rate.

It is interesting here to point out that Horner & Morton (1960), substantiating the earlier work of Green *et al.* (1957), state that the effect of cholesterol in depressing the hepatic vitamin A stores of rats is observed only when cholesterol and vitamin A are fed simultaneously. They have also ruled out the possibility of any interference of cholesterol with vitamin A deposition into liver or its utilization. March & Biely (19[illegible]) have obtained similar results from their experiments with chickens. Weitzel, Schön, Gey & Buddecke (1956) reported that the hypocholesterolaemic effect of vitamin A is not observed if the vitamin is administered to old atherosclerotic hens, indicating that once hypercholesterolaemia has developed, vitamin A has no beneficiary effect whatsoever. This again suggests that the interference between vitamin A and cholesterol occurs during absorption. Beeler *et al.* (1962) have found that inclusion of bile salts in the diet of cockerels completely eliminated the hypocholesterolaemic effect of vitamin A. Consequently, they have also proposed that vitamin A or cholesterol mutually interfered with the absorption of the other across the intestine and that vitamin A, in some way, may block the bile salts in facilitating the cholesterol absorption. Strikingly, our results provide a direct evidence for a markedly impaired absorption of cholesterol during feeding of high levels of vitamin A, thus fully supporting the existing concept that vitamin A and cholesterol do exert a mutual antagonism during absorption. It is, however, interesting to note that neither vitamin A deficiency nor a high level of vitamin A feeding has any significant effect on the cholesterol turnover rate.

REFERENCES

Ahrens, E. H. Jr, Insull, W. Jr, Hirsch, J., Stoffel, W., Peterson, M., Farquhar, J. W., Miller, T., Thompson, H. J. (1959). *Lancet* i, 115.
Anderson, J. T., Keys, A. & Grande, F. (1957). *J. Nutr.* 62, 421.
Beeler, D. A., Rogler, J. C. & Quackenbush, F. W. (1962). *J. Nutr.* 78, 184.
Bring, S. V., Ricard, C. A. & Zaehringer, M. V. (1965). *J. Nutr.* 85, 400.
Bronte-Stewart, B., Antonis, A., Eales, L. & Brock, J. F. (1956). *Lancet* i, 521.
DeGroot, A. P. & Reed, S. A. (1959). *Nature, Lond.* 183, 1191.
Green, B., Horner, A. A., Lowe, J. S. & Morton, R. A. (1957). *Biochem. J.* 67, 235.
Horner, A. A. & Morton, R. A. (1960). *Biochem. J.* 74, 301.
March, B. E. & Biely, J. (1963). *J. Nutr.* 79, 474.
Mervyn, L. & Morton, R. A. (1959). *Biochem. J.* 72, 106.
Phillips, W. E. J. (1961). *Can. J. Biochem. Physiol.* 39, 855.
Phillips, W. E. J. (1967). *Can. J. Biochem.* 45, 749.
Sampson, M. M. & Potter, L. M. (1947). *Fedn Proc. Fedn Am. Socs exp. Biol.* 6, 420.
Weitzel, G., Schön, H., Gey, F. & Buddecke, E. (1956). *Hoppe-Seyler's Z. physiol. Chem.* 304, [illegible]
Wood, J. D. (1960). *Can. J. Biochem. Physiol.* 38, 879.
Wood, J. D. & Topliff, J. (1961). *J. Fish. Res. Bd Can.* 18, 377.

Printed in Great Britain

Langman-'66
Bib. No. 5158

J. Comp. Neurol. 128(1):1-7. 1966

Effect of Vitamin A on Development of the Central Nervous System

JAN LANGMAN AND GARY W. WELCH [1]
Department of Anatomy, University of Virginia, Charlottesville, Virginia

ABSTRACT Pregnant rats and mice were treated with large doses of vitamin A to examine its effect on the closure of the neural groove in the developing embryo. In the rat the most effective dose was 30,000 U.S.P. units given at day 8, 9, and 10 of pregnancy. Twenty-six per cent of the implanted embryos showed anencephaly and/or myeloschisis. In the mouse the results of vitamin A treatment were inconsistent.

In 12-day rat embryos, the lateral walls of the diencephalon and mesencephalon were slightly everted. Mitotic neuro-epithelial cells were frequently piled up two or three rows thick, causing a disruption of the internal limiting membrane. Many cells were characterized by a bleb-like cytoplasmic evagination protruding into the lumen.

During the following days, the everted walls of the diencephalon and mesencephalon expanded farther and farther over the sides of the head, thereby often covering the lateral hemispheres and the eyes. Although the hemispheres were displaced by the everted diencephalic plates and the eyes were frequently buried deep inside the head, histological differentiation proceeded normally and a primitive cerebral cortex as well as normal eye structures were observed. The accumulation of mitotic figures, the formation of cytoplasmic protrusions, and the presence of small neuro-epithelial rosettes throughout the brain were the most striking cytological anomalies.

By the eighteenth day of development, small hemorrhages occurred in the mesenchyme surrounding the brain and degeneration became apparent. At birth a small amount of degenerated brain tissue was all that remained from the large exencephalic brain, and the newborn had the appearance of an anencephalic. It is concluded that large doses of vitamin A prevent the neural groove from closing, possibly by interfering with the cell membrane and/or the mitotic activity of the neuro-epithelial cells.

In a recent study on the closure of the neural tube in the chick embryo, it was found that the neuro-epithelial cells form a homogeneous population, which doubles in number every eight hours (Langman et al., '66). During the five hours of DNA-synthesis, the cells are wedge-shaped with a slender process extending toward the inner surface and a broader portion with the nucleus near the basement membrane. During the G_1-phase (two hours) the nucleus and most of the cytoplasm contract toward the inner surface to undergo mitosis. Immediately after division the daughter cells extend rapidly toward the basement membrane, reassuming a wedge shape. It was thus suggested that the spatial configuration of the cells might play an important role in the closure of the neural tube.

To examine whether a disturbance of the spatial relationship would cause an abnormal closure of the neural tube, embryos were treated with vincristine sulphate, a mitotic inhibitor (Langman et al., '66). The resulting accumulation of arrested metaphases near the inner surface, indeed, caused the walls of the neural groove to evert, thereby preventing closure of the tube. A similar observation was made by Bellairs ('54), who treated chick embryos with a solution of Synkavit (tetrasodium 2 methyl 1:4 naphthohydroquinone diphosphate). Resting and dividing cells accumulated along the inner surface, and the presumptive alar plates everted.

Little information is available about the mechanism by which vitamin A (Giroud and Martinet, '55; '57; Kalter and Warkany, '61), trypan blue (Hamburgh, '54; Wilson, '55; Warkany et al., '58) and folic acid deficiency (Nelson, '60) prevent closure of the neural tube in the mammalian embryo. It is possible that these teratogenic agents interfere with mitosis, thus

[1] This investigation was supported by a research grant (NB 06188-01) from the Institute of Neurological Diseases and Blindness of the National Institutes of Health, and by a subgrant from a National Institutes of Health Grant to the University of Virginia. In the later stages, the investigations were supported by grant R-200-66 from the United Cerebral Palsy Foundation.

causing an accumulation of dividing cells near the inner surface; they may also interfere with DNA synthesis resulting in a decrease in the number of cells; or they may prevent the formation of neuroblasts, causing overproduction of neuro-epithelial cells.

Since in preliminary experiments hypervitaminosis A was found to be the most effective agent causing anencephaly and myeloschisis in the mammalian fetus, it was decided to study the effect of the vitamin on the neuro-epithelial cells during the early stages of brain development and to examine the resulting abnormality throughout pregnancy.

MATERIALS AND METHODS

Female Wistar rats, ranging in weight from 200 to 250 gm, were treated with 30,000 to 60,000 U.S.P. units vitamin A on day 8, 9, and 10 of pregnancy. The vitamin, made water soluble with sorethytan esters (U.S. Vitamin and Pharmaceutical Corp.), was given by stomach tube. Swiss-Webster mice were similarly treated with high doses of vitamin A on two or three successive days of pregnancy. The control animals were given 0.2 to 1 ml of the vitamin solvent or saline on the same days as the experimental animals.

In the first series of experiments, the rats and mice were sacrificed on the eighteenth day of pregnancy. The uterus was removed and the number of implantations, resorptions and fetuses with abnormalities of the central nervous system recorded. As soon as the most effective teratogenic dose was determined, a second experiment was undertaken in which the treated rats were sacrificed at daily intervals starting at the twelfth day of gestation. This made it possible to study the morphogenesis of the abnormality from its earliest stage until the end of pregnancy. The abnormal embryos were photographed, fixed in Bouin's fluid, cut in serial sections (4 μ to 10 μ) and stained with hematoxylin-eosin.

RESULTS

Table 1 represents the results obtained by treating Wistar rats with various doses of vitamin A on day 8, 9 and 10 of pregnancy. A dose of 30,000 U.S.P. units vitamin A was most effective in preventing the neural groove from closing. Twenty-six per cent of all implanted embryos showed exencephaly, and a small percentage showed myeloschisis (table 1).

In addition to the abnormalities of the central nervous system, a few fetuses had a cleft palate, ocular abnormalities and malformations of the extremities. These malformations, however, were mainly seen when vitamin A was given after the tenth day of development. Exencephaly and myeloschisis did not occur when treatment was given after day ten. In the mouse the effect of hypervitaminosis A on the developing central nervous system was less consistent (table 2). The embryos were either resorbed or failed to show gross abnormalities. Only a few had exencephaly or myeloschisis.

Figures 1 and 2 show 12-day-old rat embryos in which the diencephalon and mesencephalon failed to close. The rhombencephalon was usually normal. The most prominent feature in the open part of the brain was a bilateral white hillock, formed by the everted alar plates.

By the thirteenth and fourteenth day of development, the abnormality had a more distinctive form (figs. 3, 4, 5). The walls of the diencephalon, mesencephalon and sometimes of the rhombencephalon were strongly everted, thereby expanding over the lateral sides of the head. When viewed from above, it was noted that in the mesencephalic region, the midline groove had often disappeared, resulting in a convex everted brain cap. In the diencephalic region, however, a deep midline groove was always present (fig. 3). The orifices of the lateral ventricles were seen to enter the diencephalic midline groove.

During the following days the everted diencephalic and mesencephalic brain plates enlarged greatly and expanded over the lateral hemispheres, occasionally growing over the eyes (fig. 6). Frequently the everted plates fused in the midline. A large convex plate of cerebral tissue then extended from the diencephalic to the rhombencephalic region. A tuft of choroid plexus usually protruded through a small midline opening found at the junction of the telencephalon and diencephalon (fig. 6).

TABLE 1

Effect of hypervitaminosis A on the rat embryo

No. of animals	Days of treatment	Vit. A in U.S.P. units	Implantations	Resorptions	CNS abnormalities
4	8,9,10	60,000	48	38(79%)	9(19%)
5	8,9,10	50,000	54	38(70%)	7(13%)
6	8,9,10	40,000	70	44(63%)	13(19%)
12	8,9,10	30,000	176	77(44%)	45(26%)
		Controls			
9	8,9,10	0.6–1.2 ml saline	97	4(4%)	1(1%)
5	8,9,10	0.6–1.2 ml vit. A vehicle	63	2(3%)	0

TABLE 2

Effect of hypervitaminosis A on the mouse embryo

No. of animals	Days of treatment	Vit. A in U.S.P. units	Implantations	Resorptions	CNS abnormalities
7	7	6000/7000	74	34(46%)	3(4%)
6	8	6500/7500	69	18(26%)	0
5	7,8	6000/4000	42	29(69%)	0
6	7,8,9	4000	81	26(32%)	3(4%)
7	8,9	6000	43	13(31%)	1(2.3%)
2	7,8,9	3000	26	0	0

By the eighteenth day of development the everted tissue formed a large undifferentiated mass on top of the base of the skull (fig. 7). The lateral hemispheres and eyes were usually not visible, and the fetus often appeared anophthalmic. After the eighteenth day, small hemorrhages occurred in the everted tissue and widespread necrosis became apparent. By the time of birth the exencephalic brain had almost entirely disappeared, and the fetus appeared anencephalic (figs. 8, 9).

Histologic studies showed that despite the non-closure of the diencephalon, primitive hemispheres had developed in most 12-day embryos (fig. 10). Though the dorsal portion of the diencephalon was open, the ventral part had developed normally and optic vesicles were present (fig. 11). Sometimes the abnormal position of the primitive hemispheres caused a twisting of the optic stalk, and as a result the optic vesicles either failed to make contact with the surface ectoderm or were pushed in an abnormal position (fig. 12). The mesencephalic area was always open and the neuro-epithelial cells of the alar plates continued into the ectoderm of the head without any interruption. The abundance of mitotic figures, often two or three rows thick, was one of the most striking features at the cellular level. As a result of the accumulation of dividing neuro-epithelial cells, the internal limiting membrane had a ragged appearance and was frequently ruptured (fig. 13). Another abnormal characteristic was the presence of bleb-like cytoplasmic protrusions along the surface of the everted plates and into the lumen of the diencephalon (fig. 14).

By the thirteenth day of development, the neuro-epithelial cells of the diencephalic plates began to expand along the sides of the head (fig. 15), thereby frequently losing their usual pseudo-stratified epithelial appearance. The optic vesicles were present in most embryos and lens formation was normal. The mesencephalic region formed a convex cap of neural tissue over a thick layer of mesenchyme (fig. 16). Small rosettes of neuro-epithelial cells were frequently seen under the everted cap.

By the fourteenth day of development, the hemispheres had a flattened form and abnormal position, but histological differentiation proceeded normally and distinct germinative, mantle and marginal layers could be distinguished. The everted diencephalic lips covered the hemispheres

from the outside, but remained separated by loose connective tissue with many small capillaries (fig. 17). In many embryos the developing eyes occupied an abnormal position and had lost contact with the surface (fig. 18). Though in some areas of the everted plates the neuro-epithelial cells gave rise to neuroblasts and spongioblasts, in other regions the internal limiting membrane lost its regular structure and showed many bleb-like protrusions at the surface.

During the following days the everted brain plates expanded rapidly over the developing hemispheres, which became invisible from the surface. In many areas the neuro-epithelial cells failed to differentiate and penetrated into the underlying mesenchyme, forming small rosettes (figs. 19, 20). These rosettes were found in the mesenchyme under the everted plates, but were also noted in the rhombencephalon. In this region clusters of neuro-epithelial cells were seen in the mantle layer and even in the marginal layer.

An unusual finding was made in some 18-day fetuses which by external examination appeared anophthalmic. The eyes, containing a normal lens and a well-differentiated retina, were found deep inside the head (fig. 21). Apparently, the everted diencephalic cap had grown over the hemispheres, which in turn had pushed the eyes away from the surface. Loose mesenchyme was found in front of the eyes. Another observation was that by this time of development the neuroepithelial cell layer, covering the everted brain cap from the outside, was interrupted by thick nerve bundles (fig. 22). The diencephalic and mesencephalic nerve bundles, which under normal conditions would enter the cortex or brainstem, apparently broke through to the external surface. The wall of the hemisphere, in the meantime, had developed normally and a primitive cortex could be distinguished (fig. 21).

During the last three days of development, the everted brain cap showed degeneration and necrosis, particularly in the median region of the diencephalon and mesencephalon. In addition, many capillaries in the mesenchyme between the outer surface of the hemisphere and the overlying brain cap ruptured and the tissues were filled with blood. Though in some fetuses necrosis was restricted to localized areas, in most cases a small amount of degenerated brain tissue was all that remained of the large exencephalic brain seen only a few days before.

DISCUSSION

From the results of our experiments it may be concluded that vitamin A given in large doses to Wistar rats on day 8, 9 and 10 of pregnancy is an efficient teratogenic agent, capable of preventing closure of the neural groove in a high percentage of embryos. The accumulation of dividing neuro-epithelial cells near the inner surface, followed by a disruption of the internal limiting membrane, and the formation of bleb-like cytoplasmic protrusions are in all probability the direct causes for the abnormality. Despite the non-closure of the tube, the brain vesicles continue to grow and differentiate and a large everted brain mass is formed. This large exencephalic brain degenerates during the last few days of pregnancy, resulting in anencephaly in the newborn.

The first question to be raised concerning our observations is whether vitamin A acts directly on the embryo or indirectly by disturbing the metabolic functions of the maternal organism. In this regard, Giroud et al. ('57) reported that vitamin A suspended in oil failed to enter the fetus. In hydrosoluble form, however, it passed the placenta and was found in the umbilical vein.

Giroud, Gounelle and Martinet ('57) treated rats on day 12, 13, and 14 of pregnancy with 60,000 I.U. vitamin A and determined the content of the vitamin in the maternal liver and in the embryos at day 15. In the control rats the liver contained approximately 2,000 I.U., but in the experimental animals 5,000 I.U. In the embryos the total vitamin A content increased from 4 I.U. in the controls to 10 I.U. in the experimental group. The authors concluded that vitamin A passes from the mother to the fetus and they suggested that vitamin A interferes directly with the metabolism of differentiating cells in the embryo. Cohlan ('54) similarly suggested that vitamin A is essential for the enzymatic and metabolic processes during cellular differentiation. Takekoshi ('64), or

the contrary, suggested that vitamin A causes a disturbance in the thyroid and adrenal function of the mother and that the malformations in the embryos result from a disturbance of the maternal endocrine system.

The experiments of Fell and Mellanby ('52) lend considerable support to the suggestion of Giroud and Martinet ('56) that vitamin A acts directly on the cells of the embryo. When limb bone rudiments were cultured in a medium containing vitamin A, the explants ceased to grow, began to shrink, and became soft and gelatinous. The intercellular partitions narrowed and eventually the matrix disappeared. When S^{35} labeled inorganic sulphate was used to examine the metabolism of chondroitin sulphate, it was found that in the presence of vitamin A the chondroblasts ceased to take up sulphate and lost that which had already been incorporated in the matrix (Fell, Mellanby, and Pelc, '56). These results were confirmed by Thomas et al. ('60), Fell and Thomas ('60), and McElligott ('62), and it is now generally accepted that large amounts of vitamin A inhibit the synthesis of chondroitin sulphate and cause the dissolution of that already formed. The dissolution of the cartilaginous matrix may be caused by lysosomal proteases released from the chondrocytes under influence of vitamin A (Dingle, Lucy, and Fell, '61; Lucy, Dingle, and Fell, '61).

The effect of vitamin A on the differentiation of epithelial cells is of particular interest for our studies. When Fell and Mellanby ('53) cultivated embryonic chick ectoderm in a medium containing excess vitamin A, keratinization was suppressed and the cells became mucus-secreting and ciliated (Fell, '57). Aydelotte ('63a, b) found that the metaplastic action of vitamin A is not restricted to epidermal epithelium. When esophageal epithelium was cultured in a medium containing vitamin A, stratification was inhibited, and high columnar ciliated cells with small mucous glands were formed. In the rat, epidermal explants remained stratified and keratinized under influence of vitamin A, but buccal and tongue epithelium underwent mucous metaplasia (New, '63). It is thus apparent that vitamin A in the chick as well as in the rat has a direct effect on the differentiation of epithelial cells. In all probability, the vitamin functions as a coenzyme in the mucopolysaccharide synthesis (Wolf, Varandani and Johnson, '61; Moretti and Wolf, '61).

Though we have focused our attention on the effect of vitamin A on brain development, many other organs and tissues are affected by treatment. Depending on the stage of development at which the vitamin was given, Cohlan ('54) was able to produce deformities of the brain as well as a variety of ocular abnormalities. In addition, many embryos had a cleft palate. Giroud and Martinet ('56) found that vitamin A given to pregnant animals from the eighth to the tenth day caused anencephaly, anophthalmia, microphthalmia and spina bifida. When given from the eleventh to the sixteenth day, the most frequently occurring abnormality was the cleft palate. Micromelia and syndactylia were seen only when the vitamin was given between days 11 and 13. In the mouse, Kalter and Warkany ('61) found exencephaly, spina bifida, exophthalmus as well as cardiovascular, urogenital and limb malformations as a result of treatment with excessive doses of vitamin A. Similarly in the hamster, Marin-Padilla and Ferm ('65) produced anencephaly, spina bifida, anopia, and other defects. Hence, the teratogenic action of vitamin A is neither species nor organ specific, but depends mainly on the stage of development at which the vitamin is active.

Although the brain abnormalities observed in our experiments were most impressive at the later stages of development, the primary abnormality must have occurred during closure of the neural groove. The possibility that the neural tube ruptured after closure seems unlikely, because in all abnormal embryos the neuro-epithelial cells continued without any interruption into the head ectoderm. We do not exclude, however, the possibility that the vitamin continued to exert its effect on the neuro-epithelial cells after the eleventh day of development, that is, the day that under normal conditions the neural tube closes. The accumulation of mitotic figures and the disruption of the internal limiting membrane, thought to be caused

by a direct action of the vitamin, was observed in 12-, 13- and 14-day embryos, but was not seen in older ones. Similarly, the presence of bleb-like cytoplasmic protrusions along the outer surface of the everted neural plates was seen in the younger embryos, but not after day 14. Rosette formation and irregularly formed folds, however, were seen in the early as well as the later stages of development. It seems likely, therefore, that vitamin A affects the neuro-epithelial cells during closure of the neural groove and a few subsequent days.

At present it is not clear how vitamin A causes the accumulation of dividing neuro-epithelial cells. It may be the result of an interference with one of the mitotic phases, or it may be due to the acceleration of the cell cycle resulting in an increased number of cells going through mitosis at a given time. Considering the observations of Aydelotte ('63a, b), who noted that in corneal explants cultivated in a vitamin A medium the mitotic rate was decreased, we tend to think that vitamin A arrests the mitosis of the neuro-epithelial cells. Supporting our suggestion that vitamin A also affects the cell membrane of the neuro-epithelial cells are the observations of Glauert et al. ('63). When rabbit erythrocytes were treated with vitamin A, the surface area of the cells increased greatly and large indentations and vacuoles appeared. Finally the cells became large and spherical, lost their hemoglobulin and obtained a ghost appearance. According to the authors, vitamin A acts on the lipo-proteins of the cell membrane, thus controlling the permeability of the cell. Tissue culture studies are presently undertaken to examine the action of vitamin A on the cell membrane and mitotic activity of neuro-epithelial cells.

LITERATURE CITED

Aydelotte, M. B. 1963a The effects of vitamin A and citral on epithelial differentiation in vitro. 1. The chick tracheal epithelium. J. Embryol. Exp. Morph., *11:* 279–291.

——— 1963b The effects of vitamin A and citral on epithelial differentiation in vitro. 2. The chick oesophageal and corneal epithelia and epidermis. J. Embryol. Exp. Morph., *11:* 621–635.

Bellairs, R. 1954 The effects of tetra-sodium 2 methyl 1:4-Naphthohydroquinone diphosphate on early chick and amphibian embryos. Brit. J. Cancer, *8:* 685–692.

Cohlan, S. Q. 1954 Congenital anomalies in the rat produced by excessive intake of vitamin A during pregnancy. Pediatrics, *13:* 556–567.

Dingle, J. T., J. A. Lucy and H. B. Fell 196[illegible] Studies on the mode of action of excess of vitamin A. 1. Effect of excess of vitamin A on the metabolism and composition of embryonic chick-limb cartilage grown in organ culture. Biochem. J., *79:* 479–500.

Fell, H. B. 1957 The effect of excess vitamin A on cultures of embryonic skin explanted at different stages of differentiation. Proc. Roy. Soc. B., *146:* 242–256.

Fell, H. B., and E. Mellanby 1952 The effect of hypervitaminosis A on embryonic limb-bones cultivated in vitro. J. Physiol., *116:* 320–349.

——— 1953 Metaplasia produced in cultures of chick ectoderm by high vitamin A. J. Physiol., *119:* 470–488.

Fell, H. B., E. Mellanby and S. R. Pelc 195[illegible] Influence of excess vitamin A on the sulfate metabolism of bone rudiments grown in vitro. J. Physiol. Lond., *134:* 179–188.

Fell, H. B., and L. Thomas 1960 Comparison of the effects of pepsin and vitamin A on cartilage. II. The effects on organ cultures of embryonic skeletal tissue. J. Exp. Med., *111:* 719–744.

Giroud, A., M. Gounelle and M. Martinet 195[illegible] Données quantitatives sur le taux de la vitamine A chez le rat lors d'expériences de tératogénèse par hypervitaminose A. Bull. Soc. Chim. Biol., *39:* 331–336.

Giroud, A., and M. Martinet 1955 Hypervitaminose A et anomalies chez le foetus de rat. Rev. Int. Vitamin, *26:* 10–18.

——— 1956 Tératogénèse par hautes doses de vitamine A en fonction des stades du développement. Arch. d'Anat. Micr. Morph. Exp., *45:* 77–98.

——— 1957 Morphogenèse de l'anencéphalie. Arch. d'Anat. Micr. Morph. Exp., *46:* 247–28[illegible]

Glauert, D., J. A. Lucy and J. T. Dingle 196[illegible] Studies on the mode of action of excess of vitamin A. J. Cell Biol., *17:* 111–121.

Hamburgh, M. 1954 The embryology of trypan blue-induced abnormalities in mice. Anat. Rec. *119:* 409–422.

Kalter, H., and J. Warkany 1961 Experimental production of congenital malformations in strains of inbred mice by maternal treatment with hypervitaminosis A. Am. J. Path., *38:* 1–21.

Langman, J., R. L. Guerrant and B. G. Freeman 1966 Behavior of neuro-epithelial cells during closure of the neural tube. J. Comp. Neur. (in press).

Lucy, J. A., J. T. Dingle and M. B. Fell 196[illegible] Studies on the mode of action of excess of vitamin A. 2. A possible role of intracellular proteases in the degradation of cartilage matrix. Biochem. J., *79:* 500–508.

Marin-Padilla, M., and V. M. Ferm 1965 Some necrosis and developmental malformations in

duced by vitamin A in the golden hamster. J. Embryol. Exp. Morph., *13:* 1–8.

McElligott, T. F. 1962 Decreased fixation of sulfate by chondrocytes in hypervitaminosis A. J. Path. Bact., *83:* 347–355.

Meyer, A., and G. Wolf 1961 Decrease in mucopolysaccharide-bound hexosamine of rat tissue in vitamin A deficiency. Biochim. Biophys. Acta, *46:* 392–393.

Nelson, M. M. 1960 Teratogenic effects of pteroylglutamic acid deficiency in the rat. Ciba Foundation Symposium on Congenital Malformations, pp. 134-151. London: Churchill.

New, D. A. T. 1963 Effects of excess vitamin A on cultures of skin and buccal epithelium of the embryonic rat and mouse. Brit. J. Derm., *75:* 320–325.

Takekoshi, S. 1964 The mechanism of vitamin A induced teratogenesis. J. Embryol. Exp. Morph., *12:* 263–271.

Thomas, L., R. T. McCluskey, J. L. Potter and G. Weisemann 1960 Comparison of the effects of papain and vitamin A on cartilage. 1. The effects in rabbits. J. Exp. Med., *111:* 705–718.

Warkany, J., J. G. Wilson and J. F. Geiger 1958 Myeloschisis and myelomenigocele produced experimentally in the rat. J. Comp. Neur., *109:* 35–53.

Wilson, J. G. 1955 Teratogenic activity of several azo dyes chemically related to trypan blue. Anat. Rec., *123:* 313–333.

Wolf, G., P. T. Varandani and B. C. Johnson 1961 Vitamin A and mucopolysaccharide synthesizing enzymes. Biochim. Biophys. Acta, *46:* 59–67.

Langman-'66
Bib. No. 5159

Excess Vitamin A and Development of the Cerebral Cortex

JAN LANGMAN AND GARY W. WELCH [1]
Department of Anatomy, School of Medicine, University of Virginia, Charlottesville, Virginia

ABSTRACT In previous experiments excess vitamin A, administered to pregnant rats during the early stages of gestation, was found to interfere with the mitotic activity of the neuro-epithelial cells bordering the neural groove. The result was exencephaly and anencephaly in a high percentage of the newborn. The present work was undertaken to examine the influence of hypervitaminosis A on the behavior of the neuro-epithelial cells of the cerebral hemisphere and the subsequent migration and differentiation of the neuroblasts during the later stages of development.

Swiss-Webster mice were treated with large doses of vitamin A on days 14 and 15 of gestation. When subsequently the cell cycle of the neuro-epithelial cells lining the lateral ventricle of 15-day fetuses was determined, vitamin A was found to increase both the duration of the mitosis and DNA synthetic period. In comparison with the controls, the total generation time was prolonged by approximately 40%. Since almost all neuroblasts of the cerebral cortex originate in the neuro-epithelial zone bordering the lateral ventricle, the total number of neuroblasts formed is in all probability less than normal. Indeed, preliminary data on the number of cells present in the cerebral cortex of 10-day postnatal rats treated with excess vitamin A toward the end of pregnancy showed a decrease in cell density, indicating either a reduction in the number of cells formed or a degeneration of existing cells.

In a second experiment Swiss-Webster mice were treated with excess vitamin A during three successive days in the second half of pregnancy. The cerebral cortex of the newborn was examined one to ten days after birth. Histological examination revealed a rather sharply delineated zone of abnormal cells characterized by a lightly stained cytoplasm, a thick nuclear membrane, a densely stained nucleoplasm and several dark chromatin bodies. When the position of the zone containing the abnormal cells was analyzed and correlated with the day of formation in the neuroepithelial zone, it was found that the affected cells were neuroblasts already present in the cortex before the vitamin treatment was started. This indicates that excess vitamin A, given to pregnant mice during the later stages of gestation, influences the development of the cerebral cortex, not only by interfering with the production of cells in the neuroepithelial zone, but also by affecting the differentiation of existing neuroblasts. As a result of these anomalies, some of the newborn appeared to have abnormal patterns of behavior.

In previous experiments we found that excess vitamin A, administered to pregnant rats at days eight, nine and ten of gestation (that is, prior to closure of the neural groove in the embryos) caused exencephaly and anencephaly in a high percentage of the newborn (Langman and Welch, '66). Since the accumulation of dividing neuro-epithelial cells and the appearance of cytoplasmic protrusions into the lumen of the ventricle were the only cellular abnormalities observed during the time of treatment, vitamin A was thought to interfere with the mitotic behavior and the function of the cell membranes of the neuro-epithelial cells.

Although a number of reports have been published on the effect of hypervitaminosis A on the central nervous system of the mammalian embryo during the early stages of development (Cohlan, '54; Giroud and Martinet, '55, '56, '57; Giroud et al., '57; Marin-Padilla, '66) no information is available on the influence of excess vitamin A on the development of the cerebral cortex during the final stages of pregnancy, when the formation and differentiation of neuroblasts is in full progress.

Hicks et al. ('59, '61) examined the effect of x-irradiation on the formation of the cerebral cortex in the fetal rat during the last half of gestation. By injecting

[1] This investigation was supported by research grant NB 06186-02 from the Institute of Neurological Diseases and Blindness of the National Institutes of Health, and by grant R-200-66 from the United Cerebral Palsy Foundation.

tritiated thymidine into the pregnant animals at the time of radiation, the influence of radiation was studied on the migration and differentiation of the labeled cells in the fetuses. Exposure to 200r caused extensive and rapid necrosis in primitive differentiating neuroblasts, but the cells in the DNA-synthetic phase and in a fully differentiated stage escaped damage. Brizzee et al. ('61) concluded from similar experiments that x-irradiation had primarily a lethal effect upon the proliferating neuro-epithelial cells, resulting in a reduced thickness of the cerebral cortex.

The purpose of this experiment was to examine the influence of excess vitamin A on the neuro-epithelial cells lining the lateral ventricle of the cerebral hemisphere during the later stages of pregnancy. Since the vitamin might have an effect not only on the proliferation of the neuro-epithelial cells, but also on the migration and differentiation of the neuroblasts, in our control experiments we determined the normal rate of proliferation of the neuro-epithelial cells and the subsequent migration of the neuroblasts forming the cerebral cortex of the mouse. After this information was obtained, the influence of vitamin A on the formation of the cerebral cortex was examined.

MATERIALS AND METHODS

To study the effect of vitamin A on the mitotic behavior and cell cycle of the neuro-epithelial cells lining the lumen of the lateral ventricle, Swiss-Webster mice, ranging in weight from 23 gm to 28 gm were treated with 10,000 U.S.P. units vitamin A (U.S. Vitamin and Pharmaceutical Co.) on days 14 and 15 of gestation. The vitamin, made water soluble with sorethytan esters, was given orally. The animals were bred by placing the males with the females from 9 A.M. to 1 P.M. At 1 P.M. the females were examined for vaginal plugs; the day of finding a vaginal plug was counted as day zero of pregnancy. On day 15 of pregnancy the animals were injected with tritiated thymidine (5 μc/gm body weight) and sacrificed at hourly intervals from 1 to 18 hours after injection. The control animals were similarly injected with tritiated thymidine on day 15 and sacrificed at hourly intervals.

The embryos were fixed in Bouin's, cut at 4 μ and stained with hematoxylin-eosin. The sections were prepared for radioautography by coating with Kodak NTB-3 emulsion (Kopriwa and Leblond, '62). After an exposure time varying from 27 to 90 days, the sections were developed and mounted by the usual histological techniques.

In the second experiment a group of five Swiss-Webster mice was injected with tritiated thymidine on day 12 of gestation; similar groups were treated on days 13, 14, 15, 16 and 17. One animal of each group was sacrificed one hour after injection, and two at various days thereafter. The remaining animals were allowed to go to term and the offspring sacrificed on alternate days.

In the experimental groups the mice were given 10,000 U.S.P. units vitamin A per day at two or three successive days of pregnancy. The vitamin treatment was always started after day 11 of pregnancy. On the second day of treatment with vitamin A, the animals were injected with tritiated thymidine (5 μc/gm body weight). Some of the animals were sacrificed during pregnancy; others were allowed to go to term. The embryos and the newborn which were killed after various time intervals, were processed as those in the control series. The position and morphological characteristics of the labeled cells in the vitamin A-treated animals were then compared with similar criteria in the controls.

RESULTS

Normal development of the cerebral cortex

Cell proliferation in the cerebral cortex of a 14-day mouse embryo is restricted to the neuro-epithelial cells surrounding the ventricle, with the exception of an occasional cell in the subependymal layer. One hour after treatment with tritiated thymidine, the nuclei synthesizing DNA are separated from the lumen of the ventricle by a zone of unlabeled nuclei (fig. 1). Four hours after treatment many of the labeled nuclei are adjacent to the lumen, indicating that they have migrated from the DNA-synthetic zone to the lumen (fig. 2). At the lumen they undergo division.

Fig. 1 Radioautograph of a coronal section through the cerebral hemisphere of a 14-day mouse embryo one hour after treatment with tritiated thymidine (100 ×). The labeled nuclei are almost exclusively found in the outer portion of the neuro-epithelial layer surrounding the lumen of the lateral ventricle. An occasional labeled nucleus is seen in the mantle layer, but these nuclei are always associated with blood vessels. The pia (arrow) contains many DNA-synthesizing cells.

Fig. 2 Radioautograph of a coronal section through the cerebral hemisphere of a 14-day mouse embryo four hours after treatment with tritiated thymidine (100 ×). Many of the labeled nuclei in the neuro-epithelial layer are now adjacent to the lumen of the ventricle where they undergo mitosis.

Fig. 3 Radioautograph of a similar section as in figure 2 six hours after treatment with tritiated thymidine (100 ×). The vast majority of the labeled nuclei are located along the lumen of the ventricle and only a few of the labeled nuclei are still in the DNA-synthetic zone (see fig. 1). The mitotic figures are found exclusively along the surface of the ventricle and all are labeled.

Fig. 4 Radioautograph of a similar section as in figure 2, but 11 hours after treatment with tritiated thymidine (100 ×). The total number of labeled nuclei is approximately twice that seen in figure 1. The great majority are located in the neuro-epithelial zone, but a few labeled cells have migrated into the mantle layer (arrow). The cells containing these labeled nuclei are considered to be neuroblasts.

Two hours later most of the labeled nuclei are crowded along the lumen, and only a few remain in the DNA-synthetic zone (fig. 3). At 11 hours after treatment, the majority of the labeled nuclei have returned to the DNA-synthetic zone, and the total number of labeled nuclei is approximately twice that seen at one hour after treatment (fig. 4). A few cells with labeled nuclei have moved beyond the DNA-synthetic zone and have migrated into the primitive cerebral cortex. Hence, in analogy with the interkinetic movements reported for the nuclei of the neuroepithelial cells in other areas of the central nervous system (Langman et al., '66), the proliferating cells surrounding the lateral ventricle are considered to form a pseudostratified epithelium. During DNA synthesis the cells extend over the full width of the neuro-epithelial layer; during division they become spherical and contract toward the lumen, and immediately after division they either extend again to the DNA-synthetic zone or migrate into the primitive cortex to become neuroblasts.

The duration of the cell cycle of the neuro-epithelial cells in the 15-day mouse embryo, determined by plotting the percentage of labeled metaphases against the time after tritiated thymidine treatment, is represented in figure 5. The average time required for the post-duplication (G_2) stage and prophase is approximately two hours. The percentage of labeled metaphases reaches the 100% level at three hours and begins to decrease at eight hours. At 11 hours most of the metaphases are unlabeled. Hence, the average time required for DNA synthesis is about seven and one-half hours. A new wave of labeled metaphases begins to appear 13 hours after treatment, indicating that the daughter cells formed during the first division are returning for the second mitosis. The duration of the cell cycle is therefore approximately 11 hours.

When 12- to 17-day embryos are labeled with tritiated thymidine and examined one to three hours after treatment, the label is almost exclusively limited to the neuro-epithelium. Only a few labeled cells, either associated with the blood vessels or located in the subependymal layer, are seen outside the neuro-epithelial layer. During the following days, heavily labeled cells leave the neuro-epithelium and migrate to the periphery of the cerebral cortex. These cells, considered to be neuroblasts, pass through the cell layers formed on the previous days. Just before birth, the cells formed on day 14 of gestation reach the surface of the cortex (fig. 6). On post-

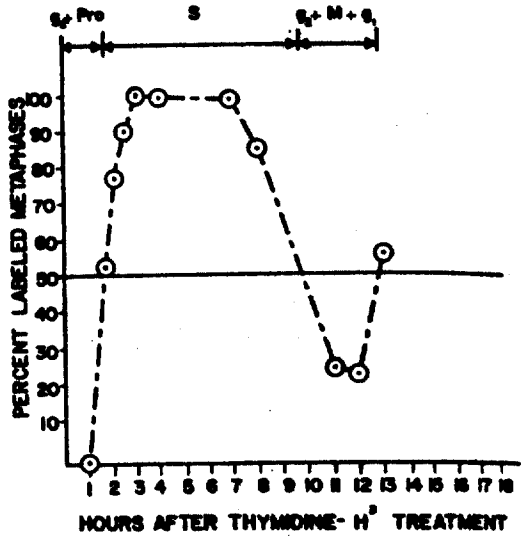

Fig. 5 Percentage of labeled metaphases in the neuro-epithelium of the cerebral cortex in 15-day mouse embryos plotted against the time after treatment with tritiated thymidine. The postduplication stage and prophase (G_2 + Pro) last approximately two hours; the DNA-synthetic period (S) is seven and one-half hours; the duration of the total cell cycle is approximately 11 hours.

Fig. 6 Radioautograph of a coronal section through the cerebral hemisphere of an 18-day mouse embryo, 96 hours after treatment with tritiated thymidine (100 ×). The lumen of the ventricle (l), surrounded by the neuro-epithelial zone (n.e.), is on the left of the figure. The heavily labeled cells, formed in the neuro-epithelial layer on day 14, are located in the marked area along the surface of the cortex. Inset shows a number of heavily labeled neuroblasts as seen along the surface of the cortex under higher magnification (540 ×).

Fig. 7 Radioautograph of a coronal section through the cerebral hemisphere of a five-day postnatal mouse treated with tritiated thymidine on day 14 of gestation. The heavily labeled cells, formed on day 14, are now located in a rather sharply delineated zone (indicated by the dotted lines), and separated from the surface of the cortex by a zone of unlabeled and weakly labeled cells formed on days 15, 16 and 17. Inset shows some heavily labeled neuroblasts in the marked area under higher magnification (1250 ×).



Figures 6–7

natal day five, however, these cells are no longer on the surface but are separated from it by the cells formed on days 15, 16 and 17. The latter have passed the layer formed on day 14 and now occupy the most superficial position (fig. 7).

Figure 8 schematically represents the final position of the neuroblasts formed in the neuro-epithelial layer on days 12 to 17 of pregnancy. The cells formed during the later stages of gestation bypass those formed at earlier days. The most superficial position in the adult cerebral cortex of the mouse is occupied by cells formed in the neuro-epithelial layer on day 17.

Cortex development under influence of vitamin A

Figure 9 represents the cell cycle of the neuro-epithelial cells of 15-day embryos, treated with excess vitamin A on days 14 and 15. The duration of the mitosis, defined as the time required to replace the unlabeled metaphases by labeled ones, is considerably increased in comparison with the control value. In addition the average duration of the DNA-synthetic phase is prolonged by almost three hours. The total generation time of the neuro-epithelial cells is approximately 16 hours, which is five hours more than in the controls. Hence, vitamin A has an inhibitory effect on mitosis and DNA synthesis, thereby prolonging the cell cycle by approximately 40% of its normal value.

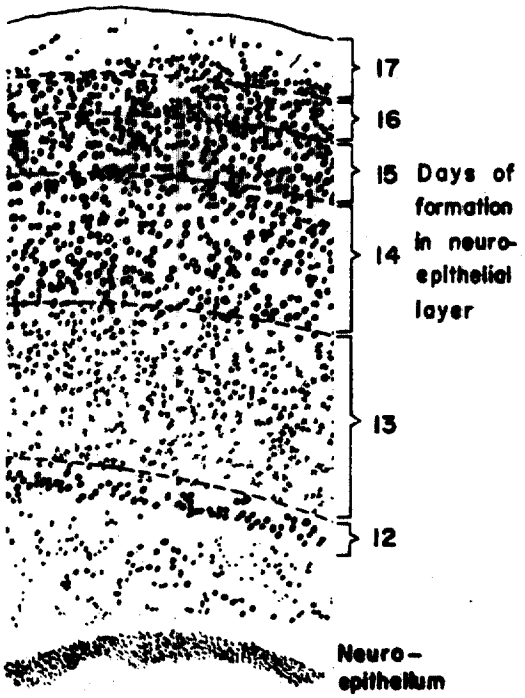

Fig. 8 Schematic drawing illustrating the layers of the cerebral cortex according to the days of formation during intra-uterine life. Neuroblasts formed in the neuro-epithelial layer surrounding the lateral ventricle during the later stages of gestation migrate through the layers of neuroblasts formed during the earlier stages. The neuroblasts formed at day 17 finally occupy the most superficial position in the cerebral cortex.

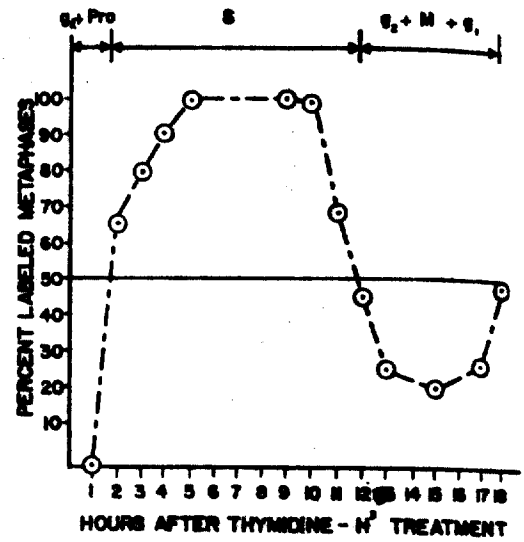

Fig. 9 Percentage of labeled neuro-epithelial metaphases plotted against the time after treatment with tritiated thymidine in 15-day mouse embryos, treated with excess vitamin A on days 14 and 15 of gestation. The postduplication stage and prophase (G_2 + Pro) last approximately two hours; the DNA-synthetic period (S) is ten hours. the total duration of the cell cycle is approximately 16 hours.

When embryos treated with excess vitamin A on days 15, 16 and 17 of pregnancy were examined just before or shortly after birth, the cerebral cortex was characterized by a zone of abnormal cells with round to ellipsoid, dark nuclei (fig. 10). These cells, frequently interspersed among apparently normal cells, have a lightly stained cytoplasm, a thick nuclear membrane, a densely stained nucleoplasm and several chromatin bodies bordering the nuclear membrane (fig. 11). The presence of the

Fig. 10 Section (1.5 μ) through the cerebral hemisphere of a mouse fetus just before birth. The embryo was treated with excessive doses of vitamin A on days 15, 16 and 17 of gestation (540 ×). Abnormal cells with dark nuclei (arrows) are interspersed among a number of normal appearing neuroblasts (n).

Fig. 11 Section (1.5 μ) through the cerebral hemisphere of the same fetus as above, illustrating in detail the darkly stained nuclei (1200 ×). Some of them have a dense nuclear membrane. The chromatin bodies are arranged along the nuclear membrane.

abnormal cells is usually restricted to rather sharply delineated areas within the cortex.

Figure 12 shows schematically the final position of the cells formed on days 15. 16 and 17 under normal conditions and under influence of excess vitamin A, respectively. The darkly nucleated cells occupy a position corresponding to the cells formed on days 12, 13 and 14 of gestation. Hence, in addition to having a delaying effect on the cell cycle of the neuro-epithelial cells, vitamin A interferes with the differentiation of existing neuroblasts.

DISCUSSION

From our observations on the behavior of the neuro-epithelial cells surrounding the lateral ventricle and from similar data obtained by Sidman et al. ('59), Sauer and Walker ('59), Fujita ('62), Källén and Valmin ('63), Atlas and Bond ('65) and Langman et al. ('66), it is evident that throughout the central nervous system of the avian and mammalian embryos the cells lining the ventricular system form a pseudo-stratified epithelium. During DNA synthesis the neuro-epithelial cells are elongated and extend over the entire width of the pseudo-stratified layer. To undergo division, they contract toward the lumen and become spherical. Immediately after mitosis the daughter cells resume their original, elongated form. Though the majority of them remain attached to the lumen, some lose contact with the ventricle and move beyond the neuroepithelial layer into the mantle zone. Here the migrating cells are generally thought to differentiate into either neuroblasts or spongioblasts (primitive glia cells), although some radioautographic experiments indicate that they

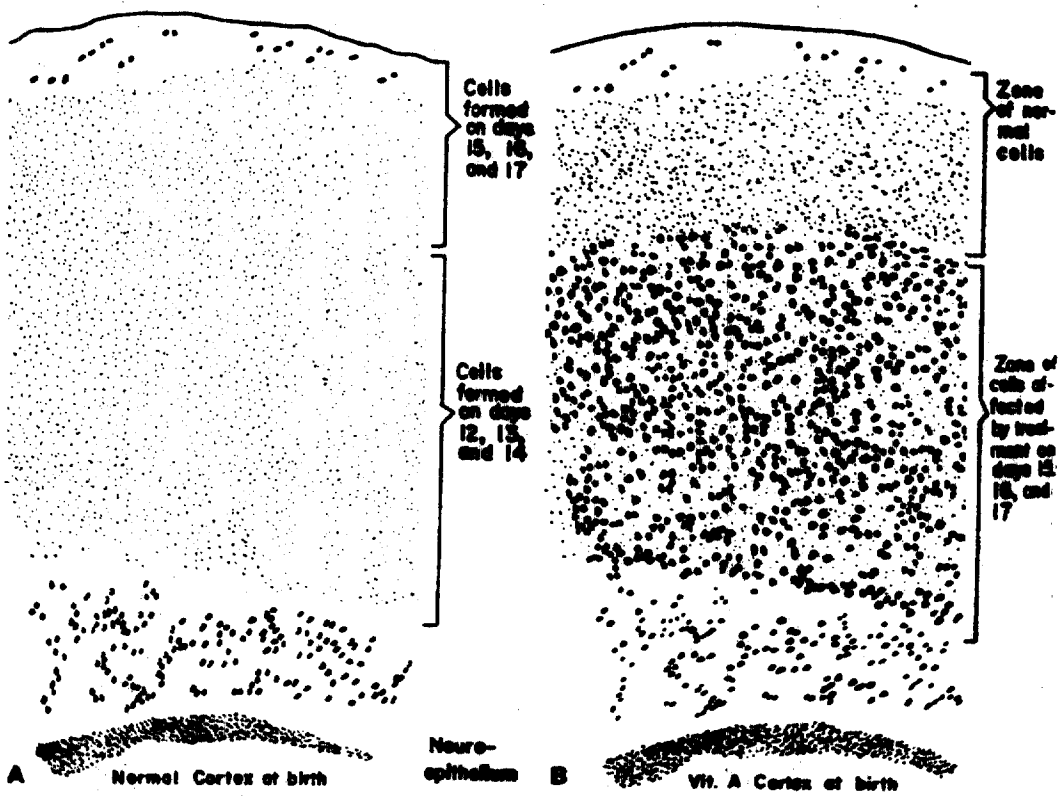

Fig. 12 Schematic drawing of a section of the cerebral cortex of a normal postnatal mouse (A and similar mouse treated with excess vitamin A on days 15, 16 and 17 of gestation (B). The neuroblasts affected by the vitamin A treatment are those formed on days 12, 13 and 14, and not those formed by the neuro-epithelium on days 15. 16 and 17.

first form neuroblasts and, only much later, spongioblasts (Fujita, '64; Martin and Langman, '65).

With regard to the cells migrating out of the neuro-epithelium surrounding the lateral ventricles, Berry and Eayrs ('63) consider them to be neuroblasts. Hicks et al. ('59, '61) and Angevine and Sidman ('61) similarly refer to these migrating cells as primitive nerve cells. Although these observations are in agreement with our experience that most of the migrating cells have the appearance of neuroblasts, it should not be overlooked that in the cerebral hemisphere the histogenesis of neuroblasts and spongioblasts is considerably complicated by the presence of the subependymal layer. This layer, according to Kershman ('38), plays an important role in the formation of spongioblasts and, possibly, neuroblasts. He believes that both types of cells are present within the subependymal layer and that they subsequently migrate out of this layer to the surface of the cortex. Smart ('61) confirms that the subependymal layer of the newborn mouse contains spongioblasts and neuroblasts. Although according to this author the subependymal layer loses its function in the production of spongioblasts shortly after birth, Altman ('66) suggests that it produces primitive glia cells for a considerable period of postnatal life. Taking into account that in the mouse embryo the subependymal layer is first seen at day 14 of development, cell formation in the cerebral hemisphere may not be restricted to the neuro-epithelial layer, but may also occur, although to a much lesser extent, in the subependymal layer. This means that some of the heavily labeled cells which we found to migrate into the cortex during embryonic life, may originate in the subependymal layer.

Tilney ('33) was the first to study the development of the laminar pattern in the cerebral cortex. Neuroblasts formed in the neuro-epithelium surrounding the lateral ventricle were seen to migrate toward the free surface of the cortex in three successive waves. These three migration waves occurred in the rat embryo on days 16 and 17, 18 and 19, and 20 and 21, respectively. The neuroblasts formed during the last days of development were believed to push the previously formed cells ahead of them with the result that the earliest formed cells occupied the most superficial position in the cortex and the later formed ones a deep position. In 1959 Hicks et al. suggested that the pattern of necrosis, produced in the cerebral cortex of young rats by x-irradiation during intra-uterine life, could be explained only if the cells formed during the last days of gestation occupied the most superficial position in the cortex. Angevine and Sidman ('61), indeed, confirmed this suggestion in a study on the chronological development of the cells layers in the occipital cortex of the mouse. By injecting pregnant mice at different days of gestation with tritiated thymidine and sacrificing the offspring 11 days after birth, they were able to determine the final position of the neuroblasts formed on each day of development. Neuroblasts formed during the later phases of development migrated through the layers of neuroblasts formed at earlier stages, to occupy a more superficial position in the cortex. Berry, Rogers and Eayrs ('64) made similar observations for the rat, but suggested that the cells, after having reached the surface, migrated in a retrograde fashion to take up a position deeper within the cortex. In our experiments we did not find any evidence to support the retrograde migration. What appears to be a migration in retrograde fashion is actually caused by the intercalation of newly arriving neuroblasts between the earlier formed layers and the surface of the hemisphere.

In previous investigations on the effect of excess vitamin A on the closing mechanism of the neural groove (Langman and Welch, '66), the accumulation of dividing neuro-epithelial cells along the surface of the lumen was found to be one of the most striking cellular abnormalities. This abnormality was thought to indicate that the vitamin either had an inhibitory effect on the mitosis, or temporarily accelerated the DNA-synthetic phase, resulting in an increased number of cells going through mitosis at a given time. The first interpretation is supported by the observations of Aydelotte ('63a, b), who suggested that the mitotic rate of corneal explants cultured in a vitamin A medium was decreased. Our present observations on the

cell cycle of the neuro-epithelial cells under influence of hypervitaminosis A indicate that the vitamin interferes with mitosis as well as with DNA synthesis. In normal neuro-epithelial cells of 14- and 15-day mouse embryos the mitosis lasts approximately two hours, the S-phase seven to eight hours and the G_2 + prophase two hours. These data, which are in agreement with the results of Cameron and Greulich ('63) for the cells of the newborn mouse, differ from those obtained with cells treated with excess vitamin A. In the latter case the time needed to replace the unlabeled metaphases by labeled ones, that is, the total duration of the mitotic phase, is considerably prolonged. Since we hardly ever observed anaphases and telophases among the mitotic figures, indicating that the time required for these phases is exceedingly short, it seems likely that vitamin A inhibits in particular the metaphase. In addition, however, vitamin A interferes wtih the DNA synthesis of the neuro-epithelial cells, resulting in a prolonged S-phase. Whether the primary action of excess vitamin A has caused alterations in the membranes of the cell, which in turn affect the functions of the mitochondria and endoplasmic reticulum as suggested by Daniel et al. ('66), or whether vitamin A causes additional malfunctions in the cell, the final result is a considerable lengthening of the total cell cycle. Despite the damage caused to the neuro-epithelial cells by excess vitamin A, they survive and proceed with their proliferation pattern, though at a decreased rate.

In similar experiments with rats (unpublished data), we counted the number of cells in certain areas of the cortex of ten-day postnatal rats treated with excess vitamin A on days 15, 16 and 17 of gestation. In comparison with the controls, a decreased cell density was found. This suggests that as a result of the vitamin A treatment either the rate of neuroblast production is decreased, or some of the neuroblasts have died shortly after their formation without leaving any trace of their existence.

When mice treated with excess vitamin A on days 15, 16 and 17 of gestation were examined shortly after birth, a zone of darkly nucleated cells interspersed among normal cells was found in the cortex. Contrary to our expectations, this zone was not located in the area of the cells formed on days 15, 16 and 17, but was found to occupy a zone which, under normal conditions, is occupied by the cells formed on days 12, 13 and 14. It may thus be concluded that excess vitamin A interferes with the differentiation of existing neuroblasts, resulting in the appearance of abnormal cell types. Whether these abnormal cells persist or gradually degenerate and disappear is presently unknown. The latter possibility seems more likely, since in some postnatal mice treated with vitamin A the zone of darkly nucleated cells is absent.

A rapid disappearance of degenerating cells in the cerebral cortex has also been reported by Berry and Eayrs ('66). They noticed that degenerating cells seen one to two days after x-irradiation had disappeared completely at the tenth postnatal day. Whatever the fate of the abnormal cells may be, excess vitamin A, given to pregnant mice during the later stages of pregnancy, causes considerable damage to the developing cerebral cortex.

The obvious question to be raised with regard to our observations concerns the effect of the brain damage on the postnatal behavior of the treated animals. In this respect it has to be realized that the congenital malformations seen in the treated mice were usually not restricted to the brain. Mouse embryos treated with excess vitamin A on days 11, 12 and 13 of gestation frequently had cleft palates or showed phocomelia at birth. As a result of these abnormalities, the animals usually did not survive. In embryos treated during the later stages of development, gross congenital malformations were absent at birth. These animals survived, but in a number of cases their behavior was different from that of the controls. Some of them seemed spastic, others had tremors, while still others appeared hyperactive.

Summarizing, the results of our experiments indicate that excess vitamin A causes damage to the developing central nervous system not only during the early stages of development, resulting in spina bifida and anencephaly (Langman and Welch, '66), but also during later stages

of proliferation by interfering with the production and differentiation of the neuroblasts.

LITERATURE CITED

Altman, J. 1966 Autoradiographic and histological studies of postnatal neurogenesis. II. A longitudinal investigation of the kinetics, migration and transformation of cells incorporating tritiated thymidine in infant rats, with special reference to postnatal neurogenesis in some brain regions. J. Comp. Neur., *128:* 431–474.

Angevine, J. D., and R. L. Sidman 1961 Autoradiographic study of cell migration during histogenesis of cerebral cortex in the mouse. Nature, *192:* 766–768.

Bass, M., and V. P. Bond 1965 The cell generation cycle of the eleven-day mouse embryo. J. Cell Biol., *26:* 19–24.

Bernstein, M. B. 1963a The effect of vitamin A and citral on epithelial differentiation in vitro. 1. The chick tracheal epithelium. J. Embryol. Exp. Morph., *11:* 279–291.

——— 1963b The effects of vitamin A and citral on epithelial differentiation in vitro. 2. The chick oesophageal and corneal epithelia and epidermis. J. Embryol. Exp. Morph., *11:* 621–635.

Berry, M., and J. T. Eayrs 1963 Histogenesis of the cerebral cortex. Nature, *197:* 984–985.

——— 1966 The effects of x-irradiation on the development of the cerebral cortex. J. Anat., *100:* 707–722.

Berry, M., A. W. Rogers and J. T. Eayrs 1964 The pattern and mechanism of migration of the neuroblasts of the developing cerebral cortex. J. Anat., *98:* 291–292.

Brunse, K. R., L. A. Jacobs and X. Kharetchko 1961 Effects of total-body x-irradiation in vivo on early postnatal changes in neuron volumetric relationships and packing density in cerebral cortex. Radiat. Res., *14:* 96–103.

Cameron, I. L., and R. C. Greulich 1963 Evidence for an essentially constant duration of DNA synthesis in renewing epithelia of the adult mouse. J. Cell Biol., *18:* 31–40.

Cohlan, S. Q. 1954 Congenital anomalies in the rat produced by excessive intake of vitamin A during pregnancy. Pediatrics, *13:* 556–567.

Dansul, M. R., J. T. Dingle, A. M. Glauert and J. A. Lucy 1966 The action of excess of vitamin A alcohol on the fine structure of rat dermal fibroblasts. J. Cell Biol., *30:* 465–475.

Fujita, S. 1962 Kinetics of cellular proliferation. Exp. Cell Res., *28:* 52–60.

——— 1964 Analysis of neuron differentiation in the central nervous system by tritiated thymidine autoradiography. J. Comp. Neur., *122:* 311–328.

Giroud, A., M. Gounelle and M. Martinet 1957 Données quantitatives sur le taux de la vitamine A chez le rat lors d'expériences de tératogénèse par hypervitaminose A. Bull. Soc. Chim. Biol., *39:* 331–336.

Giroud, A., and M. Martinet 1955 Hypervitaminose A et anomalies chez le foetus de rat. Rev. Int. Vitamin, *26:* 10–18.

——— 1956 Tératogénèse par hautes doses de vitamine A en fonction des stades du développement. Arch. d'Anat. Micr. Morph. Exp., *45:* 77–98.

——— 1957 Morphogenèse de l'anencéphalie. Arch. d'Anat. Micr. Morph. Exp., *46:* 247–264.

Hicks, S. P., C. J. D'Amato, M. A. Coy, E. D. O'Brien, M. Thurston and D. L. Jeffes 1961 Migrating cells in the developing nervous system studied by their radiosensitivity and tritiated thymidine uptake. In: Fundamental Aspects of Radiosensitivity, Brookhaven Symposia in Biology, no. 14, Brookhaven National Laboratory, Upton, New York.

Hicks, S. P., C. J. D'Amato and M. J. Lowe 1959 Development of the mammalian nervous system. I. Malformations of the brain, especially the cerebral cortex, induced in rats by radiation. II. Some mechanisms of the malformations of the cortex. J. Comp. Neur., *113:* 435–470.

Källén, B., and K. Valmin 1963 DNA synthesis in the embryonic chick central nervous system. Z. Zellforsch. Mikrosk. Anat. Abt. Histochem., *60:* 491–496.

Kershman, J. 1938 The medulloblast and medulloblastoma. Arch. Neurol. Psychiat., *40:* 937–967.

Kopriwa, B., and C. P. Leblond 1962 Improvements in the coating technique of radioautography. J. Histochem. Cytochem., *10:* 269–284

Langman, J., R. L. Guerrant and B. G. Freeman 1966 Behavior of neuroepithelial cells during closure of the neural tube. J. Comp. Neur., *127:* 399–412.

Langman, J., and G. W. Welch 1966 Effect of vitamin A on development of the central nervous system. J. Comp. Neur., *128:* 1–15.

Marin-Padilla, M. 1966 Mesodermal alterations induced by hypervitaminosis A. J. Embryol. Exp. Morph., *15:* 261–269.

Martin, A., and J. Langman 1965 The development of the spinal cord examined by autoradiography. J. Embryol. Exp.. Morph., *14:* 25–35.

Sauer, M. E., and B. E. Walker 1959 Radioautographic studies of interkinetic nuclear migration in the neural tube. Proc. Soc. Exp. Biol. Med., *101:* 557–560.

Sidman, R. L., I. L. Miale and N. Feder 1959 Cell proliferation and migration in the primitive ependymal zone; an autoradiographic study of histogenesis in the nervous system. Exp. Neurol., *1:* 322–333.

Smart, I. 1961 The subependymal layer of the mouse brain and its cell proliferation as shown by radioautography after thymidine-H^3 injection. J. Comp. Neur., *116:* 325–347.

Tilney, F. 1933 Behavior in its relation to the development of the brain. Part II. Correlation between the development of the brain and behavior in the albino rat from embryonic states to maturity. Bull. Neurol. Inst. N. Y., *3:* 252–358.

Laschet-'60
Bib. No. 5184

Reproduced by p
of the copyright owner

Internat. J. Fertility 5:317-322. 1960.

EFFECT OF VITAMIN A ON ANIMAL FERTILITY*

Ursula Laschet and Wilhelm Weise (Germany)

SINCE the investigations of Sherman and MacLeod[1] in 1925 and Evans[2] in 1928, the diminution of fertility in vitamin A-depleted animals has been known. A number of authors also reported on malformations of the fetuses from vitamin A-depleted dams. Hale[3] observed anophthalmia in young pigs, Watt and Barlow[4] microphthalmia, and Rokkones[5] hydrocephalus. Wilson and co-workers[6] saw malformations of the eyes in fetuses of vitamin A-depleted rat litters, as well as malformations of the diaphragm, urinary tract, arch of the aorta, heart, and lungs. A more recent summary of the literature on this type of research has been published by Giroud and Lefebvres.[7]

Following the administration of high doses of vitamin A to dams also there are resulting malformations of the fetuses. Above all, Giroud and co-workers[8-15] dealt with the teratogenic action of vitamin A. When the vitamin was administered daily orally in doses of 60,000 I.U. from the fifth to seventh day of pregnancy the fetuses were resorbed in 43 per cent of all cases. When vitamin A was given from the eighth to tenth day there was resorption in 35 per cent, and from the eleventh to fourteenth day in only 10 per cent. On giving vitamin A up to the tenth day these authors observed anencephalia, anophthalmia, spina bifida, and malformations of the urinary tract in full-term fetuses. Vitamin A administration from the tenth to eighteenth day caused cleft palates and malformations of the limbs, and administration after the eighteenth day produced cataracts.

Cohlan[16] also described the teratogenic effect of vitamin A in 1953. He observed diminished fertility in animals treated orally with vitamin A, 35,000 I.U. daily from the second to sixteenth day

*From the Institute for Experimental Endocrinology, Humboldt University, Berlin N-4, Charité, Germany.

Presented at the Third World Congress of the International Fertility Association, Amsterdam, Holland, June 1959.

after mating. Only 10 female rats in a group of 100 produced 74 young with a malformation rate of 54 per cent.

Gebauer[11] attempted to reproduce Cohlan's results. He stated that in 32 animals no disturbance of fertility occurred; he noted no malformations, and even following toxic doses of vitamin A he saw no influence on the general condition of the animals. Administration was intraperitoneal in all cases, and it can be assumed that a very small quantity was absorbed; for this reason no adequate effect could be observed.

Our own investigations of fertility, namely on the effect of vitamin A on impregnation and implantation of the ovum, were made on 442 female rats ranging from 145 to 180 gm. in weight. Their cycle was controlled by the vaginal smear method. The animals were mated by exposure for thirty-six hours during the pre-estrus stage. Vitamin A was given by stomach tube. The animals were killed on the eleventh day after mating.

Table I shows the results. Sixty rats served as oil-treated controls, and 50 of them (83 per cent) became pregnant. Sixty animals received one dose of 30,000 I.U. of vitamin A-palmitate* during pre-estrus. They had a fertility rate of 72 per cent. Following administration of 30,000 I. U. during pre-estrus and another dose on the following day, 30 animals showed a rate of 70 per cent. In groups of 30 animals each the results were as follows:

	Fertility Rate
Three doses of 30,000 I.U.	67%
Four doses of 30,000 I.U.	60%
Five doses of 30,000 I.U.	57%

In a second series daily doses of 60,000 I.U. of vitamin A-palmitate were given. The fertility rates were as follows:

	Fertility Rate
One dose in 75 rats	69%
Two doses in 31 rats	71%
Three doses in 32 rats	63%
Four doses in 33 rats	45%

With administration of 120,000 I.U. on the day of pre-estrus and again on the following day, the fertility rate in 31 animals was 71 per cent, the same as in the animals who received two daily doses of 60,000 I.U.

The pregnant animals of all groups bore a normal number of young, as can be seen from Table I.

Among the 63 full-time fetuses of an additional group of dams which received 30,000 I.U. of vitamin A on each of the first

*Vitamin A palmitate was kindly provided by Hoffmann-LaRoche AG, Grenzach, Baden.

TABLE I

Fertility After Vitamin A Therapy

Number of Animals	*Vitamin A Dosage*	*Number of Pregnant Animals*	%	*Number of Fetuses per Animal*
60	0.2 ml. oil	50	83	9.2
60	1 x 30 000	43	72	8.2
30	2 x 30 000	21	70	10.1
30	3 x 30 000	20	67	10.3
30	4 x 30 000	18	60	9.6
30	5 x 30 000	17	57	9.4
75	1 x 60 000	52	69	9.1
31	2 x 60 000	22	71	9.4
32	3 x 60 000	20	63	9.4
33	4 x 60 000	15	46	8.7
31	2 x 120 000 (divided in two doses)	22	71	8.7

three days of pregnancy, no malformations were seen. Even with 60,000 I.U. daily for the first four days all full-term fetuses developed normally.

The decrease of fertility in female rats following high doses of vitamin A is illustrated in Figure 1.

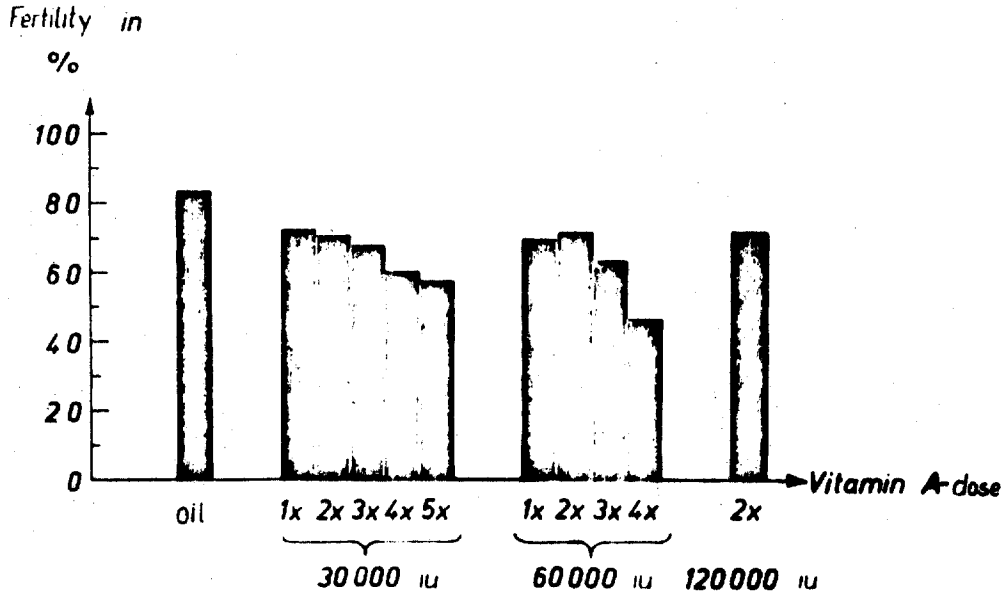

Figure 1.

Graphic representation of fertility in female rats following high doses of vitamin A.

When 30,000 I.U. was administered by stomach tube beginning with the pre-estrus, the fertility was lower than in the controls, even following a single dose. When administration was continued for two to five days, the fertility rate declined slowly to 57 per

cent following five daily doses. Thus fertility shows a reduction when compared with oil-treated controls of 13 per cent after a single dose of 30,000 I.U., 16 per cent after two doses, 19 per cent after three, 28 per cent after four, and 31 per cent after five. The reduction after one dose of 60,000 I. U. was 17 per cent, 15 per cent after two doses, 24 per cent after three, and 46 per cent after four. Following administration of 30,000 or 60,000 I.U. once or twice daily no different effects on fertility were witnessed. Even with a dose of 120,000 I.U. repeated after twenty-four hours the fertility rate was the same as after 30,000 I.U. given twice.

Administration of vitamin A for three or more days after the first day following pre-estrus serves to lessen fertility. It must be emphasized that after 60,000 I.U. given four times no symptoms of intoxication could be observed.

The relation of vitamin A effect on fertility to the duration of administration is evident. Giving the vitamin on the day of mating or the next day exerts less influence than giving it during the next three to five days. This permits the conclusion that fecundation of the mature ovum is not distrubed, but the embedding of the fertilized ovum in the uterus is disturbed.

Since the preliminary work of Moritz[14] on the inhibitory effect of vitamin A on differentiation, several groups of investigators dealt with the effect of the vitamin on the epithelium. Vitamin A depletion leads to generalized cornification of the epithelium. High doses cause anaplasia; that is, redifferentiation of the epithelium. The cornification of the vaginal epithelium caused by estrogenization in castrated female rats may be suppressed by a single oral dose of vitamin A which exceeds the threshold value. This effect was used by Hohlweg[10] for biologic standardization of vitamin A preparations. As one of us[20, 21] has established, cornification of the vagina during the estrus cycle may also be suppressed when vitamin A is given during the pre-estrus stage. A dose of 30,000 I.U. of vitamin A was ascertained as the threshold dose in estrogenized animals and 25,000 I.U. during estrus. In several investigations performed by Studer and co-workers and Hohlweg and co-workers[22] on the epidermis of the rat, 30,000 I.U. was found to be the approximate threshold dose.

Figure 2-a shows a section through the epidermis of an untreated rat, and Figure 2-b a section of the epidermis of an animal treated percutaneously with five doses of 30,000 I. U. of vitamin A-palmitate. The epidermis is thickened intensely. The stratum spinosum participates in this thickening. Its nuclei are often pale and show remarkably large nucleoli and very clearly outlined nuclear membranes. Between these one sees zones which are nearly structureless.



a b

Figure 2.

a) Skin of an untreated rat.
b) Skin of a vitamin A-treated rat (5 x 30,000 IU of vitamin A-palmitate percutaneously).

The number of mitoses is increased according to the method of Dustin,[7] by blocking mitosis with colchicine during the metaphase.

We are of the opinion that the inhibitory action of vitamin A on differentiation, with such an important proliferation of the epithelium and considerable increase in mitotic activity during the time of mating and embedding of the ovum, causes changes in the uterine membrane which result in inhibition of ovum implantation, and which in this way is responsible for the impairment of fertility in female rats. Because vitamin A passes the placental barrier in sufficient measure, the teratogenic action of high doses of vitamin A in the course of pregnancy described by other authors may be accompanied by a proportional inhibitory effect on differentiation. Woollam and Millen[8] found a potentiated teratogenic action of vitamin A and cortisone. This observation confirms the opinion that epithelial factors are highly important in the diminution of fertility in rats as a result of hypervitaminosis A.

Summary

The administration of high doses of vitamin A results in disturbance of fertility in female rats, probably caused by inhibition of embedding of the ovum, which results from inhibition of

differentiation of the epithelium. The dependence of this effect on the dosage of vitamin A and the term of its administration has been investigated.

References

1. Sherman, H. C., and Macleod, F. L. *J. Am. Chem. Soc.* 47:1658, 1925.
2. Evans, H. M. *J. Biol. Chem.* 77:651, 1928.
3. Hale, F. *Am. J. Ophthal.* 18:1087, 1935.
4. Watt, J. A., and Barlow, R. M. *Vet. Rec.* 68:780, 1956.
5. Rokkones, T. *Internat. Ztschr. Vitaminforsch.* 26:1, 1955.
6. Wilson, J. G., Roth, C. B., and Warkany, J. *Am. J. Anat.* 92:189, 1953.
7. Giroud, A., and Lefèbvres, J. *Ann. Nutrit. Aliment.* 11:15, 1957.
8. Giroud, A., and Martinet, M. *Arch. anat. Microsc. & Morphol. expér.* 45:77, 1956.
9. Giroud, A., and Martinet, M. *Compt. rend. Soc. de biol.* 148:1742, 1954.
10. Giroud, A., and Martinet, M. *Arch. franç. pédiat.* 12:1, 1955.
11. Giroud, A., and Martinet, M. *Compt. rend. Soc. de biol.* 149:1088, 1955.
12. Giroud, A., Gounelle, H., and Martinet, M. *Bull. Soc. chim. biol.* 39:331, 1957.
13. Giroud, A., and Martinet, M. *Compt. rend. Soc. de biol.* 149:452, 1955.
14. Giroud, A., Martinet, M., and Roux, C. *Arch. franç. pédiat.* 15:1, 1958.
15. Giroud, A., Martinet, M., and Roux, C. *Compt rend. Soc. de biol.* 151:1811, 1957.
16. Cobdan, S. Q. *Science* 117:535, 1953.
17. Gebauer, H. *Pharmazie* 9:684, 1954.
18. Moritz, W. *Ztschr. Anat.* 112:271, 1943.
19. Hohlweg, W. *Pharmazie* 8:280, 1952.
20. Laschet, U. *Inaug. Diss., Humboldt-Univ.* 6:12, 1955.
21. Laschet, U. *Vitamine u. Hormone* 8:157, 1958.
22. Studer, A. *Ztschr. ges. exper. Med.* 121:287, 1953.
23. Studer, A., and Frey, J. R. *Dermatologica* 104:1, 1952.
24. Hohlweg, W., and Laschet, U. *Vitamine u. Hormone* 8:164, 1958.
25. Hohlweg, W., Knappe, G., and Laschet, U. *Vitamine u. Hormone* 8:129, 1958.
26. Dustin, A. P. *Compt. rend l'Assoc. anat.* 205, 1938.
27. Millen, J. W., and Woollam, D. H. M. *Brit. M.J.* 236, 1957.
28. Woollam, D. H. M., and Millen, J. W. *Brit. M.J.* 197, 1957.

Ursula Laschet
Institute for Experimental Endocrinology
Humboldt University
Berlin N 4
Charite, Germany

J. A. M. A. 114:386-393. 1940.

Lehman-'40
Bib. No. 5297

CUTANEOUS MANIFESTATIONS OF VITAMIN A DEFICIENCY IN CHILDREN

EDWARD LEHMAN, M.D.
AND
HOWARD G. RAPAPORT, M.D.
NEW YORK

During the past eight months we have observed nine children, almost all of families on relief, attending the pediatric outpatient department, with cutaneous lesions of vitamin A deficiency similar to those described by Frazier and Hu [1] in Chinese soldiers, by Loewenthal [2] and by Nicholls [3] in prisoners in Africa and India respectively, and in various parts of the world by other observers.[4] In the United States Scheer and Keil [5] recorded two cases of scurvy in which these lesions also were present and Jeghers [6] described cutaneous manifestations in medical students that he had observed for impaired dark adaptation. Also Youmans and Corlette [7] reported a series of cases in which these cuta-

With the technical assistance of Dorothy Greenberg, B.A.
Dr. William Rosenson gave valuable cooperation in this study.

From the Pediatric Service of Dr. Bela Schick, the Mount Sinai Hospital.

The oleum percomorphum 50 per cent used in this investigation was supplied by Mead Johnson & Co., Evansville, Ind. Ampules for intramuscular injection, containing 25,000 international units of vitamin A and 800 units of vitamin D in 1 cc. of a vegetable oil, also employed in one case, were furnished by the Abbott Laboratories, North Chicago, Ill.

1. Frazier, C. N., and Hu, C. K.: Cutaneous Lesions Associated with a Deficiency in Vitamin A in Man, Arch. Int. Med. 48: 507 (Sept.) 1931; Nature and Distribution According to Age of Cutaneous Manifestations of Vitamin A Deficiency: A Study of 207 Cases, Arch. Dermat. & Syph. 33: 825 (May) 1936.

2. Loewenthal, L. J. A.: A New Cutaneous Manifestation in the Syndrome of Vitamin A Deficiency, Arch. Dermat. & Syph. 28: 700 (Nov.) 1933; An Inquiry into Vitamin A Deficiency Among the Population of Teso, Uganda, with Special Reference to School Children, Ann. Trop. Med. 29: 349 (Oct.) 1935.

3. Nicholls, Lucius: Phrynoderma: A Condition Due to Vitamin Deficiency, Indian M. Gaz. 68: 681 (Dec.) 1933; A Study of Vitamin A Deficiency in Ceylon with Special Reference to the Statistical Incidence of Phrynoderma and "Sore Mouth," ibid. 69: 241 (May) 1934; The Inspectional Value of Phrynoderma and "Sore Mouth," ibid. 70: 14 (Jan.) 1935.

4. Sequeira, J. H., in Gordon, H. L.: Xerophthalmia in Mathari Mental Hospital, East African M. J. 10: 85 (June) 1933. Giblin, W. E.: Loewenthal's New Cutaneous Manifestation in the Syndrome of Vitamin A Deficiency Observed in Papuan Natives, M. J. Australia 23: 202 (Feb. 8) 1936. Reiss, F.: A Contribution to the Cutaneous Manifestations of Vitamin A Deficiency, Chinese M. J. 50: 945 (July) 1936; Cutaneous Manifestations of Vitamin A Deficiency, Orvosi hetil. 81: 335 (March 27) 1937. Comel, M.: Dyskeratosis spinulosa melanotica, Gior. ital. di dermat. e sif. 79: 325 (April) 1938. Goodwin.[20] Scheer and Keil.[5] Keil.[5] Sweet and K'ang.[20] Aykroyd and Rajagopal.[20] Aykroyd and Krishnan.[20] Radhakrishna Rao.[20] Stuffens, Hair and Steard.[9] Youmans and Corlette.[7] Youmans.[7] Frazier and Li.[20] Jeghers.[6]

5. Scheer, Max, and Keil, Harry: Follicular Lesions in Vitamin A and C Deficiencies, Arch. Dermat. & Syph. 30: 177 (Aug.) 1934. Keil, Harry: The Follicular Lesions of Vitamin A and C Deficiencies, Am. J. Digest. Dis. 5: 40 (March) 1938.

6. Jeghers, Harold: The Degree and Prevalence of Vitamin A Deficiency in Adults, with a Note on Its Experimental Production in Human Beings, J. A. M. A. 109: 756 (Sept. 4) 1937; Vitamin A Deficiency in Adults, Internat. Clin. 1: 17 (March) 1938.

7. Youmans, J. B., and Corlette, M. B.: Specific Dermatosis Due to Vitamin A Deficiency, Am. J. M. Sc. 195: 644 (May) 1938. Youmans, J. B.: The Present Status of Vitamin Deficiencies in Practice, J. A. M. A. 108: 15 (Jan. 2) 1937.

mous lesions were present and Steffens, Bair and Sheard[8] experimentally produced this dermatosis in a healthy human subject.

CLINICAL MANIFESTATIONS

The dermal lesions of our children were symmetrical and located chiefly on the extremities. They were found particularly on the lower extremities on the anterior and lateral surfaces of the thighs and calves and in the patellar region, and less frequently and less markedly on the upper extremities on the lateral and posterior surfaces of the upper arm and in the olecranon region. Also the abdomen, buttocks, back, neck and face were at times involved. The lesions consisted particularly of horny papules formed by keratotic plugs projecting from hair follicles and frequently containing a broken off hair or a coiled unerupted hair. The diameter of the papules probably is directly proportional to the duration and severity of the deficiency and in some reported cases has equaled 0.5 cm. but in our cases rarely exceeded 0.2 cm. If the follicular keratoses are marked they may give the skin a rough grater-like feel, and this dermatosis when mild is often detected more easily by palpation than by inspection. If a large papule is picked out, a gaping hole is left. In the more severe cases the keratosis may also involve the interfollicular skin, which may be rough. Aside from this there is a suppression of the cutaneous secretions as evidenced by a marked dryness of the skin or xeroderma. There may be a moderate degree of pruritus, and there is a loss of hair in the affected areas. In the African and Asiatic races the papules may be pigmented[9] and in some regions the skin may be generally darker than normal. Negro patients say they "ash" because black skins particularly may show a whitish frosted surface, though this is usually concealed by oiling. A dryness and scaliness of the scalp occur in some cases, and the lesions, when present on the face, slightly resemble acne. The expression "gooseskin" has been applied, but the term phrynoderma, meaning toad-skin, introduced by Nicholls[8] and later used by others for this cutaneous disorder, is most descriptive.

The familial occurrence of this dermatosis in our series is interesting, but we are as yet uncertain as to its proper interpretation. In one family there were two sisters with these skin lesions, while the parents and three other siblings had normal skins although the mother had a borderline photometric test for vitamin A deficiency. In another family, containing our only patients not on relief, the mother and two daughters had had this dermatosis since early childhood, and the mother, who has symptoms of night blindness, and also her two daughters, exhibited by test markedly impaired dark adaptation, while the father, the only other member, has a normal skin. Of course the most obvious explanation for multiple cases in a family is the consumption by its various members of the same deficient diet, and the occurrence of this disorder in only some of the members might be due to differences in the food actually consumed by them because of individual tastes and preferences. However, some hereditary disturbance in vitamin A metabolism, interfering with the utilization of vitamin A or producing an increased minimal requirement for this substance, may be also considered.

PHOTOMETRIC STUDIES

There have been few reports of photometric tests made in individuals with the cutaneous manifestations of vitamin A deficiency. Youmans and Corlette[7] reported that studies with a visual photometer in some of their cases demonstrated an occasional mild hemeralopia and concluded that in some instances such cutaneous lesions may be the first clinical evidence of vitamin A deficiency, appearing before any eye symptom except a mild hemeralopia detectable only by a photometer. The single other report of which we are cognizant is that of Frazier and Li,[10] who, using a Birch-Hirschfeld instrument, arrived at the opinion that conclusions drawn from photometric testing of visual acuity are likely to be fallacious.



Fig. 1 (case 6).—*A*, arm before treatment, demonstrating keratotic plugs projecting from hair follicles and loss of hair. *B*, arm after prolonged administration of vitamin A showing normal skin and regrowth of hair. This is not a hypertrichosis.

Biophotometer studies were made in all our cases. We are aware of the different criticisms of the biophotometer made by various authors.[11] Jeans, Blanchard and Zentmire,[12] in their original paper on this instrument, pointed out many of the sources of experimental error and the methods for minimizing them. Only recently Booher and Williams,[13] testing adults, concluded that the biophotometer may be adequate for detecting marked dysadaptation. Furthermore the series of biophotometric curves obtained by Jeghers[6] during the production and cure of experimental human

8. Steffens, L. F.; Bair, H. L., and Sheard, Charles: Photometric Measurements on Visual Adaptation in Normal Adults on Diets Deficient in Vitamin A, Proc. Staff Meet., Mayo Clin. 14: 698 (Nov.) 1939.

9. Mu, J. W.; Frazier, C. N., and Pillat, A.: Melanin Pigment of the Skin and Conjunctiva in Avitaminosis A in Man, Chinese J. Physiol. 11: 347 (March) 1937.

10. Frazier, C. N., and Li, H. C.: Vitamin A Deficiency in Man: Resolution of Cutaneous Lesions Following Parenteral Administration of Carotene, Chinese M. J. 54: 301 (Oct.) 1938.

11. Snelling, C. E.: The Biophotometer as a Test for Vitamin A Deficiency, J. Pediat. 13: 506 (Oct.) 1938. Palmer and Blumberg.[14] Palmer.[15] Jung.[16] Isaacs, Jung and Ivy.[20]

12. Jeans, P. C.; Blanchard, Evelyn, and Zentmire, Zelma: Dark Adaptation and Vitamin A: A New Photometric Technic, J. A. M. A. 108: 451 (Feb. 6) 1937.

13. Booher, Lela E., and Williams, D. E.: A Study of the Biophotometer as a Means of Measuring the Vitamin A Status of Human Adults, J. Nutrition 16: 343 (Oct.) 1938.

avitaminosis A definitely demonstrate that, properly employed, this instrument can detect the presence and course of impaired dark adaptation due to vitamin A deficiency.

In none of our children were there any eye symptoms, but in every case the readings of the biophotometer have been definitely within the subnormal zone, indicating vitamin A deficiency. This test with the biophotometer was repeated several times before starting therapy both for confirmation as to existing deficiency and to eliminate the factor of training, reported by Palmer and Blumberg,[14] and also the factor of "centripetal drift," mentioned by Jung,[15] in any subsequent improvement of the retina. As additional corroboration in some of our cases we performed what we have termed a therapeutic test, based on an immediate retinal response. On the day on which treatment was begun in these cases an additional preliminary biophotometric test was made and then 200,000 international units of vitamin A was administered by mouth. Subsequent tests made one and two hours later indicated in some cases improvement in the biophotometric reading by a rise from the deficient to the borderline or normal zone. Such an immediate response of the retina has been obtained also by Edmund and Clemmesen,[16] Friderichsen and Edmund,[17] Mutch and Griffith,[18] Jeghers,[6] Wald, Jeghers and Arminio[19] and Lewis and Haig,[20] though not by Hecht and Mandelbaum,[21] and can be elicited only if an adequately large dose of vitamin A is administered. When the preliminary series of tests shows that the deficiency is very marked or when the patient is an adult or nearly adult in size, a larger test dose such as 500,000 units should be used. In this connection we refer to the immediate response of even normal individuals to a single dose of 2,000,000 units of vitamin A as reported by Getz, Hildebrand and Finn.[22] However, in some of our cases the immediate response to the dosage employed was disappointing, and betterment in visual tests was attained only after prolonged and intensive therapy. In such instances there was usually a rough parallelism between the improvement of the photometric tests and the progress of the skin, and the biophotometer was then of considerable value in gaging the dosage of vitamin A required.

In one of our cases we are discarding the evidence of the photometer because, although this child repeatedly gave readings that were in the deficient zone, the results of the tests were too erratic to be accepted as reliable. However, this child was typical in all other ways, such as clinical picture and response of the skin to treatment.

TREATMENT AND COURSE

The last three children in our series have so far had less treatment than the others and have shown a marked though not yet a maximal improvement of the skin. The other children have attained a nearly complete cutaneous recovery following a daily dose of from 100,000 to 300,000 international units of vitamin A in the form of oleum percomorphum, with no local treatment, no change in diet and with the children still in their home environment. Dosage of at least this magnitude not only may be required for visual improvement, as reported by Getz, Hildebrand and Finn,[22] but in most of our cases has been necessary also for cutaneous recovery. We hoped with such doses also to hasten the response of the skin, but nevertheless the cutaneous improvement, as reported by all authors[23] in this field, has been slow, requiring from two to four months of treatment. However, in the more severe case, in which the skin is exceedingly dry and lusterless with rough follicular keratoses, we, like Frazier and Hu,[1] have observed within two weeks renewed activity of the cutaneous glands manifested by perceptible moisture and oiliness, the appearance of a gloss and increased smoothness. The subsequent improvement noted, which requires weeks, is the gradual extrusion and desquamation of the follicular keratoses as minute ricelike bodies, which at first are partly adherent, giving the skin a shaggy appearance. Ultimately with adequate vitamin A therapy and sufficient time there is a regeneration

Summary of Cases Showing Cutaneous Manifestations of Vitamin A Deficiency

Case	Initials	Age, Years	Sex	Race	Vitamin A Diet,† Units	Skin Lesions: Duration, Years	Skin Lesions: Severity: Before Treatment	Skin Lesions: Severity: After Treatment	Visual Photometric Test,* Millifoot Candles of Light: Before Course of Treatment	Visual Photometric Test,* Millifoot Candles of Light: 2 Hours After Test Dose	Visual Photometric Test,* Millifoot Candles of Light: After Course of Treatment	Comment
1	I. S.	11	♀	W	1,500	2	+++	0	1.95	....	0.29, 0.47	
2	R. S.	7	♀	W	1,700	1	++	0	1.4, 2.4	0.76	0.69	Sister of I. S.
3	V. F.	10	♀	B	4,000	2	++	0	1.6	0.69	0.45, 0.69	
4	G. G.	13	♀	W	1,400	2	+	0	0.9, 1.3	0.84	0.63, 0.58	
5	L. D.	8	♀	W	1,500	2	+	0	1.9	....	.....	Uncooperative
6	A. L.	8	♂	W	2,500	4	+++	0	1.4?, 1.2?	....	0.69?, 0.47	Visual tests unreliable
7	E. H.	10	♀	W	5,000	9?	++	±	2.16	....	0.92	
8	E. A.	10	♀	W	2,000	7	++	+	1.9, 2.4	1.9	0.92	
9	C. H.	13	♀	W	5,000	12?	++	±	3.8	....	0.77	Sister of E. H.

* Photometric test after exposure to bright light. Normal is below 0.7, borderline is from 0.7 to 1.0, deficient is above 1.0.
† Vitamin A content of diet was estimated with Jeghers' assumed average values.

14. Palmer, C. E.; and Blumberg, Harold: The Use of a Dark Adaptation Technic (Biophotometer) in the Measurement of Vitamin A Deficiency in Children, Pub. Health Rep. **52**: 1403 (Oct. 8) 1937. Palmer, C. E.: The Dark Adaptation Test for Vitamin A Deficiency, Am. J. Pub. Health **28**: 309 (March) 1938.

15. Jung, F. T.: Centripetal Drift: A Fallacy in the Evaluation of Therapeutic Results, Science **87**: 461 (May 20) 1938. Isaacs, B. L.; Jung, F. T., and Ivy, A. C.: Vitamin A Deficiency and Dark Adaptation, J. A. M. A. **111**: 777 (Aug. 27) 1938.

16. Edmund, C., and Clemmesen, S.: On Deficiency of A Vitamin and Visual Dysaptation, London, Oxford University Press, 1936, 1937.

17. Friderichsen, C., and Edmund, C.: Studies of Hypovitaminosis A: II. A New Method for Testing the Resorption of Vitamin A from Medicaments, Am. J. Dis. Child. **53**: 89 (Jan.) 1937; III. Clinical Experiments in the Vitamin A Balance in Children After Various Diets, ibid. **53**: 1179 (May) 1937.

18. Mutch, J. R., and Griffith, H. D.: A Study of Diet in Relation to Health: Dark Adaptation as an Index of Adequate Vitamin A Intake, Brit. M. J. **2**: 565 (Sept. 18) 1937.

19. Wald, George; Jeghers, Harold, and Arminio, Joseph: An Experiment in Human Dietary Night Blindness, Am. J. Physiol. **123**: 732 (Sept.) 1938.

20. Lewis, J. M., and Haig, Charles: Vitamin A Requirements in Infancy as Determined by Dark Adaptation, J. Pediat. **15**: 812 (Dec.) 1939.

21. Hecht, Selig, and Mandelbaum, Joseph: Vitamin A and Dark Adaptation, J. A. M. A. **112**: 1910 (May 13) 1939.

22. Getz, H. R.; Hildebrand, J. B., and Finn, Milton: Vitamin A Deficiency in Normal and Tuberculous Persons, J. A. M. A. **112**: 1308 (April 8) 1939.

23. Youmans, J. B.: Newer Clinical Aspects of Vitamin Deficiency Diseases: Vitamin A Deficiency, Am. J. Trop. Med. **19**: 229 (May) 1939. Also references 1, 2, 3 and 4.

of normal follicles and interfollicular epidermis [24] and a regrowth of hair. Even after this has been achieved we have continued vitamin A therapy, because we have found that relapse of visual dysadaptation and cutaneous manifestations may occur after treatment is diminished or stopped.

There is some tendency to seasonal amelioration during warmer weather, which may be due in part to an improved diet and the higher vitamin A content of important foods during the summer, reported by various investigators.[25] Seasonal factors favored our results, but in our cases of more than one year's duration the parents felt that the improvement this year far exceeded that of previous summers when no specific therapy had been administered. Furthermore in three cases, equivalent to an untreated control group, treatment was not started until August, when, despite the hot weather and in marked contrast to the treated children, the skin of each of these three children was still strikingly abnormal and the dark adaptation still markedly impaired. Also cutaneous improvement, subsequently produced by vitamin A therapy of these three children, is progressing satisfactorily in spite of the present cold weather. In connection with the seasonal factor, the data of Sweet and K'ang [26] on the month of onset of symptoms of vitamin A deficiency in 177 cases in China showed a marked peak in January, February and March, which was attributed to the deficient winter diet, and another peak in July attributed to dysentery, in which the diarrhea prevents absorption of the vitamin.



Fig. 2 (case 7).—Arm illustrating keratoses of the hair follicles typical of vitamin A deficiency.

OCCURRENCE IN CHILDHOOD

Frazier and Hu [1] among 207 cases of this dermatosis found only two children, aged 4 and 5 years respectively, with the characteristic follicular papules and concluded that the lesions usually occur in sexually mature persons between 16 and 30 years of age and not among infants, and that in infancy and childhood vitamin A deficiency may produce a simple xerosis of the skin. Although widely quoted, this conclusion requires revision. Loewenthal [2] in Africa, while examining 1,112 individuals of whom 1,000 were school children, found that over 80 per cent had a dry skin, which he believes is the earliest cutaneous symptom of vitamin A deficiency, and 277 had the follicular lesions. Aykroyd and Rajagopal [27] in India, in examining 1,918 school children between the ages of 6 and 17 years, found 129 with these follicular papules and the number affected was higher in the "poor" schools than in the "good" schools. Calculations made from data of Aykroyd and Krishnan [28] show that the occurrence of this condition in hostels or boarding homes for school children was about 14 per cent among 719 boys and about 12 per cent among 955 girls, and the incidence varied between 0 and 53 per cent in eleven different hostels containing boys and between 0 and 46 per cent in thirteen hostels for girls. Nicholls [8] examined 4,380 school children in India and found 1,175, or 26.8 per cent, with these cutaneous lesions, and the percentage affected varied from 0 and 2.8 in two of the better schools to 83 in a charity school for destitute children where the diet was very deficient. In a subsequent report on an additional 678 children there were 216 with this dermatosis, and Nicholls recommended an inspection of the arms of school children for this condition as one test of the children's nutritional status. We have not yet seen this dermatosis in infancy or very early childhood, but Nicholls states that "Advanced cases in which there are no signs of eye lesions are fairly common in young indigent children after 6 months of age, that is from the time they are weaned." Radhakrishna Rao,[29] also in India, states that he has observed cases of this dermatosis in children's boarding and day schools and reports in detail the cases of a boy aged 9 years and a girl aged 6 years. In a later paper Radhakrishna Rao states that the condition appeared to be as common in children of both sexes as in young adults and his youngest patient was 2½ years of age. Goodwin [30] in England reported a case in a 10 year old boy and also stated that on searching in the pediatric outpatient department he found several other milder cases, which was confirmed by Mackay.[31] As a consequence of these reports and as a result of our experience, we believe that, if the possibility is kept in mind, cases presenting the typical follicular lesions of the skin characteristic of vitamin A deficiency will be found not infrequently among underprivileged school children.

Fig. 3 (case 9).—Sister of patient in figure 2. Arm with similar cutaneous lesions.

ETIOLOGY

The microscopic picture of these cutaneous lesions, reported by Frazier and Hu [1] and by Radhakrishna Rao [29] in detail, reveals a pathologic process so typical of vitamin A deficiency that it furnishes strong proof of the cause of the disorder. Briefly, cornified cells, forming a concentric lamellated mass and frequently

24. Wolbach, S. B., and Howe, P. R.: Epithelial Repair in Recovery from Vitamin A Deficiency, J. Exper. Med. 57: 511 (March) 1933.
25. Baumann, C. A.; Steenbock, Harry; Beeson, W. M., and Rupel, I. W.: The Influence of Breed and Diet of Cows on the Carotene and Vitamin A Content of Butter, J. Biol. Chem. 105: 167 (April) 1934. Wilkinson, H.: The Vitamin A and Vitamin D Contents of Butter: II. Seasonal Variation, Analyst 64: 17 (Jan.) 1939. Booth, R. G.; Ken, S. K.; Dann, W. J., and Moore, Thomas: A Study of Seasonal Variation in Butter Fat, Biochem. J. 27: 1189 (Nov. 4) 1933.
26. Sweet, L. K., and K'ang, N. J.: Clinical and Anatomic Study of Avitaminosis A Among the Chinese, Am. J. Dis. Child. 50: 699 (Sept.) 1935.
27. Aykroyd, W. R., and Rajagopal, K.: The State of Nutrition of School Children in South India, Indian J. M. Res. 24: 419 (Oct.) 1936.
28. Aykroyd, W. R., and Krishnan, B. G.: The State of Nutrition of School Children in South India: Part II. Diet and Deficiency Disease in Residential Hostels, Indian J. M. Res. 24: 707 (Jan.) 1937.
29. Radhakrishna Rao, M. V.: "Phrynoderma": A Clinical and Histopathological Study, Indian J. M. Res. 24: 727 (Jan.) 1937; Studies in Vitamin A Deficiency: Histopathology of the Skin in Human Keratomalacia, ibid. 25: 39 (July) 1937; Treatment of Phrynoderma by Vitamin A Concentrate, Indian M. Gaz. 73: 461 (Aug.) 1938.
30. Goodwin, G. P.: Cutaneous Manifestation of Vitamin A Deficiency, Brit. M. J. 2: 113 (July 21) 1934.
31. Mackay, Helen M. M., in note to article by Goodwin.[30]

containing an atrophic coiled hair, plug the greatly distended upper portion of the hair follicle, and concurrently there is an atrophy of the associated sebaceous gland even to the point of disappearance. A moderate hyperkeratinization extends beyond the follicle over the general surface of the epidermis, and a keratinizing metaplasia, similar to that of the hair follicles though milder and detectable only by the microscope, affects the ducts of the sweat glands, which also atrophy. That identical cutaneous lesions have not been observed in experimental animals [32] does not afford a reason for doubting the etiology because it is established that the distribution in the various epithelial tissues of this pathologic process varies in different species,[32] and the susceptibility to cutaneous localization seems to be a characteristic of man. On the basis of pathology alone we can conclude that the changes in the skin are very comparable to those that occur in other epithelial tissues [32] in vitamin A deficiency and are therefore strong proof of the etiology of the process.



Fig. 4 (case 7).—Thigh showing keratotic plugs in hair follicles.

The high incidence of these cutaneous lesions of a uniform character in individuals with well established symptoms of vitamin A deficiency such as keratomalacia, xerophthalmia and night blindness constitutes one of the strongest proofs that the cause of this dermatosis is a lack of vitamin A. Loewenthal [2] among 1,000 prisoners diagnosed vitamin A deficiency in eighty-one, of whom seventy-one had night blindness, forty-five had xerophthalmia and seventy-four had this dermatosis. Frazier and Hu [1] found that the majority of their soldiers with keratomalacia had these cutaneous lesions and Nicholls [3] reported that all of twenty-one prisoners with keratomalacia had this type of cutaneous involvement. Conversely the individuals with this dermatosis show a high incidence of ocular manifestations of vitamin A deficiency, as indicated by nyctalopia, xerophthalmia and keratomalacia in the severe cases of Frazier and Hu, of Loewenthal and of Nicholls, and as evidenced by impaired dark adaptation by photometric test in the less marked cases reported by Youmans and Corlette [7] and by us. However, it is possible that in the earlier and milder stages these cutaneous lesions may at least in some cases be the first symptom of vitamin A deficiency and may antedate any impairment of dark adaptation, and even in more marked cases, if photometric tests are not available, these cutaneous manifestations may be the only evidence of vitamin A deficiency.

Dietary investigations, which show that almost all the individuals or groups of individuals reported with these cutaneous lesions have been on a diet deficient in vitamin A, furnishes additional proof of etiology. For example, Nicholls [8] in India reported a mental asylum where among 232 patients on the "Ceylon diet" there were about 44 per cent with this dermatosis, while among eighty-one patients in the same institution on a "European diet," differing only by an extra two eggs and 5 ounces of milk daily, there were about 2 per cent affected. Furthermore, the data in two papers of Nicholls concerning a total of 1,823 prisoners suggests that the presence of these cutaneous lesions varies directly with the degree of deficiency of the diet in vitamin A and with the length of time a given deficient diet is consumed. Also Steffens, Bair and Sheard,[9] of the Mayo Clinic, experimentally produced these cutaneous manifestations, appearing before significant changes in light thresholds but confirmed by biopsy, in a human subject maintained for 190 days on a diet adequate in other factors but furnishing daily only 100 to 300 international units of vitamin A; and after seventeen

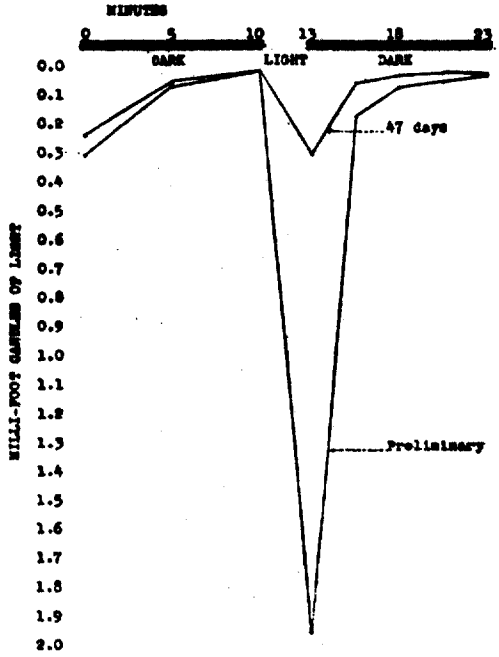

Fig. 5 (case 1).—Biophotometer curves before and after a daily dose of 100,000 international units of vitamin A for forty-seven days.

additional days with vitamin A therapy, these observers demonstrated by a second biopsy from the same subject a normal skin except for the keratotic plugs in the hair follicles. The occurrence of this dermatosis or impaired dark adaptation in some individuals on an apparently satisfactory diet is no disproof of the etiology of these symptoms. In such instances the deficiency may be due to increased or high minimum requirements or, to put it differently, may be due to various

32. Beesey, O. A., and Wolbach, S. B.: Vitamin A: Physiology and Pathology, J. A. M. A. **110**: 2072 (June 18) 1938. Wolbach, S. B.: The Pathologic Changes Resulting from Vitamin Deficiency, ibid. **108**: 7 (Jan. 2) 1937. Wolbach, S. B., and Howe, P. R.: Tissue Changes Following Deprivation of Fat-Soluble A Vitamin, J. Exper. Med. **42**: 753 (Dec.) 1925; Vitamin A Deficiency in the Guinea Pig, Arch. Path. & Lab. Med. **5**: 239 (Feb.) 1928.

33. Wilson, J. R., and DuBois, R. O: Report of a Fatal Case of Keratomalacia in an Infant, with Postmortem Examination, Am. J. Dis. Child. **26**: 431 (Nov.) 1923. Blackfan, K. D., and Wolbach, S. B.: Vitamin A Deficiency in Infants, J. Pediat. **3**: 679 (Nov.) 1933. Goldblatt, H., and Benischek, M.: Vitamin A Deficiency and Metaplasia, J. Exper. Med. **46**: 699 (Nov.) 1927. Robertson, E. C.: Recent Work on the Tissue Changes in Vitamin A Deficiency, Am. J. M. Sc. **192**: 409 (Sept.) 1936.

disturbances, some [34] of which are already known, that may occur in the series of processes from ingestation of diet at one end through digestion, absorption, conversion, storage, transportation and so on to finally, at the other end, utilization of the vitamin A by the retina and other epithelial tissues. On the other hand, the diet may be so deficient that these cutaneous lesions may occur together with scurvy [35] or pellagra.[36] However, as Frazier and Hu [1] state, "If one bears in mind the present conception of the pathologic characteristics of the two deficiency diseases, it seems reasonable to assume that the epithelial changes occasionally found in association with scurvy are related to a lack of vitamin A rather than to a lack of vitamin C. This is equally true of other types of avitaminoses, such as pellagra, in which similar lesions of the skin have been observed."

The administration of vitamin A as a therapeutic test to patients with these cutaneous manifestations constitutes one of the most convincing proofs of the etiology and, according to every author, has resulted in complete or nearly complete cutaneous recovery. Loewenthal [2] for example gave his prisoners 1 ounce of cod liver oil daily and with no other change obtained in nine weeks a cure of night blindness in 100 per cent, of xerophthalmia in 100 per cent and of this dermatosis in 98.7 per cent. Of course the fish liver oils, which have usually been employed, contain both vitamin A and D, but enough is known of the effects of deficiency of these two vitamins to establish that vitamin A is the factor concerned in changes in epithelial tissues. Furthermore, Loewenthal has cured patients with a product containing vitamin A alone, and Frazier and Li [10] have reported a typical patient cured in fifty-one days while still on a deficient diet by daily intramuscular injections of from 1 to 2 mg. of carotene. Our patients were successfully treated while remaining in their own homes with no change in diet or in any other factor except the administration of oleum percomorphum.

ETIOLOGY OF KERATOSIS PILARIS (LICHEN PILARIS, ICTHYOSIS FOLLICULARIS)

Before the etiology of the cutaneous manifestations of vitamin A deficiency had been reported in 1931 by Frazier and Hu, an entity similar both clinically [37] and pathologically [38] had long been known to dermatologists [39] under the descriptive terms keratosis pilaris, lichen pilaris, lichen spinulosus and so on, and Nicholls [8] and Radhakrishna Rao [29] without expressing a definite opinion pose the question of the etiology of the latter conditions. Icthyosis follicularis is another synonym, and many of our cases have been

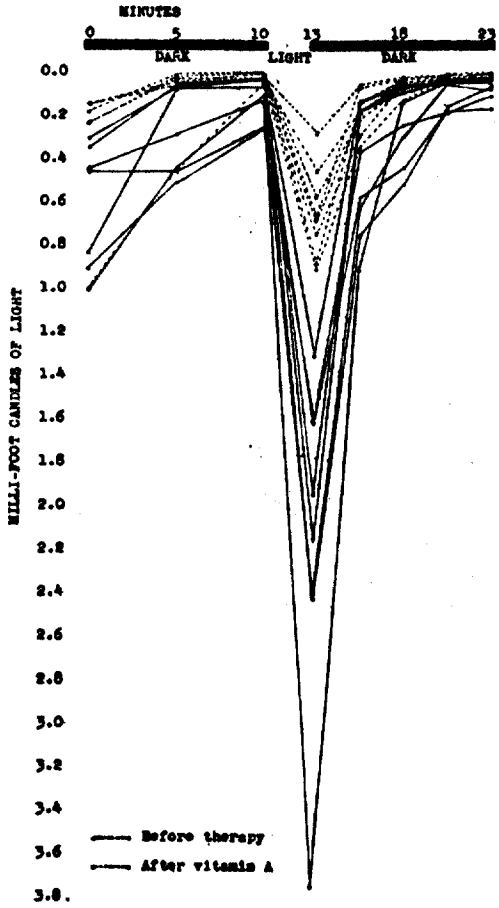

Fig. 6.—Biophotometer curves from eight children before and after prolonged treatment with vitamin A. Normal is below 0.7, borderline is from 0.7 to 1.0, deficient is above 1.0 after exposure to bright light.

diagnosed by others as "icthyosis." However, every case in the series investigated by us that might have been designated keratosis pilaris, icthyosis follicularis or the like proved by photometric test to be deficient in vitamin A and responded to vitamin A therapy with a nearly complete or a marked improvement of the skin. On this account and because of the indistinguishable clinical picture and the identical pathologic changes characteristic of vitamin A deficiency, we believe that keratosis pilaris, lichen pilaris, lichen spinulosus, icthyosis follicularis and other synonyms are merely descriptive terms for the cutaneous manifestations of a vitamin A deficiency.

HUMAN REQUIREMENTS FOR VITAMIN A

Before considering the probable incidence of vitamin A deficiency in America on the basis of the adequacy of the diets consumed by various groups of the popu-

34. Curtis, A. C., and Ballmer, R. S.: The Prevention of Carotene Absorption by Liquid Petrolatum, J. A. M. A. **113**: 1785 (Nov. 11) 1939. Van Eekelen, M., and Pannevis, W.: Absorption of Carotenoids from the Human Intestine, Nature **141**: 203 (Jan. 29) 1938. Heymann, Walter: Absorption of Carotene, Am. J. Dis. Child. **51**: 273 (Feb.) 1936. Breese, B. B., and McCord, A. B.: Vitamin A Absorption in Celiac Disease, J. Pediat. **15**: 183 (Aug.) 1939. Altschule, M. D.: Vitamin A Deficiency in Spite of Adequate Diet in Congenital Atresia of Bile Ducts and Jaundice, Arch. Path. **20**: 845 (Dec.) 1935. Ralli, Elaine P.; Pariente, A. C.; Brandaleone, Harold, and Davidson, Sidney: The Effect of the Daily Administration of Carotene on the Blood Carotene of Normal and Diabetic Individuals, J. A. M. A. **106**: 1975 (June 6) 1936. Patek, A. J., and Haig, Charles: The Occurrence of Abnormal Dark Adaptation and Its Relation to Vitamin A Metabolism in Patients with Cirrhosis of the Liver, J. Clin. Investigation **18**: 609 (Sept.) 1939. Bauman, C. A.; Riising, B. M., and Steenbock, Harry: The Absorption and Storage of Vitamin A in the Rat, J. Biol. Chem. **107**: 705 (Dec.) 1934. Wohl, M. G., and Feldman, J. B.: Vitamin A Deficiency in Disease of the Thyroid Gland, Endocrinology **24**: 389 (March) 1939. Anderson, D. H.: Cystic Fibrosis of the Pancreas and Its Relation to Celiac Disease, Am. J. Dis. Child. **56**: 344 (Aug.) 1938. Edmund, C., and Clemmesen, S.: On Parenteral A Vitamin Treatment of Dysaptatio (Nyctalohemeralopia) in Some Pregnant Women, Acta med. Scandinav. **89**: 69, 1936.

35. Jessner, S.: Haut-Anomalien bei innern Krankheiten, Berlin, A. Hirschwald, 1893, p. 85. Nicolau, S.: Study of a Follicular and Perifollicular Eruption in Scurvy, Ann. de dermat. et syph. **7**: 399, 1918-1919. Wiltshire, H.: Hyperkeratosis of the Hair Follicles in Scurvy, Lancet **2**: 564 (Sept. 27) 1919. Aschoff, L., and Koch, W.: Skorbut, Jena, G. Fischer, 1919, p. 12. Theodorescou, S.: Sur un cas de dermatite papulo-kératosique scorbutique, Ann. de dermat. et syph. **9**: 581 (July) 1928. Scheer and Keil.[8]

36. Stannus, H. S.: Pellagra in Nyasland, Tr. Soc. Trop. Med. & Hyg. **5**: 112, 1911-1912.

37. Andrews, G. C.: Diseases of the Skin, ed. 2, Philadelphia, W. B. Saunders Company, 1938, p. 679. Ormsby, O. S.: Diseases of the Skin, ed. 5, Philadelphia, Lea & Febiger, 1937, p. 483.

38. Giovanni, S.: A Contribution to the Histological Study of Keratosis Pilaris, Lo sperimentale gior. med. **49**: 661 (Dec.) 1895; abstr. Brit. J. Dermat. **8**: 151 (April) 1896.

39. Brocq, L.: Notes pour servir a l'histoire de la kératose pilaire, Ann. de dermat. et syph. **1**: 25, **1**: 97, **1**: 222, 1890. Mibelli, V.: Die Aetiologie und die Varietäten der Keratosen, Monatsh. f. prak. Dermat. **24**: 345, **24**: 415, 1897. Duhring, L. A.: Diseases of the Skin, ed. 3, Philadelphia, J. B. Lippincott Company, 1886, p. 399. Crocker, H. R.: Diseases of the Skin, ed. 3, Philadelphia, P. Blakiston's Son & Co., 1905, p. 591.

lation, it is advisable to review the efforts of various investigators to establish definite minimal and optimal standards of human requirements for vitamin A. Unfortunately the estimates arrived at by different authors vary considerably, not only because of different technics in ascertaining such standards but also because of differences in the vitamin A value assigned to foods[40] by various investigators, and also because of considerable actual variation in the vitamin A content of different specimens of a given food.

Booher[41] states that the minimal daily need both in man and in animals is from 20 to 30 units of vitamin A or from 40 to 50 units of carotene per kilogram of body weight. Lewis and Haig[20] employed a special technic for testing the vision of infants in the dark and estimated that a daily vitamin A intake of from 18 to 25 international units per kilogram just sufficed. Edmund and Clemmesen,[16] using the Edmund visual test on twenty-eight prisoners, concluded that 1,370

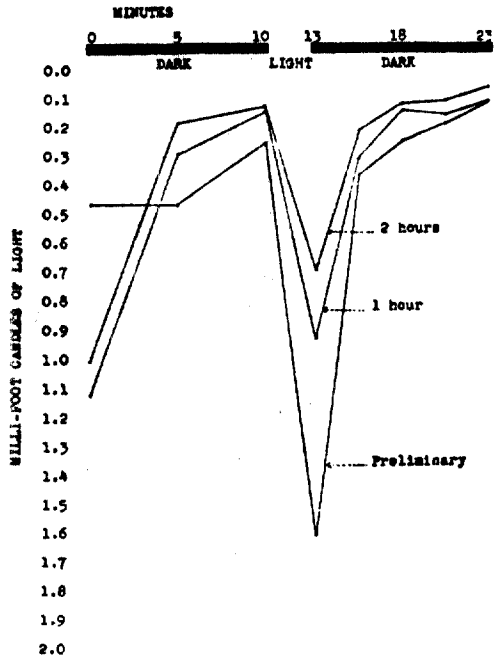

Fig. 7 (case 3).—Biophotometer curves before, one and two hours after an initial dose of 200,000 international units of vitamin A by mouth.

units per person daily exactly covered the minimal requirement. Jeghers[46] correlated the vitamin A content of the diet with dark adaptation and found that adults with normal dark adaptation consumed more than 4,000 international units of vitamin A while those with night blindness consumed less than this amount and that, the lower the vitamin A content of the diet, the worse the degree of the night blindness. The variance in these estimates may be partly due to differences in the vitamin A value assigned to foods, for Edmund and Clemmesen calculated the vitamin A content of a pint of winter milk with 3.7 per cent fat to be 150 international units, while Jeghers, using assumed average values in round numbers derived from a table of Eddy and Dalldorf,[42] calculated the vitamin A content of a pint of milk to be 800 international units. Jeans, Blanchard and Zentmire,[12] using the biophotometer, estimated that the needs of two 11 year old boys were covered by an intake by each of 3,000 units of vitamin A daily, though they did not claim this to be the boys' minimal requirement. Stiebling and Phipard[43] quote adaptometer studies of Booher, Callison and Hewston[44] indicating that the five adults investigated required from 25 to 55 (average 40) units of vitamin A or from 43 to 103 (average 70) units of carotene daily per kilogram of body weight. Stiebling and Phipard state that, in the ordinary American diet, carotene from plant food usually supplies from 60 to 80 per cent of the total vitamin A value, so that the average minimum would be from 58 to 64 units per kilogram, or 4,000 units daily for an adult. As this does not provide any reserves and does not allow for above average requirements, they suggest a 50 per cent margin of safety and estimate that an adult should take at least 6,000 units of vitamin A daily and that a child of school age should receive 5,400 units a day. Cowgill,[45] deducing the optimal supply from the vitamin A content of human breast milk, suggests that an infant should receive not less than 2,000 units a day and that school children should be given four times their calculated minimal requirements. Finally Booher[41] states that the Technical Committee of the League of Nations recommends a diet for growing children containing from 6,000 to 8,000 international units daily.

INCIDENCE OF VITAMIN A DEFICIENCY IN AMERICA

On the basis of a dietary survey made by the U. S. Department of Agriculture and U. S. Bureau of Labor Statistics covering 4,000 urban families of employed wage earners, Stiebling and Phipard[48] conclude that, "with present day choices, diets are often fairly low in vitamin A value even when expenditures for food are relatively high" and that only "about one third of the white families included in the study obtained diets high enough in average vitamin A value to insure good visual adaptation in semidarkness." The per capita weekly expenditure for food allotted in New York City to families on relief falls within the range of the low economic group of Stiebling and Phipard, which spends for food from $1.25 to $1.87 a person a week, and in this group an adult consumed an average of 2,200 international units of vitamin A daily, but almost 70 per cent of the diets furnished less than 2,000 units. We believe that, in such low economic strata, moderate deficiency of vitamin A sufficient to produce cutaneous manifestations may not infrequently occur in individual children because of inefficient purchasing and diversion of funds to amusements, clothes and other items, or because of caprice in choice of foods and seasonal variations in diet or in the vitamin A content of foods. Also one of the more important causes is an increased or a higher than average minimal requirement due to individual variation in the need for vitamin A, and we believe that this may explain the occurrence of mild vitamin A deficiency in individuals who are even on a diet ordinarily adequate. Jeghers[46] states that "the minimal

40. Daniel, E. P., and Munsell, H. E.: Vitamin Content of Foods, U. S. Dept. Agric. Misc. Pub. 275, June 1937.

41. Booher, Lela E.: Vitamin A Requirements and Practical Recommendations for Vitamin A Intake, J. A. M. A. **110**: 1920 (June 4) 1938.

42. Eddy, W. H., and Dalldorf, Gilbert: The Avitaminoses, Baltimore, Williams & Wilkins Company, 1937.

43. Stiebling, H. K., and Phipard, E. F.: Diets of Employed Wage Earners and Clerical Workers in Cities, U. S. Dept. Agric. Circular 507, January 1939.

44. Booher, Sela E.; Callison, Elizabeth C., and Hewston, Elizabeth M.: An Experimental Determination of the Minimum Vitamin A Requirements of Normal Adults, J. Nutrition **17**: 317 (April) 1939.

45. Cowgill, G. R.: The Vitamin Requirements of Man, J. Am. Dietet. A. **13**: 196 (Sept.) 1937.

46. Jeghers, Harold: Vitamin A Deficiency in Adults, Internat. Clin. **1**: 17 (March) 1938; Night Blindness as a Criterion of Vitamin A Deficiency, Ann. Int. Med. **10**: 1304 (March) 1937.

requirements may be increased by fever, rapid growth, infection, elevated basal metabolic rate, pregnancy, lack of bile or pancreatic secretion, changes in the gastrointestinal mucosa, disturbances of motility of the gastrointestinal tract and hepatic disease."

The occurrence of cases of vitamin A deficiency in America has been predicted not only by dietary surveys but also by the investigations of various authors, who report a considerable incidence both in adults and in children of impaired dark adaptation. To illustrate we will cite only Jeghers[6] in Boston, who examined 162 medical students and found that 35 per cent gave photometric evidence of vitamin A deficiency and that 12 per cent showed clinical symptoms. In the latter group were fifteen individuals with dry skin, including two cases of hyperkeratosis. At the time of the report all but four had regained with treatment a normal skin texture. Similar impairment of dark adaptation by photometric test has been reported by other investigators,[47] although the actual percentage abnormal has varied with different authors and with various groups examined and, of course, partly depends on the location of the boundaries accepted as demarcating normal from borderline and borderline from deficient. Furthermore, although refinements in the technic of these tests may influence the percentage of persons found abnormal, all results, including those of Hecht and Mandelbaum[21] with the adaptometer, show that in any group there is a marked spread between those individuals with the greatest and those with the least powers of dark adaptation. That the latter are deficient in vitamin A is probable because their capacity for dark adaptation is comparable to that of the individuals with experimental human vitamin A deficiency observed by Jeghers,[6] Booher, Callison and Hewston,[44] and by Hecht and Mandelbaum.[21] Moreover, contrary conclusions should not be drawn from a lack of response to oral administration of moderate doses of vitamin A. In our experience and in agreement with Getz, Hildebrand and Finn,[22] prolonged and intensive treatment with large oral doses may be required to improve the powers of dark adaptation, and, according to Edmund and Clemmesen[34] and the others cited by them, oral administration of vitamin A may be ineffective in cases which may respond satisfactorily to intramuscular injections. We believe, therefore, that a not inconsiderable though possibly a not yet precisely determined percentage of the population shows evidence of a mild vitamin A deficiency by impaired dark adaptation on photometric test.

The conclusions drawn from dietary surveys and from studies of impaired dark adaptation are further supported by the results obtained by Moore[48] in England, Wolff[49] in the Netherlands and other investigators[50] elsewhere from assaying human livers obtained at necropsy for their stores of vitamin A. Here too, even in supposedly normal individuals meeting an accidental death, has been found a very wide spread from low values per gram of fresh liver of zero and 10 international units of vitamin A to high values of about 1,500 units, and the medians of 130 units in children of from 4 months to 14 years and of 220 units in persons from 15 to 59 years, have been taken by Moore as "typical" values of healthy individuals. Since Moore and others have established that a very large proportion, possibly 95 per cent, of all vitamin A of man and animals is stored in the liver, apparently a portion of the population has practically no reserves of this vitamin. Furthermore, the fact that the apparently healthy individuals in the lowest range of vitamin A content had an amount in their livers similar quantitatively to that reported by various investigators[51] in the livers of experimental vitamin A deficient animals showing symptoms of night blindness corroborates, we believe, the evidence of dietary surveys and dark adaptation studies, which likewise suggest that at least the milder degrees of vitamin A deficiency are not rare.

SUMMARY

1. Nine children, almost all of families on relief, had the cutaneous manifestations of vitamin A deficiency.

2. Our diagnosis has been confirmed by photometric studies.

3. Improvement in visual tests has in some children been immediate with single adequately large doses of vitamin A but in others has required prolonged intensive therapy.

4. Maximal improvement of the skin has been attained with a daily dose of from 100,000 to 300,000 international units of vitamin A in from two to four months.

5. The typical follicular papules described by Frazier and Hu and others are not an infrequent cutaneous manifestation of vitamin A deficiency during childhood.

6. So far our investigations indicate that keratosis pilaris, lichen pilaris, lichen spinulosus, icthyosis follicularis and other synonyms are merely descriptive terms for the cutaneous manifestations of vitamin A deficiency.

247 West Ninety-Ninth Street—7 West Ninety-Sixth Street.

47. Frandsen, H.: Hemeralopia as an Early Criterion of A Avitaminosis and Clinical Symptoms and Treatment of This Disease. Acta Ophth., supp. IV, 1935. Park, I. O.: Significance of Vitamin A Deficiency, Am. J. Digest. Dis. & Nutrition 3: 193 (May) 1936. Maitra, M. K., and Harris, L. J.: Vitamin A Deficiency Among School Children in London and Cambridge, Lancet 2: 1009 (Oct. 30) 1937. Toverud, K. U.: Dysadaptation in Children, Acta paediat. 20: 225, 1937. Gridgeman, N. T., and Wilkinson, H.: Night Blindness and Vitamin A Deficiency, Lancet 1: 905 (April 16) 1938. Corlette, M. B.; Youmans, J. B.; Frank, Helen, and Corlette, Mildred J.: Photometric Studies of Visual Adaptation in Relation to Mild Vitamin A Deficiency in Adults, Am. J. M. Sc. 195: 54 (Jan.) 1938. Caussade, L.; Neimann, Thomas, and Davidsohn: Researches sur les tests oculaires d'hypovitaminose A chez les enfants d'âge scolaire, Rev. franç., de pédiat. 14: 209, 1938. Schack, Cecilia, and Miller, Wilma O.: Dark Adaptation of the Eye and Vitamin A Storage in Young Adults, Arch. Int. Med. 61: 910 (June) 1938. von Drigalski, A. W.; Kunz, H., and Schlüpmann, K.: Occurrence and Extent of Real Deficiency of Vitamin A, Klin. Wchnschr. 18: 875 (June 24) 1939. Abramson, E., and Oigaard, H.: The Prevalence of Dysadaptation in Public Elementary Schools for Children at Djursholm, Skandinav. arch. f. physiol. 82: 49, 1939. Jeans, Blanchard and Zentmire.[13] Edmund and Clemmesen.[16] Getz, Hildebrand and Finn.[22]

48. Moore, Thomas: Vitamin A Reserves of the Human Liver in Health and Disease, Lancet 2: 669 (Sept. 24) 1932; The Vitamin A Reserve of the Adult Human Being in Health and Disease, Biochem. J. 31: 155 (Jan.) 1937. Ellison, J. B., and Moore, Thomas: The Vitamin A Reserves of the Human Infant and Child in Health and Disease, Biochem. J. 31: 165 (Jan.) 1937.

49. Wolff, L. K.: De la richesse en vitamine de la population d'Amsterdam, Arch. néderl. de physiol. 14: 282, 1929.

50. Fox, F. W.: Investigations into the Vitamin A Content of the Livers of Native Mine Laborers, South African M. J. 6: 689 (Nov. 12) 1932. Green, H. N.: Vitamin A Content of the Liver in Puerperal Sepsis, Lancet 2: 723 (Oct. 1) 1932. Vogt, E.: Ueber die Vitaminbestände des weiblichen Organismus, München. med. Wchnschr. 79: 1570 (Sept. 23) 1932. Clausen, S. W.: Limits of the Anti-Infective Value of Provitamin A (Carotene) J. A. M. A. 101: 1384 (Oct. 28) 1933. Muller, G. L., and Suzman, M. M.: The Cholesterol and Vitamin A Content of the Liver in Man, Arch. Int. Med. 54: 405 (Sept.) 1934. Crumm, P. D., and Short, D. M.: Vitamin A Content of Human Liver, Am. J. M. Sc. 189: 571 (April) 1935. Vitamin A Content of Human Liver in Tuberculosis, Ann. Int. Med. 13: 61 (July) 1939.

51. Guilbert, H. R., and Hinshaw, W. R.: Vitamin A Storage in the Livers of Turkeys and Chickens, J. Nutrition 8: 45 (July) 1934. Guilbert, H. R., and Hart, G. H.: Storage of Vitamin A in Cattle, J. Nutrition 8: 25 (July) 1934. Minimum Vitamin A Requirements with Particular Reference to Cattle, ibid. 10: 409 (Oct.) 1935. Moore, Thomas: The Vitamin A Reserve of the Adult Human Being in Health and Disease, Biochem. J. 31: 155 (Jan.) 1937.

Leitner-'60
Bib. No. 5310

Reproduced by permission
of the copyright owner

Brit. J. Nutr. (1960), 14, 157

Vitamin A and vitamin E in human blood

1. Levels of vitamin A and carotenoids in British men and women, 1948–57*

By Z. A. LEITNER

52 *Welbeck Street, London, W.* 1

AND T. MOORE AND I. M. SHARMAN

Dunn Nutrition Laboratory, University of Cambridge and Medical Research Council

(*Received* 1 *May* 1959—*Revised* 28 *November* 1959)

The work to be described in these communications followed earlier studies (Leitner & Moore, 1946; Leitner, Moore & Sharman, 1947), which were mainly concerned with the lowered blood vitamin A in certain diseases. For purposes of comparison it was desired to know the levels of vitamin A prevalent in normal subjects, and the advisability of obtaining more adequate information became apparent. It was known that the blood vitamin A varied widely in different normal individuals, and that men tended to have higher levels than women (Kimble, 1938–9), but knowledge was scanty on the influence of age or season of the year. Moreover, at the time of our earlier work, dietary restrictions, imposed during the Second World War, were still in force in this country. It was of interest, therefore, to study the effect on the blood vitamin A of the changes in the national food supplies which followed the gradual relaxation of controls.

Specimens of blood were taken for a long period from numerous subjects, with the aim of collecting a mass of information large enough to counteract the disturbing effect on averages of the wide individual variations. Estimations of total carotenoids were made parallel with those of vitamin A. Vitamin E is known to be capable of intervening in the metabolism of vitamin A (Moore, 1939; Bacharach, 1940; Hickman, Harris & Woodside, 1942), so our programme was extended to include estimations of vitamin E. The presentation of our results on vitamin E has, however, been assigned to a later communication (paper no. 2 of this series), and paper no. 3 will deal with observations on chronic hospital patients.

EXPERIMENTAL

Collection of specimens. Blood was collected by venepuncture from volunteers who came to one of us (Z.A.L.) for medical examination. Some were young men in good health, who were examined for purposes of life insurance or for their fitness to do arduous work abroad. Most of the subjects, however, had some complaint, and were examined with a view to diagnosis and treatment. To this extent, therefore, their health was not completely normal. On the other hand, it was possible, as the result of

* Read in part before The Nutrition Society on 4 December 1959 (Leitner, Moore & Sharman, 1960).

the examination, to exclude any subjects in whom systemic disease of the heart, lungs, intestinal tract, liver or kidneys was present. Each examination included a thorough physical overhaul, chemical analysis and microscopic examination of the urine, blood counts, estimation of the blood sedimentation rate, and all biochemical and radiographical investigations relevant to the case. The subjects could mostly be described as middle class, but a few were manual workers.

The blood specimens were collected without the use of an anticoagulant. Specimens of whole blood or of separated serum were posted to Cambridge and examined within a few days of their arrival. Any specimen showing more than slight haemolysis was discarded.

Estimation of vitamin A and carotenoids. Our procedure differed only slightly from Yudkin's (1941) modification of Kimble's (1938–9) method. Serum, 6 ml, was mixed with the same volume of ethanol and 12 ml of light petroleum (b.p. 40–60°) and shaken for 10 min in a closed tube. After centrifugation for 30 sec, 10 ml of the light petroleum layer were withdrawn and evaporated to dryness on a water-bath under diminished pressure. The residue was dissolved in 5 ml of a mixture of 7 volumes ethanol with 20 volumes light petroleum, the ethanol being used to prevent turbidity. A portion of this solution was transferred to the cuvette of a photo-electric absorptiometer, and carotenoids were measured by their yellow colour. The solution was then returned quantitatively from the cuvette to the evaporation flask, the contents of which were again evaporated. For estimation of vitamin A the residue was dissolved in 1·0 ml chloroform, and 0·3 ml portions were added to 2·0 ml portions of antimony-trichloride reagent, which had already been placed in the cuvette in position in the absorptiometer. In order to correct for the contribution of carotenoids to the blue colour in the antimony-trichloride reaction, the value in μg found for carotenoids, multiplied by 0·42, was deducted from the gross value found for vitamin A in the serum.

Photo-electric absorptiometer. A simple, single-cell absorptiometer, of the type originally used for vitamin A estimations by Dann & Evelyn (1938), was constructed. Wratten filters red, no. 26, and blue, no. 48, were used for estimating vitamin A and carotenoids, respectively. The galvanometer readings of the absorptiometer were calibrated for vitamin A against halibut-liver oil or vitamin A acetate, and for carotenoids against β-carotene. Carotenoids were calculated as μg of carotene, the slight error introduced by the different molecular weights of other carotenoids being neglected. In making the correction for the contribution by carotenoids to the antimony-trichloride reaction the factor 0·42, mentioned above, was based on the intensity of the blue colour produced by β-carotene. Possible variations between the chromogenic powers of different carotenoids were neglected. In order to check that the calibration of the instrument was remaining constant throughout the long period of our investigation, readings were frequently made in which the cuvette was replaced by standard Lovibond glasses. No significant variations in the behaviour of the instrument were detected.

Change in international standard for vitamin A. In maintaining the constancy of the calibration of our absorptiometer for vitamin A, a special problem arose from the official adoption in 1950, as a new international unit and standard, of 0·3 μg vitamin A,

in the form of 0·344 μg of vitamin A acetate (World Health Organization, 1950). This change implied the acceptance of a factor of 1900 for converting $E^{1\%}_{1cm}$ (328 mμ) into i.u./g. Before 1950 a conversion factor of 1600 was generally accepted, and was used by us for calculating the number of i.u./g, from the value from $E^{1\%}_{1cm}$ (328 mμ) in the specimen of halibut-liver oil first chosen for our calibration. It eventually became clear, however, that the difference in conversion factor was not reflected by any corresponding difference in the intensity of the antimony-trichloride reaction produced by halibut-liver oil and vitamin A acetate. After the completion of our work, therefore, all our results up to 1950 were recalculated on a basis of a common conversion factor of 1900 for both oil and acetate. Presumably, the same correction should be applied to results obtained by most other workers before 1950, whether by measurement of ultraviolet absorption or by the antimony-trichloride reaction.

Statistical treatment of results. The large number of our results made it possible to examine the influence of several factors, including sex, age, period and season, on levels of vitamin A and carotenoids. Our general procedure was to plot the means for one variable, vitamin A, for instance, against another variable such as age. We also compared the separate graphs for men and women.

Since collections of blood had to be made whenever the subjects came for examination, and had sometimes to be discontinued during our absences on holiday, we could not ensure that equal numbers of specimens were collected in each year, or in each season of the year. Slight variations in the distribution between the sexes, and in the average age, were also unavoidable. We feel confident, however, that these imperfections were not sufficiently serious to invalidate our general conclusions.

Over the decade of the investigation blood was collected from 742 men and 526 women. Since specimens were occasionally taken more than once from the same subject the total numbers of estimations were slightly larger, being 796 for men and 536 for women. There seems no reason to believe that the repetition of the analysis for a few of the subjects, in different years, had any significant disturbing influence on the findings. In the statistical treatment of our results, therefore, all estimations have been given equal weight, irrespective of whether they were the first or later readings for the same subject. In view of the known differences between the sexes it seemed advisable first to calculate the means for vitamin A and carotenoids separately for men and women. When it was desired to combine the results for both sexes means were taken of the means for each sex.

RESULTS

Vitamin A and carotenoid levels in men and women. For men (mean age 46) throughout the whole investigation vitamin A averaged 174 i.u./100 ml serum, and carotenoids 121 μg/100 ml. For women (mean age 45) the corresponding values were 12[illegible] i.u. and 131 μg/100 ml. The means for men and women combined, giving equal weight to the mean for each sex in spite of the differences in the numbers of readings, were therefore 158 i.u. and 126 μg/100 ml.

Histograms for the distribution of various arbitrary ranges of vitamin A values in men and women are given in Fig. 1. It will be seen that for men the modal interval

for vitamin A was 150–169 i.u./100 ml. The central 95% of the observations lay between 70 and 305 i.u. For women the modal interval was 130–149 i.u. The central 95% of observations lay between 54 and 259 i.u. Similar histograms for carotenoids are given in Fig. 2. For men 90–109 μg was the modal interval range, and 95% of observations lay between 44 and 254 μg. For women the corresponding ranges were 110–129 and 54–245 μg.

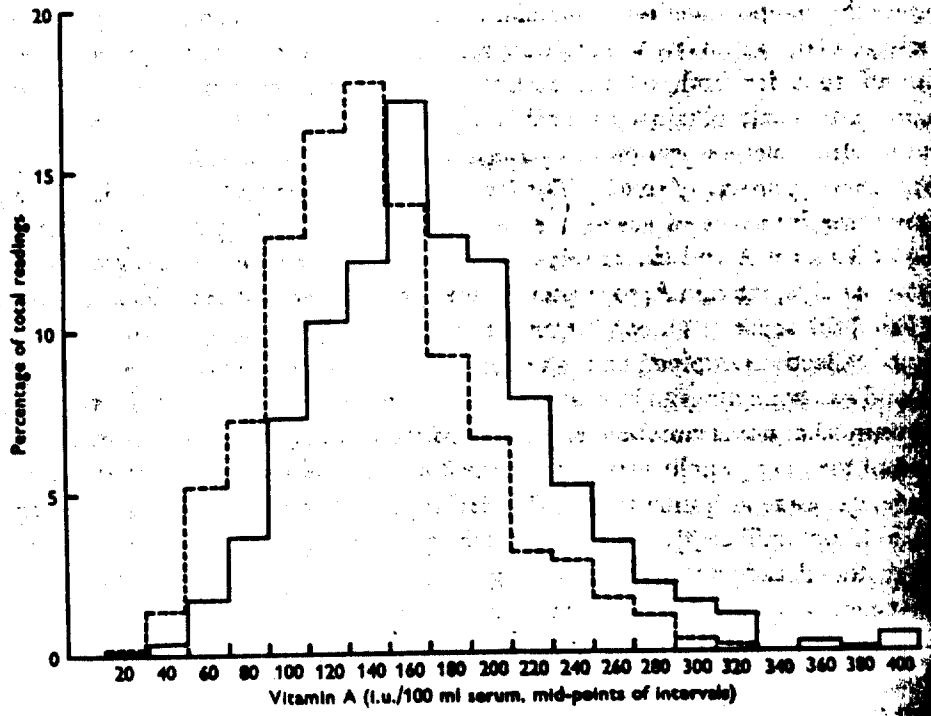

Fig. 1. Distribution of vitamin A values in the blood of British men and women. ———, males; - - - -, females.

Vitamin A and carotenoids in special groups. As already mentioned, some of our subjects had no complaints, but were healthy young men who were examined as applicants for employment or life insurance. The mean results for those groups were:

Applicant for	No. of men	Mean age (years)	Carotenoids (μg/100 ml serum)	Vitamin A (i.u./100 ml serum)
Employment	55	30	109	159
Insurance	36	34	112	168

When allowance is made for the low mean ages in these special groups (see p. 162) the means for both vitamin A and carotenoids are almost identical with those found for men throughout the whole investigation.

Vitamin A in relation to carotenoids. In Fig. 3 mean values for vitamin A have been plotted against selected ranges of carotenoid values. It will be seen that in men vitamin A rose slightly but smoothly with increasing carotenoid values. For women the

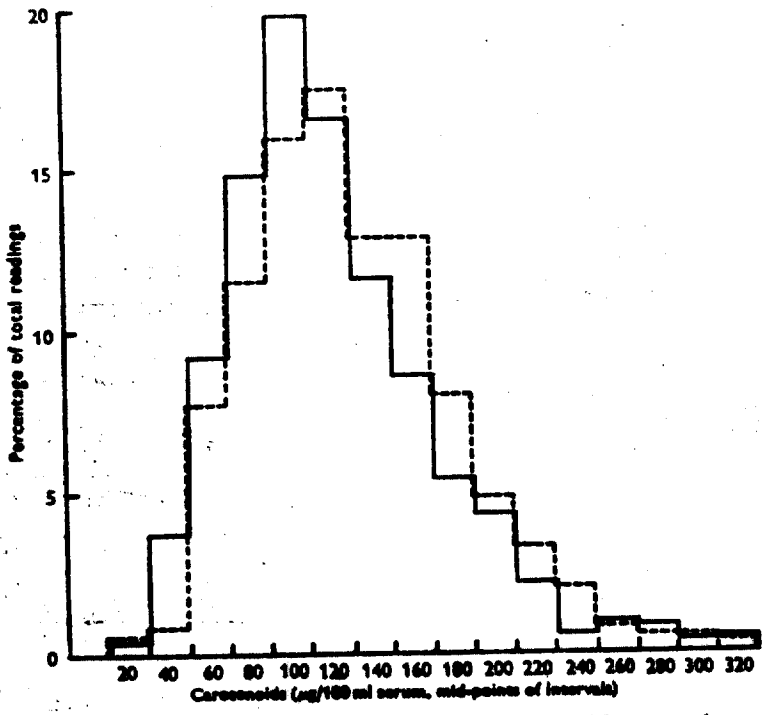

Fig. 2. Distribution of carotenoid values in the blood of British men and women. ———, males; ----, females.

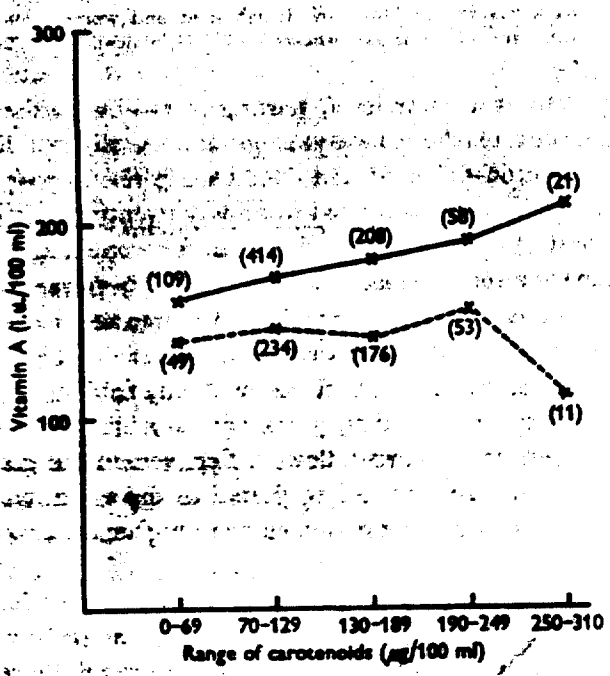

Fig. 3. Vitamin A levels compared with carotenoid levels in the blood of British men and women. (Numbers of readings are shown in parentheses.) ———, males; ----, females.

graph for vitamin A was less regular, with a slight rise for the carotenoid range 190–249 μg followed by a pronounced fall in the range 250 μg and over. Although there were only eleven readings in the last group the mean was significantly different ($0.01 < P < 0.02$) from the mean for the carotenoid range of 190–249 μg in women. For men and women in the carotenoid range 250 μg and over the difference between the means for vitamin A also was significant ($0.001 < P < 0.01$).

Influence of age. The results for each sex, divided up according to selected age groups, are shown in Fig. 4 for vitamin A. In men the mean rose steadily from 149 i.u. in the age group 10–19 years, up to a maximum of 191 i.u. in the age group 50–59 years. There was then a decline in the 60–69-year group to 178 i.u. In

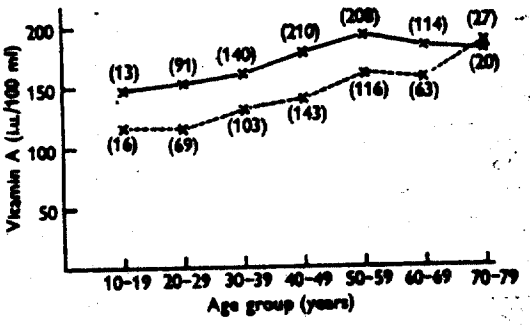

Fig. 4

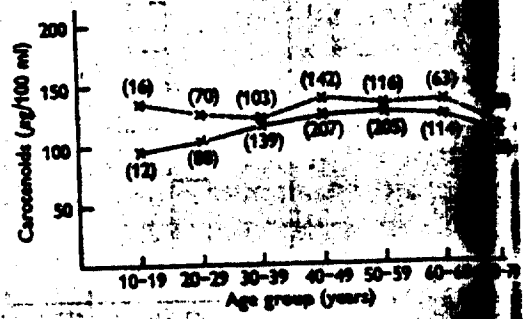

Fig. 5

Fig. 4. Vitamin A in the blood of British men and women compared with age. (Numbers of readings are shown in parentheses.) ———, males; - - - -, females.

Fig. 5. Carotenoid levels in the blood of British men and women compared with age. (Numbers of readings are shown in parentheses.) ———, males; - - - -, females.

women the graph ran at a lower level, starting at 116 i.u. in the 10–19-year group and reaching 161 i.u. in the 50–59-year group. A slight fall, not statistically significant, followed at 60–69 years, and then a sharp rise at 70–79 years. This final high mean value for women was derived from only twenty readings, but was significantly different ($0.01 < P < 0.02$) from the mean for women aged 60–69 years. The difference between the means for men and women aged 70–79 years was not significant.

Fig. 5 shows mean values for carotenoids in the same age groups as for vitamin A. As expected, the graph for carotenoids ran at a consistently higher level for women than for men. The mean values for men rose smoothly from 96 μg in the 10–19-year group to a plateau between 40 and 69 years, with a value of 126 μg at 50–59 years. A decline to 107 μg at 70–79 years followed. For women the graph ran parallel to that for men between the ages 30 and 79 years. In the age groups 10–19 years and 20–29 years, however, the means for women were higher than would have been expected from the means for men.

Seasonal changes in vitamin A and carotenoids. Means were calculated for each sex for the periods January–March (winter), April–June (spring), July–September (summer) and October–December (autumn). From Fig. 6 it will be seen that in women vitamin A remained almost constant throughout the four seasons. In men, however,

vitamin A rose slightly in summer, and considerably in autumn. The difference between the means for men in April–June and October–December was statistically significant ($0{\cdot}001 < P < 0{\cdot}01$). From Fig. 7 it will be seen that carotenoids rose in both sexes during spring and summer. The increases in those seasons were, however, greater in women than in men. The superiority of women over men in the carotenoid content of their serum also was much more pronounced in spring and summer than in autumn and winter. It may be relevant in this connexion that Kon & Mawson (1950) found no seasonal trends in the vitamin A content of human milk, but a definite one in that of carotenoids.

Vitamin A and carotenoids in successive biennial periods. When the results were averaged for periods of 1 month, or even of 1 year, fluctuations occurred for which no reasonable explanation could be found. Presumably these irregularities arose through the wide variations between individuals and through the difficulty of keeping up a

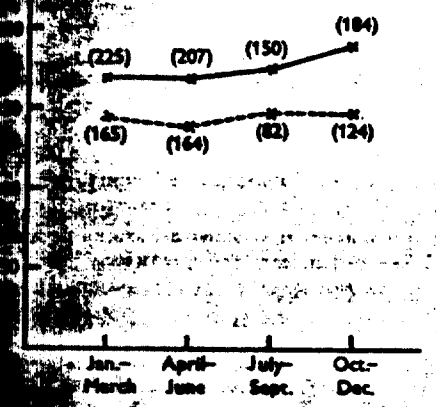

Fig. 6

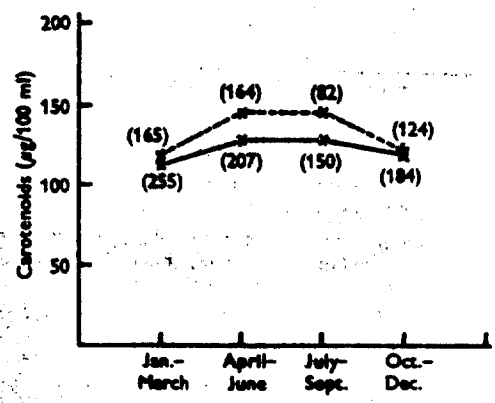

Fig. 7

Fig. 6. Vitamin A in the blood of British men and women in different seasons. (Numbers of readings are shown in parentheses.) ———, males; - - - -, females.

Fig. 7. Carotenoids in the blood of British men and women in different seasons. (Numbers of readings are shown in parentheses.) ———, males; - - - -, females.

uniformly high standard of accuracy in the estimations over a period of many years. Means were therefore calculated for periods of 2 years.

Fig. 8 shows such mean values for vitamin A in men and women, and Fig. 9 shows the means for carotenoids. It will be seen that the mean values for vitamin A were always higher for men than for women, and that the difference remained more or less constant in successive 2-year periods. For carotenoids the relationship was reversed, with the mean value for women invariably exceeding that for men. The difference between the sexes was, however, smaller for carotenoids than for vitamin A, and varied in magnitude. In Fig. 10 the results for men and women have been combined, by taking the mean of the 2-year means for each sex, and are compared with data, kindly supplied by the Ministry of Agriculture, Fisheries and Food, for the intake of sources of vitamin A, including provitamins, over the same 2-year periods. This information on intakes has been derived both from the Consumption Level Enquiry and from the

National Food Survey. Investigations under these headings have been described in reports by the Ministry of Food: National Food Survey Committee (1951, 1952, 1953, 1954) and Ministry of Agriculture, Fisheries and Food: National Food Survey Committee (1955, 1956, 1957, 1958, 1959). Two separate graphs which have run parallel during recent years are, therefore, shown for intake.

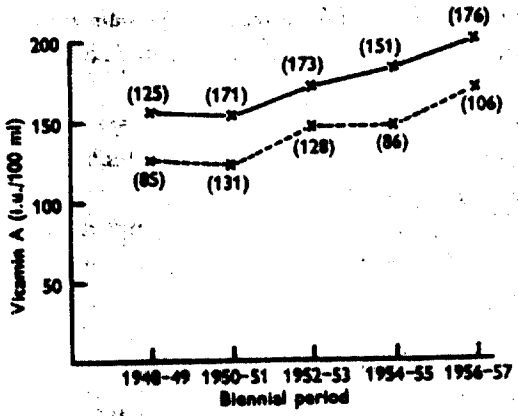

Fig. 8

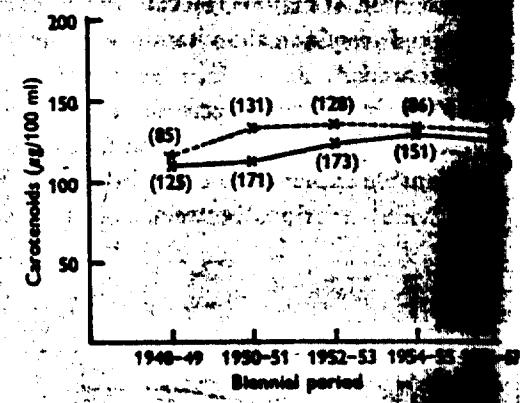

Fig. 9

Fig. 8. Vitamin A in the blood of British men and women in successive biennial periods. (Numbers of readings are shown in parentheses.) ———, males; - - - -, females.

Fig. 9. Carotenoids in the blood of British men and women in successive biennial periods. (Numbers of readings are shown in parentheses.) ———, males; - - - -, females.

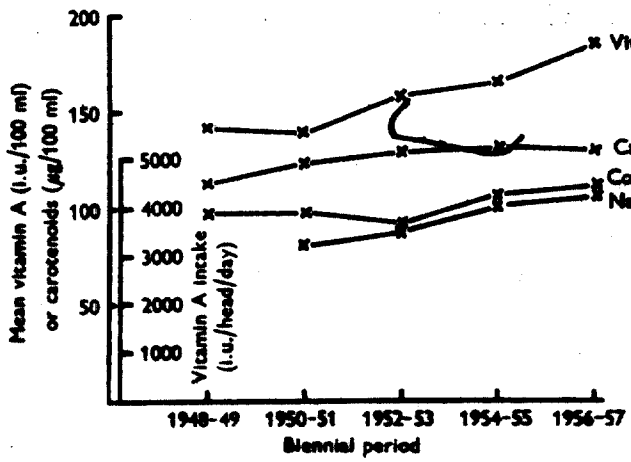

Fig. 10. Combined averages for British men and women for vitamin A and carotenoids in blood in successive biennial periods compared with daily intakes of vitamin A over the same periods according to the National Food Survey and Consumption Level Enquiry (see pp. 163, 167).

DISCUSSION

Collection of specimens. It seems inevitable that plans for collecting specimens so that the sample may be representative of a large population must always be a compromise between statistical perfection and practical convenience. This may be particularly true when the specimen has to be collected under conditions which demand the willing co-operation of the volunteer and arrangements for his comfort, as with a venepuncture. In many similar investigations the volunteers have belonged to well-defined groups, such as students or laboratory workers, or have been members of the same institution, such as a hospital or school. In such circumstances the subjects may all belong to a limited age group or have all subsisted on the same diet. Our method of collecting specimens, mostly from members of the general population who had been indisposed but in whom serious illness could safely be excluded, has therefore definite advantages to compensate for the possible criticism that most of the subjects had sought medical advice. In young men, as we have seen, mean values for both vitamin A and carotenoids were almost the same for those who had attended the doctor as patients or had merely been examined in regard to their fitness for employment or insurance.

Incidence of low vitamin A levels. Experiments in which volunteers have been kept on a diet deficient in vitamin A (Hume & Krebs, 1949) showed that dark adaptation became defective only when the level of vitamin A in the blood fell to about 40 i.u./100 ml. If we take our limit as 50 i.u., to allow for the effect on calibration of the new vitamin A international unit, it appears that only three of our male subjects and eight of our females would have been expected to be functionally deficient on this basis. For both sexes combined, therefore, the incidence of values under 50 i.u. was less than 1%.

Influence of sex and age. Our results confirm that sex has an important effect on the level of vitamin A in the blood, with a consistent superiority of the male mean over the female of about 23%. For carotenoids the difference is smaller, less regular, and in the opposite direction. Earlier reports of these findings and of other differences in vitamin A metabolism between the sexes have been discussed in detail by Moore (1957). We hope to discuss in a later communication the possibility that the conversion of carotene may be more efficient in men than in women, and so account at least partly for the sex differences in blood levels.

The influence of age also on vitamin A levels is consistent, at least until extreme old age. Thus the mean for both sexes increased steadily up to a maximum in the groups aged from 50 to 59 years (Fig. 4). In old age the means tended to decrease in both sexes, except for an unexpectedly high finding in the group of women aged from 70–79 years. Carotenoid values tended to follow those for vitamin A but with flatter curves, except for high values for women between 10 and 29 years (Fig. 5). Adlersberg, Schaefer & Steinberg (1956) have found higher levels for cholesterol and phospholipids in females than in males up to the age group 23–27 years, after which the relationship is reversed until middle age.

If it was necessary to compare results obtained from dissimilar groups of subjects,

therefore, allowances for both sex and age would be necessary. In spite of the general finding that the level of vitamin A is higher in men than in women, we might, for example, expect a slightly higher mean for a group of elderly women than of young men.

Kimble (1938–9) could find no correlation between the levels of vitamin A and carotenoids in healthy men or women. Our own findings, based on a much more extensive set of readings, suggest that in men mean levels for vitamin A rise slightly as the mean carotenoid levels rise (Fig. 3). In women the level is irregular, with the suggestion of a fall in vitamin A when carotenoids are very high. Admittedly the correction factor for carotenoids in the antimony-trichloride reaction is hard to assess with accuracy. Obviously if our correction factor were too low the rise in the curve for men could be explained on this basis, but the same consideration would necessarily imply a definite downward tendency in the curve for women. Irrespective of the correction factor, therefore, it seems clear that the ratio between the levels of vitamin A in men and in women increases as the levels of carotenoids rise. Again the possibility of a more efficient conversion of carotene in men than in women must be considered.

Influence of season. Our finding for both sexes of slightly higher mean values for carotenoids during spring and summer than during autumn and winter (Fig. 5) seems consistent with the increased supply of fresh vegetables and fruits during the warmer season. For vitamin A the seasonal variation in women was slight, but in men the means were slightly higher in summer and autumn than in winter and spring (Fig. 6). This finding suggests that vitamin A derived from the summer abundance of carotene may be first stored and later mobilized into the blood stream. Again a higher efficiency in the conversion of carotene in men than in women may be involved.

Biennial variations in vitamin A and carotenoids. The graphs in Figs. 8–10 suggest strongly that the level of vitamin A in the blood of inhabitants of this country has shown a general upward tendency since about 1950. Such an increase might well have been expected, since during and after the Second World War blood levels of both vitamin A and carotenoids appeared to be lower in Britain, where food was rationed, than in the U.S.A., where food was more freely obtainable. We have seen already that comparisons between groups of subjects may be complicated by differences in sex and age. The results of certain investigations are, however, comparable at least as concerning large groups of adults of both sexes:

Reference	Vitamin A (i.u./100 ml serum)	Carotenoids (μg/100 ml serum)
U.S.A.:		
Abels, Gorham, Pack & Rhoads (1941)	160	195
Harris, Hickman, Jensen & Spies (1946)	204	210
U.K.:		
Sinclair (1947)	86	94
Moore & Leitner (1949)	121	92
Campbell & Tonks (1949)	108	80

The dates are those of publication, and the actual dates of some of the observations may have been much earlier. The observations of Moore & Leitner, for example, were made during the years 1944–5. If we neglect, for the moment, questions of calibration

It appears that the American means for vitamin A tended to be nearly twice as high as those found in Britain, and means for carotenoids fully twice as high.

During recent years both Britain and the U.S.A. have been free from dietary restrictions, and presumably the difference between the dietary patterns in the two countries is smaller than it was during the war. It might have been expected, therefore, that the difference between the blood levels of vitamin A and carotenoids would also diminish. When comparing our most recent results for vitamin A with earlier findings, however, we must allow for the effect of the change in the factor for converting the values for E (328 mμ) to i.u./g, which occurred when the new international unit was adopted in 1950. The increase of this factor from 1600 to 1900 presumably implies that our early results must now be increased by nearly 20% to make them comparable with modern findings. Such an increase must not, however, be made to the values reported by Harris *et al.* (1946), who used a factor of 2000 even before the change. When recalculated for a conversion factor of 1900 instead of 2000 the American average is reduced to 191 i.u., which may be compared with 158 i.u. found in the whole of this present investigation, or 185 i.u. for our final biennial period. Thus the gap between current British and early American values for vitamin A seems to have closed. For carotenoids the differences remain large. Harris *et al.* (1946) found mean values of 260 μg, compared with 130 μg in the final biennial period of our investigation.

The increase in blood vitamin A which appears to have occurred in Britain since the decline of food supplies runs roughly parallel with the increases in vitamin A intake found in the National Food Survey. This Survey measures the quantities of food obtained by purchase or from gardens or allotments or other similar sources for consumption in the home or in packed meals carried and eaten away from home; other consumption outside the home is not included, nor are sweets, soft and alcoholic drinks, fish liver oil or vitamin tablets. Results are calculated each year for observations on samples of the population which are, over the year, nationally representative. There is fair agreement, for the last three biennial means, with results obtained from the Consumption Level Enquiry (see Fig. 10), which are based on the total supply of foods estimated to be available at the retail stage of distribution. These include meals, snacks and ice-cream obtained outside the home, sweets and soft drinks, and all food consumed in institutions. They do not include alcoholic drinks or fish liver oil or vitamin tablets.

The problem of whether the change in the international standard and unit from β-carotene to vitamin A, made in 1950, implied a 15% reduction in the actual amount of preformed vitamin A necessary to satisfy official assessments of human requirements is both interesting and intricate, but beyond the scope of this communication.

Significance of the blood levels of vitamin A and carotenoids. The degree of reliance which can be placed on values for blood vitamin A and carotenoids as an index of nutritional status is difficult to assess. There is ample evidence from experiments in which volunteers have subsisted on deficient diets to show that first the dietary carotenoids, and later vitamin A, fall to very low levels (Hume & Krebs, 1949). It is clear also that hospital dietaries, though not grossly deficient in vitamin A, may neverthe-

less give rise to levels of vitamin A and carotenoids in the blood which are lower than in the general population (Leitner, Moore & Sharman, 1952). From the present work it appears that the blood levels over a period of years have reflected the amount of vitamin A available in the food.

We must not forget, however, that high levels of vitamin A in groups of subjects who presumably are receiving much the same diet may be associated with characteristics such as middle age or the male sex. It is perhaps incautious, as once suggested by an American committee (New York State Joint Legislative Committee on Nutrition, 1947) to classify as 'excellent' all findings for blood vitamin A and carotenoids above arbitrarily chosen levels. We have seen that blood vitamin A is higher in men than in women, it reaches a peak in the age group from 50–59 years, and it has apparently increased in this country in recent years. The pattern of variation is thus reminiscent of the incidence of atherosclerosis and coronary heart disease. It would be just as unwise, however, to conclude that the similarity implies a causal relationship between vitamin A and these diseases as to accept high levels of vitamin A, without question, as a sign of a particularly commendable nutritional status. For the present, values of both vitamin A and carotenoids in the blood must be interpreted with caution, and with due regard to the characteristics of the subjects to whom they relate.

SUMMARY

1. Vitamin A and total carotenoids were estimated during the decade 1948–57 in the blood serum of more than 700 British men and 500 women in whom no serious disease could be detected.

2. Wide individual variations were found in both sexes. The mean values for equal numbers of each sex were 158 i.u. vitamin A and 126 μg carotenoids per 100 ml serum.

3. In groups of men, whether arranged according to age, season or biennial period, mean values for vitamin A were always about 20% higher than for women. For carotenoids the relationship was reversed, with mean values about 8% higher for women than for men. The difference between men and women in the values for vitamin A tended to widen with increasing carotenoid levels.

4. In men mean values for vitamin A increased with age until a maximum was reached in the age group 50–59 years. In women also vitamin A increased with age until at 70–79 years the usual sex difference had disappeared. Mean carotenoid values in men ran almost parallel with vitamin A, but in women unexpectedly high values were found under the age of 30 years.

5. In both sexes higher mean values for carotenoids were found in spring and summer than in autumn and winter. In women, vitamin A varied little at the different seasons, but in men the mean values in summer and autumn were slightly higher than in winter and spring.

6. In both sexes blood vitamin A appears to have increased since the removal of wartime food restrictions. The increases appear to have run roughly parallel with increases in the intake of vitamin A as estimated in the National Food Survey. Increases in blood carotenoids over the same period were less pronounced.

7. It seems probable that the sex differences in the levels of vitamin A and carotenoids may be due, at least in part, to greater efficiency in the conversion of carotene into vitamin A by men than by women.

Our thanks are due to Dr L. J. Harris for his interest and criticism, to Miss D. F. Hollingsworth for valuable advice, to Mrs Aileen Bright and Mrs Pamela Richards for technical assistance, and to Mrs Richards and Miss Margaret Smith for help in the statistical calculations.

REFERENCES

Gorham, A. T., Pack, G. T. & Rhoads, C. P. (1941). *J. clin. Invest.* 20, 749.
D., Schaefer, L. E. & Steinberg, A. G. (1956). *J. Amer. med. Ass.* 162, 619.
L. (1940). *Quart. J. Pharm.* 13, 138.
A. & Tonks, E. L. (1949). *Brit. med. J.* ii, 1499.
& Evelyn, K. A. (1938). *Biochem. J.* 32, 1008.
Hickman, K. C. D., Jansen, J. L. & Spies, T. D. (1946). *Amer. J. publ. Hlth*, 36, 155.
C. D., Harris, P. L. & Woodside, M. R. (1942). *Nature, Lond.*, 150, 91.
& Krebs, H. A. (1949). *Spec. Rep. Ser. med. Res. Coun., Lond.*, no. 264, p. 13.
(1938–9). *J. Lab. clin. Med.* 24, 1055.
Mawson, E. H. (1950). *Spec. Rep. Ser. med. Res. Coun., Lond.*, no. 269.
& Moore, T. (1946). *Lancet*, 251, 262.
A., Moore, T. & Sharman, I. M. (1947). *Brit. J. Nutr.* 1, v.
A., Moore, T. & Sharman, I. M. (1952). *Brit. J. Nutr.* 6, x.
A., Moore, T. & Sharman, I. M. (1960). *Proc. Nutr. Soc.* 19, iii.
Agriculture, Fisheries and Food: National Food Survey Committee (1955). *Domestic Food Consumption and Expenditure*, 1953. London: H.M. Stationery Office.
Agriculture, Fisheries and Food: National Food Survey Committee (1956). *Domestic Food Consumption and Expenditure*, 1954. London: H.M. Stationery Office.
Agriculture, Fisheries and Food: National Food Survey Committee (1957). *Domestic Food Consumption and Expenditure*, 1955. London: H.M. Stationery Office.
Agriculture, Fisheries and Food: National Food Survey Committee (1958). *Domestic Food Consumption and Expenditure*, 1956. London: H.M. Stationery Office.
Agriculture, Fisheries and Food: National Food Survey Committee (1959). *Domestic Food Consumption and Expenditure*, 1957. London: H.M. Stationery Office.
Food: National Food Survey Committee (1951). *The Urban Working-Class Household* 1949. London: H.M. Stationery Office.
Food: National Food Survey Committee (1952). *Domestic Food Consumption and Expenditure*. London: H.M. Stationery Office.
Food: National Food Survey Committee (1953). *Domestic Food Consumption and Expenditure*. London: H.M. Stationery Office.
Food: National Food Survey Committee (1954). *Domestic Food Consumption and Expenditure*. London: H.M. Stationery Office.
(1939). *J. Soc. chem. Ind., Lond.*, 58, 651.
(1957). *Vitamin A*, p. 421. Amsterdam: Elsevier Publishing Co.
Leitner, Z. A. (1949). In *Spec. Rep. Ser. med. Res. Coun., Lond.*, no. 264, p. 65.
State Joint Legislative Committee on Nutrition (1947). *Meals for Millions*. N.Y. State Legislative Document, no. 61.
M. (1947). *Recent Advances in Clinical Pathology*, p. 180. London: Churchill.
Organization (1950). *Tech. Rep. Wld Hlth Org.* no. 3.
(1941). *Biochem. J.* 35, 551.

Printed in Great Britain

Lewis-'52
Bib. No. 5411

Pediatrics 9:589-596. 1952.

COMPARATIVE TOXICITY OF AQUEOUS AND OILY PREPARATIONS OF VITAMIN A

By J. M. Lewis, M.D.,* and Sidney Q. Cohlan, M.D.
New York City

A PREVIOUS study[1] by the authors reported that the absorption and storage of vitamin A is inversely proportional to the particle size of its vehicle of administration. Thus superior absorption and storage followed the administration of experimental doses of vitamin A in aqueous preparations, which are of microscopic particle size, when compared with the administration of comparable unitage in the oily products, which are of macroscopic particle size. This effect of the particle size of the vehicle, amply corroborated, appears common to all the fat soluble vitamins and in retrospect explains the reported observations of the influence of the menstruum of administration on the antirachitic effectiveness of vitamin D,[2] on the blood levels,[3-7] storage[6] and excretion[6] of vitamin A, and as more recently shown[8] on the absorption curve of vitamin E. The observations on vitamin A were the result of studies in man and in the laboratory animal following administration of experimental doses large enough to effect significant blood rises, liver storage and excretion. Recently Ellingson[9] confirmed these observations of liver storage in the rat but reported no difference in the absorption and storage of aqueous and oily preparations of vitamin A when administered in low and therapeutic dosage.

In view of the increasing awareness and incidence of clinical hypervitaminosis A,[10,11] it seemed worth while to investigate whether administration of excessive amounts of the aqueous preparations of this vitamin would result in greater toxicity, due to its superior absorption, when compared with like amounts of the oily product. It was necessary by the very nature of the study to pursue this problem in the laboratory animal. The resulting data should, however, have some pertinence clinically inasmuch as the previous experiment indicated that rats responded to oily and aqueous preparations of vitamin A in much the same manner as humans.

The effects of vitamin A poisoning in the rat have been investigated by many workers since the early reports of Takahashi.[12] Rodahl,[13] in a recent comprehensive monograph, lists the manifestations of toxicity to include reduced growth, hemorrhagic diathesis, alopecia, inflammatory changes of the periorbital tissues, exophthalmos and spontaneous fractures. In all previously reported toxicity experiments in the rat, vitamin A was administered in an oily menstruum. For the purpose of this study percentage mortality and spontaneous fracture rate were the objective criteria of comparison.

Experimental Procedures

Three groups of 100 adult male rats weighing 175 to 200 gm. were fed at different dose levels,

From the Department of Pediatrics, New York University College of Medicine, and from the Children's Medical Service of Bellevue Hospital and the Department of Pediatrics of Beth Israel Hospital, New York City.

Aided by grants from Mead Johnson Company, Evansville, Ind., and the Loyal League for Therapies, New York City.

(Received for publication Oct. 31, 1951.)

* Deceased.

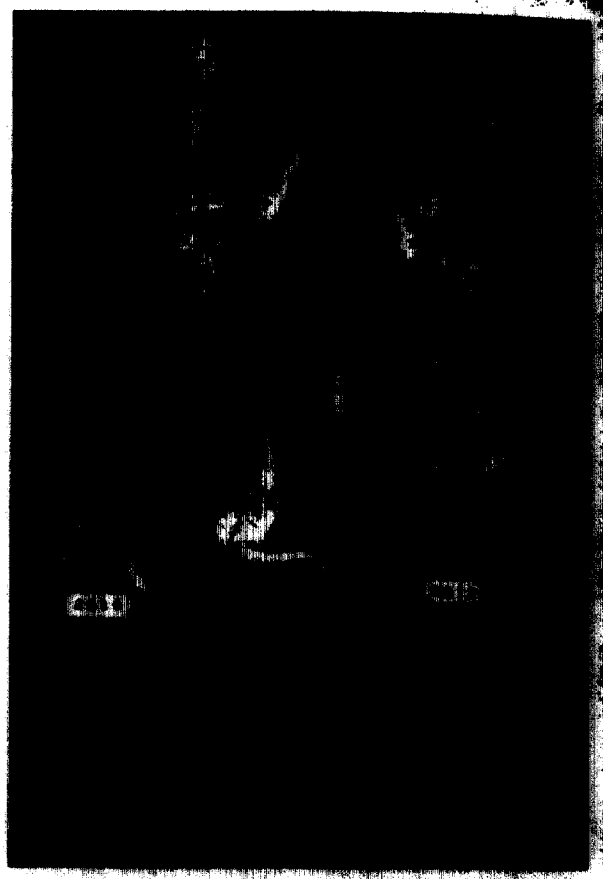

FIG. 1. A. Control animal. B. Rat fed 100,000 i.u. vitamin A in aqueous [illegible] days. Note loss of weight, scruffiness of pelt, swelling of orbital area [illegible]

comparable amounts of an aqueous* and oily† preparation of vitamin A daily for 21 [illegible] in the following manner:

Group 1.	A. (50 rats) 25,000 i.u., aqueous B. (50 rats) 25,000 i.u., oily
Group 2.	A. (50 rats) 50,000 i.u., aqueous B. (50 rats) 50,000 i.u., oily
Group 3.	A. (50 rats) 100,000 i.u., aqueous B. (50 rats) 100,000 i.u., oily

The daily volume of the oily and aqueous preparation in each group was kept constant by diluting the oily preparation with cottonseed oil and both preparations were fed by stomach tube. Each animal was examined daily for signs of toxicity. RGs were made every fourth day. At the end of the 21 day period blood was taken from the heart of the survivors in each group 48 hr. after the last feeding to determine the level of vitamin A in the blood. At the time of bleeding the animal was killed to ascertain the amount of vitamin A stored in the liver. To rule out the possible toxic effect of the vitamin A vehicle in each group 20 animals were fed equivalent amounts of cottonseed oil as a control for the oily preparation and similarly 20 animals were fed, as controls, equivalent amounts of the diluent solution used in the preparation of the aqueous vitamin A product. The vitamin A assays were done by the methods described in a previous investigation.[11]

* Aquasol (50,000 i.u. vitamin A/cc.), U.S. Vitamin Corp.

† Vitamin A concentrate, natural esters (200,000 i.u./cc.), Distillation Products.

Results

Clinical effects of poisoning were evident by the second to the third day in the group receiving 100,000 i.u. of the aqueous preparation daily. The animals became sluggish, the hair ragged, diarrhea was common and there was a marked loss of appetite and weight as compared to the control animals (Fig. 1). Deaths began to occur on the third day and by the eighth day all animals had succumbed to vitamin A poisoning. In marked contrast, as may be seen in chart 1, the group receiving 100,000 i.u. of the oily preparation daily suffered a mortality rate of only 5% during this same period. At the 50,000 dose level, the results, though not as striking, were similar: A mortality of 8% with the aqueous preparation, and of 2% with the oily product. It is noteworthy that at the end of the first week the mortality rate of the 50,000 i.u. aqueous group was comparable to that of the group fed twice this amount of vitamin A in an oily vehicle. The relative toxicity of the aqueous and oily preparations persisted to the end of the 21 day experimental period (chart 1) at which time there was a 17% mortality rate in the 100,000 i.u. oily group as compared to a 40% mortality in the group being fed half this amount daily in

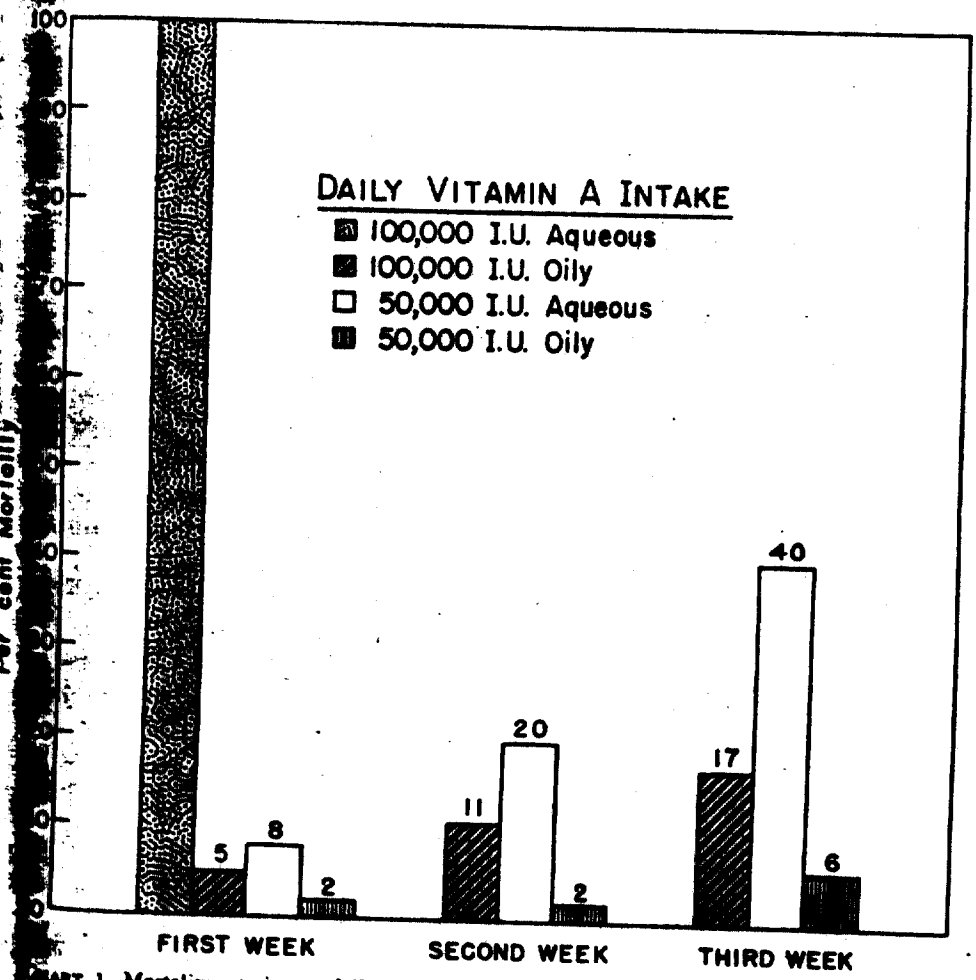

CHART 1. Mortality rate in rats following administration of excessive amounts of aqueous and oily preparations of vitamin A.

FIG. 2. RGs of rats fed 50,000 i.u. vitamin A in aqueous media daily for 16 days. Note fractures of humerus, femur and tibia. Marked scoliosis in A.

an aqueous menstruum. The animals fed 50,000 i.u. of the oily product daily suffered an over-all mortality of 6%.

During the 21 day experimental period the observed symptoms of vitamin A toxicity were: scruffiness of the pelts, drowsiness, muscular weakness, bleeding, lack of appetite, reduced growth, alopecia, swelling and redness of the palpebrae, exophthalmos, limping and spontaneous fractures. Limping was first noted in the hind legs and did not occur till the 8th to 10th day. RGs revealed a narrowing of the diameter of the shafts of the long bones with thinning of the cortex especially at the metaphysis. The bones appeared normally calcified. Spontaneous fractures were seen beginning at the twelfth to fourteenth day. The fibula was the most common site of early fracture followed by the humerus, femur and tibia in that order. Gross scoliosis of the vertebral column was noted in many animals after the second week (Fig. 2).

The comparative incidence and rate of spontaneous fractures following the administration of toxic doses of aqueous and oily preparations of vitamin A are illustrated in table 1. It will be noted that a daily dose of the aqueous preparation only one half that of the oily product produced comparable numbers of spontaneous fractures. Thus at the end of the third week RGs revealed fractures in 45 of 50 animals and 38 of 50 animals in the 50,000 i.u. aqueous and 100,000 i.u. oily groups, respectively. Six spontaneous fractures resulted in the group being fed 50,000 i.u. of the oily preparation. In view of the fact, as previously noted, that all animals fed 100,000 i.u. of the aqueous vitamin A died within 8 days, there is no comparable data on spontaneous fractures in this group.

TABLE 1

INCIDENCE OF SPONTANEOUS FRACTURES IN RATS FOLLOWING ADMINISTRATION OF EXCESSIVE AMOUNTS OF AQUEOUS AND OILY PREPARATIONS OF VITAMIN A

No. of Animals	Vitamin A Intake Daily for 21 Days	No. of Animals with Spontaneous Fractures
50	50,000 i.u. Aqueous	45
50	50,000 i.u. Oily	6
50	100,000 i.u. Oily	38

er storage and postabsorptive vitamin A blood levels in the various dosage groups corded in table 2. Control animals were fed 13,500 i.u. daily for 21 days. Liver at this dosage was comparable to results obtained in the authors' previous report[6] ing a single test dose. Storage is complicated by the fact that excessive intake of n A causes toxic liver damage; it is nevertheless apparent from table 2 that liver e is markedly decreased in both the aqueous and oily groups following toxic doses. also noteworthy that the decrease in storage is greater in the livers of animals fed ueous preparations than in those fed the oily product. Thus though the normal l will store 54% following administration of 13,500 i.u. from an aqueous ruum, the toxic animal being fed 50,000 i.u. of an aqueous preparation will store %. The decrease following the oily product in the same dose range is from 39% normal animal to 12% in the toxic animal.

TABLE 2

POSTABSORPTIVE BLOOD LEVELS AND PER CENT LIVER STORAGE IN RATS FOLLOWING INCREASING INTAKE OF AQUEOUS AND OILY PREPARATIONS OF VITAMIN A

Vitamin A Intake Daily for 21 Days	Postabsorptive Blood Level (units/100 cc. Plasma)		Per Cent Total Intake Stored in Liver	
	Aqueous	Oily	Aqueous	Oily
13,500 i.u.	117 (32)*	111 (32)	54%	39%
25,000 i.u.	190 (11)	153 (11)	10%	18%
50,000 i.u.	573 (21)	200 (21)	8%	12%
100,000 i.u. (intake for 5 days)	1,663 (9)	511 (21)	6%	10%

*Number of animals.

In view of the consistent finding[12,15] of fatty degeneration of the livers in rats fed excessive amounts of vitamin A, it is not improbable to assume from the data seen in table 2 that the liver damage resulting from vitamin A poisoning decreases storage of the vitamin and thus adds to the increased blood levels and tissue saturation of vitamin A when taken in toxic doses.

DISCUSSION

Distinction has been made between "acute" and "chronic" vitamin A poisoning in the animal as well as in man. The acute syndrome as observed in the group of animals

fed 100,000 i.u. of the aqueous preparation daily is characterized by weakness, loss of appetite, diarrhea, scruffiness of the pelt and marked loss of weight within one to two days. Rodahl and Moore[16] have reported a similar syndrome in the Eskimo manifested by drowsiness, irritability, headache, vomiting and desquamative dermatitis following ingestion of polar bear or bearded seal liver, a pound of which was found to contain 1,000,000 i.u. vitamin A. The liver of the Greenland fox, long known by the Eskimo to be poisonous, was also found to be rich in vitamin A. Though there are no reports of "acute" vitamin A intoxication in the pediatric literature, chronic poisoning is now a recognized entity occurring usually in infants over 9 months of age following daily intake of excessive amounts of vitamin A (100,000 to 500,000 i.u. daily) for periods of several months to years. Outstanding symptoms of hypervitaminosis A reported in the pediatric age group include lack of appetite, irritability, lassitude, pruritus, loss of hair, hepatomegaly, splenomegaly, anemia, pain and swelling usually of the soft tissues along the bones of the extremities and reluctance and inability to use the affected part. RGs of the involved bones reveal varying degrees of periosteal elevation and surrounding soft tissue reaction. The similarity of the roentgenographic findings in hypervitaminosis A with those of infantile cortical hyperostosis has been reported by Caffey.[17] In the present authors' limited experience with three cases of infantile cortical hyperostosis, vitamin A blood studies were normal.

There are no postmortem reports of vitamin A poisoning in man. In the rat microscopic pathologic findings include[13]: generalized hyperemia, vascular extravasation, degeneration of the renal tubules, fatty degeneration of the liver cells, massive cutaneous hemorrhages around the root sheaths of the hair and subperiosteal and osseous hemorrhages, destruction of bone spicules, thinning of the compact bone and an increased number of osteoclasts. In spite of the spontaneous fractures and disorganized bone structure, there is no change in the calcium or phosphorus content of bone ash as compared with the normal animal. The spontaneous fractures produced in adult rats in these experiments with excessive vitamin A intake are in agreement with the observations of Rodahl[13] and contrary to the findings recorded by Moore[18] and others[19] who reported fractures occurring primarily in the growing bones of the young animal.

Little is known of the mechanism of vitamin A toxicity. From the data in the authors' experiments as well as the experience of others, it is believed that the liver is first saturated with vitamin A following excessive intake. With liver saturation continued intake results in increased blood levels, tissue saturation and liver damage, which further decreases the ability of the liver to store the vitamin. It is the continued saturation of liver and bone with large amounts of vitamin A that probably effects the toxic changes. Thus, in the animal, fractures do not occur until two or more weeks of ingestion of toxic doses; in the infant and child symptoms are evident usually after months of excessive intake of vitamin A. The vitamin A saturation and impaired function of the liver may be inferred by the fact that in the infant and child a period of weeks to months may intervene between the time of cessation of vitamin A intake and return to normal blood levels.

Whether the effect on bone and bone growth of vitamin A toxicity was due indirectly to a disturbed mineral metabolism or to a direct effect of the vitamin on bone and cartilage has been uncertain. In a recent outstanding contribution, Fell and Mellanby[20] have established the fact that the effect of a high concentration of vitamin A on developing bone tissue is a direct one. By growing the bones of fetal mice in tissue culture they studied the effects of altering the concentration of vitamin A in the media. They found: "the

control bones in normal media did not lengthen much during cultivation but deposition and absorption of bone continued in vitro . . . the effect of the vitamin A acetate on the experimental bone was remarkable. In a concentration of 2,000-4,000 i.u. per ml the soft tissue grew as richly as in the controls, but in three days the bone of the shaft began to be absorbed and the cartilagenous ends to soften and shrink. The process progressed rapidly and the entire bone rudiment seemed to melt away like a 'lump of sugar in hot water': in extreme cases by the tenth day only a few crumbs of bone were left scattered in the sheet of actively growing soft tissue. . . . Histological sections of the experimental bones showed that the cartilage matrix soon lost its basophilia and at the same time shrank, while the cells appeared normal. Finally the matrix of the epiphyses vanished completely, leaving only a compact mass of chondroblasts, while the diaphysial cartilage was rapidly invaded and replaced by the highly cellular connective tissue of the marrow cavity. Exactly how the bone was absorbed was not clear, and although osteoclasts were fairly numerous it was doubtful whether they accounted for all the destruction." Although one hesitates to transpose results of in vitro and animal experiments to human physiology, these observations of Mellanby and Fell are striking enough to suggest that the bone pathology of hypervitaminosis A is due to the direct action of high concentrations of the vitamin on cartilage and bone.

It is therefore apparent that in man as in the animal repeated doses of excessive amounts of vitamin A are not without harmful effect. Since, as demonstrated in this report, aqueous preparations of vitamin A are more toxic in the rat than comparable amounts of the oily product, it is probable that in man a similar ratio will pertain. In view of the fact that clinical hypovitaminosis A is rarely seen in pediatric practice and since the minimum requirement in this age group is usually met in the normal diet, there seems to be little need for prescribing vitamin supplements which contain excessive amounts of vitamin A especially if dispersed in an aqueous menstruum.

Summary

Vitamin A toxicity in the rat as manifested by mortality rate and incidence of spontaneous fractures was greater following the administration of excessive amounts of vitamin A in an aqueous menstruum as compared to a similar intake of the vitamin in an oily vehicle.

Liver damage, due to vitamin A toxicity, impaired the ability of the liver to store the vitamin. Ingestion of toxic doses of the aqueous preparation resulted in greater depression of liver storage than comparable amounts of the oily product.

The mechanism of vitamin A toxicity is discussed.

References

Lewis, J. M., Cohlan, S. Q., and Messina, Angelina, Further observations on absorption of vitamin A: Influence of particle size of vehicle on absorption of vitamin A, Pediatrics 5:425, 1950.

Lewis, J. M., Clinical experience with vitamin D: Influence of menstruum on effectiveness of anti-rachitic vitamin, J. Pediat. 6:362, 1935.

Lewis, J. M., Further observations on comparative antirachitic value of crystalline vitamin D administered in milk, corn oil, or propylene glycol, J. Pediat. 8:308, 1936.

Clifford, S., Vitamin A absorption in premature infants, presented before the Society for Pediatric Research, Skytop, Pa., May 1946.

Mebel, A. E., Gottfried, S. P., and Kramer, B., Comparison of vitamin A serum levels in children following oral and intramuscular administration of vitamin A in oily and aqueous media, presented before the American Chemical Society, Chicago, Sept. 11, 1946.

6. Lewis, J. M., Bodansky, O., Birmingham, J., and Cohlan, S. Q., Comparative [illegible] cretion and storage of oily and aqueous preparations of vitamin A, J. Pediat. 31: [illegible]
7. May, C. P., and Lowe, C. U., Absorption of orally administered emulsified [illegible] children and children with steatorrhea, J. Clin. Investigation 27:226, 1948.
8. Sobel, A. E., and others, Aqueous dispersions of fat soluble vitamins, Fed. Proc. [illegible]
9. Ellingson, R. C., McDonald, F. G., Massengale, O. N., and Cox, W. M., Jr., Relative [illegible] of vitamins A and D in oil and in water, PEDIATRICS 8:107, 1951.
10. Gribetz, D., Silverman, S. H., and Sobel, A. E., Vitamin A poisoning, PEDIATRICS [illegible] 1950.
11. Rineberg, I. E., and Gross, R. J., Hypervitaminosis A with infantile cortical hyper[illegible] 146:1222, 1951.
12. Takahashi, K., and Nakamiya, Z., Physiological significance of biosterin (so-call[illegible] Japan M. World 5:2, 1925.
13. Rodahl, K., Hypervitaminosis A: Study of effect of excess of vitamin A in exper[illegible] Norsk Polarinstitut, Skirfter Nr. 95, p. 199, 1950.
14. Lewis, J. M., Bodansky, O., Falk, K. G., and McGuire, G., Vitamin A req[illegible] Relation of vitamin A intake to growth and to concentration of vitamin A in [illegible] liver and retina, J. Nutrition 23:351, 1942.
15. Drigalski, W., and Laubman, W., Hypervitaminosis A, Klin. Wchnschr. 12:11[illegible]
16. Rodahl, K., and Moore, T., Vitamin A content and toxicity of bear and seal [illegible] J. 37:166, 1943.
17. Caffey, J., Poisoning due to excess vitamin A: Its relation to infantile (cortical) [illegible] Am. J. Dis. Child. 79:404, 1950.
18. Moore, T., and Wang, Y. L., Hypervitaminosis A, Biochem, J. 39:222, 1945.
19. Maddock, C. L., Wollbach, S. B., and Maddock, S., Hypervitaminosis A in dog[illegible] 39:117, 1949.
20. Fell, H. B., and Mellanby, E., Effects of hypervitaminosis A on foetal mouse bone [illegible] in vitro, Brit. M. J. 2:535, 1950.

SPANISH ABSTRACT

Toxicidad Comparativa de las Preparaciones Acuosas y en Aceite de la Vitamina A

La toxicidad de la vitamina A, que en las ratas se manifiesta por un aumento de la mortalidad y de la incidencia de fracturas espontáneas, fué mayor después de la administración de una cantidad excesiva de vitamina A en un medio acuoso, comparada con una ingestión similar de dicha vitamina en un vehículo aceitoso.

La lesión hepática, por toxicidad a la vitamina A, dificultó la habilidad del hígado para almacenar esta vitamina. La ingestión de dosis tóxicas en forma ácuosa provoca una mayor disminución en el almacenamiento hepático de la vitamina A que cuando se emplean cantidades comparables del producto en aceite.

Se discute el mecanismo de toxicidad de la vitamina A.

8 Gramercy Park

Light-'44
Bib. No. 5423

VITAMIN A TOXICITY AND HYPOPROTHROMBINEMIA

RODAHL and Moore[1] have recently shown that the toxicity of bear and seal liver to humans may be due to a hypervitaminosis A. The effects of an overdosage of vitamin A have been studied by a number of investigators[2,3,4,5] and they are in general agreement on certain of the symptoms, which are roughening of the skin, rarefaction of bones, alopecia and profuse internal hemorrhage, often subcutaneous.

In an investigation of the mechanism responsible for the spontaneous hemorrhage caused by hypervitaminosis A, it was found that overdosage of vitamin A causes a pronounced hypoprothrombinemia. Doses of approximately 15,000 units of vitamin A per day produced a demonstrable hypoprothrombinemia in white rats within a period of ten days. Both the alcohol and the ester forms of vitamin A were fed in doses of 35,000 to 40,000 units per day, and appear to have had equal effect on the prothrombin level. Carotene in doses of 40,000 units per day was without effect on the prothrombin level in the blood.

This effect of vitamin A overdosage can be controlled by a simultaneous daily administration of vitamin K. A daily dose of 25 micrograms of vitamin K will maintain the normal prothrombin level in the blood of animals fed overdosages of vitamin A. Levels of 10 micrograms or less did not give complete protection.

One experiment will serve to illustrate the results obtained. Sixty-four white rats, having an average body weight of 135.3 grams, were divided into eight groups. Seven groups were fed a synthetic diet con-

[1] K. Rodahl and T. Moore, *Biochem. Jour.*, 37: 166–168, 1943.
[2] L. J. Harris and T. Moore, *Biochem. Jour.*, 22: 1461, 1928.
[3] K. Schuebd, *Med. Welt*, 11: 705, 1937.
[4] E. B. Vedder and C. Rosenberg, *Jour. Nutrition*, 16: 57–68, 1938.
[5] J. A. Collazo and J. S. Rodriguez, *Klinische Woch.*, 12: 1732, 1768, 1933.

taining 71 per cent. sucrose, 20 per cent. vitamin-free casein, 4 per cent. Osborne and Mendel mineral salt supplement, 3 per cent. Celluration and 2 per cent. of a suspension of vitamins A, D and E in Mazola oil. The eighth group was fed ground Purina dog chow. All the animals received daily supplements of the available pure components of the B complex vitamins.[6] Vitamin A was administered by means of fish liver oil concentrate (potency, 825,000 units per gram) or a preparation containing molecular distilled vitamin A (potency, 202,400 units per gram) mixed in the basal diets twice weekly to minimize vitamin A loss through oxidation. The dosage of vitamin K (2 methyl-3-phytyl-1,4-naphthoquinone) was given orally each day. Blood samples for prothrombin determinations were obtained by heart puncture after the animals were on the test diet for ten days, except in the case of those animals showing severe toxicity symptoms. From such animals blood samples were taken two to three days before the conclusion of the test. Prothrombin determinations were made according to the method of Campbell, Smith, Roberts and Link,[7] using 50 per cent. plasma dilution levels.

TABLE 1

Group	Vitamin A per 100 gms of basal ration	Vitamin K	Average clotting time
1	400,000 units (ester)*	none	5.60 min.
2	400,000 units (ester)*	100 γ per day	0.87 "
3	88,000 units (alcohol)*	none	0.30 "
4	176,000 units (alcohol)*	"	2.51 "
5	352,000 units (alcohol)*	"	5.12 "
6	352,000 units (alcohol)†	"	5.54 "
7	352,000 units (alcohol)*	25 γ per day	0.35 "
8	704,000 units (alcohol)*	none	7.17 "

* Basal ration, synthetic.
† Basal ration, ground dog chow.

The animals on this test consumed approximately 10 grams of food daily. Hypoprothrombinemia was produced within a 10-day period in white rats when fed 17,600 units of vitamin A per day. However, 8,000 to 9,000 units per day did not have any significant effect. At higher levels of vitamin A intake, 35,000 to 40,000 units per day, prothrombin levels of the blood were reduced within the comparatively short period of ten days to such an extent that many of the animals died of cerebral hemorrhage. This effect was obtained with a diet of natural ingredients (dog chow) as well as with the purified casein-sucrose ration. No difference between the effects of the alcohol or ester form of the vitamin was observed.

As shown hypoprothrombinemia is prevented by the administration of 25 micrograms of vitamin K daily.

[6] The composition of this supplement is the same as that used by Light, Cracas, Olcott and Frey, *Jour. Nutrition*, 24: 437, 1942.
[7] H. A. Campbell, W. L. Smith, W. L. Roberts and K. P. Link, *Jour. Bio. Chem.*, 138: 1–20, 1941.

The absolute requirement of the white rat for vitamin K is unknown. This species normally requires no dietary source of this factor, since vitamin K is presumably supplied by the intestinal flora. Fecal counts on the animals showed no significant differences in either the total counts or *E. coli* counts.

Although the experiments indicate that an overdosage of vitamin A results in a hypoprothrombinemia, which can be corrected by the daily administration of vitamin K, there is no evidence that vitamin K is effective in preventing any of the other toxicity symptoms occasioned by hypervitaminosis A. The mechanism by which the overdosage of vitamin A causes hypoprothrombinemia requires further investigation.

ROBERT F. LIGHT
RUTH P. ALSCHER
CHARLES N. FREY
THE FLEISCHMANN LABORATORIES,
STANDARD BRANDS, INC.,
NEW YORK, N. Y.

Vet. Rec. 84(24):594-598. 1969.

Maclean-'69
Bib. No. 5612

Observations on Coal Tar Poisoning in Pigs

C. W. MACLEAN, B.V.Sc., M.R.C.V.S.

British Oil and Cake Mills Ltd., Demonstration Farm, Risborough Road, Stoke Mandeville, Bucks

Vet. Rec. (1969). **84.** *594-598*

SUMMARY.—Two outbreaks of coal tar poisoning are described, in which the most spectacular economic loss resulted from the necessity to slaughter chronically affected pigs and not from the acute death. An increase in the stillbirth rate was seemingly related to low liver levels of Vitamin A. It is suggested that coal tar derivatives can interfere with the absorption of Vitamin A by the sow and result in low cross-placental passage of the vitamin to the piglets.

Introduction

COAL tar poisoning in pigs has been recorded in the United States by Graham *et al.* (1940), Giffee (1945), Fenstermacher *et al.* (1945), Aitken (1956) and Kernkamp (1964) who described the symptoms and pathology of the disease, but the author has been unable to find any reference to the effect of coal tar consumption on growth rate or perinatal mortality. The purpose of the paper is to record the effect of coal tar poisoning, as a herd problem, on the growth rate and on Vitamin A utilisation by the sow and new-born piglet.

As the toxic principle in coal tar pitch has not been isolated the cause is attributed to coal tar pitch mixture as a whole.

Materials and Methods

During 1967, the author investigated two herds in which a high perinatal mortality, pre- and post-weaning morbidity, and mortality with ill thrift was believed to be related to coal tar poisoning. A clinical history was taken from the owner. Herd records were consulted wherever possible and the performance of the affected litters was recorded before, during and after the outbreak. Full *post-mortem* examination, supported by laboratory work where indicated, was carried out on a total of 40 pigs.

During the first outbreak, livers were examined for Vitamin A content as part of routine investigation, but during the second outbreak, samples were examined at predetermined times in order to plot variation in the liver Vitamin A content. The livers examined were from baby pigs who had suckled colostrum for at least 12 hours. In the second herd, the liver Vitamin A status were examined both during the course of the disease and the following treatment.

The diagnosis of coal tar poisoning was made in the weaned pigs on the circumstantial evidence presented and was confirmed at autopsy. A histological examination was made of five liver samples from each herd.

Clinical History

Herd 1

This herd was situated on a 40-acre disused aerodrome in Worcester and consisted of 160 breeding sows from which the progeny were fattened to heavy hogs. The origin of the stock was from Saddleback, Landrace cross-sows which had been top-crossed with a Large White boar.

The sow herd was housed in deep litter straw yards in the winter and in summer was run in grass paddocks. In November, 1966, all the adult sows were moved into new accommodation, which was built on the old runways. The junctions of the concrete slabs, making up the floor, were filled with coal tar.

The old sow yards were used for housing replacement gilts and the bedding in these buildings was allowed to accumulate.

The sows farrowed in groups of 12 to 16 every fortnight and batches of 120 to 150 piglets were weaned at five weeks old into straw bale huts which were usually sited in grass paddocks. Three litters were reared together in ⅛-acre paddocks.

The rations fed were two proprietary creep feeds and sowmeal, weanermeal and a heavy pigmeal based on proprietary protein concentrates (Tables I and II).

TABLE I
RATION CONSTITUENTS USED IN HERD 1

Constituent		Sow ration	Post-weaning ration	Heavy pig ration
Protein concentrate	cwts.	3	3	2
Wheat	cwts.	6	4	6
Barley	cwts.	6	10	12
Wheatings	cwts.	5	3	—
Molasses	cwts.	½	½	½

TABLE II
ANALYSIS OF RATIONS USED ON HERD 1

	Sow ration per cent.	Post-weaning ration per cent.	Heavy pig ration per cent.
Oil	1·84	2·22	1·98
Protein	16·65	16·15	12·10
Fibre	3·98	3·68	3·60
Salt	0·70	0·69	0·81
Calcium	0·85	0·70	0·60
Phosphorus	0·48	0·53	0·40
Vitamin A	6,700,000 i.u.	4,800,000 i.u.	2,000,000 i.u.
Free fatty acid	27·37	41·48	35·0
Peroxide value	6	9	11

Early weaning creep feed was introduced at ten days of age and was followed by creep feed to a maximum of 1½ lb. per pig per day, or up to seven weeks of age, whichever occurred first. The weanermeal (Tables I and II) was offered from two days post-weaning and

(*Continued on page* 595)

was fed on an *ad lib* basis. The hogs were finished on a lower protein ration (Tables I and II, Diet 3).

The production record for the previous 12 months was 11·7 pigs born and 9·8 reared to eight weeks of age.

Indications of Abnormality

The sows were brought into the new yards in November, 1966, and the first indication of abnormality occurred in January, 1967 with an increase in stillbirths and mortality in the first 24 hours of life. Losses in gilts litters were low. The losses consisted of pigs born dead, or born weak and quickly crushed by the dam. Occasional foetal mummies were noted. At this stage samples of the piglets' liver showed normal Vitamin A levels (Table IV). A similar picture occurred throughout February. It was noted that affected sows came from the new dry sow yards.

At this stage four piglet livers were examined for Vitamin A content and the level was considerably lower than those previously examined. (Table IV).

During mid-February the performance of weaned pigs began to fall. From 1.9.66 to 18.1.67 the variation in the eight-week weights followed the usual seasonal decline, which is related to weather and general muddy conditions on this unit. During this period the losses from five to eight weeks were nil. (Fig. 1).

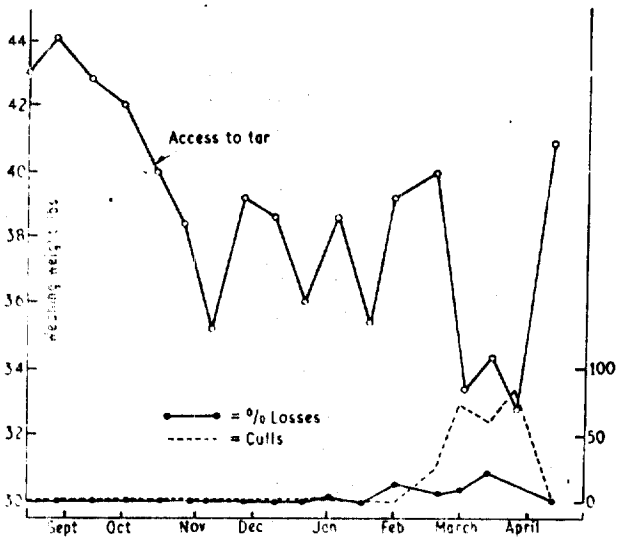

FIG. 1.—Eight-week weight, mortality and culling rate of batches of 120 pigs before and after access to coal tar.

On 2.1.67, because of the prevailing wet conditions and the resulting mud in the paddocks, the straw bale huts were moved on to the concrete runways. They were placed so that the pigs had access to the grass verge between the edge of the runway and the fence. The eight-week weights fell in the group weaned on February 2nd, but an infection was suspected and a Terramycin feed supplement was fed to all weaned pigs.

The next batch weighed showed some improvement in weight, but 12 per cent. of the batch died suddenly at varying intervals. A *post-mortem* examination was carried out on one of these pigs with the resulting diagnosis of hepatitis.

In the next group the mortality had fallen, but the morbidity had increased to about 70 per cent. Pigs were again examined *post-mortem* and a hepatitis was present in all cases. Hepatosis diatetica was suspected, but the feed analyses proved normal (Tables I and II).

Losses had commenced about one month after the pigs had had access to the runways. The straw bale huts were conventionally built and provided warm accommodation for the piglets. It was noted that the junctions of the concrete slabs forming the runway were filled with a layer of coal tar pitch. This layer was undamaged and not apparently interfered with by the pigs. An examination of the interior of the huts revealed a large number of pitch-coated granite chippings on the floor in amongst the straw. A search for the source of these stones revealed a drain at the edge of the runway consisting of a 6 in. tile at the depth of two feet covered by 2 in. stone chips with a layer of 1 in. tar-coated stone chips on the surface. Seemingly the pigs had rooted these out of the ground, played with them in their mouths and carried them inside the houses. Whilst under observation several pigs were playing with the stones.

A tentative diagnosis of coal tar poisoning was then made and the pigs were immediately moved from the runways back onto the paddocks. The next group of pigs weaned averaged 40·7 lbs. at eight weeks old, and there were no losses.

Many of the affected pigs became chronically unthrifty and were slaughtered after one month had elapsed. (Fig. 1).

Herd 2

Herd 2 was situated on a 20-acre hill farm in Derbyshire and consisted of 60 breeding sows from which the progeny were sold as stores at 12 weeks of age. The herd consisted mainly of Saddleback sows which were mated with a Large White boar. The pregnant sows were run out in 4-acre paddocks.

In 1965 during highway alterations 30 tons of tarred granite chippings were purchased to improve the surface of the farm drive. This was stored at the edge of the field nearest the drive until used on the drive in June 1966, following which another 4-acre paddock was created including the area where the chippings had been stored. In December, 1966, 25 sows were grazed on this paddock. They were fed on the ground in the area where the chippings had been stored. At this time the owner noted that many of the sows were chewing stones.

In January, 1967, one sow died suddenly and a hepatitis was diagnosed at autopsy. Because many other sows in this paddock were emaciated the author was consulted in February, 1967. As the stones which the sows were chewing were coated with coal tar an examination of piglet livers for Vitamin A content was commenced immediately. At this stage the levels were normal (Table III). In March, 1967, there was a significant rise in the number of pigs born dead and a small increase in deaths during the first 24 hours. (Table III).

Liver Vitamin A levels at this time were substantially lower than those examined at the beginning of March (Table IV). The sows were removed from the offending

TABLE III
EFFECT OF COAL TAR CONSUMPTION BY SOWS ON THE VIABILITY OF THEIR PROGENY

Farm	Date of access to tar	Date of farrowing	Mean number born alive	Mean number born dead	Mean number dead in 1st 24 hrs.	Number reared to 8 weeks
1	15.11.66	November 1966	11·5	0·4	0·3	9·6
1	15.11.66	January 1967	12·2	2·2	3·2	8·8
1	15.11.66	March 1967	8·0	3·9	2·7	5·2
2	25.12.66	March 1967	9·5	1·1	0·5	8·5
2	25·12.66	April/May 1967	5·8	3·6	1·0	4·5
2	25.12.66	July 1967	9·8	0·6	0·3	8·7

paddock. However, losses in new born pigs continued to occur until June, 1967. Further livers were examined for Vitamin A during May (Table IV), and these showed a significant fall compared with previous examinations.

In June, 1967, a group of 40 pigs were weaned at 6 weeks old onto the offending paddock. In July 25 per cent. of these piglets died. Autopsy confirmed a hepatitis identical to that occurring on Farm 1. Since July, 1967, stock has had no access to this paddock and no recurrence of toxicity, stillbirth or weakness at birth has occurred.

Symptoms in Weaned Pigs

The first pigs to be affected showed sudden death at 7 to 9 weeks old with few premonitory symptoms. An occasional pig showed a rapid clinical deterioration without any diagnostic symptoms. More commonly, however, the respiratory rate was increased and the abdomen appeared tender. The pigs showed signs of weakness and general depression and tended to remain recumbent in the sternal position for long periods.

Occasional sudden deaths occurred in groups subsequently affected. However, the general picture was one of unthriftiness, manifested by negative weight gain and a dirty anaemic skin with a hint of icterus which did not show clearly in the visible mucous membranes. "Thumping" respiratory movements were common and pigs were generally dull. Aimless wandering was common. Green mucoid faeces were occasionally passed, particularly by those pigs which had survived for 2 or 3 weeks. This chronic picture was a more constant feature of the affected pigs than were acute deaths and this resulted in the slaughter of many pigs in Herd 1 on economic grounds (Fig. 1).

Post-mortem Picture in Weaned Pigs

Jaundice was frequently observed throughout the whole carcase. In the abdomen the outstanding lesion affected the liver, which was engorged, greatly enlarged (a 2½ lb. liver in a 30 lb. pig) and showed a mottled appearance (Fig. 2). The individual lobules were very distinct and varied in colour from dark red to a yellowish green with a copper tint. The organ was very friable and its surface was covered with sheets of fibrin. Macroscopic examination revealed uniform changes throughout the liver.

The peritoneal, pericardial and pleural cavities contained excess fluid and the abdominal lymph nodes were swollen and occasionally haemorrhagic. The kidneys were pale and oedematous. There were no other consistent *post-mortem* lesions. Routine bacteriological examination revealed no consistent findings.

Laboratory Examinations

Histological examination of the liver revealed a severe and widespread centrilobular haemorrhagic necrosis. This damage was not evenly distributed, groups of badly affected lobules being seen next to lobules showing very little change. (Fig. 3).



FIG. 2.—Transverse section of the liver of an eight-week-old piglet suffering from coal tar poisoning.



FIG. 3.—Histological section of liver of a 10-week-old pig with coal tar poisoning. H. & E. ×40.

The haemorrhage appeared to have commenced in the centre of the lobule and to have extended peripherally, though this was by no means consistent. Haemosiderin laden macrophages were common. In patches, the necrotic parenchymal cells contained basophilic granules which gave a positive von kossa reaction for phosphate-carbonate. Some of the

parenchymal cells appeared amorphous, as if undergoing autolysis.

Treatment

In both herds, the sows and piglets were removed from contact with the coal tar as soon as possible. Both problems resolved within two months of removal from the source of coal tar but the losses in weaner pigs (apart from those with liver damage) ceased almost immediately.

On Farm 2 two sows were slaughtered in March, 1967. The Vitamin A liver level was 40 and 80 international units per gram respectively. As a result ten sows were given Vitamin A by intramuscular injection (100,000 international units). Two of these animals were slaughtered three months later, revealing Vitamin A liver levels of 1,500 and 2000 i.u. per gram respectively. No further Vitamin A supplementation has been given.

Farm 1 commenced injection with Vitamin A in March, 1967 and one sow was slaughtered two months later revealing a liver Vitamin A level of 1,600 i.u. per gram of wet tissue. Supplementation has continued on this farm so no control of the results has been possible.

TABLE IV
VITAMIN A LEVELS IN THE LIVER OF PIGLETS WHICH DIED FROM CRUSHING BUT WHICH HAD RECEIVED COLOSTRUM

Farm 1	Vitamin A levels i.u. per gram of wet tissue		Farm 2	Vitamin A levels i.u. per gram of wet tissue	
17.11.66			16.3.67		
Piglet 1	50		Piglet 1	56	
Piglet 2	42	Mean 38·2	Piglet 2	55	Mean 45·5
Piglet 3	23		Piglet 3	40	
Piglet 4	38		Piglet 4	31	
			2.4.67		
			Piglet 5	20	
			Piglet 6	41	Mean 21
			Piglet 7	14	
			Piglet 8	9	
19.2.67			5.5.67		
Piglet 9	6·9		Piglet 9	6	
Piglet 10	29	Mean 11·4	Piglet 10	1·5	Mean 4·1
Piglet 11	6·0		Piglet 11	5	
Piglet 12	4·0		Piglet 12	3·9	
			8.7.67		
			Piglet 13	25	
			Piglet 14	30	Mean 27·0
			Piglet 15	26	

Discussion

These two outbreaks of coal tar toxicity warrant recording for several reasons:—

1. Although chlorinated hydrocarbons have long been known to interfere with Vitamin A metabolism, few examples of this inhibition have been recorded in pigs.
2. Despite the opinion expressed by Kernkamp (1964) that coal tar poisoning is an acute and often fatal disease, the greatest economical loss in Herd 1 resulted from the chronic unthriftiness in large numbers of weaned pigs.
3. The histopathology of the liver suggests that differentiation from hepatosis diatetica can be extremely difficult, unless the overall *post-mortem* picture is assessed prior to histopathological examination, and is related to the circumstantial evidence of contact with coal tar pitch.

No histological examination was made of sow livers, but the macroscopic appearance of the liver was normal. The only abnormality discovered was a low level of Vitamin A. This reduced storage of the vitamin by the sow was reflected in the falling levels of Vitamin A in the piglet livers. However, it was still impossible to decide whether the interference with Vitamin A metabolism occurred in the intestine of the sow or as a direct result of the effect of coal tar on the liver. The piglets themselves had no access to coal tar in the first few weeks of life, and so any reduction in Vitamin A storage must have been related to a fall in sow reserves with resulting low cross-placental and colostral transfer of the vitamin.

Coal tar pitch contains many carcinogenic agents. Goerner (1938) studied the effect of 1, 2, 5 and 6 dibenzanthracene injection on the Vitamin A metabolism of rats and rabbits. Vitamin A was lost from the enlarged livers and from their mitachondria. Baumann *et al.* (1941 and 1942) found that the Vitamin A loss was not dependant on the carcinogenic effect, as loss occurred following the use of non-carcinogenic 1-2 dibenzanthracene. Abel *et al.* (1942) suggested that these agents compete with Vitamin A for some substance, probably a protein, by which either can be bound to the liver.

Graham *et al.* (1940) found that 3 grams of coal tar per day for ten days was sufficient to kill weaner pigs, and so even small doses to either sows or piglets must be considered potentially dangerous. From the response by sows to injection of Vitamin A it is clear that the actual storage of Vitamin A by the liver is not impaired once access to coal tar ceases.

In the weaned pigs in Herd 1, acute toxicity first occurred on February 8th. At this stage, these piglets had had access to the tarred chippings for 14 days. It is interesting to note that although piglets had access to the tar from January 2nd, deaths did not occur in quantity until February 8th. Although there was some inappetence in previous groups, it is likely that these animals were either suffering from some other infection or had only rooted a few of the coal tar chippings. The interior of the houses was not cleaned out between batches, so it is likely that each successive group of pigs rooted more chippings and brought more into the houses, and that the build-up was not sufficient to cause toxicity until the end of January.

As stated previously, the greatest economic loss was caused by the necessity to slaughter up to 80 per cent. of the pig groups which suffered from chronic poisoning and not from acute deaths which at maximum only killed 20 per cent. of the pigs. (Fig. 1).

The hepatic changes could be associated with either *Hepatosis diatetica* or coal tar poisoning. However, in *Hepatosis diatetica*, gastric ulceration and cyanosis is usually present and there is no red cell destruction or icterus. *Hepatosis diatetica* more commonly results in a centrilobular necrosis with distinct surrounding

(*Concluded at foot of col.* 1, *page* 598)

cellular reaction and not in the haemorrhagic hepatic necrosis described. (Dunne, 1964).

Nevertheless, the macroscopic appearance of the liver on *post-mortem* examination can create confusion between these two conditions. At the field level, differentiation should be made on the overall *post-mortem* picture, the evidence of access to coal tar pitch and on the normal peroxide and free fatty acid values of the feeding stuff in use at the time of toxicity.

Acknowledgments.—The author is indebted to the practitioners who brought these cases to his notice; to Mr. J. D. J. Harding of the Central Veterinary Laboratory, Weybridge, for help with the description of the lesion and to the directors of Unilever for permission to publish.

References

AITKEN, W. A. (1956). *J. Am. Vet. med. Ass.* **128.** 262.

ABELS, J. C., GORHAM, A. T., EBERLIN, S. C., HALTER, R., & RHOADS, C. P. (1942). *J. Exp. Med.* **76.** 143.

BAUMANN, C. A., FOSTER, E. G., & LAVIK, P. S. (1941). *J. Nutrit.* **21,** 431.

———, ———, & MOORE, P. R. (1942). *J. Biol. Chem.* **142.** 597.

FENSTERMACHER, R., Pomerby, B. S., & KERNKAMP, H. C. H. (1945). Proc. 49th Ann. Meet. U.S. Livestock San. Ass. p.86.

GIFFEE, J. W. (1945). *Vet. Med.* **40.** 97.

GOERNER, A. (1938). *J. Biol. Chem.* **122.** 529.

GRAHAM, R., Hester, H. R., & Henderson, J. A. (1940). *J. Am. Vet. med. Ass.* **96.** 135.

KERNKAMP, H. C. H. (1964). "Diseases of Swine". Ed. Dunne, H. W., Iowa State Press.

THOMAS, J. W., LOOSLI, J. K., & WILLIAMS, J. R. (1947). *J. Anim. Sci.* **6.** 141.

Maddock-'49
Bib. No. 5632

J. Nutrition 39(1):117-137. 1949.

HYPERVITAMINOSIS A IN THE DOG

CHARLOTTE L. MADDOCK, S. BURT WOLBACH AND STEPHEN MADDOCK

Department of Pathology, Harvard Medical School, Division of Nutritional Research, The Children's Hospital, and the Laboratory of Surgical Research, Boston City Hospital, Boston, Massachusetts

SIX FIGURES

(Received for publication March 30, 1949)

The production of hypervitaminosis A in the rat, the mouse and the guinea pig, with concurrent bony changes and toxic symptoms, has been reported by numerous workers—Takahashi et al. ('25), Harris and Moore ('28), Collazo, Rubino and Varela ('29), Bomskov and Seemann ('33), Collazo and Rodriguez ('33), Drigalski ('33), Moll et al. ('33), Davies and Moore ('34), Strauss ('34–'35), Weslaw et al. ('38), Cornil, Chevallier and Paillas ('39), Noetzel ('39), Wolbach and Bessey ('42), Moore and Wang ('45), Wolbach ('47). It has been recognized as a result of accidental overdosage in man (Rodahl and Moore, '43; Josephs, '44; and Rothman and Leon, '48). The dog, however, has never been studied from this viewpoint. Corroboration in a new species of the findings relating to hypervitaminosis A, and the convenience of using a larger animal because of the need of further work on the chemical aspects of the problem, have prompted the present investigation.

EXPERIMENTAL

A litter of 5 greyhound puppies born of thoroughbred greyhounds, laboratory animals of several years' standing,

was selected. These puppies were two months old and in good health when the experiment was begun. They had been with the mother until a week before the start of the experimental period. At this time they were transferred to separate cages and put on a diet of milk, bread, horsemeat, dog chow and occasional vitamin D supplement in the form of cod liver oil. Their weights at this time ranged between 4.5 and 5.5 kg. The distribution between the sexes was three males and two females. One of each sex, both of them representing the heavier dogs of the litter and weighing 5 + kg, was selected for excessive vitamin A administration.

Dosage and manner of administration

Vitamin A in the form of concentrate[1] with a potency of 500,000 I.U. per gram was used. This was fed at a level of 300,000 I.U. per kilogram of body weight and was given daily, Sundays excepted. It was administered by mouth for the first 22 days of the experiment. Since the anticipated result was not obtained after this period, it was thought wiser to discontinue the oral route of administration. The dogs were then fed the concentrate by stomach tube and this was followed by either 4.0 ml of corn oil or of olive oil, in order to rinse the vitamin preparation down the tube. No complications in tube-feeding the dogs were encountered.

Two different samples of concentrate, with similar potencies, were employed. Both of them had been repeatedly used on guinea pigs and when fed at the above-mentioned level were known to give a typical picture of vitamin A excess, with fracture of long bones, after a 12- to 16-day period.

Procedures followed during the course of the experiment

The dogs were weighed daily, Sundays excepted. X-rays to determine bony changes were taken of the experimental animals and the controls at the beginning of the experiment

[1] Purchased from Distillation Products, Inc., Rochester, N. Y.

and at intervals thereafter. The clinical course was carefully followed.

The dogs were bled at frequent intervals and except for some of the earlier bloods, which were studied merely for their cholesterol and phospholipid content, determinations were done on specimens obtained after a 12-hour fast. The dogs were followed from the standpoint of serum cholesterol and serum lipid-phosphorus throughout the period under observation. Serum inorganic phosphorus, serum alkaline phosphatase and serum vitamin A levels were followed from the 45th day on. Studies on blood sugar, non-protein nitrogen, uric acid, creatinine, serum sodium and serum chloride were done during the final stages of the experiment. The bromsulphonphthalein test was done on both experimental animals, using normals as controls, once the syndrome was well established.

Serum vitamin A levels were determined by the Lowry-Bessey method (Lowry and Bessey, '45), checked occasionally by the May method (May et al., '40). An unpublished Fiske and SubbaRow method for lipid-P was employed. Cholesterol was determined by the Lieberman-Burchard (Bloor, Pelkan and Allen, '22; Mirsky and Bruger, '32) colorimetric procedure. The Folin-Malmros (Folin and Malmros, '29) micromethod was used for blood sugars. Non-protein nitrogen, uric acid, creatinine and creatine were measured by the routine Folin procedures (Folin, '34). Bodansky's method (Bodansky, '32) for determining serum alkaline phosphatase and serum inorganic phosphorus was utilized. Serum Ca was determined by the Fiske and Adams method (Fiske and Adams, '31), serum chloride by the Whitehorn method (Whitehorn, '20–'21), and serum sodium by Butler and Tuthill's (Butler and Tuthill, '31) method. Bromsulphonphthalein retention, using a 5% solution and administering 5 mg of dye per kilogram of body weight, was measured at the end of 5-, 15-, and 30-minute periods.

RESULTS

Weight changes

The male controls showed a satisfactory weight gain throughout. During the 67-day period under observation they gained on the average 135 and 148 gm a day, respectively. The female control during the first 56 days gained an average of 93 gm daily. A sudden drop then occurred during the next 6 days due to an attack of diarrhea of unexplained origin, followed by a slower return to normal. Comparing the experimental male and female with their respective male and female controls up to the point where a drop in the weights

TABLE 1

Daily weight gain in grams — 53-day period

	CONTROL		EXPERIMENTAL
	Dog 1	Dog 3	Dog 2
Male	160	168	93
	Dog 5		Dog 4
Female	111		73

of the experimental animals took place (53rd day), the average daily weight gains are as indicated in table 1. From the 53rd day on, both experimental animals showed a precipitous fall in weight, the male losing 23% of his maximum weight in 8 days, the female 15% in 5 days.

Clinical course

The dogs seemed well and normally active up to and beyond the point where the decline in weight first began to manifest itself. On the 30th day of the experiment it was first noted that their appetites were failing. Solid food, especially meat, was refused either wholly or in part. Except for this they continued to react normally until two to three days after the rather precipitous fall in weight. From then on, both rapidly declined.

The female animal, which seemed to respond more emphatically and promptly to the excessive vitamin A, refused to stand, yelped when touched, and shivered more or less continuously. She acted as though she were in great discomfort. Twenty-four hours later her buttocks were soiled, she smelled strongly of urine, licked her front paws more or less continuously as does a dog which has sustained an injury to them, and was unable to use her hind legs. No fractures could be detected but there was extreme tenderness over all epiphyses. During the last day of life this animal seemed relatively indifferent to her surroundings. She was sacrificed under intravenous pentobarbital anesthesia on the 58th day of the experiment.

The male dog (no. 2), which was maintained on the regime for a longer period of time and was sacrificed on the 69th day under pentobarbital anesthesia, differed from the female in that he showed the effects of a greater weight loss. Skeletal landmarks seemed unusually prominent. The normal dorsal curvature of the spine was exaggerated. Movements of the shoulders would bring the medial borders of the scapulae into profile, as though there were no force to counteract the pull of such muscles around the shoulder joint as had scapular attachments. Bony protuberances, bony ridges and joints seemed more prominent because of excessive and rapid wasting. Hyperesthesia of the skin and extreme tenderness over all extremities were marked in the last few days of life. Unwillingness to stand was a symptom occurring during the last 48 hours, but at no time were gross fractures detectable. Both in this dog and the female a moderate degree of exophthalmos was noted during the last 7 to 10 days of life, but no other ophthalmological changes were noted in either dog.

X-ray findings

Satisfactory x-ray films of a few bones only were obtained at the conclusion of the experiment. The following description (dog 2) is based on the comparison with x-ray films from control dog 1.

The epiphyseal lines of all the long bones of the experimental dog are markedly narrower than those of control bones. The cortices of the femur, tibia, radius and ulna of the experimental dog are less dense and thinner. The most striking change is shown in the fibula, which is markedly reduced in width and density, almost to complete disappearance a few centimeters be-

low the proximal end, whereas the cartilaginous end is of approximately normal width. The tibia shows marked loss of density of the crest just below the epiphysis of the tuberosity and in this location the outline of the bone is fuzzy in appearance. The distal ends of the ulna are markedly expanded, fuzzy, and, in dog 2, the appearance suggests that of an impacted fracture.

The distal end of the radius shows narrowing, as compared to that of the control, and the periosteal borders for 2 cm proximal to the epiphyseal line are irregular and fuzzzy in outline.

Blood chemistry

Aside from the changes in cholesterol and lipid-phosphorus values, there was little that was remarkable in the chemical blood picture. The non-protein nitrogen rose terminally to a very moderate degree. There was a terminal increase in blood creatine, probably a reflection of excessive muscle wasting. Dog 4 showed an increase in serum calcium. Phosphatase and inorganic phosphorus values lay within normal limits. A terminal and fairly abrupt rise in serum sodium (153 milliequivalents per liter of serum) was present in dog 4. There was little difference between experimental animals and controls as regards bromsulphonphthalein retention, though a slightly increased retention in the hyper A animals was seen, an observation also noted in guinea pigs (Maddock, '42). Serum vitamin A levels, remarkably high normally in the dog (Clausen et al., '40; Wakerlin and Moss, '43), showed an 8- to 40-fold increase (table 2).

Cholesterol and lipid phosphorus values remained unaltered in both experimental animals until symptoms of acute hypervitaminosis A were well established. The female, three days before her exitus, showed a moderate decline in both of these values. This was followed on the final day by a secondary rise which, however, fell short of the previous normal levels. In the male the drop in both cholesterol and lipid-P was more abrupt, and these values remained at a low level until the animal was sacrificed (table 2).

TABLE 2

Vitamin A, cholesterol and lipid-P

DAY OF EXPERIMENT	HYPER A DOGS						CONTROL DOGS								
	Dog 2			Dog 4			Dog 1			Dog 3			Dog 5		
	Vitamin A	Cholesterol	Lipid P	Vitamin A	Cholesterol	Lipid P	Vitamin A	Cholesterol	Lipid P	Vitamin A	Cholesterol	Lipid P	Vitamin A	Cholesterol	Lipid-P
	I.U./c.c.	*mg %*	*mg %*	*I.U./c.c.*	*mg %*	*mg %*	*I.U./c.c.*	*mg %*	*mg %*	*I.U./c.c.*	*mg %*	*mg %*	*I.U./c.c.*	*mg %*	*mg %*
1					235.0	18.23									
2		230.0	16.15												
3								245.0						155.0	15.55
4											188.0	15.02			
16		255.0	18.39												
25		226.0	18.42								230.0	23.93			
26					230.0	21.35		235.0	20.2						
32		219.0	18.50											202.0	16.10
33					241.0	18.20					230.0	17.55			
40		203.0			202.0						187.0			181.0	17.75
45	20,400	207.0	17.28	10,040	211.0	17.37	909			754	183.0	16.64	660	163.0	15.29
56				15,200	151.0	15.88							581	171.0	16.02
57				10,680	159.0	12.92							577	146.0	14.64
58				12,300	194.0	16.11									
59		153.0	13.56					175.5	14.32						
65	8,380	78.0	6.83				1,182	180.0	14.11						
68	10,310	93.0	7.18												
		94.0	7.28												
120													1,065		17.76

Postmortem findings

Gross findings were not important.

Microscopic examination—

Heart. The myocardium of both dogs is normal. In dog 4 there is marked dilatation of the lymphatics of the epicardium. Some of them contain red blood corpuscles. One small artery in the myocardium shows a lesion of the media. Many smooth muscle fibers are densely stained, with pyknotic nuclei. Some of the smooth muscle cells are hyalin and acidophilic. Others stain densely with basic stain and are fragmented. In the adventitia there are many polymorphonuclear leukocytes.

Lungs. There are no lesions in the lungs of dogs 2 and 4.

Spleen. Dog 2. The follicles are small and inactive. The reticular cords contain very few lymphoid cells. In the sinuses are occasional clumps of densely stained fused red blood corpuscles. There is no erythropoiesis; no megakaryocytes. There are numerous phagocytes containing light yellow globules. The spleen of dog 4 shows some erythropoiesis and numerous megakaryocytes. The sinuses contain clumps of fused red blood corpuscles, as in dog 2. The secondary follicles show moderate activity.

Liver. In dog 2 there are many small to very large necroses. The smallest necroses appear in the mid-zonal regions. The larger necroses involve several lobules. These necroses contain very few leukocytes and are therefore regarded as of recent origin. There is fairly marked central fat vacuolization in the lobules throughout the liver. The cells lining the sinusoids are swollen and finely vacuolated. The liver of dog 4 shows no necrosis, no central fat vacuolization. The cells lining the sinusoids are swollen and vacuolated, as in dog 2. The liver cells as a whole contain more basic staining granular material than those of dog 2. In the sinusoids are occasional clumps of fused red blood corpuscles.

Gall bladder. The gall bladder from dog 2 is not preserved. That of dog 4 shows lesions in many arteries throughout the thickness of the gall bladder wall of the same nature as the lesions in the artery of the myocardium. These vascular lesions will be described more fully below.

Pancreas. The pancreas from each dog is negative. In dog 4 the larger veins contain clumps of fused red blood corpuscles.

Gastrointestinal tract. Dog 2. Esophagus, stomach and small intestine, normal. In dog 4 many blood vessels of the stomach

contain clumps of fused red blood corpuscles. In the muscularis there is one medium-sized vein with completely degenerated smooth muscle cells in the media, similar to the lesions of vessels of heart and gall bladder. Otherwise the stomach is normal. Small and large intestine normal.

Kidneys. The kidneys from both dogs are essentially normal except for atrophy of the epithelium of many of the distal convoluted tubules, more marked in dog 4. In dog 4 an occasional tubule shows the epithelium to be represented by a very narrow fringe of cytoplasm surrounding nuclei.

Adrenals. The adrenals from dog 2 are normal in appearance. Those from dog 4 show slightly less lipid vacuolization of the fascicular cells of the cortex.

Bladder. The bladder of dog 2 is normal except for a completely organized thrombosed vein on the external surface. The bladder of dog 4 is normal except for many acute vesicular lesions to be described below.

Genitalia. Testis—Dog 2. Immature, normal. *Uterus*—Dog 4. The mucosa is immature but otherwise negative. *Ovary*—Immature but otherwise negative.

Lymph nodes. The lymph nodes taken from many sources in both dogs show sinuses containing many red blood corpuscles. All of the lymph sinuses are dilated. There is only a moderate amount of phagocytosis of the red blood corpuscles. The lymphoid follicles are normal. Lymph sinuses and veins show clumps of fused red blood corpuscles. In one lymph node, from dog 4, there is an artery showing the degenerative lesion of the media noted in other arteries.

Thyroid gland. From both dogs, normal.

Skeletal muscle. That from dog 2 shows no lesion. That from dog 4 shows one vein with degeneration of the smooth muscle cells of the media.

Aorta. That from dog 4 is normal.

Skin. That from dog 2 is normal.

Vascular lesions in dog 4.[2] Degenerative lesions of the media are found in arteries and veins of the myocardium, gall bladder, urinary bladder, and one lymph node. These lesions are characterized by degeneration of smooth muscle cells and various stages in their development are present. The earliest change ap-

[2] The occurrence of clumps of fused red blood corpuscles in the sinusoids of the liver and sinuses of the spleen as an almost constant feature of hypervitaminosis A in rats and guinea pigs should be mentioned here as an early unpublished observation of one of the present authors (S. B. W.).

pears as an homogeneous dense acidophilic staining of the smooth muscle cells. More advanced lesions show infiltration of the media with strands of fibrin, proliferation of the intimal endothelium, and frequently a collection of red blood corpuscles beneath the endothelium. Mitotic figures are present in the adventitia and also in the endothelium. Some small veins show marked thickening as the result of intimal and adventitial proliferation. In such veins, while the lumen remains open, it is narrowed as a result of endothelial proliferation.

Another finding is that of mural thrombi of fused red blood corpuscles. The appearance suggests that the proliferation of the endothelium is the result of these thrombi, inasmuch as many of the thrombi are covered with one or more layers of endothelial cells. Occasionally red blood corpuscles are found intermingled with the proliferated (fibroblastic) cells of the adventitia. In some sections of the wall of the bladder practically every blood vessel shows these lesions. The lesions of the blood vessels of the gall bladder are identical and, also, in the mucosa there are many thrombosed small vessels which have resulted in small infarctions. In addition, many of the involved blood vessels are surrounded by small zones of hemorrhage.

While it seems unwarranted at present to regard these blood vessel lesions as a direct result of excessive vitamin A administration, we are at a loss to account for them, as they are quite different from any infectious lesion of the blood vessels that we know of and also quite different from the blood vessel lesions associated with the allergic reaction.

Bones. Based on knowledge of the skeletal changes resulting from vitamin A administration and gained from the study of small animals (Wolbach, '47), we selected for study in longitudinal and cross sections the epiphyseal ends of the tibia, fibula, femur, radius and ulna of dog 2. It should be kept in mind that the results on bone of excessive vitamin A administration are exhibited only in the growing animal and only in regions undergoing growth. A corollary from older studies is that the greater the rate of growth in the region the more marked are the consequences, which, in brief, consist of acceleration of the normal sequences of endochondral bone formation and the remodelling processes.

The effects on the growth sequences, including epiphyseal cartilage sequences and remodelling processes, are of the

same nature as those described for the rat and guinea pig (Wolbach, '47), though of lesser degree, which can be accounted for by the facts that the dogs were two months old when the experiment began and that the dosage of vitamin A was 300 I.U. per gram as compared to the 1,000 to 1,250 I.U. per gram used for rats and guinea pigs. The duration of the experiment on dog 2 was 68 days. With rats, the dosages used resulted, in 6 to 12 days, in the severe lesions including fractures already described (Wolbach, '47).

The epiphyseal cartilages in dog 2 of the regions chosen for study all exhibit complete consumption of fully grown cells, which has resulted in marked narrowing of the cartilage as a whole. Some of the appearances of the cartilage indicate that inanition effects have retarded the growth of the flattened cells in the cartilage columns, but here and there one sees deep penetration of the cartilage and blood vessels (fig. 1). Another indication of rapidity of growth sequences is the persistence of the bony trabeculae of the primary spongiosa.

In the shafts of the bones where remodelling normally takes place there are evidences of great increase in subperiosteal resorption of bone, just as has been described for smaller animals (figs. 2 and 3). There is, on the whole, much less evidence of new bone deposition, although newly deposited bone is present in regions of remodelling in conformity with the normal growth pattern and is much greater than deposition of bone in regions not being remodelled. The lesser amount of new bone formation as compared to rats and guinea pigs is probably the result of two factors—the slower tempo of the experiment and terminal inanition. In all regions of accelerated resorption of bone there is marked proliferation of periosteal cells and considerable hemorrhage, so that the appearances in such locations recall the hemorrhages of scurvy and a deficiency in intracellular matrix formation is to be considered as a possible factor, although it is not reconcilable with the appearances at the epiphyses and the deposit of osteoid wherever required by the normal growth pattern. Accelerated resorption of bone resulting in dimin-

ishing strength of periosteal attachments is a reasonable explanation of hemorrhages, although one we are not yet willing to commit ourselves to as a complete explanation because excessive vitamin A administration results in a depression of prothrombin levels (Light, Alscher and Frey, '44; Walker, Eylenburg and Moore, '47; Maddock, Wolbach and Jensen, '48).

Cross sections of femur, tibia and fibula reveal accelerated remodelling changes of cortical bone as required by the normal growth pattern. Cross sections of the femur show exaggeration of the flattening of the posterior surface with a great increase in the number of osteoclasts, periosteal proliferation and hemorrhage. The interior of the shaft in this region shows newly deposited osteoid and formation of compact bone in progress. The cortex, anteriorly, of the shaft shows a much less degree of the same process, indicating that at the level chosen the shaft is undergoing diminution in thickness.

The cross section of the tibia likewise shows remodelling sequences greatly in excess of the normal, most marked on the posterior surface and internal and anterior borders.

The most striking evidence of the accelerated remodelling is shown in the cross section of the fibula, of which only a small amount of compact bone remains. On one side, resorption is active. On the opposite side there is a thick layer of newly formed bone and osteoid, features required by the shift in relationships attending growth with increasing separation of tibia and fibula (figs. 4 and 5).

DISCUSSION

That characteristic skeletal changes and death as a result of the administration of excessive doses of vitamin A are phenomena present in the dog as well as in other mammals studied was doubted by some of the German workers in this field (Wendt, '35). The present study indicates that with sufficient dosage given over a sufficiently long time, the dog will respond as do the smaller laboratory animals. There is

some evidence to indicate that the dog, because of a possible lessened susceptibility to the effects of high doses of vitamin A, does not possess as delicately balanced a mechanism for the adjustment of vitamin A levels as does the rat or the human (Josephs, '42). The level of 2,420 I.U. per 100 ml of serum encountered during the course of this experiment in an adult dog on a regular diet is in excess of the maximum value of 950 I.U. per 100 ml of serum cited by Josephs in his human case of hypervitaminosis A (Josephs, '44), of the 1,200 reported by Toomey and Morissette ('47) and of the 2,081 reported by Rothman and Leon ('48) in other human cases. The dog is also unusual in his failure to respond to vitamin A administration by heightened cholesterol and phospho-lipid values, a finding noted by Wendt in 1935. Serum lipid rises after vitamin A feeding, either in large or toxic doses, have been noted in the human (Takahashi et al., '25; Harris and Moore, '28; Collazo, Rubino and Varela, '29); the rabbit (Harris and Moore, '28; Bomskov and Seemann, '33); the guinea pig (Collazo and Rodriguez, '33) and the rat (Drigalski, '33). The opposite effect, a fall in cholesterol (Drigalski, '33) and total lipids (Moll et al., '33) in the rat on vitamin A deficient diets, makes the implication that vitamin A is a factor in lipid metabolism a possible hypothesis.

The present study also emphasizes the fact that there are no detectable changes from the standpoint of the blood picture in carbohydrate, nitrogen and mineral metabolism. Except for a slightly heightened calcium level in one dog, the calcium, phosphorus and phosphatase values were essentially normal. Similar results have been noted in the rat (Davies and Moore, '34; Strauss, '34–'35; Cornil, Chevallier and Paillas, '39). Josephs' ('44) case of hypervitaminosis in a child showed normal calcium and phosphorus values but heightened phosphatase values, persisting as long as 6 months after the vitamin had been withheld.

In view of the great skeletal changes resulting from excess vitamin A administration, the absence of changes in calcium, phosphorus and phosphatase values may seem perplexing.

It must be kept in mind that the effect upon the skeleton is one of increased tempo of growth processes in complete conformity with normal growth patterns, in which removal of bone is balanced by new formations of bone and, *a priori*, the rate of metabolic activities resulting therefrom need not be reflected quantitatively in the blood.

It may be suggested that the accelerated rate of consumption of epiphyseal cartilage—essentially an acceleration of skeletal ageing— is accompanied by quantitative changes in the blood of an unknown nature.

SUMMARY AND CONCLUSIONS

1. The dog responds, as do other laboratory animals, to excessive doses of vitamin A.

2. This response is marked by loss of appetite, marked loss in weight, characteristic skeletal changes, hyperesthesia and exophthalmos.

3. Laboratory findings, with the exception of marked increases in the vitamin A content of the blood and a late drop in blood lipids (lipid-P and cholesterol), show no significant alterations.

ACKNOWLEDGMENTS

Acknowledgments are due to Dr. Blanche A. Jackson, formerly fellow in Pathology at Harvard Medical School, for the vitamin A determinations, and to Miss Dorothy Jensen of the Surgical Research Laboratory, Boston City Hospital, for some of the chemical determinations.

Preparation of this report has been aided by the Nutrition Foundation and the Waterman-Williams Fund for the Combat of Dietary Diseases.

LITERATURE CITED

BLOOR, W. R., K. F. PELKAN AND D. M. ALLEN 1922 Determination of fatty acids (and cholesterol) in small amounts of blood plasma. J. Biol. Chem., *52:* 191.

BODANSKY, A. 1932 Determination of inorganic phosphate. Ibid., *99:* 197.

Bomskov, C., and G. Seemann 1933 Über eine Wirkung des Vitamin A auf den Mineralhaushalt. Zschr. ges. exp. Med., *89:* 771.

Butler, A. M., and E. Tuthill 1931 An application of the uranyl zinc acetate method for the determination of sodium in biological material. J. Biol. Chem., *93:* 171.

Clausen, S. W., W. S. Baum, A. B. McCoord, J. O. Rydeen and B. B. Breese 1940 Mobilization of vitamin A from its stores in tissues by ethyl alcohol. Science, *91:* 318.

Collazo, J., and J. S. Rodriguez 1933 Hypervitaminose A. Klin. Wschr., [illegible] 1732.

Collazo, J. A., P. Rubino and B. Varela 1929 Hypervitaminose D. Knochenbildung u. Wachstumsstörungen bei Ratten nach grossen Dosen bestrahlten Ergosterins. Deut. med. Wschr., *55:* 1794.

Cornil, L., A. Chevallier and J. E. Paillas 1939 Etude histologique des lesions experimentales de la survitaminose A chez le cobaye. Ann. anat. path., *16:* 74.

Davies, A. W., and T. Moore 1934 Vitamin A and carotene. The distribution of vitamin A in the organs of the normal and hypervitaminotic rat. Biochem. J., *28* (1): 288.

Drigalski, W. v. 1933 Über Schädigung durch Vitamin A. Klin. Wschr., *12:* 308.

Fiske, C. H., and E. T. Adams 1931 The determination of calcium by alkalimetric titration. J. Am. Chem. Soc., [illegible]

Fiske, C. H., and Y. SubbaRow Lipid phosphorus determinations. (Unpublished observations.)

Folin, O. 1934 Laboratory Manual of Biological Chemistry. D. Appleton-Century Co., Inc., New York, N. Y., 7th ed.

Folin, O., and H. Malmros 1929 An improved form of Folin's micro method for blood sugar determinations. J. Biol. Chem., *83:* 115.

Harris, L. J., and T. Moore 1928 "Hypervitaminosis" and "vitamin balance." Biochem. J., *22* (2): 1461.

Josephs, H. W. 1942 Factors influencing level of vitamin A in blood of rats. Bull. Johns Hopkins Hosp., *71:* 253.

——— 1944 Hypervitaminosis and carotenemia. Am. J. Dis. Child., [illegible] 33.

Light, R. F., R. P. Alscher and C. N. Frey 1944 Vitamin A toxicity and hypoprothrombinemia. Science, *100:* 225.

Lowry, O. H., and O. A. Bessey 1945 Microchemical methods for nutritional studies. Fed. Proc., *4:* 268.

Maddock, C. L. 1942 (Unpublished observations.)

Maddock, C. L., S. B. Wolbach and D. Jensen 1948 Hypoprothrombinemia as a cause of death in hypervitaminosis A. Fed. Proc., *7:* 275.

May, C. D., K. D. Blackfan, J. F. McCreary and F. H. Allen, Jr. 1940 Clinical studies of vitamin A in infants and in children. Am. J. Dis. Child., *59:* 1167.

Mirsky, I. A., and M. Bruger 1932 The effect of temperature on cholesterol determinations. J. Lab. Clin. Med., *18:* 304.

MOLL, T., O. DALMER, P. DOBENECK, G. DOMAGK AND F. LAQUER 1933 Über das Vitamin A-Konzentrat "Vogan." Arch exp. Path., *170:* 176.

MOORE, T., AND Y. L. WANG 1945 Hypervitaminosis A. Biochem. J., *39:* 222.

NOETZEL, H. 1939 Morphologische Untersuchungen bei Vitamin A Überdosierung. Zschr. ges. exp. Med., *105:* 83.

RODAHL K., AND T. MOORE 1943 Vitamin A content and toxicity of bear and seal liver. Biochem. J., *37:* 166.

ROTHMAN, P. E., AND E. E. LEON 1948 Hypervitaminosis A. A report of two cases in infancy. Radiology, *51:* 368.

STRAUSS, K. 1934–35 Beobachtungen bei Hypervitaminose A. Beitr. path. Anat., *F. 94:* 345.

TAKAHASHI, NAKAMIYA, KAWAKAMI AND KITASATO 1925 Scientific papers, Inst. Phys. Chem. Res. (Tokyo), *3:* 81.

TOOMEY, J. A., AND R. A. MORISSETTE 1947 Hypervitaminosis A. Am. J. Dis. Child., *73:* 473.

WAKERLIN, G. E., AND W. G. MOSS 1943 Treatment of experimental renal hypertension with vitamin A concentrate. Proc. Soc. Exp. Biol. Med., *53:* 149.

WALKER, S. E., E. EYLENBURG AND T. MOORE 1947 The action of vitamin K in hypervitaminosis A. Biochem. J., *41:* 575.

WENDT, H. 1935 Beiträge zur Kenntnis des carotin und vitamin A Stoffwechsels. Klin. Wschr., *14:* 9.

WESLAW, W., B. WRONSKI, A. WROBLEWSKI AND B. WROBLEWSKI 1938 Symptomalogie u. Verlauf der A-Hypervitaminose bei Ratten infolge enteraler, subcutaner u. percutaner Darreichung von Vitamin A Konzentraten. Ibid., *17:* (1) 777, 879.

WHITEHORN, J. C. 1920–21 Simplified method for the determination of chlorides in blood or plasma. J. Biol. Chem., *45:* 449.

WOLBACH, S. B. 1947 Vitamin A deficiency and excess in relation to skeletal growth. J. Bone Surg., *29:* 171.

————(See also: 1946 Vitamin A deficiency and excess in relation to skeletal growth. Ludvig Hektoen Lecture. Proc. Institute of Medicine of Chicago, *16:* No. 4, April 15, 1946.)

WOLBACH, S. B. AND O. A. BESSEY 1942 Tissue changes in vitamin deficiencies. Physiol. Rev., *22:* 233.

PLATE 1

EXPLANATION OF FIGURES

1 Dog 2. Photomicrograph. Epiphyseal cartilage, proximal end of tibia. The evidences of accelerated growth sequences are illustrated by deep penetration of the cartilage by blood vessels, the character of the primary spongiosa, and the penetration of the zone of residual cells by blood vessels from the epiphyseal side.

2 Dog 2. Photomicrograph. Proximal ends of the fibula showing complete consumption of active zones of epiphyseal cartilage, resorption of the periosteal bone, and subperiosteal hemorrhage.

1

2

PLATE 2

EXPLANATION OF FIGURES

3 Dog 2. Photomicrograph. Distal end of the radius. High power detail of accelerated resorption of bone beneath the periosteum with regions of concurrent bone deposition internally.

4 Dog 2. Photomicrograph. Low power. Cross section of fibula. This shows only a remnant of old bone. The upper right hand border is undergoing resorption and in the lower left there is new bone deposition.

3

4

PLATE 3

EXPLANATION OF FIGURES

5 Dog 2. High power detail of figure 4, illustrating the accelerated compact bone formation in the fragment of old bone. Numerous osteoclasts on the site of resorption and accelerated appositional bone formation on the opposite side. In both figures 4 and 5 the arrows indicate the direction of movement of the fibula away from the tibia in conformity with the growth pattern.

6 Normal control dog. To illustrate the remodelling sequences in a normal dog. The arrow shows the direction of movement.

5

6

Mahadevan-'61
Bib. No. 5655

Reproduced by permission
of the copyright owner

Biochem. J. 81:53-58. 1961.

Further Studies on the Absorption of Vitamin A

By S. MAHADEVAN and J. GANGULY
Department of Biochemistry, Indian Institute of Science, Bangalore 12, India

(*Received* 2 *February* 1961)

Irrespective of whether vitamin A is fed to rats as the free alcohol or as its esters, 75% of it is found in the esterified form in the mucosae and muscles of the small intestine, whereas only the ester is transported exclusively through the lymphatic system, so that in the post-absorptive blood the ester shows a sharp increase (Ganguly, 1960). Gray & Cawley (1942) concluded from the molecular-distillation data on the oil obtained from rat liver that vitamin A was probably stored in the liver as its palmitate. Later work of Kaiser & Kagan (1956) showed that the vitamin A ester of blood and liver of rats was composed of higher fatty acids, and Mahadevan, Krishnamurthy & Ganguly (1959) showed that the lower esters of vitamin A were not absorbed from the intestine.

Gray, Hickman & Brown (1940) suggested that when rats are fed with different types of esters of vitamin A the liver, in time, converts them into one type of ester, probably the palmitate. We have recently demonstrated that an enzyme preparation from the intestinal mucosae of rats can rapidly esterify vitamin A with almost equal efficiency with saturated or unsaturated fatty acids containing more than 10 carbon atoms. However, it fails to esterify the vitamin with acids containing fewer carbon atoms (Murthy, Mahadevan, Seshadri Sastry & Ganguly, 1961). It might therefore be assumed that different types of esters (depending upon the availability of fatty acids of either endogenous or exogenous source) would be present in the mucosae and muscles of the small intestine, as well as in the blood and liver of rats, after a dose of the vitamin. It is demonstrated here that contrary to this expectation, it is the palmitate of vitamin A that always predominates in the mucosae, muscles and blood, and only the palmitate is deposited in the liver of rats.

MATERIALS AND METHODS

Methanol (Merck; Pro Analyst grade) and butanol (British Drug Houses Ltd.; Laboratory Reagent grade) were redistilled before use. Tweens 20, 40 and 60 (lauric, palmitic and stearic acid esters respectively of polyoxyethylene sorbitol) were obtained from Atlas Powder Co., Wilmington, Del., U.S.A. Refined coconut oil was obtained from the local market. Groundnut, sesame (*Sesamum indicum*) and safflower (*Carthamus tinctorius*) oils were expressed in an expeller from the respective oil seeds commercially available and were used without further purification. Silicone fluid F 110/300 was from Imperial Chemical Industries Ltd., London. The rest of the materials have been described in previous papers (Mahadevan *et al.* 1959; Ganguly, Krishnamurthy & Mahadevan, 1959).

Synthetic vitamin A alcohol, purified by chromatography on alumina columns (Ganguly, Krinsky, Mehl & Deuel, 1952), was dissolved in light petroleum (b.p. 40–60°) together with the Tween or the oil so as to obtain a final concentration of 6 mg. of the vitamin/ml. of the carrier. The solvent was evaporated under vacuum at 40–50°, the last traces being removed with a gentle stream of N_2. Colloidal dispersions were prepared according to Mahadevan *et al.* (1959).

Rats of either sex of this Institute strain were maintained after weaning on a vitamin-A-low diet composed of (%): starch, 65; solvent-extracted casein, 20; groundnut oil, 10; salt mixture, 5; with daily supplements of adequate amounts of the other vitamins. The animals were used after they had been on the diet for 5–6 weeks; at this stage their livers were essentially free from vitamin A.

After starvation for 24 hr. the animals were given an oral dose of 0·5 ml. of the carrier containing 3 mg. of vitamin A alcohol and were killed 2–3 hr. later by drawing as much blood as possible from the heart, while under light ether anaesthesia. Separation of the contents, mucosae and muscles of the small intestine, and extraction of these and of blood and liver were carried out as described earlier (Ganguly *et al.* 1959; Mahadevan *et al.* 1959). The extracts were chromatographed through alumina columns and the ester fractions were collected (Ganguly *et al.* 1952) for further analysis. Since the esterified vitamin A alone is transported from the intestine, this work was concerned with the study of the esters only; the alcohol fraction was not taken into account.

Separation of the higher fatty acid esters of vitamin A by reverse-phase circular chromatography on silicone-impregnated papers

Paper-chromatographic techniques were used for the separation of vitamin A alcohol, acetate and palmitate (Brown, 1953), and of the acetate and the higher esters (Kaiser & Kagan, 1956; Mahadevan *et al.* 1959). These techniques cannot resolve the higher esters of vitamin A, whereas our present work required a successful resolution of these esters. We obtained the best separation in a system where the filter paper is impregnated with silicone fluid and is irrigated with a mixture of methanol–butanol–water (85:10:5, by vol.).

The esters used as reference materials were prepared enzymically. A water extract (1 ml.) of 100 mg. of acetone-dried powder of rat pancreas and 1 ml. of ethanol containing 2 mg. of pure vitamin A alcohol plus 6 mg. of the required fatty acid were incubated at 37° for 1 hr. in 8 ml. of 0·01 M-phosphate buffer (Na_2HPO_4–NaH_2PO_4) at pH 6·6. At the end of the incubation the vitamin A was twice extracted with light petroleum after the addition of 10 ml. of ethanol. The esters formed were then separated from the unchanged vitamin A alcohol by chromatography on alumina columns (Ganguly *et al.* 1952).

Whatman no. 3 or no. 1 filter paper (45 cm. × 45 cm.) was dipped into a 7·5% (v/v) solution of silicone fluid in light petroleum for 30 sec. and allowed to dry at room temperature for 24 hr. The impregnated paper keeps for a considerable length of time without any change in its properties.

Usually the circular chromatogram was developed in the dark in large wooden chambers in an atmosphere of N_2 after spotting 10–15 μl. of light petroleum solutions containing 5–10 μg. of the ester at each point on the circumference of a circle drawn in the centre of the paper. Use of methanol alone for irrigation gave satisfactory separation, but addition of butanol cut down the length of the run, and the presence of water gave very sharp bands. With the solvent system of methanol–butanol–water (85:10:5) the separation was usually complete within 10–12 hr. The chromatogram was inspected under ultraviolet light and the fluorescent bands were marked. The rest of the procedure for the quantitative estimation of the esters was as described before (Mahadevan *et al.* 1959). Mixtures of known esters were chromatographed together with the extracts. It was extremely important to keep the chromatograms in the dark and not expose them to ultraviolet light while the irrigation was going on, as this led to the appearance of several additional fluorescent bands.

The recovery of the esters with this procedure was 90–95% and the R_F values were as follows: stearate, 0·29; palmitate, 0·32; myristate, 0·36; laurate, 0·4; oleate, 0·32; linoleate, 0·36; linolenate, 0·4. Complete separation of the saturated acid esters or of the unsaturated esters was possible but the 'critical pairs' (e.g. palmitate and oleate, etc.) could not be separated.

For convenience, throughout this paper these bands will be referred to as if the saturated acids alone were present (e.g. stearate, palmitate, myristate and laurate). It is quite possible that the bands, especially those from the contents and mucosae may contain considerable amounts of the unsaturated esters of identical R_F values. This does not affect the objects and conclusions of this work to any extent, because we are demonstrating here that only one of these critical pairs, the 'palmitate', is actively transported and deposited. Also, as will be seen later on, we have been able to prove that this fraction of the intestine, muscles, blood and liver is composed almost entirely, if not wholly, of the palmitic acid ester.

RESULTS

Effect of carriers on the fatty acid composition of the vitamin A esters in the rat

Representative results of experiments, when different types of carriers were used, are summarized in Table 1. It is most striking that in the absence of exogenous palmitic or oleic acid an almost constant amount of the 'palmitate' was always present in the contents of the small intestine, as will be seen from the experiments with colloidal vitamin A alcohol, and with Tween 20 and Tween 60 dispersions of vitamin A alcohol. This same amount of the 'palmitate' was probably common in all other cases also, so that their enhanced 'palmitate' values are obviously due to the palmitic or oleic acid contributed by the carrier. The increase in the other esters is clearly due to the exogenous fatty acids. Thus, with Tween 20 (a laurate) and Tween 60 (a stearate), the 'laurate' and 'stearate' esters respectively rose sharply, whereas Tween 40 (a palmitate) gave rise to an extra amount of the 'palmitate'. Coconut oil, containing about 48% of lauric acid, yielded considerable quantities of vitamin A 'laurate', and, since this particular oil contains practically no linolenic acid, the ester should represent the lauric acid ester. The 'myristate' band was prominent with the other three oils which have practically no myristic acid but are rich in linoleic acid, so that the materials of this band should be mostly vitamin A linoleate. It is thus obvious that the patterns of the vitamin A esters of the intestinal contents reflect the fatty acid composition of the vehicle used.

In the mucosae the ester composition in every case was very similar to that of the contents with the exception that the 'palmitate', as compared with the other esters, was more prominent. When colloidal vitamin A was given, the 'palmitate' con-

centration was very high, and was practically the only ester.

The picture of the esters in the intestinal muscles was radically different from that in the mucosae. Whereas the esters of the mucosae largely reflected the fatty acid composition of the vehicle, only the concentration of the 'palmitate' was of any real significance in the muscles, because in all cases it was present to the extent of 79–93 % of the total esters. However, smaller quantities of the other esters representing the fatty acid composition of the carrier persisted. Thus when Tween 20 and coconut oil were used, there were small amounts of the 'laurate', whereas Tween 60 gave some 'stearate' and with the other three oils some of the 'myristate' was present. The ester composition of the blood appears to resemble that of the intestinal muscles: the 'palmitate' predominated in all the samples.

The liver, on the other hand, presents a rather unique picture since only the 'palmitate' was stored in spite of the presence of other esters in the blood.

Identification of the fatty acid of the vitamin A ester of intestinal muscles, blood and liver

These results show that only one of the critical pairs, i.e. the 'palmitate', is admitted inside the animal body to any significant extent. But, as pointed out earlier, the chromatographic procedure adopted here cannot resolve the critical pairs. Attempts were therefore made to obtain more definite information about the nature of the fatty acid of the 'palmitate' band of the muscles, blood and liver. These tissues from 10 rats, dosed with similar amounts of vitamin A alcohol dissolved in groundnut oil and killed 2–3 hr. later, were extracted according to Ganguly *et al.* (1959). The tissue extracts in light petroleum were shaken in separatory funnels five or six times with equal volumes of fresh aq. 85 % (v/v) ethanol each time. The ethanol layers were discarded: the light petroleum layers were twice chromatographed on alumina columns when the ester fractions were eluted with 1 % (v/v) of acetone in light petroleum. The esters were now chromatographed in batches on silicone-impregnated filter papers; the other smaller bands were discarded and only the 'palmitate' band was recovered. The paper-chromatographic procedure was repeated once more, after which the eluate was finally passed through an alumina column. The esters, thus purified, were saponified by heating with alcoholic potassium hydroxide (20 %, w/v) on a water bath at 60–80°; the fatty acids were then extracted with light petroleum after acidification with hydrochloric acid.

Duplicate samples of the liberated fatty acids were now separately subjected to reverse-phase chromatography on paraffin-impregnated papers with two different solvent systems. One of the chromatograms was developed with 90 % acetic acid and the other with acetic acid–formic acid–20 % hydrogen peroxide (6:1:1, by vol.). The latter system is known to destroy all the unsaturated acids and to carry the products to the solvent front

Table 1. *Vitamin A ester composition of the contents, mucosae and muscles of the small intestine, and of the blood and liver, of rats 2 to 3 hr. after feeding with vitamin A alcohol in different carriers*

Each rat was given orally 3·0 mg. of vitamin A alcohol in 0·5 ml. of the Tween or oil or in 0·5 ml. of water containing 1 % of sodium taurocholate. The results are averages of three separate experiments with individual rats. Values are expressed as μg. of vitamin A alcohol present as ester per whole organ in contents, mucosae, muscles and liver, and per 10 ml. of blood. S, 'Stearate'; P, 'palmitate'; M, 'myristate'; L, 'laurate'.

Carrier used	Main fatty acid(s) present	Intestine: Contents				Intestine: Mucosae				Intestine: Muscles				Blood				Liver			
		S	P	M	L	S	P	M	L	S	P	M	L	S	P	M	L	S	P	M	L
Colloidal dispersion in water	None	8	27	0	0	6	143	2	4	2	78	1	1	0	30	0	0	0	153	0	0
Tween 20	Lauric	11	26	3	70	15	107	19	67	3	133	3	12	2	39	2	8	0	116	0	0
Tween 40	Palmitic	14	92	0	0	19	219	9	13	2	207	3	5	0	45	0	0	0	179	0	0
Tween 60	Stearic	62	23	3	0	53	99	8	7	14	115	1	1	3	37	0	0	0	115	0	0
Coconut oil	Lauric	10	48	12	48	28	104	12	86	6	126	2	17	1	29	1	3	0	136	0	0
Groundnut oil	Oleic, linoleic	4	60	30	7	23	126	58	9	5	128	15	2	1	28	3	1	0	159	0	0
Sesame oil	Oleic, linoleic	2	47	43	0	9	117	93	7	3	135	22	2	2	23	6	1	0	145	0	0
Safflower oil	Linoleic, oleic	2	42	52	3	6	113	67	3	2	83	19	1	1	18	4	1	0	127	0	0

leaving the saturated ones unaffected (Buchanan, 1959). The positions of the fatty acids were located by treating the papers with cupric acetate solution followed by potassium ferrocyanide (Wagner, Abisch & Bernhard, 1955). In both chromatograms of samples from intestinal muscles, blood and liver only one band, corresponding to palmitic acid, was present, and by visual comparison no difference in the intensity of the colour between the peroxide-treated and untreated chromatograms could be observed.

Since the liver contained larger amounts of the ester, we were able to use other methods to prove that it is a palmitate. Representative samples of the liver ester were purified as described above. From a portion of the purified ester fraction the exact amount of vitamin A present was accurately determined, expressed as vitamin A alcohol (1·36 mg.). From this vitamin A alcohol value, the theoretical amount of palmitic acid, that should combine with it, was calculated (1·22 mg.). The rest of the sample was saponified and the fatty acids were chromatographed on paper with and without H_2O_2 as described above. The paper was treated with 0·1% mercuric acetate solution, washed thoroughly with running tap water, dried and sprayed with a solution of 0·2% diphenylcarbazide reagent. The coloured bands thus formed were eluted with toluene and methanol, and the quantity of fatty acids present was determined colorimetrically (Viswanathan & Meera Bai, 1961). There was no difference in the values between the peroxide-treated and untreated samples. Also, the amount of palmitic acid estimated (1·27 mg.) agreed closely with the theoretical value as calculated above. Finally, the iodine vapour test of another chromatogram was negative. Thus although oleic acid is more abundant than palmitic acid in groundnut oil, there was practically no vitamin A oleate in the intestinal muscles, blood or liver of rats.

Changes in the ester composition of vitamin A in the rat with time

Gray *et al.* (1940) indicated that several esters of vitamin A might reach the liver to be eventually converted into one type, probably the palmitate. The above experiments have demonstrated that irrespective of the ester composition of the contents and mucosae, the liver can store only the palmitate. These experiments, however, were carried out within a very short time interval (2–3 hr.) after dosing and hence it remained a possibility that given longer time intervals the liver might store the other esters in addition to the palmitate. Rats were therefore fed with vitamin A alcohol in coconut oil and killed at the stated time intervals. The relative appearances of the different esters with respect to time in the various tissues of these rats are tabulated in Table 2. Up to 6 hr. the ester patterns in all the samples were similar to those obtained with the same oil in the experiments of Table 1. However, after 10 hr. the palmitate became the most prominent constituent, and after 24 hr. it was the sole component. Here again despite the fact that lauric acid is the major acid of coconut oil, at no time did the liver show any traces of any other ester but the palmitate, even though the total ester stored per liver increased from 125 μg. at 2 hr. to 1200 μg. after 24 hr.

Fatty acid specificity for the esterification of vitamin A by the enzymes of the intestinal muscles

The ester patterns in the contents and mucosae are probably due to the rather non-specific nature of esterification of vitamin A by the enzymes of the pancreas and mucosae. The predominance of the palmitate in the intestinal muscles, on the other hand, might well be due to a specific esterification of vitamin A brought about by the muscle enzyme with palmitic acid. The esterifying activity of the acetone-dried powder of the muscles with different

Table 2. *Vitamin A ester composition of the contents, mucosae and muscles of the small intestine, and of the blood and liver of rats, at different time intervals after feeding with vitamin A alcohol in coconut oil*

Each rat was given orally 3·0 mg. of vitamin A alcohol in 0·5 ml. of coconut oil. The results are averages of three separate experiments with individual rats. Values are expressed as μg. of vitamin A alcohol present as ester per whole organ in contents, mucosae, muscles and liver, and per 10 ml. of blood. S, 'Stearate'; P, 'palmitate'; M, 'myristate'; L, 'laurate'.

	Time after dosing																							
	2 hr.				3 hr.				4 hr.				6 hr.				10 hr.				24 hr.			
Tissue	S	P	M	L	S	P	M	L	S	P	M	L	S	P	M	L	S	P	M	L	S	P	M	L
Intestine																								
Contents	9	37	8	56	8	53	7	58	4	42	3	37	4	39	4	26	5	23	3	15	2	12	0	0
Mucosae	6	59	6	38	14	128	5	92	13	132	5	89	10	78	4	47	1	39	1	5	0	5	0	0
Muscles	4	67	4	18	6	132	5	15	6	138	4	19	4	84	3	13	0	48	1	4	0	8	0	0
Blood	1	14	1	3	1	23	1	4	1	32	1	8	1	27	1	5	0	18	0	2	0	9	0	0
Liver	0	125	0	0	0	170	0	0	0	376	0	0	0	729	0	0	0	820	0	0	0	1200	0	0

fatty acids was therefore tested as described by Murthy *et al.* (1961). The relative esterification with the different acids, as shown in Table 3, was similar to that obtained with the mucosal and pancreatic enzymes, inasmuch as no preference for any particular acid was exhibited. In a separate experiment, where an ethanolic solution of 1 mg. of vitamin A alcohol was similarly incubated with a mixture containing 1 mg. each of lauric, myristic, palmitic and stearic acids, no significant preference for esterification with palmitic acid was noticed.

It is also possible that blood and liver might bring about the formation of larger amounts of the palmitate by means of a mechanism of transesterification with other lipid materials, without going through the processes of hydrolysis and re-esterification [these two latter processes have been shown to be absent from these tissues (Mahadevan, Murthy, Krishnamurthy & Ganguly, 1961)]. Experiments were therefore carried out in which 0·5 ml. of an ethanolic solution of the esters (laurate, myristate, palmitate and stearate) containing 250 μg. of each was separately incubated in 4 ml. of phosphate buffer (pH 6·6; 0·1 M) with 1 mg. of Tween 40 and 1 ml. of rat-liver homogenate (equivalent to 500 mg. of wet liver) or 1 ml. of plasma for 1 hr. at 37°. No formation of any additional palmitate was observed.

Nature of vitamin A esters in the livers of other species

Samples of vitamin A ester fractions from the livers of chickens, sheep, shark and rats, when chromatographed in our system, revealed that shark and rat liver display only one band, corresponding to the 'palmitate', whereas the chicken-liver sample resolved itself into two distinct bands representing about 70 % of 'palmitate' and 30 % of 'stearate'. In sheep liver the 'palmitate' was prominent, accounting for about 90 % of the total esters.

Table 3. *Fatty acid specificity for the esterification of vitamin A by the enzymes of rat intestinal muscles*

Conditions and procedures were as described by Murthy, Mahadevan, Seshadri Sastry & Ganguly (1961) except that the enzyme extract added contained 20 mg. of protein.

Fatty acid	Vitamin A alcohol esterified (μg.)
Lauric	64·2
Myristic	54·9
Palmitic	53·7
Stearic	51·4
Oleic	57·5
Linoleic	58·3
Linolenic	54·6

DISCUSSION

The techniques employed in the earlier work of Kaiser & Kagan (1956) and of Mahadevan *et al.* (1959) were not suitable for the resolution of the higher esters of vitamin A, so that it was possible to arrive only at the broad conclusion that the higher esters are admitted into the rat. With the successful separation of these esters (or pairs of esters), we have been able to conclude in the present report that this ester in the rat is a palmitate. In no case have we been able to detect in the tissues of the rat vitamin A esters with acids shorter than lauric acid, fully confirming the earlier findings of Kaiser & Kagan (1956), Mahadevan *et al.* (1959) and of Bruggemann & Tiews (1960). However, Loran & Althausen (1959) have claimed that in an isolated intestine *in vitro* the long-chain esters of vitamin A are hydrolysed on the lumen side and are re-esterified inside the mucosae with acetic acid. This is in sharp disagreement with the information given in our earlier experiments (Mahadevan *et al.* 1959) and in the present paper. We have already demonstrated that the intestinal enzymes preferentially esterify vitamin A with long-chain acids, whereas no esterification could be obtained with acetic acid. On the other hand, as compared with the higher esters, vitamin A acetate is more rapidly hydrolysed by the enzymes of this tissue (Mahadevan *et al.* 1961).

The fatty acid composition of the carrier employed for vitamin A is reflected by the patterns of the esters in the lumen and mucosae of the small intestine of rats. This can readily be explained, because the pancreas and mucosae of rats esterify vitamin A non-specifically with long-chain acids. But 'palmitate' is almost the sole constituent in the absence of exogenous fatty acids, e.g. after feeding with colloidal vitamin A. It appears preferentially in the intestinal muscles, in spite of the presence of considerable amounts of other esters in the mucosae, as found when Tween 20 or 60 or one of the four oils is used as the carrier. This cannot be explained on the basis of the assumption of any preferential esterification of the vitamin in this tissue with palmitic acid alone, because the muscle enzyme, like the mucosal enzyme, seems to be rather non-specific towards the fatty acid for this process. Nor can this be explained by assuming ready availability of palmitic acid in the intestine, because according to Coniglio & Cate (1958) this acid is not the only major fatty acid in the normal intestinal tissue of rats. The failure to demonstrate any transesterification mechanism in the blood and liver rules out the possibility of such reactions accounting for the presence of 'palmitate' only in these tissues.

One possible explanation seems to be that a certain amount of specificity for the vitamin A

palmitate exists in the mechanism of its transport from the mucosae onwards and in its final storage in the liver. Indeed Krinsky, Cornwell & Oncley (1958) have demonstrated the specificity of lipoproteins in their binding with vitamin A ester and vitamin A alcohol in post-absorptive human blood. In an earlier paper we also have discussed and suggested a similar possibility in the transport and storage of vitamin A in the rat (Ganguly *et al.* 1959), and this aspect has been more exhaustively reviewed by Ganguly (1960). Krinsky *et al.* (1958) are of the view that the specific lipoprotein, responsible for the transport of vitamin A ester in blood, occurs in the Kupffer cells of the liver. It is possible that this lipoprotein exists in the Kupffer cells, in blood and in the central lacteals of the intestinal villi. The 'palmitate', even in the mucosae, could then be in actual combination with this lipoprotein and probably inside the central lacteals. The picture in the intestinal muscles would then appear to represent that phase of absorption where the ester, after entering the lymphatic system in the lipoprotein-bound state, has travelled far away from the actual site of esterification (the mucosae) on its way to the systemic blood, so that mostly the palmitate is found. Since the Kupffer cells of the liver contain the same lipoprotein, it preferentially removes only the palmitate from the systemic blood and totally rejects the others.

McGillivery, Thompson & Worker (1957) have demonstrated that, on intravenous injection of emulsions of vitamin A alcohol or palmitate in rats and goats, the palmitate is more efficiently taken up by the liver, whereas more of the administered alcohol keeps on circulating in the blood. Preliminary experiments being carried out by us also indicate that, after intravenous injection of vitamin A stearate dispersed in water with Tween 40, no stearate could be detected in rat liver. These observations would lend further support to the hypothesis that rat liver selects only the palmitic acid ester of vitamin A.

There were, however, traces of the other esters in the intestinal muscles and blood, but not in the liver. Since the liver has no acceptors for them, they tend to accumulate in the circulating blood either to be detoxicated or to be hydrolysed and re-esterified with palmitic acid in the intestine or pancreas during their rapid circulation, so as to be deposited ultimately in the liver as the palmitate.

To summarize, it would thus appear possible that the lipoprotein exerts its selective binding probably at the mucosal cells for the palmitate only, the bound palmitate then travels through the lymphatic system and finally finds its way to the Kupffer cells, where it is deposited and the free lipoprotein comes back to the intestine to carry more palmitate.

SUMMARY

1. A circular paper-chromatographic procedure for the separation of higher fatty acid esters of vitamin A, with silicone-impregnated paper and a solvent system of methanol–butanol–water (85:10:5, by vol.), is described.

2. Rats raised on a vitamin-A-low diet and starved for 24 hr. were dosed with vitamin A alcohol in the carriers Tweens 20, 40 and 60, groundnut oil, sesame oil, coconut oil or safflower oil; the vitamin A ester fractions of the contents, mucosae and muscles of the small intestine, and of blood and liver, were analysed by the above method 2–3 hr. after the dose.

3. After the feeding of colloidal vitamin A, most vitamin A palmitate was found in the contents, mucosae and muscles of the small intestine, and in the blood and liver, of rats.

4. The types of the esters of the contents and mucosae in all other cases were governed by the fatty acids of the carrier. No such relationship was found for the ester composition of intestinal muscles and blood, which contained almost entirely the palmitic acid ester. The liver, under the conditions studied, stored exclusively the palmitate.

This work was supported by a research grant from the Indian Council of Medical Research.

REFERENCES

Brown, J. A. (1953). *Analyt. Chem.* **25**, 774.
Bruggemann, J. & Tiews, J. (1960). *Int. Z. Vitaminforsch.* **30**, 279.
Buchanan, M. A. (1959). *Analyt. Chem.* **31**, 1616.
Coniglio, J. G. & Cate, D. L. (1958). *J. biol. Chem.* **232**, 381.
Ganguly, J. (1960). *Vitam. & Horm.* **18**, 387.
Ganguly, J., Krinsky, N. I., Mehl, J. W. & Deuel, H. J. jun. (1952). *Arch. Biochem. Biophys.* **38**, 275.
Ganguly, J., Krishnamurthy, S. & Mahadevan, S. (1959). *Biochem. J.* **71**, 756.
Gray, E. Le B. & Cawley, J. D. (1942). *J. Nutr.* **23**, 3[illegible].
Gray, E. Le B., Hickman, K. C. D. & Brown, E. F. (1940). *J. Nutr.* **19**, 39.
Kaiser, E. & Kagan, B. M. (1956). *Arch. Biochem. Biophys.* **63**, 118.
Krinsky, N. I., Cornwell, D. G. & Oncley, J. L. (1958). *Arch. Biochem. Biophys.* **73**, 233.
Loran, M. R. & Althausen, T. L. (1959). *Amer. J. Physiol.* **197**, 1333.
McGillivery, W. A., Thompson, S. Y. & Worker, N. A. (1957). *Brit. J. Nutr.* **11**, 57.
Mahadevan, S., Krishnamurthy, S. & Ganguly, J. (1959). *Arch. Biochem. Biophys.* **83**, 371.
Mahadevan, S., Murthy, S. K., Krishnamurthy, S. & Ganguly, J. (1961). *Biochem. J.* **79**, 416.
Murthy, S. K., Mahadevan, S., Seshadri Sastry, P. & Ganguly, J. (1961). *Nature, Lond.*, **189**, 482.
Viswanathan, C. V. & Meera Bai, B. (1961). *J. Chromat.* (in the Press).
Wagner, H., Abisch, L. & Bernhard, K. (1955). *Helv. chim. acta*, **38**, 1536.

Mahadevan-'66
Bib. No. 5663

THE JOURNAL OF BIOLOGICAL CHEMISTRY
Vol. 241, No. 1, Issue of January 10, 1966
Printed in U.S.A.

Hydrolysis of Retinol Palmitate by Rat Liver*

(Received for publication, April 12, 1965)

S. MAHADEVAN,† N. I. AYYOUB,‡ AND O. A. ROELS§
From the Institute of Nutrition Sciences, Columbia University, New York, New York 10032

SUMMARY

Retinol acetate hydrolase is localized in rat liver microsomes whereas the retinol palmitate-hydrolyzing activity was found in the nuclear and in the mitochondrial lysosome-rich fractions. Acetone-dried powder from whole rat liver retained all of its retinol palmitate-hydrolyzing activity. Ammonium sulfate fractionation of the acetone-dried powder yielded a partially purified enzyme liberating 240 mμmoles of retinol per mg of protein per 60 min when retinol palmitate was used as substrate. The pH optimum was 8.6 and K_m was 1.6×10^{-4} M. The enzyme was inhibited by ethanol, acetone, and Tween 80 and activated by bile salts. The activity of the enzyme was greatest for retinol palmitate. 60% lower for retinol acetate, and 70 to 90% lower for retinol oleate, linoleate, linolenate, stearate, myristate, and laurate. The liver enzyme efficiently hydrolyzed the retinol ester stored in the liver.

Most of the vitamin A in the animal body is stored in the liver mainly in the esterified form with small, but definite amounts of the free alcohol always present (1). The retinol esters in rat liver are composed only of the longer chain fatty acid type, and palmitate is the predominant ester (2, 3). In the postabsorptive blood, the vitamin is present mainly as the free alcohol with small amounts of the ester (1). Many workers have studied the enzyme systems involved in the hydrolysis and synthesis of retinol esters (4). Thus, in rat liver, retinol acetate hydrolase activity (EC 3.1.1.12) is almost quantitatively localized in the microsomal fraction of the tissue homogenate (5-7). However, it has been repeatedly stressed that the liver hydrolyzes only the short chain esters of retinol, but does not hydrolyze the higher esters like the palmitate (8-13). Therefore, it has been suggested that the retinol in liver and in blood is produced extrahepatically in tissues like the intestine and the pancreas (12, 13).

On the other hand, recent studies by Mahadevan, Deshmukh, and Ganguly (14) on the fate of intracardially injected retinol esters in the rat, have indicated that, contrary to the earlier beliefs, the liver tissue is perhaps capable of hydrolyzing and synthesizing esters of retinol with higher fatty acids also. The synthesis of higher fatty acid esters of retinol by rat liver microsomes has been demonstrated recently (3). Moreover, if it is accepted that retinoic acid is an intermediate in the conversion of the stored retinol ester to the "active" form of the vitamin in the body, then it is logical to expect the liver to be capable of carrying out all of the required metabolic transformations, including the initial hydrolysis of retinol ester. It has already been demonstrated that rat liver can oxidize retinol to retinal and further to retinoic acid (15). Retinoic acid is metabolized to still unknown derivatives (16). We have therefore studied the hydrolysis of longer chain fatty acid esters of retinol by liver tissue. This paper reports the purification and properties of a retinol palmitate hydrolase isolated from rat liver and its subcellular localization.

* This work was supported by Grants A 4164 and 5-K3 AM11,151 from the National Institutes of Health, and in part by the Whitehall Foundation. An abstract was presented at the 1965 Annual Meeting of the Federation of American Societies for Experimental Biology (*Federation Proc.*, **24**, 562 (1965)).

† Present address, Department of Food Science and Technology, University of California, Davis, California.

‡ Present address, Central Government Laboratories, Amman, Jordan.

§ Present address, Marine Biology Division, Lamont Observatory, Columbia University, Palisades, New York.

EXPERIMENTAL PROCEDURE

Materials—Pure crystalline retinol, its acetate, and palmitate were generously supplied by Hoffmann-La Roche, Inc. The other higher fatty acid esters of retinol were prepared enzymatically according to Mahadevan and Ganguly (2), and were purified by chromatography on alumina columns. Sodium taurocholate, glycocholate, and Tris were obtained from Sigma. Tween 80 (polyoxyethylene sorbitan monooleate) was from Atlas Powder Company. Triton X-100 (alkylphenoxypolyethoxyethanol) was a gift of Rohm and Haas. All of the other chemicals, reagents, and solvents used were obtained from Merck and were of the highest purity available.

Preparation of Substrate—Pure retinol palmitate and acetate were quickly weighed and dissolved in light petroleum ether (30-60°). In the case of the other esters, the retinol content of an aliquot of the 4% acetone in petroleum ether fraction, eluted from the alumina column, was determined and suitable quantities were taken for the preparation of the substrate. The dispersions of the retinol esters used as substrate for the enzyme were prepared essentially according to Seshadri Sastry, Krishnamurthy, and Ganguly (11) except that no α-tocopherol or ascorbic acid was included and, more importantly, Triton X-100 was used instead of Tween 80. The final aqueous dispersion contained 6 μmoles of the retinol ester, and 20 mg of Triton X-100 per ml.

Preparation of Acetone-dried Powder and Purification of Enzyme—Young male rats of the Sherman strain, maintained on labora-

TABLE I

Distribution of retinol palmitate and retinol acetate hydrolases in rat liver fractions

The fractions were prepared as described under "Experimental Procedure." The incubation mixtures contained the quantity of substrate indicated, 50 mg of sodium taurocholate, 3 ml of 0.1 M Tris-HCl buffer, pH 8.6, 10 mg of Triton X-100, and 1 ml of the fraction corresponding to 100 mg of the original wet tissue in 0.25 M sucrose. Incubations were for 60 min at 37°. Values are averages of 8 experiments.

Fraction	Retinol palmitate,* 3 μmoles, as substrate			Retinol acetate,* 6 μmoles, as substrate		
	Retinol liberated in 60 min†		Distribution of enzyme in liver	Retinol liberated in 30 min†		Distribution of enzyme in liver
	Per mg of protein	Per g of liver, wet weight		Per mg of protein	Per g of liver, wet weight	
	mμmoles		%	*mμmoles*		%
Nuclear	24.5	700	41	21.9	625	4
Mitochondrial lysosome rich	13.5	400	27	7.3	250	1.5
Microsomal	1.3	300	18	236.6	13,250	82.0
Supernatant	1.1	230	14	32.0	2,119	13.0

* The concentration of retinol palmitate used here was the optimal substrate concentration found with the purified enzyme (see "Effect of Time, Enzyme, and Substrate Concentration"). The concentration of retinol acetate used was the optimal concentration for the rat liver retinol acetate hydrolase reported by Seshadri Sastry, Krishnamurthy, and Ganguly (11).

† Incubation for 30 min was used for the retinol acetate hydrolase, because it has been reported before that the activity of this enzyme falls off rapidly if incubated longer (11). The activity of purified retinol palmitate hydrolase remained constant up to 90 min incubation (see "Effect of Time, Enzyme, and Substrate Concentration").

tory chow and weighing about 120 to 150 g, were killed by decapitation and their livers were frozen immediately. A portion of the frozen tissue was thawed, minced, and blended in a cooled Servall omnimixer at full speed with 15 volumes of cold (−20°) acetone for 1 min and filtered rapidly under suction. Drying of the residue with acetone was repeated twice more and the final traces of acetone were removed under reduced pressure. The acetone-dried powders thus prepared retained the full enzyme activity of the original tissue and were fully active even after 3 months storage in the freezer.

Extraction and Fractionation of Enzyme—The acetone-dried powder, 10 g, was suspended in 200 ml of cold 0.9% sodium chloride solution and stirred in the cold for 1 hour. The suspension was centrifuged at 18,000 × *g* for 20 min (precipitate = Step 1, Table III) and solid ammonium sulfate to a concentration of 30% was added to the supernatant (Step 2, Table III). The mixture was stirred for 20 min and the precipitate formed (Step 3, Table III) was removed by centrifugation and discarded. The concentration of ammonium sulfate in the supernatant was raised to 45% by the addition of more solid salt. The precipitate formed after stirring the mixture for 20 min was collected by centrifugation at 18,000 × *g* for 20 min (Step 4, Table III). More solid ammonium sulfate, to a concentration of 60%, was added to the supernatant; the mixture was stirred in the cold for 20 min and centrifuged. The precipitate formed (Step 5, Table III) had some enzyme activity but was usually discarded. The precipitate which had been formed at 45% ammonium sulfate concentration (Step 4, Table III) was dissolved in 25 ml of cold distilled water and dialyzed against 4 liters of cold water overnight with two changes of the water and constant stirring. The turbid contents of the dialysis bag were centrifuged at 18,000 × *g* for 30 min. The supernatant is referred to as Step 6 in Table III. When the precipitate was extracted with water, the aqueous extract (Step 7, Table III) had relatively little enzymatic activity. However, re-extraction of the residue by stirring it with cold 0.9% NaCl solution followed by centrifuging at 18,000 × *g* for 20 min yielded a supernatant (Step 8, Table III) which had the highest enzymatic activity and was used in all of the subsequent experiments unless otherwise stated. The corresponding precipitate (Step 9, Table III) had relatively little activity. This procedure and the results obtained are summarized in Table III.

Assay of Enzyme—Usually the reaction mixture contained 3 ml of 0.1 M Tris-HCl buffer (pH 8.6), 50 mg of sodium taurocholate, 0.5 ml of the substrate dispersion containing 3 μmoles of retinol palmitate, and 10 mg of Triton X-100, and 0.5 ml of the enzyme solution (1.5 to 2 mg of protein); the final volume was always adjusted to 5 ml with water. Appropriate blanks were included in every assay. The mixture was incubated at 37° for 60 min and the reaction was stopped by adding 5 ml of ethanol. The reaction mixture was extracted twice with 25-ml portions of light petroleum ether (30–60°). The free and esterified retinol in the extracts was determined by the Carr-Price method after chromatographic separation of the two forms of the vitamin on alumina columns (11). In all of the experiments, the recovery of the total vitamin A (alcohol plus ester) was in the range of 95 to 100%.

Fractionation of Liver Homogenates—Liver fractionation to obtain nuclear, mitochondrial lysosome-rich, microsomal, and supernatant fractions was done generally according to de Duve *et al.* (17) as fully described by Roels, Trout, and Guha (18). Assay of the fractions for β-glycerophosphate phosphatase showed that the nuclear fraction was probably contaminated

TABLE II

Effect of acetone drying on rat liver retinol ester hydrolases

Normal rat liver was homogenized in 0.25 M sucrose to give 100 mg of original tissue, wet weight, per ml. Acetone-dried powder was prepared from 5 g of the same liver and the enzyme was extracted with 0.9% NaCl as described under "Experimental Procedure." The incubation mixtures were prepared as described in Table I, with an amount of enzyme corresponding to 10 mg of protein in 0.5 ml of the NaCl extract for the acetone-dried powder and 100 mg (wet weight) of liver homogenate for the fresh tissue.

Fraction	Retinol liberated in 60 min with retinol palmitate as substrate		Retinol liberated in 30 min with retinol acetate as substrate	
	Per mg of protein	Per g of liver, wet weight	Per mg of protein	Per g of liver, wet weight
	mμmoles		*mμmoles*	
Homogenate	7	1,540	58	12,780
Acetone powder extract	55.2	4,233*	8	1,760*

* Calculated on the basis of the weight of acetone-dried powder obtained from 1 g of tissue, wet weight.

with not more than 15 to 20% of unbroken cells (18). However, assay of this fraction for retinol acetate hydrolase activity (characteristic of the microsomal fraction) indicates that probably the contamination was even less. Protein was estimated by the method of Lowry *et al.* (19).

RESULTS

Intracellular Distribution of Retinol Palmitate and Retinol Acetate Hydrolases—Table I gives the subcellular distribution of both enzymes in rat liver. It can be seen that the specific activity and the total activity per g of liver tissue is maximum in the microsomal fraction for the acetate hydrolase. On the other hand, the retinol palmitate hydrolase seems to be concentrated in the nuclear and mitochondrial lysosome-rich fractions.

Effect of Acetone Drying on Rat Liver Retinol Ester Hydrolases—Table II shows that acetone drying increases the specific activity of retinol palmitate hydrolase whereas the opposite is true for the retinol acetate hydrolyzing enzyme.

Ammonium Sulfate Fractionation of Retinol Palmitate Hydrolase from Rat Liver Acetone-dried Powder—Table III shows that the major portion of the enzyme was precipitated at 45% ammonium sulfate concentration (Step 4). Prolonged dialysis of the precipitate obtained in Step 4 did not result in any appreciable loss of activity (see Step 6). The aqueous extract (Step 7) of the precipitate formed during dialysis contained variable amounts of activity from experiment to experiment, but it was never more than about 30% of all of the activity present in the precipitate. As is indicated by the high specific activity of the preparation in Step 8, 0.9% aqueous NaCl extracted the enzyme more efficiently from the precipitate. Since the purpose of this investigation was chiefly to demonstrate the enzyme in liver tissue, no attempts were made to purify the enzyme further.

TABLE III

Fractionation of retinol palmitate hydrolase from extract of actone-dried powder of rat liver

The extraction and fractionation are described under "Experimental Procedure." All of the incubations were conducted under the standard conditions described, except that 2 to 10 mg of protein were used depending on the activity of the enzyme. All of the incubations were for 60 min.

Fraction	Retinol liberated	Total activity in fraction
	mμmoles/mg protein	
1. Precipitate after NaCl extraction	10	30,975
2. NaCl extract, 0.9%	55	180,375
3. Ammonium sulfate precipitate, 30%	37	3,862
4. Ammonium sulfate precipitate, 45%	145	139,055
5. Ammonium sulfate precipitate, 60%	48	46,804
6. Supernatant after dialysis of enzyme solution from Step 4	134	108,808
7. Aqueous extract of precipitate formed after dialysis	72	4,320
8. NaCl extract, 0.9%, of residue in Step 7	240	14,400
9. Residue left after Step 8	70	4,394

TABLE IV

Effect of substrate dispersing agents on rat liver retinol palmitate hydrolase

The incubation mixtures contained 1.8 mg of protein (see Step 8, Table III), 3 μmoles of retinol palmitate, 50 mg of sodium taurocholate, and 3 ml of 0.1 M Tris-HCl buffer, pH 8.6, in 5 ml. Retinol palmitate was added dissolved in different amounts of acetone or in 0.5 ml of ethanol. Tween 80 and Triton X-100 dispersions were prepared as described under "Experimental Procedure." The colloidal dispersion in taurocholate was prepared by mixing 5 ml of 10% aqueous sodium taurocholate and 1 ml of petroleum ether (30–60°) containing 30 μmoles of retinol palmitate, and evaporating off the petroleum ether under reduced pressure at 40° while constantly stirring.

Dispersing agent for retinol palmitate used	Retinol liberated
	mμmoles/60 min
Triton X-100, 2%	416
Triton X-100, 5%	355
Tween 80, 2%	100
Tween 80, 5%	45
Acetone, 0.1 ml	42
Acetone, 0.2 ml	15
Acetone, 0.5 ml	10
Ethanol, 0.5 ml	92
Colloidal dispersion in taurocholate	120

TABLE V

Effect of adding ethanol, acetone, and Tween 80 on hydrolysis of retinol palmitate dispersed with Triton X-100

Each 5 ml of the incubation mixture contained 1.2 mg of protein (see Step 8, Table III), 3 μmoles of retinol palmitate, 50 mg of sodium taurocholate, 10 mg of Triton X-100, and 3 ml of 0.1 M Tris-HCl buffer, pH 8.6, and the indicated amounts of ethanol or acetone, or 0.5 ml of an aqueous solution of Tween 80. The final volume was 5 ml.

Addition	Retinol liberated
	mμmoles/60 min
None	280
+ Acetone, 0.5 ml	55
+ Ethanol, 0.5 ml	102
+ Tween 80, 20 mg	96

It was felt that NaCl might activate the enzyme and thus give an apparent purification effect in Step 8. However, addition of NaCl to reaction mixtures containing the enzyme preparation in Step 6 did not increase the enzymatic activity. The enzyme in Step 8 had only about 9% of the total activity present in Step 2, but its specific activity was increased 5 fold. When compared to the whole liver homogenate, the enzyme obtained in Step 8 was 34 times more active.

Effect of Substrate Dispersing Agents on Retinol Palmitate Hydrolase—Various dispersing agents for the substrate in the incubation medium were tested for their effect on the enzymatic activity. Previous investigators had used ethanol (20), acetone (21), or Tween 80 (11, 22). Table IV shows that these reagents inhibit the enzyme whereas the enzymatic activity is high when Triton X-100 is used as dispersing agent. Table V shows that the addition of acetone, ethanol, or Tween 80 to the enzymatic assay in which Triton X-100 was used to disperse the substrate, also causes inhibition. Seshadri Sastry and Ganguly (23) ob-

served that Lissapol N (a condensate of *p*-nonylphenol ether with polyethylene glycol) activated the cholesterol esterase of chicken liver nuclei but did not increase retinol acetate hydrolase activity. Table VI shows that Triton X-100 up to a concentration of 30 mg per 5 ml of reaction mixture had no effect on rat liver retinol palmitate hydrolase. The lowest concentration we tried was 8 mg/5 ml of reaction mixture; at lower concentrations, it was difficult to maintain the retinol palmitate in dispersion.

TABLE VI

Effect of concentration of Triton X-100 on hydrolysis of retinol palmitate

Each 5 ml of incubation mixture contained 1.2 mg of protein (Step 8, Table III), 3 μmoles of retinol palmitate, 50 mg of sodium taurocholate, and 3 ml of 0.1 M Tris-HCl buffer, pH 8.6. The Triton X-100 was added as an aqueous solution.

Triton X-100 added	Retinol liberated
mg	*mμmoles/60 min*
10	350
20	325
30	300
40	280
60	176

pH Optimum—The purified enzyme (Step 8, Table III) had a pH optimum at 8.6 as shown in Fig. 1. Mahadevan *et al.* (2) reported the same pH optimum for rat pancreatic and mucosal retinol palmitate hydrolase. Tris-HCl buffer gave slightly higher activity than Veronal buffer. The nuclear and mitochondrial lysosome-rich fractions also showed maximum activity at pH 8.6 although there was a small hump in the curve at pH 6.0.

Effect of Time, Enzyme, and Substrate Concentration (Fig. 2)—The amount of retinol formed increased steadily with the amount of protein in the reaction mixture up to a concentration of 3 mg of protein per 5 ml of reaction mixture. At higher enzyme concentrations, the increase in activity was no longer linear. When 3 mg of protein were used, the activity was linear up to 90 min. To determine the effect of substrate concentration on enzymatic activity, purified enzyme (obtained as indicated in Step 8, Table III) corresponding to 2 mg of protein was incubated at 37° for

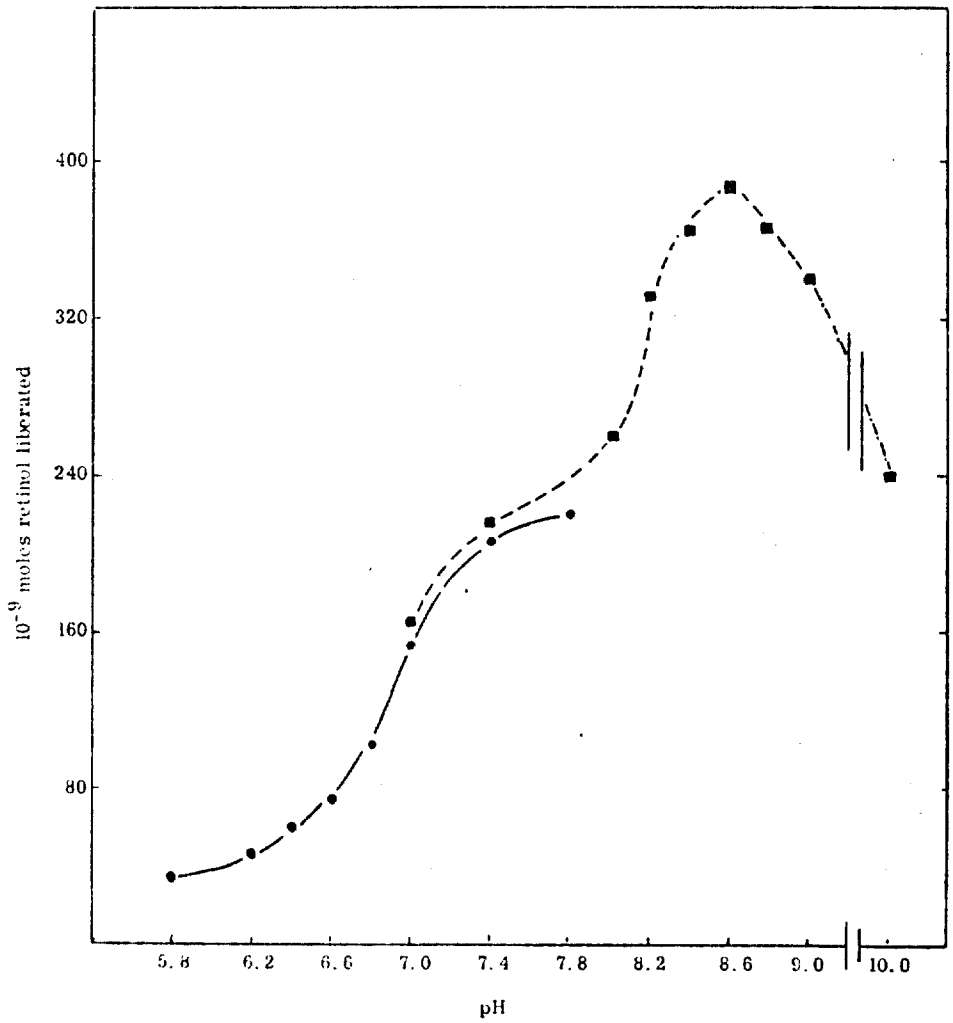

FIG. 1. Effect of pH on the hydrolysis of retinol palmitate. Each 5 ml of incubation mixture contained 3 μmoles of retinol palmitate, 50 mg of sodium taurocholate, 10 mg of Triton X-100, 1.6 mg of protein (Step 8, Table III), and 3 ml of the appropriate buffer. Incubations were for 60 min. ●——●, Na_2HPO_4-NaH_2PO_4 buffer, 0.1 M; ■- - -■, Tris-HCl buffer, 0.1 M; at pH 10, glycine-NaOH buffer, 0.1 M, was used.

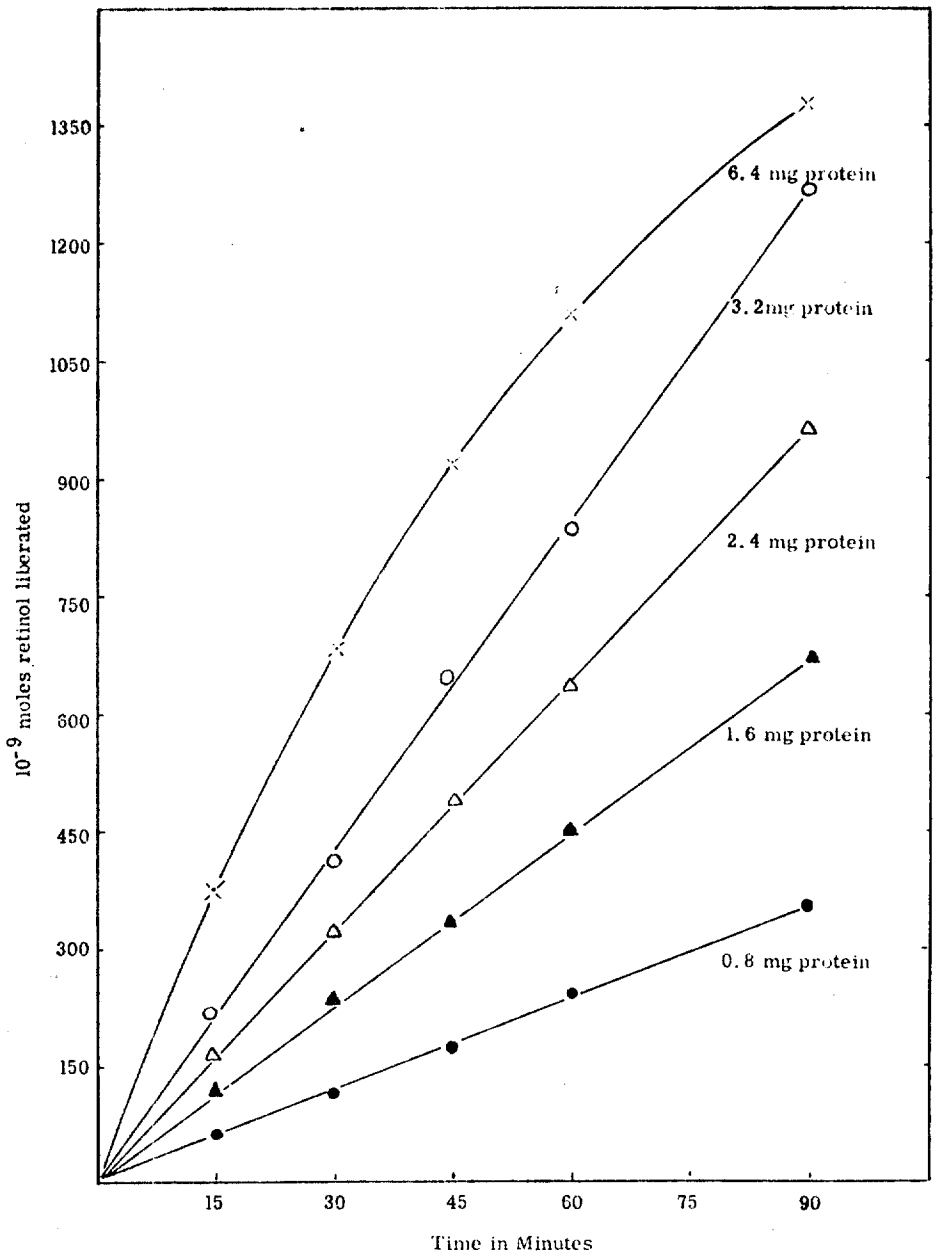

FIG. 2. Effect of time and protein concentration on the hydrolysis of retinol palmitate. Each 5 ml of incubation mixture contained 3 μmoles of retinol palmitate, 10 mg of Triton X-100, 50 mg of sodium taurocholate, and the indicated amount of protein (Step 8, Table III).

60 min in a total volume of 5 ml, containing 3 ml of 0.1 M Tris-HCl buffer, pH 8.6, 50 mg of sodium taurocholate, 10 mg of Triton X-100 with different amounts of substrate varying from 0.4 to 4.0 μmoles of retinol palmitate. The enzymatic activity was directly proportional to the substrate concentration up to 1.6 μmoles of retinol palmitate. The rate of increase in enzymatic activity with increasing substrate concentration slowed down beyond this substrate concentration and the reaction velocity did not increase any further when more than 3.2 μmoles of retinol palmitate were added. The substrate optimum was about 3 μmoles per reaction mixture and the K_m value, as calculated from the substrate concentration at half maximum velocity, is 1.6×10^{-4} M.

Effect of Bile Salts—In the absence of sodium taurocholate, there was very little activity (Table VII). However, even as little as 5 mg of taurocholate were sufficient to cause the liberation of 75 mμmoles of retinol. Increasing concentrations of the bile salt up to 30 mg of taurocholate per reaction mixture increased the amount of retinol liberated. Even though there was no activation or inhibition of the activity beyond this concentration, 50 mg of the bile salt were always added to the reaction mixture. Sodium glycocholate also had an activating effect which was not as pronounced as that of taurocholate.

Effect of Albumin—Since it is known that retinol in blood is bound to protein (1), it was thought that the inclusion of albumin in the reaction mixture might increase the hydrolysis of palmitate

by binding either the retinol or the palmitic acid. However, no increased hydrolysis was observed by the addition of bovine serum albumin.

Effect of Metal Ions—At 10^{-3} M concentration, most of the compounds listed in Table VIII inhibited the enzyme. These results are similar to those already reported for the intestinal enzyme (20) and for rat liver retinol acetate hydrolase (23). However, in sharp contrast to the activation of the hydrolysis of retinol palmitate by Ca^{++} observed with the intestinal enzymes (20), the liver enzyme reported here was inhibited by 10^{-3} or 10^{-4} M Ca^{++}. Whereas Seshadri Sastry and Ganguly (23) observed inhibition of retinol acetate hydrolase by Hg^{++}, the hydrolysis of retinol palmitate does not seem to be sensitive to 10^{-4} M Hg^{++}, although at 10^{-3} M concentration, the inhibition is quite evident.

Enzyme Specificity—The activity of the enzyme on different retinol esters as compared to its action on synthetic retinol palmitate is presented in Table IX. The activity of the enzyme on enzymatically prepared retinol palmitate was about 20% lower

TABLE VII

Effect of different amounts of sodium taurocholate and glycocholate on hydrolysis of retinol palmitate

Incubations were conducted under the standard conditions described under "Experimental Procedures." The different amounts of the bile salts were added in 0.5 ml of water; 1.2 mg of protein (Step 8, Table III) was used.

Bile salt in incubation mixture	Retinol liberated	
	Taurocholate	Glycocholate
mg	*mμmoles/60 min*	
0	2*	2*
5	75	47
10	137	90
20	229	190
30	296	205
40	295	210
50	305	215
100	300	215

* In this experiment, 10 mg of protein were used.

TABLE VIII

Effect of metal ions on hydrolysis of retinol palmitate by rat liver enzyme

Each mixture, containing 3 ml of 0.1 M Tris-HCl buffer, pH 8.6, 1 ml of enzyme equivalent to 2 mg of protein (Step 8, Table III), 50 mg of sodium taurocholate, and 0.5 ml of an aqueous solution of the compound tested, was incubated for 15 min at 37°. After this, 0.5 ml of substrate containing 3 μmoles of retinol palmitate and 10 mg of Triton X-100 were added and the incubation was continued for 60 min. The table lists the final concentration of the compound tested in 5 ml of the incubation mixture. The uninhibited enzyme liberated 468 mμmoles of retinol in 60 min.

Compound	Activity retained at a concentration of	
	10^{-3} M	10^{-4} M
	%	%
$HgCl_2$	20	126
$MgCl_2 \cdot 6H_2O$	27	70
$CaCl_2 \cdot 2H_2O$	29	77
$CuCl_2 \cdot 2H_2O$	14	82
$ZnCl_2$	17	56
NaF	33	100
$NaAsO_2$	52	100

TABLE IX

Hydrolysis of different retinol esters

Pure, crystalline synthetic retinol acetate and palmitate were used where indicated. For all of the other experiments, enzymatically prepared and chromatographically purified retinol esters were used (see "Experimental Procedure"). Each incubation mixture contained 3 μmoles of the ester, 50 mg of sodium taurocholate, 3 ml of Tris-HCl buffer, pH 8.6, and 10 mg of Triton X-100. Protein, 3, 2.1, and 2.2 mg (Step 8, Table III), was used in Experiments 1, 2, and 3, respectively. All of the incubations were for 60 min at 37°.

Retinol ester	Retinol liberated		
	Experiment 1	Experiment 2	Experiment 3
	mμmoles		
Acetate (synthetic)	205	140	138
Palmitate (synthetic)	620	430	455
Palmitate	500	350	366
Laurate	35	55	54
Myristate	128	80	85
Stearate	57	55	53
Oleate	206	112	106
Linoleate	145	85	88
Linolenate	98	82	78

TABLE X

Hydrolysis of naturally occurring rat liver retinol esters

Rats, 200 g, maintained on laboratory chow were given one dose of 0.5 ml of peanut oil containing 20 mg of retinol acetate. One week later, they were killed and their livers were fractionated as described. The nuclear and mitochondrial fractions were recombined and suspended in 0.9% NaCl to give 300 mg of original tissue, wet weight, per ml. That portion of the homogenate remaining after the removal of the nuclear and mitochondrial fractions was centrifuged at 100,000 × *g* for 60 min. The top "creamy" layer containing the retinol ester was carefully removed, mixed with fresh, cold 0.25 M sucrose, and recentrifuged at 100,000 × *g* for 60 min. This creamy layer was diluted with water and homogenized with sufficient Triton X-100 so that 0.5 ml of the suspension contained about 2 to 3 μmoles of retinol ester (calculated as the palmitate) and 10 mg of Triton X-100. Incubation mixtures contained 3 ml of 0.1 M Tris-HCl buffer, pH 8.6, 50 mg of sodium taurocholate, and the indicated amounts of nuclear and mitochondrial fraction or cream or both. Water was added, if necessary, to bring the volume to 5 ml. In the case of the purified enzyme, 0.5 ml of the preparation obtained as described in Step 8 of Table III, containing 2 mg of protein, was used. Incubation was for 2 hours at 37°.

Experiment	Retinol ester	Retinol
	mμmoles	
Nuclear and mitochondrial fraction unincubated, 1 ml	85	4
Nuclear and mitochondrial fraction incubated, 1 ml	24	68
Cream unincubated, 0.5 ml	1350	60
Cream incubated, 0.5 ml	1330	86
Cream, 0.5 ml, + nuclear and mitochondrial fraction incubated, 1 ml	867	633
Cream, 0.5 ml, + nuclear and mitochondrial fraction incubated, 1 ml	887	610
Cream, 0.5 ml, + purified enzyme incubated, 2 mg	980	520

than on the synthetic substrate. The enzyme is obviously most active for retinol palmitate.

The enzyme preparation was tested for its cholesterol esterase activity, with cholesterol oleate in acetone as substrate according to Deykin and Goodman (24). The free and esterified cholesterol was extracted from the reaction mixture and separated on alumina columns as described by Murthy and Ganguly (25), and the free cholesterol was determined with the colorimetric method described by Hansen and Dam (26). No hydrolysis of the cholesterol oleate could be detected. Addition of cholesterol oleate dispersed in Triton X-100, the presence or absence of sodium taurocholate, change of pH from 7.0 to 8.6, or change of buffer from Tris-HCl to phosphate did not result in any detectable hydrolysis of cholesterol oleate.

Hydrolysis of Rat Liver Retinol Esters.—Table X shows that the cell fractions from rat liver homogenates and the enzyme purified from acetone-dried powders of whole rat liver are capable of hydrolyzing the naturally occurring retinol esters present in the liver.

DISCUSSION

The microsomal localization of retinol acetate hydrolase is in complete agreement with the results reported by Ganguly and Deuel (5) and by Krishnamurthy, Seshadri Sastry, and Ganguly (7). However, the higher fatty acid ester hydrolyzing system is not a microsomal enzyme. Similarly, Deykin and Goodman (24) found that among the cholesterol esterases, the one acting on cholesterol acetate is microsomal, whereas the higher fatty acid ester splitting activity was found in the supernatant fraction. Thus, it seems that the microsomal cholesterol esterase and vitamin A esterase are probably not physiologically important, because the acetate esters of these alcohols have not been detected in liver so far. In the present investigation, it is shown that most of the palmitate-hydrolyzing activity is sedimented at centrifugal speeds commonly used for the isolation of mitochondria from cell homogenates. In this connection, it is interesting to note that Laughland (22) centrifuged the homogenate to remove nuclei and cell debris and Seshadri Sastry *et al.* (11, 12) removed the nuclei and mitochondria from the homogenate in their studies of retinol ester hydrolases.

Many enzymes found to be localized in the nuclear fraction of tissue homogenates have subsequently been shown to be associated with the cell membrane (27, 28). It is quite conceivable, although admittedly highly speculative, that the retinol palmitate-hydrolyzing activity may be associated with the liver cell membrane. This would be consistent with its probable function in regulating the release of retinol into the bloodstream. Preliminary results in this laboratory indicate that whereas the retinol acetate-hydrolyzing enzyme of the microsomes is not very significantly affected by dietary levels (or liver content) of retinol, α-tocopherol, and other treatments of the animals, the activity of the palmitate-hydrolyzing enzyme is profoundly affected; thus lending further support to the concept that this enzyme might be important as a regulatory mechanism. However, it should be kept in mind that the retinol esters are probably stored in the Kupffer cells and retinol in the parenchymal cells (29). The homogenization and fractionation procedures used in the present investigation do not give any indication about the type of cell with which the retinol palmitate hydrolase is associated.

Even though a considerable fraction of the activity is recovered in the mitochondrial lysosome-rich fraction, it could not be ascertained whether it was associated with the lysosomes because of the inevitable use of detergents and prolonged incubation time required for our assays. Furthermore, the pH optimum for the retinol ester hydrolase associated with the mitochondrial lysosome-rich fraction was 8.6, whereas the usual pH optimum for lysosomal hydrolases is in the acid range.

The use of Triton X-100 and sodium taurocholate in the reaction mixture was very important in demonstrating the hydrolytic activity. In most of the earlier work with liver tissue, acetone, ethanol, or Tween 80 dispersions of the retinol esters were used (11, 20, 23). We found these agents to be highly inhibitory. Further, Laughland (22) did not include sodium taurocholate in his system. Where sodium taurocholate was used (11, 12), the cell fraction containing the bulk of the enzyme had been discarded. The activation of the hydrolysis of retinol palmitate by bile salts has been described previously for the intestinal enzyme (20). Seshadri Sastry, Krishnamurthy, and Ganguly (11) reported that the addition of bile salts to the liver microsomal retinol acetate hydrolase increased its activity by 30%. It is conceivable that in the intestine, the bile may have some function in the absorption of the vitamin. In our liver preparations, however, the role of the bile salts in retinol ester hydrolysis does not seem to be limited to mere emulsification of the substrate since the Triton X-100 dispersions used were very clear.

The fatty acid specificity experiments indicate that the enzyme preparation has the highest activity for retinol palmitate. This is in agreement with the observation that retinol palmitate is the predominant ester in liver (2, 3). The hydrolytic activity of the enzyme for other retinol esters might explain the slower disappearance of these esters from the liver of rats injected with Tween dispersions of these esters (14). It is not possible to conclude from our data whether the hydrolysis of retinol acetate by our purified enzyme preparation is due to the palmitate-hydrolyzing enzyme or to any residual microsomal enzyme left in the acetone-dried powder.

Glover, Goodwin, and Morton (30) found that prolonged autolysis of liver tissue does not appreciably hydrolyze liver retinol ester. Subsequently, Krishnamurthy, Seshadri Sastry, and Ganguly (12) incubated combined rat liver microsomes and supernatant with and without sodium taurocholate and did not observe hydrolysis of the liver retinol esters. Krishnamurthy *et al.* (12) and more recently High and Bryant (13) suggested that the liver cannot hydrolyze retinol esters present in liver; they therefore suggested that the pancreas and intestine were the probable sites of liver retinol ester hydrolysis. We have demonstrated that subcellular fractions from rat liver can hydrolyze the retinol ester present in the liver.

REFERENCES

1. Ganguly, J., *Vitamins and Hormones*, **18**, 387 (1960).
2. Mahadevan, S., and Ganguly, J., *Biochem. J.*, **81**, 53 (1961).
3. Futterman, S., and Andrews, J. S., *J. Biol. Chem.*, **239**, 4077 (1964).
4. Olson, J. A., *J. Lipid Research*, **5**, 281 (1964).
5. Ganguly, J., and Deuel, H. J., Jr., *Nature*, **172**, 120 (1953).
6. Ganguly, J., *Arch. Biochem. Biophys.*, **52**, 186 (1954).
7. Krishnamurthy, S., Seshadri Sastry, P., and Ganguly, J., *Arch. Biochem. Biophys.*, **75**, 6 (1958).
8. McGugan, W. A., and Lagiland, D. H., *Arch. Biochem. Biophys.*, **35**, 428 (1952).
9. Krause, R. F., and Powell, L. T., *Arch. Biochem. Biophys.*, **44**, 57 (1953).
10. High, E. G., Bright, H. B., and Powell, J. F., *Fed. Proc.*, **15**, 556 (1956).
11. Seshadri Sastry, P., Krishnamurthy, S., and Ganguly, J., *Indian J. Med. Research*, **45**, 203 (1957).

12. Krishnamurthy, S., Seshadri Sastry, P., and Ganguly, J., *Indian J. Med. Research*, **45**, 391 (1957).
13. High, E. G., and Bryant, W. M., *Federation Proc.*, **20**, 453 (1961).
14. Mahadevan, S., Deshmukh, D. S., and Ganguly, J., *Biochem. J.*, **93**, 499 (1964).
15. Mahadevan, S., Murthy, S. K., and Ganguly, J., *Biochem. J.*, **85**, 326 (1962).
16. Zachman, R. D., and Olson, J. A., *Nature*, **201**, 1222 (1964).
17. de Duve, C., Pressman, B. C., Gianetto, R., Wattiaux, R., and Appelmans, F., *Biochem. J.*, **60**, 604 (1955).
18. Roels, O. A., Trout, M., and Guha, A., *Biochem. J.*, **93**, 23C (1964).
19. Lowry, O. H., Rosebrough, N. J., Farr, A. L., and Randall, R. J., *J. Biol. Chem.*, **193**, 265 (1951).
20. Mahadevan, S., Murthy, S. K., Krishnamurthy, S., and Ganguly, J., *Biochem. J.*, **79**, 416 (1961).
21. Pollard, C. J., and Bieri, J. G., *Arch. Biochem. Biophys.*, **87**, 9 (1960).
22. Laughland, D. H., *Arch. Biochem. Biophys.*, **73**, 95 (1958).
23. Seshadri Sastry, P., and Ganguly, J., *Biochem. J.*, **80**, 397 (1961).
24. Deykin, D., and Goodman, D. S., *J. Biol. Chem.*, **237**, 3649 (1962).
25. Murthy, S. K., and Ganguly, J., *Biochem. J.*, **83**, 469 (1962).
26. Hansen, P. W., and Dam, H., *Acta Chem. Scand.*, **11**, 1658 (1957).
27. Wheeler, K. P., and Whittam, R., *Biochem. J.*, **8**, 495 (1962).
28. Emmelot, P., Bos, C. J., Benedetti, E. L., and Rumke, Ph., *Biochim. et Biophys. Acta*, **90**, 126 (1964).
29. Krishnamurthy, S., and Ganguly, J., *Nature*, **177**, 575 (1956).
30. Glover, J., Goodwin, T. W., and Morton, R. A., *Biochem. J.*, **54**, 177 (1953).

Marie-'54.
Bib. No. 5785

Am. J. Diseases Children. 87:731. 1954.

ACUTE HYPERVITAMINOSIS A OF THE INFANT

Its Clinical Manifestation with Benign Acute Hydrocephalus and Pronounced Bulge of the Fontanel; a Clinical and Biologic Study

JULIEN MARIE, M.D.
AND
GEORGES SEE, M.D.
PARIS

CHRONIC hypervitaminosis A accidents are now well known, through the works of Rodahl and Moore and Josephs, and especially through the mainly experimental observations of Toomey and Morisette and, later of Rothman and Leon There are various publications on this subject in the medical literature.

Our purpose is to draw attention to the acute incidents which may follow the administration of very large quantities of vitamin A in the infant. These incidents are especially characterized by acute hydrocephalus, with spontaneous and intensive bulging of the fontanel, frequent vomiting, agitation, or insomnia, and this without any meningeal sign or disorder in the general status. The disturbances begin 12 hours after ingestion of the drug and end 24 to 48 hours later, spontaneously or after lumbar puncture.

Since we first described, in February, 1951,[1] the syndrome of acute and benign hydrocephalus in the infant following the ingestion of a large amount of vitamin A, the observation has been confirmed by many pediatricians. Some of them remembered infants presenting extreme bulging of the fontanel, vomiting, and normal temperature, but with the cause of the disorder unknown. Informed by our observations, they conducted a written or oral inquiry of the families, and they were able to retrace the ingestion, 24 hours before the incident, of a large dose of vitamin A, plain or associated with vitamin D. Such are the cases reported by S. Thieffry (Paris), in dizygotic twins, and by M. L. Jammet (Paris), l'Hirondel (Caen) and Cluet Garcia[3] (Barcelona). Finally, after our communication, many French and foreign pediatricians observed the syndrome as we described it—in particular, Fleurier, Vonderveit, in France; Montero Rodriguez,[4] in Spain; Caruana and Hanna,[5] in Tunisia; Demoulin[6] and Hooft, in Belgium, and Knudson and Rothman[7] (Dr. Mary Mulloy's case), in the United States.

I. ACUTE HYDROCEPHALUS FOLLOWING INGESTION OF LARGE QUANTITY OF VITAMIN A ASSOCIATED WITH VITAMIN D

We shall here report three cases we presented on Feb. 20, 1951, at the Society of Pediatrics in Paris.

CASE 1.—B. Gilles, aged 3½ months, weighing 5,600 gm., on July 7, 1949, vomited at 7 p. m. the feeding he had just drunk. He was pale and fell asleep very soon and did not awaken at

From the Service of Professor Julien Marie, Hôpital des Enfants-Malades, Paris XV.

10 p. m. for his feeding, although he usually had a good appetite. On the next day the child was gay and drank well, but he was still pale, and the mother noticed a bulge of the fontanel.

The child was brought to the hospital; he was strictly afebrile and looked normal, but his anterior fontanel was very protruding and distended, even when he sat up, the fontanel resembling the head of a cap mushroom on the cranial surface. The neck was flexible, and there was no neurological anomaly. The fundus oculi was normal, and the ear examination revealed no abnormality. The lumbar puncture showed a clear fluid, with 1.4 cells per cubic millimeter and 25 mg. of albumin per 100 cc.

The next day the child seemed to have recovered; the fontanel was rather depressed, but one could notice edema at the point of lumbar puncture, proving the persistence of a subcutaneous flow of the spinal fluid. The condition had returned to normal on July 10.

The history showed that on the morning of July 7 the infant had drunk in his bottle the contents of an ampule which had contained a large amount of vitamins A and D.

Case 2.—I. Jean-Louis, aged 7½ months, on Sept. 27 presented cerebral vomiting at 1 and 4 p. m., soon after having drunk his feeding. During the afternoon he was very sleepy, but at night he played and smiled normally.

On Sept. 28 this child, of 7,000 gm., presented a very prominent bulge of the fontanel, more conspicuous when he cried and without any pathological sign.

The lumbar puncture showed a clear fluid containing 1.8 cells per cubic millimeter, and 15 mg. of albumin, 80 mg. of sugar, and 730 mg. of chlorides per 100 cc.

The day ended well, and the next day the child had recovered completely.

Investigations showed that the child had taken an ampule containing the same large amount of vitamins A and D as in the preceding case.

Case 3.—M. Claudine, 3 months old, on Jan. 20 presented projectile vomiting 10 minutes after having drunk her feedings at 7 and 10 a. m. The child's father noticed that the fontanel was distended and protruding. In the afternoon she took her feedings but had a diarrheal stool. The temperature was normal.

On Jan. 21, the child vomited at 7 a. m., but she was gay, had good color, and was smiling. The fontanel was easily seen, protruding and tense. There was no meningeal or neurological sign.

The blood pressure was 85/40. The lumbar pressure, measured with Claude's manometer in the lateral position, was 31 cm. of water; after jugular pressure it increased to 42 cm., and on abdominal pressure, to 56 cm. of water.

The spinal fluid was clear and contained 2.2 cells per cubic millimeter and 35 mg. of albumin, 60 mg. of glucose, and 700 mg. of chloride per 100 cc.

On the night of Jan. 21 the fontanel was still a little distended and prominent, but the child retained her feedings. The next day there was no disturbance.

The child had never been ill, except for a slight cold the previous week. On Jan. 19, at 7 p. m., she took with her feeding the contents of an ampule of the same composition as those ingested by the other two children, the three ampules coming from the same pharmaceutical laboratory.

Claudine retained this feeding and the following one, and it was 12 hours later that the first prominent vomiting occurred.

These three children had all received 12 to 24 hours before the disorders an ampule of Vitadone Forte, containing 350,000 units of vitamin A and 7.5 mg. of vitamin D_2 (calciferol), that is, 300,000 units.

We managed to reproduce the same syndrome in two hospitalized infants, 4 and 7 months old, after ingestion of this same drug. We also observed an acute hydrocephalus produced by hypervitaminosis A in a 2-month-old infant who received nose drops containing 50,000 units of vitamin A, supplemented with vitamin D. The summary of the case follows.

Case 4.—R. Alain, aged 2 months, weighing 4,700 gm., presented on Oct. 20, 1950, a prominent bulge of the fontanel, without any vomiting, discomfort, or increased temperature. The lumbar puncture showed a clear fluid containing 2.8 cells per cubic millimeter and 25 mg. of albumin per 100 cc.

On Oct. 24, the child seemed cured.

Four weeks previously he had had a slight rhinopharyngitis, which was initially treated with a product containing penicillin. During the preceding week, he had been given nose drops of a preparation containing 50,000 units of vitamin A per gram and vitamin D. The child received 3 drops in each nostril, i. e., 6 drops four times daily, which amounts to about 1 gm. This totaled in six days a large quantity, of approximately 300,000 units, similar to the dose received by our other patients.

The fact is known that the pituitary mucosa is an excellent way of absorption for certain drugs, not excluding the possibility that a certain amount of the oily substance instilled in the nostrils might have been swallowed, penetrating the gastric passage.

II. ACUTE HYPERVITAMINOSIS A IN THE INFANT

In the previous cases, the role of vitamin A seems significant to us. Excess of vitamin D, well known from the works of Professor Debré and his collaborators, Thieffry and Brissaud, produces quite different effects. Nevertheless, the addition of vitamin D, even in very small quantity, to vitamin A, as it occurred in our preceding case, does not necessarily validate our observation.

We have therefore studied the result of administration of plain vitamin A to the infant, and in three cases out of six we managed to reproduce the acute hydrocephalus.

We shall report only one of these cases here.

CASE 5.—C. Joel, 4 months, was treated in our service beginning Dec. 12, 1951, for purulent staphylococcal pleuritis, which was cured, but he presented a periscissural softening, his fontanel was wide and normally tense.

On March 5, at 5 p. m., the child ingested an ampule containing 350,000 units of natural vitamin A.

On March 6, at 6 a. m., the nurse that fed him, who was not aware of the ingestion of the drug, noticed that the fontanel was bulging and formed a knob on the child's head; the child vomited after he drank. At 8 a. m. the bulging was considerable; there was no meningeal sign. On March 7, the fontanel was still a little tense. On March 8, all abnormalities had disappeared.

The child vomited only once, but, although the child's weight increased regularly, there was a slight loss of weight on March 6 and 7.*

Vitamin A alone, given orally and in very great dosage, is therefore the cause of this unexpected and transitory incident.

In our subsequent studies, we continued to use plain vitamin A, and we systematically observed the status of the fontanel, the cerebrospinal fluid pressure, the fundus oculi, and, especially, the blood vitamin A level. Several times we reproduced the same disturbances in infants, from the age of 24 days to 15 months.

The precise clinical study of six infants who presented disorders after ingestion of a single dose of 350,000 units of vitamin A induces us to describe a special syndrome characterized by the signs to be noted.

1. *Functional Disorders.*—We noticed 12 to 24 hours after the ingestion, almost always, repeated projectile vomiting, twice, cerebral vomiting and diarrhea, and

* With other infants, we proceeded exactly in the same way, but using synthetic vitamin A instead of the natural vitamin; yet we could not reproduce the syndrome. Neither could we reproduce it with subcutaneous injections of natural vitamin A (60,000 to 90,000 units).

usually, restlessness, discomfort, insomnia, or drowsiness. Four infants showed a rise in temperature to 102.2 F. (39 C.); most of them did not gain weight for 48 hours; one of them even lost weight.

The disorders were, however, not proportional to the severity of the hydrocephalus; they perhaps were even inversely proportional; in fact, the child whose fontanel was most bulging had no disorder whatsoever.

2. *Clinical Study.*—We insist on the isolated character of the distended fontanel, which in the most typical cases produces a proper mushroom-like protuberance on the child's head, but there is no meningeal sign or any neurological anomaly. The blood pressure is not modified.

We have systematically studied the cerebrospinal fluid, and it appeared chemically and cytologically normal. The study of the spinal fluid tension was more interesting. Measured with Claude's manometer, the child being in lateral position and not crying, the fluid tension showed values from 15 to 23 cm. of water, and from 22 to 30 cm. after jugular pressure. In another group of infants, not receiving vitamin A, we found under the same conditions the following values: 11 to 13 cm., and 22 to 23 cm. after jugular pressure.

This slight hypertension of the spinal fluid is not proportionate to the height of the tension of the fontanel, but after evacuation of a certain amount of fluid there is a marked reduction of the bulge.

In these six infants, we systematically studied the fundus oculi and the electroencephalogram, without noticing any alteration. Likewise, there was no modification of the prothrombin rate.

3. *Chemical Study.*—Much more interesting was the measure of plasma vitamin A absorption rate, which we studied through Carr and Price's color test.†

For infants of less than one year, the level was, on an empty stomach, from 75 to 132 I. U., the average for six children being 102 I. U. In opposition to Mr. H. Aron's statements, the individual variations seemed to us to be proportionate to the alimentary diet and to the drugs taken by the children. In fact, the highest level (132 I. U.), was observed in a case of cured rickets.

Six hours after ingestion of the drug, the values reached 400 to 714 I. U.; the average value for the six children was 513 I. U. The increase seemed proportionate to the values at the start and reached five times that value. A few exceptions, however, were noticed, and they certainly pertained to different individual capacities of absorption and assimilation.

Twelve hours later, the values fell to about 170 and 353 I. U., that is, to two to three times the value at the start. It should be noticed that the most bulging fontanels are not accompanied by the highest values.

In a second series of six children, of less than 2 years of age, but whose fontanels were closed, the values at the start were 110 to 170 I. U., or an average of 140 I. U.

Six hours after ingestion, they reached 308 to 1,060 I. U., or an average of 690 I. U., i. e., five times the initial value. Twelve hours later, they dropped to values between 160 and 297 I. U.

Altogether, these values were higher than those of the infants.

We can add that we never found vitamin A in the cerebrospinal fluid.

† Miss Larrue and Mr. Chaix assisted with this test.

III. COMMENT AND EXPERIMENTATION

Acute hydrocephalus is, therefore, certainly produced by oral ingestion and absorption of a large amount of vitamin A. This is in connection with an excessive secretion of cerebrospinal fluid, evidenced by the increase of cerebrospinal fluid pressure. The hydrocephalus develops in parallel with the increase of vitamin A, but with a few hours' delay.

The connection between the spinal fluid and the vitamin A absorption rate are well known from studies by the veterinarians.[8] But, to our great surprise, it is hypovitaminosis which accompanies an excess of cerebrospinal fluid pressure. This fact seems so consistent that Canadian veterinarians rely on an increase of the spinal fluid pressure to reveal a hypovitaminosis A, and to treat it in time, in certain breeds of calves.

We succeeded in reproducing the syndrome of acute hydrocephalus ‡ in puppies from 3 to 4 months old.

One of them, weighing 4,000 gm., received an ampule of 350,000 units of vitamin A by mouth. It showed a very distinct tension of the fontanel. The initial level of plasma vitamin A was 310 I. U.; 6 hours later it was 1,700 I. U.; 12 hours later it fell to 850 I. U.

Two other puppies took only the oily solvent (vitamin A destroyed); they showed no modification.

Two other puppies received during three days 100,000 units of vitamin A a day, and they showed no disorder.

In the dog, as in the human being, vitamin A produces an acute and transitory hydrocephalus, provided one gets a massive and rapid absorption, expressed by an important increase in plasma vitamin.

SUMMARY

Our clinical observations and our work on infants and animals convinces us that the acute hydrocephalus, with intensive bulge of the fontanel, produced by the rapid absorption of vitamin A is a transitory and harmless disorder in both its immediate and its remote prognosis.

It seems to us, however, quite harmful to use this treatment in such excessive dosage. On our request, this drug is now being prepared in the concentration of 70,000 units of vitamin A and 2 mg. of vitamin D, and in this dosage it has thus far been perfectly tolerated.

REFERENCES

1. Marie, J., and Sée, G.: Hydrocéphalie aigüe bénigne du nourrisson après ingestion d'une dose massive et unique de vitamines A et D, Arch. franç pédiat. **8**:563, 1951; Semaine hôp. Paris **27**:1744, 1951.

2. Cluet Garcia, J.: Otro caso de hidrocefalia aguda benigna del lactante de una dosis masiva de vitamina A. Acta pediat. espagn. **9**:1448, 1951.

3. Fleury, J.: Hydrocéphalie éphèmere après dose forte de vitamines T et D2, Arch. franç. pédiat. **10**:1061, 1952.

‡ Dr. Thieblot helped in this work.

4. Montero Rodriguez, A.: Hidrocefalia aguda benigna del lactante de una dosis masiva de vitamina A, Acta pediat. españ. **10**:648, 1952.

5. Caruana, M., and Hamza, B.: Hydrocéphalie aigüe bénigne du nourrisson par hypervitaminose A aigüe (syndrome de Julien Marie-Sée), Soc. pédiat. Paris **19**:5, 1952.

6. Demoulin, P.: Des influences accidentelles pouvant résulter d'un excés quantitatif de la vitaminothérapie A et D chez le nourrisson, Rev. méd. **9**:310, 1953.

7. Knudson, A. G., Jr., and Rothman, P.: Hypervitaminosis A: Review with Discussion of Vitamin A, A. M. A. Am. J. Dis. Child. **85**:316, 1953.

8. Moore, L.; Sykes, J.; Jacobson, W., and Wiseman, H.: Carotene Requirements for Guernsey and Jersey Calves as Determined by Spinal Fluid Pressure, J. Dairy Sc. **31**:533, 1948.

9. Hentges, J. F., Jr.; Grummer, R. H.; Phillips, P. H.; Bohstedt, G., and Sorensen, D. K.: Experimental Avitaminosis A in Young Pigs, J. Am. Vet. M. A. **120**:213, 1952.

Marin-Padilla-'65
Bib. No. 5793

J. Embryol. Exp. Morph. 13:1-8. 1965.

Somite necrosis and developmental malformations induced bv vitamin A in the golden hamster

by MIGUEL MARIN-PADILLA *and* VERGIL H. FERM[1]

From the Department of Pathology, Dartmouth Medical School

WITH THREE PLATES

INTRODUCTION

THE primary teratogenic effects of vitamin A in young embryos, when the vitamin is administered to their pregnant mothers are unknown. The morphogenesis of experimental cranioschisis and sacral rachischisis, commonly induced by vitamin A, is also still unknown. A variety of methods is now available for the induction of anencephaly (cranioschisis) and sacral spina bifida (sacral rachischisis) in some experimental animals. A method frequently used is the administration of a high dose of vitamin A to the pregnant mother. This has been employed in the rat (Cohlan, 1953; Giroud & Martinet, 1955) and in mice (Kalter & Warkany, 1961). In the present experiments, the golden hamster was used as the experimental animal.

This study is divided into two parts. The first part consists in the establishment of a method for the induction of developmental malformations in the golden hamster by vitamin A. This part will include an analysis of the results, the study of the vulnerability of the different embryonic stages to the drug and it will establish the critical period for the induction of a given malformation by this method. The second part consists of the study of the effect of vitamin A upon embryonic tissues when administered on the 8th day of gestation, this day being the critical period for the induction of cranioschisis and sacral rachischisis. Investigations of the teratogenic effects of vitamin A on young hamster embryos and its probable mode of action in causing cranioschisis and sacral rachischisis are the objectives of this paper.

MATERIALS AND METHODS

Fifty virgin female golden hamsters, *Mesocricetus auratus*, were used for the first part of the experiment. The females were placed with the males in the early evening hours and, if observed to be in estrus, they were left together overnight.

[1] *Authors' address:* Department of Pathology, Dartmouth Medical School, Hanover, New Hampshire, U.S.A.

The following day was considered to be the first day of gestation. The impregnated females were placed in separate cages. Fifty pregnancies were obtained: thirty-three pregnant hamsters were treated and seven used as controls for the first part of this study.

A single dose of 20,000 U.S.P. units of vitamin A was administered by gavage (stomach tube). The vitamin was administered to groups of hamsters (first part of the study) in the morning hours of the 5th, 6th, 7th, 8th, 9th, 10th and 11th day of gestation. All animals were sacrificed on the 14th day of gestation. Gross examination of all embryos was made at that time and the types of malformation as well as the number of malformed fetuses in each group were recorded. From these data, the 8th day of gestation was established as the critical teratogenic period for the induction of cranioschisis (anencephaly) and sacral rachischisis (spina bifida) in the golden hamster.

For the second part of this study ten additional pregnant hamsters were used. They all received the same amount of vitamin A (20,000 U.S.P.) by gavage on the 8th day of gestation. The animals of this group were sacrificed 6, 12 and 24 hr. and 4, 5 and 6 days after the administration of vitamin A. Serial sections were made of the gestation sacs of the animals sacrificed on the 8th and 9th days, and of the isolated embryos of later stages. All sections were stained with hematoxylin and eosin.

RESULTS

First part

The first part of this study is summarized in the two tables and the Text-figure. Table 1 shows the number of treated animals with the total number of living, malformed and resorbed fetuses for each day of gestation treated. Table 2 summarizes the number of fetuses affected and the percentages of each malformation obtained by this method. The terms used in this table need some comments. Anencephaly is synonymous with cranioschisis and exencephaly. Anopia includes unilateral or bilateral microphthalmia and anophthalmia. Bulging eyes corresponds to hypoplasia of the orbits with protrusion of grossly normal eyes. Spina bifida, in the majority of cases, refers to an occult sacral rachischisis, only few fetuses showing an open meningomyelocele. Rib defects include fusion, hypoplasia and hyperplasia of one or more ribs. Harelip is commonly associated with cleft palate. Limb defects include gross malformations

TABLE 1

Number of treated pregnant hamsters with the total number of living, abnormal and dead fetuses obtained per treated (vitamin A) day of gestation

	5th	*6th*	*7th*	*8th*	*9th*	*10th*	*11th*	*Controls*
Mother treated	4	4	3	10	4	5	3	7
Living fetuses	45	53	14	89	40	48	33	71
Abnormal fetuses	0	4	5	58	20	36	0	0
Resorbed fetuses	2	2	23	34	2	14	2	4

TABLE 2

Types and percentages of malformations obtained per treated (vitamin A) day of gestation in the golden hamster

Day	*Anen-cephaly*	*Anopia*	*Bulging eye*	*Spina bifida*	*Rib defect*	*Harelip*	*Limb defect*	*Hernia*
5th	—	—	—	—	—	—	—	—
6th	—	—	—	—	4 (7·5)	—	—	—
7th	1 (7·1)	3 (21·4)	—	1 (7·1)	—	3 (21·4)	—	—
8th	14 (15·7)	2 (2·2)	28 (31·4)	11 (12·3)	33 (37·0)	2 (2·2)	—	2 (2·2)
9th	—	—	18 (45·0)	—	3 (7·5)	—	—	—
10th	—	—	—	—	5 (10·4)	—	36 (75·0)	—
11th	—	—	—	—	—	—	—	—

of the fingers and toes and anomalous position of the limbs. No phocomelic fetuses were found in these series. Hernia refers to a large umbilical hernia.

The sensitivity of hamster embryos to the teratogenic effects of vitamin A shown by fetal mortality and the incidences of malformations on different days of gestation are shown in Text-fig. 1. The sensitivity of the embryos varies greatly with the stage of embryonic development. The early embryonic stages before implantation, including the blastocyst stage (5th day of gestation), appear to be resistant to the dose of vitamin A used. Mild teratogenic effects begin to

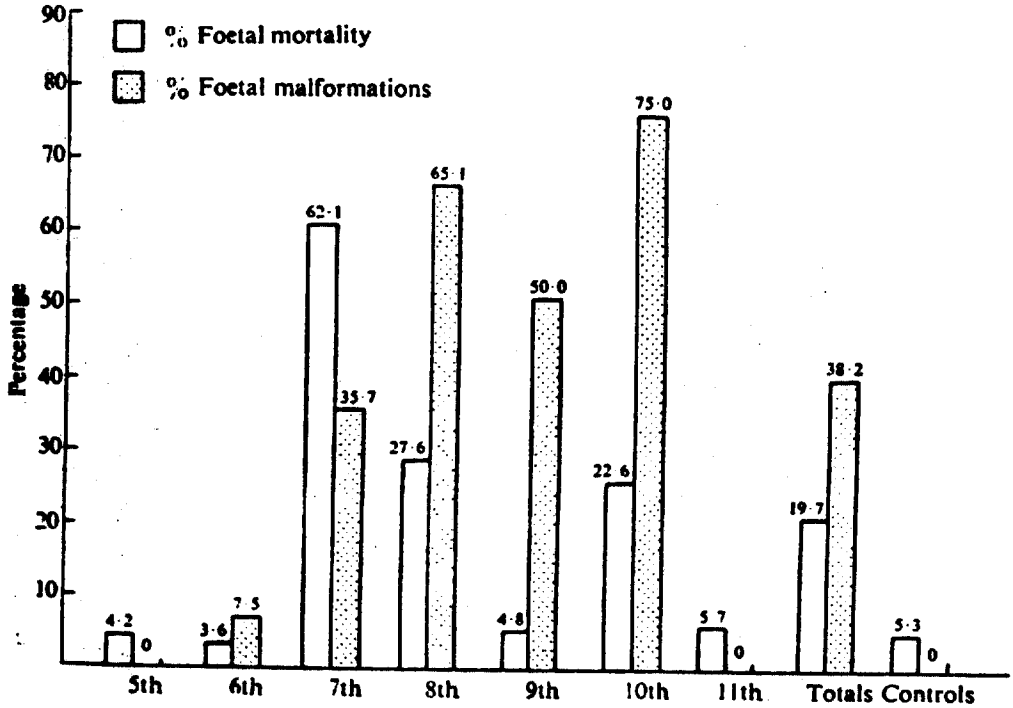

TEXT-FIG. 1. Sensitivity of hamster embryos to vitamin A expressed as the percentages of fetal mortality and of fetal malformations.

appear on the 6th day of gestation which corresponds to the beginning of implantation (Graves, 1945). Minor malformations (rib defects) are induced on that day. The administration of vitamin A on the 7th day of gestation produces the highest embryonic mortality in the present study. Major developmental malformations (anencephaly, cleft palate and cleft lip) are first observed after treatment on that day which corresponds to the beginning of development of the embryonic body. The results obtained after administration of vitamin A on the 8th day of gestation show that the number of major malformations increases and the fetal mortality decreases. The administration of the vitamin on the 9th day produces minor developmental malformations (bulging eyes and rib defects) and a further decrease in embryonic mortality. The 10th day of gestation in the hamster marked another critical period of sensitivity to vitamin A with a new increase in fetal mortality, and frequent malformations of the extremities. On the 11th day the hamster embryos are resistant to the teratogenic effect of this amount of vitamin A. No congenital malformations are found in the control hamsters and their resorption rate is considered to be within normal limits.

Second part

In the second part of the study all embryos were obtained from mothers which received 20,000 units of vitamin A on the 8th day of gestation. Sections of the embryos, 6 hr. after the administration of vitamin A to the mother, did not show any appreciable histologic change or cellular necrosis. The embryos of this group differ in their developmental stage from late presomite to early somite stages. Twelve hours after the administration of vitamin A to the mother the first appreciable changes are found in the embryos. These changes, found only in the somites, consist of cellular necrosis, represented by rupture of the cells, diffusion of the cytoplasm and the formation of small, round, dense and dark bodies. These bodies may persist in the areas of necrosis and can be found later in older embryos. The changes observed in this group of embryos are minimal, localized and are not present in all the sections of the same embryos. The necrosis is restricted to the somites of the cephalic end of the embryo. The embryos in this group have approximately 7–9 somites and the neural tube has begun to close (Plate 1, Figs. A & B).

Twenty-four hours after administration of vitamin A massive cellular necrosis of the somites (Plate 2, Fig. C) is observed in all embryos, the surrounding embryonic tissues being unaffected. There is no necrosis or apparent damage to the neural tissue, the entoderm, or the ectoderm of the embryos (Plate 2, Fig. D). In this group of embryos focal necrosis of the notochord is found for the first time (Plate 2, Fig. D, insert). The embryos of this group belong to a 10-somite or later stage. The neural tube appears to be closed except for a small anterior and a posterior neuropore. It is not possible from the study of these embryos to predict the type of malformation that will later appear. All embryos studied in

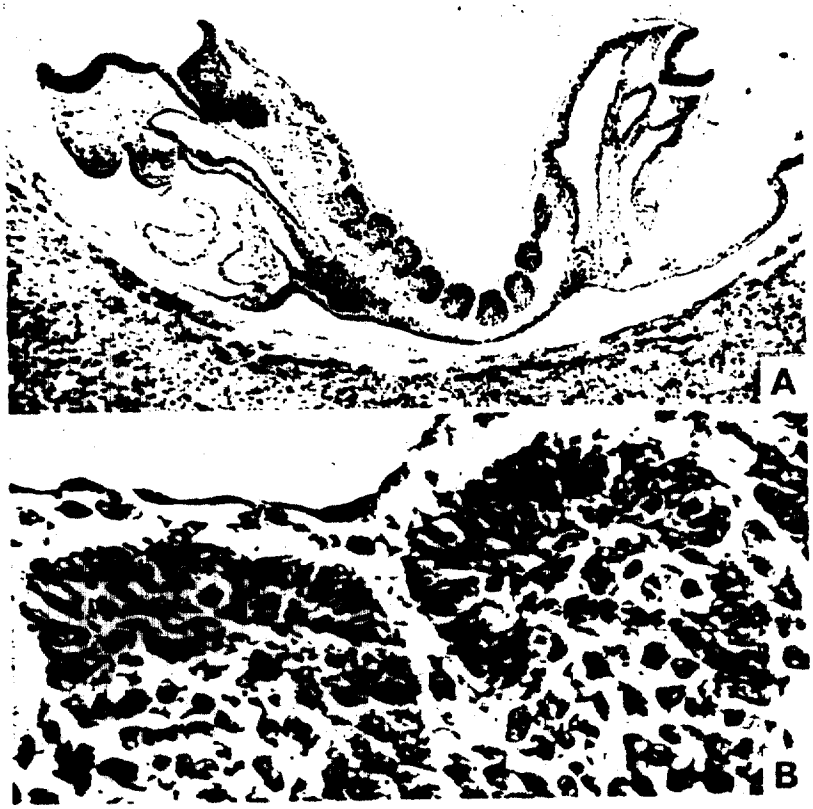

PLATE 1

FIG. A. Longitudinal section of an embryo (inside uterus) obtained 12 hr. after the administration of vitamin A to its mother. The anterior and posterior neuropores are open. The cephalic somites show focal necrosis. (H. & E. × 25.)

FIG. B. Detail of two cervical somites of the embryo depicted in Fig. A, showing focal cellular necrosis (arrows). (H. & E. × 200.)



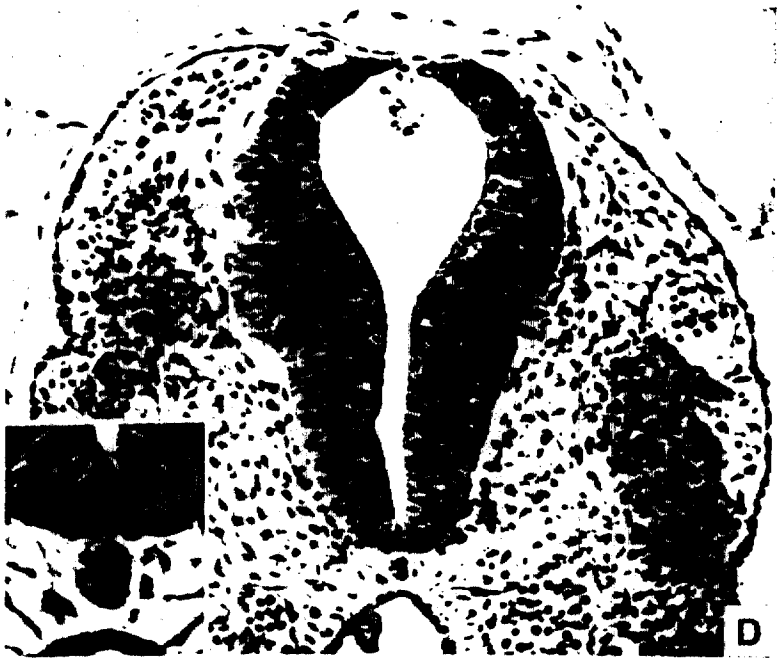

PLATE 2

FIG. C. Somite of the cephalic region of an embryo obtained 24 hr. after administration of vitamin A to the mother. Maximum necrosis in the somite is observed at this time. (H. & E. × 200.)

FIG. D. Gross section of the cephalic region of an embryo (24 hr. after vitamin A administration) showing bilateral somite necrosis. Notice the absence of necrosis or any change in the neural tube. This section is inferior to the anterior neuropore. Focal notochordal necrosis is found in this section and in the inset. (H. & E. × 100; Inset × 200.)

M. MARIN-PADILLA and V. H. FERM

(*Facing page 5*)

this group are affected by cellular necrosis of the somites; some are more severely and extensively affected than others.

The fetuses obtained on the 12th, the 13th or the 14th day of gestation from mothers treated on the 8th day with vitamin A, show the malformations clearly. Fetuses with cranioschisis and exencephaly were serially sectioned for microscopic study. There are no embryos in this group with an open sacral meningomyelocele. However, some show the typical bulging sacral area characteristic of an occult sacral rachischisis. These cases were also serially sectioned for microscopic study. Gross sections of the head of fetuses with cranioschisis, obtained on the 12th day of gestation, show focal necrosis of the notochord with fragmentation of its capsule. Also, areas of necrosis are found in the superior aspect of the cartilaginous blastema of the basilar portion of the sphenoid bone. This last necrosis, in longitudinal sections of the head, accompanies and surrounds the cephalic end of the notochord. The necrosis of the notochord and of the surrounding tissue is indistinguishable from the necrosis seen in the somites of the early embryos described previously.

In a well-established experimental cranioschisis with exencephaly (fetuses obtained on the 14th day of gestation) the cephalic notochord (the portion of notochord anterior to the odontoid process of the second cervical vertebra) is narrower, shorter and less well outlined than in the normal fetus. Plate 3, Figs. I & J, show longitudinal sections of an abnormal skull (cranioschisis) and of a normal one. There is no cellular necrosis in any of the structures of the head in this group of fetuses. In experimental sacral rachischisis a notochordal abnormality is found in all embryos studied on the 14th day of gestation. Portions of the sacral notochord are affected, usually a region two or three segments in length. No changes in the notochord of other regions of the vertebral column are found (Plate 3, Fig. G). The abnormal notochord consists of hyperplastic tissue occupying a large part of the vertebral body. The vertebrae with notochordal changes are morphologically abnormal. The shape (Plate 3, Figs. G & H) of the abnormal notochord varies from case to case, assuming all kinds of anomalous configurations. Occasionally, a centrally placed area of necrosis is found in the notochord. This necrosis is surrounded by what appears to be fragments of necrotic notochordal capsule (Plate 3, Figs. E & F) and because of the central location of this necrotic material it may represent an area of previous notochordal necrosis. These necrotic areas are always surrounded by a hyperplastic notochord.

DISCUSSION

The 8th day of gestation was selected for special study because it yields the highest percentage of cranioschisis and sacral rachischisis. The first indication of the teratogenic effects of vitamin A are observed in the somites of the cephalic end of the embryos 12 hr. after administration of the vitamin. These changes are minimal and localized to the somites of the cephalic portion of the embryo. At 24 hr. the maximum effect is apparently obtained. The changes at this time are

more generalized, affecting other somites, but the most severely affected still are the most cephalic in location. At this time (24 hrs. after treatment) the first notochordal changes are observed, consisting of focal necrosis in the cervical and cephalic portions of the notochord. Later, 4 and 6 days after treatment, some embryos show schisis of the skull and exencephaly with areas of degeneration, while others show a bulging of the sacral region. Some cellular debris is found in the sphenoid blastema in embryos 4 days after treatment. Six days after treatment, in induced cranioschisis, the cephalic portion of the notochord is narrower and shorter than normal. In sacral rachischisis, focal necrosis and hyperplastic changes in the notochord are found.

The predominant cephalic location of the somite necrosis induced by vitamin A on the 8th day is significant, since these embryos are known to have the highest percentage of cranioschisis. This developmental malformation is considered to be the result of a failure of closure of the anterior portion (anterior neuropore) of the neural tube due to primary somite necrosis. Somite necrosis is considered to cause an abnormality of the axial mesoderm (from abnormal segmental dermatomes and sclerotomes) which then fails to support and protect the neural tube. The neural tube remains open and exposed and soon begins to degenerate. Those embryos with an open anterior neuropore show somite necrosis only. No changes are noted in the neural tube which is still open in these early stages. The neural tube presumably degenerates thereafter for lack of closure and protection.

The occult variety of sacral rachischisis induced by this method shows an hypertrophied neural tube in contact with the skin and subcutaneous tissue. Hyperplasia and focal necrosis of the notochord are found in the sacral regions in these embryos. The associated sacral vertebrae are always severely malformed, in that they lack the posterior neural arches or they may have short and deviated arches which never completely enclose the neural tube. The neural tube, then, lacks protection from the vertebral skeleton in the affected area. The neural tube in these cases appears to be relatively normal, which suggests that it was closed at the time of somite injury. This malformation is considered to be the result of somite necrosis occurring after the closure of the posterior neuropore. The abnormal mesodermal tissue resulting from somite necrosis then fails to give proper support to the neural tube and is responsible for the vertebral abnormalities.

All embryos studied 12 and 24 hr. after treatment have shown somite necrosis. The only difference between them is in the number of somites affected and the severity of the necrosis in a given somite. Rarely, the entire somite is destroyed. These differences are due to the developmental stage of the somite and are reflected in the type of malformation induced upon mesodermally derived tissue. Minimal damage to the somites may account for the rib defects. Moderate damage may account for vertebral malformations, e.g. occult sacral rachischisis. Extensive destruction may account for the most severe malformation of the head skeleton in cranioschisis.

PLATE 3

FIGS. E and F. Low- and high-power views of a sacral vertebra in an embryo with an occult sacral rachischisis (6 days after vitamin A administration) showing focal notochordal necrosis and notochordal hyperplasia. Notice in Fig. F the rupture and fragmentation of a probable capsule around the necrotic notochord. (H. & E. × 100 and 200 respectively.)

FIGS. G and H. Low- and high-power views of a longitudinal section of the sacral region in an embryo with an occult sacral rachischisis (6 days after treatment) showing the abnormal shape of the notochord and anomalies of the sacral vertebrae. (H. & E. × 100 and × 150 respectively.)

FIG. I. Longitudinal section of the base of the skull in a fetus with cranioschisis showing the course of the cephalic notochord. (H. & E. × 50.)

FIG. J. Longitudinal section of the base of the skull in a normal fetus (same age as fetus of Fig. J) showing the cephalic notochord. (H. & E. × 50.)

Note: Figures I and J have been marked with India ink to show the course of the cephalic notochord as it was found in subsequent serial sections.

M. MARIN-PADILLA and V. H. FERM

(Facing page 6)

SUMMARY

1. A simple method for the induction of developmental malformation in the golden hamster is presented. The teratogenic agent used consists of a single dose of vitamin A. Correlations between the day of gestation at which the vitamin A is administered and the type and percentage of malformations induced are reported. Young embryos obtained from treated mothers on the 8th day of gestation show somite necrosis within 12 hr. of the administration of vitamin A, reaching its maximum at 24 hr. The somite necrosis is considered to be a basic alteration resulting in an abnormal axial mesoderm which then fails to fulfil its function of lodging and protecting the neural tube. The unprotected and exposed neural tissue secondarily degenerates. Somite necrosis is considered to be the primary defect induced by vitamin A causing developmental malformations such as cranioschisis and sacral rachischisis. When somite necrosis occurs before neural tube closure extensive degeneration of the neural tube follows (e.g. cranioschisis). Somite necrosis occurring after closure of neural tube results in only minimal change in the neural tube (e.g. occult sacral rachischisis).

2. Notochordal alterations (hypertrophy and necrosis) are also found in the young hamster embryo after administration of vitamin A to their mother on the 8th day of gestation.

RÉSUMÉ

Nécroses des somites et malformations du développement induites par la vitamine A *chez le Hamster doré*

1. On présente une méthode simple pour l'induction des malformations du développement chez le Hamster doré. L'agent tératogène utilisé consiste en une seule dose de vitamine A. On signale des corrélations entre le jour de la gestation auquel la vitamine A est administrée et le type et le pourcentage des malformations induites. De jeunes embryons obtenus de mères traitées le 8e jour de la gestation montrent une nécrose somitique dans les 12 heures de l'administration de la vitamine A, atteignant son maximum au bout de 24 heures. La nécrose des somites est considérée comme étant une altération fondamentale donnant naissance à un mésoderme axial anormal qui ne remplit pas alors sa fonction de protection du tube neural. Le tissu nerveux non protégé et exposé dégénère secondairement. On considère que la nécrose somitique est la déficience primaire induite par la vitamine A, provoquant des malformations du développement telles que la cranioschisis et la rachischisis sacrée. Quand la nécrose somitique survient avant la fermeture du tube neural, une dégénérescence étendue du tube neural s'ensuit (p.ex. cranioschisis). La nécrose somitique intervenant après la fermeture du tube nerveux n'entraîne que des modifications minimes dans ce dernier (rachischisis sacrée occulte).

2. On trouve aussi chez les jeunes embryons de Hamster des altérations de la notochorde (hypertrophie et nécrose), après administration de vitamine A à leur mère le 8e jour de la gestation.

ACKNOWLEDGEMENTS

We wish to acknowledge the technical assistance of Miss Marjorie Stearns and Mrs Linda Wilmot.

This investigation was supported by USPH grant GM-10210.

REFERENCES

COHLAN, S. Q. (1953). Excessive intake of vitamin A as a cause of congenital anomalies in the rat. *Science*, **117**, 535.

COHLAN, S. Q. (1954). Congenital anomalies in the rat produced by excessive intake of vitamin A during pregnancy. *Pediatrics*, **13**, 556.

GIROUD, A. & MARTINET, M. (1955). Hypervitaminose A et anomalies chez le foetus de rat. *Rev. int. vitamin.* **26**, 10.

GRAVES, A. P. (1945). Development of the golden hamster *Cricetus auratus* during the first 9 days. *Amer. J. Anat.* **77**, 219.

KALTER, H. G. & WARKANY, T. (1961). Experimental production of congenital malformations in strains of inbred mice by maternal treatment with hypervitaminosis A. *Amer. J. Path.* **38**, 1.

(*Manuscript received 2nd June 1964*)

Marin-Padilla-'66
Bib. No. 5794

J. Embryol. exp. Morph., Vol. 15, 3, pp. 261–269, June 1966
With 2 plates
Printed in Great Britain

Mesodermal alterations induced by hypervitaminosis A

By MIGUEL MARIN-PADILLA[1]
From the Department of Pathology, Dartmouth Medical School

INTRODUCTION

In a recent experimental study (Marin-Padilla & Ferm, 1965) of the teratogenic effects of vitamin A, a distinct cellular necrosis in the somites of young hamster embryos was found. This necrosis appeared at 12 h and the maximum degree of damage was reached some 24 h after the administration of the vitamin. The somite damage was considered then to be the earliest alteration induced by vitamin A which, in turn, causes disturbances in the axial mesoderm. Disturbances in the axial mesoderm could explain the vitamin A induced cranioschisis and sacral rhachischisis. The study of human cranioschisis (Marin-Padilla, 1965*b*) and craniorhachischisis (Marin-Padilla, 1966) has also shown that unknown mesodermal conditions, affecting the cephalic and the axial mesoderm respectively, are the most likely underlying causes of these two malformations. Similar axial mesodermal conditions may also explain the notochordal alteration encountered in human cranioschisis (Marin-Padilla, 1966). ('Cranioschisis' ('cranium' and 'schisis') is another term for anencephaly, and 'craniorachischisis' ('cranium' and 'rachis-schisis') is a term for the combination of anencephaly and the total failure of closure of the spinal canal (vertebral column). These terms express better the basic developmental defect in these malformations, namely, failure of closure of the neural tube.) Furthermore, a study (Marin-Padilla, 1965*a*) of the sphenoid bones of unequally affected human cases of cranioschisis and craniorhachischisis has shown that the sphenoid bones are similarly malformed. This was considered to be suggestive of the existence of a common, segmental disturbance of the cephalic mesoderm in these malformations. It was suggested, in view of the experimental observations, that somite alterations could explain the common, segmental condition affecting the cephalic mesoderm of these malformations.

However, the possibility of a condition affecting primarily the presomite cephalic and the axial non-segmented mesoderm (embryonic body) and thus secondarily involving the somites has not yet been investigated. This possibility, on the other hand, could better explain the embryogenesis of cranioschisis and

[1] *Author's address:* Department of Pathology, Dartmouth Medical School, Hanover, New Hampshire, U.S.A.

craniorhachischisis. Primary presomite disturbances with secondary somite damage have been previously suggested by Gallera (1951), Stephan & Sutter (1960), Grüneberg (1963) and Jurand (1963).

Both the investigation of this possibility and the necessity for a sequential study of the earliest possible teratogenic effects of vitamin A to clarify the nature of the previously reported somite necrosis were indicated. This double objective was carried out using vitamin A as the teratogenic agent and with the golden hamster as the experimental animal. Vitamin A was selected for this study not only for its known teratogenic effects but also because it is known to affect mesodermal tissues (Chung & Houck, 1964; Weissmann, 1964; Nelken *et al.* 1965; Harrison, 1965; Marin-Padilla & Ferm, 1965). The observations made in this investigation are presented and discussed.

MATERIALS AND METHODS

Twenty female golden hamsters were used in this investigation. The animals were separated in five groups of four animals. The four animals in each group were bred on the same day, at the same time, and kept under identical general conditions. Two animals in each group received 20000 u of vitamin A by gavage on the 8th day of gestation at 8 a.m. The other two animals in each group were used as controls and received nothing. The use of a control animal for each experimental animal was an absolute requirement in this investigation since the observations of early changes must be based on a continuous comparative analysis of treated and control animals.

The two treated and the two control animals in each group were sacrificed as follows. The first group at 3 h; the second at 6; the third at 8; the fourth at 10; and the fifth at 12 h after the administration of vitamin A to their pregnant mothers.

The pregnant uteri of treated and control animals were submitted to the following procedure. Dissection of the uterus in its individual gestational areas was followed by a superficial coronal incision of the uterine musculature at each gestational area. By this method the decidual casts with the embryonic cavities were released from the uterine cavity either spontaneously or after gentle manipulation. These decidual casts are egg-shaped with a superior pointed area containing the embryonic cavity and an inferior rounded one composed of decidua. The decidual casts were then divided into two halves. The superior one with the embryonic cavity was fixed immediately in Bouin's solution; the inferior one was discarded. After 24 h of fixation, nine to twelve embryonic cavities thus obtained can be mounted as a single group in paraffin. The paraffin blocks were serially sectioned. Approximately one-third of these sections contain embryonic tissue. All sections were stained with hematoxylin and eosin. A total of 64 000 sections from both treated and control animals were examined.

RESULTS

First group

No appreciable changes or alterations were noted in the embryos recovered 3 h after the administration of vitamin A when compared with the control embryos.

Second group

Alterations become apparent in embryos recovered 6 h after the administration of vitamin A. These alterations are minimal and subtle, and only appreciated after extensive comparative analysis with control embryos. The alterations are only present in the mesodermal tissue of the cephalic region. They consist of a slight shrinkage of the cytoplasm of the mesodermal cells and an increase in the size of the intercellular spaces. No changes are seen in the nuclei of the mesodermal cells. The enlargement of the intercellular spaces appears to be the result of accumulation of fluid. Dilatation of the marginal vascular spaces (sinusoids) directly under the cephalic neuro-ectoderm is encountered in some embryos. No appreciable changes are seen in the axial non-segmented mesoderm of the embryonic body or in the somites of the embryos of this group.

Third group

Similar but more marked alterations in the cephalic mesoderm are found in embryos recovered 8 h after the administration of vitamin A. Also, shrinkage of the cytoplasm and an enlargement of the intercellular spaces become apparent in the axial non-segmented mesoderm of the embryonic body in the embryos of this group. No distinct alterations in the somites are found in these embryos.

Fourth group

The mesodermal damage induced by vitamin A reaches a maximum 10 h after the administration of the vitamin to the pregnant hamsters. In view of this, the mesodermal alterations and changes observed in this group of embryos will be presented in more detail. All mesodermal elements are affected.

The cephalic mesoderm is the more severely affected region of these embryos. The alterations observed in this region remain the same as in the previous groups of embryos, namely shrinkage of the cell cytoplasm and enlargement of the intercellular spaces due to accumulation of fluid (compare Plate 1, figs. A–B and C–D). The shrinkage of the cytoplasm of the mesodermal cells is so severe that some of them appear to be totally deprived of it. In the cephalic mesoderm the number of mesodermal cells (compare figs. A–B and C–D) and the number of mitoses appeared to be reduced in the treated embryos when compared with the controls. The enlargement of the intercellular spaces has reached its maximum in these embryos (compare figs. A–B and C–D), and the vascular spaces are also greatly dilated, especially branches of the dorsal aortae and the marginal vascular sinusoids under the cephalic neuro-ectoderm. The neuro-ectodermal

tissue covering the altered cephalic mesoderm does not appear to be affected and shows a normal number of mitoses (compare figs. C–D). However, a slight reduction in the thickness of the cephalic neuro-ectoderm is observed in some embryos.

The axial non-segmented mesoderm of the embryonic body of the treated embryos show similar but less marked changes to those observed in the cephalic mesoderm. The mesodermal cells show shrinkage of their cytoplasm and the intercellular spaces are enlarged (compare figs. E–F and G–H). The number of cells of the axial non-segmented mesoderm appears to be reduced as well as the number of mitoses in the treated embryos when compared with the controls. Some treated embryos appear slightly retarded in their development and the neural tube has not yet closed (compare figs. G–H). The neuro-ectoderm of these embryos appears to be within normal limits.

The somites of some embryos of this group appear also affected, they are not as clearly established and well delineated as in the control embryos (compare

---

Explanation of Plates

Note. All the sections depicted in the figures belong to embryos recovered 10 h after the administration of vitamin A unless otherwise stated.

Plate 1

Fig. A. Cross-section of the superior portion of the cephalic region of a control embryo showing the neuro-ectoderm in the superior and inferior edges and the endodermal tube in the center. Notice the richness and abundance of cells of the cephalic mesoderm. (H and E., × 160.)

Fig. B. Cross-section of the superior portion of the cephalic region of a treated embryo, showing the neuro-ectoderm in the superior and inferior edges and a central endodermal tube. Notice the shrinkage of mesodermal cells, the enlargement of intercellular spaces and the dilatation of the vascular and of the marginal sinusoids. (H. and E., × 160.)

Fig. C. Cross-sections of the head region of a control embryo showing the anterior (left) and the posterior (right) areas of the neuro-ectoderm and the central endodermal tube. Notice the richness and abundance of cells in the mesodermal tissue and in the maxillary process (arrows). The neuro-ectoderm shows abundant superficial mitosis. (H. and E., × 160.)

Fig. D. Cross-section of the head region of a treated embryo showing the anterior (left) and the posterior (right) areas of the neuro-ectoderm and a central endodermal tube. Notice the mesodermal changes, the dilatation of the intercellular and vascular spaces and the reduction of the number of mesodermal cells elsewhere and in the maxillary process (arrow). The neuro-ectoderm shows abundant superficial mitosis. (H. and E., × 150.)

Fig. E. Cross-section of the middle thoracic region of a control embryo, showing the neural tube and the somite (left) and the pericardial cavity with the heart (right). Notice the richness and abundance of cells in both the non-segmented and in the somitic mesoderm and the superficial mitosis of the neural tube. (H. and E., × 140.)

Fig. F. Cross-section of the middle thoracic region of a treated embryo showing the neural tube and somite (above) and the pericardial cavity with the heart (below). Notice the scanty cellularity in both the non-segmented and the somite mesoderms and the superficial mitosis of the neural tube. The somites are poorly formed and cannot be easily identified. (H. and E., × 140.)

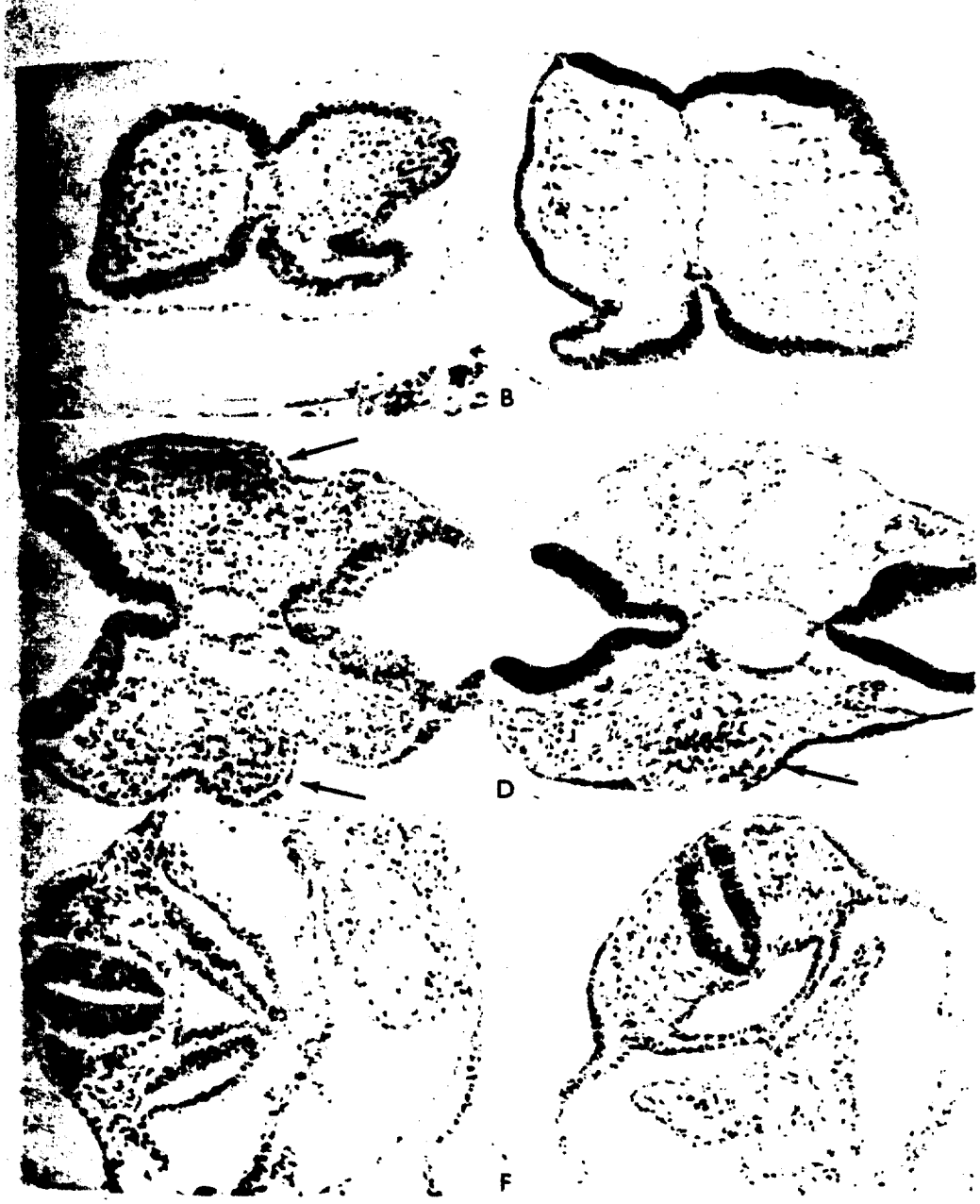

MARIN-PADILLA

facing p. 264

M. MARIN-PADILLA

facing p.

figs. I–J). The affected somites have also a smaller number of cells (compare figs. E–F and I–J). The somites most frequently affected are those of the cephalic and cervical regions. The dorsal, lumbar and sacral somites are little affected or not at all. The mesodermal concentrations in the cephalic region such as the maxillary processes, although not affected themselves, are surrounded by an altered mesoderm. In some treated embryos the maxillary processes give the impression of a loose arrangement of their cellular component when compared with controls (compare figs. C–D).

In addition to the alterations described, the mesoderm of the treated embryos shows generalized changes. These changes appear to be the direct consequence of the mesodermal alterations. The changes consist of a mesodermal derangement and, more importantly, of a mesodermal collapse. The first consists of a disorganization of the mesodermal and somitic cells. The second, as its name indicates, is literally a collapse of the mesodermal tissue, or, in other words, a breakdown of the mesoderm as a whole. The term collapse, however, describes better the phenomenon observed in the mesoderm of these embryos (figs. K, L). It is most frequently encountered in the cephalic region of the embryo. The cephalic mesoderm collapse causes an exterioration, an exposure and a flattening of the cephalic neuro-ectoderm (fig. K). The exposed and flat neuro-ectoderm of the cephalic region does not appear to be affected. It gives the false impression of an overgrowth over the cephalic mesoderm (figs. K, L). However, the

---

PLATE 2

Fig. G. Cross-sections of the thoracic and lumbar regions of a control embryo, showing the richness and cellularity of the non-segmented and somitic mesoderms. (H. and E., ×80.)

Fig. H. Cross-sections of the thoracic and lumbar regions of a treated embryo, showing the alteration in the non-segmented and somitic mesoderms. Also, this embryo shows a retardation in the closure of the neuro-ectoderm which may be caused by the altered underlying mesoderm. (H. and E., ×80.)

Fig. I. Longitudinal section of the body of a control embryo to show the somites. Notice the richness and abundance of cells in the somites and the clear demarcation of the individual somite. (H. and E., ×140.)

Fig. J. Longitudinal section of the body of a treated embryo to show the affected somites. With the exception of the large somite (left) the other somites (arrows) are not clearly established and they are composed by a smaller number of cells. (H. and E., ×140.)

Fig. K. Oblique section of the cephalic and thoracic region of a treated embryo to show the typical mesodermal collapse with the exposure and flattening of the cephalic neuro-ectoderm. The cephalic mesoderm also depicts the typical alterations. The neuro-ectoderm gives the false impression of overgrowth above the collapsed mesoderm. This embryo represents the earliest example of vitamin A induced cranioschisis (10 h after administration). (H. and E., ×100.)

Fig. L. Oblique section of the cephalic and thoracic regions of a treated embryo recovered 12 h after the administration of vitamin A to show the persistence of the typical mesodermal collapse. This embryo represents another example of the earliest form of experimentally induced cranioschisis (12 h after administration). (H. and E., ×100.)

reason for this false impression is actually the collapse of the underlying cephalic mesoderm.

Occasionally an abnormal focus of cellular necrosis is encountered in the cephalic mesoderm of treated embryos. No necrosis in the somites is present at this time.

Fifth group

The mesodermal alterations, shrinkage of cell cytoplasm and enlargement of intercellular spaces are also present in treated embryos of this group. However, these alterations are less accentuated than in the previous group as if these embryos were already recovering from the teratogenic insult. The mesodermal collapse of the cephalic region with flattening and exposure of the neuro-ectoderm is still present and prominent in these embryos (fig. L). Cellular necrosis of mesodermal cells of the cephalic region and of the cephalic neuro-ectoderm are observed in the treated embryos. An occasional somite in the cephalic and in the cervical region may depict focal cellular necrosis.

DISCUSSION

The administration of vitamin A to the pregnant hamster is followed almost immediately (6 h) by mesodermal alterations in the embryos which reach their maximum severity after 10 h.

The mesodermal regions of the embryo are affected in the following order: the cephalic mesoderm, the axial non-segmented mesoderm and, finally, the segmented mesoderm, especially the somites, The nature of these mesodermal alterations is not known. From other sources it is known that vitamin A plays an important role in the permeability of the cellular membrane and that in excess causes instability of the membranes (Lucy & Dingle, 1964). Also, it has been shown that vitamin A in excess inhibits the formation of new blood vessels (Nelken *et al.* 1965) and the growth of a rabbit's papilloma by apparently affecting its dermal (mesoderm) support (Harrison, 1965). It is possible then that biochemical alterations of the cell metabolism and disturbance of the cell membrane may explain the shrinkage of the cell cytoplasm and the accumulation of fluid in the extracellular space of the vitamin A induced mesodermal alteration in young embryos.

The somite alterations induced by vitamin A occur later than the mesodermal alterations and consist of the formation of abnormal somites, and later in somite necrosis. The cause of these somite alterations is not known. Two possibilities may be considered. They may be the result of a direct effect of vitamin A upon the somite cells as previously suggested (Marin-Padilla & Ferm, 1965), or they may be the result of an indirect effect secondary to the primary alterations in the axial non-segmented mesoderm. This last possibility appeared more likely in view of the present observations. It is also supported by the observations

of other investigators. Gallera (1951) suggested that early mesodermal (chordo-mesodermal) disturbances may cause somite alterations and platyneuria (craniorhachischisis) in chicks. Stephan & Sutter (1960) described blockage of cellular proliferation in the undifferentiated axial mesoderm and in the somitic centers and also the formation of edema fluid in chick embryos treated with trypan blue. Jurand (1963) observed early mesodermal disorganization, lack of segmentation and, later, somite necrosis (in severe cases) in the mouse after the administration of a nitrogen mustard derivative. Grüneberg (1963), discussing some malformations of the axial skeleton, states that disturbances of segmentation may secondarily cause somite alterations. Hicks (1954) induced severe skeletal malformations (anencephaly) after X-irradiation of young mammalian embryos before the formation of somites, or during one or two somite stages. Whatever the nature of the mesodermal alterations may be, they are of great significance for the understanding of vitamin A induced malformations. They are the first appreciable alterations induced by vitamin A and the cause of significant changes in the mesodermal tissue.

In view of the observations presented here, those made from the previous experimental studies described above, and those made from the study of human axial skeletal malformations, the embryogenesis of these malformations can now be better understood. Axial skeletal malformations such as cranioschisis, craniorhachischisis and rachischisis are the result of the same fundamental disturbances of the mesoderm. This disturbance affects primarily the presomite cephalic and axial non-segmental mesoderm of the body of the embryo and secondarily the somitic mesoderm. Direct consequences of these alterations are a derangement of mesodermal cells and, more significantly, a mesodermal collapse. If the mesodermal collapse occurs before the closure of the neural tube it will cause exposure, exterioration and flattening of the neuro-ectoderm. The neuro-ectoderm thus affected and exposed obviously will fail to close, not as a primary neuro-ectodermal disturbance but as a failure of the collapsed mesoderm to enclose it. The exposed neuro-ectoderm which is not affected at first continues its development causing the false impression of an overgrowth over the collapsed mesoderm. Later the neuro-ectoderm starts to fold, causing the typical appearance of exencephaly. This phenomenon of apparent overgrowth and folding of an exposed nervous tissue has been beautifully shown in the experimentally induced exencephaly which follows the opening of the roof of the rhombencephalon in the chick (Jelínek, 1960; Klika & Jelínek, 1961). Even later in development, a degeneration of the exposed neuro-ectoderm begins, ending in its destruction (anencephaly). Thus, the embryos depicted in figs. K and L may be regarded as the youngest known examples of vitamin A induced cranioschisis. If the mesodermal alterations occur after the closure of the neural tube only skeletal malformations will occur. The secondary alterations of the somites (abnormal somites and somite necrosis) and of the notochord (duplication and deviations) appear to influence the final morphology of

the skeletal malformations (Marin-Padilla, 1965*a*; Marin-Padilla, 1966). The teratogenic effects of vitamin A in the golden hamster in relation to the embryogenesis of the skeletal malformations are graphically expressed in Table 1.

Table 1. *Tetratogenic effects of vitamin A on the hamster embryo*

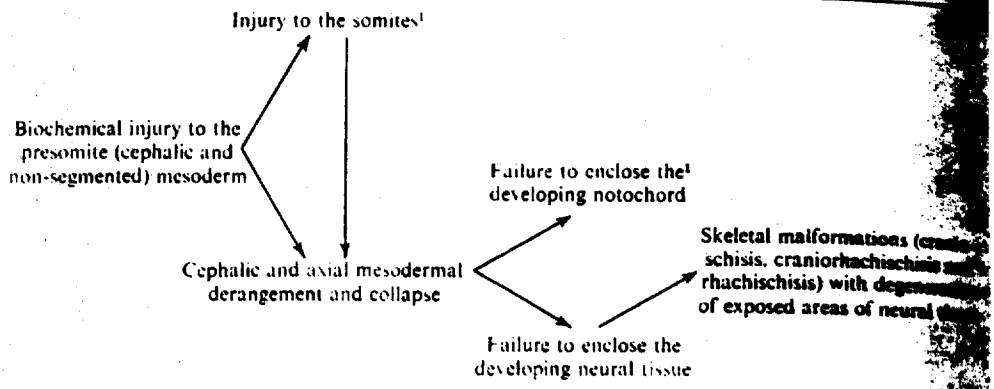

[1] Interaction of these factors influence the final morphology of the skeletal malformations.

SUMMARY

The administration of a single dose (20000 u) of vitamin A by gavage to the pregnant hamster is followed almost immediately by changes in the mesoderm of the embryos. These changes appear 6 h after the administration and after 10 h they have reached their maximum severity. The alterations appear first in the cephalic mesoderm, later in the axial non-segmented mesoderm of the body of the embryo and finally in the somitic mesoderm. They consist of shrinkage of the cell cytoplasm, enlargement of the intercellular spaces (fluid accumulation) and reduction of the mitotic rate of mesodermal cells. These alterations precede the cellular necrosis which appeared later in the somites and is considered a secondary change. An analysis of the embryogenesis of the vitamin A induced skeletal malformation based on the changes described is discussed.

RÉSUMÉ

Altérations du mésoderme produites par une hypervitaminose A

L'administration d'une dose unique (20.000 μ) de vitamine A par le gavage d'une hamster gravide est suivie presque immédiatement par des changements dans le mésoderme de l'embryon. Ces altérations apparaissent 6 heures après l'administration et atteignent leur maximum après 10 heures. Elles se manifestent d'abord dans le mésoderme céphalique, ensuite dans le mésoderme axial non segmenté et finalement dans le mésoderme somitique. Elles consistent en une rétraction du cytoplasme des cellules, agrandissement des espaces intercellulaires

cellulaires (accumulation de liquide) et une réduction du taux des mitoses des cellules mésodermiques. Ces altérations précèdent les nécroses cellulaires qui sont apparues ultérieurement dans les somites et qui sont considérées comme secondaires. Une analyse de l'embryogenèse des malformations squelettiques induites par la vitamine A, et basées sur les changements qui ont été décrits, est discutée.

This investigation was supported by USPHS Grant GM 10210.

REFERENCES

CHUNG, A. C. & HOUCK, J. C. (1964). Connective tissue. IX. Effects of hypervitaminosis A upon connective tissue chemistry. *Proc. Soc. exp. Biol. Med.* **115**, 631–3.

GALLERA, T. (1951). Influence de l'atmosphère artificiellement modifiée sur le développement embryonnaire du poulet. *Acta Anat.* **11**, 549–85.

GRÜNEBERG, H. (1963). *The Pathology of Development. Disorder of Segmentation.* Pp. 170. Oxford: Blackwell.

HARRISON, M. (1965). Inhibition of growth of Shope rabbit papilloma by hypervitaminosis A. *Cancer Res.* **25**, 947–55.

HICKS, S. (1954). Mechanism of radiation anencephaly, anophthalmia and pituitary anomalies. Repair in the mammalian embryo. *A.M.A. Archs Path.* **57**, 363–78.

JELÍNEK, R. (1960). Development of the experimental exencephalia in the chick. *Čslká Morf.* **8**, 368–78.

JURAND, A. (1963). Anti-mesodermal activity of a nitrogen mustard derivative. *J. Embryol. exp. Morph.* **11**, 689–96.

KLIKA, E. & JELÍNEK, R. (1961). Histogenesis of the experimental exencephalia in the chick. *Čslká Morf.* **9**, 162–73.

LUCY, J. A. & DINGLE, J. T. (1964). Fat soluble vitamins and biological membranes. *Nature, Lond.*, **204** (1), 156–60.

MARIN-PADILLA, M. (1965*a*). Study of the sphenoid bone in human cranioschisis and craniorhachischisis. *Virchows Arch. path. Anat. Physiol.* **339**, 245–53.

MARIN-PADILLA, M. (1965*b*). Study of the skull in human cranioschisis. *Acta Anat.* **62**, 1–20.

MARIN-PADILLA, M. (1966). Study of the vertebral column in human craniorhachischisis. The significance of the notochordal alteration. *Acta Anat.* (in the Press).

MARIN-PADILLA, M. & FERM, V. (1965). Somite necrosis and developmental malformation induced by vitamin A in the golden hamster. *J. Embryol. exp. Morph.* **13**, 1–8.

NIELKEN, D., PICK, E., GABRIEL, M., BITTERMAN, W. & BOSS, J. H. (1965). Vitamin A induced injection of autographs and homographs. *Nature, Lond.*, **205** (2), 1022.

STEPHAN, F. & SUTTER, B. (1960). Action du blue trypan sur la différenciation du mésoderm axial chez l'embryon de Poulet. *C. r. Séanc. Soc. Biol.* **154**, 1620–2.

WEISSMANN, G. (1964). Labilization and stabilization of lysosomes. *Fedn. Proc. Fedn. Am. Socs. exp. Biol.* **23**, 1038–44.

(*Manuscript received 8 November 1965*)

Mauer-'64
Bib. No. 5924

Reproduced by permission
of the copyright owner

Biol. Neonat. 6: 26–37 (1964)

Department of Genetics, McGill University, Montreal, Canada

Vitamin A-Induced Congenital Defects in Hairless Mice[1,2]

Malformations congénitales par la vitamine A chez la souris sans poils (Mus musculus, lignée «hairless»)

Vitamin A induzierte Mißbildungen bei haarlosen Mäusen

By Irving Mauer[3]

Introduction

An excess, as well as a deficiency, of vitamin A during pregnancy produces congenital defects in the offspring of treated experimental animals (Cohlan, 1953, 1954; Giroud and Martinet, 1955, 1959; Kalter and Warkany, 1959, 1961). During the course of an investigation into the effects of vitamin A in hairless and normal mice (Mauer, 1961), 31 of 182 offspring from females fed excessive amounts of the vitamin were born grossly abnormal, displaying defects similar to those already described in the literature. Because of certain features not heretofore reported, this series is considered worth reporting at this time.

Materials and Methods

Normal and hairless (Crew and Mirskaia, 1931–32) females were kept continuously with hairless males, and received synthetic vitamin A palmitate in corn oil[4] by mouth for up to 6 months at daily doses

[1] From a thesis submitted in partial fulfillment for the degree of Doctor of Philosophy at McGill University, Montreal, Quebec.

[2] Aided in part by a Grant-in-Aid from the National Research Council of Canada.

[3] Present address: Neuro-Endocrine Research Unit, Willowbrook State School, Staten Island 14, N.Y.

[4] Generously supplied by Dr. Rita L. Wolfe, (former) Medical Director, Hoffman-La Roche Ltd., Montreal.

ranging from 50 to 200 I.U. per gram body weight (ca. 1250–5000 I.U. per animal), by means of a blunt 22-gauge hypodermic needle attached to a tuberculin syringe. Controls were fed an equivalent amount of the corn oil vehicle. Parenteral administration of vitamin A was by intramuscular injection at the same daily dose range alternately into right and left thighs.

Two days before the expected day of delivery, pregnant females were isolated in a cage into which a wire basket had been inserted, such that newborn could drop through the mesh to the cage floor.

Results

Oral Administration

The majority of treated animals (15/26) received 100 I.U. vitamin A per gram daily (ca. 2500–3000 I.U.), while 7 received 50 I.U. per gram, two 200 I.U. per gram, and the remaining two 75 or 150 I.U. respectively. Litters containing defective young were produced at all dose levels of vitamin A, and no dose response pattern was evident when treatment groups were tabulated according to dosage.

Only three of the 7 treated hairless females produced litters, and of these a single litter of three from a female fed 50 I.U./g/day contained two grossly defective young. One newborn had a monstrously malformed skull, with a wide median mandibular-maxillary cleft bisecting the entire snout which, together with bilateral exophthalmia, gave it a bull-dog appearance. The second had exencephaly, associated with cleft lip and palate. The remaining newborn of this litter appeared to be normal except for a subdermal hemorrhagic spot at the junction of the parietal and frontal bones of the calvarium. Of the 29 defective offspring from 16 of the 19 treated normal mice, 20 had clefts of the palate only (12 ♂, 8 ♀), 4 had microphthalmia (3 unilateral, and one with left microphthalmia and apparent right anophthalmia), one had an acute tail kink (skeletal), while there were 4 with multiple malformations (two with short snouts, bilateral anophthalmia and malformed palates—shorthead syndrome; one with exencephaly and median cleft palate; one with unilateral microphthalmia and cleft palate). In addition, 5 newborn exhibited subdermal cranial hemorrhagic spots, but no detectable gross defects. There were no gross congenital defects among the young born to hairless and normal females fed the corn oil vehicle (Table I).

TABLE I

Effect of Vitamin A on Reproductive Performance and on the Production of Congenital Malformations in Normal and Hairless Mice

Influence de la vitamine A sur les possibilités de reproduction et sur la formation de difformités de souris normales et chauves

Einfluß von Vitamin A auf die Reproduktionsfähigkeit und auf die Erzeugung von Mißbildungen in normalen und haarlosen Mäusen

Treatment group[1]	No. of ♀ treated	Total litters[2]	No. born	Av. litter size	No. born dead[3]	No. with congenital defect[3]
			NORMAL			
1	19	31 (16)	165	5.3	28 (17)	29 (17.8)
2	7	10 (6)	76	7.6	4 (5.3)	0 (0.0)
3	4	3 (2)	18	6.0	0 (0.0)	0 (0.0)
4	2	1 (1)	6	–	1 (16.6)	0 (0.0)
5	7	10 (7)	79	7.9	10 (12.7)	2 (2.5)
			HAIRLESS			
1	7	4 (3)	17	4.3	9 (53)	2 (11.8)
2	5	8 (2)	43	5.4	6 (14)	0 (0.0)
3	3	1 (1)	4	–	0 (0.0)	0 (0.0)
4	1	3 (1)	24	8.0	3 (12.5)	0 (0.0)
5	5	5 (5)	32	6.4	10 (31.3)	2 (6.3)

[1] Treatment: 1, oily vitamin A, continuously administered orally
2, corn oil (control), continuously administered orally
3, oily vitamin A, continuously administered parenterally (i.m.)
4, corn oil (control), continuously administered parenterally (i.m.)
5, aqueous vitamin A, administered parenterally (i.m.) only during pregnancy (D9 through D19)

[2] Number of females producing litters in parenthesis.

[3] Percentage affected in parenthesis.

Seven normal females produced more than one litter during the continuous oral administration of vitamin A (Table II). Of the 40 offspring from the first pregnancies of these multiparous dams, 10 (or 25%) had congenital defects. In the 15 litters from subsequent pregnancies of the same females, 17 of 71 offspring (*i.e.*, 23.9%) were grossly abnormal, indicating that continued treatment with vitamin

TABLE II

Incidence of Congenital Defects in Offspring From Multiparous Dams Fed Vitamin A Continuously

Fréquence de difformités dans la descendance d'animaux mères (multipares) nourris exclusivement avec la vitamine A

Häufigkeit von Mißbildungen in den Nachkommen multiparer Muttertiere, die ununterbrochen mit Vitamin A gefüttert wurden

Dose level of vitamin A (I.U./g/day)	No. of ♀	No. with defects/no. born in litter 1	2–6	Total defects (% incidence)
50	2	3/11	5/24	22.9
100	4	4/22	10/38	23.3
200	1	3/7	2/9	31.2
Totals and % incidence	7	25	23.9	$\chi^2 = 0.0155$

A did not alter the frequency of congenital defect ($\chi^2 = 0.0155$, P = 0.9). The remaining 9 treated, primiparous normals gave birth to 54 young, two of which (*i.e.*, 3.7%) were grossly abnormal. No explanation for the discrepancy between the incidence of congenital defect in first litters of treated multiparous dams and that in litters from primipara ($\chi^2 = 7.5436$, $P < 0.01$) was forthcoming when the following variables were taken into account: coat color, age, maternal weight, dose of vitamin A, percent of young born dead. Among multiparous dams, however, there was a non-significant tendency for lighter mothers to bear litters containing no defective offspring.

Parenteral Administration

The teratogenic activity of hypervitaminosis A was studied further, employing parenteral routes of administration. Three hairless and 4 normal females were given 50 or 100 I.U. per gram daily of the same preparation of vitamin A in corn oil by intramuscular injection continuously for up to 6 weeks. Three of these females gave birth to a total of 22 apparently normal live offspring. Three control females injected with equivalent volumes of the corn oil vehicle produced 4 litters, containing 26 living and 4 dead offspring, all apparently nor-

mal. In all mice, injection sites were swollen by depots of material which persisted throughout the courses of treatment. An aqueous preparation of vitamin A[5] (containing polysorbate-80) was tested according to the same dosage schedules as employed with the oily vitamin A, but was administered only during pregnancy, beginning on the eighth or ninth day (established by palpation or vaginal plug), and terminating on the eighteenth or nineteenth day. No swelling remained at the site of injection one day later, suggesting that absorption was much more rapid than for the oily preparation. (Since the aqueous vehicle was not available at the time, no positive controls were run.) As shown in Table I, only 4 newborn among a total of 111 offspring from treated females were grossly abnormal, and displayed malformations similar to those induced by the oral administration of vitamin A in corn oil. There were two with the shorthead syndrome noted above, *viz.*, short snouts, minute nares, harelip and microphthalmia (one from a hairless female given 100 I.U./g/day; one from a normal receiving 75 I.U./g/day), and two had median cleft palates alone (one from a hairless female, the other from a normal, both treated at a daily dosage of 100 I.U./g).

Discussion

Except for certain internal congenital anomalies apparently found only by KALTER and WARKANY (1961), the types of gross congenital defects observed in offspring from hypervitaminotic-A animals may constitute a particular syndrome specific to this teratogenic procedure. The syndrome features exencephaly and other calvarial defects, eye defects, cleft palate and other defects of fusion (spina bifida, etc.), the relative frequency of which depends upon such variables as species and strain of animal used, stage of gestation when treatment is begun and length of treatment, as well as on the dose, route of administration and vehicle of vitamin A. As reported by other investigators (COHLAN, 1954; GIROUD and MARTINET, 1955; WOOLLAM and MILLEN, 1957; KALTER and WARKANY, 1961: etc.), cleft palate was a frequent malformation, sometimes associated with other defects. In the present series, considering only the 29 offspring with defects among the 165 born to non-mutant females fed vitamin A continuously, cleft palate was the most frequently found single malfor-

[5] Acon®, Endo Synthetic Vitamin A Palmitate, donated by Dr. SAMUEL M. GORDON, Vice-President, Endo Products, Inc., Richmond Hill, Long Island.

mation induced (75.8% of all defectives). The second most frequent malformation in this series was microphthalmia (17.2% of all defectives), while newborn with other skull and face defects were found less frequently. The shorthead syndrome found in this series as a result of maternal hypervitaminosis A bears a resemblance to the spontaneous shorthead mutation in mice recently described by FITCH (1961).

In litters from treated rats which were allowed to deliver spontaneously, COHLAN (1954) also found newborn without major cranial defect, but with small hematoma-like discolorations in the region of the anterior fontanelle (junction of the parietal and frontal bones). Subsequent examination of the denuded skulls of these animals at 30 days of age revealed defects in the bony continuity of the cranium. Subdermal cranial hemorrhages not associated with any other detectable gross defect were found at similar sites in 5 offspring of treated mice in the present series.

Since genetic differences play a role in conditioning the embryonic outcome of environmental insult during pregnancy (cf. ANDERSEN, 1949; FRASER, 1953; KALTER, 1954; FRASER *et al.*, 1957; etc.), it was of some interest that treated *hairless* females produced defective young. No spontaneous malformations were found in over 70 litters from hairless females (comprising over 400 offspring) in the author's stock of mutant animals. Although the treatment groups involved are small, the particular malformations found (exencephaly, cleft palate, multiple facial deformities) in the few affected hairless offspring were similar to those induced in the young of treated non-mutant littermates. Reproductive performance was more severely affected in treated hairless dams than in their normal sibs, especially in mice fed vitamin A continuously over long periods of time. Less than half of the treated mutant animals (3/7) produced litters. (However, only two of the 5 hairless females fed corn oil produced litters.) Although litter size was not markedly reduced in vitamin A-treated mice who became pregnant and carried to term, there were two to three times as many stillbirths among offspring from hairless than from normal dams (Table I). (Resorption sites were not counted since animals were not sacrificed after gestation.) The numbers are too small for a meaningful discussion of the possible role of a single gene difference (such as hairless vs. hair) on the incidence of congenital defect in offspring of hypervitaminotic mice. Further work along these lines would be interesting. In keeping with the experience of MILLEN and WOOLLAM (1960) in rats, vitamin A by parenteral administration was terato-

genic in mice when it was dispersed in an aqueous vehicle, but was not when administered in an oily vehicle.

How vitamin A exerts its teratogenic potential remains unsettled despite strong circumstantial evidence that it interferes directly with prenatal development at critical stages of organogenesis and tissue differentiation. The administration of massive doses to pregnant rats results in increases in vitamin A content of fetal livers and whole embryos (HENRY *et al.*, 1949). In fifteen-day old rat embryos from pregnant animals fed 60,000 I.U. on the twelfth day of gestation, GIROUD *et al.* (1957) found a two-fold increase in total embryonic vitamin A content over that from controls, and 92% of the embryos from treated mothers displayed cleft palates and/or other gross defects, whereas no congenital defects were found in embryos from controls. In addition, vitamin A has a direct action on growing bone and epithelia, *in vitro* (BARNICOT, 1948; FELL, 1953, 1957; FELL and MELLANBY, 1952), as well as *in vivo* (IRVING, 1949; WOLBACH, 1954). The teratogenic potential of excess vitamin A can also be modified. Potentiation of the incidence of congenital malformations due to maternal hypervitaminosis A has been obtained with the concurrent administration of cortisone (MILLEN and WOOLLAM, 1957; WOOLLAM and MILLEN, 1957), as well as with the anti-thyroid drug, 4-methyl-2-thiouracil (WOOLLAM and MILLEN, 1958), whereas protection has been afforded through the use of vitamin B complex (MILLEN and WOOLLAM, 1958a) and insulin (MILLEN and WOOLLAM, 1958b). However, COHLAN and STONE (1961) found no effect of insulin, cortisone, or growth hormone on the frequency of vitamin A-induced malformation in the rat. Experiments exploring the metabolic interrelationships of vitamin A along these lines might provide some clues as to the biochemical pathways by which hypervitaminosis A products its teratogenic effects.

Summary

1. The oral administration of excess vitamin A to 7 hairless and 19 normal female mice at daily doses of the order of 1250 to 5000 I.U. for periods up to 6 months resulted in the production of gross congenital defects in 31 of their 182 offspring (17%).
2. Whereas the parenteral administration of vitamin A in corn oil was not teratogenic, when administered in an aqueous vehicle, it resulted in the production of 4 offspring with defects among 111 born to treated females (3.6%).

3. The types of malformation induced by hypervitaminosis A in newborn from hairless dams were similar to those induced in offspring of treated normal littermates.
4. The most frequent malformation induced in the offspring of hypervitaminotic females was cleft palate (71.4% of all newborn with defects), most often found alone (in 22 of the 25 affected newborn), but associated with exencephaly in two cases and with microphthalmia in one case. The next most frequent single malformation was microphthalmia, which was found in 5 newborn (14.3% of all newborn with defects). Five newborn displayed multiple skull and face defects; in 4 of these, the defects were similar and appeared to constitute a syndrome involving shortened snout, minute nares, bilateral microphthalmia and malformed palates. In addition to the 35 offspring with gross congenital defect, 6 newborn had subdermal cranial hemorrhages in the region of the anterior fontanelle, not associated with any other detectable defect.
5. The continuous treatment with vitamin A through 15 subsequent pregnancies of 7 multiparous normal females did not alter the frequency of gross congenital defect in their offspring.
6. Although the present series of treated hairless females is small, it is suggestive that the frequency and type of congenital malformation induced in offspring by excess vitamin A did not differ from those induced in the young of treated non-mutant littermates. There were, however, two to three times as many stillbirths among offspring from hairless than from normal dams.
7. The role of hypervitaminosis A as a teratogenic procedure is discussed.

Résumé

1. L'Administration orale de la vitamine A en excès à 7 souris sans poils, femelles (lignée «hairless») et à 19 normales à des doses quotidiennes de 1250 à 5000 I.U. pendant des laps de temps allant jusqu'à 6 mois a produit de grosses malformations congénitales chez 31 nouveau-nés sur 182 (17%).

2. Tandis que l'administration par injection de la vitamine A en solution dans l'huile de maïs n'était pas tératogène, l'administration en solution aqueuse donnait 4 nouveau-nés malformés sur 111 naissances des femelles traitées (3,6%).

3. Les types de malformation produites par l'hypervitaminose A

chez les nouveau-nés des mères sans poils étaient semblables à celles produites chez les nouveau-nés de mères normales.

4. La malformation la plus fréquente était la division palatine (71.4% de toutes les naissances avec malformation), trouvée seule le plus souvent (22 des 25 nouveau-nés affectés); associée avec l'exencephalie dans deux cas, et avec la microphtalmie dans un cas. La microphtalmie seule fut trouvée chez 5 nouveau-nés (14,3% de toutes les naissances). Cinq nouveau-nés ont eu des malformations multiples du crâne et de la face; chez 4 d'entre eux, les malformations étaient ainsi constituées: un raccourcissement du museau, de petites narines, une microphtalmie bilatérale, et un palais malformé. En plus des 35 naissances avec grosses malformations congénitales, il y en avait 6 avec des hémorragies sous-cutanées du crâne, dans la région de la fontanelle antérieure, non associées à d'autres malformations.

5. Le traitement continu à la vitamine A pendant le cours de 15 grossesses consécutives chez 7 femelles normales multipares ne modifie pas le taux des grosses malformations congénitales.

6. Bien que cette série de femelles sans poils traitées ne soit pas grande, elle suggère que la fréquence et le type des malformations congénitales induites chez les nouveau-nés dont la mère à été traitée par la vitamine A en excès, ne diffère pas de celles produites chez les nouveau-nés de femelles normales, de même portée (non mutantes). Il y eut cependant, deux à trois fois plus de mortnés dans la série des mères sans poils («hairless») que dans celle des mères normales.

7. Le rôle de l'hypervitaminose A comme procédé tératogène est discuté.

Zusammenfassung

1. Die orale Verabreichung von Vitamin A im Überschuß (Dosen von 1250–5000 I.U.) an 7 haarlosen und 19 normalen weiblichen Mäusen während einer Periode bis zu 6 Monaten erzeugte in 31 von 182 Nachkommen (17%) grobe kongenitale Mißbildungen.

2. Während die parenterale Verabreichung von Vitamin A in Samenöl nicht teratogen wirkte, erzeugte dieses in wäßriger Lösung bei 4 Nachkommen von 111 (3,6%) kongenitale Defekte.

3. Die Art der durch Hypervitaminose A erzeugten Mißbildungen war bei Nachkommen haarloser Muttertiere ähnlich denen der normalen Tiere.

4. Die häufigste Mißbildung, die in den Nachkommen der hypervitaminotischen Muttertiere erzeugt wurde, war die Gaumenspalte (71,4% aller neugeborenen Tiere mit Defekten). Meistens wurde diese allein vorgefunden (22 von 25 betroffenen Tieren), sie war aber in 2 Fällen mit einer Exencephalie und in einem Fall mit einer Mikrophthalmie, welche bei 5 Neugeborenen gefunden wurde (14,3% aller Neugeborenen mit Defekten). Fünf Tiere wiesen multiple Defekte des Schädels und des Gesichtes auf; 4 davon waren sich sehr ähnlich und schienen ein Syndrom darzustellen, bestehend aus kurzer Schnauze, sehr kleinem Nasenflügel, bilateraler Mikrophthalmie und mißgebildetem Gaumen. Neben den 35 grob mißgebildeten Tieren hatten 6 weitere Tiere im Bereiche der vorderen Fontanelle Blutungen unter die Haut, ohne andere Mißbildungen aufzuweisen.

5. Die ununterbrochene Behandlung mit Vitamin A während 15 hintereinanderfolgenden Schwangerschaften bei 7 multiparen Weibchen änderte die Häufigkeit der erzeugten Mißbildungen der Nachkommen nicht.

6. Obwohl die Anzahl der behandelten haarlosen weiblichen Mäuse klein ist, scheint es, als ob die Häufigkeit und die Art der in den Nachkommen durch Vitamin A-Überschuß erzeugten Mißbildungen nicht verschieden sei von den Mißbildungen der Nachkommen nicht mutierter Muttertiere. Allerdings traten zwei- bis dreimal so viele Totgeburten bei den Nachkommen der haarlosen Tiere gegenüber den normalen auf.

7. Die Rolle der Hypervitaminose A als teratogenetisches Verfahren wird diskutiert.

ACKNOWLEDGEMENTS

For providing laboratory facilities, deep appreciation is expressed to Professor J. W. Boyes. An enduring debt of gratitude is owed Dr. F. C. Fraser for his patient guidance of the author's doctoral research program, and for generous comments and suggestions in the preparation of this manuscript.

REFERENCES

Andersen, D. H.: Effect of diet during pregnancy upon the incidence of congenital diaphragmatic hernia in the rat. Amer. J. Path. *25:* 163–185 (1949).

Barnicot, N. A.: Local action of calciferol and vitamin A on bone. Nature *162:* 848 (1948).

Cohlan, S. Q.: Congenital anomalies in the rat produced by excessive intake of vitamin A during pregnancy. Pediatrics *13:* 556–567 (1954).

COHLAN, S. Q.: Excessive intake of vitamin A as cause of congenital anomalies in rat. Science *117:* 535–536 (1953).

COHLAN, S. Q. and STONE, S. M.: Observations on the effect of experimental endocrine procedures on the teratogenic action of hypervitaminosis A in the rat. Biol. Neonat. *3:* 330–342 (1961).

CREW, F. A. E. and MIRSKAIA, L.: The character hairless in the mouse. J. Genet. *35:* 17–24 (1931–32).

FELL, H. B.: The effect of vitamin A on organ cultures of skeletal and other tissues. *In:* "Connective tissue (Trans. 4th Conf.)", ed. by C. Ragan, pp. 142–184 (Josiah Macy, Jr., Foundation, New York 1953).

FELL, H. B.: The effect of excess vitamin A on cultures of embryonic chick skin explanted at different stages of differentiation. Proc. roy. Soc. B *146:* 242–256 (1957).

FELL, H. B. and MELLANBY, E.: The effect of hypervitaminosis A on embryonic limb-bones cultivated *in vitro*. J. Physiol. *116:* 320–349 (1952).

FITCH, N.: A mutation in mice producing dwarfism, brachycephaly, cleft palate and micromelia. J. Morph. *109:* 141–149 (1961).

FRASER, F. C.: *In:* "Prematurity, congenital malformations and birth injury." (Ass. for Aid to Crippled Children, New York 1953.)

FRASER, F. C.; WALKER, B. E. and TRASLER, D. G.: Experimental production of congenital cleft palate; genetic and environmental factors. Pediatrics *19:* 782–787 (1957).

GIROUD, A.; GOUNELLE, H. and MARTINET, M.: Données quantitatives sur le taux de la vitamine A chez le rat lors d'expériences de tératogénèse par hypervitaminose A. Bull. Soc. Chim. biol. *39:* 331–336 (1957).

GIROUD, A. and MARTINET, M.: Extension à plusieurs espèces de mammifères des malformations embryonnaires par hypervitaminose A. C.R. Soc. Biol. *153:* 201–202 (1959).

GIROUD, A. and MARTINET, M.: Malformations embryonnaires par hypervitaminose A. Arch. franç. Pédiat. *12:* 1–9, 292–300 (1955).

HENRY, K. M.; KON, S. K.; MAWSON, E. H.; STANIER, J. E. and THOMPSON, S. Y.: The passage of vitamin A from mother to young in the rat. Brit. J. Nutr. *3:* 301–319 (1949).

IRVING, J. T.: The effects of avitaminosis and hypervitaminosis A upon the incisor teeth and incisal alveolar bone of rats. J. Physiol. *108:* 92–101 (1949).

KALTER, H.: The inheritance of susceptibility to the teratogenic action of cortisone in mice. Genetics *39:* 185–196 (1954).

KALTER, H. and WARKANY, J.: Experimental production of congenital malformations in strains of inbred mice by maternal treatment with hypervitaminosis A. Amer. J. Path. *38:* 1–21 (1961).

KALTER, H. and WARKANY, J.: Teratogenic action of vitamin A in strains of inbred mice. Anat. Rec. *133:* 396–397 (1959) (abstract).

MAUER, I.: The effect of vitamin A in hyperkeratotic mouse mutants. J. exp. Zool. *146:* 181–208 (1961).

MILLEN, J. W. and WOOLLAM, D. H. M.: Potency of parenteral vitamin A. Nature *185:* 249–250 (1960).

MILLEN, J. W. and WOOLLAM, D. H. M.: Effect of vitamin B complex on the teratogenic effect of hypervitaminosis A. Nature *182:* 940 (1958a).

MILLEN, J. W. and WOOLLAM, D. H. M.: Insulin-cortisone relationship in experimental teratogenesis. Nature *181:* 418 (1958b).

MILLEN, J. W. and WOOLLAM, D. H. M.: Influence of cortisone on teratogenic effects of hypervitaminosis A. Brit. med. J. *ii:* 196–197 (1957).

WOLBACH, S. B.: Effects of vitamin A deficiency and hypervitaminosis A in animals. *In:* "The vitamins: Chemistry, physiology, pathology,," ed. by W. H. Sebrell, Jr. and R. S. Harris, pp. 106–137 (Academic Press, New York 1954).

WOOLLAM, D. H. M. and MILLEN, J. W.: Influence of 4-methyl-2-thiouracil on the teratogenic activity of hypervitaminosis A. Nature *181:* 992–993 (1958).

WOOLLAM, D. H. M. and MILLEN, J. W.: Effect of cortisone on the incidence of cleft-palate induced by experimental hypervitaminosis A. Brit. med. J. *ii:* 197–198 (1957).

Author's address: Irving Mauer, Ph. D., Neuro-Endocrine Research Unit, Willowbrook State School, *Staten Island* 14, N. Y. (U.S.A.)

Mavligit-'70
Bib. No. 5925

J. Reprod. Fert. (1970) 22, 331–333

THE EFFECT OF HYPERVITAMINOSIS A ON OPENING OF THE VAGINAL MEMBRANE IN THE RAT

GIORA MAVLIGIT AND GERSHON GITLIN

Department of Anatomy, The Hebrew University–Hadassah Medical School, Jerusalem, Israel

(*Received* 14*th April* 1970)

Summary. Opening of the vaginal membrane in rats occurred earlier in animals receiving large doses of vitamin A than in control animals receiving olive oil.

Breakdown of the rat's vaginal membrane is heralded by development of cornification centres within the stratified squamous epithelium composing the membrane (Haldeman, 1921). Vesicles containing desquamated, cornified material and leucocytes appear; these enlarge and coalesce to form a lumen.

Vitamin A deficiency is associated with squamous metaplasia and cornification of various epithelia (Wolbach & Howe, 1928; Salley & Bryson, 1957; Hicks, 1968) and with prolonged cornification in the rat vagina (Evans & Bishop, 1922). Vitamin A excess inhibits keratinization and produces mucous metaplasia *in vivo* and *in vitro* (Fell & Mellanby, 1953; Lasnitzki, 1958; Bern & Lawrence, 1962; Rothberg, 1967; Polliack & Levij, 1968).

Premature opening of the rat's vaginal membrane follows the administration of oestrogen (Curtis & Doisy, 1931). On vaginal epithelium of the adult rat, vitamin A, either topically applied (Kahn, 1954) or orally administered (Hohlweg, 1951), appears to exert an effect antagonistic to that of oestrogen. A similar effect has been noted on mouse vaginal epithelium *in vitro* (Lasnitzki, 1961).

The present investigation was undertaken to see whether large doses of vitamin A in the rat could affect vaginal opening, in which process keratinization plays a central rôle.

In the first experiment, vaginal opening occurred earlier in the experimental animals than in the controls. This was unexpected and the experiment was therefore repeated twice, with slight modifications; the results in both these instances were similar to those in the first experiment.

All animals were of the Hebrew University Sabra strain of albino rats.

In Exp. 1, from the age of 29 days, each experimental animal received 37,500 i.u. of vitamin A every 3 days, in the form of 0·3 ml of Avitan (Vitamin A palmitate in olive oil. Zori Pharmaceutical and Chemical Industries, Tel-Aviv). Administration was by means of a narrow polyethylene tube which was passed into the stomach.

In Exp. 2, the animals were 23 days old and weighed 38±1 g when received. From the age of 26 days, each was given 30,000 i.u. of vitamin A subcutaneously every 3 days, in the form of 0·1 ml of Avipur (Vitamin A palmitate in olive oil. Taro Pharmaceutical Industries, Haifa).

In Exp. 3, the animals were 15 days old and weighed 27±1 g when received. Vitamin A administration was started when they were 18 days old. Dosage and route of administration were as in Exp. 2.

In each experiment, the controls received the same volume of olive oil by the same route as the experimental animals.

All animals were observed once daily. The commencement of vaginal opening was seen as a small central or paracentral perforation (Stage 1) which enlarged laterally until complete vaginal opening was evident (Stage 2).

In all three experiments, Stages 1 and 2 of vaginal opening occurred earlier in the experimental animals than in the controls (Table 1). The differences are statistically significant in all instances. At the younger age (Exp. 3), the difference between experimental and control groups was smaller than in Exps 1 and 2. This may imply that younger animals are less sensitive to excess vitamin A.

TABLE 1

AGE AT VAGINAL OPENING IN RATS RECEIVING LARGE DOSES OF VITAMIN A

Exp. No.	*No. of animals*		*Stage 1*			*Stage 2*		
	Vit. A	*Controls*	*Vit. A*	*Controls*	P	*Vit. A*	*Controls*	P
1	7	9	44·4(2·4)*	53·0(3·8)	<0·001	45·4(2·2)	54·5(3·3)	<0·001
2	7	15	40·0(2·1)	49·5(5·5)	<0·001	43·7(1·7)	55·0(5·7)	<0·001
3	19	20	36·5(3·2)	40·1(3·8)	<0·005	38·7(3·3)	41·5(4·0)	<0·02

Stage 1. Central or paracentral perforation of vaginal membrane.
Stage 2. Complete vaginal opening.
* Mean age (in days) at vaginal opening. S.D. in parentheses.

In view of the evidence quoted above, it was anticipated that vitamin A administration would delay vaginal opening. The earlier opening of the vagina in the vitamin A-treated rats is difficult to interpret. Of interest in this connection are the experiments of Reiter (1965) on the development of squamous keratinizing metaplasia in the uteri of oestrogen-treated rats. He found that simultaneous administration of large doses of vitamin A did not prevent the development of such lesions. Recent studies on carcinoma of the hamster cheek pouch induced by topical application of 9,10-dimethyl-1,2-benzanthracene (DMBA) are also significant. Application of vitamin A potentiated the action of DMBA (Polliack & Levij, 1969); in castrated males, oestrogen had an effect similar to that of vitamin A (Polliack, Charuzy & Levij, 1969). These authors have suggested that the similarity in the action of vitamin A and oestrogen may be related to the effect of these substances on cellular and subcellular membranes. Vitamin A is known to increase the permeability of such membranes, with release of proteolytic lysosomal enzymes (Dingle & Lucy,

1965; Dingle, Sharman & Moore, 1966; Brandeis & Anton, 1966). Bangham, Standish & Weissmann (1965) found that stilboestrol and a number of sex hormones increase the permeability of concentric lamellae of phospholipids which have characteristics similar to those of biological membranes. It is conceivable that intracellular and extracellular liberation of proteolytic enzymes may have been a factor in causing earlier breakdown of the vaginal membrane in the vitamin A-treated rats in the present experiments.

We wish to thank Dr J. Cohen and Dr E. Peritz for generous help in the statistical aspects of the work and Mrs S. Hajman for much technical assistance.

REFERENCES

Bangham, A. D., Standish, M. M. & Weissmann, G. (1965) The action of steroids and streptolysin S on the permeability of phospholipid structures to cations. *J. molec. Biol.* 13, 253.

Bern, H. A. & Lawrence, D. J. (1962) *Influence of vitamin A on keratinization.* In: Fundamentals of Keratinization. Eds. E. O. Butcher and R. F. Sognaes. Publ. No. 70. Am. Assoc. Adv. Sc.

Brandeis, D. & Anton, E. (1966) The role of lysosomes in cellular lytic processes. III. Electron histochemical changes in mammary tumours after treatment with cytoxan and vitamin A. *Lab. Invest.* 15, 987.

Green, J. M. & Dorsey, E. A. (1931) The bio-assay of theelol. *J. biol. Chem.* 91, 647.

Dingle, J. T. & Lucy, J. A. (1965) Vitamin A, carotenoids and cell function. *Biol. Rev.* 40, 422.

Dingle, J. T., Sharman, I. M. & Moore, T. (1966) Nutrition and lysosomal activity. *Biochem. J.* 98, 476.

Evans, H. M. & Bishop, K. S. (1922) On an invariable and characteristic disturbance of reproductive function in animals reared on a diet poor in fat soluble vitamin A. *Anat. Rec.* 23, 17.

Fell, H. B. & Mellanby, E. (1953) Metaplasia produced in cultures of chick ectoderm by high vitamin A. *J. Physiol., Lond.* 119, 470.

Halberman, K. O. (1921) The method of opening of the vagina in the rat. *Anat. Rec.* 21, 60.

Hess, R. M. (1968) Hyperplasia and cornification of the transitional epithelium in the vitamin A deficient rat. Changes in the fine structure of the cells. *J. Ultrastruct. Res.* 22, 206.

Hohlweg, W. (1951) Ueber die Hemmung der Oestrusreaktion durch Vitamin-A-Ueberdosierung. *Klin. Wschr.* 29, 193. Quoted by Kahn (1954).

Kahn, R. H. (1954) Effect of locally applied vitamin A and estrogen on the rat vagina. *Am. J. Anat.* 95, 309.

Lasnitzki, I. (1958) The effect of carcinogens, hormones and vitamins on organ cultures. *Int. Rev. Cytol.* 7, 79.

Lasnitzki, I. (1961) Effect of excess vitamin A on the normal and oestrone-treated mouse vagina grown in chemically defined medium. *Expl Cell Res.* 24, 37.

Pelliack, A., Charitzy, I. & Levij, I. S. (1969) The effect of oestrogen on 9,10-dimethyl-1,2-benzanthracene (DMBA)-induced cheek pouch carcinoma in castrated and non-castrated male Syrian golden hamsters. *Br. J. Cancer*, 23, 781.

Pelliack, A. & Levij, I. S. (1968) Epithelial atypia in the hamster cheek pouch, induced by topical application of vitamin A. *Oncology*, 22, 129.

Pelliack, A. & Levij, I. S. (1969) The effect of topical vitamin A on papillomas and intraepithelial carcinomas induced in hamster cheek pouches with 9,10-dimethyl-1,2-benzanthracene. *Cancer Res.* 29, 327.

Reuber, R. J. (1965) Estrogen-induced uterine metaplasia in rats given oral supplements of vitamin A. *Experientia*, 21, 207.

Rosenberg, S. (1967) The cultivation of embryonic chicken skin in a chemically defined medium and the response of the epidermis to excess of vitamin A. *J. invest. Derm.* 49, 35.

Salley, J. J. & Bryson, W. F. (1957) Vitamin A deficiency in the hamster. *J. dent. Res.* 36, 935.

Wolbach, S. B. & Howe, P. R. (1928) Vitamin A deficiency in the guinea pig. *Archs Path.* 5, 239.

Am. J. Physiol. 210(4):807-816. 1966.

McDonald-'66
Bib. No. 5985

Reproduced by permission of the copyright owner

Effects of vitamin A on mucopolysaccharides of rat blood platelets[1,2]

T. P. McDONALD[3]
Agricultural Research Laboratory, The University of Tennessee, Oak Ridge, Tennessee[4]

McDonald, T. P. *Effects of vitamin A on mucopolysaccharides of rat blood platelets.* Am. J. Physiol. 210(4): 807–816. 1966.—Male Sprague-Dawley rats were given vitamin A orally or fed a vitamin A-deficient diet, a standard laboratory diet, or a vitamin A-deficient diet with vitamin A added. Analysis of blood platelet sizes showed that platelets from vitamin A-deficient rats were larger and platelets from vitamin A-treated rats were smaller than those of a normal population. Platelets from vitamin A-excess rats incorporated from 40 to 100% more S^{35} per platelet than did control platelets. The larger platelets from the vitamin A-deficient rats also had an increased S^{35} uptake (about 18%) as compared to the smaller control platelets. Vitamin A deficiency decreased hexosamine content of platelets by 27% and vitamin A treatment increased hexosamine content by 26% as compared to controls. The percent composition of S^{35}-labeled mucopolysaccharides (MPS) from normal rat platelets was about 58% chondroitin sulfate (ChS) A; 6%, ChS B; 17%, ChS C; and 13.5%, heparin. Platelets from vitamin A-treated rats had greater adhesive qualities than normal platelets. Rat blood platelets contained significantly more MPS as a result of vitamin A-treatment, and less MPS from deficiency.

mucopolysaccharides of platelets; platelet labeling with sulfate-S^{35}; platelet hexosamine content; platelet size; platelet adhesiveness

Vitamin A has an important influence on mucopolysaccharide (MPS) biosynthesis (11, 12, 31, 33). In addition, hemorrhages are commonly associated both with deficiency and excess of vitamin A (13, 26–28) and are believed to be a cause of death associated with this vitamin (17). Blood platelets are involved in prevention of hemorrhage and have MPS as one of their components (1, 14, 22, 24).

Of the three hemostasis-producing roles of blood platelets commonly listed: *1*) clumping and fusing of the platelets at the site of blood vessel injury, *2*) clotting, and *3*) maintaining the resistance of the capillaries to red cell extravasation, the least understood is the platelets' role in maintaining the integrity of the capillaries (35). Vitamin A has long been known to be involved in maintaining the integrity of certain specialized epithelial tissues. Of these tissues, the capillary endothelium is the one most commonly associated with vitamin A deficiency (27), a condition leading to capillary fragility and hemorrhages.

Since blood platelets contain MPS and vitamin A has already been demonstrated to control MPS biosynthesis, it seems possible that an excess or deficiency of vitamin A may affect the synthesis of mucopolysaccharides within blood platelets. MPS compounds of various kinds have been linked both to the coagulation process and to anticoagulation and may be among the constituents of platelets responsible for their hemostatic effect. Therefore, since both blood platelets and vitamin A are known to be involved in maintenance of the integrity of the capillary endothelium, the influence of vitamin A on capillary endothelium may be indirect by way of its effect on MPS synthesis in blood platelets.

MATERIALS AND METHODS

Male Sprague-Dawley rats weighing approximately 350 g were given orally, by a stomach tube, 100 or 500 IU vitamin A/g body wt[5] in addition to vitamin A in the normal diet.[6]

Other rats approximately 4 weeks of age and weighing 51–92 g were fed a vitamin A-deficient diet (purchased from Nutritional Biochemicals Corp., Cleveland, Ohio), the same ration with vitamin A added (Pamilets, type M250 A, containing 250,000 IU vitamin A/g) at the

Received for publication 10 June 1965.

[1] This is a portion of a dissertation submitted to The University of Tennessee in partial fulfillment of the requirements of a Doctor of Philosophy Degree in Animal Science.

[2] This manuscript is published with the permission of the Director of The University of Tennessee Agricultural Experiment Station, Knoxville.

[3] Present address: The University of Tennessee Memorial Research Center and Hospital, 1924 Alcoa Highway, Knoxville, Tenn.

[4] Operated by The Tennessee Agricultural Experiment Station for the U.S. Atomic Energy Commission under Contract AT-40-1-GEN-242.

[5] Water-solubilized natural vitamin A (Aquasol), US Vitamin and Pharmaceutical Corp., Arlington-Funk Labs, New York City.

[6] Purina laboratory chow which contains approximately 21.44 IU vitamin A/g feed.

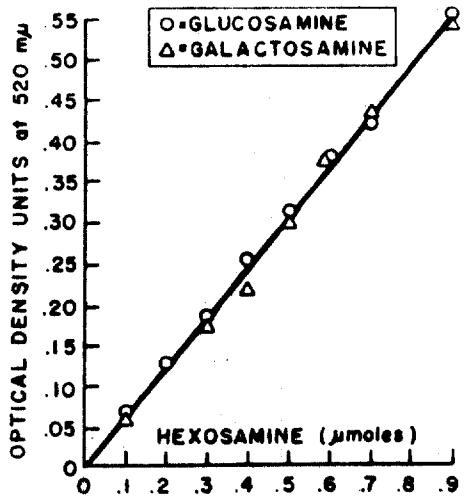

FIG. 1. Optical density of varying concentrations of hexosamine.

rate of 21.44 IU/g feed, or a standard laboratory diet for 12 weeks before sacrifice.

Preparation and injection of isotope. The pH of sodium sulfate-S^{35} in dilute HCl was adjusted to 6.3–6.9. The final dilution with distilled water was made so that the concentration[7] was approximately 1 mc/ml. Animals were injected intraperitoneally with 1 μc $Na_2S^{35}O_4$/g body wt.

Uptake of S^{35} by blood platelets and plasma. Rats were killed 24 hr after the last of 2–10 daily isotope injections or 48 hr after single isotope injections (25). Ten minutes before killing, 2 ml of 1:10 dilution of heparin (Heparin sodium, 1,000 IU/ml, Drake Laboratories, Chicago) were injected intraperitoneally. The animals were anesthetized with ether, and blood was drawn from the abdominal aorta into cold, siliconized, 20-ml syringes containing 1 ml of a 1% solution of ethylenediaminetetraacetic acid (EDTA) in 0.538% saline. In most cases, a standard volume of 9 ml blood was collected from each rat and was diluted with 6.25 ml saline to obtain a better yield of platelets. The blood-saline mixture of each rat was equally divided into two 15-ml conical centrifuge tubes, and the platelets were separated by differential centrifugation in a refrigerated centrifuge (5 C). After a slow centrifugation of the blood (107 × *g* for 40 min), the platelet-rich plasma-saline was removed and spun more rapidly (760 × *g* for 30 min) to obtain a platelet button. The platelets were then washed twice with 4 ml saline and resuspended in 0.5 ml saline. WBC and platelet counts were made on each platelet suspension. Two 200-μl samples of platelet suspensions (containing 3.240–12.660 × 10^6 platelets/mm^3) were placed on planchets and dried for radioactivity counting in a windowless gas-flow proportional counter in some experiments. In other experiments, the platelet suspensions were added to polyethylene counting vials containing 5 ml scintillation mixture of the following composition: 1 liter 1,4-dioxane; 175 g naphthalene; 7 g 2,5-diphenyloxazole; and 0.375 g 1,4-bis-2-(4 methyl-5-phenyloxazoyl)-benzene. This scintillation mixture was shown in preliminary experiments to correct for 200 μl water with 92–93% efficiency in a liquid-scintillation spectrometer. The radioactivity of two 100- or 200-μl samples of platelet-free plasma-saline and one 200-μl sample of each wash was also determined.

Platelet size. Platelet size was determined by *1*) measuring the volume of packed platelets and *2*) estimating the platelet size distribution with a Coulter electronic-particle counter model B, coupled with a particle-size distribution plotter. Washed platelets from the S^{35} uptake experiments were used for both size determinations.

The volumes of packed platelets in the suspensions were measured in quadruplicate in microhematocrit tubes according to the method of Detwiler et al. (9). The average platelet volumes were expressed as:

$$\frac{\text{(platelets/ml suspension)}}{\text{(length of platelet column)/(length of total column)}} = \text{platelets/ml packed vol.}$$

Platelet sizes were measured using a Coulter counter according to the method of McDonald et al. (19). The amplification and aperture current were set so that the mode (peak window) was near the center of the plot. The same settings were used throughout the experiments so that results between experiments could be compared. The suspensions for counting were made by placing 10–20 μl of platelet suspensions into 100 ml filtered saline solution (filtered through a 0.45 μ pore-size filter) to give concentrations of 9–25 × 10^3 platelets/50 μl. Silicone glassware was used throughout.

After sizing was accomplished, the plotter was disengaged and the number of particles per 50 μl determined. The lower threshold was set at 8 and the upper threshold at its maximum, 100, in counting the platelets without the plotter.

Windows 1, 2, and 3 were omitted from the size distribution since they contained counts due mainly to background noise. Counts were not possible on sizes corresponding to window numbers greater than 25, and a statistical method for truncation was used (6) to obtain unbiased estimates of the mean and variance of the size distributions which are expressed here as mean windows.

Determination of hexosamines. Quantitative measurements of hexosamines were made on blood platelets of one group of rats that received 100 IU vitamin A/g body wt daily, a second group that received 500 IU/g body wt at *day 0*, a third that was fed a vitamin A-deficient diet, and a fourth group that was fed the standard laboratory diet. Hypervitaminotic rats were killed on *days 4, 5, 6,* and *7*. Blood platelets of each rat were collected as previously described and resuspended in ap-

[7] The amount of radioactivity per volume of isotope was given by Oak Ridge National Laboratory with a range of accuracy of ±20%. The amounts injected are, therefore, not directly comparable among experiments.

proximately 1.2 ml physiological saline solution. One milliliter of the platelet suspension was added to 1 ml 2 M HCl and immersed in a hot-water bath (100 C) for 4 hr. To prevent evaporation in the water bath, the tubes were capped with marbles. A modification of Belcher and co-workers' (2) technique for determining glucosamine was used in further treatment. After heating, the samples were cooled and 1 ml water was added. One milliliter of freshly prepared acetylacetone (2,4-pentanedione) mixture (1 ml actylacetone in 50 ml 1 M Na_2CO_3) was added to the platelet samples and 0.1–1.0 μmoles glucosamine or galactosamine. The samples were reimmersed in the hot-water bath for 10 min, cooled and 5 ml 95% ethanol was added. The tubes were placed in a thermostatically controlled water bath (75 C) for 5 min. Then, 1 ml *p*-dimethylaminobenzaldehyde in 60 ml concentrated hydrochloric acid was added and mixed thoroughly with a Vortex mixer. The tubes were reimmersed in a water bath (75 C) and were held there for another 30 min with occasional shaking. After removal from the bath the tubes were allowed to cool to room temperature. The optical density (OD) of the samples was then determined with a Bausch and Lomb Spectronic 20 spectrometer set at 520 mμ. The OD readings were compared to readings of known amounts of glucosamine and galactosamine, and the amounts of hexosamine were determined from a standard graph prepared using the above technique (Fig. 1).

Determination of protein. Other platelets from the platelet suspensions used in hexosamine determinations were used for protein determinations: 100 μl of platelet suspensions were added to 3.9 ml water, mixed, and 0.5 ml of this suspension was pipetted into a test tube. To each tube 5.0 ml of an alkaline solution (4% filtered Na_2CO_3, 2% $CuSO_4$, 4% sodium potassium tartrate, 100:1:1 by volume) were added, mixed well, and the tubes placed in a 40 C water bath for 15 min. One-half milliliter of Folin-Ciocalteu reagent (Phenol reagent, Harshaw Scientific), diluted 1:2 with water immediately before use, was added to each tube and mixed well. After 30 min of color development, the samples were read at 660 mμ with a spectrometer. OD readings were compared to readings of known amounts of bovine serum albumin (Fig. 2).

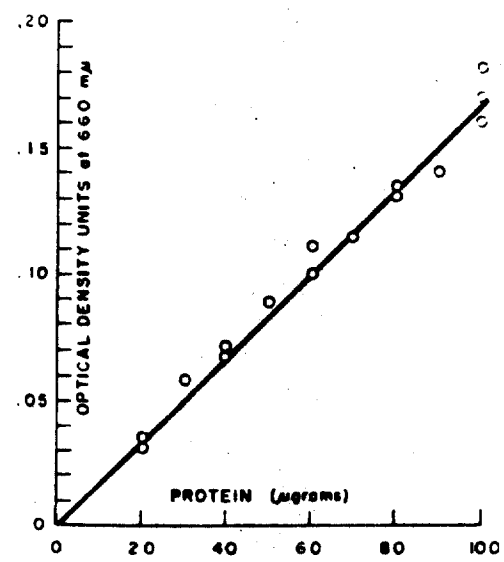

FIG. 2. Optical density of varying concentrations of protein (bovine serum albumin).

Identification of MPS. Platelets of rats from the same treatment groups as for hexosamine determinations were used in the identification of MPS experiments. The platelets were labeled in vivo by daily intraperitoneal injections of 1 μc $Na_2S^{35}O_4$/g body wt for 5 days before killing. Rats killed at *day 4* after vitamin A treatment, for example, were given the isotope on *days* −*1*, *0*, *1*, *2*, and *3*. Rats were killed at 4, 5, 6, and 7 days after treatment with vitamin A or when they were vitamin A deficient. The platelets were harvested as described above. The material was kept cold (0–5 C) throughout the experiment. At each time period the platelets of three rats were pooled and resuspended in saline to a final volume of 2.5 ml. These suspensions contained a concentration of 4.070–8.170 × 10^6 platelets/mm^3. The radioactivity of two 200-μl samples of the platelet suspensions and two 200-μl samples of plasma-saline, and one 200-μl sample of each wash was determined using the liquid-scintillation technique discussed above.

To extract mucopolysaccharides from platelets, duplicate 1-ml samples of S^{35}-labeled platelets were added to 4 ml 1 M NaOH and hydrolyzed for 7 hr at 5 C with constant mixing. The samples were then neutralized with 1 ml 4 M acetic acid. (One sample was titrated with the 4 M acetic acid, using bromthymol blue as the indicator, to determine the 1-ml volume.) The samples were then treated four times with chloroform-amyl alcohol reagent (0.67 ml amyl alcohol and 2.0 ml chloroform/10 ml of sample) to remove protein. No precipitate was visible after the third treatment. The first treatment was carried out overnight with continuous agitation, while subsequent treatments lasted for about 10 min with agitation. After each treatment, the samples were centrifuged for 10 min at 760 × *g* and the upper layer containing the MPS was transferred to another tube. The final supernatant fluid was placed in a dialysis bag and dialyzed (dialysis tubing 404, Visking Co., Chicago) for 40 hr against four 1,000-ml portions of distilled water at 5 C. After lyophilization, the material that remained in the bag was dissolved in 500 μl water.

Samples of the extracted MPS-S^{35} were subjected to ascending chromatography (5). Twenty microliters of the sample were spotted 1 inch from the bottom of a ¾ x 5½-inch paper strip (Blue Ribbon no. 589, Schleicher and Schuell Co.) and air dried. To fix the MPS on the paper, the paper was immersed for 3 min in 0.1% cetylpyridinium chloride (CPC), in 0.004 M phosphate buffer, pH 7.0, and allowed to dry overnight at room temperature. The paper strips with the MPS

spots were then suspended in 8 x 1.2-inch tubes with 0.5 M $MgCl_2$, 1.0 M $MgCl_2$, 0.4 M $AlCl_3$, or 0.5 M $FeCl_3$ as solvents. After the solvent was allowed to migrate approximately 2⅝ inches, the paper strips were removed and air dried, placed in the 0.1 % CPC solution again for 3 min, followed by washings with 95 % ethanol for 3 min to free the solvents from the paper; absolute alcohol, 3 min; acetone, 2 min; and then air dried. After the samples were dried, pieces were cut from the strips as follows: *a)* ½ inch on either side of the origin; *b)* ¼ inch above the solvent front and ¾ inch behind the front. A third piece consisted of the paper between cuts. Each of the samples was placed in a polyethylene-scintillation vial that contained 10 ml of the previously described scintillation fluid, and counted as in the S^{35}-uptake experiments. After developing in solvents and clearing, other strips of paper containing MPS were stained for 5 min in 1 % Alcian blue, 8G × 300 (Arnold, Hoffman and Co., Providence, R.I.) made up in a 9:1 acetic acid and water solution, washed well with tap water, and then with four alternate concentrated acetic acid and water washings.

Platelet adhesiveness. Five milliliters of whole blood, drawn from the abdominal aorta without an anticoagulant, were used for platelet adhesiveness studies (18). A glass tube was filled with glass beads and stoppered at each end with rubber stoppers that contained cut-off 20-gauge needles. The stoppers were covered heavily with silicone stopcock grease and all components of the column were siliconed except the beads. For each animal, two siliconed test tubes (13 x 100 mm) containing 1 mg EDTA (made by evaporating 0.5 ml of a 0.2 % solution) were used. One-half milliliter of blood was placed in one of the tubes before the column was filled with the remaining 4.5 ml. The syringe containing the blood was connected to the needle in the rubber stopper. The column was then inverted so that the blood was forced from the bottom to the top; when blood was seen at the top of the column a stop watch was started and the blood was allowed to remain in the column 35 sec. One-half milliliter of the withdrawn blood was then placed in the other tube containing EDTA. The two tubes were covered with Parafilm (Marathon, Division of American Can Co., Menasha, Wis.), mixed gently, and the platelets immediately diluted and counted as before. The index of adhesiveness is expressed as percent of platelets lost after filtration.

RESULTS

Platelet size measurements. The results of platelet size determinations are shown in Table 1. In the Coulter counter method (19) size-distribution curves of platelets from vitamin A-deficient rats were shifted to the right, indicating larger platelets. In some of the platelet curves from the vitamin A-treated rats the shift was to the left, indicating smaller platelets than those of a normal population. The window number values (obtained directly from the Coulter counter plot) were converted to logarithms, thereby transforming the skewed distributions to distributions that were approximately Gaussian (4). Statistical analysis by Duncan's multiple range test (10, 15) revealed that platelets from vitamin A-deficient rats were significantly larger ($P < 0.05$), than platelets from normal or vitamin A-treated rats. In addition, platelets collected on *days 3, 4, 7,* and *10* from rats receiving 100 IU/g body wt daily of the vitamin were smaller than platelets from untreated rats ($P < 0.05$), and platelets collected from rats 6 days after 500 IU vitamin A/g body wt were smaller ($P < 0.05$) than normal platelets. Other platelet values from rats given the vitamin at the times investigated were not statistically different from control platelets.

TABLE 1. *Platelet size from vitamin A-treated rats and rats on vitamin A-deficient and normal diets*

Treatment	Time After Treatment, Days	No. of Rats	$\bar{X}$ Window	No. of Rats	Platelets ml × 10^{10}
A-deficient diet		17	11.24^{a}	12	10.76^{a}
Deficient diet plus A		10	11.49^{a}		
Normal diet		34	9.90^{b}	9	13.02^{b}
		100 IU/g body wt daily			
Vitamin A given orally	1	3	9.42^{be}		
	2	6	9.67^{be}		
	3	5	9.04^{e}		
	4	6	9.27^{e}		
	5	6	9.45^{be}		
	6	6	9.40^{be}		
	7	6	9.21^{e}		
	10	6	9.21^{e}		
		500 IU/g body wt at day 0			
	1			3	12.50^{ab}
	2	2	9.58^{be}	2	12.30^{ab}
	3	3	9.20^{be}		
	4	3	9.41^{be}	3	12.99^{b}
	5	3	9.26^{be}	3	12.87^{b}
	6	3	9.00^{c}	3	11.97^{ab}
	7	3	9.27^{be}	3	11.58^{ab}
	10	3	9.13^{be}	3	11.14^{ab}

[a-e] Treatment means having different superscript letters are significantly ($P < 0.05$) different using Duncan's multiple range test.

When vitamin A was added to the vitamin A-deficient diet at the rate of 21.44 IU/g feed the platelet size change was not corrected. It appears that the amount of vitamin added to the deficient diet was not sufficient to correct platelet sizes to normal.

Similar results were obtained with the cells-per-packed-volume technique. Analysis of the data demonstrated significant differences between platelets from vitamin A-deficient rats and normal rats. Platelet sizes from the vitamin A-treated rats were not different, however, from those of normal rats, and at 5 of the 7 days investigated, the platelets per packed volume were not different from the deficient group. The cells-per-milliliter values obtained in these experiments are larger (indicating smaller cells) than those reported by Detwiler et al. (9). A possible explanation may be that in our earlier report polyvinylpyrrolidone (PVP)

was added to the blood in equal volume to improve platelet yield, whereas in the present work only saline solution was used. The PVP, a plasma expander, is more viscous than saline solution and may have prevented complete settling in the microhematocrit tubes.

Uptake of S^{35} by blood platelets and plasma. In normal rats or rats given vitamin A and injected intraperitoneally daily with 1 μc $Na_2S^{35}O_4$/g body wt, the radioactivity of whole, washed platelets increased rapidly during the first 4 days and was widely variable thereafter, although without definite upward or downward trends. Mean platelet activity of the rats receiving vitamin A is presented in Fig. 3. Average platelet activities of all rats on *days 5–10* showed that the activity of platelets from normal rats leveled off at 40 × 10^{-7} counts/min per platelet in agreement with earlier work (23). The activity of the vitamin A-treated groups, however, tended to level off higher, which is suggestive of greater incorporation of S^{35}. Platelets from 100-IU rats reached a plateau at about 58 × 10^{-7} counts/min per platelet and platelets from rats treated with 500 IU leveled off at about 49 × 10^{-7} counts/min per platelet, results that lead one to believe that the greater S^{35} incorporation indicates a greater amount of sulfated MPS per platelet.

Blood platelets from rats given 500 IU/g body wt at *day 0* and single S^{35} injections 48 hr before killing (Fig. 4) contained significantly more label than control platelets on *days 4, 5,* and *6.* Increased platelet S^{35} activity, approximately 87% greater, was probably due to increased MPS content per platelet.

Platelets from rats given vitamin A at the rate of 100 IU/g body wt daily and single intraperitoneal injections of 1 μc/g body wt of the isotope 48 hr before sacrifice took up more S^{35} than those from rats not receiving the vitamin. The average activity for *days* 5, 6, 7, and *10* was 28 × 10^{-7} counts/min per platelet, and platelets incorporated significantly more (2×) S^{35} than did platelets from control rats, which had 14 × 10^{-7} counts/min per platelet. The plasma-saline values were not statistically different between control rats and vitamin A-treated rats, in contrast to previous reports (7, 29).

Uptake of S^{35} by platelets from control and vitamin

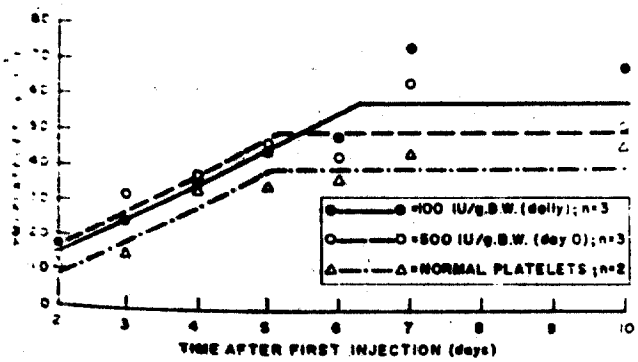

FIG. 3. Radioactivity of platelets from normal or vitamin A-treated rats after daily intraperitoneal injections of $Na_2S^{35}O_4$.

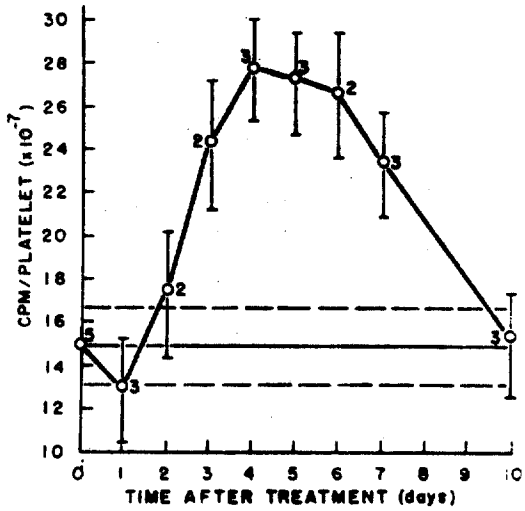

FIG. 4. Radioactivity of platelets from vitamin A-treated and normal rats after single intraperitoneal injections of $Na_2S^{35}O_4$. Vertical bars indicate SE of mean and numbers at points indicate number of rats. Rats were given 1 μc S^{35}/g body wt 48 hr before killing and vitamin A-treated rats were given 500 IU/g body wt at time 0. Horizontal solid line indicates control mean and broken lines indicate SE of mean.

A-deficient groups is shown in Fig. 5. Activity of platelets from vitamin A-deficient rats reached a plateau at about 65 × 10^{-7} counts/min per platelet, whereas the normal controls reached a plateau at about 57 × 10^{-7} counts/min. Platelet activity from rats fed a vitamin A-deficient diet with vitamin A added at the rate of 21.44 IU/g feed was even higher (about 67 × 10^{-7} counts/min).

Hexosamine and protein content of blood platelets. The influence of vitamin A on total hexosamines of platelets is illustrated by the data in Table 2. In blood platelets, "total hexosamines" are primarily MPS-bound hexosamines since small-molecular-weight intermediates containing hexosamines are probably nonexistent or are found in very small quantities.

Vitamin A deficiency results in a decrease of total hexosamine content by about 27% in blood platelets as compared to controls. Five days after vitamin A was given to rats at the rate of 500 IU/g body wt, hexosamine values were about 26% higher than controls. At other time periods, no difference was noted between control and vitamin A-treated platelets. Again, the vitamin added to the deficient diet failed to restore the normal situation, the amount of hexosamine in platelets from deficient animals and from rats fed the deficient diet with vitamin A added being not significantly different (5.5 and 6.2 × 10^{-3} μmoles hexosamine mg protein).

Identification of MPS. On the basis of the chromatographic methods described by Castor and Dorstewitz (5) it appeared feasible to identify heparin and ChS A, B, and C with some degree of certainty. They found in their study that ChS C isolated from human umbilical cord or shark cartilage was soluble in 0.5 M $MgCl_2$,

1.0 M $MgCl_2$, and 0.4 M $AlCl_3$ after precipitation with acetylpyridinium chloride. ChS A (from human skin) was shown to be soluble in the same solvents plus 0.5 M $FeCl_3$, and ChS B (also isolated from human skin) was shown to be soluble only in 0.5 M $MgCl_2$ and 1.0 M $MgCl_2$. Commercially available heparin was dissolved only by 1.0 M $MgCl_2$. Figure 6 shows the results of chromatographic migration on paper strips of the control platelet extracts, commercially available ChS, and heparin. It is shown here that heparin moves from the origin with the solvent front only when developed by 1.0 M $MgCl_2$. This is in complete agreement with the findings of Castor and Dorstewitz (5). The ChS used in this study probably contained a mixture of ChS A, B, and C, since in Fig. 6 it appears that the 0.5 M $FeCl_3$ solvent moved only a part of the ChS with the solvent front and a greater amount moved with the 0.4 M $AlCl_3$ solvent. The platelet extract (PE) appears to be composed largely of compounds that are soluble in all the solvents used. By Castor and Dorstewitz's (5) results this compound has solubilities characteristic of ChS A; therefore it is interpreted to be ChS A.

With the above information a system was developed to ascertain the relative amounts of MPS-S^{35} in blood platelets by counting prescribed portions of paper strips. Other paper strips were treated as described, except not stained, and were subjected to radioactivity determinations. Each strip was cut into three pieces which were counted individually for radioactivity, and the percent of the total activity found in the solvent front was calculated. The relative percent composition of blood platelet MPS was derived by the following equations:

% of activity present in solvent front of strips chromatographed in 0.5 M $FeCl_3$ = ChS A (1)

% of activity present in solvent front of strips chromatographed in 0.4 M $AlCl_3$ − ChS A = ChS C (2)

% of activity present in solvent front of strips chromatographed in 0.5 M $MgCl_2$ − (ChS A + ChS C) = ChS B (3)

% of activity present in solvent front of strips chromatographed in 1.0 M $MgCl_2$ − (ChS A + ChS B + ChS C) = heparin (4)

This procedure yields a workable method for the estimation of the MPS-S^{35} components of blood platelets. Table 3 shows the results of these calculations.

Table 3 indicates that blood platelets contain largely a labeled MPS component that behaves like ChS A. Staining methods also indicated that the PE was largely ChS A and determinations of radioactivities of various parts of the paper chromatograph strips suggested the presence of additional MPS. The values for ChS A of extracts of control platelets range from 54 to 63% of the labeled sulfated MPS. Materials designated ChS B and C are found in lesser amounts, with extracts from control platelets averaging about 6% ChS B and about 17% ChS C. Heparinlike materials make up about 13.5% of the fractions obtained. In this system about 94% of the radioactivity (MPS-S^{35}) moved with the

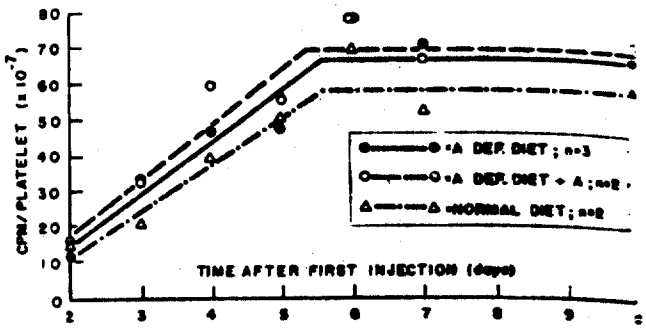

FIG. 5. Radioactivity of platelets from normal rats and rats fed a vitamin A-deficient diet after daily intraperitoneal injections of $Na_2S^{35}O_4$.

1.0 M $MgCl_2$ solvent. The 6% of activity that remained at the origin may be MPS-bound protein that was not soluble with these solvents.

It is not clear from Table 3 whether differences in quality (percent makeup) of MPS from vitamin A-treated, normal, or vitamin A-deficient platelets exist. The values obtained are not greatly different with treatment within experiments. Heparin may be reduced (percentagewise) in the vitamin A-treated and the vitamin A-deficient groups compared to the control values (9–10% compared to about 13.5%). It is concluded, therefore, that vitamin A excess or deficiency did not result in noticeable alterations of platelet MPS makeup.

The radioactivity of platelets subjected to these analyses is also shown in Table 3. Although platelet activity differs considerably between experiments (probably due to different batches of isotopes), the trends are identical to those discussed previously. For example, in *experiment 2*, platelets from rats fed a vitamin A-deficient diet with vitamin A added showed the greatest uptake of S^{35} (121×10^{-7} counts/min per platelet) and platelets from vitamin A-deficient rats showed greater S^{35} uptake (95×10^{-7} counts/min per platelet) than did the controls (72×10^{-7} counts/min per platelet). Also the platelets from the vitamin A-treated rats, in the first experiment, showed generally more S^{35} uptake than did control platelets.

Blood platelet adhesiveness. The data on adhesiveness of blood platelets obtained from 21 rats treated with vitamin A and 5 control rats are shown in Table 4. Although the number of animals in each time period is small, significant increases in adhesiveness of blood platelets were seen at *day 4* after 100 IU/g body wt daily and at *day 5* after a single treatment with 500 IU/g body wt. In the 500-IU group the greatest adhesiveness occurred at the same time (*day 5*) that a significant increase in hexosamines was also observed (Table 2). No evidence was seen of a decrease in platelet numbers of control or treated animals (from blood that had not been passed through the column), since the number of platelets counted was in the normal range (about 0.9–1.1 $\times 10^6$ platelets/mm^3). It appears, therefore, that platelets from vitamin A-treated rats have greater

TABLE 2. *Hexosamine and protein content of platelets from vitamin A-treated, normal, and vitamin A-deficient rats*

	Time After Treatment, Days,	No. of Rats	μmoles Hexosamine/mg Protein, × 10^{-3}
A-deficient diet		6	5.55[a]
Deficient diet plus A		6	6.19[ab]
Normal diet		12	6.97[bcd]
	100 IU Vit. A/g body wt daily		
Vitamin A given orally	4	3	7.56[d]
	5	3	6.61[abcd]
	6	3	6.53[abc]
	7	5	7.01[bcd]
	500 IU Vit. A/g body wt at day 0		
	4	3	6.87[bcd]
	5	3	8.83[e]
	6	3	7.72[cd]
	7	5	7.38[cd]

[a-e] Treatment means having different superscript letters are significantly ($P < 0.05$) different using Duncan's multiple range test.

adhesiveness than normal platelets, since a greater number of platelets was removed by the glass beads in the vitamin A-treated rats. Whether or not the added adhesive quality of these platelets is due to increased MPS remains to be shown, but the data indicate a causal relationship.

DISCUSSION

The changes in platelets that are responsible for the increase or decrease in size with vitamin A-deficiency or excess remain to be determined. Results by McDonald et al. (19) demonstrated a shift toward larger-than-normal size in young platelets and smaller size for older platelets. Detwiler et al. (9) suggested that the content of ATP decreases with age, which may imply a gradual decrease of functional factors with age, in contrast to a complete utilization or destruction of the platelet components only at the time the platelet is lost from the circulatory system. The loss of ATP was correlated with a decrease in size of blood platelets. It remains to be determined, however, if vitamin A-treated platelets are affected in the same way.

The size differences may be related, however, to effects on platelet membranes by the vitamin, since evidence has been presented that one site of action of vitamin A is at lipoprotein membranes (16). Bell (3) has suggested that a sulfated polysaccharide is necessary for membrane structure and hence some of its properties. The polysaccharide is visualized as the outer layer, with the sulfate groups a possible reactive site. If this is the case, changes in the amounts of MPS may cause changes in permeability. It seems possible that blood platelets would be affected in the same way and, if so, changes in permeability might lead to changes in sizes of blood platelets.

The greater sulfate-S^{35} uptake by blood platelets due to vitamin A excess is in agreement with other workers. For example, Dziewiatkowski (11) observed greater S^{35} incorporation in chondroitin samples isolated from epiphyseal cartilage after administration of vitamin A.

The activity per platelet increased in the 100-IU group until about *day 6*, compared to *day 5* for the control animals, leading one to believe that life span of platelets has been lengthened. Crimm and Short (8) observed that vitamin A caused an increase in the number of WBC senile forms. They suggested that the system for destruction of leukocytes was working inefficiently because of the effects of excess vitamin A. Perhaps this same explanation holds for platelets or perhaps excess vitamin A lengthens platelet life spans in another way. Increased MPS per platelet may have significant effects on the life span of platelets.

Sulfate-S^{35} uptake in platelets due to the deficiency appears to differ from that of Wolf and Varandani (34)

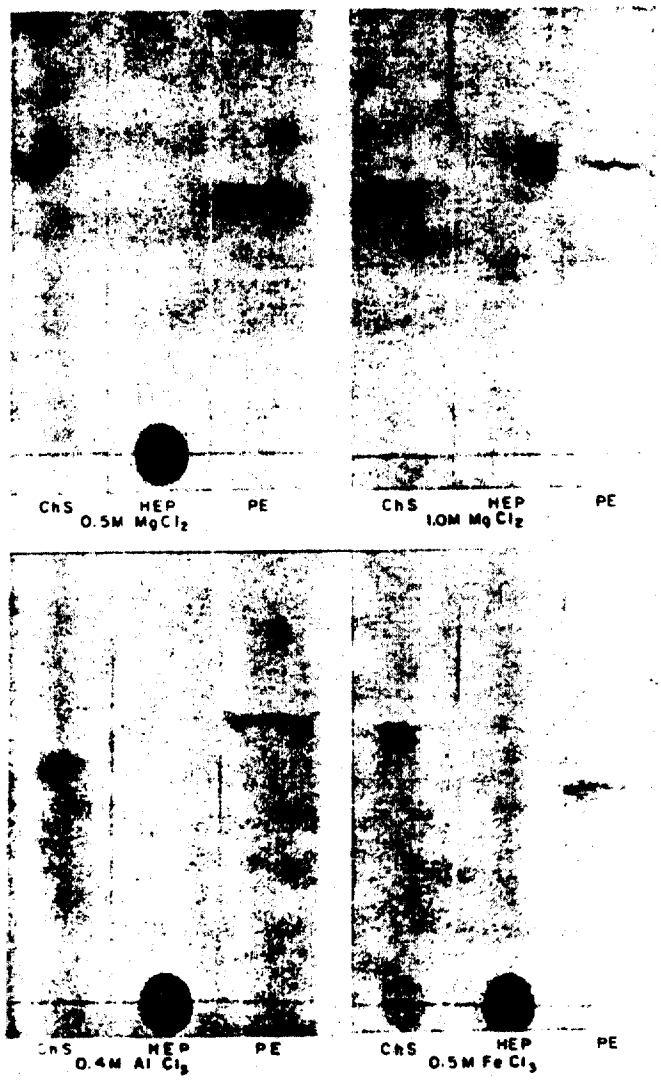

FIG. 6. Chromatographic migration on paper strips of 20 μl platelet extract (PE), 20 μg chondroitin sulfate (ChS), and 20 μg heparin (HEP); developed in 0.5 M $MgCl_2$, 1.0 M $MgCl_2$, 0.4 M $AlCl_3$, or 0.5 M $FeCl_3$. The material was located on the paper strip by staining with Alcian blue 8G × 300.

and Varandani et al. (31), who observed that vitamin A deficiency decreased the incorporation of sulfate-S^{35} into the MPS of the rat colon. Platelet sizes probably have an important influence on this apparent difference since the platelets with the highest activity were shown to be significantly largest. Thus the increased S^{35} uptake of vitamin A-deficient platelets may be related simply to the size and not to a seeming increase in total MPS per volume of mass. The fact that the activity of platelets from the control group was higher in this experiment than in the S^{35}-multidosed-vitamin A-treated one was due to the use of different batches of isotopes.

In the present study plasma-saline S^{35} uptake values were not altered by treatment. Thomas et al. (29) observed that in rabbits given 1 M U/day of vitamin A, a rise in serum chondroitin sulfate resulted by 72 hr after treatment. Cohen and co-workers (7) found greatly increased levels of mucoprotein in blood of rats after administration of 1,000 IU of the vitamin per day. The difference in MPS levels of the plasma in the present experiment and those previously reported may have been due to differences in vitamin A doses.

TABLE 3. *Relative amounts of several S^{35}-labeled mucopolysaccharides* in blood platelets of rats ($Na_2S^{35}O_4$ injected 5 days before killing)*

Treatment	Time After Treatment, Days	Platelet Activity, $\times 10^{-7}$	Relative % of MPS			
			ChS A	ChS B	ChS C	Hep
First experiment						
Normal platelets		36.12	54	10	13	17
		38.37	61	0	20	13
		26.39	59	4	19	12
		25.80	63	8	11	11
Mean		31.67	59	6	16	13
Vitamin A given orally 100 IU/g body wt	4	41.35	57	4	20	10
	5	46.78	61	11	13	9
	6	46.52	69	9	7	10
	7	44.81	62	9	12	11
500 IU/g body wt	4	27.53	62	10	10	10
	5	48.31	60	5	19	10
	6	38.08	66	6	13	9
	7	31.47	65	8	10	11
Second experiment						
Normal platelets		70.93	54	2	24	14
		73.61	58	14	13	14
Mean		72.27	56	8	18	14
A-deficient diet		92.78	62	13	9	10
		102.63	64	13	6	8
		90.16	62	16	7	9
Mean		95.19	63	14	7	9
Deficient diet plus A		134.25	64	8	10	13
		123.16	51	2	17	14
		106.01	62	15	8	8
Mean		121.14	59	8	12	12

* Mucopolysaccharide chromatograms were performed on pooled samples from 3 rats in quadruplicate.

It has been shown that the label undergoes little turnover in normal circulating platelets (24) which perhaps means that MPS is formed while the platelet is still part of the cytoplasm of the megakaryocyte. One could infer that since MPS is not formed in the platelet, but in its precursor, there are probably no intermediates of small molecular weight present in platelets; therefore, total hexosamine determinations were made in these experiments.

Since hexosamine (glucosamine or galactosamine) is ordinarily present as a component of MPS, it is reasonable to assume that the decrease of hexosamine content in the platelets of vitamin A-deficient rats is directly proportional to a decrease in mucopolysaccharides. Conversely, an increase in hexosamine is interpreted as an increase in MPS. The results of these experiments are in agreement with those of other workers. For example, it has been established that decreased hexosamine values are found in colon homogenates (21), vagina, uterus, and colon (30) as a result of vitamin A deficiency. Moretti and Wolf (21) reported that the colon MPS-hexosamines of vitamin A-deficient rats were lower by about 60% in one experiment, and 37–38% in another. In the present study only about 27% reduction was attributed to the deficiency of the vitamin.

Hexosamine studies of rat colons by Moretti and Wolf (21) showed—in addition to about a 60% reduction of total hexosamines due to the deficiency—a decrease in the content of galactosamine-containing MPS with a shift in the glucosamine-to-galactosamine ratio. MPS from rat blood platelets in these experiments was not so altered. In fact the data are suggestive of a decrease in heparin (glucosamine-containing MPS) in the deficiency or excess, and an increase in galactosamine-containing MPS (ChS).

Qualitative measurements of the kinds of MPS in human platelets suggested that they are composed of a mixture of chondroitin sulfates B and C (14). Odell and Anderson (22) and Anderson and Odell (1) have shown that rat blood platelets contain two MPS fractions. Paper electrophoresis and chromatography of the MPS demonstrated that the first fraction was similar to chondroitin sulfate. Fraction 2 was shown to be uronic acid free. The present results agree with these findings in that the chief component was chondroitin sulfate. More specifically it was ChS A. ChS B, ChS C, and heparin are present, but they are found in lesser quantities. According to Kerby and Taylor's (14) results on human blood platelets, it seems possible that these platelets may differ from rat blood platelets in relative percent composition of MPS.

It has not been established conclusively if adhesiveness of blood platelets affects platelet role(s) in the body, but a relationship is strongly suggested. Weiner et al. (32) reported that patients with thrombocytopenic

TABLE 4. *Adhesiveness of blood platelets from vitamin A-treated and normal rats*

Time After Vitamin A Treatment, Days	No. of Rats	$\bar{X}$ Adhesiveness Index, %
	Control	
	5	96[b c]
	100 IU/g body wt	
4	3	78[a]
5	3	97[c]
6	1	96[bc]
7	3	93[bc]
	500 IU/g body wt	
4	2	96[bc]
5	3	77[a]
6	3	84[ab]
7	3	98[c]

[abc] Treatment means having different superscript letters are significantly ($P < 0.01$) different using Duncan's multiple range test.

purpura exhibited deficient adhesiveness of the thrombocytes and this was the only demonstrable defect noted in the coagulation mechanism.

In this report it has been established that vitamin A influences the metabolism of MPS in blood platelets. Although the relative amounts of several mucopolysaccharides within blood platelets were not altered significantly, the total amount of MPS was altered by vitamin A deficiency or excess. It was also shown that blood platelets of vitamin A-treated rats, which contained significantly more MPS, showed increased adhesive qualities. These results suggest that the quantity of MPS in blood platelets determines the platelet's adhesiveness.

Both blood platelets and vitamin A are known to be involved in maintenance of the integrity of the capillary endothelium. Zucker and Borrelli (35) suggested that blood platelets contribute some chemical component to capillaries that in some way improves their resistance to red blood cell extravasation. This study suggests that this chemical component may be a sulfated mucopolysaccharide.

Mucopolysaccharides of blood platelets have also been implicated in thrombotic thrombocytopenic purpura (20). The lesions, which were found in the capillaries and terminal arterioles, consistently contained an accumulation of acid MPS similar to chondroitin sulfate or hyaluronic acid. The authors suggested that these lesions could be caused by a diffuse platelet thrombosis. It is tempting to speculate that capillary endothelium loses its integrity during vitamin A deficiency not entirely by a direct action on the endothelium, as has been previously proposed, but indirectly through the blood platelets. More data concerning this problem are needed in order to clarify these functions.

My thanks are due to Dr. T. T. Odell, Jr. of the Biology Division, Oak Ridge National Laboratory, for guidance and cooperation throughout the course of this investigation. The author is indebted to Dr. M. C. Bell for cooperation, encouragement, and advice.

REFERENCES

1. Anderson, B., and T. T. Odell, Jr. Chemical studies of mucopolysaccharides of rat blood platelets. *Proc. Soc. Exptl. Biol. Med.* 99: 765–768, 1958.
2. Belcher, R., A. J. Nutten, and C. M. Sambrook. The determination of glucosamine. *Analyst* 79: 201–208, 1954.
3. Bell, L. G. E. Polysaccharide and cell membranes. *J. Theoret. Biol.* 3: 132–133, 1962.
4. Bercher, G., E. F. Jakobek, M. A. Schneiderman, G. Z. Williams, and P. J. Schmidt. Size distribution of erythrocytes. *Ann. N. Y. Acad. Sci.* 99: 242–261, 1962.
5. Castor, C. W., and E. L. Dorstewitz. Identification of acid mucopolysaccharides by paper chromatography. *J. Chromatog.* 13: 157–165, 1964.
6. Cohen, A. C. On the solution of estimating equations for truncated and censored samples from normal populations. *Biometrika* 44: 225–236, 1957.
7. Cohen, J., C. L. Maddock, and S. B. Wolbach. The effect of parathyroidectomy on the evolution of hypervitaminosis A in rats. *Am. Med. Assoc. Arch. Pathol.* 59: 723–726, 1955.
8. Crumm, P. D., and D. M. Short. Qualitative blood cell changes in the rat due to vitamin A. *Am. J. Physiol.* 111: 397–405, 1935.
9. Dettwiler, T. W., T. T. Odell, Jr., and T. P. McDonald. Platelet size, ATP content, and clot retraction in relation to platelet age. *Am. J. Physiol.* 203: 107–110, 1962.
10. Duncan, D. B. Multiple range and multiple F tests. *Biometrics* 11: 1–42, 1955.
11. Derwiatkowski, D. D. Vitamin A and endochondral ossification in the rat as indicated by the use of sulfur-35 and phosphorus-32. *J. Exptl. Med.* 100: 11–24, 1954.
12. Fell, H. B., E. Mellanby, and S. R. Pelc. Influence of excess vitamin A on the sulphate metabolism of chick ectoderm grown *in vitro*. *Brit. Med. J.* 2: 611–615, 1954.
13. Frank, M. Beitrag zur Hämatologie der A-avitaminose. *Z. Kinderheilk.* 60: 350–355, 1934.
14. Kerby, G. P., and S. M. Taylor. The acid mucopolysaccharide and 5-hydroxytryptamine content of human thrombocytes in rheumatoid arthritic and nonarthritic individuals. *J. Clin. Invest.* 38: 1059–1064, 1959.
15. LeClerg, E. L. Mean separation by the functional analysis of variance and multiple comparison. *U.S. Dept. Agri. ARS* 20–3, 1957.
16. Lucy, J. A., M. Luscombe, and J. T. Dingle. Studies on the mode of action of excess of vitamin A. No. 8. Mitochondrial swelling. *Biochem. J.* 89: 419–425, 1963.
17. Maddock, C. L., S. B. Wolbach, and D. Jensen. Hypoprothrombinemia with hemorrhage as a cause of death in the rat in hypervitaminosis A. *Federation Proc.* 7: 275, 1948.
18. Maschauf, C., R. W. Robinson, and R. J. LeBeau. Evaluation of nialamide on the coagulation of blood. A new technic for measuring adhesiveness of the platelets. *Blood* 24: 289–298, 1964.
19. McDonald, T. P., T. T. Odell, Jr., and D. G. Gosslee. Platelet size in relation to platelet age. *Proc. Soc. Exptl. Biol. Med.* 115: 684–689, 1964.
20. Moore, R. D., and M. D. Schoenberg. A polysaccharide component in the vascular lesions of thrombotic thrombocytopenic purpura. *Blood* 15: 511–516, 1960.
21. Moretti, A., and G. Wolf. Decrease in mucopolysaccharide-bound hexosamine of rat colon in vitamin A deficiency. *Biochim. Biophys. Acta* 46: 392–393, 1961.
22. Odell, T. T., Jr., and B. Anderson. Isolation of a sulfated mucopolysaccharide from blood platelets of rats. *Proc. Soc. Exptl. Biol. Med.* 95: 151–156, 1957.
23. Odell, T. T., Jr., and B. Anderson. Production and life

span of platelets. In: *The Kinetics of Cellular Proliferation*. New York: Grune & Stratton, 1959, p. 278–280.

24. ODELL, T. T., JR., AND T. P. McDONALD. Two mechanisms of sulfate-S^{35} uptake by blood platelets of rats. *Am. J. Physiol.* 206: 580–584, 1964.
25. ODELL, T. T., JR., AND T. P. McDONALD. Methods for the estimation of the life span of platelets. In: *Blood Coagulation, Hemorrhage and Thrombosis: Methods of Study*, edited by L. M. Tocantins and L. A. Kazal. New York: Grune & Stratton, 1964, p. 68–73.
26. RICHARDSON, L. R. Investigation to determine the mechanism for production of the hemorrhagic syndrome which develop in male rats that receive diets containing irradiated beef. Carried out under Contract DA-49-007-MD-582 with the Office of the Surgeon General.
27. RODAHL, K. Hypervitaminosis A in the rat. *J. Nutr.* 41: 399–421, 1950.
28. RODAHL, K., AND T. MOORE. The vitamin A content and toxicity of bear and seal liver. *Biochem. J.* 37: 166–168, 1943.
29. THOMAS, L., R. T. McCLUSKEY, J. L. POTTER, AND G. WEISSMANN. Comparison of the effects of papain and vitamin A on cartilage. I. The effects in rabbits. *J. Exptl. Med.* 111: 707–718, 1960.
30. USHIMI, C., S. SASAMOTO, AND S. HOMMA. Hexosamine contents in various tissues of rats fed on vitamin A deficient diet. *Natl. Inst. Animal Health* 3: 150–153, 1963.
31. VARANDANI, P. T., G. WOLF, AND B. C. JOHNSON. Function of vitamin A in the synthesis of 3′-phosphoadenosine-5′-phosphosulfate. *Biochem. Biophys. Res. Commun.* 3: 97–100, 1960.
32. WEINER, M., K. SELTMACHER, C. REICH, AND S. SHAPIRO. Platelet adhesiveness. *Blood* 3: 1275–1282, 1948.
33. WOLF, G., J. G. BERGAN, AND P. R. SUNDARESAN. Vitamin A and mucopolysaccharide biosynthesis by cell-free particle suspensions. *Biochim. Biophys. Acta* 69: 524–532, 1963.
34. WOLF, G., AND P. T. VARANDANI. Studies on the function of vitamin A in mucopolysaccharide biosynthesis. *Biochim. Biophys. Acta* 43: 501–512, 1960.
35. ZUCKER, M. B., AND J. BORRELLI. A survey of some platelet enzymes and functions: The platelets as the source of normal serum acid glycerophosphatase. *Ann. N. Y. Acad. Sci.* 75: 203–213, 1958.

McElligott-'62
Bib. No. 5997

J. Path. Bact. 83:347-355. 1962.

DECREASED FIXATION OF SULPHATE BY CHONDROCYTES IN HYPERVITAMINOSIS A

T. F. McElligott
Department of Pathology, University of Sheffield

(Plates XCII–XCV)

In 1952, Fell and Mellanby showed that in organ cultures the addition to the medium of excess vitamin A severely affected cartilaginous limb-bud rudiments from 5–6-day-old chick embryos. The cartilage matrix was greatly altered; it shrank, softened, and lost its basophilia and metachromasia. In a more recent study, it was found that in intact young rabbits hypervitaminosis A resulted in a depletion of cartilage matrix, most evident in the epiphyseal plate and in articular surfaces (Thomas, McCluskey, Potter and Weissmann, 1960). These workers further found that the administration of small amounts of crude papain to young rabbits caused histological changes in cartilage similar to those seen in animals treated with large doses of vitamin A: and Fell and Thomas (1960), using crystalline papain protease, made similar observations on organ cultures of embryonic bone rudiments. As a result of these investigations, both groups of authors suggest that changes in cartilage produced by hypervitaminosis A, *in vivo* and in explants, may be due to the action of a proteolytic enzyme or enzymes.

Loss of cartilage matrix can result from increased breakdown of preformed protein-polysaccharide in the presence of unimpaired cartilage cells; it could equally well result from diminished synthesis of chondroitin sulphate in the presence of normal degradation, and indeed both factors might operate at the same time.

From measurements of the amount of sulphate fixed by chondrocytes *in vitro*, it has already been shown, both in human osteoarthritis (Collins and McElligott, 1960) and in young rabbits given intravenous injections of crude papain (McElligott and Potter, 1960), that loss of cartilage matrix is associated with increased chondrocyte activity. By contrast, the present investigation shows that matrix depletion produced by hypervitaminosis A has no such effect. Indeed, administration of large doses of vitamin A to young rabbits greatly impairs the ability of cartilage cells to fix inorganic sulphate.

Material

Rabbits. Young male rabbits of a stock laboratory strain and weighing approximately 1 kg. were used. They were fed on M.R.C. Diet S.G.1 *ad libitum* and allowed unlimited water. A weekly supplement of cabbage was given.

Vitamin A. Sterile solutions of vitamin A acetate in arachis oil were specially

prepared by Boots Pure Drug Co., Ltd, Nottingham, England. Sterile ampoules of arachis oil without the vitamin were also provided by this Company.

Papain. Crude papain (B.D.H. Laboratories) was prepared for injection by grinding the latex to a fine powder, dissolving this in physiological saline to a concentration of 10 mg. of powder per ml., and removing insoluble components by paper filtration.

^{35}Sulphur. ^{35}S was obtained as carrier-free sulphate in sterile isotonic saline from Radiochemical Centre, Amersham.

Incubation medium. The medium used for incubating cartilage was that described by Kodicek and Loewi (1955–56). ^{35}S was added in amounts sufficient to provide a level of radioactivity of approximately 2 μc per ml.

Methods

General. Vitamin A was injected in high dosage since Barlow and Kocher (1942) found that parenteral vitamin A in oil was only 10–15 per cent. as effective as when orally administered.

(*a*) Four equal groups each of 6 rabbits were used. Group I received intraperitoneal (i.p.) injections of one million International Units (I.U.) of vitamin A in oil. Group II were given intravenous (i.v.) injections of 0·2 ml. papain solution. Group III received i.p. injections of oil without the vitamin. Group IV received no treatment. All injections were given daily for 5 days. No treatment was given on the 6th day and on the 7th day each animal was killed instantaneously by a blow on the back of the neck.

The perichondrium and surrounding tissues were immediately removed from both 5th costal cartilages and these were then cut transversely into slices approximately 0·5 mm. thick. Slices from each side of individual rabbits were pooled together for incubation in radioactive medium. The 4th right costal cartilage from each rabbit was preserved for histological examination.

Apart from the lateral condyle of the right femur, as much articular cartilage as possible was shaved from the lower ends of both femora and from the upper ends of the tibiæ. All the articular cartilage slices from both knees of individual rabbits formed a pool for quantitation of sulphate uptake *in vitro*. The lower lateral ends of the right femora were incubated in radioactive medium and used for autoradiographic and histological studies as will be described.

(*b*) A further 8 rabbits were given ^{35}S, as carrier-free sodium sulphate in saline, by the intraperitoneal route. Each animal received 0·5 μc per g. body weight. Two weeks later, daily intraperitoneal injections of one million I.U. of vitamin A were begun in 4 of these animals and continued for 5 days. Two rabbits received 0·2 ml. of papain solution intravenously daily for the same length of time and the remaining 2 animals received no treatment. The animals were killed on the 7th day and the lower ends of the right femora were immediately fixed in 10 per cent. neutral formalin for histological and autoradiographic examinations.

Radiochemical techniques. The quantitative estimation of sulphate uptake *in vitro* has been described in detail by McElligott and Collins (1960). Uptake of ^{35}S was calculated as counts per minute (c.p.m.) per mg. dried cartilage. Weights of sulphate fixed were not calculated.

Autoradiographs. The lateral half of the lower end of the right femur was taken from every animal not given ^{35}S in life. Each bone-end was incubated in radioactive medium for 3 hr at 37° C. and was then fixed in 10 per cent. neutral formalin.

Bone-ends were also removed from the 8 animals that had received intraperitoneal ^{35}S. These were placed in formalin immediately after the animals were killed, without preliminary incubation. After adequate fixation, all the blocks were decalcified, dehydrated, and double embedded by Peterfi's method (Culling, 1957), and sections were cut at 7 μ. Autoradiographs were prepared

SULPHATE FIXATION BY CHONDROCYTES

FIG. 1.—Untreated rabbit. Articular cartilage and subchondral bony trabeculæ give a strong metachromatic reaction. Toluidine blue. × 125.

FIG. 2.—Vitamin A-treated rabbit. Loss of stainable metachromatic matrix from articular cartilage; metachromatic material persists in the subchondral bony trabeculæ. Toluidine blue. × 125.

FIG. 3.—Untreated rabbit. Normal basophilic epiphyseal cartilage. Cartilage cells, arranged in columns, become swollen and disintegrate near the metaphysis. Hyaline intercolumnar material persists. Hæmatoxylin and eosin. × 125.

FIG. 4.—Vitamin A-treated rabbit. Epiphyseal cartilage. Epiphyseal plate reduced in thickness with loss of basophilia. Hypertrophic cells fewer than in the normal, and metaphyseal capillaries appear to penetrate more deeply into the plate. Metaphyseal bony trabeculæ stout. H. and E. × 125.

SULPHATE FIXATION BY CHONDROCYTES

[illegible].—Untreated rabbit. Metaphyseal border of the epiphyseal plate. Disintegration of hypertrophic cartilage cells leaves canals bordered by calcified hyaline pillars; metaphyseal capillaries and connective tissue permeate these spaces. H. and E. × 500.

FIG. 6.—Vitamin A-treated rabbit. Metaphyseal border of epiphyseal plate. Deeply penetrating metaphyseal vessels branch into adjacent chondrocyte columns, forming capillary tufts. H. and E. × 500.

[illegible] 7.—Papain-treated rabbit. Epiphyseal cartilage. Loss of basophilia with gross thinning and disorganisation of columnar pattern. Marked osteoblastic activity in the metaphysis. H. and E. × 125.

by the stripping film technique of Doniach and Pelc (1950) using Kodak A.R.10 or A.R.50 film. Some sections were stained with 1 per cent. neutral red through the overlying film after exposure and development.

Histological methods. Serial sections from the same blocks, from which autoradiographs were made, were stained with Ehrlich's acid-hæmatoxylin and eosin, alcian blue with chlorantine fast red (Zugibe, Brown and Last, 1959), and toluidine blue for metachromasia (Robinson and Bacsich, 1958).

Results

Gross findings

None of the ten rabbits given daily injections of 1 million units of vitamin A showed unequivocal signs of depletion of cartilage matrix *in vivo*, as judged by curling of the tips of their ears. On palpation, the tips of the ears of some animals felt slightly more flaccid than those of control animals, but this sign was considered to be highly subjective.

All of the papain-injected animals developed slight curling of the ear tips. This change never proceeded to the gross flopping of the ears that is seen in rabbits injected with larger doses of the enzyme. Rabbits given intraperitoneal injections of arachis oil alone showed no changes.

Histological findings

Normal animals. Both articular and epiphyseal cartilage are basophilic with Ehrlich's hæmatoxylin, stain positively with alcian blue, and give a metachromatic reaction with toluidine blue. The cores of the subarticular and metaphyseal bony trabeculæ give similar staining reactions. The epiphyseal plate presents the normal picture of regular pre-ossification columns of cartilage cells. These are illustrated in figs. 1, 3, and 5 to compare with the abnormal.

Vitamin A-treated animals. Changes occur both in the articular cartilage and in the epiphyseal plates of rabbits treated with large doses of vitamin A. All changes are not present in every rabbit and, even in a single section, the microscopic appearance may vary from field to field.

In all animals, both in articular and epiphyseal cartilage, there is a considerable loss of basophilia and metachromasia together with a decrease in alcian blue-staining material. This loss is more pronounced in articular cartilage (figs. 1 and 2) and in the lateral thirds of the epiphyseal plates, but, in some cases, the loss involves the entire epiphyseal cartilage (figs. 3 and 4). The staining of the cores of the subarticular and metaphyseal bony trabeculæ is unaltered.

In most animals the epiphyseal plate is narrowed. This is largely due to a loss of hypertrophic cells at the metaphyseal border of the plate (fig. 4). Capillaries from the metaphysis penetrate more deeply than usual into the epiphyseal cartilage (cf. figs. 3 and 4). In places the hyaline pillars between the epiphyseal columns are broken down and capillaries branch into neighbouring columns, forming capillary loops (figs. 5 and 6). In several animals the metaphyseal bony trabeculæ

are thicker than usual (fig. 4), but neither osteoclastic nor osteoblastic activity is obviously stimulated.

Papain-treated animals. In all rabbits given repeated small doses of crude papain, changes are severe and characteristic both in articular and epiphyseal cartilage. In both situations there is gross thinning of cartilage with loss of stainable ground-substance. The articular cartilage is otherwise unaltered but, in places, the epiphyseal plate is hardly recognisable as such, being reduced to a thin eosinophilic line with no recognisable columnar pattern of cells (fig. 7). In places there is evidence of incipient closure of the epiphysis, with metaphyseal capillaries penetrating the epiphyseal cartilage into the epiphysis.

TABLE

In-vitro *uptake of* $^{35}SO_4''$ *by cartilage*

Rabbit no. in each group*	Uptake of ^{35}S expressed as counts per minute per mg. dried cartilage in							
	articular cartilage				costal cartilage			
	Group I	Group II	Group III	Group IV	Group I	Group II	Group III	Group IV
1	156	4004	1943	4828	107	2884	1218	1335
2	306	3521	2473	3858	140	2250	885	1429
3	171	1983	2387	2470	125	754	1338	879
4	487	2708	1786	2202	132	602	1748	701
5	896	2906	2673	2327	376	1019	1828	1339
6	519	4638	2812	1084	472	1373	1270	783
Mean uptake	422	3294	2346	2795	225	1480	1381	1078

* Group-I rabbits given 5 injections of 10^5 I.U. vitamin A in arachis oil i.p., group II given 5 injections of 0·2 ml. crude papain i.v., and group III given 5 i.p. injections of arachis oil alone; group IV are untreated controls.

Marked osteoblastic activity is seen in the metaphysis with the formation of thick bony trabeculæ. The enzyme has failed to deplete the basophilic and metachromatic material in the cores of these trabeculæ.

Costal cartilage. The histological and histochemical characteristics of costal cartilage are unaltered by vitamin A and papain in the dosage administered.

Fixation of $^{35}SO_4''$ *by cartilage slices* in vitro

Quantitative assays. Measurements of sulphate fixation were made in duplicate in costal and articular cartilage from a total of 24 animals (table). In every case, both in articular and costal cartilage, injection of vitamin A led to greatly diminished chondrocyte activity, as judged by the ability of the cartilage slices to fix radioactive sulphate *in vitro*. By contrast, neither papain nor arachis oil interfered with chondrocyte function when cartilage slices from treated animals were subsequently incubated in sulphated medium.

Qualitative findings. Autoradiographs made from the lower ends of femora incubated in medium containing $^{35}SO_4''$ strongly confirmed the quantitative findings (figs. 8–10). An intense image forms over articular cartilage from control and papain-treated animals. On the other hand, the autoradiographic image of articular cartilage from vitamin A-treated rabbits is comparatively weak, indicating a diminished ability of chondrocytes to fix sulphate.

The effect of vitamin A and papain on incorporated $^{35}SO_4''$

The effect of hypervitaminosis A and papain on incorporated sulphate is seen in autoradiographs prepared from thel ower ends of femora of rabbits given radioactive sulphate *in vivo* two weeks before initiating treatment (figs. 11–13). In control animals, a strong image forms over the articular cartilage and epiphyseal plates, and in the subarticular and metaphyseal bony trabeculæ. By contrast, small amounts of papain effect almost complete removal of radioactive material from cartilage at these sites, but radioactivity in bony trabeculæ is unaffected. Injections of large doses of vitamin A have a similar, though less complete, effect. There is almost complete absence of radioactive sulphate from articular cartilage and a greatly diminished amount in epiphyseal cartilage. Here again radioactivity in bony trabeculæ is unaffected.

Discussion

The intraperitoneal injection of large doses of vitamin A brings about changes in young rabbits that, with conventional histological techniques, resemble those caused by small doses of the proteolytic enzyme papain. Histochemical reactions indicate that after the administration of either agent there is a loss of chondroitin sulphate from both articular and epiphyseal cartilage (figs. 2, 4 and 7), and this depletion of cartilage matrix is confirmed by the removal of radioactive sulphate, previously incorporated in chondroitin sulphate (Dziewiatkowski, 1951; Boström, 1952), after its in-vivo injection (figs. 12 and 13). In addition, both vitamin A and papain bring about considerable disorganisation of the epiphyseal plate (figs. 4, 6 and 7). However, in contrast to the effect of papain, hypervitaminosis A considerably inhibits the ability of chondrocytes to fix sulphate *in vitro*, even in costal cartilage where histological changes are absent (table). This difference is shown qualitatively by autoradiographs (figs. 9 and 10).

There is much evidence that the fixation of radioactive sulphate by cartilage *in vitro* depends upon vital cellular processes directly involved in the synthesis of chondroitin sulphate (Boström and Månsson, 1953; Boyd and Neuman, 1954; Curran and Gibson, 1955–56), and McElligott and Collins (1960) have concluded that estimation of sulphate utilisation *in vitro* measures the rate of synthesis of chondroitin sulphate in a sample of cartilage by the cells it contains. Therefore, it is apparent

that hypervitaminosis A considerably inhibits chondrocyte function, whereas papain has no such effect.

Generalised depletion of cartilage matrix by intravenous papain was first reported by Thomas (1956). Detailed studies of the action of this enzyme on epiphyseal cartilage have been made in the dog by Engfeldt, Hulth and Westerborn (1959) and in rabbits, mice, rats, guinea-pigs and cats by Hulth and Westerborn (1959). Histological changes are characteristic and in keeping with those described in the present investigation. It has also been demonstrated that the loss of basophilic staining of the matrix seen after injection of papain represents an enzymic breakdown of preformed protein-polysaccharide complex with the release of large amounts of chondroitin sulphate into the circulation (Bryant, Leder and Stetten, 1958; Tsaltas 1959; Weissmann, Potter, McCluskey and Schubert, 1959).

Wolbach (1947) described the changes brought about by hypervitaminosis A in the epiphyseal cartilage of the guinea-pig and rat. He found narrowing of this structure and penetration of the cartilage by metaphyseal capillaries, which agrees with the present findings, and, although specific histochemical methods were not employed, he noted deficient matrix production. Despite this latter observation he considered that large doses of vitamin A caused rapid maturation of cartilage cells, but offered no direct evidence in support of this view. Later, Wolbach and Hegsted (1952) came to the same conclusion from a study of hypervitaminosis A in young chicks. In both cases observations were made on epiphyseal cartilage only.

Tissue-culture studies have shown that a loss of stainable matrix occurred in chick limb-bud explants grown in medium containing excess vitamin A (Fell and Mellanby, 1952) and this depletion of embryonic cartilage is accompanied by a loss of sulphate already present (Fell, Mellanby and Pelc, 1956).

Although it has been demonstrated that the loss of basophilic staining of matrix seen after injection of papain represents an enzymic breakdown of preformed protein-polysaccharide, no direct information has been presented so far as to the mechanism whereby vitamin A brings about depletion of cartilage matrix, and Fell and Thomas (1956) consider that this is a major question to be answered.

It is possible that large doses of vitamin A may interfere with an enzyme system involved in the synthesis of chondroitin sulphate. In this respect, it is of interest that Collins (1952), in studies on the liver of a single rat, found, by differential centrifugation in isotonic sucrose, that the major portion of vitamin A in this organ was present in the mitochondria. Most, if not all, of the cytochrome oxidase and succinic dehydrogenase activity of liver cells has been found to be associated with these structures (Hogeboom, Claude and Hotchkiss, 1946); hypervitaminosis A may therefore act by interfering with these enzymes. Boyd and Neuman (1954) conclude that anything that inhibits respiration of cartilage cells inhibits sulphate fixation in that tissue.

SULPHATE FIXATION BY CHONDROCYTES

Untreated rabbit. ...ograph of articular ... of lower end of ...after incubation in ...containing $^{35}SO_4''$. ... image formed over ...fixing chondro- ...A.R.10 film, exposed ... Neutral red. ×50.



FIG. 9.—Vitamin A-treated rabbit. Autoradiograph of articular cartilage of lower end of femur after incubation in medium containing $^{35}SO_4''$. Many chondrocytes do not fix sulphate and fail to form an image. A.R.10 film, exposed 5 weeks. Neutral red. ×50.

— Papain-treated ... Autoradiograph of ... cartilage of lower ...femur after incubation ...containing $^{35}SO_4''$. ...phate-fixing ability ...rocytes in the de- ...cartilage is unim- ...A.R.10 film, exposed ... Neutral red. ×50.

SULPHATE FIXATION BY CHONDROCYTES

FIG. 11.—Untreated rabbit. Autoradiograph of lower end of femur 3 weeks after intraperitoneal injection of $^{35}SO_4''$. An image forms over articular and epiphyseal cartilage and over the subchondral bony trabeculæ. A.R.50 film, exposed 8 weeks. Unstained. × 6.

FIG. 12.—Vitamin A-treated rabbit. Autoradiograph of lower end of femur 3 weeks after intraperitoneal injection of $^{35}SO_4''$. A greatly diminished image is formed by both articular and epiphyseal cartilage. Radioactive material remains in bony trabeculæ. A.R.50 film, exposed 8 weeks. Unstained. × 6.

FIG. 13.—Papain-treated rabbit. Autoradiograph of lower end of femur 3 weeks after intraperitoneal injection of $^{35}SO_4''$. Little radioactivity remains in articular or epiphyseal cartilage, but bony trabeculæ are unaffected. A.R.50 film, exposed 8 weeks. Unstained. × 6.

In the doses used in this investigation, both the vitamin and the enzyme induced histologically visible changes only in articular and epiphyseal cartilage and not in the rib. Thomas *et al.* (1960) also found little change in other cartilages. It is of interest that marked inhibition of sulphate fixation occurs in costal cartilage in hypervitaminosis A in the absence of any microscopic change. This strongly suggests that the primary action of hypervitaminosis A is an inhibition of chondrocyte function and not the activation of a proteolytic enzyme, even though this may be a secondary effect.

Further evidence that vitamin A interferes directly with the elaboration of chondroitin sulphate by acting on the cell is deduced from the behaviour of tissue cultures. When chick embryonic limb rudiments had been depleted of matrix by treatment with papain and then transferred to normal medium, broad intensely metachromatic partitions were formed throughout the rudiments ; recovery of vitamin A-treated explants occurred only in the terminal cartilage of the rudiments (Fell and Thomas, 1960). Herbertson (1955) found that no restoration of lost matrix occurred when vitamin A-treated chick-limb-bone rudiments were transferred to normal incubation medium, although the cells of the epiphysis continued to divide ; they now, however, resembled osteoblasts rather than chondroblasts. These observations suggest that changes brought about by vitamin A are intrinsic to the cell whereas the action of papain appears to be on the matrix only.

Although the primary action of hypervitaminosis A is on the chondrocyte, it is possible that inhibition of chondroitin sulphate synthesis in the presence of normal degradation does not fully explain the changes seen. Cohen, Maddock and Wolbach (1955) report that a rise occurs in the level of rat serum mucoprotein in hypervitaminosis A, and suggest that this may be related to the dissolution of skeletal tissues. Using radioactive sulphate, Thomas *et al.* (1960) present further evidence in support of this view. These latter authors, together with Fell and Thomas (1960), suggested that the changes produced in cartilage by hypervitaminosis A may be due to the action of a proteolytic enzyme, although no direct evidence for this hypothesis was presented and in neither study was chondrocyte activity investigated. There is, indeed, some evidence for the presence of an intrinsic proteolytic enzyme in cartilage. Einbinder and Schubert (1950) noted that chondroitin sulphate could easily be extracted from stored wet bovine cartilage (though not from the fresh wet substance), and suspected that the linkage between chondroitin sulphate and collagen might be broken down by an intrinsic enzymic process. More positive evidence has been advanced for the presence, in embryonic cartilage, of an enzyme capable of depleting matrix. After limb rudiments had been treated with water at 4° C. for 1 hr, followed by incubation at *p*H 3–5 in buffer for 2 hr at 37° C., the metachromatic staining was greatly reduced, half the hexosamine was lost, and the protein components were liberated into the buffer (Fell, Lucy and Dingle, 1961). The water extract was

found to contain a protease with an acid *p*H optimum; a protease with a similar *p*H optimum is localised in the cytoplasmic particles obtained by centrifugal fractionation of embryonic cartilage, and can be liberated by treatment with hypotonic solutions (Dingle and Lucy, 1961). These workers also found that rat liver lysosomes, suspended in 0·25*M* sucrose and treated with vitamin A, release a proteolytic enzyme with an acid *p*H optimum.

It is thus apparent that inhibition of chondrocyte function by vitamin A may not be the exclusive cause of depletion of cartilage matrix. However, inhibition of polysaccharide synthesis appears to be the primary defect, since this occurs in costal cartilage in the absence of matrix depletion. Furthermore, small doses of papain consistently deplete articular and epiphyseal cartilage matrix, whereas hypervitaminosis A is less reliable in this respect. On the other hand, inhibition of sulphate uptake is quite consistent in hypervitaminosis A. The action of large doses of vitamin A on the chondrocyte may, however, at times bring about changes that release an enzyme or enzymes which accelerate degradation of protein-polysaccharide and, in the absence of normal synthesis, result in obvious depletion of matrix.

Summary

The effects of large doses of vitamin A on articular, epiphyseal and costal cartilage have been studied in young rabbits and contrasted with the effects of repeated small doses of crude papain.

Intraperitoneal injections of vitamin A lead to depletion of articular and epiphyseal cartilage matrix, thinning of the epiphyseal cartilage and vascularisation of the metaphyseal border of the plate; costal cartilage, on the other hand, shows no detectable histological or histochemical change. All these effects are similar to, though less severe than, those seen after repeated injections of crude papain.

Both in costal and articular cartilage, however, hypervitaminosis A markedly inhibits chondrocyte activity *in vitro*, whereas injections of papain fail to inhibit cell function.

Both agents cause loss of preformed chondroitin sulphate from articular and epiphyseal cartilage.

Depletion of cartilage matrix in hypervitaminosis A may be due to the degradation of protein-chondroitin sulphate complex in the absence of synthesis, but the accelerating effects of a proteolytic enzyme have not been excluded. However, the absence of histochemical changes in costal cartilage when chondrocyte activity is inhibited shows that the primary action of hypervitaminosis A, unlike that of papain, is on the cartilage cell.

I am indebted to Professor D. H. Collins for his advice and criticism and to Miss P. M. Wilson for technical assistance. The work was supported by Professor Collins' research grant from the Empire Rheumatism Council.

REFERENCES

BARLOW, O. W., AND KOCHER, H.	1942.	*Amer. J. Physiol.*, **137**, 213.
BOSTRÖM, H.	1952.	*J. Biol. Chem.*, **196**, 477.
BOSTRÖM, H., AND MÅNSSON, B. .	1953.	*Ark. Kemi*, **6**, 23.
BOYD, E. S., AND NEUMAN, W. F.	1954.	*Arch. Biochem. Biophys.*, **51**, 475.
BRYANT, J. H., LEDER, I. G., AND SCHITTEN, D., JR	1958.	*Ibid.*, **76**, 122.
COHEN, J., MADDOCK, CHARLOTTE L., AND WOLBACH, S. B.	1955.	*Arch. Path.*, **59**, 723.
COLLINS, D. H., AND MCELLIGOTT, T. F.	1960.	*Ann. Rheum. Dis.*, **19**, 318.
COLLINS, F. D.	1952.	*Biochem. J.*, **51**, xxxviii.
CULLING, C. F. A.	1957.	Handbook of histopathological technique, *London*, p. 88.
CURRAN, R. C., AND GIBSON, T. .	1955–56.	*Proc. Roy. Soc.* B, **144**, 572.
DINGLE, J. T., AND LUCY, J. A. .	1961.	*Biochem. J.*, **78**, 11P.
DONIACH, I., AND PELC, S. R.. .	1950.	*Brit. J. Radiol.*, **23**, 184.
DRIEWIATKOWSKI, D. D. . . .	1951.	*J. Biol. Chem.*, **189**, 187.
EINBINDER, JULIA, AND SCHUBERT, M.	1950.	*Ibid.*, **185**, 725.
ENGFELDT, B., HULTH, A., AND WESTERBORN, O.	1959.	*Arch. Path.*, **68**, 600.
FELL, HONOR B., LUCY, J. A., AND DINGLE, J. T.	1961.	*Biochem. J.*, **78**, 11P.
FELL, HONOR B., AND MELLANBY, E.	1952.	*J. Physiol.*, **116**, 320.
FELL, HONOR B., MELLANBY, E., AND PELC, S. R.	1956.	*Ibid.*, **134**, 179.
FELL, HONOR B., AND THOMAS, L.	1960.	*J. Exp. Med.*, **111**, 719.
HERBERTSON, M. A.	1955.	*J. Embryol. Exp. Morphol.*, **3**, 355.
HOGEBOOM, G. H., CLAUDE, A., AND HOTCHKISS, R. D.	1946.	*J. Biol. Chem.*, **165**, 615.
HULTH, A., AND WESTERBORN, O.	1959.	*J. Bone Jt Surg.*, **41B**, 836.
KODICEK, E., AND LOEWI, G. . .	1955–56.	*Proc. Roy. Soc.* B, **144**, 100.
MCELLIGOTT, T. F., AND COLLINS, D. H.	1960.	*Ann. Rheum. Dis.*, **19**, 31.
MCELLIGOTT, T. F., AND POTTER, J. L.	1960.	*J. Exp. Med.*, **112**, 743.
ROBINSON, R. L., AND BACSICH, P.	1958.	*Stain Technol.*, **33**, 171.
THOMAS, L.	1956.	*J. Exp. Med.*, **104**, 245.
THOMAS, L., MCCLUSKEY, R. T., POTTER, J. L., AND WEISSMANN, G.	1960.	*Ibid.*, **111**, 705.
TRALTAS, T. T.	1958.	*Ibid.*, **108**, 507.
WEISSMANN, G., POTTER, J. L., MCCLUSKEY, R. T., AND SCHUBERT, M.	1959.	*Proc. Soc. Exp. Biol. Med.*, **102**, 584.
WOLBACH, S. B..	1947.	*J. Bone Jt Surg.*, **29**, 171.
WOLBACH, S. B., AND HEGSTED, D. M.	1952.	*Arch. Path.*, **54**, 30.
ZOGBE, F. T., BROWN, K. D., AND LAST, J. H.	1959.	*J. Histochem. Cytochem.*, **7**, 101.

Millen-'56
Bib. No. 6179

J. Neurol. Neurosurg. Psychiat., 1956, **19**, 17.

THE EFFECT OF THE DURATION OF VITAMIN-A DEFICIENCY IN FEMALE RABBITS UPON THE INCIDENCE OF HYDROCEPHALUS IN THEIR YOUNG

BY

J. W. MILLEN and D. H. M. WOOLLAM

From the Department of Anatomy, University of Cambridge

When female rabbits are subjected to an experimental vitamin-A deficiency before mating, their offspring show signs of a nervous disorder from three to six weeks after birth (Millen, Woollam, and Lamming, 1953; Lamming, Woollam, and Millen, 1954). This disorder was attributed to hydrocephalus which was present in the young animals. In a subsequent paper (Millen and others, 1954) it was reported that a congenital hydrocephalus was constantly found in young stillborn rabbits when their dam had been maintained on a vitamin-A deficient diet for periods of from 14 to 38 weeks before mating.

The initial observations on the production of hydrocephalus by a maternal vitamin-A deficiency were made on a small number of litters from an inbred strain of rabbits. Attention was drawn to the need for the substantiation of these findings (Annotation, *Brit. med. J.*, 1954). In order, therefore, to study more closely with larger numbers this relationship between maternal vitamin-A deficiency and the incidence of hydrocephalus in the young a colony of rabbits was established in 1953. In this paper the effect of maternal hypovitaminosis A upon the incidence of hydrocephalus in the young in a large number of litters is reported.

Materials and Methods

Rabbits aged 4 or 5 months were purchased from accredited dealers at monthly intervals. These does were of mixed breeds, including Dutch and Flemish rabbits and crosses. In addition some albino rabbits from the general laboratory stock were included in the experiment. It may be noted here that although litters with hydrocephalus were obtained from all the breeds used, the majority of the litters came from the smaller rabbits of the Dutch type. Five males of different varieties were employed for breeding purposes.

The rabbits were housed in standard metal cages and transferred to wooden breeding hutches one week before the expected date of parturition. Sawdust was used for both cages and hutches, and wood wool was supplied as nesting material. The animals were fed on a vitamin-A deficient pellet diet made according to the formula given by Lamming and others (1954). Water was supplied *ad libitum*. All adult animals received a weekly supplement by mouth of 50 mg. α-tocopheryl acetate and 1,500 i.u. vitamin D in 2 ml. arachis oil. The control animals received in addition 7,500 μg. vitamin A weekly in arachis oil. The males received the normal laboratory diet.

No attempt was made to breed from does on the deficient diet (deficient rabbits) until they were at least 9 months old and had been on the diet for 12 weeks or longer. Surviving rabbits from litters born to deficient dams were separated from their mothers after four weeks and fed on the same diet. Some of these young animals were subsequently killed for examination but others are still surviving in the colony. Up to the present 50 rabbits have been used in the experiment.

The presence or absence of hydrocephalus in the young rabbits was determined either by sectioning the head after freezing or by dissection after fixation. Histological examination of the material is being carried out with the object of determining the mechanism producing the hydrocephalus and it is intended to publish a report on this in a subsequent communication.

Cerebrospinal fluid pressure measurements were made on a small number of the young born to deficient dams. The pressures were measured by cisternal puncture and recorded by means of a bubble manometer (Griffith and Farris, 1942).

An outbreak of snuffles due to *Pasteurella septica* occurred in the colony in December, 1954. This disease has been responsible for the deaths of a number of the experimental animals. Apart from this outbreak the deficient animals generally remained in good condition, although xerophthalmia has appeared in some does and others have shown a tendency to develop conjunctivitis.

Results

The Incidence of Hydrocephalus in the Colony.—Thirty-two deficient animals were successfully mated. These produced, in first pregnancies, 32 litters of which one was aborted before term. In the 31 litters carried to term 142 young were born and, of these, 82 showed varying degrees of hydro-



FIG. 1.—Diagram illustrating the incidence of hydrocephalus in first litters.

cephalus at post-mortem examination. In 42 young the ventricles of the brain appeared normal on section, and a further 18 are still alive. The length of time on the deficient diet before mating varied from 12 to 28 weeks. No hydrocephalus was found in 23 control young from six litters.

The results are shown in Fig. 1. The most important points which emerge are the following.

1. Dams which had been on the deficient diet for 24 to 28 weeks before mating produced many more hydrocephalic young than those which had been on the deficient diet for shorter times.

2. Of the young recorded as hydrocephalic two, born to a 24 weeks deficient doe, appeared normal at birth and were killed when 41 days old. At necropsy hydrocephalus was found in both these animals. Three litter mates of these animals are still alive.

3. Twenty-four "normal" young (including seven with increased cerebrospinal fluid pressures) were born to five does which in subsequent litters gave birth to hydrocephalic young.

4. In 27 litters the young in any one litter were either all normal or all hydrocephalic.

Measurement of the Cerebrospinal Fluid Pressure.—Cerebrospinal fluid pressure measurements made on seven young gave readings which ranged from 120 mm. to 265 mm. of water. (The average cerebrospinal fluid pressure in the rabbit is less than 100 mm. of water.) These animals were not hydrocephalic when examined later at necropsy.

Post-mortem Findings.—There was no difficulty in distinguishing the small, slit-like ventricles of the normal young (Fig. 2) from the grossly dilated ventricles seen in the hydrocephalic young (Fig. 3). In none of the hydrocephalic young examined after death was any congenital abnormality discovered other than the presence of hydrocephalus. There was no evidence of bony overgrowth in the skull. On the contrary the calvaria was very thin in the young which were stillborn or survived only a few weeks.

Discussion

The effects of a vitamin-A deficiency in the diet upon the nervous system have been frequently recorded. They include muscular incoordination and weakness, paresis, fits, and sometimes death. The mechanism by which the lesions of the nervous system are produced, however, has been a subject of controversy. Theories have ranged from a

FIG. 2.—Coronal section through head of control rabbit aged 1 day. × 2·5.

FIG. 3.—Coronal section through head of hydrocephalic rabbit aged 20 days. × 2·5.

primary degeneration of the nervous system (Rigdon, 1952) to the implication of a toxic factor allied to ergot (Mellanby, 1926). Current opinion has tended to accept the view that the lesions of the nervous system are due to a disturbance of normal bone growth, itself an immediate consequence of vitamin-A deficiency. There have been two conflicting views on the nature of the disorganization. Mellanby (1938) considered that there was an overgrowth of apparently normally formed bone in certain places, whilst Wolbach and Bessey (1941) held that the fault lay in the cessation of endochondral bone formation. The present experiments would appear to show that there is a direct relationship, in rabbits, between the duration of the maternal hypovitaminosis A and the production of hydrocephalic young. There is no evidence in this study that the production of the hydrocephalus is in any way dependent upon a disturbance of bone growth. These observations make it necessary to reconsider the causes of the nervous disorders found in association with a vitamin-A deficiency in other animals.

The experiments reported in this paper suggest that the majority of the young will appear normal at birth when the degree of maternal vitamin-A deficiency is slight. It is probable, however, that many of these young have increased cerebrospinal fluid pressures. This view is supported not only by the limited number of pressure measurements made during this study but also by observations on chicks (Woollam and Millen, 1955). Some of the apparently normal young may have a minor degree of hydrocephalus at birth which produces no clinical signs and remains undiscovered until the animal either dies or is killed for examination. After more prolonged maternal deficiencies more live young can be diagnosed as hydrocephalic at birth, and, as might be expected, there are more stillborn young with hydrocephalus. Indeed, the longer the mother has been deprived of vitamin A the greater the proportion of hydrocephalic to normal live young and the greater the number of hydrocephalic stillborn.

These studies support the view that an increased cerebrospinal fluid pressure is one of the earliest signs of hypovitaminosis A (Woollam and Millen, 1955). In the absence of any evidence of pressure on the central nervous system due to a disorganization of bone growth, it must be concluded that the increase in the intraventricular pressure of the cerebrospinal fluid is responsible for the production of the hydrocephalus. Whether hydrocephalus appears or not depends largely, according to this interpretation, upon the period of growth during which the rise in pressure occurs. If the pressure rises early in gestation hydrocephalus will be present at birth. This results in stillbirth or in the production of young with enlarged and deformed heads produced by a hydrocephalus which progresses rapidly and leads to the early death of the animal. If the severity of the hypovitaminosis is less and the rise in pressure begins later in development or, perhaps, occurs more slowly, ossification of the calvaria proceeds more or less normally. Once this ossification is relatively complete it hinders or prevents further enlargement of the head. Under these circumstances an increased cerebrospinal fluid pressure is present at birth and moderate degrees of hydrocephalus may be discovered at necropsy several months later. The essential factor which determines the appearance of a gross hydrocephalus seems to be the state of ossification of the skull at the time when the rise in cerebrospinal fluid pressure is initiated.

The hypothesis that the primary factor in the pathogenesis of the condition is an over-production of cerebrospinal fluid (Millen and others, 1954) receives additional corroboration from the results of the present experiments. Moreover, only by a hypothesis such as this can the results of experiments be explained in which increased cerebrospinal fluid pressures were recorded in vitamin-A deficient animals and rapid falls in pressure occurred after the restoration of the vitamin (Helmboldt, Jungherr, Eaton, and Moore, 1953; Sorensen, Kowalczyk, and Hentges, 1954). Indeed so sensitive to vitamin-A deficiency is the cerebrospinal fluid pressure that Sorensen and others (1954) suggest it may be used as a guide to the onset of deficiency. Such a sensitivity would be extremely difficult to explain on the basis of any hypothesis which involves gross bony changes or the presence of an aqueductal stenosis as the cause of the increase in the cerebrospinal fluid pressure.

Summary

The relationship between the duration of maternal vitamin-A deficiency in rabbits and the incidence of hydrocephalus in their young has been studied.

Thirty-one litters were born at term to deficient does in first pregnancies. The length of time on the vitamin-A deficient diet for these does before mating varied from 12 to 28 weeks.

One hundred and forty-two young were born of which 82 were hydrocephalic. Eighteen are still alive and 42 showed no hydrocephalus.

The proportion of hydrocephalic young was much greater in litters from animals which had been

fed on the diet for 24 to 28 weeks before mating than from those so fed for 12 to 15 weeks.

Increased cerebrospinal fluid pressures have been recorded in seven young which were not hydrocephalic.

These results are discussed in relation to previous accounts of the effects of hypovitaminosis A in animals.

We wish to thank Professor J. D. Boyd for his advice and encouragement in the preparation of this paper: Miss I. Dean and Miss A. Smith for technical assistance; and Mr. J. F. Crane for the photographs.

This work has been supported by a grant from the Nuffield Foundation, which is gratefully acknowledged.

References

Annotation (1954). *Brit. med. J.*, **1**, 609.
Griffith, J. Q., and Farris, E. J. (1942). *The Rat in Laboratory Investigation*. Lippincott, Philadelphia.
Helmboldt, C. F., Jungherr, E. L., Eaton, H. D., and Moore, L. A. (1953). *Amer. J. vet. Res.*, **14**, 343.
Lamming, G. E., Woollam, D. H. M., and Millen, J. W. (1954). *Brit. J. Nutr.*, **8**, 363.
Mellanby, E. (1926). *J. Physiol. (Lond.)*, **61**, xxiv.
——(1938). *Ibid.*, **94**, 380.
Millen, J. W., Woollam, D. H. M., and Lamming, G. E. (1953). *Lancet*, **2**, 1234.
——, ——, ——,(1954). *Ibid.*, **2**, 679.
Rigdon, R. H. (1952). *Arch. Path. (Chicago)*, **53**, 239.
Sorensen, D. K., Kowalczyk, T., and Hentges, J. F. (1954). *Amer. J. vet. Res.*, **15**, 258.
Wolbach, S. B., and Bessey, O. A. (1941). *Arch. Path. (Chicago)*, **32**, 689.
Woollam, D. H. M., and Millen, J. W. (1955). *Nature (Lond.)*, **175**, 41[illegible]

Millen-'57
Bib. No. 6180

Brit. J. Nutr. 11:440-446. 1957.

The effect of vitamin A upon the cerebrospinal-fluid pressures of young rabbits suffering from hydrocephalus due to maternal hypovitaminosis A

By J. W. MILLEN
Anatomy School, University of Cambridge

and A. D. DICKSON
Department of Anatomy, University of Aberdeen

(*Received* 24 *May* 1957)

The role of vitamin A deficiency in producing lesions of the central nervous system has interested investigators since attention was first drawn by Hart, Miller & McCollum (1916) to a syndrome of ataxia, muscular incoordination and paralysis occurring in pigs fed on a diet deficient in vitamin A. Amongst the effects noted by several workers (Moore & Sykes, 1940; Mellanby, 1940–1) has been an increased cerebrospinal-fluid pressure sometimes associated with hydrocephalus. The increased cerebrospinal-fluid pressure has, however, generally been regarded as a secondary effect due to compression of the central nervous system produced by disorganized growth of the bony coverings of the brain and spinal cord. For the most part these experiments have been carried out on young animals subjected to a gross vitamin A deficiency after birth. Recently, however, it was found that the young born to female rabbits fed on a vitamin A-deficient diet for 24 weeks before and during pregnancy suffered from a congenital hydrocephalus accompanied by an increased cerebrospinal-fluid pressure. When the period of deficiency was shorter the cerebrospinal-fluid pressure was increased, but the animals were not hydrocephalic (Millen & Woollam, 1956). In the young hydrocephalic animals the vault of the skull was expanded and the anterior fontanelle was widely open. It seemed unlikely therefore that the increased cerebrospinal-fluid pressure could be secondary to bony compression of the brain, and the hypothesis was put forward that the increased pressure was the primary event. It appeared further that an overproduction of cerebrospinal fluid might be responsible for the rise in pressure.

The work reported in this paper was carried out to determine the effect of vitamin A on the cerebrospinal-fluid pressures of live-born hydrocephalic young rabbits.

EXPERIMENTAL

Twenty-eight hydrocephalic young rabbits were used in the experiment. These young were born to female rabbits maintained on a pellet ration, containing less than 1 μg carotene/g, for various periods before mating (Lamming, Woollam & Millen, 1954). The young were fed on the same diet after weaning. Each adult rabbit received

25 mg α-tocopheryl acetate and 750 i.u. vitamin D weekly. The diagnosis of hydrocephalus was based on the presence of a persistent anterior fontanelle in the young at 7 days of age. The intraventricular pressure was measured, under ether anaesthesia, by means of a bubble manometer when the animal was from 8 to 56 days old. Further pressure measurements were made at intervals of about 1 week.

With four exceptions, the initial intraventricular-pressure measurement was combined with the introduction of air for ventriculography. A three-way tap, one outlet of which was attached to a 2 ml. syringe, was inserted between the needle and the manometer. Immediately after the intraventricular-pressure measurement a small quantity of cerebrospinal fluid was withdrawn and replaced by air, the procedure being repeated until a total amount of between 0·5 and 1·5 ml. of air had been introduced. Lateral X-rays of the head enabled the size of the dilated ventricles to be assessed. After the initial pressure measurement 10,000–20,000 i.u. synthetic vitamin A acetate were given by mouth or by subcutaneous injection, and this dose was repeated at weekly intervals.

RESULTS

All the hydrocephalic animals exhibited increased cerebrospinal-fluid pressures. The giving of vitamin A to the hydrocephalic young led to a rapid fall in the cerebrospinal-fluid pressure determined by intraventricular puncture. As a rule the pressure continued to fall steadily and reached normal limits within 3–4 weeks from the beginning of treatment. The results are shown diagrammatically in Figs. 1 and 2. Intraventricular puncture only was performed in the animals whose cerebrospinal-fluid pressures

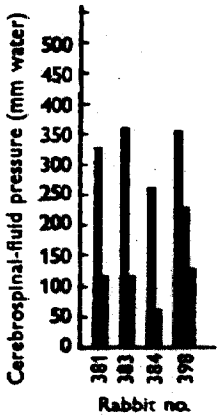

Fig. 1

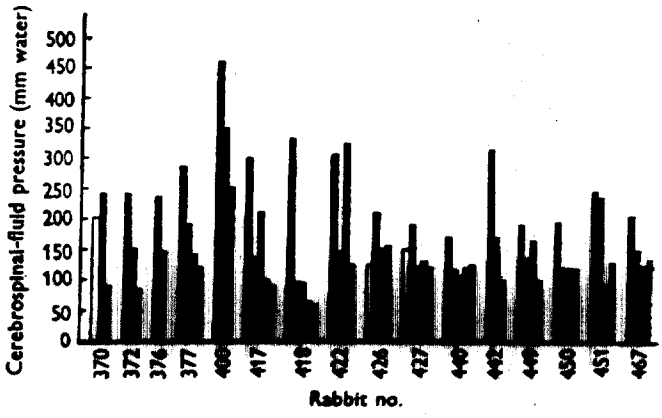

Fig. 2

Fig. 1. Effect of vitamin A on cerebrospinal-fluid pressures of young hydrocephalic rabbits suffering from hypovitaminosis A. Intraventricular puncture only. Each column represents a cerebrospinal-fluid pressure measurement. The interval between measurements was 75 days in rabbits nos. 381, 383 and 384 and 1 week in rabbit no. 398. Vitamin A was given after the initial measurement.

Fig. 2. Effect of vitamin A on cerebrospinal-fluid pressures of young hydrocephalic rabbits suffering from hypovitaminosis A. Intraventricular puncture and ventriculography. Each column represents a cerebrospinal-fluid pressure measurement. The interval between measurements was about 1 week. Vitamin A was given after the initial measurement except in three animals. In these animals vitamin A was withheld until after the second measurement and the first pressure reading is shown as a blank column.

are recorded in Fig. 1, whereas the pressures shown in Fig. 2 are for animals in which ventriculography was also carried out. There appeared to be no difference in the efficiency of vitamin A given by mouth or subcutaneous injection, but the number of animals treated was too small to permit an unequivocal answer to this question. Pressure measurements were discontinued when readings within normal limits were obtained, and further progress was judged by the closure of the anterior fontanelle and the general well-being of the animal. In three rabbits weekly pressure measurements were not carried out, a second estimation being deferred until the animals were over 2 months old. Readings within the normal range were then obtained from these animals.

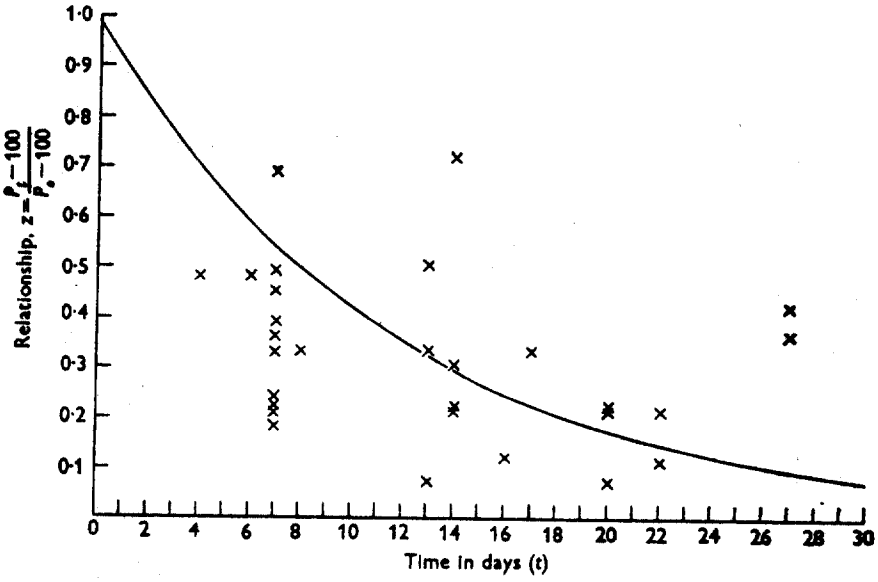

Fig. 3. Relationship between cerebrospinal-fluid pressure of young hydrocephalic rabbits suffering from hypovitaminosis A and duration of treatment with vitamin A. The ratio of the pressure in excess of 100 mm water to the initial excess of pressure is plotted against length of time, in days, for which treatment was carried out. Further details are given on p. 443.

In three animals, in which the initial cerebrospinal-fluid pressures were 200 mm water or below, vitamin A was withheld for a week. (The initial pressure measurements in these animals are represented by blank columns in Fig. 2.) At the end of this time the pressures were found to have increased and vitamin A therapy was begun. The cerebrospinal-fluid pressures then began to fall, as in the other animals.

Eight animals with initial pressures ranging from 190 to 410 mm water died before a second measurement was made. These animals included several of those on which the early attempts at ventriculography were made. Death appeared to be due to the too rapid and excessive removal of cerebrospinal fluid before the replacement by air and, as already noted, in subsequent operations the replacement was carried out in several steps.

A statistical analysis of the results showed that there was a highly significant drop in the cerebrospinal-fluid pressures after 6–7 days of treatment and that the pressures

ultimately stabilized at about 100 mm water. Denoting by P_t the pressure after t days, and by P_0 the initial pressure, the quantity $z = \frac{P_t - 100}{P_0 - 100}$ was plotted against t (Fig. 3). It might seem natural to expect that z decreases to zero exponentially with t, and the best fitted curve, to $z = e^{-0 \cdot 088t}$, is shown in Fig. 3. It was found, however, that this formula did not adequately represent the decrease in pressure, the mean value of z at $t = 7$ days being significantly lower than the value given by the exponential curve.

Of the twenty-eight hydrocephalic animals treated with vitamin A, nine still survive. Six of them are over 12 months old and have remained in good health. They are indistinguishable on examination from control animals of the same age. Various causes were responsible for the deaths of animals used in the experiment. In some death occurred accidentally during anaesthesia, in others intracranial haemorrhage succeeded the removal of cerebrospinal fluid or injury to a cerebral blood vessel. Still others succumbed to infection of the lungs. These causes, however, did not account for all the deaths among the experimental animals. Some animals, in general those with initial cerebrospinal-fluid pressures of 300 mm or more of water, failed to survive for more than 4–7 weeks after birth. In these young the amount of cerebral damage was perhaps so great as seriously to interfere with their general well-being and survival.

DISCUSSION

The finding of considerably increased cerebrospinal-fluid pressures in the hydrocephalic animals is in agreement with previous observations upon the effects of a hypovitaminosis A on the cerebrospinal-fluid pressure in rabbits (Millen & Woollam, 1956) and in other animals (Moore & Sykes, 1940; Eveleth, Bolin & Goldsby, 1949; Sorensen, Kowalczyk & Hentges, 1954; Woollam & Millen, 1956). It also accords with the view put forward in a previous paper (Millen & Woollam, 1956) that the increase in the cerebrospinal-fluid pressure is the immediate effect of the hypovitaminosis A and that hydrocephalus occurs in consequence of this increase.

There seems to be little doubt that the rapid fall in the cerebrospinal-fluid pressure was a direct result of giving vitamin A to the animals. It might be argued that the carrying out of ventriculography was a factor in lowering the cerebrospinal-fluid pressure. But against this argument can be put the similar reductions of pressure observed in those animals in which ventriculography was not performed (Fig. 1). Further, in three animals vitamin A was withheld for 1 week after ventriculography and the cerebrospinal-fluid pressure was higher at the second reading than at the first (Fig. 2).

The reductions in the cerebrospinal-fluid pressures produced by vitamin A in rabbits suffering from congenital hydrocephalus parallel similar findings in young animals subjected to a vitamin A-deficient diet after birth. In deficient calves Helmboldt, Jungherr, Eaton & Moore (1953) recorded values for cerebrospinal-fluid pressure of 220–380 mm water, which fell to 159–118 mm after 2–4 weeks treatment with vitamin A. Sorensen *et al.* (1954) were able to produce substantial reductions

in cerebrospinal-fluid pressure in vitamin A-deficient pigs by giving them a carotene supplement.

Few reports have appeared on the effects of gross vitamin A deficiency in infants, but the findings do strongly support the view that the cerebrospinal-fluid pressure is increased in hypovitaminosis A and that a rapid reduction in pressure can be brought about by administering vitamin A. Cornfeld & Cooke (1952) described an infant aged 5½ months who had been fed on an artificial diet deficient in vitamin A. Lumbar puncture revealed a cerebrospinal-fluid pressure of 280 mm water, the anterior fontanelle was bulging and the sutures of the skull were separated. Xerophthalmia was also present. Treatment with large doses of vitamin A produced amelioration. Recently, Bass & Caplan (1955) recorded two cases of gross vitamin A deficiency in infants associated with increased intracranial pressure. A 7-month infant, who had received from the age of 1 month a diet lacking in vitamin A, was admitted to hospital with severe keratitis and marked bulging of the anterior fontanelle. Two days after the beginning of treatment with 100,000 i.u. vitamin A the fontanelle was flat and the keratitis began to improve. Two months later the baby was reported to be in excellent health. In their other case a bulging anterior fontanelle was observed in a 3-month-old infant with congenital absence of the bile ducts. Blood vitamin A was 34 i.u/100 ml. Within 1 week of the beginning of parenteral treatment with vitamin A the fontanelle was normal. In another infant with allergy to cow's milk, Bass (1956) found keratitis, widening of the skull sutures and a bulging anterior fontanelle, associated with complete absence of vitamin A in the blood. Institution of parenteral therapy with vitamin A led to immediate improvement.

The problem still remains of the mechanism by which a deficiency of vitamin A influences the cerebrospinal-fluid pressure. An increase in the cerebrospinal-fluid pressure must be due, if one excludes new growths, to a disproportion between the size of the brain and the skull, as suggested by Mellanby (1938–9) and Wolbach & Bessey (1941), or to increased production, underabsorption or interference with the free circulation of the cerebrospinal fluid. Disproportion between the brain and its bony coverings has been considered as unlikely to be the cause in the newborn rabbit (Millen, Woollam & Lamming, 1954), and Bass & Caplan (1955) were unable to accept such a growth disorganization as the origin of the increased cerebrospinal-fluid pressures observed by them in infants suffering from gross hypovitaminosis A. Up to the present, evidence from experiments on rabbits and other animals points to an overactivity of the chorioid plexuses, unaccompanied by gross histological changes, as the most probable cause of the condition. The apparent fall in cerebrospinal-fluid pressure to normal within 2 days, noted by Bass & Caplan, would also seem to favour this interpretation.

It is not clear how this view on the effect of vitamin A deficiency on the production of the cerebrospinal fluid can be reconciled with the reports of acute hydrocephalus in infants from the ingestion of massive doses of vitamin A. The increased intracranial pressure in these infants has also been attributed to an oversecretion of the cerebrospinal fluid by the chorioid plexuses (Marie & Sée, 1954). If the hypothesis put forward by Marie & Sée is correct, and, as has been pointed out, other possibilities

have not been excluded (Anonymous, 1955), it would seem that there is a fine balance in the amount of vitamin A required by the chorioid plexuses for their normal functioning. Any gross alteration towards hypo- or hyper-vitaminosis may be sufficient to disturb this balance, with a consequent increase in the activity of the plexuses.

From the experiments reported in this paper, and from the accounts that have appeared elsewhere of increased cerebrospinal-fluid pressures in infants and experimental animals suffering from a deficiency of vitamin A, it appears that an adequate supply of the vitamin is essential for the maintenance of normal cerebrospinal-fluid pressures. If insufficient vitamin A (or carotene) is present in the diet or if, as in the present investigation, the animal suffers from deprivation of vitamin A during its foetal development, the cerebrospinal-fluid pressure increases. There seems also to be strong evidence that a rapid reduction in the abnormal pressures can be brought about by the administration of vitamin A.

SUMMARY

1. Intraventricular cerebrospinal-fluid pressures were measured in twenty-eight hydrocephalic young rabbits. In all but four animals ventriculography was also carried out.

2. After the pressure measurement the animals were given 10,000–20,000 i.u. vitamin A acetate orally or subcutaneously.

3. The administration of the vitamin A led to a rapid fall in the cerebrospinal-fluid pressure and the fall generally continued until the pressure reached normal limits.

4. Six of the animals have survived for over 12 months and have remained in good health.

5. From these results it is suggested that the increased cerebrospinal-fluid pressure found in animals suffering from vitamin A deficiency is a direct consequence of the hypovitaminosis.

6. The findings are discussed in relation to previous observations on the relationship between hypovitaminosis A and increase of intracranial pressure.

Our thanks are due to Professor J. D. Boyd for his advice and encouragement. We wish also to express our indebtedness to Dr H. E. Daniels and Miss Jean Millar of the Statistical Laboratory, Cambridge, for the statistical analysis. Thanks are also due to Mr J. F. Crane and Miss I. Dean for technical assistance.

The investigation was supported by a grant from the Nuffield Foundation, which is gratefully acknowledged.

REFERENCES

Anonymous (1955). *Brit. med. J.* i, 715.
Bass, M. H. (1956). Personal communication.
Bass, M. H. & Caplan, J. (1955). *J. Pediat.* 47, 690.
Cornfeld, D. & Cooke, R. E. (1952). *Pediatrics, Springfield*, 10, 33.
Eveleth, D. F., Bolin, D. W. & Goldsby, A. I. (1949). *Amer. J. vet. Res.* 10, 250.

Hart, E. B., Miller, W. S. & McCollum, E. V. (1916). *J. biol. Chem.* **25**, 239.
Helmboldt, C. F., Jungherr, E. L., Eaton, H. D. & Moore, L. A. (1953). *Amer. J. vet. Res.* **14**, 343.
Lamming, G. E., Woollam, D. H. M. & Millen, J. W. (1954). *Brit. J. Nutr.* **8**, 363.
Marie, J. & Sée, G. (1954). *Amer. J. Dis. Child.* **87**, 731.
Mellanby, E. (1938–9). *J. Physiol.* **94**, 380.
Mellanby, E. (1940–1). *J. Physiol.* **99**, 467.
Millen, J. W. & Woollam, D. H. M. (1956). *J. Neurol. Psychiat.* **19**, 17.
Millen, J. W., Woollam, D. H. M. & Lamming, G. E. (1954). *Lancet*, **267**, 679.
Moore, L. A. & Sykes, J. F. (1940). *Amer. J. Physiol.* **130**, 684.
Sorensen, D. K., Kowalczyk, T. & Hentges, J. F. Jr. (1954). *Amer. J. vet. Res.* **15**, 258.
Wolbach, S. B. & Bessey, O. A. (1941). *Arch. Path.* (*Lab. Med.*) **32**, 689.
Woollam, D. H. M. & Millen, J. W. (1956). *Brit. J. Nutr.* **10**, 355.

Nature 209:910-911. 1966.

Misra-'66
Bib. No. 6219

Reproduced by permission of the copyright owner

Lipid Metabolism in Hypervitaminosis A

SINCE the report of Moore and Wang[1] on hypervitaminosis A in rats, it is now recognized that administration of excessive doses of vitamin A influences the general metabolism of the host. Ray and Sadhu[2] reported that administration of large doses of vitamin A to rats caused an increase in liver fat. March and Biely[3], and Wood[4] reported that administration of vitamin A to young chickens lowered the elevated plasma cholesterol which resulted from the inclusion of 1 per cent cholesterol in their diet. Kinley and Krause[5] also reported the hypocholesteraemic action of vitamin A in atherosclerotic patients. Pallotatta and Krause[6] reported that administration of vitamin A elevated serum phospholipids. Van Bruggen and Straumfjord[7], on the other hand, observed that long-term administration of large doses of vitamin A to patients

raised their plasma cholesterol and phospholipid levels. Misra[8] observed that administration of excessive doses of vitamin A to rats lowered their plasma cholesterol and raised phospholipid-levels. This communication describes the results obtained on the tissue lipids of rats given excessive doses of vitamin A.

Male Wistar albino rats weighing 145–150 g were divided into two groups of six each and were kept on stock diet and water *ad libitum*. To one group 10^5 I.U. of retinol (Prepalin, Glaxo Ltd., India) were given intramuscularly daily for ten days. Rats without retinol were the control. A daily record of their food consumption and a weekly record of their body-weight were maintained. On the tenth day rats in both groups were intraperitoneally given a saline solution of $NaH_2{}^{32}PO_4$ (100 μc./100 g body-weight). After 6 h, rats were killed by decapitation, and liver, kidney, small intestine (about 30 cm), brain and heart tissues were quickly removed, cleaned, weighed and transferred to a volume of chloroform : methanol (2 : 1, v/v) for lipid extraction. Intestine was rinsed thrice with ice-cold saline before lipid extraction. Blood was drawn before killing the animals for vitamin A assay in plasma by the method of Bessey *et al.*[9]. Lipids from the tissues were extracted according to the method of Folch *et al.*[10], and dissolved in 5 ml. chloroform. Weights of the tissue lipids were determined by weighing an aliquot to a constant weight. Lipid extracts of the tissues were analysed for cholesterol[11] and phosphorus[12]. ^{32}P activity of lipid solutions was determined in a window-less gasflow counter.

No difference was observed in the daily food consumption and body-weights of the rats in both groups at the time of death. Vitamin A values in plasma were: control, 60–80 I.U.; experimental, 600–800 I.U. per 100 ml. plasma. Rats given excessive doses of vitamin A showed rawness of the skin, epilation, bleeding around the nose and bent and limping posture. Effect of hypervitaminosis A on tissue lipids of rats is shown in Table 1. Total lipids of liver, intestine, and brain showed a significant increase and kidney lipids a marked decrease in rats given excessive doses of vitamin A than the control group. Administration of large doses of vitamin A also caused significant elevations in the cholesterol levels of liver, kidney, intestine, and brain tissues as compared with the control group. Hypervitaminosis A did not affect phospholipid phosphorus levels and their specific activities of the above tissues except kidney where a marked increase in its phospholipid specific activity is noted (Table 1). Heart tissue lipids, cholesterol, and phospholipid phosphorus were not significantly affected in hypervitaminosis A.

Table 1. EFFECT OF HYPERVITAMINOSIS A ON TISSUE LIPIDS OF RAT

Tissues	Lipids (mg/g wet wt.)		Cholesterol (mg/g wet wt.)		Phospholipid phosphorus (mg/g wet wt.)		Sp. act. (counts/min/μg P)	
	Cont.	Exp.	Cont.	Exp.	Cont.	Exp.	Cont.	Exp.
Liver	37·0 ± 0·47	46·7 ± 1·29	1·78 ± 0·04	3·81 ± 0·05	0·77 ± 0·01	0·80 ± 0·02	109·7 ± 3·8	113·7 ± 3·9
	$P < 0·01$		$P < 0·001$		$P > 0·20$		$P > 0·40$	
Kidney	54·7 ± 2·34	35·7 ± 1·51	2·46 ± 0·21	3·44 ± 0·43	0·60 ± 0·05	0·64 ± 0·03	63·5 ± 1·3	83·4 ± 2·4
	$P < 0·01$		$P < 0·05$		$P > 0·40$		$P < 0·01$	
Intestine	39·7 ± 2·34	47·7 ± 1·47	1·65 ± 0·10	3·74 ± 0·14	0·34 ± 0·02	0·32 ± 0·01	74·3 ± 3·6	69·7 ± 4·1
	$P < 0·01$		$P < 0·001$		$P > 0·50$		$P > 0·40$	
Brain	53·5 ± 0·70	69·3 ± 2·19	11·74 ± 0·76	14·10 ± 0·67	1·31 ± 0·10	1·43 ± 0·13	3·7 ± 0·5	2·5 ± 0·4
	$P < 0·01$		$P < 0·05$		$P > 0·40$		$P > 0·05$	
Heart	33·9 ± 1·45	36·1 ± 2·83	1·46 ± 0·04	1·46 ± 0·11	0·82 ± 0·01	0·77 ± 0·02	5·3 ± 0·3	5·0 ± 0·4
	$P > 0·05$		$P > 0·80$		$P > 0·10$		$P > 0·10$	

The values are mean ± standard error of six animals.
P values < 0·05 are significant.

Reported results are in agreement with those observed by Ray and Sadhu[2]. It is difficult to arrive at any conclusion regarding the mechanism by which administration of excessive doses of vitamin A brings about the observations made on rat tissue lipids. It is also not certain whether vitamin A influences the lipid metabolism directly, or these changes result due to an indirect and unspecific reaction of vitamin A or a substance or substances derived from it.

I thank Mr. N. Srivastava for technical assistance.

U. K. MISRA

Department of Radioisotopes and Biochemistry,
V.P. Chest Institute, University of Delhi,
India.

[1] Moore, T., and Wang, Y. L., *Biochem. J.*, **39**, 222 (1945).
[2] Ray, R., and Sadhu, D. P., *Nature*, **184**, 1323 (1959).
[3] March, B. E., and Biely, J., *J. Nutrit.*, **79**, 474 (1963).
[4] Wood, J. D., *Canad. J. Biochem. Physiol.*, **40**, 530 (1962).
[5] Kinley, L. J., and Krause, R. F., *Proc. Soc. Exp. Biol. and Med.*, **102**, 353 (1959).
[6] Pallotatta, M. A., and Krause, R. F., *Amer. J. Clin. Nutrit.*, **13**, 201 (1963).
[7] Van Bruggen, J. T., and Straumfjord, J. V., *J. Lab. Clin. Med.*, **33**, 67 (1948).
[8] Misra, U. K., *Naturwissen.*, **53**, 188 (1965).
[9] Bessey, O. A., Lowry, O. H., Brock, M. J., and Lopez, J. A., *J. Biol. Chem.*, **166**, 177 (1946).
[10] Folch, J., Lees, M., and Sloane-Stanley, G. H., *J. Biol. Chem.*, **226**, 497 (1957).
[11] Hanel, H. K., and Dam, H., *Acta Chem. Scand.*, **9**, 677 (1955).
[12] Bartlett, G. R., *J. Biol. Chem.*, **234**, 466 (1959).

Cand. J. of Biochem. 44:1539-1542. 1966.

Misra-'66
Bib. No. 6220

Reproduced by permission of the copyright owner

FATTY ACIDS OF BRAIN IN HYPERVITAMINOSIS A IN RATS

U. K. MISRA
Department of Radioisotopes and Biochemistry, V.P. Chest Institute, University of Delhi, Delhi, India

Received March 22, 1966

Abstract

The effect of administration of retinol (100,000 I.U. daily for 10 days) on the fatty acid composition of brain in rats has been studied. The administration of large doses of retinol to rats did not significantly affect the saturated fatty acids of brain, i.e. C 16:0, C 18:0, C 20:0, C 21:0, C 23:0, and C 24:0 as compared with untreated control. A significant increase in the concentration of brain oleic acid was found in hypervitaminotic A rats (27.9 ± 1.74%) as compared with the untreated controls (22.0 ± 2.70%). The concentrations of polyunsaturated fatty acids, i.e. C 20:4 and 22:6 were significantly reduced in hypervitaminotic A rats as compared with untreated controls.

The toxic effects of administration of large doses of vitamin A (retinol) were reported by Moore and Wang (1). An increase in liver fat in rats given large doses of retinol was observed by Ray and Sadhu (2) and Misra (3). The hypocholesteremic effect of vitamin A has been reported in chickens (4, 5) and humans (6). Administration of large doses of vitamin A to rats caused an elevation in the liver fatty acids and increased the incorporation of acetate-1-^{14}C into small intestine fatty acids (7). These relationships between administration of retinol and lipid metabolism led us to study the effect of administration of large doses of retinol on the composition of fatty acids in the brain of rats. A significant increase in the concentration of oleic acid was observed in hypervitaminotic A rats. Hypervitaminosis A also resulted in significant lowering of the polyunsaturated fatty acids of brain, i.e. 20:4, 22:4, and 22:6.

Methods and Materials

Male albino rats (Wistar strain) weighing 145–150 g were divided into two groups of six each and maintained on stock diet and water ad libitum. One group was given 100,000 I.U. of retinol (Prepalin, Glaxo Ltd., India) intramuscularly daily for 10 days. Rats that were not given retinol were used as the control. Daily records of food consumption and weekly records of body weights were made. On the 10th day, rats in both groups were decapitated and their brains were quickly removed, wiped, weighed, and transferred to a volume of chloroform : methanol (2:1, v/v). The lipids from brain were extracted and purified as described earlier (8). Before the rats were killed, blood was withdrawn by heart puncture into heparinized tubes, for vitamin A assay in plasma (9). The brain lipid extract in chloroform was analyzed for total lipids (gravimetrically) and total cholesterol (10). The fatty acid methyl esters of total brain lipids were prepared according to Misra and Turner (11). The fatty acid methyl esters were analyzed in a Pye Argon gas chromatograph with ^{90}Sr

detector in glass columns (5 mm × 1.524 m) packed with polyethylene glycol adipate (10%) under an argon pressure of 1054 g/cm². The identification of brain fatty acids was done by comparing their retention time with N.I.H. standard fatty acid mixtures analyzed under similar conditions. The area under each peak was measured as described earlier (11).

Results and Discussion

Retinol values in the plasma of control rats were 18–24 μg per 100 ml and of rats given excessive doses of retinol were 180–240 μg per 100 ml. No difference was observed in the daily food consumption and body weights of the rats in both groups at the time of killing. Rats given excessive doses of vitamin A showed rawness of the skin, epilation, bleeding around the nose, and bent and limping posture. A significant elevation of total brain lipids (66.3 ± 2.19 mg/g wet weight) was observed in rats given large doses of retinol as compared with controls (53.5 ± 0.70 mg/g wet weight). Similarly, the brain cholesterol also increased significantly (14.10 ± 0.67 mg/g wet weight) in rats given large doses of retinol as compared with the control group values (11.74 ± 0.76 mg/g wet weight). The percentage composition of brain fatty acids in the control and hypervitaminotic A rats is shown in Table I, and their typical distribution

TABLE I

The effect of administration of large doses of retinol on the fatty acid composition of brain lipids

Fatty acids	Control	Hypervitaminotic A
14:0	—†	—
15:0	—	—
16:0	24.2±5.65	26.6±2.20
16:1	Trace‡	1.8±0.95
17:0	Trace	Trace
18:0	18.0±1.65	23.2±0.45
18:1	22.0±2.70	27.9±1.74§
18:2	Trace	0.3±0.02
Un*	Trace	Trace
18:3	Trace	Trace
20:0	1.0±0.70	2.1±0.38
Un	Trace	Trace
21:0	5.7±1.00	7.9±0.64
20:4	1.5±0.10	Trace
Un	Trace	Trace
22:0	Trace	Trace
23:0	1.0±0.20	5.8±3.32
22:4	2.5±0.49	0.3±0.01§
22:5	Trace	—
24:0	4.1±0.81	6.9±2.18
22:6	10.3±5.25	—

*Un = Unidentified.
†Absent.
‡Below 0.1%.
§p value <0.05.
NOTE: The results are expressed as percentage of total fatty acid methyl esters. Each figure is the mean ± S.E. of three values (brains from six animals pooled in pairs); p values <0.05 are significant.

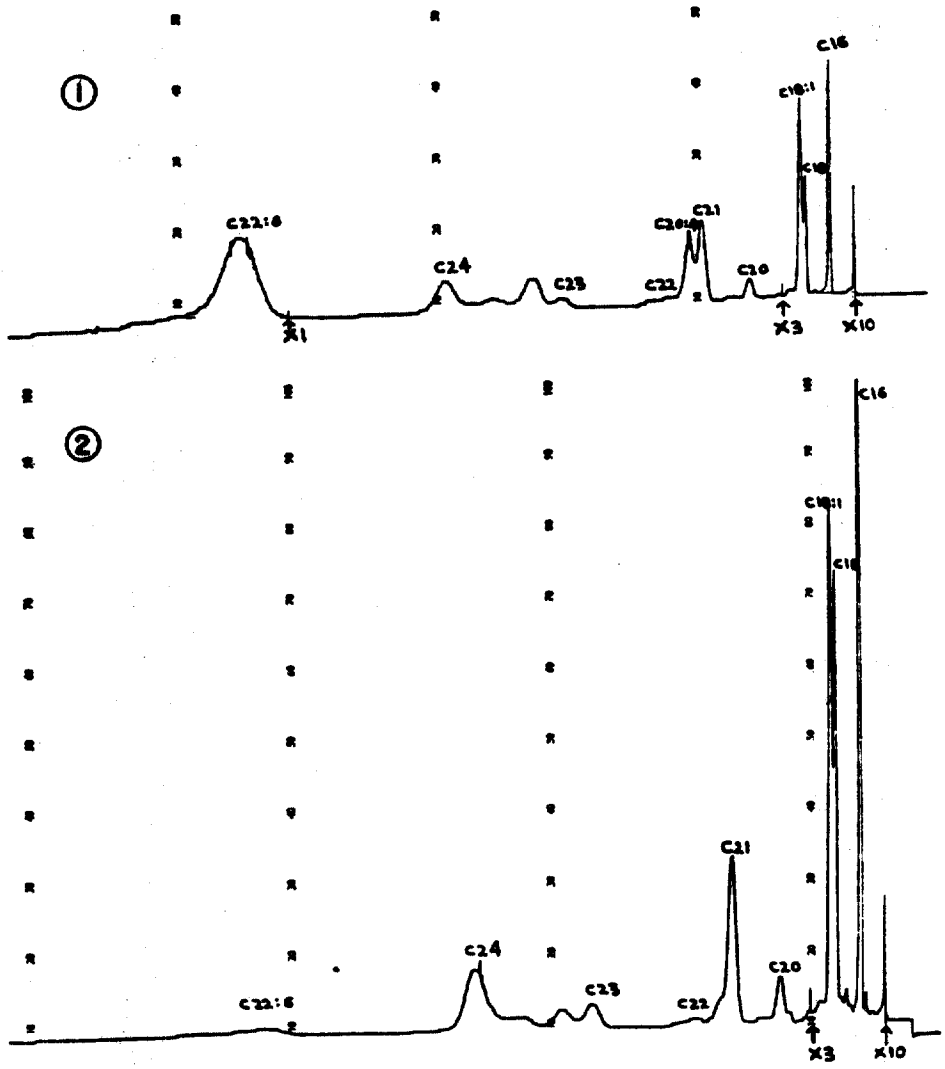

FIG. 1. A typical gas–liquid chromatogram of brain fatty acids of untreated control rats. The numbers at the top of each peak represent the carbon chain length of the fatty acid methyl esters. The numbers below the base line of the chromatogram represent the sensitivity controls of the recorder.

FIG. 2. Same as in Fig. 1, but representing a typical gas–liquid chromatogram of brain fatty acids of hypervitaminotic A rats.

patterns as obtained by gas–liquid chromatographic analysis are shown in Figs. 1 and 2. The results show that administration of large doses of retinol does not significantly affect the amounts of brain palmitic and stearic acids. A significant elevation ($p < 0.05$) in the concentration of oleic acid is noticed in rats given excessive amounts of retinol as compared with controls (Table I).

The concentrations of 20:4 and 22:4 fatty acids in hypervitaminotic A rats is significantly reduced and 22:6 is practically absent as compared with the controls (Table I). Mohrhaner and Holman (12) have reported that the concentration of 20:4 and 22:4 in tissue lipid may be used as a parameter to determine the linoleate content of the diet. Dietary linoleate may contribute to the increase in the arachidonate concentration in brain lipids either by being transported into brain and then converted by enzyme systems of the brain into 20:4, or by synthesis taking place in other organs and arachidonate then being transported (12). The results (Table I) on the fatty acid composition of brain in experimental hypervitaminosis A in rats show that large doses of retinol interfere in the synthesis or transport of polyunsaturated fatty acids, i.e. 20:4, 22:4, and 22:6.

Acknowledgments

Thanks are given to Dr. T. A. Venkitasubramanian for discussions. The technical assistance of Mr. N. Srivastava is acknowledged.

References

1. T. Moore and Y. L. Wang. Biochem. J. **39**, 222 (1945).
2. R. Ray and D. P. Sadhu, Nature, **184**, 1323 (1959).
3. U. K. Misra, Nature, **209**, 910 (1966).
4. B. E. March and J. Biely. J. Nutr. **79**, 474 (1963).
5. J. D. Wood. Can. J. Biochem. Physiol. **40**, 530 (1962).
6. L. J. Kinley and R. F. Kranse. Proc. Soc. Exptl. Biol. Med. **102**, 353 (1960).
7. U. K. Misra. Can. J. Biochem. **43**, 1885 (1965).
8. R. Misra, U. K. Misra, and T. A. Venkitasubramanian. Nature, **207**, 869 (1965).
9. O. A. Bessey, O. H. Lowry, M. J. Brock, and J. A. Lopez. J. Biol. Chem. **166**, 177 (1946).
10. H. K. Hanel and H. Dam. Acta Chem. Scand. **9**, 677 (1955).
11. U. K. Misra and D. A. Turner. Can. J. Biochem. **42**, 309 (1964).
12. H. Mohrhaner and R. T. Holman. J. Neurochem. **10**, 523 (1963).

Canad. J. of Biochem. 45:1414-1418. 1967.

Misra-'67
Bib. No. 6221

Reproduced by permission
of the copyright owner

EFFECT OF HYPERVITAMINOSIS A ON INTESTINAL LIPIDS OF RATS

U. K. MISRA
Department of Radioisotopes and Biochemistry, V.P. Chest Institute, University of Delhi, Delhi, India

Received December 16, 1966[1]

The effect of intramuscular administration of retinol (100,000 I.U. daily for 13 days) on intestinal lipids of young rats has been studied. The administration of toxic doses of retinol significantly increased the total lipids of intestine as compared with the control. A significant increase in intestinal monoglycerides, and in phosphatidic acid and polyglycerol phosphatide (present in the phospholipid fraction eluted from a silicic acid column with 5% methanolic chloroform) was observed in the hypervitaminotic A rats. There was no significant difference in the daily food consumption and body weight between the hypervitaminotic A and control rats at the time of sacrifice.

The effect of administration of toxic doses of retinol on tissue and plasma lipid metabolism in animals and humans has been reported by several workers (1–14). Ray and Sadhu (2) reported that administration of large doses of vitamin A to rats caused an increase in liver fat. Misra (8) reported that large doses of retinol caused an increase in the total lipids and total cholesterol in the liver and intestine of rats without any change in the phospholipid concentration. It has also been reported that toxic doses of retinol caused a significantly increased incorporation of acetate-1-^{14}C into intestinal fatty acids, although the amounts of intestinal fatty acids were not affected (12). The hypercholesteremic effect of vitamin A has been reported by March and Biely (4) and Wood (5). Wood (5) suggested that the hypocholesteremic activity of vitamin A occurs before or during the absorption of cholesterol through the intestinal wall. However, no detailed study has been carried out on the effect of large doses of retinol on neutral lipids and phospholipids in the small intestine of rats. This paper describes the effect of administration of retinol (100,000 I.U. daily for 13 days) on the intestinal lipids of rats.

Material and Methods

Young male rats (Wistar strain, 35–40 days old, weighing 40–50 g) were used in this study. They were housed in separate cages, and were fed stock diet and water ad libitum.

Prepalin (Glaxo Laboratories, Private Ltd., India), a vitamin A alcohol concentrate, was used as a source of retinol.

The rats were divided in two groups of six each. To one group, 100,000 I.U. of retinol was given intramuscularly each day for 13 days. Control animals received no vitamin A injections. Rats in both groups were fed stock diet, and daily records of their food consumption and biweekly records of their body weights were made. On the 13th day, rats in both groups were sacrificed

[1]Revised manuscript received February 27, 1967.

by decapitation and a portion of the small intestine (about the upper 30 cm) was quickly removed. The intestine was quickly transferred to ice-cold saline, rinsed three times with ice-cold saline, blotted on filter paper, and homogenized in 5 volumes of chloroform–methanol (2:1 v/v). Five more volumes of chloroform–methanol (2:1, v/v) was added to the homogenate, and lipids from the homogenate were extracted and purified as described in an earlier report (15). The final dried lipid residue was dissolved in 10 ml of hexane, and stored in glass-stoppered tubes under nitrogen at −8 °C.

Analysis

The total lipids in the intestine were estimated gravimetrically. Total cholesterol was estimated by the method of Hanel and Dam (16). Esterified and free cholesterol were estimated by a modification of the method of Sperry and Webb (17). The dried dignitonin–cholesterol complex was dissolved in 0.5 ml glacial acetic acid, followed by 1.5 ml chloroform, and the color development carried out according to the method of Hanel and Dam (16). Phospholipid phosphorus was estimated by the Bartlett method (18), as modified by Marinetti (19). Free fatty acids were estimated by Dole's method (20), and glyceride glycerol by the method of Van Handel and Zilversmit (21). Amino nitrogen was assayed by the method of Lea and Rhodes (22).

Solvents

All solvents used in this study were of reagent grade and were redistilled before use. Ether and hexane were dried over metallic sodium wires.

Silicic Acid Column Chromatography

The fractionation of intestinal lipids into individual neutral lipids and phospholipids was done by means of silicic acid (Mallinckrodt, 100–200 mesh) column chromatography. The conditions of column chromatography were essentially the same as described earlier (23). The volume and composition of the eluting solvents are given in Table I. Individual lipid peaks from the silicic acid columns were pooled separately, evaporated to dryness *in vacuo* at 45°, and the dried lipid residues dissolved in 5 ml chloroform. All the lipid solutions were stored in glass-stoppered tubes under nitrogen at −8°. The lipid fractions (1.0 ml) were analyzed gravimetrically for total lipid content. Cholesterol (16), glyceride glycerol (21), free fatty acids (20), and phosphorus (19) were assayed in the appropriate lipid fractions.

Identification of Lipid Fractions

The neutral lipid and phospholipid fractions, separated from silicic acid columns, were identified on silica gel G coated glass plates. The plates with the neutral lipid fractions were developed in hexane (b.p. 65–70°) – ether – glacial acetic acid (90:10:1, v/v/v) for 40 min (15 cm) and the components located by exposing the dried plates to I_2 vapors (24). Authentic standards of neutral lipids were co-chromatographed with each mixture. The plates with the phospholipid fractions were developed in chloroform – methanol – 7 *M*

TABLE I

Solvent systems used for eluting intestinal lipids (50 mg) from a 10 g silicic acid column

Solvent composition	Volume (ml)	Fraction eluted
100% hexane	100	Hydrocarbon
1.5% ether in hexane	150	Esterified cholesterol
4.0% ether in hexane	225	Triglycerides
8.0% ether in hexane	150	Free fatty acids
15.0% ether in hexane	300	Free cholesterol
30.0% ether in hexane	200	Diglycerides
100% ether	200	Monoglycerides
5.0% methanol in chloroform	150	Phosphatidic acid + polyglycerol phosphatide
15.0% methanol in chloroform	250	Phosphatidyl ethanolamine
25.0% methanol in chloroform	150	Phosphatidyl serine + phosphatidyl inositol + lysophosphatidyl ethanolamine
40.0% methanol in chloroform	350	Phosphatidyl choline
70.0% methanol in chloroform	150	Sphingomyelin
100% methanol	150	Lysophosphatidyl choline

ammonium hydroxide (115:45:7.5 v/v/v) for 60 min (15 cm) and the spots located by exposing the dried plates to I_2 vapors, or by spraying with a 0.4% solution of ninhydrin in acetone, with molybdenum blue reagent, or with Dragendorff reagent (24, 25). Authentic standards of neutral lipids and phospholipids (purchased from Sigma Chemical Co., St. Louis, Missouri) were co-chromatographed with each mixture.

The phospholipids were also chromatographed on silicic acid impregnated paper, according to Marinetti *et al.* (19), and identified by their staining characteristics and by comparing their R_f values with those of authentic phospholipid standards co-chromatographed with the mixture (26).

The intestinal phospholipid fractions were deacylated and the hydrolysates chromatographed according to the method of Dawson (27). The glyceryl phosphoryl esters were identified by dipping the developed chromatogram in Hanes–Isherwood reagent (28) as modified by Burrow's *et al.* (29), and comparing their R_f values with those authentic phospholipid standards treated similarly.

Results and Discussion

The effect of intramuscular administration of retinol (100,000 I.U. daily for 13 days) on the body weight and daily food consumption of rats is shown in Table II. The results show that there was no significant difference in the daily food consumption and body weight between hypervitaminosis A and control rats at the time of death (Table II). The amount of retinol in the livers of control and retinol-treated rats were 27.54 ± 7.631 and 893.61 ± 86.913 μg/g, respectively. Though the rats given excessive amounts of retinol intramuscularly did show toxicity symptoms (e.g. rawness of skin, epilation, bleeding around the nose, and bent and limping posture) 5–6 days after the treatment, these symptoms were not as severe as those reported by Moore and Wang (30). The rats in the present study did not show any loss in body weight

TABLE II

Effect of administration of excessive doses of retinol on the daily food consumption and body weight of young rats

Animals	Body weights (g)		Average food consumption (g/day per rat)
	Initial	Final	
Control	41.8±2.54	62.1±3.51	8.3±0.61
Hypervitaminotic A	47.6±3.70	61.6±4.58	8.1±0.55

NOTE: Each value is the mean ± S.E. of six animals in each group.

and daily food intake (Table II). These differences in the degree of toxicity could have been due to the method of retinal administration, oral versus intramuscular (Moore and Wang).

The effect of large doses of retinol on intestinal lipids, cholesterol, glycerides, and phospholipids is shown in Table III. Glycerides (tri-, di-, and monoglycerides) were not affected significantly in hypervitaminotic A animals. Total phospholipids were not significantly increased in hypervitaminotic A rats. A significant increase in the total intestinal lipids was observed in hypervitaminotic A rats (Table III). Total cholesterol before saponification, showed a significant increase in hypervitaminotic A rats, but cholesterol values obtained after saponification were not significantly different from those of control (Table III). Higher values of cholesterol in intestinal unsaponified lipids were due to the presence of retinol which also gives color with Hanel–Dam reagents, having an absorption maximum at 385 mμ. Because of this interference, significantly higher values of cholesterol were reported in the intestine of hypervitaminotic A rats (8).

The elution pattern of intestinal neutral lipids and phospholipids was reproducible for both control and hypervitaminotic A rats, under the experimental conditions used. The recoveries of applied lipid, cholesterol, and phospholipid phosphorus from the silicic acid columns were between 97 and 102%. From chemical analysis and by thin-layer chromatography of the appropriate lipid fractions, the neutral lipids eluted from silicic acid columns have been identified as cholesterol esters, triglycerides, free fatty acids, free cholesterol, diglycerides, and

TABLE III

Effect of intramuscular administration of retinol (100,000 I.U. daily for 13 days) on the lipids of young rats

Animals	Lipids	Cholesterol	Glycerides	Phospholipids
Control	22.6±1.34*	a. 2.310±0.17** b. (2.309±0.21)	3.387±0.51	13.961±0.85
Hyper-vitaminotic A	28.1±2.01	a. 4.340±0.17 b. 2.912±0.45	3.997±0.31	17.501±1.93

*$p < 0.05$.
**$p < 0.01$.
NOTE: Each value is the mean ± S.E. of six animals and is expressed as mg/g wet tissue weight. (a) Before saponification, (b) after saponification. p values less than 0.05 are considered significant.

TABLE IV

Effect of intramuscular administration of retinol (100,000 I.U. daily for 13 days) on the percentage composition of rat intestinal lipid constituents

Lipids	Control	Hypervitaminotic A
Esterified cholesterol	0.51±0.08	0.49±0.00
Triglycerides	21.59±4.57	17.98±0.54
Free fatty acids	4.68±0.94	3.06±1.19
Free cholesterol	6.89±1.52	6.93±1.19
Diglycerides	2.26±0.94	2.58±1.86
Monoglycerides	1.15±0.21	4.19±1.08*
Phosphatidic acid + polyglycero phosphatide	1.86±0.36	4.76±0.79**
Phosphatidyl ethanolamine	18.54±0.77	15.54±1.69
Phosphatidyl serine + phosphatidyl inositol + lysophosphatidyl ethanolamine	7.66±1.94	6.00±0.815
Phosphatidyl choline	29.11±7.45	31.14±4.39
Sphingomyelin	3.93±0.50	5.23±0.58
Lysophosphatidyl choline	1.77±0.72	1.69±0.85

*$p < 0.05$.
**$p < 0.001$.
NOTE: Each value is the mean ± S.E. of three animals (six animals paired in three groups); p values less than 0.05 are considered significant.

monoglycerides. Similarly, the phospholipids eluted from silicic acid columns have been identified as phosphatidic acid, polyglycerol phosphatide, phosphatidyl ethanolamine, phosphatidyl serine, lysophosphatidyl ethanolamine, phosphatidyl inositol, phosphatidyl choline, sphingomyelin, and lysophosphatidyl choline.

The administration of toxic doses of retinol did not influence the amounts of intestinal neutral lipids and phospholipids except monoglycerides, and phosphatidic acid plus polyglycerol phosphatide (present in the phospholipid fraction eluted with 5% chloroform in methanol from silicic acid column), which showed significant elevations in their amounts as compared with those of the control rats (Table IV). The increase in intestinal monoglycerides observed in rats given excessive doses of retinol could possibly be due to lipolysis of triglycerides in the intestine during absorption and then the interference in its re-esterification process during transport to liver (31). This interference in the esterification of monoglycerides to triglycerides may be due either to the non-availability of fatty acids, which are preferentially utilized for the esterification of retinol to retinyl ester for transport to the liver (32), or in the inhibition of the conversion of monoglycerides to triglycerides (33). The former possibility seems more likely since it has been observed that intestinal fatty acids show an increased turnover in hypervitaminotic A rats (8).

The administration of retinol did not influence the percentage distribution of total phospholipids in intestine, but the phosphatidic acid plus polyglycerol phosphatide content increased significantly ($p \angle 0.05$) as compared with the control rats (Table IV). This increase in the amounts of phosphatidic acid plus polyglycerol phosphatide in retinol-treated rats is not clearly understood. It

could arise either in their increased synthesis or decreased utilization for the conversion into other phospholipids under the influence of retinol.

Acknowledgment

The skilled technical assistance of Mr. N. Srivastava is gratefully acknowledged.

References

1. J. T. VAN BRUGGEN and J. V. STRAMFJORD. J. Lab. Clin. Med. **33**, 67 (1948).
2. A. RAY and D. P. SADHU. Nature, **184**, 1323 (1959).
3. L. J. KINLEY and R. F. KRAUSE. Proc. Soc. Exptl. Biol. Med. **102**, 353 (1959).
4. B. E. MARCH and J. BIELY. J. Nutr. **79**, 474 (1963).
5. J. D. WOOD. Can. J. Biochem. Physiol. **40**, 530 (1962).
6. M. A. POLLOTATTA and R. F. KRAUSE. Am. J. Clin. Nutr. **13**, 201 (1963).
7. U. K. MISRA. Biochem. J. **95**, 30 (1965).
8. U. K. MISRA. Nature, **209**, 910 (1966).
9. U. K. MISRA. Naturwissenschaften, **52**, 188 (1965).
10. U. K. MISRA. Naturwissenschaften, **52**, 306 (1965).
11. U. K. MISRA. Proc. Nutr. Soc. Engl. Scot. **24**, 16 (1965).
12. U. K. MISRA. Can. J. Biochem. **43**, 1885 (1965).
13. U. K. MISRA. Can. J. Biochem. **44**, 1539 (1966).
14. R. L. CRUESS and I. CLARK. Biochem. J. **96**, 262 (1965).
15. R. MISRA, U. K. MISRA, and T. A. VENKITASUBRAMANIAN. Nature, **207**, 869 (1965).
16. H. K. HANEL and H. DAM. Acta Chem. Scand. **9**, 677 (1955).
17. W. M. SPERRY and M. WEBB. J. Biol. Chem. **187**, 97 (1950).
18. G. R. BARTLETT. J. Biol. Chem. **234**, 466 (1959).
19. G. V. MARINETTI. J. Lipid Res. **3**, 1 (1962).
20. V. P. DOLE. J. Clin. Invest. **35**, 150 (1956).
21. E. VAN HANDEL and D. B. ZILVERSMIT. J. Lab. Clin. Invest. **50**, 152 (1957).
22. C. H. LEA and D. N. RHODES. Biochem. J. **56**, 613 (1954).
23. U. K. MISRA. Indian J. Biochem. **1**, 95 (1964).
24. H. K. MANGOLD. J. Am. Oil Chemists Soc. **43**, 708 (1961).
25. D. WALDI. *In* Thin layer chromatography. *Edited by* E. Stahl. Academic Press, Inc., New York. 1965. p 483.
26. U. K. MISRA. Can. J. Biochem. **43**, 711 (1965).
27. R. M. C. DAWSON. Biochem. J. **75**, 45 (1960).
28. C. S. HANES and F. A. ISHERWOOD. Nature, **164**, 1107 (1949).
29. S. BURROWS, F. S. M. GRYLLS, and J. S. HARRISON. Nature, **166**, 444 (1950).
30. T. MOORE and Y. L. WANG. Biochem. J. **39**, 222 (1945).
31. K. J. ISSELBACHER. Federation Proc. **24**, 16 (1965).
32. S. MAHADEVAN, P. MALATHI, and J. GANGULY. World Rev. Nutr. Dietet. **5**, 210 (1965).
33. B. CLARK and G. HUBCHER. Biochim. Biophys. Acta, **70**, 43 (1963).

Indian J. Biochem. 4:175-178. 1967

Misra-'67
Bib. No. 6222

Effect of Retinol Administration on Kidney Lipids of Rats

Reproduced by permission of the copyright owner

U. K. MISRA

Department of Radioisotopes & Biochemistry, Vallabhbhai Patel Chest Institute, University of Delhi, Delhi 7

Manuscript received 29 *April* 1967

The effect of intramuscular administration of 100,000 IU of retinol daily for 13 days to rats on their kidney lipids has been studied. Administration of excess retinol significantly decreases the concentration of esterified cholesterol as compared to untreated controls. The neutral lipids and phospholipids of kidney have been fractionated by thin layer chromatography. A significant increase is noted in the levels of phosphatidyl ethanolamine in rats treated with retinol as compared to untreated controls.

A RELATIONSHIP between tissue lipid metabolism and the administration of large amounts of retinol has been demonstrated from several laboratories[1-13]. A striking deposition of fat in the endothelial cells of the glomeruli of the kidney on administration of massive doses of retinol to mice[14] and rats[15] has been reported. Preliminary work from this laboratory showed that intramuscular administration of 100,000 IU of retinol to adult rats affected the kidney lipids[8,10,12]. However, except for the gross changes in kidney lipids, no detailed study has been done on the effect of administration of large doses of retinol on the individual neutral lipids and phospholipids of rat kidney. This communication describes the effects of intramuscular administration of 100,000 IU of retinol on the neutral lipid and phospholipid content of rat kidney.

Materials and Methods

Animals—Young male rats (Wistar strain), about 35-40 days old and 40-50 g. in weight, were used in this study. The rats were housed in separate cages and were fed stock diet and water *ad libitum*.

Vitamin A — Prepalin[R] (Glaxo Laboratories Private Ltd, India), a vitamin A alcohol concentrate, was used as a source of retinol. The concentration of retinol in this commercial preparation was checked by saponifying Prepalin with 30 per cent methanolic KOH (wt/vol.) and repeatedly extracting the non-saponifiable portion with hexane (b.p. 65-70°C.). The combined hexane extracts were washed with distilled water, dried over anhydrous sodium sulphate, evaporated to dryness *in vacuo* at 45°C. and dissolved in a known volume of chloroform[16]. Retinol was estimated by the antimony trichloride method. The values obtained for retinol were between 96 and 98 per cent of those given in the literature supplied with Prepalin, i.e. 100,000 IU/ml.

The rats were divided in two groups of six each. To one group of rats 100,000 IU of retinol were given intramuscularly daily for 13 days. Control rats received no retinol injections. Daily records of their food consumption and biweekly records of their body weights were maintained. On the 13th day, both groups of rats were sacrificed by decapitation, their kidneys removed quickly, cleaned, weighed and immersed immediately in a volume of chloroform-methanol (2: 1, vol./vol.) solvent mixture. The kidneys were minced with a pair of scissors and ground separately in a mortar and pestle, transferred to 10 volumes of chloroform-methanol (2: 1, vol./vol.) solvent mixture, allowed to stand at room temperature for 4 hr with occasional shaking and filtered. The residue was re-extracted with 10 more volumes of the above solvent mixture for 2 hr, filtered, and the two filtrates combined. The combined filtrates were evaporated to dryness *in vacuo* at 45-50°C. in a rotary evaporator, and the dried residue dissolved in chloroform-methanol (2: 1, vol./vol.) solvent mixture containing 4 per cent water (vol./vol.) and evaporated to dryness *in vacuo* at 45-50°C. This step was repeated twice to liberate the protein bound lipids[17]. The final dried residue was dissolved in chloroform-methanol (2: 1, vol./vol.) solvent mixture, filtered, and the filtrate treated with 20 volumes of saline (0·89 per cent) in a separatory funnel, and allowed to stand at room temperature till the two phases separated (4 hr). The lower chloroform layer was collected, evaporated to dryness *in vacuo* at 45°C., and the dried lipid residue dissolved in a known volume of chloroform.

Analyses — Total lipids of each kidney lipid extract were estimated by weighing an aliquot of the chloroform solution in a glass thimble to constant weight. Total cholesterol was assayed by saponifying each lipid extract separately with 30 per cent methanolic KOH (wt/vol.) and extracting the non-saponifiable fraction repeatedly with hexane (b.p. 65-70°C.). The hexane extracts of all kidney samples were combined separately, evaporated to dryness and cholesterol precipitated with digitonin[18]. The digitonide was recovered by centrifugation, washed thrice with acetone-ether (3: 1, vol./vol.) and dissolved in 0·5 ml. of warm glacial acetic acid, followed by the addition of 1·5 ml. of chloroform. Cholesterol was assayed in this solution by the method of Hanel and Dam[19]. Phospholipid phosphorus was assayed by the method of Bartlett[20] as modified by Marinetti[21]. Glyceride-glycerol was assayed by the method of Van Handel and Zilversmit[22].

Separation of neutral lipids and phospholipids by silicic acid column chromatography — Neutral lipids and phospholipids were first separated by silicic acid column chromatography. The activation of

Mallinckrodt silicic acid (100-200 mesh size) was done as published earlier[23]. The lipid samples in hexane solution were applied on the column and first eluted with hexane. Neutral lipids were then eluted with chloroform and phospholipids with methanol. The chloroform and methanol eluates were evaporated to dryness separately *in vacuo* at 45°C. and dissolved in a known volume of chloroform, and used immediately for thin layer chromatographic separation of individual lipids.

Separation of individual lipids by thin layer chromatography — The neutral lipids and phospholipids were separated into individual lipid components by thin layer chromatography. The glass plates (20×20 cm.) were coated (250 μ thickness) with E. Merck silica gel G according to Abramson and Blecher[24]. A slurry of 30 g. silica gel was made in 63 ml. of freshly prepared 0·01*M* sodium carbonate solution, shaken vigorously and applied on glass plates by means of a spreader devised by Shandon Scientific Co. Ltd. London. The dried plates were activated for 90 min. at 110°C. and cooled in a sealed chamber.

Neutral lipids (2-3 mg.) were applied in streaks in duplicate and developed in hexane (b.p. 65-70°C.)-diethyl ether-glacial acetic acid (90:10:1, vol./vol.) solvent mixture. The solvent was allowed to run for a distance of 15 cm. from the baseline. Authentic standards of cholesterol esters, cholesterol, tristearin and palmitic acid were cochromatographed with each run. The relative R_f values of diglycerides and monoglycerides, whose standards were not available, were compared with those reported in the literature. The lipid spots on dried plates were located by exposing them to iodine vapours. The spots on the gel corresponding to authentic standards were scraped out into 15 ml. tubes and extracted from the gel with four successive 5 ml. portions of hexane (b.p. 65-70°C.)-diethyl ether (1:1, vol./vol.). All the extracts recovered by centrifugation were pooled separately, evaporated to dryness and the respective fractions analysed for cholesterol and glyceride-glycerol. The recoveries of the applied cholesterol and glyceride-glycerol were between 90 and 96 per cent. Suitable aliquots of blank silica gel from the plates were treated similarly and appropriate corrections made in cholesterol and glyceride-glycerol values. Free fatty acids were not estimated.

Phospholipids (40-45 μg. lipid phosphorus) were applied on the activated plates in duplicate, and the plates developed in chloroform-methanol-7*M* ammonia (115:45:7·5, vol./vol.) solvent mixture. The solvent was allowed to move a distance of 15 cm. from the baseline. Authentic standards of phospholipids, viz. phosphatidyl ethanolamine, phosphatidyl choline, sphingomyelin, lysophosphatidyl choline, lysophosphatidyl ethanolamine and polyglycerol phosphatide, were cochromatographed with each run. The relative R_f values of phospholipids, viz. phosphatidyl inositol, phosphatidyl serine and phosphatidic acid, whose authentic standards were not available, were compared with those reported in the literature. The phospholipid spots on the plates were located by (i) exposing them to iodine vapours, (ii) ninhydrin spray (0·4 per cent, vol./vol.) in acetone and (iii) molybdenum blue spray[23]. The spots corresponding to authentic phospholipid standards were scraped out into 15 ml. tubes and phospholipids extracted with four successive 5 ml. portions of 1*N* methanol HCl at 60°C. All the phospholipid extracts, recovered by centrifugation, were pooled separately, evaporated to dryness and assayed for phosphorus. The plasmalogen phospholipid phosphorus was not estimated. Suitable aliquots of blank silica gel G portions from the plates were treated similarly and appropriate correction made in phospholipid values. The recoveries of applied phospholipid phosphorus were between 96 and 98 per cent.

Results and Discussion

The results presented in Table 1 indicate the effect of intramuscular administration of 100,000 IU of retinol daily for 13 days on body weight, kidney weight and daily food consumption of rats. A significant difference was noted in the kidney weight of the rats given excess retinol as compared to untreated controls. The daily food consumption and body weights of the retinol treated rats at the time of sacrifice were not significantly different from those of the control group rats. The amount of retinol in livers of control and retinol treated rats were 27·54±7·631 and 893·6±86·913 μg./g. wet tissue weight respectively. Though the rats given excessive doses of retinol did show retinol toxicity symptoms such as rawness of skin, epilation, bleeding around the nose, and a bent and limping posture 5-6 days after treatment, these symptoms after 13 days

TABLE 1 — EFFECT OF INTRAMUSCULAR ADMINISTRATION OF 100,000 IU OF RETINOL DAILY FOR 13 DAYS ON BODY WEIGHT, DAILY FOOD CONSUMPTION, KIDNEY WEIGHT AND KIDNEY LIPIDS OF RATS

(Results are expressed as mean ± SE from six animals in each group. *P* values<0·05 are considered significant)

	Control	Retinol treated
Body wt, g.		
Initial	41·8±2·59	47·6±1·70
Final	62·1±3·51	61·6±4·58
Daily food consumption, g. day/rat	8·3±0·61	8·1±0·55
Tissue wt, g.	0·61±0·011	0·81±0·031*
Total lipids, mg./g. wet tissue wt	47·5±4·78	49·9±2·24
Cholesterol, mg./g. wet tissue wt		
Total	4·44±0·334	4·38±0·385
Esterified	0·91±0·136	0·36±0·090†
Free	3·53±0·258	4·03±0·142
Glycerides‡, mg./g. wet tissue wt	19·77±2·653	22·76±4·462
Monoglycerides§	10·71±1·089	13·78±0·658
Diglycerides§	20·80±2·082	24·13±1·915
Triglycerides§	68·48±3·478	61·88±2·331
Phospholipids, mg./g. wet tissue wt	23·32±1·705	22·77±3·601

*$P<0·001$. †$P<0·02$. ‡By difference. §Percentage of total glycerides.

were not as severe as those reported by Moore and Wang[26] who administered retinol orally. The rats did not show any loss in body weight and daily food consumption (Table 1). These differences in the degree of retinol toxicity may be due to the mode of administration of retinol.

Administration of excessive amounts of retinol to rats did not influence the levels of kidney total lipids, cholesterol, phospholipids and glycerides (Table 1), as compared to the control group rats. In an earlier report[12], a decrease in kidney total lipids was reported, and Domagk and Dobeneck[14] and Noetzl[15] observed a striking deposition of fat in kidney. These differences in total kidney lipids can perhaps be explained on the basis of the degree of retinol toxicity. Various factors such as age of the animals, amount of vitamin A administered and its physical form and route of administration have been shown to affect the absorption of vitamin A in animals[27]. Moore has reported decreased absorption of vitamin A in young rats when massive doses of vitamin A are given intramuscularly[27]. Lemley *et al.*[28] have shown that the efficiency of absorption of vitamin A given in oil medium by intramuscular injection was only 2 per cent of that obtained by oral administration. It has been reported recently that retinol interferes in the estimation of cholesterol by Hanel and Dam method[19] and gives higher values for cholesterol[29]. Because of this interference, significantly higher values for cholesterol were reported in the kidney of hypervitaminotic A rats[12]. Though total and free cholesterol contents of kidney are not affected by retinol administration, a significant reduction in esterified cholesterol content is noted as compared to the control group rats (Table 1). The decrease in kidney esterified cholesterol content in retinol treated rats could result either by an increased hydrolysis of esterified cholesterol or by the inhibition of the esterification of free cholesterol. A number of hypotheses have been advanced to explain the mechanism of action of retinol in cellular metabolism. Dingle and Lucy[30], Dingle *et al.*[31] and Lucy and Dingle[32] have shown in *in vitro* studies that excess vitamin A causes an increase in the permeability of erythrocyte membrane and interacts with lipoprotein membrane, thereby lowering the stability of biological membranes. The work of Bangham *et al.*[33] on the action of compounds of vitamin A series on monolayers of lecithin-cholesterol suggests that penetration of lipid monolayers and lipoprotein membranes may be an initial step in certain physiological functions of vitamin A. The administration of excess vitamin A has been reported to increase the rate of release of lysosomal enzyme[34]. It is likely that decrease observed in the concentration of cholesterol esters in the kidney of retinol treated rats (Table 1) is due to an analogous effect of retinol on kidney lysosomes.

Administration of large amounts of retinol to rats did not affect their kidney total glycerides, mono-, di- and triglycerides as compared to control group rats (Table 1). This observation, which is in variance with those reported by Domagk and Dobeneck[14] and Noetzl[15], is due to the differences in the mode of administration of retinol to rats.

TABLE 2 — EFFECT OF INTRAMUSCULAR ADMINISTRATION OF 100,000 IU of RETINOL DAILY FOR 13 DAYS ON PERCENTAGE COMPOSITION OF KIDNEY PHOSPHOLIPIDS OF RATS

(Results are expressed as mean ± SE from six animals in each group. P values < 0.05 are considered significant)

Phospholipids	Control	Retinol treated
Phosphatidyl inositol + origin	18·36 ± 3·670	16·80 ± 1·577
Phosphatidyl serine	8·36 ± 0·217	6·66 ± 0·670
Lysophosphatidyl choline	17·26 ± 1·554	16·34 ± 2·719
Lysophosphatidyl ethanolamine	12·06 ± 0·327	12·52 ± 0·342
Sphingomyelin	14·50 ± 1·115	16·04 ± 1·820
Phosphatidyl choline	16·07 ± 5·785	13·83 ± 3·942
Phosphatidyl ethanolamine	5·98 ± 0·425	9·46 ± 1·202*
Phosphatidic acid + polyglycerol phosphatide	7·54 ± 1·433	8·70 ± 1·312

*$P < 0.05$.

The results presented in Table 2 indicate the effect of administration of large doses of retinol on the kidney phospholipids of rats. Retinol administration did not affect the levels of kidney phospholipids with the exception of phosphatidyl ethanolamine which showed a significant increase ($P < 0.05$) as compared to that of control group rats. The mechanism by which retinol alters the metabolism of phosphatidyl ethanolamine is not clearly understood. The increase observed in phosphatidyl ethanolamine concentration may be due to its increased synthesis or decreased utilization in retinol treated rats.

Acknowledgement

The author is thankful to the Biochemicals Unit of this Institute for the generous gifts of the phospholipid standards used in this investigation. The technical assistance of Shri N. Srivastava is acknowledged.

References

1. RAY, R. & SADHU, D. P., *Nature, Lond.*, 184 (1959), 1323.
2. MARCH, B. E. & BIELY, J., *J. Nutr.*, 79 (1963), 474.
3. WOOD, J. D., *Can. J. Biochem. Physiol.*, 40 (1962), 530.
4. KINLEY, L. J. & KRAUSE, R. F., *Proc. Soc. Exp. Biol. Med.*, **102** (1959), 353.
5. POLLOTATTA, M. A. & KRAUSE, R. F., *Am. J. Clin. Nutr.*, **13** (1963), 201.
6. VAN BRUGGEN, J. T. & STRAUMFJORD, J. V., *J. Lab. Clin. Med.*, **33** (1948), 67.
7. CRUESS, R. L. & CLARK, I., *Biochem. J.*, **96** (1965), 262.
8. MISRA, U. K., *Biochem. J.*, **95** (1965), 30.
9. MISRA, U. K., *Naturwissenschaften*, **52** (1965), 188, 306.
10. MISRA, U. K., *Proc. Nutr. Soc.*, **24** (1965), xvi.
11. MISRA, U. K., *Can. J. Biochem.*, **43** (1965), 1885.
12. MISRA, U. K., *Nature, Lond.*, **209** (1966), 910.
13. MISRA, U. K., *Can. J. Biochem.*, **44** (1966), 1559.
14. DOMAGK, G. & DOBENECK, P. V., *Virchows Arch. Path. Anat. Physiol.*, **290** (1933), 385.
15. NOETZL, H., *Z. ges. exp. Med.*, **105** (1939), 83.
16. OLSON, J. A., *J. biol. Chem.*, **236** (1961), 349.

17. FOLCH, J., LEES, M. & SLOANE-STANLEY, G. H., *J. biol. Chem.*, **226** (1957), 497.
18. SPERRY, W. M. & WEBB, M., *J. biol. Chem.*, **187** (1950), 97.
19. HANEL, K. H. & DAM, H., *Acta chem. scand.*, **9** (1955), 677.
20. BARTLETT, G. R., *J. biol. Chem.*, **234** (1959), 466.
21. MARINETTI, G. V., *J. Lipid Res.*, **3** (1962), 1.
22. VAN HANDEL, E. & ZILVERSMIT, D. B., *J. Lab. clin. Invest.*, **50** (1957), 152.
23. MISRA, U. K., *Indian J. Biochem.*, **1** (1964), 95.
24. ABRAMSON, D. & BLECHER, M., *Biochim. biophys. Acta*, **98** (1964), 117.
25. DITTMER, J. C. & LESTER, R L., *J. Lipid. Res.*, **5** (1964), 136.
26. MOORE, T. & WANG, Y. L., *Biochem. J.*, **39** (1945), 222.
27. MOORE, T., *Vitamin A* (Elsevier Publishing Co., London), 1957, 205.
28. LEMLEY, J. M., BROWN, R. A., BIRD, D. & EMMETT, A. D., *J. Nutr.*, **33** (1947), 53.
29. SRINIVASAN, C. N. & MISRA, U. K., *Indian J. Biochem.*, **3** (1966), 256.
30. DINGLE, J. T. & LUCY, J. A., *Biochem. J.*, **84** (1962), 611.
31. DINGLE, J. T., GLAUERT, A. M., DANIEL, M. & LUCY, J. A., *Biochem. J.*, **84** (1962), 76.
32. LUCY, J. A. & DINGLE, J. T., *Biochem. J.*, **84** (1962), 76.
33. BANGHAM, A. D., DINGLE, J. T. & LUCY, J. A., *Biochem. J.*, **90** (1964), 133.
34. DINGLE, J. T., SHARMAN, I. M. & MOORE, T., *Proc. Nutr. Soc.*, **22** (1963), x.

Misra-'68
Bib. No. 6223

Canad. J. of Biochem. 46:697-701. 1968.

Reproduced by permission of the copyright owner

Liver lipids of rats administered excessive amounts of retinol

U. K. MISRA
Department of Radioisotopes and Biochemistry, V.P. Chest Institute, University of Delhi, Delhi-7, India

Received March 5, 1968

MISRA, U. K. Liver lipids of rats administered excessive amounts of retinol. Can. J. Biochem. 46, 697 (1968).

Effect of intramuscular administration of 100 000 I.U. of retinol daily for 13 days on the liver lipid metabolism of young rats was studied. Intramuscular administration of excessive amounts of retinol did not affect the body weights or the daily food consumption. Retinol-treated rats showed a significant enlargement of the liver compared with controls. The values for liver total lipids, total cholesterol, total glycerides, total fatty acids, and retinol were 59.9 ± 0.9, 2.5 ± 0.1, 24.2 ± 1.3, 27.9 ± 1.8, and 1.35 ± 0.14 mg/g wet tissue, respectively, in retinol-treated compared with control values of 37.0 ± 0.9, 1.8 ± 0.06, 9.5 ± 0.46, 17.6 ± 1.5, and 0.024 ± 0.008. The effect of excess retinol administration on liver neutral lipids and phospholipids was studied by thin-layer chromatography. Retinol administration caused significant increases in the concentrations of free cholesterol, esterified cholesterol, monoglycerides, triglycerides, lysophosphatidylcholine, phosphatidylcholine, and phosphatidylethanolamine, and significant decreases in the concentration of phosphatidylinositol.

The administration of excessive amounts of retinol to rats and mice has been shown to bring about alterations in lipid metabolism in plasma and several tissues (1–17). Liver plays a central role in the storage of retinol and in lipid metabolism. Earlier reports have shown that administration of retinol to rats either orally or by intramuscular injection causes an increase in the liver fat (8, 12, 15). However, except for the information on gross changes in liver lipids, no study has been done on the effects of administration of toxic amounts of retinol on the liver neutral lipids and phospholipids of rats. This communication describes the effects of intramuscular administration of 100 000 I.U. of retinol daily for 13 days on the liver neutral lipids and phospholipids of young rats.

Material and Methods

Animals

Male rats (Wistar strain) weighing 40–50 g and 30–35 days old, from the colony maintained at our institute, were used. They were housed in individual cages and fed a stock diet and water ad libitum.

Stock Diet

The diet consisted of 20 parts casein, 10 parts hydrogenated fat, 60 parts potato starch, 5 parts salt mixture (18), and 5 parts dried yeast powder. In addition, each rat received 4 g germinated chick-peas daily.

Retinol

Propalin (Glaxo Pvt. Ltd., India), a vitamin A alcohol concentrate, was used as the source of retinol. The concentration of retinol in this commercial preparation was checked by saponifying it with 30% methanolic KOH and estimating retinol in the nonsaponifiable fraction (extracted with hexane) by the antimony trichloride method (19). The concentration of retinol was found to be 96–98% of that mentioned in the literature supplied with it.

Treatment

Rats were divided into 2 groups of 12 each. Those in one group each received 100 000 I.U. of retinol intramuscularly daily for 13 days. Each of those in the other group (control) was injected with 1.0 ml of normal saline daily for the same period. Daily records of food consumption and triweekly records of body weights were maintained. On the 13th day, rats in both groups were killed and their livers removed quickly. The livers were cleaned, washed with ice-cold normal saline, wiped, weighed, cut into pieces with a pair of scissors, and immersed immediately in an equal volume of chloroform–methanol (2:1, v/v) for extraction of lipids (see below). Blood was drawn from the jugular vein into heparinized tubes before death. The plasma was separated by centrifugation.

Lipid Extraction

Livers from control and retinol-treated rats were ground separately with a mortar and pestle in chloroform–methanol (2:1, v/v). The slurry was transferred to 10 volumes of chloroform–methanol (2:1, v/v), and the mixture allowed to stand with occasional shaking at room temperature for 4–6 h, then filtered. The residue was re-extracted with 10 more volumes of chloroform–methanol (2:1, v/v) for 2 h at room temperature, and filtered. The two filtrates were combined, evaporated to dryness *in vacuo* at 45–50° in a rotary evaporator, the dried residue was dissolved in chloroform–methanol (2:1, v/v) solvent mixture containing 4% water (v/v), and evaporated to dryness *in vacuo* at 45–50°. This step was repeated twice to liberate the protein-bound lipids (20). The final dried residue was dissolved in chloroform–methanol (2:1, v/v), filtered, the filtrate layered with ¼ volume of normal saline in a separatory funnel, gently mixed, and allowed to stand at room temperature until the two phases separated clearly. The lower chloroform layer was collected, evaporated to dryness *in vacuo*

at 45-50°, and the dried lipid residue dissolved in a known volume of chloroform. The plasma lipids were similarly extracted and purified. Liver and plasma-lipid solutions in chloroform were stored at −8 °C until used for analysis.

Analysis

The estimation of total liver lipids was done by drying under N_2 an aliquot of the chloroform solution to constant weight in a glass thimble. Total and free cholesterol were estimated by the combined methods (21) of Sperry and Webb (22) and Hanel and Dam (23). Phospholipid phosphorus was estimated by the Bartlett method (24) as modified by Marinetti (25). Glycerides were assayed by estimating glyceride glycerol (26) and by difference (total lipids − cholesterol − phospholipids). Amino nitrogen was estimated by the method of Lea and Rhodes (27), and choline by the method of Appleton *et al.* (28). Retinol was estimated by the antimony trichloride method (29).

Separation of Liver Neutral Lipids and Phospholipids

Liver neutral lipids and phospholipids of both control and retinol-treated rats were separated by thin-layer chromatography (21, 30) and identified by comparison of their R_f values with those of authentic neutral-lipid and phospholipid standards run on the same plate. As some neutral-lipid (monoglycerides and diglycerides) and phospholipid (phosphatidylinositol, phosphatidylserine) standards were not available, they were prepared by fractionating liver lipids on silicic acid columns, as described elsewhere (21, 30). The recoveries of applied neutral lipids and phospholipids from chromatoplates were 96-99%.

For quantitative thin-layer chromatography of neutral lipids, liver-lipid samples of both control and retinol-treated rats, along with authentic neutral-lipid standards, were spotted on glass plates coated with silica gel G (250 mμ thickness). The plates were developed in the solvent system hexane (b.p. 65-70°) – diethyl ether – glacial acetic acid, of (*i*) 60:40:1 (v/v/v) and (*ii*) 90:10:1 (v/v/v) composition, in the same direction. The plates were developed first vertically for a distance of 7.5 cm from the base line in solvent system *i*, air-dried, and then developed in solvent system *ii* for a distance of 15 cm from the base line in the same direction as the first one. The plates were air-dried, and the spots located by exposure to I_2 vapor. The spots corresponding to authentic neutral-lipid standards were scraped out into 15-ml tubes and extracted with three successive 5-ml portions of hexane–ether (1:1, v/v). Suitable silica-gel blank portions from the plates were treated similarly and appropriate corrections made in respective neutral-lipid values.

Liver phospholipid samples which were prepared by silicic acid column chromatography for use as phospholipid standards in thin-layer chromatography were identified by the following procedures: (*a*) phospholipid phosphorus assay (24, 25), (*b*) amino phospholipids by the estimation of amino nitrogen (27), and (*c*) choline phospholipids by the estimation of choline (28). The glycerol, inositol, and amino acid moieties in respective phospholipid fractions were determined by the complete acid hydrolysis of phospholipid fractions with 2 *N* HCl for 48 h at 110 °C in sealed tubes. The hydrolysates were extracted with ether and evaporated to dryness *in vacuo* at 60 °C. The dried residues were dissolved in water and aliquots were chromatographed for glycerol, inositol, and amino acids (20). Glycerol (26) and phosphorus (24, 25) were estimated in other aliquots to determine the glycerol to phosphorus ratio in each phospholipid fraction. The phospholipid components were further identified by mild alkaline deacylation, and chromatography of their water-soluble esters, according to the method of Dawson (31).

For quantitative thin-layer chromatography of phospholipids, liver lipids from both control and retinol-treated rats were spotted on glass plates coated with silica gel G (250 mμ thickness) along with authentic phospholipid standards, the plates were developed, and the phospholipid spots were located by methods published earlier (30). The spots on thin-layer chromatoplates corresponding to authentic phospholipid standards were scraped off, transferred quantitatively into tubes, 3 or 4 glass beads were added to each tube, the contents were digested with 1.0 ml 60% perchloric acid, and the phosphorus determined colorimetrically (24, 25) after brief centrifugation to remove silica gel. Suitable aliquots of blank silica-gel portions from the plates were treated similarly and appropriate corrections made in the phosphorus values.

Solvents

All solvents were freshly redistilled before use. Ether and hexane were dried over metallic sodium wire.

Results

Body Weights and Food Consumption

The effect of intramuscular administration of 100 000 I.U. of retinol daily for 13 days on the body weights and daily food consumption of young rats is shown in Fig. 1 and Table I.

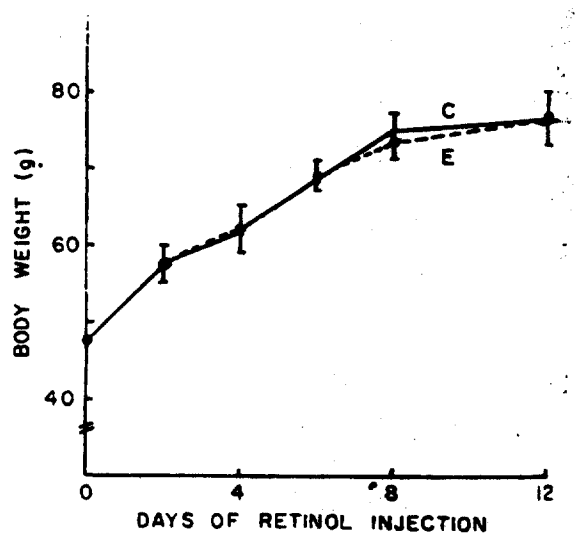

FIG. 1. Effect of intramuscular administration of 100 000 I.U. of retinol daily for 13 days on the body weights of young rats. Each value is the mean ± S.E. from 12 animals in each group. C, control; E, experimental.

TABLE I

Effect of intramuscular administration of 100 000 I.U. of retinol on body weight, daily food consumption, tissue weight, and the total vitamin A, lipids, cholesterol, and phospholipids of livers of rats[a]

	Control	Retinol-treated
Body weight (g)		
Start	47.5±1.8	47.7±0.7
End	76.3±2.2	76.3±3.3
Food consumption (g/day per rat)	9.4±0.3	8.6±0.4
Liver weight (g)	2.8±0.1	3.5±0.1***
Retinol (μg/g wet tissue)	24.4±8.2	1345.2±142.2***
Liver lipids (mg/g wet tissue)		
Total lipids	37.0±0.9	59.9±0.9***
Total cholesterol	1.8±0.1	2.5±0.1***
Phospholipids	22.6±1.6	26.8±3.0
Glycerides	9.5±0.5	24.2±1.3***
Total fatty acids	17.6±1.5	27.9±1.8***
Plasma lipids (mg/100 ml)	388.3±30.3	536.7±72.7**
Plasma glycerides (mg/100 ml)	245.5±29.5	334.7±34.3*

[a]Values are mean ± S.E. from 12 animals in each group. Values significantly different from control are indicated: *$p < 0.05$; **$p < 0.01$; ***$p < 0.001$.

The administration of an excess amount of retinol did not significantly affect the body weights and daily food consumption compared with those of the untreated controls.

Toxicity Symptoms

Rats given excessive amounts of retinol started showing toxicity symptoms such as rawness of skin, epilation, bleeding around the nose, and bent and limping posture 5–6 days after the treatment.

Liver Vitamin A

The administration of excessive amounts of retinol to rats significantly raised their liver vitamin A (1345 ± 142 I.U./g wet tissue) as compared with control values (24.4 ± 8.2 I.U.) (Table I).

Liver Weight

A significant enlargement of the liver was noted in rats given excessive amounts of retinol compared with untreated controls (Table I).

Liver Lipids

There were significant increases in the liver total lipids, cholesterol, fatty acids, and glycerides of the hypervitaminotic A rats compared with controls, but the phospholipid level did not change significantly (Table I).

Neutral Lipids

The distribution of liver lipids in young rats and the effect of intramuscular administration of 100 000 I.U. of retinol daily for 13 days on it are shown in Table II. Non-esterified fatty acids were not estimated. The liver neutral lipids of both control and retinol-treated rats were identified as free cholesterol, esterified cholesterol, and mono-, di-, and tri-glycerides. Retinol administration resulted in significant increases in the concentrations (mg/g wet tissue) of liver free and esterified cholesterol, and mono- and tri-glycerides compared with those of control rats. The concentration of diglycerides was not significantly affected in retinol-treated rats.

TABLE II

Effect of intramuscular administration of 100 000 I.U. of retinol on neutral lipids of livers of rats[a]

Neutral lipids	Control	Retinol-treated
Free cholesterol	1.6±0.1	1.9±0.1*
Esterified cholesterol	0.2±0.01	0.6±0.1*
Monoglycerides	0.3±0.1	1.3±0.2*
Diglycerides	1.7±0.3	1.8±0.4
Triglycerides	7.5±0.5	21.1±0.8*

[a]Values are mean ± S.E. from 12 animals in each group and are expressed as mg/g wet tissue. Values significantly different from control are indicated: *$p < 0.001$.

Phospholipids

The distribution of phospholipids in livers of control and retinol-treated rats is shown in Table III. They were identified as phosphatidic acid, polyglycerol phosphatide, phosphatidylethanolamine, phosphatidylcholine, sphingomyelin, lysophosphatidylethanolamine, lysophosphatidylcholine, phosphatidylserine, and phosphatidylinositol. Occasionally the separation of phosphatidic acid and polyglycerol phosphatide

TABLE III

Effect of intramuscular administration of 100 000 I.U. of retinol on liver phospholipids of rats[a]

Phospholipids	Control	Retinol-treated
Phosphatidylinositol	63.1±3.4	51.1±1.8**
Phosphatidylserine	48.9±1.6	41.2±4.3
Lysophosphatidylcholine	55.1±3.0	74.0±3.8***
Lysophosphatidylethanolamine + sphingomyelin	44.0±3.1	46.1±2.4
Phosphatidylcholine	369.9±12.7	497.7±25.5***
Phosphatidylethanolamine	247.2±8.1	298.4±19.9*
Phosphatidic acid + polyglycerol phosphatide	68.6±3.6	66.4±3.3

[a]Values are mean ± S.E. from 12 animals in each group and are expressed as μg phospholipid phosphorus/g wet tissue. Values significantly different from control are indicated: *$p < 0.05$; **$p < 0.01$; ***$p < 0.001$.

and of sphingomyelin and lysophosphatidylethanolamine was not clear-cut on thin-layer chromatoplates, and in such cases they were estimated together.

Administration of 100 000 I.U. of retinol daily for 13 days resulted in significant increases in the concentrations (μg phospholipid phosphorus/g wet tissue) of lysophosphatidylcholine, phosphatidylcholine, and phosphatidylethanolamine, and a significant decrease in the concentration of phosphatidylinositol, as compared with controls (Table III). The concentrations (μg phospholipid phosphorus/g wet tissue) of phosphatidylserine, lysophosphatidylethanolamine + sphingomyelin, and phosphatidic acid + polyglycerol phosphatide were not affected significantly in retinol-treated rats.

Discussion

The differences in the retinol-toxicity symptoms observed in the present experiment and those observed by Moore and Wang (32) could have been due to the age of the rats, mode of administration of the vitamin, its amounts, and the physical form in which given. A decreased absorption of vitamin A has been reported in young rats when massive amounts are given by injection as compared to the oral route (33). This is corroborated by the retention of vitamin A in the liver, which in injected rats was 1.2% as compared with about 11–37% reported by Lemley *et al.* in orally fed rats (34).

The increase observed in the amounts of hepatic free and esterified cholesterol in retinol-treated rats may arise by either increased synthesis or decreased utilization. In view of the recent report on the stimulation by vitamin A of isoprene metabolism (35), it seems likely that the increase in liver cholesterol of retinol-treated rats could have resulted from such an action of vitamin A on cholesterol metabolism (Tables I, II). The increase in esterified cholesterol in retinol-treated rats suggests also an increased rate of esterification of cholesterol, possibly because of the large increase in total fatty acids available (Table I).

The accumulation of lipids, largely triglycerides, in the liver of retinol-treated rats as compared with controls points to the formation of a fatty liver (Tables I, II). Factors such as decreased oxidation of fatty acids (36), decreased turnover of phospholipids (37), loss of mitochondrial integrity (38), and defective triglyceride-secretory mechanism in liver (39) have been adduced as the possible causes of lipid retention in liver. Decreased oxidation of fatty acids may result in their increased accumulation in liver, as in retinol-treated rats (Table I). Though no direct evidence for the decreased oxidation of fatty acids has been reported in hypervitaminotic A rats, the observations of Dianzani and Marinari (36) of decreased oxidation of octanoate by fatty-liver slices suggest that this may be so.

The increased levels of hepatic triglycerides in fatty liver induced by CCl_4, ethionine, phosphorus, puromycin, and choline-deficient diets have been attributed to an impairment in secretion of glycerides into plasma due to a block in the synthesis of the protein moiety of lipoproteins (40). A minor block in the synthesis of lipoprotein, perhaps the impairment of availability of the protein moiety of lipoprotein, may result in increased accumulation of triglycerides in the livers of retinol-treated rats

(Table I). This view is corroborated by reports that an increased proteolytic activity in liver (41) and increased breakdown of body proteins occur in acute excess of vitamin A (42). In contrast to lowered plasma lipids in the fatty livers induced by CCl_4, ethionine, choline-deficient diets, and puromycin, there is hyperlipemia in retinol-treated rats (Table I). In fatty livers resulting from increased hepatic synthesis of triglycerides, as observed in ethanol-induced fatty liver, hyperlipemia similar to that in retinol-treated rats has been observed (Table I).

There seems to be no clear-cut evidence that any one of the factors considered above may alone be the cause of accumulation of triglycerides in the liver of rats given an excessive amount of retinol. It appears more likely that multiple defects, such as a minor block in the rate of hepatic triglyceride secretion into the plasma or in the oxidation of triglyceride fatty acids, are responsible for triglyceride accumulation in livers of hypervitaminotic A rats.

It has been reported that phospholipids are unaltered in fatty livers induced by feeding rats choline-deficient diets (43). Decreased turnover of liver phospholipids has been adduced as one of the factors causing fatty liver (37). Although the total content of liver phospholipids in retinol-treated rats was not significantly affected as compared with controls (Table I), marked differences were noted in the concentration of some of the liver-phospholipid components of retinol-treated rats (Table III). The increases in the concentration of phosphatidylcholine, phosphatidylethanolamine, and lysophosphatidylcholine in livers of hypervitaminotic A rats may have resulted from an increased rate of synthesis, a decreased rate of utilization, or both. Dingle *et al.* (44) and Lucy *et al.* (45) have reported that retinol administration results in the swelling of liver mitochondria, and this perhaps may result in the altered metabolism of phospholipids in hypervitaminotic A rats.

Acknowledgments

The technical assistance of Mr. N. Srivastava is gratefully acknowledged. The author thanks Dr. O. Isler of Hoffmann - La Roche, Basle, Switzerland for the generous gift of vitamin A.

1. Van Bruggen, J. T., and Straumfjord, J. V. J. Lab. Clin. Invest. 33, 67 (1948).
2. Kinley, L. J., and Krause, R. F. Proc. Soc. Exptl. Biol. Med. 102, 353 (1959).
3. Pallotatta, M. A., and Krause, R. F. Am. J. Clin. Nutr. 13, 201 (1963).
4. March, B. E., and Biely, J. J. Nutr. 79, 474 (1963).
5. Wood, J. D. Can. J. Biochem. Physiol. 40, 530 (1962).
6. Misra, U. K. Naturwiss. 52, 188 (1965).
7. Misra, U. K. Naturwiss. 52, 306 (1965).
8. Ray, A., and Sadhu, D. P. Nature, 184, 1323 (1959).
9. Cruess, R. L., and Clark, I. Biochem. J. 96, 262 (1965).
10. Domagk, G., and Dobeneck, P. V. Virchows. Arch. Pathol. Anat. Physiol. 290, 385 (1933).
11. Noetzel, H. Z. Ges. Exptl. Med. 105, 83 (1939).
12. Misra, U. K. Biochem. J. 95, 30 p (1965).
13. Misra, U. K. Proc. Nutr. Soc. Engl. Scot. 24, 16 (1965).
14. Misra, U. K. Can. J. Biochem. 43, 1885 (1965).
15. Misra, U. K. Nature, 209, 910 (1966).
16. Misra, U. K. Can. J. Biochem. 44, 1539 (1966).
17. Misra, U. K. Can. J. Biochem. 45, 1413 (1967).
18. Steenbock, H., and Nelson, E. M. J. Biol. Chem. 56, 355 (1923).
19. Olson, J. A. J. Biol. Chem. 236, 349 (1961).
20. Folch, J., Lees, M., and Sloane-Stanley, G. H. J. Biol. Chem. 226, 497 (1957).
21. Misra, U. K. Indian J. Biochem. 4, 125 (1967).
22. Sperry, W. M., and Webb, M. J. Biol. Chem. 187, 97 (1950).
23. Hanel, H. K., and Dam, H. Acta Chem. Scand. 9. 677 (1955).
24. Bartlett, G. R. J. Biol. Chem. 234, 466 (1959).
25. Marinetti, G. V. J. Lipid Res. 3, 1 (1962).
26. VanHandel, E., and Zilversmit, D. B. J. Lab. Clin. Invest. 50, 152 (1959).
27. Lea, C. H., and Rhodes, D. N. Biochem. J. 56, 613 (1954).
28. Appleton, H. D., LaDu, B. N., Levy, B. B., Steele, J. M., and Brodie, D. B. J. Biol. Chem. 205. 803 (1953).
29. Carr, F. H., and Price, E. A. Biochem. J. 20, 497 (1926).
30. Misra, U. K. Indian J. Biochem. 4, 136 (1967).
31. Dawson, R. M. C. Biochem. J. 75, 45 (1960).
32. Moore, T., and Wang, Y. L. Biochem. J. 39, 222 (1945).
33. Moore, T. Vitamin A. Elsevier Publishing Co. Ltd., London. 1957. p. 340.
34. Lemley, J. M., Drown, R. A., Bird, D., and Ennett, A. D. J. Nutr. 33, 53 (1947).
35. Rao, K. S., and Olson, R. E. Biochim. Biophys. Acta, 136, 406 (1967).
36. Dianzani, M. V., and Marinari, U. Biochim. Biophys. Acta, 48, 552 (1961).
37. Perlman, I., and Chaikoff, I. L. J. Biol. Chem. 127, 211 (1939).
38. Christie, G. S., and Judah, J. D. Proc. Roy. Soc. London, Ser. B, 142, 241 (1954).
39. Recknagel, R. O., and Lombardi, B. J. Biol. Chem. 236, 564 (1961).
40. Lombardi, B. Lab. Invest. 15, 1 (1966).
41. Dingle, J. T., Sherman, I. M., and Moore, T. Biochem. J. 98, 476 (1966).
42. Rodahl, K., Kesseknitz, B., and Shuman, D. M. J. Nutr. 85, 174 (1965).
43. Lombardi, B., Ugazio, G., and Raick, R. A. Am. J. Physiol. 210, 31 (1966).
44. Dingle, J. T., Lucy, J. A., and Fell, H. B. Biochem. J. 79, 497 (1961).
45. Lucy, J. A., Luscombe, M., and Dingle, J. T. Biochem. J. 89, 419 (1963).

Misra-'68
Bib. No. 6224

Reproduced by per
of the copyright owner

Effect of hypervitaminosis A on rats: observations on growth and liver storage of vitamin A

By U. K. MISRA

Department of Radioisotopes and Biochemistry, V.P. Chest Institute University of Delhi, Delhi 7, India

(*Received* 25 *October* 1967—*Accepted* 22 *March* 1968)

1. The effect of giving 14400, 28800, 57600 or 93600 i.u. retinol daily for 10 days to adult rats on their daily food consumption, body-weight and liver vitamin A content has been studied.

2. Rats given retinol lost weight and ate less food and showed toxicity symptoms dependent upon the amount of retinol fed.

3. The retention of vitamin A (as a percentage of the dose) in liver was highest (27·4 %) in rats given 14400 i.u. retinol daily for 10 days and lowest (11·6 %) in rats given 93600 i.u. daily for 10 days.

It is known that feeding massive amounts of vitamin A to experimental animals is harmful (Moore, 1957*a*). Differences in absorption, liver storage of vitamin A and the intensity of toxic symptoms, due to the amount of vitamin A given, the route of administration of vitamin A and the age of the animals have been reported (Moore, 1957*b*). Thus the storage of vitamin A in liver has been reported to be less when vitamin A was given in oily solution by parenteral injection than when it was given orally or in emulsified form by intramuscular injection (Lemley, Brown, Bird & Emmett, 1957*a*; Bolin, Eveleth & Bolin, 1950). The liver is the main organ of vitamin A storage (Sherman & Boynton, 1925; Moore, 1931; McCoord & Luce-Clausen, 1934) and the liver concentration of vitamin A is usually proportional to its intake (Baumann, Riising & Steenbock, 1934). This communication describes the effects of giving various doses of retinol to adult rats on their body-weights, food consumption and liver storage of vitamin A.

EXPERIMENTAL

Male rats (Wistar strain) weighing 160–170 g, and 9–10 months old, from our institute-maintained colony were used. The rats were housed in individual cages. They were fed on a diet of the following composition: casein 20 parts, potato starch [illegible] parts, hydrogenated groundnut oil 10 parts, salt mixture 5 parts (Steenbock & [illegible], 1923) and dried yeast powder 5 parts. In addition each received 4 g germinated [illegible] grams (chick-pea) daily. The rats had free access to water.

Rats were divided at random into five groups of six each. To four groups retinol (Prepalin; Glaxo Pvt. Ltd., India) was given orally in amounts of 14400, 28800, [illegible], or 93600 i.u. daily for 10 days. The fifth group served as the control and was given saline for the same period. The amount of retinol in the Prepalin preparation was checked (Olson, 1961) and was found to be 96–98 % of that (72000 i.u./ml) stated in the literature supplied with it. Daily records of the food consumption of the rats and

tri-weekly records of their body-weights were kept. On the 10th day rats in all groups were killed by decapitation and their livers were removed quickly, cleaned, rinsed with ice-cold saline, weighed and immersed in a mixture of chloroform: methanol (2:1, v/v). Lipids from liver were extracted and purified as described previously (Misra, 1967). Vitamin A was measured in liver lipid extracts by the method of Olson (1961).

Analysis of variance was conducted to test the significance of differences in liver weights, total liver vitamin A, and liver vitamin A (μg/g tissue) between the rats given retinol and control rats.

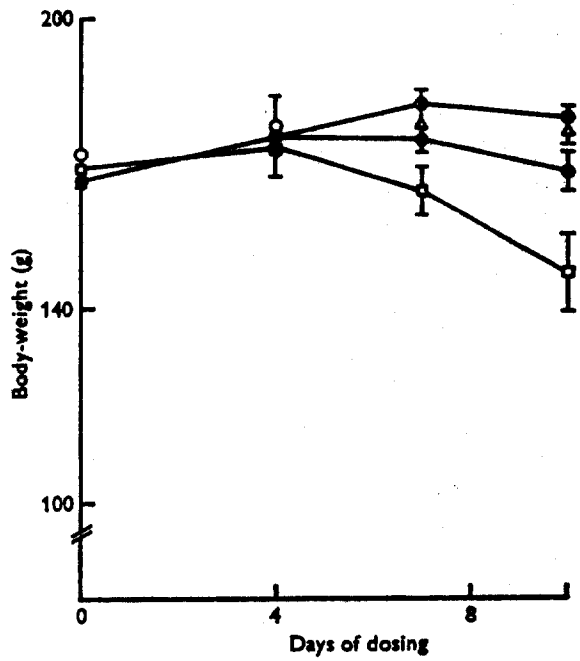

Fig. 1. Effect of giving retinol by mouth on body-weight of adult rats given daily no retinol (●), 14400 i.u. retinol (○), 28800 i.u. retinol (△), 57600 i.u. retinol (◆) or 93600 i.u. retinol (□). Mean values for six, six, six, four and five rats respectively; standard errors are shown for the first group and the last two groups.

RESULTS AND DISCUSSION

The effect of giving different large amounts of retinol to rats on their body-weights and daily food consumption is shown in Figs. 1 and 2. When rats were given these large amounts of retinol there was a decrease in daily food consumption and body-weight, usually starting within 4–5 days. These effects were much more severe in rats given 93600 i.u. retinol daily than in those given 14400, 28800 and 57600 i.u. retinol. In addition, the rats developed signs of retinol toxicity dependent on the dose, such as epilation, bent and limping posture, bleeding around the nose and eyes and internal haemorrhages on both right and left front and back limb joints and neck. Similar signs, in rats given vitamin A orally, have been reported by Moore & Wang (1945). The toxicity of retinol depends on the route of administration. Thus, toxicity signs were

not as severe in rats given 100000 i.u. by intramuscular injection daily for 13 days (Misra, 1967*b*) as those produced by oral dosage in the present experiment.

The mean and standard error of the mean of liver weights, liver total vitamin A and liver vitamin A (μg/g tissue) are shown in Table 1. The results show that liver weights of rats given retinol were not significantly different from those of the control rats.

Total liver vitamin A and liver vitamin A (μg/g tissue) concentration in rats given retinol were significantly higher than in the control rats. Significant differences in the amounts of liver vitamin A (total and μg/g tissue) were also noted between rats given

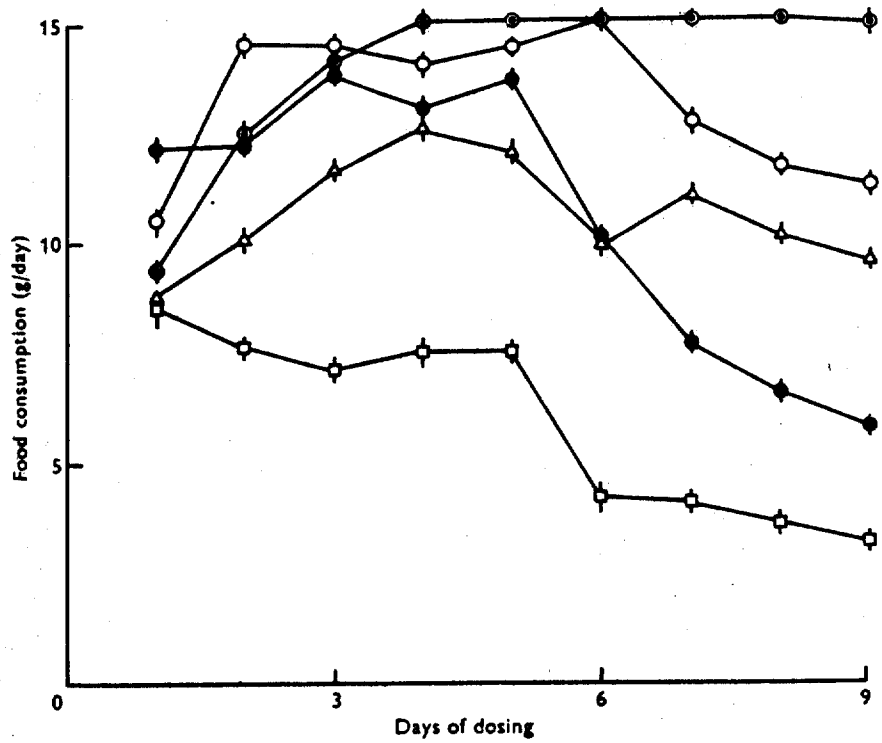

Fig. 2. Effect of giving retinol by mouth on the daily food consumption of adult rats given daily no retinol (◎), 14400 i.u. retinol (○), 28800 i.u. retinol (△), 57600 i.u. retinol (●) or 93600 i.u. retinol (□); mean values with their standard errors for six, six, six, four and five rats respectively.

Table 1. *Effect of giving retinol by mouth for 10 days on liver vitamin A of adult rats*

(Mean values with their standard errors; figures in parentheses are the numbers of rats/group)

Retinol given (i.u./day)	Liver wt (g)	Liver total vitamin A content (μg)	Liver vitamin A storage (%)	Liver vitamin A concentration (μg/g)
None (6)	4·27 ± 0·23	324·0 ± 92·3	—	76·18 ± 21·20
14400 (6)	4·43 ± 0·17	1163·8 ± 195·2	27·4	258·15 ± 34·63
28800 (6)	4·50 ± 0·18	1893·8 ± 350·4	22·3	422·38 ± 73·84
57600 (4)	4·28 ± 0·09	3430·3 ± 548·5	20·2	808·71 ± 142·10
93600 (5)	4·85 ± 0·24	3219·0 ± 559·7	11·6	668·46 ± 118·95

various amounts of retinol. The liver vitamin A concentration increased with the amount given up to a dose of 57600 i.u., after which it decreased (Table 1). The retention of vitamin A in liver was found to be highest (27·4 %) in rats given 14400 i.u. retinol, and increasing the amount of retinol resulted in a decreased retention of vitamin A in liver (Table 1). Similar results have been reported by Lemley *et al.* (1947*a*) in rats given 63–118400 i.u. vitamin A daily for 3 days. The decreased storage and retention of vitamin A in the liver of rats given these large doses may result either from its decreased absorption from the intestine or from its extensive degradation in liver, or both. The decreased absorption may result from one or more of a number of factors such as (1) a change in the epithelial lining of the intestine affecting its absorption capacity, or (2) the lack of an available carrier, e.g. palmitic acid, which has been shown to be the major fatty acid utilized for the absorption and transport of vitamin A to the liver (Ganguly, 1967), and (3) the saturation of the absorptive system, which, after a certain level, may not function in proportion to the increasing influx of dietary vitamin A. A decrease in liver tocopherol levels has been reported in conditions in which massive amounts of vitamin A are given (Pudelkiewicz, Webster & Matterson, 1964). Vitamin A is a highly unsaturated compound and is prone to oxidative degradation in the absence of tocopherol. The administration of adequate amounts of tocopherol along with a massive amount of vitamin A has been reported to increase the storage of vitamin A in liver (Lemley, Brown, Bird & Emmett, 1947*b*). Thus it is possible that the decreased retention of retinol observed in the present instance might have been caused by one or more of the factors considered above.

The technical assistance of Mr N. Srivastava is acknowledged. Thanks are also due to Mr C. K. Gupta, Statistitian of this Institute, for his help in the statistical analysis.

REFERENCES

Baumann, C. A., Riising, B. M. & Steenbock, H. (1934). *J. biol. Chem.* **107**, 705.
Bolin, F. M., Eveleth & Bolin, D. W. (1950). *Vet. Med.* **45**, 451.
Ganguly, J. (1967). *J. scient. ind. Res.* **26**, 110.
Lemley, J. M., Brown, R. A., Bird, O. D. & Emmett, A. D. (1947*a*). *J. Nutr.* **33**, 53.
Lemley, J. M., Brown, R. A., Bird, O. D. & Emmett, A. D. (1947*b*). *J. Nutr.* **34**, 205.
McCoord, A. B. & Luce-Clausen, E. M. (1934). *J. Nutr.* **7**, 557.
Misra, U. K. (1967*a*). *Indian J. Biochem.* **4**, 125.
Misra, U. K. (1967*b*). *Can. J. Biochem.* **45**, 1413.
Moore, T. (1931). *Biochem. J.* **25**, 275.
Moore, T. (1957*a*). *Vitamin A*, p. 340. London: Elsevier Publishing Co.
Moore, T. (1957*b*). *Vitamin A*, p. 208. London: Elsevier Publishing Co.
Moore, T. & Wang, Y. L. (1945). *Biochem. J.* **39**, 222.
Olson, J. A. (1961). *J. biol. Chem.* **236**, 349.
Pudelkiewicz, W. J., Webster, L. & Matterson, D. C. (1964). *J. Nutr.* **84**, 113.
Sherman, H. C. & Boynton, L. C. (1925). *J. Am. chem. Soc.* **47**, 1646.
Steenbock, H. & Nelson, E. M. (1923). *J. biol. Chem.* **56**, 355.

Printed in Great Britain

Misra-'68
Bib. No. 6226

J. of Vitaminology 14:239-246. 1968.

Effect of Administration of Large Doses of Retinol on Spleen Lipids of Rats

U. K. MISRA

Department of Radioisotopes and Biochemistry
V.P. Chest Institute, University of Delhi
Delhi-7, India

(Received January 8, 1968)

After the intramuscular administration of 100,000 I.U. of retinol (Prepalin) daily for 13 days to a group of young rats, their daily food consumption, body weights, total spleen lipids, total spleen cholesterol and phospholipid phosphorus did not differ significantly from a control group. A significant enlargement of spleen was observed in the treated rats. A significant increase in the concentration of triglycerides and a significant decrease in the concentration of diglycerides was observed in the spleens of retinol treated rats. Of spleen phospholipids, phosphatidyl choline and crude phosphatidyl inositol fraction showed significant elevation, whereas phosphatidyl ethanolamine and sphingomyelin and lysophosphatidyl ethanolamine fraction showed significant decrease in the treated group.

Vitamin A is highly toxic to experimental animals when given in great excess. A relationship between lipid metabolism and excessive intake of vitamin A has been indicated from several laboratories (1-13). Earlier observations reported a striking deposition of fat in pulp cells of the spleen of mice (14) and rats (15) on administration of large doses of the vitamin. Some reports are available on the effect of administration of large doses of vitamin A on lipids of human and rat plasma (1-3, 6, 9), rat liver, intestine, brain, heart (8) and rat bone marrow (13), but no detailed study on the effect of administration of large doses of vitamin A on spleen lipids of rats has been reported. This paper describes the effect of administration of excessive doses of vitamin A on neutral lipids and phospholipids or rat spleen.

MATERIALS AND METHODS

Animals — Young male rats (Wistar strain) about 35-40 days old and 40-50 g weight, were used in this study. The rats were housed in separate cages and were fed a stock diet and water *ad libitum*. The stock diet consisted of 20 parts casein, 60 parts potato starch, 10 parts fat (Dalda, a hydrogenated vegetable oil supplemented with vitamin A and D), 5 parts salt mixture (16) and 5 parts dried

yeast powder. In addition, each rat received 4 g germinating grams.

Vitamin A — Prepalin (Glaxo Laboratories, Pvt. Ltd., India), a vitamin A alcohol concentrate was used as a source of retinol. The concentration of retinol in this commercial preparation was checked by saponifying Prepalin with 30% methanolic KOH and repeatedly extracting the nonsaponifiable portion with hexane (bp 60 65°) (17). The combined hexane extracts were washed with distilled water, dried over anhydrous sodium sulphate, evaporated to dryness *in vacuo* at 45° and dissolved in a known volume of chloroform. Retinol was estimated by the antimony trichloride method. The values obtained were between 96-98% of those mentioned in the literature supplied with Prepalin.

The rats were divided in two groups of twelve and fifteen each. To one group (fifteen rats) 100,000 I.U. of retinol were given intramuscularly daily for 13 days. Control group (twelve rats) was injected intramuscularly 1.0 ml of normal saline daily for 13 days. Daily records of their food consumption and tri-weekly records of their body weights were maintained. On the 13th day the rats in both groups were sacrificed by decapitation and their spleens quickly removed, cleaned, weighed and immersed immediately in a volume of chloroform-methanol (2 : 1, v/v) solvent mixture. The spleens were ground separately in a mortar and pestle, transferred to a chloroform-methanol (2 : 1, v/v) solvent mixture, allowed to stand at room temperature for 4 hours and filtered. The residue was re-extracted with 10 more volumes of the above solvent mixture for 2 hours, filtered, and the two filtrates combined. The filtrates were evaporated to dryness *in vacuo* at 45° in a rotary evaporator, the residue was dissolved in a chloroform-methanol (2 : 1, v/v) solvent mixture containing 4% water, and evaporated to dryness *in vacuo*. This step was repeated twice to disrupt the proteolipids (18). The final dried residue was dissolved in chloroform-methanol (2 : 1, v/v), filtered and the filtrate was layered with 1/20 volume of normal saline (0.89%) in a separatory funnel, and allowed to stand at room temperature till the two phases separated (4 hours). The lower layer was collected, evaporated to dryness *in vacuo*, and dissolved in a known volume of chloroform.

Analysis — Total lipids of each spleen were estimated by weighing an aliquot in a glass thimble to a constant weight. Total cholesterol was assayed by saponifying the lipid extract with 30% alcoholic KOH and extracting the nonsaponifiable fraction repeatedly with hexane. All the hexane extracts were combined, evaporated to dryness and free cholesterol was precipitated with digitonin (19). The digitonide was recovered by centrifugation, washed thrice with acetone-ether (3 : 1, v/v) and twice with ether, and dissolved in 0.5 ml glacial acetic acid followed by the addition of 1.5 ml $CHCl_3$. The cholesterol was assayed on this solution by the Hanel and Dam method (20). Phospholipid phosphorus was assayed by the Bartlett (21) method as modified by Marinetti (22). Glyceride-glycerol was assayed by the method of Van Handel and Zilversmit (23).

Separation of Neutral Lipids and Phospholipids — Spleen neutral lipids and phospholipids prior to thin layer chromatography were first separated by silicic acid column chromatography (24). The activation of Mallinckrodt silicic acid (100-200 mesh size) was done as published earlier (25). The lipid samples in hexane solution were applied on the column and first eluted with hexane. Neutral lipids

were then eluted with chloroform and phospholipids with methanol. Chloroform and methanol eluates were evaporated to dryness separately *in vacuo* at 45° and each was dissolved in a known volume of chloroform.

Thin Layer Chromatography—The neutral and phospholipids were separated into individual lipid components by means of thin layer chromatography. The glass plates were coated (250 μ thickness) with silica gel G, according to Abramson and Blecher (26). A slurry of 30 g silica gel was made in 63 ml of 0.01 *M* sodium carbonate solution, shaken vigorously and applied on glass plates by means of spreader devised by Shandon Scientific Co. Ltd., London, England. The dried plates were activated for 90 min at 110°, and cooled in a desiccator.

Neutral lipids were applied (0.5-1 mg) in duplicate on the plates and developed in the solvent system hexane (bp 65-70°)-diethyl ether-glacial acetic acid (90 : 10 : 1, v/v/v) (26). The solvent was allowed to run for a distance of 15 cm from the base line. Authentic standards of cholesterol esters, free cholesterol, tristearin, palmitic acid, and diglycerides were co-chromatographed with each run. Lipid spots on dried plates were located by exposing them to I_2 vapours. The spot corresponding to authentic standards were scrapped out into 15 ml tubes and extracted from the gel with four successive, 5 ml portions of hexane (bp 65-70°)-diethyl ether (1 : 1, v/v). All the extracts, recovered by centrifugation, were pooled separately, evaporated to dryness and assayed for cholesterol (20), and glyceride-glycerol (23). The recoveries of the applied cholesterol, and glyceride glycerol were between 94-96 per cent. Suitable aliquots of blank silica gel from the plates were treated similarly. Free fatty acids were not estimated.

Phospholipids (40-50 μg lipid phosphorus) were applied to the activated plates and the plates were developed in solvent system: chloroform-methanol-7 *M* ammonia (230 : 90 : 15, v/v/v) (26) for a distance of 15 cm. Authentic standard of phospholipids, *viz.*, phosphatidyl ethanolamine, phosphatidyl serine, phosphatidyl choline, sphingomyelin, phosphatidyl inositol, lysophosphatidyl ethanolamine, polyglycerol phosphatide and phosphatidic acid were co-chromatographed with each run. The phospholipid spots on the dried plates were located by (*a*) exposing them to I_2 vapours, (*b*) ninhydrin (0.4 % in acetone-lutidine, 9 : 1, v/v) spray, (*c*) Dragendorff reagent (27) and (*d*) molybdenum blue reagent (28). The spots corresponding to authentic phospholipid standards were scrapped out into 15 ml tubes and the gel were extracted with four successive 5 ml portions of *N* methanolic HCl at 60°. Subsequent extracts, recovered by centrifugation, were pooled separately, and evaporated to dryness. Suitable aliquots of blank silica gel G portions from the plate were treated similarly. Phosphorus was estimated on each sample. The recoveries of applied phospholipid phosphorus were between 94-97 per cent.

Spleen lipids of both control and retinol given rats were also separated into individual neutral lipids and phospholipids by silcic acid column chromatography. Pooled lipid samples of each group (about 20 mg) were applied separately on a 5 g activated silicic acid (Mallinckrodt, 100 mesh for chromatography) column. Neutral lipids were eluted with increasing concentration of diethyl ether in hexane and phospholipids with increasing concentration of methanol in chloroform. The conditions of column chromatography were essentially the same as published earlier (25) except the amounts and compositions of the eluting solvents. The column fractions

were pooled according to the size of the peaks, evaporated to dryness *in vacuo* at 45°, and dissolved in 2.0 ml of chloroform. Column neutral lipids and phospholipid fractions were spotted along with spleen total neutral lipids and phospholipids, respectively, on silica gel G coated glass plates and the plates developed as described in the preceding section.

Spleen phospholipid fractions from the column were deacylated and hydrolysates chromatographed according to the method of Dawson (29). The glyceryl phosphoryl esters on the chromatogram were identified by dipping them in Hanes-Isherwood reagent (30) as modified by Burrows, Grylls and Harrison (31), and comparing their *Rf* values with authentic phospholipid standards treated similarly.

The alkali-labile and acid-labile phosphorus of spleen total phospholipids was estimated by the method of Dawson (29).

Solvents —— All the solvents used in this study were redistilled before use.

Results and Discussion

The effect of intramuscular administration of 100,000 I.U. retinol (Prepalin) daily for 13 days on the body weights and daily food sonsumption of rats is shown in Table 1. No significant differences were noticed in the daily food consumption and body weights at the time of sacrifice of retinol treated rats as compared to the control group rats. The amount of retinol in livers of control and retinol treated rats were 25.9 ± 7.89 and 1119.3 ± 113.55 $\mu g/g$ respectively. Although rats given excessive doses of retinol started showing retinol toxicity symptoms such as rawness of skin, epilation, bleeding around the nose and bent and limping posture 5–6 days after the treatment, the symptoms after 13 days were not as severe as those reported by Moore and Wang (32). Treated rats neither lost weight nor ate less. Various factors such as age of the animals, route of administration of vitamin A, amount and physical form of the vitamin affect the absorption of the vitamin (33). Moore has reported a decreased absorption of vitamin A in young rats when they were given massive doses of the vitamin A by intramuscular injection (33). Lemley *et al.* (34) have shown that the efficiency of absorption of vitamin A when given in an oily solution by intramuscular injection was only 2% of the efficiency obtained in oral dosing. These differences in the degree of retinol toxicity could have been due to the mode of administration of retinol which in Moore-Wang's (32) experiment was oral as compared to intramuscular in the present case.

The effect of administration of toxic doses of retinol to rats on their spleen total lipids, cholesterol and phospholipid phosphorus is shown in Table 1. No significant differences were noted between the control and treated groups in any of these measurements. A significant enlargement of spleen was observed in rats given excessive amounts of retinol (p 0.05) as compared to control group rats (Table 1).

The percentages of neutral lipids in the spleen of control and retinol treated rats are given Table 2. Free fatty acids were not estimated. The percentages of total cholesterol and total glycerides of retinol given rats, *i.e.* 14.43 ± 2.909 and 85.57 ± 3.137 per cent respectively were not significantly different from those of control group rats, *i.e.* 19.91 ± 2.864 and 80.09 ± 2.919 per cent respectively. Similarly the concentration of free and esterified cholesterol in the spleens of treated and

TABLE 1

Effect of Intramuscular Administration of 100,000 I.U. of Retinol Daily for 13 Days on the Body Weights, Daily Food Consumption, Spleen Weight, Spleen Total Lipids, Cholesterol and Phospholipid Phosphorus of Rats. Each value is mean ± S.E.

	Control (12)[a]	Retinol treated (15)[a]
Body weights	*g*	
Start	44.6 ± 2.19	47.6 ± 2.19
End	69.2 ± 2.84	68.9 ± 3.92
	g/day/rat	
Food consumption	8.8 ± 0.43	8.3 ± 0.48
	g	
Spleen weight	0.24 ± 0.029	0.31 ± 0.035[b]
	mg/g wet tissue weight	
Total lipids	32.60 ± 6.963	29.11 ± 5.512
Total cholesterol	3.33 ± 0.211	3.15 ± 0.139
Phospholipid phosphorus	0.597 ± 0.0220	0.616 ± 0.0222

[a] No. of animals.
[b] Significantly different from control values ($p<0.05$).

control rats were about the same. On the other hand, the spleens of retinol treated rats contained markedly more triglycerides and less diglycerides than the control spleens (Table 2). Monoglycerides did not show any significant alteration in retinol treated rats as compared to the control group rats. The increase in the concentration of triglycerides in spleen may be either due to their decreased lipolysis or in increased synthesis in the animals given excess retinol. The mechanism by which the concentration of diglycerides is decreased in spleens of retinol given animals is not clearly understood. It may be that administration of toxic doses of retinol stimulates the utilization of diglycerides for triglyceride synthesis by acylation pathway. Although the direct information of triglycerides from mono-and diglycerides has not been demonstrated in the spleen, it does occur in the intestinal mucosa (35–37). Alternatively the decrease observed in diglyceride concentration in spleens of retinol treated rats as compared to the control group animals could also arise from its increased utilization for the synthesis of phospholipids by the CDP-diglyceride pathway (38).

TABLE 2

Effect of Intramuscular Administration of Retinol on Percentage Composition of Neutral Lipids of Spleen of Rats.
The values are mean ± S.E.

Animal	Esterified cholesterol	Free cholesterol	Triglycerides	Diglycerides	Monoglycerides
Control (12)[a]	0.68 ± 0.162	13.74 ± 2.703	36.15 ± 3.671	28.62 ± 3.699	20.67 ± 3.084
Retinol treated (15)[a]	0.69 ± 0.158	19.22 ± 2.953	48.62 ± 1.638[b]	14.66 ± 1.652[b]	17.01 ± 2.583

[a] No. of animals.
[b] Significantly different from control values ($p<0.01$).

The effect of retinol treatment on the percentage composition of spleen phospholipids, as compared to the control group is shown in Table 3. By the staining characteristics, by comparing the *Rf* values with authentic phospholipid standards, and silicic acid column eluted fractions and by alkaline hydrolytic procedures, the spleen phospholipids have been identified on the plate from top to the bottom as: phosphatidic acid, polyglycerol phosphatide, phosphatidyl ethanolamine, phosphatidyl choline, sphingomyelin, lysophosphatidyl ethanolamine, lysophosphatidyl choline, phosphatidyl serine and phosphatidyl inositol. Lysophosphatidyl ethanolamine and sphingomyelin did not separate very well on the plates. Therefore, they were eluted and estimated together. Since phosphatidyl inositol only moved slightly from the origin and was a diffused band, it was eluted with the material remaining at the origin.

A significant increase in the concentration of phosphatidyl choline ($p < 0.01$) and phosphatidyl inositol ($p < 0.01$) and a significant decrease in sphingomyelin and lysophosphatidyl ethanolamine fraction ($p < 0.01$) and phosphatidyl ethanolamine ($p < 0.05$) was observed in the spleen of retinol treated rats (Table 3) as compared with control spleens. The percentages of acid-labile phosphorus in spleen phospholipids of both control (12.5 %) and retinol treated rats (14.2 %) were not significantly different. The alterations observed in the concentration of phosphatidyl choline in spleens of retinol treated rats as compared to the control spleen (Table 3) may arise by either their decreased utilization or by their increased *de novo* synthesis. The decrease noted in the concentration of diglycerides in retinol treated rats (Table 2) perhaps indicate towards an increased synthesis of phosphatidyl choline by the cytidine diphosphate-diglyceride pathway (38). Similarly on increased conversion of phosphatidyl ethanolamine to phosphatidyl choline by the transmethylation mechanism (39) could give rise to lower concentration of phosphatidyl ethanolamine and high concentration of phosphatidyl choline in the spleens of retinol treated rats as compared to the control group (Table 3).

A number of hypotheses have been advocated to explain the mechanism of

TABLE 3

Effect of Intramuscular Administration of 100,000 I.U. *of Retinol Daily for 13 Days on the Percentage Composition of Spleen Phospholipids.* The values are mean ± S.E.

Phospholipids	Control (12)[a]	Retinol treated (15)[a]
Origin + phosphatidyl inositol	11.82 ± 1.261	21.14 ± 2.630 [c]
Phosphatidyl serine	6.06 ± 1.081	4.85 ± 0.690
Lysophosphatidyl choline	4.69 ± 0.539	4.77 ± 0.523
Lysophosphatidyl ethanolamine + sphingomyelin	11.79 ± 1.050	6.02 ± 0.438 [c]
Phosphatidyl choline	33.54 ± 2.076	40.49 ± 1.222 [c]
Phosphatidyl ethanolamine	25.66 ± 4.157	16.97 ± 3.326 [b]
Phosphatidic acid + polyglycerol phosphatide	6.33 ± 0.424	6.54 ± 1.096

[a] No. of animals.
[b] Significantly different from control values ($p < 0.05$).
[c] Definitely different from control values ($p < 0.01$).

action of retinol in various aspects of cellular metabolism. It has been demonstrated that *in vitro* excess vitamin A causes an increase in the permeability of erythrocyte membrane and interacts with lipoprotein membranes thereby lowering their stability (40-43). The work of Bangham, Dingle and Lucy (44) on the action of retinol on monolayer of lecithin-cholesterol suggests that penetration of lipid monolayers and lipoprotein membranes may be an initial step in certain physiological functions of vitamin A. The administration of excess vitamin A has been reported to increase the rate of release of lysosomal enzymes (45). It is likely that changes observed in spleen lipids in retinol treated rats as compared to the control group animals (Tables 2 and 3) may have been due to an analogous effect of retinol on spleen lysosomes. Lucy, Luscombe and Dingle (46) have shown that high dosages of vitamin A cause the swelling of spleen mitochondria. This mitochondrial swelling has been attributed to the change in structure or function or both of mitochondria. The changes observed in spleen phospholipids in retinol treated rats may have been due to such an action of retinol on spleen.

Acknowledgements

Competent technical assistance of Mr. N. Srivastava is gratefully acknowledged.

References

1. Van Bruggen, J. T., and Straumfjord, J. V., *J. Lab. Clin. Invest.*, **33**, 67 (1948).
2. Ray, A., and Sadhu, D. P., *Nature*, **184**, 1323 (1959).
3. Kinley, L. J., and Krause, R. F., *Proc. Soc. Exptl. Biol. Med.*, **102**, 353 (1959).
4. March, B. E., and Biely, J., *J. Nutr.*, **79**, 474 (1963).
5. Wood, J. D., *Canad. J. Biochem. Physiol.*, **40**, 530 (1962).
6. Pollotatta, M. A., and Krause, R. F., *Am. J. Clin.* Nutri., **13**, 201 (1963).
7. Misra, U. K., *Biochem. J.*, **95**, 30 p (1965).
8. Misra, U. K., *Nature*, **209**, 910 (1966).
9. Misra, U. K., *Naturwissen.*, **52**, 188, 306 (1965).
10. Misra, U. K., *Proc. Nutr. Soc.*, **24**, 16 (1965).
11. Misra, U. K., *Canad. J. Biochem.*, **43**, 1885 (1965).
12. Misra, U. K., *Canad. J. Biochem.*, **44**, 1539 (1966).
13. Crues, R. L., and Clark, I., *Biochm. J.*, **96**, 262 (1965).
14. Domagk, G., and Dobeneck, P. V., *Virchow's Arch. Path. Anat. Physiol.*, **290**, 385 (1933).
15. Noetzel, H., *Z. Ges. Exp. Med.*, **105**, 83 (1939).
16. Steenbock, H., and Nelson, E. M., *J. Biol. Chem.*, **56**, 355 (1923).
17. Olson, J. A., *J. Biol. Chem.*, **236**, 349 (1961).
18. Misra, U. K., *Ind. J. Biochem.*, **1**, 95 (1964).
19. Sperry, W. M., and Webb, M., *J. Biol. Chem.*, **187**, 97 (1950).
20. Hanel, H. K., and Dam, H., *Acta Chem. Scand.*, **9**, 677 (1955).
21. Bartlett, G. R., *J. Biol. Chem.*, **234**, 466 (1959).
22. Marinetti, G. V., *J. Lipid Res.*, **3**, 1 (1962).
23. Van Hadel, E., and Zilversmit, *J. Lab. Clin. Invest.*, **50**, 152 (1957).
24. Borgstrom, B., *Acta Physiol. Scand.*, **25**, 101 (1952).
25. Misra, U. K., *Biochim. Biophys. Acta*, **106**, 371 (1965).
26. Abramson, D., and Blecher, M., *Biochim. Biophys. Acta*, **98**, 117 (1964).
27. Vakh, D., in *Thin Layer Chromatography* ed. by E. Stahl, Academic Press, Inc., New York, p. 483 (1965).

28. Dittmer, J. C., and Lester, R. L., *J. Lipid Res.*, **5**, 136 (1964).
29. Dawson, R. M. C., *Biochem. J.*, **75**, 45 (1960).
30. Hanes, C. S., and Isherwood, F. A., *Nature*, **164**, 1107 (1949).
31. Burrows, S., Grylls, F. S. M., and Harrison, J. S., *Nature*, **166**, 444 (1950).
32. Moore, T., and Wang, Y.L., *Biochem. J.*, **39**, 222 (1945).
33. Moore, T., in *Vitamin A*, Elsevier Publishing Co. London, p. 340, (1957).
34. Lemley, J. M., Brown, R. A., Bird, D., and Emmett, A. D., *J. Nutri.*, **33**, 53 (1947).
35. Isselbacher, K. J., *Federation Proc.*, **24**, 16 (1965).
36. Johnson, J. M., and Ananda Rao, G., *Biochim. Biophys. Acta*, **106**, 1 (1965).
37. Hubscher, G., Clark, G., Webb, M. E., and Sherratt, H. S. A., in *Biochemical Problems of Lipids* ed. by A. C. Frazer, Elsevier Publishing Co., Amsterdam, p. 201 (1959).
38. Kennedy, E. P., *Federation Proc.*, **20**, 934 (1961).
39. Bremer, J., and Greenberg, D. M., *Biochim. Biophys. Acta*, **37**, 173 (1960).
40. Dingle, J., Glauert, A. M., Daniel, M., and Lucy, J. A., *Biochem. J.*, **84**, 76 p (1962).
41. Dingle, J. T., and Lucy, J. A., *Biochem. J.*, **84**, 611 (1962).
42. Lucy, J. A., and Dingle, J. T., *Biochem. J.*, **84**, 67 p (1962).
43. Glauert, A. M., Daniel, M., Lucy, J. A., and Dingle, J. T., *J. Cell Biol.*, **17**, 111 (1963).
44. Bangham, A. D., Dingle, J. T., and Lucy, J. A., *Biochem. J.*, **90**, 133 (1964).
45. Dingle, J. T., Sherman, I. M., and Moore, T., *Proc. Nutri. Soc.*, **22**, X (1963).
46. Lucy, J. A., Luscombe, M., and Dingle, J. A., *Biochem. J.*, **89**, 419 (1963).

Moore-'45
Bib. No. 6329

Reproduced by permission
of the copyright owner

[From THE BIOCHEMICAL JOURNAL, Vol. 39, No. 3, pp. 222-228, 1945]
[*All rights reserved*]
PRINTED IN GREAT BRITAIN

Hypervitaminosis A

By T. MOORE and Y. L. WANG, *Dunn Nutritional Laboratory, University of Cambridge, and Medical Research Council*

(*Received* 22 *March* 1945)

Many forms of injury are known to occur in experimental animals when they are dosed with greatly excessive amounts of oils or concentrates containing vitamin A. Takahashi, Nakamiya, Kawakami & Kitasato (1925) tested the effect of excess of their crude concentrate 'Biosterin' when given orally to rats and mice, and observed loss of hair, emaciation and paralysis of the hind legs. After periods varying from a few days to several weeks the animals died, and at autopsy fatty degeneration of the liver,

kidney and heart was found, together with hyperaemia, and sometimes haemorrhage in the intestines and lungs. Both Takahashi *et al.* and later Matsuoka (1934) found that excess of vitamin A concentrate was also toxic when injected, usually causing death with cramp in less than an hour. The principal observations of the Japanese workers in regard to the ill effects of excess of vitamin A concentrates when given orally were confirmed by Harris & Moore (1928), Chevallier, Cornil & Chabré (1934), Simola & Kalaga (1934), Lewis & Reti (1934), Ypsilanti (1935) and Ocana (1935).

Another remarkable lesion, which escaped notice until highly potent concentrates became available, was described by Collazo & Rodriguez (1932) and Bomskov & Seeman (1933). The skeletons of rats which had received excess of concentrate became so fragile that the animals incurred fractures of the large bones of the legs and shoulders in the course of the limited movements possible while in captivity in small cages. Sometimes the broken ends of the bone were ankylosed with the formation of large irregular calluses (Davies & Moore, 1934). Further observations on these skeletal lesions were made by Strauss (1934), Hoff & Jeddeloh (1934), Vedder & Rosenberg (1938) and Wesaw, Wronski, Wroblewski & Wroblewski (1938). Recently, a further injury has been reported by Rodahl & Moore (1943), whose rats often died from severe internal haemorrhage after receiving excess of rich sources of vitamin A. This bleeding was much more profuse and sudden than the diffuse bleeding in various membranes described by previous workers. If not a distinct phenomenon it must at least be considered a separate aspect of a general liability to haemorrhage.

While, however, it is well established that concentrated sources of vitamin A are toxic when given in great excess, some doubt has remained as to whether vitamin A itself is responsible for the toxicity, and if so whether it produces all, or only some of the lesions which have been reported. Undoubtedly fish liver and body oils may be injurious for several distinct reasons unrelated to their content of vitamin A. Agduhr (1926, 1928) noticed the ill effects of cod-liver oil on the musculature of various animals, and pointed out that the oil was still injurious after its vitamin A had been destroyed. Yamamoto (1934) and later Yoshida (1937) concluded that the glyceride fraction, and not vitamin A, was responsible for the adverse action of many marine oils on rats. Hartwell (1927), who found that female rats succumbed to uterine haemorrhage when allowed to become pregnant on diets rich in cod-liver oil, tentatively ascribed this lesion not to vitamin A but to the destructive action of the oil on the vitamin E in the diet. In our experience sperm oil is toxic to rats on account of the presence of cetyl alcohol, which resists absorption; while we have found a stale specimen of sardine oil to be toxic although devoid of vitamin A. It must also be remembered that concentrates rich in vitamin A are often equally rich in vitamin D, which is known to be toxic when given in great excess. Even the original experiments of Takahashi *et al.* (1925) may now be taken as evidence that the toxic effects observed were not all due to vitamin A, since a preparation made from seaweed, and presumably free from preformed vitamin, was no less toxic than their cod-liver oil concentrates.

In crude sources of vitamin A, therefore, many components other than the vitamin might well be responsible for toxicity. Experience with comparatively pure concentrates, moreover, has also suggested to some investigators that the vitamin may not be implicated after all. Although Drigalski (1933) found that concentrates given orally to rats were harmless if the vitamin had been destroyed by ultra-violet irradiation, Matsuoka (1934) observed convulsions in rats after the injection of concentrates which had been freed from vitamin by oxidation or hydrogenation. Conversely a distillate containing the vitamin was not toxic. Hamano (1935), who prepared various crystalline derivatives of vitamin A, found that toxic factors accompanied vitamin A into the unsaponifiable fraction, but could be separated by their inferior solubility in methanol. The purified vitamin did not appear to be toxic. Finally, Vedder & Rosenberg (1938) found no close relationship between vitamin A content and toxicity, as measured by the incidence of bone fractures, in distillates prepared from jew-fish liver oil.

The main purpose of the present experiments, of which a preliminary description has already been given (Moore & Wang, 1943), has been to test the toxicity of vitamin A in its purest available form, i.e. as a crystalline ester. The uterine haemorrhage described by Hartwell (1927) has been reinvestigated to decide whether vitamin A may not be directly involved. The opportunity has also been taken to test the claims of Vedder & Rosenberg (1938) and others that liberal doses of vitamins C and D are beneficial to animals given excess of vitamin A concentrate.

EXPERIMENTAL

The toxicity of pure vitamin A acetate to young rats

Exp. 1. A specimen of crystalline vitamin A acetate ($E^{1\%}_{1cm.} = 1500$ for the acetate) was kindly provided by British Drug Houses Ltd. To facilitate administration to rats it was dissolved in arachis oil. Five young male rats weighing 69–79 g. were given a basal diet consisting of casein 200, sugar 500, dried yeast 50, and salt mixture 50 parts. A measured amount of the solution of vitamin A acetate, equivalent to 50,000 i.u. daily during the first days of

the experiment, was given to the animals, after they had fasted overnight, mixed with 3–4 g. of the basal diet. When the dose had been finished the basal diet was given *ad libitum* for the rest of the day. After the first 4 days the dose of vitamin was reduced to 25,000 i.u., since some of the animals would not accept the previous dose.

On the eighth day of the experiment a limping gait, suggestive of tenderness in the legs, was observed in some of the animals. X-ray examination on the tenth day revealed fractures of the limbs in one instance, and the general condition of all the animals was poor. By the twentieth day all the rats had sustained fractures. Care had to be taken to avoid additional fractures during X-ray examination. Exophthalmos was seen in all cases, and in one rat a denudation around the eyes was observed. Post-mortem examination revealed subcutaneous and intramuscular haemorrhages in some of the animals.

X-ray photographs were taken of the rats after excess of vitamin A had been given for 20 days (Pl. 3). It will be seen that the bones become abnormally thin. In one case only there was detachment of the epiphysis from the shaft of the bone, a lesion frequently observed in rather different form in human infantile scurvy. Fractures occurred most often, however, near the centre of large bones. The ends of the bones were sometimes ankylosed with the formation of calluses.

Exp. 2. Young male rats of weight 48–86 g. were given a basal diet similar to that used in Exp. 1, but the dried yeast was increased to 100 parts with a view to improving appetite. Group 1 ('Control') of five animals received 4·5 g. of the basal diet daily mixed with 1·5 g. of plain arachis oil. The vitamin A allowance was 1000 i.u. per week. Group 2 ('Vitamin A excess') received the same diet, but the arachis oil contained 40,000 i.u. of vitamin A acetate daily. Group 3 ('Oxidized vitamin A') had the same diet as group 2, but the oil had been aerated on a boiling water-bath until the vitamin A, as measured by the antimony trichloride reaction, had all been destroyed.

In the group given excess of vitamin A acetate one rat had a limb fractured after 7 days, while within 14 days all the rats in this group had fractures. The animals were miserable in appearance, and gained no weight during the experiment. At autopsy intramuscular haemorrhages were found in some instances. In contrast the rats, both in the control group and in the group given oxidized vitamin A, remained well, had neither fractures nor haemorrhage, and made average gains in weight of 18 and 12 g. respectively during the first 14 days of the experiment.

Mineral content of the bones in hypervitaminosis A. The ash content of the pooled tibiae of the control group, on a fat-free basis, was 52·1 %, while for the group given excess of vitamin A the ash content was 51·3 %. Contrary to expectations no significant difference was therefore detected in hypervitaminosis A.

Ascorbic acid and hypervitaminosis A. In parallel with the preceding groups another five rats were given excess of vitamin A, but with the addition of 10 mg. daily of ascorbic acid. Two animals had fractures on the seventh day of the experiment, and the remaining three had developed fractures, and were in a miserable condition, when they were killed between the ninth and eleventh days. At autopsy intramuscular or subcutaneous haemorrhage was found in all these rats. The ascorbic acid did not therefore alleviate the injurious effects of the excess of vitamin A at the doses in which the two vitamins were given.

Estimations of ascorbic acid by the indophenol method in the livers, adrenals and urine of the preceding groups 1 and 2 also failed to reveal any significant effect of excessive vitamin A on ascorbic acid metabolism:

	Mean wt. of liver (g.)	Ascorbic acid in Liver (mg./g.)	Adrenals (mg./g.)	Urine/rat for 24 hr. (mg.)
Group 1 (control)	6·0	0·11	3·7	0·4
Group 2 (excess of vitamin A)	5·3	0·09	3·3	0·4

Calciferol and hypervitaminosis A. Five more rats received the same diet with excess of vitamin A, and with the addition of 1 mg. daily of calciferol. Fractures developed in all these animals within 11 days, and in some rats haemorrhagic lesions round the eyes were noticed. At autopsy no intramuscular haemorrhage was found, but the muscles of the legs had a purple colour suggestive of venous congestion.

The injection of vitamin A. When young rats were injected with massive doses of vitamin A their reaction never amounted to more than a temporary cramping and twitching of the muscles of the hind legs. In no instance did an animal die as the result of this treatment.

In six rats, which had single doses of 40,000–90,000 i.u. of vitamin A acetate dissolved in arachis oil by either intraperitoneal or subcutaneous injection, no cramping, nor any other injury, was observed. Another animal received an intraperitoneal injection of about 400,000 i.u. of free vitamin A alcohol, prepared from the acetate and dissolved in arachis oil, without developing cramp. An intraperitoneal injection of 25,000 i.u. of vitamin A as halibut-liver oil, however, caused cramping in one rat after 40 min. The condition persisted for over 2 hr., but the rat had recovered by the following

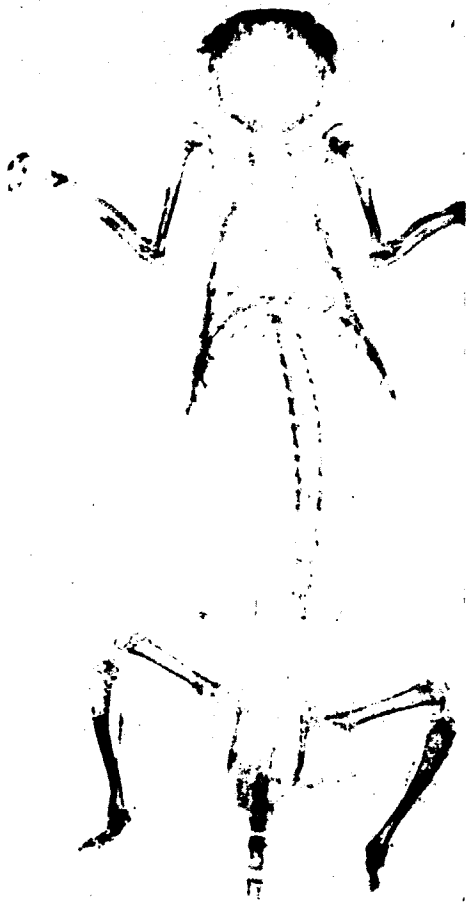

Fig. 1.

Fig. 3.

Fig. 4.

Fig. 2.

Fig. 1. Normal rat.

Fig. 2. Hypervitaminosis A of 20 days' standing. Among the abnormalities are: (i) fractured femurs; (ii) fractured tibia; (iii) ulna and radius are abnormally thin.

Fig. 3. Hypervitaminosis A. Another rat. Fracture of radius and detachment of epiphysis from shaft of bone.

Fig. 4. Hypervitaminosis A. Another rat. Fracture of tibia and fibia. The bones are ankylosed with callus formation.

day. Three other rats after intraperitoneal injections of 50,000 i.u. as halibut-liver oil had no cramp, but an animal injected with 100,000 i.u. had a short attack which started within 5 min. after the injection. Of three rats which had massive injections of a crude commercial concentrate of fish-liver oil containing 25,000 i.u. of vitamin A/g. two developed cramping within about an hour, but recovered. The third appeared miserable for a short time, but had no cramp and recovered rapidly. In all instances in which abnormality was observed it was difficult to decide whether the cramp was genuine, or merely the voluntary effort of the animal to adopt a position to overcome discomfort.

The effect of excessive vitamin A on gestation in the rat

Several series of experiments were carried out to decide whether the uterine haemorrhage observed by Hartwell in pregnant rats given large amounts of cod-liver oil can be ascribed to vitamin A. The usual procedure was to take mature females, which had received a mixed diet of natural foodstuffs, and to place them together with males until spermatozoa were detected in the vaginal smear. The male was then removed, and the diet of the female was changed, immediately or after an interval, to a purified ration which contained vitamin A dissolved in an oily medium. In most of the experiments the diet used contained casein 20 %, sugar 40 %, dried yeast 5 %, salt mixture 5 % and fat 30 %, the solid components and fat being mixed together just before feeding. In some experiments the composition of the diet was varied slightly, the main differences being a reduction in the fat to 20 % and the replacement of the dried yeast by an equal amount of marmite. No evidence was obtained to suggest that these minor alterations significantly affected the course of gestation. On the other hand, the incidence of haemorrhage was vitally affected by the stage at which excess of vitamin A was introduced into the diet.

Massive doses of vitamin A. Vitamin A acetate was given at the rate of 45,000 i.u. daily made up in arachis oil as 20 % of the diet. Other rats received 30,000–40,000 i.u. vitamin A daily as halibut-liver oil. The specimen used was kindly supplied by Allen & Hanburys Ltd., and contained 50,000 i.u. g. It was diluted with arachis oil to make 30 % of the diet. Similar results were obtained with both sources of vitamin A and for the sake of simplicity they may be combined (see table at head of next column). Haemorrhage was first noticed between the fifteenth and twenty-first day of pregnancy in different animals. Inspection at autopsy of the uteri of rats which had died from haemorrhage suggested that the bleeding occurred at the junction of the placenta

Vitamin A given	Total no. of rats in group	No. of cases of: Uterine haemorrhage	Failure of implantation or resorption	Litters, dead or alive, without fatal haemorrhage
(*a*) Within 10 days after coitus	13	6	6	1
(*b*) More than 10 days after coitus	12	0	0	12

and endometrium. The placenta was sometimes partially detached, and the endometrium eroded. Histological examination indicated the presence of extensive extravasations of blood at the junction of the placenta and endometrium, but in view of the presence of maternal blood sinuses in this region during normal pregnancy the certain detection of abnormality was difficult. In agreement with the view that the retro-placental haemorrhage had occurred suddenly the structure of the foetuses appeared to be more or less normal.

It must be emphasized that litters have been counted as 'delivered' whether alive or dead. In practice the animals could not be watched continuously, and often it was difficult to decide whether neglected litters had been born alive or dead. Even when the young were born alive they were not reared unless the mother's ration was changed to a mixed diet of natural foodstuffs.

High doses of vitamin A. A veterinary cod-liver oil 'compound', containing 500 i.u. of vitamin A g., was given as 20 % of the diet from the time of fertilization. The daily intake of vitamin was about 1000 i.u. The results were:

	Total no. of rats	No. of cases of: Uterine haemorrhage	Failure of implantation or resorption	Litters, dead or alive, without fatal haemorrhage
Vitamin A given at coitus	6	1	1	4

In this experiment marmite was given in place of the usual dried yeast. In one of the four rats which survived parturition the latter was accompanied by more profuse haemorrhage than is usual. Of five other rats which were given the oil as 30 % of their diet, four had litters. In the remaining rat no signs of implantation were found at autopsy.

Dosing with marine oils low in vitamin A. A stale specimen of sardine oil, several years old and brown in colour, was given to two rats as 30 % of the diet from the time of coitus. Fresh whale oil was given to six other rats. For the purpose of another in-

vestigation a diet containing 30% of the oil was given not only during pregnancy but for 4 months before mating. Three of these animals had been dosed with tocopherol since first receiving the whale oil, while the other three had not. The results were:

Oil given at coitus	Total no. of rats	No. of cases of: Uterine haemorrhage	Failure of implantation or resorption	Litters, dead or alive, without fatal haemorrhage
Stale sardine oil	2	0	1	1
Whale oil + tocopherol	3	0	1	2
Whale oil − tocopherol	3	0	3	0

Both rats having sardine oil declined in weight throughout the experiment and became very emaciated. The rats having whale oil were not emaciated, and all appeared superficially to be in good health. No abnormal haemorrhage was noticed in any of the rats receiving either oil.

The incidence of uterine haemorrhage in relation to the vitamin A intake. In all these experiments on reproductive abnormalities uterine haemorrhage therefore only resulted when excess of vitamin A was given within 10 days after coitus. The incidence of haemorrhage in rats given oils within this period may be summarized:

Daily vitamin A intake (i.u.)	Incidence of uterine haemorrhage
40,000	6 out of 13
1,000	1 out of 11
0–200	0 out of 8

Haemorrhage in adult non-pregnant rats given excess of vitamin A. In the experiments on the effects of vitamin A acetate on pregnant rats, described in a preceding paragraph, haemorrhage in sites other than the uterus was observed in three instances. In two animals subcutaneous haemorrhages were found in the hind legs. A careful examination failed to reveal any corresponding fracture of the bones. The third rat apparently bled to death as the result of a minor injury caused by self-inflicted scratching behind the ear.

We have also observed haemorrhage in some male rats which for the purpose of another investigation had been given a diet deficient in vitamin E, with the subsequent addition of 36,000 i.u. of vitamin A daily as halibut-liver oil. Only two out of six rats were affected. One died suddenly after receiving the halibut-liver oil for 17 days. There was no premonitory loss in weight, and at autopsy normal intraperitoneal and subcutaneous fat deposits were found. The cause of death was massive haemorrhage in the spleen, the capsule of which was detached and greatly distended with blood. The second rat, which in addition to halibut-liver oil received adequate doses of tocopherol, suffered sudden and complete paralysis of the hind legs after 18 days, again without any loss in weight. Post-mortem examination revealed haemorrhage in and around the bladder, in the pectoral muscles, and inside the cranial cavity at the base of the skull.

DISCUSSION

The lesions in hypervitaminosis A. The results described above indicate that vitamin A in the purest available form is toxic when given in great excess. It is improbable, however, that all the types of lesions which have been reported as the result of overdosing with crude concentrates are equally specific. Skeletal fractures and haemorrhages are, in our experience, the most characteristic lesions in genuine hypervitaminosis A. The fractures occur most consistently in young growing rats, and were found without exception in the present experiments. Haemorrhage is also frequent, if not invariable, in the fractured limbs. In adult rats the bones are probably more resistant to fractures, since we detected no breakages in our older animals. Haemorrhage, however, was frequent, although irregular in its incidence, distribution and severity. Bleeding was sometimes found in the limbs of rats which appeared to be in good health before they were killed. In others heavy internal haemorrhage into the viscera, or external haemorrhage through a minor wound, was rapidly fatal. The uterine haemorrhage in pregnant rats, originally described by Hartwell (1927), appears to be a special manifestation of the general liability to haemorrhage in hypervitaminosis A.

In many of our animals a rawness of the skin was often seen around the eyes, nose and mouth. This injury was undoubtedly due to overdosing with vitamin, but in view of the wide variety of oils which produce skin lesions it is to be considered a less specific lesion than fracture or haemorrhage. We have been unable to reproduce the fatal cramps which Matsuoka (1934) observed as the result of injecting vitamin A concentrates. He was, however, fully aware that the effect could be produced by substances other than vitamin A.

Hypervitaminosis A and scurvy. Mouriquand & Michel (1922) claimed that cod-liver oil antagonized vitamin A in guinea-pigs, causing scurvy even when lemon juice was given. Collett & Eriksen (1938) supported this contention with regard to cod-liver oil, but found that a moderate excess of vitamins A and D had no injurious effect. Although normally the rat is not liable to scurvy, since it is able to synthesize ascorbic acid, Vedder & Rosenberg (1938)

have more recently pointed out that the symptoms which they observed in their animals given excess of fish-liver oil suggested this disease. Thus failure of growth and abnormal fragility of the bones were associated with haemorrhage. In their experiments bleeding occurred particularly at the eyes and nose, but also in mucous membranes in other sites. Our observations of intramuscular and subcutaneous haemorrhage in the limbs brings the picture in hypervitaminosis A even nearer to that seen in scurvy. According to Hess (1920) haemorrhages into the muscles or between the muscle planes are very common in scurvy in adult human subjects, while similar haemorrhages are also frequent in experimental scurvy in the guinea-pig. Massive haemorrhages in the viscera, which often occurred in our adult rats, are less frequent in the human subject, but Eddy & Dalldorf (1941) state that bleeding may take place in any organ, and may vary in size from petechiae to huge extravasations. Their report of a case of fatal haemorrhage into the pericardium in a human subject recalls the observation of the same lesion in a hypervitaminotic rat by Rodahl & Moore (1943).

The finding that young rats are more prone to bone fractures than older animals also recalls the greater incidence of skeletal lesions in infantile than in adult human scurvy. It must be noted, however, that in rats with hypervitaminosis fractures near to the centre of the shaft of the bone are the most prominent feature. The separation of the epiphysis, and fractures in the region near the growing end of the bone to which the human infant is particularly vulnerable, are sometimes present, but perhaps less conspicuous.

A detailed discussion of the points of similarity and difference between the gross lesions in hypervitaminosis A and in scurvy is made difficult by the variations which exist between the three modifications of scurvy as found in juvenile and adult human subjects and in the experimental guinea-pig. Even if we were to make the assumption that the symptoms in hypervitaminosis A are due to a conditioned form of scurvy, it would be too much to expect that the combination of lesions in the rat should either resemble one particular form of scurvy as found in another animal, or should include all the lesions which are found in all forms of scurvy. While, however, the anatomical resemblance between the lesions in hypervitaminosis A and in scurvy is in our opinion largely dependent on our interpretation of what the term 'scurvy' implies, we have been unable to confirm the view that a secondary deficiency of vitamin C can be detected in hypervitaminosis A by biochemical means. Thus we were unable with pure vitamin A acetate either to repeat the observation of Vedder & Rosenberg (1938) that ascorbic acid affords protection against excess of vitamin A concentrate, or to detect any abnormality in ascorbic acid metabolism in our hypervitaminotic rats.

Hypervitaminosis A and vitamins D and B. Thoenes (1935) has asserted that vitamins A and D are antagonistic, and Gross-Selbeck (1935) has reported that liberal dosing with vitamin A affords protection against injury through excess of vitamin D. The reverse finding of Vedder & Rosenberg (1938) that vitamin D (50,000 i.u. daily) gives protection against excess of vitamin A concentrate is therefore not surprising. In our experiments, however, no benefit was derived from doses of 1 mg. of calciferol. In view of the toxicity of great excess of calciferol it may be necessary to adjust the dose carefully in order to provide protection against excess of vitamin A, and our findings must be taken to indicate only that no protection was exerted at the levels chosen. Additional allowances of the vitamin B complex have also been found to be beneficial to animals given excess of marine oils (Harris & Moore, 1928; Bell, Gregory & Drummond, 1933). According to Yamamoto (1934) and Yoshida (1937), however, the extra vitamin B complex, of which the active constituent is riboflavin, counteracts the injurious effect of higher unsaturated acids rather than of vitamin A. In the present experiment the effect of varying the allowance of the vitamin B complex was not investigated systematically, but such changes as were made from time to time had little or no obvious effect on the development of hypervitaminosis A.

SUMMARY

1. Hypervitaminosis A was induced in rats by giving them orally massive doses of either crystalline vitamin A acetate or halibut-liver oil.

2. The most characteristic lesions were skeletal fractures, which occurred most consistently in young animals, and internal or external haemorrhage. These injuries bore some superficial resemblance to those found in human and experimental scurvy.

3. The uterine haemorrhage in pregnant rats given excess of cod-liver oil, first reported by Hartwell, was reproduced in animals given excess of cod-liver oil, halibut-liver oil or vitamin A acetate. This haemorrhage appears to be a special manifestation of the general liability to haemorrhage in hypervitaminosis A.

Our thanks are due to Dr L. J. Harris for his valuable criticism, to British Drug Houses Ltd. for a generous gift of vitamin A acetate, to Prof. W. J. Hamilton of St Bartholomew's Hospital for histological examinations, to Miss A. C. Cooper and Miss J. E. Payne for the care of the experimental animals and to Mr A. W. Davies for X-ray photography. Y. L. Wang is indebted to the Medical Research Council for a personal grant.

Note added in proof 30 *July* 1945. Since this paper was written, Light, R. F., Alscher, R. P. & Frey, C. N. (1944, *Science*, **100**, 225) have reported that hypoprothrombinaemia, which often causes cerebral haemorrhage, may be induced in rats by massive doses of vitamin A, and may be prevented by the simultaneous addition of vitamin K.

REFERENCES

Agduhr, E. (1926). *Acta paediatr., Stockh.*, **6**, 165.
Agduhr, E. (1928). *Acta paediatr., Stockh.*, **7**, 289.
Bell, M. E., Gregory, E. & Drummond, J. C. (1933). *Z. Vitaminforsch.* **2**, 161.
Bomskov, C. & Seeman, G. (1933). *Z. ges. exp. Med.* **89**, 771.
Chevallier, A., Cornil, L. & Chabré, P. (1934). *C.R. Soc. Biol., Paris*, **115**, 541.
Collazo, J. A. & Rodriguez, J. S. (1932). *Klin. Wschr.* **12**, 1732, 1768.
Collett, E. & Eriksen, B. (1938). *Biochem. J.* **32**, 2299.
Davies, A. W. & Moore, T. (1934). *Biochem. J.* **28**, 288.
Drigalski, W. (1933). *Klin. Wschr.* **12**, 308.
Eddy, W. H. & Dalldorf, G. (1941). *The Avitaminoses*, 2nd ed., p. 327. London: Baillière, Tindall and Cox.
Gross-Selbeck, C. (1935). *Klin. Wschr.* **14**, 61.
Hamano, S. (1935). *J. agric. chem. Soc. Japan*, **11**, 341.
Harris, L. J. & Moore, T. (1928). *Biochem. J.* **22**, 1461.
Hartwell, G. A. (1927). *Biochem. J.* **21**, 1076.
Hess, A. F. (1920). *Scurvy Past and Present.* Philadelphia and London: J. B. Lippincott Co.
Hoff, F. & Jeddeloh, B. (1934). *Z. ges. exp. Med.* **95**, 67.
Lewis, J. T. & Reti, L. (1934). *Rev. Soc. argent. Biol.* **10**, 302.
Matsuoka, M. (1934). *Bull. Inst. phys. chem. Res. Japan*, **13**, 1267.
Moore, T. & Wang, Y. L. (1943). *Biochem. J.* **37**, *Proc.* viii.
Mouriquand, G. & Michel, P. (1922). *C.R. Soc. Biol., Paris*, **1**, 1170.
Ocana, T. (1935). *Rev. Soc. argent. Biol.* **11**, 147.
Rodahl, K. & Moore, T. (1943). *Biochem. J.* **37**, 166.
Simola, P. E. & Kalaga, T. (1934). *Skand. Arch. Physiol.* **71**, 31.
Strauss, K. (1934). *Beitr. path. Anat.* **94**, 345.
Takahashi, K., Nakamiya, Z., Kawakami, K. & Kitasato, T. (1925). *Sci. Pap. Inst. phys. chem. Res., Tokyo*, **3**, 81.
Thoenes, F. (1935). *Dtsch. med. Wschr.* **61**, 2079.
Vedder, E. B. & Rosenberg, C. (1938). *J. Nutrit.* **16**, 57.
Wesaw, W., Wronski, B., Wroblewski, A. & Wroblewski, B. (1938). *Klin. Wschr.* **17**, 777.
Yamamoto, I. (1934). *Bull. Inst. phys. chem. Res. Japan*, **13**, 1.
Yoshida, M. (1937). *J. agric. chem. Soc. Japan*, **13**, 120.
Ypsilanti, P. H. (1935). *Klin. Wschr.* **14**, 90.

Moore-'65
Bib. No. 6346

Reproduced by permission
of the copyright owner

Proc. Nutr. Soc. 24:129-135. 1965.

Vitamin A deficiency and excess

By T. MOORE, *Dunn Nutritional Laboratory and Strangeways Research Laboratory, Cambridge*

The pathological effects of deficiency of vitamin A (Wolbach, 1954; Moore, 1957, 1960) and of excess (Rodahl, 1949; Wolbach, 1954; Moore, 1957) have already been extensively reviewed. It is difficult, therefore, for me to contribute any new ideas as a start for this important Symposium. I can only recapitulate salient points in our knowledge, and so provide an introduction for various topics which will be discussed by subsequent authors.

Vitamin A seems rivalled only by vitamin E in the wide variety of lesions which

can be produced in its absence. Its distinction in producing characteristic lesions, when given in great excess, is shared only by vitamin D. Obviously a short paper must be highly selective in the choice of material, and must omit mention of many interesting pathological findings. The quotation of references must be very incomplete.

The occurrence of avitaminosis and hypervitaminosis A. Vitamin A is present in substantial amounts in the livers of most human subjects, and of most animals living under natural conditions. An important point established in the famous Sheffield experiment on adult human volunteers (Hume & Krebs, 1949) was the confirmation of the ability of the reserves of vitamin A known to be stored in the liver (Moore, 1937) to prevent signs of deficiency for months, or even years.

The presence of these reserves in well-nourished subjects, however, must not give rise to feelings of false security. Diets which are largely based on cereal foods, other than yellow maize, and from which green vegetables and preformed vitamin A are excluded, are always a source of danger. Outbreaks of vitamin A deficiency occur only too readily in pigs, poultry and calves fed on conventional diets, unless adequate sources of vitamin A are provided. The old story seems to keep repeating itself in different modifications: thus the most recent outbreak of deficiency has been in young cattle raised intensively on barley (Abrams, Bridge, Palmer, Spratling & Sharman, 1961). Other cattle foods conducive to vitamin A deficiency are sugar-beet pulp and poor-quality straw. Parched pastures can cause deficiency: Blaxter (1951) drew attention to a biblical reference (Jeremiah, Ch. 14, v. 6) about wild asses which showed behaviour highly characteristic of vitamin A deficiency 'because there was no grass'. In human subjects deficiency can arise from the excessive consumption of farinaceous foods. The classical cases described by Bloch (1920–1) occurred mainly in infants fed upon oatmeal gruel. A diet of sweetened skim milk, however, can also cause deficiency (de Haas & Meulemans, 1938).

Poisoning by excess of vitamin A occurs in animals only under experimental conditions. Man, however, has sustained injuries in three ways. (1) Arctic explorers have unwisely eaten polar bear's liver, which is very rich in vitamin A (Rodahl & Moore, 1943); (2) young infants have been given more vitamin A than they can tolerate, purely as a protective measure (Josephs, 1944; Marie & Sée, 1954); (3) adult patients with certain rare skin diseases, such as ichthyosis and Darier's disease, have been treated by prolonged and heavy dosing for the purpose of ameliorating the skin lesions (Gerber, Raab & Sobel, 1954).

Hypervitaminosis A can only arise from excess of preformed vitamin A, and not from excess of provitamins. In man a minor abnormality called 'carotenaemia' or 'hypercarotenosis', involving yellow discoloration of the palms of the hands and soles of the feet, can result, *inter alia*, from an excessive liking for carrots (von Noorden, 1907; Moro, 1908). In itself it is harmless, but it may accompany diabetes or thyroid imbalance.

The lesions in avitaminosis A. The following list (Moore, 1957, 1960) includes abnormalities observed in one or other of several species, such as the rat, rabbit, dog, ox, hen, monkey and man:

(1) Defective dark adaptation.
(2) Failure of growth.
(3) Xerosis and keratinization of mucous membranes. Xerophthalmia. Secondary infections.
(4) Faulty bone modelling, with the production of thick, cancellous bones instead of thinner, more compact bones.
(5) Nerve lesions, often associated with bone lesions.
(6) Increased pressure of the cerebrospinal fluid, developed independently or in association with deformed skull bones. Hydrocephalus.
(7) Abnormalities of reproduction, including degeneration of the testes and abortion, or the production of malformed offspring.
(8) Certain forms of skin disease.
(9) Death.

The first effect of dietary deficiency of vitamin A, apart from congenital malformations, is usually defective dark adaptation. This abnormality was, indeed, the only functional defect observed in the Sheffield experiment. Work on rats, by Dowling & Wald (1960), has demonstrated an important difference between defective dark adaptation and most of the other characteristic lesions. The animals were given a diet deficient in vitamin A, but with supplements of vitamin A acid, a substance which first came to light as a step in the chemical synthesis of vitamin A. On this regime the animals grew well and survived for indefinite periods, but they became totally blind. This was not due to xerophthalmia, which was avoided, but to a failure of the retina to respond to light, and finally to degeneration of the retina. Apparently the visual function of vitamin A, for which vitamin A alcohol was necessary, could be divorced from its functions in the general system, for which vitamin A acid could replace vitamin A alcohol. Subsequently, however, Thompson, Howell & Pitt (1964) disturbed this simple picture by demonstrating that vitamin A alcohol is also required for the reproductive functions, which cannot be supported by vitamin A acid.

Defective dark adaptation can be conveniently regarded as a biochemical lesion, since in its early stages it can respond very rapidly to vitamin A therapy. The response of the other lesions to therapy will depend on the severity of the resulting structural damage, and to some extent on the growth period still available before maturity is reached.

Death in avitaminosis A. Death has been listed among the characteristic 'abnormalities' because avitaminosis A seems to be one of the most lethal of all dietary deficiencies. If weanling rats are given a diet deficient in vitamin A they will usually grow for 4 or 5 weeks, survive for 2 or 3 weeks more at steady or declining body-weight, and then promptly die. In contrast, young rats given a diet deficient in vitamin E usually show clear signs of deficiency, by the dialuric acid haemolysis test, within 1 or 2 weeks. Abnormalities in the testes or uterus will be demonstrable at 3-4 months, but the rat will still remain in good health, and continue to grow. Eventually, after 8-10 months, a long decline in body-weight will set in, accompanied by the development of severe muscular dystrophy. The animal may linger on, however, to the age of 15 or 18 months, before finally succumbing to intercurrent

disease. In my own experience rats may also continue to linger on for long periods, although obviously abnormal, in deficiencies of protein, calcium, copper, riboflavine and essential fatty acids.

Emphasis of the lethal aspect of vitamin A deficiency may possibly provoke criticism, particularly on the grounds that conclusions drawn from experiments on growing rats cannot safely be applied to other species, and indeed to other stages in the life cycle of the rat. Thus vitamin E deficiency is rapidly fatal to foetal rats (Evans & Burr, 1927), and even to weanlings if they are also deficient in protein (Schwarz, 1949; Lindan & Himsworth, 1950). Chicks also succumb rapidly to avitaminosis E (Adamstone, 1942). Moreover, lack of vitamin A is perhaps a less rapid cause of death in larger animals such as cattle (Guilbert & Hart, 1934; Madsen & Earle, 1947) and pigs (Hughes, Lienhardt & Aubel, 1929–30) than in rats. According to McLaren (1960), however, untreated vitamin A deficiency is notorious as a cause of death, no less than of eye lesions, in young children. If vitamin A deficiency were less dangerous to life, the incidence of permanent blindness, as the aftermath of xerophthalmia, would be much increased.

As McLaren has also pointed out, death may forestall the development of xerophthalmia in young rats. Similarly, the full development of all the other lesions, except presumably failure in dark adaptation, may depend upon the time of survival of the animal. Another important factor is the rate of growth, and the resulting stress imposed on the developing tissues. It is probably for such reasons that some of the lesions of avitaminosis A are more common in some species than in others. In particular, gross bone lesions are produced more readily in larger animals, such as dogs and cattle, than in rats. Presumably rats succumb to other lesions, such as the xerosis and infection of membranes, before the bone lesions have time to reach full development.

Delayed lesions after vitamin A deficiency. In young growing rats, and in human subjects who have suffered from the early stages of night-blindness, adequate vitamin A therapy should produce complete cures. Other lesions, such as perforation of the cornea as a sequel of xerophthalmia, may lead to permanent injury, even if the general health of the subject can be restored.

Another type of response is less familiar, but of considerable pathological interest. Thus instances are known, in at least two species, of the restoration of vitamin A to the diet first causing a cure, but with the subsequent development of lesions.

(1) In calves a period of vitamin A deficiency may cause retardation of growth and also malformation of the bones of the skull, but for a time may leave the optic nerve intact. The restoration of a diet rich in carotene, such as fresh green pasture, will restore growth, and improve the general condition of the animal. Expansion of the malformed bone, however, may distort or break the optic nerve, and so cause sudden and permanent blindness at a time when the diet is adequate in carotene (Blakemore, Ottaway, Sellers, Eden & Moore, 1957).

(2) In rats a prolonged period of partial vitamin A deficiency may be imposed by restriction to a deficient diet, supplemented either with daily small doses of vitamin A, or with larger doses given only occasionally. This treatment will at first allow

survival and slow growth. More liberal dosing will promote more rapid growth. Eventually, however, growth may cease, and the rat will decline in weight and die. Autopsy will show that death has been caused by cystitis, provoked by the accumulation of stones in the bladder. The culmination of this lesion can occur at a point when substantial reserves of vitamin A have accumulated in the liver. It can therefore be regarded as a 'hangover' from an earlier period of deficiency. A lesion then started has gone on developing, unchecked and for a time not lethal, until the point is reached when it becomes intolerable to the organism (Moore, 1957).

Diseases which precipitate vitamin A deficiency, or affect vitamin A metabolism. A comprehensive review of this wide field is impossible, but in view of its great importance it must not be completely overlooked. The relationships between vitamin A and disease can perhaps be divided into three types, although overlapping is inevitable.

(1) In human subjects receiving diets deficient in vitamin A the typical lesions of avitaminosis may be precipitated by intercurrent illness, or other forms of nutritional stress. Thus in the observations of Bloch (1920–1) xerophthalmia usually followed a period of general ill-health and diarrhoea in infants whose diet was usually deficient in protein.

(2) In subjects receiving a diet adequate in vitamin A, secondary deficiency may result from failure of absorption of the vitamin, or defects in its metabolism. Blegvad (1924), to cite a single example, reported on the occurrence of severe night-blindness in a man with cancer of the liver. The diet appeared to be adequate in vitamin A, and there was no response to oral therapy. Parenteral injections of a vitamin A concentrate, however, rapidly corrected the night-blindness.

(3) In many diseases, defects in the absorption or metabolism of vitamin A may be demonstrated by measurements of the level of vitamin A in the blood or liver, but without functional or pathological evidence of vitamin A deficiency. Thus the level of vitamin A in the blood falls during fever (Lindqvist, 1938) and excretion of the vitamin in the urine sometimes occurs (Boller & Brunner, 1936). In subjects who have died from certain diseases, the liver reserves found at autopsy are low. In chronic nephritis, for example, the reserves average only about one-tenth of those in cases of accidental death, and indeed often virtually disappear (Moore, 1937).

It would be rash to exclude the possible occurrence of undetected secondary deficiency of vitamin A, severe enough to increase the ill effects of the primary disease, in many common diseases. Up to the present, however, there has been no positive evidence that any beneficial results can be obtained by dosing with vitamin A. Further research on this topic is obviously desirable.

As already mentioned, there is considerable overlapping under the above three headings. Protein deficiency, for example, not only precipitates vitamin A deficiency when the diet is low in vitamin A (Bloch, 1920–1), but interferes with the carriage of the vitamin in the blood when the dietary intake of the vitamin is adequate (Friend, Heard, Platt, Stewart & Turner, 1961).

The lesions in hypervitaminosis A. The lesions caused by grossly excessive intakes of

vitamin A, which can also be induced by excess of vitamin A acid (Thompson & Pitt, 1960), have been reviewed by Moore (1957). They include:

(1) Cessation of growth (rat).
(2) Skin abnormalities (rat, man).
(3) Increased pressure of the cerebrospinal fluid (human infant). Nausea and vomiting (adult man).
(4) Bone abnormalities (man). Bone fractures (rat).
(5) Profuse, fatal internal haemorrhage (rat). Secondary vitamin K deficiency (rat).
(6) Congenital malformations (rat).

Some similarity is apparent between the lesions in deficiency and excess of vitamin A. Thus both these conditions can cause increased cerebrospinal fluid pressure, abnormalities in the bones, and congenital malformations. The lesions in the bones caused by deficiency, however, are very different from those caused by excess. Congenital malformations can occur in many other forms of nutritional deficiency, in infections, and in poisoning by drugs. The early and more recent workers who studied the effect of vitamin A deficiency (Hale, 1935; Andersen, 1941; Warkany & Schraffenberger, 1946) and excess (Cohlan, 1953; Giroud & Martinet, 1954) on the development of the foetus, can be honoured as pioneers in a field which extended far beyond their original interests.

In passing, I may mention some recent experiments which I have made on combined hypervitaminosis A and calcium deficiency in rats. It has long been known, of course, that hypervitaminosis A does not cause decalcification of the bones. Nevertheless, I have myself described the hypervitaminotic bones as soft, and have implied that this softness is the cause of their spontaneous fracturing. It occurred to me that if the bones were made soft by a diet deficient in calcium, they should become much more vulnerable to hypervitaminosis A. Rats were therefore fed on a diet of meat, either alone or with added calcium carbonate, and with or without toxic overdoses of vitamin A. To my surprise the absence of calcium from the diet had virtually no influence on the incidence, or speed of development, of skeletal fractures. Under the conditions of my experiment, softness depended on calcium deficiency, and fracturing on hypervitaminosis A.

A characteristic of the hypervitaminotic bones, seen best in the femurs, was growth in length without corresponding growth in thickness. Fracture was probably the final result of extreme attenuation of the bone. This thinning of the bones in hypervitaminosis A had already been noticed by Rodahl (1949). It may be contrasted with a thickening, or stubbiness of the bones, which has been reported by Wolbach (1954) as an effect of vitamin A deficiency. Irrespective of the details of the mechanisms involved, therefore, the changes observed are consistent with vitamin A having a single overall effect on development of the bone length, which is hindered in deficiency, and overemphasized in excess.

Summary

Vitamin A deficiency occurs readily in farm animals that are fed on diets based mainly upon cereals, or other foodstuffs low in carotene. Cereal diets, or diets based on skim

milk, can also cause deficiency in human subjects, particularly infants. The lesions in avitaminosis A in various species include defective dark adaptation, xerosis of membranes, skeletal abnormalities, raised cerebrospinal fluid pressure and congenital malformations. Infections frequently follow xerosis. Vitamin A deficiency is usually characterized by a high mortality rate, and by the short period of survival after the first signs of deficiency have appeared. Instances are known of the delayed appearance of injuries resulting from a past period of vitamin A deficiency. The functions of vitamin A in the retina and in reproduction differ from its general functions in failing to accept vitamin A acid as a substitute for vitamin A alcohol. Various forms of interaction are known to occur between vitamin A deficiency, disease, and other dietary deficiencies. Hypervitaminosis A has resulted in man from the consumption of polar bear's liver, or from grossly excessive vitamin A therapy. It can also be induced readily in experimental animals. The injuries sustained in various species include skeletal abnormalities, raised cerebrospinal fluid pressure, secondary vitamin K deficiency and congenital malformations.

REFERENCES

Abrams, J. T., Bridge, P. S., Palmer, A. C., Spratling, F. R. & Sharman, I. M. (1961). *Vet. Rec.* **73**, 683.
Adamstone, F. B. (1942). *Amer. J. med. Tech.* **8**, 76.
Andersen, D. H. (1941). *Amer. J. Dis. Child.* **62**, 888.
Blakemore, F., Ottaway, C. W., Sellers, K. C., Eden, E. & Moore, T. (1957). *J. comp. Path.* **67**, 277.
Blaxter, K. L. (1951). *J. R. agric. Soc.* **112**, 25.
Blegvad, O. (1924). *Acta ophthal., Kbh.*, **1**, 172.
Bloch, C. E. (1920-1). *J. Hyg., Camb.*, **19**, 283.
Boller, R. & Brunner, O. (1936). *Klin. Wschr.* **15**, 1106.
Cohlan, S. Q. (1953). *Science*, **117**, 535.
de Haas, J. H. & Meulemans, O. (1938). *Lancet*, i, 1110.
Dowling, J. E. & Wald, G. (1960). *Vitam. & Horm.* **18**, 515.
Evans, H. M. & Burr, G. O. (1927). *Mem. Univ. Calif.* no. 8.
Friend, C. J., Heard, C. R. C., Platt, B. S., Stewart, R. J. C. & Turner, M. R. (1961). *Brit. J. Nutr.* **15**, 231.
Gerber, A., Raab, A. P. & Sobel, A. E. (1954). *Amer. J. Med.* **16**, 729.
Giroud, A. & Martinet, M. (1954). *C.R. Soc. Biol., Paris*, **148**, 1742.
Guilbert, H. R. & Hart, G. H. (1934). *J. Nutr.* **8**, 25.
Hale, F. (1935). *Amer. J. Ophthal.* **18**, 1087.
Hughes, J. S., Lienhardt, H. F. & Aubel, C. E. (1929–30). *J. Nutr.* **2**, 183.
Hume, E. M. & Krebs, H. A. (1949). *Spec. Rep. Ser. med. Res. Coun., Lond.*, no 264.
Josephs, H. W. (1944). *Amer. J. Dis. Child.* **67**, 33.
Lindan, O. & Himsworth, H. P. (1950). *Brit. J. exp. Path.* **31**, 651.
Lindqvist, T. (1938). Stüdien über das Vitamin A beim Menschen. Uppsala: Appelbergs Boktrykeri AB.
McLaren, D. S. (1960). *Trans. 1st Congr. Asia-Pacific Acad. Ophthalmol., Manila*, p. 88.
Madsen, L. L. & Earle, I. P. (1947). *J. Nutr.* **34**, 603.
Marie, J. & Sée, G. (1954). *Amer. J. Dis. Child.* **87**, 731.
Moore, T. (1937). *Biochem. J.* **31**, 155.
Moore, T. (1957). *Vitamin A.* Amsterdam: Elsevier.
Moore, T. (1960). *Vitam. & Horm.* **18**, 499.
Moro, E. (1908). *Münch. med. Wschr.* **55**, 1637.
Rodahl, K. (1949). Norsk Polarinstitutt, Skrifter, no. 92. Oslo: Dybwad.
Rodahl, K. & Moore, T. (1943). *Biochem. J.* **37**, 166.
Schwarz, K. (1949). *Ann. N.Y. Acad. Sci.* **52**, 225.
Thompson, J. N., Howell, J. McC. & Pitt, G. A. J. (1964). *Proc. roy. Soc. B*, **159**, 510.
Thompson, J. N. & Pitt, G. A. J. (1960). *Nature, Lond.*, **188**, 672.
von Noorden, C. H. (1907). *Die Zuckerkrankheit und ihre Behandlung*, 4th ed., p. 149. Berlin.
Warkany, J. & Schraffenberger, E. (1946). *Arch. Ophthal., N.Y.*, **35**, 150.
Wolbach, S. B. (1954). In *The Vitamins*. Vol. 1, p. 106. [W. H. Sebrell Jr. and R. S. Harris, editors.] New York: Academic Press Inc.

Am. J. Med. 50:129-136. 1971.

Muenter-'71
Bib. No. 6499

Reproduced by permission of the copyright owner

Chronic Vitamin A Intoxication in Adults

Hepatic, Neurologic and Dermatologic Complications

MANFRED D. MUENTER, M.D.
HAROLD O. PERRY, M.D.
JURGEN LUDWIG, M.D.

Rochester, Minnesota

Two cases of chronic vitamin A intoxication in adults are described, and the literature is reviewed. Hepatocellular damage, portal fibrosis and eventual cirrhosis may result from chronic vitamin A intoxication in man. Neurologic complications are frequent and consist predominantly of increased intracranial pressure, muscle stiffness aggravated by exercise, and mental changes. Teratogenic effects have been documented in animal experiments and affect primarily the development of the central nervous system. Large doses of vitamin A, if prescribed at all for dermatologic conditions, should be given only for limited periods under close medical supervision and should not be given during pregnancy.

Vitamin A intoxication is a well recognized clinical entity. The acute form is self-limited and rarely presents a diagnostic problem. The chronic form has been observed predominantly in children, but an increasing number of cases have been described in adults. We report two cases of chronic vitamin A intoxication because of some findings hitherto undescribed.

CASE REPORTS

Case 1. An eighteen year old white women presented in November 1967 complaining of tiredness, dry and cracking skin, soreness and stiffness of muscles after exercise, and infected toe and finger nails. A diagnosis of McArdle's disease had been made elsewhere.

Her illness began in March 1966 as a flu-like syndrome with a skin eruption which was treated with vitamin A (Aquasol A), 300,000 IU daily. She had continued this medication beyond the recommended period of one month, taking 100,000 to 200,000 IU daily because of its favorable effect on her dry skin.

In July 1966 she noticed painful muscular stiffness and fatigue after exercise, more marked in the lower than in the upper extremities, which would subside within half an hour of rest; for example, after riding a bicycle she would be unable to walk because of muscle stiffness in both legs. She also complained of pain in bones and joints, nosebleeds, anorexia, swollen feet, cold forearms and generalized pruritus which was followed within two days by scaling. Severe generalized headache of one week's duration occurred in August 1966. A generalized maculoerythematous eruption, scaling and dryness of the skin were noted. A diagnosis of Stevens-Johnson syndrome was considered. Severe infections of ingrown toe and finger nails then occurred and were resistant to medical and surgical therapy. A diagnosis of McArdle's disease was made in

From the Sections of Neurology, Dermatology and Experimental and Anatomic Pathology, Mayo Clinic and Mayo Foundation, Rochester, Minnesota 55901. Requests for reprints should be addressed to Section of Publications, Mayo Clinic, Rochester, Minnesota 55901. Manuscript received January 23, 1970.

Figure 1. Case 1. Marginal discoloration (bright red) of gingiva.

September 1966. In March 1967 a bright red discoloration of the gingival margin was noted. In summer 1967 the maculoerythematous skin eruption cleared but recurred again for several weeks in the fall. For one year the patient had had an intense craving for carrots and eggs.

The medical and family histories were noncontributory.

Examination in November 1967 disclosed a healthy appearing woman in no distress (temperature 98.7°F, pulse 72/minute, respiration 17/minute, blood pressure 130/90 mm Hg). The skin was dry and scaly. An angular stomatitis and bleeding fissures of the paronychial tissues were noted. Several ingrown toe and finger nails had produced excessive granulation tissue. The gingiva was brightly red at its margin (Figure 1). Cafe-au-lait spots were noted on the left mid-abdomen and the anterior right thigh. The liver was palpable 4 to 5 cm below the xiphoid in the midline and 3 cm below the right costal margin; it was soft, smooth and not tender. The spleen descended 2 cm with deep inspiration. Neurologic examination showed bilateral subacute papilledema with less than 1 diopter elevation of the disk margins, confirmed by fluorescein studies. The myotatic reflexes were symmetrically increased to a moderate degree, but no pathologic reflexes could be elicited. The remainder of the examination disclosed no abnormalities.

Laboratory data included hemoglobin 11.3 gm/100 ml, leukocytes 4,100/cu mm, erythrocyte sedimentation rate 64 mm in one hour (Westergren), alkaline phosphatase 129 International Units/L, serum glutamic oxalacetic transaminase (SGOT) 80 units/L, sulfobromophthalein retention 32 per cent after one hour, urinalysis grade 1 protein, grade 1 white blood cell count, serum vitamin A 737 μg/100 ml (normal 37 to 45 μg/100 ml), serum carotene 88 μg/100 ml, cholesterol 178 mg/100 ml, cholesterol esters 127 mg/100 ml, phospholipids 173 mg/100 ml, fatty acids 355 mg/100 ml, triglycerides 64 mg/100 ml. Other laboratory tests giving normal results were differential leukocyte count; blood sugar; serum bilirubin, sodium, calcium, phosphorus and creatinine; protein-bound iodine, creatinine phosphokinase; glucose tolerance test; serologic test for syphilis (VDRL); urine screening test for inborn errors of metabolism; twenty-four hour urinary creatinine; electroencephalogram; echoencephalogram; electromyogram; ischemic exercise tolerance test. Roentgenograms of the head showed increased diploic vascular channels in the right frontal area and calcification of the choroid plexus. Roentgenograms of the thorax, lumbar and thoracic spinal regions, feet, right hand and both legs did not disclose any abnormalities.

A bone biopsy specimen was taken from the left ninth rib; the results have been reported elsewhere [1].

The diagnosis of chronic vitamin A intoxication was made, and all intake of supplementary vitamin A was discontinued.

When seen again in January 1968, the patient had recovered from all symptoms. The subacute papilledema was unchanged. Spleen and liver were unchanged in size. Ingrown nails continued to be inflamed, infected and resistant to therapy. Laboratory data were hemoglobin 10.8 gm/100 ml, red blood cell count 3.44×10^6/cu mm, sedimentation rate 87 mm in one hour, alkaline phosphatase 105 units/L, SGOT 55 units/L, prothrombin time twenty-nine seconds; bromsulfalein retention 24 per cent, serum total protein 7.2 gm/100 ml, albumin 3.3 gm/100 ml, serum iron 48 μg/100 ml, serum vitamin A 155 μg/100 ml, serum carotene 251 μg/100 ml. Vitamin K (Synkamin®), 4 mg daily, was prescribed.

In March 1968 the patient still felt well. The liver was palpable 4.5 cm below the xiphoid and the spleen, 2 cm with inspiration. One spider nevus was noted on the dorsum of the right wrist. The subacute papilledema was unchanged. The intraocular pressure was 12 mm in each eye as measured by applanation. Laboratory data included hemoglobin 11.0 gm/100 ml, sedimentation rate 80 mm in one hour, alkaline phosphatase 117 units/L, SGOT 49 units/L, prothrombin time 25 seconds, thymol turbidity 3 units, cephalin flocculation 4+, bromsulfalein retention 34 per cent, total serum protein 7.58 gm/100 ml, albumin 3.42 gm/100 ml, serum vitamin A 119.7 μg/100 ml. Urinalysis disclosed protein 1+, white blood cells 1+, red blood cells 1+. Treatment with vitamin K was continued. The patient was instructed to adhere to a low vitamin A diet with high protein and low fat content.

In July 1968 the optic disks were normal. The liver was palpable 6 cm below the xiphoid and the right costal margin, and the spleen, 3 cm below the costal margin with inspiration. Several spider nevi were noted. The gingival discoloration was barely visible.

Paronychia and infected toenails had healed. Laboratory data included sedimentation rate 82 mm in one hour, alkaline phosphatase 129 units/L, SGOT 53 units/L, prothrombin time twenty-nine seconds, bromsulfalein retention 32 per cent, serum total protein 7.46 gm/100 ml, albumin 3.44 gm/100 ml. serum vitamin A 97.2 μg/100 ml. Urinalysis disclosed protein 1+, white blood cells 1+. In view of persistent signs of active inflammatory liver disease, steroid therapy was recommended, 30 mg of prednisone daily for three weeks followed by 20 mg daily for four weeks and 15 mg daily for one week. However, the patient took only approximately half of the recommended dosage spread over a two month period.

In September 1968, she reported nosebleeds on eight occasions and fatigue. The liver was no longer enlarged; the spleen was palpable 2 cm with inspiration. Four spider nevi were noted on the hands. Laboratory data included a sedimentation rate of 72 mm in one hour, bromsulfalein retention 36 per cent, thymol turbidity 4 units, cephalin flocculation 4+, alkaline phosphatase 94 units/L, bilirubin direct negative, indirect 2.0 mg/100 ml, SGOT 50 units/L. serum total protein 7.65 gm/100 ml, albumin 3.41 gm/100 ml, prothrombin time twenty-one seconds. Needle biopsy of the liver (Figure 2) showed marked periportal and centrilobular fibrosis. Ill defined bands of connective tissue subdivided the lobules and caused distortion of the normal hepatic architecture. There was proliferation of the Kupffer cells and fibroblasts. Small groups of hepatic cells were encased by connective tissue fibers which had formed in the walls of the sinusoids. There was fibrosis of the portal fields. Some of the portal vein branches were markedly dilated. The walls of these veins were thin, and there were no signs of thrombosis. There was some atypical bile duct proliferation. A moderate number of polymorphonuclear leukocytes were found in the areas of intralobular fibrosis. The Prussian blue method (Perl) failed to demonstrate reactive ferric iron. Frozen sections of the specimen showed marked fatty changes with small and large isotropic Sudan IV-positive droplets, predominantly in the hepatic cells and to a lesser degree in the Kupffer cells. The fat showed a marked vitamin A fluorescence, fading from green to blue after about fifteen seconds [2]. The histologic diagnosis was severe hepatic fibrosis and fatty changes of the liver, secondary to vitamin A intoxication.

In March 1969 the patient was feeling well. The liver was palpable 3 cm below the costal margin and the spleen, 3 cm with inspiration. Several spider nevi were unchanged. Laboratory data included hemoglobin 12.6 gm/100 ml, sedimentation rate 85 mm in one hour, bilirubin direct negative, indirect 2.5 mg/100 ml, alkaline phosphatase 71 units/L. SGOT 53 units/L. serum total protein 6.94 gm/100 ml. albumin 3.12 gm/100 ml. bromsulfalein retention 26 per cent. thymol turbidity 4 units. cephalin flocculation 4+. prothrombin time twenty-seven seconds. serum vitamin A 92.1 μg/100 ml. carotene 216 μg/100 ml. cholesterol 454 mg/100 ml. cholesterol esters 295 mg/100 ml, triglycerides 164 mg/100 ml. phospholipids 392 mg/100 ml. total lipids 1,010 mg/100 ml.

Case 2. A 52 year old woman was first seen at the Mayo Clinic in June 1947 complaining of severe gen-

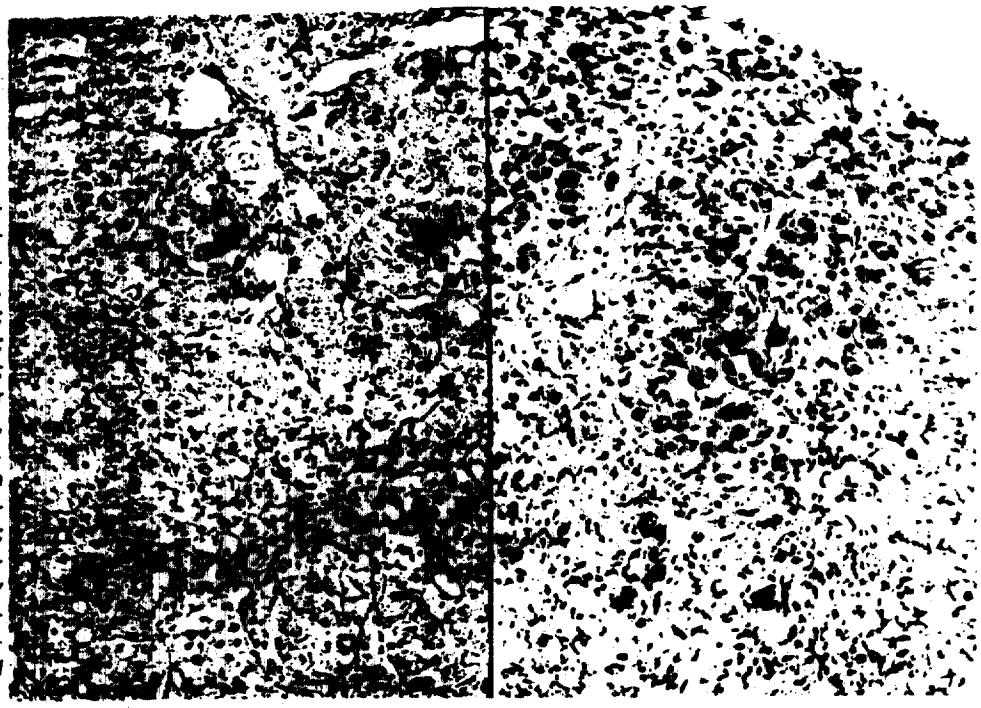

Figure 2. Case 1. Liver biopsy specimen. Left, periportal, intralobular and centrilobular fibrosis; fatty changes, predominantly of hepatic cells; inflammation of portal tracts; proliferation of Kupffer cells; clusters of polymorphonuclear leukocytes. Van Gieson stain, original magnification × 150. Right, hepatic fibrosis with lymphohistiocytic and granulocytic inflammatory infiltrates; small cluster of partly degenerating hepatic cells with fatty changes; loss of normal hepatic architecture. Hematoxylin and eosin stain, original magnification × 165.

eralized pruritus, predominantly of the scalp, shoulders and nuchal area, which had developed in September 1946. The skin had become rough and dry, and she had lost hair. The diagnosis of pityriasis rubra pilaris was made after a skin biopsy. Laboratory data were normal, including sedimentation rate 10 mm in one hour, serum vitamin A 35 μg/100 ml and carotene 131 μg/100 ml. The patient was treated with 3 per cent ichthammol (Ichthyol®) ointment, aluminum subacetate wet dressings, tripelennamine (Pyribenzamine®), and vitamin A (100,000 IU daily); the vitamin A was to be discontinued after three months. She was dismissed to the care of her local dermatologist. Her condition improved approximately 50 per cent. Because symptoms recurred whenever she discontinued vitamin A, she increased the vitamin A intake to 400,000 IU daily for one year and took 200,000 to 300,000 IU/day thereafter for the ensuing eight years.

The family history was noncontributory. The medical history included a hysterectomy in 1945. The patient had never had symptoms of hepatitis nor was there a history of exposure to known hepatotoxins. She had received one blood transfusion in 1950 without complication. In 1949 she had been treated for cystitis with sulfonamides. In 1950 cholecystectomy was performed because of cholelithiasis. In 1952 a deep vein phlebitis healed after conservative therapy. In 1952 she was hospitalized for severe low back pain which subsided with traction. In 1954 she had "low grade arthritis" for which she was treated with phenylbutazone (Butazolidin®) and thyroid preparations.

In September 1954 she experienced pain in the dorsal spinal region. In early summer of 1955, anorexia, nausea and a 16 pound weight loss occurred. At this time the liver was found to be tender and enlarged to the umbilicus. Laboratory data included hemoglobin 11.7 gm/100 ml, red blood cells 3.91 × 10^6/cu mm, bromsulfalein retention 45 per cent after thirty minutes, icteric index 13.9 units, prothrombin time twenty-four seconds, serum total protein 7.6 gm/100 ml, albumin 2.03 gm/100 ml, globulin 5.57 gm/100 ml, sedimentation rate 20 mm in one hour, basal metabolic rate −11 per cent, glucose tolerance test indicative of mild diabetes mellitus. Leukocyte count, urinalysis and plasma cholesterol levels were within normal limits.

An open liver biopsy was performed in October 1955 (in Denver). When the slides were later reviewed at this clinic, the histologic diagnosis was cirrhosis of the liver, probably postnecrotic and cause unknown. No fluorescence studies were carried out. (The paraffin sections were not available for study.) According to the original description by Dr. S. K. Kurland, Denver, the biopsy specimen was firm and gray-yellow: the sectioned surface was lobulated, nodular and varied in color from gray-brown to gray-yellow. Histologically there was marked disorganization of individual lobules with, in many instances, complete loss of the normal central vein and portal triad relationship. The fibrous tissue around the portal triads was increased and contained proliferating bile ducts, focal accumulation of lymphocytes and occasional histiocytes. The histiocytes in many instances were lipoid laden. The fibrous tissue was increased both between portal triads and occasionally between hepatic cell plates. The hepatic cells were finely reticulated. Within some of the liver cells and bile canaliculi was inspissated bile. Regenerative and degenerative changes of hepatic cells were evident in some areas. The diagnosis was cirrhosis, moderately advanced. Subsequent to this biopsy, a high protein, low fat diet was prescribed, and crude liver injections were given intramuscularly twice weekly.

The patient returned to the Mayo Clinic in March 1956, for the first time since 1947, complaining of increasingly severe, nonradiating, midthoracic back pain, anorexia, fatigue, somnolence and yellowish discoloration of the skin.

On examination the vital signs were normal; there was slight generalized icterus, pallor of the face and erythema of the fingers and palms. The liver was palpable at the umbilicus, firm and not tender. The spleen was slightly enlarged. Mild pitting edema of the legs was noted. Neck motions were moderately limited. A mild static and movement tremor of the head, lips, tongue and arms was present. The gait was stiff and slightly unsteady; all muscle groups showed moderately increased tone. The myotatic reflexes were symmetrically hyperactive, but no pathologic reflexes were found. Axillary hair was absent and pubic hair was sparse. The nails were spooned and dystrophic. The remainder of the examination was noncontributory.

Laboratory data included hemoglobin 11.2 gm/100 ml, red blood cells 3.9 × 10^6/cu mm, sedimentation rate 66 mm in one hour, bilirubin direct negative, indirect 1.16, alkaline phosphatase 14.8 Bodansky units, prothrombin time 22 seconds, thymol turbidity 3 units, cephalin flocculation 3+, bromsulfalein retention 26 per cent in one hour, serum total protein 6.66 gm/100 ml, albumin 3.79 gm/100 ml, serum vitamin A 250 μg/100 ml, serum carotene 90 μg/100 ml, cholesterol 234 mg/100 ml, cholesterol esters 167 mg/100 ml, phospholipids 240 mg/100 ml, fatty acids 359 mg/100 ml, total lipids 593 mg/100 ml. A roentgenogram of the thorax showed narrowing of the eighth and ninth thoracic intervertebral spaces.

The diagnosis of chronic vitamin A intoxication was made. Vitamin A intake was discontinued and, within four weeks, the back pain disappeared; the patient's level of energy, alertness and appetite returned to normal, she gained 4 pounds, and there was no abnormality of the skin. She was dismissed on a regimen consisting of a high protein, low fat diet and vitamin K. The vitamin A level four weeks after discontinuation of vitamin A intake was 85.8 μg/100 ml.

On follow-up examination in August 1956 the patient complained of fatigability but otherwise felt well. The scalp hair had become thicker, and the skin was less dry. The liver size was unchanged; the spleen was no longer palpable. One spider nevus was present on the forehead. Laboratory data included hemoglobin 12.1 gm/100 ml, red blood cell count 3.91 × 10^6/cu mm, sedimentation rate 63 mm in one hour, bilirubin direct negative, indirect 1.4 mg/100 ml, prothrombin time twenty-three seconds, thymol turbidity 3 units, cephalin flocculation 3+, bromsulfalein retention 26 per cent, serum total protein 6.5 gm/100 ml, albumin 3.8 gm/100 ml, serum vitamin A 75.0 μg/100 ml, plasma cholesterol 333 mg/100 ml, cholesterol esters 217 mg/100 ml, phospholipids 313 mg/100 ml, fatty acids 527 mg/100 ml, total lipids 860 mg/100 ml.

In September 1957 the patient had no complaints and looked well. The liver was unchanged in size and palpable at the umbilicus; the spleen was not palpable. The myotatic reflexes remained hyperactive. Laboratory data included hemoglobin 13.4 gm/100 ml, sedimentation rate 42 mm in one hour, bilirubin direct negative, indirect 1.34 mg/100 ml, prothrombin time 22 seconds, thymol turbidity 4 units, cephalin flocculation 4+, bromsulfalein retention 36 per cent, serum total protein 6.8 gm/100 ml, albumin 4.1 gm/100 ml, serum vitamin A 31.5 μg/100 ml, serum carotene 181 μg/100 ml, plasma cholesterol 311 mg/100 ml, cholesterol esters 200 mg/100 ml, phospholipids 333 mg/100 ml, fatty acids 507 mg/100 ml, total lipids 818 mg/100 ml.

In December 1961 bromsulfalein retention was 31.3 per cent in one hour cephalin flocculation 4+. In December 1963 bromsulfalein retention was 18.7 per cent in one hour.

In October 1968 the patient felt well and had no complaints. On reexamination by her local physician, the liver was no longer palpable; a roentgenogram of the abdomen showed a normal liver outline. Laboratory data included a hemoglobin of 16.0 gm/100 ml, sedimentation rate 7 mm in one hour, bilirubin direct negative, indirect 1.0 mg/100 ml, alkaline phosphatase 60 units/L, cephalin flocculation 2+, bromsulfalein retention 17.3 per cent after forty-five minutes, serum total protein 6.3 gm/100 ml, albumin 4.03 gm/100 ml, SGOT 38 units/L, cholesterol 257 mg/100 ml.

COMMENTS

The literature contains seventeen case reports of chronic vitamin A intoxication in adolescents or adults, including those reported in this paper [3–15]. They are summarized in Tables I and II.

Sixteen patients were female, and one was male. The age range was fourteen to sixty-two years. The daily vitamin A intake ranged from 41,000 to 600,000 IU, and the duration was two months to nine years. The smallest daily dose leading to intoxication was 41,000 IU taken for eight years [12]. Intoxication after a two-month period of vitamin A intake occurred on a daily dose of 200,000 to 275,000 IU [4].

In the past, vitamin A has been used in large doses over protracted periods for the management of a wide variety of dermatologic conditions, but without adequate therapeutic basis. The reason for vitamin A therapy in the cases reviewed was acne in eight cases, "cold prevention" in two and pityriasis rubra pilaris, nonspecific skin eruption, ichthyosis, food fadism, "to improve vision" and for "dry skin" in one case each.

Our cases confirm the clinical picture characteristic of chronic vitamin A intoxication in adults: the invariably present skin changes, increased intracranial pressure, bone and joint pain, fatigue and anorexia. In addition they exemplify clinical features which have not been emphasized in the past.

Both patients showed marked impairment of liver function, one and a half and twelve years, respectively, after vitamin A intake was discontinued. In

TABLE I Symptoms and Signs in Seventeen Cases of Chronic Vitamin A Intoxication in Adults and Adolescents

Symptom or Sign	Cases (no.)
Skin (dryness, maculopapular rash, fissures, desquamation, pigmentation, pruritus)	17
Hair loss	14
Generalized weakness and fatigue	14
Pain in bones and joints	13
Marked tenderness of bones to palpation	11
Anorexia	9
Headache	9
Hepatomegaly	8
Muscle stiffness	7
Endocrine (absent or decreased menorrhea)	7
Papilledema	6
Diplopia	6
Weight loss	6
Splenomegaly	6
Polyuria, polydipsia, urinary frequency	6
Psychiatric symptoms	6
Edema of lower extremities	6
Insomnia	5
Bleeding (nose and lips)	5
Brittle nails	4
Somnolence	3
Exophthalmus	2
Yellow discoloration of skin	2
Other neurologic symptoms	2
Gingivitis	1*
Lymphadenopathy	1

*A similar case of gingivitis in vitamin A intoxication has been described by Smith [16] but was not included in this review of seventeen cases.

TABLE II Laboratory Findings in Seventeen Cases of Chronic Vitamin A Intoxication in Adults and Adolescents

Test	Cases (no.)	
	Normal	Abnormal
Sedimentation rate (mm in one hr)	1	7 (range: 22-87)
Sulfobromophthalein retention (%)	3	3 (17, 26, 32)
Alkaline phosphatase	3	7 (increased)
Serum total protein	8	1 (decreased)
Serum total albumin	1	7 (decreased)
Serum bilirubin: total	7	5 (increased)
direct	7	1 (increased)
indirect	7	1 (increased)
Prothrombin time	4	3 (increased)
Thymol turbidity	9	1 (increased)
Cephalin flocculation	9	2 (increased)
Hemoglobin (gm/100 ml)	8	6 (decreased; range 10.2-12.0)
Leukocyte count (per cu mm)	8	3 (3,200, 4,100, 4,300)
Protein-bound iodine (μg/100 ml)	4	2 (1.8, 10.8)
Cholesterol	6	2 (decreased)
Urinalysis	6	3 (protein 1+)
Cerebrospinal fluid: Pressure (cm water)	3*	3 (35, 60 "increased")
Cells, protein	5	0
Roentgenogram of long bones and spine	11	2 (demineralization)
Electroencephalogram	4	2 (diffuse abnormality, projected type)
Serum vitamin A (μg/100 ml)	0	17 (range, 83-2,000)
Serum carotene (μg/100 ml)	6	3 (slightly increased; range 264-375)

*These normal values were 13/13, and 7 cm water.

Case 2, liver size returned to normal, and liver function improved slowly. Neither patient gave any history of hepatitis or exposure to hepatotoxic substances other than vitamin A. This, the fluorescence microscopic findings in Case 1 and the improvement after discontinuation of vitamin A intake in Case 2 suggest strongly that the impaired liver function and the morphologic changes in hepatic tissue were a result of the hepatotoxic effect of vitamin A. Hepatomegaly has been noted in six other cases of chronic vitamin A intoxication [4,6,7,10,11,15]. A liver biopsy was normal in one case [11]. Hepatic cell necrosis, fatty changes and other pathologic findings in the liver of experimental animals reported by numerous investigators seem to confirm the hepatotoxic effects of excess vitamin A [17]; the cause of death in these animals frequently was widespread hemorrhage due to hypoprothrombinemia secondary to marked loss and impairment of hepatic parenchyma. These experimental findings, however, refer to results of acute intoxication. The biopsy findings in our two cases suggest that, in man, chronic hypervitaminosis A may lead to hepatocellular damage, portal fibrosis and eventual cirrhosis.

A marked increase in plasma lipid levels was noted in both of our cases after discontinuation of vitamin A therapy and may be related to impaired liver function. However, it is of interest that the increase occurred shortly after vitamin A intake was discontinued. Misra [18] reported an increase in total brain lipids and cholesterol in vitamin A intoxication.

The cerebrospinal fluid pressure was measured in six of the cases reported in the literature; it was increased in three [6,8,14] and normal in three [9,12,13]. In the three cases in which pressure was increased, it was associated with papilledema twice, diplopia three times and headache twice. In the three cases in which the pressure was found to be normal, it was measured several weeks after vitamin A therapy was discontinued in one case, was not associated with papilledema or diplopia in the second case, and was measured after pneumoencephalography in the third case. In the case reported by Gerber and associates [6] the cerebrospinal fluid was found to be under increased pressure when ventriculography was performed. A craniotomy was carried out on this patient; she continued to take vitamin A, and the craniotomy site was repeatedly found to be tense and markedly bulging. Jennekens and Van Veelen [13] reported a case of subacute vitamin A intoxication (not included in our review of chronic cases) in a nineteen year old patient with diplopia, papilledema and headache; an elevated cerebrospinal fluid pressure (300 mm water) was found. These findings strongly suggest that chronic vitamin A intoxication in adult man causes increase of cerebrospinal fluid pressure with diplopia, papilledema and headache. This is in contrast to the results of animal experiments

[19,20] but is in accord with the prompt bulging of fontanels observed in acute vitamin A intoxication in infants [21] as well as the observation of increased intracranial pressure and hydrocephalus in offspring of rats fed excessive doses of vitamin A [22].

Only few neurologic signs, other than increased intracranial pressure with associated diplopia, somnolence and headache, have been reported in man. Gerber and co-workers [6] described nystagmus, atrophy of selected muscles and sensory symptoms in the saddle area in their patient.

We would like to call attention to a neurologic symptom which, in one of our patients, led to the mistaken diagnosis of McArdle's disease. It consists of muscle stiffness which may or may not be present spontaneously but will occur or be markedly increased with activity and subside with rest. This sympton can become severe enough to make walking impossible, was observed in seven of the seventeen cases reported in the literature [6–8,11,15] and may lead to bizarre postures. It is not known whether this symptom is of myogenic or neurogenic origin.

Psychiatric manifestations have been prominent in several cases and may lead to social isolation of the patient; in mild cases they presented as depression or irritability.

Numerous central nervous system changes have been reported to occur in vitamin A intoxication of experimental animals, including exencephaly and anencephaly in offspring of vitamin A-intoxicated rats [22], neuronal changes in the neuroepithelial zone in offspring of mice [23], higher incidence of postvaccinal encephalomyelitis in rabbits [24] and widespread neuronal degeneration in guinea pigs [25].

The rather striking gingivitis present in one of our patients has been reported on only one other occasion [16].

Paronychia and infected ingrown toenails associated with abnormal granulation tissue in one of our patients subsided after vitamin A therapy was discontinued and were probably related to the hypervitaminosis.

We have no explanation for the craving for food with high vitamin A content which has been reported by others and was present in one of our patients. It occurs during the state of hypervitaminosis.

Laboratory tests in the reported cases showed variable results except for consistently increased serum vitamin A levels. Other abnormal findings were increased cerebrospinal fluid pressure and abnormal liver function tests. Anemia, leukopenia and proteinuria were present in a few cases. Electroencephalographic abnormalities were reported in two cases in which there was evidence of increased intracranial pressure. Demineralization of bones was detected roentgenologically in only two cases, in contrast to marked bone abnormalities with spontaneous fractures usually noted in acute animal experiments. In one of our cases there were no grossly detectable roentgenologic bone changes, but marked alterations in bone turnover were noted in the biopsy specimen [1].

It is of importance that, in chronic vitamin A intoxication, storage of vitamin A in the liver and serum levels of vitamin A are not proportionally related. During early stages of intoxication much of the vitamin A is stored in the liver, and the serum level remains low. Once the capacity for storage is exhausted, the serum level increases rapidly. For this reason, serum vitamin A levels may be high if a relatively small amount of vitamin A is given for a sufficiently long period. The serum vitamin A level may remain low if large amounts of vitamin A are given for short periods.

REFERENCES

1. Jowsey J, Riggs BL: Bone changes in a patient with hypervitaminosis A. J Clin Endocr 28: 1833, 1968.
2. Thompson SW: Selected Histochemical and Histopathological Methods, Springfield, Ill, Charles C Thomas, 1966, p 1249.
3. Sulzberger MB, Lazar MP: Hypervitaminosis A. Report of a case in an adult. JAMA 146: 788, 1951.
4. Shaw EW, Niccoli JZ: Hypervitaminosis A. Report of case in an adult male. Ann Intern Med 39: 131, 1953.
5. Bifulco E: Vitamin A intoxication. Report of a case in an adult. New Eng J Med 248: 690, 1953.
6. Gerber A, Raab AP, Sobel AE: Vitamin A poisoning in adults with description of a case. Amer J Med 16: 729, 1954.
7. Elliott RA Jr, Dryer RL: Hypervitaminosis A. Report of a case in an adult. JAMA 161: 1157, 1956.
8. Oliver TK Jr: Chronic vitamin A intoxication. Report of a case in an older child and review of the literature. Amer J Dis Child 95: 57, 1958.
9. Morrice G Jr, Havener WH, Kapetansky F: Vitamin A as a cause of pseudotumor cerebri. JAMA 173: 1802, 1960.
10. Stimson WH: Vitamin A intoxication in adults. Report of a case with a summary of literature. New Eng J Med 265: 369, 1961.
11. Soler-Bechara J, Soscia JL: Chronic hypervitaminosis A. Report of a case in an adult. Arch Intern Med (Chicago) 112: 462, 1963.
12. Bergen SS Jr, Roels OA: Hypervitaminosis A. Report of a case. Amer J Clin Nutr 16: 265, 1965.

13. Jennekens FGI, Van Veelen CWM: Hypervitaminosis A. Presse Med 74: 2925, 1966.
14. Wisse Smit J, Pott Hofstede D: Vitamine a-intoxicatie bij volwassenen. T Geneesk 110: 10, 1966.
15. Di Benedetto RS: Chronic hypervitaminosis A in an adult. JAMA 201: 700, 1967.
16. Smith JH: Hypervitaminosis A. Report of a case. Oral Surg 17 (supp 3): 305, 1964.
17. Nieman C, Klein Obbink HJ: The biochemistry and pathology of hypervitaminosis A. Vitamins Hormones (NY) 12: 69, 1954.
18. Misra UK: Fatty acids of brain in hypervitaminosis A in rats. Canad J Biochem 44: 1539, 1966.
19. Nelson EC, Dehority BA, Teague HS, Grifo AP Jr, Sanger VL: Effect of vitamin A and vitamin A acid on cerebrospinal fluid pressure and blood and liver vitamin A concentrations in the pig. J Nutr 82: 263, 1964.
20. Hurt HD, Eaton HD, Rousseau JE Jr, Hall RC Jr: Rates of formation and absorption of cerebrospinal fluid in chronic bovine hypervitaminosis A. J Dairy Sci 50: 1941, 1967.
21. Knudson AG Jr, Rothman PE: Hypervitaminosis A. A review with a discussion of vitamin A. Amer J Dis Child 85: 316, 1953.
22. Cohlan SA: Excessive intake of vitamin A as a cause of congenital anomalies in the rat. Science 117: 535, 1953.
23. Langman J, Welch GW: Excess vitamin A and development of the cerebral cortex. J Comp Neurol 131: 15, 1967.
24. Ehrengut W: Hypervitaminosis A and infection: Experimental studies on a model of vaccine infection. Vitamins Hormones (NY) 8: 501, 1961.
25. Brusa A, Testa F: Lesioni nel sistema nervoso centrale di cavie in ipervitaminosi A. Int Z Vitaminforsch 25: 55, 1953–1955.

Ann. Rept. of the Res. Inst. of
Envir. Med. Nagoya Un. 14:53-60

Murakami, U., and Y. Kameyama
Bib. No. 6537

PARALLEL EXPERIMENT ON TERATOGENIC EFFECTS OF HYPERVITAMINOSIS-A UPON MICE EMBRYOS OF TWO STRAINS

UJIHIRO MURAKAMI* and YOSHIRO KAMEYAMA**

It has been well known that hypervitaminosis-A during the stage of major organogenesis of embryos in laboratory animals caused malformations. Cohlan (1953)[3] discovered the fact in the rat. Thereafter, Giroud and Martinet (1955-58),[7,9] Millen and Woollam (1957),[16] Woollam and Millen (1957),[22] and Millen (1962)[17] confirm the finding also in the rat or the mouse. Deuschle, Geiger and Warkany (1959),[6] Kalter and Warkany (1961)[12] who employed the mouse noted visceral changes. In Japan, similar studies were done by Baba and his collaborators (1958-60)[1,2,10,26,33] employing the rat, by Takekoshi (1961-64)[18,30] using the mouse and Ohzu and Shoji (1965)[27] also employing the mouse. The authors of the present paper carried out experiments administering excessive amounts of vitamin A solution intraperitoneally in the pregnant mouse. In the results, the pattern of malformations manifested were characteristic, and the incidence was very high. Data employing the CF#1 strain was shown elswhere (1965).[24] Recently, Mizutani, Ihara and Kaziwara (1966)[18] attempted a parallel experiment employing the mouse, rat and rabbit administering by the same route done by Murakami and Kameyama (1965).[24] In this paper, some differences seen in the two different strains of mice will be discussed.

METHODS

Animals employed were the ddN-JCL and CF#1-JCL strains of mice, thirteen weeks or older and weighing on an average 24.2 g in the ddN strain and 31.2 g in the CF#1 strain. One oestrous female was kept overnight in a cage with one male and the next morning, all the females with a vaginal plug were considered to be in the 1st day of pregnancy. The pregnant mice were divided into six groups, i.e., group A corresponding to the 8th, group B to the 9th, group C to the 10th, group D to the 11th, group E to the 12th and group F to the 13th day of pregnancy. Each group contained twenty animals. The control group had twenty animals in the both strains. Each group of mice was subjected to a single intraperitoneal injection of a dose of 15,000 I.U. vitamin A water miscible solution respectively.

Fetuses were removed surgically from mother animals on the 19th day of pregnancy and studied under a low power microscope for gross malformations. All fetuses were examined once more under the same binocular after being cleared according to the Dawson method, i.e., clearing tissues with one per cent potassium hydroxyde solution and staining the bone with alizarin red S solution. Besides the

* Professor ** Instructor

above group of animals, some pregnant animals were treated on the 9th, 10th or 11th day of pregnancy and the fetuses were examined on the 15th, 16th and 19th day of pregnancy in sections and stained with hematoxyline and eosin for the observation of the changes in cranio-facial patterns[2] or malformations of the extremities.

RESULTS

In the ddN strain, all embryos were dead in group A. While in the CF#1 strain, 7.35 per cent of fetuses survived. The incidence of embryonic losses were marked in groups B, C and D. Among these three groups it was highest in both strains in group C. Incidence of malformations were very high in every group except for group A in the ddN strain in which all embryos were dead. In the CF#1 strain, malformations were also highly manifested from group A to group E (Tables 1 & 3).

TABLE 1. Pregnancy status in the ddN strain of mice treated with 15,000 I.U. vitamin A water miscible solution at different stage of pregnancy.

Groups of animals classified by the day of treatment	Day of pregnancy when treated	No. of mice treated	Total number of implantations	Average number of estimated implantations	Embryonic & fetal losses: Dead fetuses	Embryonic & fetal losses: Resorptions & placental remnants	Fetuses examined	Fetuses without gross malformations	Fetuses with gross malformations	Fetuses retarded in development (including malformed ones)
A	8th	20	167	8.4	9	158	0	0	0	0
					(100%)					
B	9th	20	178	8.9	18	64	96	2	94	59
					(46.08%)		(53.92%)	(2.08%)	(97.92%)	(61.46%)
C	10th	20	156	7.8	46	43	67	5	62	40
					(57.05%)		(42.95%)	(7.46%)	(92.54%)	(59.70%)
D	11th	20	160	8.0	50	20	90	3	87	35
					(43.75%)		(56.25%)	(3.33%)	(96.67%)	(38.80%)
E	12th	20	153	7.7	18	23	117	0	117	14
					(23.53%)		(76.47%)		(100%)	(11.97%)
F	13th	20	151	5.6	10	21	120	61	59	10
					(20.53%)		(79.47%)	(40.40%)	(59.60%)	(8.33%)
Control		20	181	9.05	19		162	162	0	0
					(10.50%)		(89.50%)	(89.50%)		

Gross malformations: Malformations manifested were classified according to their patterns and presented in Tables 2 & 4. It was characteristic that almost all malformed fetuses were not simple but they were complicated with more than two kinds of malformations. Those with exencephalias were usually associated with malformations of the eye, face, tail, etc., and sometimes with spina bifida aperta. Such cases were seen in groups A and B in the CF#1 strain. Spina bifida was seen in both strains in the embryos treated prior to the 11th day of pregnancy.

TABLE 2. Classification of malformations in the ddN mouse fetus caused by hypervitaminosis-A upon the mother mouse during pregnancy

Classification of malformations		Day of pregnancy when treated						
		8th (Group A)	9th (Group B)	10th (Group C)	11th (Group D)	12th (Group E)	13th (Group F)	Control
Malformations of the central nervous system	Exencephalia							
	Brain hernia							
	Hydrocephalus							
	Microcephalia*		80(83.33%)	7(10.45%)	13(14.45%)			
	Spina bifida		2(2.08%)	3(4.48%)				
Malformations of the eye	Anophthalmos							
	Microphthalmos		1(1.04%)	1(1.49%)				
	Exophthalmos*		82(85.42%)	20(29.85%)				
	Open eye*		66(68.75%)	20(29.85%)	6(6.67%)			
Malformations of the face	Malformations of the maxilla							
	Short snout		66(68.75%)	28(41.79%)	55(61.11%)	35(29.92%)		
	Malformations of the mandible							
	Abnormally big sized mandible		7	1				
	Micrognathia*		66 (76.04%)	15 (23.88%)	44(48.89%)	4(3.42%)		
	Agnathia*							
	Malformations of the mouth							
	Microstomia*		13	10	23			

TABLE 2. Classification of malformations in the ddN mouse fetus caused by hypervitaminosis-A upon the mother mouse during pregnancy

Classification of malformations		Day of pregnancy when treated						Control
		8th (Group A)	9th (Group B)	10th (Group C)	11th (Group D)	12th (Group E)	13th (Group F)	
Malformations of the central nervous system	Exencephalia							
	Brain hernia							
	Hydrocephalus							
	Microcephalia*		80(83.33%)	7(10.45%)	13(14.45%)			
	Spina bifida		2(2.08%)	3(4.48%)				
Malformations of the eye	Anophthalmos							
	Microphthalmos		1(1.04%)	1(1.49%)				
	Exophthalmos*		82(85.42%)	20(29.85%)				
	Open eye*		66(68.75%)	20(29.85%)	6(6.67%)			
Malformations of the face	Malformations of the maxilla							
	Short snout		66(68.75%)	28(41.79%)	55(61.11%)	35(29.92%)		
	Malformations of the mandible							
	Abnormally big sized mandible		7	1				
	Micrognathia*		66 (76.04%)	15 (23.88%)	44(48.89%)	4(3.42%)		
	Agnathia*							
	Malformations of the mouth							
	Microstomia*		14 (65.62%)	10 (22.39%)	23 (25.56%)			
	Anostomia*		50	5				
	Cleft palate		3(3.13%)	42(62.69%)	69(76.67%)	77(65.81%)	43(35.83%)	
	Malformations of the auricle							
	Microtia*		24 (70.83%)	20 (47.76%)				
	Anotia*		44	4				
	Dislocation of the auricle			8	4(4.45%)			
Malformations of the trunk	Abdominal hernia		2(2.08%)	5(7.46%)	1(1.11%)			
	Atresia ani		60(62.50%)	27(40.30%)				
Malformations of the tail	Tailessness		46 (76.04%)	11 (73.14%)	8(8.89%)		1(0.83%)	
	Shorttailedness		24	35				
	Curvature of the tail		3	3				
Malformations in the forelimb	Micromelia: higher grade			1 (28.36%)	70 (98.89%)	16 (37.61%)		
	Micromelia: moderate			6	14	9		
	Micromelia: lower grade		9(9.38%)	12	5	19		
	Ectrodactylism: one finger is defective			7(10.45%)	26 (98.89%)	35 (49.57%)		
	Ectrodactylism: two or more fingers are defective				63	23		
	Brachydactylism		15(15.63%)	10(14.93%)	1(1.11%)	22(18.80%)	11(9.17%)	
	Syndactylism		4(4.17%)	6(8.96%)		1(0.86%)	1(0.83%)	
Malformations in the hindlimb	Micromelia: higher grade			1 (13.43%)	57 (88.89%)	32 (64.96%)		
	Micromelia: moderate			3	22	29		
	Micromelia: lower grade		5(5.21%)	5	1	15	7(5.84%)	
	Clubfoot (without micromelia)		15(15.63%)	4(5.97%)			2(1.67%)	
	Ectrodactylism: one finger is defective		2(2.08%)	1(1.49%)	54 (75.56%)	52 (72.65%)	6(5.00%)	
	Ectrodactylism: two or more fingers are defective				14	33		
	Brachydactylism		2(2.08%)		3(3.33%)	6(5.13%)	18(15.00%)	
	Syndactylism		1(1.04%)	3(4.48%)	11(12.22%)	21(17.95%)	1(0.83%)	
	Annular groove in the 5th digit				2(2.22%)	8(6.84%)		

* These malformations were associated.

Characteristic malformations of the eye were exophthalmoses with or without open eye. The incidence was very high in groups A and B in the CF♯1 strain, and in group B in the ddN strain. Such kind of malformations were limited to those treated prior to the 11th day. Malformations to be called cranio-facial patterns[24] were also characteristic. They were chiefly detected in B, C and D groups in the ddN strain, while in B, C, D and E groups in the CF♯1 strain. Such cranio-facial patterns were characterized by reduction in size of the mandible with microstomia or anostomia. Further, such cases were usually associated with the above exophthalmos with or without open eye and micro- or anotia. In those of which oral cavities were able to be examined, cleft palates were often found. However, incidence of cleft palate was highest in E group in both the ddN and CF♯1 strains.

In malformations of the trunk, anal atresias were usually associated with the above cranio-facial patterns, but this pattern was limited to groups B and C. Malformations of the tail such as taillessness, shorttailedness, curvature or flexure of the tail were also seen chiefly in B, C and D groups in the ddN strain. While in the CF♯1 strain, those were found chiefly in A, B and C groups. Such fetuses with tail malformations were also complicated with other malformations.

Micromelias with or without ectrodactylism were also one of the characteristic patterns manifested by this treatment. Incidence of micromelias in the forelimb were chiefly concentrated in groups C and D in the CF♯1 strain, while in the ddN

TABLE 3. Pregnancy status in the CF♯1 strain of mice treated with 15,000 I.U. vitamin A water miscible solution at different stage of pregnancy

Groups of animals classified by the day of treatment	Day of pregnancy when treated	No. of mice treated	Total number of implantations	Average number of estimated implantations	Embryonic & fetal losses: Dead fetuses	Embryonic & fetal losses: Resorptions & placental remnants	Fetuses examined	Fetuses without gross malformations	Fetuses with gross malformations	Fetuses retarded in development (including malformed ones)
A	8th	20	191	9.6	1	175	15	0	15	5
					(92.15%)				100%	33.33%
B	9th	20	177	8.9	1	28	148	0	148	12
					(16.38%)				100%	8.11%
C	10th	20	203	10.2	20	40	143	12	131	21
					(29.56%)			(8.39%)	91.61%	(14.69%)
D	11th	20	188	9.4	8	17	163	18	145	29
					(13.30%)			(11.04)	88.96%	(17.74%)
E	12th	20	179	8.9	5	7	167	32	135	10
					(6.70%)			(19.16)	(80.84%)	5.99%
F	13th	20	195	9.8	2	11	182	143	39	3
					(6.67%)			(78.57%)	21.43%	(1.65%)
Control		20	233	11.7	0	19	214	214	0	0
					(8.15%)			100		

TABLE 4. Classification of malformations in the CF#1 mouse fetus caused by hypervitaminosis-A upon the mother mouse during pregnancy

Classification of malformations		Day of pregnancy when treated						
		8th (Group A)	9th (Group B)	10th (Group C)	11th (Group D)	12th (Group E)	13th (Group F)	Control
Malformations of the central nervous system	Exencephalia	2(13.33%)	2(1.35%)					
	Brain hernia			1(0.7%)				
	Hydrocephalus			4(2.8%)				
	Microcephalia*		77(52.03%)	10(6.99%)				
	Spina bifida	2(13.33%)		1(0.7%)	3(1.84%)			
Malformations of the eye	Anophthalmos	3(20.0%)		5 } (6.29%)				
	Microphthalmos			4				
	Exophthalmos*	14(93.33%)	108(72.97%)	15(10.49%)				
	Open eye*	9(60.00%)	66(44.59%)	2(1.4%)				
Malformations of the face	Short snout		84(56.76%)	38(26.57%)	17(10.43%)	8(4.79%)		
	Malformations of the mandible							
	Abnormally big sized mandible		21 } (81.76%)	5 } (24.48%)	20(12.27%)	8 } (17.96%)		
	Micrognathia*		84	29		22		
	Agnathia*	1(6.67%)	16	1				
	Malformations in the mouth							
	Microstomia*	2 } (73.33%)	72 } (81.76%)	8(5.59%)		9(5.39%)		
	Anostomia*	9	49					
	Cleft palate		27(18.24)**	98(68.53%)	122(74.85%)	113(67.66%)	33(18.13%)	2(1.96%)
	Malformations of the auricle							
	Microtia*		30 } (70.27%)	6 } (13.29%)				
	Anotia*	12(80.00%)	29					
	Dislocation of the auricle		45	13	4(2.45%)			
Malformations in the trunk	Abdominal hernia			3(2.1%)				
	Anal atresia		27(18.24%)	2(1.4%)				
Malformations of the tail	Tailessness	3 } (80.00%)	1 } (40.54%)	1 } (30.07%)		12(7.36%)		
	Shorttailedness	9	56	41				
	Curvatur of the tail		1	1				
Malformations in the forlimb	Micromelia (higher grade)		12 } (34.46%)	73 } (72.03%)	98 } (76.07%)			
	Micromelia (lower grade)		39	30	26	9(5.39%)		
	Malformations in the digit							
	Ectrodactylism		13(8.78%)	99(69.23%)	126(77.30%)	28(16.77%)	2(1.1%)	
	Brachydactylism	5(33.33%)	26(17.57%)	5(3.5%)	10(6.13%)			
	Syndactylism		3(2.03%)	25(17.48%)	7(4.29%)			
Malformations in the hindlimb								
	Micromelia (higher grade)	2(13.33%)	2 } (25.40%)	35 } (51.75%)	106 } (71.17%)	7 } (40.12%)		
	Micromelia (lower grade)		33	39	10	60		
	Club foot (excluding micromelias)	1(6.06%)	3(2.03%)	12(8.39%)	4(2.45%)			
	Malformations in the digit							
	Ectrodactylism		8(5.41%)	54(37.76%)	103(63.19%)	75(44.91%)	2(1.1%)	
	Brachydactylism			17(11.89%)	4(2.45%)	11(6.59%)	3(1.65%)	
	Syndactylism	1(6.06%)	2(1.35%)	14(9.79%)	18(11.04%)	9(5.4%)		
	Annular groove in the 5th digit				7(4.29%)			

* These malformations were associated.

** Among examined 148 fetuses, there were 27 cases or 18.24% of cleft palates. Remaining ones were microstomias or anostomias and the palate was not able to examine. Examined 27 cases had cleft palates and the incidence was 100 per cent.

in an exophthalmos was also deformed and its longitudinal axis extended. The posterior part of the retina was sometimes involved in plications. In those with micrognathia, agnathia, microstomia or anostomia the palate was not completely formed. In some cases, only the rudiment of the lateral palatine process was observed. In such members, the tongue formed was also very small.

COMMENT

In both strains employed, it was evident that the effect of the agent was more intense the earlier the stage administered. Generally, the effect was higher in the ddN strain in either the rate of embryonic losses or malformations. The development in surviving fetuses was also influenced.

There were some characteristic malformations due to this agent such as spina bifida aperta, cranio-facial patterns, anal atresia and micromelias with ectrodactylism. In the mouse, spina bifida aperta was usually not seen or quite rarely seen in the experiments with X-radiations, hypoxias or trypan blue administration. Malformations of this trait after the closure of the neural tube, such as those seen in groups C or D, suggests that this trait may be resulted from a rupture of the neural tube once closed.

Cranio-facial patterns of microcephalia associated with exophthalmos, open eye, micrognathia or agnathia, microstomia or anostomia, and microtia or anotia centered around the group treated on the 9th day. To all appearance, those members with the above cranio-facial patterns are likely to be classified to otocephalia and its allied conditions. Werthemann (1965)[21] also indicated that this trait may be classified to a subgroup of otocephalia. Otocephalia is morphogenetically related to the cyclopia-arrhinencephalia group of malformations. Further, a coincidence was seen between the critical period for arrhinencephalia caused by X-radiation (Murakami et al., 1962)[10] and that for the cranio-facial patterns due to hypervitaminosis-A. However, in the above cranio-facial patterns the auricle did not show a coincidental location compared with the genuine otocephalia in animals or human beings. Further, in experiments employing the rabbit, the auricle was neither absent nor dislocated (Murakami, 1964).[23] Deuschle et al. (1959)[6] called this condition anomalous oculodentofacial pattern, and thereafter, Kalter (1960)[12] also analyzed this trait in detail.

High incidence of cleft palate may be due to the amount of the agent and the route of administration. While in experiments employing subcutaneous injection of the agent done by Woollam and Millen (1957),[22] cleft palate was not detected. On anal atresias, Kalter and Warkany (1961)[13] also described, though the critical period was one day later in their experiment. Such difference may be caused by the difference of progression in the development among the strain of mice employed, or by the difference of the dosage, or the route of administrations.

Malformations of the extremities were conspicuous and most of them were micromelias to be called phocomelia with ectrodactylism. Such malformations were described by Giroud and Martinet,[7,8] and Kalter and Warkany.[13] However, monopus sympus as shown in Millen's report (1962)[15] was not detected. There were differences in the results, especially in incidence of each malformation in

experiments of each investigator. It may be due to the fact that species, strain of animals used, amounts of the agent and the route of administration were different, though, kinds of malformations were similar. In experiments of the authors of the present paper, long bones of the extremities presented a specific involvement and the degree of the micromelia was high. The condition was different from that seen in experiments with X-radiations (Murakami et al., 1963).[21] The time span of the critical period was longer than that of the time span in X-radiations. This may be caused by the fact that X-radiation will attack the primordium in a very short time. On the other hand the action of vitamin A is manifested over a much longer period of time. The effect persists until the excessive vitamin A is excreted or metabolized by the body. In other series of experiments with X-radiation done by the author of the present paper it was presumed that the progression of the development of the eye (Murakamai, 1966)[25] and dight (Kameyama, 1965)[15] were earlier by a half to one day in the CF♂1 strain than in the ddN strain. In this series of experiments employing hypervitaminosis-A, a similar finding was evident.

Based on the above facts, the following conclusion will be summarized. In both strains used the type of malformations was quite similar. However, in general, incidence of manifestation of each malformation was higher in the ddN strain. Further, from the result of manifestation of ectrodactylism, in the ddN strain the critical period was chronologically a little later than in the CF♂1 strain, and in the group treated on the 8th day, all embryos were lost. Such differences of the result in the two strains may be due to two factors. One was the difference in the body weight. The CF♂1 strain was a little heavier than the ddN strain. The ratio was 6 : 5. Another factor may be the difference in the progression of development, i.e., the differences in the developmental potencies.

Hypervitaminosis-A influences a serious effect upon the formation of the cranium when it affects embryos in the developmental stage at which the head fold of the neural tube will close. While the formation of the tail seemed to be hardly influenced when the embryo was treated after the stage at which the primordium was formed.

Accordingly, hypervitaminosis-A influence chiefly upon the mesenchymal tissue which is just before its differentiation to the primordium or the mesenchymal tissue in differentiation. Also the closure of the neural tube sustains an effect. Foreign investigators have shown that ectodermal organs also seemed to be more susceptible than in the result of this experiment. The cause may be explained when an investigator employs different species or strains of animals and also different routes of administrations.

Intraperitoneal administration of excessive amounts of water miscible vitamin A solution will be an efficient method in the field of experimental teratology, because it produces a wide spectrum of malformations at a very high frequency.

SUMMARY

1. The CF♂1-JCL and ddN-JCL strains of mice were subjected to a single intraperitoneal injection of a dose of 15,000 I.U. water miscible vitamin A solution on the 8th, 9th, 10th, 11th, 12th and 13th day of pregnancy respectively. Fetuses

were examined for gross malformations and skeletal changes. Some of them were also studied in sections.

2. There were some characteristic malformations and these were complicated with more than two kinds of traits. A few cases of spina bifida aperta were found in the groups treated prior to the 11th day. Cranio-facial patterns were one of the conspicuous malformations and they were produced by administrations mostly to the 9th day. These were characterized with microcephalia with exophthalmos, micro- or agnathia, micro- or anostomia, micro- or anotia or dislocation of the auricle. Many of them were also complicated with anal atresia. They had some similarities to otocephalias. Abundant cleft palates were detected in the groups treated on the 11th day. Phocomelia-like micromelias were abundantly seen in groups treated on the 10th or 11th day in the CF#1 strain, while these were chiefly found in the group administered on the 11th day in the ddN strain. This pattern was quite characteristic in the treatment, and further, they were frequently associated with ectrodactylism. The incidence of ectrodactylism was highest in the group treated on the 12th day in both strains.

3. Skeletal changes of the ribs or extremities were characteristic in those with craniofacial patterns.

4. In both strains used, the type of malformations was quite similar. However, in general, incidence of malformations was higher in the ddN strain. The critical period of some malformations was chronologically a little later in the ddN strain than in the CF#1 strain. Such differences may be due to two different factors. One may be due to differences in the body weight. Another factor may be the divergence in the progressions of development.

This study was aided by a Scientific Research Grant (Co-operative Research) from the Ministry of Education of Japan.

REFERENCES

1) Araki, E.: Morphogenesis of congenital malformations due to excessive vitamin A. J. Osaka Med. Center. **7** : 445-452, 1958. (Japanese)

2) Baba, T. & Araki, E.: Morphogenesis of malformation due to excessive vitamin A (I). Morphogenesis of exencephaly. Osaka City Med. J. **5** : 9-15, 1959.

3) Cohlan, S. Q.: Excessive intake of vitamin A as a cause of congenital anomalies in the rat. Science. **117** : 535-536, 1953.

4) Degenhardt, K.-H.: Durch O.-Mangel induzierte Fehlentwicklungen der Axialgradienten bei Kaninchen. Z. Naturf. **9** : 530-536, 1954.

5) Degenhardt, K.-H.: Experimentelle Grundlagen der Wirbelsaurefehlentwicklungen — Sauerstoffmangel und Roentgenstrahlen. Die Wirbelsaure in Forschung und Praxis. **15** : 19-28, 1959.

6) Deuschle, F. M., Geiger, J. E. and Warkany, J.: Analysis of an anomalous oculodentofacial pattern in newborn rats produced by maternal hypervitaminosis A. J. Dent. Res. **38** : 149-155, 1959.

7) Grosud, A. et Martinet, M.: Malformations embryonaires par hypervitaminosis A. Arch. Franç. Pediat. **12** : 792-800, 1955.

8) Grosud, A. et Martinet, M.: Hyperivtaminose "A" et anomalies chez le foetus de rat. Revue internat. Vitaminol. **26** : 10-18, 1956.

9) Grosud, A. et Martinet, M.: Feratogenese par hypervitaminose A chez le rat, la souris, le cobaye et le lapin. Arch. Franç. Pediat. **16** : 1-5, 1958.

10) Inaba, T.: Experimentally reproduced congenital malformations of rats by excessive vi-

tamin-A diet. J. Osaka City Med. Center, **7** : 558–566, 1960.

11) Ingalls, T. H. and Curley, F. J.: Principles governing the genesis of congenital malformation induced in mice by hypoxia. New Engl. J. Med. **257** : 1121–1127, 1957.

12) Kalter, H.: Teratogenic effects of hypervitaminosis A upon the face and mouth of inbred mice. Ann. New York Acad. Sci. **85** : 42–55, 1960.

13) Kalter, H. and Warkany, J.: Experimental production of congential malformation in strains of inbred mice by maternal treatment with hypervitaminosis A. Am. J. Pathol. **38** : 1–21, 1961.

14) Kameyama, Y., Nogami, H. and Murakami, U.: Study on micromelias in the mouse fetus caused by X-radiation, hypoxia, trypan blue injection or hypervitaminosis-A upon mother animals during pregnancy. Ann. Rep. Environ. Med. Nagoya Univ. **12** : 29–41, 1964.

15) Kameyama, Y.: Strain differences in malformations of the extremities of the mouse fetus caused by X-radiation, hypoxia or hypervitaminosis-A of the mother during pregnancy. Ann. Rep. Environ. Med. Nagoya Univ. **13** : 49–55, 1965.

16) Millen, J. W. and Woollam, D. H. M.: Influence of cortisone on teratogenic effects of hypervitaminosis-A. Brit. Med. J. **5038** : 196–197, 1957.

17) Millen, J. W.: Thalidomide and limb deformities. Lancet, **7256** : 599–600, 1962.

18) Mizutani, M., Ibara, T. and Kaziwara, K.: Effect of hypervitaminosis A on the fetus of several species of rodents, with special reference to malformation of the extremities. Jap. J. Genet. **41** : 141–153, 1966.

19) Murakami, U., Kameyama, Y., Majima, A. and Sakurai, T.: Radiation malformations belonging to the cyclopia-arrhinencephalia-otocephalia group in the mouse foetus. J. Embryol. exp. Morph. **10** : 64–72, 1962.

20) Murakami, U. and Kameyama, Y.: Vertebral malformation in the mouse foetus caused by maternal hypoxia during early stages of pregnancy. J. Embryol. exp. Morph. **11** : 107–118, 1963.

21) Murakami, U., Kameyama, Y. and Nogami, H.: Malformation of the extremity in the mouse foetus caused by X-radiation of the mother during pregnancy. J. Embryol. exp. Morph. **11** : 549–569, 1963.

22) Murakami, U. and Kameyama, Y.: Vertebral malformation in the mouse foetus caused by X-radiation of the mother during pregnancy. J. Embryol. exp. Morph. **12** : 841–850, 1964.

23) Murakami, U.: Unpublished data, 1964.

24) Murakami, U. and Kameyama, Y.: Malformations of the mouse fetus caused by hypervitaminosis-A of the mother during pregnancy. Arch Environ. Health. **10** : 732–741, 1965.

25) Murakami, U.: Effects of X-radiation on the central nervous system of mice embryo. Proc. V. Internat. Cong. Neuropath. Zurich, 1965, 747–752, Excerpta Medica, Amsterdam, 1966.

26) Nakamura, S.: Morphogenesis of experimental cleft palate due to excessive vitamin A. J. Osaka City Med. Center, **7** : 725–734, 1958. (Japanese)

27) Ohzu, E. and Shoji, R.: Some aspects on the effects of vitamin A on developing mouse embryo. Proc. Jap. Acad. **41** : 83–85, 1965.

28) Takekoshi, S.: Teratogenesis due to hypervitaminosis-A in combination with other teratogenic factos (cortisone, trypan blue, noise stimulation, urethane and condroitinsulfate). Jap. J. Otol. Tokyo. **64** : 1489–1497, 1961.

29) Takekoshi, S.: On teratogenicity of overdose of vitamin A. Kita Kanto Igaku, **11** : 104–118, 1964. (Japanese)

30) Takekoshi, S.: The mechanism of vitamin A induced teratogenesis. J. Embryol. exp. Morph. **12** : 261–271, 1964.

31) Wertheimann, A.: Personal communication, 1965.

32) Woollam, D. H. M. and Millen, J. W.: Effect of cortisone on the incidence of cleft plate induced by experimental hypervitaminosis-A. Brit. Med. J. **5038** : 197–198, 1957.

33) Yukoka, K.: Morphogenesis of experimental cleft palate due to excessive vitamin A. J. Osaka City Med. Center, **7** : 725–734, 1958. (Japanese)

Murakami-'65
Bib. No. 6538

Arch. Environ. Health 10:732-741. 1965.

Reproduced by permission of the copyright owner

Original Articles

Malformations of the Mouse Fetus Caused by Hypervitaminosis-A of the Mother During Pregnancy

UJIHIRO MURAKAMI, MD, AND YOSHIRO KAMEYAMA, MD, NAGOYA, JAPAN

Introduction

A TERATOGENIC effect of hypervitaminosis-A upon the rat embryo was reported by Cohlan in 1953.[3] Giroud and Martinet (1955-59),[5] extended the study. Woollam and Millen (1957-61),[13,26,27] and Millen (1962)[16] also carried out similar experiments in the rat. Using rodents, Deuschle, Geiger and Warkany (1959),[4] and Kalter (1960)[11] have described the occurrence of visceral changes. In Japan, Baba and his collaborators (1958-1960)[1,2,9,23] and Takekoshi (1961)[24,25] studied the effect of hypervitaminosis-A upon the fetus of the rat and mouse. Authors of the present paper carried out experiments in the mouse using hypervitaminosis-A of the mother during pregnancy. As a result, there were many fetal malformations of the same type previously described in the literature. Among such malformed fetuses were many showing a certain combination of defects called the oculodentofacial pattern by Deuschle et al, as well as apparent micromelias. This paper stresses these unique patterns due to hypervitaminosis-A.

Methods

Animals used in these experiments were of the ddN and CF_1 strains of mice, originally supplied by the Zikkendobutsu Chuo Kenkyujo, Tokyo (Central Laboratories for Experimental Animals), 90 days or older, and weighing an average of 31 gm. In each case, one estrous female was kept overnight in a cage with one male. The next morning, all the females having a vaginal plug were considered to be in the first day of pregnancy. The pregnant mice were divided into six groups, ie, group A8 corresponding to the 8th day of pregnancy, group B 9 to the 9th, group C 10 to the 10th, group D 11 to the 11th, group E 12 to the 12th, and group F 13 to the 13th day. Each group contained 20 animals. The control group had ten animals.

Each test animal was given a single, intraperitoneal injection of 15,000 international units (IU) vitamin A water miscible solution. Experiments employing the ddN strain of mice were done as a pilot study; results will be published elsewhere (Kameyama and Murakami, 1964).[18]

Fetuses were removed surgically from mother animals on the 19th day of pregnancy and examined under a low power microscope for gross malformations. All fetuses were reexamined under the same binocular after being processed by the Dawson method of clearing tissues with one percent potassium hydroxyde solution and staining bones with alizarin red S solution.

Besides the above groups of animals, the fetuses of some mice treated on the 9th day of pregnancy were examined for changes of craniofacial patterns on the 15th and 16th days of pregnancy in sections stained with hematoxylin and eosin.

Results

As shown in Table 1, in each group administered vitamin A the mean litter size was smaller than in the controls. Group A 8 showed the most effect and embryonic and fetal deaths including resorptions and placental remnants

Submitted for publication Aug 31, 1964; accepted Sept 1.

From the Research Institute of Environmental Medicine, Nagoya University.

Reprint requests to Furo-Cho, Chikusa-Ku, Nagoya, Japan.

TABLE 1.—*Pregnancy Status of Mice Treated With 15,000 IU Vitamin A Water Miscible Solution at Different Stages of Pregnancy*

Group Designation and Day of Pregnancy Treated	Number of Treated Mice	Total Number of Conceptuses	Total Number of Fetuses	Mean Litter Size	Intrauterine Mortality: Dead Fetuses	Intrauterine Mortality: Resorptions—Remnants	Fetuses Without Gross Malformations	Fetuses with Gross Malformations	Fetuses Retarded in Development
A-8	20	191	15	0.8	1	175	0	15 (100%)	5 (33.3%)
					92.2%				
B-9	20	177	148	7.4	1	28	0	148 (100%)	12 (8.1%)
					16.4%				
C-10	20	203	143	7.3	20	40	12 (8.4%)	131 (91.6%)	21 (14.7%)
					29.6%				
D-11	20	188	163	8.2	8	17	18 (11.0%)	145 (89.0%)	29 (17.7%)
					13.3%				
E-12	20	179	167	8.4	5	7	32 (19.2%)	135 (80.8%)	10 (6.0%)
					6.7%				
F-13	20	195	182	9.1	2	11	143 (78.6%)	39 (21.4%)	3 (1.7%)
					6.7%				
Untreated control	10	111	102	10.2	0	9	100 (94.0%)	2 (2.0%)	0
					8.1%				

totalled 176 or 92% of all conceptuses. The 15 fetuses which were alive had gross malformations. In group B 9, the incidence of embryonic and fetal deaths was only 16%, but all living fetuses were malformed. In group C 10, the frequency of embryonic and fetal deaths reached nearly 30%, and 92% of living fetuses were malformed. In the three remaining groups which were treated on or after the 11th day of pregnancy intrauterine mortality rates approximated control levels but the frequency of gross malformations remained at high levels of 89%, 81%, and 21% respectively.

Among gross malformations, two cases each of exencephalia were found in group A 8 and B 9—the frequency was 13.33% in group A 8 and 1.33% in group B 9. There were two cases or 13.33% of spina bifida aperta (Fig 7A) in group A 8, but the defect was also detected in groups C 10 and D 11, although the incidence was very low (Table 2). Many microcephalic fetuses were seen in group B 9. However, the defect was not simple microcephalia, but was usually associated with other malformations as described later (Fig 1 and 7B). Malformations of the eye for the greater part were exophthalmoses manifested following treatment on the eighth or ninth day of pregnancy (Fig 2 and 7B). In almost all cases the eyelid was open. Cases of micro- or anophthalmoses were few (Table 2). Malformations of the jaw and mouth were manifested in fetuses treated on the eighth and ninth day of pregnancy. Micrognathia, agnathia and microstomia were usually associated with microtia. Anotia, and abnormalities of the auricle such as absence, lobulations, or dislocation were also associated with the above malformations (Fig 3 and 7B). Fetuses with such complicated malformations usually manifested microcephalia and exophthalmos with open eye. Such malformations were unique to experiments with hypervitaminosis-A. The incidence of cleft palate was highest (of the order of 70%) in middle pregnancy; the incidence was reduced somewhat in groups B 9 and F 13

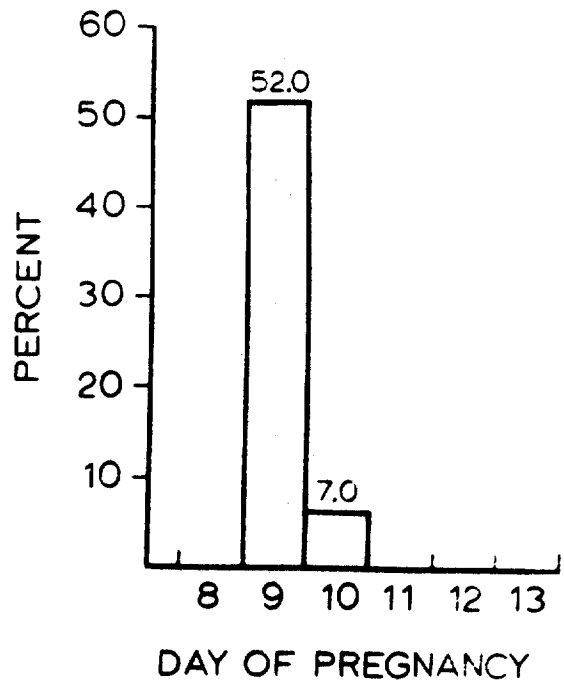

Fig 1.—Rates of microcephalia by day of pregnancy on which vitamin A was administered.

TABLE 2.—*Distribution of Malformations in Mouse Fetus Caused by Hypervitaminosis-A in Mother Mouse During Pregnancy*

	Malformation Classification	Day of Pregnancy When Treated						
		8th (Group A)	9th (Group B)	10th (Group C)	11th (Group D)	12th (Group E)	13th (Group F)	Control
CNS	Exencephalia	2(13.33 %)	2(1.35 %)					
	Brain hernia			1(0.7 %)				
	Hydrocephalus			4(2.8 %)				
	Microcephalia *		77(52.03 %)	10(6.99 %)				
	Spina bifida	2(13.33 %)		1(0.7 %)	3(1.84 %)			
Eye	Anophthalmos	3(20.0 %)		5 } (6.29 %)				
	Microphthalmos			4				
	Exophthalmos *	14(93.33 %)	108(72.97 %)	15(10.49 %)				
	Open eye *	9(60.00 %)	66(44.59 %)	2(1.4 %)				
Face	Short snout		84(56.76 %)	38(26.57 %)	17(10.43 %)	8(4.79 %)		
	Mandible malformations							
	Abnormalities		21 } (81.76 %)	5 } (24.48 %)	20(12.27 %)	8 } (17.96 %)		
	Incomplete		84	29		22		
	Agnathia	1(6.67 %)	16	1				
	Mouth malformations							
	Microstomia	2 } (73.33 %)	72 } (81.76 %)	8(5.59 %)		9(5.39 %)		
	Anostomia	9	49					
	Auricula malformations							
	Microtia		30 } (70.27 %)	6 } (13.29 %)				
	Anotia	12(80.00 %)	29	13	4(2.45 %)			
Trunk	Cleft palate		27(18.21) †	98(68.53 %)	122(74.95 %)	113(67.66 %)	33(18.13 %)	2(1.[illegible] %)
	Abdominal hernia			3(2.1 %)				
	Anal atresia		27(18.24 %)	2(1.4 %)				
Tail	Tailless	3 } (80.00 %)	1 } (40.54 %)	1 } (30.07 %)		12(7.36 %)		
	Short-tail	9	56	41				
	Curvature		1	1				
Limb and digit	Forelimb malformations							
	Micromelia (higher grade)		12 } (34.46 %)	73 } (72.03 %)	98 } (76.07 %)			
	Micromelia (lower grade)		39	30	26	9(5.39 %)		
	Forelimb digit malformations							
	Ectrodactylia		13(8.78 %)	99(69.23 %)	126(77.30 %)	28(16.77 %)	2(1.1 %)	
	Brachydactylia	5(33.33 %)	26(17.57 %)	5(3.5 %)	10(6.13 %)			
	Syndactylia		3(2.03 %)	25(17.48 %)	7(4.29 %)			
	Hindlimb malformations							
	Micromelia (higher grade)	2(13.33 %)	2 } (25.40 %)	35 } (51.75 %)	106 } (71.17 %)	7 } (40.12 %)		
	Micromelia (lower grade)		35	39	19	60		
	Clubfoot (excluding micromelia)	1(6.06 %)	3(2.03 %)	12(8.39 %)	4(2.45 %)			
	Hindlimb digit malformations							
	Ectrodactylia		8(5.41 %)	54(37.76 %)	162(92.19 %)	75(44.91 %)	2(1.1 %)	
	Brachydactylia			17(11.90 %)	4(2.45 %)	11(6.59 %)	3(1.66 %)	
	Syndactylia	1(6.06 %)	2(1.35 %)	14(9.79 %)	18(11.04 %)	9(5.4 %)		
	Annular groove of 5th digit				7(4.29 %)			

* These malformations were associated.

† Only 27 or 18.2 % of 148 fetuses could be examined for cleft palate, and all had the defect. The remaining fetuses had microstomia or anostomia and the palate could not be studied.

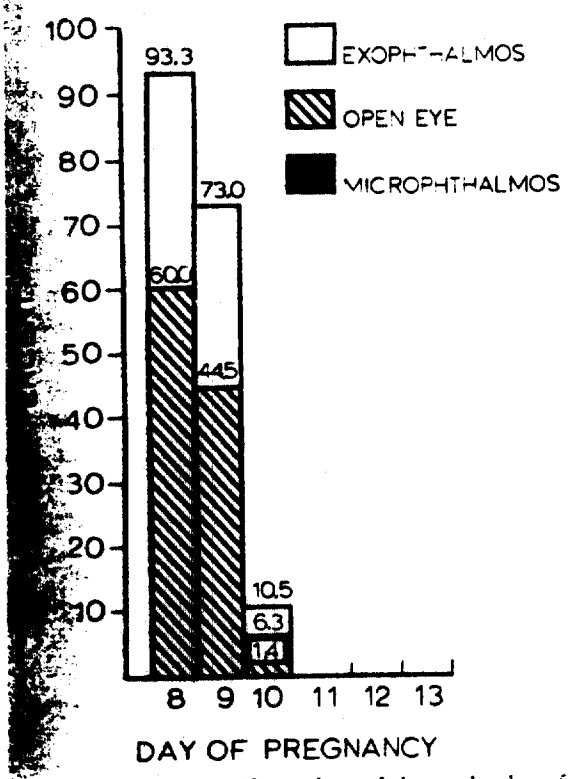

Fig 2.—Rates of malformations of the eye by day of pregnancy on which vitamin A was administered.

about 18%) but was still 10 times greater than was to be observed among controls (Table 2, Fig 4). However, in group B 9, all fetuses could not be examined for cleft palate because

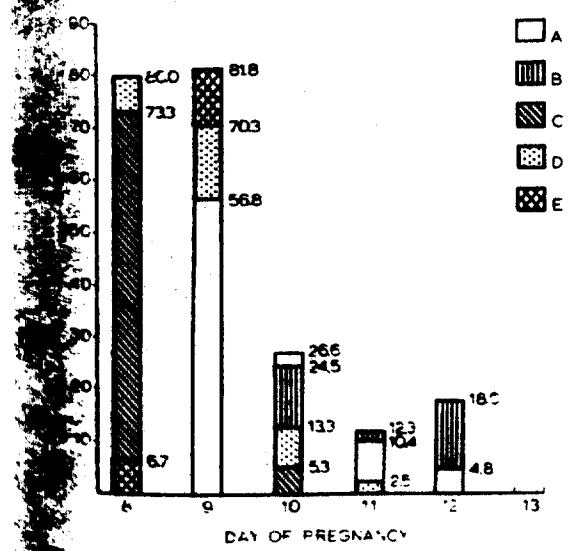

Fig 3.—Rates of malformations with craniofacial patterns by day of pregnancy on which vitamin A was administered. A, shortening of the snout; B, incomplete formation of the mandible and micrognathia; C, microstomia and anostomia; D, microtia, anotia, and dislocation of the auricle; E, agnathia.

the high incidence of microstomias and anostomias made it difficult to inspect the oral cavity; all 27 fetuses that were examined presented cleft palates. Also, in group B 9, there were 27 cases (18%) of anal atresia (Table 2). This malformation is one of the characteristic results of experiments using hypervitaminosis-A. The incidence of malformations of the tail was highest in group A 8—80%. In other groups, the frequency was gradually reduced as the embryo grew older (Table 2, Fig 5). There were many fetuses with noticable malformations of the extremities. The most prominent defects were micromelia and ectrodactyly (Table 2, Fig 6, *7C*, and *7F*). Both malformations were detected chiefly in groups C and D treated on the 10th or 11th day of pregnancy, respectively. The incidence was highest in group D. The incidence of micromelia in groups B 9 and C 10 was higher for the forelimb than for the hindlimb, while in group E 12 the incidence in the hindlimb was higher than in the forelimb. Also in group E 12 the frequency of ectrodactylism was much higher in the hindlimb than in the forelimb. The developmental stage at which the frequency of syndactylism was the highest was one day later for the hindlimb than for the forelimb.

In the skeletal system, characteristic changes were presented in the cranium, vertebrae, and extremities. In the cranium, remarkable deformities were detected chiefly in fetuses with craniofacial patterns such as microcepalia, hypoagnathia, micro- or astomia, micro- or anotia etc in groups A 8, B 9, and C 10. Each cranial bone, especially the frontal bone, was reduced in size and abnormally shaped. As a result, the head was formed small and abnormally shaped. The most marked change was in the zygomatic arch which was often incomplete, and the orbit formed was too shallow to hold an eyeball. In such fetuses the mandible was usually incompletely formed. In many cases only a rudiment could be detected or only the anterior part of the mandible was present, and even when the mandible was present, the posterior part was incompletely formed. These rudimentary mandibles were usually involved in an ankylosis, or fused with the maxilla or premaxilla (Fig *7D*). The nasal and premaxillary bones were small, and the snout was short. Ossification of the tympanic bulla was usually absent. In histologic

sections it was found that the auditory ossicles were not formed and that differentiation of the internal ear was abnormal.

In these experiments with hypervitaminosis-A, the phenomenon called head-to-tail gradient shift of malformations in the vertebrae as demonstrated in previous experiments with hypoxia (Murakami and Kameyama, 1963)[18] or x-radiation (Murakami and Kameyama, 1964)[21] did not occur. In the group treated on the tenth day, malformations of lumbar vertebrae were marked, and seen in association with malformations of the tail. In the group treated on the 11th day, malformations were seen chiefly in upper cervical vertebrae. In the group treated on the 12th day, involvement of vertebrae apparently increased in frequency. Ribs are often involved in malformations of developing buds, and such involvement was also a characteristic in the present experiments (Fig 7*E*).

In the extremities, the long bones were involved in malformation and presented micromelia. The defects in the long bone ranged from slight curvatures to complete deficiency often associated with ectrodactylism. Cases in

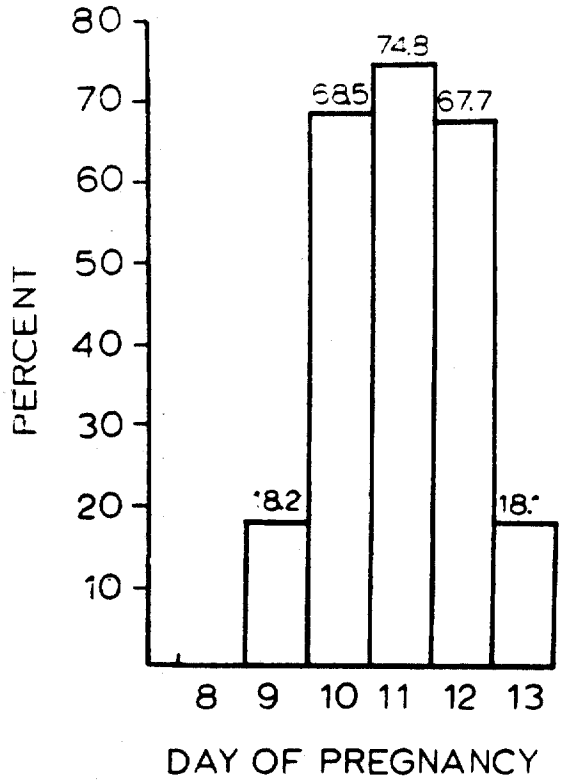

Fig 4.—Rates of cleft palate by day of pregnancy on which vitamin A was administered.

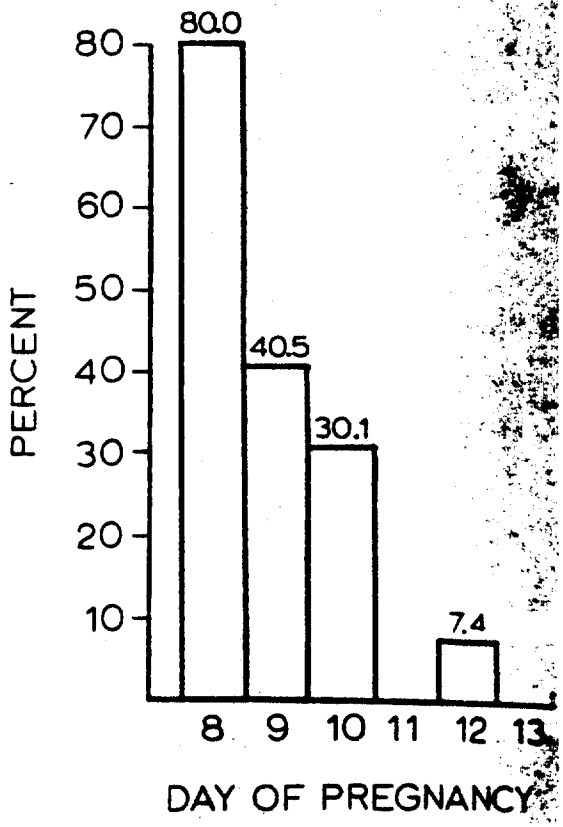

Fig 5.—Rates of tail abnormalities by day of pregnancy on which vitamin A was administered.

which the long bone was foreshortened were associated with thickening and curvature. In those with extensive involvement, the radius and the tibia were deformed in a corneous mass (Fig 7*F*).

Among fetuses examined in histologic sections, there was a case with a rosette formation in the brain. It was formed in the mesencephalon from its superficial part to its surface in the form of a small tumor. The eye itself in exophthalmos was also abnormal and its longitudinal axis extended. This resulted in the folding of the posterior part of the retina. In fetuses with micrognathia, agnathia, microstomia, or anostomia, the palate was incompletely formed. In some, only a rudiment of the lateral palatine process was observable. In such instances, the tongue was also very small.

Comment

In these experiments, the teratogenic effects following injection of mice with vitamin A on the 8th to 13th days of pregnancy were more intense the earlier the agent was administered. In

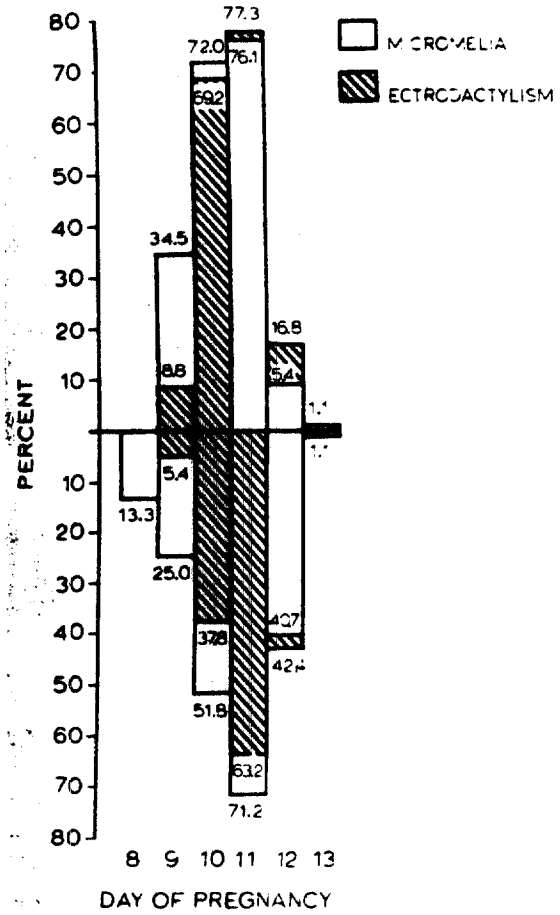

Fig 6.—Rates of malformations of the limbs and digits by day of pregnancy on which vitamin A was administered.

group A treated on the eighth day of pregnancy, the incidence of embryonic deaths was 92%, and all surviving fetuses presented malformations. In the ddN strain of mice which were used in a pilot test, all embryos died following treatment on the eighth day. The incidence of malformations was reduced, but only gradually, in mice treated at later stages of pregnancy, and over 21% malformed fetuses were still observable in group F treated on the 13th day. The effects of the agent were extensive, therefore, for at least five or six days.

Exencephalia in rats was not a frequent manifestation after administration of vitamin A as shown in papers by Giroud and Martinet (1956),[7] Woollam and Millen (1957),[26] and Araki (1958).[1] Spina bifida aperta was rarely induced in mice when they were treated with another kind of agent. However, some cases of spina bifida were manifested in the present experiment, and the ratio of the manifestation was about the same as in exencephalia. This circumstance is similar to the results of Kalter and Warkany (1961).[11]

There were some characteristic malformations observed. One example was the craniofacial-pattern microcephalia associated with malformations of the jaw, mouth and auricle. The principal features of the defect were as follows; foreshortening of the frontal region and snout with incomplete formation of the lower jaw, and variously micrognathia, agnathia, microstomia, anostomia, anotia and absence, dislocation, or malformation of the auricle. Such fetuses presented a strange appearance. The internal ear was also abnormally formed. A similarly induced abnormality of the internal ear of the rat has been studied by Nakamura (1958)[23] in detail. To all appearances, those fetuses with the above malformations could be classified as otocephalia and its allied conditions. Treatment on the ninth day of gestation produced the highest frequency of the defects—81.75%. The next highest frequency followed treatment on the eighth day—80%. After the tenth day, the incidence was markedly reduced. Otocephalia has a close relationship to the cyclopia-arrhinencephalia group of malformations in morphogenesis. When pregnant mice were exposed to x-radiation on the ninth day of pregnancy, malformations belonging to the cyclopia-arrhinencephalia group, especially arrhinencephalias, were manifested in considerable numbers (Murakami et al, 1962).[17] Thus, a coincidence is seen in the period critical for arrhinencephalia caused by x-radiation, and the above malformations with their characteristic craniofacial pattern due to hypervitaminosis-A. However, in the above fetuses with craniofacial patterns, the auricle did not show an incidental location when compared with real otocephalia in animals or human beings. Furthermore, in experiments employing the rabbit, the auricle was neither lost nor dislocated (Murakami, 1964).[22] Therefore, in the specially complicated malformations with craniofacial pattern there is no definite evidence to classify them with otocephalia or its allied conditions. Deuschle et al (1959)[4] called the condition an anomalous oculodentofacial pattern, and later Kalter (1960)[10] also analyzed the condition in detail.

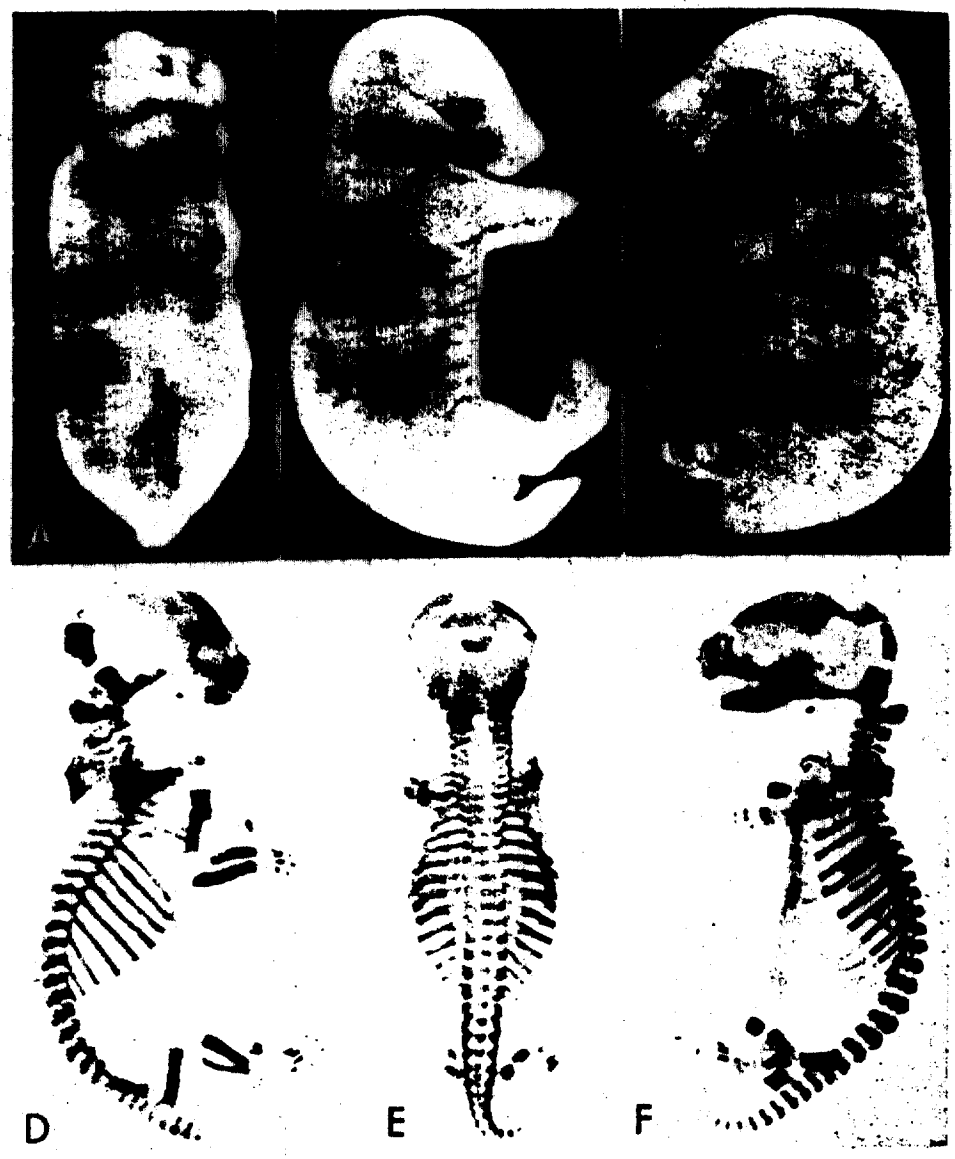

Fig 7.—*A*, abnormal fetus with exencephalia, anostomia, exophthalmos, spina bifida aperta, and taillessness after intraperitoneal injection of the mother with 15,000 IU vitamin A on the eighth day of pregnancy.

B, abnormal fetus with microcephalia, agnathia, anotia, exophthalmos, open eye, brachydactylism and short-tailedness after intraperitoneal injection of the mother with 15,000 IU vitamin A on the eighth day of pregnancy.

C, abnormal fetus with micromelia after similar treatment on the 11th day of pregnancy. This fetus also had micrognathia and cleft palate.

D, skeleton of an abnormal fetus with similar cranio-facial pattern shown in B after similar treatment on the ninth day of pregnancy. The shape of the cranial bone, especially the frontal, temporal, and premaxillar bones are abnormal. A rudimental mandibular bone is fused with the maxilla.

E, skeleton of an abnormal fetus with malformed vertebrae and ribs after similar treatment on the tenth day of pregnancy. Rami of the posterior arch of the cervical vertebrae are involved in fragmentations and the rib has buds. Bones forming the limb-girdle and limbs are also involved in deformity.

F, skeleton of an abnormal fetus with micromelia after similar treatment on the 11th day of pregnancy. Long bones of the extremity are involved in malformation: ossification of the humerus and femur is absent. Bones of the forearm and lower leg are also malformed.

Kalter and Warkany (1961)[11] stated that exophthalmos resulted from disturbances in formation of the cranial bone such as deformity in the zygomatic arch. This point is in agreement with observations of the authors of the present paper. Such exophthalmoses could not be produced in rabbit fetuses by hypervitaminosis-A of the mother during pregnancy (Murakami, 1964).[22]

There were no cases of harelip, although the incidence of cleft palate was high particularly in mice treated with vitamin A on the 11th day of pregnancy. However, in contrast to the results with x-radiation, the manifestation of cleft palate did not present two phasic elevations of incidence. Giroud et al and Kalter et al succeeded in getting cleft palates by oral administration of vitamin A, whereas in experiments employing subcutaneous injection of the agent done by Wollam et al (1957),[26] cleft palate was not detected. Takekoshi (1961)[24,25] produced cleft palate by intramuscular injection. The high incidence of the defect seen by the authors of the present paper may be due to the amount of the agent used and the route of administration.

Anal atresia was another of the characteristic malformations caused by hypervitaminosis-A. Kalter et al have also described this pattern of defect, although the critical stage seemed to be a day later. Such differences in the critical stage may be caused by differences in progression of development between the strains of mice or by differences in the timing of treatment. Malformations of the tail were manifested chiefly in groups treated on the eighth, ninth, and tenth days, and the earlier the time of administration the higher the frequency. Kalter et al[11] also stated that malformations of the tail were manifested following treatment at 8½ and 9½ days of pregnancy, which corresponds roughly to the 9th and 10th day of pregnancy in the present experiment.

Malformations of the extremities were frequently seen. Most of the defects were typical micromelias such as what are sometimes called phocomelias. These were seen especially in the forelimbs of mice treated from the 10th to 11th day, and in the hindlimbs of mice treated on the 11th day. Reduction in number of digits was associated with micromelia. The difference in incidence of malformations of the extremities between fore-and hindlimbs may be due to differences in the time of formation of limb buds in fore- and hindlimbs. Such malformations in the extremities were described also by Giroud et al and Kalter et al. Similar findings were shown both in experiments of the present paper and those of Kalter and Warkany.[11] Millen (1962)[16] injected the agent subcutaneously in the rat and produced monopus sympus and amelias in about 43% of fetuses. No such cases were found in experiments by the present authors. It is hard to compare results of experiments done by different investigators because species and strains of animals used, as well as amount of the agent and route of its administration, may be different. However, the kind of malformations produced have been similar. In the present experiment, many micromelias were produced. Long bones of the extremities presented specific involvement and the degree of the micromelia was high, but no synostosis in bones of the forelimb as seen following x-radiation was detected. Also, ectrodactylism was manifested in the forelimb of fetuses treated on the 10th and 11th day, but it was manifested in the hindlimb in groups of the 10th, 11th and 12th day. With x-radiation, ectrodactylism was detected chiefly in the forelimb in the group treated on the 12th day of pregnancy (Murakami et al, 1963).[20] While administration of hypervitaminosis-A caused exencephalias and spina bifida aperta, hypervitaminosis-A during early stages of pregnancy seemed to have destructive effects directly upon the primordial retina. Therefore, further development of the eye was not disturbed as in experiments with x-radiations. Hypervitaminosis-A exerts a serious effect upon formation of bones of the face. Formation of the snout, mandible, and the temporal bone, especially the zygomatic arch, were involved in the disturbance. Many cleft palates were also [illegible] Presumably, the agent affected the [illegible] of the palate, ie, the maxillary arch itself, thus disturbing further development. This agent does not seem to interfere with formation of the tail after the primordium is formed. The limb-bud, and hand or foot plate, seem to be susceptible to hypervitaminosis-A. Therefore, hypervitaminosis-A exerts a suppressive effect chiefly upon mesenchymal tissue just before its differentiation into the primordium, or on mesenchymal

tissue during differentiation. Also closure of the neural tube sustains an effect.

In the results of experiments done by foreign investigators, ectodermal organs also seemed to be more susceptible than observed in the results of the present experiments. The cause may be explained when an investigator uses different species of animals and also different ways of treating the animals.

In our experiments, marked rises in the frequency manifestation of specific malformations ranged over a period of two to three days, whereas, with x-radiation, such rises are usually limited to only one day. This point may be due to the fact that x-radiation affects embryos for relatively short times and only in the radiosensitive stage of development. However, with hypervitaminosis-A, injected intraperitoneally, the teratogenic effect apparently undergoes a gradual decrease until a certain level is reached.

Summary

Pregnant (CF_1 strain) mice were divided into six groups from the 8th to 13th day of pregnancy. Each group was administered a single dose of 15,000 IU vitamin A water miscible solution intraperitoneally, and the fetuses were examined for gross malformations and skeletal changes. Some fetuses were also studied in histologic sections.

Many characteristic malformations were manifested according to the stage of pregnancy at which the agent was administered. Exencephalias were detected in groups treated on the eighth or ninth day. Spina bifida aperta was found following treatment on the 8th, 10th and 11th days of pregnancy. Complicated malformations with craniofacial patterns such as microcephalia, reduction malformations of the jaw, mouth, and auricle in various degrees were seen in groups treated on the eighth and ninth days. In overall appearance, these defects seem to have some resemblance to otocephalias, but there was no evidence conclusive enough to classify them as otocephalias. Many cleft palates were produced by treatment on the 10th day; next in line were groups treated on the 9th and 11th days. In groups treated on the 10th and 11th day, many fetuses with micromelia showing a typical phocomelia were detected. In many of those cases, ectrodactylism was an associated condition. In the group treated on the 12th day of pregnancy, ectrodactylism was demonstrated more often in the hindlimb.

There were characteristic changes in the skeletal system. Those changes were marked in the craniofacial region, vertebrae, and extremities.

In hypervitaminosis-A, the time range of the critical period for each malformation seemed to be a little longer than in experiments with x-radiation. This may be due to the nature of the agent and the continued effect it exerts until a certain level is reached.

Generally, in these experiments, involvement of mesenchymal tissue was prominent.

REFERENCES

1. Araki, E.: Morphogenesis of Congenital Malformation Due to Excessive Vitamin A (Japanese), J Osaka City Med Center 7:445-452, 1958.

2. Baba, T., and Araki, E.: Morphogenesis of Malformation Due to Excessive Vitamin A (I), Osaka City Med J 5:9-15, 1959.

3. Cohlan, S. Q.: Excessive Intake of Vitamin A as a Cause of Congenital Anomalies in the Rat, Science 117:535-536, 1956.

4. Deuschle, F. M.; Geiger, J. F.; and Warkany, J.: Analysis of an Anomalous Oculodentofacial Pattern in Newborn Rats Produced by Maternal Hypervitaminosis-A, J Dent Res 38:149-155, 1959.

5. Giroud, A., and Martinet, M.: Malformations embryonnaires par hypervitaminose A, Arch Franc Pédiat 12:292-300, 1955.

6. Giroud, A., and Martinet, M.: Hypervitaminose A et anomalies chez le foetus de rat, Internat Z Vitaminforsch 26:10-18, 1955.

7. Giroud, A., and Martinet, M.: Tératogenèse par hautes doses de vitamine A en fonction des stades de développement, Arch Anat Micr Morph Exp 45(2):77-98, 1956.

8. Giroud, A., and Martinet, M.: Tératogenèse par hypervitaminose A chez le rat, la souris, le cobaye et le lapin, Arch Franc Pédiat 16:1-5, 1958.

9. Inaba, T.: Experimentally Reproduced Congenital Malformations of Rats by Excessive Vitamin-A Diet (Japanese), J Osaka City Med Center 7:558-566, 1960.

10. Kalter, H.: Teratogenic Effects of Hypervitaminosis A Upon Face and Mouth of Inbred Mice, Ann NY Acad Sci 85:42-55, 1960.

11. Kalter, H., and Warkany, J.: Experimental Production of Congenital Malformations in Strains of Inbred Mice by Maternal Treatment With Hypervitaminosis A, Amer J Pathol 38:1-21, 1961.

12. Kamei, T.: Embryological and Histological Studies on the Artificially Induced Cleft Palate in Mice (Japanese), Acta Anat Nippon 37:140-158, 1962.

13. Kameyama, Y., and Murakami, U.: Study on Micromelias in Mice Foetuses Caused by X-Radiation, Hypoxia, Trypan Blue Injection and Hypervitaminosis-A Upon Mother Animals During Pregnancy, 1964. To be published.

14. Kotani, S.: Morphogenesis of Ophthalmic Malformation of Rats Produced by A-Hypervitaminosis (Japanese), J Osaka City Med Center 7:445-452, 1958.

15. Millen, J. W., and Woollam, D. H.: Influence of Cortisone on Teratogenic Effects of Hypervitaminosis-A, Brit Med J 5038:196-197, 1957.

16. Millen, J. W.: Thalidomide and Limb Deformities, Lancet 2:599-600 (Sept) 1962.

17. Murakami, U., et al: Radiation Malformations Belonging to Cyclopia-Arrhinencephalia-Otocephalia Group in Mouse Foetus, J Embryol Exp Morph 10:64-[illegible] (March) 1962.

18. Murakami, U., and Kameyama, Y.: Vertebral Malformation in Mouse Foetus Caused by Maternal Hypoxia During Early Stages of Pregnancy, J Embryol Exp Morph 11:107-118 (March) 1963.

19. Murakami, U.: Studies on Mechanisms Manifest-[illegible] Congenital Anomalies, Jap J Hum Genet 8:202-226, [illegible]

20. Murakami, U.; Kameyama, Y.; and Nogami, H.: Malformation of Extremity in Mouse Foetus Caused by X-Radiation of Mother During Pregnancy, J Embryol Exp Morph 11:549-569, 1963.

21. Murakami, U., and Kameyama, Y.: Vertebral Malformation in Mouse Foetus Caused by X-Radiation of Mother During Pregnancy, 1964, to be published.

22. Murakami, U.: Unpublished data, 1964.

23. Nakamura, S.: Experimental Studies on Auditory Organs, Especially on Inner Ear of Rat Fetuses Born to Mother Animals Fed With Excessive Vitamin A (Japanese), J Osaka City Med Center 7:456-498, 1958.

24. Takekoshi, S.: Teratogenesis Due to Hypervitaminosis A in Combination With Other Teratogenic Factors (Cortisone, Trypan Blue, Noise-Stimulation, Urethan and Chondroitinsulfate) (Japanese), J Otorhinolaryng Soc Jap 64:1489-1497 (Sept) 1961.

25. Takekoshi, S.: On Teratogenicity of Overdose of Vitamin A (Japanese), Kita Kanto Igaku, 11:104-118, 1961.

26. Woollam, D. H., and Millen, J. W.: Effect of Cortisone on the Incidence of Cleft-Palate Induced by Experimental Hypervitaminosis-A, Brit Med J 99: 197-198 (No. 5038) 1957.

27. Woollam, D. H., and Millen, J. W.: Influence of Uterine Position on Response of Mouse Embryo to Teratogenic Effects of Hypervitaminosis-A, Nature (London) 190:184-185, 1961.

28. Yukioka, K.: Morphogenesis of Experimental Cleft Palate Due to Excessive Vitamin A (Japanese), J Osaka City Med Center 7:725-734, 1958.

Murray-'59
Bib. No. 6564

Reproduced by permission
of the copyright owner

ISOMERIZATION OF VITAMIN A IN VIVO[1]

T. K. MURRAY, D. W. STAINER,[2] AND J. A. CAMPBELL

Abstract

Pure all-*trans* and neovitamin A alcohol were administered orally to young, vitamin-A-deficient rats and the vitamin A and proportion of neovitamin A in the intestinal tract, liver and kidney were measured. In both cases considerable isomerization occurred in the stomach and the resulting mixture of isomers appeared to be absorbed by the intestine. The dose of all-*trans* vitamin A was taken up by the intestine more quickly than was the neovitamin A dose. An oral or subcutaneous dose of neovitamin A resulted in a relatively high proportion of neovitamin A in the liver but this proportion decreased during depletion to that found after a dose of all-*trans* vitamin A. The proportion of neovitamin A varied inversely with the size of dose of all-*trans* vitamin A and directly with the size of dose of neovitamin A. The significance of these results is discussed.

Vitamin A can exist in one of several isomeric forms, all-*trans*, neovitamin A (13-mono-*cis*), *neo-b* (11-mono-*cis*), 9-mono-*cis*, 11,13-di-*cis*, and 9,13-di-*cis*, which vary widely in their biological activity (1, 2). Neovitamin A has been reported to occur to the extent of about 30% in many fish-liver oils (3, 4, 5) and synthetic sources (6, 7, 8), although Lambertsen and Braekkan (9) doubt its occurrence in vivo. Other *cis* isomers have been found in various crustacea (10, 11, 12), but Morton and Bro-Rasmussen (13) were unable to detect them in fish oils. The fact that the spectrophotometric method (2) has been found to yield a good estimate of biological potency of fish-liver oils is also evidence against the occurrence in quantity of *cis* isomers other than neovitamin A, for these isomers would contribute proportionately much more to the absorbance at 325 mμ than to biological activity. Plack (14) fed the 11-*cis* isomer to rats and found very little of the liver vitamin A stores in this form. Brown (15) was unable to find any evidence of the *neo-b* isomer in cattle liver or serum and in experiments on rats Dowling and Wald (16) obtained results similar to those of Plack.

There is evidence, however, that an equilibrium mixture of isomers is formed in rat livers. Harris, Ames, and Brinkman (17) found that the livers of rats fed all-*trans* or neovitamin A contained approximately the same neovitamin A content, i.e. 11–19%. Preliminary experiments in this laboratory (18) showed that after a dose of all-*trans* or neovitamin A, considerable interconversion occurred in the intestinal tract and the liver with the all-*trans* isomer being the predominant form found. Such data, however, are still incomplete and since neovitamin A is a common constituent of commercial sources of vitamin A activity a more exhaustive study was deemed necessary in order to understand better the metabolism of vitamin A by animals.

It is the purpose of this paper to report on the proportion of isomers found in the various tissues after dosing with all-*trans* or neovitamin A and to attempt to explain the lower biological potency of the latter as compared with all-*trans*.

[1]Manuscript received August 5, 1959.
Contribution from Food and Drug Laboratories, Department of National Health and Welfare, Ottawa.
[2]N.R.C. Postdoctorate Fellow 1958.

Procedure and Results

Isomer Content of the Various Tissues Following All-trans or Neovitamin A Dosing

Weanling male rats of an inbred Wistar strain were fed the vitamin-A-free diet (2) for 2 weeks, after which time no vitamin A could be detected in the liver, and were then divided into two groups. One group received 4916 units of all-*trans* vitamin A alcohol, the other 2500 units of neovitamin A alcohol* dissolved in corn oil and administered orally with a tuberculin syringe and blunted needle. Five rats from each group were killed by decapitation after intervals of 1, 2, 3, 4, 5, 24, and 48 hours from dosing. The intestinal tract, liver, and kidneys were removed and analyzed for vitamin A and neovitamin A. The stomach and caecum were analyzed with their contents, intestinal contents were expressed manually, and the intestine washed with 0.9% saline. The kidneys from both groups of animals were divided into three fractions: 1–5 hours, 24 hours, and 48 hours. The method of Ames, Risley, and Harris (19) was used to estimate the vitamin A content of the tissues except in the case of the intestinal contents which were saponified prior to extraction with petroleum ether. Neovitamin A was measured by the maleic anhydride method (3), which distinguishes between fast- and slow-reacting isomers, but the results were expressed in terms of the principal isomers in these groups, all-*trans* and neovitamin A. Hayes and Petitpierre (5) found this procedure to have a precision of ±1.5%.

The values in Tables I and II are, in most cases, average values for five rats but bulking of tissues was necessary in certain cases to obtain sufficient vitamin A for analysis.

TABLE I

Neovitamin A found in the various tissues following all-*trans* or neovitamin A dosing expressed as percentage of the total vitamin A content

	% neovitamin A found in the tissues, hours after dose													
	2500 units* neovitamin A							4916 units* all-*trans* vitamin A						
Tissue	1	2	3	4	5	24	48	1	2	3	4	5	24	48
Stomach	26	42	40	35	45	34	ND†	25	35	18	20	23	30	ND
Intestine	33	37	44	42	42	26	ND	18	18	20	16	10	27	ND
Intestinal contents	33	23	29	29	32	ND	ND	25	22	11	18	25	ND	ND
Liver	32	18	26	24	23	11	11	12	12	4	5	3	3	4
Caecum	78	40	56	41	36	32	59	58	57	39	25	30	26	58
Kidney			20			25	29			18			13	12

*Determined by $SbCl_3$ reaction.
†Not detectable.

The percentage neovitamin A found in the tissues following the above dosing regimes is shown in Table I. When neovitamin A was given, less than 50% of the vitamin A in the stomach was in this form and a similar mixture of isomers was found in the intestine and intestinal contents throughout the experimental period. The liver contained from 18% to 30% of its vitamin A as *neo* for the first 5 hours but within 24 hours the *cis* isomer content had significantly

*Kindly donated by Distillation Products Industries, Rochester, N.Y., through the courtesy of Dr. S. R. Ames.

TABLE II

Vitamin A distribution in the tissues following all-*trans* or neovitamin A dosing

	Vitamin A stores expressed as % of the dose, hours after dose													
	2500 units* neovitamin A							4916 units* all-*trans* vitamin A						
Tissue	1	2	3	4	5	24	48	1	2	3	4	5	24	48
Stomach	36	43	30	15	19	0.7	ND†	48	38	15	14	14	0.2	ND
Intestine	3	3	5	4	5	2	ND	7	6	10	5	4	2	ND
Intestinal contents	14	10	22	15	5	ND	ND	17	13	15	3	4	ND	ND
Liver	2	2	8	11	12	30	36	4	8	10	16	20	32	42
Caecum	0.2	1	0.2	1	7	3	2	0.2	0.2	0.4	4	7	2	0.6
Kidney ($SbCl_3$ units)						4.8	3.2						6.5	4.5
% recovery	55	59	2.7 65	46	48	36	41	76	65	3.8 50	42	49	36	53

*Determined by $SbCl_3$ reaction.
†Not detectable.

dropped to 11% ($P = 0.05$). Some isomerization of the all-*trans* vitamin A dose also occurred in the stomach but the all-*trans* form predominated and a smaller proportion of the *cis* isomer was found than when neovitamin A was fed. The liver initially contained 12% neovitamin A but this quickly dropped ($P = 0.01$) to about 4% and changed little thereafter. Compared to this reduction, kidney and caecum neovitamin A remained high ever after 48 hours, although somewhat less *cis* isomer was found in the kidneys of all-*trans* dosed animals. The absolute amounts of *cis* isomer found in these tissues were, however, very low.

The actual vitamin A distribution in the tissues differed with *neo* and all-*trans* dosing as shown in Table II. When all-*trans* vitamin A was fed, significantly more of the dose was found in the intestinal walls ($P = 0.01$) during the first 3 hours. Liver stores also appeared to increase more rapidly after an all-*trans* dose but the difference was not significant. No differences were noticed in the kidney or caecum vitamin A levels following either all-*trans* or neovitamin A dosing.

Vitamin A Depletion Studies

Weanling, vitamin-A-deficient rats were dosed orally or subcutaneously with a water-soluble dispersion of either *neo* or all-*trans* vitamin A, prepared immediately before use in the following manner. The vitamin A and 50 mg α-tocopherol were dissolved in a few drops of ethyl ether and 2 g of Tween 80 was added. After mixing, the ether was removed under vacuum and the mixture warmed gently to 50° C with stirring. A solution of 0.1% ascorbic acid was then added, with shaking, to make a final volume of 8 ml. In a further experiment vitamin-A-deficient animals were injected subcutaneously with a commercial preparation containing 70% all-*trans* and 30% neovitamin A, while another group was given a similar dose of all-*trans* vitamin A. In both experiments five rats from each group were killed after various time intervals, the livers and kidneys removed and analyzed for total vitamin A stores and isomer content.

The results are shown in Table III. Vitamin A stores in the liver progressively decreased with time except that after subcutaneous injection there was a delay before maximum storage was attained. The percentage neovitamin A in

TABLE III

Vitamin A and neovitamin A content of liver and kidney during depletion

		Days after dosing							
		2		7		21		35	
Tissue	Dose	Vit. A, units*	Neo, %	Vit. A, units*	Neo, %	Vit. A, units*	Neo, %	Vit. A, units*	Neo, %
(1) Liver	All-*trans* (920 units* orally)	317	5.2	264	4.2	132	5.8	67	6.4
(2) Liver	All-*trans* (920 units* subcutaneously)	262	4.9	293	3.8	217	1.9	76	4.9
(3) Liver	*Neo* (860 units* orally)	227	10.6	202	8.8	98	4.8	28	3.3
(4) Liver	*Neo* (860 units* subcutaneously)	243	14.9	222	4.1	118	5.5	38	5.3
(5) Kidney	All-*trans* (1 and 2 bulked)	1.8	18.9	2.1	27.4	2.5	14.9	3.4	3.3
(6) Kidney	*Neo* (3 and 4 bulked)	2.6	14.2	2.4	16.1	2.6	29.7	2.4	6.1
(7) Liver	All-*trans* (1250 units* subcutaneously)	430	3.1	535	5.5	500	2.3	—	—
(8) Liver	30% *neo* (1250 units* subcutaneously)	495	12.0	565	7.7	470	2.8	—	—

*Determined by $SbCl_3$ reaction.

the liver after a dose of all-*trans* did not alter appreciably with time, but after administration of either neovitamin A or the 30% *neo* preparation, the proportion of *cis* isomer found in the liver quickly dropped ($P = 0.01$) from an initial high value to that found after all-*trans* had been fed. Following a dose of either all-*trans* or neovitamin A the kidney contained a relatively large proportion of neovitamin A, but in both cases the percentage neovitamin A had decreased by the end of the depletion period. Because only small amounts of vitamin A are stored in the kidney it was necessary to bulk these organs and statistical analysis of the results was not possible.

Effect of Dosage Level on Isomer Composition of the Liver

Corn oil dilutions of all-*trans* or neovitamin A were given orally in single doses ranging from 4900 I.U. to 300 I.U. to weanling, male, vitamin-A-deficient rats. Animals were killed after 48 hours, the livers removed and analyzed for total vitamin A and isomer content.

The results are presented in Table IV. With all-*trans* dosing the percentage of *neo* stored varied inversely with the dose, high doses producing low proportions of *cis* isomers in the liver ($P = 0.01$). The percentage neovitamin A found did not exceed the relatively low value of 5.8%. Following neovitamin A intake a direct relationship was found between dosage level and proportion of neovitamin A in the liver ($P = 0.05$).

TABLE IV

Comparison of liver vitamin A following graded doses of *neo* and all-*trans* vitamin A (after 48 hours)

	Neo dose, units*				All-*trans* dose, units*			
	2500	1250	625	313	4916	2458	1229	615
Vitamin A, units* liver	912	426	166	85	2759	1340	607	304
Neovitamin A, %	19.4	12.3	7.7	10.3	0.8	1.9	2.9	5.8

*Determined by $SbCl_3$ reaction.

Discussion

It has been shown that in the 24 hours following an oral dose of all-*trans* vitamin A the proportion of neovitamin A in the stomach varied from 18% to

35%. Individual rats showed great variability in this regard but there was no trend toward higher or lower values with time. A similar mixture was found in the intestinal contents and walls and under these conditions maximum storage was obtained in the liver. When neovitamin A was given, the proportion of neovitamin A in the stomach varied from 26% to 45% and while the intestine absorbed this mixture it did not do so as efficiently and liver stores smaller than after an all-*trans* dose resulted.

Early in the experiment the proportion of neovitamin A in the liver resembled that found in the intestine, but this proportion dropped within a few hours, suggesting that isomerization occurred in the liver. This observation was supported by later experiments. Apart from the initial change in the stomach no reduction in neovitamin A was observed in any part of the intestinal tract.

Over the first 3 hours more vitamin A was found in the intestinal walls following all-*trans* dosing than after administration of neovitamin A. Although the difference was not significant it is also worthy of mention that during the first 5 hours after dosing with all-*trans*, the liver stores reached 41% of their final (48-hour) value whereas in the same interval a neovitamin A dose produced only 33% of the final liver stores. Dowling and Wald (16) observed a similar delay in the action of the 11-*cis* isomer in the curing of night blindness in the rat.

If the intestine absorbed less of a dose of neovitamin A then more should have been found in the caecum but this was not the case. This may have been due to a high rate of destruction in the caecum which could eliminate small differences in the total amount of vitamin reaching it. Unpublished work in this laboratory has shown that very rapid destruction of vitamin A occurs upon incubation with caecal contents.

The proportion of neovitamin A in the liver was rapidly reduced during depletion to a very low level, presumably by isomerization in the liver. This conversion of neovitamin A to all-*trans* appears to be efficient because there was no detectable difference in depletion rates whether the proportion of neovitamin A in the liver was initially high or low. The kidney does not seem able to perform this isomerization easily because the proportion of neovitamin A remained fairly high until the later stages of depletion.

Large oral doses of neovitamin A resulted in a higher proportion of this isomer in the liver stores than did smaller doses. The most likely explanation for this observation is that the intestine absorbs the same proportion of isomers, regardless of size of dose, but the large doses provide greater absolute amounts of neovitamin A to be isomerized by the liver; hence there is a delay before this is fully accomplished.

These experiments suggest that while *cis* isomers can be absorbed by the intestine they are converted to all-*trans* in the liver before they are utilized by the body. A similar conclusion was reached by Dowling and Wald (16) and Plack (14), both of whom worked with the 11-*cis* isomer. Plack was unable to decide from his results whether the low biological activity of the 11-*cis* isomer (23% of that of all-*trans*) was due to 23% efficient isomerization followed by fully efficient absorption, 23% efficient absorption followed by fully efficient conversion, or a combination of both factors. The results reported here suggest

that the lower potency of neovitamin A may best be explained by the latter alternative and indicate that the stomach and liver are the major sites of isomerization. The formation of neovitamin A from all-*trans* or vice versa also occurs in vitro. When either all-*trans* or neovitamin A is dispersed in water considerable isomerization occurs but at a much slower rate than in the above experiments (21).

The isomer composition of rat-liver oil is still a subject of controversy. Ames, Swanson, and Harris (22) found that rat-liver oil had a low relative biological potency. They attributed this to the presence in the oil of an equilibrium mixture of isomers, including those of low biological activity. On the other hand, Dowling and Wald (16) and Plack (14) found only all-*trans* and the isomer administered (11-*cis*) in the livers of rats. Biological assays in this laboratory (18) have not confirmed the results of Ames and his group. Furthermore the very low *cis* isomer content of vitamin A in rat liver reported here is not consistent with a low biological potency.

References

1. Ames, S. R., Swanson, W. J., and Harris, P. L. J. Am. Chem. Soc. **77**, 4134 (1955).
2. Murray, T. K. and Campbell, J. A. J. Pharm. and Pharmacol. **9**, 596 (1953).
3. Robeson, C. D. and Baxter, J. G. J. Am. Chem. Soc. **69**, 136 (1947).
4. Meunier, P. and Jouanneteau, J. Bull. soc. chim. biol. **30**, 260 (1948).
5. Hayes, E. and Petitpierre, M. A. J. Pharm. and Pharmacol. **4**, 879 (1952).
6. Cawley, J. D., Robeson, C. D., Weisler, L., Shantz, E. M., Embree, N. D., and Baxter, J. G. Science. **107**, 346 (1948).
7. Schwarzkopf, O., Cahnmann, H. J., Lewis, A. D., Swidinsky, J., and Wüest, H. M. Helv. Chim. Acta. **32**, 443 (1949).
8. Robeson, C. D., Cawley, J. D., Weisler, L., Stern, M. H., Eddinger, C. C., and Chechak, A. J. J. Am. Chem. Soc. **77**, 4111 (1955).
9. Lambertsen, G. and Braekkan, O. R. Biochemical problems of lipids (Proceedings of the Second International Conference held at the University of Ghent, 27–30 July, 1955). Butterworth Scientific Publications, London. 1955. p. 56.
10. Wald, G. and Burg, S. P. J. Gen. Physiol. **40**, 609 (1957).
11. Fisher, L. R., Kon, S. K., and Plack, P. A. Proc. Roy. Soc. (London), B, **147**, 220 (1957).
12. Barnholdt, B. and Hjarde, W. Acta Physiol. Scand. **41**, 49 (1957).
13. Morton, R. A. and Bro-Rasmussen, F. Analyst, **80**, 410 (1955).
14. Plack, P. A. Brit. J. Nutrition. **13**, 111 (1959).
15. Brown, P. K. Unpublished observations (*quoted in* Wald and Burg 1957).
16. Dowling, J. F. and Wald, G. Proc. Natl. Acad. Sci. U.S. **44**, 648 (1958).
17. Harris, P. L., Ames, S. R., and Brinkman, J. H. J. Am. Chem. Soc. **73**, 1252 (1951).
18. Murray, T. K. and Campbell, J. A. Federation Proc. **17**, 486 (1958).
19. Ames, S. R., Risley, H. A., and Harris, P. L. Anal. Chem. **26**, 1378 (1954).
20. Brown, P. K. and Wald, G. J. Biol. Chem. **222**, 865 (1956).
21. Stainer, D. W. Unpublished observations.
22. Ames, S. R., Swanson, W. J., and Harris, P. L. Federation Proc. **16**, 145 (1957).

Murray '62. Anal. Chem. 34(10):1241-4
Bib. No. 6570

Purification of Vitamin A by Partition Chromatography in the Analysis of Pharmaceuticals and Margarine

T. K. MURRAY

Food and Drug Laboratories, Department of National Health and Welfare, Ottawa, Canada

▶ Partition chromatography was applied to the separation of vitamin A from various types of interference, such as oxidized vitamin A and vitamin E, commonly found in pharmaceuticals. Vitamin A was also separated from β-carotene and other interfering material found in margarine. Recovery of the vitamin was almost complete and the absorbance curves of the chromatographed samples resembled that of pure vitamin A. The column was easily prepared, required no standardization, could be used for successive samples, and made possible the application of the spectrophotometric method to samples which could not otherwise be assayed by this method.

VITAMIN A is usually estimated in pharmaceuticals by the spectrophotometric method described in the USP XVI (*10*). Lehman *et al.* (*5*) pointed out the shortcomings of this method when applied to mixtures of *cis* and *trans* isomers, but for most samples it gave an accurate estimate of biological potency (*6*). Although no guidance on this matter was given in the USP method, it cannot be applied to samples with grossly distorted absorbance curves. The need for purification in such cases was recognized by the British Pharmacopoeia (*3*), but no procedure was recommended. The International Union of Pure and Applied Chemistry (I.U.P.A.C.), in a report of collaborative experiments (*1*), recommended that chromatography on alumina be used when the absorbance ratio, 300 mμ/325 mμ exceeded 0.730, and demonstrated the use of such a procedure in the purification of a

Table I. Recovery of Vitamin A from Polyethylene Glycol Column

Test	Vitamin A Added, I.U.	Vitamin A Recovered after Chromatography, I.U.	% Recovery
1	90,345	89,030	98.5
2	97,435	95,200	97.8
3	98,320	97,650	99.3
4	96,800	96,310	99.5
Mean	95,725	94,570	98.8

whale-liver oil and a fish-liver oil. The AOAC recently tested (*3*) a similar system for the separation of vitamin A and carotene from margarine.

While alumina sometimes provided a good separation of vitamin A from interfering materials, each batch had to be standardized to ensure uniform retentiveness and, as applied in the I.U.P.A.C. studies (*1*), required a series of eluting mixtures. Furthermore, this system did not yield a typical vitamin A absorbance curve in the AOAC assay of margarine (*3*). Tardif's (*8*) proposed method involving the destruction of vitamin A with sulfuric acid for the assay of vitamin A in the presence of interfering substances was criticized on theoretical grounds by Gridgeman (*4*).

The use of partition chromatography for the purification of vitamin D was proposed by Theivagt and Campbell (*9*), who noted that the same system would probably be useful in the determination of vitamin A. It was used by Wilkie, Jones, and Morris (*11*) to improve the absorbance curve of several vitamin A preparations, but these authors did not demonstrate that chromatography improved the accuracy of the results.

This paper describes the separation of vitamin A from a variety of interfering substances by partition chromatography and demonstrates the recovery of the vitamin from such samples.

PROCEDURE

Reagents. The reagents for the saponification and extraction of vitamin A are those specified in the USP **XVI**. For the chromatographic step *n*-hexane, iso-octane, polyethylene glycol 600 (PEG 600 Union Carbide Chemicals Co.), and Celite 545 (Johns-Manville) are required.

Column Preparation. Mix 25 grams of Celite 545 in 125 ml. of iso-octane and add 10 ml. of polyethylene glycol (PEG) 600. Mix for 1 minute with a high-speed blender. Pack firmly into a 15-mm. chromatographic tube to a height of 150 mm. with the aid of a perforated plunger. Wash the column with *n*-hexane and keep it covered with this solvent until the sample is applied. The column may be re-used as long as it gives good results providing it is kept covered with solvent.

Method. Saponify and extract pharmaceuticals as described in USP **XVI** (*10*) and margarine according to the method of Rice, Prinm, and Coombs (*7*). Evaporate to dryness and dissolve the sample in *n*-hexane so that 2 ml. contains from 400 to 1200 I.U. Apply the sample to the column (preferably in 1 to 2 ml. of *n*-hexane) and elute with the same solvent, at a flow rate of 40 to 50 drops per minute which may be maintained with gentle suction. Follow the vitamin A band by occasional examination in low intensity ultraviolet light and begin collection when this band is about 5 mm. from the outlet. Collect as little as possible of the eluent following the vitamin A band. β-Carotene precedes vitamin A on the column and may be observed without the aid of the ultraviolet light. The completeness of the collection is judged by visual examination. Complete the determination of vitamin A according to the method of the USP **XVI** and of carotene as described by Friedman (*3*). For the purpose of evaluating the method compare the absorbance ratios, 300 mμ/325 mμ, 310 mμ/325 mμ, and 334 mμ/325 mμ with the ratios found for pure vitamin A.

RESULTS AND DISCUSSION

Recovery of Standard. Samples of the USP reference solution of vitamin A acetate were saponified and assayed either directly or after passage through the column. The results of four separate tests, shown in Table I, indicate that loss on the column compared favorably with the 2.4% loss on alumina columns reported by the I.U.P.A.C. (*1*).

Separation of Oxidized Vitamin A. Vitamin A acetate was saponified and then treated with heat, light, and air until it gave no color with antimony trichloride. A sufficient quantity was then added to samples of the vitamin A standard to alter significantly the absorbance curve and the mixture assayed (Table II). The USP method—i.e., without chromatography—did not accurately estimate the vitamin A because of the interference of the oxidized vitamin. The removal of the interference by chromatography as indicated by the absorbance ratios resulted in a good recovery of vitamin A.

Separation of Vitamins A and E. Table III illustrates the interference of vitamin E in the spectrophotometric determination of vitamin A and the manner in which the PEG–Celite column eliminated this interference and made possible the accurate estimation of vitamin A. Without chromatography it was not possible to estimate the vitamin A content of the mixture by the spectrophotometric method.

Assay of Multivitamin Preparations. Multivitamin preparations sometimes contain unknown substances which interfere with the estimation of vitamin A. When known amounts of the vitamin were added to three such samples, the distortion of the absorbance curve made an accurate estimation of potency impossible. The results obtained by two analysts before and after chromatography (Table IV) illustrate the quantitative recovery of the latter procedure.

Vitamin A and Carotene in Margarine. Vitamin A and β-carotene were added to two samples of unfortified margarine to the extent usually found in commercial margarine.

Table II. Absorbance Ratios and Recovery of Vitamin A in the Presence of Oxidized Vitamin A

		Unchromatographed			Chromatographed		
		310 mμ/325 mμ	334 mμ/325 mμ	% Recovery	310 mμ/325 mμ	334 mμ/325 mμ	% Recovery
Standard		0.852	0.857	...	0.852	0.857	...
Standard + Oxidized "A"	1	0.939	0.852	78	0.869	0.856	103
	2	0.932	0.857	91	0.870	0.854	103
	3	0.953	0.838	80	0.882	0.861	98
	4	0.957	0.849	103	0.883	0.853	103

Table III. Absorbance Ratios and Recovery of Vitamin A in the Presence of Vitamin E

Sample		Unchromatographed			Chromatographed			
Vitamin A, I.U.	Vitamin E, I.U.	300 mμ/325 mμ	310 mμ/325 mμ	334 mμ/325 mμ	300 mμ/325 mμ	310 mμ/325 mμ	334 mμ/325 mμ	% Recovery
Standard	...	0.600	0.852	0.857	0.600	0.852	0.857	...
1000	12.5	1.50	1.14	0.851	0.640	0.872	0.852	95
1000	6.25	1.09	1.01	0.847	0.613	0.861	0.854	95

Table IV. Absorbance Ratios and Recovery of Vitamin A Added to Liquid Multivitamin Preparations

Sample	Analyst	Unchromatographed 300/325	Unchromatographed 310/325	Unchromatographed 334/325	% Recovery	Chromatographed 300/325	Chromatographed 310/325	Chromatographed 334/325	% Recovery
Standard	...	0.600	0.852	0.857	...	0.600	0.852	0.857	...
Pharmaceutical No. 1	A	0.788	0.930	0.866	92	0.602	0.862	0.854	98
	B	0.819	0.944	0.866	88	0.621	0.852	0.863	101
Pharmaceutical No. 2	A	0.884	0.986	0.855	70	0.600	0.853	0.859	101
	B	0.988	1.000	0.860	73	0.632	0.846	0.852	99
Pharmaceutical No. 3	A	0.919	0.990	0.861	94	0.664	0.869	0.855	100

Table V illustrates the results obtained by two analysts when these samples were assayed spectrophotometrically after chromatography. The assay of several commercial margarines by this method as well as by the antimony trichloride method (without chromatography) is also shown. The interference usually caused by margarine was almost completely eliminated by chromatography and the spectrophotometric method gave a good estimate of the vitamin A added. The separation and recovery of β-carotene which preceded vitamin A on the column presented no difficulty. In two samples (Nos. 2 and 3) of commercial margarine, the antimony trichloride method gave a greater value than did the spectrophotometric method.

The chromatographic system used in these studies offered several advantages over others that have been proposed. It separated vitamin A from a wide variety of interfering substances without modification of the procedure; its components could be used as received and no pretreatment or standardization was necessary; only one eluting solvent was necessary and the column could be used for successive samples. The results were readily duplicated by a second analyst.

Lehman *et al.* (*5*) pointed out the errors that occurred when the USP XVI method was applied to samples containing *cis*- isomers of vitamin A. The method described here does not separate these isomers and, in the absence of other interference, provides the same results as the USP method. Its greatest value is its ability to separate vitamin A from interfering substances commonly encountered such as vitamin E, oxidized vitamin A, and anhydrovitamin A.

For margarine, separation on PEG 600 provided an almost pure sample of vitamin A and made possible the use of the USP spectrophotometric procedure. In this respect, it was much superior to alumina (*5*). Recovery of added vitamin A was good. This method provides a convenient means of separating vitamin A and β-carotene in colored margarine and should give a better estimate of potency than the antimony trichloride method when the added vitamin A is a mixture of all-*trans* and 13-*cis*. This may be the explanation of the higher values found by the antimony trichloride method in two samples of commercial margarine. When only all-*trans* vitamin A is present, the antimony trichloride method should be satisfactory but there is no assurance that this will be the case. It should be noted that Wilkie and Jones (*12*) did not achieve a good separation of vitamin A from the interference of margarine with the chromatographic system described here. These workers used a larger (25 mm.) column and it may be that the column size is critical.

Table V. Purification and Recovery of Vitamin A and Carotene from Margarine

Sample	Analyst	Absorbance Ratios 310 mμ/325 mμ	Absorbance Ratios 334 mμ/325 mμ	% Recovery Vitamin A	% Recovery β-Carotene
Standard		0.852	0.857		
Unfortified margarine No. 1 and	A	0.892	0.850	98	
Vitamin A	A	0.886	0.850	98	
	A	0.898	0.848	93	
	B	0.876	0.829	112	
	B	0.862	0.858	94	
	B	0.867	0.850	94	
	A	0.871	0.852	96	
and carotene	A	...	...	92[a]	100
and carotene	A	...	...	100[a]	100
Unfortified margarine No. 2 and	A	0.856	0.842	99	
Vitamin A	A	0.861	0.848	92	
	A	0.865	0.846	98	
	A	0.865	0.853	98	
	A	0.865	0.849	101	
	B	0.871	0.852	107	
Commercial margarine No. 1	A	0.861	0.851	102[b]	
No. 2	A	0.861	0.851	88[b]	
No. 3	A	0.861	0.851	90[b]	
No. 4	A	0.861	0.870	99[b]	

[a] Determined by antimony trichloride reaction.
[b] Relative to antimony trichloride reaction on unchromatographed aliquot.

Because chromatography adds considerably to the time spent in computing an assay it is not desirable or necessary to use it for all samples. Purification is obviously necessary when the absorbance peak is displaced and should also be applied in cases of less obvious distortion of the absorbance curve. The I.U.P.A.C. (*1*) recommends that chromatography be applied when the absorbance ratio 300 mμ/325 mμ exceeds 0.730, and in our experience this is a safe criterion. Most of the interference dealt with in this study was much more severe. The analyst must also be on the alert for irrelevent absorbance on the long wavelength side of 325 mμ such as occurs when anhydrovitamin A is present. This compound can be detected by an examination of the absorbance curve between 325 mμ and 400 mμ and can readily be removed by the chromatographic procedure described in this paper.

ACKNOWLEDGMENT

The author acknowledges the generosity of Canada Packers Co. Ltd., Lever Brothers, and Frank W. Horner Co. Ltd. for samples of vitamin A-free margarine and pharmaceuticals. H. S. Lakke Gowda, Colombo Plan Fellow from the Public Health Institute, Bangalore, India, and Paula Erdody of this laboratory performed some of the analyses.

LITERATURE CITED

(1) Brunius, E., *J. Assoc. Off. Agri. Chemists* 42, 657 (1959).

(2) "British Pharmacopeia" Pharmaceutical Press London, p. 956, 1958.
(3) Friedman, L., *J. Assoc. Offic. Agri. Chemists* **43**, 6 (1960).
(4) Gridgeman, N. T., *J. Pharm. Sci.* **50**, 449 (1961).
(5) Lehman, R. W., Dieterle, J. M., Fisher, W. T., Ames, S. R., *J. Am. Pharm. Assoc., Sci. Ed.* **49**, 363 (1960).
(6) Murray, T. K., Campbell, J. A., *Can. J. Biochem. Physiol.* **39**, 1087 (1961).
(7) Rieu, E. E., Primm, E., Coombes, A. I., *J. Assoc. Offic. Agri. Chemists* **31**, 621 (1948).
(8) Tardif, [illegible], *J. Am. Pharm. Assoc., Sci. Ed.* **49**, 741 (1960).
(9) Theivagt, J. G., Campbell, D. J., *Anal. Chem.* **31**, 1375 (1959).
(10) "United States Pharmacopeia," XVI, p. 938, Mack Publishing Co., Easton, Pa., 1960.
(11) Wilkie, J. B., Jones, S. W., Morris, W. W., *J. Assoc. Offic. Agri. Chemists*, **42**, 422 (1959).
(12) Wilkie, J. B., Jones, S. W., Food and Drug Administration, Washington 25, D. C., personal communication (1962).

RECEIVED for review March 16, 1962. Accepted July 8, 1962.

Natanson-'65
Bib. No. 6657

Problemy Endokrinologii i Gormonoterapii, vol. 11 no. 1, p. 87, 1965

Role of hypophysis in development of adrenal hypertrophy in rats with hypervitaminosis A

A. O. NATANSON, N. I. MITASHOVA and A. V. CHUVAEV

Department of Biochemistry and Physiology of Vitamins, Research Institute of Vitaminology, USSR Ministry of Health, Moscow

Most of our information on the influence of vitamin A on the functional status of the adrenal cortex derives from experiments on vitamin A deficient animals. The vitamin A of the adrenal cortex is located mainly in the fascicular zone, where glucocorticoid hormones are synthesized. Deprivation or inadequate dietary supply of vitamin A in animals causes a decrease in weight of the adrenals (1), change in the distribution of vitamin A among the different zones of the cortex (2), disturbance of corticosteroid hormone synthesis (3), and a decrease in the output of corticosteroids in the urine (4). The reduction of the capacity of the adrenal cortex to synthesize corticosteroid hormones in animals (rats) deprived of vitamin A is due to decreased synthesis of cholesterol, the primary material for the formation of these hormones (synthesis blocked of the stage of conversion of squalene into cholesterol) (5,6) and also to disturbance of desoxycorticosterone conversion into corticosterone (7). Thus, the impairment of corticosteroid hormone synthesis during vitamin A deficiency indicates that vitamin A plays a role in those processes; it apparently acts as a cofactor of one of the enzymes required for conversion of cholesterol into corticosterone (8). The hormones of the adrenal cortex in their turn constitute one of the factors for the conversion of provitamin A (carotene) to vitamin A in the animal body (9).

Changes in adrenal cortical function are an early manifestation of vitamin A deficiency, and precede the appearance of overt signs of avitaminosis A (1). These changes are reversible and can be abolished by administration of vitamin A or its derivative, vitamin A acid (3). The influence of vitamin A on the adrenocortical function is also indicated by a number of other studies (10, 11, 12). It has been shown that vitamin A exerts a definite action on the adrenals during cold stress (13, 14). Signs of increase of adrenocortical function during the stress reaction are depressed by administration of vitamin A to animals (15).

In contrast to the changes occurring in the adrenals in vitaminosis A, administration to animals of vitamin A in doses producing signs of hypervitaminosis A causes adrenal hypertrophy (16) and increased urinary excretion of 17-ketosteroids. The latter indicates an increased synthesis of corticosteroid hormones and occurs both in experimental animals and humans receiving large doses of vitamin A for therapeutic purposes (17).

It is not known why large doses of vitamin A cause hypertrophy of the adrenals. Nor is it known whether this hypertrophy results from a direct effect of vitamin A on the adrenals or whether such effect is mediated via the hypophysis. According to some reports, the hormones of the hypophysis, like cortisone administered exogenously, have no influence on the course of experimentally induced hypervitaminosis A, although other evidence indicates that the administration of cortisone may

TABLE 1. Weight of adrenals and thymus in growing rats with hypervitaminosis A[a]

Rats	Weight of rats (g)		Weight of thymus (mg)	Weight of thymus (mg/100 g body weight)	Weight of adrenals (mg)	Weight of adrenals (mg/100 g body weight)
	Initial	Final				
Controls, n = 39	44	48.5	185 ± 9.57	351 ± 16.8	16.2 ± 0.48	33 ± 0.96
Received 50,000-75,000 I. U. vitamin A daily for 4-5 days, n = 36	44	41.5	88.5 ± 7.9	186 ± 12.46	25.6 ± 1.04	62.2 ± 1.82

[a]Relative weight of adrenals and thymus were calculated separately for each animal, and from these figures a variance series was derived and the mean relative weight for each group calculated.

alleviate some of the disturbances caused by large doses of vitamin A (18).

To elucidate the action of large doses of vitamin A on the adrenals we set out to ascertain the role of the hypophysis in the development of hypertrophy of the adrenals in rats with hypervitaminosis A.

METHODS

Experiments were carried out on normal male rats weighing 40-50 g, hypophysectomized rats weighing 150-200 g, baby rats 4-5 days old, and rats weighing 40-50 g whose adrenocorticotropic function had been blocked with desoxycorticosterone acetate (DCA).

The animals were fed the standard vivarium diet. Vitamin A acetate in oil (100,000 and 500,000 I. U. per g) was administered via a gastric catheter (in one series of experiments on newborn rats, vitamin A was injected intraperitoneally).

Depending on the conditions of the experiment, the animals received a daily quota of 8000-200,000 I. U. of vitamin A dissolved in 0.5 ml of vegetable oil.

Preliminary experiments showed that neither administration of 0.5 ml of oil nor likewise the manipulations involved in administering the oil or the preparation of vitamin A in oil substantially influenced the weight of the adrenals and of the thymus gland. Accordingly, in succeeding experiments the control animals received solely the standard vivarium diet.

Vitamin A was administered for 5 days. Animals were sacrificed 24 hr after the last dose of vitamin. Control animals were sacrificed at the same times.

The hypophysis was removed by Smith's method as modified by Ulovich (19). Hypophysectomized rats were used for experiment 8-29 days after operation. Animals were divided into three groups according to the time elapsed since hypophysectomy. Following sacrifice, the removal of the hypophysis was checked by the state of the gonadal system (atrophy of seminal vesicles.

Adrenocorticotropic function was blocked by means of DCA dissolved in oil (20 mg DCA per 1 ml of oil) and injected subcutaneously in a dose of 10 mg per diem for 5 days. In the case of simultaneous administration of DCA and vitamin A, the latter was started on the day after the first DCA injection. Controls for this group consisted of intact rats and rats which received only DCA or only vitamin A.

The effect of vitamin A was assessed from the weight of the adrenals and thymus, which were weighed on a torsion balance (accurate to 0.5 mg) after removing the surrounding tissues from the glands.

An increase in adrenal weight accompanied by a decrease in the weight of the thymus was taken to indicate increase in the secretion of corticosteroids.

RESULTS

EXPERIMENTS ON NORMAL RATS

Rats weighing 40-50 g that received 50,000 I. U. vitamin A daily for 5 days lost weight rapidly, showed slow growth in length and became lethargic and untidy, with disheveled fur, falling out in some areas (abdomen and head). They showed hyperemia and inflammation of the conjunctivae, multiple fractures of the diaphyseal parts of the tibiae and femora, considerable increase in diuresis and loss of appetite. Autopsy revealed hemorrhagic extravasations in the viscera (especially lungs and liver), edema of the brain, enlargement of the liver and distention of the stomach. All these features pointed to the development of hypervitaminosis A. The weight of the adrenals had increased by 88%, while the weight of the thymus was approximately halved (Table 1), a situation indicating stimulation of the adrenocortical function.

EXPERIMENTS ON HYPOPHYSECTOMIZED RATS

To elucidate the role of the hypophysis in the reaction of the adrenals to vitamin A, experiments were performed on hypophysectomized rats weighing 150-200 g. Normal rats of the same weight were investigated first to determine the dose of vitamin A required to produce adrenal hypertrophy.

It was found (Table 2) that in adult rats, just as in the young rats given correspondingly smaller doses of vitamin A, a course of 200,000 I. U. vitamin A daily for 5 days caused a 52% increase in adrenal weight and a 56% decrease in thymus weight as compared with the levels in control adult animals.

In hypophysectomized rats not given vitamin A, the weight of the adrenals was markedly (by 54%) lower than in normal animals of the same weight. The decrease in thymus weight was not statistically significant, due possibly to aspects related to age in adult animals.

When hypophysectomized rats were given vitamin A, 200,000 I.U., daily for 5 days the adrenals showed no change in weight. The weight of the thymus decreased a little under these conditions, which may indicate a direct effect of vitamin A on the thymus.

TABLE 2. Weight of adrenals and thymus in adult rats with hypervitaminosis A after hypophysectomy

Rats	Weight of rats (g)		Weight of thymus (mg)	Weight of thymus (mg/100 g body weight)	Weight of adrenals (mg)	Weight of adrenals (mg/100 g body weight)
	Initial	Final				
Controls, n = 5	167	164	285 ± 40.7	171 ± 17.7	35.3 ± 2.8	21.4 ± 1.04
Receiving 200,000 I. U. vitamin A daily for 5 days, n = 5	166	141	123 ± 15.7	86.7 ± 10.0	53.7 ± 7.0	37.7 ± 5.0
Hypophysectomized, n = 9	167	169	228 ± 17.0	143 ± 10.0	16.0 ± 0.75	10.3 ± 0.18
Hypophysectomized and given vitamin A, n = 6	169	171	176 ± 19.0	105 ± 11.03	16.5 ± 1.45	10.0 ± 1.3
Hypophysectomized and given ACTH, 25 units daily, subcutaneously for 5 days, n = 5	167	160	136 ± 9.3	109 ± 12.3	34.7 ± 3.54	29.7 ± 2.08

The results of this series of experiments thus showed that large doses of vitamin A produce adrenal hypertrophy only in rats with a normal hypophysis. Hypophysectomy did not, however, prevent the development of other typical manifestations of hypervitaminosis A.

EXPERIMENTS ON NEWBORN RATS

The purpose of this series of experiments was to ascertain the effect of high doses of vitamin A on the functional state of the adrenals during physiologic hypofunction of the hypophysis. Secretion of ACTH by the hypophysis in rats in response to stress is weak during the first few days of life (20). In one series of experiments rats 4-6 days old, weighing 7-8 g, received 8000 I. U. vitamin A daily for 5 days via a gastric catheter, and in another series vitamin A (20,000 I. U.) was injected intraperitoneally daily for the same period. The results of the two series (Table 3) were similar; administration of vitamin A did not influence the change in weight of the adrenals, nor was there any change in the weight of the thymus. The decrease in the thymus weight noted in the case of intraperitoneal injection of vitamin A was statistically insignificant.

Thus, the experiments on newborn rats, like those on adult hypophysectomized rats, indicated the importance of the hypophysis in the response of the adrenals to the administration of large doses of vitamin A.

EXPERIMENTS ON RATS TREATED WITH DCA

To further elucidate the role of the hypophysis in the reaction of the adrenals to vitamin A, experiments were also performed on rats in which the adrenocorticotropic function of they hypophysis had been blocked by administration of DCA. Three groups of rats weighing 40-50 g were given, respectively, vitamin A, DCA, and DCA + vitamin A simultaneously. It was found (Table 4) that, as in the preceeding experiments, administration of large doses of vitamin A caused marked hypertrophy of the adrenals (53% increase of weight as compared with controls). In contrast to this, administration of DCA alone caused a decrease in weight of the adrenals, whereas with simultaneous administration of DCA and vitamin A, the weight of the adrenals did not differ from that in control animals.

In analyzing these findings, it should be borne in mind that DCA can cause adrenal atrophy resulting both from its direct effect on the adrenals and of inhibition of ACTH secretion by the hypophysis. In turn, the influence of vitamin A on the adrenals of rats receiving DCA simultaneously can be due either to a direct effect of vitamin A on the adrenals or to an increase in ACTH secretion. However, in view of the results obtained with hypophysectomized animals, showing that vitamin A does not directly affect the adrenals, it would seem that the influence of vitamin A on the adrenals during co-treatment with DCA was due not to any direct effect of the vitamin on the adrenals, but to stimulation of ACTH secretion.

CONCLUSIONS

1. Administration of vitamin A in doses causing hypervitaminosis A led to marked adrenal hypertrophy and decrease in the weight of the thymus.

2. Removal or DCA block of the hypophysis prevented the response of the adrenals to vitamin A without abolishing the toxic effect of vitamin A on the animal body. It may be presumed that the effect of vitamin A on the adrenals in the presence of hypervitaminosis A is mediated via the hypophysis.

Received August 20, 1964

TABLE 3. Weight of adrenals and thymus of newborn rats following administration of large doses of vitamin A

Rats	Weight of rats (g)		Weight of thymus (mg)	Weight of thymus (mg/100 g body weight)	Weight of adrenals (mg)	Weight of adrenals (mg/100 g body weight)
	Initial	Final				
Controls, n = 10	7.85	13.3	46 ± 4.03	320 ± 19.9	4.0 ± 0.347	27 ± 2.2
Receiving 8000 I. U. vitamin A daily for 5 days, n = 10	7.4	12.5	38.9 ± 3.47	308 ± 20.7	4.0 ± 0.394	34.0 ± 2.58
Receiving 20,000 I. U. vitamin A intraperitoneally daily for 5 days, n = 6	8.3	12.7	25 ± 4.96	184 ± 18.4	3.1 ± 0.178	27.0 ± 3.66

TABLE 4. Weight of adrenals and thymus of rats with hypervitaminosis A coupled with blocking of hypophysis with DCA

Rats	Weight of rats (g)		Weight of thymus (mg)	Weight of thymus (mg/100 g body weight)	Weight of adrenals (mg)	Weight of adrenals (mg/100 g body weight)
	Initial	Final				
Controls, n = 20	44.2	55.3	226 ± 9.6	395 ± 19.9	17.0 ± 0.47	29.1 ± 0.69
Receiving 75,000 I. U. vitamin A daily for 4 days, n = 25	44.8	47.4	133 ± 19.8	275 ± 35.1	26.0 ± 1.68	56.7 ± 4.1
Receiving 10 mg DCA daily for 5 days, n = 15	45	49.2	70.5 ± 5.32	130 ± 6.55	12 ± 0.492	24.6 ± 0.87
Receiving DCA + vitamin A, n = 25	46.8	53.8	66.7 ± 6.74	148 ± 7.05	16.2 ± 0.84	31.0 ± 0.82

REFERENCES

1. GIROUD, A. and A. R. RATSIMAMANGA. Ann. Nutr. (Paris). 15:105, 1961.
2. LOWE, J. S., R. A. MORTON and R. G. HARRISON. Nature. 172:716, 1953.
3. VAN DYKE, R. A., G. WOLF and B. C. JOHNSON. Biochem. Biophys. Res. Commun. 3:123, 1960.
4. LEUTSKII, K. M. Abstracts and Papers at Fourth All-Union Congress on Vitamins. Moscow, 1957, p. 29.
5. HOOR, U. and O. WISS. Arch. Biochem. 83:216, 1959.
6. WEBER, F., U. HOOR and O. WISS. Helv. Physiol. Pharmacol. Acta. 18:97, 1960.
7. VAN DYKE, R. A. and G. WOLF. Fed. Proc. 17 (1, Pt. 1, 1294): 327, 1958.
8. VAN DYKE, R. A., B. C. JOHNSON and G. WOLF. Ibid. 19 (1, Pt 1): 412, 1960.
9. CLARK, J. and R. W. COLBURN. Endocrinology. 56:232, 1955.
10. LEUTSKII, K. M. Vitamin A. Chernovitsy, 1959.
11. NATANSON, A. O. Vitamin A and Vitamin A Deficiency. Moscow, 1961.
12. RYSS, S. M. Klin. Med. (1): 28, 1964.
13. KETZ, H. A., J. PROLL, H. WITT et al. Biochem. Z. 335:345, 1962.
14. ODAGIRI, S. and T. KOYANAGI. J. Vitaminol. 7:86, 1961.
15. JUSA SHOIDSO. Hokkaido J. Med. Sci. 36:293, 1961.
16. STUDER, A., G. ZBINDEN and E. UEHLIGER. Allgemeine Pathol. 2:395, 1962.
17. VEDROVA, I. N. and A. S. SALUKHOV. In: Proceedings of Fourth Learned Session of Res. Inst. of Vitaminology. Moscow, 1961, p. 78.
18. WOLBACH, S., C. L. MADDOCK and J. GOHEU. Arch. Pathol. 60:130, 1955.
19. ULOVICH, A. I. Probl. Endokrinol. (5):32, 1959.
20. MIKHAILOVA, N. V. Reaction of the hypophysis and adrenal cortex of rats of various ages to adverse influences and the role of the nervous system. Dissertation. Moscow, 1963.

TRANSLATED ARTICLES

Available from the FASEB Translation Project; See Foreword

	Manuscript Number
KARDIOLOGIYA	
Vol. 5, no. 2, 1965; pp. 61-66	
Bavina, M. V.: Changes in the fatty acid composition of lipids in the serum, liver and aorta in rabbits developing hypercholesteremia and atherosclerosis.	S263-5

KLINICHESKAYA MEDITSINA	
Vol. 43, no. 4, 1965; pp. 18-21	
Tsilyurik, I. T., M. M. Ishchenko and S. V. Rusenko: The content of copper and manganese in the blood serum of patients with lung cancer.	S244-5
Vol. 43, no. 5, 1965; pp. 50-54	
Markel', A. L.: Measurement of the stroke volume using rheography.	S317-5

Neeld-'63
Bib. No. 6674

Macro- and Micromethods for the Determination of Serum Vitamin A using Trifluoroacetic Acid[1]

JOHN B. NEELD, JR. AND WILLIAM N. PEARSON
Division of Nutrition, Departments of Biochemistry and Medicine, Vanderbilt University, School of Medicine, Nashville, Tennessee

The main problems encountered in the use of the Carr-Price (antimony trichloride) method for the determination of vitamin A have been well known since its original description (Carr and Price, '26). The antimony trichloride-chloroform reagent develops turbidity in the presence of trace amounts of moisture and the characteristic blue color formed by this reagent with vitamin A is subject to rapid fading. Despite these drawbacks, the Carr-Price reaction remains the method of choice for serum vitamin A determinations when sufficient blood can be obtained. On the micro-scale, however, the turbidity problem becomes unmanageable and for this reason Bessey et al. ('46) devised a microspectrophotometric method that has been widely employed. Dugan and Frigerio[2] have recently investigated the reactions of various Lewis acids with vitamin A and its derivatives. They found that trifluoroacetic acid (TFA) retained the sensitivity and specificity of the $SbCl_3$ reaction but did not exhibit the turbidity and film-forming properties of the latter reagent in the presence of moisture. This property suggested to us that TFA might not only be used to replace $SbCl_3$ in the conventional macro-determination of serum vitamin A but might also serve as the basis for a new simple micro technique. This paper reports the details of new macro- and micro- vitamin A procedures developed with the use of TFA as the chromogenic agent that offer certain advantages over methods now used.

MATERIALS AND METHODS

Reagents

Ethanol, 95%. Reagent grade was used without further purification.

Petroleum ether. Bottled, reagent grade benzine, boiling over a range of 38 to 56.9°C, was used without further purification for the micro- procedure. A special reagent grade petroleum ether,[3] boiling over a range of 30 to 40°C, was used without further purification for the macro- procedure.

Carr-Price ($SbCl_3$) reagent. A 20% solution of $SbCl_3$ in reagent grade chloroform was filtered repeatedly through anhydrous Na_2SO_4 until clear and was then stored in a brown bottle over anhydrous Na_2SO_4.

Trifluoroacetic acid (TFA) reagent. One volume of trifluoroacetic acid[4] was mixed with 2 volumes of reagent grade chloroform just prior to use. This solution is stable for 4 hours.

Acetic anhydride. Reagent grade was used.

Saponification mixture. Ninety per cent ethanol was made 1.0 N in KOH by the addition of an appropriate weight of KOH pellets.

β-Carotene standard solution. β-Carotene stored under nitrogen was used as a standard.[5] A 50-mg sample of this was dissolved in a few milliliters of chloroform and brought to a final volume of 100 ml with petroleum ether. One milliliter of this solution was then diluted to 100 ml with petroleum ether to form an intermediate standard. This solution is stable for only a few hours and should be made up just prior to use.

Vitamin A standard solution. The USP reference standard solution of vitamin A

Received for publication November 8, 1962.
[1] Supported in part by Contract no. Nonr-2140(4) (Office of Naval Research) and by research grant AM-02565-05 from the National Institute of Arthritis and Metabolic Diseases, U.S. Public Health Service.

[2] Dugan, R. E., and N. A. Frigerio 1961 A.C.S. Abstracts, *160:* 65c.

[3] Ligroine, Baker Chemical Company, Phillipsburg, New Jersey.

[4] Eastman Organic Chemicals no. 6287.

[5] Nutritional Biochemicals Corporation, Cleveland.

acetate in cottonseed oil[6] was used. This standard contains 34.4 mg of all *trans* vitamin A acetate/gm of solution. A 100-mg sample of this standard (containing 3.44 mg of vitamin A acetate) was dissolved in chloroform and diluted to 50 ml in a volumetric flask. This solution is stable for at least two days when refrigerated and kept protected from light.

Apparatus

A Coleman Jr. Spectrophotometer equipped with 10 × 75 mm cuvettes was used for the macro- analyses. The microanalyses were carried out in a Beckman model DU spectrophotometer equipped with the micro- attachments described by Lowry and Bessey ('46). Microcuvettes measuring 2.5 × 10 × 25 mm were used.[7] For the micromethod extractions a special mixer[8] was used. The high-speed drill mixing device described by Bessey et al. ('46) also proved to be satisfactory. Lang-Levy constriction pipettes of 0.01-, 0.05-, 0.075-, and 0.100-ml capacities were used in the micromethod. Two-tenths-milliliter serological pipettes were drawn out to slender tips for use in pipetting petroleum ether in the micro- procedure.

Material for analysis

Human plasma for analysis was obtained from the Vanderbilt clinical laboratory or blood bank. It was usually necessary to pool plasma samples from the clinical laboratory to obtain enough for replicate analysis. Heparinized rat blood was obtained by heart puncture. Porcine and bovine blood was taken from individual animals at a local abbatoir. In this instance, serum was used. All samples were kept frozen until analyzed.

Macro- procedure

This procedure is basically a modification of the methods of Kimble ('39) and Kaser and Stekol ('43) except that TFA is substituted for $SbCl_3$.

Transfer in duplicate 2 ml of serum into 18 × 125 mm glass stoppered test tubes. Add, with mixing, 2 ml of 95% ethanol followed by 3.0 ml of petroleum ether (boiling range 30 to 40°C). Stopper and shake vigorously for two minutes to insure complete extraction of carotene and vitamin A. Centrifuge the tubes slowly for three minutes. Carefully pipette off 2.0 ml of the petroleum ether (upper) layer and place it in a Coleman 75 × 100 mm cuvette. Stopper immediately with a cork and read the carotene at 450 mμ against a petroleum ether blank in the Coleman Jr. spectrophotometer. Remove the cuvette and evaporate the petroleum ether to dryness in a 35 to 40°C water bath. An impinging stream of nitrogen may be used to increase the rate of evaporation but this is not necessary. Take up the residue immediately in 0.1 ml of chloroform and add 0.1 ml of acetic anhydride. Set the Coleman spectrophotometer at 620 mμ to zero optical density with a blank consisting of 0.1 ml of chloroform and 1.0 ml of TFA reagent. Place the sample cuvette in the spectrophotometer, add 1.0 ml of TFA reagent and record the reading at the pause point or alternately, exactly 30 seconds after addition of the reagent. The former may be defined as the maximal "hesitation" reading that occurs after the galvanometer has recovered from its initial swing. The timed reading is to be preferred.

Standard curves and calculations

The β-carotene intermediate standard is diluted with petroleum ether to give solutions containing 0.5, 1.0, 1.5, and 2.0 μg of β-carotene/ml, respectively. The optical densities of these solutions are read at 450 mμ against a petroleum ether blank and a standard curve plotted. It should be mentioned that β-carotene is a notoriously labile compound even when extreme care is taken in its storage. Under our laboratory conditions, F = 6.8 in the following equation:

$$F = \frac{\mu g \text{ carotene/ml}}{\text{optical density}}$$

Although it might be expected that this factor would vary slightly from laboratory to laboratory, any gross deviation should be cause to suspect the purity of the standard.

Since β-carotene also reacts with the TFA reagent to give a blue color, it is necessary to run a TFA — carotene stand-

[6] U.S. Pharmacopoeial Convention, 46 Park Avenue, New York 16, New York.
[7] Pyrocell Manufacturing Company, New York 28, New York.
[8] Cyclo-Mixer, Clay-Adams, Inc., New York 10, New York.

ard curve to permit calculation of a correction factor. Make up carotene standards in chloroform for this determination to contain 4.0, 8.0, and 10.0 μg/ml. Place 0.1-ml aliquots in Coleman cuvettes, and carry out the TFA reaction as previously described. Under our laboratory conditions:

$$OD_{450} \times 0.300 = OD_{620}$$

Vitamin A standards are prepared from the stock standard solution to give solutions containing 6.8, 13.7, 20.6 and 34.4 μg/ml, respectively. For preparation of the standard curve, pipette 0.1-ml aliquots of these standards into Coleman cuvettes for reaction with the TFA reagent. Under our laboratory conditions F = 4.49 in the following equation:

$$F = \frac{\mu g \text{ vitamin A/tube}}{\text{optical density}}$$

From the foregoing calculations and the volumes of reagents used, the amounts of β-carotene and vitamin A in the sample are calculated as

(1) carotene

$OD_{450} \times 1020 = \mu g$ carotene/100 ml serum

(2) vitamin A

$OD_{620} - (OD_{450} \times 0.300) \times 337 = \mu g$ vitamin A/100 ml serum.

The factors shown in the above equations should be derived by each operator, particularly in view of the fact that a new and relatively untested chromogen has been introduced. We have, however, found no differences in TFA — vitamin A color yields with 14 separate bottles of this reagent purchased at different times.

Micro- procedure

The micromethod is essentially the same as the macromethod except that it has been adapted to a much smaller scale. Pipette either 0.1 or 0.05 ml of serum into a 6 × 50 mm test tube. Add an equal volume of 95% ethanol (Lang-Levy pipette) and 0.15 ml of petroleum ether (38 to 56.9°C). Stopper the tube immediately with a cork and extract the vitamin A and carotene by agitation with the special mixer[9] for 45 seconds. Centrifuge the tube for 10 minutes at 3,000 × *g* and transfer 0.10 ml of the petroleum ether layer to a micro-cuvette by means of a Lang-Levy fine-tipped constriction pipette. Read the carotene optical density immediately at 450 mμ against a petroleum ether blank. Transfer as much of the sample as possible to a clean 6 × 50 mm test tube and rinse the cuvette once with 0.05 ml of petroleum ether. Add the rinsing to the sample in the test tube. Evaporate to dryness in a 40 to 50°C water bath (5 minutes). Take up the residue in 0.01 ml of chloroform and add 0.10 ml of the TFA reagent with vigorous shaking. Transfer rapidly as much of the solution as possible to the micro-cuvette by means of a 0.10-ml Lang-Levy pipette. Take the vitamin A reading at 620 mμ against a TFA reagent blank exactly 30 seconds after the addition of the TFA reagent. It is essential that this step be carried out with great care, particularly with respect to the timing because the color fades.

Carotene and vitamin A standard curves are prepared using smaller aliquots of the same standards used in the macro- procedure.

RESULTS

Trifluoroacetic acid — chloroform mixtures were tested for vitamin A color yields in the proportions of 1:1, 1:2, 1:5, 1:10 and 1:20. The 1:2 and 1:5 mixtures gave about the same color yields but the other mixtures gave considerably less. The 1:2 mixture was used throughout this study.

The blue species produced by the interaction of TFA, and vitamin A in chloroform was found to exhibit maximal absorption of 616 mμ in accordance with the observations of Dugan.[10] After standing for about two hours the original blue color decayed to a pink with a maximal absorption at about 540 mμ but of greatly reduced sensitivity. No attempts were made to use this color analytically. Various fat-soluble substances (cholesterol, calciferol, vitamin E, vitamin K) gave no color with TFA when tested at concentrations greater than those normally found in sera. An impure sample of xanthophyl gave virtually no color at concentrations deemed to lie within the physiological range.

[9] See footnote 8.

[10] Dugan, R. E., 1962, personal communication.

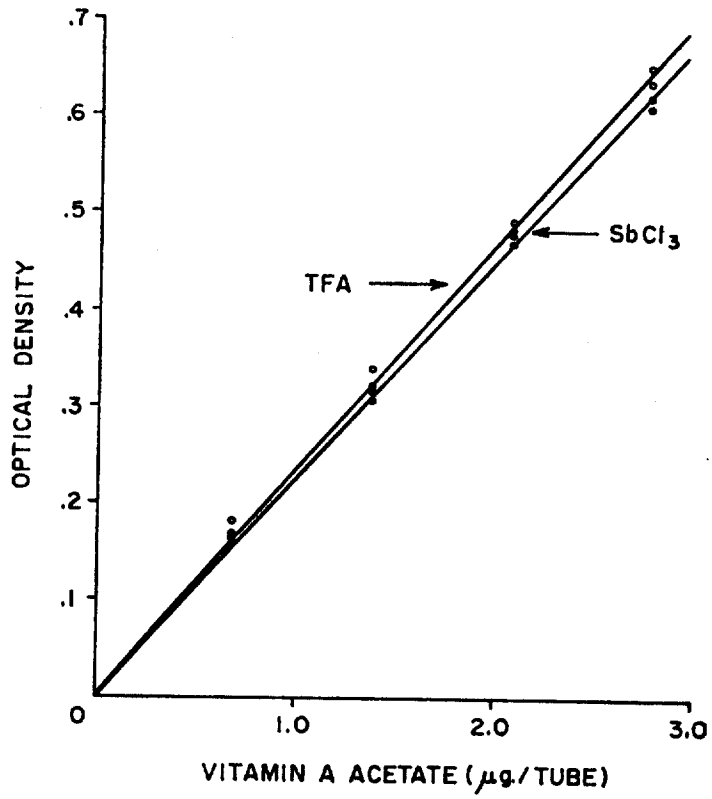

Fig. 1 Comparison of vitamin A standard curves obtained with antimony trichloride and trifluoroacetic acid. Readings were made in 75 × 100-mm cuvettes with a Coleman Jr. spectrophotometer at 620 mμ.

Typical vitamin A acetate dose-response curves measured at 620 mμ in the Coleman Jr. spectrophotometer with TFA or $SbCl_3$ are shown in figure 1. The color yield with TFA was also slightly greater than that with $SbCl_3$ with vitamin A alcohol and vitamin A acid. The yield of colored complex formed with vitamin A acid was less than half that with vitamin A acetate. This vitamin A acid — TFA complex formed slowly and was a deep purple rather than a typical Carr-Price blue. β-Carotene gave less than one-tenth the color yield of vitamin A at 620 mμ with both reagents. The carotene color yield with TFA was slightly less than that with $SbCl_3$.

The stability of the colored species formed with TFA varied depending upon the type of cuvette used. Representative time-decay curves with vitamin A acetate and serum extracts are shown in figure 2. In a micro-cuvette the color formed with a vitamin A acetate standard faded about 12% by 1 to 1.5 minutes after the initial reading, whereas the same reaction in a Coleman cuvette faded by approximately 20%. Under the same conditions the colored species formed with a serum extract faded 10% in a micro-cuvette as opposed to 25% in a Coleman cuvette.

The TFA method was compared with the classic $SbCl_3$ technique using human, rat, bovine and porcine sera (table 1). The two methods agreed quite well when human, rat, or porcine sera were analyzed. Generally TFA values were slightly higher. When bovine sera containing large amounts of carotene were analyzed, however, the vitamin A values obtained with TFA were markedly higher than those obtained with $SbCl_3$. When the carotene values were low (bovine samples 8 and 9), good agreement was obtained. This

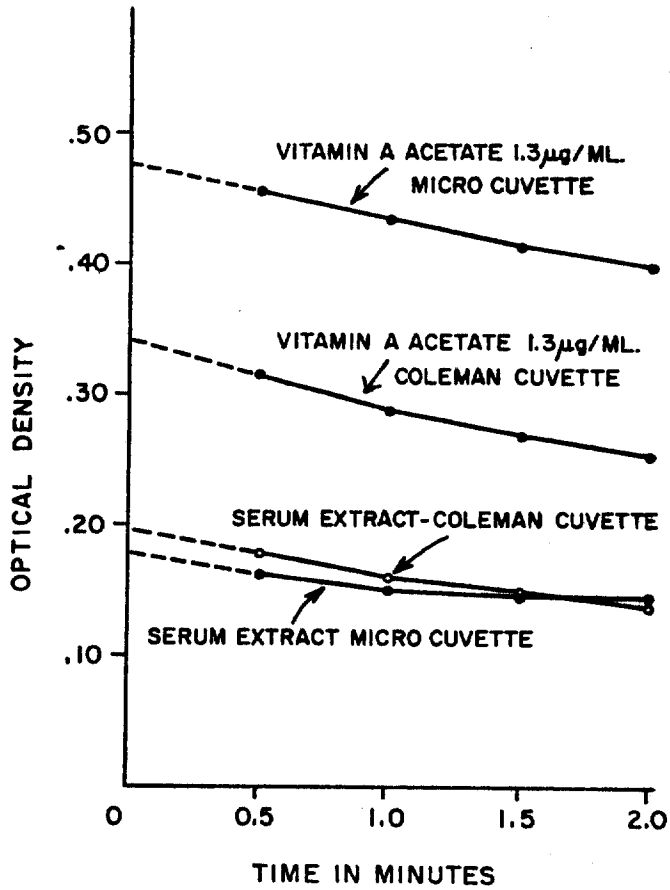

Fig. 2 Trifluoroacetic acid — vitamin A fading curves. Initial readings were taken exactly 30 seconds after addition of the TFA and then at the time intervals and in the instrument specified.

implies that the two chromogens react differently with the carotenoids or the other pigments normally present in bovine sera, or with both. Since serum carotene levels of 300 μg/100 ml are but rarely encountered in the human, this does not militate against the routine use of TFA for the analysis of human sera.

Reproducibility studies were carried out with $SbCl_3$ and TFA by analyzing the same serum sample repeatedly both on the same day and on different days (table 2). In both situations TFA performed slightly better than did $SbCl_3$. This may be a function of the $SbCl_3$ moisture problem since amounts of turbidity, sufficient to affect the optical density readings, often escape the analyst's eye and might therefore result in greater variability.

Table 3 presents a comparison of vitamin A values determined by the usual procedure or after a preliminary saponification of the serum. The vitamin A values obtained after saponification were slightly higher than those obtained without saponification, but carotene levels after saponification were distinctly lower in several samples. Our results suggest, therefore, that there is some advantage to be gained by saponification, which is in accordance with the report of Bessey and Lowry ('46).

Recovery experiments were performed on a series of human sera using both the $SbCl_3$ and TFA methods. These were determined in triplicate by comparing the increase in Carr-Price color resulting from the addition of vitamin A acetate to sam-

TABLE 1

A comparison of $SbCl_3$ and trifluoroacetic acid (TFA) plasma vitamin A values in various species

Sample	Vitamin A		TFA
	Carotene	$SbCl_3$	
	μg/100 ml	*μg/100 ml*	
	Bovine[1]		
1	848.6	40.9	55.2
2	823.4	38.9	56.1
3	476.3	21.6	35.2
4	744.5	36.9	49.9
5	722.4	27.3	41.1
6	772.9	31.9	36.8
7	1116.8	118.5	129.1
8	93.3	19.9	21.5
9	47.9	20.6	20.9
Mean	627.3	39.6	49.5
SD[2]	356.1	30.6	32.5
	Rat		
1	5.6	30.3	31.5
2	0.0	48.6	46.4
3	1.8	25.9	24.9
4	12.5	38.6	43.0
Mean	4.9	35.8	36.4
SD	5.5	9.9	9.9
	Human		
1	115.0	38.4	39.2
2	65.5	25.8	32.2
3	106.3	26.6	28.0
4	136.4	42.0	47.5
5	71.6	39.7	39.3
6	63.5	37.2	39.4
7	116.5	49.7	52.3
8	180.6	35.1	36.3
9	148.6	36.5	40.3
10	74.8	39.2	47.8
Mean	107.8	37.0	40.2
SD	39.5	7.0	7.4
	Porcine[1]		
1	4.4	26.6	30.2
2	2.5	29.3	31.2
3	6.9	39.6	38.6
4	1.8	19.9	21.8
5	0.0	25.9	26.8
6	0.0	24.6	27.4
7	0.0	29.6	34.6
8	3.7	21.9	23.0
9	1.2	13.3	16.2
Mean	2.3	25.6	27.7
SD	2.3	7.3	6.8

[1] Serum.
[2] Standard deviation.

plus of known vitamin A content. The data in table 4 show that both methods give good recoveries of the added vitamin A acetate.

In table 5 representative results obtained with the TFA macro- and micromethods are compared. The agreement of values was relatively good except in sample 24 which contained an unusually large amount of carotene.

Essentially the same values were obtained when 0.05 and 0.10 ml of serum were analyzed by the micromethod (table 6). In these analyses each serum was analyzed in triplicate at the two volume levels. The amount of alcohol added was equal to that of the serum but the same amount of petroleum ether (0.15 ml) was used for extraction.

DISCUSSION

The color reaction of TFA with vitamin A appears to be suitable for the measurement of vitamin A in serum since the values obtained in human, rat, and porcine sera are similar to those found with the Carr-Price reaction. The direct measurement of vitamin A with TFA in bovine sera without the prior removal of carotene requires further study before its validity can be assessed.

The use of TFA eliminates entirely the moisture problem encountered with $SbCl_3$. The TFA is also less toxic than $SbCl_3$ and unlike the latter does not form a tenacious film on the cuvette.

The main drawbacks of the TFA method are the evanescent nature of the blue color and the extreme volatility of the solvents used. The former has been satisfactorily controlled by reading exactly 30 seconds after the addition of TFA to the serum extract. The low boiling range petroleum ether used in the macromethod was entirely too volatile for the micromethod but the higher boiling petroleum ether product (40 to 60°C) proved to be acceptable if the various manipulations were performed rapidly. Ambient temperature in our laboratory averaged 21 to 23°C during these studies. Hexane was also found to be a suitable extractant and possessed the advantage of being considerably less volatile than petroleum ether. It would undoubtedly be a more desirable solvent for use at ambient temperatures higher than ours. Evaporation of a hexane extract in a 40°C water bath took an unduly long period of time, but an impinging stream of nitrogen from a hypodermic

TABLE 2

Reproducibility of Sb Cl₃ and trifluoroacetic acid (TFA) values for human serum vitamin A[1]

Experiment A			Experiment B		
Sample	Sb Cl_3	TFA	Sample	Sb Cl_3	TFA
	μg/100 ml			*μg/100 ml*	
1	47.6	54.9	11	48.6	45.2
2	48.6	51.4	12	48.9	53.9
3	50.9	48.3	13	49.6	51.1
4	48.9	49.6	14	45.2	51.7
5	51.2	49.2	15	46.6	49.6
6	50.2	50.2	16	50.2	52.1
7	50.6	48.9	17	41.6	50.5
8	48.2	49.2	18	43.9	52.1
9	44.9	48.6	19	40.9	53.6
10	51.2	48.6	20	42.6	51.7
Mean	49.2	49.8	Mean	45.8	51.1
SD[2]	2.0	1.9	SD	3.4	2.4
C[3]	4.0%	3.8%	C	7.4%	4.6%

[1] In experiment A, 10 aliquots of a pooled serum sample were analyzed simultaneously. In experiment B, an aliquot of the same pooled sample was analyzed daily for 10 consecutive days.
[2] Standard deviation.
[3] Coefficient of variation.

TABLE 3

Effect of saponification upon vitamin A values of human serum[1]

Sample	Saponified			Unsaponified		
	Carotene	Vitamin A		Carotene	Vitamin A	
		Sb Cl_3	TFA		Sb Cl_3	TFA
	μg/100 ml	*μg/100 ml*		*μg/100 ml*	*μg/100 ml*	
11	76.7	53.9	51.5	89.9	56.1	50.2
12	73.5	39.6	37.4	63.5	37.2	39.4
13	154.7		37.3	180.6		36.5
14	125.3		49.3	148.6		40.3
15	75.6		50.2	74.8		47.8

[1] Saponification was carried out at 60° for 20 minutes with 1 N alcoholic KOH.

TABLE 4

Vitamin A recovery from serum samples

Sample	Vitamin A content of serum	Vitamin A acetate added	Expected vitamin A	Actual vitamin A	Recovery
	μg/100 ml	*μg/100 ml*	*μg/100 ml*	*μg/100 ml*	%
			Sb Cl_3		
16	49.5	51.6	101.1	93.7	92.6
17	25.8	51.6	77.4	72.7	93.9
18	49.4	51.6	101.0	98.7	97.7
19	26.6	41.2	67.8	72.0	106.1
20	42.0	41.2	83.2	84.3	101.3
			Trifluoroacetic acid (TFA)		
16	50.4	51.6	102.0	99.6	97.6
17	32.2	51.6	83.8	82.1	97.9
18	55.5	51.6	107.1	99.9	93.2
19	28.0	48.6	76.6	73.1	95.4
20	47.5	48.6	96.1	92.7	96.4

TABLE 5

Comparison of macro- and micromethods for vitamin A analysis using trifluoroacetic acid (TFA)

Sample	Macromethod		Micromethod	
	Carotene	Vitamin A	Carotene	Vitamin A
	μg/100 ml	*μg/100 ml*	*μg/100 ml*	*μg/100 ml*
21	109.3	44.0	112.3	42.4
22	138.7	24.4	140.8	28.3
23	116.2	40.7	113.0	41.1
24	283.0	28.2	264.4	36.9
25	202.4	35.7	191.7	41.3

TABLE 6

Comparison of vitamin A levels obtained with different amounts of serum

Sample	0.050 ml serum		0.100 ml serum	
	Carotene	Vitamin A	Carotene	Vitamin A
	μg/100 ml	*μg/100 ml*	*μg/100 ml*	*μg/100 ml*
26	79.9	39.1	107.8	41.1
27	122.3	50.2	129.0	46.1
28	107.2	43.7	118.1	42.1
29	145.4	38.2	171.1	32.1

needle took it to dryness in about one minute. Heptane, benzene, and xylene were suitable extractants, but their higher boiling points made them not useful. Although much has been made of the possibility of oxidative loss of vitamin A during the evaporation step, we have been unable to demonstrate such a loss at 40°C even by the use of an impinging stream of air.

In our laboratory, saponification resulted in a slightly higher vitamin A value although not of the magnitude reported by Bessey et al. ('46) and Sobel and Snow ('47). It would therefore appear to be appropriate to carry out a saponification prior to extraction. Oser et al. ('43) recommend the use of an internal vitamin A standard to reduce the error introduced by the effect of inhibitory substances on color development. Bessey et al. ('46) found that vitamin A values were from 5 to 10% higher when calculated by this procedure than those taken from a conventional standard curve. Accordingly the use of an internal standard would increase somewhat the accuracy of the method, but in practice this approach would depend largely upon the availability of serum because duplicate samples are required. In nutrition surveys the usual quantity of blood available from finger-tip puncture normally would not be sufficient for this purpose.

Attempts to make the method more rapid by the direct addition of undiluted TFA to serum extracts were not successful. Although the TFA—vitamin A color formed readily with vitamin A standards in both hexane and benzene, some serum extracts gave no color with TFA and, for unknown reasons, TFA was insoluble in hexane extracts of sera. Whereas $CHCl_3$, CCl_4, and $C_2H_4Cl_2$ gave full color yields with vitamin A and TFA, they failed to extract quantitatively vitamin A and carotene from the serum.

The TFA method offers its greatest advantage over existing methods at the micro- level. The only micromethod in common use is that of Bessey et al. ('46), which depends upon the measurement of the ultraviolet absorption of serum extracts at 328 mμ before and after irradiation with ultraviolet light. The main source of difficulty with this technique is that ultraviolet light not only destroys vitamin A but changes other substances that absorb at 328 mμ as well. This may introduce a serious error, especially when low vitamin A levels are being measured (Caster and Mickelsen, '55). The observations of Bieri and Schultze ('51) and

Sobel and Snow ('47) that hemolysis results in consistently high values for vitamin A and carotene when measured by this method were confirmed by Utley et al. ('58). These investigators reported that a rigid purification of the kerosene-xylene extraction mixture was necessary to insure reliable results and concluded that the Carr-Price method was the method of choice when sufficient serum was available. In addition to these shortcomings, the Bessey method is tedious and time consuming and requires an ultraviolet spectrophotometer and a special irradiation device. The TFA micromethod described here is about three times more sensitive than the spectrophotometric procedure, does not require elaborate purification or drying of solvents, is not affected by hemolysis and does not require the use of an ultraviolet spectrophotometer. Although an ultraviolet spectrophotometer was used in this study, a few trials with the Beckman Spinco Model 151 microspectrophotometer[11] suggest that this instrument could also be used. The TFA method is considerably more rapid than the Bessey procedure. One operator can easily analyze 20 samples in duplicate in three hours. It is, moreover, even more rapid than the macro- procedure because the solvent evaporation time is reduced from ± 30 minutes (macro-) to ± 5 minutes (micro-).

SUMMARY

A new method for the determination of plasma or serum vitamin A levels which uses trifluoroacetic acid (TFA) as the chromogen is described. This reagent produces a typical Carr-Price color but does not exhibit the turbidity or film-forming properties of $SbCl_3$ in the presence of moisture. The new procedure gives values that agree well with those obtained by the Carr-Price method when rat, porcine, or human sera are analyzed. Significantly higher values are obtained with TFA, however, when bovine sera were analyzed. A micro- modification of the method permitting the analysis of 50 µl of serum is described and its advantages over existing methods are discussed.

ACKNOWLEDGMENT

The authors are indebted to Dr. John Bieri for calling our attention to the work of Dugan. The generosity of Dr. R. E. Dugan, who made available to us certain of his unpublished results, is also appreciated.

LITERATURE CITED

Bessey, O. A., O. H. Lowry, M. J. Brock and J. A. Lopez 1946 The determination of vitamin A and carotene in small quantities of blood serum. J. Biol. Chem., *166:* 177.

Bieri, J. G., and M. O. Schultze 1951 Microspectrophotometric determination of vitamin A and carotene in blood. Arch. Biochem. Biophys., *34:* 273.

Carr, T. H., and E. A. Price 1926 Color reactions attributed to vitamin A. Biochem. J., *20:* 497.

Caster, W. O., and O. Mickelsen 1955 Serum vitamin A level: A critique of methods and significance. Am. J. Clin. Nutrition, *3:* 408.

Kaser, M., and J. A. Stekol 1943 A critical study of the Carr-Price reaction for the determination of β-carotene and vitamin A in biological materials. J. Lab. Clin. Med., *28:* 904.

Kimble, M. S. 1939 The photocolorimeter determination of vitamin A and carotene in human plasma. Ibid., *24:* 1055.

Lowry, O. H., and O. A. Bessey 1946 The adaptation of the Beckman Spectrophotometer to measurements on minute quantities of biological materials. J. Biol. Chem., *163:* 633.

Oser, B., D. Melnick and M. Pader 1943 Estimation of vitamin A in food products. Ind. Eng. Chem. (Anal. ed.), *15:* 724.

Sobel, A. E., and S. D. Snow 1947 The estimation of serum vitamin A with activated glycerol dichlorohydrin. J. Biol. Chem., *171:* 617.

Utley, M. H., E. R. Brodovsky and W. N. Pearson 1958 Hemolysis and reagent purity as factors causing erratic results in the estimation of vitamin A and carotene in serum by the Bessey-Lowry method. J. Nutrition, *66:* 205.

[11] Beckman Instruments, Inc., Palo Alto, California.

Nerurkar-'66
Bib. No. 6708

Biochem. J. 63:344-349. 1966.

Reproduced by permission
of the copyright owner

Metabolism of Calcium, Phosphorus and Nitrogen in Hypervitaminosis A in Young Rats

By M. K. NERURKAR and M. B. SAHASRABUDHE
Biology Division, Department of Atomic Energy, Government of India, Indian Cancer Research Centre, Parel, Bombay 12, India

(*Received 28 September 1955*)

The production of toxic effects in human beings as well as in experimental animals by the administration of large doses of pure vitamin A is well recognized clinically (Josepha, 1944; Knudson & Rothman, 1953). Among the experimental animals, rats appear to be specially sensitive to these toxic effects. Skeletal fractures and haemorrhages are among the important features in this malady (Herbst, Pevcek & Elvehjem, 1944; Moore & Wang, 1945; Pevcek, Herbst & Elvehjem, 1945). Although the skeletal changes that lead to these fractures have been known for some time, the mechanism remains obscure. Further, since previous workers' preparations of vitamin A contained large amounts of vitamin D, it is not known with certainty whether the recorded effects are due to vitamin A or to vitamin D. Histological studies by Wolbach (1947) suggested that accelerated epiphyseal cartilage sequences and remodelling processes are responsible for the production of fractures, and that these are mediated independently of the pituitary (Wolbach & Maddock, 1952). Fell & Mellanby (1950), in their investigations of tissue cultures of bone, have shown that vitamin A acts directly. In an attempt to elucidate the mechanism of action of pure vitamin A, free from vitamin D, on bones, the effects of hypervitaminosis A on the chemical composition of bones

[illegible] on the general metabolism of calcium, phosphorus and nitrogen in rats have been studied. The results are reported in the present paper.

MATERIALS AND METHODS

The experimental animals were male, albino inbred rats, [illegible]-weeks' old and fed on a synthetic diet having the following percentage composition: sugar, 34·5; starch, 34·5; casein, 20·0; vegetable fat, 6·7; salt mixture (Hawk & Oser, [illegible]), 4·0; cystine, 0·2; choline hydrochloride, 0·1. The diet was further supplemented with 10 units of vitamin D, [illegible] units of vitamin A, 1 mg. of vitamin E, 0·05 mg. of vitamin K and adequate amounts of B complex. Analysis of the diet showed 0·692 % Ca, 0·440 % P and 2·430 % nitrogen. Synthetic vitamin A palmitate (1 million i.u./g. Hoffmann-La Roche) was used as the source of vitamin A in all these experiments. As this source of vitamin A is free from vitamin D, the possibility of introducing the condition of hypervitaminosis D (Moore & Wang, 1943, 1945) is ruled out in these experiments. Vitamin A (40000 i.u./rat/day) was given to these animals orally.

Metabolic studies were carried out on male rats, kept in pairs in metabolism cages provided with a device for separate collection of urine and faeces. Urine was collected into 10 ml. of a preservative consisting of equal amounts of toluene and conc. HCl. Urine collected during 2 days was pooled for assay purposes. At the end of each collection period, the cages and funnels were washed with hot water acidified with HCl to pH 4·6–4·8 and the washings pooled with the urine. Faeces were collected separately. Samples of urine and faeces were stored at 7–8° until analysed for calcium, total phosphorus and total nitrogen. These experiments were divided into three parts: (1) a preliminary control period of 10 days; (2) a period of administration of excess of vitamin A (10 days); (3) a curative period of 14 days after the administration of excess of vitamin A was stopped. The animals were weighed on alternate days. Food intake was measured daily. An amount somewhat above the daily expected intake was weighed out and put in the cages. At the end of 24 hr., the intake was calculated after weighing the residue. Food waste and its contamination with excreta were reduced by using a special feeding device on the cages. The animals had free access to water.

In another type of experiment, five groups of male albino rats 45–50 days old were used. One group served as the control, whereas the other groups received 40000 i.u. of vitamin A every day, for 3, 6, 9 and 12 days respectively. Skiagraphs of the whole body were taken at intervals. The animals were killed 24 hr. after receiving the last dose, by decapitation, without previous fasting. The chest cavity was opened and blood withdrawn from the heart into a heparinized syringe. The levels of calcium, inorganic phosphorus and vitamin A in the serum were investigated. The livers were removed, weighed and placed in 5% alcoholic KOH solution for the estimation of vitamin A content. The femora and tibiae were cut out and cleaned of all the adhering soft tissues. Slits were made longitudinally through the diaphysis and epiphysis to render the extraction more effective. The bones were defatted with two overnight extractions, first with absolute ethanol and then with ether. The dried marrow was removed as completely as possible. The bones, free of fat and marrow, were then dried in an electric oven at 105°, powdered and analysed for Ca, P and N according to the procedure outlined below.

Analytical methods

Nitrogen. N was estimated by the micro-Kjeldahl method as modified by Sobel, Yuska & Cohen (1937).

Calcium. Faeces, food and bones were ashed (A.O.A.C. 1940) before the determinations. The following methods were employed: for faeces and food, the method of Lindner & Kirk (1937): for urine, the same method after a previous treatment with potassium persulphate (Shohl & Pedley, 1922); for bone, titration directly with disodium dihydrogen ethylenediaminetetraacetate with murexide indicator. The procedure was developed by us and its principle is the same as that for the estimation of blood Ca described by Holtz & Seekles (1952). This latter method was used for the estimations in blood.

Phosphorus. Total P in urine, faeces, food or bones was estimated by the method of Fiske & Subbarow (1925), as modified by LePage & Umbreit (1949).

Faeces, food and bones were ashed as for the Ca determinations. Inorganic P in the blood serum was determined by the method of Fiske & Subbarow (1925).

Vitamin A was estimated in liver by the method of Gallup & Hoefer (1946) by saponification and extraction of vitamin A with light petroleum. Vitamin A in blood was estimated according to the technique of Yudkin (1941). Characteristic absorption was measured by means of a Beckman quartz spectrophotometer (Zscheile & Henry, 1942) with Morton & Stubbs' (1948) correction. Vitamin A (U.S.P.) was used as a reference standard (U.S. Pharmacopoeia, 1948).

RESULTS

Administration of single toxic doses of vitamin A resulted in general drowsiness and muscular weakness, accompanied by decreased activity of the animals. If no further excess of vitamin A was given they returned to normal physical condition within 24 hr. Continued administration of vitamin A at toxic dosage for a period of several days caused symptoms such as lack of appetite, loss of weight, muscular weakness, loss of hair, soreness and bleeding of the eyes, stiffness of the limbs, limping, spontaneous fractures, internal haemorrhages and eventually death. Death occurred in a high proportion of animals given more than

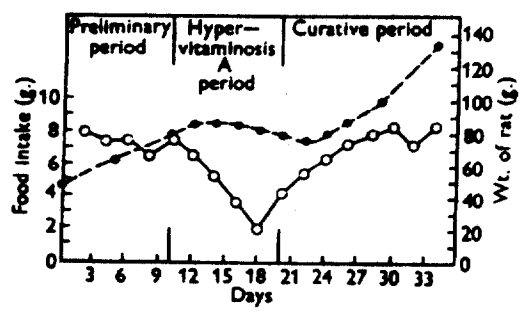

Fig. 1. Effect of hypervitaminosis A on food intake (○) and body weight (●) of rats. Dose given: 40 000 i.u. of vitamin A day rat.

Table 1. *Effect of hypervitaminosis A on the excretion of calcium, phosphorus and nitrogen in urine and faeces*

The dose of vitamin A was 40000 i.u./rat/day during the hypervitaminosis A period. The figures are the averages of results from eight rats, Each figure corresponds o a period of 2 days.

	Calcium				Phosphorus				Nitrogen			
	Intake (mg.)	Urinary excretion (mg.)	Faecal excretion (mg.)	Net retention (% intake)	Intake (mg.)	Urinary excretion (mg.)	Faecal excretion (mg.)	Net retention (% intake)	Intake (mg.)	Urinary excretion (mg.)	Faecal excretion (mg.)	Net retention (% intake)
Preliminary period (10 days)*	110·0	7·2	31·3	65·0	70·0	20·6	7·1	60·4	386	61·6	14·5	80·3
	101·0	6·5	27·6	66·4	64·6	20·6	6·3	58·4	357	51·9	17·1	80·7
	102·0	5·5	26·8	68·4	65·1	22·0	5·4	57·7	359	54·8	16·3	80·2
	90·0	5·2	26·9	64·3	57·2	18·7	4·4	59·6	315	53·1	16·8	77·8
	103·0	6·1	28·5	66·4	65·5	21·0	6·4	58·1	362	60·3	20·5	77·6
Period of hypervitaminosis A (10 days)†	90·9	7·1	34·9	53·2	57·1	22·5	6·3	49·5	306	66·8	18·7	72·1
	72·0	8·2	39·3	33·7	45·7	23·0	6·7	35·3	252	89·5	15·8	58·2
	50·5	8·9	39·3	4·37	31·8	22·0	8·0	5·68	177	114·0	14·4	27·7
	25·8	7·2	25·9	−21·0	18·8	22·8	12·5	−82·2	99	118·0	18·0	−51·7
	57·3	15·8	46·0	−7·91	36·5	25·8	12·3	−4·7	201	165·0	20·7	+8·0
Curative period (14 days)‡	75·6	14·5	56·9	5·58	47·8	28·3	10·1	19·6	266	220·0	23·5	8·76
	87·0	14·2	54·7	20·5	57·4	30·5	10·8	27·0	306	167·0	25·2	30·9
	101·0	15·5	65·4	19·8	64·2	27·7	7·6	44·6	355	185·0	21·6	41·7
	110·0	13·7	48·9	43·1	70·6	23·2	9·3	53·9	391	171·0	22·0	50·7
	115·0	11·5	55·3	42·2	73·5	21·7	9·5	58·2	405	147·0	19·8	59·0
	101·0	10·7	41·6	43·2	64·2	18·7	7·6	59·0	354	128·0	18·4	61·4
	118·0	12·7	43·8	52·6	75·3	21·2	11·0	57·2	415	98·0	17·8	72·1

* Preliminary period when animals were maintained on adequate diet.
† Period when the animals were given 40000 i.u. of vitamin A/day in addition to adequate diet.
‡ Period when excess of vitamin A was withdrawn.

twelve doses of vitamin A. In some animals, abnormal posture was observed, with marked bending of the spine, both hind legs appearing paralysed but without any apparent signs of fractures or haemorrhages. The results regarding food intake and growth rate of animals are shown in Fig. 1.

Results of metabolic studies on the urinary and faecal excretions of calcium, phosphorus and nitrogen are given in Table 1. It will be seen that there is a gradual decrease in the percentage retentions of all the components with the continuation of excess of vitamin A administration. There is a negative balance of all the three constituents in the second half of the vitamin A administration period which suggests increased catabolism. The rapidity and the extent of the negative balance closely paralleled the physical condition of the animals. It will be seen from Table 1 that the levels of calcium, phosphorus and nitrogen excretions follow a more or less identical pattern.

Table 2 shows the results of the effect of hypervitaminosis A on the calcium, phosphorus, nitrogen and ash content of the bones. The figures are expressed as percentages of water-free, fat-free and marrow-free bones. The first group of rats, which had received three doses of vitamin A on 3 consecutive days and which were killed on the fourth day were very little different from the control group. The differences become apparent in the second group, which received excess of vitamin A for 6 consecutive days. The maximum effects are seen in the group dosed for 9 days, the group dosed for 12 days showing slightly less difference from the controls than this group. Systematic X-ray examination of the animals at various stages of the experiment showed gradual thinning of the bones. Although bone calcium and phosphorus

Table 2. *Effects of hypervitaminosis A on the composition of bones*

The dose was 40000 i.u. of vitamin A/rat/day. The analyses for calcium, phosphorus and nitrogen are given on dry, fat-free and marrow-free bone.

Treatment of group	No. of animals	Ca (%)	P (%)	N (%)	Ash (%)
Control	12	26·1±0·145	12·4±0·095	4·02±0·027	69·1±0·176
3 doses	6	25·5±0·121	11·8±0·115	4·18±0·045	69·0±0·150
6 doses	6	25·1±0·170	11·5±0·156	4·23±0·030	68·4±0·218
9 doses	6	23·7±0·176	10·3±0·167	5·09±0·051	66·0±0·375
12 doses	6	24·5±0·215	11·0±0·210	4·86±0·042	67·5±0·272

Table 3. *Levels of calcium and inorganic phosphorus in blood serum of normal rats and rats with hypervitaminosis*

The dose was 40000 i.u. of vitamin A/rat/day.

Treatment of group	No. of animals	Serum Ca: Average value (mg./100 ml.)	Serum Ca: Range (mg./100 ml.)	Inorganic P: Average value (mg./100 ml.)	Inorganic P: Range (mg./100 ml.)
Control	12	10·5±0·215	9·21–11·75	4·54±0·093	3·98–5·01
3 doses	6	10·8±0·394	9·65–11·97	4·61±0·197	4·10–5·16
6 doses	6	10·6±0·483	8·81–11·93	4·73±0·169	4·15–5·25
9 doses	6	11·2±0·381	9·92–12·13	4·86±0·206	4·19–5·45
12 doses	6	10·9±0·324	9·55–11·98	5·05±0·178	4·43–5·65

Table 4. *Levels of total vitamin A in the blood and liver of normal rats and rats with hypervitaminosis*

The dose of vitamin A was at the rate of 40000 i.u./day for each animal.

Treatment of group	No. of animals	Total vitamin A received (i.u.)	Blood vitamin A (i.u./ml.)	Liver vitamin A (i.u./g.)	Liver vitamin A (Total i.u.)	Storage in liver (%)*
Control	12	—	66·10±2·84	75±3·02	418±10·8	—
3 doses	6	120 000	184·0±8·36	2750±88·4	13 300±630·0	11·12
6 doses	6	240 000	211·0±7·14	3870±97·0	22 300±930·0	9·30
9 doses	6	360 000	237·0±6·85	5000±120·0	27 300±907·0	7·57
12 doses	6	480 000	262·0±4·92	6000±71·5	31 400±990·0	6·54
15 doses	6	600 000	308·0±5·50	6810±39·5	35 200±445·0	5·86

* Percentage of the administered dose of vitamin A found in liver.

gradually decrease, the levels of calcium and inorganic phosphorus in the serum remain unaltered, as can be seen from Table 3.

Table 4 shows the concentration of total vitamin A (vitamin A alcohol and ester) in the liver and blood after various doses of the vitamin. The purpose of these estimations was to ascertain indirectly whether the absorption of vitamin A is impaired as a result of the massive dosage. Since liver is the chief storage site of vitamin A (Osborne & Mendel, 1918; McCoord & Clausen, 1934) the concentration of vitamin in this organ should be proportional to the intake (Baumann, Riising & Steenbock, 1934) and should serve as a criterion of its absorption (Guggenheim & Koch, 1944; Foy & Morgareidge, 1948). It will be observed from these results that the levels of vitamin A in the blood increased with increasing period of treatment with vitamin A, but no direct correlation could be demonstrated between total amount of vitamin A administered and that present in either the blood or the liver. Although the vitamin A content of the liver in experimental rats increased with the number of doses of vitamin A administered, the absorption, calculated as percentage of the total dose administered, decreased, indicating decreased absorption of vitamin A from the intestine, or increased catabolism of liver vitamin A, or an approach to the saturation limit of the liver. The vitamin A content of the liver in the 15-dose group is greater than that in the previous group (12 doses); thus the liver was not completely saturated.

DISCUSSION

The results described above indicate that pure vitamin A free from vitamin D is toxic when given orally at a dose of 40 000 i.u./day. The toxic effects observed were similar to those observed by other workers (Moore & Wang, 1945; Pevcek *et al.* 1945). Reduced food intake, loss of weight, skeletal fractures and haemorrhages are in our experience the most characteristic features in genuine hypervitaminosis A. Fractures occur most consistently in young growing rats and were found without exception in rats fed for 12 or more days with 40 000 i.u. of vitamin A/day. Vitamin A in the concentrations employed in these investigations appears to interfere in some way with the metabolism of calcium, phosphorus and nitrogen. The retention of these elements in the body is decreased and there is a negative balance. The severity of the interference is more or less parallel with the amount of vitamin A ingested, since the degree of negative balance of calcium, phosphorus and nitrogen becomes more and more pronounced during continued ingestion of the vitamin. This may be due to decreased absorption from the digestive tract or to an increased catabolic excretion from the system or to both; but it is not possible to decide from measurements of the excretion of these elements in urine and in faeces whether absorption from the digestive tract is interfered with or whether there is increased catabolic excretion (Brown & Shohl, 1930). This is particularly true for calcium, because systemic calcium is excreted in urine, by way of bile, etc., and in the faeces. The fraction in the faeces which comes from the catabolism of systemic calcium is known as 'endogenous faecal calcium' to distinguish it from 'exogenous faecal calcium', which is the unabsorbed calcium from the food (Schmidt & Greenberg, 19[illegible]). Because of this inherent difficulty in assessing the absorption of calcium from the intestines, we cannot say whether the calcium absorption is impaired or not. But there is no doubt that administration of large doses of vitamin A induces a negative balance in calcium, phosphorus and nitrogen. Recovery from the deleterious effects is evidently slow. The balance has not returned to normal even 10 days after the cessation of administration of excess of vitamin A.

In the early stages of hypervitaminosis A there is a definite rise in the excretion of both urinary and faecal calcium, phosphorus and nitrogen. But in the later stages, although the doses are continued, there appears, contrary to our expectations, to be a fall in the urinary and faecal excretions of all these elements. The reason for this decrease, which coincides with the decrease in the levels of calcium in bones, cannot be ascertained.

The process of bone formation consists of several phases, one of which is the precipitation of calcium phosphate. For this to occur, there must be adequate concentrations of calcium and inorganic phosphorus in the blood stream and alkaline phosphatase in the bones (Howard, 1951). The fact that in our experiments the serum concentrations of calcium and phosphorus are not disturbed and that the bone alkaline-phosphatase activity is increased in hypervitaminosis A (Nerurkar & Sahasrabudhe, unpublished work) suggests that this phase of ossification is not impaired and that the development of fragility and fractures must be ascribed to the disturbances in other phases of bone formation. Our observations that no marked changes in the relative chemical composition of the bones are apparent as a result of hypervitaminosis A are in agreement with those of Moore & Wang (1945) and Rodahl (1950). Gradual thinning of the bones observed by us in X-ray photographs, has also been reported by Wolbach (1947) and Metre (1947). This gradual thinning of the bones, coupled with the pronounced negative balance, suggests that hypervitaminosis A is draining the inorganic stores of the bones without causing any gross change in their relative composition.

SUMMARY

1. Oral administration of a pure vitamin A preparation at a dose 400 times the normal requirement has been shown to produce effects such as reduced food intake, loss of weight, skeletal fractures and haemorrhages in young albino rats. The degree of toxicity is approximately proportional to the total quantity of vitamin A administered.

2. The effects of administration of large doses of vitamin A on the metabolism of calcium, phosphorus and nitrogen have also been studied. A negative balance for calcium, phosphorus and nitrogen sets in and continues for a considerable period after the administration of large doses of vitamin A has ceased.

3. No changes were detected in the levels of calcium and inorganic phosphorus of the blood.

4. Very little change in the relative mineral composition of the bones was observed. Increased excretion of calcium and phosphorus is therefore probably due to thinning of the bones.

5. Estimation of vitamin A in the liver suggests that administration of amounts of vitamin A, several times greater than the normal requirements, reduces the absorption of vitamin A from the intestine.

Grateful thanks are due to Dr V. R. Khanolkar and Dr A. R. Gopal-Ayengar for their helpful advice and criticism; and to Volkart Brothers, agents for Hoffmann-La Roche, for the gift of the vitamin A preparations used in this investigation.

REFERENCES

A.O.A.C. (1940). *Methods of Analysis of the Association of Official Agricultural Chemists* [Washington, U.S.A.].
Bauman, C. A., Rising, B. M. & Steenbock, H. (1934). *J. biol. Chem.* **107**, 705.
Brown, H. B. & Shohl, A. T. (1930). *J. biol. Chem.* **86**, 245.
Fell, H. B. & Mellanby, E. (1950). *Brit. med. J.* **2**, 535.
Fiske, C. H. & Subbarow, Y. (1925). *J. biol. Chem.* **66**, 375.
Foy, J. P. & Morgareidge, K. (1948). *Analyt. Chem.* **20**, 304.
Gallup, W. D. & Hoefer, J. A. (1946). *Industr. Engng Chem. (Anal.)*, **18**, 288.
Guggenheim, K. & Koch, W. (1944). *Biochem. J.* **38**, 256.
Hawk, P. B. & Oser, B. L. (1931). *Science*, **74**, 369.
Herbst, E. J., Pevcek, P. L. & Elvehjem, C. A. (1944). *Science*, **100**, 338.
Holtz, A. H. & Seekles, L. (1952). *Nature, Lond.*, **169**, 870.
Howard, J. E. (1951). *J. Bone Jt Surg.* **33**, 801.
Josephs, H. W. (1944). *Amer. J. Dis. Child.* **67**, 33.
Knudson, A. G. & Rothman, P. E. (1953). *Amer. J. Dis. Child.* **85**, 316.
LePage, G. A. & Umbreit, W. W. (1949). In *Manometric Techniques and Related Methods for the Study of Tissue Metabolism*. Ed. by Umbreit, W. W., Burris, R. H. & Stauffer, J. F. Minneapolis: Burgess Publishing Co.
Lindner, R. & Kirk, P. L. (1937). *Mikrochemie*, **22**, 291.
McCoord, A. B. & Clausen, L. E. M. (1934). *J. Nutr.* **7**, 557.
Metre, V. T. E. (1947). *Johns Hopk. Hosp. Bull.* **81**, 305.
Moore, T. & Wang, Y. L. (1943). *Biochem. J.* **37**, viii.
Moore, T. & Wang, Y. L. (1945). *Biochem. J.* **39**, 222.
Morton, R. A. & Stubbs, A. L. (1948). *Biochem. J.* **42**, 195.
Osborne, T. B. & Mendel, L. B. (1918). *J. biol. Chem.* **34**, 17.
Pevcek, P. L., Herbst, E. J. & Elvehjem, C. A. (1945). *J. Nutr.* **30**, 1.
Rodahl, K. (1950). *J. Nutr.* **41**, 399.
Schmidt, C. L. A. & Greenberg, D. M. (1935). *Physiol. Rev.* **15**, 297.
Shohl, A. T. & Pedley, F. G. (1922). *J. biol. Chem.* **50**, 537.
Sobel, A. T., Yuska, H. & Cohen, J. (1937). *J. biol. Chem.* **118**, 443.
Wolbach, S. B. (1947). *J. Bone Jt Surg.* **29**, 171.
Wolbach, S. B. & Maddock, C. L. (1952). *Arch. Path. (Lab. Med)*. **53**, 273.
Yudkin, S. (1941). *Biochem. J.* **35**, 551.
Zscheile, F. P. & Henry, R. L. (1942). *Industr. Engng Chem. (Anal.)*, **14**, 422.

Nolen-'69
Bib. No. 6798

Fd Cosmet. Toxicol. Vol. 7, pp. 209–214. Pergamon Press 1969. Printed in Great Britain

Variations in Teratogenic Response to Hypervitaminosis A in Three Strains of the Albino Rat

G. A. NOLEN

Miami Valley Laboratories, The Procter and Gamble Company, P.O. Box 39175, Cincinnati, Ohio 45239, USA

(*Received 20 January 1969*)

Abstract—Groups of Sprague–Dawley, Charles River and Wistar rats received daily oral doses of 0, 50,000 or 75,000 IU vitamin A on days 6–15 of pregnancy. The percentage incidences of malformed foetuses for these three strains were 0·8, 0·9 and 0% for the control group, 10·2, 8·5 and 4·1% for the group receiving the lower dose of vitamin A and 100, 34·2 and 22·2% for the higher vitamin A group. Strain differences were seen not only in the overall incidence of malformations but also in the pattern of abnormalities in the offspring. The most common abnormalities were cleft palate, anophthalmia, exencephaly, meningocele and hydronephrosis. No skeletal deformities were induced by excessive vitamin A intake.

INTRODUCTION

The variable responses to teratogens in animals are dependent upon complex environmental and genetic interactions. Thus, there are not only species differences to the action of a specific teratogen, e.g. thalidomide, but also strain and even individual differences (Warkany, Nelson & Schraffenberger, 1942; Loosli, 1965).

During the past decade we have used several strains of albino rat in our laboratory and have observed many differences in their response to experimental conditions, including a higher rate of fat absorption in a Caesarean-derived strain compared with two conventional strains (Nolen & Alexander, 1965). Lewis & Cohlan (1952) showed in tests on aqueous and oily preparations that the toxicity of hypervitaminosis A was related to the form of preparation used and its consequent degree of absorption, and it seemed probable that a difference in strain response to excessive vitamin A would also be seen.

This report compares the response of three widely-used strains of rat to teratogenesis induced by hypervitaminosis A.

EXPERIMENTAL

Animals and diet. The study was based on 35 sexually mature (200-g) female rats and 15 males of each of the following strains: Sprague–Dawley (conventional) obtained from Sprague–Dawley Inc., Madison, Wisconsin; Sprague–Dawley (Caesarean-derived) from Charles River Breeding Laboratories, Inc., Wilmington, Mass., and Wistar (conventional) from Harlan Industries Inc., Cumberland, Indiana. Each strain was isolated in a separate room of the animal quarters and after a 3-day acclimatization period the rats within each strain were distributed by body weight into three groups of 11 females, caged individually.

The males were utilized as a common 'stud pool' and were not divided into groups. Conditions of temperature, lighting and sound were carefully controlled. Purina Laboratory Chow and tap water were offered *ad lib.* throughout the study.

Experimental procedure. Pregnancies were timed by the vaginal smear method (Long & Evans, 1922), and the day of mating or presence of sperm in the vaginal smear was taken as day 0 of the gestation period. Aqueous vitamin A palmitate, from Nutritional Biochemicals Corp., Cleveland, Ohio, was dispersed in distilled water in such concentrations that the appropriate doses were contained in 1 ml. Doses were administered by oral intubation on days 6–15 of gestation at levels of 50,000 or 75,000 IU/day. These levels were chosen on the basis of previous experience with hypervitaminosis A in another strain of rat, in which 50,000 IU produced very few malformed pups. Controls received the same volume of water alone.

On day 21 of pregnancy, the females were sacrificed using excessive ether and were laparotomized. The uterine horns were examined for resorption or other pathological phenomena and the corpora lutea of pregnancy were counted. The position of each foetus in the uterine horn was recorded and subsequently the foetuses were sexed, dried of amniotic fluid, weighed and carefully examined for gross abnormalities.

Every third foetus, unless exhibiting anomalies such as exencephaly or cleft palate, which are often associated with soft-tissue abnormalities, was eviscerated and later cleared and stained (Staples & Schnell, 1964) for study of the skeleton. The remaining foetuses were fixed in Bouin's solution and examined for soft-tissue abnormalities by sectioning (Wilson, 1965).

The data obtained were analysed by the analysis of variance (Snedecor, 1948) and the Tukey minimum significant difference test (Scheffe, 1952).

RESULTS

A vitamin A intake of neither 50,000 nor 75,000 IU/day hindered conception significantly, nor were there significant differences in the numbers of corpora lutea. However, there was an increase in the number of resorptions in the groups treated with 75,000 IU vitamin A during organogenesis (Table 1). The difference was statistically significant in the two Sprague–Dawley strains, but not in the Wistar strain. The lower level of vitamin A had little or no effect in any strain on the number of resorptions and consequently on the number of live foetuses, but the higher level significantly reduced the number of live foetuses in conventional Sprague–Dawley animals. Although the average number of live foetuses was not depressed in the Charles River rats, the number of females in this group with total resorption was twice that of the other Sprague–Dawley rats. Vitamin A administration had no significant effect on foetal weights in any of the groups.

Table 2 shows the types and percentage incidence of the malformations observed. Both the Sprague–Dawley and Charles River strains were more sensitive to hypervitaminosis A than the Wistar strain at both dose levels. In fact, the Wistar strain not only had a lower incidence of abnormalities in the control group, but was also quite refractory to excessive vitamin A.

Of the two Sprague–Dawley strains, the conventional rats were much more sensitive to vitamin A teratogenesis at 75,000 IU, but both strains responded similarly at 50,000 IU. The Charles River strain, on the other hand, was more likely to resorb its young.

Cleft palate was the most common abnormality in all strains, followed by abnormalities

Table 1. *Reproductive performance of three strains of rat given daily oral doses of 0–75,000 IU vitamin A on days 5–16 of pregnancy*

Reproductive findings	Strain ...	Sprague–Dawley			Charles River			Wistar		
	Vitamin intake (IU/day) ...	0	50,000	75,000	0	50,000	75,000	0	50,000	75,000
No. pregnant		11	11	9	10	10	9	10	10	9
No. with total resorption		0	0	3	0	0	6	0	0	1
Mean no. of corpora lutea		12·8±1·7	13·9±1·5	13·0±3·1	12·7±1·7	13·4±3·1	15·2±3·4	12·4±2·5	12·6±2·1	13·0±2·1
Mean no. of resorptions		0·6±1·3	0·0	6·8±5·5*	1·8±3·2	2·7±5·1	7·9±6·6*	0·5±0·7	0·3±0·5	4·1±5·8
No. of dead foetuses		0	0	9	1	0	0	0	2	0
Mean no. of live foetuses		11·2±2·1	11·4±2·7	6·6±3·9†	10·1±4·1	12·0±3·2	13·0±2·2	10·9±2·6	9·1±3·8	11·8±1·7

*Minimum significant difference at $P \leq 0{\cdot}05 = 5{\cdot}7$.
†Minimum significant difference at $P \leq 0{\cdot}05 = 5{\cdot}0$.

Table 2. *Types and incidence of foetal abnormalities in three strains of rat following administration of daily oral doses of 0–75,000 IU vitamin A on days 6–15 of pregnancy*

Type of malformation	Percentage incidence of malformations in								
	Sprague–Dawley			Charles River			Wistar		
Strain ...									
Vitamin A intake (IU/day)...	0	50,000	75,000	0	50,000	75,000	0	50,000	75,000
No. of foetuses examined ...	86	90	22	67	78	36	76	57	65
Cleft palate	0	12·0	52·0	0	2·6	32·2	0	0	10·8
Dermal aplasia	0·8	0	0	0	0	0	0	0	0
Exencephaly	0	1·1	40·9	0	0	0	0	1·7	4·5
Anophthalmia	0	1·1	52·2	0	0	0	0	0	1·5
Microphthalmia	0	0	9·1	0	0	0	0	0	0
Encephalocele	0	1·1	4·5	0	0	0	0	0	1·5
Meningocele	0	0	13·6	0	0	0	0	1·7	4·5
Haematoma	0	1·1	0	0	1·3	0	0	0	0
Intraventricular septal defect	0	0	4·5	0	0	0	0	0	0
Ventricular hyperplasia	0	0	0	0	0	2·8	0	0	0
Hydronephrosis	0	0	13·6	0	0	2·8	0	1·7	0
Hydro-ureter	0	0	4·5	0	0	0	0	0	0
Facial dysgenesis	0	0	11·3	1·1	1·3	0	0	0	0
Micrognathia	0	0	3·5	0	0	0	0	0	0
Gastroschisis	0	0	0	0	0	2·8	0	0	0
Percentage of abnormal foetuses†...	0·8	10·2	100*	0·9	8·5	34·2*	0	4·1	22·2

*Minimum significant difference at $P \leq 0{\cdot}05 = 23{\cdot}2$.
†Percentages are based upon the numbers of foetuses examined for a given type of abnormality. Thus, grossly evident abnormalities are based on total number examined, while those seen only by sectioning are based on the number sectioned. In some cases, a single rat had multiple abnormalities.

of the eyes and encephalon in the two conventional strains (Sprague–Dawley and Wistar). Although there were more malformed foetuses from Charles River rats than from the Wistar, almost all of the abnormalities in the Charles River foetuses at the higher dosage level were cleft palates. Thus, strain differences were seen both in the relative incidence and in the pattern of malformations in the offspring of groups treated with excessive vitamin A.

No skeletal deformities resulted from the feeding of excessive vitamin A during gestation. Nevertheless, variations in the numbers of ribs and sternebrae were evident. These were seen mainly in the test groups, although some occurred in the control groups (Table 3). Most of the supernumerary ribs were bipartite; in fact, only bipartite fourteenth ribs were noted in all three strains treated with 75,000 units. Single extra ribs, either right or left, occurred only in the Sprague–Dawley (50,000 units) and Charles River (control) groups. These extra ribs varied in size from small primordial buttons to the size of the thirteenth ribs, although they were not always bisymmetrical. The Charles River rats had the highest incidence of extra ribs among the control animals and the Wistar foetuses had the lowest incidence among the treated animals.

Compared with the control findings for the ribs, there was more variation from the normal in the sternebrae of the controls, but in this case, too, the incidence increased in the

Table 3. *Percentage incidence of rib and sternebral variations in foetuses of three strains of rat given daily oral doses of 0–75,000 IU vitamin A on days 6–15 of pregnancy*

		Percentage incidence* in								
	Strain...	Sprague–Dawley			Charles River			Wistar		
	Vitamin A intake (IU/day)...	0	50,000	75,000	0	50,000	75,000	0	50,000	75,000
Skeletal findings	No. of foetuses examined...	38	35	7	25	30	16	33	25	26
Extra ribs										
Total		2·6	82·9	85·7	16·0	73·3	87·5	0	52·0	50·0
Right		0	8·6	0	4·0	0	0	0	0	0
Left		2·6	8·6	0	4·0	0	0	0	0	0
Bipartite		0	65·7	85·7	8·0	73·3	87·5	0	52·0	50·0
Atrophic sternebrae										
Total		10·6	22·9	71·5	8·0	16·6	43·7	18·1	40·0	40·9
No. 1		0	0	0	0	0	0	3·0	0	0
2		2·6	0	14·3	0	0	0	3·0	12·0	7·7
3		0	0	0	0	0	0	0	4·0	0
4		0	0	0	0	0	0	0	4·0	0
5		8·0	20·0	28·6	8·0	16·6	25·0	12·1	12·0	19·2
6		0	2·9	28·6	0	0	18·7	0	8·0	3·9
Missing sternebra (no. 5)		0	0	0	0	3·3	0	0	4·0	7·7

*Percentage incidences are based on the numbers of foetuses examined for skeletal abnormality.

treated groups. Atrophy of the fifth sternebra was seen most often, followed by atrophy of the sixth. The second sternebra was affected only in conventional rats.

DISCUSSION

Hypervitaminosis A has been suggested as a standard teratogen for use as a positive control in teratogenicity testing, but various reports in the literature do not always indicate similarities in the response of rats to it. Some of these differences were due, undoubtedly, to the type of vitamin A utilized and the period of dosing, but the strain of animals was also an important contributory factor.

The present data show differences in the response of three rat strains to teratogenicity induced by hypervitaminosis A, somewhat analogous to those obtained in rat strains treated with Trypan Blue (Gunberg, 1958). However, the Wistar rats used here were much less susceptible to 75,000 IU vitamin A than the Wistar strain used by Cohlan (1954). He reported a 52% incidence of malformations in rats treated with 35,000 IU vitamin A, whereas in this study the incidence was only 22% in rats treated with 75,000 IU and 4% in those treated with 50,000 IU.

Since the effect of most teratogens is dependent on the genotype of the animal (Rokos, Kithierova & Palounkova, 1966), the data from this study indicate that even rats of the same strain (i.e. Wistar or Sprague–Dawley obtained from different suppliers) represent separate genetic pools and are in effect separate strains.

Although no skeletal deformities were seen, variations were found in the number of extra ribs present and in the number of atrophic or missing sternebrae and these were

related to the level of excessive vitamin A fed. The significance of this phenomenon is not understood, although it may be an indicator of modified gene action.

REFERENCES

Cohlan, S. Q. (1954). Congenital anomalies in the rat produced by excessive intake of vitamin A during pregnancy. *Pediatrics, Springfield* 13, 556.

Gunberg, D. L. (1958). Variations in the teratogenic effects of Trypan Blue administered to pregnant rats of different strain and substrain origin. *Anat. Rec.* 130, 310.

Lewis, J. M. & Cohlan, S. Q. (1952). Comparative toxicity of aqueous and oily preparations of vitamin A. *Pediatrics, Springfield* 9, 589.

Long, J. A. & Evans, H. M. (1922). *The Oestrous Cycle in the Rat and its Associated Phenomena.* The University of California Memoirs, The University Press, Berkeley.

Loosli, R. (1965). The prognosis of spontaneous congenital malformations in animal experimental studies on drug-induced teratology. *Z. VersTierk.* 6, 48.

Nolen, G. A. & Alexander, J. C. (1965). A comparison of the growth and fat utilization of Caesarean-derived and conventional albino rats. *Lab. Anim. Care* 15, 295.

Rokos, J., Kithierova, E. & Palounkova, E. (1966). The morphogenesis of developmental malformations of the central nervous system. III. Genetics in experimental teratology. *Folia morph.* 14, 50.

Scheffe, H. (1952). An analysis of variance for paired comparisons. *J. Am. statist. Ass.* 47, 381.

Snedecor, G. W. (1948). *Statistica. Methods.* 4th ed. p. 253. Iowa State College Press, Ames, Iowa.

Staples, R. E. & Schnell, V. L. (1964). Refinements in rapid clearing technique in the KOH-Alizarin Red S method for fetal bone. *Stain Technol.* 39, 62.

Warkany, J., Nelson, Rose C. & Schraffenberger, Elizabeth (1942). Congenital malformations induced in rats by maternal nutritional deficiency. II. Use of varied diets and of different strains of rats. *Am. J. Dis. Child.* 64, 860.

Wilson, J. G. (1965). Embryological considerations in teratology. In *Teratology, Principles and Techniques.* p. 262. Edited by J. G. Wilson and J. Warkany. University of Chicago Press, Chicago, Illinois.

Variations des conséquences tératogènes de l'hypervitaminose A sur trois souches de rats albinos

Résumé—Des groupes de rats Sprague–Dawley, Charles River et Wistar ont reçu des doses orales quotidiennes de 0, 50 000 ou 75 000 UI de vitamine A du 6e au 15e jour de gestation. Les fréquences de foetus anormaux chez ces trois souches ont été de 0,8, 0,9 et 0% dans le groupe témoin, de 10,2, 8,5 et 4,1% dans le groupe qui recevait la dose la plus faible et de 100, 34,2 et de 22,2% dans le groupe qui recevait la dose la plus forte de vitamine A. On a relevé des variations selon la souche non seulement dans la fréquence générale des malformations, mais aussi dans les types d'anomalies de la progéniture. Les anomalies les plus courantes étaient la fissure du palais, l'anophtalmie, l'exencéphalie, la méningocèle et l'hydronéphrose. L'ingestion exagérée de vitamine A n'a pas entrainé de déformations du squelette.

Unterschiede der teratogenen Reaktion auf Vitamin-A-Hypervitaminose bei drei Stämmen der Albinoratte

Zusammenfassung—Gruppen von Sprague–Dawley-, Charles-River- und Wistar-Ratten erhielten tägliche Dosen von 0, 50 000 oder 75 000 IE Vitamin A am 6. bis. 15. Tag der Trächtigkeit. Die prozentuale Häufigkeit missgebildeter Fetusse betrug bei diesen drei Stämmen in der Kontrollgruppe 0,8, 0,9 and 0%, in der Gruppe der geringeren Vitamin-A-Dosis 10,2, 8,5 und 4,1% und in der Gruppe der grösseren Vitamin-A-Dosis 100, 34,2 und 22,2%. Stammesunterschiede wurden nicht nur hinsichtlich der Gesamthäufigkeit von Missbildungen beobachtet, sondern auch bei der Verteilung der Missbildungen in der Nachkommenschaft. Die häufigsten Anomalitäten waren Gaumenspalte, Anophthalmie, Exencephalie, Meningocele und Hydronephrose. Zu Skelettdeformationen durch übermässige Vitamin-A-Aufnahme kam es nicht.

Ordog, S.
Bib. No. 6935

Acta biol. Acad. Sci. hung., 18(3), 329—335 (1968)

EFFECT OF VITAMIN A ON THE NUCLEIC ACID AND PROTEIN METABOLISM OF THE RAT

S. ÖRDÖG and K. HÖCSAHAI

DEPARTMENT OF PHYSIOLOGY, RESEARCH INSTITUTE OF ANIMAL HUSBANDRY (HEAD: J. KESERÜ), BUDAPEST

(Received June 10, 1967)

Synopsis

The effect of vitamin A on the nucleic acid contents of various organs has been studied in adult male rats. In the first experiment, the organs of animals kept on vitamin-free diet were compared with those of animals treated with 1,500 I.U. of vitamin A. The kidneys, suprarenal glands, duodenum and diaphragm of the vitamin-fed animals showed a statistically significant increase in the concentration of DNA. In the second experiment, the organs of control animals kept on normal diet were compared with those of animals which received in addition an oral dose of 4,000 I.U. vitamin A. More than half of the examined organs of the vitamin-fed animals contained a significantly higher concentration of nucleic acids than those of the controls. The third experiment showed that the level of serum proteins was 9% higher in the vitamin-fed animals than in the controls. The results seem to prove that vitamin A affects the metabolism of nucleic acids by inhibiting their decomposition and, probably, by promoting their biosynthesis.

Introduction

The mechanism of action of vitamin A in some respects is still obscure. Although it is known that it promotes the production of visual purple (rhodopsin) and stimulates the growth of young animals, its effect on intermediary metabolism is still unelucidated.

Deficiency of vitamin A, by damaging epithelial tissues, causes a pathological change in cellular development, besides, the disturbance of the physiological equilibrium of vitamin A promotes the abnormal growth of certain tissues (neoplasms).

The present experiments were designed to reveal possible correlations between the mode of action of vitamin A on the one hand and the metabolism of DNA and RNA on the other.

In the first experiment male rats of about 300 g body weight were divided into two groups. The control group was kept on a diet free from vitamin A, each member of the test group received, in addition to the same diet, 1,500 I.U. of vitamin A.

In the second experiment, male rats of 140 to 160 g body weight, serving as test animals, received orally 4,000 I.U. of vitamin A, while the control animals were given the same volume of sunflower oil.

Changes in serum proteins, caused by vitamin A, were studied in the third experiment. The idea was that, if vitamin A causes the amount of nucleic acids to increase and promotes the development of young animals, its effect would manifest itself in the intermediary metabolism as well.

Material and method

Extraction of nucleic acids from organs was performed by the method of KOSTERLITZ [2]. Accordingly, pieces weighing 1 g were taken from each of the organs to be examined and treated with trichloroacetic acid, after the removal of the lipid fractions by mixture of ethyl alcohol and ether, the sedimented nucleic acids were hydrolysed by a 6% solution of perchloric acid. DNA and RNA were determined photometrically as described by BERGOLD and PISTER [1] and MEJBAUM [3], respectively.

Serum samples were diluted with veronal buffer (pH 8.5) and dialysed, before the serum proteins were determined by electrophoretical analysis in a micro-Tiselius apparatus.

Results

Experiment 1. Twenty-six male Wistar rats of our laboratory stock, with a body weight of 300 g, were used in this group of experiments. The diet on which the animals were kept for 3 to 4 weeks had the following composition:

casein	18%
starch	54%
dried yeast	10%
edible oil	13%
salt mixture	5%

Although this fodder was practically free from vitamin A, it was kept for 5 to 6 days in an exsiccator (102°C) in order to remove possible traces of the vitamin. The animals received, in addition, vitamins D and E. The test animals received on each of the 7th, 14th and 21st days intramuscular injections of 1500 I.U. vitamin A dissolved in 0.1 ml of oil. The control animals, of about the same weight, age and constitution as the test animals, were given in the same manner 0.1 ml of sunflower oil on the same days. After decapitation and exsanguination, the following organs were removed from the members of both groups.

Testicles with fasciae and epididymides with ducts were examined after the removal of the vessels. Pieces of 1 to 2 g were taken from the intestine at a distance of about 3 cm from the pylorus. Contents of the intestine were removed by perfusing it with Ringer's solution. The entire spleen, both kidneys and suprarenal glands were worked up after the removal of the attaching connective tissues. After the removal of the connective tissue and the vessels, pieces of 1 to 2 g were taken from the liver, while the entire lung, heart, diaphragm and brain were used.

The organs of the test animals were richer in DNA than those of the controls. The increment was statistically significant in respect of the kidneys, suprarenal glands, duodenum and diaphragm. The amount of RNA was like-

Table 1

Comparison of the amount of nucleic acids contained in the organs of animals kept on diet free from vitamin A, with the corresponding data of animals treated with 1,500 I.U. of vitamin A

Organs	Mean values for untreated animals (mg/g of fresh weight)		Mean values for vitamin-treated animals (mg/g of fresh weight)		Percentage increment of nucleic acids in the organs of test animals as compared to controls			
	DNA	RNA	DNA	RNA	DNA	$P < 0.05$	RNA	$P < 0.05$
Testicles	3.396	2.676	3.623	2.730	6.7		2.0	
Liver	2.604	3.711	2.724	4.657	4.6		25.5	
Kidneys	4.248	3.314	4.991	3.840	17.5	+	15.9	
Suprarenal glands	10.676	24.715	13.612	27.021	27.5	+	9.3	
Duodenum	10.826	14.772	13.023	15.199	20.3	+	2.9	
Spleen	11.287	6.865	12.491	6.857	10.7		0	
Heart	2.216	2.101	2.219	2.460	0.1		11.0	
Lungs	7.894	4.717	8.379	5.072	6.1		7.5	
Diaphragm	1.767	2.664	2.678	2.617	51.6	+	0	
Brain	2.352	2.024	2.418	2.097	2.8		3.6	

Table 2

Comparison of the amount of nucleic acids contained in the organs of animals kept on normal diet and perorally treated with 4,000 I.U. of vitamin A, with the corresponding data of untreated animals kept on the same diet

Organs	Mean values for untreated animals (mg/g of fresh weight)		Mean values for vitamin-treated animals (mg/g of fresh weight)		Percentage increment of nucleic acids in the organs of test animals as compared to controls			
	DNA	RNA	DNA	RNA	DNA	$P < 0.05$	RNA	$P < 0.05$
Testicles	4.620	4.597	5.029	4.263	8.9		0	
Liver	3.032	6.572	3.153	6.434	4.0		0	
Kidneys	5.176	4.504	5.725	5.004	10.6	+	11.1	+
Suprarenal glands	8.190	36.210	18.763	40.500	107.1	+	12.1	
Spleen	18.975	9.008	21.180	9.294	11.6		3.2	
Duodenum	10.265	19.517	21.494	33.853	111.0	+	73.5	

wise found to have increased in all examined organs except the spleen and diaphragm, but with the given number of animals these were not statistically significant differences from the controls.

Table 3

Comparison of serum-protein values in rats kept on a diet free from vitamin A, with those of animals treated with 1,500 I.U. of vitamin A

Animal No.	Total protein %	Albumin %	Globulin %	A/G	γ-globulin in serum %	γ-globulin in total protein %
Control animals						
1	4.83	3.16	1.67	1.88	0.74	15.40
2	4.46	3.07	1.39	2.20	0.65	14.60
3	4.46	3.16	1.30	2.43	0.55	12.50
4	4.18	2.97	1.21	2.45	0.55	13.30
5	4.92	3.25	1.67	1.94	0.65	13.20
6	5.30	3.63	1.67	2.16	0.74	14.00
7	4.55	3.16	1.39	2.27	0.65	14.30
8	5.48	3.72	1.76	2.10	0.83	15.20
Average	4.77	3.27	1.50	2.18	0.67	14.00
Standard deviation	0.43	0.26	0.20	0.20	0.09	0.97
Vitamin-treated (test) animals						
1	6.60	4.46	2.14	2.06	0.93	14.10
2	5.12	3.16	1.96	1.62	0.93	18.20
3	5.02	3.35	1.67	2.00	0.75	14.80
4	5.77	3.90	1.87	2.10	0.93	16.10
5	4.57	3.07	1.50	2.30	0.56	12.90
6	4.83	3.07	1.76	1.78	0.93	19.20
7	4.28	3.07	1.21	2.50	0.56	13.00
8	5.68	4.01	1.67	2.38	0.93	16.40
Average	5.24	3.51	1.73	2.09	0.82	15.60
Standard deviation	0.74	0.54	0.28	0.29	0.16	2.30
Percentage increment of serum-protein values in test animals as referred to controls						
	8.9o	6.83	13.29	—	18.20	10.20

Experiment 2. Four thousand I.U. of vitamin A dissolved in oil was introduced through a gastric tube into 13 male test animals. The control animals received the same volume of sunflower oil. All animals were decapitated and exsanguinated 12 hours later.

As can be seen in Table 2, the concentration of DNA increased in all animals, the increment was significant in the kidneys, suprarenal glands, spleen and duodenum. The amount of RNA increased in all organs except the testicles and the liver, increase was significant in the kidneys and the duodenum.

Experiment 3. Animals used in this experiment were kept on the same diet as the first group. Table 3 shows that the concentration of serum proteins of the test animals exceeded that of the controls by about 9% (7% increment in respect of albumin, 13% in respect of globulin, with an A/G ratio of about 2). There was also some increase in the amount of gamma globulin in the test animals.

Discussion

It is evident from the experiments that vitamin A affects the metabolism of nucleic acids in the animal organism. The degree of the effect varies in the different organs. Results obtained in the first two experiments show that — in comparison to the controls — the amount of DNA increased in the examined organs of all test animals, the increase was statistically significant in the kidneys, suprarenal glands, spleen, duodenum and diaphragm. That the change in the DNA content of the brain and heart was slight is probably due to that DNA is decomposed at a slower rate in these vitally important organs or that treatment with vitamin A produced but a weak effect on them.

The amount of RNA showed a similar increase under the effect of vitamin A. The increment was statistically significant in respect of the kidneys and the duodenum. Mean values were influenced in some cases by individual fluctuation, e.g. in respect of the spleen and diaphragm in the first experiment.

That vitamin A influences intermediary metabolism is shown by the approximately 9% increase in the concentration of serum proteins in the test animals.

Two kinds of experiments are now in progress in order to elucidate the mechanism through which vitamin A increases the amount of nucleic acids in the examined organs. According to the preliminary results of these experiments, vitamin A seems to inhibit the decomposition of RNA and DNA, and may, on the other hand, promote the biosynthesis of nucleic acids. Determination of the urinary output of allantoin, the final product of nucleic acids, has the purpose to test the correctness of the first supposition. Preliminary results suggest that the administration of vitamin A is followed by a reduction in the excretion of allantoin and this is interconnected with the simultaneous accu-

mulation of nucleic acids in the organs. While this phenomenon points to an inhibition of the decomposition of nucleic acids, it is still possible that the amount of nucleic acids may increase irrespective of changes in decomposition and excretion. This supposition is supported by the preliminary results of another experiment in which vitamin A appeared to promote the incorporation of ^{32}P.

We regard the results of these experiments as preliminary since the small number of animals used (5 pairs) caused a considerable scattering of values. The effect of vitamin A on the amount of nucleic acids in the various organs has been studied also in sections. Qualitative results obtained in this way were in perfect accord with the quantitative results, and were submitted by us to the recent International Histological Congress in Frankfurt [4].

REFERENCES

1. Bergold, G., Pister, L. (1948) The quantitative microdetermination of desoxy- and ribonucleic acids. *Z. Naturforsch.*, **3b**, 406—410.
2. Kosterlitz, H. W. (1947) The effects of changes in dietary protein on the composition and structure of the liver cell. *J. Physiol.*, **106**, 194—210.
3. Mejbaum, W. (1939) Über die Bestimmung kleiner Pentosemengen, insbesondere in Derivaten der Adenylsäure. *Hoppe-Seyler's Z. phys. Chem.*, **258**, 117—120.
4. Takács-Tomity, E., Ördög, S., Takács, Ö. (1964) Hystochemistry of nucleic acids in A-avitaminosis. *Zweiter Internationaler Kongress für Hist. Cytochemie, Frankfurt/Main.*

NEUE BEITRÄGE ZUM WIRKUNGSMECHANISMUS VON VITAMIN A

An ausgewachsenen männlichen Ratten wurde die Wirkung von Vitamin A auf den NS-Gehalt verschiedener Organe untersucht. In der ersten Versuchsreihe wurde der NS-Gehalt der bei vitaminfreier Diät gehaltenen Tiere verglichen mit den NS-Werten von Tieren, die 1500 IE Vitamin A erhalten hatten. In bezug auf den Gehalt an DNS ließ sich in den Nieren, den Nebennieren, im Duodenum und im Diaphragma bei den Tieren der zweiten Gruppe (A-Vitamingabe) eine signifikante Erhöhung aufzeigen. In der zweiten Serie wurde der NS-Gehalt der Organe von Tieren, denen bei normaler Kost 4000 IE Vitamin A peroral zugeführt wurden, den entsprechenden Werten der ähnlich, jedoch ohne Vitamingabe ernährten Gruppe gegenübergestellt. Der signifikante Anstieg der NS-Konzentration in den Organen der Versuchstiere gegenüber den Kontrollen ließ sich auch in diesem Experiment in etwa der Hälfte der untersuchten Organe nachweisen. In der dritten Versuchsreihe wurden die auf Vitamin-A-Wirkung eintretenden Bluteiweißveränderungen untersucht und bei den Versuchstieren ein nahezu 9%iger Anstieg des Proteingehaltes beobachtet. Die erhaltenen Ergebnisse zeigen, daß das Vitamin A auf den Nukleinsäurestoffwechsel zweifellos wirksam ist. Seine Wirkung manifestiert sich einesteils in der Hemmung des Nukleinsäureabbaus, anderenteils in der Erhöhung der NS-Biosynthese.

НОВЫЕ ДАННЫЕ К ПАТОМЕХАНИЗМУ ВИТАМИНА А

На взрослых крысах-самцах были проведены исследования по выяснению действия витамина А на содержание нуклеиновых кислот в различных органах. В первой части опытов проводилось сравнение содержания нуклеиновых кислот в органах животных, содержанных при режиме питания, лишенном витамина А, с соответствующими величинами животных, получивших 1500 МЕ витамина А. Относительно дезоксирибонуклеиновой кис- [illegible] найдено, что ее содержание в почках, надпочечниках, двенадцатиперстной

[redacted]ние и диафрагме животных, получивших витамин А, достоверно выше. Во второй серии [redacted]ов величины содержания нуклеиновых кислот в органах животных, получивших при [redacted]льном режиме питания 4000 МЕ витамина А перорально, были сопоставлены с [redacted] животных, содержавшихся при однообразной диете, но без дачи витамина А. По [redacted]ению с контролями содержание нуклеиновых кислот и в этой серии опытов в около [redacted]ирование исследованных органов было повышенным. В третьей серии опытов исследовались изменения содержания белков крови, возникающие под влиянием витамина А. У подопытных животных наблюдалось почти 9%-ое повышение содержания белков. Эти результаты доказывают, что витамин А безусловно оказывает действие на обмен нуклеиновых кислот. Данное действие сказывается, отчасти в ускорении распада нуклеиновых кислот, а отчасти в повышении их биосинтеза.

Szilveszter Ördög
Kálmán Hőcsabai } Budapest I., Attila utó 93. Hungary.

Pallotta-'63
Bib. No. 6986

Am. J. of Clin. Nut. 13:201-208. 1963

Original Communications

Effect of Vitamin A on Certain Blood Constituents of Geriatric Subjects

MARY A. PALLOTTA, M.S.* AND R. F. KRAUSE, M.D., PH.D.†

NTEREST in the metabolic role of vitamin A has increased during the past decade. olf[1] recently reviewed some of the effects vitamin A on specific metabolic processes animals. This laboratory has reported t vitamin A reduced elevated serum choles- ol levels in patients with atherosclerosis.[2] ackenbush et al.[3] confirmed this finding in cks and reported that this vitamin inhibited formation of vascular lesions associated h a high cholesterol diet. Heaton et al.[4] erved an elevation of liver ubiquinones in amin A-deficient rats and suggested that may result from a possible block in the ation of cholesterol from squalene. Van ggen and Straumfjord[5] found an elevation erum phospholipids from human subjects itamin A supplementation. Weitzel et al.[6] d a similar response in old hens receiving amin A without any change in the other m lipids. These investigators also noted a nution of the lipid content, especially esterol, of aortic placques in hens given min A. These findings suggest that min A may exert an influence on lipid bolism.

rious workers have shown a relationship een vitamin A and protein metabolism. e investigators have linked this association e albumin fraction, although others have d it to the globulin component of protein.[7-9] Friend et al.[10] have found that dietary protein deficiency limits the production of a protein fraction or fractions which aid in the transport of vitamin A. They suggest that insufficient protein carrier prevents the mobilization of stored vitamin A as well as its absorption through the intestinal wall. Recently, Anderson and co-workers[11] have substantiated this belief by noting significant decreases in serum albumin, plasma vitamin A and body weight in sheep on a protein-deficient diet. They showed that adequate protein rations aided the storage of vitamin A in the liver. Another relation between protein and vitamin A has been demonstrated by Harmon and associates[12] who found a reduced response of antibody formation in vitamin A-deficient baby pigs. These reports suggest a possible cause-effect relationship between vitamin A and protein metabolism.

Large doses of vitamin A have been reported to influence the role of vitamin K in animals. For example, Moore and Wang[13] observed hemorrhagic tendencies in rats after overdosing with halibut oil. Light and co-workers[14] produced similar effects by the administration of large doses of vitamin A. However, they were able to prevent these hemorrhages by the administration of vitamin K. Walker et al.[15] developed a vitamin K deficiency by administering excessive amounts of vitamin A. Quick and Stefanini[16] confirmed the need of vitamin K to inhibit the development of hypothrombinemia in newly-hatched chicks given 50,000 I.U. of vitamin A daily. Doisy and Matschiner[17] further verified this effect of vitamin A by showing that hypoprothrom-

m the Department of Biochemistry, Medical r, West Virginia University, Morgantown, West ia.

raduate Assistant; † Professor and Chairman.

s work was supported in part by U. S. Public h Service Grant H-5738.

binemia could develop with physiologic levels of vitamin A if an adequate amount of vitamin K was not present These observations imply an interrelation between the role of vitamin A and vitamin K in blood coagulation.

Recently, Lucy et al.[18] and Dingle[19] observed that vitamin A causes the release of a proteolytic enzyme and perhaps other enzymes from the interior of cells by altering the permeability of the lysosome particles or the cell membrane. Additional evidence that vitamin A might cause the release of intracellular enzymes has been presented by Previti and Rizzo.[20] They showed that the administration of large doses of vitamin A resulted in an increase in serum alkaline phosphatase in children between one and eight years of age. Guzman et al.[21] have related low serum vitamin A levels in children to low alkaline phosphatase levels. From these reports one may imply that vitamin A plays a role in regulating the level of some enzymes in the blood.

In light of present knowledge it is apparent that vitamin A exerts an influence upon many biochemical reactions. It is generally recognized that these effects may vary considerably between different species of animals. Since relatively few studies have dealt with the role of vitamin A in man, it was decided to conduct such an experiment. This paper reports the effect of vitamin A on a selected group of human blood constituents. These blood components were chosen on the basis of a previously proposed relationship with vitamin A.

METHODS

Geriatric subjects were selected for this study because our previous work dealt with the effect of vitamin A on serum cholesterol of elderly subjects. In this selected group were twenty-four senior citizens who ranged in age from sixty-four to eighty years. The group was divided at random; there were eight members in the control group (one man and seven women) and sixteen members in the experimental group (three men and thirteen women). No attempt was made to exclude members from either group because of existing maladies of the aged. All participants were ambulatory and apparently in good health.

A monthly supply of capsules was given to each subject in the control and experimental groups [illegible] directions to take one capsule after breakfast [illegible] one after the evening meal. The control gro[illegible] ceived placebo capsules, and the experimental [illegible] received capsules containing 50,000 I.U. of vit[illegible] A acetate. This supplementation was carri[illegible] for a period of six months. The double-blind [illegible] nic was used in the experimental design for di[illegible] ing the capsules.

Blood samples were collected at the follo[illegible] times: (1) prior to supplementation (Octo[illegible] (2) after three months' supplementation (Jan[illegible] (3) after six months' supplementation (April); [illegible] (4) three months after the termination of sup[illegible] mentation (July). All blood samples were colle[illegible] from subjects fasted for fourteen hours. Serum [illegible] plasma were separated from the formed elem[illegible] within two hours after collection. Aliquots of [illegible] serum were frozen at minus 20°c. until anal[illegible] (within two weeks). Serum for electrophoresis [illegible] stored for three days at 4°c. Serum protein [illegible] terns were developed by the Beckman B proce[illegible] for the Spinco apparatus. The analytrol d[illegible] ometer was used to determine percentage conce[illegible] tion of each protein fraction. The protein fracti[illegible] were calculated and reported in grams per c[illegible] The total serum protein was determined by W[illegible] son's biuret method.[22] Within two hours after [illegible] lection of the blood, the prothrombin time t[illegible] were performed by the Warner-Chilcott C[illegible] pany's* modification of Quick's method.[23] On t[illegible] day after blood collection, alkaline phosphatase [illegible] tivity was estimated by Natelson's microada[illegible] tion[24] of the method of Shinowara et al.[25] and p[illegible] phorus measured by the method of Fiske and S[illegible] barow.[26] May's microadaptation[27] of Kimble's p[illegible] cedure was used for the estimation of vitamin [illegible] and carotene. Total cholesterol was measured [illegible] the method of Schoenheimer and Sperry[28] with t[illegible] Zlatkis and Zak color reaction.[29] The latter t[illegible] procedures were combined in order to eliminate [illegible] interference from excess vitamin A or tryptop[illegible] Lipid phosphorus was measured by the method [illegible] Youngburg[30] adapted to a microscale by Natels[illegible] A factor of 25 was used to convert the lipid p[illegible] phorus to phospholipids.

One day recall diet histories were taken on all s[illegible] jects at the beginning of the study.

Fisher's t test was applied to each independ[illegible] group to determine if there was a significant vari[illegible] tion within the serum levels of the experimental a[illegible] control groups. If the experimental group showed [illegible] significant variation, then the group comparison [illegible]

* Chilcott Laboratories, Morris Plains, New Jers[illegible]

TABLE I

The Mean Blood Levels of Various Constituents from the Control and the Experimental Group Before, During and After Vitamin A Supplementation

Time of Supplementation	Vitamin A (μg. %)	Carotene (μg. %)	Total Cholesterol (mg. %)	Pro-thrombin Time (%)	Alkaline Phosphatase (SJR units)	Phospholipids (mg. %)
Control Group						
Initial	74 ± 58	194 ± 20	220 ± 32	73 ± 21	3.9 ± 1.1	254 ± 34
At 3 mo.	70 ± 62	194 ± 45	252 ± 38	85 ± 12	6.7 ± 2.08	250 ± 67
At 6 mo.	75 ± 46	176 ± 45	232 ± 28	82 ± 13	5.4 ± 1.2	284 ± 30
mo. after	71 ± 38	154 ± 40	274 ± 36	81 ± 15	3.7 ± 1.8	211 ± 37
Experimental Group						
Initial	55 ± 25	236 ± 106	226 ± 51	78 ± 15	4.0 ± 1.9	219 ± 30
At 3 mo.	161 ± 246 (P < 0.05)	190 ± 101	251 ± 51	81 ± 13	7.2 ± 1.7	326 ± 66 (P = 0.001)
At 6 mo.	167 ± 129 (P < 0.025)	154 ± 60 (P < 0.05)	228 ± 43	95 ± 8	5.8 ± 1.2	282 ± 83 (P = 0.075)
mo. after	73 ± 21	161 ± 90	285 ± 65	86 ± 9	3.6 ± 1.1	194 ± 42

NOTE: All values are given ± standard deviation; probabilities were calculated on a group comparison basis only in those cases in which there were significant independent group variations. From SNEDECOR, G. W. Statistical Methods. Ames, Iowa, 1956. The Iowa State University Press.[22]

was applied to determine if variations between experimental and control groups were significant.[22]

RESULTS

Dietary

The data collected from a single recall diet history indicated that all subjects consumed approximately 1,500 cal. per day. The daily protein intake of 60 per cent of the subjects was below 60 gm. Approximately 65 per cent of the subjects reported a daily vitamin A intake of less than 4,000 I.U. Twenty-five per cent of the group had a daily calcium intake of less than 0.45 gm. According to the recommended daily allowances (Food and Nutrition Board, National Research Council) about 25 per cent of the group had an inadequate intake of niacin, thiamine, riboflavin and iron.

Vitamin A and Carotene Concentration in Serum

Table I and Figure 1 compare average serum vitamin A and carotene levels. Initially, prior to supplementation, the average levels of serum vitamin A and carotene fell within the normal range. After three months' supplementation with vitamin A, the serum vitamin A level increased 106 mg. per cent ($P < 0.05$), and the carotene level decreased 46 mg. per cent ($P < 0.10$). The serum carotene level decreased 36 mg. per cent ($P < 0.05$) further after six months' supplementation, and the vitamin A level remained at approximately the same level it was at three months. In comparison, the control group showed no significant variation in either vitamin A or carotene.

Serum Cholesterol and Phospholipid

The average serum cholesterol level of the experimental group was not significantly affected by vitamin A supplementation (Table I). However, the average serum phospholipid value did increase significantly over that of the control group after three months' vitamin A supplementation ($P < 0.001$). The increase continued into the sixth month, but it was slightly above the significant level ($P = 0.075$).

It was interesting to note that three subjects in the experimental group with initially high serum cholesterol levels showed a decrease in this fraction in the presence of excess vitamin A and a simultaneous increase in their

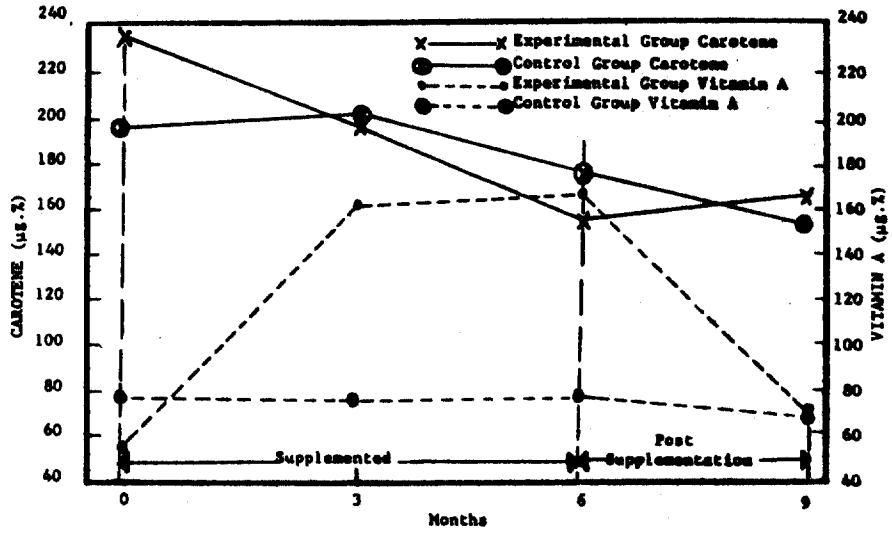

FIG. 1. Comparison of mean serum carotene and vitamin A levels during and after supplementation with vitamin A.

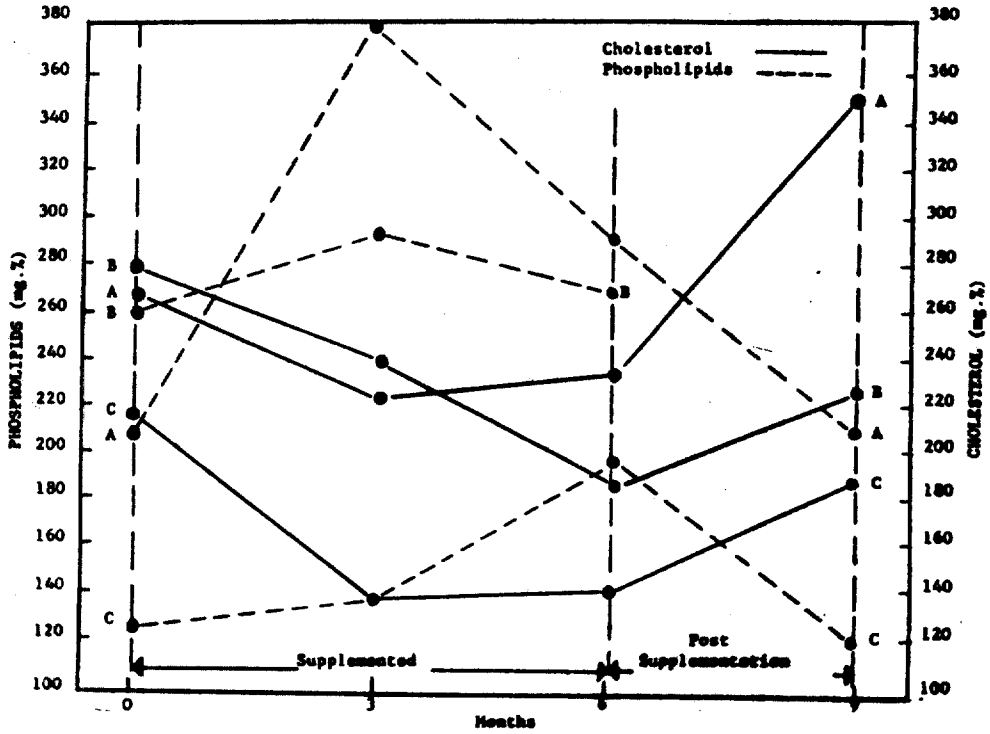

FIG. 2. Comparison of mean selected individual values of initially elevated serum cholesterol levels and the corresponding phospholipid levels during and after supplementation with vitamin A. The selected subjects are designated A, B and C.

serum phospholipid levels. Figure 2 graphically illustrates these relationships in these subjects.

Serum Alkaline Phosphatase

The serum alkaline phosphatase level was not significantly affected by excess vitamin A. The increase, approximately 3 units above initial normal value, which occurred at the third and sixth month testing period in the experimental group was also found in the control group (Table I). All serum alkaline phosphatase values fell within normal limits.

TABLE II

The Mean Serum Protein Level and Its Fractions from the Control and the Experimental Groups Before, During and After Vitamin A Supplementation

Time of Supplementation	Total Protein (gm. %)	Albumin (gm. %)	Globulin (gm. %)			
			Alpha$_1$	Alpha$_2$	Beta	Gamma
Control Group						
Initial	6.9 ± 0.42	3.32 ± 0.45	0.30 ± 0.11	0.42 ± 0.02	0.66 ± 0.16	1.2 ± 0.38
At 3 mo.	6.8 ± 0.42	4.03 ± 0.38	0.31 ± 0.05	0.51 ± 0.07	0.82 ± 0.18	1.17 ± 0.28
At 6 mo.	6.9 ± 0.41	4.36 ± 0.30	0.26 ± 0.04	0.50 ± 0.08	0.77 ± 0.21	1.02 ± 0.22
3 mo. after	6.9 ± 0.4	4.62 ± 0.25	0.19 ± 0.04	0.45 ± 0.08	0.67 ± 0.11	0.93 ± 0.28
Experimental Group						
Initial	7.06 ± 0.51	4.40 ± 0.35	0.26 ± 0.06	0.52 ± 0.12	0.69 ± 0.12	1.19 ± 0.22
At 3 mo.	7.07 ± 0.52	4.17 ± 0.38	0.32 ± 0.05 (P = 0.02)	0.57 ± 0.11	0.82 ± 0.13	1.21 ± 0.23
At 6 mo.	7.03 ± 0.48	4.42 ± 0.42	0.24 ± 0.03	0.52 ± 0.11	0.80 ± 0.11	1.05 ± 0.11
3 mo. after	7.07 ± 0.65	4.66 ± 0.40	0.19 ± 0.05	0.53 ± 0.12	0.65 ± 0.12	1.05 ± 0.20

NOTE: All values are given ± standard deviation; probability was calculated on a group comparison basis only in this case in which there was a significant independent group variation. From SNEDECOR, G. W. Statistical Methods. Ames, Iowa, 1956. The Iowa State University Press.[22]

Prothrombin Time

Plasma samples obtained prior to supplementation gave average prothrombin times for the experimental group as 78 per cent and for the control group as 73 per cent of a normal standard. These initial prothrombin times are slightly lower than the accepted normal values. There was a gradual increase in the prothrombin times in both groups over the testing period; therefore, the variations could not be attributed to vitamin A (Table I).

Serum Protein

Table II gives the average initial levels for total serum protein, albumin, alpha$_1$ globulin, alpha$_2$ globulin, beta globulin and gamma globulin for both groups. It may be seen that all values were within normal limits and, except for the alpha$_1$ globulin, did not vary significantly over the experimental period. The alpha$_1$ globulin value did increase after three months' supplementation (P = 0.02); whereas after 6 months of vitamin A administration it returned to approximately normal as it was initially.

All constituents that varied in the presence of excess vitamin A returned or showed trends of returning to the initial level three months after the discontinuation of vitamin A therapy (Tables I and II).

Throughout the testing period no untoward subjective effects were noted from the dosage of vitamin A used.

COMMENTS

When this study was planned it was thought that an elderly group of subjects would show a variety of laboratory signs of malnutrition and have elevated blood cholesterol levels. From a nutritional viewpoint it was gratifying to find, despite the many inadequacies in their dietary intakes, that in the majority of subjects the initial blood levels of the constituents studied fell within the generally accepted limits of normal. This state of initial "normalcy" of blood levels of vitamin A and carotene and other selected blood constituents may account in part for the few significant effects noted from vitamin A administration.

All members of the experimental group showed an increase in serum vitamin A after three months of supplementation. This was taken as evidence that the supplement was absorbed.

The effect of vitamin A administration on lowering serum carotene levels is interesting and confirms previous findings.[33–35] We have likewise observed in the rat that the simultaneous oral administration of vitamin A with C^{14} beta carotene decreased the absorption of carotene as compared to the absorption when carotene was administered alone. The mechanism of this effect remains obscure.

It may be noted that the final mean serum carotene levels of the control and experimental groups (three months after terminating supplementation) were considerably lower than their initial values. This we attributed to seasonal variation, since it has been reported that serum carotene levels are generally highest in the fall and lowest in the spring.[36]

The lack of a significant effect of vitamin A on the average serum cholesterol levels of the experimental group was expected, since so few subjects had high cholesterol values initially. However, we have demonstrated again that vitamin A does have an antihypercholesterolemic action in those subjects with elevated serum cholesterol levels. Work is in progress to elucidate the mechanisms responsible for this effect.

Closely associated with the effect of vitamin A on cholesterol levels is its influence on serum phospholipids. All subjects who received this vitamin had an increase in phospholipid levels. Those on a regimen of vitamin A who showed the largest decrease in serum cholesterol levels showed the greatest increase in serum phospholipid levels. These latter two observations lend credence to the belief that vitamin A does in some manner affect lipid metabolism.

From the data collected, vitamin A had no detectable effect on the blood levels of alkaline phosphatase and prothrombin time. The only serum protein fraction significantly affected was the alpha$_1$ globulin. This effect was seen three months after supplementation and then disappeared after six months of administration. Two partial explanations for this finding are suggested: First, since this fraction has been implicated as a vehicle for the transport of serum vitamin A, the increase in this globulin may have been due to the increased need for a material to carry the additional serum vitamin A; second, since the alpha$_1$ globulin parallel the increase in serum phospholipids at the end of three months of supplementation, this association may relate to an alteration in the serum lipoprotein pattern during vitamin A administration. We are unable to explain why this protein returned to its initial level at the end of six months of supplementation when the serum vitamin A level was still elevated. At present no evidence can be cited to support such a theory.

Three months after terminating vitamin A administration, the serum vitamin A levels of the experimental group were only slightly higher than their initial values and at about the same level as those of the control group. This rapid decline in serum vitamin A after the withdrawal of supplements is interesting and has been noted by others.[37] This finding raises the question of the nutritional significance of vitamin A blood levels and its relation to stored vitamin A. If there is a positive correlation between serum levels and the amount of stored vitamin A, then the reduction of serum levels after discontinuing supplementation must be the result of considerable destruction or loss of stored vitamin A.

Whatever the explanation for this rapid decline in serum vitamin A levels, this study clearly indicates the need for additional information on the relation between blood levels and vitamin A storage in man.

SUMMARY

The effects of vitamin A supplementation on serum levels of vitamin A, carotene, cholesterol and phospholipid, prothrombin time, serum protein and its various fractions were studied at three and six month periods during supplementation and three months after terminating vitamin A administration. The subjects were studied between sixty-four and eighty years of age. A dose of 50,000 I.U. of vitamin A acetate was given twice a day.

The administration of vitamin A significantly increased the serum vitamin A levels, reduced serum carotene levels, increased serum phospholipid levels and reduced initially elevated cholesterol values. No effect was noted on the

blood levels of alkaline phosphatase and prothrombin time. The alpha$_1$ globulin fraction was increased after three months of supplementation. The other serum proteins were not affected.

Three months after discontinuing vitamin A administration, the vitamin A blood levels of the experimental group returned to approximately their initial level.

ACKNOWLEDGMENT

We are grateful to Hoffmann-La Roche, Inc., Nutley, New Jersey, for supplying the vitamin A acetate and placebo capsules used in this study.

REFERENCES

1. Wolf, G. Some thoughts on the metabolic role of vitamin A. *Nutrition Rev.*, 20: 161, 1962.
2. Kinley, L. J. and Krause, R. F. Influence of vitamin A on cholesterol blood level. *Proc. Soc. Exper. Biol. & Med.*, 102: 353, 1959.
3. Beeler, D. A., Roger, J. and Quackenbush, F. W. Effects of levels of certain dietary lipids on plasma cholesterol and atherosclerosis in the chick. *J. Nutrition*, 78: 184, 1962.
4. Heaton, F. W., Lowe, J. S. and Morton, R. A. Aspects of vitamin A deficiency in the rat. *Biochem. J.*, 67: 208, 1957.
5. Van Bruggen, J. T. and Straumfjord, J. V. High vitamin A intake and blood levels of cholesterol, phospholipids, carotene, and vitamins C, A, and E. *J. Lab. & Clin. Med.*, 33: 67, 1948.
6. Weitzel, G., Schon, H. and Gey, F. Antiatherosklerotische Wirkung fettlöslicher Vitamine. *Klin. Wchnschr.*, 33: 772, 1955.
7. Palmer, L. S. and Eales, C. H. The yellow lipochrome of blood serum. *J. Biol. Chem.*, 17: 223, 1914.
8. Erwin, E. S., Varnell, T. R. and Page, H. M. Relationship of vitamin A and carotene to bovine serum proteins. *Proc. Soc. Exper. Biol. & Med.*, 100: 373, 1959.
9. Gabbers, C. F., Gillman, J. and Peisach, M. The transport of vitamin A in rat serum with special reference to the occurrence of unidentified metabolites of vitamin A in the rat. *Biochem. J.*, 75: 124, 1960.
10. Friend, C. J., Heard, C. R. C., Platt, B. S., Stewart, R. J. C. and Turner, M. R. The effect of dietary protein deficiency on transport of vitamin A in the blood and its storage in the liver. *Brit. J. Nutrition*, 15: 231, 1961.
11. Anderson, T. A., Hubbert, F., Jr., Roubicek, C. B. and Taylor, R. E. Influence of protein depletion on vitamin A and carotene utilization by vitamin A deficient sheep. *J. Nutrition*, 78: 341, 1962.
12. Harmon, B. G., Miller, E. R., Haefer, J. A., Ullrey, D. E. and Luecke, R. W. Relationship of specific nutrient deficiencies to antibody production in swine. I. Vitamin A. *J. Nutrition*, 79: 263, 1963.
13. Moore, T. and Wang, Y. L. Hypervitaminosis A. *Biochem. J.*, 39: 222, 1945.
14. Light, R. F., Alscher, R. P. and Frey, C. N. Vitamin A toxicity and hypoprothrombemiia. *Science*, 100: 225, 1944.
15. Walker, S. E., Eylenburg, E. and Moore, T. The action of vitamin K in hypervitaminosis A. *Biochem. J.*, 41: 575, 1947.
16. Quick, A. J. and Stefanini, M. The relation of vitamin K deficiency to the intensity of Dicumarol action and to the effect of excess vitamin A intake; with a simplified method for vitamin K assay. *J. Biol. Chem.*, 175: 945, 1948.
17. Doisy, E. A. and Matschiner, J. T. Role of vitamin A in induction of vitamin K deficiency in the rat. *Proc. Soc. Exper. Biol. & Med.*, 109: 139, 1962.
18. Lucy, J. A., Dingle, J. T. and Fell, H. B. A possible role of intracellular proteases in the degradation of cartilage matrix. *Biochem. J.*, 79: 500, 1961.
19. Dingle, J. T. Release of a bound protease by the action of vitamin A. *Biochem. J.*, 79: 509, 1961.
20. Previti, A. and Rizzo, A. Vitamin A and enzymatic properties of the blood (alkaline phosphatase, lipase and cholinesterase). *Arch. atti. soc. med.-chir. Messina*, 3: 257, 1959.
21. Guzman, M. A., Arroyave, G. and Scrimshaw, N. S. Serum ascorbic acid riboflavin, carotene, vitamin A, vitamin E, and alkaline phosphatase values in central American school children. *Am. J. Clin. Nutrition*, 9: 164, 1961.
22. Wolfson, W. Q., Cohn, C., Calvary, E. and Ichiba, F. A rapid procedure for the estimation of total protein, true albumin, total globulin, alpha globulin, beta globulin and gamma globulin in 1.0 ml. of serum. *Am. J. Clin. Path.*, 18: 723, 1948.
23. Quick, A. J. The clinical application of the hippuric acid and the prothrombin tests. *Am. J. Clin. Path.*, 10: 222, 1940.
24. Natelson, S. Acid and alkaline phosphatase. In Microtechniques of Clinical Chemistry, p. 340. Publisher, Springfield, Ill., 1957. Charles C. Thomas.
25. Shinowara, G. Y., Jones, L. M. and Reinhart, H. L. The estimation of serum inorganic phosphate and acid and alkaline phosphatase activity. *J. Biol. Chem.*, 142: 921, 1942.
26. Fiske, C. H. and Subbarow, Y. The colorimetric determination of phosphorus. *J. Biol. Chem.*, 66: 375, 1925.
27. May, C. D., Blackfan, K. D., McCreary, J. F. and Allen, J. H. Clinical studies of vitamin A

in infants and in children. *Am. J. Dis. Child.*, 59: 1169, 1940.

28. SCHOENHEIMER, R. and SPERRY, W. M. A micromethod for the determination of free and combined cholesterol. *J. Biol. Chem.*, 106: 745, 1934.
29. ZLATKIS, E. and ZAK, B. A new method for direct determination of serum cholesterol. *J. Lab. & Clin. Med.*, 41: 486, 1953.
30. YOUNGBURG, G. E. and YOUNGBURG, M. V. A system of blood phosphorus analysis. *J. Lab. & Clin. Med.*, 16: 158, 1930.
31. NATELSON, S. Phosphate. In: Microtechniques of Clinical Chemistry, p. 303. Springfield, Ill., 1957. Charles C Thomas.
32. SNEDECOR, G. W. Group comparison. In: Statistical Methods, p. 85. Ames, Iowa, 1956. The Iowa State University Press.
33. JENSEN, C. W., BOYER, P. D., PHILLIPS, P. H., RUPEL, I. W. and LINDQUIST, N. S. The effect of shark liver oil on milk and butter fat production. *J. Dairy Sc.*, 25: 931, 1942.
34. EATON, H. D., SPIELMAN, A. A., LOOSLI, J. [illegible] THOMAS, J. W., NORTON, C. L. and TURK, [illegible] The effect of a massive dose at birth of vita[illegible] A and D upon blood plasma levels and liver [illegible] age in Holstein calfs. *J. Dairy Sc.*, 30: 795, 19[illegible]
35. PULLIAM, R. P., DANNENBURG, W. N., BURT, R. [illegible] and LEAKE, N. H. Carotene and vitamin A [illegible] pregnancy and the early puerperium. *Proc. [illegible] Exper. Biol. & Med.*, 109: 213, 1962.
36. MERROW, S. B., KRAUSE, R. F., BROWE, J. [illegible] NEWHALL, C. A. and PIERCE, H. B. Relati[illegible] ships between intake and serum levels of ascorbi[illegible] acid, vitamin A, and carotene of selected grou[illegible] of children with physical signs of vitamin [illegible] ficiencies. *J. Nutrition*, 46: 445, 1952.
37. KIRK, J. E. and CHIEFFI, M. Effect of vitamin A[illegible] administration on plasma vitamin A concentra[illegible] tion, conjunctival changes, dark adaptation and [illegible] toad skin. *J. Clin. Nutrition*, 1: 37, 1952.

Palludan '66
Bib. No. 6992

BIOCHEMISTRY

Direct Effect of Vitamin A on Boar Testis

ABOUT 40 years ago the effect of vitamin A deficiency on male sexual organs was investigated in rats by Wolbach and Howe[1] and Gross[2], and in guinea-pigs by Wolbach and Howe[3]. Later the influence of this vitamin on reproduction was investigated in various species of domestic animals, for example, in bulls by Hodgson *et al.*[4] and Madsen *et al.*[5,6], and in rams by Lindley *et al.*[7], but until I reported my investigations[8], it would seem that boars had not been examined. Termination—or a marked reduction—of the spermatogenesis as a consequence of the A-avitaminosis characterized all findings in the species of animal examined. It was demonstrated in these experiments that the administration of vitamin A to an A-avitaminotic boar resulted in complete normalization of the spermatogenesis within 3 months.

Investigations were continued with the view of elucidating whether vitamin A acted directly on the spermatogenetic epithelium or whether a hormonal factor was involved.

As with previous experiments, Danish Landrace boars were used, and from the age of 6 weeks were fed a diet deficient in vitamin A. The vitamin A status was controlled by analysis of liver biopsies which, together with the markedly increased cerebrospinal pressure, formed the basis by which it was checked that the animals (at the age of 4–5 months) were depleted of vitamin A. At this stage, daily doses of vitamin A acid were supplied to some of the boars, the clinical condition of which remained normal but in which a vitamin A deficiency was manifest in the spermatogenetic tissue. This feature was investigated earlier in boars (unpublished data), and is in accordance with findings of Thompson *et al.*[9] in rats. About a month later, vitamin A alcohol or vitamin A aldehyde in peanut oil containing small quantities of indian ink was injected into one of the testicles. The doses of vitamin A alcohol injected varied between 6,000 and 8,000 I.U., and vitamin A aldehyde between 0·6 and



Fig. 1. Testis from vitamin A-deficient boar. The septula testis, which contains vacuoles and grains of indian ink, separates normal spermatogenetic tubules (right) from degenerating tubules (left). (Stained with haematoxylin-eosin. × 60)

1·6 mg. In a few boars, both preparations were applied to the same testicle, one preparation being injected at a distal, the other at a proximal site. At intervals of 3–4 weeks this treatment was repeated on four or five occasions after which the animals were killed.

The weight of the testicles was found to be much lower in all experimental boars than in their normal littermates; members of the former group were about a third or a half the normal weight. There was no characteristic difference in weight between treated and non-treated testicles. Histological examination of the testes, however, revealed a distinct difference between the testicular areas into which the vitamin had been injected and the surrounding tissue and the non-treated testicle. In some boars spermatogenesis was found to be normal at the site of application (Fig. 1), yet at the same time there was total degeneration of the spermatogenetic epithelium in the surrounding tissue and the non-treated testis as the tubules were found to contain only Sertoli's cells and a few inactive spermatogonia. Generally the areas treated with vitamin A were well defined, and radial septa of testicular connective tissue separated the vitamin A-rich from the vitamin A-deficient areas (Fig. 1). Besides the normal spermatogenesis in the former areas, grains of indian ink could be seen embedded in the interstitial tissue which also contained some circular or oval vacuoles of somewhat variable sizes. These vacuoles represented the 'negative picture' of the vitamin A-containing peanut oil used for the injection, and fat-staining of frozen sections of the testicles with Sudan III gave a positive result. Vitamin A alcohol and vitamin A aldehyde thus seem to have similar direct effect on the spermatogenetic tissue, with the exception that vitamin A aldehyde seems to result in a more well-defined demarcation between the active, vitamin-treated and the vitamin-deficient testicular tissues.

As already mentioned, the way in which the vitamin A deficiency provokes the characteristic testicular changes remains unknown. An explanation which immediately suggests itself is that it might be a matter of hormonal interference, and for this reason interest has been focused primarily on the gonadotropic hormones of the pituitary. The results obtained in investigations using experimental as well as domestic animals have been most contradictory. Whereas Mason and Wolfe[10] found that the content of gonadotropins in the pituitary increases in vitamin A-deficient rats, Van Os[11] and Mayer and Goddard[12] considered that supplies of gonadotropic hormones would counteract the degenerative influence on the sexual organs otherwise involved in such vitamin deficiency. Hodgson *et al.*[4] and Gunn *et al.*[13] (the former group used A-avitaminotic bulls, while the latter group used rams) found that the spermatogenesis was accelerated after administration of pregnant mare serum; however, Lindley *et al.*[7] in more comprehensive experiments with rams showed that supplies of pregnant mare serum failed to prevent the development of A-avitaminotic, testicular changes.

As early as in 1952 Fell and Mellanby[14] demonstrated in tissue cultures that high dosages of vitamin A might be responsible for a cellular A-hypervitaminosis and that consequently they might be considered to act directly on cells *in vitro*. Numerous experiments carried out by Fell[15] substantiated this finding, not merely in A-hypervitaminosis but also in A-hypovitaminosis.

Thus our findings show that the degenerative changes of the spermatogenetic tissue caused by A-avitaminosis are not indirectly provoked by changes—arising from the avitaminosis—in the hormonal regulation, but instead that they are of a direct nature. That is to say, they can be attributed to a disturbed function of the spermatogenetic tissue brought about by the vitamin A deficiency and thus can be counteracted by direct application of vitamin A alcohol or vitamin A aldehyde to the tissue, but not by application of vitamin A acid.

BIRTHE PALLUDAN

Department of Physiology,
Endocrinology and Blood-grouping,
The Royal Veterinary and Agricultural College,
Copenhagen, Denmark.

[1] Wolbach, S. B., and Howe, P. R., *J. Exp. Med.*, 42, 753 (1925).
[2] Gross, L., *J. Path. Bact.*, 27, 27 (1924).
[3] Wolbach, S. B., and Howe, P. R., *Arch. Path.*, 5, 239 (1928).
[4] Hodgson, R. E., Hall, S. R., Sweetman, W. J., Wiseman, H. G., and Converse, H. T., *J. Dairy Sci.*, 29, 669 (1946).
[5] Madsen, L. L., Hall, S. R., and Converse, H. T., *J. Nutrition*, 24, 13 (1942).
[6] Madsen, L. L., Eaton, O. N., Heemstra, L., Davis, R. E., Cabell, C. A., and Knapp, B., *J. Animal Sci.*, 7, 60 (1948).
[7] Lindley, C. E., Brugman, H. J., and Warwick, E. J., *J. Animal Sci.*, 8, 530 (1949).
[8] Palludan, B., *Acta Vet. Scand.*, 4, 136 (1963).
[9] Thompson, J. N., Howell, J. Mc., and Pitt, G. A. J., *Proc. Roy. Soc.*, B, 159 (2), 510 (1964).
[10] Mason, K. E., and Wolfe, J. M., *Anat. Rec.*, 45, 232 (1930).
[11] Van Os, P. M., *Acta Brev. Neerl. Physiol.*, 6, 151 (1936).
[12] Mayer, J., and Goddard, J. W., *Proc. Soc. Exp. Biol. and Med.*, 76, 149 (1951).
[13] Gunn, R. M., Sanders, R. W., and Granger, W., *C.S.I.R.O. Res. Bull.*, 146, 140 (1942).
[14] Fell, H. B., and Mellanby, E., *J. Phys.*, 116, 320 (1952).
[15] Fell, H. B., *Vitamins and Hormones*, 22, 81 (1964).

Pavcek-'45
Bib. No. 7078

J. Nutr. 30:1-9. 1945.

THE NUTRITIONAL VALUE OF TELANG LIVERS[1]

PAUL L. PAVCEK, EDWARD J. HERBST AND C. A. ELVEHJEM
Department of Biochemistry, College of Agriculture, University of Wisconsin, Madison

TWO FIGURES

(Received for publication January 24, 1945)

Telangiectasis in cattle livers has been noted since 1900 and has been the subject of various reports (Schote, '36, and Carta, '38). The abnormality is characterized by dark red or purplish depressed areas beneath the capsule of the liver which vary in size from a few millimeters to 15 mm. in diameter. On gross sections, the dark areas can be seen distributed through the entire liver, although in some cases only one lobe may be involved. The dark areas are soft and spongy and are usually engorged with blood.

It has been reported by Smith ('40) that nearly 3% of all beef livers inspected each year in the United States are condemned for telangiectasis. In the meat packing industry the common name of these livers is telang livers. Only a few suggestions as to the possible pathogenesis of the condition are available. Experiments at Kansas State College ('40) disclosed a high incidence of telang lesions in the livers from cattle fed high fat rations. Frederick ('43) pointed out that the incidence of telangiectasis tends to be greatest in steers which have been on highly concentrated fattening rations for extended periods of time.

The experiments to be reported in this paper were undertaken with the aim of establishing the nutritional value of these livers and possibly to cast some light on the pathogenesis of the condition. Feeding tests and certain chemical and vitamin analyses were made on representative samples of both normal and telang livers.

MINERAL AND PROXIMATE COMPOSITION

Twenty-six livers exhibiting severe telang lesions and thirty-three normal livers were selected for the analytical work. The fat content was determined by ethyl ether extraction of dried samples from each liver. The telang livers showed a range of 19.7 to 27.6% while the

[1] Published with the approval of the Director of the Wisconsin Agricultural Experiment Station. Supported in part by a grant from the National Live Stock and Meat Board.

Copyright, 1945
The Wistar Institute of Anatomy and Biology.
All rights reserved.

normal livers contained from 15.0 to 21.3% of fat. No significance is attached to these variations in fat content. The iron content of the telang livers ranged from 27.5 to 35.0 mg. and the normal livers from 21.0 to 24.0 mg. per 100 gm. of dry matter. The copper values for the telang livers showed a wider variation from 2.0 to 13.8 mg. per 100 gm. dry matter and were somewhat lower than those for the normal liver 7.0 to 16.0 mg. per 100 gm. The higher iron content of the telang livers may have been due to the blood held in the telangiectatic lesions.

VITAMIN CONTENT OF LIVERS

Carotene and vitamin A. In the same series of twenty-six telang livers, carotene values ranged from 0.2 to 2.15 mg. per 100 gm. of fresh material. The normal livers showed a comparable spread of 0.25 to 2.0 mg. per 100 gm. Of twenty-six telang livers assayed for preformed vitamin A (Davies, '33), eighteen of them had vitamin A values of 10 to 60 mg. per 100 gm. In contrast to this, only one of the thirty-three normal samples had an especially high content, 55 mg., and the majority of the samples contained less than 10 mg. per 100 gm. of fresh liver.

Ascorbic acid. Vitamin C determinations by the indophenol technique (Mindlin and Butler, '38) indicated that both normal and telang livers contained about the same concentration, i.e., 15 to 30 mg. per 100 gm. of fresh tissue.

Choline. Determination of this substance in the dried livers was made colorimetrically after precipitation of the choline as the reineckate. Values for both types of liver were in the narrow range of 1500 to 1600 mg. per 100 gm. of dried material.

Pantothenic acid. The microbiological method for assay showed telang and normal livers to contain from 14 to 18 mg. per 100 gm. on the dry weight basis.

Niacin. Microbiological assay for this factor demonstrated that both types of liver contained between 40 and 50 mg. per 100 gm. of dried liver.

Biotin. Assays for this compound were also made microbiologically. The one sample of dried telang liver tested had a biotin content of 0.34 mg. while a normal liver assayed at the same time contained 0.63 mg. per 100 gm. It is doubtful whether this variation has any significance.

FEEDING EXPERIMENTS WITH FRESH, NORMAL AND TELANG LIVER

Preliminary work on the selection of a suitable laboratory animal to study the growth promoting effect and possibly toxicity of telang liver as compared to normal beef liver, indicated that the rat was most de-

sirable. Dogs, cats, chicks and monkeys were also investigated as possible experimental animals.

These early studies revealed that rats could be maintained from weaning to maturity, without any deleterious effects, on rations consisting of fresh normal beef liver supplemented only with 50–100 mg. of calcium carbonate per day. However, it was observed that certain telang livers fed under identical conditions were quite toxic to weanling rats. Animals fed these livers failed to grow, developed severe paralysis of the front and hind quarters which very shortly progressed until the front legs were useless. This paralysis together with bone fractures was observed in 7 to 10 days and the animal usually died within 3 weeks unless the liver feeding was discontinued. These observations suggested that the telang liver contained a specific toxic substance, not present in normal beef liver. Preliminary results (Herbst et al., '44) indicated a relationship between the toxicity and the high vitamin A content. The following experiments were carried out to study this relationship further.

Weanling Sprague-Dawley male albino rats (40–50 gm.) were used to assay forty-eight different telang livers. The livers were obtained from the Oscar Mayer Co. of Madison and from Wilson and Co., Chicago. They were received in a frozen condition and immediately stored at 0°F. Large representative samples of each liver were ground and stored at all times under freezing conditions to prevent spoilage. The degree of telang lesion formation was recorded for each liver. If the lesions comprised about one-half the total liver area, the liver was graded "Very Extensive Lesions"; if the lesions were quite numerous but made up less than one-half of the liver area, the grade "Extensive Lesions" was applied; if the lesions were scattered and limited to only a small part of the total liver area, the liver was graded "Slightly Marked".

The ground liver was placed in the feed cups in the frozen condition. The excess was washed out of the cups on the following day and fresh frozen liver was again fed. Fifty to 100 mg. of calcium carbonate were added to the liver fed each rat to correct the undesirable Ca : P ratio (about 1 : 16) existing in beef liver. Two drops of halibut liver oil (diluted 1 : 5 with corn oil) were fed to each rat per week to insure an adequate intake of vitamin D.

Seventeen normal beef livers, obtained from a local butcher shop, were assayed for toxicity under conditions identical to those that existed during the telang liver assay.

The effect of the addition of 25 and 50% of fresh normal liver to toxic telang liver was studied. Equal portions of three normal livers, that had proved non-toxic in previous feeding experiments and of three toxic telang livers were ground together and thoroughly mixed. Mixtures of the same livers containing 25% of normal liver and 75% of toxic telang liver were prepared in a similar manner.

Each of the six mixtures was fed to weanling Sprague-Dawley male rats; three control rats received the undiluted toxic telang liver. Supplements of calcium carbonate and halibut liver oil were fed and in general the conditions that existed during the assay of the livers for toxicity were maintained.

RESULTS

The results of feeding the forty-eight telang livers, three of which were graded as "Very Extensive", twenty-six as "Extensive" and nineteen as "Slightly Marked", can be summarized as follows: The livers with the extensive or very extensive lesions usually showed toxicity and in a few cases designated as "Slightly Marked" also produced the typical paralysis.

Fig. 1 Weanling rat fed a toxic telang liver plus calcium carbonate ad libitum. The typical paralysis of the legs is evident.

The extreme brittleness of the leg bones appearing in the animals fed telang liver designated as toxic was the most constant symptom observed. Fractures, often multiple, occurred usually in the tibia of the rear legs and in the radii and ulnae of the forelegs. When fractures occurred in the bones of the forelegs, the legs became twisted and the animal would crawl about on the deformed limbs. Figure 1 shows

an animal typical of those which had been on the toxic telang liver diet for 7–10 days.

Growth failure always preceded the bone fragility. If the liver feeding was continued after the onset of the symptoms the animals died, usually within a week. Respiratory involvements were evident in those animals that succumbed to telang liver toxicity. The affected animals would breath laboriously and bloody discharges were often observed around the nostrils. Paralysis of the hind legs was quite common and enuresis occurred frequently.

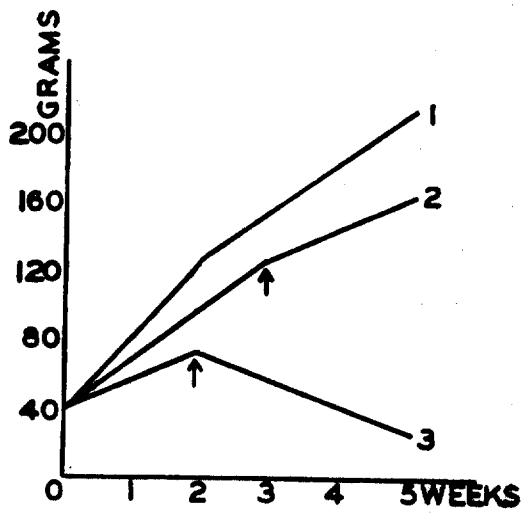

Fig. 2 Growth curves of male albino rats on fresh toxic telang-normal beef liver mixtures.
(1) Received equal portions of normal liver and toxic telang livers.
(2) Received 25% normal liver and 75% toxic telang liver.
(3) Received 100% toxic telang liver.
Arrows indicate time at which bone fractures occurred.

Post mortem examination of the animals revealed severely congested lungs indicating that death may have been due to pneumonia. The livers were unusually yellow but all other organs were normal. Since fatty livers were also observed in animals fed normal liver and non-toxic telang liver, this observation is not of great significance.

None of the seventeen normal livers assayed proved toxic to weanling rats. All animals fed calcium supplemented normal liver as the sole dietary grew extremely well and in no case were symptoms of bone fragility observed.

The results of one experiment in which mixtures of toxic telang liver and normal liver were fed to weanling rats are shown graphically in figure 2. Growth and toxicity data in two additional experiments were

quite similar to the results illustrated. Weanling rats were completely protected from the toxic effects of telang liver if their rations contained 50% of normal beef liver. The inclusion of 25% of normal liver did not afford complete protection. However, the onset of the symptoms of bone fragility was delayed and growth was considerably better than in the case of the animals fed 100% toxic liver.

VITAMIN A TOXICITY EXPERIMENTS

The literature contains frequent reports of the toxicity of large dosages of vitamin A to laboratory animals and humans. These studies have recently been reviewed by Josephs ('44).

An almost constant feature of hypervitaminosis A in rats is the development of multiple spontaneous fractures of the bones of the extremities. The close similarity of these symptoms to those observed in rats fed toxic telang liver suggested that excessively high stores of vitamin A might be present in certain of the abnormal livers.

The studies referred to above on the comparative vitamin A content which to date have involved over 100 samples of telang and normal beef liver, disclosed that the abnormal livers were consistently higher in vitamin A potency. It was impossible to establish a correlation between animal toxicity and the vitamin A storage in every liver studied since toxicity data were not available for all the samples assayed.

To illustrate the correlation which existed between the toxicity of certain samples of telang liver and their content of vitamin A, several livers of varying vitamin A content were fed to weanling rats. Total vitamin A intakes of the rats were calculated from the vitamin A potency of the liver and the amount ingested per rat per day. Data on six telang livers, two of which were toxic and four non-toxic, are summarized in table 1.

TABLE 1

Summary of vitamin A content and toxicity of telang livers.

DESCRIPTION OF RATION [1]	VITAMIN A CONTENT OF LIVER	INTAKE OF VITAMIN A PER RAT PER DAY [2]	DAYS REQUIRED TO PRODUCE BONE FRACTURES	GROWTH OF RATS
	I.U./100 gm.	*I.U.*		*gm./week*
Telang liver, no. 43	121,000	22,990	7	0
Telang liver, no. 44	132,000	25,080	7	0
Telang liver, no. 45	68,400	12,996	No fractures	15
Telang liver, no. 46	50,800	9,652	No fractures	20
Telang liver, no. 47	45,200	8,588	No fractures	29
Telang liver, no. 48	59,000	11,210	No fractures	26

[1] Each rat received a daily supplement of 50–100 mg. of calcium carbonate.
[2] Daily intake of vitamin A calculated from food consumption data.

As further demonstration that the toxic symptoms manifested by bone fracturing were related to the high intake of vitamin A, halibut liver oil [2] and also crystalline vitamin A alcohol [3] were fed as supple-

TABLE 2

The toxicity of crystalline vitamin A and haliver oil supplements to weanling rats.

DESCRIPTION OF RATION [1]	TOTAL INTAKE OF VITAMIN A/ RAT/DAY [2]	DAYS REQUIRED TO PRODUCE BONE FRACTURES			GROWTH OF RATS IN GM./WEEK		
	I.U.	Rat number			Rat number		
		1	2	3	1	2	3
1. Fresh telang liver, no. 47 plus 5 drops corn oil	8,588				31	39	13
2. Fresh telang liver, no. 47 plus 10 drops corn oil	8,588				31	33	33
3. Fresh telang liver, no. 47 plus 10,000 I.U. of crystalline vitamin A	18,588	11	14	11	8	14	2
4. Fresh telang liver, no. 47 plus 10,000 I.U. of vitamin A as haliver oil	18,588	11	11	7	5	3	17
5. Fresh telang liver, no. 47 plus 20,000 I.U. of crystalline vitamin A	28,588	7	8	3	2	— 4	2
6. Fresh telang liver, no. 47 plus 20,000 I.U. of vitamin A as haliver oil	28,588	7	7	6	1	— 17	— 13
7. Steenbock stock ration plus 20,000 I.U. of crystalline vitamin A	20,000	11		8	3	23	3
8. Steenbock stock ration plus 20,000 I.U. of vitamin A as haliver oil	20,000		7	12	24	15	0

[1] Supplements of corn oil and vitamin A to liver and stock rations are in terms of daily intake per rat.

All animals fed liver rations received daily a supplement of 50,000 mg. of calcium carbonate. Vitamin A supplied by rations plus supplement.

ments to rats in doses reported to be toxic by Josephs ('44). These supplements were fed at levels calculated to furnish 10,000 and 20,000 I.U. of vitamin A in addition to the amount furnished by the basal diet of fresh telang liver. The sample of liver chosen for the basal diet was

[2] Supplied by Abbott Laboratories, North Chicago, Ill. The oil contained [illegible] I.U. of vitamin A per gram.

[3] Obtained from Distillation Products, Inc., Rochester, N. Y.

sample number 48 which previous assay (table 1) had indicated to be non-toxic. The high vitamin A supplements were also fed in conjunction with a natural ration (Steenbock Stock Ration). Three animals in each group were used to establish the toxicity or lack of toxicity of the supplemented ration. The results of this series of experiments are given in table 2.

These data reveal that the toxicity of a liver and its vitamin A content are closely related. Furthermore, the amount of the vitamin ingested by rats which succumbed to the paralysis was in excess of the toxic dosage of 15,000 I.U. per day reported by Josephs ('44).

The results of the experiments with crystalline vitamin A alcohol and halibut liver oil supplements, summarized in table 2, have definitely identified the telang liver toxicity as a hypervitaminosis A.

The toxic effects of vitamin A supplements and of telang liver were identical. Bone fractures were observed in sixteen of the eighteen animals fed vitamin A supplements approximately equivalent to the intake of the vitamin by weanling rats on toxic telang liver rations. The two animals that failed to show symptoms of bone brittleness resisted the feeding of vitamin A supplements and did not always take the entire dose. All the constant symptoms observed in rats fed telang liver (growth failure, respiratory involvements, etc.) were reproduced in the animals receiving toxic doses of vitamin A.

DISCUSSION

It is clear from the results reported in this paper that the toxic effects resulting from the ingestion of very high amounts of telang liver are due to the accumulation of extra amounts of vitamin A in these livers. At present it is impossible to decide whether the telang liver lesions are the result of the abnormal storage of vitamin A or the increased storage is related to a disturbance in the structure of the liver due to other causes. The high vitamin A content makes the telang liver more valuable from a strictly nutritional point of view since a level high enough to produce hypervitaminosis A would never be used in ordinary rations.

The toxic dosage of vitamin A for growing rats which we have set at approximately 20,000 I.U. per day agrees favorably with the work reported by Rodahl and Moore ('43) and Josephs ('44).

SUMMARY

Telang and normal livers were quite similar in their content of carotene, ascorbic acid, choline, pantothenic acid, niacin, biotin and of

fat. The iron content of the telang livers was about 50% higher than observed in normal livers. The copper content of the two types of liver showed wider fluctuations but were of the same order.

About 20% of fresh telang livers tested were toxic to weanling rats receiving the calcium supplemented liver as their sole dietary. The symptoms observed in the affected rats were growth failure, paralysis and multiple spontaneous fractures of the bones of the extremities.

The toxicity of certain telang livers was due to their abnormally high stores of vitamin A. When these livers supplemented only with calcium carbonate were fed to rats, the daily intake of the vitamin was in excess of the toxic dosage of 15,000 I.U. per day. Equivalent amounts of crystalline vitamin A alcohol or of vitamin A supplied by halibut liver oil produced identical symptoms of toxicity when fed to weanling rats.

LITERATURE CITED

CARTA, A. 1938 Indagini sulle macchie teleangectasiche del tegato dei bovini. Profilassi, vol. 11, pp. 43–53.

DAVIES, W. A. 1933 The colorimetric determination of vitamin A by the alkali digestion method. Biochem. J., vol. 27, p. 1770.

FREDERICK, L. D. 1943 The economic and nutritional importance of bovine hepatic disturbances. J. Am. Vet. Med. Assn., vol. 52, p. 338.

HERBST, E. J., P. L. PAVCEK AND C. A. ELVEHJEM 1944 Telang liver and vitamin A toxicity. Science, vol. 100, p. 338.

JOSEPHS, H. W. 1944 Hypervitaminosis A and carotenemia. Am. J. Dis. Child., vol. 67, p. 33.

KANSAS STATE COLLEGE EXPERIMENT STATION 1940 Color in beef studies.

MINDLIN, R. L., AND A. M. BUTLER 1938 The determination of ascorbic acid in plasma. A macromethod and micromethod. J. Biol. Chem., vol. 122, p. 673.

RODAHL, K., AND T. MOORE 1943 The vitamin A content and toxicity of bear and seal liver. Biochem. J., vol. 37, p. 166.

SCHOTE, F. 1936 Beiträge zur Pathogenese der Telaeangiecktasie der Rinderleber. Inaug. Diss. Friedrich-Wilhelms U. of Berlin.

SMITH, H. R. 1940 Beef liver condemnations. Proc. 23rd ann. meeting Am. Soc. Animal Prod., p. 272.

Pinkus-'64
Bib. No. 7238

J. Invest. Derm. 42:131-136. 1964.

BIOMETRIC ANALYSIS OF THE EFFECT OF ORAL VITAMIN A ON HUMAN EPIDERMIS*

HERMANN PINKUS, M.D. AND ROSIE HUNTER

In a previous paper Hunter and Pinkus (1) reported that the oral administration of 150,000 units of vitamin A daily for one month decreased epidermal keratin cell counts in all of ten healthy volunteers. The question of the biologic mechanism that brought about this decrease is the subject of the present paper.

MATERIAL AND METHODS

Ten healthy adults (7 male and 3 female) ranging in age from 25 to 40 years volunteered for the study. The keratin layer was stripped off an area approximately 6 × 1.25 cm on the flexor surface of one forearm by repeated application of Scotch Tape® until a dry glistening surface was obtained. The stripped-off material was saved for counting horny cells as reported (1). Under local procaine anesthesia, 2 mm punch biopsy specimens were removed from the stripped area 24, 48, 72, and 96 hours later (Series 1), and a control specimen was taken from normal skin at least 2 cm distant to avoid spill-over of mitotic activation (2). The subjects then took one buccal dose† of vitamin A, 150,000 units daily for 30 days. A similar area was stripped on the other forearm at the end of this period, and control and 24, 48, 72 and 96 hour biopsy specimens were taken (Series 2). A final strip and third series of specimens were taken at the end of another month during which no vitamin A was taken.

The specimens were fixed immediately in Bouin's-alcohol and embedded in paraffin. Cells were counted in serial sections cut at 8μ and counts corrected according to Abercrombie's formula as described by Pinkus (3). The number of resting and dividing nuclei was determined for one square millimeter. The number of horny cells per square centimeter was taken from published data (1) and divided by 100.

RESULTS

The experiment had two parts and two purposes.

A. Control biopsy specimens of each of the three series combined with counts of stripped-off horny (keratin) cells furnished information on possible effects of vitamin A on skin in its normal, "static" condition.

B. Specimens taken after stripping measured the ability of the epidermis to restore the lost keratin layer under the influence of vitamin A.

Table 1 lists corrected cell counts of one representative case.‡ All other data have been summarized in graphs in which the values of the control specimen of Series 1 are set at 100%. This was done to eliminate considerable variations of initial numbers of cells between individuals (Table 2). Because of this great variability of individual values, no statistical analysis was attempted. It may be mentioned that cell counts done by one experienced observer are reproducible with ±10% accuracy. Larger deviations may be considered significant.

A. *Effect of vitamin A on number of epidermal cells.*

Figures 1–8 represent percentage changes in the number of various classes of cells in the epidermis. As was shown in the preceding paper, the number of stripped-off horny cells (Fig. 1) was decreased in all 10 cases in Series 2 after one month of vitamin A, reversed the trend in Series 3, taken one month after vitamin A had been discontinued, in 7 cases and exceeded initial values in 4 subjects. It is seen in Fig. 2 that in contrast the number of all nucleated elements, including basal cells, prickle cells, granular cells, and often a few parakeratotic cells, was increased in 9 of the 10 cases in Series 2. The trend was reversed in 7 of these 9 subjects in Series 3, but remained above initial values in 6. The 10th subject (Case 6) showed a smaller number of nucleated cells in Series 2 and remained below the control value in Series 3. There was no apparent explanation except that his initial cell count had been unusually high and actually exceeded values found in some of the other subjects in Series 2.

By adding the figures for stripped-off horny

* From the Department of Dermatology, Wayne State University, College of Medicine, and the Detroit Receiving Hospital, Detroit, Michigan.
Supported in part by grants from the U. S. Public Health Service through the National Institutes of Health.
† Vi-Dome-A Oral Tabs® were supplied by Vitamins Chemicals Inc., N.Y.C.
Received for publication June 24, 1963.

‡ Complete data may be obtained from the authors on request.

TABLE 1

Corrected cell counts of Case 3 per square millimeter

Phase of Experiment	Time after Stripping	Basal Cell Nuclei	Prickle Cell Nuclei	All Intermitotic Nuclei	Keratohyalin Nuclei	Parakeratotic Nuclei	All Post-mitotic Nuclei	All Nuclei	All Mitoses	% of Intermitoses
Initial, Series 1	Control	15,000	34,300	49,300	5,100	100	5,200	54,500	20	0.041
	24 hrs	11,700	24,100	35,800	6,300	16,400	22,700	58,500	120	0.34
	48 hrs	13,200	32,900	46,100	13,600	14,200	27,800	73,900	1,600	3.47
	72 hrs	18,400	52,400	70,800	14,300	13,600	27,900	98,700	1,575	2.2
	96 hrs	13,400	29,900	43,300	9,900	16,400	26,300	79,600	178	0.41
One month, Series 2	Control	23,800	51,300	75,100	4,400	200	4,600	79,700	133	0.18
	24 hrs	14,100	33,600	47,700	6,100	6,400	12,500	60,200	0	0.00
	48 hrs	12,600	30,400	43,000	17,600	9,400	27,600	70,000	891	2.07
	72 hrs	13,900	34,000	47,900	9,300	4,500	13,800	61,700	280	0.59
	96 hrs	16,800	42,800	69,600	13,200	8,400	21,600	91,200	120	0.17
Two months, Series 3	Control	16,000	43,700	59,700	7,000	300	7,300	67,000	29	0.04
	24 hrs	15,000	37,400	52,400	5,900	8,100	14,000	66,400	50	0.08
	48 hrs	14,900	28,900	43,800	22,100	23,600	45,700	89,500	2,171	4.9
	72 hrs	15,300	41,700	57,000	14,600	26,300	40,900	97,900	444	0.77
	96 hrs	12,900	29,400	42,300	10,800	30,700	41,500	83,800	422	0.99

cells per square mm to the sums of all nucleated cells counted in sections, an approximate value is obtained for all cells per square mm of skin surface. Fig 3 shows that these values fluctuate less, are close to initial figures in 4 cases, definitely higher in 5, and lower only in the exceptional case 6. The generally higher counts in Series 2 are due to the fact that the number of prickle cells which account for the main mass of the epidermis is elevated in 9 cases (Fig. 6). Basal cells (Fig. 5) and post-mitotic cells (granular plus parakeratotic cells, Fig. 8) are more numerous in 7 cases. Most cell counts show a tendency to return closer to initial values at the end of the second month (Series 3), except the granular cells which are widely scattered and mostly elevated.

B. Effect of vitamin A on forced regeneration after stripping.

Stripping-off the keratin layer produces a predictable mitotic burst in normal human epidermis as shown by us (2, 3) and others (4). Highest mitotic counts usually are found 48–72 hours after stripping and may reach 4–5% of intermitotic (basal and prickle) cells. Cell division usually takes place in the basal layer and the one immediately above (suprabasal). In this series of experiments, peak mitotic counts of 3% or more were encountered initially in 8 cases (Fig. 9). The remaining 2 showed peaks of

TABLE 2

Cell counts (per square mm) in control specimens before vitamin A (Series 1)

Case Number	Basal Cells*	Prickle Cells*	All Post-mitotics*	All Nucleated Cells*	Keratin Cells†
1	14,800	35,300	7,000	57,100	17,200
2	15,300	26,600	8,000	49,900	14,000
3	15,000	34,300	5,200	54,500	13,600
4	16,500	33,800	11,300	61,600	13,300
5	14,900	30,300	6,000	51,200	11,600
6	18,800	41,700	6,900	67,400	11,200
7	16,800	34,100	9,800	60,700	10,900
8	17,400	32,900	8,400	58,700	10,900
9	18,100	33,000	6,900	58,000	10,600
10	12,800	29,300	8,900	51,000	8,600

* Counted in paraffin sections.

† Counted in tape strips.

only 1 and 1.5%, and one of these, a 38 year old female subject, had even lower counts in Series 2 and 3 without deviating from the average in other respects.

Peak mitotic counts were lower in Series 2 in 7 subjects, higher in 3. This trend reversed itself in Series 3 in 6 (3 up, 3 down) and was farther down in 4. Because of the possibility that the mitotic effort may have been lower at any one time, but more prolonged after vitamin

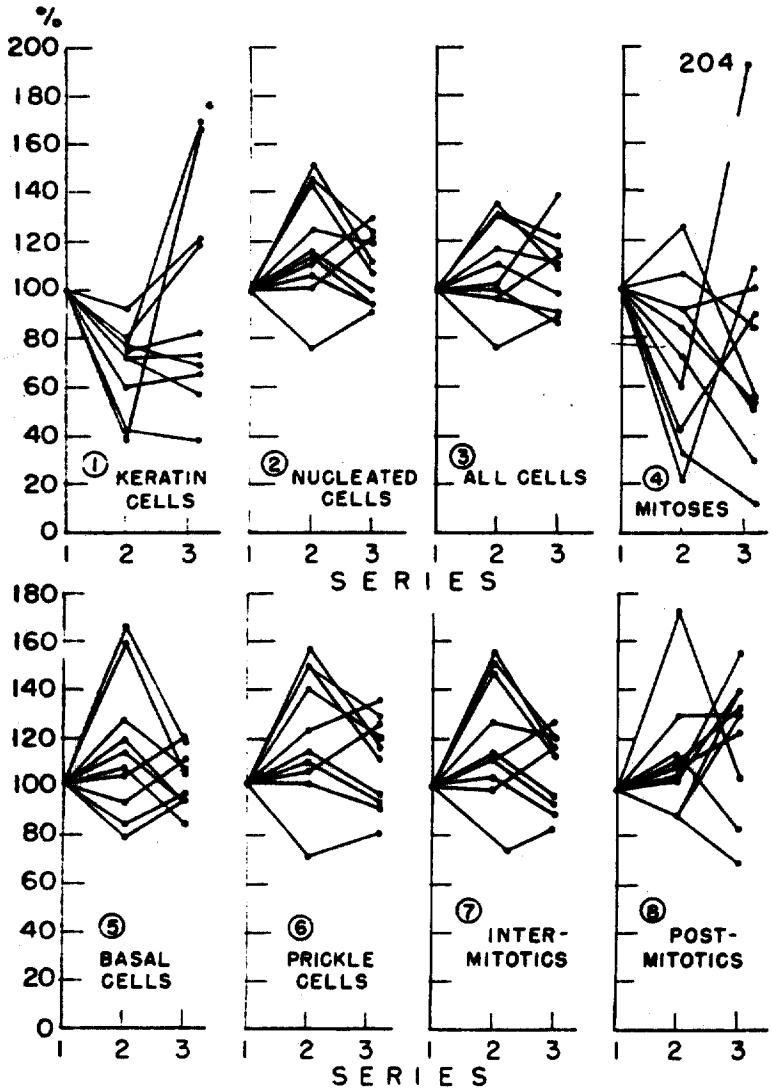

FIGS. 1–8. Percentage changes of cell counts in the three phases of the experiment. All initial values (Series 1) given as 100% norm. Series 2 shows values in the control specimens taken after one month on vitamin A. Series 3 shows values at the end of the second month, 30 days after vitamin A was discontinued. Horny cells were counted in strips, nucleated cells in paraffin sections.

A, the sum of all mitoses seen in the 5 specimens of each series was obtained. This did not change the overall result as evidenced by the fact that 7 subjects had lower total counts and 3 had higher values in Series 2. Mitotic peaks were lower in Series 3 than in Series 1 in 7 subjects, total counts also lower in 7 subjects.

DISCUSSION

From the rather bewildering diversity of individual responses, three facts stand out as probably having some significance.

1) After one month of a daily dose of 150,000 units of vitamin A, the number of horny cells that could be stripped from a given area was decreased in all 10 subjects.

2) The number of nucleated cells in a similar area was increased in 9 of the 10.

3) The mitotic response to stripping was decreased in 7, definitely higher in only 1 subject of the 10.

It must be emphasized in discussing these results that we are not concerned with statistical

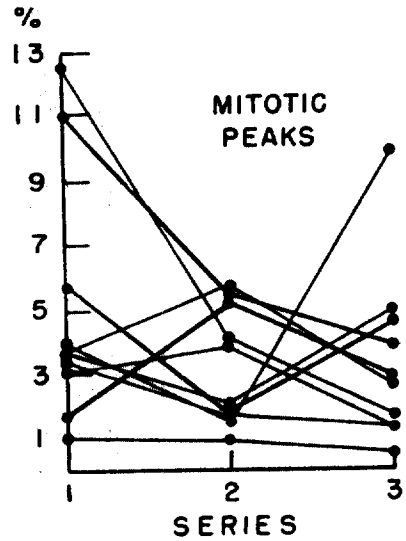

FIG. 9. Peak mitotic counts expressed as per cent of intermitotic (basal plus prickle) cells in Series 1, 2 and 3.

significance, but are content to point out trends. It seems then that there is no overall decrease of cells in the epidermis, rather a shift from fully keratinized cells to less mature forms in the majority of cases. Basal cells, prickle cells, and granular cells have a tendency to increase in percentage under the influence of vitamin A, although this trend is not consistent. The data seem to support the often voiced view that vitamin A has an "antikeratinizing" effect and suggest that this is achieved by cells remaining immature longer. Total cell counts remained the same or were somewhat higher. Thus, there is no evidence that vitamin A in the doses and during the time of our experiment led to general epidermal atrophy. Visual examination of representative control sections of the three series show that the epidermal cells look somewhat larger and more succulent in Series 2 (Fig. 10 A-C.)

Another point that is obvious in sections of most 24 hour specimens of Series 2 is the somewhat less complete denudation of the surface. This observation is at once disturbing and revealing. When epidermis is stripped with Scotch Tape® in our laboratory, there is an end point at which the denuded surface appears somewhat reddened and glistening, but dry. Experience has shown us that from this point on, repeated applications produce very few additional cells, that stripping comes to a natural end. The most likely reason is that the more cohesive and somewhat moister granular cells do not adhere to the pressure sensitive tape. Our experience in this respect differs from that of some other authors who have stated that they can strip off living epidermis and produce a moist and even bleeding surface with the tape they have used. While we do not question these results, we state that stripping with the ordinary brand of Scotch Tape® in our hands leads to a rather sharp end point in gross clinical observation. It seems, however, that histologically this end point changes slightly under the influence of vitamin A. It may be that the youngest (lowest) horny cells are more cohesive and perhaps more moist, or it may be that in the first 24 hours after stripping, new keratin cells are quickly produced by the hypertrophic granular layer. The latter possibility is less likely as no definite decrease and often an increase of granular cells was observed between the control and the 24 hour specimens.

In any case, since the entire number of horny cells is not more than 15–20% of the total number of epidermal cells in any of our subjects, the few cells left on the skin surface in Series 2 (and therefore not counted) do not materially influence our conclusions concerning the number of cells.

The next point for discussion is the restitution of the keratin layer after stripping and the mitotic effort that is responsible for it. Neither microscopic examination nor differential cell counts suggested any impairment of the ability of the epidermis to keratinize. On the other hand, the mitotic effort seemed to be somewhat less vigorous under the influence of vitamin A. This does not imply changes in the normal turnover of the epidermal cells. This process is slow and our counts did not reflect any changes. However, under the conditions of forced regeneration after stripping, the majority of subjects exhibited lower mitotic peaks and lower total number of mitoses.

It is known, especially through the work of Bullough (5) that lifespan of keratinocytes and mitotic activity are reciprocally connected. Not only does increased mitosis lead to faster exfoliation (shorter lifespan), but factors leading to decreased exfoliation inhibit mitosis. It is tempting to assume that the retarded maturation of keratinocytes that is suggested by our figures is

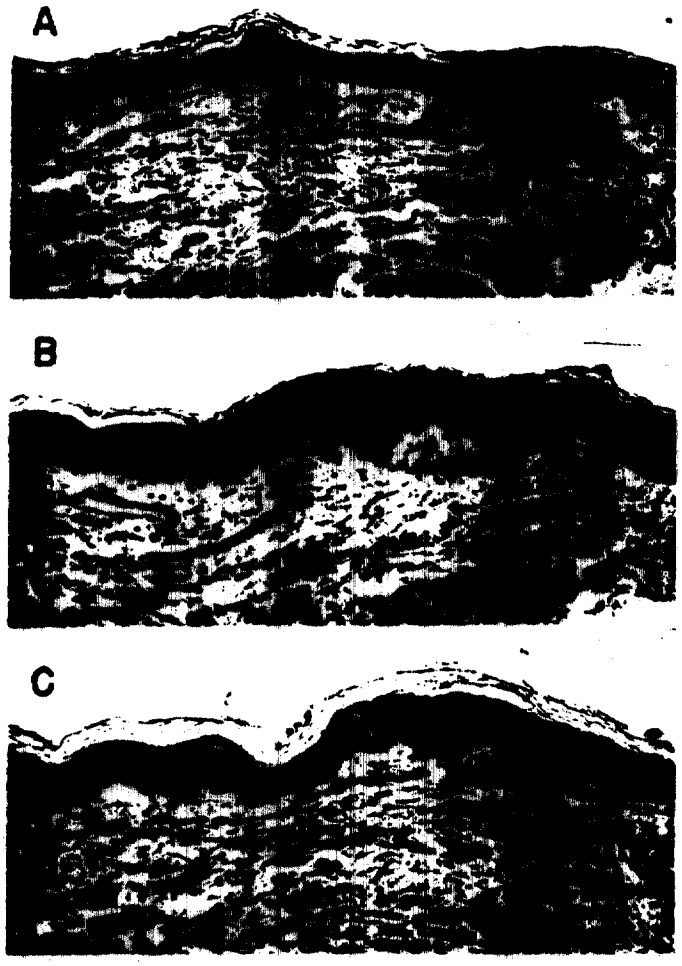

FIG. 10. Control sections of series 1, 2 and 3 of Case 9, stained with H & E, 90 ×. A: Initial stage before vitamin A. B: After one month of vitamin A. C: One month after discontinuing vitamin A.

responsible for the decrease of regenerative activity. However, Pinkus showed in his first experiments (3) that the force of regeneration is directly proportional to the completeness of denudation. It is possible therefore that the somewhat less complete stripping in Series 2 is responsible for the lessened mitotic vigor, and that this is not due to a direct metabolic effect of vitamin A.

SUMMARY

Daily administration of 150,000 units of vitamin A for one month in the form of buccal tablets to 10 adult volunteers produced the following effects on the epidermis:

1) The number of horny cells that could be stripped off a unit area by pressure-sensitive tape was decreased in all ten subjects.

2) The number of nucleated cells per unit area of skin surface was increased in nine subjects.

3) Total number of cells (nucleated plus non-nucleated) was moderately increased in six subjects.

4) Mitotic effort after denudation by tape stripping was somewhat less vigorous in seven subjects and slightly elevated in three. It seems possible that the decrease is due to less complete stripping of vitamin A-influenced skin rather than to a direct metabolic effect.

5) Vitamin A in the doses administered appears to have a retarding effect on the maturation of human keratinocytes.

REFERENCES

1. HUNTER, R. AND PINKUS, H.: The effect of oral vitamin A on the number of keratin cells of human epidermis. J. Invest. Derm., 37: 459, 1961.
2. WILLIAMS, M. G. AND HUNTER, R.: Studies on epidermal regeneration by means of the strip method. J. Invest. Derm., 29: 407, 1957.
3. PINKUS, H.: Examination of the epidermis by the strip method, II. Biometric data on regeneration of the human epidermis. J. Invest. Derm., 19: 431, 1952.
4. LOBITZ, W. C. AND HOLYOKE, J. B.: The histochemical response of the human epidermis to controlled injury: glycogen. J. Invest. Derm., 22: 189, 1954.
5. PINKUS, H.: Biology of epidermal cells. In Rothman, S.: Physiology and Biochemistry of the Skin, Chicago, University of Chicago Press, 1954.

Poole-'58
Bib. No. 7301

Quart. J. Exptl. Physiol. 43:427-437. 1958.

Reproduced by permission
of the copyright owner

THE EFFECT OF HYPERVITAMINOSIS A ON BLOOD COAGULATION IN THE RAT.

By J. C. F. Poole.* From the Sir William Dunn School of Pathology, Oxford.

(*Received for publication 8th July* 1958)

Rats fed vitamin A in doses of 40,000 i.u. daily develop a coagulation defect after about 10 days. The same result is produced by synthetic vitamin A as by naturally occurring vitamin A in a fish-oil concentrate. The thrombin generation test is a more sensitive indicator of the coagulation defect than either the calcium time or the one-stage prothrombin time.

The development of this defect can be prevented by the simultaneous administration of vitamin K_1 or menaphthone provided that treatment is continued for long enough. The nature of the defect, appears, however, to be different from that induced by dicoumarol poisoning.

The appearance of defective coagulation is accompanied by a striking localization of sudanophil material in the liver in the Kupffer cells: this change is not prevented by vitamin K_1 or menaphthone. Several other manifestations of hypervitaminosis A are also unaffected by vitamin K_1 or menaphthone.

Harris and Moore [1928] showed that overdosage with vitamin A led, among other things, to a hæmorrhagic condition. Rodahl and Moore [1943] demonstrated that the hæmorrhagic illness in man caused by eating polar bear or seal liver could be accounted for by the very high concentrations of vitamin A which they found in the livers of these animals; they produced a hæmorrhagic disease in rats by feeding polar bear liver. Light, Alscher and Frey [1944] measured the one-stage prothrombin time [Quick, 1935; Campbell *et al.*, 1941] in rats fed vitamin A in excess and showed that it was prolonged; the prolongation could be prevented by giving vitamin K_1 (2-methyl-3-phytyl-1:4-naphthoquinone) at the same time. The findings of Light *et al.* were confirmed and extended by Walker, Eylenberg and Moore [1947] who found that menaphthone (2-methyl-1:4-naphthoquinone) acted similarly to vitamin K_1 in preventing the development of a prolonged one-stage prothrombin time after excessive vitamin A feeding. These findings suggested that the concentration of some clotting factor might be controlled by the action of two of the fat-soluble vitamins. In view of current interest in the effects of fat feeding on blood coagulation, a re-investigation of the effects on coagulation of hypervitaminosis A seemed desirable.

Methods

Animals.—Experiments were carried out on Wistar strain albino rats, of either sex, bred in this laboratory. In all, 104 animals were used. Weights ranged from 200–350 g.

* Locke Research Fellow of the Royal Society.

Diet and Administration of Vitamin Preparations.—The rats were given a stock diet and water *ad libitum* during the course of the experiments. Vitamin A was given as liquor vitaminæ A concentratus B.P., which is a fish-oil concentrate and contains approximately 40,000 i.u./ml. in a vegetable oil, or as synthetic vitamin A palmitate dissolved in olive oil in equivalent concentration. The rats receiving vitamin A were given 1 ml. of one of these preparations daily by stomach tube under light ether anæsthesia. This method allows the natural route of absorption with precise control of the dose. Control animals were given 1 ml. olive oil daily in the same way. Vitamin K_1 (Mephyton, Merck) and Menaphthone (Synkavit, Roche) were diluted with normal saline to give 65 μg. and 25 μg. respectively in 0·2 ml., which amount was given daily by subcutaneous injection.

Collection of Blood.—Blood was obtained by cannulation of the aorta using the method of French [1955] and mixed with 3·8 per cent trisodium citrate solution in the proportion of 9 parts of blood to 1 part of citrate solution. In each case the first 4·5 ml. of blood obtained was run directly into the citrate. Plasma was collected after centrifuging the citrated blood at 4000 r.p.m. for 20 min.

Clotting Tests.—(1) Calcium time. A mixture of 0·1 ml. plasma + 0·1 ml. 0·85 per cent sodium chloride solution was recalcified with 0·1 ml. of 0·025 M calcium chloride solution and the clotting time was recorded. (2) One-stage prothrombin time. A mixture of 0·1 ml. plasma + 0·1 ml. brain extract was recalcified with 0·1 ml. 0·025 M calcium chloride solution and the clotting time was recorded. The brain extract was prepared as follows. The brains of thirty normal rats were freed from meninges and vessels and ground up in acetone with a pestle and mortar. The residue was collected in a Buchner filter and the acetone extraction repeated three times. It was then dried on filter paper at 37° C. in an incubator and stored at room temperature; 200 mg. of this residue was extracted with 4 ml. of 0·85 per cent sodium chloride solution at 37° C.; the saline suspension was allowed to stand for 30 min. and the opalescent supernatant liquid pipetted off and used for the tests. (3) Thrombin generation test [based on the methods of Macfarlane and Biggs, 1953; and Pitney and Dacie, 1953]. A mixture of 0·5 ml. plasma + 0·5 ml. 0·85 per cent sodium chloride solution was recalcified with 0·5 ml. 0·025 M calcium chloride solution. At 1-min. intervals up to 10 min. after adding the calcium chloride, 0·1 ml. of this mixture was added to 0·4 ml. of a 1 in 1000 solution of fibrinogen. The clotting times of the fibrinogen samples were determined: graphs were drawn in which the time after recalcification was plotted against the reciprocal of the fibrinogen clotting time (which is approximately proportional to the concentration of thrombin). The thrombin generation test was the principal test used in this investigation and it was necessary to find some way of reducing the mass of data collected to manageable proportions. Inspection of the results suggested that the area enclosed by the curve was the most important parameter of the thrombin generation curves as far as changes revealed in this study are concerned. Therefore most of the results of thrombin generation tests are reported as a quantity which it is proposed to call the cumulative thrombin production, this being defined as $\sum_{t=0}^{t=10} \frac{1}{F}\delta t$, where F is the fibrinogen clotting time in seconds and t is the time after recalcification in minutes. (4) Two-stage prothrombin time. A mixture of 0·5 ml. plasma + 0·5 ml. brain extract (prepared as described above) was recalcified with 0·5 ml. 0·025 M calcium chloride solution. At 1-min. intervals up to 6 min. after adding the calcium chloride solution, 0·1 ml. samples of this mixture were added to 0·4 ml. of 1 in 1000 fibrinogen solution, and the clotting times of the fibrinogen samples were determined.

Histological Preparations.—Sections of liver, spleen and retrosternal lymph nodes were examined. The material was fixed in formalin and frozen sections were stained by Harris' hæmatoxylin and Herxheimer's Sudan IV.

Results

The Effects of Hypervitaminosis A on the Calcium Time, the One-stage Prothrombin Time and the Thrombin Generation Test

The results of typical clotting tests on two pairs of rats are shown in fig. 1. In each case, a rat which had received vitamin A was compared with one which had received olive oil for the same period. The duration of treatment

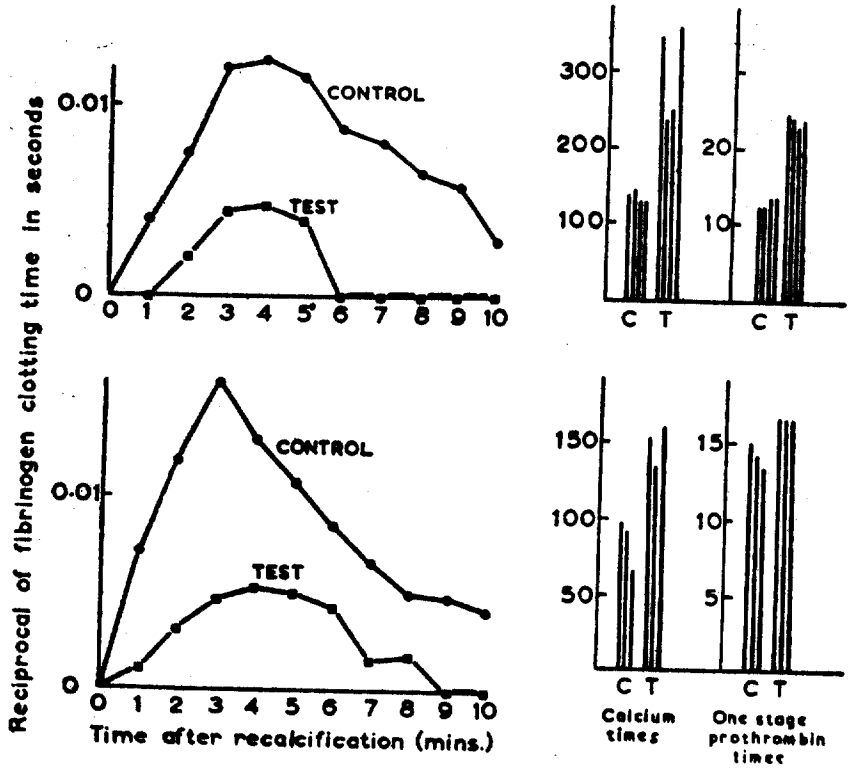

Fig. 1.—Thrombin generation tests, calcium times and one-stage prothrombin times for two pairs of rats. In each, the control rat (C) had received 1 ml. olive oil daily and the test rat (T) 1 ml. liquor vitaminæ A conc. B.P. daily. Three or four replicate determinations of the calcium time and one-stage prothrombin time are recorded for each animal, the columns representing individual determinations.

was from 11–14 days. It is seen that all three tests demonstrated a coagulation defect in the rats given excess vitamin A, but that the thrombin generation test was the most sensitive indication of abnormality. Indeed, when the extreme ranges of the values obtained in the thrombin generation test for five pairs of control and test animals are plotted on the same graph (fig. 2) there is practically no overlap. For most of the remaining animals used in this study, only the thrombin generation test will be reported.

The Effect of Olive Oil Feeding on the Thrombin Generation Test

Control animals used in this investigation were given 1 ml. of olive oil daily. This was done because the vitamin A preparation used was dissolved in a vegetable oil and was given in doses of 1 ml. daily. To justify this control procedure it was necessary to examine what effects, if any, such olive oil feeding has on the thrombin generation test. The cumulative thrombin production in rats fed olive oil for periods of from 1 to 31 days showed no tendency to increase or decrease significantly during this period of time. In

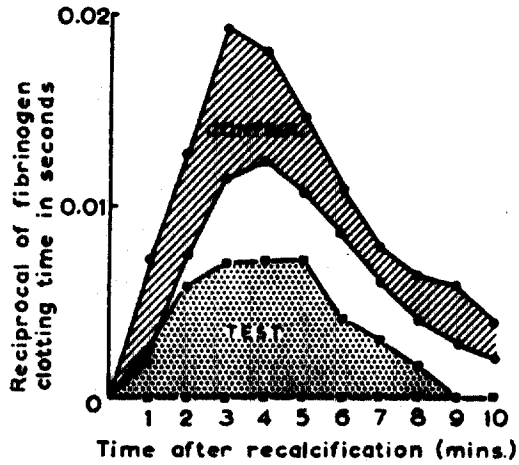

FIG. 2.—The extreme ranges of the results of thrombin generation tests carried out on five pairs of rats.

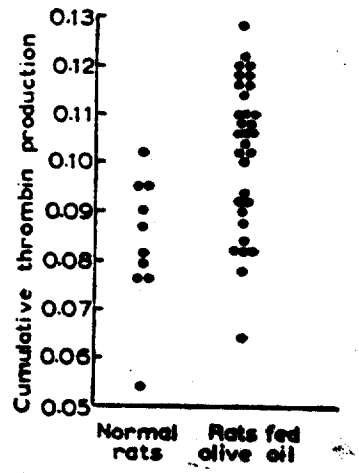

FIG. 3.—Cumulative thrombin production values for normal rats compared with rats fed olive oil.

fig. 3 these cumulative thrombin production figures are compared with those for ten normal rats (*i.e.* rats fed the stock laboratory diet without any supplement). The mean value for the rats fed oil is 21 per cent higher than that for the normal rats, but there is considerable overlap and the difference is in any case small compared with the difference demonstrable after vitamin A feeding. Indeed it seems likely that the results would have been closely similar if normal rats had been used as control animals.

The Extent of the Clotting Defect produced by Vitamin A in relation to Duration of Treatment

Fig. 4 shows cumulative thrombin production figures for thirty-two rats given vitamin A (as liquor vitaminæ A concentratus B.P.) and killed at periods ranging from 1 to 31 days after starting treatment. All the rats which had had vitamin A for more than 10 days showed substantially defective thrombin production and so did one rat treated for 7 days, but the other seven rats which had been treated for less than 10 days showed figures within the normal range (*cf.* fig. 3). Each rat treated with vitamin A was killed at the same

time as a control rat fed olive oil for the same period, so it is possible to express the same results in a different way, namely, as percentages of the control value. This has been done but the elimination of certain technical errors which can be achieved in this way did not significantly reduce the overall variability of the results. It seems likely, therefore, that there is a considerable variation in the response of individual animals to the same dosage of vitamin A. Because of this variation, it is impossible to decide, on the basis of these results, whether or not there is a further progressive change in coagulability of the blood after the defect has become established.

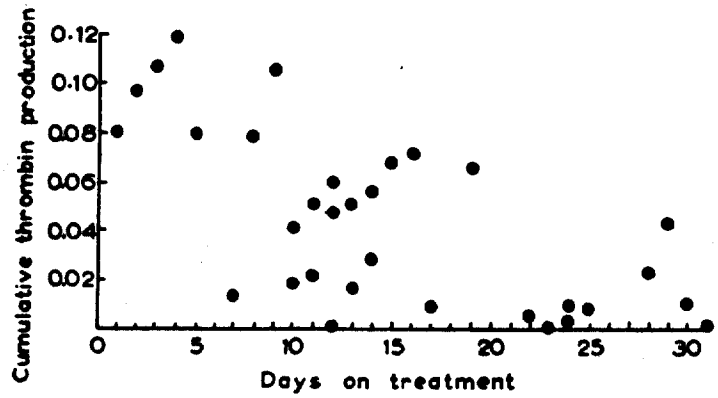

FIG. 4.—Cumulative thrombin production values for rats fed 1 ml. liquor vitaminse A conc. B.P. daily for varying periods.

The Effect of Synthetic Vitamin A Palmitate

Fig. 5 shows thrombin generation curves obtained with the plasma of three rats which had been fed synthetic vitamin A palmitate compared, in each case, with a rat fed olive oil and a rat fed liquor vitaminse A concentratus B.P. for the same length of time. The two vitamin A preparations, which were administered in equimolar amounts gave closely similar results. These findings would seem to remove any doubt as to whether the activity of the fish-oil concentrate is due to vitamin A or to some other substance.

The Effect of Vitamin K_1 and Menaphthone in opposing the Anticoagulant Effect of Vitamin A

The results of the present investigation are in general agreement with those of Light *et al.* and Walker *et al.* in that it was found that both vitamin K_1 and menaphthone are capable of abolishing the anticoagulant effect of vitamin A under certain circumstances. This statement must be made, however, with the reservation that in three rats menaphthone apparently did not have this effect; these animals had been treated for 10, 13 and 16 days respectively. No such case occurred among animals given vitamin K_1 but the numbers involved are not sufficiently large to warrant the conclusion that the action of vitamin K_1 differs in this respect from that of menaphthone.

Examples of cases where menaphthone did and did not abolish the effect of vitamin A are shown in fig. 6. The complete set of results with menaphthone and vitamin K_1 are expressed as cumulative thrombin production values in figs. 7 and 8.

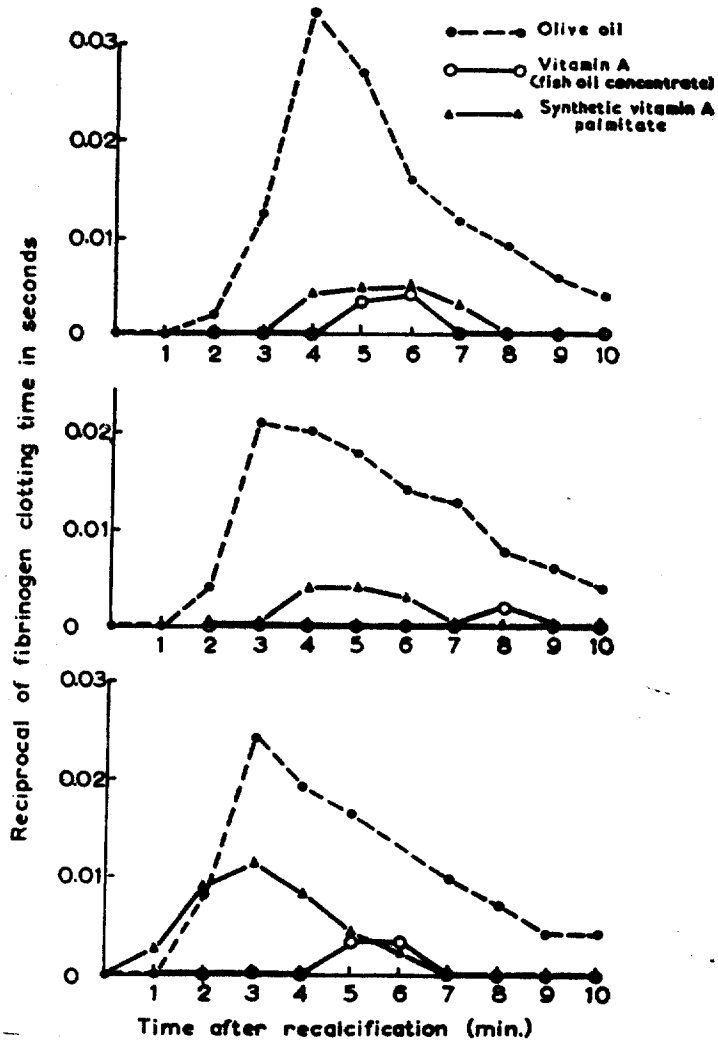

FIG. 5.—Thrombin generation tests on three sets of three rats. In each set, one rat had received 1 ml. olive oil daily, one had received 1 ml. liquor vitamine A conc. B.P. daily, and one had received 1 ml. synthetic vitamin A palmitate in olive oil daily.

Correlation of Clotting Deficiency with Changes in the Histological Pattern of Fat Distribution in the Liver

Two strikingly different patterns of incorporation of fat in the liver were encountered. The animals fed olive oil, and also the animals fed vitamin A which showed no clotting defect, had sudanophil material in most of the

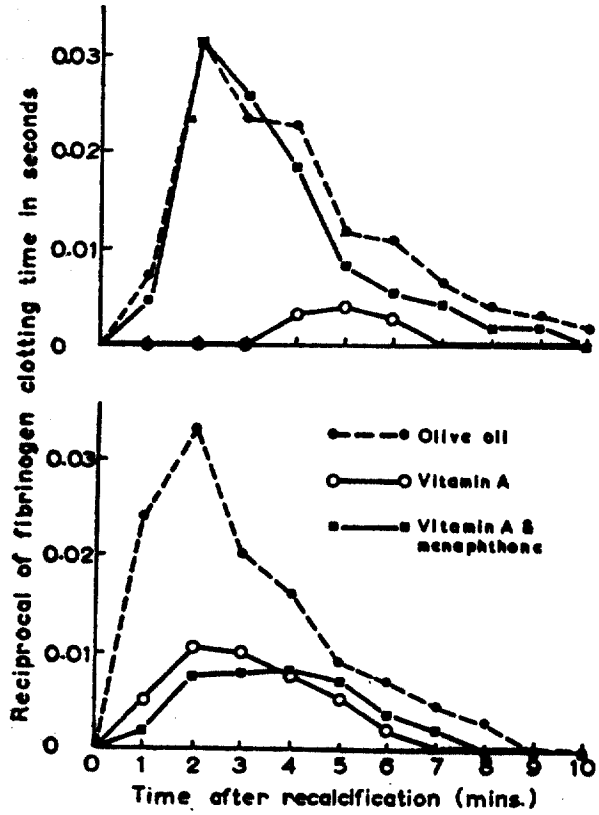

FIG. 6.—Thrombin generation tests showing the varying effects of simultaneous administration of vitamin A and menaphthone.

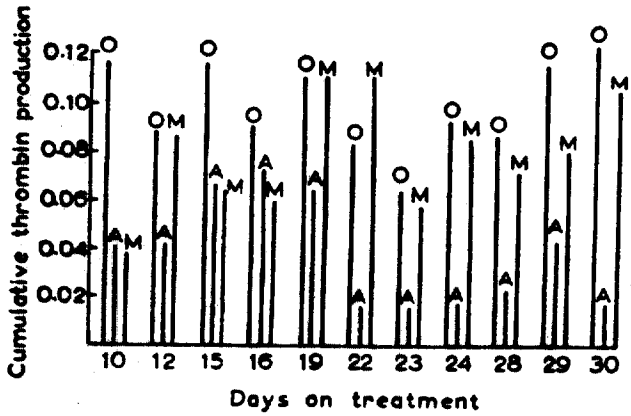

FIG. 7.—Cumulative thrombin production values for rats receiving olive oil (O), vitamin A (A) and vitamin A with menaphthone (M).

liver cells arranged in a random fashion. The other animals all showed marked concentration of sudanophil material in the Kupffer cells as has been observed before in hypervitaminosis A [see Popper, 1944]. In the animals fed vitamin A the correlation between defective coagulation and accumulation of fat in Kupffer cells was striking: all the animals with defective coagulation showed this pattern; none did whose clotting tests gave values in the normal

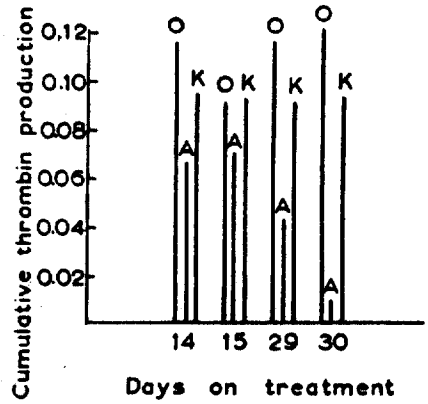

FIG. 8.—Cumulative thrombin production values for rats receiving olive oil (O) vitamin A (A) and vitamin A with vitamin K_1 (K).

range. However, the animals which had received both vitamin A and menaphthone or vitamin K_1 showed accumulation fat in the Kupffer cells whether they exhibited defective coagulation or not. Some of the animals which were given vitamin A and had this type of fat distribution in the liver also showed sudanophil material in macrophages in the lymph nodes. Where this occurred not all the lymph nodes examined were involved. It is possible that if more lymph nodes had been examined the phenomenon would have been observed more often. In no case did the spleen show any significant deposition of sudanophil material.

The Relationship of Menaphthone and Vitamin K_1 to other Manifestations of Hypervitaminosis A

The animals treated with vitamin A showed marked loss of weight as is illustrated in the following table:

Treatment	Olive oil	Vitamin A	Vitamin A + menaphthone	Vitamin A + Vitamin K_1
Weights (g.) of 4 rats in each group.	370	290	285	170
	380	230	260	220
	300	230	250	240
	300	360	250	270

Period of treatment: 4 weeks.
All rats weighed between 300 and 350 g. at the beginning of the experiment.

It is clear that menaphthone and vitamin K_1 do not prevent loss of weight. Many of the rats which had been given vitamin A for 3 weeks or more showed

a tendency for the hair to fall out. The hair could easily be removed by plucking. Loss of hair in rats with hypervitaminosis A was observed by Harris and Moore [1928]. The simultaneous administration of vitamin K_1 or menaphthone did not prevent this occurrence. Most animals given excess vitamin A for more than 10 days showed a greater lipæmia than did control animals given the same volume of olive oil for the same period. A moderate depression of the packed cell volume was also often noticed. These conditions were not affected by simultaneous administration of vitamin K_1 or menaphthone.

Further Observations on the Nature of the Coagulation Defect produced by Hypervitaminosis A

In cases where the plasma showed a prolonged calcium time, mixing it with an equal volume of normal plasma produced a normal calcium time. This indicates that the abnormality is brought about by a deficiency of some clotting factor and not by the presence of a circulating anticoagulant. The prolonged calcium time is not restored to normal by adding normal serum to the plasma.

The two-stage prothrombin time showed changes analogous to those revealed in the thrombin generation test. A representative example of the findings with the two-stage prothrombin time in a hypervitaminotic and a control rat is shown in the following table:

Minutes after recalcification	1	2	3	4	5	6
Fibrinogen clotting times in seconds for test carried out with:						
(a) Control rat . . .	23	71	540	>600	>600	>600
(b) Rat fed excess vitamin A	364	223	590	>600	>600	>600

Discussion

At the time when Light *et al.* and Walker *et al.* carried out their earlier studies on the coagulation defect in hypervitaminosis A in the rat, it was generally believed that prolongation of the one-stage prothrombin time indicated prothrombin deficiency. This view is no longer tenable for reasons which were fully discussed by Biggs [1953]. The belief that both excessive feeding with vitamin A and the administration of dicoumarol (and similar naphthoquinone derivatives) caused prothrombin deficiency led naturally to the successful attempt to correct the deficiency in hypervitaminosis A with vitamin K_1 and its synthetic analogue menaphthone. In the light of subsequent knowledge the apparent antagonism between vitamin A and substances with vitamin K activity is puzzling. Dicoumarol and its analogues are generally believed to act by competing with vitamin K, their similar chemical structure suggesting that they might be antimetabolites of vitamin K [Hunter and Shepherd, 1955; Albert, 1956]. But the chemical structure of

vitamin A shows no obvious similarity to that of the active naphthoquinone derivatives. In any case, the results of the present study would seem to rule out the possibility of a direct competition between vitamin A and vitamin K inasmuch as all the other manifestations of hypervitaminosis A which were observed were unaffected by substances having vitamin K activity. Moreover it appears that the nature of the coagulation defect in hypervitaminosis A is different from that in dicoumarol poisoning; in the latter case the defect in plasma coagulation can be corrected by adding normal serum. Indeed, the coagulation defect in hypervitaminosis A appears to be a genuine prothrombin deficiency in so far as this can at present be defined [see Biggs and Douglas, 1953].

The findings in those animals treated with both vitamin A and menaphthone were unexpected and may be of wider interest. There have been many reports of the ineffectiveness of menaphthone treatment in experimental and clinical situations where it might have been expected on theoretical grounds to correct a clotting defect [see Mann, Mann and Bollmann, 1950, for a full discussion]. The possibility that such treatment might have been effective if it had been continued longer does not seem to have been considered. The present results probably indicate that there is a considerable delay period before menaphthone treatment becomes effective in abolishing the anticoagulant action of vitamin A.

The correlation between defective coagulation and accumulation of fat in the Kupffer cells of the liver is striking: the coagulation defect correlates much better with this histological change than it does with the duration of vitamin A administration. It is difficult to believe, however, that there is a direct causal connexion, as vitamin K_1 and menaphthone do not influence the histological appearances.

The fact that vitamin A has an anticoagulant effect must raise the question whether it could be of value for therapeutic purposes in man. It would have several obvious advantages: it is cheap, readily available and can be given by mouth; an antidote is available. Nevertheless it would seem that there are serious toxic effects of vitamin A which accompany its anticoagulant action. Unless these changes are readily reversible, or do not occur in man, it is unlikely that vitamin A has any future as a therapeutic measure in thrombotic conditions.

Acknowledgments

I thank Professor Sir Howard Florey, F.R.S. and Dr. R. G. Macfarlane, F.R.S., for constant advice and encouragement; Mr. H. W. Wheal, Mr. P. Harvey and Mr. D. W. Jerrome for technical assistance; and Dr. H. Harris who read the manuscript and made valuable suggestions.

REFERENCES

ALBERT, A. (1956). *Brit. med. Bull.* **12**, 67.
BIGGS, R. (1955). *Brit. med. Bull.* **11**, 5.
BIGGS, R. and DOUGLAS, A. S. (1953). *J. clin. Path.* **6**, 15.
CAMPBELL, H. A., SMITH, W. K., ROBERTS, W. L. and LINK, K. P. (1941). *J. biol. Chem.* **138**, 1.
FRENCH, J. E. (1955). Thesis for the degree of Doctor of Philosophy, Oxford.
HARRIS, L. J. and MOORE, T. (1928). *Biochem. J.* **22**, 1461.
HUNTER, R. B. and SHEPHERD, D. M. (1955). *Brit. med. Bull.* **11**, 56.
LEGET, R. F., ALSCHER, R. P. and FREY, C. N. (1944). *Science*, **100**, 225.
MACFARLANE, R. G. and BIGGS, R. (1953). *J. clin. Path.* **6**, 3.
MANN, F. D., MANN, J. D. and BOLLMAN, J. L. (1950). *J. Lab. clin. Med.* **36**, 234.
PITNEY, W. R. and DACIE, J. V. (1953). *J. clin. Path.* **6**, 9.
POPPER, H. (1944). *Physiol. Rev.* **24**, 205.
QUICK, A. J. (1935). *J. biol. Chem.* **109**, Proc. lxxiii.
RODAHL, K. and MOORE, T. (1943). *Biochem. J.* **37**, 166.
WALKER, S. E., EYLENBURG, E. and MOORE, T. (1947). *Biochem. J.* **41**, 575.

Pudelkiewicz-'64
Bib. No. 7405

Reproduced by permission
of the copyright owner

Poultry Sci. 43:1157-1164. 1964.

Some Physiological Effects of Feeding High Levels of Vitamin A Acetate to Chicks[1,2]

W. J. PUDELKIEWICZ, LORNA WEBSTER, G. OLSON AND L. D. MATTERSON
Department of Poultry Science, University of Connecticut, Storrs, Connecticut

(Received for publication March 16, 1964)

TOXICITY due to the ingestion of large amounts of vitamin A by animals has been reviewed by Nieman and Klein Obbink (1954), Moore (1957), and Deuel (1957). Only limited information could be found as to the gross and physiological effects of large intakes of vitamin A by the avian species.

The effects of hypervitaminosis A on bone fragility in rats have been well described by Wolbach (1947). Failure to show any pathologic changes in the duck skeleton after feeding 200,000 I.U. (International Units) per day for the first three weeks of life was reported by Rigdon *et al.*

[1] Scientific Contribution No. 72, Agricultural Experiment Station, University of Connecticut, Storrs.

[2] Supported in part by Yantic Grain and Products Company, Norwich, Connecticut and Central Connecticut Cooperative Farmer's Association, Inc., Manchester, Connecticut.

(1951). Depigmentation of the feet and failure to gain in body weight were observed in the ducks but they failed to show the bone fragility which is a common sign of hypervitaminosis A in mammals.

Wolbach and Hegsted (1952) fed chicks 50,000 I.U. of vitamin A daily by dropper (660 to 900 I.U. per gram of body weight) during the second and third weeks of age. The clinical signs were weight loss, swelling and crusting of eyelids, and inflamatory lesions of the nares, the mouth and adjacent skin, and the skin of the feet. Although no fractures of the bones were demonstrated, it was reported that the skeletal responses in these young chicks were precisely of a nature similar as those in young mammals. The same workers (1953) reported that the only gross change observed in young ducks was a decreased food intake which resulted in a slower growth rate. The birds were fed diets supplemented with vitamin A from 3 to 22 days of age with a daily intake which varied from 100,000 to 600,000 I.U.

Neither Gurcay *et al.* (1950), who fed turkey poults up to 32,000 I.U. of vitamin A acetate per pound of diet, nor Castano *et al.* (1951), who fed up to 24,000 I.U. per pound to chicks for 8 weeks (6 on supplemented diets) achieved saturation of the liver with vitamin A. A slight retardation of growth was reported by the latter workers at the highest level of supplementation.

Some gross and physiological observations made while feeding chicks up to 5,000 mg. of vitamin A acetate per kg. of diet (6,600,000 I.U. per lb.) will be presented in this report. An attempt to determine the level of intake required to produce saturation of the liver and plasma with vitamin A will also be reported.

EXPERIMENTAL

Day-old White Plymouth Rock male chicks were kept in electrically-heated thermostatically-controlled batteries with hardware cloth floors during the 5-week experiment. For the first 15 days, the chicks were fed a vitamin A-low basal diet. They were then distributed into 6 groups of approximately equal weight consisting of 24 chicks per group and were given diets which were supplemented with 0, 0.5, 5, 50, 500, and 5,000 mg. of crystalline vitamin A acetate per kg. of diet (0, 660, 6,600, 66,000 660,000 and 6,600,000 I.U. per lb.). The vitamin A acetate was dissolved in an amount of olive oil which, when added to the diet, gave a final formulation of 2% of oil. The daily amount of feed given was regulated by the slowest eating group (500 mg. per kg. level), except that at the 5,000 mg. per kg. level where feed consumption decreased considerably after 24 hours on the supplemented diet, it was given *ad libitum*. All feed requirements for the duration of the experiment were mixed at one time and kept refrigerated at 5°C. On the 5th, 10th, and 20th day after supplementation, 8 chicks were randomly removed from each of the 6 groups for blood and liver samples. After weighing, 5 ml. of blood was removed from each bird by heart puncture using a 1½" No. 19 short bevel needle. The anticoagulant used was heparin (40 mg. per 100 ml. of 0.90% saline). The amount remaining in the needle of the syringe (0.10 ml.) was sufficient to prevent the 5 ml. of blood from clotting. The pooled blood and pooled liver samples of each group were blended and sampled for plasma (Kimble, 1939) and liver vitamin A (Bunnell *et al.*, 1954) determinations. The lipids in liver tissue were determined by a method used in this laboratory in conjunction with vitamin E determinations which were made on these high vitamin A liver samples but which will be reported elsewhere. The method consisted of the extraction of the liver sample with hot absolute ethanol for 20 hours followed by a single extraction with

hexane (Skellysolve B). An aliquot of the hexane extract was evaporated to dryness in a tared container, weighed, and the amount of lipid calculated.

The vitamin A-low basal had the following composition in parts per hundred pounds: degermed, debranned white corn meal 68.9, soybean meal (50% protein) 10, crude casein 15, limestone 1.50, dicalcium phosphate 2.75, sodium chloride 0.25, manganese sulfate 0.025, potassium chloride 0.025, vitamin D_3 (3,000 I.C.U. per gm.) 0.05, vitamin E (20,000 I.U. per lb.) 0.04, vitamin B_{12} concentrate (Proferm 6)[3] 0.10, choline chloride 60 gm., niacin 1.50 gm., biotin 4.54 gm., calcium pantothenate 635 mg., folic acid (crude, 3%)[4] 605 mg., inositol 227 mg., para-aminobenzoic acid 227 mg., pyridoxine HCl 227 mg., riboflavin 227 mg., thiamine HCl 90.8 mg., and vitamin K_3 (menadione) 45.4 mg.

RESULTS AND DISCUSSION

Gross observations show that after an initial adjustment period, chicks tolerated vitamin A acetate up to 500 mg. per kg. of diet with no visible ill effects. Only at the highest level of intake (5,000 mg. per kg.) did the chicks show signs of distress. Within 24 hours after supplementation began, all chicks on this level were huddled together, eyes closed and heads drooping. The average feed consumption of these birds receiving the highest vitamin A intake dropped from 12.50 to 2.92 gm. per bird from the first to the second day of supplementation. On the fourth day, it was observed that approximately 35% of the birds had either one or both eyes stuck closed, probably due to drying out of the crusty exudate when the eyes were closed during the periods of inactivity. When the eyelids were forced open several times a day, the chicks began feeding immediately upon being able to see. The eyelids and corners of the mouth of most chicks were reddened, a condition similar to that reported by Wolbach *et al.* (1952). By the tenth day this reddened crusty condition of the eyelids and mouth was noted to have cleared up completely with a concomitant return to the normal activity and feed consumption of chicks on lower vitamin A intakes (Figure 1). None of the signs described above was observed in chicks at any other level of vitamin A intake. It is believed that, had the eyelids not been forced open, emaciation would have rapidly ensued.

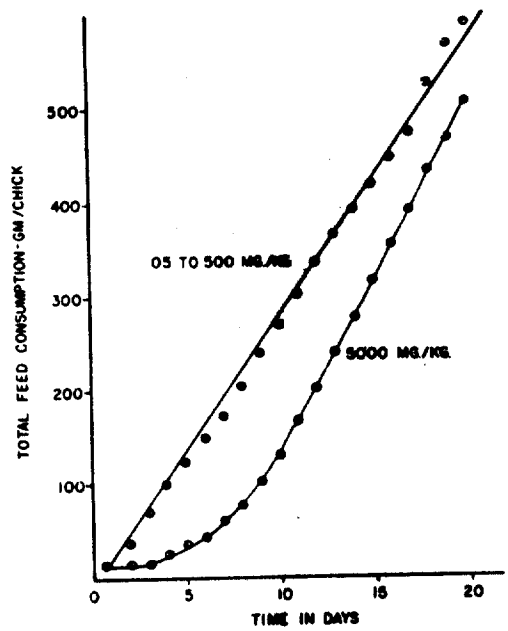

FIG. 1. Comparisons of total feed consumption between birds getting 5,000 mg. of vitamin A acetate per kg. of diet (*ad libitum*) and birds getting up to 500 mg. per kg. of diet (restricted).

The loss of vitamin A in the diets during the 20 days of supplementation was assumed to have been negligible, since the diets were kept at 5°C. However, after 9½

[3] A proprietary product of Commercial Solvents Corporation, New York, guaranteed to contain vitamin B_{12} activity equivalent to 6 milligrams of vitamin B_{12} per pound.

[4] Parvo—a proprietary product of American Cyanamid Company, New York, which contains not less than 3% folic acid.

TABLE 1.—*Summary of the results of feeding increasing amounts of crystalline vitamin A acetate to chicks for 5, 10, and 20 days*

1 Vit. A in feed, mg./kg.	2 Feed* intake, gm.	3 Body wt., gm.	4 Vit. A intake, mg.	5 Liver wt., gm.	6 Lipid in liver %	7 Vit. A in liver mcg./liver	7 Vit. A in liver mcg./gm.	8 Efficiency of storage %	9 Vit. A** intake/gm body wt., I.U.	10 Vit. A in plasma, mcg./100 ml.	11 Vit. A per gm. liver lipid, I.U.×10³
Five days of supplementation											
0.0	119	242	0.00	6.98	5.49	0	0	0.0	0.0	4	0.0
0.5	125	234	0.06	6.81	4.44	4	1	6.5	0.2	16	<0.1
5.0	125	244	0.62	6.85	4.80	283	33	35.7	1.5	64	2.2
50.0	125	248	6.25	7.18	5.11	3,491	486	55.9	14.7	103	32.0
500.0	123	249	61.60	9.59	5.47	19,800	2,064	32.2	144.0	314	126.0
5,000.0	34	168	170.00	5.70	4.16	17,110	3,006	10.1	881.0	250	241.0
Ten days of supplementation											
0.0	260	300	0.00	5.06	4.36	0	0	0.0	0.0	3	0.0
0.5	270	323	0.14	7.79	4.43	6	1	4.3	0.1	19	<0.1
5.0	270	318	1.35	7.64	4.45	452	59	33.4	1.4	63	4.4
50.0	270	321	13.50	8.30	4.86	7,149	861	53.0	14.0	96	59.0
500.0	267	344	133.50	10.50	5.61	51,400	4,896	38.5	127.0	342	291.0
5,000.0	131	220	665.00	7.82	6.44	24,280	3,104	3.7	1,823.0	207	161.0
Twenty days of supplementation											
0.5	590	472	0.30	10.20	4.13	16	2	5.3	0.1	14	<0.1
5.0	590	462	2.95	11.42	4.24	1,020	89	34.6	1.3	66	7.1
50.0	590	466	29.50	9.79	4.66	8,350	853	28.3	12.0	87	61.0
500.0	597	480	298.00	14.79	5.63	87,360	5,908	29.3	121.0	399	350.0
5,000.0	504	451	2,522.00	11.54	5.06	28,100	2,437	1.1	1,290.0	119	160.0

Initial weight of chicks was 162 grams at the zero and 163 grams at the supplemented levels.

* Figures in columns 2, 3, 4, 5, 7, and 9 are averages per chick unless otherwise specified.
** Calculations are based on weight and vitamin A intake on the 5th, 10th, and 20th day of supplementation.

months of storage at this temperature, no vitamin A remained in the feed of the 5,000 mg. per kg. level as measured by the Carr-Price reaction.

Body weights shown in Table 1, column 3, generally reflect feed consumption (column 2); *i.e.*, when chicks on the highest vitamin A intake refused their feed during the early part of the experimental period, weight gain was negligible. However, by the 20th day of the supplemental period, when the feed consumption (*ad libitum*) of these chicks increased considerably, the final body weight was approximately 85% of the weight of chicks at the restricted intake and nontoxic levels of supplementation.

No differences in bone fragility of either the tibia, metatarsus, or ulna were observed among chicks of any groups when tested on the final day of the experimental period. Perhaps, bone fragility in chicks is a condition associated with chronic hypervitaminosis A and would not be observed in as short a period as 20 days.

The livers from chicks on the 500 mg. per kg. level (Table 1, column 5) were significantly heavier (1% level) than livers from the other groups at all three sampling periods.

The control chicks had no measurable (<0.1 mcg. per gm.) vitamin A in the liver when determined on the fifth day of supplementation (20 days of age on the vitamin A-low basal) and showed typical vitamin A deficiency signs with heavy mortality by the end of the experimental period.

When results were expressed as micrograms of vitamin A per liver (Table 1, column 7), the vitamin A content of the liver reached a maximum at the 500 mg. per kg. level at all three sampling times: *i.e.*, at the end of 5, 10, and 20 days of supplementation, but dropped at the 5,000 mg./kg. level. When expressed as micrograms per gram, the only deviation from the above occurred at the fifth day when the order of liver vitamin A content at the two highest levels of intake was reversed. A graph of the liver vitamin A mcg.

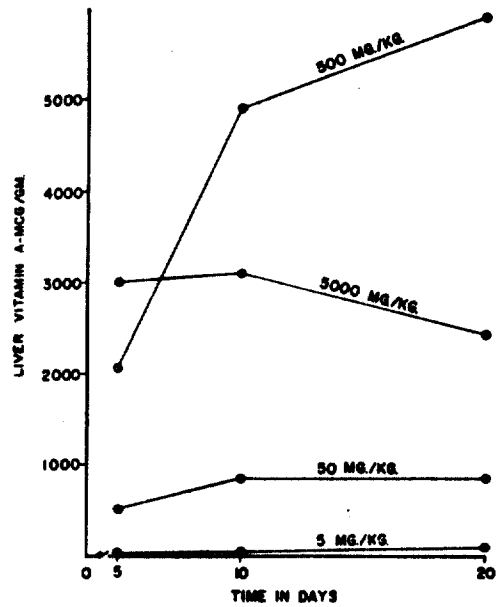

FIG. 2. Effect of increasing levels of dietary vitamin A acetate on vitamin A in the liver at 5, 10, and 20 days of supplementation.

per gm. plotted against time in days is shown in Figure 2. Up to the 50 mg./kg. level the indication is that vitamin A is not being stored very rapidly in liver tissue. Therefore an equilibrium must be coming into effect between the daily intake and body reserves. Chicks on the 500 mg./kg. level showed a rapid rate of incorporation of vitamin A into the liver with time, while the chicks on the 5,000 mg./kg. intake showed a gradually decreasing incorporation with time. It would appear from the data presented that saturation of the liver with vitamin A would occur between the levels of 500 and 5,000 mg. per kg., since vitamin A in the liver is still increasing at the former and dropping at the latter level with time.

That age may be a factor in toxicity was indicated to the authors by some unpublished exploratory work where liver tissue with a high vitamin A content was required for studies dealing with the interference of vitamin A in vitamin E analyses. Six 4-week old chicks, with an average weight of 509 grams which had previously been fed a good quality broiler diet, were placed on a vitamin A-low basal diet to which vitamin A acetate was added at a level of 3,700 mg. per kg. of diet for the first two days and then increased to 5,000 mg. from the third to the 13th days, at which time they were killed. Average feed consumption per chick for days 1, 3, 4, 6, 7, 8, 10, and 13 was 70, 53, 51, 30, 15, 14, 13, and 10 grams respectively. The average body weight for the 13-day supplementation period increased from 509 to 567 grams per bird. Both eyes of two of the chicks were sealed shut with dry exudate on the 10th day. Even though treatment of the younger and older birds prior to supplementation with vitamin A was not identical, there was a general indication that, whereas the younger birds showed a marked decrease in feed consumption after 24 hours on the high vitamin A intake and showed an exudate which sealed eyes of some birds in four days, the older birds showed a more gradual drop in feed consumption and the eyes were not sealed shut until the 10th day of supplementation. This greater apparent tolerance of the older birds could not be explained by a lower vitamin A intake per unit of body weight because the initial intake was approximately 1,500 I.U. per gm. of body weight compared with 1,120 I.U. for the younger birds. Average feed intake of the younger chicks, however, began to increase on the 4th day at the 5,000 mg. per kg. level of supplementation (Figure 1) but that of the older birds continued to decrease even after 13 days of supplementation.

Kidney tissue was analyzed for its vitamin A content at the termination of the experiment. Values of 0.1, 5, 98, 1,409, and 169 mcg. per gm. of tissue were obtained

at vitamin A intake levels of 0.5, 5, 50, 500, and 5,000 mg. per kg. of diet respectively. Average kidney weights per bird for the same respective levels of vitamin A intake were 3.01, 3.22, 3.30, 4.35, and 4.54 grams. The values obtained for vitamin A in kidney tissue were higher than those obtained by Rodahl (1950b) in rats, where up to 1,800 I.U. per gram (540 mcg. per gm. as the alcohol) were reported.

Lemley *et al.* (1947) reported that the efficiency of vitamin A stored in the liver reached an optimum which depended upon the intake. In the present study (Table 1, column 8), the best storage efficiencies, based upon liver values alone, were 55.9 and 53.0% which occurred at the 50 mg. per kg. level after 5 and 10 days of supplementation respectively. After 20 days, the best efficiency (34.6%) occurred at the 5 mg. per kg. level of vitamin A intake. Efficiencies of vitamin A storage at the 5,000 mg. per kg. level dropped rapidly from 10.1 to 3.7 and finally to 1.1% at 5, 10, and 20 days respectively.

It is generally accepted that toxicity levels are, to a great extent, related to body weight. Rodahl (1950a), working with rats, guinea pigs, rabbits, and young cockerels reported that toxic signs developed when dosages ranged from 50 to 130 I.U. per gm. of body weight. Van Metre (1947) noted fractures of bones in rats when the daily dose was 1,250 I.U. per gm. of body weight. Rigdon *et al.* (1951), after feeding ducks 1,000 to 1,800 I.U. per gm. of body weight per day for the first 13 days of life reported no abnormal features. Column 9 of Table 1 shows intakes of vitamin A in I.U. per gm. of body weight which were calculated from body weights and feed intakes determined for the 5th, 10th, and 20th day of the experiment. The daily intakes per gram of body weight ranged up to 1,823 I.U. On the first day of supplementation (not shown), daily intakes at the 500 and 5,000 mg. levels were calculated to be 220 and 1,120 I.U. per gm. of body weight respectively. The latter intake caused the chicks to go into an inactive state within 24 hours, but once the initial toxic reaction was overcome, they tolerated 1,823 I.U. per gm. with no apparent ill effects. Chicks at the 500 mg. level tolerated 220 I.U. per gm. of body weight with no apparent ill effects up to 20 days of vitamin A supplementation. Many of the gross signs of hypervitaminosis A observed by Wolbach and Hegsted (1952) in chicks at 660 to 900 I. U. per gm. of body weight were confirmed in this study at the initial feeding of 1,120 I.U. per gm. of body weight (5,000 mg. per kg. level). As a comparison, vitamin A requirements of 2,646 I.U. per kg. (1,200 I.U. per lb.) for growing chicks, as recommended by the Subcommittee on Poultry Nutrition of the National Academy of Sciences-National Research Council's Committee on Animal Nutrition, would result in an intake of 0.466 I.U. of vitamin A per gram of body weight on the first day of the experimental period.

Plasma vitamin A levels followed the general form of the liver vitamin A, (Table 1, column 10); *i.e.*, the maximum amount appeared in the 500 mg. per kg. level followed by a drop at the 5,000 mg. level. Figure 3 shows a plot of plasma vitamin A (mcg. per 100 ml. of plasma) on time in days. The pattern was very similar to that shown for vitamin A in the liver (Figure 2). The increasing rate of plasma vitamin A (500 mg. per kg. level) indicated that, over a period of 20 days of supplementation, the plasma was not as yet saturated. The fact that at the 5,000 mg. per kg. level plasma vitamin A was dropping showed that other forces were in play (possibly lack of absorption) and again in-

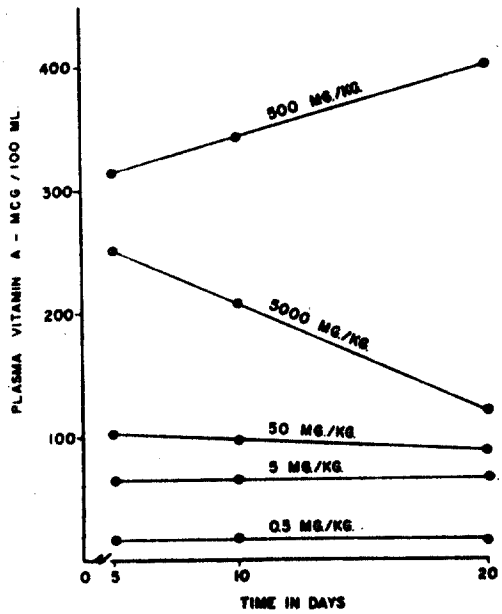

FIG. 3. Effect of increasing levels of dietary vitamin A acetate on blood plasma vitamin A at 5, 10, and 20 days of supplementation.

dicated that the saturation point would take place between the intakes of the two highest levels.

No significant difference occurred in the amount of lipid in liver tissue either at the *levels* or *duration* of vitamin A supplementation (5, 10, or 20 days). However, at equal feed intakes of the diets supplemented with vitamin A, a trend toward increasing levels of liver lipid with increasing vitamin A intakes was indicated and agreed with the findings of Squibb (1963) and Hazzard (1963).

An interesting sidelight is presented in Table 1, column 11. In comparing the I.U. of vitamin A per gram of liver lipids with those generally found in fish liver oils, it can be seen that livers taken from chicks 350,000 I.U. of the vitamin per gram of that received the 500 mg. level of vitamin A after 20 days of supplementation contained extractable lipids. The vitamin A represents 10% of the weight of the lipid and although obtained experimentally, is higher in potency than most of the fish liver oils, being surpassed only by the oil of the ling cod and red steenbras where values of up to 500,000 and 1,130,000 I.U. per gm. oil respectively have been reported (Moore, 1957).

SUMMARY

Two-week old chicks, which were depleted of most of their vitamin A reserves, were fed vitamin A acetate at 0, 0.5, 5, 50, 500, and 5,000 mg./kg. of diet and the following gross and physiological effects were obtained after 5, 10, and 20 days of supplementation.

1. Toxic effects such as, lower feed consumption, reddened and crusty eyelids and mouth, and inactivity were observed only at the 5,000 mg. per kg. level of intake and only during the first week of supplementation. When the encrusted eyelids were manually opened for a period of approximately 100 hours, the birds at the end of 10 days appeared to be comparable in all respects except body weight to chicks that received the lower levels of intake.
2. Livers of chicks at the 500 mg. per kg. level were significantly heavier than those from chicks at other intake levels.
3. Vitamin A in the liver reached a maximum at the 500 mg. per kg. level where 5,908 mcg. per gm. were determined.
4. Plasma vitamin A levels peaked at 399 mcg. per 100 ml. at the 500 mg. per kg. level of vitamin A intake.
5. The efficiency of storage of vitamin A in the liver varied with both intake and time, however, the poorest efficiency occurred at the 5,000 mg. per kg. level of intake.
6. A level of intake of 220 I.U. per gm. body weight had no apparent toxic effect but an intake of 1120 I.U. per

gm. body weight caused a sharp drop in feed consumption within 24 hours.

ACKNOWLEDGMENTS

The authors are grateful to Mr. P. G. McManus, Mrs. M. Gruhn, and Mrs. D. Whitehouse for technical assistance; Dr. R. H. Bunnell, Hoffmann-LaRoche, Nutley, New Jersey for the crystalline vitamin A acetate; and to Dr. E. P. Singsen for helpful suggestions during the preparation of the manuscript.

REFERENCES

Bunnell, R. H., J. E. Rousseau, Jr., H. D. Eaton and G. Beall, 1954. Estimation of vitamin A and carotenoids in calf liver. J. Dairy Sci. 37: 1473–1474.

Castano, F. F., R. V. Boucher and E. W. Callenbach, 1951. Utilization by the chick of vitamin A from different sources. J. Nutrition, 45: 131–141.

Deuel, H. J., Jr., 1957. The Lipids, Vol. III; Chapter IX, Interscience Publishers, Inc., New York.

Gurcay, R., R. V. Boucher and E. W. Callenbach, 1950. Utilization of vitamin A by turkey poults. J. Nutrition, 41: 565–582.

Hazzard, D. G., 1963. Chronic hypervitaminosis in the bovine. Ph.D. Thesis, University of Connecticut.

Kimble, M. S., 1939. The photocolorimetric determination of vitamin A and carotene in human plasma. J. Lab. Clin. Med. 24: 1055–1065.

Lemley, J. M., R. A. Brown, O. D. Bird and A. D. Emmett, 1947. Absorption and storage of vitamin A in the liver of the rat. J. Nutrition, 33: 53–64.

Moore, T., 1957. Vitamin A, Elsevier Publishing Company, New York.

Nieman, C., and H. J. Klein Obbink, 1954. The biochemistry and pathology of hypervitaminosis A. Vitamins and Hormones 12: 69–99. Academic Press, New York.

Rigdon, R. H., J. C. Rude and J. G. Bieri, 1951. Effect of hypervitaminosis A and hypovitaminosis A on the skeleton of a duck. Arch. Path. 52: 299–314.

Rodahl, K., 1950a. Hypervitaminosis A. Norsk Polarinstitutt Skr., No. 95: 1–206; cited by H. J. Deuel, Jr., 1957. The Lipids, Vol. III, p. 614, Interscience Publishers, Inc., New York.

Rodahl, K., 1950b. Hypervitaminosis A in the rat. J. Nutrition, 41: 399–421.

Squibb, R. L., 1963. Vitamin A toxicity and its effect on liver nucleic acids, protein and lipids in the chick. Poultry Sci. 42: 1332–1335.

Van Metre, T. E., 1947. John's Hopkins Hospital Bull. 81: 305–311; cited by H. J. Deuel, Jr., 1957. The Lipids, Vol. III, p. 612, Interscience Publishers, Inc., New York.

Wolbach, S. B., 1947. Vitamin A deficiency and excess in relation to skeletal growth. J. Bone Surg. 29: 171.

Wolbach, S. B., and D. M. Hegsted, 1952. Hypervitaminosis A and the skeleton of growing chicks. Arch. Path. 54: 30–38.

Wolbach, S. B., and D. M. Hegsted, 1953. Hypervitaminosis A in young ducks. Arch. Path. 55: 47–54.

Ray-'59
Bib. No. 7568

Am. J. Physiol. 196:1274-1276. 1959.

Reproduced by permission
of the copyright owner

Oxidative processes in hypervitaminosis A in albino rats

AMAL RAY AND D. P. SADHU
Department of Physiology and Nutrition, Bengal Veterinary College, Calcutta, India

RAY, AMAL AND D. P. SADHU. *Oxidative processes in hypervitaminosis A in albino rats.* Am. J. Physiol. 196(6): 1274-1276. 1959.—Albino rats were made hypervitaminotic A by feeding 30,000 IU of vitamin A daily by mouth; the effect of this hypervitaminosis was compared with a similar pair-fed group. Food consumption and body weight gain were reduced. Study of liver and kidney slices shows that the latter manifest no significant increase in oxygen consumption in presence of succinate or acetate. There is slight increase in O_2 consumption in brain homogenates. Liver homogenate shows 15.2% inhibition with succinate and 5.6% with ascorbate oxidation. Liver homogenate shows 19.3% inhibition of succinate dehydrogenase activity by Thunberg technique with methylene blue indicator. It is concluded that hypervitaminosis A inhibits liver respiration by affecting the dehydrogenase, or any immediate step following it, and the cytochrome *c*-cytochrome oxidase end of the succinoxidase system is little affected.

ADMINISTRATION OF LARGE DOSES of vitamin A reduces basal metabolism (1, 2) and the weight of the thyroid gland and increases the size of the adrenal glands (3). A single dose of 30,000 IU vitamin A to rats weighing 55 gm causes drowsiness and muscular weakness in 24 hours; the general activity is depressed and the excretion of urinary neutral 17-ketosteroids is increased (4). Prolonged hypervitaminosis A causes anorexia, skeletal fracture and hemorrhages (5-7). As hypervitaminosis A depresses basal metabolism and the general body activity, the metabolic activity of individual organs such as the liver, kidney and brain has been studied in the present series of investigations.

EXPERIMENTAL METHODS

In *series 1* albino rats weighing 54-58 gm were fed on stock laboratory diet for 1 week and hypervitaminosis A was induced in one group of 10 rats (*group T*) by feeding 30,000 IU vitamin A daily in the form of Arovit (generously supplied by Hoffmann-LaRoche, Inc. and their agents, Voltas Ltd. (India)). To obviate the effects of partial starvation of *group T*, rats were pair-fed in another group of 10 rats (*group C*). The animals were killed by decapitation after 10 days of treatment. Slices of liver and kidney were cut freehand (8). O_2 consumption was measured in Warburg manometers in Krebs-Ringer phosphate medium (pH 7.4) at 38°C at 100% O_2. Sodium succinate and acetate 0.8 M were used as substrates. Q_{O_2} values were expressed in microliters of O_2 uptake per milligram dry weight of tissue per hour. In *series 2* two groups of 12 rats each were treated as in *series 1*, but were killed after 12 days of treatment. A 10% homogenate (w/v) was prepared by homogenizing the liver with ice-cold 15 M phosphate buffer (pH 7.4); 0.5 ml of this homogenate was used for the measurement of O_2 consumption in Warburg manometers at 38°C and measured as microliters of O_2 per milligrams N of tissue per hour. The vessels contained 0.5 ml of 10% homogenate, 0.2 ml or 0.4 ml cytochrome *c* (1.6×10^{-5} M), 0.3 ml of distilled water or 0.1 M soldium succinate, or 0.114 M sodium ascorbate in the side arm, with 0.2 ml of 20% KOH and 1 cm^2 filter paper in the center well, and the total volume of the flask adjusted to 3.0 ml with phosphate buffer (pH 7.4). After 10 minutes' temperature equilibration, substrate was tipped into the main compartment from the side arm. In *series 3* another two groups of 10 albino rats each were treated as in *series 2* and liver homogenate prepared. The dehydrogenase activity of the homogenate was studied at 38°C in Thunberg tubes with 0.4 ml of methylene blue (1:2000) as indicator, 0.3 ml of 1 M sodium succinate as substrate, 0.5 ml of liver homogenate and 1.8 ml of 15 M phosphate buffer (pH 7.4). Dehydrogenase activity was expressed in terms of time in seconds required for 90% decolorization of methylene blue per gram of wet weight of tissue. Thus, activity will be inversely proportional to the time in seconds.

RESULTS AND DISCUSSION

In *series 1* the average food consumption and weight gain of rats are shown in table 1. Both food consumption and weight gain decreased in the treated rats (*group T*) fed 30,000 IU vitamin A per rat daily by mouth, while the body weight of pair-fed controls (*group C*) increased slightly. Results of O_2 consumption of liver and kidney

Received for publication November 10, 1958.

TABLE 1. *Effect of Feeding 30,000 IU Vitamin A Day Rat (Group T) on Food Consumption and Body Weight Compared With Pair-Fed Controls (Group C)*

Days	0	1	2	3	4	5	6	7	8	9
Food intake, gm	4.8	4.7	4.5	3.8	2.9	1.9	1.0	0.8	0.5	
Body weight, gm, group T	58±5			59±6			56±6			55±7
Body weight, gm, group C	54±5			57±4			60±2			61±2

Average of 10 rats in each group ± S.D.

slices in the presence of sodium succinate and acetate substrates, and of brain homogenate in the presence of succinate substrate, are presented in table 2. There is no significant change in oxygen consumption in the presence of acetate by liver and kidney slices of the treated rats over the control group. The effect of acetate on oxygen uptake was small and hence the relative variation was large. This might, of course, be the reason that no differences were seen, rather than that none occurred. Kidney slices of the treated rats do not show much change in O_2 consumption over that of the control, but the O_2 consumption of liver slices of the treated rats is 21.6% lower with the succinate substrate, compared to the control. In *series 2* the oxygen consumption of liver homogenate with succinate and ascorbate substrates are presented in figure 1 and table 3. Liver homogenate showed an inhibition of O_2 consumption of 15.2% with succinate and 5.6% with ascorbate in the treated rats, compared to the pair-fed controls, the inhibition being far greater with the succinate substrate. Table 2 shows a slight increase in the succinoxidase activity of the brain of the hypervitaminotic-A rats. In *series 3* the succinic dehydrogenase activity of liver homogenate of the treated rats was compared with

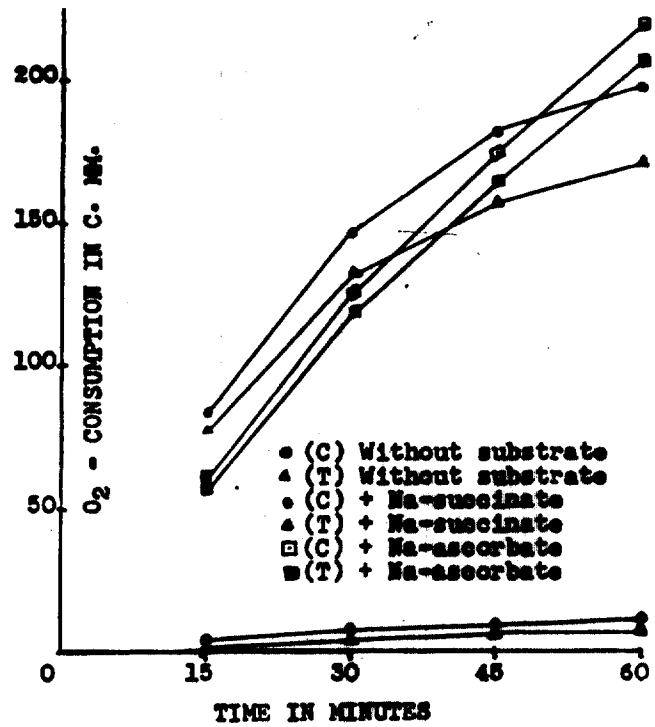

FIG. 1. Oxygen uptake in µl/min/mg of nitrogen of liver of rats fed 30,000 IU vitamin A/rat/day (*group T*) and of their pair-fed controls (*group C*). Average of 12 rats in each group. Each point represents average of 10 estimations.

TABLE 2. *O_2 Intake of Liver and Kidney Slices and Brain Homogenate of Rats Fed 30,000 IU Vitamin A/day/rat (T) and Their Pair-Fed Controls (C) With 0.08 M Succinate or Acetate in Excess of That Without Substrate as Q_{O_2}*

	Liver		Kidney	Brain Homogenate*	
	Succinate	Acetate	Succinate	Acetate	Succinate
Group C	−26.4±2.1	−2.8±0.8	−27.8±5.7	−5.6±1.8	−125±10.5
Group T	−20.6±1.8	−2.5±0.9	−26.6±6.3	−5.3±1.5	−134±11.8
% Diff.†	−22.0±3.6	−10.7±13.9	−3.9±9.5	−5.3±12.9	+6.4±3.7

Average of 12 rats in each group ± S.D. Q_{O_2} is µl O_2 uptake per mg dry weight of tissue per hour; temperature—38°C; gas phase—O_2; fluid medium-Krebs-Ringer phosphate (pH 7.4). * O_2 uptake in µl by 0.5 ml of 10% of brain homogenate in 1 hr. † % difference of the means of the 2 groups ± % changes of standard errors.

TABLE 3. *Effect of Hypervitaminosis A on O_2 Consumption in Presence of Succinate and Ascorbate by Liver Tissue of Rat*

Substrate	15 Minutes			30 Minutes			45 Minutes			60 Minutes		
	Control	Treated	Inhibition, %	Control	Treated	Inhibition, %	Control	Treated	Inhibition, %	Control	Treated	Inhibition, %
None	3	2		7	4		9	6		11	7	
Na-succinate	82±0.8	77±1.2	7±1.5	147±2	131±2	11±2.8	181±1.7	156±2.9	14±3.4	198±1.6	168±2	15±2.6
Na-ascorbate	60±1.9	57±1.8	5±2.6	125±2	118±2	6±3	174±2	164±2	6±2.8	218±2	206±2	6±2.6

Oxygen uptake per mg of nitrogen of the tissue in µl ± S. E.

that of the control rats and the results expressed in terms of 90% decolorization time of methylene blue in seconds per gram of wet weight of tissue. The activity was depressed in the treated (22.2 ± 2.5 sec.) rats by 19.3 ± 5.3% of the control rats (18.6 ± 2.1 sec.) and the difference between the groups is slightly significant.

The succinoxidase system in liver tissue is significantly affected by the hypervitaminosis A treatment. The results of the dehydrogenase activity and the ascorbic acid oxidase activity suggest that the dehydrogenase part, or the immediate next stage of the succinoxidase system, loses the activity by excess vitamin A treatment and the cytochrome *c*-cytochrome oxidase end of the succinoxidase system is not affected at all. The effect of acetate on the increase of O_2 consumption was small, with a large relative variation, so it cannot be concluded from the present experiments that there were no differences between the groups. This apparently suggests that the site of inhibition might be at the dehydrogenase level or any immediate step following it. The site of inhibition may also be at the region where Slater (9) identified the presence of an unknown factor. This inhibition of tissue respiration in liver is a more or less specific process in contrast to other organs and this bears an important relationship to the decrease in energy metabolism of the body. In hypervitaminosis A there is an increased concentration of thyroxine in blood (10), probably due to decreased activity of liver cells, as shown by decreased respiration of liver in the present experiments and elsewhere (11–13). This decreased destruction of thyroxine leads to hyperthyroxinemia, which causes diminished secretion of anterior pituitary thyrotrophin and small sized thyroid gland (3).

The authors express their thanks to Major J. M. Lahiri, Director of Veterinary Services and Animal Husbandry, West Bengal, and Dr. K. C. Mukerjee, Principal of the Bengal Veterinary College, for their interest, and to Dr. J. Ghosh for helpful discussions.

REFERENCES

1. Drill, V. A. *Physiol. Rev.* 23: 335, 1943.
2. Sadhu, D. P. and S. Brody. *Am. J. Physiol.* 149: 400, 1947.
3. Sadhu, D. P. *Am. J. Physiol.* 152: 263, 1948.
4. Ray A. and D. P. Sadhu. *Indian J. Physiol. and Allied Sci.* 11: 1, 1957.
5. Herbst, E. J., P. L. Pevceck and C. A. Elvehjem. *Science* 100: 338, 1944.
6. Pevceck, P. L., E. J. Herbst and C. A. Elvehjem. *Nutrition* 30: 1, 1955.
7. Moore, T. and Y. L. Wang. *Biochem. J.* 39: 222, 1945.
8. Umbreit, W. W., R. H. Burris and J. F. Stauffer. *Manometric Techniques.* Minneapolis: Burgess, 1957.
9. Slater, E. C. *Biochem. J.* 45: 1, 1949.
10. Sadhu, D. P. and B. L. Truscott. *Endocrinology* 43: 120, 1948.
11. Sadhu, D. P. and B. L. Truscott. *Anat. Rec.* 100: 123, 1948.
12. Truscott, B. L. and D. P. Sadhu. *Anat. Rec.* 100: 87, 1948.
13. Truscott, B. L. and D. P. Sadhu. *Proc. Soc. Exper. Biol. & Med.* 68: 253, 1948.

Ray-'59
Bib. No. 7569

Nature 184:1323. 1959.

Carbohydrate Metabolism in Hypervitaminosis A.

Excess vitamin A ingestion increases bleeding tendency[1], depresses basal metabolism[2] and increases excretion of neutral 17-ketosteroids in urine of albino rats[3]. The Qo_2 of liver slices of hypervitaminotic A rats is lower than that of control rats (Ray, Amal and Sadhu, D. P., unpublished observations), the weight of the thyroid is diminished and that of the adrenal increased[3]. In an attempt to elucidate the mechanism of hypometabolism induced in hypervitaminosis A, liver was studied for glycogen and fat contents and diaphragm as an index of glucose utilization in peripheral tissues.

Twelve young albino rats of 55 - 60 gm. weight were fed 30,000 I.U. vitamin A ('Arovit' Roche) daily for 10 days and were fed with twelve control rats and were killed by decapitation. A small piece from the upper part of the right lobe of the liver was taken for estimation of glycogen and fat content by a method previously described[4]. The diaphragm was divided into two halves and each hemidiaphragm was used for studying glucose utilization and glycogen synthesis[5] and the values compared with that of the pair-fed control rats. In hypervitaminosis A liver glycogen is decreased from the control value of 15·1 ± 1·8 (standard deviation) mgm. per gm. liver tissue to 12·2 ± 0·93 mgm. while the fat percentage is increased from control 8·1 ± 0·71 to 10·1 ± 0·62. Diaphragms show a decrease of glucose utilization from the control value of 0·31 ± 0·02 mgm./100 mgm. wet diaphragm per hour to 0·213 ± 0·05 mgm., while glycogen synthesis which is 0·163 ± 0·024 mgm./100 mgm. wet diaphragm per hour in the control rats is decreased to 0·068 ± 0·013 mgm. in the hypervitaminotic A rats.

These experiments show that the depression of metabolism is not restricted to liver alone, but that in muscles is also depressed, in spite of hyperthyroxinaemia in hypervitaminosis[6] A.

We are grateful to Voltas Ltd. (India) and to Hoffman La Roche for a generous grant of 'Arovit' and to Principal K. C. Mukerjee for advice and interest.

AMAL RAY
D. P. SADHU

Department of Physiology and Nutrition,
Bengal Veterinary College,
Calcutta-37, India.

[1] Poole, J. C. F., *Quart. J. Exp. Physiol.*, 43, 427 (1958).
[2] Sadhu, D. P., and Brody, S., *Fed. Proc.*, 6, 420 (1947); *Amer. J. Physiol.*, 149, 400 (1947).
[3] Ray, Amal, and Sadhu, D. P., *Ind. J. Physiol. and Allied Sci.*, 11, 1 (1957).
[4] Sadhu, D. P., *Nature*, 177, 1286 (1956).
[5] Garner, R. J., and Roberts, R., *Biochem. J.*, 59, 224 (1955).
[6] Sadhu, D. P., and Bruscott, B. Lionel, *Endocrinol.*, 43, 180 (1948).

Ray-'65
Bib. No. 7570

Reproduced by permission
of the copyright owner

Ascorbic acid activity in adrenal glands of rats with hypervitaminosis A

By A. K. RAY,* N. R. RAY* and D. P. SADHU†
Department of Physiology and Nutrition, Bengal Veterinary College, Calcutta, India

(*Received* 9 *September* 1964—*Accepted* 8 *March* 1965)

Toxic effects of administering large doses of vitamin A have been known for a long time to occur in human beings as well as in laboratory animals (Josephs, 1944; Knudson & Rothman, 1953). Polar bear liver is an unusually potent source of vitamin A and is toxic as a food even for Eskimo's dogs (Rodahl & Moore, 1943). In hypervitaminosis A basal metabolism is lowered (Sadhu & Brody, 1947) and liver metabolic activity is depressed (Ray & Sadhu, 1959*a*, *b*). Excess intake of vitamin A causes an increased urinary excretion of ascorbic acid, so that the vitamin C reserve of the body can become exhausted and vitamin C deficiency can occur (André & Gauzin, 1954). The investigation described here was planned as a study of the general activities of the body in hypervitaminosis A in relation to body-weight and the weights of different tissues and also to the oxidation of ascorbic acid in the adrenal gland.

EXPERIMENTAL

Animals and diets

Forty albino rats weighing between 44 and 49 g were used from the laboratory stock. They were given the basal diet in the form of a thick paste (Sinha & Ray, 1964, unpublished). The diet was:

Wheat flour	50 g
Fried gram (*Cicer arietinum* L.) powder without husk	50 g
Whole milk	165 g

The composition (parts) was:

Carbohydrate	27·71	Calcium	0·09
Fat	3·54	Phosphorus	0·17
Protein	8·58	Iron	0·0031

The calorific value was 177·26 kcal/100 g.

One group of twenty rats (*T*) was given orally for 10 days vitamin A in the form of Arovit (generously supplied by Hoffman-La Roche Inc. and their agents, Voltas Ltd,

* Present address: Department of Physiology, Bihar Veterinary College, Patna, India.
† Present address: P. G. College of Animal Science, Indian Veterinary Research Institute, Izatnagar, UP, India.

India) at the rate of 30000 i.u./rat daily. The other group of twenty rats (*C*) was pair-fed with group *T* but had no vitamin A supplement. All the rats had drinking water *ad lib.*

Sampling of tissues

Animals were killed on the 10th day of experiment; their different tissues were immediately removed and weighed quickly after removal of all adhering fatty and connective tissue.

Study of ascorbic acid oxidation

The oxidation of ascorbic acid effected by the adrenal glands was measured in a Warburg manometer at 38° with sodium ascorbate as substrate, as described by Umbreit, Burris & Stauffer (1957). The homogenate was prepared with 1/15M-phosphate buffer at pH 7·4 with a dilution ratio 1:80 (w/v). Control experiments were also performed without substrate. The control experiment showed negligible activity, and hence is not recorded in detail. The vessel contained 0·5 ml homogenate, 0·5 ml cytochrome *c* solution ($1{\cdot}6 \times 10^{-5}$M), 0·2 ml of 20% (w/v) KOH solution in the centre cup, 0·3 ml sodium ascorbate (0·114M) in the side-arm and sufficient 1/15M-phosphate buffer at pH 7·4 to make a final volume of 3 ml. The gas phase was air, and the ascorbate solution was tipped into the main compartment from the side-arm after 10 min of temperature equilibration.

RESULTS AND DISCUSSION

After administration of excess vitamin A, the amount of food eaten remained normal for the first 2 or 3 days. After that time the intake was less and became almost negligible within a period of from 8 to 10 days. Body-weights also decreased gradually. It was found that after a single toxic dose of 30000 i.u. vitamin A, drowsiness and muscular weakness appeared within 24 h in young rats. Body activity in general also decreased. When the daily toxic dose of vitamin A was continued, the animals showed typical signs of hypervitaminosis A within 6–8 days. The signs included loss of appetite, loss of body-weight, muscular weakness, loss of hair, appearance of crust around the eyes, sometimes internal haemorrhage, and at a late stage paralysis. Death occurred within 12–15 days. In an unpublished preliminary experiment it was found that, if vitamin A administration was stopped after the first toxic dose, the rats returned quickly to normal. When administration of excess vitamin A was stopped after 10 days, the rats recovered from hypervitaminosis A in about another 2–3 weeks.

It is evident from Table 1 that, expressed as a percentage of body-weight, the weights of heart, liver, kidney and adrenal glands were greater in the experimental group (*T*), whereas the weights of brain and spleen did not differ significantly. Excretion of 17-ketosteroids is increased in hypervitaminosis A (Ray & Sadhu, 1957). The results are, however, complicated owing to effects of inanition and stress acting simultaneously, though the effect of inanition was counterbalanced to some extent by pair feeding. The action of stress in these rats is also proved by the increased weight of adrenal glands. The increased relative weights of heart, liver, kidney and adrenal glands could have been due to shift of fluid from the circulation to the tissue space as

Table 1. *Mean organ weights, expressed as percentage of body-weights, of twenty rats suffering from hypervitaminosis A (group T) compared with pair-fed control rats (group C)*

Organ	Group *C*	Group *T*	Mean difference with its standard error	*t* value
Heart	0·498	0·653	0·155 ± 0·0028	55·71*
Liver	5·019	6·058	1·039 ± 0·00331	313·29*
Kidney	1·039	1·453	0·414 ± 0·0051	80·92*
Adrenal glands†	0·0396 (18·61 mg)	0·0744 (31·25 mg)	0·0348 ± 0·00026 12·64 ± 0·636 mg	133·69* 65·38*
Brain	2·798	2·791	0·007 ± 0·0023	2·21
Spleen	0·821	0·809	0·012 ± 0·00175	3·42

* Significant at the 1 % level.
† Values in parentheses are the absolute weights.

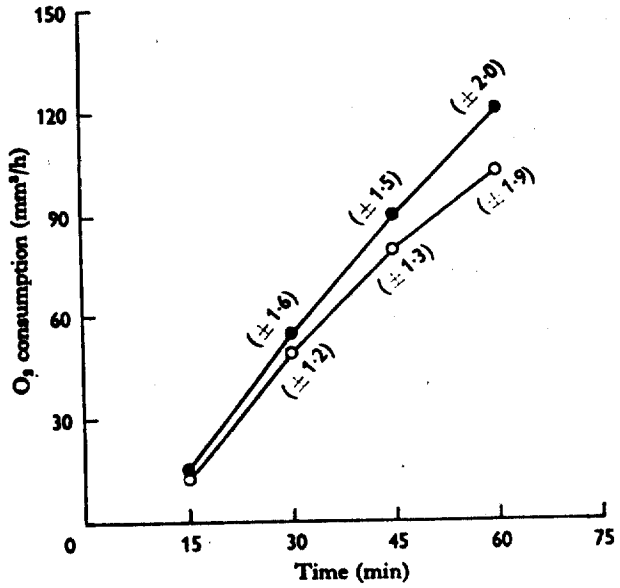

Fig. 1. Ascorbic acid activity in the adrenal glands of control rats (group *C*) and rats given excess vitamin A (group *T*), expressed as the rate of oxygen consumption, with sodium ascorbate (0·114 M) as substrate, against time course of reaction in min. Each point is the mean value from twelve experiments with its SE. ○—○, group *C*; ●—●, group *T*.

a result of stress (Megel, Wozniak, Sun, Frazier & Mason, 1962). The absolute weights of the adrenal glands are also shown in Table 1.

The ascorbic acid content of the adrenal glands is diminished by stress (Goswami, Trivedi & Gupta, 1961). Our work (see Fig. 1) showed 18% more ascorbic acid oxidation, expressed as percentage stimulation of oxygen consumption in mm³ during the time course of reaction for a period of 1 h, in group *T* than in group *C*.

The bleeding tendency in hypervitaminosis A could have been due to hyperheparinaemia (unpublished). The molecules of both heparin and ascorbic acid oxidase contain the sulphydryl group along with glucosamine (Jorpes, 1935; Stark & Dawson,

1962). Vitamin A modifies the formation of mucopolysaccharides by affecting the activities of sulphate (Wolf, Varandani & Johnson, 1961). Vitamin A may contribute to the increased synthesis of heparin and ascorbate oxidase in the system, although further investigation is needed on this point. Ascorbate oxidase present in the adrenal cortex catalyses ascorbic acid oxidation (Harrow, 1950); hence it might be the cause of the reduction in ascorbic acid.

SUMMARY

1. A single oral dose of 30000 i.u. vitamin A given to albino rats weighing about 44–49 g produced drowsiness and muscular weakness within 24 h.

2. Similar doses of vitamin A given daily for 10 days to twenty rats resulted in gradual loss of appetite and loss of body-weight in comparison with pair-fed control rats.

3. The weights of the hearts, livers, kidneys and adrenal glands of the treated rats, expressed as percentages of their final body-weights, were greater than for the controls.

4. Oxidation of ascorbic acid in the adrenal glands was increased by 18% in the hypervitaminotic rats compared with the controls. Possible explanations are discussed.

The authors express their gratitude to Dr M. S. Das, Principal, Bengal Veterinary College, Calcutta, India, for his interest and helpful suggestions.

REFERENCES

André, L. M. & Gauzin, M. (1954). *Bull. Acad. nat. Méd.* **11**, 357.
Goswami, S. L., Trivedi, C. P. & Gupta, R. K. (1961). *Arch. int. Pharmacodyn.* **134**, 1.
Harrow, B. (1950). *Textbook of Biochemistry*, 5th ed., p. 175. Philadelphia, Pa: W. B. Saunders Co.
Jorpes, E. (1935). *Naturwissenschaften*, **23**, 196.
Josephs, H. W. (1944). *Amer. J. Dis. Child.* **67**, 33.
Knudson, A. G. & Rothman, P. E. (1953). *Amer. J. Dis. Child.* **85**, 316.
Megel, H., Wozniak, H., Sun, L., Frazier, E. & Mason, H. C. (1962). *J. appl. Physiol.* **17**, 759.
Ray, A. & Sadhu, D. P. (1957). *Indian J. Physiol.* **11**, 1.
Ray, A. & Sadhu, D. P. (1959*a*). *Amer. J. Physiol.* **196**, 1274.
Ray, A. & Sadhu, D. P. (1959*b*). *Nature, Lond.*, **184**, 1323.
Rodahl, K. & Moore, T. (1943). *Biochem. J.* **37**, 166.
Sadhu, D. P. & Brody, S. (1947). *Amer. J. Physiol.* **149**, 400.
Stark, G. R. & Dawson, C. R. (1962). *J. biol. Chem.* **237**, 712.
Umbreit, W. W., Burris, R. H. & Stauffer, J. F. (1957). *Manometric Techniques*, 3rd ed., p. 175. Minneapolis, Minn.: Burgess Publishing Co.
Wolf, G., Varandani, P. T. & Johnson, B. C. (1961). *Biochim. biophys. Acta*, **46**, 59.

Printed in Great Britain

Reiter-'65
Bib. No. 7619

Uterine Metaplasia and Plasma Levels of Vitamin A [1]

RUSSEL J. REITER [2]
Department of Anatomy, Bowman Gray School of Medicine, Winston-Salem, North Carolina

ABSTRACT The relationship between vitamin A deficiency and estrogen as etiological agents of uterine stratified squamous metaplasia (keratinizing metaplasia) was studied using the rat. This is the initial attempt to correlate plasma levels of vitamin A with the uterine lesions. From the results the following conclusions can be drawn. Uterine metaplastic lesions which develop in estrogen-treated rats are not a result of generalized hypovitaminosis A, since plasma levels of vitamin A are not altered in animals treated with estrogen. Estrogen per se can cause uterine keratinizing metaplasia. The histopathologic lesions occur more frequently in vitamin A-deficient estrogenized rats having decreased plasma vitamin A levels as compared to rats with normal vitamin A intake. The two insults are complementary in producing epithelial metaplasia of the endometrium of the rat.

Uterine stratified squamous metaplasia (keratinizing metaplasia) occurs both in vitamin A-deficient and in estrogen-treated rats. Wolbach and Howe ('25) initially described the characteristic alterations of the endometrium in avitaminotic A rats. These investigators concluded that the primary effect of vitamin A deficiency was the withdrawal of factors necessary for the differentiation and maintenance of the epithelia concerned. In 1935, Selye et al noted that the normal columnar epithelium was partially replaced by stratified squamous cells when rats were chronically treated with estrone. The definitive lesions which are found in the uteri of avitaminotic A rats and those which appear in uteri of rats stimulated excessively with estrogen have been reported to be morphologically identical (Bern, '52).

McCollough and Dalldorf ('37) theorized that uterine metaplasia induced by estrogen may be a manifestation of vitamin A deficiency. From their studies, they concluded that the causative agent of uterine metaplasia in rats was vitamin A deficiency and that estrogen was acting as a growth stimulant. Likewise, Cramer ('42) found that Progynon (an estrogen compound) induced metaplasia of the uterus and cervix of virgin female rats. This change could be inhibited by the injection of vitamin A into the uterine horns. Cramer believed, like McCollough and Dalldorf ('37), that the epidermalization process induced by estrogen may, in fact, be a manifestation of hypovitaminosis A.

More recently, Gilten ('54), Fluhmann ('55), and Bo ('57) independently presented comprehensive discussions on the origin and development of estrogen-induced uterine metaplasia in the rat. Although these investigators differ on the description of the mode of development of the histopathologic lesions, because of their results they concluded that estrogen per se can cause keratinizing metaplasia of the uterine epithelium.

The difference of opinion which exists as to the causative agent of endometial keratinizing metaplasia prompted the present investigation. In the investigations discussed in the previous paragraphs, no attempt was made to correlate blood levels of vitamin A with the metaplastic changes seen in the uterus. A low level of vitamin A in the blood is known to be an absolute criterion of generalized hypovitaminosis A (Dowling and Wald, '58). Thus, correlation of the plasma levels of vitamin A with uterine lesions seen in estrogen-treated rats fed normal or vitamin A-free diets would help to elucidate the role of estrogen and hypovitaminosis A as causative agents of uterine keratinizing metaplasia.

MATERIALS AND METHODS

Twenty-eight to 30-day-old ovariectomized rats were divided into three groups of

[1] In part from a thesis prepared by the author as a partial requirement for the Doctor of Philosophy degree at the Bowman Gray School of Medicine, Winston-Salem, N. C. Supported by a grant from the National Vitamin Foundation.

[2] Present address: Physiology Division, Directorate of Medical Research, Edgewood Arsenal, Maryland.

ten rats each. The rats of groups I and III were fed a vitamin A-free diet. The animals of group II were fed a normal Purina Chow diet and each was paired with an animal of group I.

The animals of group I began to develop the regular signs of vitamin A deficiency after approximately 13 weeks. When the weight of these rats reached a plateau, the animals of group II were increasing in weight normally. During the subsequent 14 days, each rat of groups I and II received 2 μg of estrogen (depoestradiol, Upjohn Co.) subcutaneously per diem. At the end of the two-week period, all rats of group I and their group II mates were sacrificed. Rats of group III were treated similarly to those of group I. When the weights of the vitamin A-deficient rats of group III began to decrease, 2 μg of estrogen were given daily for 14 days. In addition, 200 International Units (I.U.) of vitamin A (diluted from vitamin A ester concentrate) per day in cottonseed oil was administered orally for the same period of time, after which the animals were sacrificed.

At the time of sacrifice, blood was taken from the thoracic aorta according to the technique of Lushbough and Moline ('61) for plasma vitamin A determinations. The blood from each animal was collected directly into a graduated centrifuge tube and centrifuged immediately. No anticoagulant was used. Plasma determinations of vitamin A were conducted using the technique of Kimble ('39). Uteri were excised and after processing, serial sections were stained with Harris' hematoxylin and counterstained with eosin.

OBSERVATIONS

In the hypovitaminotic A rats of group I, the endometria were hyperplastic and the columnar cells appeared hypertrophic. The cylindrical epithelial cells became multilayered in many cases (fig. 2), and not uncommonly epithelial polyps of the endometrium were observed. Focal absence of the endometrial epithelium was noted and occasionally, columns of epithelial cells extended into the lamina propria. These structures were occasionally associated with small metaplastic lesions (fig. 3). Of the ten animals in this group, nine developed partial keratinizing metaplasia and six of these showed extensive lesions (table 1). Both the luminal and glandular epithelial were involved. The endometrial epithelium of one uterus was nearly replaced by stratified squamous metaplasia and keratinized lamellae were being desquamated into the uterine lumen (fig. 4). Frequently the lesions originated in the necks of glands or occasionally in association with polypoid structures. The stratified squamous lesions usually appeared to originate beneath the columnar epithelium (fig. 2) and supplant it by peripheral growth.

The uterine columnar epithelium of the rats from group II was also hyperplastic, often becoming stratified into several layers and epithelial polyps were infrequently noted. Only three of ten animals had small areas of uterine metaplasia (table 1).

Seven of the uteri of rats of group III had keratinizing metaplastic lesions, however, the changes involved only small areas of the endometrial surface. Not uncommonly the focus or origin appeared to be

TABLE 1

Uterine metaplasia in rats injected with estrogen for 14 days

Group	No. of rats	Treatment	No. rats with uterine metaplasia	Extent of lesions [1,2]
I	10	Estrogen	9	+(3); ++(5); +++(1)
II	10	Estrogen	3	+(3)
III	10	Estrogen and vit. A	7	+(6); ++(1)

[1] + indicates one to several metaplastic foci of the glandular or luminal epithelium; ++ indicates more numerous small metaplastic lesions; +++ indicates very extensive metaplastic lesions involving the entire or nearly the entire endometrium.
[2] Number in parentheses indicates number of animals with a lesion of this extent.

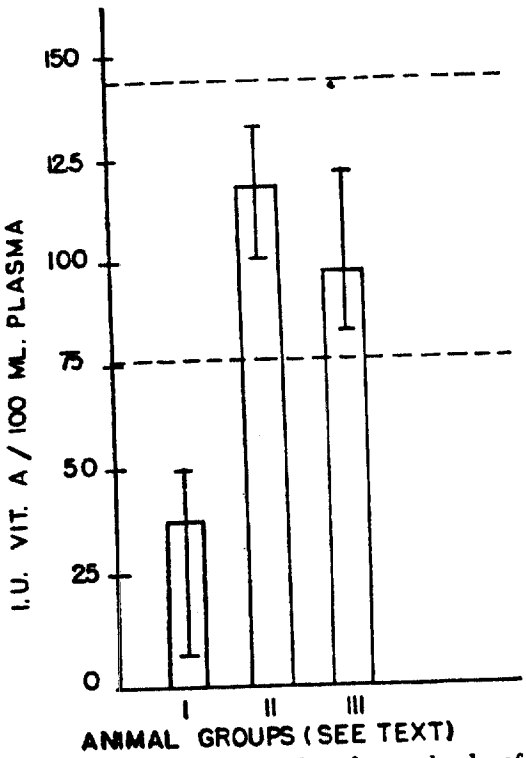

Fig. 1 Estimations of the plasma levels of vitamin A (vertical lines indicate range of values) in rats injected with estrogen for 14 days. Area between broken lines represents the average normal plasma levels of vitamin A for the albino rat (Moore, '57).

in the necks of the uterine glands (fig. 5). Epithelial polyps were rarely observed.

The mean plasma vitamin A level of the ten rats of group I was 35 I.U. per 100 ml. This average is significantly lower than the normal range of plasma vitamin A in the albino rat (fig. 1). The levels of vitamin A in the blood of rats of groups II and III were within normal limits.

DISCUSSION

In the present investigation, nine of ten uteri of hypovitaminotic A rats had metaplastic changes when stimulated with estrogen for 14 days. In this group of animals, the plasma levels of vitamin A were greatly reduced from normal. On the other hand, if the rats were fed a standard laboratory chow diet prior to the estrogen injections, rarely did metaplasia appear. This demonstrates that the combined effect of the two insults, estrogen stimulation and vitamin A deficiency, leads to a rapid replacement of the columnar epithelium by stratified squamous metaplasia. Recently, Aydelotte ('63) studied chick tracheal epithelium in tissue culture and noted that the basal cells had a low mitotic rate. However, if the cells were subjected to a vitamin A deficiency, they divided more rapidly and became stratified. She speculated that the mitotic rate of the basal cells is inhibited by the normal concentration of vitamin A in the blood, but when a deficiency develops, the cells are released from this inhibition. Also, the *in vivo* production of a hypovitaminosis A leads to a proliferation of mucous membranes culminating in a stratified squamous metaplasia. It is theorized that the stimulation of mitotic activity by vitamin A deficiency coupled with the proliferative action of estrogen in the uterus results in the rapid replacement of the uterine mucosa with epidermoid heteroplasia, as seen in the present investigation. This would explain the high index of squamous metaplasia in group I, even when estrogen was administered for only 14 days.

Only three of ten animals fed a normal chow diet (containing adequate vitamin A) prior to estrogen injections exhibited histopathologic endometrial changes. Several workers (Hohlweg, '51, '52; Kahn and Bern, '50) have demonstrated an antagonism between vitamin A and estrogen. The plasma levels of vitamin A were within the normal limits in rats fed a normal chow diet prior to the estrogen injections. This tends to preclude the idea that the pathologic changes were an indirect manifestation of vitamin A deficiency. Rather, the results can be attributed to excess exogenous estrogen stimulation. Since estrogen stimulation did not alter blood vitamin A levels, the uterine keratinizing metaplastic lesions induced by estrogen are not a result of generalized hypovitaminosis A. Furthermore, the other common signs of vitamin A deficiency (e.g., unkempt fur, dyspnea) were not obvious, although the time interval was so short they may not have become manifested.

Most animals treated simultaneously with oral vitamin A and subcutaneous estrogen after being fed a diet deficient in vitamin A developed endometrial changes.

Analyses of vitamin A in the blood of these animals showed the levels to be within normal limits, and yet seven of ten uteri exhibited changes. However, the animals became hypovitaminotic A before estrogen and vitamin A were administered. At this time, the uterine endometrial cells were also subjected to the deficit of vitamin A. Since Jensen ('60) has shown that carbon-14-labeled estrogens can be detected within the endometrial cells very shortly after injection, the endometrial epithelial cells may have responded while still in the dysvitaminotic A condition to produce squamous metaplasia. Had the animals continued for a greater period of time to receive both vitamin A and estrogen, the incidence of stratified squamous lesions may have decreased. The concentration of vitamin A used in the present investigation lowers the incidence of uterine keratinizing metaplasia induced by estrogen (unpublished observations).

That chronic or acute septic states accompanying vitamin A deficiency and/or chronic estrogen treatment may have caused the metaplastic lesions must be considered a possibility. Vitamin A deficiency in experimental animals is often associated with infection (Tyson and Smith, '29). However, it has never been established conclusively that the septic state is always the cause of epithelial metaplasia in these hypovitaminotic A animals. Also, it is known that vitamin A deficiency can cause metaplastic lesions in many organs of germ-free rats precluding the possibility that they are invariably a result of secondary infection (Beaver, '61). If the uterine metaplastic changes seen in the uteri of animals of the present investigation resulted from septic states produced by estrogen administration, the number and extent of the lesions should have been similar in the three groups since all the rats were given identical estrogen injections.

If the postulation, propounded by previous investigators (McCollough and Dalldorf, '37; Cramer, '42) — that the etiology of estrogen-induced uterine metaplasia is vitamin A deficiency — is correct, then it would be necessary to explain how excess estrogen stimulation causes an absolute or relative avitaminotic A condition within the endometrial cells. The findings of the present investigation show that treatment with exogenous estrogen for two weeks does not alter the plasma vitamin A level. Therefore, the uterine changes noted in these animals cannot be attributed to generalized hypovitaminosis A.

ACKNOWLEDGMENTS

The author expresses his gratitude to Dr. Walter J. Bo for his help in preparing this manuscript.

LITERATURE CITED

Aydelotte, M. B. 1963 The effects of vitamin A and citral on epithelial differentiation in vitro. 1. The chick tracheal epithelium. J. Embryol. Exp. Morph., *11:* 279–291.

Beaver, D. L. 1961 Vitamin A deficiency in the germ-free rat. Am. J. Path., *38:* 335–357.

Bern, H. A. 1952 Alkaline phosphatase activity in epithelial metaplasia. Cancer Res., *12:* 85–91.

Bo, W. J. 1957 Relation of vitamin A deficiency and estrogen to induction of keratinizing metaplasia in the uterus of the rat. Amer. J. Clin. Path., *5:* 666–673.

Cramer, V. H. 1942 Wachstumssteuerung Gefährdeter Epithelial gebiete. Deut. Med. Wschr., *68:* 809–814.

Dowling, J. E., and G. Wald 1958 On the mechanism of vitamin A deficiency and night-blindness. Fourth International Congress of Biochemistry, Vol. XI — Vitamin Metabolism, Vienna, pp. 185–197.

Fluhmann, C. F. 1955 Squamous metaplasia in the rat uterus. Arch. Path., *59:* 238–256.

Gilten, G. 1954 On the mode of development of stratified squamous epithelium in the rat's uterus following prolonged estrogen administration. Anat. Rec., *120:* 637–662.

Hohlweg, W. 1951 Über die Hemmung der Oestrusreaktion dürch Vitamin-A-Überdosierung. Klin. Wschr., *29:* 193–195.

——— 1952 Die Testierung von Vitamin A-Preparation mit Hilfe der Antioestrusreaktion. Die Pharmazie, *7:* 280–284.

Jensen, E. V. 1960 Fate of steroid estrogens in target organs. First International Congress of Endocrinology, Copenhagen, p. 733.

Kahn, R. H., and H. A. Bern 1950 Antifolliculoid activity of vitamin A. Science, *111:* 516–517.

Kimble, M. S. 1939 The photo-colorimetric determination of vitamin A and carotene in human plasma. J. Lab. Clin. Med., *24:* 1055–1065.

Lushbough, C. H., and S. W. Moline 1961 Improved terminal bleeding method. Proc. Animal Care Panel, *11:* 315–318.

McCollough, K., and G. Dalldorf 1937 Epithelial metaplasia. Arch. Path., *24:* 486–496.

Moore, T. 1957 Vitamin A. Elsevier Publishing Company, Amsterdam.

Selye, H., D. L. Thompson and J. B. Collip 1935 Metaplasia of the uterine epithelium produced by chronic oestrin administration. Nature, *135:* 65–66.

Tyson, M. D., and A. H. Smith 1929 Tissue changes associated with vitamin A deficiency in the rat. Am. J. Path., *5:* 57–70.

Wolbach, S. B., and P. R. Howe 1925 Tissue changes following deprivation of fat-soluble A vitamin. J. Exp. Med., *42:* 753–778.

PLATE 1

EXPLANATION OF FIGURES

2 Uterine section of a hypovitaminotic A rat treated with estrogen for 14 days. Note the pronounced stratification of the columnar epithelium and the metaplastic lesion. × 100.

3 Uterine section of a hypovitaminotic A rat treated with estrogen for 14 days. Note the column of epithelial cells extending into the lamina propria and the underlying squamous metaplastic lesion. × 100.

4 Uterine section of a hypovitaminotic A rat treated with estrogen for 14 days. The columnar epithelium is nearly replaced by stratified squamous metaplasia. × 100.

5 Uterine section of a rat treated with vitamin A and estrogen showing small lesion originating in the neck of the gland. × 100.

2

3


5

4

Reiter-'65
Bib. No. 7620

Texas Rept. Biol. Med. 23(2):488-493. 1965.

UTERINE KERATINIZING METAPLASIA AND PLASMA LEVELS OF VITAMIN A IN RATS FED VITAMIN A-DEFICIENT DIETS*

RUSSEL J. REITER†

Department of Anatomy, Bowman Gray School of Medicine, Winston-Salem, N.C.

Introduction

The occurrence of stratified squamous metaplasia (keratinizing metaplasia) has been demonstrated repeatedly in intact (Wolbach and Howe, 1925; Bo, 1956), but not in ovariectomized (McCullough and Dalldorf, 1937; Bo, 1955) rats fed a vitamin A-deficient diet. Likewise, prolonged treatment of rats with excess estrogen causes uterine keratinizing metaplasia (Selye, et al., 1935; Gilten, 1954; Fluhmann, 1956; Bo, 1957), the definitive lesions of which are morphologically identical to those caused by hypovitaminosis A (Bern, 1952). This has led to considerable speculation as to the causative agent (or agents) of stratified squamous metaplasia in the rat uterus (McCullough and Dalldorf, 1937; Cramer, 1942).

A paucity of information exists concerning the blood levels of vitamin A in rats fed vitamin A-free diets. This is unfortunate since a low level of vitamin A in the blood is a primary prerequisite for systemic hypovitaminosis A (Dowling and Wald, 1958). The confusion that has arisen concerning the etiological agent of uterine keratinizing metaplasia could be partially resolved by studying the uterine lesions relative to the plasma concentrations of vitamin A.

The following is a report of uterine metaplasia induced by hypovitaminosis A with an ancillary study of plasma levels of vitamin A. In some animal groups a vitamin E-deficient ration was combined with a vitamin A-free diet to produce a more rapid depletion of vitamin A (Horwitt, 1961).

Materials and Methods

Seventy one bilaterally ovariectomized and 62 intact female Wistar rats were utilized. At the commencement of the experiment the animals ranged in age from 25-50 days and were divided into the following experimental groups: I, intact rats

* In part from a thesis prepared by the author as a partial requirement for the Doctor of Philosophy degree at the Bowman Gray School of Medicine, Winston-Salem, N.C. Supported by a grant from the National Vitamin Foundation. Received for publication January 18, 1965.

† Present address: Physiology Division, Directorate of Medical Research, Edgewood Arsenal, Maryland 21010.

fed a vitamin A-deficient diet (-A diet); II, castrated rats fed a -A diet; III, intact rats fed a vitamin E-deficient diet (-E diet); IV, castrated rats fed a -E diet; V, intact rats fed a diet deficient in both vitamins A and E (-A-E diet); VI, castrated rats fed a -A-E diet.

The appearance of certain characteristic signs of vitamin A deficiency (weight loss, dyspnea, and reduced food intake) dictated the time of sacrifice of the rats given -A or -A-E diets. The hypovitaminotic E rats were killed at the same time as the animals on a combined avitaminotic A-E diet. All animals were weighed weekly.

When the animals were killed, blood was taken from the thoracic aorta of etherized animals using the technique of Lushbough and Moline (1961). The samples were centrifuged immediately and plasma vitamin A was measured using the method of Kimble (1939), slightly modified. Uteri were excised and processed by standard techniques, and every fifth to eighth section was mounted and stained with hematoxylin-eosin.

Results

Signs of vitamin A deficiency appeared in the rats of groups I and II at approximately 20 weeks and these animals were sacrificed during the 22nd week of the experiment. In contrast, in animals given the doubly deficient diet (Groups V and VI) the signs appeared much earlier, which necessitated killing these animals after about 10 weeks. The early signs of the condition included nasal bleeding and dull, unkempt fur, with some loss of hair in the cervical and periorbital regions. At the time the animals were killed, weight losses ran between 20 and 30 g and some of the rats showed diarrhea, lethargy, and slight ataxia. Rats in group III and IV were also killed at 10 weeks, before signs of vitamin E deficiency normally appear (Atkinson, et al., 1949).

The uteri of the ovariectomized animals (groups II, IV, and VI) were infantile and the endometrial lining consisted of a single layer of epithelial cells ranging from cuboid to low columnar (Figures 1 and 2). No keratinizing metaplasia was found in the 71 uteri from the castrated rats (Table 1). The uteri of the intact animals of group III exhibited normal cyclic variations and the endometria were unremarkable. No endometrial metaplasia was observed in the 21 animals and pigmentation of the myometria was not apparent(Mason and Emmel, 1945).

Fifteen of 19 animals of group I developed varying degrees of uterine keratinizing metaplasia (Table 1). In most cases the lesions consisted of small foci of stratified squamous cells supplanting the columnar epithelium (Figure 3). The heteroplastic changes involved both the luminal and glandular mucosae and several lesions in the latter area were cornified.

A large percentage of the animals of group V also developed uterine metaplastic changes (Table 1). A typical uterus from an animal of

FIGS. 1 and 2. **Photomicrographs of the endometrium of a castrated rat fed a vitamin A-deficient diet for 22 weeks. Fig. 1 (×100); Fig. 2 (×475).**

TABLE I

Incidence and extent of metaplastic lesions observed in the uteri of the animals within the six experimental groups

Group	No. of rats	No. rats with uterine metaplasia	Extent of lesions[1,2]
I	19	15	+(11);++(4)
II	22	0	.....
III	21	0	.....
IV	24	0	.....
V	22	15	+(11);++(3); +++(1)
VI	25	0	.....

[1] + indicates one to several metaplastic foci of the glandular or luminal epithelium; ++ indicates more numerous small metaplastic lesions; +++ indicates very extensive metaplastic lesions involving the entire or nearly the entire endometrium.
[2] Number in parentheses indicates number of animals with a lesion of this extent.

this group showed foci of squamous cells, occasionally cornified, originating both within the glandular and luminal epithelia (Figure 4).

Plasma levels of vitamin A were found to be greatly depressed in rats of groups I, II, V, and VI, reflecting the deficiency in the diets, whereas lack of vitamin E (groups III and IV) did not affect the plasma level of vitamin A (Figure 5). Even though many factors are

FIG. 3. Photomicrograph of a focus of stratified squamous cells supplanting the columnar epithelium in the uterus of an intact rat fed an avitaminotic A diet for 22 weeks. ×475.

FIG. 4. Photomicrograph of a uterus from an intact rat fed a diet lacking vitamins A and E. Note the replacement of both the glandular and luminal epithelia by the metaplastic changes. ×100.

known to affect the plasma content of vitamin A (Moore, 1957), all values measured in groups III and IV fell within the normal range.

Discussion

Although previous investigators (McCullough and Dalldorf, 1937; Bo, 1955) reported an absence of keratinizing metaplasia in ovariectomized avitaminotic A rats, they made no attempt to study plasma levels of vitamin A in these animals. The blood levels of vitamin A are maintained until all stores are depleted, therefore, a low level of this vitamin in the plasma is an absolute sign of systemic hypovitaminosis A (Dowling and Wald, 1958). The results of the present investigation demonstrate conclusively that, even with blood levels of vitamin A far below normal, the uterine lesions do not develop if the animals

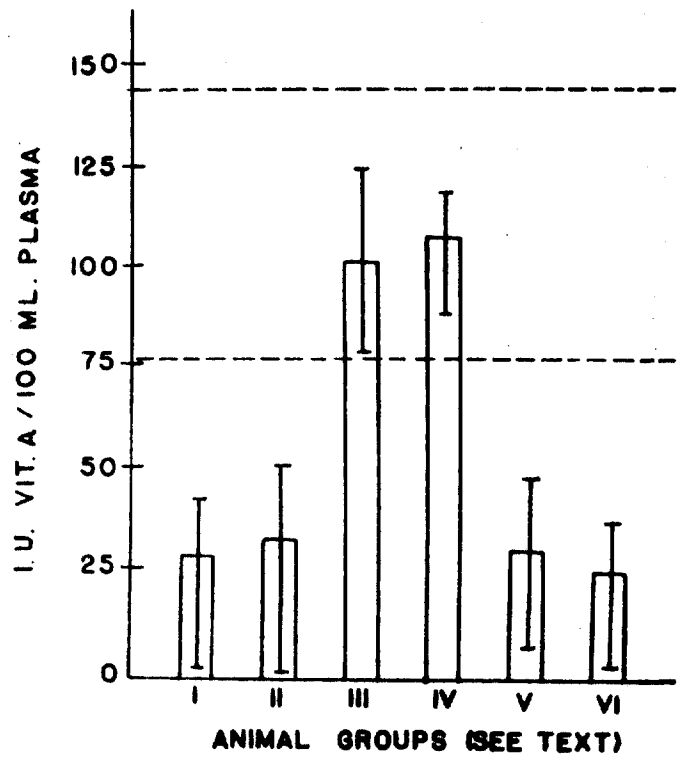

FIG. 5. Estimations of plasma levels of vitamin A (vertical lines indicate range of values) in the various groups of rats utilized. Area between broken lines represents the normal plasma level of vitamin A for the albino rat.

have been ovariectomized previously. On the other hand, low levels of plasma vitamin A are not a *sine qua non* for uterine keratinizing metaplasia induced by exogenous estrogen stimulation since Reiter (1965a) found that these changes are produced in uteri of rats after injection of excess estrogen for 14 days in spite of normal plasma concentrations of vitamin A. Yet, the oral administration of excess vitamin A (at certain doses) apparently is capable of decreasing the incidence of uterine metaplasia in estrogen-treated rats (Reiter, 1965b).

McCullough and Dalldorf (1937) and Bo (1956) suggested that if ovariectomized rats were fed the -A diet for a period of time greater than 13 weeks, squamous metaplasia would develop in the uteri. In the present investigation, however, when rats were maintained on the -A diet up to 22 weeks, uterine metaplasia did not occur. These animals die from other manifestations of vitamin A deficiency before uterine changes develop, the most common cause of death being systemic infections following ulceration of the gastrointestinal and/or respiratory epithelia. It seems unquestionable that, in the absence of the ovaries or exogenous estrogen stimulation, uterine keratinizing metaplastic lesions do not develop, regardless of the length of time the animals are subjected to the deficient diet. The probable explanation is that without estrogen stimulation mitotic activity of the endometrial epithelium is practically abolished and therefore proliferation of the squamous cells is not possible.

The "sparing" action of vitamin E on vitamin A was demonstrated by the fact that animals of the -A-E diet exhibited signs of vitamin A deficiency earlier and lived only half as long as those on a -A diet alone. However, the incidence and extent of the uterine lesions were no greater in rats of group I than in rats of group V. Since group I rats required 22 weeks to reach the same condition as the rats of group V, and since the blood levels of vitamin A remain normal until all stored vitamin A is depleted, it may be assumed that the development of the uterine lesions parallels the decrease in tissue vitamin A. Further experiments will be required to show correlations, if any exist, between the development of the metaplastic lesions and such external signs of hypovitaminosis A as unkempt fur, epistaxis, epilation and loss of weight.

Bo (1957) suggested that uterine changes tend to originate in the glandular mucosa. This tendency could not be detected in the present study, but rather the results corroborate the findings of Wolbach and Howe (1925) that in the rat the metaplastic lesions originate as numerous foci in both the uterine glands and in the luminal epithelia.

Summary

The incidence of uterine stratified squamous metaplasia was studied in intact and ovariectomized rats fed diets lacking vitamin A or vitamins A and E. The lesions are morphologically identical and of similar extent in both groups of intact animals, but occur earlier in rats given a combined -A-E diet. Unlike several other signs of vitamin A deficiency, uterine keratinizing metaplasia apparently develops subsequent to the drop in plasma levels of vitamin A. Uterine metaplastic changes did not occur in ovariectomized rats even when they were maintained on the -A diet for 22 weeks and despite low plasma levels of vitamin A. These findings suggest that estrogen stimulation is an important factor in the production of endometrial metaplasia in vitamin A-deficient rats. The results support the hypothesis that endometrial lesions due to vitamin A deficiency originate as multiple foci in the glandular and luminal epithelia.

Acknowledgment

The author wishes to express thanks to Dr. Walter J. Bo for his help and advice during the course of the investigation.

REFERENCES

1. Atkinson, W. B., H. Kaunitz and C. A. Slanetz: Effects of ovarian hormones upon uterine pigmentation in vitamin A deficient rats. *Ann. N.Y. Acad. Sci.*, 52: 68–71, 1949.
2. Bern, H. A.: Alkaline phosphatase activity in epithelial metaplasia. *Cancer Res.*, 12: 85–91, 1952.
3. Bo, W. J.: The effect of ovariectomy on metaplastic changes of the uteri of vitamin A deficient rats. *Anat. Rec.*, 121: 241–250, 1955.
4. ———: The relationship between vitamin A deficiency and estrogen in producing uterine metaplasia in the rat. *Anat. Rec.*, 124: 619–628, 1956.
5. ———: Relation of vitamin A deficiency and estrogen to induction of keratinizing metaplasia in the uterus of the rat. *Amer. J. Clin. Nutr.*, 5: 666–673, 1957.
6. Cramer, V. H.: Wachstumssteureung gefährdeter Epithelialgebiete. *Deutsch Med. Wschr.*, 68: 809–814, 1942.
7. Dowling, J. E. and G. Wald: On the mechanism of vitamin A deficiency and night blindness, pp. 185–197. In: *4th Intern. Congr. Biochem., Vol. XI.* Pergamon Press, London, 1958.
8. Fluhmann, C. F.: Squamous metaplasia in the rat uterus. *Arch. Path.*, 59: 238–246, 1955.
9. Gilten, G.: On the mode of development of stratified squamous epithelium in the rat's uterus following prolonged estrogen administration. *Anat. Rec.*, 120: 637–662, 1954.
10. Horwitt, M. K.: Vitamin E in human nutrition—An interpretative review. *Borden's Rev. Nutr. Res.*, 22: 1–17, 1961.

11. Kimble, M. S.: The photo-colorimetric determination of vitamin A and carotene in human plasma. *J. Lab. Clin. Med.*, 24: 1055–1065, 1939.

12. Lushbough, C. H. and S. W. Moline: Improved terminal bleeding method. *Proc. Anim. Care Panel*, 11: 315–318, 1961.

13. Mason, K. E. and A. F. Emmel: Vitamin E and muscle pigmentation in the rat. *Anat. Rec.*, 92: 33–45, 1945.

14. McCullough, K. and G. Dalldorf: Epithelial metaplasia. *Arch. Path.*, 24: 486–496, 1937.

15. Moore, T.: Vitamin A. Elsevier Publishing Co., Amsterdam, 1957, p. 210.

16. Reiter, R. J.: Uterine metaplasia and plasma levels of vitamin A. *Anat. Rec.*, 1965a, (in press).

17. ————: Estrogen-induced uterine metaplasia in rats given oral supplements of vitamin A. *Experientia*, 1965b, (in press).

18. Selye, H., D. L. Thompson and J. B. Collip: Metaplasia of the uterine epithelium produced by chronic oestrin administration. *Nature*, 135: 65–66, 1935.

19. Wolbach, S. B. and P. R. Howe: Tissue changes following deprivation of fat-soluble A vitamin. *J. Exp. Med.*, 42: 753–778, 1925.

Arch. Pathol. 53(3):239-249

Rigdon, R. H.
Bib. No. 7683

PATHOLOGIC LESIONS IN THE NERVOUS SYSTEM OF THE DUCK FED A RATION DEFICIENT IN VITAMIN A

R. H. RIGDON, M.D.
GALVESTON, TEXAS

NUMEROUS observations have been made on the neurological manifestations of vitamin-A deficiency; however, there are now two opposing views relative to this mechanism. One group of workers [1] considers that a degenerative change occurs in the central nervous system and in the peripheral nerves, whereas Wolbach and Bessey [2] believe that the lesions in the nervous system result from a mechanical distortion produced by a differential rate of growth between the vertebrae and the spinal cord, resulting in pressure on the spinal nerves.

Recently muscular weakness, incoordination, ataxia, and paralysis were observed in vitamin-A-deficient ducks.[3] The significant pathologic changes within the central nervous system were hemorrhages and necrosis of the gray and white matter, degeneration in the fiber tracts and nerve cells, and the formation of foci of cartilage and bone within the brain and spinal cord. The mechanism by which these lesions occurred was not satisfactorily explained by Fletcher and Rigdon.[3] Wolbach,[4] commenting on these pathologic lesions in the ducks, stated that they were the result of a disproportion in the rate of growth of the nervous and osseous tissues and that the presence of bone and cartilage represented only artifacts. In a detailed study

From the Laboratory of Experimental Pathology, University of Texas Medical Branch.

This investigation was supported by a research grant from the National Institutes of Health, United States Public Health Service.

1. Hughes, J. S.; Lienhardt, H. F., and Aubel, C. E.: Nerve Degeneration Resulting from Avitaminosis A, J. Nutrition **2**:183, 1929. Irving, J. T., and Richards, M. B.: Early Lesions of Vitamin A Deficiency, J. Physiol. **94**:307, 1938. Mellanby, E.: The Experimental Production and Prevention of Degeneration in the Spinal Cord, Brain **54**:247, 1931. Zimmerman, H. M.: Lesions of the Nervous System in Vitamin Deficiency: I. Rats on a Diet Low in Vitamin A, J. Exper. Med. **57**:215, 1933. Zimmerman, H. M., and Cowgill, G. R.: Lesions in the Nervous System in Vitamin Deficiency: IV. The Effect of Carotene in the Treatment of the Nervous Disorder in Rats Fed a Diet Low in Vitamin A, J. Nutrition **2**:411, 1936. Aberle, S. B. D.: Neurological Disturbances in Rats Reared on Diets Deficient in Vitamin A, ibid. **7**:455, 1934.

2. Wolbach, S. B., and Bessey, O. S.: (*a*) Tissue Changes in Vitamin A Deficiency, Physiol. Rev. **22**:233, 1942; (*b*) Vitamin A Deficiency and the Nervous System, Arch. Path. **32**:689 (Nov.) 1941. (*c*) Wolbach, S. B.: Vitamin A Deficiency and Excess in Relation to Skeletal Growth, Proc. Inst. Med. Chicago **16**:118, 1946; (*d*) Pathology in Relation to Nutritional Research, Nutrition Rev. **3**:193, 1945.

3. Fletcher, D. E., and Rigdon, R. H.: Neurologic Manifestations Associated with Vitamin A Deficiency in Young Ducks: A Clinical and Pathologic Study, Arch. Neurol. & Psychiat. **61**:199 (Feb.) 1949.

4. Wolbach, S. B.: Letter to the Editor, Nutrition Rev. **6-7**:319, 1948-1949.

of the long bones of ducks, some of which were fed a hypovitaminosis-A and some a hypervitaminosis-A ration, no osseous lesions were found.[5]

This paper is a report of additional studies on the pathologic changes observed in ducks fed a ration deficient in vitamin A.

METHODS AND MATERIALS

The ducks were young white pekins obtained from the same hatchery when 2 to 3 days of age. The vitamin-A-deficient ration[6] contained the following:

	Per Cent
Mineralized salt	0.25
Purifiavin (250)® *	1.00
Calcium carbonate	2.00
Wheat germ	5.00
Soybean-oil meal	18.00
Fish meal (60%)	6.00
Meat scraps	4.00
Brewers' yeast	5.00
Ground wheat	19.65
White corn	29.00
Ground oats	5.00
Molasses	5.00
Dry vitamin D (2,000 U. S. P. units of vitamin D)	0.10

* Purifiavin® is a mixture of components of the B complex, as follows:

	Mg./100 Gm. of Ration
Thiamine hydrochloride U. S. P.	0.5
Riboflavin U. S. P.	0.5
Choline chloride	200.0
Folic acid	0.5
Nicotinic acid U. S. P.	5.0

The controls were fed commercial rations.[7] Food and water were available at all times.

Some of the ducks fed the vitamin-A-deficient ration were given by mouth capsules containing a vitamin-A supplement, 10,000 units per capsule.[5] Usually a capsule was given every 48 hours. Some of the ducks fed the vitamin-A-deficient ration were given gelatin capsules containing 100 units of vitamin A prepared by Eli Lilly & Company specifically for use in this experiment.[9]

The ducks were observed for approximately 10 weeks. They were usually killed after the development of clinical symptoms. The spinal cord and adjacent nerves and ganglia were carefully removed and fixed in a dilute solution of formaldehyde U. S. P. (1:4). Subsequently, multiple sections were removed from the spinal cord, and paraffin sections were prepared. Histologic sections were stained routinely with hematoxylin and phloxine, while selected sections were stained with thionine for Nissl's substance. From some birds portions of the brachial and sacral plexus were removed for histologic study. Microscopic studies were made only on ducks that were killed and submitted to autopsy immediately.

From some of the ducks the vertebral columns were removed. They were also fixed in a dilute solution of formaldehyde and subsequently cut with a band saw. They were cut in either the anteroposterior or the lateral plane. The spinal cord with attached dura was removed, and the vertebral foramen was examined macroscopically.

5. Rigdon, R. H.; Rude, J. C., and Biere, J. G.: Effect of Hypervitaminosis A and Hypovitaminosis A on the Skeleton of a Duck. A. M. A. Arch. Path. 52:299 (Oct.) 1951.

6. The vitamin-A-deficient ration was prepared by Dr. H. C. Schaefer, of the Ralston Purina Company, St. Louis.

7. These were duck startena® and growena,® made by the Ralston Purina Company, St. Louis.

8. This preparation was alphalin,® made by Eli Lilly & Company, Indianapolis.

9. This special vitamin preparation was made available by Dr. C. E. Roach, of Eli Lilly & Company, Indianapolis.

CLINICAL OBSERVATIONS ON VITAMIN-A-DEFICIENT DUCKS

The clinical manifestations of vitamin-A deficiency in the duck have been described in previous publications.[10] In the present study the first abnormal symp-



Fig. 1.—*A*, *B*, *C*, and *D* show Duck 1, aged 26 days, fed a vitamin-A-deficient ration; weight, 500 gm. This duck is weak and unstable on its feet. It shows increased lacrimation, indicated by the moist area around the eye.

E and *F* show Duck 2, aged 26 days, fed a vitamin-A-deficient ration supplemented with large amounts of vitamin A; weight, 775 gm. This duck is normal.

10. (*a*) Rigdon, R. H.: Clinical Observations on Vitamin A Deficiency in Young Ducks, Texas Rep. Biol. & Med. 5:438, 1947. (*b*) Fletcher and Rigdon.[8]

tom observed was weakness, accompanied with increased lacrimation. Frequently the down was moist in a zone around the eyes. Sometimes the nares were either partially or completely occluded and the birds would breathe by opening their bills. At times the ducks would move their heads and necks in a purposeless manner to and fro and to right and left. They became ataxic, progressively weaker, unstable, and finally unable to eat and drink. Death occurred soon thereafter. Figure 1 illustrates some of these clinical observations. The vitamin-A-deficient duck shown

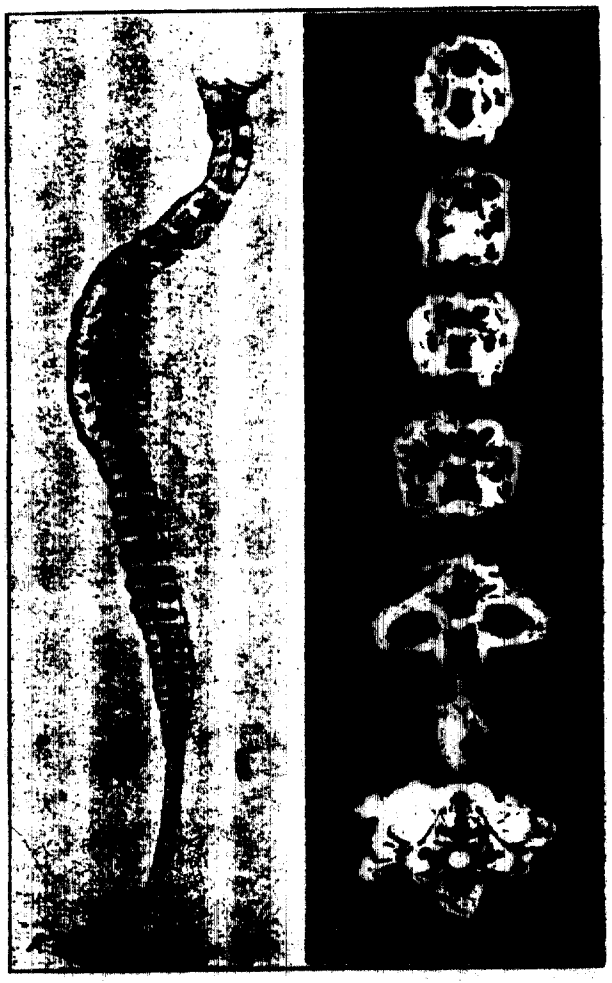

Fig. 2.—*A*, drawing of the vertebral column of a normal duck. This is a lateral view and shows concavities where the spinal nerves leave the vertebral foramen.

B, transverse sections through the vertebral bodies of a normal duck. Note that the space is extradural. This is located laterally and dorsal to the spinal cord. The size of this space is much less in the lower thoracic and lumbar region.

in Figure 1*A*, *B*, *C*, and *D* was 26 days of age and weighed 500 gm. The control shown in Figure 1*E* and *F* was fed the same deficient ration supplemented with vitamin A and weighed 775 gm. at 26 days of age.

The time of onset of neurological symptoms varied in different ducks and also in different groups of ducks. Usually the symptoms appeared about the third week, and by the sixth week most of the birds were moribund. Although this study was

Fig. 3.—Vertebrae from a normal duck: *A*, lateral view of the cervical region. Note the concavities between the vertebral bodies.

B, ventral surface of the vertebral bodies. Note the absence of any concavities here.

C, dorsal half of the vertebral bodies. Note the concavities between the bodies of the vertebrae similar to those described on the lateral surfaces in *A*.



Fig. 4.—Vertebrae from a duck fed the deficient ration for 38 days: *A*, lateral view of the vertebrae showing concavities. This aspect is the same as that observed in normal ducks.

B, dorsal view of the vertebral foramen showing concavities between each two bodies. This aspect is also the same as that observed in normal ducks.

In *C*, note the space between the spinal cord and the vertebral bodies.

D, spinal cord and nerves from a duck fed the deficient ration for 30 days. No gross lesions are present in the spinal cord, ganglia, or nerves.

carried on throughout most of the year, it would seem that clinical symptoms develop earlier in ducks obtained during the summer months than in those observed in the winter and early spring.

Ducks fed the vitamin-A-deficient ration supplemented with adequate doses of vitamin A grew at a normal rate.[5] Birds fed the deficient ration and given only 100 units of vitamin A ultimately had symptoms of vitamin-A deficiency. All ducks fed the vitamin-A-deficient ration showed an absence of yellow pigments in the skin. Previous observations had shown an absence of vitamin A in the livers of ducks fed this vitamin-A-deficient ration.[11]

OBSERVATIONS ON THE VERTEBRAE OF THE DUCK

The vertebral columns of 35 normal ducks varying in age from 2 to 10 weeks were studied. Figure 2*A* is a drawing of the spinal column of a duck. The number of vertebrae, determined by roentgenograms, varied between 47 and 50. Sometimes it was difficult, in young birds, to determine the number of vertebrae in the distal end of the column. There were large concavities in the areas of the intervertebral foramina. A similar concavity was present in the midline in the dorsal area of the vertebral foramen (Fig. 3*A* and *C*). The size of these concavities varied; the largest were present in the cervical and thoracic portions of the vertebral column. They were essentially absent in the lumbar and sacral region. Transverse sections of the vertebral column showed these potential spaces within the foramen to be extradural (Fig. 2*B*).

Similar observations were made on the vertebrae of 10 ducks, 3 to 7 weeks of age, fed the vitamin-A-deficient ration. No abnormal variations were present. Portions of the vertebral column from a duck 37 days of age fed the deficient ration and showing the clinical manifestations of vitamin-A deficiency are shown in Figure 4*A*, *B*, and *C*. Concavities are present here in this vertebral foramen (Fig. 4*A* and *B*) similar to those in the ducks fed the standard ration.

The spinal cord of a vitamin-A-deficient duck is shown in Figure 4*C*. There are no areas where the cord appears to be compressed by an overgrowth of bone. The cord, with attached nerves and ganglia, of a duck fed the vitamin-A-deficient ration for 30 days is shown in Figure 4*D*. No macroscopic abnormalities are present.

The vertebral columns of six ducks fed the vitamin-A-deficient ration supplemented with vitamin A did not show any macroscopic variations as compared with the controls.

PATHOLOGIC STUDY OF THE NERVOUS TISSUE

The spinal cords from 50 normal ducks, 14 to 42 days of age, were examined macroscopically, and no abnormalities were observed. Histologic studies were made on 20 of these. The only feature of particular interest noted was a clumping of Nissl's substance in many of the nerve cells, much more than one finds routinely in normal human nerve cells. No areas of either cartilage or bone formation were found in any of the ducks fed the standard ration.

Similar macroscopic observations were made on the spinal cords of 30 ducks, 24 to 65 days of age, fed the vitamin-A-deficient ration. The majority of these birds were killed after clinical symptoms of vitamin-A deficiency had developed, and a few were killed before any symptoms appeared. No macroscopic lesions were found

11. Fletcher and Rigdon.[3] Rigdon, Rude, and Biere.[5] Rigdon.[10a]

Fig. 5.—In *A* the nerve cells on the left are pyknotic. The nuclei are not visible. The four cells on the right show some clumping of Nissl's substance. This duck was on the deficient ration for 23 days. Hematoxylin and phloxine stain; × 516.

In *B* the cell on the right is pyknotic and atrophic. Note the large space around this cell. The cell on the left shows some clumping of Nissl's substance; however, it is less severely injured. Duck J-4, aged 44 days; deficient ration. Hematoxylin and phloxine stain; × 731.

C shows a cell a portion of which is absent. Note the space about it. Duck J-3, aged 45 days; deficient ration. Hematoxylin and phloxine stain; × 731.

Fig. 6.—In *A*, the nerve cells in the anterior horn are atrophic, and several are absent. The vitamin-A-deficient ration was fed this duck for 44 days. Hematoxylin and phloxine stain; × 22.8.

B, control for *A*. The standard ration was fed this duck, N-2. Hematoxylin and phloxine stain; × 22.8.

Fig. 7.—In *A*, note the many spaces where nerve cells previously were located. No cellular reaction accompanies this degeneration. Duck J-4, aged 45 days; deficient ration. Hematoxylin and phloxine stain; × 87.3.

In *B*, anterior horn cells are present. Duck N-5; standard ration. Hematoxylin and phloxine stain; × 87.3.

in any of these birds; however, histologically a few petechiae were present. Usually they were located within the gray substance of the cord. The nerve cells frequently were shrunken and dark-staining, and the nuclei were invisible (Fig. 5*A*). A clear space surrounded many of these pyknotic nerve cells (Fig. 5*B* and *C*). Fragmented nerve cells were present (Fig. 5*C*). It is of interest to note the absence of a cellular reaction about these degenerating nerve cells, such as that occurring about degenerated nerve cells in the human. The degenerative lesions within the nerve cells were more conspicuous within the anterior horns; however, they were present in the posterior horns of the spinal cords and in the root ganglia. Similar changes of a lesser degree could be demonstrated within the cells in the area of the basal nuclei. This lesion was not uniform within the spinal cord, the nerve cells at some levels being more involved than others. Figures 6*A* and 7*A*, showing sections of the spinal cords of ducks fed the deficient ration for 44 and 45 days, respectively,

Fig. 8.—*A*, nerve root ganglion from a duck (J-11) fed the deficient ration for 57 days. The nerve cells are pyknotic and atrophic. Some are absent. Hematoxylin and phloxine stain; × 91.6.

B, control for *A*. Duck N-5; fed standard ration. Hematoxylin and phloxine stain; × 91.6.

reveal spaces within the anterior horn formerly filled by nerve cells. At the time these ducks were killed there were clinical symptoms of vitamin-A deficiency.

The spinal ganglia of both the normal and the deficient birds were studied. A few pyknotic nerve cells were found in the former group, and a few spaces were present, indicating the sites where nerve cells previously were located. On the contrary, degenerative changes were conspicuous in the ganglia of some of the vitamin-A-deficient ducks. Many of the nerve cells had disappeared in some of the ducks fed the vitamin-A-deficient ration (Fig. 8*A*).

In view of the degenerative changes demonstrated within the spinal cord and ganglia, sections of the peripheral nerves and spinal cords were stained with osmic acid. A few minute areas of degeneration were present in the peripheral nerves of ducks fed the vitamin-A-deficient ration. Since similar areas were present in the nerves of ducks fed the standard ration, no significance was attributed to the lesion.

No changes were demonstrated with osmic acid in the spinal cords of ducks whether these were on the deficient or on the standard rations.

In Figure 9 are some of the lesions observed in ducks fed this same vitamin-A-deficient ration and reported by Fletcher and Rigdon [3] in 1949. The hemorrhages were very conspicuous. Focal areas of cartilage and osseous tissues frequently occurred in the nervous tissue. Since the original publication did not have good

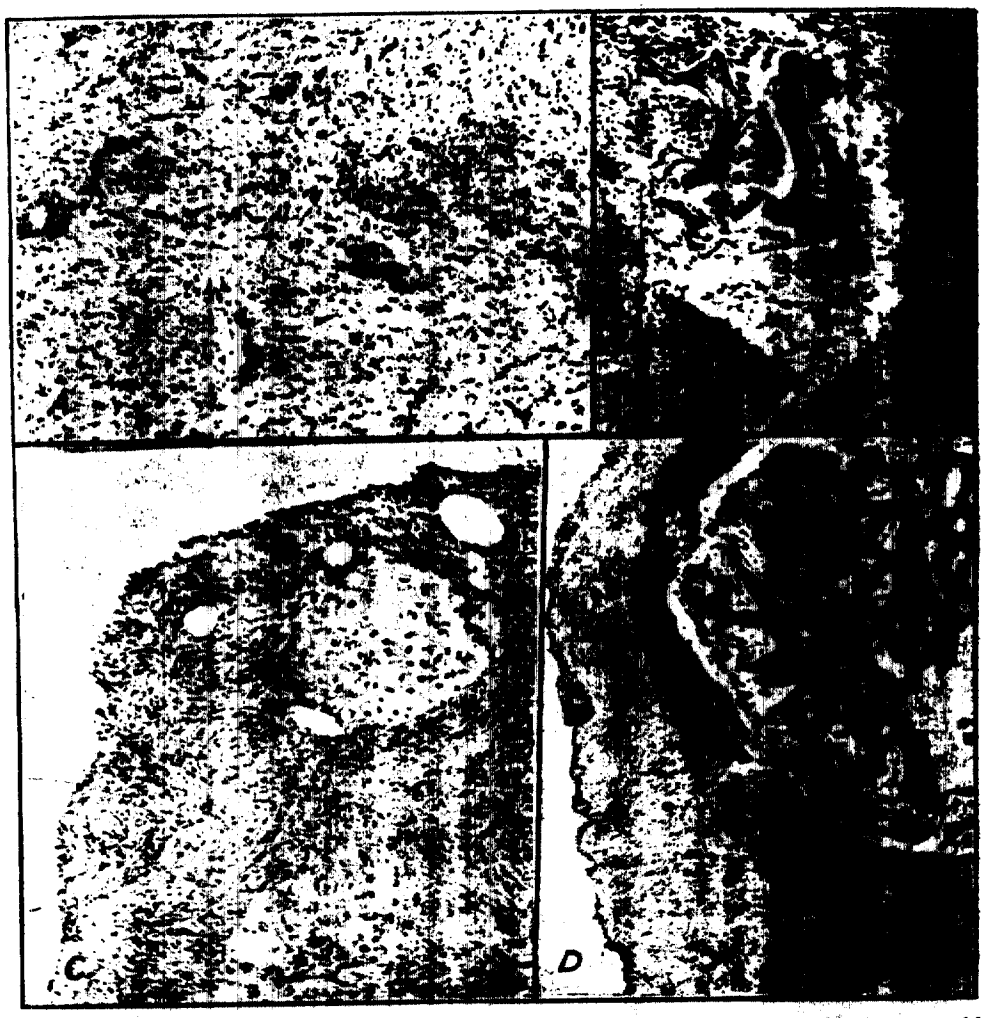

Fig. 9.—*A*, Duck 525, aged 14 days; weight, 315 gm.: deficient ration. The bird was unable to walk, falling from side to side. It moved its head and neck to and fro. Note the large area of hemorrhage. Hematoxylin and phloxine stain: × 85.7.

B, Duck A-8-4, aged 13 days; deficient ration. The bird was weak and shaking all over. Note the bone and myeloid tissue in the spinal cord. Hematoxylin and phloxine stain; × 97.

C, Duck A-8-5, aged 13 days; deficient ration. It was weak and shaking all over. A focal area of cartilage is present in the cord. Hematoxylin and phloxine stain; × 97.

D, Duck A-8-2, aged 11 days; deficient ration. No vitamin A was demonstrated in the liver. There is a focal area of osteoid tissue in the spinal cord. Hematoxylin and phloxine stain; × 57.

illustrations of these pathologic lesions, they are included in this paper. Why there is an absence at this time of large hemorrhages and of foci of cartilage and bone formation in ducks fed the same ration is unknown.

COMMENT

In any study on vitaminosis it is preferable to use a synthetic ration. That the present ration was deficient in vitamin A and apparently adequate in other nutritional requirements is supported by the observations on the growth of ducks when vitamin A was supplemented.[5] Furthermore, the liver was deficient in vitamin A in ducks fed this ration.[12] When this ration was used by Fletcher and Rigdon in 1949,[3] the ducks showed earlier and more pronounced clinical manifestations; the hemorrhages within the nervous tissue were larger and more frequent, and foci of bone and cartilage were present. In the present study there were few petechiae and no foci of bone and cartilage formation. Degenerative changes were present in the nerve cells at both times, but they were more conspicuous in the latter experiment. In the present study a larger number of ducks were studied than in the previous one.

There is no evidence in the present study to show that the degenerative changes in the nervous system are secondary to osseous changes resulting in mechanical pressure on the nerves. It would appear that the absence of vitamin A is the basis of the degenerative changes within the nerve cells. The absence of degenerative changes within the peripheral nerves of these ducks may be attributed to an insufficient length of time for such to occur secondarily to the degeneration of the nerve cells within the spinal cord.

The absence of macroscopic lesions in the vertebrae in this study and the failure to demonstrate either histologic or roentgenographic lesions in the long bones of the extremities in a previous study[5] would suggest that the metabolic processes referable to vitamin A are different in the bird from those described by Wolbach[2c] in rats and guinea pigs.

In removing the spinal cord, if the pia is torn, the cord will herniate producing a small nodule on the surface. Such an artifact did not occur in the spinal cords that Fletcher and Rigdon[3] formerly described as having nodules in the lateral and dorsal regions. These nodules apparently resulted from the hemorrhages, bone, and cartilage occurring within the cord. The normal concavities located in the lateral and dorsal portions of the vertebral foramen are adequate to permit considerable local swelling of the spinal cord. The nodules previously described as occurring on the spinal cord apparently occurred in these specific areas.

SUMMARY

The pathologic changes occurring in young ducks fed a vitamin-A-deficient ration are found primarily in the nerve cells of the spinal cord and the spinal root ganglia. Few petechiae are present in the gray substance of the cord. The vertebral column was carefully examined to see whether the osseous tissue had compressed the cord. Such pressure was not demonstrated. Foci of cartilage and bone and large hemorrhages also were not present in the central nervous system of these ducks; however, they were fed the same vitamin-A-deficient ration as was used previously by Fletcher and Rigdon.[3] The explanation of this variation in the occurrence of lesions in ducks is not known.

The photographs were made by Mr. F. W. Schmidt, director of the Department of Medical Photography, University of Texas Medical Branch.

12. Fletcher and Rigdon.[3] Rigdon, Rude, and Biere.[6]

Boll. Soc. Hal. Biol. Sper. 42(4):194-196. 1966.
(Italian publication, pp. 194-6)

Rinaudo-'66
Bib. No. 7686

Reproduced by permission
of the copyright owner

Uridine diphosphoglucose-glycogen glucosyl transferase, glycogen phosphorylase and alpha-amylase in rat liver under hypervitaminosis A

M. T. Rinaudo, M. L. Antoniotti and P. C. Montecucchi

(From the Institute of Biological Chemistry, University of Torino)

Torino Chapter - Session of December 6, 1965

Ray et al. (1), when administering strong doses of vitamin A to albino rats for 10 days, observed a reduction of the glycogen content in the liver, and, in the diaphragm, kept in a Ringer solution to which glucose had been added, a decrease in the capacity to use the monosaccharide of the medium and to form glycogen. These changes seemed to originate from an alteration of the enzymes involved in the synthesis and breakdown of the polysaccharide.

We therefore focused our attention on the reactions catalyzed by uridine diphosphoglucose-glycogen glucosyl transferase and by glycogen phosphorylase in the liver of rats under hypervitaminosis A. In the same tissue and under the same experimental conditions, we also determined the alpha-amylase, in case of any relationship with the glycogen synthesis.

The research was conducted on male albino rats, body weight 60-70 g. The hypervitaminosis A was obtained by subcutaneous administration of 7,000 I.U. of vitamin A in oil (preparation of the firm "Glaxo" of Verona) (*), for a period of 7 days, and 14,000 I.U. per day for the following 7 days. In the course of the treatment the rats lost weight and developed hemorrhagic symptoms on the skin and keratinization of the tail.

The treated animals and the controls were kept fasting for 36 h before being used for the experiments.

To determine the uridine diphosphoglucose-glycogen glucosyl transferase we used a preparation obtained by homogenizing 1 g of liver with 8 ml of sucrose 0.25 M, disodium ethylene diaminotetra acetate 0.001 M, and then

centrifuging at 1200 rpm for 10 min at 0°; 0.05 ml of the supernatant was used for the test, carried out as described by Leloir and Goldenberg (2).

To measure the glycogen phosphorylase, use was made of an extract obtained by centrifuging at 1,200 rpm for 10 min at 0° a 5% homogenate, prepared according to Danforth et al. (3). Also the composition of the assays, in which 0.1 ml of enzymatic preparation was brought to a final volume of 0.5 ml, was that described by Danforth et al. (3). The reaction was allowed to proceed for 30 min at 30° and was stopped with 1 ml of trichloroacetic acid 5%. After centrifugation, the orthophosphate formed was determined colorimetrically on the clear liquid according to Youngburg and Youngburg (4).

A homogenate prepared with 1 g of liver and 10 ml of KCl 0.15 M was used for the determination of the alpha-amylase. The assays contained 0.25 ml of starch 2%; 0.125 ml of NaCl 0.268 M; 0.125 ml of regulating solution of K_2HPO_4-KH_2PO_4 0.08 M pH 7, and 0.5 ml of the homogenate. After 40 min at 25°, the reaction was stopped by adding 1 ml of perchloric acid 5%. The glucose formed was measured enzymatically according to Hugget and Nixon (5).

In the liver of rats treated with strong doses of vitamin A, the uridine diphosphoglucose-glycogen glucosyl transferase is reduced 29%, while the glycogen phosphorylase is increased 25%; the hydrolysis of the glycogen, supported by the alpha-amylase, occurs more slowly; the percentual variation equals -36.

The table gives the values obtained.

These results suggest that the decrease of the glycogen found by Ray and Sadhu (1) in the liver of rats under hypervitaminosis A may be attributable to a deceleration of the synthesis and to an increased breakdown of the polysaccharide. In fact, uridine diphosphoglucose-glycogen glucosyl transferase, considered as an enzyme which limits the formation of glycogen in the liver, diminishes in the treated animals, while the glycogen phosphorylase,

which brings about the breaking down of the glycidic molecule, increases.

TABLE - Uridine diphosphoglucose-glycogen glucosyl transferase, glycogen phosphorylase and alpha-amylase in the liver of rats under hypervitaminosis A.

Enzymes	Normal rat	Rat under hypervitaminosis A
Uridine diphosphoglucose-	82/12 ± 4.03(6)	58.19 ± 5.94 (6)
Glycogen phosphorylase, µg Pi	44.00 ± 2.09(6)	55.30 ± 2.05 (6)
alpha-amylase, µg glucose	54.83 ± 5.72(6)	35.00 ± 4.42 (6)

With regard to the alpha-amylase, the reduction observed, together with that of the glycogen synthetase and the glycogen level, would lead to assume, at least in the conditions examined by us, a participation of the hydrolase in the formation of new polysaccharidic molecules. That would be in accordance with the hypothesis of Bernfeld (6), according to whom alpha-amylase has the function of supplying those short chains of glucosylic radicals which act as acceptors of the glucose units transferred to them by the glycogen synthetase; it is, however, not confirmed under other experimental conditions (7).

(*) We are indebted to "Glaxo" for donating the sample of Vitamin A in oil solution used in the research.

(1) A. Ray, D. P. Sadhu, Nature, 1959, 184: 1323.

(2) L. F. Leloir, S. H. Goldenberg, J. Biol. Chem. 1954, 208: 149.

(3) W. H. Danforth et al., Proc. Nat. Acad. Sc. 1962, 48: 1191.

(4) G. E. Youngburg, M. V. Youngburg, J. Lab. Clin. Med. 1930, 16: 158.

(5) A Hugget, D. A. Nixon, Biochem. J. 1956, 66: 12 P.

(6) P. Bernfeld, "Biogenesis of Natural Compound", Pergamon Press, 1963,

(7) N. Bargoni, C. Lenti, Enzymologia, 1965, 29: 299.

Translated by Carl Demrick Associates, Inc./LH/db

URIDINDIFOSFOGLUCOSO-GLICOGENO GLUCOSIL TRANSFERASI, GLICOGENO FOSFORILASI ED α-AMILASI NEL FEGATO DI RATTI IN IPERVITAMINOSI A. — M. T. RINAUDO, M. L. ANTONIOTTI e P. C. MONTECUCCHI.

(*Dall' Istituto di Chimica Biologica dell' Università di Torino*).

Sezione di Torino — Seduta del 6 dicembre 1965.

Ray e coll., (1), somministrando a ratti albini forti dosi di vitamina A per 10 giorni, osservarono nel fegato una diminuzione del contenuto di glicogeno e nel diaframma, mantenuto in una soluzione di Ringer addizionata di glucoso, una caduta della capacità di utilizzare il monosaccaride del mezzo e di formare glicogeno. Queste modificazioni sembrano originare da una alterazione degli enzimi, che intervengono nella sintesi e nella demolizione del polisaccaride.

Abbiamo pertanto rivolta la nostra attenzione all'esame delle reazioni catalizzate dalla uridindifosfoglucoso-glicogeno glucosil transferasi e dalla glicogeno fosforilasi nel fegato di ratti in ipervitaminosi A. Inoltre abbiamo determinato, nello stesso tessuto e nelle medesime condizioni sperimentali, l'α-amilasi, nell'eventualità di un suo rapporto con la glicogenosintesi.

Le indagini venivano condotte su ratti albini maschi, del peso corporeo di g 60–70. L'ipervitaminosi A era ottenuta somministrando, per via sottocutanea, 7.000 U.I. di vitamina A in soluzione oleosa (preparato della ditta « Glaxo » di Verona) (*), per un periodo di 7 giorni e 14.000 U.I. al giorno per i 7 giorni successivi. Nel corso del trattamento i ratti perdevano di peso, andavano incontro a manifestazioni emorragiche a livello della cute e a cheratinizzazione della coda.

Gli animali di controllo e quelli trattati erano tenuti a digiuno per 36 h prima di essere utilizzati per gli esperimenti.

Per la determinazione dell'uridindifosfoglucoso-glicogeno glucosil transferasi serviva un preparato ottenuto omogenando g 1 di fegato con ml 8 di saccarosio 0.25 M– etilendiaminotetraacetato bisodico 0,001 M e quindi centrifugando a 1.200xg per 10 min a 0°; ml 0,05 del surnatante erano utilizzati per il saggio, effettuato secondo le indicazioni di Leloir e Goldenberg (2).

Per la misura della glicogeno fosforilasi si faceva uso di un estratto ottenuto centrifugando a 1.200xg per 10 min a 0° un omogenato al 5%, preparato secondo le indicazioni di Danforth e coll. (3). Anche la composizione delle prove, in cui si portavano ml 0.1 di preparato ezimatico in un volume finale di ml 0.5, era quella descritta da Danforth e coll. (3). La reazione si lasciava procedere per 30 min a 30° e si arrestava con ml 1 di acido tricloroacetico al 5%. Dopo centrifugazione sul liquido limpido si determinava colorimetricamente l'ortofosfato formato secondo Youngburg e Youngburg (4).

Un omogenato preparato con g 1 di fegato e ml 10 di KCl 0,15 M era adoperato per la determinazione dell'α-amilasi. Le prove contenevano ml 0,25 di amido al 2%: ml 0.125 di NaCl 0,268 M; ml 0.125 di soluzione regolatrice di K_2HPO_4–KH_2PO_4 0,08 M pH 7 e ml 0,5 dell'omogenato. Dopo 30 min a 25°, si arrestava la reazione per aggiunta di ml 1 di acido perclorico al 5%. Il glucoso formato era misurato per via enzimatica secondo le indicazioni di Hugget e Nixon (5).

Nel fegato di ratti, trattati con forti dosi di vitamina A, l'uridindifosfoglucoso-glicogeno glucosil transferasi risulta diminuita del 29%, mentre la glicogeno fosforilasi aumenta del 25%; l'idrolisi del glicogeno, promossa dall'α-amilasi si svolge più lentamente; la variazione percentuale è pari a –36.

Nella tabella sono riportati i valori ottenuti.

Alla luce dei risultati riferiti la diminuzione del glicogeno riscontrata da Ray e Sadhu (1) nel fegato di ratti in ipervitaminosi A sembra quindi potersi addebitare ad un rallentamento della via di sintesi e ad un incremento di quella demolitiva del polisaccaride. Infatti l'uridindifosfoglucoso-glicogeno glucosil transferasi, considerato quale enzima limitante la formazione di glicogeno nel fegato, diminuisce negli animali trattati, mentre

(*) Ringraziamo sentitamente la ditta « Glaxo » per averci donato il campione di vitamina A in soluzione oleosa, utilizzato nella ricerca.

aumenta la glicogenofosforilasi, che avvia la demolizione della molecola glicidica.

TABELLA. — *Uridindifosfoglucoso-glicogeno glucosil transferasi, glicogeno fosforilasi ed α-amilasi nel fegato di ratti in ipervitaminosi A.*

Enzimi		Ratto normale	Ratto in ipervitaminosi A
Uridindifosfoglucoso-glicogeno glucosil transferasi	μg UDP	82,12 ± 4,03 (6)	58,19 ± 5,94 (6)
Glicogeno fosforilasi	μg Pi	44,00 ± 2,09 (6)	55,30 ± 2,05 (6)
α-amilasi	μg glucoso	54,83 ± 5,72 (6)	35,00 ± 4,42 (6)

Per quanto riguarda l'α-amilasi, la diminuzione osservata, insieme con quella della glicogeno sintetasi e del livello del glicogeno, porterebbe ad ammettere, almeno nelle condizioni da noi esaminate, una partecipazione dell'idrolasi alla formazione di nuove molecole polisaccaridiche. Tale affermazione sarebbe in accordo con l'ipotesi di Bernfeld (6), secondo la quale l'α-amilasi avrebbe il compito di fornire quelle brevi catene di radicali glucosilici, che fungerebbero da accettori delle unità di glucoso ad essi trasferite dalla glicogeno sintetasi; essa non trova tuttavia riscontro in altre condizioni sperimentali (7).

(1) Ray A., Sadhu D. P., Nature, 1959, 184, 1323.
(2) Leloir L. F., Goldenberg S. H., J. Biol. Chem., 1954, 208, 149.
(3) Danforth W. H. e coll., Proc. Nat. Acad. Sc., 1962, 48, 1191.
(4) Youngburg G. E., Youngburg M. V., J. Lab. Clin. Med., 1930, 16, 158.
(5) Hugget A. St. G., Nixon D. A., Biochem. J., 1956, 66, 12 P.
(6) Bernfeld P., « Biogenesis of Natural Compound », Pergamon Press, 1963, p. 282.
(7) Barconi N., Lenti C., Enzymologia, 1965, 29, 299.

Robens, J.
Bib. No. 7705

TOXICOLOGY AND APPLIED PHARMACOLOGY 16, 88–99 (1970)

Teratogenic Effects of Hypervitaminosis A in the Hamster and the Guinea Pig

JANE F. ROBENS[1]

Division of Pharmacology and Toxicology, Food and Drug Administration, Department of Health, Education, and Welfare, Washington, D.C. 20204

Received March 7, 1969

Teratogenic Effects of Hypervitaminosis A in the Hamster and the Guinea Pig. ROBENS, JANE F. (1970). *Toxicol. Appl. Pharmacol.* 16, 88–99. The teratogenic effects resulting from hypervitaminosis A in the hamster and the guinea pig were studied. Hamsters were treated with 75,000 or 400,000 USP units of vitamin A palmitate per kilogram body weight as single or multiple oral doses during organogenesis. Guinea pigs were treated with 200,000 USP units/kg as a single oral dose during organogenesis. These doses were up to several hundred times the minimum daily requirement of each species. Similar, but not identical, soft tissue and skeletal anomalies, including the following, were produced in each species: exencephaly, brachygnathia, agnathia and other head malformations, shortened, curved legs with impaired or absent calcification at the highest dosage levels, fused ribs, spina bifida, shortened tails, and heart and genitourinary system anomalies. The percentage of fetal resorptions and the nature of the anomalies depended on the time of administration and the dose administered. Multiple administration in the hamster at the higher dosage levels produced a higher level of fetal mortality than did any level of single administration. Average fetal weight in the hamster fetuses was decreased by the same dosage level. Fetal growth in the guinea pig was not affected by vitamin A.

The teratogenic effects of hypervitaminosis A in laboratory animals are well documented (Cohlan, 1953, 1954; Deuschle *et al.*, 1959; Kalter and Warkany, 1961; Giroud and Martinet, 1955; Mizutani *et al.*, 1966). Most of these studies were with rats, mice, and rabbits. Few were performed with either guinea pigs (Giroud and Martinet, 1959a,b) or hamsters (Marin-Padilla and Ferm, 1965).

Since previous studies reported anomalies of several body systems, we treated hamsters and guinea pigs on several different days during organogenesis in an attempt to produce the spectra of teratogenic effects of hypervitaminosis A. Our studies confirm and expand the observations reported by Giroud and Martinet (1959a,b) and Marin-Padilla and Ferm (1965).

METHODS AND MATERIALS

Golden Syrian hamsters, *Mesocricetus auratus*, and Coulson strain guinea pigs, *Cavia porcellus*, were used. The hamsters were shipped to our laboratories by the

[1] Present address: Hoffman-La Roche, Inc., Nutley, New Jersey 07110.

commercial supplier the second day after breeding. The guinea pigs were mated in our laboratory. The first day after mating was considered as day 0 of gestation.

Vitamin A was administered as individual oral doses during the period of organogenesis. A water-dispersible vitamin A palmitate,[2] 250,000 USP units/g, was suspended in distilled water. The various concentrations were prepared to give a uniform dose volume of 1 ml/100 g body weight. Control animals received vehicle by intubation.

In the hamster, single administration was on day 7, 8, 9, or 10 of gestation; multiple administration was from days 6 through 10. On each of days 14 through 20 of gestation, different groups of guinea pigs were given single doses.

On day 15 of pregnancy, the hamsters were killed with carbon dioxide. The uterus was opened and examined for the presence of resorption sites; the fetuses were removed, weighed, and examined for external malformations. The viability of the living fetuses was checked by placing them in a chicken hatching incubator for 6 hours. Most guinea pigs were allowed to deliver normally since they do not cannibalize their young. A few were sacrificed at 50 days of gestation. All pups were weighed at birth and examined for external malformations. In addition, fetuses showing gross abnormalities were examined further for bone defects by fixation in alcohol, clearing, and staining in Alizarin red and for internal malformations with the aid of a dissecting microscope when necessary.

Both fetuses dying in late embryonic life and resorption sites were counted as dead fetuses. This number as a fraction of the total number of implantation sites is the percent fetal mortality. The percentage of terata was based on the total number of fetuses in which abnormalities could be recognized, that is, both living and dead fetuses.

Average fetal weight for the hamster fetuses was calculated by totaling litter weights and dividing by the total number of fetuses. Newborn guinea pigs were weighed individually, and the weights were averaged. Average individual fetal weights rather than litter weights are reported since the former generally reflect more accurately the size and condition of the fetuses. Total weight varies more as a function of the number of fetuses than of their individual size.

RESULTS

Hamsters

Tables 1 and 2 summarize the results of vitamin A administration to the hamsters.

Head anomalies were common as a result of maternal treatment on day 7. The pale fetuses often had severe exencephaly. Others had lesser degrees of the same anomaly; in a few the exencephaly was so slight that only a cutaneous pimple in the center of the cranium could be seen on gross examination. Microcephaly, a shortening of the premaxillae, maxillae, and/or mandibles, and a few cases of hydrocephalus are included in the category of malformed heads. At 400,000 USP units/kg, severe shortening of the jaws occurred, particularly of the lower jaw (agnathia). Maxillomandibular ankylosis was present in these fetuses, and the oral opening was small or nonexistent. Lower doses generally produced greater shortening of the upper jaw than of the lower jaw (Fig. 1).

Associated with the arrested development of the head, the orbital cavity was shallow. Many fetuses had unilateral or bilateral bulging eyes not covered by lids (exophthalmos), and in a few cases, the eyes were small or absent.

[2] Nutritional Biochemical Corporation, Cleveland, Ohio.

TABLE 1

EFFECTS OF HYPERVITAMINOSIS A ON FETAL DEVELOPMENT IN THE HAMSTER

Day of gestation treated	Dose by oral intubation (USP units/kg)	No. of mothers	Live fetuses		No. dead fetuses at term	No. resorption sites	Fetal mortality (%)	Av. fetal weight (g)	% of fetuses dead in 6 hr	Terata	
			Total	Per litter						No.	%
7	400,000	5	36	7.2	5	6	23.4	1.8	100	41	100
7	200,000	17	139	8.2	14	32	24.9	2.0	63.3	123	88.4
7	150,000	4	38	9.5	9	4	25.5	2.1	76.5	29	61.5
7	100,000	5	55	11.0	—	—	—	2.2	7.3	14	25.5
7	75,000	4	50	12.5	—	2	3.8	2.3	4.0	0	—
8	400,000	7	65	9.3	—	15	18.8	2.1	67.7	65	100
8	300,000	5	47	9.4	1	6	13.0	2.0	74.5	47	100
8	200,000	23	248	10.8	—	17	9.7	2.0	33.5	196	79.0
8	100,000	3	32	10.7	—	—	—	2.3	—	0	—
9	400,000	13	137	10.5	1	7	5.5	2.1	31.4	91	65.9
9	200,000	13	138	10.6	2	2	2.9	2.2	1.5	73	52.1
9	100,000	3	31	10.3	—	—	—	2.3	—	0	—
10	400,000	5	48	9.6	—	5	9.4	2.1	6.3	48	100
6–10	400,000/day	3	—	—	—	32	100	—	—	0	—
6–10	200,000/day	8	42	5.3	—	54	56.3	1.9	83.3	32	76.2
6–10	150,000/day	5	45	9.0	2	8	18.2	2.0	62.2	29	61.7
6–10	100,000/day	8	78	9.8	3	4	8.2	2.2	5.1	6	7.4
6–10	75,000/day	5	57	11.4	1	—	1.7	2.1	10.5	3	5.2
Controls		99	1081	10.9	3	29	2.9	2.3	0.6	4	0.4

TABLE 2

SPECIFIC FETAL ANOMALIES ASSOCIATED WITH HYPERVITAMINOSIS A IN THE HAMSTER

Day of gestation treated	Dose by oral intubation (USP units/kg)	No. of mothers	No. malformed/ total No. fetuses	Exen-cephaly	Mal-formed heads	Bulging eyes	Cleft palate	Spina bifida	Fused ribs	Short tail	Leg anoma-lies	Umbil-ical hernia
7	400,000	5	41/41	8	36	41	—	16	16	30	—	1
7	200,000	17	123/153	16	63	61	2	10	38	1	—	2
7	150,000	4	29/47	11	7	8	2	1	17	—	—	1
7	100,000	5	14/55	—	12	5	—	—	—	—	—	—
7	75,000	4	0/50	—	—	—	—	—	—	—	—	—
8	400,000	7	65/65	—	5	2	—	1	—	65	1	3
8	300,000	5	47/48	—	3	5	10	—	—	47	—	—
8	200,000	23	196/248	—	7	8	4	1	1	188	1	2
8	100,000	3	0/32	—	—	—	—	—	—	—	—	—
9	400,000	13	91/138	—	—	—	—	—	21	2	89	—
9	200,000	13	73/140	—	1	—	4	—	—	—	71	1
9	100,000	3	0/31	—	—	—	—	—	—	—	—	—
10	400,000	5	48/48	—	3	—	5	—	—	—	48	—
6–10	400,000/day	3	0/0	—	—	—	—	—	—	—	—	—
6–10	200,000/day	8	32/42	—	3	26	14	1	10	—	—	—
6–10	150,000/day	5	29/47	—	4	1	2	—	26	—	—	—
6–10	100,000/day	8	6/81	—	—	—	—	1	5	—	—	—
6–10	75,000/day	5	3/58	—	—	—	1	1	1	—	—	—
Controls		99	4/1081	1	1	—	—	—	1	—	—	1

FIG. 1. Hamsters, Alizarin red stain. Top fetus: Maternal treatment (oral intubation) with vitamin A (200,000 USP units/kg body weight) on day 7 of gestation, resulting in shortened maxillae and mandibles. Lower fetus: Control.

Malformations from treatment on day 7 occurred from doses as low as 100,000 USP units/kg. None appeared in the litters of the 4 animals treated at 75,000 USP units/kg.

A high percentage of fetuses had short or curved tails as a result of treatment at 200,000–400,000 USP units/kg on day 8. The highest dose on day 7, 400,000 USP units/kg, but not the lower doses, also caused shortened tails. When radiographed or stained with Alizarin red, these fetuses with shortened tails had irregular lumbar, sacral, and/or coccygeal vertebrae. Examination of internal organs showed that the kidneys were often small, absent, or hydronephrotic. Several fetuses had imperforate anus; one at the highest treatment level had an ectopic heart.

Treatment on day 9 produced a high percentage of leg defects (Figs. 2 and 3). These included short, thickened legs (micromelia), fused and missing toes (ectrodactylia), and abnormal fixation of joints (arthrogryposis). The most severely affected animals lacked any calcification centers in either the fore or hind limb. All limb anomalies are reported together in Table 2. As at day 8, a level of 200,000 USP units/kg produced anomalies but 100,000 USP units/kg did not.

Leg anomalies from treatment on day 10 were confined to shortened feet and toes except for 6 fetuses which also had arthrogryposis in one or more legs.



FIG. 2. Hamsters. Right fetus: Maternal treatment on day 9 of gestation, resulting in small size, micromelia, and ectrodactylia. Left fetus: Control.

FIG. 3. Feet of hamsters. Left: Maternal treatment on day 9 of gestation, resulting in short, thick leg and micromelia; no calcification when radiographed. Right: Control.

At the highest single dose, 400,000 USP units/kg, most of the fetuses from treatment at any given day were extremely malformed and small and did not survive for the 6-hour period. Usually these fetuses and those from other levels and days of administration which died in the incubator did so within the first hour. When they were examined internally with the aid of a dissecting microscope, heart and great vessel anomalies were found; these included underdevelopment of the left auricle and ventricle, and truncus arteriosis in the most severe cases. Several fetuses were stillborn from mothers dosed on day 7. No respiratory movements could be elicited, although from their condition they apparently had not been dead *in utero*. In most cases they were extremely pale and often edematous.

Litters from mothers treated 5 times (days 6–10) had a large percentage of resorptions. Those fetuses living until term had a wide variety of both external and internal defects but did not have leg anomalies. Many of those treated at 150,000 or 200,000 USP units/kg/day died in the incubator and had heart anomalies. Few terata resulted from treatment with 75,000 or 100,000 USP units/kg/day.

Guinea Pigs

Table 3 shows the results of vitamin A administration to guinea pigs. Litters sacrificed at 50 days of gestation were similar to those delivered at term but, to simplify tabulation of data, are not included; however, results are discussed when applicable.

TABLE 3

EFFECTS OF HYPERVITAMINOSIS A ON FETAL DEVELOPMENT IN THE GUINEA PIG (ORAL ADMINISTRATION)[a]

Day of treatment	No. of litters	No. malformed/ total No. fetuses	Av. fetal weight	Anomalies found
14	4	11/13	95.8	Agnathia, crooked incisors, malformed pinna, ataxia, hypoplastic tympanic bullae, microcephaly
15	7	21/28	95.0	Agnathia, crooked incisors, malformed pinna, hypoplastic tympanic bullae, uterus unicornis, microcephaly, ataxia, atresia ani
16	8	13/33	83.7	Short tails, shallow thoracic cavity, malformed pinna, hyperdontia, microcephaly, agnathia, synotia, ataxia
17	6	10/26	85.3	Short tails (missing coccygeal vertebrae), agnathia
18	5	2/16	95.0	Arthrogryposis hind legs—shortened crooked tibia and fibula
19	5	5/14	96.4	Short bowed front legs, dicheiria and syndactylia of front toes
20	4	9/13	89.6	Short and bowed front and hind legs
Controls	59	1/226	88.9	Conjoined twins

[a] Treatment in all cases was 200,000 USP units/kg.

Most pups from mothers treated on day 14 had microcephaly, micrognathia, or even agnathia (Figs. 4 and 5). Their upper molars were long and malpositioned. The animals which were less seriously affected had both upper and lower incisors, but these teeth were also malpositioned, and all had microstomia. Radiographs of the head showed unilateral or bilateral hypoplastic or absent tympanic bullae. The severely affected animals were all stillborn; one with an apparently normal head was ataxic.

The external ears or pinnae of some pups were small and/or notched in the outer margin, rather than being round and full as in the normal guinea pig. This anomaly was

FIG. 4. Heads of guinea pigs, stained with Alizarin red. Top: Maternal treatment on day 15 of gestation, resulting in micrognathia, malpositioned incisors, and elongated and narrow head. Bottom: Control.

present in stillborn animals as well as in some which were apparently otherwise normal at birth. In some litters sacrificed at 50 days of gestation, fetuses had open eyes. Normally the eyes are still closed at this time. The head anomalies resulting from administration on day 15 were generally similar to those from day 14. In addition, one animal had uterus unicornis; another had atresia ani with the urogenital tract also ending blindly.

Following administration on day 16, fewer pups had agnathia; however, one had synotia combined with agnathia. The larynx and pharynx opened to the exterior on the ventral side of the neck between the ears. One fetus had hyperdontia (a third lower incisor), and 2 others with short tails had missing coccygeal vertebrae.

After treatment on day 17, some of the same defects were present; 7 fetuses from one litter had agnathia, and 3 in another had short tails. Their shortened tails were not associated with atresia ani as with some of the hamsters; thus viability was not

affected and the animals grew normally. A fetus from a litter sacrificed at 50 days had a missing left kidney and a heart anomaly.

FIG. 5a. Radiograph of guinea pig head. Maternal treatment on day 15, resulting in agnathia and absence of tympanic bullae.

FIG. 5b. Radiograph of head of control guinea pig.

Two pups from administration on day 18 had shortened, bowed tibias and fibulas and arthrogryposis of the tarsal joint. Another sacrificed at 50 days had an extremely hypoplastic left ovary and uterus.

As a result of treatment on day 19, 3 pups from one litter had thickening and bowing of the radius and ulna (Fig. 6). Two animals in another litter had fusion of digits 3 and 4 of the front feet (syndactylia). Dicheiria or partial duplication of digit 2 was also present in one foot.

Following treatment on day 20, all fetuses in 2 litters had shortening and bowing of the radius and ulna; in 2 other litters the tibia and fibula were shortened and the tarsal joint twisted.

Fetal growth was not affected by vitamin A. The average fetal weights at birth for the 139 fetuses in the 39 treated litters and that of the 226 fetuses in the 59 control litters were both 89 g.

FIG. 6. Guinea pig forelimbs stained with Alizarin red. Left: Maternal treatment on day 20 of gestation, resulting in shortening and bowing of radius and ulna. Right: Control.

DISCUSSION

The times of administration in both the hamster and the guinea pig were chosen to coincide with the most critical period in organogenesis. Days 7, 8, or 9 were chosen for single, and 6 through 10 for multiple, administration in the hamster since implantation in the hamster is completed on day 5 and the most rapid period of organogenesis is 7–8.5 days (Boyer, 1948). Days 14–20 were chosen for treatment in the guinea pig to coincide with days of comparable organogenesis in the hamster (Scott, 1937).

A wide variety of visceral and skeletal abnormalities were produced in both species. Cranial anomalies and shortened maxillae were common in the hamster but were not found in the guinea pig. Agnathia, however, was much more pronounced in the

guinea pig. Hamster development at term was not complete enough to demonstrate possible effects on the tympanic bullae. Extreme micromelia was produced in the hamster, but only at doses higher than those used in the guinea pig.

The incidence of fetal deaths in the hamster was dependent upon both developmental stage and dose administered. Fetal death and resorption were high in the hamster after administration at day 7, at the highest level of administration, on day 8, and after multiple administration (days 6–10). The incidence of fetal death in the guinea pigs is not known since a sufficient number of mothers were not sacrificed for examination of the uterus and ovaries for resorption sites and number of corpora lutea. It is not likely that vitamin A caused fetal death in the guinea pig litters carried to term since treated litters averaged 3.6 fetuses per litter and the controls averaged 3.8 fetuses per litter. However, vitamin A may have caused early fetal death. Some of the days of treatment occurred before normal estrous recycling, and even a presumptive diagnosis of pregnancy could not be made at this time. Lethality to all the embryos could have been determined only by sacrificing the mothers soon after treatment or by comparing pregnancy rates in a large number of treated and control guinea pigs.

These studies demonstrate (in contrast to Marin-Padilla and Ferm, 1965) that additional abnormalities in hamsters can be produced and recognized, both by using higher doses and by using more methods of examination of fully developed term hamster fetuses. Extremely retarded limb and tail development, imperforate ani, hydronephrosis and anephrosis, and a comparison of fetal viability were not reported previously.

Giroud and Martinet (1959a,b) treated their guinea pigs on days 12–14 of gestation and reported a large number of abortions or resorptions, in addition to fissure of the mandible and bifid tongue. The present studies with administration slightly later in gestation demonstrated more severe mandibular abnormalities, synotia, small or absent tympanic bullae, and limb abnormalities. Although it was not the purpose of this study to establish a minimum teratogenic level of vitamin A, some comparison of the doses used and the effects which resulted with that of the vitamin A requirement is of interest. A satisfactory level of vitamin A to meet the nutritional requirements of the hamster is reported as 1300 IU/100 g of diet (NAS—NRC, 1962). If we assume that the hamster consumes 10 g of food per day, his daily requirement is 130 IU (1300 IU/kg if the body weight is 100 g). The dose of 75,000 USP units/kg for 5 days is probably near the minimum teratogenic dose for the hamster. This is 60 times the daily requirement, and the dose of 200,000 USP units needed to produce severe anomalies is 150–160 times the daily requirement.

Bentley and Morgan (1945) stated that the vitamin A requirement of the guinea pig was 2 mg/kg of body weight when fish liver oil was the source of the vitamin. Gil *et al.* (1968) stated that the minimum requirement was 0.2 mg of vitamin A per animal on the basis of 30 g of food consumed daily. Since the latter study used crystalline retinyl palmitate as a source of vitamin A, we can assume that the requirement was 360 IU per animal daily. If we further take 500 g as an average weight for their animals, then the requirement is 720 IU/kg. Anomalies in guinea pigs were produced in this study with a dose of 200,000 IU/kg or nearly 300 times the daily requirement.

The method of action of hypervitaminosis A in producing teratogenesis is not known. Direct action of vitamin A on the fetus, excessive production of adrenocortical

hormone, and fall in blood concentration of thyroid hormone have been considered (Takekoshi, 1964). Koehhar (1968) believed that at least the cephalic malformations caused by vitamin A occurred from disrupted inductive relation between epithelium and mesoderm. In his studies of rat embryos treated on days 10, 11, and 12 of gestation, decreased rates of thymidine-^{3}H uptake inhibited cell proliferation in liver, some cephalic areas, skin, and the trigeminal nucleus.

On the cellular level, vitamin A may effect change by participating in cellular metabolism, or the adverse effects may be caused by physical characteristics of the vitamin on the developing cells. Lucy (1964) stated that excessive vitamin A *in vitro* on embryonic chick limb bone rudiments changed membrane permeability by affecting the lipoprotein membrane of cell organelles.

REFERENCES

BENTLEY, L. S., and MORGAN, A. F. (1945). Vitamin A and carotene in the nutrition of the guinea pig. *J. Nutr.* **30**, 159–168.

BOYER, C. C. (1948). Development of the golden hamster *Cricetus auratus* with special reference to the major circulatory channels. *J. Morphol.* **83**, 1–38.

COHLAN, S. Q. (1953). Excessive intake of vitamin A as a cause of congenital anomalies in the rat. *Science* **117**, 535–536.

COHLAN, S. Q. (1954). Congenital anomalies in the rat produced by excessive intake of vitamin A during pregnancy. *Pediatrics* **13**, 556–567.

DEUSCHLE, F. M., GEIGER, J. F., and WARKANY, J. (1959). Analysis of an anomalous oculodentofacial pattern in newborn rats produced by maternal hypervitaminosis A. *J. Dental Res.* **38**, 149–155.

GIL, A., BRIGGS, G. M., TYPPO, J., and MACKINNEY, G. (1968). Vitamin A requirement of the guinea pig. *J. Nutr.* **96**, 359–362.

GIROUD, A., and MARTINET, M. (1955). Malformations embryonnaires par hypervitaminose A. *Arch. Franc. Pediat.* **12**, 292–300.

GIROUD, A., and MARTINET, M. (1959a). Tératogénèse par hypervitaminose A chez le rat, la souris, le cobaye et le lapin. *Arch. Franc. Pediat.* **16**, 971–975.

GIROUD, A., and MARTINET, M. (1959b). Estension à plusieurs espèces de mammifères des malformations embryonnaires par hypervitaminose A. *Compt. Rend. Soc. Biol.* **153**, 201–202.

KALTER, H., and WARKANY, J. (1961). Experimental production of congenital malformations in strains of inbred mice by maternal treatment with hypervitaminosis A. *Am. J. Pathol.* **38**, 1–21.

KOEHHAR, D. M. (1968). Studies of vitamin A-induced teratogenesis: effects on embryonic mesenchyme and epithelium and on incorporation of H^3 thymidine. *Teratology* **1**, 299–310.

LUCY, J. A. (1964). Membrane permeability and the control of cellular function. *Natl. Cancer Inst. Monograph* **13**.

MARIN-PADILLA, M., and FERM, V. H. (1965). Somite necrosis and developmental malformations induced by vitamin A in the golden hamster. *J. Embryol. Exptl. Morphol.* **13**, 1–8.

MIZUTANI, M., IHARA, T., and KAZIWARA, K. (1966). Effect of hypervitaminosis A on the fetus of several species of rodents, with special reference to malformation of the extremities. *Japan J. Genet.* **41** (2), 141–153.

NAS—NRC (1962). Nutrient Requirements of Laboratory Animals. *Natl. Acad. Sci.—Natl. Res. Council, Publ.* **990**.

SCOTT, J. P. (1937). The embryology of the guinea pig. I. Table of normal development. *Am. J. Anat.* **60**, 397–432.

TAKEKOSHI, S. (1964). The mechanism of vitamin A induced teratogenesis. *J. Embryol. Exptl. Morphol.* **12**, 263–271.

Roberts-'67
Bib. No. 7706

Biochem. J. 102:600-605. 1967.

Reproduced by permission of the copyright owner

Pathways of Retinol and Retinoic Acid Metabolism in the Rat

By ANITA B. ROBERTS and H. F. DeLUCA
Department of Biochemistry, University of Wisconsin, Madison, Wis. 53706, U.S.A.

(*Received* 17 *June* 1966)

1. The metabolism of retinoic acid and retinyl acetate labelled with ^{14}C in various positions was studied after intravenous injection of physiological amounts of these compounds into retinol-deficient rats. 2. Analysis of the resultant radioactivity in the urine, carbon dioxide and faeces led to a postulation of the existence of three major pathways for the metabolism of these two compounds. 3. Evidence is presented that retinoic acid and retinol are metabolized by either the same or at least similar pathways and that retinol becomes oxidized to the carboxyl state before any degradation of the isoprenoid side chain occurs. 4. It is not possible to decide from these data whether retinoic acid is an intermediate in the retinol pathway. 5. Possible sites for the regulation of retinol metabolism are discussed.

Since the discovery of retinol early in this century, much fruitful effort has been expended in the elucidation of the physiological effects of retinol deficiency. On the other hand, surprisingly little is understood about the metabolism of the vitamin molecule itself and the molecular events leading to its action in supporting growth. The discovery by Arens & van Dorp (1946*a*) (see also Sharman, 1949) of the growth-promoting activity of retinoic acid in retinol-deficient rats opened up the possibility of its involvement in the main pathway of retinol metabolism.

It is known that, though retinol and retinal are readily interconvertible (Wald & Hubbard, 1948–49; Zachman & Olson, 1961; Futterman & Saslaw, 1961), the conversion of retinal into retinoic acid is enzymically irreversible *in vitro* (Dmitrovskii, 1961; Futterman, 1962; Elder & Topper, 1962; Mahadevan, Murthy & Ganguly, 1962). This is borne out by repeated failures to detect any retinol in liver even after massive dosing with retinoic acid (Sharman, 1949; Arens & van Dorp, 1946*b*; DeMan, Leeuwen & Roborgh, 1964) and also by the failure of retinoic acid to substitute for retinal in the visual cycle (Dowling & Wald, 1960). Conversely, most attempts to trap retinoic acid formed as a product of administered retinol or retinal have been unsuccessful (Krishnamurthy, Bieri & Andrews, 1963; Wright, 1960). But recently it has been shown that large doses of retinal do lead to the production of small amounts of retinoic acid in the tissues (Deshmukh, Malathi & Ganguly, 1965) and in the bile, where a water-soluble conjugate of retinoic acid is found as well (Dunagin, Zachman & Olson, 1964). These experiments leave little doubt that the necessary enzymes for the conversion of retinol into retinoic acid are present. However, whether or not retinoic acid is an intermediate in the main pathway of retinol metabolism with a high turnover rate or is on a shunt that can in some manner still lead to a compound with 'retinol activity' remains an open question.

The experiments described in the present paper provide evidence that, regardless of whether retinoic acid is on a shunt or directly participates in the main pathway of retinol metabolism, its degradation follows a pathway common to the degradation of retinol, for the overall metabolism of retinyl acetate and retinoic acid have similar patterns.

MATERIALS AND METHODS

Radioactive compounds. [6,7-$^{14}C_2$]Retinoic acid, [6,7-$^{14}C_2$]retinyl acetate and [15-^{14}C]retinoic acid were gifts from Hoffmann-La Roche and Co. (Basel, Switzerland, and Nutley, N.J., U.S.A.). [14-^{14}C]Retinoic acid was obtained from Tracerlab (Waltham, Mass., U.S.A.) and [15-^{14}C]retinyl acetate was obtained from Nuclear-Chicago Corp. (Des Plaines, Ill., U.S.A.). All compounds were purified by thin-layer chromatography on plain silica gel immediately before each experiment. The chromatograms were developed with 10% (v/v) methanol in benzene for retinoic acid and 20% (v/v) ether in cyclohexane was used for retinyl acetate. The compounds were eluted with ethanol in the dark under N_2, evaporated to dryness under a stream of N_2 and redissolved in 0·9% NaCl containing 0·1% of Tween 40 (polyoxyethylene sorbitan monopalmitate; obtained from the Atlas Powder Co., Wilmington, Del., U.S.A.). For the retinoic acid experiments, the concentration was approx. 15μg./0·2ml. and the solution was adjusted to pH 8·5 with NaOH. For retinyl acetate, the concentration was 2μg./0·2ml. and the solution also

[illegible]ained approx. 100 μg. of α-tocopherol/0·2 ml. These [illegible]entrations were chosen to approach the minimum dose [illegible]ary to support growth (Zile & DeLuca, 1965). The [illegible] spectra of these solutions were read on a Cary model [illegible] recording spectrophotometer immediately before [illegible]tion to determine the exact concentrations; specific [illegible]ity was also determined. All solvents were A.R. [illegible].

Preparation of animals. Weanling male albino rats [illegible]man Co., Madison, Wis., U.S.A.) weighing 40–50 g. [illegible] placed on a purified retinol-deficient diet (DeLuca, [illegible], Madsen & Olson, 1963). In about 4 weeks they [illegible] a plateau in growth rate and were placed on [illegible] acid supplements (50 μg./day) until they weighed [illegible]-575 g. Rats for the retinyl acetate experiments were [illegible] supplemented for 1–2 weeks with 1·5–2 μg. of retinol/[illegible] and were used 4 days after the last such supplement.

Administration of retinoic acid or retinyl acetate. The [illegible] were lightly anaesthetized with ether and were given [illegible] μg. of radioactive retinyl acetate by intrajugular [illegible]. They were placed in glass metabolism cages [illegible] Science Laboratories, Chicago, Ill., U.S.A.) for [illegible], where respiratory CO_2, urine and faeces were col[illegible]. The rats were then transferred to open metabolism [illegible] for further collection of urine and faeces. Rats [illegible] 100 μg. of non-radioactive retinoic acid (retinoic [illegible] experiments) on the third day of the experiment or [illegible] of non-radioactive retinol (retinol experiments) on [illegible] fifth day of the experiment.

Radioactivity of respiratory carbon dioxide. The CO_2 was [illegible] from the metabolism cage by a stream of CO_2-free [illegible] flowing at a rate of 500–700 ml./min. It was trapped in [illegible] portions of ethylene glycol monomethyl ether–[illegible]ethanolamine (2:1, v/v). Samples (3 ml.) were counted in [illegible] Tri-Carb model 314 EX scintillation counter, the [illegible] solution consisting of toluene–ethylene glycol [illegible]thyl ether (2:1, v/v) containing 5·5 g. of 2-phenyl-[illegible]/l. (Jeffay & Alvarez, 1961) (efficiency 43%).

Radioactivity of urine. The urine was diluted approxi[illegible] 1:1 (v/v) with ethanol and centrifuged to remove [illegible] precipitate, which was subsequently found to contain [illegible] radioactivity. A sample of the supernatant was counted [illegible] the scintillation counter by using a counting solution [illegible] of 1500 ml. of dioxan, 150 g. of naphthalene, 7 g. of 2-phenyloxazole and 300 mg. of 1,4-bis-(5-phenyloxazole-2-yl)benzene (efficiency 45%).

Radioactivity of faeces. The faeces were stored at −17° and immediately before combustion were freeze-dried, pulverized and weighed. Duplicate samples (30–80 mg.) were weighed into combustion bags, and binder (0·2 ml. of 10% sucrose) was added (Kelly, Pesta, Gorden & Buyake, 1961). The samples were dried again and burnt in O_2. The CO_2 was collected in 15 ml. of trapping solution and 3 ml. samples were counted as described above.

RESULTS

Partitioning of the ^{14}C label among the respiratory carbon dioxide, urine and faeces. Carbon dioxide, urine and faeces samples were collected and measured until it was evident that no more radioactive material was being excreted or until 8 days had passed, whichever occurred first. The average recovery of the dose in each of these fractions is given in Tables 1 and 2. For the retinoic acid experiments almost all of the original radioactivity was recovered within 2–3 days, whereas for those with retinyl acetate a much longer time was needed. The excretion of radioactivity from the [^{14}C]retinyl acetates continued in an almost linear fashion during the 8-day experimental period (Fig. 2). For convenience, the $^{14}CO_2$ excretion was followed for only 2 days in most experiments. To estimate the degree of participation of each of the three excretory routes of ^{14}C derived from retinyl acetate and to compare it with the retinoic acid data, the radioactivity excreted in the faeces, the urine and the carbon dioxide in the 2-day period was calculated as a percentage of the total amount excreted in that period. It is to be expected that a lag must exist between the time of formation of the faecal products and their appearance in the faeces. This lag appeared to be 1 day for the retinyl acetate experiments, since little radioactivity was detected in the faeces during the first

Table 1. *Recovery of ^{14}C from rats given radioactive retinoic acid*

The values are given as means ± S.D., where S.D. was based on values obtained from individual rats. The numbers in parentheses indicate the numbers of rats. The dose of labelled retinoic acid was 14·5 μg. in each case.

Fraction	Recovery of ^{14}C (% of dose)		
	[6,7-$^{14}C_2$]Retinoic acid	[14-^{14}C]Retinoic acid	[15-^{14}C]Retinoic acid
CO_2	0·8 ± 0·4 (2)	18·9 ± 3·4 (3)	35·0 ± 4·5 (2)
Urine	38·0 ± 4·4 (4)	18·3 ± 0·3 (3)	19·9 ± 1·7 (5)
Faeces	64·5 ± 1·3 (4)	61 (3)*	43·7 ± 3·0 (4)
Total	103·3	98·2	98·6

* The values obtained were all low owing to bacterial decomposition of the radioactive products in the faeces. However, a plot of the three values obtained (38·3, 46·6 and 52·9%) versus the time lapse from the completion of the experiment to the time of combustion of the samples (41, 27 and 15 days) was linear and extrapolated to a value of 61% recovery of the dose at zero time.

Table 2. *Recovery of ^{14}C from rats given radioactive retinyl acetate*

The values are given as means ± S.D. The numbers in parentheses indicate the numbers of rats. The values for urine and CO_2 represent the radioactivity recovered after 2 days; the values for faeces represent 3 days' collection to allow for the time lag in elimination. For the 1·46μg. dose of [15-^{14}C]retinyl acetate, CO_2 collection was continued for 4 days, and 4 and 5 days respectively have been used for the analysis.

	[6,7-$^{14}C_2$]Retinyl acetate		[15-^{14}C]Retinyl acetate			
	(2·0μg.)		(2·0μg.)		(1·46μg.)	
Fraction	Recovery (% of dose)	% of recovered ^{14}C	Recovery (% of dose)	% of recovered ^{14}C	Recovery (% of dose)	% of recovered ^{14}C
CO_2	1·5 (2)	4·1	9·9±1·4 (2)	29·4±4·2	8·8 (2)	32·1
Urine	17·0±2·3 (4)	47·2±6·4	9·7±1·9 (2)	28·8±5·6	8·3±0·8 (2)	30·3±2·9
Faeces	17·5±2·5 (4)	48·7±7·0	14·1±1·6 (2)	41·8±4·7	10·3±2·5 (2)	37·6±9·1
Tota	36·0	100·0	33·7	100·0	27·4	100·0

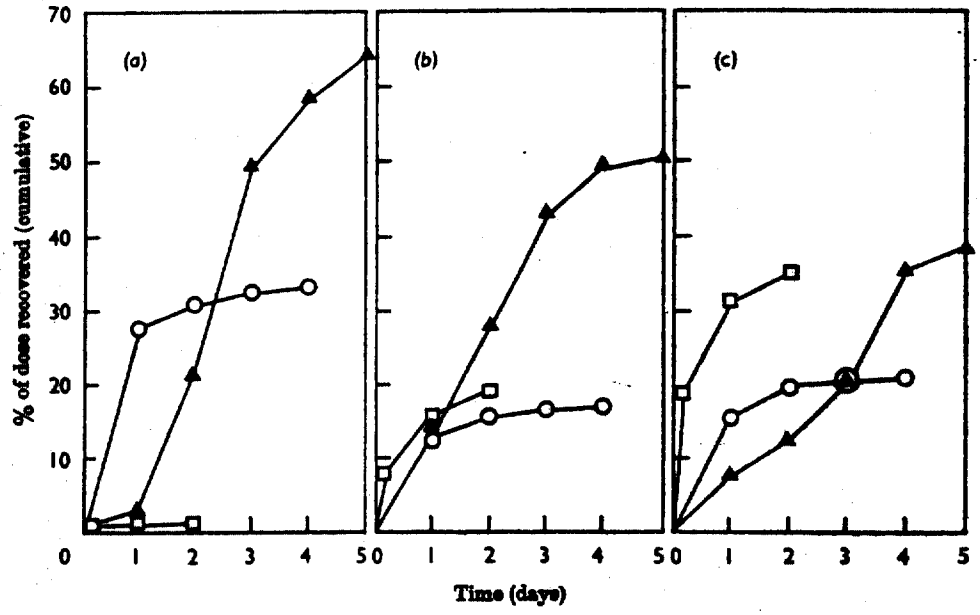

Fig. 1. Metabolism of a 14·5μg. dose of [6,7-$^{14}C_2$]retinoic acid (*a*), [14-^{14}C]retinoic acid (*b*) or [15-^{14}C]retinoic acid (*c*). The recovery of ^{14}C is shown as partitioned between the urine (○), the respiratory CO_2 (□) and the faeces (▲). Each experimental point represents the average for two rats.

24hr. of the experiment. For this reason the radioactivity found in the faeces 3 days after injection of the retinyl acetate was considered to be a measure of the radioactive products formed in the 2 days after the injection.

The data in Table 1 reveal several aspects of the metabolism of retinoic acid. Almost none of the 6,7-$^{14}C_2$ label appeared in the carbon dioxide, but it was found in an approximately 3:2 ratio in the faecal and urinary fractions respectively. With the 14-^{14}C- or 15-^{14}C-labelled compounds, on the other hand, a considerable portion of the radioactivity was recovered in carbon dioxide. With retinyl acetate, again the 6,7-$^{14}C_2$ label appeared in the urinary and faecal fractions and not in the carbon dioxide. However, the 15-^{14}C label was recovered in carbon dioxide, urine and faeces in approximately equal amounts.

Rate of retinoic acid and retinyl acetate metabolism. Radioactive retinoic acid was metabolized quite rapidly (Fig. 1). The rate was greatest in the period up to 5hr. after injection of the dose. After 2 days

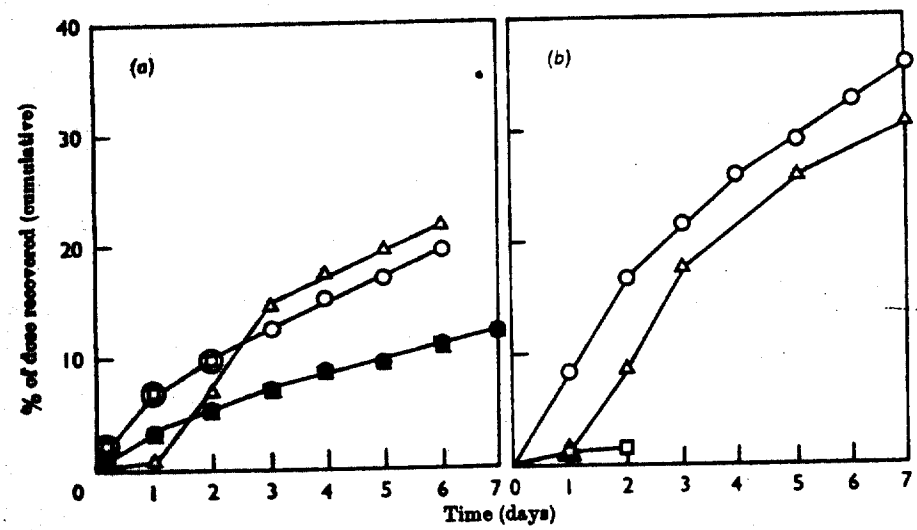

Fig. 2. Metabolism of [15-^{14}C]retinyl acetate (*a*) or [6,7-$^{14}C_2$]retinyl acetate (*b*) in retinol-deficient rats. The black symbols (●, ■, ▲) represent a dose of 1·46 μg., the others (○, □, △) represent a dose of 2·0 μg. The recovery of ^{14}C is shown as partitioned between the urine (○, ●), the respiratory CO_2 (□, ■) and the faeces (△, ▲). (The ●, ■ and ▲ symbols are superimposed.) Each experimental point represents an average for two to four rats.

almost all of the dose had been recovered in the three excretory fractions, taking into account the lag in elimination of the faeces. Retinyl acetate, however, was metabolised at a much lower but almost constant rate (Fig. 2). The rate of retinyl acetate metabolism by retinol-deficient rats was dependent on the dose (Fig. 2). However, the partitioning of that amount metabolised between urine, carbon dioxide and faeces remained unchanged (Table 2). Radioactivity from the labelled retinyl acetate continued to be excreted after 8 days, when measurement of the samples was discontinued.

DISCUSSION

The availability of radioactive retinyl acetate and retinoic acid labelled with ^{14}C in different positions made it possible to study the breakdown of these compounds and the excretory routes of the products after metabolism by retinol-deficient rats. The amounts of the compounds used in these experiments approached the minimum daily dose necessary for maximum growth (Zile & DeLuca, 1962). It was hoped that this procedure would minimise the degradation of the labelled compounds by other pathways that might be unrelated to the growth-supporting function.

On the basis of the present results outlines of at least three pathways for the metabolism of retinoic acid and retinyl acetate can be postulated (Scheme 1). These pathways were developed from the retinoic acid data, but it was found that they could be applied to the retinyl acetate data as well. The extent of the participation of each pathway for both retinyl acetate and retinoic acid is given in Table 3. In deriving these pathways, the basic assumption was that radioactivity appearing in the faeces and urine from [15-^{14}C]retinoic acid resulted from an intact isoprenoid chain; therefore such a product should also contain an equivalent amount of radioactivity from C-6, C-7 and C-14. On this basis, the percentage of the dose accounted for by the radioactivity from 15-^{14}C-labelled compounds in the urine and faeces was designated pathway I.

Since more [15-^{14}C]- than [14-^{14}C]-retinoic acid was metabolized to $^{14}CO_2$, some metabolism involved decarboxylation of the terminal carbon atom of the side chain. If the rest of the side chain were left intact, the product should still be 14-^{14}C- and 6,7-$^{14}C_2$-labelled. Because the percentage of the dose appearing in the urine from [15-^{14}C]-retinoic acid was approximately equal to that from the corresponding 14-^{14}C-labelled compound, the product of such a pathway would appear to be excreted in the faeces. Thus pathway II was postulated to involve a decarboxylation of C-15 to yield a product, retaining C-6, C-7 and C-14, which is excreted in the faeces. In agreement with this postulate, the radioactivity in the carbon dioxide from [15-^{14}C]retinoic acid minus that from the 14-^{14}C-labelled compound equals the faecal 14-^{14}C label minus the faecal 15-^{14}C label, and the faecal

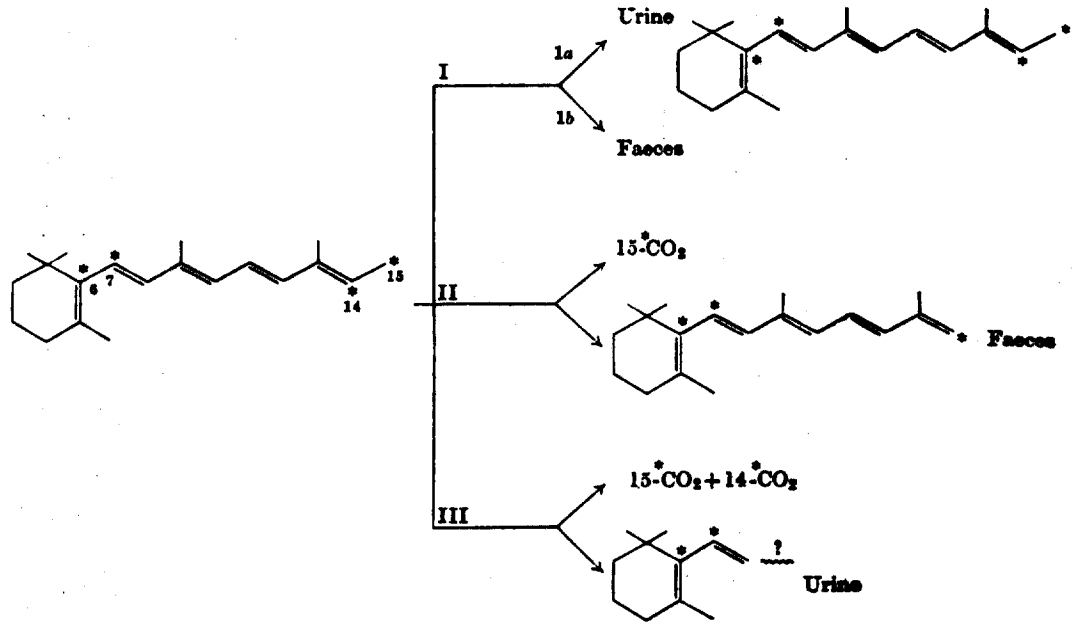

Scheme 1. Possible metabolic pathways for retinoic acid or retinyl acetate: * indicates the position of the ^{14}C label. The structures shown represent the portion of the retinoic acid or retinol molecule that would become incorporated into a product after metabolism by the suggested pathways.

Table 3. *Estimates of percentages of retinoic acid or retinyl acetate metabolized by the postulated pathways at low dosage levels*

Pathways 1a and 1b are subdivisions of pathway I, and represent the distribution of the presumed intact side chain in the urinary and faecal products respectively.

Pathway	Retinoic acid (%)	Retinyl acetate (%)
I	62–65	67–79
1a	(18–20)	(30–32)
1b	(43–45)	(36–38)
II	18–20	9–12
III	18–20	17–19

$6,7\text{-}^{14}C_2$ label is approximately equal to the faecal $14\text{-}^{14}C$ label.

Finally, a pathway that accounts for the elimination of $^{14}CO_2$ from both [15-^{14}C]- and [14-^{14}C]-retinoic acid may be postulated. The products of such a pathway must retain the $6,7\text{-}^{14}C_2$ label, since it is evident that oxidative degradation of the side chain to carbon dioxide does not proceed as far as these positions. Only in the urine is there a greater percentage of the radioactivity from [$6,7\text{-}^{14}C_2$]- than from [14-^{14}C]-retinoic acid. By subtracting the percentage of the $14\text{-}^{14}C$ label in the urine from the percentage of the $6,7\text{-}^{14}C_2$ label in the urine, a measure of this pathway is obtained. As might be expected, it is approximately equal to the percentage of the $14\text{-}^{14}C$ label found as $^{14}CO_2$. Without more data, it cannot be said whether the elimination of C-14 as carbon dioxide operates in sequence with terminal decarboxylation, or whether C-14 and C-15 are cleaved as part of a C_2 or larger fragment that is then metabolized to carbon dioxide. In the foregoing discussion the data for the metabolism of retinoic acid have been treated in the simplest possible fashion: the actual metabolic processes are probably more complex.

The calculations discussed above can be represented by the following formulae:

Pathway I = 15-^{14}C in urine (pathway 1a) and 15-^{14}C in faeces (pathway 1b)

Pathway II = 15-^{14}C in CO_2 − 14-^{14}C in CO_2 = 14-^{14}C in faeces − 15-^{14}C in faeces

Pathway III = 14-^{14}C in CO_2 = $6,7\text{-}^{14}C_2$ in urine − 15-^{14}C in urine

Other relationships:

$6,7\text{-}^{14}C_2$ in faeces = 14-^{14}C in faeces

15-^{14}C in urine = 14-^{14}C in urine

Here, for example, the designation '15-^{14}C in urine' refers to that amount of radioactivity (expressed as percentage of dose) recovered in the urine after administration of [15-^{14}C]retinoic acid.

Once derived for retinoic acid, these same

formulae were used for retinyl acetate. Here, only data on the 15-^{14}C and 6,7-$^{14}C_2$ labels were available, but the equalities, together with the pathway formulae, made the calculation possible without the 14-^{14}C label. The 14-^{14}C label only adds clarity to pathway III and provides support for pathways I and II. The data for both compounds can be handled by the same formulae, or in other words administration of both compounds results in a 'pathway I' type of metabolism as well as two types of oxidation, the product of one type appearing in the faeces and the other in the urine. This is evidence that the metabolism of the two compounds proceeds along similar or identical routes.

Most significant in comparing the metabolism of these two compounds is that about one-third of the administered dose of either retinoic acid or the retinyl acetate is terminally decarboxylated (pathways II and III). For this to occur, the terminal carbon atom of retinol must become oxidised to the carboxyl state before any loss of the carbon atom can occur. Although it might be that the oxidised retinol differs chemically or isomerically from retinoic acid, it nevertheless appears that the metabolism of the side chains might be carried out by the same enzyme systems and that retinol metabolism might proceed through retinoic acid as an intermediate. It remains to be shown, however, whether retinoic acid itself is a normal intermediate in retinol metabolism or whether it feeds into the retinol pathway at some later point.

The metabolism resulting in the retention in the urine and faeces of the radioactivity of C-6, C-7, C-14 and C-15 is of major importance, for it accounts for nearly two-thirds of the metabolism of both retinoic acid and retinyl ester. It has been assumed that this metabolism leaves the isoprenoid side chain intact, for the alternative possibility, that each of the three labelled positions could be on different fragments of the molecule, seems remote. The excretion of the products of such a pathway in the urine and faeces varies somewhat between retinoic acid and retinyl acetate; this might arise from the great difference in their rate of metabolism. The greater extent of incorporation into faecal products found for retinoic acid might be related to the large initial concentration of retinoic acid derivatives in the bile (Zachman, Dunagin & Olson, 1966). Products with an intact isoprenoid chain might include retinoyl β-glucuronic acid, which Dunagin, Meadows & Olson (1965) have characterised in the bile of rats treated with retinoic acid. Another possibility is that retinoic acid and retinyl acetate are eliminated unchanged or as polar conjugates.

It is apparent from these experiments that the rate of metabolism of retinyl acetate is regulated and that it is much lower when smaller doses are given. The dose of retinoic acid is almost entirely metabolized within 48hr., whereas the metabolism of retinol, even at the 1·5μg. and 2μg. dosage level, proceeds at a constant rate for 5 days or longer (Figs. 1 and 2). This indicates a control mechanism at a step before the entrance of retinoic acid into the pathway. It is possible that this occurs by feedback control by retinoic acid or some other metabolite, or that it is due merely to a low turnover rate for some enzyme between retinol and retinoic acid.

We thank Hoffmann-La Roche and Co. for their generous gift of the [6,7-$^{14}C_2$]- and [15-^{14}C]-retinoic acid. This work was supported by Grant GB3066 from the National Science Foundation, and A.R. received support from Grant 2T1GM236BCH of the National Institutes of Health and as a Predoctoral Fellow by Public Health Service Fellowship 1F1GM-30014-01. The work is published with the approval of the Director of the Wisconsin Agricultural Experiment Station.

REFERENCES

Arens, J. F. & van Dorp, D. A. (1946*a*). *Nature, Lond.*, **157**, 190.
Arens, J. F. & van Dorp, D. A. (1946*b*). *Nature, Lond.*, **158**, 522.
DeLuca, H. F., Manatt, M. R., Madsen, N. & Olson, E. B. (1963). *J. Nutr.* **81**, 383.
DeMan, Th. J., van Leeuwen, P. H. & Roborgh, J. R. (1964). *Nature, Lond.*, **201**, 77.
Deshmukh, D. S., Malathi, P. & Ganguly, J. (1965). *Biochim. biophys. Acta*, **107**, 120.
Dmitrovskii, A. A. (1961). *Biokhimiya*, **26**, 109.
Dowling, J. E. & Wald, G. (1960). *Proc. nat. Acad. Sci., Wash.*, **46**, 587.
Dunagin, P. E., Meadows, E. H. & Olson, J. A. (1965). *Science*, **148**, 86.
Dunagin, P. E., Zachman, R. D. & Olson, J. A. (1964). *Biochim. biophys. Acta*, **90**, 432.
Elder, T. D. & Topper, Y. J. (1962). *Biochim. biophys. Acta*, **64**, 430.
Futterman, S. (1962). *J. biol. Chem.* **237**, 677.
Futterman, S. & Saslaw, L. D. (1961). *J. biol. Chem.* **236**, 1652.
Jeffey, H. & Alvarez, J. (1961). *Analyt. Chem.* **33**, 612.
Kelly, R. G., Peets, E. A., Gorden, S. & Buyske, D. A. (1961). *Analyt. Biochem.* **2**, 267.
Krishnamurthy, J., Bieri, J. G. & Andrews, E. L. (1963). *J. Nutr.* **79**, 503.
Mahadevan, S., Murthy, S. K. & Ganguly, J. (1962). *Biochem. J.* **85**, 326.
Sharman, I. M. (1949). *Brit. J. Nutr.* **3**, viii.
Wald, G. & Hubbard, R. (1948–49). *J. gen. Physiol.* **32**, 367.
Wright, G. J. (1960). *Amer. J. clin. Nutr.* **9**, 26.
Zachman, R. D., Dunagin, P. E. & Olson, J. A. (1966). *J. Lipid Res.* **7**, 3.
Zachman, R. D. & Olson, J. A. (1961). *J. biol. Chem.* **236**, 2309.
Zile, M. & DeLuca, H. F. (1965). *Biochem. J.* **97**, 180.

Robertson-'46
Bib. No. 7716

J. Nutr. 31:471-484. 1946.

THE EFFECTS OF ADDED VITAMIN A ON THE CONJUNCTIVA AND THE LEVEL OF VITAMIN A IN THE BLOOD

ELIZABETH CHANT ROBERTSON[1] AND A. LLOYD MORGAN

Departments of Pediatrics and Ophthalmology, University of Toronto, and the Hospital for Sick Children, Toronto

ONE FIGURE

(Received for publication May 2, 1945)

Kruse ('41) reported that 99% of 166 adults in a low income group showed diminished transparency of the bulbar conjunctiva which he claimed was due to avitaminosis A. In 39% of his subjects elevations or spots which could be seen with the naked eye were present. Following the administration of 100,000 I.U. of vitamin A daily for 8 months to 70 adults, Kruse reported the following results:

"One person with spots has been completely restored and discharged. In all others with spots, the conjuctiva has become less vascular, thinner, clearer and more lustrous. The spots are much diminished in size; in many no longer grossly elevated; in some detectible only by microscope. Of the persons with 'nonspot' lesions, eight have been fully restored and discharged. Naturally, since the 'nonspot' lesions are usually less severe, more in this group were among the first to show complete recovery. Nevertheless, they have required not less than 6 months' intensive therapy.

"In both groups those who have not received therapy have shown no improvement."

EXPERIMENTAL

In the following test, forty pupil nurses, who needed 1 to 2 years more to complete their training, agreed to act as sub-

[1] Under the direction of Alan Brown, M.D., F.R.C.P. (Lond.).

jects. Thirty-four of the forty were 19 to 21 years of age. Five were 22 to 23 years old; one was 26 years of age. Their general health was good and their physical examinations at the beginning of their training showed no defects. As far as was known they came from families that were comfortably off financially.

Initial examination of conjunctiva

The bulbar conjunctiva, which is relatively transparent, contains numerous small blood vessels. It is attached by means of lax connective tissue to the opaque, firm sclera (Fuchs, '24). That it is freely movable on the sclera can be demonstrated by having the patient blink gently while observing the conjunctiva through a slit lamp. Another method of showing the mobility of the conjunctiva is to pull down the lower lid. During either of these procedures the blood vessels in the conjunctiva can be seen to move. The deep conjunctival blood vessels which are presumably attached to the outer surface of the sclera do not move (Wolff, '40). Using the slit lamp, Kruse ('41) described changes in both the superficial and deep parts of the conjunctiva, which he described as transparent, translucent or opaque according to their ability to transmit light. The present authors were unable to see any difference in transparency between the deep and the superficial parts of the conjunctiva. Consequently it was not possible to follow Kruse's method exactly. Instead, the transparency of the conjunctiva was estimated by the clearness with which the deeper, non-movable blood vessels could be seen through a slit lamp. The method used in this study was planned to demonstrate the conjunctival changes described by Kruse.

When examined with the slit lamp, all of the subjects showed some thickening of their bulbar conjunctivae. If one accepts Kruse's ('41) hypothesis, this thickening has occurred because these young women have suffered from a deficiency of vitamin A sometime prior to the examination. In other words,

100% of these subjects showed signs of avitaminosis A, according to Kruse.

As a result of this first examination with the slit lamp, the subjects were divided into three groups depending on the transparency of their bulbar conjunctivae. Group 1 had fairly clear conjunctivae. There were fifteen subjects in this group and five of them showed elevations or pingueculae in one or more of the limbic areas, at the equator (fig. 1). These elevations are raised areas roughly circular or triangular in outline. The elevations, according to Fuchs ('24) are due chiefly to an increase in the number and size of the elastic fibers. In some cases they are of a yellow color, due to the presence of a yellowish hyaline substance. These elevations are thought by ophthalmologists (Parsons, '38) to be more common in individuals exposed to much dust, wind, or other such conditions (see below).

Group 2 had somewhat more opaque conjunctivae and of the thirteen subjects in this group, eight showed elevations.

Group 3 had still more opaque conjunctivae and ten of the twelve subjects in this group showed elevations. Three of these individuals had three to four elevations each, which was more than any of the subjects in groups 1 or 2 showed.

None of the subjects showed markedly opaque conjunctivae or deeply pigmented elevations. Thirty-nine per cent of Kruse's patients showed one or more elevations that were visible to the naked eye, while in the present series, 57% showed such elevations. Kruse's subjects varied in age from 17 to 65 years, and were from low income groups, while in this series they were from 19 to 26 years old and were from higher income groups.

The relation of outdoor sports to the presence of elevations

To check roughly whether there was any relation between indulgence in outdoor sports and the presence of elevations, the subject was asked whether she had gone in for outdoor

sports freely or whether she had taken little of such exercise before coming into training. Then it was determined whether elevations were commoner in the girls who had taken much outdoor exercise and conversely whether the girls who did not indulge in much outdoor exercise rarely had conjunctival elevations. This seemed to be true in general — as 70% of the girls who took much outdoor exercise showed elevations, whereas of the girls who did not indulge in such exercise to any extent only 20% showed elevations. These figures suggest that exposure to wind and the other elements favors the development of these elevations.

Amount of vitamin A in the meals

The nurses received palatable meals which were planned by a dietitian, who held a university degree in Home Economics. As far as could be ascertained no reliable method for determining the total amount of both vitamin A and carotene in the meals was available, but the carotene alone could be fairly readily assayed by a method suggested by Jackson ('43). Carotene determinations were therefore made on 3 successive days each month for the last 9 months of the study. As was expected, the results of the carotene assays showed considerable variation. On 9 of the days the amount of carotene varied from 492 to 1000 μg; on 9 other days it ranged from 1000 to 5000 μg; on 10 days it was between 5000 and 25,000 μg. When these figures are expressed in terms of vitamin A, using the conversion figure of 0.6 μg carotene as equivalent to 1 I.U. of vitamin A, they are as follows: 820 I.U. to 1666 I.U.; 1666 I.U. to 8330 I.U.; 8330 I.U. to 41,650 I.U.. The vitamin A Sub-Committee of the Accessory Food Factors Committee (Lister Institute and Medical Research Council) have recently (1945) reported tests on human beings in which only 25 to 40% of the carotene ingested in the form of green or yellow vegetables was retained in the body. It is probable therefore that about one-third of the carotene that is ingested is available to the body.

As we were not able to measure the vitamin A in the food by chemical methods, we estimated, using recent food tables, the amount of it present in the milk, cream, butter, cheese, eggs and liver eaten by a nurse on the same days. The amount of vitamin A in these foods varied from 2500 to 6000 I.U. per day, with an average of 4000 I.U., except on 3 days when it ranged from 12,000 to 14,000 I.U., due to the fact that liver had been served. These figures are approximations, at best, as even the figures given in the food tables show great variations, but they indicate that the meals contained good amounts of vitamin A. Therefore if the conjunctival changes are due to a deficiency of vitamin A, this must have occurred some time previously.

Dosage of vitamin A

Half of each group was given 50,000 I.U. of vitamin A[2] daily in two capsules. Usually half of this was taken at breakfast and the remainder at bedtime. Occasionally the two capsules were taken together at bedtime. The other half of each group received identical looking capsules containing corn oil.[2] Care was taken to see that in each group, half, as nearly as possible, of the subjects with elevations received therapy. All of the nurses were under the impression that they were receiving vitamin A. The authors, who carried out all the examinations, did not know which subjects were receiving vitamin A and which were not. A responsible assistant distributed the capsules every 2 months. The nurses were reminded frequently — that is at least once every few weeks — of the importance of taking the capsules regularly. They also kept records of the number of capsules missed. In regard to the latter, during their annual 3 weeks' holiday and during the 12% of their time that they spent on night duty, the capsules were taken irregularly. During the rest of the year the nurses took them quite faithfully. About 40% reported that they took them very regularly; about 50% missed about

[2] We are indebted to Mead Johnson and Company, for supplies of this material in the form of gelatin capsules.

two per week; and about 10% forgot from three to six capsules per week. However even though some of the nurses forgot to take a fair number of the capsules, the total amount of vitamin A ingested during the 2 years of the test was very great.

Vitamin A blood levels

Blood vitamin A values were determined in thirty of the subjects using the method of May, Blackfan, McCreary and Allen ('40). The first blood samples were taken after the test had been in progress for 9 to 10 months and the blood was drawn in the morning, 2 to 4 hours after the nurse had taken her capsule. The average level in the therapy group was about 9 blue units higher than in the control group (table 1, column 3) — no doubt due to the 25,000 I.U. of vitamin A which had been taken a few hours previously.

TABLE 1

Blood vitamin A values in blue units.

SUBJECTS	NUMBER OF SUBJECTS	AFTER 9–10 MOS. THERAPY		AFTER 22–23 MOS. THERAPY	
		Average	Usual range	Average	Usual range
Taking vitamin A	14	26.8 [1]	21 –33 [1]	22.3 [2]	14–30 [2]
Controls	16	17.9 [1]	12.4–21.5 [1]	21.4 [2]	14–25 [2]

[1] Blood was drawn 2 to 4 hours after 25,000 I.U. of vitamin A had been ingested.
[2] Blood was drawn 11 to 13 hours after 25,000 I.U. of vitamin A had been ingested.

In the second test, after 22 to 23 months on therapy, the nurses were asked to omit the capsule on the morning on which they were to be bled. Consequently the blood was drawn 11 to 13 hours after the last dose of vitamin A had been taken. As is shown in column 5 of table 1, the average blood vitamin A levels of the subjects on therapy and of the controls were very similar, as were also the ranges of the readings. It appears therefore that the addition of 50,000 I.U. of vita-

min A to the daily diet for a period of 22 to 23 months does not raise the blood vitamin A level except for the first few hours after a dose has been taken.

Technique of slit lamp examination

Except during the months of July and August, each nurse was very carefully examined with the slit lamp approximately every 2 months, always by the same observer. Each examination required about 45 minutes' time for each nurse. The subject who was seated in front of the window, but not in direct sunlight, was first examined with the naked eye. The evenness of the surface of the conjunctiva, the number, position, shape and color of the elevations, any enlargement or engorgement of the plica and the extent of the vascular network were recorded. No regular changes in any of these tissues could be observed. This result is contrary to that of Kruse ('41) who described such changes following the ingestion of large amounts of vitamin A daily.

A large scale drawing (8″ x 6″) was made of all the deep bulbar conjunctival vessels that could be seen through the slit-lamp (fig. 1). The fact that the deep vessels do not move when the subject blinks or the observer pulls down the lower lid quickly, allows one to differentiate between the deep and the superficial vessels. The upper lid was held up and the lower lid held down by the subject so that all of the bulbar conjunctiva could be examined. The clarity with which the deep vessels could be seen and the number of them that were visible were used as a measure of the transparency of the conjunctiva. The clearness with which the various parts of the vessels could be seen was indicated by means of numbers written beside the vessels. The clearest parts were designated as 1: those parts just visible as 4, with gradations between designated 2 and 3. After each examination the drawing was traced on a thin sheet of paper — the vessels being shown in red (solid lines in fig. 1) and no figures being copied. At the next examination the vessels seen through the slit lamp were

compared with those shown in the drawing and the clearness with which they were now seen was marked in again by figures. Any new vessels seen at this examination were drawn in with a blue pencil (shown by dotted lines in fig. 1). Any vessels previously recorded and not seen on this examination were surrounded by blue circles and these were omitted in the next tracing. The aim of these drawings was to demonstrate whether the conjunctiva was becoming more transparent and by drawing in the vessels, one could be sure of their loca-

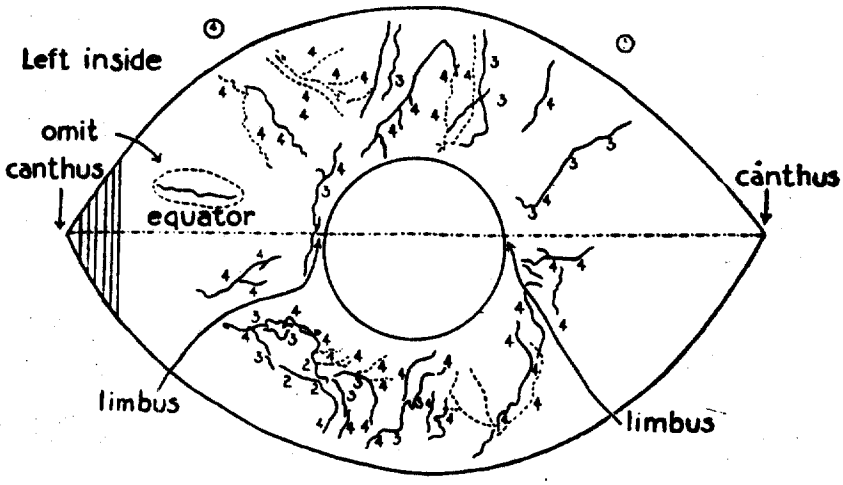

Fig. 1 Large scale drawing of deep conjunctival vessels; the examiner could not see the blood vessels enclosed by the dotted circle at this particular examination, although these vessels were seen in this area in the previous examination. Therefore in the tracing that was made from this drawing these blood vessels were omitted. This tracing served as a guide at the next examination.

tion in the conjunctiva. The subject whose deep conjunctival vessels are shown in figure 1, belonged to the group which had the most opaque conjunctiva (group 3), and therefore few vessels were seen and only parts of two of the vessels were relatively clear (marked 2). No vessels were very clear.

Kruse ('41) states that the thickness of the conjunctiva can often be estimated by counting the number of vessels seen crossing over each other in each zone (area between limbus and canthus). This was therefore done and the number of

vessels seen crossing over each other was recorded above each canthus. These numbers are enclosed in circles in figure 1. For example, 4 means that four strata of vessels crossing over each other could be seen on the average in that zone. This was recorded in the successive examinations but no regular change was noted.

Results of slit lamp examinations after beginning of therapy

At the end of each examination, the record and the drawings of the subject's eyes were compared with her previous drawings and records and the observer decided from this evidence whether more or fewer deep vessels were seen, whether some of these vessels were seen more or less clearly, or whether there was no change.

If the deep vessels were seen more clearly or if more of them were visible, either of which findings would indicate that the conjunctiva was more transparent, the subject was said to be receiving vitamin A. After the whole group of subjects had been examined each time, the assistant, who knew which nurses were receiving vitamin A, checked the results, removed the nurses' names from the sheet and reported in what percentage of the subjects the diagnosis of therapy was correct. From her report it was evident that it was quite impossible to determine by the use of this method who was receiving vitamin A and who was not.

The results of all the slit lamp examinations on each subject were summarized to decide whether any change had occurred from the beginning. Six of the subjects could be kept in the test for only 1 year. Five were on therapy and in three of these the conjunctivae seemed clearer after the year of therapy. The sixth, who was a control, showed no change in her conjunctivae.

Thirty-four of the patients took therapy for 2 years and a summary of the slit-lamp examinations on them is shown in table 2. In the subjects of group 1 (clearest conjunctivae)

none of those on therapy showed clearing, whereas 43% of the controls apparently had clearer conjunctivae at the end than at the beginning of the test. Of the subjects in group 2 (moderately opaque conjunctivae) 40% of those on therapy showed some clearing, but 33% of the controls showed similar clearing. Of the ten subjects with the most opaque conjunctivae (group 3), none showed any clearing, whether they had taken vitamin A or not.

TABLE 2

Percentage of subjects showing more transparent conjunctiva at end of test — determined from 8–9 slit lamp examinations on each subject.

INITIAL APPEARANCE OF CONJUNCTIVA	SUBJECTS GIVEN VITAMIN A (2 YRS.)		CONTROLS	
	Number of subjects	% clearer	Number of subjects	% clearer
Group 1 — Clearest	6	0	7	43
Group 2 — Moderately opaque	5	40	6	33
Group 3 — Most opaque	5	0	5	0

Two of the control subjects showed no change consistently throughout the 2 years of the study. One of the subjects taking vitamin A showed progressive and regular clearing of her conjunctivae but her elevations did not disappear. In all the other thirty-one subjects who were studied for the full 2 years (fifteen on therapy and sixteen controls) the conjunctiva on some examinations seemed to have become more transparent, but on subsequent examinations it seemed to show no change or to have become less transparent.

If the conjunctival thickening is caused by a lack of vitamin A, one would certainly expect that the administration for 2 years of enormous daily doses (50,000 I.U.) of vitamin A would cause the conjunctivae to become definitely thinner. The conjunctivae did not become clearer in these subjects and one would therefore conclude that the thickening was not due to a deficiency of vitamin A.

Photographic studies of conjunctiva

A kodachrome photograph, approximately life size, was taken of each subject's eyes every 6 months. All the conditions, i.e., camera, type of film, flash bulbs, etc., were identical as far as could be determined on each occasion. However the photographs taken at different times varied greatly in their color tones, due to uncontrollable variations in the films and their processing. It was therefore very difficult to compare the pictures taken at different times. Nevertheless at the end of the test after a study of the complete series of pictures of each of the subjects both in a viewing box and by projection in pairs on a smooth screen, a tentative conclusion was reached as to any change in the transparency of the conjunctiva. It is felt, however, that the photographic records are of doubtful value because of the technical difficulties involved. The results are shown in table 3. No difference could be detected between the nurses on therapy and the controls.

TABLE 3

Percentage of subjects showing more transparent conjunctiva at end of test — as shown by photographs.

INITIAL APPEARANCE OF CONJUNCTIVA	SUBJECTS GIVEN VITAMIN A	CONTROLS
	%	%
Group 1 — Clearest	33	43
Group 2 — Moderately opaque	60	66
Group 3 — Most opaque	40	60

Time lost due to infections

While this study was in progress a record was kept of the number of days the nurses were off work due to illness during the 2 years (table 4). Seven of the sixteen subjects on vitamin A therapy, or 44%, lost time from work because of respiratory infections during the 2 years of the test. These nurses suffered from a total of fifteen infections, which resulted in a loss of 109 working days.

TABLE 4

Incidence of respiratory infections in subjects that did or did not take extra vitamin A.

WITH VITAMIN A		WITHOUT VITAMIN A	
Total no. of nurses given vitamin A	16	Total no. of nurses serving as controls	18
No. of these nurses with respiratory infections	7	No. of these nurses with respiratory infections	11
Per cent of these nurses with respiratory infections	44	Per cent of these nurses with respiratory infections	61
Time lost because of respiratory infections — days	109	Time lost because of respiratory infections — days	198
Number of infections	15	Number of infections	24

DETAILS OF RESPIRATORY INFECTIONS IN NURSES GIVEN VITAMIN A

Name	No. infections	Time off	Diagnosis
		days	
Au	1	5	"Flu"
Ec	2	12	Sore throat, cough
		1	Cold
Jk	3	2	Cold
		2	Cold
		6	"Flu"
N	1	8	Cold
R	5	13	Strept. throat
		9	Cold
		1½	Swollen cerv. glands
		10½	Tonsillitis
		13	Strept. throat
T	1	5	Cold
Ew	2	11	Bronchitis
		10	Cold (fever)
7 pts.	15 infec.	109 days	

DETAILS OF RESPIRATORY INFECTIONS IN CONTROL NURSES

Name	No. infections	Time off	Diagnosis
		days	
Bu	2	30	"Flu" (fever 2 wks.)
		7	"Flu"
Br	3	14	Bronchitis
		4	Cold
		13	Sinusitis
Ed	1	3	Tonsillitis
G	2	5	Cold
		2	"Flu"
Ho	2	1	Cold
		1	Cold
Bk	1	7	Cold
M	4	2	Cold
		7	"Flu"
		14	"Flu"
		15	Cold
Ro	1	14	"Flu"
Ry	1	6	Cold
Sch	4	8	"Flu"
		9	Tonsillitis, sinusitis
		18	Cold
		4	Cold
Tu	3	6	Cold
		3	Laryngitis
		5	Cold
11 pts.	24 infec.	198 days	

The records of the control group (no vitamin A given) were less good. Eleven of these 18 nurses, or 61%, were off duty because of respiratory infections. They suffered from twenty-four respiratory infections, necessitating 198 days off duty.

No record was kept of the slight respiratory infections which did not put the nurses off work.

As for non-respiratory infections, the difference between the two groups was slight. Four nurses in the group receiving therapy lost 50 days' time; seven control nurses lost 59 days' time. These infections included appendicitis, conjunctivitis, food poisoning, "digestive upsets," mumps and infected fingers.

The group receiving therapy did show a lower incidence of incapacitating respiratory infections but the numbers are so small that the results are not conclusive.

CONCLUSIONS

1. The eyes of forty healthy young pupil nurses were examined with a slit-lamp; 100% of them showed thickening of the bulbar conjunctivae. In other words, if one accepts the hypothesis of Kruse ('41), all of these nurses had suffered from avitaminosis A at some time prior to this examination. The forty nurses were then divided into two groups as nearly alike as possible as far as the transparency of their conjunctiva was concerned. One group was given 50,000 I.U. of vitamin A per day in two divided doses. The other group received similar placebos containing corn oil. All of the nurses believed that they were receiving vitamin A and the observer did not know to which group any subject belonged. Thirty-four of the subjects took the capsules for a period of 2 years. Their conjunctivae were examined with a slit lamp at frequent intervals. With the use of this method it was not possible to determine which nurses were receiving vitamin A and which were not, except in the case of three individuals (two controls and one on therapy). In none of the subjects with conjunctival elevations at the beginning did therapy cause the elevations to

disappear. Therefore one would conclude that the conjunctival thickening is not caused by a deficiency of vitamin A.

2. Except for the first few hours after the 25,000 I.U. dose of vitamin A was taken, the blood vitamin A levels were similar to those in the control group.

LITERATURE CITED

FUCHS, E. 1924 Textbook of Ophthalmology. Lippincott, Philadelphia.

JACKSON, S. H. 1943 Personal communication.

KRUSE, H. D. 1941 Medical evaluation of nutritional status. IV. The ocular manifestations of avitaminosis A. Milbank Memorial Fund Quart., vol. 19, p. 207.

MAY, C. D., K. D. BLACKFAN, J. F. MCCREARY, AND F. H. ALLEN, JR. 1940 Clinical studies of vitamin A in infants and in children. Am. J. Dis. Child., vol. 59, p. 1167.

PARSONS, J. H. 1938 Diseases of the Eye. Churchill, London.

Vitamin A Sub-Committee of the Accessory Food Factors Committee (Lister Institute and Medical Research Council) 1945 Nature, vol. 156, p. 11.

WOLFF, E. 1940 The Anatomy of the Eye and Orbit. Blakiston, Philadelphia.

Rodall-'43
Bib. No. 7731

Biochem. J. 37:166-168. 1943.

The Vitamin A Content and Toxicity of Bear and Seal Liver

By K. RODAHL and T. MOORE, *From the Dunn Nutritional Laboratory, University of Cambridge, and Medical Research Council*

(*Received 23 October 1942*)

It has long been known among Eskimos and arctic travellers that the ingestion of polar-bear liver by men and dogs causes severe illness. It has also been reported that the liver of a certain seal (*Phoca barbata*) is poisonous, although opinion on this point is less unanimous.

Richardson [1861] recounts that when members of an expedition led by Barentzoon to Novaya Zembla in 1596 ate bear liver they all became ill. In three cases the illness was severe, with loss of skin from head to foot. Another early account of the phenomenon was given by Kane [1856], who experimented with bear liver and found the incidence of the poisoning to be inconsistent. On two occasions the whole company on a journey became sick after eating bear liver, but in other instances there were no ill effects. According to Koettlitz [1897], several members of an English expedition to Franz Josef Land, 1894–7, ate polar-bear liver and all suffered in consequence. Lindhard [1913] has also reported poisoning among members of another expedition. A bear was shot which, although thin, appeared to be healthy, and on the following day a stew was prepared from the liver, heart and kidneys. Although the heart and kidneys of bears had often been eaten without ill effects, the 19 men who partook of the stew all became sick. The first signs of distress occurred in two victims 2–4 hr. after the meal, and most of the others became ill during the night. The symptoms described

were drowsiness, sluggishness, irritability or irresistible desire to sleep, and severe headache and vomiting. During the second 24 hr. the skin of 10 out of 19 of the patients began to peel around the mouth, beginning in spots and gradually spreading over larger areas. In some cases the peeling was confined to the face, but in several it was general. Lindhard also described three other cases in which the skin peeled from head to foot after eating bear liver. The Norwegian explorer Nansen [1924] has mentioned that on two occasions he ate small amounts of bear liver without ill effects. It seems probable therefore that the poisonous effects only occur when large quantities are consumed. The most recent cases of poisoning have been described by Doutt [1940].

During a recent expedition made by one of us to north-east Greenland, 1939–40, specimens of polar-bear liver were collected with a view to identifying the toxic substance. On chemical and biological examination these specimens were found to be very rich in vitamin A, as also was a specimen of liver from *P. barbata*. It seems probable that this high concentration of vitamin A is the cause of toxicity, and that the ingestion of more than small amounts of liver leads to hypervitaminosis A.

METHODS

Vitamin A estimations. Specimens were brought from Greenland preserved in brine. Small portions were digested with alkali, and vitamin A was extracted according to the technique described by Davies [1933]. Vitamin A was then estimated by the $SbCl_3$ method, using a factor of 0·6 for the conversion of blue units into international units [Moore, 1937]. The first bear liver to be examined was taken from a 2-year-old female and contained 18,000 i.u./g. of wet material. A second specimen was taken from a 4-year-old male, and also contained 18,000 i.u./g. From a third specimen a value of 13,000 i.u./g. was obtained. A single specimen of seal liver contained 13,000 i.u./g. In biological tests groups of rats were given the liver oils in doses calculated to be equivalent to either 2·6 or 10·3 i.u. daily; other animals were given the international standard carotene at the same level. The weight increases observed were as follows:

	Calculated daily dose i.u.	Mean wt. increase in 28 days (g.)	Approx. i.u./g. liver by biol. test
Seal-liver oil (*Phoca barbata*)	2·6	25	14,000
	10·3	48	12,000
Bear-liver oil (no. 1) (*Ursus maritimus*)	2·6	29	26,000
	10·3	56	24,000
Carotene	2·6	23	—
	10·3	47	—

Since only a few rats were used (usually 3 males per group) these results do not allow accurate independent estimates to be made of the vitamin A contents of the livers. It is obvious, however, that they agree with the high contents found by the $SbCl_3$ method.

Tests for toxicity. According to Jackson [1899], V. Harley, of University College, London, examined bear liver in order to find the reason of its toxicity. Intraperitoneal and subcutaneous injections of alcoholic, ethereal and aqueous extracts had no toxic action on dogs and guinea-pigs, and a dog given an aqueous extract by mouth was also unaffected. Two mice died 3 days after subcutaneous inoculation with an ethereal extract, but the result was possibly accidental. Mice were unaffected by injections of alcoholic and aqueous extracts.

The very high content of vitamin A in the liver suggested that it might give rise to hypervitaminosis A if eaten in more than small amounts. This condition was first described by Takahashi, Nakamiya, Kawakimi & Kitasato [1925], and has since been investigated by many workers. Although it is not quite certain that vitamin A itself is poisonous, the toxicity is at least closely associated with the vitamin in its concentrates. In our laboratory the lesions produced have varied remarkably according to the size of the rat and the magnitude and duration of the overdosage. Skin lesions, ranging from a slight roughening of the hair to seborrhoea and alopecia, are common at all ages. When the vitamin is given in the form of drops of concentrate into the mouth, peeling of the skin at the corners is frequently observed. There may be enteritis, emaciation and pneumonia. More specific lesions, however, are softening and fracturing of the bones, seen most frequently in growing rats, and profuse and sudden internal haemorrhage, often seen in adult animals. In one series of experiments a dose of 30,000 i.u. vitamin A daily in the form of halibut-liver oil was found to be definitely excessive for rats of about 200 g. body weight, invariably causing roughening of the skin, and occasionally death through haemorrhage.

The liver tested for toxicity in the present experiments was from the 2-year-old female bear. Although a value of 18,000 i.u. of vitamin A/g. had originally been obtained the portions now tested contained only 10,000 i.u./g. Carefully planned tests were difficult because of the reluctance of the rats to eat the liver. We have observed the same disinclination in rats when given the livers of other rats which had been allowed to accumulate very high reserves of vitamin A. One rat ate a total of 33·1 g. of the bear liver during a period of 22 days, an amount containing an average of 15,000 i.u. of vitamin A/day. It became anaemic and the hind legs were paralysed. When moribund it was killed.

At autopsy, the profuse internal haemorrhage typical of hypervitaminosis A was found, particularly under the skin, but also in the pericardium. Another rat ate 5·3 g. of liver during a period of 9 days. It then accidentally cut a paw on the side of the cage and bled to death. On superficial examination the wound appeared too slight to have caused death in a normal animal. Another rat ate 24 g. of liver in 22 days without any ill effects. Two other rats which received smaller doses were also unaffected.

Attempts to fractionate the liver into toxic and non-toxic constituents were unsuccessful. An aqueous extract of the liver, and also the residue obtained after the removal of most of the vitamin A from the liver by extraction with alcohol, were readily consumed without ill effects, in amounts corresponding to 1–2 g. of fresh liver daily. Two rats given the residue after aqueous extraction of the liver, however, also sustained no injury, although almost all the vitamin A was contained in this fraction. It is probable that the absence of ill effects was due to the refusal of the animals to accept the liver in amounts sufficient to poison them.

DISCUSSION

It is questionable what factor should be taken to convert doses used for rats to the corresponding doses for man, but the ratio of 75 taken from the relative food intakes of the 100 g. rat and 70 kg. man would seem reasonable. If we take 100,000 i.u. of vitamin A as sufficient to cause immediate illness in the rat, then about 7,500,000 units should cause illness in man. This amount would be present in 375 g. of bear liver containing 20,000 i.u. of vitamin A/g., not an excessive portion to be eaten at a single meal.

Some years ago Mr J. F. Ward of the Crookes Laboratories mentioned to one of us a case of presumed poisoning through excessive halibut-liver oil consumption, which may be of interest in the present connexion. One of the men engaged in the manufacture of the oil took, without instruction, 4–5 oz. daily. After 5 days he became severely ill, the main symptom being giddiness. The ingestion of oil was then discontinued, and he rapidly recovered, returning to normal in 8–10 days. The daily dose must have been about 6,000,000 i.u.

In our tests with rats one animal succumbed with lesions specific for hypervitaminosis A. Other rats which ate almost as much of the liver showed no obvious sign of injury. If bear liver is toxic to the rat for any reason other than its high content of vitamin A, therefore, the amounts which must be eaten to cause poisoning must be so large as to render the animal liable to concurrent hypervitaminosis A. As far as can be concluded from experiments with rats, which may of course differ widely from man in their toleration of toxic substances, there seems no reason to look beyond vitamin A for the cause of toxicity in man although there is good evidence for the presence of other toxic substances in the tissues of arctic animals which would be unlikely to be rich in vitamin A. There would seem to be no objection to the use of preparations made from bear-liver oil as sources of vitamin A in therapeutic doses.

SUMMARY

1. Specimens of the livers of the polar bear and the seal, *Phoca barbata*, were found to be very rich in vitamin A. Three specimens of bear liver contained 18,000, 18,000 and 13,000 i.u./g. respectively of wet material. A specimen of the seal liver contained 13,000 i.u./g.

2. The ingestion of excessive amounts of bear liver by rats led in one instance to fatal hypervitaminosis A. Other rats which ate slightly smaller amounts of liver showed no obvious sign of injury. The well-known poisonous action of bear liver in man is probably due to its high content of vitamin A.

Our thanks are due to Dr Vernon Booth and Mr Alan Davies for help in parts of the work, to Dr L. J. Harris for his valuable criticism, and to the Scott Polar Research Institute for library facilities. One of us (K. R.) is indebted to the Nansenfondet, Oslo, Freiafondet, Oslo, and Vareknigs Forskningsfond, Oslo.

REFERENCES

Davies, A. W. [1933]. *Biochem. J.* 27, 1770.
Doutt, J. K. [1940]. *J. Mammal.* 21, 356.
Jackson, F. G. [1899]. A Thousand Days in the Arctic, 1, 129. London: Harper and Bros.
Kane, E. K. [1856]. Arctic Exploration in the Years 1853, 1854, 1855, 1, 392–93. Philadelphia: Childs and Peterson.
Kesteltis, R. [1897]. *Proc. R. phys. Soc. Lond.* 14, 80.
Lindhard, J. [1913]. *Medd. Grønland*, 44, 461.
Moore, T. [1937]. *Biochem. J.* 31, 155.
Nansen, F. [1924]. Blant sel og bjørn. Kristiania.
Richardson, J. [1861]. Polar Regions, p. 71. Edinburgh: A. and B. Black.
Takahashi, K., Nakamiya, Z., Kawakimi, K. & Kitasato, T [1925]. *Sci. Pap. Inst. phys. chem. Res., Tokyo*, 3, 81.

Rodahl-'50
Bib. No. 7735

J. Nutrition 41:399-415. 1950.

HYPERVITAMINOSIS A IN THE RAT

KAARE RODAHL
Institute of Physiology, Oslo University, Oslo, Norway

EIGHTEEN FIGURES

(Received for publication January 9, 1950)

In a previous investigation (Rodahl, '49a, b) the toxic effect of polar bear liver was found to be due to its very high content of vitamin A, causing hypervitaminosis A in rats when ingested in large quantities.

This condition was first described by Takahashi et al. ('25) and has since been studied by many workers. Apart from symptoms such as emaciation, exophthalmos, soreness in the skin, and alopecia, the more specific lesions in hypervitaminosis A have been found to be spontaneous fractures of the bones (Collazo and Rodriguez, '33; Bomskov and Seeman, '33; and others) and hemorrhages (Rodahl and Moore, '43; Moore and Wang, '45; and others). Histologically, Drigalski and Laubmann ('33) found degeneration of the renal tubules and glomeruli, of the testes, cardiac muscle and, to a small extent, of hepatic cells. A number of investigators have detected rarefaction of the bones with extreme thinning of the cortex (Bomskov and Seeman, '33; Wolbach and Bessey, '42) and increased deposits of fat in the reticuloendothelial cells, especially the Kupffer cells of the liver and the spleen (Domagk and Von Dobeneck, '33; Collazo and Rodriguez, '33; Drigalski and Laubmann, '33; Uotila and Simola, '38; Noetzel, '39). Some authors have found evidence of changes in the internal secretory glands in hypervitaminosis A, such as increased activity of the thyroid gland (Uotila, '38) and hypertrophy of the island tissue of the pancreas

(Cornil, Chevallier and Paillas, '39). Bomskov and Sievers ('33) observed no effect on the formation of blood in hypervitaminotic rabbits, while the sedimentation rate was reduced, which has also been observed in rats (Rodahl, '49b). The serum calcium and phosphorus have been reported not to be affected (Bomskov and Seeman, '33). A temporary rise in cholesterol and in lipids of the serum following large doses of vitamin A has been reported by several workers (Wendt, '36; Josephs, '44), while a late drop in blood lipids has been observed in hypervitaminotic dogs (Maddock, Wolbach and Maddock, '49).

As an extension of previous work (Rodahl, '49b), the purpose of the present investigation was to examine in further detail the effect of an excess of vitamin A on rats, including a study of the relation between the symptoms and lesions in hypervitaminosis A.

EXPERIMENTAL

Experimental animals

For these experiments a total of 157 albino and piebald rats of both sexes and at different stages of development were used. All rats received daily as much as they wanted of a basal diet which had the following composition: oatmeal, 10.7%; corn meal, 19.5%; coarse wheat flour, 14.6%; wheat embryo, 9.8%; coarse rye flour, 14.6%; dried milk (skimmed), 23.4%; sodium chloride, 0.5%; calcium carbonate, 0.5%; dried yeast, 4.0%; and peanut oil, 2.4%. In addition to this, all rats in these experiments received 150 I.U. of vitamin A and 100 I.U. of vitamin D per rat once a week. Whole maize was given once or twice a week, and ordinary bread once a week. Fresh milk and water were given every day, and occasionally cabbage and carrots. Liver of pig, ox or calf was given once a week.

The rats were kept separated in special cages for each group, and all experimental animals lived under identical conditions. A number of experiments were carried out simultaneously, which allowed strict comparison.

Sources of vitamin A

Whale liver oil concentrate (200,000 I.U. vitamin A/gram) was used as the source of vitamin A in most of the experiments, since it had been found in previous work (Rodahl, '49b) that this source of vitamin A was readily consumed by the animals and contained no vitamin D. The possibility of introducing the condition of hypervitaminosis D is thus ruled out in the experiments where this source of vitamin A is used. In some cases vitamin A alcohol and acetate, obtained from fish oil concentrates, and in one case synthetic vitamin A acetate, were used for comparison. In one experiment rats were fed with the liver of a dog which had received huge doses of vitamin A concentrate during a period of 57 days prior to being killed, the liver containing 90,000 I.U. vitamin A/gram.

Arrangement of the experiment

In one experiment the effect of whale liver oil concentrate was compared with the effect of vitamin A alcohol and acetate. In a second experiment the effect of the various fractions of the whale liver oil were examined: the fraction containing the vitamin A, the oil after the vitamin A had been destroyed, the kitol, and the sterol fraction. In a third experiment the effect of excess vitamin A was compared when given to the rats mixed in the diet and when given by a catheter or pipet. In a 4th experiment the effect on rats of the subcutaneous injection of large doses of vitamin A was examined and compared with the effect of equivalent doses given orally. In a 5th experiment the effect of local application of vitamin A on the skin of rats was examined. In a 6th experiment the effect of single massive doses was compared with the effect of prolonged administration of an excess of vitamin A. In a 7th experiment the approximate gross dose of vitamin A sufficient to cause symptoms of hypervitaminosis A in young growing rats was determined by giving doses ranging from 47 to 625 I.U. vitamin A/gram body weight daily. In a final experiment the effect of an excess of vitamin A

on rats at various stages of development was examined in 5 groups of animals with initial body weights of from 21 to 246 gm.

The control groups were given either the basal diet only, or the vitamin A oil freed of its vitamin A content in addition to the basal diet. In some cases peanut oil was given to the control rats in the same quantities as the vitamin A oil was given to the experimental animals.

Clinical examination

Each experimental animal was carefully examined clinically every day. The animals were weighed every other day, and roentgenograms were taken of the long bones at intervals.

Post mortem examination

In all cases where the animals died the organs were examined as soon after death as possible. In all other cases they were anesthetized by ether for a few minutes to allow blood samples to be collected from living animals for examination, after which they were killed by decapitation and examined. Tissue sections were prepared of the liver, kidney, adrenals and other internal secretory glands, intestines, spleen, lungs, and heart, as well as the bones of both experimental and normal control animals. The following staining methods (Romeis, '24; Mallory, '38) were used: hematoxylin-eosin, van Gieson, Mallory, Kossa, Best's glycogen staining, and Turnbull's staining for blood pigment. Frozen sections of some of the internal organs, such as the liver, adrenals and in some cases the kindey, spleen, pancrease, intestines, lungs, heart and thymus gland, were stained by Sudan III. In the case of bones, the vacuum method described by Wærhaug ('49) was employed for decalcification, using formic acid (Lillie, '48).

When the weight of the adrenals was to be recorded, the organs were carefully removed immediately after death,

quickly placed in a small glass tube supplied with a cork, and weighed. In all cases the left adrenal was weighed and the tissue sections prepared from the other adrenal.

Blood examination

Hemoglobin was determined in all cases by the same Zeiss-Ikon hemoglobinometer (standard 13.8 gm Hb/100 ml blood = 100%). Blood counts were made in the usual manner. Vitamin A was determined in the serum by a modification of the usual antimony trichloride method (Rodahl, '50). For the determination of the total base, the electrodialysis method was used. Calcium was determined by the Kramer-Tisdall method (Kramer and Tisdall, '21) and phosphorus by Kuttner and Lichtenstein's method (Kuttner and Lichtenstein, '36). Blood sugar was determined by the Hagedorn-Jensen method (Hagedorn and Jensen, '23a, b) and the serum iron by Heilmeyer and Ploetner's method (Heilmeyer and Ploetner, '37), using *o*-phenanthroline hydrochloride as the indicator.

Urine examination

At intervals urine samples were collected during 24-hour periods from the various groups of rats by placing the animals in specially constructed cages where the urine was collected without being contaminated by feces. In some cases urine samples were also collected by puncture of the urinary bladder in ether anesthesia. The urine was examined with regard to the presence of protein, blood and sugar. In some cases Schlesinger's test was made.

Feces examination

At intervals feces were examined by the benzidine test in the usual manner. In some cases feces were collected during 24-hour periods, weighed and extracted by acetone in a Soxhlet's apparatus in a dark room; the vitamin A content was determined in the fat spectrographically and by the antimony trichloride method.

Determination of the ash and mineral content of the bones

The femur was removed immediately after death, cleaned and weighed. The bones were dried until a constant weight was reached at a temperature of 104°C. After this the bone was ashed at 800°C. until a constant weight resulted. The ash was dissolved in 1-n HCl and the calcium determined by the Kramer-Tisdall method. The phosphorus was determined by Kuttner and Lichtenstein's method.

RESULTS

Symptomatology

In agreement with previous findings (Rodahl, '49b, c), the symptoms following ingestion of toxic doses of vitamin A in rats may be divided into symptoms of acute intoxication and symptoms of chronic intoxication. Symptoms of acute intoxication may occur within a few hours after single toxic doses are given by pipet or catheter, in the form of general malady, changes in the pelts, drowsiness, muscular weakness and decreased activity. Simultaneously, a rapid increase of the vitamin A level in the blood was observed during the first 2 to 4 hours (up to 17 I.U. vitamin A/gram serum in rats given 50,000 to 90,000 I.U. vitamin A daily), followed by a rapid decrease. At the end of 48 hours the vitamin A level of the blood had usually reached normal levels and at the same time the animals given a single dose appeared to have recovered. If no further excess of vitamin A is given, it appears that the animal recovers without any detectable injurious effect. It is thus probable that the symptoms of acute intoxication are related to the sudden large increase of the vitamin A level of the blood.

Continued administration of toxic doses during a period of several days caused symptoms of chronic intoxication (fig. 1) such as: lack of appetite and reduced weight gain or loss of weight, muscular weakness, loss of hair (fig. 2), soreness and bleeding in the skin, swelling of the palpebrae,

exophthalmos, stiffness of the limbs, limping, spontaneous fractures, internal hemorrhages and eventually death. In some cases abnormal posture was observed, with marked bending of the spine and both hind legs appearing paralyzed, without any fractures or hemorrhages being detected in the lower extremities (fig. 3).

In hypervitaminotic rats there was a marked reduction of the food intake, which was found to be in proportion to the vitamin A doses given — that is the higher the dose of vitamin A, the lower the food intake. Thus, while normal control rats consumed an average of 14.5 gm food daily, rats of the same age given 10,000 I.U. vitamin A daily consumed 9.7 gm, those given 50,000 I.U. vitamin A daily consumed 5.9 gm, and animals given 60,000 I.U. vitamin A daily consumed only 3.6 gm food daily.

Examination of the urine usually revealed proteinuria and hematuria, and the amount of urine secreted in 24 hours was less in hypervitaminotic rats than in normal control rats. In the feces the benzidine test was often positive. In the majority of cases the hemoglobin values fell within the range of those of the normal control rats. Reduced hemoglobin values were sometimes associated with considerable hemorrhages, which may possibly explain the anemia in those cases. The incidence of spontaneous macroscopical hemorrhages in hypervitaminotic rats was lower in the present experiments than has generally been accepted. Out of 62 rats, spontaneous hemorrhages occurred in 14 cases; of these, 7 occurred in young rats, and 7 in adult animals. A considerable reduction of the serum iron was detected in only one rat (35 μg%), in which case a marked anemia was also observed (Hb: 65%). No significant difference was detected in the differential blood count in hypervitaminotic rats as compared with that of the normal control rats. The sedimentation rate was reduced to 1 to 2 mm after one hour in hypervitaminotic rats, as against the usual 5 to 10 mm in normal rats. The levels of total base, potassium, urea, calcium and phosphorus in the serum were within the normal

range. The fasting blood sugar was normal in all cases except three. In one rat, which was moribund, it was only 60 mg/100 ml, and in two cases it was 165 mg/100 ml.

The average glycogen content of the liver was 70 mg/100 gm in hypervitaminotic rats as against 110 in normal rats. In 6 cases it was abnormally low in the first-mentioned group (10 to 20 mg/100 gm). This was probably due to inanition.

No direct relation could be detected between the severity of the clinical symptoms in rats given prolonged administration of an excess of vitamin A and the vitamin A level in the blood. Thus, the vitamin A level of the blood 24 hours after the last dose of vitamin A was 2.8 to 4.9 I.U./gram both in rats receiving doses of 10,000 I.U./day — which produced practically no clinical symptoms — and in rats given toxic doses of between 50,000 and 90,000 I.U. vitamin A daily and which showed pronounced clinical symptoms.

The vitamin A content was largely increased in all the internal organs examined in hypervitaminotic rats, such as the liver, kidney, adrenals, and testes, as well as the visceral fat. In none of the cases was any vitamin A detected in the urine from hypervitaminotic rats, although the vitamin A content of the kidney was as high as 1,800 I.U. vitamin A/gram. No direct relation could be detected between the vitamin A content of the rat's liver and the manifestation of clinical symptoms of hypervitaminosis A. On the other hand, it appears that the most significant pathological changes are detected in the organs of hypervitaminotic animals where the storage of vitamin A is highest, such as in the liver and kidneys.

Systematic x-ray examination of the long bones at various stages of the experiment showed gradual thinning of the shaft. In agreement with this, it was found that in both young and adult rats the diameter of the femur was less in hypervitaminotic animals than in normal control rats when bones of the same length were compared in the two cases and the diameter was measured at corresponding places at the post mortem (fig. 4). The bones appeared normally calcified,

but lines of denser calcification were seen in the epiphyses as well as in the epiphyseal border of the metaphyses. The cortical shadow was abnormally thin, particularly toward the metaphyses, where it was usually absent. Simultaneously it was observed that the epiphyseal line became abnormally narrow as compared with that in normal rats of the same age. In very young rats roentgenograms also showed a broad dense shadow around the centre of ossification, an irregularly broadened intensely calcified zone at the epiphyseal ends of the tibia, and a glass transparency of the shaft. Healing of the fractures took place at the same rate as healing of fractures produced artificially in normal rats for comparison, in spite of the vitamin A's being given continuously in unchanged doses, although abnormally rich callus fo mation was usually observed in the former (figs. 5, 6, 7, 8).

Macroscopic post mortem examination in many cases revealed no significant pathological findings. The most constant findings were emaciation; arterial hyperemia; subcutaneous, muscular or visceral hemorrhages; fractures; enlarged adrenals (the weight of the adrenals when expressed as per cent of the body weight of the animal was up to three times higher in hypervitaminotic rats than in normal control rats of the same age); fatty appearance of the cut surface of the liver; swelling of the visceral lymph glands; and widening of the costochondral junction in some cases. In some of the rats the lungs and other internal organs were fiery red.

By microscopic examination the most constant findings were hyperemia; scattered red blood cells outside the capillaries in the internal organs, in the space of Bowman's capsule (fig. 11), and in the tubular lumen of the kidney (fig. 12); degeneration of the renal tubules (fig. 10); deposits of sudanophil droplets between the liver cells, particularly in the Kupffer cells which appeared swollen; and slight fatty degeneration of the actual liver cells (fig. 9). By Sudan staining large deposits of sudanophil droplets were usually seen in the adrenal cortex (figs. 17, 18). Histological examination of pieces of the skin taken from areas with marked alopecia

revealed hyperemia and massive hemorrhages around the root sheaths of the hair (fig. 13). This may probably be considered the cause of the alopecia. Microscopical examination of the long bones revealed marked hyperemia and subperiosteal and osseous hemorrhages, with destruction of bone spicules, an increased number of osteoclasts, and thinning of the compact bone (figs. 15, 16).

Chemical analysis of the femurs in young and adult hypervitaminotic and in normal control rats showed no significant reduction in the calcium or phosphorus content of the ash in the former animals as compared with normal rats, while the ash content of the dry bone in some cases was reduced and generally showed considerable variation among animals.

Identical effects were obtained in rats by feeding mammalian livers rich in vitamin A — such as the liver of a hypervitaminotic dog, liver oils, highly purified vitamin A concentrates, and synthetic vitamin A acetate — when these were given orally in equivalent amounts with regard to the vitamin A content. No ill effect whatever was observed in rats given liver oil where the vitamin A had been destroyed. None of the fractions of the liver oils other than the vitamin A had any ill effect on rats.

The same toxic effect was observed when an excess of vitamin A was administered orally or given by subcutaneous injection. The quantities of vitamin A oils required to give rise to toxic symptoms were considerably higher, however, when injected subcutaneously than when given orally. This is probably due to incomplete and slow absorption of the vitamin A from the subcutaneous tissue. On the other hand, vitamin A emulsions were readily absorbed following injections, the effect of equivalent doses of vitamin A in this form being identical when compared with oral administration. Local application of vitamin A concentrates to the skin of rats caused no ill effect.

Subcutaneous injection of single massive doses of vitamin A into rats has been found by some previous workers (Takahashi et al., '25; Matsuoka, '34) to cause death from cramps.

In none of our experiments did cramps occur as a result of the subcutaneous injection of large quantities of vitamin A oils — up to one million I.U. of vitamin A in a single injection — when great care was taken not to introduce the oil into the blood stream.

Identical gross doses of vitamin A oils appeared to prove slightly more injurious to rats when partly mixed in the basal diet than when given entirely by pipet or by a specially constructed catheter. In the latter case a larger proportion — approximately 20% more — of the gross dose of vitamin A was lost through the feces, and it is possible that this may account for the difference in the observed effect.

Oral administration of single massive doses of vitamin A, apart from causing symptoms of acute intoxication shortly after the dose, had only a slight delayed effect on rats, and produced no detectable pathological changes in the internal organs and bones. In no case was it possible to produce lethal effects by single doses of vitamin A, such as 1.6 million I.U. of the vitamin given in the course of three hours. Nor did a very high vitamin A level in the blood (31 I.U. vitamin A/gram serum) in itself prove lethal.

It is thus evident that the prolonged administration of an excess of vitamin A in toxic doses over a period of several days is necessary to produce the changes characteristic of the condition called hypervitaminosis A.

Toxic dose

Rodahl and Moore ('43), and Herbst, Pavcek and Elvehjem ('44) found that doses of over 15,000 I.U. vitamin A daily are toxic to rats. This has been confirmed in the present investigation. An apparent effect of age on the manifestations of hypervitaminosis A in rats given similar gross doses of vitamin A has previously been reported by Rodahl and Moore ('43); Moore and Wang ('45); and Walker, Eylenburg and Moore ('47). On the basis of the present experiments, however, it appears that under identical conditions equivalent daily doses of vitamin A produce the same clinical picture

and post mortem findings in young, adolescent and adult rats. Contrary to the findings previously reported, there was in these experiments no higher incidence of hemorrhages in adult rats than in young rats and the same bone changes occurred, with a similar frequency of spontaneous fractures, although the fractures developed later in adult than in young growing animals.

Confirming the statement made by Rodahl and Moore ('43), the clinical picture of hypervitaminosis A was found to vary remarkably with the magnitude and duration of the overdosage. In all cases daily doses of over 50 to 100 I.U. vitamin A/gram of body weight resulted in appreciable toxic manifestations in rats. Doses of between 47 and 135 I.U. vitamin A/gram of body weight produced only slight toxic symptoms, with moderately reduced weight gain and slight proteinuria and hematuria. Apart from these, no other clinical symptoms were observed even when this dose was given daily during a period of 58 days. In all cases, doses of between 200 and 500 I.U. vitamin A/gram of body weight caused pronounced clinical symptoms and pathological changes typical of hypervitaminosis A. Doses of over 800 I.U. vitamin A/gram of body weight proved lethal in all cases at the end of periods varying from 9 to 30 days. These figures must be taken as maximum values, however, since it has been shown in experiments with rats that approximately 40% of the ingested amount of vitamin A is lost through the feces.

DISCUSSION

It is a question whether all of the observed symptoms may be considered as directly caused by an excess of vitamin A as such, or whether some of them may be indirect rather than direct results.

Absence of normal weight gain is one of the first and most constant symptoms in hypervitaminotic rats. This was found to be associated with reduced food intake as a result of lack of appetite. This symptom must be considered as being attributable to the action of an excess of vitamin A, since the

oil had no adverse effect on the appetite or the weight gain when the vitamin A had been destroyed.

It would seem reasonable to assume that inanition in the most pronounced cases may have been in part responsible for some of the symptoms of hypervitaminosis A. On the other hand, a number of these symptoms were observed in direct connection with the first massive doses of vitamin A, before the effect of inanition would be noticeable. The importance of this factor, however, should be studied further by limiting the food intake of the control rats to that of the test animals.

As judged by roentgenograms and microscopical examination, it appeared that destruction and absorption of the bone substance occurred in hypervitaminotic rats, while the remaining bone, although irregular in structure, appeared to contain normal richness of calcium and normal density of bone cells. This may well explain the fact that the calcium and phosphorus contents of the ash in the remaining bone appeared unaltered in hypervitaminotic animals.

Wolbach ('46) considers that bone remodelling is greatly accelerated in hypervitaminosis A, and that a defective tissue is laid down which fractures easily. On the other hand, it seems probable that at least some of the observed bone changes may be explained as the result of the hemorrhages, particularly those which occur around the periosteal blood vessels, and of lack of nutrition caused by insufficient blood supply. In fact, a combination of several factors may be the most likely explanation of the tendency to spontaneous fractures in hypervitaminosis A.

In most cases the fractures occurred near the end of the long bones, at the places where the compact bone was thinnest and where it would be expected to offer less resistance against breakage. In some cases, however, fractures occurred at places where the compact bone was thicker, thus indicating an abnormal fragility of the bones (fig. 14).

The tendency to bleeding (hemorrhagic diathesis) is a prominent feature in the clinical and pathological picture of

hypervitaminosis A. The hemorrhages appeared to be quite general — subcutaneous, muscular and visceral — and varied from small petechia in the skin, or scattered red blood cells outside the capillaries in the internal organs, to massive blood extravasations and the formation of large hematomas. Epistaxis and bleeding from the gums were also observed. Hemorrhages often occurred in places where no serious injury was likely to start the bleeding, and an additional supply of vitamin K (Rodahl, '49b) had no beneficial effect on them.

Histologically, scattered red blood cells were seen outside the capillaries in the internal organs such as the liver, kidney and lungs, and in some cases also the adrenals, as well as in the bones, indicating an abnormal permeability of the capillary wall for the red blood cells. By the usual staining methods no morphological abnormalities were detected in the vessel walls, however.

In the kidneys, free blood was frequently observed in the tubules and in the space of Bowman's capsule, indicating an abnormal permeability of the capsule for red blood cells. This may well explain the hematuria which was a frequent finding in hypervitaminotic rats and which was sometimes very marked.

The condition of hypervitaminosis A presents a highly complex clinical picture. Several of the clinical symptoms have been found to correspond to histological changes attributed to excess of vitamin A. Nevertheless, the mechanism of the toxicity is still, on the whole, quite obscure.

SUMMARY AND CONCLUSIONS

As an extension of previous investigations (Rodahl, '49b), the effect of an excess of vitamin A on rats has been studied in further detail.

Oral administration of an excess of vitamin A produced the same toxic symptoms as subcutaneous injection.

Prolonged administration of an excess of vitamin A in toxic doses over a period of several days was necessary to

produce the changes characteristic of the condition called hypervitaminosis A.

No significant effect of age or sex was observed on the clinical picture of hypervitaminosis A in rats given equivalent daily doses of the vitamin, per gram of body weight.

Gross doses of over 50 to 100 I.U. vitamin A/gram of body weight daily resulted in appreciable toxic manifestations. While doses of between 47 and 135 I.U. vitamin A gram of body weight produced only slight toxic symptoms, doses of between 200 and 500 I.U. caused pronounced clinical symptoms, and doses over 800 I.U./gram of body weight proved lethal in all cases at the end of periods varying from 9 to 30 days.

The symptoms following ingestion of toxic doses of vitamin A were: changes in the pelts, drowsiness, muscular weakness, lack of appetite, reduced growth, soreness and bleeding of the skin, alopecia, swelling of the palpebrae, exophthalmos, stiffness in the limbs, limping, spontaneous fractures, hemorrhages, proteinuria, hematuria, intestinal bleeding, and in some cases hypochromic or normochromic anemia. The fasting blood sugar was reduced in one case and increased in two cases. No abnormalities were detected in the content of calcium, phosphorus, total base, potassium and urea in the blood, and no significant difference was detected in the differential blood count when compared with that of normal rats.

X-ray and microscopic examination of the long bones revealed characteristic changes, while no significant changes were detected in the mineral content of the bones.

Histologically, the most constant findings were hyperemia, scattered red blood cells outside the capillaries in the internal organs and in the space of Bowman's capsule in the kidney, degeneration of the renal tubules, deposits of sudanophil droplets in the liver and increased sudanophil deposits in the adrenal cortex.

Several of the clinical symptoms in hypervitaminosis A were found to correspond to histological changes attributed to the toxic effect of an excess of vitamin A. The mechanism of this toxic effect on the cells is, however, unknown.

ACKNOWLEDGMENTS

The present work has been carried out at the Institute of Physiology, Oslo University, Oslo, Norway. I am greatly indebted to the head of this institute, Professor Einar Langfeldt, for placing the necessary laboratory facilities at my disposal. The work has been carried out during a full-time grant from Norsk Polarinstitutt, for which I express my sincere thanks. My thanks are also due to the head of that institute, Professor H. U. Sverdrup, for his interest and help in the completion of this work. I am also indebted to Distillation Products, Inc., Rochester, N. Y., for furnishing the synthetic vitamin A acetate.

LITERATURE CITED

BOMSKOV, C., AND G. SEEMAN 1933 Über eine Wirkung des Vitamin A auf den Mineralhaushalt. Zschr. ges. exp. Med., *89:* 771.

BOMSKOV, C., AND G. SIEVERS 1933 Über die Wirkung des A-Vitamine auf die Zusammensetzung des Blutes. Ibid., *89:* 780.

COLLAZO, J. A., AND J. S. RODRIGUEZ 1933 Hypervitaminose A. I. and II. Klin. Wschr., *12:* 1732, 1768.

CORNIL, L., A. CHEVALLIER AND J. E. PAILLAS 1939 Histologic study of viscera in experimental hypervitaminosis A in the guinea pig. Ann. d'anat. path., *16:* 74.

DOMAGK, G., AND P. VON DOBENECK 1933 Über histologische Befunde bei der Überdosierung mit Vitamin A-konzentrat. Arch. path. Anat., *290:* 385.

DRIGALSKI, W., AND W. LAUBMANN 1933 Über Schadigung durch Vitamin A. Klin. Wschr., *12:* 1171.

HAGEDORN, H. C., AND B. N. JENSEN 1923a Zur Mikrobestimmung des Blutzuckers mittels Ferricyanid. Biochem. Zschr., *135:* 46.

——— 1923b Die Ferricyanidmethode zur Blutzuckerbestimmung. II. Ibid., *137:* 92.

HEILMEYER, L., AND K. PLOETNER 1937 Das Serumeisen und die Eisenmangelkrankheit. Fisher, Jena.

HERBST, E. J., P. L. PAVCEK AND C. A. ELVEHJEM 1944 Telang livers and vitamin A toxicity. Science, *100:* 338.

JOSEPHS, H. W. 1944 Hypervitaminosis A and carotenemia. Am. J. Dis. Child., *67:* 33.

KRAMER, B., AND F. F. TISDALL 1921 A simple technique for the determination of calcium and magnesium in small amounts of serum. J. Biol. Chem., *47:* 475.

KUTTNER, T., AND L. LICHTENSTEIN 1936 Micro colorimetric studies. Ibid., *85:* 671.

LILLIE, R. D. 1948 Histopathologie Technic. The Blakiston Company, Philadelphia and Toronto.

MADDOCK, C. L., S. B. WOLBACH AND S. MADDOCK 1949 Hypervitaminosis A in the dog. J. Nutrition, *39:* 117.

MALLORY, F. B. 1938 Pathological Technique. W. B. Saunders Company, Philadelphia and London.

MATSUOKA, M. 1934 On cramps caused by an over-dose injection of biosterol. Bull. Inst. Phys. Chem. Res., Japan, *13:* 1267 (English abstract).

MOORE, T., AND Y. L. WANG 1945 Hypervitaminosis A. Biochem. J., *39:* 222.

NOETZEL, H. 1939 Morphologische Untersuchungen bei Vitamin A — überdosierung. Zschr. ges. exp. Med., *105:* 83.

RODAHL, K. 1949a The toxicity of polar bear liver. Nature, *164:* 530.

——— 1949b The toxic effect of polar bear liver. Norsk Polarinstitutts Skrifter, no. 92.

——— 1949c Hypervitaminosis A and scurvy. Nature, *164:* 531.

——— 1950 Hypervitaminosis A. Norsk Polarinstitutts Skrifter, no. 95.

RODAHL, K., AND T. MOORE 1943 The vitamin A content and toxicity of bear and seal liver. Biochem. J., *37:* 166.

ROMEIS, B. 1924 Taschenbuch der Mikroskopischen Technik. München and Berlin.

TAKAHASHI, K., Z. NAKAMIYA, K. KAWAKIMI AND T. KITASATO 1925 On the physical and chemical properties of biosterin and on its physiological significance. Sci. Pap., Inst. Phys. Chem. Res., Tokyo. *3:* 81 (English abstract).

UOTILA, U. 1938 Über die Schilddrüsenveränderungen bei A-, B-, und D-Avitaminosen. Arch. path. Anat., *301:* 535.

UOTILA, U., AND P. E. SIMOLA 1938 Über die Beziehungen zwischen den Vitaminen und dem reticuloendothelialen System. Ibid., *301:* 523.

WAERHAUG, J. 1949 Decalcification of bone and teeth under vacuum — a rapid method for producing hard tissue preparations. J. Dent. Res., *28:* 525.

WALKER, S. E., E. EYLENBURG AND T. MOORE 1947 The action of vitamin K in hypervitaminosis A. Biochem. J., *41:* 575.

WENDT, H. 1936 Hypercholesterinämie und Vitamin A. Deut. med. Wschr., *2:* 1213.

WOLBACH, S. B. 1946 Vitamin A deficiency and excess in relation to skeletal growth. Proc. Inst. Med., Chicago, *16* (4).

WOLBACH, S. B., AND O. A. BESSEY 1942 Tissue changes in vitamin deficiencies. Physiol. Rev., *22:* 233.

PLATE 1

EXPLANATION OF FIGURES

1 Young rat (initial body weight 42 gm.) given 830–1300 I.U. vitamin A/gram body weight daily for 18 days, showing multiple fractures and scruffiness, the hair being smeared with urine and feces.

2 Alopecia and soreness of left eye, which is completely closed, in young rat given 4 drops daily of a highly concentrated vitamin A preparation, corresponding to 60,000 I.U. vitamin A daily (697 I.U. vitamin A/gram body weight).

3 Abnormal posture, with marked bending of the spine, and "paralysis" of both hind legs, without any fracture or hemorrhages being detected in the lower extremities in adult rat given 625 I.U. vitamin A/gram body weight daily for 24 days.

4 Femur of adult hypervitaminotic rat (left), compared with the femur of a normal control rat of the same age (right), showing the difference in diameter.

5, 6 and 7 Roentgenograms of right hind leg of female rat given 50,000 I.U. vitamin A daily (500–250 I.U. vitamin A/gram body weight) at the end of 53 days (5), showing abnormal thinning of the bone shafts, and at the end of 74 (6) and 106 days (7), showing healing of fractures of the tibia and fibula.

8 Healing of fractures in hypervitaminotic rat with marked callus formation.

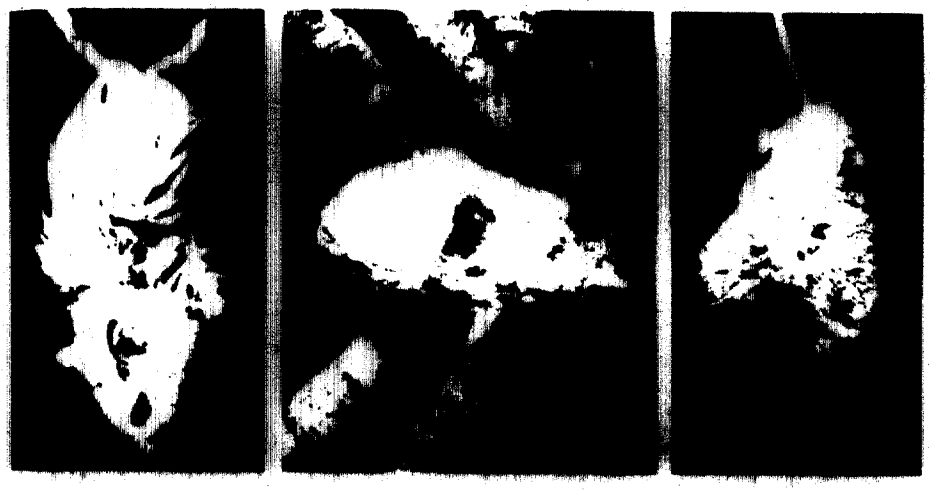

1 2 3

4 5 6 7 8

PLATE 2

EXPLANATION OF FIGURES

9 Photomicrograph (× 150). Liver, stained by Sudan III, from adult male rat given 230–390 I.U. vitamin A/gram body weight daily, showing massive deposits of sudanophil droplets between the liver cells, especially in the Kupffer cells.

10 Photomicrograph (× 285. Hematoxylin-eosin stain). Kidney from rat given 500–250 I.U. vitamin A/gram body weight daily for 119 days, showing degeneration and necrosis of convoluted tubules.

11 Photomicrograph (× 375. Mallory stain). Kidney from rat given 52,-500 I.U. vitamin A daily for 11 days, showing red blood cells in the space of Bowman's capsule.

12 Photomicrograph (× 335. Hematoxylin-eosin stain). Kidney from same rat shown in figure 11, showing red blood cells in collecting tubules.

13 Photomicrograph (× 60. Hematoxylin-eosin stain) of slide taken from the skin at the place of alopecia in a rat given 52,500 I.U. vitamin A daily for 11 days, showing marked hyperemia and hemorrhages around the root sheaths of the hair (in the dermic coat).

14 Photomicrograph (hematoxylin-eosin stain). Fracture of tibia in rat given excess of vitamin A (570 I.U. vitamin A/gram body weight daily) for 21 days.



9 10 11

12 13 14

PLATE 3

EXPLANATION OF FIGURES

15 Photomicrograph (× 22. Hematoxylin-eosin stain). Tibia from young rat given 95 I.U. vitamin A gram body weight daily for 18 days, showing no significant pathological conditions.

16 Photomicrograph (× 22. Hematoxylin-eosin stain). Tibia from rat of same age as animal in figure 15, given 500-830 I.U. vitamin A gram body weight daily for 27 days, showing narrow epiphyseal line, thinning and irregularity of compact bone and subperiosteal hemorrhage.

17 Photomicrograph (× 24). Adrenal of normal adult female rat stained by Sudan III.

18 Photomicrograph (× 24). Adrenal of adult male hypervitaminotic rat (250–390 I.U. vitamin A/gram body weight daily for 46 days) stained by Sudan III, showing dense sudanophil deposits in the cortex.

15

16

Rodahl et al-'65
Bib. No. 7739

J Nutr. 85(2):174-180. 1965

Effect of Excess of Vitamin A on Sulfur Metabolism in the Rat [1]

K. RODAHL, B. ISSEKUTZ, JR., AND D. MERRITT SHUMEN
Division of Research, Lankenau Hospital, Philadelphia, Pennsylvania

ABSTRACT The effect of acute excess of vitamin A on sulfur metabolism was studied in nondeficient rats, using $Na_2S^{35}O_4$, methionine-S^{35} and cystine-S^{35}, and the liquid scintillation technique to measure specific activity (SA) of the $BaS^{35}O_4$ precipitates in the urine. Both in hypervitaminotic and control rats given methionine-S^{35} or cystine-S^{35}, the same amount (75 to 80%) of the excreted radioactivity appeared in the inorganic SO_4 fraction of the urine. When single or repeated vitamin A injections were given to rats treated previously with methionine-S^{35}, a larger amount of inorganic $S^{35}O_4$ was excreted than in the controls. After injection of $Na_2S^{35}O_4$, vitamin A-treated rats showed a more rapid decrease in the SA of urinary inorganic SO_4 than control rats, suggesting an increased breakdown of body protein. It therefore appears that vitamin A did not inhibit the oxidation of SH or S-S groups, but that large overdosage had a proteolytic effect in intact rats.

In man, single large doses of vitamin A cause acute toxic symptoms in the form of violent headache and nausea, followed by peeling of the skin (1). Chronic overdosage of vitamin A causes a variety of symptoms. In young growing animals, the most striking changes are retarded growth, hemorrhage and bone fragility (2).

Several hypotheses have been advanced to explain the mechanism of the effect of excess vitamin A. Russian investigators (3–5) have suggested that vitamin A is an antioxidant that inhibits the oxidation of sulfhydryl groups to sulfates. Fell (6) and Thomas and co-workers (7) have suggested that an excess of vitamin A activates a proteolytic enzyme which has an effect similar to papain. Finally, Wolf and Varandani (8) have advanced the hypothesis that vitamin A regulates the formation of mucopolysaccharides, in that excess vitamin A causes an increase in the mucus type of mucopolysaccharides.

The purpose of the present study was to test the first two of these hypotheses in intact nondeficient rats and specifically to clarify the in vivo effect of acute excess of vitamin A on the sulfur metabolism by using $Na_2S^{35}O_4$, methionine-S^{35} and cystine-S^{35} and the liquid scintillation technique to measure urinary specific activity of the $BaS^{35}O_4$ precipitate.

METHODS

The experiments were carried out on 100- to 120-g male Carworth rats [2] (CFN strain). The animals were divided into groups of 8; each group was kept in a metabolic cage divided into 8 compartments by Plexiglas walls. On a total of 35 groups, 3 types of experiments were carried out. In 2 types of experiments (types 1 and 2), S^{35}-labeled L-methionine or cystine was used. In a third type (type 3), $Na_2S^{35}O_4$ was used. Each experiment consisted of 1 or 2 treated groups and of one simultaneous control group. In the type 1 experiments, the treated animals (9 groups) received daily by stomach tubing 50,000 units of vitamin A acetate, dissolved in 0.5 ml ethyl laurate, for 3 days. The controls (6 groups) were given the same amount of solvent. On the third day all rats were given intraperitoneally the radioactive amino acid. The S^{35}-labeled methionine (0.1 to 0.3 μc/rat) was administered to 7 vitamin A-treated groups and to 5 control groups, and S^{35}-labeled cystine (0.27 μc/rat) was used in 2 vitamin A-treated groups and one control group.

Received for publication July 22, 1964.

[1] This investigation was supported by Public Health Service Research Grant no. AM-06812-03 NTN from the National Institute of Arthritis and Metabolic Diseases.

[2] Carworth Farms, New City, Rockland County, New York.

the type 2 experiments, the animals pretreated with intraperitoneal injec- of S^{35}-labeled methionine (0.21 to µc/day/rat) for 2 consecutive days. the third day, vitamin A dissolved in ml ethyl laurate was administered peritoneally for 1 to 3 days in doses 5,000 to 100,000 units/day/rat, as in figure 1.

third type of experiment was sim- to type 1, except that following the pretreatment with vitamin A, O_4 (0.05 to 0.15 µc/rat) was given peritoneally instead of the S^{35}-labeled acids.

ess othterwise stated, the animals maintained with commercial labora- chow[3] ad libitum. Starting after the tion of the radioactive material, the was collected for a total of 48 to 72 . Each collection period lasted for hours during which the rats fasted; was followed by a one-hour feeding . The purpose of this schedule was vent food particles from contaminat- the urine. Drinking water containing glucose was available to the rats at .

chemical determinations. At the of each collection period the cages rinsed with a few milliliters of dis- water and the excretion of radiosul- measured in 3 fractions, each ation being carried out in dupli- cate. In the first fraction, inorganic SO_4 was determined by direct precipitation with $BaCl_2$. In the second fraction, total SO_4 was determined by precipitation with $BaCl_2$ after acid hydrolysis (boiling in 0.15 N HCl for 25 minutes). In the third fraction, total sulfur was determined by precipitation with $BaCl_2$ after oxidation according to the procedure described by Jeffay et al. (9). The $MgSO_4$ formed during the oxidation was dissolved in 2 ml of 10% HCl. In each of these fractions the amount of urine used was about 10 to 15 ml, or sufficient to provide 20 to 40 mg $BaSO_4$. In each case, the samples, at the end of the procedure described above, were placed in pre-weighed vials of a Tricarb liquid scintillation counter. The vials were placed in a warm water bath, and 2 ml of a 5% $BaCl_2$ solution were added slowly. The precipitate was then centrifuged, washed twice with distilled water and once with 96% alcohol. The final supernatant fraction was tested with sulfuric acid for traces of $BaCl_2$. The precipitate was then dried and kept for one hour in a furnace at 400°. After cooling, the $BaSO_4$ precipitate was weighed, and 10 to 12 stainless steel balls (diameter, 1.6 mm) were placed into the vials and 2 ml scintillator toluene containing 0.5% 2,5-diphenyloxazole (PPO) and 0.03% 1,4-bis-2-(4-methyl-

[3] Purina Rat Chow, Ralston Purina Company, St. Louis.

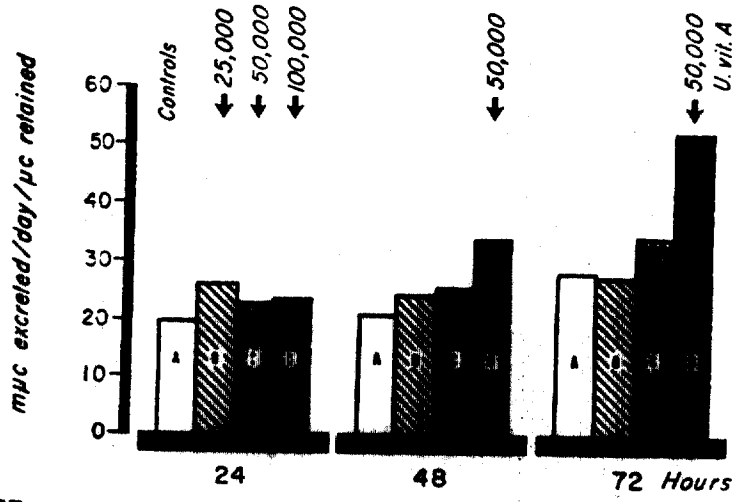

Fig. 1 Effect of excess vitamin A on the urinary excretion of inorganic $S^{35}O_4$ of rats with methionine-S^{35}. For detailed explanation, see text.

5-phenyloxazolyl)-benzene (dimethyl POPOP) added. The caps were screwed on tightly and the vials were then shaken vigorously for 10 to 20 minutes until the precipitate was broken up and finely dispersed. Following this, about 15 ml Cab-O-Sil thixotropic gel (5 g Cab-O-Sil in 100 g scintillator toluene) were added, and the vial was shaken for 10 minutes. After removing the air bubbles (by slowly rotating the vials) the radioactivity was counted either in a Tracerlab liquid scintillation counter at −12° (efficiency of about 70%) or in a Tricarb liquid scintillation counter at +2° (efficiency 63%).

This method has the advantage that no separate aliquots are used for sulfur determination and counting, and thus no transfer of the precipitate is needed. For this reason the method proved to be particularly useful for the determination of specific activity.

The radioactivity in the material injected into the rats was determined as $BaSO_4$ in an aliquot after adding the appropriate carrier to it. In experiments with methionine-S^{35}, nonradioactive methionine was the carrier and the $BaSO_4$ precipitate was obtained after complete oxidation. When $Na_2S^{35}O_4$ was used, this was precipitated along with added Na_2SO_4 and counted in the same way as the other samples.

The reliability of the described procedure was tested in the following ways:

(A) Increasing amounts of $Na_2S^{35}O_4$ of a fixed specific activity were placed in vials to provide approximately 20, 40 or 60 mg $BaS^{35}O_4$, respectively. The same specific activity was obtained regardless of the amount of precipitate, showing that within the above range "self-absorption" was not an interfering factor (table 1, section A). A similar observation was reported by Mathan et al. (10) using a Thixin thixotropic gel for counting $BaC^{14}O_3$ precipitates in amounts up to 200 mg $BaCO_3$ there was no measurable "self-absorption."

(B) Increasing amounts of nonradioactive Na_2SO_4 were precipitated to provide 25, 50, 75 or 100 mg $BaSO_4$, respectively. The precipitate was brought into suspension and 0.1 ml of C^{14}-toluene solution was added to each vial. The increasing

TABLE 1

Assessment of reliability of radioisotope determinations: [1] *effect of amount of precipitate on specific activity ("self-absorption") (A); quenching effect of increasing amount of precipitate on the C^{14} toluene (B); and "trapping" of methionine by precipitated inorganic SO_4 (C)*

	Source of radioactivity	Carrier	$BaSO_4$ precipitate	Radioactivity	Specific activity
			mg/vial	*dpm* [2]*/vial* (× 10^4)	*dpm/mg* $BaSO_4$ (× 10^4)
A	$Na_2S^{35}O_4$	Na_2SO_4	20.8	4.29	2.063
		Na_2SO_4	41.6	8.36	2.008
		Na_2SO_4	61.2	12.29	2.007
B	Toluene-C^{14}	none	—	4.29	—
		Na_2SO_4	24.3	4.19	—
		Na_2SO_4	50.0	4.29	—
		Na_2SO_4	75.6	4.38	—
		Na_2SO_4	100.0	4.27	—
C	Methionine-S^{35}	Methionine	66.4	28.48	4.289
		Na_2SO_4	73.6	0.32	0.043
		Methionine	42.7	33.22	7.788
		Na_2SO_4	72.4	0.34	0.046
		Methionine	72.9	41.98	5.758
		Na_2SO_4	73.1	0.09	0.011
		Methionine	57.5	44.27	7.700
		Na_2SO_4	75.0	0.35	0.046

[1] For details see text.
[2] dpm = disintegrations per minute.

amount of precipitate did not have any quenching effect on the C^{14}-toluene (table section B).

(C) Two aliquots were taken from a methionine-S^{35} solution; sodium sulfate was added as a nonradioactive carrier to one of the aliquots, and methionine to the other. The former was precipitated with $BaCl_2$ directly, the latter after complete oxidation. When Na_2SO_4 was used as a carrier, the measured specific activity (cpm/mg $BaSO_4$) was usually less than 1% of that found after oxidation of the methionine-methionine-S^{35} mixture (table section C). This shows that the inorganic SO_4, when precipitated, does not carry with it (absorbed or trapped) any appreciable amount of methionine.

RESULTS

Effect of vitamin A on the oxidation of methionine-S^{35} and cystine-S^{35} (experiments, type 1). When labeled methionine was administered intraperitoneally, only a relatively small portion (4 to 29%) of the injected material was excreted in the urine during the first 48 hours (table 2). There was no difference in this respect whether the rats received 50,000 IU vitamin A daily for 3 days (7 groups) or only the solvent (5 groups). As shown in table 2, there was no consistent difference between the vitamin A-treated and the control groups in the urinary excretion of S^{35}. However, in 6 out of 7 experiments, 76 to 90% of the excreted S^{35} appeared in the $BaCl_2$ fraction, the major portion of it as inorganic $S^{35}O_4$. Again, there was no difference between treated and control groups.

Essentially the same results were obtained when cystine-S^{35} was used instead of labeled methionine. Of the injected radioactivity, 23 to 33% was excreted and most of it in SO_4 form during the first 48 hours. No difference was found between control and vitamin A-treated rats. It may therefore be justified to conclude from these experiments that vitamin A does not inhibit the oxidation of the SH group of methionine or the S-S group of cystine.

Proteolytic effect of vitamin A (experiments, type 2). Theoretically the most direct way to demonstrate a proteolytic

TABLE 2

Urinary excretion of S^{35} in 48 hours in hypervitaminotic and control rats, expressed as percentage of the administered radioactive dose of S^{35}

Group no.	Radioactive dose administered		Urinary excretion of S^{35} in 48 hours									
			Hypervitaminotic rats [1]				Control rats					
	Source of radioactivity	Dose	Total radiosulfur (S^{35}) [2]	Radiosulfate ($S^{35}O_4$)			Total radiosulfur (S^{35}) [2]	Radiosulfate ($S^{35}O_4$)		
				Inorganic $S^{35}O_4$ [3]	Total $S^{35}O_4$ [4]	Total $S^{35}O_4$		Inorganic $S^{35}O_4$ [3]	Total $S^{35}O_4$ [4]	Total $S^{35}O_4$
		μc/rat	% of total excreted S^{35}							
1	L-Methionine-S^{35}	0.09	26.1	17.0	23.7	90.9	13.2	9.8	12.5	94.7
2		0.10	29.2	22.8	26.2	89.7	19.6	14.8	15.7	80.1
3		0.10	17.3	11.6	14.0	90.2				
4		0.19	12.4	9.0	10.0	80.6	21.4	15.6	18.5	86.4
5		0.21	12.5	7.7	9.5	76.0	9.2	4.5	5.9	64.1
6		0.21	8.4	4.3	5.1	60.7				
7		0.30	4.0	3.1	3.6	90.0	18.2	12.2	14.2	78.0
8	Cystine-S^{35}	0.27	33.3	24.8	30.1	90.4	26.3	18.1	21.4	81.4
9		0.27	22.5	15.5	18.3	81.3				

[1] Given 50,000 IU vitamin A/rat daily for 3 days.
[2] Total S^{35}: after oxidation with perchloric acid and precipitation with $BaCl_2$.
[3] Inorganic $S^{35}O_4$: direct precipitation with $BaCl_2$.
[4] Total $S^{35}O_4$: inorganic plus organic sulfate; precipitation with $BaCl_2$ after acid hydrolysis.

effect would be to measure the nitrogen balance. This approach, however, leads to great technical difficulties, because excess vitamin A when administered for a prolonged period of time decreases the food intake of the rats, which in itself leads to a negative balance. Short-term experiments, such as those described here, on the other hand, cannot give reliable balance values since neither the measurement of food intake nor the determination of urinary nitrogen output (loss of nitrogen in the form of ammonia during the collection period) can be carried out with the required accuracy. However, the fact that 71 to 96% of the injected methionine-S^{35} was retained in the body 48 hours after injection provided a possibility to study the proteolytic effect of a single or repeated doses of vitamin A. In this study (fig. 1), 96 rats received methionine-S^{35} for 2 consecutive days; the urine was collected, and the total excreted radioactivity was measured. The difference between this value and the injected dose was taken as the amount of radioactivity present in the rats at the end of the 48 hours when the vitamin A was given intraperitoneally. Eight animals received 25,000 IU vitamin A (group B), 24 animals received 50,000 IU in a single injection (group C), and 32 rats were given 100,000 IU once and 50,000 IU daily for the 2 following days (group D). Finally, 32 animals (group A) served as controls, receiving the solvent only. The excreted inorganic $S^{35}O_4$ (mμc/24 hours) was related to the amount of radioactivity (μc) present in the animals at the beginning of each collection period. At the end of the 3 days, vitamin A showed a marked proteolytic effect only in those rats which received altogether 200,000 IU in form of repeated injections (fig. 1, group D). During the third collection period, they excreted in the inorganic sulfate fraction 52 mμc for each microcurie present in the body at the beginning of this period, compared with 28 mμc excreted by the control rats, representing an increase of 86% in the hypervitaminotic rats. Fifty thousand international units of vitamin A in a single dose (group C) increased the excretion of $S^{35}O_4$ only about 23% above that of the controls (group A), whereas 25,000 units had no effect (group B).

3. *Experiments with $Na_2S^{35}O_4$ (experiments, type 3).* The effect of an excess of vitamin A on the breakdown of body protein could be shown also by using the isotope dilution technique. Five groups of rats were given 50,000 IU vitamin A/rat/day for 3 days, followed by an intraperitoneal injection of $Na_2S^{35}O_4$. The urine was collected for two 23-hour periods, and the specific activity of the inorganic $S^{35}O_4$ was determined. The advantage of this approach is that it does not require an accurate measurement of the daily urine output; hence any loss of urine, whether it be soaked into the pelt of the animal or trapped elsewhere in the cage, does not cause any error. Furthermore, this method as outlined above, measures directly the specific activity of the $BaSO_4$ precipitate present in the counting vial.

When the specific activity obtained in the second collection period is expressed as percentage of the specific activity obtained in the first 23 hours ($= 100 \times 10^6$ dpm/mg $BaSO_4$), this value depends only on the dilution of radioactivity by the unlabeled SO_4. It is assumed that the major part of the unlabeled SO_4 is derived from the oxidation of sulfur-containing amino acids, partly from the food and partly from the body proteins. A protein-free diet would be expected to increase this value because in this instance the only source of unlabeled SO_4 is the body protein. On the other hand, administration of unlabeled methionine should cause a more rapid decrease of the specific activity, since the oxidation of unlabeled methionine yields non-isotopic sulfate. The results obtained with 5 control groups were consistent with these assumptions (table 3). The specific activity of urinary inorganic sulfate decreased less with the protein-free diet than with ordinary laboratory chow, and decreased more rapidly in the group treated with nonradioactive methionine. As shown in table 3, the specific activity decreased more rapidly in the vitamin A-treated groups than in the corresponding controls, whether they were fed the regular or the protein-free diet. This indicates that vitamin A increased

TABLE 3

Effect of orally administered vitamin A on the specific activity ($SA = 10^3$ dpm/mg $BaSO_4$) of urinary inorganic $S^{35}O_4$ during the second 24-hour period after intraperitoneal injection of $Na_2S^{35}O_4$, expressed as percentage of the specific activity in the first 24-hour urine collection

Hypervitaminotic rats [1]		Control rats		Remarks
No. of groups of rats	SA	No. of groups of rats	SA	
5	9.52	3	14.17	$P < 0.02$
1	19.52	1	24.10	Fed protein-free diet
1	7.80	1	6.80	Nonradioactive methionine 3 × 33 mg/rat ip

[1] Given 50,000 IU vitamin A/rat daily for 3 days.

the breakdown of body proteins and that the liberated sulfur diluted the excreted isotope. When the rats were pretreated with nonradioactive methionine for 3 days, the specific activity of the $S^{35}O_4$ was very low in both groups, with no difference between them. This suggests again that excess of vitamin A does not inhibit the oxidation of the sulfhydryl groups of methionine to the inorganic SO_4.

DISCUSSION

This study showed that even large doses of vitamin A did not inhibit the oxidation of methionine or cystine, for when S^{35}-labeled amino acids were used, they were readily oxidized to inorganic $S^{35}O_4$. When $Na_2S^{35}O_4$ was administered along with nonradioactive methionine, the latter considerably decreased the specific activity of the excreted inorganic $S^{35}O_4$. Therefore, vitamin A cannot be considered as an antioxidant of the SH or S-S groups of amino acids.

The proteolytic effect of excess vitamin A was shown in 2 ways. In rats pretreated with methionine-S^{35}, massive doses of vitamin A increased the excretion of inorganic $S^{35}O_4$ considerably, and when $Na_2S^{35}O_4$ was used, the specific activity of it decreased in the urine of the treated animals more rapidly than in the urine of controls. This latter phenomenon is presumably due to an increased breakdown of body proteins in general, followed by the oxidation of the sulfur-containing amino acids or by a loss of already preformed sulfate of the mucopolysaccharides, or both. A loss of chondroitin sulfate after large doses of vitamin A has been demonstrated (7) in the articular and epiphyseal cartilages of the rabbit, an effect closely resembling that of papain proteinase. Fell and Dingle (11) have shown that the cartilaginous limb-bone rudiments from chick embryo cultivated in the presence of vitamin A (3.3 μg/ml) released an acid protease into the culture medium. Recently, Chung and Houck (12) reported that an excess of vitamin A decreased the hexosamine content of the connective tissue of the rat, and they concluded that this represented the loss of acid mucopolysaccharides.

However, in our experiments, as well as in the studies of others, referred to above, this proteolytic effect of vitamin A could be demonstrated only with massive overdoses, in the range of one million units/kg or more, and it is not at all certain that this effect is responsible for the symptoms of hypervitaminosis A in man.

LITERATURE CITED

1. Rodahl, K. 1949 The toxic effect of polar bear liver. Norsk Polarinstitutt Skrifter Nr. 92. Jacob Bybwad, Publishers, Oslo.
2. Rodahl, K. 1950 Hypervitaminosis A in the rat. J. Nutrition, *41:* 399.
3. Balakhovskii, S. D., and N. N. Drozdova 1956 Mechanism of action of carotenoids (vitamin A, retinene, and copper). Dokl. Akad. Nauk., *109:* 355.
4. Balakhovskii, S. D., and N. N. Drozdova 1957 Mechanism of action of vitamin A (retinol); copper-polyene antagonism and keratization of the epithelial tissue. Biokhimiya, *22:* 330.
5. Balakhovskii, S. D., and I. V. Kuznetsova 1958 Carotenoidal polyenes and oxidative processes in the organism. The deficiency of retinol and oxidation of sulfur in the organism. Dokl. Akad. Nauk., *118:* 331.
6. Fell, H. B., and L. Thomas 1960 Comparison of the effects of papain and vitamin A on cartilage. II. The effects on organ cultures of embryonic skeletal tissue. J. Exp. Med., *111:* 719.

7. Thomas, L., R. T. McCluskey, J. L. Potter and G. Weissmann 1960 Comparison of the effects of papain in vitamin A on cartilage. I. The effects in rabbits. J. Exp. Med., *111:* 705.
8. Wolf, G., and P. T. Varandani 1960 Studies on the function of vitamin A in mucopolysaccharide biosynthesis. Biochem. Biophys. Acta, *43:* 501.
9. Jeffay, H., F. O. Olubajo and W. R. Jewell 1960 Determination of radioactive sulfur in biological materials. Analyt. Chem., *32:* 306.
10. Nathan, D. G., J. D. Davidson, J. G. Waggoner and N. I. Berlin 1958 The counting of barium carbonate in a liquid scintillation spectrometer. J. Lab. Clin. Med., *52:* 918.
11. Fell, H. B., and J. T. Dingle 1963 Studies on the mode of action of excess of vitamin A. 6. Lysosomal protease and the degradation of cartilage matrix. Biochem. J., *87:* 403.
12. Chung, A. C., and J. C. Houck 1964 Connective tissue. IX. Effects of hypervitaminosis A upon connective tissue chemistry. Proc. Soc. Exp. Biol. Med., *115:* 631.

Rogers-'69
Bib. No. 7777

Proc. Soc. Exptl. Biol. Med. 132(2):622-624. 1969.

Vitamin A Deficiency in the Rat Prior to Weaning (34273)

W. E. ROGERS, JR.[1] AND J. G. BIERI

Laboratory of Nutrition and Endocrinology, National Institute of Arthritis and Metabolic Diseases, National Institutes of Health, Bethesda, Maryland 20014

During the last few years increasing use has been made of rats maintained on retinoic acid for studies of vitamin A deficiency (1). Since this form of the vitamin disappears rapidly from the animal when supplementation is stopped, the variable stress from infection and inanition which occurs in conventional vitamin A deficiency is largely avoided. Through the use of retinoic acid it is possible to produce animals which become vitamin A deficient prior to weaning and which are suitable for studies of the requirement of the vitamin in growth and development.

Materials and Methods. Female Sprague-Dawley rats with 10-day old litters were fed vitamin A deficient diet R-9 (2). The percentage composition of the diet was: vitamin-free casein, 22; salt mixture, 6; cottonseed oil, 4; vitamin mixture (without vitamin A), 2; and sucrose, 66. Female weanling rats from these litters were fed this diet for 18 days at the end of which time they were given 20 μg of retinoic acid in 5 drops of cottonseed oil placed on the diet each day. When the animals became sexually mature, about 5 weeks postweaning, they were mated with vitamin A normal males. Appearance of sperm in the vaginal smear or sperm plugs in the trays were used to establish the first day of pregnancy. During pregnancy and lactation the retinoic acid supplement was increased to 50 μg/day. In addition, from the ninth through the twenty-first day of pregnancy a supplement of 1 μg of retinyl acetate in oil was given orally. On the eighteenth day of pregnancy the females were tr[illegible] ferred to individual plastic cages contai[illegible] wood shavings where they were kept until [illegible] young were weaned.

Results. During first pregnancies of 30 [illegible] parturition occurred on the twenty-second [illegible] twenty-third day and the litter size aver[illegible] 9.2, indicating that the supplement of [illegible] μg/day of retinyl acetate was adequate. A[illegible] resting 3 weeks the females could produ[illegible] second litter of vitamin A-low rats, but th[illegible] pregnancies were not as successful u[illegible] the dose of retinyl acetate was doubled. D[illegible] ing the first days of life the rats n[illegible] energetically and obtained milk. Subseq[illegible] ly they exhibited varying effects of vitam[illegible] deficiency that depended on whether d[illegible] ency developed in the first or second we[illegible] life.

When symptoms developed in the [illegible] week the rats exhibited progressive weak[illegible] distension of the abdomen and narrowi[illegible] the thorax. At death, usually by the tw[illegible] day of life, the intestines were distended [illegible] liquid and gas as in older, conventio[illegible] vitamin A deficient rats. When retinyl [illegible] tate or retinoic acid (5 μg/day orally [illegible] drop of oil) was given to the young [illegible] before weakness became pronounced, surv[illegible] was almost 100% and no abnormalities [illegible] veloped.

In other litters the rats maintained [illegible] appetites and remained relatively strong [illegible] the second week of life. At about the ninth [illegible] eleventh day these rats began to app[illegible] malnourished, had a yellowish cast to th[illegible] skin and exhibited trembling and mild [illegible] coordination. In the next few days cripp[illegible] of the front legs was manifested. The p[illegible] and toes usually curled and the young r[illegible] walked stiff-legged on the under-turned p[illegible] In other cases, there was complete los[illegible]

[1] Initial work on this problem was done in the Department of Animal Sciences, University of Illinois, Urbana and was supported by USPHS Grant GM-00653-06. A preliminary report was presented at the Federation of American Societies for Experimental Biology meeting, April 16-21, 1967, Chicago, Ill.

.1. Litter-mate rats on thirteenth day of life. ing of dam supported with retinoic acid contin- y and from ninth to twentieth day of pregnancy retinyl acetate, 1 μg/day. Young rats dosed ninth day of life with either 5 μg of retinoic in droplet of cottonseed oil per day (left) or seed oil (right).

of the front legs and the rats pushed elves along on their thorax while their gs dragged from the shoulder (Fig. 1). stance of the hind legs became spread hese limbs and the rest of the muscles of imals remained relatively strong. Eyes d regularly at about the fourteenth of life and specks of porphyrin pigment to appear around the nose and eyes the seventeenth day. If the young rats able to obtain retinoic acid-supplemented from the mother's food cup, or if hand lementation was started, the crippling peared. Without supplementation the became weaker and died, usually with nded intestines as described above. The required for recovery was related to the h of time that the rats had been crippled. oung rats (*e.g.*, fourteenth day of life), ic acid supplementation restored walk- nction in 2–4 days.

was found that normal appearing rats nt in retinyl ester at weaning could be ed consistently if the dams were sup- during pregnancy by the above re and the young rats were supple- , starting at the fifth day of life, with c acid. Growth stopped quickly when retinoic acid was removed from the diet of weanling rats prepared in this fashion. A typical response is shown in Fig. 2 where growth is seen to stop 4 days after removal of the vitamin from the diet and to recommence promptly upon dosing the rats with 5 μg of retinoic acid in oil per day. By restricting vitamin A acid again a second cycle of weight changes followed but the time required for a decline in weight was longer and the response of the rats was more variable.

Discussion. Incoordination and paralysis due to vitamin A deficiency has usually been explained by either a disproportionate growth of the central nervous system and surrounding bone or by increased cerebrospinal fluid pressure (3, 4). Paralysis has generally been observed only in the hind legs of rats, but Mayer and Krehl (5) observed an involvement of the front legs in vitamin A deficient rats which was cured by dosing with ascorbic acid. We found ascorbic acid to be without effect whereas retinoic acid always produced cures.

The crippling reported here is interesting with regard to the hypothesis that this condition is due to pinching of nerve tissue by

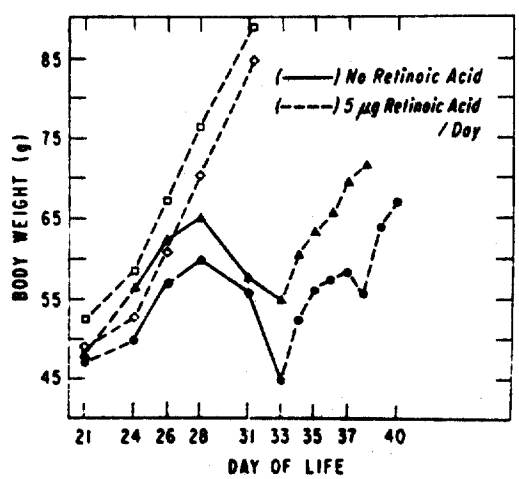

FIG. 2. Typical growth response to retinoic acid of weanling, littermate rats having low body stores of retinyl esters. Curves are for individual rats. Rats were prepared as described in text and weaned to retinoic acid-containing diet on twenty-first day of life. Retinoic acid was removed from the diet of two rats on the twenty-fourth day of life and restored on the thirty-third day of life.

bone. The fact that the paralysis is reversed in 2–4 days in its early stage would appear to suggest a more rapid process than bone remodeling. An alternative hypothesis is that nerve tissue has a direct requirement for vitamin A. Takeshita and Ko (6) reported that in the vitamin A-deficient rats changes were observed mainly in the sensory nerve endings. These investigators thought that nerve degeneration then progressed retrogradely up the sensory fibers toward the central nervous system. Also Krishnamurthy *et al.* (7) noted that chicks supported with a daily dose of retinoic acid showed ataxia each day about 20–24 hr after the supplement was given.

It has been well authenticated that retinoic acid disappears rapidly after administration to the rat. Supporting rats on retinoic acid provides a unique means of maintaining them available for the study of certain aspects of vitamin A deficiency. When the deficient condition is required, it is necessary only to remove the supplement from the test diet and in approximately 2 days the rats are free of vitamin A. Thompson *et al.* (1) reported that pregnancy could be maintained in rats supported with retinoic acid if they were given an additional supplement of very small amounts of retinyl esters. They interpreted the failure of many of the young to survive as being due to an inherent weakness resulting from the nutritional treatment of the dam during pregnancy. It seems likely that this weakness is due to lack of transport of retinoic acid to the young rats through the dam's milk for if they are hand supplemented with retinoic acid they survive. The advantages of this procedure over conventional methods of producing vitamin A de[illegible] are chiefly in the young age of the [illegible] mental animals and the minimizing of [illegible] effects of deficiency such as infection [illegible] prolonged inanition.

Summary. Female rats maintained on [illegible] inoic acid and given a supplement of [illegible] retinyl acetate during part of pregnancy [illegible] livered normal offspring that became vi[illegible] A deficient in the first 2 weeks of life. [illegible] rats were not supplemented with vitamin [illegible] reversible crippling of the front legs occ[illegible] frequently in the second week of life. [illegible] retinoic acid supplementation was start[illegible] few days after birth, the rats developed [illegible] mally but their growth would stop in 4 [illegible] whenever the supplement was removed f[illegible] the diet. Growth resumed promptly when [illegible] inoic acid was again supplied.

The careful assistance of Mrs. Mary Sue Br[illegible] caring for the young rats is gratefully acknowl[illegible]

1. Thompson, J. N., Howell, J. McC., and [illegible] A. J., Proc. Roy. Soc. (London) Ser. B [illegible] (1963-1964).

2. Bieri, J. G. and Prival, E. L., J. Nutr. [illegible] (1966).

3. Moore, T., "Vitamin A," pp. 314–328. [illegible] Amsterdam (1957).

4. Howell, J. McC. and Thompson, J. N., [illegible] Exptl. Pathol. 48, 450 (1967).

5. Mayer, J. and Krehl, W. A., Arch. Bioch[illegible] 313 (1948).

6. Takeshita, T. and Ko, J., Bitamin [illegible] (1965).

7. Krishnamurthy, S., Bieri, J. G., and Anders[illegible] L., J. Nutr. 79, 503 (1963).

Received March 18, 1969, P.S.E.B.M., 1969, Vol. [illegible]

Rogers-'69
Bib. No. 7778

THE AMERICAN JOURNAL OF CLINICAL NUTRITION
Vol. 22, No. 8, August, 1969, pp. 1003-1013
Printed in U.S.A.

Reexamination of Enzyme Activities Thought to Show Evidence of a Coenzyme Role for Vitamin A[1]

W. E. ROGERS, JR.

ONE OF THE MOST CHALLENGING problems in vitamin A research at the present time is to establish which nonvisual biochemical systems are directly dependent on the vitamin. This problem is made difficult in the case of vitamin A because infection and inanition intervene in the test animal as soon as vitamin A deficiency is established. The generally abnormal condition that results in the test animal contributes to possible misinterpretation of the cause of changes in enzyme activity observed in vitamin A deficiency. If the imposition of similar stresses on the vitamin A-normal control is found to bring about similar changes in enzyme activity then an explanation of the effect of deficiency in terms of indirect action seems highly likely. By utilizing various procedures of controlled feeding and rapid modification of vitamin A status, evidence on the nature of vitamin A involvement that has been suggested to be direct was obtained for several enzymes.

The principal, nonvisual biochemical systems that have been observed to be depressed in vitamin A deficiency are listed in Table 1. Of these systems, we have studied the second, fourth, and sixth; namely, the first step in sulfate activation catalyzed by the enzyme sulfurylase, an early step in the synthesis of adrenal steroids catalyzed by the enzyme Δ^5-3-β-hydroxysteroid dehydrogenase, and the final step in the synthesis of ascorbic acid catalyzed by the liver enzyme L-gulono-γ-lactone oxidase. Limitations of time and space will allow only a brief summary of the results of other investigators who have examined these enzymes and will prohibit discussion of effects of vitamin A observed on related metabolic activities. Also, because results that might be caused by the surface activity of vitamin A are difficult to appraise, effects obtained after in vitro addition of vitamin A to incubations will not be included in the discussion.

SULFURYLASE

Sulfate activation, in most forms of life, depends on two activation steps each utilizing a molecule of ATP as shown in Fig. 1. The sulfated nucleotide intermediates are adenylylsulfate (APS) and 3′-phosphoadenylylsulfate (PAPS). From the latter molecule, usually, sulfate is transferred to alcohols, phenols, arylamines, hydroxysterols, and sugars by enzymes that are relatively specific for these acceptors. The final sulfated forms, as well as the intermediates, are subject to enzymic hydrolysis of the sulfate radical by specific enzymes. For convenience, the enzymes, numbered 1, 2, 3, and 4 in Fig. 1 will be referred to as sulfurylase, phosphotransferase, sulfotransferase, and sulfatase.[2] Though each of

[1] From the Laboratory of Nutrition and Endocrinology, National Institute of Arthritis and Metabolic Diseases, National Institutes of Health, Bethesda, Maryland 20014.

[2] Abbreviated names used are: sulfurylase for ATP: sulfate adenylyltransferase (EC. 2.7.7.4); phosphotransferase for ATP: adenylylsulfate 3′-phosphotransferase (EC. 2.7.1.25); sulfotransferase for 3′-phosphoadenylylsulfate: phenolsulfotransferase (EC. 2.8.2.1); arylsulfatase for aryl-sulfate sulfohydro-

TABLE I

Principal biochemical systems that have been noted to be depressed in vitamin A deficiency

1) Synthesis of mucopolysaccharide-bound hexosamine (colon homogenates)
2) Sulfation (principally colon and liver fractions)
3) Gluconeogenesis from triose (in vivo)
4) Δ^5-3-β-Hydroxysteroid dehydrogenase (adrenal homogenates)
5) Steroid 11-β-hydroxylase (adrenal homogenates)
6) L-Gulono-γ-lactone oxidase (liver microsomes)
7) Various demethylations and hydroxylations of drugs (liver microsomes)
8) Synthesis of glycolic acid and aldehyde (liver)
9) Synthesis of cholesterol (liver)
10) Mitochondrial P/O (liver)

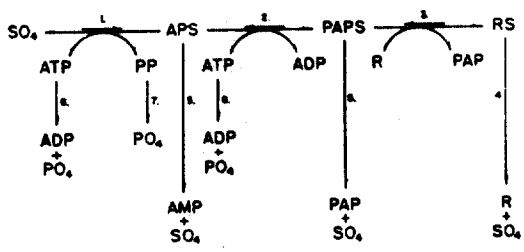

FIG. 1. Sulfate activation.

these enzymes has been implicated in vitamin A function, the one that has received chief attention and to which discussion will be limited is sulfurylase.

As the equilibrium in the sulfurylase reaction favors sulfate and ATP, high levels of these substrates, inorganic pyrophosphatase to remove pyrophosphate (PP) and an inhibitor for the phosphotransferase, must be employed to accumulate APS. In order to avoid these complications, sulfurylase activity is usually assayed by including the next enzymes under conditions so that they are not rate limiting or by reversing the reaction with synthetic APS and PP as substrates. These assays are shown in Table II. *Assay b* is the reverse reaction with APS and PP in which ATP is a product that is easily measured by coupling to TPN reduction or by luciferin luminescence. *Assay c* is a reaction that is forced in the forward direction by immediate removal of products. This is accomplished by including inorganic pyrophosphatase in the reaction and by substituting molybdate for sulfate since the molybdate analog of APS seems to be unstable and immediately hydrolyzes (1). In this assay, inorganic phosphate is measured. Finally, sulfurylase can be measured by the formation of PAPS or sulfation of acceptors such as *p*-nitrophenol under conditions where the sulfurylase enzyme is rate limiting. In these assays, $[^{35}S]SO_4$ is customarily employed and the radioactive product is separated by chromatography or electrophoresis. Corrections should be made for hydrolysis of ATP in these reactions by ubiquitous ATPase, though assumptions are made frequently that this enzyme is unchanged in vitamin A deficiency.

In 1960, evidence first was published by Varandani et al. (2) that seemed to indicate that a direct systemic function of vitamin A controlled the activity of the enzyme sulfurylase. This connection was established by comparing the activity of the enzyme in vitamin A-deficient animals and pair-fed, vitamin A normal controls and by demonstrating that the enzyme is more active after addition of vitamin A to sulfurylase

TABLE II

Assays for sulfurylase

Sulfurylase
a) $[^{35}S]SO_4 + ATP \rightarrow [^{35}S]APS + PP$
b) $APS + PP \rightarrow ATP + SO_4$
c) $MoO_4 + ATP \rightarrow [APM] + PP \rightarrow AMP + MoO_4 + PP$ unstable
Sulfurylase (+ phosphotransferase)
d) $[^{35}S]SO_4 + ATP \rightarrow [^{35}S]PAPS + PP + ADP$
Sulfurylase (+ phosphotransferase and sulfotransferase)
e) $[^{35}S]SO_4 + ATP + p\text{-}NP \rightarrow [^{35}S]p\text{-}NPS + PP + ADP + PAP$
f) $SO_4 + ATP + p\text{-}NP \rightarrow p\text{-}NPS + PP + ADP + PAP$

lase (EC. 3.1.6.1); ATPase for ATP phosphohydrolase (EC. 3.6.1.3) and inorganic pyrophosphatase for pyrophosphate phosphohydrolase (EC. 3.6.1.1).

ation reactions. Similar experiments have now been carried out in several laboratories. The evidence in these reports that is based on in vitro stimulation will not be discussed here because of the possibility of unspecific surface-active effects. In the 12 reported experiments in which sulfurylase activity was compared in different states of vitamin A deficiency, the greatest amount of research has been conducted with the rat using either the soluble supernatant fraction of liver or a mitochondria-like particle from the colon as a source of enzyme. Among these 12 experiments evidence is presented in 7 for depression of enzyme activity to levels as low as 25% of that in the normal control (2–8). On the other hand, in the remaining five experiments the activity of the enzyme from the deficient animal was not found to be significantly different from activity in the normal control (9–13).

In the investigations being reported here on sulfurylase,[3] the assay based on electrophoretic separation of [^{35}S]PAPS proved time consuming and poorly reproducible. Therefore, reactions based on the reverse reaction with APS as substrate or based on molybdolysis were employed. In the first experiment, the reverse reaction was used and the formed ATP was measured through coupled triphosphopyridine nucleotide (TPN) reduction. The 1.33-ml incubation mixture contained (in micromoles): pH 7.4 Tris, 50; glucose, 1.5; $MgCl_2$, 0.1; KF, 0.5; TPN, 1.5; 1 unit of glucose 6-phosphate dehydrogenase, 1 unit of hexokinase, and approximately 0.7 mg of liver-soluble supernatant protein. This assay was carried out easily in 0.5-cm cuvettes in a Beckman DU spectrophotometer and TPN reduction was absolutely dependent on the presence of enzyme protein and on APS. Typical triphosphopyridine nucleotide, reduced form, (TPNH) formation curves are shown in

[3] The experiments with the sulfurylase enzyme were carried out in the laboratory of B. Connor Johnson, at that time Professor in the Department of Animal Sciences, University of Illinois, Urbana.

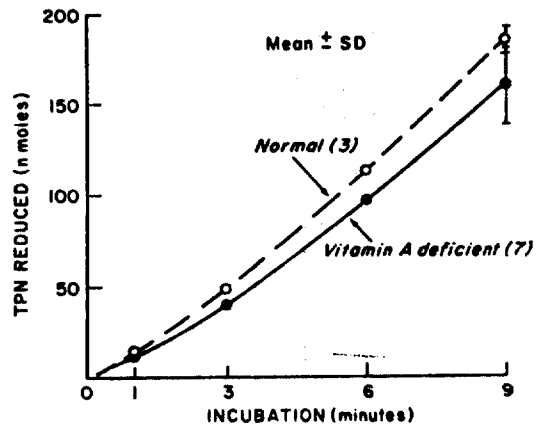

FIG. 2. Hepatic sulfurylase rats, at similar body weights. Vitamin A-deficient rats (●) were sacrificed after exhibiting moderate symptoms of deficiency and an average weight loss of 13 g. Vitamin A-normal rats (○), ad libitum fed and of approximately the same weight (Table III), were sacrificed simultaneously. For reaction coupling sulfurylase to TPN reduction see text.

Fig. 2. In this experiment, a 25–60% ammonium sulfate fraction of liver-soluble supernatant was prepared as identically as possible from seven vitamin A-deficient and three normal rats.

Protein in these preparations was determined by the method of Warburg and Christian (14). The TPNH formation by each of these preparations was rationalized to the same level of protein (0.586 mg) and averaged for normal and deficient groups to obtain these curves. Average specific activities during the interval between 6 and 9 min for the two types of preparations are shown in Table III. As can be seen, these values are not significantly different. The treatment of the Sprague-Dawley male rats used in this experiment should be described further. The deficient animals were fed the vitamin A-free diet of Wolf et al. (15) and had lost between 4 and 20 g (average 8%) of their body weight at sacrifice. Controls ad libitum fed the same diet plus 5,000 IU stabilized vitamin A/kg were approximately 10 days younger and chosen to be of the same weight as the deficient rats at the time of sacrifice.

TABLE III

Liver sulfurylase in vitamin A deficient and ad libitum-fed normal rats of same body weight

Vitamin A status[a]	Average body weight, g		Liver sulfurylase[b]
	Maximum	At sacrifice	
A− (7)[c]	159	146	36 ± 3.3
A+ (3)		154	41 ± 4.8

[a] Conditions as in Fig. 2. [b] Nanomoles TPN reduced per milligram protein per minute. (For reaction coupling sulfurylase to TPN reduction, see text.) [c] Rats per group. [d] Standard deviation for grouped assays.

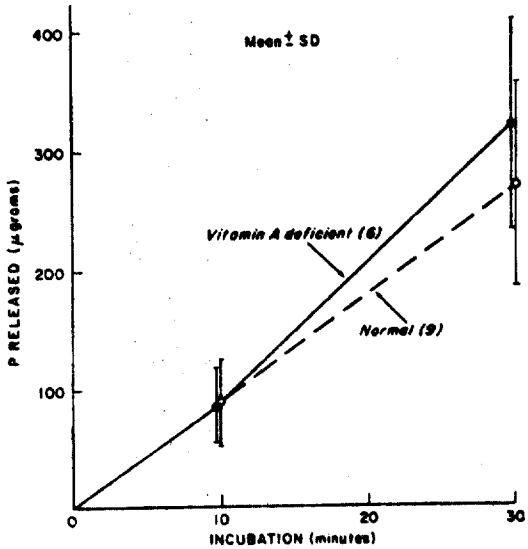

FIG. 3. Hepatic sulfurylase in tube-fed rats. Vitamin A-deficient rats (●) exhibiting incipient plateau in body weight and vitamin A-normal control (○) were tube-fed 6–6.5 g/day of respective diets for 15 days when sulfurylase was assayed. Activity is in terms of micrograms P released through molybdolysis by 3 mg protein.

In the experiment being reported next, the rats were tube-fed and the molybdolytic assay for sulfurylase was employed. For this assay the 2.0-ml reaction mixture contained (in micromoles): pH 7.4 Tris, 200; $MgCl_2$, 20; pH 7.4 ATP, 20; Na_2MoO_4, 100; 1 unit of inorganic pyrophosphatase; and 3 mg of liver-soluble supernatant protein in 0.[illegible] M sucrose. For each enzyme preparation, [illegible] incubation mixtures were prepared wi[illegible] molybdate and six were without molybd[illegible] to measure ATPase activity. Two of ea[illegible] six systems were incubated for either 10 [illegible] 30 min and two were not incubated. Af[illegible] the reaction was stopped by boiling, nucle[illegible] tides were adsorbed onto charcoal, whic[illegible] was then removed along with precipitate[illegible] protein by light centrifugation. The supe[illegible] natant, clarified by passage through a Mil[illegible] pore filter (0.45-μ pores) was assayed [illegible] duplicate for phosphate by a standa[illegible] phosphomolybdous acid method. After co[illegible] rection for phosphate liberated by ATP[illegible] ase and the phosphate present in unin[illegible] bated controls the data were averaged f[illegible] the enzyme preparations of six deficie[illegible] and nine normal rats as shown in Fig. [illegible] These rats had been raised on the diet [illegible] Wolf et al. (15) modified by supplemen[illegible] tion with cystine and ascorbic acid and [illegible] duction in the level of *dl*-α-tocopherol a[illegible] tate (13). When the growth curves of t[illegible] deficient rats indicated that they were ju[illegible] reaching the weight plateau, tube-feedi[illegible] of the 15 rats commenced. The level o[illegible] diet given the rats was 6 g/day during t[illegible] first 13 days and 6.5 g/day for the last [illegible] days. This dietary level does not maint[illegible] body weight but is typical of the amou[illegible] that a vitamin A-deficient rat consumes a[illegible] libitum during the post plateau period (Ta[illegible] ble IV). With this treatment the specific a[illegible] tivity of the hepatic sulfurylase is not fou[illegible] to be lower in the deficient rats than in co[illegible] trol rats. However, despite all the precau[illegible] tions taken in this experiment the standard deviation of the data remained relatively large.

Finally, with respect to this enzym[illegible] data will be presented on the effects of sta[illegible] vation in vitamin A normal rats and effects of feeding limited quantities of normal die[illegible] to deficient rats (13). In these experiments the procedures were not significantly di[illegible] ferent from those already described exce[illegible]

that in the molybdolytic assay inorganic pyrophosphatase was not added since adequate amounts of this enzyme seemed to be present endogenously. In the first experiment, vitamin A normal rats were starved either 4 or 8 days and then sacrificed with unstarved controls (Table v). Two severely vitamin A-deficient rats of approximately the same body weight as the 8-day starved normal rats were killed at this time, also. The results show that complete restriction of the diet in the normal rat decreases specific activity of hepatic sulfurylase to levels reached in the vitamin A-deficient rat. A similar observation on the effect of starvation has been reported by Levi et al. (8). In another experiment, vitamin A-deficient rats just approaching weight plateau were arranged in four groups of which three were fed vitamin A normal diet in varying amounts for 1 week (Table vi). The fourth group was kept on a deficient diet and reached the plateau in body weight during this time. The sulfurylase specific activity of the rats pair-fed normal diet was only slightly greater at the end of the week than that of the rats consuming an equal quantity of deficient diet. On the other hand, if the rats were allowed to eat significantly larger or smaller amounts of normal diet for this period the specific activity of their hepatic sulfurylase was appreciably greater or smaller, respectively, than that of the rats consuming the intermediate quantity of either supplemented or unsupplemented diet.

TABLE IV

Liver sulfurylase in vitamin A-deficient and tube-fed normal rats

Vitamin A status[a]	Average body weight, g			Liver sulfurylase[b]
	At start of tube feeding	Loss in 15 days	Loss during last 2 days	
A− (6)[c]	218	42	3.0	3.57 ± 0.97[d]
A+ (9)	210	42	3.3	3.00 ± 0.95

[a] Conditions as in Fig. 3. [b] Micrograms P liberated by molybdolysis per milligram protein per minute for 30 min incubation from data, Fig. 3. [c] Rats per group. [d] Standard deviation of averaged duplicate assays.

TABLE V

Liver sulfurylase activity after starvation[a]

Vitamin A status	Days of starvation	Body weight at sacrifice, g	Liver sulfurylase[b]
A+ (4)[c]	0	266 ± 6[d]	1.39 ± 0.07[e]
A+ (3)	4	211 ± 13	1.05 ± 0.08
A+ (2)	8	174 ± 16	0.86 ± 0.08
A− (2) Severely deficient	0	170 (approx.)	1.01

[a] Geison et al. (13). [b] Micromoles phosphate liberated by molybdolysis per milligram. [c] Rats per group. [d] Range if two rats per group; standard error of mean if more than two rats per group. [e] Range of averaged duplicate assays if two rats per group; standard error of mean of averaged duplicate assays if more than two rats per group.

$\Delta^{5,3}$-β-Hydroxysteroid Dehydrogenase

One of the initial steps in the transformation of cholesterol into steroid hormones by adrenal gland and gonads is the conversion of Δ^5-3-β-hydroxysteroids into Δ^4-3-ketosteroids, i.e., oxidation of the hydroxyl group in the 3-position of ring A followed by an isomeric shift of the double bond from ring B to ring A. The enzyme system responsible for these two steps is referred to as the Δ^5-3-β-hydroxysteroid dehydrogenase (EC. 1.1.1.51) and converts pregnenolone into progesterone, 17-α-hydroxypregnenolone into 17-α-hydroxyprogesterone and androstenolone (dehydroepiandrosterone) into androstenedione. A subsequent steroid conversion is the introduction of a hydroxyl group in ring C by the enzyme steroid 11-β-hydroxylase (EC. 1.14.1.6) which converts 11-deoxycorticosterone into corticosterone and 17-α-hydroxy-11-deoxycorticosterone into 17-α-hydroxycorticosterone.

TABLE VI

Liver sulfurylase activity after realimentation with controlled amounts of vitamin A-normal diet[a]

Vitamin A status[b]	Restriction of diet during week	Average body weight, g			Liver sulfurylase[c]
		At start of week	Maximum	At sacrifice	
A− (3)[d]	None	188	197	193 ± 12[e]	1.81 ± 0.17[f]
A+ (3)	None	183	Continuous increase	230 ± 6	2.42 ± 0.36
A+ (3)	Pair-fed to A−	183	208	206 ± 6	1.97 ± 0.17
A+ (3)	5 g/day	182	192	170 ± 6	1.56 ± 0.18

[a] Geison et al. (13). [b] Rats on vitamin A-deficient diet and approaching weight plateau were arranged in four groups. Vitamin A-supplemented diet was fed in different amounts to these groups. Vitamin A-normal diet was fed ad libitum to the fourth group. Sulfurylase activity was assayed by molybdolysis for all rats after 1 week. [c] Micromoles phosphate liberated by molybdolysis per milligram protein for 15 min incubation. [d] Rats per group. [e] Standard error of mean. [f] Standard error of mean of averaged duplicate assays.

Utilizing [^{14}C] cholesterol and comparing amounts of radioactivity of these intermediates in adrenal homogenates of vitamin A-deficient and normal rats, Johnson and Wolf (16) concluded that the 11-β-hydroxylase was depressed in mild deficiency and that the Δ^5-3-β-hydroxysteroid dehydrogenase was depressed, also, in severe deficiency. Subsequently, Juneja et al. (17) using homogenates of adrenal, testes, and ovaries found that Δ^5-3-β-hydroxysteroid dehydrogenase activity was decreased in the mildly vitamin A-deficient rat to levels between 42 and 64% of that in the pair-fed normal rat with each of the three substrates named above. In acute deficiency, associated with approximately 15 g loss in body weight, there was a further decrease in specific activity to about 32% of that of the pair-fed control in the case of the adrenal enzyme with dehydroepiandrosterone as substrate. The effect of vitamin A deficiency on this adrenal enzyme has been investigated also by Grangaud et al. (18–21) who found that, in deficiency, activity of this enzyme was at levels that were 75–90% of normal.

We have investigated this relationship, also, but have confined our attention to the adrenal gland and have used only pregnenolone alone and androstenolone as substrates (22). The assay that we employed, similar to those used by Juneja and Grangaud and their co-workers, depends upon extraction from the incubation mixture of formed Δ^4-3-ketosteroid and measurement of its absorption at 240 mμ. The 1.9-ml incubation mixture contained: Δ^5-3-β-hydroxysteroid (in 0.2 ml propylene glycol), 1.6 μmoles and DPN, 9.0 μmoles adrenal homogenate containing approximately 1 mg protein and 0.9% NaCl–0.1 M PO_4 buffer, pH 7.4 (1:1). The mixture was incubated up to 30 min in a shaking water bath at 37.5 C. For each datum point at least two incubations were made with substrate and two without. Our results showed that, at low levels of adrenal protein, as determined by the Lowry method (14), and during short incubations, the rate of Δ^5-3-β-hydroxysteroid dehydrogenase activity was linear for both vitamin A deficient and normal preparations (Fig. 4). Then we compared activity between pairs of vitamin A-deficient rats and controls receiving 1 g less diet per day (Table VII). It was found that over a wide range in severity of vitamin A deficiency, as indicated by weight loss, there was no decrease in the

specific activity of the enzyme in the deficient rats. Furthermore, the activity in the deficient preparations was not less than in the normal preparations. In another experiment, rats were rapidly depleted of vitamin A by removing retinoic acid from their diet, but there was no change in the specific activity of the enzyme (13). Finally, an investigation was made of possible effects on activity of this enzyme when deficient rats were realimented with retinoic acid for 4 days (13). Again there was no increase in activity relative to rats left deficient.

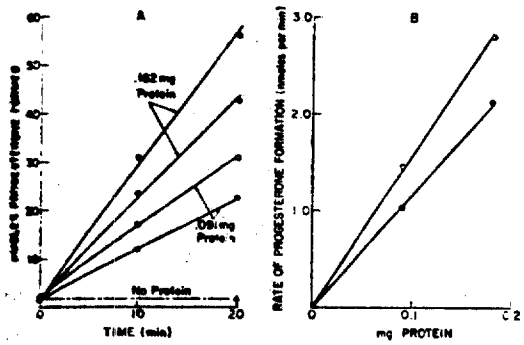

FIG. 4. Kinetics of adrenal Δ^5-3-β-hydroxysteroid dehydrogenase at short incubation periods and low protein levels for a representative vitamin A-deficient rat (●) and control rat (○) pair-fed (minus 1 g/day) the same diet with retinol.

L-GULONO-γ-LACTONE OXIDASE

The L-gulono-γ-lactone oxidase found in liver microsomes of most animals carries out the final enzymatic reaction in the formation of L-ascorbic acid from glucose. The reaction is coupled through a microsomal electron transport system to oxygen.

TABLE VII

Δ^5-3-β-Hydroxysteroid dehydrogenase activity of adrenals from rats conventionally depleted of vitamin A

Substrate	Loss in body weight of deficient rats			Specific activity nmoles product per milligram protein per minute		Difference from control, %
	g	%	days	Deficient	Control	
Experiment A						
Pregnenolone	40	14	7	12.5	12.0	+4
	38	16	23	8.5	12.9	−34
	66	24	7	15.5	11.5	+35
	54	26	30	15.2	10.2	+49
Androstenolone	16	6	7	6.1	7.25	−16
	27	13	27	6.23	7.8	−20
	58	27	17	14.1	12.1	+17
	60	27	19	8.2	11.7	−30
Experiment B						
Pregnenolone	3	1	1	12.8	11.5	+11
	6	3	3	13.7	11.1	+23
	17	11	5	12.7	11.9	+7
	19	11	4	11.8	13.1	−10
Androstenolone			0	7.1	7.9	−10
	2	1	1	6.1	5.5	+11
	8	6	10	7.8	6.6	+18
	12	6	3	7.1	6.0	+18
	26	12	4	9.0	8.9	+1
	37	18	11	9.8	8.0	+22

Rats were sacrificed the indicated number of days after reaching maximum body weight. Deficient and control rats, pair-fed (minus 1 g/day) the same diet with retinol, had similar losses in weight. Pairs of animals are arranged in order of increasing percentage weight loss of the deficient member of the pair.

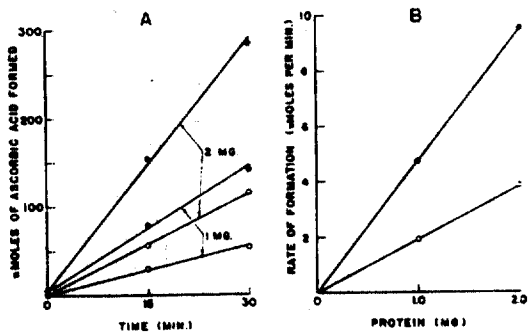

FIG. 5. Kinetics of hepatic L-gulono-γ-lactone oxidase at short incubation periods and low protein levels for mixed microsomal preparations from vitamin A-deficient rats (○) and control rats (●) ad libitum fed the same diet with retinol.

In recent years several publications have appeared concerning depressed activity of this enzyme in vitamin A deficiency. Malathi and Ganguly (23) found that the activity of this enzyme in rats in mild and severe stages of vitamin A deficiency was 52% and 13% of that in pair-fed controls. Ghosh et al. (24) also have observed depression of this enzyme in vitamin A deficiency, though only to a level of 65% of that in pair-fed controls.

In examining this phenomenon we have utilized a simple 2.5-ml incubation system containing: pH 7.4 Tris, 80 μmoles; L-gulono-γ-lactone, 4.4 μmoles; and 1 ml of liver microsomes containing 1 mg protein as determined by the Lowry method. Microsomes used in the incubation were prepared, washed, and resuspended in 0.25 M mannitol–0.02 M Tris pH 7.4. After incubation in a shaking water bath at 37.5 C, formed ascorbic acid was assayed by the method of Roe and Kuether (25). For each microsomal preparation at least six incubations were carried out; two for 15 min, two for 30 min, and two were not incubated. We found that there were only traces of endogenous ascorbic acid in the washed microsomes and that ascorbic acid destruction, though detectable in some cases, was not significant in determining rates of ascorbic acid synthesis in this system. Our results showed that with incubations up to 30 min and with amounts of microsomal pro[illegible] in the range of 1–2 mg, the rate of asco[illegible] acid synthesis was linear for both defici[illegible] and normal preparations (Fig. 5). This [illegible] was employed in experiments compar[illegible] the specific activity of the L-gulono-γ-lac[illegible] oxidase in vitamin A-deficient rats and th[illegible] controls, which were pair-fed as descri[illegible] previously. The pairs of rats were killed [illegible] that the deficient rats would be at vari[illegible] stages of vitamin A deficiency, as defined [illegible] body weight loss. In seven of eight pairs th[illegible] activity of the deficient preparation was l[illegible] than that of the normal preparation. Fu[illegible] thermore, the specific activity of the def[illegible] cient preparation was progressively low[illegible] as deficiency became more severe (Fig. [illegible]

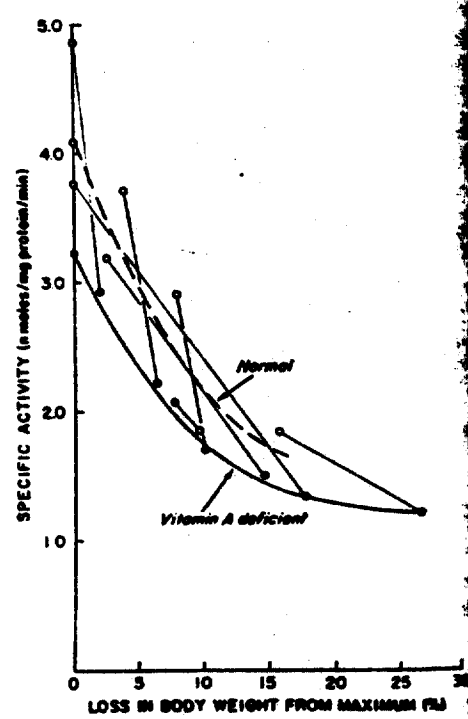

FIG. 6. Hepatic-L-gulono-γ-lactone oxidase [illegible] pair-fed rats. Eight vitamin A-deficient rats ([illegible]) and controls (○), pair-fed (minus 1 g) the same [illegible] with retinol, were killed after varying amoun[illegible] weight loss. Specific activity of the enzyme ([illegible] of ascorbic acid synthesis) is plotted against p[illegible] centage loss in body weight from the maxim[illegible] weight achieved. Pairs of rats are connected by a li[illegible] line. Curves were drawn by eye to show the tr[illegible] in the data points.

On the other hand, the activity of microsomes from pair-fed normal rats decreased also. This result is quite different from that obtained by Malathi and Ganguly who found no decrease in pair-fed controls, but would be expected from the effects of starvation on this enzyme reported by Stirpe and Comporti (26) and by Chatterjee and McKee (27). The pattern in Fig. 6 suggests that if, by some experimental means, body weights within pairs could be made more identical then the relative activities of the enzymes of the two animals would maintain a constant proportion as deficiency progresses.

DISCUSSION

Of approximately 10 biochemical systems that have been reported to be depressed in vitamin A deficiency, three that are single enzymes were selected for reexamination. For each of these enzymes assays were chosen or developed so that rates of reaction were linear with respect to incubation time and level of protein in preparations from vitamin A-deficient as well as normal rats. This allowed a relatively valid comparison of the enzyme activity of identical preparations from these animals and provided measurements of rate that approximated those of the truly initial reaction.

In trying to detect an enzyme requirement for vitamin A, one would like to be able to make measurements of enzyme activity after tissue stores of the vitamin vanish. This ideal experiment is not feasible under conventional conditions since as the vitamin A level of the blood vanishes the animal becomes infected and succumbs after variable recovery and reinfection that are accompanied by changes in appetite and body weight. The stress of infection and decreased food consumption causes large changes in the levels of many enzymes, so part of the problem of proving that a change is due primarily to vitamin A deficiency is in obtaining evidence that a corresponding change does not occur in the vitamin A-normal animal when it is limited to a similar amount of diet or when it is stressed to a similar degree. A control on inanition is only partly successful, however, since utilization of diet is faster in the pair-fed or tube-fed normal control than in the deficient animal. Another type of evidence that could be adduced for direct involvement of vitamin A in the activity of an enzyme would be that subsequent to a sharp change in vitamin A status the time required for the enzyme to respond is less than the time required for general metabolic effects to be observed.

Effects of vitamin A deficiency on the enzyme sulfurylase were examined in many ways. Of the experiments reported here, the first may be interpreted as showing that in rats whose vitamin A stores were inadequate for growth or resistance to infection, the specific activity of hepatic sulfurylase was not significantly different from that in rats of the same size, eating ad libitum and having adequate stores of the vitamin. The second experiment shows that exact duplication of diet levels through tube feeding, at levels utilizable by the deficient rat and commensurate with energetic life in the normal rat, led to similar specific activities in the enzyme. The third experiment shows that total food restriction has large effects on the enzyme, and the last experiment indicates that levels of food consumption are more important than vitamin A in the recovery of sulfurylase activity following vitamin A realimentation of the deficient rat.

In the case of the adrenal Δ^5-3-β-hydroxysteroid dehydrogenase, feeding experiments were carried out similar to those employed with sulfurylase. However, no pattern of consistent decrease of the specific activity of the dehydrogenase was found as deficiency became more acute either in terms of body weight loss or duration of exposure to deficient diet. Activity calculated on the basis of milligrams adrenal tissue or total activity calculated per adrenal pair was similarly unrelated to vitamin A status.

In other experiments dramatic body weight responses to rapid changes in vitamin A status were demonstrated with no change in the activity of this enzyme.

The third enzyme, L-gulono-γ-lactone oxidase, like sulfurylase, was found to be depressed by food limitation in a pattern similar to that occurring during prolonged vitamin A deficiency. Rather consistently, the activity of this enzyme was found to be higher in the pair-fed normal control than in the deficient animal, but the difference seems too small to be due to a local effect of vitamin A.

The evidence presented here does not seem to allow any possible interpretation that vitamin A is functioning in the rat as a coenzyme with any of these enzymes. Furthermore, the possibility of vitamin A induction of these enzymes seems excluded also. It seems most probable that the effects of vitamin A deficiency reported for these enzymes are due to inanition and stress and that the different effects obtained with pair-fed controls are due to the particular feeding protocol used in different laboratories.

REFERENCES

1. Wilson, L. G., and R. S. Bandurski. Enzymatic reactions involving sulfate, sulfite, selenate and molybdate. *J. Biol. Chem.* 233: 975, 1958.
2. Varandani, P. T., G. Wolf and B. C. Johnson. Function of vitamin A in synthesis of 3′-phosphoadenosine-5′-phospho-sulfate. *Biochem. Biophys. Res. Commun.* 3: 97, 1960.
3. Subba Rao, K., and J. Ganguly. Studies on metabolism of vitamin A. 6. The effect of vitamin A deficiency on the activation of sulfate and its transfer to *p*-nitrophenol in rat liver. *Biochem. J.* 90: 104, 1964.
4. Subba Rao, K., and J. Ganguly. Studies on metabolism of vitamin A. The effect of the stage of vitamin A deficiency on sulfate activation in rat liver. *Biochem. J.* 98: 693, 1966.
5. Hall, M. O., and B. R. Straatsma. The synthesis of 3′-phosphoadenosine-5′-phospho-sulfate by retinae and livers of normal and vitamin A-deficient rats. *Biochim. Biophys. Acta* 124: 246, 1966.
6. Sundaresan, P. R. Vitamin A and the sulfate activating enzymes. *Biochim. Biophys. Acta* 11[illegible] 95, 1966.
7. Perumal, A. S., and H. R. Cama. Role of 3,[illegible] monoepoxyretinoic acid in the activation of ATP-sulfate adenylyltransferase. *Indian J. Biochem.* 4: 132, 1967.
8. Levi, A. S., S. Geller, D. M. Root and G. Wolf. The effect of vitamin A and other dietary constituents on the activity of adenosine triphosphate sulfurylase. *Biochem. J.* 109: 69, 1968.
9. Pasternak, C. A., S. K. Humphries and A. Pirie. The activation of sulfate by extracts of cornea and colonic mucosa from normal and vitamin A-deficient animals. *Biochem. J.* 8[illegible] 382, 1963.
10. Pasternak, C. A., and A. Pirie. Sulfate activation in the cornea. *Exptl. Eye Res.* 3: [illegible] 1964.
11. Mukherji, B., and B. K. Bachhawat. Role of vitamin A in sulfate metabolism. Studies on the enzymic activation of sulfate by various tissue extracts of normal and vitamin A-deficient rats. *Biochem. J.* 104: 318, 1967.
12. Havivi, E., and G. Wolf. Vitamin A, sulfation and bone growth in the chick. *J. Nutr.* 92: [illegible] 1967.
13. Geison, R. L., W. E. Rogers, Jr. and B. C. Johnson. Comparative effects of vitamin A deficiency and controlled food consumption on adenosine 5′-triphosphate: sulfate adenylyltransferase. *Biochim. Biophys. Acta* 165: 448, 1968.
14. Layne, E. Spectrophotometric and turbidimetric methods for measuring proteins. In: *Methods in Enzymology*, edited by S. P. Colowick and N. O. Kaplan. New York: Academic, 1957, vol. 3, p. [illegible]
15. Wolf, G., M. D. Lane and B. C. Johnson. Studies on the function of vitamin A in metabolism. *J. Biol. Chem.* 225: 995, 1957.
16. Johnson, B. C., and G. Wolf. The function of vitamin A in carbohydrate metabolism; its role in adrenocorticoid production. In: *Vitamins and Hormones*, edited by R. S. Harris and D. J. Ingle. New York: Academic, 1960, vol. 18, p. [illegible]
17. Juneja, H. S., S. K. Murthy and J. Ganguly. The effect of vitamin A deficiency on the biosynthesis of steroid hormones in rats. *Biochem. J.* 99: 138, 1966.
18. Grangaud, R., M. Nicol and J. Delaunay. Activité globale de la 3-β-hydroxystéroïde déshydrogénase et de la Δ^5-isomérase surrénaliennes chez la ratte albinos carencée en vitamine A. *Compt. Rend.* 260: 2339, 1965.
19. Grangaud, R., and M. Nicol. Action du rétinol sur la transformation *in vitro* de la prégnénolone en progestérone par le cortex surrénalien du rat blanc. *Compt. Rend.* 262 (série D): [illegible] 1966.

20. GRANGAUD, R., AND M. NICOL. Action du rétinal sur la transformation *in vitro* de la transdéhydroépiandrostérone en androstènedione par le cortex surrénalien du rat blanc. *Compt. Rend.* 263 (série D): 446, 1966.

21. GRANGAUD, R., M. NICOL AND D. DESPLANQUES. Action du rétinal sur la transformation *in vitro* de la 17-α-hydroxyprégnénolone en 17-α-hydroxyprogestérone par le cortex surrénalien du rat blanc. *Compt. Rend.* 264 (série D): 2822, 1967.

22. ROGERS, W. E., JR., AND J. G. BIERI. Adrenal Δ^{5}-3-β-hydroxysteroid dehydrogenase as related to vitamin A. *J. Biol. Chem.* 243: 3404, 1968.

23. MALATHI, P., AND J. GANGULY. Studies on metabolism of vitamin A. 7. Lowered biosynthesis of ascorbic acid in vitamin A-deficient rats. *Biochem. J.* 92: 521, 1964.

24. GHOSH, N. C., I. CHATTERJEE, AND G. C. CHATTERJEE. Effects of vitamins A and D on the biosynthesis of L-ascorbic acid by rat-liver microsomes. *Biochem. J.* 97: 247, 1967.

25. ROE, J. H., AND C. A. KUETHER. The determination of ascorbic acid in whole blood and urine through the 2,4-dinitrophenylhydrazine derivative of dehydroascorbic acid. *J. Biol. Chem.* 147: 399, 1943.

26. STIRPE, F., AND M. COMPORTI. Regulation of ascorbic acid and xylulose synthesis in rat-liver extracts. The effect of starvation on the enzymes of the glucuronic acid pathway. *Biochem. J.* 95: 354, 1965.

27. CHATTERJEE, I. B., AND R. W. MCKEE. Biosynthesis of L-ascorbic acid in rat liver microsomes: Influences of age, sex, dietary changes, and whole-body X-irradiation. *Arch. Biochem. Biophys.* 109: 62, 1965.

Rowe-'59
Bib. No. 7866

J. Dent. Res. 38(1):72-83. 1959.

THE EFFECT OF VITAMIN A DEFICIENCY UPON EXPERIMENTAL ORAL CARCINOGENESIS

NATHANIEL H. ROWE AND ROBERT J. GORLIN

School of Dentistry, University of Minnesota, Minneapolis, Minn.

THE clinical and histologic changes seen in oral epithelium in both avitaminosis A and some precancerous conditions bear many similarities to one another. This study was initiated to investigate any possible relationship among these conditions.

Despite the fact that oral cancer, including cancer of the lip, constitutes 8 to 10 per cent of all cancer seen in the United States and is responsible for about 4 per cent of cancer deaths,[1] experimental oral carcinogenesis has only recently begun to receive attention. Levy,[2] in 1948, published a preliminary report of the effect of 20-methylcholanthrene on the labial gingiva of hamsters. Painting of this material for varying periods up to 10 weeks yielded negative results. In 1950, Levy and Ring[3] described methods for the implantation of crystals of 9,10-dimethyl-1,2-benzanthracene into the fundus of the hamster jaw. Sarcomas were produced in 80 per cent of the experimental group. Lutz, Fulton, Patt, Handler, and Stevens,[4] in 1951, reported success in the transplantation of methylcholanthrene-induced sarcomas to hamster cheek pouches. The first experimentally induced oral squamous-cell carcinomas were reported by Salley[5] in 1954.

Vitamin A deficiency has been primarily studied in the rat,[6] but epithelial changes have also been reported in the guinea pig,[7] fox,[8] mouse,[9] and monkey.[10] Recently, the hamster also has been subjected to vitamin A deficiency. Hirschi[11] studied bone healing in vitamin A deficient hamsters in 1950 and Salley and Bryson[12] described various tissue changes seen in the vitamin A deficient hamster in 1957.

The earliest recorded experimental production of neoplasms in animals fed a diet deficient in vitamin A was by Fibiger[13] in 1913. Fibiger produced tumors in the stomachs of rats fed bread and water using a parasitic worm which he named *Spiroptera neoplasticum*. In 1926, a Japanese investigator, Fujimaki[14] reported gastric papillomas when rats were fed a diet deficient in vitamin A. In 1936, Cramer[15] concluded that tumors could be produced by unbalanced diets, particularly those lacking in vitamin A, but that these were only contributory factors and not primary causes of the neoplasia. Rosicky and Halschek,[16] in 1944, reported that vitamin A had a retarding effect when it was added to benzpyrene and painted on the interscapular region of mice.

This work was made possible by a grant, No. 8722, from the U. S. Public Health Service.
Received for publication, June 20, 1958; revised by authors Sept. 29, 1958.

Carminati and Baglioni,[17] late in 1955, investigated the relationship between the epithelial changes due to vitamin A deficiency, and subcutaneous carcinogenesis.

MATERIALS AND METHODS

One hundred and twenty golden hamsters *(Cricetus auratus)*, 25 days of age, were singly housed in an air-conditioned room. They were fed Nutrena Rabbit Chow for 20 days at the end of which period they were weighed and assigned to different groups. Each group contained an equal number of male and female hamsters of comparable weight. Table I indicates the total number of animals in each of the groups, their feeding regimen, and treatment. Water ad libitum was available to all animals.

TABLE I
EXPERIMENTAL DESIGN

GROUP	NUMBER OF ANIMALS	MALES	FEMALES	FEEDING REGIME	TREATMENT
I	40	20	20	(a) Vitamin A deficient diet (b) Ad libitum	0.5 per cent solution of 7,12-dimethyl-1,2-benzanthracene twice per week
II	30	15	15	(a) Vitamin A deficient diet (b) Ad libitum (c) Supplemented with 400 I. U. vitamin A per week	0.5 per cent solution of 7,12-dimethyl-1,2-benzathracene twice per week
III	30	15	15	(a) Vitamin A deficient diet (b) Pair-fed with Group I (c) Supplemented with 400 I. U. vitamin A per week	0.5 per cent solution of 7,12-dimethyl-1,2-benzanthracene twice per week
IV	10	5	5	(a) Vitamin A deficient diet (b) Ad libitum	Liquid petrolatum (solvent) twice per week
V	10	5	5	(a) Vitamin A deficient diet (b) Ad libitum (c) Supplemented with 400 I. U. vitamin A per week	Liquid petrolatum (solvent) twice per week

At 45 days of age, the hamsters were placed on an experimental vitamin A deficient diet. The diet was prepared to order in the form of bread and contained 6 ounces sugar, 4 ounces salt, 8 ounces lard, 4 ounces yeast, 1 gallon water, and 12 pounds flour. The flour was one third Pillsbury whole wheat flour and two thirds Pillsbury white flour.

All animals were fed the vitamin A deficient diet. Animals in Groups II, III, and V received, in addition, a weekly supplement of 400 I.U. of water-solubilized, natural vitamin A given orally. All groups were fed ad libitum with the exception of Group III which was pair-fed with Group I.

The carcinogen, 7,12-dimethyl-1,2-benzanthracene, was dissolved in liquid petrolatum heavy grade, U.S.P., to give a solution of 0.5 per cent concentration by weight. The carcinogen was topically applied to the left buccal cheek pouch with a cotton swab in Groups I, II, and III. Groups IV and V were treated in an identical manner applying only the solvent, liquid petrolatum.

The carcinogen was applied every Tuesday and Friday for 13 weeks. However, only 21 applications were given during this period for when more than one hamster showed marked suppurative reaction within the pouch the following application was not given. A waiting period of 7 weeks was allowed after applications ceased to permit latent changes to manifest themselves.

The animals were sacrificed by ether inhalation 20 weeks after they were started on the vitamin A deficient diet. The left buccal cheek pouch along with the submaxillary salivary gland, regional lymph nodes, and lung were dissected out and fixed in 10 per cent formalin. At the moment of death, cardiopuncture was performed and the blood of 5 to 8 animals from each group was drawn and pooled for a determination of the serum level of vitamin A by the Price-Carr antimony trichloride color reaction method. The cheek pouch and other organs were embedded in paraffin and sectioned at a thickness of 6 μ and stained with hematoxylin and eosin. The slides were "blinded" and examined microscopically.

OBSERVATIONS

After 5 weeks on the vitamin A deficient diet, symptoms of mild vitamin A deficiency began to appear in the unsupplemented groups when the fur of these hamsters lost its characteristic smoothness and became slightly ruffled in appearance. About the sixth or seventh week the weight gains began to level off. Fur changes became marked at 7 to 8 weeks. Very slight xerophthalmia became noticeable after about 9 weeks. From the eleventh week the animals began to lose weight.

TABLE II
AVERAGE WEIGHTS

GROUP	AVERAGE WEIGHT AT 45 DAYS OF AGE (GM.)	AVERAGE WEIGHT AT 195 DAYS OF AGE (GM.)	AVERAGE GAIN OR LOSS (GM. PER CENT)	
I	74.0	69.5	-6.0	-4.5
II	72.6	78.9	+8.7	+6.3
III	73.6	69.6	-5.4	-4.0
IV	80.0	81.1	+0.4	+0.3
V	74.3	86.9	+17.0	+12.6

The serum level of vitamin A in the animals receiving the supplement of vitamin A increased sharply shortly after administration and fell slowly until the next administration of the vitamin. At no time did the serum level in the

animals supplemented with vitamin A fall to the low level of the unsupplemented animals. Serum of the pooled blood of 5 to 8 vitamin A deficient animals (independent samples) was found to contain 19 μg per cent vitamin A. The serum of the pooled blood of 5 to 8 vitamin A supplemented animals varied in its vitamin A content from 57 μg per cent 5 hours after vitamin A administration to 26 μg per cent a week later when the next vitamin A administration was due.

The incidence of clinically observable tumors (Fig. 1) was greater in the unsupplemented group than in either of the other treated groups.

Fig. 1.—Hamster pouch, surgically opened, demonstrating multiple tumor masses.

On microscopic examination, the histologically prepared pouches were graded into 5 categories: (1) normal pouch epithelium (Fig. 2); vitamin A deficient epithelium (Fig. 3); (2) hyperkeratosis (Fig. 4); (3) benign papilloma (Figs. 5 and 6); (4) carcinoma in situ (Figs. 7 and 8); and (5) invasive squamous-cell carcinoma (Figs. 9 and 10). The incidence of malignant lesions in the unsupplemented animals was about 26 per cent greater than the supplemented ad libitum fed animals and about 34 per cent greater than those animals supplemented with vitamin A but kept on a paired-feeding regimen. Table III summarizes the histologic findings.

Fig. 2.—Normal cheek pouch epithelium of vitamin A supplemented hamster. (Orig. mag. ×415.)



Fig. 3.—Atrophic, hyperkeratotic cheek pouch epithelium of vitamin A deficient hamster. (Orig. mag. ×415.)

TABLE III
TUMOR INCIDENCE AND HISTOLOGIC ANALYSIS

GROUP	NUMBER OF ANIMALS EXAMINED	NUMBER WITH CLINICALLY OBSERVABLE TUMORS	PER CENT CLINICAL TUMOR INCIDENCE	NORMAL EPITHELIUM	HYPERPLASTIC EPITHELIUM	BENIGN PAPILLOMA	CARCINOMA IN SITU	INVASIVE SQUAMOUS-CELL CARCINOMA	NUMBER WITH MALIGNANCIES	PER CENT INCIDENCE OF MALIGNANCIES
I	27	22	81.5	1	3	7	14	2	16	59
II	27	20	74.0	5	4	9	7	2	9	33
III	12	7	58.3	1	2	6	3	0	3	25
IV	6	0	0	6	0	0	0	0	0	0
V	8	0	0	8	0	0	0	0	0	0

Fig. 4.—Hyperplastic epithelium cheek pouch of hamster. (Orig. mag. ×415.)

DISCUSSION

Vitamin A deficiency in the rat can be readily produced experimentally. However, attempts in this laboratory to produce oral carcinogenesis in this animal have not been successful. The hamster, because of its unique pouch, in which cancer has been successfully induced by several investigators,[5, 18] was selected as the more suitable animal. The hamster is also subject to vitamin A deficiency and therefore fulfilled both requirements for this investigation.

Fig. 5.

Fig. 6.

Fig. 5.—Cheek pouch epithelium exhibiting benign papilloma. (Orig. mag. ×22.)
Fig. 6.—Benign papilloma. (Orig. mag. ×125.)

Fig. 7.

Fig. 8.

Fig. 7.—Cheek pouch epithelium exhibiting carcinoma in situ. (Orig. mag. ×22.)
Fig. 8.—Carcinoma in situ. (Orig. mag. ×125.)

Fig. 9.

Fig. 10.

Fig. 9.—Cheek pouch epithelium exhibiting invasive squamous-cell carcinoma. (Orig. mag. ×22.)

Fig. 10.—Invasive squamous-cell carcinoma. (Orig. mag. ×415.)

Producing the two conditions simultaneously presents difficulty. The production of deficiency symptoms appears relatively early while neoplasia appears only after extensive periods. Animals deficient in vitamin A are subject to numerous intercurrent diseases and therefore are likely to die before tumors are visible. Therefore, a carcinogen with potency sufficient to produce tumors in a relatively short time must be used. Furthermore, hamsters do not survive when fed vitamin A test diet (U.S.P.) for the rat. A special vitamin A deficient diet able to supply all other nutritive requirements of the hamster had to be prepared in order that the animals would live sufficiently long to exhibit neoplasia.

Since animals fed a vitamin A deficient diet often lost their appetite, their caloric intake was thus reduced. Tannenbaum[19] has established that a diet with a restricted caloric content plays a definite inhibitory role in the development of tumors. In order that we might compare vitamin A deficient animals with animals fed identically except for the vitamin A supplement and not animals with restricted caloric intake with normal animals, a third group to be pair-fed with the vitamin A deficient group was added.

Vitamin A deficiency produces metaplastic changes in the epithelial linings of the trachea and bronchi which predispose the animal to pneumonia and other respiratory disorders. The observed death rates reflect this fact, the fatality rate of the vitamin A deficient animals being two to three times as high as for animals supplemented with vitamin A weekly.

While the average weight loss of the various groups may in part have been related to the group death rate, other factors undoubtedly exist. This inference is substantiated by the fact that while Group I had a death rate of 27.5 per cent and an average weight loss of 6 per cent, Group III had a death rate which exceeded that of Group I by more than twice the value and yet had a smaller average weight loss.

Vitamin A determinations were made on serum rather than on liver because several investigators[20-23] have demonstrated that vitamin A may be absent from the liver while still present in serum and other sites. The samples of blood, drawn when animals were sacrificed, demonstrated that even though the animals on the vitamin A deficient diet had received no vitamin A for 20 weeks, the serum still contained a low level of the vitamin. This is in agreement with the work of these investigators who have shown that the serum vitamin A level falls very slowly until total depletion of the labile body stores has been achieved, death occurring shortly thereafter. Thus, much as it is desirable to compare totally depleted animals with normal animals, in a study of this duration, this was not possible. The serum determinations showed that the serum vitamin A level of the vitamin A deficient group was lower than that of the serum of the vitamin A supplemented animals. The results, then, compare 2 groups of animals where vitamin A is present in the serum at two different levels rather than two groups in which vitamin A is present in one and absent in the other. The data obtained from this investigation must be evaluated in this light.

A comparison of Group I with Group III would be the most logical method of analyzing the effect of vitamin A deficiency upon carcinogenesis without clouding the results by dissimilar caloric intake. Neoplastic changes were observed more frequently both grossly and microscopically in the vitamin A deficient group. In both Groups II and III (receiving oral vitamin A supplements) a greater number of animals exhibited either no epithelial change or changes within the range of benign hyperplasia. In contrast, the vitamin A deficient animals demonstrated epithelial changes suggestive of various degrees of malignancy.

A statistical evaluation of the histologic data indicated that the probability that the numerical difference between Group I and Group III would be exceeded by chance error alone is less than 5 per cent. We may conclude from the data obtained that a deficiency of vitamin A in the hamster may promote malignant changes in the epithelium of the cheek pouch when a carcinogen is applied.

SUMMARY AND CONCLUSIONS

This study indicates that:

1. In the carcinogen-treated cheek pouch of the golden Syrian hamster, vitamin A deficiency promotes epithelial tumor production.

2. A higher tumor incidence in the group fed ad libitum than in the group with restricted caloric intake is in agreement with the findings of Tannenbaum, namely, that tumor production is inhibited by a diet with restricted caloric intake. However, this effect appears to be more than offset if the diet is deficient in vitamin A.

REFERENCES

1. Lane, S. L.: Oral Cancer, *Oral Surg., Oral Med., & Oral Path.* 6: 258, 1953.
2. Levy, B. M.: The Effect of a Chemical Carcinogen (20-Methylcholanthrene) on the Oral Tissues. A Preliminary Report, *Oral Surg., Oral Med., & Oral Path.* 1: 582, 1948.
3. Levy, B., and Ring, J.: Experimental Production of Jaw Tumors in Hamsters, *Oral Surg., Oral Med., & Oral Path.* 3: 262, 1950.
4. Lutz, B. F., Fulton, G. P., Patt, D. I., Handler, A. H., and Stevens, D. F.: The Cheek Pouch of the Hamster as a Site for the Transplantation of a Methylcholanthrene-Induced Sarcoma, *Cancer Res.* 11: 64, 1951.
5. Salley, J. J.: Experimental Carcinogenesis in the Cheek Pouch of the Syrian Hamster, *J. D. Res.* 33: 253, 1954.
6. Wolbach, S. B., and Howe, P. R.: Tissue Changes Following Deprivation of Fat-Soluble A Vitamin, *J. Exper. Med.* 42: 753, 1925.
7. Wolbach, S. B., and Howe, P. R.: Vitamin A Deficiency in the Guinea Pig, *Arch. Path.* 5: 239, 1928.
8. Smith, S. E.: The Minimum Vitamin A Requirement of the Fox, *J. Nutrition* 24: 97, 1942.
9. Wolfe, J. M., and Salter, H. P., Jr.: Vitamin A Deficiency in the Albino Mouse, *J. Nutrition* 4: 185, 1931.
10. Tilden, E. B., and Miller, E. G.: The Response of the Monkey (Macacus Rhesus) to Withdrawal of Vitamin A From the Diet, *J. Nutrition* 3: 121, 1930.
11. Hirschi, R. G.: Postextraction Healing in Vitamin A Deficient Hamsters, *J. Oral Surg.* 8: 3, 1950.
12. Salley, J. J., and Bryson, W. F.: Vitamin A Deficiency in the Hamster, 35th Gen. Meeting, I. A. D. R., Atlantic City, March, 1957, Preprinted Abstracts, p. 1.
13. Fibiger, J.: In Oberling, C., The Riddle of Cancer, Revised Edition, New Haven, 1952, Yale University Press, p. 66.

14. Fujimaki, Y.: Formation of Gastric Carcinoma in Albino Rats Fed on Deficient Diets, *J. Cancer Res.* **10**: 469, 1926.
15. Cramer, W.: Papillomatosis in the Forestomach of the Rat and Its Bearing on the Work of Fibiger, *Am. J. Cancer* **31**: 537, 1937.
16. Rosicky, J., and Halschek, R.: Über die BeeinfluBbarkeit der Krebsbildung nach Benzpyrenpinselung, *Ztschr. f. Krebsforsch* **54**: 26, 1943.
17. Carminati, V., and Baglioni, R.: Modificazioni Epitheliali Secondarie ad Avitaminiosi a nell' oncogenesi sperimentale del ratto, *Tumori* **41**: 655, 1955.
18. Chaudhry, A. P.: Personal communication, 1958.
19. Tannenbaum, A.: The Dependence of the Genesis of Induced Skin Tumors on the Caloric Intake During Different Stages of Carcinogenesis, *Cancer Res.* **4**: 673, 1944.
20. Bodansky, O., and Markardt, B.: Effect of Reichstein's Compound L Acetate on Plasma, Liver, and Kidney Vitamin A, *J. Biol. Chem.* **190**: 83, 1951.
21. Brenner, S., Brookes, M. C. H., and Roberts, L. J.: Relation of Liver Stores to the Occurrence of Early Signs of Vitamin A Deficiency in the White Rat, *J. Nutrition* **23**: 459, 1942.
22. Glover, J., Goodwin, R. W., and Morton, R. A.: Studies in Vitamin A. The Relationship Between Blood Vitamin A Levels and Liver Stores in Rats, *Biochem. J.* **41**: 97, 1947.
23. Lewis, J. M., Bodansky, O., Falk, K. G., and McGuire, G. M.: Vitamin A Requirements in the Rat. The Relation of Vitamin A Intake to Growth and to Concentration of Vitamin A in the Blood Plasma, Liver, and Retina, *J. Nutrition* **23**: 351, 1942.