Food and Drug Administration
Center for Food Safety and Applied Nutrition
Office of Special Nutritionals

ARMS#

13418

5 - SUMMARIES

000001

FIRST HOSPITALIZATION

[redacted]

NAME: [redacted]
ADMISSION: 12/29/98
PHYSICIAN: [redacted]
TRANSCRIBED: [redacted]

ACCT. #: [redacted]
DISCHARGED: 12/30/98
DICTATED: 12/30/98 1638
TRANSC: 12/31/98 0901
ROOM: [redacted]

DISCHARGE SUMMARY

JOB #: [redacted]

DATE OF ADMISSION: 12/29/98

DATE OF DISCHARGE: 12/30/98

DISCHARGE DIAGNOSES:

1. RIGHT CEREBROVASCULAR ACCIDENT WITH A MIDDLE CEREBRAL ARTERY OCCLUSION.
2. MIGRAINE HEADACHE.

PROCEDURES:

1. MRI.
2. MRA.
3. CT SCAN OF THE HEAD.

HOSPITAL COURSE: This 29-year-old gentleman while on a treadmill developed sudden onset of severely tense right supra-orbital headache. He subsequently developed a left hemiparesis. His symptomatology improved upon presentation to the emergency room. CT scanning was performed which was unremarkable. He underwent lumbar puncture which showed a clear spinal fluid protein of 69, a glucose of 53, 1 white blood cell, and 5 red blood cells. Only 1-2 had been counted. The patient was admitted to the Telemetry Unit. He had persistent complaints about the right supra-orbital headache; however, his motor strength had improved markedly. His strength was graded 4+/5. He was doing well, until the following morning when he started developing complaints of left arm numbness. Within an hour, he had total hemiplegia on the left side. An emergent MRI and MR angiography was performed which showed what appeared to be a complete occlusion of the right middle cerebral artery. In addition an early infarction was noted in the right putamen and caudate, suggestive of a vertebral stride occlusion. The patient had been initiated on heparin with bolus given as well as aspirin given at the onset of his progression. His coagulopathy evaluation was largely pending at the time of this dictation. his prothrombin time and partial thromboplastin time were normal. His comprehensive metabolic panel was normal, except for an AST of 48 and a total bilirubin of 2.4. Potassium was slightly low at 3.3. He did receive supplementation. The patient's admission white blood cell count was 4,700. Echocardiogram was not obtained by the time of transfer. Thus, a discussion was held with [redacted] It was recommended that this patient be transferred to their facility for cerebral angiography with consideration of angioplasty, that is in fact a slow flowing MCA is discovered rather than a complete occlusion. Of note, this patient also had a urine drug screen which was unremarkable. However, he has been taking re-enhancers prior to working out. The family

000003

[redacted]

NAME: [redacted]
ADMISSION: 12/29/98
PHYSICIAN: [redacted]
TRANSCRIBED: [redacted]

ACCT. #: [redacted]
DISCHARGED: 12/30/98
DICTATED: 12/30/98 1638
TRANSC: 12/31/98 0901
ROOM: [redacted]

DISCHARGE SUMMARY

brought in the re-enhancers for review. Once consisted of DHEA and Ansterodione. The other one called, Ultimate Orange contained Fedrin. It was felt that this may have induced vasculitis with subsequent thrombus or vasospasm with resultant thrombus. As mentioned, [redacted] is pending at the time of discharge. [redacted]

Ultimate Orange

cc: [redacted] M.D.

000004

[redacted]

NAME: [redacted]
ADMISSION: 12/29/98
PHYSICIAN: [redacted]
TRANSCRIBED: [redacted]

ACCT. #: [redacted]
DISCHARGED:
DICTATED: 12/29/98 2053
TRANSC: 12/29/98 2107
ROOM: [redacted]

HISTORY & PHYSICAL

JOB #: [redacted]

HISTORY OF PRESENT ILLNESS: The patient is a 29-year-old gentleman who, today while on a treadmill, developed a sudden onset of severe, intense, right, supraorbital headache. It had essentially made him collapse. It is unclear if he had true loss of consciousness. However, he was unable to move his left side. His weakness persisted upon arrival to the emergency room. The headache has also persisted, and it is the worse of his life.

The patient has had persistent left-sided weakness without any sensory changes. He did have dysarthria. He denied any diplopia, vertigo or tinnitus. His strength has improved, but it has not completely returned to normal. He did have CT imaging done which was unremarkable. A lumbar puncture was performed under fluoroscopy. This revealed a CSF protein of 69, glucose 53, one white cell and five red blood cells. Only one tube was counted. Gram stain was negative. Antigen panel was negative.

PAST MEDICAL HISTORY: Remarkable for migraine headaches. He states his migraines used to begin with scintillation. He subsequently within fifteen minutes starts to develop a unilateral to bilateral throbbing headache. This headache is completely different. He has had no prior hospitalizations. He has no other medical problems.

ALLERGIES: No known drug allergies.

HABITS: He does not smoke. He is a social alcohol drinker.

MEDICATIONS: He denies any medications but takes Ultimate orange and Andro 6. These have been over the last two weeks.

FAMILY HISTORY: Remarkable for diabetes and hypertension. There is no family history of aneurysms.

SOCIAL HISTORY: He is a student at [redacted]

REVIEW OF SYSTEMS: Remarkable for the headache. He denies any dyspnea, hypertension, palpitations, dyspepsia, melena, dysuria, hematuria, diabetes or an elevated cholesterol.

000005

[redacted]

[redacted]

NAME: [redacted]
ADMISSION: 12/29/98
PHYSICIAN: [redacted]
TRANSCRIBED: [redacted]

ACCT. #: [redacted]
DISCHARGED:
DICTATED: 12/29/98 2053
TRANSC: 12/29/98 2107
ROOM: [redacted]

HISTORY & PHYSICAL

PHYSICAL EXAMINATION:

VITAL SIGNS: Blood pressure 118/51. Pulse 55. Respirations 16. Afebrile.

GENERAL: He is a well-hydrated, well-nourished gentleman.

NECK: Supple without thyromegaly, adenopathy or masses. He is in obvious pain, lying in a darkened room.

HEENT: He has no frontal or temporal artery tenderness. Mucous membranes are moist without lesions. No conjunctival injection is noted. No petechiae were noted.

CHEST: Clear.

CARDIOVASCULAR: Regular rate and rhythm without an appreciable murmur.

ABDOMEN: Soft without hepatosplenomegaly.

GU/RECTAL: Deferred.

PERIPHERAL PULSES: 2+ with no clubbing, cyanosis or edema noted.

NEUROLOGIC: He is somewhat sleepy. He has no significant dysarthria. Cranial nerves are intact. Motor strength testing revealed a slight reduction of tone on the left side. Strength is graded 4/5.

Extremity sensation was intact. Coordination is in proportion to weakness. Deep tendon reflexes are hypoactive, and he has a left extensor plantar response.

CT imaging was reviewed. This was unremarkable. CBC showed a white blood cell count of 4.7, otherwise, it is unremarkable. PT and PTT are within normal limits. Chemistry panel shows an AST of 48, a total bilirubin of 2.4 and potassium is slightly low at 3.3.

000006

[redacted]

[redacted]

NAME: [redacted]
ADMISSION: 12/29/98
PHYSICIAN: [redacted]
TRANSCRIBED: [redacted]

ACCT. #: [redacted]
DISCHARGED:
DICTATED: 12/29/98 2053
TRANSC: 12/29/98 2107
ROOM: [redacted]

HISTORY & PHYSICAL

IMPRESSION: (1) RIGHT CEREBROVASCULAR ACCIDENT IN A YOUNG MALE.

I suspect that his enhancers may have precipitated this stroke. He may have had Ephedrine as part of his supplementation. This has been associated with strokes, as well as seizures. However, with the sudden onset of the most intense headache in his life, one needs to consider the possibility of an aneurysm with a sentinel leak. However, the spinal tap showed no significant elevation of red blood cells, making this less likely.

The sudden onset argues against a central nervous system vasculitis. Given his young age, it is also necessary to rule out a hypercoagulable state or a primary cardiac abnormality.

Recommendations: An MRI will be obtained. An echocardiogram will be obtained. I will obtain a urine drug screen. Protein C, protein S, anti-thrombin III, lupus anticoagulant and anticardiolipin antibody will all be checked.

He has been placed on aspirin.

(2) MIGRAINE HEADACHE.

I do not feel this represents a migraine variant given the abrupt onset of the headache.

[redacted]

cc: [redacted] M.D.
M.D.

000007

[redacted]

SECOND HOSPITALIZATION

[redacted]

[redacted]

[redacted]

DISCHARGE SUMMARY

[redacted]

[redacted]

[redacted]

[redacted]

[redacted] **ID** [redacted]

DATE OF ADMISSION:

DATE OF DISCHARGE:

CHIEF COMPLAINT: His chief complaint on admission is a stroke.

HISTORY OF PRESENT ILLNESS: The patient is a 29-year-old right-handed white male with no significant past medical history who was running on a treadmill on December 29, 1998, and collapsed with sudden headache. He developed a left hemiparesis affecting his left arm and leg. He also had slurring of speech. At an outside emergency room, a head CT was negative for bleed, and a lumbar puncture revealed no blood but increased level of protein. Evaluation of the initial CT by Dr. [redacted] revealed an increased middle cerebral artery distribution density on the right. He was admitted to the outside hospital and started on aspirin and observed for possible complicated migraine. At 10:30 a.m. on December 30, 1998, the day of transfer to [redacted] he worsened after showing some improvement to 4+ strength on the left. By 10:30 a.m. on the day of transfer, he developed a left flaccid hemiparesis affecting his face, arm, and leg with a pronounced right gaze preference and a question of left hemineglect. MR angiogram done at the outside hospital was suggestive of a right middle cerebral artery occlusion. Intravenous heparin was started and he was transferred to [redacted] Intensive Care Unit for further evaluation and care.

PAST MEDICAL HISTORY: Significant for migraines. His typical headache is described as "seeing dots" in his eyes and stars that are bright. The visual phenomena are followed by headache in the right temple area with nausea and vomiting. These headaches occur approximately one time per month. His past medical history is otherwise noncontributory.

PAST SURGICAL HISTORY: None.

FAMILY HISTORY: Positive for diabetes. Negative for migraines, strokes, miscarriages, clotting disorders, pulmonary emboli, deep venous thrombosis. He has two brothers, ages 20 and 18, who are healthy. His parents are living and well. He has a healthy 4-year-old son.

SOCIAL HISTORY: No smoking, no drugs, and no alcohol.

REVIEW OF SYSTEMS: There are no recent illnesses, no preceding neurologic symptoms. He has had no headache this month before the onset of this headache.

MEDICATIONS: He took a medication for migraine which he could not recall. It is believed to be Naprosyn. Other drugs that he was taking include a nutritional mixture called "Ultimate Orange," which contained per serving "20 mg of ephedra alkaloids." The patient reports taking one and a half servings prior to working out in the gym on the day of his event. He also has taken "Andros VI." This Andros VI contains DHEA and androstenedione. His wife reports that he had not taken any of the Andros VI since December 25.

ALLERGIES: No known drug allergies.

PHYSICAL EXAMINATION: On arrival, he was afebrile and had normal vital signs. Mental status: He was awake, alert, oriented to name, time, hospital, and his speech was fluent. Cranial nerves II-XII were significant for a right gaze preference, a left homonomous hemianopsia and a left upper motor neuron facial palsy. His extraocular movements were intact and his pupils

equal, round, and reactive to light. His motor function was significant for 0/5 motor function in the left arm and leg. Sensation was decreased to pain and light touch over the left face, arm, and leg. His deep tendon reflexes were 2+ and equal bilaterally. His toes were upgoing on the right and downgoing on the left. His gait was not tested. Coordination was not tested. Head CT without contrast on arrival revealed a large frontal MCA distribution heterogeneous low-density area with a small punctate area of hemorrhage.

HOSPITAL COURSE: He underwent a cerebral arteriogram on December 31, 1998, which revealed filling deficits in the M1, and to a lesser extent the proximal A1 segments, with thrombus. There were multiple truncated M2 and M3 branches with slow flow consistent with embolic showering on the right. There was collateral flow in the following distributions: leptomeningeal from the right ACA; 3 to ACOM on the left internal carotid artery injection. There was PCA to MCA leptomeningeal filling. There was no PCOM filling. He became less responsive on January 1, 1999, with a CT revealing evidence of increased edema with petechial blood and mass effect and midline shift and closing of the basal cisterns. He was started on mannitol for increased edema. Transesophageal echocardiogram on January 2, 1999, revealed mild aortic regurgitation, no valvular calcification, no left ventricular thrombus, and no evidence of other valvular abnormalities. No patent foramen ovale was observed.

On the evening of January 3, 1999, he underwent a significant neurologic deterioration with decreased mental status and developed an enlarged right pupil and right cranial nerve III palsy but was still able to follow some simple commands. He developed extensor posturing in response to stimuli. He continued to deteriorate neurologically and was felt to be suffering from impending herniation secondary to increased intracranial pressure from continued worsening of his edema and continued infarction. The neurosurgery service who had been following was consulted, and he underwent a right frontotemporal lobectomy for decompression on January 4, 1999. He transiently improved but underwent a further neurologic deterioration on January 5, 1999, and was taken to the operating room for further debridement of the right frontotemporal lobe.

He initially did well postoperatively but became febrile and was treated for a presumed aspiration pneumonia. On January 6, 1999, he again worsened and MRI was performed which showed a great degree of shift and a tight posterior fossa with a midline shift of the midbrain, and he underwent a right hemispherectomy on January 6, 1999. On postoperative day number one, January 7, 1999, he was remarkably improved. He was responsive and interactive, breathing over the vent and controlling the TV remote control. He was oriented to name, location, and year by nodding yes or no. He had spontaneous movement of his right arm and leg. He responded to complex yes or no questions with head nods, and he was able to add simple numbers and indicate the results with his fingers. He followed commands with his right hand. He did, however, have no spontaneous eye opening and had a bilateral ptosis when his eyes were opened, and he did track, moving to the right. He had increased tone in his left and decreased movement on the left. His toes were strongly upgoing on the right and very strongly upgoing on the left.

Postoperatively from the complete right hemispherectomy, he continued to improve. He was successfully weaned from the ventilator and extubated on January 10, 1999. He was able to sit in a chair for 90 minutes, and on exam, he was alert, interactive, and would say hello and state his last name. He continued to improve, and on January 15, 1999, he had a ventriculoperitoneal shunt placed. Following shunt placement, he had an increased level of alertness and was more interactive. On January 16, 1999, he was transferred to the floor. Tube feeds were restarted. Heparin was restarted on January 20, 1999, and he was initiated on Coumadin on the 21st of January.

000010

I will now outline our current management by systems:

FLUIDS, ELECTROLYTES, NUTRITION: The patient has SIADH with a low sodium level of 130. He was started on fluid restriction to 1500 cc per day. Over the last five days, his sodium has increased to the current 135. His electrolytes on January 25, 1999, were as follows: sodium 135, potassium 3.9, chloride 94, CO2 of 28. BUN was 14, creatinine 0.9, glucose 121. Our current plan is to continue him on this 1500 cc per day fluid restriction and follow his electrolytes daily. He is on a regular soft mechanical diet.

HEMATOLOGY: Hematologically, the neurology team has decided to coumadinize him for an extended time period, at least six months, with reevaluation at that time by Dr [redacted] Currently he remains on a heparin drip while Coumadin is initiated. LABORATORY DATA: His current laboratory values include a PTT of 61.5 with our PTT goal to be in the 40-70 range initially on Coumadin, and his current INR is 1.4. His Coumadin dosage is increased from 5 mg p.o. q.h.s. to 7.5 mg p.o. q.h.s. last night, and our goal for his INR is in the 2-3 range. When the INR reaches the 2-3 range, our current plan is to discontinue his heparin at that point. An extensive workup to evaluate him for a hypercoagulable state revealed no clear abnormalities. It is not clear if the etiology of his stroke was related to a coagulopathy or ingestion of one of the ingredients in his dietary supplements, most likely ephedrine.

GASTROINTESTINAL: He is tolerating a soft mechanical diet at this point, but for the last two weeks, he has been reporting mild generalized abdominal pain. His amylase and lipase levels have been elevated to the several-hundred range. When tube feeds were discontinued and he was continued only on a regular soft mechanical diet, these levels began to fall. Our plan was to continue him on his current diet and intermittently follow his amylase and lipase as well as abdominal exam. Abdominal ultrasound revealed only sludge in the gallbladder and no evidence of stones or pancreatic disease. His latest labs include an ALT of 177, an AST of 44, alkaline phosphatase of 118, GGT of 290, amylase of 87, and a lipase at 358. For gastrointestinal prophylaxis, he is continued on famotidine. For constipation, he is on Colace 100 mg p.o. b.i.d. with bisacodyl suppository 10 mg p.r.n.

NEUROLOGIC: Neurologically he is obviously status post a right hemispherectomy and doing amazingly well for a gentleman who had an impending herniation times three. He now is more awake, alert, and interactive. He recognizes friends and family, and his mental status has improved after the initiation of Ritalin. He still has severe inattention and obviously a grossly altered affect as well as a dense left hemiparesis.

For seizure prophylaxis, he is on Dilantin, requiring a relatively high dose of 300 mg p.o. b.i.d. His Dilantin level on the morning of January 25, 1999, was 11.8. Our goal was to maintain this in the 14-18 range for his inattention and "aboulia." He was started on a trial of Ritalin 5 mg p.o. b.i.d. at 0800 and 1300 hours, and on this regimen, he has improved greatly and become far more interactive with his family and the medical staff. We were considering an increase to his dose further, and leave this to the next medical team.

CARDIOVASCULAR: He experienced a slight increase in blood pressure which we attributed to the initiation of Ritalin and was started on felodipine 5 mg p.o. q.d. and has had a normal blood pressure since initiation.

000011

Best Quality FDA

[redacted]

[redacted]

DISCHARGE SUMMARY

RE[redacted]BILITATION: He has received intensive physical therapy, occupational therapy, and speech therapy at [redacted] bra[redacted] and is being transferred to [redacted] for even more intense rehabilitative care following this major trauma and very successful surgical procedure.

PH[redacted]CAL EXAMINATION: On examination at discharge, he is afebrile. His heart rate is 90 and blood pressure was 144/20. cle[redacted] breathing at 20. HEENT: His cranial incision is healing well. Neck: Supple. No lymphadenopathy. Chest: Lungs nou[redacted] auscultation bilaterally. Heart: Regular rate and rhythm with no murmurs, rubs, or gallops. Abdomen: Soft and pai[redacted]der, nondistended, although he does report slight pain on palpation. There is no guarding. He indicated that it is a minor les[redacted] Genitourinary: He has normal male genitalia. He has a slight irritation at the meatus, and there is no bleeding or other lef[redacted] noted. Extremities: There is no clubbing, cyanosis, or edema, although he does have a dense and increasingly spastic kee[redacted]miparesis and he is in braces to prevent contractures. Neurologically he is much more awake and alert. He is talking and inte[redacted] his eyes open for several minutes at a time, although he does not have very frequent blinking at all. He tracks objects and nou[redacted] is well with people. He responds to humor but has a flat affect. He did begin using his hands more to gesture and use ner[redacted]bal communication in preference to speaking. He has some restlessness of behavior and impersistence at tasks. Cranial ext[redacted] His pupils are equal, round, and reactive to light. He has a left cranial nerve VII upper motor neuron weakness. His gre[redacted]ular movements are intact but he does have a left homonomous hemianopsia. His motor function on the left is 0/5 with 3+ [redacted] increased tone. Strength on the right is 5/5. Sensation is decreased on the left to pain and light touch. His reflexes are [redacted] the left, 2+ on the right. His toes are upgoing on the right and downgoing on the left.

PS[redacted]IOSOCIAL: He has a very supportive wife and a 4-year-old son. I think one of his great advantages is that he is a former me[redacted] of the [redacted] and certainly has a will to succeed in rehabilitation following this injury.

[redacted]

D: [redacted]
T: [redacted] 25/99 18:28
Job[redacted]
cc: [redacted]

000012

[redacted]

[redacted]

HISTORY AND PHYSICAL EXAMINATION

Source Pt + Pts wife,

HISTORY

Chief Complaint: STROKE.

Present Illness: 29 yo RHW ♂ with no significant PMH who yesterday was running on treadmill and collapsed with sudden onset HA and developed (L) HP in ARM + leg with slurring of speech. At outside [redacted] Head CT was (−) for Bleed and LP revealed. ∅ Blood but ↑ Prot. Eval of initial CT by [redacted] revealed ? MCA ↑ density on (R) He was admitted + started on ASA + observed for possible complicated migraine. At 10:30 AM Today he worsened. He had improved on to 4+ strength - but after 10:30 had (L) flaccid HP of F, A, L (R) Gaze pref + ? (L) neglect.

MRA suggestive of (R) MCA occlusion. Heparin IV was started + then he was transferred for further eval + care. He reportedly was using Ephedrine - to improve his physical workout tolerance.

Past History:

Family & Social History:

PMH ∅ PSH ∅ (+) for Migraines

HA: See "Dots" in eyes - stars - bright. Followed by HA on (R) Temporal area with (+) N/O V Freq 1x/month.

(+) for DM (−) for Migraines (−) for Stroke, Miscarriages, Clotting disorders, PE, DVT 2 Brothers 23, 18 healthy Parents living + well. Son 4 yo healthy.

Review of Systems: ∅ recent illness ∅ Preceding Nerve SX ∅ HA this month before onset

000013

Medications: EPHEDRINE 2 Medicine of Migraines I cannot recall (Per wife NAPROSIN)

"ANDROS 6" "Ultimate Orange" "Supplements"

Took "ultimate orange" before ~~at~~ workout yesterday.

(See reverse)

[redacted] (BACK) [redacted]

PHYSICAL EXAMINATION

General: WDWN W♀

Head and Neck: AT/NC ∅ Bruits ∅ LAD Supple neck

Skin: ∅ lesions

Chest and Lungs: CTA (B) (+) Cough

Heart: RRR no M/R/G

Abdomen: Benign

Genital and Rectal: Deferred.

Extremities: (−) C/C/E

Neurological:
MS: A&Ox3
CN: PERRL ? (R) Gaze Pref (L) Homonomous hemianopsia
(L) UMN facial weakness EOMI
Motor: Arm (L) 0/5 leg (L) HIP 2-3/5 Knee F/E 2/5 Ankle 2/5
Sensory ↓ to Touch in (L) F, A, L
Reflexes

Impression:

Plan:
29 yo with large Frontal MCA infarct
Angiogram in AM / TEE to follow
Heparinate Continue.
Baseline Stroke labs - ESR / LIPID [redacted]



ULTIMATE ORANGE
contains (Per "serving")
20 mg of Ephedra alkaloids
[redacted] reports taking 1½ serving
Prior to working out in the Gym
~~With~~ Wife reports he has not taken
ANDRO-6 (with DHEA and
Androstenedione) since Xmas.

000014

[redacted] 12/30/98 Date

[redacted] 12/30/98 Date

[redacted]

CONSULTATION SHEET

[redacted]

000015

Department Requesting Consultation:	Neurosurgery	Date and Hr.	1/8/99
Department Giving Consultation:	Transfusion Services		
Tentative Diagnosis:			

Pertinent History: 29 year old male s/p hemispherectomy. Has a history of being multiply transfused with platelets, FFP, and RBCs since 1/4/99. Now with a suspected transfusion reaction to an apheresis platelet product [redacted] intraoperatively with symptoms of severe hypotension and hypoxia. The patient was resuscitated with epinephrine and the symptoms resolved. Pre- and post-transfusion vitals as follows:

	BP	Temp (C)	Pulse (bpm)	Date@Time
Pre	110/50	37	70	1/6/99@1530
Post	56/37	37	60	1/6/99@1545

M.D.

Consultant's Note: Suspected transfusion reaction

Date, Hour: January 8, 1999

[redacted] is blood group O, Rh positive. This patient underwent a suspected transfusion reaction during infusion with an apheresis platelet product [redacted] with the signs/symptoms reported above. A clerical check was done on the unit in question and found to be correct. A post transfusion urine and serum sample showed no evidence of free hemoglobin. A post-transfusion direct antiglobulin test was negative. Based on these clerical and laboratory findings, there is no evidence of red cell incompatibility.

Since this patient underwent severe hypotension, a gram stain and culture was sent to rule out bacterial contamination of the platelet product. The gram stain was negative and the culture is pending. A positive culture result will be called to the floor. Additionally there was some concern that this patient may be congenitally IgA deficient and from his recent exposure to plasma and plasma containing products would be at risk for forming anti-IgA alloantibodies. This concern was communicated to the clinician (Dr. [redacted] who elected to transfuse additional plasma containing products with extreme caution since the patient had such urgent need for platelets and coagulation factors. An IgA level was ordered, but would not be available before the urgent need for transfusion. Subsequent infusions of plasma containing products did not produce any adverse effect, essentially ruling out the diagnosis of IgA deficiency with anti-IgA alloantibodies. The patient's IgA level was within the normal range at 137.0 mg/dL. This reaction was most likely temporally related, instead of causally related, to the blood product infusion. Regardless, further transfusion in this patient should be monitored carefully and additional work-up will be necessary if further reactions are noted. [redacted]

[redacted] MD

I personally reviewed the diagnostic information and agree with the interpretation

Signature [redacted]

[redacted]

WHITE - CHART CANARY - PHYSICIAN

FOURTH HOSPITALIZATION

[redacted]

[redacted]

13418

DISCHARGE SUMMARY

[redacted]

DATE OF ADMISSION: 02/27/99

DATE OF DISCHARGE: 03/26/98

ADMISSION DIAGNOSIS: Shunt malfunction/overshunting.

DISCHARGE DIAGNOSIS; Shunt infection/distal portion.

CONSULTANTS:
1. Neuroanesthesiology.
2. Hematology/Oncology.
3. General Surgery.
4. Gastroenterology Medicine.

PROCEDURES:
1. 03/10/99: Removal of medium pressure valve. Placement of a right parietal/occipital Medos programmable valve set at 140 mm of water.
2. 03/23/99: Removal of VP shunt.

HISTORY OF PRESENT ILLNESS: This is a 29-year-old white male who is status post craniotomy x three for diffuse right cerebral edema secondary to MCA/ACA distribution infarction ultimately resulting in a right hemispherectomy on 01/06/99.

A VP shunt was placed on the right on 01/15/99. The patient was discharged on 01/25/99, to [redacted] Rehab facility, at which time he was lethargic but arousable, following commands, with a dense left hemiplegia and spasticity.

He returned this admission from Rehab after making a very good recovery. Approximately nine days ago, he developed a headache which is worse than his usual and has persisted. His CT scan shows enlarged left lateral ventricle with a left-to-right shift. The patient is admitted now for switching him over from Coumadin to heparin and the plan is to revise his right shunt and/or placement of a left shunt.

HOSPITAL COURSE: The patient was admitted to the hospital on 02/27/99, and was switched from Coumadin to heparin and his coags were monitored over the next few days.

After reviewing his CT scan, it was felt that he was potentially overshunting due to his shift, as well as the headaches that he developed that generally occur after being up for a couple of hours. Neurologically, he was alert, awake, and oriented x three and was tolerating a regular diet.

The plan was to replace his shunt valve when his coags became normal. By 03/05/99, he began to complain of left costal pain overnight which did improve by the following day. We continued to monitor his coags over the next few days and ultimately we were able to get them into normal range and he was taken on 03/10/99, for shunt revision, at which time his valve was changed to a programmable shunt valve.

Over the following days, he continued to complain of left upper quadrant abdominal pain. General Surgery was consulted for this and he was ultimately worked up for this problem with abdominal sonogram, abdominal CT, lab work, all of which were negative. However, the patient continued to have the abdominal pain. He continued to have abdominal pain over the following days, which we were still monitoring and attempting to work up. However, everything remained normal.

Ultimately, Gastroenterology was called, still with no avail to the cause of his left upper quadrant abdominal pain. Finally, after much investigation, his abdominal CT did reveal a fluid collection at the distal portion of his VP shunt which was aspirated and was infected. Therefore, the decision was made to remove the VP shunt totally and place him on antibiotics for two weeks and send him back to Rehab to assess the necessity of another shunt placement at another time. This was done on 03/26/99, at which time he was discharged back to [redacted] facility.

[redacted] M.D.
By [redacted]

[redacted]
D: 04/06/99 08:19
T: 04/17/99 11:51
Job No: [redacted]
cc: [redacted]

000018

[redacted]

[redacted]

[redacted]

HISTORY AND PHYSICAL EXAMINATION

13418

HISTORY

Tx for Hydrocephalus

Chief Complaint:

Present Illness: Mr [redacted] is a 29 yo wm s/p craniotomy x 3 for diffuse (R) cerebral edema 2°/2 MCA/ACA distribution infarct, ultimately resulting in (R) hemispherectomy 1/6/99; a (R) VPS was placed 1/15/99. The pt was dic'd 1/25/99 [redacted] & that time lethargic c̄ but arousable oriented & following commands c̄ dense (L) plegia/spasticity. He returns now f/ rehab after making a very good recovery. Approx 9d ago he developed a HA which is worse than us. & was persisted. CT shows enlarged (L) lat ventricle c̄ L → R shift; pt admitted now for Coumadin → heparin changeover & plan for revision of R shunt & for placement (L) shunt.

Past History:

Family & Social History:

Migraine HA

PSH - alone

4yo son

Review of Systems:

000019

[redacted]

007

[redacted]

PHYSICAL EXAMINATION

General: Aman & [illegible] in NAD

Head and Neck: Healing R FTP scar
R parietal shunt scar

Skin:

Chest and Lungs:
LTA

Heart:
RRR

Abdomen:
SUSX XBS

Genital and Rectal:
dd

Extremities:
[illegible]

Neurological:

Impression:
Admit
D/C Comadin
Hepsin
CT Scar

Plan:

'99 JUN -4 A11:55

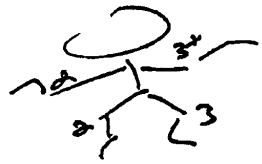

RECEIVED
CLINICAL RESEARCH
& REVIEW/OSN RES

A&OX3
comprehensible, simple speech
PERRL Eom
FC's 5/5 (R)
0/5 LUE
0/5 LLE

000020

[redacted]

[redacted]

CONSULTATION SHEET

[redacted]

[redacted]

Department Requesting Consultation:	NSG	Date and Hr.	3/17/99
Department Giving Consultation:	GI		1740
Tentative Diagnosis:			
Pertinent History:	VERBAL		

M.D.

Consultant's Note:

Date, Hour:

2940 ↑ c̄ new onset abd pain
He has LUQ peritoneal signs.
and his abd pain is worse acc. to pt
CT → ? (R) colon inflamm
DDx incl. Colitis, Splenic infarct, nephrolithiasis, pancreatitis, etc.

Plan
1. Review films
2. ✓ CBC c̄ diff tonight
3. ✓ UA.
4. Send - C.diff toxin.
5. Will ask Surg to re-examine his abdomen

[redacted]

- Simethicone - 160 mg PO
- Golyte tonight 4 + 8 802 glycerin

000021

008

Signature

[redacted] WHITE - CHART CANARY - PHYSICIAN [redacted]

PFC Abd Pain.

CONSULTATION SHEET

Mr. [redacted] is a 29 40 ♂ adm. for VP shunt revision 2/27. 9 d PTA developed HA CT head – enl. ⊕ lat. ventricle c̄ shift. Shunt revised 3/10 (placent of programmable valve). Pain began 3/13 constant, crampy, worst pain in his life. Acc. by N/V 3/13, 3/14, now resolved. Pain has gotten worse. Never had pain like this before. Last BM – small yesterday. c̄ enemas, Suppositories.

PMHx ① ⓡ MCA/ACA CVA
→ severe edema
craniotomy x 3
ⓡ hemispherectomy 1/6/99
ⓡ VPS 1/15/99

FHx ⊕ CRC / ⊕ colitis.

All NKDA.
MEDS Coumadin D/C'd
Dulcolax / MOM
Odansetron / Lortab

PSHx ① NSG as above.

PE Thin man in pain non-toxic
VS 132/60 20 98 Tm 100.2 Tn 98.8
Heart NCAT s/p craniotomy (R)
⊕ LAP
Pulm CTA
Cor RR
Abdomen Soft. ⊕ BS.
exquisitely tender LUQ c̄
percussion + shake tenderness
volunt guarding
⊕ rebound..
moderate tenderness RUQ, LLQ
palpation in LLQ → pain in LUQ
Rectal nl tone, nl prostate
⊕ stool in vault

3/17 LAB 136 / 3.6 | 99 / 26 | 6 / 0.7 < 135
3/15 9.6 > 14.1 / 40.9 < 188 75 P148

NA 3/14 ⊖ RBC ⊖ WBC.
3/14 AST 15 / ALT 70
AP 88 GGT 181
AML / Lip 39/48

OXR 3/15 · NAD
KUB 3/15 NSBGP 3/17 ↑ (R) colon.
CT 5⊕ 3/15 VP shunt mid upper abd c̄ tip just lat. to stomach. ⊕ fluid collect. al lin. borderline spleen. ⊕ adenopathy. Stranding s/s c/w edema or inflamm. ant. lat. to (R) colon.

000022

[redacted]

CONSULTATION SHEET

[redacted]

Department Requesting Consultation: [redacted]	Date and Hr. 3/22/99
Department Giving Consultation:	
Tentative Diagnosis:	
Pertinent History:	
	M.D.
Consultant's Note:	
Date, Hour:	

Imp: 29 yo WM. Catastrophic etiologic stroke. Now c̄ ABD pain, fluid collection by CT scan c/w VP shunt infection. Cx c̄ GPC & GPR. Cart c̄ Vanc/Fortaz. Add flagyl. Await Cx.

[redacted]

000023

Inf Dis Attending Pt seen + examined at the request of [redacted] Mr [redacted] is an unfortunate male s/p multiple craniotomies, a hemispherectomy and most recently a VP shunt revision, which was removed today. The LUQ collection has developed at the distal shunt site and preliminary culture results reveal gpcs (probable coag ⊖ staph) and gprs/diptheroids (identity pending. No anaerobic culture results are available, but anaerobes are commonly present in similar collections. Agree c̄ coverage c̄ Vanco/Ceftaz/Flagyl pending final culture results. As there is fluid remaining in the LUQ (i.e. not drained) would plan for IV ABx for a minimum of two weeks. IV therapy would need to be prolonged (and the collection drained) if the [illegible] fever or [illegible] other complications [illegible] the consult

Signature

[redacted] (4/93) WHITE CHART CANARY - PHYSICIAN [redacted]

CONSULTATION SHEET

HPI: 29 yo W♂ admitted 3/27/99 for VPS revision, s/p procedure 3/19, developed abd pain (LUQ), N/V 3/13, CT 3/15 c̄ minimal stranding (R) omentum, KUB wnl; 3/19 w/ EGD/Golo → fever (102°), chills, 22% bands, 3/20 CT c̄ LUQ fluid collection, begun on Vanc/Fortaz for shunt infxn. Consulted to assist c̄ mgmt.

PMH: # (1) CVA - MCA/ACA 12/27/98 → severe edema, s/p craniotomy x 3, s/p (R) hemispherectomy 1/6/99, (R) VPS 1/25/99. Developed HA 9d PTA → CT c̄ (L) Vent ↑ & L → R shift. Now s/p shunt revision 3/10/99 c̄ persistent hematoma

(2) h/o migraines

MED: 3/20 Vanc 1gm IV Q12°
3/20 Ceftaz 2gm IV Q12°

ASA QD	Prevacid	Colace	Paxil
Restoril	Dilantin	Clavil	Burpirone
Trazodone	Felodipine		

NKDA
Social: ϕ Tob/EtOH/drugs; manual
Family: ϕ h/o hem/clotting disorders

000024

Exam 36.8 37.4 90 128/70 20
WDWN young ♂, NAD
(+) surgical scars c/d/I
PERRL EOMI OP clear
Supple ϕ LAD
CTA (B)
RRR ϕ mgr
NABS, (+) LUQ discomfort c̄ palpation/tap/shake o/w nontender, ϕ rebound/guarding
ϕ L/L/L
GU/Rectal defered

micro
3/20 Blood Cx (−) to date
3/20 Abd fluid Cx (+) c̄ colony GP Cocci
(+) c̄ colony GP Rods → ? diptheroid
Fungal (P)
3/19 CDiff (−)
3/20 CSF (−) to date
3/20 Urine (−) final

Labs (3/20)
9.1 12.1 299
34.9
59P/22 BAND/14L/4M/1E
HBsAg (−)
αHBS (−)
UA (3/8) 0-4 WBC, 2+ Bact, cloudy
Abd fluid 3/20: 260 RBC, 3541 WBC (pred N ϕ)
CSF 3/20: yellow, hazy, 3+ xanthochromic
22 WBC, 3938 RBC
82L/15M/3 neut
Protein 689, gluc 88

Labs (3/18)
137 | 99 | 6
3.8 | 29 | 0.6
Prot 5.7
Alb 2.7

ALT 29
AST 10
Ad 114
GGT 419
Amy <39
Lip 42