Food and Drug Administration
Center for Food Safety and Applied Nutrition
Office of Special Nutritionals

ARMS#

13203

7 - PROCEDURES

========== PHYSICIAN COPY FOR DR: ==

COLL: 11/13/1998 11:47 REC: 11/13/1998 11:48 PHYS:

AUTOMATED DIFF (CONTINUED)

TYPE OF DIFF	AUTOMATED		
NEUTROPHILS	72.9	[44.0-76.0]	%
LYMPHOCYTES	18.7	[15.0-43.0]	%
MONOCYTES	8.0	[3.5-12.3]	%
EOSINOPHILS	0.0	[0.0-5.3]	%
BASOPHILS	0.4	[0.1-0.8]	%
ABSOLUTE NEUTROPHILS	4.1	[1.8-7.4]	x10^3/uL
ABSOLUTE LYMPHOCYTES	1.0	[0.8-3.2]	x10^3/uL
ABSOLUTE MONOCYTES	0.4	[0.2-0.9]	x10^3/uL
ABSOLUTE EOSINOPHILS	0.0	[0.0-0.4]	x10^3/uL
ABSOLUTE BASOPHILS	0.0	[0.0-0.1]	x10^3/uL

MANUAL DIFF TEST REQUEST CREDITED
AUTOMATED DIFF PERFORMED
STAT

RPR [NR] STAT
NONREACTIVE

FEBRILE AGGLUTININS SENT TO

TSH - 3RD GENERATION SENT TO
STAT

F3082 COLL: 11/13/1998 11:47 REC: 11/13/1998 11:48 PHYS:

BLOOD CULTURE STAT
SPECIMEN DESCRIPTION BLOOD
CULTURE NO GROWTH AFTER 5 DAYS INCUBATION
REPORT STATUS FINAL REPORT: 11181998

COLL: 11/13/1998 13:00 REC: 11/13/1998 13:29 PHYS:

BLOOD CULTURE #2 STAT
SPECIMEN DESCRIPTION

========== PHYSICIAN COPY FOR DR: ==

COLL: 11/13/1998 11:47 REC: 11/13/1998 11:48 PHYS:

COMPREHENSIVE METABOLIC PA (CONTINUED)

CALCIUM	9.5	[8.5-10.5]	mg/dL
BILIRUBIN,TOTAL	1.1	[0-1.3]	mg/dL
TOTAL PROTEIN	7.2	[6.0-8.0]	g/dL
ALBUMIN	4.0	[3.2-5.0]	g/dL
AST	11	[0-45]	U/L
ALK PHOS	62	[35-120]	U/L

LIPID PROFILE

CHOLESTEROL	166	[50-200]	mg/dL
	PT IS FASTING		
TRIGLYCERIDES	101	[20-160]	mg/dL
HDL CHOLESTEROL	47	[>35]	mg/dL
LDL CHOLESTEROL, CALC.	99	[65-175]	mg/dL
CHOL / HDL RATIO	3.5		

THE RISK FACTOR FOR C.A.D. (CARDIAC ARTERY DISEASE)
IS AS FOLLOWS:

	MALE	FEMALE
1/2 RISK OF C.A.D.	3.4	3.3
NORMAL RISK OF C.A.D.	5.0	4.4
2X RISK OF C.A.D.	9.6	7.0
3X RISK OF C.A.D.	23.4	11.0

VLDL, CALC.	20	[5-35]	mg/dL

CHEMISTRY COMMENT 1: NOTIFY

CBC STAT

WBC	5.6	[4.0-11.0]	x10^3/uL
RBC	4.76	[3.83-5.11]	x10^6/uL
HEMOGLOBIN	13.9	[12.0-15.5]	g/dL
HEMATOCRIT	40.8	[36.5-46.0]	%
MCV	85.8	[84.0-99.0]	fL
MCH	29.1	[28.3-34.3]	pg
MCHC	33.9	[32.5-35.7]	g/dL
PLATELET COUNT	268	[150-450]	x10^3/uL
RDW-CV	12.2	[11.2-14.6]	%
MPV	8.6	[7.4-10.2]	fL

CBC COMMENTS FLOOR NOTIFIED RESULTS AVAILABLE TO AT 1220.

AUTOMATED DIFF STAT

46 YEARS FEMALE

Page 1 From FOR D
COLLECTED: 11/13/1998 11:50
RECEIVED: 11/14/1998
REPORTED: 11/14/1998
PATIENT ID: ROOM/BED:

TESTS	RESULTS	REF. RANGE	UNITS
TSH - 3rd Generation	1.607	0.390-5.600	uIU/mL

Reference range was obtained from 318 healthy adults from the Mid-Atlantic region.

Febrile Agglutinins

Salmonella Antibodies:

(typhoid O) <1:20

Studies at indicate that approximately 20% of clinically healthy individuals have titers of 1:20, while 80% have titers < 1:80.

(typhoid H) Titer >= 1:320

Studies at indicate that approximately 8% of clinically healthy individuals have titers as high as 1:40, while 92% have titers < 1:20.

(paratyphoid A) Titer 1:20

Studies at indicate that over 90% of clinically healthy individuals have titers < 1:20.

(paratyphoid B) Titer 1:80

Studies at indicate that over 90% of clinically healthy individuals have titers < 1:20.

Proteus OX-19 Antibodies <1:20

Studies at indicate that approximately 16% of clinically healthy individuals have titers of 1:80, while 80% have titers <= 1:40.

Brucella abortus Ab <1:20

Studies at indicate that over 95% of clinically healthy individuals have titers < 1:20.

*** FINAL REPORT ***

========== PHYSICIAN COPY FOR DR: ===

COLL: 11/15/1998 05:45 REC: 11/15/1998 06:23 PHYS:

ANTI-STREPTOLYSIN O AB (CONTINUED)
SENT TO

COLL: 11/17/1998 04:55 REC: 11/17/1998 05:46 PHYS:

CBC

WBC		4.3	[4.0-11.0]	x10^3/uL
RBC		3.90	[3.83-5.11]	x10^6/uL
HEMOGLOBIN	L	**11.5**	[12.0-15.5]	g/dL
HEMATOCRIT	L	**34.2**	[36.5-46.0]	%
MCV		87.4	[84.0-99.0]	fL
MCH		29.4	[28.3-34.3]	pg
MCHC		33.6	[32.5-35.7]	g/dL
PLATELET COUNT		185	[150-450]	x10^3/uL
RDW-CV		12.3	[11.2-14.6]	%
MPV		9.5	[7.4-10.2]	fL

MANUAL DIFF

TYPE OF DIFF	MANUAL		
BAND NEUTROPHILS	1	[0-4]	%
SEG NEUTROPHILS	62	[45-74]	%
LYMPHOCYTES	31	[16-45]	%
MONOCYTES	6	[4-10]	%
RBC MORPHOLOGY	NORMAL		
PLATELET ESTIMATE	ADEQUATE	[ADEQ]	

========== PHYSICIAN COPY FOR DR: [redacted] ==

[redacted] COLL: 11/13/1998 13:00 REC: 11/13/1998 13:29 PHYS: [redacted]

BLOOD CULTURE #2	(CONTINUED)	
	BLOOD	
CULTURE	NO GROWTH AFTER 5 DAYS INCUBATION	
REPORT STATUS	FINAL REPORT: [redacted]	

[redacted] COLL: 11/13/1998 23:00 REC: 11/13/1998 23:02 PHYS: [redacted]

SED RATE	**H**	**21**	[0-20]	mm/hr	STAT
		PHONED RESULTS			
		[redacted] **AT 0012**			

[redacted] COLL: 11/14/1998 22:00 REC: 11/15/1998 00:40 PHYS: [redacted]

PERIOD & VOLUME		
URINE VOLUME, 24HR	2325	ml
5HIAA	SENT TO [redacted]	
METANEPHRINES,FRACT	SENT TO [redacted]	
VMA	SENT TO [redacted]	

[redacted] COLL: 11/15/1998 05:45 REC: 11/15/1998 06:23 PHYS: [redacted]

C-REACTIVE PROTEIN		<0.4	[0.0-0.8]	mg/dL
SED RATE	**H**	**22**	[0-20]	mm/hr
PROTIME				
PROTIME		14.0	[11.5-14.0]	secs
INT NORMALIZED RATIO		1.19		
APTT		28.1	[24.0-36.0]	secs
ANA		SENT TO [redacted]		
ANTI-STREPTOLYSIN O AB				

[redacted]

Report printed on: 11/19/1998 at: 14:00 Interim Report

========== PHYSICIAN COPY FOR DR: ==

COLL: 11/13/1998 11:41 REC: 11/13/1998 11:49 PHYS:

URINALYSIS-ROUTINE STAT

URINE COLOR		YELLOW	[YEL]	
URINE APPEARANCE	**	**CLOUDY**	[CLEAR]	
GLUCOSE,URINE		NEGATIVE	[NEG]	mg/dL
BILIRUBIN	**	**SMALL**	[NEG]	
KETONES	**	**>=80**	[NEG]	mg/dL
SPECIFIC GRAVITY	**H**	**1.025**	[1.005-1.020]	
BLOOD	**	**SMALL**	[NEG]	
PH		5.0	[5.0-7.5]	
TOTAL PROTEIN	**	**30**	[NEG]	mg/dL
UROBILINOGEN		0.2	[0.2-1.0]	mg/dL
NITRATES		NEGATIVE	[NEG]	
LEUKOCYTES		NEGATIVE	[NEG]	
URINE WBC'S		5-10	[0-5]	#/HPF
URINE RBC'S		2-5	[0-3]	#/HPF
URINE EPITH CELLS		10-20	[1-3]	#/HPF
BACTERIA	**	**SLIGHT**	[NONE]	
MICROSCOPIC COMMENTS		FLOOR NOTIFIED RESULTS AVAILABLE TO AT		
URINE SOURCE		VOIDED		
ICTOTEST		NEGATIVE	[NEG]	
URINE REDUCING SUBS			[NEG]	%
MUCUS	**	**SLIGHT**	[NONE]	

COLL: 11/13/1998 11:47 REC: 11/13/1998 11:48 PHYS:

COMPREHENSIVE METABOLIC PA STAT

GLUCOSE		106	[70-110]	mg/dL
BLOOD UREA NITROGEN		14	[6-22]	mg/dL
CREATININE		1.1	[0.5-1.3]	mg/dL
SODIUM	**L**	**132**	[136-145]	mmol/L
POTASSIUM		4.6	[3.5-5.0]	mmol/L
CHLORIDE		102	[101-111]	mmol/L

MED RECORDS #: Patient Name:
ACCOUNT #: LOC: ROOM: DOB:
PHYSICIAN: AGE46Y SEX: F

000007

Discharge Date: 11/19/1998

[redacted]

13 NOV 98 11:55:41

[redacted]

000000

ECG REQUEST BY [redacted]
ATR. RATE 104
VENTR. RATE 104
INTERVALS: P-R 0.16
QRS 0.08 QTc 0.36
AXIS NAD
RHYTHM [redacted]
INTERPRETED BY [redacted]

Sinus tachycardia
Poor r-wave progression $V_1 - V_3$

[redacted]

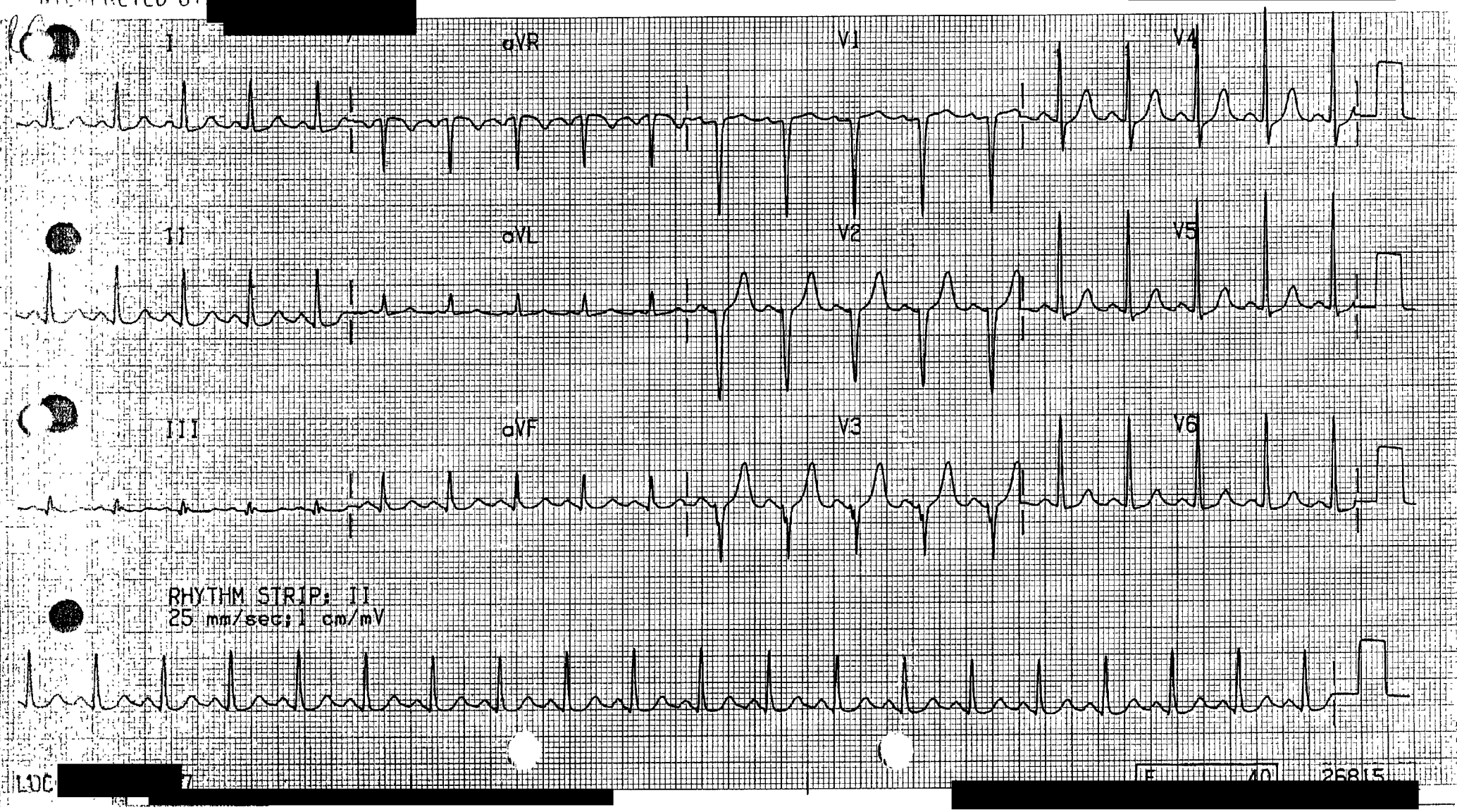

LOC [redacted]

[redacted]

[redacted]

Radiology Department
RADIOLOGY REPORT

PATIENT NAME: [redacted]
ACCT#:
PT AGE: SEX: F
ORD PHYSICIAN: MD
REF PHYSICIAN: MD
ATT PHYSICIAN: MD

ORDER#: [redacted]
MR#:
DOB:
ROOM#:
ADMDATE: 11/13/98
DISDATE:
PT TYPE: [redacted]

EXAM: CHEST 2 VIEW
X-RAY#: [redacted]

EXAMDATE: 11/13/98

CLINICAL INDICATIONS: DOS 11-13-98 PAT ADMISSION -

CHEST, PA AND LATERAL VIEWS: Lung fields are clear. Cardiac silhouette is normal in size. Calcified granuloma is noted in the right middle lobe.

IMPRESSION: No acute lung process.

[redacted] MD

^1
^2

/: [redacted] \: [redacted] DD: 11/13/98 DT: 11/14/98 [redacted]
ID: [redacted]

cc: [redacted]
>

[redacted]

[redacted]

Radiology Department
CT SCAN REPORT

PATIENT NAME: [redacted]
ACCT#:
PT AGE:
ORD PHYSICIAN: [redacted] MD
REF PHYSICIAN: [redacted] MD
ATT PHYSICIAN: [redacted] MD

ORDER#: [redacted]
MR#:
DOB:
ROOM#:
ADMDATE: 11/13/98
DISDATE:
PT TYPE: [redacted]

EXAM: CHEST CT W CONTRAST
EXAMDATE: 11/16/98
X-RAY#: [redacted]

CLINICAL INDICATIONS: DOS [redacted] R/O MASS - DOS-DATE-REASON (DATE RANGE FOR FUTURE CXR'S-INDICATE IF AM REQUEST)

CT OF THE CHEST WITH CONTRAST: The study was done with intravenous contrast material and correlated with a chest film examination of 11/13/98.

The lungs and pleural spaces appear unremarkable. The mediastinum appears normal. There is no evidence of any vascular or aortic abnormality. The scans through the upper abdomen appear normal.

IMPRESSION: Chest appearing normal by CT.

[redacted] MD

^1
^2

/: [redacted] \: [redacted] DD: 11/16/98 DT: 11/16/98 [redacted]
ID: [redacted]

cc: [redacted]
>

[redacted]

[redacted]

Radiology Department
MRI REPORT

PATIENT NAME: [redacted] ORDER#: [redacted]
ACCT#: MR#:
PT AGE: 46Y SEX: F DOB:
ORD PHYSICIAN: ROOM#:
REF PHYSICIAN: MD ADMDATE: 11/13/98
ATT PHYSICIAN: MD DISDATE:
PT TYPE: [redacted]

EXAM: MRI BRAIN & STEM EXAMDATE: 11/13/98
X-RAY#: [redacted]

CLINICAL INDICATIONS: - DOUBLE VISION, ELEVATED BP, FEVER, DIPLOPIA

MRI OF THE BRAIN: Multiplanar T1 and T2 weighted images of the brain as well as post-Gadolinium T1 weighted images were done. There is no intra or extra-axial fluid accumulation or mass effect. Ventricles are normal in size. The post-Gadolinium images show no evidence of an enhancing lesion. No evidence of a demyelinating disease process.

IMPRESSION: Normal MRI of the brain.

[redacted] MD

^1
^2

/: [redacted] \: [redacted] DD: 11/13/98 DT: 11/13/98 [redacted]
ID: [redacted]

cc: [redacted] MD [redacted]
[redacted] MD [redacted]
>

[redacted]

[redacted]

[redacted]

Radiology Department
CT SCAN REPORT

PATIENT NAME: [redacted] ORDER#: [redacted]
ACCT#: MR#:
PT AGE: 46Y SEX: F DOB:
ORD PHYSICIAN: MD ROOM#:
REF PHYSICIAN: MD ADMDATE: 11/13/98
ATT PHYSICIAN: MD DISDATE:
PT TYPE: [redacted]

EXAM: ABD SCAN W&W/O CONTRAST EXAMDATE: 11/16/98
X-RAY#: [redacted]

CLINICAL INDICATIONS: DOS 11698 R/O MASS - DOS-DATE-REASON (DATE RANGE FOR FUTURE CXR'S-INDICATE IF AM REQUEST)

CT OF THE ABDOMEN: The study was done with oral and intravenous contrast material. The liver, gallbladder, pancreas and spleen and kidneys appear normal. There is no evidence of an adrenal tumor. The kidneys bilaterally show even and prompt opacification and are both normal in size and contour. The bowel structures appear normal.

IMPRESSION: Abdomen appearing normal by CT.

[redacted]
[redacted] MD

^1
^2

/: [redacted] \: [redacted] DD: 11/16/98 DT: 11/16/98 [redacted]
ID: [redacted]

cc: [redacted]
>

[redacted]

[redacted]

Radiology Department
RADIOLOGY REPORT

PATIENT NAME:	[redacted]	ORDER#:	[redacted]
ACCT#:		MR#:	
PT AGE:	46Y SEX: F	DOB:	
ORD PHYSICIAN:	[redacted] MD	ROOM#:	
REF PHYSICIAN:	MD	ADMDATE:	11/13/98
ATT PHYSICIAN:	MD	DISDATE:	
		PT TYPE:	I

EXAM: IVP EXAMDATE: 11/14/98
X-RAY#: [redacted]

CLINICAL INDICATIONS: DOS [redacted] HTN PLEASE DO HYPERTENSIVE IVP - DOS-DATE-REASON (DATE RANGE FOR FUTURE CXR'S-INDICATE IF AM REQUEST)

IVP: Scout tomograms of the kidneys show no evidence of renal calcification. Following the administration of 100 cc's of Optiray, radiographs were obtained at 1, 3 and 5 minute intervals. There is no asymmetry in the nephrogram at the 1st and 3rd minutes. There is a significant amount of gas in the colon, which is superimposed over the renal parenchyma.

The pyelocalyceal and ureteral systems, as well as the urinary bladder are unremarkable.

IMPRESSION: The nephrographic phase shows no asymmetry between the two kidneys to suggest a severe renal artery stenosis. The remainder of the examination is unremarkable. If clinically warranted a Captopril renal scan should be considered.

[redacted] MD

^1
^2

/: [redacted] \: [redacted] DD: 11/14/98 D[redacted]14/98 [redacted]
ID: [redacted]

cc: [redacted], MD [redacted]
MD
>

[redacted]

Radiology Department
RADIOLOGY REPORT

PATIENT NAME: [redacted]
ACCT#:
PT AGE: F
ORD PHYSICIAN: MD
REF PHYSICIAN: MD
ATT PHYSICIAN: MD

ORDER#: [redacted]
MR#:
DOB:
ROOM#:
ADMDATE: 11/13/98
DISDATE:
PT TYPE: I

EXAM: N CAPTOPRIL RENAL SCAN
EXAMDATE: 11/17/98
X-RAY#: [redacted]

CLINICAL INDICATIONS: DOS [redacted] R/O RAS -

APTOPRIL RENAL SCAN: Radiotracer: Tc99 MAG3 10mCi intravenously

The patient was given an oral dose of 50 mg. of Captopril approximately 1 hour and 15 minutes prior to radiotracer injection.

Initial blood flow images appear unremarkable.

The first dynamic image demonstrates normal appearing renal contours and relatively symmetric renal radiotracer accumulation. The differential renal function is calculated at 54% left and 46% right.

Subsequent images demonstrate the timely wash-out of radiotracer from both kidneys.

IMPRESSION: Normal renal Captopril scan. There is no evidence of renovascular hypertension. [redacted]

^1
^2

/: [redacted] \: [redacted] DD: 11/17/98 DT: 11/17/98 [redacted]
ID [redacted]

cc: [redacted]

> [redacted]

[redacted]

ECHOCARDIOGRAM

PATIENT: [redacted] ACCT#: [redacted] MR#: [redacted]

ATTENDING: [redacted] MD DOB: [redacted] ROOM#: [redacted]

READING PHYSICIAN: [redacted] MD

DATE PERFORMED: 11/16/98

INDICATIONS: Patient with hypertension, evaluate for left ventricular hypertrophy and structural heart disease.

TAPE:

DIMENSIONS	ACTUAL	NORMAL	DIMENSIONS	ACTUAL	NORMAL
LVID (ed)		3.5-5.7 cm	RVID (ed)		9.0-2.5 cm
LVID (es)		2.0-4.0 cm	MV slope		
IVS (ed)		0.6-1.0 cm	Aortic root		2.0-4.0 cm
IVS (es)		0.8-1.7 cm	Left atrium		1.9-4.0 cm
LVPW (ed)		0.6-1.1 cm	Eject.Fract.		53-77%
LVPW (es)		0.9-1.4 cm			
Short Fract		24-40%			

INTERPRETATION:

SUMMARY OF RESULTS:

1. This is a technically adequate 2-D, M-mode and Doppler study.
2. Left ventricular size is normal.
3. The LV wall thickness is upper limits of normal; however, there is no definite left ventricular hypertrophy.
4. Right ventricular size is normal.
5. The mitral, tricuspid and aortic valves are structurally normal. There is trivial MR and trivial TR.
6. Using the tricuspid jet velocity, the estimated PA pressure is 25 mmHg which is within normal limits.
7. There were no effusions, masses or thrombi seen.

[redacted]

PATIENT: [redacted]
MR#: [redacted] ACCT#: [redacted]

IMPRESSION: This is a technically adequate echocardiogram demonstrating normal [redacted]ular function.

[redacted] MD

\: [redacted] /: [redacted] DD: 11/17/98 JOB: [redacted]
ID: [redacted] DT: 11/17/98 [redacted]

cc: [redacted]

> [redacted]