Food and Drug Administration
Center for Food Safety and Applied Nutrition
Office of Special Nutritionals

ARMS#

12888

6 - MD NOTES

PROGRESS NOTES

DATE/TIME	NOTES TO BE SIGNED BY PHYSICIAN
12/25/97	- fine yesterday. No Sy PMH -
	- Sees Dr [redacted] usually. awakened
	this AM - 2:00 AM - with Being in (R) Eye -
	Got up + went to the Bathroom. Noted numbness
	in left side - of body + mild weakness in
	the left side. Speech at that time - was
	OK - Wit Now Slurred Speech. Taken to [redacted]
	[redacted] + still was C/O numbness - Speech
	went "in + out" Having a problem with Left
	Arm + left leg.
	PMH Surgeries - 0 Dy. Fx leg -
	Med - 0.
	Meds 0
	Allgs 0
	Tobacco - 0
	Alcohol Occas
	61 P1001 - On No BC. SMP - 3 wks ago
	FH - CVA - moms side - Mom Had angioplasty
	GFhad CVA - Cousin Bells palsy Uncle with
	CVA Uncle + MI.
	SH - Teaches Kindergarten - [redacted] district.
	(ROS) -
	- heartrick - H10 Migraines - with flashing
	lights. No H10 weakness with Migraine before
	- Lg CV - No C/O SOB or chest pain
	Does Some Exercise
	- SI - Sy
	SU - Sy
	MS - No joint pain No past H10 episodes
	of numbness a tingly (over) [redacted]

[redacted]

PATIENT INFORMATION

[redacted]

PROGRESS NOTES

PROGRESS NOTES

DATE/TIME	NOTES TO BE SIGNED BY PHYSICIAN
12/25/97,	VS B/P = 150/85 – P=90 R=76 – Afebrile
	Heart pupils Pink Eome/fundi flat
	lenty
	Neck supple – No JVD carotids Equal –
	No bruits
	Lg clear
	Ht Rx – Short Sp tube (M) at [redacted] – No
	radiation
	Hd Soft No organ No masses or tenders
	Ext (+) pulses – No edema
	CNS – ++ marked dysarthria
	(L) Sided nasolabial fold flattening
	(L) Upper extremity 0-1/5 c̄ flaccidity
	(L) Lower Extremity → ↓ sensation
	(L) Leg ↓ reflexes (L) Side from
	(N) Side
	A= Soft sided weakness –
	R/O CVA
	R/O MS –
	R/O ? complicated migraine ([redacted])
	P= Admit to Unit
	monitor
	neuro consults

[redacted]

[redacted]

PATIENT INFORMATION

[redacted]

PROGRESS NOTES

000003

[redacted]

PROGRESS NOTES

DATE/TIME	NOTES TO BE SIGNED BY PHYSICIAN
12/25/97	PM Clinically improved Neuro
	OS OK
	hearing
	[illegible]
	[illegible]
	CNS → [illegible]
	improved strength (L) UE
	[redacted]
12/26/97 1030	IM
	still = (L) side weakness but - sl better than yesterday. HA. Having echo now
	135/80 98 20 98'
	alert, NAD
	power 4 ext
	MRI to be done
	await [redacted] F/U
	[redacted]
12/26/97 1530	Neurology
	Pt is getting stronger. She has mild bifrontal HA
	T=98.1 BP=147/82 P=95 R=20
	Alert, mild dysarthria, continues to have
	↓ light touch on (L) face + body, strength in
	LUE is Gr 4 prox and Gr 2 distal, strength in
	LLE is Gr 1 distal and Gr -4 prox
	MRI of Head shows (R) Pontine Infarct
	MRA looks good to me ESR=2 Urine Tox = Neg
	Transfer to [redacted] Continue ASA Start PT, OT and Speech Therapy

[redacted]

PATIENT INFORMATION

[redacted]

PROGRESS NOTES

PROGRESS NOTES

DATE/TIME	NOTES TO BE SIGNED BY PHYSICIAN
12/27/97 1055	Pulm / Im
	appreciate [redacted] help & advice
	pt feels better, still numb (L) side, weakness
	(L) leg > (L) arm. better grip
	133/82 60 98° 20
	alert NAD
	ENT - anicteric
	Lung - clear
	CR. reg
	Abd - NT (+)BS
	Ext - ~~ec~~ CE
	CNS - sl dysarthria, (L)LE 4/5 LUE 4/5
	IMP pontine infarct
	Plan OT/PT/ST
	[redacted] eval
	can't get out of bed -> not really fashioned
	[redacted]
12/27/97	Speech Pathology Note: Speech Evaluation Completed
	Pt. presents c̄ mild cognitive deficit & mild dysarthria
	Recommend speech therapy 3-5 x week. If you concur, please
	order. Thank you for this referral.
	[redacted]

[redacted]

PATIENT INFORMATION

[redacted]

PROGRESS NOTES

PROGRESS NOTES

DATE/TIME	NOTES TO BE SIGNED BY PHYSICIAN
12/27/97 1610	Neurology Pt continues to feel better, Walked with [redacted] today T=98.8 BP=133/82 P=60 R=20 Mild dysarthria, strength in LUE is Gr+4 prox and Gr+3 distal, strength in LLE is Gr-4 prox and Gr-2 distal Carotid Ultrasound = normal ANA=1:40 Advance to Regular diet Continue ASA [redacted]
12/28/97 1600	Neurology No new problems, Tolerating regular diet well T=97.0 BP=132/90 P=79 R=20 Neuro exam is unchanged Continue ASA DC IV [redacted]
12/29/97 0915	Neurology Status quo T=98.9 BP=120/76 P=79 R=20 Dysarthria is almost gone, (L) hemiparesis and hypesthesia are unchanged Continue ASA [redacted]

[redacted]

PATIENT [redacted]

[redacted]

PROGRESS NOTES

PROGRESS NOTES

DATE/TIME	NOTES TO BE SIGNED BY PHYSICIAN
12/29/97 0935	Pt [illegible]
	feels well but still can't get out of bed by herself.
	tries c̄ walker.
	d/w Dr [redacted] - stroke rehab is appropriate
	S - (L) leg weak, (L) arm improved, speech improved
	120/76 79 20 98"
	alert, NAD 0+3
	Lung - clear
	c dk reg
	Ab - [illegible]
	Ext - [illegible]
	IMP pontine stroke
	(L) hemiparesis
	Plan stroke rehab [redacted] eval & transfer
	[redacted]
12-29-97 1200	[redacted] Rehab eval: 41 Y.O. CVA c̄ Lt hemiparesis requires min A c̄ mobility + ADLs. Would be appropriate for acute rehab pending authorization. Discussed c̄ Dr [redacted] and will try to obtain authorization. [redacted]

[redacted]

PATIENT INFORMATION

[redacted]

PROGRESS NOTES

[redacted]

[redacted]

[redacted]

DATE	HOUR	Progress notes should include date and time of examination, state of positive findings noted previously, new signs and symptoms, complications, changes of impression or diagnosis, record and results of treatment given, and the signature of the physician making observations.
12/29/97		Rehab Consult
		Seen and examined, full
		consult dictation.
		(1) Problems (1) Brainstem CVA c̄ ↓mob/ADLs
		(2) Dysarthria
		Recommendation/discussion: Very active PTA,
		lives (I) c̄ daughter, employed as
		school teacher. Has had some neuro
		improvement. Will benefit from
		short acute rehab stay for following:
		(1) P.T. gait, transfer, balance, may need
		AF [redacted]
		(2) O.T. ADLs, adaptive equipment
		(3) Clarify c̄ [redacted] was on ASA, not
		transferred over on ASA.
		Goals SV all mob/ADLs
		[redacted] 10 days
		Thanks
		[redacted] MD

[redacted]

PROGRESS NOTES

[redacted]

[redacted]

DATE	HOUR	Progress notes should include date and time of examination, state of positive findings noted previously, new signs a symptoms, complications, changes of impression or diagnosis, record and results of treatment given, and the signature of physician making observations.
12-31-97		Rem
		Pt Alert & Cooperative Education Given
		AFVSP
		Nerro Hemiparesis c Pattern Mvt LLE
		? Fall - Isolated Mvt LLE
		L2HA c Gait ~ 15 ft
		Cl
		- Curtis Reeves Pulmon
		[redacted]
1-1-98		Rem
		Pt c Cooperative. He Noticed Emotional Lability
		AFVSP
		L2HA c Gait ~ 60 ft
		CS/Mi Acct c ADL
		Cl
		- Curtis Reeves Pulmon
		[redacted]

[redacted]

PROGRESS NOTES

[redacted]

[redacted]

DATE	HOUR	Progress notes should include date and time of examination, state of positive findings noted previously, new signs ar symptoms, complications, changes of impression or diagnosis, record and results of treatment given, and the signature of th physician making observations.
1-2-98		Rehab
	12:30	Pt 5 New Complaints.
		Nurse
		LCHA c̄ Gait & Vocal Loss.
		Nurse Dr Stirling to Show Isolated Mut
		Disease
		CVA - Cerebral
		- Cerebral Rehab [redacted]
1-3-98		Rehab
		Pt 5 New Complaints
		Nurse
		Gait c̄ Cane Still @ [redacted] c̄ ↑
		Foot Pulsant
		Still c̄ Yt Isolated DF of Ankle
		CVA
		- Cerebral Rehab Pro[redacted]

000010

[redacted]

PROGRESS NOTES

[redacted]

[redacted]

[redacted]

DATE	HOUR	Progress notes should include date and time of examination, state of positive findings noted previously, new signs a symptoms, complications, changes of impression or diagnosis, record and results of treatment given, and the signature of t physician making observations.
1/5/98		Rehab
		Pt feels numbness RUE ~ 2-3 min episodes &
		slurred speech occ. Neurologist fu today &
		possible LP.
		Afsp
		RUE subt & LT during episode [redacted] dist to
		elbow.
		Family Trang / Conference Tom
		Fu Neurology today re: Transient neuro Sx
		Cuff Bed Pressure 1 Am
		[redacted]
1/5/98		Neurolo[redacted]
1915		Pt had 8 episodes of (L) eye pain, slurred
		speech and (R) hand numbness today
		T=97.9 BP=103/62 P=83 R=20
		Alert, oriented x3, slight dysarthria,
		& Light touch on (L) V2 and LUE + LLE
		Strength in LUE is Gr +4 prox and Gr -4 distal
		Strength in LLE is Gr +4 prox and Gr +2 distal
		A: TIAs vs Complex Migraines
		P: LP to R/O subacute meningitis Start Hepsin / Coumad and Sinderal

000011

[redacted]

PROGRESS NOTES

[redacted]

[redacted]

[redacted]

DATE	HOUR	Progress notes should include date and time of examination, state of positive findings noted previously, new signs a symptoms, complications, changes of impression or diagnosis, record and results of treatment given, and the signature of t physician making observations.
1/5/97	1940	LP performed in L3-4 interspace in the sitting position 10cc of clear CSF obtained and sent for Cell Count, Protein, Glucose Pt tolerated procedure well [redacted]
1/6/98	0845	Neurology Pt awoke this AM with more difficult talking and recurrent numbness of (R) hand + forearm Speech is more dysarthric, light touch is normal on (R) side - (+) phalens at (R) wrist, ↓ sensation on (L) side and (L) hemiparesis are unchanged A: 1) Right Pontine Infarct PTT=54.4 Protime=1.2 2) Worse dysarthria and Right UE Numbness - Probably from progression of infarct R/O Myasthenia Gravis + Carpal Tunnel 3) CSF WBC=50 100% Mono Protein=50 Gluc=44 - Probably from previous infarct - R/O chronic meningitis P: MRI of Head Continue Coumadin / Heparin, Inderal MS Panel, CSF Cocci / Cryptotiters, Myasthenia Gravis Panel

000012

[redacted] PROGRESS NOTES [redacted]

[redacted]

[redacted]

[redacted]

DATE	HOUR	Progress notes should include date and time of examination, state of positive findings noted previously, new signs an symptoms, complications, changes of impression or diagnosis, record and results of treatment given, and the signature of th physician making observations.
1-6-98		Rehab
		Team Conference Today
		See Dictation.
		Eggs ~ T wk.
		[redacted] Consent Accounted - Dx w/u
		In Province
		[redacted]
1/7/98		Neurology
0815		Pt has continued to have some numbness of her (R) hand and slurring of her speech
		T=97.2 BP=115/75 P=64 R=20
		Alert, moderate dysarthria, strength in (R) hand is Gr 4 otherwise strength in RUE is full, RLE is full; strength in LUE is Gr +4 prox and Gr -4 distal and LLE is Gr +4 prox and Gr 2 distal (unchanged)
		MRI of Head => less (R) Pontine hyperintensity
		Protime INR = 2.19 PTT = 65.3
		A: Complicated situation - Differential is spread of pontine infarct, CNS vasculitis, subacute meningitis or unusual presentation of MS.
		P: Hold Coumadin + continue Hepain. Cerebral angiogr tomorrow or Friday depending on [redacted] on Ice coagulation

000013

[redacted]

PROGRESS NOTES

[redacted]

[redacted]

DATE	HOUR	Progress notes should include date and time of examination, state of positive findings noted previously, new signs and symptoms, complications, changes of impression or diagnosis, record and results of treatment given, and the signature of the physician making observations.
1-7-98		Rehab
	3:25	Pt calm, slurred speech noise Hand feels numb
		Tx 99' dg vss
		Neuro Rue mild ↓ coord, ↓ LT
		Dysarthria noise
		Dysphagia noise → thick liq
		Gait still good c̄ HHA LICHA ↑
		Disease
		Ap Geva c/o other Patient
		- Contine Hearing Dx w/u per [redacted]
		- Contine Rear Room
		- ✓ Videoswallow Study c̄ thick liquids
		until then
		[redacted]

000014

[redacted]

PROGRESS NOTES

[redacted]

[redacted]

[redacted]

DATE	HOUR	Progress notes should include date and time of examination, state of positive findings noted previously, new signs a symptoms, complications, changes of impression or diagnosis, record and results of treatment given, and the signature of t physician making observations.
1/8/98		Neurology
1320		Pt was ~~staining~~ for a BM and had hypotension and almost fainted this AM.
		No new neuro problems
		T=98.5 BP=118/74 P=67 R=20
		Neuro exam is unchanged
		West Sed Rate=5 Protime INR=3.11 PTT=45.
		DC Inderal
		↑ Heparin
		Reverse Coumadin with Vit K for Cerebral Angio
		[redacted]
1/8/97		Neuropsych — Pt is a 41 yr old [redacted] with recent ~~dx~~ acute (R) CVA. Pt is divorced for 10 yrs & has daughter [redacted] 11 yrs old. Pt's parent are at bedside & supportive. Pt is a school teacher & has Masters dep. in education. She was very active & high functioning prior to hospt. She has no sig psychiatric history but did see psychol. for support during "bitter divorce." She is alert & well oriented with slurred speech but able to express herself fairly well. She is very anxious & apprehensive & has been on Xanax PRN. She was quite tearful [redacted]

000015

[redacted]

PROGRESS NOTES

[redacted]

[redacted]

[redacted]

DATE	HOUR	Progress notes should include date and time of examination, state of positive findings noted previously, new signs a symptoms, complications, changes of impression or diagnosis, record and results of treatment given, and the signature of t physician making observations.
		during session & needed considerable reassurance. She is very concerned with ability to be indep following DC. She reports poor appetite & disturbed sleep & emotional distress. I was able to discuss pt's adjustment issues with pt's parents & daughter. I will begin to see pt for emotional support. DX Adjustment Disorder, anxiety [redacted]
1-8-88		Rehab
		Pt c̄ LH Episode Daily Rm - Better Now - Recurrent
		Neuro S Neuro Eval
		AFSS
		Neuro Dysarthria / Dysphagia Sec ↓ c̄ ↓ Intensity of Speech
		Rec'd no Δ ↓ Fun
		Plan - Dx w/c to p/c other causes
		- Angio Pomp
		- Neuro Eval for Emotional Support
		- Continue Rehab Program
		[redacted]

000016

[redacted]

PROGRESS NOTES

[redacted]

[redacted]

DATE	HOUR	Progress notes should include date and time of examination, state of positive findings noted previously, new signs and symptoms, complications, changes of impression or diagnosis, record and results of treatment given, and the signature of the physician making observations.
1/9/98	0930	Neurology
		Pt feels that her speech is a little better
		T=97.8 BP-104/81 P=62 R=20
		Neuro exam is unchanged
		Protime INR= 2.51 PTT=60.7
		Lymes Disease Titer = Neg FTA= Neg
		Continue Heparin Vit K to reverse Coumadin
		Will plan on Cerebral Angio on Monday
		[redacted]
1-9-98		Rehab
		Pt ≅ non complaints. Still ≅ slurred speech ≅ ↓
		intelligibility.
		PE:
		Neuro: [illegible]
		Dysarthria Mod-Severe
		Dysphagia - US [illegible] / → Pureed / thick liq.
		[illegible] [redacted] [redacted]
		A/ CVA - [illegible] R/O other disease in process
		- Anticoagulation per Neuro
		- ↑ Diet & possible Swallow next week
		- Continue Rehab efforts [redacted]

000017

PROGRESS NOTES

[redacted]

[redacted]

[redacted]

DATE	HOUR	Progress notes should include date and time of examination, state of positive findings noted previously, new signs a symptoms, complications, changes of impression or diagnosis, record and results of treatment given, and the signature of t physician making observations.
1/14/98		Resp
		Sum Spec
		VSS AT CS
		M-S gait VC
		Vocabulary — mild Aphasia thin / thick liquids
		① CVA Lost Rehab
		② Dysphagia on puree c thick
		[redacted]
1/12/98		Neurology
0930		Pt feels that speech and (L) hand strength is improving
		T=97.0 BP=117/78 P=76 R=20
		Alert, speech is less dysarthric, (R) hand and LUE + LLE weakness are unchanged
		Protime INR=1.23 PTT=32.3
		Cerebral Angiogram today

[redacted]

PROGRESS NOTES

000018

[redacted]

[redacted]

[redacted]

DATE	HOUR	Progress notes should include date and time of examination, state of positive findings noted previously, new signs an symptoms, complications, changes of impression or diagnosis, record and results of treatment given, and the signature of th physician making observations.
		POST-ANGIOGRAPHIC FINDINGS
7/12/98		PRE-ANGIOGRAPHIC DIAGNOSIS:
	1130	ADVERSE REACTIONS: PULSES: BEFORE AFTER
		Hematoma Femoral R L R L
		Artery P.T. R L R L
		Other D.P. R L R L
		PULSE RATE: Radial R L R L
		BEFORE AFTER Brachial R L R L
		BP: BEFORE AFTER
		CONTRAST MATERIAL: TYPE VOLUME
		DRUGS: CATHETERS:
		TECHNOLOGISTS: RADIOLOGIST:
		FINDINGS: ? OLD INTIMAL INJURY BASILAR ARTERY
		NO EVIDENCE VASCULITIS

[redacted]

RADIOLOGY PROGRESS NOTES

000019

[redacted]

[redacted]

DATE	HOUR	Progress notes should include date and time of examination, state of positive findings noted previously, new signs and symptoms, complications, changes of impression or diagnosis, record and results of treatment given, and the signature of physician making observations.
1-15-98		Rehab
		Pt c̄ Complaints
		AF-SC
		1 HG c̄ Lat in 30 ft
		Dx Mem Bath & Intellig
		Dx Dysph Still c̄ Thick Liquids
		JCVA
		Dx Lat Underw
		- IVF overnight 2° Cnrst
		- Cont Rehab Pump Ar [redacted]
		- Rehab VS Stud / MTX week
		[redacted]
1/13/98		Neurology
0810		Pt tolerated angiogram well
		T=97.5 BP=103/68 P=66 R=18
		Neuro exam is unchanged
		Sigmoid Angio ⇒ slight irregularity of Basilar artery
		otherwise normal
		Will restart Coumadin
		No Heparin for now

[redacted]

000020

[redacted]

PROGRESS NOTES

[redacted]

[redacted]

DATE	HOUR	Progress notes should include date and time of examination, state of positive findings noted previously, new signs a symptoms, complications, changes of impression or diagnosis, record and results of treatment given, and the signature of t physician making observations.
1-13-98		Rear
		Team Conference Today
		See Dictation
		ECOS 2 days of OK idx. [redacted]
		CS in Mary & ADL c̄ Video Surveillance in Am
		& focus Family Training
		Discussed c̄ [redacted]
1/13/98		Neuropsych - Pt & family seen for followings & emotional support. Speech is somewhat more articulate today & able to express herself verbally. She reports upcoming DC & she is looking forward to returning home. She & family asked many question regarding daughter's adjustment & future expectations. Pt remains labile but very appropriate & motivated to improve independent skills. Will follow as outpt, if possible [redacted]

000021

[redacted]

PROGRESS NOTES

[redacted]

[redacted]

[redacted]

DATE	HOUR	Progress notes should include date and time of examination, state of positive findings noted previously, new signs a symptoms, complications, changes of impression or diagnosis, record and results of treatment given, and the signature of t physician making observations.
1/14/98		Neurology
	0830	No new problems
		T=97.9 BP=102/60 P=76 R=20
		Speech is a little clearer otherwise neuro exam is unchanged
		M.S Panel, MG Panel, Crypto/Cocci titers and Lupus Panel are unremarkable [redacted]
		Protime pending
1/14/98		Rehab
		Dt c̄ new Complaints
		Afrsc BP 100-130/60-90
		Neuro Discretion Stable - 80%-100% Intelligible
		Dysphagia Regular Tol
		Gait c̄ Fnw @ CS & Family Training Emphasis
		Tol
		CVA
		- d/c Hunt Tomorrow
		- Outpoint PT
		- Pt Coumann @ [redacted]

000022

[redacted]

PROGRESS NOTES

[redacted]

[redacted]

DATE	HOUR	Progress notes should include date and time of examination, state of positive findings noted previously, new signs symptoms, complications, changes of impression or diagnosis, record and results of treatment given, and the signature of physician making observations.
1/15/98		Neurology
	1120	No new problems
		T=97.8 BP=103/78 P=70 R=18
		Right hand strength seems better - Gr +4, otherwise
		neuro exam is unchanged
		Protime INR=1.48
		Continue Coumadin
		Pt to be discharged today
		[redacted]

000023

[redacted]

PROGRESS NOTES

[redacted]

[redacted]

DATE	HOUR	Progress notes should include date and time of examination, state of positive findings noted previously, new signs & symptoms, complications, changes of impression or diagnosis, record and results of treatment given, and the signature of physician making observations.

2/5/98

H+P Dictated

41 y.o. RH ♀ c Hx (1) (L) sided weakness 12/25/97 (2) (R) arm weakness + dysarthria 1/5/98 (3) Mild ↑ (L) sided weakness yest. c further ↑ today. Extensive w/u Thus far has not shown etiology.

Exam Mild dysarthria.

(R) arm + leg ~ 4+/5

(L) arm prox 3-4/5 distal 1-2/5

(L) leg 1-3/5.

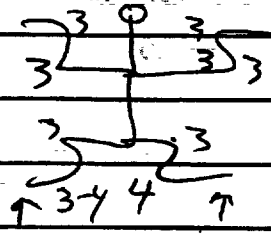

↓ sensation (L) face + leg.

Lab PT = 2.38

Mg = 0.2 !!!

Imp (1) Recurrent strokes - ? etiology

Rec: (1) Add Eiotrin to Coumadin — discussed risks/benefits c pt., father, + mother who want to proceed. They understand risk of ↑ bleeding problem.

(2) Per Dr. [redacted] in AM.

[redacted]

000024

[redacted]

PROGRESS NOTES

[redacted]

[redacted]

DATE	HOUR	Progress notes should include date and time of examination, state of positive findings noted previously, new signs symptoms, complications, changes of impression or diagnosis, record and results of treatment given, and the signature of physician making observations.
2/6/98	-2050	Neurology Above noted, Pt and her parents frustrated about the deterioration T=97.9 BP=119/80 P=68 R=21 Alert, moderate dysarthria, mild (L) facial weakness, ↓ sensation on (L) face, strength in LUE is Gr+2, strength in LLE is Gr+2, strength in RUE + RLE are full, ↓ light touch on (L) side MRI of Head with Gad shows T2 high intensity in (A) > (L) Pons, no enhancement, no mass effect A: New (A) Pontine infact - R/O tumor P: Continue Coumadin + Ecotrin Neurosurgery Consult with Dr [redacted] Serum Homocysteine level Start Therapy - PT, OT, Speech Start Elavil for migraine prophylaxis

000025

[redacted]

PROGRESS NOTES

[redacted]

[redacted]

DATE	HOUR	Progress notes should include date and time of examination, state of positive findings noted previously, new signs and symptoms, complications, changes of impression or diagnosis, record and results of treatment given, and the signature of physician making observations.
2/7/98		Neurology
	1100	No new problems
		T=98.1 BP=115/74 P=68 R=18
		Dysarthria, (L) hemiparesis and (L) hypesthesia are unchanged
		Protime INR=2.19
		Transfer to Regular floor
		Continue Coumadin + Ecotrin [redacted]
2-7-98		Neurosurgery — Will dictate narrative consult day Prob Infarct of brain stem.
		Unlikely tumor
		Recomm — C.T. cerebral angio.
		Thank you
		[redacted]

000026

[redacted]

PROGRESS NOTES

[redacted]

[redacted]

[redacted]

DATE	HOUR	Progress notes should include date and time of examination, state of positive findings noted previously, new signs a symptoms, complications, changes of impression or diagnosis, record and results of treatment given, and the signature of t physician making observations.
2/8/98		Neurology
1315		Dr [redacted] help appreciated
		T=97.2 BP=108/60 P=67 R=18
		Dysarthria and (L) hemiparesis are unchanged
		Protime INR=2.28
		Will not get CT Angio (Cerebral Angio is more sensitive as done in 1/98 - discussed with Dr [redacted])
		Pt wishes to pursue 2ND opinion at [redacted] will check with insurance tomorrow
		Continue Ecotrin + Coumadin [redacted]
2-9-98		REHABILITATION EVALUATION
		SEE [redacted] FOR [redacted]
		THANK YOU FOR THE OPPORTUNITY TO SEE MS. [redacted] A 41 YO ♀ WELL KNOWN TO ME FROM PRIOR ADM. NOW ADM c̄ NEW ONSET (L) HEMIPARESIS. HAD RECOVERED TO (F) FCN ∅ ASSISTIVE DEVICE & GETTING READY FOR RTW. NOW REQUIRE ASSIST c̄ ALL MOBILITY @ PREGNANT LEVEL <10 FT.
		EXAM ALERT/DYSARTHRIC/DYSPHAGIA ([redacted])
		(L) HEMIPARESIS UE ~ 2/5 LE 3-4/5 c̄ ↓↓ FINE MOTOR MVT
		SENSORY OK LT/PCUP.

000027

[redacted]

PROGRESS NOTES

[redacted]

[redacted]

DATE	HOUR	Progress notes should include date and time of examination, state of positive findings noted previously, new signs a symptoms, complications, changes of impression or diagnosis, record and results of treatment given, and the signature of physician making observations.
2/9/98		Rehab - Continued
		Assess 1) Gr Acute CVA c (R) Hemiparesis
		2) Dysarthria
		3) Dysphagia
		4) Decline Mobility & ADL.
		Recommend.
		1) Excellent Acute Rehab Unit Candidate for BID PT/OT/SP c Goal of CS & Household Distances c Renal Swallowing c Dysphagia Program.
		2) Can Accept 1. Transfer when Medically Cleared by Dr. [redacted] Thank You [redacted]
2/9/98 1840		Neurology
		Pt walked with assistance today. Dr [redacted] help appreciated. [redacted] Rehab Unit will probably accept pt in transfer tomorrow and 2nd neuro opinion will be obtained there.
		T=97.6 BP=116/78 P=67 R=20
		Speech seems a little less dysarthric, strength in LUE is Gr 2 distal and Gr 3 prox, strength in LLE is Gr-4 prox and Gr 2 distal
		Continue Coumadin and ASA Probable transfer to [redacted] tomorrow

000028

[redacted]

PROGRESS NOTES

[redacted]

[redacted]

DATE HOUR	Progress notes should include date and time of examination, state of positive findings noted previously, new signs symptoms, complications, changes of impression or diagnosis, record and results of treatment given, and the signature of physician making observations.
2/10/98	Neurology
- 0810	No new problems
	T=98.8 BP: 128/76 P:78 R:18
	Neuro exam is unchanged
	Hopefully transfer to [redacted] Rehab today
	Continue Coumadin + ASA [redacted]

000029

[redacted]

PROGRESS NOTES

PROGRESS NOTES

DATE	NOTE PROGRESS OF CASE, COMPLICATIONS, CONSULTATIONS, CHANGE IN DIAGNOSIS, CONDITION ON DISCHARGE, INSTRUCTIONS TO PATIENT

2/10/98

Rehab

41yo ♀ Kindergarten school teacher is admitted for Rehab of pontine Stroke with Ⓛ hemiparesis <UE > LLE 2/5/98 after transient visual loss 2/4/98 and 2 prior ischemic episodes c pontine infarct on MRI

Initial event Ⓡ hemiparesis 12/25, then Ⓡ hemiparesis 1/5/98 each time c transient eye Sx

Hx of migraine but none x 2 yrs

much social stress c holiday + family custody conflict re 11yo daughter

W/u MRI → pontine infarct

angiogram 4 vessel — ? irregularity of basilar artery

Neg Anticardiolipin Abs -

ANA low titer 1:40

Neg RF / RPR Duplex of carotid Neg

Pt Rx c coumadin 1/98 + had been on this when 2/5 Stroke occurred —

& cannot find record of 2D echo

Exam

No arrhythmia

No rubs

[redacted]

[redacted]

000030

[redacted]

PROGRESS NOTES

DATE	NOTE PROGRESS OF CASE, COMPLICATIONS, CONSULTATIONS, CHANGE IN DIAGNOSIS, CONDITION ON DISCHARGE, INSTRUCTIONS TO PATIENT

HEENT
nl fundi
tongue coated
chest nl breath sounds
COL Reg No chch
abd nl
gu pelvic/rectal
extremities
Neuro
dysarthria, nl language
reflexes brisk
Strength poor LUE, Fair LUE
Sensation intact

A Pontine stroke
- ② hemiparesis
- Dysarthria

Anticoagulation
? abn. basilar artery

P> ① 2 Decho
② family to bring in outside films
③ OT/PT/Speech
④ Coumadin + ASA
⑤ Neuro opinion
⑥ will recheck ANA which was
min low titer 1:40

[redacted]

[redacted]

PROGRESS NOTES

[redacted]

PROGRESS NOTES

DATE	NOTE PROGRESS OF CASE, COMPLICATIONS, CONSULTATIONS, CHANGE IN DIAGNOSIS, CONDITION ON DISCHARGE, INSTRUCTIONS TO PATIENT

Neuro Consult

2/11/98

41 yr old female.

PMH - Migrant Ø Except CVA.
Med. Coumadin.
SH. Ø Cig Ø Clot

Pt who is known to have some unrelated personal problem related to her divorce status on 12/25/97 woke up & some burning sensation in the (R) Eye & (L) side weakness & difficulty walking CAT head was normal but MRI showed (R) brain stem ic. pontine infarct For this pt. had rehab & [redacted] & mild improvement of motor power in (L) side.
On 01/05/98 900 - pt on walking up again noted burning (L) Eye & (R) sided weakness tingling & dysarthria & Ø change of symptom on (L) side Ø comprehension problem
f/u. MRI ⊖ Angio ⊖
LP was done 50 WBC 100% mono protein 50 Glucose 50
an extensive vasculitis, hypercoagulation w/u was ⊖

On 2/4/98 pt had another episode of vision problem which lasted 2 hr. & ~~today~~ ~~pt~~ 2/5/98 pt woke up & ↑ weakness in (L) side Ø vision problem for which pt admitted. Since then pt on Coumadin.
As per H/P this is the 3rd event when pt had some neurologic event & all the 3 just prior to menstrual cycle period. ? link.

MRI - (12/26/97) ↑ signal density pons R>L 3mm ↑ signal (L) thalamus + periventricular white matter changes
Angio - normal (12/26/97)
Doppler - normal

[redacted]

[redacted]

PROGRESS NOTES

[redacted]

[redacted]

PROGRESS NOTES

DATE	NOTE PROGRESS OF CASE, COMPLICATIONS, CONSULTATIONS, CHANGE IN DIAGNOSIS, CONDITION ON DISCHARGE, INSTRUCTIONS TO PATIENT

Neuro Exam. AOx4 Clear sensorium ø memory defect
Stimulus speech MM 27/30
Pupil b/L sym ⊕ light ⊕ Acc. EOMI ø nystagmus
ø diplopia disc sharp.
Normal facial tone b/L ↓ sensation ⓛ side $V_1V_2V_3$.
⊕ gag tongue midline. palate elevation symetrical
ø neuro defect. St. mastoid & shoulder shrug ⓞ

		(R)	(L)	
Power	UE	~~[illegible]~~ 5-/5	3/5.	
	LE	~~[illegible]~~ 5/5	3+/5 (prox)	2/5 (distal)

Sensory normal.

Cerebral normal

Gait unsteady 2° weak

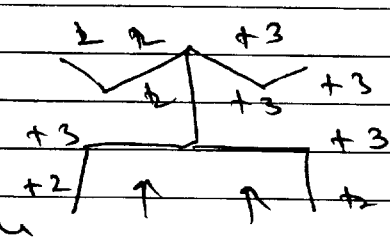

Imp. 41 yr old ♀ h/o 3 episode of neurologic defect
Ass. Ischemic stroke. ? Vascular
Pla. Repeat ANA & Lupus panel. ESR
f/u.

Seen examination [redacted]
See Staff [redacted]

[redacted]

Addressograph

PROGRESS NOTES

[redacted]

PROGRESS NOTES

DATE	NOTE PROGRESS OF CASE, COMPLICATIONS, CONSULTATIONS, CHANGE IN DIAGNOSIS, CONDITION ON DISCHARGE, INSTRUCTIONS TO PATIENT

Memo Staff
See Resident note for details

Unfortunate 41 yo c̄ 3 episodes of prob posterior circulation stroke over 6 weeks. Each episode 2 3D prior to menses + involving visual/eye sx. There is a prior hx of MIGRATINE. MRI c̄ partial infact

Exam - Dysarthria, (L) HP, (R) motor tr weakness
DTR'S BRISK ATTOS

Imp: She has had an extensive w/v at [redacted]. Clearly she has suspicious sx for post circulation vascular abnormality/spasm.
Will re-eval Angiogram c̄ memo rad when family obtains films, would repeat ANA + LUPUS panel. Will ask stroke service to eval. ? consider use of carbonic anhydrase inhibitor given hx of per menstrual events.

[redacted]

2/11/98

Return

Appreciate neurology evaluation

Angiogram being brought in by family for review by our radiology department

Pt's deficit is stable c̄ dysarthria

[redacted]

Addressograph

[redacted]

PROGRESS NOTES

[redacted]

000034

[redacted]

PROGRESS NOTES

DATE	NOTE PROGRESS OF CASE, COMPLICATIONS, CONSULTATIONS, CHANGE IN DIAGNOSIS, CONDITION ON DISCHARGE, INSTRUCTIONS TO PATIENT
	and (c) weakness
	[redacted]
2/12	Neurology Attending
	Pt examined and arteriogram reviewed.
	Please see Dr. [redacted] notes in detail.
	Pt is 41 yr old ♀ with 3 strokes, ischemic, pontine region, beginning 12/97. Hx of common migraine but no obvious risk factors otherwise. LP reportedly showed 50 WBCs (monos). Arteriogram shows multi-focal narrowing of basilar artery. Note: most of studies (MR & Angio) not available at this time. Hx of ingestion of "herbal diet pills".
	Impression: Isolated incranial angiitis
	Plan: 1) D/C Warfarin & ASA
	2) Repeat LP when PT normalized
	3) Info: Factor V Leyden, cardiolipin antibodies, HIV, skin tests, other coagulation studies when off warfarin
	4) Review composition of "diet pills" [redacted]

[redacted]

PROGRESS NOTES

Addressograph

[redacted]

[redacted]

DATE | NOTE PROGRESS OF CASE, COMPLICATIONS, CONSULTATIONS, CHANGE IN DIAGNOSIS, CONDITION ON DISCHARGE, INSTRUCTIONS TO PATIENT

Neurology - Cerebrovascular Clinic

12/17/96
16:50

Pt. is a 41-y.o. RHWF c 10+ years of neurological illness, c/c/w the onset in the setting of superficial learning in the R eye c retinal vessel changes, followed by (1) F/N/L weakness + dysarthria, (2) diplopia, vertigo, nausea, vomiting, NKDA, [redacted] reported (3) generalized pounding HA, right > left, (4) R side, apparent inferior quadrant field cut, (5) R sided sensory changes. Had c LOC, recovery, with a 911/96 in each case by husband, (6) R eye c visual changes, followed by worsening dysarthria + RUE weakness + clumsiness which resolved completely. Pt. c/o R eye pain + loss of vision [R eye monocular vision (B)], c/w possible intermittent optic nerve involvement. Also described (7) R sided, throbbing HA, followed by significant (8) R sided weakness, again c/o sensory, motor changes. This episode occurred on 11/96 (approx. 1 wk PTA). Pt. had been in the hospital for 10 days, with extensive w/u for underlying CVD or inflammatory process. CSF c WBC 7, RBC 0, protein 50 mg/dL (N: 15-45), glucose 60 mg/dL (N: 40-70). No micro. available re: cultures. Lupus panel (-), SS-A + SS-B not done. Hem w/u c/w mild microcytic anemia, c MCV + HCT. Rheumatoid factor (-). ANA (-). Pt. had TTE - results not currently available from record. CSF electrophoresis c/w oligoclonal bands (+).

Pt. has reported h/o migraines 1991 & 1992, for which time all been midline occipital HA's, at times throbbing, with nausea (+) N/V, (-) photophobia. Still at time for "regular HA's", however, infrequent, helped by ASA. Pt's last period was 12/97 - 01/97, has occurred just prior to onset of menstruation.

PMH: As above. (-) h/o P.E., DVT, gestational diabetes.

MEDS: Herbal diet pill 11-12/97

Remote hx. only (5 yrs.) of O.C.

FH: Cerebrovascular disease on mother's side age 60's + beyond.

(+) Migraines.

ROS: (-) weight loss, F&O's, chest pain, peripheral claudication, visual A's, atrial arrest incidences, skin lesions, & c bowel habits.

[redacted] Addressograph [redacted]

PROGRESS NOTES

[redacted]

000036

PROGRESS NOTES

DATE	NOTE PROGRESS OF CASE, COMPLICATIONS, CONSULTATIONS, CHANGE IN DIAGNOSIS, CONDITION ON DISCHARGE, INSTRUCTIONS TO PATIENT

[redacted]

PROGRESS NOTES

DATE	NOTE PROGRESS OF CASE, COMPLICATIONS, CONSULTATIONS, CHANGE IN DIAGNOSIS, CONDITION ON DISCHARGE, INSTRUCTIONS TO PATIENT
2/12/98	
	Rehab
	Appreciate neurology eval
	Pt's deficit stable
	2 Decho No intracardia lesion
	Will discuss re [redacted]
	[redacted]
[redacted]	

[redacted]

[redacted]

PROGRESS NOTES

[redacted]

PROGRESS NOTES

DATE	NOTE PROGRESS OF CASE, COMPLICATIONS, CONSULTATIONS, CHANGE IN DIAGNOSIS, CONDITION ON DISCHARGE, INSTRUCTIONS TO PATIENT

Neurology f/u.

2/13/98.

Pt seen & examined today.

✓ Angiogram c̄ Dr [redacted]. Basilar atherosclerosis. mild
✓ MRI shows ↑↑ density b/L pons R>L
as compared to previous studies

At present above films c̄ Radiology dept USC

On examining the pt.
Pt burst in tears & crying.
States she is extremely depressed about
the whole situation.
✓ Recommend psych input.
further recommendation as by stroke team

[redacted]

2/13/98 orthotic
pt fitted c̄ (L) AFO. to be worn with shoe while ambulation
Please check skin for excess pressure area

[redacted]

[redacted]

PROGRESS NOTES

Addressograph

[redacted]

000039

[redacted]

PROGRESS NOTES

DATE	NOTE PROGRESS OF CASE, COMPLICATIONS, CONSULTATIONS, CHANGE IN DIAGNOSIS, CONDITION ON DISCHARGE, INSTRUCTIONS TO PATIENT

2/13/98

Rehab

Pontine stroke

Dysarthria + weakness stable

Pt anxious about recurrence of stroke b/o her experience

INR was 1.89 — Anticardiolipin Abs neg

Imp s/p Pontine infarct
CSF mononuclear cell pleocytosis
Some emotional lability

Pg ① recheck protime in AM - if <2 INR will need additional coumadin + pharmacy to adjust

② Cocci comp fix, HIV Ab, fasting lipids homocysteine levels in AM. Will check re protein S+C levels

③ Stu Ppd

④ Therapies + social support. If not improving affect as she improves to have psychiatry eval. Currently on Elavil Hs -

[redacted]

Addressograph

[redacted]

PROGRESS NOTES

000040

[redacted]

PROGRESS NOTES

DATE	NOTE PROGRESS OF CASE, COMPLICATIONS, CONSULTATIONS, CHANGE IN DIAGNOSIS, CONDITION ON DISCHARGE, INSTRUCTIONS TO PATIENT

2/14 Rehab

Cooperative. Wants to go home when ready. Ataxia better, improving. Rehab progressing well. V.S. stable & nl.

[redacted]

2/15 Rehab

Light headed last pm. Otherwise feels well today. V.S. stable & nl. No N or V. No headache. Speech unchanged.

[redacted]

2/16/98

Rehab

Ataxia 1 episode Saturday of eye sx + light headedness

No new sx beyond this + exam stable

Pt progressing goal c PT

[redacted]

[redacted]

PROGRESS NOTES

Addressograph

[redacted]

000041

[redacted]

DATE | NOTE PROGRESS OF CASE, COMPLICATIONS, CONSULTATIONS, CHANGE IN DIAGNOSIS, CONDITION ON DISCHARGE, INSTRUCTIONS TO PATIENT

2/17/98 Neuro Staff

9:30A Pt seen neurologically stable. Stroke service c concern that pt may have a vascular inflammatory vasculitis given mild aom on angiogram + ↑ WBC CSF.

Will plan to stop coumadin in preparation for repeat LP to eval WBC count. Will also schedule MR Angio to eval basilar system. Pt will need sedation for this.

Will review old Angio again c neurosurgery staff. Given patients emotional stability & depression will ask [redacted] to eval.

[redacted]

2/17/98

Rehab

Reviewed vitamin + natural products she has been using PTA

Of these none seem likely to be problematic except Diet Phen which includes 12 mg Ephedra alkaloids per tablet and she had

[redacted]

Addressograph

[redacted]

PROGRESS NOTES

[redacted]

000042

[redacted]

PROGRESS NOTES

DATE	NOTE PROGRESS OF CASE, COMPLICATIONS, CONSULTATIONS, CHANGE IN DIAGNOSIS, CONDITION ON DISCHARGE, INSTRUCTIONS TO PATIENT

taken 1 bottle and much of 2ND bottle before 1st stroke but none since then.

Will check i pharmacy to review whether any reports of stroke syndrome reported in association with this product -

Agree i neuro that we need to clarify the status of CSF mononuclear cells as these not explained. Also MR Angio to further assess the basilar artery status - She will need Atwan b/o 1 claustrophobic so i MR —

[redacted]

4/8/98

Rehab

MRA done last pm but report pending

Dysarthria is less
Pt still i mod. ① weakness

Off Coumadin and Neuro to arrange LP later this week

[redacted]

PROGRESS NOTES

Addressograph

[redacted]

000043

[redacted]

PROGRESS NOTES

DATE	NOTE PROGRESS OF CASE, COMPLICATIONS, CONSULTATIONS, CHANGE IN DIAGNOSIS, CONDITION ON DISCHARGE, INSTRUCTIONS TO PATIENT

We will review in our team conference — anticipating another 2 weeks min inpt Rx, However some of this will depend on MRA findings

[redacted]

11 30 AM Discussed MR studies c̄ Dr [redacted] Current. MR shows thrombosis of basilar artery and MR angio being considered

Dr [redacted] discussing with Dr [redacted] re possible angiogram to clarify status of the basilar artery as more definitive study than MRA even c̄ gadolinium

Discussed c̄ pt + her parents re angio which is being scheduled

[redacted]

Note
INR this AM = 1.46
PTT pending
ASA = 1/d 325/d

[redacted]

[redacted]

Addressograph

[redacted]

PROGRESS NOTES

[redacted]

PROGRESS NOTES

DATE	NOTE PROGRESS OF CASE, COMPLICATIONS, CONSULTATIONS, CHANGE IN DIAGNOSIS, CONDITION ON DISCHARGE, INSTRUCTIONS TO PATIENT

Neurology.

2/18/98
300pm

Pt seen & examined.
✓ MR Angio thrombosis of Basilar artery.
Pt off coumadin. INR = 1.46 (am today)
will f/u hold on LP & ✓ INR am tomorrow

Called the [redacted]
Med. Rec.
to get results of LP. done last month.
fax available.

Pt offers no complain.
Pt seen by psych.
will f/u c Dr. [redacted] & Dr. [redacted]

2/18/98
600pm

Addendum

Under aseptic condition.
Lumbar Puncture prepared.
Site consent & check
Dr. [redacted] present
& complication & bleeding.
10 cc of CSF obtained sent for w/b

[redacted]

[redacted]

[redacted]

PROGRESS NOTES

DATE | NOTE PROGRESS OF CASE, COMPLICATIONS, CONSULTATIONS, CHANGE IN DIAGNOSIS, CONDITION ON DISCHARGE, INSTRUCTIONS TO PATIENT

2/18/98

Rehab

From pharmacy search found report of Ma Huang with ephedra alkaloids associated & Stroke syndromes as well as other adverse RxN's

I have called FDA line 800-FDA-1088 - to report - and see if any further specific info can be obtained from FDA about this product and specific findings in such patients →

[redacted]

1400 Radiology - special procedures.
Pt s/p (L) vertebral artery angiogram via (R) femoral approach. Angiogram shows irregularity of the proximal basilar a. w/ complete occlusion in the mid portion. The pt tolerated the procedure well w/out complications. Full report to follow.

[redacted]

[redacted]

PROGRESS NOTES

Addressograph

[redacted]

000046

[redacted]

PROGRESS NOTES

DATE	NOTE PROGRESS OF CASE, COMPLICATIONS, CONSULTATIONS, CHANGE IN DIAGNOSIS, CONDITION ON DISCHARGE, INSTRUCTIONS TO PATIENT
2.19.98	Psychiatry Initial portion of consultation. 41 y.o. div woman c̄ 11 y.o. daughter S/P CVA & pt had been taking Ephedrine. Public reports about problems with this group of drugs and FDA has been investigating Mood depressed c̄ hx of depression in the past. No family hx of depression in immediate family M uncle - EDA distant cousin - suicide
	A: Mood disorder 2° to CVA
	P: Suggest SSRI when pt stable will follow

[redacted]

[redacted]

PROGRESS NOTES

Addressograph

[redacted]

000047

[redacted]

PROGRESS NOTES

DATE	NOTE PROGRESS OF CASE, COMPLICATIONS, CONSULTATIONS, CHANGE IN DIAGNOSIS, CONDITION ON DISCHARGE, INSTRUCTIONS TO PATIENT

2/19/98

Rehab

Angio results yesterday discussed c neurologist

LP done → ↑ CSF protein 58 + persistant mononuclear cells 2/ 100% mono

Heparin has been resumed and will move to anticoagulate c coumadin if no further diagnostic studies

Also to begin steroid if OK c neurology to Rx whatever inflammatory component may be present in basilar artery—

[redacted]

[redacted]

PROGRESS NOTES

Addressograph

[redacted]

000048

[redacted]

PROGRESS NOTES

DATE	NOTE PROGRESS OF CASE, COMPLICATIONS, CONSULTATIONS, CHANGE IN DIAGNOSIS, CONDITION ON DISCHARGE, INSTRUCTIONS TO PATIENT

2/19/98. Neurology

Pt seen & examined.
41 yr old ♀ h/o b/l CVA Last (3rd) episode
5/Feb/98. MRI persistent ē basilar a. occlusion
2° ~~ATCH~~ atherosclerosis Vs Dissection.
Pt now on Rehab ē improving motor function.

— S/P LP Last night. Ø complication.
& pt started on Heparin IV.

(LABS) # CSF fluid analysis
Tube ① WBC/RBC = 21/0 100% Mono
Tube ④ WBC/RBC 19/1 100% Mono
Glucose = 59
Protein = 58 Gram Stain ⊖ Ø growth.
India Ink ⊖.

# Fasting Lipid profile Chol = 213
Trig = 177
HDL = 57.4
LDL = 120
VLDL = 35.

a.m PT = 12.5
✓ PTT = 60.8
INR = 1.11.

Further blood w/u results awaited.
Coagulation profile acceptable but on Heparin 800 u/hr.
Cont. present management. Will f/u.
Start Steroid for ? Vasculitis.

[redacted]

Addressograph [redacted]

[redacted]

PROGRESS NOTES

000049

[redacted]

PROGRESS NOTES

DATE	NOTE PROGRESS OF CASE, COMPLICATIONS, CONSULTATIONS, CHANGE IN DIAGNOSIS, CONDITION ON DISCHARGE, INSTRUCTIONS TO PATIENT
2/19/98	
	Rehab
1620	Discussed c pt and earlier c Dr [redacted] —
	Pt understands the nature of basilar artery thrombosis, + CSF mononuclear cells and that this may be an isolated CNS vasculitis related or not to the ephedra she took previously in Diet Phen
	① Discussed steroid therapy — risk/benefit and w/f Start Solumedrol 16g 6
	② Resume coumadin per pharmacy
	③ Discussed c pt + her parents
	[redacted]

[redacted]

PROGRESS NOTES

Addressograph [redacted]

000050

[redacted]

PROGRESS NOTES

DATE	NOTE PROGRESS OF CASE, COMPLICATIONS, CONSULTATIONS, CHANGE IN DIAGNOSIS, CONDITION ON DISCHARGE, INSTRUCTIONS TO PATIENT
	Neurology f/u.
2/20/98	
	Pt seen & examined today.
	much better emotionally
	stable ↑ motor function in (L) UE.
	started on Steroid i.e Solumedrol IV 16mg q6.
	started on Coumadin.
	Pt to Cont. Steroid & Coagulation.
	∅ further complaints.
	Coagulation profile f/u. by Clinical pharmacology.
	Neuro -
	AO x 3 Clear sensorium
	Slurred speech but improved.
	Memory Intact.
	Cr. Nu. ↓ sen (L) side of face
	otherwise ∅ change.
	Motor - (R) 5/5 UE & LE.
	(L) UE < prox 3+/5. ✓ improved
	< dist - 3/5
	LE - 3+5.
	Sensory Cardinal ∅ change
	Gait more stable

[redacted]

PROGRESS NOTES

Addressograph

[redacted]

000051

[redacted]

PROGRESS NOTES

DATE	NOTE PROGRESS OF CASE, COMPLICATIONS, CONSULTATIONS, CHANGE IN DIAGNOSIS, CONDITION ON DISCHARGE, INSTRUCTIONS TO PATIENT

A/P. Multiple CVA.
c̄ Basilar a. Stenosis

- Cont. anticoagulation
- PL stated on Coumadin & Stenosis
- Rehabilitation
- will f/u. [redacted] ogne's above. [redacted]

4/20/98 1340 Neurology staff - Addendum

If we're going to treat an inflammatory vasculitis due to an exposure, not 1° CNS angiitis, then I would use Medrol 500 mg IVPB qd x 5 then taper over 4-6 weeks.

Discussed c̄ [redacted], [redacted]

will Δ as per above

[redacted]

PROGRESS NOTES

Addressograph

[redacted]

000052

[redacted]

PROGRESS NOTES

DATE	NOTE PROGRESS OF CASE, COMPLICATIONS, CONSULTATIONS, CHANGE IN DIAGNOSIS, CONDITION ON DISCHARGE, INSTRUCTIONS TO PATIENT

02/10/98 Cerebrovascular Fellow

Pt. is clinically ↓ change, received one dose of Coumadin last night. Has slight headache, not different than usual, & postural component.

CSF confirmed some degree of inflammation, reduced from [illegible]. Stains are (-), cultures (P).

(A). 1. Pt. ↓ at least 2 pontine infarcts, basilar artery vasculitis + distal basilar occlusion.
2. CSF indicate continued but less prominent, evidence of inflammation.
3. Continued anticoagulation i Coumadin a Heparin may ↑ hemorrhagic risk. More specific antithrombotic action of low molecular weight heparins may reduce the risk.

(R). 1. D/C Coumadin + IV heparin
2. Start Lovanox 30 → 40 BID
3. Repeat LP in 2 weeks + repeat MRA @ that time unless altered clinical course suggests earlier re-testing.
4. Taper of p.o. steroids ↓ Solumedrol pulsing.
5. Monitor K+ + glucose on steroids

Above discussed ↓ Dr. [redacted]

[redacted]

2/20/98

Rehab

Discussed i DR [redacted] re Solumedrol 500/d x 5 d and then tapering

Also discussed i DR [redacted] re

[redacted]

PROGRESS NOTES

Addressograph

[redacted]

000053

[redacted]

DATE	NOTE PROGRESS OF CASE, COMPLICATIONS, CONSULTATIONS, CHANGE IN DIAGNOSIS, CONDITION ON DISCHARGE, INSTRUCTIONS TO PATIENT

Ding from coumadin to lovenox, pt did have stroke while on coumadin and there is at least theoretical risk of bleeding on coumadin

Discussed c family + pt re above changes and plan for repeat MR angio + LP to follow up on the mononuclear cells—

[redacted]

[redacted]

[redacted]

PROGRESS NOTES

DATE	NOTE PROGRESS OF CASE, COMPLICATIONS, CONSULTATIONS, CHANGE IN DIAGNOSIS, CONDITION ON DISCHARGE, INSTRUCTIONS TO PATIENT
	Lung - CTA
	Ca - UM
	[illegible]
	[illegible] - CIME
	(A/P) 1/2 TNA 2° [illegible]
	CNI
	[illegible] [illegible] [illegible] - [redacted]

[redacted]

Addressograph

[redacted]

PROGRESS NOTES

[redacted]

000055

[redacted]

PROGRESS NOTES

DATE	NOTE PROGRESS OF CASE, COMPLICATIONS, CONSULTATIONS, CHANGE IN DIAGNOSIS, CONDITION ON DISCHARGE, INSTRUCTIONS TO PATIENT
2.22.98	Psychiatry
	Pt interviewed further. Has great difficulty talk about most aspects of her life 2° affective lability. Notes not only inapprop crying but also excessive laughter
	A: Mood disord 2° to CVA + steroids
	P: will F/U
	start SSRI before D/C
	[redacted]
2-22	[illegible]
	[illegible]
	[illegible]
	[illegible]
	[illegible]

[redacted]

[redacted]

PROGRESS NOTES

000056

[redacted]

PROGRESS NOTES

DATE	NOTE PROGRESS OF CASE, COMPLICATIONS, CONSULTATIONS, CHANGE IN DIAGNOSIS, CONDITION ON DISCHARGE, INSTRUCTIONS TO PATIENT

Neuro [redacted] f/u Note

(S) Pt feels like she is doing better. No new c/o. OT/PT/speech all report pt doing very well & improving in rehab. Good appetite. Wants to know if vitamin C might help her neuro rehab. Wants to know if a cane would allow her to ambulate independently.

(O) Tm 99² BP 107/56 (107-137/56-90) HR74 RR20
Awake, Alert, pleasant, NAD, cooperative, appropriate.
CN'S 2-12 (I) (B) x̄ (+) dysarthria (VA & VF not checked)
motor strength 5/5 throughout RUE/RLE
strength 4-/5 distal & 4/5 prox LUE
strength 5-/5 prox & dist LLE
} tone Normal
Sensory (I) to ST & temp throughout
coord (+) difficulty c̄ RAM's & FTN (L)UE, (I) (R)UE
HTS (I)(B). Able to ambulate when holds onto examiners hand for stability c̄ (+) limp.

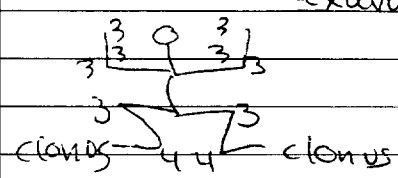

Meds tonights dose of solumedrol will be 3rd 500mg dose (also on lovenox 30mg SQQ12°, elavil/Rancho Pocipe/lactulose/ducosate/tyl/MOM)

LABS 2/18 AT3 = 114% (81-123)
Homocystine = 8.1 (5-18)
Von Willebrand Ag = 15% Normal (60-150)
2/14 HIV (−)
2/19 Chol = (213), TG = (177), HDL = 57, LDL = 120
2/14 Prot C activity = 58 (70-140)
Prot S activity = 43 (58-130)
2/14 CSF cocci: pending
2/14 CSF varicella: pending
2/18 factor V: pending

[redacted]

PROGRESS NOTES

Addressograph

[redacted]

000057

[redacted]

DATE	NOTE PROGRESS OF CASE, COMPLICATIONS, CONSULTATIONS, CHANGE IN DIAGNOSIS, CONDITION ON DISCHARGE, INSTRUCTIONS TO PATIENT

2/18 Activated Prot C Resistance: pending

(A/P) S/p multiple ~~post~~ cerebellar strokes with basilar artery occlusion of unknown etiology, but thought secondary to vasculitis (either primary CNS angiitis or secondary to ephedra alkaloids. Doing very well with rehab with definite improvement in strength & speech. Day #3 today of solumedrol 500mg IV [redacted]

Recommendations:

1) ~~Pt's~~ In regards request/question of whether Vit C would help: No direct though some indirect evidence in literature of antioxidant benefit → OK to Give Vit C/Vit A/Vit E/Selenium/ ~~Riboflavinoids~~ bioflavinoids.
2) Would have hematology comment on the low von Willebrand Ag & low Prot C & S activity
3) Repeat lipid panel fasting as outpt in few weeks
4) Very low likelihood for sarcoidosis in this pt, but probably worthwhile to send ACE level.
5) ~~PPD~~ results/control results not in chart notes, but would not be helpful to repeat test now that on steroids
6) Recommend H_2-blocker & K+ supplement while on high dose steroids
7) Please send ANA panel (on [redacted] ANA sent as far as I can tell & ANA is borderline).

[redacted]

PROGRESS NOTES

DATE	NOTE PROGRESS OF CASE, COMPLICATIONS, CONSULTATIONS, CHANGE IN DIAGNOSIS, CONDITION ON DISCHARGE, INSTRUCTIONS TO PATIENT

Neuro [redacted] f/u Note

(S) Pt feels she is continuing to improve in strength & speech. States she had a 1° episode of (R) eye burning again Monday night, which frightened her, but did not have Δ in neurofunction. Concerned re her intermittent uncontrolled laughing & crying. No Δ to mood c steroids.

(O) ~~Tm 99.8, Tc 97.7, BP 118/71 enroute~~ [redacted]

Tm 99.3, Tc 97.4, BP 123/53, HR 74, RR 20

Awake, Alert, NAD

Dysarthria & gait seem slightly improved as c/w Monday exam. Today she ambulated for me without any assistance at all! (R) limp. O/w exam unchanged neurologically.

LABS ACE & ANA panel ordered

CSF cocci & Van cells: still pending

factor V: still pending

Act protein C Resistance: still pending

(A/P) S/p multiple posterior circulation strokes with basilar artery occlusion of unknown etiology, but thought 2° vasculitis.

Continues to do very well with rehab c further improvement noted as c/w Monday! Today will be day #5 of her 5 day solumedrol course of 500mg IVQD, so tomorrow we recommend to start her taper.

I appreciate the clarification in regards to her PPD/control results.

Will await results of above labs & hematology analysis of her low von Willebrand Ag & low Prot C & S activity. No new recommendations at this time.

Addressograph

[redacted]

PROGRESS NOTES

000059

[redacted]

PROGRESS NOTES

DATE	NOTE PROGRESS OF CASE, COMPLICATIONS, CONSULTATIONS, CHANGE IN DIAGNOSIS, CONDITION ON DISCHARGE, INSTRUCTIONS TO PATIENT

2.23.98 Neurology staff

Evaluation as per Dr [redacted] note, ĉ Gov exam - She's definitely stronger, and speech clearer, spirits OK.

Rec as above [redacted]

2/23/98

Rehab

7pm Appreciate neurology F/U

Pt clearly better c̄ ↑ speech c̄ ↓ dipartheria though ⊖ clumsiness about the same

Some episodes of laughing "out of control" likely reflect steroid.

Protein S&C low but only modestly so and likely not significant deficiency + may reflect recent coumadin, but this can be reviewed c̄ heme service.

Ppd done 2/14 Neg at 48h and control only "slight" response at 48 [redacted]

[redacted]

PROGRESS NOTES

Addressograph

[redacted]

000060

PROGRESS NOTES

DATE	NOTE PROGRESS OF CASE, COMPLICATIONS, CONSULTATIONS, CHANGE IN DIAGNOSIS, CONDITION ON DISCHARGE, INSTRUCTIONS TO PATIENT

2/24/98

Rehab

Exam stable deficits —

lytes OK c K = 3.6 on 2/22
but agree c ↑ steroid K tabs BID

glucose was 114 mg%

The ANA is not of any significance
but occasion ANA neg lupus
will have + anti SM or rarely
other auto antibody but typically
such pts have abundent evidence
of lupus clinically which is
not case here —

[redacted]

[redacted]

PROGRESS NOTES

Addressograph

[redacted]

[redacted]

PROGRESS NOTES

DATE	NOTE PROGRESS OF CASE, COMPLICATIONS, CONSULTATIONS, CHANGE IN DIAGNOSIS, CONDITION ON DISCHARGE, INSTRUCTIONS TO PATIENT

2.25.98 Neurology staff

Significant improvement in motor fxn and mood.
Day 5/5 10 Medrol
No complications

Rec: Continue Medrol 32mg qd; taper off by 4mg qd perhaps on a q 7d basis to 16 and hold there.
Continue Lovenox SQ
Repeat MRA Intracranial / MRI 3/2 in week of 3/9. I don't think a repeat LP is necessary.
I will talk c Dr [redacted] about Lovenox if MRA shows improvement.
etc to D/C if stable this week

[redacted]

2/26/98 ANTICOAGULATION SERVICE – [redacted] Pharmacy
0400 41yrs @ admitted 2/10 for Rehab because of Pontine stroke w/ (L) Hemiparesis w/ 2/10. Yesterday evening pt's felt numbers on left side. Dr. [redacted] wanted to start pt on heparin w/ Rhinny to manage @ 2-2.5 x control.
Neurology consult to Plan of pt status also.

Allgs: NKA

LABS 2/22 10 > 12.6 / 37.8 < 241 PTL 29.7 @ 2200 on 2/25

WT: 68 kg HT: 5'6"

MEDS: Lovenox 30mg SQ Q12h

Plc (1) Dr [redacted] started pt on Heparin @ 900 cu/kg. since Pt had Lovenox Therapy.

[redacted]

PROGRESS NOTES

Addressograp[redacted]

[redacted]

000062

PROGRESS NOTES

DATE	NOTE PROGRESS OF CASE, COMPLICATIONS, CONSULTATIONS, CHANGE IN DIAGNOSIS, CONDITION ON DISCHARGE, INSTRUCTIONS TO PATIENT
	Cinemac Pharmacy - Cont
(2)	Ideally pt should have started w/ Heparin 1200 u/hr (15 u/kg)
(3)	Check PTT @ 0500 along w/ CBC.
(4)	PT numbness ~~[illegible]~~ [redacted] Right side.
(5)	will continue FW.
	[redacted]
2/26/98	
	Reliab
830	Pt had additional neurologic Sx last night u/hr numbness around (L) mouth and (L) eye twitching. Those Sx ↓ post starting heparin 900 u/hr but pt continues with numbness in extremities and also with ↑ dysarthria and more emotionally labile —
	LUE remains weakest but able to finger to nose point clumsily and LLE remains weaker than R which is 3/5 or more except ankle dorsiflex or ~~hip~~. Knee extension —
	ASA was stopped on 2/18 by neurology + pt on Lovenox since
P→	Neurology planning CT Continue heparin + I favor adding back ASA if CT ≤ hemorrhage

[redacted]

PROGRESS NOTES

[redacted]

PROGRESS NOTES

DATE	NOTE PROGRESS OF CASE, COMPLICATIONS, CONSULTATIONS, CHANGE IN DIAGNOSIS, CONDITION ON DISCHARGE, INSTRUCTIONS TO PATIENT

Neurology fl

2/26/98 (S) Pt c neurodeterioration overnight:
At 9:45 pm last night, when pt was in bathroom she suddenly c/o pain in the back of the Neck, numbness in the mouth & tongue & burning of (L) eye. Her speech was noted to be more slurred. Heparin drip was started VS @ the time were T 97.1, HR 115, RR 20, BP 155/75. @ 11:30 pm pt c/o numbness (R) hand. At 5 am Noted no longer to be able to talk understandably or move tongue from side-to-side. She was noted to have (B) weak hand grasp. Bladder distension noted @ 6 am & pt unable to void → I/O cath produced 1L urine. → Now c indwelling foley cath.

(O) T 98 HR 89 RR 19 BP 156/77
GEN/MS. Awake. Alert, very upset / crying
No receptive aphasia
severe dense expressive aphasia vs. dysarthria.

HEENT Neck supple, fundi c sharp disk margins (B)
Skin of face very flushed.

CN's PERRL, EOM (I), VF (I) to finger count (B)
Sensory (I) to ST V_1-V_3 (B)
face (B) weak c difficulty maintaining eyes closed against examiners resistance, but symmetric & c good corneal reflex (B)
Pt unable to protrude tongue. unable to evaluate palate elevation 2° difficulty keeping mouth open
SCM/trap strength (I)(B) Hearing (I) to finger rub (B)

[redacted]

PROGRESS NOTES

Addressograph

[redacted]

000064

[redacted]

PROGRESS NOTES

DATE	NOTE PROGRESS OF CASE, COMPLICATIONS, CONSULTATIONS, CHANGE IN DIAGNOSIS, CONDITION ON DISCHARGE, INSTRUCTIONS TO PATIENT

Motor ↑ tone (B) LE's.
strength 3/5 (L) VE / (L) LE throughout
2/5 (R) VE / (R) LE throughout

Sensory (I) to ST throughout
though (+) subjective numbness complained of last night on (R) side

Coord (+) past pointing to FTN (B) (? weakness vs. in coord?). Unable to do HTS (R) 2° weakness. (I) on (L). Difficulty c̄ RAM's (B) VE's but worse on (R)

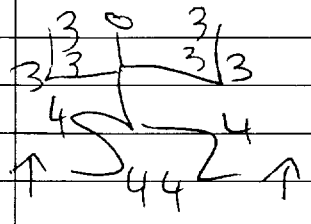

A/P Significant worsening Neuro status that does Not localize well.

Recommend:
1) Move to ICU
2) STAT head CT s̄ to R/O ICH
3) p̄ Results of head CT will decide what further management/eval is indicated
4) keep NPO → IVF's.
5) bed rest for now

[redacted]

Addressograp[redacted]

[redacted]

PROGRESS NOTES

000065

[redacted]

PROGRESS NOTES

[redacted]

DATE	NOTE PROGRESS OF CASE, COMPLICATIONS, CONSULTATIONS, CHANGE IN DIAGNOSIS, CONDITION ON DISCHARGE, INSTRUCTIONS TO PATIENT

2/26/98 3:15 pm

Pt's Neuro Exam re checked → unchanged from this AM. BP 144/82

MRI → ↑ infarct (L) pons

MRA → propagation of basilar clot; Now occluding entire basilar artery & both proximal & distal vertebral arteries c̄ small central area of flow each vertebral. Posterior cerebral arteries supplied through anterior circulation

A/P) Recommend
- continue Solumedrol @ 32 mg IV QD
- give NS @ 120-130 cc/o in attempt to keep DBP in goal range 90-100
- we will return with further recomm's later this afternoon.

[redacted]

2/26 1745

Neurology Staff

Events of today, and exam, as per above note, done by Dr [redacted] and myself on several occasions this day.

She has developed new ischemia and edema in the (L) midpons. 's mass effect, added to previous R pontine infarct. The MRA shows Ø flow & ? string sign

[redacted]

Addressograph

[redacted]

PROGRESS NOTES

[redacted]

DATE

NOTE PROGRESS OF CASE, COMPLICATIONS, CONSULTATIONS, CHANGE IN DIAGNOSIS, CONDITION ON DISCHARGE, INSTRUCTIONS TO PATIENT

in R vert, for post. circulation. The rostral circulation (R SCA) is probably filling retrograde. This is likely over-estimation of occlusion, as she clearly has spared medullary tissue clinically.

However, she is at substantial risk for continued progression of deficit, as small perforators can be occluded as this thrombosis worsens, and from hemorrhage in this vasculitic lesion.

The etiology is still unclear but is presumed to have initiated as drug-induced vasculitis. Why it continues now is even less clear. I presume an autoimmune component c̄ inflammation; the present worsening may have occurred 2° hypoperfusion, but BPs have not shown symptomatic hypotension. 0400 dBPs consistently may be normal circadian wnt or bad readings. A vagotomic/parasympathetic event may have occurred p̄ vomiting attempt ~~[illegible]~~ last night.

Plan

Continue hypoxia INR 2-3.0
ASA 325 when able to swallow.
Keep DBP > 94 c̄ ~~[illegible]~~ UF; Dopamine pm
x 45-120.
Eolus
Nucs/OS 4 [illegible] now
Medrol 32 4 [illegible]
DPO for now.

[redacted]

PROGRESS NOTES

Addressograph

[redacted]

000067

PROGRESS NOTES

DATE	NOTE PROGRESS OF CASE, COMPLICATIONS, CONSULTATIONS, CHANGE IN DIAGNOSIS, CONDITION ON DISCHARGE, INSTRUCTIONS TO PATIENT

We discussed the indications for elective nasogastric tube and endotracheal intubation placement, for nutrition, and airway / secretion control, respectively, c̄ patient & parents. Per this discussion, we will place NGT or ETT to control symptoms and safeguard her during treatment.

She does not wish to have ETT remain in place if she requires it on a long term basis, and if the resulting quality of life doesn't allow her independent life, as agreed by her and/or her parents.

They will all execute a directive tomorrow.

[redacted]

[redacted]

PROGRESS NOTES

Addressograph

[redacted]

PROGRESS NOTES

DATE	NOTE PROGRESS OF CASE, COMPLICATIONS, CONSULTATIONS, CHANGE IN DIAGNOSIS, CONDITION ON DISCHARGE, INSTRUCTIONS TO PATIENT
2/26/98	[redacted] attending - Pt seen + examined in ICU, hx reviewed. Pt seen + examined by me this afternoon. Young female with neurological problems ~~[illegible]~~ with thrombosis of the basilar ~~[illegible]~~ artery. Patient is currently on heparin and aspirin. Past medical history prior to these neurological problems are not significant.
	Currently pt is awake alert + oriented dysarthric
	VS - BP 135/85 pn 107 RR 14-16 T° afebrile
	An exam - pleasant + responsive but dysarthric + ⊖ gag ↓ motor strength 4-/5+ bilat
	HEENT - ⊖ gag reflex deviation of tongue to (R) ⊕ dysarthria.
	Cns - S1 S2 (+) no (M)
	Ins - normal BS no rales/rhonchi
	abd - [illegible]
	✓ agree ✓ lungs clean cated bilaterally.
	Neur - awake + alert general weakness all limbs 2 to ? cerebellar dysfunction ⊖ dysarthria ⊕ absent gag
	Labs
	[redacted]

[redacted]

Addressograph

[redacted]

PROGRESS NOTES

[redacted]

000069

PROGRESS NOTES

DATE | NOTE PROGRESS OF CASE, COMPLICATIONS, CONSULTATIONS, CHANGE IN DIAGNOSIS, CONDITION ON DISCHARGE, INSTRUCTIONS TO PATIENT

MRI / MRA : (+) basilar artery } thrombosis
vertebral artery }

hp
CVA : c̄ thrombosis of posterior circulation.
? cause
? vasculitis
FW by neuro, cont steroids / Heparin.
Will DW neurology / int neuro radiology for further care

Case discussed c̄ Dr. [redacted] + Neuro Team
Agree c̄ conservative Rx, would protect airways & follow labs for ↑ glucose ↑ WBC, infection
. IS. Aspiration precaution
. Chronic steroid, ? Bacterium

keep NPO
tube feeds

2/26/98

Rehab / Rheum

8pm Discussed c̄ Dr [redacted] earlier + reviewed MR / MRAngiox + discussed as outlined by Dr [redacted]

Pt has selective motion all extremities but is diffusely weak, especially LUE and has no gag + ↓ oral motor lingual movements as well

MR angio confirms more proximal thrombosis of basilar artery and

Addressograph

[redacted]

PROGRESS NOTES

000070

DATE | NOTE PROGRESS OF CASE, COMPLICATIONS, CONSULTATIONS, CHANGE IN DIAGNOSIS, CONDITION ON DISCHARGE, INSTRUCTIONS TO PATIENT

unequal vertebral artery changes
c/w vasculopathy/ vasculitis

Repeat ANA reportedly 1:80 but no other systemic evidence of any systemic process

P → heparin
ASA
asp. precautions
Foley tonight but Foley + steroids markedly ↑ risk so would like to change to IC tomorrow if not voiding when foley out
PTT ↑ 120 sec but was from arm where she is receiving heparin + is being repeated goal 2× control
BP support, IV fluids

[redacted]

2/26/98 Clinical Pharmacy
S/O. Pt currently on Heparin drip @ 750u/hr. for S/P CVA.
No signs of bleeding noted.
PTT reported at 126sec. but was drawn from arm heparin infusing
Re-drawn PTT = 87.1sec. Control (2/26) = 30.8 sec.
Goal PTT ratio = 2-2.5x control Ratio = 2.83 sec.
A/P. PTT ratio slightly above desired range.
Will ↓ rate by 2 units/kg/hr. (~100u/hr). = 850u/hr.
Will √ check PTT in 6 hrs.
Will continue to follow. Thank You [redacted]

[redacted]

000071

PROGRESS NOTES

[redacted]

PROGRESS NOTES

DATE	NOTE PROGRESS OF CASE, COMPLICATIONS, CONSULTATIONS, CHANGE IN DIAGNOSIS, CONDITION ON DISCHARGE, INSTRUCTIONS TO PATIENT
2/26/98	
	Rehab
	Pt going to 7 CU → 23 hr hold for now
	See separate progress notes
	Anticipate she will need to be D/c'd to acute if evidence of further thrombosis —
	[redacted]

[redacted]

PROGRESS NOTES

[redacted]

[redacted]

[redacted]

PROGRESS NOTES

DATE	NOTE PROGRESS OF CASE, COMPLICATIONS, CONSULTATIONS, CHANGE IN DIAGNOSIS, CONDITION ON DISCHARGE, INSTRUCTIONS TO PATIENT
2/26	Procedure note:

Procedure TLC placement (LL) groin

Indication: Administration of pressure (dopamine).

Verbal Consent obtained and the procedure explained to the patient.

Under aseptic technique the (LL) groin sterilized c̄ betadine, draped. Lidocaine 1% for local anaesthesia, and TLC placed c̄ seldinger technique

ϕ Complication

[redacted]

[redacted] Anticoagulation Service - Hepar

Hepar 850 on 1 pm

PTT = 47 control = 71.5 RATIO - 1.49

Gen'l 2 28 yr

[redacted]

A/P (1) ↑ Hepar [illegible] ↑ [illegible] PTT [illegible] anticoagulation of 2-25

(2) PT [illegible] to [illegible] [illegible] [illegible]

(3) [illegible] of [illegible] or further [illegible] [illegible]

(4) check PTT in [illegible]

(5) will contact FW at [illegible]

[redacted]

[redacted]

PROGRESS NOTES

Addressograph

[redacted]

000073

[redacted]

PROGRESS NOTES

DATE	NOTE PROGRESS OF CASE, COMPLICATIONS, CONSULTATIONS, CHANGE IN DIAGNOSIS, CONDITION ON DISCHARGE, INSTRUCTIONS TO PATIENT

Neurology [redacted] follow-up

2/27/98 (S) Pt feels unchanged. No new c/o.

(O) Tm 99Σ, BP = 164/83, HR 66, RR 16, I/O ⊖ 830cc
Dopamine drip started at 2200 last night with resultant ↑↑ in urine output & no ↑ in BP, even though drip rapidly tapered up to 20ug/kg/°.

GEN — asleep, but easily awoken to alert state, NAD, interacting appropriately.
PULM — CTA (B) (anteriorly)
CAR — RRR 5 m
ABD — NABS, soft, ⊕ mild-mod tenderness lower mid abdomen
NEURO — Initially in exam, pt verbalized a sentence ("I'm doing ok") That was severely dysarthric, but understandable. Thereafter she did not attempt to verbalize again.
Strength is improved today! It is now 4/5 LUE/LLE & 3 to 4-/5 (R)UE/(R)LE.
Still has great difficulty opening jaw and protruding tongue.
c/w Neuro exam unchanged

A/P
(1) S/P extension of basilar thrombosis c̄ resultant neuro deterioration night of 2/24-2/25. Today has clear small improvement in strength all 4 ext. The plan to try to ↑ BP c̄ a dopamine drip has been unsuccessful, even at 20ug/kg/min & rather has caused diuresis of almost a liter → discussed c̄ Dr [redacted] → would

[redacted]

Addressograph

[redacted]

PROGRESS NOTES

[redacted]

000074

DATE | NOTE PROGRESS OF CASE, COMPLICATIONS, CONSULTATIONS, CHANGE IN DIAGNOSIS, CONDITION ON DISCHARGE, INSTRUCTIONS TO PATIENT

like to taper her off of the dopamine drip since it does not appear to be accomplishing the goal intended. Will also give pt a few boluses IVF to try to replace what was diuresed. Continue Heparin/ASA/Solumedrol.

2) Abd mild tenderness → send U/A.

[redacted]

3-27-98 Neurology staff

Best Quality FDA

[illegible]

[redacted]

PROGRESS NOTES

DATE	NOTE PROGRESS OF CASE, COMPLICATIONS, CONSULTATIONS, CHANGE IN DIAGNOSIS, CONDITION ON DISCHARGE, INSTRUCTIONS TO PATIENT

2/27/98

Rehab

9[30] Despite the BP lower than we would like she has improved slightly –

Able to lift each leg off the bed and grip on © stronger through both UE

Dysarthria severe but also slightly better –

P→ Add Florinef to help support BP – discussed c [redacted] DR
Continue heparin/ASA/steroid –

[redacted]

NPO right now so will check c pharmacy re IV preparation until able to take PO – dysphagia eval pending

[redacted]

[redacted]

PROGRESS NOTES

Addressograph

[redacted]

000076

PROGRESS NOTES

DATE | NOTE PROGRESS OF CASE, COMPLICATIONS, CONSULTATIONS, CHANGE IN DIAGNOSIS, CONDITION ON DISCHARGE, INSTRUCTIONS TO PATIENT

7/8 [redacted] [redacted] HD [redacted] [redacted] attending Pt seen + examined, improved neurologically slightly (subjectively); Reviewed of sx as below.
Patient reports feeling same as yesterday. Denies N/V/F/C/HA/dizziness, visual Δ's. Reports generalized weakness
Aox3 noted Still ± ØGag. Responsive, disorientation/speech somewhat better.
Neuro: E_4 M_6 V_5 = GCS 15 . OS/OD 6→4 PERRL, EOMI
alert (+)corneal, (+) J.J (+)gag. ↓ tongue protrusion, unable to assess deviation
oX4 V_{1-3} intact to LT SCM, trapezius 4+/5
Motor: (B) UE 3/5, (B) LE 4/5 proximal < distal Jafee
Cerebellar dysmetria, ataxia F→N, H→S, RAM ↓rate/rhythm, F→T
Sensory: report paresthesia (B) LE > UE, (+) numbness
proprioception, vibratory intact
PTR. 3+ T, B, Br (B), (B) KJ AJ 4+ (+) Babinski (B) (+)clonus
Free ± remainder of exam. RRR ØS3/4
CV NSR BP 119-171 / 72-104 HR: 112 / 75 RR: 16-20 S1 S2 (N) S murmurs
drip: Dopamine 5 µg/kg/m pulses: 2+ radial, DP (B)
- clear Ø crackles Ø wheezes
Resp: 16-20 on Room air sat O_2 98
Renal in 2841.6 / out 3670 } (-)828.4
HP. (Tm 99.5)

Meds:
ASA 325 mg
Heparin 25,000 U/250 cc
Solumedrol 32mg IV q12°
Pepcid 20mg IV q12°

Labs. PT 87.1
Urine 0-2 WBC 4-6 RBC

A/P 41 yo WF ± basilar s (B) vertebral thrombosis, (L) posterior inferior
(1) Patient stable, dysarthria ± weakness no progression of sx
(2) cont. solumedrol, Heparin
CT Scan from PM - results (P).
Low grade T Lungs clear, pt at risk for aspiration. Neurology to advance feeding, will suggest swallowing e[redacted] first. Meanwhile start PT/OT, encourage [redacted] out of bed

Addressograph [redacted]

[redacted]

PROGRESS NOTES

000077

PROGRESS NOTES

DATE	NOTE PROGRESS OF CASE, COMPLICATIONS, CONSULTATIONS, CHANGE IN DIAGNOSIS, CONDITION ON DISCHARGE, INSTRUCTIONS TO PATIENT

2/27/98 Speech Pathology
Orders received for speech + swallowing eval.
Swallow eval completed + filed in H+P section.
Pt able to manage pureed diet + honey thick
fluids via teaspoon c̄ chin tuck for liquids.
Dr's [redacted] notified. Speech
eval will be completed over the weekend.
Thank you. — [redacted]
Addendum: ST to follow 5-6 days wk 2-3
wks. [redacted]
Addendum: Speech lang/ccg eval completed. Please
see H+P section. [redacted]

2-27-98 PT x 15'
orders received + chart reviewed —
Spoke c̄ Dr. [redacted] re: Evaluation
+ mobilization as pt is to have duplex
study do r/o ~~IVC~~ Superior Vena
cava clot — will hold evaluation
until cleared by MD —
will check on pt in the AM
[redacted]

Addressograph

[redacted]

PROGRESS NOTES

[redacted]

000078

DATE | NOTE PROGRESS OF CASE, COMPLICATIONS, CONSULTATIONS, CHANGE IN DIAGNOSIS, CONDITION ON DISCHARGE, INSTRUCTIONS TO PATIENT

2/28/98 Clinical Pharmacy Re: Heparin

[redacted] yo female on heparin for stroke.

Currently @ 900u/hr PTT @ 1400 - 53.4s (R=1.7x control)
H/H 13.4/40 (2/26)
meds: ASA
UA: trace blood (will watch); pt has foley catheter

A/P
1) PTT below desired range of 2-2.5x control
2) will ↑ heparin to 1,000 u/hr
3) √PTT @ 6hrs
4) √ hemogram in AM

[redacted]

Neuro Addendum

Chest CT done to R/O SVC thrombosis because of erythematous/flushed face. CT Chest was normal. Flushing most likely 2° steroid effect.

[redacted]

2/27/98
Rehab/Rheum

Basilar artery Thrombosis
Dysarthria and weakness better
She has stronger R grip + able to do finger to nose fairly well c R but remains clumsy c R

[redacted]

PROGRESS NOTES

Addressograph

[redacted]

000079

[redacted]

PROGRESS NOTES

DATE	NOTE PROGRESS OF CASE, COMPLICATIONS, CONSULTATIONS, CHANGE IN DIAGNOSIS, CONDITION ON DISCHARGE, INSTRUCTIONS TO PATIENT

Did adequately on swallow to take po c̄ chin tuck + tolerated flormef + ASA po

BP 140/94 Right where it should be for mon

P→ Dr [redacted] to follow for me over weekend + Dr [redacted] to see for neuro

I would like to see if foley can be removed tomorrow b/o high risk infection
heparin → PTT 2x control
ASA 5gr
Solumedrol 32/d
PT/speech

[redacted]

2/25/98 Clinical RX Note
Re: Heparin

Patient cont on Heparin gtt @ 1,000 units/hr
PTT = 63.3 sec @ 0018 (Ratio ~ 2x control)
No S/Sx of bleeding (per RN)

A/P ① PTT ratio w/i desired range
② Cont. Heparin gtt @ same rate
③ PTT, hemogram in AM lab

[redacted]

Addressograph

[redacted]

[redacted]

PROGRESS NOTES

000080

[redacted]

PROGRESS NOTES

DATE	NOTE PROGRESS OF CASE, COMPLICATIONS, CONSULTATIONS, CHANGE IN DIAGNOSIS, CONDITION ON DISCHARGE, INSTRUCTIONS TO PATIENT

-28-98 SpeechPath 1:1 x 30 Pt. seen bedside for dysphagia tx as per plan. Pt awake, cooperative, pleasant. Pt. oriented x3 c̄ min cue for specific date. Pt. performs basic lingual/labial tasks c̄ F-accuracy; verbal/visual cues min ↑ RM. Pt. tolerates 5.5 oz pear nectar thickened to honey c̄ overt signs of aspiration. Pt. presented c̄ 1/2-1 tsp trials; requires occasional verbal cue for chin tuck. Intellig of speech judged to be ~60% intellig. at basic phrase level c̄ context. Cont. [redacted]

/28/98 Clinical Pharmacy Note: Heparin per Rx Protocol

S/O. PTT @ 0400 today = 70.5 Heparin gt at 1000 u/hr
PTT control: 30.0 PTT goal: 2-2.5x
Hgb/Hct: 12/36.1 PH: 275K
pt bleeding from femoral line & blood in urine.

A/P. 1) PTT within desired range
2) Bleeding - blood from foley & from IV line - MD to be informed.
~~3) Will cont heparin gt until further orders from MD.~~
~~Will cont to follow.~~
3) HOLD heparin for now - per Dr [redacted]
Will resume per MD OK - consider ↓PTT goal range.
Will flu c̄ you. [redacted]

/28/98 PT (45')
Pt was gotten up by mising, PT evaluation was done or completed out of bed/in chair. Pls. see PT eval. form for details.
[redacted]

Addressograph

[redacted]

[redacted]

PROGRESS NOTES

000081

PROGRESS NOTES

DATE	NOTE PROGRESS OF CASE, COMPLICATIONS, CONSULTATIONS, CHANGE IN DIAGNOSIS, CONDITION ON DISCHARGE, INSTRUCTIONS TO PATIENT

2/25/98 [redacted]

pt with posterior circulation thrombosis ? 2° to vasculitis.

VS - stable BP 136/93 PR 96 AL 18/min T° 98.4

neuro - no new neuro changes
still dysarthric ⊕, cerebellar findings ⊕

ens - S, S, ⊕
R - clear

- no gum bleeding / mucous membrane bleeding
- mild hematuria

⊕ bleeding around TLC site in ⊕ groin
also small hematoma ⊕ groin.

labs
.14 | .06 | .22 TP 5.8/3.7 Ca 8.7/3.2/2.0
4 | 21 | 7/6.5 AP 55 AST 15/17 LDH 131

.07) 12 / 36 (27.5 P 14 C 18 M 6

PTT @ 4 am on 1000 units/hr 70.5.

I discussed with Dr. [redacted], neurology
reporting pts bleeding. Agree with her

Addressograph

[redacted]

[redacted]

PROGRESS NOTES

000082

[redacted]

PROGRESS NOTES

DATE	NOTE PROGRESS OF CASE, COMPLICATIONS, CONSULTATIONS, CHANGE IN DIAGNOSIS, CONDITION ON DISCHARGE, INSTRUCTIONS TO PATIENT

Convern about stopping heparin 2 to stroke.
will hold heparin x 30 min restart @ lower
dosage of 900 units/hr. tim for PTT
Contin x2 @ 60 sec and FW PTT in 4 hrs
with CBC

multiple UA 2 to pmt insulation thrombosis
possibly 2 to vasculitis
FW by neuro, on steroids / heparin
will FW.

Dysphagia diet pel speech path [redacted]

Neurology [redacted] f/u

1/28/08 (S) Pt is feeling better. Had some modest
bleeding @ triple lumen site & mild blood in urine
→ heparin held x 30' & restarted at lower rate c̄
new goal PTT = 2x control. No new c/o. feels stronger.
(C) Tm 98.7, BP = 131/72, HR83, RR 16, I/O @ 2538
Mental status Awake, alert, oriented
anxious but seems less overwhelmed
today.
CN'S improved movement (B) facial muscles &
jaw muscles still very difficult to
protrude tongue. c/w CN exam
unchanged. dysarthria not improved
as compared c̄ yesterday

motor strength improved in (R) UE:
grip 5-/5 (B) UE

[redacted]

PROGRESS NOTES

Addressograph

[redacted]

000083

[redacted]

DATE | NOTE PROGRESS OF CASE, COMPLICATIONS, CONSULTATIONS, CHANGE IN DIAGNOSIS, CONDITION ON DISCHARGE, INSTRUCTIONS TO PATIENT

elbow flex/ext 4+/5 (B)
shoulder flex 4-/5 (R) UE; 3/5 (L) UE
In lower ext:
3 to 4-/5 (R) hip flex, 2-3/5 (L) hip flex
5/5 (B) knee flex/ext
5/5 (B) ankle plantar flex
5/5 (R) ankle dorsiflex 4-/5 (L) ankle dorsiflex

Sensory (I) to ST throughout

coord/DTR Not retested today.

LABS $\frac{141}{4.0}\ \frac{106}{21}\ \frac{7}{0.5}$ (122 Alb 3.7 Phos 3.2 Ca 8.7 Mg 2.0

$10.7 \big) \frac{12}{36}$ (275 N 74 L 18 M 6

A/P (1) S/p extensive basilar thrombosis c neurodeterioration night of 2/24-25. Pt has small but definite improvement in strength of (R) UE & (B) face/jaw today as c/w yesterday. Had small pen-triple lumen bleed & hematuria → heparin held x 3c min & restarted @ 900 units/h (1.1a) at 1000 units/h) c new goal PTT range 1.75-2.0 x control. Still having drop in BP in early morning hours (101/55 @ 0200, 107/60 @ 0300 today) despite (I) I/O & florinef 0.1mg PO QD. Will Δ to florinef 0.1mg PO BID.

(2) foley catheter — would like to remove when possible 2° risk of UTI, but will have to wait until hematuria resolved. UA 2/27 was (-) for UTI & urine cx showed only Staph coag (-) (40,000), which I assume is a contaminant

[redacted]

PROGRESS NOTES

DATE	NOTE PROGRESS OF CASE, COMPLICATIONS, CONSULTATIONS, CHANGE IN DIAGNOSIS, CONDITION ON DISCHARGE, INSTRUCTIONS TO PATIENT

2/28/98 Rehab
& Emotionally labile → cries easily
BP → 101/55 early thinam
Significant dysarthria still
Legrain 3/P=4, o/w motor symmetrical
→ on Florinef 0.1 mg po gum / I spoke to [redacted] RN, who definitely gave the hired thinam
- Fluid balance = positive
- will ∴ ↑ Florinef to 0.1 mg po sid, c̄ which neuro agrees.

- note bleeding around cath → ∴ legrain held x 30', and new goal = 2 x control.

[redacted]

2/28/98 O.T. NOTE x 60'
Order received, chart reviewed, M.D. clearance for therapy c̄ care taken for triple lumen site - initial eval. completed - see H & P for details.

[redacted]

28/98 [redacted] ATTENDING
4:25pm Patient seen & examined by me today. Chart, labs & CXR reviewed. Agree c̄ Dr [redacted] physical findings & assessment above with following additions
- still dysarthric but overall improved since yesterday
- CXR 2/27 clear c̄ infiltrates

A & P
① Basilar thrombosis - on heparin, will ↓ to ↓ hematuria & oozing

[redacted]

Addressograph

[redacted]

PROGRESS NOTES

000085

PROGRESS NOTES

ATE	NOTE PROGRESS OF CASE, COMPLICATIONS, CONSULTATIONS, CHANGE IN DIAGNOSIS, CONDITION ON DISCHARGE, INSTRUCTIONS TO PATIENT

- try to find peripheral IV site & p/c central line.

② nutrition - tolerating dysphagia diet.

[redacted]

8/98 Clinical Pharmacy Note: ~~Ad~~ Heparin follow-up

S/o: PTT @ 1500 = 55.2 Heparin ↓'d to 900 u/hr @ 1030
$\bar{p}$ 30 min hold.

CBC @ 1500 = Hgb/Hct: 12.6/37.5 Plt: 308

⊕ blood in urine & IV site - MD aware

New PTT goal: 1.75 - 2.0X control

a/p: 1) PTT within new goal (= 1.8x control)
continue current rate for now (ok c̄ Dr. [redacted]

2) Hct stable

3) PTT, CBC in am
will cont. to monitor & flu.

[redacted]

Clinical Pharmacy Note: Heparin

S/o. PTT @ 0420 = 55.8 Heparin gtt at 900 u/hr
Hgb/Hct: 11.7/35.1 Plt: 212

⊕ hematuria & sl. bleed @ periph arm line - MD aware

PTT control = 29.9

a/p. 1) PTT = 1.9x control - within goal of 1.75 - 2.0X

2) cont. same rate - confirmed c̄ Dr [redacted]

3) ~~watch~~ will cont. to follow c̄ you

4) PTT, CBC in am.

[redacted]

[redacted]

Addressograph

[redacted]

PROGRESS NOTES

000086

PROGRESS NOTES

DATE	NOTE PROGRESS OF CASE, COMPLICATIONS, CONSULTATIONS, CHANGE IN DIAGNOSIS, CONDITION ON DISCHARGE, INSTRUCTIONS TO PATIENT

Improved
~~XT~~ 4+-5/5 (B)
Swallowing (chewing) thick pure 100%

BUE prox 4 + dist 4
BLE 4 range p=2
DTRs ↑ symmetrically, toes ↓
Sensory ↓

Lab chem 0. Dpost 5.8 ABB 3.6
LTZ 14.3 11.7 / 35.1 pl 282
PTT 55.2

I Bass on ordinary floor basis, c̄ multiple up sorts of reproperation
No evidence of hyperperfusion. I have not used Levophed to blink of vasoconstriction/worsening the mild vasospasm. We continue c̄ ↑ IVF & Florinef.

P Try Post Circ TCD's regularly to follow regression of clot
Continue hyperion for ≥ 3 days; can flow to Dow 3/2
Δ to 60 Liquors BID + ASA 325 later this week.
Repeat MRA in 1 week
Add Encore TID to ↑ protein

[redacted]

Addressograph

[redacted]

[redacted]

PROGRESS NOTES

000087

PROGRESS NOTES

DATE	NOTE PROGRESS OF CASE, COMPLICATIONS, CONSULTATIONS, CHANGE IN DIAGNOSIS, CONDITION ON DISCHARGE, INSTRUCTIONS TO PATIENT

3/1/98 [redacted]

Pt seen + examined by me today
Young female with basilar artery thrombosis

B - stable afebrile. 138/74 ~~[illegible]~~ 64 - 100/min.

(1) groin TLC was [illegible] yesterday 2° to bleeding peripheral iv

CS → [illegible] +
RS } clear.

new - slight improvement in facial muscles
able to protrude tongue today
upper extremity strength has improved though not normal.

appears less anxious today

Labs

14.3 > 11.7 / 35 < 262

137 | 102 | 127
4 | 24 | 6
4

TP 5.8 / 3.6
Ca 8.8 / 3.8 / 1.8
Ap 50 / 31 / 67 / 139

PTT 55.8 on heparin 900 units/hr

Imp

(1) CVA : 2° to thrombosis [redacted]
the basilar and vertebral

Addressograph

[redacted]

[redacted]

PROGRESS NOTES

000088

[redacted]

PROGRESS NOTES

DATE	NOTE PROGRESS OF CASE, COMPLICATIONS, CONSULTATIONS, CHANGE IN DIAGNOSIS, CONDITION ON DISCHARGE, INSTRUCTIONS TO PATIENT

arteries and progression.

- currently on heparin will follow up neuro status closely

- on steroids 2° to possibility of vasculitis as the etiological factor for stroke.

[redacted]

3/11/18 [redacted] ATTENDING

3:30pm patient seen & examined by me today. I agree with Dr [redacted] physical findings & assessment above patient feels overall improved. speech somewhat easier to understand. Tolerating dysphagia diet. continues on heparin 900 u/hr

A&P

① Basilar artery thrombosis
- on heparin
- TLC o/ced 2° oozing + peripheral line
- continue steroids; random glucose 127
- hematuria resolving
- mobilize OOB

② Nutrition - tolerating dysphagia diet

[redacted]

[redacted]

Addressograph

PROGRESS NOTES

000089

PROGRESS NOTES

DATE	NOTE PROGRESS OF CASE, COMPLICATIONS, CONSULTATIONS, CHANGE IN DIAGNOSIS, CONDITION ON DISCHARGE, INSTRUCTIONS TO PATIENT

3/1/98 [illegible]

- lowest SBP x 24° = 108 @ midnight
- now on Flarinet 0.1 mg po Sil + continuing IVF
- ✓ transmitted doppler mest week + Δ to Lovenox as permeno, + continue [illegible].

- SBP's today = 116-142

- [illegible]
- continue current care/nothing to add
- anticipate transfer back to [redacted]

3/1/98 - P.T. 30'
Pt seen for thru Ex - all 4 Ext - all major muscle groups - all directions, A+AA Ex. Pt very cooperative + motivated - but very tired - had been up all morning [redacted] (before breakfast) + had just returned to bed (pt communicates well c use of communication letter board). attempted some bed mobility - pt too fatigued [redacted] PT

3-1-98 Vascular Lab: TCD performed.
Please see ~~following~~ gray "Misc" tab.
Thank you.
[redacted]

[redacted]

[redacted] sograph [redacted]

PROGRESS NOTES

000090

[redacted]

DATE | NOTE PROGRESS OF CASE, COMPLICATIONS, CONSULTATIONS, CHANGE IN DIAGNOSIS, CONDITION ON DISCHARGE, INSTRUCTIONS TO PATIENT

Neurology [redacted] flu

3/2/98

(S) Pt feels speech unchanged but that strength in general a little improved. No new c/o. triple lumen catheter removed.

(O) Tm 98.3 BP min = 107/63 @ 22^{00} & 109/66 @ 03^{00} yesterday BP now = 129/94, HR 78, RR 11, I/O ⊖426cc
Awake, Alert, NAD
CNS No improvement in dysarthria noted - Still c most difficulty c movement of tongue. CN unchanged since last exam.
Motor } unchanged as c/w 2/28 (satisfactory)
Sensory }
coord mild dysdiadokokesis FTN (B) 2° weakness

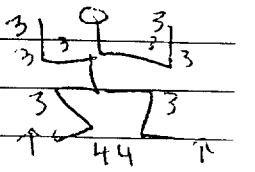

LABS 13 > 11 < 264 (91) N 79 L 15 M 5
33

142 / 4.1 | 106 / 23 | 8 / 0.4 < 104 Alb 3.7 Phos 4.C
Ca 9.1 Mg 1.8
AST (46) ALT (87) LDH 142 Alk ϕ 61
PTT = (64.9) @ 04^{45}

A/P) No further neurodeterioration since propagation of basilar thrombosis on night of 2/24-2/25 & continues show improvement of neuro deficits C.K. to transfer to DCU today, [redacted] full reinitiation of PT/OT. However, pt is not to stand up between the hours of 11pm & 6am for now until the risk of early morning drops in BP is resolved. Continue flomax & IVF's @ current rate. Check electrolytes @ 10am QD →

[redacted]

Addressograph

[redacted]

PROGRESS NOTES

[redacted]

000091

PROGRESS NOTES

DATE	NOTE PROGRESS OF CASE, COMPLICATIONS, CONSULTATIONS, CHANGE IN DIAGNOSIS, CONDITION ON DISCHARGE, INSTRUCTIONS TO PATIENT

but immediately sit/lay back down for DBP ~~≤ 65~~ ≤ 70 [redacted]
PT to ~~keep~~ monitor bp's during therapy c̄ the same parameters as above. Continue IV heparin c̄ goal PTT = 1.75–2.0x control for at least 2 more days, then will switch to lovenox 60 BiD. Continue ASA QD. Continue to follow transcranial doppler exam on regular basis & will recommend repeat MRA this friday or upcoming Monday. I think we can try to d/c the foley now, but monitor for urinary retension. Advance diet as speech feels she is ready. Continue Solumedrol at 32mg/d IV for now. [redacted] Hematology consulted last week by phone & felt all recommended tests re coagulopathy had been sent, but will be formally reviewed by Dr. [redacted] who returns today, including the low Von Willebrand factor & slightly low prot S & prot C.

12 Neurology staff
1:30 As above, if pt examined and discuss [redacted]
I'm hopeful RDs can be used to monitor therapy - See chart. [redacted]

3/2/98 Speech Pathology 1x7.5'
Pt seen in bed. Tolerated nectar thick fluids c̄ chin tuck. Unable to assess Dys II diet c̄ this time will attempt tomorrow.
Focused session on speech strategies to improve intelligibility 1) overenunciation, 2) ↓ rate, 3) stress syllables, 4) final sounds, 5) phrasing. Pt requires max verbal cues for strategies. Will continue to train strategies. Intelligibility same as last Fri but overall ↑ in tongue ROM + protrusion.

[redacted]

Addressograph [redacted]

[redacted]

PROGRESS NOTES

[redacted]

PROGRESS NOTES

DATE	NOTE PROGRESS OF CASE, COMPLICATIONS, CONSULTATIONS, CHANGE IN DIAGNOSIS, CONDITION ON DISCHARGE, INSTRUCTIONS TO PATIENT

3/2/98 [redacted] / [redacted] attending Pt seen + examined.

Pt Awake NAD stable over weekend, able to swallow purees. 3 slight ↑ strength

Pt feels well, only concerned about her speech

Exam as noted

PE Tm 98 80-90's SBP 120-140's NN 16 Neuro A+O fully

J 10 425 gnt 98% on RA

Chest: NPR ✓ clear to Auscultation

Lung: Clear (B) ✓ afeel - benign

Abd: soft NTND (+B) ✓ OLR

EXT: (-) CCCIE

Neuro: dysarthric strength 4+/5+

13/33 (20 142/109 8 4.1/23 0.7 (1.9 PTT + NN 25

Sol-medrol 32 qd
ASA
Pfrid
Florinef
Elmal
Ensure
Heparin

A1 Pt Neuro: CVA / Basilar / Art Thrombosis (Vertebral) (Probable vasculitis)

- neurostatus unAld per Neuro
- cont heparin → Lovenox 3/4 (OBID)
- cont ASA → adjusting for PTT Rat. PT. 20
- MRA end of week
- Rehab (speech/OT)

2. Adrenal insuf / AM ↓BP: cont bed rest @ night:
- 2° steroids → Florinef

3. PVY / LE prophylaxis

4. Atelectasis prevention

5. PWBC: ↓ing daily → stable to PVY

[redacted]

Unfortunate young woman c̄ presumed vasculitis
Basilar, artery thrombosis / Neurologically stable on steroid
mild hyperglycemia + Leukocytosis c̄ evidence of infection
Continue c̄ PT/OT, careful [redacted] precautions
OK to Tx to [redacted]

Addressograph

[redacted]

PROGRESS NOTES

[redacted]

000093

PROGRESS NOTES

DATE	NOTE PROGRESS OF CASE, COMPLICATIONS, CONSULTATIONS, CHANGE IN DIAGNOSIS, CONDITION ON DISCHARGE, INSTRUCTIONS TO PATIENT

·2·98 OT Note 45x1

S: when will I get better?

O: Pt seen for OOB & chair mine for dyn. motor control + balance. Pt made c UB bathing. 2° to LUE w/ cnes BUE ↓ motor control/coord. Neuro: facilitation BUE's c PNF Diagonals + wt bearing activity

A: Cognitive Intact Motor recovery

P: Neuro-programming!

[redacted]

3/2/98 Neurology staff - add

The AM hypotension may be related to hormone, the high dose Medrol was a nighttime dose.

Will split medrol to 16 BID.

[redacted]

[redacted]

Addressograph

[redacted]

PROGRESS NOTES

000094

PROGRESS NOTES

DATE	NOTE PROGRESS OF CASE, COMPLICATIONS, CONSULTATIONS, CHANGE IN DIAGNOSIS, CONDITION ON DISCHARGE, INSTRUCTIONS TO PATIENT

3/2/98 PT x45'
S: No c/c. Pt communicates via letter board.
O: Pt rec'd in bedside chair. Worked on sit ↔ stand min Ⓐ. Pt has weakness overall & was only able to stand min Ⓐ x 3'. AFO on Ⓛ foot. Txfr mod Ⓐ chair → bed. Bed therex AP, SLR, SAQ, heel slides 1x10. Pt performed therex slowly & did not complete full arc of motion. T. SLR, pt req'd min Ⓐ & quickly fell into extension, indicated ↓d quad strength. Pt left in care of Nsg + txford to Dou.
A/P: ↓d strength & motor control.
Cont. txfr trng, bed mobility. Progress as tol to GT.
[redacted]

3/2/98 Speech Pathology 1x30'
Orders received to reassess swallowing as pt was transfered to [redacted]. Recomm: Dysphagia II diet and nectar thick liquids using chin tuck. Ensure shakes + mighty shakes are OK. ST to continue 5-6 x wk 2-3 weeks. – [redacted]

3/2 Intensive Med
He's talent. Moves about. Osmole down. Interior under better control. Monitoring [redacted]

3/2/98 Vascular Lab – TCD performed
Please see gray "miscellaneous tab for prelim results.
Thank you.
[redacted]

Addressograph

[redacted]

PROGRESS NOTES

[redacted]

000095

PROGRESS NOTES

DATE	NOTE PROGRESS OF CASE, COMPLICATIONS, CONSULTATIONS, CHANGE IN DIAGNOSIS, CONDITION ON DISCHARGE, INSTRUCTIONS TO PATIENT

3/2/98 clinical pharmacy note: Heparin.
S/O: Pt. currently on Heparin drip @ 850 u/hr.
PTT @ = 52.7
control = 30.6
H/H = 11.0/33.3 plt = 269.
A/P: PTT ratio = 1.72
within desired range.
will continue same rate.
✓ Hemogram in AM.
Will continue to follow.

[redacted]

3/2/98

Rehab/Rheum

Basilar artery thrombosis
Improved as noted
Swallowing ↑
Dysarthria less
Moving all extremities c̄ ↑ strength
Though still ↓ coordination

Very ~~excep~~ excited re basilar doppler flow on TCD

P→ Continue heparin + ASA
Bedside PT/Speech
Solumedrol dose per neurology

[redacted]

[redacted]

PROGRESS NOTES

PROGRESS NOTES

DATE	NOTE PROGRESS OF CASE, COMPLICATIONS, CONSULTATIONS, CHANGE IN DIAGNOSIS, CONDITION ON DISCHARGE, INSTRUCTIONS TO PATIENT
3/3/98	Speech Pathology 1x75'
	Pt a+ox4 but labile. Trying to cope c̄ illness + prolonged hospitalization & SLP (A) c̄ bfast. Cough x2 when drinking thickin liquids c̄ chin tuck c̄ 300cc fluid. Wet vocal quality x2 1-2 minutes p̄ swallow; pt cued to dry swallow. Trained additional OM exercises + reviewed diaphragm breathing. Intelligibility severly impaired c̄ 2 word level but discrete OM mvmts improved. Continue.
	[redacted]

[redacted]

PROGRESS NOTES

Addressograph

[redacted]

000097

PROGRESS NOTES

DATE	NOTE PROGRESS OF CASE, COMPLICATIONS, CONSULTATIONS, CHANGE IN DIAGNOSIS, CONDITION ON DISCHARGE, INSTRUCTIONS TO PATIENT

Neurology [redacted] f/u

3/3/98
1050 am

(S) ~~Pt~~ [redacted] Pt states she is feeling stronger c̄ no new c/o x̄ feels a little bloated. foley cath removed & pt states no difficulty urinating (VO x2 today) & ⊕ bm recently.

(O) Tm 98.9, BP 126/83, HR 76, RR 20, I/O ⊕626cc
BP min = 118/78 @ Midnight last night.

~~Ex~~ able to protrude tongue slightly more today. Dysarthria slightly improved.
Strength (B) VE's unchanged
↑strength (R) LE (Now 4+/5 (R) hip flexion & 5/5 knee flex/ext & ankle dorsi/plantar flex (R) LE).
C/W exam unchanged neuro exam

Meds
ASA 325mg PO QD
florinef 0.1mg PO BID
Solumedrol 16mg IV Q12°
heparin drip 850 units/°
pepcid
elavil 30mg PO Qhs.
ensure

ABD — mildly distended abdomen.

LABS 14 > 11 / 34 < 90 / 274 142 / 39 | 104 / 28 | 11 / 0.4 < 112 Alb 3.9 Ca 9.6 Phos 4.9 Mg 1.9

ALT = (90) AST = 38, LDH = 90, Alk Φ = 66. No PTT yet today.
LC Doppler flow @ 45cm/sec in B.A. yesterday.
technical diff c̄ visualization of V.a.'s yesterday.

A/P) Continues to improve slowly neurologically s/p the last post-circulation infarct of 2/24/98. 2° basilar artery thrombosis extension. Unsure if can rely on the trans-cranial doppler finding of basilar artery recannalization (would not have expected it so soon). Will discuss c̄ Dr [redacted] when to switch from IV heparin to SQ lovenox. Please make sure PTT checked today. Night-time BP's seem improved. Awaiting today's orthostatic check results. Recommend to ✓ post-void

[redacted]

Addressograph

[redacted]

PROGRESS NOTES

[redacted]

[redacted]

000098

PROGRESS NOTES

DATE	NOTE PROGRESS OF CASE, COMPLICATIONS, CONSULTATIONS, CHANGE IN DIAGNOSIS, CONDITION ON DISCHARGE, INSTRUCTIONS TO PATIENT

residual c̄ mild abdominal distension. Pt is doing very well clinically c̄ continued neurodeficit improvements. [redacted]

3-98 OTNote 45X1

S: Need to go bathroom pointing c̄ comm. board.

O: Pt seen for ODB to BR [redacted] motor control for UE Advancement toility c̄ IVPA. Pt then seen for UE motor control. initiated clipboard to facilitate c̄ use c̄ communication + simple writing tasks.

A: motivated toward recovery

P: cont c̄ neuro programming.

[redacted]

3/5/98 1:02 S) Pt reports that she feels much better of complaints.

O7 VSS Tmax 98.9

14.3 > 11.4 / 33.8 < 274 142 / 3.9 | 104 / 28 | 11 / 04 < 112

HEENT: pinto palmbal conjunctivae, anisotropic sclerae of nasal & aural DLE

Neck: supple

Lung: CTA bilaterally

Abdomen: soft, nontender BS present

Ext: no edema

Neuro - motor 5/5 CN II-XII grossly intact still with dysarthria

[redacted]

PROGRESS NOTES

Addressograph

[redacted]

PROGRESS NOTES

DATE	NOTE PROGRESS OF CASE, COMPLICATIONS, CONSULTATIONS, CHANGE IN DIAGNOSIS, CONDITION ON DISCHARGE, INSTRUCTIONS TO PATIENT

3/3/98 PTx30'

S: No c/c. Denies numbness/tingling.

O: Pt seen for functional mobility training. Bed mobility min (A). Txfr to commode min (A). Standing c̄ FWW sup (A) x 5' 10'. Therex of APs, OS, Heel slides, SLR (B) LE.

Pt able to contract abdominals 1x10 for trunk control training. Light touch intact.

A: Good gains over 3/2/98 tx. Pt had more control over volitional movements. They were steadier s̄ collapse @ end range of movement.

P: Cont. therex + WB activities. Begin gait when cleared by MD.

[redacted]

3/3/98 Clinical Pharmacy note: Re-Heparin

S/O: Pt cont. on Heparin @ 850 u/hr s/p stroke.

PTT = 61.1 sec (Ratio = 2.05x control) 2N reports oozing from periph IV site only

H/H = 11.4/33.8

plats = 274

A/P: 1) Above PTT w/in desired goal range of 1.75-2.0x control as dictated per neurology.

2) H/H is stable

3) Will continue Heparin at current rate for now; recheck PTT, hemogram in am.

4) Will follow up c̄ Neurology c̄ future goals of Heparin or time to Δ therapy to LMWH or Coumadin

5) Will follow c̄ you.

[redacted]

[redacted]

Addressograph

[redacted]

PROGRESS NOTES

[redacted]

PROGRESS NOTES

DATE	NOTE PROGRESS OF CASE, COMPLICATIONS, CONSULTATIONS, CHANGE IN DIAGNOSIS, CONDITION ON DISCHARGE, INSTRUCTIONS TO PATIENT

3/3/98

Rehab

Discussed c DR [redacted] course and prior studies. He will see for eval and additional opinion re Rx

The transcranial doppler study noted.

Pt continues on heparin for present & ASA. May be a candidate for SQ heparin dose adjusted to maintain therapeutic PTT

In view of doppler findings a repeat MRI of angio will be planned at some point in hospital course

Bedside PT / speech / OT to continue

Rehab transfer later in week once decision re heparin / Lovenox

[redacted]

Addressograph

[redacted]

[redacted]

PROGRESS NOTES

PROGRESS NOTES

DATE	NOTE PROGRESS OF CASE, COMPLICATIONS, CONSULTATIONS, CHANGE IN DIAGNOSIS, CONDITION ON DISCHARGE, INSTRUCTIONS TO PATIENT
	[redacted]
8/3/98	A/P ① CVA 2° to thrombosis of basilar artery / vertebral artery. continue with heparin / ASA. Agree with switching ones to Lesonoy. continue ASA
	② probable vasculitis - continue with steroids.
	③ Probable adrenal insufficiency, continue solumedrol on BID,
	④ stable to floor. will sign off from case
3/3 12:15	[redacted] Staff: [redacted] Seen & examined [redacted] me today on rounds to Dr [redacted] Pt sitting in chair. Alert awake. Has expressive aphasia. Afebrile. I [illegible] to Dr [redacted] [illegible]. Pt. ↑ WBC likely 2° [illegible]. - pt [illegible] stable - I agree pt can be transferred to Ward today
	[redacted] Addendum - CVR is clear 3/7/98

[redacted]

Addressograph

[redacted]

PROGRESS NOTES

000102

[redacted]

DATE | NOTE PROGRESS OF CASE, COMPLICATIONS, CONSULTATIONS, CHANGE IN DIAGNOSIS, CONDITION ON DISCHARGE, INSTRUCTIONS TO PATIENT

3/3/98 Hematology

Reason for consult: Recurrent strokes and basilar artery thrombosis

History from chart - patient dysarthric and old records not available

Patient is a 42 y.o. ♀ with history of thrombotic strokes x 4. Patient was recently transfered to the rehabilitation units with a left pons infarct and clot in the basilar artery on 2/10/98. During her evaluation the patients heparin & aspirin were temporarily stopped and patient had an increase in her L pons infarct, & basilar artery clot with extension into the vertebral arteries. Also question of new lesion in Rt pons.

Prior to the third thrombotic stroke the patient was in compliance with an INR of ≈ 2.0.

PMH - One successful pregnancy, h/o past hx of DVT & thrombosis. No hx of hypertension, diabetes & smoking

Family Hx - mother with atherosclerotic cardiovascular disease, strong hx of maternal family atherosclerosis and strokes

ROS. Predominately neurologic

Physical exam:

[redacted]

PROGRESS NOTES

Addressograph

[redacted]

000103

[redacted]

PROGRESS NOTES

DATE	NOTE PROGRESS OF CASE, COMPLICATIONS, CONSULTATIONS, CHANGE IN DIAGNOSIS, CONDITION ON DISCHARGE, INSTRUCTIONS TO PATIENT

BP = 120/70 Pulse = 110/m Resp = 18 Temp = 99.
WD, WN female in NAD
HEENT - normocephalic no skin lesion
Eyes - Pupils 4mm ERRRLA EOM intact
mouth - tongue no lesion. Cannot protrude
neck - carotids 2+ & bruits. no adenopathy.
no palpable thyroid
chest - clear to AAP
back - no CVA or spinal tenderness. No skin lesion
cor - Rate 100/min Regular S1 & S2 normal
no murmur
abdomen soft & liver or spleen or no
bruise nor abdn
extremity - no lesion. Pulses 2+ symmetrical
in all extremities
neurological - Strength 4/5 LUE/RUE, 3/5 RLE,
4/5 RLE.
significant disorientation

Assessment. Patient has negative studies for hypercoagulable syndrome; Protein C, Protein S, ATIII and homocysteine. Uncertain if APCR was performed. In view of family history I am suspicious that this patient has lipoprotein A elevation. I will repeat appropriate studies in LAC-VSC lab.

I recommend continuing full dose heparin with anti-Factor Xa level = 0.7-0.5 U/ml and daily aspirin 375mg P.O.. The use of medical is reasonable in view of suspicion of vasculitis right. It should be noted that most cases of

Addressograph

[redacted]

[redacted]

PROGRESS NOTES

000104

[redacted]

DATE | NOTE PROGRESS OF CASE, COMPLICATIONS, CONSULTATIONS, CHANGE IN DIAGNOSIS, CONDITION ON DISCHARGE, INSTRUCTIONS TO PATIENT

Vasculitis should have elevated levels of von Willebrand factor, so I am uncertain as to the low levels reported. I will repeat ristocetin co-factor assay at [redacted]. Also Blood group O patients have significantly lower vWF than non group

Recommend: 1. Continue full dose IV heparin with anti-factor Xa level of 0.5-0.7
2. Continue ASA 325mg q day
3. Continuous coverage as outpatient is [illegible] difficult, I would recommend when she is stable resuming coumadin with INR of 3-3.5 (as per valve patient or lupus anticoagulant patient) along with ASA

[redacted]

3/4/98 Neuro [redacted] fm Note — Much Appreciate Hematology Input

(S) Pt is frustrated and discouraged by her condition and states she feels like "a baby" No New c/o. No longer feels abdomen is distended

(O) Tm 99.1 BP = 132/75 (BP min = 121/71 @ MN last night)
Orthostatic check yesterday:
supine 136/76
sitting 146/83
standing 134/95

[redacted]

PROGRESS NOTES

Addressograph

[redacted]

000105

[redacted]

DATE | NOTE PROGRESS OF CASE, COMPLICATIONS, CONSULTATIONS, CHANGE IN DIAGNOSIS, CONDITION ON DISCHARGE, INSTRUCTIONS TO PATIENT

Exam ↓'d abdominal distension crying.
No Δ to Neuro exam c/w yesterday: difficulty c posterior tongue movements → dysarthria
(R) facial weakness (mild-mod)
weakness all 4 ext unsd
No numbness

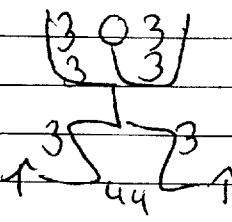

LABS PTT = 67.3
142/3.9/104/24/17/0.6 (111 Alb 3.8, Ca 9.0, Phos 3.7, Mg 2.0
ALT (105), AST 40, LDH 170, Alkφ 93
20 > 11/34 (272 N78 L16 M5 E1

TC Doppler 3/3: BA = 45 cm/sec velocity
(R) VA = 14 cm/sec velocity
(L) VA = 13 cm/sec velocity
(R) PCA = 26 cm/sec velocity
(L) PCA = 34 cm/sec velocity

A/P) Neuro exam [redacted] plateauing over last 2 days after initial good recovery s/p last posterior circulation infarct of 2/24/98, and pt quite discouraged.
- continue PT/OT/speech
- continue heparin for now per hematology recommendations c plan for coumadin at later time. Continue ASA.
- No new recommis
- Nighttime BP's stabilizing.

[redacted]

PROGRESS NOTES

Addressograph [redacted]

000106

PROGRESS NOTES

DATE	NOTE PROGRESS OF CASE, COMPLICATIONS, CONSULTATIONS, CHANGE IN DIAGNOSIS, CONDITION ON DISCHARGE, INSTRUCTIONS TO PATIENT

— OK from Neuro standpoint to move to regular bed
— check orthostatics when do BP check in middle of Night tonight XT (sometime between midnight & 4 AM) but immediately place pt back to supine position if DBP falls to below 60. (so we know if her bedrest restrictions at night can be lifted).

Neurology staff
Seen, agree c̄ above findings.
I would like to add Prozac to Elavil for [redacted]

3/4/98 Clinical Pharmacy note: Re- Heparin depression & HA prophylaxis [redacted]
Also Ant. oxidants [redacted]

S/O: Pt cont. on Heparin drip @ 850 u/hr as anti-coagulation for h/o recurrent stroke.

PTT = 67.3 sec (R = 2.2 x control)
H/H = 11.2/33.5
plats = 272

A/P: 1) Above H/H stable relative to previously reported (11.4/33.8) on 3/3
2) Per RN assessment, no S/Sx of bleed, but still some old bruises in thigh area.
3) Above PTT is therapeutic @ 2.2x control, but perhaps trending above desired range of 1.75-2x control as defined by neurology.
4) Will recheck PTT @ 1400 today and reassess @ that time.

[redacted]

[redacted]

PROGRESS NOTES

[redacted]

[redacted]

PROGRESS NOTES

DATE	NOTE PROGRESS OF CASE, COMPLICATIONS, CONSULTATIONS, CHANGE IN DIAGNOSIS, CONDITION ON DISCHARGE, INSTRUCTIONS TO PATIENT

3/4/98 PT x 45'

S: No c/c

O: Pt telemetry hooked up to PROPAQ. Pt seen for functional gait training. BP monitored during gait. GT x 100' FWW min A for safety. 3 rest stops BP highest @ 188/136. Pt back to room & seated in chair BP 136/88.

A: Pt eager for therapy. Reciprocal gait but unsteady steps & ↓d step length. 2° to weak glads. Pt used B UE extensively to assist c gait. VC given to maintain erect posture as pt wanted to watch feet during gait.

P: Cont. GT. Cont theex to strengthen LE.

[redacted]

[redacted]

[redacted]

PROGRESS NOTES

DATE	NOTE PROGRESS OF CASE, COMPLICATIONS, CONSULTATIONS, CHANGE IN DIAGNOSIS, CONDITION ON DISCHARGE, INSTRUCTIONS TO PATIENT

3/4/98 Rehab Consult
Preadmission assessment completed. Pt well known on unit. Preapprove obtained from insurance. May view to rehab unit to [illegible] [illegible] [redacted]

3/4/98 Speech Pathology 1x45'
Pt seen while sitting @ bedside for swallowing + speech. Pt managed bite sized meals c̄ some difficulty, ie occasional coughing. Uses chin tuck 96% of time 5 cueing. Reviewed strategies for speech intelligibility. Pt requires mod (A)/cues to overenunciate single words - ~40% accurate using strategy. Initiated soft blowing exercises c̄ straw in water for palatal elevation. Pt given strict instructions to do only 4 @ one time + then to rest @ least 10 minutes in between. So continue. [redacted]

3-4-98 Vascular Lab
TCD performed

[redacted]

3/4/98 Clinical Rx Note: Re-Heparin
S/O: Pt cont. on heparin 550u/hr s/p h/o recurrent stroke
PTT = 49.3 sec (ratio = 1.6x control)
A/P: 1) Given slightly below desired range per Neurology, (1.7x - 2.0x control) will recheck @ 2100 tonight.
2) PTT, hemogram c̄ am labs
3) Per RN, PTT might be slightly low [redacted] ow, if off while pt [redacted]

PROGRESS NOTES

DATE	NOTE PROGRESS OF CASE, COMPLICATIONS, CONSULTATIONS, CHANGE IN DIAGNOSIS, CONDITION ON DISCHARGE, INSTRUCTIONS TO PATIENT

3/4/98 Hematology

Patient remains well anticoagulated. Will sent for anti-factor Xa to [redacted] lab in Am. I strongly recommend that pharmacy only draw aPTTs once a day. Too frequent adjustment of anticoagulation frequently results in poorer control

[redacted]

3/4/98

Rehab

Pt moved to [redacted]
PTT to be done 1x/d
She is tired / fatigued this pm but walked to bathroom c̄ walker

BP doing better but may help to hold Elavil. Not sure that this dose doing any more than adding anticholinergic sx —

P → ① heparin for now —
② anti factor Xa
③ Rehab 1 - 2 days.

[redacted]

[redacted]

PROGRESS NOTES

PROGRESS NOTES

DATE	NOTE PROGRESS OF CASE, COMPLICATIONS, CONSULTATIONS, CHANGE IN DIAGNOSIS, CONDITION ON DISCHARGE, INSTRUCTIONS TO PATIENT
3/4/98	Anticoagulation SERVICE - Chinese Pharmacy
2245	Heparin 850 u/hr
	PTT = 22.5 (2100) subtherapeutic (goal 1.7-2x control)
	∅ S/Sx of Bleeding, ∅ SOB
	(1) A/D ↑ Heparin 900 u/hr, correct PTT is subtherapeutic in pt.
	(2) ∅ S/Sx of increased weakness of limbs or extremities
	(3) check PTT in 6 hours
	(4) ∅ Bleeding, ∅ SOB
	(5) will continue FW w/ team

[redacted]

3/5/98
900 Rehab

Discussed c̄ nursing re med. error
Pt was on Dopamine over night
instead of heparin as ordered

PTT ↓ as above

∴ bolus heparin + resume 900 u/hr
and dopamine

Exam stable this AM
Will move to Rehab soon

[redacted]

Addressograph

[redacted]

[redacted]

PROGRESS NOTES

000111

PROGRESS NOTES

DATE	NOTE PROGRESS OF CASE, COMPLICATIONS, CONSULTATIONS, CHANGE IN DIAGNOSIS, CONDITION ON DISCHARGE, INSTRUCTIONS TO PATIENT

3/5/98 Speech Pathology 1x45'
Pt seen [redacted] for speech tx: breathing; velopharyngeal + labial strengthening. Still ↓ ROM + strength alternating labial mvmts, 1° weakness (R) corner c̄ air + liquid leakage frequently. Used incentive spirometer for breath support - able to achieve 250 ml normally but when plugging nasal passage able to achieve 750 to 1000 ml consistently - [redacted] air pressure 2° compensating velopharyngeal insufficiency. Pt given 2 additional exercises + can perform (I). ST to continue.

[redacted]

-5-98 OTNote 45x1
S:
O: Pt seen for motor control w/ bearing act OOB c̄ mina. Static standing ISBA. Pt LUE Motor control is w/in VION synergy patterning. Able to deviate from pattern c̄ w/ bearing + isolation of mm groups. RUE isolated control c̄ ↓ coordination + STR.
A: ↑ Activity tolerance, dysarthric speech
P: DC to Rehab

[redacted]

[redacted]

PROGRESS NOTES

Addressograph

[redacted]

000112

PROGRESS NOTES

DATE	NOTE PROGRESS OF CASE, COMPLICATIONS, CONSULTATIONS, CHANGE IN DIAGNOSIS, CONDITION ON DISCHARGE, INSTRUCTIONS TO PATIENT

3/5/98 Clin. Pharmacy note

15 Re: Heparin Therapy for stroke

S/O. Currently on Heparin 900u/hr c̄ bolus earlier this AM.

PTT 69 @ 13^{35} INR 0.85.

control = 29.6 H/H 12.2/36

PTT, Ratio = 2.3x PLT 292

No signs/symptoms of bleeding per pt & RN

A/P:

1. PTT Ratio is slightly higher than goal of 1.8-2x control
2. ↓ Heparin slightly to 850u/hr - PLT & Hct in good range - no bleeding
3. ✓ PTT, Hemogram in AM as per Hematology recom. to only ✓ PTT once/day - Follow Factor XA per Hematology.

Whether we can start/need coumadin in this pt will defer to Dr [redacted] & Hematology to decide - We will follow pt c̄ you.

[redacted]

3/5/98 Hematology

Patient anti-factor Xa level this AM was since it was drawn while patient was off of heparin will recheck tomorrow AM. A aPTT ratio of 2.3 is not significantly higher than 2. Hopefully we will have a better concept of the level of the patient's anticoagulation when we have anti-factor Xa tomorrow AM

[redacted]

[redacted]

[redacted]

PROGRESS NOTES

[redacted]

[redacted]

000113

[redacted]

State Zip

Nearest Relative Relationship

Address Phone: Home
Business

Phone Marital Status [redacted]

Admitting Date | Surgery Date | Discharge Date

Admitting Diagnosis

Age D.O.B. Sex Religion

Admitting Physician Phone

Social Security No | Medicare No.

Previous SNF

REPORT OF PHYSICIAN

Complete all blanks
Enter "N/A" or "none" as needed

Medi-Cal No. | Insurance Group No.

Primary Diagnosis (dates, onset) Basilar artery thrombosis with multiple episodes of reprogagation 2/26/98.

Discharge Diagnosis: S/P CVA

Prognosis: ☑ good ☐ fair ☐ poor
Patient knows Diagnosis: ☑ yes ☐ no
Rehab. Potential: ☑ good ☐ fair ☐ poor

Physician Transferring Orders:

Diet: Dysphagia II diet & nectar thick liquids using clun tuck wyauthickened; Ensure TID po

Activity:

Physicial Therapy: PT/OT/speech eval. and treatment bid

Treatments: orthostatic blood pressure and heart rate bid; if DBP falls <60 place supine immediately.

MEDICATIONS: ① Pepcid 20mg. IV q 12h
~~Stool Softner~~ ② Aspirin 325mg. crushed in applesauce qd.
~~Sleeper~~
~~Pain~~ ③ Florinef 0.1mg. crushed bid
④ Solu-Medrol 12mg. IVP q 12h
⑤ Prozac 20mg. PO qam
⑥ ACES (antioxidant) 1 cap po qd

Will physician continue care for patient? ☑ yes ☐ no

If no, physician for continued care: Address Phone

3/6/98 [redacted]
Date Physician Signature

[redacted]

NURSING EVALUATION

Patient Profile	INDEP.	ASSIST	UNABLE		USUALLY	OCC	RARELY
Bath			✓	Able to communicate	✓		
Dress		✓		Relates to others	✓		
Eating	✓			Motivated to self care	✓		
Personal Hygiene		✓		Follows directions	✓		
Transfers		✓		Bowel control (Date last BM ____)			
Ambulate		✓		Bladder (Date cath inserted ____)			

Ambulates with: ☐ cane ☐ crutches ☑ walker

☑ Alert ☐ Confused
☐ Comatose ☐ Noisy
☐ Visual impair ☐ Hard of hearing

SKIN CONDITION
Decubitus Ulcers ☐ yes ☑ no
Description
Stage Ulcer
Cultured ☐ yes ☐ no

PATIENT POSSESSIONS SENT
☐ dentures ☐ money ☐ none
☐ hearing aid ☐ jewelry
☑ glasses ☐ other
☐ cane ☐ walker
☐ wheelchair ☐ raised toilet seat
☐ egg crate ☐ sheepskin

MEDICATIONS	Freq.	Route	Last Dose	Date
PEPCID	Q12H	IV	0900	3/6
ASA	QD	PO	0900	3/6
FLORINEF	BID	PO	0900	3/6
ENSURE	TID	PO	0900	3/6
PROZAC	QAM	PO	0900	3/6
ACES	QD	PO	0900	3/6
SOLU-MEDROL	Q12H	PO	0900	3/6

HOSPITAL NURSE REPORT: (observations, treatments, education needed)

Diet: DYSPHAGIA II Time of last meal:

ALLERGIES: NKA

Vital Signs 145/90 98 - 98.1 - 16

Languages Spoken & Understood ENGLISH

3/6/98 [redacted] R.N./LVN [redacted]
Date Signature Ext

RECORDS SENT: (Xeroxed) ☐ Face Sheet ☐ H & P
☐ Results ☐ Lab ☐ X-Ray-Chest ☐ EKG
☐ Physical Therapy ☑ Other Send acute chart and old rehab chart

Type of Transportation ☐ Amb. Co. _____ ☐ Other

Date Social Worker

[redacted]

[redacted] INTERFACILITY REFERRAL FORM

[redacted]

State Zip

Address Phone: Home

Business

hone Marital Status

S M W D SEP

Admitting Date | Surgery Date | Discharge Date

Admitting Diagnosis

Age D.O.B. Sex Religion

Admitting Physician Phone

Social Security No. | Medicare No.

Previous SNF

REPORT OF PHYSICIAN

Complete all blanks
Enter "N/A" or "none" as needed

Medi-Cal No. | Insurance Group No.

Primary Diagnosis (dates, onset)

Discharge Diagnosis: see page (1)

Prognosis: ☐ good ☐ fair ☐ poor
Patient knows Diagnosis: ☐ yes ☐ no
Rehab. Potential: ☐ good ☐ fair ☐ poor

Physician Transferring Orders: medications:

~~Diet:~~ (7) Heparin drip continuous 900u/hr. check PTT in AM 3/7/98

~~Activity:~~

~~Physicial Therapy:~~ Hemogram in AM 3/7/98

~~Treatments:~~ (8) Heparin per pharmacy protocol.

~~MEDICATIONS:~~
~~Stool Softner~~
~~Sleeper~~
~~Pain~~ monitor intake and output
(9) D5 1/2 NS c̄ 20mEq/L KCL @ 50cc/hr.

Will physician continue care for patient? ☑ yes ☐ no

If no, physician for continued care: Address Phone

3/6/98 [redacted]
Date

Transferred to: [redacted] Address [redacted]

RECORDS SENT: (Xeroxed) ☐ Face Sheet ☐ H & P
☐ Results ☐ Lab ☐ X-Ray-Chest ☐ EKG
☐ Physical Therapy ☑ Other Send quite chart and old rehab chart.

Type of Transportation ☐ Amb. Co. _____ ☐ Other

Date Social Worker

NURSING EVALUATION

Patient Profile	INDEP.	ASSIST	UNABLE		USUALLY	OCC	RARELY
Bath				Able to communicate			
Dress				Relates to others			
Eating				Motivated to self care			
Personal Hygiene				Follows directions			
Transfers				Bowel control (Date last BM _____)			
Ambulate				Bladder (Date cath inserted _____)			

Ambulates with: ☐ cane ☐ crutches ☐ walker

☐ Alert ☐ Confused
☐ Comatose ☐ Noisy
☐ Visual impair ☐ Hard of hearing

SKIN CONDITION
Decubitus Ulcers ☐ yes ☐ no
Description
Stage Ulcer _____
Cultured ☐ yes ☐ no

PATIENT POSSESSIONS SENT
☐ dentures ☐ money ☐ none
☐ hearing aid ☐ jewelry
☐ glasses ☐ other _____
☐ cane ☐ walker
☐ wheelchair ☐ raised toilet seat
☐ egg crate ☐ sheepskin

MEDICATIONS	Freq.	Route	Last Dose	Date

HOSPITAL NURSE REPORT: (observations, treatments, education needed)

Diet: Time of last meal:

ALLERGIES:

Vital Signs

Languages Spoken & Understood

Date Signature R.N./LVN. Ext.

PAGE (2) of 2

[redacted]

[redacted]

INTERFACILITY REFERRAL FORM

[redacted]

000115

PROGRESS NOTE

DATE | NOTE PROGRESS OF CASE, COMPLICATIONS, CONSULTATIONS, CHANGE IN DIAGNOSIS, CONDITION ON DISCHARGE, INSTRUCTIONS TO PATIENT

Neurology Progress Note [redacted]

3/5/98 (S) Pt feels well today. She is very happy that she was up and walking today, at first with the walker, then 150' just leaning on the PT. Pt feels voice unchanged. Events of last 24° Noted including break in Heparin Rx → Now anticoagulated aga

(O) Tm 99.4 BP = 117/70, HR 94, RR 18
Was on dopamine last night? BP min overnight was 118/89.
No orthostatic Δ recorded for overnight.
Neuro exam including tongue coordination/movement unchanged x definite ↑ in strength in (R) UE, Now 5/5 proximally (!) & 5-/5 distally c only mild dysdiadokinesis [redacted] on FTN (R).

LABS PTT/R = 69 @ 1335
143 | 101 | 20 / 132
4.2 | 28 | 0.7
19 / 12 / 242
36

TCD 3/4/98:
BA 41 cm/se
(R) VA 46 cm/s
(L) VA 24 cm/

Current Meds Pepcid
ASA 325 QD
Elavil 30 qd → d/c'd
flonase 0.1 BID
Solumedrol 16 Q12° IV
Prozac 20mg QAM
Antiox formula QD
Heparin Drip
D5½NS @ 50cc/°

(A/P) ↑ strength in (R) UE today as c/w last few days c/s/p multiple posterior circul. strokes 2° progressive b.a. & va. Thrombosis; last stroke 2/24/98). Agree c transfer back to rehab. Will continue →

[redacted]

PROGRESS NOTES

Addressograph

[redacted]

000116

PROGRESS NOTES

DATE	NOTE PROGRESS OF CASE, COMPLICATIONS, CONSULTATIONS, CHANGE IN DIAGNOSIS, CONDITION ON DISCHARGE, INSTRUCTIONS TO PATIENT

N heparin & ASA & Solumedrol for Now @ current doses. Will reorder the orthostatic check for tonight. Hematology has ordered anti factor Xa level for tomorrow AM. By TCD, flow continues to open up in posterior circulation → [redacted] confirmatory MRA on Monday. [redacted]

3/5 1600 Neurology Staff

- She continues to clinically improve in body fxn, and pseudobulbar state; she tongue position lies in the low pons, anteriorly, or medulla, though MRI didn't show latter lesion.
- The choice of coumadin c̄ INR 3-4 + ASA 325 vs heparin SQ adjusted to PTT is not a decision I can make based on literature. I would want to know of a probable ~~coag~~ coagulation pathway defect that one or other remediates in sup-or fashion, if possible. The coumadin failure in past doesn't obviate success at higher INR.
- Will defer to Dr [redacted] on this point.
- Agree c̄ [redacted] to frozen alone, sho no literature on orthostatic hypotension c̄ Ebrial, that has guided Rx for me.
- Agree c̄ [redacted] to 20mg x 7d then 16mg c̄ aim to stabilize in 2 wks more to 8mg. [redacted]

[redacted]

[redacted]

Addressograph

[redacted]

PROGRESS NOTES

[redacted]

000117

PROGRESS NOTES

DATE	NOTE PROGRESS OF CASE, COMPLICATIONS, CONSULTATIONS, CHANGE IN DIAGNOSIS, CONDITION ON DISCHARGE, INSTRUCTIONS TO PATIENT

3/5/98
Rehab
7pm Transfer will be tomorrow on heparin over weekend c̄ F/u MR angio next week

[redacted]

3/6 Clin/Pharmacy note
Re: Heparin Anticoag for stroke c̄ basilar artery thrombosis

S/O Currently on Heparin 850u/hr
PTT 41.7 PTT Ratio = 1.4x
PT/INR 9.9/0.88
H/H 11.7/34.9 PLT 286
No signs bleeding / bruises per pt & RN.

A/P ① PTT Ratio is lower than desired range of 1.8-2x control (range was per neurology request due to her bleeding episodes while on heparin!) (↓ from before goal 2-2.5x).
② Discussed c̄ Dr [redacted] from Hematology, ↑ Heparin slightly to 900 u/hr. ✓ Anti Factor XA today for correlation
PLT, Hct stable. Hold warfarin for now
③ ✓ PTT & Hemogram in AM —
④ Will follow pt c̄ you. Thank you [redacted]

[redacted]

PROGRESS NOTES

Addressograph

[redacted]

[redacted]

PROGRESS NOTES

DATE	NOTE PROGRESS OF CASE, COMPLICATIONS, CONSULTATIONS, CHANGE IN DIAGNOSIS, CONDITION ON DISCHARGE, INSTRUCTIONS TO PATIENT

3/6 P.T. x 45'

S: Pt c/o (L) knee weakness p session. Said that the knee "keeps going backward."

O: Pt seen for gait training + strengthening. GT x 250' c FWW. Tactile + VC given to facilitate normal gait. Pt locks (L) foot dorsiflexion rapidly locks out (L) knee for stability 2° to weakness. Pt did not lock out (L) knee today. Therex given to (B) dorsiflexors, quads, hamstrings, hip flexors & plantarflexors. Pt had 5cd excursion in (L) musculature. Clonus noted (B) plantarflexors that abated p 5 seconds.

A/P: Continued muscular weakness (L) > (R). Significant gait deficits of (L) dorsiflexion lack & (L) knee hyperextension still in evidence. Cont. strength & gait training M.D. Planning to D/C pt to rehab today.

[redacted]

[redacted]

PROGRESS NOTES

Addressograph

[redacted]

[redacted]

PROGRESS NOTES

DATE	NOTE PROGRESS OF CASE, COMPLICATIONS, CONSULTATIONS, CHANGE IN DIAGNOSIS, CONDITION ON DISCHARGE, INSTRUCTIONS TO PATIENT

Neurology [redacted] f/u Note

3/6/98

(S) Feeling stronger today. Ambulated again with physical therapy. Speech feels tongue movement is improving but palatal movement is completely lost & not improving. Nevertheless, speech feels she should soon be ready for thin liquids.

(O) Tm 98.3 BP @ ~5AM 123/77 HR 72
RR 16 127/87 HR 84
118/84 HR 117

Awake, Alert, NAD
Neuro exam - No clear change as c/w yesterday
(? mild ↑ strength prox (R.LE)

LABS [redacted] antifactor Xa level not yet back.

(A/P) s/p multiple posterior circulation strokes 2° progressive b.a. & v.a. thrombosis c̄ last stroke 2/24/98. Neuro exam stable. No new recomm's. Pt returning to rehab today, c̄ TMVF's ordered 2° orthostasis by HR on last night's exam & only taking in thickened liquids @ this time. Let's check orthostatics one more time in early morning hours [redacted] lifting her nighttime bed rest restrictions.

Ass above. No new recommendations. Will ✓ MRA on [illegible] and compare c̄ TCD

[redacted]

graph

[redacted]

PROGRESS NOTES

000120

[redacted]

PROGRESS NOTES

DATE	NOTE PROGRESS OF CASE, COMPLICATIONS, CONSULTATIONS, CHANGE IN DIAGNOSIS, CONDITION ON DISCHARGE, INSTRUCTIONS TO PATIENT
3/6/98	Speech Pathology 1x60' + DC Summary Reviewed OM + breathing exercises c̄ pt - supervised level for technique. Able to prolongue tone 15 seconds x1 but subsequent trials only up to 6 seconds - difficulty c̄ coordination. DC summary written as pt will return to rehab this pm. ST to continue 5-6x wk 2-3 wks. [redacted]
3/6/98	O.T. NOTE x 60' S: Pt. in good spirits this a.m. O/A: Pt. seen in a.m. for therapeutic activity. Pt. supine → sit c̄ supv; sit → stand c̄ supv, engaged in card game activity in standing manipulating cards in bilat. UE's dealing cards in various ways to work on fine motor coordination. Pt. tolerated 45 min. standing during activity, improved handling of cards during cour[redacted]ession. P: Pt. D/C'd to rehab to continue toward long term goals [redacted]

[redacted]

[redacted]

PROGRESS NOTES

000121

PROGRESS NOTES

DATE	NOTE PROGRESS OF CASE, COMPLICATIONS, CONSULTATIONS, CHANGE IN DIAGNOSIS, CONDITION ON DISCHARGE, INSTRUCTIONS TO PATIENT
03/06/98	Cerebrovascular fellow
	Pt. still c difficulty attempting speech, swallowing, also has some residual (R) sided weakness
	PE: MS: Fully intact. Still emotionally labile at times. CN: EOMI, VFF, corneal slightly more brisk on (R) than (L). Good facial movement (B), symmetrical tongue, midline bulk, very little palatal movement. Tongue slightly toward (R) at rest, poor lateral movement (B). MOTOR: 9'd tone throughout. (R) extremities near-normal strength, slightly slow limb movement. (L) side generally 4+, slow limb movement. SENS: Tap, prop-intact.
	TCD's: Slow improved flow from 1st study on 03/01. Continued flow to the level studied does not confirm basilar tip patency - blood may be exiting through SCA's. Indication of basilar patency should be tracked by PCOM signals (not part of standard testing). ~~Reversal~~ Reversal cessation or prominent diminution of ~~[illegible]~~ posterior flow in PCOM's would indicate opening of basilar tip. PCA's are still well-perfused.
	(A) 1. Posterior vessel vasculitis c overlying thrombosis. 2. Pt. c some improvement from latest (L) partial infarct. 3. Doppler indicate improved flow in vertebral + basilar arteries. (R) 1. Continue anticoagulation, steroids. 2. Maintain DBP generally 90-100. 3. Follow [redacted] signals on Doppler to assess basilar tip patency. [redacted]

[redacted]

PROGRESS NOTES

Addressograph

[redacted]

000122

DATE | NOTE PROGRESS OF CASE, COMPLICATIONS, CONSULTATIONS, CHANGE IN DIAGNOSIS, CONDITION ON DISCHARGE, INSTRUCTIONS TO PATIENT

3/6/98

Rehab

41yo F bilingual ed kindergarten teacher returns for further Rehab of stroke 2° to basilar artery thrombosis associated c vasculopathy/vasculitis that is suspected to be ephedra related c mild CSF monocytosis

Initial stroke 12/25, 2ND stroke 1/6, 3RD 2/6 and 4th event while in Rehab 2/25 while on lovenox ~~Coumadin~~ c INR = 1.11 on 2/19

Pt placed on IV hyparin and ASA after MRA showed progressive basilar artery / vertebral a. thrombosis and evolving pontine stroke

BP supported c flowing after dopamine DC and also Elavil has been DC

The pt received 5 daily 500 mg Solumedrol doses just prior to most recent stroke + now on tapering Medrol

~~90~~ +

Exam 97 - 20 - 145/90

Alert dysarthric

HEENT normal funds / pharynx

chest clear

[redacted]

[redacted]

PROGRESS NOTES

000123

PROGRESS NOTES

DATE	NOTE PROGRESS OF CASE, COMPLICATIONS, CONSULTATIONS, CHANGE IN DIAGNOSIS, CONDITION ON DISCHARGE, INSTRUCTIONS TO PATIENT

Cor Reg
abd. soft/ne bowel sounds

extremities full ROM / intact pulse
neuro
Dysarthria improved
swallowing po meals / liquids
motor
LUE/LLE clumsy but 3+/5 strength
throughout
Ø sensory deficit

Imp ① S/P basilar artery infarct
pontine infarct
② suspected ephedra vasculitis

③ Anticoagulation

Rx Resume full Rehab OT/PT/speech/dysph

PTT daily

heparin IV until angion (MR) next week
then higher dose Coumadin INR 3-3.5

Keep BP ~ 90-100 diastolic

[redacted]

[redacted]

PROGRESS NOTES

Addressograph

[redacted]

000124

PROGRESS NOTES

DATE | NOTE PROGRESS OF CASE, COMPLICATIONS, CONSULTATIONS, CHANGE IN DIAGNOSIS, CONDITION ON DISCHARGE, INSTRUCTIONS TO PATIENT

3/17/98 Clinical Pharmacy Rx: Heparin

S/O 41 y.o. female on heparin for basilar artery thrombosis.

Heparin @ 900u/hr
PTT this am - 60.9s (~2x control)
H/H 11.4/34.3 Plt 266

A/P 1) PTT ratio within desired 1.75-2x control
2) H/H, platelets stable
3) continue Heparin @ 900u/hr
4) ✓ PTT, hemogram in am.

[redacted]

Neurology [redacted] f/u

I/E

(S) PI feels well 5 c/o. LABS Ristocetin cofactor = 166% (>50)
Antifactor Xa activity from 3/6 pending

(O) T 98.1, HR 16 @ 0410 this AM P 130/64 HR 82
T 130/91 HR 102

Neuro Exam dysarthria maybe slightly improved today. When asked to say "I like walking" she was able to say the "I" "Li" "Wa" & "Ng" sound, not the "K" sounds. Palate still c minimal movement & still difficulties protruding tongue. CN's/motor/sensory exam unchanged.

(A/P) S/p multiple infarcts 2° progressive posterior circulation thrombosis, thought 2° vasculitis, c pt now c no further strokes since 2/25/98 & slowly recovering/improving in neuro deficits. Nighttime low BPs seem to have resolved.

[redacted]

PROGRESS NOTES

Addressograph [redacted]

000125

PROGRESS NOTES

DATE	NOTE PROGRESS OF CASE, COMPLICATIONS, CONSULTATIONS, CHANGE IN DIAGNOSIS, CONDITION ON DISCHARGE, INSTRUCTIONS TO PATIENT

Would keep on IV fluids for now c̄ the expectation that she will soon be able to tolerate thin liquids in her diet & then will be able to d/c the IVF's. Continue heparin c̄ PTT goal 1.75-2x Normal & monitoring antifactor Xa activity. Continue Solumedrol @ 12mg IV BID for Now. continue ASA. We will flu again on monday p̄ her MRA. Please call if any new neuro issues or any questions before then.

[redacted]

Neology
Attendg [redacted] by me
3-7 [illegible] stable Neurologically, findgs on pre-Ar [redacted] severe [illegible] effect on Solumedrol/Heparin/ASA & [illegible] [illegible] [redacted]

10 [illegible]
[illegible]
[illegible]
[illegible]
[illegible]
[illegible]
[illegible]
[illegible]
[illegible]
[illegible]

[redacted]

3/7/98 Hematology

Check patients anti-factor Xa from 3/6/98 was 0.47 units which is mid-therapeutic range. I would consider starting Coumadin on monday with therapeutic goal being an INR of 3 to 3.5, combined with ASA. Hypercoagulation w/u is continuing.

[redacted]

[redacted]

PROGRESS NOTES

000126

PROGRESS NOTES

DATE

NOTE PROGRESS OF CASE, COMPLICATIONS, CONSULTATIONS, CHANGE IN DIAGNOSIS, CONDITION ON DISCHARGE, INSTRUCTIONS TO PATIENT

3.8.98 Psychiatry

Pt examined & chart review. Still has extreme lability of affect Pt attempts to speak and then begins crying.

A: affective lability

P: When stable SSRI's

[redacted]

[illegible]

(1) Pt Frustrated by [illegible] a little [illegible] no [illegible] (1/2)

(2) [illegible] 130/84 → 151/97 [illegible]

[illegible]

[illegible]

[illegible]

(−) [illegible]

(−) [illegible]

[redacted]

PROGRESS NOTES

Addressograph

[redacted]

000127

PROGRESS NOTES

DATE	NOTE PROGRESS OF CASE, COMPLICATIONS, CONSULTATIONS, CHANGE IN DIAGNOSIS, CONDITION ON DISCHARGE, INSTRUCTIONS TO PATIENT

16.4 / 34.3 266

PTT 66.9

(A) (1) post CVA [illegible]
(2) Hypertension [illegible]
(3) hypertension
(4) steroids.

(P) [illegible] 30g Q 6° for SBP > 140
will see [illegible]
[illegible] steroid [illegible] 12 Q 12 [illegible]
MRA in AM.

[redacted]

3/8/98 Clinical Pharmacy Re: Hepatin
Hepatin @ 900u/hr

PTT 66.0s H/H 11.2/32.4 platelets 251

P/P 1) PTT within desired range 1.75-2x control
2) continue hepatin @ 900u/hr
3) PTT, hemogram in am
4) H/H stable

[redacted]

Addressograph

[redacted]

[redacted]

PROGRESS NOTES

000128

PROGRESS NOTES

DATE	NOTE PROGRESS OF CASE, COMPLICATIONS, CONSULTATIONS, CHANGE IN DIAGNOSIS, CONDITION ON DISCHARGE, INSTRUCTIONS TO PATIENT

3/8/98 Neurology [redacted]

3:05 pm Called for pt c̄ c/o some blurring of vision c̄ near vision → reading this AM. This ~~etc~~ complaint has improved since. No associated A/A or dizziness. No diplopia, no vertigo.
No reports of worsening of SX's p̄ therapy.
BP 145/89

EXAM. Pt c̄ baseline B/L ~~[illegible]~~ Facial weakness (weak grimace), ∅ palatal rise, weak tongue movements.
Pt is awake, conversant. No confusion
Pt able to read print of her book c̄ B/L eye, s̄ difficulty.
Pupils 4-2.5 mm B/L c̄ light + near.
EOMI s̄ nystagmus.
Fundi c̄ ? of small plaque ∴ blood vessel ∴ (2) ~~retinal~~ retina (at "7 oclock") c̄ no evidence of more fine layer infarction.

3/8/98 PTT 66.0 20.5 32/251

(1) Pt c̄ baseline artery thrombosis on antiplatelet / anticoagulation / corticosteroids. Pt's exam appears unchanged.
Blurred vision etiology uncertain. The pt has had slightly higher BP's today 96-102 DBP.
Pt started on diltiazem 30 mg p.o. Q6° prn to avoid HTN in this pt on anticoagulation.
Would be careful to avoid any lowering of BP below the pt's baseline as this may decrease perfusion pressure c̄ her posterior circulation.
I spoke c̄ nursing ~~[illegible]~~. to monitor this.

[redacted]

Addressograph

[redacted]

[redacted]

PROGRESS NOTES

PROGRESS NOTES

DATE	NOTE PROGRESS OF CASE, COMPLICATIONS, CONSULTATIONS, CHANGE IN DIAGNOSIS, CONDITION ON DISCHARGE, INSTRUCTIONS TO PATIENT

Neuro f/u

3/9/98 (S) Feels well today/stronger. Had c/o lightheadedness (both o- & ♀ & ♀) yesterday c̄ ass'd blurry vision, but the lightheadedness resolved & blurry vision is almost back to Normal. No eye pain/weakness/numbness. No other c/o.

(O) Tm 98.4 BP125/86 HR86 RR 20
BP min 125/86. Awake, Alert, NAD
Tongue protrudes further today & speech is clearer, though still c̄ no palatal movement → still quite dysarthric.
O/W CN's/motor/sensory/coord unchanged as c/w last exam.

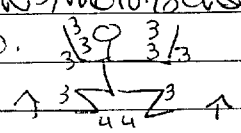

Ambulating c̄ walker safely as long as she takes her time & concentrates. Clearly still weak (B) LE's c̄ gait & has to work to avoid hyperext (B) knee. Also diff # dorsiflexing (L) ankle.

LABS

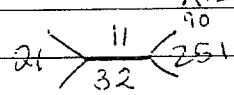

N^{78} $Bnds^{7}$ L^{8} M^{6}



Alb 4.0 TP = (4.5) Ca 9.1 Phos 3.8 TB 0.3 Mg 2.0
Alk ϕ 28 AST 15 ALT 38 LDH 143 Chol (224)

PTT = 66

~~3/8~~ 3/6 Antifactor Xa = 0.47 (0.35-0.67)
→ Dr. [redacted] recomm = 0.5-0.7

A/P S/p multiple pontine infarcts (B) 2° b.a/v.a. thrombosis 2° vasculitis. No further strokes since 2/24/98, and responding to rehab efforts c̄ continued slow but steady improvement.
- MRA & TCD will be repeated today.
- Would D/C the PRN diltiazem ordered over the weekend, since for now I am much more concerned re low bp than mildly elevated, & in fact we have been trying to keep the BP slightly elevated.
- Discussed Antifactor Xa level above c̄ Dr. [redacted] who feels this level is adequate
- Dr. [redacted] recommends to start coumadin tonight (7.5 mg tonight → 7.5 mg tomorrow night) & continue →

MEDICATIONS
- Solumedrol 12mg IV BID
- ASA 325mg PO QD
- heparin drip
- Depcid 20mg IV Q12°
- florinef 0.1mg PO BID
- Antioxidant formula
- Prozac 20mg PO QAM
- Rancho Recipe
- DSS liquid
- Ensure
- PRN NoM/dulcolax/tyl.
- Diltiazem 30mg PO PRN SBP>140

[redacted]

PROGRESS NOTES

Addressograph

[redacted]

000130

PROGRESS NOTES

DATE	NOTE PROGRESS OF CASE, COMPLICATIONS, CONSULTATIONS, CHANGE IN DIAGNOSIS, CONDITION ON DISCHARGE, INSTRUCTIONS TO PATIENT
	Heparin until INR ~3.0 x 24°.
	[redacted]
3/9	Clinical Pharmacy Re Heparin Pt continues on heparin currently @ 900 u/hr PTT 54.5 PLT 268 H/H 11.8/35 1) Current PTT in desired range, goal 1.7-2 x control will continue current rate. 2) H/H stable
	[redacted]
3/9/98	Rehab. 12:00 noon Pt. scheduled for repeat MRA today. Pt. anxious and requesting to be premedicated prior to procedure Plan: Ativan 1mg po x 1 prior to MRA.
	[redacted]
3-9-98	Vascular Lab TCD performed. Please see brown tab. Thank you
	[redacted]

[redacted]

Addressograph

[redacted]

PROGRESS NOTES

[redacted]

PROGRESS NOTES

DATE	NOTE PROGRESS OF CASE, COMPLICATIONS, CONSULTATIONS, CHANGE IN DIAGNOSIS, CONDITION ON DISCHARGE, INSTRUCTIONS TO PATIENT

3/9/98

Retrial

Pt had MR angio earlier
Preliminary report looks
similar to last MRA

Anticipate starting coumadin
soon but prob. best to
wait until we have MR
reviewed Pt continues on heparin

The exam is stable c̄ less
dysarthria and stable
strength

Note vaginal discharge - KOH
pending but will Rx c̄
Fluconazole / local lotrimin
b/o steroid Rx

[redacted]

[redacted]

PROGRESS NOTES

Addressograph

[redacted]

000132

PROGRESS NOTES

DATE	NOTE PROGRESS OF CASE, COMPLICATIONS, CONSULTATIONS, CHANGE IN DIAGNOSIS, CONDITION ON DISCHARGE, INSTRUCTIONS TO PATIENT
3/10	Clinical Pharmacy Re Heparin Pt continues on heparin currently on 900 u/hr PTT 48.1 PLT 260 H/H 11.5/33.9 1) PTT slightly below desired range (goal 1.5 - 2 x control (30)) will ↑ rate to 950 u/hr 2) H/H stable 3) Coumadin to be initiated pending review of MR [redacted]
3.10.98 1220	Neurology staff MRA shows complete occlusion of VB system (Ø change from previous) TCD shows some occlusion ↑ from previous, but ± ion not sure the Δ is significant After discussing case with Dr [redacted] & [redacted], we will recommend anti-coagulation to INR 3-3.5 ô coumadin, + ASA 81mg Conduct TCD 3 x (wk (good) Ø contrast angiogram at this time -- no Δ therapy would result from any finding beyond complete resolution Ø Biopsy [redacted]

[redacted]

PROGRESS NOTES

Addressograph

[redacted]

PROGRESS NOTES

DATE	NOTE PROGRESS OF CASE, COMPLICATIONS, CONSULTATIONS, CHANGE IN DIAGNOSIS, CONDITION ON DISCHARGE, INSTRUCTIONS TO PATIENT

3/10/98 Hematology

Question now is whether patient has underlying vasculitis. However, I still believe that the patient should do well on combined coumad/ASA with Hemocrit INR 2-3.5. Will discuss this case further with Dr [redacted] at Dr [redacted]

[redacted]

3/10/98

Rehab

Discussed c Dr [redacted] and coumadin being started

Dr [redacted] discussed c Dr [redacted] + plan will be coumadin to INR 2-3.5 c 81 mg ASA/d when this level achieved

[redacted]

[redacted]

PROGRESS NOTES

Addressograph

[redacted]

000134

PROGRESS NOTES

DATE	NOTE PROGRESS OF CASE, COMPLICATIONS, CONSULTATIONS, CHANGE IN DIAGNOSIS, CONDITION ON DISCHARGE, INSTRUCTIONS TO PATIENT
3/11	Clinical Pharmacy Re anticoagulation Pt continues on heparin @ 950 u/hr & received Coumadin 7.5 mg last PM PT/INR 10.5/0.93 PLT 258 PTT 65.6 H/H 11.6/34.3 1) PT/INR below desired goal of INR-3.5 will give 7.5 mg this PM 2) PTT slightly above desired range (1.75-2x control) will ↓ to 900 u/hr 3) H/H stable 4) PT/INR, PTT, hemogram in AM [redacted]
3-11-98	Vascular Lab - TCD Study performed. Please see "OPER/PROC/NEUROPHY/NON VAS LAB" tab for results. [redacted]
3.11.98 1800	Neurology staff 4BP M8/104 Examine. Doing well. Walks out side hospital. Speech clearer. Speaks good. Occupation of Pt TCD continues its improvement trend. It correlates c clinical status; MRA does not. Plan Anticoagulate ↓ ASA to 81 mg qd

[redacted]

Addressograph

[redacted]

PROGRESS NOTES

000135

[redacted]

PROGRESS NOTES

DATE	NOTE PROGRESS OF CASE, COMPLICATIONS, CONSULTATIONS, CHANGE IN DIAGNOSIS, CONDITION ON DISCHARGE, INSTRUCTIONS TO PATIENT

3/11/98

↑ medial to 48mg PO qd
watch BPs - ↑ dig > 150/100 persistently

[redacted]

3/11/98

Rehab

Agree c above. Some fluctuation
in BP but if remains
in current range we can
D/C the flounef -

Also TCD studies look like
↑ flow - ? collateral or recanalization

P> ① Monitor BP
② Steroid per DR [redacted]
③ possibly D/C flounels
④ ASA ↓
⑤ Coumadin / hep -

[redacted]

[redacted]

PROGRESS NOTES

Addressograph

[redacted]

PROGRESS NOTES

DATE	NOTE PROGRESS OF CASE, COMPLICATIONS, CONSULTATIONS, CHANGE IN DIAGNOSIS, CONDITION ON DISCHARGE, INSTRUCTIONS TO PATIENT
3/12	Clinical Pharmacy Re anticoagulation Pt continues on heparin @ 900 u/hr & received Coumadin 7.5 mg last 2 evenings. PT/INR 15.9/1.41 PTT 71.9 Ø S/Sx of bleeding 1) INR below desired range (3-3.5) but ↑ significantly from yesterday 2) PTT above desired range (1.25-2x control) will ↓ rate to 800 u/hr 3) PT/INR, PTT, hemogram in AM [redacted]
3/13/98	Clinical pharmacy Re: Anticoagulation Ø S/Sx bleeding Heparin gtt @ 800 u/hr Coumadin 7.5 mg given yesterday PTT 80.1 sec PT/INR 27.7 sec / 2.45 Control 30 sec 11.0 / 32.7 / 253 ratio 2.6 1. INR below desired range 3-3.5 but ↑'d from yesterday 2. Coumadin 5 mg PO tonight. 3. PTT above desired range 1.25-2X 4. ↓ Heparin gtt to 700 u/hr. 5. ✓ PTT, PT/INR in AM 6. Hct Stable [redacted]

[redacted]

PROGRESS NOTES

[redacted]

000137

PROGRESS NOTES

DATE	NOTE PROGRESS OF CASE, COMPLICATIONS, CONSULTATIONS, CHANGE IN DIAGNOSIS, CONDITION ON DISCHARGE, INSTRUCTIONS TO PATIENT

Neurology [redacted] f/u

3/13/98

(S) Pt feels as if she is improving & is in a good mood. She tells me d/c is tentatively planned for saturday 3/21/98.

(O) Afeb 135-154/80-96 HR70 RR19
Awake, Alert, NAD
Speech slightly more clear
Strength slightly ↑ prox (L)UE/prox (L)LE

(A/P) INR almost @ goal range 2.4,5 ⇒ desired ~3-3.5
No Δ to current recomm's; continue same management.

[redacted]

Staff
Agree c̄ present mgmt. Mildly elevated BPs OK, c̄ max 150/100-110. ØØ c̄ meds needed at this time (ie Florinef) will keep on standard of unchanged dose. ✓ Chem 7 weekly for 4 glucose & KT.

[redacted]

3-13-98 TCD performed.
Please see brown tab.

Thank you.

[redacted]

[redacted]

PROGRESS NOTES

Addressograph

[redacted]

000138

DATE | NOTE PROGRESS OF CASE, COMPLICATIONS, CONSULTATIONS, CHANGE IN DIAGNOSIS, CONDITION ON DISCHARGE, INSTRUCTIONS TO PATIENT

3/13/98

Rehab

stable transcranial doppler studies
Now more confident of her improvement

Taking pills po tablets OK and gait ↑ c FNW to 150 feet c min assist —

[redacted]

3/14 Clin. Pharmacy Note

Re: Anticoagulation for basilar artery thrombus, CVA

S/O: Cont. on Heparin at 700 u/hr
Coumadin 7.5mg x 2d ; 5mg x 1 day
PTT 64.1 PT/INR 39.5/3.5
control 30 PT/INR ~~27.7~~/2.45 3/13
Ratio = 2.1x PT/INR 15.9/1.41 3/12
H/H 11.1/32.5 PLT 237 no unusual bruises/bleeding

A/P (1) PTT Ratio is w/in desired range of 1.75-2x control — Cont same rate
(2) INR is now w/in desired range of 3-3.5 per Hematology recom. but the 4° INR very quick in short time; ↓ warfarin to 2.5mg PO x 1 today to avoid further ↑ to above goal range. H/H PLT stable
(3) Would cont Heparin for 1 more day overlap c first time therap. INR. Would defer decision to 1° team or Hematology recom - if want to d/c Hep PTT, PT/INR, Hemogram in AM.

[redacted]

PROGRESS NOTES

DATE	NOTE PROGRESS OF CASE, COMPLICATIONS, CONSULTATIONS, CHANGE IN DIAGNOSIS, CONDITION ON DISCHARGE, INSTRUCTIONS TO PATIENT

3/14/98 Relias

@ [illegible], improved spirits over past [illegible] 10.2 / 11.1 / 32.1 / 237

AVSS

Pt. highly motivated, making respectable progress

continue current program.

[redacted]

3/15/98 Relias.

@ [illegible], good spirits

AVSS → I had very transient quivering - lower lip, [illegible] + [illegible] if [illegible]

speech [illegible] Δ

[illegible] per [illegible]

[illegible] in desired course

[redacted] [illegible] tomorrow

[redacted]

3/15/98 Clin Pharmacy

Re. Anticoag therapy

S/O: On Heparin @ 700 u/hr also on ASA.

Warfarin 2.5 mg yesterday

PT/INR 329/2.91 H/H 11.2/33.2 PLT 252

PTT: 73.5 Ratio: 2.45x control Pt in PT therapy

A/P ① PTT is above goal of 1.75-2x control, ↓ to 600 u/hr Heparin

② INR is w/in goal of 3-3.5 but ↓ now from yesterday — Pt v. sensitive to slight Δ in dose — Will give 5 mg warfarin today — Hot stable

③ PTT/PT/INR, Hemogram in AM — [redacted]

[redacted]

Addressograph [redacted]

[redacted]

PROGRESS NOTES

[redacted]

000140

PROGRESS NOTES

DATE	NOTE PROGRESS OF CASE, COMPLICATIONS, CONSULTATIONS, CHANGE IN DIAGNOSIS, CONDITION ON DISCHARGE, INSTRUCTIONS TO PATIENT

3/16/98 Clinical pharmacy
Re: Anticoagulation
pt. cont on. Heparin gtt 600u/hr
Q8/Sx bleeding 11.5 / 335 / 238

PTT 73.7 sec PT/INR 36.4 sec / 3.22

1. INR within desired range of 3-3.5 and pt has had overlap c̄ heparin x 2 days now.
2. Will dc heparin
3. Coumadin 5mg po tonight
4. Hct stable.

[redacted]

[redacted]

PROGRESS NOTES

Addressograph

[redacted]

000141

PROGRESS NOTES

DATE	NOTE PROGRESS OF CASE, COMPLICATIONS, CONSULTATIONS, CHANGE IN DIAGNOSIS, CONDITION ON DISCHARGE, INSTRUCTIONS TO PATIENT

3.16.98 Neurology [redacted] f/n

(S) feels well. Had some clonus (L)LE & jaw off & on yesterday & today, but otherwise no c/o

(O) Afebrile VSS
Awake, Alert, NAD
↑ strength (L)LE & (L)UE as c/w last week
Speech improving

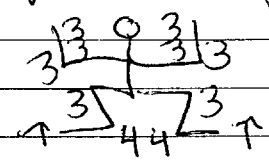

brisk jaw jerk

(A/P) Doing well
Shaking jaw / (L)LE intermittently represents clonus.
No Δ to plan

[redacted]

3.16.98
1805 Staff
Seen, agree. INR in therapeutic range 3.0-3.5.
now coumadin / ASA as of today.
TCD tonight
will follow

[redacted]

3/16/98

Rehab

Stroke –
Deficit very stable c̄ persistent

[redacted]

Addressograph

[redacted]

PROGRESS NOTES

000142

PROGRESS NOTES

DATE	NOTE PROGRESS OF CASE, COMPLICATIONS, CONSULTATIONS, CHANGE IN DIAGNOSIS, CONDITION ON DISCHARGE, INSTRUCTIONS TO PATIENT

dysarthria hyperreflexia and ↑ reflexes + ⓒ hemiweakness but ↑ functional status c̄ PT/OT and appears she will be ready for D/C this week on Coumadin + ASA –

TCD to be repeated X2 – 3 before D/C —

[redacted]

3/17/98

Rehab

Stroke

Deficit stable brisk reflexes, dysarthria
(1) Clumsiness
Will check on TCD result

Coumadin to maintain INR 3 – 3.5
ASA 81/d –

Pulmonary
Treatments to be D/C as lungs clear and anticipate

[redacted]

Addressograph

[redacted]

PROGRESS NOTES

DATE | NOTE PROGRESS OF CASE, COMPLICATIONS, CONSULTATIONS, CHANGE IN DIAGNOSIS, CONDITION ON DISCHARGE, INSTRUCTIONS TO PATIENT

d/c home this week —

[redacted]

3/17/98 Clinical pharmacy
Re: Anticoagulation
0 S/Sx bleeding reported
PT/INR 46.8/see / 4.14 3/16 INR → 3.22

1. INR above desired range of 3-3.5 with ~~substantiate~~ significant ↑ from yesterday.
2. Will hold coumadin tonight.
3. ✓ PT/INR in am.

[redacted]

3/17/98 Vascular Lab - TCD study performed. Please see "OPER/PROC/NEUROPHY/NON VASC LAB" tab for results.

[redacted]

3/18/98

Rehab

Reviewed TCD studies which show ↑ vertebral velocities and basilar a (or collaterals) = 50 which is relevant Stable. Pt continues to progress

[redacted]

Addressograph

[redacted]

PROGRESS NOTES

000144

PROGRESS NOTES

DATE	NOTE PROGRESS OF CASE, COMPLICATIONS, CONSULTATIONS, CHANGE IN DIAGNOSIS, CONDITION ON DISCHARGE, INSTRUCTIONS TO PATIENT

c̄ PT c̄ ② AFO beginning gait 5 device but uses FWW for household distances and for longer distances still c̄ WC

Will be reviewed in team conference later today anticipating home d/c Sat

[redacted]

Neurology ~~#~~

3/18/98 ⑤ Pt feels well & is eager to go home this Saturday, No new c/o

⓪ Afebrile VSS
Speech slightly improved
Walking stabily c̄ the walker.
Pharmacy adjusting coumadin dose for goal INR 3-3.5
flow improving in vertebral aa's by TCD 3/17/98

A/P) continue flonnef until post circulation thrombus recanulated
continue ASA & coumadin

[redacted]

TCD from 3/17 shows improved flows again. I can't predict whether recanalization will proceed & function

[redacted]

Addressograph

[redacted]

PROGRESS NOTES

000145

PROGRESS NOTES

DATE	NOTE PROGRESS OF CASE, COMPLICATIONS, CONSULTATIONS, CHANGE IN DIAGNOSIS, CONDITION ON DISCHARGE, INSTRUCTIONS TO PATIENT

3 complications, but TINR + ASA is best bet for protection. Baseline deficits assess ē avoid of possibly reversible ischemic damage, + expect continued improvement.

Will pickup TCD on Friday
Will want to have mr flr to me [redacted] 2-3 wks ↑ 2/2.

[redacted]

3/18/98 Clinical Pharmacy Re: Coumadin

Coumadin held yesterday 2° TINR,

PT/INR 39.4/3.48 today

O/P 1) INR within desired range 3-3.5
2) Coumadin 2.5 mg po today
3) INR in am

[redacted]

3/18/98 Hematology

Patient is well anticoagulated on coumadin. I suggest careful monitoring of INR over the first 2 months to keep ratio in 3-3.5 range. Otherwise patient is doing well.

[redacted]

[redacted]

Addressograph

[redacted]

PROGRESS NOTES

000146

[redacted]

PROGRESS NOTES

DATE	NOTE PROGRESS OF CASE, COMPLICATIONS, CONSULTATIONS, CHANGE IN DIAGNOSIS, CONDITION ON DISCHARGE, INSTRUCTIONS TO PATIENT

3/19/98

Rehab

Anticipate D/C home 4hrs
weekend c̄ INR 3-3.5

APO may not be needed
in view of improvement →

[redacted]

3/19 Clinical Pharmacy
Re Warfarin
Pt continues on warfarin, received 2.5mg
last PM

PT/INR 33 4/2.96 & S/Sx of bleeding

1) INR in desired range (goal 3-3.5) but ↓ from yesterday. Will give 5mg tonight hooks as if 5mg alt c̄ 2.5mg may be appropriate regimen to achieve therapeutic INR's.
2) PT/INR on VAM

[redacted]

[redacted]

PROGRESS NOTES

Addressograph

[redacted]

000147

PROGRESS NOTES

DATE	NOTE PROGRESS OF CASE, COMPLICATIONS, CONSULTATIONS, CHANGE IN DIAGNOSIS, CONDITION ON DISCHARGE, INSTRUCTIONS TO PATIENT

3/20/98.

Rehab

Basilar artery thrombosis

Taking adequate po fluids to D/C night time fluids —

Strength stable still very dysarthric —

Anticoag

INR = 2.87 after INR 4.7 2d ago —

P→ 2.5 this AM

Pharmacy to review pm dose

[redacted]

[redacted]

PROGRESS NOTES

Addressograph

000148

[redacted]

PROGRESS NOTES

DATE	NOTE PROGRESS OF CASE, COMPLICATIONS, CONSULTATIONS, CHANGE IN DIAGNOSIS, CONDITION ON DISCHARGE, INSTRUCTIONS TO PATIENT
3/20	Clinical Pharmacy Re Warfarin PT continues on coumadin. received 5 mg last evening. PT/INR 1287 H/H 11/32.1 1) INR below desired range (goal 3-3.5) current INR ↓ due to dose held 2 days ago. Spoke c̄ Dr [redacted] will give 2.5 mg this AM & 3 mg this PM. PT received ~ 4 mg/d over past 7 days which resulted in therapeutic PT/INR. 2) PT/INR in AM [redacted]
3-20-98	Neurology staff 1100 S: Excellent spirits. O: stable dysarthria Tongue movement impaired c̄ good side to side, not quite extended completely. Ø asymptomatic or fasc. Ø ossific cyan Strength in 4/5 range BUE P=D LLE 3/5 prox 4-/5 dist RLE 4-4+ range DKRs ↑ L>R side, (B) persisting ankle clonus, non persisting knee clonus. Some spastic [illegible] but she is

[redacted]

[redacted]

[redacted]

PROGRESS NOTES

DATE	NOTE PROGRESS OF CASE, COMPLICATIONS, CONSULTATIONS, CHANGE IN DIAGNOSIS, CONDITION ON DISCHARGE, INSTRUCTIONS TO PATIENT
3/20	adamant about not wanting add'l and need works c̄ 4WW, stable
	TCD - continue improvement in direct & collateral flow velocities and character. PT 2.7 INR
	I Basilar system isolated thrombo occlusive vasculitis
	R: No reason to Ophan. I talked c̄ Dr [redacted], who pt/family accede to having to local f/u. [redacted] would be of potential benefit for specificity, but she wants to hold off. Continue Medical 48 for at least 4 wks more c̄ slow taper. Flowing maintained - need to watch rising BPs for elevation. We're antsy about any hyperperfusion units. Repeat TCD's q weekly. Repeat MRA in 4 wks. I would be very interested in keeping track of low progress [redacted]
3/20/98	Ophthalmic Adjusted (L) AFO Brace ↑ flexion amount. [redacted]

[redacted]

PROGRESS NOTES

Addressograph

[redacted]

000150

PROGRESS NOTES

DATE	NOTE PROGRESS OF CASE, COMPLICATIONS, CONSULTATIONS, CHANGE IN DIAGNOSIS, CONDITION ON DISCHARGE, INSTRUCTIONS TO PATIENT
3/21/98	Rehab Reviewed Rx plan + meds w pt & family Exam stable Pt moldly emotional labile today

[redacted]

[redacted]

PROGRESS NOTES

Addressograph

[redacted]

000151