Food and Drug Administration
Center for Food Safety and Applied Nutrition
Office of Special Nutritionals

ARMS#

13405

3 - OUTPATIENT

[redacted]

[redacted]

PATIENT PROGRESS RECORD

PATIENT'S NAME (LAST, FIRST, MIDDLE) | LAST NAME | FIRST NAME | INITIAL

ADDRESS [redacted]

CITY

BIRTH DATE [redacted] PHO[redacted] GROUP [redacted] BER | ACCOUNT NUMBER | SUB GROUP

DATE | TIME

Wt 169 Temp 96.8° (T)
P 92
BP 128/76 RAS Reg cuff

[redacted]

TOBACCO USE ☐ YES ☒ NO

COUNSELLED ☐

Hx of: hx enlarged thyroid, underactive.
Rx: Synthroid in past. Recent (5/98) TSH unk.
pt brings outside records to document thyroid US x2
7/96 solid nodule (L), 8/97 cyst (L). She had a biopsy - neg.

O: thyroid gland 4 size (L) lobe exp to (R) no discrete mass (cyst/nodule) appreciated.

A: clinically enlarged (L) lobe thyroid.

P: rev c US thyroid to evaluate for cysts/nodules
Flu [redacted] for exam and biopsy if nec.
Flu here p Surg Clinic Visit, to discuss replacement or suppressive synthroid. [redacted]

000002

[redacted]

[redacted]

9-15-98

[redacted]

REQUEST FOR CONSULTATION & REPLY

TO (DOCTOR) [redacted]		[redacted]	
DEPT. OR C[redacted]	LOCATION [redacted]		
FROM (DOCTOR) [redacted]		PH[redacted]	PHONE (WORK)
DEPT. OR CLINIC [redacted]	LOCATION [redacted]	AD[redacted] CITY	STATE
REASON FOR CONSULTATION: Brief Abstract of Clinical Problem(s)		DATE 9/14/98	TIME ☐ Indus ☐ TPL

36 yo ♀ for thyroid nodule/cyst evaluation*. She has had ultrasound x2 outside [redacted] & biopsy x1. Now notes + size of gland. Repeat US here @ [redacted] ordered. Please examine w/ US results. Is biopsy needed? Thanks.

(copies of old records in [redacted])

☐ REFERRED FOR OPINION ☐ FOR TREATMENT ☐ REPLY REQUESTED BY TELEPHONE ☐ REQUESTED BY MAIL

SPACE FOR REPLY BY CONSULTANT: [redacted] results 7/96 solid nodule (L) 8/97 cyst (L)

sent 9-14-98

[redacted]

OCT 06 [redacted]

MINS: Co-30 APPT 945 REG [redacted]

PROBLEM: Thyroid DR. [redacted]

WHEN: off synthroid x 1 yr. ASx.

SURGEON: [redacted]

DATE/TIME: ⊖ RT Hx TSH 5/98 = 0.2

WT ~~BP~~: 171 PE: ⊖ LN's (Here c̄ friend)

BP 120/80 ⊖ thyroid masses

P: 80 US: (9/98) (R) 7.1 mm nodule

(L) 10 mm cyst

3.2 mm cyst

6.2 mm nodule

AP: Incidental multicystic/multinodular thyroid of no clinical significance at this point. Can not palpate any of them at this time — ∴ FNA not feasible or practical. Will recheck TSH, Cat, US 5/99 → RTC p̄.

☐ PATIENT INSTRUCTED TO COMPLETE TREATMENT HERE ☐ PATIENT TO RETURN TO YOU FOR TREATMENT

OTHER INSTRUCTIONS:

000003

[redacted] M.D. 10/6/98, 19

Referring doctor should complete in triplicate; hold one copy for information; send original and one copy to consultant. Consultant should complete form, file original with patient's chart and return other copy to the referring doctor.

[redacted]

[redacted]

[redacted]SE IMPRINT OR PRINT

PATIENT PROGRESS RECORD

DATE OF SERVICE	LOCATION	STATION

PATIENT'S NAME (LAST, FIRST, MIDDLE)

LAST NAME | FIRST NAME | INITIAL

ADDRESS

BIRTHDATE | HEALTH INSURANCE CLAIM NUMBER

MO. [redacted]

CITY

MEDIC

BIRTH DATE	PHONE	CODE	GROUP	SEX

DATE [redacted]

NOV 09 1998

APPT 945 REG. 945 [redacted]

WT 167 T99.1 BP 120/69 P110

O_2 100 PF 500

NKDA

- Current Smoker
- Non-Smoker
- Recent Quit/Last 12 Mos.
- Smoking Advice Given

Began c pre Thrust last wk
non URI Sx's. chest cgsh ↑ brown
sputum chest tightness. feels like
bronchitis dc'd cgs 11/98

been 7/17 O → OR in post
hx tachycardia
2-3 cokes qd
choc. x zrs
5/98 TSH 0.4

O ENT - pharynx clear
neck - [redacted]
Chest clear Cardiac P=110

A URI / bronchitis tachycardia
P try ↑ fluids if ↓ better
Amox 250 mg/g TID #21 ←
then expec 2 cod ½-¾ tsp qx ↓ #8 or
gradually ↓ caffeine to avoid cebo
avoid stimulants ✓ pulse
if still > FU sooner
ret 2-3 wks / prn [redacted]

000004

[redacted]

[redacted]

DATE TIME

_Current Smoker
_Non-Smoker
X Recent Quit/Last 12 Mos.
_Smoking Advice Given

1/98

[redacted]

Allergies: None ☒

NOV 27 1998

APPT. 1115 REG. 1101

[redacted]

pregnant ___ LMP ___

T. 99.6 B
P 82
R 12m
B/P 134/74
wt 170

CC. Arm pain

S. Client is cook - noticed arm pain
x1 day - starts at anticubital area down
to wrist denies numbness into hand

[redacted]

O. Strength in arm good ROM excellent
Tinels negative Phalens negative -
no pain to percussion over ulnar near in elbow
DR's sharp & brisk - no spasm posterior shoulder -
swelling noted over entire anterior arm
width of 4" & anticubital space.

A. Synovitis

P. Motrin 800mgm 1 PO Q8Hr to food (client has meds)
self care instruction

[redacted]

[redacted]

[redacted]

[redacted]

PLEASE IMPRINT OR PRINT

DATE OF SERVICE	LOCATION	STATION

[redacted]

MO DAY YEAR

[redacted] CHECK DIGIT

SUB GROUP

PATIENT PROGRESS RECORD

PATIENT'S NAME (LAST, FIRST, MIDDLE)

ADDRESS

CITY

BIRTH DATE	PHONE	CODE	GROUP
[redacted]	[redacted]	[redacted]	[redacted]

DATE TIME

[redacted]

JAN 15 1999

APPT 7:30 p REG 7:19 p

ear pain

T: 100?

P: 100 CS bodyache chills, ↓ grade temp

R: 18 ↑ ear pain @ side, ST

BP: 138/91 O. Ears canal erythematous & narrowed @

air fluid levels Bilaterally - tm pearly gray

all NKA Nose mucosa pink

pcp [redacted] Throat - mucosa pink + lymphoid patch

pro [redacted] Glands + submandibular nodes

A. Serous otitis media

Otitis extrema

P. Entex LA ÷ PO BID

Cortisporin 4 gtts q ID x 7 day

RTC if sx worsen - self care

_Current Smoker ✓_Recent Quit/Last 12 Mos.

_Non-Smoker _Smoking Advice Given

[redacted]

000006

[redacted]

[redacted]

PLEASE IMPRINT OR PRINT

DATE OF SERVICE	LOCATION	STATION

LAST NAME	FIRST NAME	INITIAL
[redacted]		

BIRTH DATE	PHONE	CODE	GROUP	SEX	COVERAGE	GROUP NUMBER	ACCOUNT NUMBER	SUB GROUP

DATE	TIME
	[redacted]

JAN 2 0 1999

APPT 11 REG [redacted]

_Current Smoker _Recent Quit/Last 12 Mos.
X Non-Smoker _Smoking Advice Given

WT: 167
BP: 123/66
P: 79
T: 97.0
All: NKDA

MVA 1/15/99 traveling 5 miles, slowing down
hit from behind other car ~ 35 miles
⊕ seat belt, recalls chest went
forward head back to LOC.
1/17/99 evening felt myalgia
LBP next d 1/18 burning sensat
radiating partially LLE → thigh
wish v'd.
O HEENT - ears clear
neck to pt tender full Rom
2 mid cervical tender → hit trapezius
chest to wall tender lungs clear
Cor NSR
Back ⊕ tender hit LS area
full Rom forward flexion → 6" floor
SLR 90° = ⊖ tender sciatic notch
Ext full Rom strength UE/LE 4/4 =
heavy fundi benign
DR's 2+ = ↓↓ ~~position pseu intact~~ amb heel/toes/Btoal wal
LBP neck pain 2°
A MS strain
Pice, heat, has motrin
[redacted]
[redacted]

000007

[redacted]

[redacted]

[redacted]

Ordering Prov: [redacted]
Copy To:

Performing Lab: [redacted]

Med. Rec. No. [redacted]
Patient Name [redacted]
Sex: F *DOB:* [redacted]
Loc: [redacted]

CHEMISTRY

05/21/98 [redacted]

..... General Chemistries				REFERENCE
Glucose Random	104		mg/dL	[60-199]
..... Lipid Studies				REFERENCE
Cholesterol	244	*f	mg/dL	[< 240]
HDL Cholesterol	40	*	mg/dL	[> 45]

Cholesterol (11/08/94 -- Current)

Adult Reference Ranges for Cholesterol:

Low Risk:	<200 mg/dL
Borderline High:	200 - 240 mg/dL
High Risk:	>240 mg/dL

SPECIAL CHEMISTRY

05/21/98 [redacted]

..... Hemoglobinopathies			
Hemoglobin A1C	5.6	%	[3.8-6.5]

IMMUNOASSAY CHEMISTRY

Collect Date: 05/21/98
Day of Week: THU
Collect Time: 1456

		UNITS	REFERENCE
Thyroid Studies -			
TSH	0.4	uIU/mL	[0.2-5.5]

(01/05/98 -- Current)
TSH >0.2 uIU/mL is desirable for patients on thyroxine for benign conditions.

REFERENCE LAB NOTATION

Tests performed at: [redacted]

05/21/98	1456	CHOL
05/21/98	1456	GLUCR
05/21/98	1456	HDL
05/21/98	1456	HGBA1C
05/21/98	1456	TSH

Legend
* = Low, * = High, * = Abnormal, f = Footnote

000008

END OF CHART

FINAL REPORT Outpatient

Admit: 05/21/98 *Discharge:*

Date / Time Printed: 05/25/98 [redacted]

[redacted])

CHEMISTRY

[redacted]

PATIENT NAME: [redacted]
ADDRESS.....: [redacted]
CITY/ZIP....:
DAY PHONE...:
EVE PHONE...:
LOCATION....:
CLINICIAN...:

M.R. # .....: [redacted]
AGE.....: 36
SEX.....: F
TOTAL FILMS.: 3
TECHNOLOGIST: [redacted]
REQ#.....: [redacted]
TIME OF EXAM: 07:56

DATE OF EXAM: 09/21/1998

THYROID ULTRASOUND

HISTORY:
Known to have nodule, left lobe; was 6.2mm on outside exam 07/96. Follow-up for cysts or nodules.

FINDINGS:
Per the patient's flash card there are no relevant [redacted] studies for comparison. On the current exam, the right thyroid lobe measures approximately 4.0 X 1.9 X 1.7cm, and the left approximately 3.8 X 1.8 X 1.5cm. There is a subtle, slightly hypoechoic nodule in the anterior right upper-mid pole, measuring approximately 7.1 X 4.6mm. The left thyroid lobe shows two simple cysts, the largest lying anteriorly, measuring approximately 10.0 mm X 5.0mm, and the second also anteriorly, measuring approximately 3.0 X 1.3mm. There is a subtle hypoechoic nodule laterally in the left lower pole, measuring 6.2 X 4.0mm.

[redacted] *MD*

DD: 09/21/1998 DT: 09/23/1998 [redacted]

(R) 7.1

(L) 10 mm

6.2 mm

3.0 mm

[redacted]

[redacted] 5 MAR 1999 12:18:33 [redacted]

000010

36 yrs Female White

PR 149 (ST). Sinus tachycardia, rate 119
QRSD 68 (CRAE). Consider right atrial enlargement
QT 297 - OTHERWISE NORMAL ECG -
QTc 418

--AXES--
P 65
QRS 4
T 44

COMMENTS
[redacted]

Requested by
[redacted]

[redacted] [redacted]MD - 8 MAR 1999 15:05:00

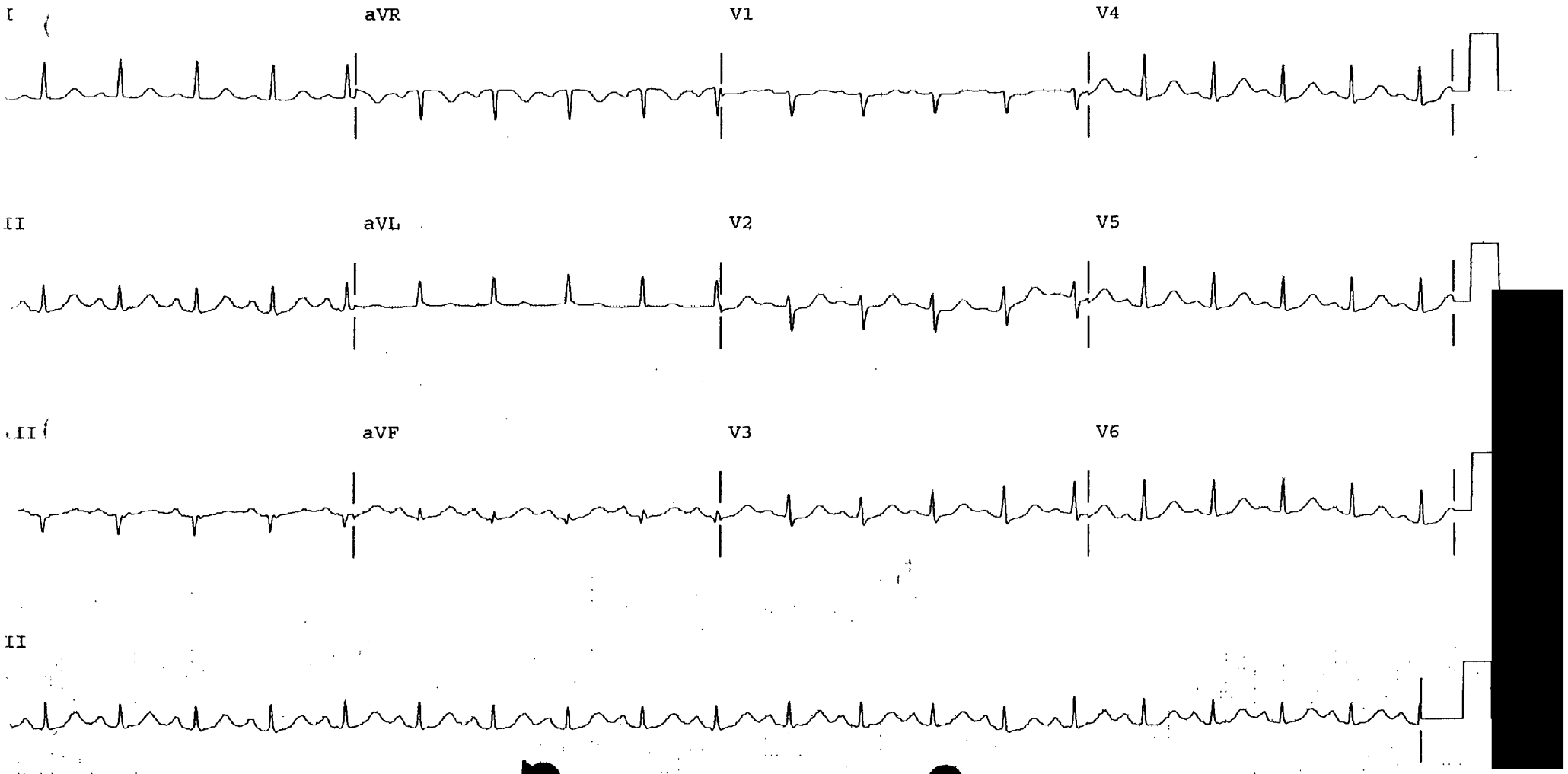

[redacted]

25 mm/sec 10.0 mm/mV F ~ W 0.50-40