Food and Drug Administration
Center for Food Safety and Applied Nutrition
Office of Special Nutritionals

ARMS#

12460

7 - PROCEDURES

[redacted] [redacted] DOB: [redacted] 02/27/97 PAGE: 1:1

------CHEM I------

Locale [redacted]

SERUM	11/10/96 23:52	11/12/96 07:00	11/14/96 07:00	12/10/96 13:11	02/26/97 10:41	Units	Reference Ranges
GLUCOSE	125 H	127 H	92	141 H	103	mg/dl	70-110
UREA N	14	4 L	10	12	10	mg/dL	5-19
CREAT	1.0 H	0.7	0.8	0.8	0.8	mg/dL	.5-.9
NA	145	143	145	144	141	mmol/L	135-146
K	3.6	3.6	3.9	3.6	3.7	mmol/L	3.5-4.9
CL	108	107	108	105	100	mmol/L	100-108
CO2	23.7	25.9	26.5	22.7	28.5	mmol/L	21-32
URIC AC	4.6			5.3	6.5	mg/dl	2.5-7.5
PO4	2.5			3.5	3.7	mg/dl	2.4-4.9
CA	9.4			9.5	9.9	mg/dL	8.5-10.5
PROTEIN	7.3			7.5	7.8	gm/dL	6.4-8.2
ALBUMIN	3.6			3.7	4.1	gm/dL	3.4-5
ALK PHO	139			211 H	109	U/L	55-145
T. BIL	0.23			0.31	0.46	mg/dL	0-1
D.BIL						mg/dL	0-.3
ALT	42			171 H	62	U/L	30-65
G-GTP					62	U/L	5-85
AST						U/L	15-37
LDH						U/L	100-190
CK						U/L	21-215
CKMB						U/L	0-6
AMYLASE						U/L	25-115
MG						mg/dl	1.7-2.5
CHOL	219 H			209 H	271 H	mg/dL	127-200
TRIGLYC	219 H			155	171	mg/dL	30-200
HDL						mg/dL	32-96
LDL						mg/dL	130-159
CHO/HDL							0-4.4

- - - - - - - - - C O M M E N T S - - - - - - - - -

KEY: "L"=Abnormal low, "H"=Abnormal high, "*"=Critical value

[redacted] ROUTING: [redacted] **PERMANENT** CHART COPY [redacted]

[redacted] PAGE: 1:1

CHEMISTRY I

000002

1

---HEMATOLOGY---

Locale [redacted]

BLOOD	11/10/96 23:52	11/11/96 07:00	12/18/96 13:11	02/26/97 10:41	Units	Reference Ranges
WBC	10.9	8.5	8	6.7	K/cmm	4-12
RBC	4.62	4.31	4.78 H	4.85 H	M/cmm	3.5-4.7
HGB	14.2	13.3	14.8	14.9	g/dL	12-16
HCT	41.1	38.4	43	43.7	%	37-47
MCV	89	89	90	90	cmu	81-99
MCH	30.7	30.9	31	30.7	uug	25-34
MCHC	34.5	34.6	34.4	34.1	gm/dL	32-40
PLT	266	217	303	248	K/cmm	150-450
GRAN %	85 H	81.2 H	80.3 H	78.2	%	37-80
LYMPH %	11.3	14.2	15.5	18.6	%	10-50
MID%	3.7	4.6	4.2	3.2	%	
GRN ABS	9.3 H	6.9	6.4	5.2		2-7.8
LYM,ABS	1.2	1.2	1.2	1.2		1-3
MID,ABS	.4	.4	.3	.2		
ESR					mm/hr	0-20
RETIC					%	.5-1.5
NORMOCY						
NORMOCH						
SEGS					%	50-75
BANDS					%	0-3
LYMPHS					%	25-40
MONOS					%	4-10
EOSINO					%	1-3
BASO					%	0-1
A. LYMP					%	
META					%	
MYELO					%	
BLASTS					%	
PLT.E						
NRBC					#/100 WBC	

- - - - - - - - - C O M M E N T S - - - - - - - - -

KEY: "L"=Abnormal low, "H"=Abnormal high, "*"=Critical value

----COAGULATION----

Locale	PLASMA	PTT	PT	INR	THROMBI
	Ref range	25-35 Seconds	10-14 Seconds		5-15 Sec
[redacted]	11/10/96 23:52	25.4	11.8	0.97	

C O M M E N T S

KEY: "L"=Abnormal low, "H"=Abnormal high, "*"=Critical value

[redacted]

10 NOV 1996 23:49:29

64 years ♀
181 lb 63 in
BP 160/90

American Indian
Rx: No known Rx
Dx: No known Dx

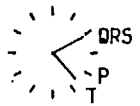

HORIZONTAL

RATE	80
PR	130
QRSD	90
QT	372
QTC	429

. NORMAL SINUS RHYTHM, RATE ..80 - - - - - NORMAL P AXIS, PR, RATE & RHYTHM

-NORMAL ECG-

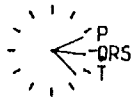

--AXIS--

P	-23
QRS	7
T	44

FRONTAL

[redacted]

PRELIMINARY. MD must review.

Normal

[redacted]

Req'd by [redacted]
Oper [redacted]

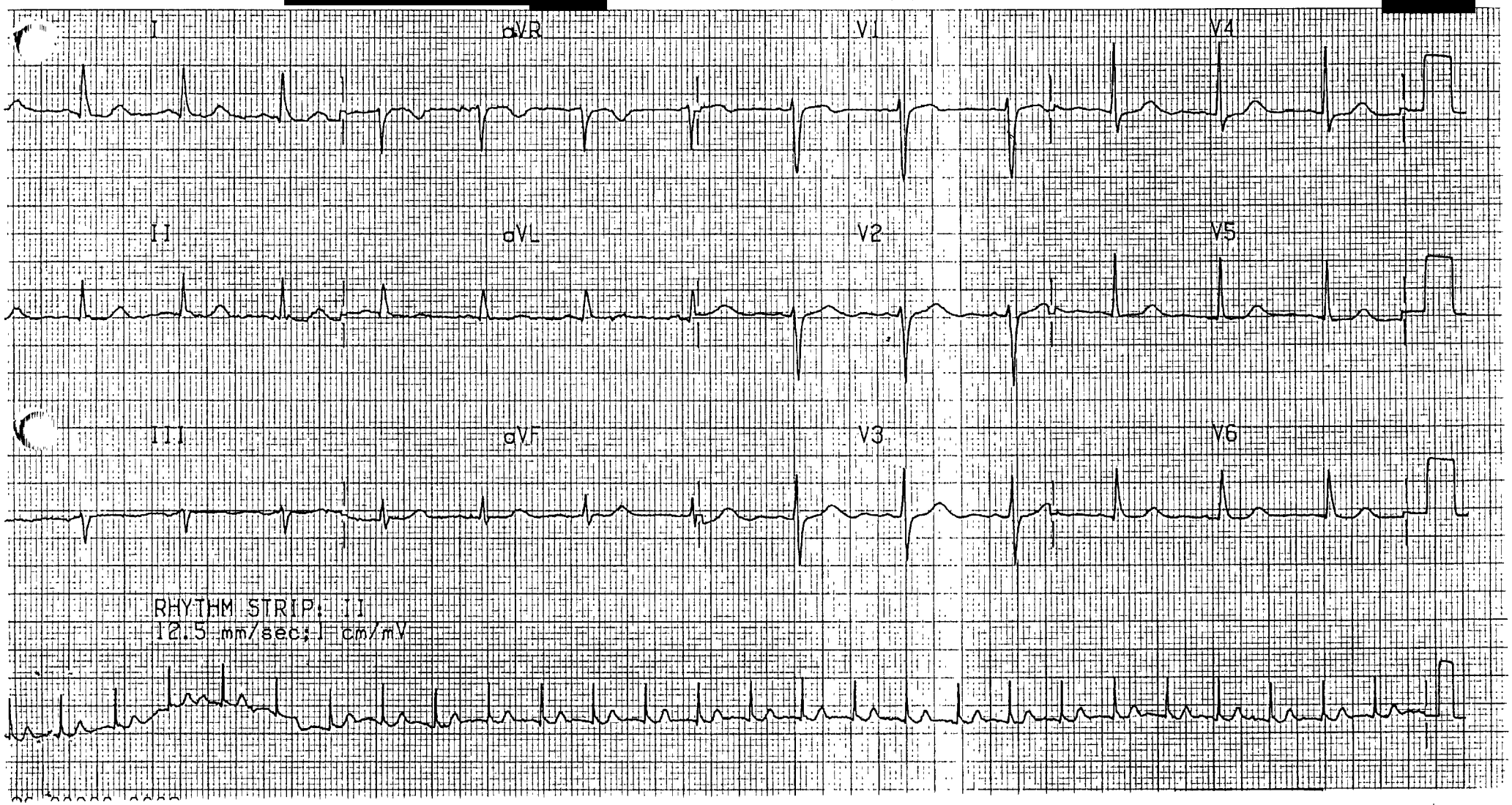

-----URINALYSIS-----

Locale [redacted]

URINE	11/11/96 00:22	11/11/96 11:54	Units	Reference Ranges
APPEAR	Clear	Clear		
COLOR	Yellow	Yellow		
SP.GRAV	1.020	1.005		1.001-1.035
PH	6.0	6.0		5-9
LEU ASE	Small	Negative		Negative
NITRITE	Negative	Negative		Negative
PROTEIN	Negative	Negative		Negative
GLUCOSE	Negative	Negative	mg/dL	Negative
KETONES	Negative	Negative	mg/dL	Negative
UR. BLD	Negative	Negative		Negative
BILIRUB	Negative	Negative		Negative
UROBILI	.2	.2	E.U./dL	.1-1
WBC/HPF	5-10		/LPF	0-5
RBC/HPF	NoneObs		/HPF	0-10
EPITH C	Comment		/HPF	None Obs
UR.BACT	Few		/HPF	None Obs
CRYSTAL	NoneObs		/HPF	None Obs
CASTS	NoneObs		/LPF	None Obs
Comments:	a	b		

- - - - - - - - - C O M M E N T S - - - - - - - - -

KEY: "L"=Abnormal low, "H"=Abnormal high, "*"=Critical value

a. Occasional squamous epithelial cell
   Not cultured - ER says not a clean sample
b. MICROSCOPIC NOT INDICATED.

000006

[redacted]

MEDICAL RECORD | CONSULTATION SHEET

REQUEST

TO: [redacted] FROM: (Requesting physician or activity) | DATE OF REQUEST

RE [redacted]

S/O 11-11-96

Inpatient Nutrition Screen

Serum/Albumin 3.6 Bun 14 Hct 38.4 Glu 125H Chol 219H Trig 219H

Admission Date/Time: 11-11-96 0130 Room/Bed: [redacted] Name: [redacted] BP 174/70

Admission Diet Order: Cl. flds - 7As to/ Screening Date/Time: 11-12-96 130 PM

Diagnosis (from chart): L Side CVA Height: 63" Weight: 181# 1BW 115# = 10%

(Circle YES or NO)

English Speaking:	YES	NO	Explain
Patient Conscious & Able to Answer:	YES	NO	Explain
Nausea/Vomiting/Poor Appetite:	NO	YES	Explain
Chewing/Swallowing Problems	NO	YES	Explain CVA
Diarrhea/Constipation: (Circle one)	NO	YES	Explain
Hospitalization/surgery in last 3 months:	NO	YES	Explain
Special food restrictions at home:	NO	YES	Explain
Unplanned weight loss:	NO	YES	Explain
Special diet ordered this admission:	NO	YES	Explain Cl flds

2 ← TOTAL NUMBER IF ITEMS CIRCLED
Refer to Dietitian if total is 3 or more.

Does patient eat these foods? (Circle yes)

Liver	Coffee	Mushrooms
Fish	Tea	Orange/grapefruit
Eggs	Milk	Fresh Apple
Tuna	Chicken/Turkey	

Visual Assessment: Good Poor

Dietitian Receipt of Referral: _____ Date/Initials

Comments/Notes:

Pt#: [redacted] Pt Name: [redacted] Age 64 YO ♀ [redacted] 11-12-96

[redacted] FORM# 151-0190 MRC APPROVED 5-4-93

A/P Glucose, Cholesterol + trig levels are high. Plan to talk to Caregiver, daughter or husband.

(Continue on reverse side)

SIGNATURE AND TITLE | DATE 11-12-96

IDENTIFICATION NO. | ORGANIZATION | REGISTER NO. | WARD NO.

PATIENT'S IDENTIFICATION (For typed or written entries give: Name—last, first, middle, grade, rank; rate; hospital or medical facility)

[redacted]

000007

CONSULTATION SHEET

Medical Record

[redacted]

[redacted]

RADIOLOGY DEPARTMENT
X-Ray
Mammography
UltraSound

[redacted]

RADIOLOGIC CONSULTATION REQUEST/REPORT

DATE REQUESTED	EXAMINATION REQUESTED	REQUESTED BY
11-11-96	CT Head	[redacted] M.D.

SPECIFIC REASON(S) FOR REQUEST (Complaints and findings)

Right Sided Weakness; Fall; R/O Stroke.

"WET READING"

RADIOLOGIC REPORT

(INITIALS OF READER)

CT SCAN OF THE HEAD WITHOUT CONTRAST: CT imaging of the head is performed using 5 mm axial cuts at 5 mm intervals through the posterior fossa continuing with 10 mm axial cuts at 10 mm intervals through the supratentorial segment. No contrast is given.

Ventricles are normal in size and position. Mild-to-moderate cerebral atrophy. Benign calcifications in the basal ganglia bilaterally. No focal areas of abnormal attenuation identified in the cerebral hemispheres, cerebellum, and brainstem. There are no CT findings of an acute intracranial hemorrhage. No abnormal extra-axial fluid collections found. The skull, scalp, paranasal sinuses, and mastoids are unremarkable.

IMPRESSION: Mild-to-moderate cerebral atrophy. No acute intracranial findings. Specifically, no hemorrhage or acute CVA detected.

Addendum: Duplex Carotid US performed 11-12-96 shows occlusion of left internal carotid artery - probably acute.

D&T: 11/12/96

[redacted] M.D.

RADIOLOGIST SIGNATURE

[redacted]

AGE	SEX	ROOM/EXT NO.

FILM NO./TECH

DATE OF EXAMINATION

FEMALES BETWEEN AGES 12 - 50

Are you pregnant or trying to be: ☐ YES ☐ NO

If NO, method of birth control: _____

Date of last menstrual period: _____

Signature: _____

Todays Date: _____

PATIENT IDENTIFICATION: NAME, BIRTHDATE, REG NO.

MEDICAL RECORD

10> 11 NOV 96 0241 TELE 1 [redacted] HR 72 VPB-2- LEARNING ECG

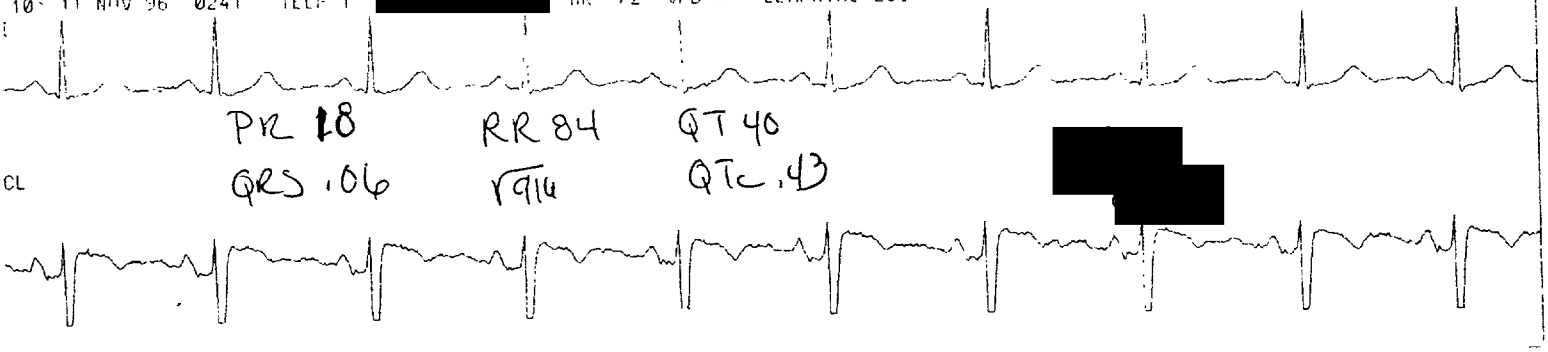

[redacted]

<10> 11 NOV 96 0622 TELE 1 [redacted] HR 88 VPB 2 SINUS RHYTHM VPBs 2

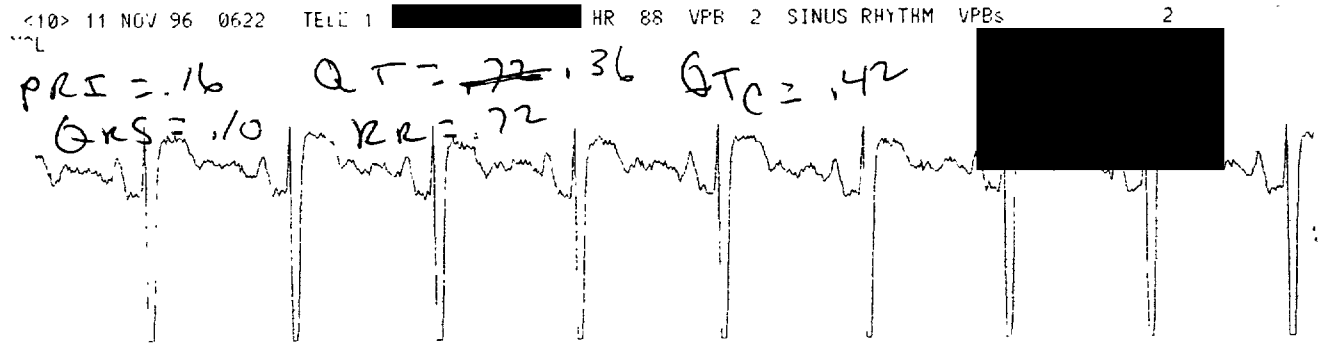

[redacted]

<10> 11 NOV 96 0948 TELE 1 [redacted] HR 82 VPB 0 SINUS RHYTHM



[redacted]

TELE 1 [redacted] HR 68 VPB 0 SINUS RHYTHM

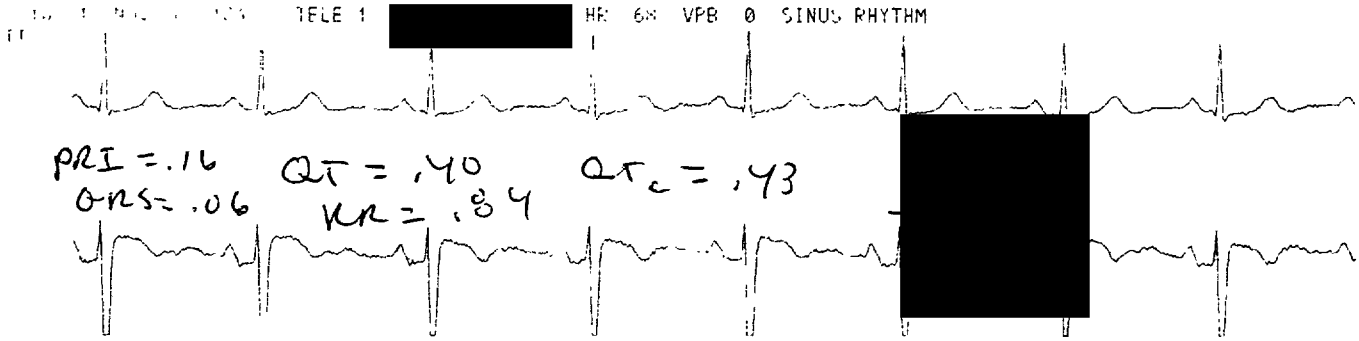

[redacted]

[redacted]

[redacted]

ECHOCARDIOGRAM

EXAMINATION DATE	DATE OF REPORT
11-12-96	11-14-96
DIAGNOSIS	
REFERRING PHYSICIAN [redacted] M.D.	
PHYSICIAN [redacted] M.D.	SONOGRAPHER [redacted]

DESCRIPTION OF PROCEDURE

INDICATION: [redacted] is a 64-year-old female status post CVA, referred for echo to evaluate for embolic source.

2-D: Underlying rhythm is normal sinus rhythm. There is no pericardial effusion. The mitral valve appears normal. The aortic valve is trileaflet with no abnormal calcifications. The pulmonic and tricuspid valves appear normal. The chamber size is normal. There is some thickening of the intraventricular septum, but no segmental wall motion abnormalities, and overall ejection fraction is normal. There was no left ventricular or left atrial thrombus identified.

M-MODE: The aorta has normal excursion. The aortic valve closes in the midline with no abnormal calcifications. The aortic diameter in diastole is 27 mm, and left atrial diameter in systole is 35 mm. The posterior mitral valve leaflet has normal motion. The anterior mitral valve leaflet has normal excursion of 12 mm and normal EF slope of 94 mm/sec. There is no mitral valve prolapse. M-mode of the LV was a limited study.

DOPPLER: There was no tricuspid regurgitation. There was mild pulmonic regurgitation. Flow across the mitral valve was laminar with no mitral regurgitation. Flow across the aortic valve was laminar with no evidence of aortic stenosis, and no significant aortic regurgitation.

SUMMARY:

1. Technically adequate study.
2. Normal-appearing mitral, aortic, pulmonic, and tricuspid valves with normal hemodynamics.
3. Normal chamber size.
4. Slight thickening of the intraventricular septum, but no segmental wall motion abnormalities, and overall normal ejection fraction.
5. No left ventricular or left atrial thrombus.

NOTE: There was no source for embolic CVA noted, and no indication for anticoagulation based on this study.

[redacted]

SIGNATURE OF PHYSICIAN — DATE: 11/15/96

[redacted] M.D.

PATIENT'S IDENTIFICATION (CHART NUMBER, NAME-LAST, FIRST, HOME TOWN, DOB)

[redacted]

[redacted]

[redacted]

RADIOLOGY DEPARTMENT
X-Ray
Mammography
UltraSound

[redacted]

RADIOLOGIC CONSULTATION REQUEST/REPORT

DATE REQUESTED	EXAMINATION REQUESTED	REQUESTED BY
11/12/96	Carotid U/S	[redacted] M.D.

SPECIFIC REASON(S) FOR REQUEST (Complaints and findings)

64 yo. ♀ S/P CVA, ε dense (R) hemiplegia
Please eval. Area of induration in (R) submandible area

"WET READING"

RADIOLOGIC REPORT

(INITIALS OF READER)

DUPLEX CAROTID ULTRASOUND: The cervical segments of the common, internal, and external carotid arteries are imaged with Realtime ultrasound using Color and Doppler flow analysis.

No unusual findings in either of the common carotid arteries. There is a small calcified plaque at the origin of the right internal carotid artery. This plaque does not appear to be producing a hemodynamically significant stenosis. No findings of ulceration or hemorrhage into the plaque. The right ICA distal to the plaque, and the right ECA are sonographically normal.

There is absent flow in the left ICA just distal to the bifurcation. Low level echoes are seen throughout the lumen in the proximal 2 cm of the ICA. There is no visible calcification within the center or at the periphery of the ICA at this level. No plaques are seen in the left CCA or ECA, and flow direction is normal in both the CCA and ECA on the left. External tapping on the left temporal artery, the major branch of the left ECA, produces visible wave impulses at the left CCA, a phenomenon seen with occlusion of the ICA. Both vertebral arteries are patent with normal direction of flow.

IMPRESSION:

1. There is a complete occlusion of the proximal left internal carotid artery. From the sonographic appearance, this appears to be a fairly fresh thrombus. I do not see any calcified ~~clot~~ plaque, obvious dissection, or other explanation for thrombus development in the proximal left ICA.
2. No significant disease found in the left common and external carotid arteries, both of which are patent.
3. Small calcified plaque at the origin of the right internal carotid artery. This does not produce any hemodynamically significant lesion.
4. Both vertebral arteries are patent with normal direction of flow.

D&T: 11/12/96 [redacted] M.D. [redacted]

RADIOLOGIST SIGNATURE

[redacted]

AGE	SEX	ROOM/EXT. NO.
64	F	[redacted]

FILM NO./TECH [redacted]

DATE OF EXAMINATION 11-12-96

FEMALES BETWEEN AGES 12 - 50

Are you pregnant or trying to be: ☐ YES ☐ NO

If NO, method of birth control: _____

Date of last menstrual period: _____

Signature: _____

Todays Date: _____

PATIENT IDENTIFICATION: NAME, BIRTHDATE, REG NO.

MEDICAL RECORD

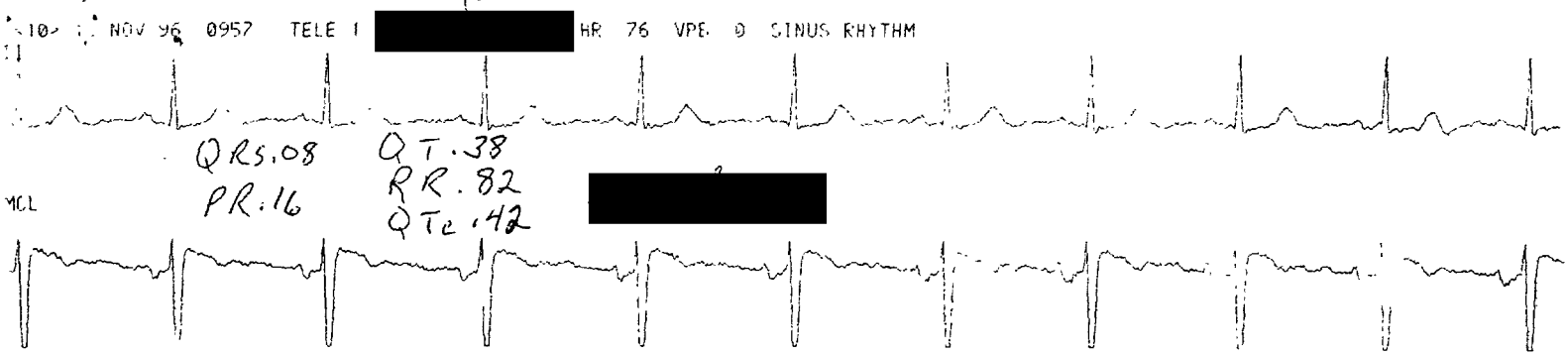
NOV 96 0957 TELE 1 [redacted] HR 76 VPB 0 SINUS RHYTHM
QRS.08
PR.16
QT.38
RR.82
QTc.42
MCL

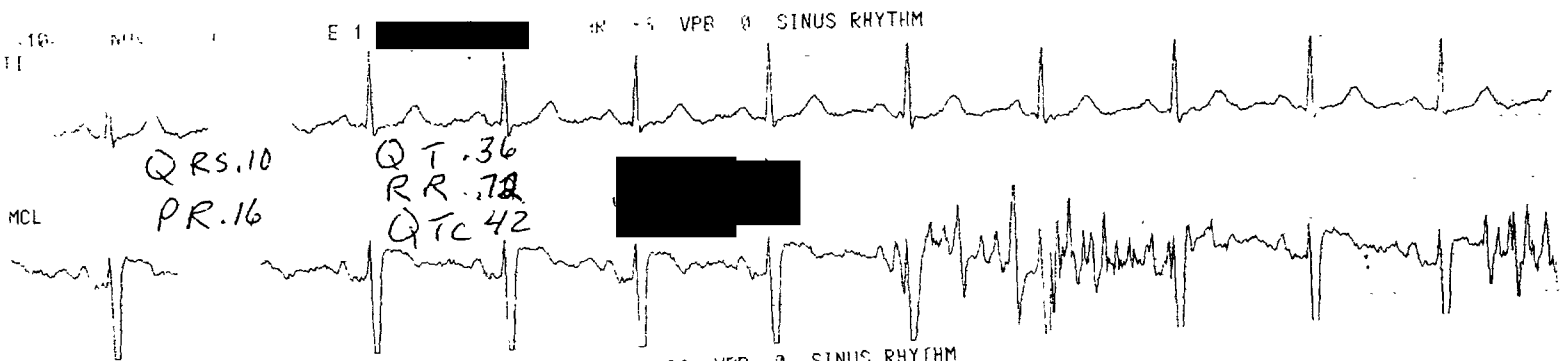
E 1 [redacted] VPB 0 SINUS RHYTHM
QRS.10
PR.16
QT.36
RR.72
QTc 42
MCL

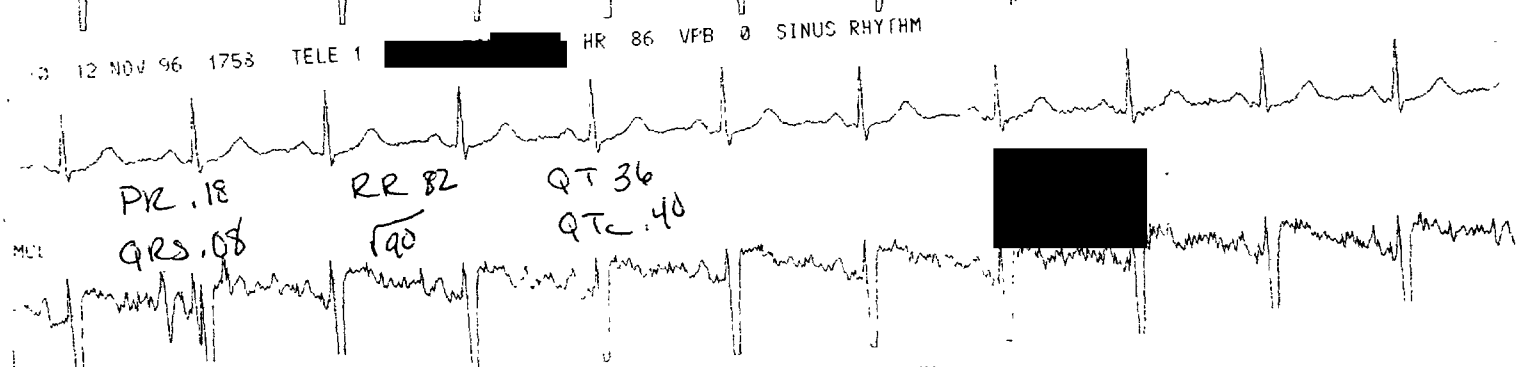
12 NOV 96 1758 TELE 1 [redacted] HR 86 VPB 0 SINUS RHYTHM
PR.18
QRS.08
RR 82
90
QT 36
QTc.40
MCL

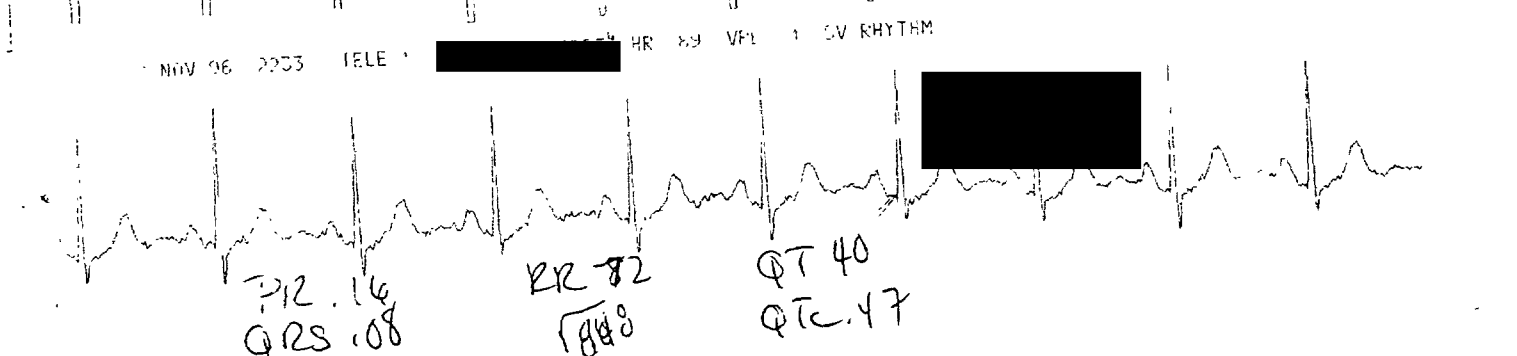
NOV 96 2253 TELE [redacted] HR 89 VPB 1 SV RHYTHM
PR.16
QRS.08
RR 82
89
QT 40
QTc.47

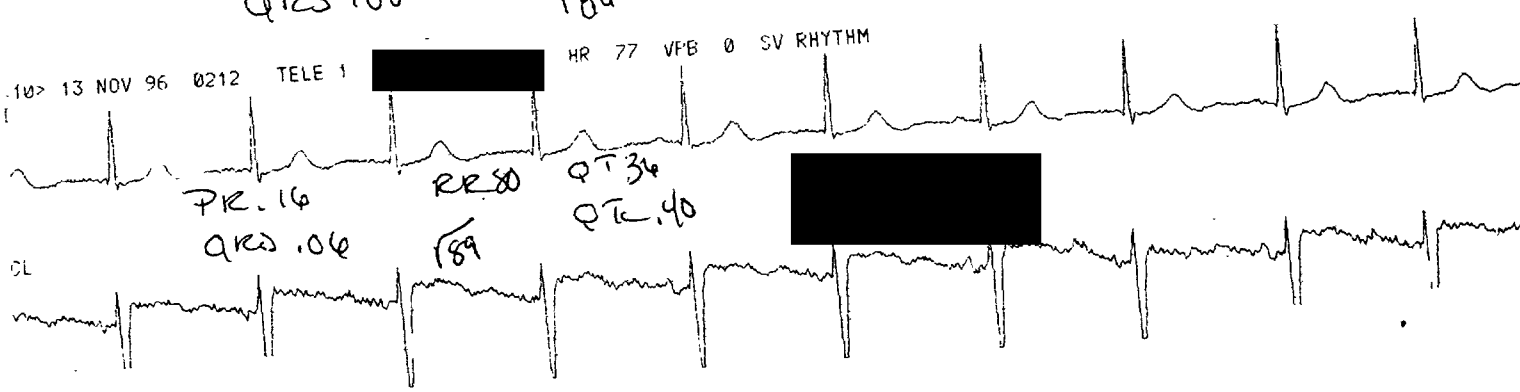
13 NOV 96 0212 TELE 1 [redacted] HR 77 VPB 0 SV RHYTHM
PR.16
QRS.06
RR80
89
QT 36
QTc.40

[redacted]

RADIOLOGY DEPARTMENT
X-Ray
Mammography
UltraSound

[redacted]

RADIOLOGIC CONSULTATION REQUEST/REPORT

DATE REQUESTED	EXAMINATION REQUESTED	REQUESTED BY
11-13-96	X-RAY (R) HIP & (R) UPPER FEMUR	[redacted] M.D.

SPECIFIC REASON(S) FOR REQUEST (Complaints and findings)	"WET READING"
R/O FRACTURE 2° TO FALL	(INITIALS OF READER)

RADIOLOGIC REPORT

RIGHT HIP AND PROXIMAL FEMUR: Normal bone density in the pelvis and proximal right femur. No fracture or dislocation involving the right hip and proximal half of the femur. Pelvic girdle is intact. Degenerative changes in the lower lumbar spine.

D&T: 11/13/96

[redacted] OGIST SIGNATURE

[redacted]

AGE	SEX	ROOM/EXT. NO
69	[redacted]	[redacted]
FILMING TECH		
[redacted]		[redacted]
DATE OF EXAMINATION		
11-13-96		

FEMALES BETWEEN AGES 12 - 50

Are you pregnant or trying to be: ☐ YES ☐ NO

If NO, method of birth control: _____

Date of last menstrual period: _____

Signature: _____

Todays Date: _____

PATIENT IDENTIFICATION: NAME, BIRTHDATE, REG NO.

MEDICAL RECORD

[redacted]

RADIOLOGY DEPARTMENT
X-Ray
Mammography
UltraSound

[redacted]

RADIOLOGIC CONSULTATION REQUEST/REPORT

DATE REQUESTED	EXAMINATION REQUESTED	REQUESTED BY
11-14-96	C.T. head/Neck (rm Contrast)	[redacted] M.D.

SPECIFIC REASON(S) FOR REQUEST (Complaints and findings)
(1) Follow up CVA
(2) (R) Neck mass

"WET READING"

RADIOLOGIC REPORT

(INITIALS OF READER)

CT SCAN OF THE HEAD WITHOUT CONTRAST: CT imaging of the head is performed with 5 mm axial cuts at 5 mm intervals through the posterior fossa with 10 mm axial cuts through the supratentorial structures. No contrast is given.

There has been a significant change in head CT since 11/11/96. There is now a band of hemorrhage, over 5 cm in length, within the left basal ganglia, primarily within the internal capsule, surrounded by focal edema. Edema extends into the white matter of the corona radiata of the left parietal lobe. While there is focal mass effect on the frontal horn and mid portion of the left lateral ventricle, there is no noticeable shift in midline structures, and the occipital horn is not affected. Early effacement of the sulci along the posterolateral left parietal lobe. I believe some of the edema extends into the left temporal lobe. The left frontal, posterior parietal, and occipital lobes are unremarkable. No acute findings in the right cerebral hemisphere, in the cerebellum, or at the brainstem. No intraventricular or extra-axial blood seen.

IMPRESSION: Hemorrhagic infarction involving primarily the left basal ganglia with edema seen extending into the left parietal and temporal lobes. Relatively mild focal mass effect without any noticeable shift in the midline structures or ventricular obstruction.

D&T: 11/14/96

[redacted] M.D. [redacted]

RADIOLOGIST SIGNATURE

[redacted]

PATIENT IDENTIFICATION: NAME, BIRTHDATE, REG NO.

AGE	SEX	ROOM/EXT. NO.
		[redacted]

FILM NO./TECH

DATE OF EXAMINATION

FEMALES BETWEEN AGES 12 - 50

Are you pregnant or trying to be: ☐ YES ☐ NO

If NO, method of birth control: _____

Date of last menstrual period: _____

Signature: _____

Todays Date: _____

MEDICAL RECORD

RADIOLOGY DEPARTMENT
X-Ray
Mammography
UltraSound

[redacted]

RADIOLOGIC CONSULTATION REQUEST/REPORT

DATE REQUESTED	EXAMINATION REQUESTED	REQUESTED BY
11-14-96	CT neck	M.D.

SPECIFIC REASON(S) FOR REQUEST (Complaints and findings)

"WET READING"

(INITIALS OF READER)

RADIOLOGIC REPORT

CT SCAN OF THE NECK WITHOUT CONTRAST: Ct imaging of the neck performed using 5 mm axial cuts at 5 mm intervals. No contrast is given.

Small calcified plaque is seen at the right carotid bifurcation. No calcified plaques seen in the carotid artery within the neck on the left. Right jugular vein is much larger than the left. The patient has a known left internal carotid artery occlusion, and perhaps there is a differential in venous blood return from the head accounting for this discrepancy. The body and distal portion of the right sternocleidomastoid muscle is also thicker and more prominent than corresponding portions of the left sternocleidomastoid.

shows that the patient's head is cocked to the right. This could be positional or the result of a torticollis with right sternocleidomastoid muscle spasm. I do not see any enlarged lymph nodes, soft-tissue masses, cysts, or irregular fluid collections within the soft tissue of the neck on either side. No lesions are seen within the inferior parotic glands, submandibular glands, or in the thyroid gland. Mild degenerative hypertrophy is seen at multiple cervical disc levels.

IMPRESSION:

1. No soft-tissue mass, lymphadenopathy, or cystic lesions found in the soft-tissues of the neck.
2. The jugular vein is noticeably more distended on the ~~left~~ right, and there appears to be at least partial contraction of the right sternocleidomastoid muscle. Perhaps these changes are simulating a mass in the right neck.
3. Small calcified plaque at the right carotid artery bifurcation. No calcified plaques visible in the cervical segment of the left carotid artery.

D&T: 11/14/96

[redacted] I.D./[redacted]

RADIOLOGIST SIGNATURE

[redacted]

AGE	SEX	ROOM/EXT. NO
		[redacted]

FILM NO./TECH

DATE OF EXAMINATION

FEMALES BETWEEN AGES 12 - 50

Are you pregnant or trying to be: ☐ YES ☐ NO

If NO, method of birth control: _____

Date of last menstrual period: _____

Signature: _____

Todays Date: _____

PATIENT IDENTIFICATION. NAME, BIRTHDATE, REG NO

MEDICAL RECORD

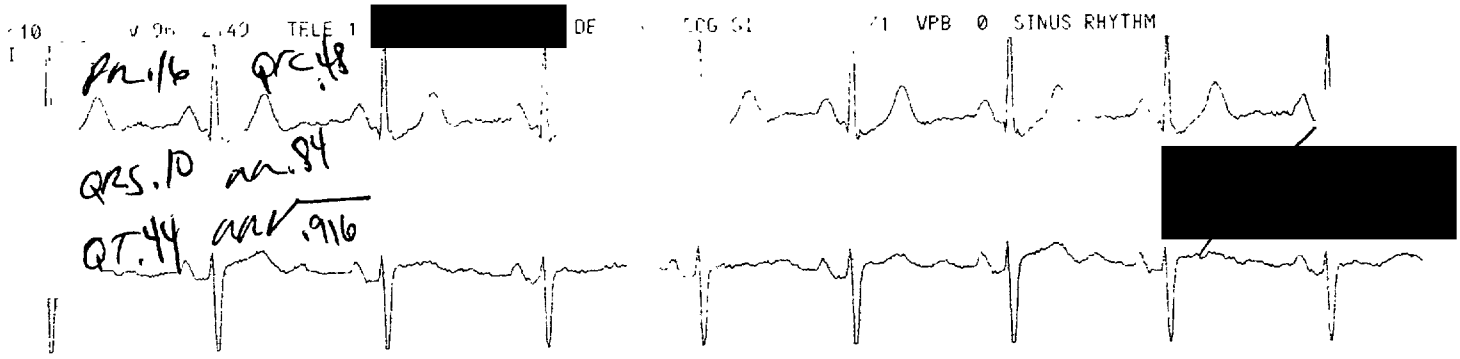
TELE 1 [redacted] DE
VPB 0 SINUS RHYTHM
PR.16 QTC.48
QRS.10 RR.84
QT.44 RR√.916
[redacted]

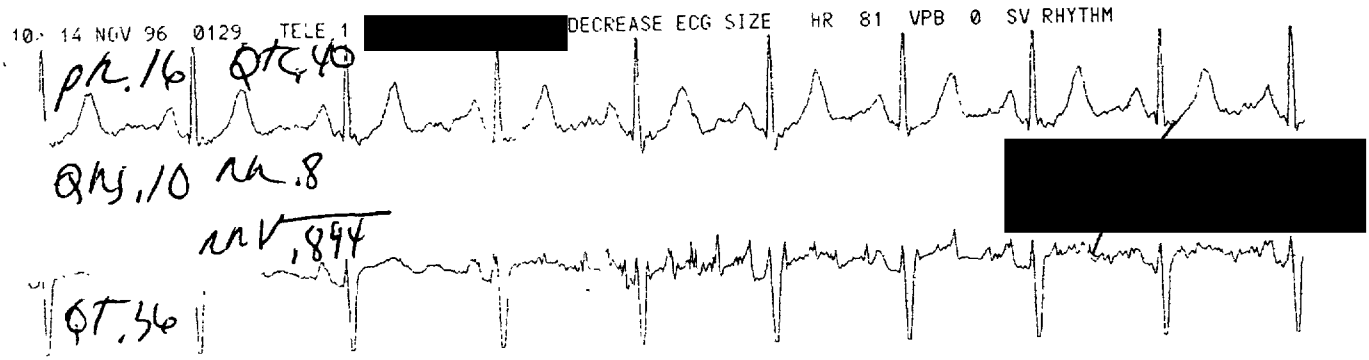
14 NOV 96 0129 TELE 1 [redacted] DECREASE ECG SIZE HR 81 VPB 0 SV RHYTHM
PR.16 QTC.40
QRS.10 RR.8
RR√.894
QT.36
[redacted]

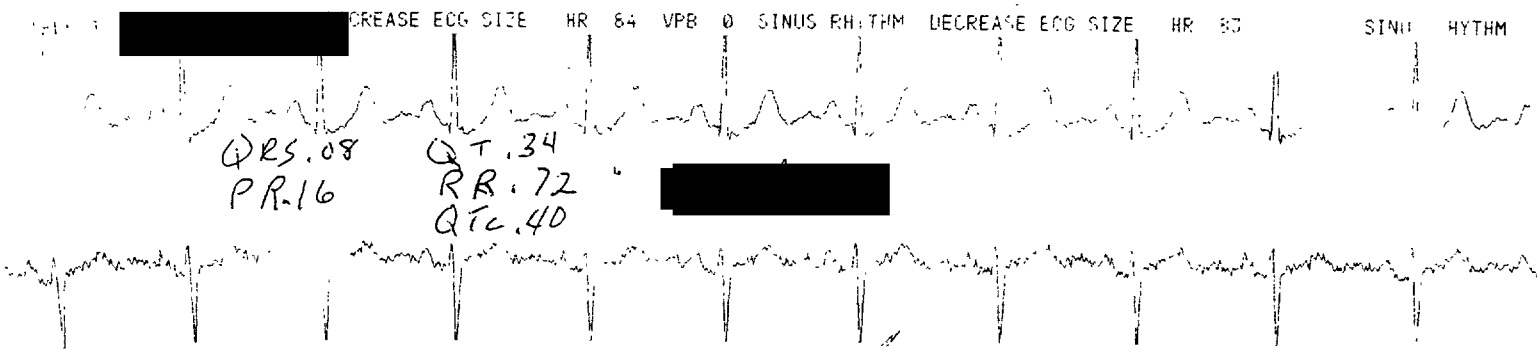
[redacted] CREASE ECG SIZE HR 84 VPB 0 SINUS RHYTHM DECREASE ECG SIZE HR 83 SINUS RHYTHM
QRS.08
PR.16
QT.34
RR.72
QTc.40
[redacted]

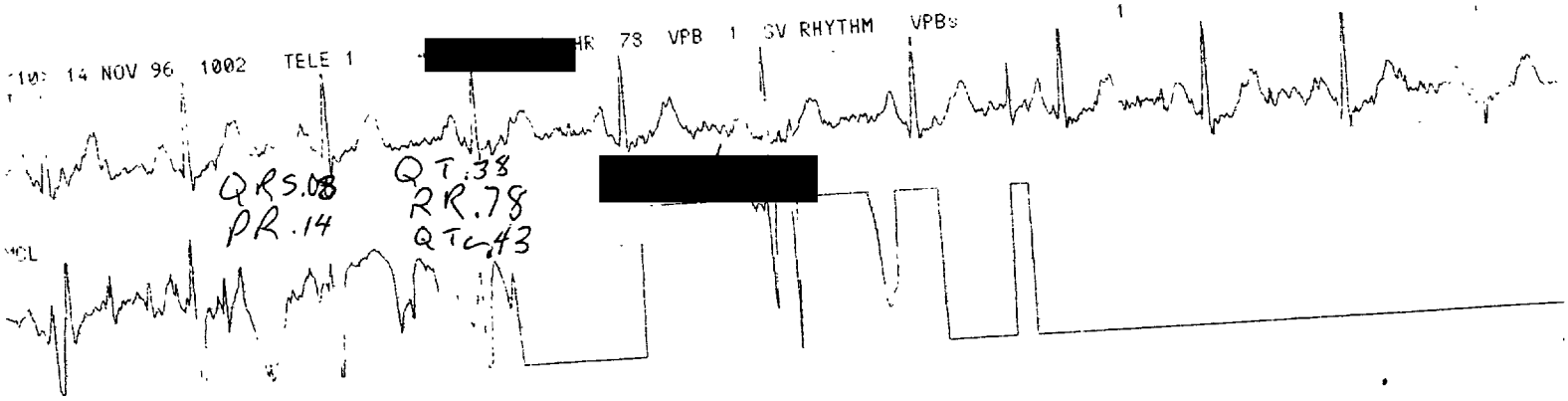
14 NOV 96 1002 TELE 1 [redacted] HR 78 VPB 1 SV RHYTHM VPBs
QRS.08
PR.14
QT.38
RR.78
QTc.43
[redacted]

#1-41-72

-----THYROID STUDIES-----

Locale	SERUM	T-3 UP	T4	FTI	TSH
	Ref range	.72-1.24	4.5-11.4	5-12	.5-5
			ug/dl	ug/dl	uIU/mL
[redacted]	12/18/96 13:11			2.71	

- - - - - - - - - C O M M E N T S - - - - - - - - -

KEY: "L"=Abnormal low, "H"=Abnormal high, "*"=Critical value

000017

[redacted]

CHART COPY