BRACCO

LIFE FROM INSIDE

Nicole Vesely, Pharm.D.
LT, United States Public Health Service
Division of Advisory Committee and
Consultant Management
Center for Drug Evaluation and Research
Food and Drug Administration
10903 New Hampshire Avenue
Silver Spring, MD 20993-0002

March 25, 2011

Re: Joint Meeting of the Cardiovascular and Renal Drugs Advisory Committee and the Drug Safety and Risk Management Advisory Committee

Dear Ms Vesely,

Reference is made to your letter dated January 26, 2011 regarding Bracco's participation in the upcoming Advisory Committee Meeting on safety considerations of ultrasound contrast agents scheduled for May 2, 2011.

Bracco provides herewith the briefing materials for the Advisory Committee.

The letter outlines the committee will discuss safety considerations of ultrasound contrast agents, particularly related to new information and developments since the prior Advisory Committee meeting on the same topic on June 24, 2008. The discussion will include the results of required postmarketing safety studies, interval U.S. and international postmarketing surveillance data, as well as other interval safety developments.

We are enclosing 40 electronic copies in Adobe PDF Version 8 on separate CDs and 12 paper copies of our background package.

On the day of the meeting, we will also provide you with copies of the slides which will be presenting at the meeting.

Please feel free to contact me if there is anything additional we can provide for you.

Yours sincerely

William B. Gray, BSMT, MS
Senior Director North and Latin America Regulatory Affairs
Bracco Diagnostics Inc

Tel: (609)-514-2234
Fax: (609)-514-2539

Advisory Committee Briefing Document

SonoVue®
(sulfur hexafluoride microbubbles)

Summary of Clinical Safety Experience

Bracco Diagnostics Inc.

DATE: March 23, 2011 (FINAL)

AVAILABLE FOR PUBLIC DISCLOSURE WITHOUT REDACTION

Table of Contents

List of Tables 3
List of Figures 4
1 Executive Summary 5
2 Introduction 8
3 Safety of SonoVue in Clinical Studies 9
3.1 Exposure to SonoVue in Clinical Studies 9
3.2 Exposure to Ultrasound by Mechanical Index in Patients Receiving SonoVue 10
3.3 Adverse Events 10
3.3.1 Non-serious Adverse Events 11
3.3.2 Serious Adverse Events 12
3.3.3 Fatal Events 12
3.4 Safety of SonoVue in Clinical Pharmacology Studies 13
3.4.1 Hemodynamic Effects in Patients with Congestive Heart Failure and Pulmonary Hypertension 13
3.4.2 Patients with Chronic Obstructive Pulmonary Disease (COPD) 14
3.4.3 Patients with Diffuse Interstitial Pulmonary Fibrosis 15
3.4.4 Patients with Documented Coronary Artery Disease (CAD) 15
3.4.4.1 Prospective Continuous ECG Monitoring in Patients with CAD 15
3.4.4.2 Retrospective Analyses of Patients with Angiographically Documented CAD 17
3.4.5 Planned Safety Studies 17
3.4.5.1 Pulmonary Hemodinamic Study Including Patients with Pulmonary Hypertension 17
3.4.5.2 Retrospective Safety Study 18
3.4.6 Conclusion from Clinical Studies 18
4 Safety of SonoVue Based on Worldwide Post-Marketing Surveillance 20
4.1 Serious Allergy-like or Anaphylactoid Reactions 21
4.2 Serious Cardiac Reactions 22
4.3 Other Serious Reactions 23
4.4 Fatal Events 23
4.5 Conclusion from Post-Marketing Surveillance 26
5 Literature Review 27
5.1 Overall Literature Review of SonoVue Safety in Humans 27
5.1.1 Methodology for SonoVue Safety Literature Review 27
5.1.2 Results from SonoVue Safety Literature Review 28
5.1.2.1 SonoVue Exposure 28
5.1.2.2 Imaging Modes 28
5.1.2.3 Safety Results from Cardiac Studies 29
5.1.2.4 Non-Cardiac Studies 30
5.1.2.5 Conclusion from SonoVue Literature Review 30
5.2 Review and Analysis of 24-hour Mortality Rate in Critically Ill Patients 30
6 Overall Conclusions 33
7 References 34

List of Tables

Table A: Comparison of Safety Data from Clinical Trials for USCAs* 6
Table B: Comparison of Data from Post-marketing Surveillance of USCAs* 7
Table C: Exposure to Study Agent, All Completed Studies, SonoVue 10
Table D: Exposure to Mechanical Index, Completed Studies 10
Table E: Summary of Adverse Events, All Completed Studies Included in Pooled Safety Database (Healthy Volunteers and Patients) 11
Table F: Adverse Events by System Organ Class Reported in ≥0.5% of the Subjects, All Completed Studies (Healthy Volunteers and Patients), SonoVue 12
Table G: Published Articles Included in Meta-Analysis 32

List of Figures

Figure 1. Postmarketing Surveillance Serious Cases by Month From April 1, 2001 Through December 31, 2010 21
Figure 2. Postmarketing Surveillance Serious Allergy-Like Cases by Month From April 1, 2001 Through December 31, 2010 22
Figure 3. Postmarketing Surveillance Serious Cardiac Cases by Month From April 1, 2001 Through December 31, 2010 23

1 Executive Summary

SonoVue® (sulfur hexafluoride microbubbles) is an ultrasound contrast agent (USCA) developed by Bracco that has been commercialized in Europe and Asia since 2001. It is under development in the United States for use in echocardiography in patients with suspected or established cardiovascular diseases to improve visualization of cardiac chambers and endocardial border delineation.

This briefing document has been assembled at the request of the United States (US) Food and Drug Administration (FDA) to provide background information for the Members of the Cardiovascular and Renal Drugs Advisory Committee and the Drug Safety and Risk Management Advisory Committee and the other invited experts for the joint meeting scheduled for May 2, 2011, to discuss safety considerations of USCAs, particularly new information and development since the last Advisory Committee meeting in 2008. This document is intended to complement the presentation which will be made by Bracco on the day of the meeting.

At a previous Cardiovascular and Renal Drugs Advisory Committee meeting on safety considerations in the development of USCAs conducted on June 24, 2008, Bracco presented a comprehensive summary of SonoVue safety that included preclinical, clinical and post-marketing experiences. Since then, there have been no significant activities or results from preclinical studies, but there has been more clinical experience with SonoVue in both clinical studies and post-marketing surveillance (PMS). Hence, this document mainly focuses on the updated clinical safety information of SonoVue based on results from clinical studies and data from PMS, as well as safety information reported in peer-reviewed medical literature.

Safety Data from Clinical Trials of SonoVue

The current Bracco clinical trial safety database contains pooled data for 70 completed clinical trials, during which 5275 subjects were exposed to SonoVue and 162 subjects received only control agents (placebo or comparator). Overall, the incidence of adverse events (AEs) in clinical trials has been 10.8% in subjects exposed to SonoVue. The most frequently reported AEs were headache (2.1%), nausea (0.9%), chest pain (0.6%), chest discomfort (0.6%), and injection site pain (0.5%). The majority of AEs (97.2%) were non-serious and rapidly self-resolving. The incidence of serious AEs is also very low (21 cases, 0.4%) with only 3 cases (0.06%) in whom the relationship with SonoVue could not be completely ruled out.

Clinical pharmacology studies have been conducted to detect any specific effect of SonoVue on:

- oxygen saturation, vital signs and ventricular repolarization in patients with coronary artery disease by 12-lead continuous ECG monitoring (one study with insonation at low and high mechanical index);
- pulmonary hemodynamics in patients with congestive heart failure and pulmonary hypertension;

- oxygen saturation, vital signs, and pulmonary function in patients with moderate to severe chronic obstructive pulmonary disease;
- SonoVue pharmacokinetics, oxygen saturation, vital signs, and ECG in patients with diffuse interstitial pulmonary fibrosis.

None of these studies showed any significant effect on pulmonary hemodynamics, pulmonary function, blood pressure, oxygen saturation, vital signs, cardiac function, electrocardiographic parameters and laboratory test results.

In the continuous ECG studies, there were no statistically significant differences in the maximum increases from baseline in corrected QT interval following administrations of SonoVue and a placebo (physiologic saline), no evidence of a dose-response relationship or relationship to different mechanical index of ultrasound applied during echocardiography.

In a subset of patients who underwent special laboratory tests (histamine, tryptase, IgE, C3, C4, CH50) to assess the immunologic potential of SONOVUE, there was no evidence of antibody production or complement activation.

The above results from SonoVue studies are comparable to that from similar studies of the other USCAs already approved by the FDA and commercialized in the US, i.e., Definity and Optison (Table A).

Table A: Comparison of Safety Data from Clinical Trials for USCAs*

	SonoVue®	***Definity®***	***Optison™***
Patients Dosed	5275	3985	279
% of Patients with AEs	10.8%	26%	16.8%
% of Patients with treatment related AEs	5.7%	7.6%	Not reported
% of Patients with SAEs	0.4%	0.85%	0.4%
Most frequently reported AEs	*(>0.5%)* headache (2.1%) nausea (0.9%) chest pain (0.6%) chest discomfort (0.6%) injection site pain (0.5%)	*(>1%)*** Fatigue, headache, dyspnea, back pain nausea, flushing. dizziness	headache (5.4%) nausea/vomiting (4.3%) warm sensation or flushing (3.6%) dizziness (2.5%)

* *Data for SonoVue is from completed clinical trials. Data for Definity and Optison are from 2008 Advisory Committee Briefing Documents for the respective compound.*[a,b]

** *Treatment related AEs*

[a] *2008 Advisory Committee Meeting Briefing Package – Definity® (Perflutren Lipid Microsphere). From FDA website: http://www.fda.gov/ohrms/dockets/AC/08/briefing/2008-4369b1-04.pdf. Accessed on: March 23, 2011*

[b] *2008 Advisory Committee Meeting Briefing Package – Optison™ Perflutren Protein-Type A Microspheres Injectable suspension, USP. From FDA website: www.fda.gov/ohrms/dockets/AC/08/briefing/2008-4369b1-05.pdf. Accessed on: March 23, 2011.*

Upon request from the FDA, Bracco has also initiated a study to evaluate the effect of intravenous SonoVue on the pulmonary hemodynamics in patients with and without pulmonary hypertension undergoing clinically indicated right heart catheterization.

In addition, following multiple interactions with the Division of Medical Imaging, Bracco is planning a large, retrospective observational safety study of the same day or second day mortality in critically ill patients who underwent ultrasound examination with SonoVue compared to that in control patients who underwent ultrasound examination without contrast.

Post-Marketing Surveillance

SonoVue® is an USCA that was first approved in Europe in 2001. It has been registered in a total of 36 countries worldwide and is currently marketed in 25 countries. It is recommended to be administered using a 5-mL single vial per investigation (doses: 2.0 mL for endocardial border detection or 2.4 mL for Doppler sonography of vessels, repeated once if necessary). Denominators are estimated from sales statistics, with each unit sold representing a patient exposed to the agent.

Experience from post-marketing surveillance of the estimated 1,651,451 patients exposed to SonoVue from April 1, 2001 through December 31, 2010 during the market use of this product (including events from observational studies, investigator-initiated studies and publications) shows a total of 217 cases of serious AEs (reporting rate: 0.013%), of which, 213 patients were considered to have AEs with some kind of relationship to the administration of SonoVue (probable, possible or unlikely) and 4 patients were considered to have AEs clearly unrelated to SonoVue administration. In Table B reporting rates following USCAs are compared.

Table B: Comparison of Data from Post-marketing Surveillance of USCAs*

	SonoVue®	***Definity®***	***Optison™***
Timeframe	Apr 2001 to Dec 2010	Oct 2001 to Dec 2007	1998 to 2008
Exposure	1,651,451	≈ 2million	> 1 million
Serious AEs	217 (0.013%)	277 (0.014%)	12 (< 0.001%)
Fatal cases	9	14	1

** Data for SonoVue is from post marketing surveillance database for the period April 1, 2001 to Dec 31, 2010. Data for Definity and Optison are from 2008 Advisory Committee Briefing Documents for the respective compound.* [a,b]

A total of 162 cases after SonoVue administration were allergy-like or anaphylactoid in nature (0.0098%). In more than half of the hypersensitivity cases, symptoms of other system organ classes were also reported, among which events of cardiac, vascular, respiratory, neurology and skin/subcutaneous tissue were the most frequently reported, consistent with the typical signs and symptoms of serious hypersensitivity reactions with multi-organ system involvement. No significant temporal trend in the incidence of serious AEs was ever observed.

In general, the observed pattern of serious hypersensitivity reactions is similar to that reported for anaphylactic or anaphylactoid reactions to other USCAs or intravascular imaging agents. In most of these cases of apparent hypersensitivity, the initial signs or symptoms started within

5 minutes from the injection of SonoVue. The initial symptoms ranged from mild to severe and could progress to medically important or life-threatening events.

As of December 31, 2010, a total of 9 deaths occurred during spontaneous reporting since the launch of the product in 2001 (0.0005%). Of the 9 reported deaths, 3 were clearly unrelated to the administration of SonoVue and 3 are still unassessable. In all death cases, the poor underlying conditions of the patients played a major role in the fatal outcome. In two cases, SonoVue was administered to patients with ongoing acute myocardial infarctions and no symptoms of hypersensitivity were observed, so that it is not clear if SonoVue played any role in the genesis of those events. Of note, in both cases, no specific treatment for the underlying myocardial infarction was given, but only for anaphylaxis.

Data From Literature

The above information was complemented by an extensive literature search and review of the information contained in peer-reviewed papers of SonoVue studies in both cardiac and non-cardiac applications involving 39,722 patients. The literature evidence showed that SonoVue did not increase the 24-hour mortality rate in 528 critically ill patients undergoing SonoVue-enhanced echocardiography.

Comparable results were also reported in a recently published meta-analysis for all-cause mortality after the use of contrast agents for echocardiography. The cumulative incidence of all-cause mortality in the contrast group was 0.34% (726/211,162) compared to 0.9% (45,970/5,078,666) in the non-contrast group. [1]

Conclusions

The safety profile of SonoVue looks comparable to that of the other USCAs already marketed in the United States, Definity and Optison.

2 Introduction

SonoVue is characterized by a microbubble structure consisting of a low solubility gas (sulfur hexafluoride, SF_6) stabilized by a phospholipid shell. Following intravenous injection, it remains in the intravascular space and strongly increases the ultrasound backscatter from blood. SF_6 is rapidly removed from the blood by the pulmonary route, with 40% to 50% of the injected dose eliminated within the first minute after administration and 80% to 90% eliminated by 11 minutes after administration.

SonoVue has been approved in 15 EU countries under the centralized procedure. These 15 countries were granted the market authorization of sulfur hexafluoride microbubbles under the trade name of SonoVue on March 26, 2001 by the Commission of the European Communities. SonoVue is registered in an additional 12 EU countries (Cyprus, Czech Republic, Estonia, Hungary, Latvia, Lithuania, Malta, Poland, Slovakia, Slovenia, Bulgaria, and Romania) who joined the EU. Norway and Iceland have granted a national authorization corresponding to the Commission Decision issued on March 26, 2001. Iceland implemented it on June 8, 2006.

Outside the EU, SonoVue has been registered in Switzerland, China, Singapore, Hong Kong, South Korea, Canada, and India. The product is currently marketed in 25 countries with the following indications:

- Echocardiography: for use in patients with suspected or established cardiovascular disease to provide opacification of cardiac chambers and enhance left ventricular endocardial border delineation. The recommended dose of SonoVue for visualization of cardiac chambers and endocardial borders delineation is 2 mL administered as a bolus injection during echocardiography performed at rest or stress. During a single examination, a second injection of 2 mL may be administered when deemed necessary by the physician.
- Doppler of macrovasculature: to increase the accuracy in detection or exclusion of abnormalities in cerebral arteries, extracranial carotid arteries, abdominal arteries, peripheral arteries or portal vein by improving the Doppler signal-to-noise ratio. The recommended dose of SonoVue for diagnostic assessment of vessels is 2.4 mL administered as a bolus injection during Doppler ultrasound. During a single examination, a second injection of 2.4 mL may be administered when deemed necessary by the physician.
- Doppler of microvasculature - Improves display of the vascularity of liver and breast lesions during Doppler sonography, leading to more accurate lesion characterization. The recommended dose of SonoVue for diagnostic assessment of liver or breast lesions is 2.4 mL administered as a bolus injection during Doppler ultrasound. During a single examination, a second injection of 2.4 mL may be administered when deemed necessary by the physician.

In the United States, SonoVue is being developed for use in echocardiography in patients with suspected or established cardiovascular diseases to improve visualization of cardiac chambers and endocardial border delineation.

3 Safety of SonoVue in Clinical Studies

Clinical trial data for SonoVue safety are derived from Bracco's clinical trial safety database for completed trials and from information provided to Bracco for ongoing studies.

The current Bracco clinical trial safety database contains pooled data for 70 completed clinical trials conducted in patients and healthy volunteers, during which 5275 subjects were exposed to SonoVue and 162 subjects received only control agents (placebo or comparator).

3.1 Exposure to SonoVue in Clinical Studies

From the completed studies included in pooled safety database, of 5239 subjects (patients and healthy volunteers) with known exposure to SonoVue, the administration route was always intravenous and the mean cumulative volume of SonoVue administered was 10.32 mL (range 0.2 to 161.3 mL). This includes subjects who received multiple bolus doses of SonoVue in crossover studies aimed at comparing 2-4 doses in the same patient, as well as infusion dosing. The majority (73%) of the subjects received cumulative doses ranging from >1 mL to 10 mL, and 23% received cumulative doses in excess of 10 mL.

See Table C below for more details in exposure to SonoVue in patients and healthy volunteers.

Table C: Exposure to Study Agent, All Completed Studies, SonoVue

Total Volume of SonoVue (mL)	Patients (N=5144)	Healthy Volunteers (N=95)	All Subjects (N=5239)
Mean	10.25	14.18	10.32
SD	14.47	11.91	14.44
Median	4.80	10.94	4.80
Minimum	0.3	0.2	0.2
Maximum	161.3	52.0	161.3
Cumulative Dose Categories	**N (%)**	**N (%)**	**N (%)**
≤1 mL	220 (4.3)	8 (8.4)	228 (4.4)
>1 to 5 mL	2456 (47.7)	12 (12.6)	2468 (47.1)
>5 mL to 10 mL	1310 (25.5)	26 (27.4)	1336 (25.5)
>10 mL to 50 mL	1043 (20.3)	48 (50.5)	1091 (20.8)
>50 mL	115 (2.2)	1 (1.1)	116 (2.2)

3.2 Exposure to Ultrasound by Mechanical Index in Patients Receiving SonoVue

The mechanical index (MI) is an estimate of the maximum amplitude of the pressure pulse in tissues and an indicator of the likelihood of mechanical bioeffects. It is used to modulate the output signature of USCAs and to incite different microbubble responses. It has been suggested that the higher the MI, the higher the likelihood of effects in tissues and possible untoward side effects.[2]

In some of the earlier clinical trials, the ultrasound exposure measured as mechanical index (MI) was not displayed on the screen of all or some of the ultrasound machines. From the completed studies, a total of 2864 patients had available MI values displayed on the ultrasound machines. The majority of patients were exposed to low to medium MI. Only 20% of patients were exposed to MI of 1.0 or higher (Table D).

Table D: Exposure to Mechanical Index, Completed Studies

Mechanical Index	No. (%) of Patients
<0.7	1948 (68.0)
0.7 – <1.0	360 (12.6)
≥1.0	556 (19.4)
Total	2864 (100.0)
Only patients with available MI were included in the analysis.	

3.3 Adverse Events

The overall incidence of AEs following administration of SonoVue in completed studies (all subjects including healthy volunteers and patients) was 10.8% (572/5275) and the incidence of

study agent-related AEs was 5.7% (303/5275). The overall incidence of AEs following the administration of placebo or a comparator in completed studies was 24.1% (39/162) and the incidence of study agent-related AEs was 13.6% (22/162). A summary of AEs for all completed studies is presented below in Table E.

Analysis of AEs by normalized dose groups and by different ultrasound MI exposures did not reveal any trend or relationships between AEs and different SonoVue doses or exposure to different ultrasound MIs.

Table E: Summary of Adverse Events, All Completed Studies Included in Pooled Safety Database (Healthy Volunteers and Patients)

	SonoVue No. of subjects dosed: 5275		**Placebo/Comparator** No. of subjects dosed: 162	
Category	**Related [a]**	**All**	**Related [a]**	**All**
No. (%) of subjects with at least 1 AE	303 (5.7)	572 (10.8)	22 (13.6)	39 (24.1)
No. (%) of subjects with at least 1 serious AE	3 (0.1)	21 (0.4)	0	1 (0.6)
No. (%) of subjects who discontinued due to AEs	7 (0.1)	16 (0.3)	0	0
No. (%) of deaths	0	8 (0.15)[d]	0	0
No of AEs[b]	491	931	39	63
No. (%) of subjects with at least 1 non-serious AE by intensity:[c]	300 (5.7)	555 (10.5)	22 (13.6)	38 (23.5)
Mild AEs	260 (4.9)	446 (8.5)	19 (11.7)	31 (19.1)
Moderate AEs	39 (0.7)	100 (1.9)	3 (1.9)	7 (4.3)
Severe AEs	1 (<0.1)	9 (0.2)	0	0

[a] Includes definite, probable, possible, doubtful, unknown, and missing relationship.
[b] Multiple occurrences of the same adverse event in a subject are counted individually.
[c] If a subject experienced more than 1 non-serious adverse event, the subject was counted only once at the maximum intensity.
[d] One additional death was reported in 1 patient who died of myocardial infarction before receiving SonoVue.

3.3.1 Non-serious Adverse Events

The AEs experienced by ≥0.5% of the 5275 subjects (including patients and healthy volunteers) exposed to SonoVue in all Completed Studies are summarized in Table F below. The most frequently reported adverse event was headache (2.1%), followed by nausea (0.9%), chest pain (0.6%), chest discomfort (0.6%), and injection site pain (0.5%). All other AEs occurred at a frequency of <0.5%. When compared to rest studies, the incidence of headache and chest pain was higher in stress studies (1.72% and 7.9%, respectively for headache; 0.67% and 3.32%, respectively for chest pain).

Table F: Adverse Events by System Organ Class Reported in ≥0.5% of the Subjects, All Completed Studies (Healthy Volunteers and Patients), SonoVue

System Organ Class / Preferred Term	No. of subjects dosed: 5275	
	Total	Related[a]
No. (%) of subjects with at least 1 AE	572 (10.8)	303 (5.7)
Gastrointestinal Disorders		
Nausea	47 (0.9)	29 (0.5)
General Disorders/Administration Site Conditions		
Chest discomfort	30 (0.6)	16 (0.3)
Chest pain	33 (0.6)	9 (0.2)
Injection site pain	26 (0.5)	20 (0.4)
Nervous System Disorders		
Headache	109 (2.1)	59 (1.1)

[a] Includes definite, probable, possible, doubtful, unknown, and missing relationship.

3.3.2 Serious Adverse Events

No serious AEs or deaths were reported in the healthy volunteer population.

Of the 5275 subjects dosed with SonoVue in completed clinical trials, serious AEs occurred in 21 patients (0.4%). In 18 of the 21 cases, the events were considered clearly unrelated to SonoVue administration by the investigators, while only in 3 patients (0.06%) the relationship with SonoVue could not be ruled out. Of these 3 patients:

- one experienced chest pain, ST segment elevation and a drop in blood pressure at the peak of the dobutamine dose. Treated and transferred to Coronary Care Unit, he recovered completely in 10 minutes. The patient had a prior history of anterior myocardial infarction;
- one had a skin rash approximately 1 minute after 2 mL SonoVue and was administered dexchlorpheniramine and 2 minutes later methylprednisolone. Immediately after methylprednisolone (and about 10 minutes after SonoVue), the patient developed a severe vaso-vagal reaction with nausea, syncope and complete AV block, which resolved immediately after atropine injection while skin manifestations disappeared within 15 minutes;
- one patient, with previous diagnosis of complete occlusion of the left internal cerebral artery and hospitalized 9 days prior to SonoVue administration for a left abducens nerve paresis. About 20 hrs after SonoVue administration, the patient experienced sensory motor paresis of right arm, which was treated and resolved.

3.3.3 Fatal Events

A total of 8 deaths have been reported in all completed clinical studies conducted with SonoVue since 1993. All deaths were considered to be unrelated to study agent by both the investigators and Bracco. Deaths occurred in both cardiac and non-cardiac studies. In particular:

- 1 patients had procedural complications during percutaneous coronary interventions following a well-tolerated echocardiographic exam with SonoVue;
- 1 patient died 3 days after SonoVue administration and shortly after undergoing right hepatectomy;
- 6 patients died 10 to 19 days after exposure to SonoVue. In none of these 6 cases did the death follow any reaction or complication related to the administration of SonoVue.

In addition 1 death has been reported in the completed clinical studies for one patient who died of acute myocardial infarction before receiving SonoVue.

3.4 Safety of SonoVue in Clinical Pharmacology Studies

Clinical pharmacology studies have been conducted to detect any specific effect of SonoVue on:

- pulmonary hemodynamics in patients with congestive heart failure and pulmonary hypertension;
- oxygen saturation, vital signs, and pulmonary function in patients with moderate to severe chronic obstructive pulmonary disease;
- SonoVue pharmacokinetics, oxygen saturation, vital signs, and ECG in patients with diffuse interstitial pulmonary fibrosis;
- oxygen saturation, vital signs and ventricular repolarization in patients with coronary artery disease by 12-lead continuous ECG monitoring, (one study with insonation at low and high mechanical index).

3.4.1 Hemodynamic Effects in Patients with Congestive Heart Failure and Pulmonary Hypertension

The effects of intravenous bolus injections of SonoVue on pulmonary hemodynamics and cardiac function of 19 patients with congestive heart failure were evaluated in a single centre, randomized placebo-controlled study (BR1-016).

The study population consisted of patients with NYHA functional Class II-IV congestive heart failure and ejection fraction <45% who were referred for right cardiac catheterization as well as radionuclide angiography (MUGA).

Nineteen patients were randomized to receive either two boluses of 2 mL and 4 mL of SonoVue and matching placebo, given alternately at intervals of at least 15 minutes (active group, n=13), or matching doses of placebo only (control group, n=6). Pulmonary hypertension (defined as systolic pulmonary arterial pressure, SPAP >30 mmHg or diastolic pulmonary arterial pressure DPAP > 15 mmHg) existed in 11 (84.6%) of the active group patients and 5 (83.3%) of the control group patients.

The effects of SonoVue compared with placebo on pulmonary hemodynamics and cardiac function were monitored by right heart catheterization before the first administration and again at 30 seconds, 2, 4, 6, 10 minutes after each administration. Oxygen saturation, 12-lead ECGs, lab tests and AEs were also evaluated.

Baseline peripheral vascular resistance (PVR), mean pulmonary artery pressure (MPAP), pulmonary capillary wedge pressure (PCWP), cardiac function and oxygen saturation values were comparable for the two study groups. Within the active group, there were no apparent differences between SonoVue and placebo or between the 2 mL and 4 mL SonoVue doses with respect to mean maximum increases and decreases from baseline. In addition, there were no apparent differences between the active and control groups with respect to maximum increases and decreases from baseline. There were no trends across timepoints for any of these parameters.

No patients in the active group had clinically significant worsening of any cardiac function parameter relative to baseline. One patient in the placebo group had a clinically significant worsening of systemic systolic arterial pressure. There were no discontinuations due to AEs and no serious AEs in either group.

In summary, the administration of a cumulative dose of 6 mL of SonoVue (4 mL and 2 mL) did not result in significant changes in clinical, ECG, laboratory or hemodynamic parameters compared to placebo. This was equally true for patients with and without pulmonary hypertension at baseline. The lack of any significant change in pulmonary arterial pressure, capillary wedge pressures, and oxygen saturation suggests that the administration of this agent is not associated with any worsening of left ventricular function in this specific population of patients with severe left ventricular dysfunction and pulmonary artery hypertension.

3.4.2 Patients with Chronic Obstructive Pulmonary Disease (COPD)

The safety and tolerability of SonoVue in patients with moderate or severe COPD was evaluated in a single centre, single blind, crossover, placebo-controlled study (BR1-022).

The study population consisted of 12 patients with chronic COPD and forced expiratory volume (FEV_1) <70% (six patients with moderate COPD, FEV_1 = 51% to 69%; six patients with severe COPD, $FEV_1 \leq 50\%$). Each patient received two 4.0 mL bolus injections in randomized order, one of SonoVue and one of placebo (0.9% sodium chloride) in two separate sessions with a 48- to 72-hour period between doses.

Pre- and post-injection physical examination, pulmonary function tests, blood oxygen saturation, vital signs, 12-lead ECG, continuous ECG monitoring, clinical laboratory tests, injection site tolerability and AEs were evaluated up to 24 hours.

The pulmonary function tests, including FVC, FEV_1 and FEF_{25-75} were obtained using a Vitalograph spirometer at baseline, and at 1-3 minutes (FEV_1 only) and 9-11 minutes after each injection. Additional FEV_1 measurements were obtained at 30 minutes, 1 hour, and 5 hours after each injection.

Thirteen patients were randomized to receive SonoVue and placebo and 12 patients actually received both study agents (one patient prematurely discontinued the study due to an adverse event prior to receiving SonoVue). Of the 12 patients, 6 (50.0%) had moderate COPD (FEV_1 = 51% to 69%), and 6 (50.0%) had severe COPD ($FEV_1 \leq 50\%$).

Mean values of pulmonary function tests decreased from baseline after both SonoVue and placebo. Overall, mean differences between SonoVue and placebo and differences between the two study agents for each individual patient were small. No consistent trends in the differences in

FEV_1, FVC, and $FEF_{25\%–75\%}$ at the post-injection timepoints and no statistically significant differences between the study agents in terms of change from baseline were observed.

In summary, the results of this study indicate that a single 4 mL injection of SonoVue in patients with moderate or severe COPD is safe and well tolerated as shown by lack of effect on pulmonary function tests, oxygen saturation, electrocardiographic pattern, and laboratory tests.

3.4.3 Patients with Diffuse Interstitial Pulmonary Fibrosis

The safety of SonoVue in patients with diffuse interstitial pulmonary fibrosis was evaluated in a single centre, single dose, phase I study (BR1-036).

The study population consisted of 13 patients with a known diagnosis of diffuse interstitial pulmonary fibrosis associated with any autoimmune, industrial, occupational, infectious, or connective tissue disease, previously confirmed with appropriate specific methodologies. Each patient received a single intravenous bolus injection (20 seconds) of SonoVue 0.3 mL/kg.

Mean changes from baseline in oxygen saturation were minimal (<1%) through 1 hour postdose and there were no changes from baseline that met the criteria for potential clinical importance.

Changes from baseline in vital signs were minimal through 1 hour postdose. Vital sign changes exceeding sponsor-defined criteria of potential clinical importance (two consecutive measurements) were observed in one patient who had an elevated blood pressure at baseline (189/109 mmHg) and postdose had decreases in systolic and diastolic blood pressure that actually represented a normalization of values.

Two patients (15.4%) had ECG changes that were considered by the investigator to represent worsening from baseline, both having a normal ECG at baseline: one patient had frequent premature ventricular contractions (PVCs) noted at 5 minutes and at 1 hour postdose while the other had occasional PVCs noted at 24 hours postdose. Neither of these findings was reported as an AE.

Two of the 3 AEs, namely chest pain (verbatim: burning feeling in chest) and pharyngitis (verbatim: burning feeling in throat) were considered of unknown relationship to the study agent. There were no discontinuations due to AEs and no serious AEs reported.

3.4.4 Patients with Documented Coronary Artery Disease (CAD)

3.4.4.1 Prospective Continuous ECG Monitoring in Patients with CAD

Two placebo-controlled prospective clinical trials of continuous ECG monitoring (Studies BR1-112 and BR1-113) did not indicate any detrimental effects on cardiac electrophysiology.

Study BR1-112, a 3-way crossover study of placebo and 2 doses of SonoVue (0.1 mL/kg and 0.5 mL/kg, corresponding to 1-5 fold of the highest human recommended dose), was performed in 49 subjects with documented coronary artery disease (CAD). The administration of each study agent was separated by at least 48 hours.

Study BR1-113, a 4-way crossover study, was performed in 53 patients with documented CAD during insonation of the heart at low (0.4-0.5) and high (1.5-1.6) mechanical index (MI)

(hereafter referred to as MI 0.4 and MI 1.5). Patients were randomized to receive 4 intravenous doses (i.e., SonoVue 0.1 mL/kg at MI 0.4, SonoVue 0.1 mL/kg at MI 1.5, placebo 0.1 mL/kg at MI 0.4, and placebo 0.1 mL/kg at MI 1.5) according to 1 of 4 sequences. B-mode echocardiography of the left cardiac chambers was performed starting 30 seconds before study agent administration and continued for approximately 20 minutes after conclusion of study agent administration. The administration of each dose was separated by at least 48 hours (i.e., Days 1, 3, 5, and 7).

For both studies, continuous 12-lead ECG was collected from 3 hours predose to 12 hours postdose following each administration of study agent. The ECG recordings were analyzed by a central laboratory. Other safety assessments, including clinical and laboratory markers for potential microembolism, were assessed through AEs, vital signs, pulse oximetry, laboratory evaluations, physical examination, Mini Mental Status Examination (MMSE), and neurological examination following each dose of study agent. Safety was monitored for up to 48 hours after the last administration of study agent.

There were no serious AEs reported in both studies. Seven subjects had AEs reported during study BR1-112, all of which were mild to moderate in severity, 1 was considered as probably related and 1 of unknown relationship; five of the seven subjects (10.20%) had AEs after SonoVue administration. Eight subjects reported AEs during study BR1-113, all of which were mild in severity and only 1 was considered probably related to SonoVue; only four (7.55%) subjects experienced AEs after SonoVue administration, whereas 5 subjects had AEs after placebo.

The results from these 2 studies showed that SonoVue was not associated with an increased risk of prolonged cardiac repolarization, and was safe and well tolerated regardless of insonation regimen during echocardiography. The effect of SonoVue on ventricular repolarization and, in general, on cardiac electrophysiology was superimposable to that with placebo. There was no evidence of a dose-response relationship in the incidence of changes of potential clinical importance for ECG parameters. Neurological examination did not reveal any new abnormalities following administration of study agents. There were no clinically significant changes in MMSE scores at any timepoint following administration of study agents. Postdose changes from baseline in vital signs and oxygen saturation did not indicate any differences between SonoVue and placebo or any dose-related trends.

The results of the continuous ECG studies support the following conclusions:

- Administration of SonoVue at doses 0.1 or 0.5 mL/kg does not appear to cause prolonged cardiac repolarization in patients with CAD undergoing B-mode echocardiography with a wide range of MI settings - from low (0.4-0.5), to medium (0.7- 0.8), to high (1.5-1.6).
- There was no statistically significant difference between SonoVue and placebo in the maximum increase from baseline in corrected QT interval following administration of study agent and no evidence of a dose-response relationship.
- Administration of SonoVue was not associated with any increased incidence of cardiac abnormalities as evaluated by quantitative and qualitative ECG parameters.

- Consistent with the previously reported safety profile of SonoVue, there is no evidence that administration of SonoVue is associated with an increased risk of microembolism.

3.4.4.2 Retrospective Analyses of Patients with Angiographically Documented CAD

Bracco has also conducted 2 subset analyses of safety in patients with angiographically documented CAD for the studies in which a subset of the patients underwent coronary angiography, i.e., Studies BR1-012 and study BBG-012.

Study BR1-012 included pharmacological stress echocardiography. SonoVue was administered at rest and then at peak pharmacological stress, using one of the four different doses (0.5, 1.0, 2.0 or 4.0 mL) in parallel-group comparison. Contrast echocardiography was performed under moderate mechanical index (MI = 0.6-0.8). Of the 219 patients with known or suspected CAD included in this study, coronary angiography results were available for 84 patients. No serious AEs were observed. Nearly half (41/84) of the patients had stenosis ≥90%, among whom no increased incidence or severity of cardiac AEs attributable to SonoVue was observed. During or after pharmacologic stress, 2 events (mild and self-resolving chest pain) were observed in 2 patients with > 90% stenoses and 3-vessel disease. Similar minor events were observed and reported during pharmacologic stress in 3 out of 43 patients with stenoses <50% or no stenoses at all.

Study BBG-012 was a multicenter study to compare unenhanced and contrast-enhanced echocardiography with calibrated biplane cineventriculography and cardiac MRI for determination of left ventricular volumes and ejection fraction, and to assess myocardial perfusion at rest. Coronary angiography was performed in all 120 patients within 24 hours. SonoVue was administered as continuous infusion at a mean infusion rate of 1.34 mL/min. The mean total dose was 28.8 mL per patient (7-fold multiple of the highest recommended total dose for echocardiography where the product is marketed). Of the 120 patients, 71 (59%) had stenoses ≥ 70 % and 46 (38%) had stenoses ≥90 %. There were no serious AEs in the study. No signs or symptoms of myocardial ischemia were reported. No patient was discontinued due to an AE following administration of SonoVue. A total of two non-serious post-dose events (one extrasystole, one malaise) were observed. Both were minor and rapidly self-resolving.

3.4.5 Planned Safety Studies

3.4.5.1 Pulmonary Hemodinamic Study Including Patients with Pulmonary Hypertension

Bracco has also agreed with the FDA to conduct an additional multi-center, double-blind, randomized, placebo-controlled within-subject crossover comparative safety study to evaluate the potential systemic and pulmonary hemodynamic effects caused by intravenous bolus administration of SonoVue and a placebo in at least 30 subjects who are scheduled to undergo standard right heart catheterization. These subjects will be divided into two groups based on their baseline mean pulmonary arterial pressure (MPAP). Group A will include at least 15 subjects with pulmonary hypertension defined as baseline MPAP ≥ 25.0 mmHg. Group B will include subjects without pulmonary hypertension with baseline MPAP < 25.0 mmHg.

Each subject will receive one intravenous bolus dose of 4.8 mL Sonovue and one intravenous bolus dose of 4.8 mL placebo. The order of Sonovue and placebo injections will be randomized within each group. There will be a minimum of 10-minute interval between the two injections to allow the scheduled hemodynamic and other safety evaluations. All subjects in this study will undergo a standard right heart catheterization using a Swan-Ganz catheter from a jugular or femoral venous access. The right atrial pressure (RAP) and right ventricular pressure (RVP) will be measured at baseline. Systolic and diastolic AP, MPAP, pulmonary capillary wedge pressure (PCWP), cardiac output (Qp), heart rate (HR), stroke volume (SV), pulmonary vascular resistance (PVR) will be obtained from the right heart catheter during the study at predefined time points, as well as systemic hemodinamics from a sphygmomanometer. In addition, oxygen saturation, ECG, and AEs will be evaluated at the same time points. Physical examination and laboratory blood and urine analyses will be performed before and 24 hours after the administration of SonoVue and placebo.

3.4.5.2 Retrospective Safety Study

A retrospective observational safety study in critically ill patients has been planned and the protocol is under FDA review. The primary objective of the study is to compare in-hospital mortality (on the same or the next calendar day) between critically ill patients undergoing contrast echocardiography with SonoVue and critically ill patients undergoing echocardiography without the use of a contrast. Critically ill patients are defined as hospitalized patients with unstable cardio-pulmonary conditions identified according to predefined ICD-9 codes.

The patient population will include SonoVue Group, with a target sample size of 2008 hospitalized critically ill patients from European sites who underwent echocardiography with SonoVue, and a minimum of 10,036 matched controls that are critically ill patients who underwent echocardiography without an ultrasound contrast agent. This Group includes a pool of data from two patient sources: 1) hospitalized critically ill patients at European investigational sites who underwent at least one clinically indicated echocardiogram without any contrast agent; 2) hospitalized critically ill patients in the Premier Perspective database (Premier Inc., Charlotte, NC) who underwent at least one clinically indicated echocardiogram without any contrast agent. Each individual SonoVue patient will be matched to several control patients by a propensity score, consistent with the approach utilized by GE Healthcare for the Optison safety study in critically ill patients.[65]

3.4.6 Conclusion from Clinical Studies

No significant differences were observed in mean changes from baseline to post dose time points following SonoVue administration compared to placebo in patients with congestive heart failure and pulmonary hypertension. SonoVue had no negative effect on pulmonary function in patients with COPD and diffuse interstitial pulmonary fibrosis. In the continuous ECG studies, there were no statistically significant differences in the maximum increases from baseline in corrected QT interval following administrations of SonoVue and placebo, no evidence of a dose-response relationship or relationship to different MIs of ultrasound applied during echocardiography. SonoVue was safe in patients with documented severe CAD and in patients undergoing stress echocardiography.

The rate of AEs observed in the SonoVue studies are comparable to that from similar studies of the other USCAs approved by the FDA and commercialized in the US, i.e., Definity and Optison (see Table A on page 6).

Based on the 2008 Advisory Committee Meeting briefing document for Definity prepared by Lanthaeus, the clinical safety evaluation was provided for 3985 subjects (60 healthy subjects and 3925 patients, 369 subjects received placebo and 3616 received Definity) in 48 completed studies that are basis of regulatory approvals and post-NDA/MAA clinical experience.[a]

A total of 26% subjects had at least one new-onset AEs and 7.6% of them were treatment related AEs. The most common drug related AEs (reported >1%) are fatigue, headache, dyspnea, back pain, nausea, flushing, and dizziness. Less commonly reported AEs (0.5%~1%0.) are dysgeusia, chest discomfort, pain NOS, altered sensation, and pain at the injection site.

There were 33 serious AEs reported in dosed patients (0.91%) and 1 serious AE in a placebo subject; 8 events had fatal outcomes. None of the non-fatal serious AEs was considered by the investigators to be related to the use of DEFINITY®. All of these fatal outcomes occurred at least one day after the administration of DEFINITY® and were considered to be unrelated to drug by the investigators. No fatal outcome occurred in placebo subjects.

Based on the 2008 Advisory Committee Meeting briefing document for Optison prepared by GE Healthcare, the agent was administered in clinical studies in 279 patients, 47 (16.8%) of whom reported at least one AE. Of these one event was serious and required treatment with antihistamines for hypersensitivity manifestations of dizziness, nausea, flushing and temperature elevation. The most frequently reported AEs with Optison were headache (5.4%), nausea and/or vomiting (4.3%), warm sensation or flushing (3.6%), and dizziness (2.5%). These 6 Optison clinical studies for NDA were performed in the US under an Investigational Device Exemption (IDE).**Error! Bookmark not defined.**

Based on the December 2008 Cardiovascular and Renal Advisory Committee briefing document for Imagify,[c] safety data were summarized for 3 studies (including 1 phase II and 2 phase III studies) comprised of 911 subjects who received the test agent AI-700 (Imagify), of whom 652 (72%) experienced at least one AE (a total of 1879 AEs were reported). A total of 11 (<1%) subjects experienced non-life-threatening serious AEs, all in phase III studies.

The most frequently reported AEs among 106 healthy volunteers who received AI-700 were flushing (21%), headache (12%), cough (10%), dizziness (9%), and dyspnea (8%). Dose-dependent increases were observed in flushing, cough, dyspnea, and nausea. In CAD patients, dose-dependent increases were observed in flushing only. Of note, in Phase II and III studies, this agent was used in conjunction with a pharmacological stressor.

---

[c] *Acusphere, Inc. Cardiovascular and Renal Advisory Committee Briefing Document: AI-700 (Perflubutane Polymer Microspheres) For Injectable Suspension Imaging Agent for the Detection of Coronary Artery Disease (Imagify™). From FDA website: http://www.fda.gov/ohrms/dockets/ac/08/briefing/2008-4390b1-03-Acusphere.pdf December 10, 2008. Accessed on March 23, 2011.*

4 Safety of SonoVue Based on Worldwide Post-Marketing Surveillance

SonoVue should be administered using a 5-mL single vial per investigation (doses: 2.0 mL for endocardial border detection or 2.4 mL for Doppler sonography of vessels, repeated once if necessary). An estimate of patient exposure is thus calculated on the basis of the number of single dose vials sold from April 1, 2001 to December 31, 2010. Denominators are estimated from sales statistics, with each unit sold representing a patient exposed to the agent.

Spontaneously reported serious AEs including those with fatal outcome, regardless of the causal relationship, received in the period of April 1, 2001 through December 31, 2010 from the countries where SonoVue is marketed (including events from observational and investigator initiated studies) are summarized. The AE terminology provided reflects the diagnosis or terminology used by the reporters. The spontaneous reporting system is a voluntary system of reporting AEs. Consequently, reports sometimes do not contain diagnoses, but simply describe the signs and symptoms that occurred, or may include preliminary diagnoses and incomplete information.

Experience from post-marketing surveillance of the estimated 1,651,451 patients exposed to SonoVue from April 1, 2001 through December 31, 2010 during the market use of this product (including events from observational studies, investigator-initiated studies and publications) shows a total of 217 cases of serious AEs (reporting rate: 0.013%), of which, 213 patients were considered to have AEs with some kind of relationship to the administration of SonoVue (probable, possible or unlikely) and 4 patients were considered to have AEs clearly unrelated to SonoVue administration.

No significant temporal trend in the incidence of serious adverse events has been observed (Figure 1).

Figure 1. Postmarketing Surveillance Serious Cases by Month From April 1, 2001 Through December 31, 2010

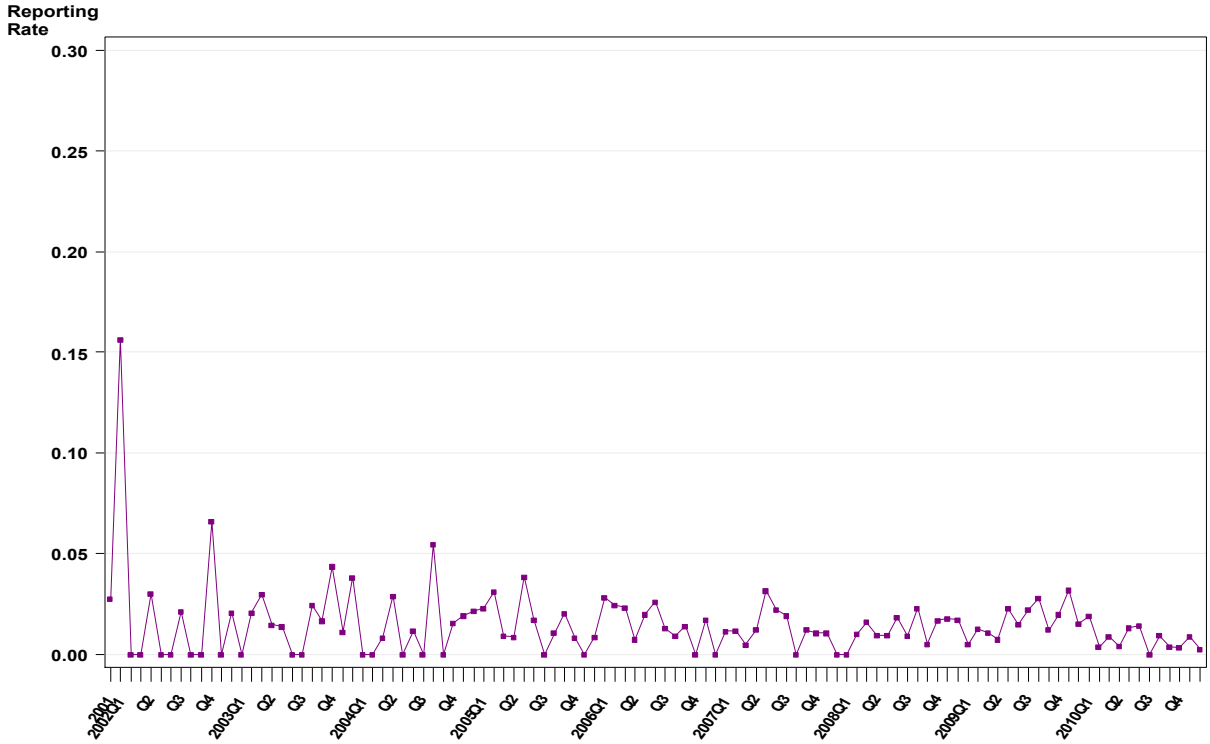

4.1 Serious Allergy-like or Anaphylactoid Reactions

All reported serious AEs under the immune system disorders SOC were allergy-like reactions included terms indicating "hypersensitivity". These reactions were reported in 162 cases, representing 75% of all serious AE cases reported for SonoVue. In most of these cases, the initial signs or symptoms started within 5 minutes from the injection of SonoVue. The overall estimated reporting rate of serious allergy-like or anaphylactoid cases by month from April 1, 2001 to December 31, 2010 is provided below in Figure 2. No significant temporal trend in the incidence of serious hypersensitivity events has been observed (Figure 2).

Figure 2. Postmarketing Surveillance Serious Allergy-Like Cases by Month From April 1, 2001 Through December 31, 2010

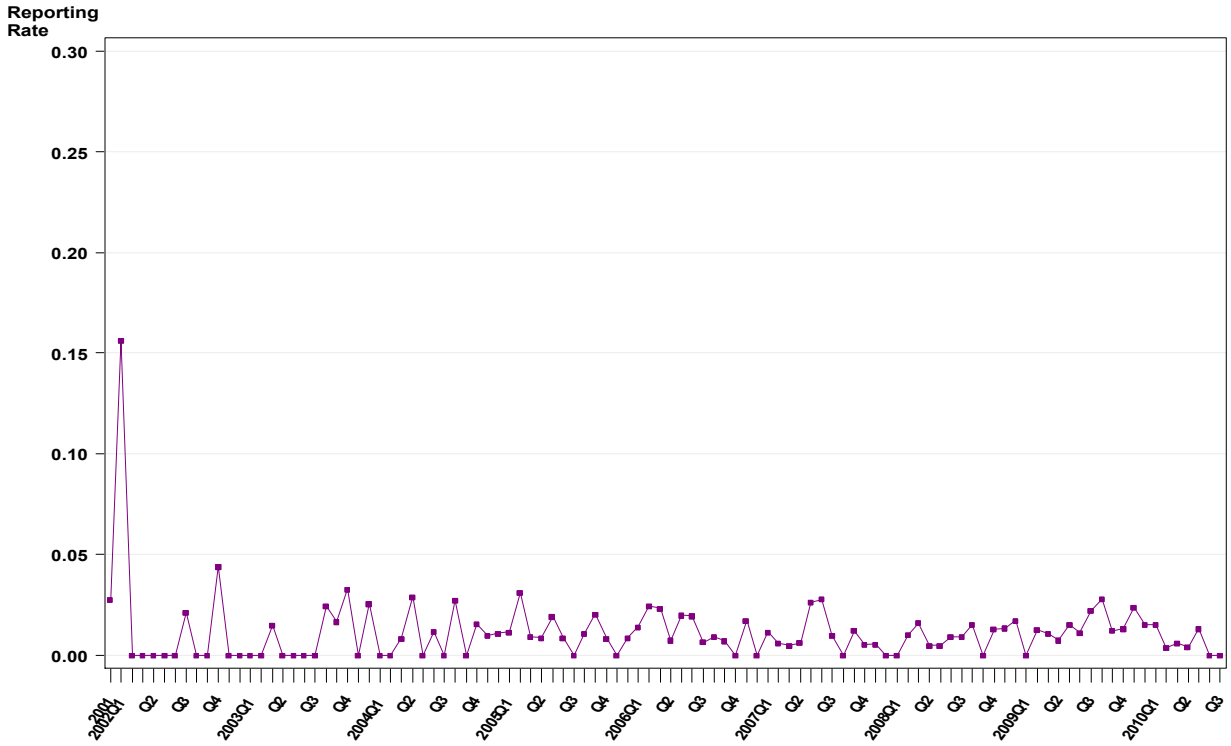

4.2 Serious Cardiac Reactions

A total of 60 cases (0.003633% of subjects exposed to SonoVue) with cardiac symptoms have been reported so far. In over half of these cases (33/60), the cardiac events were the result of or part of an anaphylactoid or allergy-like reaction.

The overall estimated reporting rate of serious cases with cardiac reactions by month from April 1, 2001 to December 31, 2010 is provided below in Figure 3. No significant temporal trend in the incidence of serious hypersensitivity events has been observed.

Figure 3. Postmarketing Surveillance Serious Cardiac Cases by Month From April 1, 2001 Through December 31, 2010

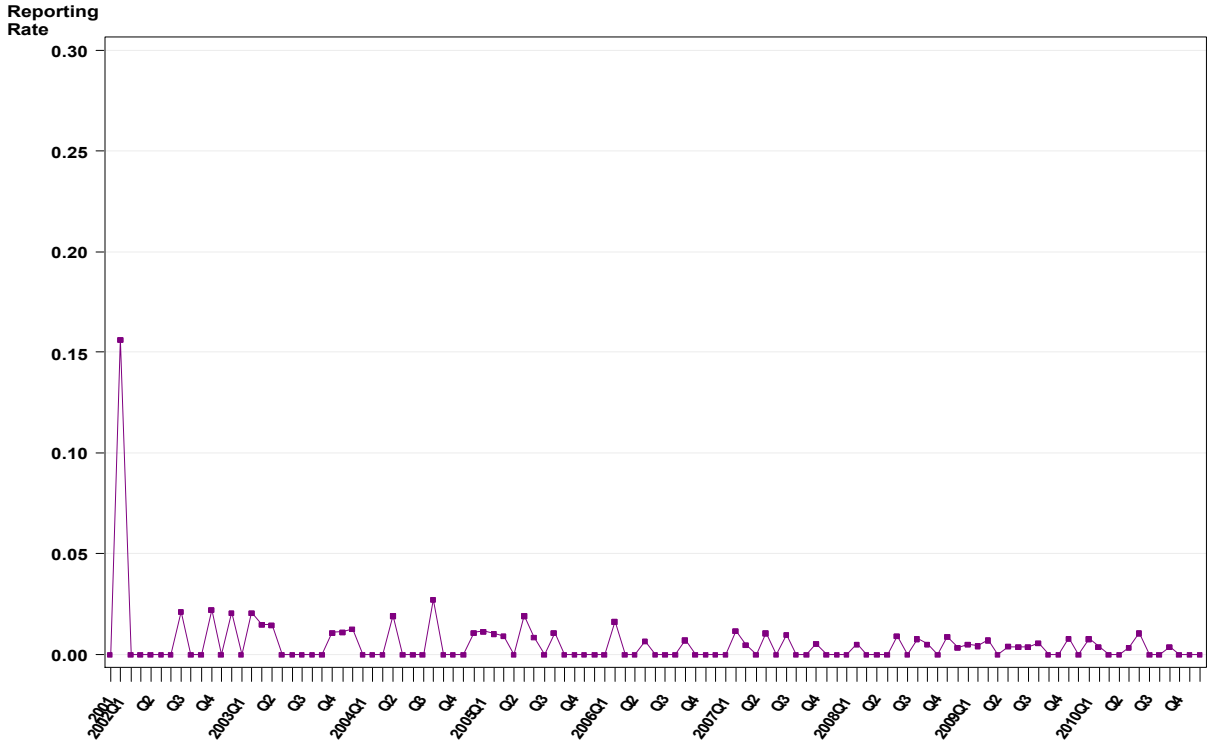

4.3 Other Serious Reactions

Besides the above discussed immune system disorders and cardiac disorders, other symptoms that have been reported more than 5 times included: hypotension (34), blood pressure decreased or blood pressure immeasurable (17), dyspnea (23), cough (6), loss of consciousness (14), syncope (5) or presyncope (8), erythema (10), urticaria (8), rash (7), ECG ST segment elevation (6) and paresthesia (6). Almost all symptoms were reported in the context of hypersensitivity or vaso-vagal reactions.

4.4 Fatal Events

As of December 31, 2010, a total of 9 deaths occurred during spontaneous reporting since the launch of the product in 2001, 3 before 2005, 6 in 2005 or later. Narrative summaries for each case follow.

- **Case BRO-005943 (Germany, 2002)** describes a 69-year-old male patient with history of anterior and posterior myocardial infarction, percutaneous transluminal coronary angiography (PTCA) and stent placement in left anterior descending coronary artery (LAD) was admitted for an angiographic follow-up, which showed 3-vessel disease (occlusion of right coronary artery, RCA, high grade restenosis in distal LAD stent, and several stenoses in left circumflex artery, LCx). A new revascularization of LAD in-stent-restenosis was

performed successfully. The following day, the patient was feeling well except for an unusual restlessness and before undergoing echocardiography with SonoVue. About 4-5 minutes following the 2nd injection of 2-2.5 mL SonoVue, the restlessness increased, heart rate decreased from 90 bpm to 50 bpm, blood pressure also decreased, accompanied by cold sweat. An anaphylactic shock was initially suspected and the patient treated accordingly, but the patient's conditions continued to deteriorate. An emergency coronary angiography performed after the SonoVue study showed a complete, new thrombotic reocclusion of the LAD-stent and PTCA was performed successfully with restored TIMI III Flow. The patient's blood pressure was recorded as approximately 100 mmHg and cardiac rhythm was normalized. The patient was transferred to ICU with intra-aortic balloon pump. Later at ICU, the patient developed bradycardia and a ventricular escape rhythm and despite treatment, the patient died of a cardiogenic shock. The fatal outcome was considered by the reporter to be related to the underlying severe cardiac disease and unrelated to the administration of SonoVue.

- **Case BRO-006772 (Germany, 2003)** concerns a 49 year-old male patient with 3-vessel coronary artery disease and a history of multiple myocardial infarctions, severe reduction of left ventricular function (ejection fraction 31%) due to a new, recent acute anterior myocardial infarction. The patient underwent multiple percutaneous coronary interventions (PCIs) of the LAD, but no revascularization procedure was performed on the significant, 80% to 90% narrowing of the LCx and RCA. One month after PCI, he underwent a rest echocardiogram with SonoVue to assess left ventricular function. The exam was eventless. The patient became unconscious after the exam while getting up from the examination table. No ECG was available at the onset of event. During the event the ECG showed asystole, blood pressure and pulse were not measurable. The patient was immediately treated with cardiopulmonary resuscitation measures. Despite treatment, the patient developed pulseless electrical activity followed by ventricular fibrillation. The patient was announced dead 40 minutes after the resuscitation was started. No autopsy was performed. Due to the temporal relationship, a role of SonoVue in the development of the initial hypotension was considered possible.
- **Case BCM-000767 (Italy, 2003)** describes a 51-year-old patient suffering from 40% occlusion of the common trunk and recent anterior myocardial infarction treated with PTCA of LAD. The patient developed a bundle branch block. An echocardiogram with SonoVue was performed one month later. About 2 minutes after SonoVue injection, the patient reported throat burning and back pain. Echocardiogram showed asystole**.** Despite the reanimation procedures and pharmacological treatment with adrenaline, cortisone and fibrinolytic agents, the patient died. The autopsy showed a 90% stenosis at the ostium of the common trunk and a thrombus completely occluding the distal common trunk. The autopsy report indicated the cause of death as "presence of thrombus occluding common trunk". Based on the autopsy report, the reporting physician excluded a role of SonoVue in the onset of the reported event and subsequent fatal outcome and considered the observed events related to the thrombotic occlusion of the common trunk.
- **Case BRO-008552 (Sweden, 2004)** describes a 61-year-old hypercholesterolemic female patient suffering from lung cancer with cerebral metastases who also had a history of a small

myocardial infarction. Her overall clinical condition was compromised and she had stayed in bed for the previous 5 days. The patient underwent a contrast-enhanced liver ultrasound with SonoVue, which confirmed the metastases to the liver. Nine hours after the examination, the patient complained of abdominal pain and dyspnea. Morphine was administered subcutaneously. A few minutes after the administration of morphine, she became unconscious and died 15 minutes after the onset of symptoms. No autopsy was performed. The reporting physician stated that neither death nor the observed AEs were related to SonoVue.

- **Case BRO-011933 (Norway, 2007)** concerns a 65-year-old female patient, suffering from metastatic colon cancer with lung metastases treated with chemotherapy, radiotherapy and surgical removal of the colon cancer, developed hydronephrosis due to radiation fibrosis with insertion of urethral stents and a fistula between a pelvic artery and a urethra that required urgent surgical intervention. The patient was on treatment for asthma with inhalation of steroids and beta-agonists and had previous allergic reactions to acetylsalicylic acid, one of which had occurred 4 months before SonoVue administration described as an anaphylactoid reaction requiring treatment with steroids and adrenaline. She underwent an ultrasound liver imaging with SonoVue for staging. Fifteen seconds after SonoVue injection she complained of a strange taste sensation and experienced cough, dyspnea, and frothing around her mouth, followed by loss of consciousness and generalized seizure with regular pulse. The emergency team arrived 2 minutes later and found no pulse and started resuscitation (heart compression, intravenous adrenaline, defibrillation). After 40 minutes of advanced cardiopulmonary resuscitation, the patient was pronounced dead. The autopsy showed highly elevated blood tryptase level (>200 micrograms/L [reference level 0-13.5]); and elevated IgE 147 kU/L (normal 0-122). SonoVue was considered as the probable cause of an allergic reaction, while the underlying conditions played a role in the severity and outcome of the reaction.
- **Case NL-000008 (Netherlands, 2008)** describes a 53-year-old male patient with a history of recent (a month earlier) severe acute coronary syndrome and acute apical myocardial infarction with subsequent PCI of the RCA. An echocardiography revealed reduced left ventricle function and suspected an apical thrombus. An additional exam with SonoVue was ordered, which revealed no sign of an apical thrombus. A few minutes after SonoVue injection the patient felt indisposed. Shortly thereafter, reanimation and pharmacological intervention was started and electromechanical dissociation was observed. The patient died about 40 minutes later. The autopsy report showed that the patient had an ongoing myocardial infarction while he received SonoVue. It is difficult to conclude if the reaction was entirely caused by the developing myocardial infarction or if a possible reaction to SonoVue complicated the clinical course of the underlying acute myocardial infarction. Of note, treatment consisted of anti-allergy drugs, while the myocardial infarction had not been detected or treated.
- **DE-000545 (Germany, 2009)** describes s a 50-year-old male patient with history of nicotine abuse and CAD, including transmural infarction with apical akinesis and PTCA with stent about 2 months before he underwent a routine echocardiography with SonoVue. About 30 seconds after SonoVue injection, the patient reportedly experienced dyspnea, tachypnea and respiratory arrest. The patient died after 2 hours of resuscitation. The reporter made a

diagnosis of anaphylaxis. Bracco tried multiple times but could not obtain additional information on this case, in vain.

- **DE-000635 (Germany, 2010)** describes a 56-year-old male patient with no history of allergy, who underwent an ultrasound with SonoVue for an apical left ventricular thrombus. One minute after SonoVue injection, the patient felt hot, became agitated and subsequently experienced a drop in blood pressure. The symptoms were considered to be an anaphylactoid reaction by the reporter. The patient was treated with dimethindene maleate, corticosteroids and catecholamines; cardio-pulmonary resuscitation was performed. After an unspecified time the patient died and the cause of death is unknown. No additional information could be obtained despite multiple attempts by Bracco to obtain more information regarding the time and cause of death.
- **CN-000162 (China, 2010)** describes a 69-year-old male who was referred to radiology for loss of appetite, after unspecified tests revealed possible liver cirrhosis and suspected liver absesses. No concomitant medications or known allergies were reported. The patient underwent a liver ultrasound with SonoVue. Within 1 minute after SonoVue injection, the patient appeared to be nauseated and was helped to an upright position to prevent aspiration. He coughed, but did not vomit. Later (time not specified) the patient became unresponsive and went into a coma. The patient was treated in the ICU but died of an unknown cause, 13 days later. Autopsy was not performed. The reporter considered the casual relationship to be unassessable, reported the event only because of the temporal relationship between SonoVue injection and event onset.

4.5 Conclusion from Post-Marketing Surveillance

In general, the observed pattern of serious AE cases possibly related to the administration of SonoVue is similar to that reported for anaphylactic or anaphylactoid reactions to other intravascular imaging agents. Symptoms started from a few seconds to minutes after contrast administration. The initial symptoms ranged from mild to severe and progress to circulatory and/or respiratory arrest and/or loss of consciousness. Of note, no skin or mucosal symptoms were ever observed in any of these cases. In all death cases, the poor underlying conditions of the patients played a major role in the fatal outcome. Of the 9 reported deaths, 6 underwent contrast echocardiography and 3 underwent contrast liver ultrasound. Among the 6 cardiac patients, 5 (BRO-005943, BRO-006772, BCM-000767, NL-000008 and DE-000545**)** had severe underlying coronary artery disease with ongoing or recent acute myocardial infarction, several were treated with coronary intervention and several had left ventricular dysfunction. In two cases (BRO-005943 and NL-000008), SonoVue was administered to patients with ongoing acute myocardial infarctions, so that it is not clear if SonoVue played any role in the genesis of the events. Of note, in both cases no specific treatment for the underlying myocardial infarction was given, but only that for anaphylaxis. One patient (DE-000635) had limited information on his cardiac condition except an apical left ventricular thrombus, which is often associated with myocardial infarction. All 3 radiology patients (BRO-008552, BRO-011933, CN-000162) had advanced stage cancer.

The above results from SonoVue Post-Marketing Surveillance database are comparable to that from Post-Marketing data of Definity and Optison.

Based on the 2008 Advisory Committee Meeting briefing document for Definity, approximately 2 million patients worldwide, had received Definity for the time period October 2001 through December 30, 2007. The majority of global use was from 2005 onwards. A total of 3113 events in 1632 cases, including 695 serious events from 277 cases, were received during the post-marketing period from December 28, 2000 to December 27, 2007.

About one third (33.8%) of the AEs reported are related to: 1) back pain (28.6%) and 2) flank pain, muscle spasm, arthralgia, neck pain (5.2%).

The most frequently reported serious AEs following Definity administration were either cardiopulmonary, hypersensitivity or CNS reactions.

From the 2008 Advisory Committee Meeting briefing document for Optison, the global PV database contains 57 reports concerning Optison with more than 1 million doses administered, including 27 serious reactions in 12 patients and 83 non-serious reactions in 45 patients. The most frequently reported serious reactions are chest pain (3 events), ECG abnormality/change (3 events), and hypoxia (3 events). One fatal AE of cardiac arrest was reported in a subject in the post-MI phase, attributed by the reporter to the subject's underlying medical condition. The most frequently reported non-serious reactions are nausea (9 events), dysgeusia (6 events), and abdominal pain (5 events). (See Table B on page 7.)

5 Literature Review

5.1 Overall Literature Review of SonoVue Safety in Humans

Bracco conducted a systematic review and analysis of the literature on the safety of SonoVue to update the experience of SonoVue use with various echocardiography techniques as well as the safety of SonoVue use in various cardiac and non-cardiac indications, in order to provide an evidence-based safety profile of SonoVue.

5.1.1 Methodology for SonoVue Safety Literature Review

An independent research firm with access to a number of major medical literature databases was contracted by Bracco to conduct an extensive search of the literature databases (Medline, CancerLit, Derwent Drug File, Biosys Preview, International Pharmaceutical Abstracts, Embase, Biobase, Biological Abstracts, CAB Abstracts, CSA Life Science Abstracts, Cochrane Database for Systematic Reviews, Cochrane Controlled Trials Register) with predefined search strategy.

The search strategy included the following search terms:

- “SonoVue” or “sulfur hexafluoride” or “BR1” or “BR-1”, and
- “echocardiography” or “ultrasound”

Other strategy for this search included:

- Language: no limit on language
- Time period: January 1, 1990 to February 2010 (when the search was performed)

- Humans/animals: Humans only (animal or in vitro studies were excluded)
- Abstracts from conferences or scientific meetings were excluded

All articles (abstracts) resulted from the search were reviewed and sorted and duplicate articles from different databases were consolidated. Then full-text articles were reviewed to identify those that reported safety results from human studies with the use of SonoVue during echocardiography or other ultrasound studies. A Bracco physician performed the review and data analysis. During the review, any other relevant publications that were not captured in the above search and any new publications coming to the attention of the reviewer were added to the list of publications for review.

Publications that met all the following inclusion criteria were included in this analysis:

1) Original publication of a clinical study in human subjects with prospective or retrospective enrollment
2) SonoVue was used during an echocardiography or a non-cardiac ultrasound examination, and
3) Information on safety related to the administration of SonoVue including AEs was reported

5.1.2 Results from SonoVue Safety Literature Review

A total of 445 publications were reviewed, among which 53 articles involving 39,722 patients met the above inclusion criteria for SonoVue safety analysis. [3-55]

5.1.2.1 SonoVue Exposure

Doses of SonoVue and other USCAs used in these studies, when available, vary significantly depending on the indication for contrast use, type of imaging mode and, perhaps, authors experience or preference. The differences are more pronounced in cardiac studies than in non-cardiac studies.

Among cardiac studies, even though there is a trend of using bolus for left ventricular opacification (LVO) or endocardial border delineation (EBD) studies and intravenous infusion for MCE studies, there are also studies using intravenous bolus for MCE and infusion for LVO/EBD. A single intravenous bolus ranged from 0.3 mL to 2 mL (mostly 1-2 mL), whereas infusion doses ranged from 1.6 mL to 20 mL (mostly <10 mL).

The dosing regimen of SonoVue was more uniform in the non-cardiac studies. Most of the studies used the approved doses for non-cardiac indications in the respective countries outside the United States, i.e., 2.4 mL per each intravenous bolus for a maximum for 2 boluses or 4.8mL.

5.1.2.2 Imaging Modes

In the majority of publications where information is available for imaging modes, low-MI contrast specific imaging modes were used, both for cardiac and for non-cardiac contrast-enhanced examinations. The MI used in these examinations were usually very low (<0.08) to low (<0.2). High MI (>1) were mainly used in myocardial perfusion studies during flash imaging, and occasionally for clearance of contrast between injections.

5.1.2.3 Safety Results from Cardiac Studies

Almost one third of the included publications (17/53) were from cardiac studies involving 11,101 patients, including rest and/or stress contrast-enhanced echocardiography.

The majority of patients (10,405/11,101, or 93.7%) underwent stress imaging with or without rest imaging for evaluation of CAD or myocardial viability. Among cardiac studies performed under stress, AEs are not uncommon, mostly attributable to stress induced by exercise or pharmaceutical agents such as dobutamine, adenosine and dipyridamole and other concomitant medications such as atropine and beta-blockers, as evidenced in 3 studies that included 1328 patients who received SonoVue or another USCA (Luminity in 621 and Optison in 120 patients) and underwent stress imaging compared to 2918 control patients who underwent the same stress imaging without the use of USCA.[15,41,42] The studies did not find statistically significant differences in AEs among different groups with or without contrast with different pharmaceutical stress agents.

Side effects observed in stress echo studies (in both non-contrast and contrast groups) included headache, dry mouth, dizziness, hypertension, hypotension, fatigue, vasovagal episodes, slight tremor, dyspnea, back pain, vomiting and pain at injection site. Arrhythmia observed during stress studies (in both non-contrast and contrast groups) included atrial fibrillation/flutter, supraventricular/ventricular premature beats, sustained/nonsustained supraventricular/ventricular tachycardia, 2nd degree atrio-ventricular block (AVB) and left bundle branch block (LBBB). Several studies observed the occurrences of cardiac arrhythmia during stress imaging, but did not find increase or worsening of arrhythmia with the use of contrast.[15,35, 42,49,55]

Hypersensitivity reactions occurred in rare cases. All of them were expeditely reported to the FDA and other Authorities through routine post-marketing surveillance systems and operations.

In a large series of prospective safety study with 5250 patients who underwent dobutamine-atropine stress echo with SonoVue (most of the patients also received a beta-blocker Esmolol), 0.44% reported hypersensitivity reactions (which consisted mainly of itching, skin rash or urticaria). [35] Other studies reported no allergic or hypersensitivity reactions to SonoVue. One study reported allergic reaction to Luminity (shivering and maculopapular rash) in 2 (0.32%) patients.[15]

A total of 422 patients underwent rest imaging only for evaluation of myocardial perfusion or left ventricular function, and no adverse event was observed. One study evaluated SonoVue cardiac safety using tissue Doppler in 28 healthy volunteers and concluded that contrast echocardiography does not cause alterations of myocardial function.[39]

One study reported follow-up results of major cardiac AEs (MACE) following rest contrast echocardiography with SonoVue in patients with AMI. No MACE was observed at 6-month follow-up in 110 patients.[8]

In a single-center retrospective review of 352 consecutive contrast examinations performed in 274 patients over a period of 4 years, it was impossible to determine the number of patients undergoing stress and/or rest contrast imaging.[54] This study reported mild AEs (including skin erythema and mild sinus tachycardia) in 4 patients and severe AEs (anaphylactic reaction) in 3 patients.

In summary, the incidence of AEs in contrast echocardiography performed at rest is negligible (0 in this analysis). The incidence of AEs in contrast echocardiography performed during stress is similar to that in non-contrast echocardiography during the same stress conditions, and most, if not all, AEs may be attributable to the pharmaceutical agents used to induce stress. No significant difference in incidence of AEs was found between SonoVue and other USCAs.

5.1.2.4 Non-Cardiac Studies

Over two thirds (36/53) of the included publications involving 28,621 patients were for non-cardiac indications, including contrast-enhanced ultrasound for liver (12 studies in 4,513 patients), abdominal (including 1 large retrospective survey of 23,188 patients and 6 studies in 218 patients), brain (4 studies in 104 patients), musculoskeletal (6 studies in 221 patients), breast (2 studies in 57 female patients), prostate (2 studies in 144 male patients), peripheral lung lesions (2 studies in 158 patients) and thyroid imaging (1 study in 18 patients). SonoVue was the only USCA used in these non-cardiac studies.

A large retrospective survey of 23,188 patients undergoing abdominal CEUS with SonoVue reported 27 (0.11%) non-serious (23 mild, 3 moderate and 1 severe) and 2 (<0.01%) serious AEs.[44] Non-serious AEs included itching, mild dizziness, moderate hypertension, headache, warm sensation, nausea and vomiting. Serious AEs included anaphylactoid reaction in one patient and clouding of consciousness, dursolumbar pain, severe hypotension and cutaneous rash in a patient with suspected renal artery in-stent restenosis. The causality of these events could not be assessed.

Adverse events reported from other studies included nausea in 1 patient, burning during contrast injection in 2 patients, dizziness in 1 patient, erythema and edema of the thorax and the upper extremities in 1 patient.

One study in patients with small vessel disease did not detect blood brain barrier disruption following SonoVue administration using contrast-enhanced MRI.

In summary, the incidence of AEs in non-cardiac CEUS with SonoVue is very low (0.11% for non-serious AEs and <0.01 for serious AEs in this analysis). No trend was shown between occurrences of AEs and doses of SonoVue or imaging parameters.

5.1.2.5 Conclusion from SonoVue Literature Review

This literature review did not allow the identification of any safety concern. The rate of AEs related to SonoVue was extremely low. Use of SonoVue in stress echocardiography studies did not cause excessive AEs. There was no evidence of tissue level damage with the use of SonoVue. There was no detectable trend in the safety of SonoVue across various cardiac and non-cardiac populations, under various imaging modes, with a wide range of doses or between bolus and infusion of SonoVue.

5.2 Review and Analysis of 24-hour Mortality Rate in Critically Ill Patients

A literature search was conducted in order to perform a systematic review and analysis of the published literature of SonoVue use in critically ill cardiac patients in order to compare the

24-hour mortality rate in this population following echocardiography with SonoVue versus patients undergoing echocardiography without the use of any contrast agent.

The literature search was conducted by accessing PubMed and identifying echocardiography studies conducted in critically ill patients with the use of SonoVue based on the following specifications published from January 2001 to March 2010 (when the last search was performed), excluding meeting abstracts and review articles for lack of detailed patient level information.

The key terms used for the search included "SonoVue", "sulfur hexafluoride", "BR1" or "BR-1", "echocardiography" or "ultrasound", "cardiac disease", "critically ill patients", "cardiac disease", "acute coronary syndrome", "clinically unstable ischemic cardiac disease", "AMI", "acute cardiac failure", "typical angina at rest within last 7 days", "coronary artery intervention", "PTCA", "cardiac ablation", "class III/IV cardiac failure", "ventricular remodeling", "ventricular arrhythmia", "severe emphysema", "pulmonary emboli", "severe pulmonary hypertension", "adult respiratory distress syndrome" and "respiratory failure".

This search was confirmed with a search that was conducted using the following databases to assure that all articles had been retrieved: Medline, CancerLit, Derwent Drug File, Biosys Preview, International Pharmaceutical Abstracts, Embase, Biobase, Biological Abstracts, CAB Abstracts, CSA Life Science Abstracts, Cochrane Database for Systematic Reviews, Cochrane Controlled Trials Register.

Since there were difficulties in retrieving articles containing data for both SonoVue-treated patients and patients who did not receive contrast reported in the same article, the collected articles were classified into 2 groups:

(a) SonoVue-treated group: articles must report information on patients undergoing SonoVue-enhanced echocardiography; information on patients undergoing non-contrast enhanced echocardiography or that enhanced by contrast agents other than SonoVue may be present

(b) Control group: articles must report information on patients undergoing non-contrast enhanced echocardiography; information on patients undergoing echocardiography enhanced by contrast agents other than SonoVue may be present

A total of 27 articles potentially matching the SonoVue-treated group and 12 articles for the control group were further reviewed using the following inclusion/exclusion criteria to select the articles useful to reach the stated objective:

- Articles had to focus on critically ill cardiac patients only;
- Subjects had to be consecutive patients or selected at random;
- If 2 or more treatments were involved, patients had to be randomized;
- In the case of 2 or more treatments, it had to be possible to extract the number of deaths within the arms of interest;
- Availability of 24-hour mortality data, either from the article or directly from the authors;
- Patients could not have been reported in more than one article;
- Articles reporting crossover studies were excluded;
- Case report, or articles reporting short series of selected patients, were excluded;
- Review articles were excluded;

- Articles reporting meta-analyses only were excluded;
- Articles reporting on off-label route of administration (i.e., non intravenous administration) of SonoVue were excluded.

The 24-hour mortality was defined as:

- For the SonoVue group: any death occurred within 24 hours following intravenous administration of SonoVue for contrast enhanced echocardiography, whether the death was related to SonoVue or not;
- For the control group: any death occurred within 24 hours following unenhanced echocardiography.

Based on the above criteria, 10 published articles were included for the SonoVue-treated group and 1 article was included for the control group in the statistical analysis (Table G).

Table G: Published Articles Included in Meta-Analysis

Article	Patient Population	No. of Patients	No. of Patients with Fatal Outcomes Within 24 Hours
SonoVue Group			
Agati et al, 2002[56]	CAD patients with AMI	23	0
Galiuto et al, 2006[57]	Patients within 12 hr onset of STEMI referred for PCI	50[a]	0
Galiuto et al, 2008[58]	Patients with AMI undergoing PCI	110 [a, b]	0
Guiducci et al, 2005[59]	Patients with anterior AMI undergoing PCI or thrombolysis	62 [a]	0
Korosoglou et al, 2004[60]	Patients with first occurrence of chest pain	100 [a]	0
Serra et al, 2005[61]	Patients with AMI undergoing PCI	49	0
Soman et al, 2000[62]	Patients with severe left ventricular dysfunction and congestive heart failure	13	0
Streb et al, 2008[63]	Patients with first MI undergoing angioplasty	39 [a]	0
Winter et al, 2005[64]	Patients with acute coronary syndrome	36 [a]	0
Wita et al, 2009[12]	Patients with first AMI treated with PCI with and without thromboaspiration	46	0
Subtotal		**528**	**0**
Control Group			
Exuzides et al, 2009[65]	Critically ill patients	11,600	129
Subtotal		**11,600**	**129**

[a] Number of patients with fatal outcomes within 24 hours was based on information collected from the authors as it was not reported in the article.
[b] Same cohort of patients was published in Funaro et al, 2009[8]

The mortality rates for both SonoVue-treated group and control group were estimated from the data extracted from the articles and then compared using Fisher's exact test. The 95% exact

confidence interval was also provided for both mortality rates. Statistical calculations were performed using SAS System.

A total of 528 patients were included in SonoVue-treated group and 11,600 patients in the control group. No death was reported within 24 hours following SonoVue administration in the SonoVue group and 129 deaths were reported within 24 hours following non-contrast echocardiography in the control group. Therefore, the 24-hour mortality rate for the SonoVue treated patients was 0% (95% CI: 0-0.7%), whereas that for the control group was 1.1% (129/11,600, 95% CI: 0.9-1.3%). The difference between the mortality rates from the 2 groups was statistically significant (chi-square = 5.9349, DF = 1, exact p = 0.0072).

Comparable results were also reported in a recently published meta-analysis for all-cause mortality after the use of contrast agents for echocardiography. The cumulative incidence of all-cause mortality in the contrast group was 0.34% (726/211,162) compared to 0.9% (45,970/5,078,666) in the non-contrast group.[1]

6 Overall Conclusions

In clinical trials, no significant effect on pulmonary hemodynamics, pulmonary function, blood pressure, oxygen saturation, vital signs, cardiac function, electrocardiographic parameters and laboratory test results were observed.

In the continuous ECG studies, there were no statistically significant differences in the maximum increases from baseline in corrected QT interval following administrations of SonoVue and placebo, no evidence of a dose-response relationship or relationship to different mechanical index of ultrasound applied during echocardiography.

In clinical trials, the overall incidence of AEs was relatively low (10.8% overall, 5.7% drug related) in subjects receiving SonoVue. The most frequently reported AEs were headache (2.1%), nausea (0.9%), chest pain (0.6%), chest discomfort (0.6%), and injection site pain (0.5%). All other AEs occurred at a frequency of <0.5%. Most AEs were mild and resolved spontaneously within a short time without sequelae. Serious AEs occurred in 0.47% of patients and only 0.08% were possibly drug-related. No drug-related deaths were reported within Bracco-sponsored trials.

Experience from post-marketing surveillance showed that, of the estimated 1,651,451 patients exposed to SonoVue during the market use of this product, a total of 217 patients experienced serious AEs (reporting rate: 0.013%), of which, 213 patients were considered to have related AEs and 4 patients were considered to have AEs unrelated to SonoVue administration. Serious hypersensitivity reactions were observed in in less than 1:10,000 exposures. No significant temporal trend in the incidence of any of the serious adverse events was observed.

An extensive literature search and analysis of the use of SonoVue in a number of indications, in a variety of patient populations and using a wide range of ultrasound settings showed no significant differences were detected in safety between SonoVue and placebo, or between SonoVue and other USCAs of the same class, namely, Definity® and Optison®. The review of literature in critically ill patients undergoing echocardiography did not reveal any increase in 24-hour mortality following the use of SonoVue.

It can be concluded that SonoVue has a safety profile similar to that of other USCAs marketed in the United States.

7 References

(Copies of published literature will be available on request.)

[1] Khawaja OA, Shaikh KA, Al-Mallah MH. Meta-analysis of adverse cardiovascular events associated with echocardiographic contrast agents. Am J Cardiol. 2010;106(5):742-7.

[2] Barnett SB, Duck F, Ziskin M. Recommendations on the safe use of ultrasound contrast agents. Ultrasound in Med & Biol. 2007;33:173-4.

[3] Jung EM, Prantl L, Schreyer AG, Schreyer, CI, Rennert J, Walter M, et al. New perfusion imaging of tissue transplants with Contrast Harmonic Ultrasound Imaging (CHI) and Magnetic Resonance Imaging (MRI) in comparison with laser-induced Indocyanine Green (ICG) fluorescence angiography. Clin Hemorheol Microcirc. 2009;43(1-2):19–33.

[4] Giannoni MF, Fanelli F, Citone M, Acconcia MC, Speziale F, Gossetti B. Contrast ultrasound imaging: the best method to detect type II endoleak during endovascular aneurysm repair follow-up. Interact CardioVasc Thorac Surg. 2007;6:359-362.

[5] Prantl L, Pfister K, Kubalec R, Schmitt S, Stockhammer V, Jung W, et al. Value of high resolution ultrasound and contrast enhanced US pulse inversion imaging for the evaluation of the vascular integrity of free-flap grafts. Clin Hemorheol Microcirc. 2007;36(3):203–16.

[6] Bernard S, Leen E, Cooke T, Angerson W. A contrast-enhanced ultrasound study of benign and malignant breast tissue. S Afr Med J. 2008;98:386-91.

[7] Song IH, Burmester GR, Backhaus M, Althoff CE, Hermann KG, Scheel AK, et al. Knee osteoarthritis. Efficacy of a new method of contrast-enhanced musculoskeletal ultrasonography in detection of synovitis in patients with knee osteoarthritis in comparison with magnetic resonance imaging. Ann Rheum Dis. 2008;67(1):19-25.

[8] Funaro S, La Torre G, Madonna M, Galiuto L, Scara A, Labbadia A, et al. Incidence, determinants, and prognostic value of reverse left ventricular remodelling after primary percutaneous coronary intervention: results of the Acute Myocardial Infarction Contrast Imaging (AMICI) multicenter study. Euro Heart J. 2009;30(5):566–75.

[9] Taymoorian K, Thomas A, Slowinski T, Khiabanchian M, Stephan C, Lein M, et al. Transrectal Broadband-Doppler sonsography with intravenous contrast medium administration for prostate imaging and biopsy in men with an elevated PSA value and previous negative biopsies. Anticancer Res. 2007;27:4315-20.

[10] Wang Y, Yu X, Tang J, Li H, Liu L, Gao Y. Solitary necrotic nodule of the liver: Contrast-enhanced sonography. J Clin Ultrasound. 2007;35:177–81.

[11] Bartolotta TV, Midiri M, Galia M, Runza G, Attard M, Savoia G, et al. Qualitative and quantitative evaluation of solitary thyroid nodules with contrast-enhanced ultrasound: initial results. Eur Radiol. 2006;16:2234–41.

[12] Wita K, Lelek M, Filipecki A, Turski M, Wrobel W, Tabor Z, et al. Microvascular damage prevention with thrombaspiration during primary percutaneous intervention in acute myocardial infarction. Coronary Artery Dis. 2009;20(1):51-7.

[13] Sperandeo M, Sperandeo G, Varriale A, Filabozzi P, Decuzzi M, Dimitri L, et al. Contrast-enhanced ultrasound (CEUS) for the study of peripheral lung lesions: A preliminary study. Ultrasound Med & Biol. 2006;32 (10):1467–72.

[14] Klauser A, Demharter J, De Marchi A, Sureda D, Barile A, Masciocchi C, et al. Contrast enhanced gray-scale sonography in assessment of joint vascularity in rheumatoid arthritis: results from the IACUS study group. Eur Radiol. 2005;15:2404–10.

[15] Anantharam B, Chahal N, Chelliah R, Ramzy I, Gani F, Senior R. Safety of contrast in stress echocardiography in stable patients and in patients with suspected acute coronary syndrome but negative 12-hour troponin. Am J Cardiol. 2009;104(1):14-18.

[16] Seidel G, Meyer-Wiethe K, Berdien G, Hollstein D, Toth D, Aach T. Ultrasound perfusion imaging in acute middle cerebral artery infarction predicts outcome. Stroke. 2004;35(5):1107-11.

[17] Kumar P, Domian J, Bhandari P, Ellis R, Higginson A. Is there an association between intestinal perfusion and Crohn's disease activity? A feasibility study using contrast-enhanced ultrasound. Br J Radiol. 2009;82(974):112-17.

[18] Iezzi R, Basilico R, Giancristofaro D, Pascali D, Cotroneo AR, Storto ML. Contrast-enhanced ultrasound versus color duplex ultrasound imaging in the follow-up of patients after endovascular abdominal aortic aneurysm repair. J Vasc Surg. 2009;49(3):552-60.

[19] Wang Z-L, Tang J, Weskott HP, Li J-L, Wang W, Luo Y-K, et al. Undetermined focal liver lesions on gray-scale ultrasound in patients with fatty liver: Characterization with contrast-enhanced ultrasound. J Gastroenterol Hepatol. 2008;23(10):1511-19.

[20] Bartolotta TV, Taibbi A, Galia M, Runza G, Matranga D, Midiri M, et al. Characterization of hypoechoic focal hepatic lesions in patients with fatty liver: diagnostic performance and confidence of contrast-enhanced ultrasound. Eur Radiol. 2007;17(3):650–61.

[21] Duerschmied D, Maletzki P, Freund G, Olschewski M, Seufert J, Bode C, et al. Analysis of muscle microcirculation in advanced diabetes mellitus by contrast enhanced ultrasound. Diabetes Res Clin Pract. 2008;81(1):88-92.

[22] Xu H-X, Liu G-J, Lu M-D, Xie X-Y, Xu Z-F, Zheng Y-L, et al. Characterization of focal liver lesions using an innovative contrast-enhanced ultrasound technique. Chinese J Surg. 2005;43(21):1375-78.

[23] Bartolotta TV, Midiri M, Quaia E, Bertolotto M, Galia M, Cademartiri F, et al. Liver haemangiomas undetermined at grey-scale ultrasound: contrast-enhancement patterns with SonoVue and pulse-inversion US. Eur Radiol. 2005;15(4):685–93.

[24] Manetta R, Bultrini PC, Stavroulis E, Di Cesare E, Masciocchi C. Ultrasound enhanced with sulphur-hexafluoride-filled microbubbles agent (SonoVue) in the follow-up of mild liver and spleen trauma. Radiol Med. 2009;114(5):771-9.

[25] Droste DW, Boehm T, Ritter MA, Dittrich R, Ringelstein EB. Benefit of echocontrast-enhanced transcranial arterial color-coded duplex ultrasound. Cerebrovas Dis. 2005;20(5):332-6.

[26] Jungehulsing GJ, Brunecker P, Nolte CH, Fiebach JB, Kunze C, Doepp F, et al. Diagnostic transcranial ultrasound perfusion-imaging at 2.5 MHz does not affect the blood-brain barrier. Ultrasound Med Biol. 2008;34(1):147-50.

[27] Terslev L, Torp-Pedersen S, Bang N, Koenig MJ, Nielsen MB, Bliddal H. Doppler ultrasound findings in healthy wrists and finger joints before and after use of two different contrast agents. Ann Rheum Dis. 2005;64(6):824-77.

[28] Van Esser S, Veldhuis WB, Van Hillegersberg R, Van Diest PJ, Stapper G, ElOuamari M. Accuracy of contrast-enhanced breast ultrasound for pre-operative tumor size assessment in patients diagnosed with invasive ductal carcinoma of the breast. Cancer Imaging. 2007;7:63-8.

[29] He W, Jiang X-Q, Wang S, Zhang M-Z, Zhao J-Z, Liu H-Z, et al. Intraoperative contrast-enhanced ultrasound for brain tumors. Clin Imaging. 2008;32(6):419-24.

[30] Malm S, Frigstad S, Sagberg E, Larsson H, Skjaerpe T. Accurate and reproducible measurement of left ventricular volume and ejection fraction by contrast echocardiography. J Am Coll Cardiol. 2004;44(5):1030-5.

[31] Janardhanan R, Moon JCC, Pennell DJ, Senior R. Myocardial contrast echocardiography accurately reflects transmurality of myocardial necrosis and predicts contractile reserve after acute myocardial infarction. Am Heart J. 2005;149(2):355-62.

[32] Clevert D-A, Weckbach S, Kopp R, Meimerakis G, Clevert D-A, Jauch KW, et al. Imaging of aortic lesions with color coded duplex sonography and contrast-enhanced ultrasound versus multislice computed tomography (MS-CT) angiography. Clin Hemorheol Microcirc. 2008;40(4):267-79.

[33] Ricci P, Cantisani V, D'Onofrio M, Sahani D, Pagliara E, Calliada F, et al. Behavior of hepatocellular adenoma on real-time low-mechanical index contrast enhanced ultrasonography with a second-generation contrast agent. J Ultrasound Med. 2008;27(12):1719-26.

[34] Cosyns B, Van Camp G, Droogmans S, Weytjens C, Schoors D, Lancellotti P. Analysis of regional wall motion during contrast-enhanced dobutamine stress echocardiography: effect of contrast imaging settings. Eur J Echocardiogr. 2009;10(8):956–60.

[35] Aggeli C, Giannopoulos G, Roussakis G, Christoforatou E, Marinos G, Toli C, et al. Safety of myocardial flash-contrast echocardiography in combination with dobutamine stress testing for the detection of ischaemia in 5250 studies. Heart. 2008;94(12):1571-7.

[36] Ridolfi F, Abbattista T, Marini F, Vedovelli A, Quagliarini P, Busilacchi P, et al. Contast-enhanced ultrasound to evaluate the severity of chronic hepatitis C. Dig Liver Dis. 2007;39(10):929-35.

[37] Malm S, Frigstad S, Helland F, Oye K, Slordahl S, Skjarpe T. Quantification of resting myocardial blood flow velocity in normal humans using real-time contrast echocardiography. A feasibility study. Cardiovas Ultrasound. 2005,3(16):1-9.

[38] Bilotta F, Agati L, Fiorani L, Madonna M, Pinto G, Rosa G. Pulmonary transit of echocontrast agents during mechanical ventilation: a clinical transthoracic echocardiographic study. Echocardiography. 2005;22(5):395-401.

[39] Cosyns B, Weytjens C, Vanderhoogstrate M, Daniels C, Schoors D, Van Camp G. Tissue Doppler imaging does not show infraclinical alteration of myocardial function after contrast echocardiography. Eur J Echocardiogr. 2005;6(4):238-42.

[40] Liu D-C, Ling Z-Y, Wang Z-G, Zhang M-H, Ran H-T, Deng C-M, et al. Noninvasive assessment of myocardial microcirculation in patients with syndrome X by myocardial contrast echocardiography. Clin J Med Imaging Technol. 2006;22(2):180-2.

[41] Gaibazzi N, Squeri A, Ardissino D, Reverberi C. Safety of contrast flash-replenishment stress echocardiography in 500 patients with a chest pain episode of undetermined origin within the last 5 days. Eur J Echocardiogr. 2009;10(6):726-32.

[42] Timperley J, Mitchell ARJ, Thibault H, Mirza IH, Becher H. Safety of contrast dobutamine stress echocardiography: a single center experience. J Am Soc Echocardiogr. 2005;18(2):163-7.

[43] Wijkstra H, de la Rosette JJMCH, Von Busch H, Powers J. Contrast-enhanced ultrasound for prostate cancer imaging. MedicaMundi. 2007;51(2-3):74-9.

[44] Piscaglia F, Bolondi L, on behalf of the Italian Society for Ultrasound in Medicine and Biology (SIUMB) study group on ultrasound contrast agents. The safety of Sonovue® in abdominal applications: retrospective analysis of 23188 investigations. Ultrasound Med Biol. 2006;32(9):1369-75.

[45] Bartolotta TV, Midiri M, Galia M, Rollandi GA, Cademartiri F, Lagalla R, Cardinale AE. Characterization of benign hepatic tumors arising in fatty liver with SonoVue and pulse inversion US. Abdom Imaging. 2007;32(1):84-91.

[46] Dietrich CF, Mertens JC, Braden B, Schuessler G, Ott M, Ignee A. Contrast-enhanced ultrasound of histologically proven liver hemangiomas. Hepatology. 2007;45(5):1139-45.

[47] Meloni MF, Livraghi T, Filice C, Lazzaroni S, Calliada F, Perretti L. Radiofrequency ablation of liver tumors: The role of microbubble ultrasound contrast agents. Ultrasound Quarterly. 2006;22(1):41-7.

[48] Clevert D-A, Hornga A, Clevert D-A, Jung EM, Sommer WH, Reiser M. Contrast-enhanced ultrasound versus conventional ultrasound and MS-CT in the diagnosis of abdominal aortic dissection. Clin Hemorheol Microcirc. 2009;43(12):129–39.

[49] Dijkmans PA, Juffermans LJM, Van Dijk J, Musters RJP, Spreeuwenberg, Kamp O. Safety and feasibility of real time adenosine myocardial contrast echocardiography with emphasis on induction of arrhythmias: A study in healthy volunteers and patients with stable coronary artery disease. Echocardiogr. 2009;26:807-14.

[50] Van den Bosch AE, Meijboom FJ, McGhie JS, Roos-Hesselink JW, Ten Cate FJ, Roelandt JRTC. Enhanced visualization of the right ventricle by contrast echocardiography in congenital heart disease. Eur J Echocardiogr. 2004;5:104-10.

[51] Caruso G, Martegani A, Aiani L, Borghi C, Verderame F, Campisi A, et al. Heterogeneous delayed enhancement of hepatic parenchyma after intravenous infusion of sonographic contrast agent: a new hypothesis. Radiol Med. 2007;112:56–63.

[52] Caremani M, Benci A, Lapini L, Tacconi D, Caremani A, Ciccotosto C, et al. Contrast enhanced ultrasonography (CEUS) in peripheral lung lesions: A study of 60 cases. J Ultrasound. 2008;11:89-96.

[53] Staub F, Tournoux-Facon C, Roumy J, Chaigneau C, Morichaut-Beauchant M, Levillain P, et al. Liver fibrosis staging with contrast-enhanced ultrasonography: prospective multicenter study compared with METAVIR scoring. Eur Radiol. 2009;19:1991-7.

[54] Geleijnse ML, Nemes A, Vletter WB, Michels M, Soliman OII, Caliskan K, et al. Adverse reactions after the use of sulphur hexafluoride (SonoVue) echo contrast agent. J Cardiovasc Med. 2009;10:75-7.

[55] Korosoglou G, Labadze N, Giannitsis E, Bekeredijian R, Hansen A, Hardt SE, et al. Usefulness of real-time myocardial perfusion imaging to evaluate tissue level reperfusion in patients with non-ST-elevation myocardial infarction. Am J Cardiol. 2005;95(9):1033-8.

[56] Agati L, Funaro S, Madonna M, Volponi C, Veneroso G, Tonti G. Clinical utility of contrast echocardiography in the management of patients with acute myocardial infarction. Eur Heart J Supplements. 2002;4:C27-C34.

[57] Galiuto L, Garramone B, Burzotta F, Lombardo A, Barchetta S, Rebuzzi AG, Crea F. Thrombus aspiration reduces microvascular obstruction after primary coronary intervention a myocardial contrast echocardiography substudy of the remedia trial. J Am Coll Cardiol. 2006;48:1355-60.

[58] Galiuto L, Garramone B, Scarà A, Rebuzzi AG, Crea F, La Torre G, et al. The extent of microvascular damage during myocardial contrast echocardiography is superior to other

known indexes of post-infarct reperfusion in predicting left ventricular remodeling: results of the multicenter AMICI study. J Am Coll Cardiol. 2008;51:552–9.

[59] Guiducci V, Fioroni S, Giacometti P, Manari A, Gaddi O. Early evaluation of coronary microcirculation by echocardiography with contrast medium in patients with acute myocardial infarction treated with primary percutaneous transluminal coronary angioplasty. Minerva Cardioangiol. 2005;53:157-64.

[60] Korosoglou G, Labadze N, Hansen A, Selter C, Giannitsis E, Katus H, Kuecherer H. Usefulness of real-time myocardial perfusion imaging in the evaluation of patients with first time chest pain. Amer J Cardiol. 2004;94:1225-31.

[61] Serra V, Perez de Isla L, Zamorano J, Almeria C, Rodrigo JL, Perez M, Florit J, Azcona L, Hernandez RA, Macaya C. Usefulness of parametric imaging-based quantitative myocardial contrast echocardiography in predicting the functional recovery of akinetic segments following primary angioplasty in acute myocardial infarction patients. Rev Esp Cardiol. 2005;58:649-56.

[62] Soman P, Lahiri A, Senior R. Safety of an intravenous second generation contrast agent in patients with severe left ventricular dysfunction. Heart. 2000;84:634–5.

[63] Streb W, Duszanska A, Stabryla-Deska J, Pluta S, Swierad M, Was T, et al. The comparison of contrast echocardiography and tissue Doppler imaging for evaluation of reperfused myocardium in patients with acute anterior myocardial infarction. Cardiol J. 2008;15:548-54.

[64] Winter R, Gudmundsson P, Willenheimer R. Real-time perfusion adenosine stress echocardiography in the coronary care unit: a feasible bedside tool for predicting coronary artery stenosis in patients with acute coronary syndrome. Eur J Echocardiogr. 2005;6:31-40.

[65] Exuzides A, Main ML, Colby C, Grayburn PA, Feinstein SB, Goldman JH. A retrospective comparison of mortality in critically ill hospitalized patients undergoing echocardiography with and without an ultrasound contrast. J Am Col Cardiol Img. 2010;3:578-85.