Food and Drug Administration
Center for Food Safety and Applied Nutrition
Office of Special Nutritionals

ARMS#

13408

6 - MD NOTES

000001

Attachment # 4
Memo FLA-9339
CFSAN Project #13408
4/5/99
SJH

[redacted]

Date | Notes should be sig[redacted]

ER-[redacted] 21-FEB-1999 22:48

VITAL SIGNS	21-FEB 21:45	21-FEB 22:00	21-FEB 22:15	21-FEB 22:30	21-FEB 22:45
HR	96	90	94	124	118
PVC	0	0	0	0	0
RR	17	17	15	20	22
NBP-S				164	130
NBP-D				63	39
NBP-M				109	90
NBP-R				130	90
SPO2-%				100	100
SPO2-R				124	118
ST-I	0.3	0.5	0.3	0.2	0.6
ST-II	0.7	0.6	0.9	0.0	0.4
ST-III	0.3	0.0	0.5	-0.4	-0.2
ST-V1	0.1	0.3	0.1	0.4	0.0
ST-AVR	-0.5	-0.6	-0.6	-0.1	-0.5
ALARMS					

NBP (mmHg)

ER-[redacted] 21-FEB-1999 22:48

VITAL SIGNS	21-FEB 20:45	21-FEB 21:00	21-FEB 21:15	21-FEB 21:30	21-FEB 21:45
HR	76	100	106	112	96
PVC	0	0	0	0	0
RR	9	17	17	12	17
NBP-S					
NBP-D					
NBP-M					
NBP-R					
SPO2-%	90	97	98	99	
SPO2-R	76	100	98	110	
ST-I		0.3	0.3	1.0	0.3
ST-II		0.5	0.8	1.0	0.7
ST-III		0.2	0.3	0.0	0.3
ST-V1		0.1	0.0	0.0	0.1
ST-AVR		-0.4	-0.6	-1.0	-0.5
ALARMS					

NBP (mmHg)

2/22 Dictated [redacted]

2/23 Had multiple breakthrough seizures this am, now has post ictal VSS

GA: sleepy.
L & C -
Abd & + NBS
Impr - seizures ? etiology not clear will need an LP
- Rhabdo.
Plan & - Transfer to [redacted]
- LP ?! as per [redacted]
Dr [redacted] JN/S.

[redacted]

PROGRESS NOTES

[redacted]

[redacted]

Date	Notes should be signed by Physician
	Neurology:
2/23/99	Unusual case of new onset SZ.
1342	Had CP episodes c̄ GTC SZ and (F) facility
[redacted]	as more reported eyes turned to (L).
	O/E (N) Co, Mg
	USS Afebrile.
	Bit tip of his tongue.
	Post ictal confusion.
	EEG c̄ interictal slowing. No pleds or
	sharp waves.
	contrast CT (N).
	A) ~~Frequent~~ New onset SZ c̄ frequent episodes.
	P) - pt fact charts to transfer to [redacted]
	I recommended that till he gets to [redacted] to ~~start~~ do
	LP. R/O Encephalitis.
	D/w Dr. [redacted] t [redacted] and they said they will get
	back as to meeting pt.
	See orders.

Attachment # 4
Memo FLA-9339
CFSAN Project #13408
4/5/99
SJH

PROGRESS NOTES

[redacted]

[redacted]

000003

[redacted]

Date	Notes should be sign[redacted]
2/23/99	Procedure Note.
14:30	LP done after 3g IV ultimum and help of Nurses and security team.
[redacted]	Done in sitting position but L3 4 c 20 G needle
	Steril conditions and 1% Lido used.
	Initial drops were traumatic, rest as clear. 13cc removed.
	See orders.

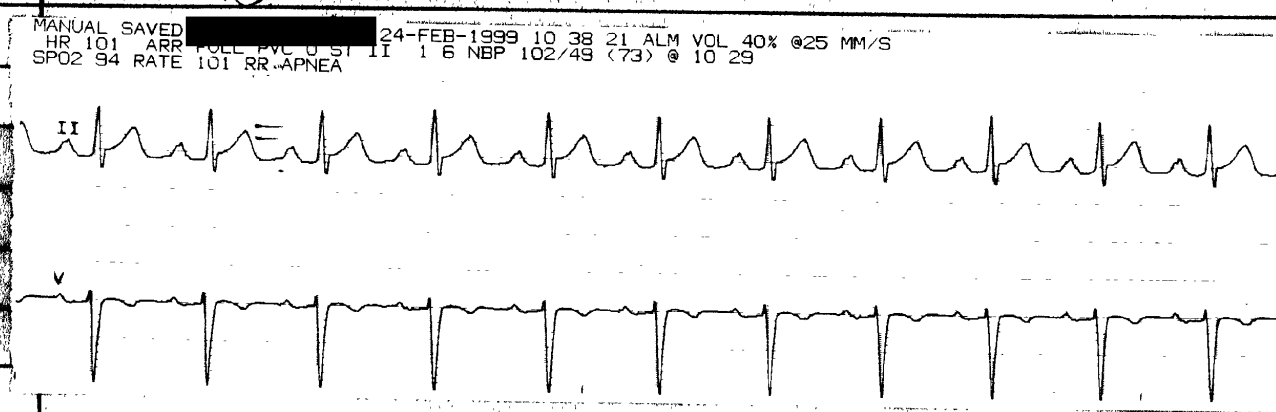

Attachment # 4
Memo FLA-9339
CFSAN Project #13408
4/5/99
SJH

PROGRESS NOTES

[redacted]

A[redacted]

[redacted]

Date	Notes should be signed [redacted]
2/24/99	Neurology: [redacted]
1140AM	Was notified last PM of one sz
[redacted]	Apparently had another. Had multiple
	Ativan dosages.
	O/E Arousable very sedated.
	(V) CSF protein glucose and WBC.
	DPH 15.2.
	A) Frequent seizures very unusual for
	new onset.
	P) Elective intubation
	Stat Ø hab.
	Had a very difficult and long discussion c
	pt's wife explaining reasoning: She finally agreed.
	See orders.
2/24	Events noted, discussed. in Dr [redacted]
	- will attempt to discuss in wife.
	VSS
	GAC sedated / Intubated
	L s clear -

Attachment # 4
Memo FLA-9339
CFSAN Project #13408
4/5/99
SJH

[redacted]

PROGRESS NOTES

[redacted]

Addressograph

000005

[redacted]

[redacted]

Date	Notes should be signed by Physician
	Enhanced — up noted
	Ass: — Status epileptic etiology not clear ? encephalitis ?! will ask ID to see patient can while will [illegible] & [illegible] phenobarb
	Plan & [illegible]
	[illegible]

[redacted]

MANUAL SAVED [redacted] 24-FEB-1999 18 54 50 ALM VOL 40% @25 MM/S
HR 100 ARR FULL PVC 0 ST II 1 5 NBP 129/66 (90) @ 18 31
SPO2 100 RATE 100 RR 10

2/24

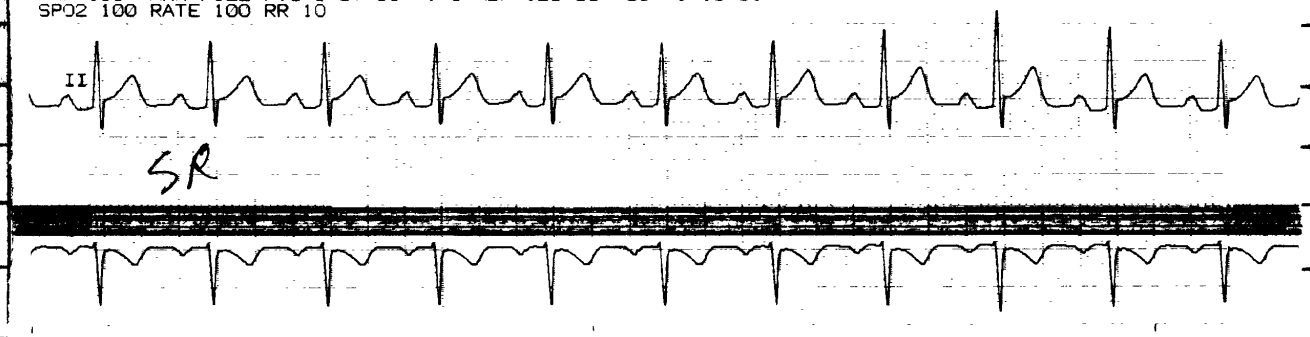

Attachment # 4
Memo FLA-9339
CFSAN Project #13408
4/5/99
SJH

PROGRESS NOTES

[redacted]

000006

Addressograph

[redacted]

Department Codes:

N	= Nursing	**ST**	= Speech Therapy	**Rad**	= Ra[redacted]		
Nutr	= Food & Nutrition Service	**Rec**	= Recreational Therapy	**Card**	= Ca[redacted]		
PT	= Physical Therapy	**R**	= Respiratory Therapy	**Neuro**	= Ne[redacted]		
OT	= Occupational Therapy	**SW**	= Social Work Services	**Rad X**	= Ra[redacted]		
PO	= Perioperative	**CR**	= Cardiac Rehab	**PH**	= Pharmacy		
				CM	= Case Manager		

[redacted]

E=Evaluation / Outcome

Date & Time	Dept	Notes

CH 16 [redacted] HR=100 05:17:42 AM 2.22.99 MANUAL GN=1 [redacted]



St Hr: 100 RR: 18 BPS: 08

CH 16 [redacted] HR=94 10:21:00 AM 2 22 99 ALL REC # GN=1 FILTER CH 1

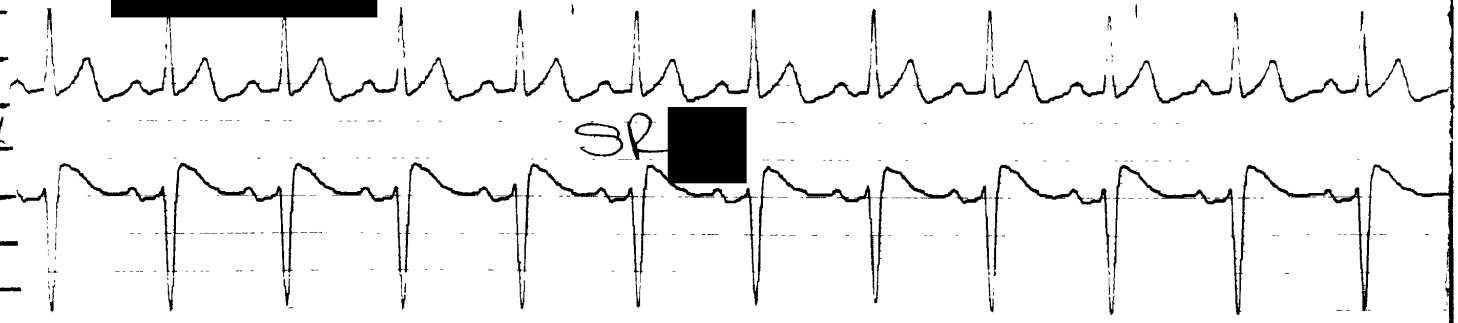

SR [redacted]

FILTER CH

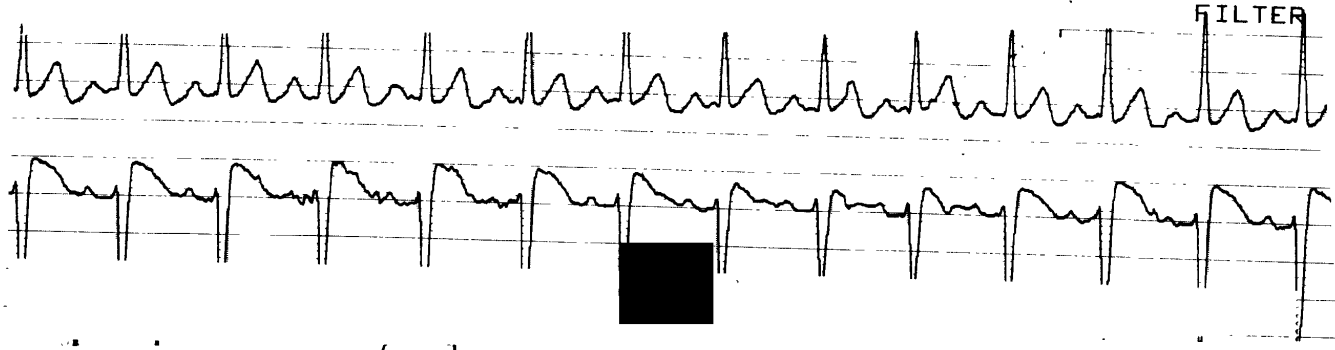

[redacted]

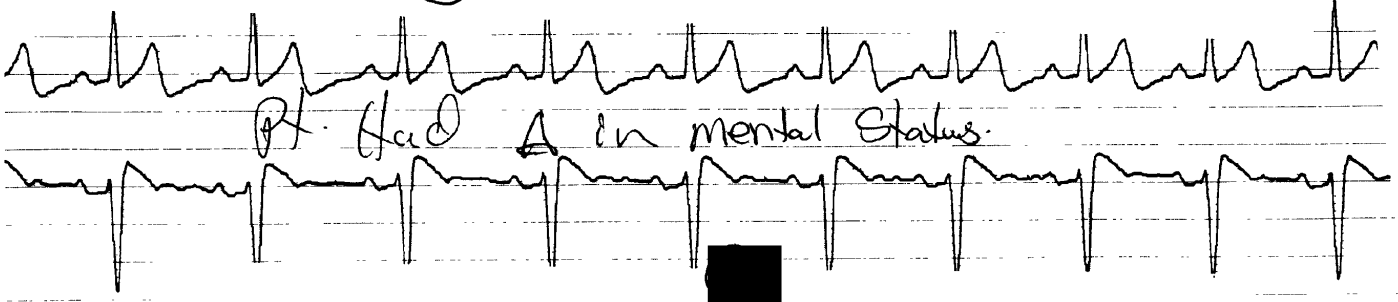

Pt. Had Δ in mental Status.

[redacted]

[redacted]

000007

Attachment # 4
Memo FLA-9339
CFSAN Project #13408
4/5/99
SJH

[redacted]

Department Codes:

N	= Nursing	ST	= Speech Therapy	Rad	= Radi[redacted]		
Nutr	= Food & Nutrition Service	Rec	= Recreational Therapy	Card	= Card[redacted]		
PT	= Physical Therapy	R	= Respiratory Therapy	Neuro	= Neur[redacted]		
OT	= Occupational Therapy	SW	= Social Work Services	Rad X	= Radi[redacted]		
PO	= Perioperative	CR	= Cardiac Rehab	PH	= Pharmacy	CM	= Case Manager

E=Evaluation / Outcome

Date & Time	Dept	Notes

CH 16 [redacted] HR=93 10:04:24 PM 2 22 99 MANUAL GN=1

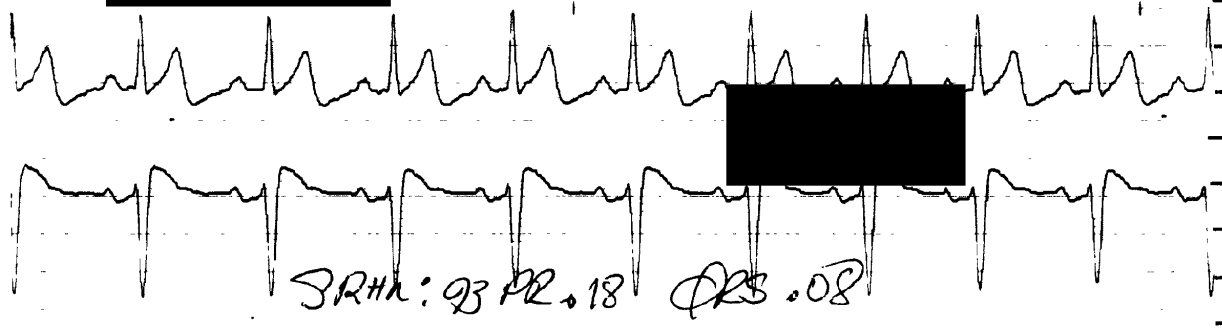

SRHR: 93 PR .18 QRS .08

CH 16 [redacted] HR=95 03:44:49 AM 2 23 99 MANUAL GN=1 FIL

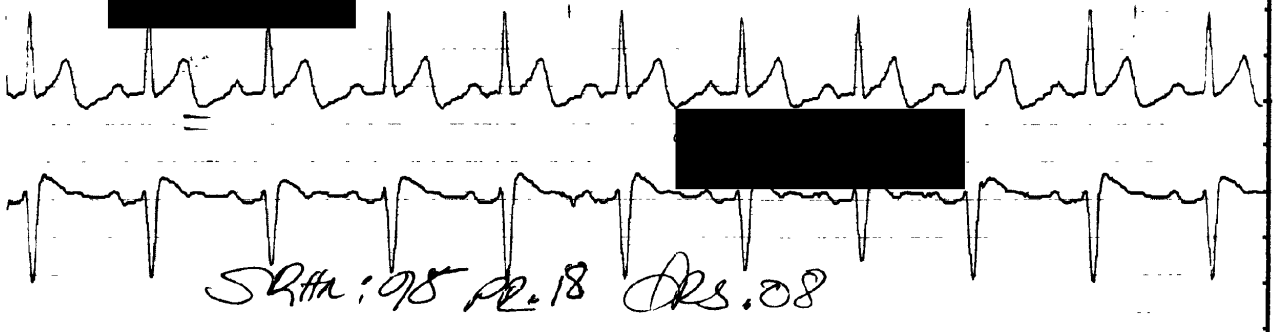

SRHR: 95 PR .18 QRS .08

CH 16 [redacted] HR=48 08:10:34 AM 2/23/99 MANUAL * # GN=1 FILTER CH

Pt. unResponsive Pt. Having a Seizure.

[redacted]

CH 16 [redacted] HR=72 08:11:14 AM 2/23/99 MANUAL * # GN=1 FILTER



Pt. out of Siezure Pt Still unResponsive

[redacted]

000008

[redacted]

Attachment # 4
Memo FLA-9339
CFSAN Project #13408
4/5/99
SJH

Department Codes:					
N	= Nursing	ST	= Speech Therapy	Rad	= Radiology
Nutr	= Food & Nutrition Service	Rec	= Recreational Therapy	Card	= Cardiology
PT	= Physical Therapy	R	= Respiratory Therapy	Neuro	= Neuro diagnostics
OT	= Occupational Therapy	SW	= Social Work Services	Rad X	= Radiation Therapy
PO	= Perioperative	CR	= Cardiac Rehab	PH	= Pharmacy
				CM	= Case Manager

Note Format:
V=Variation
I=Intervention
E=Evaluation / Outcome

Date & Time	Dept	Notes
2-23-99	N	Special Note: Entered Room Wife States "I
0600		Was talking c̄ him (PT) and he went Completely
		Blank Staring at the Wall".
		Pt un responsive to all but Pain.
		Retracts to Pain Eyes do not open. Pt
		Placid. [redacted]
0610	N	Special Note: VS P105 R18 BP
		122/64. Eyes open Responds to Verbal
		Stimuli Confused Oriented x1 Un-
		Cooperative c̄ Attempting VS. Repeated Calm
		Reality orientation and assurance.
		That BP will be done in 1 min helped
		Pt to Relax Wife's voice assists c̄
		Calming Pt. [redacted]
0625	N	Special Note: Pt Sleeping Resp Easy
		Skin W/D Color good Wife @
		bed Side Do [redacted]
		Dilantin level Drawn @ 0515 Report
		Off to Day Shift to Call Neurology to
		Report Seizure and Dilantin level
		@ same time [redacted]

Attachment # 4
Memo FLA-9339
CFSAN Project #13408
4/5/99
SJH

000009

Addressograph [redacted]

INTERDISCIPLINARY TEAM PROGRESS NOTES

[redacted]

Attachment # 4
Memo FLA-9339
CFSAN Project #13408
4/5/99
SJH

Department Codes:

N	= Nursing	**ST**	= Speech Therapy	**Rad**	= Radiology
Nutr	= Food & Nutrition Service	**Rec**	= Recreational Therapy	**Card**	= Cardiology
PT	= Physical Therapy	**R**	= Respiratory Therapy	**Neuro**	= Neuro diagnostics
OT	= Occupational Therapy	**SW**	= Social Work Services	**Rad X**	= Radiation Therapy
PO	= Perioperative	**CR**	= Cardiac Rehab	**PH**	= Pharmacy
				CM	= Case Manager

Note Format:
V=Variation
I=Intervention
E=Evaluation / Outcome

Date & Time	Dept	Notes
2/23/99 2100	N	V- Family reports "seizure" of aprox 30 sec duration. State pt's eyes rolled back in his head and he wouldn't answer us. Pt discovered post-ictal. PERRL purposeful movements but no response to verbal stimuli. HR 100, BP 131/88. Respirs reg et even. I. Maintain seizure precautions and frequent observation — [redacted]
2300	N	V- Pt again became non responsive c̄ eyes rolled up. Duration <30 sec. No incontinence. Awake s̄ verbal response. Restless and picking at IV, attempting to get DDB pulling leads. Routine Dilantin given response I Ativan 2 mg IVP given 2310 pt continues agitated. Tele ST 110. Ativan 2 mg IVP Repeated @ 2335 E. Pt resting quietly @ 12 mn. Wife @ bedside. [redacted]
0550	N	V- Wife reports "another seizure". Pt c̄ eyes open & staring for ~20 sec. During this time, pt held breath. Immediately returned to apparent normal sleep, respirs reg & even @ 16, moving to position of comfort. I E- Offered appropriate reassurance to [redacted] wife continue to monitor closely. [redacted]

Addressegr[redacted]

INTERDISCIPLINARY TEAM PROGRESS NOTES

[redacted]

[redacted]

Department Codes:

N	= Nursing	**ST**	= Speech Therapy	**Rad**	= Radiology		
Nutr	= Food & Nutrition Service	**Rec**	= Recreational Therapy	**Card**	= Cardiology		
PT	= Physical Therapy	**R**	= Respiratory Therapy	**Neuro**	= Neuro diagnostics		
OT	= Occupational Therapy	**SW**	= Social Work Services	**Rad X**	= Radiation Therapy		
PO	= Perioperative	**CR**	= Cardiac Rehab	**PH**	= Pharmacy		
				CM	= Case Manager		

Note Format:
V=Variation
I=Intervention
E=Evaluation / Outcome

Date &Time	Dept	Notes
		CH 16 [redacted] HR=90 04:12:26 AM 2/24/99 MANUAL * # GH=1
		SR HR:90 PR .20 QRS .10 [redacted]
		Attachment # 4 Memo FLA-9339 CFSAN Project #13408 4/5/99 SJH

000011

Addressograph [redacted]

INTERDISCIPLINARY TEAM PROGRESS NOTES

[redacted]

Date	Notes should be signed by Physician

-1999 22:22:54 ALM VOL 70% @25 MM/S
5-40Hz NBP X/X (X) RR 35

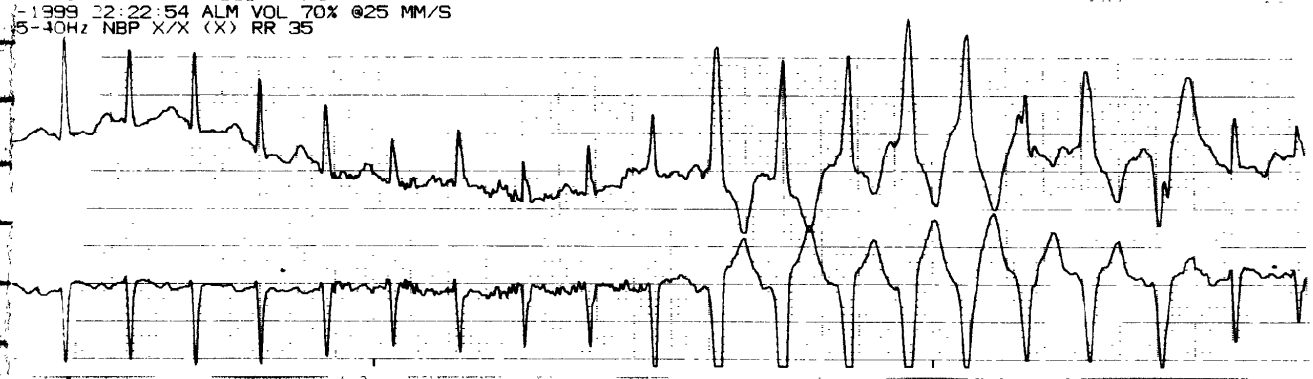

MANUAL SAVED [redacted] 21-FEB-1999 22:30:46 ALM VOL 70% @25 MM/S HR 126
APP FULL PVC 0 ST III -0.5 .05-40Hz NBP 164/63 (109) @ 22:24 SPO2 100 RATE 127
RR 23

[redacted] 21-FEB-1999 22:45

VITAL SIGNS	21-FEB-1999 22:45 21-FEB 18:30	21-FEB 18:45	21-FEB 19:00	21-FEB 19:15	21-FEB 19:30
HR			104	102	98
PVC			0	0	0
RR			18	17	17
NBP-S		112			
NBP-D		51			
NBP-M		90			
NBP-R		114			
SPO2-%			97	98	99
SPO2-R			106	102	98
ST-I			0.2	0.7	0.5
ST-II			0.4	0.6	0.5
ST-III			0.1	-0.1	0.0
ST-V1			0.5	0.0	0.3
ST-AVR			-0.3	-0.7	-0.5
ALARMS	OFF	OFF			
	NBP (mmHg)				

[redacted] 21-FEB-1999 22:45

VITAL SIGNS	21-FEB-1999 22:45 21-FEB 18:30	21-FEB 18:45	21-FEB 19:00	21-FEB 19:15	21-FEB 19:30
HR			104	102	98
PVC			0	0	0
RR			18	17	17
NBP-S		112			
NBP-D		51			
NBP-M		90			
NBP-R		114			
SPO2-%			97	98	99
SPO2-R			106	102	98
ST-I			0.2	0.7	0.5
ST-II			0.4	0.6	0.5
ST-III			0.1	-0.1	0.0
ST-V1			0.5	0.0	0.3
ST-AVR			-0.3	-0.7	-0.5
ALARMS	OFF	OFF			
	NBP (mmHg)				

Attachment # 4
Memo FLA-9339
CFSAN Project #13408
4/5/99
SJH

PROGRESS NOTES

[redacted]

[redacted]

Date

Notes should be signed by Physician

[redacted]

21-FEB-1999 22:45

VITAL SIGNS

	21-FEB 19:30	21-FEB 19:45	21-FEB 20:00	21-FEB 20:15	21-FEB 20:30
HR	98	126	110		94
PVC	0	0	0		0
RR	17	43			15
NBP-S					
NBP-D					
NBP-M					
NBP-R					
SPO2-%	99	99	98		98
SPO2-R	98	108	118		94
ST-I	0.5	0.6			0.3
ST-II	0.5	0.7			0.6
ST-III	0.0	0.0	0.0		0.2
ST-V1	0.3	0.2			0.2
ST-AVR	-0.5	-0.7			-0.5
ALARMS					

NBP (mmHg)

[redacted]

21-FEB-1999 22:45

VITAL SIGNS

	21-FEB 20:30	21-FEB 20:45	21-FEB 21:00	21-FEB 21:15	21-FEB 21:30
HR	94	76	100	106	112
PVC	0	0	0	0	0
RR	15	9	17	17	12
NBP-S					
NBP-D					
NBP-M					
NBP-R					
SPO2-%	98	90	97	98	99
SPO2-R	94	76	100	98	110
ST-I	0.3		0.3	0.3	1.0
ST-II	0.6		0.5	0.8	1.0
ST-III	0.2		0.2	0.3	0.0
ST-V1	0.2		0.1	0.0	0.0
ST-AVR	-0.5		-0.4	-0.6	-1.0
ALARMS					

NBP (mmHg)

[redacted]

21-FEB-1999 22:45

VITAL SIGNS

	21-FEB 21:30	21-FEB 21:45	21-FEB 22:00	21-FEB 22:15	21-FEB 22:30
HR	112	96	90	94	124
PVC	0	0	0	0	0
RR	12	17	17	15	20
NBP-S					164
NBP-D					63
NBP-M					109
NBP-R					130
SPO2-%	99				100
SPO2-R	110				124
ST-I	1.0	0.3	0.5	0.3	0.2
ST-II	1.0	0.7	0.6	0.9	0.0
ST-III	0.0	0.3	0.0	0.5	-0.4
ST-V1	0.0	0.1	0.3	0.1	0.4
ST-AVR	-1.0	-0.5	-0.6	-0.6	-0.1
ALARMS					

NBP (mmHg)

Attachment # 4
Memo FLA-9339
CFSAN Project #13408
4/5/99
SJH

PROGRESS NOTES

[redacted]

Addressograph

[redacted]

000013

DATE

2/25 Meningitis

(-) Seizures

(+) Tremor.

agitated at times

afebrile VSS

Peoria LA

(-) Myoclonus

(-) facial Asymmetry

with chronic equally to pain

DDR symmetric

Pan Tp.

Cats. ABG

144 / 32 / 7.5 / 99% / 25

CBC wnl

Impression:

(1) Intractable Seizures

(2) Encephalopathy

(3) H/o hypokalemia

✓ EEG meting (when ✓ on IT

Vasculitis w/ [redacted]

may need to repeat CPC

[redacted]

M.D.

signature [redacted]

M.D.

signature

PROGRESS NOTES

[redacted]

DATE

2/25/99	EEG done [redacted]
2/26	Pulmonary
0945	Sedated. Nursing reports that he
	moves all extremities but
	nothing to command
	Tm 99.3 P100 R10 BP 118/52
	Lungs - Clear
	CV - Reg
	Abdomen Soft. + BS
	No leg edema Hands edematous
	WBC 14,900 Hgb 15.3
	Na 139 K3.6 Bun 10 Glc 124
	ABG 113-35 - 7.45
	A: Seizures
	Resp failure
	Rec: Add PSV
	HCl
	Cont Pepcid / SCD's
	Begin Nutritional support if unable to wean today

[redacted]

[redacted]

[redacted] M.D.

signature [redacted]

M.D.

signature [redacted]

PROGRESS NOTES

[redacted]

DATE

2/26 Neurology:
- agitated when off sedation
- Seizures (-) (+)
- EEG improved
- diffuse slowing
- Excessive Beta 2° to medicating
- afebrile VSS
- more both Extremities
- occ. follows commands
- sedated

Labs: ↑ WBC
- dilution 97
- Na 139
- Antibiotic IV (81) K 3.6 Gl. 124
- BUN 10 Cr. 0.9

Impression:
1. Seizure disorder
2. Encephalopathy
3. ↑ WBC

Cure ✓ MRI Brain today
- restart dilution 200 tid
- start tube feeds ✓ CSF again
- Exhibit if MRI, CSF work

[redacted]

[redacted] M.D.

signatur[redacted]

M.D.

signatur[redacted]

PROGRESS NOTES

[redacted]

000016

DATE

2/27 Neurology:

Sedated

intubated

Seen agitation last night

(-) Seizures witnessed

Pitabile hemodynamically stable

PSNRL

(-) facial Asymmetry

moves all extremities spont.

withdraw equally to pain

Too ↓

Diz symmetric

Dilantin 7.1

WBC 7.2

HCT 42.4

PCO2 34 PO2 87

PH 7.47

MRI / MRV are completed will ✓

Taper off depravan / extubate

following ✓ MRI, MRV.

after Haldol pain

[redacted]

[redacted]

[redacted] M.D.

signature [redacted]

M.D.

signature [redacted]

PROGRESS NOTES

[redacted]

DATE

[illegible]

SEDATED

120/50 90 98.90

Lng - clear [illegible] 10/900/306/PS10

W - [illegible] ↳ 83/34/7.47

[illegible] - [illegible] WBC 7.2 plan 300

414 14.3/42.4

(1) Intermittable Sz.

(2) Resp. Failure

(1) Pavulon

(2) [illegible]

(3) Haldol for [illegible]

(4) ↑ Tube feed

(5) [redacted] when prophylaxis

[redacted]

[redacted]

PROGRESS NOTES

[redacted]

[redacted] M.D.

signature

[redacted] M.D.

signature

000018

Attachment # 4
Memo FLA-9339
CFSAN Project #13408
4/5/99
SJH

Department Codes:							
N	= Nursing	ST	= Speech Therapy	Rad	= Radiology		
Nutr	= Food & Nutrition Service	Rec	= Recreational Therapy	Card	= Cardiology		
PT	= Physical Therapy	R	= Respiratory Therapy	Neuro	= Neuro diagnostics		
OT	= Occupational Therapy	SW	= Social Work Services	Rad X	= Radiation Therapy		
PO	= Perioperative	CR	= Cardiac Rehab	PH	= Pharmacy		
				CM	= Case Manager		

Note Format:
V=Variation
I=Intervention
E=Evaluation / Outcome

Date & Time	Dept	Notes 98 8-80-18 116/6
2/25/99	0830	V Seizure lasting apx 7'. Pt unresponsive even to sternal manipulation. Eyes closed & not moving limbs. Limbs flaccid. Resp slow/deep. HR ↓ 40s c̄ short misc. run during sez. Dilantin level 16.6 I Dr [redacted] called. Dilantin 300 mg IV over 30' given. [redacted] E Cont watch for sez activity [redacted]
	0945	V Short seizure 1½' then post ictal No outward movements Pt unresponsive for 5' p̄ seizure. [redacted]
	1041	3'15 sec seizure BP 15/63-81-20 Pt thrashing around & twitching jaw Eyes deviated to (L). Bit tongue c̄ sm amt bleeding No airway distress I Ativan 2 mg IVP given slowly. Ca & Mg WNL & reported to Dr [redacted] who is kept aware of pts status.
	1224	4½' seizure c̄ small twitches lower legs & feet no facial movement. Dr [redacted] called & Dr [redacted] aware of pts status.
	1405	Dr [redacted] here & lumbar puncture done p̄ consent obtained & 3.0 mg Ativan IVP given by Dr [redacted] Rocephin gm T IVPR started c̄ ½ NS @ 100 cc/hr via LA 22g IV. Pt able to assist c̄ puncture to minor degree. Staff code [redacted] called & assistance obtained. Pt tolerated procedure well s̄ further seizures. Tampa Gen called by [redacted] for transfer Consent for transfer obtained by wife. S [redacted]
	1730	Proladin level 65 called to [redacted]

Addressograph [redacted]

INTERDISCIPLINARY TEAM PROGRESS NOTES

[redacted]

[redacted]

DATE

2/28 Meningy

Spinal tap was completed
Wife signed informed consent
Pt. was placed in LLat position
Clear CSF is obtained using
20 gauge sp. needle
will ✓ CSF - reaction + viral studies
- cytology
- AFB. VDRL
will start Acyclovir empirically
awaiting test results [redacted]

2/28 CT HEAD is complete
[redacted]

[redacted]

M.D.

signature

M.D.

signature

PROGRESS NOTES

[redacted]

[redacted]

000020

DATE

2/28 Mulgy:

Pt. had recurrent seizures
noted by RN.
each lasted < 30 sec.
afebrile VSS

Brain MRI → WNL ⊖ Edema
⊖ infarcts
⊖ Hse.
⊖ infect

EEG → diffuse slowing
diffuse. cumulant spikes
x wave. epileptogenic in nature

Labs: Dilanti (15.6)
NL Na / K / BUN
K 3.8

CBC 8 / 13.3 / 90 / 40.1 316

Impression: recurrent seizures
will ✓ CSF for all possible
infectious. viral Bacterial
phenobarb / dilantin / mimarbin
✓ free dilantin level
would start empiric Acyclovir for
possible Herpetic infection.

[redacted]

M.D.

signature [redacted]

M.D.

signature

PROGRESS NOTES

[redacted]

000021

DATE

2/28 [illegible]

[illegible] = [illegible]
120/55 [illegible] 100% [illegible] 4625/4580
[illegible] - Clear
[illegible] [illegible]
[illegible] - [illegible]
[illegible] [illegible] Clear
[illegible] 10/900/306 106/33/7.40
143/107 < 98 [illegible] 13.3/40.1
3.8/28 5/07 [illegible] 15.0

(1) [illegible]
(2) [illegible]
(3) [illegible]

(1) [illegible] line over [illegible] to [illegible] [illegible] [illegible] at home
(2) [illegible]
(3) [illegible]
(4) [illegible]

[redacted]

[redacted] M.D.

[redacted] M.D.

signature

PROGRESS NOTES

[redacted]

DATE

3-1-99	Primary / [redacted]
	Remains in Pentobarb Coma for persistent seizure
	activity.
	Secretions Thick
	T°100 4 118/48 Spo2 100% RR10
	I= 4337 O=3620
	Chest Clear
	No m/g
	Abd soft
	Edema @ ankles. Trace hands.
	Po2 106 Pco2 35 pH 7.46 (900 10/min .3 +10)
	13.2 | 10,100 K+3.5
	295,000 Alb 3.2
	Chest x - Clear lung fields.
	A - Status Epilepticus
	Low grade fever
	↓ Alb
	Mild volexass
	Ventilator Dependence.
	P - Vent Support
	KCl
	↓ IV fluids.
	If no improvement may need to start tube feedings.

[redacted]

[redacted] M.D.

signature

PROGRESS NOTES

[redacted]

M.D.

signature

[redacted]

[redacted] 000023

DATE

3/1/99 Epilepsy Attdg

Unexplained repetitive seizures / status x T week in a healthy pt $\bar{s}$ h/o seizures

Extensive etiologic w/u ⊖

Now in pentobarb coma

EEG: Burst suppression pattern, $\bar{c}$ suppressions ~ 10 sec currently

PLAN: 1) Maintain in burst-suppression till tomorrow

2) Load $\bar{c}$ PHT to level of 25-30

3) Agree $\bar{c}$ poison / toxic consult

4) Prognosis is overall poor because of duration of status ... but lack of structural lesion / pathology is a good factor

[redacted]

[redacted]

PROGRESS NOTES

[redacted]

signature [redacted] M.D.

signature [redacted] M.D.

000024

[redacted]

DATE

3/1/99 Social Wrk Note

D- Consult received to assist pt. + family w/ HIV consent

A- Pt. unable to participate - Pt's wife was counseled on testing rights + procedures. In agreement w/ plan.

P- HIV consent signed + in chart.

[redacted]

[redacted]

M.D.

signature

signature

[redacted]

PROGRESS NOTES

[redacted]

[redacted]

000025

DATE

3/1 Neurology:

pt. had recurrent Seizures despite continuous versed drip, dilantin Neurantin X' phenobarb.

Seizures were mostly facial twitches.

⊖ GTCs.

pt. required pentobarb Coma.

Continuous EEG monitoring reviewed

Burst suppression is noted. no recurrent Seizures

CSF → 1 WBC

36 RBCs / 1 Traumatic

⊖ Xanthochrome

O/S —

C+S pending

viral studies are pending

afebrile hemodynamically stable.

Labs reviewed

WBCs 10.1

H/H 13.2/38/3.

Plat. 295

140 / 105 / 8 — 94 Ca 8.2

3.5 / 27 / 0.7

→ 5m

[redacted]

M.D.

signature

[redacted]

M.D.

signature

PROGRESS NOTES

[redacted]

[redacted]

[redacted]

000026

DATE

Ingram

Intractable Seizures
w/u in program for viral / Bact
Toxic / metabolic / vascular.
So far all w/u is negative

will ✓ T-cell Counts
✓ HIV
Continue Acyclovir.

Plan CT Scan Brain → WNL.

Continue Pentobarb drips
epileptology Consult Dr [redacted]

[redacted]

PROGRESS NOTES

[redacted]

M.D.

signature [redacted]

M.D.

signature [redacted]

000027

DATE

3/2

Neurology:

above is noted

ID. Boron Cantwell. Epilepsy

Consultants notes are reviewed

& appreciated

intractable, refractory seizures despite

maximum multi-antiepileptic therapy

required reloading c̄ Pento-bark last

night?

Dilution levels 27.5

phobarb ↓ 6.2

↑ WBC. 13.5

CSF is -ve so far.

Mrs ex:

Comatose unresponsive to all stimuli

Impr: refractory seizures

?° to toxic Encephalopathy

Continue Cant rx

will ↑ Neurotic may need to

add Tegretol to possibly wean

off phobarb.

[redacted]

[redacted]

M.D.

signature

PROGRESS NOTES

[redacted]

M.D.

signature

[redacted]

[redacted]

000028

DATE

3/4/99 Epilepsy Progress Note

0830 #1 unresponsive.

101 112/55 37° Vent. 10 97% SAT

Exam. pupils 3mm + reactive

- comatose

EEG. Bursts every 3-4 seconds.

Dilantin 30.6.

A/P Status Epilepticus: On Dilantin T. therapeutic level

E 30.6 On Pentobarb coma in submaximal

burst suppression. Will discuss T D- [redacted]

on whether to wean today or attempt better

burst suppression.

[redacted]

Agree

[redacted]

[redacted]

M.D.

signature

M.D.

signature

[redacted]

PROGRESS NOTES

[redacted]

DATE

3/2/99 ID Attendg

26 y/o WM Presented to [redacted] ~ 2/18 c̄ S2 D/o seen evaluated D/ced then presented to [redacted] c̄ S2 Admitted c̄ Status epilepticus transferred to [redacted] on 2/24/99 for evaluation. ID is Consulted on Hospital Day #6 c̄ Status on Pentobarbital drip / [redacted] ~ 48 hrs for. Unable to obtain history but review of chart of history reveals? HA 3d Prior to S2 & ingestion of over the counter Metabolic enhance c̄ Mahong extract & guarana (ephedrine) & Caffeine H/O Cocaine Mary No fever during hospital Course until today LP originally 2/23 Prot = 57 Glu = 73 4 WBC 1 RBC ⊖ Direct Lyme labs unremarkable except AST = 109 (⊖ CT). Since transfer MRI Brain ⊖ Spect scan ⊖ EEG c̄ status resolving c̄ Pentobarbital drip. Repeat CSF c̄ Prot ↑55 Glucose 75 1 WBC 36 RBC Clear All CSF cx ⊖.

PMHX See Consult

Meds Trovan #0 Pentobarb
Pepcid
Neurontin
Acyclin 400 Q8
Dilantin
Tylenol

over →

[redacted]

PROGRESS NOTES

[redacted]

signature [redacted]

signature [redacted]

000030

DATE

(4) TL #2

PE Tm = 101.5 Tc = 101.5 HR = 95 BP = 95/50 Pulse ox = 100%

Good ue

Intubated Continual leads for EEG

Face c̄ some erythem

Purulent Sputum → Trach / mouth

COR: Reg

Lys: Clear (B)

Abd: benign - (+) BS

Ext: RUE edema / swelling

CXR ⇒ Clear lungs

143 / 3.8 | 107 / 28 | 5 / .7 < 98

9.0 | 2.7 < 272

CSF 1WBC, 36 RBC, Pmt = 55, Glu = 75 — 10 dy — All cx (−), Viral (−), Crypt Ag (−) CMV (−)

TSH = 1.8

Alb = 3.8

AST = 18

Serum HSV Ig G (+) (Nonspecific)

VZV Ig G (+) (Nonspecific)

CDy 481, 296

Impression: Infx - Sinusitis / UTI / Bacteria / line / lung / DVT / Cellular

(1) ~~Sever~~: Noninfx - Seizure / (R) Arm Chemical [redacted]

(2) S/P Status epileptics Infx - (Doubt bacterial

Viral < HIV, HSV, CMV, Arboviruses

Noninfx: Malignancy

Connective tissue

other Metabolic → Cocaine / Metabolic

(3) H/O Cocaine / Marijn

(4) H/O + CDy HIV (P)

(5) Infiltration (R) Arm

PLAN:

(1) ΔTROVAN (CNS effects) → Cefepime

(2) BC for Next Temp

(3) ✓ HSV pcR / Arboviral / VDRL

(4) Δ Aqla 10 mg/kg a 8 (P) M.D.

pcR

(5) Doppler RUE

(6) Sinus Xr (7) UAC [redacted] M.D.

[redacted]

PROGRESS NOTES

signature

[redacted]

000031

DATE

3/2/99	SW
1410 D:	Consult rec'd. for HN counselling. Counselling is no longer required for this test
A:	MD should proceed as c̄ any other test & simply get consent
P	None further [redacted]

[redacted]

M.D.

signature

PROGRESS NOTES

[redacted]

M.D.

signature [redacted]

[redacted]

DATE

3-2-99 Pub fr (ans)
P Minor earlier notes & secretion different
c̄ suction Peak/Plateau pressure OK
good chest ypsum bilaterally and non
suction easy for me
will - OK, start on Antibiotic
and start on albuterol, mucomyst
Treatments

[redacted]

3/2/99 ID cons on chart

[redacted]

3/2 EPILEPSY FACULTY.
EEG shows continued burst-suppression on
Pentobarb @ 1.5 mg/kg/hr.
Drug-induced coma
Poison ctrl: overdose of Ephedrine + Caffeine
Will attempt weaning - PHT ~ 30.
May have severely sequelae 2° to prolonged status

[redacted]

[redacted] M.D.

signature [redacted]

PROGRESS NOTES

[redacted]

[redacted] M.D.

signature [redacted]

[redacted]

DATE

3-2-95 Pub fl
S ~~O~~
O T 98 9 BP 90/50 PR 10 P 92
I 4538 O 2550
Chest. fu shoud
Cr pr
Ded Sept BS ⊕
Cut 5 edema
ABG pH 79 pCO 37
pH 746
Cr pend

101/107 Br 9
4.1/26 p 116
Vac 9.0 1p 12.7 1ct 38.0
Plat 272,000
6 States Epilepsies refracts seizures
Pentobarbito Coma
Pregnant Tuelen
(WT)

[redacted]

[redacted]

M.D.

signature

M.D.

signature [redacted]

PROGRESS NOTES

[redacted]

DATE

3/2 neurology:

Dr. [redacted] input is appreciated

I had a conference yesterday with wife & father. Both denied any H/O recent Drug abuse, but wife reported H/O Marijuana abuse. H/O Cocaine abuse. not recent

pt was c/o headache for 3 days prior to his first seizure. was anxious prior to his seizure.

Labs reviewed.

+ve IGG HSV. VZV.

CD Counts

↓ absolute CD3 / CD4 / CD8

Abs. Natural Killer ↓

pt is on pentobarb Coma.

(-) seizure on EEG → diffuse burst suppression pattern.

Pernal (-) nystagmus

Roving eye movement

Tox ? ?

Brain SPECT scan → WNL (-) Perfusion defect

A/P (1) Refractory seizures ? Toxic etiology

[redacted] will tapper off pentobarb

ID Consult ASAP

[redacted] M.D.

signat[redacted]

M.D.

signat[redacted]

PROGRESS NOTES

[redacted]

000035

[redacted]

DATE

2/28 Sput = SA

(L) TLC #3

3/3/99 ID Cef

No Real Δ

Tmp/c 100.4 HR = 95 BP = 110/55 RR 12

Good UO

Dop EEG leads on

Pentobarb Mouth (−)

RUE edema/erythem

COR: Reg

Lys. Clear c̄ Occ Rhonch

Abd: soft (+) BS

Ext: edem 3+

Impression

(1) Fever line/lys/urine/DVT seizures/Atelectasis

(2) Status Epilepticus Metabolic

(3) Resp failure/Atelectasis/Hypoxem

(4) RUE edem ? DVT/Chemical Phlebitis

(5) Volume Overload

(6) H/o Polysubstance Abuse

(7) + CD4 HIV (−)

(8) HSV IgG/VZV IgG C/W

Previous infx Not C/r Acute

2/28 CSF (−)

2/26 BC (−)

3/2 UC (−)

Sinus Xray = (−).

Hg B SAg (−)

Hep C Abd

Salicylate < 2.0

Theoph < .8

LFT's N1 Alb = 3.3

13.5 12.6 370 38.6

BUN/cre = 11/.8

56/45/7.41

CXR ⇒ Clear c̄ Abd

PLAN:

(1) FU CSF studies

(2) FU BC

(3) Suspect SA in Sputum

Could Be MRSA

Will fu

(4) Doppler RUE

[redacted]

[redacted] M.D.

PROGRESS NOTES

[redacted]

[redacted] M.D.

[redacted]

000036

[redacted]

DATE

3-3-99 RUE venous doppler completed

[redacted]

3-3-99 [redacted]

Comatose (Pentobarb). Ongoing seizure activity when sedation lightened.

T099 10/min SpO_2 99% 116/54 I=4633 O=3610

Chest clear

nomlg

Abd soft

mild generalized edema

Chest ty slight atelectatic change

PO_2 56 PCO_2 45 pH 7.41 (900 10/min. 3 +10)

BMP OK

12.6 | 13,500

310,000

A- Status epilepticus

Ventilator Dependence, Atelectasis

Volexcess

Hypoxemia

P. Diuresis

Add PEEP, ↑FCO_2. [redacted]

[redacted]

M.D.

signature

PROGRESS NOTES

[redacted]

M.D.

signature [redacted]

000037

[redacted]

DATE

3/3/99 Neuro Epilepsy Consultant -

The situation remains extremely serious -
On pentobarb @ 3 /kg/hr.
Attempts to ↓ drip results in highly suspicious
discharges -

A/P Nonstructural toxic status.
Extremely grave prognosis
Maintain as is x 24°.
Tomorrow will attempt weaning and review EEG [redacted]

[redacted]

3/3/99 Neurology Resident acyclovir³ cefepime³ ICU #6
Pt Rh pentobarb coma - restarted seizure
activity after attempt to wean. Now in
burst suppression 4-7 secs

PE: 99.6 BP: 110/50 P: 95 Rate 10 SIMV 7 PEEP/PSI
PERRL (transiently dilated + fixed) [redacted]
No focal asymmetry
0 movement
QTRS ↓

[redacted]

M.D.

signature

M.D.

signature [redacted]

PROGRESS NOTES

[redacted]

000038

[redacted]

DATE

Meds Coramine 8 mcg (mow) — Dilantin 27.5
Acyclovir 10 mg/kg/ q8° — PMD 6.2
Cefepime 1 mg q12
Dilantin 500 mg qd — 141 | 105 | 11 < 143
Neurontin 300 mg q4° — 4.2 | 27 | .8
Zantac 150 mg
Mystatin SS — 13.5 > 12.6 / 35.6 < 143

Sputum / Gram & diphase

Assessment: 26 y/o c̄ mo medical history in status. Etiology possibly caffeine/ephedrine in "Ripped Fuel." Poison Control discussed possibility of a bezoar in gut continuing to "fake" caffeine/acetaminophene/salicylate

Plan: - Continue burst suppression until tomorrow then wean @ 1 mg/kg/hr
- Dilantin & Neurontin
- maintain BP c̄ dopamine
- Continue vent - pulmonary following
- Check levels of caffeine, salicylate, acetaminophene + theophylline
- Add B6, thiamine, folate
- Alf Carriage - I6 following
- TSH, LFTS
- ABG
- U/A

[redacted]

[redacted] M.D.

signature

[redacted] M.D.

signature

PROGRESS NOTES

[redacted]

[redacted]

[redacted] 000039

DATE

3/4 Neurology:

Above is noted.

Breakthrough recurrent brief seizures despite
pentobarb Cosmo / Neurontin / Tegretol.
& dilantin

EEG → burst suppression ē intermittent
myoclonic discharges

Unresponsive

periods of desaturation ; V. Q scan.
? r/o PE ; internal rupture. ⊖ PE.
Pupils reaction to light
⊖ focal seizure
⊖ Tremor.

Cars reviewed
A/: Refractory status epilepticus
Plan:
agree ē current treatment
DVT prophylaxis
✓ phenobarb level in A
Trial of weaning - // pentobarb
again in A

[redacted]

[redacted]

M.D.

signature

PROGRESS NOTES

M.D.

signature [redacted]

[redacted]

[redacted]

000040

DATE

3/4/99 SD Cefipime 2 / Acycl 2 (L) TL 4

Paralyzed.	2/28 Sp - S aureus (MSSA)
TM 102° Tc 37.6° 120/10-90	2/28 CSF - Ø
Mally intubated	2/26 BC - Ø
Conj: Clear	3/2 UC - Ø
Heart Reg Lungs: CTA B/L	Sinus - reg
Abd: Soft, NT	CXR - Ø Infil
Ext: Edema	TSH 0.14
erythematous patch on Rt arm	Doppler - (R) Basilic V. clot
A) 1) Fever - lines	
- lungs, sinuses	BUN 12/Cr 0.6
- urine	
- drugs - endocrine	11.4 / 11.8 / 377
- central ↓TSH	
- DVT	
2) RUE DVT	
3) Status epilepticus	
4) Resp failure / Vent	
5) ? phlebitis	P) Add Anex to cover S. aureus
6) H/o sub abuse	May be able to D/C Cefipime soon
	Cont Acyclovir for now
	? Anticoagulation
	[redacted]

[redacted]

M.D.

PROGRESS NOTES

[redacted]

signature [redacted]

signature

[redacted]

DATE

3/14 Epilepsy Attdg

Currently on Pentobarb @ 1.3.

Down to 1 → clonic tongue movements.

Will try complete weaning tomorrow

Prognosis remains grim

[redacted]

[redacted]

M.D.

PROGRESS NOTES

signature

M.D.

[redacted]

[redacted]

000042

DATE

3-4-99 [redacted] (Acyclovir, Cefipime)

Fatter @ bedside

Pt remains in Pentobarb Coma

I= 5877 O= 6055 T°102 + 122/50 (Dopamine 10 µg/kg/min)

Chest c̄ ↓ Bs bases

No m/g

Abd soft

Tedema ankles Both arms / hands edematous.

PO2 92 PCO2 50 pH 7.41 (900 10/min . 5 +5/+10)

Gluc 178 11.8 / 11,400 Alb 3.3

377,000

Chest ↓ bibasal infiltrates / atelectasis / effusions (R>L)

A - Status epilepticus

Pentobarb Coma

Ventilator Dependence, Resp failure, Atelectasis / effusions

Fever

Hemodynamic instability

Volexcess

Anemic

P - Diuresis

↓ V/Q scan. [redacted]

↓ I V fluids

Lovenox

[redacted]

M.D.

signature

PROGRESS NOTES

[redacted]

[redacted] M.D.

signature [redacted]

000043

[redacted]

DATE

Neurology Resident acyclovir⁴ cefepine⁴

3/4/99 Pt continues in Phenobarb Coma; unresponsive, no movement

P:90 T: 102.4 BP 120/40 R:Vent R10 PEEP/PSV 7/10

FiO_2 51%

⊕ (B) UE edema NSR

Pupils ERRL no "hippus" (dilate/constrict..)

Face symmetrical PO_2 92 PCO_2 50 PH 7.41

Ø DTRs HCO_3 31

11.4 | 11.8 | 377
38.1

Hep B sur Ant ⊖

Hep C abdy ⊖ Dilantin 27

Salicylate <2 } WNL

Theoph .8

CMV IgG ⊖

139 | 101 | 12 | 178
5.1 | 38 | .6

LFT: AST ALT T.B ALK ↓ Alb
31 36 .4 74 3.3

pentobarb 1.8 mg/kg

A/P 26 y/o c̄ no medical history, Status

→ epilepticus of unknown etiology

① Seizure-burst suppressed on ~~phenobarb~~ pentobarb

② intermittent activity (Ø suppressed) x2

a fast sharps generalized

b sleep? slow 4 hz generalized

dopamine 10 mg

[redacted]

[redacted] M.D.

signatu[redacted]

M.D.

PROGRESS NOTES

[redacted]

000044

DATE

(3) Discuss suggested by person team to
D/C dilantin & team
(4) Maintain normothermia

→ hypotension - dopamine

→ will wean pentobarb today, if possible

→ Abx coverage, ID following

→ Ventilator, pulmonary following

→ 3rd spacing, low albumin noted

[redacted]

[redacted]

M.D.

signature

PROGRESS NOTES

[redacted]

M.D.

signature [redacted]

[redacted]

DATE

3-5-95 Pub ff

S ~~O~~

O T 100.6 BP 110/50 P 92 RR 10

I 5534 O 5735

Chest shoot

L RR

Abd Soft

Gt no pedal edema

Hands edematous

ABG pH 106 pPC 45

pH 7.45

VBO 9.3 Hg 115 Hct 35+

Plat 433,000

135/116 BW 15

43/31 1 132

G State Epilepsies

Pentobarbital Coma

Pregnant Tech

P Lorenz

antibiotic

Maintain vent support

000046

[redacted]

[redacted]

D.

signature [redacted]

D.

signature

PROGRESS NOTES

[redacted]

DATE

3/5/89 ID Aneef° / Cefipime 3 / Acyc 1 3 (i) TL 5

Sedated

Tc 100.6° Tm 101° 2/28 - Sp - Sawyers

Oral mucosa intact

Heart: Reg

Lungs: Coarse breath sounds BUN 15

Abd: Soft, NT Cr 0.6

Ext: hands edematous 9.3 \ 11.5 < 433

A) 1) Fever - Lungs

- Line CSF - No virus

- Drug

- Central

- DVT

2) RUE DVT

3) Status epilepticus

4) Resp failure / Vent P) D/c Cefipime

5) Sub abuse Doubt HSV encephalopathy - will consider D/c'ing Acyclovir as well.

[redacted]

[redacted]

000047

M.D.

signature

PROGRESS NOTES

[redacted]

M.D.

signature

[redacted]

DATE

3/5 EPILEPSY ATTDG.

3:15pm EEG: not in status, on 2 mg/kg/hour (Pentobarb)

MRI pending

Recommendation

Attempt ↓ Pentobarb to 0.5

Observe clinically

If no clonic activity, would d/c in another 24-48°.

If clonic activity is seen clinically, then resume @ 2.

[redacted]

[redacted]

M.D.

PROGRESS NOTES

signature

000048

M.D.

signature

[redacted]

DATE

3/5 Nutrition

O - Consult completed ; FT in mid duodenum (per radiology report 3/1)

A - Acceptable to provide enteral support (despite no audible bsb) via N-I Fdg Tube

P - Sug cont. progression of fwity towards 100-105 ahr with monitoring of tolerance [redacted]

3/5 Neurology:

recurrent electrical status

despite maximal pentobarb Rx

Tofrenal ↑ 400 mg 96°

Dilantin level 26.8

ABG wnl pH 7.45

No further desaturating

WBC 9.3

H/H 11.5 / 35.7

Phenobarb 5.2

No clinical seizure seen

unresponsive to all stimuli

pupils minimally reactive

Impression: (1) Refractory Seizures mostly 2° to toxic Encephalopathy

[redacted]

000049

M.D.

PROGRESS NOTES

[redacted]

signature [redacted]

signature

DATE

(2) resp. failure
(3) H/O substance abuse

plan MRI flu (Brain) today
Taper off pentobarb after MRI
discussed in a conference [illegible]
the details of Cont status
[illegible] prognosis

[redacted]

[redacted]

000050

M.D.

signature

PROGRESS NOTES

[redacted]

[redacted]

M.D.

signature

[redacted]

DATE

3/6/99 JD Amy[2]/Acyclovir[4] (c) TZ[6]

Still seeing 2/28 Sp-Saunders

T 102° - persistent 8.6 > 12 < 333

122/50 - 106 Eyes - injected conjunctiva

Heart: Tachy 138/99/15 < 136

Lungs: Scattered rhonchi 4.8 / 0.6

Abd: Soft, NT

Ext: + edema, erythematous patch @ arm

A) 1) Fever, nl WBC ct - suspect due to status

also R/O drug fever, line + DVT, sinuses

2) Status epileptiques

3) CUE DVT

4) Resp failure/Vent

5) Sub abuse

P) Will reculture

~~Add Tuvon~~

D/c Acyclovir

Try Naprosyn for fever

D/w Dr [redacted]

[redacted]

[redacted]

M.D.

signature

M.D.

sign[redacted]

PROGRESS NOTES

[redacted]

000051

DATE

3/6 Neurology:

RN reported recurrent facial & tongue seizures required increased pentobarb.

EEG → monitoring → intermittent poly-spikes & waves, incomplete burst suppression despite maximal pentobarb

Tegretal / dilantin / Neurantin

a bolus of pentobarb was given.

Phenobarb level 5.4 → 4.0

hemodynamically stable dilantin 26.4

Spiked Temp 102°

↓ H/H 12.0/34.7

Plat 333

Na/K/BUN WNL

BS 136

PO2 67 pH 7.55 PCO2 35

Pupils → 3mm minimally reactive

⊖ Dolls eyes

Impression: 1) Refractory status epilepticus.

2) fever

3) Anemia

Plan: rebolus c̄ pentobarb. ∴ Cooling blanket

- Antipyretics, Tylenol / Naprotyn.
- Endocrinology Consult to help for hypermetabolic dysfunction

[redacted]

M.D.

signature [redacted]

M.D.

signature [redacted]

PROGRESS NOTES

[redacted]

000052

[redacted]

DATE

3-6-96 Pub [redacted]
[illegible] to Sim
Alimentation
De [illegible]
[redacted] will come to Track

[redacted]

3/1/11
Dilaton
Acyclovir
Nerotin
Zantac
Thiam
Folate
Tegretol
Nyquist
Dopar
Retech 2 T

- Patient is under Peterson Care, no [illegible]
1/0 - 5537/5135 Tmp 100°F RR - 0/10.
Neuro - Pupil small & slightly reactive, not
more extremities, no abnormal motor activity
noted at this time [illegible] BL [illegible].
Lab Phenobarb 4.0 138/39/11 1.6 Dilat 2.64
4.0 30
8 ( ) 120 / 90
347 335
HIP - [illegible] Stem epilepsy [illegible] [illegible]
[illegible] [illegible] [illegible], [illegible] [illegible]
Subbasin I Pentobarb (2.[illegible]/hr) [illegible] [illegible] [illegible]
[illegible] [illegible] [illegible] [illegible] [illegible] [redacted]
[illegible]

[redacted]

[redacted]

M.D.

signature

PROGRESS NOTES

000053

M.D.

signature

[redacted]

[redacted]

DATE

3-6-99 Pub fl

S ~~O~~

O T 102 Ap 120/40 P 104 Ap 10

I 4969 O 3210

Chest - Snowish

Cr Tree, m

Ord Soft, BS(+)

Ext no edema

Mo pc 6+ pec 35

pH 7.55

138/99 Bw 15

48/30 Cent 06

g 136

Bc 8.6 Hc 12 Ict 34+

Plat 353,000

Ex 3-5 shown ignorant

in attitude

is State Epileptics S+ actual still

present via EEG

Prognosis Fair

attitude

Controllable Comm

[redacted]

[redacted] M.D.

signature

PROGRESS NOTES

000054

M.D.

[redacted]

signature

[redacted]

[redacted]

DATE

3/6 62

Cmlt [illegible]

Adynic Thus suspected

no h/o 1° 62 [illegible]

Abd [illegible] NY

→ Thus → Sedentary / [illegible]

Suspected

→ [illegible]

Gdyfed x 1 (? no Bm x 15 d ?)

[redacted]

[redacted]

M.D.

signature

PROGRESS NOTES

000055

M.D.

[redacted]

signat[redacted]

DATE

3/7/99 ID Anuf 3 (L) TL 7

afebrile today on Laprosyn 2/28 Sp-Saureus

& cooling blanket.

Heart: Reg

Lump: Bibaxilar rhonchi

Abd: Soft

Ext: + edema

Lab/ HSV PCR of CSF - neg.

3/6 UA ϕ

Sp-Many WBCS

ϕ org.

BC-pend

A) 1) Fever - likely central, metabolic

2) Status epilepticus

3) RUE DVT

4) Resp failure/vent

5) Sub abuse

P) Cont Anuf

F/u cultures

[redacted]

[redacted]

000056

M.D.

signature [redacted]

M.D.

signature

PROGRESS NOTES

[redacted]

DATE

3/4/99 Resp Care Note: Metabolic study completed.
1300 Results posted in resp. section — [redacted]

3/7 Neurology:
no clinical seizure
EEG c̄ intermittent Burst suppression
& recurrent polyspike myoclonic
epileptiform discharges
Quasiperiodic Rt/Lt x diffuse
Olle afebrile hemodynamically stable
Comatosed under pentobarb loss
(−) Seizures
(−) Trauma
Cats Phobarb 3.9
dilution 22.6
24 hr Catecholamine is pending
Endocrinology Consult is appreciated
will start thorazine 25 mg IV tid
hypothermia, pharmacotherapy consults
will rebolus c̄ pentobarb to achieve
Burst suppression

[redacted]

[redacted]

M.D.

signature

000057

M.D.

sig[redacted]

PROGRESS NOTES

[redacted]

DATE

3/7 Endocrine Consult in chart. Thanks.
. History reviewed
. will order metabolic studies, thyroid
studies, plasma catecholes.
. ? depot of tabs in GI tract which
may be continually releasing
ephedrine - give fluids now, consider
laxative to clear GI tract
. ? use of thorazine to control α-effects

[redacted]

Neuro

3/7/99 Dyspnea old WM c̄ Stenosis Cause Collapse + Some other meds
- no abnormal movement seen at the time of 6 am, but [redacted]
has some, perhaps ↑ 2.5.

Vital 97.6 PP - BP 110/50 P-72 1m
Sa 99, 1104606/2.80

Neuro - no response to painful stimuli
- Pupil B/L slightly reactive to light
- Pyrex n ↓ Plas B/L mure

Lab Plasma tab - 3.9 D 11 am 22.6 MRI (4)

A/P - Stenosis epilepsy Cause dyspnea on Pericardiomyo
[redacted] Cause Some meds in Sz activity clinical Lab ↑ Perhaps
to 3.10, tomorrow will try to wear off [redacted]

PROGRESS NOTES [redacted] nature [redacted]

[redacted]

000058

DATE

3-7-94 Pub fl

S ⊖

O T 97° Pr 3 Rp 110/50 Pr 20

Sub 97 I 9600 O 300

Chest Shoul

& BS @ bases

Cr Mr

Ard distinctive, BSO

Est edematic

Cr arm of Basal atelectic, ? pleural effus

A States Epilepsies

Pregnant Fuck

DUT

Alcohol

Recitabilities Cerm

C Tz need to rectify alimentation &

elemental mutations

✓ CR, Tz need CT Mrs of Chest

Architectural pre ID

Transmit present report

[redacted]

[redacted]

PROGRESS NOTES

signature

M.D.

signature

[redacted]

000059

[redacted]

DATE

3/8/99 [redacted] (6) TL #8

Afebrile on Naprosyn Sp-Jaunus

Heart: Reg

Lung: Coarse breath sounds 6.2 > 117 < 283

Ant: Soft, quiet

Ext: + edema CO.4

A) 1) Fever - likely central or metabolic

2) Jaunus in sputum

3) RUE DVT

4) Resp failure / vent

5) Sub abuse

B) Cause of Anxy for lung. [redacted]

3/9

[redacted]

M.D.

signature

M.D.

signature [redacted]

PROGRESS NOTES

[redacted]

000060

[redacted]

DATE

Neurology ICU [redacted] Ancef 4; (acyclovir D/C'd)

3/8/99 S: Pentobarb coma 2° status; unresponsive

admit WT: 97 kg

O: T: 96.8; BP (105-130/35-55) 130/55 now; P 92; on Vent; I/O 4205.9 / 3595

ABG 4AM PO2/PCO2/pH/HCO3: 86/64/7.32/32 F102 50% VT: 900 R: 8 PEEP/PSV 5/10 (↑ to 12)

Pentobarb 3.5/kg
Dopamine 14

143 | 103 | 10 < 114
3.7 | 35 | 0.4

6.2 > 11.7 < 283
35.1

3/6

Dilantin 3/07/99 22.6

Lactic Acid 1.5
V2V IGM AB <20
Cortisol 8.6

TSH 0.091
T4 3.30
T3 Resin Uptake 0.94
T7 3.51

U/A ⊖
Bld cit ⊖
sputum ∅ organisms ∅ fungal
pentobarb 3.5
dopamine 14

Tegretol 3/7/99 5.9

Pheno 3/7/99 3.9

PE: NSR, edema UE
Unresponsive ∅
PER very sluggish/fixed mid size
⊕ face symmetrical
∅ Movement ∅ DTR Toes mute

Meds: Dilantin 200 mg Tid
Neurontin 300 mg q4°
- Thorazine 25 mg Tid
Tegretol 400 mg q6°
Lantac 150 q12°
Naproxin 500 mg Bid
Thiamine 100 mg qd
Folate 0.50 mg qd
Lovenox 30 mg q12°
Nystatin sts
Haldol PRN
Ativan PRN
Tylenol PRN

Cont

[redacted]

[redacted] M.D.

PROGRESS NOTES

[redacted] M.D.

[redacted]

signature [redacted]

000061

[redacted]

DATE

Assessment: 26 y/o ♂ c̄ continuous seizure activity / status unable to wean off pentobarb:
burst suppressed
3/4/99 PM - 3/5/99 AM pt seized, pento titrated to 3.5 mg/kg then pt was ↓ 1 mg/kg/hr 3/5/99 @ 12:20 pt stable.

10:30 3/6/99 tongue twitch & hippus → pento ↑ 2 mg/kg/hr

13:30 3/6/99 rebolus pentobarb 5 mg/kg for "sz activity" + 2 mg ativan → 4 mg total

19:00 3/6/99 rebolus pentobarb 2° cont. electrical activity ↑ pentobarb drip to 2.5 mg/kg/hr

16:30 3/7/99 20-30 sec "brisk EEG activity" c̄ stimulation

17:00 3/7/99 rebolus pentobarb ↓ rate to 2.0 mg/kg/hr

21:30 3/7/99 2-3 sec burst suppression c̄ intermittent 1-2 min of myoclonic activity → pento bolus 10 mg/kg rate - 2.5 mg/kg/hr

3/8/99 3.5

Plan: - Continue Pentobarb coma, monitoring, Dilantin, tegretol added
- Continue Vent - noted acidoses thus AM + ↑ rate
→ Endocrine Consulted - note ↓ T3 Resin Continue; T7? T4, TSH not in range also?
- Noted tube feeding D/C'd, pt on D5W
- Keep normothermic
- Hypotense on 14 mg dopamine - would feeding ↑ intravascular protein, allow Δ from D5 to NS?

[redacted]

[redacted] 3/8/99 M.D.

PROGRESS NOTES

[redacted] M.D.

[redacted]

000062

[redacted]

DATE

3/8 Endocrine Co Follow Up

. Patient remains intubated

. Poorly responsive

Vitals: 143/54 87

lungs: clear anteriorly

(-) wheeze

C: ul rate/rey

A: soft

Lab: Thyroid Panel -

TSH 0.091 ↓
T7 3.51 ↓
T4 total ↓

consistent c̄ Central Hypothyroidism

Basal Metabolic Rate: (Metabolic Studies)

- 2160 kcal/24° + 6%
- within normal for body build
- Result Not Consistent c̄ a Hyper-metabolic State

Plasma Catecholamines - pending.

Pr. Repeat TFT's tonight - if still the same values - will do a TRH stimulation test.

[redacted]

[redacted] M.D.

signature [redacted]

[redacted] .D.

signature [redacted]

PROGRESS NOTES

[redacted]

[redacted]

000063

DATE

3/8 Neurology:

(-) Seizures

EEG ē improved / more effective

Pentobarb Burst Suppression pattern.

afebrile hemodynamically stable

pharmacotherapy recommendations x Consults

are appreciated

discussed ē Toxicology Consult. will advise

for any further recommendations

Labs reviewed.

↓ phenobarb. subtherapeutic

TFTS ↓ TSH.

Lactic acid 1.5

Impression:

(1) Refractory Seizure

20 to toxic Encephal.

(2) resp. failure

(3) ileus

(4) H/O substance abuse

Plan: - Toxicology f/u.

- Continue Pento-barb for Burst suppression

5-10 sec.

- GI evaluation. Ileus

- f/u / Continue EEG

[redacted]

[redacted] M.D.

signature

PROGRESS NOTES

[redacted]

000064

M.D.

signature

[redacted]

DATE

3/8 Epilepsy Attending -

EEG looks very poor as soon as Pentobarb is ↓

Currently on | Pentobarb
| Tegretol
| Neurontin

Will ↑ CBZ

Will add IV VPA - then attemp

Situation is becoming increasingly desperate. [redacted]

3/8 Pulmonary

Afebrile

Lungs Clear — CXR - B.bar. lun atelectasis

CV - Reg — ABG 86-64-1.32

Abdomen Soft

Arms edematous

A: Resp failure / Atelectasis

Refractory Seizures

Upper extremity DVT

Rec: ↑UE (↑UT and f)

[redacted]

[redacted]

M.D.

signature

PROGRESS NOTES

000065

M.D.

signature

[redacted]

DATE

3/8/99 Pharmacotherapy

1240 Phenytoin 200mg IV TID

Zantac Gabapentin 300mg NG q 4hrs

Thiamine Carbamazepine 400mg NG q 6hrs

Folate Pentobarbital 3.5mg 1kg/hr

Levenox I/O 4205/3595, Tmax = 98, Tc = 98

Nystatin BP = 125/55, RR = 0/12, HR = 80

Aneef ⊙ DA = 13 mcg/kg/min

Naprosyn Drug levels

Thorazine 3/7 - phenytoin 22.6 (10-20)

- phenobarbital - 3.9 (15-40)

3/7 - carbamazepine 5.9 (6-10)

143/3.7 | 103/35 < 10 / 0.0

This 26 y.o. ♂ was admitted from [redacted] intractable seizures thought ~~also~~ to be 2° to an OTC product Ripped Fuel by Twin Labs (167mg Mahuang to provide 10mg ephedra alkaloid, 455mg Guarana to provide 22% caffeine, 50mg L-carnitine, 100mcg chromium picolinate) per capsule. Other medications/OTC include "Ecstasy", "GHB", creatine and "Winstrawl." Winstrawl is a street veterinary product ≡ anabolic steroid activity. The Winstrawl was apparently used on a cyclic basis @ 3 x "usual" dose.

This afternoon patient suppressed on pentobarb drip

[redacted]

[redacted]

M.D.

signature

M.D.

signature

PROGRESS NOTES

[redacted]

000066

[redacted]

DATE

3/8/99 Pharmacotherapy continued

of 3.5mg/kg/hr.

Initial drug screen revealed ⊕ barbs, ⊕ bdz ⊖ pcp, ⊖ cocaine, ⊖ EtOH; barbs & bdz may be positive due to drug administration @ outside hospital prior to transfer.

There are several approaches that could be tried to assist c̄ burst suppression being our therapeutic goal. Depending on incidence of bursts > 5-6 per 10 seconds can bolus c̄ 5-10mg/kg/hr pentobarb (given over 1hr) c̄ a concurrent increase in continuous infusion of 0.5mg/kg/hr. Other barbiturates including phenobarbital as boluses can be tried. At times a drug of the same category but with different lipophilic capabilities may have a faster onset — so bolus c̄ phenobarbital while increasing rate of pentobarb infusion.

Diprivan (propofol) as a continuous infusion at higher than usual rates (50-150mcg/kg/min) can essentially "anaesthetize" the brain. Hypotension is a possible side effect thus start @ 5mcg/kg/min and increase q15 mins until burst suppression obtained.

Occasional dosing of lidocaine 100mg (max 300mg/day as boluses) followed by continuous infusion.

[redacted]

Minimize exposure to eleptogenic agents; thorazine and NSAIDS. Monitor LFTs as history of anabolic steroid abuse, and currently receiving lepatic-ally eliminated meds.

M.D.

signature

M.D.

signature

Thanksgiving Willfolk

[redacted]

PROGRESS NOTES

000067

[redacted]

DATE

3/9 Nutrition FILL

O- Per orders of D20/5.7% a.a. @ 80ml/hr, 250ml of 20% lipids - will receive 1800+ Calories, 110gms Pro. gd via parenteral support

A- Initial TPN/Lipids meet 70%/100% of est cal/pro goals [redacted]

3/9/99 [redacted]:

Examined & Rounds CXR's chart reviewed

① Status Epilep

② Polysubstance abuse

③ ~~Dep~~ Hypotensive to Dopamine.

④ Resp Failure. 7.53/60/36/30/93
SIPS 12/950/5/60, 0.5.

⑤ Rio Sepsis. - ~~day~~ day 9.

⑥ Comatosed - [redacted]

[redacted]

M.D.

signature

PROGRESS NOTES

[redacted]

M.D.

signature [redacted]

000068

[redacted]

DATE

(7) Desat. Rlo pluggs.
⇒
V/Q lin probability.

(8) Rlo. Abr Third Fund

[redacted]

3/9/99 Epilepsy Attending
No better
Recommendations
— Would not use Propofol or Lidocaine
— Would keep on Pentobarb and keep burst-supp pattern x 48 hll next attempt at weaning
— Would add Phenobarb @ 60 mg q 8°
— Try weaning pentobarb in 48°

[redacted]

3/9/99 Bronchiopy Thuhar.
— Normal Lungs. a clear mucus

[redacted]

[redacted] M.D.

signature

M.D.

signatu[redacted]

PROGRESS NOTES

[redacted]

000069

DATE

3/9 Endocrine F/4

- Patients remains unresponsive
- Still on pressors
- TRH stim test:
  - 0.127 → 0.827 → 0.547
  - TSH normalizes à stimulation, ?
    ? adequacy of ↑ in level
- Metabolic Rate is only 6% + BMR – not hypermetabolic
- Cortisol, Ucatechols ?

[redacted]

[redacted]

M.D.

signature

M.D.

signature

PROGRESS NOTES

[redacted]

000070

DATE

3/9/99 ID Anuf^s ⓒ TL #9

Remains afebrile on Naprosyn

Heart: Reg

Lungs: CTA

Bod: Soft, ϕBS

Ext: te edema

A) 1) Fever - resolved c̄ Naprosyn, cooling blanket

P) Watch for NSAID ulcers/gastritis

Could try ↓ Naprosyn to 250-375 mg bid

2) Saucers in xp - Cont Anuf ~10d.

3) RUE DVT

4) Resp failure/Vent

5) Sub abuse

6) Would Δ TLC

[redacted]

[redacted]

M.D.

signature

M.D.

signature

PROGRESS NOTES

[redacted]

000071

DATE

3/9

1050

Pulmonary

Unresponsive

T 37.2 PAR RR BP 105/48 Dopamine 11 mg/kg/min

Lungs: Clear anteriorly

CV - Reg

Abdomen - Soft

Arms edematous

CXR - Better aeration [illegible] bases

ABG 60-36-7.53 FiO2 .5 SIMV 12 PSV 10 PEEP 5

A: Refractory hypoxemia

Resp failure / Atelectasis

Compromised Nutrition

Thrombus RUE

Acc. Vent Support

[redacted]

[redacted]

PROGRESS NOTES

[redacted]

signature [redacted] M.D.

signature [redacted] M.D.

000072

DATE

3/9/99 Pharmacotherapy - continued
in 50-150 mcg/kg/min range (ie much higher than usual). Monitor for hypotension as this is very common.

Lidocaine bolus c̄ 100 mg @ a time (300 mg max) concurrent c̄ infusion initiation of ~2 mg/min. Monitor levels as excess lidocaine can also induce seizures.

Naprosyn discontinued. Concerned about the possibility of any drug lowering seizure threshold or inducing seizures (DIC Naprosyn and Thorazine). This is a risk vs benefit vs potential to cause seizures issue.

Discussed differential pharmacokinetics of agents. ie: phenobarb may produce on an intermittent basis quicker seizure control than the "background" continuous infusion of pentobarb. The same is true for patients receiving ~~[illegible]~~ midazolam & diazepam while on lorazepam infusion.

Can monitor ~~[illegible]~~ tegretol and valproic acid levels, gabapentin will take 4-6 days as done by outside facility. Thank you. Will follow

[redacted]

[redacted]

PROGRESS NOTES

[redacted]

signature [redacted]

signature [redacted] M.D.

[redacted]

000073

[redacted]

DATE

3/9/99 Pharmacotherapy
D.S. Pentobarbital drip
Ancef Valproic Acid 250mg IV q 6 hrs
Nuprosyn Carbamazepine 400mg NG BID & 600mg BID.
Lovenox Gabapentin 300mg NG q 4 hrs.
TPN = thiamine Folate Depot [redacted] dopamine 12 mcg/kg/min
(3/9) Phenytoin (discontinued) total = 16.0, free = 3.49

This Hexa-ot was transferred to [redacted] to intractable seizures possibly due to Methane +/- other stimulants (in Ripped by Twin labs). Initial [redacted] drug screen only positive for bdz & opiates - probably administered @ hospital.

Liver profile AST-49 Tbili 0.2 ALT-30 Alk ∅ 68 Alb = 2.5

Thyroid profile TSH 0.127 (0.4-4.2)

Discussed c̄ Dr. [redacted] thoughts of hepatic induction of metabolism. Yesterday noted increased activity as noted by (EEG) post AM meds activity decreased. Barbiturates may increase clearance of antiepileptics thus producing greater peak-to-trough ratios - may increase time serum concentration is below - patient's therapeutic threshold.

Other therapeutic options are: Diprivan at near → anesthetic doses. Data on [redacted]

[redacted]

[redacted] M.D.

signature [redacted]

M.D.

signature [redacted]

PROGRESS NOTES

[redacted]

[redacted] 000074

DATE

3/9 Neurology:
a brief episode of electrical
seizures when pentobarb drip ↓ 2 mg/kg/hr
⊖ clinical seizures
afebrile T max 37.2 → 36.8
required ↑ Dopamine for hypotension
↑ urinary output
Unresponsive, Comatosed
Pupils minimally reactive
subcutaneous edema diffuse.
Labs reviewed,
Bl. C ⊖ so far.
PCX2 → atelectasis 'basal'
EEG → Burst suppression diffuse
= interrupted every 10-15 sec. Cortical
Myoclonic bursts of epileptic discharge
discussed = family / Toxicology / ID
& Epileptology Consultants Prognosis
is poor.
Brain MRI → WNL
crimes disease
Plan: Continue Pentobarb drip
Abnormal pressure / Dopamine / Tegretol
with D/C Dilation from LTB TFT

[redacted]

M.D.

signature [redacted]

signature [redacted]

PROGRESS NOTES

[redacted]

000075

[redacted]

DATE

3/9/99 Neurology ICU # [redacted] Ancef 5

26 y/o ♂ c̄ h/o OTC-Herbal-Steroid abuse still in pentobarb coma 2° refractory electrical, and intermittant clinical, seizure. Now in burst suppression

T: 37.2° Tmax (98.9°F) BP: 110/48 (93-125/45-55) P: 80 R: Ø spontaneous (Vent)

PO2/PCO2/PH/HCO3 ABG 60/36/7.53/30 SIMV R: 12 V: .95 PSV: 10 PEEP: 5 (7 measured)

Alb 2.5
Ast 49
Alt 30
T.B 0.2
Alk Φ 68
Lactic A 1.1

Arbo Virus ⊖
(East, West Eq; St. Louis, Calif encep)

143 | 103 | 10
3.7 | 35 | .4

Med Changes:
Dilantin D/C'd
⊕ Tegretol ↑ 600 ~~qid~~ 400 BID
⊕ Depakote 250 mg q6°
(had 500 mg bolus)
Thorazine D/C'd

Meds, Continuing
Pentobarb
Neurontin 300 mg q6°
Dopamine 13.2 mcg
Naproxin 500 mg bid
Levenox 30 mg q12°
Zantac 150 mg q12°
Thiamine 100 mg qd
Folate 0.50 mg qd
Nystatin S+S
Haldol
Ativan } PRN
Tylenol

Dilantin Free 3.49
Total 16

[redacted] CONT

[redacted] M.D.

PROGRESS NOTE[redacted]

[redacted] M.D.

signature [redacted]

[redacted]

[redacted]

000076

DATE

B/P: ① Refractory Sz, prob 2° to: GHB, "Winstrom" (Vet. anabolic steroids), ecstasy, "creatine", "Ripped fuel" (+) Tegretol

→ Pento-barb coma, burst suppression Depakote Neurontin

(*) → Pharmacotherapy consult suggestions (see note)

Diprivan 50-15 mg/kg/min

③ Lidocaine, occasional, 100 mg + infusion ①

② Phenobarb (dif. L. pophilically from Pent); Diprivan (*) ↑ dose

O/C (minimize) epileptogenic: (NSAID, thorazine). ✓ LFTS

↳ consider Δ to demerol

→ Endocrine:

↓ TSH, T4tot, T7 c/w central hypothyroidism

TRH stimulation test in progress

NOTE: Plasma Catechols NOT in progress; were D/c'd

See attached for procedure, discuss c [redacted]

→ ID: afebrile on NSAID; fever 2° metabolic/central

Ancef

→ Pul: resp failure, atelectasis on Vent

impaired nutrition → TPN consult in prog

RUE thrombus → U.S. for DVT ordered

→ GI consult (P), ileus, now (+) BS

TPN consult ordered

①

Summary: Will discuss pharm. suggestion of added Diprivan,

② substituting demerol for fever control, and investigate

③ cyclic pattern of sz, possibly related to dosing schedule and hepatic metabolism. [redacted]

[redacted] M.D.

PROGRESS NOTES

[redacted] 000077 M.D.

signature

[redacted]

DATE

Procedure Note

Cordis / SG catheter:

3/9/99 area of (R) subclavian

prep c̄ betadine in

7:00 PM ordinary fashion lidocaine 1% use as local anesthetic.

c̄ CEG weakly (R) subclavian vein found guide wire passed through c̄ problem a cordis introduce s̄ difficulty & secure to skin c̄ sutures x2 a SG was floated s̄ problem nor PA & wedge waves [illegible] s̄ problems. SG AT 45 cm

CXR ordered.

[redacted]

[redacted]

[redacted]

000078 M.D.

PROGRESS NOTES

[redacted]

sign[redacted]

M.D.

si[redacted]

DATE

7/10 [illegible]

[illegible]

[illegible]

[illegible]

[illegible]

[illegible]

[illegible]

[illegible]

[illegible]

[illegible]

[illegible]

[illegible]

[illegible]

[illegible]

[illegible]

[illegible]

[illegible]

[illegible]

[illegible]

[redacted]

[redacted] M.D.

PROGRESS NOTES

signature [redacted]

[redacted]

signature [redacted]

[redacted]

[redacted] 000079 [redacted]

DATE

3/10/99	Pharmacotherapy Ancef
1530	O: T98°F BP 110-130/40-60 HR 75-80 I/O 4045/6510
Dopamine 9 mcg/kg/min	143 / 4.1 + 105 / 36 + 11 / 0.4 < 147 11.1 / 3 77 82.1% poly
Pentobarbital 2.5 mg/kg/min	7.9 / 32.4
Carbamazepine 600 g FT Q12 / 100 FT Q12 } Alt	AST 223 ↑ (was 68 3/9) Alb. 2.7
Phenobarb 60 g IV Q8°	ALT 135 ↑ (was 25 3/9)
Depakote 250 g IV Q6°	Serum Drug Concentrations obtained:
Neronin 300 mg IV Q4°	- Phenobarbital 4.4 mg/L
Lovenox 30 g SQ Q12°	- Carbamazepine 6.9 mg/L
Naprosyn 500 g FT Q12°	- Valproic acid 19.9 mg/L

TPN 5.7% Alt } @ 70 ml/hr
20% Dex }
250 ml 20% Lipids

A/P

(1) 26 yo male transfered to [redacted] from outlying hospital S/P intractable seizures possibly due to Mattuang (ephedrine) as well as other stimulants.

(2) Anti seizure regimen - Continues on Pentobarbital as continuous infusion for EEG burst suppression. Also receiving Phenobarbital, Valproic acid, Carbamazepine & Neronin. Neronin is only anti seizure medication which is renally eliminated ∴ should not be affectly by alterations in hepatic enzyme induction activity. Although, Phenytoin has been discontinued, would still expect it to influence drug interactions for at least the remainder of the week (specifically protein binding effects).

[redacted]

[redacted] M.D.

PROGRESS NOTES

[redacted]

signat[redacted]

signatu[redacted]

[redacted]

DATE

3/10/99 Pharmacotherapy

(2) continued.

Carbamazepine serum level within desired range as reported by the lab. Valproic acid & phenobarbital currently sub-therapeutic.

In theory, Valproic acid should inhibit phenobarbital metabolism. Both of these medications have recently been started and the low levels may reflect a pre-steady state picture or 2° to ↑ hepatic metabolism by enzyme induction.

~~Oxc~~ Depakote still remains as a therapeutic option.

Will follow.

[redacted]

[redacted]

M.D.

PROGRESS NOTES

signature

000081

M.D.

signature

[redacted]

DATE

3/10/99 [redacted]

Dr. [redacted] is the [redacted] unlined hosp

will sign off

[redacted]

3/10/99 JD Anex 6 (R) S-G 0

Unresponsive Sp-Saurus

Afebrile 98° 132/58-78 AST 223

CI 37 PCWP 15 SVR 607 ALT 135

NGT, Dobhoff Alb 2.7

Orally intubated 7.8 / 11.1 / 377

Heart: Reg, ~~Tachy~~

Lungs: Coarse breath sounds

Abd: Soft, acc bowel sounds

Ext: Edema

A) 1) Fever - resolved on NSAIDS - called & Naprosyn to 250 bid

2) Saurus in sputum

3) Status epilepticus 5) ↑ Rft's - R/o hepatitis vs drugs

4) Resp failure

P) 10d course of Anex

Monitor for infection [redacted]

[redacted]

M.D.

signature

PROGRESS NOTES

000082

M.D.

signature [redacted]

[redacted]

DATE

3/10 Neurology:
above is noted.
RN reported intermittent focal tongue seizure
EEG monitoring → acceptable Burst Suppression
= Cement pentobarb cose 2.5 mg/kg/h
afebrile hemodynamically stable
on Dopamine drip. #2 SCS
BP 110/130—/54-60
Comatosed Sedative
Lab ↓ H/H 11.1/32.4
Plat 377
↑ LFTS AST / Alt / ↓ Alb
Phenb 4.4
off dilantin VA 19.8
wire Flu. ID / GT / Pulm. cc / Pharmco / Epilep Endo
recommendations
Plan: attempt weaning off
pentobarb in Am
? Tegretol ↓ ↑ LFTS
Depakote ↑ ↑ LFTS
may need to D/C both
wire discuss c GT
Prognosis is poor.

[redacted]

[redacted]

M.D.

signature [redacted]

M.D.

signature [redacted]

PROGRESS NOTES

[redacted]

000083

[redacted]

DATE

5/10 . Patient remains unresponsive
. Vitals BP - 129/83 HR 80's
lungs - (-) wheezes anteriorly
C - nl rate/reg
A - soft, NT
Catecholamines/steroid cortisol still
pending
Will rev TSH, thyroid profile - no
urgent need to treat immediately
T4 is marginal.

[redacted]

[redacted]

M.D.

PROGRESS NOTES

signature

000084

M.D.

[redacted]

signature [redacted]

DATE

3-10-99 Primary [redacted]

Comatose - Pentobarb.

I=4045 O 6510 A febrile 120/56

RR12 PA 31/21

Chest - bilateral rhachi / scant secretions.

No S_3

Abdsoft

Arms edematous

Gluc 147 BUN 11 K+4.1

11.1 | 7900 AST 223 ALT 135 Alb 2-7

377,000 PO_2 99 PCO_2 41 pH 7.47 (.55 12/mi 90 75/40)

Chest xy - much improved. Less congestion / effusion / atelectasis

A - Status Epilepticus

Anemia, AbnLFTs, ↓Alb

Volexcess / Atelectasis

Ventilator Dependence

Thrombus R brachial v.

P - Diuresis, ↓IMV [redacted]

[redacted]

000085

M.D.

signature

PROGRESS NOTES

[redacted]

M.D.

signature [redacted]

DATE

3/10/99

3-11-99 (B) UE venous doppler completed [redacted]

3/11 Pulmonary

1350 On Pentobarb

Tm 99.2 P70 R10 BP 145/55

Lungs Reduced - course BS

CV - Reg PA 22/13 PCWP 8

Abdomen - Soft

Extremities - Edematous Arms > legs

Chem Cr 8.0 SOOT 326 Alb 2.5

WBC 7100 Hgb 11.1 <XR - Somewhat better basilar aeration

A: Status Epileptiques

Ventilator dependence / Bil pleural - atelectatic changes

Hypotensive - Dopamine / Substance Abuse

Impaired Nutrition

Thrombus RUE

Rec: Vent. Reeps

Spoke = Father

[redacted]

[redacted]

M.D.

signature [redacted]

PROGRESS NOTES

000086

M.D.

signature [redacted]

[redacted]

DATE

3/11 Epilepsy Attdg
Events noted
Has been in burst-suppression
On Phenobarb [redacted]
Agree = weaning attempt
[redacted]

[redacted]

M.D.

signature

PROGRESS NOTES

000087

M.D.

signature [redacted]

[redacted]

DATE

3/11/99 Neurology:

(−) Seizures

- EEG burst suppression pattern.

Intermittent Myoclonic polyspikes

afebrile tss.

(+) Pupillary response.

Comatosed pentobarb.

(+) Flaccid vs. LE

Cases

Col 36 NL Na 143

K 4.6

AST 326 Ca+ 8.0

Alb 2.5 Alk phos 99.

H/H 11.1/32.5

Impression: Refractory Seizures

- better burst suppression pattern

will taper off pentobarb

Continue phenobarb / dreamstime

flex (D) / pulse / Endo reconsult

repeat pt / cases / case int

[redacted]

[redacted]

M.D.

signature

PROGRESS NOTES

000088

M.D.

signature

[redacted]

[redacted]

DATE

	(R) SG/Cordis Sput = SA
3/11/99	ID Ancef 7/10
	No Δ
2:50pm	Tm 99.2 Tc = 99 HR = 75 BP = 145/55
	Intubated / Sedated
	Injected sclera Foley
	(R) line ok Rectal tube
	Con: Reg
	Lup: Clear
	Abd: soft ⊕BS
	Ext SCD's / Anasarca
	Impression PLAN
	(1) Fever Resolved on Naprosyn (1) Complete Course of Ancef
	(2) SA in sput
	(3) Resp failure
	(4) Status epilepticus
	(5) ↑LFT's Meds vs hepatitis
	(6) RUE DVT

[redacted]

M.D.

signature

PROGRESS NOTES

000089

M.D.

signature

[redacted]

DATE

3/12 Neurology:

off pentobarb

(−) clinical seizures except for

Tongue twitches

unresponsive to pain

occ. blinking

flaccid vs. [illegible]

(−) Dermas

Tox o/o

Dis symptoms o/o

Labs

BS 160 AST ↑ / Alk Phos ↑ / T. Prot ↓

Ca 8.2 Na 142 PT 17.7

H/H 11.8/35.5

PCO2 50 HCO3 1

Phenobarb 6.8

EEG → [illegible] spikes, sharp waves (−) states

Impression: (1) Toxic Encephalopathy

(2) refractory seizures

(3) [illegible]

(4) [illegible]

(5) ? Pancreatitis

agree w/ phenobarb, Diagnosis as [redacted]

[redacted]

M.D.

signature

PROGRESS NOTES

000090

M.D.

signature

[redacted]

DATE

3/12/99 | JD Anerf 8 | (R) S-G d#2

No real Δ

T 101.2° BP↑ CI 4.1

NGT SVR 542 6.3 / 11.8 / 352.

DHT

Heart: leg 142 / 104 / 17 / 160

Lamp: Coarse breath sounds 5.1 / 0.6

Abd: soft, NT, quiet

Ext: Ledema

A) 1) New fever (but ↑ in S2 activity) - WC WBC et

Central

Drugs

Infection — lungs

— sinuses

— fungal

2) Status epilepticus

3) Resp failure 4) ↑ lft's - ? Meds

Hepatitis profile pending

P) Pancultur

Sinus films

Cont Anerf for now

[redacted]

[redacted]

M.D.

signature

PROGRESS NOTES

000091

[redacted]

M.D.

signature [redacted]

DATE

3/12 Epilepsy

Worried : off Pentobarb x hours

Clinically:

- unresponsive ± mild resp to noxious stim
- clonic jerking of hands

EEG Not clearly status @ this point,

- but repetitive / frequent spike

Rec Would ↑ Phenobarb

Keep off Pentobarb and observe for responsiveness

[redacted]

3/12 Endocrine

- Patient remains unresponsive

Repeat TFTs noted

T3 RU	- normal	- 1.07	labs still consistent c central hypothyroidism
Tg (total)	- low	- 3.74	
Free T4	- low	- 3.5	
TSH	- low	- 0.134	

- will give low dose Synthroid 0.025 mg QD

[redacted]

[redacted]

M.D.

PROGRESS NOTES

signature

[redacted]

M.D.

signature

[redacted]

[redacted]

000092

DATE

3-12-99 Pol Mmay [redacted]

Some ongoing seizure activity.

I= 4075 O= 5090 T° 101.6 PA 33/20

Chest c̄ ↓BS bases

Nom lg

Abd soft

mild generalized edema

Some ↓ SpO_2, hypotension (70% and 86mmHg) when turned earlier.

Gluc 160 AST 660 Alb 2.7

PO_2 111 PCO_2 50 pH 7.4 (900 10/min .6 +8/+10)

11.8 6300 PT 13.75 (INR 1.2)

352,000 Chest xy - ongoing improvement

A- Status epilepticus

Anemia

↑AST, ↓Alb

Volexcess, Atelectasis

Thrombus R brachial vein.

Fever

P- ↓ liver profile, BD; Vent Support

[redacted]

[redacted]

M.D.

signature

PROGRESS NOTES

000093

M.D.

signature

[redacted]

[redacted]

DATE

3/12/99 Pharmacotherapy

1030 Neurontin 300 mg NG 4 hrs

Lovenox Phenobarb 90 mg IV q 8 hrs level = 6.8 mg/L

Ancef (M) DA @ 9 mcg/kg/min AST = 660

Naprosyn BP = 117/45, HR = 105, Temp = 101.2 Alk Ø = 197 142 | 104 | 17

Alb = 2.7 5.1 | 34 | 160 | 0.6

This 26 y.o.o → is currently receiving anticonvulsants secondary to the induction of intractable seizures thought to be due to Ma Huang; caffeine found in Ripped fuel®; other ingredients include L-carnitine, chromium picolinate.

Mr. [redacted] has been receiving phenytoin, carbamazepine and valproic acid in the past. Unfortunately, there has been little beneficial effect on complete seizure control. At this time see a tongue-flicking activity / movements. Currently there is an attempt to wean off of most of the medications (will maintain scheduled phenobarb & gabapentin); gabapentin levels take 4-6 days. Realize that barbiturates will increase metabolism of other AED's. Diprivan available to control "clinical" seizures. Diprivan may be tried @ higher than usual rates to control FEG-seizures

[redacted]

[redacted]

[redacted]

PROGRESS NOTES

signature

[redacted]

signature

[redacted]

000094

[redacted]

DATE

3/12/95 - Pharmacotherapy - continued.

(50-150 mcg/kg/min). Would be interesting to see if complete burst suppression by high-dose propofol for a scheduled period would have any beneficial effects (a type of chemical defibrillation).

Discussed c̄ Dr [redacted] other agents such as limotrigine & vigabatrine. No data to show superiority over those agents already tried, but may act as agents with differing pharmalogic mechanism of action. Understand that there may be thoughts of induction of permanent reentrant circuits which may be non-response to AED's. Neurology has planned family discussion.

Fever still present. central vs. metabolic (Endocrine following) vs infective (ID following). LFT's are elevated - good chance this is due to medications; some meds have been discontinued - ~~the~~ maintaining the rest will be a risk versus benefit issue.

- chromium picolinate (not an AED)
- gabapentin
- carbamazepine
- valgroic acid

TPN written.

Expect metabolic cart to be inaccurate in this hypermetabolic patient in barbiturate-induced coma.

Thankyou. Will follow.

[redacted]

[redacted]

M.D.

signature

M.D.

signature [redacted]

PROGRESS NOTES

[redacted]

000095

DATE

3/13 Pulmonary

0800 TM 101.6 P100 R10 BP 152/80 - off Dopamine

Lungs - Reduced bases

CV - Reg

Abdomen - Soft

No leg edema

Sinus x-rays - Rt Maxillary Haziness

Copious oral secretions

Chem - BUN 25 Gcc 155 Ca 8.4 Mg 2.2 PO4 2.7 SGOT 939 Alb 3.1

WBC 9300 Hgb 13.2

A: Status epilepticus

Resp failure / Atelectasis

Prob sinusitis

Fever

Thrombus Rt Brachial Vein

Impaired Nutrition / ↓ Ca

Central Hypothyroidism

Abn LFT

Rec - Vent / Resp Tx

Dec No tube

Broaden antibiotic Tx for sinusitis - defer to ID

Increase volume (azotemic and Na 147)

[redacted]

[redacted]

M.D.

PROGRESS NOTES

signature

000096

[redacted]

signature

[redacted]

DATE

3/13/99 Pharmacotherapy
1030 Neurontin 300mg NG q 4 hrs
Lormox Phenobarbital 180mg IV q 8 hrs
Anaef off of dopamine, IV rate ↑'d by palm.
Naprosyn Patient exhibiting both
Colace tongue "flicking" and rhythmic
Synthroid eye closing and jaw moving.

147 | 109 | 25
4.3 | 29 | 155
0.7

AST 939
ALT 850
Alk ∅ 294
Alb = 3.1

chili 0.7 chili = 0.4

A/P TPN written = less glucose, protein & lipid load as a result of PLFT's. Potential PLFT's secondary to medications. Prior exposure to anabolic steroids, chromium picolinate in Ripped Fuel®, Valproic acid, barbiturates, carbamazepine & neurontin (rare), & naprosyn. Will also check amylase, lipase & triglycerides as if there is drug-induced hepatotoxicity, there may also be drug-induced pancreatitis; triglycerides may also be elevated. Will empirically, as noted above, decrease nutrient load → will try to decrease potential for protein induced encephalopathy by tong nitrogen load (to 0.7 g/kg). Phosphorus increased slightly in TPN.

Urine output stable but color dark brown.

Will await neurology's note & input - No note so far today. Neurontin levels not readily available in house but available from referral lab ≈ 4-1 day turnaround.

[redacted]

[redacted] M.D.

signature

PROGRESS NOTES

000097

M.D.

[redacted]

signature [redacted]

DATE

3/13/99 Pharmacotherapy - continued

time. Last phenobarbital level yesterday - still

Clinical seizures.

Will monitor LFT's & pancreatitis enzymes, decrease nutrient load for prevention outweigh encephalopathy. Meds so far minimized to + further liver toxicity; phenobarb still onboard (liver toxicity may be associated c barbiturates). This will be a risk v.s. benefit scenario - defer to M.D.'s.

Endocrinology initiated thyroxine for central hypothyroidism. I.D. service monitoring infective status.

Thankyou, Will follow

[redacted]

3/13/99 Pharmacotherapy addendum Phenobarb level = 12.0 mg/L

13:18 Amylase - 167, Lipase - 400, Triglyceride 197 (upper limit 200)

Discussed c Dr. [redacted] this AM LFT's & and this afternoon "pancreatitis profile". Have D/C'd lipids (from TPN) for now, but many drugs are potentially implicated in drug-induced pancreatitis. We are attempting to minimize drugs which are being used. Hepatology has been consulted. Thankyou, Will follow

[redacted]

[redacted]

M.D.

PROGRESS NOTES

signature [redacted]

signature

[redacted]

[redacted]

000098

DATE

3/13/99 ID anc 9 S6³ CSF ⊖

3 - status BC10 ⊖

v. 101⁶ → 101 146/78 UC12 ⊖

erythematous conjunctivae CXR ⊖ inf.

lung clear

CV Reg tachy S6 CO 13

abd + BS soft SUR 499

EXT ⊖ edema lipase 400

A) 1) fever < sinus, lung, CNS, ear 9³ > 13² (356

2) ↑ transaminases < delaunton, tegretol/depakote, other. AST/ALT ↑ 939/850

3) resp flume Bili 0.4

4) Status epilepticus

5) Brachial out Creat 0.7

6) sinusitis.

CT - (R) max cloudy

Play 1) ✓ sput (3/12) U/A - OK

2) ✓ cdiff

3) ↓ abx coverage - needs broader coverage -

zosyn ~~fortaz/cefepime~~ + vanc [redacted]

Trovan - [redacted]

Agree - see attending note -

[redacted]

[redacted]

M.D.

signature

PROGRESS NOTES

[redacted]

000099 M.D.

signature [redacted]

DATE

3/13 Neurology:

intermittent lingual myoclonic jerks.

(-) GTC seizures

EEG → disorganized intermittent sharp epileptic discharges multifocal. diffuse. followed by diffuse 3-4 Hz high voltage delta.

fabric 101.1

Bp / hemodynamically stable

intermittent blinking

(2) side abd. jerky movements

unresponsive. (1) gaze eye deviating

pupils 3 mm reactive

tue conneals

Lab. ↑ LFTs all (AST / ALT / Alkph.

Ca 8.4 Mg 2.2 ↑ lipase

↑ Amylase

Impression:

(1) Statutes epilepticus refractory seizures

(2) Toxic Encephalopathy 2° ? ult substance abuse (6) ↑ LFTs

(3) DVT.

(4) resp failure.

(5) fever

[redacted] → [redacted]

M.D.

signature

PROGRESS NOTES

[redacted]

[redacted] M.D.

signa[redacted]

000100

[redacted]

DATE

✓ GI fam. ? ↑ LFTs

hepatology Consult

[redacted]

[redacted]

M.D.

PROGRESS NOTES

signature

M.D.

signature [redacted]

[redacted]

DATE

3/13/99 ID Attending:
5:43 PM ID note reviewed, pt. examined, chart reviewed -

PE: ③ conj. injection
OP: ⊕ myoclonic jerking movements
Line site OK
Lungs: clear
CV: RRR
Abd: ⊕ BS, soft nontender
Ext: LUE edema o/w ⊖ cords/edema

Plan: ① Agree c̄ broadening antibiotic coverage pending cultures.
② r/c diff

[redacted]

3/14/99 Pharmacotherapy
0950 Vancomycin 1g IV q 12 hrs (day 1)
Levinox Neurontin 300 mg NH q 4 hrs
Naprosyn Phenobarbital 180 mg IV q 8 hrs
Colace Zosyn 3.375 g IV q 6 hrs (day 1)
Synthroid

AST 675 (yest = 939)
ALT 976 (yest = 850)
Alk Ø 257 (yest = 294)
AMY 160 (yest = 167)
LIP 276 (yest = 400)
TRG 174 (yest = 197)

Phenobarb 19.0 (yest = 12.0)

143 | 106 | 22
3.4 | 26 | 731 → ori
o.v. clear
150 mg %

[redacted]

[redacted]

M.D.

signature

PROGRESS NOTES

[redacted]

M.D.

signature [redacted]

000102

[redacted]

DATE

3/14/99 Pharmacotherapy

This 26 y.o. ♂ is currently receiving barbiturates & gabapentin for intractable seizures. Previously receiving phenytoin, carbamazepine, valproic acid, for ~~treatment~~ therapy of seizures. This AM still note rhythmic mouth movements, and some slow eyeblinking. Phenobarbital level 19.0 mg/L (yest = 12.0)

Noted yesterday urine to be dark brown in color. LFT's recorded on chart - hepatologist consulted. TPN protein load decreased in attempt to decrease potential for nitrogen-related encephalopathy (serum creatinine 0.6). Amylase, lipase and triglycerides ordered yesterday; amylase & lipase elevated - lipids DIC'd yesterday - will provide essential fatty acid replacement on a several times per week basis vs daily. Was receiving 1428 kcal as CHO, 500 kcal as fat & 95g/100kg body wt protein as maximal intake. Met cart 3/6 was RQ=0.63, VO_2=348, VO_2=232. Ē an REE of 2300 kcal (on pentobarb gtt & feeds were on hold during peri-reading period). Awaiting hepatology's input.

We have no specific data on liver function; initiated Zosyn (piperacillin is hepatically eliminated). No PT/PTT available. Will maintain current Zosyn dose; Vancomycin ($k_e \cong 0.1 hr^{-1}$, Vd ~ 85 L, $t_{1/2} \cong 7$ hrs) could start ≅ 2g IV q 12 hrs for pre ~ 10 mg/L & post ~ 30 mg/L. Will

[redacted] let I.D. decide, based up their goals. Electrolytes repeated glucose down (drawn from IV/TPN line?) Thankyou, Will follow.

M.D.

PROGRESS NOTES signature [redacted]

M.D.

[redacted]

000103

DATE

3/14 Neurology

intermittent lingual myoclonic Jerry
rhythmic movement
occ. (R) side trunk Twitching
(-) Gic Seizures witnessed

Spikey Temp 102.6 Tmax.
BP Stable 147/81 off Dopa.
Pupils reactive to light
(-) Dolls eyes
Unresponsive to all Stimuli.
Flaccid all 4 ext.
Dir Oto Tor 66

Labs.

. Phenobarb 19.0
. BUN 21
. glucose 344 → accuchecks 157
Amylase 160 Cr. 0.4 Ca 8.2
WBC 13.8 H/H 12.6/37.8
K 3.4 Plat 427

Impression: (1) Refractory Seizures
(2) Resp. failure
(3) Hepatitis ? T LFTs
(4) DVT (5) fever.

Continue Cont 2x. Flu ID/hepatology
Diprivan for Seizure Control. Pnd

[redacted]

M.D.

PROGRESS NOTES

signature [redacted]

000104

M.D.

[redacted]

signature [redacted]

DATE

3/14 Pulmonary

1300 Tm 102.6 P88 R14 BP 145/82

Lungs - Rhonchi

CV - Reg

Abdomen - Soft

Trace edema

Chem K 3.4 BUN 22 Glc 731 (Accucheck does not confirm) Repeat K 3.5 + Glc 344

WBC 14,600 Hgb 13.0 Platelet 435,000

Amylase 160 SGOT 675 Alb 3.0 Lipase 276

CXR - Rt basilar atelectasis / pleural changes

A: Refractory Sequence

Resp failure / Atelectasis

Sinusitis / Fever / Leukocytosis

Thrombus Rt Brachial Vn

Impaired Nutrition / ↓ Ca

Central Hypothyroidism

Abn LFT / ↑ Lipase

Thrombocytosis

Rec: Vent - prob trach in near future

Resp Rx + Antibiotic Rx per ID

Adjust IVF

Spoke c̄ Father

[redacted]

[redacted]

M.D.

signature

PROGRESS NOTES

[redacted]

[redacted]

M.D.

signature

[redacted]

000105

DATE

G I.

3/14/99 Asked to see pt for ↑ LFT's

Full consult to follow (#31,158)

IMP:

① ↑ Liver enzymes, esp. transaminases Pdx — Drugs (esp Depakote, Naprosyn, Tegretol, others?, Hulda) — viral (prior viral serology ⊖) — ischemic? (no hypotension)

Given the timing, I am most suspicious of Depakote (Valproic Acid). It has since been stopped. Follow liver enzymes and if not ↓ further (AST ↓ today, but ALT somewhat ↑) will w/u for other cause

② Diarrhea - ↓ today. ✓ stool studies

(3) mildly ↑ amylase / lipase - suggests biochemical pancreatitis - would follow for now

(4) Fever - on Naprosyn → if LFT's do not ↓, would suggest ↓ to alternative

(5) Ileus - resolved, tolerating tube feed.

[redacted]

[redacted]

M.D.

signature

PROGRESS NOTES

[redacted]

M.D.

signature [redacted]

DATE

8/14/99	ID - Vanco 1/Zosyn 1	BC 12 (-)
4:43 PM	Sedated -	UC 12 (-)
	Tm 102.6 136/56 105 24/16 W 11.2 SvR 714	Sput 13 CIP - Stain (-)
	1/w = 3222/1320	CSF (-) 2/28
	E: (3) cong injection	↑ 14 6)13 (435
	OP poorly visualized	AS/AL 939 → 675
	line site OK	850 → 916
	Lungs: fairly clear anteriorly	K 3.4
	W. RRR	Cr 0.6
	Abd: (+)BS, soft.	Glu 731 → 344
	Ext: (+) UE edema, SLD's in	alb 3
	place - on cooling blanket	lipase 276 ↓
		UXR: No acute Δ
	A - (1) Sinusitis /? Tracheobronchitis	
	(2) Hypotensive episode 3/13	
	(3) Refractory seizures	
	(4) ↑LFT's	
	(5) ↑WBC - ? 2° to #1 vs. #2 vs. seizures	
	(6) (R) Brachial DVT	
	P - (1) Continue present abx pending cultures	
	(2) Ophthalmology to evaluate eyes → suspect exposure keratopathy -	
	continue Lacrilube.	

[redacted]

[redacted] M.D.

signature

PROGRESS NOTES

[redacted]

M.D.

signature [redacted]

000107

DATE

GI

3/15/99 (S) unresponsive

(O) T 100.0 144/74 P 96

HEENTS Anicteric (+) conjunctivitis (mild)

(+) Anisocoria L>>R

Lungs: clear ant

Hearts Reg

Ant BS (+), somewhat hypoactive, soft.

Labs Hgb 11.3 WBC 7.9 plt 364

anglase 92 Lipase 283

Ø bank 29.6

GGT 903 AG 181 ALT 602 AST 276 TBL 1.1

Imp

(1) ↑ LFT's improving on suspect 2° valproate. Watch c̄ TPN

(2) ↑ lipase - mild, no lipids in TPN

(3) Nutrition - VICUB, if ~~trans~~ feeding tube is transpyloric, would start enteral feeding challenge.

(4) Diarrhea - resolved

(5) Anisocoria - call into Dr. [redacted] by nurses, ? 2° dilation by ophthalmo?

[redacted]

M.D.

PROGRESS NOTES

[redacted]

signature [redacted]

signature

[redacted] 000108

DATE

3/15 Pulmonary Procedure Line

Δ TLC over a wire.
Tol well
Tip C+S
TLC [illegible] in place.
good venous return all ports

[redacted]

3/25 C+ of head complete [redacted]

[redacted]

M.D.

PROGRESS NOTES

signature

M.D.

[redacted]

signature [redacted]

DATE

3/15 Pulmonary

Comfortable

125/70 95 99.6° 210 3225/1220

[illegible] - [illegible]

[illegible] - [illegible]

[illegible] - [illegible] [illegible] 10/900/6012/[illegible]/[illegible]

[illegible] - [illegible] 205/46/7.46

143/105 169 WBC 7.9 [illegible] 360

3.4/34 1910.3 4/4 11.3/33.6

1. Sz. Dis
2. [illegible]
3. [illegible]
4. [illegible] [illegible]

1. [illegible] [redacted]
2. [illegible]
3. [illegible]
4. will [illegible]

[redacted]

[redacted]

PROGRESS NOTES

signa[redacted]

[redacted]

signa[redacted]

[redacted]000110

DATE

3-15-99 | 10 [illegible]

Pt 5 [illegible] today

not [illegible]

Tm 100° [illegible] midnight

mouth - [illegible] (R) [illegible] -

[illegible] - [illegible]

[illegible] (R) [illegible]

Sat - [illegible]

[illegible] chest

SGOT 276 (L) WBC 7.9 (R)

GGT 903 AIK (8)

SGPT 612 (L)

A - (1) Fever - better

WBC L

(2) Sonuntion

(3) Refrigerating [illegible] - ?toxin

(4) ↑ LFTs - better likely meds

(5) (R) [illegible] DUT

Rec - Continue [illegible] Abx [redacted]

[illegible]

[redacted]

000111 M.D.

PROGRESS NOTES

[redacted]

signature [redacted]

signature

DATE

3/15 Neurology

Sedated / on Diprivan.

Still c̄ intermittent myoclonic Jerks

Jaw & tongue.

(−) GTC Seizures

Hepatology Consult is appreciated

w/u for ↑ LFTs in progress

Low grade fever 100°

Hemodynamically stable.

Flaccid all U.L. LL

Pupils minimally reactive

the Corneals

the occulo Cephalic reflex

EEG → Generalized. low voltage 2-3 delta

(−) Seizures (−) Asymmetry

Labs ↑ LFTs GGT/903 ALT/602

Alk ph/181 lipase/283

AST/276

ABGs PCO2 46 pH: 7.44 PO2 205

H/H 11.3/33.6 Plat 366

K 3.4 BUN/Cr. 19/0.3 Na 143

Impression:

(1) Refractory Seizures stable.

(2) Resp. f. (4) ↑ LFTs

(3) DVT (5) Toxic Encephal.

[redacted]

M.D.

signature

[redacted]

M.D.

sign[redacted]

PROGRESS NOTES

[redacted]

[redacted]

000112

DATE

Plan. D/C Dipravan. x watch for 24 hr
D/C Swan Ganz.
Hepatology / ID ecomedetics
Consider Tracheostomy.
Will discuss c̄ Pulm / CC
Continue phenobarb / Neuroantim.

[redacted]

[redacted]

M.D.

PROGRESS NOTES

signature 000113

[redacted]

M.D.

signature [redacted]

DATE

3/15/99	Phenobarbital 180mg IV q 8hrs	
1000	Neurontin 300mg IV q 4hrs	Amy 90
Levinex	19 Phenob = 24.6	Lipase 283
~~[illegible]~~	143/34 | 105/34 | 169	Tibil 1.1
Naprosyn	0.3	Alk ø 183
Colace	Vancomycin 2g IV q 12hrs (day 2)	Alb = 2.9
Synthroid	Zosyn 3.375g IV q 6hrs (day 2)	AST = 276
SSI	Vancomycin levels due tonight	ALT = 602
Lacrilube		GGT = 903
HAL	This 26 y.o. ♂ is currently receiving phenobarbital for	
Diprivan	therapy of seizures. Previously receiving phenytoin, valproic	
	pentobarb and carbamazepine. Currently receiving diprivan, ~~and~~	
	phenobarbital and Neurontin. Some twitching noted in jaw this	
	AM - otherwise not disturbed by sound in room. This	
	AM's phenobarbital level 24.6 mg/L.	
	Red non-raised, non-maculopapular, non-vesicular,	
	blanching rash noted on chest and medial (bilateral) bicep	
	area. Recently added meds Zosyn & Vancomycin;	
	No history of drug allergy, not temporally related to	
	Vancomycin administration.	
	From an LFT perspective, AST ↑, ALT ↑, Alk ø ↑, from	
	pancreatitis perspective Amy ↑, Lipase ↑ 283, trig ↑. Gamma GT	
	elevated @ 903. TPN adjusted in response to initial Δ's in	

[redacted]

[redacted]

PROGRESS NOTES

signature

000114

M.D.

[redacted]

signature [redacted]

[redacted]

DATE

3/15/99 - Pharmacotherapy - continued.

LFTs. However patient receiving 20mL/hr of diprovan for clinical seizures; could this be why lipase elevated? Hepatology evaluated patient - concur with thoughts of valproic and tegretol, previously patient was taking anabolic steroids plus Ripped fuel® contains chromium picolinate. See previous note on naprosyn may try low dose 15-25 mg demerol for temp spikes (limited data but anecdotal experience available)

1.D directing Atbr care. Have adjusted doses of Vancomycin and will respond to levels when available. Both Zoryn & Vancomycin have a component of hepatic elimination - Doses are appropriate at this time.

Have sent off Neuronatin level this AM.

Discussed c DR [redacted]

Thank [redacted]

[redacted]

M.D.

signature

PROGRESS NOTES

000115 M.D.

signature [redacted]

[redacted]

DATE

GI

3/16/99 (S) Unsegmented

(O) 101.8 142/76 P14 (+) Stool

HEENT Anisotric

Lung Clear AW

Heart Ry

Ab, BS(+), but very hypoactive

soft, ~~no ascites~~ no ascites

Labs: Hgb 11.5 WBC 13.2 plt 400

BUN 17 Creat 0.5

TBili 1.0 / DBili 0.7 AST 338↑ ALT 642↑

Alt 179↑ GOT 930

amylase 321↑ lipase 354↑

IMP (1) Pancreatitis? – amylase / lipase ↑.

Keep NPO

(2) ↑ LFTS suspect 2° Valproate / Depakote, ↑ further. Follow.

(3) Nutrition – CONT TPN while amylase / lipase are ↑-ing. May worsen LFT's, however

[redacted]

[redacted]

M.D.

signature

PROGRESS NOTES

000116

M.D.

signature

[redacted]

[redacted]

DATE

3-16-99 (1) vomiting³ / 20 yrs³ TC¹

Pt c̄ more seizures today

Tmlow (constant fever)

mouth ⊖

lungs - clear ant

and soft ⊖ BS, nt

Ext - ⊖ edema

⊖ rash

WBC 13.2

A 1 (1) Fever - ? infection

? non infect - central / seizures

(2) NVTs - ? meds - improved

(3) intractable seizures

(4) vomiting -

(5) ⊖ bronchial out

Rec - Flu ix

Continue IV Abx

[redacted]

3-16-99 TCD completed [redacted]

[redacted]

M.D.

signature

000117

M.D.

signature [redacted]

PROGRESS NOTES

[redacted]

DATE

3/16 Pulmonary

COMfortable

136/65 105 38.50 ALO 3355/1170

Lg - clear

Cv - m

Mm - [illegible]

Plan LOD

143 | 103 146 WBC 13.2 [illegible] 410

3.9 | 32 17/0.5 414 11.5/33.8

[illegible] 10/900/50%/+5/PO10

→ 121/47/7.40

(1) Intractable Sz.

(2) Resp. Failure

(3) Rover

(1) Needs [illegible]

(2) No

(3) [illegible]

[redacted]

[redacted]

M.D.

signature

PROGRESS NOTES

000118

M.D.

signature

[redacted]

[redacted]

DATE

3/16/99 Pharmacotherapy

0900 Neurontin 300mg NG q 4hrs level (P) ordered 3/15 anticipate 4-6 day turnaround

Levinox Phenobarbital 180mg IV q 8hrs

Naprosyn Zosyn 3.375g IV q 6hrs (day 3) Pbar = 31.2mg/L

Colace Vancomycin 2g IV q 12hrs (day 3)

Synthroid Vancomycin level pre = 2.8mg, post = 17.9mg/L (taken 2hrs post)

PCK's Ke = 0.25hrs⁻¹, Cmax = 29mg/L

Vd = 57L

There is a minor component of Vancomycin elimination which is affected by hepatic elimination. Currently, Mr [redacted] is receiving phenobarbital, a known hepatic inducer. Based upon the above Vancomycin levels the patient would need to receive q6hrs dosing of Vancomycin to receive a pre-dose (trough) of 8mg/L

Options: 1500mg IV q 6hrs < 29mg/L, 8mg/L

2000mg IV q 8hrs < 31.0, 7.1mg/L

AST 335 (yest=265)
ALT 642 (602)
GGT 930 (903)
AMY 324 (90)
LIP 354 (283)

Awaiting identification of possible organisms in most recent sputum culture. HSV on lip culture so far negative.

Awaiting lytes to write TDN.

Thankyou Will follow

[redacted]

[redacted]

M.D.

signature

000119

M.D.

signature

[redacted]

PROGRESS NOTES

[redacted]

DATE

3/16 Neurology:

No GTC Seizures

facial twitches, Myoclonic

Tongue tremors

Hemodynamically stable

Off Diprivan

RN noted Pupillary asymmetry yesterday

Stat CT Scan Brain → (−) noted

edema (−) Hge

(−) Ischemic Δs

O/E Comatosed

Unresponsive to all stimuli

+ve Dolls

Pupils reactive mildly to light

(−) ~~tre~~ NL tone → Flaccid

EEG → diffuse

Slowing but suppress

(−) seizures

Labs:

Na 143 / K. 3.4

BUN/Cr 19/0.3

WBC 7.9 H/H 11.3/37.6

Plumbate Pending

Impression: (1) Bilat hemispheric dysfunction

2° to toxic Encephalopathy

Plan: Trach / PEG as long term Prognosis

is poor. will discuss in family

Base line EEG D/C EEG monitoring

[redacted]

M.D.

signature

→ over

PROGRESS NOTES

[redacted]

000120 M.D.

signature

[redacted]

DATE

(2) Intractable Seizures
plumbed / Neurotic

(3) ↑ LFT. ? Depakin
followed by Dr [redacted]

(4) Resp. Familiar 2 #1

Progress for a meaningful unlogical
recovery is poor

✓ SW Consult

[redacted]

[redacted]

M.D.

PROGRESS NOTES

signature

000121

M.D.

[redacted]

signature

[redacted]

DATE

3/17 Neurology:

intermittent breath through

Seizures described by RN as

occ. facial twitches, shoulder tremors

was given Ativan PMN.

(-) GTC Seizures SBP DBP.

Spikes temp 101. BP 110/140 → 60/80

No response to all stimuli.

(-) withdrawal to pain

(-) nystagmus

Flaccid VEPLE

DTR 0/0.

Dos +/-

Labs: phenobarb (31.6)

↑ WBC 16.5 H/H 12.2/36.5 Plat/423

↑ LFTS Na 141 BUN/Cr ok

↑ Amylase/Lipase

TCD → Severe Bilat Vasospasm (R) MCA (L) ...

(R) TICA (L) TICA

Impression:

(1) Toxic Encephalopathy →

(2) Cerebral Vasospasm →

(3) Resp. failure → ...

[redacted]

M.D.

PROGRESS NOTES

signature

000122

[redacted]

signature

[redacted]

DATE

(4) fever
(5) ↑ LFTs.

Discussed c̄ wife / father for ≈ 1 hr
The Current Medical status, Prognosis
Treatment Plans, & Prognosis
I have answered all questions.
~~As~~ Patient Prognosis is Poor. I have
discussed c̄ wife / Father the needs for
long term Plans. Gastric tube feeding
& Tracheostomy. They agreed to get
back to me & to if agreed to sign
an informed Consent for both procedures
~~[illegible]~~
Continue current rx.

[redacted]

[redacted]

M.D.

PROGRESS NOTES

signature

000123

[redacted]

signature

[redacted]

DATE

	ID Vanco[4] / Zosyn[4]	TLC[2]
3/17/99	S: sedated on vent.	cultures ⊖
	O: Tm 101[6] Tc 101 130/70 120	sputum - rare staph
	CV Regular tachy	
	lungs - coarse	165 \ 122 / 36.5 +23 ↑LFT's
	And - soft	↑lipase / amylase
	mouth ⊖	
	A. ① fever / ↑WBC's infectious vs central → stress	
	- pan cultures ⊖ so far but will continue broad	
	spectrum coverage pending final cultures	
	② intractable seizure activity	
	③ ↑LFT's - drug related?	
	④ ↑amylase / lipase - drugs / TPN?	
	⑤ DVT (⑥ bracket DVT)	
	Plan - continue present ABx coverage	
	- flu cultures	
	ID - addendum [redacted]	
3/17/99	P Tressains Febrile	
	Fever DDx - ? infection	
	nonint - DVT, meds, central etc / pancreatitis, liver	
	↑ DIC Vanco	
	continue Zosyn	[redacted]
	Progress - very poor	

[redacted]

M.D.

signature

PROGRESS NOTES

000124

M.D.

[redacted]

signature

[redacted]

DATE

Poly

3-1799 S. —

O 101.2 142/77

Lg - Clear [illegible]

[illegible] - No S,

[illegible] - [illegible]

[illegible] No [illegible]

[illegible] 142/246 [illegible] 110/50

3L top - [illegible]

I [illegible] / [illegible] 524 / [illegible]

[illegible] ? [illegible] 2 [illegible]

[illegible] - [illegible] [illegible]

Not [illegible] support

[illegible]

[illegible] [illegible] [illegible] [redacted]

16,500

120/36.5

4271

141 / 106 — 140

36 / 31 \ 4/102

[redacted]

000125

M.D.

PROGRESS NOTES

[redacted]

signature

signature

[redacted]

DATE

3/17 EPILEPSY ATTDG

Situation reviewed

Off drip

On | PB 180 q8°

| Ativan 1mg pon.

GBP 300 q4°

EXAM • 2 focal seizures within my 20 min of observation, both self-limited and terminate within 1-2 min.

• Reacts to noxious stim

A/P • Status epilepticus improved. No GTC but persistent partial seizures

• Now in severe anoxic encephalopathy $\bar{p}$ uncontrolled GTC status

• Would double dose of Gabapentin and use Ativan around the clock ~ 1-2 mg q8° at least

• Discussed $\bar{c}$ family [redacted]

[redacted]

000126

M.D.

signature [redacted]

M.D.

signature [redacted]

PROGRESS NOTES

[redacted]

DATE

3/17/99 Pharmacotherapy

0914 Nemontin 300mg NG q 4hrs Level (P) ordered 3/15 should have result back by Monday 3/22

Lovenox Zoryn 3375g 1V q 6hrs (day 4)

Nuprosyn Vancomycin 2g 1V q 12hrs (day 4)

Colace Phenobarbital 180mg 1V q 8hrs. Phar level = 37.9 mg/L

Synthroid

Lactulose Vancomycin levels drawn 3/15 pre = 2.8, post = 17.9 mg/L

SSI could increase to 2g 1V q 12hrs for levels

TPN Repeat of pre = 7.1 mg%, post = 37.8 mg/L - ID following

Review of current cultures

2/26 bld arm (C) ø, 2/26 bld arm (R) ø, 2/26 urine cath ø, 2/28 CSF ø - fungus - CMV - HSV - AFB

3/2 sputum light Saureus, rare yeast, 3/2 urine ø, 3/2 bld arm (R) ø

3/2 bld cent line ø, 3/2 urine ø, 3/6 bld cent line ø, 3/6 bld (other) ø

3/6 sputum rare Saureus (OX(S)), rare C-alb, 3/10 cath tip (TCC) ø

3/12 bld arm (C) ø, 3/12 bld (C) foot ø, 3/12 urine ø, 3/13 sputum rare Saureus

3/15 upper lip HSV ø, 3/15 swan gang cath tip ø, 3/16 feces ø C diff.

~~A/D~~ (A/P) This 26 yr. o→ is currently intubated and receiving high-dose Nemontin & continued Phenobarbital for intractable seizures thought to be secondary to the ingredients of Ripped Fuel (Mahuang, ephedra, caffeine & chromium picolinate).

AST 246 (ugest = 338)
ALT 626 (642)
Alk ø 189 (189)
TBT 1031 (930)
tbili 1.1 (1.1)
Amy 260 (321)
LIP 735 (335)

141 | 106 | 14
3.6 | 31 | 148
0.2

Various agents were tried carbamazepine, Valproic acid [redacted]

[redacted]

M.D.

PROGRESS NOTES

signature

000127

M.D.

[redacted]

signature [redacted]

DATE

3/17/99 Pharmacotherapy - continued

pentobarbital continuous infusion, diprivan; all monitored by continuous intermittent (q/hr) EEG. Bedside EEG now removed.

On 3/10th LFT's started to rise; Hepatologist consulted. We reviewed possible causes: anabolic steroids, chromium, Naprosyn, VPA, CBZ, Barbs, TPN. As many meds stopped as safely possible. Still receiving Naprosyn - rec. 3/9 - had also concern regarding to seizure threshold. Some anecdotal experience with meperidine (still has good renal function + monitor for possible effects of neuroexcitatory nor meperidine).

We have requested neurontin serum level; scant information regarding level vs efficacy; but may be able to use re prevention of toxicity (phase II data).

Athx started initially in response to elevated temps still elevated today (consistently in 101 range). Athx broadened to cover for possible sinusitis. Suggestions re: Vanco dosing earlier in note.

Future plan trach & G-tube; at this time can convert TPN to enteral feeds. For now feeding at probably lower than optimal as want to decrease stress in liver and toxic encephalopathy. (Ind protein, + CHO, & eliminated fats based upon Amy & Lipase) Will replace essential fatty acids intermittently. Discussed c̄ hepatologist.

[redacted]

Thankyou, Will follow

[redacted] M.D.

signature

PROGRESS NOTES

[redacted]

000128 M.D.

signature [redacted]

DATE

G.I.

3/17/99 (S) Some gymnasium? (+) stools

(O) 101.2 148/77 P 107 R17

HEENT: [illegible]

Lungs: Clear ant

Heart Reg s/ tachycardia

Abd: BS hypoactive, soft.

Extr: tr edema

Labs: TB 1.0 / DBili 0.7 AST 246 L ALT 626 L

Ad 157 GGT 1031

amylase 260 Lipase 335 s/ ↓

BUN 14 Creat 0.2 Hgb 12.2 WBC 16.5 plt 423

Cdiff [illegible]

Imp (1) ? Pancreatitis - amylase / lipase s/ ↓.

Keep NPO

(2) Ahn LFT's s/ ↓ today.

Please re-consider Dc nasogastric.

? worsened by TPN?

(3) Nutrition - Keep on TPN until bowel function improved.

(4) H2 blocker prophylaxis (in TPN) [redacted]

[redacted]

M.D.

signature

PROGRESS NOTES

000129

M.D.

signature

[redacted]

DATE

3/18/09

GI

(S) unresponsive, (+) stool

(O) T102 128/54 P118

HEENTS An. clear

Lungs: Clear ANT

Heart: Tach

Ab: BS hyperactive, soft

Extr: +1 edema

Labs Hgb 12.1 Plt 2189

WBC 17.1

amylase 525 ↑ lipase 317

GGT 1039 AST 220 ↓ ALT 592 ↓ + Bile 1.2 ↑

Ab 190

BUN 11 Cont 0.3

Imp (1) Abn LFTs - improving

(2) ? Pancreatitis - Amylase ↑↑ today

→ keep NPO ? exacerbated by stroid

→ ✓ KUB

(3) Nutrition - Agree c̄ PEG tube → would

like pt off NSAID's (Naprosyn) for 5 days

* infection cause of fever b/c + Pancreatitis

resolved before placing PEG

[redacted]

M.D.

signature

PROGRESS NOTES

[redacted]

000130 [redacted]

M.D.

signature

[redacted]

DATE

3/18 Neurology:

No new neurological event.
Local facial seizures intermittent
@ GTC seizures
Unresponsive to all stimuli
Fever Tmax 101.3 Pupils reactive
BP stable ~140/50-55 HR 90-100
Na K 135/3.8 Bs 144
BUN/Cr 11/0.3 ↑ LFTs
Ca 7.8 ↑ Amylase 525
pH 7.47
plans for tracheostomy / PEG in progress
Social worker for DC planning

Continue phenobarbs / Neurontin.
Ativan prn
↑ Neurontin to 400 mg 84°
Continue Antibiotics Coverage.

[redacted]

[redacted]

M.D.

PROGRESS NOTES

signature

000131

M.D.

[redacted]

signature [redacted]

DATE

3/18/99	Pharmacotherapy
1000	Nimodipine 300mg NG q4hrs ← Level Pending ordered 3/15 anticipate 4-6 weeks, dangerous for result.
Lovenox	Phenobarbital 180mg IV q8hrs phenobarbital = 33.3mg IL
Colace	Zoryx 3.375g IV q6hrs
Synthroid	Nimodipine 60mg NG q4hrs
HAL/Repod	
Lavulate	135/99 3.8/30 < 11 / 0.3 144
	~~Ca~~ 2.8, mg = 1.9, Ca = 7.8

AST 220 (yest = 246)
ALT 582 (626)
Alk ø 196 (189)
Alb = 2.8
γGT 1039 (1031)
Tbili 1.2 (1.0)
Amy 525 (260)
Lipase (335)

This 26 y.o. → is currently receiving phenobarb & gabapentin for history of intractable seizures; EEG removed from bedside 2 days ago - still exhibiting occasional jaw movement. Past exposure to Ripped Fuel by Twin Labs; Mattinang - ephedra caffeine & chromium picolinate. Pharmacologic agents of various categories tried - Hilantin, carbamazepine, valproic acid, pentobarb, & diprivan. Current meds as above. Epilepsy attending note (3/17) suggested doubling dose of gabapentin & ATC lorazepam. Nimodipine initiated for cerebrovascular vasospasm.

Potentially drug-induced hepatitis & pancreatitis. As many meds as possible discontinued. TPN adjusted → will Δ to enteral nutrition when possible. Protein load & carbohydrate

[redacted]

[redacted] M.D.

signature [redacted] M.D.

signature

PROGRESS NOTES

[redacted]

[redacted]

DATE

3/18/99 Pharmacotherapy - continued.

Lead decreased. Lipids held since 3/13. Providing decreased protein load to minimize TPN induced nitrogen excess, and to CHO to minimized "stress" on liver; GI note 3/17 noted.

Zoryx initiated for maxillary sinusitis. Synthroid initiated for central hypothyroidism.

Thanksgiving, Will follow

[redacted]

3/18/99

1030 Adverse Drug Reaction (ADR).

An FDA Medwatch report has been initiated and sent by both pharmacotherapy & toxicology services.

[redacted]

[redacted]

M.D.

signature [redacted]

M.D.

signature [redacted]

PROGRESS NOTES

[redacted]

[redacted]

DATE	
3/18/99 8:30 Am	ENT Pt seen, Full Report in Consult section. Plan Tracheotomy for 3/19/99 @ 12 Noon (scheduled in [redacted] OR) Please hold Lovenox this afternoon and ~~hold~~ have wife sign consent. I will discuss procedure c̄ her as well. Thanks [redacted]
3/18/99	Length of Stay Review LOS: 21 days. Awaiting tracheostomy. Need to develop long term care plan. Continue icu care. [redacted]

[redacted]

M.D.

PROGRESS NOTES

signature 000134

[redacted]

signature [redacted]

DATE

3-18-99 TCD completed - [redacted]

3/18/99 SW

1240 D: Consulted by [redacted] for placement.

A: Wife still hopeful for treatment.

P: Will discuss [redacted] options c̄ wife

MD please complete transfer form on chart, physician's orders section.

[redacted]

3-18-99 Poly

S, ___

0 100 E 110 20 140 IN

Lg - [illegible]

Cr - No [illegible]

[illegible]

Ext [illegible]

[illegible] - No [illegible]

84 / 41 / 242 - 503 / 10 / 5[illegible] / [illegible]

I [illegible] / [illegible] / Sz

Fam [illegible] [illegible]

[illegible] - [illegible]

[illegible] - [illegible]

TF

135 / 59 / 144
3.8 / 30 / 11105

[redacted]

M.D.

signature

PROGRESS NOTES

000135

M.D.

signature

[redacted]

DATE

3/18 Endocrine F/U

- Patient's eyes open, closes eyes when lashes are touched
- No other significant response noted.
- Has been on Synthroid 0.025 g x 6 days.
- Will ✓ T4, FTI level in AM

[redacted]

[redacted]

M.D.

PROGRESS NOTES

signature

000136

M.D.

[redacted]

signature

[redacted]

DATE

2/18/99	VD Zosyn[5] TL[3]
	No real Δ 3/13 sp - rare S. aureus
	Remains febrile ~1010
	Heart: Tachy AST/ALT 220/502
	Lung: Coarse BS 8GT 1039
	Abd: Soft, NT Amy/Lipase 525/317
	Ext: + edema 17-1 > 12 < 489
	A) 1) Fever - Prob non-infectious vs sinuses
	2) Intractable seizures
	3) Elevated lft's
	4) ↑ amylase, lipase
	5) DVT
	P) Pt. remains afebrile despite ABX. All cx neg
	~~X~~ (5) S aureus (rare) in sputum. His fever
	is likely central. Will finish 7d. of Zosyn then
	D/C & follow off ABX
	[redacted]

[redacted]

000137

M.D.

signature [redacted]

M.D.

signature [redacted]

PROGRESS NOTES

[redacted]

DATE

[illegible]

[illegible]

[illegible]

[illegible]

[illegible]

[illegible]

[illegible]

[illegible]

[illegible]

[illegible]

[illegible]

[illegible]

[illegible]

[illegible]

[illegible]

[illegible]

[illegible]

[illegible]

[illegible]

[illegible]

[illegible]

[illegible]

[illegible]

[illegible]

[illegible]

[illegible]

[illegible]

[illegible]

[illegible]

[illegible]

[illegible]

[redacted]

M.D.

PROGRESS NOTES

signature

000138

M.D.

signature

[redacted]

DATE

3-1999 Poly

S. —

O 100± 120 10 120/60

4350 / 3725

Lg - [illegible] 135 / 98 — 141

CV - No Sy 31 / 30 — 14/04

[illegible] - [illegible] 1.7, [illegible]

[illegible] 11.8/35.6

[illegible] 4531

118 / 41 / 248 - 900 / 10 / 5[illegible] / 75 / 110

[illegible] [illegible] / [illegible] / [illegible]

[illegible] - [illegible] + [illegible]

[illegible] - LFT's / [illegible]

[illegible] [illegible] - [illegible]

[illegible] / TF [redacted]

[redacted]

M.D.

PROGRESS NOTES

signature 000139

[redacted]

signature [redacted]

DATE

3/19/99 Pharmacotherapy

0945 O: Tm 101.6 BP 120-130/40-60 HR 110-120 I/O 4390/3705 UOP 60-150 ml/hr

Lovenox 30 q12° SQ (Hold 3/18) Colace 100 q 0.12°

135 / 3.9 | 98 / 30 | 14 / 0.4 | 144 Ca 7.9 PO4 3.3 Mg 1.9 | 11.8 / 17.2 | 453 / 55.6

Phenobarb 180 mg IV q8° TPN currently at 4.25% AA + 20% Dextrose at 70 ml/hr, ∅ lipids (last given 3/13/99)

Synthroid 0.025 mg IV q10

Zosyn 3.375 g IV q6° A/P

Neurontin 400 mg NG q4° (1) 26 yo S/P intractable seizures 2° to exposure to Ripped fuel® by

Decadron 4 mg IV q6° Twin labs as well as Ma Huang + other stimulants.

Nimodipine 60 mg Q4° (2) Seizures - Continues to receive Phenobarbital and gabapentin. A

Pepcid 40 mg GD TPN gabapentin level has been sent out for assay; however, results are not back as yet.

(3) Hepatitis/Pancreatitis - possibly drug induced; TPN also has been adjusted to lower protein + carbohydrate load.

(4) Sinusitis - continues on Zosyn

(5) Nutrition - Noted plan for G tube in ~5 days from 3/18. TPN continues. Last lipids administered on 3/13; may need to give some in next few days to prevent essential fatty acid deficiency.

(6) Cerebral Vasospasm - Nimodipine initiated.

Will follow.

[redacted]

[redacted]

M.D.

signature

PROGRESS NOTES

000140

[redacted]

M.D.

signature

[redacted]

DATE

3/14/99 (S) GI
unresponsive
(O) T=101° 134/64 P 78
HEENT Anicteric
Heart Reg
Abd BS(+), soft, NT, ∥ hypoactive
Labs no pancreatic or hepatic
enzymes avail today
Ind PT 18.2 WR 2.1 WBC 17.2 pH 553
(1) Abn LFTs - ✓ tomorrow
(2) ? Pancreatitis - keep NPO until
pancreas enzymes improved
(3) Nutrition - proceed c̄ PEG
once pt off Naprosyn/NSAIDS x 3 days,
once Dehydrogen resolved + coags improved
dx VTK.

[redacted]

[redacted]

M.D.

PROGRESS NOTES

signature

000141

M.D.

[redacted]

signature

[redacted]

DATE

3/19 Neurology:

intermittent facial breakthrough
Seizures. treated c̄ versed
(-) GTCs s/p tracheostomy
febrile 101° Bp is stable 135/62
unresponsive to all stimuli
flaccid US. LE.
DTR 0/0
Tor (-) resp.
(-) tremors
(-) Seizures
pupils +3 reactive
(-) facial Asymmetry

TCD → Bilet sever cerebral vasospasm

Lab

PH 7.48
BUN/Cr 14/0.4
WBC 17.2
H/H 11.8/35.6

Impression

- Neurologically is unchanged
s/p tracheostomy
- intractable Seizures / Breakthrough
- Anoxic/Toxic Encephalopathy
- ↑ LFT
- will ✓ CT scan brain for cerebral antigen

[redacted]

M.D.

signature

PROGRESS NOTES

[redacted]

M.D.

[redacted]

000142

[redacted]

DATE

3-19-99	Ane. note
	20 yr old for permanent Trach placement
	GA, TF 200cc
	[redacted]
3/19/99	JO Zosyn 6
	S/P trach. Family at bedside TL 4
	T's ~101° consistently 3/13 Sp-rare Saurus
	Oral lesions
	Heart: Reg, tachy 3/5 MRI - sinusitis
	Lungs: CTA
	Abd: Soft, NT
	A) 1) Fever - likely central vs pancreatitis
	2) Sinusitis - has had >3 wks IVABX
	3) Intractable seizures
	4) 9 left's, amylase, lipase
	5) DVT
	P) Would favor Dc'ing Zosyn in am and.
	following off ABX.
	Could re image sinuses, aspirate fluid if still
	present.
	[redacted]

[redacted]

M.D.

PROGRESS NOTES

[redacted]

M.D.

[redacted]

DATE

3/19/99 FNR:
26 y.o. w/ H/o poly substance abuse Now in status epilepticus. TCDs show possible vasospasm. Angio requested to evaluate for vasculitis/vasospasm. Phone consent from wife obtained after explaining R/B/A. She voices understanding and gives consent over the phone, witnessed by [redacted] the nurse.
[redacted]

3/19 Ct of head complete [redacted]

3/19/99 FNR - angio completed -
No vasospasm, No vasculitis by angio.
No aneurysm or AVM.
Full report to follow [redacted]

[redacted]

M.D.

PROGRESS NOTES

signature

[redacted]

M.D.

sign

[redacted]

[redacted]

000144

DATE

Poly

3-20-99 S,

O. 101.2 120/70

1830 / 2390 136 / 58 150

4.3 / 28 14/0.3

Lyn Clm

Cr No. 1 14,700

Alb Sulf 11.8 / 35.2

Ext Nuc 472k

I Resp failure / Seizures / Ehrl

tAlb Fam Abn LFTs TT Bayley

M Vent / MT - try to wean some

new that trached

Abn / TF [redacted]

[redacted]

PROGRESS NOTES

[redacted]

signature [redacted] M.D.

signature M.D.

[redacted]

DATE

3/20/99	Pharmacotherapy
0835	O:T101.2 Tc 100.6 BP 140/80 HR 120 I/O 1850/2390
Lovenox 30mg SQ Q12°	gabapentin level of 3 mcg/ml (collected at 1100 HM 3/15/99)
Colace 100mg BID	136 / 98 / 16 / 150 — 11.8 / 472
Phenobarb 180mg IVQ8°	19.8 / 28 / 0.3 — 14.7 / 35.2
Synthroid 0.025mg IVQD	AST 136 ALT 398 TB.li 1.3 Alk Phos 187 Alb 3.1 GGT 970
Zosyn 3.375mg IVQ6°	Amylase 1436 Lip 206
Versed 5mg IV PRN seizure	TPN 4.25% AA, 20% Dextrose at 70ml/hr; Ø lipids (last given on 3/13/99)
Vit K 10mg given yest x1	A/P
Neurontin 100mg Q4°	1) 26 yo male S/P intractable seizure 2° to exposure to Ripped fuel ®
Repeat in TPN	by Twin labs as well as Ma Avary & other Simulants. ↑ seizure activity
	yesterday noted. CT scan noted. Cerebral angiography noted.
	2) Seizures - continues to receive phenobarbital 180mg IVQ8° and gabapentin.
	Last phenobarb level obtained on 3/18 & reported as 33.3 mg/L. The
	gabapentin level returned and reported as above. Note, pt was
	receiving a lower dose at the time of level.
	(3) Hepatitis/Pancreatitis - Noted ↑ in Amylase but reduction in lipase. Last TG level
	obtained on 3/15. TPN adjusted recently to lower protein & carbohydrate load.
	Will need to give a 1x dose of lipids to prevent fatty acid defic eng.
	Will add TG level to AM labs. Discussed c̄ Dr [redacted] yesterday.
	(4) Nutrition - Continues on TPN. 1x dose of Lipids today.
	Will follow.

[redacted]

[redacted]

M.D.

signatur[redacted]

M.D.

signatur[redacted]

PROGRESS NOTES

[redacted]

[redacted]

DATE

3/20 Neurology:

Intermittent facial myoclonic seizures

Rt then left

(−) GTC seizures

on versed drip

CT Scan Brain → diffuse cerebral edema

Cerebral anteriogram → (−) focal vasospasm

(−) vasculitis

↑ CBF

febrile. hemodynamically stable

Tachycardia 110–120

Comatose

Pupils normally responsive

Flaccid [illegible]

s/p Tracheostomy

Labs reviewed

. Catecholamine level

. Dermatin level 3.0 mcg/ml

Impression: 1) Refractory seizures

2) Toxic Encephalopathy

3) Cerebral edema

4) ↑ LFTs . Poor prognosis

5) fever Plans for long term placement

6) resp. f . ↑ Mentation to [illegible]

[redacted]

[redacted] M.D.

signature

PROGRESS NOTES

000147 [redacted]

[redacted] M.D.

signature [redacted]

[redacted]

DATE

3/20/99 ENT POD 1

9:45 AM Continued status epilepticus.

Low grade temps as before.

Trach stable, ∅ bleeding.

Ventilating well.

Plan 1st trach change POD 5.

Please call if any questions/problems c̄ trach.

Thanks / [redacted]

3-20-99 Proud - 3L

Tolerance Point 3L almost completely withdrawn

After stable range, 1% xylocaine,

3L cut of [illegible] [illegible] [illegible]

[illegible] [illegible]. Point 3L removed, new

3L [illegible]. Good blood flow all points.

Sutured in place. [redacted]

[redacted]

M.D.

signature

PROGRESS NOTES

000148

M.D.

signature

[redacted]

[redacted]

DATE

	TLC #0 Sput = Rou SA
3/20/99	ID Zosyn 7 Track #1
	No Δ
1:50pm	Tm = 10.12 HR = 120's BP = 135/70 Cdiff ⊖
	TLC New all cx ⊖
	Con: Tachy
	Lys: Clear 14.7 1.8 472
	Abd: soft ⊕ N
	Ext: ⊖ BUN/cre 16/.3
	Impression AST/ALT = 136/398
	① Fever Central vs Pancreatitis T.B.Li = 1.3
	② Sinusitis Alb = 3.1 Amylase = 1436
	③ ↑ LFTs / Amylase Lipase = 206
	④ Sz D/O / Convulsion
	⑤ DVT
	⑥ Leukocytosis tiz
	PLAN: ① D/C Zosyn
	② Repeat LFTs Mon
	[redacted]

[redacted]

000149

M.D.

signature

PROGRESS NOTES

[redacted]

[redacted] M.D.

signature [redacted]

DATE

3/20/99 (Hep)
14:45 S: Pt having facial twitching — stopped after few minutes. Nursing aware.

O: 101.8F - 101.2F BS/70-125-S/10

1850 | 940
2390 | 480

~~Gen: Dedated~~ Anal: (+) BS, - mildly hyperactive, mildly distended. Lower 12cm.
Eyes Anisotria, Nonallids
Mouth: Dry mouth Ext ϕ sig edema.
CV: NCG Fady
Lungs: Clear

Lab: ↓14.7) 11.3/35.2 < 472 (112) 136/4.3 | 98/28 | 16/150 < 63 AST-136↓ ALT-398↓ TBA-1.3↑ AG-187↓ AG-3.1 GG-970↓ Amylase-1436↑ Lipase-206↓
114/38/747/98/27
50%, R-10, TV-900, PS(8), PS

A: 1) Abn LFTs — trend ↓ - ? med related. F/U trend Q few days.
2) ? pancreatitis keep on TPN until enzymes improved. Amylase ↑ but lipase ↓.
3) Peg — waiting improvement leukocytosis, fever. ? Early or mid next week. Need for pancreatitis to be improved as well.
4) Neuro Tear [redacted]
Acc: 1) ✓ F/U labs

[redacted]

M.D.

PROGRESS NOTES

signature

000150

M.D.

[redacted]

signature [redacted]

[redacted]

DATE

3/20/99 Neurology Consult 3rd opinion of family's request

Discussed i [redacted]

Chart reviewed

Pt examined

Assessment

(1) Intractable Seizures most likely toxic related to suppressive pharmacy!!

(2) Pancreatitis / Hepatitis pros ? to TPN, Depacon

Rec PEG tube and start using the gut for nutrition to stop TPN

cont Phenoxybenzamine

cont Neurontin

Consider changing Depacon for Vigrabatrin, Topamax!

Consider Atrium i.v. IV Q 6 regularly rather than prn

Continue Decadron

totally agree i Nimotop use

Agree i Excellent attempts made so far to dx and tx this unfortunate young man

[redacted] 3/20/99 8pm M.D.

signature [redacted]

PROGRESS NOTES

[redacted]

000151 [redacted]

signature [redacted]

[redacted]

DATE

3/2/99 <Hep/97> S/P Zosyn 8 TCC #1

17.3L S: Pt continue c̄ occ seizure.

O: ID. 21F--125/55-115-16/6

2601 | 1062 Versed drip.

1630 | 450

Gen: Sedated

Eyes: Anicteric. Normal lids

Mouth: dry mouth

CV: Reg tachy

Lungs: Wheezes

Abd: ~~[illegible]~~ ~~[illegible]~~ BS more hypoactive. mildly distended. Cannulas

Ext of sig edema.

Labs: 13.1 > 12.5 < 560 137 | 14 | 14 / 38 | 25 | 152 < 0.2 AST=118 ↓ AP=206 ↑ Amylase 235 ↓ ALT=370 ↓ ~~[illegible]~~ Lipase 201 ↓ 703-10 ↓ 991-1122 ↑

A. 1) Abn LFTs - monitor trend. ? med related.

✓ Serologies. ✓ Q few days

2) Pancreatitis - Still c̄ ileus - F/U for ileus recovery. This delays peg as peg feeds would not be able to be done c̄ this ileus induced distension ↑ Complication rate. Once able to reuse gut then do peg.

3) Nutrition - as above - TPN until ileus resolves then peg.

4) Fevers - ID stopped Abx. Monitor off.

5) Neuro Tx as per Pn [redacted]

Plan: 1) F/U on pancreatitis / ileus resolution

2) ? peg middle of week ?

[redacted]

[redacted] M.D.

signature

PROGRESS NOTES

000152

M.D.

signature

[redacted]

DATE

TLC#1

3/21/99 ID Zosyn 8 Track #2

No Δ

Tm = 100 Tc = 100

(R) TLC site ok

COR: Reg

Lep: Clear

abd: soft ⊕ BS

Ext: ⊕ C/C / edema

13.1 > 12.5 < 56

Impression

(1) Low grade fever

(2) Sinusitis

(3) Pancreatitis / ↑LFTs

(4) DVT

(5) Leukocytosis

PLAN (1) D/C Zosyn

follow off Abx

[redacted]

[redacted]

PROGRESS NOTES

[redacted]

[redacted] M.D.

signat[redacted]

M.D.

signat[redacted]

000153

DATE

3/21 Neurology:

Neurologically unchanged.

on versed drip

Naurantin 400 mg 92°

Phenobarb. 180 mg IV 980

~~Periodic~~ Periodic of alternating facial myoclonic seizures.

(-) Cotic seizures

Temp. 99° Hemodynamically stable

Comatose

flaccid both UE. LE.

(-) withdraw to pain

Labs: WBC 13.1

H/H 12.5/38.4 Plat 560

Na 137 K 3.8 BUN 14 / Cr 0.2

LFTs → ↓

Impression:

1) Refractory Seizures

2) Toxic Encephalopathy.

3) ↑LET. 5) Cerebral edema.

4) H/O Substance abuse

Prognosis is poor

for PEG per Dr. [redacted]

for phenobarb [redacted]

[redacted]

M.D.

PROGRESS NOTES

[redacted]

M.D.

000154

DATE

3/21/99	Pharmacotherapy
0945	O:T 98.2 BP 130/70 HR ~100 I/O 2601/1630 UOP ~80-100 ml/hr
Levenox 30g SQ Q12°	137 / 3.8 | 101 / 25 | 14 / 0.2 | 152 | 12.5 / 13.1 | 37.9 | 560 78.3 bp
Colace BID	
Synthroid 0.025g IVQD	AST 118 Alk Phos 206 Amylase ↓↓ 239 TG 140
Zosyn 3.375g IVQ6°	ALT 370 Alb 3.2 Lip 201 GGT ~~[illegible]~~ 1122
Neoeim 400g MG Q2°	TPN 4.25 AA%, 20% dextrose at 70 ml/hr, 250 ml 10% Lipids X1
Decadron 4g IVQ6°	A/P
Vit K 10g QD Sq	1) 26 y/o male S/P intractable seizures 2° to exposure to Ripped Fuel (R) i
Versed gtt	Ma Huang + other stimulants/substances.
Nimotop 60g Q4° NGT	2) Seizures - continues on phenobarbital and high dose gabapentin.
Phenobarb 180g IVQ8°	Renal fxn normal.
	3) Hepatitis/pancreatitis - Noted reduction in Amylase. TG level within normal range after dose of lipids.
	4) Nutrition - Continues on TPN, maximally reduced to decrease cho + protein load.
	Will follow.

[redacted]

[redacted]

PROGRESS NOTES

[redacted]

[redacted]

M.D.

M.D.

DATE

3/22/95 Pharmacotherapy 3/15

0830 Neuronton 400 mg NG q 2 hrs Neuronton level (P)

Lavenox Phenobarbital 180 mg IV q 8 hrs (Phenobarb = 39.7 mg/L

Levinox Nimodipine 60 mg NG q 4 hrs Δ = 3.0 mcg/mL

Colace I/O 2086/1355, T max = 100.6, T = 99.8

Synthroid BP = 135/78, HR = 123, RR = 19/6

Dexamethasone

Midzolam 4 mg/hr 130/4.8 | 103/29 < 19/0.4 173 AST 117 (yest = 118)

ALT 413 (370)

(P) This 26 y.o. → was admitted AIK ∅ 226 (206)

2° to intractable seizures thought γ GT 1254 (1122)

to be resultant from "Ripped Amy 76 (239)

Fuel". Off of conditions Lipase 155 (201)

FEG. No obvious seizure activity

this AM. Currently receiving midzolam, γ H & scheduled phenobarbital. (Level = 39.7 mg/L). Initiated on nimodipine due to evidence of vasospasm.

Anticipate documentation of neuronton level - Now on doubled dose. Neurology services & elaptology following.

Received lipids c̄ TPN on 3/20. Amylase & lipase continue to drop. There is a spurious increase in serum amylase 3/20 - drawn before ~~TPN~~ lipids. Anticipate [redacted]

[redacted]

M.D.

signature

PROGRESS NOTES

[redacted]

M.D.

signature [redacted]

000156

[redacted]

DATE

3/22/94 Pharmacotherapy - continued

conversion of TPN to enteral nutrition once G-tube placed (unless @ this time).

Liver function tests & Elevation of enzymes since yesterday; Hepatology following. Believed to be drug-induced. Adverse drug reaction reports per [redacted] completed. Med Watch (FDA program) paperwork completed for Ripped Fuel.

Receiving Synthroid for central hypothyroidism - followed by endocrinology.

Infectious status being monitored by I.D service.

TPN written for this AM - lipids administer 3 to 3 1/2 for essential fatty acid replacement. Due to pancreatitis - minimizing use of lipids. Little change of Amy & Lipase may be able to administer lipids more frequently. Usually see elevations of amylase & lipase c̄ enteral versus parenteral nutrition. Wanted to minimize any potential for exacerbation of pancreatitis thus told interval of lipid administration.

Thank you, Will follow [redacted]

[redacted]

M.D.

signature

PROGRESS NOTES

000157

M.D.

signature

[redacted]

DATE

3/22/99 (Hep 191)

1966 S: Pt events noted

O: 100.6F - 100.4F 145/65-130-19/6

Stool = 450

gen: not responsive — lungs: Qwhizes ant

eyes: miniatura, hemorrhoids — Abd: Hypoactive BS,

Mouth: Qthrush — mod distended, lower 2g

CV: neg tachy — Neuro: not responsive

Labs: 17 > 13.8 < 709 — 139/4.8 | 103/24 | 19/173 < 0.4

AS2 117↓ TB 2.2↑ Alb 3.2 Amylase 76

Alc 413↑ Ag 226 99 1254↑ Lipase 155

A: 1) Abn LFTs ↑ - ? HAL vs infection vs 10 d2 prev flu trend

2) Ileus - ✓ KUB - if improves as stool ↑ output suggests, then could try peg later if family desires. If he declines further, can reassess also.

3) Neuro status To as per Dr [redacted]

Plan: 1) ✓ KUB tomo

2) F/U Amylase / Lipase

2) ✓ LFTs

[redacted]

M.D.

PROGRESS NOTES

signature

000158

M.D.

[redacted]

signature [redacted]

[redacted]

DATE

7-22-95 Pub fl

S ~~O~~

O T 100° BP 140/N Pr 19 R 120

I 2656 O 1315

Chest. Shoulder

Cr Tang, Br

Wd mild dealt

Apparent BS

Cat 5 edu

Cr clear, no crab

A.

135 ppm Br 19

48/45 , 173

GGT 1254

Bc 170 Lp. 138 Ict 41.8

Plat 709,000

MG pl. 113 pCC, 3+

pH 7.69

C Intermittent Sequence

Repeat Fuller

P LGT

[redacted] C Sam Vent appear

[redacted] M.D.

signature

PROGRESS NOTES

000159

[redacted] M.D.

signature

[redacted]

DATE

3-22-99 | ID Ø Abx TLC²

Pt F D

Tm 100t (Gley)

mouth ⊖

Lungs - clear ant

Abd soft ⊖ Br

SCOT 117 Cr 0.4

Bili 7.2 (T) WBC 17.0

GGT 1254

A - ① Low grade temp - ? central / recurrence

? infection - recent cx ⊖

② Sinusitis s/p 1 Abx

③ Intractable recurrence

④ + VTG -

⑤ DVT

Rec. Follow off Abx

Reculture if T > 101

[redacted]

[redacted]

PROGRESS NOTES

[redacted]

M.D.

signature

[redacted]

M.D.

signature

[redacted]

000160

DATE

3/28/99 ID Cipro 2 Tce 8
no response urine soli

1237 Tm 101.3 → 99.6 130/65
u/vol trend of
the site & of OP @ ulcer 3/25 BCE
Is mostly clean some coars
Abd sept sl distal 3/25 sept
ext ⊖ rash Polyn (c⊖ multiple
(s. ane

M 1) Fever - urine vs other
c telectasis / pneum / line etc
2) Abnormal LFT
3) p̄ 21 d Abx for sinus
4) Resp fcile / vent
5) Toxic encepl
6) Pnt

N 1) Cont Cipro
2) Repeat ucx
3) ↓ cont T + ⊖ cx → further w/u

[redacted]

[redacted]

M.D.

PROGRESS NOTES

signature

[redacted]

[redacted]

M.D.

[redacted]

000161

DATE

3/22/99 Clinical Toxicology Note:

Unresponsive. No change in Clinical Status, VSS

S/P Status Epileptics

elevated LFT's

on maintenance Anticonvulsants

An FDA Adverse Drug Reaction Report was submitted to the FDA on the suspected toxicity of "Ripped Fuel" from Twin Labs a metabolic enhancery diet supplement which may have been implicated in this patient's neurotoxicity.

[redacted]

[redacted]

M.D.

signature

PROGRESS NOTES

[redacted]

M.D.

signature [redacted]

000162

[redacted]

DATE

3/22 Neurology:

no changes in [illegible] status,
ileus on KUB per GI.
intermittent facial myoclonic seizures
despite IV versed / neurontin / phenobarb
↑ LFTs.
unresponsive to all stimuli
pupils reactive to light
+ve occulocephalic reflex.
Facial both VE ill
Tox o/o
DTR o/o.
Twss 17-0 H/H 13.8/41.8 ↑ LFTs
Plat #09
Na 139 BUN/Cr 19/0.4 Gl. 177
off Zosyn Temp 99.7 Tmax 100.4
Hemodynamically stable

Impression: (1) Toxic Encephalopathy
(2) Intractable seizures
(3) ↑ LFTs
(4) Cerebral edema.
(5) ileus / Pancreatitis
(6) resp. failure.

Continue current management
PEG per GI

[redacted] [redacted] M.D.

signature

PROGRESS NOTES [redacted]

000163

M.D.

[redacted]

signature

[redacted]

DATE

3/22
2:30

Neurology:

Spoke to Mrs. [redacted] regarding [redacted] Current Neurological Status & Prognosis

Mrs. [redacted] requested a DNR
No CPR
No Heroic Measures
No Chemical Code
But Continued all Treatment & Supportive Care
will follow Mrs [redacted] recommendations

[redacted]

[redacted]

M.D.

PROGRESS NOTES

signature

000164

M.D.

[redacted]

signature

[redacted]

DATE

3/23/99

G.I.

(S) ⊕ makes chewing motions ⊂ mouth

(O) T100.2 148/70 P128 R 15

General: critically ill OD on vent

HEENT: Anicteric pupils midrange.

Throat: ∅ lip lesions

Throat: Tracheostomy

Lungs: Clean anteriorly

Heart: Tachycardic, Regular

Abd: BS ⊕ but hypoactive.

Distended, tympanetic.

∅ def ascites. ∅ spleen.

Ext: ∅ edema

Neuro: Unresponsive.

Labs:

TB 2.3 ↑ AΦ 1.73 ↓

AST 70 ↓ ALS 3.0

ALT 267 ↓ GGT 886 ↓

D Bili 1.7 ↑

138 | 105 | 16 | 158

4.5 | | 0.2

amylase 131 ↑ ⊕ Hgb 11.3 plt 617K

Lipase 125 ↓ WBC 16.0

[redacted]

M.D.

signature

PROGRESS NOTES

000165

M.D.

[redacted]

signature [redacted]

DATE

IMP

(1) Pancreatitis - amylase s/ ↑
Distended.. Keep NPO
(2) Ileus - prob 2° #1 ✓KUB ✓ TFT's again.
(3) Liver enzymes - Bili ↑, but
o/w overall enzymes ↓.
? ↑ Bili 2° TPN or infection?
· Resolving probable Depakote
hepatotoxicity as well.
(4) Nutrition - once ileus +
pancreatitis resolves,
will consider PEG
(5) Neuro - continues surgical needs

[redacted]

[redacted]

M.D.

signature

PROGRESS NOTES

[redacted]

M.D.

signature [redacted]

[redacted]

DATE

3/23/99 ENT POD 4.

545 p. Status Quo.

Afebrile. VSS. (Tm 101.6 @ 0500)

Ventilating adequately via trach

O_2 sats 99%.

Trach Δ'd uneventfully - Track well formed.

Moderate amount thick yellowish mucus suctioned from tracheal lumen.

A) Resp. failure 2° to toxic encephalopathy

S/P Tracheotomy.

P) Routine trach care. Please call if any questions or problems c̄ trach.

Thanks [redacted]

3/23/99 Neurology Ecoring for [redacted] VS T100 140/70 15

no definite seizures noted P-98

redness @ arm, not hard, not fluctuating

very mild, no EVs in @ arm

tone slightly ↑ all exact

Taurine suggestions noted, will consider

Exp Seizure Thursday 1st to ingestion of Mahwang, Ripped fast

Redness @ arm possibly just from pressure in sev

Lic- cont present ix

[redacted]

[redacted]

M.D.

signature

M.D.

signa[redacted]

PROGRESS NOTES

[redacted]

000167

DATE

3 23 99 | 10 [illegible] | RC 3

Pt c̄ facial twitching

Tmlol

mouth ⊖

lungs - clear mt

Abd soft ⊖ [illegible]

Cat ⊖

A: ① fever - ? central infection

② smoker - [illegible]

③ intractable [illegible] -

④ [illegible] -

⑤ DVT

Rec Continue to watch for new nosocomial infection

[redacted]

[redacted]

M.D.

PROGRESS NOTES

signature 000168

[redacted]

[redacted]

signature [redacted]

[redacted]

DATE

3-23-95 Pub fl

S O

O T 99 BP 130/80 Vol 14 P 120

I 2016 O 15-5

Mouth Tonsils

Uvula clear

C Tory Mr

And Distinction RS ⊕

Cat no edema

C.R. clear

Uvulae 13.

Vo 160 Ip. 113 Ict 35-5 Plat 617 ...

Ab pl. 131 pcc 32

pH 7.46

138/103 Vol 16

4.5/25 p 138

L Intermittent Seizures

Pregnant Faulk

DNR stats

P Same Vent agreement

→ Fuller ⊥ pt info.

[redacted]

[redacted] M.D.

signature

PROGRESS NOTES

000169

[redacted] M.D.

signature

[redacted]

DATE

7/23/99	Pharmacotherapy
0915	Neurontin 400mg NG q2hrs — Midazolam 8mg 1hr
Lovenox	Phenobarbital 180mg NG q8hrs
Colace	Nimodipine 60mg NG q4hrs
Synthroid	I/O 2016/1525, Tmax = 101.6, TC = 100.1
Decadron	BP = 147/82, HR = 130, RR = 14/6. — 138/103 (16) / 4.5 23 (0.2) 158
VitK qAM	
Lanoxine	(A/P) This 26 y.o. O→ was admitted c intractable seizures thought to be secondary to Ripped Fuel® by Twin Labs. Possible concurrent agents include GHB, and an anabolic steroid.
TPN	

AST = 70 (yest = 117)
ALT = 267 (413)
Alk Ø = 173 (226)
Alb = 3.0 (3.2)
γGT = 886 (1254)
Amy = 131 (76)
Lip = 125 (155)
Phar = (39.7)

Has received a variety of anticonvulsant meds: Carbamazepine, phenytoin, Valproic acid, ~~and~~ diprivan, & pentobarbital coma. Currently on meds as above. Nimodipine for vasospasm. No current phenobarbital level. Both LFT's & pancreas enzymes (amylase & lipase) have elevated. Hepatology following to evaluate & monitor organ functions. Currently patient is tracked & exhibiting some jaw movements.

Receiving TPN at lower than goal rate due to ↑ LFT's & amylase/lipase. Will convert to enteral feeds as soon as gut starts to function (being determined by GI service) lipids weekly. Thankyou, will follow [redacted]

[redacted]

M.D.

PROGRESS NOTES

signature

000170

M.D.

[redacted]

signature [redacted]

DATE

3/24 Phlmorum

NO D MS

140/80 130 99.4° Ho 2158/10

Lung - rough

CO - NO3

ABD - [illegible]

PM - essentially clear

[illegible] 6/900/406/55/[illegible]

WBC 14.2 → 97/39/7.40

H/H 11.4/35.3 [illegible] 544

(1) [illegible]
(2) Resp [illegible]
(3) [illegible]
(4) [illegible]

(1) [illegible]
(2) [illegible]
(3) [illegible]
(4) [illegible]

[redacted]

[redacted]

M.D.

PROGRESS NOTES

signature

000171

[redacted]

[redacted]

M.D.

signature

[redacted]

DATE

GI

3/24/99 (S) unresponsive

(O) 100.8 140/70 P134

HEENT: Anicteric

Lungs: Harsh expiration

Heart tachycardia

Abd: Distended, tympanitic,

BS (+) but hypoactive.

Ext: Edema

Neuro: Actively seizing

Data: BUN 13 creat 0.2

amylase 71 ↓ lipase 91 ↓

Hgb 11.4 WBC 14.2 plt 544

1 mg KUB: distended small + lg bowel loops

Feeding tube coiled in stomach

(1) Ileus - Keep to NG suction.

? 2° air from vent plus pancreatitis

Repeat KUB in a.m. ? overnight decompression

(2) Pancreatitis - Biochemically improved

(3) TCFTS - see ✓ tomorrow. ? worse 2° TPN?

(4) Nutrition - once ileus resolves, will

need to replace dobhoff into

duodenum before use.

[redacted]

M.D.

signature [redacted]

PROGRESS NOTES

[redacted]

000172 [redacted]

signature

[redacted]

DATE

3/24/99 Neurology

Remains comatose

Partial seizure @ face still recur occasionally

flaccid all 4 ext

(+) corneal

(+) pupil reaction except during seizure

T100 NH3 79 ul in spite of LFT: ↑↑

Top - Partial Seizure

Secure diffuse encephalopathy

2° strain

Remains extremely ē faring

prognosis bleak for meaningful recovery

agree ē DNR

Consider PEG when abdomen problem quiet

[redacted]

[redacted]

000173 M.D.

signature [redacted]

M.D.

signature [redacted]

PROGRESS NOTES

[redacted]

DATE

3 24-99 | 1D Ø Abx TC 4

Pt c̄ mouth movements

Tm 100° (R)

mouth ⊖

lungs clear unit

Abb distended, ⊕ Bs

Ext ⊖

A: (1) low grade temp - central / recurrent

vs other

(2) smoothly - s/p Abx

(3) intractable recurrent - 2° toxin

(4) ↑ UFTs

(5) DVT

(6) leukocytosis - steroids or other

Rec - Resolve c̄ next temp >101

[redacted]

[redacted]

M.D.

signature

PROGRESS NOTES

000174

M.D.

signature

[redacted]

[redacted]

DATE

3/25/99 pharmacotherapy

Nitrotin 400n NG @ 2hrs

Phenobarbital 180n IV 28°

Nimodipene 60n NG 24°

99 120/70 22 T/O = 2.35 / 2.010

A/P: This is a 26 y/o WM was admitted c intractable seizures thought to be 2° to Ripped fuel & other possible agent which include GHB, anabolic steroids

Pt currently on nimodipene for vasospasm

Both LFTS + pancreas enzymes have elevated

Nutrition: Pt on TPN at lower therapeutic rate due to ↑LFTS + Amylase / lipase.

Lipids weekly. Will F/U

[redacted]

[redacted]

M.D.

PROGRESS NOTES

signature

000175

M.D.

[redacted]

signature [redacted]

DATE

3/25/99 Length of Stay REVIEW
LOS: 28 days. Neurologically unimproved.
Chronic ventilatory dependence.
Please consider transfer to chronic
ventilator care facility

[redacted]

3/25 Pulmonary
NO DMS.
115/70 115 99° (on 101.8°) Alo 2354/2010
Lungs - [illegible]
CV - RRR [illegible] 8/900/50%/75/PSD
[illegible] - [illegible] 154/39/7.40
140/102 111 WBC 12.6 [illegible] 458
4.0/27 11/0.1 [illegible] 11.4/34.0

(1) [illegible] / [illegible]
(2) [illegible]
(3) [illegible]
(4) [illegible]
(5) [illegible]

(1) [illegible]
(2) [illegible]
(3) [illegible]
(4) [illegible]
(5) [illegible]

[redacted]

PROGRESS NOTES

[redacted]

DATE

3/25/99 ID ØAb TLC#5

Tmax 101.8 | 140 | 102 | 111

(S) Hang seizures - Family | 4.0 | 27 | 11/0.1

Decadron visity | ag 80

PE mouth (+) secretion | lip 94

chest fewer bronchi | AST 142

CV (+) | ALT 314

abd distended, tympanitic | TB 2.9

bs (+) hyp | alb 3.1

extr (-) | 12.6 11.4 / 34 < 458K

(I) (1) Fever - a little higher

- ? source infection vs central vs other (DVT etc)

(2) Sinusitis p course of Ab

(3) Resp tendence / Vent / trach

(4) Status / Intractable seizures / TOXINS

(5) ILFT -

(6) TPN

(7) DVT

Pl (1) Cultures / CXR / vc diff

Will hold off on Ab - but

low threshold to Rx

Discussed c̄ Family - all questions

answered

Poor prognosis

[redacted]

[redacted]

M.D.

signature

PROGRESS NOTES

000177

M.D.

signature

[redacted]

DATE [redacted]

3/25 Neurology:

above is noted

(-) GTCS

intermittent Bilat-faced myoclonic seizures

Comatosed

unresponsive to all stimuli

flaccid UE. LE -

(-) withdrawn to pain

- on versed drip 12mg/hr.

- phenobarb 180 9 80

- Neuroantim Yoomy 9 20

Labs: ↓ WBC 12.6.

H/H 11.4/34.0

Plat 458

↑ LFTs T. Bile 2.9

PH 7.5 HCO2 28

Na 140 K 4.0

BUN/ 11/ 0.1

Diagnosis: Neurologically unchanged

- Refractory seizures

- Resp. failure

- ↑ LFTs, ileum / DVT

[redacted]

→ over

M.D.

signature

PROGRESS NOTES

000178

M.D.

signature [redacted]

[redacted]

DATE

Bilat Carbon dysfunction
2° to toxic Encephalopathy
Supportive Care
PEG is pending for improvement
of ileus discussed c̄ Dr.
[redacted]
wise — sw. for ? [redacted] transfer
[redacted]

[redacted]

M.D.

signature

PROGRESS NOTES

000179

M.D.

signature

[redacted]

DATE

3/25/99 (Hep) TCC #5

0900 pm S: Pt having seizures. Being recultured by ID

Q 8M. Ng ~ 200 total out. Appears less distended

V: 101.8°F-100.2°F-(4 5)75-125-19

2354 / 768 / 768
2070 / 920 / 75

Ng = 150 tonk

Gen: Having seizure. Ghd: Distended, occ BS, NR.

Eyes: Ictaic & Nonmellic (somewhat better but still distended)

Ex: Neg tacky Ext Qedem

Lungs: occ Rhonchi.

Labs. 140/102/11 / 4.0/27/111 < 0.1 Amylase = 80 ↑ TB = 2.9 ↑ 126 / 114 / 95 -11.4

Lipase = 94 ↑ AQ = 188 ↑

AST = 142 ↑ Alk = 3.1

ALT = 314 ↑ 997 = 817 ↓

3/23 - Ileus

A: 1) Ileus - ? Pancreatitis - vs med - pt: infection -

Pt ⊖ Ng in place. Somewhat better but still

distended. F/U KUB. Hold on Peg till resolved

2) Pancreatitis - ↓ Amylase/Lipase. F/U trend. ? cause

3) Seizure - w/ vs on ID. Recultured.

4) Abn LFTs - ? TPN vs infection vs meds.

F/U for [redacted] unfortunately, unable to go off

TPN until ileus resolved

5) Nutrition - via TPN

6) Seizures refractory - Tocs per Pn [redacted]

[redacted] Plan: 1) F/U KUB

2) Pegonia ileus resolved.

3) F/U LFTs

[redacted] M.D.

signature

PROGRESS NOTES

[redacted]

000180 M.D.

signature

[redacted]

DATE

3/24/99 Pharmacotherapy
1040 Neurontin 400mg NG Q2°
Phenobarbital 180mg IV 28°
Nimodipine 60mg NG Q4°

AST/ALT 113/311 GGT 763 Phenobarbital = 42.5
Alk Phos = 193 Amy 71
Alb = 29 Lip 87

Review of new culture
3/25 urine >100,000 E coli

A/P: This is a 26 y/o wm was admitted
c̄ intractable seizures thought to be 2° to ripped
fuel & other possible agents
Pt currently on nimodipine for vasospasm, phenobarbital
for seizures. Current level obtained today 42.5.
therapy TPN - Pt on TPN at lower than goal rate
due to ↑ LFT'S, Amylase / Lipase. Lip lds weekly.
ID: ID following ⊕ urine >100,000 E coli ē .10 ABX
will FU

[redacted]

[redacted]

M.D.

PROGRESS NOTES

signature

000181

[redacted]

signature

[redacted]

DATE

3/26/99 SOD

1120 D: Consult rec'd.

Met c̄ wife

A: Mrs. [redacted] wants to discuss Rx plan, prognosis, care needs c̄ Dr. [redacted]

P: Will meet again c̄ Mrs. [redacted] on Monday.

Possible transfer to [redacted] in near future @ mol's discretion [redacted]

3/26/99 JD ØABX TL6 UC-E.coli

+S2 activity Sp-rare Farmers

T101° VS stable CX2-no infil.

Conj clear Teach c̄ scant secretions

Heart: Tachy @ 140 Lungs: Coarse breath sounds

Abd: distended, soft, +BS

A) 1) UTI

2) Fever - UTI, Ileus, central

3) P̄ sinusitis - 21d IVABX

4) Resp Failure / Vent

5) Seizures / Status

6) DVT P) Start Cepio for UTI

7) ↑LFT's

8) TPN / Ileus

[redacted]

[redacted]

M.D.

signature

PROGRESS NOTES

000182

[redacted]

M.D.

signature

[redacted]

DATE

GI

3/26/99 (S) unresponsive

(O) 100.8 P138 151/72 R26

HEENT: Anisotropic

Neuro: (+) facial twitching

Heart: tachy

Abd: BS hypoactive, ~~NT~~ soft

Labs: amylase 71

lipase 87

TB2.3 AST113 ALT311 Alk193 GGT763

IMP (1) Ann LFT's - ? exacerbated by TPN? consider Actigall

pre-NG

(2) Chemical pancreatitis - resolved

(3) Ileus - persists - DSI worse on today's exam. consider prophylaxis if OK = neuro + pharmacotherapy

(4) Nutrition - No PEG tube until ileus resolved [redacted]

[redacted]

000183

M.D.

PROGRESS NOTES

signature [redacted]

M.D.

signature

[redacted]

DATE

3/26 Neurology:

intermittent facial myoclonic

(-) Cocks. Seizures. despite versed rx

Phenobarb. / Neurontin.

Unresponsive to all stimuli.

Pupils are equally

Flaccid UE-LE

DTR 0/0

Tone +

Cabs

Na/K 140/4.1 UBC 12.6

BUN/Cr. 11/0.1 H/H 11.4/34.0

Plat 458

Phenobarb (42.5)

↑ LFTs

Diagnosis: (1) Toxic Encephalopathy

(2) Myoclonic intermittent

Seizures focal facial

(3) Resp. Disturb

(4) ↑ LFTs

(5) DNR.

May DIL versed drip today

Sw. Consult is appreciated [redacted]

Continue Amt Margaret [redacted]

[redacted]

M.D.

PROGRESS NOTES

signature

000184

[redacted]

M.D.

signature

[redacted]

DATE	
3-26-99	[redacted] / [redacted]
	Occasional L sided facial grimacing.
	T°101 RR20 136/88
	I=2304 O=2295 Spo2 100%
	Chest Clr
	No m/g
	Abd soft
	Edema
	Chest-Clr
	AST 113 ALT 311 Bili 2.3 Alb 2.9 Alk Phos 193
	11.4 | 12,600
	458,000
	PO2 174 PCO2 36 pH 7.5 (.5 4/min 900 +5/+10)
	A- Status epilepticus
	Ventricular Dysrhythmia
	Fever
	Anemia
	Abn LFTs, ↓Alb
	P- D/C Chest-Clr, ABGs
	↓ IMV
	Once off Versed drip (per Neuro) will wean to
	trach mask. [redacted]

[redacted]

M.D.

signature

PROGRESS NOTES

[redacted]

000185

M.D.

signature [redacted]

[redacted]

DATE

3/27/99 FM TLC 7 Cipro 1

1345 Wrespond urine - Echi pan ⊕

T — 102 → 100 — 130 / 50 SCOT 55

135 Secretion thin / yellow SCAT 290

[redacted] TLC ol CCT 841

Fred ⊕ and ulcers seen 3/25 BL

Sy fever abnormal Cry cdiff ⊖

And ⊕ fever / liquids too /

A 1) Fever - urine vs other

↳ same ↓

2) Abnormal LFT

3) $\bar{p}$ 21 d Abx for sinuses

4) Resp failure / vent

5) DVT

6) Seizures

7) nutrition

n 1) Cont Cipro [redacted]

2) f/c final cx

[redacted]

M.D.

PROGRESS NOTES

signature 000186 [redacted]

[redacted]

signature [redacted]

DATE

3-27-99 Pharmacotherapy

Neurontin 400mg NG @2°

Phenobarbital 180mg IV @8°

Nimotop 60mg NG @4°

Cipro 400mg IV @12° (day 2)

~~Grabs~~ 100 140/80 120 17

Review of new cultures

3/25 ⊖ C. diff

3/25 blood (R) NG

3/25 Distal port - NG

3/25 sputum many WBC, few gram (+) cocci in pairs

rare gram (+) bacilli, rare gram (-) bacilli

3/25 sputum LGSA

RG multiple gram (-) organisms

A/P: 26 y/o wm admitted c̄ intractable seizures thought to be 2° to ruptured fuel & other possible agents

1. UTI - on Cipro IV
2. Respiratory failure
3. Seizures - on Phenobarbital & neurontin
4. Vasospasm - Nimotop
5. Nutrition - on TPN ⊖ peg tube until ileus resolved TPN at lower than goal rate due to ↑LFT's. Lipids weekly. Wed [redacted]
6. DVT prophylaxis - on Lovenox
7. Stress ulcer - on Pepcid

[redacted] M.D.

signature

PROGRESS NOTES

[redacted]

000187

signature

[redacted]

DATE

3-27-99 [redacted]

Opens eyes briefly when name called. Did not answer questions

I= 2222 O= 3270

T°102 RR 20 148/82

Chest clear

No m/g

Abd distended. BS hypoactive

Trace edema

AST 88 ALT 290 Bili 2.6

Alb 3.2

A. Status epilepticus

Ventilator Dependence

Abn LFTs, ↓ Alb

Fever

Anemia, Ileus

P- Wean

NG to suction. [redacted]

[redacted]

M.D.

PROGRESS NOTES

signature

000188

[redacted]

M.D.

signature [redacted]

DATE

3/27 Neurology:
off sedation, off-versed
unresponsive to all stimuli.
occ. Grimace to suction
Pupils reactive to light.
intermittent facial dysclonic jerks
↑ stimulating
(−) Coic seizures
Flaccid U.E. LE.
Dis o/o Tos o/o
Hemodynamically stable Tmax 102

Impression: (1) Bilat. Cerebral dysfunction
2° to toxic Enceph.
(2) refractory seizures
(3) ileus
(4) resp. failure
(5) ↑ ↑ LFTs.
(6) fever (7) DNR
Continue Phenobarb / Neurontin.
Continue supportive care
fever w/o Gen ID.

[redacted]

[redacted]

M.D.

PROGRESS NOTES

signature 000189

[redacted]

M.D.

signature [redacted]

DATE

3/25/99 Pharmacotherapy

Neurontin 400mg NG 22°

Phenobarbital 180mg IV 28°

Nimotop 60mg NG 24°

Cipro 400mg IV 212° (day 3)

Labs 100 7 130/75 15

new

A/P 26 y/o WM admitted c intractable seizures

1. UTI (+) E. coli on Cipro (ID following)
2. Resp failure
3. Seizures on Phenobarbital / Neurontin
4. Vasospasm - Nimotop
5. Nutrition - on TPN - PEG tub unrelated ileus resolved. TPN at lower than good rate due to ↑LFT'S. Lipids weekly. Will give lipids today.
6. Stress Ulcer on Repod
7. DVT - on Lovenox / SCD

Will F/U

[redacted]

[redacted]

M.D.

signature

PROGRESS NOTES

000190

M.D.

signature

[redacted]

DATE

3/28 Neurology:

No new neurological events
minimal response to painful stimuli
intermittent facial myoclonic seizures.
⊖ GTCs.
Low grade temp.
Hemodynamically stable.
Quadruplegia c̄ ↑ tone.
diffuse muscle atrophy
distended abd.

Impression:

Neurologically unchanged
will add Klonopin 0.5 mg tid
& increase as needed
Continue phobarb / Neurontin
Transfer to step down when bed
available

[redacted]

[redacted]

[redacted] M.D.

PROGRESS NOTES

[redacted] M.D.

[redacted]

000191

DATE

3-28-99 [redacted]

Opens eyes when name called.

I=2420 O=3515 T°100 7 130/75 RR15

Chest - harsh exp sounds

NoS3

Abd mildly distended, nontender

Noedema

A - Status Epileptici

Ventricular Dysfunction

Ileus

Fever

Anemia, Abn LFTs, & Alb

P - Trachmast.

VLabs

KUB pending. [redacted]

[redacted]

000192

M.D.

signature

[redacted]

M.D.

signature

PROGRESS NOTES

[redacted]

DATE

GI

3/28/99 (S) still unresponsive

(O) T 100 120/56 P132 50cc stool

HEENT: Anicterse

Lungs: rhonchi

Heart: Rg

Abd: BS (+) but very hypocentric but still distended.

Labs: Pancreatic / LFT's NA

IMP

- Ileus - ✓ KUB tomorrow
- ✓ LFT's / pancreatic enzymes tomorrow
- No PEG until ileus resolved.

[redacted]

3/29/99 Pharmacotherapy (7A2)

1100 Phenobarbital 180mg NG q 8hrs

Lovenox Nimodipine 60mg NG q 4hrs (vasospasm)

Colace Klonazepam 0.5mg TID

Cipro Neurontin 400mg NG q 4hrs → NOT ON [redacted]!

Cisapride

Dexamethasone

Synthetic

[redacted]

[redacted] M.D.

signa[redacted]

M.D.

signa[redacted]

PROGRESS NOTES

[redacted]

0193

DATE

/29/99 (Hep/GI) Cipro³ / vanco

08:56 PM S: Pt moving more. Family updated on ileus, its slow resolution preventing Peg. Vanco restarted.

O: 101.6 F. 148/65-90-20 → 153 now 131/73

2380 / 750 / 1860 / 900 NG 200/shift CO: NG tacking

Gen: Not following commands. Lungs: Quiltings

Eyes: mini ictericia. Nonmellitus. Abd: Hypoactive BS, NR, Mod distended.

Neck: Masses. Extremities: Neuro occasions moves more

Labs: 9.6 > 11.6 < 449 135/97/8 / 4.1/24/114 < 0.3 AST = 104 ↑ ALT = 269 ↑ Amylase = 80 ↑ Alt = 269 ↓ Alb = 3.0 Lipase = 144 ↑ Tr = 2.1 ↓ Mg = ?

PT = 13

A: 1) Ileus - await resolution of ileus to do Peg. Pt family aware of this.

2) Pancreatitis - #'s ↑ - F/U trend.

3) Nutrition - via TPN. Await ileus resolution

4) Abn CFTs - TR ↓. F/U trend

- Infection vs meds vs TPN - F/U (x few days).

5) Seizure Tx as per Pn [redacted].

6) Dep - on Tx as per Pn [redacted]

Plan: 1) F/U for ileus resolution

[redacted]

[redacted]

M.D.

signature

PROGRESS NOTES

[redacted]

M.D.

signature [redacted]

000194

[redacted]

DATE

3/29 Neurology:

Pt: desaturated on Trach mask
required to ventilatory support.
facial myoclonic seizures -
⊖ CGTC seizures
occ moments of UE, LE.
non-purposful movement
⊖ Eye contact
don't follow commands
but relatively more awake today.
flaccid UE, LE.
DTR 0/0
Tone ↓↓
No response No withdrawal to pain
Family at bed side wife / Father requested
reversal of DNR order.
Pt. is now full code.
Plan ↑ Klonopin to 1 mg 9 8°
Continue current rx
CBC, BMP in AM

[redacted]

[redacted]

M.D.

signature [redacted]

PROGRESS NOTES

[redacted]

M.D.

signatu[redacted]

000195

[redacted]

DATE

3/29/99 Sw

1315 D: Re-met c̄ family (wife + father) re: D/C planning
Sugar Friday.

A: (1) Pnt. much more alert, making eye contact,
responding to touch + voice.

(2) Pnt. needs DT + OT assessments + rehab.
consult

D: Await rehab. assessment for appropriate level
of rehab ([redacted] vs. Acute)

[redacted]

3/29/99 JD Cipro[3] TZ[4] 3/25 UC = 9 coli

Seizing actively, T↑ Ca 0.3

T 101.6° 132/68 - 160 9.6 / 11.6 < 449

Blood from mouth

Heart: Lacky 3/25 Sp. Saurus

Lung: CTA + rectal tube 3/27 UC - Ø

Abd: Soft c̄ BS

A) 1) Fever, ↑ today - line - lungs - urine - central, Sz's

2) Seizures / Status

3) Resp failure / trach P) ΔTZ

4) DVT 5) p̄ sinusitis BC's

6) ↑ lft's restart Vanco

[redacted]

[redacted] [redacted] M.D.

signature

PROGRESS NOTES

000196

[redacted]

signature

[redacted]

DATE

3-29-99	Mmmay
	Makes eye contact, then looks away. Grimacing /
	masticatory movements.
	I=2380 O=1860
	T°101² RR24
	Secretions profuse
	Chest c̄ rhachi
	Abdvoffer
	Techa
	BMP OK
	AST 104 Bili 2.1 Alb3
	A - Resp failure
	Atelectasis RLL/RML
	Status Epilepticus, Encephalopathy
	↓ Alb, Abn LFTs
	Fever
	Ileus
	Anemia
	P - Ballard
	Keep Cuff inflated
	Spuk C/S
	IPPB
	Chest tx pending

[redacted]

[redacted] M.D.

PROGRESS NOTES [redacted] signature

M.D.

[redacted] signature [redacted]

000197

[redacted]

DATE

3/29/99 Pharmacotherapy - continued.

	3/29	3/27
AST	164	88
ALT	265	290
GGT	892	763
Amy	80	75
Lip	144	114

No labs 3/28

This 26 yo ♂ is currently receiving Phenobarb & Neurontin for intractable seizures. Neurontin not transcribed on [redacted], New order written.

TPN written for today. Lipids ordered once weekly. Appears enzymes (amylase, lipase) jumped upwards 2° to lipid administration. Would like to administer lipids once weekly so that essential fatty acid requirements are met. GI note outlines that we are awaiting for resolution of ileus (on high-dose phenobarb).

Discussed (by [redacted] if cisapride could be started to modulate GI contractility. There have been isolated cases of cisapride-induced seizures; complex patients. Options include meto clopramide & erythromycin.

Synthroid for central hypothyroidism, I.D following re: VII

Thankyou, W. [illegible]

[redacted]

[redacted]

M.D.

signature [redacted]

[redacted].D.

signature

PROGRESS NOTES

[redacted]

000198

[redacted]

DATE

TLC #10 3/28 Sput G⊖ Rod

3/30/99 ID Vanco 1/Cipro 4. SA

Opens eyes Moves head 3/28 UC ⊖

Tm = 103.5 Tc = 100.7 other stable 3/29 BC (P)

(R) TLC Oropharyngeal Covered 12.4 > 11.5/33.7 < 462

COR Reg Lys Rhonchi BUN/cre = 13/.3

Abd distended but soft (+) BS Alb = 3.1

Impression Ext Boots

(1) Fever line/lung/urine/Central/SZ/Cdiff/Sinuse

LFT's Drug fever

(2) Seizure/Status/Encephalopathy

(3) Resp failure/Trach

(4) DVT (R) Arm

(5) ↑LFTs

(6) S/p 2nk Abx for Sinusitis

(7) S/p Pancreatitis

PLAN (1) ΔTLC & Cx tip

(2) Cont Abx & fu Cx

(3) Discussed c̄ wife [redacted]

[redacted]

[redacted] M.D.

signature

PROGRESS NOTES

[redacted]

[redacted] M.D.

signature

000199

[redacted]

DATE

3/30/99

[redacted]

FULL CONSULT IN CHART. IT IS NOT APPROPRIATE FOR THE [redacted] AT THIS TIME

WILL FOLLOW

[redacted]

3/30 [illegible]

MOVING EXTREMITIES.

[illegible]

[illegible]

[illegible]

[illegible]

136 | 102 < 133

4.1 | 27 13/0.3

[illegible] 8/1050/[illegible]/55/[illegible]

→ 223/37/7.48

[illegible] 12.4 [illegible] 11.5/33.7

[illegible] 4GL

(1) [illegible]

(2) [illegible]

(3) [illegible]

(4) [illegible]

(1) [illegible]

(2) [illegible]

(3) [illegible]

(4) [illegible]

[redacted]

[illegible] | [redacted] M.D.

PROGRESS NOTES

signature [redacted]

[redacted]

000200

[redacted]

DATE

3/30/99	Pharmacotherapy
1020	Phenobarb 150mg NG q 8hrs Phenobarb level + 34.4mg
Novenor	Nimodipine 60mg NG q 4hrs (Vasospasm)
Valace	Klonazepam 1mg NG TID → QID
Copro	Neurontin 400mg NG q 4hrs
Dexamethasone	Vancomycin 1g IV q 12hrs Was on 2g IV q 12hrs before
Synthroid	

AST	72	(yest-104)
ALT	208	(269)
Alk ø	257	(264)
Alb	3.1	(3.0)
tbili	2.5	(2.1)

(A/P) This 26 yo. o → ε reigures toxic encephalopathy, is currently receiving anticonvulsants for control of reigures. Therapy guided by use of agents tere likely to be hepatotoxic. Phenobarbital level down slightly from previously documented level, probably due to IV → NG route change and presence of ileus. Will s route of administration back to IV.; same ε dexamethasone.

TPN written; CHO 1305 kcal, FAT ø, protein 81.6g. Amylase/lipase elevated in response to the other day lipid administration, thus giving one weekly for essential fatty acid replenishment. Goal after resolution of ileus & hepatic/pancreatitic dysfunction would be ~2600 kcal. PEG-tube inserted

[redacted]

[redacted] M.D.

PROGRESS NOTES

[redacted]

signature [redacted] 000201 M.D.

signature [redacted]

DATE

3/30/99 Pharmacotherapy: continued

Vancomycin - previously on 2g IV q 12hrs.
Phenobarbital is a metabolic ~~[illegible]~~ inducer;
Vancomycin is partially hepatically metabolized,
also initially due to critical-illness volume of
distribution was elevated. Will increase
dose to minimize time below therapeutic (based upon clinic vs. [illegible]
desired serum concentration

Discussed c̄ Dr [redacted]

Phankyen [redacted]

[redacted]

[redacted]

M.D.

signature [redacted]

M.D.

signature [redacted]

PROGRESS NOTES

[redacted]

[redacted]

000202

DATE

3/30 Neurology:

No new neurological event

unresponsive to all stimuli

occ. spontaneous LE, UE movements

given Ativan PRN for facial

myoclonic seizure

Fever 102 Tachycardia 145/min. Bp 140/69

Pupils reactive to light

(-) facial Asymmetry

flaccid UE. LE

DTR 0/0

Tor 0/0.

(-) withdrawal to pain

Cats 136 / 102 / 13

4.1 / 27 / 0.3

WBC 12.4 Plat 462

phenobarb level pending

Diagnosis (1) Toxic Encephalopathy

(2) Myoclonic Seizure.

(3) ↑ LFTs

(4) fever. (5) ileus

Continue / phenobarb / Flonipor / Neurotin / Decadron.

for CT scan Brain!

[redacted]

[redacted] M.D.

signature [redacted] 000203

[redacted] M.D.

signature [redacted]

PROGRESS NOTES

[redacted]

DATE

3/30/99 (91 / Hy) Cipro 4 / Vanco 2

0700 S: Pt not having as much spont movement as last night
No BM.

O: 102.8F 100.7F 145/65 – 130 – 26.

970
430

Gen: Not following commands. Not having spontaneous movements like last night.

Eyes: Abnormal Vanallids

CV: Neg Ketchy
Lungs: Quiky,
Abd: distended, hypoactive BS,
NR.

Ext: Brisedens
Neuro: Following commands

Labs: 12.4 > 11.5 < 462 | 136 | 102 | 13 < 0.3 | 4.1 | 27 | 133

AST = 72 ↓ Alp = 257
ACT = 208 ↓ Alb = 3.1
TB = 2.5 ↑

223/37/348/100%
35%, N-8, TV-1050, P-5, PS-16

A: 1) Ileus – overall resolution to consider Peg tube.
on TPN.
2) Pancreatitis – F/U Trend @ few days.
3) Nutrition – via TPN.
4) Abn LFTs – TB ↑ today but AST / ACT ↓. ?
related to infection vs TPN vs multifactorial
F/U trend.
5) Seizures – Tx as per Dr [redacted]
6) Resp – weaning as per Dr [redacted].
Plan: F/U Ileus resolution to then place Peg

[redacted]

[redacted] M.D.

signature [redacted] 000204

[redacted] M.D.

signature

PROGRESS NOTES

[redacted]

[redacted]

[redacted]

DATE

3/31 Submarine Procedure Note

Tripple lumen cath. placed
(L) subclavian vein under
sterile tech. (R) subclavian
CVL → ~~[illegible]~~ is only 4 cm & [illegible]
appears [illegible]).
Tol. well / [illegible]
[illegible] / [illegible] (R) CVL → [illegible]

[redacted]

[redacted]

M.D.

signature

M.D.

signature [redacted]

PROGRESS NOTES

[redacted]

000205

[redacted]

DATE

3/31 Neurology:

. No neurological Δs
intermittent focal facial myoclonic
Xerosis
Low grade fever
moves both 2 > L UL spontaneously
not to command
(-) response to vertical or painful
stimuli.
. Pernl . roaming eye movements
CT scan brain is completely well
discussed c̄ father
plans for ? [redacted] placement
will discuss c̄ SW. for arrangement

[redacted]

[redacted]

[redacted]

[redacted] M.D.

signature

[redacted] M.D.

signature

PROGRESS NOTES

[redacted]

000206

[redacted]

DATE

3/31/99	JO Vanco[2] / Cipro[5]	2°
	+ facial grimacing	3/25 UC - E. coli
	Moved RUE spontaneously	3/28 Sp - Saurus (Rare) Aureus Sartor
	~~Afeke~~ T100°	
	Heart: Reg	3/29 BC - Ø
	Lungs: Coarse breath sounds	3/29 C diff Ø
	Abd: Soft, NT	
	A) 1) UTI	CXR: RLL tubes
	2) Fever - central / lens / lungs (+ infil) / meds	
	3) Seizures / Encephalopathy	
	4) RUE DVT	
	5) H/o sinusitis - treated	
	6) S/P pancreatitis	
	7) ↑ lft's	
	P) F/U cath tip cx - If BC & cath tip neg, D/C Vanco	
	[redacted]	

[redacted]

M.D.

signature

[redacted] M.D.

signature

PROGRESS NOTES

[redacted]

000207

[redacted]

DATE

3-31-99 CT NOTE - pt. CT Done [redacted]

3/31

[illegible]

NO DMS

120/75 100.4° 105

[illegible]

[illegible]

[illegible]

(1) Resp Rashes

(2) Intractable Sz. Dis

(3) Encyclopaedia

(4) Lever

(1) [illegible] / (1) [illegible] TLC - Np Cas

(2) [illegible]

(3) RT

(4) [redacted]

[redacted]

[redacted]

M.D.

signature

[redacted]

M.D.

signature

000208

[redacted]

PROGRESS NOTES

[redacted]

DATE

4-1-99 Mommy / [redacted]

Chewing motions / grimaces.

T° 99 8 RR 14 142/86

Chirt c̄ ↓ BS R-bau

NoS3

Abd soft, distended, Borborygmi

Noedma

BUN 16 Gluc 132

A - Status Epilepticus / Encephalopathy

Resp failure

Atelectasis

Fever

Ileus

Amia, ↓ Alb

P - Δ vent settings

Antibiotics

Nutritional Support c̄ TPN

[redacted]

[redacted]

[redacted]

M.D.

signature [redacted]

D.

signature

000209

[redacted]

PROGRESS NOTES

[redacted]

DATE

4/1/99 ID Vanco 3/Cipro 6 TL 1

Opens eyes, moving extremities

Tc 99.7° 3/25 UC-E coli

Heart: Leg 3/28 Sp- Saurus (rare)

Lung: CTA Acinetobacter

Abd: Soft, NT 3/29 BC - Ø

A) 1) UTI 138 | 103 | 16 | 132
2) Trachitis 3.7 | 29 | 0.3

3) Sz / Encephalopathy AST/ALT = 127/278 TB 2.6

4) RUE DVT γGT = 745

5) S/P pancreatitis Vanco < 3

6) Prin sinusitis

7) ↑ lfts 3/31 cath tip - in progress

P) D/C Vanco if cath tip Ø

Cont Cipro

4/1 Neurology: [redacted]

Above is noted

unresponsive to verbal stimuli

moves UL, LE spontaneously unpurposefully

⊖ GTCs

occ. focal myoclonic seizures. less in frequency

⊖ withdrawn to pain

Labs. Nor ice 16/0 ↑ LFTs [redacted]

Improving Angiogram, Lipase

[redacted]

M.D.

signature

PROGRESS NOTES

M.D.

signature [redacted]

[redacted]

000210

[redacted]

DATE

4/1/99 Dep Y 92 >

10:24 S: Pt having eye twitching now. [redacted]

O. 101.9F 99.7F 140/85 -120 - 26

2440/1910

1500/350 Na=250

Gen: having focal seizure Ent: ↓ edema

Mouth: ∅ lesions. Neuro: having focal seizure

CV: Reg tachy

Lungs: ∅ wheezes.

Abd: hypoactive BS, high pitched

tinkling. Distended

Labs: 138/103/16 3.7/29/132 <0.3 AST=127↑ AQ=227↑ ACT=270↑ Alb=3.0 TP=2.6↑ GGT=745 3/31 Amylase-91 Lipase-168

A: 1) Ileus - await resolution to place peg ? Phenobarb vs P.

2/ Pancreatitis - prob med related - appears resolved

3/ Nutrition on TPN

4/ ↑ LFTs - prob TPN vs infection vs meds

FIU trend Hopefully will be able to get off TPN

+ on TF

5) Seizure - To as per Neurology

6/ Resp as per Dr [redacted]

Plan: 1/ Await ileus resolution.

[redacted]

[redacted] M.D.

signature

M.D.

signature [redacted]

PROGRESS NOTES

[redacted]

000211

DATE

4/1/99	Pharmacotherapy
0950	Phenobarbital 180mg IV q 8hrs (last level 3/30)
Lovenox	Klonopin 1mg NG q 6hrs
Colace	Vancomycin 1.5g IV q 12hrs (pass D/C)
Decadron	Cipro 400mg IV q 12 hrs
Synthroid	Nimodipine 60mg NG q 4hrs
	Neurontin 400mg NG q 4hrs

AST 127 thru 2.6 (T) / 1.8 (C)
ALT 278
Alk Ø 227
Alb = 3.0
Bilt = 745

(A/P) Thus 26 y.o. → s/p ingestion of Ripped fuel is currently receiving multiple therapy for intractable seizures. Meds changed to I.V. route due to question of absorption; hx of ulcers (Ø movement so far)

Endocrinology following central hypothyroidism; may consider reevaluating thyroid hormones to evaluate response to synthroid.

Infectious diseases following patient. Pre-dose Vancomycin level 3.0 mg/L - if the Vancomycin is to be continued may consider increasing Vancomycin to 1750mg IV q 12hrs (on barbiturates - which increases hepatic clearance component).

Neurontin increased since last level of 3.0 mg/L based upon clinical evaluation.

[redacted]

[redacted] M.D.

signature

M.D.

signature [redacted]

PROGRESS NOTES

[redacted]

000212

[redacted]

DATE

4/1/99 Pharmacotherapy - continued.

TPN: 1305 kcal CHO, & 81.6g protein.

We have been keeping nutrient intake to a minimum to minimize further adverse effects of toxic encephalopathy. Also replacing essential fatty acids on a weekly basis due to possible drug-induced pancreatitis. There appeared to be an increase in army, lipase & some transaminases in response administration of lipids. Discussed c̄ hepatologist data regarding increasing carbohydrate & protein load to further meet nutritional requirements. Daily alterations could be due to repair, etc but feel that ΔTPN → enteral would provide the best chance for normalization of LFT's. Unfortunately elevs still present (poss barbiturate-induced). → requires barbiturates to control seizures. Will maintain current TPN. Thankyou, Will follow

→ frequency of LFT's assessment

[redacted]

[redacted]

[redacted] M.D.

PROGRESS NOTES

signature 000213

[redacted]

signature [redacted]

DATE

4/2 1640

Pulmonary

No purposeful response

TM 102.3 P125 R24 BP 152/88

Lungs - Rhonchi

CV - Reg

Abdomen - Soft

No leg edema

WBC 9600 Hgb 10.4

A: Encph / s/p Refractory seizures

Resp failure / Atelectasis

Fever

Immunized & Nutrition

Rec Cont Vent / Resp Rx

[redacted]

[redacted]

M.D.

PROGRESS NOTES

signature [redacted]

000214

M.D.

signature [redacted]

[redacted]

DATE

1/2/99	1D Vanco 4 / Cipro 7	TL 2
	Sleeping	
	Tm 102.3° Tc 100.3°	3/25 UC-Ecoli
	+ facial grimacing + NGT	3/28 Sp-rare Saurus
	Heart Reg + DHT	Acinetobacter
	Lungs: + rhonchi B/L	3/29 BC ∅
	Abd: Soft, NT	3/31 Cath tip - 9 col GNR, 9 CNS
	A) 1) Fever ↑ again	9.6 } 10.4 < 399
	2) UTI	
	3) Trachiitis	
	4) Sz / Encephalopathy	
	5) RUE DVT	
	6) S/P pancreatitis	
	7) Prior sinusitis	
	8) ↑ lft's	
	P) Δ to Cefipime. Monitor temps	

[redacted]

[redacted]

M.D.

signature

PROGRESS NOTES

000215

[redacted]

M.D.

signature

[redacted]

[redacted]

DATE

4/2/99	Pharmacotherapy
1300	Phenobarbital 180 mg IV q 8 hrs
Lovenox	Klonipin 1 mg NG q 6 hrs
Colace	Vancomycin 1.5 g IV q 12 hrs
Decadron	Ciprofloxacin 400 mg IV q 12 hrs
Cisapride	Nimodipine 60 mg NG q 4 hrs
Synthroid	Nexiontin 400 mg NG q 4 hrs
Motrin pr	
TPN & peptid	

No lytes
Amy = 79
Lipase = 176
Last phenobarb level 3/3, 1
Last Vanco pre-dose level 4/1 = 3.0

This Hexo 0 → is currently receiving anticonvulsants for intractable seizures thought to be secondary to Ripped Quad by Twin Labs → caffeine & ephedra & chromium picolinate. Received various anticonvulsants due to recalcitrant seizures. Possibly sustained drug-induced hepatic and pancreatic insult; Valproic acid, tegrabe vs others. < TPN / infection / etc

Receiving TPN for nutritional support - Goal would be to change nutrition to enteral route. This would potentially assist c̄ returning LFT's & possibly pancreatic enzymes to normal. TPN supplying 1305 kcal by CHO & [illegible] protein. Only receives essential fatty acid replacement [illegible]

[redacted]

[redacted]

[redacted]

PROGRESS NOTES

signature

M.D.

signature [redacted]

[redacted]

000216

[redacted]

[redacted]

DATE

4/2/94 Pharmacotherapy.

Unfortunately liver and pancreatic enzymes do rise in response to lipid administration. Roadblock to enteral administration of feeds is ileus; this may be also drug-induced (barbiturates). Historically, phenobarbital is efficacious and safer from a hepatic/pancreatic perspective.

Due to central hypothyroidism patient receiving synthroid. Probably ready to follow up c̄ T&H to monitor therapy.

I.D. service following for sinusitis, UTI & possible line related infection. Discussed previously if to continue Vancomycin 1750mg IV q12hrs would be appropriate.

Thankyou. Will follow

[redacted]

[redacted]

M.D.

signature

PROGRESS NOTES

000217

M.D.

signature

[redacted]

DATE

4/2 Neurology:

unresponsive to all stimuli
moves both UE. Lx spontaneously
not to commands
occ. facial myoclonic seizures.
Lens frequent
(-) GTC seizure.
febrile 102 Hemodynamically stable

CT scan Brain → white matter "diffuse disease"
(-) Hge (-) further edema (-) shift.

Diagnosis:
(1) Toxic Encephalopathy
(2) Seizure disorder
(3) respir failure
(4) fever
(5) ileus

Plan taper off Decadron.
Continue current Rx [redacted]
discussed in wife and [redacted]
medical status, she agreed to [redacted] transfer

[redacted]

[redacted] M.D.

signature

000218

M.D.

signature

[redacted]

PROGRESS NOTES

[redacted]

DATE

4/2/99 (9IS

07.46 S: Pt reported nonreactive last night

Ileos appears to be improving – less distended

a. 102.3F 145/80 – 120 – ØBM

Ng ~ 700 24° Ext d Arg edema

Head: OA gromach Neuro OCC gromach

CV: Neg tachy

Lung: Ø rhonchi

Abd: hypoactive BS, Less distended.

Low ~ 12g

Labs 9.6 > 10.9 < 399

A1) Ileus – awaiting resolution to consider peg or TF. ØBM yet

2) Pancreatitis – #'s improved at last check.

3) Seminoma – Tx as per Dr [redacted]

4) MLFT – ? TPN vs infection vs. meds

FIV response

Plan 1) ✓ for ileus resolution

[redacted]

[redacted]

M.D.

PROGRESS NOTES

signature [redacted]

000219

M.D.

[redacted]

signature [redacted]

DATE

4/3/99	JD Cefipime'	TL 3
	Getting a CXR now	
	Spiked last pm to 105.7°	3/28 UC - E. coli
	Te 102° 110/60-134	3/28 Sp-rare Saurus
	+ grimacing & biting movements	Acinetobacter
	Ø oral lesions	4/2 UA - Ø
	Heart lacky	
	Lungs: Coarse breath sounds	
	Abd: Soft, + BS, NT	
	Ext: Ø edema	
	A) 1) Fever - Infection - lungs	
	- sinuses	
	- abd	
	vs central, drugs; hepatitis, pancreatitis	
	2) Seizures, encephalopathy	
	3) UTI	
	4) RUE DVT	
	5) Peri sinusitis	
	6) Tift's	
	P) Recultured last night	
	Δ to Vanco + Meropenam	
	May need to scan sinuses again	
	Spoke c̄ family [redacted]	

[redacted]

M.D.

PROGRESS NOTES

signature [redacted] 000220

M.D.

[redacted]

signature [redacted]

DATE

4/3/99 1100AM

Pharmacotherapy

Cefepime #1 2 gm IVQ12

S/P vanco x 4 days + Cipro x 7 days

135	99	8	< 104
4.2	27	0.4	

Ca-8.4, PHOS-3.5, Mg-1.4

TPN + pepcid
Lomox
Colace
Decadron
Motrin PRN
~~Decadr~~
Lisopride
Sutrol

Last Phenobarb - 3/31

A/P 26 yo currently receiving anticonvulsants for intractable sgs thought to be secondary to ripped fuel by Thin Labs → caffeine + ephedra + chromium picolinate. Received various anticonvulsants due to recalcitrant sgs. Possibly sustained drug-induced hepatic + pancreatic insult due to valproic acid, tegretol vs < TPN, infen, other

Pt. receiving TPN for nutritional support c̄ goal to change to enteral route in hope that LFTs + pancreatic enzymes return to normal. TPN supplying 1305 Kcal by CHO + 81.6 g protein, receives essential fatty acids once per/week (Saturday)

At this time, roadblock to enteral feeds is ileus; also possibly drug-induced (barbituates); historically Pb is efficacious + safer from a hepatic/pancreatic perspective.

Pt. receiving septroid for central hypothyroidism

In service following for sinusitis + UTI ~~+ [illegible]~~ ~~[illegible]~~ + tracheitis

[redacted]

[redacted] M.D.

signature

PROGRESS NOTES

[redacted]

[redacted] 000221 M.D.

signature

[redacted]

DATE

4/3 [illegible]

NO D MS.

117/60 145 102° (in 105.7°)

Lung - Clear

[illegible] - [illegible]

[illegible] - [illegible]

135 | 99 < 104

4.2 | 27 8/0.4.

Ap. (1) Fever

(2) Sp Respiratory Sz. Dis.

(3) Resp. Failure

(1) [illegible]

(2) [illegible]

(3) [illegible]

(4) [illegible]

(5) [illegible]

[redacted]

[redacted]

M.D.

signature [redacted]

000222

M.D.

signature [redacted]

PROGRESS NOTES

[redacted]

DATE

9/3/99 (Hep/9I) Vanco 5/CeF 1/Cipro 8

08:21 S: Pt does not commands.

Having BM. Ileus improving.

O: 105.7F - 102F - 115/55-145-27 BM x 2 yest/x 7 today

2420 | 910
3725 | 725

Na = 1500
Na - 300

Gen: Opens eyes.
Eyes: Dissociation Nonallids
Mouth Ø lesions. Nonalip.
Cur neg tachy
Lungs Ø wheeze

Abd: CTCUBS, less distended.
Liver nizer
Ext Ø sig edema
Neuro Ø following command.

Labs: 135 | 99 | 8 <0.4
4.2 | 27 | 164

Ca = 8.4
Mg = 1.6
Pry = 3.5

A: 1) Ileus resolved - Na clamping trial +
F/U KUB If stable, keep Na clamped
2) Pancreatic - Stable at this time.
3) Resp Cardiac - Tx as per Dr [redacted]
4) Nutrition - ✓ KUB. If Dobhoff in place,
Start TF. Need to ask ID re: fever,
aspt moving towards Peg placement - 105°F today.
5) ID - Tx as per Dr [redacted]
6) Seizure - as per Dr [redacted] 6) ↑ LFTs - ? infection
vs TPN vs med.
Plan: 1) ✓ FF
2) Na clamping as ileus better.

[redacted]

[redacted]

[redacted] M.D.

signature

PROGRESS NOTES

000223

[redacted] M.D.

signature

[redacted]

[redacted]

DATE

4/4/99 | 10 Vanco' / Meropenam' | TL 4

Mac alert.

TC 102.2° TM 103.4° | 3/25 UC-E Coli

Oral lesions | 3/28 Sp - rare Saurus

Tachy | Several erythematous patches on arms & scale | Acinetobacter

Coarse breath sounds

distended abd, + BS, soft | 4/3 VA 3-5 WBC

2+ bacteria

A) 1) fever - lungs, sinuses | 4/3 BC-pend

- urine, prostate

- central, DVT, meds

- fungal, abd (ileus)

- pancreatitis, hepatitis

2) ↑ Lft's, pancreatitis

3) Sinuses

P) Aqua ē LP

Re CT sinuses - If there is free fluid then would have ENT tap for cultures.

Latersone to rough red patches on arms

[redacted]

[redacted]

[redacted] M.D.

signature

PROGRESS NOTES

000224

[redacted]

signature [redacted]

DATE

4/4 Neurology:

(-) GTC seizure

Less facial myoclonic seizures

febrile 102² T max 103⁴ Tachycardia

Awake, alert

follows simple command inconsistently

moves both UE, LE spontaneously

↑ Tone Both UE

Impression:

1) Improving Toxic Encephalopathy

2) Seizure disorder

3) fever

4) ↑ LFTS

5) resp. failure

6) Sinusitis

7) DVT

Spoke c̄ Dr [redacted] will attempt weaning off vent if tolerable

- will fly GI recommendation

✓ ID plans for fever

lumbar puncture of CSX again

EEG c̄ Am

[redacted]

[redacted]

M.D.

signature [redacted]

000225

M.D.

signature

[redacted]

PROGRESS NOTES

[redacted]

DATE

4/4 [illegible]

[illegible]

[illegible]

[illegible]

[illegible]

[illegible]

1 [illegible]

2 [illegible]

3 [illegible]

1 ↓ [illegible]

2 [illegible]

3 [illegible]

[redacted]

[redacted]

M.D.

signature [redacted]

PROGRESS NOTES

[redacted]

000226

M.D.

signature [redacted]

[redacted]

DATE

4/4/99 Pharmacotherapy Vancomycin 1750mg Q12 #1 | Meropenem #1 1 gm IV Q8

1100AM Tm 103⁴ BP 130/80 HR-111 RR32 I/O 2220/2025

- no labs today

S/P Vanc x 4 days, restart Cefep x 1 day

TPN + pepcid
Klonopin
Lovenox
Colace
Phenobarb
Decadron
Propulsid
Nimotop
Neurotin
Synthroid
Motrin
Tylenol

A/P 26 yo currently receiving anticonvulsants for intractable seizures thought to be secondary to ripped fuel (by Twin Labs) → caffeine + ephedra + chromium picolinate. Has received various anticonvulsants due to recalcitrant sys. most likely sustained drug-induced hepatic + pancreatic insult due to valproic acid, tegretol vs. TPN, infection, other

Pt receiving TPN for nutritional support, goal to place PEG + Δ to enteral feeds in hope that LFTS + pancreatic enzymes will normalize. Question if ileus delaying initiation of PEG, TPN supplying 1305 Kcal CHO + 81.6 g protein; pt received fatty acids yesterday.

ID Service following for sinusitis, tracheitis + UTI, pt. febrile, abx changed yesterday, currently receiving Meropenem + Vancomycin empirically

[redacted]

[redacted]

M.D.

signature

M.D.

signature [redacted]

PROGRESS NOTES

[redacted]

000227

[redacted]

DATE

4/4/99 (91)

07:10 S: Spoke gest c his wife. Advised her we are hopeful that ileus will resolve so that peg could be placed. NG had to be started to suction for ↑ distension. More distended this AM than gest.

O: 105.4F-103.4F- 101F- 135/85-111-14.

500 Pr...

1050 NG=400 last shift.

750 BN-Scant.

Gen: Occ grimaces. occ open eyes

Eyes: mini cteric. Nonallich.

Mouth: Ø lesions. normal

Labs: pending. BSAbong. HepCAbong. BSAgong BcAbong

A11) Abn LFTs - ? TPN vs med vs other - order additional screening as trend ↑ recently. ✓ Q few days.

2) Ileus - more distended - ✓ KUB. FIUFT position. consider replacing under flouroton

3) Nutrition - Peg once ileus resolved. Need them to be off Motrin x 1 week to do also.

4) S/P pancreatitis

5) Fevers - 1 ox as per ID

6) Neuro as per Pn [redacted]

Plan: 1) ✓ KUB.

2) Monitor distension

3) Will need to hold Motrin x 1 week to do peg (pt meaning pt allow mass [illegible] to do [illegible] restart TF).

[redacted]

M.D.

signature

[redacted] M.D.

signature

000228 [redacted]

[redacted]

PROGRESS NOTES

[redacted]

DATE	
4/4/99	EEG done [redacted] EEG Tech

[redacted]

M.D.

PROGRESS NOTES

signature [redacted]

000229

M.D.

signature [redacted]

DATE

4/5/99 Neurology:

Moves arms, alert, collective
follows simple commands, communicating better
with (c) facial Myoclonic seizures
spiked 105° last night
ID Consult & Fen recommendations are noted
family at bed side
moves both UE. LE spontaneously

Impression:
- Improving Toxic Encephalopathy
- Seizure disorder
- ↑ LFTs
- Fever.
- DVT

will ↑ Klonopin to 1mg 9/4°
Continue Neurotic, [illegible] [redacted]

[redacted]

M.D.

signature [redacted]

PROGRESS NOTES

000230

M.D.

signature [redacted]

[redacted]

DATE

4/4/99 Physical Therapy.

Dr.'s orders to evaluate and treat were received. Pt was evaluated for specifics see P.T. section of chart. Pt could benefit from EZ Boot to prevent Plantarflexion Contractures Bilat. Please order at these EZ Boots. Thank you for your referral

[redacted]

4/5/99 (M1)

08.22 S: Nagest in Duodenum → repelled 4 inches. PKUB take down this AM. Need to hold motion for eventual peg (T d hana bleeding) and also need to FT position -

O: 103F 101.3F 135/60 -110-26 3510 | 440 / 3110 | 415

NG - 100 stool - 800/50 Abd: soft, (+) BI, → Dull hypoactive, NP

Gen: Asleep - did not awake Lungs ~ 12a

Eyes closed

Mouth ∅ lesions, hoarse lips Ext ↓ edema

Cutting teeth Neuro asleep

Lab. 133 | 101 | 8 / 3.6 | 30 | 151 <0.3 Mg-1.6 Po-2.9 Amylase-63

A: 1) Ileus - ↓ KUB. If ileus resolved, trial Tube feeds + then move to Peg once off NSAIDS x 2 weeks

2) Abn UFTs - F/U trend. ? TPN vs infection vs meds.

3) Sp. pancreatitis - Stable

4) Neuro as per 1° teor

5) Fever - ID eval

Plan 1) F/U KUB

[redacted]

000231

[redacted] M.D.

signature

[redacted] M.D.

signature

PROGRESS NOTES

[redacted]

DATE

4/5/99 9:30	Occupational Therapy eval complete. Please see Rehab section for details. Thank you for this referral. [redacted]
4/5/99	Pharmacotherapy
1010	Phenobarbital 150mg IV q 8hrs — level = 39.0 mg/L this AM
Levenox	Neuronton 400mg NG q 4hrs. — level ordered expect 4-6 day turnaround
TPN & Pepcid	Nimodipine 60mg NG q 4hrs
Cisquide	Klonipin 1mg NG q 4hrs
Synthroid	Dexamethasone 2mg IV q 8hrs
Meropenem	Unasyn 1750mg IV q 12hrs
Colace.	This 26 y.o. 0→ 2 intractable seizures, is currently exhibiting greater response to stimulation. Receiving anticonvulsants for clinical left facial "twitches". To have EEG this AM for further assessment of seizure status. TPN written this AM. Noticed little rise in amylase & lipase in response to Saturday's lipid "dose". Will give another "dose" of lipids today and follow-up amylase & lipase analysis tomorrow. Giving further lipids would allow us to come closer to nutritional goals. If there is evidence of tolerance to increased nutrition load then would like to advance intake to meet estimated goals; realizing patient has lost wt.

[redacted]

[redacted] [redacted] M.D.

signature [redacted] 000232

M.D.

signature

[redacted]

PROGRESS NOTES

[redacted]

DATE

4/5/99 Pharmacotherapy

In the interim, placement of feeding tube and bowel function being evaluated.

Infectious diseases following; Vancomycin dose increased and meropenem initiated.

Endocrinology initiated Synthroid would be of interest to reevaluate TSH to follow response to replacement for central hypothyroidism.

Gabapentin level ordered: expect 4-6 day turnaround.

Thankyou, Will follow [redacted]

P.S. Family had commented to me that they would be interested in obtaining copies of portions of chart regarding data supporting Ripped Fuel ingestion. Would suspect at this point in time metabolites of Maltaring, caffeine, ephedra would be out of the system. Potentially basis for chromium analysis would support prior ingestion of Ripped Fuel [redacted]

[redacted]

[redacted]

M.D.

signature

PROGRESS NOTES

000233

[redacted]

M.D.

signature

[redacted]

[redacted]

DATE

4/5/

L/P Procedure:

Indicating: fever ? origin.

1% Lidocaine 20 gage spinal needle is used

Signed informed consent

Pt. is placed in lt lat. position

Clear CSF is obtained

will send for Rotum CSF studies

Bact./viral/fungal

Pt. tolerated procedure well

will follow

[redacted]

[redacted]

[redacted]

M.D.

signature

[redacted]

M.D.

signat[redacted]

PROGRESS NOTES

[redacted]

000234

[redacted]

DATE

4/5 Neurology:
Lethargic, arousable.
opens eyes to stimulation
follows verbal response & visual
Tracking
(+) Facial myoclonic seizures.
moves both UE, LE spontaneously
NO to Commands.
(−) GTC seizures.
pupils reaction to light
+ve corneal
febrile T max CO_2 4
EEG - Completed will ✓

A/P: - Toxic Encephalopathy some improvement
in COC
- Seizure disorder
"myoclonic"
- resp failure
- fever
- DVT
- ↑ LFTs
will ✓ CSF. Continue Antibiotics (per ID)
- D/C Motrin. Continue phenobarbital / [illegible] / Klonopin

[redacted]

M.D.

signature [redacted]

M.D.

sig[redacted]

PROGRESS NOTES

[redacted]

000235

DATE

4/5 Pulmonary

S: No purposeful response

O: Tm 102.4

Lung - Course BS

No Ulcer

A. Encepa / S/P Refractory sequence

Resp failure / Atelectasis

Fever

Abn LFT / S/P Pancreatitis / Nonfasting Nutrition

Rec: Daytime PSV/CPAP with

Nighttime SIMV rate

[redacted]

4/5/99 Speech Pathology - order received. Eval completed. Pt. c̄ significantly impaired cognition / communication. Will continue to follow. Provide ST as pt's progress indicated [redacted]

[redacted]

M.D.

PROGRESS NOTES

signature [redacted]

M.D.

[redacted]

[redacted]

DATE

4-5-99 | ID vanco 2 / mero 2 | TC 5

Pt. more awake per family | 3-25 urine - E. coli

Tm 102 4 | 3-28 sputum - S. aureus

mouth ⊖ lesions | Amoeba

Facial twitching

lungs - clear

CV - reg

Abd soft ⊕ BS, NT / ND

Ext - ⊖ edema

pitting rash leg thigh ⊖

arm ⊕ arm

recent bld / urine CX ⊖

A - ⊖ fever - ? infection - line

lungs

sinus [redacted]

fungal

? central

? DVT / dvgs [redacted]

(2) ↑ LFTs -

(3) seizures

(4) pancreatitis

Rec - F/V CT sinuses

for LP -

[redacted]

[redacted]

M.D.

signature

[redacted]

M.D.

signa[redacted]

ERROR 4/5/99

PROGRESS NOTES

[redacted]

000237

DATE

9/8/99 (PT)
0630 S: Pt having BM: He pulled my + FT → Tube almost in place. Replaced now - Hopefully this will migrate over 24-48. Pt should be able to start TF as soon as this in place. Want it past C-loop area. More awake last night purposes

Ot 101.4F 100.9F 135/75 - 125-20

3100 | 970
1150 | 100 BM x2

Gen: ATOX3
Eyes: [illegible]
Cv: Neg Fwdy
Lung: Clinkers

Abd: (+) BS, Not distended
NR Lower [illegible]
Exit [illegible]
Neuro awake. Does not follow commands.

Labs 9.6 | 10.9 < 362 135 | 96 | 81 < 0.3 AST-57 ↑ TB-17 ↓
3.5 | 32 | 15 AST-126 ↓ AP-323 ↑
Cornylase-EST Lipase-126 ↑ 997-[illegible] ↑

A. 1) Flexs - appear resolving.
2) Nutrition - Once FT in position → Start TF
3) Ann LFTs - ? role new med in ↑ AP / 997 - Flu ✓ other serologies from earlier in week should start to return
4) Pancreatitis - Ø lipids via TPN.
5) Neuro as per Dr [redacted]
6) Fever as per ID

[redacted] Plan: 1) FIV [illegible]
2) ✓ serologies sent already.

[redacted] M.D.

signature

[redacted] M.D.

PROGRESS NOTES

[redacted]

000238

DATE

4/6 Pulmonary Addendum

Central line low-functional

↳ attempted (L) CVL under
sterile tech. not successful

↳ (1) ✓ PAR
(2) consult [illegible] / [illegible]
for [redacted]

[redacted]

9/6/99 (BI)
0700 PM KUM still c̄ SB/LB distension - FT moving. - 2nd point [illegible]
Hopefully can start TF soon. [redacted]

[redacted]

M.D.

PROGRESS NOTES

signature [redacted] 000239

M.D.

signature [redacted]

[redacted]

DATE

11/6 Neurology:

Lethargic, [illegible] response today

inappropriate spontaneous UE-LE movement

withdrawn minimally to pain.

(-) GTC seizure

febrile 102

CSF → WBC 0 T. Prot 22

RBC 5 Glucose 73

(-) ve G/S. (-) growth

Impression:

- Myoclonic seizures / Epilepsia Partialis Continua
- Toxic Encephalopathy
- Fever ? origin. ↑ LAB
- Intractable seizures
- Plan: D/C Nimodipine

Taper Decadron off

Pulm ID recommendation [redacted]

[redacted]

M.D.

signature

PROGRESS NOTES

[redacted]

M.D.

signature [redacted]

000240

[redacted]

DATE

4-6-99	ID vanco³/mero³	RC out
	Pt. less alert per wife	3 25 urine - [illegible]
	TM102 - After currently	E. coli
	mouth ⊖	3 28 sput - S. aureus
	lungs - clear ant	Aumetis
	Abd not ⊖ Brunt	3-31 cath - few
	patchy rash arms/legs	bacteria
	A ⊖ fever - ? infection - lungs / lime / other / fungal	
	? non-infectious - central	
	OUT	
	drugs	
	② seizures - intractable	
	③ Tefts -	
	④ pancreatitis	
	RCC - s doppler legs - (for fever source)	
	F/V CBC	
	D/C Abx non if no infectious	
	source found	
	F/V CXR	

[redacted]

[redacted]

[redacted] M.D.

signature

PROGRESS NOTES

[redacted]

[redacted] M.D.

signature [redacted]

000241

[redacted]

DATE

4/6/99 Occupational Therapy - pt may benefit from @ resting hand splints for positioning - Please sign order if agree. Thank you

[redacted]

[redacted] - Pt. seen & evaluated.

4/6/99. 26yo M c̄ encephalitis, ? refractory Sz, resolving ileus
c̄ recent temp to 102°F
On vent now.
- medically inappropriate for [redacted]

[redacted]

4/6/99 Pharmacotherapy Addendum.
1800 Called to see "rash". Discussed c̄ Dr. [redacted]
Small 10 x 5cm rash located bilaterally on lateral side of triceps. Entire body, including rash-area warm to touch. Blanches to touch, slightly raised, well demarkated edges. Will watch to see relationship to initiation of lamactil to rash as there are reports of serious rashes + anemia. 8 Bc = diff in Ad.
Thank you [redacted]

[redacted]

M.D.

signature [redacted]

M.D.

signature

PROGRESS NOTES

[redacted]

[redacted]

000242

DATE

4/6 Pulmonary

1340 Father relates that [redacted] is less

alert today

Tm 102

Lungs - Rhonchi bilaterally - increased

CV - Reg

Abdomen - Soft

No edema

A: Enceph / S/P Refractory seizures

Resp failure / Atelectasis

Fever

Abn LFT / S/P Pancreatitis / Impaired Nutrition

Rec: Vent / ✓ ABG

Resp X

✓ CXR

Spoke c̄ Father

[redacted]

[redacted]

M.D.

signatu[redacted]

M.D.

[redacted]

PROGRESS NOTES

[redacted]

000243

DATE

4/6/99 CT Notes

0930 [redacted] CT scan of Sinuses is complete

[redacted]

4/6/99 Pharmacotherapy

133 | 90 / 4.0 | 3.0 — 6 / 115 / 0.1

Amy = 133 (yest = 65)

Lipase = 175 (yest = 128)

Lipids administered SAT & MON. Appears lipids tolerated well on Saturday, but enzymes did increase slightly c̄ Monday's lipid dose. May consider twice weekly lipids given 3 days-4 days apart. Today will slightly increase CHO & AA load by increasing TPN rate. Hopefully an increased rate of fluid will also correct alkalosis. To check tolerability to increased CHO & AA will check LFT's tomorrow. Ileus resolving.

Lamaitil initiated yesterday will watch response in light of phenobarbital (increased hepatic metabolism).

Thanks on Will follow [redacted]

[redacted]

[redacted] M.D.

signature

PROGRESS NOTES

[redacted]

[redacted] M.D.

sig[redacted]

000244

[redacted]

DATE

4/6/99 (M2)
06:00

S: Pt c̄ some distension but better than yesterday. Tolerating occ Ng clamping. Stool ~ 25a overnight

O: 102.4 - 102.7F 175 - 121/78.

2230	920
2125	775

Gen: less [illegible] Lungs: [illegible]
Eyes: open, [illegible] Abd: less distension, (+)BS, [illegible]
Mouth: [illegible] NR
CV: Neg [illegible] Ext: [illegible]

Labs: 133 | 90 | 6 / 4.0 | 30 | 115 < 0.1 Amylase 1739 pg. 2-8
Lipase 175↑

A: 1) Ileus - resolving. Having BM, Ng off suction now. If KUB ok, will clamp Ng continuously. unable to locate Xray yest. will reduce AM Xray for Ng + FT position. Report of KUB yest given was of ↓ distension
2) Nutrition - Amylase/Lipase ↑ - would hold lipids. FT once able to be placed, will allow for feeds past area where pancreatitis could worsen.
3) Resp as per Pulmonary
4) Neuro - [illegible] per [illegible]

[redacted]

Plan: 1) ✓ KUB
2) Consider Ng clamping if stays better c̄ [illegible] to [illegible]

[redacted]

M.D.

PROGRESS NOTES

Signature [redacted]

[redacted]

M.D.

[redacted]

000245

[redacted]

DATE

4/7/99 (9 5)

07.7 S: Ng staging clamped majority of time as no Sig distension. Ng on mid stomach. FT progressing FIU xray. Rash noted - ID monitoring.

O: 102.7F-100.7F-99.2F 150/80-120-25

2200 / 3200 Stool = 125 yest.

Gen: Moore awake
Eyes: Mini [illegible]
Mouth: [illegible]
CV: Regularly.

Lungs: [illegible]
Abd: Softer, (+)BS - but still mildly hypoactive. N.R. [illegible]
Skin: Macular rash 1° Arms/chest

Labs. 10.1 > 10.1 < 34.2 LFTs. pending

A: 1) Ileus - [redacted] appears to be staging stable off Ng suction. Pt c̄ ↓ distension FT migration → advanced. ✓ FIU KUB. ? Start TF 7am or today if in place. Peg next week once off Motrix 1 week
2) LFTs ✓ today FIU serologies sent off - ? Role TPN, meds, infection.
3) Rash - w/ vasp ID
4) Resp - as per Dn [redacted]
5) Neuro as per Dn [redacted]
Plan: FIU KUB

[redacted]

[redacted]

M.D.

signature [redacted]

M.D.

signature

PROGRESS NOTES

[redacted]

000246

[redacted]

DATE

4/7/99	Pharmacotherapy
1120	Phenobarbital 180mg IV q 8hrs
Lotrisonal	Neurontin 400mg NG q 4hrs
Levaroc	Vancomycin 1750mg IV q 12hrs (day 4)
Colace	Lamictal 200mg NG BID
Cirquide	Klonopin 1mg NG QID
Nimodipine	133 / 94 / 3.5 / 33 < 131 / 0.2
Synthroid	AST=49 ALT=131 ALK V=221 γGT=562 ALB=27 Amy=63 Lip=105
TPN	
Mesopenem	This 26 y.o. → s/p exposure to "Ripped Fuel" is currently
Nizoral Cr	receiving anticonvulsants for intractable seizures.
	TPN written: Slowly increasing carbohydrate & amino acid load i goal to reach 2200 kcal. Patient appears to have lost significant amount of weight since admission. Unfortunately unable to meet estimated nutritional needs due to possibly anticonvulsant-induced liver & pancreatic dysfunction. [redacted] Providing lipids recently once a week due to elevated amylase & lipase values. We did see for a while a peak in amylase & lipase after each lipid administration. Now trying to provide lipids q3 days; monitor amylase & lipase and readminister daily if possible [redacted]

[redacted]

M.D.

PROGRESS NOTES

signature [redacted] 000247 M.D.

[redacted]

signature [redacted]

DATE

4/7/95 Pharmacotherapy - continued

1145 Investigated rash last night. Found rash to be located on same area; lateral triceps (bilaterally). Found rash to be directly under B.P. cuff. Seems to respond to antifungal cream [less red, less warm to touch]. Was originally concerned c̄ possibility of lamictal-induced rash.

Feeding tube pulled out this AM accidently. Will be replaced this AM. Once tube located past duodenum will Δ to tube feeds.

Thank you for all follow

[redacted]

[redacted]

M.D.

signature [redacted]

M.D.

signature

PROGRESS NOTES

[redacted]

000248

[redacted]

DATE

	Vanco 4/Meropenem 9	3/25 UC = Ecoli
	ID	3/28 Sput = SA Aciet
4/7/99	More awake today	
	Tm = 100.7 Tc = 99.2 HR = 120 BP: 135/55	3/31 Cath = Few Bacteria
TPN	Mouth ⊖ Trach ok	
D5	COK Tachy Abd soft ⊕ 5	4/5 CSF ⊖
	Lup: Coarse breath sounds	4/3 BC ⊖ 4/3 UC ⊖
	Impression	4/5 Amlos
	① Fevers Vinyl BC ⊖ UC ⊖ → Abnl UA	133 / 3.5 | 94 / 33 | 6 / .2 < 131
	② Leukocytosis	
	③ Ileus H/o Pancreatitis	Alb = 2.7
	④ SZ	
	⑤ Abnl UA	
	⑥ H/o Sinusitis	
	PLAN ① ✓ Dopplers LE	
	② Short Course Abx	
	③ CBC in Am [redacted]	

[redacted]

M.D.

signature

PROGRESS NOTES

[redacted]

[redacted] M.D.

signature

000249

[redacted]

DATE

4/7/99 1pm

EPILEPSY.

Pt known to me.

Refractory status epilepticus thought to be toxic in etiology.

Completely unresponsive when last seen by me 2 wks ago

Has improved since.

Reportedly responsive to light stimuli

Some daily episodes of facial twitching x minutes

EXAM

Arousable to voice.

Opens eyes

Does not follow commands

Placid tone

Occasional clonic seizures x 1 min on several occasions

AED: GBP 400 q4°
LTG 200 bid
PB 180 q8°

A/P Improved from Generalized status epilepticus to now partial status epilepticus — status should continue to slowly improve ... but main concern is how much cognitive/cortical recovery will occur.

Current state ~ PVS .. but improving

[redacted]

[redacted] M.D.

PROGRESS NOTES

signature [redacted] M.D.

[redacted]

signature

000250

[redacted]

DATE

4/7 Neurology:

focal myoclonic facial seizures are less frequent & less severe relatively

Temp → 100° hemodynamically stable

Awake, alert, follow simple commands inconsistently

apraxic

alexic

CSF (-ve) so far

moves both UE, LE

↑ tone Bilat legs > arms

withdraw to noxious stimuli

Na/K 133/4.5 BUN/Cr 6/0.2

LFT improving

A/P: Neurological stable

1) Epilepsia Partialis Continua

2) H/V stable

3) Toxic Encephalopathy

4) ↑ LFTs

5) DVT

Plan D/C Decadron

D/C Mimodopium

Continue AED

[redacted]

[redacted] M.D.

signature

PROGRESS NOTES

[redacted] M.D.

signature

[redacted]

000251

[redacted]

DATE

4-7-99 Pub fl

S O

O T 95 Bp 150/10 Pr 25

I 2200 O 2200

Chest [illegible], + BS

[illegible]

and Soft

Ct no edema

Bu 6

133/94

35/33 / 131

L Partial State Graphite

Repeat [illegible]

P Same [illegible] report

✓ [illegible]

→ Sub @ [illegible] [illegible]

[redacted]

4-8-99 (B) LE venous doppler computed

[redacted]

[redacted]

M.D.

signature [redacted]

PROGRESS NOTES

000252

M.D.

signature [redacted]

[redacted]

[redacted]

DATE

4/8/99 Pharmacotherapy - continued

Have increased nutritional intake by increasing TPN rate 70 → 80 → 90 mL/hr. Now we have attempted to give lipids more than once per week and increase CHO & FAT load. The last attempts to give further doses of lipids has been abandoned → did not receive lipids as ordered - yet still saw elevation in anyone lipase level. Also saw increase in NK4 & 8GT. Would try lipids twice per week and increase proteins & carbohydrates separately to see which is better tolerated. Δ to TF when FT placed appropr.

Vancomycin PCK's - empirically 2g IVq12hrs would probably provide trough serum concentrations ~10mg/L - have stayed ≈ 1750mg IVq12hrs due to Δ in volume status from 1 cc.

Initiated on synthroid for central hypothyroid [redacted] could be due for TSH +/- FT4 evaluations (~4 weeks past initiation).

Still awaiting neurontin level was 3 mg/L on 200mg NG q4hrs. Takes 4-6 working days to receive results. Thank you

[redacted]

[redacted]

M.D.

signature [redacted]

M.D.

signa[redacted]

PROGRESS NOTES

[redacted]

000253

[redacted]

DATE

4/8/99	Pharmacotherapy - TPN.
1201	Gabapentin 400 mg NG q 4 hrs
Lotrisone	↳ level pending - (usually 4-6 working day turnaround)
Lovenox	
Colace	Lamictal 200 mg NG BID
Cisapride	Phenobarbital 180 mg IV q 4 hrs
Nimodipine	Vancomycin 1750 mg IV q 12 hrs (day 6)
Synthroid	Klonipin 1 mg NG QID
Menpenem	

135 / 35 | 96 / 32 | 3 / 0.2 | 175

AST = 51 AlKO = 325
ALT = 126 Alb = 2.7
Amy = 33 γGT = 701
LIP = 126

This 26 y.o. → sip ingestion of Ripped Fuel and possibly history of anabolic steroid & GHB use. Adm UDS ⊖. Presented from outside hospital c intractable generalized seizures. Required multiple therapeutic modalities (phenytoin, pentobarbital coma, carbamazepine, valproic acid, diprivan) for control; now on the above meds.

Over time (have been monitoring since adm) generalized seizures have decreased to partial status epilepticus (⑤ facial & oral).

Therapies as listed above may have induced drug-induced hepatic dysfunction & pancreatic dysfunction. Nutrition has been difficult as; historically attempting to approach goal CHO, FAT & protein intake has resulted in further elevations of LFT's or amylase/lipase

[redacted]

[redacted] M.D.

signature

PROGRESS NOTES

[redacted]

[redacted] M.D.

signature

[redacted]

000254

DATE

4/8 [illegible]

[illegible]

120/75 130 100.0

[illegible]

[illegible]

[illegible]

WBC 9.4 plan 362 135/96/175

H/H 10.9/32.6 3.5/32 3/0.3

(1) Resp. Failure

(2) [illegible]

(3) [illegible]

(1) [illegible]

(2) [illegible]

(3) [illegible]

(4) OK to TX to [illegible]

[illegible] = [redacted]

[redacted]

[redacted]

M.D.

PROGRESS NOTES

signature

M.D.

[redacted]

[redacted]

000255

DATE

[redacted]

04/8/99 Pt. c̄ minimal response
- on Vent Support
- fevers to 105°F
- medically inappropriate for txfer to [redacted]

[redacted]

[redacted]

[redacted]

M.D.

PROGRESS NOTES

[redacted]

[redacted]

M.D.

[redacted]

000256

DATE

4/8/99 JD Vanco 5 / Meropenam 5 3/25 UC - E coli

Awake, following simple commands. 3/2 r Sp - S aureus

Tc 100.2° TM 100.9° Acinito

Heart: Reg

Lung: few rales in rt base PSF Ø

left clear

Abd: Soft, NT, +BS 9.9 / 10.4 / 36.2

Ext: Ø edema

A) 1) Fever - about the same Cr 0.3

2) Leukocytosis - improved

3) Sleus / H/o pancreatitis

4) Sz

5) H/o sinusitis

P) Short course of ABX ~ 7d.

[redacted]

Attachment # 5
Memorandum-FLA-9339
4/13/99
CFSAN Project #13408
SJH

4/8 Neurology:

More alert today

follows simple commands at times

intermittent (1) facial focal myoclonic

seizure precipitated by stimulating

(2) CoTC seizure

Low Grade Temp. Hemodynamically stable

WBC 9.9. Na/K / Dun on [redacted]

[redacted]

M.D.

PROGRESS NOTES

si[redacted]

M.D.

si[redacted]

[redacted]

000257

DATE

4/8 Neurology Continues

Impression: . Neurologically stable.
. Intractable / Epilepsia Partialis Continuum
. Toxic Encephalopathy
. ↑ LFTs

Continue current rx
(Lamictal 200 bid)
Neurontin 400 mg 83°
Klonopin 1 mg 94°
Phenobarb 180 98°
Pt is neurologically stable for
Transfer to [redacted]
discussed e family
appreciate SW efforts

[redacted]

Attachment # 5
Memorandum-FLA-9339
4/13/99
CFSAN Project #13408
SJH

[redacted]

[redacted] M.D.

signature

M.D.

sign[redacted]

PROGRESS NOTES

[redacted]

000258

[redacted]

DATE

Attachment # 5
Memorandum-FLA-9339
4/13/99
CFSAN Project #13408
SJH

4-9-95 Pub fi
S eyes open
does not follow command
O T 98³ 126/66
Quiet. Moved
Q Tony, M
and Dystonia, Tyrannit
for RS
at 5 edem

A Respirat. insufficiency
Stem
Sequence Disorder
Renovation

R Same vent support
will continue to follow while in [redacted]

[redacted]

[redacted]

M.D.

signature [redacted]

M.D.

signature [redacted]

PROGRESS NOTES

[redacted]

000259

[redacted]

tachment # 5
Memorandum-FLA-9339
4/13/99
CFSAN Project #13408
SJH

DATE

4/9/99 (AI)

07:37 S: Pt's KUB yest - c̄ ↑SB/LB dilation.
Ng replaced to suction. FT slowly
migrating - not where would like to
see it. BM x 2 yest - early - ∅ since.

O: 103.4F - 101.4F - 135/75 - 120 - 20
gen on vent. ∅ sleep. Extr ∅ sig edema
Eyes: Anicteric. Nonallid. Neon ∅ sleep.
EV: RRR tachy
Lung: ∅ wheeze.
Abd: More distended than last few
days. GRCBS, NR. Lower ~12.

Labs: Amylase - 66 ↑ 133/94/5 / 4.2/36/107 <0>
Lipase - 113 ↑

A: 1) Spiceuses - 7x as per Dr [redacted]
2) Ileus - ? med related vs related to pancreatitis.
Ng restarted to suction 2 to ↑ distension seen
KUB - FLU x rays. ~~FF~~
3) Nutrition - TF migrating - hopefully as
ileus finally resolves, then can start FF
+ plan Peg to follow.
4) Vent - as per Dr [redacted]
5) Fever - as per ID
6) Pancreatitis - mm ↑ amylase/lipase - FLU ∅ lipids
7) Ani, LFT - FLU trend ∅ few days - ✓ serologies sent off and
Plan: ~~FLU~~ Nacl
1) FLU LFTs 2) ✓ KUB 3) keep Ng to suction

[redacted]

PROGRESS NOTES

[redacted]

M.D.
signature [redacted]

M.D.
signature [redacted]

000260

[redacted]

DATE

PM & R

5/21/99

2:30 128/80 98² 91

eating well

EEG → pending

Xray (L) hip pending

parents at bedside

OT eval in progress

single staring episode

earlier today lasted

a few seconds

Trach site closed

G tube site less macerated

heart RRR

abd soft (+) bs NT ND

calves soft (-) cords / warmth

continued pt tenderness over (L) hip

no rash greater trach

140 | 102 | 82
4.1 | 35 | 0.5

AST = 22

Alk phos = 166

TP = 5.9

Alb = 3.8

4.8 | 13.5
41.9 PLT = 318

A/P

1. eg d/o → EEG pending
   medication management per Dr. [redacted]
2. ✓ (L) hip Xray prior to mobilization
3. prefer to continue G tube for purpose of medication administration (despite good po intake for food) (meds are Q4h)

[redacted]

M.D.

signature

[redacted]

M.D.

signature

[redacted]

PROGRESS NOTES

[redacted]

[redacted]

[redacted]

000261

DATE	
5/21/99	Physical Therapy: Consult recieved. History and precautions noted. Eval to be initiated after (L) hip X-ray cleared. [redacted] — P.T —
5/21/99	Speech Pathology Speech/Language + swallowing consults received + appreciated. Chart reviewed + precautions noted. Evaluation to begin today. Full report to follow. — [redacted]
5/21/99	EEG Completed → [redacted]
5/21/99	Nutrition Calorie count in progress. & consult complete re: @ AOB for difficulty swallowing. See consult section for details. Unit RD to follow [redacted]
5/21/99	Occupational Therapy - Chart reviewed & hx and precautions noted. Evaluation to follow [redacted]

[redacted]

[redacted] M.D.

signature

PROGRESS NOTES

[redacted]

[redacted] M.D.

signat[redacted]

[redacted]

DATE AND HOUR	SPEECH PATHOLOGY	NOTES	
5/21/99	(S) Alert and pleasant		
	(O) Bedside Swallow Assessment		
	(A) Oral Facial Functioning	Normal	Abnormal
	Comments:		
	Oral Phase		
	Lip Closure	WNL	Spillage L R Absent
	Mastication	Impaired	Adequate
	Bolus Formation/Control	Impaired	Adequate
	Pocketing	L R	Absent
	Transit Time	Delayed	Adequate
	Pharyngeal Phase		
	Swallow Reflex	Delayed ____ (secs)	WFL
	Laryngeal Elevation	Absent/Decreased	Adequate
	Number of Swallows		
	Vocal Quality	Wet	Clear
	Coughing/Choking/Throat Clearing	none	
	Other (Cognition/REspiration, etc.):		
	Comments: Supervision required during all feedings [redacted] to minimize activity		
	(P) Recommendation(s): Dysphagia Therapy ____	MBS ____	NPO ____
	Diet Levels Regular	Mech. Soft	Mech. Soft Dys. ____
	Liquids ____	Thin	Thick-it consistency.
	Strategies: Cues to take small bites & sips & supervision *Guidelines posted in room.		

PROGRESS NOTES

[redacted]

[redacted]

Dept.: _____

[redacted]

000263

[redacted]

DATE

5/22/99 MB

Ages. 5 pk. awake alert.
Resident Cooperative. 6 site
ok. Chart, Mar & labs
reviewed.
Heart RR
Lungs clear.
LE 3 No edema.
Family present.
Xray - hip ∃ neg for [redacted]
& repeated sz.
May - ok for cos [redacted]

[redacted]

M.D.

PROGRESS NOTES

[redacted]

signature [redacted] [redacted]

signature

000264

[redacted]

DATE

5/23/94 PMB

Aged Bloc No Sy.
Awake Alert. Family present.
Wife reports he is not recovering
anything via GT.
A eager to have it ble. Apparently
Dr. [redacted] put it in.
(E) No edema No swelling.
Plan - GT out next week & yet
Dr [redacted]

5/23 Neurology:
Asymptomatic
no seizure recurrence reported
(-) headache
(-) N/V
moves both VE. LE equally
(-) Tremors
generalized LE > VE mis atrophy
Dist. Symmetric
Impression: (1) intractable seizure
(2) H/o Toxic Encephalopathy

[redacted]

M.D.

signature [redacted] [redacted]

M.D.

signature [redacted]

PROGRESS NOTES

[redacted]

000265

DATE

H/O DVT

Continue Lanicktal 200/25 Bid
Neurontin 400 96°
Klonopin 1mg 96°
Phenobarb. 90 mg 96°
✓ phenobarb level in Am

[redacted]

5/24/99 Psychology. orders received. Chart reviewed. Pt to be scheduled for evaluation. [redacted]

[redacted]

M.D.

PROGRESS NOTES

signature

[redacted]

M.D.

signature

[redacted]

000266

[redacted]

[redacted]

Department of Psychological Services
Initial Evaluation

PATIENT NAME: [redacted]
DATE OF EVALUATION 5-24-99

MEDICAL RECORD# [redacted]
DOB: [redacted]

BACKGROUND INFORMATION

INJURY HISTORY: This 26-year-old white man was originally admitted to [redacted] 2/24 following an toxic encephalopathy after taking an herbal product Ripped Fuel. He was admitted to [redacted] on 4/9/99. He then was admitted to [redacted] on 5-20-99.

PREVIOUS MEDICAL HISTORY: No previous significant illnesses or accidents according to his mother.

PREVIOUS MENTAL HEALTH HISTORY, INCLUDING SUBSTANCE USE PATTERNS: Family denies pt has hx of tobacco, alcohol or illegal substance abuse, or any mental health history. Had history of abuse of an herbal product.

PSYCHOSOCIAL HISTORY:

MARITAL/CHILDREN/FAMILY/LIVING SITUATION: Patient was married for 2 years and has 19-year-old daughter. Has a very supportive mother and step father.

EDUCATIONAL/VOCATIONAL: Has a high school diploma. Worked full-time at [redacted] as assis mgr.

LEGAL: No legal issues at this time per family.

LEISURE ACTIVITIES: –

PLANNED DISCHARGE DISPOSITION: Patient's parents and his spouse are discussing possibility of pt & spouse moving into his parents' house.

Further detail can be found in the medical record.

ASSESSMENT:

Patient was assessed with Neurobehavioral Cognitive Status Exam (Cognistat). He was oriented to location, date & self but not time. He knew why he was in Hospital. He had moderate deficits in attention, calculation, severe deficits in naming, visual-perceptual skills, short-term memory and judgement. Insight was very poor and presented safety issues and he was impulsive. His mother and step father were very supportive as was his wife. Wife was present nightly at patient's bedside at his insistance and appears to have some stress due to the demands of caring for him and child. Patient denied depression [redacted]ely.

continued next page

[redacted]

SUMMARY AND RECOMMENDATIONS: This 26-year-old man was oriented but suffered widespread moderate to severe cognitive deficits, which were worst in insight and judgement. His wife and parents are very supportive.

TREATMENT PLAN

GOALS (check all that apply)

- ✓ Verbalize and demonstrate limited/fair/good awareness of abilities and disabilities.
- ___ Participate in rehabilitation program with limited behavioral interference.
- ___ Improve coping skills leading to decreased depression/anxiety.
- ✓ Caregivers verbalize and demonstrate limited/fair/good knowledge related to providing support and care to patient after discharge.
- ✓ Caregivers verbalize and demonstrate limited/fair/good knowledge related to providing the level of assistance required to assist patient in being independent in the home and community.
- ___ Other ___

INTERVENTIONS (check all that apply)

- ✓ Individual counseling when pt able to
- ___ Group counseling
- ✓ Family therapy
- ___ Behavioral management
- ___ Family support group
- ___ Cognitive remediation
- ___ Sexuality counseling
- ___ Marital counseling
- ___ Stress management
- ___ Pre-vocational counseling
- ___ Pain management
- ___ Substance use counseling
- ___ Parenting training
- ___ Other ___

BARRIERS TO REHABILITATION (Check all that apply)

- ___ Financial limitations
- ___ Primary language other than English (please specify) ___
- ___ Transportation (please explain) ___
- ___ Caregiver's job obligations
- ___ Also primary caregiver to others (children, disabled adults)
- ___ Cultural differences (please explain) ___
- ___ Other (please specify) ___

RECOMMENDATIONS: None at this time.

[redacted]

5/24/99
Date

ADDRESSOGRAPH
[redacted]

[redacted]

[redacted]

[redacted]

Department of Psychological Services
Discharge Summary

PATIENT NAME: [redacted]
MEDICAL RECOR[redacted]

DATE OF DISCHARGE: 6-19-99
DOB: [redacted]

INITIAL STATUS: This 26-year old white man, recovering from encephalopathy 2° herbal abuse, exhibited undesired moderate to severe cognitive deficits when seen on 5-24-99. These deficits were most severe in naming, visual-perceptual skills, short-term memory, and particularly in insight and judgement. Safety was a major issue. His stepfather, mother and wife were highly supportive and present daily.

Further detail can be found in the medical record.

TREATMENT PLAN/INTERVENTION:

RESPONSE TO GOALS (check all that apply)

✓ Verbalize and demonstrate limited/fair/good awareness of abilities and disabilities:
Pt demonstrates extremely poor insight and safety awareness on issue.

__ Participate in rehabilitation program with limited behavioral interference:

__ Improve coping skills leading to decreased depression/anxiety:

✓ Caregivers verbalize and demonstrate limited/fair/good knowledge related to providing support and care to patient after discharge:
Parents and wife help in pt care daily and all handle pt well.

✓ Caregivers verbalize and demonstrate limited/fair/good knowledge related to providing the level of assistance required to assist patient in being independent in the home and community:

__ Other (specify):

INTERVENTIONS (check all that apply)

not done
__ Individual counseling
__ Group counseling
✓ Family therapy
__ Behavioral management
__ Family support group
__ Other

__ Cognitive remediation
__ Sexuality counseling
__ Marital counseling
__ Stress management

[redacted]
__ Parenting training

000269

[redacted]

SUMMARY AND RECOMMENDATIONS: This patient has shown obvious improvements, for example, in episodic memory and impulsivity. However, insight remains poor "they tell me I can't drive, but I know I can." Family continues very supportive. His prognosis for ongoing neuropsychological improvement is fair. His discharge poor has changed (he is going home with wife).

The following recommendations are offered:

✓ If difficulty with mood or adjustment occur after discharge, supportive counseling may assist in the adaptation process. Returned/spoke with pt sponse

__If symptoms of severe depression/anxiety continue after interventions are applied, a psychiatric consultation for psychopharmacologic intervention may be helpful.

__Consider pursuing treatment for substance use; recommendations for community treatment resources provided.

__Provided with information regarding the [redacted] regular and [redacted] programs.

__Provided information about the [redacted]

__Provided with contact number for questions or concerns after discharge.

__Other (specify):_____

Should you require further information, please call [redacted].

Addressograph:

[redacted] 6/19/99

Name: Date

Title: Psychology

[redacted]

[redacted]

[redacted]

[redacted]

000270

DATE

5/24/99 10P

family requests assistance c̄ lab draw for test they want to send out (purple top)

124/78 98.6 a0 eating 100% meals & taking meds p0

Tmax 5/23 = 98.8

now in Speech therapy

Ø barb level = 20.0 (15-40)

will see [redacted] in therapy

EEG report - [illegible] seizures ongoing per verbal report

A/P

1. toxic encephalopathy 2° intractable sz - management of anti convulsants per Dr. [redacted]

2. D/C G tube [redacted]

5/24/99 nurses report 2 episodes in which [redacted] was staring for a few seconds c̄ grinding jaws lasted a few sec.

no toxic / clonic movement

no other c/o G tube site mildly [illegible]

no c/o (L) hip pain

[redacted] defer seizure treatment to Dr [redacted]

M.D.

signature

[redacted]

signature

[redacted]

PROGRESS NOTES

[redacted]

000271

[redacted]

DATE	
5/24/99 3:00pm	Occupational Therapy - Pt was observed to have one episode of staring which lasted 10 seconds. He then proceeded to have 2 more episodes c̄ staring and jaw grinding, lasting 30 seconds and 15 seconds. No tonic clonic movements observed. All episodes were followed c̄ slurred words and minimal chatting. [redacted]
5/24/99	Nutrition O: Diet: Mech Soft - Double Portions. 3 day Calorie Count Complete. A: Average po intake: 3000 Calories - 117% of requirement and 106 gm protein - 129% of requirement. Very good appetite. P: D Please weigh pt weekly. If pt gains > 2# please D/C Double Portions. (2) Calorie Count D/C'd. [redacted]

[redacted]

M.D.

PROGRESS NOTES

signature [redacted]

signature

[redacted]

000272

DATE

5/24/99 Physical Therapy:

Pt. was observed to have 4 episodes of staring c̄ jaw grinding lasting 15-20 seconds during 45 min session of therapy. All episodes were followed by slurred speech for approx. 20-30 seconds c̄ minimal drooling.

Earlier pt. had 1 such episode in the a.m session of 1/2 hr.

[redacted] — P.T —

5/24 Neurology:

Brief breakthrough seizures are reported today.

@ GTCs

facial @ facial myoclonic seizures with altered LOC

No changes in seizure characteristics

Now: Asymptomatic

@ seizure recurrence.

Labs: phenobarb level 2020

Plan: ↑ phenobarb to 120 mg 98°

x recheck level in 3-4 days

fall precaution is recommended

[redacted]

[redacted] M.D.

signature [redacted]

[redacted] D.

signature

[redacted]

PROGRESS NOTES

[redacted]

000273

DATE	
5-24-99	Psychology have met at length with pt's stepfather [redacted] and also separately today at length with pt's [redacted] mother. Provided the couple with much information also support. Discussed their feelings regarding pt. progress and status. Plan: (1) meet with pt's wife tomorrow a.m. (2) complete evaluation. [redacted]
5-25-99	Psychology [redacted] met with pt's spouse at length. Discussed her feelings about pt's progress, caring, and caregiver issues. Provided her with information, materials. [redacted]

[redacted]

M.D.

PROGRESS NOTES

signature [redacted]

[redacted] M.D.

signature [redacted]

DATE

5/25/99 PM & R

128/68 97⁹ 88 eating 100% meals

T max 5/24 = 98⁶

participating in all therapies

ambulating short distances per patient

no staring episodes reported today

no facial twitching observed

mom reports ~~(R)~~ rash (R) knee

earlier today - resolved now

A/P

1. toxic encephalopathy 2° intractable sz

2. good po intake - will ask Dr [redacted]

to remove G tube

[redacted]

[redacted]

5/26/99

130/64 97 78 eating 100% meals

T max 5/25 = 97⁹ taking meds well

[redacted] is upset about acne on his

forehead which he attributes to

"seizure meds" and he wants to

stop those medications

[redacted]

M.D.

signature [redacted]

[redacted]

M.D.

signature

[redacted]

[redacted]

[redacted]

000275

DATE

5/26 I made it clear to [redacted] that
he can not stop his gz medicines
and he appeared to agree
PEG to be removed tomorrow
no further staring spells today
per parents
ambulating around gym
no drowsiness since Ø barb dose
A/P ↑ by Dr. [redacted]

1. continue OT/PT
2. gz d/o
3. PEG ~~[illegible]~~ to be
removed on 5/27

[redacted]

[redacted]

M.D.

PROGRESS NOTES

signature [redacted] [redacted] M.D.

[redacted]

signature

[redacted]

DATE

	PM&R
5/27/99	Scheduled for G tube removal this am
9:30	no problems per nursing staff
Lovenox	140/70 - 115/69 97b 91-111
30mg Q12	eating 100% mech soft diet
Synthroid	no further starring episodes
0.025mg/d	chest clear
Colace	abd soft (+)bs
VITE	
VITC	A/P 1. encephalopathy 2° intractable sz
Klonopin	anticonvulsants per Dr. [redacted]
1mg Q6	2. G tube removal today
Neurontin	[redacted]
400mg Q6°	
Lamictal	
25 bid	
Ø barb	
120mg Q8°	

[redacted]

M.D.

PROGRESS NOTES

signature [redacted] [redacted] M.D.

[redacted]

signature

[redacted]

000277

DATE

5/27 GE

Old → ① mild gords / gardens
② PBC Removal

→ VBx
Wound Care
Pain Control

[redacted]

[redacted]

M.D.

PROGRESS NOTES

[redacted]

signature [redacted]

signature

[redacted]

000278

DATE

PM & R

5/28/99 ambulating S100ft

11A PEG removed yesterday

126/63 979 84-96

Tmax 5/27 = 98

no c/o chest conversant

wife at bedside

chest clear PEG site almost closed

heart RRR

calves soft ⊖ cords/warmth

A/P 1. encephalopathy 2° sieque

2. S/P PEG removal - local care

3. D/C [redacted]

Dr [redacted] on call today thru Tuesday AM [redacted]

[redacted]

M.D.

signatu[redacted]

M.D.

signature

[redacted]

PROGRESS NOTES

[redacted]

000279

DATE

5/28 Neurology:

no reported seizure recurrence.

However, pt. reported occ. shining of spuds. [redacted] reported occ. staring

(-) GTC seizures

Tube feeding is removed

(+) ambulating well c̄ support.

(-) Focal vs. Lt weakness.

↑ DTR Bilat.

. dysphasic speech

apraxic.

Impression:

Neurologically improving

. Breakthrough partial seizures

. Dementia / Toxic Encephalopathy

. Continue current rx

Spoke c̄ family at bedside

[redacted]

5/29/99 PMR

Cafeb. Good PO. OCO PSG. Wife present. WSoft scores. [redacted]

Lumpdear.

Plan - Same.

parking permit from same [redacted]

[redacted]

M.D.

signature [redacted]

M.D.

signat[redacted]

PROGRESS NOTES

[redacted]

000280

DATE

5/30/99 PMB -
Afeb. BPOK awake alert
Good RO. ¢ c/o. Spin.
Heartsk
Lungs clear.
[illegible] edema/cardi.
Any Same.

5/31/99 PMB
Afeb. BPOK. awake alert & sc.
¢ Sr activity. Good co-
Med-Stable
Pleasant.

[redacted]

[redacted]

M

signature [redacted]

signature

M

PROGRESS NOTES

[redacted]

000281

DATE

continued

6/1 Dad reports [redacted] got up
and showered by himself
this am $\bar{s}$ assistance
He is to be moved closer to
nursing station today
ambulating $\bar{c}$ gait belt CG per Dad
PEG site small ascher/healed
no erythem or drainage

A/P 1. will receive ELOS Thursday
also whether he can go on
day pass for weekend
2. anti convulsants per Dr [redacted]

[redacted]

[redacted]

[redacted] D.

signature

[redacted] M.D.

signature

[redacted]

PROGRESS NOTES

[redacted]

[redacted]

000282

DATE

5/1 Neurology:

(-) Seizures reported.

(-) Tremors

Asymptomatic.

mother reported no breathing [illegible] seizures

afebrile [illegible]

A-ex-2 mild dysarthria

Poor [illegible]

Billet [illegible]

(-) Focal weakness

Dysmorphic

neurologically improving

Seizures are better controlled

will ✓ phenobarb level

[redacted]

6/1/99 PM&R

116/63 97T 90 no staring episodes

Tmax 5/31 = 97.4 per family

no drowsiness on higher dose Ø barb

cooperative conversant

Dad requests p[redacted] weaken d

continued

[redacted]

M.D.

PROGRESS NOTES

[redacted]

M.D.

[redacted]

000283

[redacted]

DATE

PM&R

6/2/99 Seen in Speech therapy
no starting episodes observed by therapists
over the last 2 days
[redacted] still has severe cognitive deficits
as well as impaired ~~naming~~
naming and social pragmatics
112/50 ◯ 97⁹ P=88-100
Tmax 6/1 = 97⁷ Ø bar blood = 26.9
conversat cooperative
wants to go on pass → d/w wife & father
K/P staffing on 6/3
pass for daytime on weekend
sf ok c̄ team
[redacted]

PM&R

6/3/99 8:00 AM CTSP by nurses who reported
[redacted] fell from bed last evening
(unwittnessed) found sitting on floor
at bedside 122/82 973 86 Tmax 98
patient reports he was wet and
needed to go to the br
no assistance was available
so he got up himself [redacted]

[redacted]

[redacted] M.D.

signature continued [redacted]

signatu [redacted]

PROGRESS NOTES

[redacted]

[redacted]

000284

DATE

6-3-99 CT NOTE: CT HEAD ≤ DONE

[redacted]

6/3/99 Staffing

[redacted] is intermittently Labile

social - mother has hx of difficulty

saying 'no' to [redacted]

Limited adjustment, poor insight

(S) feeding, dressing, grooming

(S) for bed mobility

easily distractable

CG assist for gait unlimited distances

no safety awareness

car transfers completed c̄ fairly

ok for pass c̄ limitations provided

impaired comprehension 2° delayed processing

v. concrete difficulty c̄ word retrieval

Limited reasoning

improved orientation

all higher level cognitive skills impaired

ELOS 3-5 wks

[redacted]

[redacted]

[redacted] M.D.

signa[redacted]

M.D.

signature

[redacted]

PROGRESS NOTES

[redacted]

DATE

6/3/99 [redacted] says he hit the (L) side of his head, back and (L) hip on floor.

Synthrod 0.025mg pq d — HC c/o pain in his low back (L) hip and ha (SQ Lowenox dc'd 5/28)

no abrasions or lacerations on head hip or back

Colace 100mg b.d — mild swelling & erythema (L) temporal area

VITE

VITC — CN II - XII intact — alert conversant

Klonopin — chest clear — OX3 except date

~~Q~~ 1mg Q6° — heart RRR — knows mo & year

abd (+) bs, soft NT ND

neurontin 400mg Q6° — (L) hip mild discomfort & int rotation

Lamictal 25mg b.d — no erythema or abrasion

back mildly tender to palpation

Phenobarb 120mg Q8h — lower lumbar region

calves soft (-) cords warmth

motor exam 5/5 as before

Tylenol — N/P due to baseline encephalopathy

will ✓ CT head — neuro checks

also X ray (L) hip and T-L spine

spoke & wife & nurses at length

[redacted] will need 1:1 or pro[redacted] bed or posey vest

[redacted] D.

signatu[redacted]

M.D.

signatu[redacted]

PROGRESS NOTES

[redacted]

[redacted]

000286

DATE

	9 M & R
6/4/99	awake alert
	at baseline MS now in protective bed
	127/66 98 ≈ 93
	T max 6/3 = 94.7
	CT brain Ø abnormalities
	X ray T-L spine Ø abnormalities
	(L) hip & pelvis - calcifications about
	soft tissues of pelvis & (L) hip
	chest clear
	PEG site healed (-) drainage
	A/P 1. encephalopathy 2° ag
	anticonvulsant management per Dr [redacted]
	2. family training completed
	~ list of limitations for pass
	prescriptions written

[redacted]

[redacted]

[redacted]

M.D.

signa[redacted]

M.D.

signa[redacted]

[redacted]

PROGRESS NOTES

[redacted]

000287

DATE

6/4 Neurology:
No reported seizures.
Neuroexam intelligent
A.O.X3 dysarthric speech
Poor Conc.
(-) fixed weakness
Gait apraxia
(-) Sensory Asymmetry

phenobarb level (26.9) 6/2

Impression: Neurologically stable
Continue current anticonvulsant
- phenobarb 120 q 80
- Neurontin 400 q 6
- Klonopin 1 mg q 6
- Lamictal 225 bid.
Pt. will need Helmet for
fall / breakaway prevention
Spoke to mother.

[redacted]

[redacted]

[redacted] M.D.

signature [redacted]

PROGRESS NOTES

[redacted]

[redacted] M.D.

signature [redacted]

[redacted]

000288

DATE

PMB

4/5/99 Ages B Bde. Dad present for training. Chart reviewed.
Q40 today. In good spirits
[illegible]
[illegible]
[illegible]
[illegible] xray - Thanks [redacted]
[illegible]
add - [illegible]
Thanks xrays.

PMB

6/6/99 Ages B Bde [illegible]
[illegible]. [illegible] (6 A) - Wide
Base of support. Endurance F.
[illegible]
[illegible] [redacted]

[redacted]

[redacted]

PROGRESS NOTES

[redacted]

signatu[redacted] M.D.

signature [redacted] M.D.

000289

DATE

6/7/99 PMB
Ofob BPK. Q83. No c/o of
pain. Discussed what [illegible] pt,
Good no. Gains [illegible]
[illegible].
[illegible]
[illegible].
[illegible]

6/8/99 PMB
Ofob. BPK. Awake [illegible] 75 c/o
No seizures. Expression a bit more
animated
Med stable.
Plan - [illegible] - Determine [illegible]

[redacted]

[redacted] M.D.

signature

[redacted] M.D.

signature

PROGRESS NOTES

[redacted]

[redacted]

[redacted]

000290

DATE	
6-2-99	Psychology - met with pt and his mother. Discussed their feelings about pt progress and need for therapy. Mother expresses more optimism about pt progress and she demonstrates awareness of his limitations and need for supervision. Patient insight remains poor. — Have spoken with pt's spouse briefly several times this week. She demonstrates awareness of his deficits but at times appears to have difficulty enforcing some safety issues. Plan: continue family education [redacted]
6-7-99	Psychology - met with pt together with his father at length. Discussed their feelings about pt progress and about his LOA to home. Patient apparently did well over weekend on LOA. Father reports that pt shows a small improvement in his insight into his deficits. Pt was able to voice a cognitive limitation but insight is still poor. Will continue to follow to provide education to family. [redacted]

[redacted] [redacted] [redacted] M.D.

signature

PROGRESS NOTES

[redacted]

[redacted] M.D.

signature

[redacted]

DATE

6/8 Neurology:

. No reported Seizure

Pt. denies any Complaints.

afebrile hemodynamically stable.

(-) Tremors

(-) facial Asymmetry

(-) focal weakness

Spastic LE.

gait ataxia.

(-) Sensory Asymmetry

Skin rash over face. Chest ? allergy

Impression:

- Seizure disorder
- Improving Toxic Encephalopathy.
- Cognitive impairment

Continue Current rx

will ↓ lamictal to 200 mg bid

& Continue observation

[redacted]

[redacted]

[redacted]

[redacted]

M.D.

M.D.

PROGRESS NOTES

[redacted]

signature

[redacted]

000292

DATE

[illegible] Ago BRBC No [illegible] problems reported. [redacted] continues to make gains (balance again. [illegible] [redacted]

plan [illegible] Thursday [redacted]

C/S Neurology:

Asymptomatic
(-) [illegible]
(-) Tremors
anosmia [illegible] / [illegible]
[illegible] [illegible] stable

off [illegible]
[illegible] [illegible] in 2-3 days

[redacted]

[redacted]

[redacted]

M.D.

PROGRESS NOTES

[redacted]

si[redacted]

M.D.

si[redacted]

[redacted]

000293

DATE

PM & R staffing

6/10/99 adjustment improved

[redacted] recognizes he has some cognitive impairment poor memory/attention

cooperative c̄ therapy

poor safety awareness

requires Protective bed

(S) for transfers & mobility

requires cues for stairs

unlimited ambulation → but can not find location

no carry over or planning

communicates his wants & needs

v: attentive family - who are attending training sessions

ELOS c̄ wk

will need 24h (S)

neuropsych c̄ approx c̄ mother

[redacted]

SPM 126/63 98² 89 off lamina [redacted] [illegible]

Tmax 6/9 = 98 [illegible] per staff

[redacted] eating well [redacted] [illegible] to cafeteria c̄ mother

M.D.

signature

PROGRESS NOTES

[redacted]

M.D.

signature [redacted]

000294

DATE

	PM&R
6/11/99	off Lamictal
	2 episodes yesterday of "slurred speech per wife"
Ø barb 120mg Q8°	each lasting ≈ 10 seconds
	127/80 97⁶ 94 looking forward to pass
Neurotin 400mg Q6°	T max 6/10 = 98³ again c̄ family
Klonopin T mg Q6h	facial rash slightly improved nonelsewhere
	abd PEG site small eschar
Synthroid 0.025 mg Q6	closed ⊖ drainage
	⊕ bs, soft
VITE	
VITE	A/P
	1. encephalopathy 2° sz
	anticonvulsants per Dr. [redacted]
	2. facial rash 2° Lamictal? which
	has been dc'd
	3. early HO ⊖ hip [redacted]

[redacted]

[redacted] M.D.

signature

PROGRESS NOTES

[redacted]

M.D.

signature [redacted]

[redacted]

DATE

6/13/99 Rehab. Med
No problem reported
Pt [illegible] pass

[redacted] [redacted]

[redacted]

[redacted] M.D.

signature [redacted] M.D.

sign[redacted]

PROGRESS NOTES

[redacted]

DATE

6/11 Neurology:

Doing well.

(-) Seizures reported.

(-) Tremors.

impaired cognitive function

Spastic LE.

Impress:

Neurologically stable

off Lamictal.

Contin / Klonopin / Neurotin / Phobalin

Cognitive therapy

[redacted]

6/12/09 Rehab. Med—

No problem reported.

STM impaired — Alert — Solitary appropriate

118/78 97.2 80/6

Chemical

~~Heart~~ NSR.

Bdb Cardiol

A- Encephalopathy — due to 2 ergonomic doses

[redacted]

[redacted]

M.D.

[redacted]

signature

PROGRESS NOTES

M.D.

[redacted]

[redacted]

000297

DATE

	PM & R
6/14/99	no seizures over weekend
	pain went well
	rash on face improved
	no rash on chest/back or axillae
	124/70 97282
	T max 6/13: 97.4
	PEG site well healed
	gait slightly wide based no Romberg
	A/P
	1. encephalopathy 2° sepsis
	antimicrobials per Dr. [redacted]
	2. (L) hip HO
	3. face rash improved
	perhaps 2° Lamictal → which has been d/c'd
	ELOS this week [redacted]

[redacted]

PROGRESS NOTES

[redacted]

[redacted] M.D.

signature

M.D.

sign [redacted]

000298

DATE

6/14 Neurology:

(-) Seizure
went home this weekend.
(-) reported fall
(-) new neurological event -
Awake, alert, oriented x3
Poor Conc. Poor VTM.
(-) Facial Asymmetry
Right LE spasticity
mild gait ataxia
(-) Tremor

Impression:
Neurologically stable.
Cognitive impairment 20 to
Toxic Encepth.
intractable Seizure improving
eff Lamictal.
on Neurontin / Phenobarb / Klonopin

[redacted]

[redacted]

[redacted] M.D.

signature

PROGRESS NOTES

[redacted]

[redacted] M.D.

signat[redacted]

[redacted]

000299

DATE

6-15-99 Psychology - have met with pts sparse - briefly. Sparse demonstrates good understanding of pts deficits verbally and appears to interact with him effectively. She states she is excited about pts discharge Friday and further states she feels confident about her ability to care for him. Pts family is present daily (father, mother, and/or sponse) and all demonstrate understanding of pt's limitations.

— Have met with pt. His mood is quite good, and he smiles frequently. He lacks insight into his deficits ("I'm ready to go back to work" "they say I couldn't drive, but I know I could"). Recommend: patient would be a good candidate for [redacted] as an outpatient.

— Plan: 1- recommend pt to attend [redacted]

6-18-99 Psychology - have spoken with pt & sparse today. They state change in D/C plan i.e. pt. to go to live with wife in their condo, and they are comfortable with this. Pts mood & affect bright, sparse likewise. Family may benefit from psychological follow-up during [redacted] to cope with any problems/o[redacted] [illegible] arise.

[redacted] M.D.

PROGRESS NOTES

[redacted] M.D.

sign[redacted]

[redacted]

000300

DATE

6/15/99 104/65 - 138/78 97⁶ 95

eating well Tmax 6/14 = not recorded

no seizures

1 episode "slurred speech" earlier today

last a few seconds per mother

no tonic / clonic movement

[redacted] is looking forward to discharge

Friday

PEG site healed

A/P

1. encephalopathy c̄ significant

residual cognitive deficits

2. ~~[illegible]~~ seizure d/o 2° #1 [redacted]

6/16/99 will upgrade to regular diet

116/67 97⁵ 93 no c/o

Tmax 6/15 = 97⁶ no problems per nursing

no further episodes slurred speech

no seizures

working on stairs c̄ gait belt &

assist of 1 better concentration

[redacted] A/P staffing tomorrow

M.D.

signature [redacted]

M.D.

signature

PROGRESS NOTES

[redacted]

[redacted]

000301

DATE

6/16 Neurology:

Mother reported 2 brief sharing in speech

? Seizure Pt. is unable to recall

(-) GTCs

(-) Tremors

improving gait / ambulation

[illegible] exam is unchanged

Poor [illegible].

Diagnosis: (1) Partial Seizure

(2) H/o intractable Seizure

2° to toxic Encephalopathy

(3) Dementia 2° #2

Continue Current rx

[illegible] & [illegible]

for possible DC on Friday

stable for DC neurologically

[redacted]

[redacted]

[redacted] M.D.

signature

[redacted] M.D.

signatu[redacted]

PROGRESS NOTES

[redacted]

DATE

6/17 Stuffing

good family support

psychology - v. poor insight

(S) for self care impaired safety awareness

negotiating stairs c̄ assist CG / verbal cues

1000 ft (S) no assistive devices

needs cues for safety

rec OT 5x week Speech 5x week

PT

poor short term memory

needs cues & written reminders

poor processing

helmet

24h (S)

no driving

therapies OT/PT/Speech 5x week for 3 wks

then 3x week for 1 wk

[redacted]

[redacted]

[redacted]

[redacted] M.D.

signature

[redacted] M.D.

sig[redacted]

PROGRESS NOTES

[redacted]

DATE	
6-17-99	Orthotic Note:
	pt has been measured/fitted c̄ soft shell protective
	helmet as ordered; pt is c̄ complaint and helmet was given
	to dad. Thank You,
	[redacted]

[redacted]

PROGRESS NOTES

[redacted]

signature [redacted] M.D.

si [redacted] M.D.

DATE AND HOUR	NOTES
	D/c Note:
6/18/99:	Pt. D/c'ed home c̄ wife and parents as primary caregiver.
	Functional status at D/c:
	Bed mobility, transfers & gait c̄ (S).
	Stairs c̄ C6 (A) x 1 & min v.c's for technique
	Balance sitting good.
	standing Fair.
	Pt. met all D/c goals.
	Family training completed c̄ family & wife. All safety issues discussed.
	Family verbalized understanding of all safety issues.
	Pt. will need 24° (S) post D/c.
	Recommend. outpatient P.T to work on strengthening, stretching of tightness & higher level balance activities.
	[redacted] P.T.

[redacted]

ADDRESSOGRAP[redacted]

PROGRESS NOTES

[redacted]

Dept.: [redacted]

[redacted]

000305

[redacted]