Food and Drug Administration
Center for Food Safety and Applied Nutrition
Office of Special Nutritionals

ARMS#

13110

7 - PROCEDURES

[redacted]

[redacted]

DISCHARGE REPORT

PATIENT: [redacted]
LOCATION: [redacted]
DOB: [redacted] AGE: 42 SEX: F
Billing#: [redacted] DISCH.: 07/03/98

MRN: [redacted]
ATT.PHYSICIAN: [redacted]

H E M A T O L O G Y

	[redacted]		
COLLECTED	07/02/98 22:30		REFERENCE RANGE
Collected	07/02/98 22:30 [redacted]		

C O A G U L A T I O N

PT	12.5			11.0-13.0 SECONDS
INR	1.1	L	M2	2.0-3.5 SEE BELOW
PTT	22			20-32 SECONDS

M1: ROOM [redacted]
CATH

M2:
NORMAL THERAPEUTIC RANGE = 2.0-3.0
PROSTHETIC HEART VALVE = 2.5-3.5
INR APPROVED ONLY FOR MONITORING PATIENTS
STABILIZED ON ORAL ANTICOAGULANTS

H E M O G R A M

WBC	16.5	H	4.0-11.0 K/UL
RBC	3.88	L	4.20-5.40 M/UL
HEMOGLOBIN	12.6		12.0-16.0 G/DL
HEMATOCRIT	36.2	L	38.0-47.0 %
MCV	93.2		80.0-100.0 FL
MCH	32.4		26.0-34.0 PG
MCHC	34.8		31.0-37.0 G/DL
RDW	11.8		11.5-14.5 %
PLATELET COUNT	242		150-400 K/UL

D I F F E R E N T I A L

% BAND NEUTROPHI	5		0-12 %
% SEG. NEUTROPHI	77		37-80 %
% LYMPHOCYTES	15	L	22-40 %
% MONOCYTES	2		1-10 %
% EOSINOPHILS	1		1-7 %
% BASOPHILS	0		0-2 %
COMMEN	*	M1	

KEY FOR ABNORMAL COLUMN: L-LOW, H-HIGH, AB-ABNORMAL, P-PANIC

[redacted]

[redacted]

[redacted]

DISCHARGE REPORT

PATIENT: [redacted] MRN: [redacted]
LOCATION: [redacted] ATT.PHYSICIAN: [redacted]
DOB: [redacted] AGE: 42 SEX: F
Billing#: [redacted] DISCH.: 07/03/98

continued

H E M A T O L O G Y

	[redacted]	
COLLECTED	07/02/98 22:30	REFERENCE RANGE

MI:
MANUAL DIFFERENTIAL PERFORMED TO VERIFY INSTRUMENT FLAGS.

M O R P H O L O G Y

RBC MORPHOLOGY	NORMAL	
WBC MORPHOLOGY	NORMAL	
PLATELET ESTIMAT	ADEQUATE	ADEQUATE

KEY FOR ABNORMAL COLUMN: L-LOW, H-HIGH, AB-ABNORMAL, P-PANIC

[redacted]

[redacted]

Thu Jul 16, 1998 12:06 am

Discharge Cumulative Trend Report from 07/03/98 1320 to 07/15/98 0910

Patient Name: [redacted] HEMATOLOGY-Page 6
Med Rec #: Adm: 07/03/98
Dis Date 07/15/98
Phys-Service: [redacted] - *NEUROLOGY

****

Hematology Profile

Results: / Units:	WBC	Hgb	Hct	MCV	Plt	RDW	NRBC /100 WBC
LO:	5.0	12.0	37	80	150	11.5	
HI:	11.0	16.0	47	100	450	14.5	
07/03/98 1430	26.7 H	15.4	44.4	91	285	12.8	
07/04/98 0600	16.9 H	11.8 L	33.9 L	93	181	12.5	
07/05/98 0500	12.6 H	10.1 L	29.2 L	92	127 L	12.7	
07/06/98 0516	9.0	9.2 L	28.0 L	93	122 L	12.9	
07/06/98 1437	12.2 H	10.2 L	30.4 L	93	128 L	12.9	
07/07/98 0600	10.1	9.7 L	28.9 L	93	143 L	12.7	
07/08/98 0525	7.8	9.1 L	26.9 L	92	175	12.7	
07/09/98 0155	6.4	11.3 L	33.4 L	90	236	14.7 H	
07/10/98 0610	7.2	11.6 L	34.3 L	91	268	14.3	
07/11/98 0530	8.4	11.4 L	33.5 L	90	285	14.4	
07/12/98 0550	12.6 H	12.6	36.3 L	90	326	14.0	
07/14/98 0600	9.6	13.3	39.8	91	322	14.2	

Automated Differential

Results: / Units:	Gran %	Lymph %	Mono %	Eos %	Baso %
LO:					
HI:					
07/04/98 0600	86	8	6	0	0
07/05/98 0500	86	9	5	0	0
07/06/98 0516	81	12	6	1	0
07/06/98 1437	87	7	5	1	0
07/07/98 0600	87	6	5	2	0
07/08/98 0525	79	10	7	4	0
07/09/98 0155	66	21	8	5	0
07/10/98 0610	61	25	9	5	1
07/11/98 0530	69	19	8	3	1
07/12/98 0550	77	15	6	1	1
07/14/98 0600	73	17	7	2	0

Lab Director- [redacted]
** DO NOT DISCARD **
*Discharge Cumulative Trend Report

[redacted]

[redacted]

Thu Jul 16, 1998 12:06 am

Discharge Cumulative Trend Report from 07/03/98 1320 to 07/15/98 0910

Patient Name: [redacted]
Med Rec #:
Dis Date
Phys-Service: *NEUROLOGY

HEMATOLOGY-Page 7
Adm: 07/03/98

****

Manual Differential (1)

Results: / Units: / LO: / HI:	Bands	Segs	Lymphs	Mono	Eos	Baso
07/03/98 1430	13	78	4	5		
07/06/98 0516	General Comments - CBC-RBC Morph: Normochromic, Normocytic Red Cells					

Sedimentation Rate

Results: / Units: / LO: / HI:	Sed Rate mm/Hr 0 25	Comment
07/08/98 1020	117 H	

Eosinophil Smear Urine

Results: / Units: / LO: / HI:	Eosinophil Count Neg	Eosinophil %
07/08/98 1920	None Seen	

Lab Director- [redacted]
** DO NOT DISCARD **
*Discharge Cumulative Trend Report

[redacted]

[redacted]

Thu Jul 16, 1998 12:06 am

Discharge Cumulative Trend Report from 07/03/98 1320 to 07/15/98 0910

Patient Name: [redacted] COAGULATION-Page 8

Med Rec #: Adm: 07/03/98

Dis Date 07/15/98

Phys-Service: [redacted] *NEUROLOGY

****

Coagulation Profile (1)

Results: / Units: / LO: / HI:	INR-PT Therapeutic 2.00 3.00	INR-PT Ref Range 0.89 1.11	PTT seconds 21 31		Fibrinogen mg/dl 185 395	
07/04/98 0150			57	H		
07/04/98 0600			53	H		
07/04/98 1010					415	H
07/04/98 2205			49	H		
07/05/98 0500			49	H		
07/06/98 0516					739	H
07/06/98 0516			42	H		
07/06/98 1437			43	H		
07/07/98 0215			51	H		
07/07/98 1230			48	H		
07/08/98 0525			40	H		
07/08/98 2109			37	H		
07/09/98 0155			42	H		
07/09/98 0845			42	H		
07/09/98 1715			50	H		
07/10/98 0805			50	H		
07/11/98 0810			38	H		
07/11/98 1600			62	H		
07/12/98 0550			62	H		
07/13/98 0600			75	H		
07/13/98 1540			51	H		

Coagulation Profile (3)

Results: / Units: / LO: / HI:	Fibrin Split Products ug/ml		Bld Time minutes 1 9
07/04/98 1010	10 to 40	H	
07/06/98 0516	< 10		

Lab Director- [redacted] M.D.

** DO NOT DISCARD **

*Discharge Cumulative Trend Report

[redacted]

[redacted]

[redacted]

Thu Jul 16, 1998 12:06 am

Discharge Cumulative Trend Report from 07/03/98 1320 to 07/15/98 0910

Patient Name: [redacted] SPEC COAG-Page 9
Med Rec #: Adm: 07/03/98
Dis Date
Phys-Service: *NEUROLOGY

****

In: 07/04/98 1030
Out: 07/09/98 1018
Coll Time: 07/04/98 1010
Order Phys: [redacted]

| D-DIMER |

Spec: Blood
Techs: [redacted]

*STAT*STAT*STAT*

Result Name	Result	Reference Range
D-Dimer(mcg/ml):	1.0 H	0.0-0.5

Performed by: [redacted]

Lab Director- [redacted]
** DO NOT DISCARD **
*Discharge Cumulative Trend Report

[redacted]

000007

[redacted]

DISCHARGE REPORT

PATIENT: [redacted] MRN: [redacted]
LOCATION: [redacted] ATT.PHYSICIAN: [redacted]
DOB [redacted] AGE: 42 SEX: F
Billing#: [redacted] DISCH.: 07/03/98

C H E M I S T R Y

	[redacted]		[redacted]		[redacted]	REFERENCE RANGE
COLLECTED	07/03/98 06:00		07/02/98 22:30		07/02/98 21:35	
Collected	07/03/98 06:00 [redacted]		07/02/98 22:30 [redacted]		07/02/98 21:35 [redacted]	
G E N E R A L C H E M I S T R Y						
SODIUM	138		139			133-145 MMOL/L
POTASSIUM	3.7		3.1	L		3.3-5.1 MMOL/L
CHLORIDE	98		103			96-108 MMOL/L
BICARBONATE (HCO	14.2	L				22.0-29.0 MMOL/
GLUCOSE	146	H	155	H		70-105 MG/DL
BUN	12		12			6-19 MG/DL
CREATININE	1.0		0.9			0.4-1.1 MG/DL
CALCIUM			8.7			8.4-10.2 MG/DL
BILIRUBIN-TOTAL			0.5			0.0-1.0 MG/DL
PROTEIN, TOTAL			6.9			5.9-8.4 G/DL
ALBUMIN			4.1			3.2-5.2 G/DL
ALKALINE PHOSPHA			37	L		39-117 U/L
AST			42	H		0-31 U/L
CK			347	H		24-170 U/L

M1: ROOM [redacted]
CATH
M2: ROOM [redacted]

S P E C I A L C H E M I S T R Y

CK		347	H		24-170 U/L
CK-MB		6.49	H	M1	0.15-5.00 NG/ML
RELATIVE INDEX		1.9		M2	%
TROPONIN-T		0.181		M3	NG/ML

M1:
CK-MB VALUES GREATER THAN 5.00 NG/ML ARE SUGGESTIVE OF MYOCARDIAL INFARCTION. SERIAL CK-MB ASSAYS ARE SUGGESTED.

M2:
RELATIVE INDEX - NORMAL RANGE = 0 - 4 %
POSSIBLE MI = > 3.0 %

M3:
RULE OUT AMI <= 0.100 WITH NO CHANGE.
RULE IN AMI >= 0.200 WITH SERIES RISE.

KEY FOR ABNORMAL COLUMN: L-LOW, H-HIGH, AB-ABNORMAL, P-PANIC

[redacted]

[redacted]

DISCHARGE REPORT

PATIENT: [redacted]
LOCATION [redacted]
DOB: [redacted] AGE: 42 SEX: F
Billing# [redacted] DISCH.: 07/03/98

MRN: [redacted]
ATT.PHYSICIAN: [redacted]

continued

C H E M I S T R Y

	[redacted]	[redacted]	[redacted]	
COLLECTED	07/03/98 06:00	07/02/98 22:30	07/02/98 21:35	REFERENCE RANGE
D R U G S O F A B U S E				
PCP			NEGATIVE	NEGATIVE
BENZODIAZEPHINES			POSITIVE AB	NEGATIVE
COCAINE, SCREEN			NEGATIVE	NEGATIVE
AMPHETAMINE SCRE			POSITIVE AB	NEGATIVE
CANNABINOID			NEGATIVE	NEGATIVE
OPIATES			NEGATIVE	NEGATIVE
BARBITUATES, SCR			NEGATIVE	NEGATIVE
TRICYCLIC SCREEN			NEGATIVE	NEGATIVE

KEY FOR ABNORMAL COLUMN: L-LOW, H-HIGH, AB-ABNORMAL, P-PANIC

[redacted]

[redacted]

Thu Jul 16, 1998 12:06 am

Discharge Cumulative Trend Report from 07/03/98 1320 to 07/15/98 0910

Patient Name: [redacted] CHEMISTRY-Page 1

Med Rec #: [redacted] Adm: 07/03/98

Dis Date 07/15/98

Phys-Service: [redacted] *NEUROLOGY

****

Chem Profile (1)

Results: / Units: / LO: / HI:	Na mmol/L 137 146	K+ mmol/L 3.5 4.8	Cl- mmol/L 98 107	CO2 mmol/L 22 31	Gluc mg/dl 78 114	BUN mg/dl 7 24	Creat mg/dl 0.7 1.4
07/03/98 1430	139	5.2 H	109 H	18 L	220 H	11	1.1
07/04/98 0600				23			
07/04/98 0600	138	3.2 L	109 H		144 H	11	1.0
07/04/98 1010		4.0					
07/05/98 0500	136 L	3.8	109 H		117 H	6 L	.9
07/05/98 0500	136 L	3.8	109 H	25	117 H	6 L	.9
07/05/98 1940		3.5					
07/06/98 0015		4.1					
07/06/98 0516	137	4.0	107	26	101	7	.9
07/07/98 0600	136 L	3.5	105	26	120 H	8	.8
07/08/98 0525	140	3.9	107	28	96	8	.9
07/09/98 0155	140	3.7	105		100	10	1.0
07/10/98 0610	142	4.1	106		106	11	1.0
07/11/98 0530	143	4.2	109 H	28	102	12	.9
07/12/98 0550	142	4.1	107	27	97	11	1.0
07/14/98 0600	141	4.1	105		90	15	1.1

Chem Profile (2)

Results: / Units: / LO: / HI:	Uric Ac mg/dl 2.2 6.8	T Prot gm/dl 6.3 8.5	Albumin gm/dl 3.6 5.1	Calcium mg/dl 8.4 10.2	Phos mg/dl 2.2 4.3	T Bil mg/dl 0.2 1.3	D Bil mg/dl 0.0 0.3
07/04/98 0600			2.8 L			.5	0.0
07/04/98 0600	5.5 L		2.8 L	6.8 L		.5	
07/05/98 0500				7.0 L			
07/05/98 0500	5.0 L		2.5 L	7.0 L		.5	
07/05/98 0500			2.5 L			.5	0.0
07/07/98 0600				7.3 L			
07/07/98 0600					2.7		
07/09/98 0155	5.9 L		2.9 L	7.7 L		.3	
07/10/98 0610	6.1 L		2.9 L	8.0 L		.3	
07/14/98 0600	6.8		3.3 L	8.7		.4	

Lab Director- [redacted]

** DO NOT DISCARD **

*Discharge Cumulative Trend Report

[redacted]

000010

[redacted]

Thu Jul 16, 1998 12:06 am

Discharge Cumulative Trend Report from 07/03/98 1320 to 07/15/98 0910

Patient Name: [redacted] CHEMISTRY-Page 2

Med Rec #: [redacted] Adm: 07/03/98

Dis Date 07/15/98

Phys-Service: [redacted] *NEUROLOGY

****

Chem Profile (3)

Results:	CK	CK-MB	LDH	AST	ALT	AlkPho	GGT
Units:	U/L	RI	U/L	U/L	U/L	U/L	U/L
LO:	15	<4.2	313	14	9	40	5
HI:	170		618	59	72	125	85
07/04/98 0600	Hep Func Panel			105 H	32	39 L	
07/04/98 0600	Renal			105 H		39 L	
07/04/98 1010	3554 H	0.6					
07/05/98 0500	9524 H	0.1					
07/05/98 0500	Renal			128 H		39 L	
07/05/98 0500	Hep Fulminant			129 H	44	39 L	
07/05/98 1940	10471 H	0.0					
07/06/98 0516	10689 H	0.0					
07/06/98 2045	12623 H						
07/06/98 2045	12623 H	0.0					
07/07/98 0600	12496 H						
07/08/98 1020	4973 H						
07/08/98 1020	4973 H	0.0					
07/09/98 0155	3404 H						
07/09/98 0155	3404 H	0.0					
07/09/98 0155				150 H		81	
07/10/98 0610				100 H		89	
07/11/98 0530	780 H						
07/11/98 0530	780 H	0.0					
07/14/98 0600				53		66	

Chem Profile (5)

Results:	Amylase	Lipase	Magnesiu	Prealbum	Ammonia	Hgb A1C	Acetone
Units:	U/L	U/L	mg/dl	mg/dl	umol/L	%	
LO:	30	23	1.6	15	11	4.1	Negative
HI:	110	208	2.3	36	35	6.5	
07/04/98 1010			1.7				
07/05/98 0500			1.7				

Lab Director- [redacted] M.D.

** DO NOT DISCARD **

*Discharge Cumulative Trend Report

[redacted]

[redacted]

Thu Jul 16, 1998 12:06 am

Discharge Cumulative Trend Report from 07/03/98 1320 to 07/15/98 0910

Patient Name: [redacted] CHEMISTRY-Page 3
Med Rec #: Adm: 07/03/98
Dis Date 07/15/98
Phys-Service: [redacted] *NEUROLOGY

****

Cardiac Marker Panel

Results:	CK		CK-MB	Trop-I		Myoglobi	
Units:	U/L		RI	ng/ml		ng/ml	
LO:	15		<4.2	<0.15		<70	
HI:	170						
07/03/98 1535	3506	H	1.9	1.42	H	153.8	H
07/03/98 2328	1546	H	2.5	0.81	H	225	H

Arterial Blood Gases (1)

Results:	FIO2	pH		pCO2		HCO3		pO2		O2 Sat		BE
Units:	%			mm Hg		mmol/L		mm Hg		%		
LO:		7.350		32		20				96		
HI:		7.450		42		25				97		
07/03/98 1320	70.0	7.450		27	L	19	L	141		99	H	
07/03/98 1415		7.396		29	L	17	L	103		98	H	
07/03/98 1725		7.423		25	L	16	L	94		98	H	
07/03/98 2100	70.0	7.483	H	24	L	18	L	75		96		
07/04/98 0150	55.0	7.434		31	L	20		105		98	H	
07/04/98 0600	50.0	7.424		32		21		82		96		
07/04/98 1010	40.0	7.443		31	L	21		78		96		
07/05/98 0500	100.0	7.437		34		22		52		89	L	
07/05/98 0630	100	7.438		33		22		84		97		
07/05/98 1125	90.0	7.411		38		24		33	P	72	L	
07/05/98 1505	50	7.469	H	32		23		61		94.5	L	
07/05/98 1945		7.495	H	32		24		71		96		
07/06/98 0015	55.0	7.451	H	35		24		59		93	L	
07/06/98 0516	60.0	7.457	H	34		24		64		94	L	
07/07/98 0215		7.464	H	33		23		84		97		
07/07/98 0600	90	7.459	H	34		23		106		98	H	
07/07/98 1025	65.0	7.459	H	35		24		80		97		
07/07/98 1125		7.420		41		26	H	34	P	67	L	
07/07/98 1126		7.410		41		25		33	P	68	L	
07/08/98 0525	50.0	7.480	H	34		25		102		99	H	
07/09/98 1000	35	7.458	H	37		26	H	56		91	L	
07/09/98 2140	45.0	7.436		39		25		75		96		
07/10/98 0705	45	7.449		38		26	H	60		93	L	

Lab Director- [redacted] M.D.
** DO NOT DISCARD **
*Discharge Cumulative Trend Report

[redacted]

[redacted]

[redacted]

Thu Jul 16, 1998 12:06 am

Discharge Cumulative Trend Report from 07/03/98 1320 to 07/15/98 0910

Patient Name: [redacted] SEROLOGY-Page 12
Med Rec #: Adm: 07/03/98
Dis Date 07/15/98
Phys-Service: [redacted] *NEUROLOGY

****

Rheumatoid Arthritis (RA) Testing

Results: / Units: / LO: / HI:	RA Serum	RA Fluid	RA Titer	Source
	Neg (<1 to 20)	Neg (<1 to 20)		
07/08/98 1020	Negative			

Antinucleolar Antibody (ANA)

Results: / Units: / LO: / HI:	ANA	Titer 1	Pattern	Source
	Neg (<1 to 40)			
07/08/98 1020	#			Blood
07/08/98 1020		1 to 40	Speckled	Blood
	Specific Comments			
07/08/98 1020	ANA-ANA: Positive- Titer Reported Separately			
	General Comments			
07/08/98 1020	ANA TITER-ANA Interpretation: Low Levels Of Non-Specific ANA's Present. May Not Be Of Clinical Significance.			

Lab Director- [redacted] M.D.
** DO NOT DISCARD **
*Discharge Cumulative Trend Report

[redacted]

[redacted]

[redacted]

Sat Jul 18, 1998 12:20 am
Post Discharge Work Report

Pat Name: [redacted]
Unit #/Acct #:
Dis Date 07/15/98
Phys-Service: [redacted] *NEUROLOGY

Page: 1

****

In: 07/09/98 0217
Out: 07/17/98 1328
Coll Time: 07/09/98 0155
Order Phys: [redacted]

CMV AB IGM

Spec: Blood
Techs: [redacted]

Result Name	Result	Reference Range
CMV IgM:	ABSENT	Present = Presumptive Evidence Of A Recent Or Current Infection

Performed by: [redacted]

Lab Director- [redacted] M.D.

*Post Discharge Work Report

[redacted]

[redacted]
Wed Jul 22, 1998 12:10 am
Post Discharge Work Report

Pat Name: [redacted]
Unit #/Acct #:
Dis Date 07/15/98
Phys-Service: [redacted] - *NEUROLOGY

Page: 1

****

In: 07/09/98 0217
Out: 07/21/98 1311
Coll Time: 07/09/98 0155
Order Phys: [redacted]

EBV AB IGG/IGM BY IFA

Spec: Blood
Techs: [redacted]

Result Name	Result	Reference Range
VCA-IgG(Absorbance Unit):	119 H	< 20
VCA-IgM(Absorbance Unit):	11	< 20

Performed by: [redacted]

In: 07/09/98 0217
Out: 07/21/98 0937
Coll Time: 07/09/98 0155
Order Phys: [redacted]

ENTEROVIRUS AB PANEL

Spec: Blood
Techs: [redacted]

Result Name	Result	Reference Range
Specimen:	Random serum	
Coxsackie A Ab Titer:	< 1 to 8	
Coxsackie B Ab Titer:	< 1 to 8	
Echo Virus Ab Titer:	< 1 to 8	
Comment :	The above CF results for these agents are of uncertain significance. Please submit a convalescent serum collected in 2-3 weeks to aid in diagnosis.	

Performed by: [redacted]

End of Report - 07/22/98 00:10

Lab Director- [redacted] M.D.

*Post Discharge Work Report

[redacted]

[redacted]

Thu Jul 16, 1998 12:06 am

Discharge Cumulative Trend Report from 07/03/98 1320 to 07/15/98 0910

Patient Name: [redacted] CHEMISTRY-Page 4
Med Rec #: Adm: 07/03/98
Dis Date 07/15/98
Phys-Service: [redacted] *NEUROLOGY

****

Arterial Blood Gases (1) (Cont)

	Corrected Results
07/07/98 0600	BLOOD GASES ART-FIO2: Corr 07/07/98 0622 Prev Result: 21.0
	General Comments
07/07/98 1125	BLOOD GASES ART-Comment: prox. port. rt atrial
07/07/98 1126	BLOOD GASES ART-Comment: pulmonary artery

Lactic Acid Venous

Results:	Lactic Acid	
Units:	mmol/L	
LO:	0.5	
HI:	2.2	
07/03/98 1415	4.7	HP
	General Comments	
07/03/98 1415	LACTIC ACID-Comment: specimen from 1415 abg's	

Thyroid Screen

Results:	TSH Ultr	T4 Free
Units:	uIU/ml	ng/dl
LO:	0.34	0.73
HI:	5.60	1.73
07/04/98 0600	1.58	
07/05/98 0135	1.66	

Lab Director- [redacted] M.D.
** DO NOT DISCARD **
*Discharge Cumulative Trend Report

[redacted]

[redacted]

Thu Jul 16, 1998 12:06 am

Discharge Cumulative Trend Report from 07/03/98 1320 to 07/15/98 0910

Patient Name: [redacted] URINE REFFERAL-Page 5
Med Rec #: [redacted] Adm: 07/03/98
Dis Date 07/15/98
Phys-Service: [redacted] *NEUROLOGY

****

In: 07/07/98 0654
Out: 07/11/98 0922
Coll Time: 07/07/98 0200
Order Phys: [redacted]

| MYOGLOBIN QUAN URINE |

Spec: Urine
Techs: [redacted]

Result Name	Result	Reference Range
Myoglobin(ng/ml):	14867 H	<20

Performed by: [redacted]

Lab Director-[redacted] M.D.
** DO NOT DISCARD **
*Discharge Cumulative Trend Report

[redacted]

DISCHARGE REPORT

PATIENT: [redacted]
LOCATION [redacted]
DOB: [redacted] AGE: 42 SEX: F
Billing#: [redacted] DISCH.: 07/03/98

MRN: [redacted]
ATT.PHYSICIAN: [redacted]

B L O O D G A S / C O - O X I M E T R Y

	[redacted]		[redacted]		
COLLECTED	07/03/98 08:00		07/03/98 04:30		REFERENCE RANGE
Collected	07/03/98 08:00 [redacted]		07/03/98 04:30 [redacted]		
SOURCE	ARTERIAL		ARTERIAL		
PH	7.445		7.399		7.350-7.450
PCO2	26.1	L	30.5	L	35.0-45.0 MMHG
PO2	81.0		52.1	L	75.0-100.0 MMHG
HCO3, ACTUAL	17.5	L	18.4	L	20.0-26.0 MMOL/L
BASE DEFICIT/EXC	-4.7	L	-5.0	L	-3.0-3.0 MMOL/L
O2 SATURATION	96.6		87.4	L	95.0-100.0 %
OXYGEN DELIVERY	VENTILATOR		VENTILATOR		
VT	900		900		ML
SIMV. RATE	16		16		RESP/M
PEEP	5				CM H20
FIO2	100		100		%
TCO2	18.3	L	19.4	L	24.0-30.0 MMOL/L
* * * * * * * *	* * * * *		* * * * *		
HEMOGLOBIN	15.4		15.5		12.0-16.0 G/DL
OXYHEMOGLOBIN	97.6		86.8	L	95.0-100.0 %
CARBOXYHEMOGLOBI	0.0		0.1		0.0-1.5 %
METHEMOGLOBIN	0.2		0.3		0.0-1.5 %
DEOXYHEMOGLOBIN	2.2		12.8	H	0.0-5.0 %
O2 CONTENT	20.9		19.0		15.8-22.2 mL/DL

KEY FOR ABNORMAL COLUMN: L-LOW, H-HIGH, AB-ABNORMAL, P-PANIC

[redacted]

[redacted]

[redacted]

DISCHARGE REPORT

PATIENT: [redacted]
LOCATION: [redacted]
DOB: [redacted] AGE: 42 SEX: F
Billing#: [redacted] DISCH.: 07/03/98

MRN: [redacted]
ATT.PHYSICIAN: [redacted]

BODY FLUID CHEMISTRY

	[redacted]	
COLLECTED	07/02/98 23:40	REFERENCE RANGE

Collected	07/02/98 23:40 [redacted]		

CEREBROSPINAL FLUID PANEL

APPEARANCE	ALL TUBES		
COLOR	COLORLESS		COLORLESS
CLARITY	CLEAR		CLEAR
CELL COUNT	TUBE 3		
RBC, MANUAL	2		0-10 /UL
WBC, MANUAL	1		0-5 /UL
CHEMISTRY	TUBE 1		
GLUCOSE, CSF (	78		40-80 MG/DL
PROTEIN,CSF	35	M2	15-45 MG/DL

M1: ROOM [redacted]
M2:
CALLED [redacted] RE: GRAM STAIN TO FOLLOW-HIGH HUMIDITY.

BODY FLUID PANELS

FLUID TYPE	SPINAL FLUID

KEY FOR ABNORMAL COLUMN: L-LOW, H-HIGH, AB-ABNORMAL, P-PANIC

[redacted]

[redacted]

DISCHARGE REPORT

PATIENT: [redacted] MRN: [redacted]
LOCATION ATT.PHYSICIAN: [redacted]
DOB: [redacted] AGE: 42 SEX: F
Billing# [redacted] DISCH.: 07/03/98

U R I N A L Y S I S

	[redacted]		
COLLECTED	07/02/98 21:35		REFERENCE RANGE
Collected	07/02/98 21:35 [redacted]		

U R I N E M A C R O

CULTURE SET UP:	UNKNOWN		
COLLECTION TYPE	CATHETERIZED		
COLOR	YELLOW		YELLOW
CLARITY	MOD CLOUDY	AB	CLEAR
GLUCOSE	NORMAL		NEGATIVE
BILIRUBIN	NEGATIVE		NEGATIVE
KETONES	50 MG/DL	AB	NEGATIVE
SPECIFIC GRAVITY	1.030		1.003-1.040
PH	5.0		5.0-9.0
PROTEIN	500 MG/DL	AB	NEGATIVE
UROBILINOGEN	NORMAL		0.2-1.0 EU/DL
NITRITE	NEGATIVE		NEGATIVE
BLOOD	25/uL	AB	NEGATIVE
LEUKOCYTES	NEGATIVE		NEGATIVE

M1: ROOM 1
CATH

U R I N E M I C R O S C O P I C

WBC	15-25 /HPF	AB	0-5/HPF
RBC	5-10 /HPF	AB	0-3 /HPF
BACTERIA	NONE SEEN		NONE SEEN
EPITHELIAL CELLS	5-10 /HPF	AB	NONE SEEN

KEY FOR ABNORMAL COLUMN: L-LOW, H-HIGH, AB-ABNORMAL, P-PANIC

[redacted]

[redacted]

Thu Jul 16, 1998 12:06 am

Discharge Cumulative Trend Report from 07/03/98 1320 to 07/15/98 0910

Patient Name: [redacted] URINALYSIS-Page 10

Med Rec #: [redacted] Adm: 07/03/98

Dis Date 07/15/98

Phys-Service: [redacted] *NEUROLOGY

****

Urinalysis Macro (1)

Results: / Units:	Sp Gr	pH	Protein	Blood	Glucose
LO:	1.003	5.0	NEGATIVE	NEGATIVE	NEGATIVE
HI:	1.030	8.0			
07/03/98 1540	1.025	5.0	2+	3+	TRACE
07/08/98 1920	1.010	6.0	1+	2+	NEGATIVE
07/11/98 1340	1.015	8.0	NEGATIVE	TRACE	NEGATIVE
07/13/98 1405	1.020	6.0	NEGATIVE	2+	NEGATIVE
07/15/98 0910	1.020	5.0	NEGATIVE	NEGATIVE	NEGATIVE

Urinalysis Macro (2)

Results: / Units:	Ketones	Bilirubin	Nitrite	Leukocyte	Type
LO:	NEGATIVE	NEGATIVE	NEGATIVE	NEGATIVE	
HI:					
07/03/98 1540	NEGATIVE	NEGATIVE	NEGATIVE	NEGATIVE	CATH
07/08/98 1920	NEGATIVE	NEGATIVE	NEGATIVE	1+	MID
07/11/98 1340	NEGATIVE	NEGATIVE	NEGATIVE	2+	CATH
07/13/98 1405	NEGATIVE	NEGATIVE	NEGATIVE	TRACE	CATH
07/15/98 0910	NEGATIVE	NEGATIVE	NEGATIVE	NEGATIVE	MID

Urinalysis Microscopic

Results: / Units:	WBC /HPF	RBC /HPF	Epith /LPF	Bacteria /HPF	Casts /LPF
LO:	0	0	Rare	Few	0
HI:	5	3			2 Hyaline
07/03/98 1540	2-4	25-50	FEW	FEW	2-4 HYALINE
07/08/98 1920	25-50	10-25	MOD	FEW	
07/11/98 1340	25-50	2-4	FEW	MOD	
07/13/98 1405	10-25	50-100	MOD	MOD	2-4 HYALINE

Lab Director- [redacted]

** DO NOT DISCARD **

*Discharge Cumulative Trend Report

[redacted]

[redacted]

Thu Jul 16, 1998 12:06 am

Discharge Cumulative Trend Report from 07/03/98 1320 to 07/15/98 0910

nt Name: [redacted] URINALYSIS-Page 11

c #: Adm: 07/03/98

te 07/15/98

ervice: [redacted] *NEUROLOGY

****

Urinalysis Microscopic (Cont)

	General Comments
07/03/98 1540	URINALYSIS ROUTINE AUTO-UA Comment: MICROSCOPIC PERFORMED ON < 10 CC OF URINE
07/08/98 1920	URINALYSIS ROUTINE AUTO-UA Comment: BUDDING YEAST WITH MYCELIUM
07/11/98 1340	URINALYSIS ROUTINE AUTO-UA Comment: BUDDING YEAST WITH MYCELIUM
07/13/98 1405	URINALYSIS ROUTINE AUTO-UA Comment: BUDDING YEAST WITH MYCELIUM

Lab Director-[redacted].

** DO NOT DISCARD **

*Discharge Cumulative Trend Report

[redacted]

[redacted]

PATIENT: [redacted]
I.D.#:
ORDER#:

MRN: [redacted] LOCATION: [redacted]
DOB: [redacted] AGE: 42 SEX: F
DISCHARGED: 07/03/98 ORDERED BY: [redacted]

M I C R O B I O L O G Y

COLLECTED: 07/02/98 23:40
RECEIVED: 07/03/98 00:06

SOURCE: CSF
ANTIBIOTICS AT COLL. :
ORDER ENTRY COMMENTS:

CALLED [redacted] tel [redacted] 07/03/98, 10:09, [redacted] to call

1.GRAM STAIN ■ FINAL 07/03/98 04:54
07/03/98 NO POLYMORPHONUCLEAR LEUKOCYTES. NO BACTERIA SEEN.

2.CSF CULTURE ■ FINAL 07/06/98 10:49
07/06/98 NO GROWTH / 72 HR.

KEY FOR RESULTS: ■ - NEW RESULT

[redacted]

M I C R O B I O L O G Y

PRINTED: 07/06/98 12:15 REGULAR

4

[redacted]

ATIENT: [redacted] MRN: [redacted] LOCATION: [redacted]
.D.#: DOB: [redacted] AGE: 42 SEX: F
RDER#: [redacted] DISCHARGED: 07/03/98 ORDERED BY: [redacted]

M I C R O B I O L O G Y

OURCE: CSF COLLECTED: 07/02/98 23:40
NTIBIOTICS AT COLL. : RECEIVED: 07/03/98 00:06
RDER ENTRY COMMENTS:

ALLED [redacted] 07/03/98, 10:09, [redacted] to call

1. GRAM STAIN ■ FINAL 07/03/98 04:54
7/03/98 NO POLYMORPHONUCLEAR LEUKOCYTES. NO BACTERIA SEEN.

2. CSF CULTURE ■ FINAL 07/06/98 10:49
07/06/98 NO GROWTH / 72 HR.

KEY FOR RESULTS: ■ - NEW RESULT

[redacted]

M I C R O B I O L O G Y

000024

[redacted]

Thu Oct 15, 1998 12:06 am

Discharge Cumulative Trend Report from 07/03/98 1320 to 07/15/98 0910

Patient Name: [redacted]
Med Rec #:
Dis Date 07/15/98
Phys-Service: [redacted] *NEUROLOGY

BLOOD-Page 14
Adm: 07/03/98

****

>> CULTURE BLOOD <<
Source: Blood BC Cath-
Coll. Time: 07/03/98 2100
In at: 07/03/98 2110
Acct #: [redacted]
Order Phys: [redacted]
Techs : [redacted]

Out at: 07/11/98 0707
Final [redacted]
Techs: [redacted]

Comment**Cath drawn cultures difficult to evaluate. In the absence of a positive peripheral culture, likely represents contamination.

Comment** A single positive culture with CN Staph usually represents contamination.

COAGULASE NEGATIVE STAPHYLOCOCCI (STAPH SP)
7/5 0745
gm(+) cocci

(MIC - ug/ml)	STAPH SP	
Cefazolin:	S	<=8
Clindamycin:	S	<=0.5
Nafcillin:	S	<=2
Penicillin:	R	>=16

COAGULASE NEGATIVE STAPHYLOCOCCI (STAPH SP)
gm(+) cocci #2

(MIC - ug/ml)	STAPH SP	
Cefazolin:	S	<=8
Clindamycin:	S	<=0.5
Nafcillin:	S	<=2
Penicillin:	S	<=0.03

Lab Director- [redacted] M.D.
** DO NOT DISCARD **
*Discharge Cumulative Trend Report

[redacted]

[redacted]

Thu Jul 16, 1998 12:06 am

Discharge Cumulative Trend Report from 07/03/98 1320 to 07/15/98 0910

Patient Name: [redacted]
Med Rec #: [redacted]
Dis Date 07/15/98
Phys-Service: [redacted] *NEUROLOGY

BLOOD-Page 13
Adm: 07/03/98

****

>> CULTURE BLOOD <<
Source: Blood BC

Coll. Time: 07/03/98 2100 In at: 07/03/98 2110 Acct #: [redacted]
Order Phys: [redacted] Techs : [redacted]

Out at: 07/11/98 0712 Final [redacted] Techs: [redacted]

No growth

Lab Director- [redacted] M.D.
** DO NOT DISCARD **
*Discharge Cumulative Trend Report

[redacted]

[redacted]

Sat Jul 18, 1998 12:20 am
Post Discharge Work Report

Pat Name: [redacted]
Unit #/Acct #:
Dis Date
Phys-Service:

****

>> CULTURE BLOOD <<

Specimen: Blood BC Cath-
Coll. Time: 07/05/98 0135 In at: 07/05/98 0148 Acct #: [redacted]
Ordering Phys: [redacted] Techs : [redacted]
Out at: 07/17/98 1452 Final [redacted] Techs: [redacted]

No growth

>> CULTURE BLOOD <<

Specimen: Blood BC
Coll. Time: 07/05/98 0140 In at: 07/05/98 0149 Acct #: [redacted]
Ordering Phys: [redacted] Techs : [redacted]
Out at: 07/17/98 1452 Final [redacted] Techs: [redacted]

No growth

End of Report - 07/18/98 00:20

Lab Director- [redacted] M.D.

*Post Discharge Work Report

[redacted]

[redacted]

Thu Jul 16, 1998 12:06 am

Discharge Cumulative Trend Report from 07/03/98 1320 to 07/15/98 0910

Patient Name: [redacted]
Med Rec #: [redacted] BLOOD-Page 15
Dis Date 07/15/98 Adm: 07/03/98
Phys-Service: [redacted] *NEUROLOGY

****

>> CULTURE BLOOD <<
Source: Blood BC Cath-
Coll. Time: 07/05/98 0135 In at: 07/05/98 0148 Acct #: [redacted]
Order Phys: [redacted] Techs : [redacted]
Out at: 07/06/98 0627 Preliminary 1 [redacted] Techs: [redacted]

No growth

>> CULTURE BLOOD <<
Source: Blood BC
Coll. Time: 07/05/98 0140 In at: 07/05/98 0149 Acct #: [redacted]
Order Phys: [redacted] Techs : [redacted]
Out at: 07/06/98 0627 Preliminary 1 [redacted] Techs: [redacted]

No growth

>> CULTURE BLOOD <<
Source: Blood BC Cath-
Coll. Time: 07/06/98 1730 In at: 07/06/98 1739 Acct #: [redacted]
Order Phys: [redacted] Techs : [redacted]
Out at: 07/14/98 0625 Final [redacted] Techs: [redacted]

No growth

Lab Director- [redacted]
** DO NOT DISCARD **
*Discharge Cumulative Trend Report

[redacted]

[redacted]

Thu Jul 16, 1998 12:06 am

Discharge Cumulative Trend Report from 07/03/98 1320 to 07/15/98 0910

Patient Name: [redacted]
Med Rec #: [redacted]
Dis Date 07/15/98
Phys-Service: [redacted] *NEUROLOGY

BLOOD-Page 16
Adm: 07/03/98

****

>> CULTURE BLOOD <<
Source: Blood BC

Coll. Time: 07/06/98 1735 In at: 07/06/98 1739 Acct #: [redacted]
Order Phys: [redacted] Techs : [redacted]

Out at: 07/14/98 0625 Final [redacted] Techs: [redacted]

No growth

Lab Director- [redacted] M.D.
** DO NOT DISCARD **
*Discharge Cumulative Trend Report

[redacted]

[redacted]

Thu Jul 16, 1998 12:06 am
Discharge Cumulative Trend Report from 07/03/98 1320 to 07/15/98 0910
Patient Name: [redacted] RESPIRATORY-Page 18
Med Rec #: [redacted] Adm: 07/03/98
Dis Date 07/15/98
Phys-Service: [redacted] *NEUROLOGY

****

>> CULTURE RESPIRATORY <<
Source: Sputum Trach/Endo-10ml

Coll. Time: 07/07/98 0430 In at: 07/07/98 0654 Acct #: [redacted]
Order Phys: [redacted] Techs : [redacted]

Out at: 07/09/98 0830 Final [redacted] Techs: [redacted]

*** Result may be misleading. Microscopic exam indicates excessive oropharyngeal contamination. ***

CULTURE
Light growth resembling oral flora

CITROBACTER FREUNDII COMPLEX (CITROBACTER)
Light gm(-) rod, enteric-like #1

(MIC - ug/ml)	CITROBACTER	
Amp/Sulbactam:	I	16/8
Ampicillin:	R	>=32
Cefazolin:	R	>=32
Ceftriaxone:	S	<=8
Ciprofloxacin:	S	<=0.5
Gentamicin:	S	<=0.5
Piperacillin:	S	<=8
Trimeth/sulfa:	S	<=10

KLEBSIELLA PNEUMONIAE (KLEB PNEUMO)
Light gm(-) rod, enteric-like #2

(MIC - ug/ml)	KLEB PNEUMO	
Amp/Sulbactam:	I	16/8
Ampicillin:	R	>=32
Cefazolin:	S	<=8
Ciprofloxacin:	S	<=0.5
Gentamicin:	S	<=0.5
Piperacillin:	S	<=8
Trimeth/sulfa:	S	<=10

Lab Director- [redacted] M.D.
** DO NOT DISCARD **
*Discharge Cumulative Trend Report

[redacted]

[redacted]

[redacted]

Thu Jul 16, 1998 12:06 am
Discharge Cumulative Trend Report from 07/03/98 1320 to 07/15/98 0910
Patient Name: [redacted] RESPIRATORY-Page 19
Med Rec #: [redacted] Adm: 07/03/98
Dis Date 07/15/98
Phys-Service: [redacted] - *NEUROLOGY

****

>> LEGIONELLA AG URINE <<
Source: Urine, Random

Coll. Time: 07/08/98 1920 In at: 07/08/98 1934 Acct #: [redacted]
Order Phys: [redacted] Techs : [redacted]

Out at: 07/09/98 1156 Final [redacted] Techs: [redacted]

No Legionella pneumophila serogroup 1 antigen detected

>> CULTURE RESPIRATORY <<
Source: Sputum Trach/Endo-2 ml

Coll. Time: 07/10/98 1140 In at: 07/10/98 1212 Acct #: [redacted]
Order Phys: [redacted] Techs : [redacted]

Out at: 07/12/98 1017 Final [redacted] Techs: [redacted]

GRAM STAIN
Moderate pmn's
No bacteria seen
CULTURE
No growth

>> CULTURE RESPIRATORY <<
Source: Bronchial Wash-10 ml

Coll. Time: 07/11/98 0935 In at: 07/11/98 0958 Acct #: [redacted]
Order Phys: [redacted] Techs : [redacted]

Out at: 07/13/98 0803 Final [redacted] Techs: [redacted]

GRAM STAIN
Moderate pmn's
No bacteria seen
CULTURE
Bacterial growth resembling oral flora

Lab Director- [redacted] M.D.
** DO NOT DISCARD **
*Discharge Cumulative Trend Report

[redacted]

[redacted]

Thu Jul 16, 1998 12:06 am

Discharge Cumulative Trend Report from 07/03/98 1320 to 07/15/98 0910

Patient Name: [redacted] RESPIRATORY-Page 17
Med Rec #: Adm: 07/03/98
Dis Date 07/15/98
Phys-Service: [redacted] *NEUROLOGY

****

>> CULTURE RESPIRATORY <<
Source: Bronchial Wash-5ml

Coll. Time: 07/05/98 1030 In at: 07/05/98 1134 Acct #: [redacted]
Order Phys: [redacted] Techs : [redacted]

Out at: 07/07/98 0947 Final [redacted] Techs: [redacted]

GRAM STAIN
Many pmn's
No bacteria seen
CULTURE
No growth

Lab Director- [redacted] M.D.
** DO NOT DISCARD **
*Discharge Cumulative Trend Report

[redacted]

[redacted]

Thu Jul 16, 1998 12:06 am
Discharge Cumulative Trend Report from 07/03/98 1320 to 07/15/98 0910
Patient Name: [redacted] ROUTINE/ANAEROBIC-Page 20
Med Rec #: Adm: 07/03/98
Dis Date 07/15/98
Phys-Service: [redacted] *NEUROLOGY

****

>> CULTURE ROUTINE <<
Source: Cath Tip-arterial

Coll. Time: 07/08/98 1415 In at: 07/08/98 1451 Acct #: [redacted]
Order Phys: [redacted] Techs : [redacted]
Out at: 07/12/98 1137 Final [redacted] Techs: [redacted]

No growth

>> CULTURE ROUTINE <<
Source: Cath Tip-triple lumen

Coll. Time: 07/08/98 1920 In at: 07/08/98 1925 Acct #: [redacted]
Order Phys: [redacted] Techs : [redacted]
Out at: 07/12/98 1137 Final [redacted] Techs: [redacted]

No growth

Lab Director- [redacted] M.D.
** DO NOT DISCARD **
*Discharge Cumulative Trend Report

[redacted]

[redacted]

Fri Jul 17, 1998 12:13 am
Post Discharge Work Report

Pat Name: [redacted]
Unit #/Acct #:
Dis Date 07/15/98
Phys-Service: [redacted] *NEUROLOGY

Page: 1

****

>> CULTURE URINE <<

Specimen: Urine Midstream
Coll. Time: 07/15/98 0910 In at: 07/15/98 0928 Acct #: [redacted]
Ordering Phys: [redacted] Techs : [redacted]

Out at: 07/16/98 0740 Final [redacted] Techs: [redacted]

<10,000 col/ml - probable contamination. No further ID.

End of Report - 07/17/98 00:13

Lab Director- [redacted] M.D.

*Post Discharge Work Report

[redacted]

[redacted]

Thu Jul 16, 1998 12:06 am

Discharge Cumulative Trend Report from 07/03/98 1320 to 07/15/98 0910

Patient Name: [redacted] URINARY TRACT-Page 21
Med Rec #: Adm: 07/03/98
Dis Date 07/15/98
Phys-Service: [redacted] *NEUROLOGY

****

>> CULTURE URINE <<
Source: Urine Cath Indwell

Coll. Time: 07/03/98 1540 In at: 07/03/98 1710 Acct #: [redacted]
Order Phys: [redacted] Techs : [redacted]

Out at: 07/05/98 0807 Final [redacted] Techs: [redacted]

No growth (<100 col/ml)

>> CULTURE URINE <<
Source: Urine Cath Indwell

Coll. Time: 07/06/98 1920 In at: 07/06/98 1935 Acct #: [redacted]
Order Phys: [redacted] Techs : [redacted]

Out at: 07/09/98 0949 Final [redacted] Techs: [redacted]

CANDIDA ALBICANS
10,000 col/ml
yeast

>> CULTURE URINE <<
Source: Urine Cath Indwell

Coll. Time: 07/10/98 1140 In at: 07/10/98 1216 Acct #: [redacted]
Order Phys: [redacted] Techs : [redacted]

Out at: 07/11/98 1030 Final [redacted] Techs: [redacted]

GRAM STAIN
Few yeast
CULTURE

CANDIDA ALBICANS
>10,000 but <100,000 col/ml
yeast

Lab Director- [redacted] M.D.
** DO NOT DISCARD **
*Discharge Cumulative Trend Report

[redacted]

[redacted]

Thu Jul 16, 1998 12:06 am
Discharge Cumulative Trend Report from 07/03/98 1320 to 07/15/98 0910
Patient Name: [redacted] URINARY TRACT-Page 22
Med Rec #: [redacted] Adm: 07/03/98
Dis Date 07/15/98
Phys-Service: [redacted] *NEUROLOGY

****

>> CULTURE URINE <<
Source: Urine Cath Indwell

Coll. Time: 07/11/98 1340 In at: 07/11/98 1434 Acct #: [redacted]
Order Phys: [redacted] Techs : [redacted]

Out at: 07/12/98 0742 Final [redacted] Techs: [redacted]

CANDIDA ALBICANS
10,000 col/ml
yeast

>> CULTURE URINE <<
Source: Urine Cath Indwell

Coll. Time: 07/13/98 1405 In at: 07/13/98 1424 Acct #: [redacted]
Order Phys: [redacted] Techs : [redacted]

Out at: 07/15/98 1028 Final [redacted] Techs: [redacted]

CANDIDA ALBICANS
>10,000 but <100,000 col/ml
yeast

Lab Director- [redacted] M.D.
** DO NOT DISCARD **
*Discharge Cumulative Trend Report

[redacted]

[redacted] HR=153 02:23:00 AM 07/03/98 RATE [redacted]

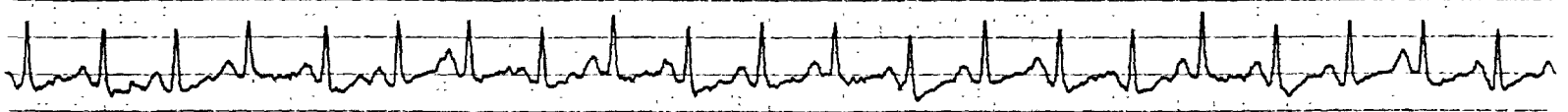

PR: 152 NIBP: 131/70 102 O2: ---

[redacted] ? HR=123 04:00:00 AM 07/03/98 ALL [redacted]



[redacted] HR=114 08:00:00 AM 07/03/98 ALL [redacted]



PR: 114 NIBP: 149/92 116 O2: 96

[redacted] HR=130 09:28:31 AM 07/03/98 MANUAL [redacted]

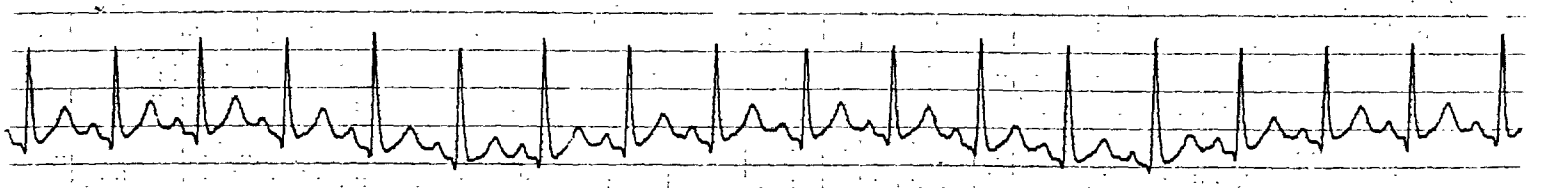

PR: 130 O2: 93

[redacted] ID: [redacted] 03-JUL-1998 14:22 [redacted]

[redacted] 42 yr)
Female Caucasian
Room: [redacted]
Loc [redacted]

Vent. rate	144	BPM
PR interval	136	ms
QRS duration	88	ms
QT/QTc	276/427	ms
P-R-T axes	76 -14	92

Sinus tachycardia
POOR R PROGRESSION - DIFFUSE LOW VOLTAGE
Abnormal ECG

000038

Technician: [redacted]

Meds: Unknown

Referred by: [redacted]

Confirmed by: [redacted]

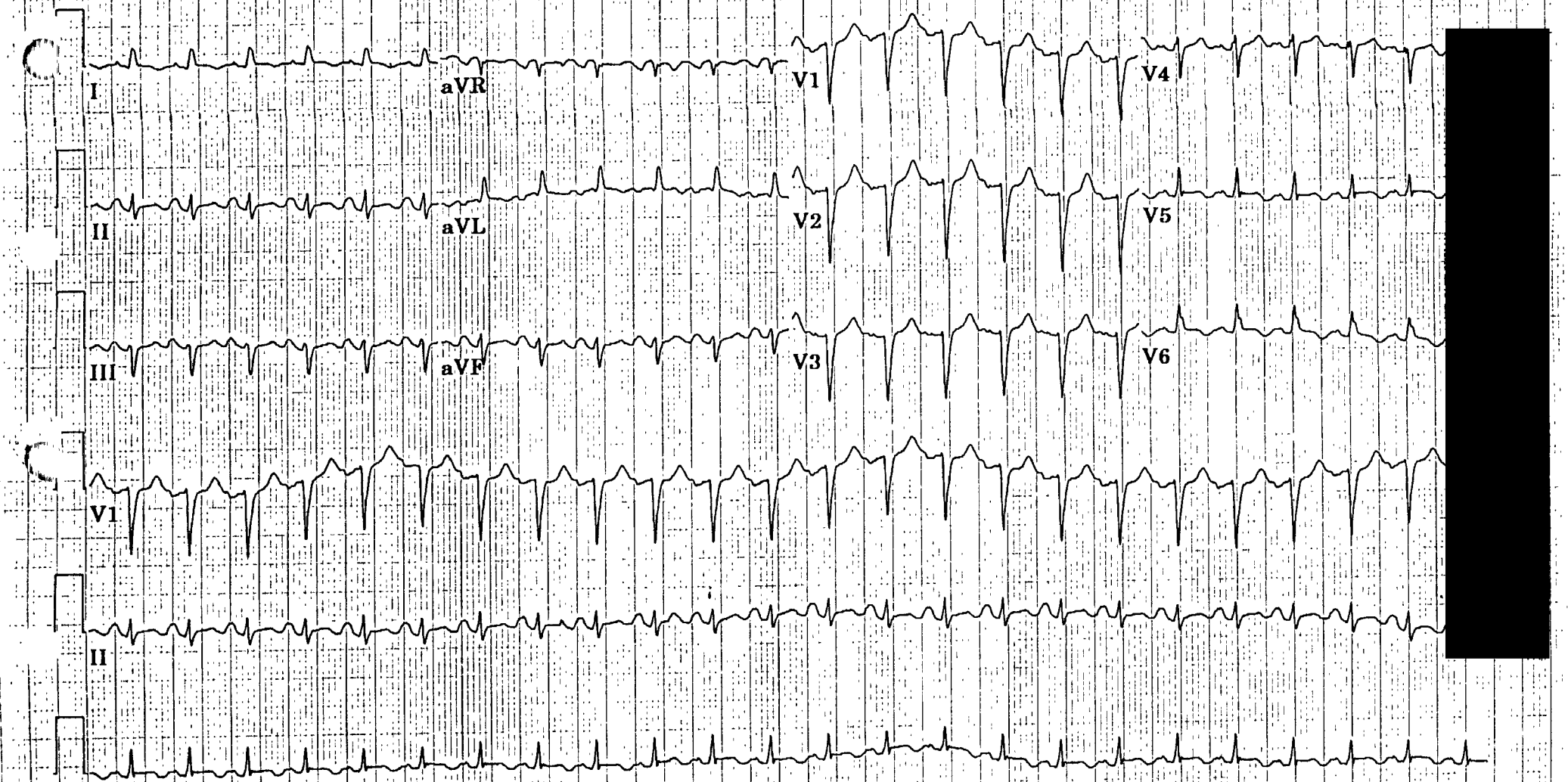

[redacted]

25mm/s 10mm/mV 100Hz [redacted] 12SL 78 CID: 1

EID:5 EDT: 21:43 04-JUL-1998 ORDER:

[redacted]

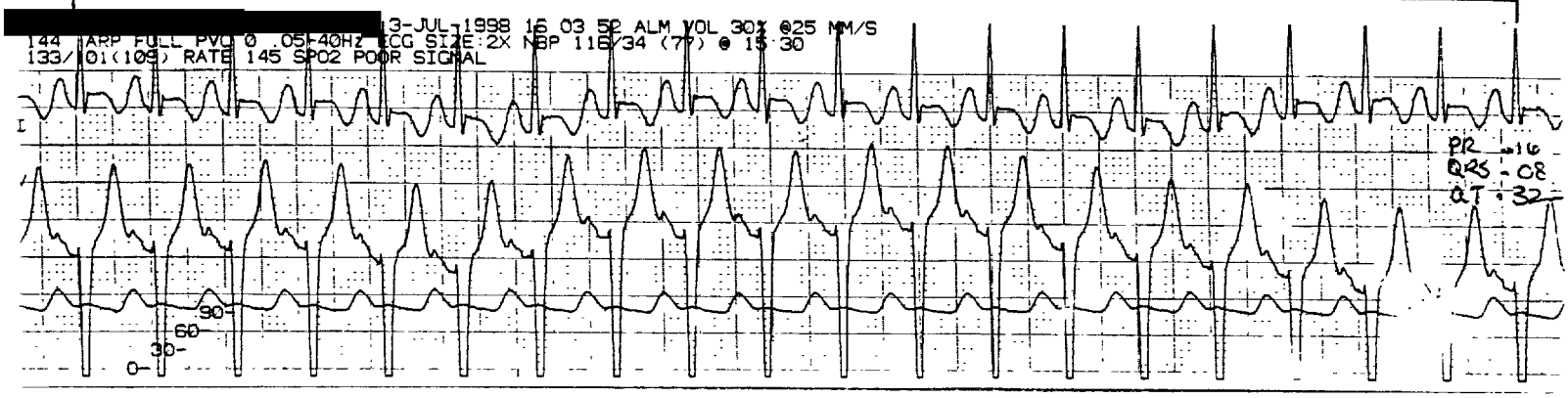

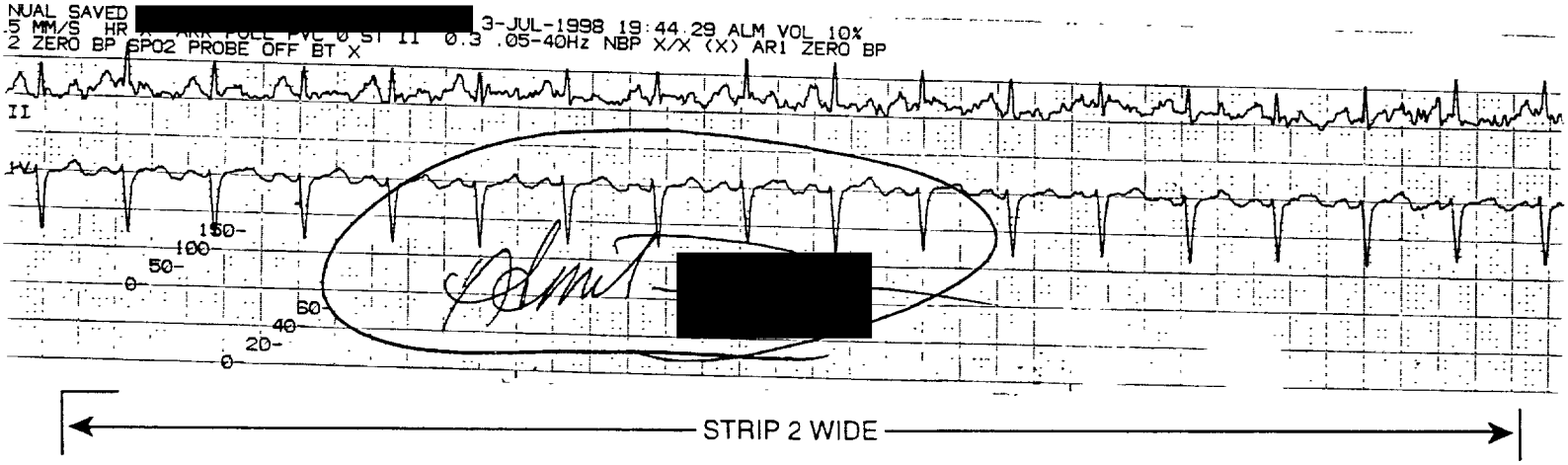

STRIP 2 WIDE

000039

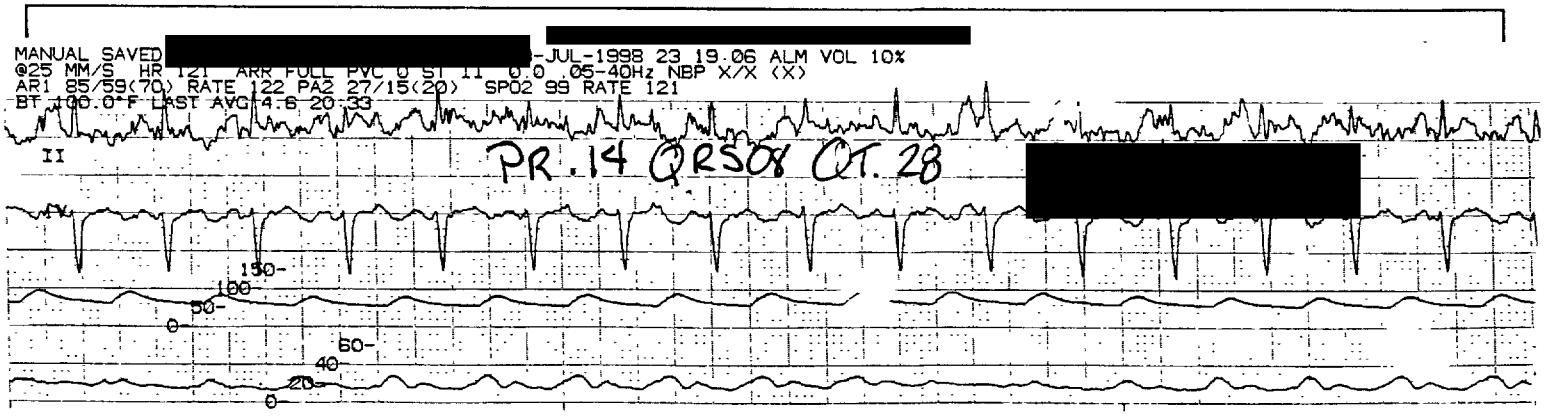

MONITOR STRIPS

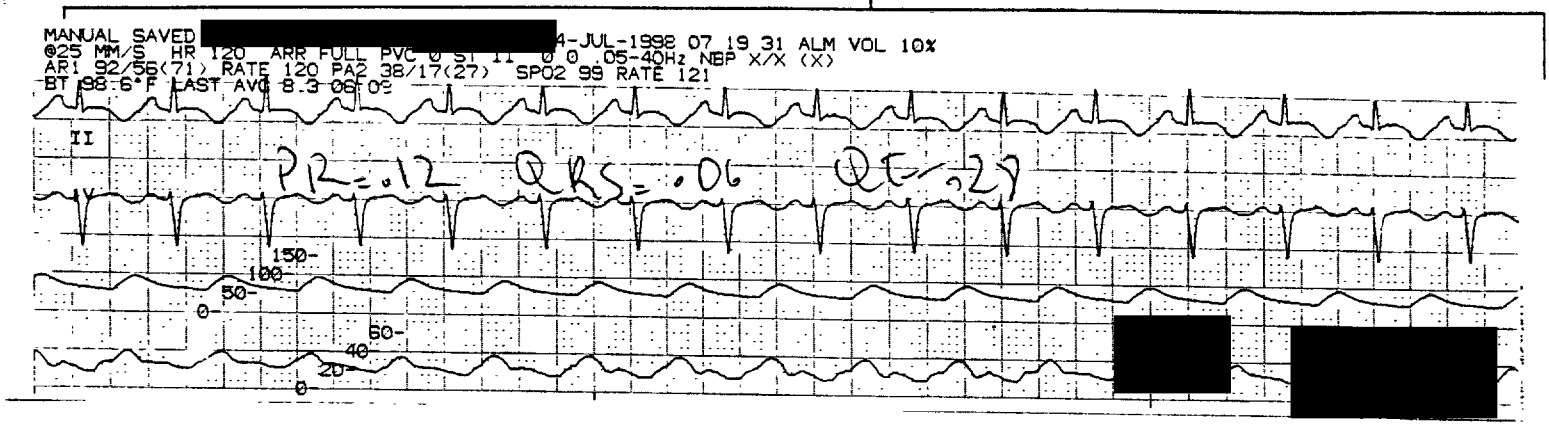

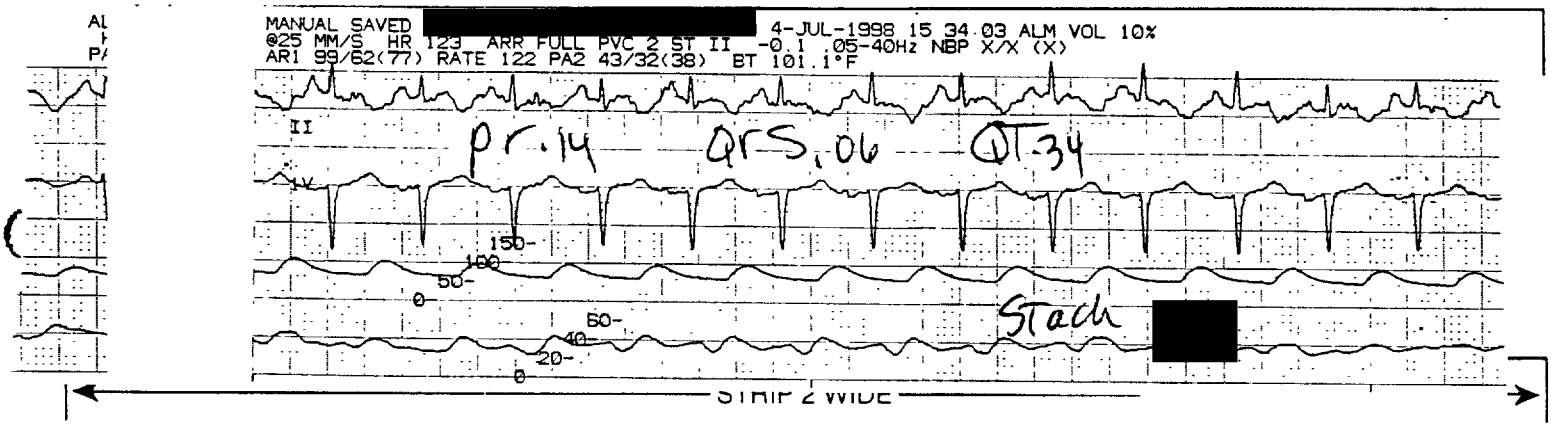

Best Quality FDA

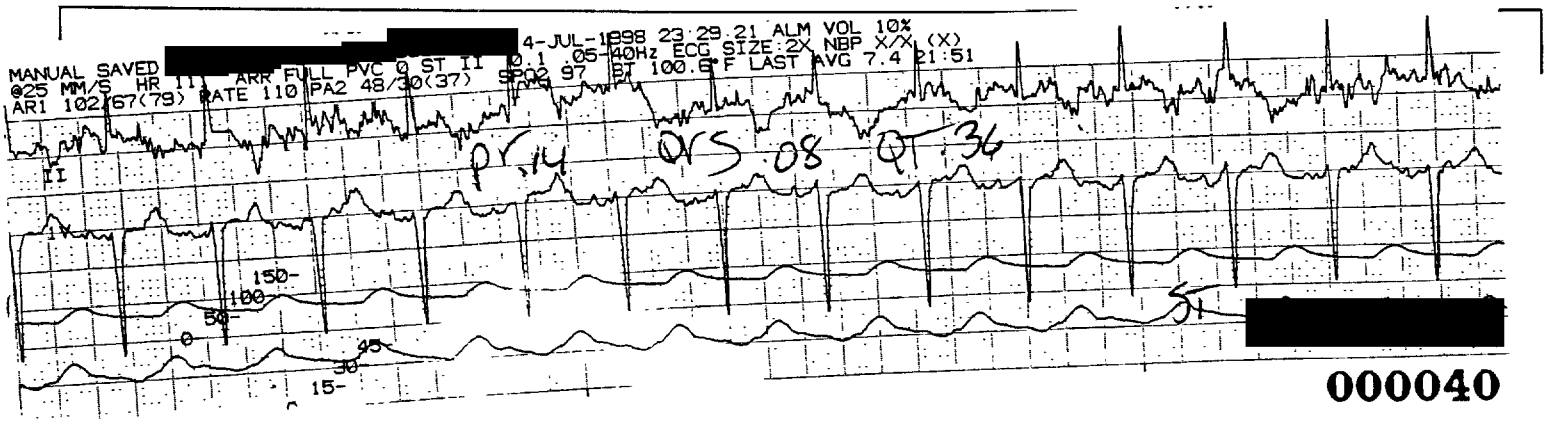

[redacted]

STRIP 1 NARROW AND WIDE

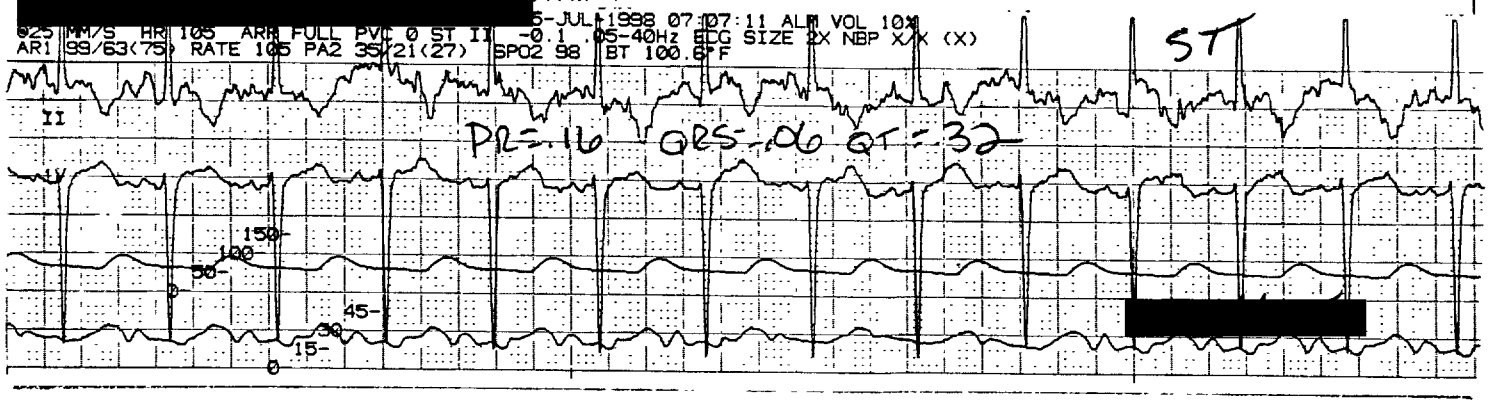

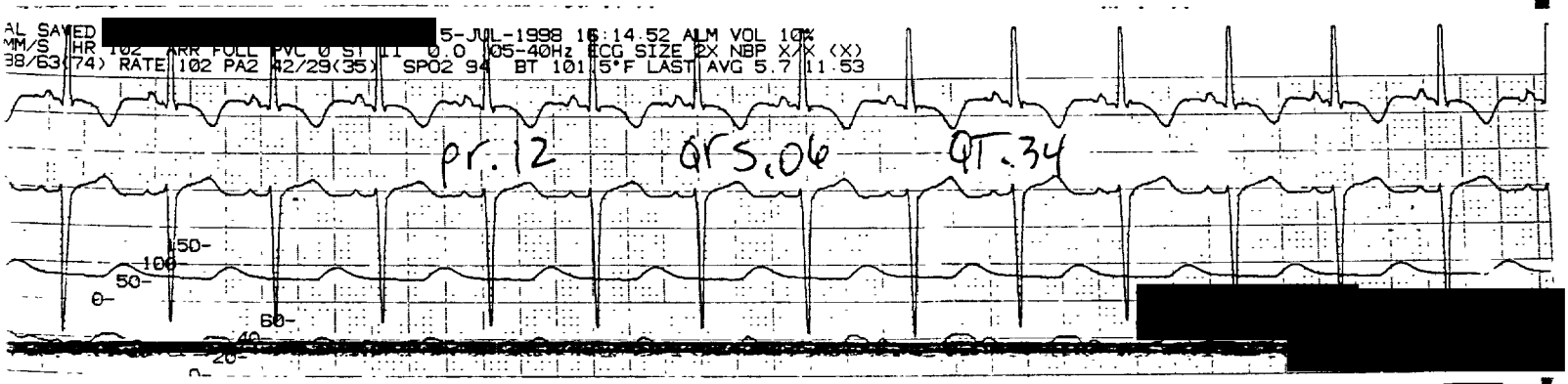

STRIP 2 WIDE

000041

STRIP 3 NARROW ONLY

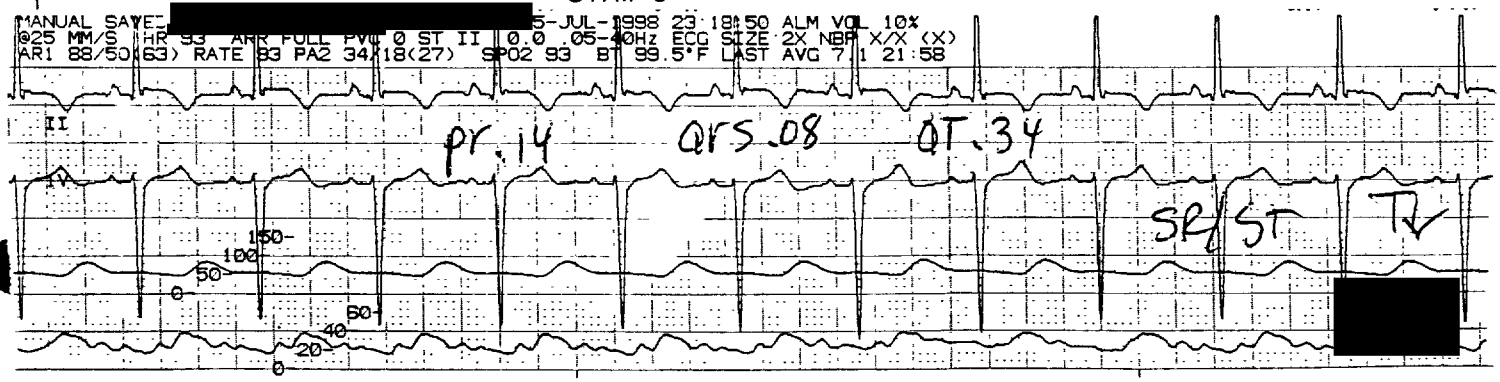

[redacted]

[redacted] (42 yr)
Female Caucasian

Room: [redacted]
Loc: [redacted]

ID: [redacted]

05-JUL-1998 06:36

[redacted]

ROUTINE RECORD

000042

Vent. rate	110	BPM
PR interval	132	ms
QRS duration	72	ms
QT/QTc	328/444	ms
P-R-T axes	-7 73	-77
BP	111/73	

Sinus tachycardia
Low voltage QRS consistent with cardiomyopathy
T wave abnormality
Abnormal ECG

Technician: [redacted]

Referred by: M.D. [redacted]

Confirmed by: [redacted] M.D.

Meds: Unknown

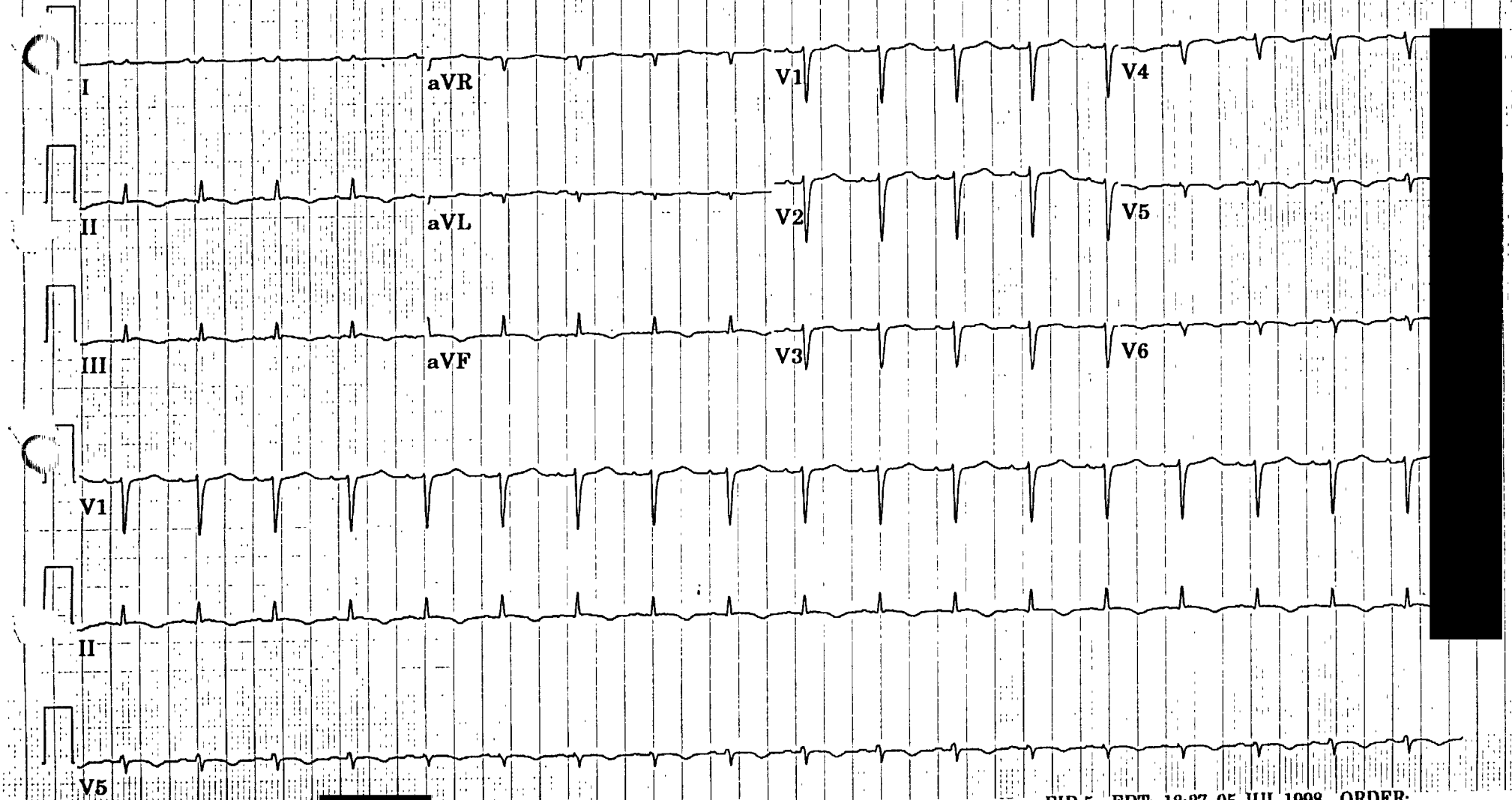

[redacted]

25mm/s 10mm/mV 100Hz [redacted] 12SL 78 CID: 1

EID:5 EDT: 18:27 05-JUL-1998 ORDER:

MONITOR STRIPS

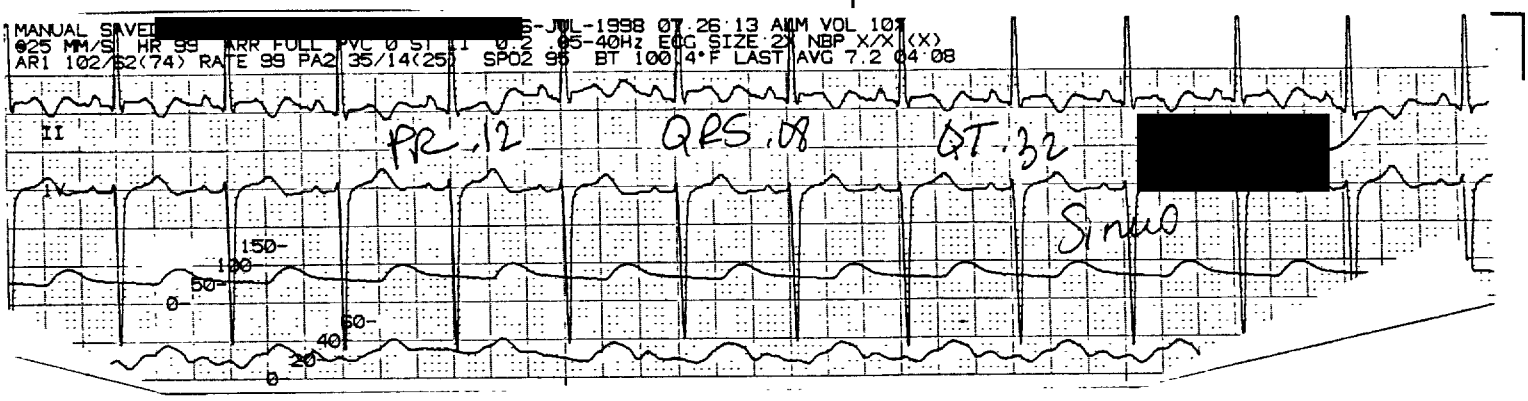

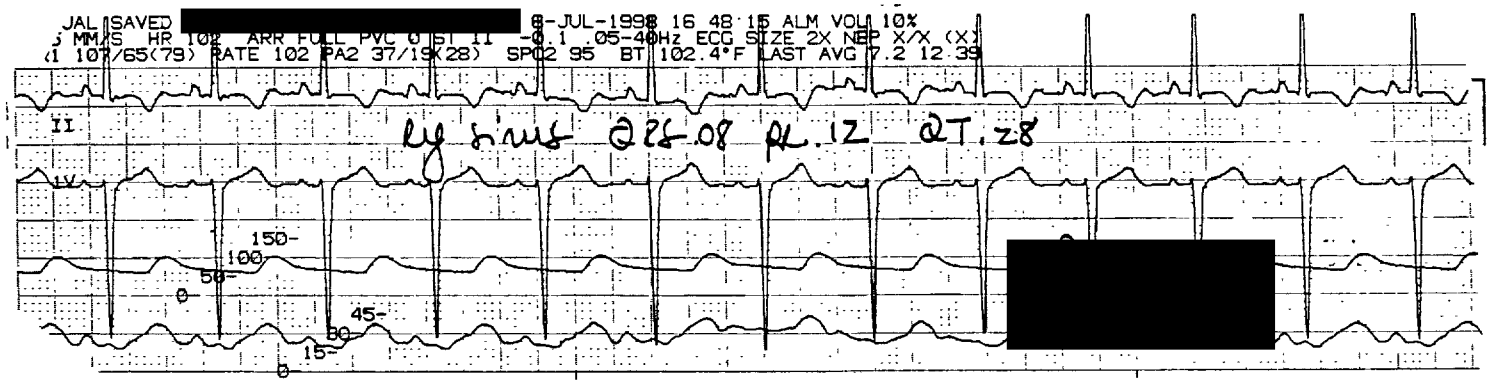

STRIP 2 WIDE

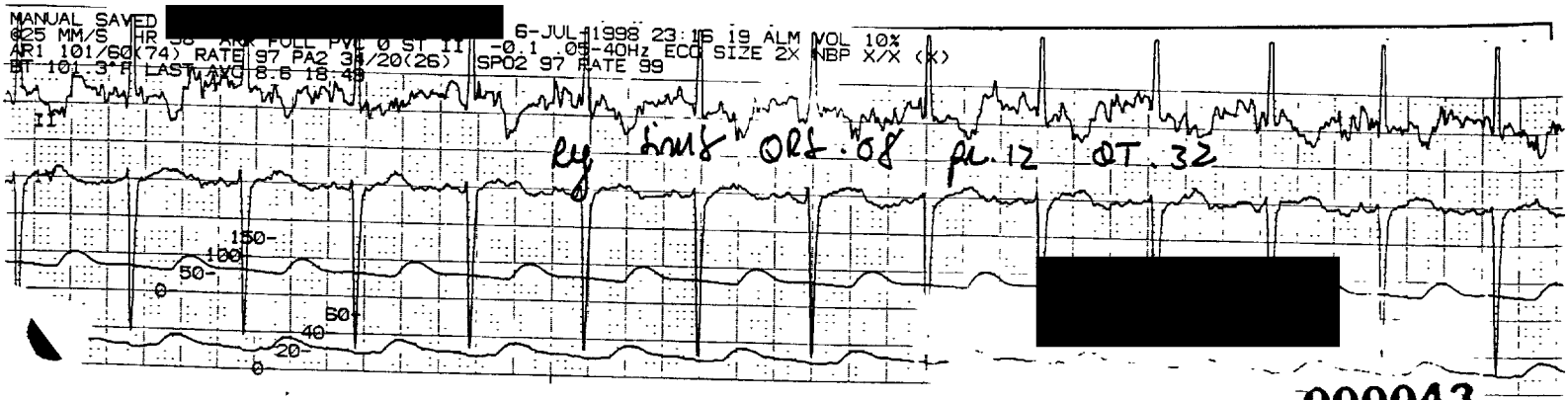

[redacted] MONITOR STRIPS

[redacted]

[redacted] (42 yr)
Female Caucasian

Room [redacted]
Loc: [redacted]

ID: [redacted]

07-JUL-1998 18:05

[redacted] ROUTINE RECORD

Vent. rate	76	BPM
PR interval	128	ms
QRS duration	80	ms
QT/QTc	392/441	ms
P-R-T axes	-11 82	-121
BP	88/47	

Normal sinus rhythm
Low voltage QRS, consider pulmonary disease, pericardial effusion, or normal variant
ST & T WAVE ABNORMALITY,DIFFUSE NONSPECIFIC
Abnormal ECG

000044

Technician: [redacted]

Referred by: M.D. [redacted]

Confirmed by: [redacted] M.D.

Meds: Unknown

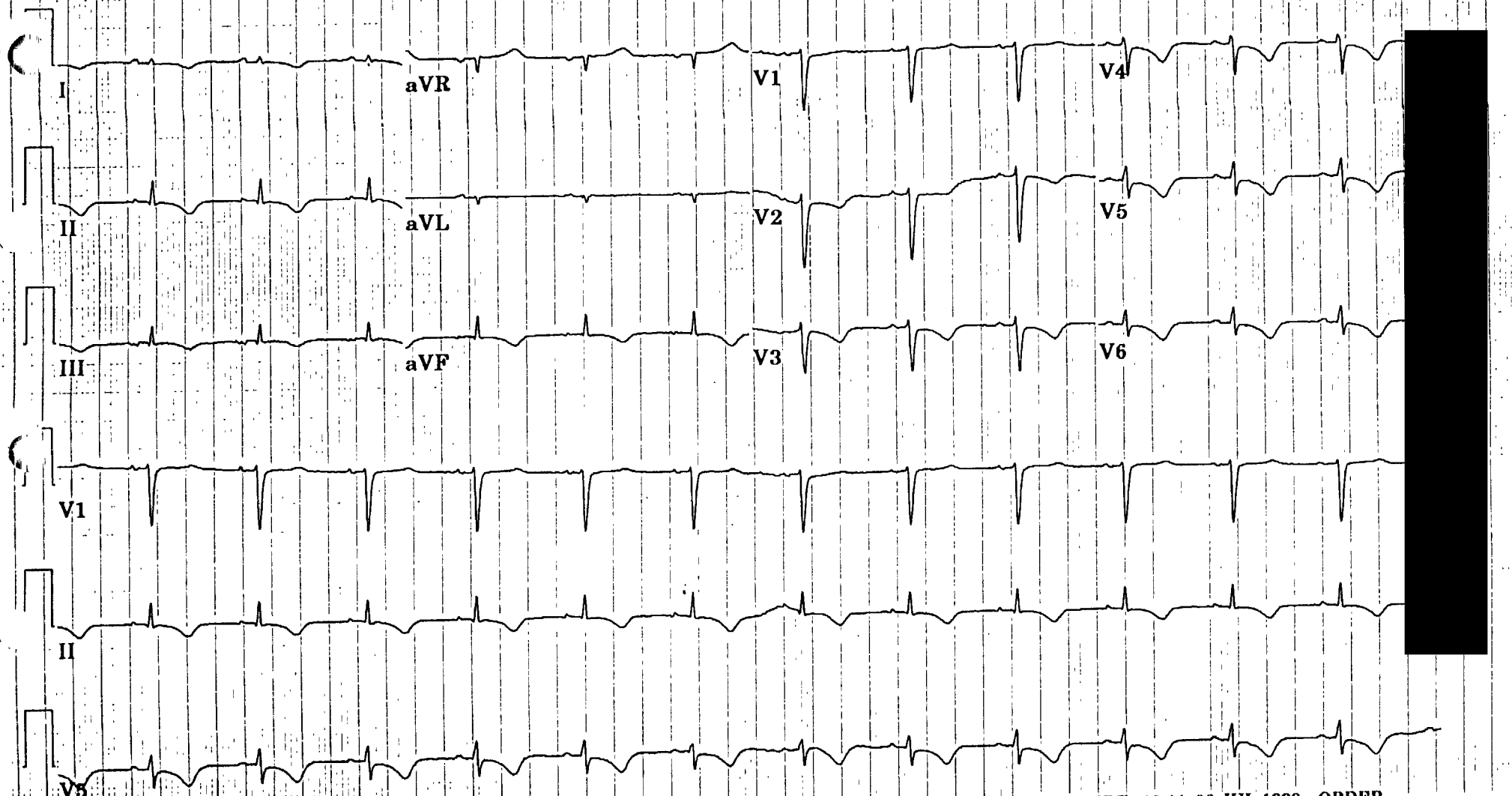

[redacted]

25mm/s 10mm/mV 100Hz [redacted] 12SL 78 CID: 1

EID:1 EDT: 09:11 08-JUL-1998 ORDER:

[redacted]

STRIP 1 NARRO

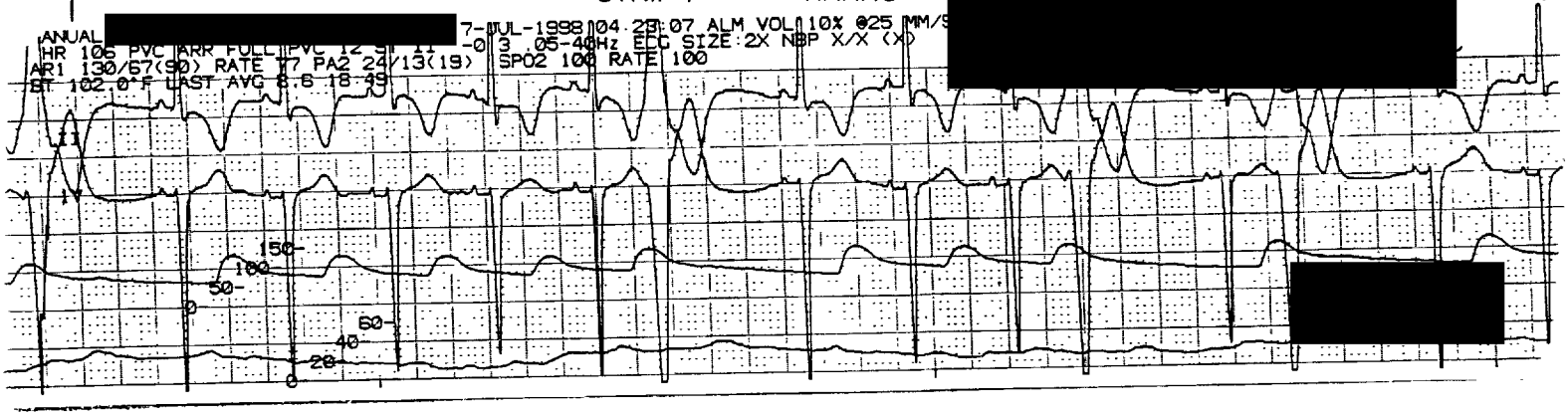

[redacted]

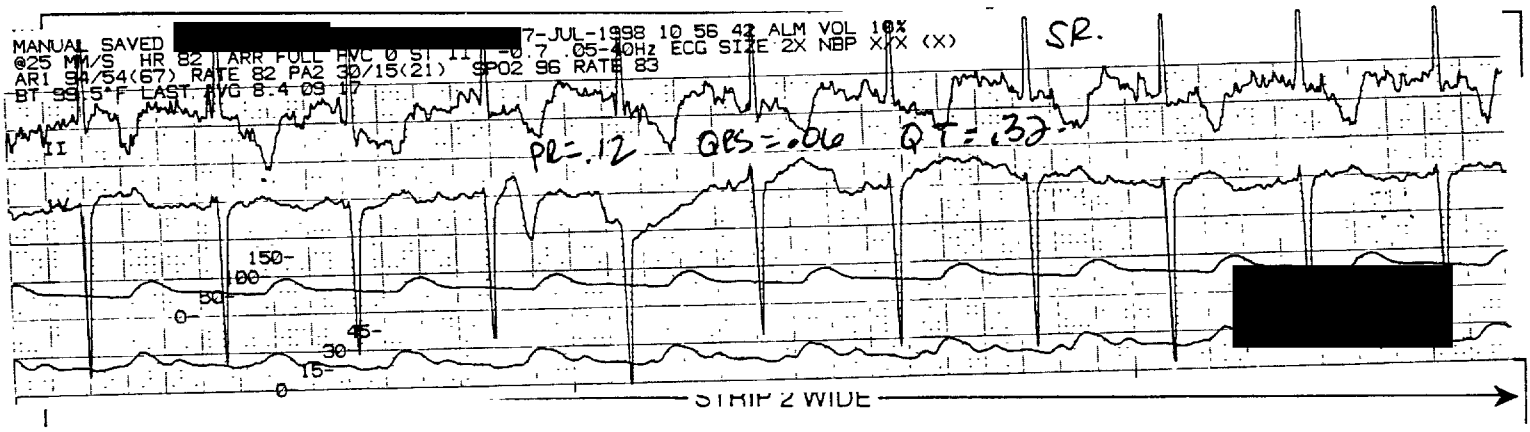

[redacted]

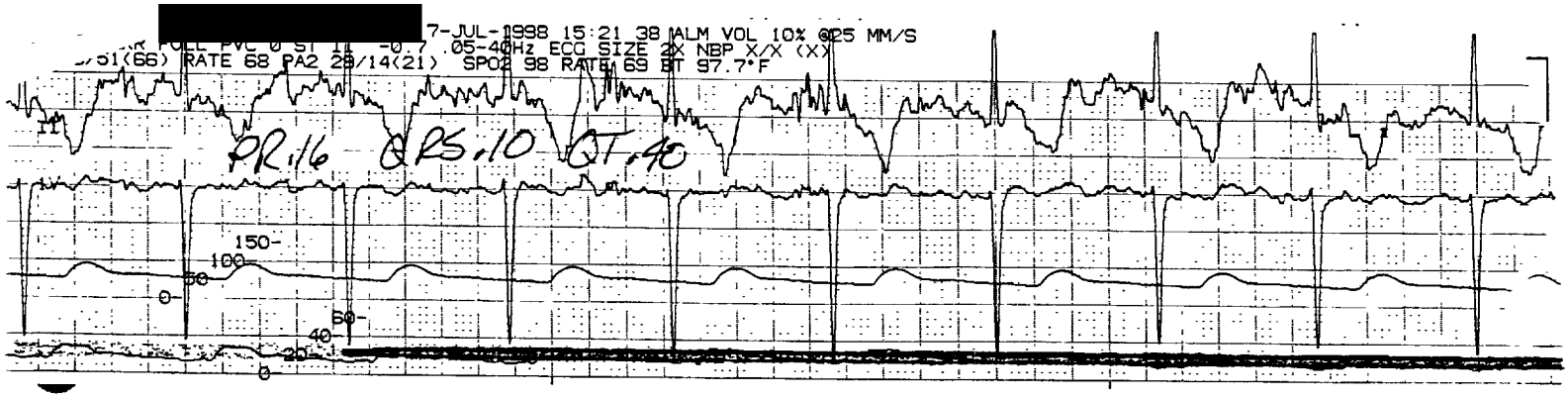

MONITOR STRIPS

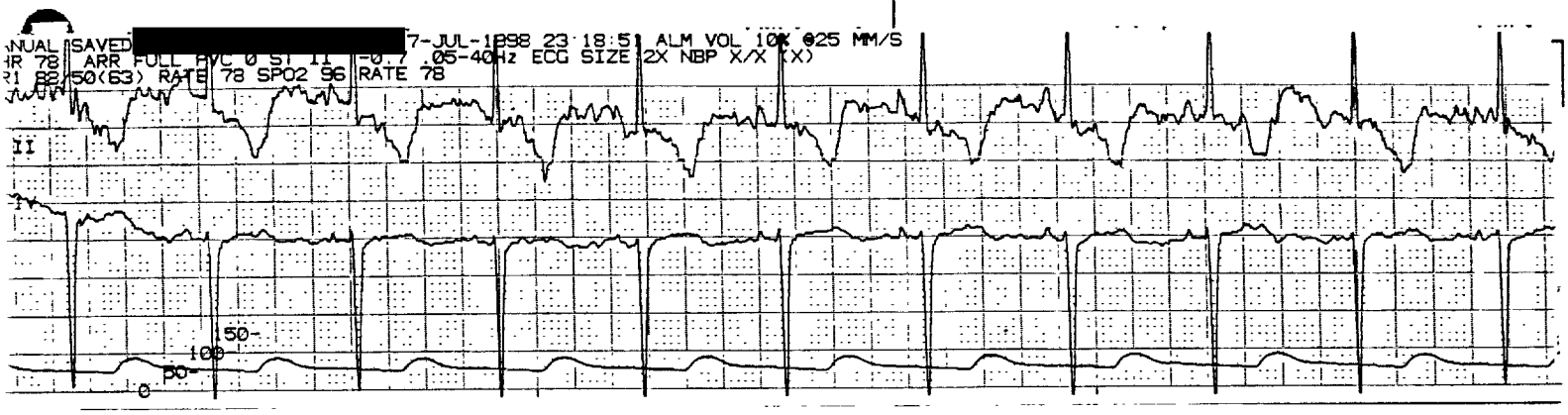

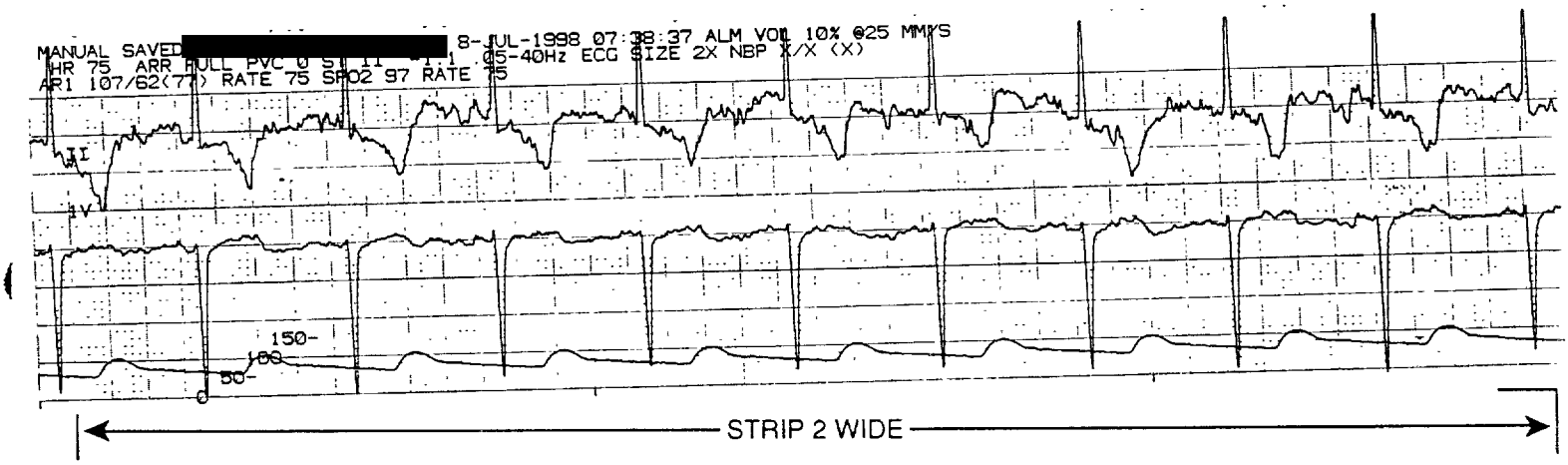

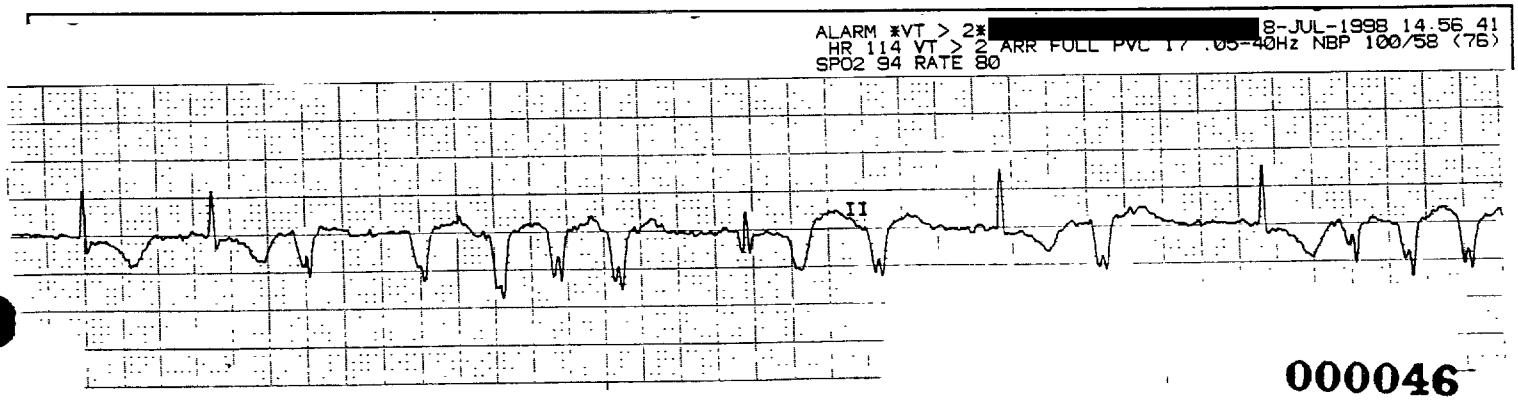

[redacted]

STRIP 1 NARROW AI

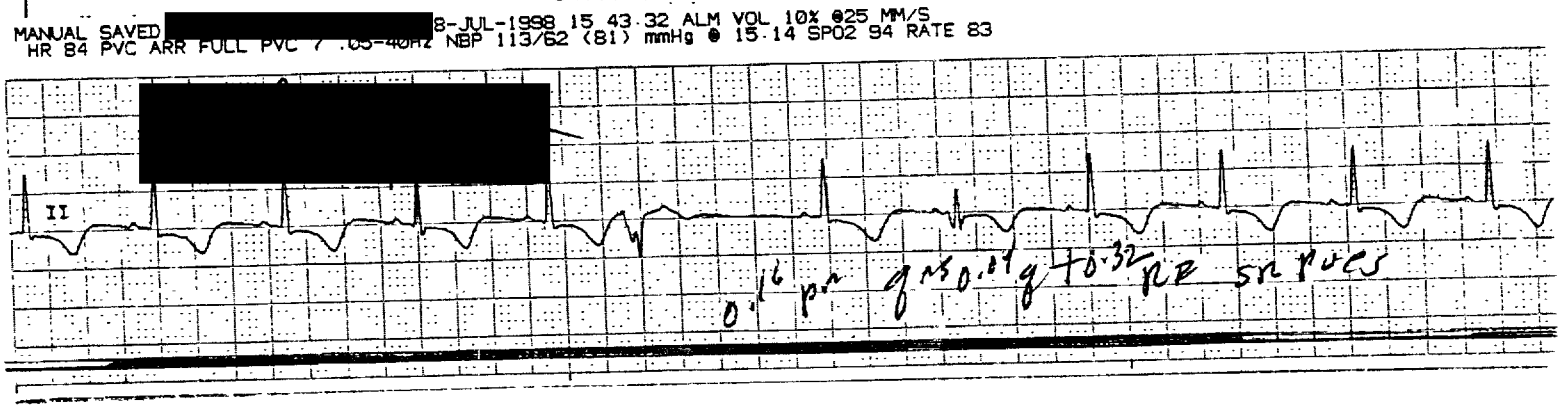

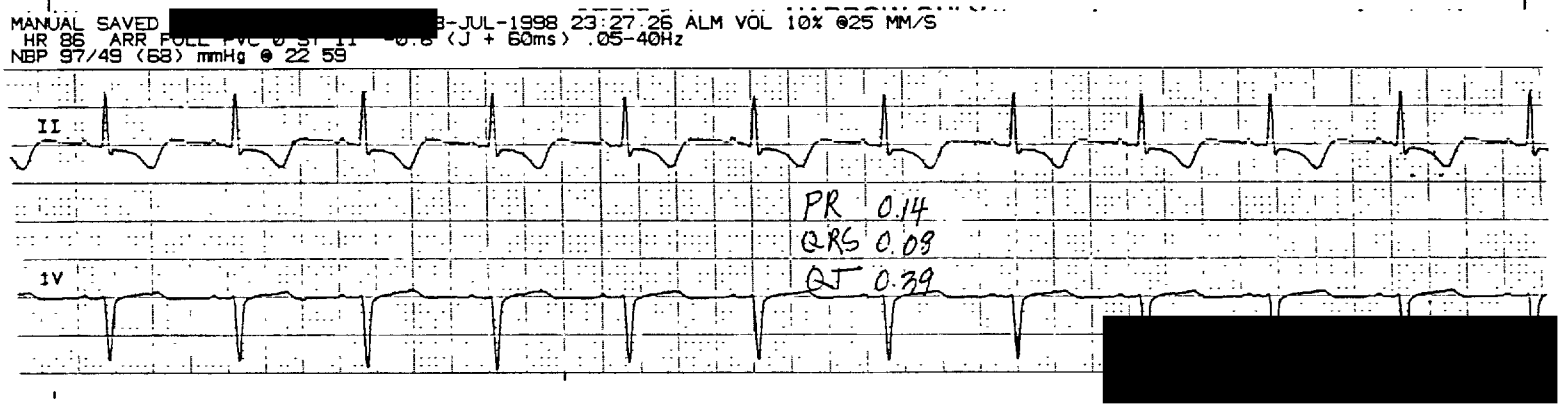

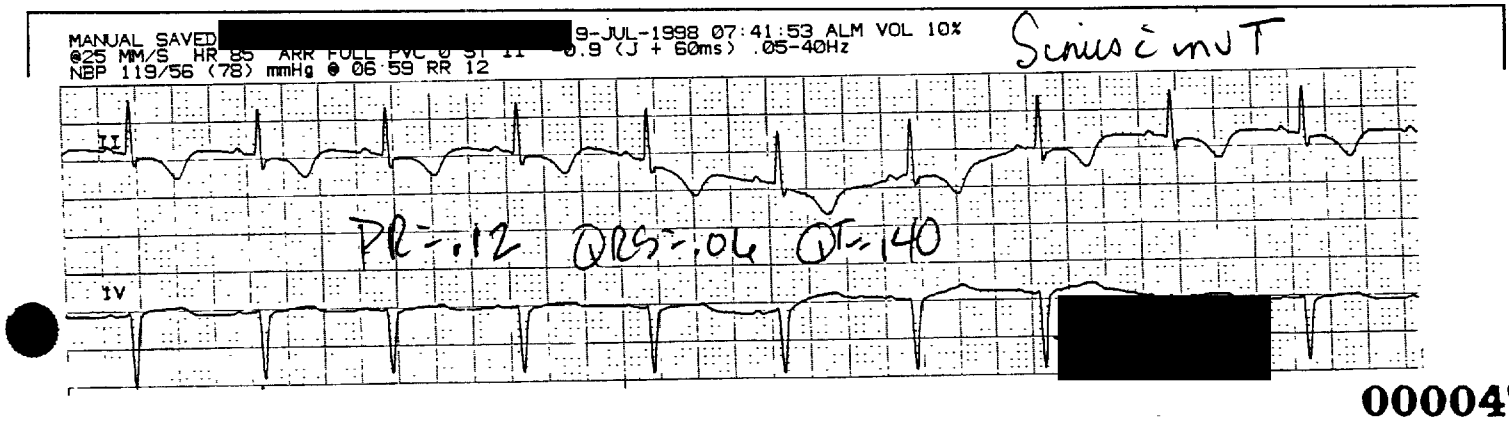

000047

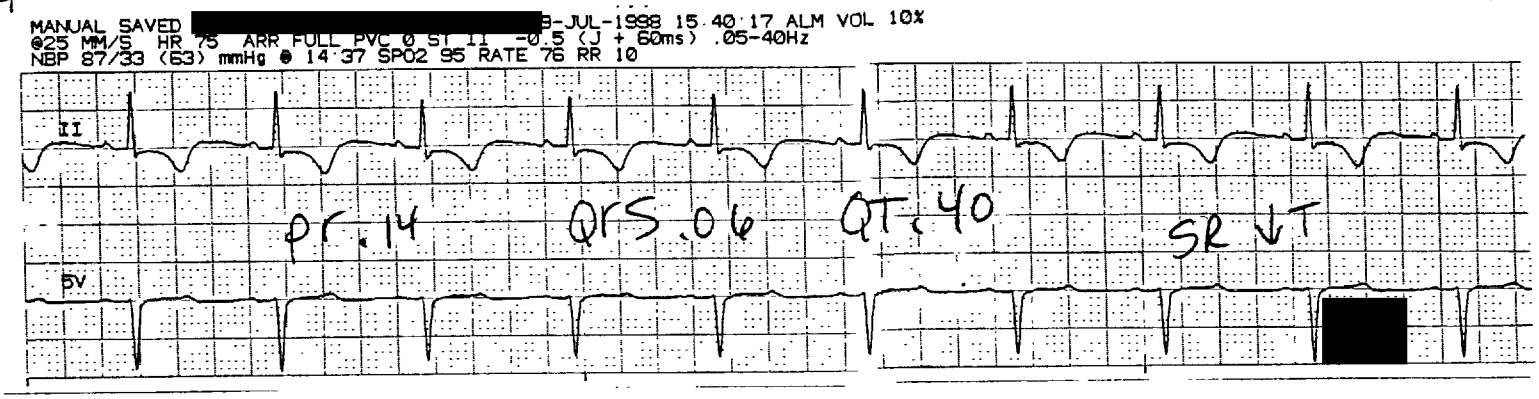
MANUAL SAVED [redacted] 8-JUL-1998 15:40:17 ALM VOL 10%
@25 MM/S HR 75 ARR FULL PVC 0 ST II -0.5 (J + 60ms) .05-40Hz
NBP 87/33 (63) mmHg @ 14:37 SPO2 95 RATE 76 RR 10
II
5V
pr.14 QRS.06 QT.40
SR ↓T

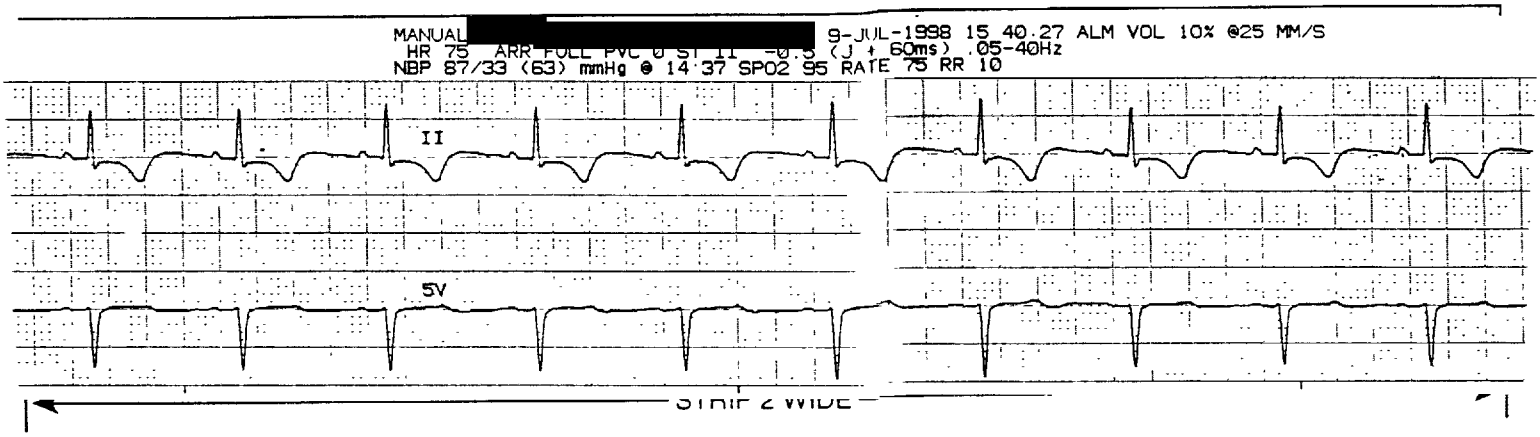
MANUAL [redacted] 9-JUL-1998 15:40:27 ALM VOL 10% @25 MM/S
HR 75 ARR FULL PVC 0 ST II -0.5 (J + 60ms) .05-40Hz
NBP 87/33 (63) mmHg @ 14:37 SPO2 95 RATE 75 RR 10
II
5V
STRIP 2 WIDE

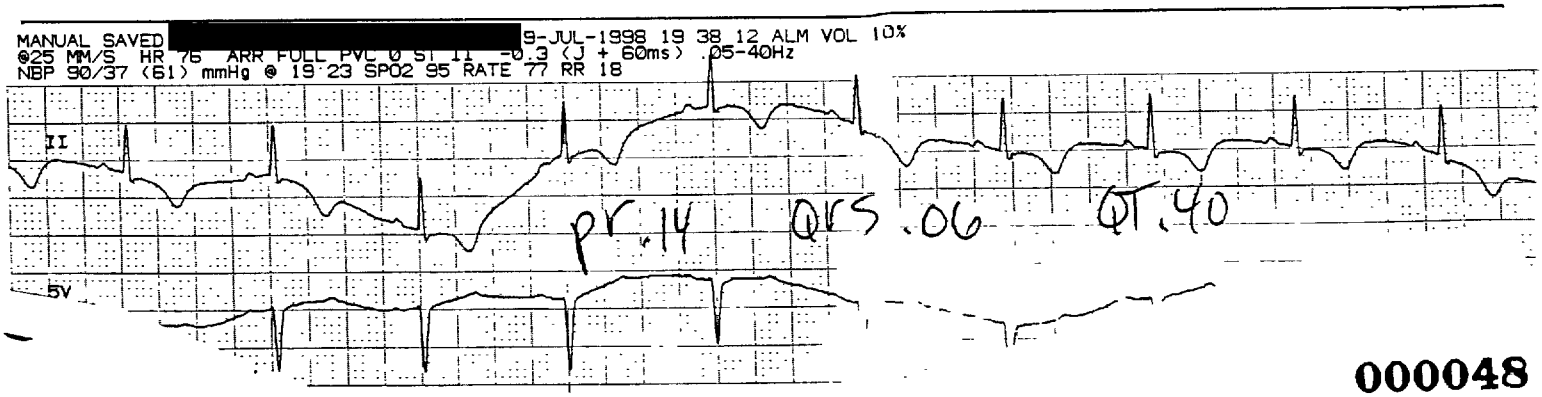
MANUAL SAVED [redacted] 9-JUL-1998 19:38:12 ALM VOL 10%
@25 MM/S HR 76 ARR FULL PVC 0 ST II -0.3 (J + 60ms) .05-40Hz
NBP 90/37 (61) mmHg @ 19:23 SPO2 95 RATE 77 RR 18
II
5V
pr.14 QRS.06 QT.40

MONITOR STRIPS

[redacted]

STRIP 1 NAR

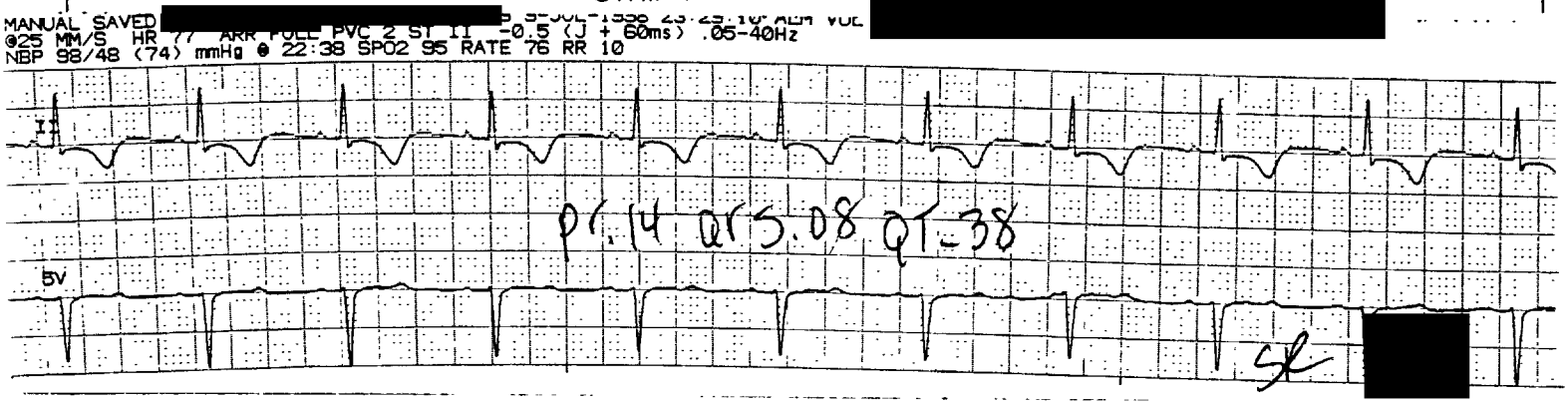

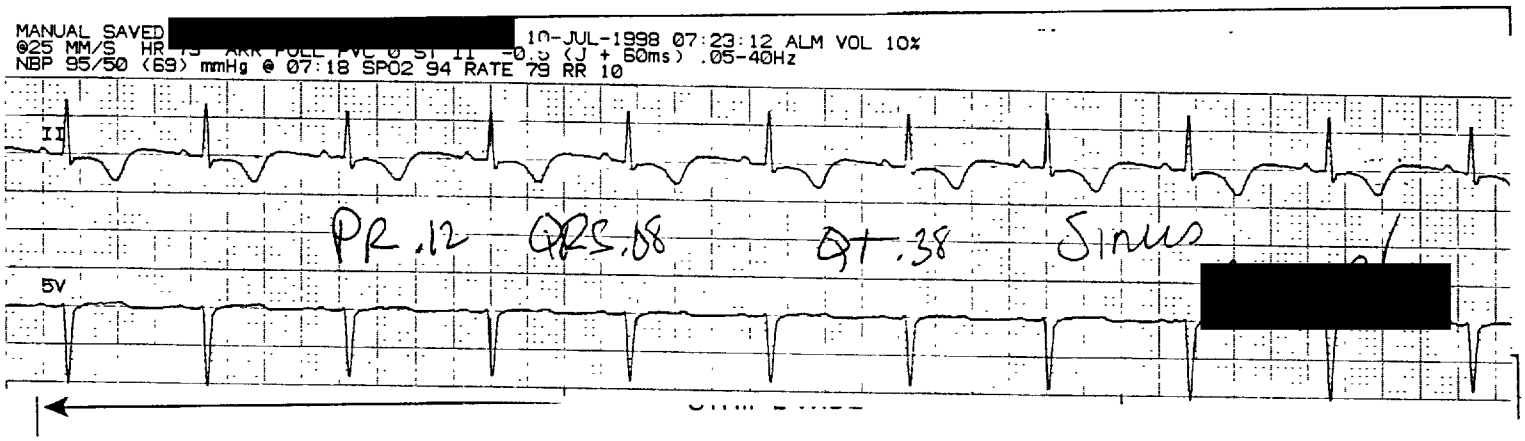

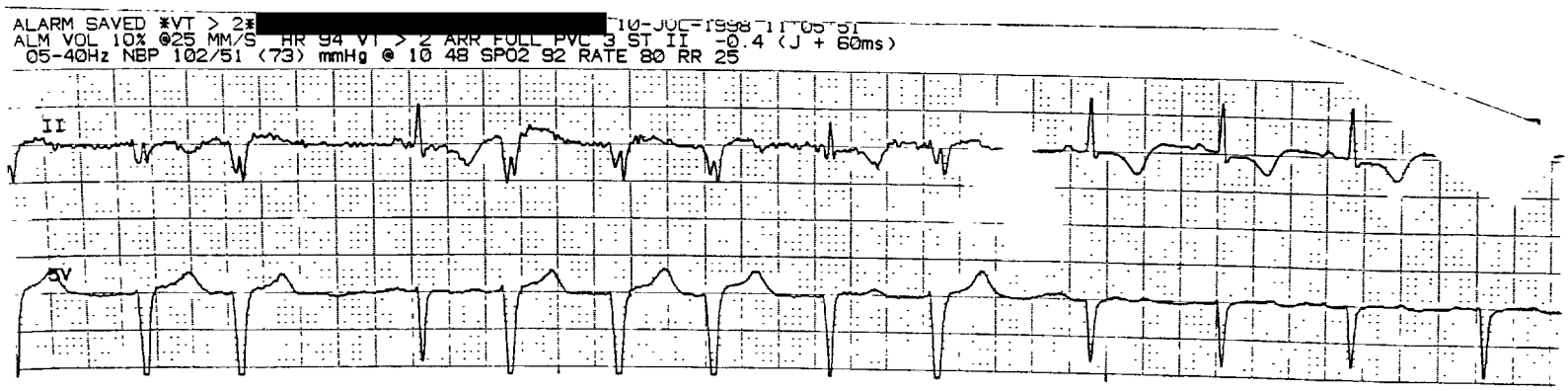

000049

MONITOR STRIPS

[redacted]

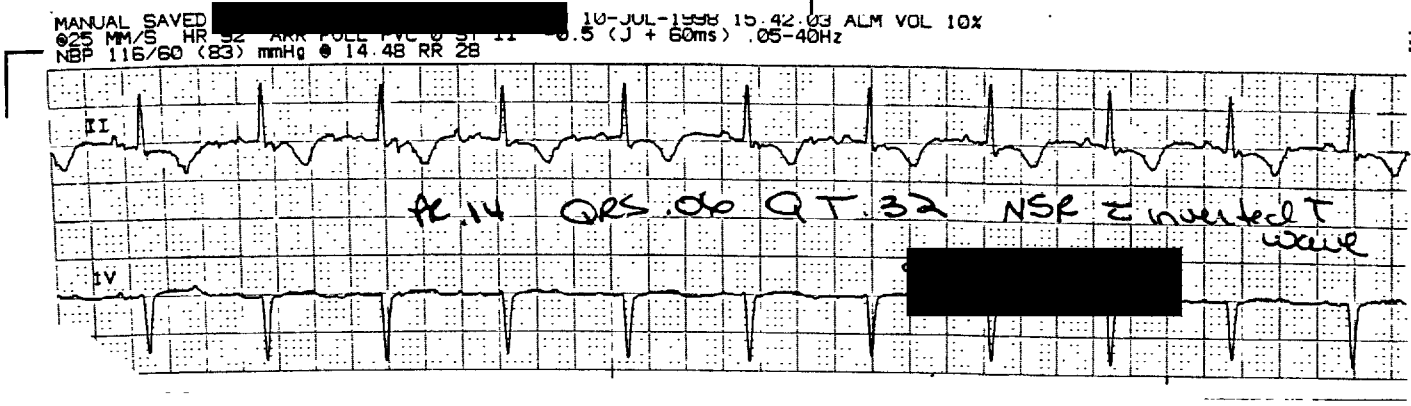

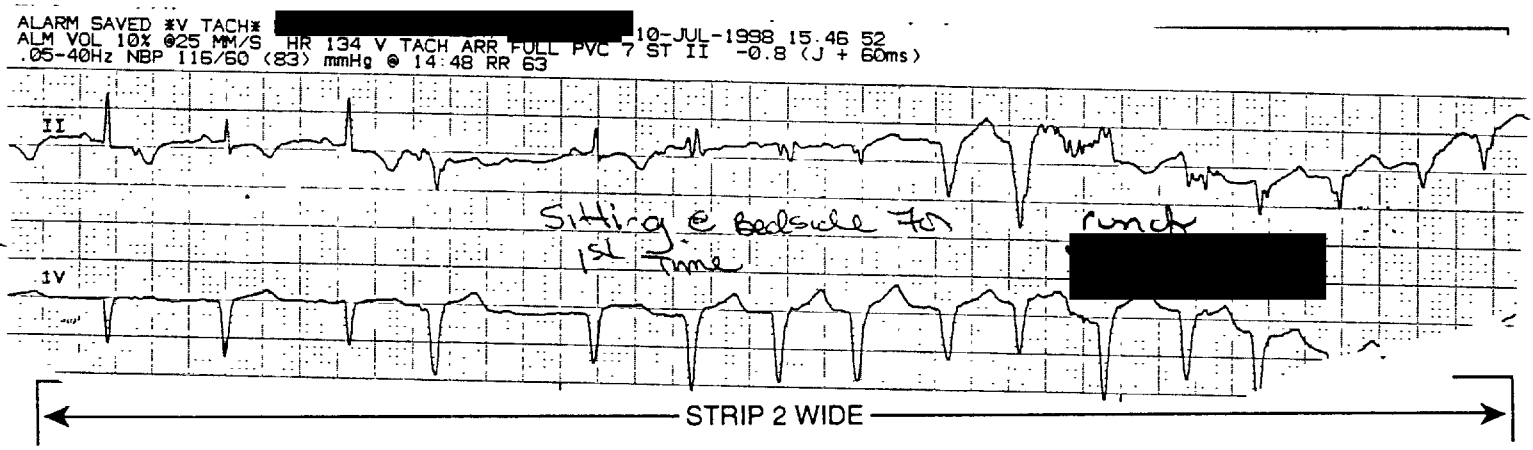

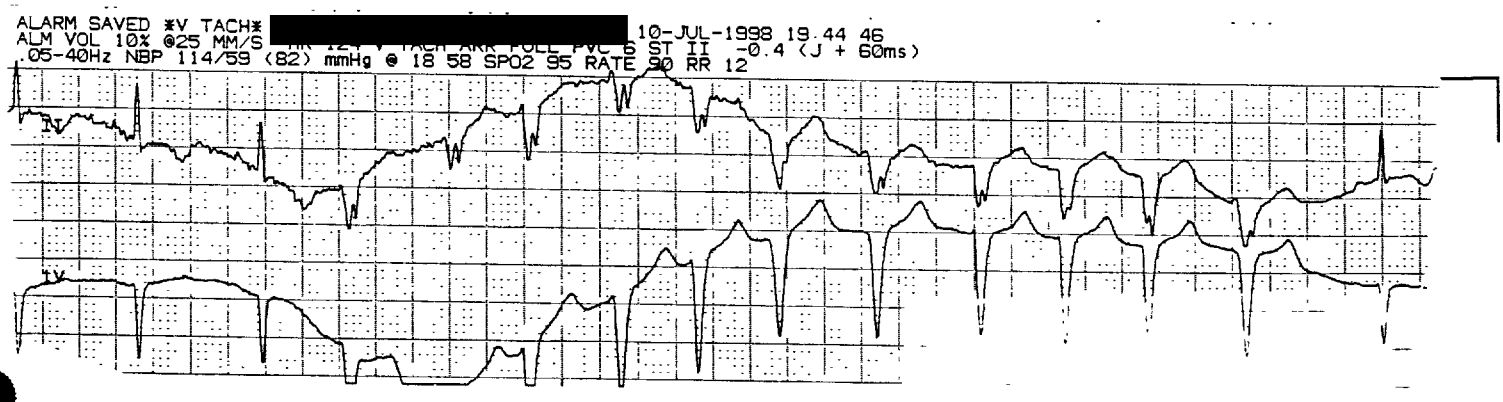

000050

[redacted] MONITOR STRIPS

[redacted]

STRIP 1 NARROW A

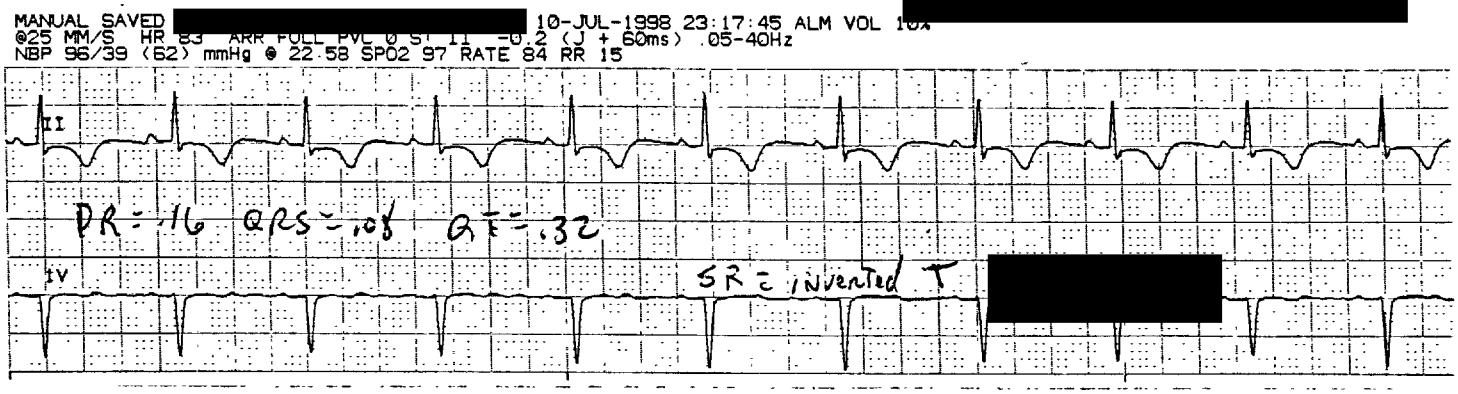

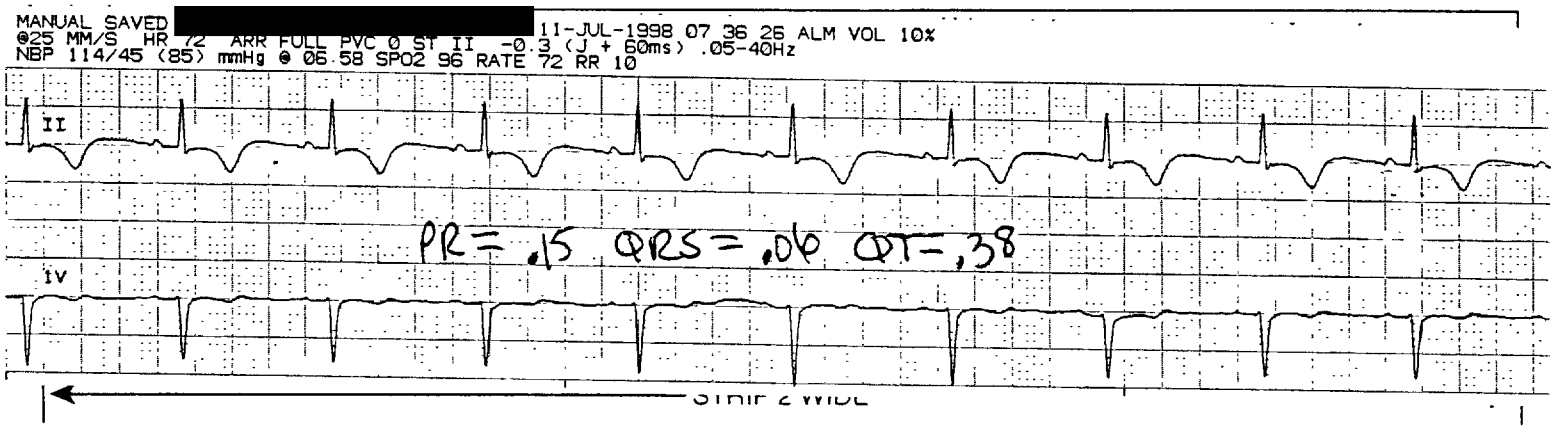

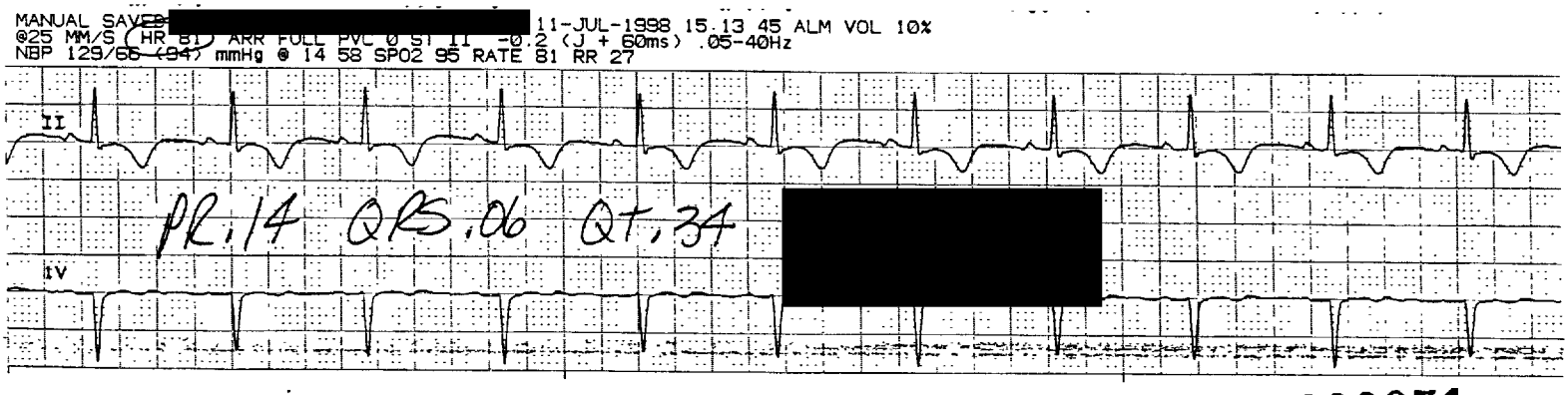

MONITOR STRIPS

[redacted]

[redacted]

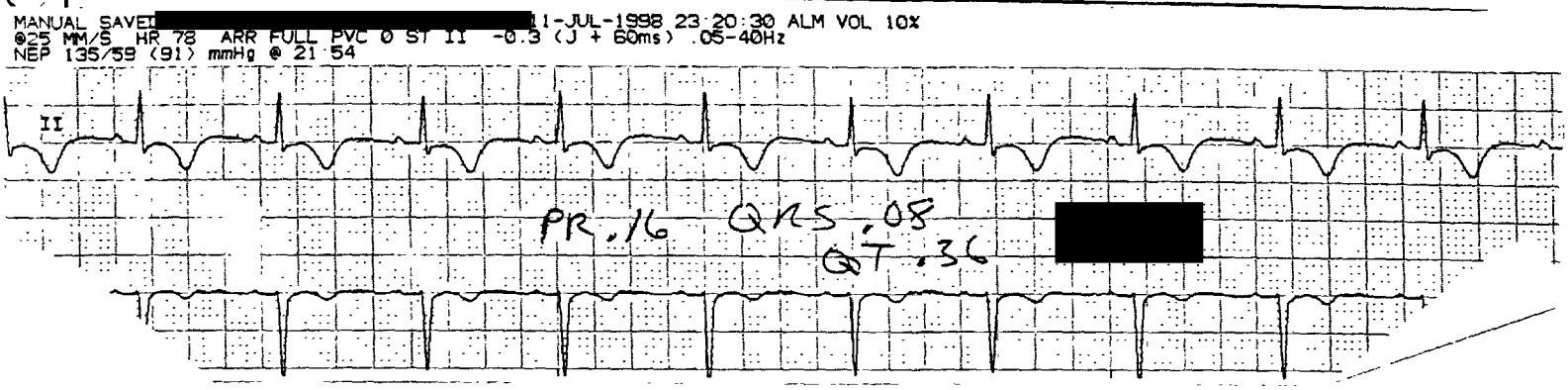

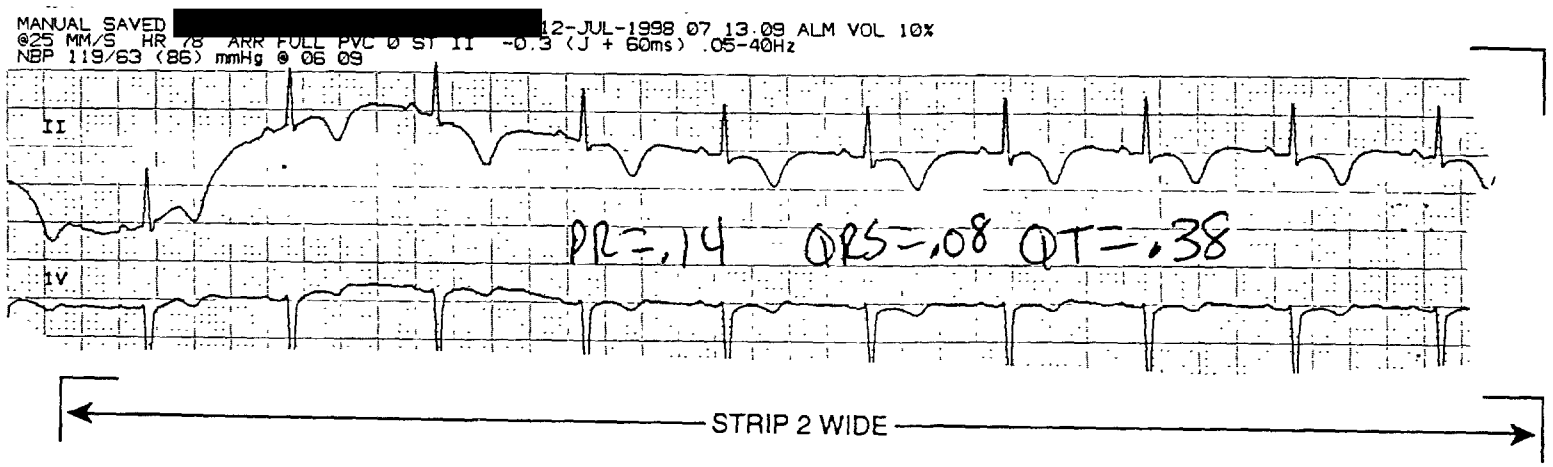

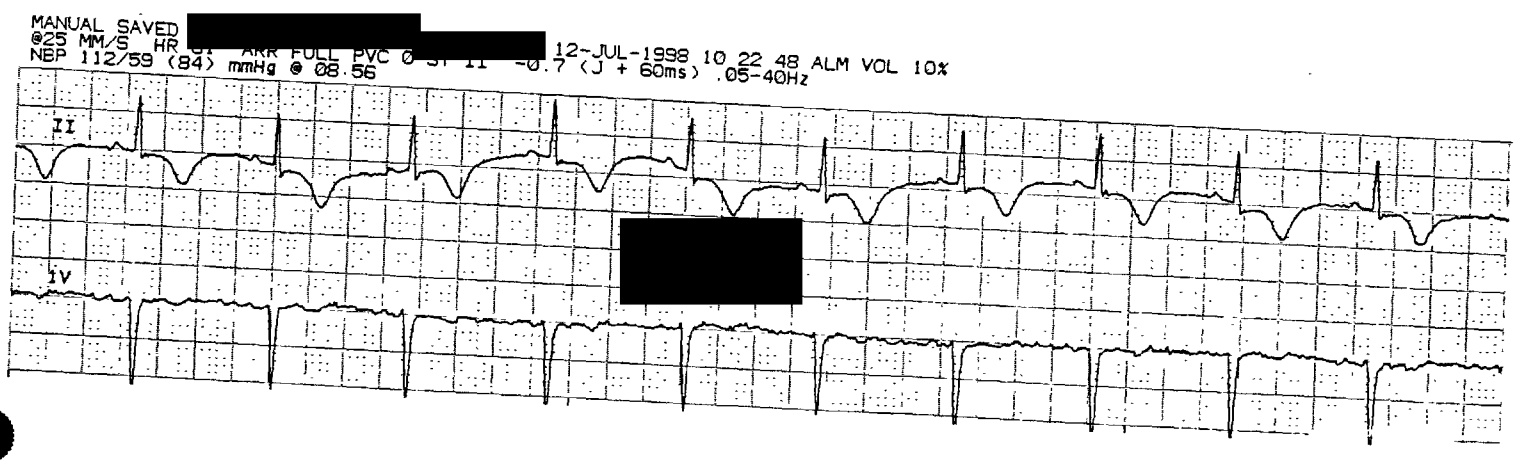

000052

[redacted] MONITOR STRIPS

[redacted] MANUAL SAVED 12-JUL-1998 11:13:33 @25 MM/S

HR 79 PVC 0 ST II -0.6

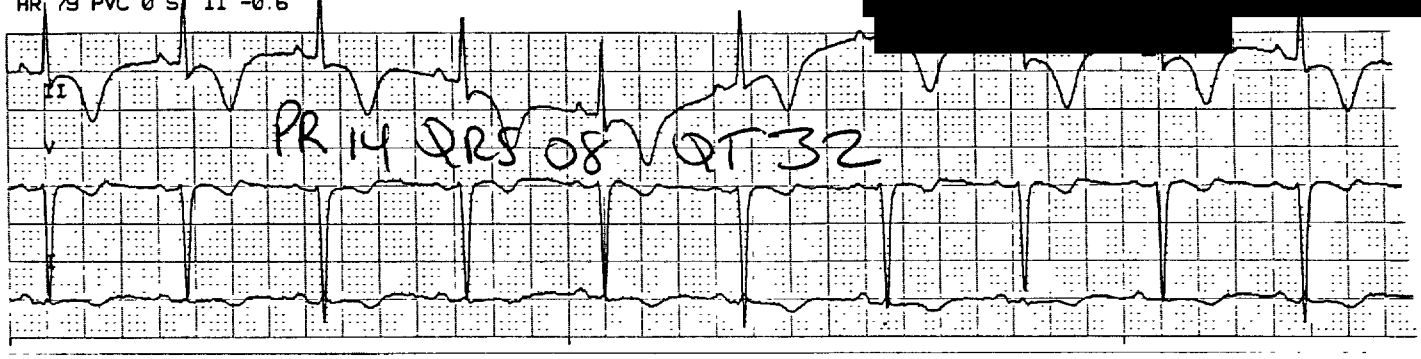

[redacted] MANUAL 12-JUL-1998 16:31:34 @25 MM/S HR 80

PVC 0 ST II -1.0

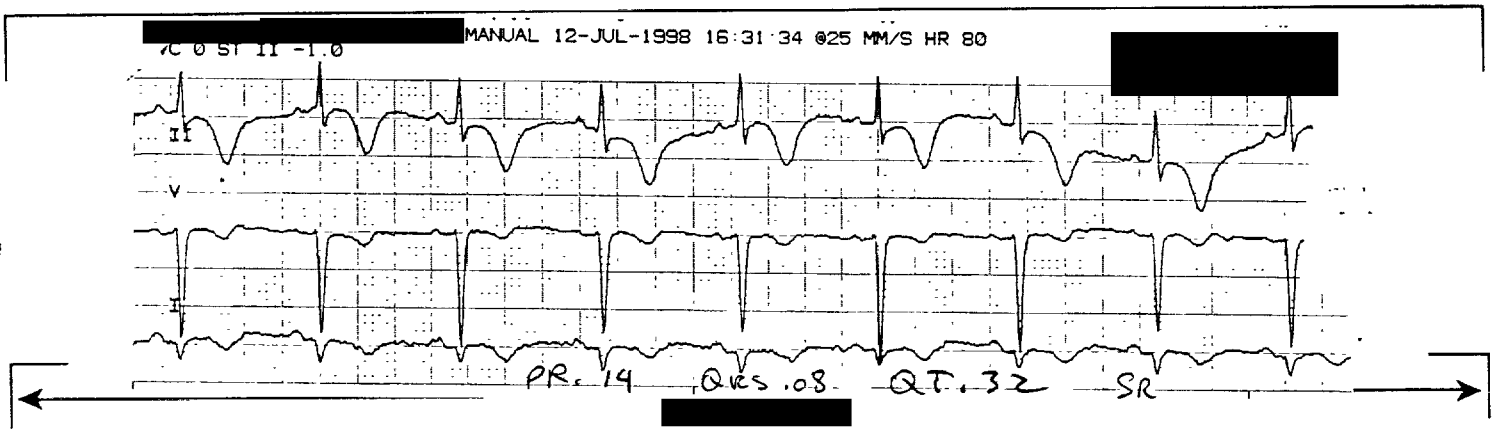

[redacted] MANUAL SAVED 12-JUL-1998 23:36:24 @25 MM/S

HR 78 PVC 0 ST II -0.4

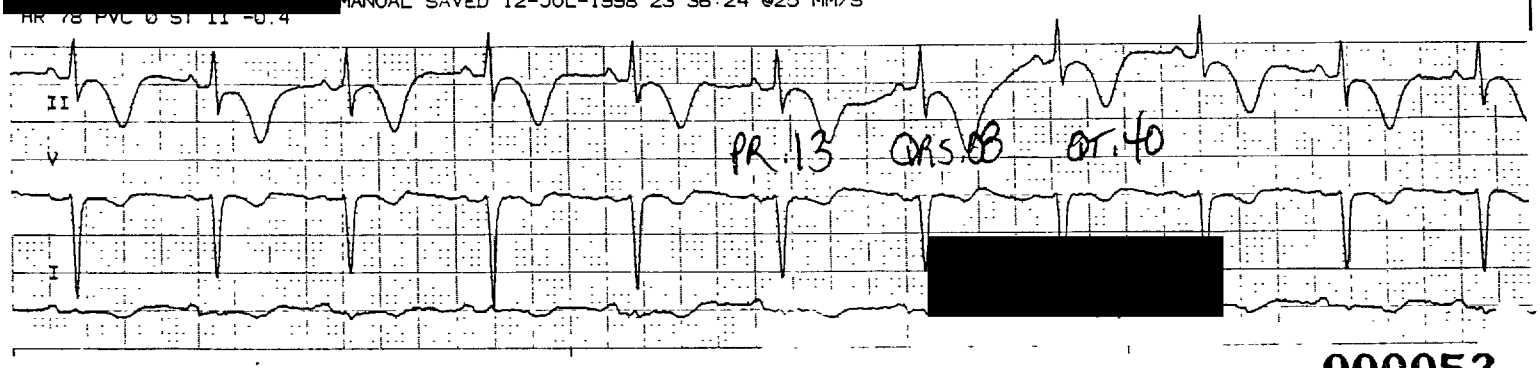

000053

MONITOR STRIPS

[redacted]

[redacted] MANUAL SAVED 13-JUL-1998 07:15:58 @25 MM/S
LA FAIL HR 70 PVC 0 ST II -0.2

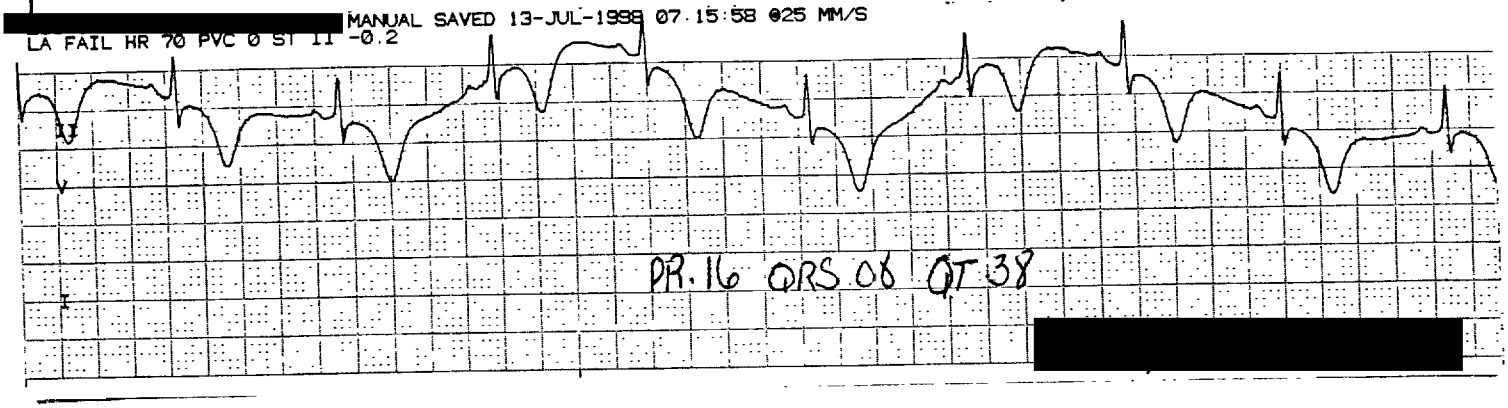

[redacted] MANUAL 13-JUL-1998 15:15 48 @25 MM/S HR 76
PVC 0 ST II -0.5

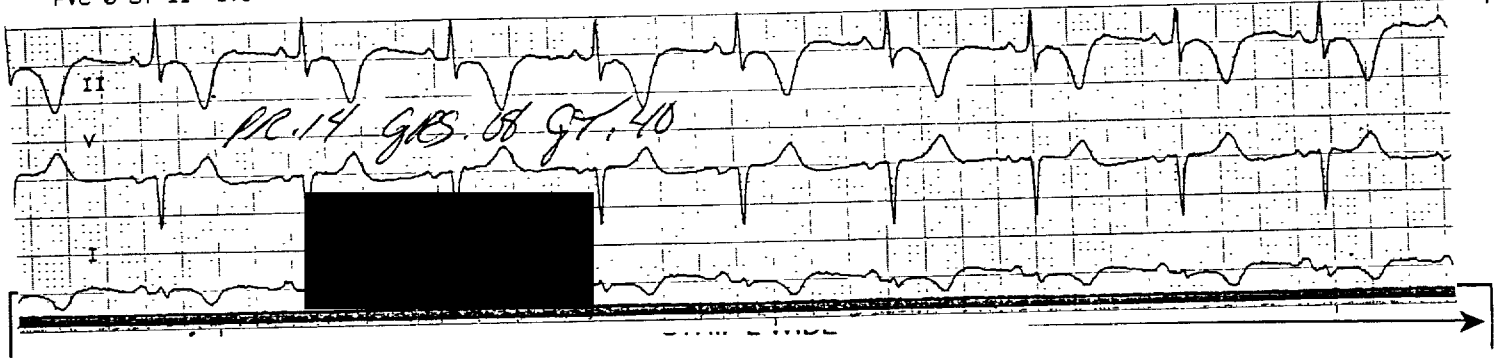

[redacted] MANUAL SAVED 13-JUL-1998 23:19:01 @25 MM/S
HR 81 PVC 0 ST II -0.7

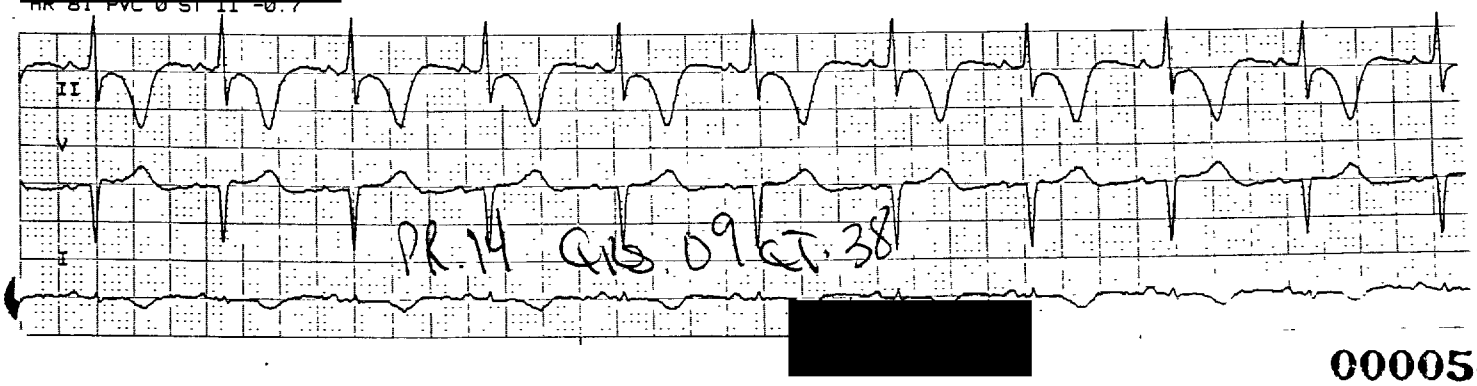

000054

[redacted] MONITOR STRIPS

[redacted] MANUAL SAVED 14-JUL-1998 07:01:09 @25 MM/S

HR 83 PVC 0 ST II -0.6

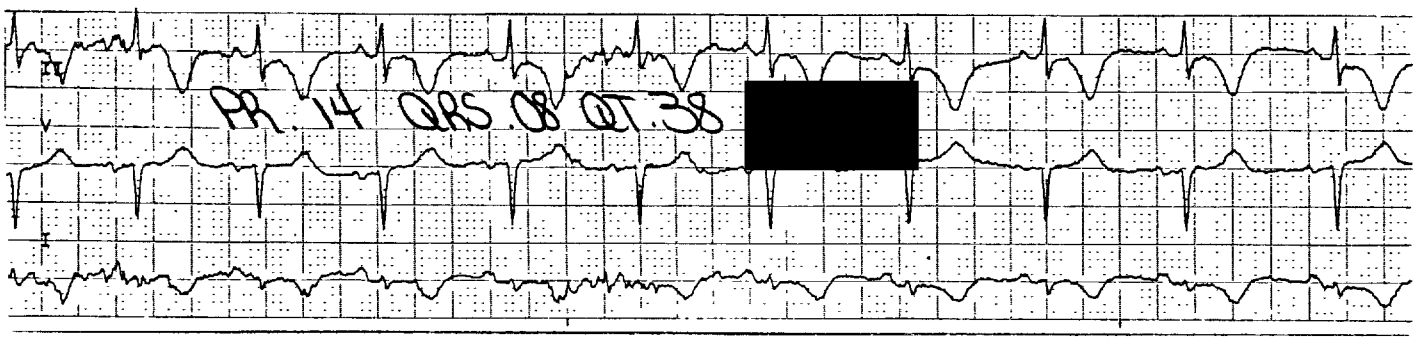

[redacted] MANUAL SAVED 14-JUL-1998 15:02 44 @25 MM/S

HR 74 PVC 1 ST II -0.2

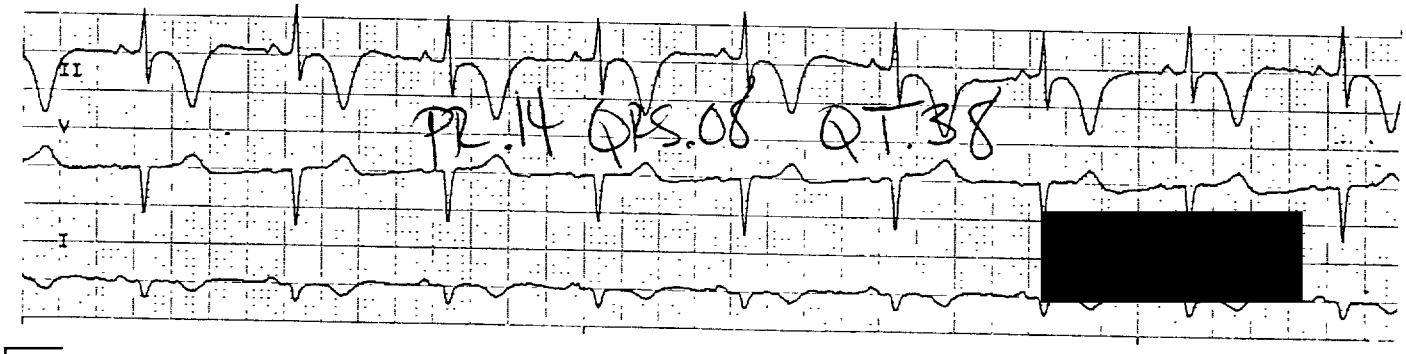

STRIP 2 WIDE

[redacted] MANUAL SAVED 14-JUL-1998 23:23:39 @25 MM/S

HR 84 PVC 0 ST II -0.1

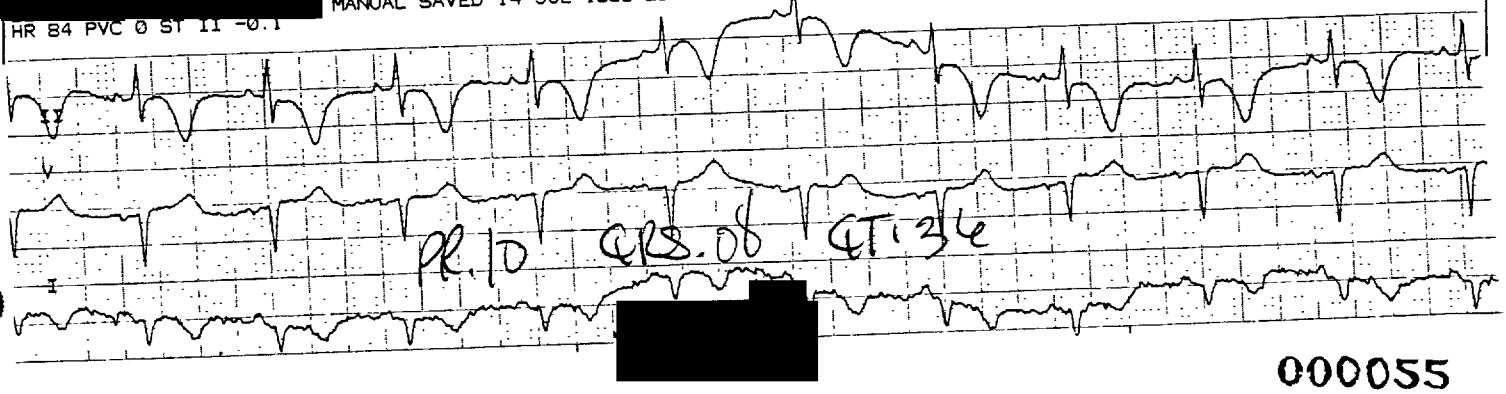

000055

[redacted] Radiology Report

[redacted]

INPATIENT

I. RECUMBENT AP PORTABLE CHEST FROM 2156 HOURS ON 7-02-98:

PERTINENT HISTORY: Seizures. Patient is comatose.

FINDINGS: An endotracheal tube is seen in the projection of the trachea with its tip approximately 2.5 cm above the carina. An NG tube has been placed and its tip is located in the fundus of the stomach. The markings are somewhat prominent centrally with a normal-sized heart. Findings could represent the early signs of interstitial edema. This could be noncardiogenic in origin. No discrete air space disease is seen. There is no evidence of pneumothorax or pleural effusion.

IMPRESSION: The markings are somewhat prominent centrally. The heart size is within normal limits. Findings could represent signs of early vascular congestion.

II. RECUMBENT AP PORTABLE CHEST FROM 0313 HOURS ON 7-03-98:

FINDINGS: Comparison is made with study from 2156 hours on 7-02-98. Bilateral diffuse air space disease is seen. Findings suggest a pulmonary edema pattern. The heart size is within normal limits and this suggests possible noncardiogenic pulmonary edema. It is possible that this is neurogenic in origin in association with a postictal state. Multiple other etiologies can show this pattern, such as aspiration embolism, drugs, or CNS abnormality. Correlation with the clinical findings is suggested.

IMPRESSION: Findings suggest a pulmonary edema pattern. Differential considerations are given above.

III. RECUMBENT AP PORTABLE CHEST FROM 0753 HOURS ON 7-03-98:

FINDINGS: Comparison is made with study of 0313 hours on 7-03-98. Air space disease persists in the right lung, but appears to have cleared from the left lung. Atelectatic changes are likely present in the left lung base. The heart size remains within normal limits. Air space disease in the right chest could be on the basis of an aspiration. Another possibility would be unilateral pulmonary edema secondary to contralateral thromboembolism. Findings could also represent resolving interstitial edema, although the asymmetry is somewhat contrary to this diagnosis. Correlation with the clinical findings is suggested.

IMPRESSION: Air space disease persists in the right chest, but has somewhat cleared from the left chest. Findings could represent an aspiration in the right lung. Another possibility would be thromboembolism to the left lung. Could consider a ventilation-perfusion lung scan for further evaluation.

[redacted] dd 7-03-98 dt 7-03-98

[redacted] RADIOLOGY REPORT [redacted]

Signature [redacted]

Confidential information: Not to be forwarded without written consent of patient

[redacted]

DIAGNOSTIC IMAGING

Name: [redacted]
DOB: [redacted] Age: 42Y Sex: F
Date: 07/03/98 1435

Med Rec # [redacted]
ACCT: [redacted]
Pt Locati[redacted]

[redacted]

Exam
XR CHEST ONE VIEW PORTABLE

Check-In # [redacted]
Order Diagnosis
Ord Diag: [redacted]-OTH CONVULSION

History: Question seizures.

No previous study is available for comparison.

An endotracheal tube and nasogastric tube are in place. The heart is normal in size. There is diffuse bilateral airspace disease which may reflect pulmonary edema, pulmonary hemorrhage or less likely overwhelming infection.

IMPRESSION: Diffuse bilateral airspace disease.

/Read By/ [redacted]D
/Released By [redacted] MD
Report Released 07/04/98 0806

[redacted] 07/03/98 2010
Admitting Physician:
Attending Physician: [redacted]
REFER MD

FINAL

[redacted]

DIAGNOSTIC IMAGING

Name: [redacted]

DOB: [redacted] Age: 42Y Sex: F

Med Rec # [redacted]
ACCT:
Pt Locatic [redacted]

Date: 07/04/98 0607

[redacted]

Exam
XR CHEST ONE VIEW PORTABLE

Check-In # [redacted] Order Diagnosis
Ord Diag: CARD SHOCK-

History: Cardiac shock. Comparison dated 07/03/98.

Findings: AP view of the chest shows femoral Swan-Ganz catheter with tip projecting over the proximal left pulmonary artery, new. Endotracheal tube has tip approximately 5 cm above the carina. Nasogastric tube has tip projecting over the gastric cardia. Bilateral parenchymal opacities are present suggesting a pulmonary contusion or pulmonary edema.

IMPRESSION: Support lines and tubes as above. Evidence for pulmonary edema, however, pulmonary contusion could also add to this appearance.

/Read By/ [redacted] MD
/Released By/ [redacted] MD
Report Released 07/04/98 1109

[redacted] 07/04/98 1058
Admitting Physician:
Attending Physician: [redacted]
REFER MD

FINAL

[redacted]

DIAGNOSTIC IMAGING

Name: [redacted]

DOB: [redacted] Age: 42Y Sex: F

Med Rec # [redacted]
ACCT: [redacted]
Pt Location: [redacted]

Date: 07/05/98 0442

[redacted]

Exam
XR CHEST ONE VIEW PORTABLE

Check-In # [redacted]
Order Diagnosis
Ord Diag: [redacted]-OTH CONVULSION

History: Convulsions. Comparison is made with the prior examination from 07/04/98.

Findings: AP view of the chest shows diffuse bilateral ground glass opacities. Femoral Swan-Ganz catheter has tip projecting over the pulmonary artery. Endotracheal tube has tip approximately 6 cm above the carina. Nasogastric tube has tip projecting over the stomach.

Monitoring leads and wires project over both hemithoraces.

IMPRESSION: Increased bilateral ground glass opacities. This suggests pulmonary edema. Support lines and tubes are as above.

/Read By/ [redacted] MD
/Released By/ [redacted] MD
Report Released 07/06/98 0800

[redacted] 07/05/98 1359
Admitting Physician
Attending Physician [redacted]
REFER MD

FINAL

[redacted]

DIAGNOSTIC IMAGING

Name: [redacted]

DOB: [redacted] Age: 42Y Sex: F

Med Rec # [redacted]
ACCT:
Pt Locatic

Date: 07/05/98 0710

[redacted]

Exam
XR CHEST ONE VIEW PORTABLE

Check-In # [redacted]
Order Diagnosis
Ord Diag: SEIZURES,CARDIOGENIC

History: Seizures. Cardiogenic shock. Comparison dated 07/05/98.

Findings: AP view of the chest dated 07/05/98 at 06:40 hours shows endotracheal tube, nasogastric tube, and Swan-Ganz catheter to be stable. Monitoring leads and wires project over both hemithoraces. Ground glass opacities are seen bilaterally, stable.

IMPRESSION: Stable chest examination.

/Read By/ [redacted] MD
/Released By/ [redacted] MD
Report Released 07/06/98 0800

[redacted] 07/05/98 1415
Admitting Physician:
Attending Physician: [redacted]
REFER MD

FINAL

[redacted]

DIAGNOSTIC IMAGING

Name: [redacted]

DOB: [redacted] Age: 42Y Sex: F

Date: 07/06/98 0719

Med Rec # [redacted]
ACCT:
Pt Locatic [redacted]

Check-In # [redacted] Order Diagnosis
Ord Diag: [redacted]OTH CONVULSION

Exam
XR CHEST ONE VIEW PORTABLE

History: Convulsions.

Findings: A supine AP view of the chest is compared 7/5/98. Nasogastric and endotracheal tubes are again seen. The endotracheal tube tip remains in satisfactory position. A femoral Swan-Ganz catheter is noted with the tip in the left pulmonary artery. Prominence of the pulmonary interstitial markings is again noted diffusely and bilaterally, without significant change.

IMPRESSION: Stable pulmonary edema.

/Read By/ [redacted] MD
/Released By/ [redacted] MD
Report Released 07/06/98 1224

[redacted]07/06/98 1151
Admitting Physician:
Attending Physician [redacted]
REFER MD

FINAL

[redacted]

DIAGNOSTIC IMAGING

Name: [redacted]

DOB: [redacted] Age: 42Y Sex: F

Date: 07/06/98 2302

Med Rec #: [redacted]
ACCT: [redacted]
Pt Location: [redacted]

[redacted]

Exam
XR CHEST ONE VIEW PORTABLE

Check-In # [redacted]
Order Diagnosis
Ord Diag: [redacted] OTH CONVULSION

Comparison is made with a previous film of earlier in the same date. Tubes and lines are stable in position. The heart size is stable. There continues to be bilateral air space disease which may reflect pulmonary edema, hemorrhage, or pneumonia. It has improved bilaterally.

IMPRESSION: Interval improvement in bilateral air space disease.

/Read By/ [redacted] MD
/Released By/ [redacted] MD
Report Released 07/09/98 0807

[redacted] 07/08/98 1928
Admitting Physician:
Attending Physician: [redacted]
REFER MD

FINAL

[redacted]

DIAGNOSTIC IMAGING

Name: [redacted]

DOB: [redacted] Age: 42Y Sex: F

Date: 07/07/98 0407

Med Rec # [redacted]
ACCT: [redacted]
Pt Location: [redacted]

[redacted]

Exam
XR CHEST ONE VIEW PORTABLE

Check-In # [redacted]
Order Diagnosis
Ord Diag: [redacted] OTH CONVULSION

Portable chest 7/7. Current study at 0605 hours is compared to 7/6 and shows there remains some central congestion. Nasogastric tube has been removed.

SUMMARY: Little change on progress chest.

/Read By/ [redacted] MD
/Released By/ [redacted] MD
Report Released 07/07/98 1402

[redacted] 07/07/98 1338
Admitting Physician
Attending Physician
REFER MD [redacted]

FINAL

[redacted]

DIAGNOSTIC IMAGING

Name: [redacted]

DOB: [redacted] Age: 42Y Sex: F

Med Rec # [redacted]
ACCT: [redacted]
Pt Location: [redacted]

Date: 07/08/98 0404

[redacted]

Exam
XR CHEST ONE VIEW PORTABLE

Check-In # [redacted]

Order Diagnosis
Ord Diag: [redacted]OTH CONVULSION

History: Convulsions.

Comparison is made with a previous film dated 07/07/98. The tubes and lines are stable in position. The heart size is stable. The bilateral opacification is improved markedly and the right lung is now nearly clear. There continues to be vague density over the left lung.

IMPRESSION: Interval improvement in bilateral air space disease.

/Read By/ [redacted] MD
/Released By/ [redacted] MD
Report Released 07/09/98 0807

[redacted] 07/08/98 1934
Admitting Physician:
Attending Physician: [redacted]
REFER MD

FINAL

[redacted]

DIAGNOSTIC IMAGING

Name: [redacted]

DOB: [redacted] Age: 42Y Sex: F

Date: 07/08/98 1015

Med Rec #: [redacted]
ACCT: [redacted]
Pt Location: [redacted]

[redacted]

Exam
XR CHEST ONE VIEW PORTABLE

Check-In # [redacted]
Order Diagnosis
Ord Diag: [redacted] OTH CONVULSION

History: Convulsions.

The PICC line has been placed. The tip of which lies in the superior vena cava. The remaining tubes and lines are stable in position. The heart and pulmonary vasculature appear stable. There is again vague density over the left lung, unchanged since the prior study. There is minimal atelectasis at the right base.

IMPRESSION: PICC line in the superior vena cava.

/Read By/ [redacted] MD
/Released By/ [redacted] MD
Report Released 07/09/98 0807

[redacted] 07/08/98 1936
Admitting Physician: [redacted]
Attending Physician:
REFER MD

FINAL

[redacted]

DIAGNOSTIC IMAGING

Name: [redacted]

DOB: [redacted] Age: 42Y Sex: F

Med Rec # [redacted]
ACCT: [redacted]
Pt Location: [redacted]

Date: 07/09/98 0504

[redacted]

Exam
XR CHEST ONE VIEW PORTABLE

Check-In # [redacted]

Order Diagnosis
Ord Diag: [redacted] OTH CONVULSI

History: Convulsions.

Findings: The study is compared to that of the previous day and shows continued left lower lobe atelectasis with evidence of pulmonary vascular congestion. No other new abnormality can be seen.

OPINION: Persistent congestion and left lower lobe atelectasis.

/Read By/ [redacted] MD
/Released By/ [redacted] MD
Report Released 07/20/98 1730

[redacted] 07/20/98 1115
Admitting Physician:
Attending Physician: [redacted]
REFER MD

000066

SUPPLEMENTAL

[redacted]

DIAGNOSTIC IMAGING

Name: [redacted]

DOB: [redacted] Age: 42Y Sex: F

Med Rec # [redacted]
ACCT:
Pt Location: [redacted]

Date: 07/10/98 0507

[redacted]

Exam
XR CHEST ONE VIEW PORTABLE

Check-In # [redacted]

Order Diagnosis
Ord Diag: [redacted] OTH CONVULSION

Support tubes are unchanged from prior exams. Effusion and basilar consolidation on the left is stable. The lungs are otherwise unchanged.

IMPRESSION: Stable chest.

/Read By/ [redacted] MD
/Released By/ [redacted] MD
Report Released 07/10/98 1521

[redacted] 07/10/98 1301
Admitting Physician:
Attending Physician: [redacted]
REFER MD

FINAL

[redacted]

DIAGNOSTIC IMAGING

[redacted]

Name: [redacted]

DOB: [redacted] Age: 42Y Sex: F

Date: 07/11/98 0403

Med Rec # [redacted]
ACCT:
Pt Location: [redacted]

[redacted]

Exam
XR CHEST ONE VIEW PORTABLE

Check-In # [redacted]

Order Diagnosis
Ord Diag: [redacted] OTH CONVULSION

Portable chest on 7/11 at 0635 hours.

Support tubes are unchanged from prior exams. Left sided effusion and basilar consolidation persists. Lungs are otherwise clear.

IMPRESSION: Stable chest.

/Read By/ [redacted] MD
/Released By/ [redacted] MD
Report Released 07/11/98 1237

[redacted] 07/11/98 1043
Admitting Physician:
Attending Physician: [redacted]
REFER MD

FINAL

[redacted]

DIAGNOSTIC IMAGING

[redacted]

Name: [redacted]

DOB: [redacted] Age: 42Y Sex: F

Date: 07/12/98 0443

Med Rec # [redacted]
ACCT:
Pt Location: [redacted]

[redacted]

Exam
XR CHEST ONE VIEW PORTABLE

Check-In # [redacted] Order Diagnosis
Ord Diag: [redacted]TH CONVULSION

An AP film is compared with the study of the previous day. The endotracheal tube has been removed and the diaphragm is somewhat higher. On the right there is some minor atelectasis from poor inspiration. At the left base there is considerable improvement with better aeration and decrease in the atelectasis at the left lobe.

IMPRESSION: A follow- study of the chest shows improvement with considerable decrease in the left lower lobe atelectasis.

/Read By/ [redacted]MD
/Released By/ [redacted] MD
Report Released 07/12/98 1333

[redacted] 07/12/98 1202
Admitting Physician:
Attending Physician: [redacted]
REFER MD

FINAL

[redacted]

DIAGNOSTIC IMAGING

Name: [redacted]

DOB: [redacted] Age: 42Y Sex: F

Date: 07/14/98 1618

Med Rec # [redacted]
ACCT: [redacted]
Pt Location: [redacted]

[redacted]

Exam
XR CHEST 2 VIEWS

Check-In # [redacted]

Order Diagnosis
Ord Diag: [redacted] CORONARY ATH

History: Coronary atherosclerosis.

Comparison dated 7/12/98.

Findings: PA and lateral views were obtained of the chest which show the cardiac silhouette to be in the upper limits of normal with respect to size. No acute infiltrates or effusions are demonstrated. Minimal atelectatic change is seen in the lung bases. However, the extensive left lower lobe atelectasis seen on 7/11/98 has resolved.

IMPRESSION: Atelectatic changes in the lung bases. Significantly improved aeration in the left lung base since 7/11/98.

/Read By/ [redacted] MD
/Released By/ [redacted] MD
Report Released 07/15/98 1345

[redacted] 07/15/98 1054
Admitting Physician:
Attending Physician: [redacted]
REFER MD

[redacted]

Radiology Report

INPATIENT

[redacted]

CT OF THE HEAD 7-02-98:

PERTINENT HISTORY: Seizures.

FINDINGS: 5 mm axial sections were obtained from the base of the skull through the posterior fossa with 10 mm sections through the remainder of the cranium pre-IV contrast infusion. Images were filmed in soft tissue and bone windows.

The study is somewhat limited due to motion artifact. There is no evidence of intracranial hemorrhage, midline shift, or mass effect. No discrete cortical ischemic infarcts are noted. The ventricles appear of appropriate size and contour. There is no evidence of extra-axial fluid collections. No fractures are seen. The paranasal sinuses and mastoidal air cells appear aerated. A nasogastric tube is evident.

IMPRESSION: The study is somewhat limited due to motion artifact. No intracranial abnormalities are seen. If symptomatology persists, could consider an MRI or a contrast-enhanced CT for further evaluation.

[redacted]
dd 7-03-98
dt 7-03-98

[redacted]

RADIOLOGY REPORT

[redacted]

Radiology Dept [redacted]

Signature [redacted]

[redacted]

COMPUTERIZED TOMOGRAPHY

000071

Confidential information: Not to be forwarded without written consent of patient

[redacted]

DIAGNOSTIC IMAGING

Name: [redacted]

DOB: [redacted] Age: 42Y Sex: F

Date: 07/03/98 1506

Med Rec # [redacted]
ACCT: [redacted]
Pt Location: [redacted]

[redacted]

Exam
CT BRAIN W/O CONTRAST

Check-In # [redacted]

Order Diagnosis
Ord Diag: [redacted] RESPIRATORY FA

History: Question seizures.

The ventricles are normal in size and configuration. No mass or other focal abnormality is demonstrated. There is no evidence of intracranial hemorrhage.

IMPRESSION: Negative CT scan of the head type A.

/Read By/ [redacted] MD
/Released By/ [redacted] MD
Report Released 07/04/98 0806

[redacted] 07/03/98 2009
Admitting Physician:
Attending Physician: [redacted]
REFER MD

FINAL

[redacted]

DIAGNOSTIC IMAGING

Name: [redacted]

DOB: [redacted] Age: 42Y Sex: F

Med Rec # [redacted]
ACCT:
Pt Location: [redacted]

Date: 07/09/98 0900

[redacted]

Exam
US GALLBLADDER

Check-In # [redacted]
Order Diagnosis
Ord Diag: [redacted] OTH CONVULSION

History: Right upper quadrant pain and fever.

Findings: No stones are seen within the gallbladder. However, gallbladder wall thickening is seen. The gallbladder wall thickness measures 7 mm (normal = 3 mm or less). The common hepatic duct measures 8 mm in diameter, which is mildly dilated. No focal hepatic lesion is seen. The visualized portions of the pancreas appear normal. The left kidney is not well visualized. The right kidney demonstrates normal cortical echogenicity without evidence of hydronephrosis. Pleural effusions are noted.

IMPRESSION: Gallbladder wall thickening and mild extrahepatic biliary ductal dilatation. Findings may represent acalculus cholecystitis.

/Read By/ [redacted] MD
/Released By/ [redacted] MD
Report Released 07/09/98 1305

[redacted] 07/09/98 1305
Admitting Physician:
Attending Physician: [redacted]
REFER MD

FINAL

[redacted]

DIAGNOSTIC IMAGING

Name: [redacted]

DOB: [redacted] Age: 42Y Sex: F

Date: 07/09/98 1418

Med Rec # [redacted]
ACCT:
Pt Location: [redacted]

[redacted]

Exam
NM HEPATOBILIARY FUNCTION IMAGE

Check-In # [redacted]

Order Diagnosis
Ord Diag: [redacted]-OTH CONVULSION

History: Right upper quadrant pain. Follow-up gallbladder ultrasound exam.

Dose: 5.4 mCi of Tc 99m Choletec intravenously.

Findings: There is prompt hepatic uptake of radiopharmaceutical. Gallbladder activity is first visualized on the image labeled 10 minutes. Bowel activity is first visualized on the image labeled 30 minutes. These findings are normal.

IMPRESSION: Normal nuclear medicine hepatobiliary scan.

/Read By/ [redacted] MD
/Released By/ [redacted] MD
Report Released 07/10/98 1007

[redacted] 07/09/98 2017
Admitting Physician:
Attending Physician: [redacted]
REFER MD

FINAL

[redacted]

OPERATIVE PROCEDURE

[redacted]

SURGEON: Dr. [redacted] DATE: 7-02-98

ASSISTANT:

PREOPERATIVE DIAGNOSIS:

POSTOPERATIVE DIAGNOSIS:

PROCEDURE: Lumbar puncture.

PERTINENT HISTORY: New onset seizures. Patient is comatose. It was requested by Dr. [redacted] that I do a lumbar puncture under fluoroscopy.

PROCEDURE: With the patient in the left anterior oblique position, the skin over the L3-L4 interspace was sterilely prepped and draped. Local anesthetic was administered. Using a right paracentral approach, a 20-gauge spinal needle was introduced into the subarachnoid space at the L3-L4 level without difficulty. Approximately 5 cc of clear cerebrospinal fluid was obtained and sent to the laboratory for analysis. The needle was then removed. The patient was then returned to the Emergency Room. There were no apparent complications.

[redacted]
dd 7-03-98
dt 7-03-98

Name: [redacted]
DOB:
Room #:

Physician: [redacted] MD

Unit #: [redacted]
Exam Date: 07/04/98

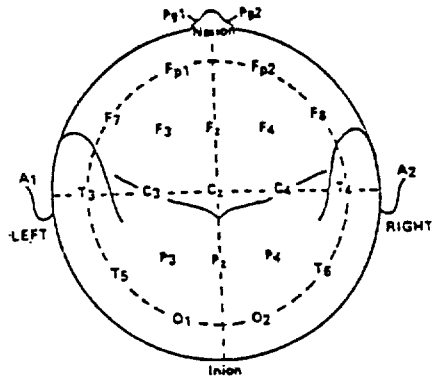

EEG

DATE OF PROCEDURE: 07/04/98
DATE OF DICTATION: 07/04/98

EEG #: [redacted]

This is the EEG of a 42-year-old woman with a history of heart failure and possible seizures. Medications include a Versed drip, Dopamine, dobutamine, vecuronium, heparin, ranitidine, Unasyn and morphine.

The patient was sedated but arousable during this bedside recording. The background rhythm when awakened consistent of brief bursts of 9-10 Hz activity that was bilaterally synchronous and symmetrical, although brief. Diffuse bilateral Beta activity was noted. Occasional intermittent diffuse slow activity was seen. Photic stimulation and hyperventilation was omitted. The patient quickly went in and out of sleep, responding quickly to arousal. Only normal patterns were seen.

IMPRESSION: This EEG is remarkable for diffuse Beta activity which is consistent with the patient's history of being on Versed. No epileptiform activity was seen. Brief, but otherwise normal, periods of arousal with stimulation were also noted.

Read By: [redacted] MD

[redacted]
07/06/98 8:26 A
cc: [redacted] MD

[redacted]

PATIENT DA[redacted]

Name [redacted]
Unit #
Room #
Admitted 07/03/98
Referring Doctor
Interpreting Docto[redacted] MD

DOB [redacted]
Age 42
Sex F

DATE OF EXAM: 07/03/98 STUDY NO.: [redacted] TAPE NO.: [redacted] COUNT: [redacted]
REASON FOR EXAM: PULMONARY EDEMA
HEIGHT: _____ WEIGHT: _____ BSA: _____

2 DIMENSIONAL FINDINGS (adult range)

AORTA	: _____ mm.	(20-40)	ESTIMATED EJECTION FRACTION:	10-15 %	(50-75)
LEFT ATRIUM minor axis	: _____ mm.	(20-40)	SHORTENING %	: _____ %	(30-45)
VENTRICULAR SEPTUM	: _____ mm.	(6 -12)			
POSTERIOR WALL	: _____ mm.	(6 -11)	INFERIOR VENA CAVA		
LVed	: _____ mm.	(37-56)	respiratory collapse	: Y( ) N( ) Vent( )	
LVes	: _____ mm.				

DOPPLER ECHOCARDIOGRAPHIC FINDINGS

AORTIC VALVE
insufficiency grade : 0
maximal velocity : _____ m/s
maximum gradient : _____ mmHg
mean gradient : _____ mmHg
est. AV area : _____ cm2

MITRAL VALVE
insufficiency grade : 1+
Inflow profile : E_____A wave:Afib
maximum velocity : _____ m/s
mean gradient : _____ mmHg
pressure half time : _____ msec
est. MV area : _____ cm2

TRICUSPID VALVE
insufficiency grade : 0
maximal TR velocity : _____ m/s
pulmonary artery
systolic pressure est.: _____ mmHg

OTHER

COMMENTS AND CONCLUSIONS

The left ventricle is dilated with severe depression of systolic function which looks global. The estimated ejection fraction is around 15%. The mitral valve is normal. The aortic valve is tricuspid and normal. The proximal aorta has very normal size. No definite dissection flap is visualized. The left atrium is enlarged with spontaneous contrast. The interatrial septum is aneurysmal and bowed prominently to the right. The right atrium is upper normal in size. The right ventricle is hypocontractile.

Doppler echocardiography including color flow Doppler demonstrates 1+ mitral insufficiency and left to right shunting through the patent foramen.

CONCLUSION: 1. Severely myopathic left ventricle with biventricular dysfunction as well. 2. Mild mitral insufficiency. 3. Interatrial septal aneurysm with left to right shunting. 4. Spontaneous left atrial contrast.

[redacted]
[redacted] MD

[redacted]
DT: 07/06/98 9:55 A
cc: [redacted] MD

000077

[redacted] CARDIAC SERVICES
ECHOCARDIOGRAM REPORT

PATIENT DAT

Name [redacted]
Unit #
Room #
Admitted 07/03/98
Referring Doctor [redacted] MD
Interpreting Doctor [redacted] MD, [redacted]

DOB [redacted]
Age 42
Sex F

DATE OF EXAM: 07/04/98 STUDY NO.: [redacted] TAPE NO.: [redacted] COUNT: [redacted]
REASON FOR EXAM: F/U LV FUNCTION
HEIGHT: _____ WEIGHT: _____ BSA: _____

2 DIMENSIONAL FINDINGS (adult range)

AORTA	: _____ mm.	(20-40)	ESTIMATED EJECTION FRACTION: 15-18 %		(50-75)
LEFT ATRIUM minor axis	: _____ mm.	(20-40)	SHORTENING %	: _____ %	(30-45)
VENTRICULAR SEPTUM	: _____ mm.	(6 -12)			
POSTERIOR WALL	: _____ mm.	(6 -11)	INFERIOR VENA CAVA		
LVed	: 50 mm.	(37-56)	respiratory collapse	: Y( ) N( ) Vent( )	
LVes	: 75 mm.				

DOPPLER ECHOCARDIOGRAPHIC FINDINGS

AORTIC VALVE
insufficiency grade : 0
maximal velocity : _____ m/s
maximum gradient : _____ mmHg
mean gradient : _____ mmHg
est. AV area : _____ cm2

MITRAL VALVE
insufficiency grade : 0
Inflow profile : E_____A wave:Afib__
maximum velocity : _____ m/s
mean gradient : _____ mmHg
pressure half time : _____ msec
est. MV area : _____ cm2

TRICUSPID VALVE
insufficiency grade : _____
maximal TR velocity : _____ m/s
pulmonary artery
systolic pressure est.: _____ mmHg

OTHER

COMMENTS AND CONCLUSIONS

This is a limited follow-up echocardiographic study, technically difficult with the patient still ventilator dependent.

The left ventricle is at least mildly dilated. The study is again remarkable for the demonstration of severe diffuse left ventricular hypokinesis. The ejection fraction remains in the range of 15-18%. Despite the significant improvement in cardiac output by Swan Ganz monitoring, there has been essentially no improvement in the ventricular graphic appearance since prior studies of July 3rd. There is no gross pathology of the aortic or mitral valves. No tricuspid insufficiency is noted.

IMPRESSION: Persistent severe diffuse hypokinesis with a markedly depressed ejection fraction.

[redacted]

[redacted]
DT: 07/13/98 11:49 A
cc: [redacted]

000078

[redacted] CARDIAC SERVICES ECHOCARDIOGRAM REPORT

PATIENT DA .

Name [redacted]
Unit # [redacted]
Room # [redacted]
Admitted 07/03/98
Referring Doctor [redacted] MD
Interpreting Doctor [redacted], MD

DOB [redacted]
Age 42
Sex F

DATE OF EXAM: 07/13/98 STUDY NO.: [redacted] TAPE NO.: [redacted] COUNT: [redacted]
REASON FOR EXAM: FOLLOW-UP LVF
HEIGHT: _____ WEIGHT: _____ BSA: _____

2 DIMENSIONAL FINDINGS (adult range)

AORTA	: 29 mm.	(20-40)	ESTIMATED EJECTION FRACTION:		% (50-75)
LEFT ATRIUM minor axis	: 32 mm.	(20-40)	SHORTENING %	: 38	% (30-45)
VENTRICULAR SEPTUM	: 11 mm.	(6 -12)			
POSTERIOR WALL	: 11 mm.	(6 -11)	INFERIOR VENA CAVA		
LVed	: 50 mm.	(37-56)	respiratory collapse	: Y(X) N( ) Vent( )	
LVes	: 31 mm.				

DOPPLER ECHOCARDIOGRAPHIC FINDINGS

AORTIC VALVE
insufficiency grade : _____
maximal velocity : 1.3 m/s
maximum gradient : _____ mmHg
mean gradient : _____ mmHg
est. AV area : _____ cm2

MITRAL VALVE
insufficiency grade : _____
Inflow profile : E_____A wave:Afib__
maximum velocity : _____ m/s
mean gradient : _____ mmHg
pressure half time : _____ msec
est. MV area : _____ cm2

TRICUSPID VALVE
insufficiency grade : _____
maximal TR velocity : _____ m/s
pulmonary artery
systolic pressure est.: _____ mmHg

OTHER

COMMENTS AND CONCLUSIONS

A technically good 2-D Doppler echocardiographic study is performed. Evaluation of the left ventricle reveals no chamber dilatation. There is mild concentric hypertrophy. Overall ejection fraction is at the lower limits of normal. There are no segmental wall motion abnormalities. The left atrium is normal size. Right ventricular size and function are normal. The right atrium is normal. There is a catheter that passes from the SVC into the right atrium. There is no pericardial effusion. The aortic root is normal. The aortic valve and mitral valve are structurally unremarkable. Doppler examination reveals very mild mitral insufficiency. No other significant abnormalities are identified.

CONCLUSION: 1. Normal left ventricular function with border[redacted]ncent[redacted]rtrophy. 2. Compared to the previous echocardiogram, this represents a[redacted]tic[redacted]ent in left ventricular function.

[redacted]

DT: 07/14/98 9:05 A
cc: [redacted] MD

000079

[redacted] CARDIAC SERVICES
ECHOCARDIOGRAM REPORT

[redacted]

NOV 1998
Received
[redacted]
Business Services

Name: [redacted]
DOB:
Room #:

Physician: [redacted] MD

Unit #: [redacted]
Exam Date: 07/03/98

Vascular Lab Evaluation

DATE OF PROCEDURE: 07/03/98
DATE OF DICTATION: 07/06/98

This patient is apparently done as an emergency. There was no palpable pulse in the left hand and a decreased pulse on the right.

Duplex imaging is obtained and at the right subclavian, wave forms are seen with very slow flow velocities. This continues into the right axillary and right brachial artery. There is no flow demonstrated at the right radial artery. On the left side, flow is seen at the subclavian, brachial, axillary, ulnar and radial arteries. These again are rather slow flow but wave forms are present.

FINAL IMPRESSION: Decreased velocity bilaterally in the lower extremities with flow being present to the level of the right radial where no flow is seen. Flow is seen at other locations in both lower extremities.

Read By: [redacted] MD

[redacted]
07/06/98 4:20 P
cc: [redacted] MD

[redacted]

EXTRA COPY

NAME: [redacted]
UNIT #:
ROOM #:

DOB: [redacted]
AGE: 42
SEX: F

PROCEDURE DATE: 07/03/98
PREOP DIAG: Cardiomyopathy; rule out acute myocardial infarction.
POSTOP DIAG: Cardiomyopathy; no coronary artery disease.
OPERATION: Left and right heart catheterization; coronary angiography and left ventriculography.
SURGEON: [redacted] MD

INDICATIONS FOR SURGERY: This is a patient who presents acutely with shock. She has had an episode suspicious for arm embolus. A transesophageal echocardiogram has suggested severe left ventricular dysfunction. Initial CPK/MB enzymes are elevated. Therefore she is brought to the catheterization laboratory.

PROCEDURE: After consent the patient was brought to the catheterization laboratory. She is already intubated and on a Versed drip. She is receiving dopamine and dobutamine is started in the catheterization laboratory. Both femoral areas were prepped and draped in the usual sterile fashion. The left femoral area was anesthetized with 1% Xylocaine. The left femoral artery is entered using the modified Seldinger technique and a 6-French sheath is inserted. Then a 6 French pigtail catheter was advanced over the guide wire and positioned in the ascending aorta. An aortogram was performed in the 45 degree LAO projection using Optiray injected at 15 cc/sec for a total of 50 cc. Of note, the contrast is diluted 1:1 with normal saline. Pigtail catheter was then withdrawn. A 6 French JL-4 catheter was then advanced over the guide wire and positioned in the ascending aorta. The left main coronary artery was cannulated. Angiography was performed in multiple views. The JL-4 was then removed. A 6 French JR-4 was then inserted over the guide wire and positioned in the ascending aorta. The right coronary artery was cannulated and angiography was performed in multiple views. At this juncture, right heart catheterization was performed. Venous access was obtained in the left femoral vein. An 8 French introducer sheath was inserted and a Baxter 7.5 French thermodilution monitoring Swan-Ganz catheter was inserted under fluoroscopic guidance. Right heart pressures are measured and recorded. A 6 French pigtail catheter was then advanced over the guide wire and positioned across the aortic valve into the left ventricle. Simultaneous pressure measurements were recorded. Left ventriculography was then performed in the 30 degree RAO projection using Optiray injected at 15 cc/sec for a total of 45 cc. Notably the Optiray is diluted 1:1 with normal saline. Pressure pullback measurements were then recorded. The pigtail catheter was withdrawn. The catheters were sutured in place

[redacted]

including the monitoring Swan-Ganz catheter and the patient was returned to the ICU on a ventilator in critical condition. She is receiving dobutamine and dopamine.

FINDINGS:
Hemodynamics - reveal an aortic pressure of 116/72. There is no transaortic gradient. The left ventricular end diastolic pressure is 13. The pulmonary artery pressure is 34/18. The Fick cardiac index is 3.5 L/min/m^2.

Aortography - reveals no evidence for aortic dissection or aortic dilatation. There is no aortic insufficiency.

Left ventriculography - reveals a dilated diffusely hypokinetic left ventricle. Visually the ejection fraction is 20-25% The computer calculated ejection fraction is 31%. There is no mitral valve calcification or prolapse. There is no mitral insufficiency.

Coronary angiography - reveals normal coronary arteries. The right coronary artery is dominant.

CONCLUSIONS:
Dilated hypokinetic ventricle with reduction in ejection fraction.
Normal hemodynamics.
Normal coronary arteries.
Normal aortic root injection.

[redacted] MD

DD: 08/05/98
DT: 08/07/98 1:36 P
cc: [redacted] MD

[redacted]

CARDIAC LAB HEMODYNAMIC SUMMARY

Name [redacted]
Unit #
Room #
Procedure Date 07/03/98
Discharged
Cardiologist [redacted] MD

DOB [redacted]
Age 42
Sex F
Ht. 5.6 Wt. 197
Hgb 13.9 BSA 2.0
CD [redacted]

SITE	PRESSURE mmHg	MEAN		% 02 SATURATION	
SUPERIOR VENA CAVA	"a" wave = "v" wave =				
HIGH RIGHT ATRIUM					
RIGHT ATRIUM	"a" wave = 9 "v" wave = 10	8			
LOW RIGHT ATRIUM					
INFERIOR VENA CAVA	"a" wave = "v" wave =				
HIGH RIGHT VENTRICLE					
RIGHT VENTRICLE	36/8	e.d.= 9			
RIGHT VENTRICLE (OUT FLOW)					
PULMONARY ARTERY	34/18	22		74	14.3
PULMONARY ARTERY WEDGE	"a" wave = 9 "v" wave = 10	10			
LEFT VENTRICLE	116/4	e.d.= 18 e.d.= 22	(PreAngio) "a" wave (PostAngio)"a" wave		
AORTA	116/72	/86		95	18.2
FEMORAL ARTERY					

CARDIAC OUTPUT
Dye Dilution
Indirect Fick

Systemic: $\frac{2.01(\text{BSA}) \times 138 \text{ (Assumed } O_2 \text{ consumption)}}{18.2 \text{ (aoVol\%)} - 14.3 \text{(paVol\%)} \times 10}$ 277 = 7.1L./min.

Pulmonary: $\frac{(\text{BSA}) \times \text{(Assumed } O_2 \text{ consumption)}}{(\text{Vol\%}) - (\text{Vol\%}) \times 10}$ = L./min.

CARDIAC INDEX

Systemic: $\frac{7.1\text{L./min. Systemic Flow}}{2.01 \text{ (BSA)}}$ = 3.5L./min.M^2

Pulmonary: $\frac{\text{L./min. Pulmonary Flow}}{\text{(BSA)}}$ = L./min.M^2

RESISTANCES

Systemic: $\frac{(86\text{Mean Arterial} - 8\text{(Mean Rt Atrial)} \times 80}{7.1 \text{ L./min.Systemic Flow}}$ = 879Dynes sec.cm.-5

Pulmonary: $\frac{22\text{(Mean Pulmonary} \times 80}{7.1 \quad \text{L./min.Systemic Flow}}$ = 248Dynes sec.cm.-5

L → R Shunt		Peak Aortic Value Gradient		Referring MD
R → L Shunt		Mean Mitral Gradient		[redacted] MD Cardiologist

[redacted]

[redacted] 000084

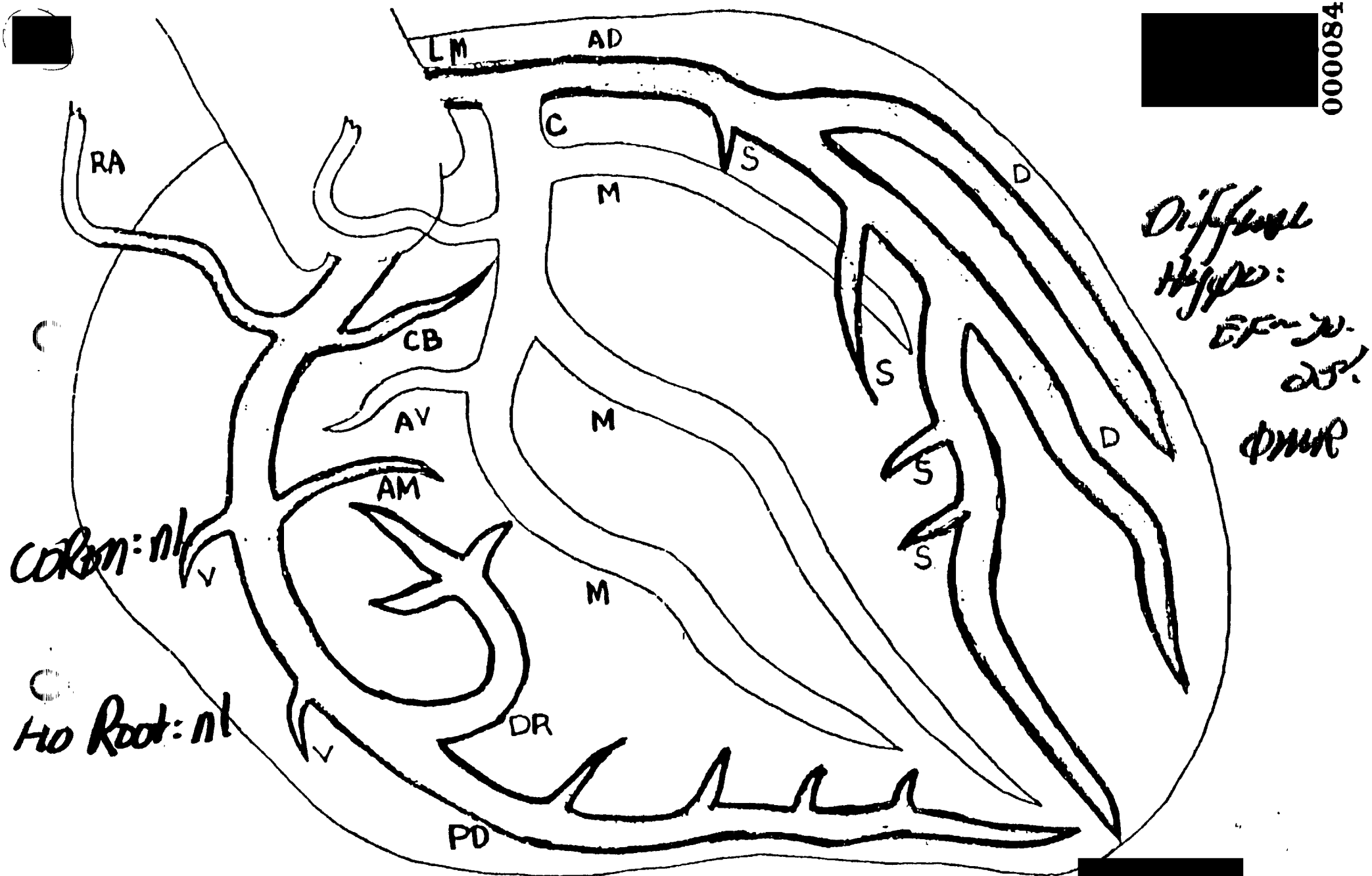

Name : [redacted]

Cine No [redacted] 42Y F 07/03/98

Date :

Doctor : [redacted]

CARDIAC CATHETERIZATION HEART DIAGRAM

PATIENT [redacted]

CD # [redacted]

PROCEDURE DATE 07/03/98

CARDIOLOGIST [redacted]

The left coronary system.

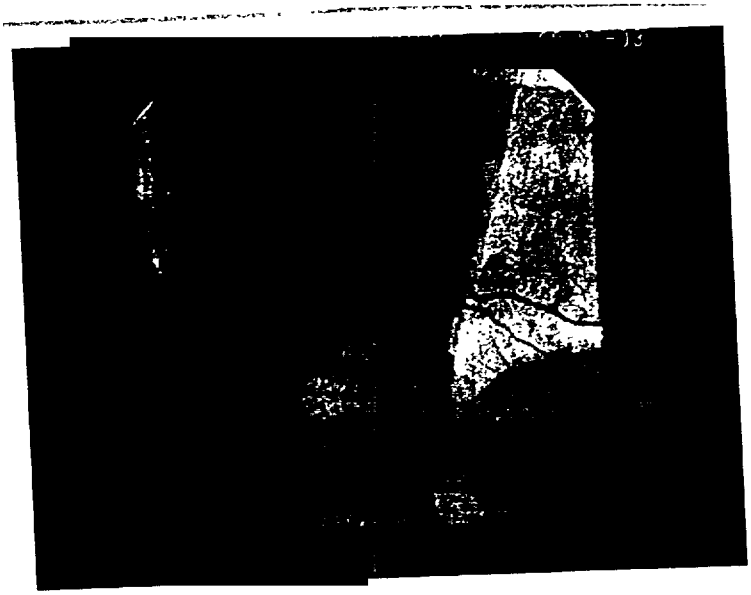

The right coronary artery.

PATIENT [redacted] PROCEDURE DATE 07/03/98

CD # [redacted] CARDIOLOGIST [redacted] MD

An aortic root injection.

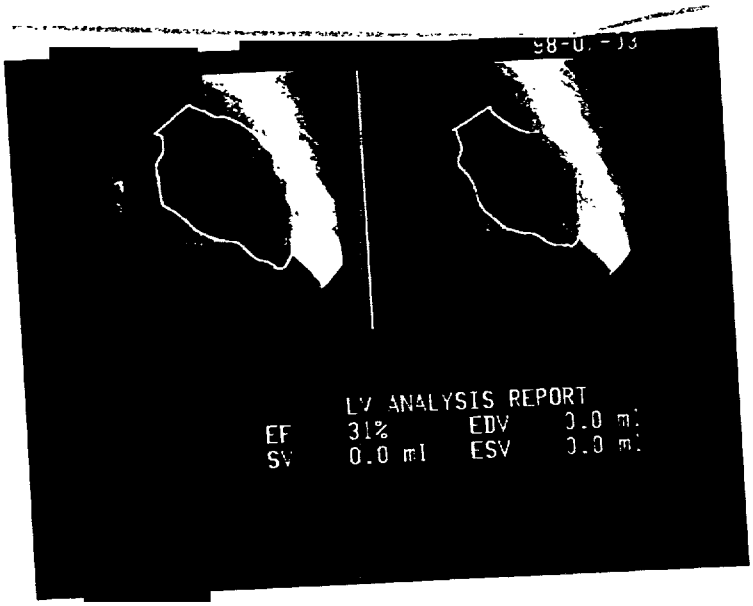

An RAO view of the left ventriculogram.

[redacted]

DD: 08/05/98
DT: 08/06/98 1:14 P

[redacted]

DIAGNOSTIC IMAGING

Name: [redacted]
DOB: [redacted] Age: 42Y Sex: F
Date: 07/05/98 0833

Med Rec # [redacted]
ACCT: [redacted]
Pt Location: [redacted]

[redacted]

Exam
NM LUNG VENTILATION/PERFUSION(VQ)

Check-In # [redacted] Order Diagnosis
Ord Diag: SEIZURES,CARDIOGENIC

History: Cardiogenic shock.

Findings:
PERFUSION SCAN:
Multiple images were obtained after intravenous injection of 6.0 mCi of Tc 99m MAA which was injected into an IV line. These images show minimal inhomogeneity of perfusion without segmental or subsegmental defects demonstrated.

VENTILATION SCAN:
Images were obtained while the patient inhaled 30.0 mCi of xenon 133 gas. These images show a very unusual pattern of radiotracer localization with patchy ventilation bilaterally and almost complete absence of ventilation, left mid lung zone and the right upper lung zone. Washout images show retention in focal rounded areas which appear peripheral. These may represent bullous change with significant air trapping.

IMPRESSION:
1. Low probability scan for evidence of acute pulmonary embolism.
2. Markedly abnormal ventilation study. This has the appearance of chronic lung disease with retention in peripheral bullae.

Clinically, the patient has a physiologic right to left shunt. Image was obtained over the skull which shows free Technetium within the salivary glands. No abnormal activity is seen within the brain. This indicates that there is no anatomic right to left shunt.

/Read By/ [redacted] MD
/Released By/ [redacted] MD
Report Released 07/06/98 1144

[redacted] 07/06/98 1047
Admitting Physician
Attending Physician [redacted]
REFER MD

SUPPLEMENTAL

[redacted]

Name: [redacted] Med Rec #[redacted]
ACCT:[redacted]
DOB: [redacted] Age: 42Y Sex: F Pt Location: [redacted]
Date: 07/05/98 0833

[redacted]

Exam Check-In # Order Diagnosis
NM LUNG VENTILATION/PERFUSION(VQ) [redacted] Ord Diag: SEIZURES,CARDIOGENIC

The lung ventilation perfusion scan and the initial report for that study are reviewed. That report was incomplete with portions of the final paragraph omitted. That paragraph should read that an image was obtained over the skull which shows free pertechnetate within the salivary glands. No abnormal activity is seen within the brain. This indicates that there is no anatomic right-to-left shunt.

[redacted] dd: 07/06/98 dt: 07/06/98

/Read By/ [redacted] MD
/Released By/ [redacted] MD
Report Released 07/06/98 1224

[redacted] 07/06/98 1204
Admitting Physician:
Attending Physician: [redacted]
REFER MD

NAME: [redacted]
UNIT #:
ROOM #:
DOB: [redacted]
AGE: 42
SEX: F
PROCEDURE DATE: 07/05/98
PREOP DIAG: Rule out retained secretions.
POSTOP DIAG: Sparse secretions.
OPERATION: Bronchoscopy.
SURGEON: [redacted] MD

INDICATIONS FOR PROCEDURE: Widened AA gradient and abnormal ventilation scan.

PROCEDURE: The patient was intubated, sedated, and mechanically ventilated in the Medical Intensive Care Unit. She had an FIO2 of 100% with 7.5 of PEEP and O2 sats of 99%. The bronchoscope was placed via the endotracheal tube after the instillation of viscous lidocaine. A bite block had been placed. Other than suction trauma, only sparse secretions were demonstrated. There was no proximal or central obstruction of the left main-stem bronchus or any lobar bronchi that could be visualized with the bronchoscope. 10 cc of normal saline were lavaged into the left side with return of only one purulent plug. The right side was clear. The bronchoscope was removed, and the patient tolerated the procedure without vital sign change.

[redacted] MD

DD: 07/05/98
DT: 07/07/98 11:23 A
cc: [redacted] MD

[redacted]

[redacted]

ate: 5 [illegible]

ronchoscopist: [redacted]

ssistant: [redacted]

one In: RT OR m ICU Other

iagnosis: ↑A/a gradient

uspect Organism:

Microbiology:

2) Legionnaire Culture + DFA

BAL

Biopsy

Brush

Washing

- ☐ Routine Culture
- ① ☑ Routine Culture/Gram Stain
- ☐ Gram Stain
- ☐ Fungus/Yeast Culture
- ☐ Direct Smear Fungus/Yeast (KOH, Other)
- ☐ TB/AFB Culture/Smear
- ☐ Other

Cytology:

Washing

Brush

Biopsy

Transbronchial Needle Aspirate

PROCEDURE

Pre-Medication IV drips

Medication During Procedure

Dose of Topical Lidocaine

1%

2%

1% Lido. c̄ Epi.

[redacted]

VITAL SIGNS

	ā	during	p̄
BP	nonotensive		
SPO_2	99	→	
HR	80's	→	

Complications:

Findings:

min secretions

[redacted] M.D.

000090

FIBEROPTIC
BRONCHOSCOPY REPORT

[redacted]

NAME: [redacted] **DOB:** [redacted]
UNIT #: [redacted] **AGE:** 42
ROOM #: [redacted] **SEX:** F
PROCEDURE DATE: 07/11/98
PREOP DIAG: Left lower lobe atelectasis with respiratory failure.
POSTOP DIAG: Same.
OPERATION: Fiberoptic bronchoscopy.
SURGEON: [redacted] MD

INDICATIONS FOR SURGERY: This is a 42-year-old woman with prolonged respiratory failure which was multifactorial. In an effort to facilitate weaning in the face of left lower lobe atelectasis, bronchoscopy was performed to rule out significant mucous plug.

PREMEDICATION: The patient received 5 mg of intravenous Versed and topical anesthesia with 1% lidocaine and 2% lidocaine gel.

PROCEDURE: The fiberoptic scope was passed through the endotracheal tube which was in good position. The airways were diffusely erythematous and swollen. There was some thick secretions in the left lower lobe orifice which were suctioned until clear. The patient tolerated the procedure well with some cough. At the termination of the procedure, she was extubated. She was left in the MICU in stable condition.

[redacted] MD

DD: 07/11/98
DT: 07/13/98 10:35 A
cc: [redacted] MD

[redacted]

[redacted]

Date: 7/14/98

Bronchoscopist: [redacted]

Assistant: [redacted]

Done In: RT OR m ICU Other

Diagnosis: Resp Failure, LLL atelect.

Suspect Organism:

[redacted]

Microbiology:

Legionnaire Culture

BAL

Biopsy

Brush

Washing

- ☐ Routine Culture
- ☑ Routine Culture/Gram Stain
- ☐ Gram Stain
- ☐ Fungus/Yeast Culture
- ☐ Direct Smear Fungus/Yeast (KOH, Other)
- ☐ TB/AFB Culture/Smear
- ☐ Other

VITAL SIGNS

	$\bar{a}$	during	$\bar{p}$
BP	120-130	→	→
SPO_2	94-95	90-95	88-95
HR	80-90	→	→

Cytology:

Washing

Brush

Biopsy

Transbronchial Needle Aspirate

Complications:

PROCEDURE

Pre-Medication Versed 5 IV

Medication ~~During~~ Post Procedure

Romazicon 0.2 mg IV

Findings: Some thick mucos LLL Suctioned clear Airways hyperemia

Dose of Topical Lidocaine

1% 10 cc

2% 10 cc Visum

1% Lido. $\bar{c}$ Epi.

[redacted] M.D.

000092

[redacted]

FIBEROPTIC BRONCHOSCOPY REPORT