Food and Drug Administration
Center for Food Safety and Applied Nutrition
Office of Special Nutritionals

ARMS#

12483

7 - PROCEDURES

[redacted]

PATIENT: [redacted]
MR #: [redacted] ACCT [redacted]
SEX: F AGE: 34

PHYSICIAN: [redacted]

LOCATION: [redacted] DATE: 8/03/97 TIME:1731

SUMMARY COVERS TESTS COMPLETED >= 7/28/97

P E R M A N E N T L A B O R A T O R Y R E P O R T

******* H E M A T O L O G Y *********

TEST NAME	7/28/97	7/29/97	7/30/97	7/31/97	REFERENCE RANGE
PROTIME	13.8 H				10.8-13.4 SECONDS
INR	1.4				ONLY FOR PATIENTS ON STABLE WARFARIN THERAPY
PTT	31				25-35 SECONDS
ESR					
PLATE COUNT	232	130 L	99 L	96 L	150-400 TH/UL
WBC	20.6 H	17.1 H	13.6 H	10.6	4.5-11.0 TH/UL
RBC	4.32	4.11 L	3.36 L	3.19 L	4.15-4.87 MIL/UL
HEMOGLOBIN	13.5	13.0	10.3 L	9.9 L	12.7-14.7 GM/DL
HEMATOCRIT	39.5	38.0	31.0 L	29.2 L	37.9-43.9 %
MCV	91.5	92.2	92.3	91.5	80.0- 95.0 FL
MCH	31.2	31.5	30.7	31.1	28.0-32.0 PG
MCHC	34.0	34.1	33.3	34.0	32-36 GM/DL
RDW	13.3	13.1	13.0	13.1	11.5-14.5 UNITS
LYMPH(AUTO)	4.9 L	2.9 L	6.4 L	5.8 L	25-35 %
MONO(AUTO)	3.0	4.1	4.1	5.3	1-10 %
GRANS(AUTO)	92.5 H	92.8 H	89.1 H	88.2 H	57-75 %
EOS(AUTO)	0.3	0.2	0.2	0.4	0-5 %
BASO(AUTO)	0.3	0.0	0.2	0.3	0-1 %
LYMPH(ABS)	1.0 L	0.5 L	0.9 L	0.6 L	1.5- 4.0 TH/UL
MONO(ABS)	0.4	0.7	0.6	0.6	0.1-2.0 TH/UL
GRANS(ABS)	19.0 H	15.9 H	12.1 H	9.4 H	2.0- 8.0 TH/UL
EOS(ABS)	0.1	0.0	0.0	0.0	0.0-0.7 TH/UL
BASO(ABS)	0.1	0.0	0.0	0.0	0.0-0.2 TH/UL

TEST NAME	8/01/97	8/02/97	8/03/97	REFERENCE RANGE
ESR				

(PATIENT REPORT CONTINUED ON PAGE: 2)

[redacted]

[redacted]

[redacted]

PATIENT: [redacted]
MR #: [redacted] ACCT [redacted]
SEX: F AGE: 34

PHYSICIAN: [redacted]

LOCATION: [redacted] DATE: 8/03/97 TIME:1731

SUMMARY COVERS TESTS COMPLETED >= 7/23/97
(PERMANENT LABORATORY REPORT CONTINUED)

******* H E M A T O L O G Y *********

TEST NAME	7/31/97	8/02/97	8/03/97		REFERENCE RANGE	
PLATE COUNT	106	135 L	189		150-400	TH/UL
WBC	6.7	8.1	12.4	H	4.5-11.0	TH/UL
RBC	3.07 L	3.02 L	3.52	L	4.15-4.87	MIL/UL
HEMOGLOBIN	9.7 L	9.4 L	10.9	L	12.7-14.7	GM/DL
HEMATOCRIT	28.0 L	27.6 L	32.0	L	37.9-43.9	%
MCV	91.1	91.3	91.0		80.0- 95.0	FL
MCH	31.4	31.2	30.7		28.0-32.0	PG
MCHC	34.5	34.0	33.7		32-36	GM/DL
RDW	13.2	13.4	13.6		11.5-14.5	UNITS
LYMPH(AUTO)	12.5 L	11.6 L	7.7	L	25-33	%
MONO(AUTO)	8.0	9.9	11.6	H	1-10	%
GRANS(AUTO)	78.2 H	76.5 H	78.9	H	57-75	%
EOS(AUTO)	1.0	1.6	1.8		0-5	%
BASO(AUTO)	0.3	0.4	0.1		0-1	%
LYMPH(ABS)	0.8 L	0.9 L	1.0	L	1.5- 4.0	TH/UL
MONO(ABS)	0.5	0.8	1.5		0.1-2.0	TH/UL
GRANS(ABS)	5.3	6.3	10.6	H	2.0- 8.0	TH/UL
EOS(ABS)	0.1	0.1	0.2		0.0-0.7	TH/UL
BASO(ABS)	0.0	0.0	0.0		0.0-0.2	TH/UL

(PATIENT REPORT CONTINUED ON PAGE: 3)

[redacted]
7-30/8-5-97 JAN(144)
Exhibit J Page 2 of 21

[redacted]

[redacted]

PATIENT: [redacted]
MR #: [redacted]
AGE: 34 SEX: F

PHYSICIAN: [redacted]

LOCATION: [redacted]

DATE: 8/05/97 TIME:0133

************ H E M A T O L O G Y ************

TEST NAME	8/03/97	8/04/97	8/05/97	REFERENCE RANGE	
	[redacted]				
CBC			T/F		
PLATE COUNT	189	199		150-400	TH/UL
WBC	17.4 H	11.5 H		4.5-11.0	TH/UL
RBC	3.52 L	3.36 L		4.15-4.87	MIL/UL
HEMOGLOBIN	10.8 L	10.4 L		12.7-14.7	GM/DL
HEMATOCRIT	32.0 L	30.6 L		37.9-43.9	%
MCV	91.0	91.1		80.0- 95.0	FL
MCH	30.7	30.9		28.0-32.0	PG
MCHC	33.7	34.0		32-36	GM/DL
RDW	13.6	13.3		11.5-14.5	UNITS
LYMPH(AUTO)	7.7 L	12.1 L		25-35	%
MONO(AUTO)	11.6 H	10.3 H		1-10	%
GRANS(AUTO)	78.8 H	77.1 H		57-75	%
EOS(AUTO)	1.8	2.1		0-5	%
BASO(AUTO)	0.1	0.4		0-1	%
LYMPH(ABS)	1.0 L	1.4 L		1.5- 4.0	TH/UL
MONO(ABS)	1.6	1.2		0.1-2.0	TH/UL
GRANS(ABS)	10.6 H	8.7 H		2.0- 8.0	TH/UL
EOS(ABS)	0.2	0.2		0.0-0.7	TH/UL
BASO(ABS)	0.0	0.0		0.0-0.2	TH/UL

(PATIENT REPORT CONTINUED ON PAGE: 2)

[redacted]
7-30/8-5-97 JAN(144)
Exhibit J Page 15 of 21

[redacted]

[redacted]

SEX: F AGE: 34

PHYSICIAN: [redacted]

LOCATION: [redacted] DATE: 8/03/97 TIME:1731

SUMMARY COVERS TESTS COMPLETED >= 7/28/97
(PERMANENT LABORATORY REPORT CONTINUED)

********** C H E M I S T R Y **********

TEST NAME	7/28/97	7/28/97	7/29/97	7/30/97	REFERENCE RANGE
CHEM PROF	[redacted]				
SODIUM	140	142	142	148 H	135-145 MEQ/L
POTASSIUM	3.9	4.2	3.9	3.4 L	3.5-5.3 MEQ/L
CHLORIDE	104	101	103	116 H	100-110 MEQ/L
CO2	18 L	20 L	20 L	27	25-36 MEQ/L
BUN	12	12	13	14	5-25 MG/DL
CREATININE	0.7	0.8	0.8	0.6 L	0.7-1.5 MG/DL
GLUCOSE	157 H	201 H	154 H	153 H	70-110 MG/DL
ANION GAP	18 H	21 H	19 H	6 L	7-15
URIC ACID			5.6		1.0-6.0 MG/DL
CALCIUM			9.6		8.5-10.5 MG/DL
PHOSPHORUS			3.3		2.5- 4.5 MG/DL
TOTAL PROT			6.3		6.0-8.0 GM/DL
ALBUMIN			3.8		3.5-5.0 GM/DL
ALK PHOS			57		25-107 U/L
TOT BILI			0.40		0.0-1.2 MG/DL
SGOT (AST)			69 H		0-40 U/L
SGPT (ALT)			13		0-39 U/L
LDH			375 H		95-190 U/L
CPK			624 H		38-173 U/L
GAMMA GT			14		10- 49 U/L
GLOBULIN			3.0		1.9-4.0 GM/DL
A/G RATIO			1.3		
CHOLESTEROL			211 H		DESIRABLE <200 MG/DL
					BORDERLINE 200-239
					HIGH >240

(PATIENT REPORT CONTINUED ON PAGE: 6)

[redacted]

[redacted]

[redacted]

PATIENT: [redacted]
MR #: [redacted]
SEX: F AGE: 34

PHYSICIAN: [redacted]

LOCATION: [redacted] DATE: 8/03/97 TIME:1731

SUMMARY COVERS TESTS COMPLETED >= 7/28/97
(PERMANENT LABORATORY REPORT CONTINUED)

********** C H E M I S T R Y **********

TEST NAME	7/31/97		7/21/97	8/01/97		8/01/97		REFERENCE RANGE	
[redacted]									
CHEM PROF									
SODIUM	141		142	139		143		135-145	MEQ/L
POTASSIUM	3.4	L		3.3	L			3.5-5.3	MEQ/L
CHLORIDE	111	H		114	H			100-110	MEQ/L
CO2	22	L		23				25-35	MEQ/L
BUN	11			13				5-25	MG/DL
CREATININE	0.5	L		0.6	L			0.7-1.3	MG/DL
GLUCOSE	139	H		139	H			70-110	MG/DL
ANION GAP	8							7-17	
URIC ACID	1.8			1.5				1.0-6.0	MG/DL
CALCIUM	8.3	L		8.4	L			8.5-10.5	MG/DL
PHOSPHORUS	1.8	LL		3.2				2.5- 4.5	MG/DL
TOTAL PROT	5.7	L		5.5	L			6.0-8.0	GM/DL
ALBUMIN	3.0	LL		2.9	L			3.5-5.0	GM/DL
ALK PHOS	80			90				25-107	U/L
TOT BILI	0.50			0.40				0.0-1.2	MG/DL
SGOT (AST)	22			21				0-42	U/L
SGPT (ALT)	19			14				0-39	U/L
LDH	244	H		317	H			95-190	U/L
CPK	136			195	H			38-173	U/L
GAMMA GT	7	L		10				10- 60	U/L
GLOBULIN	2.7			2.6				1.9-4.0	GM/DL
A/G RATIO	1.1			1.1					
CHOLESTEROL	138			141				DESIRABLE <200 MG/DL	
								BORDERLINE 200-239	
								HIGH >240	

(PATIENT REPORT CONTINUED ON PAGE: 7)

[redacted]

[redacted]

[redacted]

PATIENT: [redacted]
MP #: [redacted] ACCT: [redacted]
SEX: F AGE: 34

PHYSICIAN: [redacted]

LOCATION: [redacted] DATE: 8/03/97 TIME:1731

SUMMARY COVERS TESTS COMPLETED >= 7/28/97
(PERMANENT LABORATORY REPORT CONTINUED)

********** CHEMISTRY **********

TEST NAME	8/02/97	9/02/97	8/03/97	REFERENCE RANGE
CHEM PROF	[redacted]			
SODIUM	142	144	142	135-145 MEQ/L
POTASSIUM	3.4 L	3.8	3.9	3.5-5.3 MEQ/L
CHLORIDE	110		105	100-110 MEQ/L
CO2	25		27	25-36 MEQ/L
BUN	12		11	5-25 MG/DL
CREATININE	0.3 L		0.5 L	0.7-1.5 MG/DL
GLUCOSE	127 H		121 H	70-110 MG/DL
ANION GAP	7		10	7-16
URIC ACID	1.5		1.5	1.0-6.0 MG/DL
CALCIUM	8.3 L		8.2 L	8.5-10.5 MG/DL
PHOSPHORUS	3.2		2.1 L	2.5- 4.5 MG/DL
TOTAL PROT	5.5 L		6.0	6.0-8.0 GM/DL
ALBUMIN	2.8 L		3.0 L	3.5-5.0 GM/DL
ALK PHOS	53		57	25-107 U/L
TOT BILI	0.40		0.20	0.0-1.2 MG/DL
SGOT (AST)	15		17	0-40 U/L
SGPT (ALT)	4		22	0-39 U/L
LDH	296 H		342 H	95-180 U/L
CPK	138		86	38-173 U/L
GAMMA GT	29		21	10- 60 U/L
GLOBULIN	2.7		3.0	1.9-4.0 GM/DL
A/G RATIO	1.0		1.0	
CHOLESTEROL	133		149	

DESIRABLE <200 MG/DL
BORDERLINE 200-239
HIGH >240

********** CPK/LDH ENZYMES **********

TEST NAME	7/28/97	7/29/97	7/29/97	7/29/97	REFERENCE RANGE
CK/MB RO MI	[redacted]				

(PATIENT REPORT CONTINUED ON PAGE: 8)

[redacted]

[redacted]

[redacted]

PATIENT: [redacted]
HP #: [redacted] ACCT: [redacted]
AGE: 34 SEX: F

PHYSICIAN: [redacted]

LOCATION: [redacted]

DATE: 8/05/97 TIME:0133

(CONTINUED)

C H E M I S T R Y

TEST NAME	8/03/97	8/04/97	8/04/97	8/04/97	REFERENCE RANGE	
CHEM PROF	[redacted]					
SODIUM	142	139	145	139	135-145	MEQ/L
POTASSIUM	3.9	3.7	2.8 * (A)	4.7	3.5-5.5	MEQ/L
CHLORIDE	105	102	111 H		100-110	MEQ/L
CO2	27	29	23 L		25-34	MEQ/L
BUN	11	12	7		5-25	MG/DL
CREATININE	0.5 L	0.4 L	0.3 L		0.7-1.5	MG/DL
GLUCOSE	121 H	131 H	95		70-110	MG/DL
ANION GAP	10	9	11		7-15	
URIC ACID	1.5	1.6			1.0-6.0	MG/DL
CALCIUM	9.2 L	9.3 L			8.5-10.5	MG/DL
PHOSPHORUS	2.1 L	3.7			2.5- 4.5	MG/DL
TOTAL PROT	6.0	5.9 L			6.0-8.0	GM/DL
ALBUMIN	3.0 L	2.9 L			3.5-5.0	GM/DL
ALK PHOS	57	53			25-107	U/L
TOT BILI	0.20	0.20			0.0-1.2	MG/DL
SGOT (AST)	17	13			0-40	U/L
SGPT (ALT)	22	23			0-39	U/L
LDH	342 H	305 H			95-190	U/L
CPK	86	68			38-173	U/L
GAMMA GT	31	33			10- 60	U/L
GLOBULIN	3.0	2.9			1.9-4.0	GM/DL
A/G RATIO	1.0	1.0				
CHOLESTEROL	149	147			DESIRABLE <200 MG/DL BORDERLINE 200-239 HIGH >240	

(A): CRITICAL VALUE,RECHECKED AND CALLED

TEST NAME	8/05/97	REFERENCE RANGE
CHEM PROF	[redacted] T/F	

(PATIENT REPORT CONTINUED ON PAGE: 4)

[redacted]

[redacted]

[redacted]

PATIENT: [redacted]
MR #: [redacted] ACCT [redacted]
SEX: F AGE: 34

PHYSICIAN: [redacted]

LOCATION: [redacted] DATE: 8/03/97 TIME:1731

SUMMARY COVERS TESTS COMPLETED >= 7/23/97
(PERMANENT LABORATORY REPORT CONTINUED)

******** C P K / L D H E N Z Y M E S ********

TEST NAME	7/23/97	7/29/97	7/29/97	7/29/97	REFERENCE RANGE	
CPK	401 H	503 H	622 H	419 H	38-173	U/L
CPK-MB	24.4 H	42.1 H	54.3 H	29.4 H	0.0-5.0	NG/ML
MB-INDEX	6.6 H	8.0 H	8.8 H	7.0 H	0.0-4.0	

TEST NAME	7/29/97	REFERENCE RANGE
TROPONIN I	10.04	NG/ML
		< 0.6 NEGATIVE
		0.7 - 1.4 INDETERMINATE
		>= 1.5 SUGGESTIVE OF MYOCARDIAL INJURY

******** C H E M I S T R Y **********

TEST NAME	7/23/97	REFERENCE RANGE
PREGNANCY,QUAL-SERUM	NEGATIVE	

******** M I C R O B I O L O G Y **********
********** S T A I N S A N D S M E A R S **********

TEST NAME
7/23/97 [redacted]
GRAM STAIN
SOURCE/BODY SITE INDUCED SPUTUM

[redacted]

(PATIENT REPORT CONTINUED ON PAGE: 9)

[redacted]

[redacted]

PATIENT: [redacted]
MR #: [redacted] ACCT [redacted]
SEX: F AGE: 34

PHYSICIAN: [redacted]

LOCATION: [redacted] DATE: 8/03/97 TIME:1731

SUMMARY COVERS TESTS COMPLETED >= 7/28/97
(PERMANENT LABORATORY REPORT CONTINUED)

* ******** N E U R O B I O L O G Y *********
******* LABORATORY DIRECTOR - [redacted]
******** [redacted]
******** *********

7/23/97 [redacted]

ANA PROFILE		
dsDNA	NEGATIVE	SPECIFIC FOR SYSTEMIC LUPUS ERYTHEMATOSUS (SLE) >95%. FOUND IN SJOGRENS SYNDROME (SS) 20-30%, MIXED CONNECTIVE TISSUE DISEASE (MCTD) 20-25% AND PROGRESSIVE SYST. SCLEROSIS (PSS) <5%.
J1-RNP	NEGATIVE	PRESENT IN MCTD >95%, SLE 20-40%, AND PSS 15-25%
SMITH (Sm)	NEGATIVE	SPECIFIC FOR SLE (15-30%), OFTEN ASSOC.WITH RENAL DISEASE
RNP-Sm	NEGATIVE	INDICATIVE OF RNP AND/OR SMITH ANTIBODIES
SS-A (RO)	NEGATIVE	PRESENT IN SJOGRENS SYNDROME (SS) 70-85%, SUBACUTE CUTANEOUS LE (SCLE) 70-90%, NEONATAL LE >90%, COMPLEMENT DEFICIENT (C2 AND C4) LE >90%, AND SLE 24-60%
SS-A (LA)	NEGATIVE	PRESENT IN SS 70-85%, NEONATAL LE 75%, AND SLE 9-35%
CENTROMERE(ACA)	NEGATIVE	PRESENT IN LIMITED SCLERODERMA 60-80%, PSS-CREST 50-70%, DIFFUSE SCLEPODERMA 8%, AND RAYNAUD'S SYNDROME 25%

(PATIENT REPORT CONTINUED ON PAGE: 14)

[redacted]

[redacted]

[redacted]

PATIENT: [redacted]
MR #: [redacted] ACCT [redacted]
SEX: F AGE: 34

PHYSICIAN: [redacted]

LOCATION: [redacted] DATE: 8/03/97 TIME:1731

SUMMARY COVERS TESTS COMPLETED >= 7/28/97
(PERMANENT LABORATORY REPORT CONTINUED)

---

* ******** IMMUNOBIOLOGY **********
******** LABORATORY DIRECTOR - [redacted] PH.D. *********
******** [redacted] **********
******** **********

7/29/97
[redacted]

SCL-70 (DNA-TOPOISOMERASE 1)	NEGATIVE	PRESENT IN SCLERODERMA 4-20%, AND DIFFUSE SCLERODERMA 13%
JO1 (HISTIDYL tRNA SYNTHETASE)	NEGATIVE	PRESENT IN POLYMYOSITIS (PM) 13-36%, DERMATOMYOSITIS (DM) 18-36%, AND PM/DM 43%

[redacted]

[redacted]

[redacted]

SLI ACC. # [redacted]
CLIENT #

[redacted]

PATIENT NAME [redacted]
PHYSICIAN
NOTES
PATIENT ID [redacted]
AGE: 34Y SEX: F
DRAWN 07/29/97 7:49
RECEIVED 07/30/97 04:14
REPORTED 07/31/97 15:37

PERMANENT
CHART COPY

TEST NAME	RESULTS	REFERENCE RANGES
ANTI-CARDIOLIPIN ANTIBODIES EIA		
CARDIOLIPIN IgG Abs	Less than 15	Less than 15 GPL
CARDIOLIPIN IgM Abs	12 *	Less than 10 MPL
CARDIOLIPIN IgA Abs	Less than 10	Less than 10 APL

CUTOFF POINTS FOR CARDIOLIPIN Ab IgG:

Less than 15.	Not detected
15 - 20	Indeterminate
21 - 40	Weakly positive
> 40	Positive

Results are reported as PHOSPHOLIPID UNITS; GPL for the IgG isotype of cardiolipin antibodies.

CUTOFF POINTS FOR CARDIOLIPIN Ab IgM:

Less than 10.	Not detected
10 - 20	Indeterminate
21 - 40	Weakly positive
> 40	Positive

Results are reported as PHOSPHOLIPID UNITS; MPL for the IgM isotype of cardiolipin antibodies.

CUTOFF POINTS FOR CARDIOLIPIN Ab IgA:

Less than 10.	Not detected
10 - 20	Indeterminate
21 - 40	Weakly positive
> 40.	Positive

Results are reported as PHOSPHOLIPID UNITS; APL for the IgA isotype of cardiolipin antibodies.

ANTI-CARDIOLIPIN ANTIBODIES (ACA), EIA: ACA are found in patients with SLE and in recurrent spontaneous abortions, fetal

[redacted]

President and Medical Director

[redacted]

Continued on page: 2

[redacted]

[redacted]

SLI ACC. # [redacted]
CLIENT #

[redacted]

PATIENT NAME [redacted]
PHYSICIAN
NOTES
PATIENT ID [redacted]
AGE: 34Y SEX: F
DRAWN
RECEIVED 07/30/97 04:14
REPORTED 07/31/97 15:37

TEST NAME	RESULTS	REFERENCE RANGES

distress and arterial and venous thrombosis. While high concentrations of ACA are often accompanied by lupus anticoagulant (LA), LA can also be present in the absence of ACA. In suspect patients, if clinically indicated, testing for both ACA and LA should be performed. Standardization of the ACA procedure has been accomplished by using standards for IgG and IgM isotypes of ACA which are traceable to primary standards prepared by the Anti-Phospholipid Standardization Laboratory. This important new feature, coupled with improved precision, eliminates the need to perform paired testing to discern significant changes in ACA in monitoring high risk patients.

[redacted]

[redacted]

[redacted]

PATIENT: [redacted]
MR #: [redacted] ACCT: [redacted]
SEX: F AGE: 34

PHYSICIAN: [redacted]

LOCATION: [redacted] DATE: 8/03/97 TIME:1731

SUMMARY COVERS TESTS COMPLETED >= 7/28/97
(PERMANENT LABORATORY REPORT CONTINUED)

******** U R I N A L Y S I S **********

TEST NAME	7/31/97	8/01/97	REFERENCE RANGE
URINALYSIS			
COLOR	YELLOW	YELLOW	
CLARITY	HAZY	CLEAR	
SPECIF GRAV	1.025	1.015	1.003-1.040
PH	5.5	7.0	5-8
GLUCOSE	NEG	NEG	NEGATIVE GM/DL
BILE	NEG	NEG	NEGATIVE
KETONES	NEG	NEG	NEGATIVE
OCCULT BLD	1+	NEG	NEGATIVE
PROTEIN	1+	NEG	NEGATIVE
UROBILI	NEG	NEG	NEGATIVE
NITRITE	NEG	NEG	NEGATIVE
LEUK. ESTER	NEG	NEG	NEGATIVE
RBC	5-10		0 - 2/HPF
WBC	2-5		0 - 2/HPF
SQUAM EPI	1+		
MUCOUS	2+		
URIC ACID CRY	2+		
COMMENT		(A)	

(A): MICRO EXAM PRECLUDED BY NEG CHEM SCR

(PATIENT REPORT CONTINUED ON PAGE: 5)

[redacted]

[redacted]

[redacted]

PATIENT: [redacted]
MR #: [redacted] ACCT: [redacted]
SEX: F AGE: 34

PHYSICIAN: [redacted]

LOCATION: [redacted] DATE: 8/03/97 TIME:1731

SUMMARY COVERS TESTS COMPLETED >= 7/28/97
(PERMANENT LABORATORY REPORT CONTINUED)

******* S P I N A L F L U I D S T U D I E S *********

TEST NAME	7/31/97 [redacted]	REFERENCE RANGE	
CSF DESCRIPTION			
SOURCE	VENTRICULAR FLUID		
TUBES RECD	1		
TOTAL VOLUME	1		ML
COLOR UNSPUN	BLOODY		
APPEARANCE UNSPUN	CLOUDY		
CELL COUNT			
TUBE #	1		
RBC	56800		/UL
NUCLEATED CELLS	44 H		/UL
NEUTROPHILS	67		%
LYMPHOCYTES	27		%
MONONUCLEAR PHAGOC	6		%
GLUCOSE	75. H	40-70	MG/DL
TOTAL PROTEIN	36	15- 45	MG/DL
COLOR CSF SPUN	XANTHOCHROMIC		

(PATIENT REPORT CONTINUED ON PAGE: 4)

[redacted]

[redacted]

[redacted]

PATIENT: [redacted]
MR #:
AGE: 3

PHYSICIAN: [redacted]

LOCATION: [redacted]

DATE: 8/05/97 TIME:0133

(CONTINUED)

********** S P I N A L F L U I D S T U D I E S **********

TEST NAME	8/04/97 [redacted]	REFERENCE RANGE	
CSF DESCRIPTION			
SOURCE	VENTRICULOSTOMY		
TUBES REC'D	1		
TOTAL VOLUME	1		ML
COLOR UNSPUN	BLOOD TINGED		
APPEARANCE UNSPUN	HAZY		
CELL COUNT			
TUBE #	1		
RBC	11150		/UL
NUCLEATED CELLS	22 H		/UL
NEUTROPHILS	82		%
LYMPHOCYTES	11		%
MONONUCLEAR PHAGOC	7		%
GLUCOSE	83. H	40-70	MG/DL
TOTAL PROTEIN	70 H	15- 45	MG/DL
COLOR CSF SPUN	XANTHOCHROMIC		
	(A)		

(A): SLIGHT

(PATIENT REPORT CONTINUED ON PAGE: 3)

[redacted]

[redacted]

[redacted]

PATIENT: [redacted]
AR #: [redacted]
SEX: F AGE: 34

PHYSICIAN: [redacted]

LOCATION: [redacted] DATE: 8/03/97 TIME:1731

SUMMARY COVERS TESTS COMPLETED >= 7/23/97
(PERMANENT LABORATORY REPORT CONTINUED)

******** MICROBIOLOGY *********
********* STAINS AND SMEARS *********

TEST NAME
7/29/97 [redacted]
DATE OF FINAL 7/29
CELLS A >25 WBCS/LPF SEEN
CELLS B <10 EPITHELIAL CELLS/LPF SEEN
GRAM STAIN: ORG A FEW GRAM POSITIVE COCCI

TEST NAME
7/31/97 [redacted]
GRAM STAIN
SOURCE/BODY SITE SPUTUM
DATE OF FINAL 7/31
CELLS A >25 WBCS/LPF SEEN
CELLS B <10 EPITHELIAL CELLS/LPF SEEN
GRAM STAIN: ORG A FEW GRAM POSITIVE COCCI

TEST NAME
7/31/97 [redacted]
GRAM STAIN
SOURCE/BODY SITE VENTRICULOSTOMY
DATE OF FINAL 7/31
REPORTED RESULT NO ORGANISMS SEEN

********* BLOOD CULTURES *********

TEST NAME
7/31/97 C [redacted]
BLOOD CULTURE T/F
SOURCE/BODY SITE BLOOD
REPORTED RESULT NO GROWTH IN 2 DAYS

(PATIENT REPORT CONTINUED ON PAGE: 10)

[redacted]

[redacted]

[redacted]

PATIENT: [redacted]
MR #: [redacted]
SEX: F AGE: 34

PHYSICIAN: [redacted]

LOCATION: [redacted] DATE: 8/03/97 TIME:1731

SUMMARY COVERS TESTS COMPLETED >= 7/23/97
(PERMANENT LABORATORY REPORT CONTINUED)

******** BLOOD CULTURES ********

TEST NAME
8/01/97 [redacted]
SOURCE/BODY SITE BLOOD
REPORTED RESULT NO GROWTH IN 2 DAYS

******** CSF CULTURES ********

TEST NAME
7/31/97 [redacted]
SOURCE/BODY SITE VENTRICULOSTOMY
REPORTED RESULT NO GROWTH IN 2 DAYS

******** RESPIRATORY CULTURES ********

TEST NAME
7/29/97 [redacted]
RESPIRATORY CULT
SOURCE/BODY SITE INDUCED SPUTUM
DATE OF FINAL 7/31
REPORTED RESULT NORMAL FLORA ISOLATED

TEST NAME
7/31/97 [redacted]
RESPIRATORY CULT
SOURCE/BODY SITE SPUTUM
DATE OF FINAL 8/02
REPORTED RESULT NORMAL FLORA ISOLATED

(PATIENT REPORT CONTINUED ON PAGE: 11)

[redacted]

[redacted]

PATIENT: [redacted]
MR #:
SEX: F AGE: 34

PHYSICIAN: [redacted]

LOCATION: [redacted] DATE: 8/03/97 TIME:1731

SUMMARY COVERS TESTS COMPLETED >= 7/23/97
(PERMANENT LABORATORY REPORT CONTINUED)

******* M I S C E L L A N E O U S C U L T U R E S ********

TEST NAME		
7/31/97 [redacted]		
CATH TIP CULTURE		
SOURCE/BODY SITE	RIGHT ARTERIAL LINE TIP	
DATE OF FINAL	8/02	
COLLECT CATHTIP	TNTC	COLONIES/TIP
PRELIM RESULT 1	RARE GRAM POSITIVE RODS	
FINAL RESULT 1	BACILLUS SPECIES;NO SUSCEPTIBILITY TESTS PERFORMED	
PRELIM RESULT 2	MODERATE GRAM POSITIVE COCCI	
FINAL RESULT 2	MODERATE STAPH,COAG NEG;OXACILLIN RESISTANT	

ISOLATE NAME	MODERATE STAPH,COAG NEG;OXACILLIN R	
SENSITIVITY VITEK		
CIPROFLOXACIN	<=0.5	S
CLINDAMYCIN	<=0.5	S
ERYTHROMYCIN	>=8	R
OXACILLIN	4	R
PENICILLIN G	>=16	R
TRIMETHOPRIM/SULF	<=10	S
VANCOMYCIN	1	S

******* B L O O D B A N K T E S T S ********

7/29/97 [redacted]
TYPE AND SCREEN — AVAILABLE FOR X-MATCH WITHIN 72 HR COLLECTION

ABO	A
RH	POS
INDIRECT ANTIGLOB	NEG

(PATIENT REPORT CONTINUED ON PAGE: 12)

[redacted]

[redacted]

[redacted]

PATIENT: [redacted]
MR #:
AGE: 34 SEX: F

PHYSICIAN: [redacted]

LOCATION: [redacted]

DATE: 3/03/97 TIME:0133

(CONTINUED)

MICROBIOLOGY
STAINS AND SMEARS

TEST NAME
3/04/97 [redacted]
GRAM STAIN
SOURCE/BODY SITE VENTRICULOSTOMY VENTRICULAR FLUID
DATE OF FINAL 3/04
REPORTED RESULT NO ORGANISMS SEEN

BLOOD CULTURES

TEST NAME
3/01/97 [redacted]
BLOOD CULTURE T/F
SOURCE/BODY SITE BLOOD
REPORTED RESULT NO GROWTH IN 7 DAYS

TEST NAME
3/01/97 [redacted]
SOURCE/BODY SITE BLOOD
REPORTED RESULT NO GROWTH IN 5 DAYS

CSF CULTURES

TEST NAME
3/01/97 [redacted]
SOURCE/BODY SITE VENTRICULOSTOMY
REPORTED RESULT NO GROWTH IN 3 DAYS

TEST NAME
3/04/97 [redacted]
SOURCE/BODY SITE VENTRICULOSTOMY VENTRICULAR FLUID
REPORTED RESULT CULTURE PENDING

(PATIENT REPORT CONTINUED ON PAGE: 5)

[redacted]

PATIENT: [redacted]
AD #:
AGE: 34 SEX: F

PHYSICIAN: [redacted]

LOCATION: [redacted]

DATE: 8/05/97 TIME:0134

(CONTINUED)

********** M I S C E L L A N E O U S C U L T U R E S **********

TEST NAME		
7/31/97 [redacted]	[redacted]	
CATH TIP CULTURE		
SOURCE/BODY SITE	RIGHT ARTERIAL LINE TIP	
DATE OF FINAL	8/03	
COL CT CATHTIP	TNTC	COLONIES/TIP
PRELIM RESULT 1	RARE GRAM POSITIVE RODS	
FINAL RESULT 1	BACILLUS SPECIES;NO SUSCEPTIBILITY TESTS PERFORMED	
PRELIM RESULT 2	MODERATE GRAM POSITIVE COCCI	
FINAL RESULT 2	MODERATE STAPH,COAG NEG;OXACILLIN RESISTANT	

ISOLATE NAME	MODERATE STAPH,COAG NEG;OXACILLIN R	
SENSITIVITY VITEK		
CIPROFLOXACIN	<=0.5	S
CLINDAMYCIN	<=0.5	S
ERYTHROMYCIN	>=8	R
OXACILLIN	>=8	R
PENICILLIN G	>=16	R
TRIMETHOPRIM/SULF	<=10	S
VANCOMYCIN	1	S

[redacted]

[redacted]

[redacted]

MR# [redacted]

[redacted]

[redacted] DOB: [redacted]

[redacted]

REPORT ID: [redacted]

SEX: F

NOT [redacted]

ADMITTING DX: CHECK FOR INFILTRATES

ORD. PHYS: [redacted]

ATT. PHYS:

ORD#: [redacted] 07/29/1997 DR CHEST PORTABLE

ORD#: 07/28/1997 DR CHEST PORTABLE

ORD#: 07/28/1997 DR CHEST PORTABLE

FINAL Report

CLINICAL HISTORY: A 34-year-old female with subarachnoid hemorrhage.

CHEST
July 28, 1997, 1100 hours

FINDINGS: AP supine radiograph of the chest demonstrates normal cardiac and mediastinal silhouette. There is moderate increase in interstitial and alveolar process throughout the lung parenchyma with air bronchogram. There is no pleural effusion or pneumothorax. The bony structures appear intact.

IMPRESSION
1. Increased interstitial markings and alveolar process throughout both lung parenchyma, suggestive of neurogenic pulmonary edema.

CHEST
July 28, 1997, 1300 hours

FINDINGS: AP supine radiograph of the chest now demonstrates placement of ET tube, with the distal tip projected 3 cm above the carina. There is a left Swan-Ganz catheter with the distal tip projected over the right pulmonary artery. There is better aeration of the lung parenchyma, although interstitial and alveolar processes are still noted bilaterally. There is no pleural effusion or pneumothorax.

IMPRESSION
1. Endotracheal tube and Swan-Ganz catheter in good position.
2. Probable noncardiogenic pulmonary edema. Better aeration of the lung parenchyma.

CHEST

[redacted]

7-3078-5-97 JAN(144)

Exhibit C Page 6 of 7

000022

[redacted]

[redacted]

MR# [redacted] REPORT ID: [redacted]

[redacted]

DOB: [redacted] SEX: F

Continued from previous page:

July 29, 1997, 0330 hours

FINDINGS: AP supine radiograph of the chest demonstrates interval placement of nasogastric tube. The ET tube and Swan-Ganz catheter are stable in position. There has been interval development of consolidation in both upper lobes and left lower lobe, with slight silhouetting out of the left hemidiaphragm. There is no pleural effusion or pneumothorax.

IMPRESSION
1. Probable noncardiogenic pulmonary edema, with increased consolidation in both upper lobes and left lower lobe.
2. Interval placement of nasogastric tube, with the distal tip projected below the gastroesophageal junction.

Job [redacted]

THE ATTENDING RADIOLOGIST BELOW HAS PERSONALLY REVIEWED THIS EXAMINATION.

[redacted], M.D.

ELECTRONICALLY SIGNED BY:

DD: 07/30/1997 DT: 07/30/1997 17:54

[redacted] 07/31/1997 09:31

DF: 07/31/1997

DATE PRINTED: 07/31/1997 **FINAL** TIME PRINTED:09:40

[redacted]

7-30/8-5-97 JAN(144)
Exhibit C Page 7 of 7

000023

[redacted]

[redacted]

[redacted] DOB: [redacted] REPORT ID: [redacted]
SEX: F
NOT [redacted]

ADMITTING DX: INFILTRATES

ORD. PHYS:
ATT. PHYS: [redacted]

ORD#: [redacted] 07/31/1997 DR CHEST PORTABLE

FINAL Report

PORTABLE CHEST
July 31, 1997, 0300 hours

FINDINGS: There is a left subclavian Swan-Ganz catheter, with its tip in the right pulmonary artery. There is an endotracheal tube seen 3 cm above the carina. There is patchy left lower lobe infiltrate or atelectasis, unchanged. There is bilateral perihilar air-space disease extending into both upper lung zones, which is without significant change. No pneumothorax is seen. A nasogastric tube courses into the stomach.

Job [redacted]

[redacted] M.D.

ELECTRONICALLY SIGNED BY:

DD: 07/31/1997 DT: 07/31/1997 16:58

[redacted]

DF: 08/01/1997
DATE PRINTED: 08/01/1997 **FINAL** TIME PRINTED:11:21

[redacted]
7-30/8-5-97 JAN(144)
Exhibit C Page 3 of 7

[redacted]

[redacted]

[redacted] DOB: [redacted]

REPORT ID: [redacted]
SEX: F
NOT [redacted]

ADMITTING DX: INFILTRATES

ORD. PHYS:
ATT. PHYS: [redacted]

ORD#: [redacted] 08/01/1997 DR CHEST PORTABLE

FINAL Report

PORTABLE CHEST:
8/01/97, 3:00 a.m., portable AP supine chest.

COMMENT: Swan-Ganz catheter tip again projects to the right central pulmonary artery and hilum and is unchanged in position. Tip of endotracheal tube is difficult to identify, thought I believe is ends midway between the thoracic inlet and carina. There are two feeding tubes. Tip of a regular nasogastric tube extends to the midstomach. The other tube is coiled in the gastric fundus with its distal ends toward the distal stomach, though the inferior tip is not included on the film.

Cardiomediastinal structures are normal. Pulmonary vasculature is mildly diffusely engorged. There are scattered bilateral pulmonary infiltrates in somewhat of a batwing pattern, indicative of pulmonary edema. These are most pronounced over the mid-to-upper lung fields and are similar in appearance to 7/31/97. Pattern is that of pulmonary edema. Noncardiogenic causes in this young person should be considered, including fluid overload, neurogenic edema, etc. There are no definite pleural effusions, air leaks, or other chest complications.

Job #[redacted]

[redacted] M.D.

[redacted] M.D.

ELECTRONICALLY SIGNED BY: [redacted]

DD: 08/01/1997 DT: 08/01/1997 21:55

[redacted]

DF: 08/02/1997

7-30/8-5-97 JAN(144)
Exhibit C Page 1 of 7

000025

[redacted]

[redacted]

[redacted]

REPORT ID: [redacted]

SEX: F

Continued from previous page:

DATE PRINTED: 08/02/1997 FINAL TIME PRINTED:14:21

[redacted]

7-30/8-5-97 JAN(144)
Exhibit C Page 2 of 7

[redacted]

000026

[redacted]

MR# [redacted]

[redacted] DOB: [redacted]

[redacted] REPORT ID: [redacted]
SEX: F
NOT [redacted]

ADMITTING DX: F/U SAH

ORD. PHYS:
ATT. PHYS: [redacted]

ORD#: [redacted] 07/29/1997 CT HEAD SCAN BASIC

FINAL Report

CLINICAL HISTORY: Followup subarachnoid hemorrhage.

CT SCAN OF THE BRAIN:
7/29/97

COMPARISON: There are no prior studies available for comparison at this time.

PROCEDURE: Multiple axial contiguous sections of the brain were obtained from the skull base to the skull vertex in 10-mm-slice thickness without the use of intravenous contrast.

FINDINGS: There is a small amount of subarachnoid hemorrhage and intraventricular hemorrhage. There is a right anterolateral ventriculostomy shunt with its distal tip in the right lateral ventricle. The temporal horns are somewhat prominent consistent with mild hydrocephalus. There is effacement of the paramesencephalic cisterns, which may be secondary to subacute hemorrhage vs impending uncal herniation.

IMPRESSION:
1. Intraventricular and subarachnoid hemorrhage.
2. Mild dilatation of the temporal horns of the lateral ventricles.
3. Effacement of the paramesencephalic cistern, which may be secondary to subacute hemorrhage vs impending uncal herniation.

Job #[redacted]

THE ATTENDING RADIOLOGIST BELOW HAS PERSONALLY REVIEWED THIS EXAMINATIO[redacted] M.D.

[redacted] MD [redacted] M.D. NEURORADIOLOG

ELECTRONICALLY SIGNED BY:

[redacted]

7-30/8-5-97 JAN(144)
Exhibit C Page 4 of 7

000027

[redacted]

[redacted] 29 JUL 1997 6:41:38 [redacted]

000028

34 yrs Female

PR 135
QRSD 61
QT 283
QTc 405

(ST). Sinus tachycardia, rate 123 - - - - - - - - - - Normal P axis, rate >= 100
(TOLA). Nonspecific Lateral T abnormalities - - - - T neg, T/QRS ratio <.07 I,L,V5-V6
*Consider acute lateral injury
*jmb

HOSP # [redacted]

--AXES--
P 66
QRS 77
T 100

[redacted]

7-30/8-5-97 JAN(144)
Exhibit K Page 5 of 6

[redacted]

[redacted]

Tech [redacted]
Room [redacted]
Edited [redacted]

[redacted] M.D.

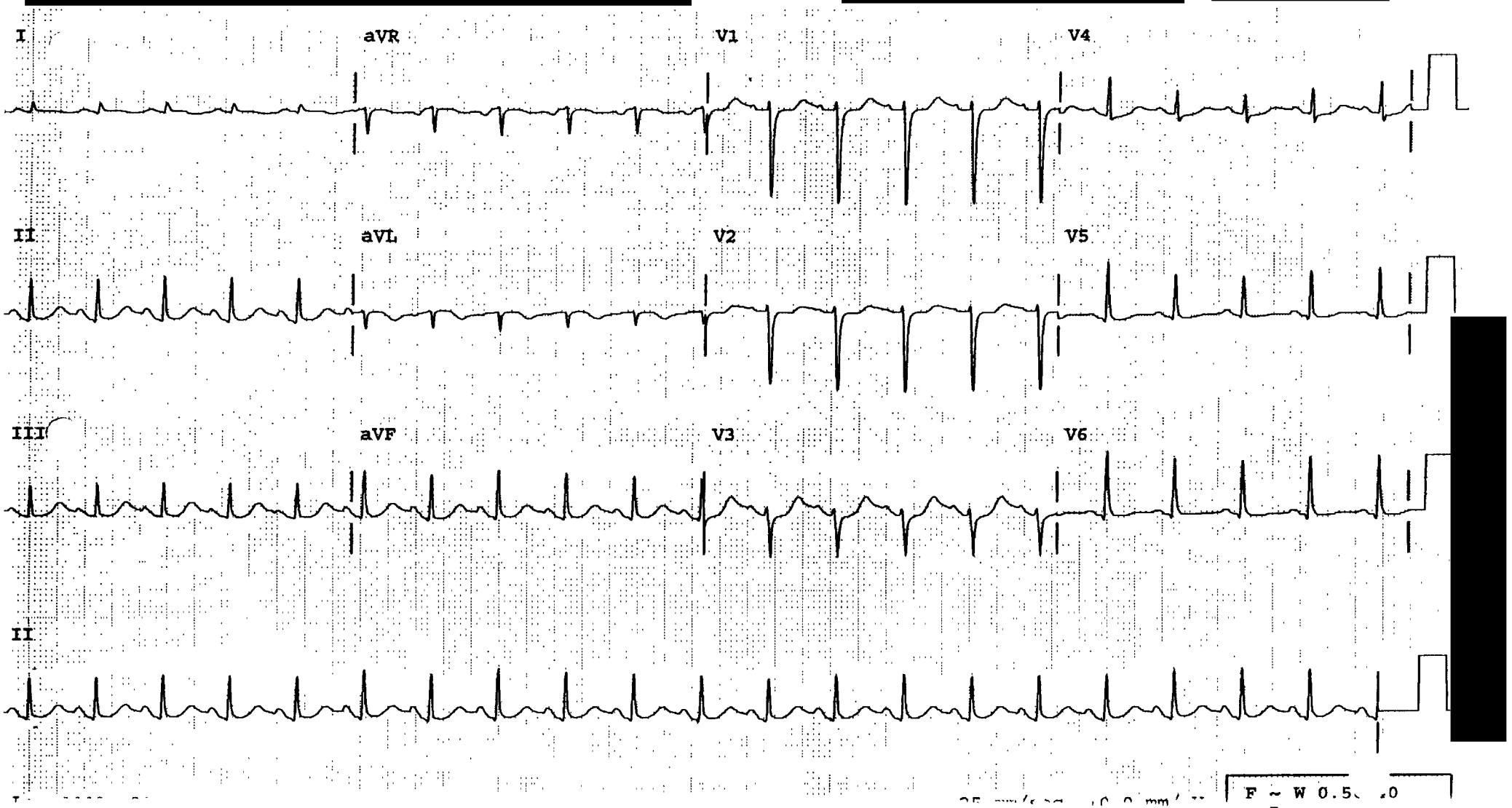

[redacted]

F ~ W 0.5

Memorandum to ARMS # 12483

Date: 05/16/99

From: Medical Officer, Clinical Research and Review Staff, Office of Special Nutritionals, HFS-452

Subject: Medical Records Place in Permanent Storage.

The following types and amounts of records (more than 20 pages total) were place in permanent storage on this date because they were not considered essential for interpretation of this adverse event.

Approx Pages	Type of Records
13	Nursing notes (most 2-sided
	Dietitian notes
	Respiratory therapy/occupational therapy/physical therapy notes
	Clergy notes
19	Medication records
12	Physician's orders
	Vital signs, fluids, input/output records
	Ventilator records
	Hospital administrative records (e.g., insurance information, living will, etc)
5	misc. VE 6/14/99

VE