# U.S. Department of Health & Human Services

**Food and Drug Administration**

## FOIA RESPONSE

| | |
|---|---|
| **USER:** | (ixg) |
| **FOLDER:** | K081960 - 446 pages (FOI:10005140) |
| **COMPANY:** | ALIGN TECHNOLOGY (ALIGTECH) |
| **PRODUCT:** | ALIGNER, SEQUENTIAL (NXC) |
| **SUMMARY:** | Product: INVISALIGN SYSTEM |
| **DATE REQUESTED:** | Jun 23, 2011 |
| **DATE PRINTED:** | Jun 23, 2011 |
| **Note:** | Releasable Version |

K081960

**Align Technology, Inc.,**

**Modified Invisalign® system**

DEC 17 2008

**510(k) Premarket Notification Summary**

This summary of 510(k) safety and effectiveness information is being submitted in accordance with the requirements of 21 CFR 807.92 and SMDA 1990.

The assigned 510(k) number is _____.

**1. Manufacturer's Information:**

| | |
|---|---|
| a. Company Name: | Align Technology, Inc. |
| b. Company Address: | 881 Martin Ave.,<br>Santa Clara, CA 95050 |
| c. Company Phone: | (408) 470-1244 |
| d. Company Fax: | (408) 470-1011 |
| e. Contact Person: | Sangeeta Sachdeva<br>Manager,<br>Regulatory Affairs<br>Align Technology, Inc. |

**2. Prepared on:** June 26th, 2008

**3. Device Identification:**

| | |
|---|---|
| a. Current Trade (proprietary) Name: | Invisalign system |
| b. Generic Name: | Invisalign, Aligners |
| c. Classification Name: | Orthodontic Plastic Brackets (Sequential Aligners) |
| d. Classification regulation | 21CFR 872.5470 |
| e. Product Code | NXC |
| f. Device class: | II |
| g. Advisory panel | Dental |

## 4. Predicate Device Identification:

| | |
|---|---|
| a. Current Trade (proprietary) Name: | Invisalign system |
| b. Generic Name: | Invisalign, Aligners |
| c. Classification Name: | Orthodontic Plastic Brackets - 21CFR 872.5470 (Sequential Aligners) |
| d. Product Code | NXC |
| e. Device class: | II |

## 5. Indications for Use:

The Invisalign system is indicated for the alignment of teeth during orthodontic treatment of malocclusion.

## 6. Device Description:

The current Invisalign system is a series of clear plastic aligners that are used to replace traditional orthodontic wires and brackets for the alignment of maloccluded or misaligned teeth. This series of aligners moves the teeth gently, and in small increments, from their original to their final treated position for improved dental alignment.

This 510(k) Premarket Notification is being submitted because Align Technology, Inc. is making labeling changes that affect the indications for use, contra-indications, and precautions of the currently-commercialized Invisalign system. The technological characteristics of the modified and currently-marketed predicate device, such as design, raw material, and chemical composition, and their manufacturing processes and related software, are identical.

The labeling modifications include:

I. Expansion of the indications of use to permit treatment of patients who present with malocclusion without the limitation of permanent dentition.
II. Removal of certain contra-indications that excluded patients with certain complex malocclusions from getting treated with the Invisalign system. These patients may or may not need additional orthodontic procedures to achieve the desired treatment outcome, and this is captured in the added precautions.

III. Addition of precautions corresponding to the removal of contra-indications.

Thus, the modified Invisalign system with the proposed labeling changes will allow the treatment of patients with malocclusion, including, but not limited to, those with primary dentition present (including mixed dentition), as well as of patients with severe open bite, severe overjet, skeletally narrow jaw, dental prostheses/implants, and/or those who require surgical correction.

7. **Software:**

There are no changes in the software compared to the existing Invisalign system. The software design and development, software development methodology, software development process and environment are identical for the existing predicate device and the modified Invisalign system.

8. **Technological Characteristics**:

A comparison of the current and proposed Invisalign system demonstrates that the devices are equivalent in terms of technology, material-based physical and performance characteristics.

9. **Substantial Equivalence Information:**

This Premarket Notification is being submitted solely to incorporate the above listed labeling changes to the existing Invisalign system (K981095).

- There are no changes in the technological characteristics of the modified device when compared to the predicate device. The design, raw material, and chemical composition, device features as well as technical characteristics of the modified device and existing predicate device are identical.
- There are no changes in the manufacturing processes and related software required to accommodate the labeling changes.

Thus, based on the similar indications for use and same technological, material, and performance characteristics of the currently marketed, predicate device (K981095) and the Invisalign system with the modified labeling, the two are considered substantially equivalent (21 CFR 807.100).

DEPARTMENT OF HEALTH & HUMAN SERVICES

Public Health Service

Food and Drug Administration
9200 Corporate Boulevard
Rockville MD 20850

Ms. Sangeeta Sachdeva
Manager, Regulatory Affairs
Align Technology, Incorporated
881 Martin Avenue
Santa Clara, California 95050

DEC 17 2008

Re: K081960
Trade/Device Name: Invisalign® System
Regulation Number: 21 CFR 872.5470
Regulation Name: Orthodontic Plastic Bracket
Regulatory Class: II
Product Code: NXC
Dated: December 10, 2008
Received: December 12, 2008

Dear Ms. Sachdeva:

We have reviewed your Section 510(k) premarket notification of intent to market the device referenced above and have determined the device is substantially equivalent (for the indications for use stated in the enclosure) to legally marketed predicate devices marketed in interstate commerce prior to May 28, 1976, the enactment date of the Medical Device Amendments, or to devices that have been reclassified in accordance with the provisions of the Federal Food, Drug, and Cosmetic Act (Act) that do not require approval of a premarket approval application (PMA). You may, therefore, market the device, subject to the general controls provisions of the Act. The general controls provisions of the Act include requirements for annual registration, listing of devices, good manufacturing practice, labeling, and prohibitions against misbranding and adulteration.

If your device is classified (see above) into either class II (Special Controls) or class III (PMA), it may be subject to such additional controls. Existing major regulations affecting your device can be found in the Code of Federal Regulations, Title 21, Parts 800 to 898. In addition, FDA may publish further announcements concerning your device in the Federal Register.

Please be advised that FDA's issuance of a substantial equivalence determination does not mean that FDA has made a determination that your device complies with other requirements of the Act or any Federal statutes and regulations administered by other Federal agencies. You must comply with all the Act's requirements, including, but not limited to: registration and listing (21 CFR Part 807); labeling (21 CFR Part 801); good manufacturing practice requirements as set forth in the quality systems (QS) regulation (21 CFR Part 820); and if applicable, the electronic product radiation control provisions (Sections 531-542 of the Act); 21 CFR 1000-1050.

This letter will allow you to begin marketing your device as described in your Section 510(k) premarket notification. The FDA finding of substantial equivalence of your device to a legally marketed predicate device results in a classification for your device and thus, permits your device to proceed to the market.

If you desire specific advice for your device on our labeling regulation (21 CFR Part 801), please contact the Center for Devices and Radiological Health's (CDRH's) Office of Compliance at (240) 276-0115. Also, please note the regulation entitled, "Misbranding by reference to premarket notification" (21CFR Part 807.97). For questions regarding postmarket surveillance, please contact CDRH's Office of Surveillance and Biometric's (OSB's) Division of Postmarket Surveillance at 240-276-3474. For questions regarding the reporting of device adverse events (Medical Device Reporting (MDR)), please contact the Division of Surveillance Systems at 240-276-3464. You may obtain other general information on your responsibilities under the Act from the Division of Small Manufacturers, International and Consumer Assistance at its toll-free number (800) 638-2041 or (240) 276-3150 or at its Internet address http://www.fda.gov/cdrh/industry/support/index.html.

Sincerely yours,

Chiu S. Lin, Ph. D
Division Director
Division of Anesthesiology, General Hospital,
Infection Control and Dental Devices
Office of Device Evaluation
Center for Devices and
Radiological Health

Enclosure

K081960

**Align Technology, Inc.,**

**Modified Invisalign® system**

**Indications for Use**

| | |
|---|---|
| **510(k) Number if Known:** | To be assigned by FDA |
| **Device Name:** | Invisalign® system |
| **Indications of Use:** | The Invisalign® system is indicated for the alignment of teeth during orthodontic treatment of malocclusion. |

Please do not write below this line.

---

Concurrent of CDRH, Office of Device Evaluation (ODE)

Susan Runner

(Division Sign-Off)
Division of Anesthesiology, General Hospital
Infection Control, Dental Devices

510(k) Number: K081960

**Prescription Use:** X AND/OR **Over the Counter Use:** _____
(Part 21 CFR 801 Subpart D) (Part 21 CFR 801 Subpart C)

A L I G N

K081960/A1

invisalign

FDA CDRH DMC
AUG 18 2008
Received

August 7, 2008

Dr. Kevin Mulry, DDS, MA
510(k) Document Mail Center (HFZ-401)
Food and Drug Administration
Center for Devices and Radiological Health
9200 Corporate Blvd.
Rockville, MD 20850

**Re: Supplemental Information requested for 510(k) No. K081960 (Invisalign system)**
**a. Clinical case reports requested**
**b. Name of material used to make the aligners.**

Dear Dr. Mulry,

Thank you for taking the time to do a preliminary review of the 510(k) Premarket Notification submitted by Align Technology on July 2nd 2008. As per our phone conversation on the 5th of August, I am mailing three sets of copies of the Clinical Case Reports, as requested.

In response to your second informational request, the thermoplastic polymer Align Technology uses in the manufacture of the Invisalign system is a proprietary polyurethane plastic (Clear Exceed Aligner Material also known as "Clear EX"), similar to commercially available retainer or positioner material made by Raintree Essix.

Please do not hesitate to contact me if you have any questions or require additional information. Please consider the information provided as COMPANY CONFIDENTIAL.

Thank you.
Sincerely,

Sangeeta Sachdeva

Sangeeta Sachdeva
Manager, Regulatory Affairs
Align Technology, Inc.
881 Martin Ave.
Santa Clara, CA 95050
Direct: (408) 470-1244
Fax: (408) 470-1011
ssachdeva@aligntech.com

K7

119

# Open Bite
# (OB1-OB7)

120

OB-1



121

# invisalign® TREATMENT SUMMARY

*L INFORMATION MUST BE TYPEWRITTEN.*

**DOCTOR:** M.P. **INVISALIGN CASE #:** (b)(6)

**GENDER:** ☒ MALE ☐ FEMALE

**AGE:** 35 yrs.

**PATIENT INITIALS:** (b)(6

**TREATMENT START DATE:** 01/27/2003 **TREATMENT END DATE:** 12/072004 **TOTAL TREATMENT TIME:** 24 months

**CHIEF CONCERN:** Crowding.

**DIAGNOSTIC SUMMARY:** Class I with right Class III tendency; narrow arches, right lingual cross bite; anterior crowding; excessive overjet; simple anterior open bite.

**CEPHALOMETRIC SUMMARY:** Excessive lower anterior facial height; upper anterior protrusion; normal naso-labial angle.

**TREATMENT GOAL:** Reduce overjet and open bite; correct cross bite, crowding; improve right Class III tendency.

**TREATMENT PLAN:** Broaden arches, retract upper anteriors, lower right IPR to improve canine relations using the Invisalign appliance.

**NUMBER OF REFINEMENTS DURING TREATMENT:** 2

**TOTAL NUMBER OF UPPER ALIGNERS (including refinements):** 32

**TOTAL NUMBER OF LOWER ALIGNERS (including refinements):** 24

**SUPPLEMENTAL TREATMENT NEEDED TO ACHIEVE TREATMENT GOAL:**

☒ Plier detailing ☒ Interarch elastics ☒ Buttons ☐ Spring aligner

☐ Positioner ☐ Orthognathic surgery ☐ Conventional braces ☐ None

**RESULTS ACHIEVED/DOCTOR'S ANALYSIS:** Cross bite correction; crowding corrected; positive overbite obtained. Right Class III canine relation improved. 1mm additional overjet and overbite would have been preferred.

**RETENTION:** Upper: Essix Lower: Essix

122

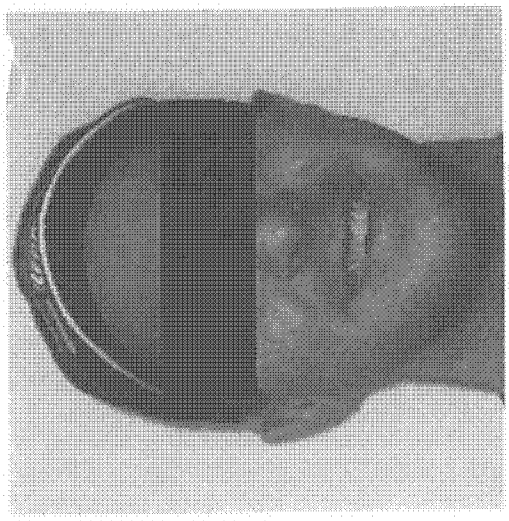

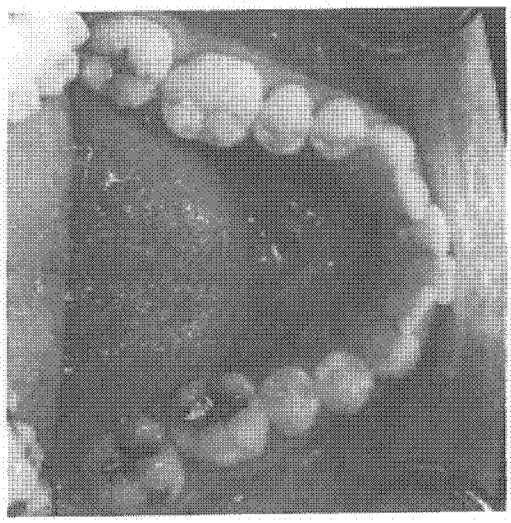

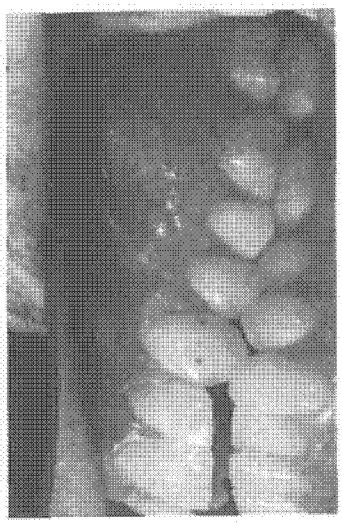

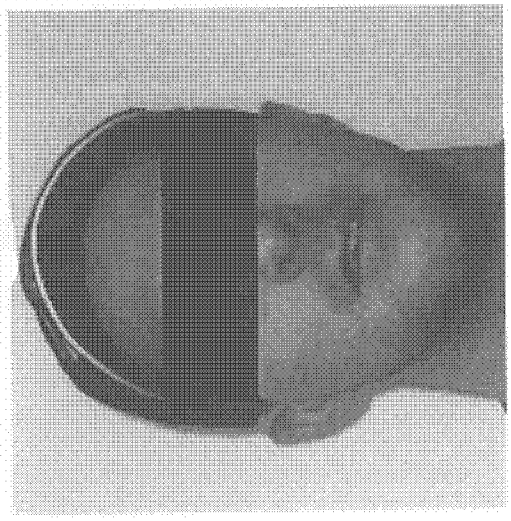

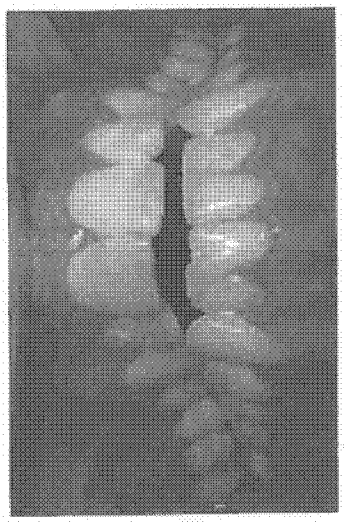

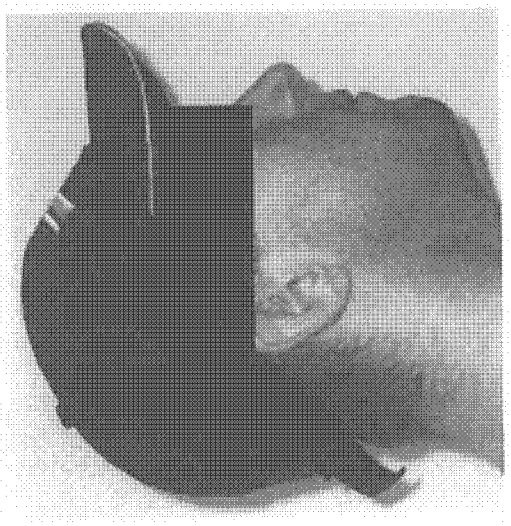

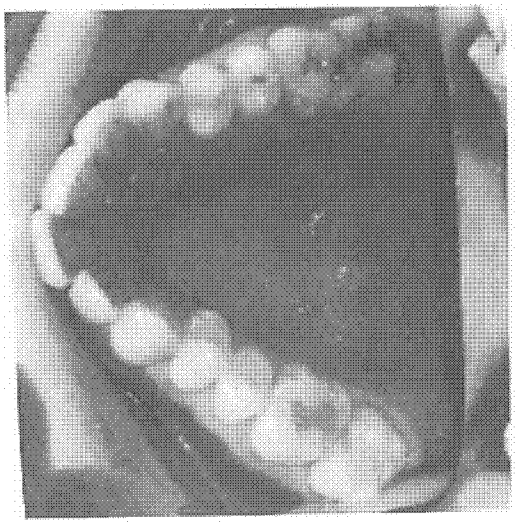

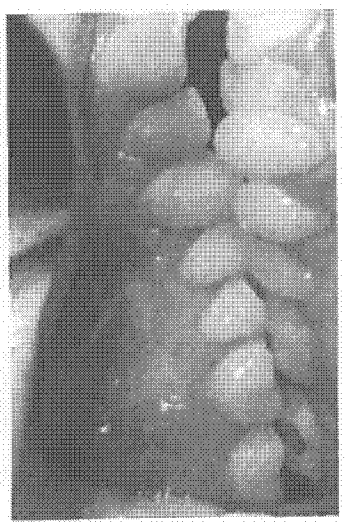

123

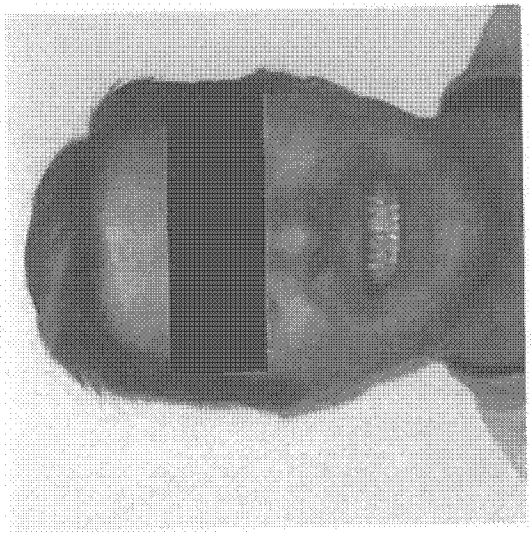
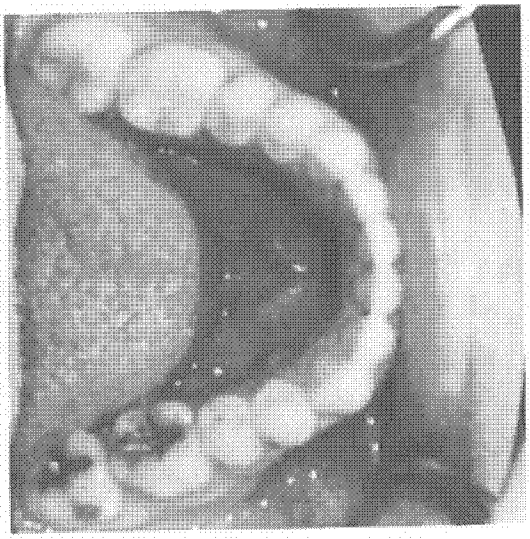
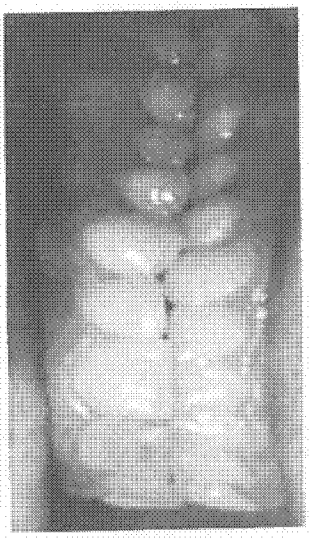
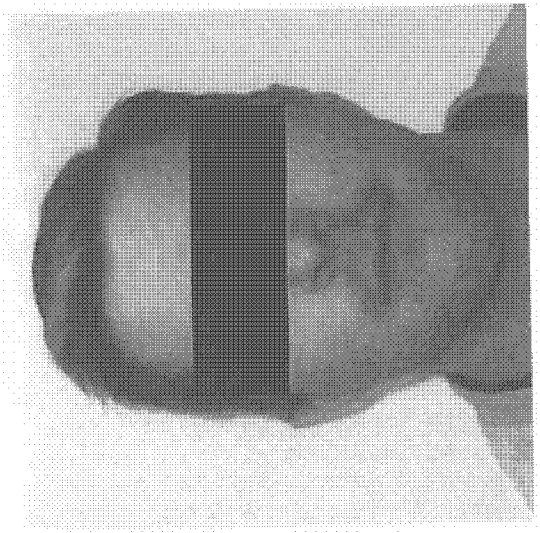

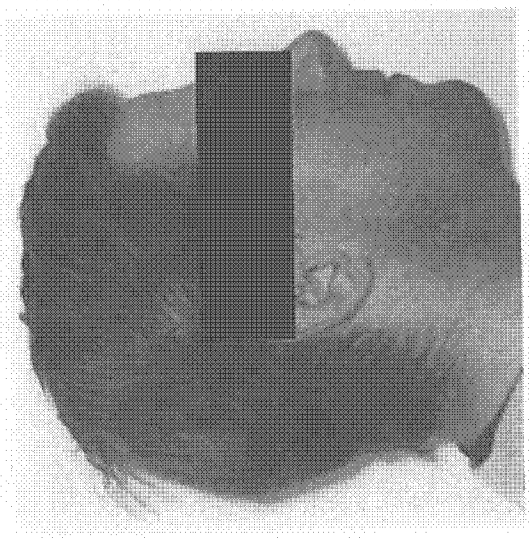
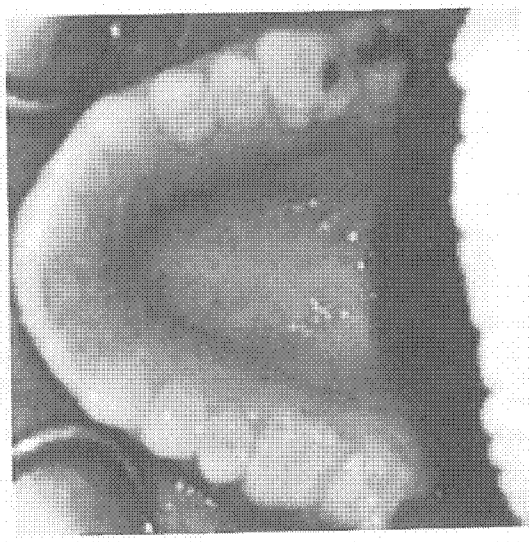
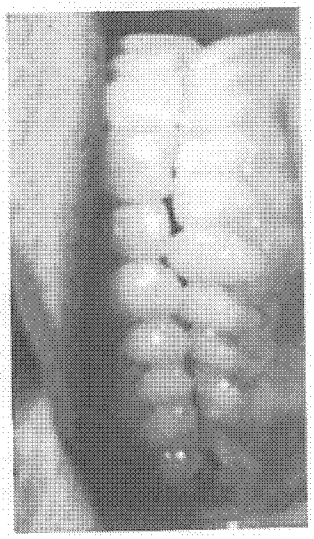

124

# OB-2

125

# invisalign® TREATMENT SUMMARY

*INFORMATION MUST BE TYPEWRITTEN.*

**DOCTOR:** M.P. **INVISALIGN CASE #:** (b)(6)

**GENDER:** ☐ MALE ☒ FEMALE

**AGE:** 42 yrs.

**PATIENT INITIALS:** (b)(6)

**TREATMENT START DATE:** 05/06/2004 **TREATMENT END DATE:** 05/26/2005 **TOTAL TREATMENT TIME:** 12 months

**CHIEF CONCERN:** Bite is changing.

**DIAGNOSTIC SUMMARY:** Class II malocclusion with mild anterior crowding, narrow arches and complex open bite. History of orthodontics with extraction of 4 bicuspids.

**CEPHALOMETRIC SUMMARY:** Excessive lower anterior facial height, mandibular deficiency, excessive overjet.

**TREATMENT GOAL:** Close openbite, broaden arches, correct crowding, reduce (but not correct) Class II and overjet.

**TREATMENT PLAN:** Distalize upper posteriors, broaden arches and improve Class II and overjet with Invisalign appliance and Class II elastics. Close open bite with bite block effect of aligners and posterior enameloplasty.

**NUMBER OF REFINEMENTS DURING TREATMENT:** 0

**TOTAL NUMBER OF UPPER ALIGNERS (including refinements):** 23

**TOTAL NUMBER OF LOWER ALIGNERS (including refinements):** 24

**SUPPLEMENTAL TREATMENT NEEDED TO ACHIEVE TREATMENT GOAL:**

☒ Plier detailing ☒ Interarch elastics ☐ Buttons ☐ Spring aligner

☐ Positioner ☐ Orthognathic surgery ☐ Conventional braces ☐ None

**RESULTS ACHIEVED/DOCTOR'S ANALYSIS:** Mild occlusal equilibration was performed at 5 mos. post-treatment.

**RETENTION:** Upper: Nocturnal Essix retainer Lower: Nocturnal Essix retainer

126

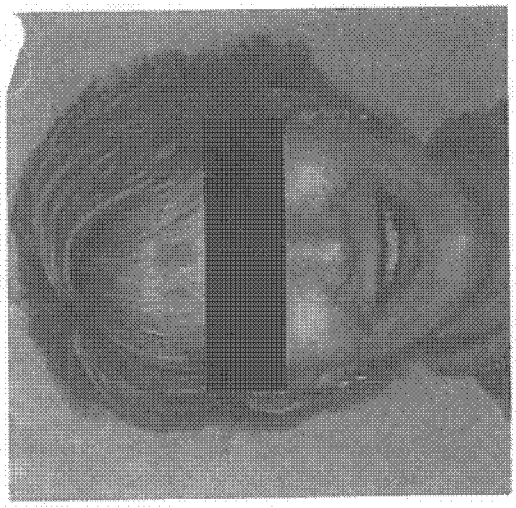

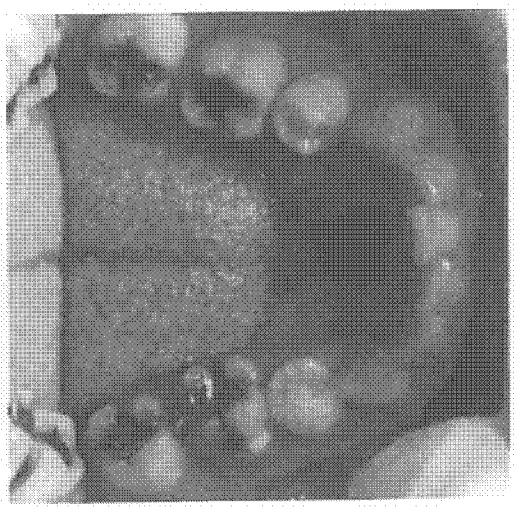

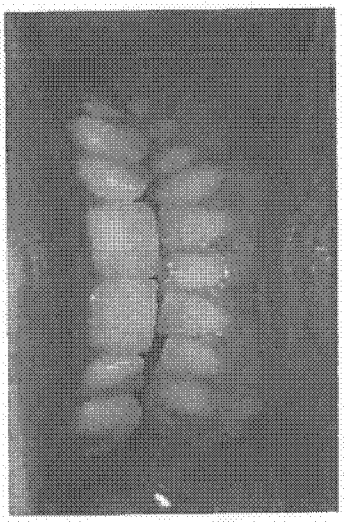

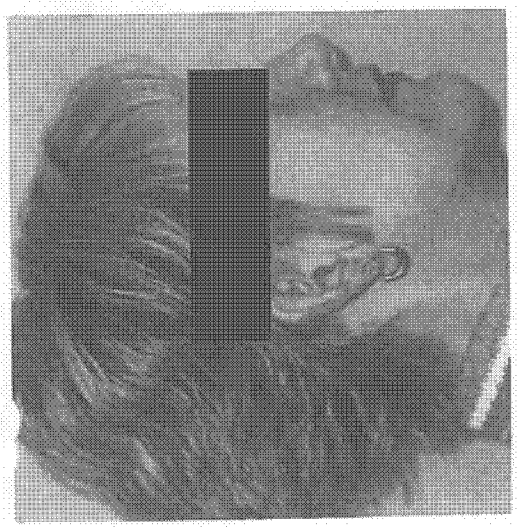

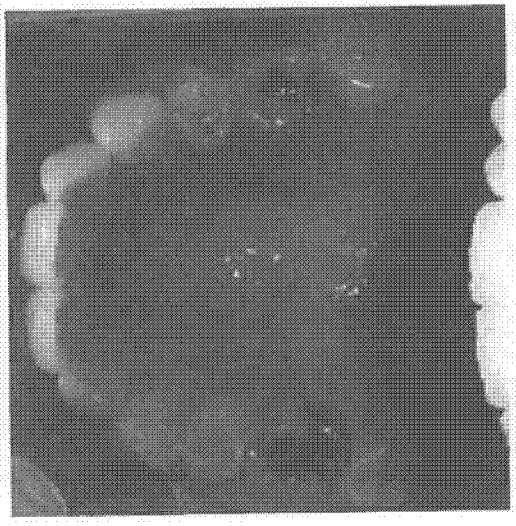

129

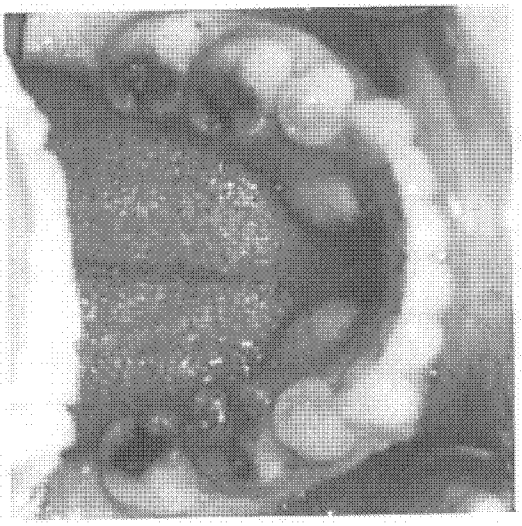

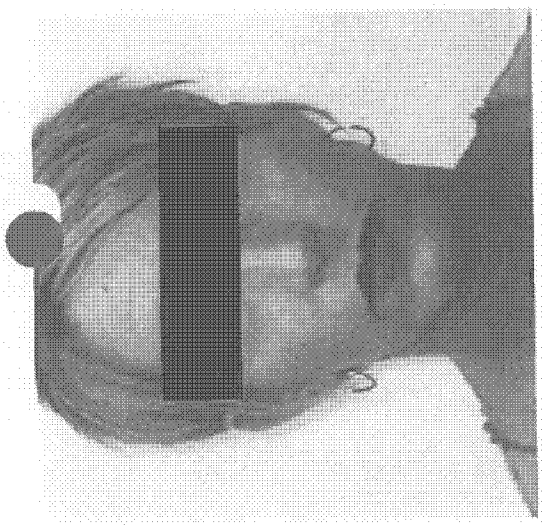

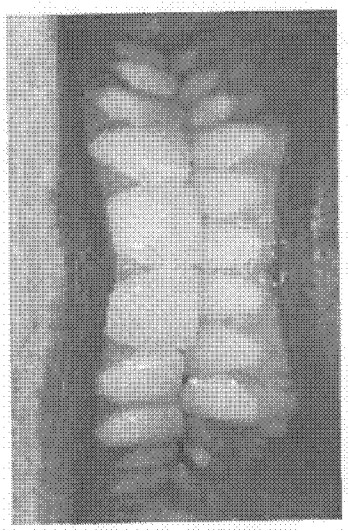

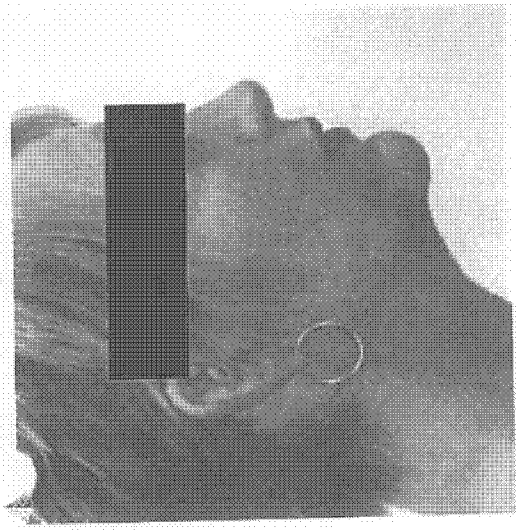

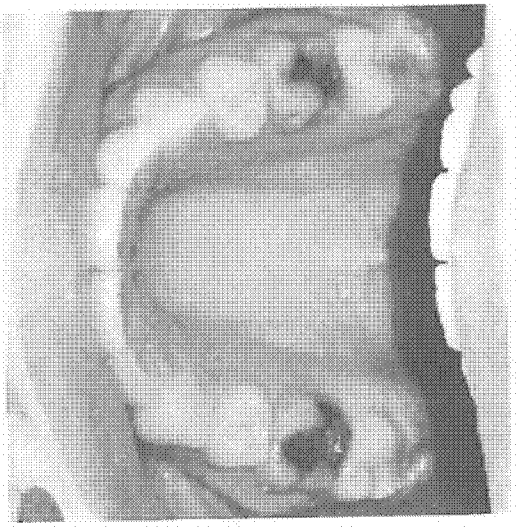

128

# OB-3

129

# invisalign® TREATMENT SUMMARY

*L INFORMATION MUST BE TYPEWRITTEN.*

**DOCTOR:** A.K. **INVISALIGN CASE #:** (b)(6)

**GENDER:** ☐ MALE ☒ FEMALE

**AGE:** 45 yrs.

**PATIENT INITIALS:** (b)(6)

**TREATMENT START DATE:** 02/14/01 **TREATMENT END DATE:** 02/25/02 **TOTAL TREATMENT TIME:** 13 months

**CHIEF CONCERN:** Anterior open bite.

**DIAGNOSTIC SUMMARY:** Class II skeletal pattern, flared anterior segments, left TMJ closing click, anterior tongue thrust.

**CEPHALOMETRIC SUMMARY:** Class II skeletal relationship due to retruded mandible, flared anterior teeth, steep mandibular plane angle.

**TREATMENT GOAL:** To retract her anterior teeth to close the bite and spaces.

**TREATMENT PLAN:** Invisalign.

**NUMBER OF REFINEMENTS DURING TREATMENT:** 0

**TOTAL NUMBER OF UPPER ALIGNERS (including refinements):** 13

**TOTAL NUMBER OF LOWER ALIGNERS (including refinements):** 31

**SUPPLEMENTAL TREATMENT NEEDED TO ACHIEVE TREATMENT GOAL:**

☐ Plier detailing ☐ Interarch elastics ☐ Buttons ☐ Spring aligner

☐ Positioner ☐ Orthognathic surgery ☐ Conventional braces ☒ None

**RESULTS ACHIEVED/DOCTOR'S ANALYSIS:** Anterior open bite and spaces were closed.

**RETENTION:** Upper: Removable Hawley & Trutain Lower: Trutain

130

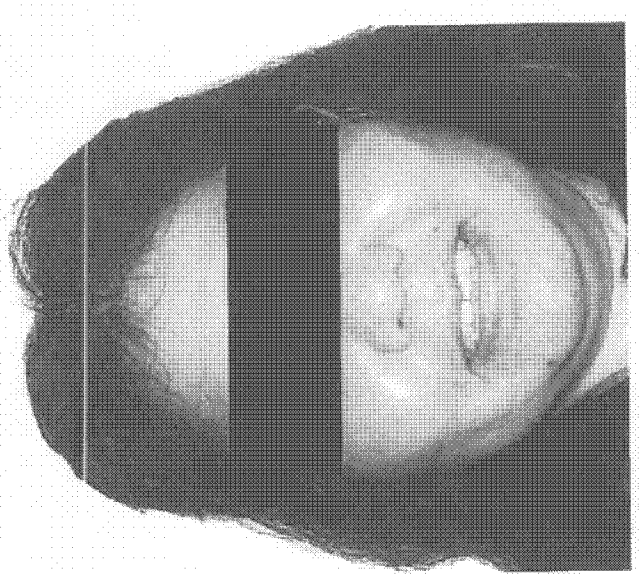

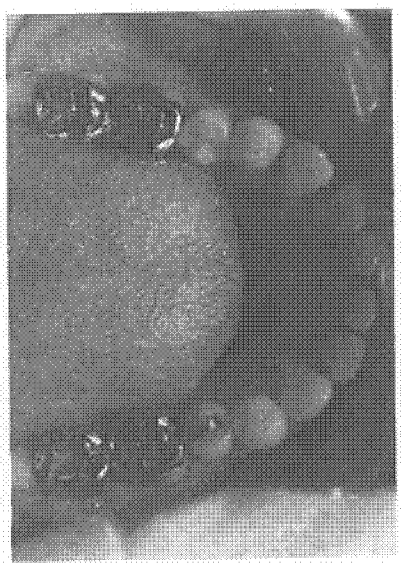

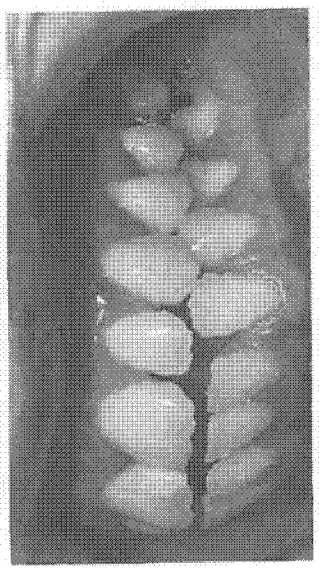

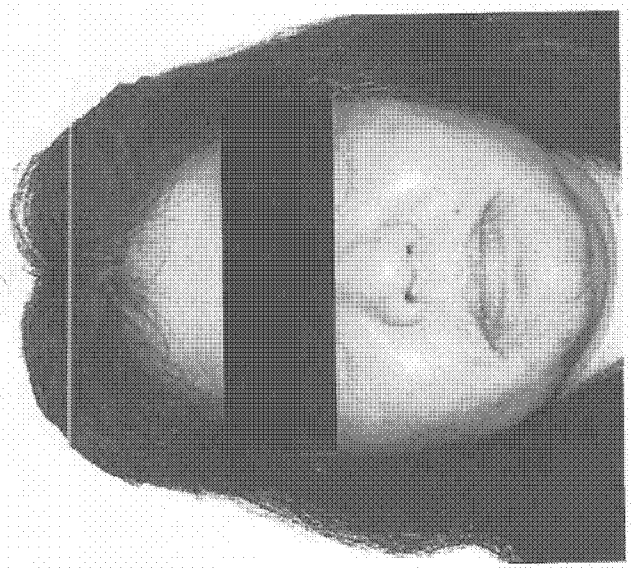

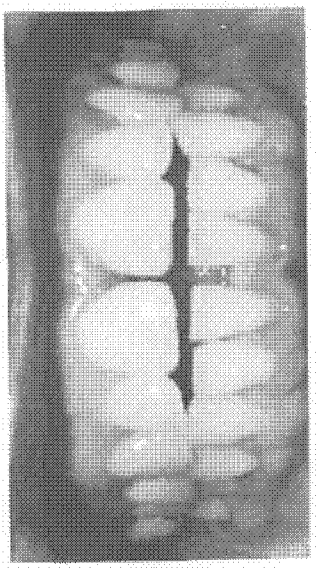

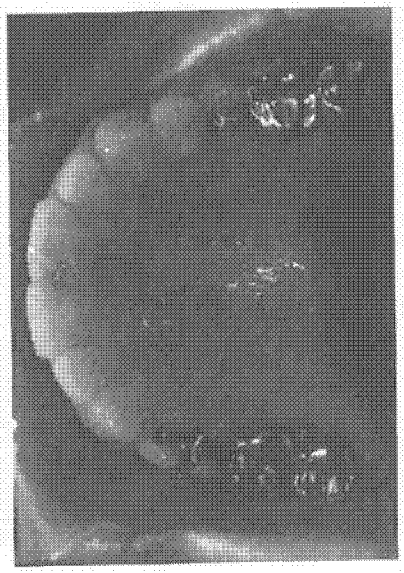

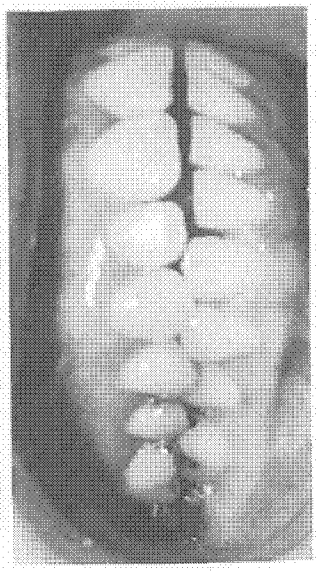

131

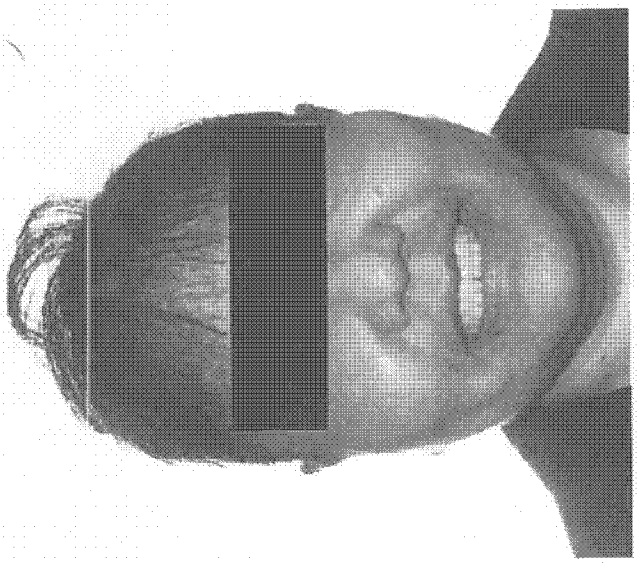

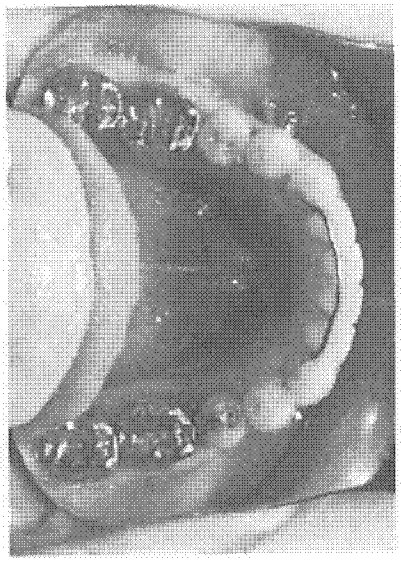

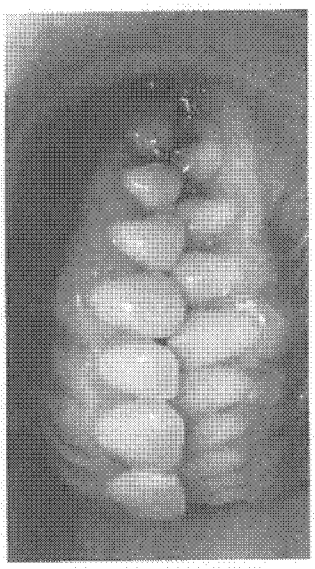

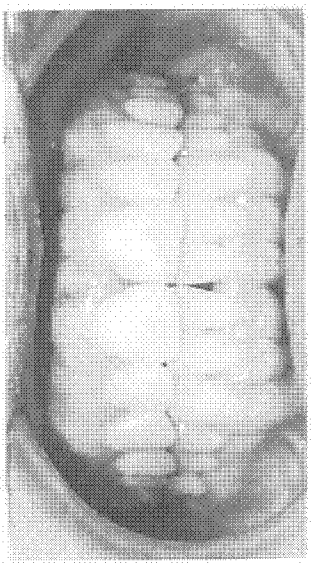

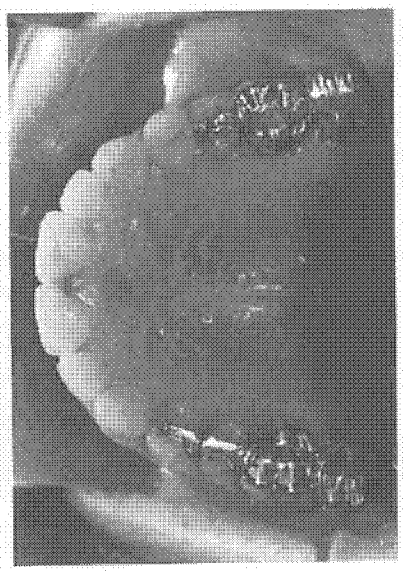

132

# OB-4

133

# invisalign® TREATMENT SUMMARY

*ALL INFORMATION MUST BE TYPEWRITTEN.*

**DOCTOR:** T.D. **INVISALIGN CASE #:** (b)(6)

**GENDER:** ☐ MALE ☒ FEMALE

**AGE:** 17 yrs.

**PATIENT INITIALS:** (b)(6)

**TREATMENT START DATE:** 03/27/02 **TREATMENT END DATE:** 03/26/03 **TOTAL TREATMENT TIME:** 12 months

**CHIEF CONCERN:** Anterior openbite, spacing.

**DIAGNOSTIC SUMMARY:** Class I dental and skeletal with anterior openbite spacing in both arches.

**CEPHALOMETRIC SUMMARY:** Class I with ANB difference of 2, proclined maxillary left cuspid was in lingual crossbite.

**TREATMENT GOAL:** Close bite if possible, consolidate both arches.

**TREATMENT PLAN:** Level and align both arches; close bite, maintain class I; consolidate spaces in both arches, maintain midline.

**NUMBER OF REFINEMENTS DURING TREATMENT:** 0

**TOTAL NUMBER OF UPPER ALIGNERS (including refinements):** 22

**TOTAL NUMBER OF LOWER ALIGNERS (including refinements):** 22

**SUPPLEMENTAL TREATMENT NEEDED TO ACHIEVE TREATMENT GOAL:**

☐ Plier detailing ☐ Interarch elastics ☐ Buttons ☐ Spring aligner

☐ Positioner ☐ Orthognathic surgery ☐ Conventional braces ☒ None

**RESULTS ACHIEVED/DOCTOR'S ANALYSIS:** Bite was closed, spaces closed, Class I molar was maintained.

**RETENTION:** Upper: Hawley Lower: Lower direct bond lingual 3-3

134

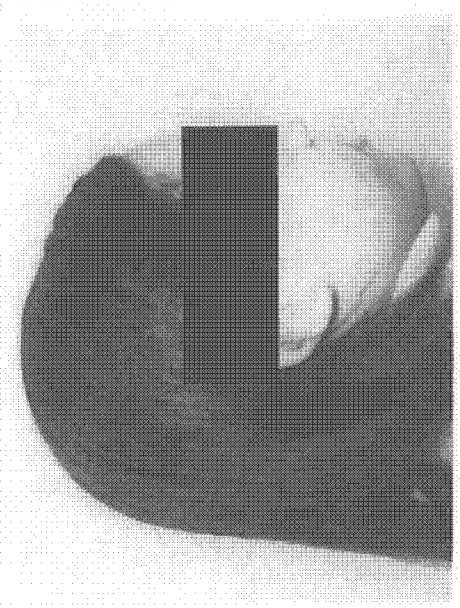

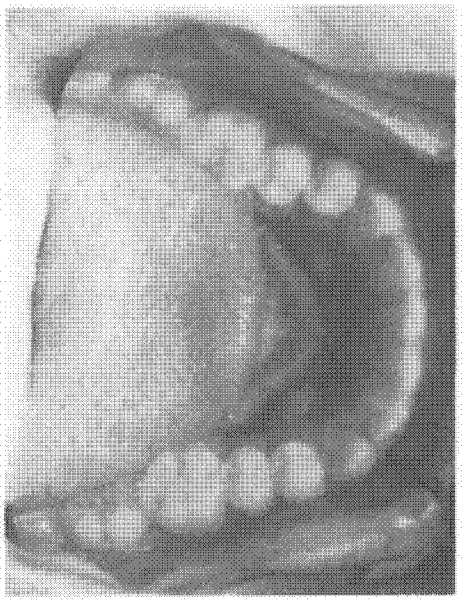

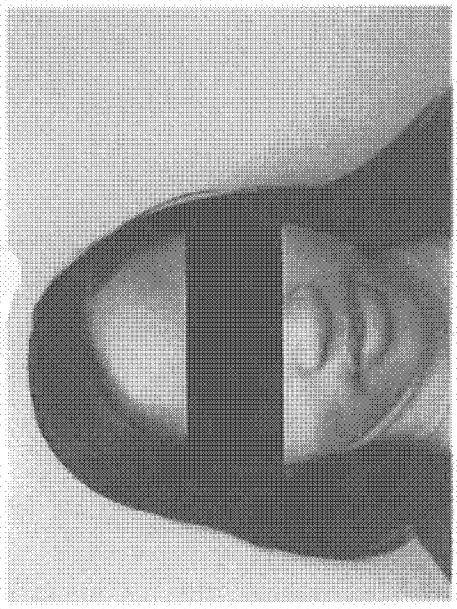

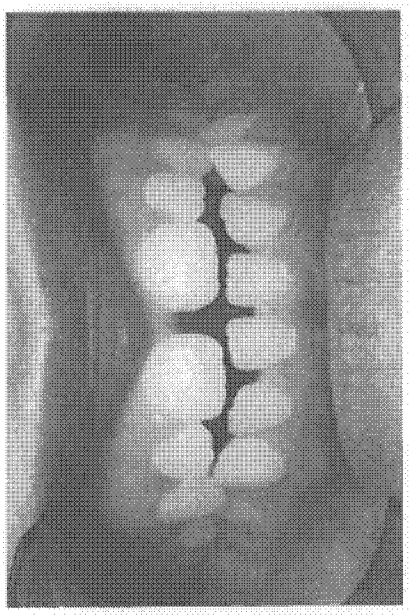

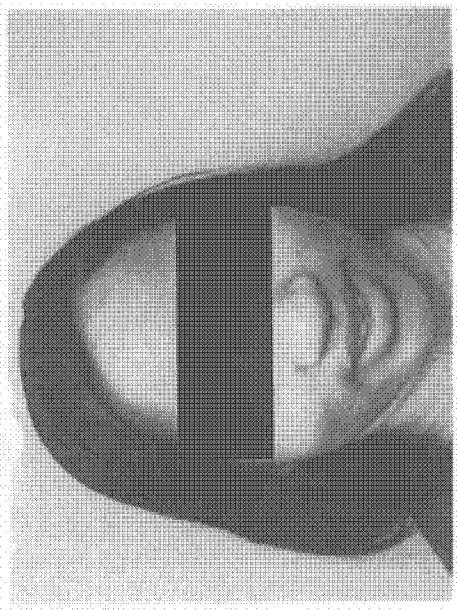

135

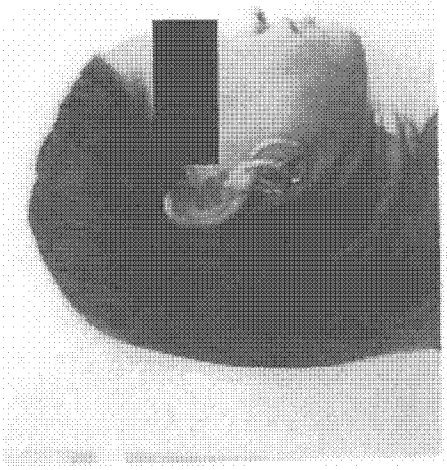

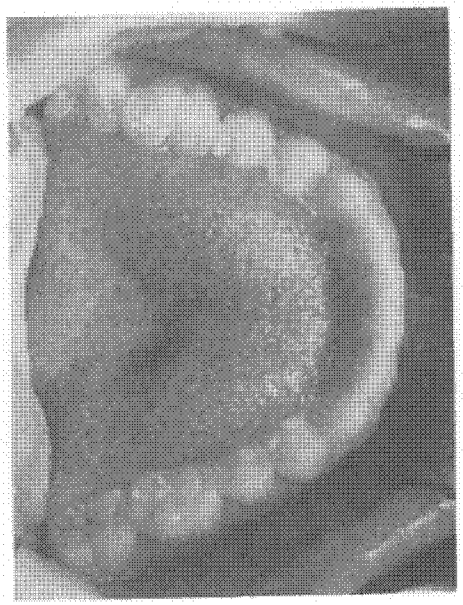

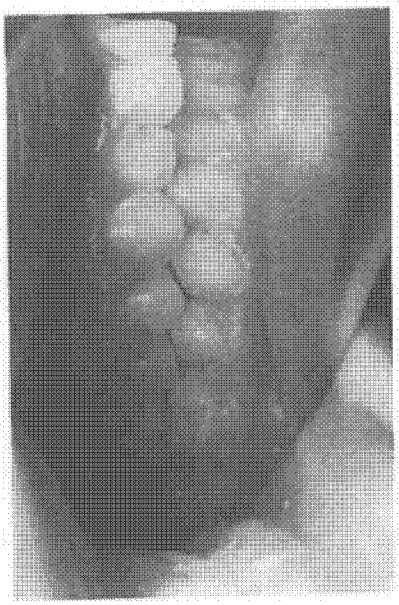

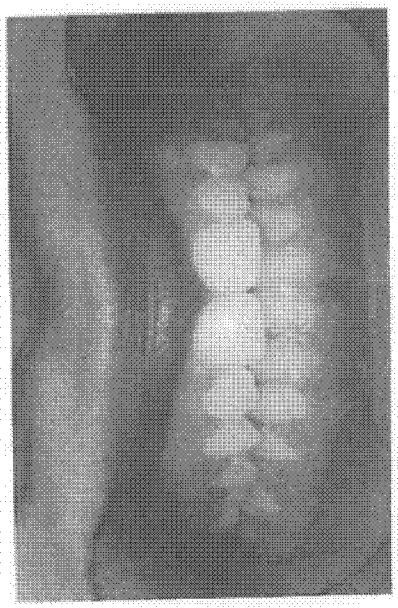

136

# OB-5

137

# invisalign® TREATMENT SUMMARY

*ALL INFORMATION MUST BE TYPEWRITTEN.*

**DOCTOR:** A.C. **INVISALIGN CASE #:** (b)(6)

**GENDER:** ☐ MALE ☒ FEMALE

**AGE:** 46 yrs.

**PATIENT INITIALS:** (b)(6)

**TREATMENT START DATE:** 05/24/00 **TREATMENT END DATE:** 03/13/02 **TOTAL TREATMENT TIME:** 22 months

**CHIEF CONCERN:** Open bite, alignment of anteriors.

**DIAGNOSTIC SUMMARY:** Class I, Bi-maxillary dental protrusion with open bite in anterior, mild crowding, tongue thrust.

**CEPHALOMETRIC SUMMARY:** Mild Brachyfacial, Bi-Maxillary dental protrusion.

**TREATMENT GOAL:** * UNABLE TO GET TREATMENT GOAL FROM DOCTOR BECAUSE DOCTOR PASSED AWAY BEFORE THIS INFORMATION COULD BE COLLECTED.

**TREATMENT PLAN:** Leave in Class I molar & cuspid. Close anterior open bite by the movement of upper anteriors downward. lign upper and lower anteriors. Attachments placed on upper central & laterals. Retain with aligner or Hawley utilizing the attachment to hold bite closed.

**NUMBER OF REFINEMENTS DURING TREATMENT:** 2

**TOTAL NUMBER OF UPPER ALIGNERS (including refinements):** 43

**TOTAL NUMBER OF LOWER ALIGNERS (including refinements):** 24

**SUPPLEMENTAL TREATMENT NEEDED TO ACHIEVE TREATMENT GOAL:**

☐ Plier detailing ☐ Interarch Elastics ☐ Buttons ☐ Spring aligner *SEE NOTE ABOVE IN TREATMENT GOAL

☐ Positioner ☐ Orthognathic surgery ☐ Conventional braces ☐ None

**RESULTS ACHIEVED/DOCTOR'S ANALYSIS:** Originally Invisalign accepted on trial basis with goal of closing to an anterior end on end position. Case refinement aligners brought anteriors to a "minimun overbite" situation. She did not wish to go further with braces. Note that the attachments were left on during initial retention and stabilization (approx. 6 months). Then upper portion of the attachments were "squared" off to make a more definite seat for the labial bow of Hawley to rest on. This is done to keep positive downward force on the anteriors as a mean of holding the bite closed. Patient did not wish to continue with aligners as a retention method.

**RETENTION:** Upper: Hawley Lower: Hawley

138

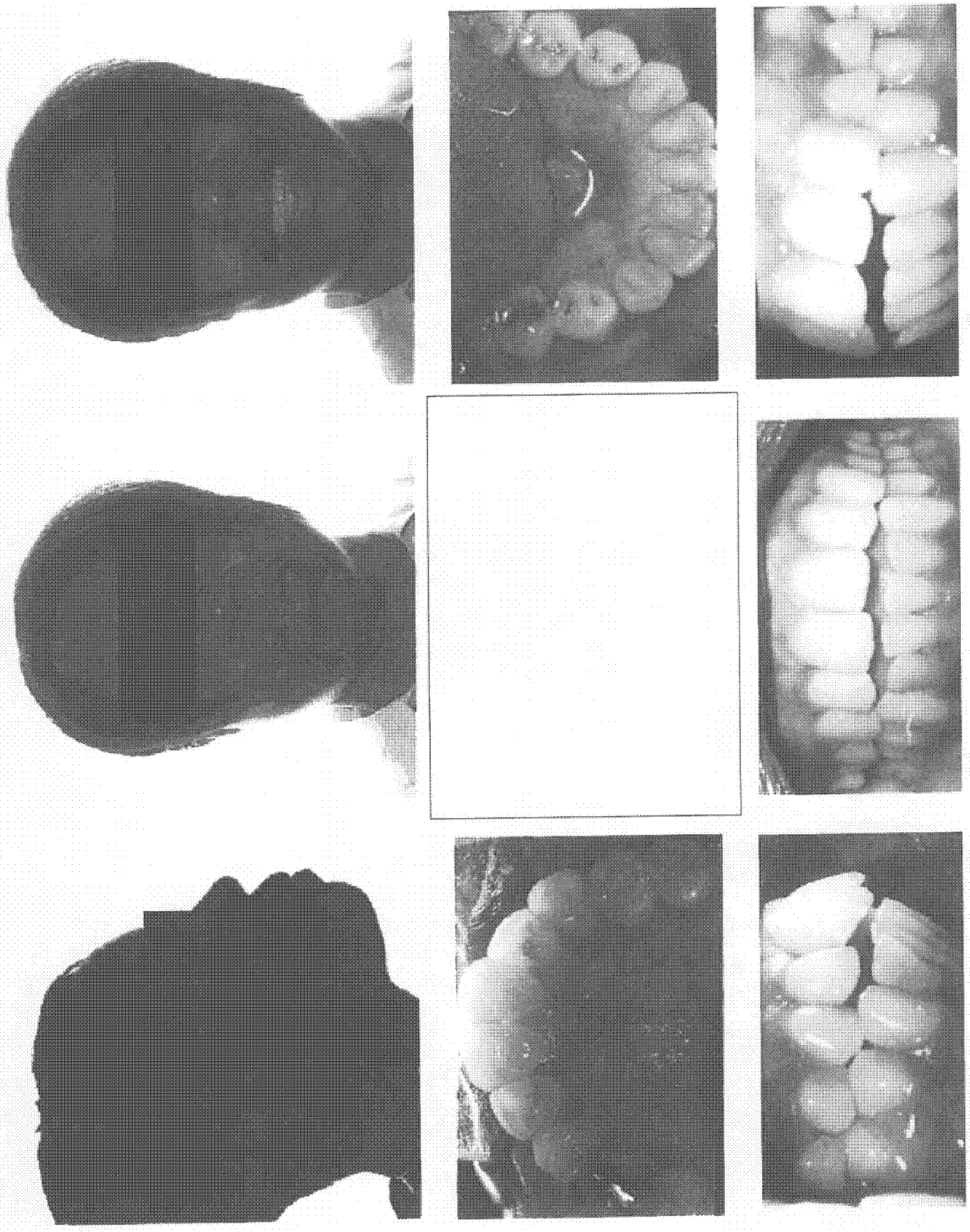

139

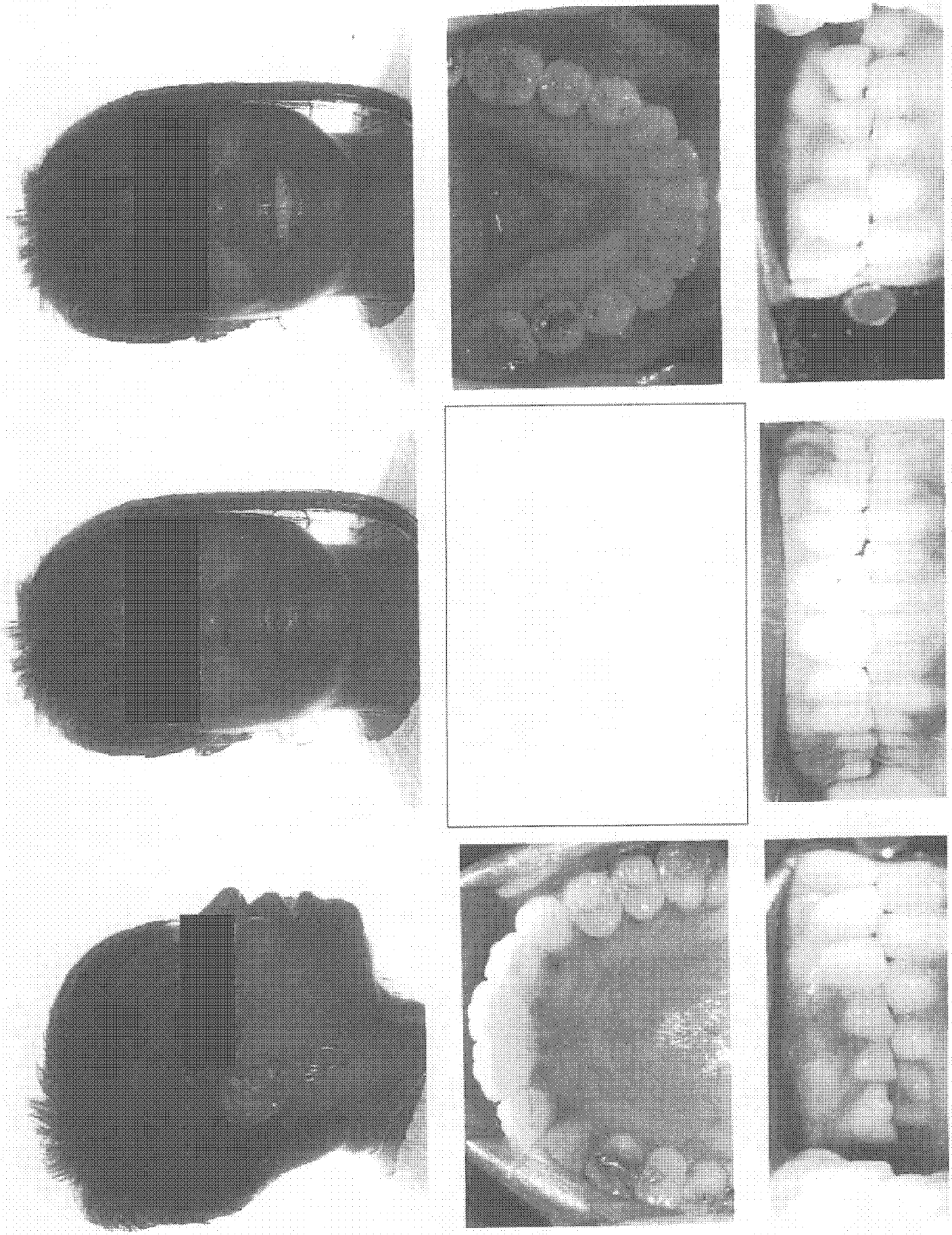

140

# OB-6

# invisalign® TREATMENT SUMMARY

*ALL INFORMATION MUST BE TYPEWRITTEN.*

**DOCTOR:** M.S. **INVISALIGN CASE #:** (b)(6)

**GENDER:** ☒ MALE ☐ FEMALE

**AGE:** 39 yrs.

**PATIENT INITIALS:** (b)(6)

**TREATMENT START DATE:** 02/06/01 **TREATMENT END DATE:** 02/12/02 **TOTAL TREATMENT TIME:** 12 months

**CHIEF CONCERN:** Upper & lower crowding, narrow jaws, discoloration of teeth.

**DIAGNOSTIC SUMMARY:** Class I, 4 bicuspids removed for prior orthodontic treatment as a child. Severe lower anterior crowding, moderate upper crowding, edge to edge anterior occlusion. Narrow maxilla and mandible.

**CEPHALOMETRIC SUMMARY:** Normal ANB angle. Increased lower facial vertical height.

**TREATMENT GOAL:** Relieve lower crowding, expand arches, close open bite.

**TREATMENT PLAN:** A lower Bolton discrepancy & narrow maxilla & mandible with no overjet/bite required removal of one lower incisor (lower right central chosen due to lingual position requiring less space to close). Upper and lower expansion, upper reproximation to round out arches to improve overjet/bite.

**NUMBER OF REFINEMENTS DURING TREATMENT:** none

**TOTAL NUMBER OF UPPER ALIGNERS (including refinements):** 28

**TOTAL NUMBER OF LOWER ALIGNERS (including refinements):** 23

**SUPPLEMENTAL TREATMENT NEEDED TO ACHIEVE TREATMENT GOAL:**

☐ Plier detailing ☐ Interarch elastics ☐ Buttons ☐ Spring aligner

☐ Positioner ☐ Orthognathic surgery ☐ Conventional braces ☒ None

**RESULTS ACHIEVED/DOCTOR'S ANALYSIS:** All objectives accomplished. The lower left central incisor could have been uprighted more-should have had more lower aligners. Attachments placed on lower right 2, lower left 1 & 2. Excellent overbite/jet & arch form. Lower 3-3 splint used for stability & upper Essix retainer used. Minimal lower "black spaces." Patient will have his teeth laminated for esthetics shortly which will correct the slightly rotated upper left central incisor. Upper midline is coincident with midline of lower left central incisor as expected.

**RETENTION:** Upper: Essix Lower: Bonded 3-3 splint

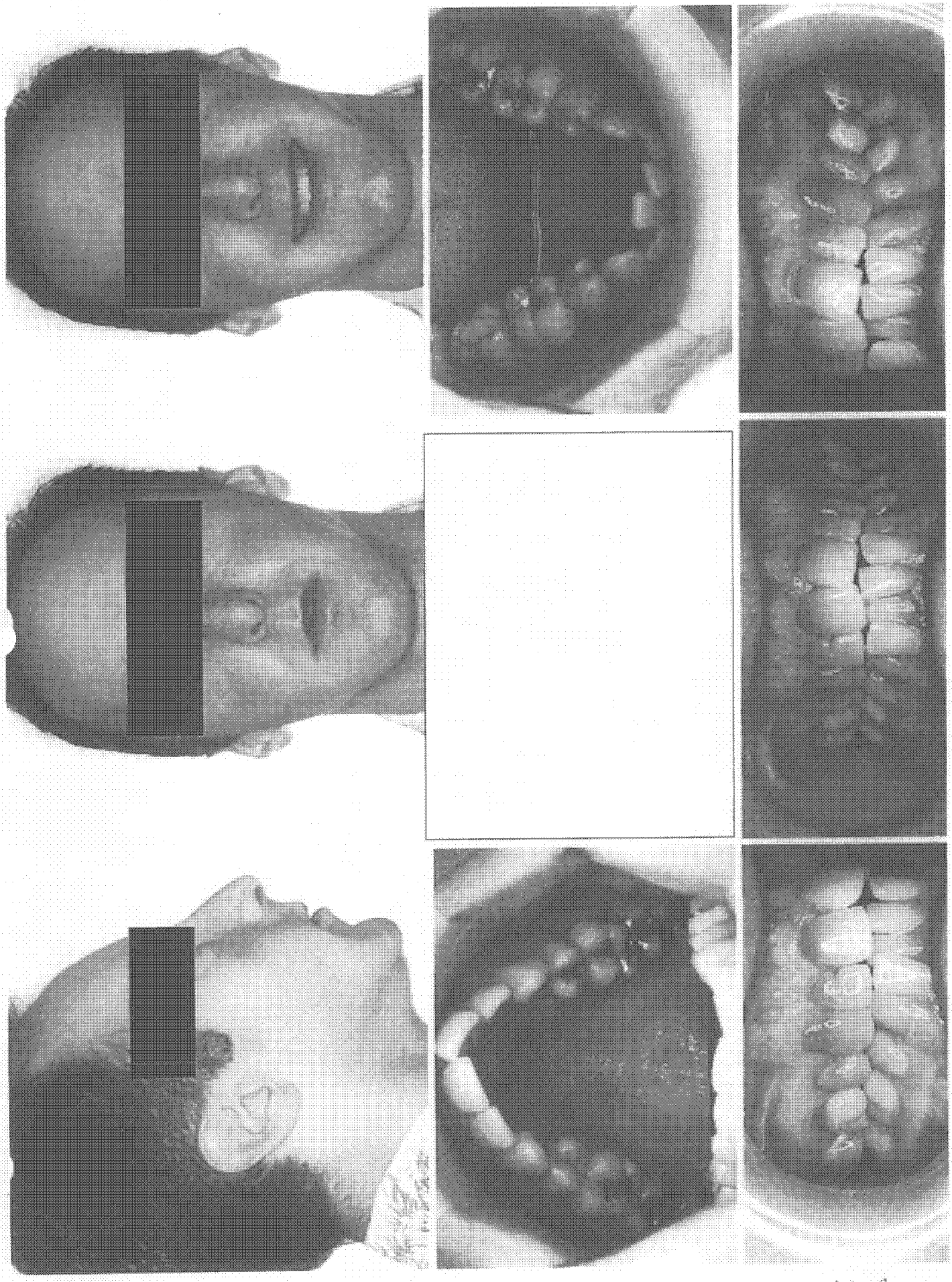

143

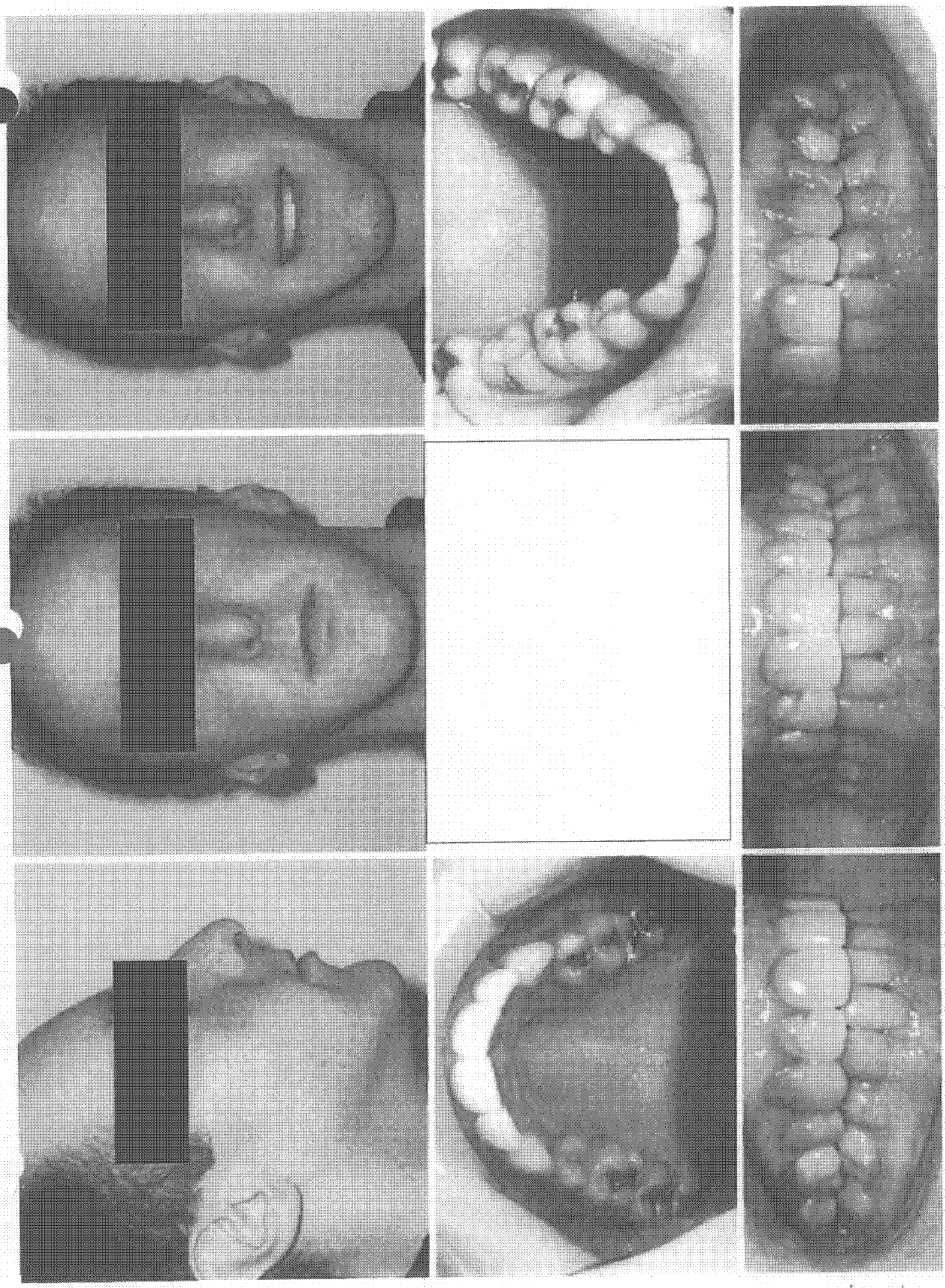

# OB-7



145

# invisalign® TREATMENT SUMMARY

*ALL INFORMATION MUST BE TYPEWRITTEN.*

**DOCTOR:** T.W. **INVISALIGN CASE #:** (b)(6)

**GENDER:** ☐ MALE ☒ FEMALE

**AGE:** 22 yrs.

**PATIENT INITIALS:** (b)(6)

**TREATMENT START DATE:** 5/02/02 **TREATMENT END DATE:** 8/31/04 **TOTAL TREATMENT TIME:** 23 months

**CHIEF CONCERN:** Anterior open bite.

**DIAGNOSTIC SUMMARY:** Class I malocclusion with proclined maxillary and mandibular incisors.

**CEPHALOMETRIC SUMMARY:** Class I skeletal with proclined maxillary and mandibular incisors.

**TREATMENT GOAL:** Retract maxillary and mandibular incisors and close open bite by relative extrusion while tipping anterior teeth back.

**TREATMENT PLAN:** Extract maxillary/mandibular 1st premolars. Invisalign to tip 3-3 segments lingual to retract and close open bite. Finish as needed with fixed appliances.

**NUMBER OF REFINEMENTS DURING TREATMENT:** 1

**TOTAL NUMBER OF UPPER ALIGNERS (including refinements):** 50

**TOTAL NUMBER OF LOWER ALIGNERS (including refinements):** 50

**SUPPLEMENTAL TREATMENT NEEDED TO ACHIEVE TREATMENT GOAL:**

☐ Plier detailing ☐ Interarch elastics ☐ Buttons ☐ Spring aligner

☐ Positioner ☐ Orthognathic surgery ☐ Conventional braces ☒ None

**RESULTS ACHIEVED/DOCTOR'S ANALYSIS:** Posterior occlusion remained stable; upper and lower teeth tipped back and close open bite; impact on profile was excellent.

**RETENTION:** Upper: Essix Lower: Essix

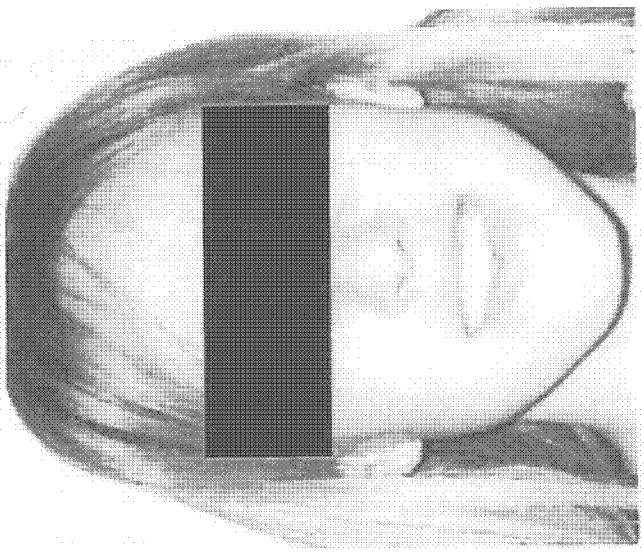

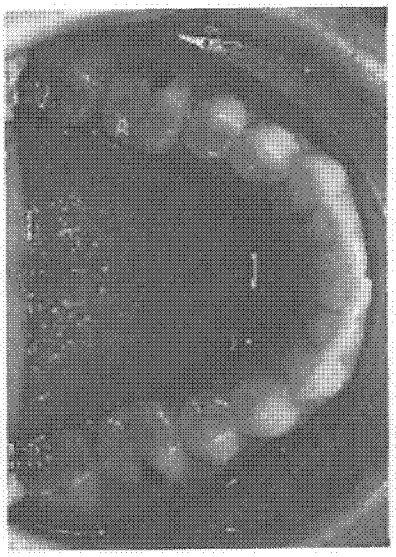

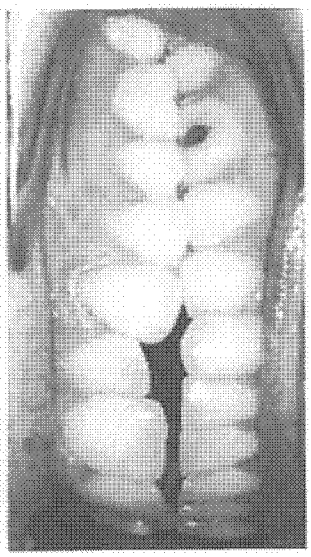

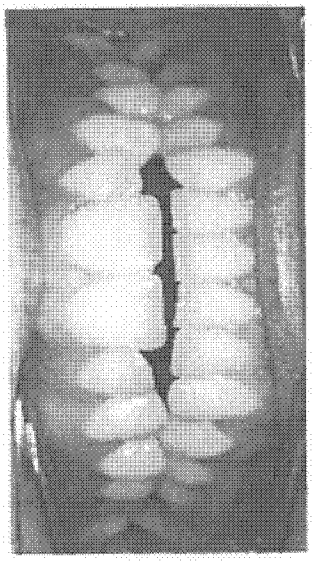

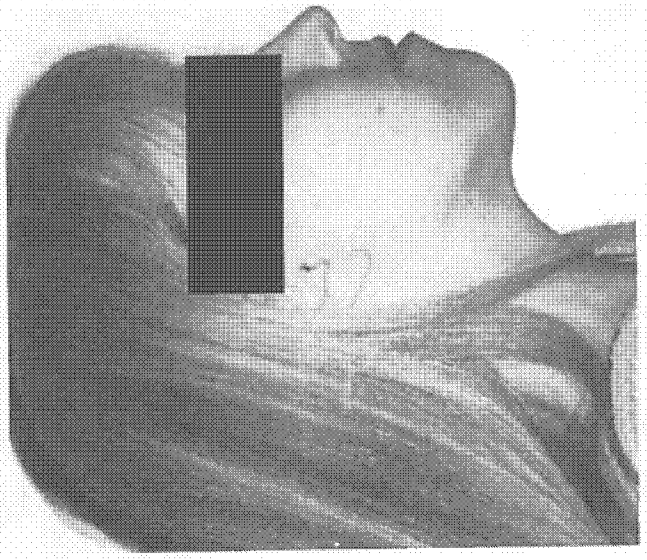

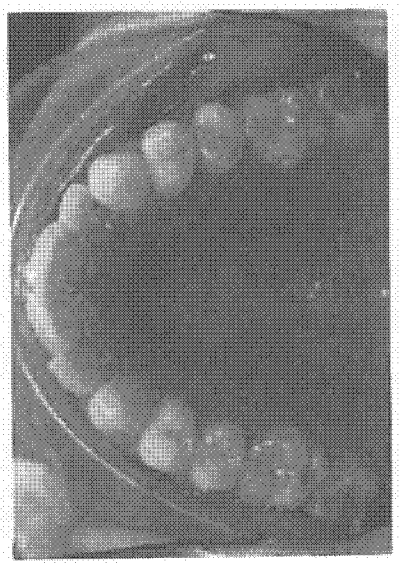

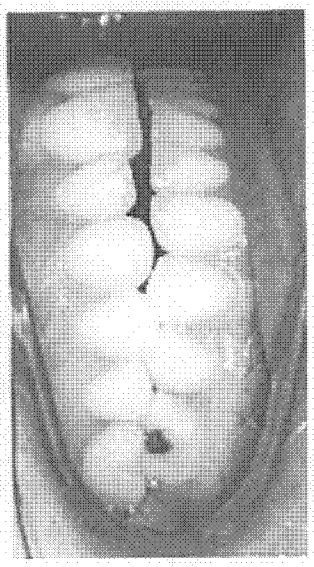

147

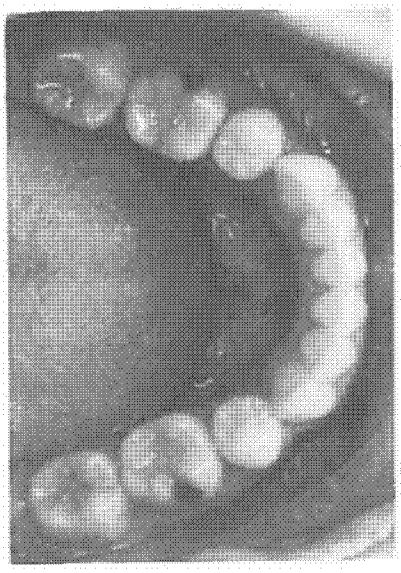

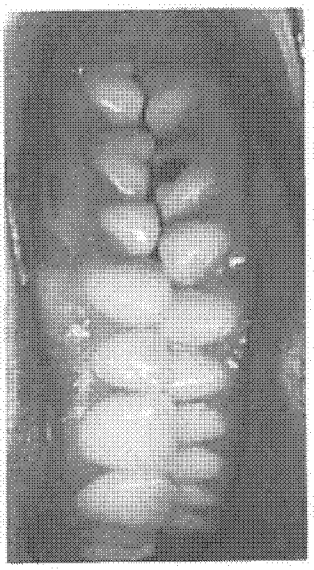

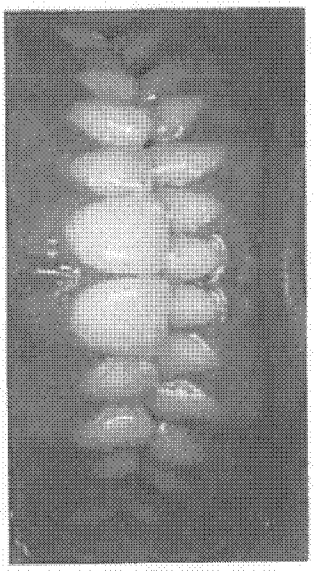

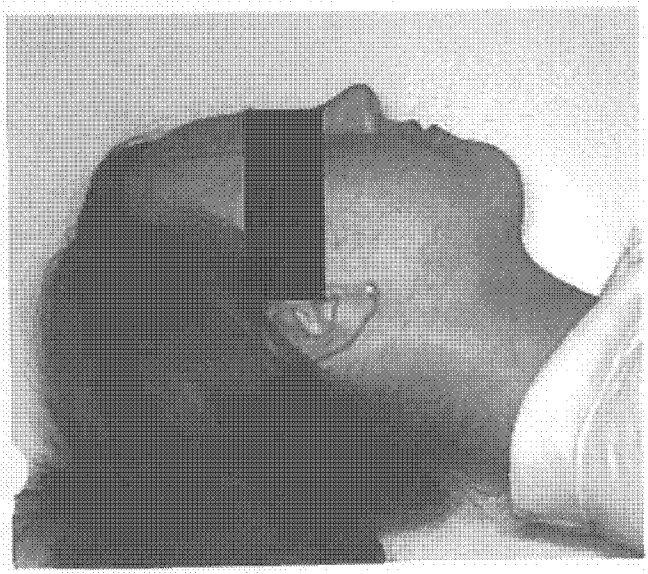

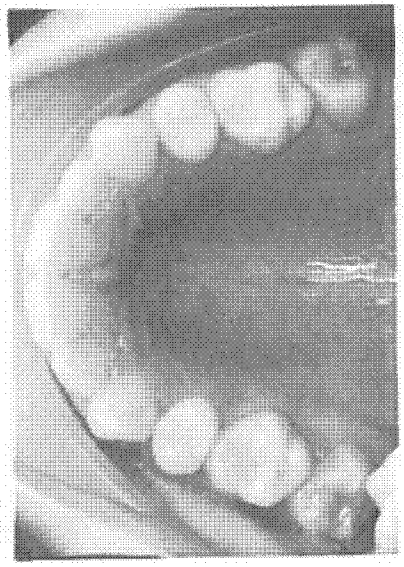

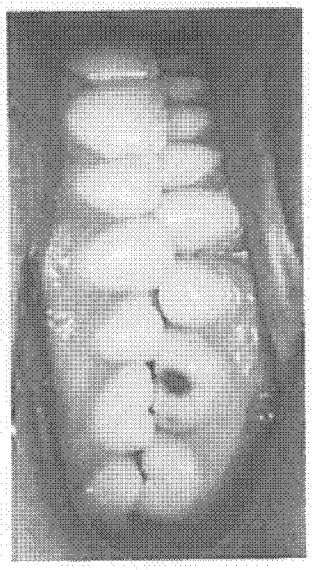

148

# Over Jet
# (OJ1-OJ6)

149

# OJ-1

# invisalign® TREATMENT SUMMARY

*.L INFORMATION MUST BE TYPEWRITTEN.*

**DOCTOR:** R.N. **INVISALIGN CASE #:** (b)(6)

**GENDER:** ☐ MALE ☒ FEMALE

**AGE:** 32 yrs.

**PATIENT INITIALS:** (b)(6)

**TREATMENT START DATE:** 08/27/01 **TREATMENT END DATE:** 06/30/03 **TOTAL TREATMENT TIME:** 22 months

**CHIEF CONCERN:** Crowding and overjet.

**DIAGNOSTIC SUMMARY:** This 32 y.o. Caucasian female presented with a unilateral Right Class II malocclusion, upper and lower crowding, and a composite veneer on the facial surface of tooth #8. Patient exhibited a Class II skeletal pattern.

**CEPHALOMETRIC SUMMARY:** SNA=84, SNB=79, ANB=5, MPA=26, IMPA=99, Upper 1 to NA=18, Lower 1 to NB=24.

**TREATMENT GOAL:** Achieve Class I cuspid relationship on R side, while improving maxillary midline and alleviating lower crowding.

**TREATMENT PLAN:** Virtually extract tooth #5 and distalize tooth #6 into a Class I cuspid relationship using 5x1x1mm curved root tipper (CRT) attachment on #6 and 3x1x1mm CRT on #3 and #4 to control tip. Remove the composite veneer and align upper anterior incisors. Overcorrect rotation of #9 by 8 degrees in Clincheck. IPR lower incisors PRIOR TO PVS impression. Restore small #7, #10 with composite buildups following orthodontic treatment.

**NUMBER OF REFINEMENTS DURING TREATMENT:** 1

**TOTAL NUMBER OF UPPER ALIGNERS (including refinements):** 42

**TOTAL NUMBER OF LOWER ALIGNERS (including refinements:** 15

**SUPPLEMENTAL TREATMENT NEEDED TO ACHIEVE TREATMENT GOAL:**

☐ Plier detailing ☐ Interarch elastics ☐ Buttons ☐ Spring aligner

☐ Positioner ☐ Orthognathic surgery ☒ Conventional braces ☐ None

**RESULTS ACHIEVED/DOCTOR'S ANALYSIS:** The lower arch treated out in 30 weeks exactly as predicted by ClinCheck with no revisions or refinements. The treatment on the upper arch progressed reasonably well. The case refinement was expected in order to capture new data following removal of the remaining composite veneer on tooth #8. The 5x1x1mm CRT attachments seemed to be a key in controlling root tipping as #6 was being distalized. Braces (1st molar to 1st molar) were placed on her maxillary teeth for 12 weeks to achieve complete uprighting of the root of tooth #6. During this time, bite turbos (central incisors only) were placed to assist

1.51

in bite opening. Patient was referred back to her general dentist for composite build-ups on teeth #7 and #10 following ortho. Patient was VERY pleased with her results!

**RETENTION:** Upper: .018 SS Bonded Retainer Lower: .018 SS Bonded Retainer

152

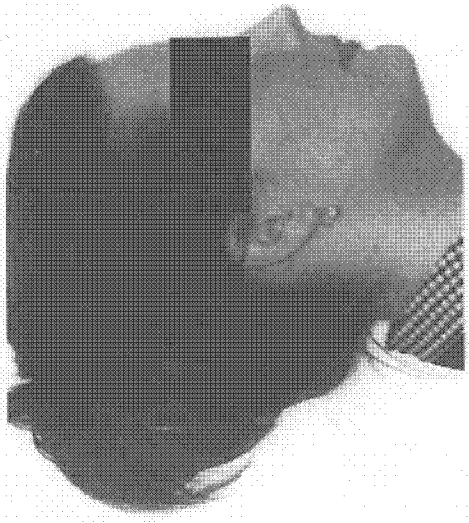

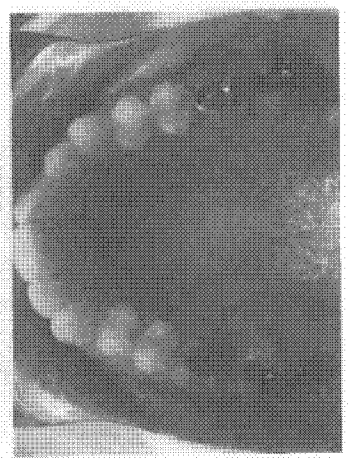

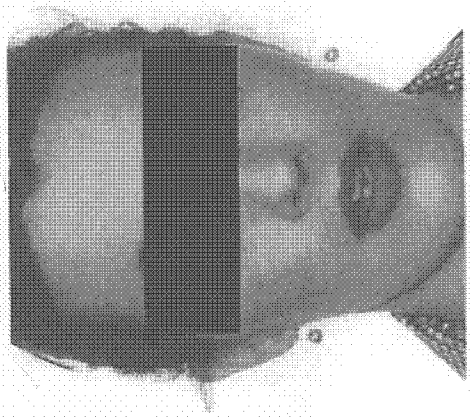

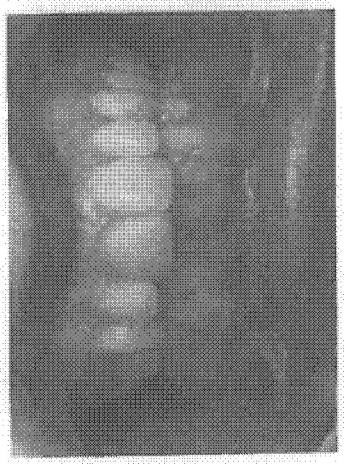

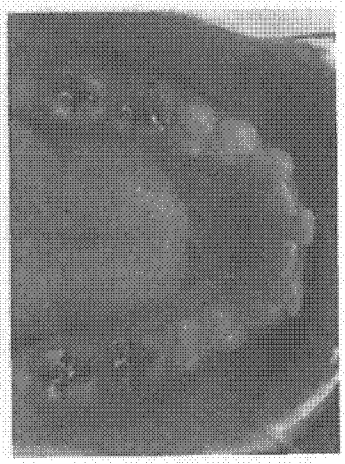

153

154

# OJ-2

155

# invisalign® TREATMENT SUMMARY

*...L INFORMATION MUST BE TYPEWRITTEN.*

**DOCTOR:** R.B. **INVISALIGN CASE #:** (b)(6)

**GENDER:** ☒ MALE ☐ FEMALE

**AGE:** 12 yrs.

**PATIENT INITIALS:** (b)(6)

**TREATMENT START DATE:** 06/03/03 **TREATMENT END DATE:** 03/17/05 **TOTAL TREATMENT TIME:** 20 months

**CHIEF CONCERN:** "Overbite"

**DIAGNOSTIC SUMMARY:** Class II division 1 with deep overbite and severe overjet.

**CEPHALOMETRIC SUMMARY:** Skeletal Class II with maxillary dentoalveolar protrusion and mandibular retrognathism.

**TREATMENT GOAL:** 1) Correct to ideal overjet/overbite. 2) Invisalign to close spaces.

**TREATMENT PLAN:** 1) Extract #'s 5 & 12. 2) Invisalign to close spaces.

**NUMBER OF REFINEMENTS DURING TREATMENT:** 0

**TOTAL NUMBER OF UPPER ALIGNERS (including refinements):** 29

**TOTAL NUMBER OF LOWER ALIGNERS (including refinements):** 16

**SUPPLEMENTAL TREATMENT NEEDED TO ACHIEVE TREATMENT GOAL:**

☐ Plier detailing ☐ Interarch elastics ☐ Buttons ☐ Spring aligner

☐ Positioner ☐ Orthognathic surgery ☐ Conventional braces ☒ None

**RESULTS ACHIEVED/DOCTOR'S ANALYSIS:** 1) Excellent occlusion considering extraction of upper first premolar. 2) Large improvement in profile.

**RETENTION:** Upper: Trutain Lower: Trutain

156

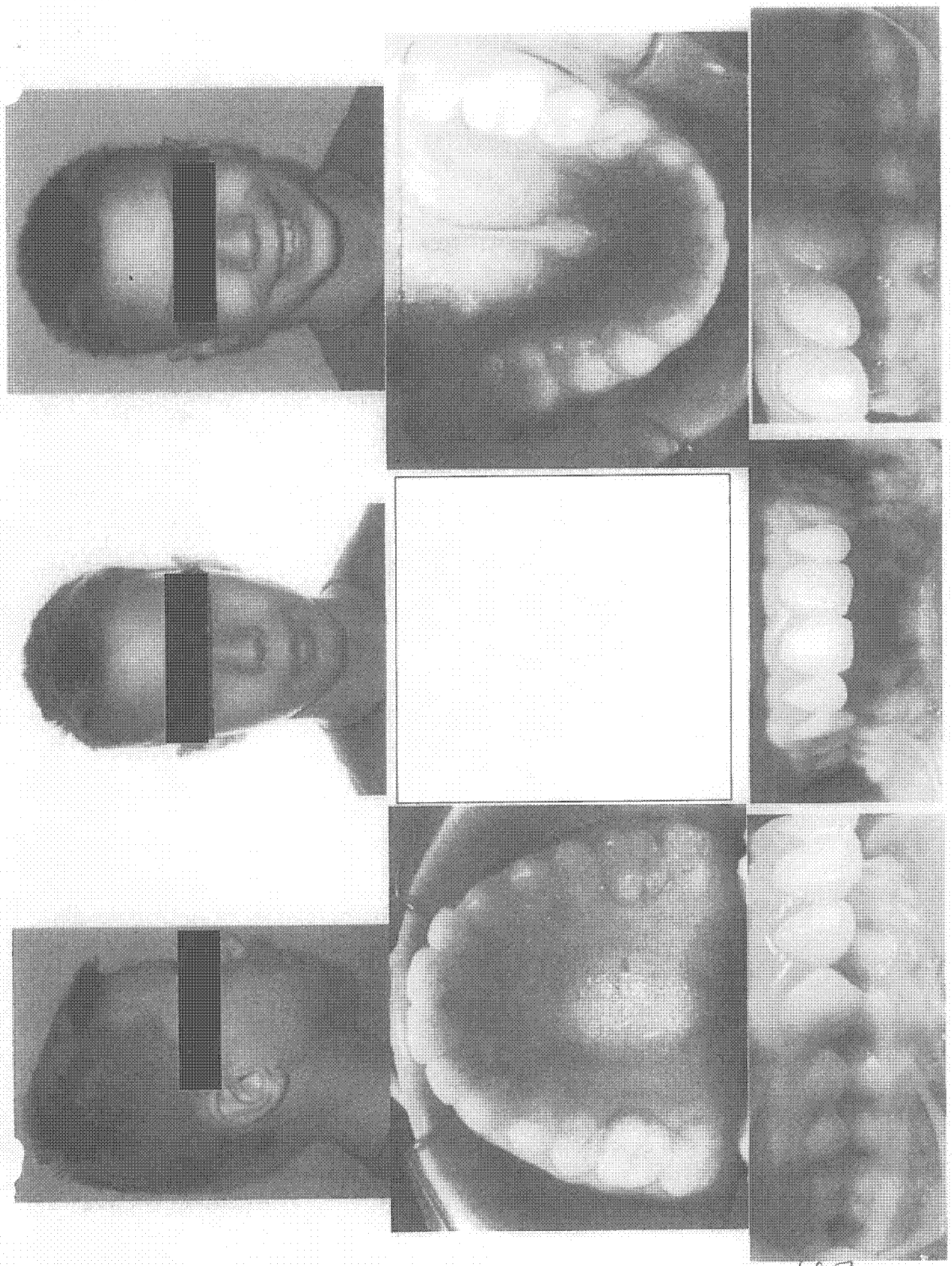

157

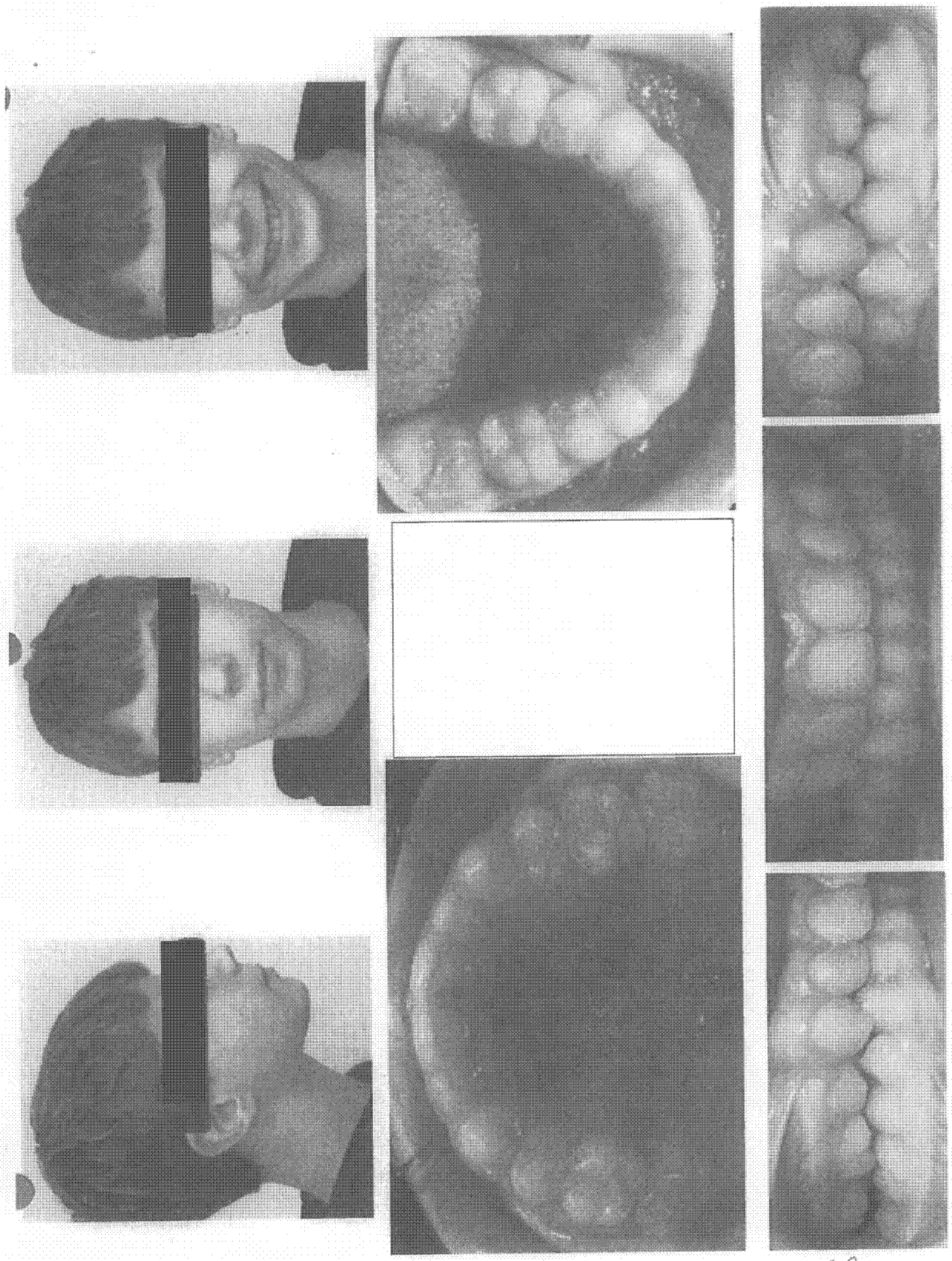

158

OJ-3

# invisalign® TREATMENT SUMMARY

*...L INFORMATION MUST BE TYPEWRITTEN.*

**DOCTOR:** R.B. **INVISALIGN CASE #:** (b)(6)

**GENDER:** ☐ MALE ☒ FEMALE

**AGE:** 62 yrs.

**PATIENT INITIALS:** (b)(6)

**TREATMENT START DATE:** 06/01/04 **TREATMENT END DATE:** 11/02/06 **TOTAL TREATMENT TIME:** 29 months

**CHIEF CONCERN:** "Crooked front teeth and large overbite"

**DIAGNOSTIC SUMMARY:** 1) Class II division 1. 2) Upper, Lower moderate crowding. 3) Severe deep overbite with palatal impingement.

**CEPHALOMETRIC SUMMARY:** Class II div one with retrognathic mandible and large chin.

**TREATMENT GOAL:** Class I occlusion with normal (2 mm) overbite and overjet.

**TREATMENT PLAN:** 1) Invisalign only to level, align and coordinate arches. 2) Class II elastics for overjet correction.

**NUMBER OF REFINEMENTS DURING TREATMENT:** 2

**TOTAL NUMBER OF UPPER ALIGNERS (including refinements):** 54

**TOTAL NUMBER OF LOWER ALIGNERS (including refinements):** 42

**SUPPLEMENTAL TREATMENT NEEDED TO ACHIEVE TREATMENT GOAL:**

☐ Plier detailing ☒ Interarch elastics ☒ Buttons ☐ Spring aligner

☐ Positioner ☐ Orthognathic surgery ☐ Conventional braces ☐ None

**RESULTS ACHIEVED/DOCTOR'S ANALYSIS:** Excellent class I occlusion with normal overbite and overjet.

**RETENTION:** Upper: Trutain Lower: Trutain

160





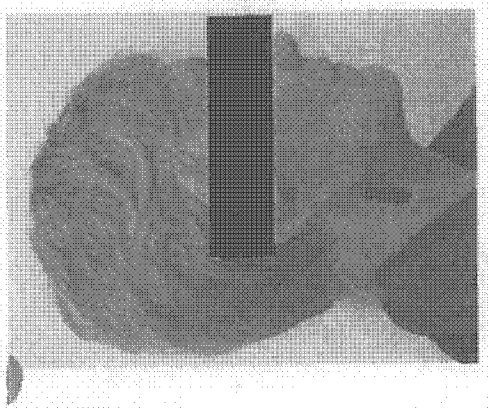

161

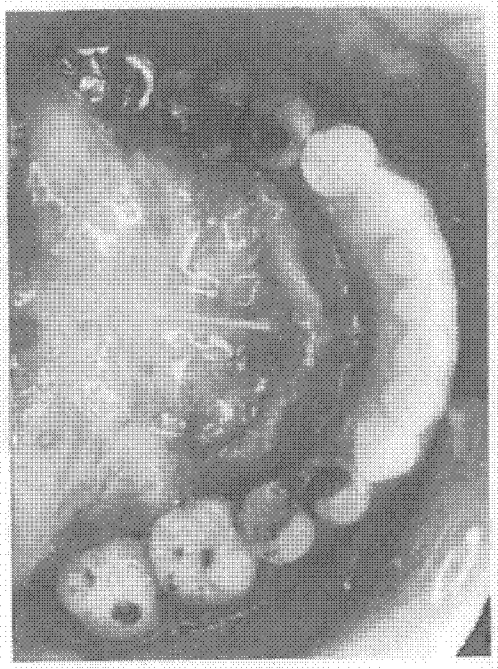

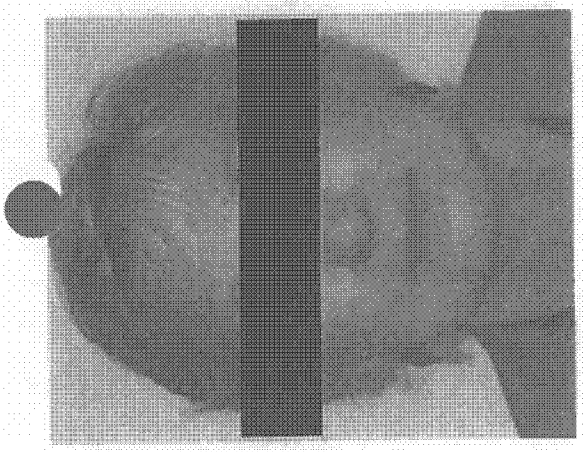

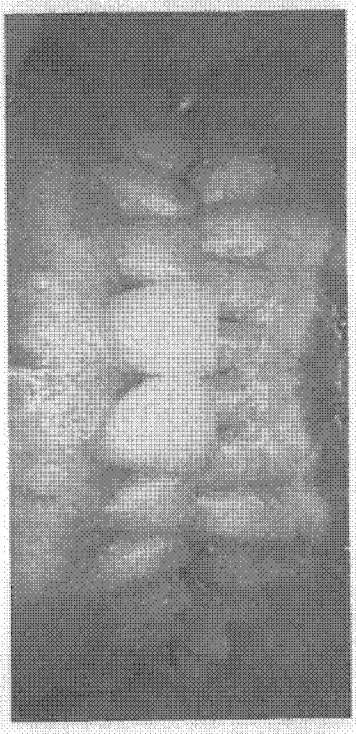

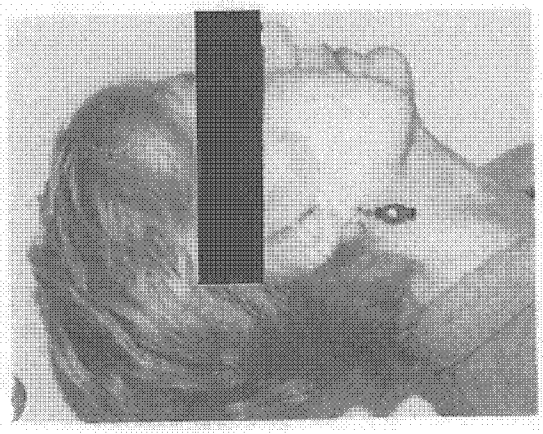

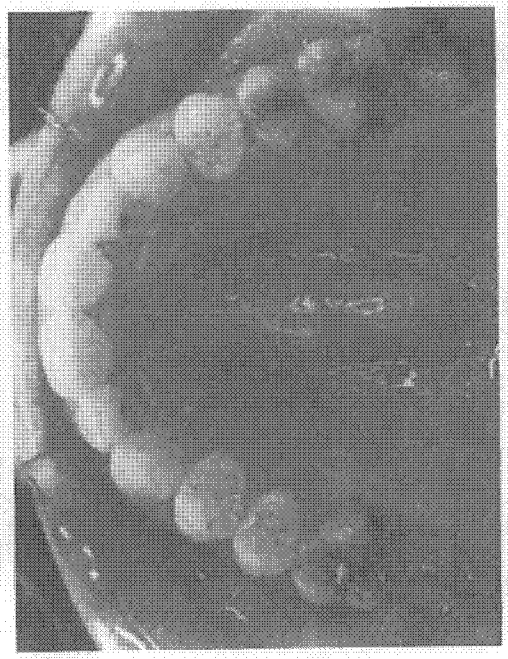

162

OJ-4

# invisalign® TREATMENT SUMMARY

*.L INFORMATION MUST BE TYPEWRITTEN.*

**DOCTOR:** R.B. **INVISALIGN CASE #:** (b)(6)

**GENDER:** ☒ MALE ☐ FEMALE

**AGE:** 35 yrs.

**PATIENT INITIALS** (b)(6)

**TREATMENT START DATE:** 06/14/04 **TREATMENT END DATE:** 11/02/06 **TOTAL TREATMENT TIME:** 28 months

**CHIEF CONCERN:** "Crooked teeth and overbite"

**DIAGNOSTIC SUMMARY:** 1) End on Class II. 2) Upper crowding. 3) Lower moderate crowding. 4) Moderate overjet. 5) Previous ortho with removal of all four first premolars.

**CEPHALOMETRIC SUMMARY:** Class II division 1 skeletal pattern caused by a retrognathic mandible.

**EATMENT GOAL:** Class I occlusion.

**TREATMENT PLAN:** 1) Level, align and coordinate arches. 2) Use class II elastics to correct overjet.

**NUMBER OF REFINEMENTS DURING TREATMENT:** 1

**TOTAL NUMBER OF UPPER ALIGNERS (including refinements):** 38

**TOTAL NUMBER OF LOWER ALIGNERS (including refinements):** 26

**SUPPLEMENTAL TREATMENT NEEDED TO ACHIEVE TREATMENT GOAL:**

☒ Plier detailing ☒ Interarch elastics ☒ Buttons ☐ Spring aligner

☐ Positioner ☐ Orthognathic surgery ☐ Conventional braces ☐ None

**RESULTS ACHIEVED/DOCTOR'S ANALYSIS:** 1) Excellent class I occlusion. 2) Improvement in profile. 3) Normal overbite and overjet.

**RETENTION:** Upper: Invisalign retainer Lower: Invisalign retainer

164

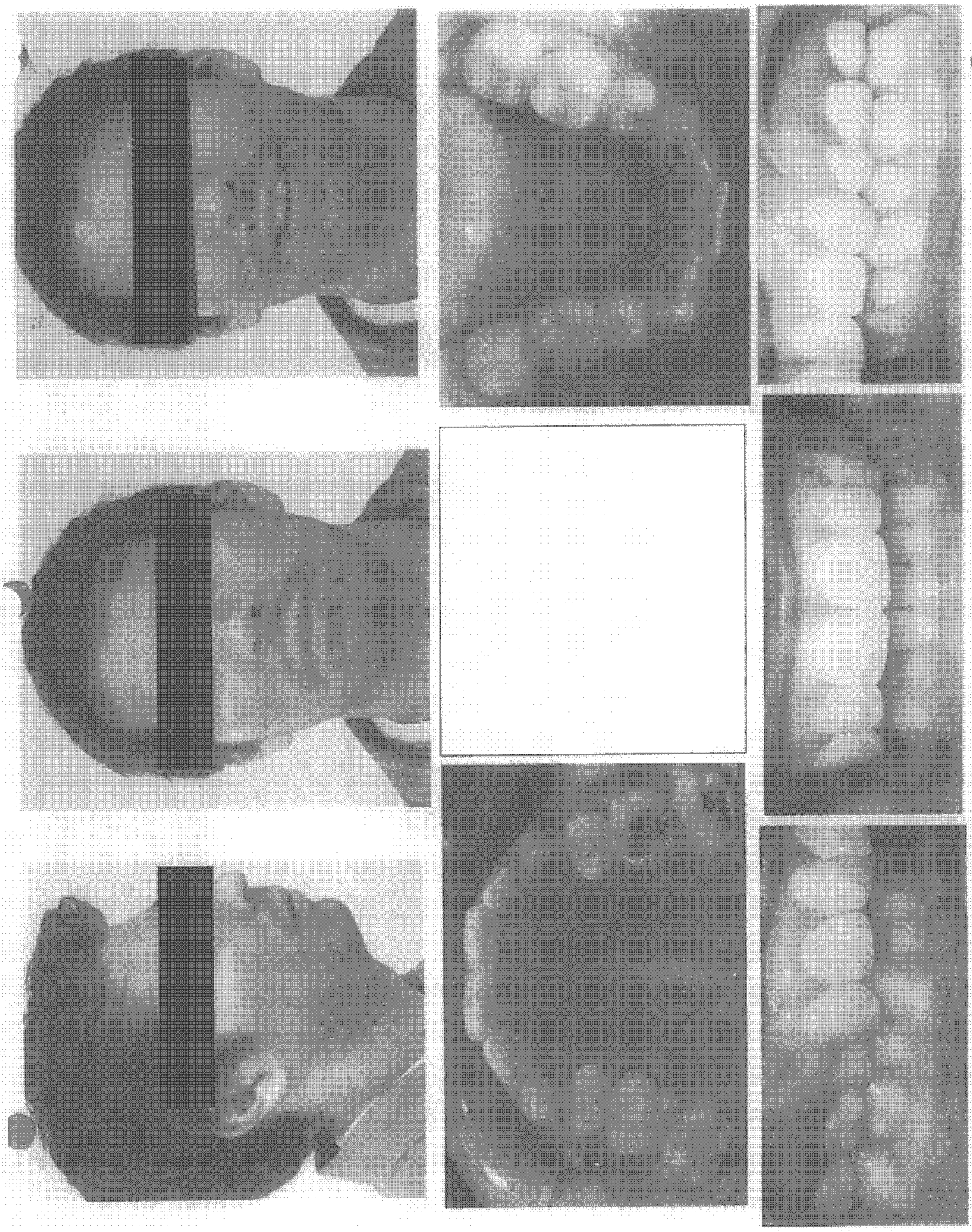

165

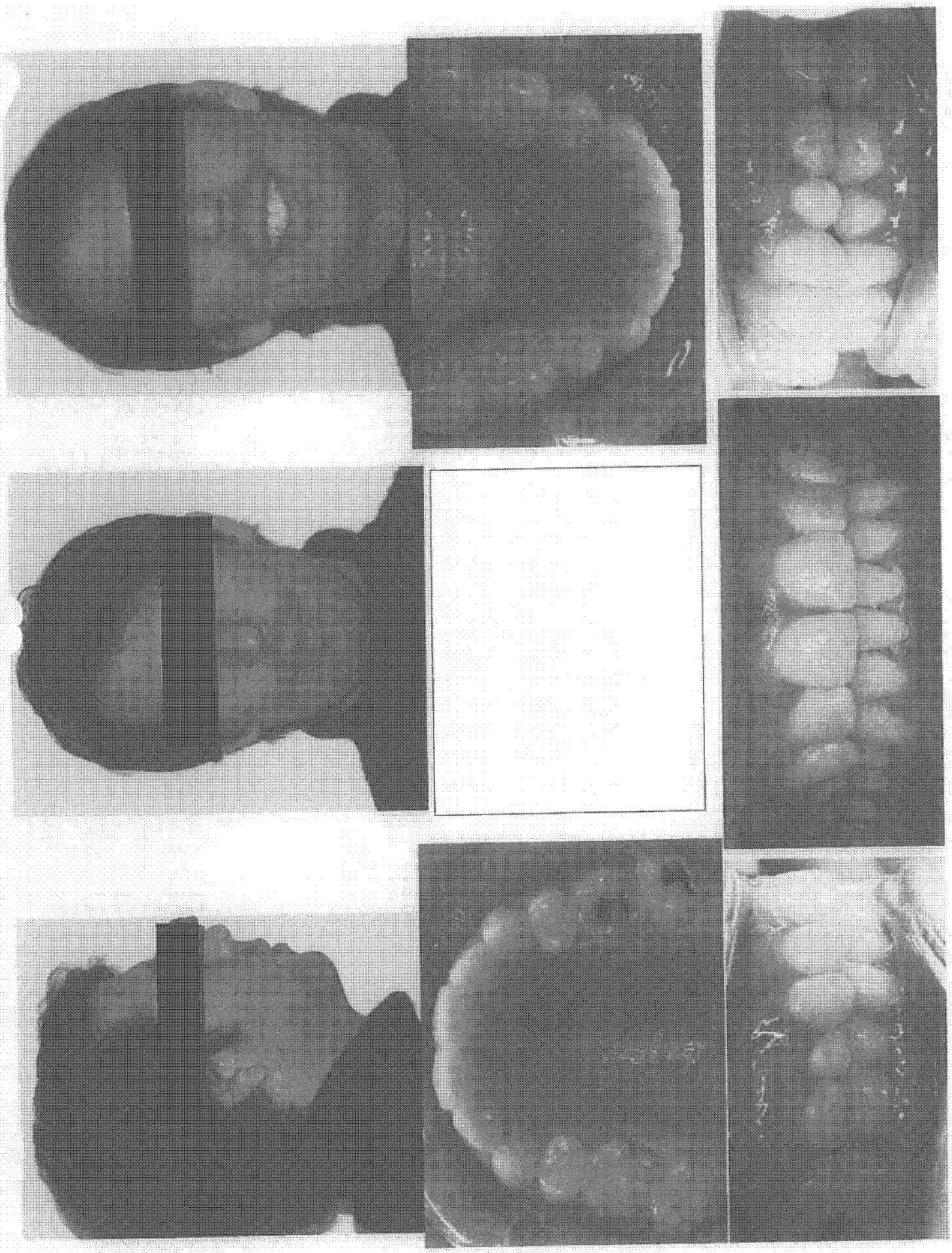

166

OJ-5

167

# invisalign® TREATMENT SUMMARY

*L INFORMATION MUST BE TYPEWRITTEN.*

**DOCTOR:** F.E. **INVISALIGN CASE #:** (b)(6)

**GENDER:** ☒ MALE ☐ FEMALE

**AGE:** 40 yrs.

**PATIENT INITIALS:** (b)(6)

**TREATMENT START DATE:** 05/10/01 **TREATMENT END DATE:** 02/13/03 **TOTAL TREATMENT TIME:** 21 months

**CHIEF CONCERN:** Lower anterior crowding.

**DIAGNOSTIC SUMMARY:** Mild Class II Division 1 malocclusion with moderate overjet (5 mm) and deep overbite (70%). Maxillary and mandibular arches are tapered with upper moderate crowding and lower severe crowding. Lower midline is shifted 1mm to the right. There is generalized occlusal wear which is particularly severe on the upper and lower six anterior teeth. The gingiva is severely recessed on the labial of protruding LR1, on the buccal of UL6 & LL6, UR4 & UR5, UL4 & UL5. Prominent lower right and left lingual tori are also present.

**CEPHALOMETRIC SUMMARY:** Skeletal Class II pattern, flat mandibular plane, obtuse nasio-labial angle, retruded upper and lower lips, prominent chin.

**TREATMENT GOAL:** Ideal occlusion with 2 mm overbite and overjet and midlines coincident.

**TREATMENT PLAN:** (1) Resolve upper and lower crowding using reproximation, transverse expansion of the canines, and flaring of incisors. (2) Reduce overjet by proclining LR2, LL1 & LL2. (3) Reduce overbite by intrusion of lower incisors. (4) Move lower midline to the left to coincide with upper midline.

**NUMBER OF REFINEMENTS DURING TREATMENT:** 1

**TOTAL NUMBER OF UPPER ALIGNERS (including refinements):** 41

**TOTAL NUMBER OF LOWER ALIGNERS (including refinements):** 37

**SUPPLEMENTAL TREATMENT NEEDED TO ACHIEVE TREATMENT GOAL:**

☐ Plier detailing ☐ Interarch elastics ☐ Buttons ☐ Spring aligner

☐ Positioner ☐ Orthognathic surgery ☐ Conventional braces ☒ None

**RESULTS ACHIEVED/DOCTOR'S ANALYSIS:** Teeth and midlines were well aligned. The gingival contour on labial of LR1 significantly improved. However, the overbite and overjet were minimally reduced.

**ETENTION:** Upper: Removable Essix retainer Lower: Fixed lingual wire-retainer bonded to canines and incisors, and removable Essix retainer.

168

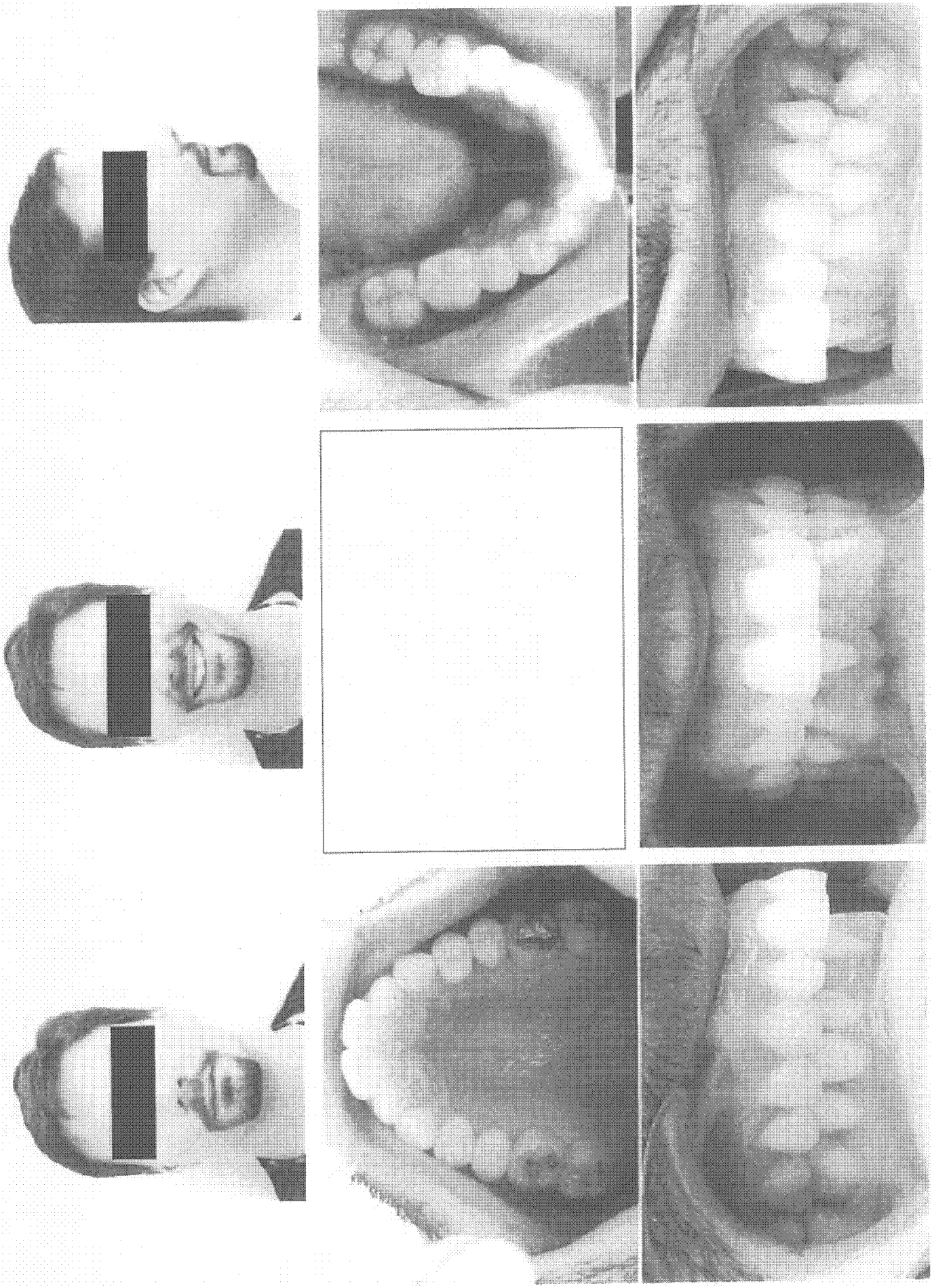

164



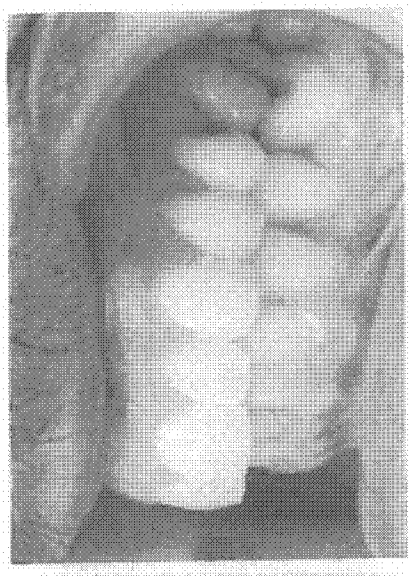



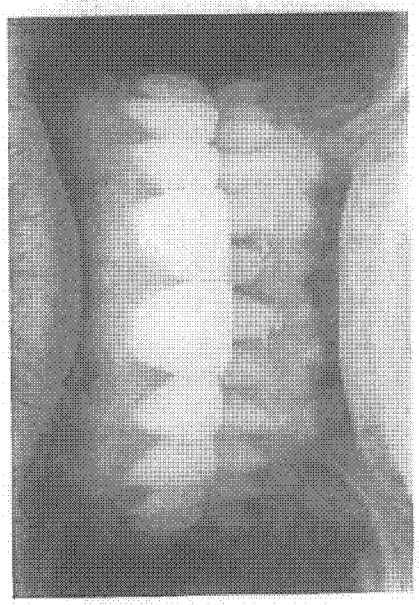



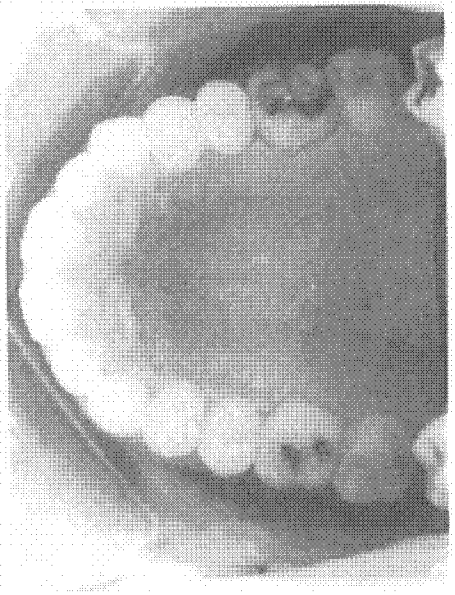

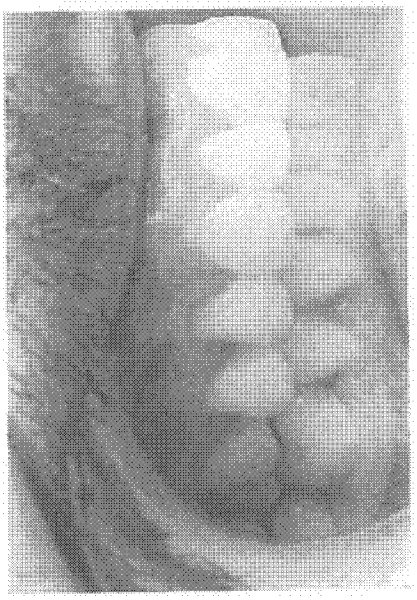

170

# OJ-6

# invisalign® TREATMENT SUMMARY

*L INFORMATION MUST BE TYPEWRITTEN.*

**DOCTOR:** D.T. **INVISALIGN CASE #:** (b)(6)

**GENDER:** ☐ MALE ☒ FEMALE

**AGE:** 13 yrs.

**PATIENT INITIALS:** (b)(6)

**TREATMENT START DATE:** 07/01/03 **TREATMENT END DATE:** 09/28/04 **TOTAL TREATMENT TIME:** 14 months

**CHIEF CONCERN:** Crowding, overjet.

**DIAGNOSTIC SUMMARY:** Class II malocclusion with 7 mm overjet in centric relation, narrow arches, and moderate crowding.

**CEPHALOMETRIC SUMMARY:** Skeletal class II, ANB= 8 degrees.

**TREATMENT GOAL:** Class II correction, widen arches, eliminate crowding.

**TREATMENT PLAN:** Distalize upper anterior for class II correction, IPR to uncrowd anteriors. Attachments on almost all upper teeth, mid-area for lower teeth.

**NUMBER OF REFINEMENTS DURING TREATMENT:** None

**TOTAL NUMBER OF UPPER ALIGNERS (including refinements):** 31

**TOTAL NUMBER OF LOWER ALIGNERS (including refinements):** 31

**SUPPLEMENTAL TREATMENT NEEDED TO ACHIEVE TREATMENT GOAL:**

☒ Plier detailing ☐ Interarch elastics ☐ Buttons ☐ Spring aligner

☐ Positioner ☐ Orthognathic surgery ☐ Conventional braces ☐ None

**RESULTS ACHIEVED/DOCTOR'S ANALYSIS:** Excellent results, good arch alignment and occlusion. Good class II correction. Post treatment overjet= 2 mm.

**RETENTION:** Upper: Trutain Lower: Trutain, followed by fixed lower cuspid to cuspid

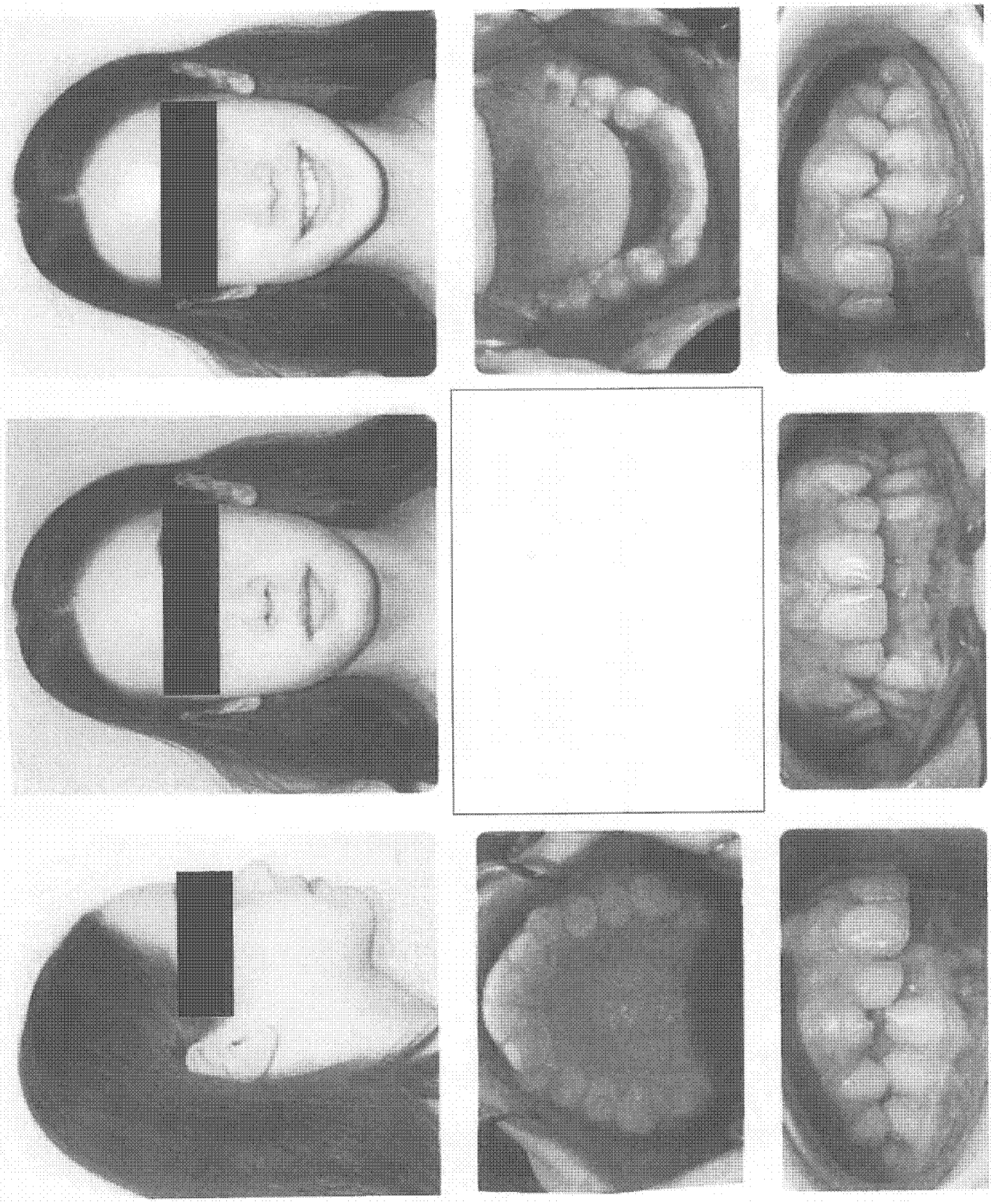

173

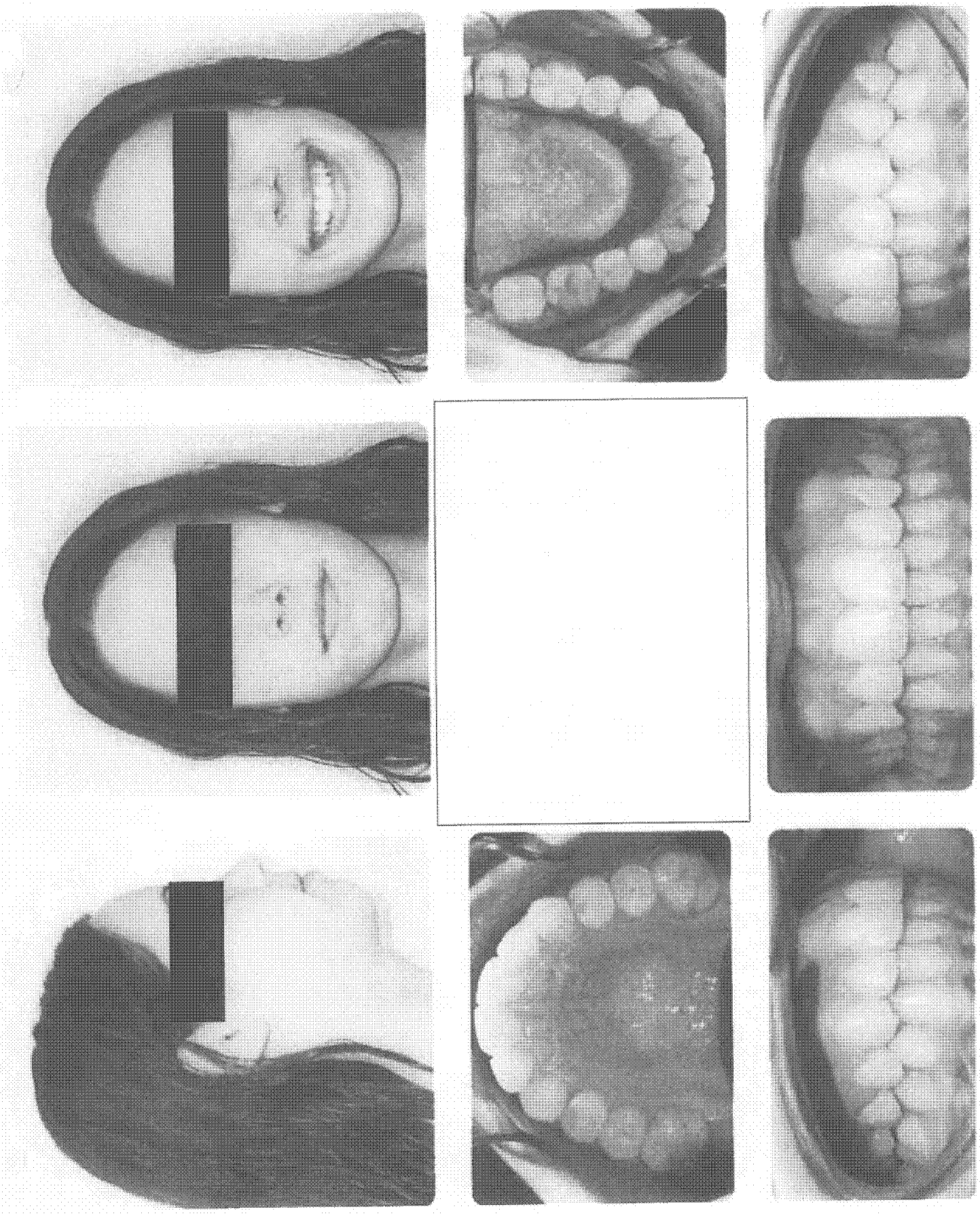

174

# Surgical Correction
# (SC1- SC4)

175

SC-1

176

# invisalign® TREATMENT SUMMARY

*L INFORMATION MUST BE TYPEWRITTEN.*

**DOCTOR:** R.M. **INVISALIGN CASE #:** (b)(6)

**GENDER:** ☒ MALE ☐ FEMALE

**AGE:** 36 yrs.

**PATIENT INITIALS:** (b)(6)

**TREATMENT START DATE:** 10/5/99 **TREATMENT END DATE:** 3/27/02 **TOTAL TREATMENT TIME:** 29 months

**CHIEF CONCERN:** Overbite.

**DIAGNOSTIC SUMMARY:** Recession, gingivitis, cross bite, scissor bite, overjet 12 mm, overbite 6 mm.

**CEPHALOMETRIC SUMMARY:** Bimax retrognathic.

**TREATMENT GOAL:** Class I / Surgery.

**TREATMENT PLAN:** Bimax surgery. Invisalign (11 mos.) and Braces (18 mos.).

**NUMBER OF REFINEMENTS DURING TREATMENT:** 0

**TOTAL NUMBER OF UPPER ALIGNERS (including refinements):** 20

**TOTAL NUMBER OF LOWER ALIGNERS (including refinements):** 31

**SUPPLEMENTAL TREATMENT NEEDED TO ACHIEVE TREATMENT GOAL:**

☐ Plier detailing ☐ Interarch elastics ☐ Buttons ☐ Spring aligner

☐ Positioner ☒ Orthognathic surgery ☒ Conventional braces ☐ None

**RESULTS ACHIEVED/DOCTOR'S ANALYSIS:** Patient lower and upper jaw were surgically advanced making him much less retrognathic. The teeth were aligned with aligners and braces. Patient went from excess overjet of 12 mm to 3 mm.

**ETENTION:** Upper: Hawley Lower: Hawley

177

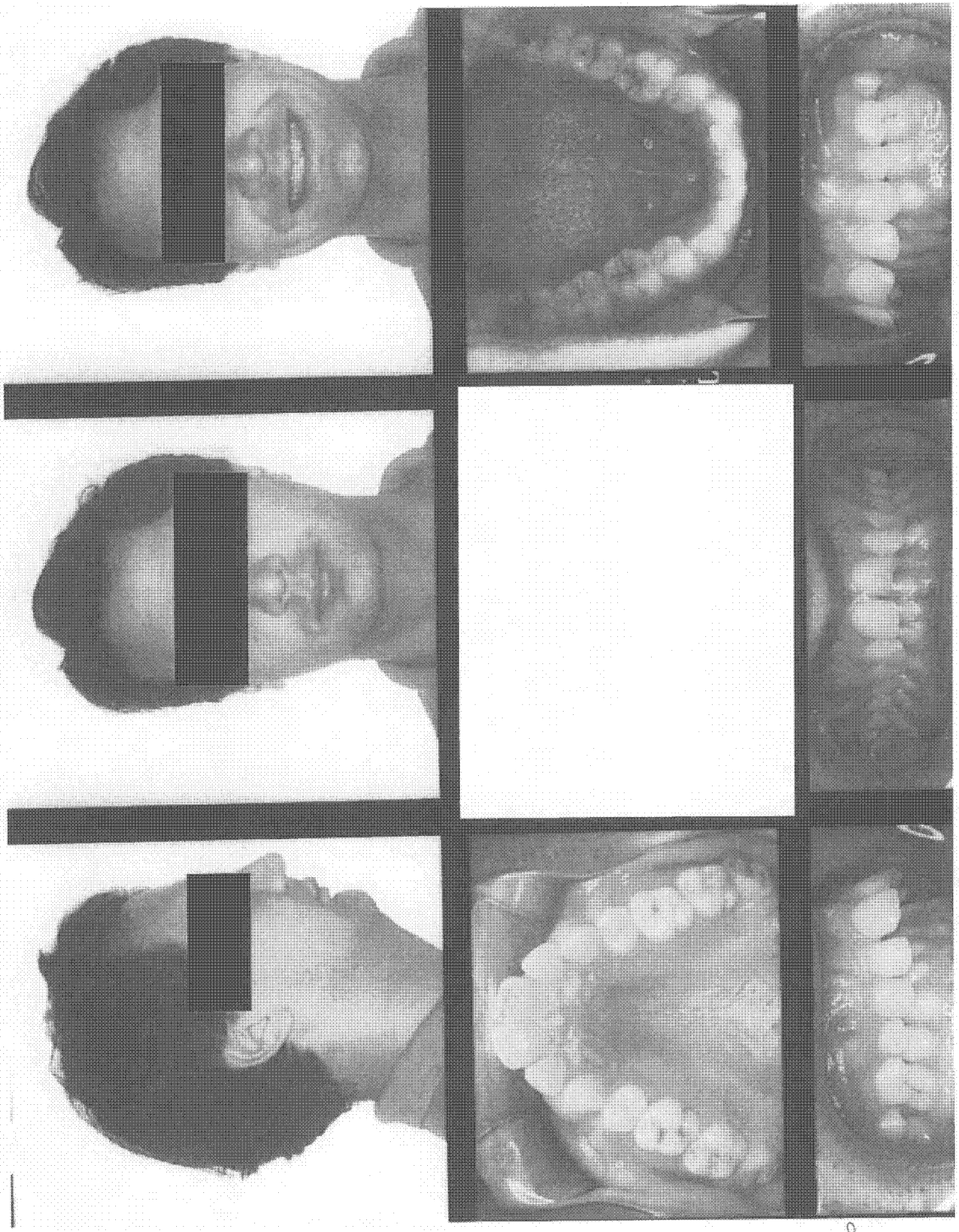

128

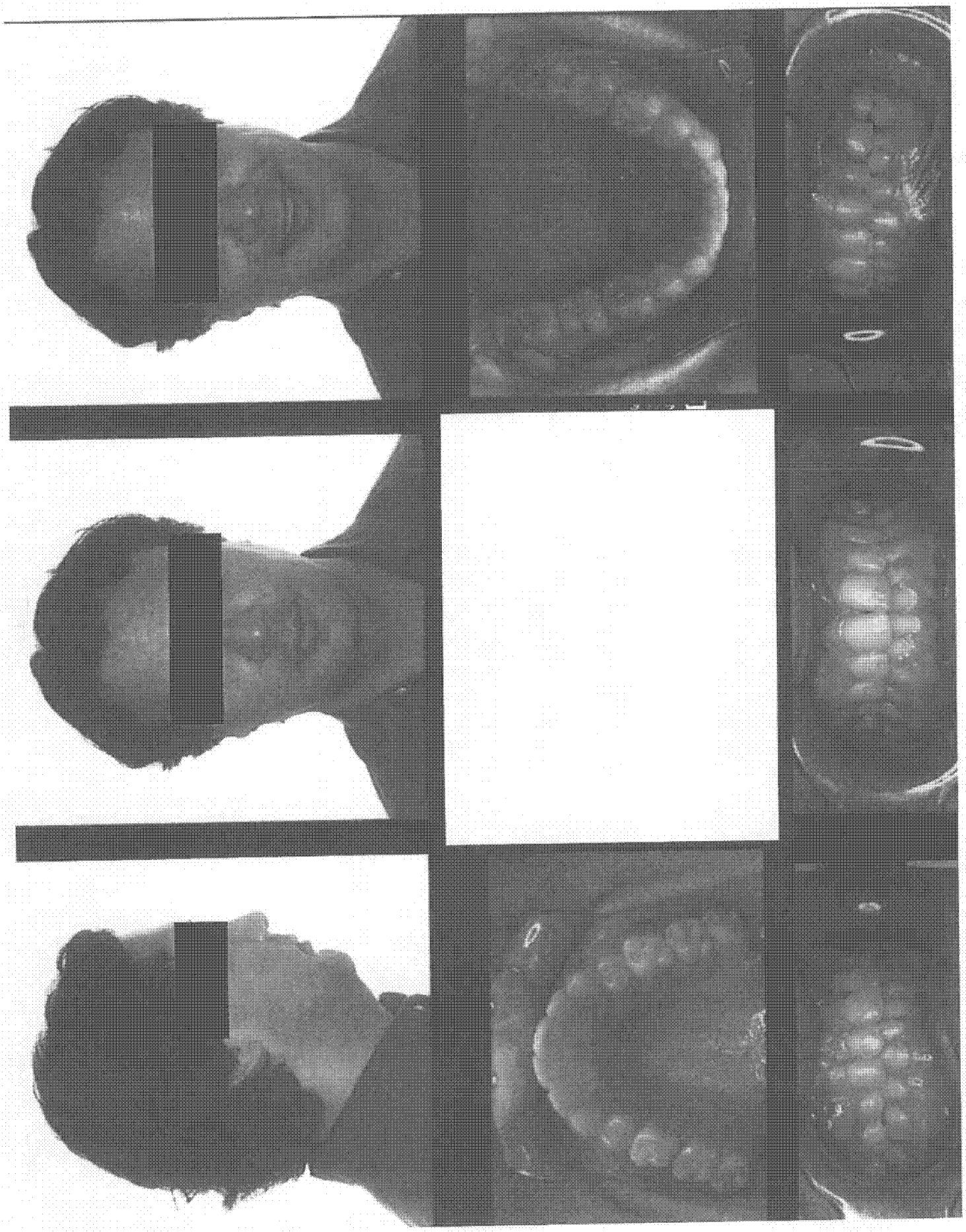

179

SC-2

# invisalign® TREATMENT SUMMARY

*.L INFORMATION MUST BE TYPEWRITTEN.*

**DOCTOR:** R.B. **INVISALIGN CASE #:** (b)(6)

**GENDER:** ☒ MALE ☐ FEMALE

**AGE:** 38 yrs.

**PATIENT INITIALS:** (b)(6)

**TREATMENT START DATE:** 3/01/01 **TREATMENT END DATE:** 4/02/04 **TOTAL TREATMENT TIME:** 35 months but this includes the jaw surgery which took about eight months of the total time for preparation and healing.

**CHIEF CONCERN:** "Crowded front teeth and underbite."

**DIAGNOSTIC SUMMARY:** 1) Class III skeletal pattern with normal mandible and retronathic maxilla. 2) Moderate upper and mild lower crowding. 3) Bilateral posterior crossbite. 4) Missing #'s 5 & 7's.

**CEPHALOMETRIC SUMMARY:** Class III skeletal pattern caused by retrognathic maxilla, normal mandible.

**TREATMENT GOAL:** 1) Level, align and coordinate arches. 2) Maxillary surgery to advance and widen maxilla.

**TREATMENT PLAN:** 1) Invisalign to level align and coordinate arches. 2) Place fixed prior to surgery. 3) Maxillary surgery 4) Finish and detail with fixed.

**NUMBER OF REFINEMENTS DURING TREATMENT:** 2

**TOTAL NUMBER OF UPPER ALIGNERS (including refinements):** 29

**TOTAL NUMBER OF LOWER ALIGNERS (including refinements):** 23

**SUPPLEMENTAL TREATMENT NEEDED TO ACHIEVE TREATMENT GOAL:**

☐ Plier detailing ☒ Interarch elastics ☒ Buttons ☐ Spring aligner

☐ Positioner ☒ Orthognathic surgery ☒ Conventional braces ☐ None

**RESULTS ACHIEVED/DOCTOR'S ANALYSIS:** Excellent class I occlusion.

**RETENTION:** Upper: Trutain Lower: Trutain



181

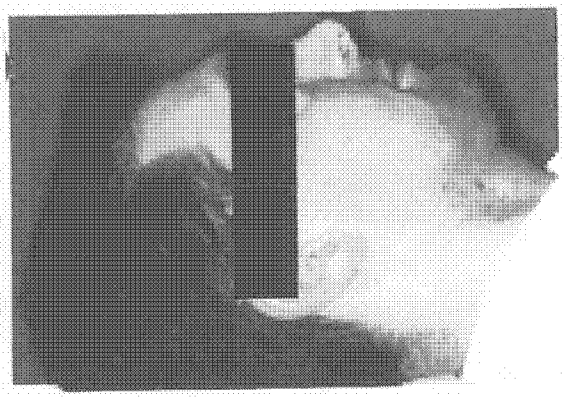
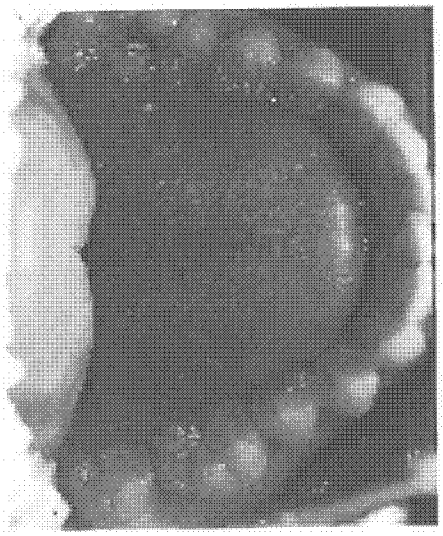
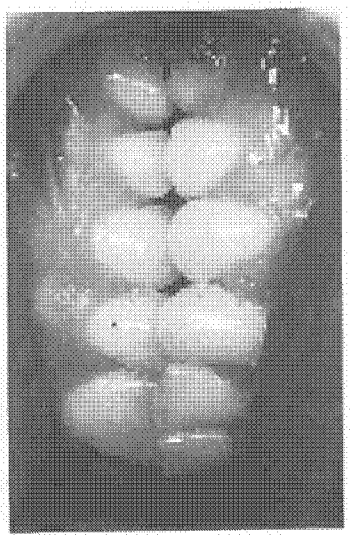
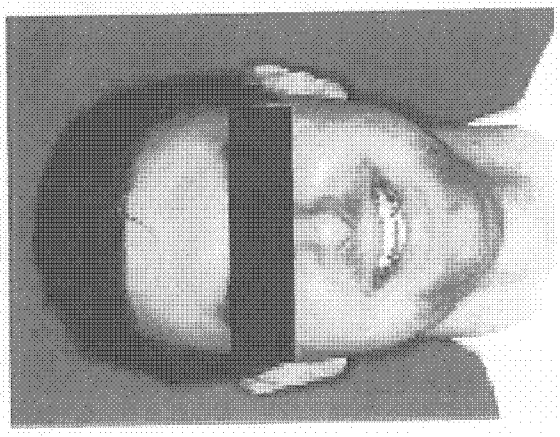
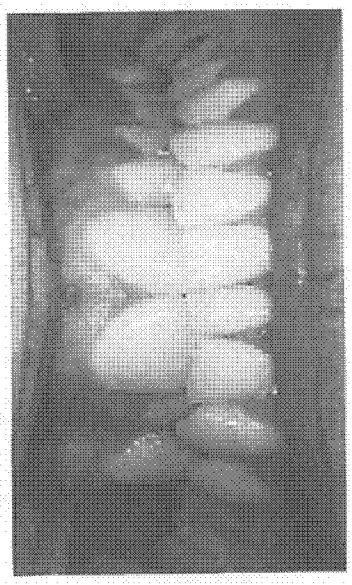
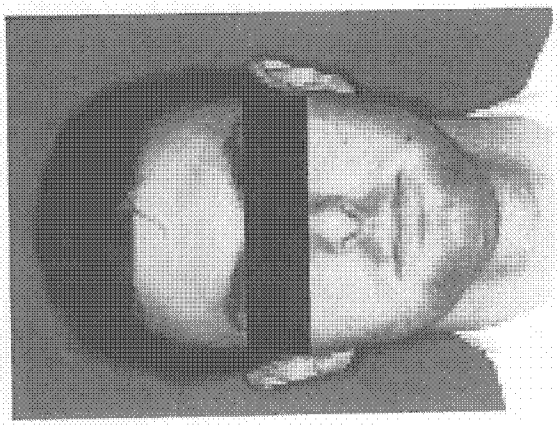

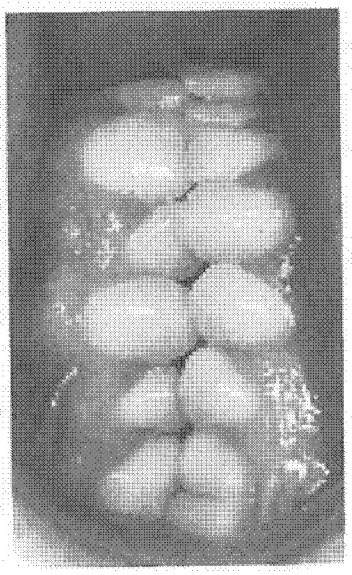

182

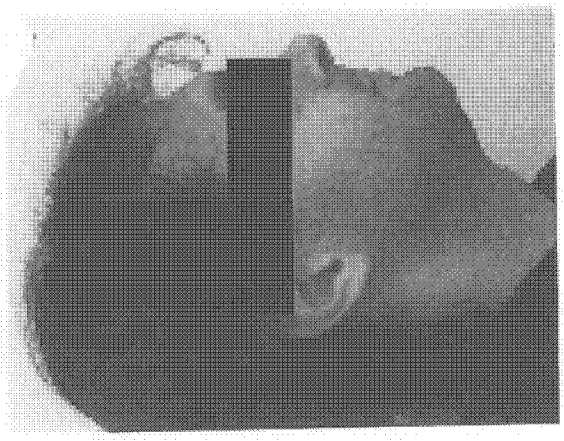

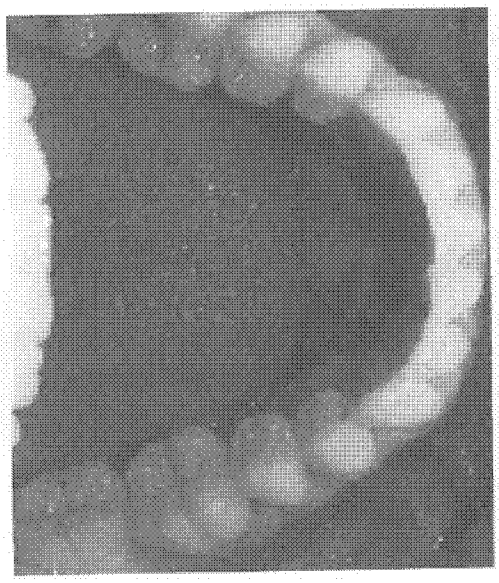

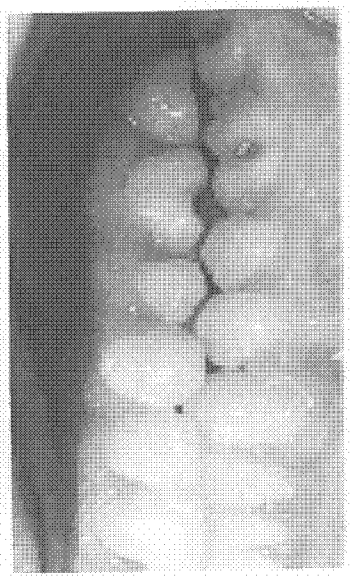

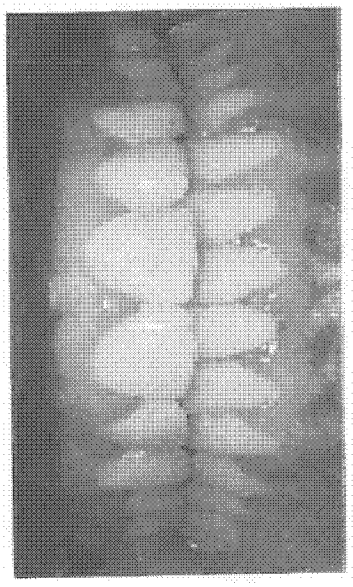

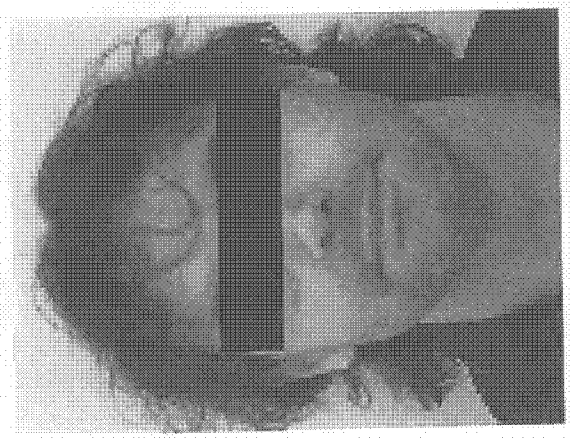

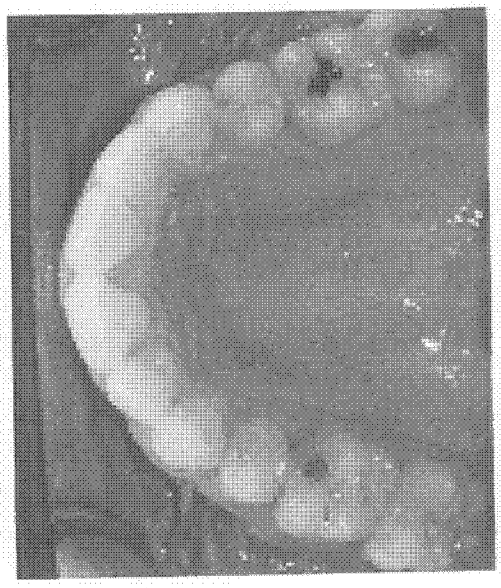

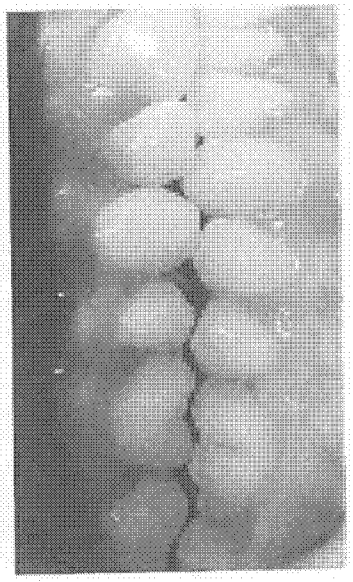

183

SC-3

184

# invisalign® TREATMENT SUMMARY

*L INFORMATION MUST BE TYPEWRITTEN.*

**DOCTOR:** R.B. **INVISALIGN CASE #:** (b)(6)

**GENDER:** ☐ MALE ☒ FEMALE

**AGE:** 33 yrs.

**PATIENT INITIALS:** (b)(6)

**TREATMENT START DATE:** 11/01/01 **TREATMENT END DATE:** 01/20/05 **TOTAL TREATMENT TIME:** 38 months

**CHIEF CONCERN:** "Crooked front teeth, jaw is to one side."

**DIAGNOSTIC SUMMARY:** 1) Class III skeletal with mandibular asymmetry & mild lower crowding. 2) The lower right canine & lateral incisor is missing. 3) The lower left first premolar is more severely rotated. 4) The lower incisors are retroclined.

**CEPHALOMETRIC SUMMARY:** Class III skeletal caused by a retrognathic maxilla & prognathic mandible.

**TREATMENT GOAL:** Level, align and coordinate the arches prior to surgical mandibular setback & rotation.

**TREATMENT PLAN:** 1) Invisalign 2) Fixed segment to rotate #21. 3) Orthognathic surgery.

**NUMBER OF REFINEMENTS DURING TREATMENT:** None (1 mid-course correction on lower).

**TOTAL NUMBER OF UPPER ALIGNERS (including refinements):** 37

**TOTAL NUMBER OF LOWER ALIGNERS (including refinements):** 43

**SUPPLEMENTAL TREATMENT NEEDED TO ACHIEVE TREATMENT GOAL:**

☐ Plier detailing ☒ Interarch elastics ☐ Buttons ☐ Spring aligner

☐ Positioner ☒ Orthognathic surgery ☒ Conventional braces ☐ None

**RESULTS ACHIEVED/DOCTOR'S ANALYSIS:** Excellent occlusion considering difficulty of malocclusion and missing teeth #'s 22 and 23.

**RETENTION:** Upper: Trutain Lower: Trutain



185

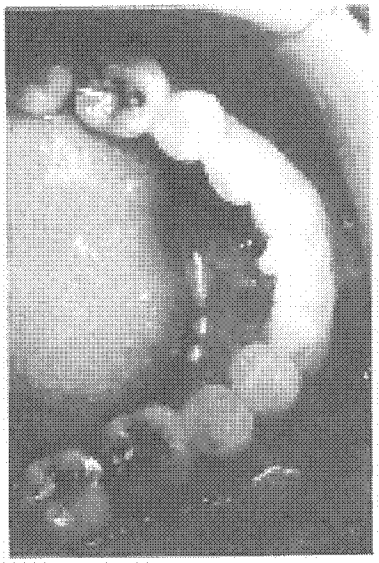

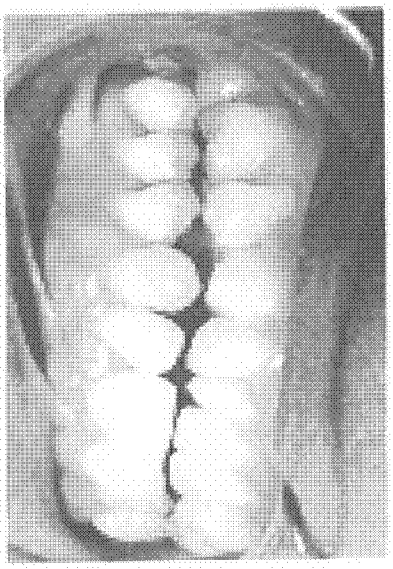

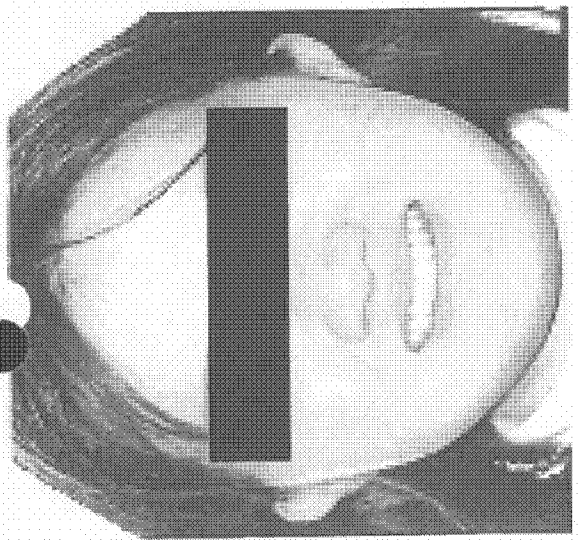

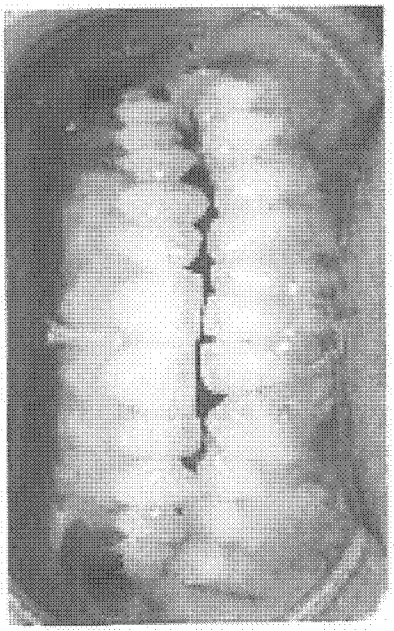

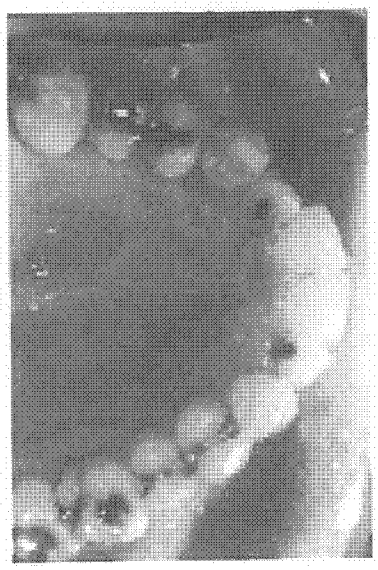

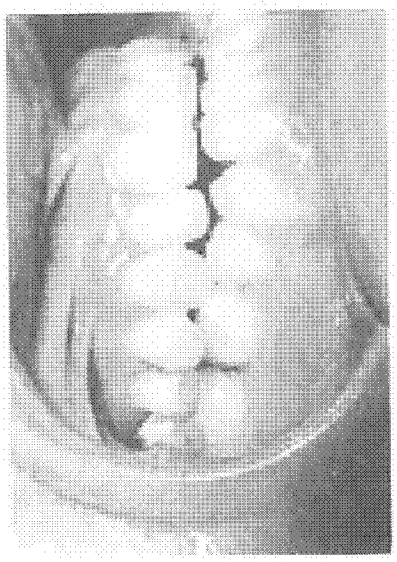

186

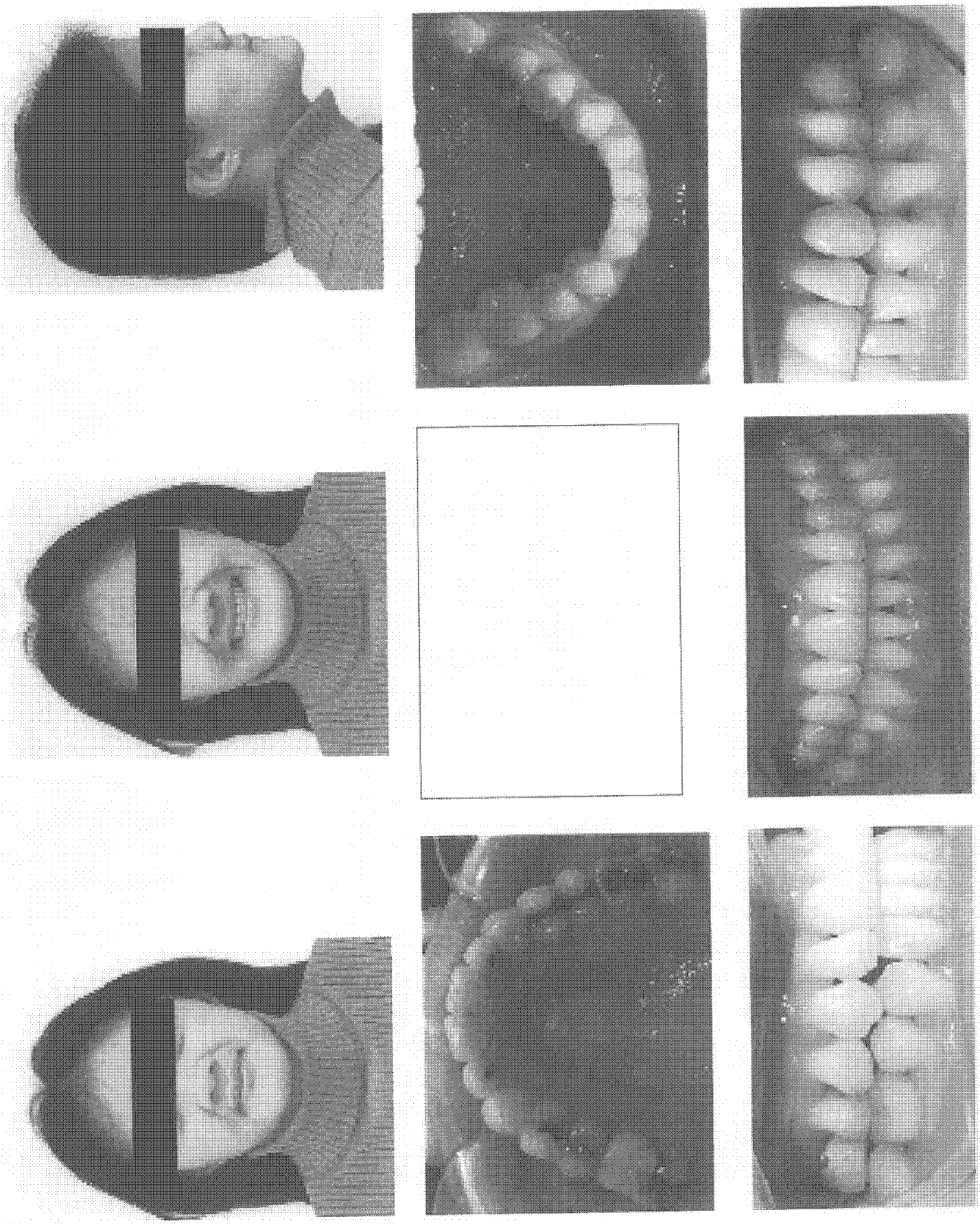

187

# SC-4

# invisalign® TREATMENT SUMMARY

*.L INFORMATION MUST BE TYPEWRITTEN.*

**DOCTOR:** J.S. **INVISALIGN CASE #:** (b)(6)

**GENDER:** ☒ MALE ☐ FEMALE

**AGE:** 44 yrs.

**PATIENT INITIALS:** (b)(6)

**TREATMENT START DATE:** 2/26/02 **TREATMENT END DATE:** 4/21/04 **TOTAL TREATMENT TIME:** 26 months

**CHIEF CONCERN:** "My underbite bothers me esthetically."

**DIAGNOSTIC SUMMARY:** Class III skeletal & dental, Anterior crossbite, Asymmetry-skeletal & dental, poor occlusion, multiple interference, no cuspid guidance, no anterior guidance, no posterior centric stops.

**CEPHALOMETRIC SUMMARY:** Class III skeletal & dental.

**TREATMENT GOAL:** To obtain Class I occlusion, skeletal and dental symmetry, cuspid & anterior guidance, posterior centric stops.

**TREATMENT PLAN:** Invisalign upper and lower with orthognathic surgery, distalized upper right buccal segment and align pre-surgically, surgery mandibular setback asymmetric, post-surgical ortho finish midline correction and distalization, open the deep bite, refine occlusion.

**NUMBER OF REFINEMENTS DURING TREATMENT:** 1

**TOTAL NUMBER OF UPPER ALIGNERS (including refinements):** 59

**TOTAL NUMBER OF LOWER ALIGNERS (including refinements):** 21

**SUPPLEMENTAL TREATMENT NEEDED TO ACHIEVE TREATMENT GOAL:**

☒ Plier detailing ☒ Interarch elastics ☒ Buttons ☐ Spring aligner

☐ Positioner ☒ Orthognathic surgery ☐ Conventional braces ☐ None

**RESULTS ACHIEVED/DOCTOR'S ANALYSIS:** Class I skeletal, even centric stops, cuspid guided occlusion, no balancing side interferences; anterior guidance.

**RETENTION:** Upper: Essix Lower: Essix



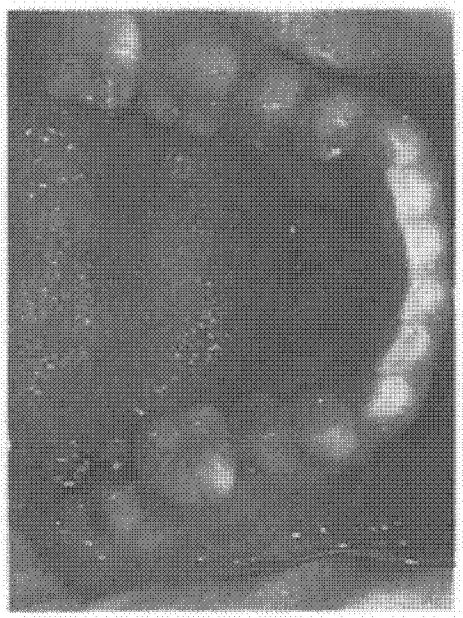

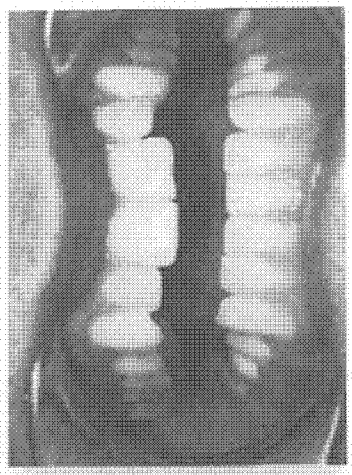

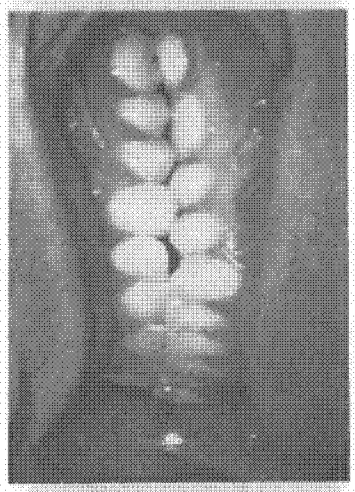



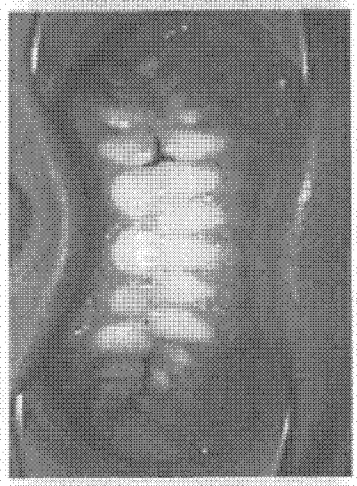



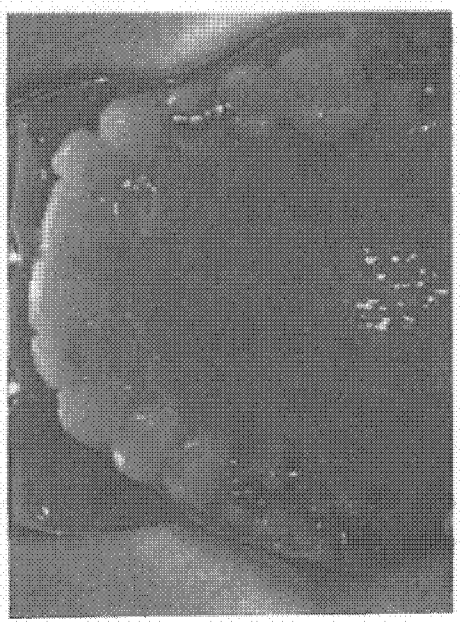

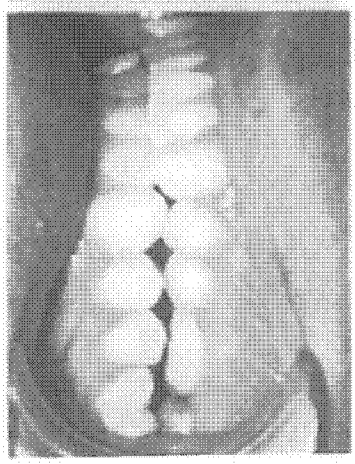

190



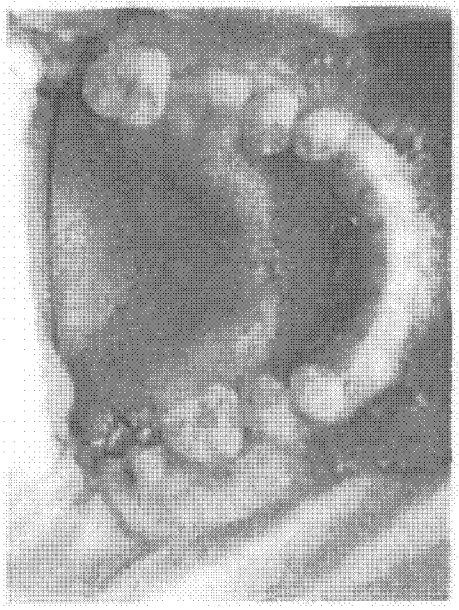

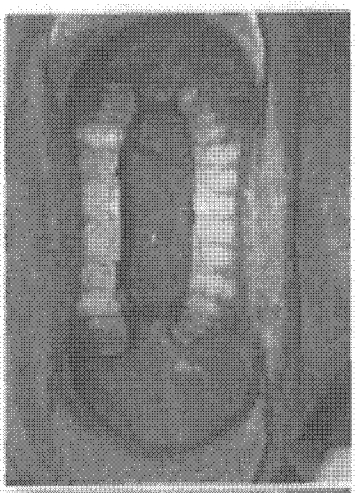

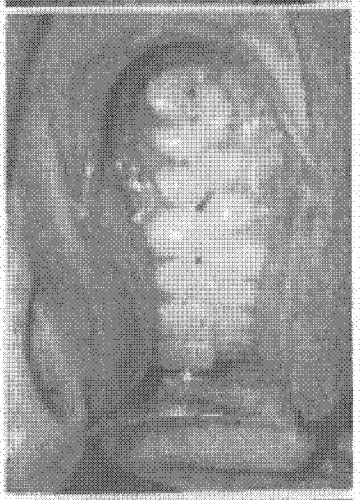

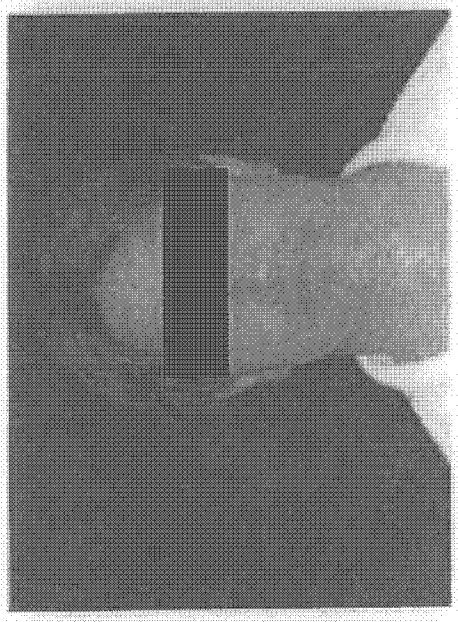

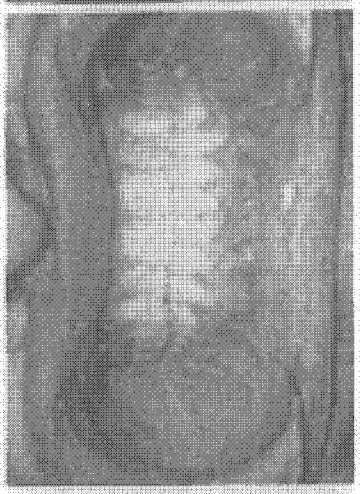

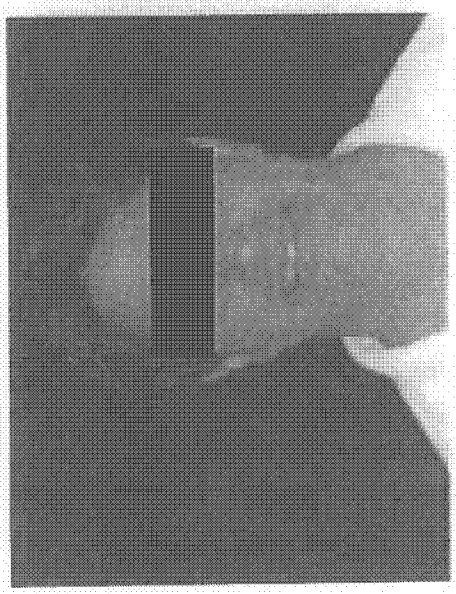

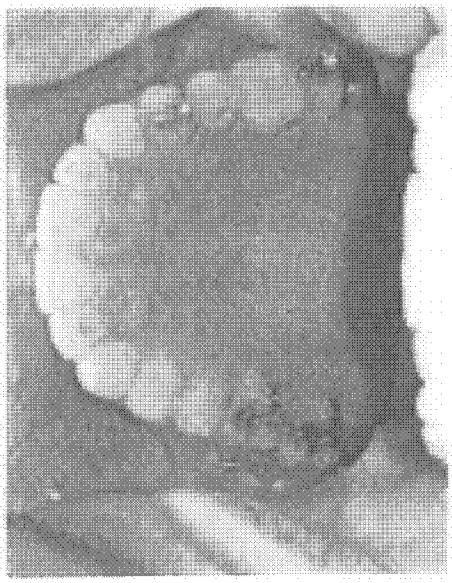

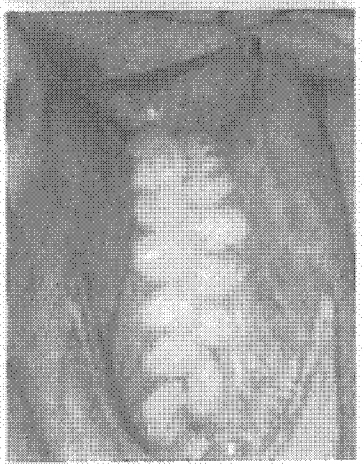

# Mixed Dentition
# (MD1-MD12)

142

# MD-1

143

# invisalign® TREATMENT SUMMARY

*L INFORMATION MUST BE TYPEWRITTEN.*

**DOCTOR:** W.S. **INVISALIGN CASE #:** (b)(6)

**GENDER:** ☐ MALE ☒ FEMALE

**AGE:** 9 yrs.

**PATIENT INITIALS:** (b)(6)

**TREATMENT START DATE:** 1/19/05 **TREATMENT END DATE:** 5/31/06 **TOTAL TREATMENT TIME:** 16 months

**CHIEF CONCERN:** Correct anterior frontal crowding and crossbite of 1.2, 2.2.

**DIAGNOSTIC SUMMARY:** Class I relationship with crowding of upper front teeth and crossbite 1.2, 2.2.

**CEPHALOMETRIC SUMMARY:** We don't have any cephalometrics because we didn't treat skeletal problems.

**TREATMENT GOAL:** Correct anterior crowding and solve crossbite by moving 1.2, 2.2 to labial.

**TREATMENT PLAN:** 23 upper arch.

**NUMBER OF REFINEMENTS DURING TREATMENT:** 1

**TOTAL NUMBER OF UPPER ALIGNERS (including refinements):** 35

**TOTAL NUMBER OF LOWER ALIGNERS (including refinements):** Upper treatment only.

**SUPPLEMENTAL TREATMENT NEEDED TO ACHIEVE TREATMENT GOAL:**

☐ Plier detailing ☐ Interarch elastics ☐ Buttons ☐ Spring aligner

☐ Positioner ☐ Orthognathic surgery ☐ Conventional braces ☒ None

**RESULTS ACHIEVED/DOCTOR'S ANALYSIS:** Solving of anterior crowding and crossbite by protrusion of 1.2, 2.2.

Refinement used for additional movement of 1.2. Treatment goal completely achieved.

**RETENTION:** Upper: Removable plate Lower: n/a

144

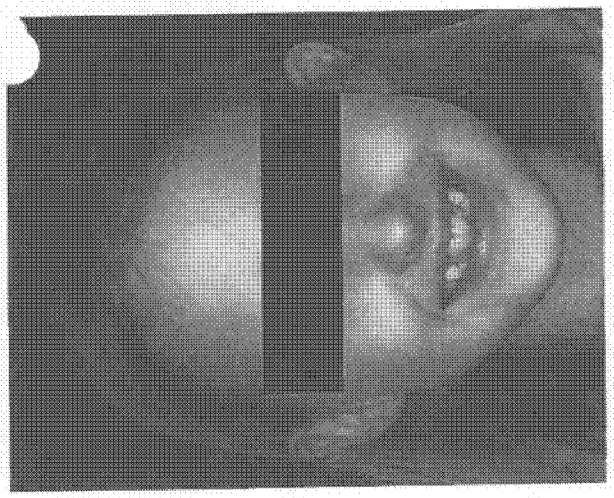

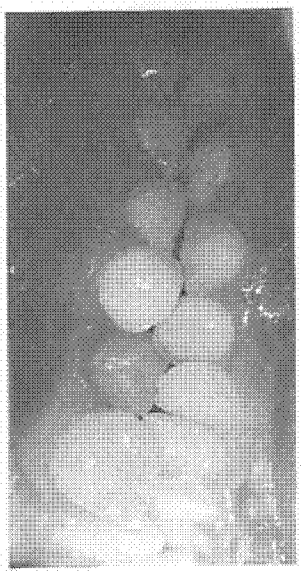

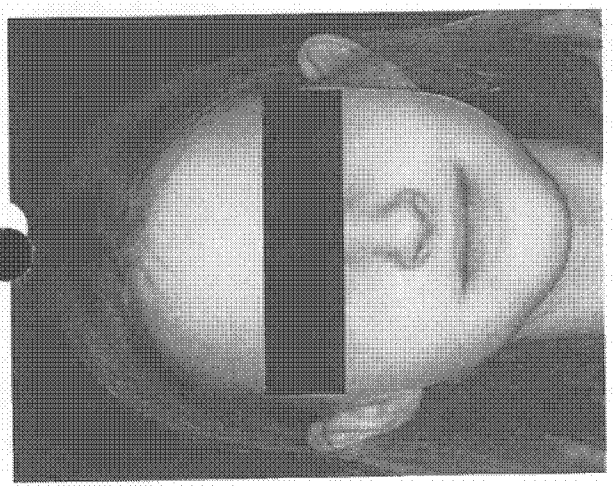

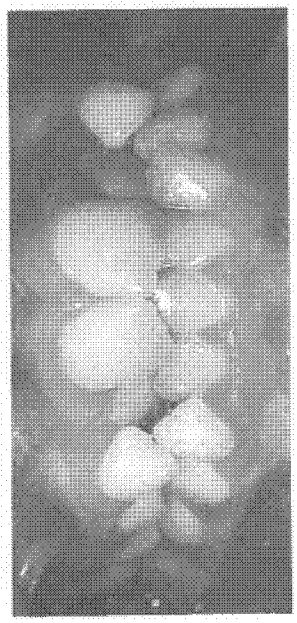

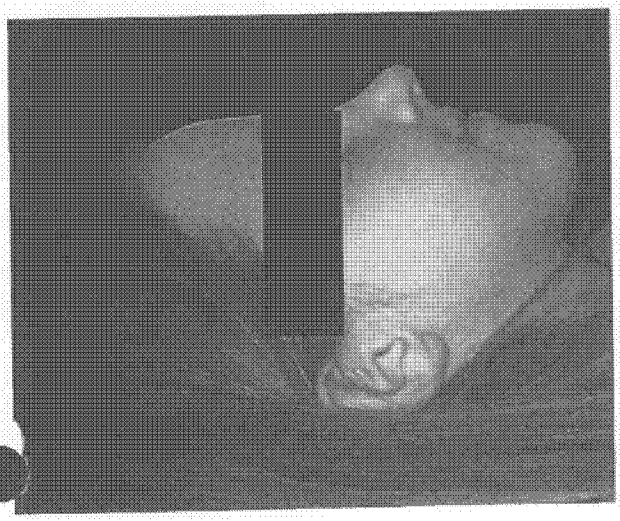

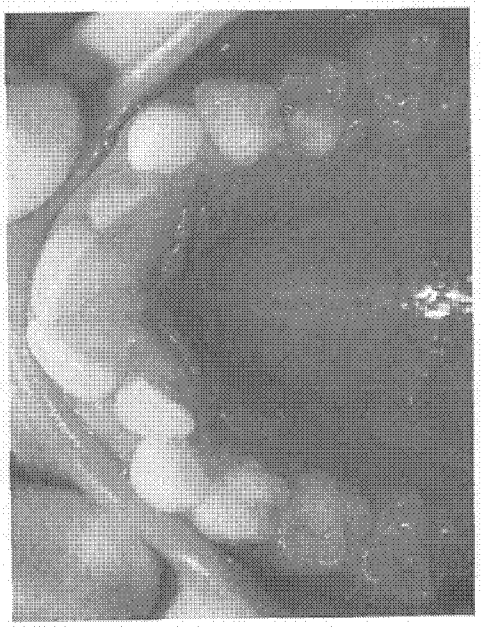

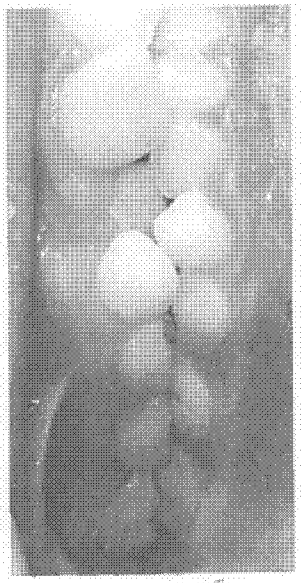

195

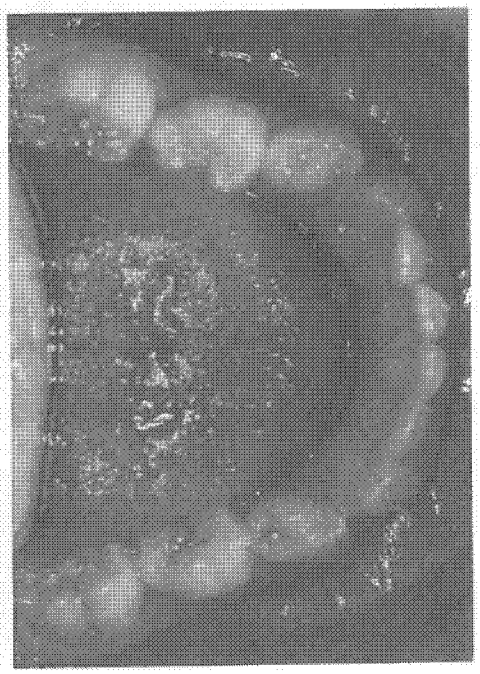

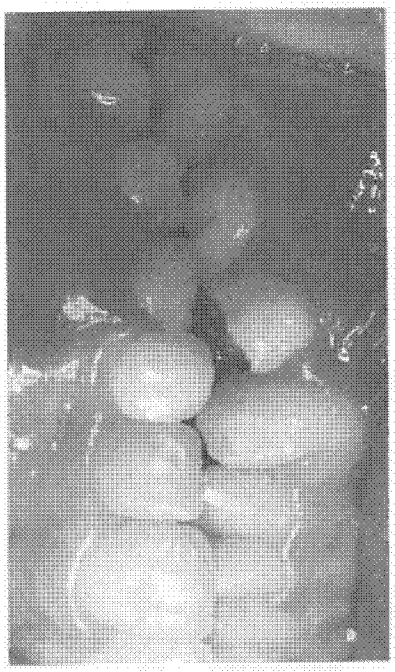

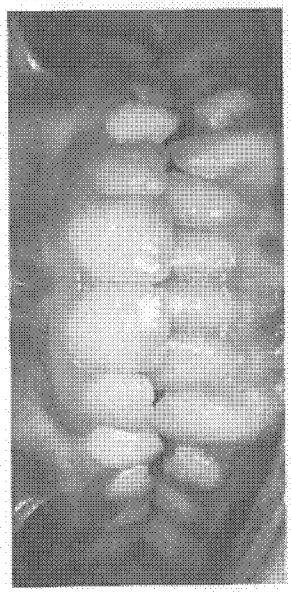

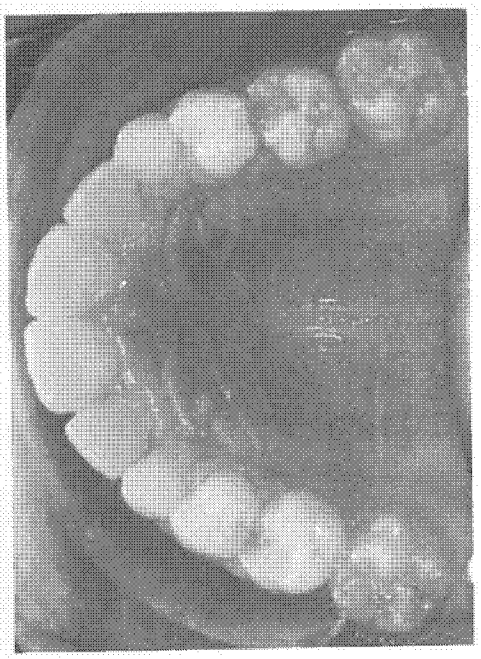

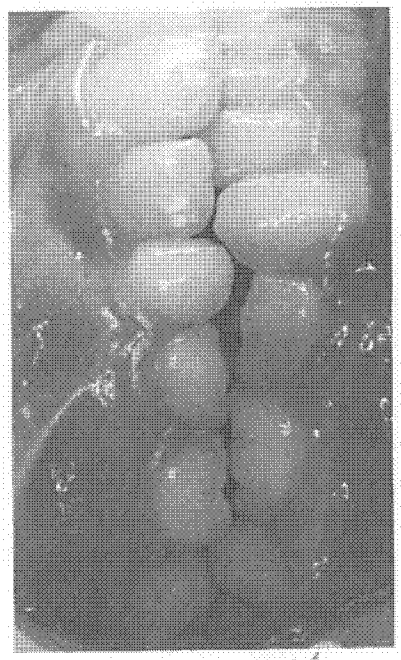

196

# MD-2

197

# invisalign® TREATMENT SUMMARY

*INFORMATION MUST BE TYPEWRITTEN.*

**DOCTOR:** W.S. **INVISALIGN CASE #:** (b)(6)

**GENDER:** ☒ MALE ☐ FEMALE

**AGE:** 10 yrs.

**PATIENT INITIALS:** (b)(6)

**TREATMENT START DATE:** 3/23/06 **TREATMENT END DATE:** 3/15/07 **TOTAL TREATMENT TIME:** 12 months

**CHIEF CONCERN:** Overbite and spacing.

**DIAGNOSTIC SUMMARY:** Overbite and spacing in mixed dentition.

**CEPHALOMETRIC SUMMARY:** We don't have any cephalometrics because we didn't treat skeletal problems.

**TREATMENT GOAL:** IPR to close spaces, correct upper midline to left, intrude lower incisors.

**TREATMENT PLAN:** Correct upper midline to left.

**NUMBER OF REFINEMENTS DURING TREATMENT:** 0

**TOTAL NUMBER OF UPPER ALIGNERS (including refinements):** 25

**TOTAL NUMBER OF LOWER ALIGNERS (including refinements):** 14

**SUPPLEMENTAL TREATMENT NEEDED TO ACHIEVE TREATMENT GOAL:**

☐ Plier detailing ☐ Interach elastics ☐ Buttons ☐ Spring aligner

☐ Positioner ☐ Orthognathic surgery ☐ Conventional braces ☒ None

**RESULTS ACHIEVED/DOCTOR'S ANALYSIS:** Treatment goal fully achieved.

**RETENTION:** Upper: Removable plate Lower: Removable plate

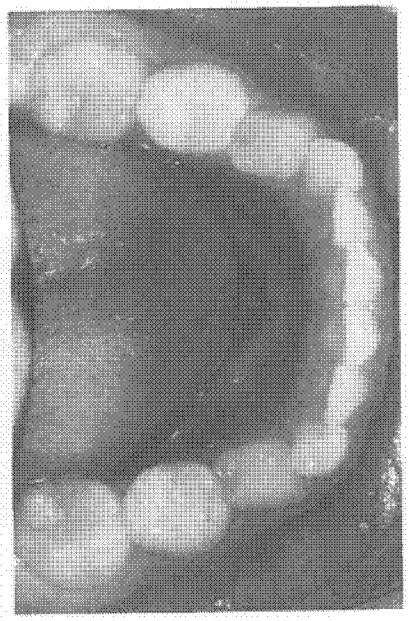

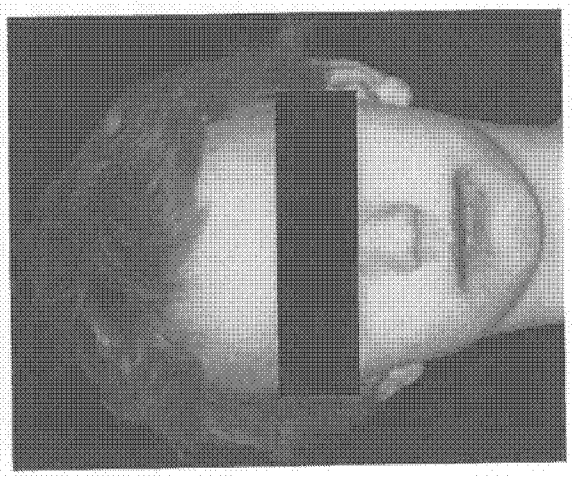

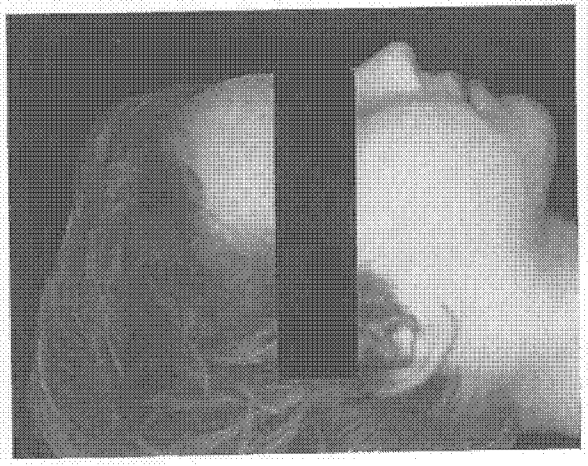

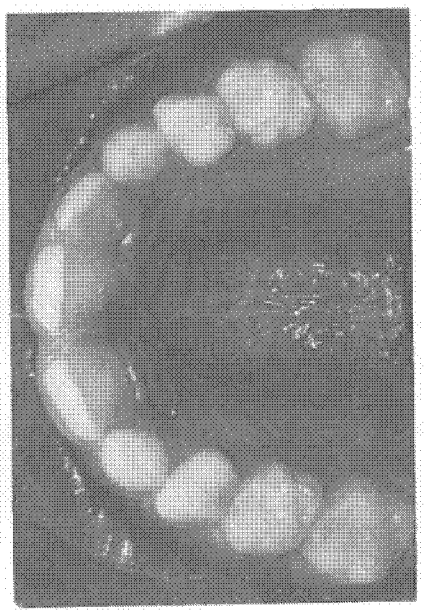

144

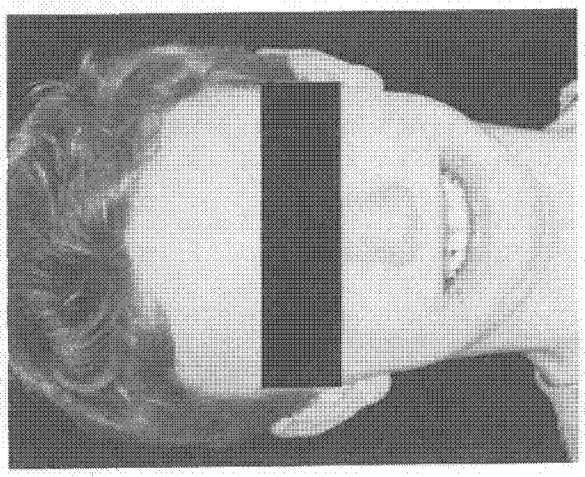

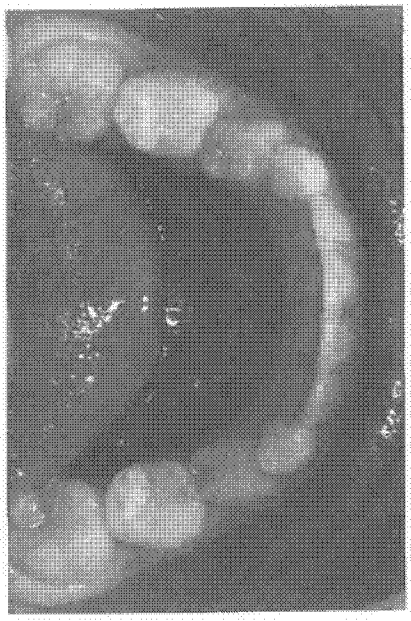

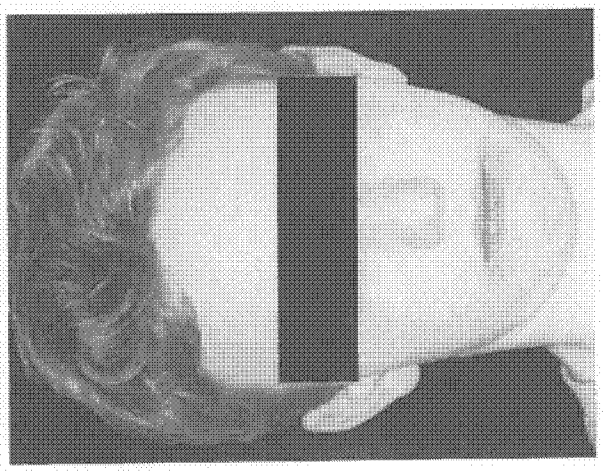

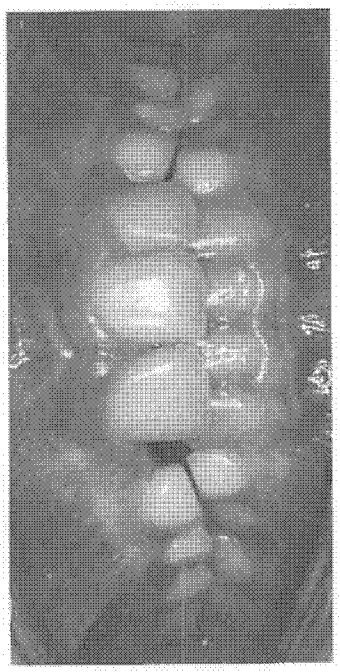

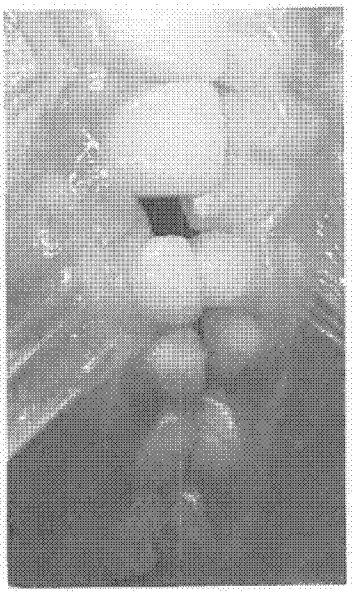

200

# MD-3

201

# invisalign® TREATMENT SUMMARY

*ALL INFORMATION MUST BE TYPEWRITTEN.*

**DOCTOR:** W.S. **INVISALIGN CASE #:** (b)(6)

**GENDER:** ☐ MALE ☒ FEMALE

**AGE:** 7 yrs.

**PATIENT INITIALS:** (b)(6)

**TREATMENT START DATE:** 11/22/05 **TREATMENT END DATE:** 4/18/06 **TOTAL TREATMENT TIME:** 5 months

**CHIEF CONCERN:** Upper incisors proclined.

**DIAGNOSTIC SUMMARY:** Molar class I relationship with proclined upper incisors.

**CEPHALOMETRIC SUMMARY:** We don't have any cephalometrics because we didn't treat skeletal problems.

**TREATMENT GOAL:** Retraction of upper anteriors and space closure.

**TREATMENT PLAN:** 14 Upper arch and Bionator.

**NUMBER OF REFINEMENTS DURING TREATMENT:** 0

**TOTAL NUMBER OF UPPER ALIGNERS (including refinements):** 14

**TOTAL NUMBER OF LOWER ALIGNERS (including refinements):** Upper treatment only.

**SUPPLEMENTAL TREATMENT NEEDED TO ACHIEVE TREATMENT GOAL:**

☐ Plier detailing ☐ Interarch Elastics ☐ Buttons ☐ Spring aligner

☐ Positioner ☐ Orthognathic Surgery ☐ Conventional Braces ☒ None

**RESULTS ACHIEVED/DOCTOR'S ANALYSIS:** Treatment goal fully achieved.

**RETENTION:** Upper: Bionator Lower: n/a

202

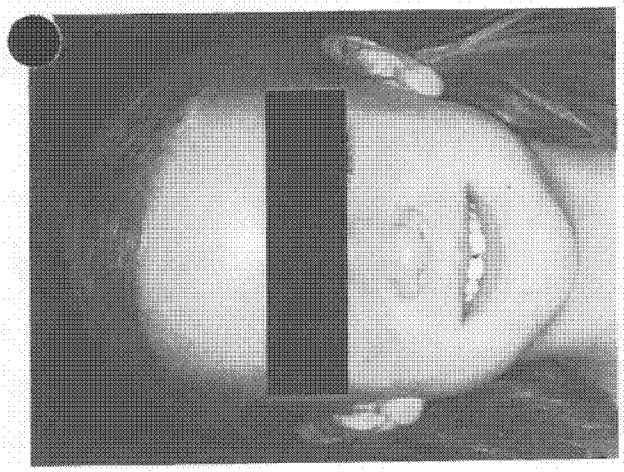

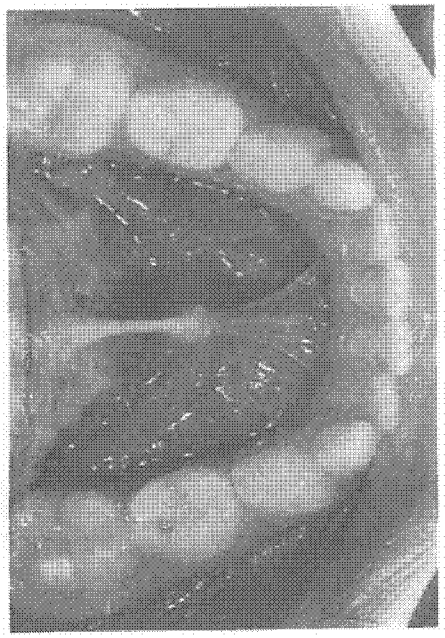

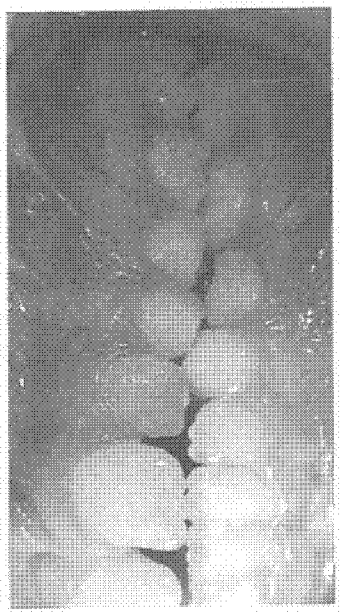

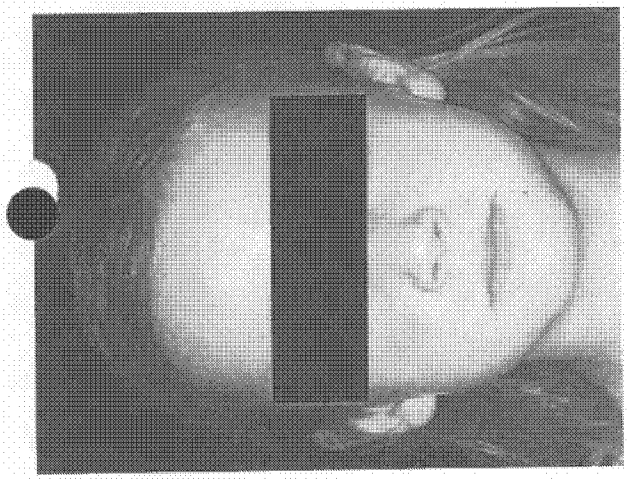

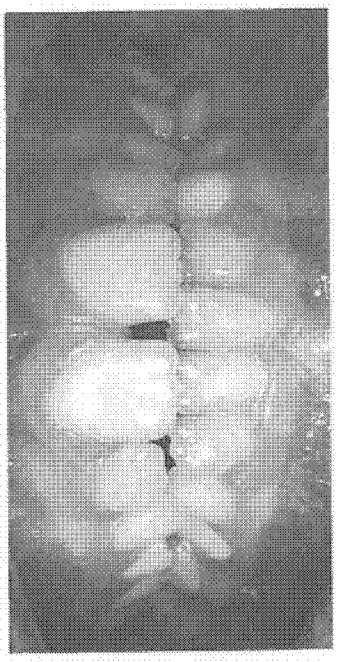

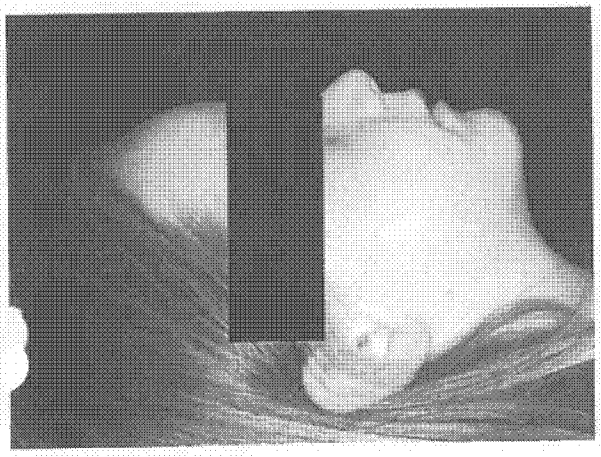

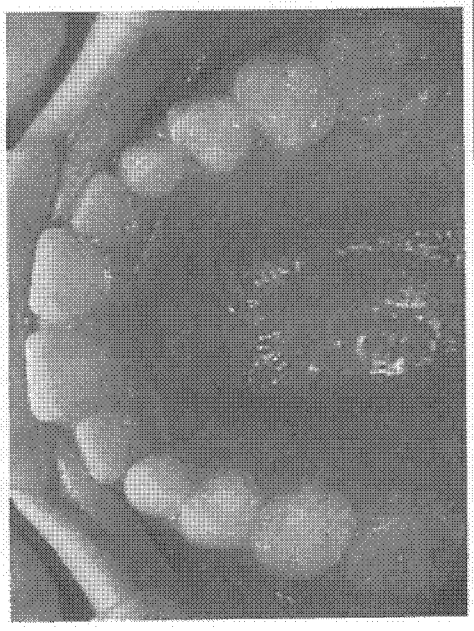

203

204

# MD-4

205

# invisalign® TREATMENT SUMMARY

*L INFORMATION MUST BE TYPEWRITTEN.*

**DOCTOR:** W.S. **INVISALIGN CASE #:** (b)(6)

**GENDER:** ☐ MALE ☒ FEMALE

**AGE:** 9 yrs.

**PATIENT INITIALS:** (b)(6)

**TREATMENT START DATE:** 3/01/05 **TREATMENT END DATE:** 2/08/06 **TOTAL TREATMENT TIME:** 11 months

**CHIEF CONCERN:** Anterior spacing.

**DIAGNOSTIC SUMMARY:** Anterior diastema and distal inclination of maxillary incisors.

**CEPHALOMETRIC SUMMARY:** We don't have any cephalometrics because we didn't treat skeletal problems.

**REATMENT GOAL:** Close space between 1.2, 1.2, 2.1, and 2.2 followed by proclination. Open space for 1.3 and 2.3.

**TREATMENT PLAN:** 20 upper arch.

**NUMBER OF REFINEMENTS DURING TREATMENT:** 0

**TOTAL NUMBER OF UPPER ALIGNERS (including refinements):** 20

**TOTAL NUMBER OF LOWER ALIGNERS (including refinements):** Upper treatment only.

**SUPPLEMENTAL TREATMENT NEEDED TO ACHIEVE TREATMENT GOAL:**

☐ Plier detailing ☐ Interarch elastics ☐ Buttons ☐ Spring aligner

☐ Positioner ☐ Orthognathic surgery ☐ Conventional braces ☒ None

**RESULTS ACHIEVED/DOCTOR'S ANALYSIS:** Closing of spaces and protrusion fully achieved.

**ETENTION:** Upper: Removable plate Lower: n/a

206

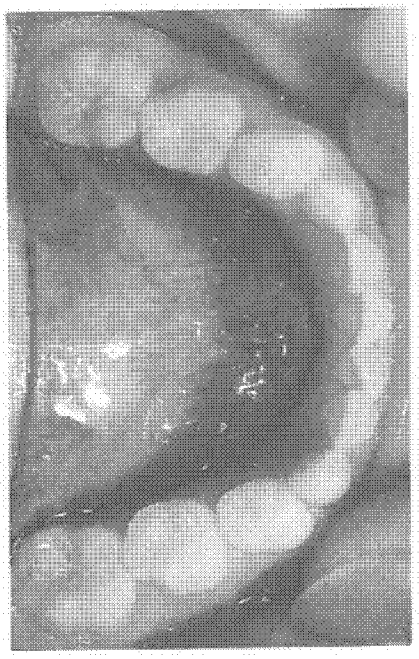

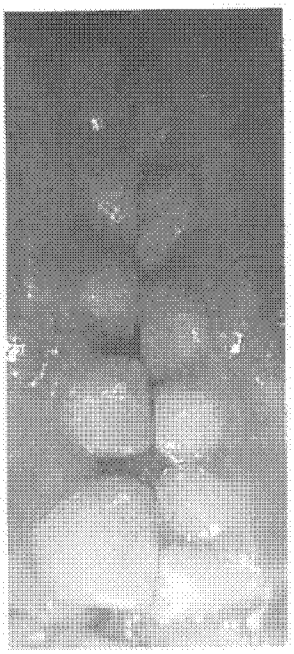

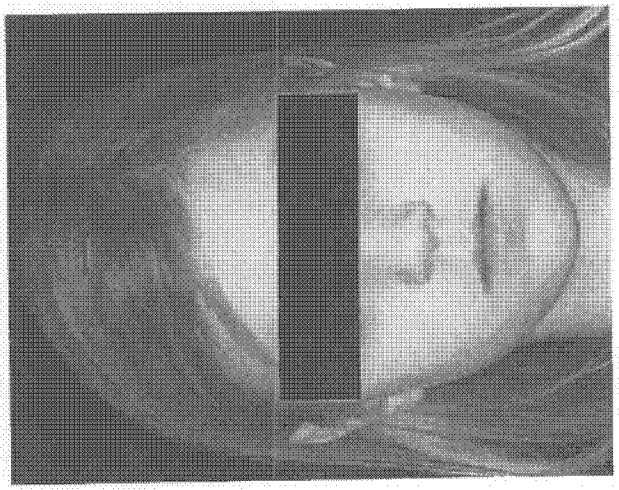

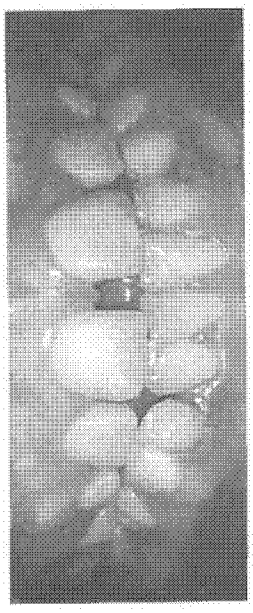

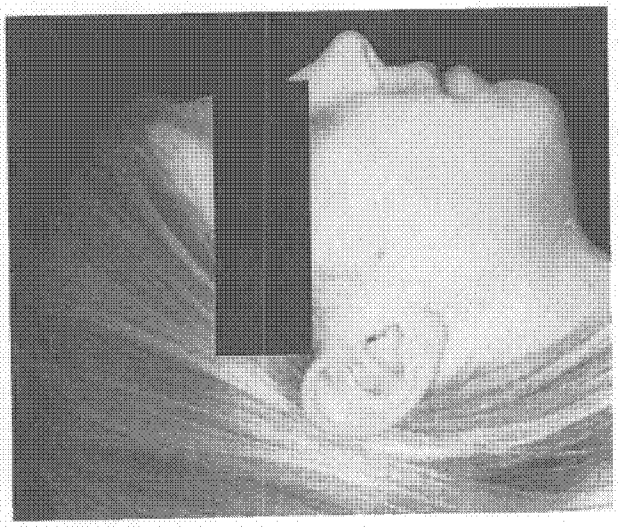

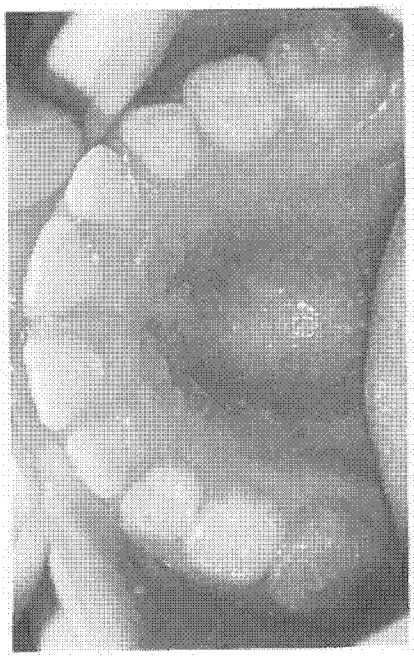

207

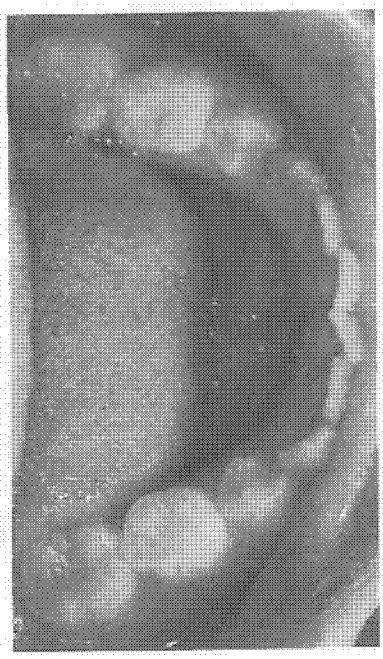

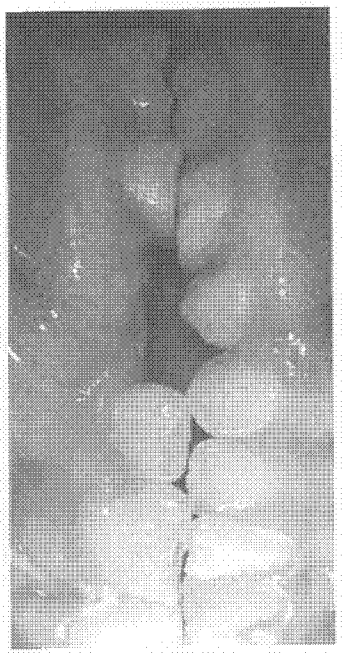

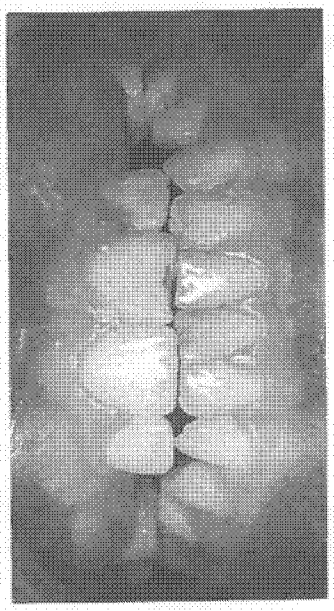

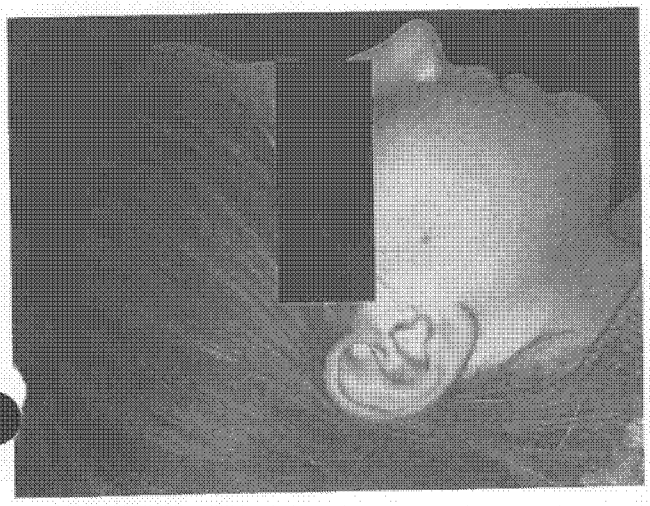

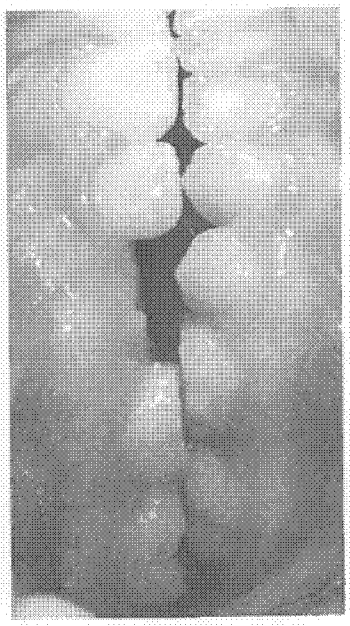

208

# MD-5

209

# inv align® TREATMENT SUMMARY

*L INFORMATION MUST BE TYPEWRITTEN.*

**DOCTOR:** W.S. **INVISALIGN CASE #:** (b)(6)

**GENDER:** ☒ MALE ☐ FEMALE

**AGE:** 8 yrs.

**PATIENT INITIALS:** (b)(6)

**TREATMENT START DATE:** 11/09/06 **TREATMENT END DATE:** 4/26/07 **TOTAL TREATMENT TIME:** 5 months

**CHIEF CONCERN:** Upper and lower anterior spacing.

**DIAGNOSTIC SUMMARY:** Class II relationship with anterior spacing.

**CEPHALOMETRIC SUMMARY:** We don't have any cephalometrics because we didn't treat skeletal problems.

**REATMENT GOAL:** Space closure in upper and lower front.

**TREATMENT PLAN:** Closure of spaces without correction of vertical dimension 23 upper aligners, 17 lower aligners.

**NUMBER OF REFINEMENTS DURING TREATMENT:** 0

**TOTAL NUMBER OF UPPER ALIGNERS (including refinements):** 23

**TOTAL NUMBER OF LOWER ALIGNERS (including refinements):** 17

**SUPPLEMENTAL TREATMENT NEEDED TO ACHIEVE TREATMENT GOAL:**

☐ Plier detailing ☐ Interarch elastics ☐ Buttons ☐ Spring aligner

☐ Positioner ☐ Orthognathic surgery ☐ Conventional braces ☒ None

**RESULTS ACHIEVED/DOCTOR'S ANALYSIS:** Treatment goal fully achieved.

**ETENTION:** Upper: Activator Lower: n/a

210

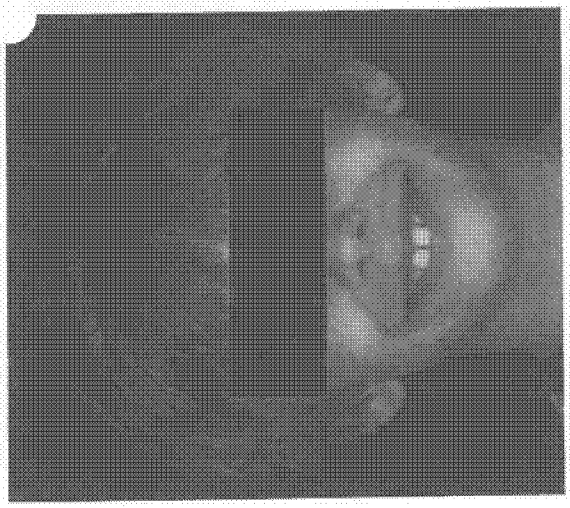

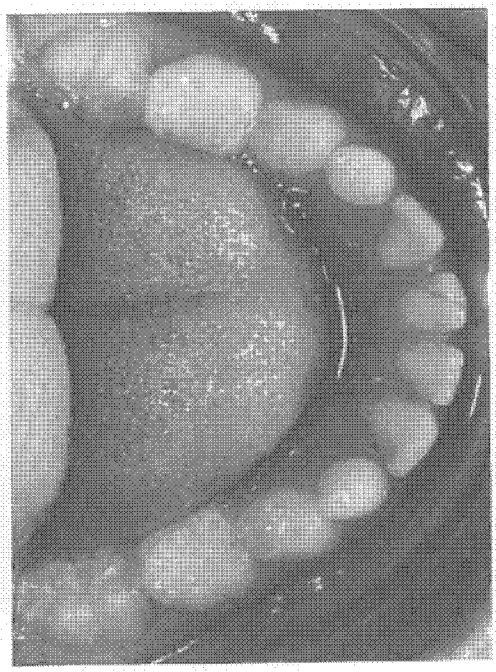

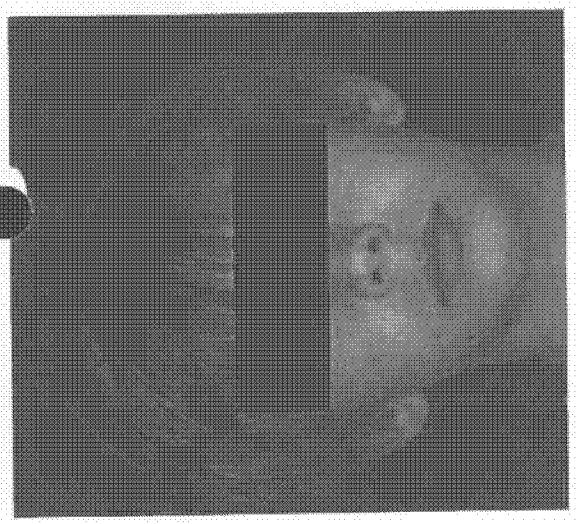

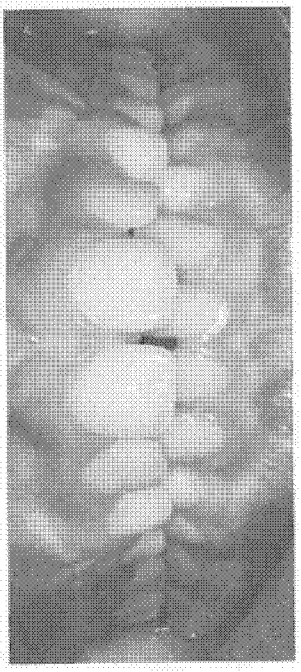



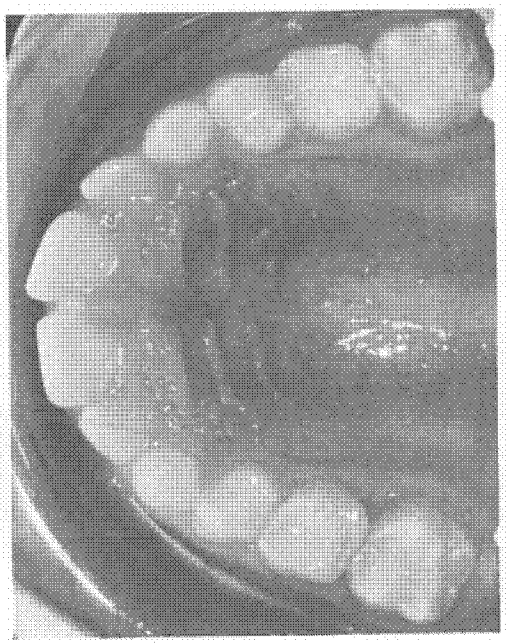

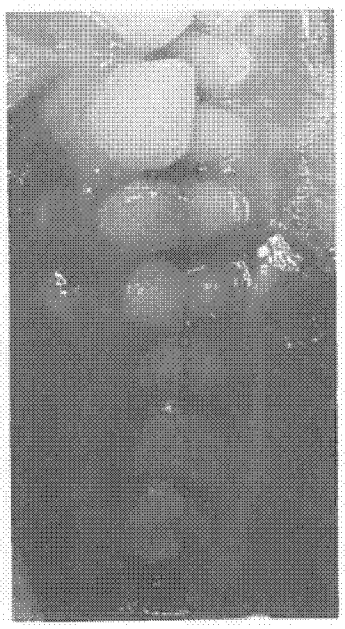

211

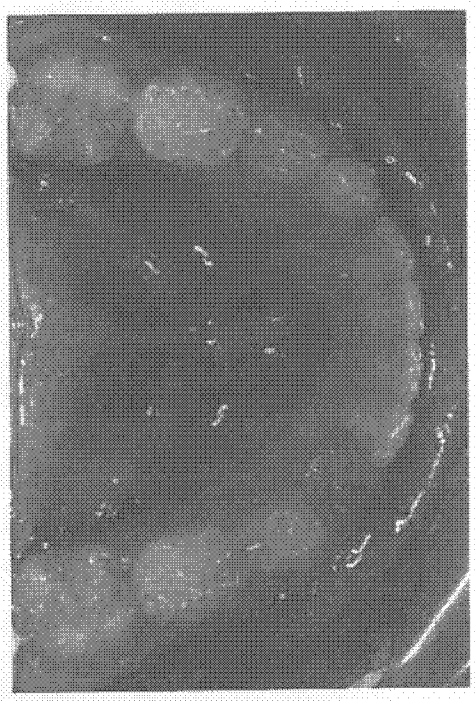

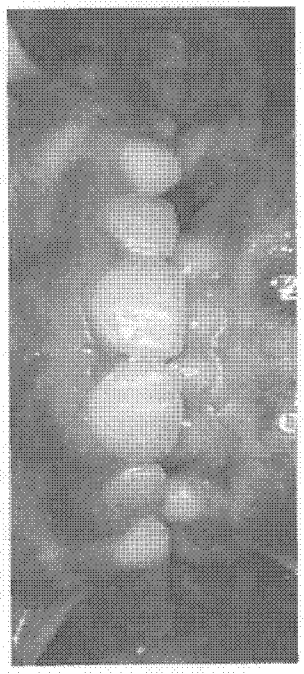

212

# MD-6

# invisalign® TREATMENT SUMMARY

*.L INFORMATION MUST BE TYPEWRITTEN.*

**DOCTOR:** W.S. **INVISALIGN CASE #:** (b)(6)

**GENDER:** ☒ MALE ☐ FEMALE

**AGE:** 10 yrs.

**PATIENT INITIALS:** (b)(6)

**TREATMENT START DATE:** 5/12/05 **TREATMENT END DATE:** 6/08/06 **TOTAL TREATMENT TIME:** ~12 months

**CHIEF CONCERN:** Future crowding.

**DIAGNOSTIC SUMMARY:** Insufficient space for proper lower canine eruption and increased overjet in Class I relationship.

**CEPHALOMETRIC SUMMARY:** We don't have any cephalometrics because we didn't treat skeletal problems.

**EATMENT GOAL:** Opening of space for teeth 3.3, 4.3 by protrusion of 3.2, 3.1, 4.2, and 4.1.

**TREATMENT PLAN:** 23 lower arch.

**NUMBER OF REFINEMENTS DURING TREATMENT:** 0

**TOTAL NUMBER OF UPPER ALIGNERS (including refinements):** Lower treatment only.

**TOTAL NUMBER OF LOWER ALIGNERS (including refinements):** 23

**SUPPLEMENTAL TREATMENT NEEDED TO ACHIEVE TREATMENT GOAL:**

☐ Plier detailing ☐ Interarch elastics ☐ Buttons ☐ Spring aligner

☐ Positioner ☐ Orthognathic surgery ☐ Conventional braces ☒ None

**RESULTS ACHIEVED/DOCTOR'S ANALYSIS:** Treatment goal fully achieved.

**ETENTION:** Upper: n/a Lower: Removable plate

214

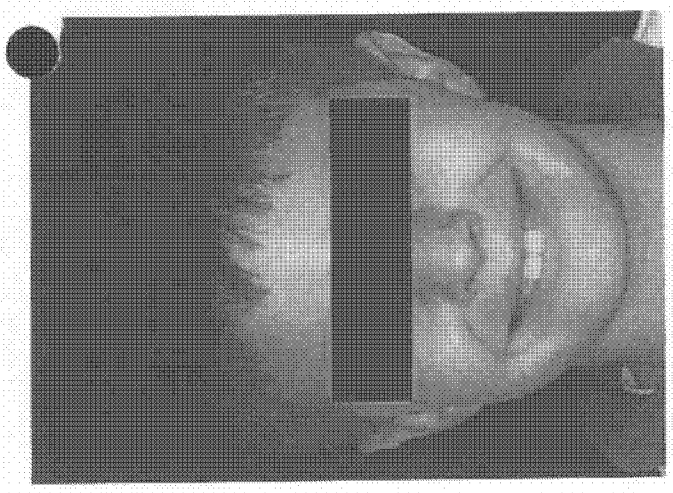

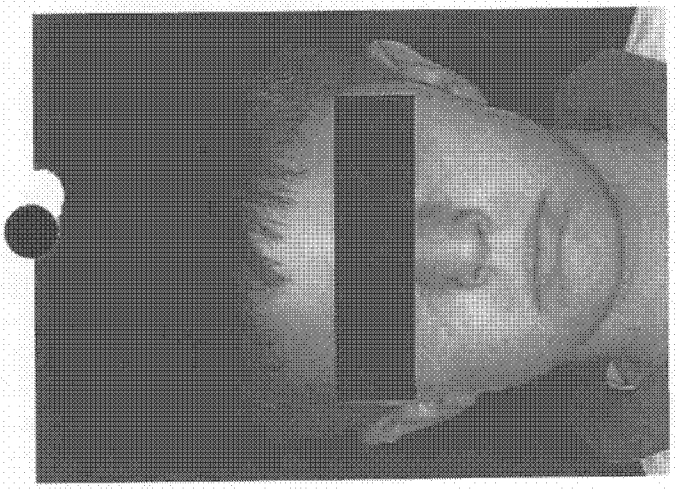





215

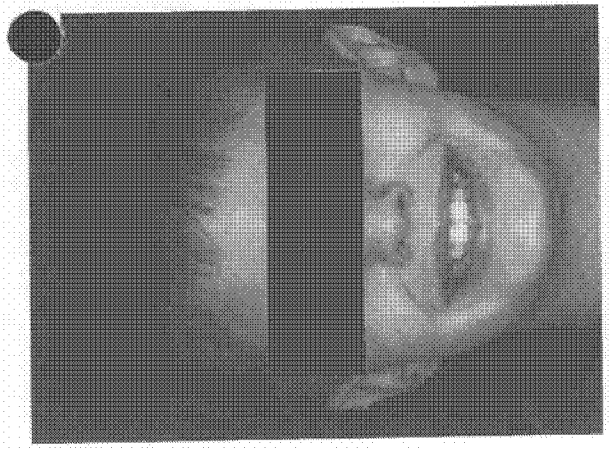

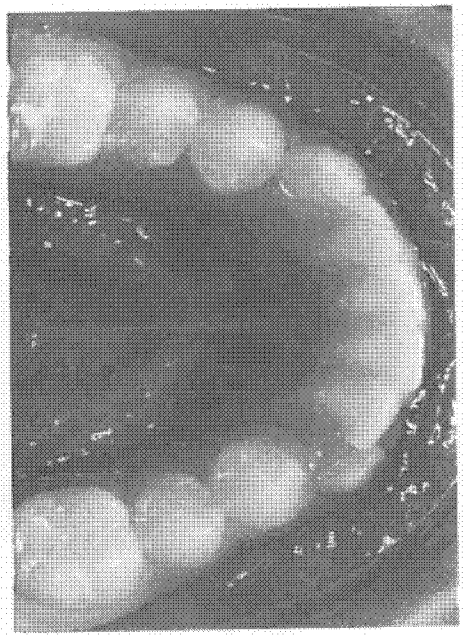

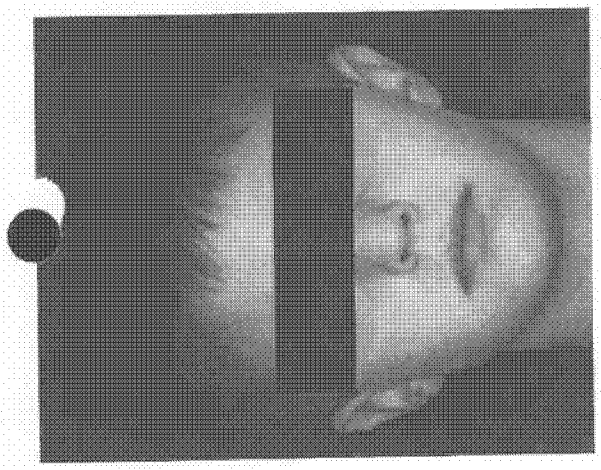

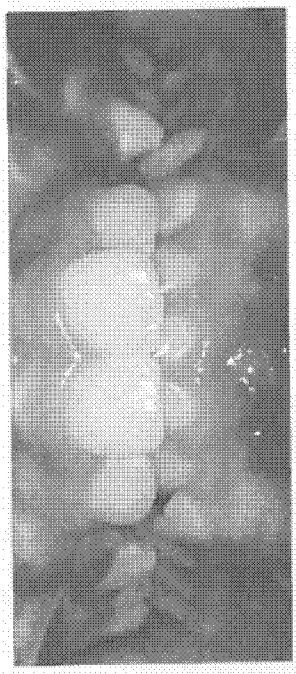

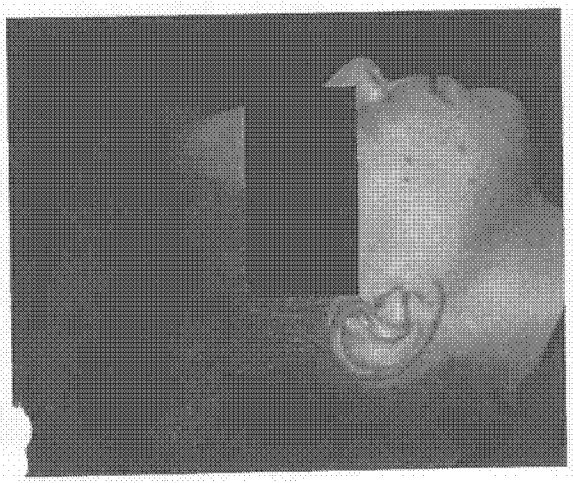

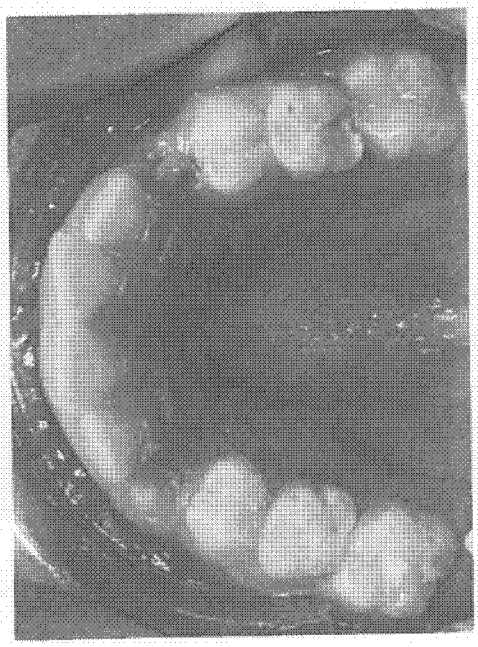

216

# MD-7

217

# invisalign® TREATMENT SUMMARY

*L INFORMATION MUST BE TYPEWRITTEN.*

**DOCTOR:** W.S. **INVISALIGN CASE #:** (b)(6)

**GENDER:** ☒ MALE ☐ FEMALE

**AGE:** 10 yrs.

**PATIENT INITIALS:** (b)(6)

**TREATMENT START DATE:** 9/22/05 **TREATMENT END DATE:** 2/01/06 **TOTAL TREATMENT TIME:** ~6 months

**CHIEF CONCERN:** Missing teeth 3.1, 4.1 and Class II division on the right side.

**DIAGNOSTIC SUMMARY:** Missing teeth 3.1, 4.1 with spaces in the lower front and posterior Class II.

**CEPHALOMETRIC SUMMARY:** We don't have any cephalometrics because we didn't treat skeletal problems.

**TREATMENT GOAL:** Opening of spaces for later implants 3.2, 4.2 by mesializing 32, 42. Distalization of 1.6, 3.0 mm.

**TREATMENT PLAN:** 11 upper and lower.

**NUMBER OF REFINEMENTS DURING TREATMENT:** 0

**TOTAL NUMBER OF UPPER ALIGNERS (including refinements):** 11

**TOTAL NUMBER OF LOWER ALIGNERS (including refinements):** 11

**SUPPLEMENTAL TREATMENT NEEDED TO ACHIEVE TREATMENT GOAL:**

☐ Plier detailing ☐ Interarch elastics ☐ Buttons ☐ Spring aligner

☐ Positioner ☐ Orthognathic surgery ☐ Conventional braces ☒ None

**RESULTS ACHIEVED/DOCTOR'S ANALYSIS:** Treatment goal fully achieved.

**RETENTION:** Upper: Removable plate Lower: Removable plate (bionator)

218

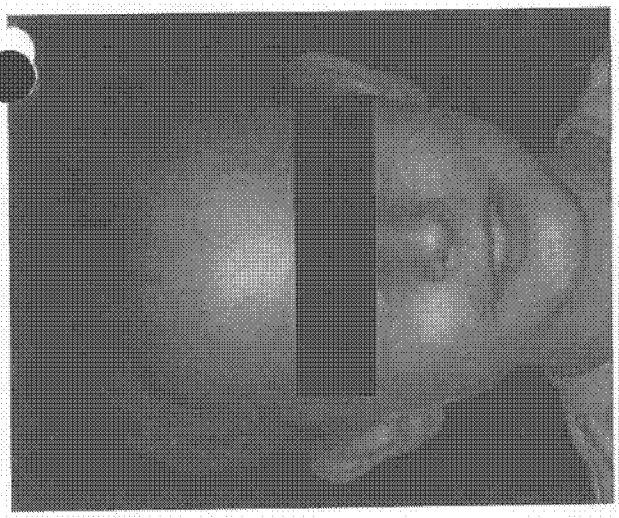

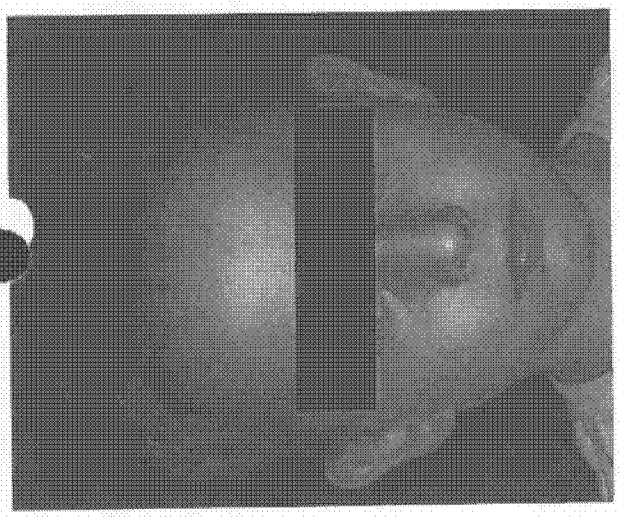



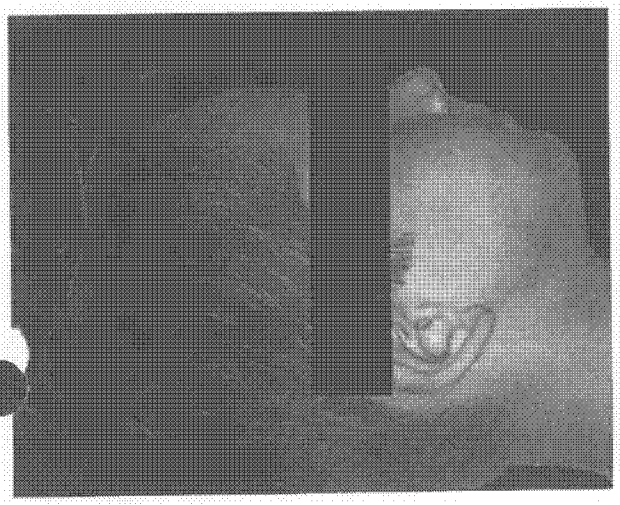

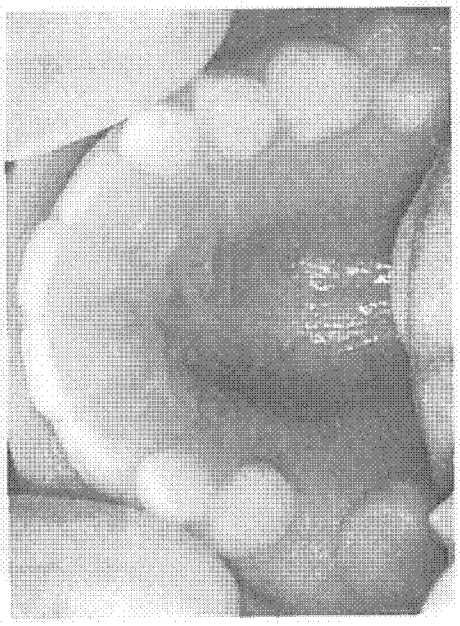

219

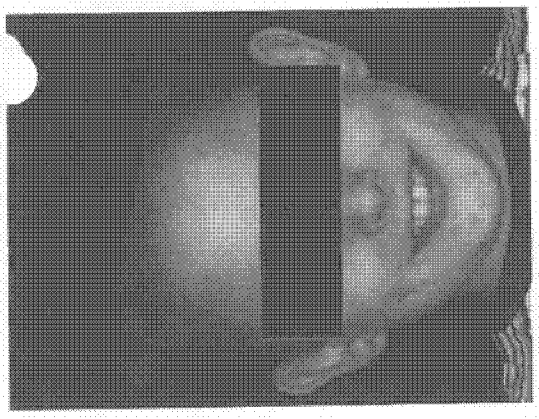

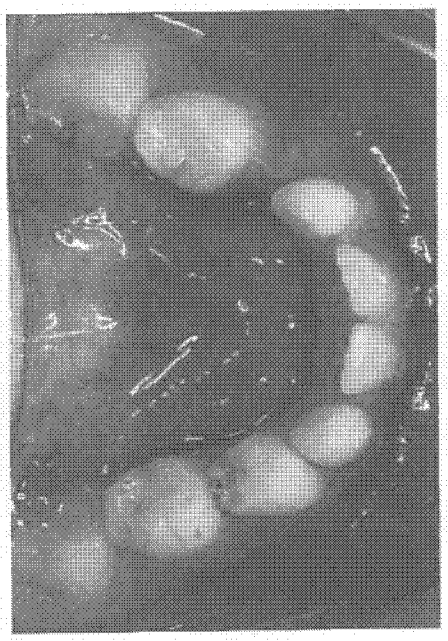

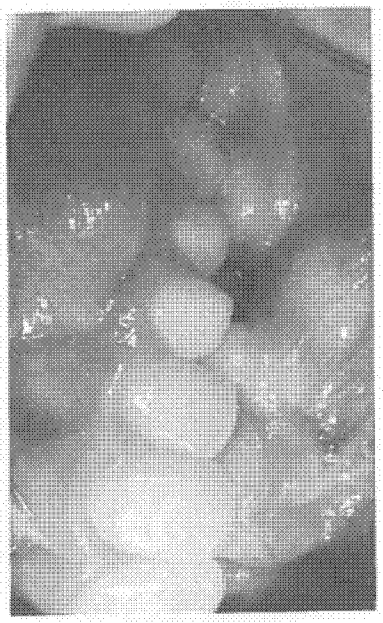

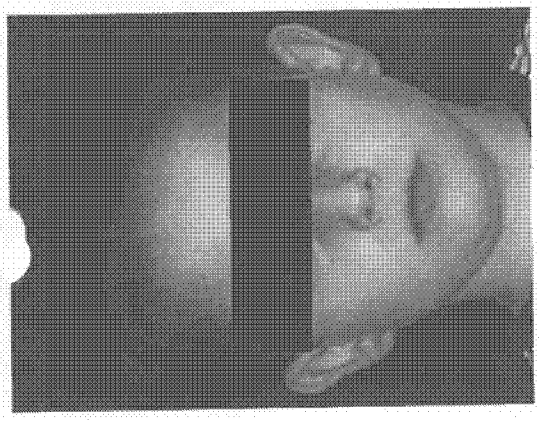

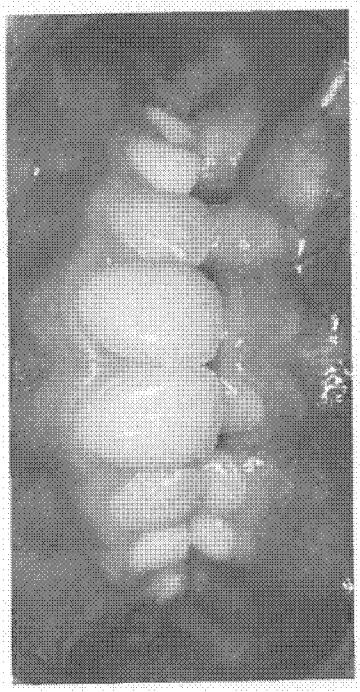

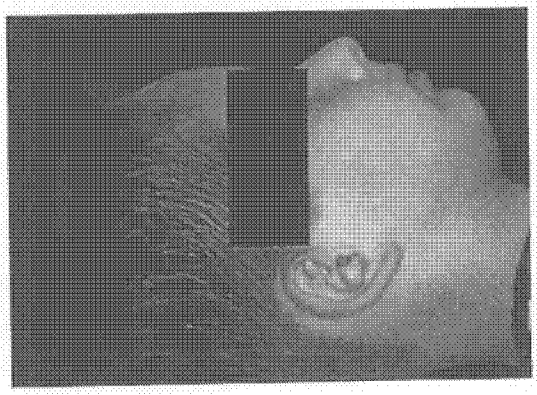

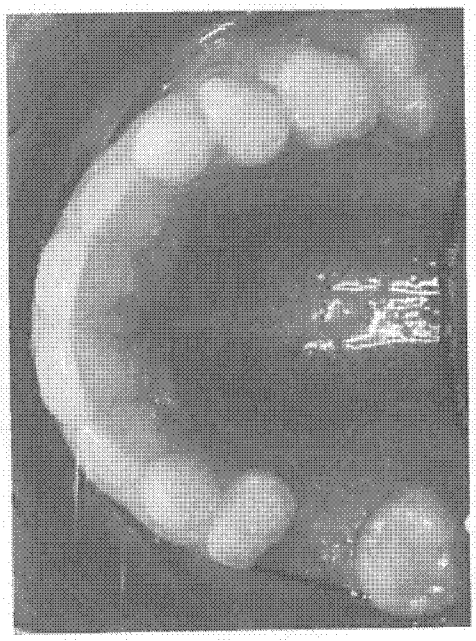

# MD-8

221

# invisalign® TREATMENT SUMMARY

*L INFORMATION MUST BE TYPEWRITTEN.*

**DOCTOR:** W.S. **INVISALIGN CASE #:** (b)(6)

**GENDER:** ☐ MALE ☒ FEMALE

**AGE:** 9 yrs.

**PATIENT INITIALS:** (b)(6)

**TREATMENT START DATE:** 3/01/05 **TREATMENT END DATE:** 9/05/05 **TOTAL TREATMENT TIME:** ~ 6 months

**CHIEF CONCERN:** Solve crowding and gain space for 1.3, distalize 1.6 to obtain Class I.

**DIAGNOSTIC SUMMARY:** Class II division on the right side, Class I on the left side, anterior crowding.

**CEPHALOMETRIC SUMMARY:** We don't have any cephalometrics because we didn't treat skeletal problems.

**REATMENT GOAL:** Create space in upper arch for 1.3.

**TREATMENT PLAN:** 11 upper arch aligners.

**NUMBER OF REFINEMENTS DURING TREATMENT:** 0

**TOTAL NUMBER OF UPPER ALIGNERS (including refinements):** 11

**TOTAL NUMBER OF LOWER ALIGNERS (including refinements):** Upper treatment only.

**SUPPLEMENTAL TREATMENT NEEDED TO ACHIEVE TREATMENT GOAL:**

☐ Plier detailing ☐ Interarch Elastics ☐ Buttons ☐ Spring aligner

☐ Positioner ☐ Orthognathic Surgery ☐ Conventional Braces ☒ None

**RESULTS ACHIEVED/DOCTOR'S ANALYSIS:** Treatment goal fully achieved.

**ETENTION:** Upper: Removable plate Lower: n/a



222

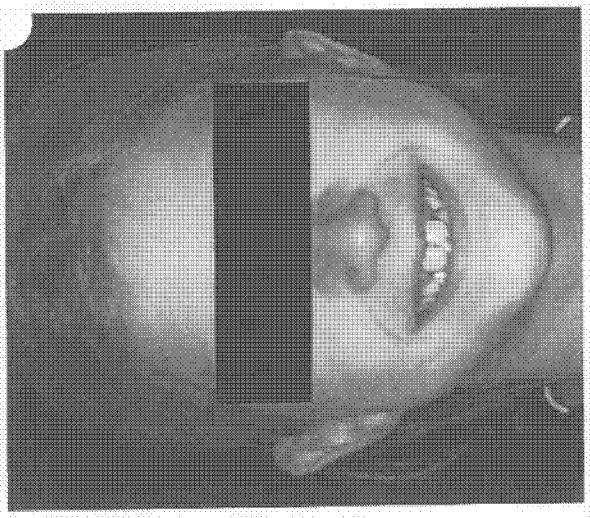

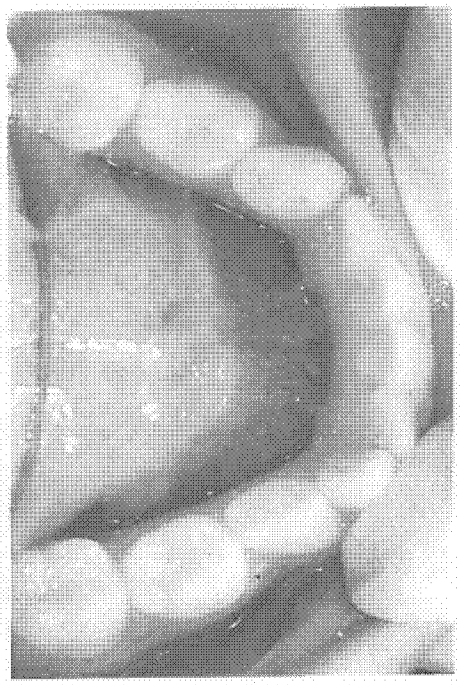

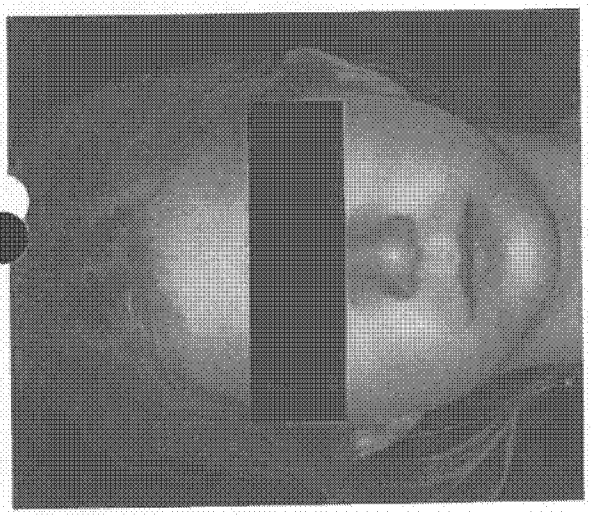

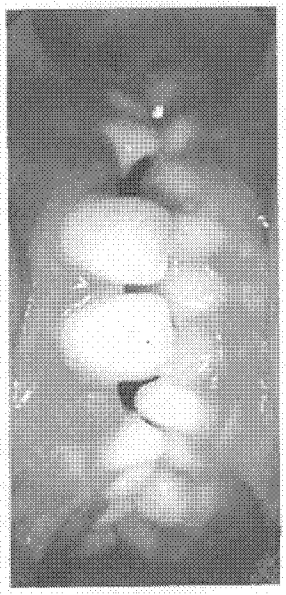

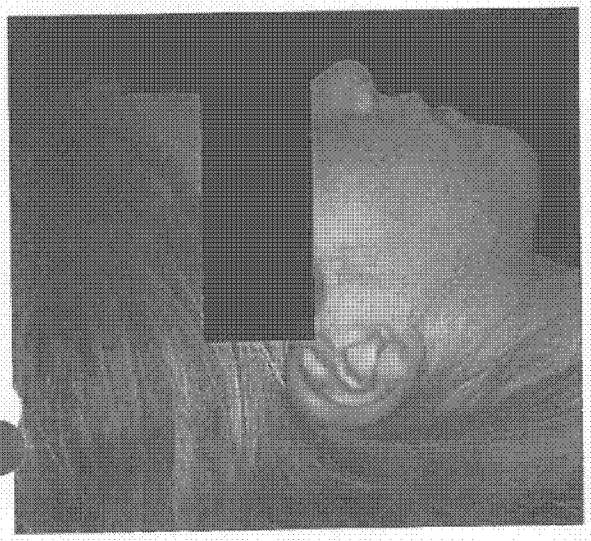

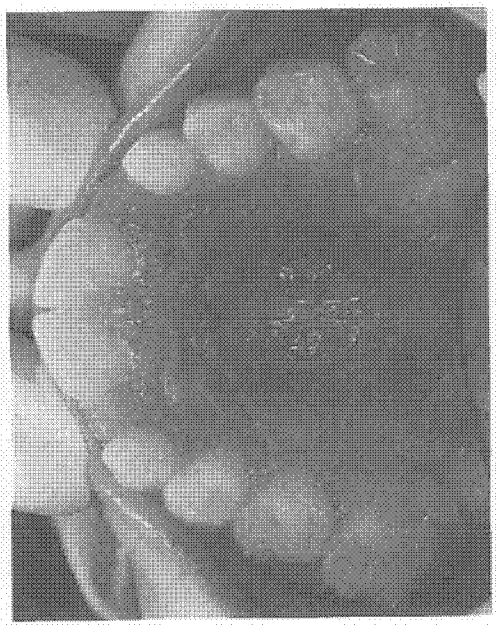

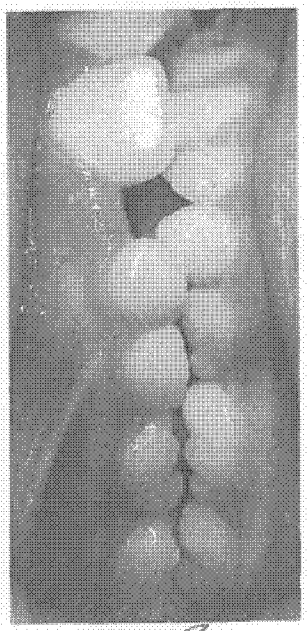

223

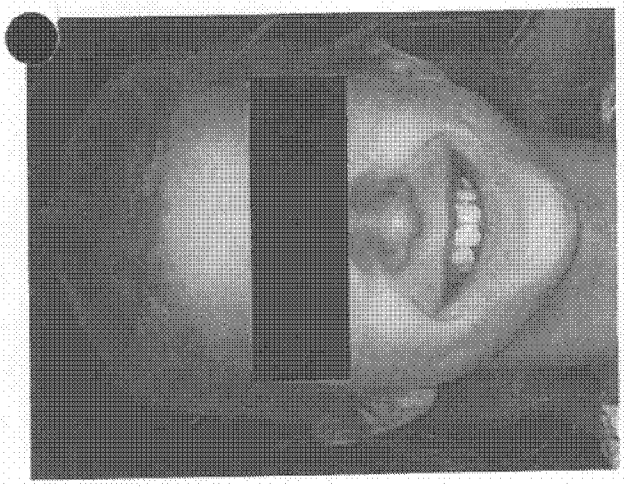

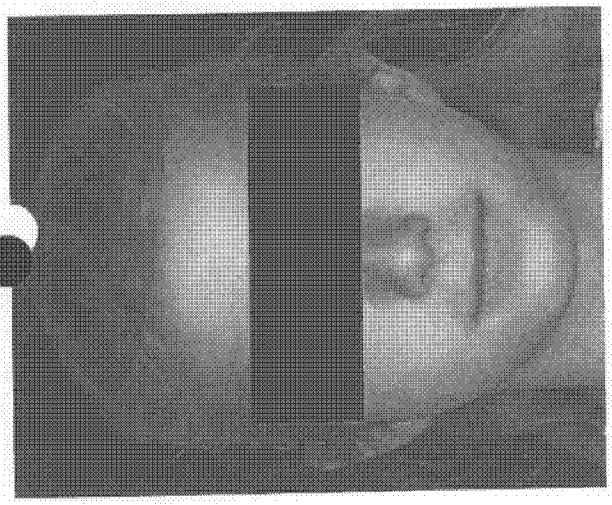

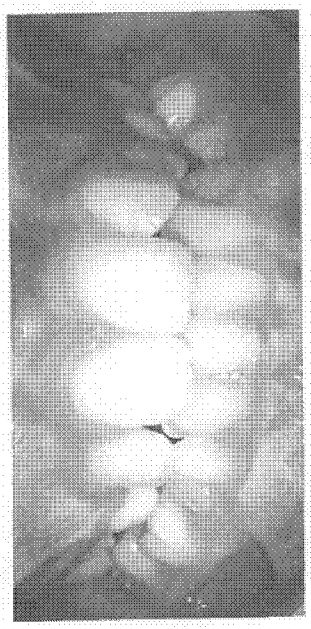

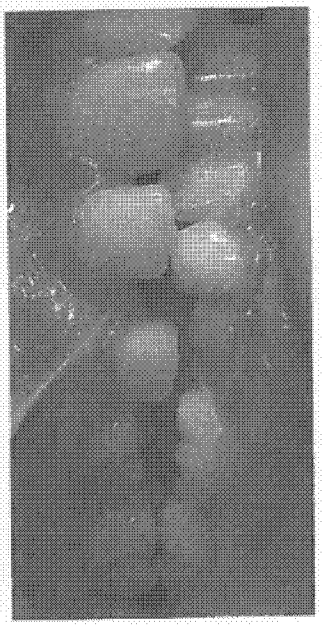

224

# MD-9



225

# inv align® TREATMENT SUMMARY

*:L INFORMATION MUST BE TYPEWRITTEN.*

**DOCTOR:** W.S. **INVISALIGN CASE #:** (b)(6)

**GENDER:** ☒ MALE ☐ FEMALE

**AGE:** 8 yrs.

**PATIENT INITIALS:** (b)(6)

**TREATMENT START DATE:** 10/23/03 **TREATMENT END DATE:** 5/04/04 **TOTAL TREATMENT TIME:** 7 months

**CHIEF CONCERN:** Correct Posterior Class II and open space for 1.5, 2.5.

**DIAGNOSTIC SUMMARY:** Posterior Class II.

**CEPHALOMETRIC SUMMARY:** We don't have any cephalometrics because we didn't treat skeletal problems.

**REATMENT GOAL:** Distalization of upper molars.

**TREATMENT PLAN:** Distalization of upper molars.

**NUMBER OF REFINEMENTS DURING TREATMENT:** 0

**TOTAL NUMBER OF UPPER ALIGNERS (including refinements):** 11

**TOTAL NUMBER OF LOWER ALIGNERS (including refinements):** Upper treatment only.

**SUPPLEMENTAL TREATMENT NEEDED TO ACHIEVE TREATMENT GOAL:**

☐ Plier detailing ☐ Interarch elastics ☐ Buttons ☐ Spring aligner

☐ Positioner ☐ Orthognathic surgery ☐ Conventional braces ☒ None

**RESULTS ACHIEVED/DOCTOR'S ANALYSIS:** Distalization and derotation fully achieved according to treatment goal.

**ETENTION:** Upper: Fixed retainers 5.4 to 1.6 and 6.4 to 2.6 for retention of gained spaces. Lower: n/a

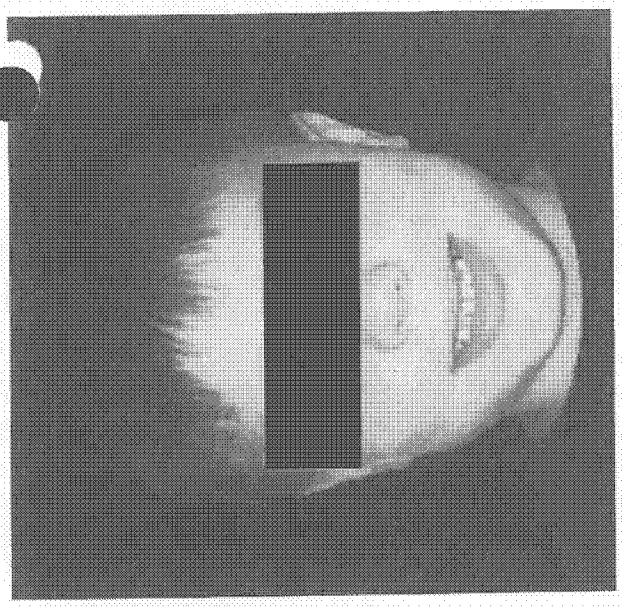

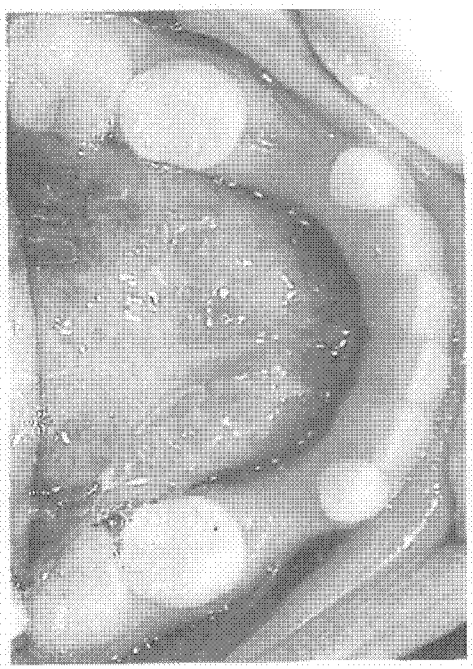



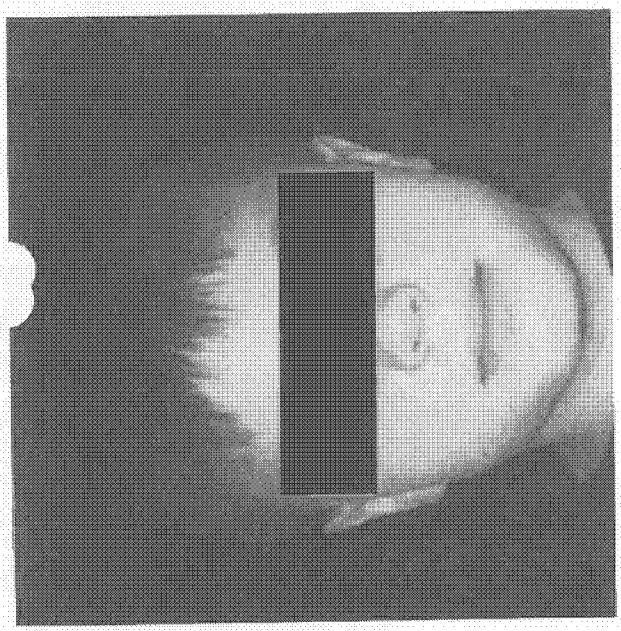

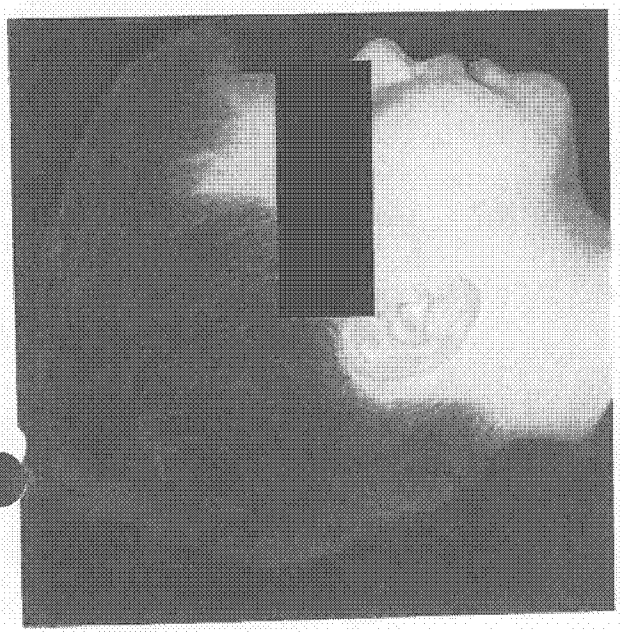

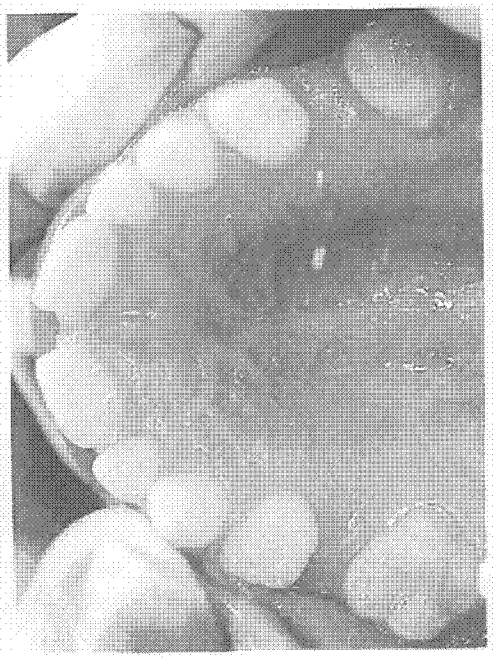

227





228

# MD-10

229

# invisalign® TREATMENT SUMMARY

*L INFORMATION MUST BE TYPEWRITTEN.*

**DOCTOR:** W.S. **INVISALIGN CASE #:** (b)(6)

**GENDER:** ☒ MALE ☐ FEMALE

**AGE:** 8 yrs.

**PATIENT INITIALS:** (b)(6)

**TREATMENT START DATE:** 10/31/05 **TREATMENT END DATE:** 9/25/06 **TOTAL TREATMENT TIME:** 11 months

**CHIEF CONCERN:** Distalization of upper molars to achieve class I relationship.

**DIAGNOSTIC SUMMARY:** Posterior Class II.

**CEPHALOMETRIC SUMMARY:** We don't have any cephalometrics because we didn't treat skeletal problems.

**REATMENT GOAL:** Distalization and derotating of upper molars.

**TREATMENT PLAN:** 20 upper arch.

**NUMBER OF REFINEMENTS DURING TREATMENT:** 1

**TOTAL NUMBER OF UPPER ALIGNERS (including refinements):** 37

**TOTAL NUMBER OF LOWER ALIGNERS (including refinements):** Upper treatment only.

**SUPPLEMENTAL TREATMENT NEEDED TO ACHIEVE TREATMENT GOAL:**

☐ Plier detailing ☐ Interarch Elastics ☐ Buttons ☐ Spring aligner

☐ Positioner ☐ Orthognathic Surgery ☐ Conventional Braces ☒ None

**RESULTS ACHIEVED/DOCTOR'S ANALYSIS:** Treatment goal fully achieved.

**ETENTION:** Upper: Removable plate Lower: n/a

230

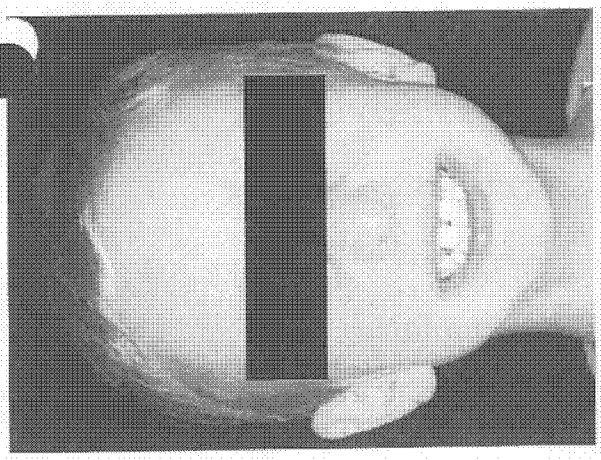

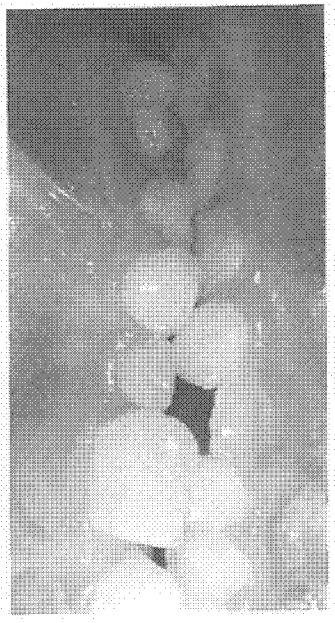

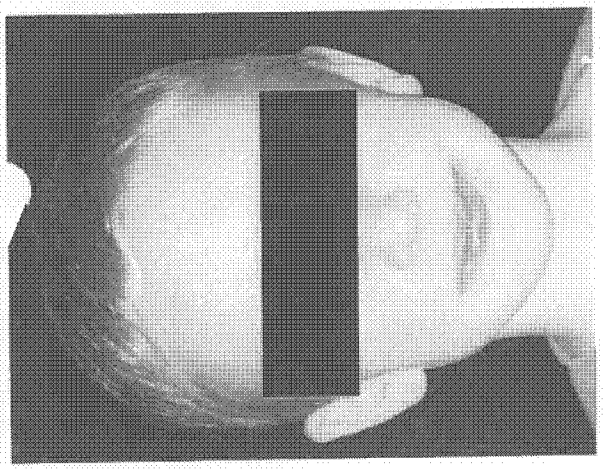

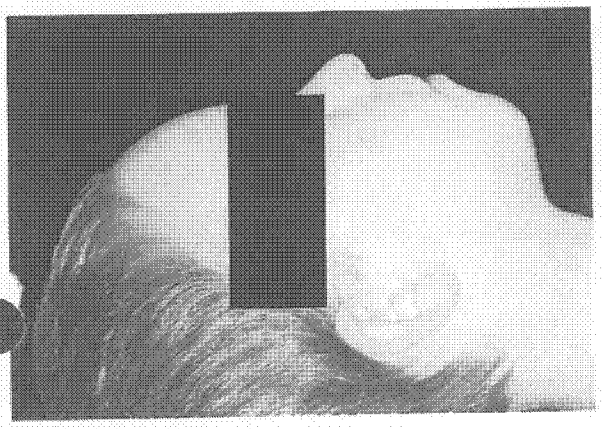

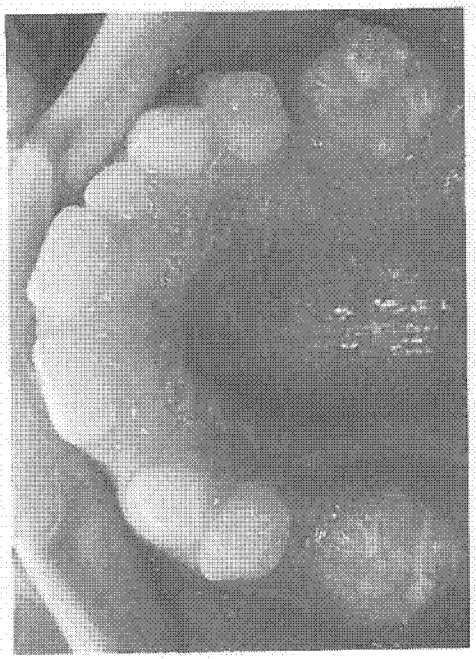

231

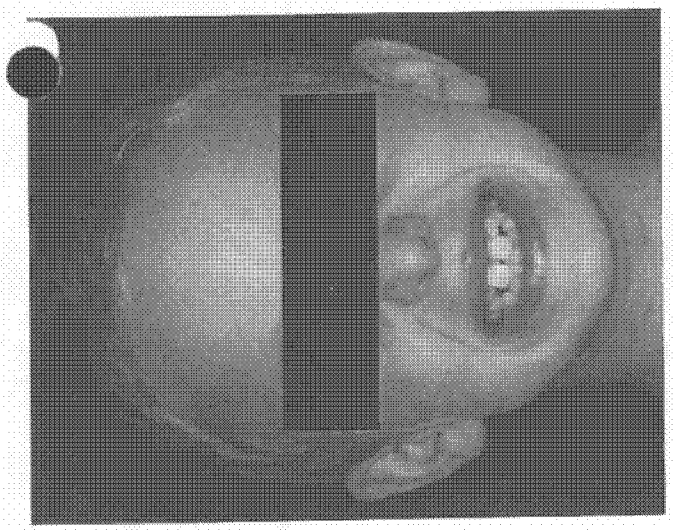

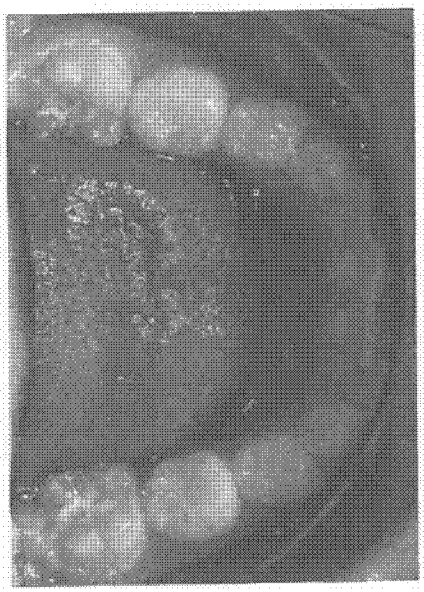



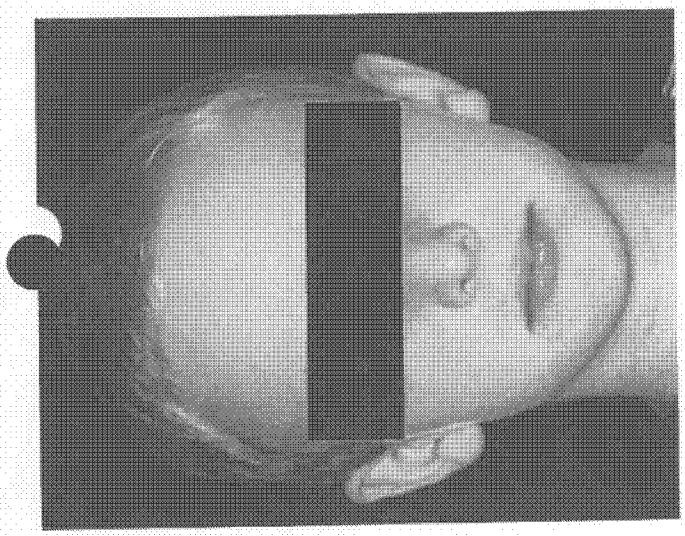

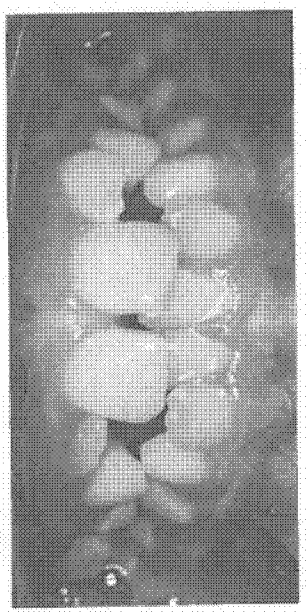

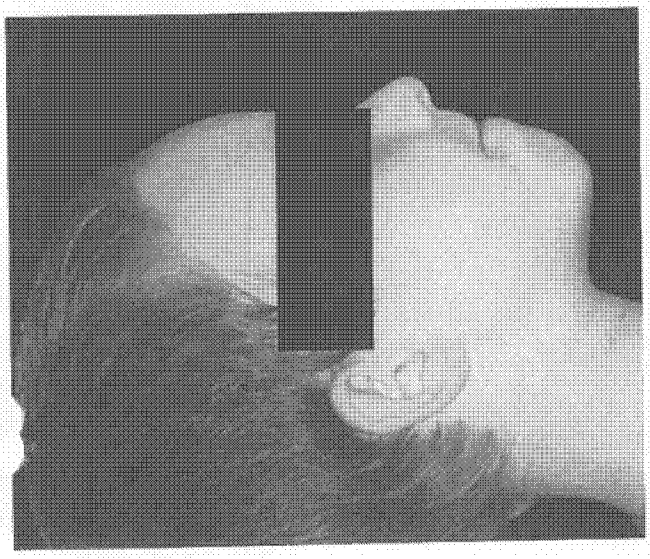

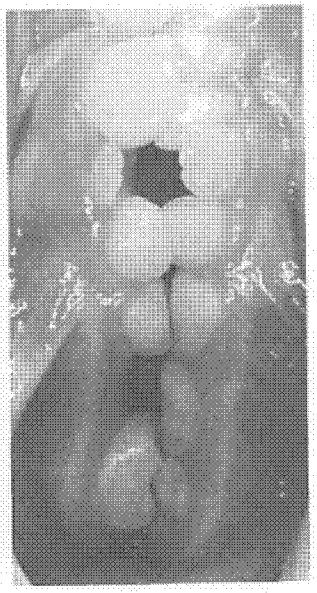

232

# MD-11

233

# invisalign TREATMENT SUMMARY

*L INFORMATION MUST BE TYPEWRITTEN.*

**DOCTOR:** W.S. **INVISALIGN CASE #:** (b)(6)

**GENDER:** ☒ MALE ☐ FEMALE

**AGE:** 10 yrs.

**PATIENT INITIALS:** (b)(6)

**TREATMENT START DATE:** 11/09/04 **TREATMENT END DATE:** 9/26/05 **TOTAL TREATMENT TIME:** 11 months

**CHIEF CONCERN:** Correction of Posterior Class II and uprighting 1.6, 2.6.

**DIAGNOSTIC SUMMARY:** Posterior Class II.

**CEPHALOMETRIC SUMMARY:** We don't have any cephalometrics because we didn't treat skeletal problems.

**REATMENT GOAL:** Distalization and derotation of upper molars.

**TREATMENT PLAN:** 17 upper arch.

**NUMBER OF REFINEMENTS DURING TREATMENT:** 0

**TOTAL NUMBER OF UPPER ALIGNERS (including refinements):** 17

**TOTAL NUMBER OF LOWER ALIGNERS (including refinements):** Upper treatment only.

**SUPPLEMENTAL TREATMENT NEEDED TO ACHIEVE TREATMENT GOAL:**

☐ Plier detailing ☐ Interarch elastics ☐ Buttons ☐ Spring aligner

☐ Positioner. ☐ Orthognathic surgery ☐ Conventional braces ☒ None

**RESULTS ACHIEVED/DOCTOR'S ANALYSIS:** Distalization and derotation fully achieved according to treatment goal.

**ETENTION:** Upper: Removable plate to maintain gained spaces Lower: n/a

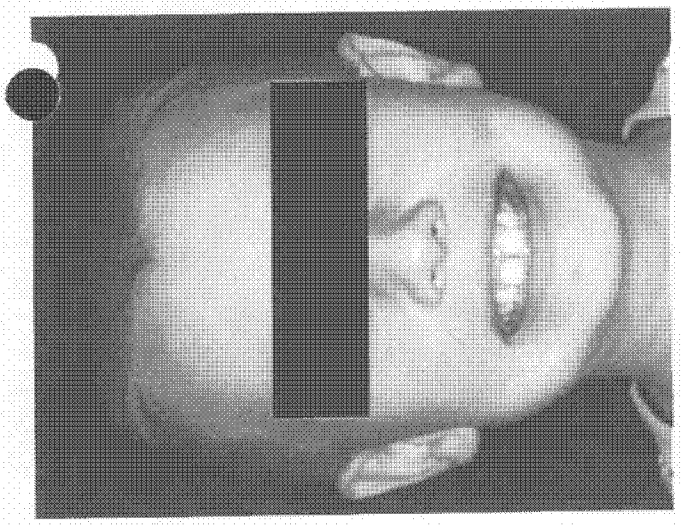

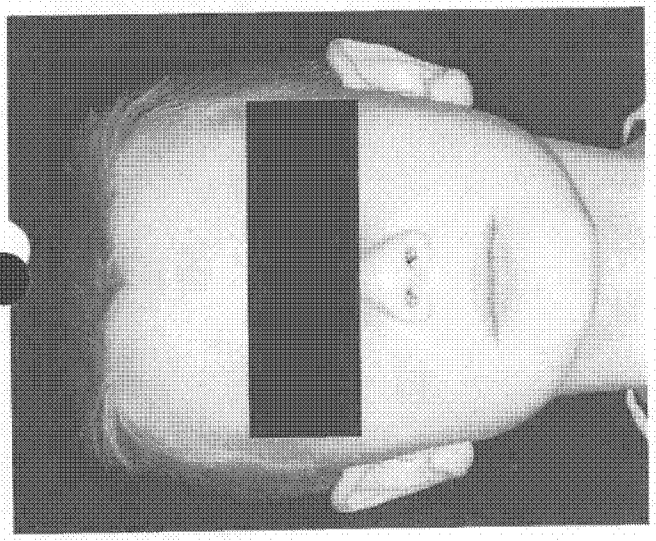



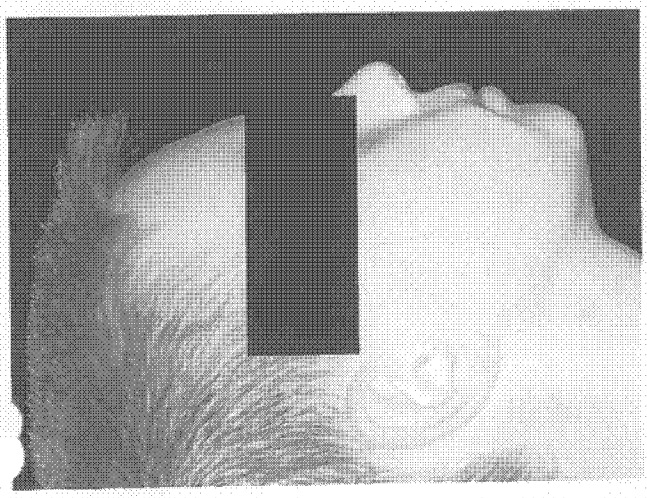



235

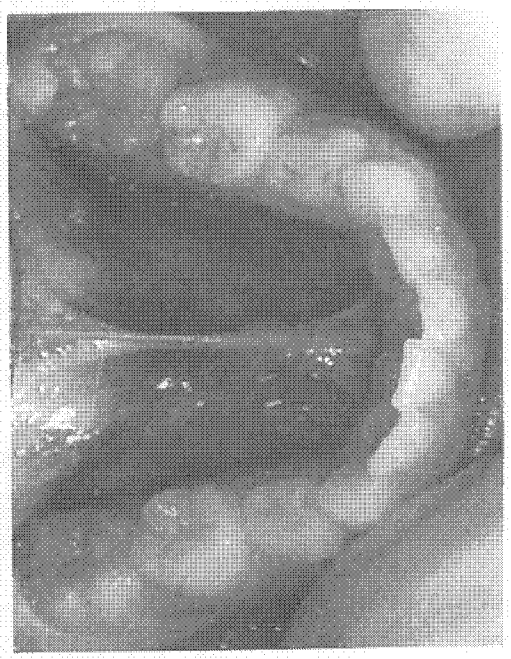

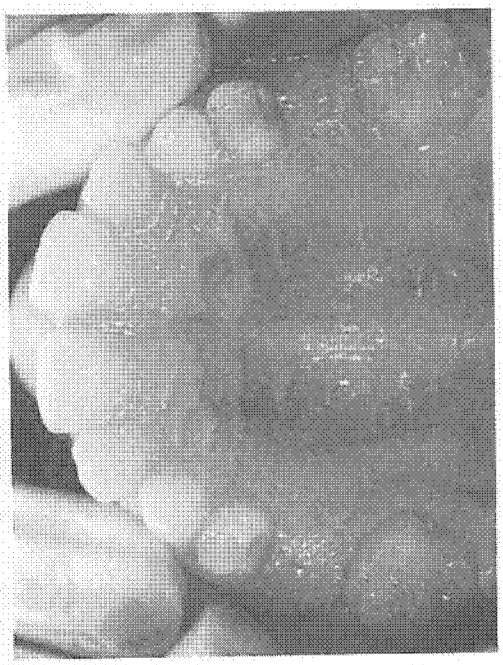



236

# MD-12

# invisalign® TREATMENT SUMMARY

*L INFORMATION MUST BE TYPEWRITTEN.*

**DOCTOR:** W.S. **INVISALIGN CASE #:** (b)(6)

**GENDER:** ☒ MALE ☐ FEMALE

**AGE:** 8 yrs.

**PATIENT INITIALS:** (b)(6)

**TREATMENT START DATE:** 2/18/03 **TREATMENT END DATE:** 10/07/03 **TOTAL TREATMENT TIME:** 7-8 months

**CHIEF CONCERN:** Posterior Class II with loss of space for 5.5, 6.5.

**DIAGNOSTIC SUMMARY:** Posterior Class II.

**CEPHALOMETRIC SUMMARY:** We don't have any cephalometrics because we didn't treat skeletal problems.

**REATMENT GOAL:** Distalization of upper molars to gain space for 1.5, 2.5.

**TREATMENT PLAN:** Distalization of upper molars with 14 upper aligners.

**NUMBER OF REFINEMENTS DURING TREATMENT:** 0

**TOTAL NUMBER OF UPPER ALIGNERS (including refinements):** 14

**TOTAL NUMBER OF LOWER ALIGNERS (including refinements):** Upper treatment only.

**SUPPLEMENTAL TREATMENT NEEDED TO ACHIEVE TREATMENT GOAL:**

☐ Plier detailing ☐ Interarch elastics ☐ Buttons ☐ Spring aligner

☐ Positioner ☐ Orthognathic surgery ☐ Conventional braces ☒ None

**RESULTS ACHIEVED/DOCTOR'S ANALYSIS:** Treatment goal fully achieved.

**ETENTION:** Upper: Fixed retainer 1.6 to 5.4, 2.6 to 6.4. Lower: n/a

238

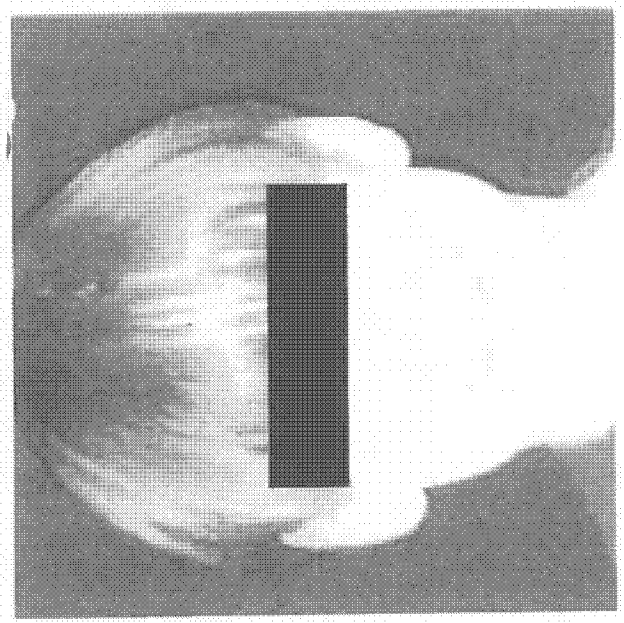

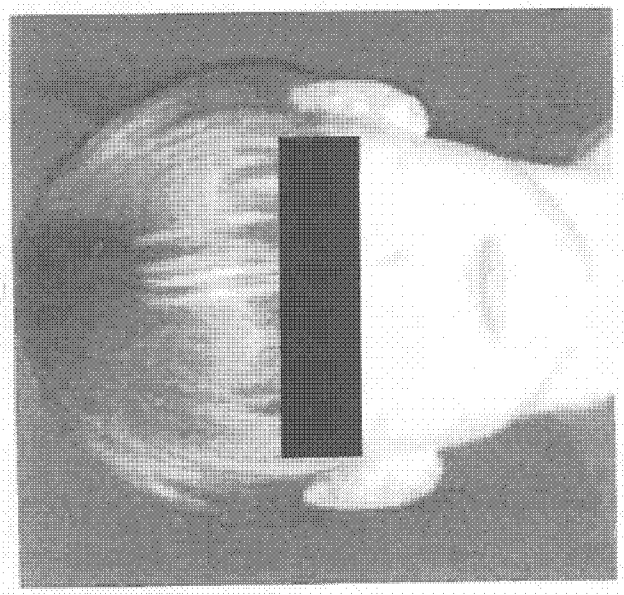





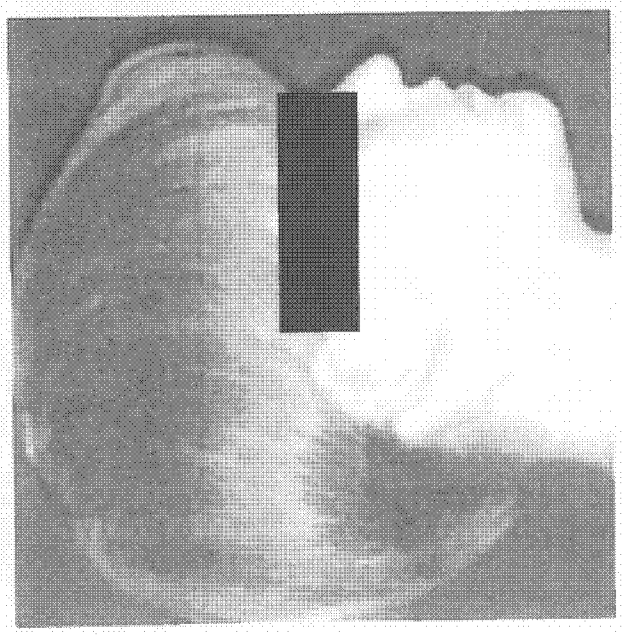

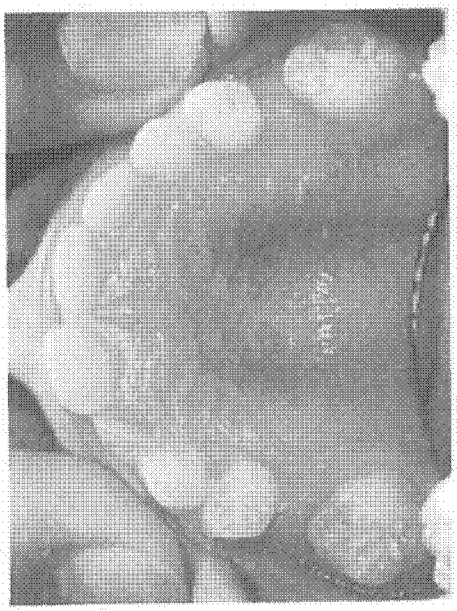



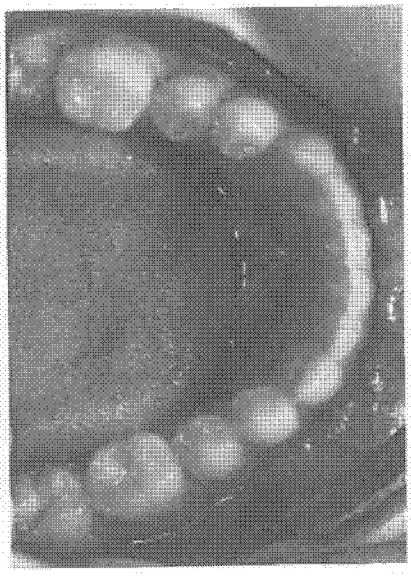

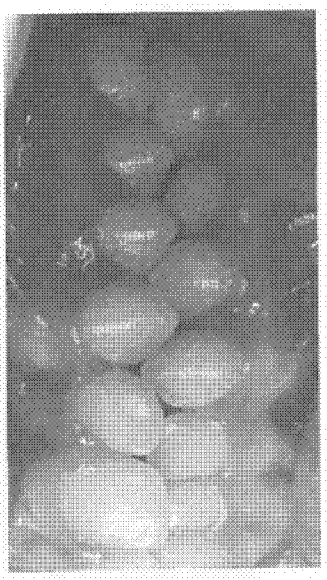



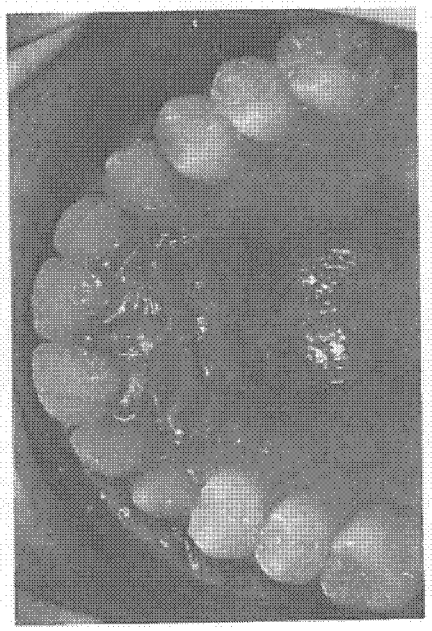

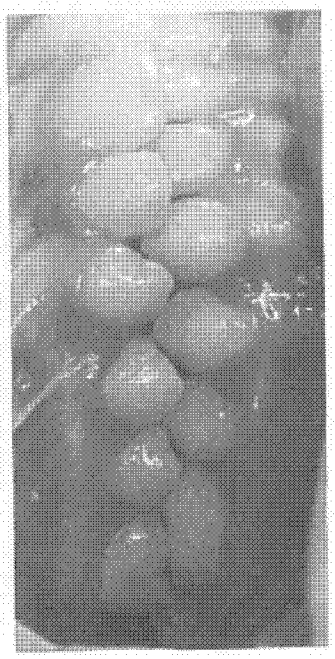

240

# Skeletally Narrow Jaw (NJ1)

241

# NJ-1

242

# invisalign TREATMENT SUMMARY

*L INFORMATION MUST BE TYPEWRITTEN.*

**DOCTOR:** E.K. **INVISALIGN CASE #:** (b)(6)

**GENDER:** ☒ MALE ☐ FEMALE

**AGE:** 17 yrs. 6 m

**PATIENT INITIALS:** (b)(6)

**TREATMENT START DATE:** 10/03/05 **TREATMENT END DATE:** 9/24/07 **TOTAL TREATMENT TIME:** 24 months

**CHIEF CONCERN:** Upper and lower crooked teeth, fix bite front and back.

**DIAGNOSTIC SUMMARY:** End on Class II right molar and R/L cuspids. Class I left molar. Moderate upper and lower anterior crowding. Constricted maxilla with crossbite tendency #3 and #4. Tooth #4 rotated 140 degrees from ideal. Incisal wear noted on upper laterals due to their lingual inclination. Third molars not present.

**CEPHALOMETRIC SUMMARY:** High mandibular plane angle, SNA = 83, SNB = 80, ANB = 3.

**TREATMENT GOAL:** Class I molar and cuspid, fix crowding, skeletal expansion of upper arch to increase maxillary transverse dimension and fix crossbite. Do not rotate #4 to ideal; rotate it to 180 degrees from normal.

**TREATMENT PLAN:** Expand maxilla with Rapid Palatal Expander. Rotate #4 tooth completely to 180 degrees with button and elastic to expander. Fix crowding with Invisalign after expansion completed. Enameloplasty #4 for proper excursives post-ortho.

**NUMBER OF REFINEMENTS DURING TREATMENT:** 1

**TOTAL NUMBER of UPPER ALIGNERS (including refinements):** 36

**TOTAL NUMBER of LOWER ALIGNERS (including refinements):** 18

**SUPPLEMENTAL TREATMENT NEEDED TO ACHIEVE TREATMENT GOAL:**

☐ Plier detailing ☐ Interarch Elastics ☒ Buttons ☐ Spring aligner

☐ Positioner ☐ Orthognathic Surgery ☐ Conventional Braces ☐ None

**RESULTS ACHIEVED/DOCTOR'S ANALYSIS:** Patient corrected to Class I molar and cuspid. Maxillary arch coordinated with mandible (#3, #4 edge-to-edge bite resolved). Upper and lower crowding corrected. Patient has slight upper midline discrepancy to right, due to the tooth-size discrepancy from aligning #4 180 degrees from normal. Patient could benefit from gingivoplasty #10 for longer crown appearance.

**RETENTION:** Upper: Essix retainer Lower: Essix retainer

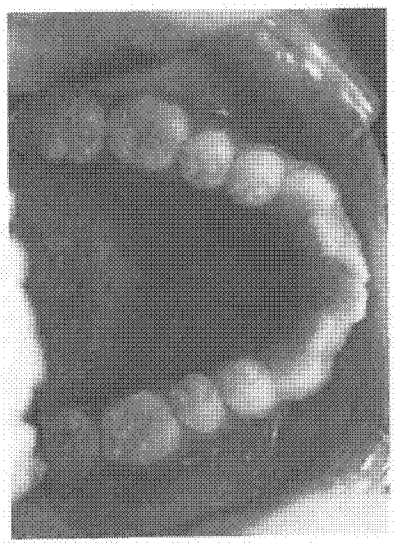

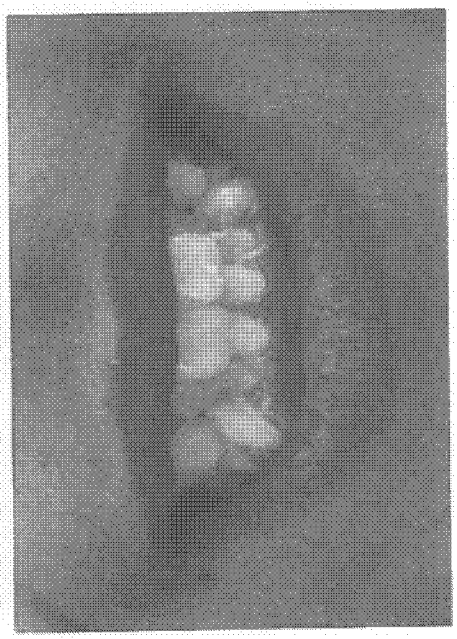

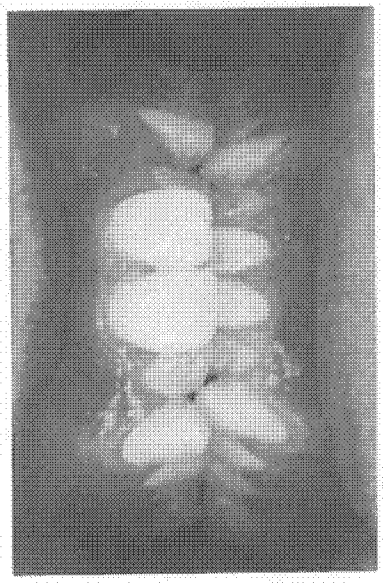

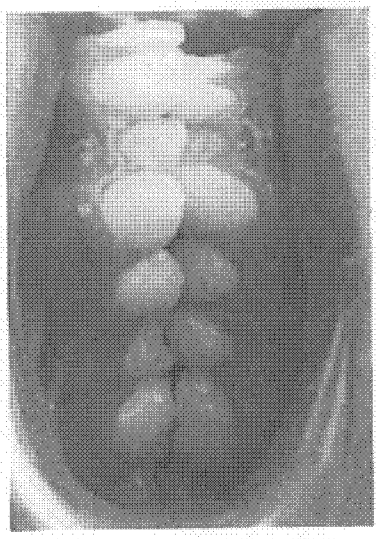

245

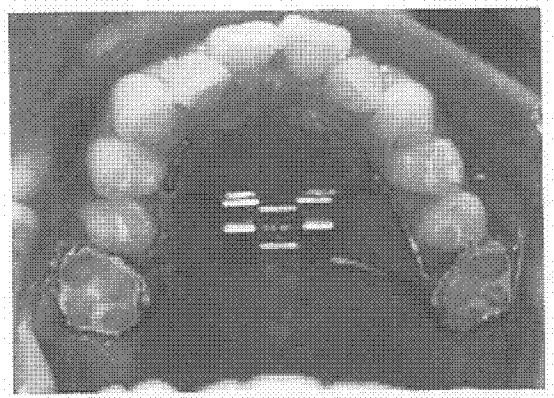

After palatal expander

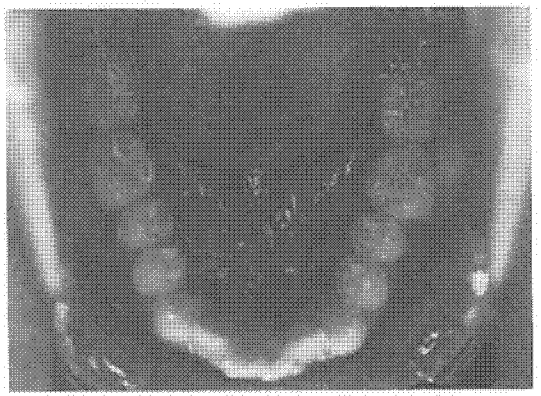

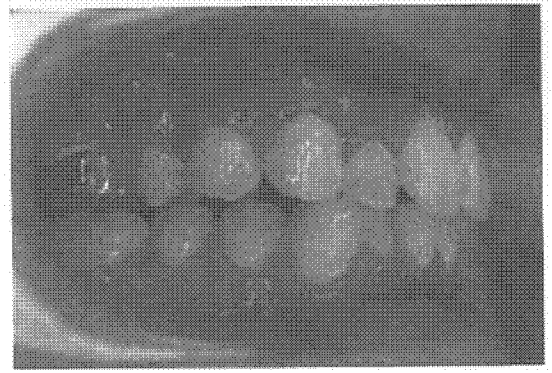

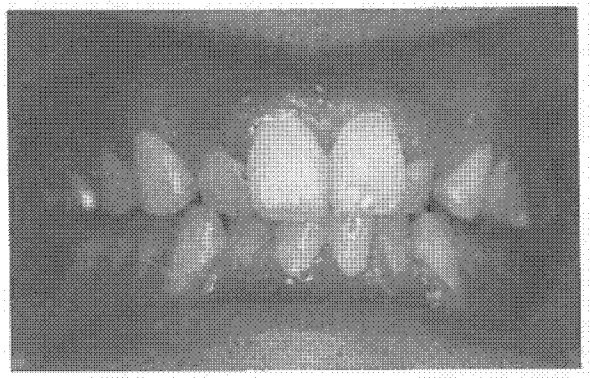

246

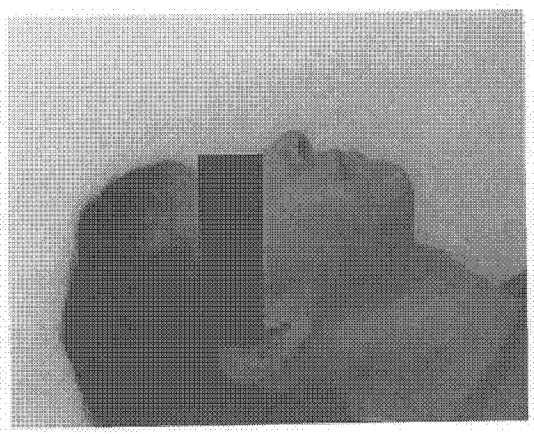

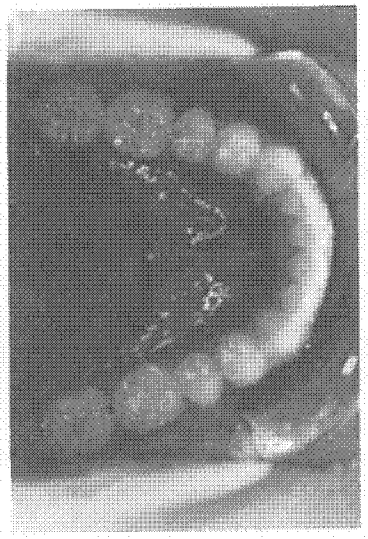

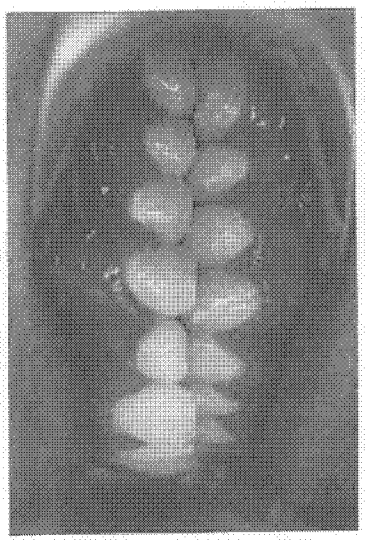

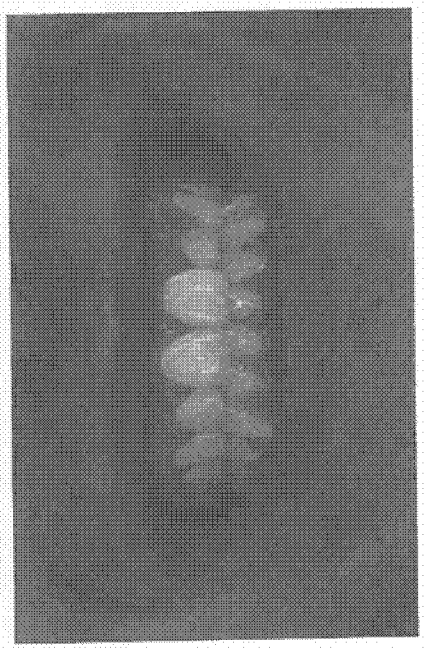

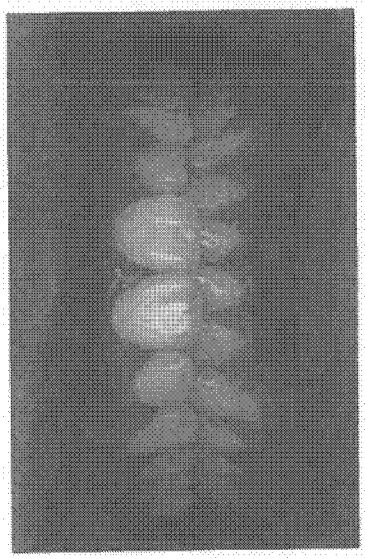



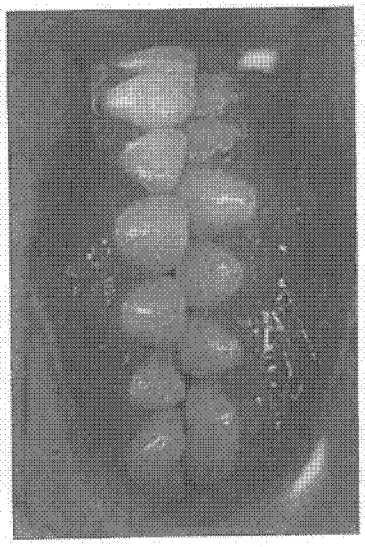

247

DEPARTMENT OF HEALTH & HUMAN SERVICES

Public Health Service

Food and Drug Administration
9200 Corporate Boulevard
Rockville MD 20850

Ms. Sangeeta Sachdeva
Manager, Regulatory Affairs
Align Technology, Incorporated
881 Martin Avenue
Santa Clara, California 95050

DEC 17 2008

Re: K081960
Trade/Device Name: Invisalign® System
Regulation Number: 21 CFR 872.5470
Regulation Name: Orthodontic Plastic Bracket
Regulatory Class: II
Product Code: NXC
Dated: December 10, 2008
Received: December 12, 2008

Dear Ms. Sachdeva:

We have reviewed your Section 510(k) premarket notification of intent to market the device referenced above and have determined the device is substantially equivalent (for the indications for use stated in the enclosure) to legally marketed predicate devices marketed in interstate commerce prior to May 28, 1976, the enactment date of the Medical Device Amendments, or to devices that have been reclassified in accordance with the provisions of the Federal Food, Drug, and Cosmetic Act (Act) that do not require approval of a premarket approval application (PMA). You may, therefore, market the device, subject to the general controls provisions of the Act. The general controls provisions of the Act include requirements for annual registration, listing of devices, good manufacturing practice, labeling, and prohibitions against misbranding and adulteration.

If your device is classified (see above) into either class II (Special Controls) or class III (PMA), it may be subject to such additional controls. Existing major regulations affecting your device can be found in the Code of Federal Regulations, Title 21, Parts 800 to 898. In addition, FDA may publish further announcements concerning your device in the Federal Register.

Please be advised that FDA's issuance of a substantial equivalence determination does not mean that FDA has made a determination that your device complies with other requirements of the Act or any Federal statutes and regulations administered by other Federal agencies. You must comply with all the Act's requirements, including, but not limited to: registration and listing (21 CFR Part 807); labeling (21 CFR Part 801); good manufacturing practice requirements as set forth in the quality systems (QS) regulation (21 CFR Part 820); and if applicable, the electronic product radiation control provisions (Sections 531-542 of the Act); 21 CFR 1000-1050.

This letter will allow you to begin marketing your device as described in your Section 510(k) premarket notification. The FDA finding of substantial equivalence of your device to a legally marketed predicate device results in a classification for your device and thus, permits your device to proceed to the market.

If you desire specific advice for your device on our labeling regulation (21 CFR Part 801), please contact the Center for Devices and Radiological Health's (CDRH's) Office of Compliance at (240) 276-0115. Also, please note the regulation entitled, "Misbranding by reference to premarket notification" (21CFR Part 807.97). For questions regarding postmarket surveillance, please contact CDRH's Office of Surveillance and Biometric's (OSB's) Division of Postmarket Surveillance at 240-276-3474. For questions regarding the reporting of device adverse events (Medical Device Reporting (MDR)), please contact the Division of Surveillance Systems at 240-276-3464. You may obtain other general information on your responsibilities under the Act from the Division of Small Manufacturers, International and Consumer Assistance at its toll-free number (800) 638-2041 or (240) 276-3150 or at its Internet address http://www.fda.gov/cdrh/industry/support/index.html.

Sincerely yours,



Chiu S. Lin, Ph. D
Division Director
Division of Anesthesiology, General Hospital,
Infection Control and Dental Devices
Office of Device Evaluation
Center for Devices and
Radiological Health

Enclosure

2

K081960

**Align Technology, Inc.,**

**Modified Invisalign® system**

**Indications for Use**

| | |
|---|---|
| **510(k) Number if Known:** | To be assigned by FDA |
| **Device Name:** | Invisalign® system |
| **Indications of Use:** | The Invisalign® system is indicated for the alignment of teeth during orthodontic treatment of malocclusion. |

Please do not write below this line.

---

Concurrent of CDRH, Office of Device Evaluation (ODE)

Susan Runner

(Division Sign-Off)
Division of Anesthesiology, General Hospital
Infection Control, Dental Devices

510(k) Number: K081960

**Prescription Use:** X AND/OR **Over the Counter Use:** _____
(Part 21 CFR 801 Subpart D) (Part 21 CFR 801 Subpart C)

DEPARTMENT OF HEALTH AND HUMAN SERVICES  Public Health Service

Food and Drug Administration
Center for Devices and
Radiological Health
Office of Device Evaluation
Document Mail Center (HFZ-40
9200 Corporate Blvd.
Rockville, Maryland 20850

September 25, 2008

ALIGN TECHNOLOGY
881 MARTIN AVE.
SANTA CLARA, CA 95050
ATTN: SANGEETA SACHDEVA

510(k) Number: K081960
Product: INVISALIGN SYSTEM

We are holding your above-referenced Premarket Notification (510(k)) for 30 days pending receipt of the additional information that was requested by the Office of Device Evaluation. Please remember that all correspondence concerning your submission MUST cite your 510(k) number and be sent in duplicate to the Document Mail Center (HFZ-401) at the above letterhead address. Correspondence sent to any address other than the one above will not be considered as part of your official premarket notification submission. Also, please note the new Blue Book Memorandum regarding Fax and E-mail Policy entitled, "Fax and E-Mail Communication with Industry about Premarket Files Under Review. Please refer to this guidance for information on current fax and e-mail practices at www.fda.gov/cdrh/ode/a02-01.html.

The deficiencies identified represent the issues that we believe need to be resolved before our review of your 510(k) submission can be successfully completed. In developing the deficiencies, we carefully considered the statutory criteria as defined in Section 513(i) of the Federal Food, Drug, and Cosmetic Act for determining substantial equivalence of your device. We also considered the burden that may be incurred in your attempt to respond to the deficiencies. We believe that we have considered the least burdensome approach to resolving these issues. If, however, you believe that information is being requested that is not relevant to the regulatory decision or that there is a less burdensome way to resolve the issues, you should follow the procedures outlined in the "A Suggested Approach to Resolving Least Burdensome Issues" document. It is available on our Center web page at: http://www.fda.gov/cdrh/modact/leastburdensome.html

106

If after 30 days the additional information (AI), or a request for an extension of time, is not received, we will discontinue review of your submission and proceed to delete your file from our review system (21 CFR 807.87(l)). Please note our guidance document entitled, "Guidance for Industry and FDA Staff, FDA and Industry Actions on Premarket Notification (510(k)) Submissions: Effect on FDA Review Clock and Performance Assessment". If the submitter does submit a written request for an extension, FDA will permit the 510(k) to remain on hold for up to a maximum of 180 days from the date of the AI request The purpose of this document is to assist agency staff and the device industry in understanding how various FDA and industry actions that may be taken on 510(k)s should affect the review clock for purposes of meeting the Medical Device User Fee and Modernization Act. You may revi this document at http://www.fda.gov/cdrh/mdufma/guidance/1219.html. Pursuant to 21 CFR 20.29, a copy of your 510(k) submission will remain the Office of Device Evaluation. If you then wish to resubmit this 510(k) notification, a new number will be assigned and your submission will be considered a new premarket notification submission. Please remember that the Safe Medical Devices Act of 1990 states that you may not place this device into commercial distribution until you receive a decision letter from FDA allowing you to do so.

If you have procedural questions, please contact the Division of Small Manufacturers International and Consumer Assistance (DSMICA) at (240)276-3150 or at their toll-free number (800) 638-2041, or contact the 510k staff at (240)276-4040.

Sincerely yours,

Marjorie Shulman
Supervisor Consumer Safety Officer
Premarket Notification Section
Office of Device Evaluation
Center for Devices and
Radiological Health

107

DEPARTMENT OF HEALTH AND HUMAN SERVICES Public Health Service

Food and Drug Administration
Center for Devices and
Radiological Health
Office of Device Evaluation
Document Mail Center (HFZ-401)
9200 Corporate Blvd.
Rockville, Maryland 20850

July 10, 2008

ALIGN TECHNOLOGY
881 MARTIN AVE.
SANTA CLARA, CA 95050
ATTN: SANGEETA SACHDEVA

510(k) Number: K081960
Received: 09-JUL-2008
Product: INVISALIGN SYSTEM

The Food and Drug Administration (FDA), Center for Devices and Radiological Health (CDRH), has received the Premarket Notification, (510(k)), you submitted in accordance with Section 510(k) of the Federal Food, Drug, and Cosmetic Act(Act) for the above referenced product and for the above referenced 510(k) submitter. Please note, if the 510(k) submitter is incorrect, please notify the 510(k) Staff immediately. We have assigned your submission a unique 510(k) number that is cited above. Please refer prominently to this 510(k) number in all future correspondence that relates to this submission. We will notify you when the processing of your 510(k) has been completed or if any additional information is required. YOU MAY NOT PLACE THIS DEVICE INTO COMMERCIAL DISTRIBUTION UNTIL YOU RECEIVE A LETTER FROM FDA ALLOWING YOU TO DO SO.

Please remember that all correspondence concerning your submission MUST be sent to the Document Mail Center (DMC)(HFZ-401) at the above letterhead address. Correspondence sent to any address other than the one above will not be considered as part of your official 510(k) submission.

On September 27, 2007, the President signed an act reauthorizing medical device user fees for fiscal years 2008 - 2012. The legislation - the Medical Device User Fee Amendments of 2007 is part of a larger bill, the Food and Drug Amendments Act of 2007. Please visit our website at http://www.fda.gov/cdrh/mdufma/index.html for more information regarding fees and FDA review goals. In addition, effective January 2, 2008, any firm that chooses to use a standard in the review of ANY new 510(k) needs to fill out the new standards form (Form 3654) and submit it with their 510(k). The form may be found at http://www.fda.gov/opacom/morechoices/fdaforms/FDA-3654.pdf.

We remind you that Title VIII of the Food and Drug Administration Amendments Act of 2007 (FDAAA) amended the PHS Act by adding new section 402(j) (42 U.S.C. ' 282(j)), which expanded the current database known as ClinicalTrials.gov to include mandatory registration and reporting of results for applicable clinical trials of human drugs (including biological products) and devices. Section 402(j) requires that a certification form (http://www.fda.gov/opacom/morechoices/fdaforms/FDA-3674.pdf) accompany 510(k)/HDE/PMA submissions. The agency has issued

248

a draft guidance titled: "Certifications To Accompany Drug, Biological Product, and Device Applications/Submissions: Compliance with Section 402(j) of The Public Health Service Act, Added By Title VIII of The Food and Drug Administration Amendments Act of 2007" (http://www.fda.gov/oc/initiatives/fdaaa/guidance_certifications.html). According to the draft guidance, 510(k) submissions that do not contain clinical data do not need the certification form.

Please note the following documents as they relate to 510(k) review:
1)Guidance for Industry and FDA Staff entitled, "Interactive Review for Medical Device Submissions: 510(k)s, Original PMAs, PMA Supplements, Original BLAs and BLA Supplements". This guidance can be found at http://www.fda.gov/cdrh/ode/guidance/1655.pdf. Please refer to this guidance for information on a formalized interactive review process.
2)Guidance for Industry and FDA Staff entitled, "Format for Traditional and Abbreviated 510(k)s". This guidance can be found at www.fda.gov/cdrh/ode/guidance/1567.html. Please refer to this guidance for assistance on how to format an original submission for a Traditional or Abbreviated 510(k).

In all future premarket submissions, we encourage you to provide an electronic copy of your submission. By doing so, you will save FDA resources and may help reviewers navigate through longer documents more easily. Under CDRH's e-Copy Program, you may replace one paper copy of any premarket submission (e.g., 510(k), IDE, PMA, HDE) with an electronic copy. For more information about the program, including the formatting requirements, please visit our web site at www.fda.gov/cdrh/elecsub.html.

Lastly, you should be familiar with the regulatory requirements for medical devices available at Device Advice www.fda.gov/cdrh/devadvice/". If you have questions on the status of your submission, please contact DSMICA at (240) 276-3150 or the toll-free number (800) 638-2041, or at their Internet address http://www.fda.gov/cdrh/dsma/dsmastaf.html. If you have procedural questions, please contact the 510(k) Staff at (240)276-4040.

Sincerely yours,

Marjorie Shulman
Supervisory Consumer Safety Officer
Office of Device Evaluation
Center for Devices and Radiological Health

249

K081960

# TRADITIONAL 510(k) PREMARKET NOTIFICATION (ORIGINAL)

## INVISALIGN® SYSTEM

## PANEL: DENTAL


ALIGN TECHNOLOGY, INC.,
881 MARTIN AVENUE
SANTA CLARA, CA 95050


**Submitted:** July 2nd 2008

**To:** Document Control Center (HFZ-401)
Center for Devices and Radiological Health
Food and Drug Administration
9200 Corporate Blvd.,
Rockville, MD 20850

**Signed:** Sangeeta Sachdeva
Sangeeta Sachdeva
**Title:** Manager, Regulatory Affairs

1C6
DE 250
II

# Align Technology, Inc.

## Modified Invisalign® system

## Table of Contents

| | |
|---|---|
| Screening Checklist for Traditional 510(k) | Section A |
| MDUFMA Cover Sheet | Section B |
| CDRH Pre-Market Submission Cover Sheet | Section C |
| 510(k) Cover Letter | Section D |
| Indications for Use Statement | Section E |
| 510(k) Summary | Section F |
| Truthful and Accurate Statement | Section G |
| Class III Summary and Certification | Section H |
| Financial Certification or Disclosure Statement | Section I |
| Declarations of Conformity and Summary Reports | Section J |
| Executive Summary | Section K |
| Device Description | Section L |
| Substantial Equivalence Discussion | Section M |
| Proposed Labeling | Section N |
| Sterilization and Shelf Life | Section O |
| Biocompatibility | Section P |
| Software | Section Q |
| Electromagnetic Compatibility and Electrical Safety | Section R |
| Performance Testing – Bench | Section S |
| Performance Testing – Animal | Section T |
| Performance Testing – Clinical | Section U |
| Performance Standards | Section V |
| Electronic Submission (CD) – a duplicate of the paper copy enclosed | |

251

# Screening Checklist for Traditional/Abbreviated Premarket Notification 510(k) Submission

## Align Technology, Inc.,

## Modified Invisalign® system

### TRADITIONAL 510(k) CHECKLIST

| Title | Related Information | Present | Inadequate | N/A |
|---|---|---|---|---|
| MDUFMA Cover Sheet | Medical Device User Fee Cover Sheet www.fda.gov/oc/mdufma/coversheet.html | Yes Section B | | |
| CDRH Premarket Review Submission Cover Sheet | CDRH Premarket Review Submission Cover Sheet www.fda.gov/opacom/morechoices/fdaforms/FDA-3514.pdf | Yes Section C | | |
| 510(k) Cover Letter | Appendix A of "Guidance for Industry and FDA Staff Format for Traditional and Abbreviated 510(k)s" updated November 17, 2005 | Yes Section D | | |
| Indications for Use Statement | Device Advice " Content of a 510(k)" Section D www.fda.gov/cdrh/devadvice/314312.html#link_6 | Yes Section E | | |
| 510(k) Summary or 510(k) Statement | Device Advice " Content of a 510(k)" Section E www.fda.gov/cdrh/devadvice/314312.html#link_7 | Yes Section F | | |
| Truthful and Accurate Statement | Device Advice " Content of a 510(k)" Section G www.fda.gov/cdrh/devadvice/314312.html#link_9 | Yes Section G | | |
| Class III Summary and Certification | Class III Summary and Certification Form www.fda.gov/cdrh/manual/stmnciii.html | Section H | | NA |
| Financial Certification or Disclosure Statement | FORM FDA 3454, Certification: Financial Interests and Arrangements of Clinical Investigators www.fda.gov/opacom/morechoices/fdaforms/FDA-3454.pdf<br><br>FORM FDA 3455, Disclosure: Financial Interests and Arrangements of Clinical Investigators www.fda.gov/opacom/morechoices/fdaforms/FDA-3455.pdf<br><br>Financial Disclosure by Clinical Investigators www.fda.gov/oc/guidance/financialdis.html. | Section I | | NA |

**Align Technology, Inc.,**

**Modified Invisalign® system**

**TRADITIONAL 510(k) CHECKLIST**

| Title | Related Information | Present | Inadequate | N/A |
|---|---|---|---|---|
| Declarations of Conformity and Summary Reports (Abbreviated 510(k)s) | Use of Standards in Substantial Equivalence Determinations www.fda.gov/cdrh/ode/guidance/1131.html.<br><br>FDA Standards program www.fda.gov/cdrh/stdsprog.html.<br><br>Declaration of conformity www.fda.gov/cdrh/devadvice/3145.html#link_9<br><br>Required Elements for Declaration of Conformity to Recognized Standard www.fda.gov/cdrh/ode/reqrecstand.html | Section J | | NA |
| Executive Summary | See section 10 in Chapter II of "Guidance for Industry and FDA Staff Format for Traditional and Abbreviated 510(k)s" updated November 17, 2005 | Yes<br><br>Section K | | |
| Device Description | See section 11 in Chapter II of "Guidance for Industry and FDA Staff Format for Traditional and Abbreviated 510(k)s" updated November 17, 2005 | Yes<br><br>Section L | | |
| Substantial Equivalence Discussion | Guidance on the CDRH Premarket Notification Review Program 6/30/86 (K86-3), www.fda.gov/cdrh/k863.html | Yes<br><br>Section M | | |
| Proposed Labeling | Device Advice " Content of a 510(k)" Section H www.fda.gov/cdrh/devadvice/314312.html#link_10 | Yes<br><br>Section N | | |
| Sterilization/Shelf Life | Updated 510(k) Sterility Review Guidance (K90-1) www.fda.gov/cdrh/ode/guidance/361.html<br><br>For reuse of single use devices, see Guidance for Industry and FDA Staff – Medical Device User Fee and Modernization Act of 2002 Validation Data in Premarket Notification Submissions (510(k)s) for Reprocessed Single-Use Medical Devices www.fda.gov/cdrh/ode/guidance/1216.html | Section O | | NA |

254

**Align Technology, Inc.,**

**Modified Invisalign® system**

**TRADITIONAL 510(k) CHECKLIST**

| Title | Related Information | Present | Inadequate | N/A |
|---|---|---|---|---|
| Biocompatibility | FDA Blue Book Memo, G95-1, Use of International Standard ISO-10993, "Biological Evaluation of Medical Devices Part 1: Evaluation and Testing" www.fda.gov/cdrh/g951.html | Section P | | NA |
| Software | Guidance for the Content of Premarket Submissions for Software Contained in Medical Devices www.fda.gov/cdrh/ode/software.html | Section Q | | NA |
| Electromagnetic Compatibility/Electrical Safety | CDRH Medical Device Electromagnetic Compatibility Program www.fda.gov/cdrh/emc<br><br>See also IEC 60601-1- 2 Medical Electrical Equipment -- Part 1: General Requirements for Safety; Electromagnetic Compatibility -- Requirements and Tests (Second Edition, 2001) | Section R | | NA |
| Performance Testing – Bench | See section 18 in Chapter II of "Guidance for Industry and FDA Staff Format for Traditional and Abbreviated 510(k)s" updated November 17, 2005 | Section S | | NA |
| Performance Testing – Animal | See section 19 in Chapter II of "Guidance for Industry and FDA Staff Format for Traditional and Abbreviated 510(k)s" updated November 17, 2005 | Section T | | NA |
| Performance Testing – Clinical | See section 20 in Chapter II of "Guidance for Industry and FDA Staff Format for Traditional and Abbreviated 510(k)s" updated November 17, 2005<br><br>Certification/Disclosure Forms: Financial Interests and Arrangements of Clinical Investigators<br><br>www.fda.gov/opacom/morechoices/fdaforms/FDA-3454.pdf<br>www.fda.gov/opacom/morechoices/fdaforms/FDA-3455.pdf | Section U | | NA |
| Performance Standards | Section 513(a)(1)(B) of the federal Food, Drug & Cosmetic Act | Section V | | NA |

255

# Medical Device User Fee Cover Sheet

256

Form Approved: OMB No. 0910-511 Expiration Date: January 31, 2010. See Instructions for OMB Statement.

DEPARTMENT OF HEALTH AND HUMAN SERVICES
FOOD AND DRUG ADMINISTRATION
**MEDICAL DEVICE USER FEE COVER SHEET**

PAYMENT IDENTIFICATION NUMBER: (b)(4)
Write the Payment Identification number on your check.

completed cover sheet must accompany each original application or supplement subject to fees. If payment is sent by U.S. mail or ɔurier, please include a copy of this completed form with payment. Payment and mailing instructions can be found at: http://www.fda.gov/oc/mdufma/coversheet.html

1. COMPANY NAME AND ADDRESS (include name, street address, city state, country, and post office code)

ALIGN TECHNOLOGY INC
881 MARTIN AVE
SANTA CLARA CA 95050
US

1.1 EMPLOYER IDENTIFICATION NUMBER (EIN)
(b)(4)

2. CONTACT NAME
David Kolesar

2.1 E-MAIL ADDRESS
dkolesar@aligntech.com

2.2 TELEPHONE NUMBER (include Area code)
408-4701455

2.3 FACSIMILE (FAX) NUMBER (Include Area code)
408-4701011

3. TYPE OF PREMARKET APPLICATION (Select one of the following in each column; if you are unsure, please refer to the application descriptions at the following web site: http://www.fda.gov/dc/mdufma

Select an application type:
[X] Premarket notification(510(k)); except for third party
[ ] 513(g) Request for Information
[ ] Biologics License Application (BLA)
[ ] Premarket Approval Application (PMA)
[ ] Modular PMA
[ ] Product Development Protocol (PDP)
[ ] Premarket Report (PMR)
[ ] Annual Fee for Periodic Reporting (APR)
[ ] 30-Day Notice

3.1 Select one of the types below
[X] Original Application
Supplement Types:
[ ] Efficacy (BLA)
[ ] Panel Track (PMA, PMR, PDP)
[ ] Real-Time (PMA, PMR, PDP)
[ ] 180-day (PMA, PMR, PDP)

4. ARE YOU A SMALL BUSINESS? (See the instructions for more information on determining this status)
] YES, I meet the small business criteria and have submitted the required ıalifying documents to FDA
[X] NO, I am not a small business

4.1 If Yes, please enter your Small Business Decision Number:

5. IS THIS PREMARKET APPLICATION COVERED BY ANY OF THE FOLLOWING USER FEE EXCEPTIONS? IF SO, CHECK THE APPLICABLE EXCEPTION.

[ ] This application is the first PMA submitted by a qualified small business, including any affiliates, parents, and partner firms

[ ] This biologics application is submitted under secion 351 of the Public Health Service Act for a product licensed for further manufacturing use only

[ ] The sole purpose of the application is to support conditions of use for a pediatric population

[ ] The application is submitted by a state or federal government entity for a device that is not to be distributed commercially

6. IS THIS A SUPPLEMENT TO A PREMARKET APPLICATION FOR WHICH FEES WERE WAIVED DUE TO SOLE USE IN A PEDIATRIC POPULATION THAT NOW PROPOSES CONDITION OF USE FOR ANY ADULT POPULATION? (If so, the application is subject to the fee that applies for an original premarket approval application (PMA).)

[ ] YES [X] NO

7. USER FEE PAYMENT AMOUNT SUBMITTED FOR THIS PREMARKET APPLICATION
(b)(4)

30-Jun-2008

Form FDA 3601 (01/2007)

"Close Window" Print Cover sheet

257

(b)(4)

(b)(4)

Security Features Included.

**ALIGN TECHNOLOGY, INC.**
821 MARTIN AVENUE
SANTA CLARA, CA 95050
PH. (408) 470-1000

080971/07-05

758

# CDRH Pre-market Review Submission Cover Sheet

259

DEPARTMENT OF HEALTH AND HUMAN SERVICES
**FOOD AND DRUG ADMINISTRATION**

# CDRH PREMARKET REVIEW SUBMISSION COVER SHEET

Form Approval
OMB No. 9010-0120
Expiration Date: August 31, 2010.
See OMB Statement on page 5.

| Date of Submission | User Fee Payment ID Number | FDA Submission Document Number (if known) |
|---|---|---|
| 7/2/2008 | MD6037254 - 956733 | |

## SECTION A — TYPE OF SUBMISSION

| PMA | PMA & HDE Supplement | PDP | 510(k) | Meeting |
|---|---|---|---|---|
| ☐ Original Submission | ☐ Regular (180 day) | ☐ Original PDP | ☐ Original Submission: | ☐ Pre-510(K) Meeting |
| ☐ Premarket Report | ☐ Special | ☐ Notice of Completion | ☒ Traditional | ☐ Pre-IDE Meeting |
| ☐ Modular Submission | ☐ Panel Track (PMA Only) | ☐ Amendment to PDP | ☐ Special | ☐ Pre-PMA Meeting |
| ☐ Amendment | ☐ 30-day Supplement | | ☐ Abbreviated (Complete section I, Page 5) | ☐ Pre-PDP Meeting |
| ☐ Report | ☐ 30-day Notice | | ☐ Additional Information | ☐ Day 100 Meeting |
| ☐ Report Amendment | ☐ 135-day Supplement | | ☐ Third Party | ☐ Agreement Meeting |
| ☐ Licensing Agreement | ☐ Real-time Review | | | ☐ Determination Meeting |
| | ☐ Amendment to PMA &HDE Supplement | | | ☐ Other *(specify):* |
| | ☐ Other | | | |

| IDE | Humanitarian Device Exemption (HDE) | Class II Exemption Petition | Evaluation of Automatic Class III Designation (De Novo) | Other Submission |
|---|---|---|---|---|
| ☐ Original Submission | ☐ Original Submission | ☐ Original Submission | ☐ Original Submission | ☐ 513(g) |
| ☐ Amendment | ☐ Amendment | ☐ Additional Information | ☐ Additional Information | ☐ Other *(describe submission):* |
| ☐ Supplement | ☐ Supplement | | | |
| | ☐ Report | | | |
| | ☐ Report Amendment | | | |

Have you used or cited Standards in your submission? ☐ Yes ☒ No *(If Yes, please complete Section I, Page 5)*

## SECTION B — SUBMITTER, APPLICANT OR SPONSOR

| | | | |
|---|---|---|---|
| Company / Institution Name<br>Align Technology, Inc. | Establishment Registration Number *(if known)*<br>2953749 | | |
| Division Name *(if applicable)* | Phone Number *(including area code)*<br>( 408 ) 470-1244 | | |
| Street Address<br>881 Martin Ave | FAX Number *(including area code)*<br>( 408 ) 470-1011 | | |
| City<br>Santa Clara | State / Province<br>CA | ZIP/Postal Code<br>95050 | Country<br>USA |
| Contact Name<br>Sangeeta Sachdeva | | | |
| Contact Title<br>Manager, Regulatory Affairs | Contact E-mail Address<br>ssachdeva@aligntech.com | | |

## SECTION C — APPLICATION CORRESPONDENT (e.g., consultant, if different from above)

| | | | |
|---|---|---|---|
| Company / Institution Name | | | |
| Division Name *(if applicable)* | Phone Number *(including area code)*<br>( ) | | |
| Street Address | FAX Number *(including area code)*<br>( ) | | |
| City | State / Province | ZIP/Postal Code | Country |
| Contact Name | | | |
| Contact Title | Contact E-mail Address | | |

## SECTION D1 — REASON FOR APPLICATION - PMA, PDP, OR HDE

- [ ] Withdrawal
- [ ] Additional or Expanded Indications
- [ ] Request for Extension
- [ ] Post-approval Study Protocol
- [ ] Request for Applicant Hold
- [ ] Request for Removal of Applicant Hold
- [ ] Request to Remove or Add Manufacturing Site

- [ ] Change in design, component, or specification:
  - [ ] Software / Hardware
  - [ ] Color Additive
  - [ ] Material
  - [ ] Specifications
  - [ ] Other *(specify below)*

- [ ] Location change:
  - [ ] Manufacturer
  - [ ] Sterilizer
  - [ ] Packager

- [ ] Process change:
  - [ ] Manufacturing
  - [ ] Sterilization
  - [ ] Packaging
  - [ ] Other *(specify below)*

- [ ] Labeling change:
  - [ ] Indications
  - [ ] Instructions
  - [ ] Performance
  - [ ] Shelf Life
  - [ ] Trade Name
  - [ ] Other *(specify below)*

- [ ] Report Submission:
  - [ ] Annual or Periodic
  - [ ] Post-approval Study
  - [ ] Adverse Reaction
  - [ ] Device Defect
  - [ ] Amendment

- [ ] Response to FDA correspondence:

- [ ] Change in Ownership
- [ ] Change in Correspondent
- [ ] Change of Applicant Address

- [ ] Other Reason *(specify)*:

## SECTION D2 — REASON FOR APPLICATION - IDE

- [ ] New Device
- [ ] New Indication
- [ ] Addition of Institution
- [ ] Expansion / Extension of Study
- [ ] IRB Certification
- [ ] Termination of Study
- [ ] Withdrawal of Application
- [ ] Unanticipated Adverse Effect
- [ ] Notification of Emergency Use
- [ ] Compassionate Use Request
- [ ] Treatment IDE
- [ ] Continued Access

- [ ] Change in:
  - [ ] Correspondent / Applicant
  - [ ] Design / Device
  - [ ] Informed Consent
  - [ ] Manufacturer
  - [ ] Manufacturing Process
  - [ ] Protocol - Feasibility
  - [ ] Protocol - Other
  - [ ] Sponsor

- [ ] Report submission:
  - [ ] Current Investigator
  - [ ] Annual Progress Report
  - [ ] Site Waiver Report
  - [ ] Final

- [ ] Repose to FDA Letter Concerning:
  - [ ] Conditional Approval
  - [ ] Deemed Approved
  - [ ] Deficient Final Report
  - [ ] Deficient Progress Report
  - [ ] Deficient Investigator Report
  - [ ] Disapproval
  - [ ] Request Extension of Time to Respond to FDA
  - [ ] Request Meeting
  - [ ] Request Hearing

- [ ] Other Reason *(specify)*:

## SECTION D3 — REASON FOR SUBMISSION - 510(k)

- [ ] New Device
- [x] Additional or Expanded Indications
- [ ] Change in Technology

- [x] Other Reason *(specify)*:

I. Expansion of the indications of use to permit treatment of patients who present with malocclusion without the limitation of permanent dentition.

II. Removal of certain contraindications that excluded patients with certain complex malocclusions from getting treated with the Invisalign system. These patients may or may not need additional orthodontic procedures to achieve the desired treatment outcome, and this is captured in the added precautions.

III. Addition of precautions corresponding to the removal of contraindications.

261

## SECTION E — ADDITIONAL INFORMATION ON 510(K) SUBMISSIONS

Product codes of devices to which substantial equivalence is claimed

| | | | | | | | |
|---|---|---|---|---|---|---|---|
| 1 | | 2 | | 3 | | 4 | |
| 5 | | 6 | | 7 | | 8 | |

Summary of, or statement concerning, safety and effectiveness information

- ☐ 510 (k) summary attached
- ☐ 510 (k) statement

.ormation on devices to which substantial equivalence is claimed *(if known)*

| | *510(k) Number* | | *Trade or Proprietary or Model Name* | | *Manufacturer* |
|---|---|---|---|---|---|
| 1 | k981095 | 1 | Invisalign system also known as Align system | 1 | Align Technology, Inc. |
| 2 | | 2 | | 2 | |
| 3 | | 3 | | 3 | |
| 4 | | 4 | | 4 | |
| 5 | | 5 | | 5 | |
| 6 | | 6 | | 6 | |

## SECTION F — PRODUCT INFORMATION - APPLICATION TO ALL APPLICATIONS

Common or usual name or classification

Orthodontic Plastic Brackets - 21CFR 872.5470

| | Trade or Proprietary or Model Name for This Device | | Model Number |
|---|---|---|---|
| 1 | Invisalign System | 1 | |
| 2 | | 2 | |
| 3 | | 3 | |
| 4 | | 4 | |
| 5 | | 5 | |

FDA document numbers of all prior related submissions *(regardless of outcome)*

| | | | | | |
|---|---|---|---|---|---|
| 1 k981095 | 2 | 3 | 4 | 5 | 6 |
| 7 | 8 | 9 | 10 | 11 | 12 |

Data Included in Submission

☐ Laboratory Testing ☐ Animal Trials ☐ Human Trials

## SECTION G — PRODUCT CLASSIFICATION - APPLICATION TO ALL APPLICATIONS

| Product Code | C.F.R. Section *(if applicable)* | Device Class |
|---|---|---|
| NXC | 872.5470 | ☐ Class I ☒ Class II |
| Classification Panel: Dental | | ☐ Class III ☐ Unclassified |

Indications *(from labeling)*

The Invisalign system is indicated for the alignment of teeth during orthodontic treatment of malocclusion.

262

| *Note:* Submission of this information does not affect the need to submit a 2891 or 2891a Device Establishment Registration form. | FDA Document Number *(if known)* |
|---|---|

## SECTION H MANUFACTURING / PACKAGING / STERILIZATION SITES RELATING TO A SUBMISSION

| | | | | |
|---|---|---|---|---|
| Original ☐ Add ☐ Delete | Facility Establishment Identifier (FEI) Number 30002519584 | ☒ Manufacturer ☐ Contract Manufacturer | ☐ Contract Sterilizer ☒ Repackager / Relabeler | |
| Company / Institution Name Align Technology, Inc. | | Establishment Registration Number 2953749 | | |
| Division Name *(if applicable)* | | Phone Number *(including area code)* ( 408 ) 470-1244 | | |
| Street Address 881 Martin Ave | | FAX Number *(including area code)* ( 408 ) 470-1011 | | |
| City Santa Clara | | State / Province CA | ZIP/Postal Code 95050 | Country USA |
| Contact Name Sangeeta Sachdeva | Contact Title Manager, Regulatory Affairs | | Contact E-mail Address ssachdeva@aligntech.com | |

| | | | | |
|---|---|---|---|---|
| ☐ Original ☐ Add ☐ Delete | Facility Establishment Identifier (FEI) Number | ☐ Manufacturer ☐ Contract Manufacturer | ☐ Contract Sterilizer ☐ Repackager / Relabeler | |
| Company / Institution Name | | Establishment Registration Number | | |
| Division Name *(if applicable)* | | Phone Number *(including area code)* ( ) | | |
| Street Address | | FAX Number *(including area code)* ( ) | | |
| City | | State / Province | ZIP/Postal Code | Country |
| Contact Name | Contact Title | | Contact E-mail Address | |

| | | | | |
|---|---|---|---|---|
| ☐ Original ☐ Add ☐ Delete | Facility Establishment Identifier (FEI) Number | ☐ Manufacturer ☐ Contract Manufacturer | ☐ Contract Sterilizer ☐ Repackager / Relabeler | |
| Company / Institution Name | | Establishment Registration Number | | |
| Division Name *(if applicable)* | | Phone Number *(including area code)* ( ) | | |
| Street Address | | FAX Number *(including area code)* ( ) | | |
| City | | State / Province | ZIP/Postal Code | Country |
| ıtact Name | Contact Title | | Contact E-mail Address | |

263

## SECTION I — UTILIZATION OF STANDARDS

Note: Complete this section if your application or submission cites standards or includes a *"Declaration of Conformity to a Recognized Standard"* statement.

| | Standards No. | Standards Organization | Standards Title | Version | Date |
|---|---|---|---|---|---|
| 1 | NA | | | | |
| 2 | Standards No. | Standards Organization | Standards Title | Version | Date |
| 3 | Standards No. | Standards Organization | Standards Title | Version | Date |
| 4 | Standards No. | Standards Organization | Standards Title | Version | Date |
| 5 | Standards No. | Standards Organization | Standards Title | Version | Date |
| 6 | Standards No. | Standards Organization | Standards Title | Version | Date |
| 7 | Standards No. | Standards Organization | Standards Title | Version | Date |

**Please include any additional standards to be cited on a separate page.**

**Public reporting burden for this collection of information** is estimated to average 0.5 hour per response, including the time for reviewing instructions, searching existing data sources, gathering and maintaining the data needed, and completing reviewing the collection of information. Send comments regarding this burden estimate or any other aspect of this collection of information, including suggestions for reducing this burden to:

Food and Drug Administration
CDRH (HFZ-342)
9200 Corporate Blvd.
Rockville, MD 20850

*...a agency may not conduct or sponsor, and a person is not required to respond to, a collection of information unless it displays a currently valid OMB control*

# 510(k) Cover Letter

265

A L I G N

**invisalign**

**Modified Invisalign system:** Traditional 510(k) Premarket Notification (21 CFR 807.90[e]).

July 2, 2008

510(k) Document Mail Center (HFZ-401)
Food and Drug Administration
Center for Devices and Radiological Health
9200 Corporate Blvd.
Rockville, MD 20850

**SUBMISSION:** 510(k) Premarket Notification

**DEVICE:** Invisalign system (Sequential Aligners)

**SPONSOR:** Align Technology, Inc.
881 Martin Avenue
Santa Clara, CA 95050

FDA CDRH DMC

**CONTACT:** Sangeeta Sachdeva
Manager, Regulatory Affairs
Ph. 1(408) 470 1244

JUL 9 2008

Received

**USER FEE PAYMENT ID#:** MD6037254 – 956733

Dear Sir/Madam,

Pursuant to the provisions of Section 510(k) of the Federal Food, Drug and Cosmetic Act and Safe Medical Devices Act of 1990, notification is made of Align Technology, Inc.'s (Align) intent to market and distribute the existing Invisalign system (K981095, cleared in 1998 under the name Align system) with labeling changes. These labeling changes were described and discussed with the FDA during Align Technology, Inc.'s meeting with Dr. Runner, Dr. Mulry and Mr. Ryan on March 6th 2008. This traditional 510(k) has all the information required in conformance with 21 CFR 807.

The current Invisalign system is a series of clear plastic aligners that are used to replace traditional orthodontic wires and brackets for the alignment of maloccluded or misaligned teeth. This series of aligners moves the teeth gently and in small increments from their original to their final treated position for improved dental alignment.

266

At present, the Invisalign system is cleared for the treatment of tooth malocclusion in patients with permanent dentition (i.e., all second molars) and is contraindicated for adult and adolescent patients presenting with the following conditions:

1. Severe open bite
2. Severe overjet
3. Tooth malocclusion requiring surgical correction
4. Patients with mixed dentition
5. Adolescent patients with a skeletally narrow jaw
6. Adult patients with dental prosthetics/implants

This is the labeling language that was originally cleared by the FDA in 1997.

Based on documented cases of the current level of orthodontic care being rendered in dental practices using the Invisalign system, citations from the literature, and feedback from discussions with the FDA (Dr. Mulry, Dr. Runner and Mr. Ryan), Align is filing this 510(k) Premarket Notification solely to update labeling, including indications for use of the device. This updated labeling will allow patients with malocclusion, including but not limited to those with severe open bite, severe overjet, mixed dentition, skeletally narrow jaw, dental prostheses/implants, and those who require surgical correction to get dental alignment with the Invisalign system.

There is no change being made to the existing predicate device itself. Thus, the modified and predicate devices' technological characteristics, such as design, raw material, and chemical composition, device's features, as well as their manufacturing processes and related software are identical.

Due to this, the modified device is also classified like the predicate device, as Sequential Aligners (Orthodontic Plastic Brackets [Sequential Aligners] - 21CFR 872.5470, Product Code NXC).

This device will continue to be manufactured and distributed by:
Align Technology, Inc. (Align)
881 Martin Avenue
Santa Clara, CA 95050

Establishment Registration Number – 2953749.

A detailed comparison between the proposed modified and current Invisalign system will be addressed under Substantial Equivalence and Predicate Decision Making Section of this submission which demonstrates

that the modified device is the same as the current device – the Align system (K981095), also known as the "Invisalign system".

The principal factors regarding the performance characteristics and clinical utility of the proposed device are summarized in the table below, which is taken from FDA's Guidance on Format for Traditional and Abbreviated 510(k).

| Questions | Yes | No |
|---|---|---|
| Is this device intended for prescription use (21 CFR 801 Subpart D)? | X | |
| Is this device intended for over the counter use (21 CFR 807 Subpart C)? | | X |
| Does the device contain any components derived from a tissue or other biological source? | | X |
| Is the device provided sterile? | | X |
| Is the device intended for single use? | | X |
| If yes, does this device type require reprocessed validation data? | | NA |
| Does the device contain a drug? | | X |
| Does the device contain a biologic? | | X |
| Does the device use a software? | | X |
| Does the submission include clinical data? | | X |
| Is the device implanted? | | X |

Enclosed in the submission you will also find the required information for Premarket Notification, including a:

- Screening Checklist (Section A)
- CDRH Premarket Submission Cover Sheet (Section C)
- Indications for Use document (Section E)
- 510(k) Premarket Notification Summary (Section F)
- Premarket Notification Truthful and Accurate Statement, submitted in accordance with 21 CFR 807.87(j), is also included (Section G) and
- Substantial Equivalence Discussion (Section M) with information of the cleared Align system (now known as Invisalign system) printed from the FDA web site.

In accordance with the provisions of the Medical Device User Fee and Modernization Act of 2007, the required fee for the review of this 510(k)

Premarket Notification has been submitted. The Medical Device User Fee payment identification number is MD6037254 – 956733. A copy of the Medical Device User Fee Cover Sheet is provided in Section B of this submission. In addition, one original and two copies of this Premarket Notification are provided for review.

Align Technology, Inc. regards information provided in support of this Premarket Notification to be confidential and proprietary and afforded protection under 21 CFR 807.95 and other applicable statutes.

Please direct all questions and letters to the undersigned.

Thank you for your attention regarding this submission.

Sincerely,

Sangeeta Sachdeva

Sangeeta Sachdeva
Manager, Regulatory Affairs
Align Technology, Inc.
ssachdeva@aligntech.com
Direct #: 1(408)4701244
Fax #: 1(408)4701011

Copy: Align Technology, Inc.

269

# Indications for Use

270

**Align Technology, Inc.,**

**Modified Invisalign® system**

**Indications for Use**

| | |
|---|---|
| **510(k) Number if Known:** | To be assigned by FDA |
| **Device Name:** | Invisalign® system |
| **Indications of Use:** | The Invisalign® system is indicated for the alignment of teeth during orthodontic treatment of malocclusion. |

Please do not write below this line.

---

Concurrent of CDRH, Office of Device Evaluation (ODE)

**Prescription Use:** X AND/OR **Over the Counter Use:** _____ 271
(Part 21 CFR 801 Subpart D) (Part 21 CFR 801 Subpart C)

# 510(k) Summary

212

# Align Technology, Inc.,

## Modified Invisalign® system

## 510(k) Premarket Notification Summary

This summary of 510(k) safety and effectiveness information is being submitted in accordance with the requirements of 21 CFR 807.92 and SMDA 1990.

The assigned 510(k) number is _____.

**1. Manufacturer's Information:**

| | |
|---|---|
| a. Company Name: | Align Technology, Inc. |
| b. Company Address: | 881 Martin Ave.,<br>Santa Clara, CA 95050 |
| c. Company Phone: | (408) 470-1244 |
| d. Company Fax: | (408) 470-1011 |
| e. Contact Person: | Sangeeta Sachdeva<br>Manager,<br>Regulatory Affairs<br>Align Technology, Inc. |

**2. Prepared on:** June 26th, 2008

**3. Device Identification:**

| | |
|---|---|
| a. Current Trade (proprietary) Name: | Invisalign system |
| b. Generic Name: | Invisalign, Aligners |
| c. Classification Name: | Orthodontic Plastic Brackets (Sequential Aligners) |
| d. Classification regulation | 21CFR 872.5470 |
| e. Product Code | NXC |
| f. Device class: | II |
| g. Advisory panel | Dental |

223

## 4. Predicate Device Identification:

| | |
|---|---|
| a. Current Trade (proprietary) Name: | Invisalign system |
| b. Generic Name: | Invisalign, Aligners |
| c. Classification Name: | Orthodontic Plastic Brackets - 21CFR 872.5470 (Sequential Aligners) |
| d. Product Code | NXC |
| e. Device class: | II |

## 5. Indications for Use:

The Invisalign system is indicated for the alignment of teeth during orthodontic treatment of malocclusion.

## 6. Device Description:

The current Invisalign system is a series of clear plastic aligners that are used to replace traditional orthodontic wires and brackets for the alignment of maloccluded or misaligned teeth. This series of aligners moves the teeth gently, and in small increments, from their original to their final treated position for improved dental alignment.

This 510(k) Premarket Notification is being submitted because Align Technology, Inc. is making labeling changes that affect the indications for use, contra-indications, and precautions of the currently-commercialized Invisalign system. The technological characteristics of the modified and currently-marketed predicate device, such as design, raw material, and chemical composition, and their manufacturing processes and related software, are identical.

The labeling modifications include:

I. Expansion of the indications of use to permit treatment of patients who present with malocclusion without the limitation of permanent dentition.
II. Removal of certain contra-indications that excluded patients with certain complex malocclusions from getting treated with the Invisalign system. These patients may or may not need additional orthodontic procedures to achieve the desired treatment outcome, and this is captured in the added precautions.

274

III. Addition of precautions corresponding to the removal of contra-indications.

Thus, the modified Invisalign system with the proposed labeling changes will allow the treatment of patients with malocclusion, including, but not limited to, those with primary dentition present (including mixed dentition), as well as of patients with severe open bite, severe overjet, skeletally narrow jaw, dental prostheses/implants, and/or those who require surgical correction.

7. **Software:**

There are no changes in the software compared to the existing Invisalign system. The software design and development, software development methodology, software development process and environment are identical for the existing predicate device and the modified Invisalign system.

8. **Technological Characteristics**:

A comparison of the current and proposed Invisalign system demonstrates that the devices are equivalent in terms of technology, material-based physical and performance characteristics.

9. **Substantial Equivalence Information:**

This Premarket Notification is being submitted solely to incorporate the above listed labeling changes to the existing Invisalign system (K981095).

- There are no changes in the technological characteristics of the modified device when compared to the predicate device. The design, raw material, and chemical composition, device features as well as technical characteristics of the modified device and existing predicate device are identical.
- There are no changes in the manufacturing processes and related software required to accommodate the labeling changes.

Thus, based on the similar indications for use and same technological, material, and performance characteristics of the currently marketed, predicate device (K981095) and the Invisalign system with the modified labeling, the two are considered substantially equivalent (21 CFR 807.100).

275

# Truthful and Accurate Statement

276

**Align Technology, Inc.,**

**Modified Invisalign® system**

**Premarket Notification**

**Truthful and Accurate Statement**

(As Required by 21CFR 807.87[k])

I certify that, in my capacity as the Manager of Regulatory Affairs of Align Technology, Inc., I believe to the best of my knowledge that all data and information submitted in the premarket notification are truthful and accurate and that no material fact has been omitted.

Sangeeta Sachdeva

Sangeeta Sachdeva
Manager, Regulatory Affairs
Align Technology, Inc.

July 2nd 2008
(Date)

Pending
Premarket Notification [510(k)] Number

277

# Class III Summary and Certification

228

# Align Technology, Inc.,

## Modified Invisalign® system

## Class III Summary and Certification

The Modified Invisalign system is not a Class III device. Therefore this section is not applicable.

279

# Financial Certification or Disclosure Statement

780

## Align Technology, Inc.,

## Modified Invisalign® system

## Financial Certification or Disclosure Statement

This submission does not include data from clinical studies conducted by sponsors. Therefore this section is not applicable.

281

# Declarations of Conformity and Summary Reports

282

# Align Technology, Inc.,

# Modified Invisalign® system

# Declarations of Conformity and Summary Report

This submission is a traditional 510(k). Therefore this section is not applicable.

283

# Executive Summary

284

# Align Technology, Inc.,

# Modified Invisalign® system

## Executive Summary

The Invisalign system is a series of clear plastic aligners that are used to replace traditional orthodontic wires and brackets for the alignment of maloccluded or misaligned teeth. This series of aligners moves the teeth, gently and in small increments, from their original to their final treated position for improved dental alignment.

The proprietary Invisalign system (b)(4)
(b)(4)
(b)(4)

In the previous Premarket notification (K981095), the use of aligners has been labeled for patients with permanent teeth, and contraindicated for patients with mixed dentition, severe overbite, severe overjet, tooth malocclusion requiring surgical correction, adolescent patients with a skeletally narrow jaw, and adult patients with dental prosthetics/implants.

The proposed labeling changes will include modifications to the current indication for use of the product, to remove the permanent dentition requirement. This change is possible based on a better understanding of the broader applications of the Invisalign system, advances in the manufacturing facility of Align Technology, Inc., and on the advances in the current practice of orthodontic treatment being rendered by dentists using the Invisalign system.

The **current Indication for Use (IFU)** is: The Invisalign system is indicated for the treatment of tooth malocclusion in patients with permanent dentition (i.e., all second molars).

The **proposed IFU** is: The Invisalign system is indicated for the alignment of teeth during orthodontic treatment of malocclusion.

In addition, certain malocclusion conditions that are currently listed as contra-indications in the current IFU will be listed as precautions instead.

The **current contra-indications** are:

285

Adult and Adolescent patients presenting the following conditions:

1. Severe open bite
2. Severe overjet
3. Tooth malocclusion requiring surgical correction
4. Patients with mixed dentition
5. Adolescent patients with a skeletally narrow jaw
6. Adult patients with dental prosthetics/implants

Since many of the contra-indications in the proposed IFU will have been moved to the Precautions section, the modified contra-indications section when compared to the IFU in the original submission (K981095), will list the following as the only contra-indication for the Invisalign system:

1. Active periodontal disease.

This proposed use of aligners to effectively align teeth in malocclusions currently listed as contra-indications has been documented in Substantially Equivalent Section M. To address the possibility that Invisalign treatment in these complex cases may at times require supplemental orthodontic treatment to achieve the desired outcome, the proposed IFU will have precautions that indicate what to expect when utilizing aligners to treat such cases.

The **proposed precautions, mentioned above,** that are in addition to the current precautions are:

1. Treatment of severe open bite, severe overjet, mixed dentition, and/or skeletally narrow jaw may require supplemental treatment in addition to aligner treatment.
2. Skeletal expanders, bonded auxiliaries, elastics, and other fixed and/or removable orthodontic appliances, may be needed for more complicated treatment plans where aligners alone may not be adequate to achieve the desired outcome.
3. Oral surgery may be necessary to correct severe crowding or jaw imbalances. If oral surgery is required, risks associated with anesthesia and proper healing must be taken into account prior to treatment.
4. Atypically-shaped, erupting, and/or missing teeth may affect aligner adaptation and may affect the ability to achieve the desired results.
5. Existing dental restorations (e.g., crowns, bridges) may become dislodged and require re-cementation or, in some instances, replacement.

With these precautions in place, the doctor can make a more informed decision if s/he wants to treat these more complex cases using Invisalign aligners, and if so, to have proper expectations regarding the potential need for supplemental treatment in addition to the aligners.

The **Summary Table** below lists the main similarities and differences between the predicate and the proposed device:

| Predicate Device | Modified Device |
|---|---|
| **Technology** of the design, raw material, and chemical composition as described in (K981095) | No change. Similar to predicate device |
| **Manufacturing** processes as described in (K981095) | No change. Similar to predicate device |
| **Software** description as described in (K981095) | No change. Similar to predicate device |
| **Technical features and properties** as described in (K981095) | No change. Similar to predicate device |
| **Indications for Use:**<br>The Invisalign system is indicated for the treatment of tooth malocclusion in patients with permanent dentition (i.e., all second molars). | **Proposed Indication for Use:**<br>The Invisalign system is indicated for the alignment of teeth during orthodontic treatment of malocclusion. |
| **Contra-indications:**<br>Adult and Adolescent patients presenting the following conditions:<br>1. Severe open bite<br>2. Severe overjet<br>3. Tooth malocclusion requiring surgical correction<br>4. Patients with mixed dentition<br>5. Adolescent patients with a skeletally narrow jaw<br>6. Adult patients with dental prosthetics/implants | **Contra-indications:**<br>Active periodontal disease |
| **Precautions:**<br>1. Keep aligners away from hot water and harsh chemicals.<br>2. Keep aligners out of reach of young children and pets.<br>3. Always store aligners in a cool, dry place.<br>4. Certain medical conditions and use of certain medications may affect orthodontic treatment outcomes. | **Proposed precautions *in addition* to the current Precautions to support the removal of Contra-indications:**<br>1. Treatment of severe open bite, severe overjet, mixed dentition, and/or skeletally narrow jaw may require supplemental treatment in addition to aligner treatment.<br>2. Skeletal expanders, bonded auxiliaries, elastics, and other fixed and/or removable orthodontic appliances, may be needed for more complicated treatment plans where aligners alone may not be adequate to achieve the desired outcome.<br>3. Oral surgery may be necessary to |

287

| | |
|---|---|
| | correct severe crowding or jaw imbalances. If oral surgery is required, risks associated with anesthesia and proper healing must be taken into account prior to treatment.<br>4. Atypically-shaped, erupting, and/or missing teeth may affect aligner adaptation and may affect the ability to achieve the desired results.<br>5. Existing dental restorations (e.g., crowns, bridges) may become dislodged and require re-cementation or, in some instances, replacement.<br>6. Aligners are not effective in the movement of dental implants. |

This Premarket Notification is being submitted solely to incorporate the above listed labeling changes to the existing Invisalign system (K981095).

1. There are no changes in the technological characteristics of the modified device when compared to the predicate device. The design, raw material, and chemical composition, device features as well as technical characteristics of the modified device and existing predicate device are similar.
2. There are no changes in the manufacturing processes and related software required to accommodate the labeling changes.

Thus, based on the similar indications for use and same technological characteristics of the currently marketed, predicate device (K981095) and the Invisalign system with the modified labeling, the two are considered substantially equivalent (21 CFR 807.100).

288

# Device Description

## Align Technology, Inc.,

## Modified Invisalign® system

## Device Description

The Invisalign system is a doctor-prescribed series of removable plastic orthodontic aligners intended as an alternative to conventional wire and bracket technology. The Invisalign system gently moves teeth in small increments from their original state to a final, treated state for improved dental alignment.

The proprietary Invisalign system software displays a series of 3-D dentition images with virtual tooth movements set up based on the doctor's prescription. The treating dental practitioner reviews these images and has the option to reject or request modifications to the set-up prior to approving it for aligner fabrication. Once the doctor approves the set-up, based on this set-up a custom-made series of thermoplastic polymer aligners are then manufactured at the aligner manufacturing facility. The custom-made aligners are then shipped to the dental practitioner to be dispensed to the patient for treatment.

In the previous Premarket notification (K981095), the use of aligners has been labeled for patients with permanent teeth, and contra-indicated for patients with mixed dentition, severe overbite, severe overjet, tooth malocclusion requiring surgical correction, adolescent patients with a skeletally narrow jaw, and adult patients with dental prosthetics/implants.

Since the device obtained clearance for commercialization, Align and the dental community have become more aware of the applicability of the Invisalign system beyond the originally-cleared indication for use. There also have been many advances in the current practice of orthodontic treatment using the Invisalign system in the dental community. During this time, the manufacturing processes at Align, described in detail in the previous submission, have improved and become more automated. In addition, innovative Invisalign-trained dental professionals have developed and used novel and inventive treatment methods with the device. These treatments with Invisalign are now being used more routinely in practices on patients with primary dentition present (including mixed dentition) and on complex malocclusions. The clinical utility information in the treatment reports from such cases was voluntarily shared with Align, and has been included in the submission in the Performance Testing Section under Summary of Clinical Utility Reports. This information has been shared with and discussed with the FDA (Dr. Runner, Dr. Mulry and Mr. Ryan) on March 6th 2008, and is instrumental in demonstrating the use of the device on the expanded patient population, including complex malocclusion cases and patients with deciduous teeth present (including mixed dentition).

Thus, based on above-mentioned documented cases of the prevailing orthodontic care being rendered in dental practices using the Invisalign system, relevant citations from 290

the literature, and feedback from discussions with the FDA (Dr. Mulry, Dr. Runner and Mr. Ryan), Align is filing this 510(k) Premarket Notification solely to update labeling, including indications for use of the device. This updated labeling will allow patients with malocclusion, including but not limited to, those with severe open bite, severe overjet, skeletally narrow jaw, mixed dentition, dental prostheses/implants, and those who require surgical correction to get dental alignment with the Invisalign system.

There is no change being made to the existing predicate device itself. Thus, the modified and predicate devices' technological characteristics, such as design, raw material, and chemical composition, device's features, as well as their manufacturing processes and related software, are identical.

The updated labeling of the modified Invisalign system will include:

I. Expand the indications for use to treat patients who present with malocclusion without the limitation of permanent dentition.
II. Remove certain contra-indications that exclude patients with severe malocclusion from getting their teeth aligned using the Invisalign system. These patients may or may not need additional orthodontic procedures for complete treatment and this is captured in the added precautions.
III. Addition of precautions to address the removed contra-indications. This will help set proper expectations for doctors when treating certain patients with the modified Invisalign system, including those addressing the contra-indications being removed.

## I. Expand the indications for use to treat patients who present with malocclusion without the limitation of permanent dentition

To date, the Invisalign system has been commercialized for the treatment of tooth malocclusion in patients with permanent dentition (*i.e.*, all second molars).

The current Indication for Use states: The Invisalign system is indicated for the treatment of tooth malocclusion in patients with permanent dentition (*i.e.*, all second molars).

The rationale behind Align Technology, Inc.'s original limitation for the use of Invisalign aligners to patients with only permanent dentition present was based on the fact that several months were required to manufacture aligners at the time of the original submission (1998), and on a lack of robust knowledge about the possible breadth of treatment applications, leading to a very basic indication for use even in 1998. The amount of time that elapsed between obtaining the prescription, manufacturing the aligner series, and delivering the aligners to the doctor could be problematic, since patients with exfoliating primary dentition may undergo a dentition change in that duration.

291

Since then, Align has come to understand the broader applications of the Invisalign system as demonstrated in the supporting case studies. Significant improvements to the aligner manufacturing process and an expansion of the workforce at Align Technology, Inc. have greatly shortened the time needed to manufacture and ship aligners, from several months to as little as two weeks or less. Furthermore, the prescribing dentist is now provided the ability to submit subsequent impressions of the patient if s/he finds that the aligners do not fit properly and precisely due to erupting or exfoliating teeth. It is this combination of the availability of aligners within a couple of weeks, and the ability to obtain aligners quickly from a new impression, if needed, that overcomes the reason that originally prevented doctors from effectively prescribing aligners for orthodontic treatment in patients with primary teeth present.

In today's practice of orthodontics, it is the norm to treat patients with deciduous dentition present using removable orthodontic devices. This treatment philosophy is supported by an official recommendation from the American Association of Orthodontists, which states that "all children get a check-up with an orthodontist no later than age 7." (www.aaortho.org). Based on all of the above, we are proposing the following indication for use:

> Proposed Indication of Use: The Invisalign system is indicated for the alignment of teeth during orthodontic treatment of malocclusion.

**II. Remove certain contra-indications that exclude patients with severe malocclusion from getting their teeth aligned using the Invisalign system. These patients may or may not need additional orthodontic procedures for complete treatment and this is captured in the added precautions.**

Orthodontic treatment today is commonly delivered using any number or combination of orthodontic devices, including fixed brackets and wires for dental alignment, elastics for inter-arch control, and expanders for transverse corrections. For correction of more complex malocclusions involving the skeletal base, surgery may also be required. Similarly, Invisalign aligners are today being used by doctors in conjunction with any number of these other orthodontic treatment modalities for supplemental orthodontic treatment as needed. This is discussed in detail in this 510(k) notification in Section U under Performance Testing – Summary of Clinical Utility Reports.

The presentation of severe malocclusion cases such as severe open bite, severe overjet, skeletally narrow jaw, and bites needing surgical correction do not preclude the use of Invisalign aligners for dental alignment. Data obtained and voluntarily shared by 14 dental practitioners, is now on file at Align, and demonstrates successful use of the Invisalign system for the alignment of teeth during orthodontic treatment of these types of malocclusion in sufficient fashion to support the proposed changes.

292

## III. Addition of Precautions

At times, supplemental orthodontic treatment (including fixed appliances) may be needed to help fully correct a severe case of the condition or conditions listed below if that is the prescribing doctor's desired treatment goal. Align recognizes that in some cases, aligners alone may not fully correct these conditions. Therefore, we are including precautions for treating adult patients that present with the following conditions, which are listed as contra-indications in the current labeling:

1. Severe open bite
2. Severe overjet
3. Tooth malocclusion requiring surgical correction
4. Patients with mixed dentition
5. Adolescent patients with a skeletally narrow jaw
6. Adult patients with dental prosthetics/implants

The proposed precautions associated with the treatment of patients presenting with the conditions listed above are:

1. Treatment of severe open bite, severe overjet, mixed dentition, and/or skeletally narrow jaw may require supplemental treatment in addition to aligner treatment.
2. Skeletal expanders, bonded auxiliaries, elastics, and other fixed and/or removable orthodontic appliances, may be needed for more complicated treatment plans where aligners alone may not be adequate to achieve the desired outcome.
3. Oral surgery may be necessary to correct severe crowding or jaw imbalances. If oral surgery is required, risks associated with anesthesia and proper healing must be taken into account prior to treatment.
4. Atypically-shaped, erupting, and/or missing teeth may affect aligner adaptation and may affect the ability to achieve the desired results.
5. Existing dental restorations (e.g., crowns, bridges) may become dislodged and require re-cementation or, in some instances, replacement.

With these precautions in place, the doctor can make a more informed decision as to whether s/he wants to treat these more complex cases using Invisalign aligners, and if so, whether supplemental treatment may be needed for the patient.

Since the above-mentioned contra-indications have been removed in the proposed IFU, the modified contra-indications section compared to the original IFU in the submission (K981095) will list as the only proposed contra-indication for the Invisalign system the following:

1. Active periodontal disease.

In conclusion, the modified Invisalign system with the proposed indication for use can be used for the alignment of teeth in patients that present with deciduous dentition

293

(including mixed dentition), severe open bite, severe overjet, skeletally narrow jaw, and dental prostheses/implants, including those that may require surgical correction as part of their treatment in addition to dental alignment.

The modified device is similar to the predicate device in all comparable areas, and there are no changes in the technological characteristics of the modified device when compared to the predicate device. The design, raw material, and chemical composition, device features as well as technical characteristics of the modified device and existing predicate device are identical. In addition, there are no changes in the manufacturing processes and related software required to accommodate the labeling changes. Thus, based on the similar indications for use and same technological, material, and performance characteristics of the currently marketed, predicate device (K981095) and the Invisalign system with the modified labeling, the two are considered substantially equivalent (21 CFR 807.100).

# Substantial Equivalence Discussion

I. Substantial Equivalence Discussion

II. Documentation from the FDA website regarding the predicate device's 510(k) clearance

795

## Align Technology, Inc.,

## Modified Invisalign® system

## Substantial Equivalence Discussion

Office of Device Evaluation Guidance Document No. K86-3, Guidance on the CDRH Premarket Review Notification Program (June 30th, 1986), was used to assess the substantial equivalence of the existing and modified Invisalign system.

The Invisalign system design or technical features have not been significantly modified since its clearance in 1998 (K981095). In this Premarket notification submission, Align Technology, Inc.'s sole purpose is to make labeling changes to:

I. Expand the indications for use to treat patients who present with malocclusion without the limitation of permanent dentition.
II. Remove certain contra-indications that exclude patients with severe malocclusion from getting their teeth aligned using the Invisalign system. These patients may or may not need additional orthodontic procedures for complete treatment and this is captured in the added precautions.
III. Addition of precautions to address the removed contra-indications.

The answers to the relevant questions, listed below, have led to the determination of substantial equivalence.

1. Does the new device have the same indications for use?
   The existing predicate and modified Invisalign system have the same intended use - "to move teeth to the final treated position".

2. Does the device have the same technological characteristics, e.g. design, materials etc.?
   Yes. The existing and modified Invisalign system are both made from the same material, by the same manufacturing processes, and therefore, have the same design, performance features and biocompatibility.

3. Are the descriptive characteristics precise enough to ensure equivalence?
   Yes. The existing predicate and the modified device are identical.

4. Does the performance data demonstrate equivalence?

796

Yes. This is due to the fact that the existing predicate and modified device are identical.

The table below compares the product use, features, technical characteristics, technology used, manufacturing procedures, and software used to manufacture the predicate and modified device, in addition to the labeling changes mentioned above.

Table 1. Substantial Equivalence.

| ***Predicate Device: Device:*** *Invisalign® system (K981095)* | ***New Device:*** *Invisalign® system with change in labeling* |
|---|---|
| **Device Name:**<br><br>Invisalign® system | **Device Name:**<br><br>Invisalign® system |
| **Indication for Use:**<br><br>The Invisalign system is indicated for the treatment of tooth malocclusion in patients with permanent dentition (i.e., all second molars). | **Indication for Use:**<br><br>The Invisalign system is indicated for the alignment of teeth during orthodontic treatment of malocclusion. |
| **Intended Use:**<br><br>The Invisalign system is indicated for treatment of individuals with permanent teeth. | **Intended Use:**<br><br>The Invisalign system is indicated for treatment of individuals with malocclusion including, but not limited to, primary and/or permanent dentition. |
| **Intended Population:**<br><br>Individuals with permanent dentition. | **Intended population:**<br><br>Individuals with primary and/or permanent dentition with mild to severe malocclusion. |
| **Technology, Performance and Compatibility** | **Features:** |
| **Anatomical Site of Use:**<br><br>Oral cavity | **Anatomical Site of Use:**<br><br>Identical to currently marketed predicate device, i.e. the oral cavity. |
| **Duration of Use:**<br><br>Each aligner is worn for 20-22 hours per day for a two-week period, after which it is replaced by the | **Duration of Use:**<br><br>Identical to the currently marketed predicate device; each aligner is worn for 20-22 hours per day for a two-week |

297

| | |
|---|---|
| next stage aligner. This is repeated for duration as prescribed by the Dental Practitioner. | period, after which it is replaced by the next stage aligner. This is repeated for duration as prescribed by the Dental Practitioner. |
| **Raw Material Used:**<br><br>Thermoplastic polymers | **Raw Material Used:**<br><br>Identical to currently marketed predicate device – i.e. thermoplastic polymers. |
| **Mode of Action:**<br><br>Orthodontic tooth movement occurs through forces applied by the appliance to the dentition as each tooth follows the programmed displacement based on a doctor's prescription. | **Mode of Action:**<br><br>Identical to currently marketed predicate device. Orthodontic tooth movement occurs through forces applied by the appliance to the dentition as each tooth follows the programmed displacement based on a doctor's prescription. |
| **Accessories Used with aligners:**<br><br>• Buttons<br>• Elastics | **Accessories Used with aligners:**<br><br>Identical to currently marketed predicate device. |
| **Biocompatibility:**<br><br>Aligners passed relevant biocompatibility studies required by ISO 10993-1 for a surface device that, in this case, is in contact with oral mucosal membranes for a prolonged period of time (24 hrs-30 days). All biocompatibility testing has been performed on finished aligners exposed to all manufacturing processes including cleaning. These are:<br>• Cytotoxicity<br>• Irritation<br>• Sensitization | **Biocompatibility:**<br><br>The modified Invisalign system aligners and the currently-marketed device are made from the identical material and have an identical biocompatibility spectrum. |
| **Aligner Material Strength:**<br><br>Aligner material must exert load of magnitude great enough to result in tooth movement. | **Aligner Material Strength:**<br><br>The modified Invisalign system aligners exhibit identical material strength as that of the aligners in the currently-marketed Invisalign system because they consist of the same material and the manufacturing process is the same. |

298

| | |
|---|---|
| **Aligner Durability:**<br><br>The aligners must be durable enough to withstand oral environmental conditions for minimum duration of two weeks. | **Aligner Durability:**<br><br>Identical to the existing predicate device. The modified Invisalign system aligners are identical to the current Invisalign system, because they are made from the same raw material by the same process of manufacturing and have the same technical features. |
| **Thermoformability – Adaptation:**<br><br>The aligners' raw material must form accurately to capture dental details. | **Thermoformability – Adaptation:**<br><br>Identical to currently marketed predicate device. The modified Invisalign system aligners conform to the dental details in the same way as the Invisalign system currently being commercialized, because they are made from the same raw material, and by the same process of manufacturing. |
| **Stain resistance:**<br><br>The aligners must have enough resistance from staining caused by soft drinks. | **Stain resistance:**<br><br>The modified Invisalign system aligners behave identically to the existing Invisalign system because they are made from the same raw material and by the same process of manufacturing. |
| **Technology, Performance and Compatibility** | **Features:** |
| **Chemical resistance to Invisalign Cleaning Crystals:**<br><br>The aligner exhibits chemical resistance to the (b)(4) | **Chemical resistance to Invisalign Cleaning Crystals:**<br><br>The modified Invisalign system aligners and the Invisalign system aligners react identically to the chemical in the (b)(4) because they are fabricated from the same raw material using the same process of manufacture. |
| **Compatibility with Invisalign Ancillary Products:**<br><br>The aligners must have sufficient bonding strength to Invisalign ancillary products such as buttons and pontics. | **Compatibility with Invisalign Ancillary Products:**<br><br>The modified Invisalign system aligners bond to the ancillary dental products in an identical manner as the currently marketed Invisalign system because they are made from the same raw material and by the same process of manufacturing. |
| **Aligner Wearing Characteristics:**<br><br>Aligners must be inert enough to minimize dry mouth, odor and irritation. | **Aligner Wearing Characteristics:**<br><br>The modified Invisalign system aligners are also inert exactly like the existing Invisalign system because they |

249

| | |
|---|---|
| | are made from the same raw material, and by the same process of manufacturing. |
| **Manufacturing Process:**<br><br>The existing Invisalign system is manufactured using an automated state of the art process. | **Manufacturing Process:**<br><br>The manufacturing process used to manufacture the modified aligners is identical to the process used for existing predicate device. |
| **Software:**<br><br>Proprietary software is used in the manufacturing process of the currently commercialized aligners. | **Software:**<br><br>There have not been any changes to the software used in the manufacture of the modified Invisalign system. |
| **Labeling Changes in the Instructions for Use.** | **Change of Contra-indications to Precautions:** |
| **Contra-indications:**<br><br>Adult and Adolescent patients presenting the following conditions:<br><br>1. **Severe open bite** | **Precautions:**<br><br>Treatment of severe open bite, severe overjet, mixed dentition, and/or skeletally narrow jaw may require supplemental treatment in addition to aligner treatment.<br><br>Skeletal expanders, bonded auxiliaries, elastics, and other fixed and/or removable orthodontic appliances, may be needed for more complicated treatment plans where aligners alone may not be adequate to achieve the desired outcome. |
| **Contra-indications:** | **Precautions:** |
| 2. **Severe overjet** | Treatment of severe open bite, severe overjet, mixed dentition, and/or skeletally narrow jaw may require supplemental treatment in addition to aligner treatment.<br><br>Skeletal expanders, bonded auxiliaries, elastics, and other fixed and/or removable orthodontic appliances, may be needed for more complicated treatment plans where aligners alone may not be adequate to achieve the desired outcome. |

300

| | |
|---|---|
| **3. Tooth malocclusion requiring surgical correction** | Oral surgery may be necessary to correct severe crowding or jaw imbalances. If oral surgery is required, risks associated with anesthesia and proper healing must be taken into account prior to treatment. |
| **4. Patients with mixed dentition** | Treatment of severe open bite, severe overjet, mixed dentition, and/or skeletally narrow jaw may require supplemental treatment in addition to aligner treatment.<br><br>Atypically-shaped, erupting, and/or missing teeth may affect aligner adaptation and may affect the ability to achieve the desired results.<br><br>The following will also be added to the Directions for Use section:<br><br>If additional aligners are needed, new impressions may be submitted for fabrication of aligners customized for current state of dentition. |
| **5. Adolescent patients with a skeletally narrow jaw** | Treatment of severe open bite, severe overjet, mixed dentition, and/or skeletally narrow jaw may require supplemental treatment in addition to aligner treatment.<br><br>Skeletal expanders, bonded auxiliaries, elastics, and other fixed and/or removable orthodontic appliances, may be needed for more complicated treatment plans where aligners alone may not be adequate to achieve the desired outcome.<br><br>The "adolescent" condition is also being removed, because these precautions should apply to all patient age groups, and not just to adolescents. |
| **6. Adult patients with dental prosthetics/implants** | Existing dental restorations (e.g., crowns, bridges) may become dislodged and require re-cementation or, in some instances, replacement.<br><br>Attachments may fall off and require replacement.<br><br>Aligners are not effective in the movement of dental implants. |

This Premarket Notification is being submitted solely to incorporate the above listed labeling changes to the existing Invisalign system (K981095).

301

- There are no changes in the technological characteristics of the modified device when compared to the predicate device. The design, raw material, and chemical composition, device features as well as technical characteristics of the modified device and existing predicate device are identical.
- There are no changes in the manufacturing processes and related software required to accommodate the labeling changes.

Thus, based on the similar indications for use and same technological characteristics of the currently marketed, predicate device (K981095) and the Invisalign system with the modified labeling, the two are considered substantially equivalent (21 CFR 807.100).

302

## 510(k) Premarket Notification Database

| | |
|---|---|
| **Device Classification Name** | Aligner, Sequential |
| **510(K) Number** | K981095 |
| **Device Name** | ALIGN SYSTEM |
| **Applicant** | ALIGN TECHNOLOGY<br>18140 Smokesignal Dr.<br>San Diego, CA 92127 |
| **Contact** | Carol Patterson |
| **Regulation Number** | 872.5470 |
| **Classification Product Code** | NXC |
| **Date Received** | 03/26/1998 |
| **Decision Date** | 09/08/1998 |
| **Decision** | Substantially Equivalent (SE) |
| **Classification Advisory Committee** | Dental |
| **Review Advisory Committee** | Dental |
| **Statement/Summary/Purged Status** | Summary Only |
| **Summary** | Summary |
| **Type** | Traditional |
| **Reviewed By Third Party** | No |
| **Expedited Review** | No |

Database Updated 06/06/2008

DEPARTMENT OF HEALTH & HUMAN SERVICES

Public Health Service

Food and Drug Administration
9200 Corporate Boulevard
Rockville MD 20850

Align Technology, Incorporated
881 Martin Avenue
Santa Clara, California 95050

MAR 2 0 2006

Re: K981095
Trade/Device Name: Align System
Regulation Number: 872.5470
Regulation Name: Orthodontic Plastic Bracket
Regulatory Class: II
Product Code: NXC
Dated: July 30, 1998
Received: July 31, 1998

Dear Mr. Kolesar:

This letter corrects our substantially equivalent letter of September 8, 1998. We are issuing this letter solely because The Align System, as described in the indication for use, is equivalent to an orthodontic plastic bracket.

We have reviewed your Section 510(k) premarket notification of intent to market the device referenced above and have determined the device is substantially equivalent (for the indications for use stated in the enclosure) to legally marketed predicate devices marketed in interstate commerce prior to May 28, 1976, the enactment date of the Medical Device Amendments or to devices that have been reclassified in accordance with the provisions of the Federal Food, Drug, and Cosmetic Act (Act) that do not require approval of a premarket approval (PMA). You may, therefore, market the device, subject to the general controls provisions of the Act. The general controls provisions of the Act include requirements for annual registration, listing of devices, good manufacturing practice, labeling, and prohibitions against misbranding and adulteration.

If your device is classified (see above) into either class II (Special Controls) or class III (PMA), it may be subject to additional controls. Existing major regulations affecting your device can be found in the Code of Federal Regulations, Title 21, Parts 800 to 898. In addition, FDA may publish further announcements concerning your device in the Federal Register.

304

Please be advised that FDA's issuance of a substantial equivalence determination does not mean that FDA has made a determination that your device complies with other requirements of the Act or any Federal statutes and regulations administered by other Federal agencies. You must comply with all the Act's requirements, including, but not limited to: registration and listing (21 CFR Part 807); labeling (21 CFR Part 801); good manufacturing practice requirements as set forth in the quality systems (QS) regulation (21 CFR Part 820); and if applicable, the electronic product radiation control provisions (sections 531-542 of the Act); 21 CFR 1000-1050.

This letter will allow you to continue marketing your device as described in your Section 510(k) premarket notification. The FDA finding of substantial equivalence of your device to a legally marketed predicate device results in a classification for your device and thus, permits your device to proceed to the market.

If you desire specific advice for your device on our labeling regulation (21 CFR Part 801), please contact the Office of Compliance at (240) 276-0115. Also, please note the regulation entitled, "Misbranding by reference to premarket notification" (21CFR Part 807.97). You may obtain other general information on your responsibilities under the Act from the Division of Small Manufacturers, International and Consumer Assistance at its toll-free number (800) 638-2041 or (301) 443-6597 or at its Internet address http://www.fda.gov/cdrh/dsma/dsmamain.html

Sincerely yours,

Chiu Lin, Ph.D.
Director
Division of Anesthesiology, General Hospital,
Infection Control and Dental Devices
Office of Device Evaluation
Center for Devices and
Radiological Health

Enclosure

305

# Proposed Labeling

306

## Align Technology, Inc.,

## Modified Invisalign® system

## Proposed Labeling

This section contains the proposed labeling for the modified Invisalign system. Please find included:

I. Copy of the proposed Instructions for Use (IFU)
II. A copy of the predicate device IFU with additions (in yellow)
III. A copy of the predicate device IFU with deletions (in red) respectively.

There are no additional promotional activities or materials planned for the proposed indication of the device.

307

## DEVICE DESCRIPTION

The Invisalign System consists of a series of doctor-prescribed, custom manufactured, thin, ar plastic removable orthodontic appliances ners) that gently move the patient's teeth in ncrements from their original state to a optimal, treated state.

## INDICATIONS FOR USE

The Invisalign System is indicated for the alignment of teeth during orthodontic treatment of malocclusion.

## CONTRAINDICATION

The Invisalign System is contraindicated for use in patients with the following condition:

- Active periodontal disease.

## WARNINGS

- In rare instances, some patients may be allergic to the plastic aligner material. In such cases, discontinue use and consult a health care professional immediately. Align Technology must also be notified.
- Orthodontic appliances, or parts thereof, may be accidentally swallowed or aspirated and may be harmful.

## PRECAUTIONS

- Keep aligners away from hot water and harsh chemicals.
- Keep aligners out of reach of young children and pets.
- Always store aligners in a cool, dry place.
- Treatment of severe open bite, severe overjet, mixed dentition, and/or skeletally narrow jaw may require supplemental treatment in addition to aligner treatment.
- Skeletal expanders, bonded auxiliaries, astics, and other fixed and/or removable odontic appliances, may be needed for e complicated treatment plans where aligners alone may not be adequate to achieve the desired outcome.
- Oral surgery may be necessary to correct severe crowding or jaw imbalances. If oral surgery is required, risks associated with anesthesia and proper healing must be taken into account prior to treatment.
- Atypically-shaped, erupting, and/or missing teeth may affect aligner adaptation and may affect the ability to achieve the desired results.
- Existing dental restorations (*e.g.*, crowns, bridges) may become dislodged and require re-cementation or, in some instances, replacement.
- Aligners are not effective in the movement of dental implants.
- Certain medical conditions and use of certain medications may affect orthodontic treatment outcomes.
- Dental tenderness may be experienced following initial aligner placement and after switching to each new aligner in the series.
- The product may temporarily affect speech and may result in a lisp, although any speech impediment associated with the product usually disappears within one or two weeks.
- Failure to wear the appliances for the prescribed number of hours per day and/or not using the product as directed by your doctor can lengthen the treatment time and affect the ability to achieve the desired results.
- ms, cheeks, or lips may be scratched or ated by the product.
- Attachments may be temporarily bonded to one or more teeth during the course of treatment to facilitate aligner retention and/or tooth movement.
- Attachments may fall off and require replacement.
- All attachments should be removed upon completion of treatment.
- Risks associated with interproximal reduction, which may be prescribed to create space for tooth movement as part of treatment must be taken into account.
- Tooth decay, periodontal disease, and permanent markings from stains and decalcification may occur if patients do not brush and floss their teeth properly during treatment or if they consume foods or beverages containing sugar while wearing aligners.
- The bite may change throughout the course of treatment and may result in temporary patient discomfort.
- At the end of treatment, the bite may require adjustment by the doctor.
- Teeth may shift position after treatment. Consistent wearing of retainers at the end of treatment should reduce this tendency.
- All teeth should be at least partially covered to help prevent supra-eruption.
- Temporary increase in salivation or dryness of mouth may occur.
- A tooth that has been previously traumatized or significantly restored may be aggravated. In rare instances, the useful life of the tooth may be reduced, the tooth may require additional dental treatment such as endodontic and/or additional restorative work, and/or the tooth may be lost.
- The health of the bone and gums which support the teeth may be impaired or aggravated.
- The length of the roots of the teeth may be shortened during orthodontic treatment, which may become a threat to the longevity of the teeth.
- In rare instances, problems in the temporo-mandibular joint (jaw joint) may result in joint pain, headaches, or ear problems.

## DIRECTIONS FOR USE

**1.** Rinse new aligners with cold water prior to using them.

**2.** If an extraction has been performed as a part of treatment, retain the space while the area is healing. Attachments should be bonded only after the extraction site has completely healed.

**3.** Review the "Use and Care Instructions for your Invisalign Aligners" brochure with your patient.

**4.** Each set of aligners is designed to be replaced after approximately 300 hours of wear (typically 14 days for 20-22 hours per day).

**5.** Seat aligner #1 on the patient's teeth and visually inspect for soft tissue impingement. If necessary, trim the aligners. Following trimming, polish the aligners using the EZ-Trim™ Polishing Wheels.

**6.** Complete any attachment placement; perform any necessary interproximal reduction (IPR) procedures using the Invisalign Interproximal Reduction Kit.

**7.** Add pontics to the aligners, if applicable, using the Invisalign Pontic System.

**8.** Provide the patient with the blue and red Invisalign aligner storage cases. The blue case is for the current set of aligners; the red case is for the most recent previously worn set.

**9.** At each appointment, check teeth for tight interproximal contacts and, if needed, perform IPR as prescribed. Check for appropriate aligner stage and their fit, and review the ClinCheck® setup to monitor treatment progress as needed.

**10.** Dispense the next set of aligner stages. The patient should be allotted enough aligners to last until the next appointment.

**11.** If additional aligners are needed, new impressions may be required.

**12.** At the end of treatment, retainer wear is highly recommended.

**13.** For other procedural details, consult the Invisalign training materials.

## HOW SUPPLIED

Each aligner is cleaned, disinfected, and packaged prior to delivery. Each aligner contains the Invisalign logo and a number which identifies the patient's case number and treatment stage.

**Caution: Federal law restricts this device to sale by or on the order of a licensed dental professional.**

© 2007 Align Technology, Inc. All rights reserved. Invisalign and ClinCheck are registered trademarks of Align Technology, Inc.

The Invisalign System is covered under one or more of the following U.S. Patents: D457,638; 5,975,893; 6,210,162; 6,217,325; 6,227,850; 6,299,440; 6,309,215; 6,318,994; 6,371,761; 6,386,878; 6,394,801; 6,398,548; 6,406,292; 6,409,504; 6,450,807; 6,514,074; 6,602,070; 6,626,666; 6,629,840; 6,685,469; 6,685,470; 6,699,037; 6,705,863; 6,722,880; 6,767,208; 6,830,450; 6,948,931; 6,976,627; 6,979,196; 7,040,896; 7,059,850; 7,125,248; 6,457,972; 6,463,344; 6,471,511; 6,633,789; 6,665,570; 6,688,886; 6,726,478; 6,729,876; 7,063,532; as well as patents of other countries and pending U.S. patent applications.

Align Technology, Inc.
881 Martin Ave
Santa Clara, CA 95050
USA
888-82-ALIGN
www.invisalign.com

**EU Authorized Representative**
Align Technology BV
Arlandaweg 161
1043 HS Amsterdam
Netherlands

D0127, Rev. G

308

**Yellow highlight indicates changes that are being added into the new labeling.**

# INVISALIGN® SYSTEM INSTRUCTIONS FOR USE

## DEVICE DESCRIPTION

The Invisalign System consists of a series of doctor-prescribed, custom manufactured, thin, clear plastic removable orthodontic appliances (aligners) that gently move the patient's teeth in small increments from their original state to a more optimal, treated state.

## INDICATIONS FOR USE

The Invisalign System is indicated for the alignment of teeth during orthodontic treatment of malocclusion.

## CONTRAINDICATION

The Invisalign System is contraindicated for use in patients with the following condition:

- Active periodontal disease.

## WARNINGS

309

- In rare instances, some patients may be allergic to the plastic aligner material. In such cases, discontinue use and consult a health care professional immediately. Align Technology must also be notified.
- Orthodontic appliances, or parts thereof, may be accidentally swallowed or aspirated and may be harmful.

**PRECAUTIONS**

- Keep aligners away from hot water and harsh chemicals.
- Keep aligners out of reach of young children and pets.
- Always store aligners in a cool, dry place.
- Treatment of severe open bite, severe overjet, mixed dentition, and/or skeletally narrow jaw may require supplemental treatment in addition to aligner treatment.
- Skeletal expanders, bonded auxiliaries, elastics, and other fixed and/or removable orthodontic appliances, may be needed for more complicated treatment plans where aligners alone may not be adequate to achieve the desired outcome.

- Oral surgery may be necessary to correct severe crowding or jaw imbalances. If oral surgery is required, risks associated with anesthesia and proper healing must be taken into account prior to treatment.
- Atypically-shaped, erupting, and/or missing teeth may affect aligner adaptation and may affect the ability to achieve the desired results.
- Existing dental restorations (*e.g.*, crowns, bridges) may become dislodged and require re-cementation or, in some instances, replacement.
- Aligners are not effective in the movement of dental implants.
- Certain medical conditions and use of certain medications may affect orthodontic treatment outcomes.
- Dental tenderness may be experienced following initial aligner placement and after switching to each new aligner in the series.
- The product may temporarily affect speech and may result in a lisp, although any speech impediment associated with the product usually disappears within one or two weeks.
- Failure to wear the appliances for the prescribed number of hours per day and/or not using the product as directed by your doctor can

311

lengthen the treatment time and affect the ability to achieve the desired results.

- Gums, cheeks, or lips may be scratched or irritated by the product.
- Attachments may be temporarily bonded to one or more teeth during the course of treatment to facilitate aligner retention and/or tooth movement.
- Attachments may fall off and require replacement.
- All attachments should be removed upon completion of treatment.
- Risks associated with interproximal reduction, which may be prescribed to create space for tooth movement as part of treatment must be taken into account.
- Tooth decay, periodontal disease, and permanent markings from stains and decalcification may occur if patients do not brush and floss their teeth properly during treatment or if they consume foods or beverages containing sugar while wearing aligners.
- The bite may change throughout the course of treatment and may result in temporary patient discomfort.
- At the end of treatment, the bite may require adjustment by the doctor.

- Teeth may shift position after treatment. Consistent wearing of retainers at the end of treatment should reduce this tendency.
- All teeth should be at least partially covered to help prevent supra-eruption.
- Temporary increase in salivation or dryness of mouth may occur.
- A tooth that has been previously traumatized or significantly restored may be aggravated. In rare instances, the useful life of the tooth may be reduced, the tooth may require additional dental treatment such as endodontic and/or additional restorative work, and/or the tooth may be lost.
- The health of the bone and gums which support the teeth may be impaired or aggravated.
- The length of the roots of the teeth may be shortened during orthodontic treatment, which may become a threat to the longevity of the teeth.
- In rare instances, problems in the temporo-mandibular joint (jaw joint) may result in joint pain, headaches, or ear problems.

## DIRECTIONS FOR USE

**1.** Rinse new aligners with cold water prior to using them.

**2.** If an extraction has been performed as a part of treatment, retain the space while the area is healing. Attachments should be bonded only after the extraction site has completely healed.

**3.** Review the "Use and Care Instructions for your Invisalign Aligners" brochure with your patient.

**4.** Each set of aligners is designed to be replaced after approximately 300 hours of wear (typically 14 days for 20-22 hours per day).

**5.** Seat aligner #1 on the patient's teeth and visually inspect for soft tissue impingement. If necessary, trim the aligners. Following trimming, polish the aligners using the EZ-Trim™ Polishing Wheels.

**6.** Complete any attachment placement; perform any necessary interproximal reduction (IPR) procedures using the Invisalign Interproximal Reduction Kit.

**7.** Add pontics to the aligners, if applicable, using the Invisalign Pontic System.

**8.** Provide the patient with the blue and red Invisalign aligner storage cases. The blue case is for the current set of aligners; the red case is for the most recent previously worn set.

**9.** At each appointment, check teeth for tight interproximal contacts and, if needed, perform IPR as prescribed. Check for appropriate aligner stage and their fit, and review the ClinCheck® setup to monitor treatment progress as needed.

**10.** Dispense the next set of aligner stages. The patient should be allotted enough aligners to last until the next appointment.

**11.** If additional aligners are needed, new impressions may be required.

**12.** At the end of treatment, retainer wear is highly recommended.

**13.** For other procedural details, consult the Invisalign training materials.

## HOW SUPPLIED

Each aligner is cleaned, disinfected, and packaged prior to delivery. Each aligner contains the Invisalign logo and a number which identifies the patient's case number and treatment stage.

**Caution: Federal law restricts this device to sale by or on the order of a licensed dental professional.**

© 2007 Align Technology, Inc. All rights reserved.

Invisalign and ClinCheck are registered trademarks of Align Technology, Inc.

The Invisalign System is covered under one or more of the following U.S. Patents: D457,638; 5,975,893; 6,210,162; 6,217,325; 6,227,850; 6,299,440; 6,309,215; 6,318,994; 6,371,761; 6,386,878; 6,394,801; 6,398,548; 6,406,292; 6,409,504; 6,450,807; 6,514,074; 6,602,070; 6,626,666; 6,629,840; 6,685,469; 6,685,470; 6,699,037; 6,705,863; 6,722,880; 6,767,208; 6,830,450; 6,948,931; 6,976,627; 6,979,196; 7,040,896; 7,059,850; 7,125,248; 6,457,972; 6,463,344; 6,471,511; 6,633,789; 6,665,570; 6,688,886; 6,726,478; 6,729,876; 7,063,532; as well as patents of other countries and pending U.S. patent applications.

316

Align Technology, Inc.

881 Martin Ave

Santa Clara, CA 95050

USA

888-82-ALIGN

www.invisalign.com

**EU Authorized Representative**

Align Technology BV

Arlandaweg 161

1043 HS Amsterdam

Netherlands

D0127, Rev. G

317

Red highlight indicates changes being removed from the current labeling.

## INSTRUCTIONS FOR USE

## DEVICE DESCRIPTION

The Invisalign System consists of a series of doctor-prescribed, custom manufactured, thin, clear plastic removable orthodontic appliances (aligners) that move the patient's teeth in small increments from their original state to a more optimal, treated state.

## INDICATIONS FOR USE

The Invisalign System is indicated for the treatment of tooth malocclusion in patients with permanent dentition (i.e., all second molars). The Invisalign System positions teeth by way of continuous, gentle force.

## CONTRAINDICATIONS

The Invisalign System is contraindicated for use in adult and adolescent patients presenting the following conditions:

- Severe open bite;

• Severe overjet;

• Tooth malocclusion requiring surgical correction;

• Patients with mixed dentition;

• Adolescent patients with a skeletally narrow jaw;

• Adult patients with dental prosthetics/implants;

• Adult patients in which the malocclusion is periodontally involved.

## WARNINGS

• In rare instances, some patients may be allergic to the plastic aligner material. In such cases, discontinue use and consult a health care professional immediately. Align Technology must also be notified.

• Orthodontic appliances, or parts thereof, may be accidentally swallowed or aspirated and may be harmful.

## PRECAUTIONS

• Keep aligners away from hot water and harsh chemicals.

• Keep aligners out of reach of young children and pets.

• Always store aligners in a cool, dry place.

• Certain medical conditions and use of certain medications may affect orthodontic treatment outcomes.

## GENERAL RISKS TO PATIENTS

The use of the Invisalign System will not expose the patient to risks other than those posed by conventional orthodontic treatment. These risks may include the following:

• Dental tenderness may be experienced following initial aligner placement and after switching to each new aligner in the series;

• The product may temporarily affect speech and may result in a lisp, although any speech impediment associated with the product usually disappears within one or two weeks;

• Failure to wear the appliances for the required number of hours per day and/or not using the product as directed by your doctor can lengthen the treatment time and affect the ability to achieve the desired results;

320

• Gums, cheeks, or lips may be scratched or irritated by the product;

• Attachments may be temporarily bonded to one or more teeth during the course of treatment to facilitate aligner retention and/or tooth movement;

• Attachments may fall off and require replacement;

• All attachments should be removed upon completion of treatment;

• Risks associated with interproximal reduction, which may be required to create space to allow tooth movement as part of the prescribed treatment;

• Tooth decay, periodontal disease, and permanent markings from stains and decalcification may occur if patients do not brush and floss their teeth properly during treatment or if they consume foods or beverages containing sugar while wearing aligners;

• Supplemental treatment, including bonded auxiliaries and/or fixed orthodontic appliances, may be needed for more complicated

treatment plans where aligners alone may not be adequate to achieve the desired outcome;

• Teeth may shift position after treatment. Faithful wearing of retainers at the end of treatment should reduce this tendency;

• All teeth should be at least partially covered to prevent supra-eruption;

• Temporary increase in salivation or dryness of mouth may occur;

• Atypically-shaped teeth can affect aligner adaptation and may affect the ability to achieve the desired results;

• Existing dental restorations (e.g., crowns) may become dislodged and require re-cementation or, in some instances, replacement;

• Oral surgery may be necessary to correct severe crowding or jaw imbalances. If oral surgery is required, risks associated with anesthesia and proper healing must be taken into account prior to treatment;

• A tooth that has been previously traumatized or significantly restored may be aggravated. In rare instances, the useful life of the tooth may be reduced, the tooth may require additional dental

treatment such as endodontic and/or additional restorative work, and/or the tooth may be lost;

• Health of the bone and gums which support the teeth may be impaired or aggravated;

• The length of the roots of the teeth may be shortened during orthodontic treatment, which may become a threat to the longevity of the teeth;

• In rare instances, problems in the temporo-mandibular joint (jaw joint) may result in joint pain, headaches, or ear problems;

• The bite may change throughout the course of treatment and may result in temporary patient discomfort. At the end of treatment, the bite may require adjustment by the doctor.

**DIRECTIONS FOR USE**

1. Wash hands and rinse new aligners with cold water prior to handling aligners.

2. If an extraction has been performed as a part of treatment, retain the space while the area is healing. Attachments should be bonded only after the extraction site has completely healed.

3. Review the "Use and Care Instructions for your Invisalign Aligners" brochure with your patient.

4. Each set of aligners is designed to be changed after approximately 300 hours of wear (typically 14 days for 20-22 hours per day).

5. Seat aligner #1 on the patient's teeth and visually inspect for soft tissue impingement. If necessary, trim and polish the aligners using the EZ-Trim™ Polishing Wheels.

6. Complete any attachment placement; perform any necessary interproximal reduction (IPR) procedures using the Invisalign Interproximal Reduction Kit.

7. Add pontics to the aligners, if applicable, using the Invisalign Pontic System.

8. Provide the patient with the blue and red Invisalign aligner storage cases. The blue case is for the current set of aligners; the red case is for the most recent previously worn set.

9. Dispense the next set of aligner stages. The patient should be allotted enough aligners to last until the next appointment.

10. At each appointment, check teeth for tight interproximal contacts and perform any additional IPR, as required. Check for appropriate aligner fit, and review the ClinCheck® setup to monitor treatment progress as needed.

11. At the end of treatment, retainer wear is highly recommended.

12. For other procedural details, consult the Invisalign certification materials.

**HOW SUPPLIED**

Each aligner is cleaned, disinfected, and packaged prior to delivery. Each aligner contains the Invisalign logo and a number which identifies the patient's case number and treatment stage.

Caution: Federal law restricts this device to sale by or on the order of a licensed dental professional.

© 2006 Align Technology, Inc. All rights reserved.

Invisalign and ClinCheck are registered trademarks of Align Technology, Inc.

The Invisalign System is covered under one or more of the following U.S. Patents: D457,638; 5,975,893; 6,210,162; 6,217,325; 6,227,850; 6,299,440; 6,309,215; 6,318,994; 6,371,761; 6,386,878; 6,394,801; 6,398,548; 6,406,292; 6,409,504; 6,450,807; 6,514,074; 6,602,070; 6,626,666; 6,629,840; 6,685,469; 6,685,470; 6,699,037; 6,705,863; 6,722,880; 6,767,208; 6,830,450; 6,948,931; 6,976,627; 6,979,196; 7,040,896; 7,059,850; 7,125,248; 6,457,972; 6,463,344; 6,471,511; 6,633,789; 6,665,570; 6,688,886; 6,726,478; 6,729,876; 7,063,532; as well as patents of other countries and pending U.S. patent applications.

326

Align Technology, Inc.

881 Martin Ave

Santa Clara, CA 95050

USA

888-82-ALIGN

www.invisalign.com

EU Authorized Representative

Align Technology BV

Arlandaweg 161

1043 HS Amsterdam

Netherlands

INVISALIGN® SYSTEM INSTRUCTIONS FOR USE

D0127 Rev. F

327

# Sterilization and Shelf Life

# Align Technology, Inc.,

## Modified Invisalign® system

## Sterilization

The Invisalign system is not supplied sterile and so is not subject to sterilization validation.

329

# Biocompatibility

330

## Align Technology, Inc.,

## Modified Invisalign® system

## Biocompatibility Assessment

Relevant biocompatibility testing required by ISO 10993-1 for surface devices in contact with oral mucosal membranes for a prolonged period of time (24hrs - 30 days) was conducted on the existing predicate device. Finished aligners exposed to all manufacturing processes passed all required biocompatibility tests.

Test reports for:

- Cytotoxicity
- Irritation
- Sensitization

are included in this section of the submission for your convenience.

# REPORT

**TEST FACILITY:**

NAMSA
9 Morgan
Irvine, CA 92618

**SPONSOR:**

Li-Hung (Leo) Su
Align Technology
881 Martin Avenue
Santa Clara, CA 95050

CONFIDENTIAL

**STUDY TITLE:**

Cytotoxicity Study Using the ISO Elution Method (1X MEM Extract)

**TEST ARTICLE:**

Aligners packaged with modified aligner bag P/N 5126 rev. B

**IDENTIFICATION NO.:**

Not Supplied

## TABLE OF CONTENTS

Page


Summary ..... 3

1. Introduction ..... 4
2. Materials ..... 4
3. Test System ..... 4
4. Methods ..... 4
5. Results ..... 5
6. Conclusion ..... 5
7. Records ..... 5
8. References ..... 5

Appendix 1 - Reactivity Grades For Elution Testing ..... 6


333

## Summary

An *in vitro* biocompatibility study, based on the International Organization for Standardization 10993: Biological Evaluation of Medical Devices, Part 5: Tests for Cytotoxicity: *in vitro* Methods guidelines, was conducted on the test article, Aligners packaged with modified aligner bag P/N 5126 rev. B, Not Supplied, to determine the potential for cytotoxicity. A single extract of the test article was prepared using single strength Minimum Essential Medium supplemented with 5% serum and 2% antibiotics (1X MEM). This test extract was placed onto three separate monolayers of L-929 mouse fibroblast cells propagated in 5% $CO_2$. Three separate monolayers were prepared for the reagent control, negative control and for the positive control. All monolayers were incubated at 37°C in the presence of 5% $CO_2$ for 48 hours. The monolayer in the test, reagent control, negative control and positive control wells was examined microscopically at 48 hours to determine any change in cell morphology.

Under the conditions of this study, the 1X MEM test extract showed no evidence of causing cell lysis or toxicity. The 1X MEM test extract met the requirements of the test since the grade was less than a grade 2 (mild reactivity). The reagent control, negative control and the positive control performed as anticipated.

Study and Supervisory Personnel:

Angela K. Yi, B.S.
Sergio M. Fujino, B.S.
David N. Tran, B.S.

Approved by:

Samantha D. Amor, B.S.
Supervisor, In Vitro

03-12-07
Date Completed

/dmc

Authorization for duplication of this report, except in whole, is reserved pending NAMSA's written approval.

334

## 1. Introduction

**Purpose**
The test article identified below was extracted, and the extract was subjected to an *in vitro* cytotoxicity study for biocompatibility based on the requirements of the International Organization for Standardization 10993: Biological Evaluation of Medical Devices, Part 5: Tests for Cytotoxicity: *in vitro* Methods. The test was performed to determine whether leachables extracted from the material would cause cytotoxicity.

**Dates**
The test article was received on March 8, 2007. The cells were first exposed to the extract March 10, 2007, and the observations were concluded on March 12, 2007.

## 2. Materials

The test article provided by the sponsor was identified and handled as follows:

| | |
|---|---|
| **Test Article:** | Aligners packaged with modified aligner bag P/N 5126 rev. B |
| **Identification No.:** | Not Supplied |
| **Storage Conditions:** | Room Temperature |
| **Extraction Vehicle:** | Single strength Minimum Essential Medium supplemented with 5% serum and 2% antibiotics (1X MEM) |
| **Test Article Preparation:** | Based on the USP ratio of 4.0 g:20 ml, a 2.9 g portion of the test article was covered with 15.0 ml of 1X MEM. A single preparation was extracted with agitation at 37°C for 24 hours. |
| **Negative Control Preparation:** | High density polyethylene was used as the negative control. Based on the USP ratio of 60 $cm^2$:20 ml, a single 30.2 $cm^2$ portion of the control material was covered with 10.0 ml of 1X MEM. The preparation was subjected to the extraction conditions previously described for the test article. |
| **Reagent Control Preparation:** | A single aliquot of 1X MEM without test material was subjected to the same extraction conditions as described for the test article. |
| **Positive Control Preparation:** | The current NAMSA positive control, tin stabilized polyvinylchloride, was used. Based on the USP ratio of 60 $cm^2$:20 ml, a single 29.6 $cm^2$ portion of the control material was covered with 9.9 ml of 1X MEM and extracted with agitation at 37°C for 24 hours. |
| **Condition of Extracts:** | Test: Clear<br>Reagent Control: Clear<br>Negative Control: Clear<br>Positive Control: Clear |

## 3. Test System

**Test System Management**
L-929, mouse fibroblast cells, (ATCC CCL 1, NCTC Clone 929, of strain L, or equivalent source) were propagated and maintained in open wells containing single strength Minimum Essential Medium supplemented with 5% serum and 2% antibiotics (1X MEM) in a gaseous environment of 5% carbon dioxide ($CO_2$). For this study, 10 $cm^2$ wells were seeded, labeled with passage number and date, and incubated at 37°C in 5% $CO_2$ to obtain sub-confluent monolayers of cells prior to use. Aseptic procedures were used in the handling of the cell cultures following approved NAMSA Standard Operating Procedures.

## 4. Methods

Triplicate culture wells were selected which contained a sub-confluent cell monolayer. The growth medium contained in triplicate cultures was replaced with 2 ml of the test extract. Similarly, triplicate cultures were replaced with 2 ml of the reagent

335

control, negative control and the positive control. Each well was labeled with the corresponding lab number, replicate number and the dosing date. The wells were incubated at 37°C in 5% $CO_2$ for 48 hours.

Following incubation, the cultures were examined microscopically (100X) to evaluate cellular characteristics and percent lysis. The color of the test medium was observed. A color shift toward yellow was associated with an acidic pH range and a color shift toward magenta to purple was associated with an alkaline pH range.

Each culture well was evaluated for percent lysis and cellular characteristics using the following table (direct excerpt from USP):

| Grade | Reactivity | Conditions of all Cultures |
|---|---|---|
| 0 | None | Discrete intracytoplasmic granules; no cell lysis |
| 1 | Slight | Not more than 20% of the cells are round, loosely attached, and without intracytoplasmic granules; occasional lysed cells are present |
| 2 | Mild | Not more than 50% of the cells are round and devoid of intracytoplasmic granules; no extensive cell lysis and empty areas between cells |
| 3 | Moderate | Not more than 70% of the cell layers contain rounded cells or are lysed |
| 4 | Severe | Nearly complete destruction of the cell layers |

For the test to be valid, the reagent control and the negative control must have had a reactivity of none (grade 0) and the positive control must have been a grade 3 or 4. The test sample met the requirements of the test if the biological response was less than or equal to grade 2 (mild). The test would have been repeated if the controls did not perform as anticipated and/or if all three test wells did not yield the same conclusion.

## 5. Results

See Appendix 1 for results.

pH Observation: No pH shift observed at 48 hours.

## 6. Conclusion

Under the conditions of this study, the 1X MEM test extract showed no evidence of causing cell lysis or toxicity. The 1X MEM test extract met the requirements of the test since the grade was less than a grade 2 (mild reactivity). The reagent control, negative control and the positive control performed as anticipated.

Results and conclusions apply only to the test article tested. Any extrapolation of these data to other samples is the sponsor's responsibility. All procedures were conducted in conformance with good manufacturing practices and ISO 13485:2003.

## 7. Records

All raw data pertaining to this study and a copy of the final report are retained in designated NAMSA archive files.

## 8. References


ISO 10993-5 (1999) Biological evaluation of medical devices – Part 5: Tests for cytotoxicity, *in vitro* methods.

USP 29 – NF 24 General Chapter <87> BIOLOGICAL RAECTIVITY TESTS, IN VITRO.

Wilsnack, R. E., "Quantitative Cell Culture Biocompatibility Testing of Medical Devices and Correlation to Animal Tests," *Biomaterials, Medical Devices and Artificial Organs* 4 (1976): 235-261.

Wilsnack, R. E., F. J. Meyer and J. G. Smith, "Human Cell Culture Toxicity Testing of Medical Devices and Correlation to Animal Tests," *Biomaterials, Medical Devices and Artificial Organs* 1 (1973): 543-562.


336

## Appendix 1 - Reactivity Grades For Elution Testing

| Well | Percent Rounding | Percent Cells Without Intracytoplasmic Granules | Percent Lysis | Grade | Reactivity |
|---|---|---|---|---|---|
| Test (1A) | 0 | 0 | 0 | 0 | None |
| Test (1B) | 0 | 0 | 0 | 0 | None |
| Test (1C) | 0 | 0 | 0 | 0 | None |
| Negative Control (1A) | 0 | 0 | 0 | 0 | None |
| Negative Control (1B) | 0 | 0 | 0 | 0 | None |
| Negative Control (1C) | 0 | 0 | 0 | 0 | None |
| Reagent Control (1A) | 0 | 0 | 0 | 0 | None |
| Reagent Control (1B) | 0 | 0 | 0 | 0 | None |
| Reagent Control (1C) | 0 | 0 | 0 | 0 | None |
| Positive Control (1A) | Not Applicable | Not Applicable | 100 | 4 | Severe |
| Positive Control (1B) | Not Applicable | Not Applicable | 100 | 4 | Severe |
| Positive Control (1C) | Not Applicable | Not Applicable | 100 | 4 | Severe |

337

**STUDY TITLE:**

ACUTE ORAL TOXICITY SCREEN IN THE RAT

(Modified FHSA Method)

**TEST ARTICLE:**

Clear Exceed Material Aligners - Invisalign™ Orthodontic Appliance

**IDENTIFICATION NO.:**

Align Technology #1201-8

**TEST FACILITY:**

NAMSA
California Division

**SPONSOR:**

LOC PHAN
ALIGN TECHNOLOGY, INC.
881 MARTIN AVE.
SANTA CLARA, CA 95050

338



NAMSA
Ensuring Medical Device Safety and Compliance™

Corp. Hdqtrs: 2261 Tracy Road, Northwood, OH 43619-1397 / 419.666.9455 / Fax 419.666.2954
3400 Cobb International Blvd., Kennesaw, GA 30152-7601 / 770.427.3101 / Fax 770.426.5692
9 Morgan, Irvine, CA 92618-2078 / 949.951.3110 / Fax 949.951.3280
Affiliates: France • Germany • Israel • Taiwan • United Kingdom

FOI - Page 231 of 446 Authorization for duplication of this report, except in whole, is reserved pending NAMSA's written approval.

TABLE OF CONTENTS

| | Page Number |
|---|---|
| SUMMARY | 3 |
| INTRODUCTION | 4 |
| MATERIALS | 4 |
| METHODS | 4-5 |
| RESULTS | 6 |
| CONCLUSION | 6 |
| RECORD STORAGE | 6 |
| TABLE | |
| I - INDIVIDUAL OBSERVATIONS | 7 |

339



NAMSA
Ensuring Medical Device Safety and Compliance™
Corp. Hdqtrs: 2261 Tracy Road, Northwood, OH 43619-1397 / 419.666.9455 / Fax 419.666.2954
3400 Cobb International Blvd., Kennesaw, GA 30152-7601 / 770.427.3101 / Fax 770.426.5692
9 Morgan, Irvine, CA 92618-2078 / 949.951.3110 / Fax 949.951.3280
Affiliates: France • Germany • Israel • Taiwan • United Kingdom

 Authorization for duplication of this report, except in whole, is reserved pending NAMSA's written approval. 1003U

## SUMMARY

The test article, Clear Exceed Material Aligners - Invisalign™ Orthodontic Appliance, Identification No. Align Technology #1201-8, was screened for oral toxicity. The test was conducted in accordance with the guidelines of the Federal Hazardous Substances Act (FHSA) Regulations, 16 CFR 1500, but was modified by NAMSA to reduce the number of animals from ten to five and the number of observation days from 14 to 7.

A single dose of 5 g/kg of body weight was gavaged to five rats. The animals were then observed for up to 7 days for any signs of toxicity.

Under the conditions of this study, there was no mortality or significant evidence of toxicity observed in the rats. The test article would not be considered toxic at a dose of 5 g/kg by the oral route in the rat.

Study and Supervisory Personnel:

Brenda Gonzales, A.S., LVT
David Vergil
Enrique Vazquez

Approved by:

Lubica Mikula, B.S.
Study Director, Toxicology

5-7-9
Date Completed

/nee

340



NAMSA
Ensuring Medical Device Safety and Compliance™

Corp. Hdqtrs: 2251 Tracy Road, Northwood, OH 43619-1397 / 419.666.9455 / Fax 419.666.2954
3400 Cobb International Blvd., Kennesaw, GA 30152-7601 / 770.427.3101 / Fax 770.426.5692
9 Morgan, Irvine, CA 92618-2078 / 949.951.3110 / Fax 949.951.3280
Affiliates: France • Germany • Israel • Taiwan • United Kingdom

FOI - Page 233 of 446 Authorization for duplication of this report, except in whole, is reserved pending NAMSA's written approval.

## INTRODUCTION

The test article identified below was screened for oral toxicity. The test was conducted in accordance with the guidelines of the Federal Hazardous Substances Act (FHSA) Regulations, 16 CFR 1500, but was modified by NAMSA to reduce the number of animals from ten to five and the number of observation days from 14 to 7. The purpose of the study was to determine the potential for systemic toxicity of the material following a single gavage in the rat. The test article was received on March 28, 2001 and additional sample was received on April 9, 2001. Animals were dosed on April 27, 2001, and the observations were concluded on May 4, 2001.

## MATERIALS

The sample provided by the sponsor was identified and handled as follows:

| | |
|---|---|
| Test Article: | Clear Exceed Material Aligners - Invisalign™ Orthodontic Appliance |
| Identification No: | Align Technology #1201-8 |
| Storage Conditions: | Room temperature |
| Preparation: | A 10 gram portion of solid test article (powder) was added to 40 ml of CSO. For this study, the density of the test article was determined to be 0.25 g/ml. |

## METHODS

Test System:

| | |
|---|---|
| Species: | Rat (*Rattus norvegicus*) |
| Strain: | Crl:CD (SD) BR |
| Source: | Charles River Laboratories |
| Sex: | Male |
| Body Weight Range: | 203 grams to 227 grams at dosing |
| Age: | No particular age was prescribed for this test |
| Acclimation Period: | Minimum 5 days |
| Number of Animals: | Five |
| Identification Method: | Ear punch |

Justification of Test System:

The rat has historically been used to establish hazardous substance labeling data. The oral route of dosing is selected as the strongest challenge for materials that could be accidentally ingested.

341



NAMSA
Ensuring Medical Device Safety and Compliance™
Corp. Hdqtrs: 2261 Tracy Road, Northwood, OH 43619-1397 / 419.666.9455 / Fax 419.666.2954
3400 Cobb International Blvd., Kennesaw, GA 30152-7601 / 770.427.3101 / Fax 770.426.5692
9 Morgan, Irvine, CA 92618-2078 / 949.951.3110 / Fax 949.951.3280
Affiliates: France • Germany • Israel • Taiwan • United Kingdom

 Authorization for duplication of this report, except in whole, is reserved pending NAMSA's written approval. 

Animal Management:

| | |
|---|---|
| Husbandry: | Conditions conformed to Standard Operating Procedures which are based on the "Guide for the Care and Use of Laboratory Animals." |
| Food: | PROLAB® R-M-H 1000 Rodent Diet was provided daily. Food was withheld 16-20 hours prior to dosing. |
| Water: | Freely available, municipal (Irvine, CA) water was delivered through an automatic watering system. |
| Contaminants: | Reasonably expected contaminants in feed or water supplies did not have the potential to influence the outcome of this test. |
| Housing: | Animals were housed in groups per sex in stainless steel suspended cages identified by a card indicating the lab number, animal numbers, test code, sex, animal code and date dosed. |
| Environmental: | The room temperature was monitored daily. The temperature range for the room was within a range of 64-79°F.<br><br>The room humidity was monitored daily. The humidity range for the room was 30-70%.<br><br>The light cycle was controlled using an automatic timer (12 hours light, 12 hours dark). |
| Facility: | NAMSA is an AAALAC International accredited facility and is registered with the United States Department of Agriculture. Additionally, NAMSA maintains an approved Animal Welfare Assurance on file with the National Institutes of Health, Office for Laboratory Animal Welfare. |
| Personnel: | Associates involved were appropriately qualified and trained. |
| Selection: | Only healthy, previously unused animals were selected. |

Experimental Procedure:

The food for each rat was removed from each cage 16-20 hours prior to dosing. Each rat was weighed and gavaged with the test article via stainless steel blunt-tipped cannula at a dose of 5 g/kg of body weight. The animals were then returned to their cages and food was returned after treatment.

Animals were observed immediately after dosing, at 4 hours, and daily for up to 7 days for signs of illness or mortality. Body weights were recorded at dosing and at 7 days for survivors. Animals found dead during the study or those euthanatized (carbon dioxide inhalation) at termination of the study were subjected to a macroscopic examination of the viscera. The substance was considered "toxic" if it produced death within 7 days in 50% of the rats gavaged with a single 50 mg/kg to 5 g/kg dose.

342



NAMSA
Ensuring Medical Device Safety and Compliance™
Corp. Hdqtrs: 2251 Tracy Road, Northwood, OH 43619-1397 / 419.666.9455 / Fax 419.666.2954
3400 Cobb International Blvd., Kennesaw, GA 30152-7601 / 770.427.3101 / Fax 770.426.5692
9 Morgan, Irvine, CA 92618-2078 / 949.951.3110 / Fax 949.951.3280
Affiliates: France • Germany • Israel • Taiwan • United Kingdom


Authorization for duplication of this report, except in whole, is reserved pending NAMSA's written approval.

## RESULTS

Individual observations appear in Table I.

Body Weight: Body weight data were acceptable.

Mortality: No animals died during the 7 day study.

Clinical Observations: All animals appeared clinically normal throughout the study.

Necropsy: There were no macroscopic changes in the viscera at necropsy that could be attributed to the single oral dose.

Results and conclusions apply only to the test article tested. No further evaluation of these results is made by NAMSA. Any extrapolation of these data to other samples is the responsibility of the sponsor. All procedures were conducted in conformance with good laboratory practice and EN45001 Quality Standards (TÜV Product Services 1/96).

## CONCLUSION

Under the conditions of this study, the test article would not be considered toxic at a dose of 5 g/kg by the oral route in the rat.

## RECORD STORAGE

All raw data pertaining to this study and a copy of the final report are to be retained in designated NAMSA archive files.

343



NAMSA
Ensuring Medical Device Safety and Compliance
Corp. Hdqtrs: 2261 Tracy Road, Northwood, OH 43619-1397 / 419.666.9455 / Fax 419.666.2954
3400 Cobb International Blvd., Kennesaw, GA 30152-7601 / 770.427.3101 / Fax 770.426.5692
9 Morgan, Irvine, CA 92618-2078 / 949.951.3110 / Fax 949.951.3280
Affiliates: France • Germany • Israel • Taiwan • United Kingdom


Authorization for duplication of this report, except in whole, is reserved pending NAMSA's written approval.

TABLE I

INDIVIDUAL OBSERVATIONS

| Animal Number | Sex | Body Weight (g) | | Clinical Observations (Days 0-7) | Necropsy (Day 7) |
|---|---|---|---|---|---|
| | | Day 0 | Day 7 | | |
| 1 | M | 203 | 280 | Appeared normal | Macroscopically normal |
| 2 | M | 204 | 277 | Appeared normal | Macroscopically normal |
| 3 | M | 221 | 289 | Appeared normal | Macroscopically normal |
| 4 | M | 227 | 290 | Appeared normal | Macroscopically normal |
| 5 | M | 217 | 290 | Appeared normal | Macroscopically normal |
| Mean: | | 214 | 287 | | |

M = Male

344



NAMSA
Ensuring Medical Device Safety and Compliance™
Corp. Hdqtrs: 2261 Tracy Road, Northwood, OH 43619-1397 / 419.666.9455 / Fax 419.666.2954
3400 Cobb International Blvd., Kennesaw, GA 30152-7601 / 770.427.3101 / Fax 770.426.5692
9 Morgan, Irvine, CA 92618-2078 / 949.951.3110 / Fax 949.951.3280
Affiliates: France • Germany • Israel • Taiwan • United Kingdom

FOI - Page 237 of 446

Authorization for duplication of this report, except in whole, is reserved pending NAMSA's written approval.

**STUDY TITLE:**

ISO ACUTE INTRACUTANEOUS REACTIVITY STUDY IN THE RABBIT

(Extracts)

**TEST ARTICLE:**

Clear EX30 Aligner Material

**IDENTIFICATION NO.:**

204043

**TEST FACILITY:**

NAMSA
9 Morgan
Irvine, CA 92618-2078

**SPONSOR:**

LOC PHAN
ALIGN TECHNOLOGY INC.
881 MARTIN AVE.
SANTA CLARA, CA 95050

345



NAMSA
Ensuring Medical Device Safety and Compliance™

Corp. Hdqtrs: 2261 Tracy Road, Northwood, OH 43619-1397 / 419.666.9455 / Fax 419.666.2954
3400 Cobb International Blvd., Kennesaw, GA 30152-7601 / 770.427.3101 / Fax 770.426.5692
9 Morgan, Irvine, CA 92618-2078 / 949.951.3110 / Fax 949.951.3280
Affiliates: France • Germany • Israel • Taiwan • United Kingdom



Authorization for duplication of this report, except in whole, is reserved pending NAMSA's written approval.

TABLE OF CONTENTS

| | Page Number |
|---|---|
| SUMMARY | 3 |
| INTRODUCTION | 4 |
| MATERIALS | 4 |
| METHODS | 4 |
| RESULTS | 6 |
| CONCLUSION | 6 |
| RECORD STORAGE | 6 |
| TABLE<br>I - ISO ACUTE INTRACUTANEOUS REACTIVITY OBSERVATIONS | 7 |

346



NAMSA
Ensuring Medical Device Safety and Compliance
Corp. Hdqtrs: 2261 Tracy Road, Northwood, OH 43619-1397 / 419.666.9455 / Fax 419.666.2954
3400 Cobb International Blvd., Kennesaw, GA 30152-7601 / 770.427.3101 / Fax 770.426.5692
9 Morgen, Irvine, CA 92618-2078 / 949.951.3110 / Fax 949.951.3280
Affiliates: France • Germany • Israel • Taiwan • United Kingdom



Authorization for duplication of this report, except in whole, is reserved pending NAMSA's written approval.

## SUMMARY

The test article, Clear EX30 Aligner Material, Identification No. 204043, was extracted in 0.9% sodium chloride USP solution and cottonseed oil, NF. These extracts were evaluated for intracutaneous reactivity based on the requirements of the International Organization for Standardization 10993: Biological Evaluation of Medical Devices, Part 10: Tests for Irritation and Sensitization.

A 0.2 ml dose of the appropriate test article extract was injected by the intracutaneous route into five separate sites on the right side of the back of each rabbit. Similarly, the corresponding reagent control was injected on the left side of the back of each rabbit. The injection sites were observed immediately after injection. Observations for erythema and edema were conducted at 24, 48, and 72 hours after injection.

Under the conditions of this study, there was no evidence of irritation from the extracts injected intracutaneously into rabbits. The Primary Irritation Index Characterization for the extracts was negligible.

Study and Supervisory Personnel:

Brenda Gonzales, A.S., LVT
Parviz Ronaghi, B.S.
David Vergil
Enrique Vazquez
Daliah Lambert

Approved by:

Brenda Gonzales, A.S., LVT
Supervisor, Toxicology

7-24-02
Date Completed

/nee

347



NAMSA
Ensuring Medical Device Safety and Compliance
Corp. Hdqtrs: 2261 Tracy Road, Northwood, OH 43619-1397 / 419.666.9455 / Fax 419.666.2954
3400 Cobb International Blvd., Kennesaw, GA 30152-7601 / 770.427.3101 / Fax 770.426.5692
9 Morgan, Irvine, CA 92618-2078 / 949.951.3110 / Fax 949.951.3280
Affiliates: France • Germany • Israel • Taiwan • United Kingdom

FOI - Page 240 of 446 Authorization for duplication of this report, except in whole, is reserved pending NAMSA's written approval.

## INTRODUCTION

The test article identified below was extracted and the extracts were evaluated for biocompatibility based on the requirements of the International Organization for Standardization 10993: Biological Evaluation of Medical Devices, Part 10: Tests for Irritation and Sensitization. The purpose of the study was to determine whether leachables extracted from the material would cause local dermal irritant effects following injection into rabbit skin. The test article was received on March 6, 2002. The animals were injected on March 15, 2002, and the observations were concluded on March 18, 2002.

## MATERIALS

The sample provided by the sponsor was identified and handled as follows:

| | |
|---|---|
| Test Article: | Clear EX30 Aligner Material |
| Identification No: | 204043 |
| Storage Conditions: | Room temperature |
| Vehicles: | 0.9% sodium chloride USP solution (SC)<br>cottonseed oil, NF (CSO) |
| Preparation: | Based on a ratio of 4 g:20 ml, a 2 gram portion of the test article was covered with 10 ml of the vehicle. The test article was extracted in SC and CSO at 70°C for 24 hours. The extraction vehicles without test article were similarly prepared to serve as reagent controls. |

| | | Test | Control |
|---|---|---|---|
| Condition of Extracts: | SC: | Clear | Clear |
| | CSO: | Clear | Clear |

## METHODS

Test System:

| | |
|---|---|
| Species: | Rabbit (*Oryctolagus cuniculus*) |
| Breed: | New Zealand White |
| Source: | Myrtle's Rabbitry, Inc. |
| Sex: | Male |
| Body Weight Range: | 2.7 kg to 2.9 kg at selection |
| Age: | Young adult |
| Acclimation Period: | Minimum 5 days |
| Number of Animals: | Three |
| Identification Method: | Ear tag |

Justification of Test System:

The intracutaneous injection test in rabbits is specified in the current ISO testing standards and has been used historically to evaluate biomaterial extracts.

348



NAMSA
Ensuring Medical Device Safety and Compliance™
Corp. Hdqtrs: 2261 Tracy Road, Northwood, OH 43619-1397 / 419.666.9455 / Fax 419.666.2954
3400 Cobb International Blvd., Kennesaw, GA 30152-7601 / 770.427.3101 / Fax 770.426.5692
9 Morgan, Irvine, CA 92618-2078 / 949.951.3110 / Fax 949.951.3280
Affiliates: France • Germany • Israel • Taiwan • United Kingdom


Authorization for duplication of this report, except in whole, is reserved pending NAMSA's written approval.

Animal Management:

| | |
|---|---|
| Husbandry: | Conditions conformed to Standard Operating Procedures which are based on the "Guide for the Care and Use of Laboratory Animals." |
| Food: | PROLAB® High Fiber Rabbit Diet was provided daily. |
| Water: | Freely available, municipal (Irvine, CA) water was delivered through an automatic watering system. |
| Contaminants: | Reasonably expected contaminants in feed or water supplies did not have the potential to influence the outcome of this test. |
| Housing: | Animals were individually housed in stainless steel suspended cages identified by a card indicating the lab number, animal number, test code, sex, and date dosed. |
| Environmental: | The room temperature was monitored daily. The temperature range for the room was within a range of 61-72°F.<br><br>The room humidity was monitored daily. The humidity range for the room was 30-70%.<br><br>The light cycle was controlled using an automatic timer (12 hours light, 12 hours dark). |
| Facility: | NAMSA is an AAALAC International accredited facility and is registered with the United States Department of Agriculture. Additionally, NAMSA maintains an approved Animal Welfare Assurance on file with the National Institutes of Health, Office for Laboratory Animal Welfare. |
| Personnel: | Associates involved were appropriately qualified and trained. |
| Selection: | Only healthy, previously unused, thin-skinned animals free of mechanical irritation or trauma that could interfere with the test were selected. |

Experimental Procedure:

The day prior to treatment, each rabbit was weighed and clipped free of fur from the back and both sides of the spinal column to yield a sufficient injection area. The clipped area of the back was wiped with a 70% alcohol soaked gauze pad just before injection and allowed to dry. Three rabbits were prepared per pair of extracts. A 0.2 ml dose of test article extract was injected intracutaneously into five separate sites on the right side of the back of each rabbit; 0.2 ml of the reagent control was injected into five separate sites on the corresponding left side of the back. Injections were spaced approximately 2 cm apart. The appearance of each injection site was noted immediately after injection. The animals were returned to their respective cages following the procedure.

349



NAMSA
Ensuring Medical Device Safety and Compliance™
Corp. Hdqtrs: 2261 Tracy Road, Northwood, OH 43619-1397 / 419.666.9455 / Fax 419.666.2954
3400 Cobb International Blvd., Kennesaw, GA 30152-7601 / 770.427.3101 / Fax 770.426.5692
9 Morgan, Irvine, CA 92618-2078 / 949.951.3110 / Fax 949.951.3280
Affiliates: France • Germany • Israel • Taiwan • United Kingdom

 Authorization for duplication of this report, except in whole, is reserved pending NAMSA's written approval. 

Observations for erythema and edema were conducted at 24, 48, and 72 hours after injection. Reactions were scored on a 0 to 4 basis. Any reaction at the injection sites was also noted. The reactions were evaluated according to the following subjective rating scale:

| ERYTHEMA (ER) | | EDEMA (ED) | |
|---|---|---|---|
| 0 | No erythema | 0 | No edema |
| 1 | Very slight erythema (barely perceptible) | 1 | Very slight edema (barely perceptible) |
| 2 | Well-defined erythema | 2 | Well-defined edema (edges of area well-defined by definite raising) |
| 3 | Moderate erythema | 3 | Moderate edema (raised approximately 1 mm) |
| 4 | Severe erythema (beet redness) to eschar formation preventing grading of erythema | 4 | Severe edema (raised more than 1 mm, and extending beyond exposure area) |

For each animal, the erythema and edema scores obtained at each time interval were added together and divided by the total number of observations. This calculation was conducted separately for each test extract and reagent control. The score for the reagent control was subtracted from the score for the test extract to obtain the Primary Irritation Score. The Primary Irritation Score of each animal was added together and divided by the total number of animals to obtain the Primary Irritation Index (PII). The Primary Irritation Index was characterized by number and description as follows: 0-0.4 (negligible), 0.5-1.9 (slight), 2.0-4.9 (moderate), 5.0-8.0 (severe). Any adverse reaction noted in the test extract was compared to the corresponding reagent control.

## RESULTS

Results of scores for individual rabbits appear in Table I. All injection sites appeared normal immediately following injection. The Primary Irritation Index (PII) and Characterization for each extract are summarized below:

| Extract | Animal Number | Test Score Average | Control Score Average | Primary Irritation Score | Primary Irritation Score Total | Primary Irritation Index Characterization |
|---|---|---|---|---|---|---|
| SC | 64855 | 0.0 | 0.0 | 0.0 | 0.0 | Negligible |
| | 64856 | 0.0 | 0.0 | 0.0 | | |
| | 64857 | 0.0 | 0.0 | 0.0 | | |
| CSO | 64855 | 0.0 | 0.0 | 0.0 | 0.0 | Negligible |
| | 64856 | 0.0 | 0.0 | 0.0 | | |
| | 64857 | 0.0 | 0.0 | 0.0 | | |

Results and conclusions apply only to the test article tested. No further evaluation of these results is made by NAMSA. Any extrapolation of these data to other samples is the responsibility of the sponsor. All procedures were conducted in conformance with good laboratory practice and ISO 17025.

## CONCLUSION

Under the conditions of this study, there was no evidence of irritation from the extracts injected intracutaneously into rabbits. The Primary Irritation Index Characterization for the extracts was negligible.

## RECORD STORAGE

All raw data pertaining to this study and a copy of the final report are to be retained in designated NAMSA archive files.

350



NAMSA
Ensuring Medical Device Safety and Compliance™
Corp. Hdqtrs: 2251 Tracy Road, Northwood, OH 43619-1397 / 419.666.9455 / Fax 419.666.2954
3400 Cobb International Blvd., Kennesaw, GA 30152-7601 / 770.427.3101 / Fax 770.426.5692
9 Morgan, Irvine, CA 92618-2078 / 949.951.3110 / Fax 949.951.3280
Affiliates: France • Germany • Israel • Taiwan • United Kingdom


Authorization for duplication of this report, except in whole, is reserved pending NAMSA's written approval.

TABLE I

ISO ACUTE INTRACUTANEOUS REACTIVITY OBSERVATIONS

| Rabbit Number/ Gender | Body Weight (kg) | Extract | Scoring Interval | | | | | | | | | | | |
|---|---|---|---|---|---|---|---|---|---|---|---|---|---|---|
| | | | 24 Hours | | | | 48 Hours | | | | 72 Hours | | | |
| | | | Test | | Control | | Test | | Control | | Test | | Control | |
| | | | ER | ED | ER | ED | ER | ED | ER | ED | ER | ED | ER | ED |
| 64855 Male | 2.7 | SC | 0 | 0 | 0 | 0 | 0 | 0 | 0 | 0 | 0 | 0 | 0 | 0 |
| | | | 0 | 0 | 0 | 0 | 0 | 0 | 0 | 0 | 0 | 0 | 0 | 0 |
| | | | 0 | 0 | 0 | 0 | 0 | 0 | 0 | 0 | 0 | 0 | 0 | 0 |
| | | | 0 | 0 | 0 | 0 | 0 | 0 | 0 | 0 | 0 | 0 | 0 | 0 |
| | | | 0 | 0 | 0 | 0 | 0 | 0 | 0 | 0 | 0 | 0 | 0 | 0 |
| 64856 Male | 2.9 | SC | 0 | 0 | 0 | 0 | 0 | 0 | 0 | 0 | 0 | 0 | 0 | 0 |
| | | | 0 | 0 | 0 | 0 | 0 | 0 | 0 | 0 | 0 | 0 | 0 | 0 |
| | | | 0 | 0 | 0 | 0 | 0 | 0 | 0 | 0 | 0 | 0 | 0 | 0 |
| | | | 0 | 0 | 0 | 0 | 0 | 0 | 0 | 0 | 0 | 0 | 0 | 0 |
| | | | 0 | 0 | 0 | 0 | 0 | 0 | 0 | 0 | 0 | 0 | 0 | 0 |
| 64857 Male | 2.8 | SC | 0 | 0 | 0 | 0 | 0 | 0 | 0 | 0 | 0 | 0 | 0 | 0 |
| | | | 0 | 0 | 0 | 0 | 0 | 0 | 0 | 0 | 0 | 0 | 0 | 0 |
| | | | 0 | 0 | 0 | 0 | 0 | 0 | 0 | 0 | 0 | 0 | 0 | 0 |
| | | | 0 | 0 | 0 | 0 | 0 | 0 | 0 | 0 | 0 | 0 | 0 | 0 |
| | | | 0 | 0 | 0 | 0 | 0 | 0 | 0 | 0 | 0 | 0 | 0 | 0 |
| 64855 Male | 2.7 | CSO | 0 | 0 | 0 | 0 | 0 | 0 | 0 | 0 | 0 | 0 | 0 | 0 |
| | | | 0 | 0 | 0 | 0 | 0 | 0 | 0 | 0 | 0 | 0 | 0 | 0 |
| | | | 0 | 0 | 0 | 0 | 0 | 0 | 0 | 0 | 0 | 0 | 0 | 0 |
| | | | 0 | 0 | 0 | 0 | 0 | 0 | 0 | 0 | 0 | 0 | 0 | 0 |
| | | | 0 | 0 | 0 | 0 | 0 | 0 | 0 | 0 | 0 | 0 | 0 | 0 |
| 64856 Male | 2.9 | CSO | 0 | 0 | 0 | 0 | 0 | 0 | 0 | 0 | 0 | 0 | 0 | 0 |
| | | | 0 | 0 | 0 | 0 | 0 | 0 | 0 | 0 | 0 | 0 | 0 | 0 |
| | | | 0 | 0 | 0 | 0 | 0 | 0 | 0 | 0 | 0 | 0 | 0 | 0 |
| | | | 0 | 0 | 0 | 0 | 0 | 0 | 0 | 0 | 0 | 0 | 0 | 0 |
| | | | 0 | 0 | 0 | 0 | 0 | 0 | 0 | 0 | 0 | 0 | 0 | 0 |
| 64857 Male | 2.8 | CSO | 0 | 0 | 0 | 0 | 0 | 0 | 0 | 0 | 0 | 0 | 0 | 0 |
| | | | 0 | 0 | 0 | 0 | 0 | 0 | 0 | 0 | 0 | 0 | 0 | 0 |
| | | | 0 | 0 | 0 | 0 | 0 | 0 | 0 | 0 | 0 | 0 | 0 | 0 |
| | | | 0 | 0 | 0 | 0 | 0 | 0 | 0 | 0 | 0 | 0 | 0 | 0 |
| | | | 0 | 0 | 0 | 0 | 0 | 0 | 0 | 0 | 0 | 0 | 0 | 0 |

ER = Erythema
ED = Edema

SC = 0.9% sodium chloride USP solution
CSO = cottonseed oil, NF

351



NAMSA
Ensuring Medical Device Safety and Compliance
Corp. Hdqtrs: 2261 Tracy Road, Northwood, OH 43619-1397 / 419.666.9455 / Fax 419.666.2954
3400 Cobb International Blvd., Kennesaw, GA 30152-7601 / 770.427.3101 / Fax 770.426.5692
9 Morgan, Irvine, CA 92618-2078 / 949.951.3110 / Fax 949.951.3280
Affiliates: France • Germany • Israel • Taiwan • United Kingdom

Authorization for duplication of this report, except in whole, is reserved pending NAMSA's written approval.

# Software

352

## Align Technology, Inc.,

## Modified Invisalign® system

## Software

There is no significant change in the software compared to the previous submission including the software design and development, software development methodology, software development process and environment.

353

# Electromagnetic Compatibility and Electrical Safety

354

## Align Technology, Inc.,

## Modified Invisalign® system

## Electromagnetic Compatibility and Electric Safety

The Modified Invisalign system in not an electric or electromagnetic device. Therefore this section is not applicable.

355

# Performance Testing - Bench

356

## Align Technology, Inc.,

## Modified Invisalign® system

## Bench Testing

Since there were no design or performance changes made to the Invisalign system for this filing no additional bench testing was performed.

357

# Performance Testing - Animal

358

## Align Technology, Inc.,

## Modified Invisalign® system

## Animal Testing

Performance testing of the Invisalign system is not possible in an animal. Therefore this section is not applicable.

359

# Performance Testing – Clinical

I Summary of Clinical Utility Reports

II Relevant Publications

360

**Align Technology, Inc.,**

**Modified Invisalign® system**

**Summary of Clinical Utility Reports**

This section will summarize the results of a clinical evaluation and literature references, done to support Align Technology, Inc.'s ("Align") intention to:

1. Expand the indications for use to include patients with deciduous teeth present
2. Capture some contra-indications as precautions for Invisalign orthodontic aligners
3. Clarification of contra-indication – "Periodontally involved malocclusion"

Align evaluated case reports and before/after records of (b)(4) (b)(4) (b)(4) can be successfully treated with Invisalign aligners.

1. Severe open bite: (b)(4) cases
2. Severe overjet: (b)(4) cases
3. Surgical correction: (b)(4) cases
4. Mixed dentition: (b)(4) cases
5. Skeletally narrow jaw: (b)(4) case

In addition, enclosed with the submission are copies of the supporting reference articles (R1 – R7) to substantiate the decision to change the labeling regarding management of surgical jaw corrections, expansion of narrow jaws, dental implants, and periodontal conditions in relationship to orthodontics.

## *I. Expanded indications for use*

The indication for use in the current IFU is:

> "The Invisalign system is indicated for the treatment of tooth malocclusion in patients with permanent dentition (*i.e.*, all second molars)."

The proposed expanded Indication for Use would allow Invisalign treatment for patients with deciduous teeth. For this reason, the proposed Indication of Use has the permanent dentition/second molars requirement removed from the statement. The proposed Indications for Use is:

361

"The Invisalign system is indicated for the alignment of teeth during orthodontic treatment of malocclusion."

Align Technology, Inc. is proposing the modified intended use based on, (b)(4)
(b)(4)

The rationale behind Align's originally limiting the use of Invisalign aligners to patients with permanent dentition was based on the fact that it took several months to manufacture (b)(4)
(b)(4)

(b)(4)
(b)(4)

In addition, since then (1997), it has been documented that Invisalign aligners have the ability to effectively align teeth in patients presenting with deciduous teeth. To substantiate this fact, (b)(4)
(b)(4)
(b)(4)

(b)(4)

362

(b)(4)

(b)(4)

Therefore, the product's Indications for Use can be expanded to remove the permanent dentition/second molar requirement, and state: "The Invisalign system is indicated for the alignment of teeth during orthodontic treatment of malocclusion."

## *II. Current Contra-indications being replaced by precautions:*

Listed and individually discussed below are the Current Contra-indications that are being replaced by Precautions in the proposed IFU document:

Adult and adolescent patients presenting with the following conditions:

1. Severe open bite
2. Severe overjet
3. Tooth malocclusion requiring surgical correction
4. Patients with mixed dentition
5. Adolescent patients with a skeletally narrow jaw
6. Adult patients with dental prosthetics/implants

*1. Severe Open Bite*

(b)(4)

(b)(4)

(b)(4) of these case reports were of non-extraction treatments. Of these:

363

- Two case reports were of orthodontic treatments that used dental expansion to create arch width in order to facilitate lingual retraction of the anterior teeth with Invisalign aligners to effectively close the open bites.
- Three case reports were of successful Invisalign treatments where only retraction of the anterior teeth was used to close the open bite.

The remaining two case reports were of Invisalign treatments where dental extractions were incorporated to close the open bite. Of these:

- The first report was of a single lower-incisor extraction treatment where retraction of the remaining lower anterior teeth with the aligners closed the open bite.
- The second report was of a four-bicuspid extraction case that was originally presented as an orthognathic surgery case for open-bite closure, but surgery was declined by the patient. The treatment plan then called for fixed braces as needed in conjunction with Invisalign aligner treatment; however, at the end of the aligner treatment, the results were satisfactory enough that the braces were not actually needed.

(b)(4)

(b)(4)

(b)(4)

(b)(4)

- Treatment of severe open bite, severe overjet, mixed dentition, and/or skeletally narrow jaw may require supplemental treatment in addition to aligner treatment.

- Skeletal expanders, bonded auxiliaries, elastics, and other fixed and/or removable orthodontic appliances, may be needed for more complicated treatment plans where aligners alone may not be adequate to achieve the desired outcome.

*2. Severe Overjet*

(b)(4)

364

(b)(4)

(b)(4)

(b)(4)

(b)(4)

(b)(4) Of the non-surgical severe overjet cases mentioned above,

- Two patients were treated using aligners and bicuspid extraction. One of these two cases with severe overjet needed to have aligner treatment supplemented with fixed braces. This was a single bicuspid extraction case where braces were used for 12 weeks in the upper arch to achieve "uprighting of the root of tooth #6." In other words, the reason for needing the braces was not actually because of the severe initial overjet. The other extraction case did not have braces treatment in conjunction with aligner treatment.

- Two patients were treated with aligners and Class II interarch elastics, and

- Two patients were treated with aligners and interproximal recontouring (IPR) of enamel for space creation.

(b)(4)

- Treatment of severe open bite, severe overjet, mixed dentition, and/or skeletally narrow jaw may require supplemental treatment in addition to aligner treatment.

- Skeletal expanders, bonded auxiliaries, elastics, and other fixed and/or removable orthodontic appliances may be needed for more complicated treatment plans where aligners alone may not be adequate to achieve the desired outcome.

365

*3. Surgical correction*

(b)(4)

(b)(4)

(b)(4)

(b)(4)

- In one case, aligners alone without braces were sufficient for the treatment (fixation was through wires and elastics).
- In three of the cases, in addition to alignment with aligners, braces were placed immediately prior to surgery to assist with jaw fixation.

After Invisalign treatment was performed in conjunction with the corresponding skeletal correction surgery, all four patients had excellent results, with significant improvement to their overjet and overbite.

To support the data discussed above, we have also enclosed references from the Journal of Clinical Orthodontics (Volume 39, Number 4, 245-258, "R1") and The Invisalign System Textbook, (Tuncay, O. *ed.*, Quintessence International, 1996, 281-289, "R2") that discuss in greater detail how Invisalign aligners can be used in conjunction with orthognathic surgery.

Based on the supporting evidence from the reports and literature, Align proposes removing the "surgical correction" contra-indication and using the following language under Precautions instead:

- Oral surgery may be necessary to correct severe crowding or jaw imbalances. If oral surgery is required, risks associated with anesthesia and proper healing must be taken into account prior to treatment.

*4. Mixed Dentition*

(b)(4)

366

(b)(4)

- Treatment of severe open bite, severe overjet, mixed dentition, and/or skeletally narrow jaw may require supplemental treatment in addition to aligner treatment.

- Atypically-shaped, erupting, and/or missing teeth may affect aligner adaptation and may affect the ability to achieve the desired results.

The following will also be added to the Directions for Use section:

- If additional aligners are needed, new impressions may be required.

These three considerations are also already well known in the practice of treating patients in the mixed dentition using traditional removable orthodontic appliances.

*5. Skeletally Narrow Jaw*

(b)(4)

(b)(4)

Maxillary expansion can be achieved using a removable Schwartz-type appliance to "achieve expansion that may not be as easily obtained with thin thermoplastic appliances." (Hickory, WB, Combination Treatment to Meet Market Demands. Pre-Invisalign Combination Treatment, Part 2: Expansion, Praxis, Aug-Sep 2002, 1-3, "R3".) Maxillary expansion can also be performed using a banded/bonded fixed rapid palatal expander. These are the two main types of expanders typically used in orthodontics to correct skeletally narrow jaws. Any additional risk imposed on the patient with a skeletally narrow jaw would be associated with the treatment of the skeletally narrow jaw itself, if performed.

The Invisalign case report presented demonstrates the successful dental alignment of moderate upper and lower anterior crowding with Invisalign aligners in a patient with a skeletally narrow maxilla. The patient in the report was an

367

(b)(4)

(b)(4)

Thus, Align proposes removing the "skeletally narrow jaw" contra-indication and using the following language in the Precautions section:

- Treatment of severe open bite, severe overjet, mixed dentition, and/or skeletally narrow jaw may require supplemental treatment in addition to aligner treatment.

- Skeletal expanders, bonded auxiliaries, elastics, and other fixed and/or removable orthodontic appliances may be needed for more complicated treatment plans where aligners alone may not be adequate to achieve the desired outcome.

*6. Dental prosthetics/implants*

(b)(4)

The minor risks associated with treating patients with dental prosthetics using Invisalign aligners are:

1. The possibility of dislodging the dental prosthesis with the orthodontic aligner and
2. The risk of aligner attachments (composite shapes occasionally bonded to teeth to aid in aligner retention) falling off when bonded to a prosthetic tooth and requiring re-bonding.

These risks are captured in the proposed precautions documented below, and are being provided in lieu of the contra-indication for "dental prosthetics":

368

- Existing dental restorations (*e.g.*, crowns, bridges) may become dislodged and require re-cementation or, in some instances, replacement.

- Attachments may fall off and require replacement.

Align has not included a specific (b)(4)
(b)(4)
(b)(4)

Regarding the use of Invisalign aligners in patients with dental implants, irrespective of the type of orthodontic condition for these patients, the implants themselves cannot be moved orthodontically at all. Furthermore, "there is no statistically significant difference in the response of peri-implant bone to orthodontic loading." (Journal of Orthodontics, Vol. 29:3, Sep 2002, 239-245, "R4".) Dental implants are so orthodontically stable that they are routinely being used today in conjunction with orthodontic treatment as absolute anchors. Therefore, their presence is not a contra-indication for treatment with Invisalign aligners. Based on this information, the proposed language to support the removal of the "dental implant" contra-indication is the addition of the following precaution:

- Aligners are not effective in the movement of dental implants.

### *III. Clarification of current contra-indication – Periodontally involved malocclusion*

Based on clinical recommendations provided in peer-reviewed articles, Align believes that the current contra-indication, "Adult patients in which the malocclusion is periodontally involved" needs to be further clarified to provide better clinical guidance to the clinician. The literature recommends that "if there is evidence of periodontal disease, orthodontic treatment must be postponed. The patient must be referred for appropriate periodontal therapy, including subgingival debridement and, if appropriate, periodontal surgery, followed by a two- to four-month healing and observation period." (JADA, Vol. 130, Apr 1999, 521-527, "R5".) However, orthodontic tooth movement in patients with "a reduced but healthy periodontium does not result in significant further loss of attachment." (AJO-DO, Sep 1989, 191-198, "R6".) Therefore, we propose changing this contra-indication to:

Patients with the following condition:
- Active periodontal disease.

369

This change would provide greater clinical specificity as to the type of "periodontal involvement" that may put a prospective patient at risk.

In summary, (b)(4)
(b)(4)
(b)(4)

370

**Align Technology, Inc.,**

**Modified Invisalign® system**

**Relevant Publications**

Bibliography:


- Boyd, Robert L., DDS, MED; Surgical-Orthodontic Treatment of Two Skeletal Class III Patients with Invisalign and Fixed Appliances; Journal of Clinical Orthodontics, April, 2005, vol. XXXIX, number 4; pp. 245 – 258

- Tuncay, Orhan C., DMD (ed.); The Invisalign System; ch. 28 – Surgical Treatment and Invisalign, by Miller, Ross, DDS and Duong, Trang, DDS; pp. 281 – 289

- Hickory, Wayne B., DMD, MDS; Combination Treatment to Meet Market Demands, Part 2 – Pre-Invisalign Expansion; Praxis, August / September, 2002

- Ismail, S. F. H and Johal, A. S.; The role of implants in orthodontics; Journal of Orthodontics, vol. 29, no. 3, pp. 239 – 245, September, 2002

- Sanders, Norman L.; Evidence-Based Care in Orthodontics and Periodontics: A Review of the Literature; Journal of the American Dental Association (JADA); vol. 130, April, 1999; pp. 521 – 527

- Boyd, R. L., Leggott, P. J., Quinn, R. S., Eakle, W. E., and Chambers, D.; Periodontal implications of orthodontic treatment in adults with reduced or normal periodontal tissue versus those of adolescents; American Journal of Orthodontics, volume 1989 September; pp. 191 - 198

- Johal, Amandeep and Ide, Mark; Orthodontics in the Adult Patient, with Special Reference to the Periodontally Compromised Patient; Dental Update, April, 1999; pp. 101 – 108


371

# Surgical-Orthodontic Treatment of Two Skeletal Class III Patients with Invisalign and Fixed Appliances

ROBERT L. BOYD, DDS, MED

The Invisalign* appliance was introduced in 2000 by Boyd, Vlaskalic, and Miller.[1] Since then, a number of case reports[1-19] and two clinical trials[20-22] have demonstrated the applications of this system in many different types of orthodontic treatment. To date, more than 250,000 patients around the world have had Invisalign treatment[23]—a remarkably high number considering the appliance has been available to clinicians for less than five years.

One of the longitudinal clinical trials found that Invisalign had limitations in terms of tooth movement, with tipping movements being the most predictable.[20,21] The appliances in this study, however, were made of materials that are no longer used, and they were changed at two different time intervals (one or two weeks), before the current protocol of two weeks for each aligner was established. Another longitudinal study has been reported only as an abstract.[22] One of the primary advantages found in both studies was a statistically significant reduction in plaque and gingivitis.[21,22] With fixed appliances, patients typically show an increase in plaque and gingivitis throughout orthodontic treatment; in fact, some patients experience irreversible bone loss,[24,25] especially on banded molars,[26] as well as decalcification.[25,27-29]

The present article demonstrates the use of Invisalign appliances in two of the most difficult types of orthodontic patients—skeletal Class III cases requiring single- or two-jaw multiple-segment orthognathic surgery.

*Align Technology, Inc., 881 Martin Ave., Santa Clara, CA 95050.

Dr. Boyd is a Contributing Editor of the *Journal of Clinical Orthodontics* and Professor and Chairperson, Department of Orthodontics, School of Dentistry, University of the Pacific, San Francisco, CA.

## Case 1

A 27-year-old female presented with moderate restorations and missing lower right and left canines from previous orthodontic treatment as an adolescent in China (Fig. 1). Her chief complaint was "teeth don't come together, jaw protruding, and trouble chewing". Her problem list included Class III mandibular prognathism, an asymmetrical jaw deviating 4mm to the left, and a skeletal posterior crossbite on the left side. She had an overbite of –1mm and an overjet of 0mm; the maxillary dental midline was deviated 1mm

**TABLE 1**
**CASE 1 CEPHALOMETRIC DATA**

| | Pre-tmt. | Norm | Pre-surgery | Post-Tmt. |
|---|---|---|---|---|
| SNA | 76° | 82° | 75° | 79° |
| SNB | 80° | 80° | 78° | 78° |
| ANB | –4° | 2° | –3° | 1° |
| Wits | –9 | –1 | –9 | –5 |
| MP-SN | 42° | 33° | 42° | 43° |
| FMA | 30° | 24° | 30° | 31° |
| Po-NB | 5° | 2° | 6° | 6° |
| IIA | 140° | 130° | 137° | 136° |
| U1-NA | 34° | 23° | 34° | 27° |
| U1-NA | 6mm | 4mm | 6mm | 4mm |
| L1-NB | 10° | 25° | 13° | 17° |
| L1-NB | –.5mm | 4mm | 2mm | 2mm |
| FMIA | 83° | 65° | 78° | 72° |
| IMPA | 68° | 95° | 72° | 77° |
| E-line | –4° | –2° | –4° | –4° |
| E-line | –7mm | –6mm | –7mm | –5mm |

372


© 2005 JCO, Inc.

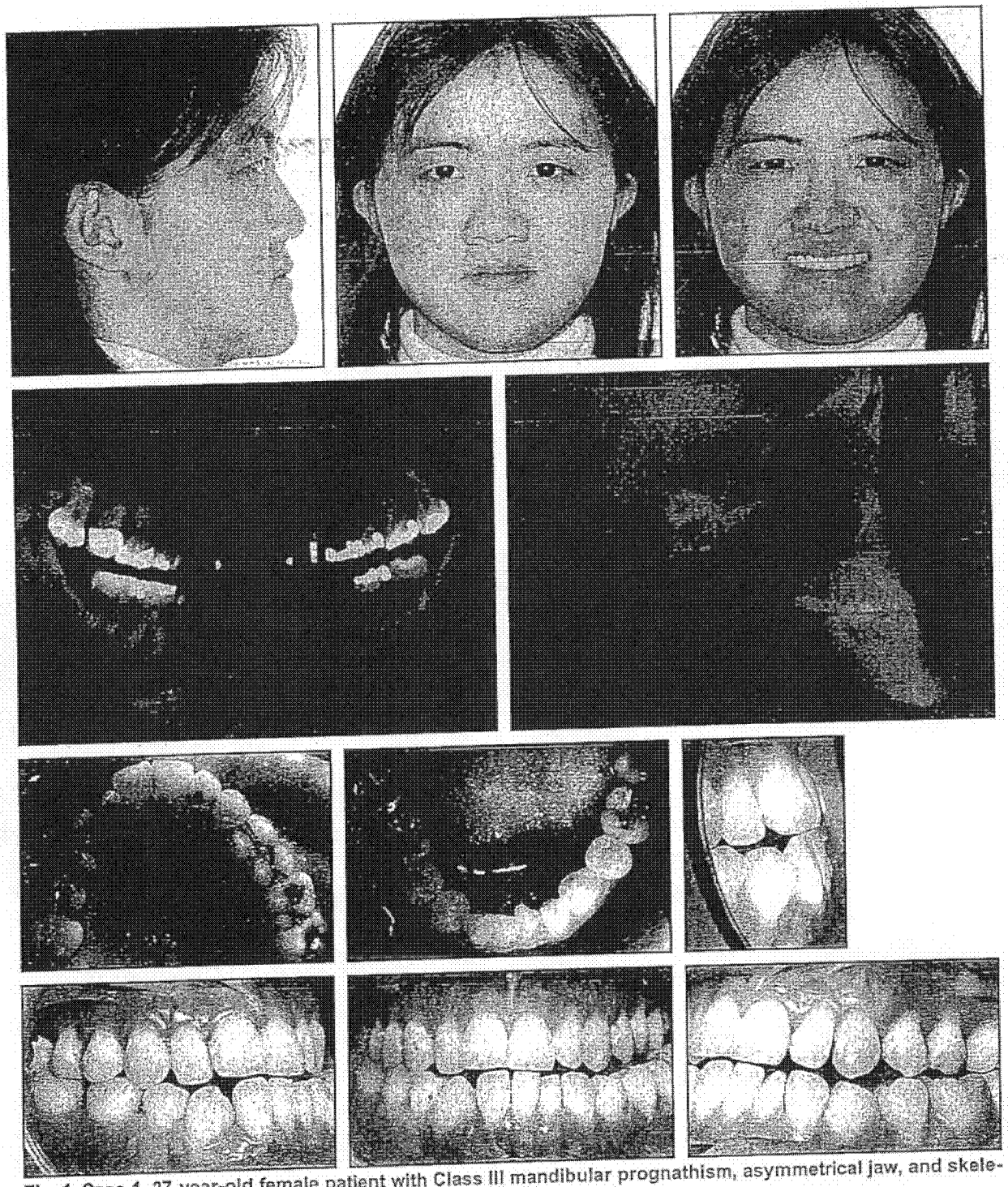

Fig. 1 Case 1. 27-year-old female patient with Class III mandibular prognathism, asymmetrical jaw, and skeletal posterior crossbite before treatment.

713

to the right, and the mandibular midline 4mm to the left. The patient had 4-5mm of lower anterior crowding and 1mm of upper anterior crowding. Her lower left first premolar was rotated 90° and locked in infraocclusion to the upper arch.

Cephalometric measurements showed that the maxillary incisors were proclined, with the upper incisor at 6mm and 34° to NA (Table 1). The lower incisors were retroclined, with an IMPA of 68° and the lower incisor at −.5° and 10mm to NB.

Panoramic evaluation revealed short, thin, and pointed roots and about 20% bone loss in most areas. Both lower permanent canines had been extracted during the previous orthodontic treatment, and the lower third molars had been removed after subsequent supereruption of the upper third molars.

The patient's periodontal status was healthy, with no bleeding on probing and no pocket depths greater than 3mm. Generalized gingival recession was found throughout the mouth, however, with thin periodontal tissues.

The treatment goals for this patient were to establish a Class I skeletal relationship with a Class III molar relationship (due to the missing lower canines), correct the mandibular asymmetry and the left posterior crossbite, align the mid-

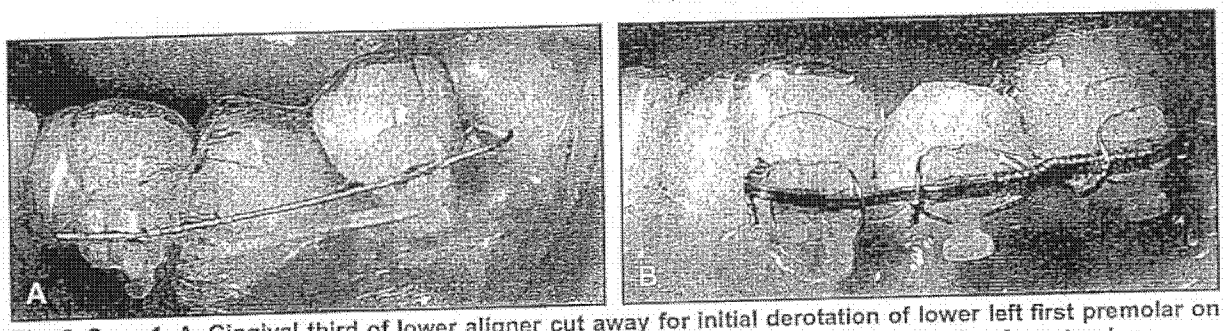


Fig. 2 Case 1. A. Gingival third of lower aligner cut away for initial derotation of lower left first premolar on .018" round TMA wire segment. B. .017" × .025" TMA wire segment used with coil spring for extrusion.

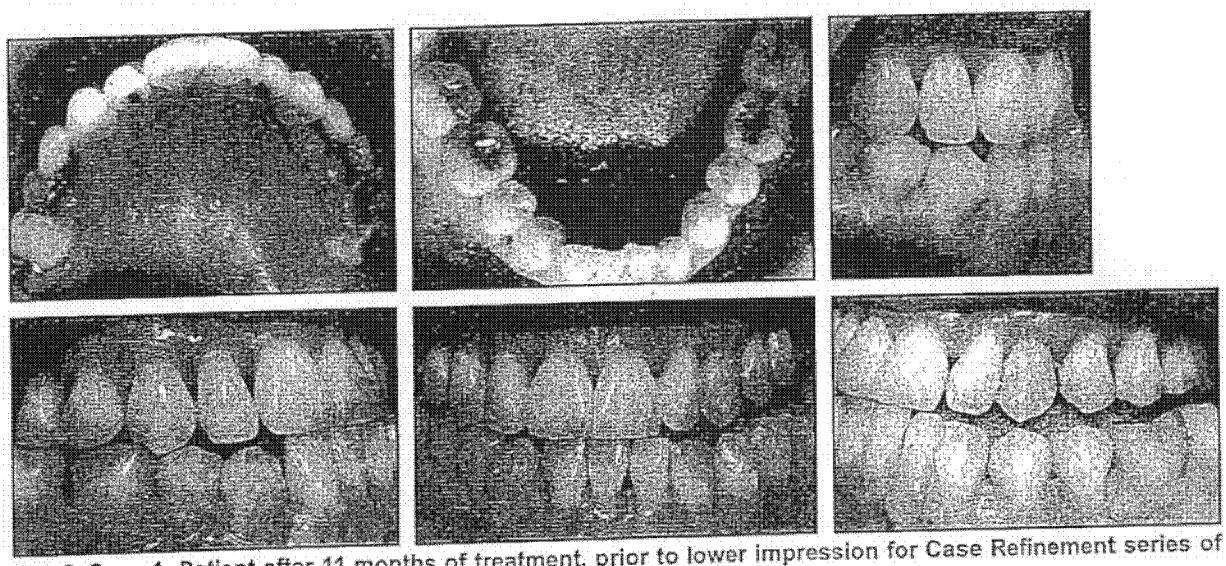

Fig. 3 Case 1. Patient after 11 months of treatment, prior to lower impression for Case Refinement series of aligners.

324

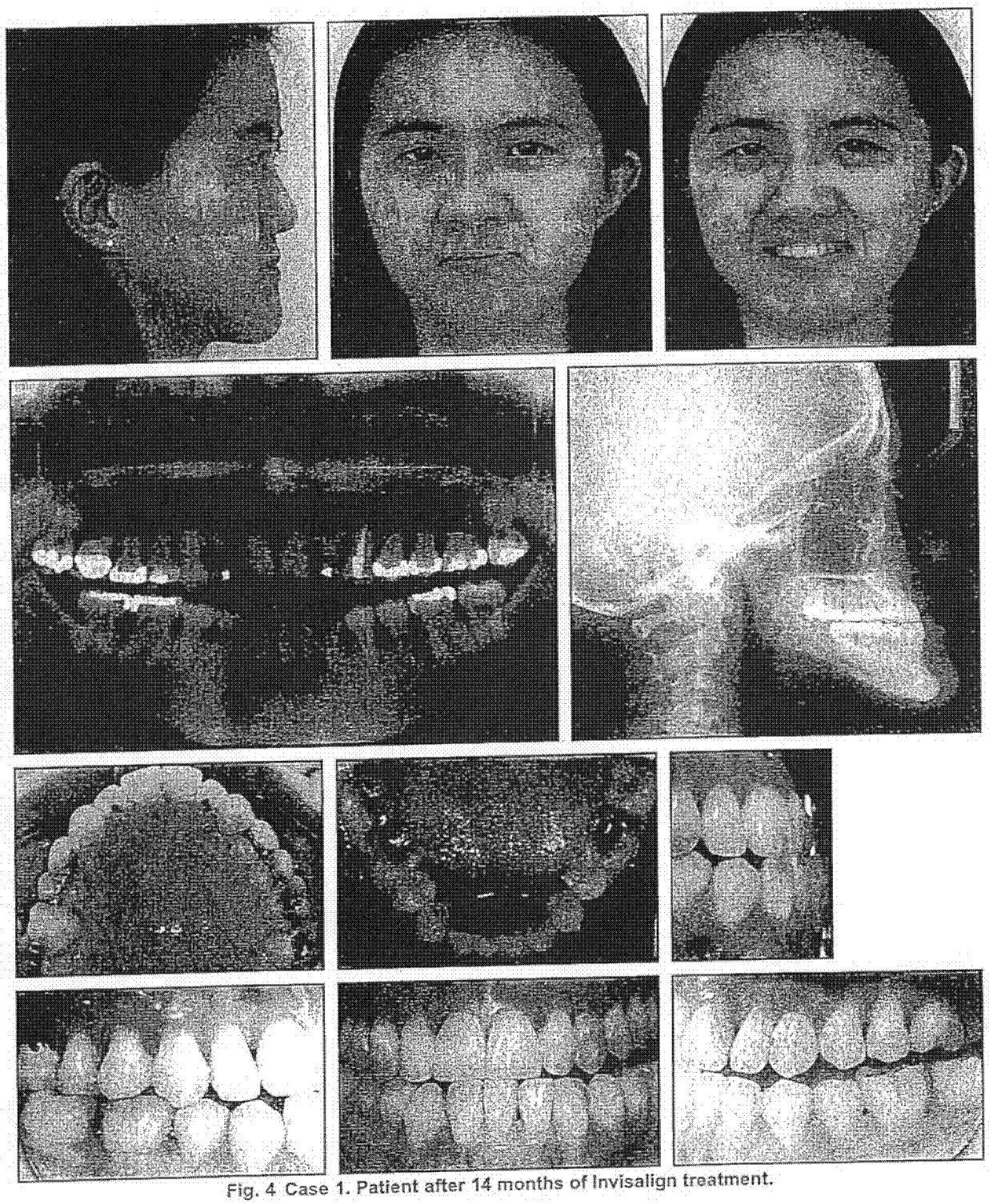

Fig. 4 Case 1. Patient after 14 months of Invisalign treatment.

375

lines, and finish with about 2mm of overbite and 2mm of overjet.

The treatment plan included presurgical Invisalign therapy with 22 upper stages and 38 lower stages (although only 28 of these lower aligners were used), with the patient wearing each aligner for two weeks. The first phase required 14 months to level, align, and coordinate the arches and to reduce the dental compensations by proclining the lower incisors.

During the initial phase of Invisalign treatment, the lower left first premolar became intruded and rotated 90°. The gingival third of the lower aligner was cut away to provide space for clear ceramic brackets,** and the rotation was corrected in four months with an .018" round TMA*** archwire and figure-8 clear elastic thread. Extrusion of the tooth into a correct relationship with the adjacent teeth required an additional three months of sectional fixed appliances, using an extrusive bend in a larger, .017" × .025" TMA sectional archwire and a coil spring (Fig. 2). Under this segmental approach, the original Invisalign treatment sequence could continue, with each subsequent lower aligner cut to allow space for the brackets.

A new polyvinyl siloxane lower impression was taken at lower stage 28 (Fig. 3) for a Case Refinement series, which required 14 more lower aligners (30 weeks). After this first phase of Invisalign treatment (Fig. 4), model surgery was performed to ensure that the dental arches were occluding properly (Fig. 5). All erupted teeth were then bonded with ceramic brackets** for the final presurgical preparation. For three months, 5oz Class II elastics were worn with the fixed appliances to increase the lower proclination and decrease the upper proclination, thus eliminating more of the dental compensations.

The Dolphin software prediction† called for a 3.5mm maxillary advancement and a mandibular osteotomy with 4mm of setback and rotation of 3mm to the right. The surgical procedure was performed using rigid fixation, and final detailing was carried out with fixed appliances during the four-month healing period after surgery (Fig. 6). The entire treatment took three years and eight months, partly because waiting for authorization and scheduling the surgery took

**Clarity, trademark of 3M Unitek, 2724 S. Peck Road, Monrovia, CA 91016.

***Registered trademark of Ormco, 1717 W. Collins Ave., Orange, CA 92867.

†Dolphin Imaging & Management Solutions, 9200 Eton Ave., Chatsworth, CA 91311.

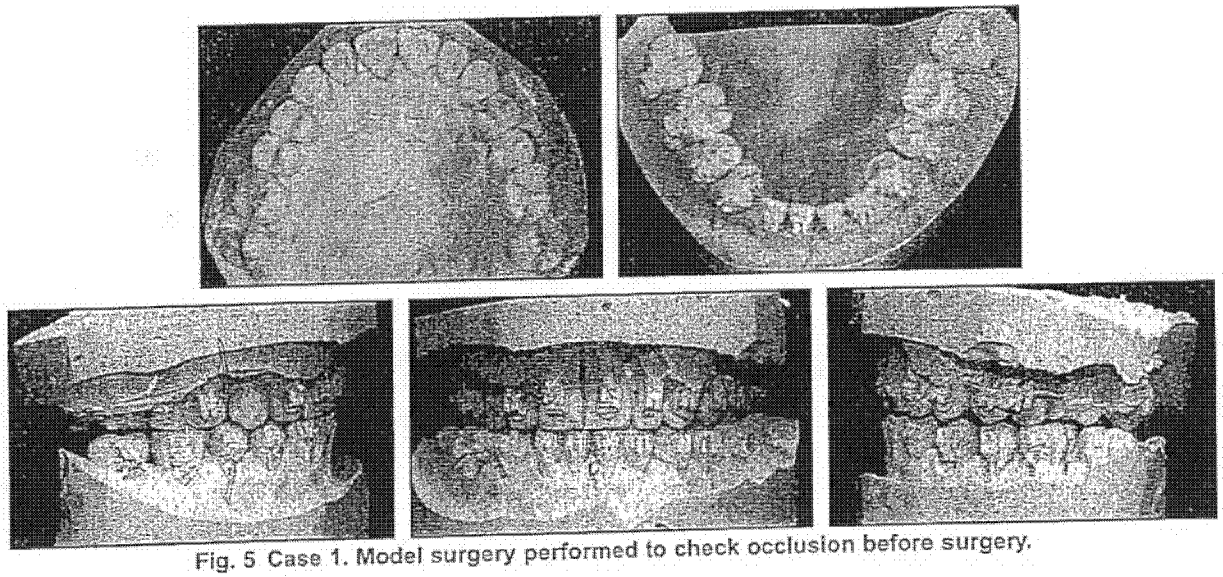

Fig. 5 Case 1. Model surgery performed to check occlusion before surgery.

316

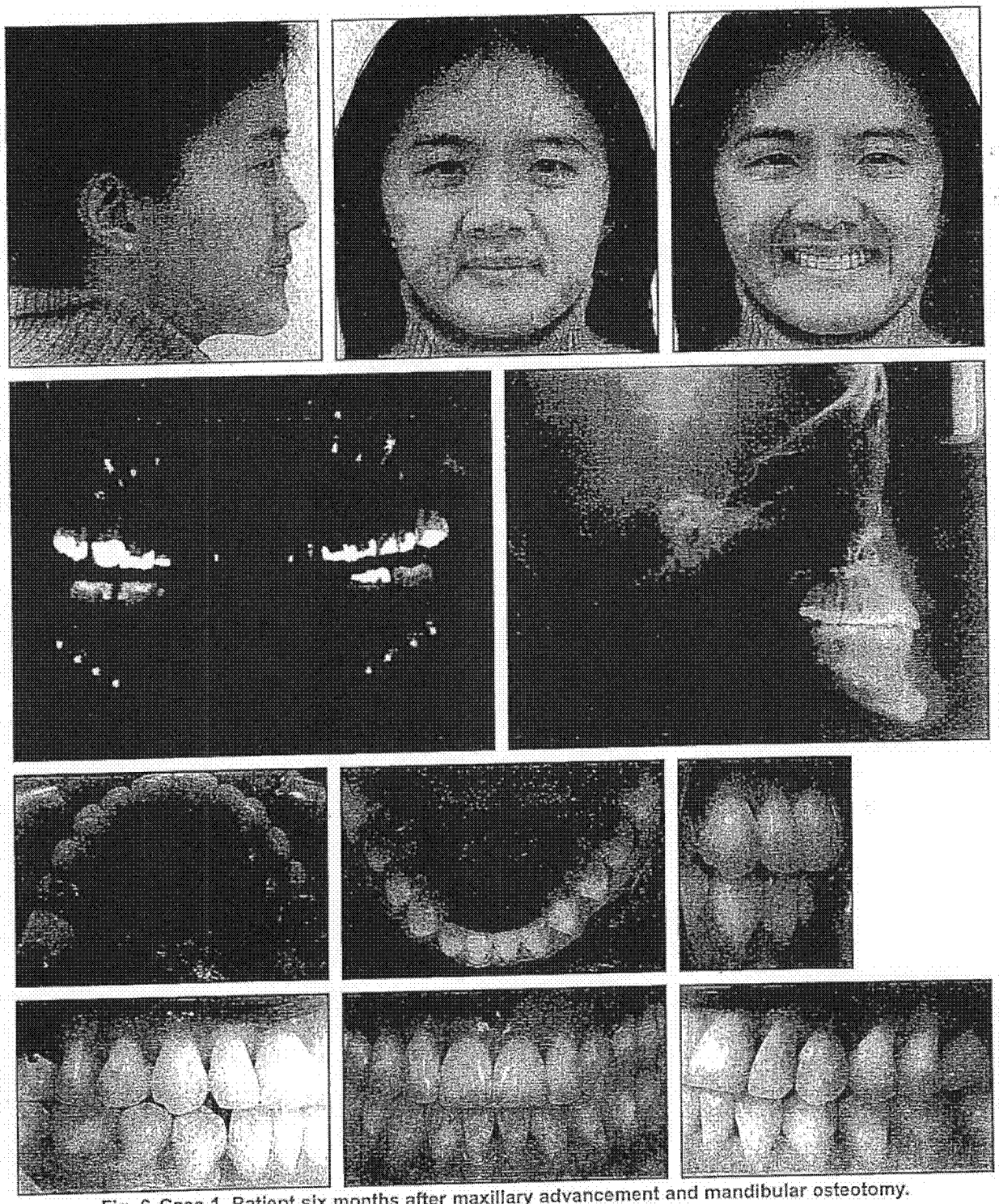

Fig. 6 Case 1. Patient six months after maxillary advancement and mandibular osteotomy.

377

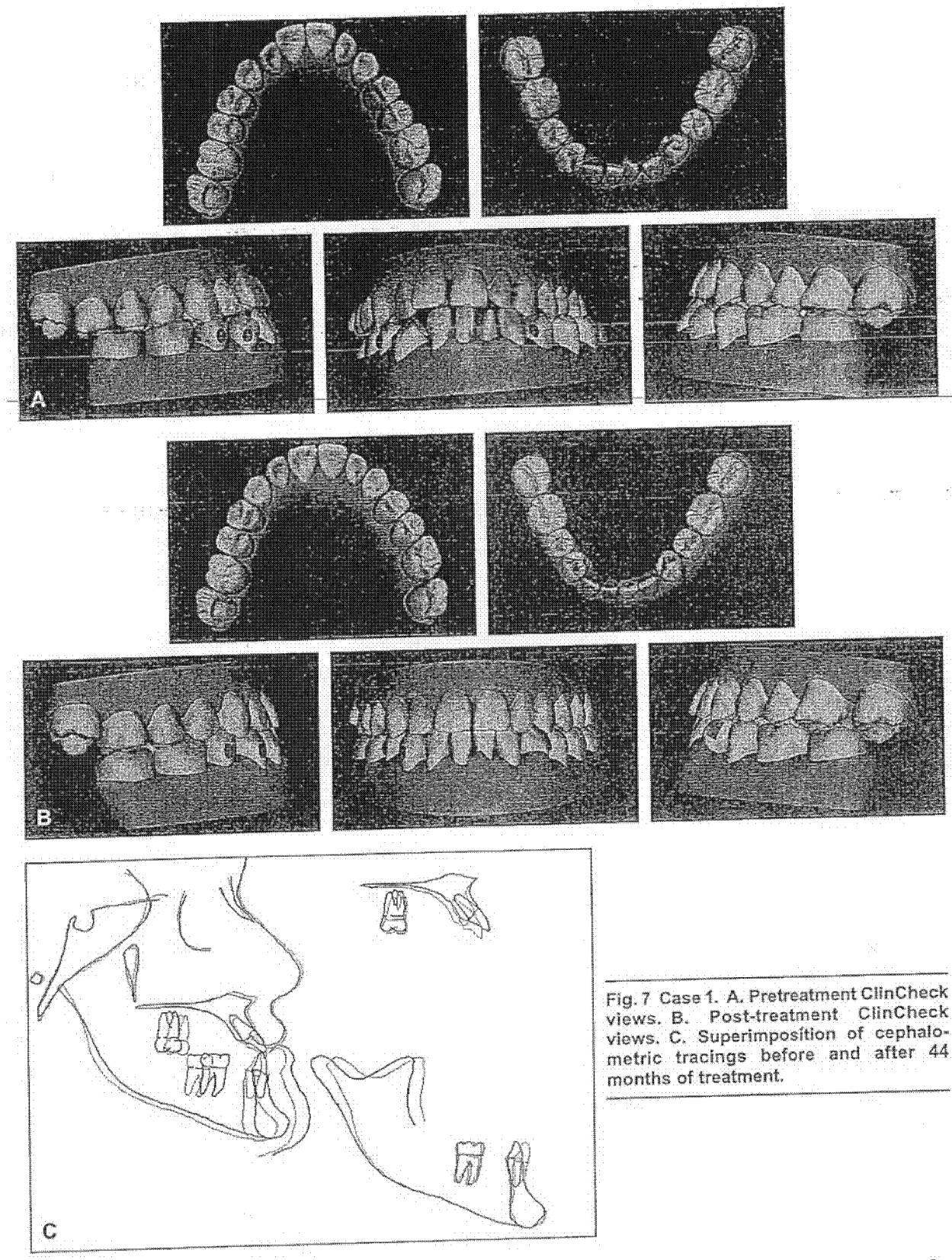


Fig. 7 Case 1. A. Pretreatment ClinCheck views. B. Post-treatment ClinCheck views. C. Superimposition of cephalometric tracings before and after 44 months of treatment.

778

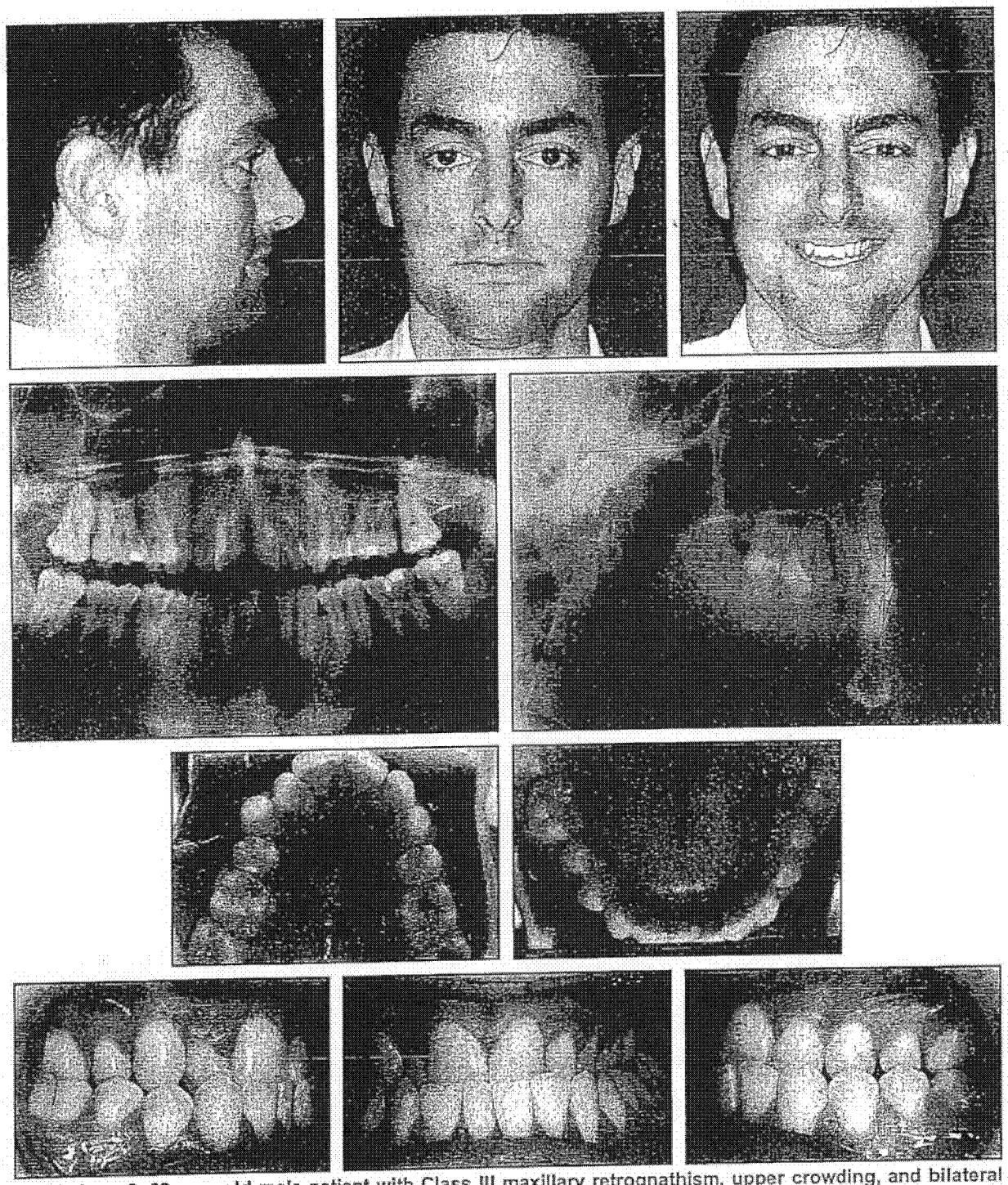

Fig. 8 Case 2. 29-year-old male patient with Class III maxillary retrognathism, upper crowding, and bilateral posterior crossbite before treatment.

379

an additional five months (Fig. 7, Table 1).

After debonding, a maxillary wraparound Hawley retainer was prescribed to allow settling of the posterior teeth into a better cusp-fossa relationship. The lower arch was retained with a vacuum-formed clear appliance. Retainers were to be worn full-time for six months, and then indefinitely at night only.

## Case 2

A 29-year-old male presented with the chief complaint of "crooked front teeth" (Fig. 8). His two upper first premolars had been extracted during previous orthodontic treatment as an adolescent in Australia. His profile was straight, with a slightly concave appearance; his lips were competent, and he had normal vertical facial proportions. The mandible was symmetrical and well-positioned in relation to the other facial structures. The patient's upper dental midline was deviated 2mm to the right, and the lower dental midline 1mm to the right. He had 4mm of upper crowding and 4mm of lower crowding. There was a severe bilateral posterior crossbite, with a narrow transverse skeletal width, a 2mm anterior crossbite, and 2mm of reverse overbite.

### TABLE 2
### CASE 2 CEPHALOMETRIC DATA

| | Pre-tmt. | Norm | Simu-lation | Pre-surgery | Post-Tmt. |
|---|---|---|---|---|---|
| SNA | 75° | 82° | 79° | 77° | 78° |
| SNB | 79° | 80° | 79° | 79° | 79° |
| ANB | –4° | 2° | –1° | –2° | –1° |
| Wits | –3 | –1 | –1 | –6 | –3 |
| MP-SN | 32° | 33° | 33° | 29° | 29° |
| FMA | 26° | 25° | 25° | 24° | 23° |
| Po-NB | 3° | 4° | 3° | 3° | 3° |
| IIA | 147° | 130° | 140° | 140° | 137° |
| U1-NA | 22° | 22° | 26° | 25° | 30° |
| U1-NA | 7mm | 4mm | 7mm | 6mm | 9mm |
| L1-NB | 15° | 25° | 14° | 18° | 14° |
| L1-NB | 4mm | 4mm | 4mm | 4mm | 3mm |
| FMIA | 71° | 65° | 72° | 67° | 71° |
| IMPA | 83° | 90° | 83° | 90° | 86° |
| Holdaway | .7 | 1 | .7 | .7 | 1 |
| E-line | –8° | –2° | –8° | –6° | –9° |
| E-line | –14mm | –8mm | –11mm | –13mm | –10mm |

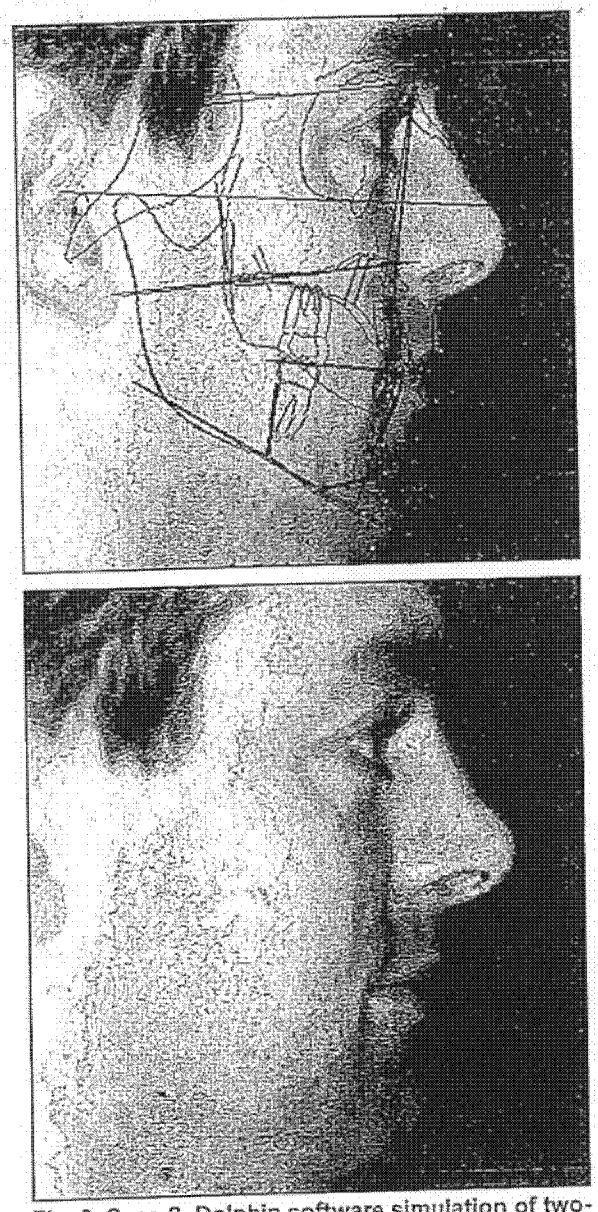

Fig. 9 Case 2. Dolphin software simulation of two-piece maxillary advancement.

380

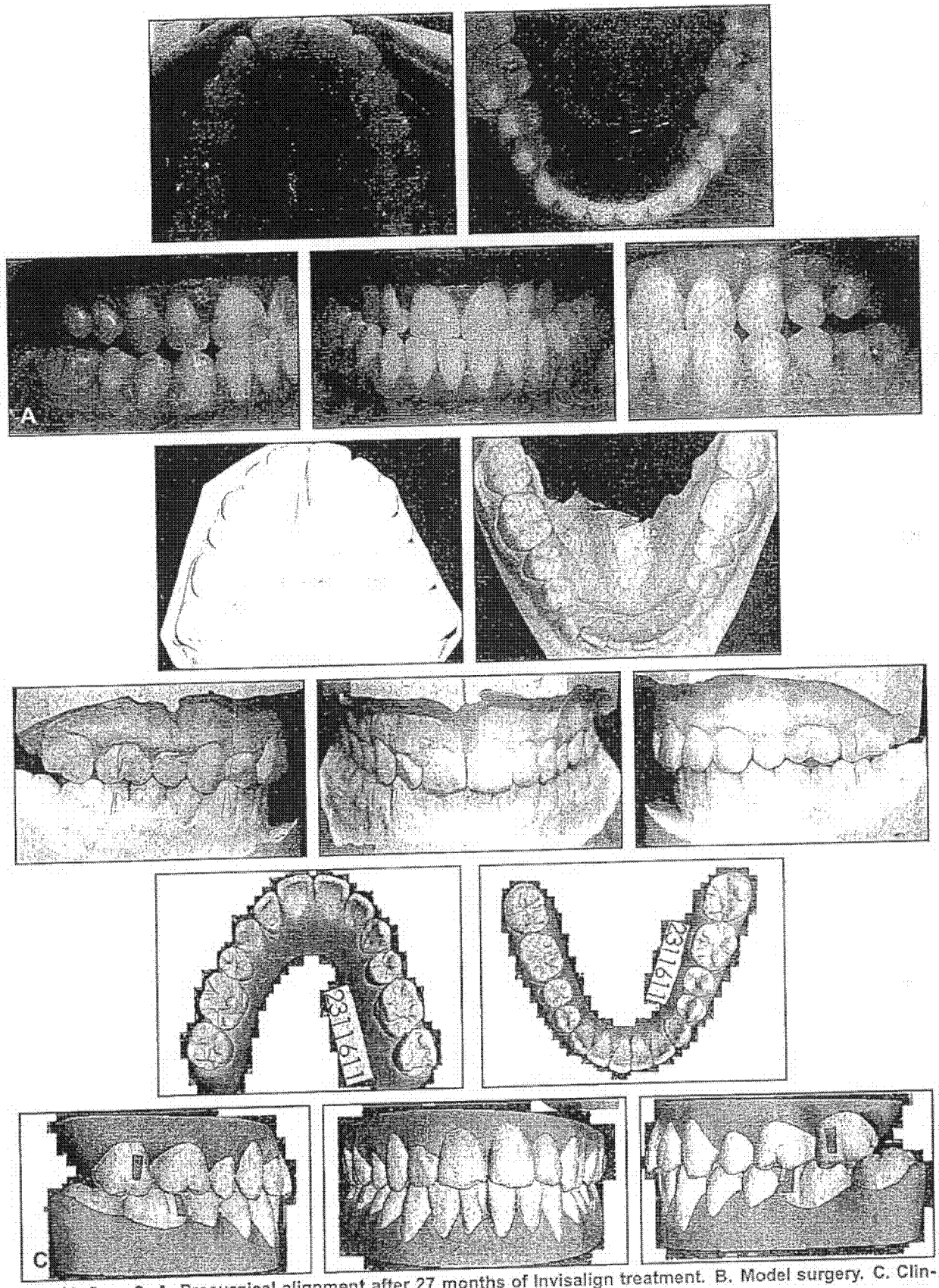


Fig. 10 Case 2. A. Presurgical alignment after 27 months of Invisalign treatment. B. Model surgery. C. ClinCheck prediction of final result.

381

The panoramic radiograph showed that all crown-to-root ratios were normal, and no periodontal bone loss was noted. Both upper second premolars and all third molars had previously been extracted.

In the cephalometric analysis (Table 2), the maxilla was deficient in the anteroposterior dimension (SNA = 75.3°), but the mandible was normal (SNB = 78.9°). The patient had an apical base discrepancy (ANB = –3.6°) and a Wits appraisal of –2.8. The upper incisors were retroclined, as shown by the measurements of 7mm and 22.4° to NA.

Treatment goals for this patient were to level, align, and coordinate the arches, establish a Class I canine relationship and a Class II molar relationship (due to the missing first premolars), achieve an overbite-overjet relationship of 2mm, and eliminate the posterior crossbite (Fig. 9).

Invisalign appliances were used to level, align, and coordinate the arches, but not to remove the posterior crossbite (Fig. 10). The first series involved 30 upper and 28 lower aligners, and the Case Refinement series used 16 more upper and 12 lower aligners. Passive fixed appliances were placed three months prior to surgery, after 27 months of Invisalign treatment (Fig. 11).

Orthognathic surgery involved a two-piece maxillary advancement osteotomy to position the maxilla 3.5mm anteriorly into a 2mm overbite-overjet relationship. Detailed finishing of the occlusion was accomplished with fixed appliances during the four months after surgery. The archwires were then cut to allow the lower arch to settle.

Vacuum-formed clear retainers were prescribed for retention. When a 1.5mm open bite was noted in the region of the molars and second premolars, bilateral elastics were used to extrude the lower posterior teeth into occlusion with the upper posterior teeth (Fig. 12, Table 2).

## Conclusion

These two cases demonstrate that the Invisalign system can be effective when used in conjunction with segmental fixed appliances, or prior to full fixed appliances immediately before and after surgery. Both of these patients wanted to have as much of their treatment as possible done with Invisalign, and we were able to limit the full-fixed-appliance phase to less than 30% of the total treatment time in each case.

Other surgical procedures, such as a one-piece, single-jaw mandibular advancement or a setback, could be accomplished without any buccal fixed appliances. Paik and colleagues, who used lingual appliances, showed that intermaxillary fixation could be achieved by connecting intermaxillary elastics or wires to four miniscrews in the upper jaw and four more in the lower[30] (Fig. 13). If the occlusion could be successfully leveled, aligned, and coordinated with only rigid fixation, no fixed appliances would be required for a single-jaw procedure.

ACKNOWLEDGMENTS: The orthognathic surgery on these two patients was performed by Drs. Felice O'Ryan and David Poor of the Oral and Maxillofacial Surgery Department at Kaiser Hospital in Oakland, California. The author wishes to thank Drs. Mark Handelin, Rebecca Doucet, and Shahram Nabipour for their valued assistance in the preparation of these case studies.



Fig. 11 Case 2. Passive fixed appliances placed three months prior to surgery.

382



FOI - Page 275 of 446

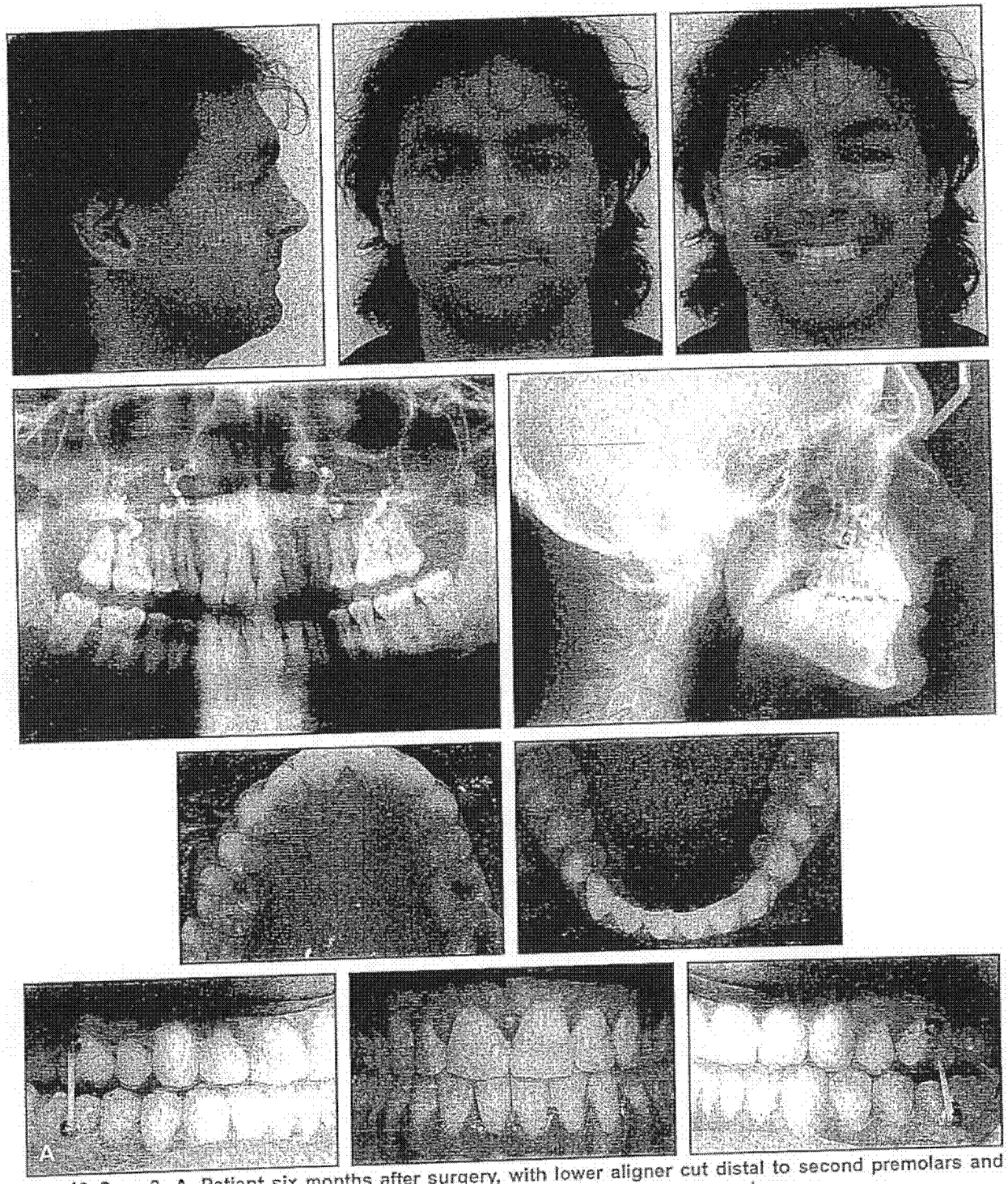


Fig. 12 Case 2. A. Patient six months after surgery, with lower aligner cut distal to second premolars and intermaxillary elastics used to close posterior open bite (continued on next page).

383

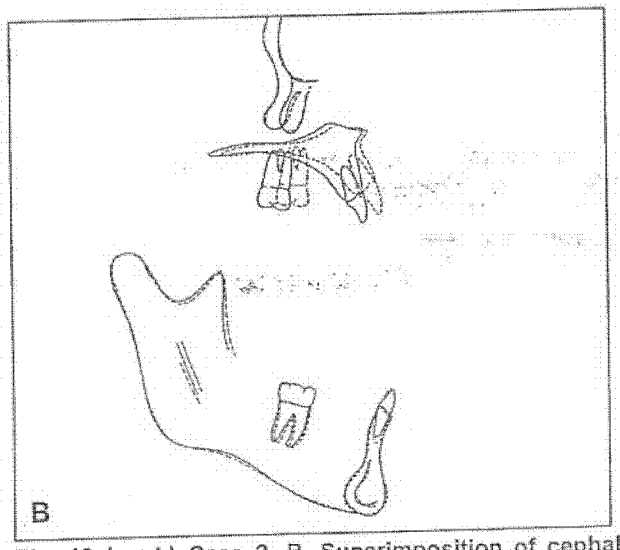


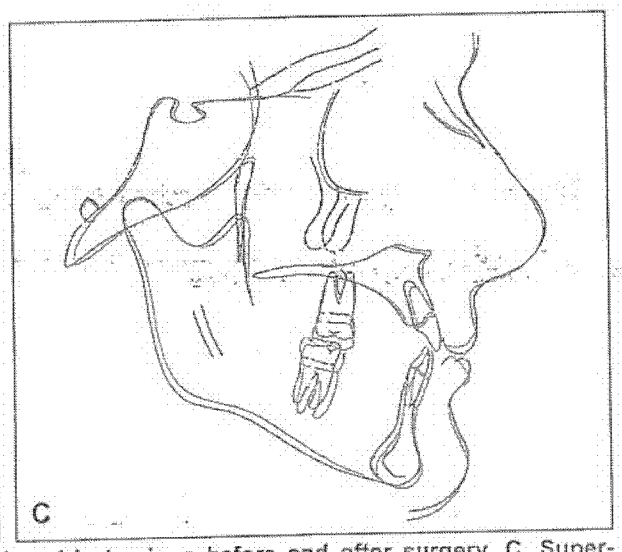


Fig. 12 (cont.) Case 2. B. Superimposition of cephalometric tracings before and after surgery. C. Superimposition of treatment simulation and actual results.



Fig. 13[Jennifer: Pick up Fig. 7B from Paik article, 3/02, p.135] Eight miniscrews inserted for intermaxillary fixation with elastics.[30]

REFERENCES


1. Boyd, R.L.; Miller, R.J.; and Vlaskalic, V.: The Invisalign System in adult orthodontics: Mild crowding and space closure cases, J. Clin. Orthod. 34:203-212, 2000.
2. Boyd, R.L. and Vlaskalic, V.: Three-dimensional diagnosis and orthodontic treatment of complex malocclusions with the Invisalign Appliance, Semin. Orthod. 7:274-293, 2001.
3. Vlaskalic, V. and Boyd, R.L.: Orthodontic treatment of a mildly crowded malocclusion using the Invisalign System, Austral. Orthod. J. 17:41-46, 2001.
4. Vlaskalic, V. and Boyd, R.L.: Clinical evolution of the Invisalign Appliance, J. Calif. Dent. Assoc. 30:769-776, 2002.
5. Miethke, R.R.; Boyd, R.; Brachwitz, J.; Hordt, C.; John, H.D.; Kuo, E.; Küch, A.; Miller, R.J.; and Vlaskalic, V.: Kieferorthopädie, Sonderheft Invisalign 15:3-58, 2001.
6. Chenin, D.A.; Trosien, A.H.; Fong, P.F.; Miller, R.; and Lee, R.S.: Orthodontic treatment with a series of removable appliances, J. Am. Dent. Assoc. 134:1232-1239, 2003.
7. Womack, W.R.; Ahn, J.H.; Ammari, Z.; and Castillo A.: A new approach to correction of crowding, Am. J. Orthod. 122:310-316, 2002.
8. Wong, B.H.: Invisalign A to Z, Am. J. Orthod. 121:540-541, 2002.
9. Kuo, E. and Miller, R.J.: Automated custom-manufacturing technology in orthodontics, Am. J. Orthod. 123:578-581, 2003.
10. McNamara, J.A. Jr. and Brudon, W.L.: Invisible retainers and aligners in *Orthodontics and Dentofacial Orthopedics*, ed. J.A. McNamara Jr. and W.L. Brudon, Needham Press, Ann Arbor, MI, 2001, pp. 475-486.
11. Owen III, A.H.: Accelerated Invisalign treatment, J. Clin. Orthod. 35:381-384, 2001.
12. Miller, R.J. and Derakhshan, M.: The Invisalign System: Case report of a patient with deep bite, upper incisor flaring, and severe curve of Spee, Semin. Orthod. 8:43-50, 2002.
13. Miller, R.J.; Duong, T.; and Derakhshan, M.: Lower incisor extraction treatment with the Invisalign System, J. Clin. Orthod. 36:95-102, 2002.
14. Miller, R.J.; Kuo, E.; and Choi, W.: Validation of Align Technology's Treat III digital model superimposition tool and its case application, Orthod. Craniofac. Res. 6:143-149, 2003.
15. Beers, A.C.; Choi, W.; and Pavlovskaia, E.: Computer-assisted treatment planning and analysis, Orthod. Craniofac. Res. 6:117-125, 2003.
16. Norris, R.A.; Brandt, D.J.; Crawford, C.H.; and Fallah, M.: Restorative and Invisalign: A new approach, J. Esth. Restor. Dent. 14:217-224, 2002.
17. Bishop, A.; Womack, W.R.; and Derakhshan, M.: An esthetic and removable orthodontic treatment option for patients: Invisalign, Dent. Assist. 71:14-17, 2002.
18. Christensen, G.J.: Orthodontics and the general practitioner, J. Am. Dent. Assoc. 133:369-371, 2002.


384



FOI - Page 277 of 446

19. Joffe, L.: Invisalign: Early experiences, J. Orthod. 30:348-352, 2003.
20. Bollen, A.M.; Huang, G.; King, G.; Hujoel, P.; and Ma, T.: Activation time and material stiffness of sequential removable orthodontic appliances, Part I: Ability to complete treatment, Am. J. Orthod. 124:496-501, 2003.
21. Clements, K.M.; Bollen, A.M.; Huang, G.J.; King, G.; Hujoel, P.; and Ma, T.: Activation time and material stiffness of sequential removable orthodontic appliances, Part II: Dental improvements, Am. J. Orthod. 124:502-508, 2003.
22. Taylor, M.G.; McGorray, S.P.; Durrett, S.; Pavlow, S.; Downey, N.; Lenk, M.; Oxford, D.; Dolce, C.; and Wheeler, T.T.: Effect of Invisalign aligners on periodontal tissues, J. Dent. Res. 82(Spec. Iss. A):1483, 2003.
23. Invisalign website, www.invisalign.com, 2005.
24. Boyd, R.L.; Leggott, P.J.; Quinn, R.; Eakle, W.S.; and Chambers, D.: Periodontal implications of orthodontic treatment in adults with reduced or normal periodontal tissues versus those of adolescents, Am. J. Orthod. 96:191-198, 1989.
25. Boyd, R.L. and Chun, Y.S.: Eighteen-month evaluation of the effects of a 0.4% stannous fluoride gel on gingivitis in orthodontic patients, Am. J. Orthod. 105:35-41, 1994.
26. Boyd, R.L. and Baumrind, S.: Periodontal considerations in the use of bonds or bands on adolescents and adults, Angle Orthod. 62:117-126, 1992.
27. Boyd, R.L.: Two-year longitudinal study of a peroxide-fluoride rinse on decalcification in adolescent orthodontic patients, J. Clin. Dent. 3:83-87, 1992.
28. Boyd, R.L.: Comparison of three self-applied topical fluoride preparations for control of decalcification during orthodontic treatment, Angle Orthod. 63:25-30, 1993.
29. Boyd, R.L. and Rose, C.M.: Effect of rotary electric toothbrush versus manual toothbrush on decalcification during orthodontic treatment, Am. J. Orthod. 105:450-456, 1994.
30. Paik, C.H.; Woo, Y.J.; Kim, J.; and Park, J.U.: Use of miniscrews for intermaxillary fixation of lingual orthodontic-orthognathic surgery patients, J. Clin. Orthod. 36:132-136, 2002.

385

# The Invisalign® System

Edited by

Orhan C. Tuncay, DMD

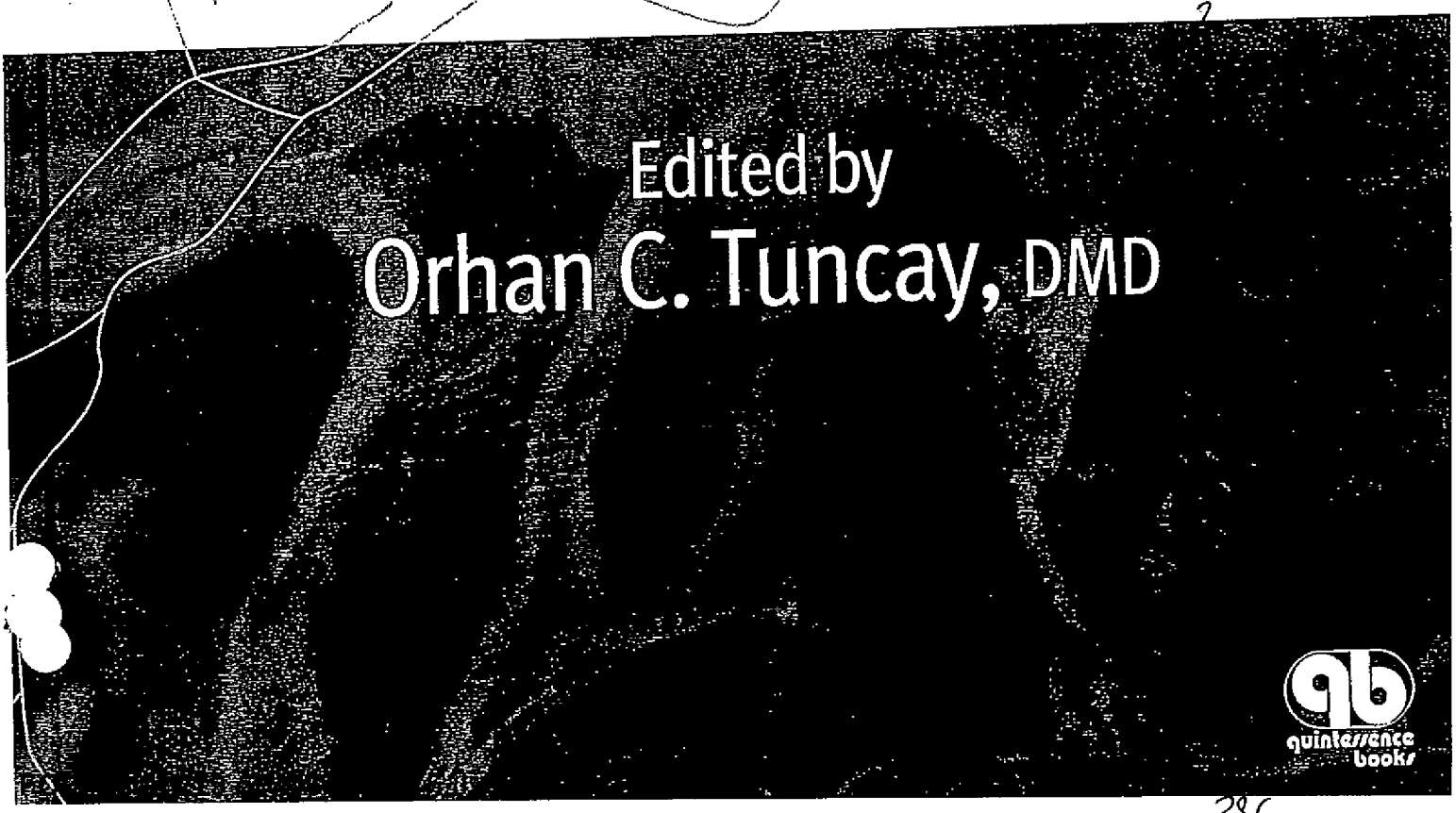

quintessence books

386

Copyrighted Material

Copyrighted Material

Copyrighted Material

Copyrighted Material

Copyrighted Material

Copyrighted Material

Copyrighted Material

Copyrighted Material

Copyrighted Material

praxis

# Combination Treatment to Meet Market Demands

PART 2: PRE-INVISALIGN® EXPANSION

BY WAYNE B. HICKORY, DMD, MDS

Some clinical topics have compelling practice management implications. Invisalign®, as a new technology, presents challenges regarding its integration into an orthodontic practice. Effective management of this integration can contribute to practice success.

This series of short articles presents strategies to complement Invisalign® with traditional or modified-traditional appliances. The goal is to achieve quality orthodontic results while satisfying patient esthetic desires.

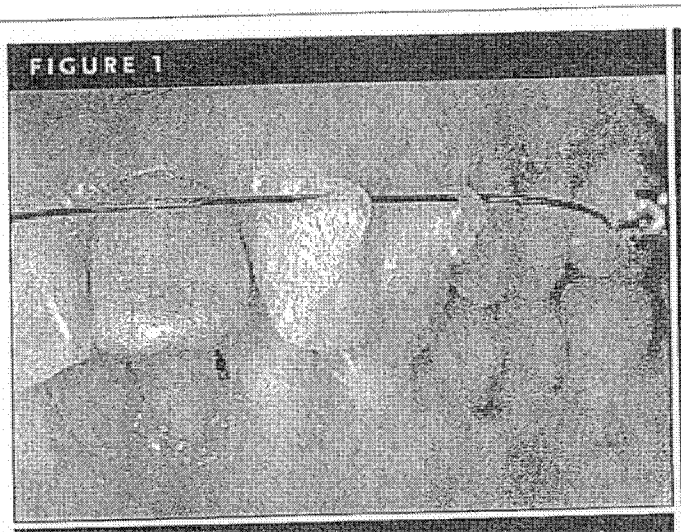
FIGURE 1

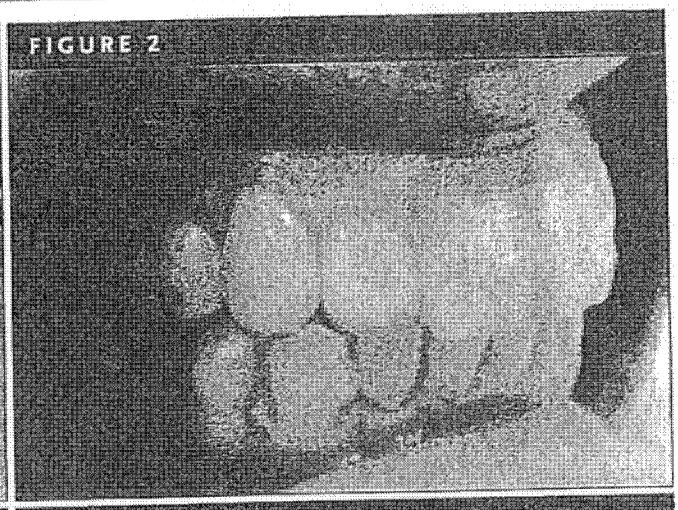
FIGURE 2

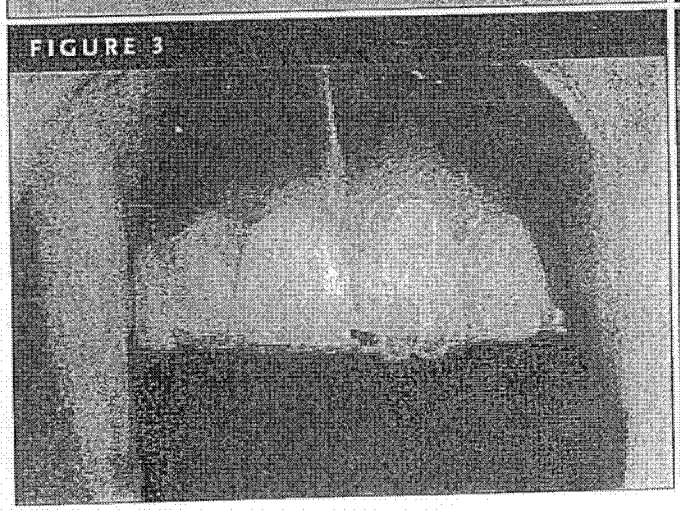
FIGURE 3

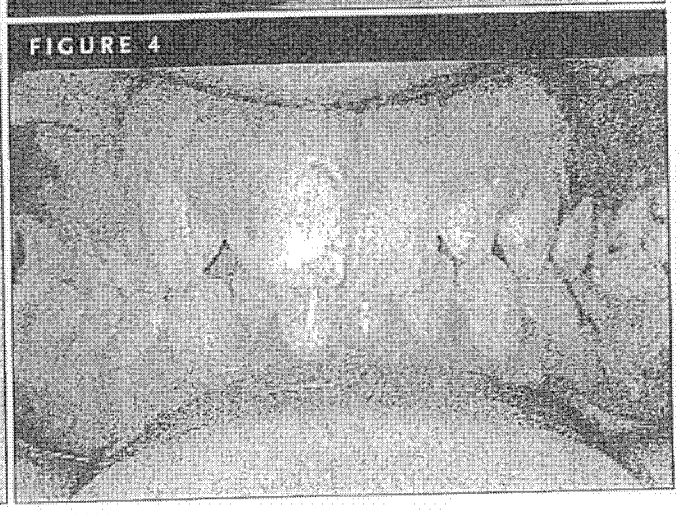
FIGURE 4

# Adjunctive procedures designed to compliment Invisalign® can also be useful for managing relapse of any orthodontic case.

**Update on Part I:**
**Pre-Invisalign® Intrusion**

Part I of this series illustrated the use of standard tip-back mechanics to intrude anterior teeth as a pre-Invisalign® treatment. This is a consideration if the amount of intrusion is great. Using clear buttons at the gingival third of the incisors, an intrusion arch system can have acceptable esthetics (Figure 1).

A new more esthetic approach is entirely removable. It consists of using buttons on the facial and palatal of an aligner in orientation to an incisor needing intrusion. An intrusive force can be applied with an elastic interconnecting the buttons running across the incisal edge (Figure 2). The aligner is cut free for a few millimiters of the incisal edge to let the elastic apply the intrusive force to the incisor(s).

A similar approach can be used for extrusion (Figure 3). In this situation, buttons are placed on the teeth. The aligner is cut at the gingival third to make space for the buttons. The elastic interconnects the buttons in the facial and palatal of the aligner running across the incisal edge of the aligner to apply an extrusive force. Conveniently, the aligner provides a stop as the tooth is pulled into the aligner.

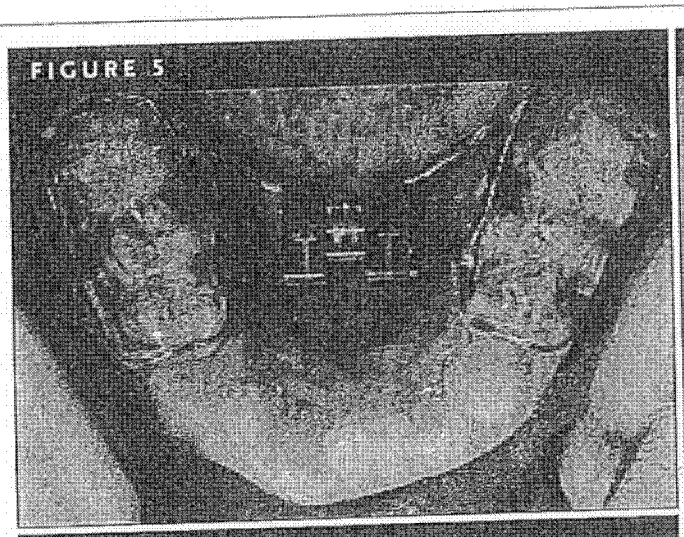
FIGURE 5

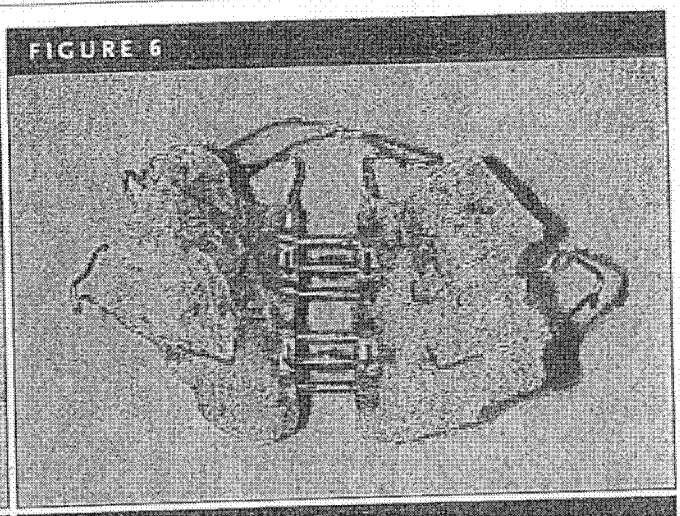
FIGURE 6

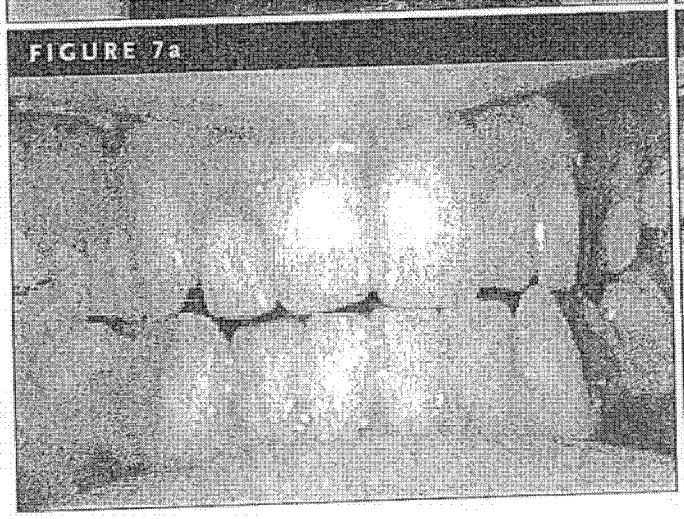
FIGURE 7a

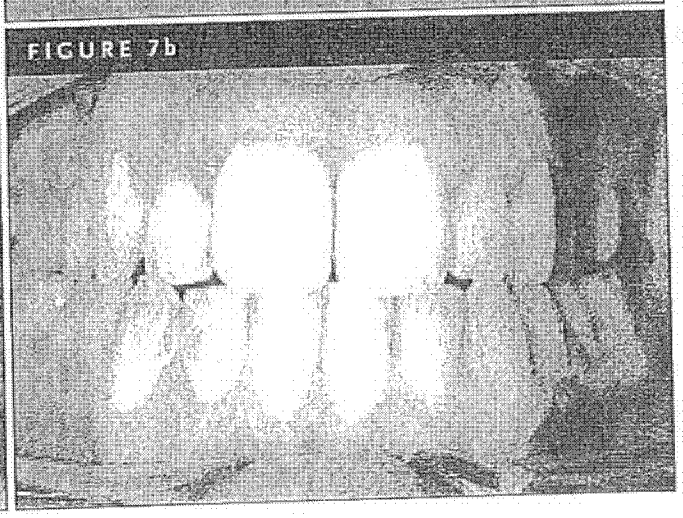
FIGURE 7b

These techniques can be used pre-Invisalign® or post Invisalign®. They are also useful for correcting vertical relapse in any orthodontic case.

**Part II: Pre-Invisalign® Expansion**

Crowding is the most common reason why adults seek orthodontic care. Invisalign® is a powerful tooth alignment system. The only challenge to resolving crowding is finding space. Extraction, proclination, expansion, interproximal reduction and molar distalization are the standard approaches available. In the next issue of PRAXIS, this section will review appliances ideal for pre-Invisalign® molar distalization. Distalizing maxillary molars also helps correct a class II occlusal relation. Orthodontic specialists, who have experience with these adjunctive modalities, can enhance the final result of Invisalign® and add great value to the whole process.

The ideal situation for expansion is arches that are collapsed such as in figure 4. Palatally tipped teeth are easy to upright and the result will be more stable. But even in this situation you may question the strength of the distal portions of flexible aligners to apply adequate expansile force. In this case, a hard acrylic appliance was used—an expander designed to be bonded but used as a removable (Figure 5). This type of appliance is bulky and may be awkward for an adult to wear.

As a pre-Invisalign® treatment, a removable Swartz-type appliance can achieve expansion that may not be as easily obtained with thin thermoplastic appliances (Figure 6). Occlusal coverage may be incorporated to facilitate expansion. The case shown in figures 7a,b benefited from the above-described appliances for pre-Invisalign® expansion.

It is the experience of an orthodontist that will dictate which cases will be worth the added effort involved in using these types of adjunctive appliances. ■

*Dr. Hickory is the Editor in Chief of Praxis. He is a graduate of Trinity College (B.S.) Connecticut. He received his DMD, orthodontic certificate and MDS from the University of Connecticut School of Dental Medicine. Dr. Hickory was a full-time faculty member of Orthodontics at the Vrije University in Holland and the University of Maryland. He has over twenty years of experience in orthodontic private practice and continues to consult and teach internationally.*

398

QUICK SEARCH: [advanced]
Author: Keyword(s):
Go
Year: Vol: Page:

Journal of Orthodontics

HOME HELP FEEDBACK SUBSCRIPTIONS ARCHIVE SEARCH TABLE OF CONTENTS

Journal of Orthodontics, Vol. 29, No. 3, 239-245, September 2002
© 2002 British Orthodontic Society

This Article
- Full Text (PDF)
- Alert me when this article is cited
- Alert me if a correction is posted

Services
- Email this article to a friend
- Similar articles in this journal
- Similar articles in PubMed
- Alert me to new issues of the journal
- Download to citation manager

Google Scholar
- Articles by Ismail, S. F. H.
- Articles by Johal, A. S.
- Articles citing this Article

PubMed
- PubMed Citation
- Articles by Ismail, S. F. H.
- Articles by Johal, A. S.

Features Section

# The role of implants in orthodontics

**S. F. H. Ismail and A. S. Johal**

Royal London Hospital, UK

Mr S. F. H. Ismail, Department of Orthodontics, Royal London Hospital, New Road, London E1 1BB, UK. E-mail: shamiqueismail@yahoo.com

## Introduction

In this article we will review the development of implants in orthodontic treatment and highlight their use in multidisciplinary cases. The use of dental implants has greatly increased over the last three decades, largely as a consequence of their successful long-term osseo-integration. This has led to increased orthodontic use, with appropriate modifications in the design when required.

It is well established that implants can offer an option when replacing missing teeth, following orthodontic treatment. This article, however, will concentrate on the use of implants *during* orthodontics, to enhance the orthodontic treatment, with particular reference to the following:

- Implants as a source of absolute anchorage
- Implants used for anchorage and as abutments for restorations
- Implant site preparation improved by orthodontics
- Implants in osteogenic distraction.

## Background to implants

*Osseo-integration*

The work of Branemark in the 1960s on osseo-integrated implants is well known.[1,2] His definition of 'a direct contact between living bone and an implant, on the light microscope level'[1] describes the objective of osseo-integration, but the essence of its clinical success is the reliability of long-term implant fixation, even in the presence of functional loading. This has been supported by many studies, including a meta-analysis,[3] which reported a 90 per cent success rate for osseo-integrated implants

399

used for bridge abutments.

*Types of implants*

The rise in the use of dental implants has led to a great diversity in their design and manufacture. The classification of implants can be based on their position, material of construction, or design.

- The position of the implant can be subperiosteal, transosseous, or endosseous, the last of which is the most commonly used type of dental implant.
- Titanium is the accepted ideal material for implant fabrication, but other variants include gold alloys, vitallium, cobalt-chromium, vitreous carbon, aluminium oxide ceramics, or nickel-chromium-vanadium alloys.[4] Even with the favoured titanium metal, the implant surface maybe rough or smooth, and may have an additional hydroxyapatite or titanium-spray coating.[5]
- There appears to be a lack of consensus among researchers and clinicians regarding the best design for an implant. The main area of dispute focuses on how an implant gains its support from the surrounding bone. A screw thread around the implant surface aids loading of the surrounding bone in compression, whereas a smooth cylindrical design increases implant support when shear forces are exerted on the bone. Both these varieties show a more uniform stress distribution under loading when compared to other designs.[6]

*Protocol of placement*

The technique for successful osseo-integration of an implant, as historically described by Branemark,[2] involves a two-stage surgical procedure. First, the implant fixture is countersunk into position and a cover screw is located over it during the required 4–6-month healing period. The second stage involves the fitting of an abutment to the osseo-integrated implant after it has been uncovered. A 2-week period is allowed for resolution of the gingivae after this procedure and, subsequent to this, restorative work can begin. There is a trend towards earlier loading of implants and possible immediate loading, to minimize the delay that results from the extensive healing period required. However, there are no long-term follow up studies of this approach as it is still in its infancy.

*Suitability for implants*

Prior to commencing any implant treatment, factors that need to be considered include the quality and quantity of bone present, the age of the patient, and the reasoning behind their seeking implant treatment.

Bone quality and the extent of ridge resorption are important factors to assess, and radiographic classification of these has been previously described.[7]

The age of the patient is an important consideration, as implants are problematic if inserted in growing children for the following reasons.[8]

- The use of implants in the anterior maxilla is contraindicated due to the possibility of the mid-palatal suture being open
- Resorption in the posterior part of the maxilla, resulting from growth changes, could lead to the exposure of the implant into the sinus

400

- The posterior aspect of the mandible continues to undergo growth changes in all three planes of space and, as such, definitive implant placement in this area would be difficult to estimate

Even when growth is complete and the teeth appear fully erupted, infra-occlusion of implant-supported crowns may occur.[9] This is a result of minimal continued eruption of the adjacent teeth, post-adolescence, and is most frequently seen with upper lateral incisors.

## Implants as a source of absolute anchorage

During active treatment, orthodontic anchorage aims to limit the extent of detrimental, unwanted tooth movement. There are methods available to reduce anchorage loss during treatment. However, these techniques are often only partially successful, for example, transpalatal arches or headgear. The ability of osseo-integrated implants to remain stable under occlusal loading has led orthodontists to use them as anchorage units without patient compliance.

*Historical background*

The concept of metal components being screwed into the maxilla and mandible to enhance orthodontic anchorage was first published in 1945,[10] with the use of vitallium screws to effect tooth movement in dogs. Despite some success, the resultant tooth movement was limited due to the implants loosening within 1 month of commencing tooth movement. Two decades later, Linkow[11] described the endosseous blade implant for orthodontic anchorage, but did not report on the long-term stability. Vitreous carbon implants showed a failure rate of 67 per cent[12] when undergoing orthodontic loading, and attempts at using Bioglass-coated ceramic implants[13] for orthodontic anchorage were almost as disappointing. Although all the above materials were compatible with bone, none of them showed consistent long-term attachment of bone to the implant interface, which means they did not achieve true osseo-integration.

*Osseo-integrated implants and orthodontics*

In malocclusions requiring a high level of anchorage control, osseo-integrated implants can be used on a temporary basis to minimize loss of anchorage. For example, Roberts[14] used conventional, two-stage titanium implants in the retromolar region, to help reinforce anchorage whilst successfully closing first molar extraction sites in the mandible. After completion of the orthodontic treatment, the implants were removed using a trephine and histologically analysed. They found a high level of osseo-integration had been maintained, despite the orthodontic loading. In another study, Turley *et al.*[15] used tantalum markers and bone labelling dyes in dogs to illustrate the stability of two-stage implants in cases of orthodontic or orthopaedic traction. This work also showed that one-stage implants were less successful in this role.

Implant-based anchorage can be of particular benefit in treating certain aspects of malocclusions, for example:

- Retracting and realigning anterior teeth with no posterior support.
- Closing edentulous spaces in first molar extraction sites.

401

- Centre-line correction when missing posterior teeth.
- Re-establishing proper transverse and antero-posterior position of isolated molar abutments.
- Intruding/extruding teeth.
- Protraction or retraction of one arch.
- Stabilization of teeth with reduced bone support.
- Orthopaedic traction.

*Design of orthodontic implants*

One of the obvious disadvantages of two-stage implants for orthodontic anchorage is the need for a long healing period of 4–6 months, which adds significantly to the treatment time. The bone height required for traditional endosseous implants may also restrict the locations available for implant placement. As a result of these problems, implants have been designed specifically for orthodontic purposes. Ideally, an implant used to enhance orthodontic anchorage should be biocompatible, inexpensive, easily inserted and removed under local anaesthesia, and be small enough to locate in multiple sites in the mouth. It should also osseo-integrate in a few days, and would be stable to orthodontic loading in all planes of space.

Block and Hoffman[16] addressed the issue of bone height by developing a disc-like structure called an 'onplant' (Figure 1); which is designed to be placed under local anaesthetic. This hydroxyapatite-coated disc is 10 mm in diameter by 3 mm thick, and is placed subperiosteally on the posterior aspect of the hard palate, using a 'tunnelling' surgical procedure. The latter minimizes the potential for infection to occur around the onplant. After a 10-week healing period, the onplant is surgically exposed and a ball-shaped abutment (which replaces the cover screw) is attached. This is subsequently connected to orthodontic bands on the upper molar teeth by a transpalatal arch. This mechanism has been shown to resist greater than 300 g of continuous orthodontic force, which is comparable to the force required for conventional space closure of orthodontic extraction sites. After correction of the malocclusion, the onplant is removed using an osteotome, but the authors do not elaborate on any complications associated with this removal technique. Although the onplant requires less bone depth compared to conventional endosseous implants and the period of consolidation is approximately half as long, the surgical procedure is complex. The secondary surgical procedure to uncover the integrated onplant involves a large area of soft tissue being re-exposed, which is quite traumatic to the patient. In addition, the use of an osteotome to remove the onplant under local anaesthetic may be disconcerting for the patient.

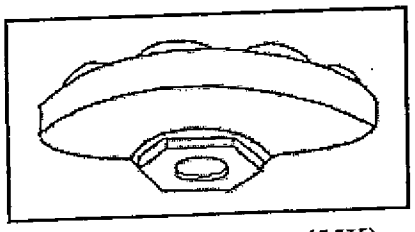

**Fig. 1** Diagram of an onplant.

**View larger version** (55K):
[in this window]
[in a new window]

402

The anterior region of the hard palate is an area that Triaca[17] first reported as having potential for orthodontic implant placement. The hard tissue in this area comprises the mid-palatal suture and a zone of compact bone adjacent to this. The degree of inter-digitation of this suture increases with age and the extent of this inter-digitation may affect the success of an implant placed in this region. A suture of narrow width, combined with a high degree of inter-digitation provides the best environment for one-stage surgery and, therefore, earlier orthodontic loading.

Wehrbein and Merz[18] have investigated the depth of bone in the mid-palatal area by measuring lateral cephalograms and have subsequently developed the Straumann Orthosystem implant (Institut Straumann AG, Waldenburg, Switzerland), which can be up to 6mm in height, based on the potential bone depth available. The Orthosystem implant (Figure 2) is a one-piece device with an 8-week healing period. It is composed of a screw-type endosseous section of between 4mm and 6mm in length (depending on palatal depth), a cylindrical transmucosal neck and an abutment, to which a transpalatal arch attaches. It is different from previously described mid-palatal implants[16,17] due to its dimensions: it has a smaller width and greater length that results in less soft tissue trauma at the time of surgery. To maximize stability, the implant uses a self-tapping screw with a sandblasted acid-etched surface. This results in a high level of direct bone contact when osseo-integrated, which helps to maintain anchorage control when supporting the length of the TPA, despite the minimal implant design.

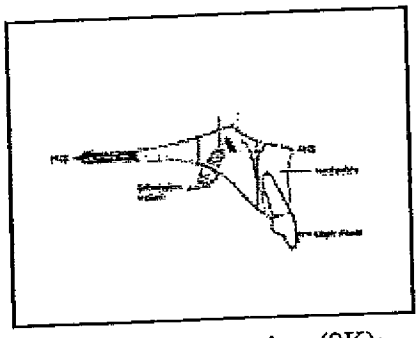

**View larger version** (9K):
[in this window]
[in a new window]

**Fig. 2** Schematic representation of an Orthosystem implant.

The placement or removal of this implant takes about 15 minutes under local anaesthetic, and is more straightforward than the onplant procedure of Block and Hoffman.[16] However, the potential problem with depth and width of the mid-palatal suture, as well as proximity of the nasal floor in children, means that this location may not always be appropriate.

Bernhart,[19] using multi-planar CT reconstruction, has identified regions 3–6 mm lateral to the midline of the anterior hard palate, that consistently have an adequate depth of bone to accept insertion of these 6-mm implants.

The increasing desire for early loading of implants used for orthodontic anchorage led Melsen to

403

develop the Aarhus implant[20] (Figure 3). Due to its small dimensions (6 mm length), this titanium anchorage screw can be located in multiple sites, including between the roots of teeth. It is said to allow osseo-integration to occur even in the presence of immediate orthodontic loading, providing the orthodontic forces (25–50 g from Sentalloy springs) pass through the screw. The strain that develops in the bone surrounding the loaded screw leads to a local environment in which increased bone formation results. Due to the size of the screw it can be used in a number of different locations and can be easily removed when no longer required.

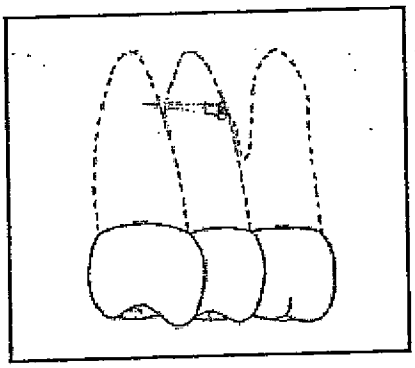

**Fig. 3** Diagram of an Aarhus implant.

**View larger version** (13K):
[in this window]
[in a new window]

In an attempt to produce an implant that is small and easy to place and remove, Kanomi[21] has described a mini-implant, which is 6 mm in length and 1.2 mm in diameter. This implant, which was developed from a mini-bone screw used for fixing bone plates, is screwed into the alveolus under local anaesthetic, to within 3 mm of the apices of the teeth. Subsequent to healing and osseo-integration, a titanium bone plate is fixed to the screw, and acts as a hook for the attachment of an orthodontic ligature wire to aid intrusion of the respective teeth (Figure 4). Due to potential oral hygiene problems, the ligature is not attached directly to the implant. The author did not clarify how long the healing period would be to allow osseo-integration, but did comment on the use of this implant for orthodontic space closure and molar distalization.

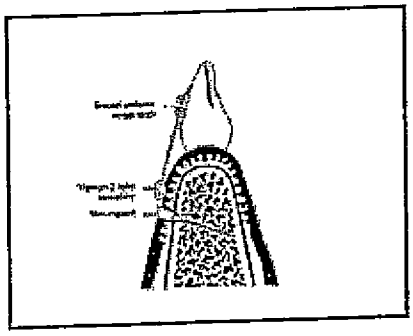

**Fig. 4** A mini-implant, as described by Kanomi.

**View larger version** (19K):
[in this window]

404

[in a new window]

*Orthopaedic traction*
Implants have been suggested in treatment aimed at orthopaedic change. One study describes osseo-integrated implants inserted into the zygomatic buttress. These were used in combination with intra-oral extensions, to act as attachments for facemask therapy.[22] The orthopaedic changes observed in the maxilla over an 8-month treatment time occurred without any dental change. Implants may therefore be used to provide an alternative to conventional orthopaedic facemask therapy, while avoiding potentially unwanted dental movements.

## Implants used for anchorage and as abutments for restorations

The previous section discussed implants used as a source of absolute anchorage. At the end of the orthodontic treatment they were then removed. However, implants can also be placed in a position that allows them to act initially as a source of anchorage, but then as an abutment for restorative work.

Cases requiring implants for both restorative management and orthodontic anchorage require extensive planning involving the orthodontist, restorative specialist, oral surgeon, and periodontist. There are cost and time implications, and the potential surgical difficulties of access and local anatomy that may prejudice against the ideal positioning of a conventional implant should be borne in mind. The restorative specialist decides on the exact location of the implants. A diagnostic wax-up of the final occlusion and a comparison of this with the original model are used to define the precise location of the implants. When this has been decided, a placement guide or stent is fabricated to ensure accuracy of placement of the implants.[23] This process may be aided by the recently developed Simplant software system (Columbia Scientific Inc., Columbia, Maryland, USA), which provides information on the optimal dimension, orientation, and inclination of the endosseous implant, through an interactive computer programme.[24]

The dimensions of the implant should conform closely to the desired emergence profile of the final restoration without compromising the inter-dental bone. For optimal aesthetics of the emergence profile, the implant head should be 2 mm below the cemento-enamel junction of the adjacent teeth.

If orthodontic treatment is necessary to create space prior to the implant being placed, then the roots of the adjacent teeth should be upright and parallel once this is complete. Adequate space is important, not only in the mesio-distal dimension, but also for the bucco-lingual width of the implant.

*Orthodontic implant attachments*
Once successfully implanted and after the bone has consolidated, the implant must be incorporated into the orthodontic appliance. It is possible to attach an orthodontic archwire directly to the implant cover screws, but movement of the teeth is faster and better controlled if single crowns or denture teeth are used as superstructures.[25] The type of attachment used depends on factors such as:

405

- The magnitude of force required.
- The need for aesthetics.
- The method of force application.

The most durable options are all metal or bonded metal crowns. The incorporation of a Class V cavity in the fabrication of these prior to casting, allows a mechanism for orthodontic bracket retention with composite resin. Other options include soldering the orthodontic bracket to a second-stage, non-rotating implant abutment[26] or bending a loop in the orthodontic archwire to secure it to part of the implant.

It is important that endosseous implants required for restorative management are not compromised during their use for orthodontic anchorage. To ensure maintenance of osseo-integration during and beyond treatment, orthodontic loading of a single two-stage endosseous implant should not commence for 6 months in the mandibular arch. However, if multiple implants are placed, occlusal loading of the implants can start sooner. This is because the cross-arch splinting that results from loading the prosthesis allows integration to occur around the functioning implants.

*Stability of implants*

Concern regarding the stability of osseo-integrated implants undergoing orthodontic loading has been addressed by Hurzeler *et al.*[27] This team looked at the bone implant interface of implants used for orthodontic anchorage in healthy mouths. Their histological findings indicated that repetitive mechanical trauma did not result in increased peri-implant bone loss. In addition, the application of any lateral load did not cause marginal bone loss, but in fact led to a compensatory increase in density of the peri-implant bone through structural adaptation.

Histologically, there is no statistically significant difference in the response of peri-implant bone to orthodontic loading, (as measured by the bone to implant contact length) for either pressure or tension forces when compared to control sites.[28] Even in implants used for orthopaedic traction, with non-axial loading of 500 g, perfect osseo-integration has been demonstrated.[29]

From a clinical standpoint, up to 400 g of orthodontic force (which is greater than the normal range required for conventional orthodontic tooth movement), has been successfully anchored against an osseo-integrated dental implant in several malocclusions.[30] The only reported problem in these cases was repeated loosening of the abutment screw, with no significant loss of anchorage.

## Implant site preparation improved by orthodontics

Orthodontics can be used before implant placement to improve the quality of the implant site. For example, where there has been bone loss associated with periodontal disease, which can significantly affect the aesthetic outcome and prognosis of implant treatment. The depth of bone available in such a diseased region may be insufficient for placement of an implant when the compromised tooth is eventually lost. Even if this is not the case, the difficulty with managing the poor gingival aesthetics that result, may caution against implant treatment.

406

Teeth that are compromised beyond the scope of periodontal treatment can be used to develop the alveolar bone in that region, through orthodontic traction, to allow the subsequent use of implants. This 'forced orthodontic eruption' of such a hopeless tooth causes an alteration in the soft tissue architecture of the periodontium as well as improving the amount and quality of bone available for implant placement.[31] The increased bone level allows better implant angulation, which will maximize the final aesthetics of the restoration. The emergence profile of the final prosthesis will also be improved by this technique due to the increased gingival depth. Once acute periodontal disease has been stabilized, the tooth is extruded. The tooth should then be allowed to stabilize for 4–6 weeks after orthodontic extrusion, and once consolidated the tooth should be extracted and immediately replaced with the implant.[31] To prevent any collapse of the gingivae around the implant, healing abutments should be placed at this stage and consideration given to replacing these with cover screws 3 months later.

## Implants in osteogenic distraction

Osteogenic distraction may provide a stable method of addressing facial skeletal deformities through bone generation, which allows adaptation of the surrounding soft tissues, due to its gradual process. It has, however, been suggested that distraction devices that are fixed using conventional bone screws, may not transmit forces evenly across the distraction site. Pilot studies on the maxilla and mandible, undertaken by Ueda *et al.*[32] have illustrated the use of osseo-integrated implants to transfer continuous distraction forces through the full width of the distraction site. This has been successfully completed in mandibular lengthening, maxillary advancement, and alveolar ridge augmentation but requires further research prior to becoming an established technique.

## Conclusion

Osseo-integrated implants may now be used to enhance more traditional orthodontic techniques. In particular, they may have the potential to provide a useful method of anchorage reinforcement, particularly in cases otherwise dependent on patient compliance. The continuing development of orthodontic implants has led to the production of smaller designs which are easy to insert and remove, and do not require a long healing period prior to loading.

With astute planning in hypodontia cases, osseo-integrated implants can be used for orthodontic anchorage to correct a malocclusion, prior to acting as the coping for the definitive restorative prosthesis.

In the future, as developments occur in implant technology, they may have a significant role as anchorage reinforcement aids and make headgear obsolete. However, there is a need for high quality research in this area.

## References

1 Branemark P-I, Adell R, Breine U, *et al.* Intra-osseous anchorage of dental prostheses. I. Experimental studies. *Scand J Plast Reconstr Surg* 1969; 3: 81.[Medline]

2 Albrektsson T, Branemark P-I, Hansson HA *et al.* Osseo-integrated titanium implants. Requirements

407

for ensuring a long-lasting, direct bone-to-implant anchorage in man. *Acta Orthop Scan* 1981; **52**: 155.

3 Lindh T, Gunne J, Tillberg A, *et al*. A meta-analysis of implants in partial edentulism. *Clin Oral Implants Res* 1999; **10**: 139–148.[CrossRef][Medline]

4 Worthington P, Lang BB, Lavelle WE. *Osseo-integration in Dentistry: an introduction*. Quintessence, Illinois, 1994.

5 Rasmussen RA. *The Branemark System of Oral Reconstruction: a colour atlas*. Ishiyaku EuroAmerica Inc., Tokyo, 1992.

6 Siegel D, Soletsz U. Numerical investigations of the influence of implant shape on the stress distribution in jaw bone. *Int J Oral Maxillofac Impl* 1989; **4**: 333–339.

7 Lekholm U, Zarb GA. Patient selection and preparation. In P-I. Branemark, G. A. Zarb and T. Albrektsson (eds) *Tissue Integrated Prostheses: osseo-integration in clinical dentistry*. Quintessence, Chicago, 1985, pp. 199–209.

8 Oesterle LJ. Implant considerations in the growing child. In: K. W. Higuchi (ed.) Orthodontic applications of oseointegrated implants. Quintessence, Illinois, 2000, pp. 156–157.

9 Thilander B, Odman J, Lekholm U. Orthodontic aspects of the use of oral implants in adolescents: a 10 year follow-up study. *Eur J Orthod* 2001; **23**: 715–731.[Abstract/Free Full Text]

10 Gainsforth BL, Higley LB. A study of orthodontic anchorage possibilities in basal bone. *Am J Orthod Oral Surg* 1945; **31**: 406–117.

11 Linkow LI. The endosseous blade implant and its use in orthodontics. *Int J Orthod* 1969; **18**: 149–154.

12 Sherman JA. Bone reaction to orthodontic forces on vitreous carbon dental implants. *Am J Orthod* 1978; **74**: 79–87.[Medline]

13 Turley PK, Shapiro PA, Moffett BC. The loading of bioglass coated aluminium oxide implants to produce sutural expansion of the maxillary complex in the pigtail monkey *Macaca Nemestrina*. *Arch Oral Biol* 1980; **25**: 459–469.[Medline]

14 Roberts WE Marshall KJ, Mozsary PG. Rigid endosseous implant utilized as anchorage to protract molars and close an atrophic extraction site. *Angle Orthod* 1989; **60**: 135–151.

15 Turley PK, Kean C, Schur J *et al*. Orthodontic force application to titanium endosseous implants. *Angle Orthod* 1988; **58**: 151–162.[Medline]

16 Block MS, Hoffman DR. A new device for absolute anchorage for orthodontics. *Am J Orthod DentoFac Orthop* 1995; **107**: 251–258.[Medline]

17 Triaca A, Antonin M, Wintermantel E. Ein neues Titan-Flaschrauben-implantat zur orthodontischen Verankerung am anterion Gaumen. *Int Orthod Kieferorthop* 1992; **24**: 251–257.

18 Wehrbein H, Merz BR. Aspects of the use of endosseous palatal implants in orthodontic therapy. *J*

4-8

*Esth Dent* 1998; **10**: 315–324.

19 Bernhart T, Vollgruber A, Dortbudak O, Haas R. Alternative to the median region of the palate for placement of an orthodontic implant. *Clin Oral Impl Res* 2000; **11**: 595–601.[CrossRef][Medline]

20 Melsen B, Verna C. A rational approach to orthodontic anchorage. *Progress in Orthodontics* 1999; **1**: 10–22.

21 Kanomi R. Mini-implant for orthodontic anchorage. *J Clin Orthod* 1997; **31**: 763–767[Medline]

22 Singer SL, Henry PJ, Rosenberg I. Osseo-integrated implants as an adjunct to facemask therapy: a case report. *Angle Orthod* 2000; **70**: 253–262.[Medline]

23 Smalley WM. Implants for tooth movement: Determining implant location and orientation. *J Esthetent* 1995; **7**: 62–72.

24 Norton MR. Single-tooth implant-supported restorations. Planning for an aesthetic and functional solution. *Dental Update* 2001; **28**: 170–175.[Medline]

25 Goodacre *et al*. Prosthodontic considerations when using implants for orthodontic anchorage. *J Prosth Dent* 1997; **77**: 162–170.[Medline]

26 Helpard PJ, Casko JS, Schneider RL, Southard TE. Soldered implant attachments. *Am J Orthod DentoFac Orthop* 1997; **111**: 650.[Medline]

27 Hurzeler MB, Quinones CR, Kohal RJ, *et al*. Changes to peri-implant tissues subjected to orthodontic forces and ligature breakdown in monkeys. *J Periodontol* 1998; **69**: 396–404.[Medline]

28 Majzoub Z, Finotti M, Miotti F, *et al*. Bone response to orthodontic loading of endosseous implants in rabbit calvaria: early continuous distalizing forces. *Eur J Orthod* 1999; **21**: 223–230. [Abstract/Free Full Text]

29 De Pauw GAM, Dermaut L, De Bruyn H, Johansson C. Stability of implants as anchorage for orthopaedic traction. *Angle Orthod* 1999; **69**: 401–407.[Medline]

30 Higuchi KW, Slack JM. The use of titanium fixtures for intra-oral anchorage to facilitate orthodontic tooth movement. *Int J Oral Maxillofac Implants* 1991; **6**: 338–344.[Medline]

31 Mantzikos T, Shamus I. Forced eruption and implant site development. *Angle Orthod* 1998; **68**: 179–186.[Medline]

32 Ueda M. Application of the principles of distraction osteogenesis using osseo-integrated implants. In: K. W. Higuchi (ed.) *Orthodontic Applications of Osseo-Integrated Implants*. Quintessence, Illinois, 2000, pp. 191–210.

409

NOTICE: THIS MATERIAL MAY BE PROTECTED BY COPYRIGHT LAW (TITLE 17 U. S. CODE). DEPT. LIB. SERV. - AMER. DENT. ASSN.

# EVIDENCE-BASED CARE IN ORTHODONTICS AND PERIODONTICS:

## A REVIEW OF THE LITERATURE

NORMAN L. SANDERS, D.D.S., M.S.

**ABSTRACT**

**Background.** In this article, the author reviews the evidence-based literature in the fields of periodontics and orthodontics to clarify the relationship between orthodontic tooth movement and various types of common periodontal disorders.

**Types of Studies Reviewed.** The first section is a review of the literature on common periodontal disorders. The second is a review of evidence-based studies in the combined fields of orthodontics and periodontics, with a focus on orthodontic treatment possibilities, limitations and risks inherent in patients with periodontal disorders, particularly active periodontal disease.

**Results.** The literature on orthodontic tooth movement as it relates to periodontal disease shows that proper orthodontic treatment in patients with excellent oral hygiene and the absence of significant periodontal disorders should not pose any significant periodontal risk. In the presence of poor oral hygiene, however, and under circumstances of certain types of periodontal disorders, fixed orthodontic appliances and tooth movement can contribute to significant deleterious periodontal consequences.

**Clinical Implications.** This review provides a clear understanding of what is known about orthodontic treatment possibilities, limitations and inherent risks in patients who may have certain types of periodontal disorders. It also underscores the importance of teamwork among the restorative dentist, periodontist and orthodontist when planning treatment for these patients. The author also offers a specific patient management protocol for this interdisciplinary dental team to follow.

The purpose of this literature review is to improve the level of understanding, communication and vision in these important areas of restorative dentistry, orthodontics and periodontics.

For any patient with orthodontic and periodontal problems, teamwork involving the restorative dentist, the orthodontist and the periodontist is essential to determine the patient's periodontal condition and to plan the appropriate interdisciplinary treatment before orthodontic tooth movement is initiated. It is essential to identify patients who have periodontal disease or are at risk of developing it, and to know what treatment approaches should be avoided to prevent negative sequelae. Teamwork is also important in monitoring the periodontal health of patients throughout the course of orthodontic therapy.

### PERIODONTAL DISORDERS

This review of the literature on common forms of periodontal disorders is intended to help members of the dental team identify patients who may have periodontal disorders or may be at high risk of developing these disorders, and to underscore the significance of this risk when contemplating orthodontic treatment.

**Periodontal disease.** Brägger and Lang[1] defined periodontal disease as an inflammatory disease triggered by bacteria that supragingivally affect the gingiva (gingivitis) and subgingivally affect the supporting connective tissue and alveolar bone (periodontitis).

The two main characteristics of periodontitis in contrast to gingivitis are connective-tissue attachment loss and alveolar bone loss, which follows various patterns around the teeth.[1]



Copyright ©1998-2001 American Dental Association. All rights reserved.



410

*Incidence.* Epidemiologic studies have shown that even though the world-wide prevalence of gingival inflammation is high, advanced periodontal disease affects only a small portion of the population (2 to 8 percent of people younger than 45 years of age and about 30 percent of people aged 65 to 75 years). In addition to the age factor, there is a greater incidence of periodontal disease in patients who have a history of the disease, as well as a greater incidence in certain teeth (especially maxillary and mandibular molars in adult periodontitis).[1-7]

*Etiology.* Most researchers agree that bacterial plaque is the main etiologic factor in periodontal disease. Specific bacterial pathogens (at least 15 have been identified) are linked to the presence of adult periodontitis. Most studies of localized juvenile periodontitis have found an association between *Actinobacillus actinomycetemcomitans* and presence of the disease.[8-22] Depending on host and environmental factors, these pathogens are believed to be responsible for the loss of periodontal attachment (possibly by triggering the production of biochemical mediators such as interleukin and prostaglandin $E_2$). Progression of the disease leads to an imbalance in the steady state between resorption of bone and apposition of osteoid, resulting in alveolar bone loss.[1]

*Nature of progression.* Most researchers now believe that periodontitis progresses via infrequent, recurrent, acute episodes; the commonly held theory up to about 10 to 15 years ago was that it is a slow, continuous, destructive process.[5,23] In fact, evidence suggests that even in areas of deep periodontal pockets, the great majority of these pockets are probably not undergoing breakdown at any given time.[24]

*Risk factors.* The microbial ecology (which varies from patient to patient and can vary from tooth to tooth in a given patient) and the patient's immune system appear to be the main elements that differentiate diseased patients from others with similar plaque levels.[1] Risk factors affecting our microbial ecology and/or immune system have been shown to alter the chances of occurrence of periodontal disease and its rate of progression.[1] These risk factors include the following:

- psychosocial stress[25];
- lifestyle factors such as diet, alcohol use and especially smoking[25-36];
- deficiencies in the immune system[37];
- the presence of specific bacteria[8-22];
- sex (disease is more common in women than in men)[38];
- age[10];
- diabetes mellitus[39];
- osteoporosis[38];
- polymorphonuclear leukocyte disorders.[32,40]

***Most researchers now believe that periodontitis progresses via infrequent, recurrent, acute episodes.***

*Treatment goals for periodontal disease sites.* The goals of periodontal treatment are to minimize or eliminate subgingival plaque and calculus, prevent recolonization of subgingival microorganisms and restore the tissue to a healthy state (that is, converting an active disease site to a passive state).[41]

Many researchers and clinicians believe that deep pockets can be successfully treated with plaque control and one or more sessions of subgingival débridement.[41,42-46] It is important to note, however, that the full effect of subgingival débridement may not be achieved until at least two to three months after the start of therapy.[42,43,47-49] Studies suggest that the critical pocket depth is 5 to 6 millimeters, beyond which surgical reduction may be necessary.[41,47] An overview of current concepts of periodontal disease and treatment modalities may be found in the synopsis by Socransky and Haffajee.[50]

**Gingival recession.** Gingival recession is frequently seen in teeth that are positioned labially relative to the supporting alveolus. The most important etiologic factor in gingival recession is thinness of the soft tissue and bone, especially on the labial surface of labially prominent teeth.[51-55] This thin soft tissue and/or bone is a predisposing factor for gingival recession.[52] In fact, vertical loss of buccal or labial bone (dehiscence) is a prerequisite for recession.[52]

Other common factors in the development of recession are trauma (caused by improper toothbrushing or gingival lesions associated with bacterial plaque), tooth position relative to the alveolus and age.[53] Several authors have confirmed that bacterial plaque control is an important factor in preventing gingival recession.[55-58]

There seems to be little importance to the "zone" or apicocoronal height of keratinized

411


Copyright ©1998-2001 American Dental Association. All rights reserved.

tissue. In fact, one long-term study of a nonorthodontic population has shown that the incidence of recession in areas without keratinized tissue is no greater than that in areas with a wide expanse of keratinized tissue.[55]

**Gingival hyperplasia.** Dental professionals frequently see gingival hyperplasia in patients who chronically breathe through their mouths and in those with delayed apical migration of the gingival margins of the teeth.[59-62] Gingival hyperplasia is also a common side effect of some antiseizure medications such as phenytoin and, more rarely, some calcium channel blocker medications such as nifedipine.

Although hyperplasia is frequently reversible, severe cases may lead to loss of periodontal attachment.[63]

## INTERRELATIONSHIP OF ORTHODONTIC TOOTH MOVEMENT WITH PERIODONTAL HEALTH

The primary focus of this section is to help members of the dental team understand the special periodontal benefits and risks that are posed by orthodontic treatment, especially in adults. This literature review is also intended to dispel some widely held misconceptions about adverse periodontal effects caused by various orthodontic procedures.

**Loss of periodontal attachment and bone relative to orthodontic therapy.** In the absence of periodontal disease and in the presence of excellent oral hygiene (including adults with reduced, but healthy, periodontium), proper orthodontic treatment causes no significant long-term effects on periodontal attachment and bone levels.[64-70] Conversely, in patients (mostly adults) with active periodontitis (that is, plaque-infected deep pockets evidenced by bleeding on probing), orthodontic tooth movement may accelerate the disease process, even when good oral hygiene is practiced.[64,70-73]

In this review of the literature, I also examined various types of orthodontic tooth movement as it relates to loss or gain of periodontal attachment. Orthodontic bodily tooth movement into plaque-induced infrabony defects can be successfully performed, provided that the periodontal lesion is eliminated before tooth movement is begun, and that excellent oral hygiene is maintained. Although there is no unfavorable effect on the level of connective-tissue attachment under these optimal conditions, neither does there appear to be a gain in soft-tissue attachment.[65] On the other hand, if subgingival plaque and periodontal disease are not controlled before and during orthodontic treatment, an accelerated loss of attachment may result.[70,74-76]

Tooth movement into areas of remodeled edentulous spaces (that is, constricted bone areas) with slow, light orthodontic forces is often possible, depending on the width ratio of tooth to bone, but alveolar bone loss and posttreatment space opening can be common sequelae, even under optimal conditions.[75,77-81]

My review of the literature uncovered no compelling evidence that new attachment gain can be predictably achieved with intrusive tooth movement unless the intrusion is done in conjunction with a barrier/new attachment procedure.[65,76,82-84]

Extrusive tooth movement in areas of one- and two-wall bony pockets leads to a coronal (favorable) positioning of intact connective-tissue attachment and a shallowing of the bony defect.[70,75,76] These changes in attachment and bone levels are a key factor in uprighting tipped molars.[76] If there is furcation involvement in the tooth to be uprighted, however, orthodontic tooth movement may exacerbate the periodontal problem.[76,85,86]

**Gingival recession relative to orthodontic therapy.** Orthodontic tooth movement per se does not cause gingival recession.[87] In areas of thin labial tissue, however, labial orthodontic tooth movement can result in bone dehiscence, creating an environment in which plaque and/or toothbrush trauma may cause sudden recession.[82,87-92] If, on the other hand, thick gingival tissue is present in these areas, gingival recession is less likely to occur.[82,87,90-92] In cases in which the labial tissue is thin, however, especially if the orthodontist plans to move the tooth labially, periodontists seem to be uniformly concerned. Many researchers and clinicians agree that this thin labial tissue should be augmented before labial orthodontic tooth movement is begun.[82,87,90-92] It is interesting to note that in areas of a labially positioned tooth with dehiscence, bone may re-form and gingival thickness may increase when the tooth is moved lingually.[93-95]

In regard to the relationship between rapid maxillary expansion procedures and gingival recession, Graber and Vanarsdall[82] stated that if the

412



Copyright ©1998-2001 American Dental Association. All rights reserved.

maxillary expansion is performed after the midpalatine suture begins to fuse (after approximately 14 to 16 years of age), there is a greater risk of recession of the buccal gingival tissue of the maxillary premolars and molars later in life.

In independent investigations, Boyd and colleagues[66] and Hamp and colleagues[96] found no differences in the postorthodontic development of mucogingival problems between groups of patients who had undergone tooth extraction and those who had not undergone extraction.

**Gingival hyperplasia relative to orthodontic therapy.** In the presence of excellent oral hygiene (provided that the appliances are properly placed, without excessive adhesive flash), no significant hyperplasia should develop as a result of orthodontic tooth movement in adolescents[64,65,96-98] or adults.[66] However, fixed orthodontic appliances in the presence of consistently poor oral hygiene can lead to moderate-to-severe hyperplasia, especially in the lower incisor region. Severe cases of gingival hyperplasia may lead to attachment loss. Several authors on the topic of risk management have recommended that orthodontic treatment be terminated if patients are at great risk of developing periodontal breakdown and attachment loss.[63,67,99]

Depending on home care and the relationship between the gingival tissue and the crown of the tooth, gingival hyperplasia is frequently reversible, especially after the orthodontic appliances have been removed. However, Graber and Vanarsdall[82] suggested that some patients may benefit from removal of excessive gingival tissue from the crowns of the teeth, which may add to the stability of the orthodontic correction.

**Risk management implications.** Evidence-based care literature (discussed above) and risk management literature[63,67,99] advise dentists of the importance of detecting active periodontal disease before and during orthodontic treatment. Because adult patients, in particular, may be at risk of having active sites of periodontal disease, and because we know that orthodontic tooth movement in this environment can accelerate the destructive process, the interdisciplinary dental team consisting of the restorative dentist, periodontist and orthodontist must be sure that the periodontium is healthy before and during the course of orthodontic therapy. For the benefit of the patient and dental team members, dentists are advised of the importance of a well-defined protocol for careful clinical examination, internal documentation and communication among team members.[63,67,99]

**Clinical assessment of the periodontal condition.** Dentists and hygienists can assess a patient's periodontal condition by evaluating the appearance of the tissue (color, texture, degree of plasticity), severity of inflammation (bleeding on probing—immediate or delayed, copious or minimal—or suppuration on probing) and changes in the level of soft-tissue attachments (that is, recession, pocket depth and attachment level).[1,63,99]

Radiographic evaluations can indirectly assess the severity of periodontal destruction or the progression rate, but it is important to note that significant radiographic underestimation of the severity of periodontal defects has been reported in the literature.[1,100-103]

## PATIENT MANAGEMENT PROTOCOL FOR DENTAL TEAM MEMBERS

For patients being considered for orthodontic treatment (especially adults), it is important to establish a careful team protocol for periodontal examination, internal documentation and correspondence as well as for regular progress evaluations, to guard against accelerated deterioration of periodontal health during orthodontic treatment. This approach is supported by risk management experts, who stress that patients with periodontal destruction pose potential liability problems.[67,99]

The interdisciplinary dental team members should carefully educate patients who are not maintaining acceptable levels of oral hygiene, and inform them that orthodontic treatment might be terminated if their chronic poor hygiene poses a significant risk of periodontal breakdown.

**Suggested protocol before orthodontic therapy.** Before orthodontic treatment is begun, each member of the dental team must be sure that the patient is practicing excellent oral hygiene and is free of active periodontal disease. Ideally, the restorative dentist or periodontist should, at the time of orthodontic referral, provide the orthodontist with the following:

- a copy of the patient's recent periodontal charting;
- recent anterior periapical radiographs and bitewing radiographs;
- a written periodontal clearance statement that the patient may safely begin orthodontic

413


Copyright ©1998-2001 American Dental Association. All rights reserved.



Dr. Sanders is in private practice in orthodontics, 220 Westchester Ave., White Plains, N.Y. 10604. Address reprint requests to Dr. Sanders.

treatment. This statement serves as a valuable medicolegal document as well as a communication tool reinforcing to the patient that each member of the dental team has the common goal of providing the finest overall dental care.

If the restorative dentist or periodontist does not provide the charting and periodontal clearance statement before orthodontic treatment begins, the orthodontist is obliged to either refer the patient to a periodontist to evaluate his or her periodontal condition or perform the evaluation (including pocket probing) himself or herself.

*Patients with excellent oral hygiene and no evidence of periodontal disease.* If the patient's oral hygiene is excellent and there is no evidence of periodontal disease, it is safe to begin orthodontic treatment.

*Patients with evidence of periodontal disease.* If there is evidence of periodontal disease, orthodontic treatment must be postponed. The patient must be referred for appropriate periodontal therapy, including subgingival débridement and, if appropriate, periodontal surgery, followed by a two- to four-month healing and observation period.

If the patient has maintained excellent oral hygiene during this period, and there are no sites of significant bleeding on probing, the periodontist or restorative dentist should provide the orthodontist with a written periodontal clearance statement. If, on the other hand, bleeding sites are still observed on probing, other appropriate forms of periodontal therapy may be indicated, followed by another observation period.

**Suggested protocol during orthodontic therapy.** Once orthodontic therapy begins, the periodontist, restorative dentist or orthodontist should reevaluate all patients, especially those with a history of periodontal disease, for any signs of recurrence. Depending on a number of circumstances, including any of the risk factors described above, this reevaluation should be performed at six-week to six-month intervals.

**Suggested protocol after orthodontic therapy.** Boyd[99] has observed that many patients (mostly adults) adopt a more aggressive brushing technique during orthodontic treatment. When the orthodontic appliances are removed, these patients may benefit from oral hygiene instruction to guard against possible gingival recession resulting from toothbrush trauma.

## CONCLUSION

The purpose of this literature review is to clarify the relationships between various types of orthodontic tooth movement and common periodontal disorders. The evidence-based literature offers dental professionals a good understanding of the orthodontic treatment possibilities, limitations and risks inherent in patients with periodontal disorders. Using this information, along with a well-defined patient management protocol (and a home care commitment from the patient), the interdisciplinary team of restorative dentist, periodontist and orthodontist can manage the majority of interrelated orthodontic-periodontal problems with minimal risk and predictably successful outcomes. ■

The author thanks Drs. Robert L. Boyd, Robert Fazio, Robert Vanarsdall and Bjorn Zachrisson for their invaluable assistance in preparing the manuscript.

1. Brägger U, Lang NP. Significance of bone in periodontal disease. Semin Orthod 1996;2(1):32-8.
2. Papapanou PN, Wennström JL, Gröndahl K. Periodontal status in relation to age and tooth type: a cross-sectional radiographic study. J Clin Periodontol 1988;15:463-78.
3. Papapanou PN, Wennström JL, Gröndahl K. A 10-year retrospective study of periodontal disease progression. J Clin Periodontol 1989;16:403-11.
4. Hugoson A, Jordan T. Frequency distribution of individuals aged 20-70 years according to severity of periodontal disease. Community Dent Oral Epidemiol 1982;10(4):187-92.
5. Lavstedt S, Bolin A, Henrikson CO. Proximal alveolar bone loss in a longitudinal radiographic investigation. II. A 10-year follow-up study of an epidemiologic material. Acta Odontol Scand 1986;44(4):199-205.
6. Löe H, Ånerud A, Boysen H, Morrison E. Natural history of periodontal disease in man. J Clin Periodontol 1986;13:431-45.
7. Grossi SG, Genco RJ, Machtei EE, et al. Assessment of risk for periodontal disease. II. Risk indicators for alveolar bone loss. J Periodontol 1995;66(1):23-9.
8. Asikainen S, Jousimies-Somer H, Kanervo A, Summanen P. Certain bacterial species and morphotypes in localized juvenile periodontitis and in matched controls. J Periodontol 1987;58:224-30.
9. Bragd L, Dahlen G, Wikstrom M, Slots J. The capability of *Actinobacillus actinomycetemcomitans, Bacteroides gingivalis* and *Bacteroides intermedius* to indicate progressive periodontitis: a retrospective study. J Clin Periodontol 1987;14(2):95-9.
10. Christersson LA, Albini B, Zambon JJ, Wikesjo UM, Genco RJ. Tissue localization of *Actinobacillus actinomycetemcomitans* in human periodontitis. I. Light, immunofluorescence and electron microscopic studies. J Periodontol 1987;58:529-39.
11. Ebersole JL, Taubman MA, Smith DJ, Hammond BF, Frey DE. Human immune responses to oral microrganisms II. Serum antibody responses to antigens from *Actinobacillus actinomyctemcomitans* and the correlation with localized juvenile periodontitis. J Clin Immunol 1983;3:321-31.
12. Jeffcoat MK. Current concepts in periodontal disease testing. JADA 1994;125:1071-8.
13. Listgarten MA, Lai CH, Evian CL. Comparative antibody titers to *Actinobacillus actinomycetemcomitans* in juvenile periodontitis, chronic periodontitis and periodontally healthy subjects. J Clin Periodontol 1981;8(3):155.
14. Newman MG, Socransky SS. Predominant cultivable microbiota in periodontosis. J Periodontal Res 1977;12(2):120-8.
15. Dzink JL, Socransky SS, Haffajee AD.

414



Copyright ©1998-2001 American Dental Association. All rights reserved.

The predominant cultivable microbiota of active and inactive lesions of destructive periodontal diseases. J Clin Periodontol 1988;15:316-23.
16. Gillespie MJ, Smutko JS, Haraszthy GG, et al. Isolation and partial characterization of the *Campylobacter rectus* cytotoxin. Microbiol Pathol 1993;14:203-15.
17. Loesche WJ. The role of spirochetes in periodontal disease. Adv Dent Res 1988;2:275-83.
18. Magnusson I, Marks RG, Clark WB, Walker CB, Low SB, McArthur WP. Clinical, microbiological and immunological characteristics of subjects with "refractory" periodontal disease. J Clin Periodontol 1991;18:291-9.
19. Socransky SS. Microbiology and periodontal disease: present status and future considerations. J Periodontol 1977;48:497.
20. van Winkelhoff AJ, van Steenbergen TJ, de Graaff J. The role of black-pigmented bacteroides in human oral infections. J Clin Periodontol 1988;15(3):145-55.
21. White D, Mayrand D. Association of oral bacteroides with gingivitis and adult periodontitis. J Periodont Res 1981;16:259-61.
22. Zambon JJ, Grossi S, Dunford R, et al. Epidemiology of subgingival bacterial pathogens in periodontal disease. In: Genco RJ, ed. Molecular pathogenesis of periodontal disease. Washington, D.C.: ASM Press; 1994:3-12.
23. Albander JM. A 6-year study on the pattern of periodontal disease progression. J Clin Periodontol 1990;17:467-71.
24. Socransky SS, Haffajee AD, Goodson JM, Lindhe J. New concepts of destructive periodontal disease. J Clin Periodontol 1984;11(1):21-32.
25. Clarke NG, Hirsch RS. Personal risk factors for generalized periodontitis. J Clin Periodontol 1995;22(2):136-45.
26. Bergström J, Preber H. Tobacco use as a risk factor. J Periodontol 1994;65:545-50.
27. Bergström J, Eliasson S, Preber H. Cigarette smoking and periodontal bone loss. J Periodontol 1991;62:242-6.
28. Bolin A, Eklund G, Frithiof L, Lavstedt S. The effect of changed smoking habits on marginal alveolar bone loss: a longitudinal study. Swed Dent J 1993;17(5):211-6.
29. Brown LF, Beck JD, Rozier RG. Incidence of attachment loss in community-dwelling older adults. J Periodontol 1994;65:316-23.
30. Genco RJ. Current view of risk factors for periodontal diseases. J Periodontol 1996;67(suppl 10):1041-9.
31. Haber J. Cigarette smoking: a major risk factor for periodontitis. Compendium 1994;15(8):1004-8.
32. MacFarlane GD, Herzberg MC, Wolff LE, Hardie NA. Refractory periodontitis associated with abnormal polymorphonuclear leucocyte phagocytosis and cigarette smoking. J Periodontol 1992;63:908-13.
33. Machtei EE, Dunford R, Hausmann E, et al. Longitudinal study of prognostic factors in established periodontitis patients. J Clin Periodontol 1997;24(2):102-9.
34. Preber H, Bergström J. The effect of non-surgical treatment on periodontal pockets in smokers and non-smokers. J Clin Periodontol 1985;13:319-23.
35. Preber H, Bergström J. The effect of cigarette smoking on periodontal healing following surgical therapy. J Clin Periodontol 1990;17:324-8.
36. Zambon JJ, Grossi SG, Machtei EE, Ho AW, Dunford R, Genco RJ. Cigarette smoking increases the risk for subgingival infection. J Periodontol 1996;67(suppl 10):1050-4.
37. Yeung SC, Stewart GJ, Cooper DA, Sindhusake D. Progression of periodontal disease in HIV-seropositive patients. J Periodontol 1993;64(7):651-7.
38. Salonen LW, Frithiof L, Wouters FR, Hellden LB. Marginal alveolar bone height in an adult Swedish population: a radiographic cross-sectional epidemiologic study. J Clin Periodontol 1991;18(4):223-32.
39. Safkan-Seppala B, Ainamo J. Periodontal conditions in insulin-dependent diabetes mellitus. J Clin Periodontol 1992;19(1):24-9.
40. Kirstilä V, Sevon L, Laine J. Periodontal disease in three siblings with familial neutropenia. J Periodontol 1993;64:566-70.
41. Zachrisson BU. Clinical implications of orthodontic-periodontic research findings. Semin Orthod 1996;2(1):4-12.
42. Axelsson P, Lindhe J, Nystrom B. On the prevention of caries and periodontal disease: results of a 15-year longitudinal study in adults. J Clin Periodontol 1991;18(3):182-9.
43. Badersten A, Nilveus R, Egelberg J. Effect of nonsurgical periodontal therapy. II. Severely advanced periodontitis. J Clin Periodontol 1984;11(1):63-76.
44. Badersten A, Nilveus R, Egelberg J. Effect of nonsurgical periodontal therapy. III. Single versus repeated instrumentation. J Clin Periodontol 1984;11(2):114-24.
45. Claffey N. Decision making in periodontal therapy: the re-evaluation. J Clin Periodontol 1991;18:384-9.
46. Lindhe J, Nyman S. Scaling and granulation tissue removal in periodontal therapy. J Clin Periodontol 1985;12:374-88.
47 Hämmerle CH, Joss A, Lang NP. Short-term effect of initial periodontal therapy (hygienic phase). J Clin Periodontol 1991;18(4):233-9.
48. Pedrazzoli V, Kilian M, Karring T, et al. Effect of surgical and nonsurgical periodontal treatment on periodontal status and subgingival microbiota. J Clin Periodontol 1991;18:598-604.
49. Renvert S, Nilveus R, Dahlen G, Slots J, Egelberg J. Five-year follow up of periodontal intraosseous defects treated by root planing or flap surgery. J Clin Periodontol 1990;17(6):356-63.
50. Socransky SS, Haffajee AD. The nature of periodontal diseases. Ann Periodontol 1997;2(1):3-10.
51. Bernimoulin JP, Curiloviec Z. Gingival recession and tooth mobility. J Clin Periodontol 1977;4(2):107-14.
52. Maynard JG, Ochsenbein LD. Mucogingival problems, prevalence and therapy in children. J Periodontol 1975;46:543-52.
53. Vanarsdall RL, Corn H. Soft-tissue management of labially positioned unerupted teeth. Am J Orthod 1977;72(1):53-64.
54. Wennström JL. The significance of the width and thickness of the gingiva in orthodontic treatment. Dtsch Zahnarztl Z 1990;45:136-41.
55. Wennström JL. Mucogingival surgery. In: Lang NP, Karring T, eds. Proceedings of the 1st European Workshop on Clinical Periodontology. Berlin: Quintessence; 1994:193-209.
56. Slots J, Rams TE. Antibiotics in periodontal therapy: advantages and disadvantages. J Clin Periodontol 1990;17:479-93.
57. Baker DL, Seymour GJ. The possible pathogenesis of gingival recession: a histological study of induced recession in the rat. J Clin Periodontol 1976;3:208-19.
58. Ericsson I, Lindhe J. Recession in sites with inadequate width of the keratinized gingiva: an experimental study in the dog. J Clin Periodontol 1984;11(2):95-103.
59. Goldman H. The development of physiologic gingival contours by gingivoplasty. Oral Surg Oral Med Oral Pathol 1950;3:879-88.
60. Kokich VG. Esthetics: the orthodontic-periodontic restorative connection. Semin Orthod 1996;2(1):21-30.
61. Prichard J. Gingivectomy, gingivoplasty, and osseous surgery. J Periodontol 1961;32:257-62.
62. Ramfjord S. Gingivectomy—its place in periodontal therapy. J Periodontol 1952;23:30-5.
63. Boyd RL. Are your patients healthier periodontically because of orthodontic treatment? Pac Coast Soc Orthod Bull 1984;56:54-7.
64. Artun J, Osterberg SK. Periodontal status of teeth facing extraction sites long-term after orthodontic treatment. J Periodontol 1987;58(1):24-9.
65. Sadowsky C, BeGole EA. Long-term effects of orthodontic treatment on periodontal health. Am J Orthod 1981;80(2):156-72.
66. Boyd RL, Leggott PJ, Quinn RS, Eakle WS, Chambers D. Periodontal implications of orthodontic treatment in adults with reduced or normal periodontal tissues vs. those of adolescents. Am J Orthod Dentofacial Orthop 1989;96(3):191-8.
67. Machen DE. Legal aspects of orthodontic practice: risk management concepts. Periodontal evaluation and updates: don't abdicate your duty to diagnose and supervise. Am J Orthod Dentofacial Orthop 1990;98(1):84-5.
68. Artun J, Urbye KS. The effect of orthodontic treatment on periodontal bone support in patients with advanced loss of marginal periodontium. Am J Orthod Dentofacial Orthop 1988;93(2):143-8.
69. Eliasson LA, Hugoson A, Kurol J, Siwe H. The effects of orthodontic treatment on periodontal tissues in patients with reduced periodontal support. Eur J Orthod 1982;4(1):1-9.
70. Thilander B. Infrabony pockets and reduced alveolar bone height in relation to orthodontic therapy. Semin Orthod 1996;2(1):55-61.
71. Ericsson I, Thilander B, Lindhe J. Periodontal condition after orthodontic tooth movements in the dog. Angle Orthod 1978;48:210-8.
72. Ericsson I, Thilander B, Lindhe J, Okamoto H. The effect of orthodontic tilting movements on the periodontal tissues of infected and non-infected dentitions in dogs. J Clin Periodontol 1977;4:278-93.
73. Zachrisson BU, Alnaes L. Periodontal condition in orthodontically treated and untreated individuals. I. Loss of attachment, gingival pocket depth and clinical crown height. Angle Orthod 1973;43:402-11.
74. Wennström JL, Lindskog-Stokand B, Nyman S, et al. Periodontal tissue response to orthodontic movement of teeth with infrabony pockets. Am J Orthod Dentofacial Orthop 1993;103:313-9.
75. Pontoriero R, Celenza F, Ricci G, Carvenale G. Rapid extrusion with fiber resection: a combined orthodontic-periodontic treatment modality. Int J Periodontics Restorative Dent 1987;7:31-43.

415


Copyright ©1998-2001 American Dental Association. All rights reserved.

76. Diedrich PR. Guided tissue regeneration associated with orthodontic therapy. Semin Orthod 1996;2(1):39-45.
77. Goldberg D, Turley P. Orthodontic space closure of edentulous maxillary first molar area in adults. Int J Adult Orthodont Orthognathic Surg 1989;4:255-66.
78. Hom BM, Turley PK. The effects of space closure of the mandibular first molar area in adults. Am J Orthod Dentofacial Orthop 1984;85:457-69.
79. Stepovich ML. A clinical study on closing edentulous spaces in the mandible. Angle Orthod 1979;49:227-33.
80. Fuhrmann RA, Bücker A, Diedrich PR. Assessment of alveolar bone loss with high resolution computed tomography. J Periodontal Res 1995;30(4):258-63.
81. Wehrbein H, Fuhrmann RA, Diedrich PR. Human histologic tissue response after long-term orthodontic tooth movement. Am J Orthod Dentofacial Orthop 1995;107(4):360-71.
82. Graber TM, Vanarsdall RL. Orthodontics: current principles and techniques. 2nd ed. St. Louis: Mosby; 1994:719-49.
83. Melsen B, Agerbaek N, Eriksen J, Terps S. New attachment through periodontal treatment and orthodontic intrusion. Am J Orthod Dentofacial Orthop 1988;94(2):104-16.
84. Melsen B, Agerbaek N, Makenstam G. Intrusion of incisors in adult patients with marginal bone loss. Am J Orthod Dentofacial Orthop 1989;96:232-41.
85. Burch JG, Bagci B, Sabulski D, Landrum C. Periodontal changes in furcations resulting from orthodontic uprighting of mandibular molars. Quintessence Int 1992;23:509-13.
86. Roberts WW 3d, Chacker FM, Burstone CJ. A segmental approach to mandibular molar uprighting. Am J Orthod Dentofacial Orthop 1982;81(3):177-84.
87. Wennstrom JL. Mucogingival considerations in orthodontic treatment. Semin Orthod 1996;2(1):46-54.
88. Årtun J, Osterberg SK, Kokich VG. Long-term effect of thin interdental alveolar bone on periodontal health after orthodontic treatment. J Periodontol 1986;57:341-6.
89. Årtun J, Krogstad O. Periodontal status of mandibular incisors following excessive proclination: a study in adults with surgically treated mandibular prognathism. Am J Orthod Dentofacial Orthop 1987;91:225-32.
90. Coatoam GW, Behrents RG, Bissada NF. The width of keratinized gingiva during orthodontic treatment: its significance and impact on periodontal status. J Periodontol 1981;52:307-13.
91. Foushee DG, Moriarty JD, Simpson DM. Effects of mandibular orthognathic treatment on mucogingival tissue. J Periodontol 1985;56:727-33.
92. Maynard JG. The rationale for mucogingival therapy in the child and adolescent. Int J Periodontics Restorative Dent 1987;7:37-51.
93. Karring T, Numan S, Thilander B, Magnusson I. Bone regeneration in orthodontically produced alveolar bone dehiscences. J Periodont Res 1982;17:309-15.
94. Steiner GG, Pearson JK, Ainamo J. Changes of the marginal periodontium as a result of labial tooth movement in monkeys. J Periodontol 1981;52:314-20.
95. Wennstrom JL, Lindhe J, Sinclair F, Thilander B. Some periodontal tissue reactions to orthodontic tooth movement in monkeys. J Clin Periodontol 1987;14(3):121-9.
96. Hamp SE, Lunstrom F, Nyman S. Periodontal conditions in adolescents subjected to multiband orthodontic treatment with controlled oral hygiene. Eur J Orthod 1982;4(2):77-86.
97. Alstad S, Zachrisson BU. Longitudinal study of periodontal condition associated with orthodontic treatment in adolescents. Am J Orthod Dentofacial Orthop 1979;76:277-86.
98. Polson AM. Long-term effect of orthodontic treatment on the periodontium. In: McNamara JA, Ribbens KA, eds. Orthodontic treatment and the periodontium. Monograph 15, Craniofacial growth series. Ann Arbor, Mich.: Center for Human Growth and Development, The University of Michigan; 1984:89-100.
99. Boyd RL. Periodontal screening examination guide. In: American Association of Orthodontists risk management program. St. Louis: American Association of Orthodontists; 1992:13.
100. Jenkins SM, Dummer PM, Addy M. Radiographic evaluation of early periodontal bone loss in adolescents: an overview. J Clin Periodontol 1992;19(6):363-6.
101. Akesson L, Håkansson J, Rohlin M. Comparison of panoramic and intraoral radiography and pocket probing for the measurement of the marginal alveolar bone level. J Clin Periodontol 1992;19:326-32.
102. Tonetti MS, Pini-Prato G, Williams R, Cortellini P. Periodontal regeneration of human infrabony defects. III. Diagnostic strategies to detect bone gain. J Periodontol 1993;64:269-77.
103. Hammerle CH, Ingold HP, Lang NP. Evaluation of clinical and radiographic scoring methods before and after initial periodontal therapy. J Clin Periodontol 1990;17(4):255-63.

416



Copyright ©1998-2001 American Dental Association. All rights reserved.

# *Periodontal implications of orthodontic treatment in adults with reduced or normal periodontal tissues versus those of adolescents*

**R. L. Boyd, P. J. Leggott, R. S. Quinn, W. S. Eakle, and D. Chambers**
*San Francisco, Calif.*

This longitudinal study monitored periodontal status in 20 adults and 20 adolescents undergoing fixed orthodontic treatment. Ten adults had generalized periodontitis and received periodontal treatment, including periodontal surgery, before orthodontic treatment. They also received periodontal maintenance at 3-month intervals during orthodontic treatment. The other 10 adults had normal periodontal tissues. Neither these latter adults nor the adolescents received periodontal maintenance during orthodontic treatment. Periodontal status was determined (1) at six standard sites before fixed appliances were placed (baseline), (2) at 1, 3, 6, 9, 12, and 18 months after appliances had been placed, and (3) 1, 3, 6, and 12 months after appliances had been removed. At each of these visits, these sites were assessed for plaque index, gingival index, bleeding tendency, and pocket depth. Loss of attachment between baseline and 3 months after appliances were removed and tooth loss were also determined. Complete data were obtained for 15 adolescents and 14 adults. During orthodontic treatment the adolescent group showed significantly more ($p < 0.05$) periodontal inflammation and supragingival plaque than the adults; after appliances were removed, this pattern was no longer statistically significant. For loss of attachment, there were no significant differences among adolescents, adults with normal periodontal tissues, or adults with reduced but healthy periodontal tissues who had undergone treatment for periodontal disease. For tooth loss, three nonstudy site teeth with pockets deeper than 6 mm and/or furcation involvements were lost because of periodontal abscesses in the adult group treated for periodontal disease.

Copyrighted Material

Copyrighted Material

417

Copyrighted Material

Copyrighted Material

Copyrighted Material

Copyrighted Material

Copyrighted Material

Copyrighted Material

Copyrighted Material

Copyrighted Material

Copyrighted Material

Copyrighted Material

Copyrighted Material

Copyrighted Material

Copyrighted Material

Copyrighted Material

Copyrighted Material

# Orthodontics in the Adult Patient, with Special Reference to the Periodontally Compromised Patient

NOTICE: THIS MATERIAL MAY BE PRO
BY COPYRIGHT LAW (TITLE 17 U. S.
DEPT. LIB. SERV. - AMER. DENT. ASS

Amandeep Johal and Mark Ide

Copyrighted Material

*Abstract:* There is increasing demand from adult patients for orthodontic treatment either purely for aesthetics, to improve aesthetics or function following previous disease, or to facilitate the stabilization, restoration or replacement of teeth. Orthodontics may have a major role in the rehabilitation of patients suffering the effects of advanced periodontal disease, but there are a number of important factors to be considered in the management of such patients if the optimal outcome is to be obtained. This paper summarizes important aspects of treatment and the potential complications and how to avoid them.

Copyrighted Material

Copyrighted Material

Copyrighted Material

Copyrighted Material

Copyrighted Material

Copyrighted Material

Copyrighted Material

# Performance Standards

# Align Technology, Inc.,

# Modified Invisalign® system

# Performance Standards

There are no established device-specific performance standards or special controls that apply to the Invisalign system (21CFR 872.5470).

440

Food and Drug Administration
Office of Device Evaluation &
Office of In Vitro Diagnostics

# COVER SHEET MEMORANDUM

From: Reviewer Name Kevin Mulry, DDS

Subject: 510(k) Number K081960/S1

To: The Record

Please list CTS decision code SE

☐ Refused to accept (Note: this is considered the first review cycle, See Screening Checklist http://eroom.fda.gov/eRoomReg/Files/CDRH3/CDRHPremarketNotification510kProgram/0_5631/Screening%20Checklist%207%202%2007.doc )

☐ Hold (Additional Information or Telephone Hold).

☒ Final Decision (SE, SE with Limitations, NSE, Withdrawn, etc.).

| Please complete the following for a final clearance decision (i.e., SE, SE with Limitations, etc.): | | YES | NO |
|---|---|---|---|
| Indications for Use Page | *Attach IFU* | X | |
| 510(k) Summary/510(k) Statement | *Attach Summary* | X | |
| Truthful and Accurate Statement. | *Must be present for a Final Decision* | X | |
| Is the device Class III?<br>If yes, does firm include Class III Summary? | *Must be present for a Final Decision* | | X |
| Does firm reference standards?<br>(If yes, please attach form from http://www.fda.gov/opacom/morechoices/fdaforms/FDA-3654.pdf) | | | X |
| Is this a combination product?<br>(Please specify category _____, see http://eroom.fda.gov/eRoomReg/Files/CDRH3/CDRHPremarketNotification510kProgram/0_413b/COMBINATION%20PRODUCT%20ALGORITHM%20(REVISED%203-12-03).DOC | | | X |
| Is this a reprocessed single use device?<br>(Guidance for Industry and FDA Staff – MDUFMA - Validation Data in 510(k)s for Reprocessed Single-Use Medical Devices, http://www.fda.gov/cdrh/ode/guidance/1216.html) | | | X |
| Is this device intended for pediatric use only? | | | X |
| Is this a prescription device? (If both prescription & OTC, check both boxes.) | | X | |
| Is clinical data necessary to support the review of this 510(k)?<br>Did the application include a completed FORM FDA 3674, *Certification with Requirements of ClinicalTrials.gov Data Bank*?<br>(If not, then applicant must be contacted to obtain completed form.) | | | X |
| Does this device include an Animal Tissue Source? | | | X |
| All Pediatric Patients age<=21 | | | X |
| Neonate/Newborn (Birth to 28 days) | | | X |
| Infant (29 days -< 2 years old) | | | X |
| Child (2 years -< 12 years old) | | X | X |
| Adolescent (12 years -< 18 years old) | | X | |
| Transitional Adolescent A (18 - <21 years old) Special considerations are being given to this group, different from adults age ≥ 21 (different device design or testing, different protocol procedures, etc.) | | | X |
| Transitional Adolescent B (18 -<= 21; No special considerations compared to adults => 21 years old) | | X | |
| Nanotechnology | | | X |

Rev. 7/2/07

4

| | | | |
|---|---|---|---|
| Is this device subject to Section 522 Postmarket Surveillance? (Postmarket Surveillance Guidance, http://www.fda.gov/cdrh/osb/guidance/316.html) | *Contact OSB.* | | X |
| Is this device subject to the Tracking Regulation? (Medical Device Tracking Guidance, http://www.fda.gov/cdrh/comp/guidance/169.html) | *Contact OC.* | | X |

| Regulation Number | Class* | Product Code |
|---|---|---|
| 872.5470 | II | NXC |

(*If unclassified, see 510(k) Staff)

**Additional Product Codes:**

**Review:** Susan Runner (Branch Chief) DEDB (Branch Code) 12/17/08 (Date)

**Final Review:** Annette Y. Michaud MD (Division Director) 12-17-08 (Date)

5

DEPARTMENT OF HEALTH AND HUMAN SERVICES MEMORANDUM

Food and Drug Administration
Office of Device Evaluation
9200 Corporate Boulevard
Rockville, MD 20850

Premarket Notification [510(k)] Review

**Traditional/Abbreviated**

**K081960**

| | | |
|---|---|---|
| **Date:** | **December 15, 2008** | |
| **To:** | The Record | **Office:** ODE |
| **From:** | Kevin Mulry, DDS, MPH | **Division:** DAGID |
| **510(k) Holder:** | **Align Technology, Inc.** | |
| **Device Name:** | Invisalign® system | |
| **Contact:** | Sangeeta Sachdeva | |
| **Phone:** | 408-470-1244 | |
| **Fax:** | 408-470-1011 | |
| **Email:** | ssachdeva@aligntech.com | |

## Purpose and Submission Summary

The 510(k) holder would like to introduce the Invisalign® System with expanded Indications for Use into interstate commerce. According to the sponsor, this 510(k) Premarket Notification is being submitted because Align Technology, Inc. is expanding the indications for use to include mixed dentition cases and making labeling changes that affect contra-indications and precautions of the currently cleared Invisalign system (K981095). The technological characteristics, including design, raw materials, chemical composition, manufacturing processes and related software, of the Align system in this submission and the currently marketed predicate device are identical.

The Invisalign® system is a series of clear plastic aligners that are used to replace traditional orthodontic wires and brackets for the alignment of maloccluded or misaligned teeth.

The Invisalign system is substantially equivalent to the Invisalign system (K981095) in intended use, materials of composition, technological characteristics, safety and effectiveness.



C

## Administrative Requirements

| | Yes | No | N/A |
|---|---|---|---|
| Indications for Use page (Indicate if: Prescription or OTC) | X | | |
| Truthful and Accuracy Statement | X | | |
| 510(k) Summary or 510(k) Statement | X | | |
| Standards Form | | | X |

## Indications for Use

The Indications for Use state: "The Invisalign® system is indicated for the alignment of teeth during orthodontic treatment of malocclusion." The Invisalign system is a prescription device.

## Device Description/Formulation

| | Yes | No | N/A |
|---|---|---|---|
| Is the device life-supporting or life sustaining? | | X | |
| Is the device an implant (implanted longer than 30 days)? | | X | |
| Does the device design use software? | X | | |
| Is the device sterile? | | X | |
| Is the device reusable (not reprocessed single use)?<br>Are "cleaning" instructions included for the end user? | X | | |

The Invisalign System is a series of clear, plastic aligners fabricated with the use of computer design software that are used to replace traditional orthodontic wires and brackets for the alignment of malocculded or misaligned teeth. The dentist provides the prescription and the impressions to Align Technology. The Invisalign® system software displays a series of 3-D dentition images with virtual tooth movements set up based on the doctor's prescription. The treating dental practitioner reviews these images and has the option to reject or request modifications to the set-up prior to approving it for aligner fabrication. Once the doctor approves the set-up, a custom-made series of thermoplastic polymer aligners are then manufactured at the aligner manufacturing facility. The custom-made aligners are then shipped to the dental practitioner to be dispensed to the patient for treatment. The series of aligners is designed to move the teeth gently and in small increments from their original to their final treated position for improved dental alignment. An aligner is worn by the patient for 20 – 22 hours per day for a two week period, after which it is replaced by the next stage aligner. This is repeated until the treatment is completed. The aligners are

composed of a polyurethane plastic, Raintree Essex. There have been no changes to the materials from the cleared Align system predicate.

The current Indications for Use for Invisalign state that the Invisalign® System is indicated for the treatment of tooth malocclusion in patients with permanent dentition (i.e., all second molars). The intent of the proposed Indications is to extend the use of Invisalign to all types of orthodontic malocclusions and not require the presence of second molars, thus treating younger mixed dentition patients. The rationale is that today dentists treat patients in mixed dentition with removable appliances.

The labeling modifications include:

I. Expansion of the indications for use to permit treatment of patients who present with malocclusion without the limitation of having completely erupted permanent dentition.

II. Removal of contra-indications that excluded patients with certain complex malocclusions from receiving treatment with the Invisalign system. These patients may or may not need additional orthodontic procedures to achieve the desired treatment outcome, and this is captured in the added precautions.

III. Addition of precautions corresponding to the removal of contra-indications from the cleared Invisalign system.

Thus, the modified Invisalign® system with the proposed labeling changes will allow the treatment of patients with malocclusion, including, but not limited to, those with primary dentition present (mixed dentition), as well as patients with severe open bite, severe overjet, skeletally narrow jaw, dental prostheses, and/or those who require surgical correction.

The **Summary Table** below lists the main similarities and differences between the predicate and the proposed device:

| **Predicate Device Invisalign system (K981095)** | **Invisalign® system (K081960)** |
|---|---|
| **Technology** of the design, raw material, and chemical composition as described in (K981095) | No change. |
| **Manufacturing** processes as described in (K981095) | No change. |
| **Software** description as described in (K981095) | No change. |

| | |
|---|---|
| **Technical features and properties** as described in (K981095) | No change. |
| **Indications for Use:**<br>The Invisalign® system is indicated for the treatment of tooth malocclusion in patients with permanent dentition (i.e., all second molars). | **Proposed Indication for Use:**<br>The Invisalign® system is indicated for the alignment of teeth during orthodontic treatment of malocclusion. |
| **Contra-indications:**<br>Adult and Adolescent patients presenting the following conditions:<br>1. Severe open bite<br>2. Severe overjet<br>3. Tooth malocclusion requiring surgical correction<br>4. Patients with mixed dentition<br>5. Adolescent patients with a skeletally narrow jaw<br>6. Adult patients with dental prosthetics/implants | **Contra-indications:**<br>Active periodontal disease |
| **Precautions:**<br>1. Keep aligners away from hot water and harsh chemicals.<br>2. Keep aligners out of reach of young children and pets.<br>3. Always store aligners in a cool, dry place.<br>4. Certain medical conditions and use of certain medications may affect orthodontic treatment outcomes. | **Proposed precautions *in addition* to the current Precautions to support the removal of Contra-indications**:<br>1. Treatment of severe open bite, severe overjet, mixed dentition, and/or skeletally narrow jaw may require supplemental treatment in addition to aligner treatment.<br>2. Skeletal expanders, bonded auxiliaries, elastics, and other fixed and/or removable orthodontic appliances, may be needed for more complicated treatment plans where aligners alone may not be adequate to achieve the desired outcome.<br>3. Oral surgery may be necessary to correct severe |

| | |
|---|---|
| | crowding or jaw imbalances. If oral surgery is required, risks associated with anesthesia and proper healing must be taken into account prior to treatment.<br>4. Atypically-shaped, erupting, and/or missing teeth may affect aligner adaptation and may affect the ability to achieve the desired results.<br>5. Existing dental restorations (e.g., crowns, bridges) may become dislodged and require re-cementation or, in some instances, replacement.<br>6. Aligners are not effective in the movement of dental implants. |

This Premarket Notification is being submitted solely to incorporate the above listed labeling changes to the existing Invisalign® system (K981095) and to expand the Indications for Use to mixed dentition.

1. There are no changes in the technological characteristics of the modified device when compared to the predicate device. The design, raw material, and chemical composition, device features as well as technical characteristics of the modified device and existing predicate device are similar.
2. There are no changes in the manufacturing processes and related software required to accommodate the labeling changes.

Contact History and Deficiencies

On August 5, 2008, I called Ms. Sangeeta Sachdeva to request that the case reports with photographs that were provided in the pre-IDE (I070795) be submitted to the present submission. In addition, the submission should clarify that the thermoplastic material in the present submission is the same as in the cleared Invisalign system (K981095). She will consult with Dr. Eric Kuo and submit the information as an Amendment. On September 19, 2008, I called Ms. Sandcheva to request the Clinical Trials Form, as clinical data are presented in the submission. Per Ms. Sandcheva, the clinical information provided was not from a clinical trial but case reports from practitioners

who had used the device beyond the cleared Indications. She did not believe that submission of the form was needed. I advised her that I would check with POS staff regarding submission of the form. Per a September 23, 2008, conversation with Sheila Brown, it was determined that the sponsor needs to submit Retrospective Informed Consent for each of the patients whose cases are presented in the submission as clinical evidence for the expanded Indications for Use. Per Ms. Brown, the case reports are considered a clinical trial and the sponsor will need to have an IRB that will determine the form in which the consent must be obtained, either written or verbal. Per Ms. Brown, the sponsor may call her to discuss the need for Informed Consent.

On September 24, 2008, I called Ms. Sandcheva to discuss the Informed Consent and Clinical Trial Form. I referred her to Sheila Brown to discuss the details of the IRB and Informed Consent. I advised her that the submission will be placed on hold pending the submission of the information on the Informed Consent, the clinical trial, and the Clinical Trial Form.

On November 13, 2008, Sheila Brown and I had a conference call with Dr. Eric Kuo, Mr. Randy Golden, and Dr. Sandy Sachdeva to discuss the clinical data and informed consent. Per Dr. Kuo the cases were collected from multiple offices and it was not the intent of Align to conduct a clinical trial. Per Ms. Brown, the sponsor would need to have an IRB and retrospective consent for the clinical data. Dr. Kuo requested whether the Dental Branch could review the submission again to consider whether the literature originally provided in the submission is sufficient to support clearance. As previously stated by Dr. Sachdeva and Dr. Kuo it was not there intent to submit the clinical cases, however, upon the request from FDA the clinical case reports were provided. I advised them that I would consult with MSR to determine if the original data was sufficient per Dr. Kuo's request.

On November 18, 2008, I met with MSR, Dental Branch Chief, to discuss the conference call and to discuss the literature provided in order to comply with the request from Dr. Kuo that we look at the literature to determine if it supports clearance. After reviewing the literature provided, MSR recommended that I call Dr. Sachdeva and recommend that they send a letter to the file requesting that the clinical case reports be removed from the submission as they are not necessary for clearance. Per MSR, the literature provided in the submission is sufficient for clearance as the sponsor is expanding the indications to reflect current clinical use of the aligners. On November 19, 2008, I called Dr. Sachdeva and advised her per MSR that they should submit a letter requesting

removal of the case reports from review in this submission. Per the request, she will submit the letter around December 1.

On December 10, Dr. Sachdeva called to inform me that she was going to submit a letter requesting removal of the clinical cases from the submission and submit additional articles from the literature supporting the expanded intended use of the Align system.

**Labeling**

Instructions for Use have been provided which include the Indications for Use, contraindications, warnings and precautions. The prescription Caution statement is bolded and included in the Instructions for Use. The modified Invisalign system with the proposed labeling changes will allow the treatment of patients with malocclusion, including, but not limited to, those with primary dentition present (including mixed dentition), as well as patients with severe open bite, severe overjet, skeletally narrow jaw, dental prostheses, and/or those who require surgical correction.

**Sterilization/Shelf Life/Reuse:**

The Invisalign® system is not provided sterile.

**Biocompatibility**

The predicate aligners and the previously cleared aligners are composed of the identical material. Biocompatibility testing was conducted for clearance in K981095 with testing performed on the finished aligners exposed to all manufacturing processes including cleaning. The biocompatibility testing according to ISO 10993 included cytotoxicity, irritation and sensitization. As the materials are identical, no further biocompatibility testing is needed.

**Software**

The sponsor states that there are no changes in the software compared to the existing Invisalign® system cleared in K981095. The software design and development, software development methodology, software development process and environment are identical for the existing predicate device and the modified Invisalign system. No further software documentation is needed.

**Electromagnetic Compatibility and Electrical, Mechanical and Thermal Safety**

No electrical components are contained in the Invisalign system.

## Performance Testing - Bench

The sponsor states that since there were no design or performance changes made to the Invisalign system from the previous submission, no additional bench testing was performed.

## Performance Testing - Animal

No animal test results are provided.

## Performance Testing - Clinical

The sponsor has provided literature to support clearance of the device. The literature includes:

- An article by Eric Kuo entitiled: "Automated custom manufacturing technology in orthodontics," published in the American Journal of Orthodontics and Dentofacial Orthopedics. The article describes the manufacturing processes for Invisalign orthodontic appliances. This includes the scanning of the impressions and models, CT impression scanning, and a description of the automated process used to manufacture the aligners.

- In a chapter from a textbook published by Quintessence and entitled: "Invisalign Attachments: Materials", Drs. Kuo and Duong describe Invisalign attachments used in conjunction with tooth movement with the Invisalign system. The attachments serve as bonded composite extensions of the teeth to help achieve specific tooth movements and add retention of the aligners. An attachment template is created to transfer the exact shape and position of the attachment from the 3-D model of the actual tooth. The clinician fills each attachment reservoir in the template with restorative composite, etches each tooth to be bonded, seats the filled attachment template on the teeth, cures the composite and removes the template leaving the attachment bonded to the teeth in the desired position. Attachments are used to assist with extrusion, intrusion, rotation and root translation without root tipping.

- In the Journal of Orofacial Orthopedics (2006), a case report is provided for the use of Invisalign in the treatment of a patient in whom four premolars had to be extracted due to dental crowding. Diagnostic findings included constriction of the maxillary and mandibular arches with anterior dental crowding, and an overjet of 6 mm and an overbite of 1 mm. Treatment was initiated with extraction of the four premolars and the placement of composite attachments. Active treatment lasted 1 year and 8.5 months and included 43 maxillary and 28 mandibular aligners. After completion of the Invisalign treatment, the anterior

segment was uprighted and retracted, the crowing resolved, and the arches well aligned.

- In the Journal of Dental Education, an article by Robert Boyd, D.D.S., entitled: "Esthetic Orthodontic Treatment using the Invisalign Appliance for Moderate to Complex Malocclusions, describes case reports of three patients treated with Invisalign. These three cases are intended to demonstrate that a variety of complex malocclusions can be treated successfully including correction of moderate crowding, correction of moderate Class II division I malocclusions and deep overbite. The new protocol for aligner use includes new methods for anterior/posterior movement at the end of treatment, staging for interproximal reduction and the use of attachments for rotation, retention and treatment of deep overbite. The article presents the pre and post-treatment photographs of the three patients treated.

- In the American Journal of Orthodontics and Dentofacial Orthopedics, an article by Keski-Nisula et. al., entitled: "Orthodontic intervention in the early mixed dentition: A prospective, controlled study on the effects of the eruption guidance appliance" is presented. It presents the results of a prospective, controlled cohort study conducted in Finland beginning in 1998 to investigate the effects of orthodontic treatment in the early mixed dentition with the eruption guidance appliance. Occlusal changes were recorded in 167 treated children and 104 controls after they reached the middle mixed-dentition stage. The findings indicated that significant improvement in the occlusion was achieved with early intervention. After reaching the middle, mixed-dentition stage, most treated children showed favorable intermaxillary relationships in the incisor, canine, and molar segments. Overbite and overjet were both close to 2 mm, the incisors had tooth-to-tooth contact and good alignment and the canines showed almost full Class I relationships. Only 22 of the 167 children in the treatment group had persisting mild deviations. In the control group, in contrast, 92 of the 104 children had at least one deviating occlusal characteristic.

- In the California Dental Association Journal (2006), Robert Boyd, D.D.S., et. al., present an article entitled: "An Update on Present and Future Considerations of Aligners." The article reviews the orthodontic treatment of six different patients treated with aligners. The cases include correction of deep overbite, open bite, mild to moderate crowding, large overjet, and cases requiring premolar extractions. The six cases are intended to demonstrate that with careful treatment planning and the use of Invisalign's ClinCheck software, the planning of the specific details of the sequence of aligners can be planned out prior to the initiation of treatment. The article presents photographs of the pre-treatment through post-treatment of each of the cases.

- An article by Robert Boyd, D.D.S., summarizes cases demonstrating surgical orthodontic treatment of two skeletal class III patients with Invisalign and fixed appliances. The author concludes that these two cases demonstrate that the Invisalign System can be effective when used in conjunction with segmental fixed appliances or prior to full fixed appliances immediately before and after surgery. The author concludes that they were able to limit the full fixed appliance phase to less than 30% of the total treatment time in each case. A class II case with use of Align and fixed appliances is also presented. The total treatment time was 27 months, of which 12 months were treatment with Invisalign and 15 months with fixed appliances.

- A textbook chapter by Ross Miller et. al., describes open bite and Class I malocclusion with upper and lower anterior crowding with crossbite. The article discusses aligner lag which is countered with virtual overtreatment. The cases were treated by the Orthodontist. The author concludes that there is a learning curve with using the appliance and evaluating ClinCheck. Reviewing and evaluating ClinCheck has two components including reviewing the setup as well as the actual movement. Not only is it important to view the end result of the final dentition, it is important to view how the teeth move from their initial to their final position.

In addition to the literature, in the pre-IDE (I070795), Align submitted case reports for (b cases from (b) dental practices, which demonstrate that patients with deciduous dentition present, as well as patients with malocclusions of the types listed below, can be successfully treated with Invisalign aligners. The case reports included a summary of the treatment and photographs of the different stages of treatment. These cases also were reviewed by MSR in I070795. The cases included:

(b)(4),(b)(5) 1. Severe open bite: cases
(b)(4),(b)(5) 2. Severe overjet: cases
(b)(4),(b)(5) 3. Surgical correction: cases
(b)(4),(b)(5) 4. Mixed dentition: cases
(b)(4),(b)(5) 5. Skeletally narrow jaw: case

For the mixed dentition, the types of orthodontic problems corrected include:

- Anterior crossbite – one case
- Diastema/incisor spacing- four cases
- Incisor crowding - -three cases which included a case from each of the above categories
- Premature space loss due to early loss of primary dentition

A meeting was held with the sponsor on March 5, 2008 to discuss I070795. At that time it was determined that the sponsor had provided adequate clinical support for the expansion of the Indications for Use.

## Substantial Equivalence Discussion

The current submission is being submitted solely to incorporate the above listed labeling changes to the existing Invisalign® system (K981095) and to expand the Indications for Use to include mixed dentition cases.

- There are no changes in the technological characteristics of the modified device when compared to the predicate device. The design, materials, device features as well as technical characteristics of the modified device and existing predicate device are identical.
- There are no changes in the manufacturing processes and related software required to accommodate the labeling changes.

Based on the similar indications for use, same technological characteristics, materials, and performance characteristics of the currently marketed predicate device (K981095) and the Invisalign system presently under review, the Invisalign system is substantially equivalent.

| | Yes | No | |
|---|---|---|---|
| 1. Same Indication Statement? | | X | If **YES** = Go To 3 |
| 2. Do Differences Alter The Effect Or Raise New Issues of Safety Or Effectiveness? | | X | If **YES** = Stop **NSE** |
| 3. Same Technological Characteristics? | X | | If **YES** = Go To 5 |
| 4. Could The New Characteristics Affect Safety Or Effectiveness? | | | If **YES** = Go To 6 |
| 5. Descriptive Characteristics Precise Enough? | X | | If **NO** = Go To 8<br>If **YES** = Stop **SE** |
| 6. New Types Of Safety Or Effectiveness Questions? | | | If **YES** = Stop **NSE** |
| 7. Accepted Scientific Methods Exist? | | | If **NO** = Stop **NSE** |
| 8. Performance Data Available? | | | If **NO** = Request Data |
| 9. Data Demonstrate Equivalence? | | | Final Decision: **SE** |

## Recommendation

The Invisalign system is substantially equivalent to the Invisalign system (K981095) in intended use, materials of composition, technological characteristics, safety and effectiveness.

Regulation Number: 872.5470
Regulation Name: Orthodontic Plastic Bracket
Regulatory Class: II
Product Codes: NXC

Kevin Mulry, D.D.S., M.P.H.

Susan Runner, D.D.S., M.A.

Food and Drug Administration
Office of Device Evaluation &
Office of In Vitro Diagnostics

# COVER SHEET MEMORANDUM

**From:** Reviewer Name Kevin Mulvey, DDS

**Subject:** 510(k) Number K081960

**To:** The Record

Please list CTS decision code TH

☐ Refused to accept (Note: this is considered the first review cycle, See Screening Checklist http://eroom.fda.gov/eRoomReg/Files/CDRH3/CDRHPremarketNotification510kProgram/0_5631/Screening%20Checklist%207%202%2007.doc )

☒ Hold (Additional Information or Telephone Hold).

☐ Final Decision (SE, SE with Limitations, NSE, Withdrawn, etc.).

| Please complete the following for a final clearance decision (i.e., SE, SE with Limitations, etc.): | | YES | NO |
|---|---|---|---|
| Indications for Use Page | *Attach IFU* | | |
| 510(k) Summary /510(k) Statement | *Attach Summary* | | |
| Truthful and Accurate Statement. | *Must be present for a Final Decision* | | |
| Is the device Class III?<br>If yes, does firm include Class III Summary? | *Must be present for a Final Decision* | | |
| Does firm reference standards?<br>(If yes, please attach form from http://www.fda.gov/opacom/morechoices/fdaforms/FDA-3654.pdf) | | | |
| Is this a combination product?<br>(Please specify category _____, see http://eroom.fda.gov/eRoomReg/Files/CDRH3/CDRHPremarketNotification510kProgram/0_413b/COMBINATION%20PRODUCT%20ALGORITHM%20(REVISED%203-12-03).DOC | | | |
| Is this a reprocessed single use device?<br>(Guidance for Industry and FDA Staff – MDUFMA - Validation Data in 510(k)s for Reprocessed Single-Use Medical Devices, http://www.fda.gov/cdrh/ode/guidance/1216.html) | | | |
| Is this device intended for pediatric use only? | | | |
| Is this a prescription device? (If both prescription & OTC, check both boxes.) | | | |
| Is clinical data necessary to support the review of this 510(k)?<br>Did the application include a completed FORM FDA 3674, *Certification with Requirements of ClinicalTrials.gov Data Bank*?<br>(If not, then applicant must be contacted to obtain completed form.) | | | |
| Does this device include an Animal Tissue Source? | | | |
| All Pediatric Patients age<=21 | | | |
| Neonate/Newborn (Birth to 28 days) | | | |
| Infant (29 days -< 2 years old) | | | |
| Child (2 years -< 12 years old) | | | |
| Adolescent (12 years -< 18 years old) | | | |
| Transitional Adolescent A (18 - <21 years old) Special considerations are being given to this group, different from adults age ≥ 21 (different device design or testing, different protocol procedures, etc.) | | | |
| Transitional Adolescent B (18 -<= 21; No special considerations compared to adults => 21 years old) | | | |
| Nanotechnology | | | |

Rev. 7/2/07



108

| | | | |
|---|---|---|---|
| Is this device subject to Section 522 Postmarket Surveillance? (Postmarket Surveillance Guidance, http://www.fda.gov/cdrh/osb/guidance/316.html) | *Contact OSB.* | | |
| Is this device subject to the Tracking Regulation? (Medical Device Tracking Guidance, http://www.fda.gov/cdrh/comp/guidance/169.html) | *Contact OC.* | | |

**Regulation Number** **Class*** **Product Code**

(*If unclassified, see 510(k) Staff)

**Additional Product Codes:**

**Review:** (Branch Chief) (Branch Code) 9/25/08 (Date)

**Final Review:** (Division Director) 9/25/08 (Date)

109

DEPARTMENT OF HEALTH AND HUMAN SERVICES **MEMORANDUM**

Food and Drug Administration
Office of Device Evaluation
9200 Corporate Boulevard
Rockville, MD 20850

Premarket Notification [510(k)] Review
**Traditional/Abbreviated**

**K081960**

| | | |
|---|---|---|
| **Date:** | **September 24, 2008** | |
| **To:** | The Record | **Office:** ODE |
| **From:** | Kevin Mulry, DDS, MPH | **Division:** DAGID |
| **510(k) Holder:** | **Align Technology, Inc.** | |
| **Device Name:** | Invisalign® system | |
| **Contact:** | Sangeeta Sachdeva | |
| **Phone:** | 408-470-1244 | |
| **Fax:** | 408-470-1011 | |
| **Email:** | ssachdeva@aligntech.com | |

## Purpose and Submission Summary

The 510(k) holder would like to introduce the Invisalign® System with expanded Indications for Use into interstate commerce. According to the sponsor, this 510(k) Premarket Notification is being submitted because Align Technology, Inc. is expanding the indications for use and making labeling changes that affect contra-indications and precautions of the currently cleared Invisalign system (K981095). The technological characteristics of the modified and currently marketed predicate device, such as design, raw materials, chemical composition, manufacturing processes and related software, are identical.

The Invisalign® system is a series of clear plastic aligners that are used to replace traditional orthodontic wires and brackets for the alignment of maloccluded or misaligned teeth.

The submission should be placed on telephone hold pending receipt of the requested information on the informed consent for the clinical trial and the Clinical Trial Form.

## Administrative Requirements

| | Yes | No | N/A |
|---|---|---|---|
| Indications for Use page (Indicate if: Prescription or OTC) | X | | |
| Truthful and Accuracy Statement | X | | |
| 510(k) Summary or 510(k) Statement | X | | |
| Standards Form | | | X |

## Indications for Use

The Indications for Use state: "The Invisalign® system is indicated for the alignment of teeth during orthodontic treatment of malocclusion." The Invisalign system is a prescription device.

## Device Description/Formulation

| | Yes | No | N/A |
|---|---|---|---|
| Is the device life-supporting or life sustaining? | | X | |
| Is the device an implant (implanted longer than 30 days)? | | X | |
| Does the device design use software? | | X | |
| Is the device sterile? | | X | |
| Is the device reusable (not reprocessed single use)?<br>Are "cleaning" instructions included for the end user? | | X | |

According to the sponsor, this 510(k) Premarket Notification is being submitted because Align Technology, Inc. is expanding the indications for use and making labeling changes that affect contra-indications and precautions of the currently cleared Invisalign® system (K981095). The technological characteristics of the modified and currently marketed predicate device, such as design, raw materials, chemical composition, manufacturing processes and related software, are identical.

The Invisalign System is a series of clear, plastic aligners fabricated with the use of computer design software that are used to replace traditional orthodontic wires and brackets for the alignment of maloccluded or misaligned teeth. The dentist provides the prescription and the impression to Align Technology. The Invisalign® system software displays a series of 3-D dentition images with virtual tooth movements set up based on the doctor's prescription. The treating dental practitioner reviews these images and has the option to reject or request modifications to the set-up prior to approving it for

aligner fabrication. Once the doctor approves the set-up, a custom-made series of thermoplastic polymer aligners are then manufactured at the aligner manufacturing facility. The custom-made aligners are then shipped to the dental practitioner to be dispensed to the patient for treatment. The series of aligners is designed to move the teeth gently and in small increments from their original to their final treated position for improved dental alignment. An aligner is worn by the patient for 20 – 22 hours per day for a two week period, after which it is replaced by the next stage aligner. This is repeated until the treatment is completed. The aligners are composed of a polyurethane plastic, similar to Raintree Essex. There have been no changes to the material from the cleared Align system predicate.

The current Indications for Use for Invisalign state that the Invisalign® System is indicated for the treatment of tooth malocclusion in patients with permanent dentition (i.e., all second molars). The intent of the proposed Indications is to extend the use of Invisalign to all types of orthodontic malocclusions and not require the presence of second molars, thus treating younger mixed dentition patients. The rationale is that today dentists treat patients in mixed dentition with removable appliances.

The labeling modifications include:

I. Expansion of the indications for use to permit treatment of patients who present with malocclusion without the limitation of permanent dentition.

II. Removal of certain contra-indications that excluded patients with certain complex malocclusions from getting treated with the Invisalign system. These patients may or may not need additional orthodontic procedures to achieve the desired treatment outcome, and this is captured in the added precautions.

III. Addition of precautions corresponding to the removal of contra-indications.

Thus, the modified Invisalign® system with the proposed labeling changes will allow the treatment of patients with malocclusion, including, but not limited to, those with primary dentition present (mixed dentition), as well as of patients with severe open bite, severe overjet, skeletally narrow jaw, dental prostheses, and/or those who require surgical correction.

The **Summary Table** below lists the main similarities and differences between the predicate and the proposed device:

| **Predicate Device Invisalign system (K981095)** | **Invisalign® system (K081960)** |
|---|---|
| **Technology** of the design, raw material, and chemical composition as described in (K981095) | No change. |

1/2

| | |
|---|---|
| **Manufacturing** processes as described in (K981095) | No change. |
| **Software** description as described in (K981095) | No change. |
| **Technical features and properties** as described in (K981095) | No change. |
| **Indications for Use:**<br>The Invisalign® system is indicated for the treatment of tooth malocclusion in patients with permanent dentition (i.e., all second molars). | **Proposed Indication for Use:**<br>The Invisalign® system is indicated for the alignment of teeth during orthodontic treatment of malocclusion. |
| **Contra-indications:**<br>Adult and Adolescent patients presenting the following conditions:<br>1. Severe open bite<br>2. Severe overjet<br>3. Tooth malocclusion requiring surgical correction<br>4. Patients with mixed dentition<br>5. Adolescent patients with a skeletally narrow jaw<br>6. Adult patients with dental prosthetics/implants | **Contra-indications:**<br>Active periodontal disease |
| **Precautions:**<br>1. Keep aligners away from hot water and harsh chemicals.<br>2. Keep aligners out of reach of young children and pets.<br>3. Always store aligners in a cool, dry place.<br>4. Certain medical conditions and use of certain medications may affect orthodontic treatment outcomes. | **Proposed precautions *in addition* to the current Precautions to support the removal of Contra-indications:**<br>1. Treatment of severe open bite, severe overjet, mixed dentition, and/or skeletally narrow jaw may require supplemental treatment in addition to aligner treatment.<br>2. Skeletal expanders, bonded auxiliaries, elastics, and other fixed and/or removable orthodontic appliances, may be needed for more complicated treatment plans |

| | |
|---|---|
| | where aligners alone may not be adequate to achieve the desired outcome.<br>3. Oral surgery may be necessary to correct severe crowding or jaw imbalances. If oral surgery is required, risks associated with anesthesia and proper healing must be taken into account prior to treatment.<br>4. Atypically-shaped, erupting, and/or missing teeth may affect aligner adaptation and may affect the ability to achieve the desired results.<br>5. Existing dental restorations (e.g., crowns, bridges) may become dislodged and require re-cementation or, in some instances, replacement.<br>6. Aligners are not effective in the movement of dental implants. |

This Premarket Notification is being submitted solely to incorporate the above listed labeling changes to the existing Invisalign® system (K981095).

1. There are no changes in the technological characteristics of the modified device when compared to the predicate device. The design, raw material, and chemical composition, device features as well as technical characteristics of the modified device and existing predicate device are similar.
2. There are no changes in the manufacturing processes and related software required to accommodate the labeling changes.

Contact History and Deficiencies

On August 5, 2008, I called Ms. Sangeeta Sachdeva to request that the case reports with photographs that were provided in the pre-IDE (I070795) be submitted to the present submission. In addition, the submission should clarify that the thermoplastic material in the present submission is the same as in the cleared Invisalign system (K981095). She will consult with Dr. Eric Kuo and submit the information as an Amendment.

On September 19, 2008, I called Ms. Sandcheva to request the Clinical Trials Form, as clinical data are presented in the submission. Per Ms. Sandcheva, the clinical information provided was not from a clinical trial but case reports from practitioners who had used the device beyond the cleared Indications. She did not believe that submission of the form was needed. I advised her that I would check with POS staff regarding submission of the form. Per a September 23, 2008, conversation with Sheila Brown, it was determined that the sponsor needs to submit Retrospective Informed Consent for each of the patients whose cases are presented in the submission as clinical evidence for the expanded Indications for Use. Per Ms. Brown, the case reports are considered a clinical trial and the sponsor will need to have an IRB that will determine the form in which the consent must be obtained, either written or verbal. Per Ms. Brown, the sponsor may call her to discuss the need for Informed Consent.

On September 24, 2008, I called Ms. Sandcheva to discuss the Informed Consent and Clinical Trial Form. I referred her to Sheila Brown to discuss the details of the IRB and Informed Consent. I advised her that the submission will be placed on hold pending the submission of the information on the Informed Consent, the clinical trial, and the Clinical Trial Form.

**Labeling**

Instructions for Use have been provided which include the Indications for Use, contraindications, warnings and precautions. The prescription Caution statement is bolded and included in the Instructions for Use. The modified Invisalign system with the proposed labeling changes will allow the treatment of patients with malocclusion, including, but not limited to, those with primary dentition present (including mixed dentition), as well as patients with severe open bite, severe overjet, skeletally narrow jaw, dental prostheses, and/or those who require surgical correction.

**Sterilization/Shelf Life/Reuse:**

The Invisalign® system is not provided sterile.

**Biocompatibility**

The predicate aligners and the previously cleared aligners are composed of the identical material. Biocompatibility testing was conducted for clearance in K981095 with testing performed on the finished aligners exposed to all manufacturing processes including cleaning. The biocompatibility testing according to ISO 10993 included cytotoxicity, irritation and sensitization. As the materials are identical, no further biocompatibility testing is needed.

## Software

The sponsor states that there are no changes in the software compared to the existing Invisalign® system cleared in K981095. The software design and development, software development methodology, software development process and environment are identical for the existing predicate device and the modified Invisalign system. No further software documentation is needed.

## Electromagnetic Compatibility and Electrical, Mechanical and Thermal Safety

No electrical components are contained in the Invisalign system.

## Performance Testing – Bench

The sponsor states that since there were no design or performance changes made to the Invisalign system from the previous submission, no additional bench testing was performed.

## Performance Testing – Animal

No animal test results are provided.

## Performance Testing – Clinical

Align evaluated case reports and before/after records of 30 cases collected from 14 dental practices, which demonstrate that patients with deciduous dentition present, as well as patients with malocclusions of the types listed below, can be successfully treated with Invisalign aligners. In the present submission and in I070795, Align submitted
(b)(4),(b)(5) case reports for the cases which included a summary of the treatment and photographs of the different stages of treatment. These cases also were reviewed by MSR in I070795.

(b)(4),(b)(5) 1. Severe open bite: cases
(b)(4),(b)(5) 2. Severe overjet: cases
(b)(4),(b)(5) 3. Surgical correction: cases
(b)(4),(b)(5) 4. Mixed dentition: cases
(b)(4),(b)(5) 5. Skeletally narrow jaw: case

For the mixed dentition, the types of orthodontic problems corrected include:

- Anterior crossbite – one case
- Diastema/incisor spacing- four cases

- Incisor crowding - -three cases which included a case from each of the above categories
- Premature space loss due to early loss of primary dentition

A meeting was held with the sponsor on March 5, 2008. At that time it was determined that the sponsor had provided adequate clinical support for the expansion of the Indications for Use. In addition, as presented at the meeting, the manufacturing process has been shortened considerably allowing for quicker delivery of the treatment trays. With the expedited manufacturing process, the prescribing dentist is provided with the ability to submit subsequent impressions of the patient if it is found that the aligners do not properly fit due to eruption or exfoliating teeth. This has allowed the treatment of mixed dentition previously not available.

## Substantial Equivalence Discussion

The current submission is being submitted solely to incorporate the above listed labeling changes to the existing Invisalign® system (K981095).

- There are no changes in the technological characteristics of the modified device when compared to the predicate device. The design, materials, device features as well as technical characteristics of the modified device and existing predicate device are identical.
- There are no changes in the manufacturing processes and related software required to accommodate the labeling changes.

Based on the similar indications for use, same technological characteristics, materials, and performance characteristics of the currently marketed predicate device (K981095) and the Invisalign system with the modified labeling, the two are considered substantially equivalent.

| | Yes | No | |
|---|---|---|---|
| 1. Same Indication Statement? | | X | If **YES** = Go To 3 |
| 2. Do Differences Alter The Effect Or Raise New Issues of Safety Or Effectiveness? | | X | If **YES** = Stop **NSE** |
| 3. Same Technological Characteristics? | X | | If **YES** = Go To 5 |
| 4. Could The New Characteristics Affect Safety Or Effectiveness? | | | If **YES** = Go To 6 |
| 5. Descriptive Characteristics Precise Enough? | | | If **NO** = Go To 8<br>If **YES** = Stop **SE** |
| 6. New Types Of Safety Or Effectiveness Questions? | | | If **YES** = Stop **NSE** |
| 7. Accepted Scientific Methods Exist? | | | If **NO** = Stop **NSE** |
| 8. Performance Data Available? | | | If **NO** = Request Data |
| 9. Data Demonstrate Equivalence? | | | Final Decision: **SE** |

**Recommendation**

The submission should be placed on telephone hold pending receipt of the requested information on the informed consent for the clinical trial and the Clinical Trial Form.

Regulation Number: 872.5470
Regulation Name: Orthodontic Plastic Bracket
Regulatory Class: II
Product Codes: NXC

Kevin Mulry, D.D.S., M.P.H.

Susan Runner, D.D.S., M.A.

DEPARTMENT OF HEALTH & HUMAN SERVICES

Public Health Service

Food and Drug Administration
9200 Corporate Boulevard
Rockville, Maryland 20850

December 12, 2008

ALIGN TECHNOLOGY
881 MARTIN AVE.
SANTA CLARA, CALIFORNIA 95050
UNITED STATES
ATTN: SANGEETA SACHDEVA

510k Number: K081960

Product: INVISALIGN SYSTEM

The additional information you have submitted has been received.

We will notify you when the processing of this submission has been completed or if any additional information is required. Pleaseremember that all correspondence concerning your submission MUST be sent to the Document Mail Center (HFZ-401) at the above letterhead address. Correspondence sent to any address other than the one above will not be considered as part of your official premarket notification submission. Also, please note the new Blue Book Memorandum regarding Fax and E-mail Policy entitled, "Fax and E-Mail Communication with Industry about Premarket Files Under Review. Please refer to this guidance for information on current fax and e-mail practices at www.fda.gov/cdrh/ode/a02-01.html. On August 12, 2005 CDRH issued the Guidance for Industry and FDA Staff: Format for Traditional and Abbreviated 510(k)s. This guidance can be found at http://www.fda.gov/cdrh/ode/guidance/1567.html. Please refer to this guidance for assistance on how to format an original submission for a Traditional or Abbreviated 510(k).

The Safe Medical Devices Act of 1990, signed on November 28, states that you may not place this device into commercial distribution until you receive a letter from FDA allowing you to do so. As in the past, we intend to complete our review as quickly as possible. Generally we do so in 90 days. However, the complexity of a submission or a requirement for additional information may occasionally cause the review to extend beyond 90 days. Thus, if you have not received a written decision or been contacted within 90 days of our receipt date you may want to check with FDA to determine the status of your submission.

If you have procedural questions, please contact the Division of Small Manufacturers International and Consumer Assistance (DSMICA) at (240)276-3150 or at their toll-free number (800) 638-2041, or contact the 510k staff at (240)276-4040.

Sincerely yours,

Marjorie Shulman
Supervisory Consumer Safety Officer
Premarket Notification Section
Office of Device Evaluation
Center for Devices and Radiological Health

18

A L I G N

**invisalign**

K081960/S1

December 10, 2008

Dr. Runner, Chief of Dental Division, CDRH
Dr. Kevin Mulry, DDS, MA
510(k) Document Mail Center (HFZ-401)
Food and Drug Administration
Center for Devices and Radiological Health
9200 Corporate Blvd.
Rockville, MD 20850

FDA CDRH DMC

DEC 12 2008

Received

**Re: 510(k) No. K081960 (Invisalign system)**

**a. Removal of Clinical case reports from the Supplemental Information mailed on 7 August 2008, and any reference to the case reports in the submission (K081960) submitted on 2 July 2008**

**b. Removal of the Clinical Utility Report in the submission (K081960) submitted on 2 July 2008**

**c. Submission of additional publications to further support the expanded use**

Dear Dr. Mulry and Dr. Runner,

Thank you for taking the time to do a preliminary review of the 510(k) Premarket Notification (K081960) submitted by Align Technology on 2 July 2008 and the supplemental documentation submitted on 7 August 2008. In accordance with our teleconference on the 12 November 2008 and the follow up telephone conversation on the 19 November 2008 Align Technology, Inc. is requesting:

(a). removal of the Clinical utility report from Section U I of the 510(k) K081960, submitted on 2 July 2008,

(b). expansion of the Relevant Publications section (Section U II of the 510(k) K081960, submitted on 2 July 2008) with additional articles enclosed, that, like previously submitted publications, further support the expanded intended use of the device, and

(c). removal of the Clinical case reports from the supplemental information submitted on 7 August 2008 and any reference to the clinical cases in the 510(k) K081960, submitted on 2 July 2008.

**Please note that we are not making any changes to intended use or labeling submitted in K081960 Premarket Notification submission.** K48

19

Align Technology, Inc. 881 Martin Avenue Santa Clara, CA 95050 Tel: (408) 470-1000 Fax: (408) 470-1010

Please do not hesitate to contact me if you have any questions or require additional information. Please consider the information provided as COMPANY CONFIDENTIAL.

Thank you.
Sincerely,

Sangeeta Sachdeva
Manager, Regulatory Affairs
Align Technology, Inc.
881 Martin Ave.
Santa Clara, CA 95050
Direct: (408) 470-1244
Fax: (408) 470-1011
ssachdeva@aligntech.com

20

Copyrighted Material

Copyrighted Material

Copyrighted Material

Copyrighted Material

Copyrighted Material

Copyrighted Material

Copyrighted Material

Copyrighted Material

Copyrighted Material

Copyrighted Material

Copyrighted Material

Copyrighted Material

Copyrighted Material

Copyrighted Material

Copyrighted Material

Copyrighted Material

Copyrighted Material

Copyrighted Material

Copyrighted Material

Copyrighted Material

Copyrighted Material

Copyrighted Material

Copyrighted Material

Copyrighted Material

Copyrighted Material

Copyrighted Material

Copyrighted Material

# Complex Orthodontic Treatment Using a New Protocol for the Invisalign Appliance

ROBERT L. BOYD, DDS, MED

The Invisalign* system was introduced at an orthodontic meeting in 1999[1] and first described in a peer-reviewed publication in 2000.[2] Controversy remains over whether the system is appropriate for moderate-to-difficult cases.[3-19]

Early longitudinal clinical trials demonstrated successful use of Invisalign for tipping movements, incisor rotations, and closure of naturally occurring spaces.[17-19] The system was less effective in more difficult procedures such as extraction space closure. These trials were conducted during the first four years of appliance development, however, when significant problems existed with bodily movement, root torquing, extrusion, and premolar and canine rotation. One of the studies tested soft and hard aligner materials that were never used commercially[17,18] (Invisalign appliances are now manufactured using a material of intermediate stiffness). It also evaluated whether a one- or two-week interval between aligners was more effective (for the past eight years, the standard protocol has been two weeks of wear for each aligner). Another study showed predictable intrusion using clear aligners.[19] Both of the longitudinal trials found a statistically significant reduction of plaque and gingivitis during treatment. Numerous other studies have shown that orthodontic treatment using fixed appliances often increases plaque and gingivitis, even when a highly structured preventive program is followed to minimize the effects on periodontal tissues and enamel.[20,21]

An early cross-sectional study compared the first 50 consecutive clear aligner cases treated by the senior author to 50 matched cases treated with fixed appliances.[12] Fixed appliances generally yielded better results than the clear aligners, but the author had more than 25 years of experience with fixed appliances, and the aligner patients were treated between 1999 and 2002.

More recently, successful outcomes have been reported from Invisalign treatment of patients with more complex malocclusions.[11,13-15] This article reports on four patients of various ages with moderate-to-severe malocclusions who were successfully treated using preliminary versions of a new Invisalign protocol.

## Case Selection

Many patients who request Invisalign treatment have previously undergone orthodontic treatment with fixed appliances and do not want to repeat the experience.[11] Esthetic concerns are often a significant factor for adult patients, many of whom are unwilling to wear braces, but teenagers also request Invisalign nowadays because they do not want the look of fixed appliances.[11] In addition, Spear reported that patients who require minor restorative dentistry or bleaching tend to

*Registered trademark of Align Technology, Inc., 881 Martin Ave., Santa Clara, CA 95050; www.alignlech.com.

Dr. Boyd is a Contributing Editor of the *Journal of Clinical Orthodontics* and is Frederick T. West Endowed Professor and Chair, Department of Orthodontics, Arthur A. Dugoni School of Dentistry, University of the Pacific, 2155 Webster St., San Francisco, CA 94115; e-mail: rboyd@pacific.edu.


© 2007 JCO, Inc.


FOI - Page 389 of 446

prefer the combination of orthodontic treatment with less invasive restorative dentistry to extensive full coronal restorations and no orthodontic treatment.[22]

Patients with short dental roots may be better candidates for clear aligners than for fixed appliances. A recent longitudinal study of 100 consecutive Invisalign patients showed no measurable root resorption.[23] In contrast, an average 10% of patients treated with fixed appliances have clinically significant root resorption of at least 3mm.[24,25]

Clear aligners may also be a good choice for patients with mild anterior open bite.[11] The double thickness of the clear plastic appliances on the occlusal surfaces, in combination with the patient's own force of mastication, exerts an intrusive force on the posterior teeth, slightly closing the bite.[26,27] Treatment with fixed appliances may also extrude the teeth, further opening the bite, especially when interarch elastics are used on the anterior teeth.[28,29]

Clear aligners may be more effective than fixed appliances in correcting deep overbite because of their more predictable intrusion mechanics; in addition, the disclusion of the teeth avoids the occlusal interferences of fixed appliances.[3,9,11] Anterior and posterior dental crossbites are also effectively treated with clear aligners, probably because of their disclusion effect.[11] Skeletal crossbite, on the other hand, should be treated with orthopedic or surgical methods. It has recently been shown that presurgical treatment involving clear aligners in combination with fixed appliances can be effective in patients requiring complex orthognathic surgery with corrections in all three planes of space.[13]

Patients with bruxism may also be good candidates for treatment with aligners, which prevent occlusal wear. After treatment, clear retainers are generally worn at night indefinitely, extending their protective benefits. Studies by Nedwed and Miethke[30] and Miller and colleagues[31] have shown that clear aligner treatment reduces myofascial discomfort from clenching and grinding, presumably because of the disarticulation of the teeth by the appliances. In general, clear aligner treatment has been found to cause much less patient discomfort than treatment with fixed appliances, which are often associated with mucosal irritation, tooth soreness, and other problems.[31]

Clear aligner treatment is especially appropriate for patients with extensive porcelain or metal restorations. These artificial surfaces do not allow as secure a bond with a fixed appliance as a natural tooth surface does, and the restorations may also be damaged in debonding.

The Invisalign ClinCheck* computer plan can be used as a virtual diagnostic setup, allowing decisions to be made on appropriate treatment strategies such as extractions, molar distalization, interarch elastics, interproximal reduction, or expansion.[32-35] Anchorage can be evaluated with the superimposition tool or surgical (interarch movement) simulation tool. The software can be used to demonstrate the limits of treatment to the patient, to create an abbreviated version of the virtual treatment plan that can be e-mailed to patients and referring doctors, and to verify proper tracking of the aligners. The program can also help the orthodontist determine the biomechanical and biological feasibility of a particular treatment plan and analyze the pathways of tooth movement.[11]

## New Treatment Protocol

In 2003, Align Technology formed a Clinical Advisory Board (CAB) consisting of 13 orthodontists who had used Invisalign treatment extensively in their practices. This group decided to adopt a new protocol already being used by several of its members. The success experienced by the CAB members with this protocol prompted Align Technology to adopt most of its elements in a "Best Practices Protocol", which would be recommended for all treatment performed after Jan. 1, 2007.[36] The principles of this new protocol are as follows:

1. Simultaneous movement of all involved teeth.

*Registered trademark of Align Technology, Inc., 881 Martin Ave., Santa Clara, CA 95050; www.alignitech.com.

49

Similar to the use of light archwires and low-friction brackets for leveling and alignment, this creates the space needed for tooth movement and slows down the movement of all teeth except the one requiring the greatest number of stages to be corrected at a given velocity (the "determining tooth").
2. Use of beveled 1mm (buccolingual dimension) horizontal rectangular premolar attachments for retention of aligners during intrusive movements such as leveling the lower curve of Spee in cases of deep overbite, for extrusion, and for control of a tooth's long axis during torquing movements.
3. Use of 1mm vertical rectangular attachments for rotation of round teeth or canines, as well as translation of teeth adjacent to an extraction site.
4. Slowing down certain types of tooth movement, including rotation, extrusion, torquing, and bodily movement, below the previous standard velocity of .25mm per stage.
5. Maintaining visible space (approximately .1mm) between teeth during movement of one tooth past another.
6. Using expansion instead of interproximal reduction as a primary method of increasing the space available for correction of crowding.
7. Delaying any interproximal reduction that may be needed to correct Bolton discrepancies and other tooth-size issues until the teeth are aligned, to avoid removing enamel at an angle.

The following four cases demonstrate successful use of the new Invisalign protocol. All four patients had non-contributory medical histories, no symptoms of TMJ dysfunction, and a strong desire to avoid fixed appliances. All were told that fixed appliances might be necessary to complete treatment. Although no fixed appliances were required, auxiliary devices such as interarch elastics were used in Cases 3 and 4. All patients were offered home bleaching using their clear aligners, primarily during the first month of wear, with 30-minute applications of a 30% carbamide peroxide gel if no dentinal sensitivity was noted, or one-hour applications of a 15% gel if sensitivity was present. All patients wore clear retainers full-time for four to six months after treatment, and then indefinitely at night.

## Case 1

A 13-year-old male presented with a Class II, division 1 malocclusion characterized by severe maxillary dentoalveolar prognathism, mild mandibular retrognathia, a 13mm overjet, and a 7mm overbite (Fig. 1). The initial panoramic radiograph showed normal root structure, unerupted third molars, and excellent bone support.

After extraction of both maxillary first premolars to gain space for retraction of the maxillary incisors (Fig. 2), 16 lower aligners and 29 upper aligners were used for a total of 14½ months. Compliance was good, with no need for Case Refinement or midcourse correction with additional aligners. Inter- and intra-arch mechanics were also unnecessary.

Vertical rectangular attachments were placed on the teeth adjacent to the extraction sites and on the maxillary molars to keep them upright during extraction space closure. After 12 upper and lower stages of Invisalign treatment, the attachment on the

**TABLE 1**
**CASE 1 CEPHALOMETRIC DATA**

| | Pre-treatment | Post-Treatment |
|---|---|---|
| SNA | 86.3° | 84.4° |
| SNB | 79.9° | 79.2° |
| ANB | 6.4° | 5.2° |
| Wits appraisal | 3.8mm | 2.1mm |
| FMIA | 55.2° | 59.5° |
| FMA | 20.3° | 20.7° |
| IMPA | 104.5° | 99.8° |
| SN-GoGn | 27.8° | 29.6° |
| U1-SN | 106.9° | 101.2° |
| U1-NA | 20.5° | 16.8° |
| U1-NA | 5.1mm | 1.2mm |
| L1-NB | 32.2° | 28.6° |
| L1-NB | 6.9mm | 5.4mm |
| Interincisal angle | 120.8° | 129.4° |
| Po-NB | 0.6° | –0.3° |

90



FOI - Page 391 of 446

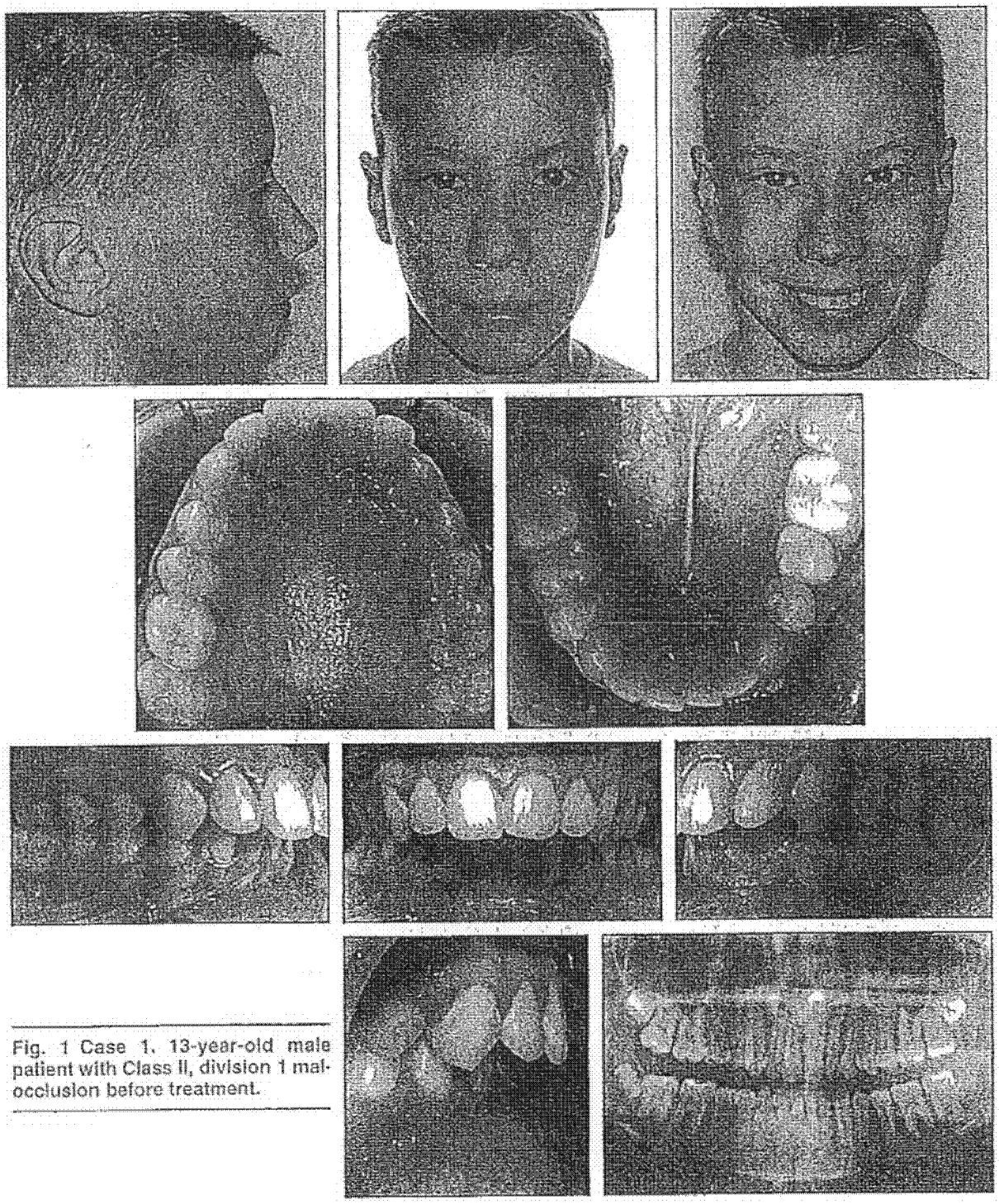

Fig. 1 Case 1. 13-year-old male patient with Class II, division 1 malocclusion before treatment.

S1

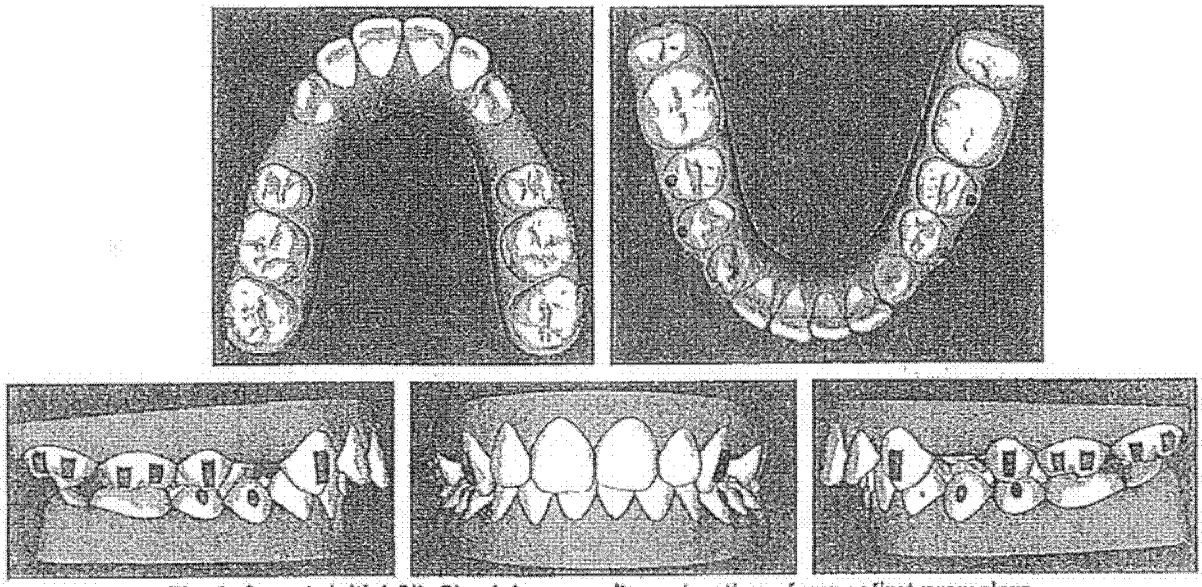

Fig. 2 Case 1. Initial ClinCheck images after extraction of upper first premolars.

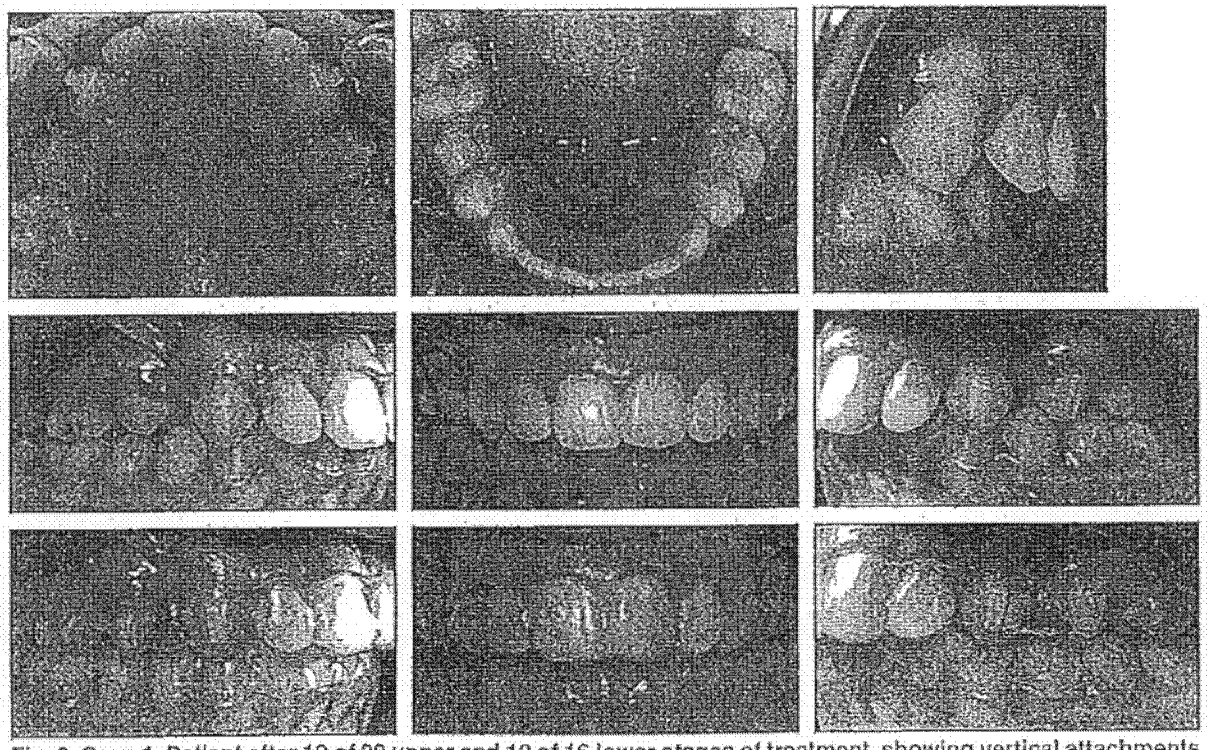

Fig. 3 Case 1. Patient after 12 of 29 upper and 12 of 16 lower stages of treatment, showing vertical attachments on aligners.

52



FOI - Page 393 of 446

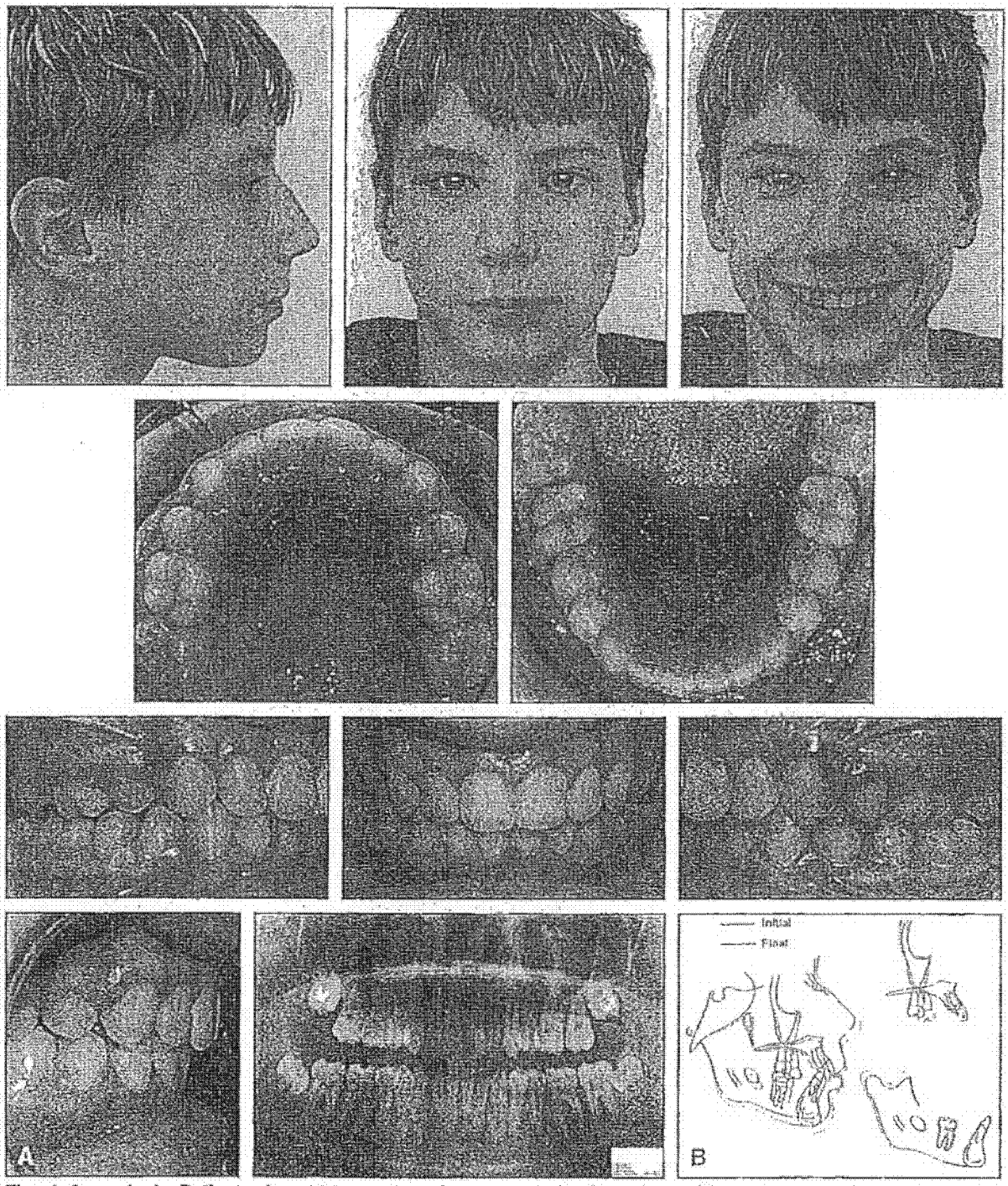


Fig. 4 Case 1. A. Patient after 14½ months of treatment. B. Superimposition of pre- and post-treatment cephalometric tracings.

53

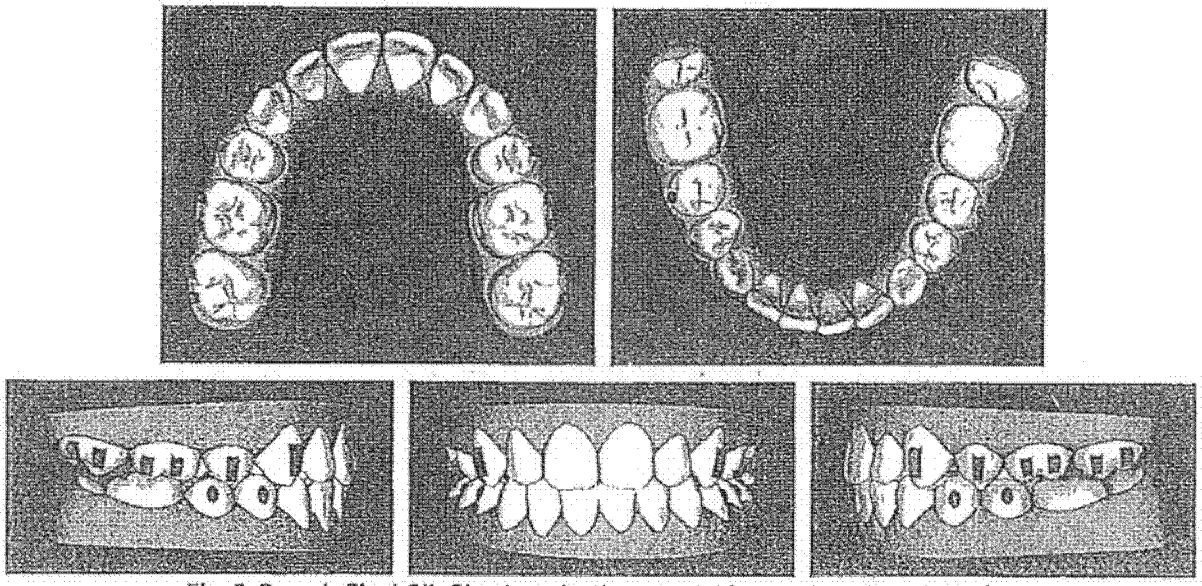

Fig. 5 Case 1. Final ClinCheck projections, matching post-treatment results.

maxillary right second premolar was lost and had to be replaced to prevent tipping (Fig. 3).

Post-treatment records showed complete closure of the upper extraction spaces and achievement of normal overjet and overbite (Fig. 4A). The slight posterior open bite on the right side is commonly seen because of intrusion caused by closure on the double thickness of the aligners. The post-treatment panoramic radiograph confirmed root parallelism adjacent to the upper extraction sites. (The pretreatment cephalometric measurements and tracings were obtained one year before the start of treatment, which explains why more growth is shown than would have been expected in 14½ months.) The reduction in overjet was most likely due to forward mandibular growth (Fig. 4B). Cephalometric analysis also showed slight flaring of the lower incisors, with no significant change in the mandibular plane angle and only slight uprighting of the upper incisors (Table 1). The final ClinCheck projections matched the post-treatment results (Fig. 5).

Two years after the end of treatment, the slight posterior open bite had closed as a result of wearing the aligners only at night, but continued growth of the patient's nose had adversely affected the profile (Fig. 6). The panoramic radiograph showed stable root positions. Gingival inflammation and tooth staining were due to a recently developed smoking habit. Because there was inadequate space for the third molars, it was recommended that they be removed.

## Case 2

A 16-year-old female presented with the chief complaint of "crooked and uneven front teeth" (Fig. 7). She had an end-on Class II canine relationship and rotated maxillary left and mandibular canines. The overbite was more than 120%. Palatal impingement and severe retroclination of the incisors were noted in both arches, and the gingival margins of the maxillary incisors were uneven because of supra-eruption of the central incisors. The panoramic radiograph showed normal roots and alveolar bone and partially erupted third molars, which were scheduled for extraction.

A total of 35 upper and 30 lower aligners were planned over 18 months of treatment, with 1mm elliptical attachments placed on all eight

54



FOI - Page 395 of 446

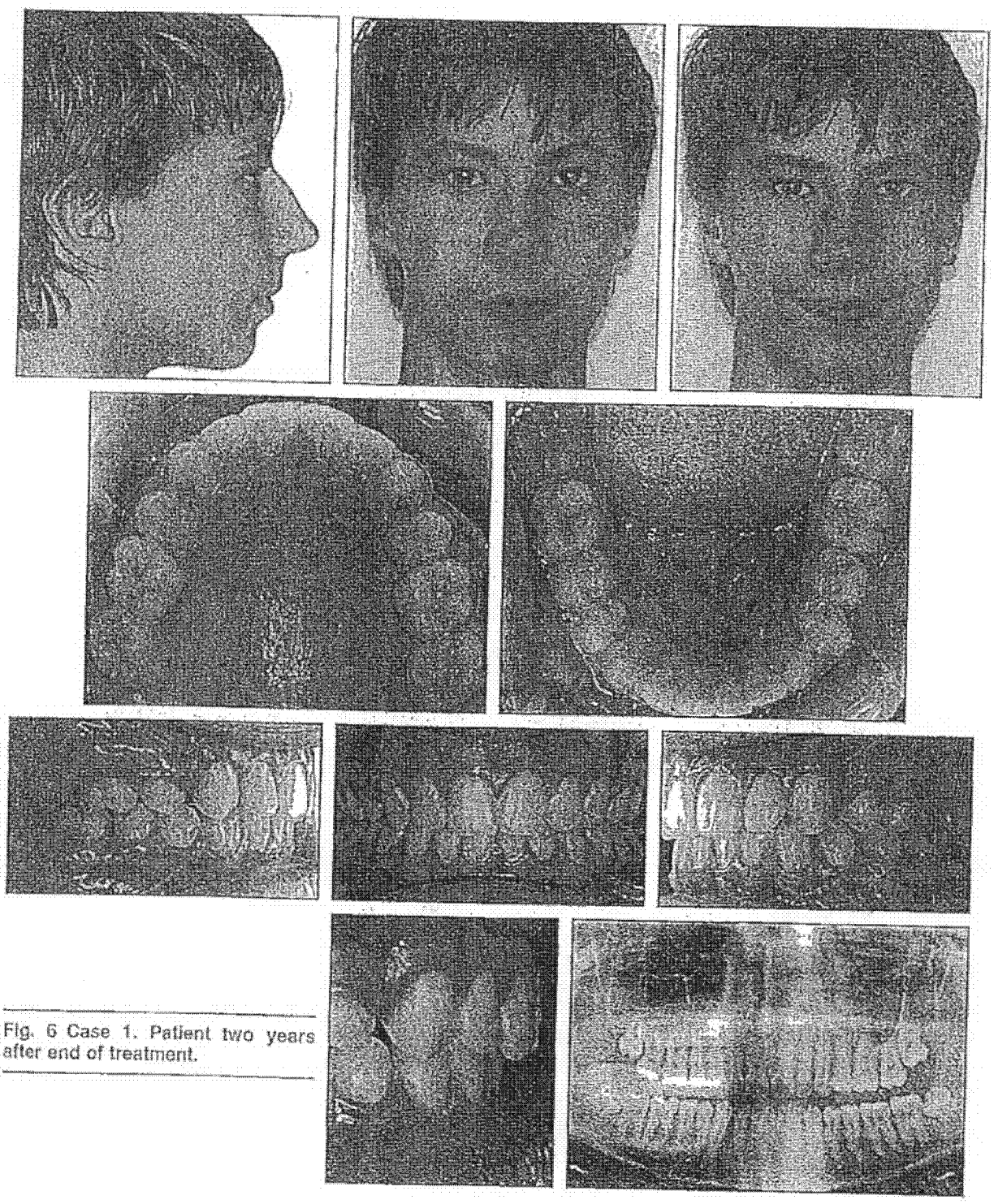

Fig. 6 Case 1. Patient two years after end of treatment.

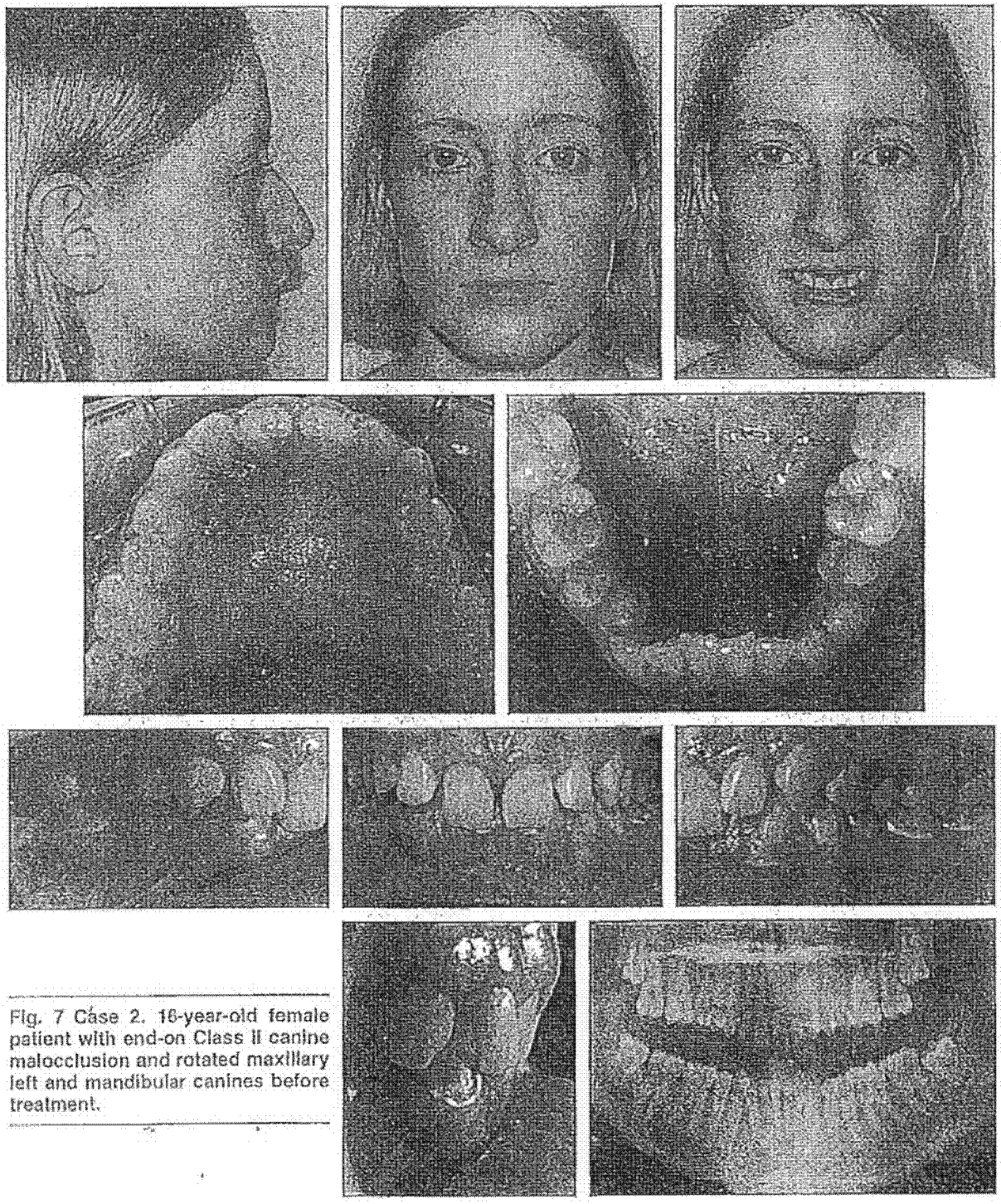

Fig. 7 Case 2. 16-year-old female patient with end-on Class II canine malocclusion and rotated maxillary left and mandibular canines before treatment.

56



FOI - Page 397 of 446

premolars to facilitate intrusion of the incisors (Fig. 8). Treatment of this patient was begun before adoption of the new protocol, which would have called for two horizontal beveled attachments on each first premolar and 4mm or 5mm × 1mm × 2mm vertical rectangular attachments on the three rotated canines.

The upper left buccal segment was distalized about 2mm to improve the canine relationship. An upper arch Case Refinement involving four additional aligners was needed for slight additional derotation of the upper left canine, probably because no vertical rectangular attachment was placed on that tooth. In fact, the tooth was still slightly rotated after the Case Refinement.

After 18 months of treatment, records showed opening of the deep overbite, good alignment of the teeth, and leveling of the upper incisor gingival margins (Fig. 9A). The panoramic radiograph demonstrated proper root alignment, with no resorption despite the significant intrusion, and adequate healing after the extraction of all four third molars. Cephalometric analysis showed significant

TABLE 2
CASE 2 CEPHALOMETRIC DATA

| | Pre-treatment | Post-Treatment |
|---|---|---|
| SNA | 73.1° | 73.0° |
| SNB | 73.2° | 73.1° |
| ANB | –0.1° | –0.1° |
| Wits appraisal | –3.3mm | –2.0mm |
| FMIA | 87.5° | 67.9° |
| FMA | 20.0° | 19.3° |
| IMPA | 72.5° | 92.9° |
| SN-GoGn | 37.5° | 36.6° |
| U1-SN | 83.9° | 93.6° |
| U1-NA | 10.8° | 20.6° |
| U1-NA | 2.5mm | 5.0mm |
| L1-NB | 3.2° | 22.6° |
| L1-NB | –3.4mm | 3.1mm |
| Interincisal angle | 166.1° | 136.9° |
| Po-NB | 5.1° | 6.2° |

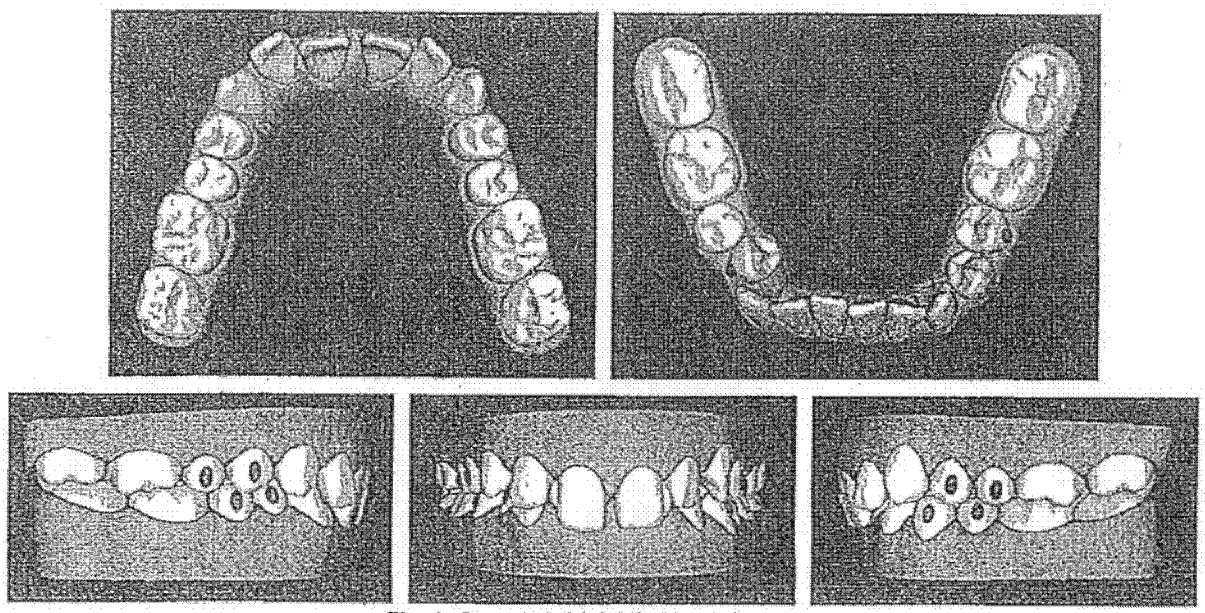

Fig. 8 Case 2. Initial ClinCheck images.

57

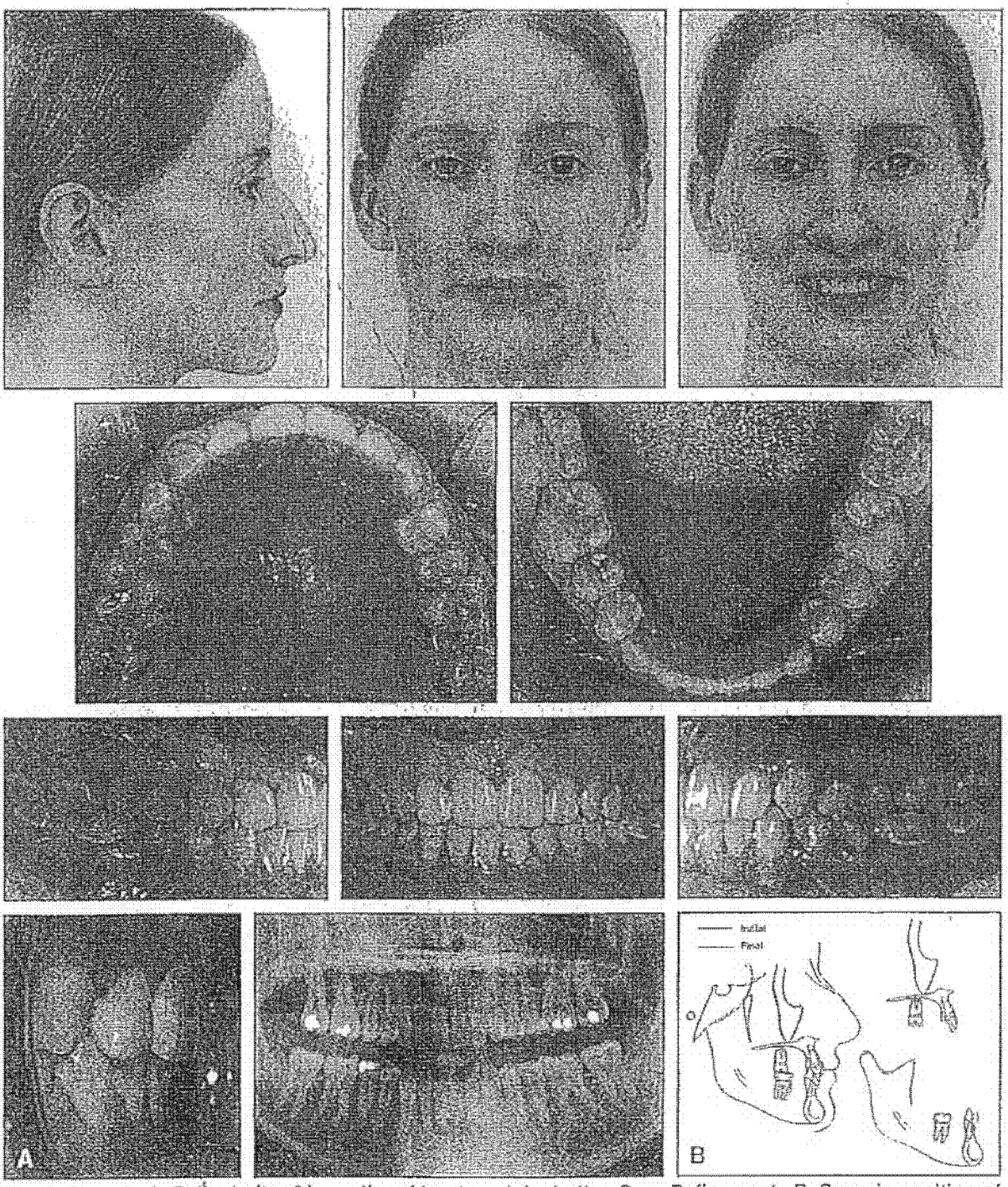


Fig. 9 Case 2. A. Patient after 21 months of treatment, including Case Refinement. B. Superimposition of pre- and post-treatment cephalometric tracings.

58



FOI - Page 399 of 446

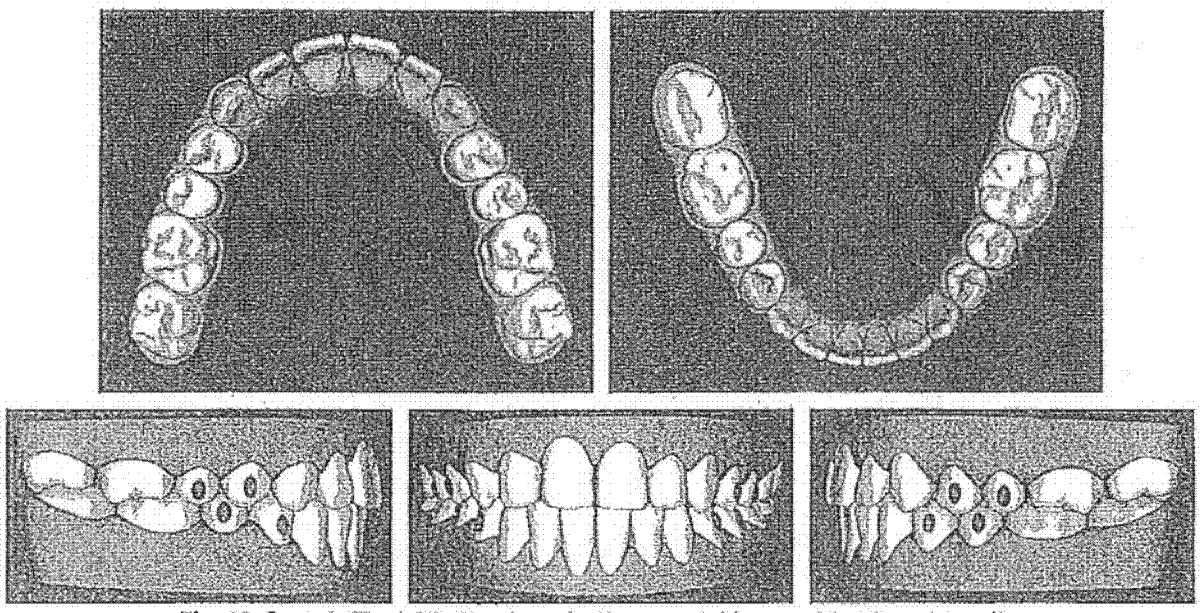

Fig. 10 Case 2. Final ClinCheck projections, matching post-treatment results.

intrusion of the upper and lower incisors, with minimal impact on the skeletal relationships (Fig. 9B, Table 2). The interincisal angle was reduced from 166° to 137°, the upper incisor to SN angle increased from 84° to 94°, and the lower incisor to mandibular plane angle increased from 72.5° to 93°. The final ClinCheck projections closely matched the post-treatment results (Fig. 10).

## Case 3

A 55-year-old woman presented with the chief complaint of "crooked front teeth that do not touch" (Fig. 11). She had undergone successful treatment for generalized periodontitis, with follow-up periodontal maintenance visits every three months. At the start of orthodontic treatment, her periodontal health was excellent, with minimal plaque accumulations and no bleeding on gentle probing. She had extensive posterior restorations. The diagnosis was maxillary vertical excess with dental and skeletal open bite and moderate crowding in both arches. Endodontic therapy had been performed on the mandibular right second premolar, and the pretreatment panoramic radiograph revealed generalized alveolar bone loss of about 20%. The maxillary left second and third molars had drifted mesially and tipped into the space left by early loss of the first molar.

The patient was advised that ideal treatment would involve Le Fort I orthognathic surgery and genioplasty with full fixed appliances. She declined this treatment, but accepted a compromise plan involving upper and lower interproximal reduction and extraction of the maxillary right first premolar, followed by clear aligner treatment to correct the midline and reduce the crowding.

A series of 37 upper and 33 lower aligners was planned. As in Case 1, 5mm × 1mm × 2mm vertical rectangular attachments were placed on the teeth adjacent to the extraction site and on the maxillary right molars (Fig. 12). In addition, 1mm elliptical attachments were placed on the mandibular premolars and on the anterior teeth as they were retracted in the upper arch and slightly proclined in the lower arch. These attachments took advantage of the natural extrusion that would occur when slow extrusive movement (half the

S9

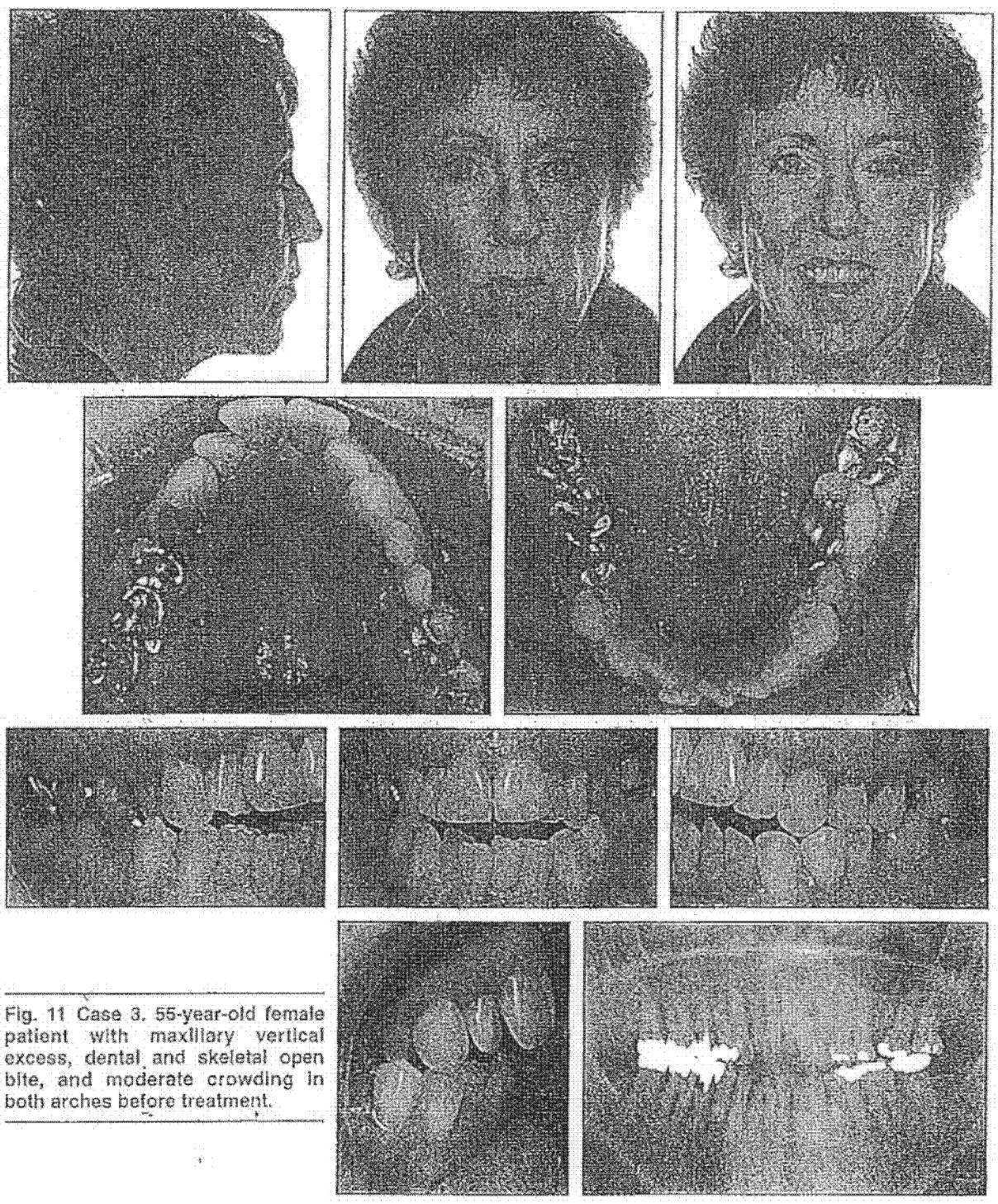

Fig. 11 Case 3. 55-year-old female patient with maxillary vertical excess, dental and skeletal open bite, and moderate crowding in both arches before treatment.

60

usual .25mm per stage) was combined with proclination and retraction movements (Fig. 13). It was decided not to upright the maxillary left second and third molars, which would have required the use of a sectional fixed appliance.

After 31 months of treatment, the open bite was partially closed, and the maxillary premolar extraction space was completely closed (Fig. 14).

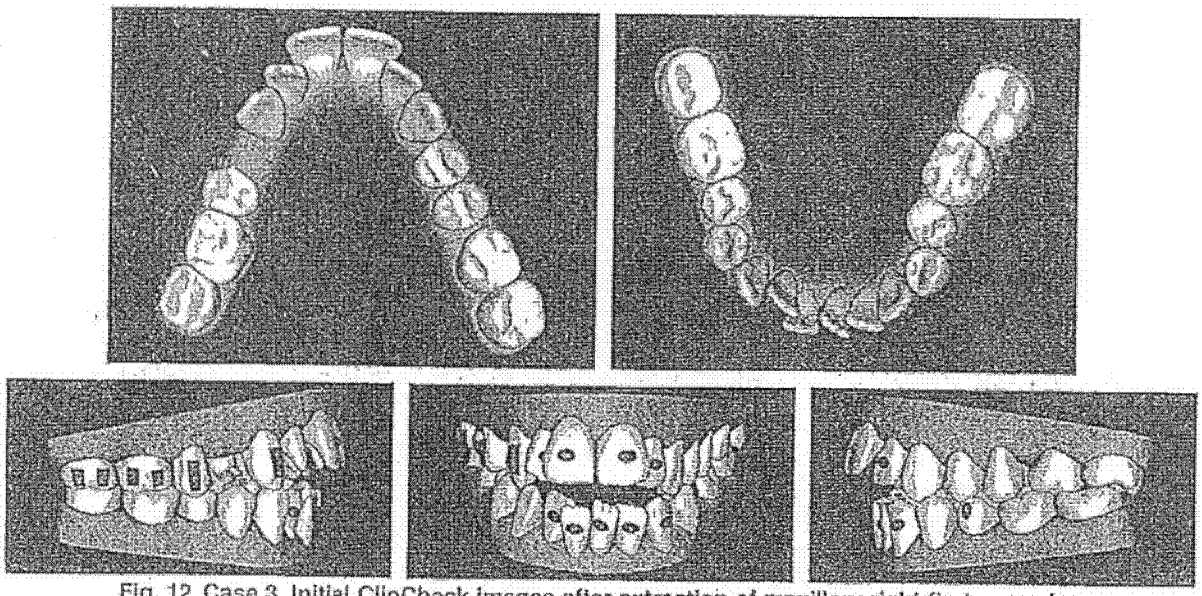

Fig. 12 Case 3. Initial ClinCheck images after extraction of maxillary right first premolar.

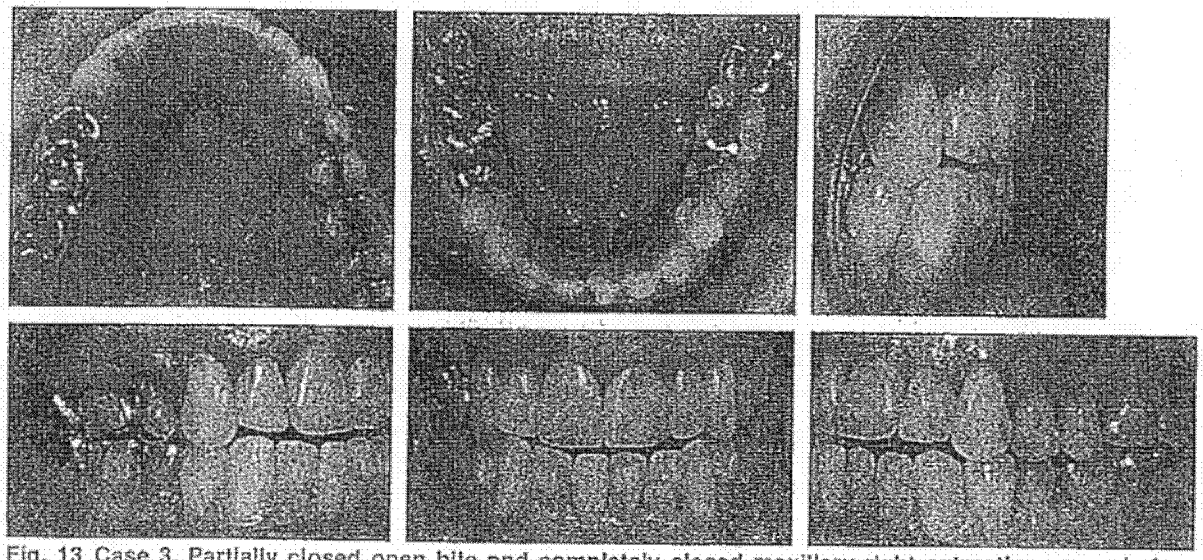

Fig. 13 Case 3. Partially closed open bite and completely closed maxillary right extraction space before Case Refinement.

61

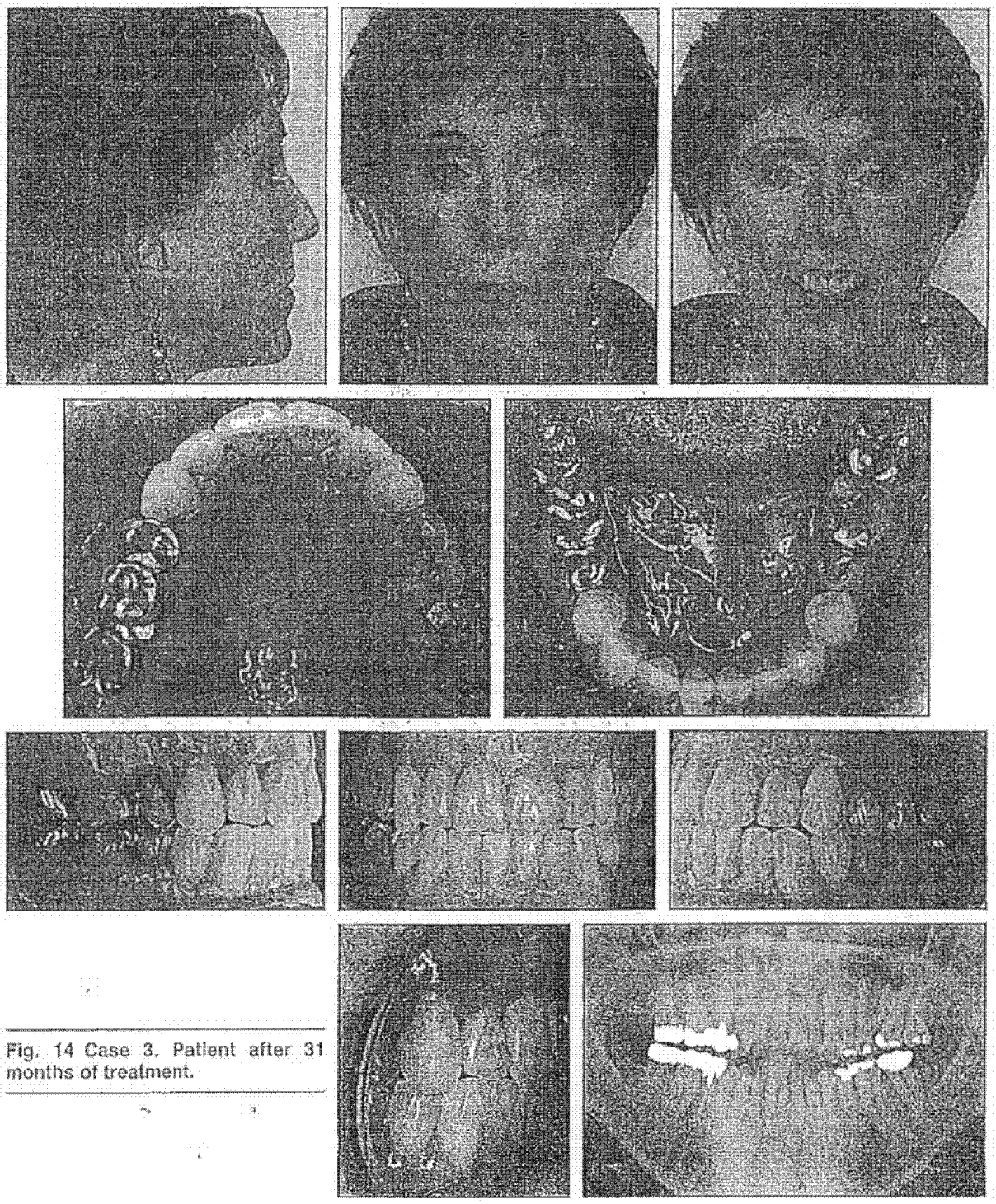

Fig. 14 Case 3. Patient after 31 months of treatment.

Two Case Refinements were performed, using 15 upper and 12 lower aligners in the first and seven upper aligners in the second.

After 31 months of treatment, excellent facial esthetics had been achieved through the improvement in occlusion, avoidance of an increase in anterior face height, and plastic surgery involving a face lift and chin implant (Fig. 14). The open bite was closed except for the maxillary lateral incisors, which were 1mm out of occlusion. The post-treatment panoramic radiograph showed parallel roots around the upper right first premolar extraction space. The midlines were not fully corrected because the patient did not want to wear interarch elastics toward the end of treatment. Final ClinCheck projections after the two Case Refinements showed the use of horizontal beveled attachments on the upper incisors to achieve the final amount of extrusion needed to correct the overbite (Fig. 15).

One year after the end of treatment, further closure of the open bite had occurred, with interincisal contact of all anterior teeth (Fig. 16A). New crowns were placed on the upper right molars to

TABLE 3
CASE 3 CEPHALOMETRIC DATA

| | Pre-treatment | Post-Treatment |
|---|---|---|
| SNA | 73.5° | 73.5° |
| SNB | 69.1° | 69.0° |
| ANB | 4.4° | 4.5° |
| Wits appraisal | −0.4mm | −1.4mm |
| FMIA | 52.0° | 54.4° |
| FMA | 49.6° | 49.1° |
| IMPA | 78.4° | 76.5° |
| SN-GoGn | 59.6° | 59.3° |
| U1-SN | 98.6° | 88.0° |
| U1-NA | 25.1° | 14.5° |
| U1-NA | 6.3mm | 1.9mm |
| L1-NB | 27.1° | 24.7° |
| L1-NB | 7.3mm | 7.0mm |
| Interincisal angle | 123.4° | 136.2° |
| Po-NB | 2.5° | 5.7° |

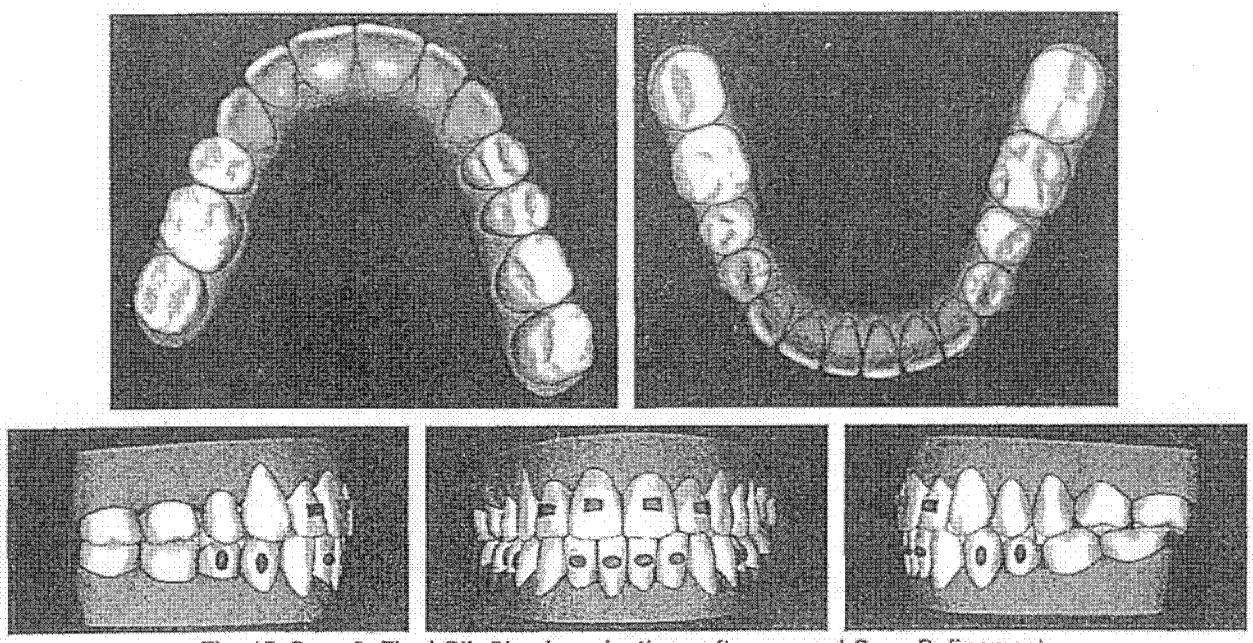

Fig. 15 Case 3. Final ClinCheck projections after second Case Refinement.

63

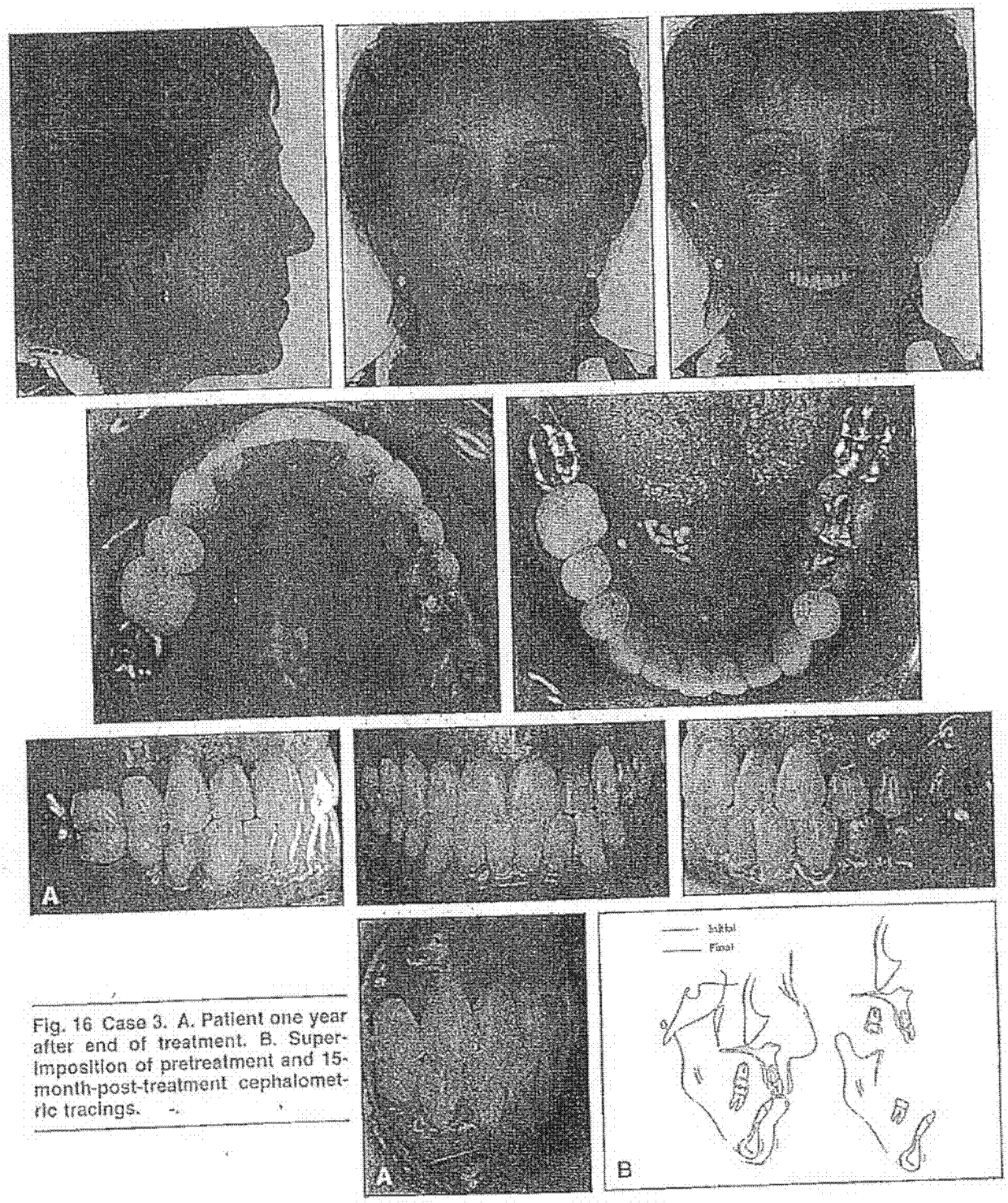


Fig. 16 Case 3. A. Patient one year after end of treatment. B. Superimposition of pretreatment and 15-month-post-treatment cephalometric tracings.

C4

improve their esthetics. The patient had worn the retainers only at night for the preceding nine months, confirming the stability of the open-bite correction. Slight rotation of the maxillary lateral incisor and mandibular central incisor had occurred during the night-only retainer wear, and the midlines remained off by 1mm. Comparison of the pretreatment and 15-month-post-treatment cephalometric tracings showed that the overall skeletal structures and the mandibular plane angle had remained remarkably similar throughout treatment, considering the closure of a substantial open bite (Fig. 16B, Table 3). The upper incisors were uprighted nearly 11° and the lower incisors 2°.

## Case 4

A 32-year-old male presented with a Class II, division 1 malocclusion, a 3mm overbite and 7mm overjet, and the chief complaint of "worsened overbite and crowded front teeth" (Fig. 17). Moderate crowding was noted in both arches, but the periodontal tissues were healthy. The patient had undergone previous orthodontic treatment as an adolescent after the extraction of all four first premolars. The pretreatment panoramic radiograph showed parallel roots in all four extraction sites. The third molars had also been extracted, and the alveolar bone height was good, although many of the roots showed multiple dilacerations.

An initial series of 43 upper and 14 lower aligners was planned over 25 months of treatment, using elliptical attachments on the maxillary second premolars and first molars and mandibular second premolars for appliance retention (Fig. 18). The Class II correction was achieved in ClinCheck with interproximal reduction, combined with a simulation of interarch movement using the surgical movement tool. After the interproximal reduction in the upper anterior segment, treatment involved 14 months of wearing 4oz Class II elastics from clear buttons on the upper canines to metal buttons on the lower first molars. The aligners were cut back about 2mm gingivally to accommodate the buttons.

A Case Refinement with 10 lower aligners was needed to complete the treatment, primarily because a 1mm vertical rectangular attachment was not initially placed on the rotated lower right canine. The Case Refinement used such an attachment to successfully derotate the tooth (Fig. 19A).

Cephalometric analysis and superimposition of pre- and post-treatment cephalometric tracings showed a 3mm distal bodily movement of the upper central incisor as measured from the apex, accompanied by upper and lower incisor intrusion to open the bite (Fig. 19B, Table 4). All skeletal and other dental measurements remained stable. The final ClinCheck projections were an excellent match with the post-treatment results (Fig. 20).

TABLE 4
CASE 4 CEPHALOMETRIC DATA

| | Pre-treatment | Post-Treatment |
|---|---|---|
| SNA | 81.1° | 81.7° |
| SNB | 74.0° | 74.6° |
| ANB | 7.1° | 7.1° |
| Wits appraisal | 5.5mm | 4.9mm |
| FMIA | 51.5° | 53.5° |
| FMA | 25.3° | 26.0° |
| IMPA | 103.2° | 100.0° |
| SN-GoGn | 33.0° | 33.8° |
| U1-SN | 98.6° | 97.0° |
| U1-NA | 17.5° | 15.3° |
| U1-NA | 3.8mm | 1.5mm |
| L1-NB | 30.0° | 28.4° |
| L1-NB | 10.2mm | 9.6mm |
| Interincisal angle | 125.2° | 129.2° |
| Po-NB | 0.0° | 0.0° |

## Discussion

Patient cooperation is a critical factor in achieving success with Invisalign treatment. The aligners should be worn at least 20 hours per day, seven days a week. The patients shown here, who had moderate-to-severe malocclusions, were all highly compliant with their aligner wear and there-

65

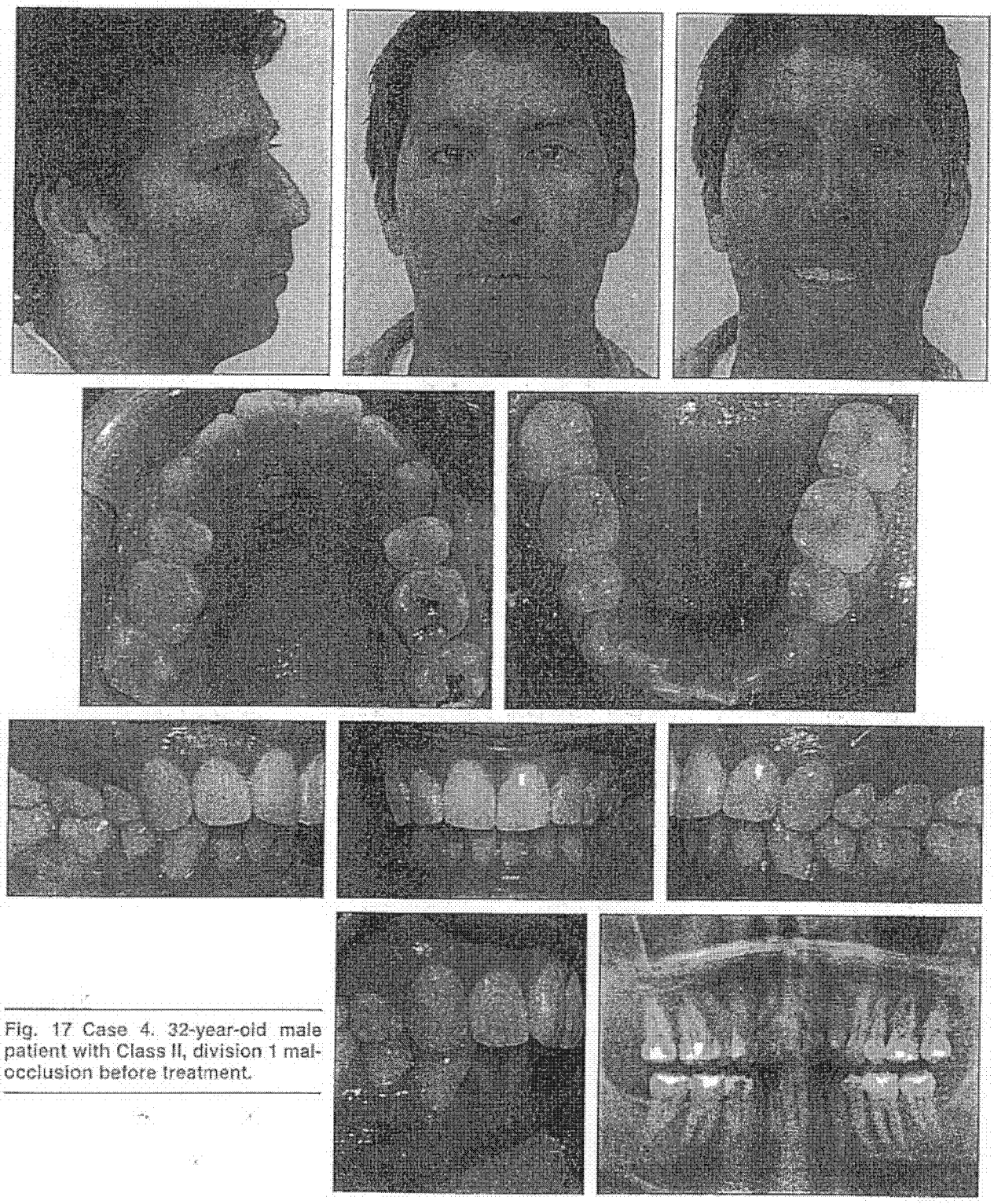

Fig. 17 Case 4. 32-year-old male patient with Class II, division 1 malocclusion before treatment.

66

fore had good treatment outcomes. Still, successful clear aligner treatment requires considerable clinical experience with other orthodontic methods, proper implementation of diagnosis and treatment planning, and a thorough knowledge of biomechanics. These skills form the basis for reviewing the staging process with the ClinCheck software before treatment.

Tipping was often a problem in premolar extraction cases during the early years of Invisalign treatment. The new protocol, using 1mm rectangular attachments, has allowed more upper premolar extraction patients to be treated exclusively with aligners. Nearly all patients needing lower extractions still require completion of treatment with fixed appliances, because the spaces are more difficult to close. In any case, if the teeth tip more than 5° from the vertical axis during space closure, fixed appliances will probably be needed to upright them. Although Invisalign can hold teeth upright during the closure of upper extraction spaces, it cannot upright teeth adjacent to an extraction space once they have developed clinically significant tipping. If tipping exceeds 10°, the clinician should either incorporate a fixed appliance segment to upright the tipped teeth or convert to full fixed appliances to finish treatment. The bottom line is that Invisalign treatment involving premolar extractions is still in the experimental stage, and Align Technology does not currently recommend Invisalign for these cases.

## Conclusion

Clinicians who tried Invisalign in the first few years after its introduction, but abandoned it because of shortcomings such as unpredictable tooth movement, may have more success with the improved protocol. As this article demonstrates, the new Invisalign protocol can be used successfully in a variety of complex cases, including malocclusions with deep and open bites, moderate-to-severe overjet, and upper premolar extractions. Three of the four patients shown here required only one series of aligners or one Case Refinement, with no midcourse corrections. Only the complex Case 3 required two Case Refinements. Further testing is needed by other clinicians to determine

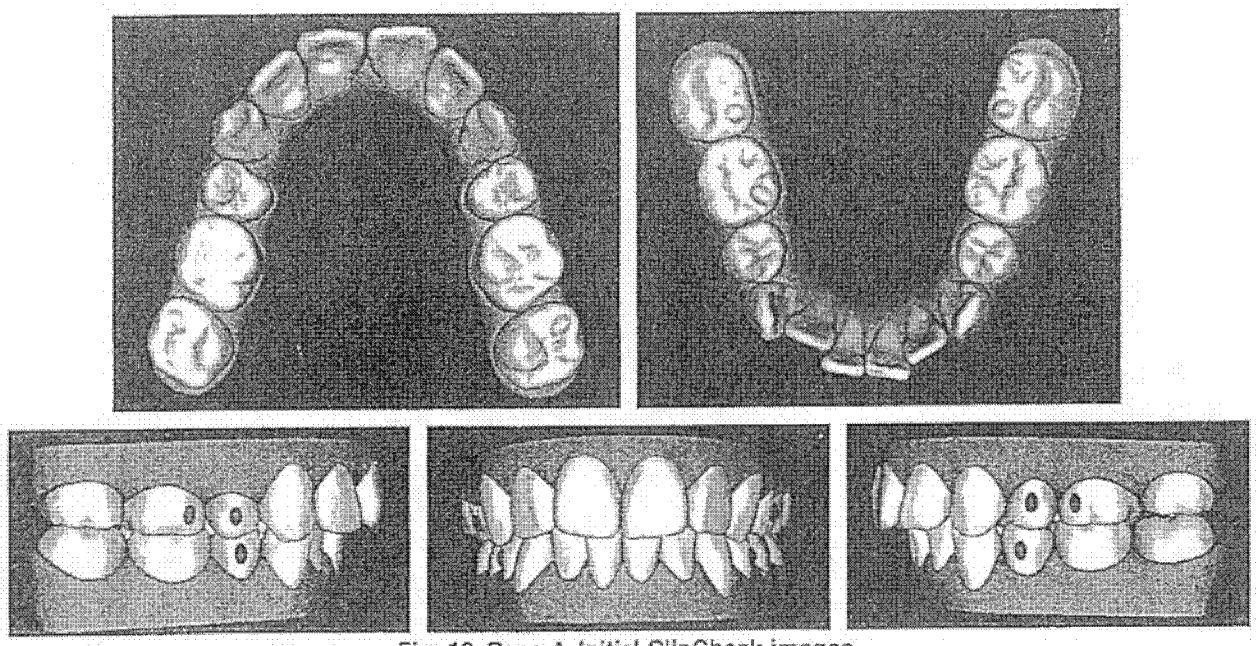

Fig. 18 Case 4. Initial ClinCheck images.

61

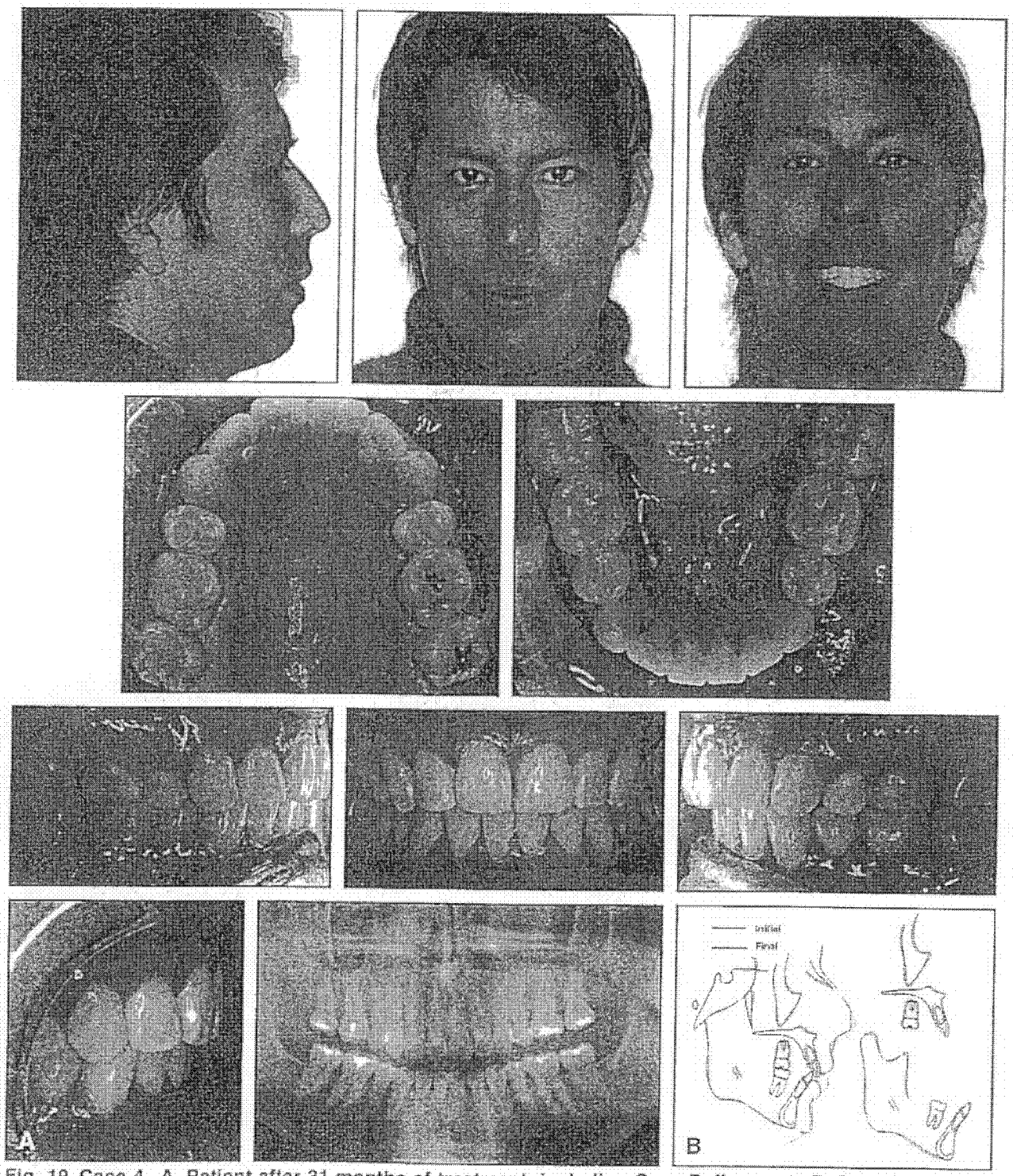


Fig. 19 Case 4. A. Patient after 31 months of treatment, including Case Refinement. B. Superimposition of pre- and post-treatment cephalometric tracings.

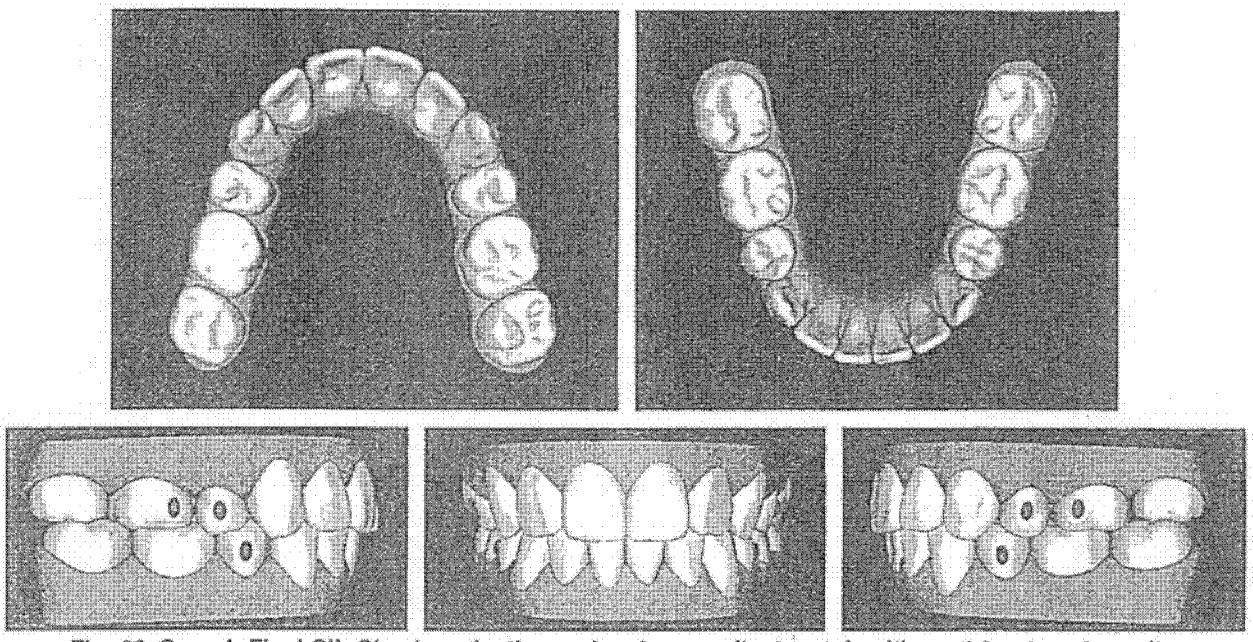

Fig. 20 Case 4. Final ClinCheck projections, showing excellent match with post-treatment results.

whether similar outcomes can be obtained in comparable cases.

Understanding the ClinCheck staging process is crucial for good results. Orthodontists will increase their chances of success with the Invisalign system if they take the time to acquire appropriate standardized instruction before using this relatively new form of treatment. They should also gain significant clinical experience in the treatment of mild malocclusions before attempting to treat more complex cases.

ACKNOWLEDGMENTS: The author wishes to thank Dr. Rebecca Doucet, Dr. Bao Nguyen, and Dr. Basma Fallah for their assistance in the treatment of Case 2. I also acknowledge the assistance of Dean Emeritus Dr. Arthur A. Dugoni, Dr. Mohamed Fallah, Dr. Maureen Valley, Dr. Vicki Vlaskalic, Dr. David Chenin, and Dr. Hee Soo Oh in the development of Invisalign. Finally, I acknowledge the members of the CAB, especially Dr. Bob Fry and Dr. Dave Paquette, for their inspiration in developing the new protocol presented here; CAB members from Align Technology, including Dr. Rene Sterental, Dr. Eric Kuo, Dr. Ana Maria Castillo, and Ms. Shannon Henderson, provided the support that made this new protocol possible.

## REFERENCES

1. Boyd, R.L.: John Valentine Mershon Lecture, AAO annual meeting, San Diego, 1999.
2. Boyd, R.L.; Miller, R.J.; and Vlaskalic, V.: The Invisalign system in adult orthodontics: Mild crowding and space closure cases, J. Clin. Orthod. 34:203-212, 2000.
3. Boyd, R.L. and Vlaskalic, V.: Three-dimensional diagnosis and orthodontic treatment of complex malocclusions with the Invisalign Appliance, Semin. Orthod. 7:274-293, 2001.
4. Vlaskalic, V. and Boyd, R.L.: Orthodontic treatment of a mildly crowded malocclusion using the Invisalign System, Austral. Orthod. J. 17:41-46, 2001.
5. Vlaskalic, V. and Boyd, R.L.: Clinical evolution of the Invisalign appliance, J. Calif. Dent. Assoc. 30:769-776, 2002.
6. Chenin, D.A.; Trosien, A.H.; Fong, P.F.; Miller, R.A.; and Lee, R.S.: Orthodontic treatment with a series of removable appliances, J. Am. Dent. Assoc. 134:1232-1239, 2003.
7. Womack, W.R.; Ahn, J.H.; Ammari, Z.; and Castillo, A.: A new approach to correction of crowding, Am. J. Orthod. 122:310-316, 2002.
8. Wong, B.H.: Invisalign A to Z, Am. J. Orthod. 121:540-541, 2002.
9. Miller, R.J. and Derakhshan, M.: The Invisalign System: Case report of a patient with deep bite, upper incisor flaring, and severe curve of Spee, Semin. Orthod. 8:43-50, 2002.
10. Lagravère, M.O. and Flores-Mir, C.: The treatment effects of Invisalign orthodontic aligners: A systematic review, J. Am. Dent. Assoc. 136:1724-1729, 2005.
11. Boyd, R.L.; Oh, H.; Fallah, M.; and Vlaskalic, V.: An update on present and future considerations of aligners, J. Calif. Dent. Assoc. 34:793-805, 2006.
12. Djeu, G.; Shelton, C.; and Maganzini, A.: Outcome assessment of Invisalign and traditional orthodontic treatment compared with the American Board of Orthodontics objective grading system, Am. J. Orthod. 128:292-298, 2005.
13. Boyd, R.L.: Surgical-orthodontic treatment of two skeletal

69

Class III patients with Invisalign and fixed appliances, J. Clin. Orthod. 39:245-258, 2005.
14. Womack, W.R.: Four-premolar extraction treatment with Invisalign, J. Clin. Orthod. 40:493-500, 2006.
15. Hönn, M. and Göz, G.: A premolar extraction case using the Invisalign system, J. Orofac. Orthop. 67:385-394, 2006.
16. Norris, R.A.; Brandt, D.J.; Crawford, C.H.; and Fallah, M.: Restorative and Invisalign: A new approach, J. Esth. Restor. Dent. 14:217-224, 2002.
17. Bollen, A.M.; Huang, G.; King, G.; Hujoel, P.; and Ma, T.: Activation time and material stiffness of sequential removable orthodontic appliances, Part 1: Ability to complete treatment, Am. J. Orthod. 124:496-501, 2003.
18. Clements, K.M.; Bollen, A.M.; Huang, G.; King, G.; Hujoel, P.; and Ma, T.: Activation time and material stiffness of sequential removable orthodontic appliances, Part 2: Dental improvements, Am. J. Orthod. 124:502-508, 2003.
19. Taylor, M.G.; McGorray, S.P.; Durrett, S.; Pavlov, S.; Downey, N.; Lenk, M.; Oxford, E.; Dolce, C.; and Wheeler, T.T.: Effect of Invisalign aligners on periodontal tissues, J. Dent. Res. 82 (Spec. Iss. A):1483, 2003.
20. Boyd, R.L.; Leggott, P.J.; Quinn, R.S.; Eakle, W.S.; and Chambers, D.: Periodontal implications of orthodontic treatment in adults with reduced or normal periodontal tissues versus those of adolescents, Am. J. Orthod. 96:191-198, 1989.
21. Boyd, R.L. and Baumrind, S.: Periodontal considerations in the use of bonds or bands on molars in adolescents and adults, Angle Orthod. 62:117-126, 1992.
22. Spear, F.M.: The esthetic correction of anterior dental malalignment: conventional vs. instant (restorative) orthodontics, J. Calif. Dent. Assoc. 32:133-141, 2004.
23. Wheeler, T.: In preparation.
24. Baumrind, S.; Korn, E.L.; and Boyd, R.L.: Apical root resorption in orthodontically treated adults, Am. J. Orthod. 110:311-320, 1996.
25. Vlaskalic, V.; Boyd, R.L.; and Baumrind, S.: Etiology and sequelae of root resorption, Semin. Orthod. 4:124-131, 1998.
26. Iscan, H.N. and Sarisoy, L.: Comparison of the effects of passive posterior bite-blocks with different construction bites on the craniofacial and dentoalveolar structures, Am. J. Orthod. 112:171-178, 1997.
27. Dellinger, E.L.: A clinical assessment of the Active Vertical Corrector—a nonsurgical alternative for skeletal open bite treatment, Am. J. Orthod. 89:428-436, 1986.
28. Arat, M. and Iseri, H.: Orthodontic and orthopaedic approach in the treatment of skeletal open bite, Eur. J. Orthod. 14:207-215, 1992.
29. Pearson, L.E.: Vertical control in fully-banded orthodontic treatment, Angle Orthod. 56:205-224, 1986.
30. Nedwed, V. and Miethke, R.R.: Motivation, acceptance and problems of Invisalign patients, J. Orofac. Orthop. 66:162-173, 2005.
31. Miller, K.B.; McGorray, S.P.; Womack, R.; Quintero, J.C.; Perelmuter, M.; Gibson, J.; Dolan, T.A.; and Wheeler, T.T.: A comparison of treatment impacts between Invisalign aligner and fixed appliance therapy during the first week of treatment, Am. J. Orthod. 131:302.e1-302.e9, 2007.
32. Boyd, R.L.: Review of the diagnostic process, in *The Invisalign System*, ed. O.C. Tuncay, Quintessence, Chicago, 2006, p. 223.
33. Nelson, G.: Invisalign Summit '05: Part I, Pac. Coast Soc. Orthod. Bull., Winter 2005, pp. 6-8.
34. Boyd, R.L.: Multidisciplinary considerations with Invisalign treatment for complex malocclusions, Pac. Coast Soc. Orthod. Bull., Spring 2006, pp. 28-29.
35. Nelson, G.: Invisalign Summit '05: Part II, Pac. Coast Soc. Orthod. Bull., Summer 2006, pp. 14-16.
36. Align Technology. http://www.invisalign.com.

70

Copyrighted Material

Copyrighted Material

Copyrighted Material

Copyrighted Material

Copyrighted Material

Copyrighted Material

Copyrighted Material

Copyrighted Material

Copyrighted Material

Copyrighted Material

Copyrighted Material

Copyrighted Material

Copyrighted Material

Copyrighted Material

Copyrighted Material

Copyrighted Material

Copyrighted Material

Copyrighted Material

Copyrighted Material

Copyrighted Material

ORIGINAL ARTICLE

# Orthodontic intervention in the early mixed dentition: A prospective, controlled study on the effects of the eruption guidance appliance

**Katri Keski-Nisula,[a] Riitta Hernesniemi,[b] Maritta Heiskanen,[c] Leo Keski-Nisula,[d] and Juha Varrela[e]**
*Vaasa, Kurikka, Jalasjärvi, Tampere, and Turku, Finland*

**Introduction:** A prospective, controlled cohort study was started in 1998 to investigate the effects of orthodontic treatment in the early mixed dentition with the eruption guidance appliance. **Methods:** Occlusal changes were recorded in 167 treated children and 104 controls after they had reached the middle mixed-dentition stage. Treatment began when the first deciduous incisor was exfoliated (T1) and ended when all permanent incisors and first molars were fully erupted (T2). The children's mean ages were 5.1 years (SD 0.5) at T1 and 8.4 years (SD 0.5) at T2. **Results:** From T1 to T2, overjet in the treatment group decreased from 3.1 to 1.9 mm and overbite from 3.2 to 2.1 mm. In the control group, overjet increased from 2.9 to 4.1 mm and overbite from 3.3 to 4.1 mm. At T2, the differences between the groups were highly significant ($P$ <.001). At T1, 18% of the children in the treatment group and 22% of the controls had tooth-to-tooth contact between the maxillary and mandibular incisors. All others had an open bite, or the mandibular incisors were in contact with the palatal gingiva. At T2, tooth-to-tooth contact was observed in 99% of the treated children and 24% of the controls ($P$ <.001). Almost half of children in both groups showed incisor crowding at T1. Good alignment of the incisors was observed in 98% of the treated children at T2, whereas maxillary crowding was found in 32% and mandibular crowding in 47% of the controls ($P$ <.001). At T1, 41% of the children in the treatment group and 53% of the controls had a Class I relationship; the rest had either a unilateral or a bilateral Class II relationship. At T2, a Class I relationship was found in 90% of the treated children and 48% of the controls ($P$ <.001). At least 1 occlusal deviation, including overjet ≥5 mm, overbite ≥5 mm, open bite, gingival contact of the mandibular incisors, crowding, or Class II relationship, was observed in 13% of the treated children, but the deviations were mild, and no child was considered to need treatment. In the control group, 88% of the children showed at least 1 occlusal deviation ($P$ <.001). **Conclusions:** Treatment in the early mixed dentition with the eruption guidance appliance is an effective method to restore normal occlusion and eliminate the need for further orthodontic treatment. Only a few spontaneous corrective changes can be expected without active intervention. Copyrighted Material
Copyrighted Material

Copyrighted Material

Copyrighted Material

Copyrighted Material

Copyrighted Material

Copyrighted Material

Copyrighted Material

Copyrighted Material

# The Invisalign® System

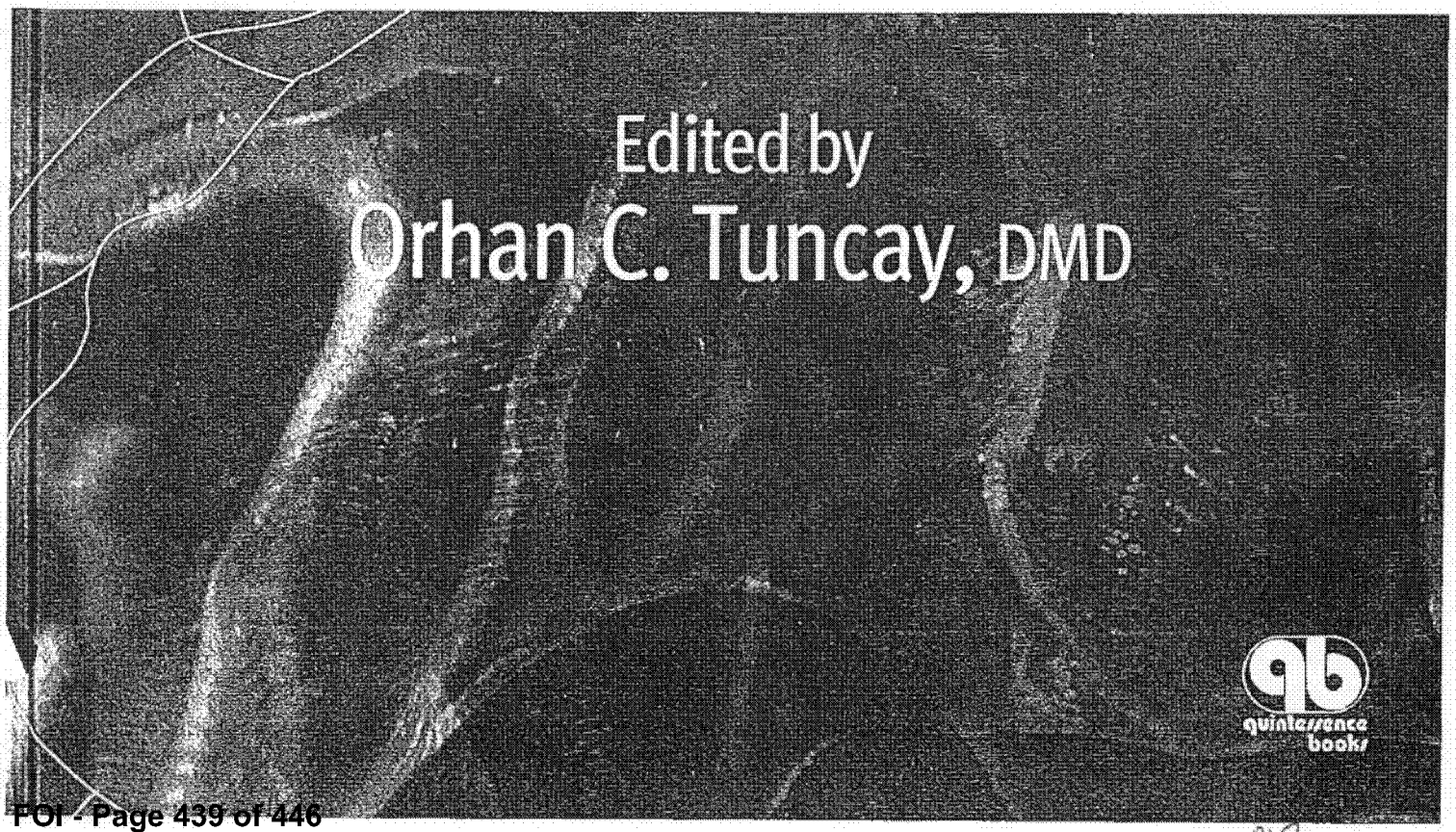




98

Copyrighted Material

Copyrighted Material

Copyrighted Material

Copyrighted Material

Copyrighted Material

Copyrighted Material

Copyrighted Material